

Holden's human osteology : comprising a description of the bones with delineations of the attachments of the muscles, the general and microscopic structure of bone and its development.

Contributors

Reid, R. W.
Holden, Luther, 1815-1905.
Stewart, Charles.
Royal College of Physicians of Edinburgh

Publication/Creation

London : J. & A. Churchill, 1887.

Persistent URL

<https://wellcomecollection.org/works/b5bbuwmb>

Provider

Royal College of Physicians Edinburgh

License and attribution

This material has been provided by This material has been provided by the Royal College of Physicians of Edinburgh. The original may be consulted at the Royal College of Physicians of Edinburgh. where the originals may be consulted.

This work has been identified as being free of known restrictions under copyright law, including all related and neighbouring rights and is being made available under the Creative Commons, Public Domain Mark.

You can copy, modify, distribute and perform the work, even for commercial purposes, without asking permission.



Wellcome Collection
183 Euston Road
London NW1 2BE UK
T +44 (0)20 7611 8722
E library@wellcomecollection.org
<https://wellcomecollection.org>





*Fd 6.22

Edwin Matthews

161

(8)

* Fd 6.22

R52871

*Fd 6. 22

Edwin Matthew

Blank page with faint markings at the top.

HOLDEN'S
HUMAN OSTEOLOGY

By the same Author,

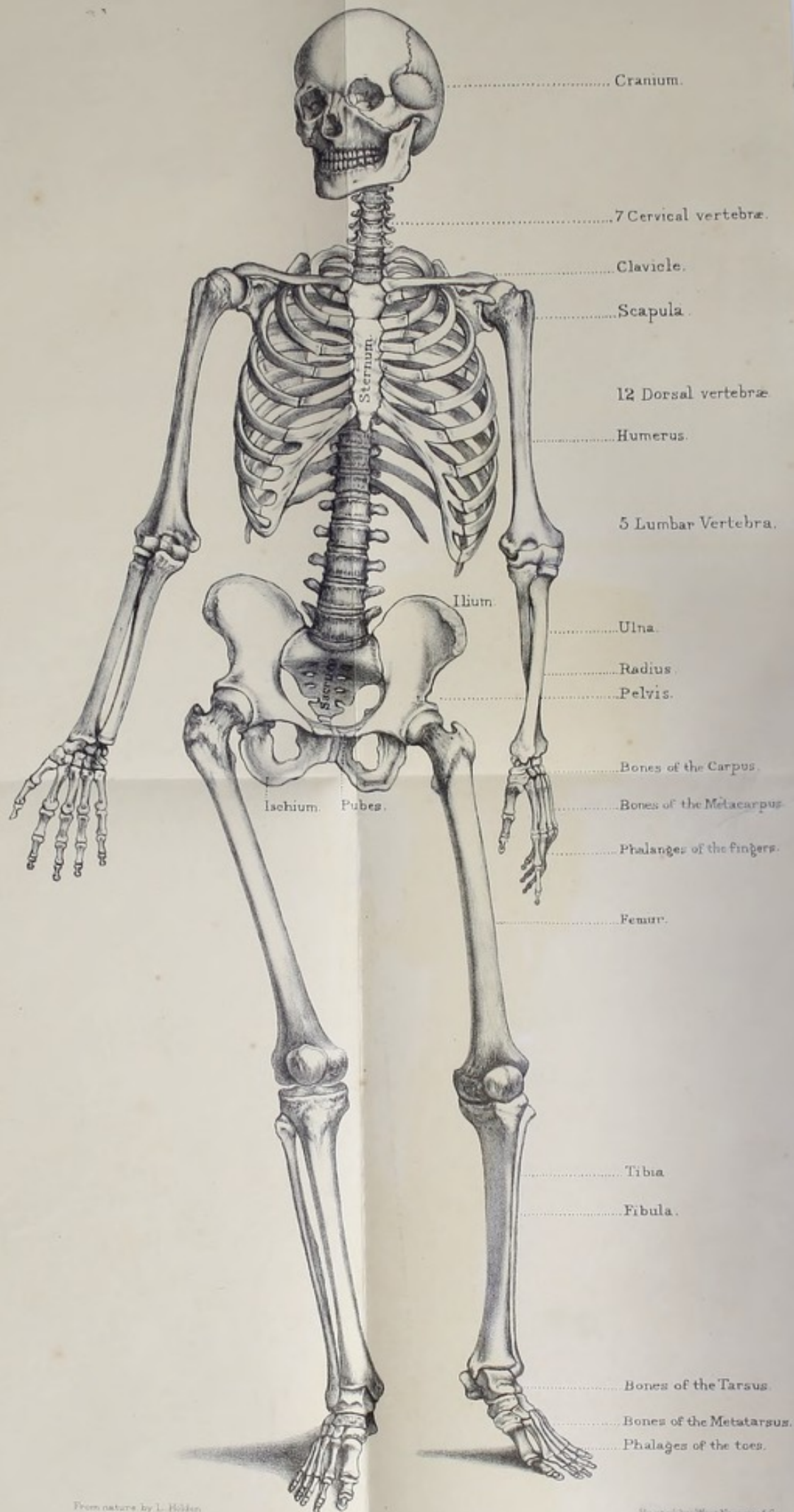
MANUAL of the DISSECTION of the HUMAN BODY.

Edited by JOHN LANGTON, Surgeon to, and Lecturer
on Anatomy at, St. Bartholomew's Hospital. Fifth
Edition, with 208 Engravings on Wood. 8vo. 20s.



Digitized by the Internet Archive
in 2015

<https://archive.org/details/b21910959>



HOLDEN'S
HUMAN OSTEOLOGY

COMPRISING

A DESCRIPTION OF THE BONES

WITH DELINEATIONS OF THE ATTACHMENTS OF THE MUSCLES
THE GENERAL AND MICROSCOPIC STRUCTURE OF BONE
AND ITS DEVELOPMENT

EDITED BY

CHARLES STEWART

CONSERVATOR OF THE MUSEUM OF THE ROYAL COLLEGE OF SURGEONS OF ENGLAND;
HUNTERIAN PROFESSOR OF COMPARATIVE ANATOMY AND PHYSIOLOGY,
ROYAL COLLEGE OF SURGEONS OF ENGLAND

AND

R. W. REID, M.D., F.R.C.S.

LECTURER ON ANATOMY, MEDICAL SCHOOL OF ST. THOMAS'S HOSPITAL; EXAMINER IN OSTEOLOGY,
CONJOINED EXAMINING BOARD BY ROYAL COLLEGE OF PHYSICIANS OF LONDON AND
ROYAL COLLEGE OF SURGEONS OF ENGLAND; FORMERLY EXAMINER
IN ANATOMY, UNIVERSITY OF ABERDEEN

SEVENTH EDITION



LONDON

J. & A. CHURCHILL

11 NEW BURLINGTON STREET

1887

1196
9/1/46

УДОЛЖИТЕЛЬНО

УДОЛЖИТЕЛЬНО

УДОЛЖИТЕЛЬНО

УДОЛЖИТЕЛЬНО

УДОЛЖИТЕЛЬНО

УДОЛЖИТЕЛЬНО

PREFACE

TO

THE SEVENTH EDITION.



It has been thought necessary in this Edition to endeavour to meet the requirements of the student, by giving a somewhat more detailed description of the Bones. This has been done by Mr. R. W. REID.

A few alterations have also been made in the account of the minute structure and development of Bone.

Some of the plates have been redrawn and several new ones added. As in former editions, the attachments of the muscles have been indicated by coloured lines, *red* being adopted for the origins or usually more fixed ends, and *blue* for the insertions or more movable ones.

The descriptions of the larynx and soft parts of the ear have been omitted, as it was considered that they belonged rather to a work dealing with General Anatomy, than to one on Human Osteology.

UNIVERSITY

OF THE STATE

OF CALIFORNIA

THE UNIVERSITY OF THE STATE OF CALIFORNIA

THE UNIVERSITY OF THE STATE OF CALIFORNIA

THE UNIVERSITY OF THE STATE OF CALIFORNIA

CONTENTS.

	PAGE	PLATE
GENERAL OBSERVATIONS ON THE STRUCTURE OF BONE	1	. . I. to IV.
MICROSCOPIC STRUCTURE OF BONE	13	
STRUCTURE OF CARTILAGE	22	
DEVELOPMENT OF BONE	23	
BONES OF THE SKULL	36	
Occipital Bone	36	. . V.
Parietal Bone	44	. . VI.
Frontal Bone	48	. . VII.
Temporal Bone	56	. . VIII., IX.
Sphenoid Bone	73	. . X., XI.
Ethmoid Bone	83	. . XI.
Wormian Bones	88	
BONES OF THE FACE	90	
Superior Maxillary Bone	90	. . XII.
Malar Bone	102	. . XIII.
Nasal Bone	105	. . XVI.
Lachrymal Bone	107	. . XIII.
Palate Bone	108	. . XIII., XIV.
Inferior Spongy or Turbinated Bone	112	. . XV.
Vomer	114	. . XVI.
Inferior Maxillary Bone	116	. . XVII.
THE SKULL AS A WHOLE	125	
Sutures	125	. . XVIII.
Skull-cap	126	. . XVIII.
Base of the Skull as seen from above	129	. . XIX.
Base of the Skull as seen from below	132	. . XX., XXI.
Temporal, Zygomatic, and Spheno-maxil- lary Fossæ	138	. . XVI., XXII.
The Orbits	139	. . XXII.
Nasal Fossæ	141	. . XXIII., XXIV.
General Observations on the Skull	144	

	PAGE	PLATE
VERTEBRAL COLUMN	154	. . XXV. to XXVII.
SACRUM	174	} . . XXVIII., XXIX.
COCCYX	177	
BONES OF LOWER EXTREMITY	180	
Os innominatum	180	} . . XXX. to XXXII.
Ilium	181	
Pubes	183	
Ischium	184	
Pelvis in general	193	
Femur	198	. . XXXIII., XXXIV.
Patella	213	} . . XXXV.
Tibia	216	
Fibula	223	
BONES OF FOOT	230	
Astragalus	232	} . . XXXVI. to XXXVIII.
Os Calcis or Calcaneum	236	
Scaphoid Bone	240	
Cuboid Bone	241	
Cuneiform Bones	242	
Metatarsus	246	
Phalanges	254	
Sesamoid Bones	255	
OBSERVATIONS ON THE FOOT AS A WHOLE	255	
INTEROSSEOUS MUSCLES OF THE FOOT .	260	
THE THORAX	261	
Sternum	262	} . . XXXIX. to XLI.
Ribs	267	
MUSCLES OF THE BACK	275	} . . XLII. to XLVII.
Muscles of the back of the Neck	277	
Muscles in front of the Spine .	278	
BONES OF THE UPPER EXTREMITY	280	
Clavicle	280	} . . XLVIII., XLIX.
Scapula	284	
Humerus	295	. . L., LI.
Radius	303	} . . LII., LIII.
Ulna	308	

CONTENTS

ix

	PAGE	PLATE
BONES OF THE HAND	317	
Carpus	317	} . . LIV. to LVI.
Metacarpus	327	
BONES OF THE FINGERS	334	} LIV.
Sesamoid Bones	337	
GENERAL SURVEY OF THE SKELETON	338	
Os HYOIDES	343	. . XXXVIII.
NOTES	347	
INDEX	351	

HUMAN OSTEOLOGY.

Importance and Interest of Osteology.—Whoever would become a good anatomist and a skilful surgeon must make himself master of Human Osteology. It must be, not only his first, but his principal and constant study. He cannot understand his dissections without continually referring to the skeleton. Nor can he fail to be interested from the first in the science, if in studying each bone he will compare it with the corresponding bone in his own body, in order that he may become familiar with what he can feel of it in the living subject. He will thus see in osteology, not death, but life. In discovering and reducing the simplest dislocation, how important it is to have a competent knowledge of the feel of the bony parts and their relations to one another! A little progress will convince him that, far from being dry, osteology is attractive, not only as conducive to professional success, but for its own sake. Undertaken in a right spirit, the study of it becomes, with many, a favourite pursuit, and creates a natural longing to know something of the skeleton of the lower animals, that we may the better judge of the advantageous construction of our own; for it is only by comparison that we can judge. When the great truth unfolds itself, that our own structure appears to be but a modification of the ‘one common pattern’ upon which all vertebrate animals are formed, we cannot but feel with the philosophic poet, that—

'Tis the sublime of man,
Our noontide majesty, to know ourselves
Parts and proportions of a wondrous whole.

COLERIDGE.

Uses of the Bones.—The bones form the framework which supports the soft parts of the body. All the bones, either separately or in conjunction with others, form levers upon which the attached muscles act and give rise to our various movements. Take a few examples. If the biceps muscle contracts, the forearm becomes flexed; this shows that the radius is a lever. It will likewise be seen that the other bones are levers, as the lower jaw in opening and shutting the mouth; the skull as a whole in nodding the head; the vertebræ in balancing and flexing the trunk; the pelvis as a whole (see fig. 27); the ribs when raised and depressed in respiration; the clavicle in shrugging or depressing the shoulders; the scapula and the humerus in raising the arm; the ulna and the radius in flexing or extending the forearm; the carpus and metacarpus as a whole in the movements of the wrist joint; the phalanges in the actions of the fingers. In like manner the bones of the lower extremities are levers, which, when acted upon by the various muscles attached to them, give rise to locomotion.

The bones contribute to the formation of the joints, which admit of more or less movement, depending in direction and extent upon the shape of the articular surfaces and the attachments of the muscles and ligaments. Besides this, the bones of the head and trunk lodge and protect delicate organs; thus, in the skull and spinal canal we find, respectively, the brain and spinal cord; in the orbits are the eyes; in the temporal bone are the internal parts of the ear; and in the bony framework of the chest are the heart and lungs, which, as well as the upper abdominal viscera, it protects.

The fact that the long bones are curved in their long axes increases their elasticity, gives them some amount of spring similar to that of a bow, and helps to diminish shocks.

Composition of Bone.—Bone is composed of a basis of animal matter impregnated with earthy salts. If a bone be boiled in water for many hours it loses some of its elasticity and animal matter. The animal matter is found in solution in the water and is called jelly or 'gelatin.' The residual bone is white and brittle, and consists chiefly of earthy salts. A like result may

be obtained by burning or calcining the bone: it first becomes black from the charring of the animal matter and then white, the animal matter having been completely burnt off and nothing left but the 'earthy salts.' If, on the other hand, a bone be soaked for a few days in a solution of hydrochloric acid (about one part of the dilute acid to six of distilled water), it loses its earthy salts, becomes soft, and may be bent in any direction. Bones are used in making soup for the gelatin they yield on boiling. Notwithstanding their antiquity, bones that have long been buried may still retain a considerable quantity of organic matter. Gimbernat made soup from the gelatin of the mastodon's tooth, as Dr. Buckland afterwards did from the fossil bones of the hyæna. The partial loss of organic matter renders bones more brittle and porous, so that when dry they readily absorb water, and by doing so they adhere when applied to the moistened lips. The latter feature is often used as a test of antiquity.

Animal and Earthy Matter.—From the above experiments bone is found to contain about one-third of animal matter, the rest being earthy salts, i.e. about 33 of animal matter and 67 of earthy salts in a hundred parts. Although bones yield gelatin on boiling, yet it is not this substance, but ossein, which exists in bone, the ossein becoming converted into gelatin by the process of extraction. The portion of the bony matrix forming the immediate walls of the lacunæ and canaliculi is said to have elastin for its organic basis. Bones of children are softer, more elastic and less likely to be broken by slight injuries than those of the aged. This is due to the sponginess and great vascularity of children's bones, as well as to the fact that in them the shafts of the bones are united to the epiphyses by a layer of cartilage. Bone when pure, i.e. when entirely divested of fat or marrow and blood-vessels, probably does not differ much in composition, whether it be from a child or from an old person, but it varies in compactness and arrangement, and on these variations the differences in the strength and elasticity of bones depend.¹

The following is a percentage analysis of adult human bone:²

¹ For this and other references see the end of the book.

Animal matter	33.30	
Earthy salts {	Tribasic phosphate of calcium	51.04
	Carbonate of calcium, Ca C O_3	11.30
	Fluoride of calcium, Ca F_2	2.00
	Phosphate of magnesium	1.16
	Soda and chloride of sodium	1.20
	100.00	

Rickety Bones.—In the disease of early life called ‘rickets,’ in which the bones grow bent and distorted, from deficiency of earthy matter, the proportions of animal and earthy matter have been found to be :³

Animal matter	79.75 per cent.
Earthy matter	20.25 „

Of all animals, the bones of birds (especially of the predaceous kind) contain the largest proportion of earthy matter. The bones of mammalia come next ; then those of reptiles ; and last of all those of fishes.

As in the birds of prey, so in the carnivora, the bones have a hard and compact structure. The tympanic bone of the whale is extremely hard ; but the skeleton most remarkable for hardness and weight is that of the manatee, which may be seen in the Osteological Series of the Royal College of Surgeons of England. When the late articulator to the College was taken to task for having charged the enormous sum of £15 (instead of about £5) for articulating the manatee, he pleaded, in justification, that the bones were so hard that it had taken him unusual labour to put them together, and had spoilt many of his tools. The truth of this assertion is at once clear to anyone who takes in his hand the weighty rib of a manatee. (See sections of ribs, No. 2741.)*

Phosphate of Lime: its Importance.—Of the earthy ingredients of bone the phosphate of lime holds by far the first rank ; hence it is commonly called ‘bone earth.’ Adult bone con-

* Throughout the work the numbers refer to specimens in the Osteological Series in the Museum of the Royal College of Surgeons of England, unless otherwise stated.

tains 51 per cent. of it, and about 11 per cent. of the carbonate of lime. Carbonate of lime is the principal ingredient in the hardening of shells. The phosphate of lime forms a harder compound with animal matter than the carbonate. What can be harder than the enamel of the teeth? And this consists of a very large proportion of phosphate of lime combined with animal matter. There is only 2 per cent. of animal matter in the enamel, and of the remaining 98 parts, 88½ consist of phosphate of lime.

Phosphate of lime enters not only as the principal earthy ingredient into the composition of bone, but is contained, more or less, in nearly all the tissues of the body. Of all inorganic materials it appears to be the most essential both for vegetable and animal life. Therefore it is not only a most important article of diet, but a necessary manure. 'Those parts of plants which experience has taught us to be the most nutritious, contain the largest proportion of the phosphates—such as bread-corn, peas, beans, and lentils.'⁴ It has been ascertained by experiment, that if animals have their entire supply of phosphate of lime cut off, after some weeks of illness, they are attacked with diarrhœa, which soon kills them. Their bones are found to be very soft; and it is not unlikely that the phosphates are absorbed from their bones and supplied to other structures, such as the nerves and muscles.

It is the quantity of phosphate of lime in the bones which makes them so valuable as manure. The bones are boiled to obtain the gelatin or glue and fat; afterwards they are crushed in a mill, and, as 'bone dust,' form an extensive article of commerce.

Strength of Bone.—The strength of bone, contrasted with other substances, is remarkable. The following materials stand in point of strength to each other thus:


Fine freestone, as	1·0
Lead	6·5
Elm and ash	8·5
Box, yew, oak	11·0
Bone	22·0

Hence bone is twice as strong as oak. A cubic inch of bone will support 5,000 lbs. weight.⁵ Besides this, we shall presently see that bone is so constructed that it gives great strength with but little expenditure of materials. The specific gravity of bone is from 1.87 to 1.97.

Elasticity of Bone.—In consequence of the animal matter they contain, bones possess a certain amount of elasticity. If a skull be thrown upon the ground, it will rebound. The degree of elasticity varies in different bones, according to their form and texture. The clavicle, for instance, owing to its curved form, is remarkably elastic—a property which enables it to break the shock of a fall upon the hand. If one end of a clavicle be placed at a right angle against a hard substance, and the other end struck smartly with a hammer, the bone will rebound to a distance of nearly two feet. The ribs, too, are exceedingly elastic. The Arab children are said to make excellent bows with the ribs of camels. Perhaps the best instance of elasticity in bone is the united clavicles (merry-thought) of the bird. All the long bones are more or less curved, which gives them the benefit of elasticity.

Classification of Bones.—Though the bones present every variety of form and size, yet, for convenience of description, anatomists divide them into three classes: 1. The long and round; 2. The broad and flat; 3. The short and cubical, or irregular. The long and round form the great levers of the limbs, and are moved by muscles. The broad and flat are found chiefly in the skull and pelvis, and protect the viscera. The short and irregular allow more limited motion combined with great strength, and serve to break shocks, as the bones of the spine, the carpal and tarsal bones.

Nomenclature.—In describing the different parts of a bone, we use terms—Latin, Greek, or English—which denote either the form of the part, or its fancied resemblance to some natural object, or the purpose it serves. We soon become familiar with such terms as ‘eminences,’ ‘depressions,’ ‘processes,’ ‘tuberosities,’ ‘spines,’ ‘foramina,’ ‘notches,’ ‘canals,’ ‘sinus,’ ‘fossæ,’ ‘trochanters,’ ‘condyles,’ &c. Again, there are parts of bones named after some celebrated anatomist who first described them :



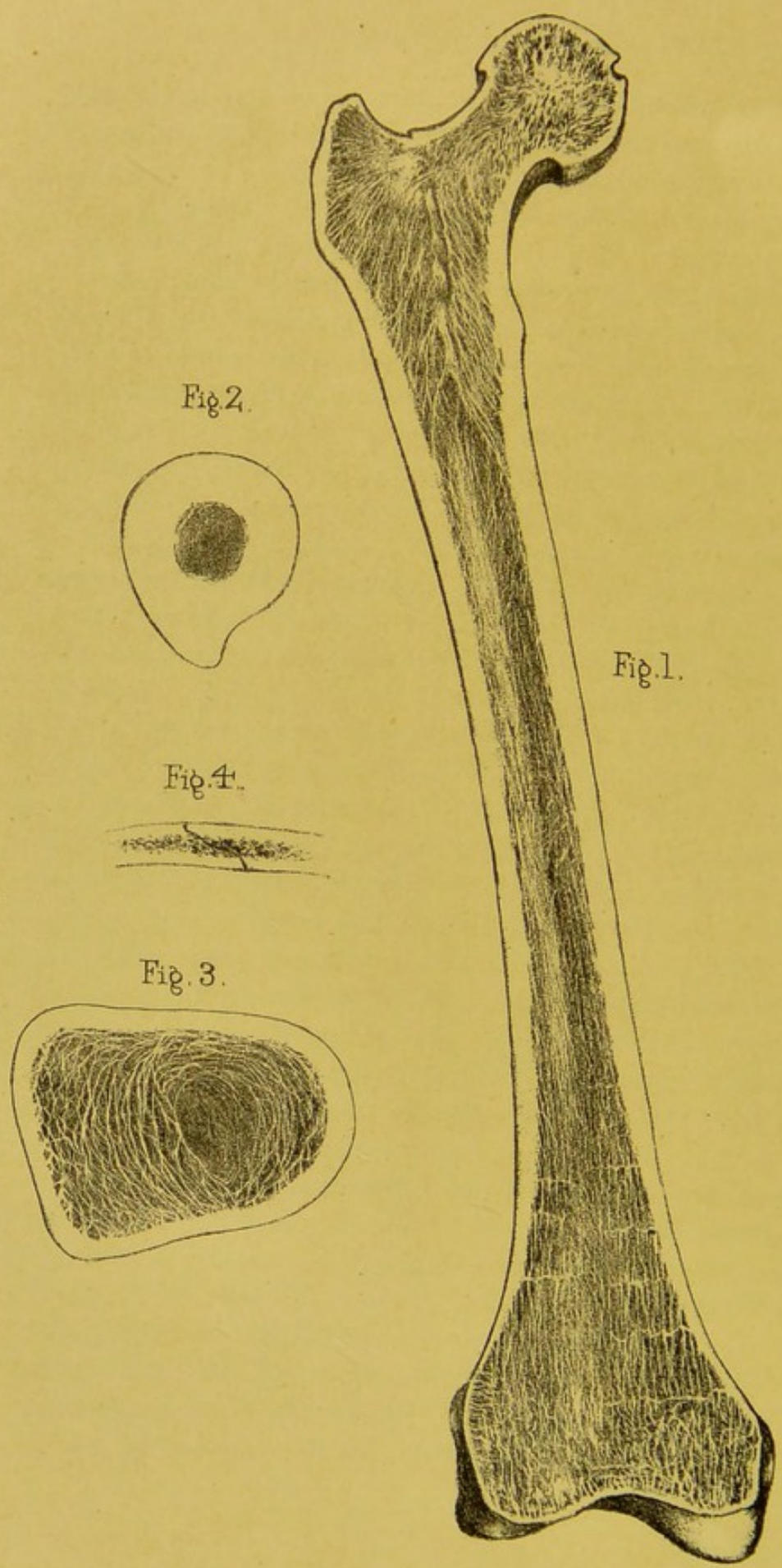


Fig. 2.

Fig. 1.

Fig. 4.

Fig. 3.

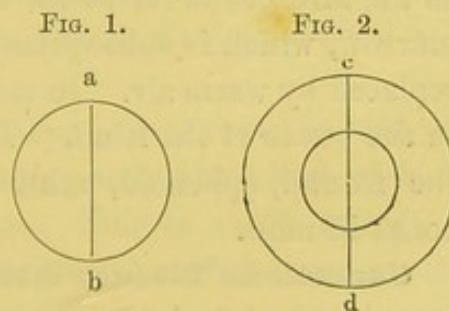
for instance, the 'aqueduct of Fallopius,' 'the antrum of Highmore,' 'the fissure of Glaser,' the 'canal of Vidius.' These memorials of anatomists, though interesting to historians, are rather encumbering to anatomical nomenclature, and are therefore very much to be deprecated.

Structure of Bone : Naked Eye.—Let us examine, first, the structure of bone, as it can be seen with the naked eye; afterwards, its minute structure with the microscope. Lastly, we will study the development and growth of bone.

The best way to obtain a rough idea of the structure of bone is to make a vertical section through one of the long bones—say the femur—all the way down. (Plate I.) We then see that the outer part, or 'wall,' of the bone is compact, like ivory; the interior is hollow, forming the 'medullary canal,' or cavity containing the marrow. The ends, which expand to form the joints, are composed of a beautiful network of plates and bars of bone, forming what is called 'cancellous or spongy tissue,' which in the recent state is also filled with marrow.

Shaft of Bone hollow.—What are the advantages of bones being hollow? The amount of material being the same, a hollow cylinder is much stronger than a solid one. It is proved that the crushing pressures of two cylinders of equal weight and length, of which one is hollow and the other solid, are, respectively, as the diameters of their transverse sections; provided always that the diameter of the tube be within certain dimensions. Thus, let $a b$, $c d$ (figs. 1 and 2) represent the sections of two cylinders; then the strength of the tube $c d$ is to that of the solid $a b$ as the line $d c$ is to the line $a b$.⁵

In some animals which seldom or never leave the water, the bones have no medullary cavities, but are completely filled by cancellous tissue. This is the case in the penguins (Nos. 1138 to 1140), the whales, and amphibia, whose solid bones appear to act as ballast.



In the early part of the seventeenth century, Galileo observed in nature a variety of instances in which the strength of bodies was made very great consistently with lightness by the arrangement of their structure. This most profound philosopher, when accused of atheistical opinions, and interrogated before the Inquisition as to his belief in a Supreme Being, picked up a straw from the floor of his prison, and replied, 'If there were nothing else in nature to teach me the existence of a Deity, even this straw would be sufficient.'

Air Cells in Bone.—Strength and lightness are thus combined in the economy of bones. This principle is carried to the extreme in certain bones of birds, which are filled with air instead of marrow. There is a communication between the lungs and the cavities in the bones of birds (Nos. 1107-8); and the air which fills the bones being warm, renders them still lighter. The great beak of the hornbill forms one large air-cell (No. 1492); even the thin columns of the cancellous tissue in the interior are hollow and filled with air. In this case as in that of other birds the air in the skull is derived from extensions of the cavity of the middle ear on each side. In this bird, as well as in the toucan, every bone of the skeleton, down to the little bones of the claws, is filled with air. In the little 'apteryx' of New Zealand, which has no available wings, and in the penguin, which rarely leaves the water, no bones of the skeleton except those of the skull receive air. In the bones of the chick there are no medullary cavities; as the bird grows its bones become hollowed out, and filled with marrow, which is subsequently, in the mature bird, removed and replaced by warm air. In mammalia there are no air-cells except in the bones of the head. There are large air-cells (sinuses) in the frontal, sphenoid, ethmoid, palate, maxillary and mastoid bones in man.

Cancellous Tissue: Arrangement.—The cancellous tissue occupies the interior of bones, and chiefly the articular ends. It is formed by plates and fine bars of bone, which form a kind of lattice-work with a most delicate and elegant arrangement. The cancellous architecture of bones is arranged upon this principle: its columns always run along the lines of greatest pres-

sure, or form arches, thus combining the greatest strength and elasticity with lightness. A beautiful example of this is seen in the section of the cancellous tissue of the thigh-bone (Plate I.). At the lower part, towards the knee, the layers run vertically—that is, in the direction of the axis of the shaft, this being the line of pressure when the body is erect. But in the neck of the thigh-bone the layers are arranged in decussating curves like Gothic arches, one within the other, and sustain with the greatest mechanical advantage the weight transmitted on to the heads of the thigh-bones. (Norm. Hum. Ost., Nos. 211 to 222.)

Cancellous Tissue: Properties.—Though so light and spongy, the cancellous tissue is able to support a great weight without giving way. We may form some idea of its strength from the following experiment: A cubic inch of cancellous texture was taken from the lower end of the femur, and placed with its principal layers upright. Four cwt. was then placed upon it, but it did not give way in the least. Six cwt. made it sink half an inch. Yet the cubic inch of bone itself did not weigh more than 54 grains. Not only is cancellous tissue strong as well as light, but it possesses another advantage—that of diminishing shocks. When a ball of ivory strikes another, as in the game of billiards, the whole force of the shock is transmitted from one to the other; but let a ball made of the cancellous tissue be interposed, and then see how the shock will be broken. This property of diminishing shocks is of course greater when the bone is in its natural state and filled with marrow.

The spaces formed by the cancellous tissue vary in size and shape, but freely communicate with each other, and with the holes on the surface of the bones. This is easily proved by boring a hole at one end of a bone, and pouring mercury into it: we shall find that the mercury will run out freely through the natural holes at the other end.

Marrow, Yellow.—The interior of the shaft of a long bone is filled with yellow marrow; a substance composed almost entirely of fat (96 per cent.); that is, in bones that are healthy.

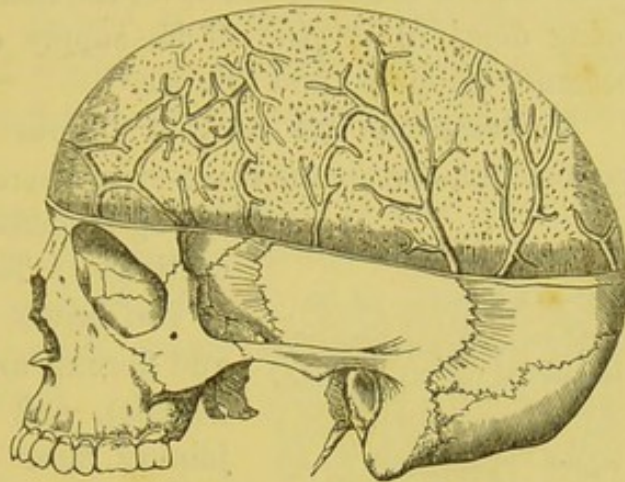
Like all other fat, it is removed in cases of great emaciation—in general dropsy, for instance; and its place is supplied by an albuminous fluid. Hence the bones of a dropsical subject are always the least greasy, and the best adapted for skeletons.

Marrow, Red.—The cancellous tissue of the articular ends of long bones, and of the bodies of the vertebræ, the sternum, the ribs, and the bones of the cranium, contain another kind of marrow of a red colour. This red marrow differs from the yellow, in that it contains little or no fat—not more than 1 per cent. It consists of 75 per cent. of water and 25 per cent. of solid matters, chiefly albumen. It is this kind of marrow which is found in all the bones of the fœtus, and in infants. Hence it is sometimes called foetal marrow. Examined with a high magnifying power, it is found to contain a number of oval or irregular-shaped many-nucleated cells. (Plate IV. fig. 9.) Cells of this form are found in many rapidly growing tumours, and are called ‘myeloid’ cells. They are especially abundant in the so-called myeloid tumours.⁸ Small round cells, like white blood corpuscles, are also found in great numbers.

Blood-supply of Bones.—At the articular ends of any long bone, or on the body of a vertebra, we observe a number of holes. Near the lower end of the thigh-bone we might soon count as many as 200 or more. What are these holes? The smaller transmit the articular arteries which nourish the vascular cancellous tissue. The larger contain veins which run by themselves. These veins of the cancellous tissue are large and numerous. They traverse and ramify through this tissue in various directions in special canals with thin walls of bone. They are well seen in a section through the body of a vertebra (Plate XXV. fig. 7), also in the cancellous tissue (termed ‘diploe’) of the cranial bones. From a surgical point of view these ‘diploic’ veins are interesting, on account of their liability to inflame after severe injuries of the head: such inflammation may lead to suppuration in the diploe, which is often fatal. The adjoining figure (3) shows the large venous canals in the ‘diploe’ of the skull-cap.

Again, on the outside of the shaft of a long bone there are a number of minute grooves, which run for the most part parallel to the shaft, and lodge blood-vessels. At the bottom of these grooves are still more minute holes, barely visible to the naked eye, but easily seen through a small pocket-lens. These holes transmit the blood-vessels from the 'periosteum,' or membrane covering the bone, to the compact tissue.

FIG. 3.



VEINS IN THE DIPLOE OF THE SKULL.

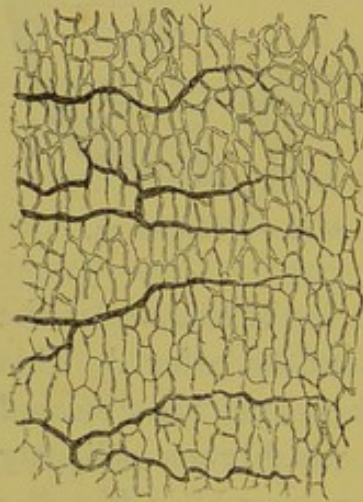
Artery of the Marrow.—The marrow in the interior of the bone is supplied with blood by the 'medullary artery.' This artery reaches the marrow through a very distinct canal (canal for the nutrient artery of the medulla), which runs obliquely through the shaft, near its middle. In a long bone like the femur, there are generally two of these, situated at the back part. As soon as the artery reaches the medullary cavity, it divides into two branches, an ascending and a descending, which ramify in and supply the marrow and the greater portion of the thickness of the shaft, and finally communicate with the 'articular' arteries already described.

Thus the several parts of a long bone are supplied with blood as follows: The outer compact wall of the shaft by blood-vessels from the periosteum; the marrow in the interior and remainder of the shaft by a special medullary artery; and the cancellous tissue of the ends by the articular arteries. The blood-vessels of these several parts are not exclusive, but communicate more or less with each other when the parts of the bone have united with the shaft. Hence they readily reciprocate their morbid actions, and inflammation arising in the one part may spread to the other, although the extremities usually retain their life when

the shaft is killed by inflammation. Notwithstanding that these three orders of blood-vessels do communicate in the bone, yet we cannot be surprised to find that when a bone is broken below the canal for the nutrient artery of the marrow, the lower fragment, being deprived of part of its supply of blood, in some cases becomes atrophied and thinner.⁹

Periosteum: its use.—A fibrous membrane, termed the periosteum, invests the bones everywhere except at the insertion of

FIG. 4.

BLOOD-VESSELS OF
PERIOSTEUM.

strong tendons, and where covered with cartilage. This periosteum consists of two layers, an external one, tough and fibrous, and an internal one (osteogenetic), soft and cellular. The adjoining figure shows the arrangement of the blood-vessels of the periosteum. The periosteum likewise provides each of the vessels entering the bone with a fibrous covering. It assists in the formation of bone, and afterwards in its nutrition. If, therefore, the periosteum be torn from the surface of a bone, there is a risk that a layer of the subjacent bone will lose its vitality, and be cast off.

Medullary Membrane.—The medullary and Haversian canals and the cells (marrow spaces) of the cancellous tissue are lined by an extremely delicate membrane, termed the 'endosteum.' It is much more delicate than the periosteum; nevertheless, it supports the marrow, and provides a stratum for the subdivisions of the medullary artery, before they penetrate the contiguous bone.

Nerves in Bone.—Periosteum and bone unquestionably possess nerves. This is proved by absolute demonstration, and by disease. Nerves may be traced into some of the minute foramina on the shaft of a long bone, and into the articular ends. A nerve also enters the medullary canal with the nutrient artery of the medulla, and divides like the artery into an ascending and a descending branch. Of all the bones, the tibia presents the largest canal for the nutrient artery of the marrow; in this bone

also it is easy to trace the entrance of the nerve with the artery. Though bone in health has but little feeling, when diseased it becomes highly sensitive. There is such a thing as 'neuralgia' of bone. Every surgeon must have witnessed how sensitive are granulations from bone. Indeed, it is probable that the severe pain attendant on the ulceration of articular cartilage is occasioned by the pressure of the cartilage on the bone-granulations beneath it.

Lymphatics of Bone.—The lymphatics of bone have been actually demonstrated by injecting the lymphatics of the body of a vertebra.¹⁰ It has been recently proved by injections that the blood-vessels of Haversian canals are surrounded by perivascular lymphatic vessels.¹¹

MICROSCOPIC STRUCTURE OF BONE.

This is a most interesting and instructive study. It reveals to us that bones are as minutely provided with blood-vessels and nerves as the softer parts of the body. Being as fully organised as other parts, we cannot wonder that they are subject to like diseases. We have to investigate how the bones are formed in early life, how they grow to maturity, how their health is maintained, how their injuries are repaired. Would anyone, looking at a solid bone, expect to find that even its hardest parts are tunnelled out by a network of minute canals containing blood-vessels; and that from these canals other tubes, infinitely more minute, and connected with a series of reservoirs, radiate in all directions and convey nutritious fluids?

General Idea: Haversian Canals.—Let us first get a general idea of the microscopic structure of bone, and go into details afterwards. If a transverse section from the shaft of a long bone be ground extremely thin, and examined with a power of about 20 diameters (Plate II. fig. 5), we see a number of holes, with dark spots grouped around them, in a series of tolerably concentric circles. These holes are sections of the canals (termed 'Haversian')¹² which transmit blood-vessels into the substance of the bone. The dark spots are minute reservoirs, called

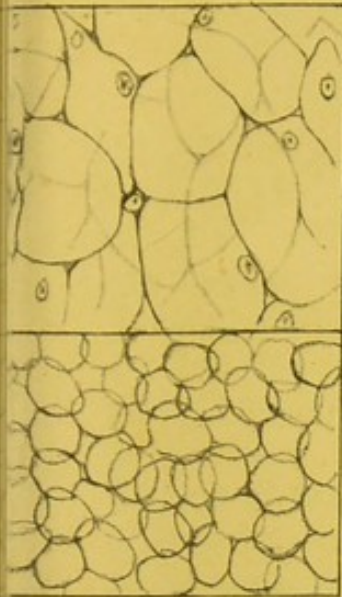
'lacunæ.' They look like solid bodies, but they are cavities and are occupied during life by soft 'bone corpuscles,' concerning which more will be said hereafter. Different parts of the section show that the Haversian canals vary considerably in size and shape. They are generally round or oval. Those nearest to the circumference of the bone are very small; but towards the medullary cavity they are seen to be larger, and at last open out into the cells of the cancellous texture.

Haversian Lamellæ.—The same section examined with a higher power (Plate II. fig. 7) shows that the Haversian canals are surrounded by a series of concentric lines, resembling the transverse section of the branch of a tree. These lines are termed the 'lamellæ.' They are so many layers or rings of bone that have been developed within the Haversian canal. Even the smallest Haversian canal was, when originally formed, a much wider space, and circumscribed by only a single layer of bone; but in process of growth the canal becomes gradually contracted by the deposit of successive layers of bone. The dark spots, before alluded to as the 'lacunæ,' are situated between the lamellæ; under a higher magnifying power (Plate II. fig. 6) they look like insects. The central part or the lacuna, representing the body of the insect, is hollow, and the dark filaments which run out from it, representing the legs, are minute tubes termed 'canaliculi.' These are exceedingly numerous, and radiate from all parts of the 'lacuna,' through the lamellæ. Now, since the canaliculi of one circle of lacunæ communicate most freely with those of the next circle, and the canaliculi nearest to the Haversian canal open directly into it, it follows that by means of this system of radiating tubes a complete communication is established between the Haversian canal in the centre, and the successive circles of bone which surround it. The nutrient material of the bone exudes from the blood-vessels in the central canal, and is transmitted through the canaliculi from one lacuna to another.

Haversian System.—Every Haversian canal taken in conjunction with its concentric layers of bone, lacunæ, and canaliculi, is termed an 'Haversian system.' (Plate II. fig. 7.)

Fig. 1.
Notochord of Lamprey

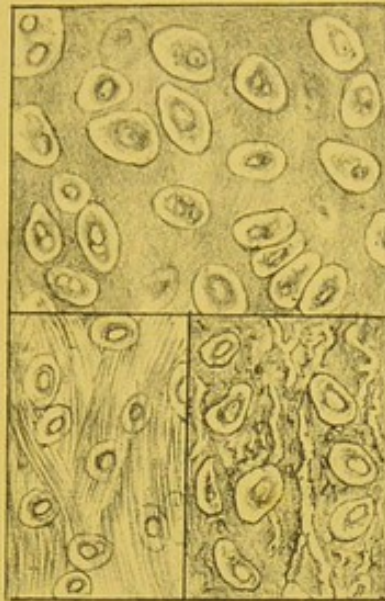33 dia²



Ear of Mouse.
Cellular cartilage.

Fig. 2
Hyaline cartilage.

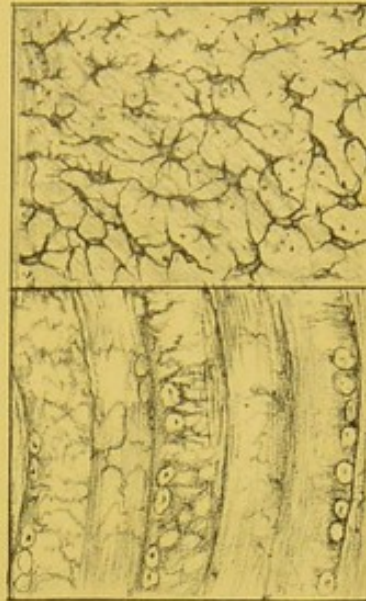
333 dia²



White Yellow.
Fibro-cartilage.

Fig. 3.
Transverse section.

333 dia²



Longitudinal section.
White fibrous tissue.

Fig. 4.

Haversian canals.

20 dia²



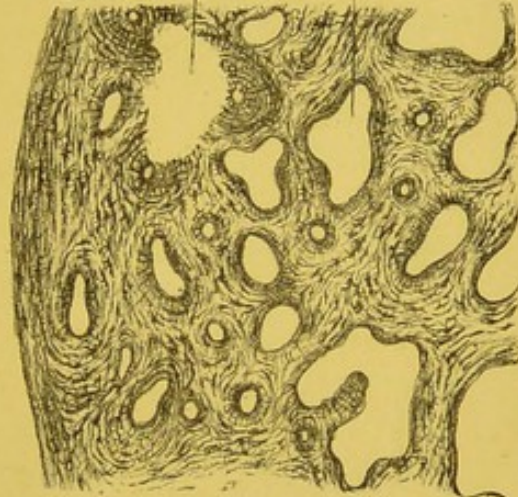
Longitudinal section of Haversian canals

Fig. 5.

Haversian space

Haversian canals.

20 dia²



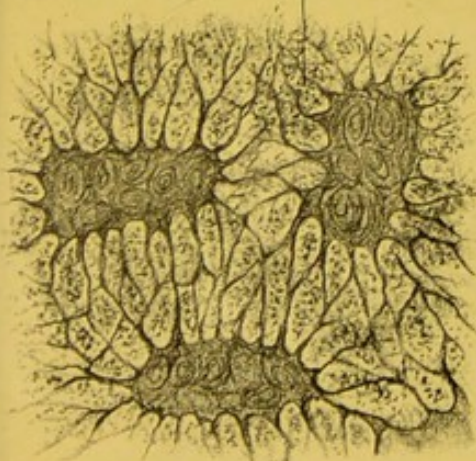
Transverse section of Haversian canals.

Bone.

Fig. 6

Osseous granules.


1200 dia²




Lacunae and Canaliculi highly magnified

Fig. 7

100 dia²



Haversian systems.



Almost all the compact substance of bone is made up of a multitude of these 'Haversian systems.' Each system is, to a certain extent, independent of its neighbour, since the lacunæ of one system communicate very sparingly with those of another. In consequence of this isolation, we sometimes find, in favourable sections, that each system is more or less circumscribed by a tolerably distinct white line, which is transparent bone with but few canaliculi.

Haversian Interspaces.—As the Haversian systems in the transverse section are for the most part circular, it is clear they cannot touch each other in all parts of their circumference; so that here and there triangular portions of bone fill up the gaps between them. Such portions are termed 'Haversian interspaces.' (Plate II. fig. 7.) They are either portions of Haversian systems, or the layer of investing periosteal bone which has elsewhere been encroached upon by other systems of more recent formation. These 'outlying' portions of bone are also provided with lacunæ and canaliculi, and they derive their nourishment from the surrounding Haversian systems, of which they are dependencies.

The section we have hitherto been examining was a transverse one. We must now make an equally thin section in the longitudinal direction of the shaft, and we then have quite a different appearance. (Plate II. fig. 4.) We cut in the course of the Haversian canals, not across them; and we find that, as a general rule, they run parallel to the surface of the bone (no matter whether long or flat), and that they communicate very frequently by transverse or more or less oblique canals. If the section be large enough to include the Haversian canals near the circumference, we find that some open on the outer surface and admit blood-vessels from the periosteum; others, again, open into the medullary canal, and admit blood-vessels from the interior. In this way the Haversian canals permeate the compact substance of the bone, with occasional communications between the blood-vessels of the periosteum and those of the medulla. These canals may, in fact, be regarded as so many multiplications of surface for the ramifications of blood-vessels, whereby

every part of the bone-substance is brought within the range of nutrition.

In this longitudinal section, the lamellæ, instead of being arranged concentrically, are seen running in lines parallel with the longitudinal Haversian canals to which they belong.

Bone Tissue.—At this stage of the investigation, a question naturally arises: Where is the earthy material, the phosphate and carbonate of lime? To see this, the transverse section must be magnified about 1,200 diameters. (Plate II. fig. 6.) We then discover that the earthy ingredient consists of an infinite multitude of minute osseous granules, which are deposited in a 'matrix' or bed of animal matter. This mixture of earthy granules and animal matter is called 'bone tissue.' It occupies all the space between the lacunæ and their canaliculi. If the specimen were steeped for a time in dilute hydrochloric acid, the osseous granules would be dissolved out of it, and the little pits in the matrix in which the granules were embedded would become apparent.

So far we have acquired a general notion of the minute structure of bone; that is to say, of the 'Haversian canals,' the 'lacunæ' and their 'canaliculi,' the 'lamellæ,' and the 'osseous granules.' We must now speak of these several parts a little more in detail; and first, of the Haversian canals.

Haversian Canals.—As said before, the Haversian canals are tunnels in the compact substance of the bone, which contain the blood-vessels. Observe, they form no part of the *essential* structure of bone. Wherever bone is so thin as to be able to derive its nutrition from the vascular membrane covering its surface, we do not find Haversian canals in it, nor does it require any. For instance, the delicate plates of bone composing cancellous tissue, the paper-like bones in the interior of the nose, have no Haversian canals in them; but they have plenty of lacunæ, which send out their canaliculi to open on the surface and imbibe the requisite nutriment. Bone so thin as to need no Haversian canals is called 'non-vascular' bone. Such bone lives upon the blood which flows through the minute vessels of its periosteum. Bone has, therefore, like all other living structures,

a *self-formative* power, and draws from the blood the materials for its own nutrition.

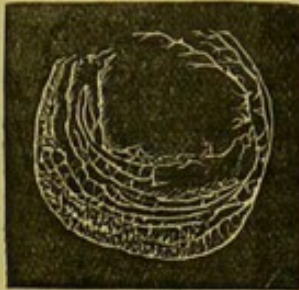The Haversian canals vary in diameter from $\frac{1}{1000}$ to $\frac{1}{200}$ of an inch, the average being about $\frac{1}{300}$. The smallest are found near the outer surface, where the bone is the most compact; but they gradually become larger towards the interior, where they open out into the cancellous tissue, or into the medullary cavity. All running in the long axis of the bone are surrounded by concentric lamellæ of bone; but the number of the lamellæ varies around different canals from 1 to 15 or more; a smaller number in young bone, and a larger in old. All are lined by a very delicate membrane, continuous with the endosteum. The smallest canals contain only a single capillary blood-vessel; the larger contain a network of vessels, while the largest, which gradually merge into the cancellous tissue, contain marrow as well as blood-vessels.

Here it may be as well to mention a fact concerning the minute structure of bone, which should never be lost sight of. It is this: that everywhere the deepest part of the membrane in contact with the surface of bone, whether it be the periosteum covering the exterior, the lining of the Haversian canals, or the medullary membrane (endosteum) lining the cancelli, is formed by a delicate layer of soft connective tissue, with a multitude of small corpuscles in it, termed '*osteoblasts*.' Now, it has been ascertained that these osteoblasts, and the soft tissue in which they are embedded, are alone concerned in the formation and the growth of the bone; and that by the successive ossification of these tissues, the concentric layers of bone are produced within the Haversian canals.

Haversian Spaces.—Irregular spaces not surrounded by any concentric lamellæ may often be seen in transverse sections. (Plate II. fig. 5.) They are called Haversian spaces, and are formed mainly or entirely by cells named osteoclasts, which eat out and absorb the bone. The space having attained a certain size, the osteoclasts are replaced by osteoblasts, which then form layers of bone and build up an Haversian system. In bone undergoing atrophy the spaces are naturally very large and numerous.

Haversian Canals dilated by Inflammation.—The knowledge of the free circulation of blood through the substance of

FIG. 5.

SEPARATION OF LAYERS
BY INFLAMMATION.

bone gives us the key to some of the effects produced by inflammation in it. For example, as inflammation in soft parts is attended by dilatation of the blood-vessels, so is it in the case of bone. When bone is actually inflamed, the blood-vessels in the Haversian canals become greatly enlarged, and cause the canals themselves to become larger by absorption of the bone tissue—so much so as to give the bone, sometimes, a reddish colour. In operations where the surgeon has to cut through inflamed bone, one may see the blood flowing from the cut surface of the bone, as it would from the soft parts. More than this, the distended blood-vessels may occasion not only a gradual enlargement of the Haversian canals, but their inflammatory deposit may, some think, cause even a general swelling of the compact substance of the bone and a natural separation of its component layers, so that it becomes light and spongy, as seen in the adjoining figure.¹³

Haversian Canals obliterated by Inflammation.—On the other hand, in some cases, e.g. in chronic inflammation, we sometimes find that bones become harder and thicker than natural. They may become as hard as ivory, and can take a polish. Here the Haversian canals are nearly filled up by successive layers of bone. Indurated bone is therefore less vascular than healthy bone. A good example of 'eburnation' of bone is occasionally seen as the result of chronic osteo-arthritis, where the articular ends of bone lose their cartilage and become hard and polished like ivory, owing to the blocking up of the Haversian canals by osseous tissue.

Lacunæ and their Contents.—The 'lacunæ' are the insect-like cavities which we find between the lamellæ, arranged in concentric circles around the Haversian canals. They are characteristic of true bone, and distinguish it from 'calcifications,' sometimes met with as products of disease. Formerly the lacunæ and canaliculi, in consequence of their dark colour, were considered

to be solid ; but later observations have proved them to be hollow spaces. Each lacuna in the living bone contains a soft nucleated substance termed a bone corpuscle, which sends its soft processes or 'outrunners' along the canaliculi. The bodies in the lacunæ and canaliculi circulate nutritious matter through the bone. The lacunæ and canaliculi can be filled with Canada balsam. It is curious that in the bones of Egyptian mummies these minute cavities are filled with the bituminous material. Such a bone corpuscle, with its processes highly magnified, is shown in Plate III. fig. 5.

As a rule, the lacunæ are oval and flattened, so that one of their broad sides is turned towards the Haversian canal. The first ring of lacunæ sends some of its canaliculi directly into the Haversian canal, while others communicate with the canaliculi of the second ring, and so on throughout the whole system. The nutrient fluid in the perivascular lymphatics in the Haversian canal enters the nearest canaliculi, and then the inhabitants of the nearest row of lacunæ, and is gradually passed on to all the others in the Haversian system. One may say, then, that the inhabitants of the lacunæ are parts of the machinery of the circulation and nutrition in the bone.

Size and Shape.—In man, the lacunæ measure about $\frac{1}{2000}$ of an inch in their long diameter, and about $\frac{1}{6000}$ in their short. It has been shown that they vary in size and shape in the classes of vertebrata, so that by means of this test it can be ascertained with certainty whether a given fragment of bone be part of a mammal, a bird, a reptile, an amphibian, or a fish. As this test is equally applicable in the case of fossil bones, it has an important bearing upon the study of geology. Another interesting fact is, that the size of the lacunæ bears very little relation to the size of the animals to which they belong. They are nearly as large in the bones of the little lizard as they are in those of the enormous extinct lizard, the Iguanodon. But their size *does* bear an exact proportion to that of the blood corpuscles in the several classes of animals. Therefore, as amphibia have the largest blood corpuscles, so have they the largest lacunæ.¹⁴

Canaliculi: Size and Office.—Respecting the ‘canaliculi’ (Plate II. fig. 6), observe how exceedingly minute they are; that they run off from all parts of the circumference of the lacunæ and communicate most freely with the canaliculi of the adjoining lacunæ. Their diameters range from $\frac{1}{14000}$ of an inch to $\frac{1}{20000}$ of an inch; but there are some even smaller. Soft nucleated corpuscles, ‘bone corpuscles,’ lie in the lacunæ, and have many delicate branching processes, by means of which they intercommunicate. These branching processes lie in the canaliculi.

Lamellæ.—The ‘circumferential’ lamellæ encircle the shaft of the bone (Plate II. fig. 5), and result from the bone growing in thickness by a deposit of new layers on the old shaft by the deep layers of the periosteum.

The ‘Haversian’ lamellæ are the concentric tubes of bone enclosing the Haversian vessel. (Plate II. fig. 7.) These result from successive layers of bone being deposited around the Haversian vessel, the one within the other, encroaching more and more on the space in which the vessel lies. This process renders the bone more dense in structure.

In transverse sections of fully formed Haversian systems there appear to be from one to fifteen concentric rings of bone, varying in thickness from $\frac{1}{3000}$ to $\frac{1}{8000}$ of an inch.

The ill-defined and interrupted layers apparent here and there in the spaces between Haversian systems are termed ‘interstitial lamellæ.’ (Plate II. fig. 7.)

Nails (Claviculi) of Gagliardi.—In carefully made preparations of bone, it may be seen that its constituent lamellæ are connected by fibres which perforate them either at a right or an oblique angle, and thus ‘bolt’ them together. These ‘perforating fibres’ or bolts appear to answer a mechanical purpose. They are best shown by separating the lamellæ of a decalcified bone. Thus you see not only some of the bolts pulled out, but also the holes through which they passed.¹⁵

Osseous Granules.—The earthy salts are deposited in the animal matrix in the form of exceedingly minute granules. The Germans call them ‘bone crumbs.’ We cannot see them,

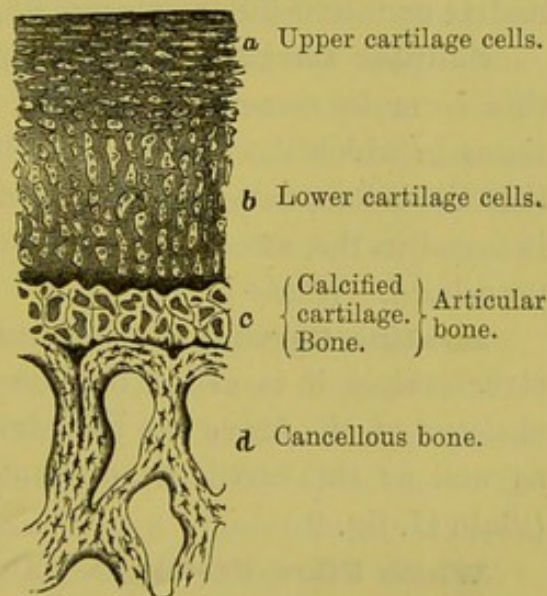
however, without a magnifying power of 1,200 diameters. (Plate II. fig. 6.) They vary in size in different specimens of bone. In man their size ranges from $\frac{1}{6000}$ to $\frac{1}{14000}$ of an inch. They can be very distinctly seen in the skulls of small birds—the canary for instance—and also in the skull of the bat, where they are so much larger than in the human subject. After a section of bone has been steeped for some time in dilute hydrochloric acid, these earthy particles will be dissolved out of the animal matrix, and the little cavities in which they are embedded can then be distinctly seen.

Found in Pus from Dead Bone.—It is an interesting and valuable practical fact, that these earthy granules are generally present in the pus which comes from dead bone. If a specimen of pus under such circumstances be examined with a power of 500 diameters, a number of earth granules may be detected among the pus cells, proving that there is dead bone somewhere.¹⁶ In pus coming from diseased bone there is as much as two and a half per cent. of phosphate of lime.¹⁷

Articular Bone.—By articular bone we understand a thin layer of hard tissue situated immediately under articular cartilage; and since there is a peculiarity about the structure of it, we will allude to it here. If a section be made perpendicularly through the articular surface of any fresh bone

with the cartilage attached, it will be observed (as seen in fig. 6) that the cartilage does not rest immediately upon the cancellous tissue of the bone, but upon a thin compact crust of calcified cartilage resting on and partly penetrated by a layer of true bone. This, which we call 'articular bone,' varies in thickness,

FIG. 6.



STRUCTURE OF ARTICULAR BONE.

and is of a remarkably white colour. The blood-vessels of the cancellous tissue run up only as high as its under surface, and then turn back in loops. This layer is much less porous than common bone, and in consequence of its closer texture is all the stronger, and supports the articular cartilage on a very unyielding surface.

Although articular bone and adult articular cartilage have no blood-vessels in health, yet they both become vascular in some cases of disease of the cartilage. Blood-vessels, when well injected, may then be seen shooting up through the heretofore non-vascular layer of bone, into the cartilage on its surface.

STRUCTURE AND VARIETIES OF CARTILAGE.

Varieties of Cartilage.—Cartilage, commonly called ‘gristle,’ is tough, flexible, and more or less elastic. There are several kinds of it, which have functions varying with their position and structure. It consists of nucleated cells embedded in a matrix or intercellular substance.

Cellular Cartilage.—Although all cartilages are cellular, this term is sometimes applied to cartilage or cartilage-like tissue in which the structureless matrix is so small in quantity that the cells are polygonal by mutual pressure. This variety is found in the external ear of many small animals, and in the notochord. (Plate II. fig. 1.)

Hyaline Cartilage.—Where the matrix is translucent and structureless it is called hyaline cartilage. Nearly the entire skeleton of the fœtus has this structure at some time or another as well as the cartilage covering the articular ends of bones. (Plate II. fig. 2.)

White Fibro-Cartilage.—The intercellular substance may be white and fibrous, then it is called ‘white fibro-cartilage.’ This variety is but slightly elastic, but is stronger than the former, and the cells are small and scattered. (Plate II. fig. 1.) The intervertebral substance consists mainly of this variety as well as the interarticular fibro-cartilages. (Plate II. fig. 2.)

Yellow Fibro-Cartilage.—The gristle of the ear, epiglottis, and the Eustachian tube is of a yellow colour, is very elastic,

and the hyaline intercellular substance is mixed with interlacing wavy fibres of elastin. It is therefore named 'yellow fibro-cartilage.' (Plate II. fig. 2.)

Temporary Cartilage.—As early as the fourth week of foetal life, when the embryo is but $\frac{3}{4}$ of an inch long, the principal part of the skeleton is mapped out by the formation of firm masses of tissue called 'temporary' cartilage, which is only a variety of the hyaline.

Cartilaginous Skeleton.—A week later the intercellular substance has more developed in this cartilage, converting it into 'hyaline' cartilage of more ordinary character, and giving it greater solidity. Thus, the whole foetal skeleton, with the exception of the skull-cap and the bones of the face, consists at one time of hyaline cartilage.

At the fifth week bony substance begins to be formed in the middle of the clavicle; at the sixth week in the lower jaw; and by the seventh week, when the foetus is about an inch long (Norm. Hum. Ost. No. 1), a small deposit of bone has made its appearance in the middle of nearly every bone in the body. The points at which the formation of bone commences are called the 'centres of ossification.' It will therefore be understood that the formation of bone does not take place at the same time in all parts of the cartilage, but only about these 'centres of ossification.'

Meaning of Centres of Ossification.—Every bone has a definite number of these centres, which always appear in the same place; and from these centres the ossification extends according to a regular plan. The number of centres varies in different bones. Some bones have only a single centre; others two, three, five, seven, &c.; and the bone called the 'sacrum' has as many as thirty-three centres from which its ossification is completed.

Observe, the centres of any given bone do not all appear at once; some appear before birth, others after it, but all in regular succession, and at stated periods, according to the degree of importance of the bone, and the function which it has to perform; e.g. the lower jaw and the ribs ossify early, because suction and

respiration are brought into play at birth. As a general rule, each centre appears first in the middle of the cartilage; and thence the ossification extends towards the circumference in the flat bones, and towards the extremities in the long bones. Almost all the bones, then, in infancy and childhood are made up of so many distinct bony pieces united together by cartilage; and these several pieces remain distinct until the stature of the individual is complete, after which they are all consolidated.

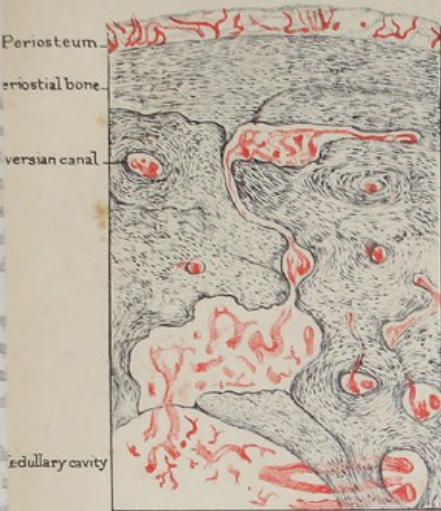
Perichondrium.—All kinds of cartilage, with the exception of that which covers the ends of the bone (articular cartilage), are invested with a white fibrous membrane, termed ‘perichondrium.’ This, like the periosteum of the bones, contains plexuses of blood-vessels ramifying all over the cartilage.

Cartilage usually contains few or no blood-vessels. But when rapidly growing or diseased, it has been proved by injection that blood-vessels do shoot into the cartilage from the adjacent parts.¹⁸

Ossification of Femur.—As an example of what can be seen of the process of ossification with the naked eye, let us follow out that of the thigh-bone. (Plate IV. figs. 1 to 6.) The future bone is at first sketched out in hyaline cartilage. About the seventh week after conception, the first centre of ossification appears in the middle of the shaft—as is the case in all the long bones (fig. 1). From this point ossification gradually extends up and down the shaft, which is all ossified before the other centres appear. About the last month of foetal life, a second centre appears in the lower end, which forms the knee (fig. 3). About the end of the first year after birth, a third centre appears at the upper end or head of the bone (fig. 4). In the course of the fourth year, a fourth centre appears in the projection termed the ‘trochanter major’ (fig. 5). In the course of the fourteenth or fifteenth year a fifth and last centre appears in the ‘trochanter minor’ (fig. 6).

‘Diaphysis’ and ‘Epiphysis.’—Thus, then, the thigh-bone has five centres of ossification. The shaft or body of the bone, which ossifies first, is called the ‘diaphysis;’ the other parts are termed ‘epiphyses.’ As these epiphyses, during the period of

Fig. 2.



Transverse section of Long bone and its Periosteum shewing Blood vessels.

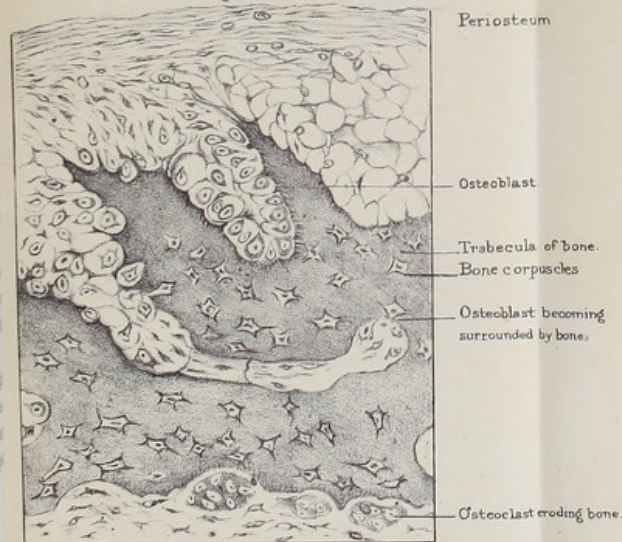
Fig. 4.

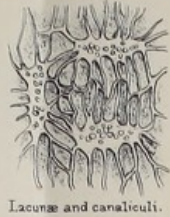

Fig. 5.

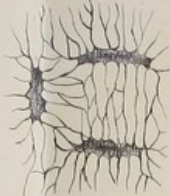

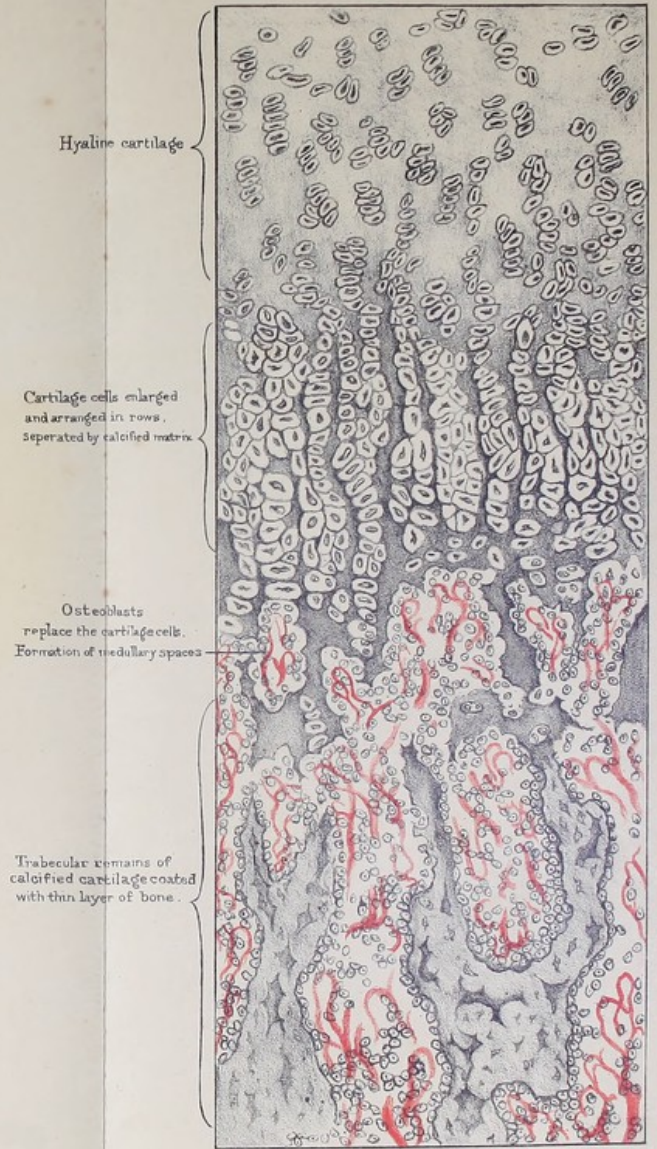
Fig. 3.




Section of bone forming in fibrous tissue.

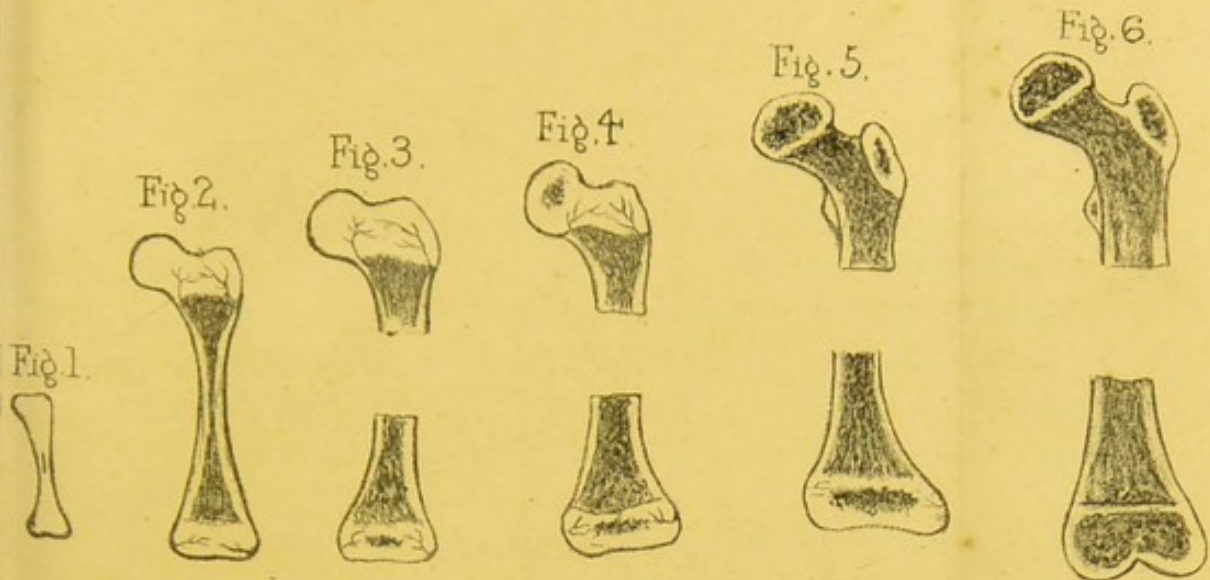
From nature by C. Stewart.
Drawn on Stone by T. Godart.

Fig. I.



Vertical Section of ossifying cartilage at the Epiphysis.





Diagrams showing the formation of the Thigh bone

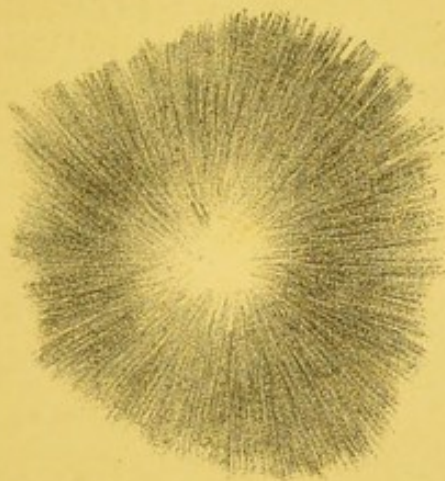
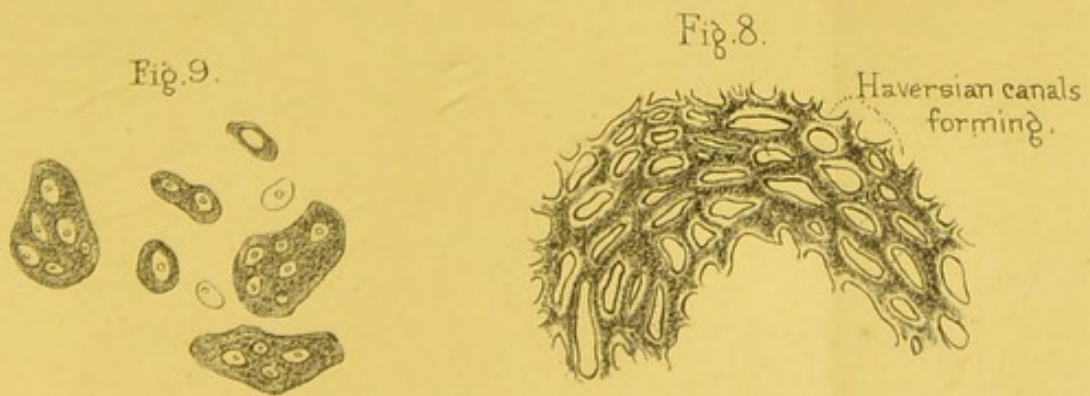



Fig. 7.

Parietal bone of a Fœtus.



Cells from Fœtal marrow.

Section of Fœtal bone.



growth, are only united to the shaft by a layer of cartilage, the separation of an epiphysis by violence is not an unfrequent accident in childhood. When growth is complete, all the epiphyses are consolidated with the rest of the bone, and no cartilage remains except at the articular surfaces, where there is a thin layer of it which breaks the shocks at the joints. An 'epiphysis,' therefore, is a portion of bone growing *upon* another, but separated from it by cartilage.

Order of Union of Epiphyses to Shaft.—It is worth observing, in the long bones, that the epiphyses of that end towards which the canal for the medullary artery runs, are the last to commence to ossify.

It is a curious fact, also, that the order in which the epiphyses unite to the shaft of a bone is just the reverse of that in which they begin to ossify. Thus, the epiphysis of the trochanter minor, though ossifying last, unites first. The same may be said of the trochanter major, of the head of the femur, and, lastly, of the lower end. At the age of twenty-one, or near it, they have all united to form a single bone. The fibula is the only exception to the above rules, its lower epiphysis ossifying first and uniting first to the shaft.

In Sauropsida, the place of the epiphyses is taken by thick pads of cartilage, which gradually ossify from the shafts. These are, therefore, not true epiphyses. Birds, however, have a centre of ossification which appears in the upper projection of cartilage on the tibia. This may be seen in the leg of a common fowl.

Advantages of several Centres.—The fact that bones are developed from several ossific centres, separated by layers of cartilage, is advantageous to the growing animal. For example, it is necessary to have the shaft of a bone ossified to support weight, while other parts remain cartilage and diminish concussion, thus acting as buffers. 'The young lamb or foal,' to use the words of Professor Owen, 'can stand on its four legs as soon as it is born; it lifts its body well above the ground, and quickly begins to run and bound. The shock to the limbs themselves is broken and diminished at this tender age by the division

of the supporting long bones—by the interposition of the cushions of cartilage between the diaphyses and the epiphyses.'

We see, moreover, a definite use in separate centres of ossification for the bones of the head, not only as facilitating growth, but also the process of birth. The bones of the skull-cap, being connected only by membrane, overlap each other a little during parturition, and thus a large head is passed through a comparatively small pelvis.

Bones developed in Membrane.—Most of the bones in the human body pre-exist in the shape of cartilage, and form what is called the 'cartilaginous skeleton,' which supports the embryo. But there are some bones which do not pre-exist as cartilage, and are formed directly in membrane, composed of felted bundles of the tough white-fibrous tissue (Plate II. fig. 3); such are the bones of the skull-cap (the frontal bone, the parietal, the upper half of the occipital, the squamous and tympanic parts of the temporal); also, the bones of the face; and lastly, the inner plate of the pterygoid process of the sphenoid. In short, none of the bones of the skull pre-exist as cartilage, except those which form the base of the skull. The base is sketched out in cartilage at a very early period of foetal life, and forms a support to the young brain. The cap of the skull, at the time we are speaking of, is simply membranous.

Ossification in Membrane.—We will examine first what can be seen of the formation of bone in membrane with the naked eye, taking the parietal bone as an example. In the early embryo (Norm. Hum. Ost., Nos. 1 to 43) the covering of the brain is composed of two closely united membranes—an outer, termed the 'pericranium;' and an inner, termed the 'dura mater:' between these the bone is laid down. About the end of the second month after conception, a centre of ossification appears in the middle of the space which is to be occupied by the parietal bone. From this point the deposition of bone spreads in radiating fibres. (Plate IV. fig. 7.) Similar centres of ossification appear simultaneously in other parts of the soft covering of the brain, and, radiating in the same manner, sketch out the rudiments of the several bones of the skull-cap. For some time the

individual bones are connected simply by membrane ; and even at birth they can overlap each other a little, and so facilitate parturition. Long after birth, indeed, there are parts of the skull-cap closed in by membrane only, as everyone knows who has felt the head of an infant. (Plate XVIII. fig. 4.) These unossified parts are called the 'fontanelles,' from the visible pulsations of the brain beneath them, like the welling up of a spring. As the child grows, the rays from the edges of the bones meet and dovetail so as to form what are called the 'sutures.' (Plate XVIII. fig. 2.) For a long period of life the sutures may be separated ; indeed, a thin film of animal matter is left unossified between the interlocking teeth of the bone, which considerably diminishes the shock to the brain from a blow on the cranium. As old age creeps on, even this film of animal matter ossifies, and the cap of the skull becomes a solid dome of bone, with all trace of the sutures lost.

Microscopic Examination.—Let us now study what can be learned with the microscope of the process of ossification in membrane, taking that of the parietal bone as an example.

The membrane or animal basis to be ossified is composed of fibres like those of common connective tissue. The fibres interlace freely, and the meshes between them are occupied by blood-vessels and closely packed granular corpuscles.

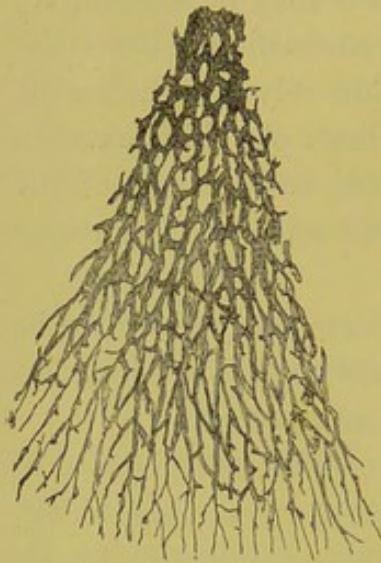
Changes in the Membrane.—The centre of ossification is at the (future) parietal eminence. Just before the appearance of the bone salts, the membrane becomes thicker and more vascular, and rich in cells. Its component fibres radiate in thicker bundles from the centre towards the circumference, sketching in advance the lines in which the bone is to be laid. Meantime the cells ('osteoblasts') have enormously multiplied.

Osteoblasts: their Function.—The 'osteoblasts' (bone buds or germs) are granular nucleated corpuscles about the size of the colourless corpuscles of the blood. They are so named because they and their descendants appear to take most important parts in the actual formation of bone. It is probable that they are not all destined to a like future. But one of their chief functions appears to be to abstract from

the blood the bone salts, to deposit them in and around the fibres of the membrane, and to become themselves buried in the fabric of the bone, as the bricks of a building are in the mortar.

From the centre of ossification the deposit of bone shoots out in needle-like rays (trabeculæ) towards the circumference, as shown in the annexed wood-cut (fig. 7). Under a high power the rays of bone can be seen covered with layers of osteoblasts,

FIG. 7.



DIAGRAMMATIC SKETCH OF PART OF AN OSSIFYING PARIETAL BONE OF A FOUR MONTHS' FÆTUS. (From a preparation in the Museum of the Royal College of Surgeons.)

by which the trabeculæ grow in thickness. The best place to study the process is at the points of the rays where the membrane is more or less transparent. From these points fine fibres (osteogenetic fibres) may usually be seen extending between the cells. The fibres may either remain soft or become hardened by lime salts; when surrounded by true bone, they are known as 'nails of Gagliardi' or perforating fibres. The osteoblasts that surround the osteogenetic fibres, or lie on the surface of bone, elaborate from the blood, and pour out upon their surface the organic substance of the matrix of bone, to which an increasing amount of the lime salts is added. Certain of the osteoblasts

getting embedded in the matrix they are forming, are spoken of as the bone corpuscles; the space which contains them, as the lacuna; the canaliculi being the fine tubes in which the processes of the bone corpuscles are contained and by which they are connected with one another and the osteoblasts on the surface. (Plate III. fig. 3.)

To see how the bone grows in thickness, a section should be made across the rays where they are a little thicker. Such a section (fig. 8) shows that the rays become connected by cross arches, and thus form channels in which the blood-vessels and

bone-building materials lie. These channels are the Haversian canals. Some of them remain as cancellous tissue; others are

FIG. 8.



VERTICAL SECTION THROUGH AN OSSIFYING PARIETAL BONE.

gradually reduced in size by concentric layers of bone, and become Haversian systems. (Plate IV. fig. 8.)

Bone Corpuscles: Origin.—The interesting but difficult question as to the origin of the bone corpuscles and their connecting processes has been for many years under discussion. But the now generally accepted doctrine is, that they are developed from some of the osteoblasts. It has been already observed that the cells where ossification is occurring have probably not all the same future. Some may degenerate and disappear. Others may remain as marrow cells, or by assuming the duty of bone formation constitute osteoblasts, these again when embedded in matrix become the bone corpuscles.

Osteoclasts.—Where bone is being absorbed either as part of the normal process of moulding the skeleton to its adult condition, or in disease, we find the removal to be chiefly if not entirely effected by large multi-nucleated cells (osteoclasts). The origin of these is doubtful, they may be the result of fusion of osteoblasts or of escaped white blood corpuscles. (Plate III. fig. 3.)

Ossification in Cartilage.—We will now endeavour to explain that the process of ossification in cartilage, rightly understood, is essentially like ossification in membrane. In both cases the materials for bone-building are similar, namely, connective tissue, blood-vessels, and the little corpuscles termed 'osteoblasts.' The old school used to teach that the cartilage was directly transformed into bone tissue. But this is not the modern doctrine. The microscope has proved that the cartilage is only a temporary structure, that, having answered a temporary purpose,

it is removed, and that true bone tissue, of which the materials are derived from the periosteum, is substituted in its place as a new product.

The first step taken when ossification is about to occur in cartilage is either the increase of its vascularity if it already contain blood-vessels; or if not, vascular processes of the perichondrium penetrate it. Coincident with this, the cartilage cells increase in number and size, by dividing chiefly in a direction at right angles with that in which the bone is going to extend, so that rows of cells are formed, the cells at the same time becoming distended with fluid. The matrix between the rows then becomes calcified, and the vascular processes penetrate and destroy the cell groups. Some of the small cells which are associated with the blood-vessels then arrange themselves on the trabeculae of calcified cartilage matrix, and form true bone on them. Other cells remain to constitute the marrow. (Plate III. fig. 1.)

Crust of Bone around Shaft.—*Pari passu* with this tunnelling of calcified cartilage by the ingrowths and the formation of bone around the calcified matrix, the deep layer of the periosteum is at work, laying down a gradually thickening crust of true bone around the shaft. This process is not preceded by cartilage, but is direct membranous ossification, as in the tabular bones of the skull.

Summing-up.—To form a correct idea of these separate processes, the mind must grasp them as going on all together, not one after the other. Their general results may be summed up as follows (fig. 9): 1. The cartilage at the middle is hollowed into a cavity (general medullary) and filled by osteoblastic or bone-building tissue and blood-vessels (*e*). 2. The lateral walls of this cavity are formed by the porous bone which has developed in the cartilage (*d*), the ends of the shaft being closed by cartilage still growing and giving place to bone (*a, b*). 3. The periosteum gives origin to a layer of porous bone which may either form a distinct ring outside that formed in cartilage or be continuous with it. 4. Whilst the bone is growing in length by ossification in cartilage, and in circumference by ossification in membrane (periosteum), the medullary cavity is

enlarging by the erosive action of osteoclasts. 5. The cartilage towards the ends is tunnelled (by periosteal ingrowths) into irregular tubular (medullary) spaces, also filled with osteoblastic tissue (c). These spaces freely communicate with the general medullary cavity, but are blocked towards the growing ends by a boundary line of cartilage (b). It is in these spaces that blood-vessels in injected preparations can be seen running up to the cartilage cells. 6. The walls of these tubular spaces are formed

FIG. 9.

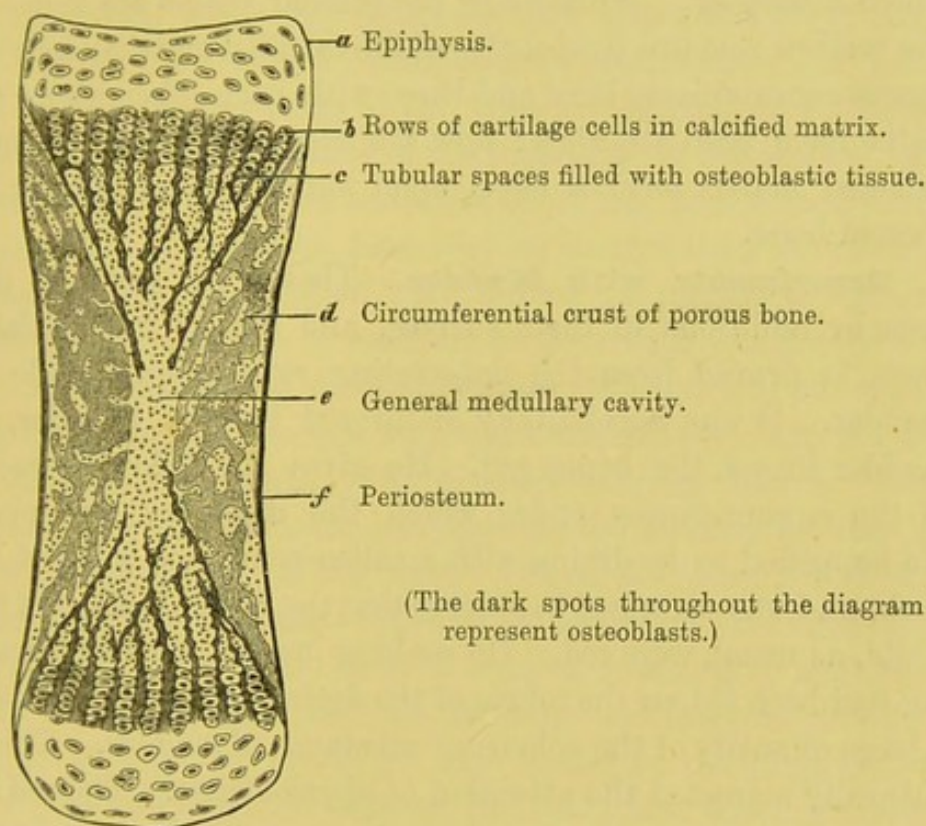


DIAGRAM OF A LONGITUDINAL SECTION OF FETAL LONG BONE.

by the slender remains (trabeculæ) of the calcified matrix. These slender remains serve as the foundation upon which the true bone is laid, and by which its cancellous architecture is directed.

For the more minute observation of the process of ossification in cartilage, it is best to take the 'line of ossification' at the epiphysis of a long bone. The drawing (fig. 1, Plate III.) is intended to illustrate it.

Near the top of the drawing the cartilage cells are seen enlarged and arranged in rows (*b*). The calcified matrix, represented by a darker tint, lies not only between the rows, but, to a certain extent, between the cells, so that it makes transverse as well as vertical septa between them. A little lower, we see the tubular spaces, filled with the bone-building materials, namely, osteoblastic tissue and blood-vessels. The blood-vessels form loops along the line of ossification, where the osteoblasts, having absorbed the transverse septa of calcified matrix, are invading the cartilage cells which disappear. We see how the tubular spaces are formed by the vertical remains (trabeculæ) of the calcified matrix; how these spaces communicate here and there with each other where their walls have been absorbed; how the remains (trabeculæ) of the calcified matrix form a basis upon which the osteoblasts have formed bone.

Experiments with Madder.—That bones grow in thickness by additions to their surface, and not by interstitial deposit, is proved from the interesting experiments made with madder. It was accidentally discovered by Mr. Belchier, that madder tinges the bones red. He gives the following account of the circumstances under which the discovery was made.¹⁹ He happened to be dining with a calico-printer on a leg of fresh pork, and was surprised to observe that the bones, instead of being white, as usual, were red. On making inquiry, he found that the pig had been fed on the refuse of the dyeing vats, which contained a large quantity of the colouring substance of madder. This fact naturally attracted the attention of physiologists. The red tinge was found to be communicated much more quickly to the bones of growing animals than to those full-grown. The bones of a young pigeon were tinged a rose colour in twenty-four hours. In the adult bird it took fifteen days to do it. The effect of madder upon bones depends upon this: The colouring principle of the madder (*Rubia tinctorum*) has a strong affinity for phosphate of lime. It appears, however, that the vegetable dye does not combine with the matrix already formed, but only with that which is actually forming. Therefore, since the dye tinges only the most recent deposit of bone, it is possible to produce alternate rings of white

and red bone, by periodically administering and withholding the madder as an article of diet. These rings will be observed not only at the circumference of the bone, but also within the Haversian systems.

Growth in Length of Bones.—Bones increase in length, not so much by interstitial deposit, as by addition to their ends; that is, by progressive ossification of the layers of cartilage which intervene between the ends of the shaft and the epiphyses. These layers of cartilage furnish the animal basis of ossification, by constantly growing, while they ossify on their upper and lower surfaces. When the cartilage ceases to grow, ossification still goes on till the component parts of the bone are all united by bony matter; and thus the stature of the individual is determined. If from inflammation or other cause the epiphyses unite sooner than they ought to do, then one limb may be shorter than the other; or inflammatory stimulation may induce an increased length. That bones grow chiefly by addition to their ends was proved by Hunter. He introduced shots at definite distances into the shaft of a growing bone of a common fowl, and examined them a fortnight or three weeks afterwards. The distance between the two shots was found only half as much increased as the distance between a given shot and the end of the bone. (Phys. Ser. Nos. 188, 189.)

Value of Periosteum.—Such is an outline of the structure and formation of bone. It is a subject interesting not only for its own sake, but because it helps us towards the explanation of what we are every day seeing of the progress of disease, and the repair of injuries in bone; and what is more, it helps us towards a rational treatment of them. To give a few examples. Look at the value of the periosteum. Suppose a portion of periosteum to be detached by injury or disease from the surface of a bone, a part of the subjacent bone will run great risk of dying. It will not *necessarily* die, because it may derive sufficient nourishment from the blood-vessels in the subjacent Haversian canals. In a case of compound fracture, where there are loose fragments of bone, we ought not to remove any that are still connected to their periosteum. Or, when a portion of the skull-cap sliced off by a sabre cut adheres firmly to a flap

of the scalp, the flap with the bone should be re-applied, and the cure will frequently be effected without death of bone. In the Hunterian Museum are several skulls which have suffered from severe sabre cuts. The portions of bone thus sliced off were once detached, and afterwards reunited a little out of their proper places, so that the lines of original separation and subsequent union can be distinctly seen. (Path. Ser. Nos. 2892 to 2899.) Again, there are cases in which, either from exposure to cold or from direct injury, acute inflammation of the periosteum of the shaft of a bone ensues, effusion of fluid takes place beneath it, and severs the connection between it and the bone. The death (necrosis) of the entire shaft may be the consequence. Then, what happens? As the inflammation subsides, the bone-secreting layer of the periosteum forms new bone around that which is dead, and by degrees incloses it in a bony case. The dead bone lies loose in this new case, having been detached from the articular ends, which do not die like the shaft, and for the reason that the epiphysial ends receive sufficient blood for their nutrition from the articular arteries, independently of what they receive from the shaft. The articular ends of the old bone become in time the articular ends of the new. Thus, the periosteum has formed a new shaft with a capacious cavity in its interior, in which the old bone is inclosed, and will remain so, and be a source of irritation for years, unless removed by a surgical operation.

Although the periosteum holds the first rank of all the structures which repair bone, still we are not to suppose that it is absolutely essential to the process. Under certain circumstances we find various other structures becoming transformed into bone. For example: in a case of compound fracture of the leg, where a portion of the entire circumference of the tibia, including its periosteum, was taken away, the vacancy in the bone was filled up by new osseous substance formed by the surrounding soft tissues, and there was no shortening of the limb.²⁰ Again, we occasionally see the intervening soft tissues forming bridges of bone, and so repairing a fracture where the broken ends themselves are widely apart.

Material which Repairs Fracture.—Fractures are repaired by a material similar to that out of which bone was originally formed. The animal matter which is first laid down is of a fibrous or cartilaginous nature—or a mixture of both, as the case may be—and then earthy salts are deposited in it. In the case of a simple fracture, where the broken ends are kept in contact and perfectly immovable by surgical appliances, the bones unite almost like an incised wound of soft parts. After all the effused blood is absorbed from between the broken ends, a soft fibrous substance (blastema) full of osteoblasts is thrown out from the ends of the broken bone, which forms a thin layer of animal matter (intermediate callus) between them. This gradually becomes firmer, and bone is formed in it by one of the processes already described. So the ends are united. This occupies a period varying from four to ten weeks, according to the bone broken; e.g. the clavicle and the ribs unite more quickly than other bones, probably from their greater vascularity. The process is simply an excess of nutrition. Apparently more new bone than is necessary is formed. The excess fills up the medullary cavity, at the seat of fracture, and rounds off corners if there be any. But when the *permanent* uniting medium is strong, all that is seemingly superfluous is gradually absorbed, and the medullary canal is restored to its original condition, after a period varying from six to twelve months. On the other hand, if the fracture be not kept steady—for instance, in the case of animals—a kind of temporary splint is formed in the shape of a broad and thick ferule of cartilage, which ossifies around the ends of the broken bone, and keeps them almost immovable, while the permanent process of repair is going on between them. This ferule, termed the provisional callus,²¹ does not disappear until the fracture has been thoroughly repaired.

BONES OF THE SKULL.

For convenience of description the bones of the skull are divided into those which form the 'cranium' or brain-case, and those which form the skeleton of the face. Each of these will be described separately, and afterwards the skull will be examined as a whole.

8 BONES OF THE CRANIUM, excluding Wor- mian bones and bones of ear.	{ Occipital, Frontal, 2 Parietal 2 Temporal, Sphenoid, Ethmoid.	14 BONES OF THE FACE, excluding teeth, which really do not belong to skeleton proper.	{ 2 Superior Maxillary, 2 Malar, 2 Nasal, 2 Palate, 2 Lachrymal, 2 Inferior Turbinated, Vomer, Inferior Maxillary.
---	--	--	---

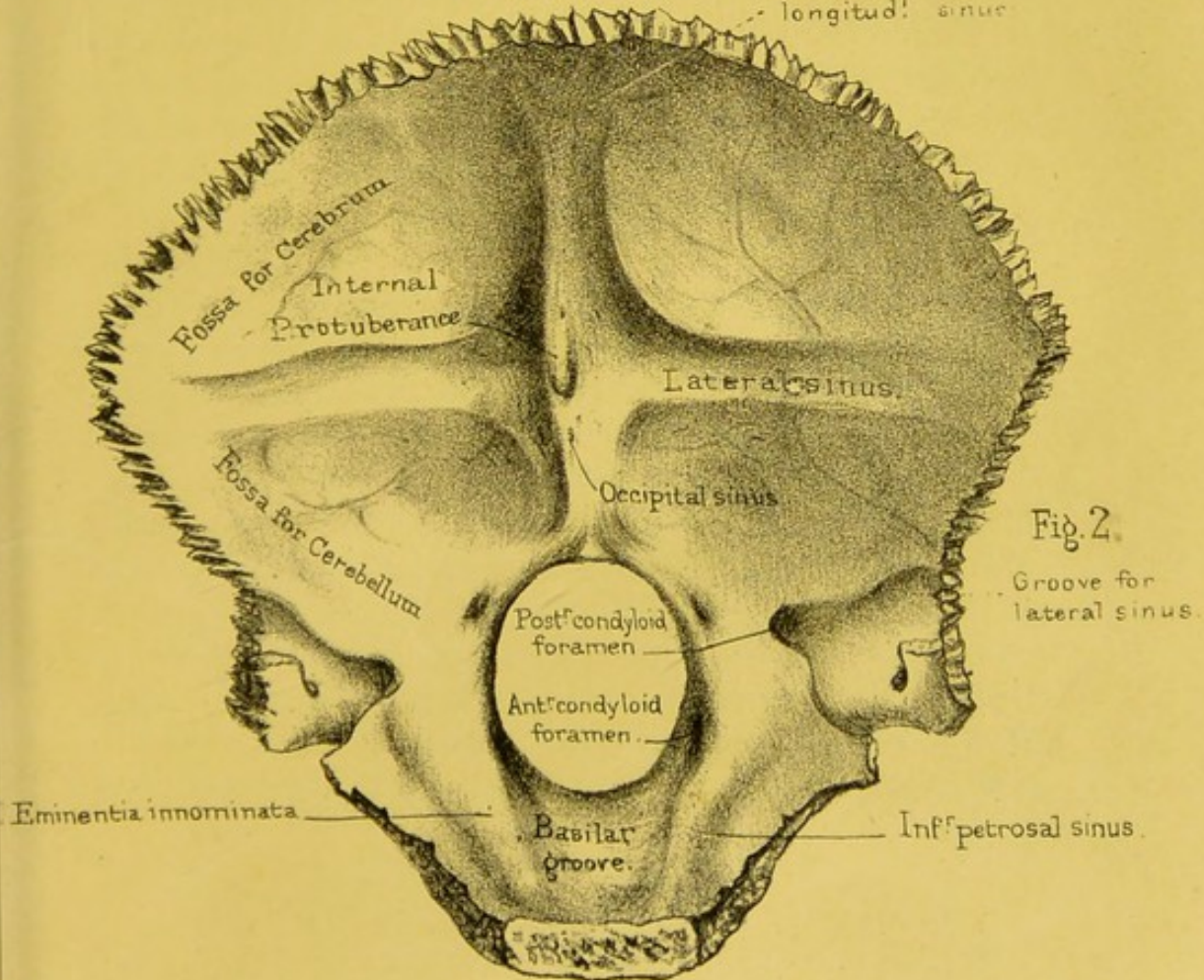
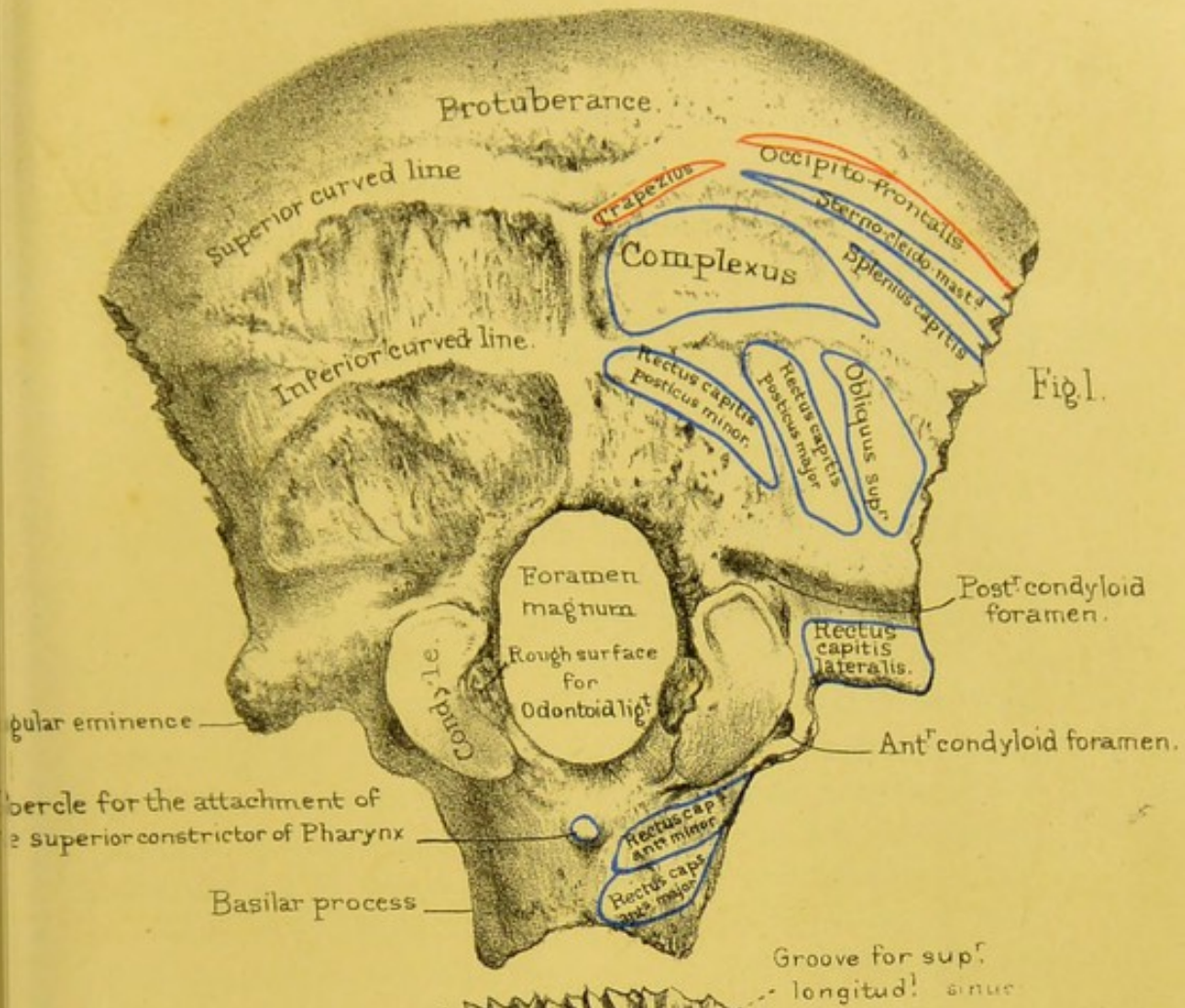
BONES OF THE CRANIUM.

THE OCCIPITAL BONE.

(PLATE V.)

THE occipital bone contributes to form part of the base of the skull as well as part of the back of the head. When viewed in the articulated skull, we notice that it is divisible into three parts: an *upper* or *vertical portion*, belonging to the skull-cap, and therefore covered by the scalp; a *middle* or *oblique portion* (the lower part of which is nearly horizontal), to which are attached the great muscles of the back of the neck; and a *lower* or *basilar portion* wedged into the base of the skull, and which ascends slightly from behind forwards.


As to describe these parts separately would involve repetition, we shall consider the bone as a whole. In general outline it is lozenge-shaped, possessing *two superior lateral* and *two inferior*



Drawn on Stone by T. Godart.

From nature by L. Holden.

Printed by West, Newman & Co.



lateral borders, a superior, inferior, and two lateral angles, and an intra-cranial and an extra-cranial surface.

SUPERIOR LATERAL BORDERS.—These are two deeply serrated edges running downwards and outwards from the superior to the lateral angles, and articulating with the posterior borders of the parietal bones. Together they form the two lambdoidal or parieto-occipital sutures.

INFERIOR LATERAL BORDERS.—These borders run from the lateral to the inferior angle. Each shows, about its middle, a prominent projection—the outer rough edge of the ‘jugular process’—for articulation with the under surface of the petrous portion of the temporal bone. The part of the border, behind this articular surface, is slightly serrated, concave from above downwards, and articulates with the mastoid portion of the temporal. The part, in front of the articular surface, is again divided into two—a posterior smooth concave part, called the ‘jugular notch,’ helping to form the jugular foramen with the petrous portion of the temporal, and an interior rough part looking forwards, outwards, and slightly downwards for articulation with the posterior border of the petrous portion of the temporal bone.

SUPERIOR ANGLE.—It is an acute one, and fits into the interval between the two posterior borders of the parietal bones. At this angle, the two posterior parieto-occipital sutures and the interparietal suture meet, the point of junction being called the ‘lambda.’

LATERAL ANGLES.—These angles are obtuse ones, and are received into the retiring ones formed by the posterior borders of the parietal bones and mastoid processes of the temporal bones.

INFERIOR ANGLE.—This, which might be called the *anterior angle*, is more a surface than an angle. It is joined to the posterior surface of the body of the sphenoid bone, in early life, by cartilage; but, in the adult, this cartilage becomes ossified. If we therefore, on examining a skull, find that the occipital and the sphenoid are completely ossified at this angle, we may say that the skull has belonged to an individual over twenty-five years of age.

EXTRA-CRANIAL SURFACE.—In the *middle line*, from the superior to the inferior angle of this surface, we notice the following

appearances: first a smooth, perhaps slightly hollowed surface, over which the aponeurosis of the 'occipito-frontalis' plays; next a prominent eminence, if well developed pointing downwards, called the 'external occipital protuberance' or 'inion,' affording attachment, centrally, to the 'ligamentum nuchæ' and, laterally, to the 'trapezius' muscles, and easily felt at the back of the head; then a ridge bifurcating below, in the middle line of the oblique part of the bone, and called the 'external occipital crest,' for the attachment of the upper border of the ligamentum nuchæ. In most skulls we see, in the occipital protuberance, one or two small foramina leading directly into the interior and lodging small veins. We then come upon the lower edge of an oval opening called the 'foramen magnum,' which transmits the spinal cord, and its membranes, the two vertebral arteries, and the two spinal portions of the spinal accessory nerves. This foramen is situated, in the European skull, practically midway between the anterior and posterior portions of the entire skull. In the negro it is a little behind the middle, approaching the character seen in the skull of the anthropoid ape. The plane of the foramen is downwards and forwards in the white man, straight downwards in the negro, and downwards and backwards in the anthropoid ape, and still more so in quadrupeds. In front of the foramen magnum we come upon the mid-line of the under surface of the basilar process, with a little prominence just behind the middle of its antero-posterior measure, and called the 'pharyngeal spine,' for the attachment of a strong part of the fibrous membrane hanging the pharynx up to the skull. On *each side of the middle line*, tracing the surface from above downwards, we notice first a smooth slightly convex space belonging to the vertical part of the bone, marked by a number of nutrient foramina, and having the 'occipito-frontalis' muscle and aponeurosis gliding over it. We next come upon a ridge, stretching from the external occipital protuberance to the lateral angle of the bone, convex upwards, and called the 'superior curved line.' To it are attached the 'occipito-frontalis' and sterno-mastoid muscles in its outer two thirds, and the 'aponeurosis of the occipito-frontalis' and the 'trapezius' in its inner third. We next come upon a somewhat

rough four-sided space, bounded, internally, by the upper half of the external occipital crest; externally, by the upper part of the inferior lateral border of the bone; superiorly by the superior curved line; and inferiorly, by a convex line which stretches between the middle of the external occipital crest and the articular edge for the mastoid process, and is parallel with the superior curved line. This convex line we call the 'inferior curved line.' In its outer half or so, it forms the upper limit of the insertion of the 'rectus capitis posticus major,' and in its inner third that of the 'rectus capitis posticus minor.' The space, between the two curved lines, gives attachment, internally, to the 'complexus' and, externally, to the 'obliquus capitis superior.' Between the inferior curved line and the foramen magnum we see a convex and somewhat rough surface giving insertion, internally, to the 'rectus capitis posticus minor' and, externally, to the 'rectus capitis posticus major.' The occipital bone is exceedingly thin here, and if the skull be held in proper position this part of it lies as near as possible horizontally. On each side of the foramen magnum we find the 'condyles.' These eminences lie against the anterior half of each side of the foramen, being separated from one another, in front, by about the distance of half an inch. Each is kidney-shaped, convex from before backwards and slightly so from side to side. The general direction of the articular surface is downwards, outwards, and forwards. About the middle of the inner and outer borders, are situated notches which may be joined together across the articular surface by a smooth elevation, or, it may be, a slight groove, and which indicate the line of junction between the part of the condyle, formed by the basilar or basioccipital portion of the bone, and the part formed by the condylar or exoccipital portion. The condyle stands so that its inner margin is lower than its outer, and it thus fits into the 'cup' of the 'atlas' or first cervical vertebra. On the inner side of each condyle is a rough depression, to which are attached the odontoid or check ligaments which limit rotation of the head. Owing to this arrangement, and the great strength of the connecting ligaments, dislocation of the head from the atlas is extremely rare. Behind the condyle is a

depression, from the bottom of which, a foramen leads upwards, forwards, and outwards, to open into the interior of the cranial cavity. It gives passage to a vein. This foramen may be reduced to a very small size, or may even be wanting on one or both sides. In front of and outside the condyle, is a large opening leading upwards, backwards, and inwards, and called the 'anterior condyloid foramen.' It transmits the 'hypoglossal' nerve, and in some cases is divided into an anterior and posterior part by a thin partial or complete bony septum. Outside the back part of the condyle, we notice the rough under surface of the 'jugular eminence,' giving attachment to the 'rectus capitis lateralis.' In most skulls there projects, from the lower surface of the jugular eminence, a very slightly prominent tubercle, forming a rudimentary '*par-occipital process.*' It is very constantly developed in the mammalian series. There is a good specimen of a largely developed process in the Nor. Hum. Ost. Ser. (No. 747) in a skull of an aboriginal of one of the Philippine Islands. The process is even longer than the mastoid process, and presents an articular surface for joining the transverse process of the atlas. A similar process is seen in a skull in the museum of St. Bartholomew's Hospital, and also on the left side of the occipital bone of the skull of a North American Indian preserved in the museum of St. Thomas's Hospital. There are also two specimens of it in the Museum of Anatomy in Richmond Street, Dublin. At a point midway between the anterior extremities of the condyles, or '*basion*' as it is called, we find, as a great rarity, a small downward projection for articulation with the anterior arch of the atlas; an example of such a process is seen in the skull of a negro in the museum of St. Thomas's Hospital. In front of the condyles we have the under surface of the 'basilar process,' rough for the attachment of the 'rectus capitis major' and 'minor.'

INTRA-CRANIAL SURFACE.—Treating this surface in the same way as we did the extra-cranial one, we notice *in the mid-line* the following objects: at a point, opposite the external occipital protuberance, a heaping up of the bone, called the 'internal occipital protuberance.' On it we notice two or three openings

of veins leading to the exterior of the bone. Above this, we have the 'groove for the superior longitudinal sinus,' bifurcating above the protuberance into a very large right branch, which is very much dilated and depressed to the right of the protuberance and called in that situation the 'torcular Herophili,' and a very small left branch which runs to the left of the protuberance, and joins the commencement of a smooth groove running outwards for the lateral sinus of the same side. Below the protuberance is a prominent crest, 'the internal occipital crest,' for the attachment of the falx cerebelli, bifurcating below into branches which fade off in the upper margin of the foramen magnum. On the ridge, and on its branches, lies the occipital sinus, joining the torcular Herophili superiorly. We then come upon the oval upper margin of the 'foramen magnum' with its long axis directed from before backwards, and more extensive than the lower margin on account of the bevelling off of the anterior half of its two sides. In front of the middle of the foramen, under cover of its upper edges, we notice the upper openings of the anterior condyloid foramina, giving passage to the hypoglossal nerves. Immediately above each 'anterior condyloid foramen,' or 'canal,' as it should be called, is a heaping up of bone, which, not having received a name, might be called the 'eminentia innominata.' It looks like a strong bony ridge over the canal, and strengthens the base of the skull like a flying arch just over the condyle. On *each side of the mid-line* we notice, tracing the bone from above downwards: first, a triangular concave fossa, marked by smooth eminences and depressions to adapt themselves to the sulci and convolutions of the brain, and here and there by fine grooves, like branches of a tree, for blood-vessels destined for the nourishment of the bone and membrane lying inside it, and hence called 'grooves for meningeal arteries.' Below this, we come upon a cross groove leading from the torcular Herophili on the right side, and from the internal occipital protuberance on the left, to the corresponding lateral angle. The groove is for the 'lateral sinus' of the corresponding side, and the lips of the groove for the attachment of the part of the dura mater between the cerebrum and cerebellum called the 'tentorium.'

Below this groove we come upon a four-sided pretty uniformly smooth and concave fossa for the lodgment of the cerebellum, and hence called the 'cerebellar fossa.' This surface shows a few smooth ridges and narrow grooves for the attachment of the dura mater and passage of vessels leading into the lateral sinus. We may here say that it is very common for the torcular Herophili to be situated on the left side instead of on the right, and therefore continuous with the groove for the left lateral sinus instead of the right. In such a case the large branch of the groove joining the superior longitudinal sinus will run to the left of the middle line instead of to the right. Below the cerebellar fossa, we come upon the upper surface of the jugular process marked by a smooth groove, which curves from without and behind inwards and forwards, and becomes continuous with the 'jugular notch.' The groove lodges the end of the lateral sinus, and is joined near its termination by the upper opening of the 'posterior condyloid foramen,' or 'canal' as it might, more properly, be called. In front of this, and close to the edge of the bone, we have a half-groove, made a whole one by the apposition of the petrous portion of the temporal, and lodging the 'inferior petrosal sinus.'

Structure.—Like the other flat bones of the skull, the occipital consists of an *outer plate* or *table* and an *inner plate* or *table*; the latter being called the vitreous table because it is so hard and brittle. Between the two tables we have the cancellous tissue or diploe, especially deposited where the bone is thick, such as at the external and internal protuberances and basilar process. It is sparingly deposited where the bone is thin, and even in some may be wanting altogether, e.g. at the lower part of the cerebellar fossæ, so as to make the bone almost semi-transparent in these situations.

Ossification.—The occipital bone is developed from seven centres. In the *tabular part* are four; one appearing on the bottom of each fossa about the seventh or eighth week. The upper two are developed in membrane; the lower two in cartilage. These four centres join one another before birth, leaving occasionally streaks, or it may be fissures, at the margin indicating their original separation. In some cases, the two upper

centres join across the middle line, and form a bone called the 'interparietal bone,' which remains permanently separate from the part of the tabular portion formed by union of the two lower nuclei of ossification. The lower part of the tabular portion is the true 'supra-occipital bone.' The outsides of the foramen magnum, the jugular processes, and the back parts of the condyles form what are called the 'condyloid' or 'ex-occipital parts' of the bone. Each 'condyloid part' has one centre of ossification, appearing in the seventh or eighth week of foetal life, near the foramen magnum and joining the supra-occipital part some time between the second and the fourth year. The basilar process, the fore part of the foramen magnum, and the anterior half or so of each condyle, form what is called the basilar or basi-occipital portion. This portion begins to appear bony in the seventh or eighth week of foetal life, and joins the ex-occipital portions some time between the third and the fifth or sixth year inclusive. The basilar portion commences to join the body of the sphenoid, by bone, about twenty years of age, and the two are completely ossified by twenty-three or twenty-four.

Connections.—The occipital bone is connected with six other bones; namely, with the two parietals by the remarkably serrated 'lambdoid' suture, with the two temporals, with the sphenoid, and with the atlas; the latter being articulated to the condyles by movable joints. The sutures are simply named after the bones which they connect: for instance, we speak of the 'occipito-parietal' suture, the 'petro-occipital,' the 'occipito-mastoid,' and the 'spheno-occipital.' All these connections are well serrated, except the 'spheno-occipital,' which is quite effaced in the adult skull, and the 'petro-occipital.'

Comparative Osteology.—In all mammalia, as in man, there are two occipital condyles, each formed in part by the basi- and in part by the ex-occipital bones, fitting into two corresponding articular surfaces on the atlas. In birds and reptiles (Sauropsida), however, there is but a single occipital condyle, in front of the foramen magnum, in the middle line formed by the basi- and ex-occipital bones. In Ichthyopsida when there are two condyles they are formed by the ex-occipitals alone. This should be seen

and noted, as it is one of the distinctive features of the above-named classes. (See separate series in the Mus. Roy. Col. Surg.)

The cells which contain air and separate the inner and outer tables of the skull in the frontal bone of man extend as far back as the occipital bone in elephants. See sections of the elephant's skull (No. 2247).

In quadrupeds the prominence of the crest and external occipital protuberance bears a direct relation to the development of the ligamentum nuchæ which supports the head, and is usually in proportion to the weight of the head and its appendages. Compare the head of a deer, elephant, and tiger with that of a man in these particulars. In the moles the ligamentum nuchæ will be seen to be nearly all ossified.

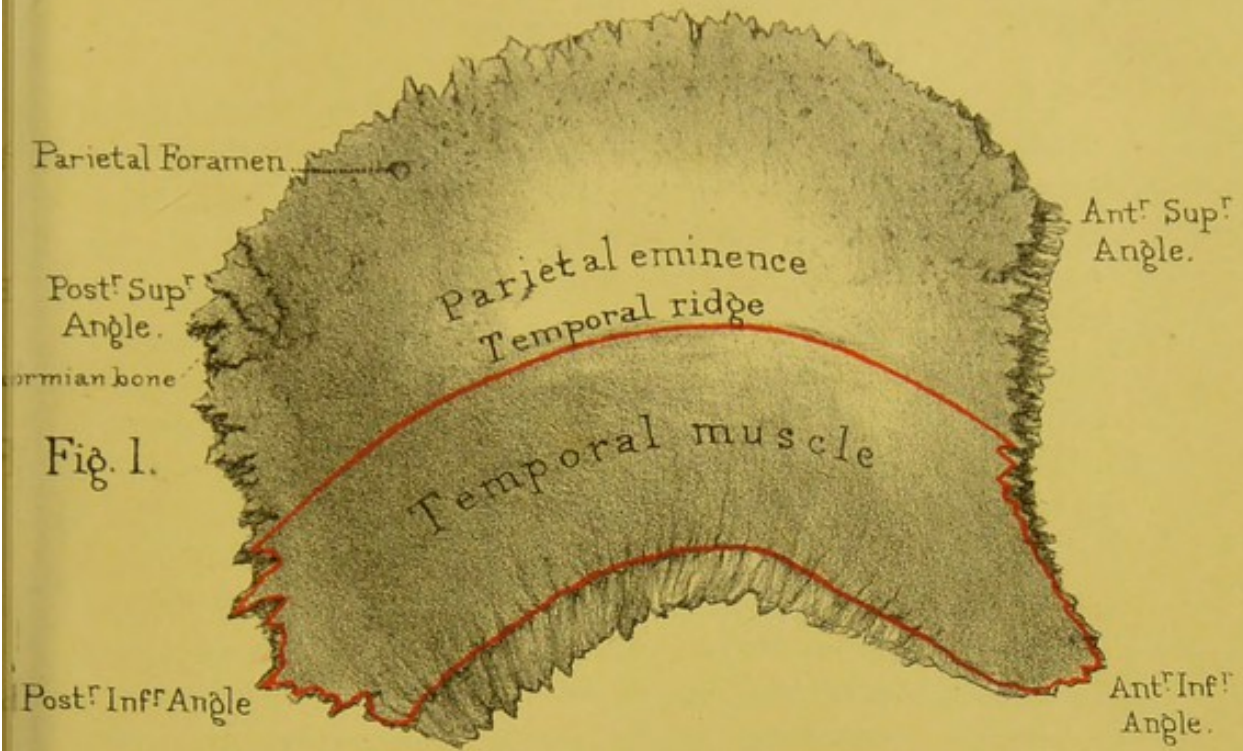
PARIETAL BONE.

(PLATE VI.)

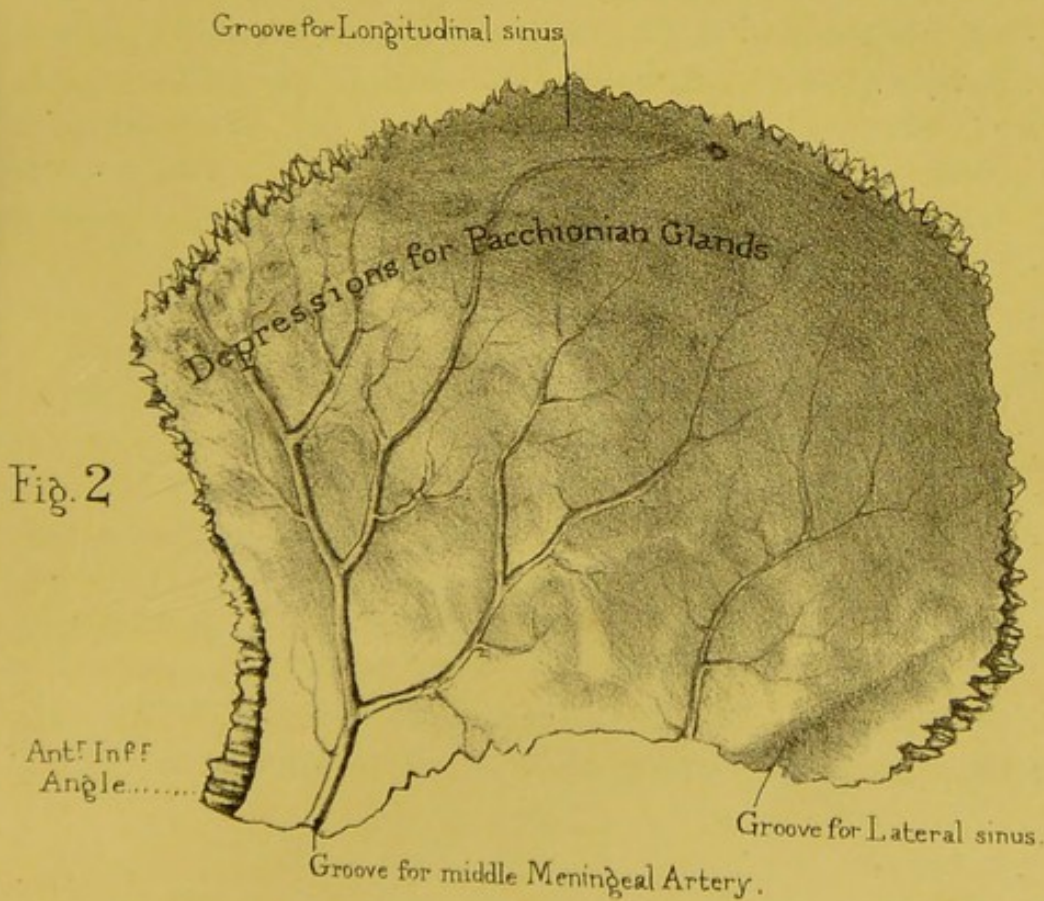
This broad, roof-like bone derives its name from *paries*, a wall, as it forms so much of the wall of the skull-cap. It is the only bone belonging exclusively to the vault of the cranium. With its fellow of the opposite side, it makes the keystone of the arch which spans the brain. It is convex on the outer surface, concave on the inner, and four-sided.

SUPERIOR BORDER.—This border is deeply serrated to interlock with the corresponding border of the opposite bone, and so, with it, to make the 'sagittal' or 'interparietal' suture. When the skull is held in its proper position the highest point of this suture is the highest point of the vault, and is called the 'vertex' of the skull. It is situated somewhere in front of the middle of the suture, depending upon the shape of the skull.

ANTERIOR BORDER.—This edge is thick, deeply serrated, and bevelled at the expense of its external surface in its upper three-fourths, thin, sharp, and bevelled at the expense of its inner surface in its lower fourth, and articulates with the frontal bone, thereby making one-half of the 'fronto-parietal' or 'coronal' suture. The point, where the interparietal and fronto-




Parietal Bone



Drawn on Stone by T. Godart.

In nature by L. Holden.

Printed by West, Newman & Co.



parietal sutures meet one another, is called the 'bregma.' The posterior border, not as long as the anterior, is thick, deeply serrated, nearly straight from above downwards, and articulates with the occipital bone, forming with it one half of the 'lambdoidal or 'occipito-parietal' suture.

The INFERIOR BORDER may be divided into: an anterior fourth, which is thin and sharp, bevelled at the expense of the external surface, slightly rough, running straight from before backwards to articulate with the great wing of the sphenoid; a middle 'two fourths,' which is also thin and sharp, rougher than the anterior fourth, bevelled at the expense of the external surface and concave downwards to articulate with the squamous portion of the temporal bone; and a posterior fourth, which is thick, serrated, set obliquely so as to look downwards and backwards, and articulating with the mastoid portion of the temporal bone.

ANGLES.—The angles made by these borders are named the *anterior superior*, helping to form the bregma; the *anterior inferior*, fitting into the angle formed by the adjacent edges of the frontal and sphenoid, and helping to form the 'pterion,' which is a space where the frontal, parietal, temporal, and sphenoid meet by an 'H'-like suture; the *posterior superior*, a slightly obtuse angle, helping to make the 'lambda' of the skull, or meeting point of the sagittal and lambdoidal sutures; and the *posterior inferior*, a still more obtuse angle, fitting into the angle between the adjacent edges of the occipital and mastoid portions of the temporal, and helping to make the 'asterion' or meeting point of three sutures in this region of the skull.

EXTERNAL SURFACE.—On the external, or convex, surface notice the 'parietal eminence,' situated about the middle. This is the spot in which the ossification of the bone began. Above this eminence the surface presents a somewhat worm-eaten appearance, caused by a number of very small nutrient foramina being lodged here. Close to the upper margin, and placed at about the junction of the posterior fourth with the anterior three-fourths, in most skulls, is a hole called the 'parietal foramen,' for the passage of a vein from a sinus which lies in a groove to be described at the upper margin of the internal surface. In the

united skull, the point, in the sagittal suture, situated midway between the parietal foramina, is called the 'obelion.' Crossing the highest point of the parietal eminence, or it may be a little below it, is a curved line, called the 'temporal ridge.' In well-marked skulls, this ridge is double, showing an upper and a lower line separated from one another posteriorly by about the distance of half an inch, but coming nearer together in front. The upper line gives attachment to the 'temporal fascia,' and the lower marks the circumference of the 'temporal' muscle. The portion of the surface below this line forms part of the 'temporal fossa,' which gives origin to the 'temporal' muscle. Inferiorly it presents a radiating and streaked appearance, the streaks diverging upwards from the bevelled articular margin for the squamous portion of the temporal bone. The point where the temporal ridge becomes continuous with the anterior border of the bone we call the 'stephanion.'

INTERNAL OF CEREBRAL SURFACE.—The concave cerebral surface has four kinds of marks or impressions upon it. Firstly, over the general surface there are wide shallow grooves with eminences between them, corresponding to the convolutions and sulci of the brain. Secondly, along the upper border is a half-groove for the superior longitudinal sinus, and opening into the groove, about the junction of the posterior fourth with the anterior three-fourths, is the inner end of the 'parietal foramen' already described. Running across the posterior inferior angle of the internal surface is a complete 'groove for the lateral sinus' on its way from the occipital to the temporal bone. Thirdly, lying close and nearly parallel to the anterior border is the groove, sometimes a complete bony canal, in the region of the anterior angle of the bone, for the anterior branch of the middle meningeal artery; also running nearly parallel to the posterior border is another groove for the posterior branch of the same artery. Both these grooves give off branches, like those of a tree, for the passage of smaller branches of the artery. Fourthly, near and along the upper border are seen a number of rounded smooth depressions, which in the recent state contain the so-called 'Pacchionian bodies.'

Connections.—The parietal bone is connected by sutures with five bones (Plate XVIII.) as follows: with the opposite

parietal bone, by the interparietal or sagittal suture; with the frontal bone, by the fronto-parietal or coronal suture; with the temporal bone by the temporo-parietal or squamous suture; with the occipital bone, by the occipito-parietal or lambdoid suture, and with the sphenoid bone by the spheno-parietal suture. In all adult skulls the sagittal suture, though for the most part extremely serrated, is much less so near the parietal foramina. When obliteration of this suture takes place in age, it always begins opposite these holes. Do not fail to notice the beautiful arrangement of the sutures of the parietal bone: the sutural edges are bevelled on alternate sides, so that the bone cannot be driven in without previous fracture.

Ossification.—It is developed from one centre, which makes its appearance at the parietal eminence, about the seventh week of foetal life.

Fontanelles.—The term 'fontanelles' is given to those membranous intervals in the foetal skull which are seen at the four angles of the parietal bone. These unossified parts are so called from the pulsations of the brain beneath them, perceptible in infants, like the welling up of water in a spring. They are produced in the following manner. Ossification commences in the centre of the bone, and advances towards the circumference; therefore, the most distant parts of the bone are the last to be ossified. These points are the angles where the several bones eventually meet. There are in all six 'fontanelles.' (Plate XVIII. figs. 4 and 5.) Observe the shape of the anterior and posterior 'fontanelles,' and of the two lateral. The *anterior*, situated between the adjacent angles of the parietal bones and the ununited halves of the frontal, is lozenge-shaped, and remains open for some time after birth; indeed, it is not (as a rule) entirely obliterated till the fourth year. The *posterior*, situated between the parietals and the apex of the occipital bone, is triangular and nearly closed at birth. These 'fontanelles' are of especial importance to the accoucheur, as by feeling them the finger can detect, during parturition, the position of the head of the child. The *lateral* 'fontanelles' are of less importance, and generally obliterated before birth.

Comparative Osteology.—In Carnivora the temporal muscles are so extensive that they meet in the middle line of the skull, where they are attached to a dense median crest of bone, which represents the temporal ridges coalesced. This is conspicuous in the skeleton of the tiger. It is interesting to note that the dog is not born with this median ridge; at birth the temporal muscle extends only partly up the side of the head. As the dog grows the muscle rises further up the head until it meets its fellow in the middle, and then the ridge begins to be developed. This progressive increase of the muscle may be due to the habit puppies have of worrying everything they meet with, or it may be the result of an hereditary tendency.

In elephants and owls the inner and outer tables of the parietal bones are separated by enormous air-cells.

In man the two originally distinct halves of the frontal unite and form one bone. In bats the two parietals, which in us remain distinct, unite and form a single bone; this is also the case in many rodents, as the hare, but in the rabbit they remain separate. In Ruminants and Solidungula the parietals are united.

FRONTAL BONE.

(PLATE VII.)

The situation of the frontal bone is implied by its name. As it forms not only the forehead, but the roof of the orbits, we naturally divide it into a 'frontal' or 'vertical portion' and an 'orbital' or 'horizontal.'

Vertical Portion.—ANTERIOR SURFACE.—The anterior surface of the vertical portion is smooth and convex, and gives breadth and height to the forehead. Sometimes we notice it divided into two lateral halves by an 'interfrontal suture,' which is always present in the bone at birth, but which ought to disappear about the second year. The median line inferiorly is somewhat hollowed transversely, and the point in it situated just above the articular surface for the nasal bones is termed the 'gla-

Fig. 1.

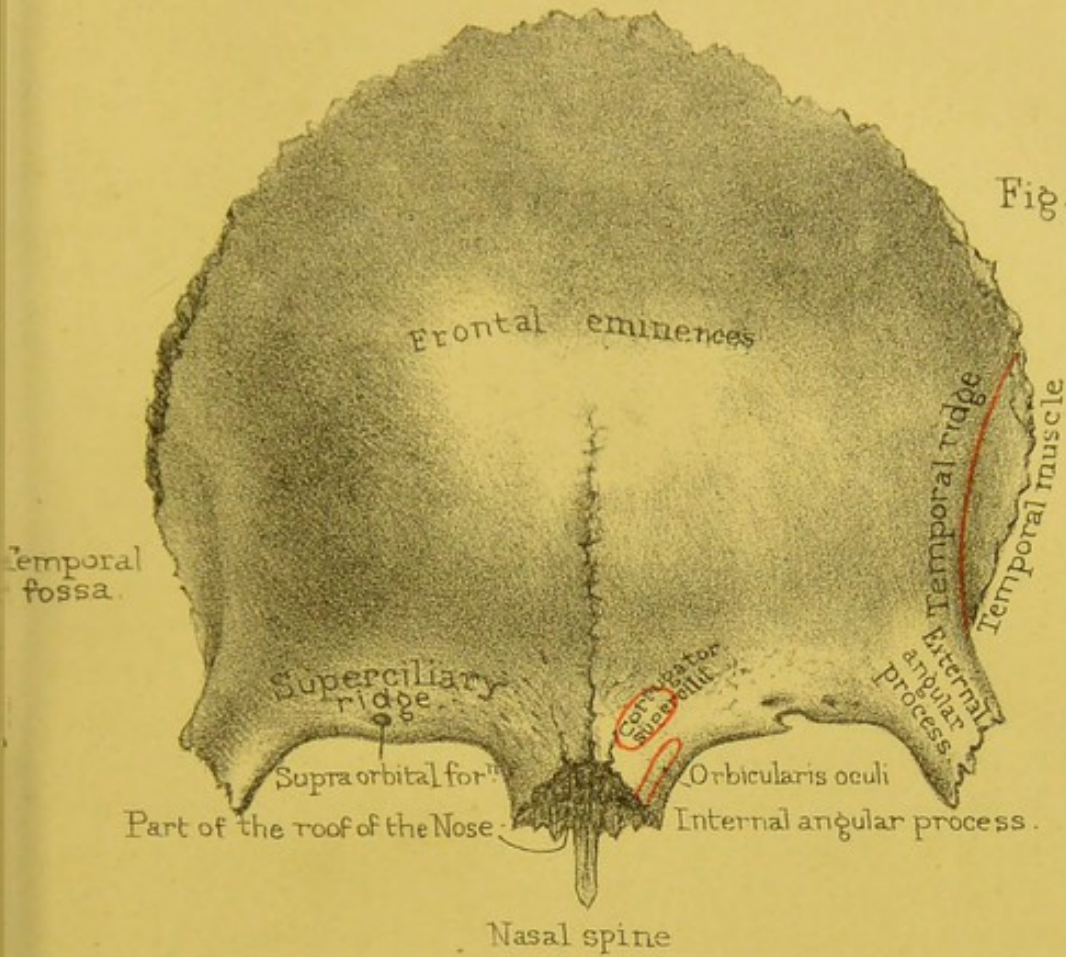
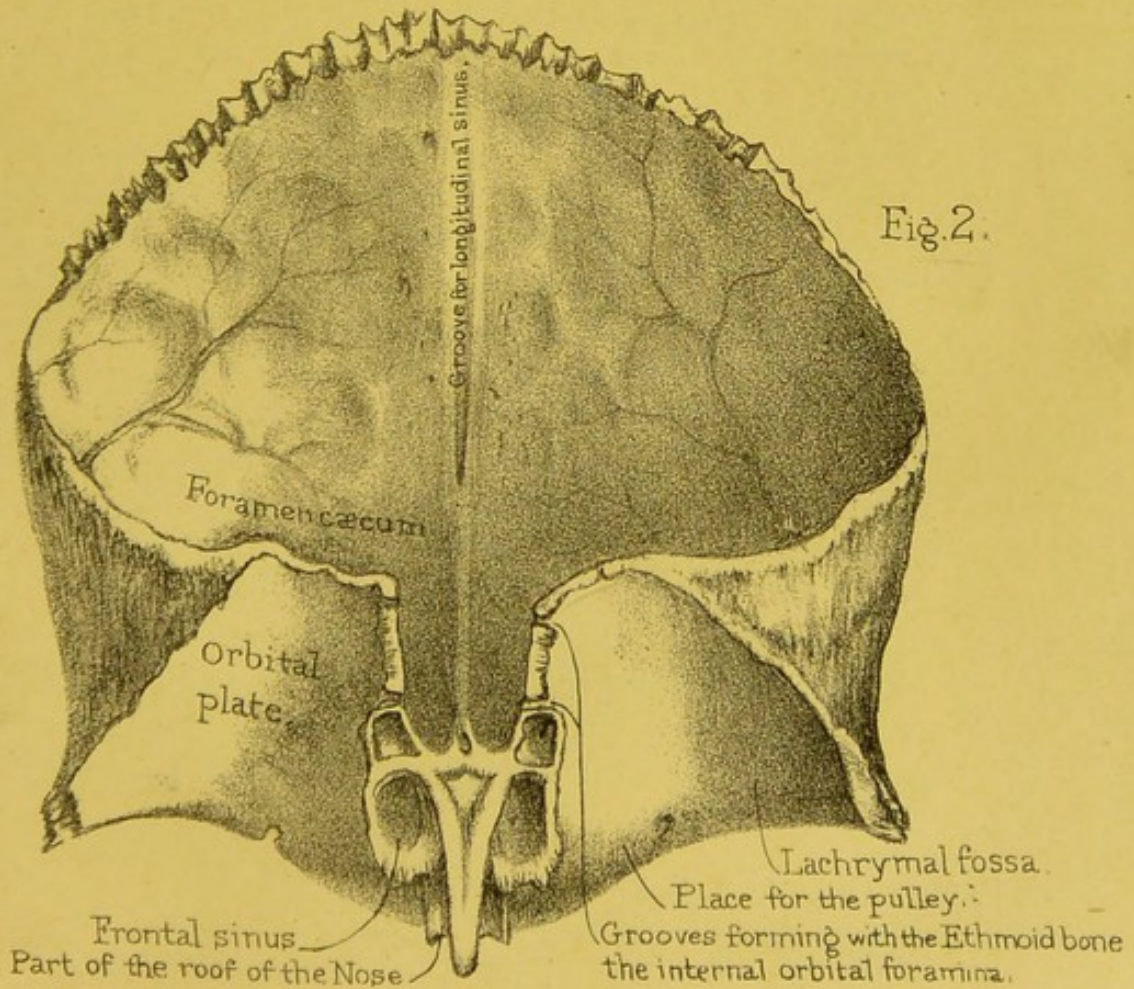


Fig. 2.





bella' or 'nasion.' Just below the articular surface for the nasal bones, to be presently described, the mid-line juts forwards and downwards as a prominent projection termed the 'nasal spine.' This process is convex from side to side superiorly, also rough and articular for the nasal bones to rest upon. Inferiorly it is concave transversely, marked in the middle line by an antero-posterior groove for articulation with the vertical plate of the ethmoid, and on each side of this a smooth narrow surface helping to make the roof of the nasal cavities.

Tracing the surface *from below upwards on each side of the middle line*, we notice first one half of the 'nasal notch.' This, with the other half, makes a rough serrated surface, arching in front of the roof of the nasal spine, and articulating internally with the nasal bones and externally with the nasal processes of the superior maxillaries. The outer extremity of the notch is termed the 'internal angular process,' for articulation with the lachrymal bone. Arching upwards and outwards from this process to terminate in a thicker projection externally—the 'external angular process,' for articulation with the malar bone—is the 'supra-orbital arch.' It is thick and rounded in the male, thin and clean cut in the female. Near the junction of the inner and middle thirds of the arch is the 'supra-orbital notch,' or it may be 'foramen,' for the transmission of the supra-orbital nerve. At the external angular process is the starting point of the 'temporal ridge.' This ridge is sharp and prominent inferiorly, arches forwards, upwards and then backwards, and becomes continuous with the corresponding ridge on the parietal. It gives attachment to the temporal fascia, and below it is a small surface of bone which contributes to form the 'temporal fossa' for the origin of the temporal muscle. Above the supra-orbital arch we notice a slight parallel depression, and above that an arched eminence termed the 'supraciliary ridge,' highest internally, where it is called the 'nasal eminence.' The supraciliary ridges and nasal eminences do not correspond to prominences of the brain, but are occasioned by air-cavities termed the 'frontal cells' or 'sinuses,' situated between the two 'tables' of the skull. And here it may be well to mention, that the cap of the skull consists

of two layers of compact bone, called, respectively, the outer and inner 'tables' of the skull, and separated by an intermediate cancellous tissue termed the 'diploe.' We shall allude to the advantage of this structure hereafter (skull as a whole, fig. 20); meantime, observe that the frontal cells are formed by the separation of these tables. To see the extent of the cells, one ought to make vertical sections as shown in Plate XXIII.

THE FRONTAL SINUSES.—There are some points of interest about the frontal sinuses. 1. They communicate freely with each nostril through a canal termed the 'infundibulum' (fig. 2); therefore it is possible for foreign bodies to reach them from the exterior of the body. 2. As they are lined by a continuation of the same mucous membrane which lines all the other passages of the nose, we have a ready explanation of the aching pain in the forehead in cases of influenza, or a common head cold. 3. In cases of fracture of the base of the skull involving the walls of the cells, it is possible for fragments of the brain to escape from the nose. The author has seen a case of this kind where the patient recovered without any permanent ill-effects except partial loss of smell. 4. If the outer wall of the cells be injured by violence or disease, the air, in sneezing or coughing, is liable to escape under the skin of the forehead; this condition is called 'surgical emphysema.'²² 5. They not only contribute to the lightness of the skull, but increase the resonance of the voice. They do not begin to be developed until about the second year, and steadily increase in size afterwards. Even in Europeans their size and extent vary exceedingly. A good idea may be formed of their size in some persons, by the fact that they may lodge a musket ball. A soldier was wounded at the battle of Talavera by a ball which struck him on the forehead and lodged in the frontal sinus. It was readily removed by enlarging the opening, and the man recovered.²³ The author has seen a case precisely similar, in a soldier who was wounded in the Crimea. The sinuses are commonly separated by a bony partition, often incomplete. The eminences or 'bumps' are not prominent in children, because the tables of the skull do not begin to separate to any great extent before puberty. From an examination of more than

100 skulls, it appears that the absence of the external prominence, even in middle age, does not necessarily imply the absence of the sinus itself, since it may be formed by a retrocession of the inner table of the skull. In old persons, as a rule, when the sinuses enlarge, it is by the inner table encroaching on the brain-case. The skull wall follows the shrinking brain. The range of the sinuses may extend even more than halfway up the forehead, and backwards for an inch or more along the orbital plate of the bone. Sometimes one sinus is larger than the other, and consequently the 'bump' on one side of the forehead may naturally be more prominent than that of the other. In the *Nor. Hum. Ost. Ser.* (Nos. 153 to 155) in the Museum of the Royal College of Surgeons, there is an instructive collection of horizontal sections through the frontal bone at the level of the sinuses. In a specimen from a man *æt.* 32, it may be observed that though the sinuses are very extensive, there is no external protuberance. In another from a man *æt.* 47, there are no sinuses, yet there is a great external protuberance. No doubt the supraciliary ridges, with overlying eyebrows, form a great protection for the delicate structures contained in the orbital cavities situated beneath them. They are better marked in the male than in the female. Above each supraciliary ridge we have a shallow groove, and above that an eminence called the 'frontal eminence.' This is the point from which each half of the bone was originally formed, and is therefore more prominent in a child's skull. Above the frontal eminence the anterior surface of the frontal bone is smooth and covered by the 'occipitofrontalis' muscle.

POSTERIOR OR CEREBRAL SURFACE (Plate VII. fig. 2).—The posterior surface of the vertical portion is concave, especially opposite the frontal eminences, when the surface presents what are called the 'frontal fossæ.' It is marked by depressions for the convolutions of the brain, by tiny grooves for the anterior meningeal and, laterally, by larger grooves for branches of the middle meningeal arteries. In the middle line is a 'groove for the superior longitudinal sinus.' Trace the groove down, and see that its margins gradually approximate and lead to a narrow

notch made into a foramen by the apposition of the ethmoid bone. The foramen is termed the 'foramen cæcum.' It sometimes leads into the frontal sinus, sometimes directly into the nose; or it may open on the posterior or anterior surface of the nasal bones. Though called 'blind,' it generally transmits a small vein from the longitudinal sinus into the frontal cells; sometimes it contains a small artery. Very often the margins of the groove for the longitudinal sinus coalesce, so as to form a small ridge—the 'crista frontis'—before they reach the foramen cæcum. They give attachment to a perpendicular sheet of the dura mater (termed, from its shape, the 'falx cerebri'), which separates the hemispheres of the cerebrum. Therefore, when we see a frontal bone with a well-marked ridge along the beginning of the longitudinal groove, it is but the ossification of part of this fibrous membrane. Pieces of bone occasionally occur in the falx cerebri, which remind us of the tentorium cerebelli in some Carnivora, as tigers, seals, and cats, in which the tentorium is for the most part bony instead of membranous (Nos. 4608 and 4483). On either side of the groove for the superior longitudinal sinus are numerous irregular pits for the reception of Pacchionian bodies.

POSTERIOR BORDER OF THE VERTICAL PORTION.—This border is thick, deeply serrated, and bevelled somewhat at the expense of the posterior surface superiorly; thin, sharp, and bevelled at the expense of the anterior surface inferiorly. In its upper three-fourths it articulates with the parietal bones, thereby helping to form the 'coronal suture,' and in its lower fourth with the anterior margins of the greater wings of the sphenoid bone.

SUPERIOR ANGLE.—This angle of the vertical plate is situated at the 'bregma' of the skull. It is an obtuse one, received into the retiring angle formed by the anterior borders of the two parietal bones.

The point in the coronal suture where the temporal ridges of the frontal and parietal meet, we call the 'stephanion.' The point situated in the mid-line of the anterior surface of the vertical plate in the narrowest part of the forehead and in a cross line drawn between the parts of the temporal ridges, which approach nearest one another, we call the 'ophryon' or 'supra-orbital point.'

Between this point and the 'occipital point' we measure both the length and the circumference of the cranium. By the occipital point, we mean a point in the mid-line of the occiput farthest away from the ophryon.

The **horizontal portion** of the frontal we divide into a single mesial 'ethmoidal notch' and two lateral 'orbital plates.'

ETHMOIDAL NOTCH.—The orbital plates are separated by a wide gap, called the 'ethmoidal notch,' because it receives the cribriform plate of the ethmoid bone, which here fits into the base of the skull. (Plate XIX.) On each side of the irregular margins of the notch, observe the incomplete cells with thin walls. These cells correspond with, and are closed in front by the lachrymal, and behind by the ethmoidal cells. (Plate XI. fig. 2.) The largest cell of all is in the front, and this, as seen in Plate VII. fig. 2, leads into the frontal sinus. All of them are filled with air, and lined by mucous membrane continuous with that of the nose. At the fore part of the ethmoidal notch we notice the under surface of the 'nasal spine,' and on each side of it, the 'nasal' and 'ethmoidal notches' are continuous with one another. Situated among the half-cells on each side of the ethmoidal notch we have two transverse and parallel grooves, converted into canals by the apposition of the ethmoid bone, and named respectively the 'anterior and posterior orbital' or 'ethmoidal grooves.' The anterior transmits the nasal branch of the ophthalmic division of the fifth nerve and the anterior ethmoidal artery and vein; the posterior, the posterior ethmoidal artery and vein.

ORBITAL PLATES.—Each 'orbital plate' extends horizontally backwards, and forms a concave roof for the corresponding orbit, and a part of the anterior fossa of the cranium. Hold it to the light, and observe how thin it is. In extreme old age, when the diploe of the skull becomes absorbed, the orbital plates have sometimes, though rarely, large holes in them. At any time of life their thinness renders them liable to be perforated by sharp instruments thrust into the orbit. Wounds of the brain from such accidents are sometimes met with.

We may describe each plate as being triangular in shape, and as having an *inferior* or *orbital surface*, a *superior* or *cerebral*

surface, an anterior, an inner and an outer border, an inner, an outer, and a posterior angle.

Inferior or orbital surface.—The long axis of this surface is backwards and inwards. It is smooth and concave all over, especially externally, under cover of the outer angle, where it shows a smooth fossa called the ‘lachrymal fossa,’ for the lodgment of the lachrymal gland. We notice small grooves for arteries and a few small nutrient foramina. About midway between the supra-orbital notch and the internal angular process, and a little behind the orbital margin, is a small depression—in some bones, a slight eminence—for the attachment of the pulley of the ‘superior oblique’ muscle. The *superior or cerebral surface* is arched upwards and marked by a number of smooth but prominent ridges fitting the sulci on the under surface of that part of the frontal lobe of the brain. The *anterior border* has already been described as the supra-orbital arch. The *internal border* forms the outer margin of the ethmoidal notch, and shows an irregular sharp articular outline, situated in which is the commencement of the anterior and of the posterior ethmoidal groove. The *external border* is rough and serrated to articulate with the great wing of the sphenoid. The *internal and external angles* have been already described as the internal and external angular processes. The *posterior angle*, more a border than an angle, runs forwards and inwards, and is serrated for articulation with the anterior border of the lesser wing of the sphenoid bone.

The frontal bone has attached to the inner parts of the supra-orbital arches the frontal bellies of the ‘orbicularis palpebrarum;’ to the inner ends of the supraciliary ridges the ‘corrugator supercillii muscles;’ and to the surface of bone below the temporal ridges, the ‘temporal’ muscles.

Connections.—The frontal is connected with twelve bones, of which two, the sphenoid and ethmoid, are single. It is united to the two parietal bones by the ‘fronto-parietal’ or ‘coronal suture.’ (Plate XVIII. fig. 2.) Concerning this suture, see how admirably it locks the bones together, and secures the arch of the skull. The margin of the frontal bone is bevelled at the expense

of its inner table above, of its outer table below : and the parietal bone is adapted accordingly. The lower half of its temporal margin unites with the greater wing of the sphenoid. Its external angular process is connected to the malar bone ; its internal angular process to the nasal bone and nasal process of the superior maxillary. Its orbital plate is connected to the sphenoid, ethmoid, and lachrymal bones. Look well into the orbits and see these several connections. They form a continuous suture from one external angular process to the other. This is called the 'transverse frontal suture.'

Ossification.—The frontal bone is developed from two centres, which appear one on each side, in the situation of the frontal eminence, about the seventh week of foetal life. These lateral halves meet and form a vertical suture down the middle of the forehead, termed the 'frontal' suture ; so that in children the two halves of the bone are easily separated. Usually this suture becomes obliterated during the second year ; but sometimes traces of it persist, as seen in the skull Plate XVIII. ; hence the practical rule not to mistake it for a fracture.²⁴

Comparative Osteology.—In some animals, such as the Carnivora (see skull of tiger), the temporal muscle extends so far forwards that there is no room for articulation between the malar bone and the external angular process of the frontal. Thus, in these skulls the temporal fossa and the orbit are not separated by bone as in man. This character runs throughout the Carnivora, Rodentia, Edentata, and Pachydermata. In some animals the air-cells are very numerous and large. Let anyone who, admiring the intelligence of the elephant, imagines him to have a huge brain, put his hand into the foramen magnum of the skull which stands on the pedestal in the Mus. Roy. Coll. Surg. and explore the cranial cavity. He will find that this forms but a small portion of the size of the head. And now looking at the sections of the skulls in the case behind it, he will see that the larger part of the skull is formed by cells or air spaces between the tables of the frontal, parietal, and occipital bones, which often separate the inner and outer tables of the skull to the extent of a foot. These make a vast increase in the size of the skull—an

increase of advantage, however, as it affords additional leverage for those muscles which are inserted into the back of the skull, and raise the massive head, including the trunk, tusks, and jaws. The place to aim at in this animal is just above the root of the trunk, where the case of the brain is not much thicker than a shilling. These sinuses are also well developed in the owl and the giraffe. In the great extinct sloths the upper, back, and side walls of the cranium were thus inflated with air; so that in these instances the brain is protected by a double skull, with air between the two. This modification not only lightened the skull, but protected the brain from the falling trees uprooted for food by these animals.

The horns of animals such as oxen, sheep, and antelopes, consist of a horny sheath supported upon a long mass of bone which grows from the surface of the frontal bone. These horns last the lifetime of the animal, excepting, indeed, in the case of the prong-horned antelope at the Zoological Gardens, which has twice shed its horns (No. 1419). The antlers of the deer consist entirely of bone, and grow from a projection on the frontal bone, and are shed annually: even the Wapiti deer sheds its huge antlers every year, and the extinct Irish elk formed no exception to this rule. Antlers are very vascular, and are covered by a vascular membrane, termed the 'velvet,' until the full growth, when they lose the 'velvet,' and are themselves ultimately shed. The horn of the rhinoceros is simply horny, and has no shaft of bone in its interior.

TEMPORAL BONE.

(PLATE VIII.)

This bone occupies the temples. It is a complicated bone, even on the surface; much more so in its interior, because it includes the organ of hearing. It consists of three parts—a *squamous* portion, situated in the temple; a *mastoid*, forming the little projection behind the ear; and a *petrous*, which contains the organ of hearing, and projects like a wedge into the base of




Fig. 1.

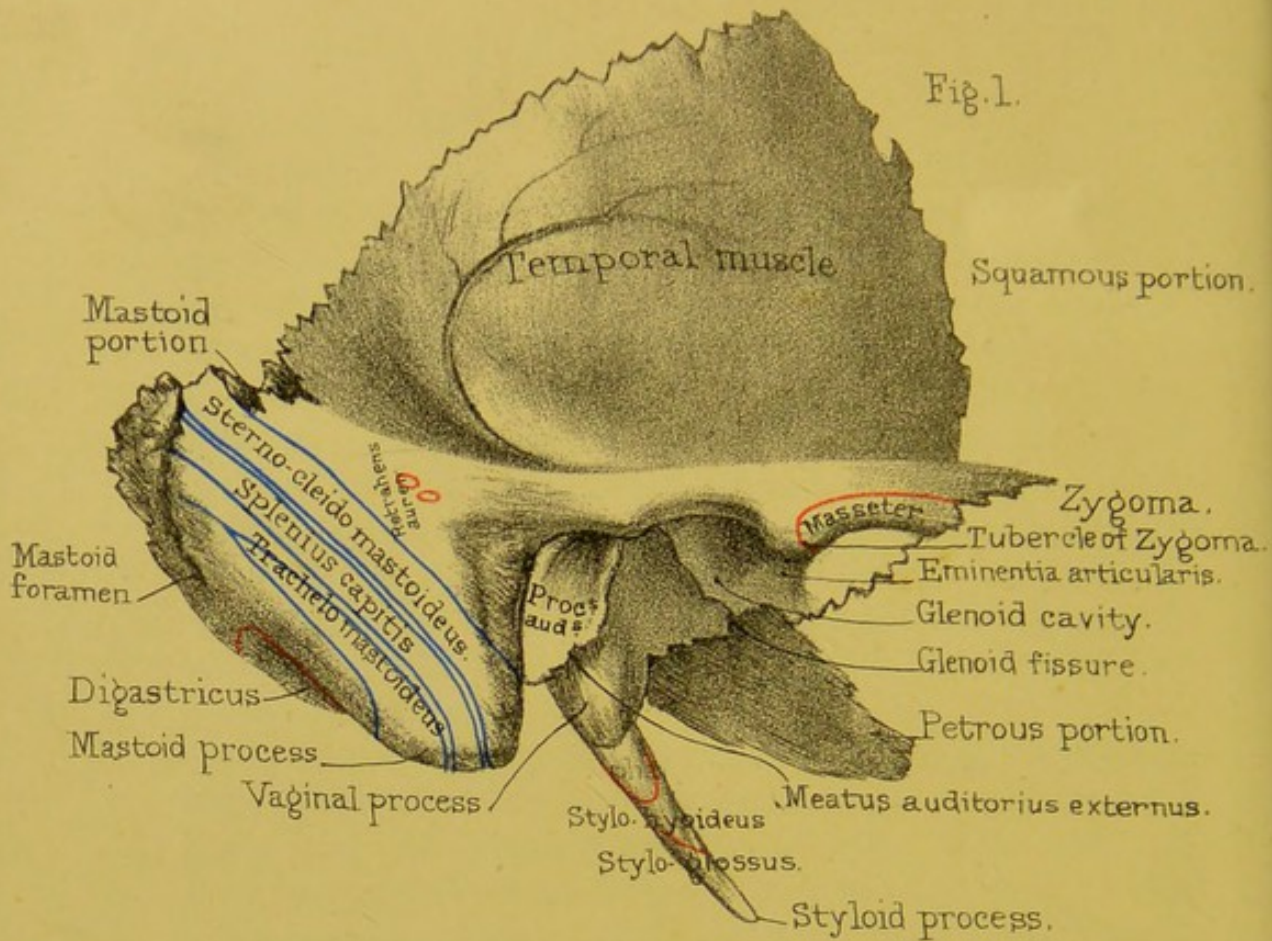
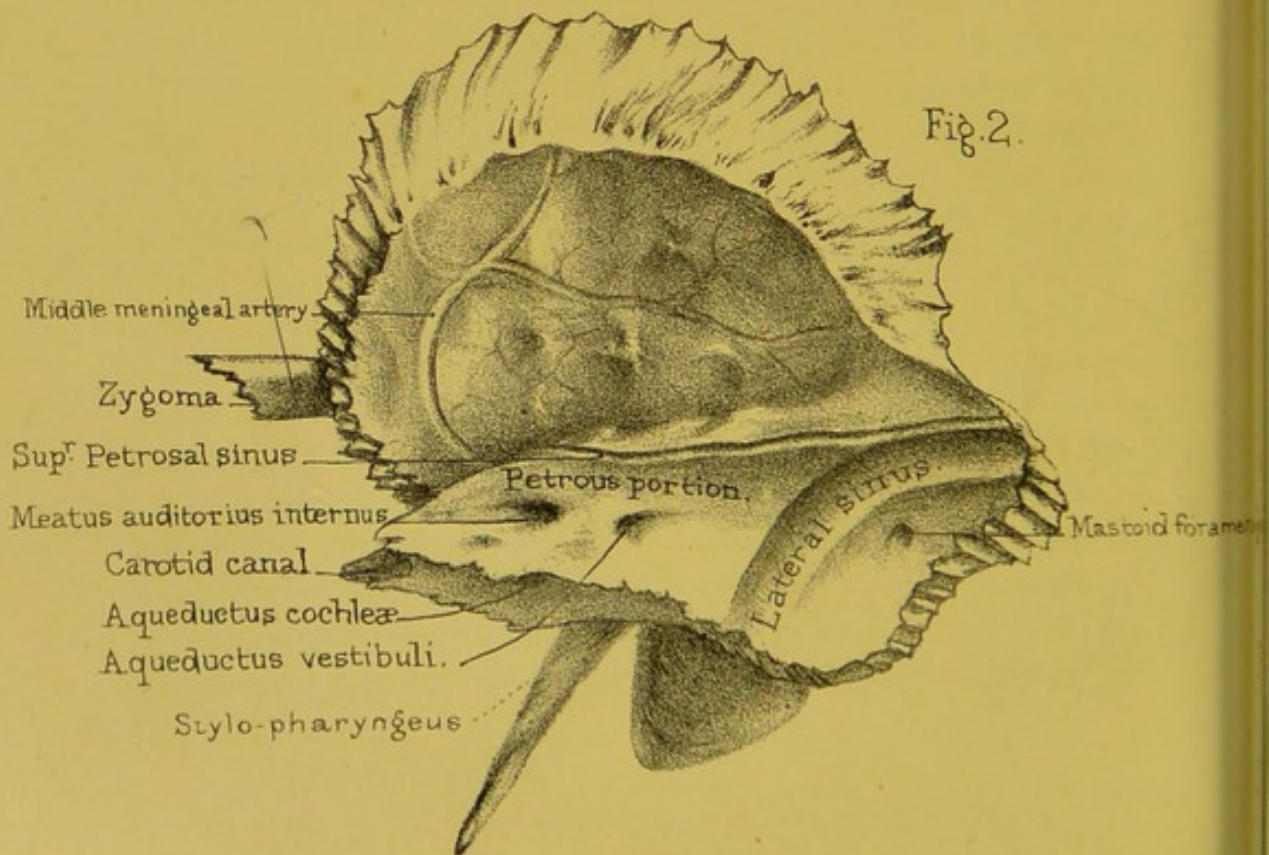


Fig. 2.



Drawn on Stone by T. Godart.

From nature by L. Holden.

Printed by West, Newman & Co.

the skull. This division is very convenient; but the natural divisions of the bone are: (1) the squamo-zygomatic; (2) the periotic, comprising the petrous and mastoid; and (3) the tympanic, or small ring of bone which surrounds the membrana tympani, and by its outward growth comes to form the greater part of the external auditory passage. These parts are separate in the human fœtus, and permanently so in many of the lower animals.

Squamous Portion.—The squamous portion, named from its scale-like appearance, forms part of the wall of the temple. It is very thin; hence the danger of a blow here.

We divide the 'squamous portion' into an external and an internal surface, with a circumferential border.

EXTERNAL SURFACE.—At the lower part of the surface there is an outgrowth of bone, termed the 'zygoma' (*ζύγωμα*, a bolt or bar). It projects horizontally forwards, and can be easily felt on the side of the face. It is connected by a strongly serrated suture, running from below and behind upwards and forwards, to a similar projection from the malar bone; so that the two together form an arch, from whose under border and inner surface the 'masseter' muscle arises, and beneath which the 'temporal' muscle plays. (Plate XV. fig. 2.)

The base of the zygoma is very broad, and appears to spring by two roots inclosing the 'glenoid' cavity, which cavity forms the socket for the lower jaw. At the point of junction of the two roots, there is a tubercle for the attachment of the external lateral ligament of the lower jaw joint.

The *anterior root* is the main one. It is very broad and strong, and forms the front boundary of the glenoid cavity. It is called the 'eminencia articularis,' and near its inner extremity it gives off a rough ridge which passes horizontally forwards to become continuous with a similar rough ridge on the great wing of the sphenoid. The 'eminencia articularis' is crusted with cartilage in the recent state, and forms an additional surface for the play of the lower jaw. Under ordinary circumstances the condyle of the lower jaw is in the glenoid cavity; but while the mouth is opening widely, the condyle can be felt sliding so far forward that the finger can be placed into the socket

behind it. In fits of laughter or yawning, the condyles may be suddenly dragged in front of the articular eminences by the muscles, and then the jaw is dislocated into the zygomatic fossa. Under such circumstances the person presents a very ridiculous appearance, since the mouth remains wide open until the dislocation is reduced.

The *posterior* root runs backwards in the same line as the zygoma, and forms the upper boundary of the glenoid cavity. It then divides into two branches: one, the 'supra-mastoid ridge,' passes over the meatus auditorius externus and then fades away, marking the line of separation between the squamous and mastoid divisions of the bone; the other, short and thick, runs inwards and slightly backwards to terminate in front of the 'Glaserian fissure,' and in front of the 'tympanic plate' of bone, which separates the glenoid cavity from the external auditory meatus. This branch shows a slight process, the 'post-glenoid process,' which affords support to the jaw, and guards against dislocation backwards. The post-glenoid process is generally well marked in African skulls, and always so in the gorilla, the animal which approaches man so nearly. In the negro race, the supramastoid ridge is strongly marked, and is characteristic of a degraded type of skull (see two Tasmanian skulls, Nor. Hum. Ost. Nos. 1096-1097).

Arising by these roots the zygoma passes horizontally outwards, and then twisting upon its axis passes horizontally forwards. The surfaces of the first part are upper and lower, and of the second inner and outer.

The *glenoid fossa* is a deep oval depression, with its long axis directed forwards, outwards, and a little downwards. It is divided into an anterior and external articular portion, and a posterior and internal non-articular portion, by a fissure termed the 'Glaserian fissure,' running inwards and slightly forwards, and indicating the separation between the squamous and tympanic parts of the bone. The part in front of the fissure is the socket for the jaw, and notice that the bottom of this part is exceedingly thin: the part behind it is occupied by a lobe of the parotid salivary gland, and is formed by the 'tympanic and vaginal plates of the temporal

bone. Pass a bristle up the fissure, to see that it leads to the tympanum of the ear. The Glaserian fissure contains the 'processus gracilis' of the 'malleus,' the tympanic artery, and is usually said to transmit the 'chorda tympani' nerve; but this nerve, strictly speaking, runs through a little canal, opening from above and behind into the under aspect of the middle third of the fissure, and termed the 'canal of Huguier.'

Above the zygoma the external surface of the squamous portion is smooth. It is marked by a few grooves for branches of the deep temporal arteries, helps to form the 'temporal fossa,' and gives origin to part of the temporal muscle.

INTERNAL SURFACE.—The internal surface of the squamous portion is marked by the convolutions of the brain, and by a narrow groove which sweeps, in a curved direction, from before backward, indicating the course of the posterior branch of the middle meningeal artery. (Plate VIII. fig. 2.)

CIRCUMFERENTIAL BORDER.—The circumference behind, above, and slightly in front, is thin, sharp, serrated, and very much bevelled at the expense of the inner surface for articulation with the parietal. The greater part of the front is thick, serrated, and somewhat bevelled at the expense of the outer surface for articulation with the great wing of the sphenoid.

Mastoid Portion.—The mastoid portion forms the prominence of bone which is felt behind the ear, and termed the 'mastoid process' (*μαστός*, a nipple). It gives insertion and great leverage to some of the muscles which move the head round. We shall describe it, as we did the squamous part, as having an *external* and an *internal surface* and a general *circumference*.

EXTERNAL SURFACE.—This surface is rough all over, and is prolonged inferiorly into the conical projection called the 'mastoid process.' At the upper and back part of the surface is a hole, called the 'mastoid foramen,' through which a vein runs from the lateral sinus to the outside of the head. This explains why leeches applied behind the ears may help to relieve congestion of the brain. Frequently this foramen is situated in the suture between the mastoid portion and the occipital, and sometimes it is absent altogether. The outer surface of the mastoid portion gives

attachment above and in front to the 'sterno-cleido-mastoid,' below and behind it to the 'splenius capitis,' and below and behind the splenius to the 'trachelo-mastoid' muscle. (Plate VIII. fig. 1.) As one would expect, the mastoid process is much more fully developed in the male than in the female. If a section be made through the process, it is found to contain large and freely communicating cells, termed 'mastoid,' which open into the back part of the middle ear, or tympanum. These cells, like the tympanum itself, contain warm air, which is admitted from the upper part of the pharynx through the 'Eustachian tube.' They not only make the bone light, but are useful to the sense of hearing, by allowing more space for the vibration of the air. They are not developed till the approach of puberty. The mastoid cells, as a whole, are sometimes termed the 'mastoid antrum.'

INTERNAL SURFACE.—The internal surface of the mastoid portion is divided into an *upper*, or *intra-cranial*, and a *lower*, or *extra-cranial*, portion by a narrow serrated surface for articulation with the occipital bone. The *intra-cranial portion* is smooth, presents posteriorly a slightly concave space for the cerebellum, with one or two small grooves on it for posterior meningeal arteries, and anteriorly a half-groove, made a whole one by the junction of a corresponding half-groove on the posterior surface of the petrous portion, for the lodgment of the lateral sinus. In this groove we notice the inner aspect of the mastoid foramen, if it be present. The *extra-cranial portion* is formed mostly by the inner surface of the 'mastoid process,' and presents from above downwards a shallow, smooth, narrow, antero-posterior groove for the occipital artery, and below and outside that a deep, rough, broad antero-posterior one for the attachment of the posterior belly of the 'digastric' muscle.

CIRCUMFERENCE.—Superiorly the circumference runs pretty straight from before backwards, and is thick and serrated for articulation with the parietal bone. Posteriorly and inferiorly it runs downwards and forwards, and is slightly serrated for articulation with the occipital bone. Anteriorly and internally the mastoid portion is continuous with the petrous part. The point

of meeting of the superior-posterior angle of the mastoid portion with the lateral angle of the occipital and the posterior-inferior angle of the parietal we call the *asterion*.

Petrous Portion.—The ‘petrous portion’ derives its name from the hardness of its constituent bone (*πέτρος*, a rock). It projects from behind forwards, inwards, and slightly upwards into the base of the skull (Plate XIX.), and so carries far out of harm’s way the delicate organ of hearing which it contains. Its shape is like a triangular pyramid with the apex inwards; so that, for descriptive purposes, it may conveniently be divided into *three surfaces*—an *anterior*, a *posterior*, and an *inferior*: *three borders*—*anterior*, *superior*, and *posterior*: then there is a *base* and an *apex*. Our best plan is to examine each of these parts separately, that we may be able to answer the question, what is seen on the anterior, what on the posterior surface, and so forth. Take the *base* first.

BASE.—At the base of the petrous portion is the orifice of the passage to the ear, termed the ‘meatus auditorius externus.’ It is situated immediately behind the glenoid cavity, and its boundaries are chiefly formed by a curved plate of bone, called the ‘processus auditorus,’ or ‘tympanic plate.’ Observe, first, that the edge of it is very jagged, for the attachment of the cartilage of the ear; and then look carefully down the passage to see that this curved plate of bone forms its boundary wall all round, except at the uppermost part. This inspection will probably suggest that the whole plate is something superadded to the rest of the bone—a sort of after-growth; which is precisely the case. In the fœtus there is no meatus, but simply a ring of bone forming three-fourths of a circle, the deficiency being at the upper part. This ring is ossified independently about the third month, is quite distinct from the other parts, and to it is attached the membrane of the drum of the ear (*membrana tympani*); so that at this early period it might be rudely compared to a hoop with a membrane stretched across it. In many animals this remains permanently a distinct bone, under the name of the ‘tympanic bone.’ (Plate XVIII. fig. 5.) In process of time, however, the hoop begins to grow out on its external side, and

thus becomes a canal or meatus, which, as it grows longer, gradually coalesces with the other constituents of the bone, and runs forwards and inwards.

Respecting the shape of the passage, observe that it is oval, with the long diameter directed downwards and backwards; therefore all specula used for examining the ear ought to be of the like shape. The narrowest part of the passage, in the recent state, is about the middle; hence if a foreign body, such as a pea, happen to get into the ear, it is generally pushed through the narrow part by clumsy efforts to extract it, and then the moisture of the ear causes it to swell, and makes its extraction most difficult and painful. In its course the external auditory canal is slightly arched upwards and backwards as it passes forwards and inwards. It is limited at its inner end by the 'membrana tympani,' which is attached to it in such a way that it strikes the anterior and inferior walls of the passage at an angle of 45° ; therefore the longest part of the external auditory canal is the line of junction between its anterior and inferior walls.

APEX.—The apex of the petrous portion is cut obliquely, so as to articulate by a slightly serrated surface with the side of the basilar portion of the occipital bone, and to bound the 'foramen lacerum medium' behind and outside. It presents the anterior opening of the 'carotid canal.'

ANTERIOR SURFACE.—The anterior surface (Plate IX. fig. 2) of the petrous portion forms part of the middle cerebral fossa, and bears cerebral impressions and small grooves for meningeal arteries. About the middle of it is a smooth eminence running forwards and outwards, indicating the position of the 'anterior semicircular canal' (a part of the internal ear). Anterior and internal to this is an elevation with a depression in front, corresponding to the roof of the middle ear or 'tympanum.' More forward is a small furrow leading backwards and outwards to an opening termed the 'hiatus Fallopii' for the passage of the 'great superficial petrosal' nerve. Immediately to the front and the outside of this is a smaller furrow and opening which give passage to the 'small superficial petrosal' nerve. Near

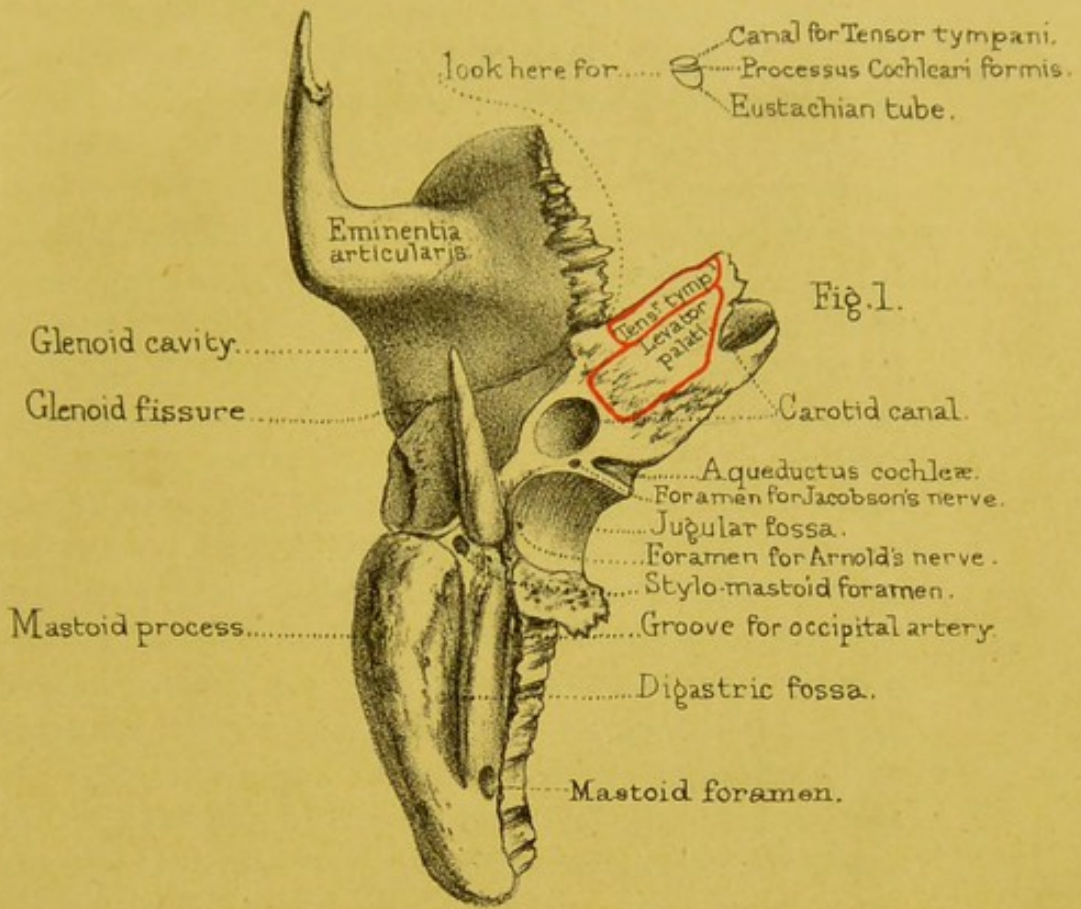
the apex is a depression for the 'Gasserian ganglion,' and in front, and external to this, is the irregular upper opening of the 'carotid canal.' In most bones, at the line of union between this surface and the inner surface of the squamous portion, one sees the remains of the suture between the petrous and squamo-zygomatic parts of the bone.

POSTERIOR SURFACE.—The posterior surface of the petrous portion forms part of the posterior fossa of the base of the skull. It looks backwards, inwards, and upwards. (Plate XIX.) The most prominent object upon it is the 'meatus auditorus internus' (Plate VIII. fig. 2), a large canal which runs nearly horizontally outwards and transmits the 'seventh' nerve, which consists of the auditory nerve (portio mollis), and the motor nerve of the face (portio dura), with the pars intermedia of Wrisberg. It also transmits the auditory artery, a branch of the basilar. The meatus is much larger than the nerves which it transmits, the space between them and the bony canal being filled by a fluid (cerebro-spinal), which surrounds and supports the brain. In fractures through the base of the skull involving the meatus, the fluid sometimes oozes out through the external ear: this, therefore, is regarded as a very grave symptom in cases of injuries to the head. A transverse section near the bottom of the meatus would show that it is divided by a small ridge of bone into two unequal parts, as seen in Plate LVIII. In the upper and smaller of the two is the commencement of a special canal (aquæductus Fallopii) for the motor nerve of the face; in the lower there are several minute apertures arranged in a spiral form. About a quarter of an inch behind the meatus is a slit-like opening which looks backwards, and is termed the '*aquæductus vestibuli*.' This, though about a quarter of an inch long, soon contracts so much that it will barely admit a bristle. It leads to the vestibule of the internal ear. Between these two openings, and just under cover of the upper border, is a small hollow, with a little opening at the bottom, for the transmission of a process of dura mater and a small vein. Below the meatus auditorius internus we frequently see part of the '*aquæductus cochleæ*,' better, however, seen on the inferior surface, and

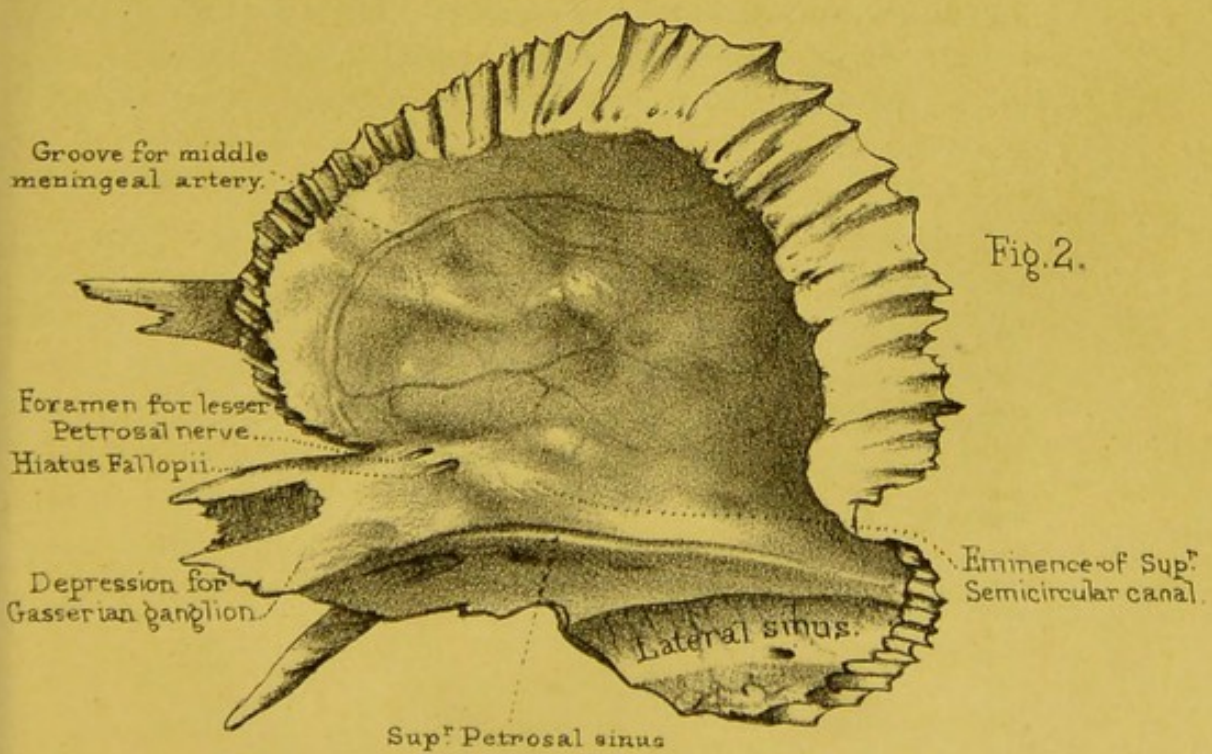
leading into the cochlear part of the internal ear. Externally we notice a smooth half-groove, made into a whole one by the fusion of the corresponding half-groove upon the mastoid portion, for the transmission of the lateral sinus.

INFERIOR SURFACE.—The inferior surface of the petrous portion presents an irregular aspect, and has many holes in it. (Plate IX. fig. 1.) Beginning near the base, notice, first, the ‘auricular fissure’ separating the processus auditorius from the mastoid process, and transmitting a small blood-vessel; next the ‘styloid process,’ so called from its resemblance to an ancient ‘style’ or pen. It is, originally, distinct from the rest of the bone, but gradually has coalesced with it by the end of the third year. This long ‘process’ descends with a slight inclination forwards, and gradually tapers to a sharp point. Its length varies in different skulls: generally it is about half an inch long. In old skulls it is sometimes longer: there is a skull in the museum of St. Bartholomew’s Hospital which has a styloid process three inches long. It gives origin to three muscles and two ligaments. The muscles are for the movement of the tongue and pharynx; they arise as follows: the ‘stylo-pharyngeus,’ from the inner side of the base; the ‘stylo-hyoideus,’ from the posterior side of the base; and the ‘stylo-glossus,’ from the front of the process. (Plate VIII. fig. 1.) To the tip itself is attached the ‘stylo-hyoid ligament,’ which runs downward and forward to the lesser cornu of the os hyoides. The other ligament attached to the process is the ‘stylo-maxillary,’ which separates the sub-maxillary from the parotid gland. Lastly, the fore part of the root of the styloid process is surrounded by a kind of bony sheath, termed the ‘vaginal process,’ about which there is nothing to be remarked except that it is a continuation of the plate of bone which forms the hinder part of the glenoid cavity.

Between the mastoid and the styloid processes is a hole termed the ‘stylo-mastoid foramen.’ (Plate IX. fig. 1.) It gives exit to the motor nerve of the face (portio dura), which entered the bone at the meatus auditorius internus. The stylo-mastoid artery, a branch of the posterior auricular, enters at the foramen of the same name, and supplies the tympanum. If you intro-




TEMPORAL BONE.



Drawn on Stone by T. Godart.

From nature by L. Holden

Printed by West, Newman & Co.



duce a stiff bristle into the hole, you will probably succeed in passing it through the bony canal traversed by the nerve from its entrance to its exit. The canal is a complete tube of bone, called the 'aqueductus Fallopii' ²⁵ after the anatomist who first described it. (Plate LVIII.) The passage of this nerve through the temporal bone renders it liable to be injured in fractures of the base of the skull, or in disease of the ear; and this explains the paralysis of one side of the face which sometimes occurs under these circumstances. On the inner side of the stylo-mastoid foramen is a four-sided, articular, and slightly serrated surface for articulation of the upper surface of the jugular process of the occipital bone, and called the 'jugular surface.' In front of this is a deep smooth depression, termed the 'jugular fossa.' This, with a corresponding part of the occipital bone, forms the 'foramen lacerum posterius.' (Plate XX.) Here the lateral sinus pours its blood into the commencement of the internal jugular vein, which forms a great bulge and fills the fossa. Here also the glosso-pharyngeal, pneumogastric, and spinal accessory nerves leave the skull (through a notch, it may be a foramen, in the front of the foramen lacerum; and here, one of the posterior meningeal arteries, a branch of the ascending pharyngeal (perhaps also a branch of the occipital) enters it, and the inferior petrosal sinus leaves it. On the outer wall of the jugular fossa, near the root of the styloid process, we find the minute foramen which transmits the auricular branch of the pneumogastric or Arnold's nerve. Anterior and internal to the jugular notch is the large circular commencement of the canal in the petrous bone, through which the carotid artery enters the skull ('carotid canal'). The canal mounts nearly perpendicularly for a short distance, and then, turning forwards, upwards, and inwards, emerges at the apex of the bone. At the bend between the vertical and horizontal portions of the carotid canal, and situated on its upper wall, we see a small foramen for the smallest petrosal nerve. On the plate separating the jugular notch from the carotid canal is a minute hole, which transmits the tympanic branch of the glosso-pharyngeal ('Jacobson's nerve'). Anterior and internal to the jugular notch, and close to the posterior border of the petrous portion, is a

wide-mouthed foramen, sometimes partially seen on the posterior surface of the petrous bone, and which is the lower opening of the 'aqueductus cochleæ,' a canal leading into the cochlear portion of the internal ear. Near the apex is a rough surface, which gives origin, close to the anterior border, to the 'tensor tympani,' and in the rest of its extent, to the 'levator palati.'

ANTERIOR BORDER.—This is partly free and partly attached. The attached part is continuous with the squamous portion, perhaps showing the remains of a suture indicating their original separation. The free portion runs forwards and inwards, is slightly serrated, and articulates with the great wing of the sphenoid bone. If we look at the angle between this free part and the adjacent serrated border of the squamous part, we shall observe two tubes running backwards and outwards parallel to each other, like a double-barrelled gun (except that they lie one above the other): they both lead to the tympanum. The upper of the two is the canal for the 'tensor tympani' muscle; the lower, which is by far the larger, is the 'Eustachian tube,' or the passage which conveys the air from the pharynx to the tympanum. The thin partition which separates the two barrels is called the 'processus cochleariformis.' Just below the lower barrel is the anterior end of the Glaserian fissure.

The **SUPERIOR BORDER** has a smooth narrow groove running along it for the superior petrosal sinus.

The **POSTERIOR BORDER** presents, from behind forwards, the lower end of the groove for the lateral sinus, next the posterior and internal border of the surface for articulation with the jugular process of the occipital, next the similar part of the jugular notch, next, perhaps, part of the lower opening of the aqueductus cochleæ, next a smooth half-groove, made a whole one by the apposition of a corresponding one on the occipital bone, and lastly, parallel with the last, a rough serrated articular surface for articulation with the basilar portion of the occipital bone.

In the recent state, the 'meatus auditorius externus' has its inner end closed by a membrane, 'membrana tympani,' on the inner side of which is a six-sided air chamber, called the 'tympanum.' It contains a series of ossicles, 'ossicula auditus'

(Plate LVIII.), whose duty it is to convey the oscillations of the membrana tympani to the fluid lying in a complicated cavity, the 'bony labyrinth,' situated in the petrous portion of the temporal bone.

Cavity of the Tympanum.—This is an irregular cube flattened from within outwards (narrowest below), and presenting, accordingly, external, anterior, posterior, superior, inferior, and internal walls or surfaces.

The *external surface* is formed by the membrana tympani, and near its upper border in front are small openings for the chorda tympani nerve and the processus gracilis of the malleus.

The *anterior surface* shows a large opening below, the 'Eustachian tube,' by which air can pass in and out from the pharynx; and above, a thin-walled channel with an orifice at its extremity for the passage of the 'tensor tympani' muscle.

The *posterior surface* presents openings leading into the air-filled cells of the mastoid process.

The *superior surface* is smooth—the bone forming it is very thin, and in cases of suppurative inflammation of the tympanum presents little impediment to the extension of the inflammation to the parts above.

The *inferior surface* is the narrowest of all, and shows no features of importance.

The *inner surface* shows an upward extension of the tympanum separated by very thin bone from the cavity of the cranium. At the lower border of this extension is a thin layer of bone which divides the tympanic chamber from the 'aqueductus Fallopii.' Below this is an oval opening, the 'fenestra ovalis,' to the border of which the base of the stapes is attached by ligament. In front of this fenestra, and projecting outwards into the tympanum, is the canal in which the 'tensor tympani' is lodged. Behind is a conical eminence, the 'pyramid,' in which arises the 'stapedius' muscle, a small opening at the extremity of the eminence giving passage to its tendon. Below and a little behind the fenestra ovalis is the 'fenestra rotunda,' closed in the fresh state by membrane. It is partially concealed by the backward projection of an anterior lip of bone, which is continuous with a

rounded projection in front, called the 'promontory.' The surface of the promontory is marked by grooves for the tympanic plexus of nerves.

Ossicula Auditûs.—Of these there are three, viz. MALLEUS, INCUS, and STAPES. See Plate LVIII.

MALLEUS.—This bone is attached by its two processes, 'processus brevis' and 'longus,' to the membrana tympani. A slender process, 'processus gracilis,' projects downwards, inwards, and forwards, at right angles to the latter. It is lodged in the Glaserian fissure, but is commonly atrophied and lost in early life. Above these processes is the 'neck,' to the posterior surface of which, at its junction with the 'processus longus,' the 'tensor tympani' is attached. The neck expands above into a subglobular head, directed upwards, and elongated from before backwards. The external and posterior sides of the head articulate with two converging articular facets upon the anterior surface of the incus.

INCUS.—This bone presents a broad, backwardly directed process, the 'processus brevis,' which has a minute notch on its inner border near its posterior extremity. At right angles to the processus brevis the 'processus longus,' having a slightly sigmoid curve, passes downwards and inwards. Its inner extremity turns abruptly upwards, and is continuous with a small rounded nodule of bone, called the 'os orbiculare,' which small nodule is flattened from above downwards and articulates with the head of the stapes.

STAPES.—This appropriately named bone consists of a 'head,' bearing a shallow concave articular surface inferiorly for articulation with the os orbiculare of the incus. On the posterior surface of the head a small bony process gives insertion to the 'stapedius' muscle. From the head spring two 'crura,' hollowed out on their apposing surfaces, the 'anterior crus' being slender, the 'posterior' more robust, and showing a knee-like thickening at one point. The 'base' is borne by the upper extremities of the crura, and fits into the fenestra ovalis on the inner wall of the tympanum. It is oval in form, but its inner or inferior border is nearly straight. The anterior extremity of

the base is frequently more pointed than the posterior, and the surfaces are slightly concave in the centre, with an elevated and rounded circumferential border.

Bony Labyrinth.—This highly complicated chamber lies concealed in the substance of the petrous portion of the temporal bone. At birth its walls are formed by a special thin layer of bone, having the vascular and foetal bone surrounding it. At this period, with care, the porous bone can be removed from the proper wall of the labyrinth, so that the form of the latter may be distinguished. (See Plate LVIII.) In adult life, the great density of the petrous bone renders this impossible. Its form is closely adapted to that of a membranous bag, the ‘membranous labyrinth,’ which is lodged in its interior, and is surrounded by fluid over the greater part of its surface. On certain parts of this bag the auditory nerve is distributed.

If such a bony labyrinth be examined from its inner surface (Plate LVIII.), it will be seen to consist of three parts, viz. (1) a central irregular chamber, the ‘*vestibule*,’ (2) *three* ‘*semi-circular canals*’ and the ‘*common canal*’ connected with the roof of the vestibule, (3) in front a snail-shell-like chamber, the *cochlea*.

The VESTIBULE shows on its inner surface in front two bulgings corresponding with depressions of its interior. The upper of these is the ‘*fovea hemi-elliptica*,’ and lodges the dilated anterior extremity of a part of the membranous labyrinth, the ‘*recessus utriculi* ;’ the lower is the ‘*fovea hemispherica*,’ and is occupied by the ‘*sacculus*’ part of the same bag. A ridge of bone, ‘*crista vestibuli*,’ separates these two depressions.

Above the vestibule are the three ‘SEMICIRCULAR CANALS,’ best named *anterior*, *posterior*, and *horizontal*. They lie in the three sides of a cube, and each has at one extremity a dilatation called the ‘*ampulla*.’ These bony canals contain portions of the membranous labyrinth, having similar names. The posterior extremity of the anterior canal and the anterior extremity of the posterior one open into a larger tube, spoken of as the ‘*common canal*.’ This common tube lodges a part of the membranous labyrinth, best considered as the ‘*sinus superioris utriculi*.’ In the

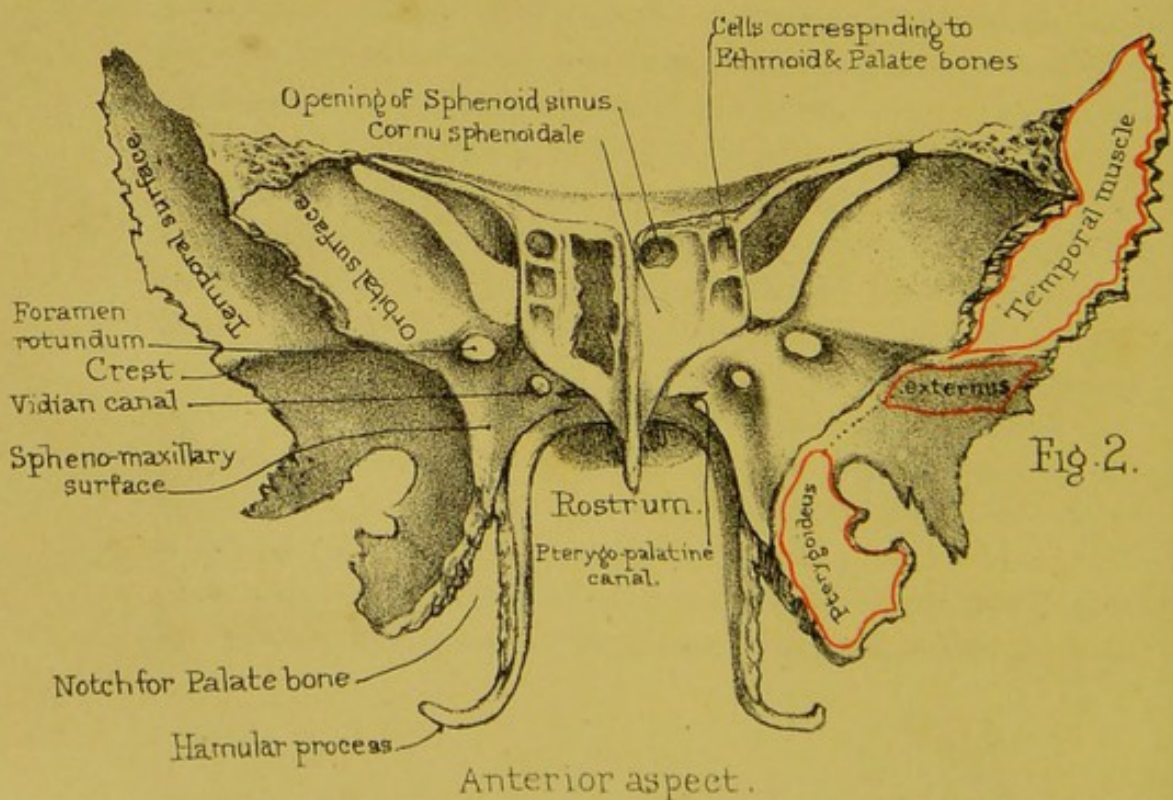
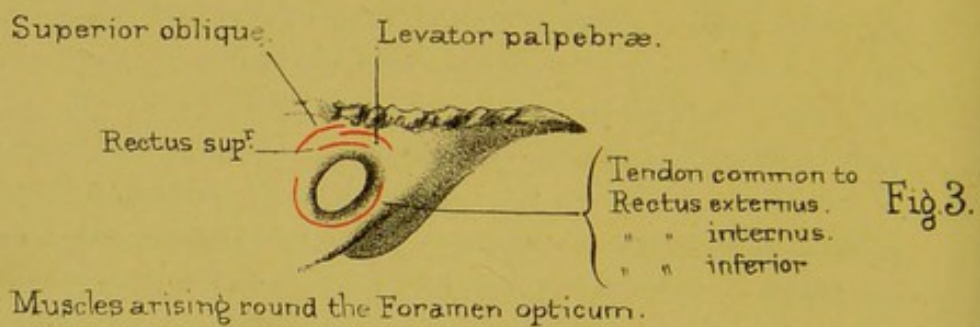
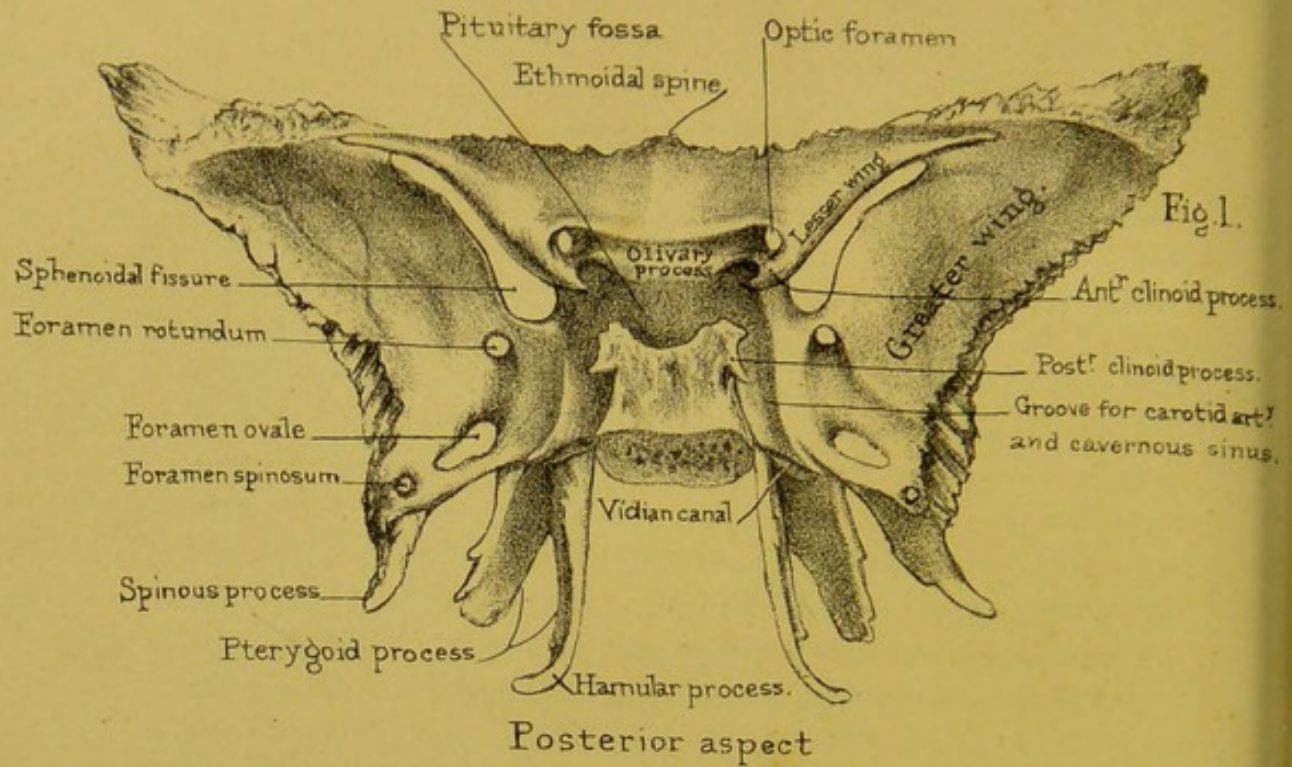
inner wall of the common canal is a minute passage, the 'aqueductus vestibuli,' opening below into the vestibule, and above into the cranial cavity. This aqueduct contains a blood-vessel and an exceedingly delicate tube, 'ductus endolymphaticus,' which terminates above in a blind and somewhat dilated extremity, the 'saccus endolymphaticus,' and below divides into two branches, of which one opens into the 'sacculus,' and the other into the 'utriculus.' The ductus endolymphaticus is interesting, as it is the remains of the inpushing of the outer surface of the embryo, from which the epithelial lining of the membranous labyrinth is derived.

The COCHLEA forms a spiral of two turns and a half round a hollow bony axis, the 'modiolus.' The axis is directed outwards, forwards, and slightly downwards in a plane parallel to that of the anterior semicircular canal. The commencement of the cochlea, as it bulges outwards into the tympanum, contributes to the formation of the promontory. A bony plate, the 'lamina spiralis ossea,' attached to the modiolus, partially divides the cavity of the cochlea into two passages, the division being completed in the fresh state by a membrane, called the 'lamina spiralis membranacea vel membrana basilaris.' The posterior of these passages is the 'scala tympani,' which would open into the tympanic cavity, in the fresh state, at the fenestra rotunda, if that opening were not closed by membrane. The anterior passage is divided by membrane, the 'membrane of Reissner,' into two; and of these the one nearest the modiolus is known as the 'scala vestibuli,' and opens into the vestibule; the other, farthest from the modiolus, is called the 'scala media,' or 'ductus cochleæ.' The scala media terminates in a blind end at the top of the cochlea, whilst in the vestibule it is continuous with the sacculus by means of a fine tube, named the 'canalis reuniens.' At the apex of the cochlea the 'scala vestibuli' and the 'scala tympani' communicate by a small hole, the 'helicotrema,' and at the same place the osseous lamina terminates in a hook-like process, termed the 'hamulus,' these parts being concealed beneath the dome-like apex or 'cupola.'

Connections.—The temporal is connected with five bones.

The squamous portion is connected to the parietal bone and the great wing of the sphenoid by the 'temporo-parietal' and 'temporo-sphenoidal' sutures respectively, concerning which the following mechanism must be noticed; namely, that the squamous part overlaps the parietal above, but is itself overlapped by the sphenoid below—an arrangement which greatly contributes to the security of the arch of the skull. The mastoid part is connected, above, to the posterior inferior angle of the parietal by the 'masto-parietal' suture, and, behind, to the occipital by the 'masto-occipital' suture. The petrous part is wedged into the base of the skull between the sphenoid and occipital bones. (Plate XIX.) The zygomatic process is connected to the malar bone by a strong suture, the 'zygomatic,' which slopes downwards and backwards. Lastly, the glenoid cavity articulates with one of the condyles of the lower jaw. In the living subject, an inter-articular fibro-cartilage, lined above and below by synovial membrane, separates the two articular surfaces, and protects this part of the skull from the effects of a blow under the lower jaw.

Ossification.—The development of the temporal is somewhat complicated. It is divided into the following parts: a squamo-zygomatic, a tympanic, and a petro-mastoid. The *squamo-zygomatic* starts from a nucleus of ossification which appears in membrane at the lower part of the squamous portion and extends outwards to form the zygomatic portion. The squamo-zygomatic part joins the petro-mastoid, which we shall presently describe, during the first year. The *tympanic ring* grows from a nucleus which appears in the membranous outer wall of the tympanum inferiorly in the third month, and which extends upwards to form an imperfect ring (wanting above) affording attachment to the membrana tympani. The upper ends of the ring are ossified to the squamo-zygomatic portion just before birth. The *petro-mastoid* or *periotic* has several nuclei appearing in cartilage, and which Huxley arranges in the following way: (1) 'prootic,' forming upper parts of petrous and mastoid portions with most of the bony internal ear; (2) 'opisthotic,' forming the lower part of the petrous, and most of the walls of the middle



Notice the immense zygomatic arch in the skeleton of the manatee. (No. 2729.)

In all the Mammalia, and in them alone, the lower jaw articulates directly with the temporal bone. By referring to No. 12 in the Nor. Hum. Ost. the tympanic bone and membrane in the foetus may be seen at the base of the skull. The fissura Glaseri is open widely, and the processus gracilis of the malleus lies in it. In all Mammalia the malleus remains very small and becomes cut off from the glenoid cavity by the outgrowth of the tympanic bone; but in birds (see Sep. Ser.) the malleus becomes largely developed, projects between the squamous and tympanic bones, and, under the name of 'quadrate bone,' comes to support and form the articulation for the lower jaw.

SPHENOID BONE.

(PLATES X. XI.)

Constituent Parts.—The sphenoid bone is so called because it is wedged in at the base of the skull between all the other bones of the cranium (*σφήν*, a wedge, *εἶδος*, form). As it not only enters into the formation of the base of the skull, the orbits, the temples, and the nasal passages, but is connected with all the bones of the cranium, and many of those of the face, one cannot be surprised that it is a difficult bone to understand. Fortunately, it bears a remarkable resemblance to a bat with extended wings; so that we can shape our description accordingly. It presents, then—1. A body, or central part; 2. The two greater wings; 3. The two lesser wings; 4. The pterygoid processes, which make the two legs of the bat.

Body: SIX SURFACES.—Commencing with the body, we must examine its six surfaces—a 'superior' and an 'inferior,' an 'anterior' and a 'posterior,' and two 'lateral.'

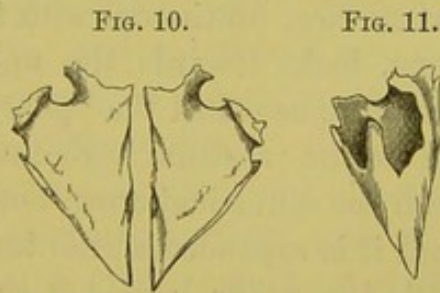
The SUPERIOR SURFACE of the body (Plate X. fig. 1) comprises what is seen of the body on the inside of the base of the skull. There is a deep depression in it, termed the 'pituitary fossa,'

which lodges the 'pituitary' body.²⁶ Another name given to it is the 'sella turcica,' from its resemblance to a Turkish saddle. In front of it is an eminence, termed the 'olivary process,' from its olive-like shape. This process supports the commissure of the optic nerve which makes a slight transverse groove (the 'optic groove') upon it, leading on each side to the 'optic foramen' through which the nerve enters the orbit. In front of the olivary process is a smooth and slightly concave surface, which supports the olfactory lobes, and terminates, in front, in the middle line in the 'ethmoidal spine,' which articulates with the ethmoid bone. Each side of the surface is more or less distinctly marked by a broad groove which winds upwards in a gentle curve, and lodges the internal carotid artery as it passes through the 'cavernous sinus,' after entering the skull. In some bones a little tubercle, called the 'middle clinoid process,' rises from the side of the groove. In some skulls this tubercle is long enough to unite with the apex of the anterior clinoid process, so that the artery, in emerging from the groove, passes through a ring of bone. The anterior and posterior clinoid processes give attachment to the 'tentorium cerebelli.' The pituitary fossa is bounded behind by a square plate of bone, which, as it represents the back of the saddle, is termed the 'dorsum sellæ.' The corners of the plate project and form what are called the 'posterior clinoid processes,' thus named from their fancied resemblance to bedposts. These are directly opposite to the 'anterior clinoid processes,' of which we shall speak presently. The posterior surface of the plate slopes very obliquely backwards, is continuous with the basilar process of the occipital bone, and forms an inclined plane which supports the 'pons varolii.' Lastly, in the side of the plate there is generally a notch which transmits the sixth nerve.

The POSTERIOR SURFACE of the body is connected with the basilar process of the occipital bone, in young subjects by cartilage, in older ones by bone, so that after twenty-one or twenty-two it is impossible to separate the 'basilar suture' without the saw. The section shows well the structure of this part of the base of the skull; namely, two layers of compact tissue separated by about $\frac{3}{10}$ of an inch of cancellous, with a thin layer of com-

compact bone forming the side walls. Thus the bone is light, and shocks transmitted to the base of the skull are broken. (Plate XI. fig. 1.)

ANTERIOR SURFACE.—The anterior surface of the body (Plate X. fig. 2) fits the posterior part of the ethmoid bone. It presents in the middle line a perpendicular ridge termed the 'sphenoidal' or 'ethmoidal crest' for articulation with the posterior border of the vertical plate of the ethmoid. It forms part of the bony septum of the nose, and terminates below in the anterior end of the 'rostrum' for articulation with the vomer, as may be seen in Plate XXIII. fig. 1. On each side of this is a smooth surface helping to make the roof of the nasal fossa. In the upper part of each of these smooth surfaces is a rounded opening leading into the sphenoidal sinus, and external to each is an irregular serrated surface for articulation with the posterior surface of the lateral mass of the ethmoid and orbital process of the palate bone. The surface of bone we have described on each side of the ethmoidal crest is made by two plates, one on each side, termed the '*cornua sphenoidalia*,' or 'sphenoidal turbinated bones.' Although apparently integral parts of the sphenoid, yet these little bones are formed each from a special centre of ossification, distinct in early life, and remain separable till adult age. The annexed drawing (fig. 10) shows the '*cornua sphenoidalia*' removed in a perfect state. The rostrum of the sphenoid would fit into the gap between them. Each cornu is triangular with the apex downwards. Each completely walls in the sphenoidal cell of its own side, except at the upper part, where there is a round opening in the base of the cornu which admits air from the upper meatus of the nose.



CORNUA SPHENOIDALIA.

Fig. 11 represents one of the cornua seen from the surface towards the sphenoidal cell. It shows the thin scales of bone which project into the cell and assist in lining its walls. However, it is right to state that these *cornua sphenoidalia* are rarely met with perfect. In consequence of their coalescence with the

sphenoid, ethmoid, and palate bones, they are generally broken in the process of separation, so that there appears in most sphenoid bones a large irregular hole leading into the cell; as shown on one side of Plate X. fig. 2. Next come the 'sphenoidal cells' or sinuses. These are large air-cavities in the body of the sphenoid, generally two in number, and separated by a more or less complete perpendicular partition. (Plate XXIII. figs. 1 and 2.) Like the other air-cells in the bones of the skull, they are not developed in young subjects; but in the adult they gradually become large enough to excavate the whole body of the bone. The air is admitted freely into them from the upper meatus of the nose through an opening in the front wall of each sinus; and they are lined with a prolongation from the nasal mucous membrane. This communication of the sphenoidal cells with the nasal cavities explains how bleeding from the nose may occur as a symptom of fracture through the base of the skull—that is, through the body of the sphenoid. Lastly, the sides of the anterior surface of the body are hollowed out into two or three small air-cells, one below the other. (Plate X. fig. 2.) Of these, the upper, one or more, are roofed by the posterior cells of the lateral mass of the ethmoid; and the lower by the cell or cells in the orbital process of the palate bone.

The INFERIOR SURFACE of the body (Plate XI. fig. 1) assists in forming the roof of the nasal fossa; and the posterior part of the surface, continuous with the 'basilar surface' of the occipital bone, looks towards the upper part of the pharynx, and may therefore be called the 'pharyngeal surface.' In the middle line we see the 'rostrum' prominent anteriorly where it is continuous with the ethmoidal crest, but fading away posteriorly. Observe that it is expanded a little towards its base, and that it articulates with the upper border of the vomer. The mode of connection is rather singular. The rostrum fits into a deep cleft between the two plates or 'wings' of the vomer, and thus serves as a foundation from which this bone passes forwards and forms the septum of the nose. But the chief thing to notice on this surface is a process or scale of bone which projects horizontally inwards, on each side, from the base of the internal pterygoid plate. These

are termed the 'vaginal plates,' and their free edges rise enough to allow the alæ or wings of the vomer to slide underneath them. Lastly, each of these plates is traversed by a small groove, made into a canal by the adjacent alæ of the vomer and the sphenoidal processes of the palate, and termed the 'pterygo-palatine groove,' and in the completed state 'canal,' for the passage of the pterygo-palatine vessels and nerve.

LATERAL SURFACES support at their anterior and superior angles the 'lesser wings,' each by two roots with the 'optic foramen' between, and at their posterior and inferior angles the common roots of the 'greater wings' and 'pterygoid processes.' Between the lesser and greater wings, on each lateral surface, we have the smooth base of the 'sphenoidal fissure,' and at the line of junction of the lateral surface with the upper surface of the body we have the groove for the cavernous sinus already described.

Lesser Wings.—The lesser wings (or orbito-sphenoids) project transversely from the upper part of each side of the body. (Plate X. fig. 1.) Their UPPER SURFACE is smooth and flat, and supports the frontal lobe of the brain; their LOWER SURFACE, also smooth, overhangs the sphenoidal fissure, and forms the back part of the roof of the orbit; hence they are sometimes called the 'orbital wings.' Their ANTERIOR borders are serrated, and articulate with the orbital plates of the frontal bone; their POSTERIOR borders are free, and in life fit into the fissure of Sylvius. Their bases are traversed by the 'optic foramina,' through which pass the optic nerves and ophthalmic arteries into the orbit, and to the circumferences of which, anteriorly, muscles are attached as shown in Plate X. fig. 3. The optic 'foramen' should be described rather as a short 'canal' directed outwards and forwards. Towards the 'sella turcica' each wing projects, considerably, in the form of a blunt angle, termed the 'anterior clinoid process;' and between this and the body of the sphenoid there is either a deep notch or a complete ring for the internal carotid artery.

Greater Wings.—The greater wings, sometimes called the 'temporal wings' or 'alisphenoids,' project from the lower and back part of each side of the body in common with the 'pterygoid

processes.' Starting from the body, each great wing runs nearly horizontally outwards and then somewhat suddenly bends upwards. It also extends back as a sharp projection called the 'spine of the sphenoid,' which fits into the retiring angle between the squamous and petrous portions of the temporal, and gives attachment inferiorly to the internal lateral ligament of the lower jaw, the 'tensor palati' and 'tensor tympani' muscles. Each wing presents three surfaces, viz.: SUPERIOR or INTRA-CRANIAL, INFERIOR or EXTRA-CRANIAL, and ANTERIOR or ORBITAL.

The SUPERIOR or INTRA-CRANIAL SURFACE is concave in every direction, and presents a number of well-marked eminences with intervening depressions for the sulci and convolutions of the temporo-sphenoidal lobe of the brain. It is marked, also, by grooves for meningeal arteries, especially superiorly and inferiorly. We may sometimes see on the surface, in the neighbourhood of the sphenoidal fissure, and of the root of the wing, a few pits for Pacchionian bodies. Situated in a line, running forwards and inwards from the spinous process to the inner end of the sphenoidal fissure, are a number of foramina. Firstly, piercing the spinous process is the 'foramen spinosum' for the passage of the 'middle meningeal artery.' This foramen will just admit the blunt end of an ordinary surgical probe. Secondly, we see the 'foramen ovale' with the long axis of the oval directed forwards and inwards, and measuring about a quarter of an inch in this axis. This hole transmits the third division of the fifth nerve, the small meningeal artery, and two or three emissary veins carrying blood from the cavernous sinus to the venous plexus situated outside the skull in this neighbourhood. Thirdly, we find usually one or more small holes, named the 'foramen' or 'foramina of Vesalius,' opening inferiorly into the 'scaphoid' or the 'pterygoid fossa' or into both, and carrying emissary veins also. Lastly, we see the 'foramen rotundum,' more a canal than a foramen, running forwards and outwards to open into the sphenomaxillary fossa. This foramen transmits the second division of the fifth nerve, otherwise called the 'superior maxillary' nerve.

The INFERIOR or EXTRA-CRANIAL SURFACE is divided into an

upper or more or less vertical part, and a lower or more or less horizontal portion, by an antero-posterior ridge known as the 'infra-temporal crest,' 'pterygoid crest,' or 'horizontal ridge upon the great wing of the sphenoid.' The part above the crest is slightly concave in every direction, and helps to form the 'temporal fossa;' the part below is also slightly concave, and helps to form the 'zygomatic fossa,' and gives attachment to the 'external pterygoid' muscle. Internally, the lower part of the extra-cranial surface shows the inferior aspects of the 'foramen spinosum' and 'foramen ovale.'

The ANTERIOR OR ORBITAL SURFACE is a smooth, nearly flat, quadrilateral plate, looking forwards and inwards, and forming more than half of the outer wall of the orbit. (Plate XVI. fig. 2.) It shows a few smooth grooves for vessels, especially one near its inner side, which runs upwards and is continuous, over the upper border of the plate, with one of the deeper meningeal grooves, described as lying upon the upper part of the intra-cranial surface. Of the four borders of the plate, notice that the *anterior* or *external* slopes downwards and a little forwards, and is sharp and serrated for articulation with the orbital plate of the malar. The *internal* or *posterior* is continuous with the front of the common origin of the great wing and pterygoid process. The *inferior* is smooth, concave, and rather rounded, to make the upper margin of the 'spheno-maxillary fissure.' The *superior* is rough and serrated in its outer half for articulation with the frontal, and in its inner is smooth, sharp, and slopes downwards, backwards, and inwards to form the lower boundary of the 'sphenoidal fissure.' As the smooth part joins the rough part, this border shows the notch for the vessel already mentioned, and, about the middle of the smooth portion, in well-marked bones, a slight projection for the outer head of the 'external rectus' muscle is seen.

As to the rest of the circumference of the greater wing: its upper part is thin, sharp, bevelled at the expense of the internal surface, and articulates with, or rather is applied to, the outer aspect of the anterior inferior angle of the parietal. Between the upper part and the spinous process the circum-

ference is concave from above downwards, thin and bevelled at the expense of the outer surface above, thick and serrated and bevelled at the expense of the intra-cranial surface below, for articulation with the squamous portion of the temporal. Between the spinous process and the root of the wing the border runs nearly directly forwards and inwards; externally this part of the circumference is slightly serrated for articulation with the anterior border of the petrous portion of the temporal, while internally it is non-articular and makes the front of the 'foramen lacerum medium.' Just as this part of the border joins the back of the root of the wing we notice that a process of bone projects backwards and outwards, for a variable distance, into the 'foramen lacerum medium,' dividing it into a very much smaller outer part for the large superficial petrosal nerve, and a larger internal portion for the internal carotid artery. This process of bone is named the 'lingula sphenoidalis.' Immediately below the lingula we have the posterior end of the 'Vidian canal,' for the Vidian nerve.

Sphenoidal Fissures.—Each greater wing is separated from the lesser one by a fissure, termed the 'sphenoidal fissure,' which has its long axis running upwards, outwards, and forwards, and is very much wider at its lower than at its upper end. The upper end is completed by a little piece of the frontal, and the fissure transmits nerves to the eye and its appendages. It gives passage to the third and fourth nerves, to the first or ophthalmic branch of the fifth, the sixth, a few filaments of the sympathetic nerve, and also to the ophthalmic vein.

Pterygoid Processes.—The 'pterygoid processes' descend nearly perpendicularly from the under part of the bone, one on either side, and act as buttresses which support the upper jaw bones. Each process consists of two parts, termed the 'internal' and 'external pterygoid' plates. These are united in front, but diverge from one another behind, forming a deep interval called the 'pterygoid fossa.' At its lower part the 'pterygoid fossa' presents a deep notch, which in the complete skull is filled up by the tuberosity of the palate bone. The external plate is broader than the internal, slopes outwards on its way backwards, and

gives origin to the 'pterygoideus externus' and the 'pterygoideus internus' muscles on its external and internal surfaces respectively. Its outer surface also forms part of the floor of the zygomatic fossa. Respecting the internal pterygoid plate, observe that it forms the lateral and part of the superior boundary of the posterior opening of the nose, and that it has a crescent-shaped margin above, leaving room for the cartilage of the Eustachian tube. At the root of the posterior border of this plate is a shallow groove called the 'scaphoid fossa,' which gives origin to the 'tensor palati' muscle, the tendon of which plays round a notch on the 'hamular' process projecting backwards and outwards from the lower end of the internal pterygoid plate. The hamular process gives attachment to the pterygo-maxillary ligament. Behind the last molar tooth we can distinctly feel this hamular process. Lastly, at the base of the internal pterygoid plate, we see the posterior end of the 'Vidian canal' for the artery and nerve of the same name. The lower third of the posterior border of the internal pterygoid plate gives attachment to the 'superior constrictor of the pharynx.' Look now at the anterior aspect of the pterygoid process, and observe a plate of bone standing off like a side buttress connecting it with the greater wing. The plane of this plate nearly corresponds in direction with that of the orbital plate of the great wing. In their upper two-thirds the external and internal pterygoid plates are united anteriorly and form a smooth surface which constitutes the posterior wall of a deep fossa, termed the 'spheno-maxillary,' which, in the perfect skull, intervenes between the sphenoid and superior maxillary bones. At the upper extremity of this surface we see the anterior opening of the 'Vidian canal' lying below and inside the anterior aspect of the 'foramen rotundum.' In the lower third the external and internal pterygoid plates diverge from one another; their anterior borders show serrated articular margins, convex from above downwards for articulation with correspondingly serrated grooves upon the 'tuberosity' of the palate bone.


Connections.—The sphenoid is connected with twelve bones, including all those of the cranium and five of the face. The 'body'

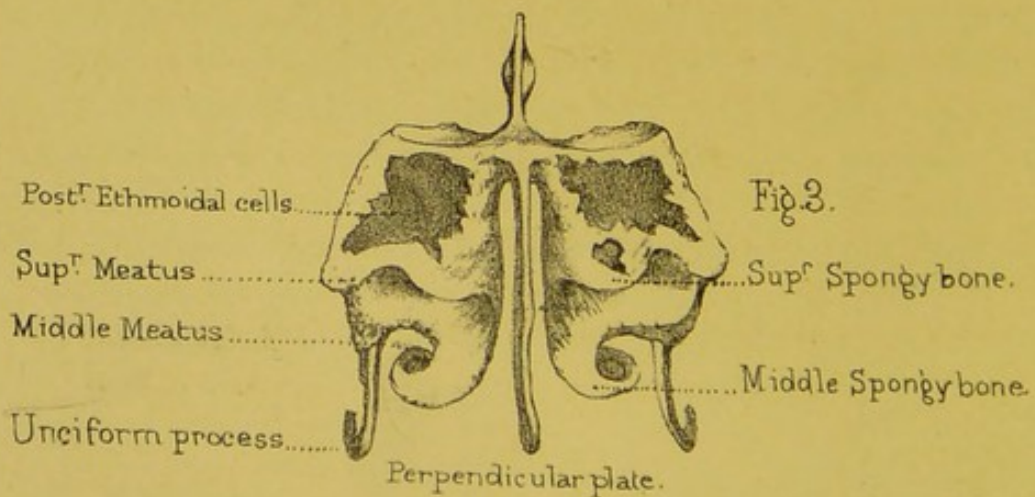
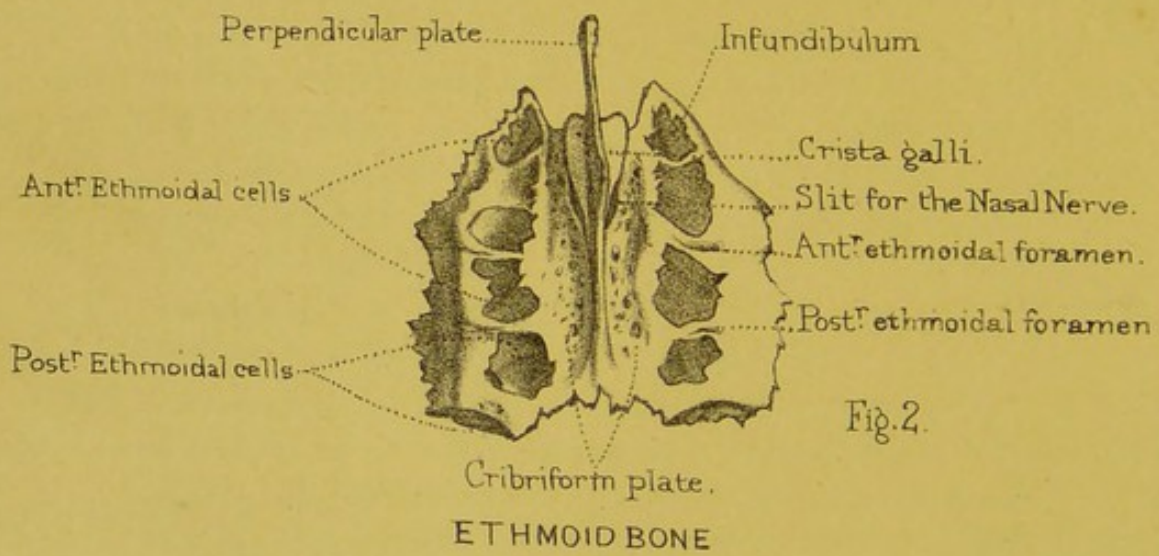
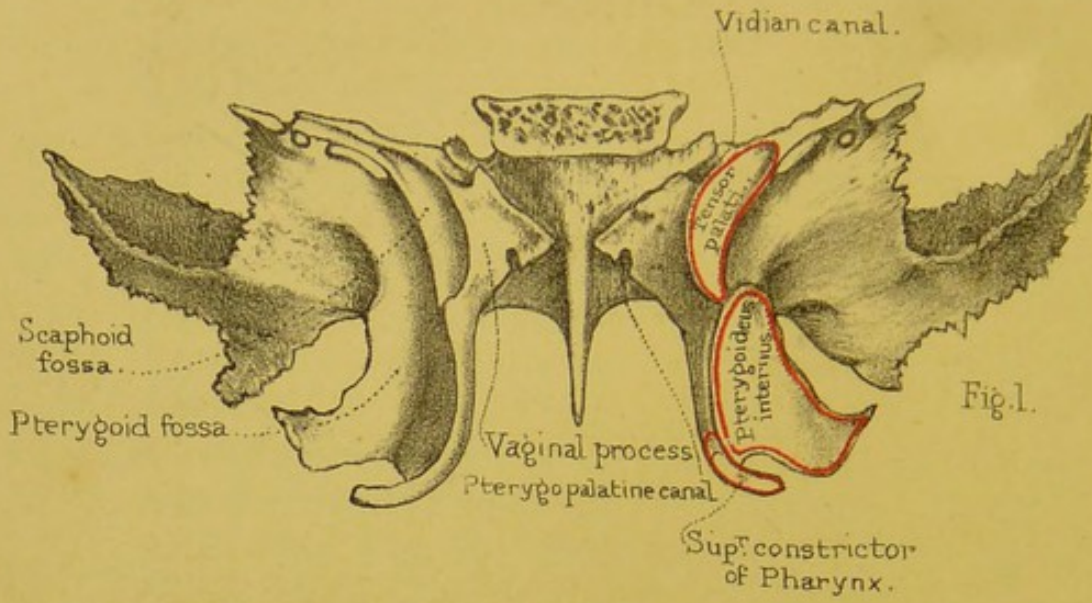
is connected behind with the occipital bone by the basilar suture; in front with the ethmoid bone, the two palate bones, and the vomer. The 'lesser wing' is connected to the orbital plate of the frontal bone: the 'greater wing' is connected to the orbital plate of the frontal by a rugged surface of considerable extent, to the anterior inferior angle of the parietal bone, to the squamous and petrous parts of the temporal bone; and to the malar bone. Lastly, the pterygoid processes are connected with the palate bones.²⁷

Ossification.—In the early foetus the sphenoid consists of several parts. Its centres of ossification appear in the base in the following way. (1) The *presphenoid*, consisting of the part of the body in front of the olivary eminence, and the lesser wings, is developed from two nuclei appearing outside the optic foramina and extending outwards so as to form the orbito-sphenoids or lesser wings. These nuclei appear about the eighth or ninth week, and join the *basisphenoid* or back part of the body about the seventh or eighth month. (2) The *alisphenoids*, consisting of the greater wings with the external pterygoid plates, are developed from nuclei which appear, one on each side, between the foramen rotundum and the foramen ovale about the eighth or ninth week, and join the body of the bone in the first year. (3) The *basisphenoid* or back part of the body is formed from two nuclei which appear, one on each side of the middle line, in the sella turcica about the eighth or ninth week, and which join one another about the fourth month, and the presphenoid part about the seventh or eighth month. (4) The *basitemporals* or parts forming the *lingulae* grow from two centres which appear just after the basisphenoids have joined one another, and which become connected with the basisphenoid part about the fifth month. (5) The *internal pterygoid plates* are developed from ossific nuclei deposited in membrane, appearing in the fourth month, and joining the external pterygoid plates in the fifth or sixth.

The *sphenoidal turbinated bones* begin to be formed after birth, and join the body of the bone at puberty.

Comparative Osteology.—The top of the great wing of the





Drawn on Stone by T. Godart.

From nature by L. Holden.

Printed by West, Newman & Co.

sphenoid, passing up between the frontal and temporal bones, articulates with the anterior inferior angle of the parietal bone. The union of these two bones separates the temporal from the frontal. In those types of men where the forehead slopes backwards, these bones approximate, and in some cases actually articulate with each other. (Nor. Hum. Ost., Nos. 1159, 1160, 1161, and 1146.) The size and strength of the external pterygoid plate bear a direct relation to the development of the pterygoid muscles which cause the grinding movements of mastication; consequently, it is highly developed in ruminants (see skulls of the deer and ox).

In old skulls the sphenoidal cells often extend into part of the basilar process of the occipital bone. In the chimpanzee the sphenoidal cells extend far into the alisphenoid and pterygoid bones.

THE ETHMOID BONE.

(PLATE XI. figs. 2 and 3.)

Constituent Parts.—This remarkably light and spongy bone contains the organ of smell. It occupies the interval between the orbital plates of the frontal bone, and enters into the formation of the cranium, the orbit, and the nose. It appears, at first sight, complicated; but it is simple when one understands its plan. It consists of a 'horizontal plate,' which forms part of the base of the skull; of a central 'perpendicular plate,' which forms part of the septum of the nose; and of two 'lateral masses' containing the air-cells. Each of these must be examined separately.

Horizontal or Cribriform Plate.—The horizontal plate fits into the 'notch' between the orbital plates of the frontal bone, and completes the anterior fossa of the base of the skull. (Plate XIX.) It is called the 'cribriform plate' (*cribrum*, ἡθμός, a sieve), because it is perforated by holes for the passage of the olfactory nerves. High above it rises a crest of bone, termed, from its resemblance to a cock's comb, the 'crista galli.' This, which is a continuation of the perpendicular plate, gradually rises

from behind, swells out as it proceeds, and, stopping suddenly short, presents two broken edges, with a groove between them, for articulation with the frontal bone. The groove contributes to form the 'foramen cæcum.'

The 'crista galli' serves for the attachment of the falx cerebri. It varies in size, and has often a slight lateral inclination. Sometimes it contains an air-cell. On each side of the fore part of the crista galli is a long 'slit,' or rather a hole, for the passage of the nasal nerve (a branch of the first division of the fifth cranial nerve), which confers common sensation to the mucous membrane as well as the skin of the nose. The cribriform plate does not come up to the level of the lateral masses, but lies at the bottom of a deep groove ('olfactory groove'), which, being divided by the crista galli in the middle, forms in the perfect skull two recesses which lodge and support the olfactory bulbs of the brain. The foramina at the bottom are arranged on each side in two somewhat irregular rows—an inner and an outer. Pass bristles down these holes, and you will find that the inner lead into olfactory grooves upon the upper part of the perpendicular plate, and the outer into grooves upon the inner surface of the superior and middle turbinated parts of the bone. By some anatomists a third set are situated midway between these two rows, simply passing through the cribriform plate and ramifying upon its under surface. These foramina and grooves lodge corresponding sets of olfactory nerves.

Perpendicular Plate.—This plate descends from the cribriform plate and assists in forming the septum of the nose. Notice the numerous grooves and perhaps minute canals in its upper third for the passage of the olfactory nerves. Its connections are well shown in Plate XXIII. fig. 1. *Behind*, it is connected along a sloping line with the ethmoidal crest of the sphenoid. *Below*, running downwards and forwards, it is very irregular for articulation with the vomer. *In front* it is divided into an upper and a lower part. The upper is the shorter, concave upwards and forwards, and shows a somewhat rough antero-posterior groove for articulation with the nasal spine of the frontal. The lower is the longer, slopes somewhat irregularly downwards and

backwards, and has two sharp edges with a rough intervening groove for the reception of the cartilage of the septum of the nose.

Lateral Masses.—The lateral masses of the ethmoid (fig. 12) are made up of irregular air cells, surrounded by paper-like walls of bone, lined by mucous membrane continuous with that of the nose. Each lateral mass is suspended from the outer side of the horizontal plate, and when viewed as a whole forms a cubical figure with its concomitant six surfaces.

The *upper surface* shows a number of incomplete cells roofed in by corresponding incomplete cells in the orbital plate of the frontal. The surface between the cells is irregular and rough for articulation with the frontal, and in it we notice two parallel transverse grooves, one in front of the other, converted into canals in the united skull by the corresponding grooves on the orbital plate of the frontal, and thereby forming the 'anterior and posterior ethmoidal canals.'

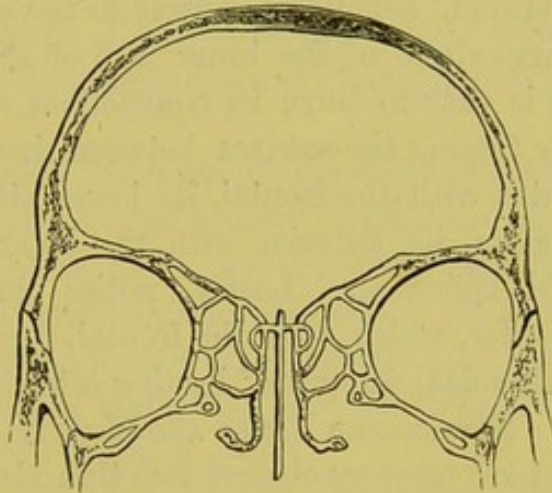
The anterior transmits the nasal nerve and the anterior ethmoidal vessels; the posterior gives passage to the posterior ethmoidal vessels.

The *anterior surface* shows several half-cells completed mostly by the lachrymal, and slightly at the upper end by the nasal process of the superior maxillary.

The *posterior surface* of the lateral mass is irregular and rough for articulation with the front of the body of the sphenoid and with the sphenoidal turbinated bone. It shows several irregular apertures leading into the posterior ethmoidal cells, communicating with the sphenoidal cells, and partly closed over by the sphenoidal turbinated bone.

The *inferior surface* is very irregular, rough, and uneven, and

FIG. 12.



TRANSVERSE SECTION, TO SHOW THE LATERAL AIR-CELLS OF THE ETHMOID BONE.

articulates in front with the orbital plate of the superior maxillary, and behind with the orbital process of the palate bone. From the anterior part of the lower surface of the lateral mass an irregular plate of bone extends downwards and backwards, and terminates in a kind of hook; hence it is called the 'unciform process.' By referring to the inferior spongy bone it is seen that this process is connected with the inferior turbinated bone, and with the thin wall of the antrum of the superior maxillary bone; it chiefly assists in narrowing the orifice of this great air-cavity.

On the *outer surface* of each lateral mass the cells are closed by a smooth and four-sided plate of bone, termed the 'os planum,' belonging entirely to the ethmoid. This plate forms a large share of the inner wall of the orbit (Plate XXII.), where it is easy to learn its connections with the surrounding bones, by tracing the sutures between them. Its upper border articulates with the frontal, its lower with the superior maxillary and palate, its anterior with the lachrymal, and its posterior with the sphenoid. Lastly, notice the two notches on its upper border, which, with the frontal, form the 'anterior and posterior ethmoidal foramina,' leading into the canals of the same names.

TURBINATED BONES AND MEATUS.—On the inner aspect of the lateral mass we observe two thin plates of bone standing out, one below the other, and slightly curled, like a turbinated shell.

These are the 'turbinated' or 'spongy' bones of the ethmoid (Plate XI. fig. 3), and can be properly seen only in a divided skull. The 'superior' is the smaller of the two, and does not reach so far forward as the other, which is called the 'middle,' because there is a third or 'inferior turbinated' bone, still lower down in the nose; but this does not belong to the ethmoid. The middle turbinated bone articulates with the 'superior turbinated crest' of the superior maxillary. Now the spaces left between these turbinated bones and the lateral masses are called respectively the superior and middle 'meatus,' or passages of the nose. Each is distinct from the other, and leads to its own particular cavities, and to no other. The *superior meatus* being farther back than the middle, leads into the *sphenoidal cells*, and into the *pos-*

terior ethmoidal cells. The *middle meatus* leads into the *anterior ethmoidal cells*, and also to the *frontal sinus*, along a funnel-shaped canal ('*infundibulum*') which traverses the foremost of the ethmoidal. (Plate XXIII. fig. 2.) The middle turbinated bone articulates with the superior turbinated crest of the upper maxillary.

Connections.—The ethmoid is connected with the following bones—namely, behind with the sphenoid (including the sphenoidal turbinated bones); above with the frontal; below with the two superior maxillary and two palate bones; in front with the two lachrymal bones. The perpendicular plate is connected behind with the sphenoid, below with the vomer, and in front, with the nasal spine of the frontal. Lastly, the unciform process on each side is connected with the inferior spongy bone and the superior maxillary.

Ossification.—Until the middle of foetal life the ethmoid is all cartilage. Ossification begins about the fourth or fifth month, from a centre for each of the lateral parts, and gradually extends into the two upper turbinated bones (ethmo-turbinals). Within a year after birth another centre appears for perpendicular and cribriform plates. In the foetus at birth there are no ethmoidal cells: these are not formed until the fifth year.

Comparative Osteology.—In man the rule is that there are three turbinated bones on each side; sometimes there is a fourth, smaller than the rest, and higher up at the back part. This fourth bone is more frequently met with in some coloured races where the sense of smell is notoriously acute.

The curled plates of the turbinated bones are covered by a very vascular membrane. The upper ones afford an extensive surface upon which the olfactory nerves are distributed after their passage through the cribriform plate. By the variation of the extent of surface of these bones it will be seen that the acuteness of the sense of smell and the capability of warming the air on its way through the nose to the lungs are regulated.

The sense of smell is remarkably keen in the deer tribe and carnivora, and their spongy bones are developed in proportion. It is curious that they should both in a measure depend for a living

upon the development of the same sense, the one to avoid its enemies, and the other to find its prey.

The spongy bones on which the nerves of smell are distributed, and those which are only covered by a vascular membrane, are widely differentiated in their conformation in the lower animals. In the seal, for instance (Nos. 1064), which inhabits the arctic regions and necessarily breathes intensely cold air, the inferior spongy bones subdivide into a multitude of plates and afford a vast surface on which is distributed a profusion of blood-vessels which warm the air before entering the lungs. The surface of these bones has been estimated at about 120 square inches in each nostril; a longitudinal section of such a nostril has the appearance of being completely plugged by the convoluted warming plates of the lower spongy bone; while those on which the olfactory nerves are distributed have a different form and are farther back and separated by a slight interval from the others.

There is no ethmoid bone in serpents, but the olfactory filaments are spread out on a plicated mucous membrane.

WORMIAN BONES.

These are irregular pieces of bone, formed by separate centres of ossification and deposited frequently in the sutures between some of the cranial bones; hence they are sometimes termed 'ossa suturarum.' We notice them as occurring most often in the lambdoidal and sagittal sutures. In the lambdoidal suture the superior angle of the occipital may be formed by one large or several small Wormian bones. Again, we may find several small ones lying in the lateral parts of the lambdoidal suture. The posterior inferior angle of the parietal may be formed by one. In the sagittal suture one, two, three, or more may occur. Occasionally one may be present in the anterior fontanelle forming the antero-superior angle of the parietal. Frequently a thin lamina termed the 'epiteric bone' is present between the antero-inferior angle of the parietal and the great wing of the sphenoid. Rarely we get a little one lying in the lesser wing of

the sphenoid, and one or more very small ones in the suture between the sphenoid and ethmoid bones. These are the chief seats of the 'ossa suturarum.' They may be found in the other sutures, although much less frequently.

Ossification commences in these Wormian bones some time during the first year after birth. When we look at an adult skull and see such irregular pieces of bone, we must not conclude that these constitute the exact number which we might have observed had we been able to look at the same skull a year or so after birth, because some of these Wormian bones may appear and very soon afterwards form the bones of the skull they are nearest to, leaving no trace of the original separation in the fully formed state. To offer an explanation of the occurrence of these 'suture bones' is somewhat difficult. Professor Humphry says, in his work on 'The Human Skeleton: 'They are evidently stop-gaps developed in the membranous covering of the brain when the extension of the regular osseous nuclei is likely, for some reason, to be insufficient to cover-in the cranial cavity.' This explanation is borne out by what we see in certain diseased states of the skull, such as in Rickets and Hydrocephalus.

BONES OF THE FACE.

THERE are fourteen bones of the face—namely, the two superior maxillary, the two malar, the two nasal, the two lachrymal, the two inferior spongy, the two palate, the vomer, and the inferior maxilla.

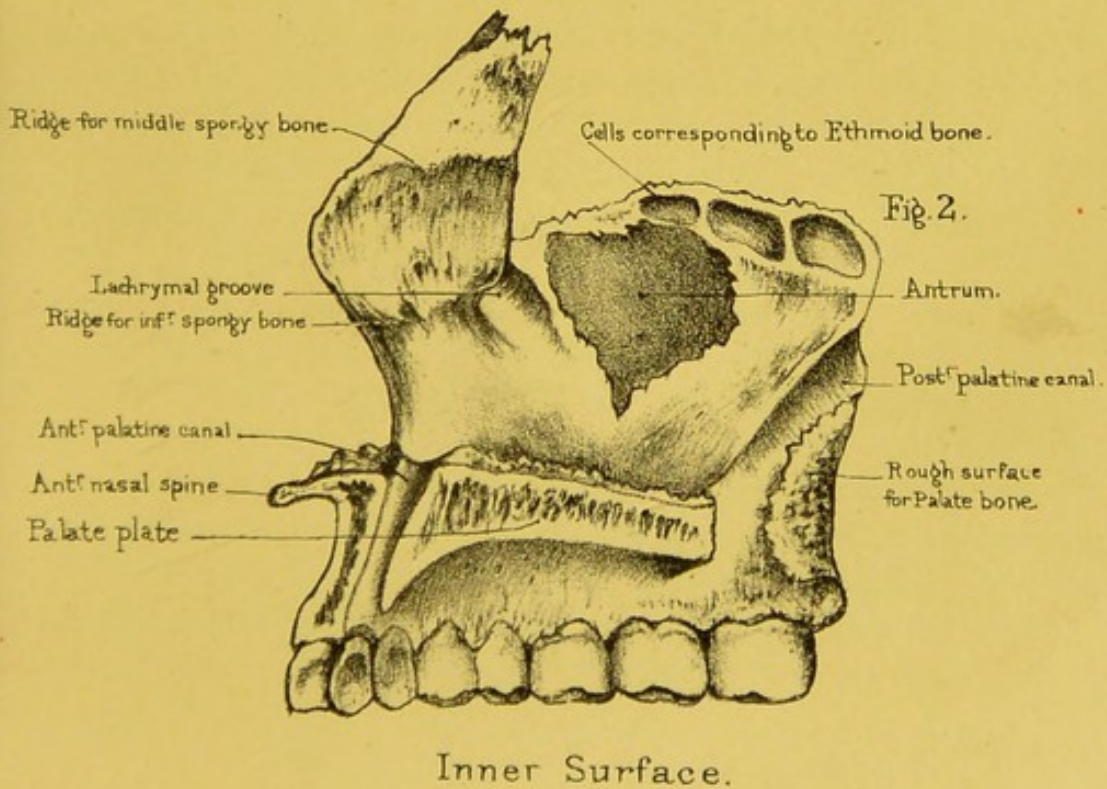
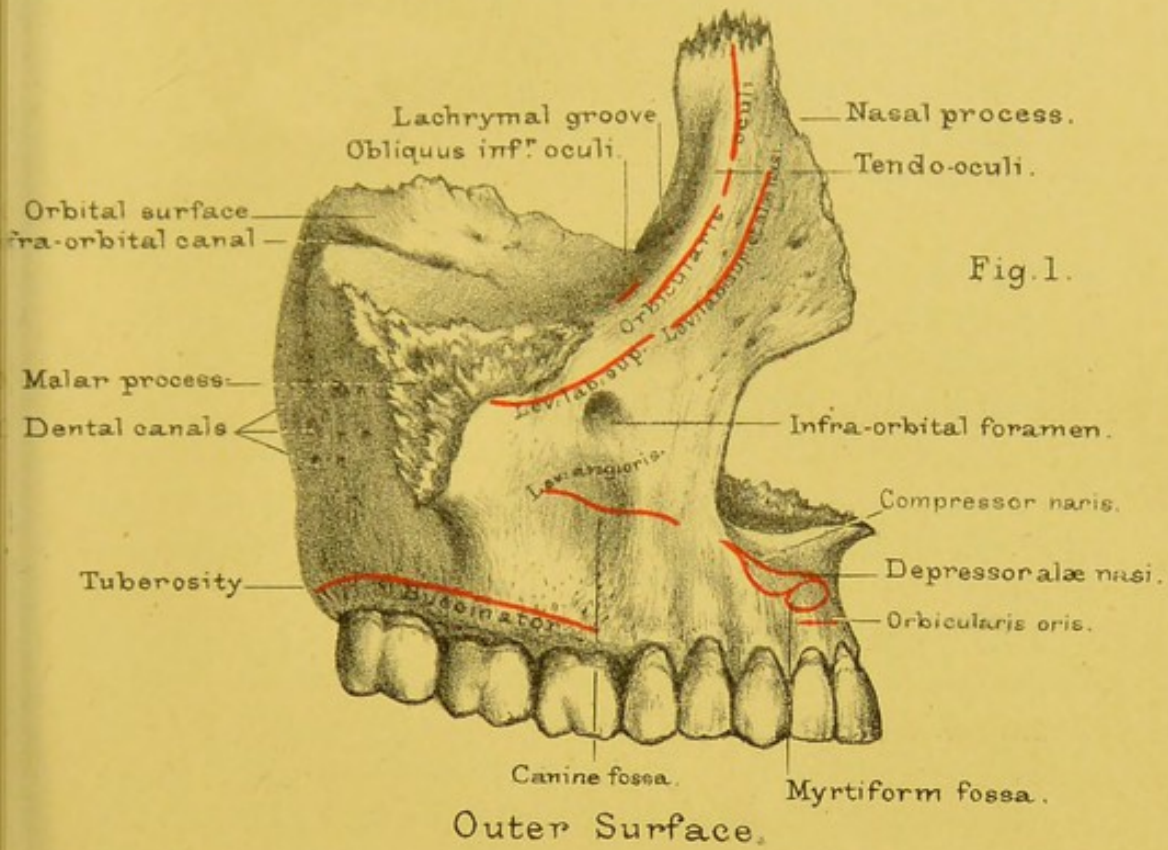
SUPERIOR MAXILLARY BONE.

(PLATE XII.)

Constituent Parts.—This bone gives much character to the human face, and forms the greater part of its framework. It is exceedingly irregular in shape, and, besides forming sockets for the teeth, enters into the composition of the nose, the orbit, the cheek, and the palate. For convenience of description, we divide it into a ‘body,’ which is hollowed out into a large air-cavity, called the ‘antrum of Highmore,’ and four outstanding ‘processes’—namely, the ‘alveolar,’ which holds the teeth; the ‘palatine,’ which forms part of the hard palate; the ‘nasal,’ which assists in forming the nose; and the ‘malar,’ which helps to form the prominence of the cheek.

Body.—Let us take the ‘body’ first and learn its various relations well, for it is a part of great surgical interest, being liable to many diseases requiring surgical operations. The first thing to notice is that it is pyramidal in shape. The *base* of the pyramid looks inwards and helps to form the cavities of the nose and mouth. The apex of the pyramid is continuous with the malar process. The *anterior surface* looks towards the face; the *posterior* looks towards the zygomatic fossa; the *superior* looks towards the orbit.


SUPERIOR MAXILLARY BONE.



Drawn on Stone by T. Godart.

From nature by L. Holden.

Printed by West, Newman & Co.



BASE.—The base or inner surface of the body is partially divided into two unequal parts—an upper or nasal, and a lower or buccal—by the palatine process. The nasal and buccal portions communicate with one another behind the palatine process. In the articulated skull they are separated from one another by the completion of the hard palate posteriorly by means of the palatine process of the palate bone.

The first thing to notice on the *nasal portion* is the orifice of the antrum itself. (Plate XII. fig. 2.) In the separate bone this orifice is very irregular, and large enough to admit the end of a finger; ²⁸ but in the perfect skull (Plate XXII.) it is very much closed in by thin plates from the ethmoid, the palate, and the inferior spongy bones. In the recent state the orifice is generally so contracted by a fold of the mucous membrane of the nose, that it will only admit a crow-quill. The orifice is not near the bottom of the antrum, but very high up; the consequence of this is, that when fluid collects in the antrum it cannot run out until the antrum is nearly full, or until the head is inclined horizontally with the opposite cheek downwards. Above this orifice are a few half-cells completed by the lateral mass of the ethmoid, while running downwards and backwards from it below, to the outer end of the posterior border of the palatine process, is a fissure to articulate with the 'maxillary process of the palate bone.' In front of and below the orifice of the antrum is a smooth surface, concave from above downwards, and slightly so from before backwards, helping to form the inferior meatus of the nose. Leading into this surface from above is the naso-lachrymal groove, and separating the surface from the inner surface of the nasal process is a rough ridge running forwards and downwards, for articulation with the inferior turbinated bone, and called the 'inferior turbinated crest of the superior maxillary bone.' Behind and below the opening of the antrum the nasal surface is rough, for articulation with the vertical plate of the palate bone, and in this rough part is seen a smooth groove, called the 'posterior palatine groove,' and converted into a canal by the apposition of a corresponding groove on the 'vertical plate' of the palate, for the passage of the posterior palatine vessels and nerve.

The *buccal* or *oral portion*, or the part below the palatine process, is rough, and marked by a large number of nutrient foramina. It is continuous inferiorly with the internal surface of the alveolar process, posteriorly and superiorly with the nasal portion, and anteriorly and superiorly with the inferior surface of the palatine process. At the line of junction between the palatine process and the buccal surface is a continuation of the posterior palatine groove already described.

APEX.—The apex is continuous with the root of the malar process, to be presently described.

ANTERIOR SURFACE.—The anterior or facial surface is continuous superiorly and anteriorly with the external surface of the nasal process; inferiorly with the outer surface of the alveolar process; posteriorly below the malar process with the zygomatic surface. It is divided into two fossæ—an anterior or ‘incisive’ or ‘myrtiform,’ and a posterior or ‘canine’—by a vertical ridge corresponding to the socket for the canine tooth, and called the ‘canine ridge.’ The incisive fossa gives attachment to the ‘orbicularis oris,’ the ‘depressor alæ nasi,’ and the ‘compressor naris.’ The canine fossa lies behind the canine ridge, and is deeper in some skulls than in others. At its upper part, about a quarter of an inch below the margin of the orbit, and in the same vertical line as the upper second bicuspid tooth, is the ‘infra-orbital foramen’ or termination of the ‘infra-orbital canal,’ which transmits the infra-orbital nerve and artery. Above this foramen we have the origin of the ‘levator labii superioris,’ and below it the origin of the ‘levator anguli oris.’

POSTERIOR SURFACE.—The posterior or zygomatic surface bulges into the zygomatic fossa.²⁹ Above it is smooth, and below it is rough, and inferiorly may show a somewhat serrated surface for articulation with the tuberosity of the palate bone. On it we notice two or three foramina for the passage of superior dental nerves from the superior maxillary, descending palatine branches of Meckel’s ganglion, and palatine branches of the internal maxillary artery.

SUPERIOR SURFACE.—The superior or orbital surface looks upwards and outwards, and enters into the formation of the floor

of the orbit. It is triangular in shape, with the base directed forwards. On the surface notice the 'infra-orbital canal,' for the passage of the superior maxillary nerve and infra-orbital artery. It commences behind as a groove, but soon becomes a canal, which terminates on the front wall of the antrum, just below the edge of the orbit. A little before its termination, the main canal gives off one or sometimes two smaller ones, termed the 'anterior dental canals.' These run down in the very substance of the front wall of the antrum, and transmit blood-vessels and nerves to the two incisor and canine teeth, and send a branch inwards which carries a nerve to the fore part of the inferior meatus. Running down from the posterior end of the infra-orbital canal is another little channel in the posterior wall of the antrum, conveying the middle superior dental nerve to the bicuspid teeth. To see these canals it is necessary to introduce a bristle as a guide, and then to rasp away the external plate of the bone. Sometimes joining the anterior and posterior extremities of the infra-orbital canal is a suture extending along the orbital surface, and across the infra-orbital margin, indicating the imperfect closure of the roof of the infra-orbital canal. Close by the anterior internal corner of the orbital surface is a very slight depression (in some cases it may be a little eminence) for the origin of the 'inferior oblique' muscle of the eyeball.

Of the margins of the orbital surface, the *anterior* is smooth, non-articular, and somewhat sharp in its inner half, forming part of the infra-orbital margin, rough and serrated in its outer half, for articulation with the malar bone. The *external* is sharp and rough anteriorly for articulation with the 'orbital process' of the malar, smooth and rounded posteriorly where it makes the lower margin of the 'spheno-maxillary fissure.' In the smooth part we notice the 'infra-orbital notch' forming the commencement of the infra-orbital groove. The *internal* margin presents, anteriorly, a smooth notch—the 'lachrymal notch'—bounding the upper aperture of the naso-lachrymal canal externally; behind that a serrated surface for articulation with the lower border of the lachrymal bone; behind that a longer serrated border, or rather a surface, with perhaps two or three half-cells in it, for

articulation with the ethmoid; and posterior to that a sloping oblique border, running downwards, outwards, and backwards, and bounding superiorly a rough concave surface for articulation with the orbital process of the palatè bone.

ANTRUM, CAVITY OF.—The ‘maxillary sinus,’ or ‘antrum,’³⁰ is by far the largest of the air-cells in the bones of the head. It begins to be formed as a depression on the inner surface of the body about the fourth month. This depression gradually enlarges, so that at birth there is a very slight interval between the plates of bone forming the orbital and the other surfaces of the body. It is lined with mucous membrane, continuous with that of the nose, and is large enough to hold a musket-ball with ease. A ball has been known to lodge in the antrum for months, and even for years, before it has been removed.³¹ It varies in size and somewhat in shape in different persons; but, as a rule, it has the form of a three-sided pyramid, with the base towards the nose, formed by the internal surface of the body, and the apex extending into the malar process. Its anterior wall supports the canine fossa, its posterior the zygomatic surface, and its superior the orbital surface of the body. Thin plates of bone often project into the antrum, making a kind of recess or pocket here and there;³² and the fangs of one or more of the molar teeth generally project into it, either quite bare or covered by a thin scale of bone. Hence the practice, adopted by some surgeons, of drawing one of these teeth (say the first or second molar) to let out matter from the antrum. Again, the fangs of decayed or otherwise injured molar teeth are liable to set up disease in the antrum; and this is the explanation commonly given why morbid growths arise in the antrum more frequently than in any other of the air-cavities of the nose.

The following case gives a good idea of the extent of the antrum: ‘A lady suffering from toothache submitted to the extraction of the canine tooth of the upper jaw, with which a portion of the alveolar process was removed, making an aperture in the antrum, from which a watery fluid constantly issued. The patient, desirous of ascertaining the source of the discharge, took a pen, and, having stripped off the barbs from the feathered part,

found that the whole of it, full six inches long, could be introduced into the cavity. At this she was greatly terrified, believing it must have gone into the brain. She consulted Highmore, who explained to her that the pen had turned spirally within the sinus, and he, besides, counselled her to submit with patience to the inconvenience of the discharge from the cavity.'³³

Alveolar Process and Teeth.—The alveolar process is a thick and strong ridge of bone, curved so as to form with that of the other side the dental arch. It consists of two plates, an outer and an inner, connected by numerous septa which form the sockets (alveoli) of the teeth. The inner plate is the stronger; therefore, in drawing a tooth, care should be taken to incline it a little outwards. The outer plate is marked by eminences corresponding to the fangs of the teeth, the eminence of the canine tooth being especially marked.

In a child, from the end of the second to the end of the sixth year, the half of each jaw contains sockets for five teeth, i.e. for two incisors, one canine, and two molars.

The formula for the 'milk dentition' is therefore :

$$i. \frac{2+2}{2+2}, \quad c. \frac{1+1}{1+1}, \quad m. \frac{2+2}{2+2} = 20 \text{ in all.}$$

The half of each jaw contains, in the adult, sockets for eight teeth—namely, two 'incisors,' one 'canine,' two bicuspid (or 'præ-molars'), and three 'molars.' Thus the dental formula of the adult human skull is :

$$i. \frac{2+2}{2+2}, \quad c. \frac{1+1}{1+1}, \quad b. \text{ or } p. \frac{2+2}{2+2}, \quad m. \frac{3+3}{3+3} = 32 \text{ in all.}$$

The eruption of the second or permanent set of teeth commences about the end of the sixth year. The first to appear is the first permanent molar, which is therefore called the six-year-old tooth, and is the oldest tooth in the adult's head. Generally speaking, the twenty milk teeth are cut between the sixth and twenty-fourth months, and the thirty-two permanent teeth between the sixth and twenty-fourth years.³⁴

SOCKETS OF TEETH.—The sockets correspond in number and size to the fangs of the teeth they receive. They vary in depth in

different instances. The deepest of all is the socket of the canine tooth; this is often $\frac{7}{10}$ of an inch in depth in the dry bone. The first two molars of the upper jaw have three fangs each, and as many sockets. Of these fangs, two are external, and one internal. In the last molar, or wisdom tooth, the fangs are generally consolidated into one. Irregularities in the shape and the direction of the fangs, whether diverging too much or converging, lead to unavoidable evils when it is necessary to extract them. Either a fang breaks, or part of the alveolus must be extracted with the fang. One cannot foresee this. At the bottom of each socket is a minute hole, through which the vessels and nerve come up and supply the pulp in the cavity of the tooth. There are also numerous holes in the bony partitions between the sockets, through which vessels supply the gums and the periosteum. These are the sources of the bleeding after the extraction of a tooth. The teeth are fixed not only by the closely fitting socket, but also by the very vascular membrane, the periosteum, which lines the socket and adheres closely to the fang. This periosteum not only retains the teeth in their places, but helps to maintain their vitality, and, being elastic, breaks shocks which would otherwise be communicated to the jaws. When the dental periosteum inflames, the tooth is partly lifted out of its socket, and the teeth cannot be clenched without pain. If the inflammation goes on to the formation of matter, the periosteum quits its hold of more or less of the fang, and abscess in the socket is the result. The matter then makes its way out by the side of the tooth, or through a small hole formed by ulceration in the alveolar wall—that is, a gumboil is the result. In the dry bones, most of the teeth fall out, because the periosteum shrinks, and thus the sockets become too large.

The alveolar process gives origin (Plate XII. fig. 1) to the 'buccinator' above the three molar teeth.

Nasal Process.—The nasal process ascends nearly perpendicularly, in a line with the canine tooth, and abuts, by means of a very rough suture, upon the internal angular process of the frontal bone. It supports the nasal bone, and contributes to form the inner margin of the orbit.

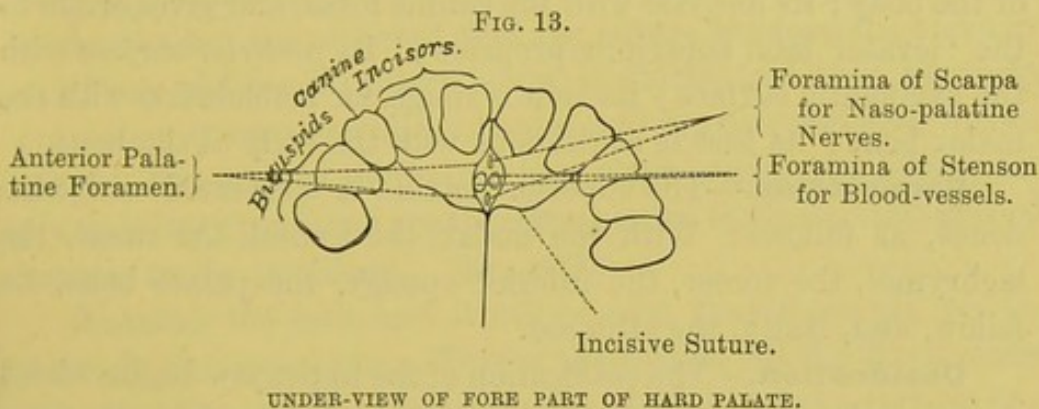
The process is flattened from within outwards, and is narrower from before backwards than from above downwards. It presents external and internal surfaces with superior, inferior, anterior, and posterior borders. The *external surface* is slightly concave in every direction, marked by a number of vascular foramina, and gives origin to the 'orbicularis palpebrarum' and the 'levator labii superioris alæque nasi.' The *internal surface* enters into the formation of the nasal cavity and presents from above downwards, first, a smooth surface which, with the fore part of the lateral mass of the ethmoid, helps to form a few of the anterior ethmoidal cells, next a rough antero-posterior ridge, or it may be a surface, and termed the 'superior turbinated crest of the superior maxillary,' for articulation with the inferior turbinated process of the ethmoid, or the middle turbinated bone of the nasal fossa. Below this is a smooth shallow antero-posterior groove, helping to form the middle meatus of the nose, and bounded below by the rough antero-posterior 'inferior turbinated crest' for articulation with the inferior turbinated bone. The *superior border* of the nasal process is thick, deeply serrated, and articulates with the nasal notch of the frontal bone. The free part of the *inferior border* is thin, sharp, irregular, runs downwards, outwards, and backwards, helping to form the side of the anterior opening of the nose. The attached part is continuous with the body of the bone. The *anterior border* runs downwards, outwards, and forwards, and is thick and bevelled at the expense of the outer surface above, thin and bevelled at the expense of the inner surface below, for articulation with the outer border of the nasal bone. The *posterior border* is more a surface than a border, and presents a groove running downwards, outwards, and backwards, called the 'lachrymal groove,' lodging the 'naso-lachrymal sac' and the 'naso-lachrymal duct.' The anterior lip of the groove is smooth and rounded above, sharper and more prominent below, is continuous with the anterior margin of the orbital surface of the body, and helps to make the inner margin of the orbit. The posterior lip is smooth and flattened at its upper end where it helps to complete the anterior ethmoidal cells, sharp and rough in the rest of its extent for articulation with the anterior border of

the lachrymal bone. The 'lachrymal' groove is converted into a canal in the lower half-inch of its course by the lachrymal and inferior turbinated bones, and is about the size of a very small goose-quill. When, from inflammation or other cause—such as a tumour—the canal becomes obstructed, the tears necessarily flow over and run down the cheek. To obviate this, it is often requisite to slit up one of the lachrymal canaliculi and introduce a probe into the naso-lachrymal duct. Therefore one must know well the direction of the lachrymal canal. It runs from above downwards, and slightly backwards, and outwards.

The anterior lip of the groove gives attachment to fibres of the 'orbicularis palpebrarum,' with the 'tendo oculi,' or 'palpebrarum,' between them.

Palatine Process.—The palatine process extends horizontally inwards, and forms the anterior two-thirds of one half of the hard palate and floor of the nose, the posterior third being completed by the palate bone. It is slightly arched from before backwards, and is thicker in front near the alveolus than behind. The process is four-sided, with an upper or nasal and a lower or palatine surface. The *upper surface* is smooth, concave from side to side, slightly so from before backwards, and helps to make the floor of the nasal fossa. Near the anterior part of its inner side we see a large foramen, the 'incisor foramen,' or 'foramen of Stenson,' leading downwards and slightly forwards into a deep groove, seen in the inner border of the palatine process, and termed the 'anterior palatine groove' (in the articulated skull, the anterior palatine canal). The incisor foramen transmits blood-vessels, and is the remains of a communication between the nose and mouth—a condition well seen in the skulls of carnivora. In young superior maxillary bones, and sometimes in adult ones, we see a faint line running towards the front of the socket for the canine tooth, and named the 'incisor fissure,' or 'incisive suture.' The *lower surface* of the palatine process is very rough and marked by a number of vascular foramina. Externally it helps to form the 'posterior palatine groove' with the inner surface of the body of the bone. At the fore part of the surface, and situated on the inner border, is the 'anterior palatine

groove,' with the incisor foramen opening into its upper end, and at the anterior and posterior extremities of the upper end of the groove two little notches formed by little grooves—the 'grooves of Scarpa'—on the inner border of the process. Always in young bones, and sometimes remaining persistent in fully formed skulls—never, however, extending across the alveolar border—is the lower aspect of the incisive suture, already seen on the upper surface and limiting the so-called 'premaxillary bone' posteriorly. The anterior border of the palatine process is smooth, concave from side to side, and usually grooved in the same direction, and forms one-half of the lower margin of the anterior opening of the nose. It is continuous with the upper border of the incisive fossa of the body of the bone. The *posterior border* is thin, sharp, serrated, bevelled at the expense of the upper sur-



face, and articulates with the horizontal plate of the palate bone. The *internal border* shows a number of parallel vertical rough sharp ridges, with corresponding grooves between, for articulation with the opposite bone. Above, the border rises towards the nose in a half-crest, made a whole one by the apposition of the opposite bone, to articulate with the vomer and form the base of the bony septum of the nose. (Plate XXIII. fig. 1.) This half-crest projects forwards, and, by joining with the corresponding part of the opposite bone, makes the 'anterior nasal spine,' to which is attached the cartilaginous part of the nasal septum. The root of the anterior nasal spine is called the 'subnasal point' by craniologists. On the inner border we see, too, the 'anterior and posterior grooves of Scarpa' (converted into canals by the

apposition of the vomer and the corresponding parts of the opposite bone), leading into the anterior palatine groove. The anterior is usually the larger of the two grooves of Scarpa, and transmits the left naso-palatine nerve; the posterior is usually the smaller, and transmits the right naso-palatine nerve. This arrangement of the nerves may, however, be reversed. The *external border* of the process is continuous with the body of the bone.

Malar Process.—The malar process stands off from the outer side of the antrum. It is remarkably thick and strong, and is connected, by a very rugged triangular surface, with the malar bone. The malar process is situated just over the first and second molar teeth, and is therefore well calculated to resist pressure in mastication. It forms the apex of the pyramidal body of the bone. Its *superior surface* is continuous with the orbital surface of the body; its *anterior* with the canine fossa, and gives origin to the 'levator labii superioris proprius'; its *posterior surface* with the zygomatic surface; its *apex* is rough for articulation with the malar bone; its *base* is continuous with the body of the bone.

Connections.—The superior maxilla is connected with nine bones, as follows: With the malar, the frontal, the nasal, the lachrymal, the vomer, the inferior spongy, the palate bone, its fellow, and, lastly, the ethmoid.

Ossification.—The ossification of the upper jaw begins about the seventh week of foetal life, and proceeds so quickly that the number of its independent centres has not yet been accurately determined. It appears to have five distinct centres: one for the alveolus behind the incisors, one for the palatine process, one for the floor of the orbit and malar process, a fourth for the portion in front of the antrum with the nasal process, and, lastly, a very distinct centre,³⁵ which includes the sockets of the two incisor teeth. In most human skulls, if not very old, one can trace the remains of the 'pre-maxillary' suture. (Plate XX.) It runs outwards from the anterior palatine canal, and then through the alveolar border of the jaw, invariably between the second incisor and the canine tooth; and here we lose all trace of it. This is interesting surgically. In cases of double hare-lip, where the fissure is not confined to the lips, the pre-maxillary bones on each side fail to

unite with the rest of the upper jaw, and often project in a hideous manner through the fissure of the lip. When removed by operation, these bones are always found to contain the capsules of the four incisor teeth.³⁶

Comparative Osteology.—The teeth which grow from the pre-maxillary bones are called incisors. On a close inspection of the narwhal hanging in the Mus. Roy. Coll. Surg. the sharp spiral tusk will be found to spring from the left pre-maxillary bone. It is therefore the left incisor tooth. The right one usually remains undeveloped; but there is a specimen in the Cambridge Museum where both are of full length. Evidence of the narwhal's power of offence or defence is given by the tusks having been found buried to a depth of ten or twelve inches in the timbers of ships. The female narwhal has no such extraordinary growth of the incisor tooth. It is interesting to notice in the skull of the elephant that the suture between the superior maxillary and pre-maxillary bones is visible, and that his tusks grow from the pre-maxillary bones, and are therefore also incisor teeth. The tusks of the walrus have their origin externally to the pre-maxillary bone, and are therefore canine teeth, and this animal belongs to the carnivora. (No. 999.)

Examine the bull, and it will be seen that there are no incisors in the upper jaw. This is the case in all the Ruminants, excepting the camel, which loses the central incisors early in life. In the bull, deer, and other Ruminants also notice that the so-called canines in the lower jaw are in a regular series with the six incisors, and much resemble them. They seize their food between this even row of teeth and the prehensile upper lip, and then chew it with the molars.

In the order Monotremata, the one member, *Echidna*, has no teeth, and the other, *Ornithorhynchus paradoxus*, has but horny plates to represent them. (See Sep. Ser.)

In many of the lower animals teeth are not confined to the alveolar margins of the jaw, but are found scattered about the upper part of the alimentary canal. Thus, in the Labroid fishes (No. 96), large teeth may be seen developed upon the palate. In the perch there are teeth in the pharynx. (No. 197.) In the

lobster there are horny teeth in the stomach, where the food is ground.

In birds the superior maxillary, with the inter-maxillary bones, are prolonged forwards, and when covered with the appropriate horny material, constitute the beak; the lower jaw also projecting forms the lower half of the beak. (Nos. 1678, 1678A.)

The upper jaw is movable in parrots (No. 1438), and has a broad transverse articulation with the frontal. It consists of the coalesced nasal, maxillary, and pre-maxillary bones.

In Primates there are never more than four incisors above, and the same number below.

In the Rodents the incisors continue to grow throughout life, and are long and curved. See the Canadian beaver (No. 3118).

In Cetacea the pre-maxillæ, which are small in proportion to the maxillæ, are prolonged far in advance of the nasal aperture, as may be seen in the skeleton of the great sperm whale in the Mus. Roy. Coll. Surg.

Examine the poison-fang in a serpent from New Holland (No. 650). It is situated in the upper jaw, and has a bristle passed through it, showing that it is tubular. This tube is continuous with the duct of the poison-gland.

Look at the plates of whalebone hanging from the upper jaw of the whalebone whale. It is by means of these plates that he entangles the small molluscs, &c., on which he feeds.

MALAR BONE.

(PLATE XIII. fig. 3.)

The malar bone forms the prominence of the cheek, a part of the margin and wall of the orbit, and the greater portion of the zygomatic arch. It is remarkably thick and strong, and resists injury, to which the face, in this situation, is so exposed. We divide it into a 'body' and an 'orbital process.'

Body.—The 'body' is diamond-shaped, with external and internal surfaces; superior, inferior, anterior, and posterior

angles; anterior-superior, anterior-inferior, posterior-superior, posterior-inferior borders.

SURFACES.—The *external* or *facial* surface is subcutaneous, marked by a number of small vascular foramina, and one large foramen, known as the 'external opening of the malar canal,' for the transmission of a malar nerve. Sometimes there may be more than one large opening. From the outer surface arise the 'zygomaticus major' and 'minor' muscles, and close to the posterior-inferior border fibres of the 'masseter.' In most skulls we see a distinct elevation where the zygomaticus major is attached. This elevation is termed the 'malar point' by cranio-logists. The *internal* surface presents a rough, triangular, deeply dentated surface to articulate with the malar process of the superior maxillary, and a smooth concave surface entering into the formation of the zygomatic fossa. The surface is marked by a few small elevations near the lower border, where it gives origin to the 'masseter' muscle, also to one or two 'temporal foramina' or openings of malar foramina leading into the zygomatic fossa and occupied by temporal branches of the temporo-malar nerve.

ANGLES.—The *superior* angle is dentated to articulate with the external angle of the frontal bone. The *inferior* angle is nearly a right angle, and articulates with the malar process of the superior maxillary. The *anterior* angle is very acute. It articulates with the superior maxillary bone at the infra-orbital margin above the infra-orbital foramen. The *posterior* angle is cut obliquely from above downwards and backwards, and is serrated for articulation with the zygomatic process of the temporal.

BORDERS.—The *anterior-superior* border is smooth and rounded, and forms the outer and part of the lower margin of the orbit. The *anterior-inferior* border is somewhat sinuous and serrated. It forms the anterior limit of the triangular serrated surface for articulation with the malar process of the superior maxillary. The *posterior-superior* border is curved like an italic *s*. It is rather sharp and rough for the attachment of the temporal fascia. The *posterior-inferior* border runs backwards and slightly upwards, and is rough for the attachment of the 'masseter' muscle.

The **Orbital Process** is continuous externally with the upper half or so of the anterior-superior border of the body of the bone. It is a four-sided plate of bone, forming part of the outer wall of the orbit and looking forwards and inwards.

SURFACES.—The *antero-internal* or *orbital* is smooth, slightly concave both from above downwards and from before backwards. It shows the internal openings of one or two of the malar canals. The *postero-external* or *zygomatic* is convex from above downwards and concave from before backwards, and helps to form the zygomatic fossa.

BORDERS.—The *superior* is serrated for articulation with the frontal bone. The *inferior* is shorter than the superior, and articulates with the anterior end of the external border of the orbital surface of the superior maxillary bone. The *postero-internal* in its upper four-fifths or so is rough and sharp for articulation with the outer border of the orbital surface of the great wing of the sphenoid. In its lower fifth it forms a smooth notch bounding the 'spheno-maxillary fissure' externally. In some cases this border is articular throughout, in which case the malar bone will not form the outer end of the spheno-maxillary fissure, and the sphenoid will articulate with the superior maxillary. In some rare cases a little Wormian bone forms the outer end of the spheno-maxillary fissure. The *antero-external* border is continuous with the body of the bone.

'The malar canal' (more fully the 'temporo-malar canals') starts by one or two openings on the orbital surface of the orbital process. They run outwards into the body of the bone, some appearing externally on the facial surface of the body as the 'malar foramina,' and others on the zygomatic surface of the body as the 'temporal foramina.' The primary canal (or canals), starting in the orbital process, lodge temporo-malar nerves; the branches contain malar and temporal divisions respectively.

Connections.—The malar bone is connected with four bones, namely, by a broad and very roughly serrated surface, with the superior maxillary; by suture, with the external angle of the frontal, the orbital plate of the sphenoid, and the zygomatic process of the temporal. These several connections are so strong

that the bone cannot be driven inwards towards the orbit, and fractures of it are very rare.

Ossification.—The malar is developed from a single centre of ossification, which appears about the eighth week. According to some anatomists, it is developed from three centres, which join one another by the fourth month. The non-union of one of these centres explains why we sometimes see the body of the bone divided by a suture into an upper or larger and a lower or smaller portion. This condition is well seen in the skull of a Japanese recently added to the collection of human skeletons in the Museum of the Royal College of Surgeons.

Comparative Osteology.—The upper process of the malar bone does not articulate with the frontal in the carnivora (Nos. 363, 365, 4562).

In the Great Kangaroo and Wombat the zygomatic process of the malar bone extends backwards so far that it forms part of the glenoid cavity and articulates with the lower jaw.

N A S A L B O N E.

(PLATE XVI. fig. 3.)

The nasal bones, situated one on either side, occupy the space between the nasal processes of the superior maxillary bones, and, together, complete the bridge of the nose. Their length, breadth, and degree of inclination, determine the shape of the nose. We have to examine their anterior and posterior surfaces, and their four borders.

SURFACES.—The *anterior* surfaces are subcutaneous, convex, and present the orifices of one or more canals, which transmit blood-vessels. The *posterior* surfaces are concave, form part of the roof of the nose, and each is marked by a groove for the passage of the external branch of the nasal division of the fifth nerve.

BORDERS.—The *upper* borders are broad, serrated, and firmly articulated with the frontal bone. The *lower* borders

are thin and free in the dry bone, but connected in the recent subject with the lateral cartilages of the nose. Each has generally a little notch in it, through which the external branch of the nasal nerve comes and supplies the skin at the tip of the nose. Their *outer* borders are serrated, slightly sloped, and rest upon the nasal processes of the superior maxillary bones. Their *inner* borders articulate with each other, in the middle line, along the 'nasal suture.' From the under surface of this suture a high 'crest' of bone projects. By putting the bones together, it is seen how their crests form the beginning of the bony septum of the nose, and how they articulate with the nasal spine of the frontal bone, and if that does not extend far enough forwards, with the perpendicular plate of the ethmoid. (Plate XXIII. fig. 1.) Hence, with a depressed fracture of the nasal bones there must be a fracture of the perpendicular plate of the ethmoid, either directly or indirectly, through the nasal spine of the frontal. In some rare instances, the injury extends through the perpendicular plate of the ethmoid to the base of the brain. Observing the great strength of the nasal bones and the massive arch they form, how the sides of the arch are supported by the nasal processes of the superior maxillary, while the centre is propped up by the nasal spine of the frontal and the perpendicular plate of the ethmoid (Plate XXIV. fig. 2), one can readily understand what makes the arch so strong, and why the bones are so seldom broken.

Connections.—The nasal bone articulates with four others, namely its fellow, the superior maxillary, the frontal, and the perpendicular plate of the ethmoid should the nasal spine of the frontal not extend so far forwards as to completely separate them.

Ossification.—Each nasal bone is developed from a single centre of ossification, which appears about the eighth week of foetal life.

Comparative Osteology.—The only difference between the skulls of a tiger and a lion is that in the lion the upper ends of the nasal bones and the nasal processes of the superior maxillary bones are on the same level, whereas in the tiger the nasal bones run up considerably beyond the nasal processes.

LACHRYMAL BONE.

(PLATE XIII. fig. 4.)

The lachrymal bones are situated, one on each side, on the inner wall of the orbit. They are exceedingly thin and delicate, and shaped somewhat like a finger-nail, hence the name 'os unguis.' In old skulls they are often as thin as silver paper, and sometimes perforated. One surface is directed towards the orbit; the other towards the nose. One of these bones is seen *in situ* in Plate XVI. fig. 2.

The bone is four-sided, with external and internal surfaces, superior, anterior, inferior, and posterior borders.

SURFACES.—The *external* or *orbital* surface has a smooth vertical ridge upon it, which terminates below in a small hook-like process or tongue, termed 'hamulus,' running forwards and outwards, then forwards and inwards, to articulate with the so-called 'lachrymal tubercle' of the superior maxillary, and thereby complete the upper opening of the naso-lachrymal canal externally. (Plate XXII.) In front of this is a vertical groove ('lachrymal groove'), which, together with the groove on the nasal process of the superior maxilla, lodges the naso-lachrymal sac or the upper dilated end of the duct for the passage of the tears into the nose. The ridge itself gives origin to the 'tensor tarsi' muscle. The bone behind the ridge is smooth, slightly concave, and forms part of the inner wall of the orbit. The *internal* or *nasal* surface presents a slight groove, corresponding to the external ridge. The surface in front of this forms part of the middle meatus of the nose; that behind it covers the anterior cells of the ethmoid bone, and sometimes a small cell or two in the frontal bone.

BORDERS.—The *superior* border is thin, straight, dentated, and articulates with the internal angular process of the frontal bone. Sometimes we notice a half-cell in it, completed by the frontal. The *anterior* border is the strongest border. It is slightly arched forwards, and is sharp and articular to join the

inner lip of the posterior border of the nasal process of the superior maxilla. The *inferior* border posteriorly is thin and rough to articulate with the orbital process of the superior maxillary, and anteriorly is prolonged downwards as a process, termed the 'angle of the lachrymal,' which forms the inner wall of the naso-lachrymal canal, and articulates with the 'lachrymal process' of the inferior turbinated bone. The *posterior* border is thin and uneven, and articulates with the anterior border of the os planum of the ethmoid.

Connections.—The lachrymal bone articulates with four bones, viz. the frontal, superior maxillary, ethmoid, and inferior turbinated. Sometimes the 'hamular process' is developed as a separate piece of bone, and called the 'lesser lachrymal bone.'

Ossification.—It has one centre of ossification, which appears about the eighth week of foetal life.

PALATE BONE.

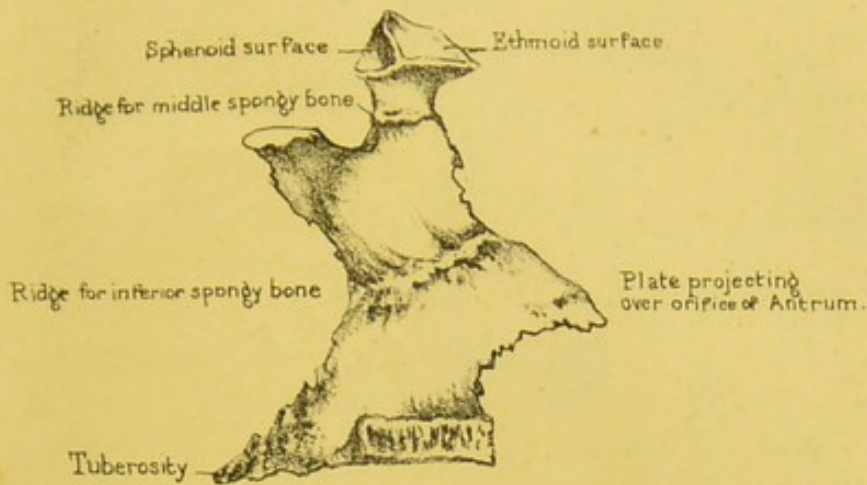
(PLATES XIII. and XIV.)

Each 'palate bone' is wedged in between the pterygoid process of the sphenoid and the superior maxillary bone. Each forms part of the nasal fossa, of the orbit, and of the palate. As the palate bone somewhat resembles the letter L in shape, we can divide it, for convenience of description, into a 'horizontal' and a 'vertical plate,' with an 'orbital' and a 'sphenoidal process' rising from the upper border of the latter plate.

Horizontal Plate.—The horizontal plate completes the bony palate by fitting on to the palate plate of the superior maxillary bone. It is quadrilateral in shape, with inferior and superior surfaces, inclosed by anterior, posterior, internal, and external borders.

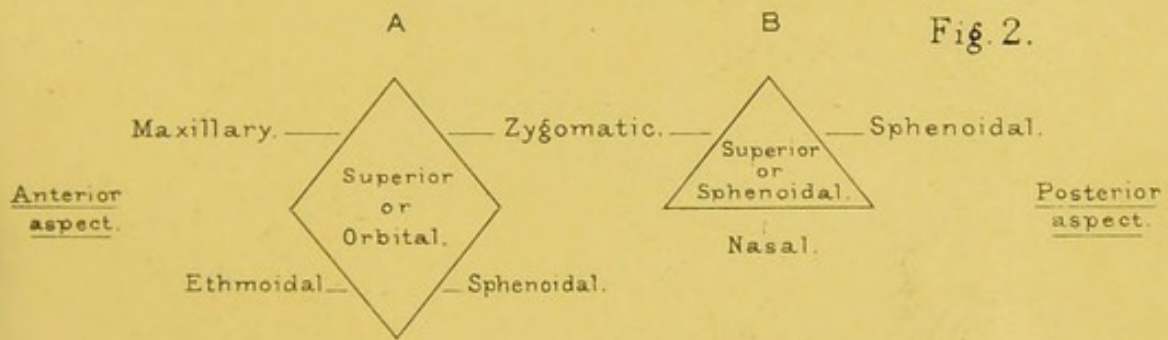
SURFACES.—The *inferior* surface (Plate XIV. fig. 2) presents a transverse ridge for the attachment of the aponeurosis of the 'tensor palati.' The rest of the surface is smooth, different therefore from the under surface of the palatine process of the

Fig. 1.



INTERNAL VIEW OF PALATE BONE.

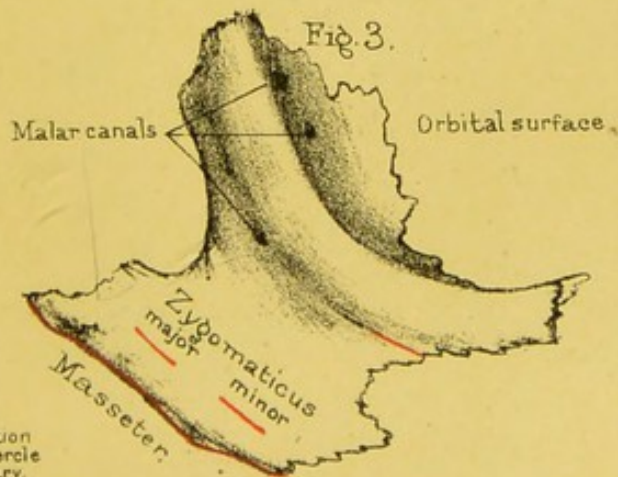
External aspect.



Internal aspect.

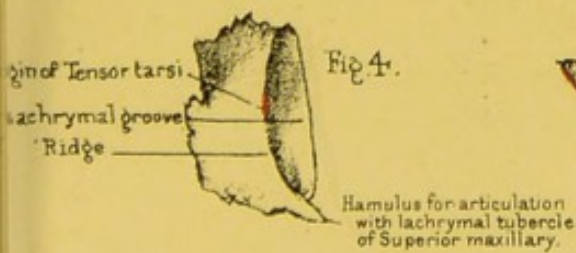
Diagram of surfaces of Orbital (A) & Sphenoidal (B) processes of Palate bone.

Fig. 3.



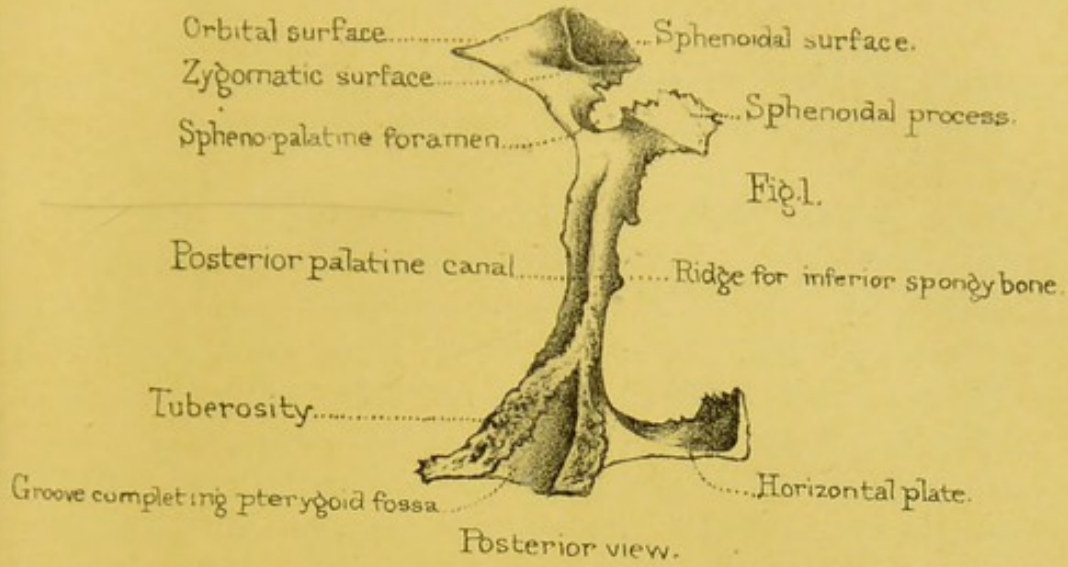
MALAR BONE.

Fig. 4.

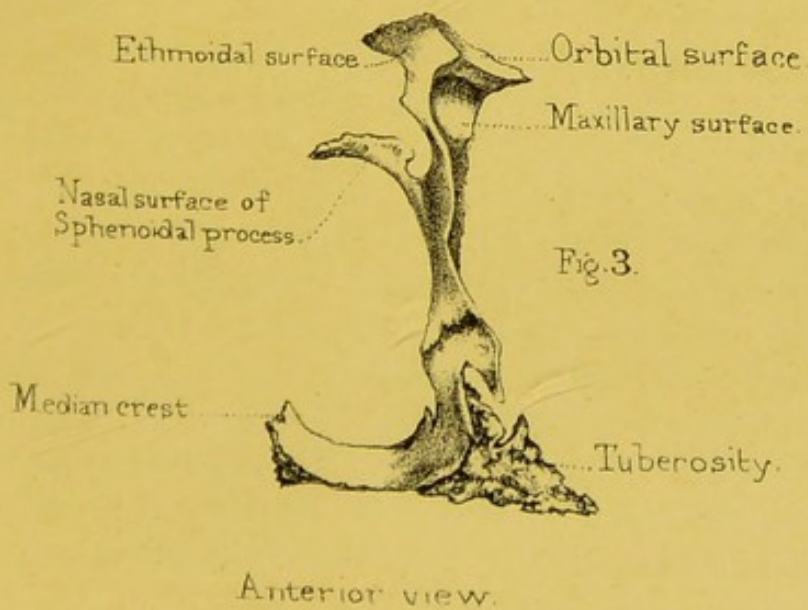
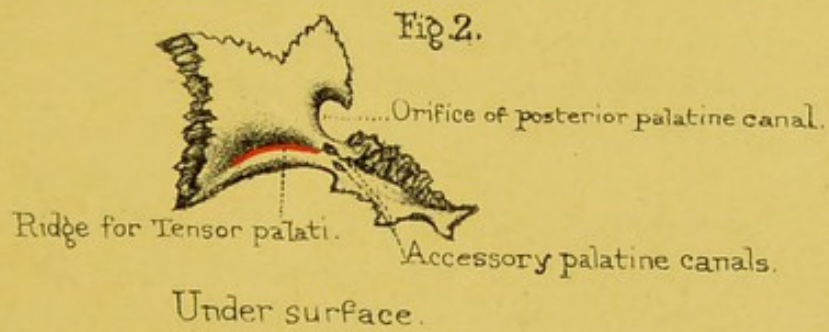


LACHRYMAL BONE.





PALATE BONE.



Drawn on Stone by T. Godart.
 From nature by L. Holden.

Printed by West, Newman & Co.



superior maxillary bone, which, we remember, was very rough. The *superior* surface is smooth and slightly concave, thus forming part of the floor of the nose.

BORDERS.—The *anterior* border of the plate is serrated and cut obliquely, so as to articulate with, and be supported by, the palate plate of the superior maxillary. The *internal* border firmly articulates with its fellow, and by means of a half-crest, made a whole one by the apposition of the half-crest of the opposite bone, precisely like the corresponding parts in the superior maxillary bone (Plate XXIII. fig. 1), supports the vomer, and forms a basis for the septum of the nose. Behind, it terminates in a pointed process, which articulates with a similar one on the opposite bone, and the two together form the ‘posterior nasal spine’ (Plate XX.) giving origin to the ‘azygos uvulæ’ muscle. The *external* border is continuous with the perpendicular plate, and, when viewed on its inferior aspect, shows anteriorly a smooth notch, or, it may be, a complete foramen, the lower end of the ‘posterior palatine groove,’ for the passage of the descending palatine vessels and the large palatine nerve from the sphenopalatine ganglion.

Vertical Plate.—The vertical plate of the palate bone contributes to form the outer boundary of the nasal fossa. It is a four-sided plate, elongated vertically and resting against the posterior part of the inner surface of the body of the superior maxillary bone.

SURFACES.—The *internal* (Plate XIII. fig. 1) presents from above downwards, first, an antero-posterior ridge, close to the upper border of the plate, and termed the ‘superior turbinated crest,’ to the fore part of which the inferior turbinated process of the ethmoid or the middle turbinated bone of the articulated skull is joined; next, a smooth antero-posterior groove, helping to form the middle meatus; next, a rough ridge, the ‘inferior turbinated crest,’ running from behind upwards and forwards, for articulation with the inferior turbinated bone; and lastly, a smooth antero-posterior groove helping to form the inferior meatus of the nose. The *external* presents a smooth groove running downwards and slightly forwards to terminate at the notch

already described upon the outer border of the horizontal plate. The groove is termed the 'posterior palatine groove,' and is converted into a canal by a corresponding groove upon the inner surface of the superior maxillary bone. In some bones the lower end of the canal is formed entirely by the palate bone. The upper end of the groove widens and makes a little triangular surface which forms the inner wall of the spheno-maxillary fossa. The posterior palatine groove lodges the descending palatine blood-vessels and the large palatine nerve. The rest of the external surface is rough and articulates with the superior maxillary bone.

BORDERS.—The *superior* supports the 'orbital' and the 'sphenoidal process' at its anterior and posterior extremity respectively. Between the two processes it forms a smooth notch, the 'spheno-palatine notch' (Plate XIV.) forming the lower part of the 'spheno-palatine foramen' of the united skull, and giving passage to nasal and naso-palatine branches of Meckel's ganglion with corresponding arteries. The *inferior* is continuous with the horizontal plate. The *anterior* is sharp and irregular. It helps to close the opening of the antrum posteriorly, and, below the level of the inferior turbinated crest, is prolonged forward into a triangular process with a sharp serrated anterior inferior edge which is received into the fissure already described on the inner surface of the superior maxillary bone. The process is termed the 'maxillary process,' and by its upper part it helps to close the opening of the maxillary sinus inferiorly. The *posterior* is sharp and rough superiorly where it articulates with the front of the pterygoid process of the sphenoid. Inferiorly it swells out into what is called the 'tuberosity of the palate bone.' This is the thickest and strongest part of the whole bone, and it fits into and fills up the 'notch' which is seen between the pterygoid plates of the sphenoid. Notice also that its posterior aspect presents a groove which completes the pterygoid fossa, and gives origin to a part of the 'pterygoideus internus.' The groove is bounded by two rough grooves, which diverge from each other like the letter V reversed. (Plate X. fig. 2.) The inner groove is the deeper and more vertical, and articulates with the anterior border of the

internal pterygoid plate; the outer is the shallower and more oblique, articulating with the anterior border of the external pterygoid plate. The anterior aspect of the tuberosity looks outwards as well as forwards, and presents a very rugged surface, which articulates with the tuberosity of the superior maxillary bone. Behind this rugged surface is a smooth portion continuous with the outer surface of the 'external pterygoid' plate; this smooth part gives origin to some of the fibres of the 'external pterygoid' muscle. The inferior aspect has nothing remarkable on it, except the orifices of one or two canals large enough to admit a pin. They are the 'accessory palatine canals,' and transmit the external and the small palatine nerves to the soft palate.

Turn now your attention to the upper part of the palate bone, and observe that at the top of the vertical plate there are two processes separated by a deep notch, which forms the greater part of the 'spheno-palatine foramen.' One of these processes is called the 'orbital,' because it fills up a little corner at the back part of the orbit; the other is called the 'sphenoidal,' because it fits under the body of the sphenoid bone.

Orbital Process.—The 'orbital process' springs from the top of the bone by a narrow 'neck,' and is hollow, so that it forms a cell. The cell contains air, admitted through one of the posterior ethmoidal cells. This little process has *five* surfaces, unequal in extent, and looking in different directions. If you hold the bone before you, precisely as it is in your own person, and remember that it is interposed between the maxillary in front and the sphenoid behind, you will have no difficulty in recognising the direction of the surfaces to be as follows (see Plate XIII. fig. 2): the *superior*, smooth, looks upwards and outwards, and contributes to form the floor of the orbit; the *antero-external* is rough, looks downwards, forwards, and outwards, and articulates with the superior maxillary bone; the *postero-external* is smooth, and contributes to form the bottom of the zygomatic fossa; the *antero-internal* is rather concave and rough for articulation with the ethmoid, presenting a large irregular opening through which the cavity is continuous with the posterior ethmoidal cells; the

postero-internal looks backwards, upwards, and slightly inwards, occasionally shows a second opening of the cell contained by the process, and articulates with the body of the sphenoid.

Sphenoidal Process.—This is a somewhat thin plate of bone, which arches inwards beneath the body of the sphenoid, and forms part of the outer wall of the nasal fossa. As it is generally broken in the separate bone, one can see it best in the perfect skull. (Plate XX.) The arch which it forms has four surfaces: the *superior* or *sphenoidal*, articulating with the body of the sphenoid and closing in the pterygo-palatine canal; the *internal* or *nasal*, smooth, and forming part of the upper meatus of the nose; the *antero-external* or *zygomatic*, helping to form the bottom of the zygomatic fossa; the *postero-external*, looking upwards and outwards, and articulating with the body of the sphenoid.

SPHENO-PALATINE NOTCH.—Respecting the spheuo-palatine notch, we need, for the present, merely observe, that it is converted into a foramen by the body of the sphenoid above; and that the opening so made leads from the spheuo-maxillary fossa, that is the bottom of the zygomatic fossa, into the cavity of the nose, and transmits, as already said, the nasal and naso-palatine nerves with their corresponding arteries. (Plate XXII.)


Connections.—The palate bone articulates with six bones—namely, its fellow, the sphenoid, the ethmoid, the inferior spongy bone, the vomer, and the superior maxilla.

Ossification.—It is developed from a single centre of ossification, which appears at the angle of the horizontal and vertical portions, about the seventh or eighth week of foetal life.

INFERIOR SPONGY OR TURBINATED BONE.

(PLATE XV. figs. 1 and 3.)

In each nasal cavity there are three spongy or turbinated bones—an upper, a middle, and a lower. The upper and middle form part of the ethmoid bone, and have been already described. We have now to examine the lower one.



Lachrymal process — Ethmoidal process.



Fig. 1.

Inferior Spongy bone, inner surface.

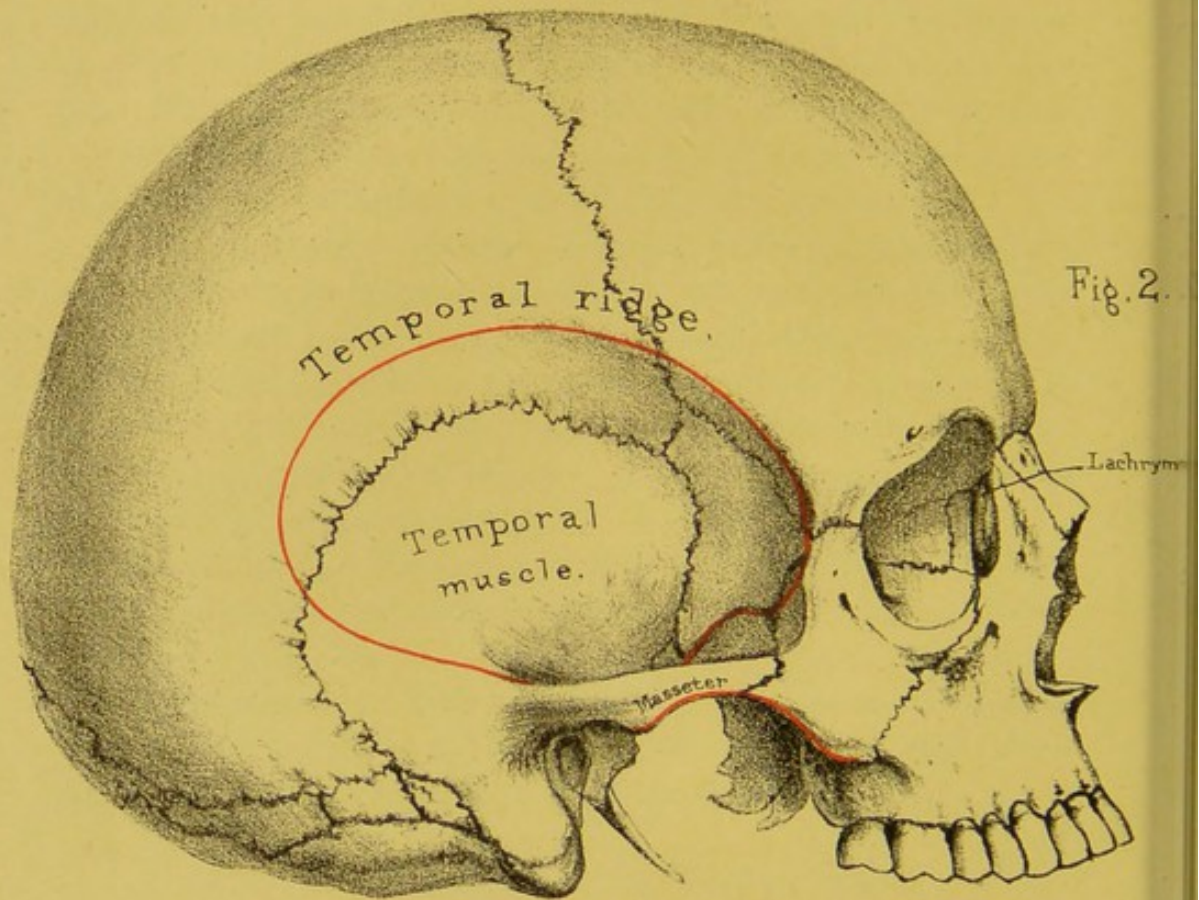


Fig. 2.

Lachrymal process —
Ethmoidal process —
Maxillary process —

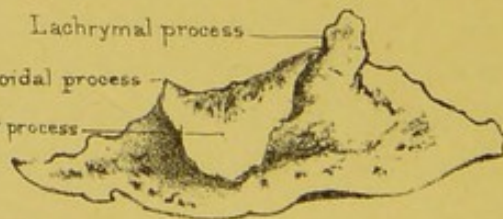


Fig. 3.

Inferior Spongy bone, outer surface.

Its Position and Use.—This thin plate of bone is well called ‘spongy,’ from its structure, and ‘turbinated,’ from its curved form. By referring to Plate XXIII. fig. 2, you see it *in situ*, and observe how much longer it is than either of the others.

SURFACES.—Its *internal* surface, forming the convex part of the roll, looks towards the septum of the nose; its *external* surface forms the concave part, and bounds the inferior meatus of the nose. Both surfaces are covered with little ridges and furrows, and more or less horizontal canals, which lodge numerous plexuses of arteries, but chiefly of veins. This quite accords with the function served by the bone, namely, of affording an additional extent of surface which warms the air on its passage to the lungs. It has nothing to do with the sense of smell. The olfactory nerves have not been traced lower than the middle spongy bone.

BORDERS.—Its *superior* border is arched upwards and is divisible into thirds, of which the anterior is the shortest. This third is sharp and rough, and slopes downwards and forwards, articulating with the inferior turbinated crest of the superior maxillary bone. Its posterior third is also sharp and slopes downwards and backwards to articulate with the inferior turbinated crest of the palate bone. Its middle third is nearly horizontal, and gives attachment to three processes—one attached to the anterior extremity and running upwards and slightly forwards for articulation with the angle of the lachrymal, helping to close the naso-lachrymal canal inferiorly, and termed the ‘lachrymal process;’ one attached to the posterior extremity, projecting upwards and slightly forwards to meet the uncinatè process of the ethmoid, and hence called the ‘ethmoidal process;’ and another attached to the whole length of the middle third, triangular in shape, turning down like a dog’s ear, helping to narrow the lower part of the orifice of the antrum, and termed the ‘maxillary process.’ Notwithstanding these numerous connections, the bone is by no means strongly fixed in its position: in the dry skull it often falls out; and in the operation of extracting a polypus from the nose, it is quite possible to pull out part of the bone or even the entire bone with the polypus. Its *inferior*

border is free, rough, thickened, perhaps containing a cell or two, and stretching nearly horizontally from before backwards with a slight sweep downwards. It is situated about half an inch above the floor of the nose, so that there is just room enough to introduce the tube of a stomach-pump through the nasal cavity.

Ossification.—The bone has one centre of ossification, which appears in cartilage about the fifth month of foetal life.

Comparative Osteology.—See the remarks at the end of ‘The Ethmoid Bone.’

THE VOMER.

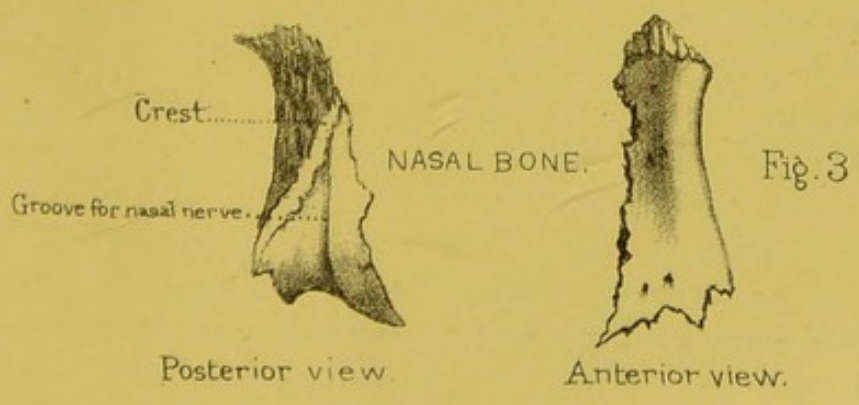
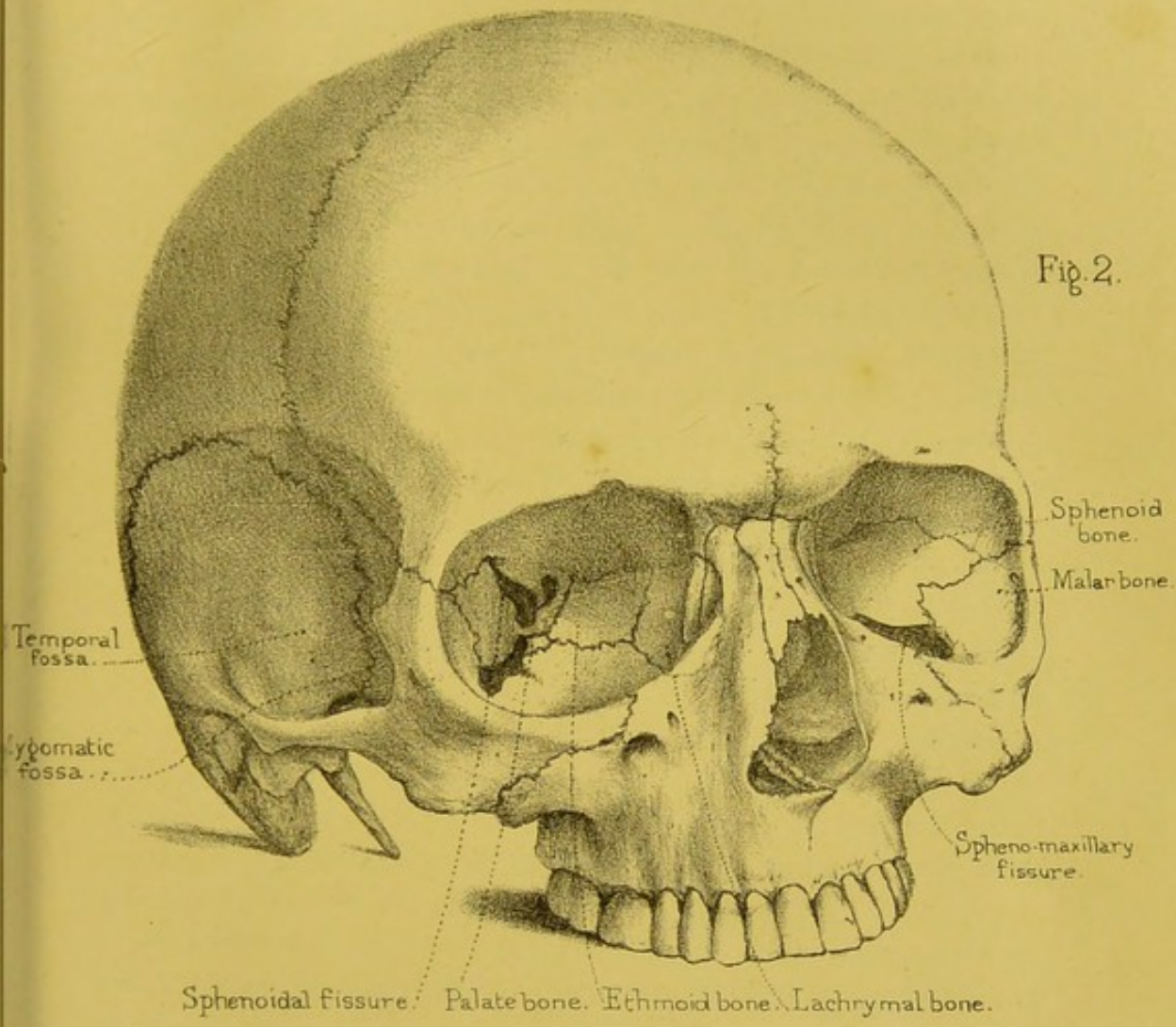
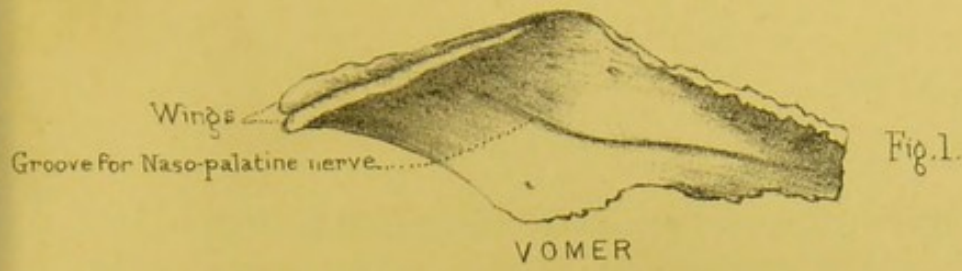
(PLATE XVI. fig. 1.)


The ‘vomer’ is so named from its resemblance to a plough-share. It is a thin and delicate plate, situated perpendicularly in the middle line, and, together with the perpendicular plate of the ethmoid bone, forms the greater part of the bony septum of the nose. (Plate XXIII. fig. 1.)

When looked at from the side the vomer is four-sided with a very sharp anterior inferior angle.

SURFACES.—Both its *lateral* surfaces are smooth and marked by grooves for blood-vessels and nerves. The only groove deserving special notice is one which descends from behind and above, downwards and forwards to terminate in the corresponding foramen of Scarpa, already described in connection with the superior maxillary bone. The groove may be a complete canal in some places, and may be better marked on one side than on the other.

BORDERS.—The *superior* border expands into two ‘alæ.’ The outer margins of these ‘wings’ articulate with and are overlapped by the vaginal plates of the sphenoid, and the smooth groove included by the wings rests against the rostrum of the sphenoid, fibrous tissue containing blood-vessels intervening between the two. The *inferior* border in its posterior three-fourths or so runs nearly straight from before backwards, and is rough to articulate with the crest formed by the palate and superior maxillary bones. In its anterior fourth it presents a deep concavity directed down-





wards and forwards to articulate with the particularly high part of the vomerine crest formed by the superior maxillary bones. The posterior half or so of the lower border is thin and sharp, and is received by the crest formed by the palate and superior maxillary bones. In the anterior half the lower border usually spreads out into two little wings, which receive from below the crest formed by the superior maxillæ. The *anterior* border slopes from behind downwards and forwards. It is usually grooved in its upper half to articulate with the vertical plate of the ethmoid, and very frequently so in its lower half to join with the septal cartilage of the nose. The *posterior* border is sharp and smooth, branches somewhat above, and is slightly concave downwards and backwards as it runs from above downwards and forwards. It forms the boundary between the posterior openings of the nasal cavities.

Connections.—The vomer is connected with six bones. Below, it articulates with the crest of the maxillary and palate bones; above, with the lower edge of the rostrum of the sphenoid; in front, with the perpendicular plate of the ethmoid.

It is necessary to know that the direction of the vomer is not, in all persons, perpendicular. In 100 skulls the vomer was found to be perpendicular only in 24. There are instances in which it projects into one side of the nose to such an unusual extent, that when covered by its vascular and swollen mucous membrane, the projection might easily be mistaken for a polypus. Such mistakes are alluded to in surgical works.³⁷

Ossification.—The vomer is developed from one centre of ossification, which appears at the lower and back part of the septum of the nose about the eighth month of fetal life, and which gradually rises up as two plates, one on each side of the middle line, embracing the septal cartilage. As they grow upwards these plates fuse with one another from below upwards and from behind forwards. At the age of puberty we find the bone consolidated into one piece with the exception of the groove between the alæ and the smaller one usually situated on the anterior border. Very frequently we notice that the ossification is incomplete in the upper and anterior half of the bone, and that the bone in that region consequently presents a rough, open, cellular

appearance. Indeed, in some cases we may find that it is completely perforated, so that the nasal fossæ of opposite sides communicate with one another in the bony state.

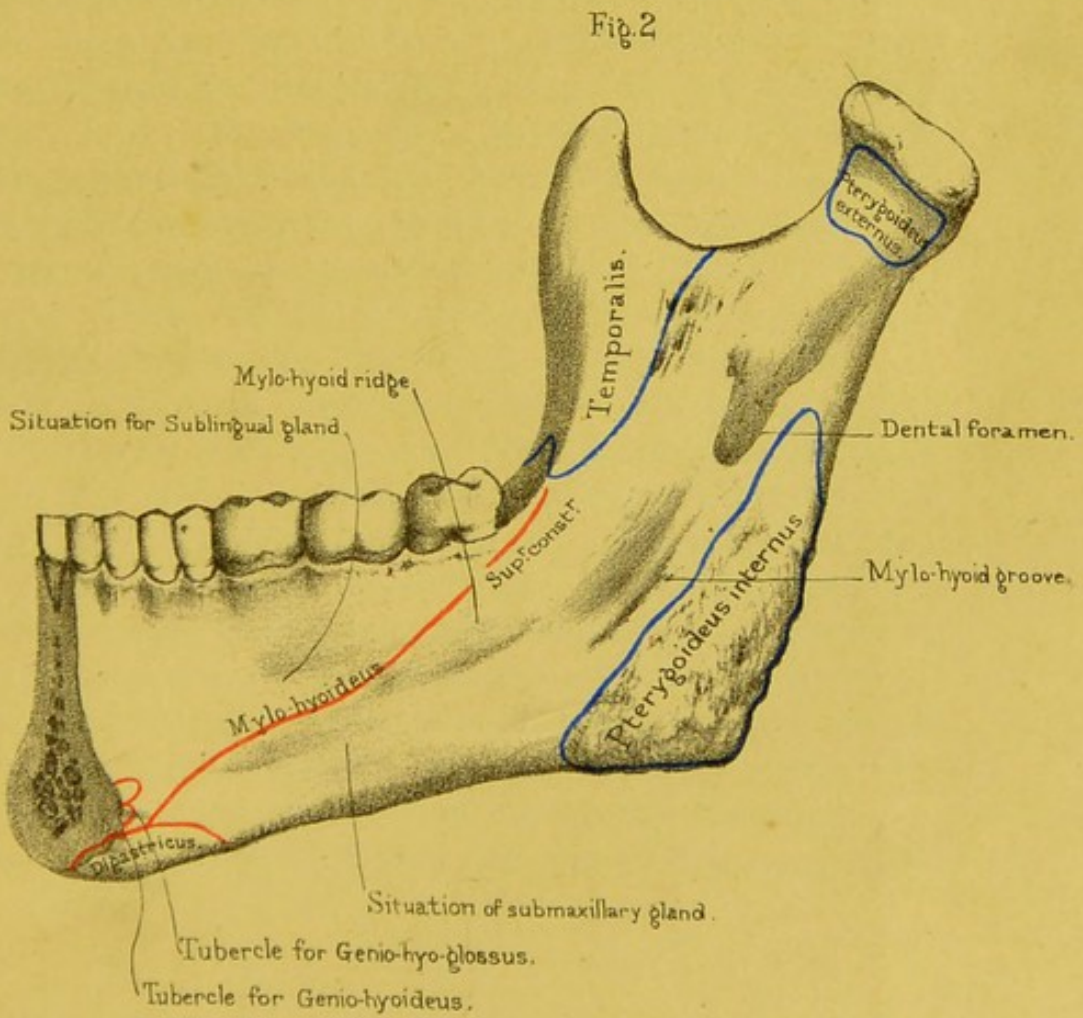
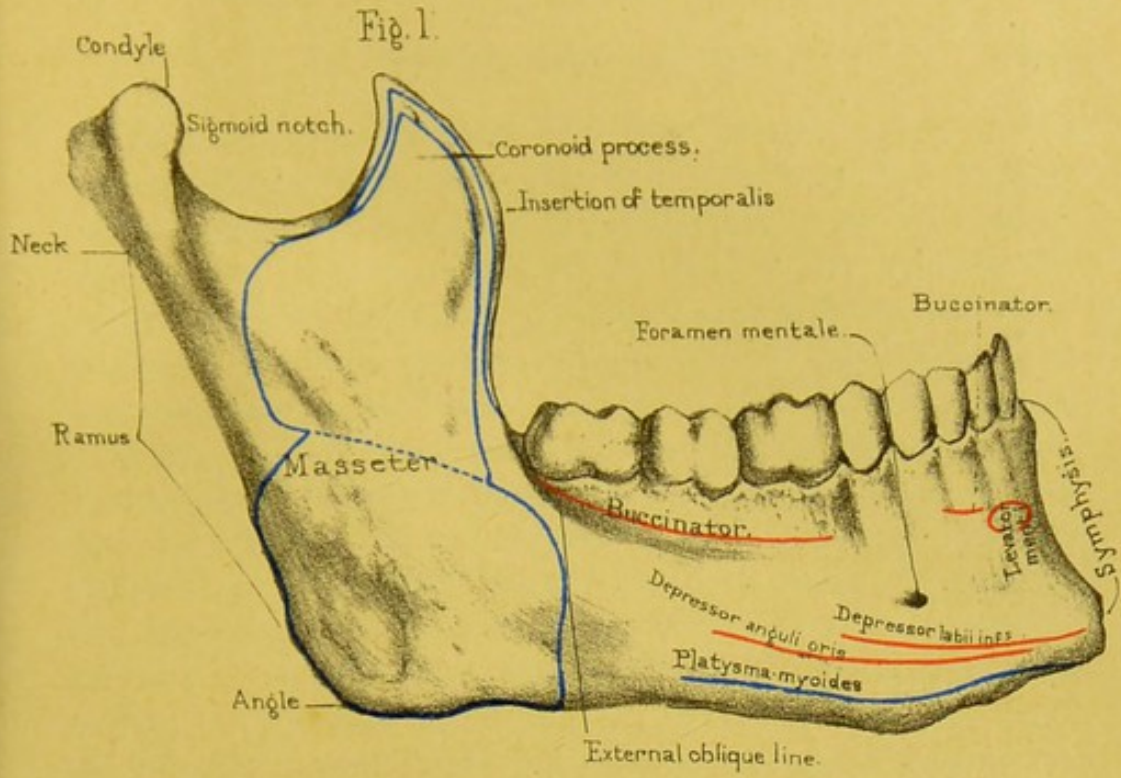
INFERIOR MAXILLARY BONE.


(PLATE XVII.)

For convenience of description we divide the lower jaw into the arched part in front, the 'body' or 'horizontal ramus,' and two ascending parts behind, the 'ascending' or 'vertical rami.' At the top of each vertical ramus are the 'condyle' or articular surface, the 'coronoid process' for the insertion of the temporal muscle, and the 'sigmoid notch.'

Body or Horizontal Ramus.—SURFACES.—The *anterior* or convex surface of the body presents, in the middle line, a slight ridge, the 'symphysis,' which is the strongest part of the bone and indicates where the two halves of the bone have grown together. Its direction is vertical or even projects forwards: this is one of the characteristics of man, who alone has a chin. The 'symphysis' terminates, below, in the triangular 'mental process.' On each side of the symphysis is a slight depression, the 'mental fossa,' which gives origin to the 'levator menti.' More externally, and generally in a line with the second bicuspid tooth, is the 'mental foramen,' which transmits the 'mental branches' of the inferior dental nerve and artery, and forms the lower opening of the 'dental canal.' From the base of the mental process we trace the 'external oblique line' running upwards and backwards to become continuous with the anterior border of the vertical ramus. From it we find the 'depressor anguli oris' arising; above it, the 'depressor labii inferioris;' and below it, the insertion of the 'platysma myoides.' Along the alveolar border adjacent to the three molar teeth is one of the origins of the 'buccinator,' and outside the mental fossa, on the ridge corresponding to the socket of the canine tooth, a few of the deep fibres of the 'orbicularis oris' take their attachment.

The *posterior* surface of the body is concave from side to side.





In the middle line in front it shows a narrow vertical groove with a nutrient foramen or two in it inferiorly, and a plane surface superiorly, indicating the symphysis menti. Placed on each side of the lower half of the middle line we have two rough tubercles, one above the other, and close by the lower border of the bone an oval, rough, shallow depression. The tubercles are named the 'superior' and 'inferior genial tubercles' for the attachment of the 'genio-hyoglossus' and 'genio-hyoid' muscles respectively—the shallow rough depression the 'digastric fossa' for the attachment of the digastric muscle. Very frequently the *four* genial tubercles are confluent and appear as one irregular vertical ridge on the posterior aspect of the symphysis. Leading obliquely upwards and backwards from the lower genial tubercle, to become continuous with the inner lip of the anterior border of the vertical ramus, is the 'internal oblique line' or 'mylo-hyoid ridge,' for the attachment of the 'mylo-hyoid' muscle, and quite at its posterior extremity the 'superior constrictor' of the pharynx. The part of the surface below the ridge is rather concave and smooth, and, because it lodges the submaxillary gland, it is named the 'submaxillary fossa.' In it we notice a few small nutrient foramina, directed towards the symphysis. Above the ridge is the place for the sublingual gland, hence termed the 'sublingual fossa.' It is not so well marked as the submaxillary fossa. These 'oblique' 'lines' or 'ridges' on the two surfaces of the body are something more than mere muscular impressions. They indicate the limit between the 'alveolar' part which contains the teeth, and the lower or 'basilar' part of the jaw. These distinctions are made because these parts come and go at different periods of life. In infancy there is only the alveolar part; towards puberty the basilar part slowly grows to perfection: in old age when the teeth fall out, and their sockets are absorbed, the basilar part alone remains, and the chin gradually approximates the nose. The absorption of the sockets (alveoli), which is natural in old persons, often occurs prematurely. It is apt to arise from long salivation, scurvy, or purpura, and is frequently hereditary.

BORDERS.—The *inferior* border of the body forms, in front, the

base of the mental process. Laterally it is rounded and rough for the attachment of the 'platysma' muscles. As the posterior extremity of the border, on each side, becomes continuous with the corresponding lower margin of the vertical ramus, it forms the anterior half of the groove of the passage of the facial artery on to the face. The *upper* border is narrower in front than behind and is marked by sockets for the teeth.

TEETH.—The teeth in the lower jaw correspond in number (eight on each side) with those in the upper, but differ from them in these particulars: 1. The first two lower molars have only two fangs, an anterior and posterior, while the upper molars have three. In the third molar or wisdom tooth the fangs are often consolidated into one; 2. When the mouth is closed the teeth of the lower jaw shut within those of the upper jaw, which form a larger arch; 3. The external tubercles or cusps of the teeth of the lower jaw fit into the hollows between the external and internal cusps of the teeth of the upper jaw; by which arrangement we are enabled to use the entire surface of the opposing teeth in grinding the food. When the jaws are closed, each tooth in one jaw is opposed by two in the opposite jaw; one good result of this is, that when we lose a tooth, the corresponding tooth in the other jaw, being still more or less opposed, is still of service in mastication.

Vertical Ramus.—The vertical ramus of the jaw mounts up from each of the posterior ends of the body at nearly a right angle in adult age, when the upper and lower jaws are kept well apart behind by the molar teeth. In infancy, before the development of the molars, and in age, when they are lost, the 'angle' between horizontal and vertical rami becomes obtuse. Excluding the outstanding processes, the vertical ramus is quadrilateral.

SURFACES.—The *outer* surface is smooth above and rough below and behind. It gives insertion, in almost the whole of its extent, to the 'masseter' muscle (fig. 1). Its posterior and inferior angle is always turned more or less outwards. The *internal* surface (fig. 2) is concave from before backwards and very slightly so from above downwards and forwards. A little above the middle,

is the large 'dental foramen,' or the upper aperture of the inferior dental canal for the transmission of the inferior dental nerve and artery. Leading from above and behind downwards and forwards to this foramen is a broad shallow groove for the passage of the same nerve and artery, and running from the foramen downwards and forwards, to lose itself in the submaxillary fossa of the body, is a small narrow groove for the passage of the mylo-hyoid nerve and artery, and termed the 'mylo-hyoidean groove.' Below the dental foramen and these two grooves, the surface is rough for the insertion of the 'internal pterygoid' muscle; above them the surface is smooth, excepting in the immediate neighbourhood of the superior and anterior borders, where it is rough for the insertion of the 'temporal' muscle. The anterior and internal lip of the dental foramen rises up into a sharp projection called the 'dental spine' for the attachment of the internal lateral ligament of the jaw.

BORDERS.—The *anterior* border presents, in its upper half which is free, the appearance of a vertical groove with an outer and an inner lip. The outer lip is the more prominent and is continuous superiorly with the anterior border of the coronoid process and inferiorly with the external oblique line of the body. The inner lip is the rounder and flatter of the two; it is continuous inferiorly with the internal oblique line of the body and superiorly gradually fades off on the inner surface of the coronoid process. Both lips of the groove between give attachment to the temporal muscle, excepting inferiorly just behind the last molar tooth, where we find, in muscular jaws, a little vertical crest rising up, to which the 'buccinator' is attached, and which is named the 'buccinator crest.' The lower half or so of the anterior border is continuous with the body of the bone. The *posterior* border is smooth and rounded superiorly, rough and narrow inferiorly. The inner aspect of the border, just below the root of the condyloid process, shows a smooth groove continuous with the one described upon the inner surface, and lodging the internal maxillary artery. The narrow rough part of the border affords insertion to the 'masseter' externally and to the 'internal pterygoid' internally. The *inferior* border is continuous with the lower

border of the body, and is rough behind for the attachment of the two last named muscles. Anteriorly it presents a smooth shallow half-groove, made a whole one by the opposition of the corresponding half on the lower border of the body, for the passage of the facial artery. The *superior* border supports the neck of the condyle posteriorly, the root of the coronoid process anteriorly, and makes the bottom of the sigmoid notch between these processes.

The *angle of the lower jaw* is formed by the meeting of the posterior with the inferior border of the vertical ramus. In the adult jaw it is rather more than a right angle. In infancy and in old age it becomes much more obtuse, for reasons we have previously mentioned.

Condylod Process.—This process projects from the posterior and superior angle of the vertical ramus to form the joint of the jaw, and fits into the glenoid cavity of the temporal bone, a pad of fibro-cartilage intervening between the two in the recent state. The upper part of the process is the ‘condyle,’ and the contracted part supporting it is called the ‘neck of the jaw’ or the ‘neck of the condylod process.’ The condyle is oblong in form, and convex both from without inwards and from before backwards. The long axis is directed from without backwards, inwards, and slightly upwards. In some jaws the long axis is horizontal, and in a still fewer number the outer end of the condyle is a little higher than the inner. The outer extremity of the condyle is termed the ‘tubercle’ for the attachment of the external lateral ligament. The neck is flattened in the same direction as the condyle, and is slightly excavated in front, forming the ‘pterygoid fossa’ for the insertion of the ‘pterygoideus externus’ muscle.

The oblique direction of the condyles of the jaw renders easy the rotatory movement necessary in mastication. In masticating we can readily feel that one condyle advances towards the anterior margin of its glenoid cavity, while the other recedes to the posterior.

Coronoid Process.—The coronoid process is a triangular, lofty plate of bone which rises upwards and slightly outwards

from the anterior superior angle of the vertical ramus beneath the zygomatic arch and increases the leverage of the 'temporal' muscle. Its *external surface* is smooth, and is occupied by the 'masseter' muscle, except close to the anterior and posterior margins, where a few fibres of the temporal are attached. The *internal surface* is rougher, shows the gradual fading off from below upwards of the inner lip of the anterior border of the vertical ramus, and gives insertion to the 'temporal' muscle. Its *anterior border* is sharp and continuous with the outer lip of the anterior border of the vertical ramus; its *posterior* is also sharp and forms the anterior part of the sigmoid notch. Both these borders and the apex between them afford attachment to the temporal muscle. Its *base* or *inferior border* is continuous with the rest of the bone.

SIGMOID NOTCH.—This is a semilunar space left by the rising up of the coronoid and condyloid processes anteriorly and posteriorly, and transmits the small masseteric vessels and nerve.

Structure.—The walls of the lower jaw, particularly at the basilar part, are exceedingly compact and tough. In operations for removal of this part of the bone, it is necessary to use the saw freely, before the bone-forceps can be of any service. The interior assumes the form of 'diploe,' and is traversed by the 'inferior dental canal,' which carries the vessels and nerves to the teeth (Nor. Hum. Ost. No. 234). This canal begins on each side on the inner side of the ramus, curves forwards, beneath the sockets of the teeth, and opposite the interval between the first and second bicuspid tooth curves backwards, upwards, and outwards to terminate on the anterior surface of the body as the mental foramen. From the convexity of the curve a small canal runs towards the symphysis menti, giving off smaller canals leading upwards to the sockets of the two incisors, canine, and first bicuspid teeth.

Ossification.—Each lateral half of the lower jaw is represented in the early fœtus by what is called the 'first visceral arch,' or 'cartilage of Meckel.' In the process of development the proximal part of this cartilage is converted into the 'malleus' bone of the middle ear. The distal part, mostly by the growth

of bone round the cartilage, but slightly by a direct ossification of the cartilage itself, is converted into one half of the lower jaw. The part between these two end portions becomes the 'internal lateral ligament' of the temporo-maxillary articulation. The *bony* lower jaw begins to be formed, with perhaps the exception of the clavicle, earlier than any other bone in the body. For each of the lateral halves of the bone, we find that several osseous nuclei appear about the sixth week of foetal life in the membrane which invests Meckel's cartilage. These nuclei speedily join one another and form a large plate outside, and a smaller one inside Meckel's cartilage. The smaller plate forms the inferior dental canal and the inner wall of the sockets for the teeth. The symphysis end of each half of the body is formed by a direct ossification of the corresponding part of Meckel's cartilage. The condyle and part of the vertical ramus are formed by ossification of cartilage *not* connected with Meckel's, and the junction of the two lateral halves of the body at the symphysis does not take place till the first year after birth.

In infancy the body is swollen and larger in proportion to the vertical ramus than it is in the adult. The alveolar portion is broad and thick, on account of its containing the growing teeth, the mental foramen being thereby thrown nearer the lower than the upper border of the body. The vertical ramus is thin as compared with the body, and the angle obtuse. In old age the whole bone is attenuated. The alveolar portion disappears almost entirely by its absorption, consequent on the falling out of the teeth. The mental foramen, consequently, is situated nearer the upper than the lower borders of the body, and the 'angle' becomes obtuse. In the adult jaw, as we have already described, the mental foramen is situated about midway between the upper and the lower borders of the body, and the angle is very little more than a right angle.

Connections.—The lower jaw articulates with the glenoid fossa of the temporal bones, and has lodged in it, in the fully formed state, four incisor, two canine, four bicuspid, and six molar teeth.

Comparative Osteology.—In the order Monotremata, ob-

serve that there is scarcely any bend or inflexion in the lower jaw (No. 3964). The jaw of the anteater is also straight, thus greatly resembling that of the pelican (see Sep. Ser.)

In snakes (Ophidia) the two halves of the lower jaw are not united by bone, but held together by an elastic ligament, which permits the two halves of the jaw to be separated from each other sideways to a considerable extent. This is one of the many arrangements by which the boa is enabled to swallow its prey though larger than its own body. This is shown in the specimen of the tiger-boa (No. 602).

In the lower animals the two halves of the jaw generally remain separate throughout life. In all mammalia each half of the lower jaw consists of a single piece which articulates with the squamosal bone of the skull. In all below the mammals it articulates with a modified malleus called the quadrate bone. This is well seen in the skull of the ostrich and other birds in the Separate Series.

[For some interesting points as to the relation between the size of the coronoid process and the temporal fossa the student should read the Comparative Osteology paragraph at the end of the chapter on 'The Skull as a Whole.']

It has been said that man is the only creature which has a chin. It is most distinct in the Caucasian race, becomes faintly marked in the Negro, and does not exist in the Apes.

Rodentia have never more than two incisors in the lower jaw; and usually only two, but sometimes four, in the upper. When there are four incisors in the upper jaw, as in hares and rabbits, there are two small ones behind the two large ones (No. 3285). These incisors have a persistent pulp, and continue to grow in adult life. They have no canines.

Carnivora have milk and permanent teeth, which are enamelled, and always consist of incisors, canines, and molars.

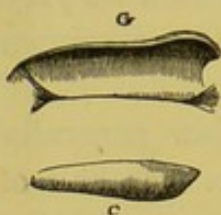
In elephants the teeth consist of tusk-like incisors, growing from persistent pulps, and molars.

Look at the lower jaw of the crocodile (No. 717 D) and see how greatly the angle projects backwards. This projection is for

the insertion of the digastricus, the muscle which opens the mouth, and which acts upon the jaw as a lever of the first order. In man it acts as a lever of the second order, as it is inserted near the symphysis.

To appreciate the mechanism of the lower jaw, look at the form of the joint in animals. In them it varies according to the

FIG. 14.



structure of their teeth and the food they eat. There are three principal types of it: the carnivorous, the ruminant, and the rodent. The *carnivorous* type is a simple transverse hinge: this form is well seen in the badger (No. 751), where the condyle of the jaw is mechanically locked in its socket. It is shown in fig. 14,

where G represents the shape of the glenoid cavity, and C the shape of the condyle which fits into it. The *ruminant* type presents a socket and a condyle nearly flat, so as to admit of the lateral movement necessary for grinding the food. This form is seen in fig. 15, which is taken from the sheep (No. 1250).

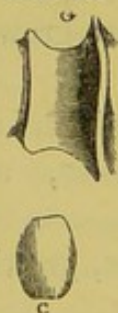FIG. 15.



In the *rodent* type there is a longitudinal groove in the temporal bone in which the condyle plays from before backwards like a plane. Fig. 16 shows the corresponding surfaces of the glenoid cavity (G), and the condyle (C), in the capybara (No. 3276).

The joint of the lower jaw in man partakes somewhat of the nature of these three types: we can move our jaw in the vertical direction, from side to side, and from before backwards. The teeth of man are likewise inter-

FIG. 16.



mediate in structure between those of carnivorous and those of ruminant animals. Man is adapted, by his dentition, to eat animal or vegetable food, and is said to be omnivorous. But the presence of grinding, tearing, and cutting teeth, equally developed, in the jaws of any animal, is no proof that he is omnivorous. Monkeys have large canines, yet live on vegetables; all bats possess well-formed in-

cisors, canines, and molars, yet some are purely frugivorous, whilst the British species live entirely on insects.




Fig. 2.

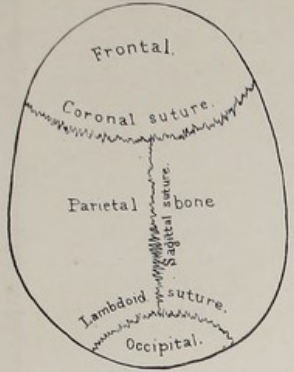


Fig. 1.

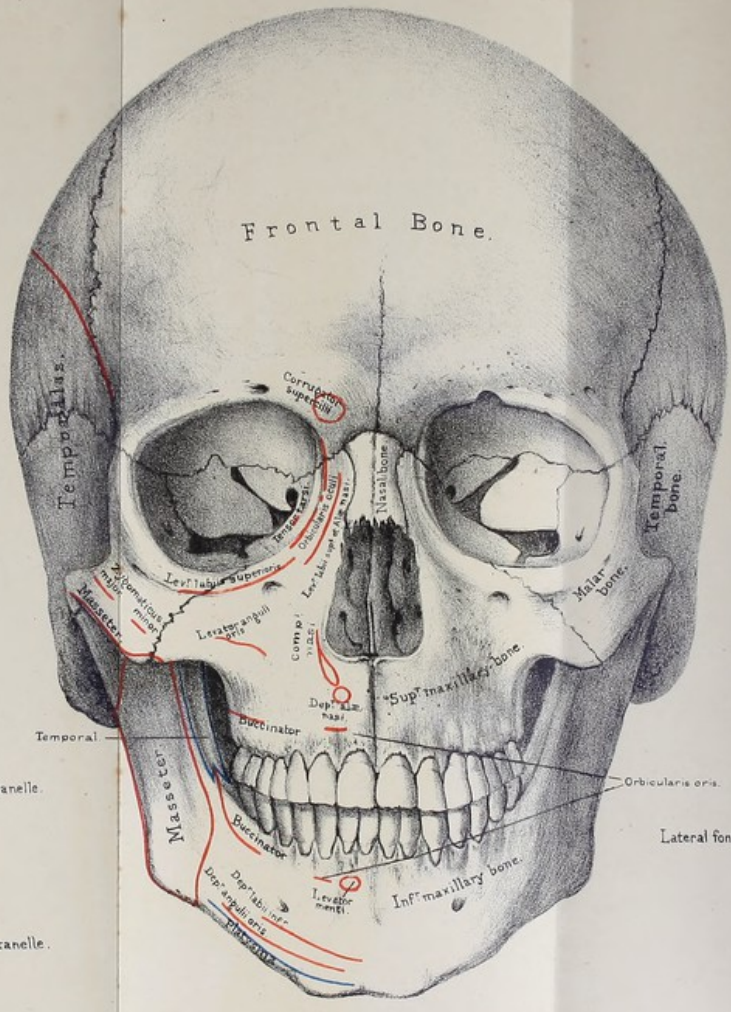


Fig. 3.

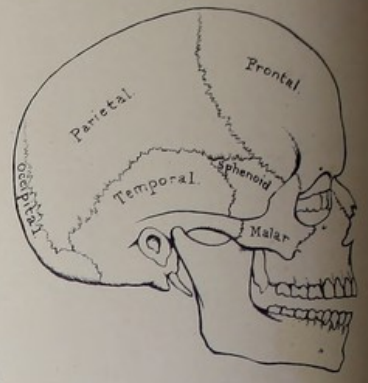


Fig. 4.

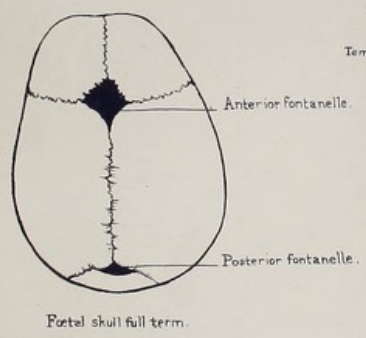
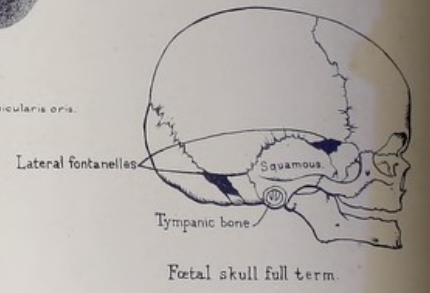


Fig. 5.



From nature by L. Holden.

Drawn on Stone by T. Godart.

Printed by West, Newman & Co

THE SKULL AS A WHOLE.

THE examination of the Skull as a whole is easy and intelligible, provided the individual bones have been carefully studied.

Course of Sutures.—A knowledge of the course of the sutures is of practical value—1, because it enables us to say with precision in what direction the head of the child is presenting during labour ; 2, because in injuries of the skull we must not commit the error of mistaking a suture for a fracture.³⁸

CORONAL SUTURE.—The ‘coronal suture’ (Plate XVIII.) (fronto-parietal) connects the frontal with the parietal bones. It extends transversely across the top of the skull, from the great wing of the sphenoid on one side to the other. In the middle the frontal overlaps the parietal bones, but at the sides the parietals overlap the frontal, by which arrangement the bones are locked together.

SAGITTAL SUTURE.—The ‘sagittal suture’ (inter-parietal) connects the two parietal bones. It runs backwards, in the middle line, from the frontal to the occipital bone. This suture is much serrated, except near the parietal foramina, where it is always much straighter than elsewhere.³⁹

FRONTAL SUTURE.—The ‘frontal suture’ is formed by the union of the two halves of the frontal bone. It runs down the middle of the forehead, from the sagittal suture to the root of the nose. It always exists in infancy and childhood, but is generally obliterated in the adult (Plate XVIII.)

LAMBDOID SUTURE.—The ‘lambdoid suture’ (Greek letter Λ) (occipito-parietal) unites the two parietals to the occipital bone.

OCCIPITO-MASTOID SUTURE.—The ‘occipito-mastoid suture,’⁴⁰

apparently a continuation of the lambdoid, connects the occipital with the mastoid portion of the temporal bone.

MASTO-PARIETAL SUTURE.—The mastoid part of the temporal is connected to the posterior inferior angle of the parietal bone by the ‘masto-parietal suture.’

SQUAMOUS SUTURE.—The squamous part of the temporal is connected to the parietal bone by the ‘squamous suture’ (squamo-parietal); and to the great wing of the sphenoid by the ‘squamo-sphenoidal’ suture. The squamous bone so overlaps the parietal as to strengthen the arch of the skull at the sides, and prevent the lateral expansion of the buttresses.

TRANSVERSE FRONTAL SUTURE.—Of the sutures which connect the bones of the cranium with the face, the chief one is the ‘transverse frontal suture.’ It extends from the external angular process of the frontal bone, from one side to the other, across both orbits and the root of the nose (Plate XVI.) It connects the frontal with the malar, sphenoid, ethmoid, lachrymal, superior maxillary, and nasal bones. Other short sutures, such as the ‘spheno-malar,’ ‘spheno-parietal,’ ‘zygomatic,’ &c., speak for themselves.

A knowledge of the sutures is of practical value in midwifery. Thus when we feel the meeting of the three sutures at the top of the occipital bone, we know that the back of the head presents; if, again, we feel the ‘anterior fontanelle,’ or lozenge-shaped space where four sutures meet (Plate XVIII.), we know it is a forehead presentation.

THE SKULL-CAP.

Skull-Cap: Outer Surface.—The skull-cap forms an oval dome which protects the brain with its greatest breadth about the parietal protuberances. In a well-formed European head, if we look at the skull-cap from above (the beginning of the sagittal suture being in the centre of the perspective plane), we see scarcely anything but the smooth expanded vault of the cranium. But in the Negro and the Australian, the narrowness of the temples allows the zygomata to come into view, and, in the most

' prognathous ' ⁴¹ examples, the incisor teeth appear in front of the frontal sinuses.

FORAMINA.—On the outer surface of the skull-cap are a multitude of small foramina, which transmit blood-vessels from the pericranium into the substance of the bone. Hence, if this membrane be torn off during life, the bone bleeds through minute pores. On each side of the sagittal suture is the ' parietal foramen,' which transmits a vein from the superior longitudinal sinus to the outside of the skull; sometimes a small artery runs with it, and communicates with a branch of the middle meningeal.

TEMPORAL RIDGE.—Along the side of the skull-cap is a curved line, the temporal ridge (Plate XV.) (or ridges, as described in connection with the temporal bone), which indicates the attachment of the temporal aponeurosis to the frontal and parietal bones, and the limit of the attachment of the ' temporal ' muscle to the fossa of the same name.

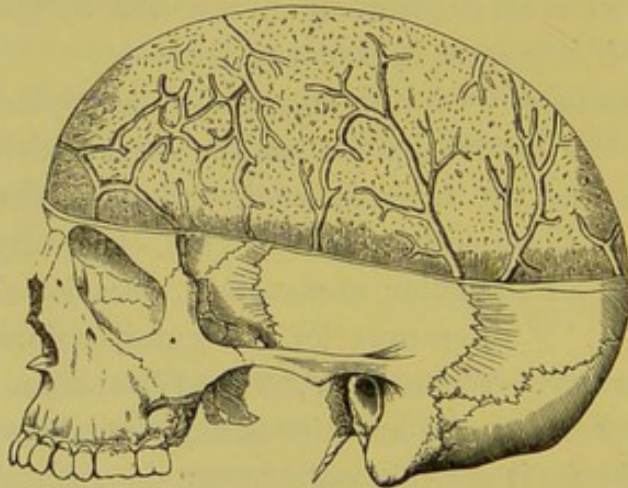
TEMPORAL FOSSA.—The ridge circumscribes the ' temporal fossa,' which is formed by the frontal, parietal, temporal, sphenoid, and malar bones. The fossa gives origin to the temporal muscle, of which the tendinous rays, converging beneath the zygoma, are inserted into the coronoid process of the lower jaw. The size of the temporal fossa in all animals depends upon the size of the temporal muscle. Hence it is largest in the carnivora.

Skull-Cap: Inner Surface.—On the inner surface of the skull-cap we observe—1, the groove in the middle line, which gradually becomes broader as we trace it backwards, for the superior longitudinal sinus; 2, on either side of this, especially in old skulls, are a number of irregular excavations, occasioned by the ' Pacchionian bodies; ' ⁴² 3, grooves for the ramifications of the middle meningeal artery. The main groove, at first sometimes a complete canal, is seen at the anterior-inferior angle of the parietal bone; from thence it spreads widely over the frontal and parietal bones, one branch of considerable size traversing the posterior-inferior angle of the parietal above the groove for the lateral sinus. In fractures of the skull, the arteries running in these grooves are liable to be injured, and thus occasion an effusion of blood, producing compression of the brain.

Thickness of the Skull-Cap.—The skull-cap differs in thickness in different parts. This is easily ascertained by holding it to the light. As a rule, it is thicker in parts which were the centres of ossification—as at the frontal and parietal eminences. It is thinnest in the temporal region. The ordinary thickness of an adult skull is about one-fifth of an inch, though it varies very much at different periods of life. Skulls vary in thickness, even in persons of the same age, and this without any obvious reason. Old age causes general thinning of the skull, as it does all bones in the body, by a process of absorption; while certain diseased states occasion either general or partial thickening or thinning of the skull.

Cerebral Impressions.—The inner surface of the skull-cap is marked by the cerebral convolutions, so that it takes, to a certain extent, an impression of the brain. But it cannot be said that a particular impression on the inner surface has a corresponding bump outside. A glance at any skull-cap is sufficient to prove this. The depressions occasioned by the convolutions take place at the expense of the diploe; and the external bumps are often caused by a mere thickening of the outer table. On the other

FIG. 17.




VENOUS CANALS IN THE DIPLOE.

hand, it holds good, as a general rule, that the external form and dimensions of the cranium may be taken as a *general* expression of the corresponding lobe of the brain, whether in the frontal, the parietal, or the occipital region. The general characters of the brain, then, may be ascer-

tained by external examination, but not the individual details.

Veins of the Diploe.—The diploe of the skull-cap is traversed by numerous venous canals. These (fig. 17) are of considerable size, and are best displayed by filing off the outer



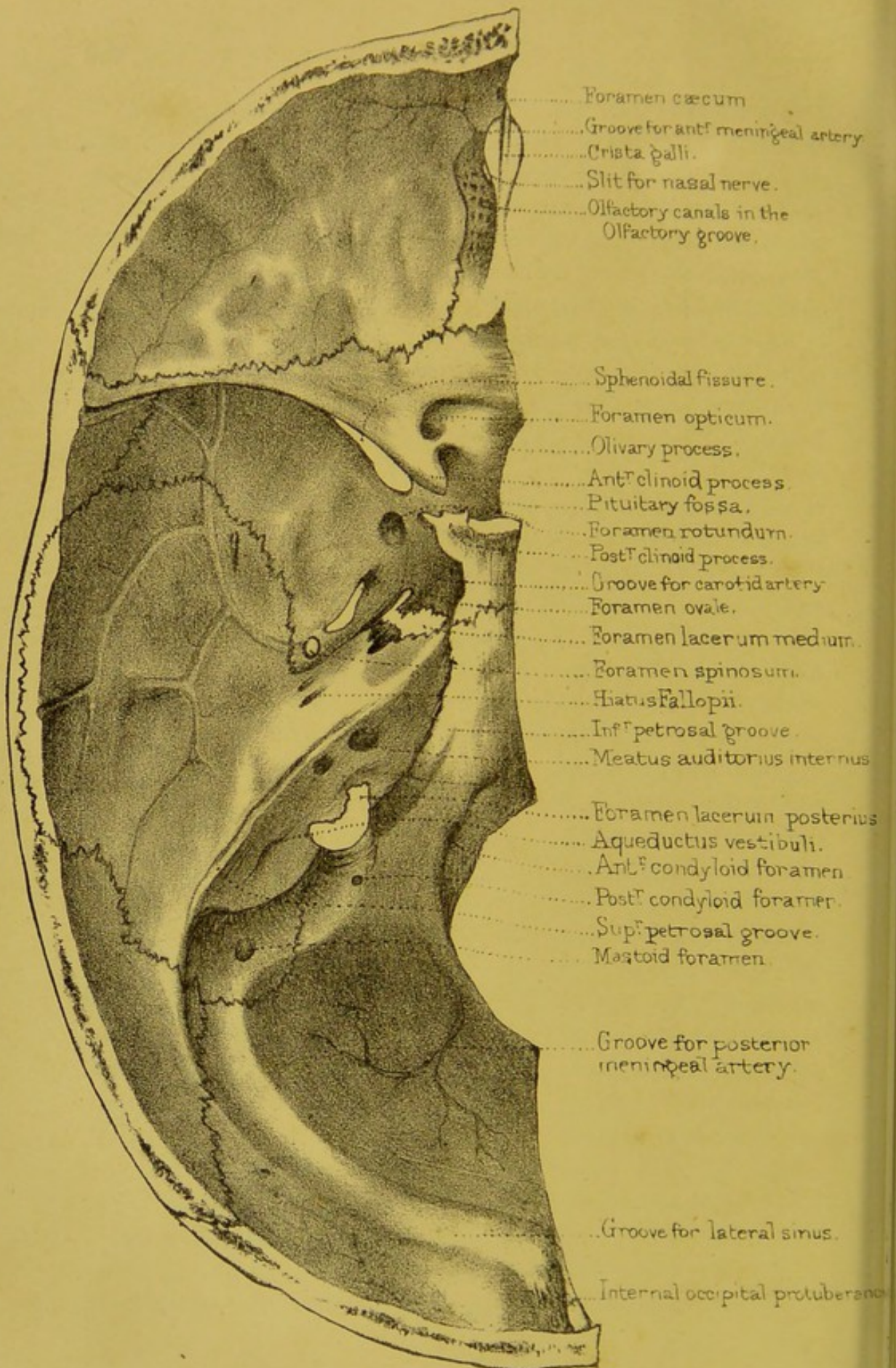


table. Their course is by no means so regular as they are commonly drawn; but, in a general way, we may speak of the frontal, anterior and posterior temporal, and occipital 'diploic' veins on each side of the skull. The frontal discharges its blood at the supra-orbital notch into the supra-orbital vein; the anterior temporal opens externally into the deep temporal vein and internally into the sphenoparietal sinus; the posterior temporal opens internally into the lateral sinus; the occipital pours its blood either externally into the occipital veins or internally into the lateral sinus. After injuries of the head, these veins are liable to inflammation, which may give rise to pus in the diploe and pyæmia. Hence the occasional occurrence of visceral abscesses, especially hepatic, after injuries of the head—a circumstance which had not escaped the notice of the old surgeons.

BASE OF THE SKULL AS SEEN FROM ABOVE.

By referring to Plate XIX. it is seen that the base of the skull presents, on each side, three fossæ,—an anterior, a middle, and a posterior,—respectively lodging the frontal and temporo-sphenoidal lobes of the cerebrum, and the cerebellum. The occipital lobe of the cerebrum rests upon the 'tentorium cerebelli,' and not upon bone. The anterior and middle fossæ are marked by the cerebral convolutions just as much as the skull-cap, especially the anterior.

Anterior Fossa of the Cranium.—The anterior fossa of the cranium is formed by the orbital plates of the frontal, the cribriform plate of the ethmoid, with the front part of the body and the lesser wings of the sphenoid. The points to be noticed in this fossa are as follows: 1. The 'foramen cæcum,' which is usually pervious, and transmits a vein from the superior longitudinal sinus into the nose. 2. The grooves for the 'anterior meningeal arteries,' branches of the anterior and posterior ethmoidal of the ophthalmics. 3. The 'crista galli,' which gives attachment to the falx cerebri. 4. The slits for the 'nasal

nerves,' branches of the first divisions of the fifth nerves. 5. The 'olfactory grooves,' perforated by foramina, which give passage to the filaments of the olfactory lobes. 6. The 'anterior ethmoidal foramina' on the outer side of the olfactory grooves for the transmission of the nasal nerves and anterior ethmoidal vessels. 7. The 'posterior ethmoidal foramina,' at the hinder extremities of the olfactory grooves, for the passage of the posterior ethmoidal vessels.

Middle Fossa of the Cranium.—The middle fossa of the cranium supports the temporo-sphenoidal lobes of the cerebrum, and is formed by the body and the great wings of the sphenoid, squamous and petrous portions of the temporal bones, and a little bit of the anterior inferior angle of the parietals. It is narrow in the middle and wide at the sides. The fossa is separated from the anterior one by the anterior edge of the optic groove, the upper margin of the optic foramina, the 'anterior clinoid processes' to which the 'tentorium' is attached, and the posterior borders of the lesser wings of the sphenoid. The basilar suture, if present, and the upper margins of the petrous portions of the temporal bones separate it from the posterior fossa. In each *lateral half* of the fossa the chief points to be noticed are: 1. 'The sphenoidal fissure' between the wings of the sphenoid, leading to the orbit, and transmitting the 3rd, the 4th, the first division of the 5th, and the 6th nerves, also filaments of the sympathetic nerve and the ophthalmic vein. 2. The 'foramen rotundum' giving passage to the superior maxillary, or second division of the 5th nerve, and behind it one or two 'foramina of Vesalius.' 3. The 'foramen ovale' giving passage to the inferior maxillary, or third division of the 5th nerve, and to the arteria meningea parva, and sometimes to the lesser petrosal nerve. 4. The 'foramen spinosum' giving passage to the arteria meningea media and its two veins—the main trunk of this artery grooving the squamous part of the temporal and the anterior-inferior angle of the parietal bone. 5. The 'foramen lacerum medium' blocked up, in the recent state, by fibro-cartilage—the Vidian (great petrosal) nerve running through the cartilage. The internal carotid artery also passes through it. 6. At the apex of the petrous portion of the

temporal bone the termination of the 'carotid canal,' through which the carotid artery enters the skull: the artery then winds along the groove on the side of the body of the sphenoid. 7. On the front surface of the petrous portion of the temporal bone the 'hiatus Fallopii,' which transmits the great petrosal nerve, and external to it is the opening of the canal for the lesser petrosal nerve. Further back, on the same surface, we may observe the eminence for the anterior (superior) semicircular canal. In the *middle line* we see the—8. 'Groove for the optic nerve,' terminating at each end in the 'optic foramen.' 9. The 'olivary eminence,' which supports the commissure of the optic nerves, and perhaps on each side of it the 'middle clinoid process.' 10. The 'pituitary fossa,' or 'sella turcica,' for the reception of the pituitary body, with the 'groove for the cavernous' sinus on each side of it. 11. The broad 'dorsum sellæ,' with the 'posterior clinoid process' formed by its free superior-external angles, and giving attachment to the tentorium cerebelli, and, under cover of each of these processes, a notch for the passage of the third nerve. In the lateral part of the fossa we notice a fairly deep groove for the passage of the middle meningeal artery.


Posterior Fossa of the Cranium.—The posterior fossa is the largest and deepest of the cranial fossæ, and is formed by the occipital bone, with the petrous and mastoid parts of the temporal bone. It supports the cerebellum and does not show eminences and depressions for the brain as the anterior and the middle fossæ do. Proceeding from before backwards, we observe, in the middle line: 1. The 'basilar groove,' which supports the medulla oblongata and the pons Varolii. 2. On each side of this is the groove for the 'inferior petrosal sinus.' 3. Along the top of each petrous bone is the groove for the 'superior petrosal sinus.' 4. Both these sinuses terminate in the corresponding great 'lateral sinus,' which grooves successively the occipital, posterior-inferior angle of the parietal, mastoid part of the temporal, and, last of all, the jugular process of the occipital bone. A line drawn on the outside of the head, from the occipital protuberance to the front border of the mastoid process, corresponds with the lateral sinus of the corresponding side. On the posterior aspect

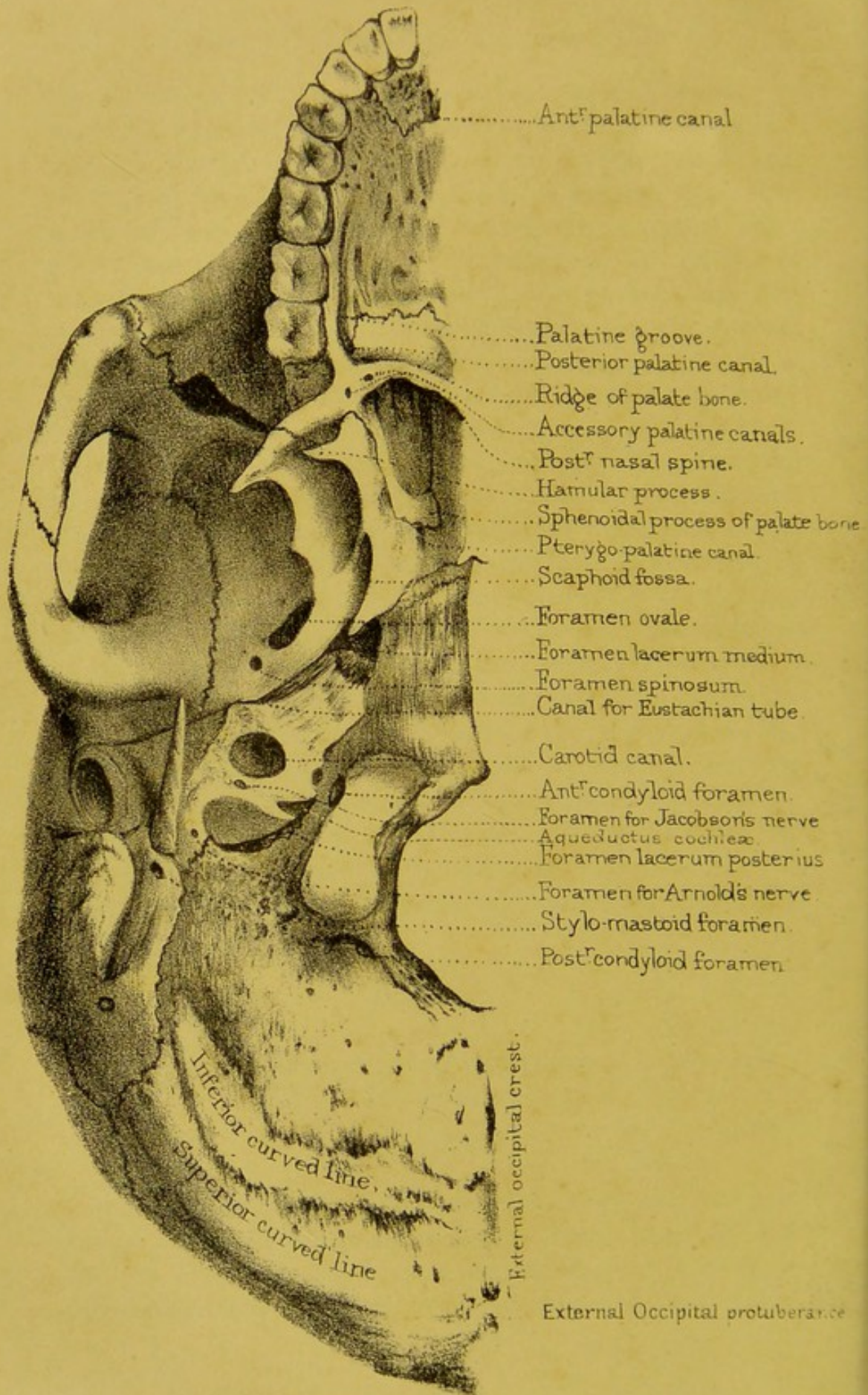
of the petrous part of the temporal bone is—5. The ‘meatus auditorius internus,’ for the facial, auditory pars intermedia nerves and the little auditory artery. 6. Some distance behind, and external to the meatus, is the ‘aqueductus vestibuli,’ somewhat concealed by an overhanging ridge of bone. This so-called ‘aqueduct’ transmits, if anything, a small vein from the vestibule of the ear. *Behind the basilar process* is—7. The ‘foramen magnum,’ which transmits the spinal cord and its membranes, the vertebral arteries, and the spinal part of the spinal accessory nerves. 8. On each side of the foramen magnum are the ‘condyloid foramina,’ of which the ‘anterior’ transmits the hypoglossal or 9th nerve (motor nerve of the tongue); the ‘posterior,’ a vein from the lateral sinus to the outside of the skull. 9. The ‘mastoid foramen’ transmitting a vein from the lateral sinus to the outside of the skull. 10. Lastly, the ‘foramen lacerum posterius’ transmitting the three divisions of the 8th nerve, the inferior petrosal sinus, and also the blood from the lateral sinus into the internal jugular vein. The nerves pass through the anterior part of the foramen, which part is separated from the posterior by a bony ridge; one or two small ‘posterior meningeal’ arteries also lie in the foramen. 11. In the mid-line, between the ‘foramen magnum’ and the ‘internal occipital protuberance,’ is the ‘internal occipital crest,’ with the ‘groove for the occipital sinus.’ 12. On the right side of the internal occipital protuberance, sometimes on the left, is the ‘torcular Herophili,’ forming the dilated beginning of the right lateral sinus.

BASE OF THE SKULL, WITHOUT THE LOWER JAW, AS SEEN
FROM BELOW.

(PLATES XX., XXI.)

When viewed from below the base of the skull, the lower jaw having been removed, presents an oval figure, bounded upon each side *in front* by the incisor, canine, bicuspid, first molar teeth and the lower border of the malar process of the superior





Drawn on Stone by T. Godart.

From nature by L. Holden.

Printed by West, Newman & Co.

maxillary bones; *laterally*, by the lower border of the zygomatic arch, the posterior root of the zygomatic process of the temporal, its upper branch, an imaginary line connecting the posterior root with the outer end of the superior curved line across the base of the mastoid process; *posteriorly*, on each side, the superior curved line terminating internally in the external occipital protuberance.

The principal points to be noticed are the:—

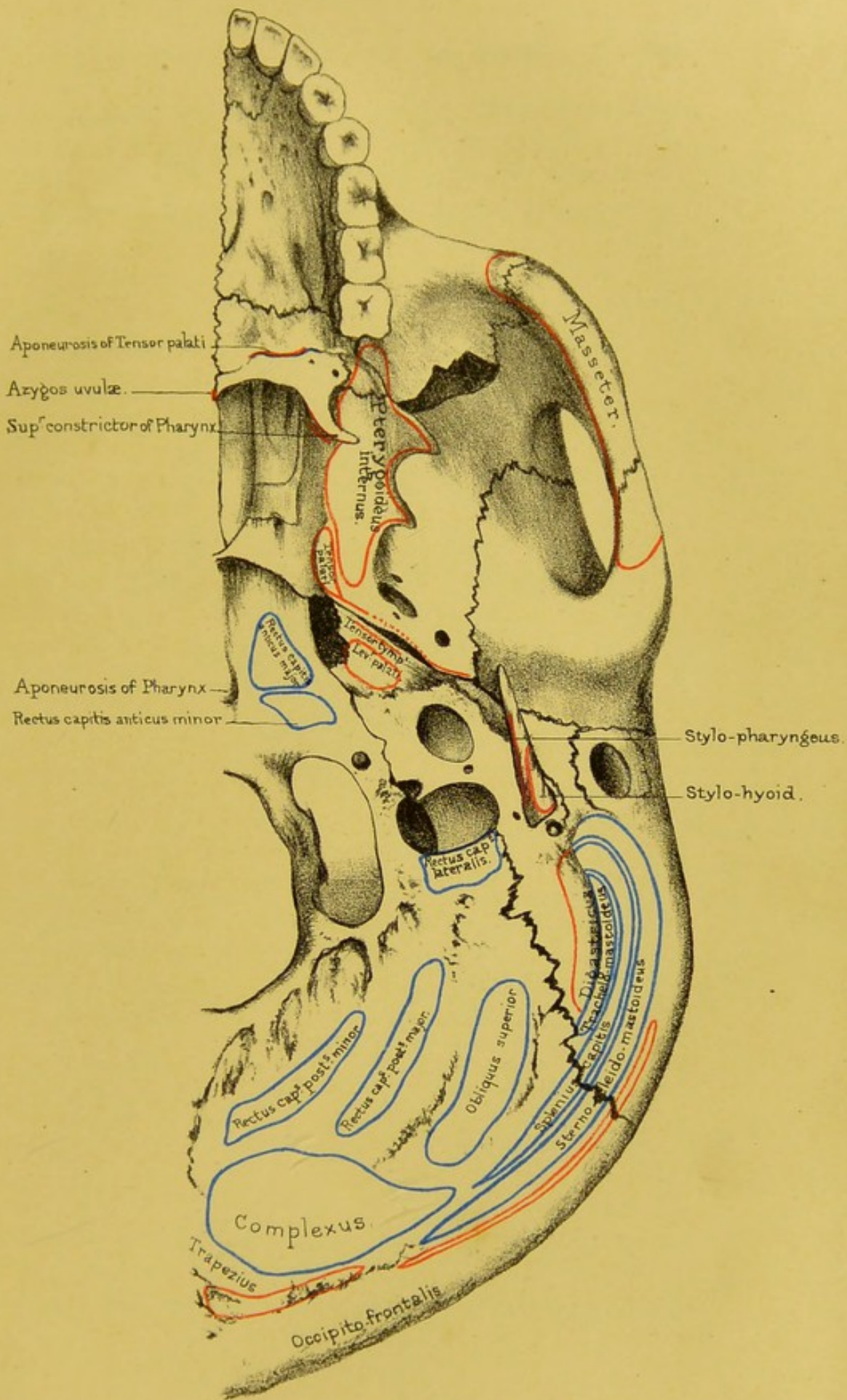
Arch of the Palate.—In front is the arch of the ‘hard palate,’ formed by the superior maxillary and palate bones: its ‘middle’ and ‘transverse’ sutures cross each other at right angles. A pin introduced at the point of crossing would touch five bones, the 5th being the vomer. Generally speaking, when the palate presents a fine arch, free from contraction in any direction, the voice is clear and sonorous. The best singers have always well-formed palates. Its surface is rugged, excepting that part formed by the palate processes of the palate bones, for the lodgment of the palatine glands, and it is riddled with minute holes for the passage of blood-vessels. Behind the incisor teeth is the ‘anterior palatine canal;’ a single orifice below, but showing, a little way up, the antero-posteriorly placed foramina of Scarpa and the two laterally situated foramina of Stenson. The antero-posterior foramina transmit the naso-palatine nerves, the lateral ones the anterior palatine blood-vessels. Near the last molar tooth, of each side, is the orifice of the ‘posterior palatine canal,’ formed conjointly by the palate and superior maxillary bones: and from this we trace forwards the ‘palatine groove’ for the lodgment of the descending palatine vessels and the large palatine nerve. Lastly, there is the ‘ridge’ on the palate bone for the attachment of the ‘tensor palati,’ and the ‘posterior nasal spine,’ to which is attached the ‘azygos uvulæ.’ Bounding the palatine arch anteriorly and laterally is the horseshoe-shaped alveolar border, with sockets corresponding to the fangs of the teeth.

Posterior Openings of Nose.—Behind the palate are the posterior openings of the nasal fossæ, separated by the sharp edge of the vomer. Each opening is somewhat oval, about one

inch in the long diameter and half an inch in the transverse. We should remember this in plugging the nostril. It is bounded, above, by the alæ of the vomer and the vaginal processes of the sphenoid; below by the horizontal plate of the palate; outside, by the internal pterygoid plate of the sphenoid; and inside, by the vomer. In the upper boundary of each is the posterior opening of the 'pterygo-palatine canal' for the transmission of a branch of the internal maxillary artery and a nerve from the sphenopalatine ganglion to the top of the pharynx.

Pterygoid Region.—On each side of the nasal openings are the 'pterygoid processes' of the sphenoid. These pterygoid processes bound the posterior openings of the nose; act as buttresses to support the upper jaw-bones behind; and serve for the origin of the powerful pterygoid muscles which grind the food. From the pterygoid fossa, or, more strictly, from the inner surface of the external pterygoid plate and the back of the tuberosity of the palate bone which fits into the gap between the pterygoid processes, arises the 'pterygoideus internus;' while the outer surface of the same plate and the adjacent outer aspect of the tuberosity of the palate bone give origin to the 'pterygoideus externus.' At the base of the internal plate is the scaphoid fossa, for the origin of the 'tensor palati,' and into which, as also into the bottom of the pterygoid fossa, open the 'foramina of Vesalius;' and at the apex is a pulley, termed the 'hamular process,' around which the tendon of this muscle plays. Besides this, the hamular process gives origin to part of the 'superior constrictor' of the pharynx. Immediately above the 'scaphoid fossa,' and really not seen when viewing the skull from below, is the posterior orifice of the Vidian canal.


Proceeding backwards from the base of the pterygoid processes, we come next upon the great foramina at the base of the skull, most of which have already been seen in the examination of the base from above. In the great wing of the sphenoid there is the 'foramen ovale.' The 'foramen rotundum' cannot be seen on the inferior aspect of the base of the skull: look for it at the back of the orbit. Behind the foramen ovale is the 'foramen spinosum;' and still farther back is the apex of the wing, termed the



Drawn on Stone by T. Godart.

From nature by L. Holden.

Printed by West, Newman & Co.



'spinous process,' which is wedged between the squamous and petrous bones, and gives attachment to the internal lateral ligament of the lower jaw. From the spinous process we trace outwards the glenoid fissure,' which runs across the 'glenoid cavity'

FIG. 18.

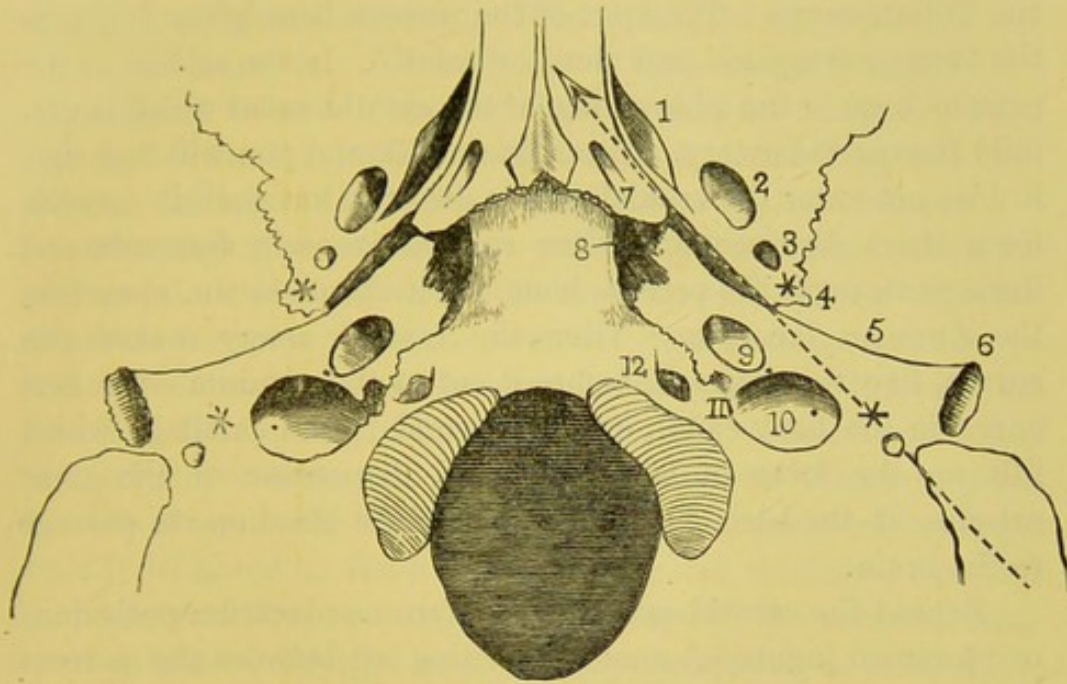


DIAGRAM OF THE RELATIVE POSITIONS OF THE MORE IMPORTANT PARTS AT THE BASE OF THE SKULL.

The dotted arrow shows that the mastoid process, the stylo-mastoid foramen, styloid process, and the spinous process of the sphenoid (represented by stars), and the Eustachian tube are pretty nearly in a line.

Outside the arrow are :

1. Scaphoid fossa.
2. Foramen ovale.
3. Foramen spinosum.
4. Spinous process.
5. Glaserian fissure.
6. Meatus auditorius externus.

Inside the arrow are :

7. Pterygo-palatine canal.
8. Foramen lacerum medium.
9. Carotid canal.
10. Foramen jugulare.
11. Notch for 8th nerve.
12. Anterior condyloid foramen.

with the 'eminencia articularis' in front of it. Between the sphenoid and petrous bones are the canals for the 'Eustachian tube' and the 'tensor tympani' muscle.

Petrous Region.—The petrous portion of the temporal bone

is wedged in between the sphenoid and the basilar process of the occipital. Observe that the apex of the wedge is cut short, so that an irregular opening, termed the 'foramen lacerum medium,' remains between the three bones. In the recent skull this space is filled with cartilage, in which lie the internal carotid artery surrounded with filaments of the sympathetic nerve, and the Vidian nerve. The apex of the petrous bone gives origin to the 'tensor tympani' and 'levator palati.' In the middle of the petrous bone is the wide orifice of the carotid canal which transmits the carotid artery. Trace this canal, and you will find that it does not enter the cranial cavity directly, but that it ascends for a short distance, and then runs horizontally forwards and inwards through the petrous bone, till it opens at the apex into the foramen lacerum. Thus the carotid artery makes two curves, like the letter S, before it enters the cranium—the first curve in the bony canal, and the second in the cartilage which fills up the foramen lacerum. This disposition of the great arteries at the base checks the force of the blood on its passage to the brain.

Behind the carotid canal is the 'foramen lacerum posterius,' or 'foramen jugulare,' another opening left between the petrous and occipital bones. The size and shape of it are subject to great variety. The right jugular foramen is usually larger than the left. It is generally divided by a projecting tongue of bone into an interior part, which transmits the eighth nerve, and a posterior, which is by far the larger, for the passage of the blood from the lateral sinus into the commencement of the internal jugular vein. The posterior meningeal arteries (from the occipital and ascending pharyngeal branches of the external carotid) and the inferior petrosal sinus pass through this aperture.

Outside the foramen lacerum posterius is the 'styloid process,' projecting, more or less, beyond the 'vaginal process' at its root. Behind this is the 'stylo-mastoid foramen, through which the facial nerve emerges from, and the stylo-mastoid artery enters, the skull. Still farther back is the 'mastoid process,' and the 'digastric fossa' for the origin of the digastric muscle. Internal

to this fossa may be generally seen a groove for the occipital artery.

Basilar Process.—The basilar process of the occipital bone projects into the base of the skull, and joins the body of the sphenoid. It affords insertion to the ‘rectus capitis anticus major’ and ‘minor,’ and (by means of a little tubercle) to the aponeurosis of the pharynx. Behind the basilar process is the ‘foramen magnum.’ On each side of this are the ‘condyles’ of the occiput, with the ‘anterior’ and ‘posterior condyloid’ foramina; and on the outside of each condyle is the ‘jugular eminence,’ which gives insertion to the ‘rectus capitis lateralis.’

Occipital Foramen.—In a well-formed European skull, the plane of the occipital foramen looks downwards with a slight inclination forwards when the body is erect, and its anterior extremity is about half-way between the tuberosity of the occipital bone and the incisors of the upper jaw. This central position of the occipital foramen and the condyles is one of the great peculiarities of man, who stands erect. His head, therefore, is almost equally balanced on the top of the spine. In monkeys, who hold a middle rank between man and quadrupeds, the foramen magnum is placed farther back: in the orang-outan, it is about twice as far from the foramina incisiva as from the back of the head. Consequently, although monkeys can stand erect for a time, they cannot do so long. In quadrupeds, again, the foramen magnum is still nearer to the back of the head, and its plane forms a considerable angle with the horizon. The weight of the head in quadrupeds is sustained, not only by the spine, but by an elastic ligament of great strength (*ligamentum nuchæ*), which arises from the lofty spines of the dorsal vertebræ, and is fixed to the crest of the occiput. Stretching from the posterior extremity of the foramen magnum to the ‘external occipital protuberance’ is the ‘external occipital crest’ for the attachment of the ‘*ligamentum nuchæ*.’ Extending from each side of the middle of this crest to the lateral angle of the occipital bone is the ‘inferior curved line.’ In the occipito-mastoid suture, or situated entirely in the mastoid portion of the temporal bone, is the ‘mastoid foramen’ for the passage of a vein, and usually a

small artery. Between the foramen magnum and superior curved lines muscles are attached as shown in Plate XXI.

TEMPORAL, ZYGOMATIC, AND SPHENO-MAXILLARY FOSSÆ.

The temporal fossa (see p. 127) leads into the zygomatic fossa, the boundary between them being the crest of the sphenoid bone.


Zygomatic Fossa.—The ‘zygomatic fossa’ is bounded externally by the zygomatic arch, which serves as a strong buttress to support the bones of the face, and gives origin to the powerful ‘masseter’ muscle which closes the mouth. In front of the fossa there is the back part of the superior maxilla, and at the bottom of it, the outer pterygoid plate of the sphenoid, which gives origin to the external pterygoid muscle. At the deepest part of the fossa are two wide fissures at right angles to each other: one, nearly horizontal, leads into the orbit, and is called the ‘spheno-maxillary fissure,’ through which the superior maxillary nerve and the infra-orbital artery enter the infra-orbital groove on the floor of the orbit.

Spheno-maxillary Fossa.—The other fissure, nearly vertical, leads to the ‘spheno-maxillary fossa,’ in which the third part of the internal maxillary artery breaks up into terminal branches. This fossa is bounded in front by the back of the superior maxilla; behind, by a smooth surface at the base of the pterygoid process; internally, it is separated from the nasal fossæ by the perpendicular plate of the palate bone.

There are five openings into the spheno-maxillary fossa (see Plate XXII.), as follows:

FIVE OPENINGS INTO SPHENO-MAXILLARY FOSSA.

- | | | |
|-----------------------------|--|---|
| 1. Spheno-palatine foramen | { transmits into
the nasal
fossa . | { Internal or nasal branches of spheno-
palatine ganglion.
Nasal or spheno-palatine branch of
internal maxillary artery. |
| 2. Posterior-palatine canal | { transmits to
the palate | { Descending palatine artery and large
palatine nerve. |
| 3. Foramen rotundum | . transmits . | { Superior maxillary nerve, or secon
division of fifth pair. |



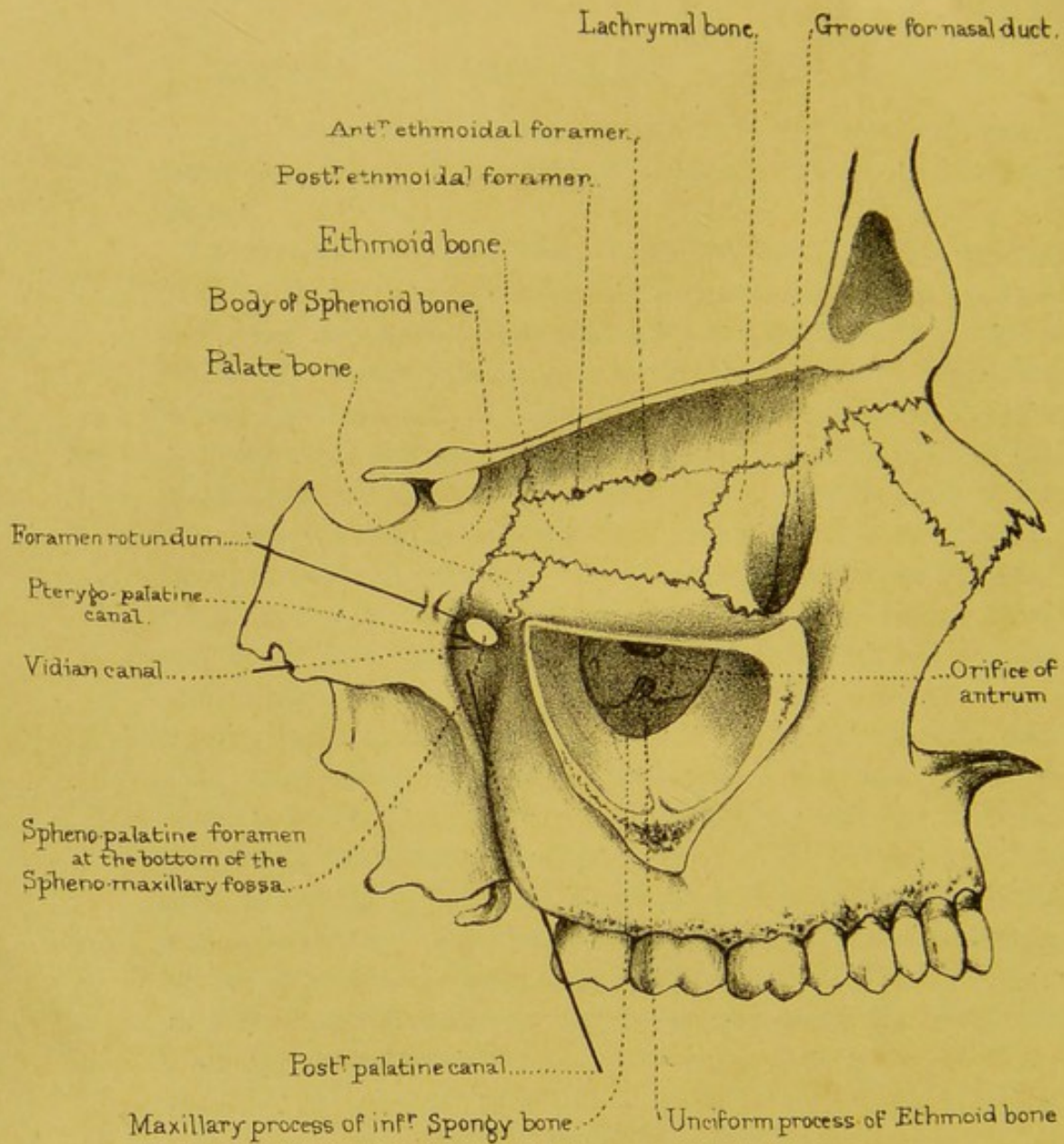


Diagram of the Bones and Foramina
on the inner wall of the Orbit, the five openings into the
Spheno-maxillary fossa, the Antrum and bones contracting its orifice.

Drawn on Stone by T. Godart.

From nature by L. Holden.

Printed by West, Newman & Co.

- | | | |
|-----------------------------|-------------|--|
| 4. Vidian canal | transmits . | Vidian artery and nerve. |
| 5. Pterygo-palatine canal . | transmits . | { Pterygo-palatine branch of internal
maxillary artery, and pharyngeal
nerve from Meckel's ganglion. |

THE ORBITS.

The orbits, or sockets for the eyes, are like crypts excavated beneath the cranium. (Plate XVIII.) To use the words of Sir Charles Bell, 'these under arches are groined;' that is to say, they are provided with strong ribs of bone, so that there is no need of thick bone in the interstices of the groinings. The plate between the eye and the brain is as thin as parchment: but look how strong is the arch forming the orbital margin, and what a strong ridge of bone runs up from the zygoma, like a buttress to support the side of the arch. When the eye is threatened, the margin of the orbit is more than strong enough to protect it from the effects of violence.

Each orbit is pyramidal, with the apex behind. Their axes, if prolonged, would pass through the optic foramina, and meet behind the pituitary fossa of the sphenoid. This divergence gives a greater range of vision. The anterior opening of the orbit is quadrilateral and consists of an upper, a lower, an inner, and an outer margin. In the higher types of man these openings are more rounded.

UPPER WALL OF ORBIT.—The upper wall of the orbit is slightly arched, and formed by the frontal bone and lesser wing of the sphenoid. On this wall are—1, the optic foramen; 2, the fossa beneath the external angular process for the lachrymal gland; 3, the little depression for the pulley of the 'superior oblique' muscle; 4, the supra-orbital foramen or notch, situated at the junction of the inner with the middle third of the orbital margin.

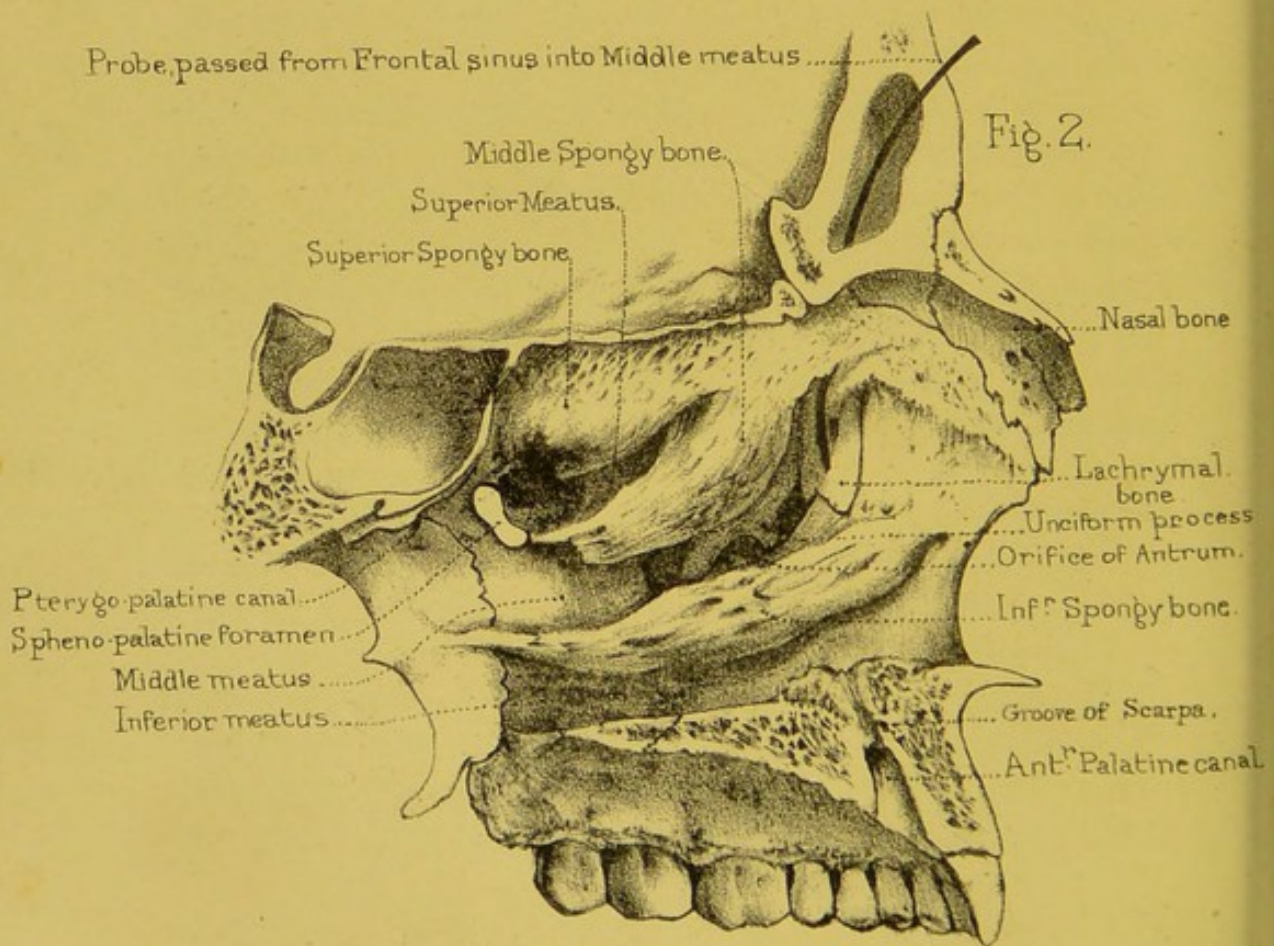
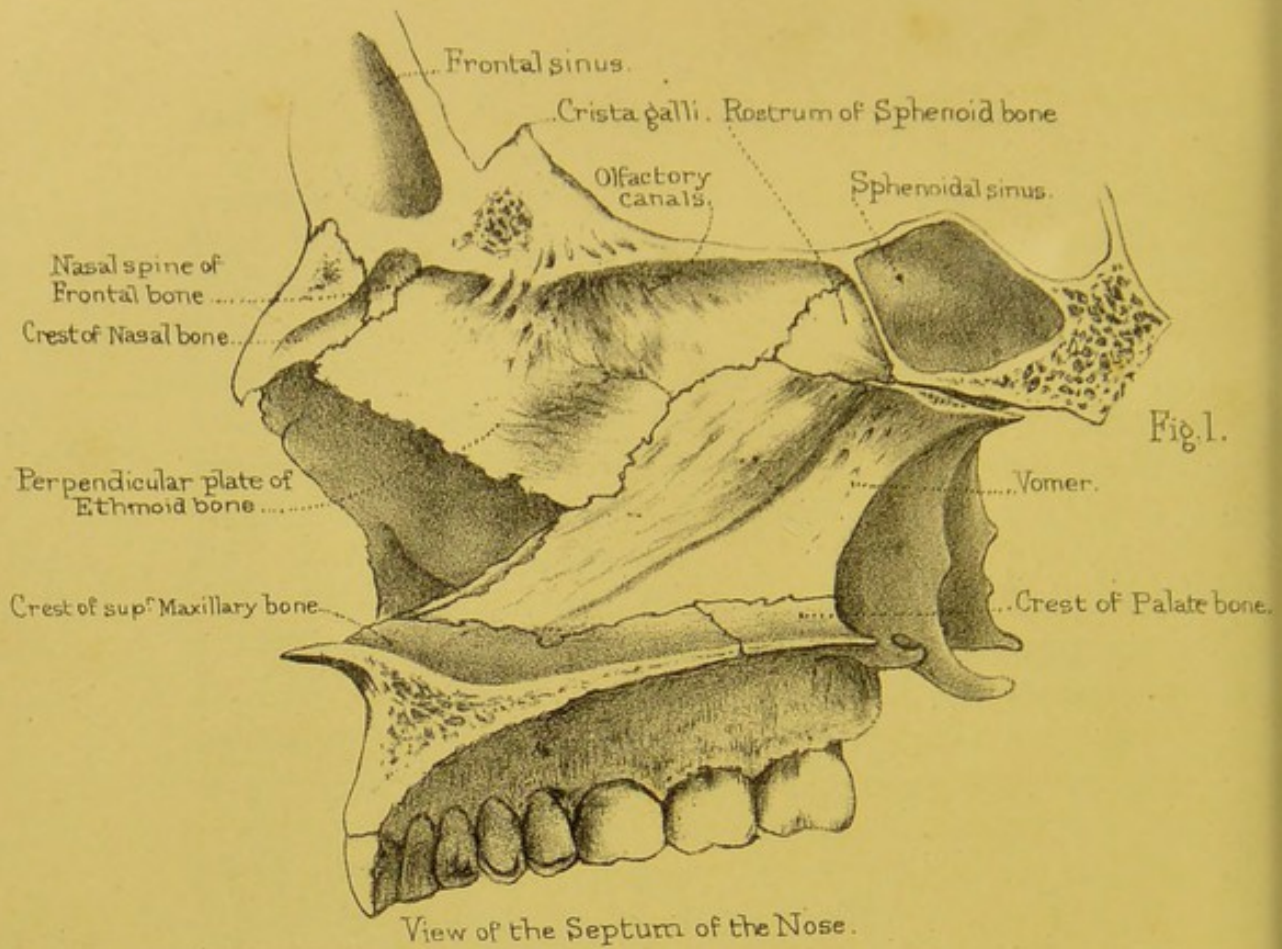
LOWER WALL OR FLOOR OF ORBIT.—The lower wall of the orbit slopes downwards and outwards, and is formed by the orbital plate of the superior maxilla, by part of the malar bone, and behind by the orbital plate of the palate bone. On this wall is the groove for the infra-orbital nerve.

INNER WALL OF ORBIT.—The inner wall (Plate XXII.) is formed by the nasal process of the superior maxilla, by the lachrymal, the os planum of the ethmoid, and the side of the body of the sphenoid bone. Here we observe the groove for the nasal duct, formed conjointly by the nasal process of the superior maxilla, the lachrymal, and the inferior spongy bone. Its direction is downwards, backwards, and a little outwards, and it leads into the inferior meatus of the nose. Besides this, there are the ‘anterior and posterior ethmoidal foramina.’

OUTER WALL OF ORBIT.—The outer wall of the orbit is formed by the malar bone and the orbital plate of the great wing of the sphenoid. Here there are one or two small foramina (malar canals), which transmit small nerves from the orbit to the skin of the cheek and temple. (See p. 104.) The outer wall of the orbit recedes more than the other parts of its circumference, giving so great a range of vision externally, that by rotating the head on each side of the spine, we can see all round.

Bones Composing Orbit.—Look into the orbit and examine two four-sided plates, one on the inner side belonging to the ethmoid, and one on the outer belonging to the great wing of the sphenoid. The four-sided plate of the ethmoid articulates above with the frontal; below with the superior maxillary bone, in front with the lachrymal and behind with the sphenoid. Besides these the orbital process of the palate bone here comes up between the sphenoid and superior maxilla (articulating with both of them) and joins the posterior inferior angle of this plate. The four-sided plate of the sphenoid articulates likewise with the frontal bone above, the frontal bone arching over from the top of the aforesaid plate of the ethmoid; below, its edge is separated from the superior maxillary bone by the speno-maxillary fissure; in front, it articulates with the malar bone, and behind, its edge is separated from the rest of the sphenoid, by the sphenoidal fissure. These articulations should be traced on the bones and thoroughly mastered. Thus, seven bones enter into the composition of each orbit: namely—the frontal, ethmoid, and sphenoid, the superior maxilla, the malar, the lachrymal, and the palate; but there are only eleven.





View of the three "Meatus" of the Nose.

Drawn on Stone by T. Godart.

From nature by L. Holden.

Printed by West, Newman & Co.

bones in the two orbits, since the first three bones are common to both.

Sphenoidal and Spheno-maxillary Fissures.—At the back of the orbit are two wide fissures for the admission of blood-vessels and nerves. The upper one is the ‘sphenoidal fissure,’ formed between the greater and lesser wings of the sphenoid bone. It leads into the cranium, and transmits the third and fourth nerves, the ophthalmic branch of the fifth, the sixth nerve, some filaments of the sympathetic nerve, and the ophthalmic vein. The lower one, the ‘spheno-maxillary fissure,’ leads into the zygomatic fossa. The borders of this fissure are formed antero-internally by the superior maxillary and palate bones, postero-externally by the sphenoid. It is completed in front and outside by the malar.⁴³ Through this fissure the infra-orbital artery and the superior maxillary nerve enter the groove along the floor of the orbit.

NASAL FOSSÆ.

(PLATE XXIII.)

These cavities open widely in front, and admit the air through the nostrils, and behind into the top of the pharynx. To study them properly it is indispensable to have a skull divided longitudinally on one side of the septum, so that we can examine the roof, the floor, the outer and inner surfaces of the cavities.

Boundaries of Nasal Fossæ.—The ‘roof’ of each of the nasal fossæ is formed by the nasal bones, by the nasal spine of the frontal, the cribriform plate of the ethmoid, and the body of the sphenoid, with the alæ of the vomer and the vaginal plates resting upon it. It does not form a horizontal plane from before backwards. It is only the cribriform plate which is horizontal; from this, the roof slopes downwards and forwards towards the nose, and downwards and backwards towards the pharynx: therefore the vertical depth is much greater in the middle than elsewhere. Notice the greater thinness of the cribriform plate, and

how easily an instrument might be thrust through this part of the roof into the brain.

The '*floor*' is nearly horizontal, and is formed by the palate plates of the superior maxillary and palate bones. In the dry bones can be seen, on each side of the septum, the foramina of Scarpa and Stenson.

The *outer wall* of the nasal fossa is made irregular by the '*meatus*' or passages in the nose, and the numerous openings leading to the air-cells, in the neighbouring bones. It is formed by the ethmoid (including its two turbinated bones), the nasal, the superior maxillary, the lachrymal, the inferior turbinated, the palate, and the internal pterygoid plate of the sphenoid. It is important to observe the position of the turbinated bones and the three '*meatus*' or passages of the nose. (Plates XXIII. and XXIV.)

SUPERIOR MEATUS.—Beneath the superior turbinated bone lies the '*superior meatus,*' into which open the posterior ethmoidal cells and the sphenoidal cells. At the back parts of this meatus is the speno-palatine foramen, which leads into the speno-maxillary fossa.

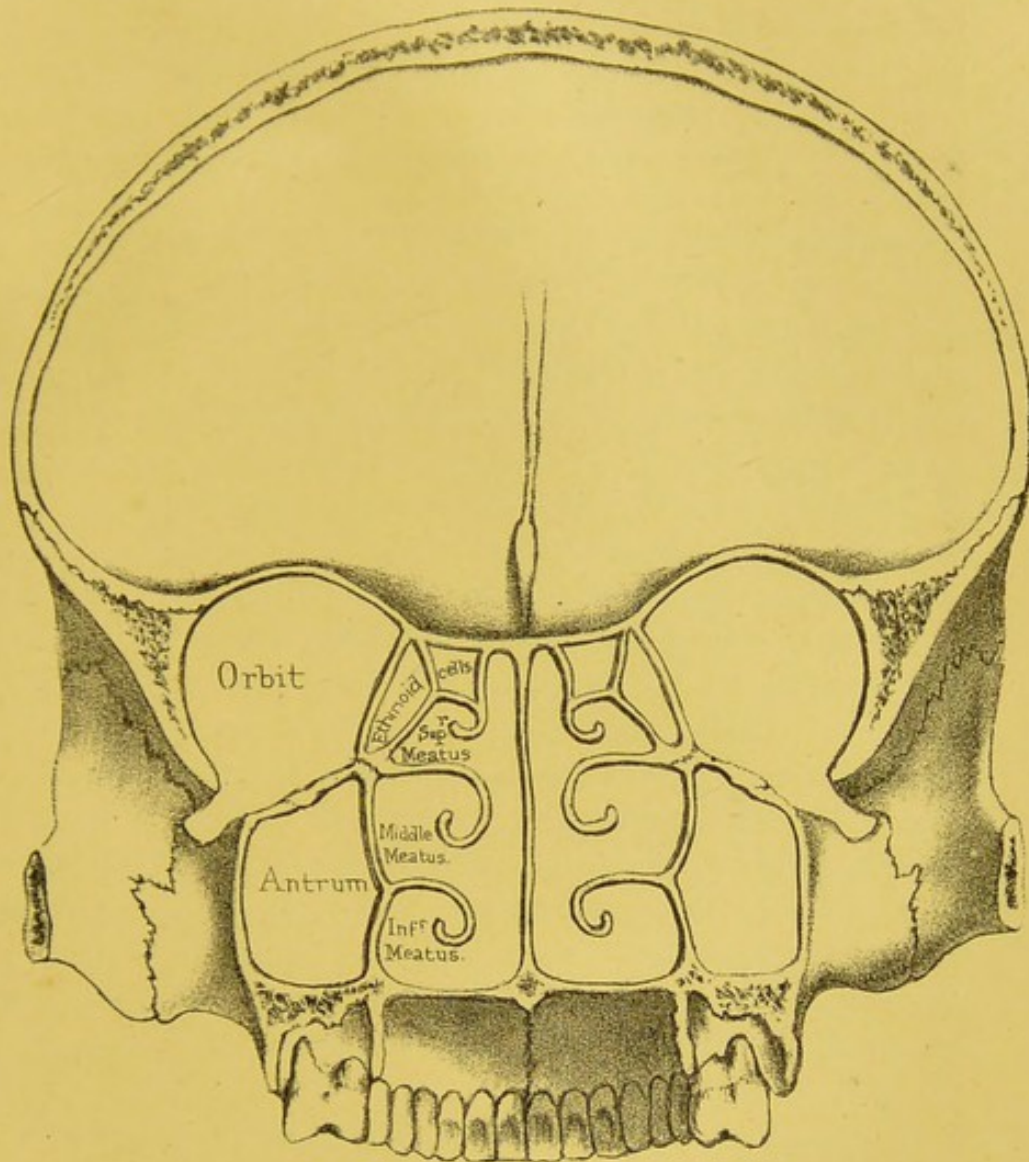
MIDDLE MEATUS.—Below the middle turbinated bone is the '*middle meatus.*' Into this open—1, towards the front, the frontal sinus (or cell), along a passage termed the '*infundibulum ;*' 2, the anterior ethmoidal cells (distinct from the posterior); 3, the antrum or maxillary sinus. The orifice of the antrum is large and irregular in the dry bones ; but in the recent state it is so narrowed by mucous membrane that it will just admit a crow-quill.

INFERIOR MEATUS.—Below the inferior turbinated bone is the '*inferior meatus.*' No air-cells open into this meatus: there is only the termination of the nasal duct or channel which conveys the tears into the nose: this cannot be seen without removing part of the turbinated bone.

The openings into the several '*meatus*' of the nose may be thus tabulated:

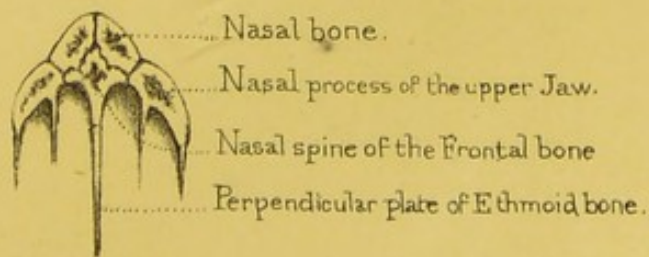
Into the SUPERIOR MEATUS. open { The sphenoidal cells.
The posterior ethmoidal cells.

Fig. 1.




Section showing the Meatus of the Nose.

Fig. 2.



Section, showing the Nasal arch.



Into the MIDDLE open	{ The anterior ethmoidal cells. The frontal cells. The antrum.	
Into the INFERIOR opens		The nasal duct.

The two upper turbinated bones (belonging to the ethmoid) are delicately channelled for the lodgment of the olfactory nerves. The lower or third turbinated bone has nothing to do with the sense of smell, and is coarser in its texture. It is traversed by several canals and grooves, which run from before backwards, and in the recent state contain large veins. The turbinated bones do not extend throughout the whole length of the outer wall. All the surface in front of a perpendicular line let fall from the nasal spine of the frontal bone is smooth, as is also all the surface behind a perpendicular line from the sphenopalatine foramen.

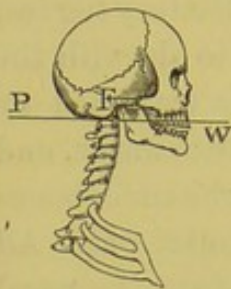
INNER WALL OF NOSE.—The bony septum of the nose, one of the principal supports of the nasal arch (Plate XXIII.), is formed chiefly by the perpendicular plate of the ethmoid and the vomer. (Plate XXIV. fig. 2.) The formation of the septum is assisted by the nasal spine of the frontal, the crests of the nasal, superior maxillary, and palate bones; also by the rostrum or crest of the sphenoid, making ten bones in all. The triangular interval left in the septum in the dry skull is filled up in the perfect one by the middle cartilage of the nose, which fits into a fissure in the bone.

The *posterior openings of the nasal fossæ* have been already described in the 'base of the skull' (p. 133). The *anterior opening* is heart-shaped, with the broad part below. It is bounded on either side by the nasal bone, and by the nasal process of the superior maxilla. Below it is bounded by the palatine processes of the superior maxillary bones, which terminate in front in a sharp projection, termed the 'anterior nasal spine,' the prominence of which is a marked feature in the higher races of mankind. This projection is very diminutive in some of the lower races, and absent in monkeys.

GENERAL OBSERVATIONS ON THE SKULL.

Skull a Lever of the First Order.—The entire skull represents a lever of the first order. The fulcrum or point of support

FIG. 19.



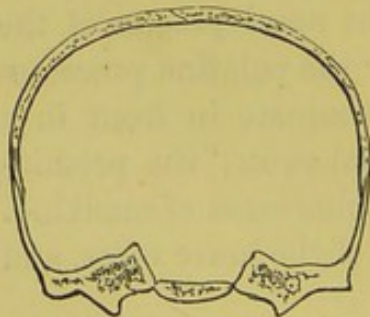
F (see fig. 19) is at the occipito-atlantoid articulation; the resistance is the weight of the head W; the power P is the mass of muscle attached to the occiput. The skull is nearly balanced on the spine, and the muscles moving it have but small leverage. Contrast this, however, with that of the elephant (see p. 44), the massive appendages of whose head have proportionally strong muscles and ligaments for their movements and support.

Three Layers or Tables of the Skull.—The cranial bones consist of three layers—an outer, an inner, and an intermediate ‘diploe.’ The outer is formed of compact and tough bone; the inner is harder, but more brittle (hence called ‘tabula vitrea’); while the diploe is softer and spongy, and diminishes the effects of shocks. Altogether, then, this structure may be coarsely compared to a case composed of wood outside, porcelain inside, and soft leather between the two.

The different structure of these three layers or ‘tables’ of the skull is interesting practically. In blows on the head, the inner table, in consequence of its great brittleness, is likely to be broken more extensively than the outer.

Locking of the Bones.—The bones are mechanically locked

FIG. 20.



together by the sutures; and in the recent state there is a thin layer of fibrous tissue between their edges, which diminishes the effects of blows. Most of the bones mutually support each other, by having their edges bevelled alternately on opposite sides, as in the frontal suture; or by one overlapping

the other, as in the squamous suture, where the temporal prevents the ‘starting’ of the parietal bone (see fig. 20). The

effect of this is, that no single bone can be taken out of the cranium without separating the whole fabric. (Nor. Hum. Ost., No. 175.)

Groins along the Sinuses.—Notice how the interior of the dome is strengthened by ‘ribs’ or ‘groins’ of bone, which run in the line of the principal sinuses. One rib extends from the centre of the frontal bone to the foramen magnum, and spans from before backwards the whole arch of the cranium. Another crosses transversely the back part of the occipital bone; the point of intersection of these two ribs being at the occipital protuberance, which is the thickest and strongest part of the skull.

Buttresses of the Skull.—Like all other arches, the cranium transmits shocks towards its buttresses; these are firmly wedged into the base, and all meet at the centre, that is, at the body of the sphenoid. The frontal part of the arch is supported by the wings of the sphenoid and the malar bones, the parietal part by the temporal bones, and the occipital part supports itself by running, wedge-like, into the base, and abutting on the sphenoid. A knowledge of the buttresses which support the respective parts of the skull-cap affords an explanation of the direction which fractures generally take along the base of the skull, according as the injury has been received on the frontal, the parietal, or the occipital region of the cranium.

Power of resisting Shocks.—The older French school generally advocates the doctrine that the cranium resists shocks after the manner of other spheres, namely, that a blow struck on one side is transmitted to the opposite one; as when a glass tumbler, struck smartly with the finger-nail, is made to crack on the opposite side. This they call fracture by ‘*contre-coup*.’ But the modern school contends that the cranium resists shocks like all architectural arches; and that vibrations, instead of going round to the base direct, are lost upon the supporting pillars. The frontal pillars are the malar and sphenoid bones—the parietal pillars are the temporal bones—the occipital pillars are the ribs of the occipital bone itself. When the head is struck, the parietal region is most often the seat of injury. The bone breaks at the part struck, and the fracture runs on through the temporal bone,

and most frequently through the tympanum—the weakest part. There are many excavations in the bone which weaken it about this part: 1, there is the ‘meatus auditorius externus’—2, the cavity of the tympanum itself—3, the jugular fossa—4, the carotid canal—5, the Eustachian tube. This accounts for the frequency of hæmorrhage from the ear in cases of fracture of the base of the skull.

Buttresses of the Upper Jaw.—In the bones of the face there are two points to be noticed—1st, the great strength of the nasal arch (Plate XXIV.); 2nd, the extreme firmness of the upper jaw, fixed by its three buttresses on each side—namely, the nasal, the zygomatic, and the pterygoid. The *nasal* buttresses rest against the internal angles of the frontal bone, and between them is the heart-shaped opening of the nose. The *zygomatic* buttresses are exceedingly strong; they are supported by the external angles of the frontal bone and the zygomatic processes of the temporal, and correspond to the molar teeth, which have to sustain the greatest pressure. The *pterygoid* buttresses descend perpendicularly from the base of the skull, and support the upper jaw behind.

Male and Female Crania.—The capacity of the cranial cavity varies, as a general rule, with the intelligence of the individual or of the race. It has been shown that in almost all races the capacity of the cranial cavities of the women is to that of the men as 9 is to 10. The mastoid and the other processes for the attachment of muscles are less pronounced in women than in men. The orbital margins, and especially the external angular processes, are thinner and sharper in females’ skulls. In women’s skulls the glabella and frontal sinuses are but slightly developed. The digastric groove is better marked in males than in females. The masticatory apparatus is more massive in the males’ skulls. The development of the frontal, parietal, and occipital regions may be taken as a general expression of the development of the corresponding lobes of the brain. Upon this is founded the study of Craniology.⁴⁴

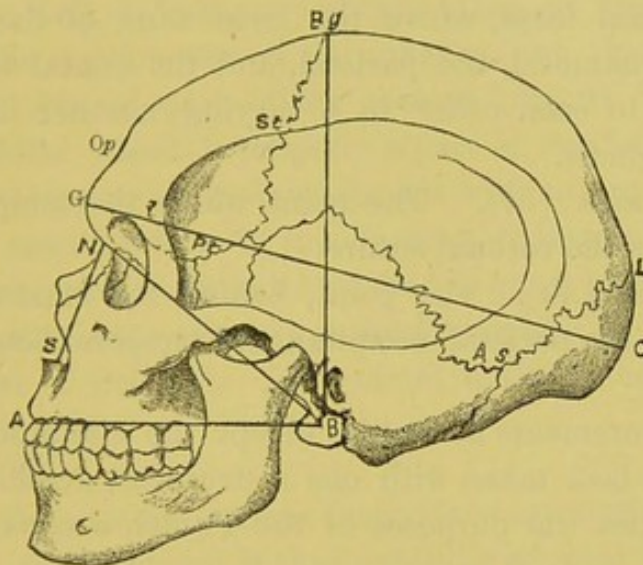
Craniology.—The accompanying diagram (fig. 21) and table of terms, introduced chiefly by Broca, are given here, as it is thought that some guide to the most important measurements of

the skull may be of use to those who, without a special knowledge of anthropology, may take an interest in that science, and have opportunities for adding to our information in some particulars.

The most important points for mensuration and descriptive purposes situated in the middle line of the cranium, taken in order, are:

1. *Alveolar point (A)*. The centre of the anterior margin of the upper alveolar arch.
2. *Subnasal point or Spinal point (S)*. The middle of the

FIG. 21.



SIDE VIEW OF SKULL OF MALE AUSTRALIAN.

- A. Alveolar point. S. Subnasal point. N. Nasion. G. Glabella. Op. Ophryon, the centre of supraorbital line (*Opt*). Bg. Bregma. L. Lambda. O. Occipital point, or most distant part of occiput from Op. B. Basion. St. Stephanion. Pt. Pterion. As. Asterion. G. Length of cranium. B Bg. Height of cranium. B N. Basinasal length. B A. Basialveolar length. N S. Nasal height.

inferior border of the anterior nasal aperture, at the base of the nasal spine.

3. *Nasion, or Nasal point (N)*. The middle of the nasofrontal suture at the root of the nose.
4. *Ophryon (Op)*. A point situated immediately above the glabella, or, more exactly, the centre of the supraorbital

line, which, drawn across the narrowest part of the forehead, separates the face from the cranium.

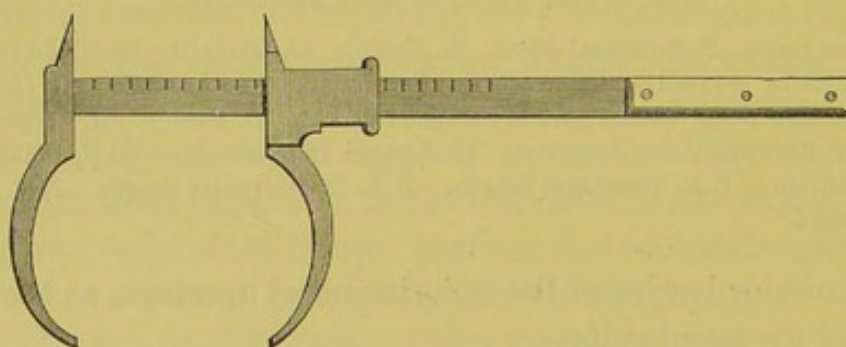
5. *Bregma* (*Bg*). The point of junction of the coronal and sagittal sutures.
6. *Lambda* (*L*). The point of junction of the sagittal and lambdoidal sutures.
7. *Opisthion*. The middle of the posterior margin of the foramen magnum.
8. *Basion* (*B*). The middle of the anterior margin of the foramen magnum.

On the lateral surface of the cranium are :

9. *Pterion* (*Pt*). The region, near the anterior part of the temporal fossa, where the great wing of the sphenoid, the squamosal, the parietal, and the frontal bones come near to each other in a varying manner in different individuals.
10. *Stephanion* (*St*). The point where the temporal ridge crosses the coronal suture.
11. *Asterion* (*As*). The point, behind the mastoid process, where the parietal, occipital, and temporal bones meet.

The measurements of crania, except the circumference and capacity, are best taken with one instrument, a sliding caliper, which combines the purposes of the French *compas d'épaisseur*

FIG. 22.



CRANIOMETER : ONE-FIFTH THE ACTUAL SIZE.

and *compas-glissière*. It has been found so convenient for all cranial as well as other osteological measurements that a sketch of it is subjoined (fig. 22). The larger dimensions of the cranium

are taken with the curved arms, the smaller ones, as those of the nose and orbit, with the shorter pointed arms.

C. Horizontal circumference. This is taken with the tape in the usual way, passing in front round the supraorbital line (above the glabella) and behind across the most prominent part of the occiput (fig. 21, *Op O*). It gives a general idea of the size of the exterior of the cranium.

L. Length. Unfortunately craniometrists are not yet in accord as to the best measure for taking this important measurement, which affects considerably the two following indices. It is in the Osteological Catalogue of the Roy. Coll. of Surgeons always taken by placing one arm of the craniometer on the optryon, and the other on the most distant part of the occiput (fig. 21, *Op O*). The glabella, which is properly a part of the face, and which may vary much in development without any alteration in the essential form of the cranium, is thus excluded. The more usual continental method is given in fig. 21.

B. Breadth, is the greatest parietal breadth.

Bi. Index of Breadth. Latitudinal index or cephalic index.

$$\frac{B \times 100}{L}$$

H. Height. Of the various methods of estimating the height, the one here used is that generally adopted by the French anthropologists—that is, the distance between the basion and the bregma (fig. 21, *B Bg*).

Hi. Index of height, or altitudinal index. $\frac{H \times 100}{L}$.

BN. Basinasal length. Basion to nasion.

BA. Basialveolar length. Basion to alveolar point, or the most distant part of the anterior margin of the alveolar arch.

Ai. Alveolar index. $\frac{BA \times 100}{BN}$. This affords the readiest

method of estimating the amount of forward projection of the jaw. It is not always perfectly accurate, as it is affected by any abnormal position of the basion,

independently of the real relation of the face to the cranium; but these cases are comparatively rare, and scarcely affect large averages. Unfortunately, in crania in which the incisor teeth have been lost during life and the alveolar margin absorbed, the basialveolar length, and consequently the alveolar index, cannot be obtained. As will be seen in the sequel, this index forms one of the most important characteristics of race.

Nh. Nasal height. A vertical line between the nasion and the lower border of the nasal aperture.

Nw. The greatest width of the nasal aperture.

Ni. Nasal index. $\frac{Nw \times 100}{Nh}$.

Ow. Orbital width. The inner point of measurement is the spot where the ridge which forms the posterior boundary of the lachrymal groove meets the fronto-lachrymal suture. This is rather behind the *dacryon* of Broca (point of junction of the frontal, ascending process of maxilla, and lachrymal), and completely excludes the lachrymal groove from the measurement. The outer point is the most distant part from this on the outer edge of the outer border of the orbit.

Oh. Orbital height. The distance between the upper and lower margins of the orbit at the middle.

The right orbit, unless injured or of abnormal form, is that usually measured.

Oi. Orbital index. $\frac{Oh \times 100}{Ow}$.

Ca. Capacity in cubic centimetres. This is one of the most important and difficult measurements. The material used is shot or sometimes mustard seed, with which the cranium is filled to its maximum. The measurement of the shot or seed is then taken with the choremometer designed and constructed by Mr. Busk.⁴⁵

Comparative Osteology.—A student may, with careful observation, discover slight points of difference between opposite sides of the same skull. For instance, the posterior condyloid

foramen of one side may be wanting, the mastoid process of one side may be larger than that of the other, or the digastric fossæ may be of unequal size; one nasal passage may be larger than the other; the lateral sinus may be much deeper on the one side than on the other, or there may be a middle clinoid process on one side only. Asymmetry may occur in men highly gifted, as in the celebrated French anatomist Bichat. This is no more than one might expect, seeing the difference often existing between features of the two sides of the same face. Such want of symmetry is greatly exaggerated in many of the lower animals, as may be seen in the Cetacea, in the head of the great sperm-whale or in that of the narwhal (Mus. Roy. Coll. Surg.), for the details of which see the comparative osteology of the superior maxillary bone. But the most striking example of asymmetry is seen in those flat fish which lie usually on their left sides, viz. soles and plaice (Pleuronectidæ, Nos. 179-190). For in them both eyes are on the right or upper side of the skull, and one orbit only is completed, the eyes being directed away from the ground on which they lie. The teeth are chiefly developed on the left side of their jaws—away from the side on which their eyes are—that is, on the white side. It is interesting to note that in these fish, when very young, the skulls are symmetrical. When the turbot is just hatched, it has an eye on each side of the head, and it is only by subsequent development that the asymmetry occurs. The turbot, unlike soles and plaice, lies on its right side.

Different habits develop different muscles; and these muscles give rise to modifications in the form of the bones as well as of the bodily configuration. It will therefore be extremely interesting to contrast the skulls of the Carnivora with those of the Ungulata, or hoofed animals. Take, for example, a tiger's skull and that of a deer. The skull of the tiger is in perfect adaptation to his enormous temporal muscle. It has a high median ridge, to which the muscles are attached, great arches of the zygoma, under which they pass, and broad and lofty coronoid processes, into which they are inserted. But his masseters are comparatively small, therefore the zygomata and the angles of the jaw are not specially strong.

Now, the sole action of this temporal muscle is to clench the teeth together as on a hinge ; so we find that his jaw articulation is hinge-like, and allows no other motion. This mechanism is admirably fitted for cutting purposes, but is quite unfit for grinding ; so his teeth are cutters. He has no grinders. Exactly the converse of all that is true of the deer : his temporals are small, he has no median ridge, the passage under the zygoma is small, and his coronoid process is delicate and scarcely deserves notice. On the other hand, his masseters and pterygoid muscles are very large, his zygomata broad, the external pterygoid plates greatly expanded, the angles of the jaw massive and extensive. The masseters acting with the internal pterygoids cause the grinding action ; so here the articulation of the jaw is nearly flat, allowing of a free grinding movement ; and in accordance with this, we find the teeth are flattened on the surface, and good grinders. It will be seen how clearly this conformation is in keeping with the habits and nature of each animal.

From what has been said of the temporal muscles of the tiger, as well as from what will be said of the pectoral muscles of the flying birds (*Carinatae*), it appears that those sets of muscles by which an animal gets its living are the most largely developed, and that their bony attachments are large in proportion. Thus the history of the animal is always written on its bones clearly enough for any careful student to read. He who learns to love osteology will soon feel that it is far from dry, and that beauty finds indelible expression even in the bones ; for he will see that low degraded types have skeletons which cannot be mistaken, while the healthy, intelligent, and upright carry their characters in their skeletons as much as they do in their faces.

In the ant-eater, which has no teeth, the zygomatic arch is incomplete (No. 3543).

In reptiles the cranial cavity is remarkably small. In a Nilotic crocodile (No. 717 D) nearly fifteen and a half feet long, the cranial cavity is only just large enough to admit the thumb.

Some heads are long, some are broad, and others round. These different forms are determined by the varying extent of

growth of bone either in the transverse or the longitudinal sutures, or by the early union of one or other of them, as may be readily understood by a reference to the Gen. Ost. Ser. (Nos. 126, 127), where, the parietal bones uniting early, the skull was unable to accommodate the growing brain by increasing in breadth, and therefore could only increase in length by growing at the fronto-parietal and the occipito-parietal sutures, thus giving rise to these extraordinarily long skulls.

The great and heavy skull of the crocodile contains large nasal passages and air-cavities which float it, so that its body can lie under water while its eyes and nostrils alone appear just above the surface (No. 712).

One of the firstfruits of the study of comparative anatomy was the discovery of the law, 'That an invariable co-relation exists not only between the different parts of an animal's body, but likewise between the parts of his body and his mode of life.' The discovery was made by Cuvier, and would of itself have been sufficient to immortalise his name. He was led to the detection of this law by the study of a number of fossil bones which were found in quarries in the neighbourhood of Paris. The following is his own account :⁴⁶

'I found myself in the position of a man who had received a confused heap of the mutilated and incomplete remains of some hundreds of skeletons belonging to a score of different kinds of animals ; each bone had to search for those with which it should articulate—it seemed almost a resurrection in miniature. I had not at my command the all-powerful trumpet, but the immutable laws prescribed to living beings answered its purpose, for at the voice of comparative anatomy every bone, every fragment of bone, resumed its natural position. I am at a loss for words to describe my delight when so soon as I discovered any characteristic feature, I saw all the sequences of this character, more or less foreseen, develop themselves in succession. I found the teeth conformed to what the feet had foretold, and the feet to what the teeth foretold, and all the bones between the feet and the teeth conformed as could be judged beforehand ; in a word, each of these species sprang up again out of one of its elements.

Those who will have the patience to follow me will be able to form an idea of the sensations I experienced in thus restoring by degrees these antique monuments of fearful revolutions. Subsequent discoveries of fossils have hardly ever contradicted my earlier conclusions.'


THE VERTEBRAL COLUMN.

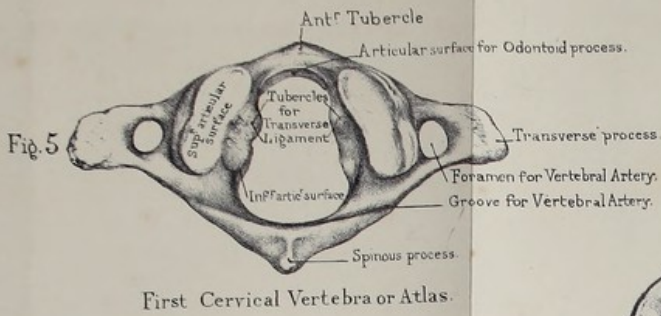
(PLATES XXV.—XXIX.)

The vertebral column, or spine (Plate XXVI.), consists of a series of bones articulated together so as to describe three slight and graceful curves, the bend being forward in the loins, backward in the chest, and again forward in the neck. These bones are called 'vertebræ,' because they permit the bending and rotation of the body (*verto*, I turn). They are 33 in number: of which 7 constitute the cervical region, 12 the dorsal, and 5 the lumbar. Below the lumbar vertebræ, the spine is supported upon a bone termed the 'os sacrum,' which consists of five vertebræ firmly coalesced into a single bone. Below the sacrum is the little bone termed the 'coccyx,' from its resemblance to the beak of a cuckoo (*κόκκυξ*). This also contains the rudiments of four, sometimes only three, vertebræ. The vertebral formula of man, therefore, is—7 cervical, 12 dorsal, 5 lumbar, 5 sacral, and 4 coccygeal, or caudal: that is, 33 in all.

Constituent Parts of a Vertebra.—The vertebræ have certain general characters which are common to all. These are modified in the different regions of the spine, according to the functions they perform. (See separate series, Mus. Roy. Coll. Surg.) Therefore, first obtain a general knowledge of a vertebra, and of the names given to its several parts; afterwards examine the characteristics of the vertebræ in each region.

Taking the first lumbar vertebra as a pattern (Plate XXV.), it is seen to consist of a 'body,' or 'centrum,' which forms the columnar part, and supports the weight of the spine. The body is convex in front from side to side, but slightly concave behind, where it assists in the formation of the 'vertebral foramen,'





First Cervical Vertebra or Atlas.

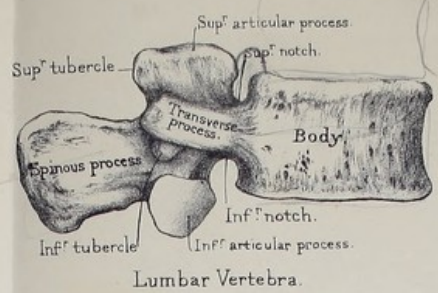
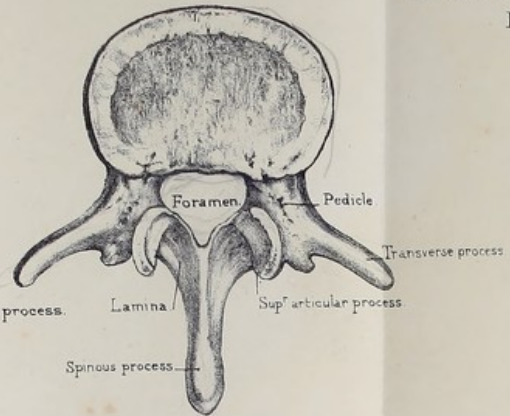


Fig. 1.

Lumbar Vertebra.

Fig. 2.



Lumbar Vertebra.

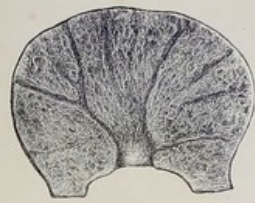

Fig. 7.

Section showing Venous canals.

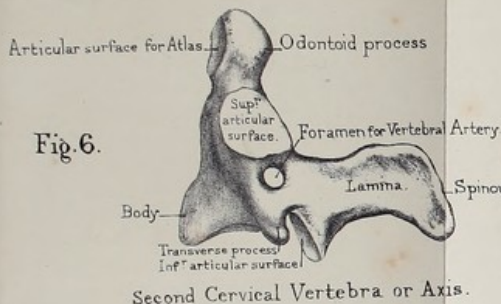


Fig. 6.

Second Cervical Vertebra or Axis.

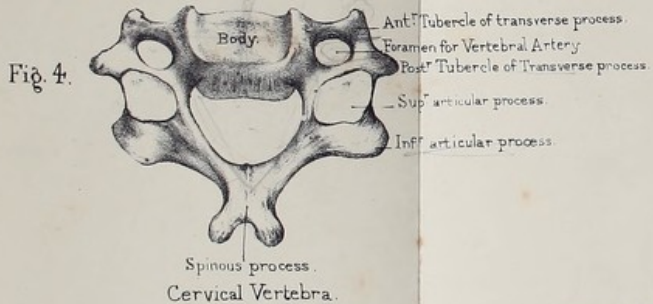


Fig. 4.

Cervical Vertebra.

From nature by L. Holden.

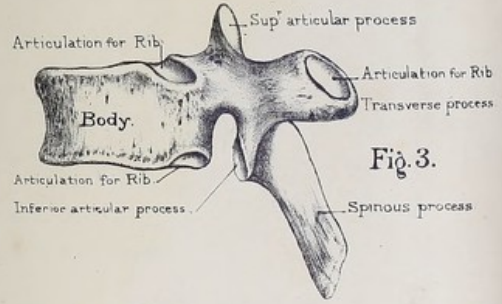


Fig. 3.

Dorsal Vertebra.

Drawn on Stone by T. Godart.

Printed by West, Newman & Co.

which transmits and protects the spinal cord. The upper and lower surfaces of the body present a disc of solid bone at the circumference (Plate XXV. fig. 2), and a slight cup in the centre which lodges the elastic 'intervertebral fibro-cartilage,' found in the recent subject, and acting as a 'buffer' between the vertebræ. These discs or rings of compact bone deserve notice, not only because they strengthen the spongy bodies, but because they have separate centres of ossification, and remain until about the 25th year, as 'epiphyses.' A section through the body of a vertebra shows it to be composed of cancellous tissue, which makes it light compared to its bulk. (Nor. Hum. Ost., Nos. 175-185.) This tissue is traversed by large 'venous canals,' of which the orifices are observable on the surface, but chiefly on the back part of the body, towards which the larger canals converge (Plate XXV. fig. 7). Behind the body is the 'vertebral foramen.' Now this foramen is formed by two thick processes of bone, which proceed, one from each side of the posterior part of the body, and gradually converging, unite and form an arch (vertebral or neural arch). The spring of the arch, where it joins the body, is called the 'pedicle;' the converging plates are termed the 'laminæ.' The arch sends off seven 'processes.' Of these, three—namely, the 'spinous' and the two 'transverse'—give attachment to muscles. The 'spinous process' arises from the top of the arch; the two 'transverse processes' pass off, nearly horizontally, one from each side of it, near the junction of the 'pedicle' with the 'lamina.' The remaining four are termed 'articular processes'—two superior articulating with corresponding processes of the vertebra above and two inferior articulating with corresponding processes of the vertebra below; they are situated on the point of union of the pedicles with the laminæ. Their articular surfaces are covered with cartilage in the fresh state, and project beyond the bodies, so that the joints are on a level with the intervertebral fibro-cartilages. Lastly, on the pedicles, we observe two 'notches' on either side—an upper and a lower, the lower being always the larger. When the vertebræ are together, these notches make what are called the 'intervertebral foramina,' in which the spinal

nerves lie. (Plate XXVII.) The 'pedicle,' or the part of the arch between the notches, is the weakest part of a vertebra, and consequently it is the principal seat of torsion in curvatures of the spine.

Such, then, are the constituent parts of a vertebra : namely, a body, an arch, a vertebral foramen : seven outstanding processes, of which four are articular, and three give attachment to muscles ; lastly, the notches which transmit the spinal nerves.

In examining a single vertebra it is necessary first to ascertain to which region it belongs, and then which vertebra it is of that region. We will therefore describe first the distinctive characters of the region, and then the peculiar characters of the individual vertebræ, as far as they can with certainty be distinguished.

Cervical Vertebræ—Distinctive Character.—All the cervical vertebræ, and they alone, have a foramen in the base of each transverse process, which (excepting that in the 7th) transmits the vertebral vessels and a plexus of sympathetic nerves.

General Characters of the Cervical Vertebræ.—There are seven cervical vertebræ. The 'bodies,' excepting the first and second, are broader from side to side than from before backwards, and a lateral ridge projects from each side of their upper borders, and fits into a corresponding depression on the sides of the vertebra above (Plate XXV. fig. 4). Each 'body' slopes a little forward, and overlaps the one below. (Plate XXVII.) By all this interlocking, lateral displacement is prevented ; this mechanism compensating for the apparently insecure connections of the articular processes. Their 'spinous processes' are horizontal, and give attachment to the ligamentum nuchæ as well as to the muscles which maintain the head erect. But the spinous processes of the third, fourth, and fifth are especially short, and permit the free extension of the neck, and are very distinctly bifurcated ; they overlap each other a little in extension, as anyone may see in the dry bones by moving them backwards over each other. There is a groove on the upper surface of each transverse process in which lodges the spinal nerve ; and this groove bifurcates the summit, so that there are two 'tubercles' formed, an anterior and a posterior (in the lower five), both for the

attachment of muscles. Observe especially the large size of the anterior tubercle of the sixth cervical vertebra. It is called the carotid tubercle, being a guide to the carotid artery. Strictly speaking, we ought to say that the transverse process of a cervical vertebra arises by two roots or bars, an anterior and a posterior, which subsequently join, and so form the foramen which transmits the vertebral artery, vein, and a plexus of nerves: the anterior root springs from the side of the body: the posterior springs from the arch. Their 'articular processes' are flat, oblique, and inclined, so that their planes make an angle of about 45° with the horizon. The upper processes look backward and upward, the lower forward and downward. They are placed nearly in the same transverse plane and the obliquity of their direction permits flexion and extension, and a motion round an oblique axis. In this oblique motion the articular process of one side glides downward and backward upon the corresponding articular surface below, and that of the other side rises upwards and forwards upon the corresponding one above. In this way a combination of rotation and lateral flexion may occur between two contiguous cervical vertebræ.

1st and 2nd Cervical Vertebræ.—The 1st and 2nd cervical vertebræ differ most remarkably from the rest, as they respectively permit the nodding and the rotation of the head.

1st Cervical Vertebra: Atlas.—The 1st cervical vertebra (Plate XXV. fig. 5) is called the 'atlas,' because it supports the head. This is the only vertebra which has no body. The odontoid process of the axis (the 2nd cervical vertebra) is the body of the atlas, and is thus transferred and fixed to the second vertebra, forming a pivot or axis upon which the atlas rotates. It seems, at first sight, rather far-fetched to say that the atlas rotates round its own body (detached); but it is nevertheless true, and borne out by the facts of philosophical anatomy. The 'spinous process' is a mere tubercle (the posterior tubercle) to which the 'rectus capitis posticus minor' is attached. A large spine here would interfere with the free backward movement of the head. This vertebra is like a ring, wider behind than in front, and thickened on each side, forming the 'lateral masses'

and the articular surfaces. In front there is a small 'anterior tubercle,' into which is inserted a portion of the 'longus colli.'

Now the form of the atlas is adapted to the rotatory movement of the head. In the first place there is a little articular surface, the odontoid articulation, on the back of the anterior part of the ring of the atlas. The 'transverse processes' are thick and strong, and project far beyond those of the other cervical vertebræ, and give great leverage to the inferior oblique muscles which assist in rotating the head from side to side. Its 'inferior articular' processes look downwards and slightly inwards; they are nearly horizontal, flat and circular, like the upper ones on the axis on which they slide, in the movement of rotation of the head. The 'superior articular surfaces' are concave, and articulate with the convex condyles of the occipital bone, and are similarly oval, converge anteriorly, and lie near the front of the foramen. The outer edges being the highest, they form two little cups looking upwards and inwards, which receive the occipital condyles, sustain the whole weight of the head, and permit its nodding movement. On the inner side of each articular process is a tubercle which gives attachment to the strong 'transverse' ligament, which confines the odontoid process in its position. The 'arch' formed by the laminae is wider than in other vertebræ, and leaves such ample space that lateral displacement of the atlas has occurred without compression of the spinal cord.⁴⁷ On the upper surface of each lamina is a groove (sometimes a complete bony canal) for the vertebral artery and suboccipital nerve; this corresponds to the superior notch in the other vertebræ. Lastly, the 'notches' for the nerves are placed behind the articular processes, while in all the other vertebræ (except the upper notch in the axis) they are in front of them. The 'vertebral foramen' is large, presenting the appearance in outline of a small uterus. It is occupied in front by the odontoid process with the transverse ligament, and behind by the spinal cord with its vessels and membranes.

2nd Cervical Vertebra: Axis.—The 2nd cervical vertebra or 'vertebra dentata' (Plate XXV. fig. 6) is called the 'axis,' because it is the axis upon which the atlas (with the head)

rotates. The pivot, termed the 'odontoid process' from its resemblance to a tooth, rises vertically from the 'body' of the axis, and fits into a ring formed in front by the atlas, and behind by the strong 'transverse' ligament which passes between the lateral masses of the atlas, and divides the vertebral foramen of that bone into two parts, an anterior for the reception of the odontoid process, and a posterior for the passage of the spinal cord. It is a mechanism resembling a tenon and mortise.⁴⁸ The odontoid process has a smooth surface in front, which articulates with the atlas; another behind, on which plays the ligament. There is a distinct synovial membrane and a layer of cartilage on each surface, so that they possess all the apparatus of a joint. Moreover, it is slightly constricted at its lower part (forming what is called the 'neck'), which the 'transverse' ligament clasps securely. Lastly, its summit or 'head' is rough and sloped laterally. From these lateral slopes proceed the 'check' or 'odontoid' ligaments, which fasten the odontoid process to the occipital bone. Considering the importance of the odontoid process, we are not surprised that its internal structure is much more compact than that of the body of the axis. The upper 'articular processes' are placed, partly on the body and partly on the root of each transverse process; they are neatly flat and circular, and slope a little downward and outward. Like those of the first vertebra, they have a very strong base, and transmit to the 'body' the weight of the head. The 'notch' is behind them. The lower 'articular processes' are oblique, and placed considerably behind the upper, and correspond with the line of the articular processes of the succeeding vertebræ which they resemble. The intervertebral 'notch' is in front of them, as in all the vertebræ below. The 'transverse processes' are comparatively small, and not grooved or bifurcated; but the hole at their base is inclined obliquely outwards, corresponding to the curve of the vertebral artery. The 'laminæ' of the arch are remarkably strong. The 'spinous process' stands well out, and bifurcates widely, giving great leverage to the inferior oblique muscles which rotate the head. The great size and projection of this *spinous* process is one of the distinguishing characters of the

axis; and with this we should associate the large size of the *transverse* processes of the atlas, these being the respective attachments of the inferior oblique muscles.

3rd, 4th, and 5th Cervical Vertebrae.—The 3rd, 4th, and 5th cervical vertebrae can be easily distinguished from the rest, although not from one another, by the following points: Their spinous processes are spread out horizontally, and are thin, bifid, and short (Plate XXV. fig. 4), thus allowing the neck to be bent backwards very considerably before the spines come into contact.

6th Cervical Vertebra.—The spine of the 6th is short, it is not bifid (or rarely so), and runs nearly horizontally backwards, but is not spread out like the 3rd, 4th, and 5th. The foramen in the transverse process is the largest of all the series.

7th Cervical Vertebra.—The 7th cervical is called the ‘vertebra prominens’ on account of its long horizontal and prominent spine, which can be easily felt at the back of the neck. It slopes a little downwards, and thus somewhat resembles those in the dorsal region, and gives attachment to the ‘ligamentum nuchæ.’ The foramen in the transverse process is never traversed by the vertebral vessels, and is small and irregular in shape. Moreover, the transverse processes, though so long and broad as to suggest a rudimentary rib, are but slightly grooved, and have no distinct tubercles. This vertebra in some rare instances has two little (cervical) ribs attached to it, one on either side, in form and situation resembling the cervical ribs of animals. A cervical rib may be mistaken for a bony tumour if the surgeon does not bear in mind that such an anomaly may exist in the skeleton. It is sometimes united with the first rib.

Dorsal Vertebrae: Distinctive Character.—All the dorsal vertebrae, and they alone, have facets on the sides of their bodies with which the heads of the ribs articulate.

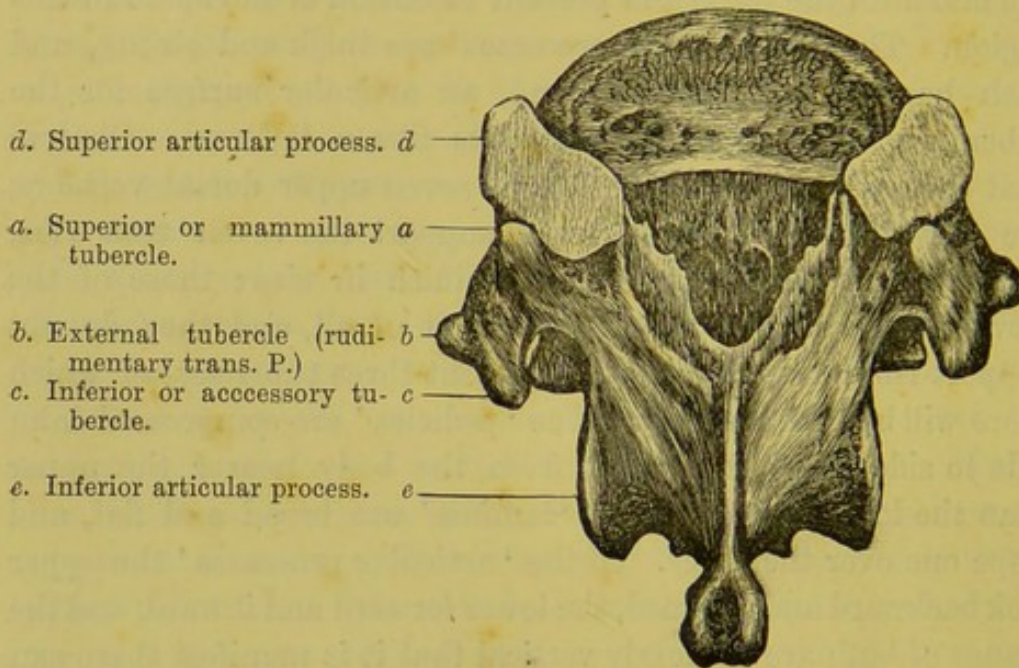
Dorsal Vertebrae: General Characters.—The general characters of the twelve dorsal vertebrae are as follows: Their ‘bodies’ are heart-shaped, and smaller than those of the lumbar, and they have less weight to bear. Their vertical depth is less in front than behind, especially near the middle of the back, in adaptation to the dorsal curve. They are slightly wider from side to

side than from before backwards. They have two little cup-like facets on each side for the articulation of the heads of the ribs, the lower cups being the larger. By referring to the spine (Plate XXVI.), we observe that the socket for the head of the rib is formed by the articular facets of two vertebræ with the intervening fibro-cartilage. These 'rib facets' distinguish a dorsal vertebra from a vertebra of any other region of the spine. Their 'spinous processes' are long, clubbed at the end, and slant downwards, so that they overlap each other, especially near the middle of the back, and prevent extension of the spine in this region. Their 'transverse processes' are thick and strong, and each has in front, near its end, an articular surface for the tubercle of a rib, which it supports like a buttress. Observe that the transverse processes of the seven upper dorsal vertebræ are very thick and strong, and support the seven true ribs, whilst the five lower gradually diminish in size; those of the eleventh and twelfth are the smallest of all, and they do not support ribs; these lower ones present three tubercles, of which more will be said hereafter. The 'pedicles' are compressed from side to side, short, and start from the body nearer the upper than the lower surface. The 'laminæ' are broad and flat, and slope one over the other. Of the 'articular processes' the upper look backward and outward, the lower forward and inward, and the planes of both are so nearly vertical that it is manifest there can be but little movement between any two dorsal vertebræ. Any that does occur consists of very slight flexion and extension, and very limited rotation. The 'vertebral foramen' is nearly round. The lower 'intervertebral notches' are larger than the upper.

1st, 9th, 10th, 11th, and 12th Dorsal Vertebræ.—The FIRST dorsal vertebra has on the side of its 'body' an articular surface for the whole of the head of the first rib, and a smaller one at the lower border for half of that of the second rib. Again, the upper surface of its body has lateral ridges like the cervical vertebræ. The NINTH dorsal has usually only half a facet on the upper part of the body. The TENTH dorsal has generally an entire facet for the tenth rib. The ELEVENTH and TWELFTH dorsal have each a single articular facet for the eleventh and

twelfth ribs respectively, and their 'transverse processes,' much reduced in size, do not articulate with the ribs. Moreover, they are smaller than in the upper dorsal region, and they resolve themselves into three tubercles (seen in fig. 23). The TWELFTH dorsal may be distinguished from the ELEVENTH by the fact that its lower articular processes look outward, like the corresponding processes in the lumbar vertebræ. Its spinous process is short and square, and more like those of the lumbar vertebræ. The

FIG. 23.



TWELFTH DORSAL VERTEBRA, SHOWING THE THREE TUBERCLES ON THE TRANSVERSE PROCESSES.

tubercles of its transverse process are always well marked. (Plate XLV. fig. 2.) It must be remarked, however, that the above description of the special characters distinguishing the so-called 'peculiar dorsal vertebræ' apply only to vertebræ which are typically normal. In many instances these appearances do not show themselves in the respective vertebræ; for example, the twelfth may have its inferior articular processes directed *forwards* as an ordinary one, or *forwards* and *outwards*, or, again, the first one may have only *one* whole facet upon the side of its body. Consequently before making up one's mind as to the exact number

of any given peculiar dorsal vertebra, one should have regard to the general features of the whole bone as well as to the so-called 'distinctive characters' ascribed to it.

Lumbar Vertebrae: Distinctive Characters.—The lumbar vertebrae have neither holes in their transverse processes nor articulations for ribs.

General Characters of the Lumbar Vertebrae.—The general characters of the five lumbar vertebrae are as follows: The 'bodies' are large, with their broad diameters transverse, and firmly support the trunk. The vertical measurement of the bodies is greater in front than behind, in adaptation to the lumbar curve. Their sides are slightly excavated, which economises weight and bulk. Their 'spinous processes' are broad, in their vertical measurement, thickest at the lower border, and give good leverage to the extensor muscles of the spine: they stand out horizontally, and so do not interfere with the extension of the back. Their 'transverse processes' are thin and long, and appear like stunted ribs, but are not true ribs. Their 'articular processes' are vertical, and very strong: the upper, slightly concave, look towards each other; the lower, slightly convex, are nearer together, and fit in between the upper ones of the succeeding vertebra. Thus, these articulations are so shaped that they admit, not only of extension and flexion of the loins, but of a certain amount of bending of the spine to one side ('lateral flexion'), which is useful in progression. The 'vertebral foramen' is triangular, with the angles rounded. The lower intervertebral notches are larger than the upper ones.

Characters of the last Lumbar Vertebra.—The last lumbar vertebra is distinguished (1) by the slope on the lower surface of its body, in adaptation to the slope of the sacrum; (2) by the transverse processes being short and very thick, and arising from the sides of the body, as well as the pedicle. In some cases the lower border of the transverse process may be prolonged downward and form a rough articular surface, meeting a corresponding upward projection of the back of the ala of the sacrum, as is well seen in a specimen in the anatomical collection at St. Thomas's Hospital; (3) by its lower articulating processes being

placed so widely apart; and (4) by its spinous process being somewhat reduced in size, thereby leaving room for the free extension in this part of the back.

The Fourth Lumbar Vertebra.—This vertebra has very frequently its inferior articular processes as far apart as its upper ones, and so appear like the fifth. We may distinguish it, however, by its slender transverse processes arising from the junction of the pedicles and laminae, and not from the body, as in the fifth.

The Third Lumbar Vertebra.—If we are shown the whole lumbar series we can distinguish this vertebra by the great length of its transverse processes.

Tubercles on the Lower Dorsal and Lumbar Vertebrae.—An observant eye looking at the back of a well-marked spinal column will find that the transverse processes of the lower dorsal vertebrae have a tendency to resolve themselves into three bony prominences at their extremities. The twelfth (often the eleventh) transverse process actually terminates in three such prominences or tubercles; one being superior, a second inferior, and a third external (see fig. 23). The 'superior or mammillary tubercle' is close behind the superior articular process. The 'inferior or accessory tubercle' is in a straight line immediately below the superior; the 'external' projects in front of the other two tubercles, and is seen to be in a line with that part of the transverse processes of the upper dorsal vertebrae which bears the ribs. Now the superior and inferior tubercles gradually fade away in the lumbar vertebrae; but the external tubercle increases in size, and forms the transverse process of the lumbar region. Hence the transverse process of a human lumbar vertebra is homologous to that part of the transverse process of a typical dorsal vertebra which articulates with the tubercle of a rib. The tubercles are shown in Plate XLV. fig. 2.

In the human subject these 'tubercles'⁴⁹ serve only as attachments for muscles; but in some animals they attain extraordinary size, and have other functions. For instance: in the armadillo (No. 2335 B), the superior tubercle is as long as the spinous process itself, and helps to support the armour. In the

Carnivora the inferior tubercles gain a conspicuous development in the lower dorsal and upper lumbar regions, and contribute to the lateral security of the spine.

TABLE CONTRASTING THE IMPORTANT PARTS OF THE VERTEBRÆ IN THE DIFFERENT REGIONS.

We have shown how the vertebræ of the different regions of the spinal column may be distinguished, within certain limits, by the examination of any one of their constituent parts. These important parts are contrasted in the annexed table.

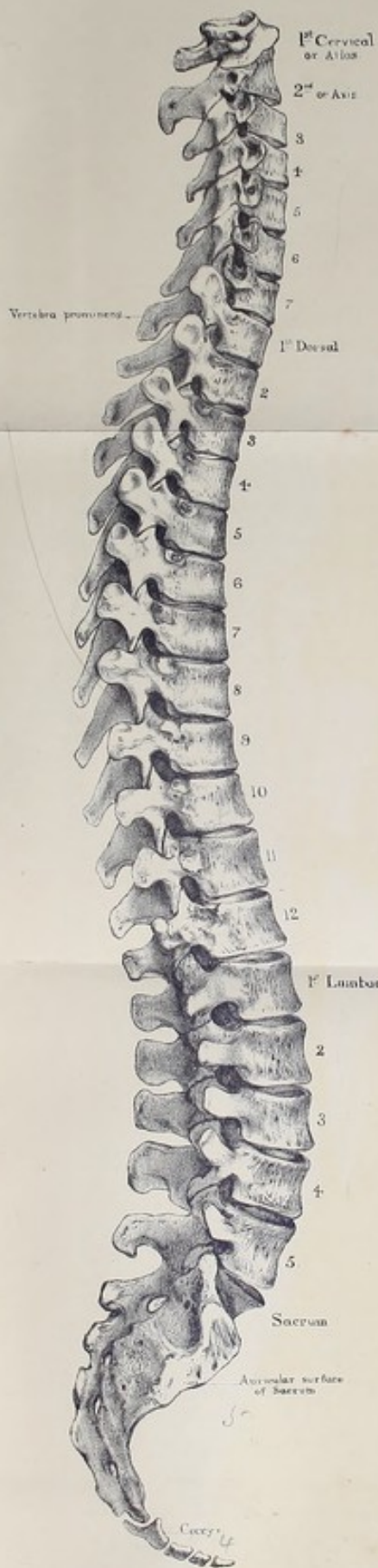
BODIES OR CENTRA.	{	<p><i>Cervical.</i>—Always broadest transversely. Lateral ridges on upper surface. <i>Concave above convex below</i> <i>vertebral foramina</i></p> <p><i>Dorsal.</i>—Greatest transverse measurement greater than antero-posterior. Facets or parts of facets on sides for heads of ribs. <i>lean to slope</i></p> <p><i>Lumbar.</i>—Always broadest transversely, somewhat kidney-shaped, no ridges, no facets.</p>
LAMINÆ.	{	<p><i>Cervical.</i>—Long, thin, and flattened. <i>C. Δ^y</i></p> <p><i>Dorsal.</i>—Short, very broad vertically. <i>ring D. O^y</i></p> <p><i>Lumbar.</i>—Very short and stout. <i>L. Δ^y</i></p>
SPINES.	{	<p><i>Cervical.</i>—Bifurcated, grooved underneath.</p> <p><i>Dorsal.</i>—Long, very oblique, tubercle at summit. <i>3 sides unbraced</i></p> <p><i>Lumbar.</i>—Broad and square. <i>Horizontal hatchet shaped</i></p>
TRANSVERSE PROCESSES.	{	<p><i>Cervical.</i>—Bifurcated, grooved on upper surface. Foramina for vertebral artery.</p> <p><i>Dorsal.</i>—Large and strong; facets for tubercles of ribs, except eleventh and twelfth.</p> <p><i>Lumbar.</i>—Thin, long and narrow.</p>
SUPERIOR ARTICULAR PROCESSES.	{	<p><i>Cervical.</i>—Surfaces plane, inclined at angle of 45°, look backward and upward. <i>B^U</i></p> <p><i>Dorsal.</i>—Surfaces plane, almost vertical, look backward and outward. <i>B^O</i></p> <p><i>Lumbar.</i>—Surfaces concave, vertical, look backward and inward. <i>B^I</i></p>

Vertebral Column as a Whole.—The spine is a most wonderful piece of mechanism, and has excited the admiration of anatomists in all ages, from the various and apparently incompatible offices it serves (Plate XXVI.) It forms a column, at once strong and firm, which supports the body in the erect position; it is flexible, and so admits the bending of the trunk in various degrees; it is elastic, diminishing concussion of the head.

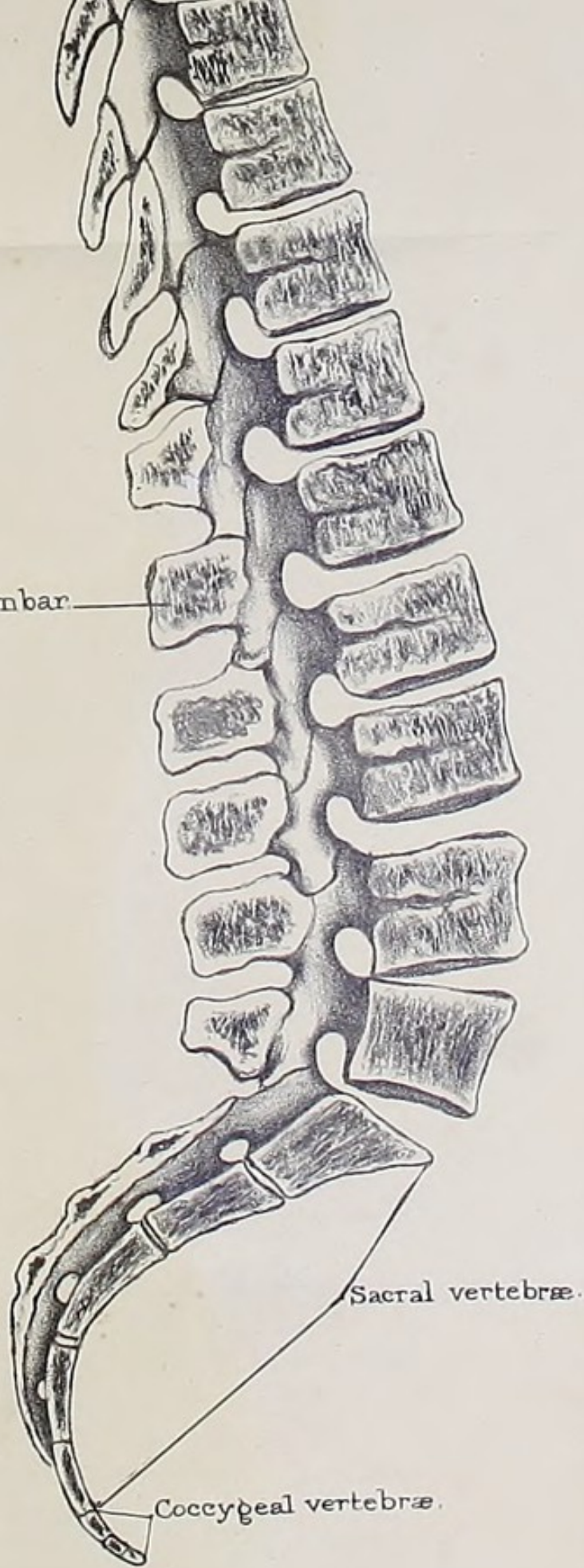
It forms a continuous canal at the back of the column, which contains and protects the spinal cord, a basis for the origin of the muscles which spread over the trunk, and a lever for the muscles which keep the body erect.

Strength of the Spine.—The main strength of the spine depends upon this: that it consists of a chain of bones so locked together that the degree of motion between any two is limited, though the sum of the whole is extensive. Another reason of the strength of the spine is its arrangement in alternate curves. The largest primary curve is situated in the dorsal region, with its concavity directed forwards to make room for the large thoracic viscera; the small counter-curves are situated above and below in the cervical and lumbar regions respectively. Mathematicians have calculated that it is many times stronger, and more adapted to resist vertical pressure, than if it were straight, the force being decomposed by the curves.⁵⁰ Look at the enormous weight which a man can carry with ease and safety on his head. Moreover, the curves convert the spine into so many elastic springs, which prevent the jarring of the brain. Besides this, the curves are admirably disposed for the lodgment of the internal organs, and the transmission of the weight of the head and trunk in the line of gravity. They are so regular and gentle withal, that the spinal cord runs no risk of compression; and lastly, they give the body that graceful form which has been the 'line of beauty' in every age. In infancy the spine above the sacrum is almost wanting in curves, forming a nearly straight column, giving the characteristic upright appearance observable in the backs of very young children.

The weakest part of the spine is about the last dorsal vertebra: firstly, because it is the narrowest part of the column; secondly, because it is not supported by the ribs like the higher dorsal vertebræ; thirdly, because it is the centre of the spine and the centre of motion in the back, and therefore exposed to the powerful leverage of the spine above and below it. Again, at the articulation between the last dorsal and the first lumbar vertebræ, the pliable lumbar part of the spine suddenly joins the comparatively rigid dorsal region.



1st Lumbar



Sacral vertebræ.

Coccygeal vertebræ.

Curves of the Spine.—The curves of the spine are produced partly by the relative thickness of the bodies of the vertebræ in the different regions, but *chiefly* by the relative thickness of the intervertebral fibro-cartilages and the tension and elasticity of the 'ligamenta subflava' which connect the laminae.


Extent of Motion in Different Regions.—The movements of the spine are fourfold—(1) flexion and extension; (2) lateral inclination; (3) rotation; (4) circumduction. Flexion and extension are freest in the cervical, less free in the lumbar, and least free in the dorsal region. The greatest extension is permitted in the cervical region and the greatest flexion in the lumbar, especially between the fourth and fifth vertebræ. This is chiefly brought about by the different thickness of the intervertebral cartilages in the different regions. The other movements are regulated by the articular surfaces. In the cervical region the articular processes are set obliquely and nearly in the same transverse plane; consequently pure rotation or pure lateral inclination cannot occur, but a gliding motion round an oblique axis takes place, the vertebræ gliding upwards and forwards on one side and downwards and backwards on the other, or *vice versâ*. In this way a mixture of lateral flexion and rotation is gained. In the dorsal region, the articular processes lying in the circumference of a circle whose centre is between the bodies of the vertebræ, a slight degree of rotation is allowed. In the lumbar region the articular processes lie in the circumference of a circle whose centre is behind the vertebra, and hence no rotation can occur; the articular processes allow of a certain amount of lateral inclination, which, mixed with flexion and extension, forms a slight degree of circumduction.

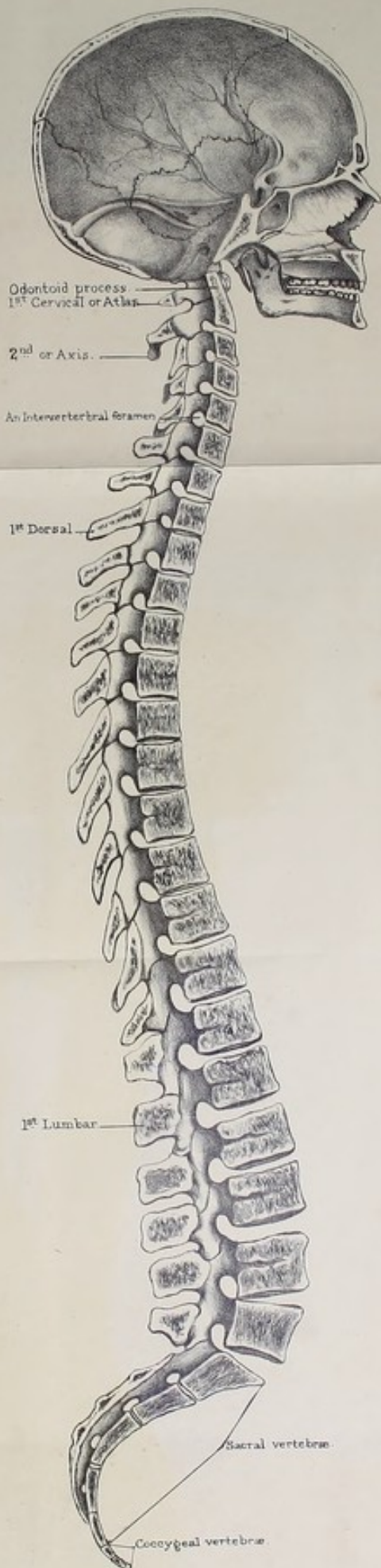
Intervertebral Fibro-Cartilage.—The intervertebral fibro-cartilage provides for the elasticity as well as the flexibility of the spine. The solidity of this substance gradually diminishes from the circumference towards the centre, where it forms a soft and almost incompressible pulp, permitting, to a limited extent, the motions of a ball-and-socket joint; namely, a gentle bend in every direction. Its great elasticity breaks the force of jars by gradually yielding, and always tends to restore the column to

its erect form. Long-continued pressure during the day will, indeed, make the intervertebral substances yield, so that a man loses in height perhaps $\frac{1}{3}$ or even $\frac{1}{2}$ an inch; but this is recovered after a night's rest. At the same time it should be remembered that a habit of leaning too much on one side will make the yielding of the intervertebral substance *permanent*. Even the bones themselves, while they are growing, will yield under such circumstances. There may be considerable distortion without actual disease.

Shape of the Column from the Front.—As to the form of the column in front, we observe that it is pyramidal, and that the bodies of the vertebræ gradually increase in size from above, and form a broader and broader base of support as the weight to be supported by each one in succession becomes greater. The atlas, in consequence of the great projection of its transverse processes, necessary for the rotation of the head, tops the pillar like a 'capital.' It is, however, necessary to remark, that there is a partial enlargement of the column about the lower part of the cervical region, which gives a broader base to the neck; and again a slight decrease in its breadth, about the third and fourth dorsal vertebræ, which allows more room for the lungs. Moreover, we commonly observe a very gentle lateral curve in the dorsal region, particularly about the third, fourth, and fifth vertebræ, with the concavity towards the left side. The cause of this curve has been much discussed. Some anatomists attribute it to the more frequent use of the right arm; others to the presence of the aorta. The solution of the question is of no practical value; all we need remember is, that the curve is natural.

Back of the Column.—At the back of the column, we observe the long row of spinous processes forming the vertical interrupted crest which gives the name to the 'spine.' The spines of the vertebræ should be examined on the living subject when the head is bent forwards and the arms folded. At the risk of repetition we will again direct attention: 1. To the suppression of the spine in the atlas, which permits the free extension of the head. 2. To the great projection and bifurcation of the spine of the axis which gives attachment to the inferior





oblique muscles which rotate the head and atlas. 3. To the shortness and horizontal position of the spines of the third, fourth, and fifth, which allow of free extension. 4. To the spine of the 'vertebra prominens,' where the ligamentum nuchæ is attached. 5. To the overlapping of the long spines of the dorsal vertebræ which limits movement in the region of the heart and lungs. These organs could not resist stretching or compression like the abdominal viscera. 6. To the square lumbar spines, the planes of which are vertical.

Vertebral Groove.—On either side of the spine is a deep furrow, termed the 'vertebral groove,' and formed by the laminae. It is bounded in the neck and back by the transverse processes, in the loins by the articular processes. The groove is narrowest about the junction between the last dorsal and first lumbar vertebræ (the weakest part of the back), and widest at the sacrum. The groove is occupied by the strong muscles of the back. The crest, being all that we can either see or feel of the spine during life, is the part we immediately examine in cases of injury or disease. In making this examination, we ought to be aware that the spines of the several vertebræ do not always succeed each other in a precisely straight line, but that one, here and there, may deviate to the right or the left, even in persons of the strongest frame.

Throughout the spine the intervertebral notches, excepting those of the atlas and the upper ones of the axis, are in front of the articular processes. But it is worth observing that the transverse processes vary in position. In the cervical region they lie between the foramina and are grooved by nerves. In the dorsal region they lie farther back between the articular processes in accommodation to the ribs which lie between the foramina. In the lumbar region the transverse processes lie between the articular processes and the intervertebral foramina.

Vertebral Canal.—Respecting the vertebral canal (shown throughout in Plate XXVII.), remark how well it is protected from injury by the breadth of the arches of the vertebræ. The arches overlap each other, so that it would be difficult for a cutting instrument to penetrate anywhere, except perhaps in the lumbar

region, and, again, between the arch of the atlas and the occiput, where animals are usually 'pithed.' The area of the canal is larger in the lower cervical and in the lumbar region than elsewhere, for the reason that the spinal cord itself presents corresponding enlargements in those parts where the great nerves of the limbs proceed from it. Observe well the relative size and mode of formation of the intervertebral foramina by the notches (Nor. Hum. Ost., No. 73).

Ossification.—As a rule, each vertebra is ossified in cartilage from eight centres, of which three are 'principal'—namely, one for the body and one on each side for the arch and its processes (Nor. Hum. Ost., No. 35): the remaining five are 'epiphyses,' and appear, soon after the age of puberty, as follows: one in the cartilaginous end of the spinous process, one in the cartilaginous end of each of the transverse processes, and one for each of the discs which form the articular surfaces of the body. The five epiphyses appear from the sixteenth to the twentieth year and become united to the vertebra by bone about the twenty-fifth year.

Ossification usually commences at the sides of the arch just before it begins in the body of the vertebra—viz. about the seventh week after conception. The sides of the arch unite first at the base of the spinous process, so that the ossification of the arch is complete in the first year after birth. During the third year the bases of the arch unite with the independently ossified 'centre' or 'body.'

It must be borne in mind that the posterior parts of the sides of the bodies are ossified from the arches; the line of junction is the 'neuro-central suture' of scientific anatomists. The mammillary processes are developed from separate centres of ossification, and occasionally the transverse processes of the first lumbar are formed from nuclei belonging to themselves. The anterior parts of the transverse processes of the seventh cervical generally present separate centres of ossification, and small nuclei have been seen in the second, fifth, and sixth.

It ought to be mentioned that some anatomists consider that the body of a vertebra is developed from *two* nuclei placed on either side of the middle line—a notion which is borne out by the fact

that we occasionally find a deficiency of a half of one or more vertebræ. A specimen in the museum of St. Thomas's Hospital shows the half of a dorsal interposed in a wedge-shaped way between the two contiguous vertebræ, and Sir William Turner has lately described the body of the tenth dorsal vertebra of a Maori skeleton as consisting of two distinct lateral wedge-shaped portions, separated by a mesial cleft.

Exceptions to the General Rule.—Where vertebræ undergo great modifications of form, we meet with exceptions to the above rule.

Thus the atlas has one or two centres of ossification for the anterior arch, which appear in the first year. The posterior arch and lateral masses are formed from two lateral centres, appearing about the seventh week. These lateral centres join behind in the third year, and unite with the anterior arch in the fifth or sixth year. Frequently there is a separate centre for the rudimentary spinous process at the back of the posterior arch. The development of the axis, as far as its neural arch and processes are concerned, is the same as in an ordinary vertebra. The body is developed from one or two centres which are common to it and the root of the odontoid process, and which appear about the fourth month. The rest of the odontoid process is formed by two lateral centres, appearing a little later than the centre for the body, and joining it in the third year, and a centre situated at the apex of the process appearing in the second year. The separate centres of ossification for the odontoid process help to justify the opinion that the odontoid process is really the body of the atlas.

Comparative Osteology.—In all known mammalia there are seven cervical vertebræ, with the following exceptions: Hoffmann's two-toed sloth—*Cholæpus Hoffmannii* (No. 3439)—has six; the Three-toed sloth—*Bradypus Tridactylus* (No. 3422)—has nine. In *Bradypus*, however, the ninth, and sometimes the eighth, bears a pair of short movable ribs; the manatee, again—*Manatus Americanus* (No. 2729)—has only six cervical vertebræ. The number of cervical vertebræ bears in no case any relation to the length of the neck. The short neck of the whale and the

long neck of the giraffe (No. 1437) contain each seven cervical vertebræ. The Greenland fin-whale in the Mus. Roy. Coll. Surg. appears to have but one cervical vertebra. An inspection of the transverse processes, however, shows that it has seven, and that they have become anchylosed. The lesser fin-whale, next to it, has the seven vertebral bodies perfectly distinct.

The bifurcation of the spines of the cervical vertebræ is almost peculiar to the human skeleton. It affords more room for the insertion of the powerful muscles which maintain the neck, and therefore the head, erect.

In the gorilla, the spines of the five lower cervical vertebræ (No. 20) are longer in proportion than those of any other known animal. They measure from three to four inches in length, and form one of the most striking features of difference between this skeleton and that of man.

The whale (Cetacea) has no odontoid process, and thus differs from the manatee (Sirenia), which has a well-marked one. See Series of Separate Bones, Mus. Roy. Coll. Surg.

In the chameleon each of the two lower cervical vertebræ bears a pair of cervical ribs (Nos. 664 *a*, 665 *a*); and in the snakes all the vertebræ, excepting those of the tail, carry movable ribs. Cervical ribs may also be seen in crocodiles (see Nilotic Crocodile, No. 717 D).

When mammalian vertebræ are very numerous, the great number is made up of caudal vertebræ; but when a bird's vertebræ are numerous, the number is made up of cervical. There are nine in the neck of the sparrow, and twenty-three in that of the swan.

In the wading birds (Grallatores), whose long legs raise the body some two feet or more above the water in which they wade, the neck is long enough to enable their beaks to reach the ground. Thus their necks are in proportion to the length of their legs. See the flamingo.

In swimming birds, as ducks and swans, the length of the neck is in no relation to the length of their short legs, but is in proportion to the depth to which they have to reach for food.

In man the upper and lower surfaces of the bodies of the vertebræ are slightly cup-shaped, and receive in their depressions

the convex surfaces of the discs of fibro-cartilage, which are placed between the bodies of the vertebræ, and give the spinal column its elasticity. In most fishes the bodies are so deeply cupped above and below, that there is a perforation in the centre through which the intervertebral substances are continuous (Nos. 433-437). In man the soft central part of this intervertebral substance is the remains of the chorda dorsalis, which persists in fishes, and is continuous through the central perforations. See the central cavities for the chorda dorsalis in the blue shark, No. 413; also No. 13. In the mud fish (Dipnoi) all the notochord is persistent, and there are no centra to the vertebræ whatever. This may also be seen in the lamprey, amphioxus, &c.

The epiphyses on the anterior and posterior surfaces of the bodies of the vertebræ should be especially examined in the whale (Separate Series). They form complete plates of great size, and being separable from the bodies of the vertebræ in many of these animals, are very abundant on the sea-shore in northern climates. It is interesting that when H.M.S. 'Hecla' was wrecked, the crew used these discs as plates.

In serpents (Ophidia) the body of each vertebra is cup-shaped in front, and receives the rounded head of the one in front of it (Nos. 604-609), and this is the same in many of those of the crocodiles, in which the upper surfaces of the bodies are cup-shaped, and each receives the convex projection from the lower surface of the vertebra above.

In many flying birds, the dorsal vertebræ are fixed to one another by fusion of the spines, and often of the transverse processes and bodies. In birds that do not fly, such as the cassowary and the ostrich, they retain their mobility (Nos. 1633, 1633 A-B, and 1634).

The vertebræ, which vary in number so widely throughout the animal kingdom, attain in the tiger-boa (*Python tigris*, No. 602) the enormous number of 291 in all.

In tortoises (*Chelonia*) the dorsal vertebræ are immovably connected, and have no transverse processes. The proximal ends of the ribs unite directly with the vertebræ, and are also immovable.

THE SACRUM.

(PLATES XXVIII., XXIX.)

Situation and Inclination.—The 'sacrum'⁵¹ is situated at the back of the pelvis, and wedged in between the two innominate bones. It forms the 'keystone' of the arch which supports the spine, and transmits the weight of it to the lower limbs. Observe that it inclines backwards, and forms, with the last lumbar vertebra, a rounded angle, termed the 'promontory' of the sacrum. This inclination answers a double purpose: it not only makes the pelvis capacious, but breaks the force of shocks transmitted from the pelvis to the spine.

Composed of Five Vertebrae.—Its general shape is triangular. It plainly consists of five vertebrae,⁵² with their bodies and processes all consolidated into a single bone. Examine its anterior and posterior surfaces, its sides, its base, and its apex.

ANTERIOR SURFACE.—Its *anterior* surface is concave from above downwards, and from side to side, in adaptation to the pelvic cavity. The curvature of the bone forwards, inferiorly, not only assists in supporting the pelvic viscera, but permits us to sit, which we could not have done had the bone projected like a tail. In the middle, are the anchylosed bodies of the five sacral vertebrae, decreasing in size from above downwards, and the four transverse ridges indicating their union. On each side of the ridges are the four anterior sacral foramina, with grooves leading from them for the passage of the anterior branches of the sacral nerves.

The bone exterior to the foramina, on each side, is made up of parts which in the three upper sacral vertebrae are homologous to ribs. These are united to the bodies, to each other, and to the transverse processes behind, so as to form a solid lateral mass. Here the 'pyriformis' arises. (Plate XLVII.)

POSTERIOR SURFACE.—The *posterior* surface of the sacrum is convex, and presents, in the middle line, the spines of the four upper sacral vertebrae, usually coalesced into a vertical crest,

SACRUM.

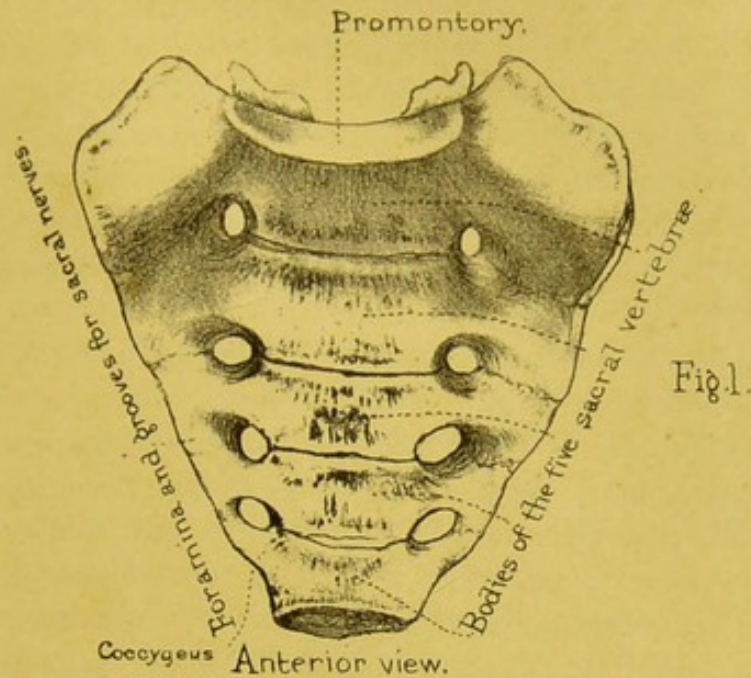


Fig. 1.

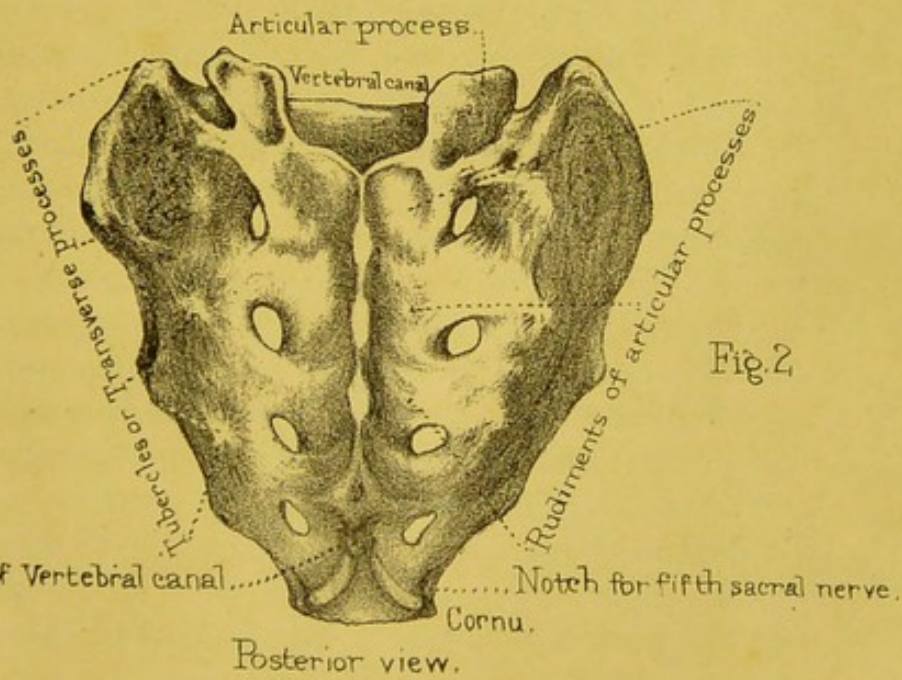


Fig. 2.

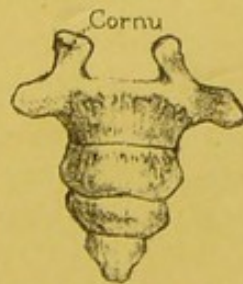



Fig. 3.

COCCYX.

Drawn on Stone by T. Godart.

From nature by L. Holden.

Printed by West, Newman & Co.



for the origin of the 'erector spinæ.' The last sacral vertebra, and sometimes the last two, have no spines, and even their arches are more or less deficient, so that the termination of the vertebral canal is here left unprotected in the dry bone; and in the recent state it is covered only by a fibrous membrane. This explains the serious effects that are apt to follow an injury to this part. Sloughs from bed-sores are sometimes deep enough to expose the vertebral canal. On each side of the crest is the vertebral groove; and here are the faint traces of the anchylosed articular processes of the sacral vertebræ. The most conspicuous of these processes are those of the last vertebra: they project like two knobs of bone, and are called the 'cornua' of the sacrum: they correspond with the cornua of the coccyx, with which they are connected by ligaments. Next to the articular processes are the four foramina which transmit the posterior sacral nerves. These posterior foramina are directly opposite the anterior, and are smaller in size. Béclard, in his lectures, relates the case of a sharp instrument running through both into the pelvic cavity. The fifth sacral nerve emerges through the little 'notch' beneath the sacral cornu. Still more externally are the 'tubercles,' indicating the anchylosed transverse processes. The posterior surface of the sacrum gives origin to the erector spinæ, *multifidus spinæ*, and *gluteus maximus*, as shown in Plate XLIII.

BASE OF SACRUM.—The *base* or upper end of the sacrum presents the oval surface of the body of the first sacral vertebra, which articulates with the last lumbar, a thick fibro-cartilage intervening. When the bone is in its proper position, this upper surface slants downwards and forwards, forming, with the lumbar vertebra, the sacro-vertebral angle, or 'promontory.' On each side of the body are its thick and strong lateral masses, expanded like wings, which transmit the weight of the trunk to the iliac bones. Each wing has a rounded edge in front, which forms part of the brim of the true pelvis. Behind the body is the triangular opening of the vertebral canal formed by the vertebral arches. Lastly, on each side of the canal are the articular processes for the last lumbar vertebra. They are set very wide apart, giving a broad base of support to the spine,

and look backwards and inwards, being slightly concave from side to side. In front of each articular process is the indication of the notch for the passage of the last lumbar nerve.

APEX.—The *apex* of the sacrum is formed by the diminutive body of the last sacral vertebra, and has an oval articular surface for the coccyx.

At the *sides* of the sacrum, notice the surface which is connected to the ilium, forming what is called the 'sacro-iliac' symphysis. Three sacral vertebræ concur to form it. The connection is effected partly by cartilage, partly by ligament. The cartilaginous part is in front, and is mapped out on the dry bone in the shape of a little ear, hence it is called the 'auricular' surface of the sacrum. We may divide the auricular surface into an anterior or vertical and a posterior or horizontal portion. The surface is irregular and concave from before backwards, and from above downwards in both portions. Behind this is a very rough surface, denoting the attachment of the posterior sacro-iliac ligaments. Lastly, the side of the sacrum below the auricular part gives origin to some of the fibres of the 'gluteus maximus.'

Ossification.—The sacral vertebræ are ossified like the others, with the addition of an independent centre on each side of the first three for the formation of the lateral mass, and appearing from the sixth to the eighth month. Now, since every vertebra has three primary centres (one for the body and two for the laminae, or arches), and two secondary centres for the body (the discs on the upper and lower surface appearing after puberty), the number of centres for the five sacral vertebræ stands thus :

$3 \times 5 = 15$ centres for the bodies.

$2 \times 5 = 10$ centres for the arches.

$2 \times 3 = 6$ additional centres for the lateral masses of the
— first three vertebræ.

that is 31.

To these add four epiphysial plates, two on each side, the upper for the auricular surface, the lower for the outer margin of the sacrum beneath that surface, and appearing from the eighteenth to the twentieth year—making in all 35 centres.

The component parts of each vertebra unite together first. Thus complete, the vertebræ remain separate until about the fifteenth year, when they begin to unite; not all at once, but in regular succession from below upwards. The lateral masses unite before the bodies. The whole bone is not consolidated before the twenty-fifth year, or thereabouts. However, even in advanced age, one sometimes finds the bodies of the upper sacral vertebræ still united in the centre by cartilage only.

Comparative Osteology.—Animals with well-developed hind-legs, which articulate with a pelvis, have a more or less developed sacrum, formed by one or more vertebræ. Supple animals, such as the tiger, will be seen to have a very rudimentary sacrum; the component parts are not welded together into a confused mass like that of man.

Snakes (Ophidia) have no sacrum, although there are rudimentary hind limbs in Typhlops, Python, and Tortrix. In the dugong and manatee (No. 2647, Sirenia) the sacrum is wanting as well as the hind limbs.

There is no sacrum in the whales (Cetacea).

The simplest form of sacrum is seen in the frog. It consists of one vertebra only, the transverse processes of which are expanded to articulate with the ilia.

THE COCCYX.

(PLATES XXVIII., XXIX.)

Constitution and Shape.—The coccyx derives its name from a fancied resemblance to the beak of a cuckoo (κόκκυξ). It consists of four or sometimes five rudimentary vertebræ, articulated (or ankylosed) together, and successively decreasing in size, the last being a mere nodule of bone. As a whole, it is triangular. The body of the first coccygeal vertebra articulates by an oval surface with that of the last sacral: and it has two little articular processes termed 'cornua' which are connected with

the 'cornua' of the sacrum, either by fibrous tissue or cartilage. The first vertebra has also two rudimentary transverse processes, and two 'notches' (one beneath each cornu) for the last sacral nerves.

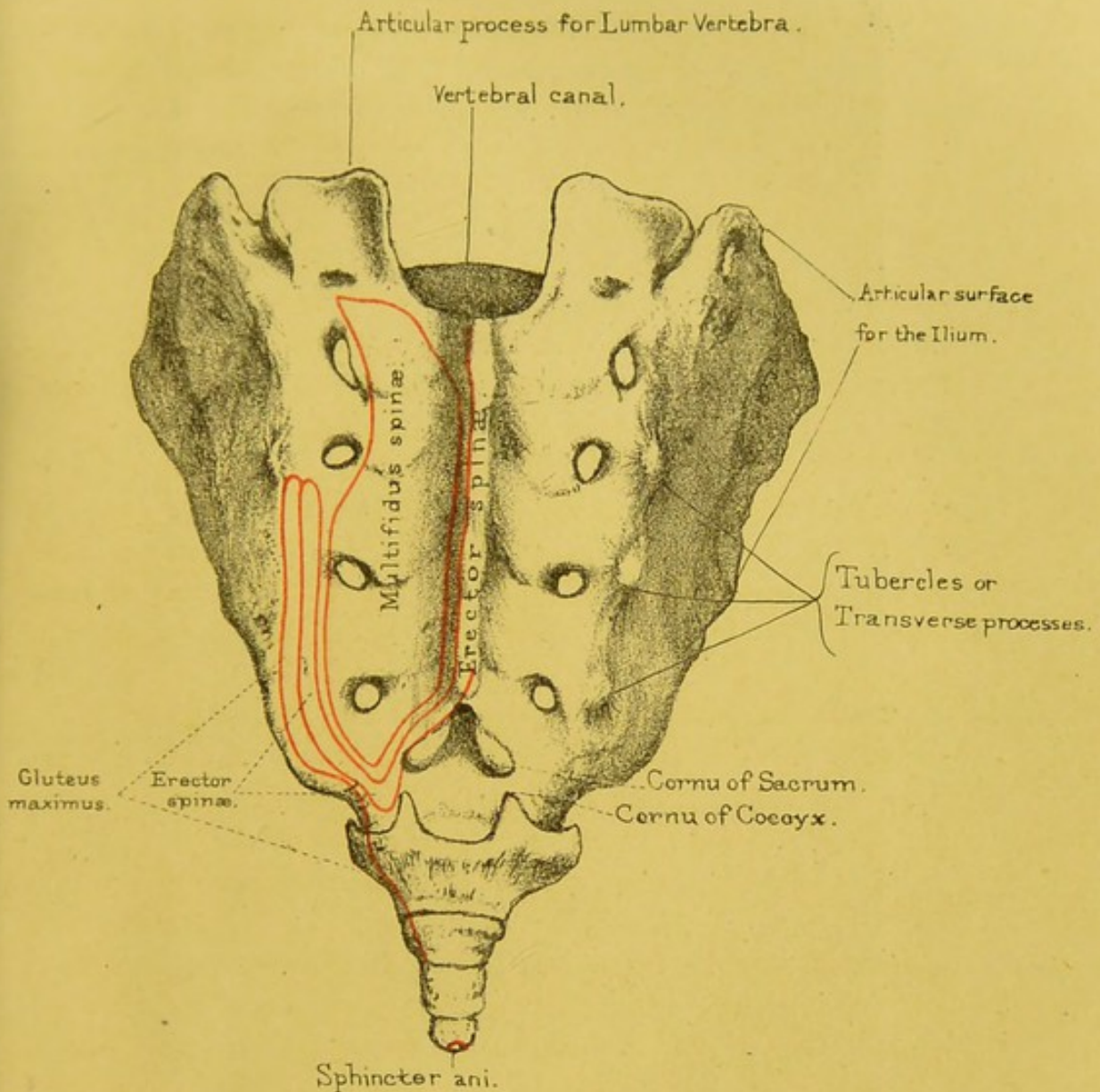
The first coccygeal vertebra articulates with the lower end of the sacrum by an intervening fibro-cartilage, and the succeeding ones are also separated by a fibro-cartilage. Thus the coccyx admits of being bent backwards and forwards, which is of great advantage in parturition, and gives as much as one inch more space in the antero-posterior diameter of the outlet of the pelvis. About the age of 45 or 50, and indeed sometimes earlier, these little bones become ankylosed to each other and often to the sacrum. This condition is one of the causes of difficult labour, and is generally met with in women bearing a first child late in life, and in those who have been accustomed to sit during the greater part of the day, as in the case of milliners.⁵³ Under these circumstances, the bone will sometimes break in labour. The coccyx gives attachment to the 'coccygeus' and 'sphincter ani externus' muscles.

Ossification.—Each bone of the coccyx is ossified from a single centre. The first begins to ossify soon after birth; the second from the fifth to the tenth year; the third about puberty; and the fourth about the fifteenth or twentieth year.


Comparative Osteology.—The coccyx in man corresponds to the tail of other animals. It now and then happens that the end of the coccyx projects somewhat, and is enclosed in a tube of integument; the man is then said to have a tail, and is looked upon by the vulgar with great suspicion.

In Mammalia the number of caudal (or coccygeal) vertebræ mostly far exceed those of any other region. This may be seen in the tail of the great ant-eater, which has forty, and that of the long-tailed Manis, which has forty-five. The Barbary ape (No. 170) has but three caudal vertebræ. The gibbon (No. 65) has two. The vampire bat (No. 3419) is the only mammalian animal which has no coccyx.

In all birds, except the extinct Archæopteryx, the caudal region of the spine is shorter than the body, and numbers only



Posterior surface of Sacrum.
with muscles attached.



eight or nine at most. In nearly all birds the terminal vertebræ will be seen to be anchylosed into a ploughshare-shaped bone, as in the ostrich and the vulture (No. 1674). In No. 70 A (the sheat-fish and the halibut) the last caudal vertebra is triangular and flat, and to the posterior edge of it articulate the rays forming the tail.

BONES OF THE LOWER EXTREMITY.

Constituent Bones.—The bones of the lower extremity consist of the ‘femur,’ the ‘patella,’ the two bones of the leg, namely, the ‘tibia’ and ‘fibula,’ the bones of the ‘tarsus,’ the ‘metatarsus,’ and the ‘phalanges’ of the toes.

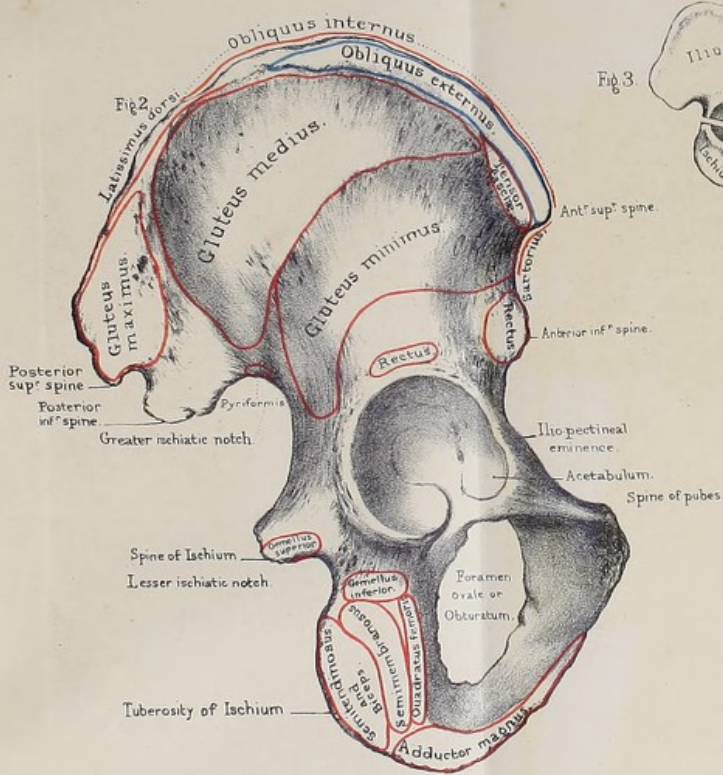
The femur articulates with the pelvis. The pelvis consists of the ‘os sacrum,’ the coccyx, and the two ‘ossa innominata.’ These bones form an arch, of which the sacrum is the keystone, and the innominate bones are the pillars. (Plate XXXII.) The weight of the spine is supported on the top of the sacrum, and the pressure is communicated down the pillars of the arch to the thigh bones which articulate with the innominate bones. It is in this way that the weight of the body is supported by the lower extremities.

OS INNOMINATUM.

(PLATE XXX.)

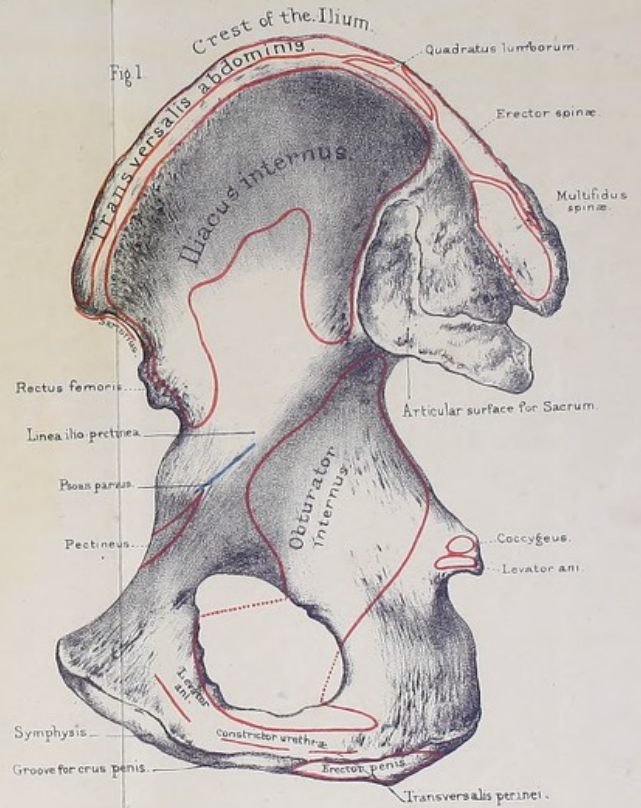
General Description.—The ‘os innominatum,’ so named by Galen, is made up of three bones, distinct in childhood, but united in the adult, and termed the ‘ilium,’ ‘ischium,’ and ‘pubes.’ Thus its constituents have received appropriate names, but the bone, consolidated, remains ‘nameless.’ The ‘ilium’ is the expanded part which supports the flank (ilia): the ‘ischium’ supports the body in the sitting posture (*ισχία*, the buttocks); the ‘pubes’ is the front part—so called from its being covered with hair. All three contribute to form the ‘acetabulum,’ or socket for the head of the femur, and in the following proportions

OS INNOMINATUM.



Outer surface

OS INNOMINATUM.




Inner surface.

Drawn on Stone by T Godart.

Printed by West Newman & Co.

Engraving by J. Holden



(Plate XXX. fig. 3): the ischium contributes rather more than two-fifths, the ilium rather less than two-fifths, and the pubes about one-fifth. Until the age of puberty they are separated at the bottom of the acetabulum by a piece of cartilage shaped like the letter Y; in the adult, however, little trace is left of the original division, so that, for practical purposes, it is better to consider the bone as *one*.

Looking at the bone generally, we notice that it is constricted in the middle, so as to assume somewhat of an hour-glass shape. The constricted portion we call the 'isthmus' of the innominate bone. At this isthmus the bone is twisted in such a way that a surface which looks upwards, inwards, and forwards above looks inwards, backwards, and slightly upwards below.

As the ilium, pubes, and ischium merge into one another at the isthmus, without any line of demarcation between them in the fully formed bone, it is more convenient to consider the os innominatum as *a whole*, and as having a general *circumference*, enclosing an *external* and an *internal surface*. In studying the relative bearings of the several parts of the bone, it is well to hold it as it lies in the erect position of the body. This position is obtained by placing the bone in such a way that the notch in the margin of the acetabulum directly faces the ground, or that the anterior superior iliac spine and the spine of the pubes are in the same vertical plane.

Circumference.—This may be divided into an *upper part*, looking more or less upwards; an *anterior part*, looking forwards and slightly upwards; a *lower part*, looking downwards and slightly forwards; and a *posterior part*, looking backwards and somewhat inwards.

The *upper part*, or *border*, presents more the appearance of a surface than of a border. It is called the 'crest of the ilium.' When looked at from side to side it is pretty uniformly convex upwards, with the highest point of the curve just behind the middle.

When viewed from above downwards it is curved so as to present from before backwards externally, first a slight concavity, next a larger convexity, next a still larger concavity, and lastly

a smaller convexity. It commences in front in a small rounded projection, called the 'anterior superior iliac spine,' which lies quite under cover of the adjacent overhanging upper border and gives attachment to the outer end of Poupart's ligament. It terminates behind in a similar projection named the 'posterior superior iliac spine,' also under cover of the overhanging upper border, and whose position in the living body is indicated by a dimple in the skin. We divide the crest of the ilium into an outer and an inner lip with an intervening rough surface. The outer lip is the more prominent of the two lips and gives attachment in its anterior half to the 'external oblique' and in its posterior half to the 'latissimus dorsi.' The inner lip is not so prominent as the outer one. It is more rounded and uniform in outline and not so rough, and gives origin in its anterior two-thirds to the 'transversalis abdominis,' and in its posterior third to the 'erector spinæ' and 'multifidus spinæ' muscles. The 'quadratus lumborum' arises also from about an inch and a half of the inner lip in front of the 'erector spinæ' (Plate XXX.) The intervening surface is rough and convex transversely. It is specially broad in its anterior and posterior small thirds and narrow in its large middle third. It gives origin in its anterior two-thirds to fibres of the 'internal oblique' and in its posterior third to parts of the 'erector' and 'multifidus spinæ' muscles.

The *anterior border* commences above at the anterior superior iliac spinous process and terminates below at the 'angle of the pubes,' i.e. the meeting of this border with the inferior one, and situated at the upper end of the surface for articulation with the bone of the opposite side. Looked at as a whole it is concave from above downwards and is directed forwards and slightly upwards. It presents immediately below the anterior superior spine a notch, called the 'anterior superior spinous notch,' rough and giving origin in its upper half to the 'sartorius' and in its lower half to part of the straight head of the 'rectus femoris;' next a rounded elevation, the 'anterior inferior iliac spine,' for the attachment of the rest of the straight head of the 'rectus femoris,' and below it a rough sharp edge forming part of

the circumference of the articular surface for the femur, and usually showing a notch indicating the point of junction of the iliac and pubic portions of the bone in this region. Running downwards and forwards from this is a crest, the 'obturator crest,' flattened in its outer third, where it gives attachment to a strong part of the capsular ligament of the hip joint, smooth, prominent, looking downwards and backwards and forming the upper edge of a groove situated immediately underneath it, in its inner two-thirds. At the inner end of this obturator crest the border is elevated into the 'spine of the pubes,' for the attachment of the inner end of Poupart's ligament. Surgically the spine of the pubes is of great importance. It can be readily felt through the skin and forms a guide to the external abdominal and the femoral rings. Starting from the spine, and running inwards and slightly downwards for about three-quarters of an inch, is a rough flattened ridge, called the 'crest of the pubes,' giving origin anteriorly to the 'pyramidalis' and posteriorly to the 'rectus abdominis' muscles.

Inferior border: Looked at as a whole, this border runs downwards, backwards, and outwards. It presents a general convexity facing downwards, forwards, and inwards, and when looked at in its long axis it appears sinuous, so as to present at the junction of its inner third with its outer two-thirds a slight convexity pointing upwards, inwards, and backwards, and in its outer two-thirds a larger convexity pointing downwards, outwards, and forwards. The border may be conveniently divided into an inner third or articular portion and an outer two-thirds or non-articular part. The articular portion is called the 'symphysis pubis,' united to the corresponding surface of the opposite bone by fibro-cartilage of at least three-eighths of an inch in thickness in front, which is elastic, completing the pelvic arch below and serving to obviate the effects of concussion. The 'symphysis pubis' is a flattened oval surface joining the inner end of the 'crest' at what we have already called the 'angle of the pubes.' Its long axis runs downwards, backwards, and slightly outwards, and measures about an inch and a half in the male and rather less in the female. In a well-marked bone it shows a series of

antero-posteriorly directed and parallel rows of rough tubercles for the firm attachment of the fibro-cartilage, excepting in a small elongated space which is flat but rough and which is placed rather above and behind the middle of the whole articular surface. The posterior edge of the symphysis is the more prominent. The non-articular part of the lower border forms one half of the so-called 'pubic arch' of the articulated pelvis. It forms a rough everted margin (more everted in the female bone than in the male one), and gradually increasing in thickness as it passes backwards. About the junction of its anterior third with its posterior third we frequently see a notch indicating the point of junction of the pubic and ischial parts of the border. Externally the border gives origin to fibres of the 'adductor magnus,' anteriorly to fibres of the 'gracilis,' internally, where the border is slightly grooved, to the 'crus penis' or 'crus clitoridis' and to fibres of origin of the 'erector penis' (Plates XXX. and XXXI.)

The *posterior border* begins superiorly at the posterior superior iliac spine and terminates below by joining the posterior end of the inferior border. Tracing it from above downwards, we notice first a small rough notch, called the 'posterior superior iliac spinous notch,' for the attachment of ligaments, next a sharp rounded prominence forming the posterior extremity of an articular surface seen on the inner surface of the bone, and called the 'posterior inferior spinous process.' Next we come on a large smooth excavation—the 'great ischiatic notch.' This notch is converted into a foramen by the greater and lesser ischiatic ligaments (fig. 24), and transmits the great vessels and nerves from the pelvis to the buttock, back of the thigh, and fore part of the pubic arch, viz.

Gluteal vessels and nerve.

Pyriformis muscle.

Greater and lesser ischiatic nerves.

Ischiatic vessels.

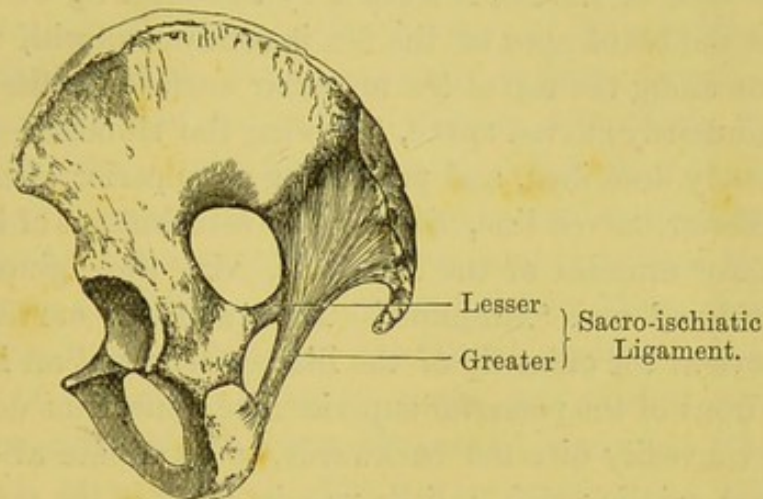
Pudic vessels and nerve (out of pelvis).

Nerve to obturator internus (out of pelvis).

The upper two-thirds of the notch belongs to the ilium, the lower third to the ischium. The lower end of the great sciatic

notch is prolonged into a flat, triangular projection, with a blunt apex, and called the spine of the ischium. It projects more inwards in the male than in the female bone, and in the latter is a very important bony prominence helping to regulate the passage of the foetal head in parturition. It gives attachment by its apex to the lesser ischiatic ligament, anteriorly to fibres of the 'coccygeus' and 'levator ani,' and posteriorly it gives origin to the 'superior gemellus.' Below this spine we come upon a smooth smaller notch—the 'lesser ischiatic notch'—covered in

FIG. 24.



the recent state by cartilage and lined by synovial membrane for the play of the tendon of the 'obturator internus' muscle. This lesser ischiatic notch is converted into a foramen by ligaments (fig. 24), and gives passage to

Tendon of the obturator internus.
Nerve to obturator internus (into pelvis).
Pudic vessels and nerve (into pelvis).

Below the lesser sciatic notch the posterior border merges into the posterior end of the inferior one and forms a prominent rough ledge in the adult bone, looking inwards and affording attachment to the falciform process of the great sciatic ligament.

The ligaments converting the notches into foramina answer three important purposes: 1. They mainly contribute to the fixation of the sacrum, which is the keystone of the pelvic arch.

2. They afford an extensive surface for the origin of the great muscle of the buttock (*gluteus maximus*). 3. They help to form the floor of the pelvis, and support the pelvic viscera, without adding much to the weight of the cavity.

External Surface.—This surface is twisted at the isthmus in such a way that the broad upper expanded portion, formed by the ilium, looks backwards and outwards, and the lower smaller portion, formed by the pubes, looks forwards, downwards, and somewhat outwards. Above the isthmus the external surface forms a fan-shaped space—the ‘*dorsum ilii*.’ The base of the fan is formed by the outer lip of the iliac crest, and the blunt apex of the fan is continuous with the rest of the bone along the top of the articular surface for the femur. It is a sinuously curved space, following the sinuosities of the crest, already described, and presenting a ‘superior,’ ‘middle,’ and an ‘inferior curved line,’ limiting the attachments of the three great rotator muscles of the hip joint, viz. the ‘*gluteus maximus*,’ ‘*medius*,’ and ‘*minimus*.’ The ‘superior curved line’ begins above at the outer lip of the iliac crest, about an inch and a half in front of the posterior superior iliac spine, runs downwards with its convexity directed backwards, to terminate at the top of the great sciatic notch, a little way in front of the posterior inferior iliac spine. Above this line is a rough surface for the origin of the ‘*gluteus maximus*.’ The ‘middle curved line’ begins above at the iliac crest, about an inch and a half behind the anterior superior iliac spine, sweeps upwards and backwards, and then downwards and backwards to terminate at the upper part of the great sciatic notch. The rough surface between it and the superior curved line gives origin to the ‘*gluteus medius*,’ and close to the line, and situated about two inches or so from its lower end, are usually found one or two large nutrient foramina. The ‘inferior curved line’ is commonly not so well marked as the other two. It begins in front at the anterior inferior spinous process, or the lower part of the anterior superior spinous notch, and runs nearly straight backwards, curving slightly upwards in its course, to terminate at the fore part of the great sciatic notch. The surface of bone between it and the middle curved line gives

origin to the 'gluteus minimus,' and in the fore part of the surface are situated a number of large nutrient foramina. Under the inferior curved line we come upon a rough, swollen surface, continuous anteriorly with the upper part of the rim of the acetabulum, and posteriorly merging into the part of the external surface of the bone formed by the body of the ischium, in some ossa innominata the line of junction being indicated by a shallow groove leading from the fore part of the sciatic notch to the margin of the acetabulum. Above the acetabulum this part of the surface is rough for the origin of the 'reflected head of the rectus muscle' and a strong part of the capsular ligament of the hip joint. Posteriorly it is smooth for the play of the overlying 'pyriformis' muscle, and all over it, especially in front, we notice a number of large nutrient foramina. Passing downwards we come upon the articular surface for the femur, called the '*acetabulum*' or '*cotyloid cavity*.' It is a hemispherical excavation, wanting below, looking downwards, outwards, and somewhat forwards, and formed, as already said, by the ischium, ilium, and pubes in the respective proportions of $\frac{2}{5}$, a large $\frac{1}{5}$, and a small $\frac{1}{5}$.

The margin of the cavity is sharp, rough, and uneven, and forms about three-fifths of the circumference of a circle. The cotyloid ligament, attached to it, fills up its inequalities and converts it into an even uniform margin. This ligament also, under the name of the transverse ligament, completes the circle, inferiorly, by bridging over the part of the cotyloid cavity which is wanting below. The cavity itself we divide into a circumferential or horseshoe-shaped articular portion and a central or inferior non-articular part. The horseshoe-shaped articular portion is slightly broader at its posterior than at its anterior end, but broadest of all superiorly, as it has there to support the greatest weight. Traced from the circumference towards the centre of the cavity, the articular surface is uniformly concave, and in some bones shows by shallow grooves the lines of junction between the iliac portion above and the pubic and ischial portions, situated respectively in front and behind, below (fig. 25). The groove is commonly best seen at the line of junction of the iliac and pubic portions. The non-articular part occupies the

bottom of the cavity and communicates with the exterior by means of a large notch, lying between the 'heels' of the 'horse-shoe' formed by the articular portion, and known as the 'cotyloid notch.' The non-articular part is depressed below the adjacent articular surface, and is formed by an exceedingly thin plate of bone. It is covered by a pad of fat, known as the pad of Havers, and is marked by a number of large nutrient foramina, especially superiorly. The 'cotyloid notch' is smooth. Its lower margin forms part of the circumference of the 'obturator foramen,' to be presently described. Its anterior and posterior extremities give attachment to corresponding branches

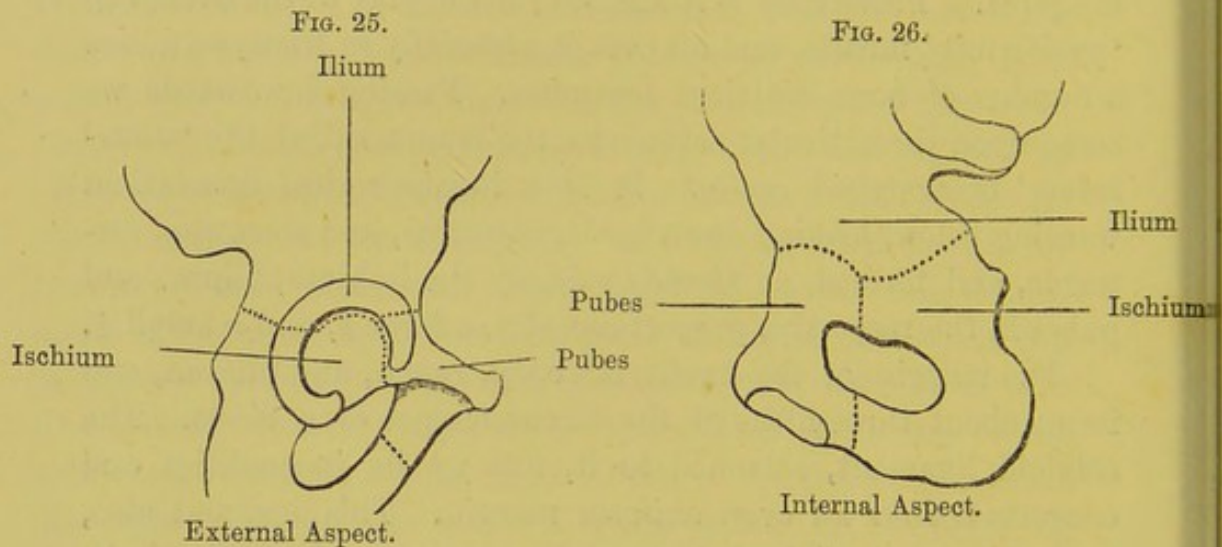


DIAGRAM OF FORMATION OF ACETABULUM BY ILIUM, ISCHIUM, AND PUBES (modified from Henle).

of the 'ligamentum teres,' and on it rest articular vessels and nerves for the ligamentum teres and the Haversian pad of fat.

Below and in front of the acetabulum is the *obturator foramen*, or *foramen ovale*. This is a wide opening of an oval form in the male, but triangular, with rounded angles, in the female. It is closed in the recent state by the 'obturator membrane,' everywhere excepting above and in front, where there is a broad groove leading downwards and forwards for the passage of the obturator vessels and nerve into the thigh. The anterior lip of the groove is rounded and formed by the 'obturator crest.' It runs from the spine of the pubes upwards, backwards, and outwards, arches



Fig. 1.

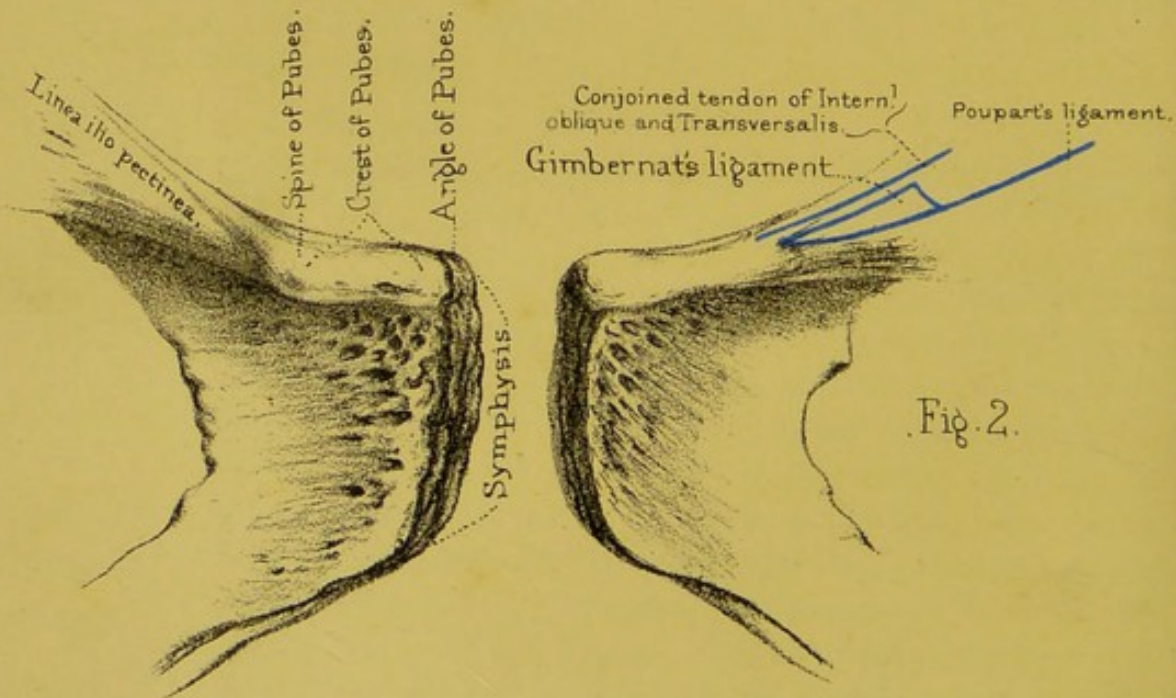
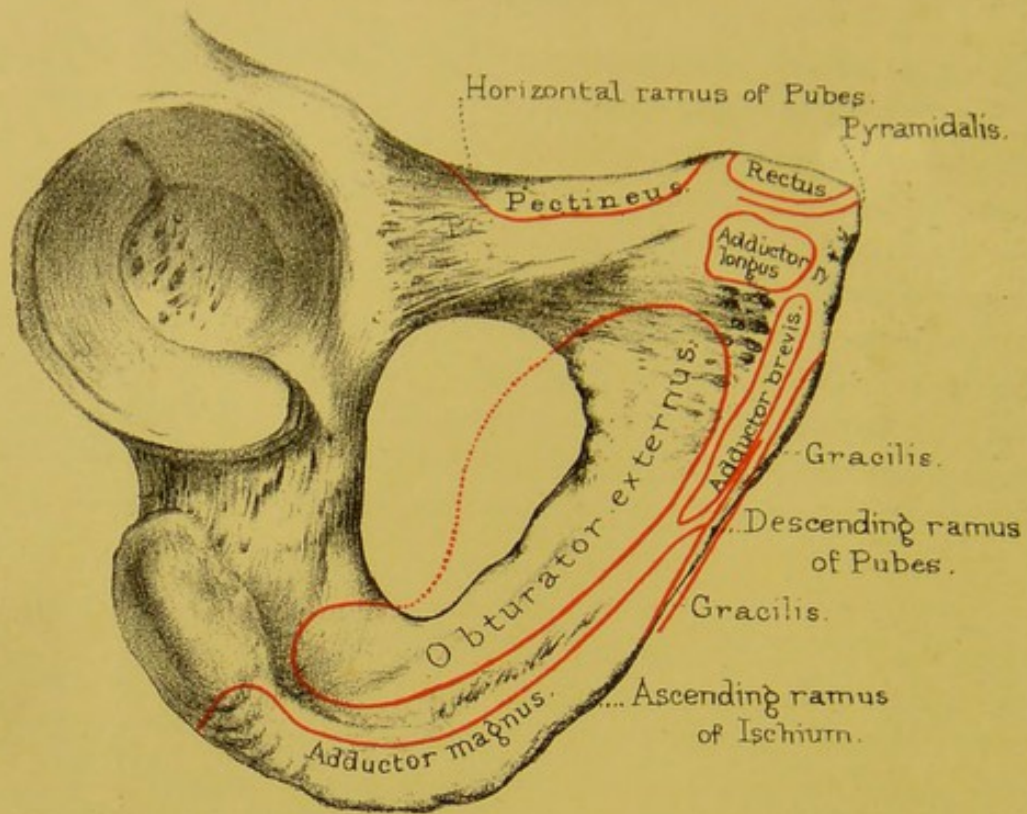


Fig. 2.

Front view of body of Pubes.

Drawn on Stone by T. Godart.

From nature by L. Holden.

Printed by West, Newman & Co.

over the highest part of the foramen ovale, and terminates posteriorly in a rough, prominent part of the upper margin of the foramen ovale; immediately below the lowest part of the cotyloid notch, and called by some anatomists the 'superior obturator tubercle.' The posterior lip of the obturator groove is sharper than the anterior lip. It begins below in a projection of the anterior margin of the foramen ovale, called the 'inferior obturator tubercle,' facing the superior one, ascends upwards, backwards, and outwards, and fades off on the inner surface of the bone just in front of the thinnest part of the acetabulum. The membrane, filling up the foramen ovale, serves for the origin of the obturator muscles just as well as if it had been a plate of bone; besides which it yields a little during the passage of the head of the child; it materially lightens the pelvis. Internal to the obturator foramen we notice a four-sided flattened surface, looking downwards and forwards, and forming the anterior surface of the 'body of the pubes.' This surface is bounded superiorly by the obturator crest, spine and crest of the pubes, internally by the symphysis, externally by the inner margin of the obturator foramen, and inferiorly is narrowed and continuous with the anterior surface of the 'descending ramus of the pubes.' At the angle between its upper and inner margins we have the 'adductor longus' attached, near the obturator foramen the 'obturator externus,' and between it and the symphysis parts of the 'adductor magnus,' the 'adductor brevis,' and the 'gracilis.' The 'obturator groove' gradually fades off in the upper and outer angle of the surface. The anterior surface of the descending ramus of the pubes runs downwards and backwards and looks forwards and outwards. It becomes continuous inferiorly and posteriorly with the anterior surface of the 'ascending ramus of the ischium,' notches in the margins, or a slight cross groove, indicating the line of junction. Close to its inner border it gives origin to part of the 'gracilis,' near the obturator foramen, the 'obturator externus,' and between the two fibres of the 'adductor magnus' and the 'adductor brevis.' The anterior surface of the 'ascending ramus of the ischium' runs as near as possible horizontally backwards to terminate in the

outer surface of the 'body of the ischium.' Its lower border is thrown forwards and outwards, especially so in the female bone, and gives attachment to the 'adductor magnus.' The surface itself gives origin to fibres of the 'obturator externus.' The anterior surface of the body of the ischium is smooth, marked by several nutrient foramina posteriorly, gives origin to the 'quadratus femoris' and becomes continuous with the 'tuberosity of the ischium.' This tuberosity is a rough, flattened eminence situated at the junction of the posterior with the inferior borders of the bone. It looks backwards and slightly outwards, and is divided into a larger upper part and a similar lower part by a diagonal line stretching across it from above downwards and outwards. The upper portion is again divided into an upper and outer part, giving origin to the 'semimembranosus,' and a lower and inner part for the common attachment of the 'biceps' and 'semitendinosus.' The part of the tuberosity below the diagonal line gives origin to a very strong part of the 'adductor magnus' muscle. The inner border of the tuberosity has already been described as being rough and prominent for the attachment of the falciform process of the great sciatic ligament. It is sometimes termed the 'falciform edge of the ischium.'

Internal Surface.—This surface is divided into two parts by a smooth ridge, 'the ilio-pectineal' crest, running from above and behind, first downwards, outwards, and forwards, and then downwards, inwards, and forwards. The part above the line or crest belongs, as we shall see afterwards, to the *false pelvis*, and looks forwards and inwards; the part below the line belongs to the *true pelvis*, and looks, taken as a whole, inwards, upwards, and backwards.


Tracing the surface from above downwards, we notice first in front a large, smooth, concave fossa looking forwards and inwards, and named the 'venter ilii,' or 'iliac fossa,' giving origin in its upper three-fourths or so to the 'iliacus' muscle. In the posterior third of this fossa we notice one or two large nutrient foramina. The fossa is limited below and inside by the iliopectineal crest, and below and outside is continuous with the groove already described upon the anterior edge of the bone, lying

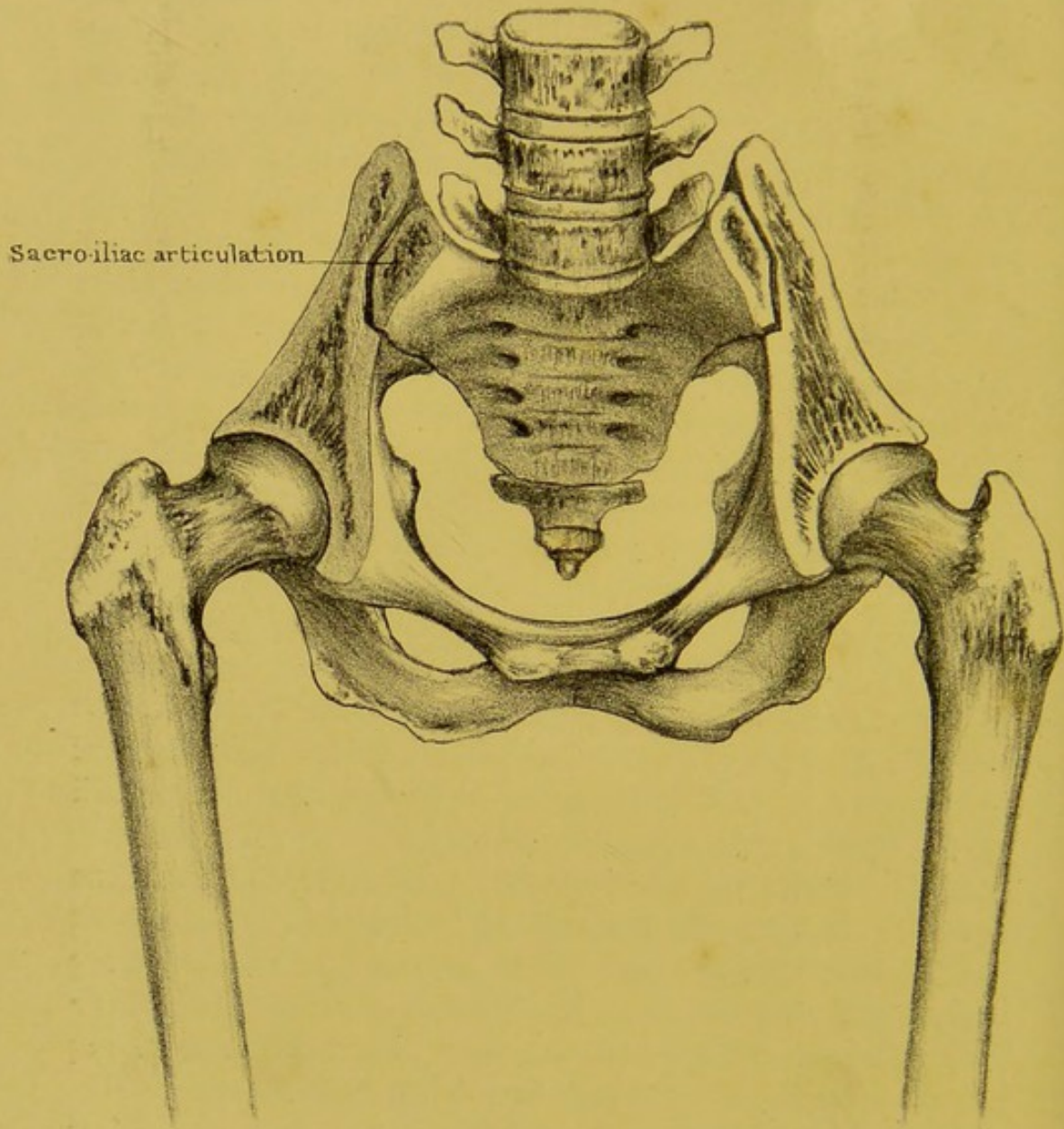
below the anterior inferior spinous process. Behind the venter ilii we come upon a part of the ilium which looks inwards and slightly forwards for articulation with and attachment to the lateral surface of the sacrum. Above and behind, this part of the internal surface is rough and tuberculated for the attachment of the posterior sacro-iliac ligaments, while below and in front it shows an 'auricular surface' for articulation with the sacrum. The auricular surface is rough and uneven, divisible into an anterior or vertical and posterior or horizontal portion. It presents first a concavity, next a convexity, and next a concavity, when traced from its convex anterior and lower to its concave posterior and upper edge. The whole of the auricular surface is covered by a thick layer of cartilage, rubbing upon a still thicker layer on the corresponding surface of the sacrum. In some cases we may have the two surfaces connected in part of their extent by fine transverse ligamentous fibres. The 'ilio-pectineal crest' or 'line' forms, in the articulated pelvis, part of what is called the 'brim of the true pelvis.' It divides the inner surface into a part above it, helping to form what is called the cavity of the *false* pelvis, and a part below forming part of the so-called *true* pelvis. It commences superiorly by two branches which join, respectively, the anterior and inferior lips of the auricular surface at about half an inch above and behind their angle of junction. These branches unite with one another about three-quarters of an inch below and in front of the auricular surface, and form a crest which runs downwards and forwards, describing a curve with the convexity directed outwards. Inferiorly and about half an inch above the pubic spine the crest divides into two branches—an anterior one, sharp and prominent, and running rapidly forwards to terminate in the spine of the pubes, and a posterior one, smooth, not so prominent, in some cases scarcely visible, stretching forwards, downwards, and inwards to join the upper end of the articular surface of the symphysis. The smooth triangular surface included by these two branches looks upwards, backwards, and inwards, and helps to make the cavity of the true pelvis.

Below the ilio-pectineal crest we have a large smooth surface

slightly concave, corresponding to the cotyloid cavity on the external surface, and giving origin to the 'obturator internus' muscle. It is marked by nutrient foramina, especially superiorly, and at the part opposite the bottom of the cotyloid cavity is exceedingly thin. At the anterior and inferior corner of the surface we have the upper end of the 'obturator groove,' limited below and behind by the inner aspect of the superior obturator tubercle. Inferiorly and posteriorly it is continuous with the smooth inner surface of the body of the ischium and the somewhat rough anterior and inner aspect of the ischial spine, the latter giving attachment superiorly to the 'coccygeus' and inferiorly to the 'levator ani.' The inner surface of the body of the ischium is smooth, covered by the obturator internus muscle, and continuous with the small sciatic notch. Below the space, corresponding to the acetabulum externally, we notice the inner aspect of the obturator foramen, already described, and below this to the inner surface of the ascending ramus of the pubes and the descending ramus of the ischium, with perhaps a slight ridge, or it may be a groove, indicating their line of junction. Below and in front of the obturator foramen we see the smooth posterior surface of the body of the pubes looking upwards as well as backwards. It is marked by an oblique line, continuous superiorly with the upper lip of the obturator groove, and running downwards and inwards to the lower end of the symphysis. The line gives attachment to part of the obturator fascia and limits in that direction the circumference of the 'obturator internus.' The 'levator ani' arises from a little space on the posterior surface of the body of the pubes immediately to the side of the lower end of the symphysis and the 'obturator internus' from the surface of bone, about half an inch wide, immediately adjoining the anterior and inferior borders of the obturator foramen. The 'constrictor urethræ' and the 'transverse perinei' muscles are attached to the inner surface of the pubic and ischial rami, close to the lower border of the bone.

Ossification.—Besides the three pieces of which it is originally formed, and whose centres of ossification appear first, for the ilium, near the sacro-sciatic notch, for the ischium near the





Section through the upper part of the Sacrum and Ilia,
so as to exhibit the construction of the
PELVIC ARCH.

acetabulum, and for the pubis in its horizontal ramus, the os innominatum has four 'epiphyses,' which begin to appear about the age of puberty. One, the marginal epiphysis, skirts the crest of the ilium. There is a second for the anterior-inferior spine; a third along the tuberosity of the ischium; and a fourth, which forms a thin plate, at the symphysis pubis. (See Nor. Hum. Ost., Nos. 64, 65.) The Y-shaped cartilage at the bottom of the acetabulum begins to ossify at puberty. The ilium begins to ossify at the eighth or ninth week of foetal life, the ischium at the end of the third month, and the pubes at the end of the fourth or fifth. The rami of the pubes and ischium unite about the seventh or eighth year. The acetabulum is all bony about the 17th year. All the epiphyses unite to the main bone about the 25th year.

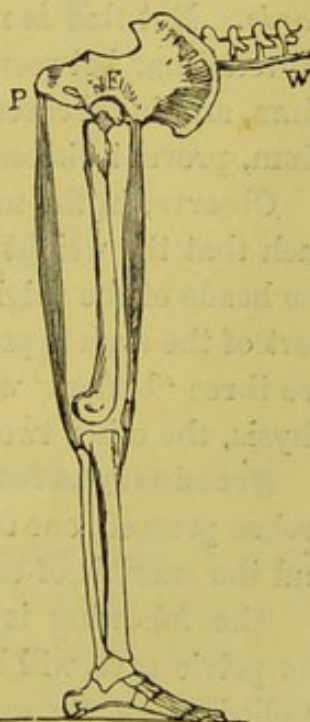
THE PELVIS IN GENERAL.

Nomenclature.—The pelvis is named from its resemblance to a basin ($\pi\acute{\epsilon}\lambda\upsilon\chi$). The French call it 'le bassin;' and in old English works it is often spoken of as 'the basin.' When accoucheurs speak of the *true* pelvis, they mean all below the brim. All above the brim they call the *false* pelvis. By the brim is understood the 'linea ilio-pectinea.' Again, they speak of the upper opening or 'inlet,' and the lower opening or 'outlet' of the pelvis.

Pelvis a Lever of the First Order.

—The pelvis forms a great arch of bone which supports the trunk, and transmits the weight of it to the lower limbs. It contains and protects the pelvic viscera, and some of the abdominal. It acts as a lever of the first order in balancing the trunk on the head of the thigh bone, as when we stand upon one leg. But the most obvious action of the pelvis as a lever of the first order, is when

FIG. 27.



THE PELVIS A LEVER OF THE FIRST ORDER.

we raise the body from the stooping to the erect attitude. In this action the fulcrum F, as seen in fig. 27, is at the hip joint; the weight W is the trunk of the body; and the power is fixed to the tuberosity of the ischium P. The power in this case is the contraction of the hamstring muscles.

Under the head of pelvis in general come—1. Its mechanism as an arch; 2. Its obliquity with regard to the spine; 3. Its axis; 4. The diameters of the inlet and outlet; 5. The difference between the male and the female pelvis.

Pelvic Arch: its Strength.—Its mechanism as an arch is best shown by sawing off the wings of the ilia, as in Plate XXXII. Such a section shows the following points: The sacrum forms the broad keystone of the arch, and supports the weight of the spine. Now the sacrum being set very obliquely, the weight tends to thrust it downwards and backwards. This tendency is resisted by the sacrum being doubly wedged, that is, wedged from above downwards, and from before backwards: thus, unless the ilia give way, which they never do, the sacrum cannot be dislocated *backwards*. But this is not all: a reciprocal irregularity, or slight ‘dovetailing,’ between the articular surfaces of the sacrum and ilium, and in all cases a ‘bite’ in front formed by the edge of the ilium, prevent dislocation of the sacrum *forwards*.

Observe, in the next place, that the inclination of the arch is such that the weight is transmitted in a perpendicular plane to the heads of the thigh bones. Again, the thickest and strongest part of the arch is precisely in the line of pressure. Lastly, there are three ‘buffers’ which break shocks; one at the pubic symphysis, the other two at the sacro-iliac symphyses.

Secondary Arches.—From the main arch, two secondary arches proceed, one on either side: these are the ‘sitting arches,’ and the summit of each is at the tuberosity of the ischium.

The following is a good instance of the enormous weight the pelvic arch will bear without injury, provided the weight be applied *along the arch*: A waggon wheel passed over a man’s pelvis from side to side, immediately over the symphysis pubis. The man stated that the waggon with the load in it weighed 5 tons 7 cwt. There was no injury beyond an ecchymosis of the

scrotum and the upper part of the thighs. After three weeks, the man left the hospital well, with the exception of a slight lameness.

Obliquity of the Pelvis.—In the erect attitude the line of gravity of the spine falls perpendicularly on the sacrum, as shown in the line *a b*, fig. 28. With this perpendicular, the inclination of the pelvis forms an angle (*a b c*, fig. 29) of 144° in the male, and 140° in the female. Now this angle is such, that the line of

FIG. 28.

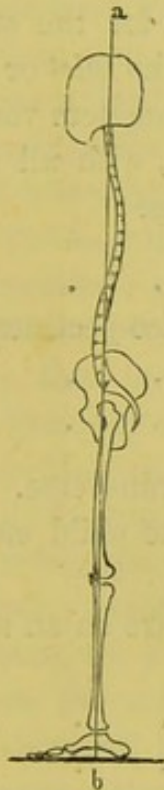
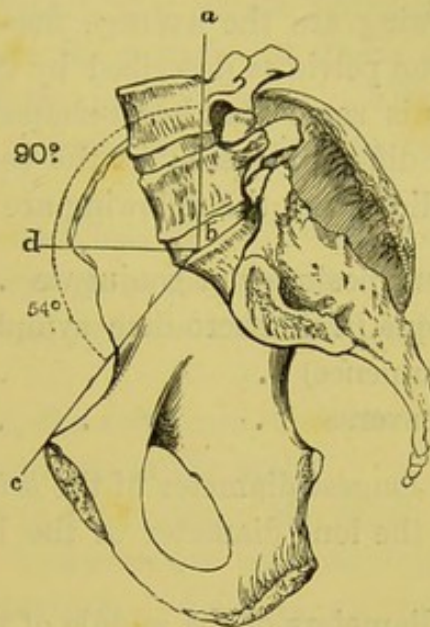


FIG. 29.



LINE OF GRAVITY OF THE BODY. ANGLE OF INCLINATION OF THE PELVIS, 144° .

gravity falls through the acetabulum, and consequently the weight is transmitted directly on to the heads of the thigh bones. For all practical purposes, one may ascertain the proper obliquity of the pelvis by holding it so that the 'notch' shall be the lowest part of the acetabulum (p. 181). The end of the coccyx will then be about half an inch higher than the lower part of the symphysis pubis.

Axes of the Pelvis.—The *axis of the brim* of the pelvis, that

is, a line passing at right angles through the centre of its plane, if prolonged, would pass from the coccyx to the umbilicus. The *axis of the outlet* would fall on the promontory of the sacrum. The *axis of the cavity* would form a curve nearly corresponding with the curve of the sacrum. In all operations about the pelvis, it is of great importance to bear in mind its different axes. As a useful practical rule, we may say, that the axis of the pelvis corresponds with a line drawn from the anus to the umbilicus.

Diameters of the Pelvis.—The next point is the diameter of the pelvis ; and it is interesting because it concerns parturition. The following are the average measurements for the standard female true pelvis as described by Gervis: The *inlet* or *brim* of the pelvis is somewhat heart-shaped. Its diameters vary more or less in different cases: in the recent state, with all the soft parts undisturbed, the following are the average:

	Inches
Antero-posterior or conjugate	4·25
Oblique (from sacro-iliac symphysis to ileo-pectineal eminence)	5
Transverse	5·25

Thus the longest diameter of the *brim* is the transverse. In this direction the long diameter of the head of the child enters the pelvis.

The diameters of the middle of the *cavity* are on an average:

	Inches
Antero-posterior	4·75
Oblique	5·25
Transverse	4·75

The longest diameter is therefore the oblique one.

The shape of the *outlet*, in the recent state, is like a lozenge, since the two ischiatic notches are blocked up by the sacro-ischiatic ligaments. Its diameters are as follows:

	Inches
Transverse (from one tuber ischii to the other)	4·25
Antero-posterior (from symphysis to tip of coccyx)	4
And from symphysis to lower end of sacrum the antero-posterior diameter will be	5

The longest diameter of the outlet, therefore, is from before backwards.

Now the head of the child enters the pelvis in the *transverse* diameter, but descends in the *oblique*, till it presses upon the spines of the ischia. Here its further progress is arrested by the spines. As the uterus goes on contracting, the slope of the ischium on each side compels the head to turn, so that the face comes to lie in the hollow of the sacrum. Consequently, the long axis of the head is brought into the long axis of the outlet, and is thus easily expelled.

Male and Female Pelvis.—The female pelvis differs very little from that of the male till puberty, at which period the brim has a heart-shaped form in both sexes. After puberty the female pelvis begins to assume its sexual characters, which are the following :

1. The sacrum is wider and less curved ;⁵⁴ the promontory less projecting ; and the coccyx more movable than in the male.

2. The cavity is shallower, and all its horizontal diameters broader, than in the male.

3. The spines of the ilia, the acetabula, and the tuberosities of the ischia, are wider apart than in the male.

4. The symphysis pubis is not so deep : the pubic arch has a much wider span⁵⁵ and its branches are more shelving than in the male, facilitating parturition. To use an architectural expression, the pubic arch in the female resembles a 'Norman' arch ; in the male, an 'early English ;' the sub-pubic angle being about 61° in males and 80° in females.

Comparative Osteology.—The ilium attains its greatest size in the elephant and mastodon. Observe the very narrow opening in the pelvis of the kangaroo (Marsupialia, *Macropus major*, Nos. 3699, 3700). This extreme narrowness necessitates the birth of the young when they are only about an inch and a quarter long. They are then almost shapeless, and are next placed in a pouch on the abdomen of the mother, with the nipple firmly fixed in their mouths until they are as far developed as the young of other animals at birth. It will thus be seen that the mammæ of the kangaroo open into the pouch. The young are attached to a long

nipple, and milk is at first forced into their mouths by the contraction of a muscle spread over the mammary gland. On the pubes are seen two small bones which do not exist in man. They are called the 'marsupial bones,' and are ossifications or chondrifications of the internal pillars of the external abdominal rings.

In the extinct Mastodon and Megatherium the great sciatic notch is converted into a foramen apparently by the ossification of the sacro-sciatic ligament.

In the Hippopotamus the transverse ligament of the acetabulum is completely ossified, and the notch becomes a bony tunnel.

In cetacea the pelvis is only represented by a small flat bone on each side of the anus, suspended in the soft parts; and there is never more than a trace of hind-limb bones.

In birds the acetabulum is perforated, the ischiatic notch is converted into a complete foramen, and there is no symphysis pubis, excepting in the ostrich.

The bones forming the os innominatum remain distinct throughout life in some of the lower animals. In No. 1011 (*Testudo elephantapos*) these bones will be seen to be fairly distinct. They articulate, but do not coalesce perfectly as in man.

In Ruminants, Pachydermata, and Solidungula, the pelvis is large and gives attachment to huge glutei muscles. This accords with the extensive development of the great trochanter of the femur, to which these muscles are attached.

Although in snakes generally, there is no sternum, upper limb, or sacrum, nor any appearance of hind legs, yet, in a few instances, viz. *typhlops*, *python regius*, and *tortrix*, there are rudiments of hind limbs in the skeleton.

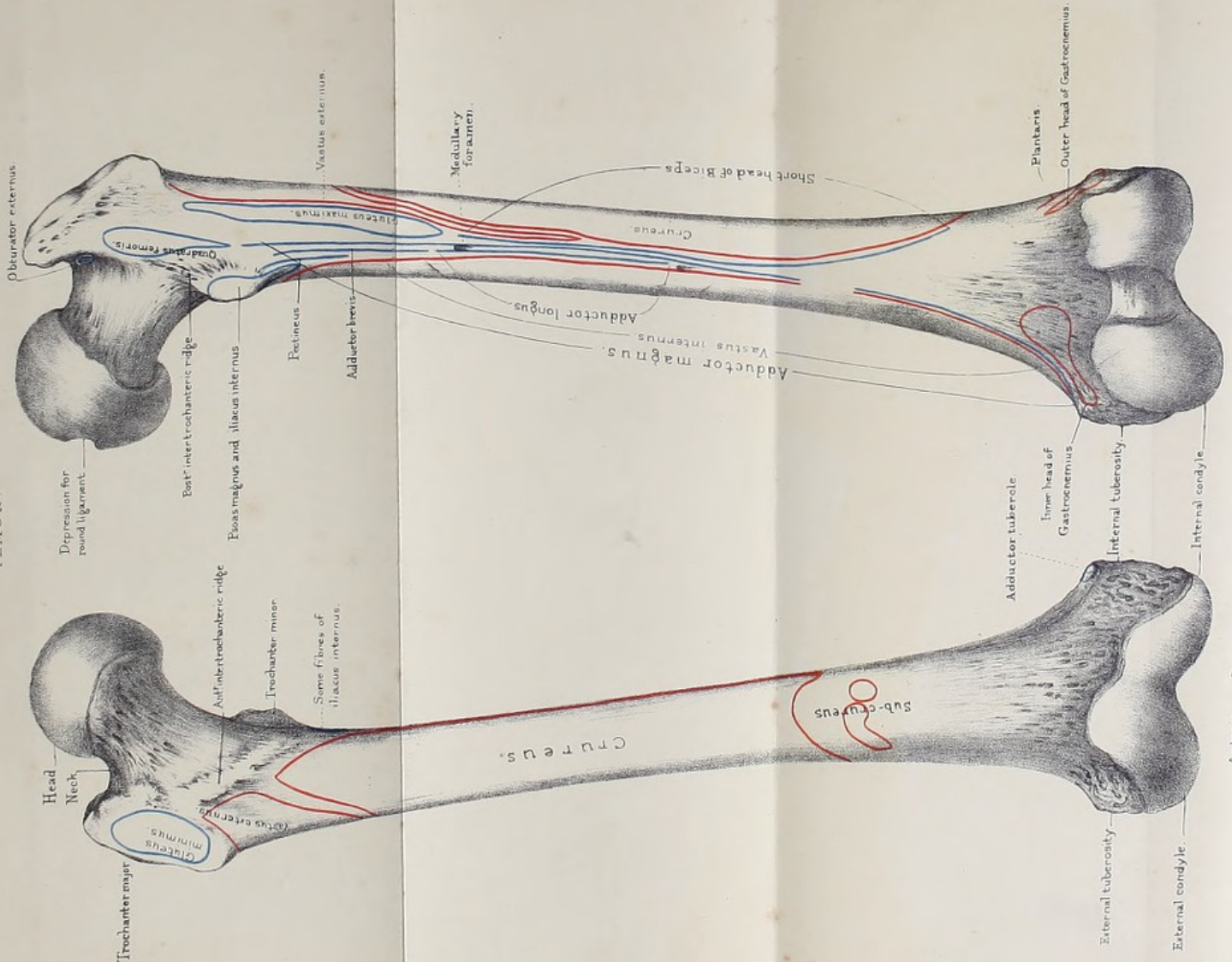
THE FEMUR.

(PLATES XXXIII., XXXIV.)

Length and Direction.—The thigh bone is the longest and strongest of all the bones. Its great length, in comparison with the other bones of the leg, is characteristic of the human skeleton.



FEMUR.



Oburator externus.
 Depression for round ligament.
 Post-intertrochanteric ridge.
 Esos magnus and iliacus internus.
 Pectineus.
 Adductor brevis.
 Vastus externus.
 Medullary foramen.
 Short head of biceps.
 Gracilis.
 Adductor longus.
 Vastus internus.
 Adductor magnus.
 Plantaris.
 Outer head of Gastrocnemius.

Head.
 Neck.
 Trochanter major.
 Gluteus minimus.
 Ant-intertrochanteric ridge.
 Trochanter minor.
 Some fibres of iliacus internus.
 Sub-cruveus.
 Adductor tubercle.
 Inner head of Gastrocnemius.
 Internal tuberosity.
 Internal condyle.
 External tuberosity.
 External condyle.

Posterior surface.

Anterior surface.

Drawn on Stone by T. Goddard.

Engraved by W. Woodbury, Massachusetts, U.S.A.

In consequence of this comparative length, and of the shortness of the arms, the ends of the fingers in the white man do not reach lower than the middle of the thigh bone. In the chimpanzee the fingers reach down to the knee; in the ourang, down to the ankle.

The direction of the thigh bone is not quite perpendicular, but slants, so that the knees are nearer together than the hips; by this means the knee joint is brought nearer the line of gravity of the body. This obliquity is necessarily greater in women, on account of the greater breadth of the pelvis, and accounts for their peculiar gait.

We have to examine the 'head,' the 'neck,' the 'trochanters' for the attachment of muscles, the 'shaft,' and the 'condyles.'

Head.—The head forms about three-fourths of a sphere, smooth and convex on every part, except at a point a little *behind and below* its centre, where there is a depression for the attachment of the 'ligamentum teres.' It forms a perfect ball-and-socket joint with the acetabulum. The margin of the head does not present a uniform line all round, but extends farther down in front and behind than above and below. The pit for the 'ligamentum teres' is situated in the line of axis of flexion and extension at the hip joint. It is somewhat trefoil in shape. The largest leaflet is situated behind, the smallest above, and the medium-sized one in front. The anterior and posterior leaflets are occupied by corresponding parts of the 'ligamentum teres,' the upper one by fat. The lower edge of the depression is rough and bulges out from the adjacent articular surface. In the bottom of the dimple we notice a number of nutrient foramina. When crusted with cartilage the ball fits so accurately into its socket, that it is retained in it by atmospheric pressure alone. It has been ascertained by experiment that this pressure is about 26 pounds; that is, more than equal to sustain the weight of the entire limb with its soft parts. More than this, in walking, the legs swing like pendulums, so that we require very little muscular force to advance one leg before the other.⁵⁶ The limb hangs freely in its socket, and the muscles do not expend any of their power in keeping it there. Boerhaave might well say, 'in mirabili articulatione femoris Creatorem adoramus.'

Neck.—The general direction of the 'neck' is upwards, inwards, and a little forwards from the shaft. As a result of this direction of the neck of the thigh bone, the lower extremity naturally turns a little outwards. Everything in the bones of the lower limb and the insertion of its muscles, conforms to this object. It is this which gives elasticity, freedom, and grace to the motion of the body: we owe this to nature, and not, as some suppose, to the dancing master.

In the adult the neck is set on to the shaft at a very open angle, about 125° . But the angle varies at different ages, in harmony with the requirements of the age. In children the neck of the thigh bone is so oblique that it forms almost a gentle curve from the axis of the shaft, as seen in fig. 30. Therefore

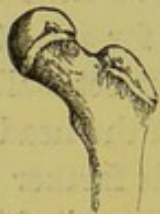

FIG. 30.

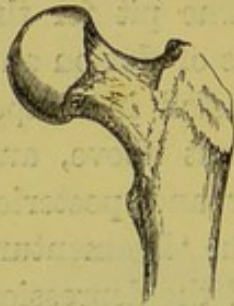

FIG. 31.

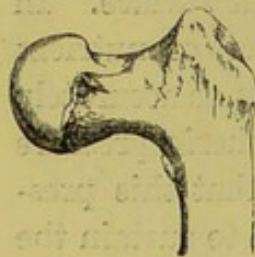


FIG. 32.

COMPARATIVE OBLIQUITY OF THE NECK OF THE THIGH-BONE IN THE CHILD, THE ADULT, AND THE AGED. (FROM MUSEUM OF St. Bartholomew's Hospital.)

the trochanters do not project nearly so much as in the adult (fig. 31). This is one reason why it is sometimes difficult to determine the precise nature of accidents about the hip in children. As age advances, the neck, in some instances, drops to nearly a right angle with the shaft, as shown in fig. 32: besides which its compact walls become thinner, and its cancellous tissue becomes expanded. No wonder, then, the neck of the femur is so liable to break in old persons. The neck is slightly constricted in the middle. It is flattened from before backward below where it joins the shaft by what is called the 'base of the neck.' It is cylindrical above where it is continuous with the head. In its long axis it is curved slightly forwards. Its upper border is short and broad, presenting large nutrient foramina at each end. Its lower

border is longer than the upper, and is concave downwards, showing nutrient foramina in the neighbourhood of the overhanging

head. The upper two-thirds of the lower border are smooth and the lower third is rough and continuous with the sudden bend upwards of the anterior intertrochanteric line, to be described. Its anterior surface is nearly flat, and at the upper and inner part it is encroached upon by the articular surface of the head, while in the rest of its extent it is marked by nutrient foramina and deep grooves running in the long axis of the neck and leading to large nutrient foramina. Inferiorly this surface is limited by the 'anterior intertrochanteric' or 'oblique line.' The posterior surface is concave in its long axis and convex from side to side. Inferiorly it is smooth and superiorly it is rough and marked by large nutrient foramina and deep grooves leading to similar foramina. (Plate I.) In falls on the trochanter the neck is sometimes broken at the base, and driven into the shaft between the trochanters, forming what is called an 'impacted' fracture of the neck. The symptoms of such a fracture are, more or less shortening of the limb, diminished projection of the trochanter major, and no crepitus.

Since the great length and obliquity of the neck of the femur are peculiar to man, let us consider what advantage his skeleton gains by it. 1. It widens the base of support for the trunk. 2. It disengages the shaft from the hip joint, and thus increases the range of motion. What animal can separate its legs so widely as man? 3. Greater space is made for the adductor muscles, which balance the pelvis on the inside of the thigh. 4. The greater trochanter being removed to a distance from the hip joint gives greater leverage to the powerful gluteal muscles which balance the pelvis on the outside. 5. The weight of the trunk, instead of falling vertically on the shaft of the femur, is transmitted to it by an arch.

Trochanters, Major and Minor.—The trochanters 'major' and 'minor' are outstanding processes which give great leverage to the muscles rotating the thigh (*τροχάω*, *verto*). Observe, they project behind the axis of rotation (which is the centre of the head of the bone), an arrangement which further conduces to the outward rotation of the lower limb as the natural position. The relation of the trochanter major to the other bony promi-

nences of the pelvis deserves special attention, because it is a great landmark in determining the nature of injuries about the hip. The top of the great trochanter in the adult is about three-quarters of an inch lower than the top of the head of the bone, and nearly on a level with the spine of the pubes.⁵⁷

TROCHANTER MAJOR.—The trochanter major is a continuation upwards of the external surface of the shaft of the bone. It is a flattened, four-sided plate of bone, presenting four borders and two surfaces. The *anterior border* is more a surface than a border, and shows an irregularly oval, rough, and depressed space for the insertion of the 'gluteus minimus' (Plate XXXIV.) The *posterior border* is free, smooth, and rounded, forms the posterior lip of the digital fossa, and is continuous with the 'posterior intertrochanteric line.' The *inferior border* is a rough ridge separating the outer surface of the trochanter from the outer surface of the shaft and giving attachment to fibres of the 'vastus externus.' The *superior border* is broad in front, where it is marked by two facets, the anterior one for the insertion of the 'obturator internus' and 'gemelli,' and the posterior one for the insertion of the 'pyriformis' (Plate XXXIV.) Behind, the superior border is narrow, and at its junction with the posterior border it forms a sharp angle for the attachment of the most posterior fibres of the 'gluteus medius.' The *external surface* is free, and looks outwards and backwards. It is divided into an anterior and a posterior smooth part by the 'diagonal' or 'oblique line' of the great trochanter—more an irregularly oval surface than a line, running from the posterior superior angle to the anterior inferior angle. The diagonal line gives attachment to the 'gluteus medius.' The smooth part below the line is for the play of the tendon of the 'gluteus maximus,' a large bursa being interposed. The smooth part above the line is for the play of the 'gluteus medius,' a smaller bursa being interposed there too. The *internal surface*, anteriorly and inferiorly, is continuous with the upper extremity of the shaft; posteriorly and superiorly, it is free and forms a deep excavation called the 'digital fossa' (Plate XXXIII.) The pit is very rough, and very often shows short spicules of bone rising

Obturator internus & Gemelli.
Pyriformis.

Fig. 1

Gluteus
minimus

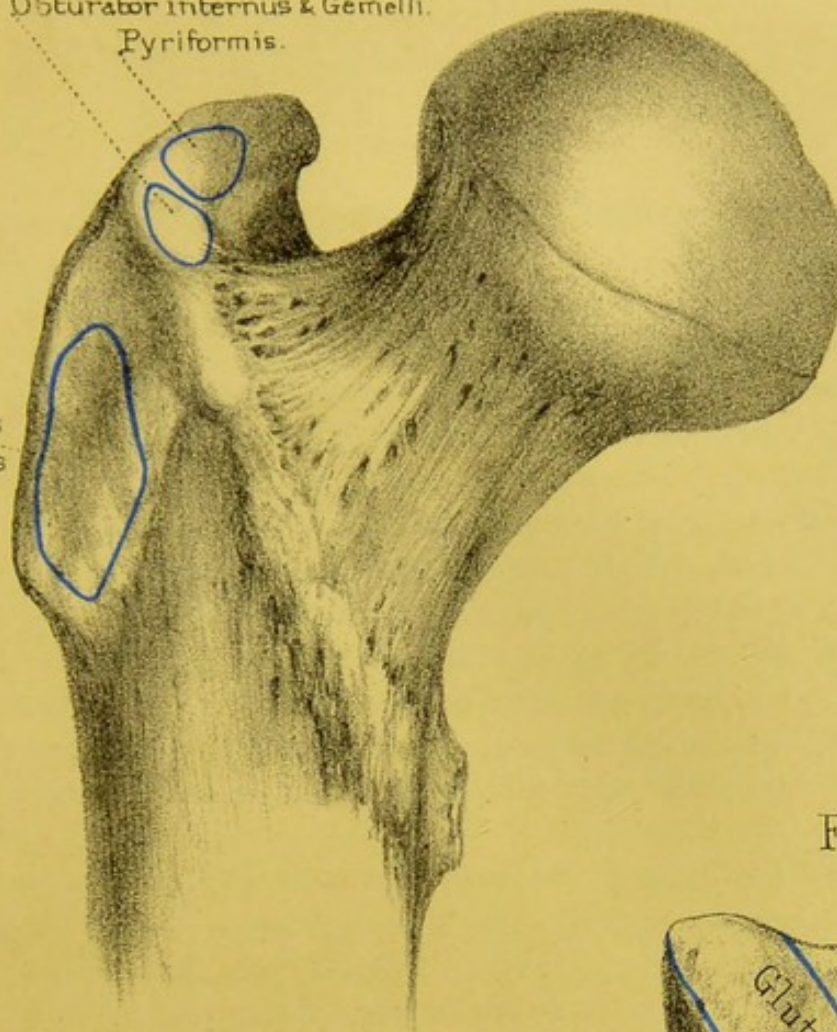


Fig. 2.

Surface over which
plays the tendon of the
Gluteus maximus.....

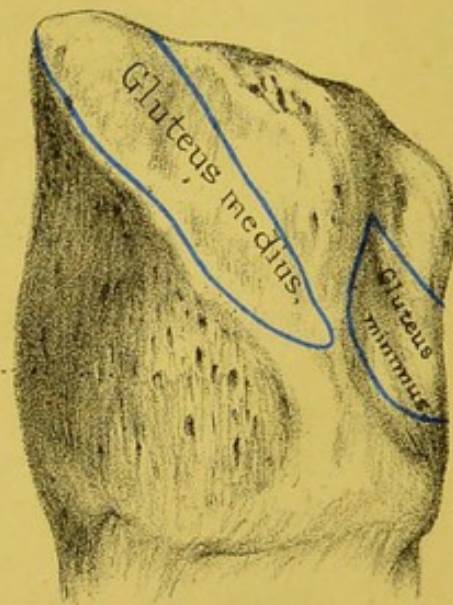
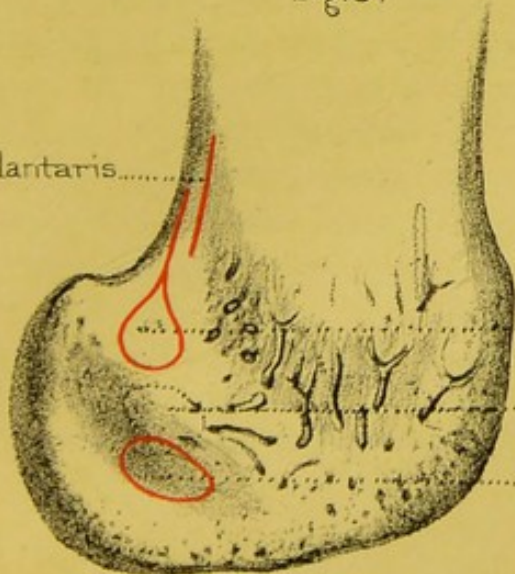


Fig. 3.

Plantaris.....



Outer head of Gastrocnemius.
Attachment of external lateral ligament
Popliteus.

External condyle.



from the bottom and running into the tendon of the 'obturator externus,' which is inserted here.

TROCHANTER MINOR.—The trochanter minor projects from the inner and *back* part of the shaft, just below the base of the neck. It is a flattened, truncated cone, rising by three roots; viz. a superior one continuous with the lower border of the neck, a posterior one continuous with the 'posterior intertrochanteric line,' and an inferior one continuous with the middle of the upward branches of the *linea aspera*. Its top is flattened and rough for the insertion of the 'psoas' part of the 'ilio-psoas.' The posterior surface is smooth and covered by the adjacent borders of the 'quadratus femoris' and the 'adductor magnus.' The superior and anterior surfaces are also smooth, and the lower root gives insertion to the iliac part of the 'ilio-psoas.' (Plate XXXIII.)

Observe that the trochanter minor is directed backwards and that the muscles inserted into it turn the thigh outwards at the same time that they raise it. These are the muscles which, in fracture of the upper third of the shaft, it is often difficult to prevent from tilting up the upper fragment.

INTERTROCHANTERIC RIDGES.—The 'anterior intertrochanteric ridge' commences above in an eminence situated on the anterior aspect of the bone at the upper part of the base of the neck and internal to the anterior border of the great trochanter, and called the 'tubercle' of the femur. It runs obliquely downwards and inwards as a flattened rough ridge, separating the anterior surface of the neck from the corresponding surface of the shaft, as far as the level of the small trochanter; it then divides into two branches, a short *upper* and rough one about an inch long, stretching upwards and inwards above and outside the small trochanter, about half an inch distant from it, and fading off in the lower border of the neck. The *lower* branch is a continuation of the main ridge, and runs downwards, inwards, and backwards in front of, and then below the level of, the small trochanter, to terminate in the upper end of the inner lip of the *linea aspera*. This branch is not well marked above, but gets better marked below, and limits the attachment of the

'vastus internus.' The main ridge and its upward branch afford attachment to the ilio-femoral and pubo-femoral parts of the capsular ligament of the hip joint. The main ridge and the lower branch are ordinarily called the 'spiral line.' The 'posterior intertrochanteric' ridge is a very short rounded ridge connecting the posterior inferior angle of the great with the posterior root of the small trochanter. It forms the lower limit of the neck below and behind.

Shaft.—The shaft of the femur presents both antero-posterior and lateral curves. The antero-posterior curves are two—one, a very distinct one, pointing forwards and occupying almost the whole of the shaft, and the other, a very much less one, pointing backwards with the greatest projection at the level of the small trochanter. The highest point of the curve forwards is situated about the middle of the shaft, and at this point too the shaft is narrowest and weakest; consequently we find it more often broken here than elsewhere. The lateral curves are not so well marked; one is situated in the upper third, with the convexity directed outwards, and the other in the lower third, with the convexity pointing inwards. Besides presenting these curvatures the whole shaft is twisted in such a way that the anterior surface looks forwards and slightly outwards at the upper extremity and straight forwards at the lower. By means of these curvatures and twisting a double advantage is gained: first, it is rendered more springy than if it were straight; secondly, more room is gained for the flexor muscles behind and the adductor muscles inside, and more power for the extensor muscles in front. In cross section the shaft at the upper end forms a four-sided figure with rounded angles, and flattened from before backwards. In the middle it is triangular with the prominent apex of the triangle pointing backwards, while at the lower end it forms a triangle with rounded angles and the blunt apex of the triangle looking inwards. For convenience of description we consider the whole shaft as prismatic, and describe it as possessing *internal, external, and posterior borders*, separating *anterior, internal, and external surfaces*.

The *internal border* commences above at the spiral line, where

that line divides into its two branches, and terminates in the front of the internal condyle. It is smooth and rounded in its whole extent, and by its upper two-thirds gives origin to fibres of the 'crureus.'

The *external border* is very indistinct. It commences at the anterior inferior angle of the trochanter major, and terminates at the front of the external condyle, separating the anterior from the external surface. Its upper two-thirds or so give attachment to the 'crureus.'

The *posterior border* forms a rough, strong buttress to the middle third of the shaft, termed the 'linea aspera.' At first sight it appears as a single ridge, but look carefully and you will find traces of two borders, termed its external and internal 'lips,' separated by a rough interval. About the lower third of the shaft these lips diverge from each other, and may be traced to the 'tuberosities' of the condyles. Of the two the external is the more prominent. The internal is interrupted at its upper end by a smooth space for the passage of the femoral artery to the back of the thigh and inferiorly it terminates in a prominence on the inner tuberosity, termed the 'adductor tubercle,' for the attachment of a strongly tendinous part of the 'adductor magnus.' The triangular interval between the divergence of these lips is termed the 'popliteal surface of the femur,' and upon it the popliteal artery rests in its passage through the ham. It is a flat space showing numerous large nutrient foramina at its lower end and giving attachment inferiorly and internally to the inner head of the 'gastrocnemius.' At the junction of the upper and middle thirds of the shaft the linea aspera divides into three branches—an *external* one, forming a low rough ridge terminating at the posterior inferior angle of the great trochanter, and affording attachment to the 'gluteus maximus;' a *middle* one, not so well marked, terminating at the lower border of the small trochanter and affording attachment to the 'pectineus' and 'adductor brevis;' and an *internal* one, already described as part of the spiral line limiting the attachment of the 'vastus internus.' Between the middle and outer branches are attached the upper fibres of the 'adductor brevis' and 'magnus' muscles.

Commencing in the middle of the posterior intertrochanteric line, and running vertically down the bone for about an inch and a half, is an indistinct line—more an elevated surface than a line, and best marked above—termed the ‘*linea quadrati*,’ for the insertion of the ‘*quadratus femoris*’ muscle.

What has been said of the *linea aspera* and its lower bifurcations or ‘*condyloid ridges*’ will help us towards understanding the muscles attached to it. Take the *outer lip*. To its whole length, and to the upper two-thirds or so of the outer condyloid ridge, is attached the ‘*short head of the biceps*.’ To the same ridge, and immediately above the condyle, arise the ‘*plantaris*’ and the upper fibres of the outer head of the ‘*gastrocnemius*.’ The *inner lip* gives attachment above to a few fibres of the ‘*adductor brevis*,’ in its lower third to fibres of the ‘*adductor magnus*,’ and in the rest of its extent to the closely connected fibres of the ‘*adductor longus*’ and ‘*vastus internus*.’ The interval between the two lips in the upper two-thirds is occupied by the ‘*adductor magnus*.’ Excepting in the smooth part above, the internal supra-condyloid line gives attachment to the closely incorporated fibres of the ‘*adductor magnus*’ and ‘*vastus internus*.’

Usually at the upper and at the lower end of the *linea aspera* is a large foramen leading to a canal, directed upwards, which conveys a nutrient blood-vessel to the marrow.

The *anterior surface* lies between the inner and outer borders. It looks forwards and outwards above and forwards below. It is convex from above downwards, excepting at its upper end, where it is slightly concave. It is convex also from side to side, excepting at its lower end, where it is slightly concave. It is broader above and below than in the middle, and gives origin in its upper three-fourths to fibres of the ‘*crureus*,’ and in its lower fourth to a few slips which constitute the ‘*sub-crureus*.’ At its lower end we notice a number of large nutrient foramina.

The *external surface* is smooth and convex from before backwards, affording attachment to the ‘*vastus externus*’ and ‘*crureus*.’ (Plate XXXIII.)

The *internal surface*, also smooth and convex from before

backwards, lies between the internal and posterior borders. It is continuous above with the lower border of the neck, immediately below which it shows part of the spiral line. Inferiorly it looks forwards and inwards, and is continuous with the inner surface of the internal condyle. Just below the spiral line, and close by the posterior border, it gives origin to the 'vastus internus.' In the rest of its extent it gives origin to no muscular fibres; here the bone is simply *covered* by the fibres of the 'vastus internus.' (Plate XXXIII.)

Condyles.—The lower end of the femur gradually expands to form the 'external and internal condyle,' separated by the 'intercondyloid notch.' Of the two condyles the external is the broader, both antero-posteriorly and laterally. It also projects more forwards and is placed more in the direction of the long axis of the shaft than the internal one. The direction of its long axis is straight from before backwards, while that of the internal one is obliquely backwards and inwards. The inner condyle projects much more downwards, and is fully half an inch lower than the outer when the bone is placed perpendicularly, but when the bone slants, as it naturally does, both condyles are on the same level. This must needs be, as the plane of the knee joint is horizontal, in adaptation to the erect posture.

Looking at the condyles individually we notice that the 'external condyle' presents upon its anterior, inferior, and posterior aspects a smooth articular surface, the anterior part of the surface being for articulation with the patella and the rest for the tibia and interposed fibro-cartilages. The *patellar part* is broad, four-sided, convex transversely as well as antero-posteriorly. It is limited above by a convex lip, the convexity being directed upwards, and behind by a faintly marked groove parallel with that lip and visible on the fore part of the inferior aspect of the bone. Internally it is continuous with the corresponding surface on the internal condyle, and externally its margin separates the external surface of the condyle from the anterior and fore part of the inferior surface of the condyle. Behind the curved line, limiting the patellar surface, we have the *condyloid surface proper*, for articulation with the upper surface of the external

tuberosity of the tibia. Looking at this surface as it lies on the inferior aspect of the condyle, we notice that it is convex from side to side and very slightly so from before backwards. As seen on the posterior aspect of the condyle, it is convex from side to side, but very much more so when traced from above downwards. The 'condyloid surface proper' forms part of the circumference of a circle of which a roughness on the external surface of the condyle, for the attachment of the external lateral ligament, is the centre. Above the articular surface, posteriorly, the condyle is rather concave in every direction, marked by several nutrient foramina, and gives origin in the immediate neighbourhood of the supra-condyloid line to the 'plantaris' and a few fibres of the outer head of the 'gastrocnemius.' The external surface of the condyle, while traced from before backwards, gradually rises up into a rough eminence called the 'external tuberosity.' The highest point of this tuberosity is situated at the junction of the posterior third with the anterior two-thirds of the surface, and is continuous with the lower end of the external supra-condyloid line. The posterior side of the summit shows a rough impression for the origin of the external head of the gastrocnemius, while the anterior side, in the immediate neighbourhood of the apex, shows a somewhat flattened space for the attachment of the external lateral ligament. Below and behind the tuberosity is a deep groove, narrower and deeper below and in front than above and behind. It is called the 'popliteal groove,' and gives attachment at its anterior and inferior end to the popliteal tendon. The upper two-thirds of the groove and of the corresponding lower lip are smooth and covered in the recent state by cartilage, to allow of free play of the tendon. The surface in front of the tuberosity is slightly rough and marked by a number of large nutrient foramina. The internal surface of the condyle is continuous anteriorly and superiorly with the rest of the bone, while posteriorly and inferiorly it is free and forms the external wall of the 'intercondyloid notch.'

The 'internal condyle' is narrower than the external condyle. Its long axis runs obliquely backwards and inwards, and it

projects from the lower end of the bone to a greater extent, both laterally and inferiorly, than the external one. Its anterior surface presents above a rough concave part marked by nutrient foramina. Next is seen the surface for articulation with the patella—*patellar surface*. This is a less extensive surface than the corresponding one on the external condyle, and with which it is continuous. It is quadrilateral, with its inner border much smaller than its outer one. In some femora the inner border does not exist at all, causing the surface to be triangular in shape with the apex pointing inwards. The inferior and posterior aspects of the condyle are occupied by the *condyloid surface proper*. Looking at this surface we notice that it presents a much more uniform curve from before backwards than the external one. If we look more closely, however, we see that its anterior part is occupied by a triangular space which does not belong to the circumference of the same circle as that belonging to the rest of the condyloid surface. The base of the triangle is formed by the inner edge of the condyloid surface. The anterior and posterior sides are formed by two smooth and curved lips with their convexities directed forwards, and converging from the ends of the base to the fore part of the intercondyloid notch. The anterior side separates the patellar surface from the condyloid surface. The triangular space is called the ‘oblique surface,’ and on it the tibia slides outwards in the last act of extension of the knee joint. At the apex of the triangle in well-marked femora we notice a facet for articulation with the patella in complete flexion. The rest of the ‘condyloid surface proper’ is not so flat inferiorly as the external one is. When traced from before backwards it forms part of the circumference of a circle of which an impression for the attachment of the internal lateral ligament, situated behind the middle of the internal surface of the condyle, is the centre. The internal margin of the condyloid surface is bevelled off inferiorly for articulation with the spine of the tibia. The internal surface of the condyle gradually rises up from before backwards into the ‘internal tuberosity.’ The summit of this eminence is situated behind the middle of the surface, and is continuous above with a prominent tubercle formed by the end

of the internal condyloid line, and called the 'adductor tubercle,' for the attachment of the lowest fibres of the 'adductor magnus.' This tubercle is sometimes very large and so interferes with the gripping of the knee in riding. It is an important landmark too, as it is situated immediately below the line of junction of the lower epiphysis with the shaft, and can be readily felt underneath the skin.

Behind the summit of the internal tuberosity we notice a flattened, rough space for the attachment of the internal lateral ligament. The posterior surface of the condyle, above the articular surface, is marked by nutrient foramina, and is rough, especially internally, for the origin of the inner head of the gastrocnemius. The free part of the external surface of the condyle forms the internal wall of the intercondyloid notch. (Plate XXXIV. fig. 3.) The tuberosities being situated nearer the back than the front of the condyles increases the strength of the knee joint, for the reason that the ligaments attached to them are fixed behind the centre of motion, so that they become stretched when the joint is extended.

Trochlea for Patella.—The patellar articular surfaces of the condyles unite to form the pulley ('femoral trochlea') over which the patella plays. It is four-sided, but very much narrower on its inner than on its outer side, so that in some bones we may describe it as triangular, with the apex pointing inwards. On its anterior, internal, and external borders we find a prominent lip separating it from the adjacent rough surfaces of the lower extremity of the bone. Posteriorly it is separated from the *condyloid surfaces proper* by the curved lines already described, and which lead from notches in the lateral edges of the articular surfaces of the corresponding condyles to the front of the intercondyloid notch. The larger share of the pulley is formed by the external condyle, and it mounts not only higher, but projects more, and is more convex transversely, than the inner, preventing the natural tendency of the patella to be drawn outwards by the quadriceps extensor muscle.

Intercondyloid Notch.—This space lies between the free parts of the condyles. Its greatest breadth is nearly equal to that

of the tibial articular surface on either condyle. It is seen on the lower, posterior, and upper aspects of the lower extremity of the bone. Its long axis looks from above downwards and backwards. Its outer side is made by the free part of the inner surface of external condyle and shows a rough depression for the attachment of the anterior crucial ligament. The inner side is formed by the free part of the external surface of the internal condyle, and is also rough, especially in front, for the attachment of the posterior crucial ligament. It is separated posteriorly from the popliteal space of the femur by a smooth transverse non-articular ridge. It is wider behind than it is in front and is marked by one or two large nutrient foramina at its deepest part. The

two woodcuts (33 and 34) show very well the attachments and the direction of the crucial ligaments *a b*, *a c*. Being attached to the condyles behind the centre, they necessarily limit extension beyond the straight line. But they do more: by crossing like braces they prevent lateral displacement of the tibia. In the erect attitude

FIG. 33.

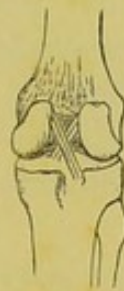
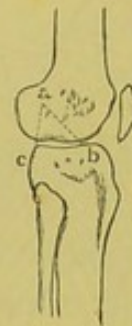
FIG. 34.



CRUCIAL LIGAMENTS
'OF THE KNEE.

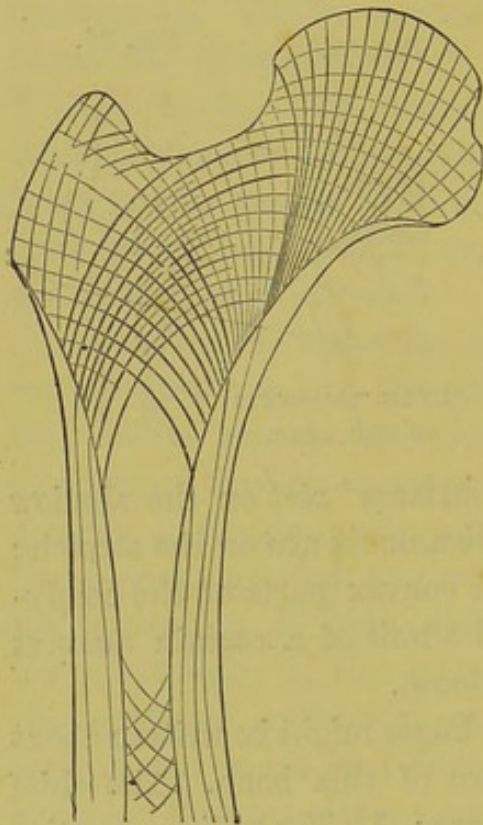
the flatter parts of the 'condyloid surfaces' rest on the shallow excavation of the tibia, and all the ligaments are on the stretch; but when the knee is bent the more convex parts of the condyloid surfaces rest on the tibia, and admit of a certain amount of rotation, all the ligaments being loose.

Mechanism and Structure.—Pages might be written about the wonderful mechanical structure of this bone. The chief points, however, which strike one are: 1. *The oblique position of the head and the acetabulum*, with which it articulates. This allows of greater freedom of antero-posterior motion than a simple ball-and-socket joint, placed vertically, would admit of. 2. *The obliquity of the neck*. This permits more of the head to rest in the acetabulum, by converting flexion and extension into rotation. It allows, too, more room for the adductors, and gives increased power to the great rotators by throwing their inser-

tions away from the head. 3. *The obliquity, curves, and twisting of the shaft* give elasticity to the bone, and so break shocks transmitted to the bone from below. 4. *The obliquity of the lower end.* This, we have seen, is apparent, not real; the plane of the articular surface for the tibia is horizontal, the internal condyle projecting downwards to allow for the divergence of the upper end of the bone caused by the breadth of the pelvis.

The internal structure of the bone exhibits in a wonderful way the arrangement of the compact and cancellous tissue, so as to give the greatest strength, elasticity, and lightness to the bone. The fibres of the cancellous tissue at the upper extremity are

FIG. 35.



arranged in a beautiful way to support the articular surface of the head, as seen in fig. 35. The medullary cavity is well developed, and is interrupted at irregular intervals by thin transverse septa of cancellous tissue.

The lower end is enlarged by cancellous tissue whose fibres follow the ordinary law in being arranged so as to strike the plane of pressure at right angles.

Ossification.—The femur is ossified from three primary centres (one for the shaft and neck, and one for each articular end), and two secondary centres, one for each trochanter. (See Plate IV.)

The centre for the shaft appears about the seventh week of foetal life. The centre of the lower epiphysis does not appear until within the last fifteen days of the full term of gestation. Hence the existence of this centre enables us to pronounce with something like certainty as to the age of a foetus.⁵⁸ It is the only epiphysis in which ossification commences before birth. As this is the first of all the epiphyses to ossify, so, in accordance with the general law, it remains the

longest a separate piece. The epiphysis at the upper end of the femur includes only the head of the bone, and begins to ossify about one year after birth. The great trochanter begins to ossify about the third or fourth year; the lesser about the fourteenth. All the pieces have united about the age of twenty-one.

Comparative Osteology.—In the horse, the rhinoceros, and the tapir (*Perissodactyla*) the gluteal ridge is so largely developed that it has received the name of a 'third trochanter.' The lower end of the femur in most mammals presents three separate articular surfaces, viz. the patellar articulation and two condyles. In man these three are blended into one, although there can be seen a trace of the separation along the lower border of the surface for the patella. The actual separation in man does exist in the fœtus, but becomes obliterated, the three articulations merging into one. The ligamenta alaria and the ligamentum mucosum are the only remains of the originally separate synovial membranes of the knee joint.

In elephants (*Proboscidea*) when standing, the bones of the leg and thigh are vertical, as in man.

If you examine the femurs of birds you will find they have but one trochanter, viz. that corresponding to our trochanter major.

In two or three serpents, e.g. *Python tigris* (No. 602), *Python regius* (No. 629), there are rudimentary hind limbs ending in hook-like claws sheathed in horn. These claws are put in action by certain muscles, and, serving as antagonists to the tail, give it greater prehensile power.

The ventral fins of fish correspond to the hind limbs of other animals.

THE PATELLA.

(PLATE XXXV.)

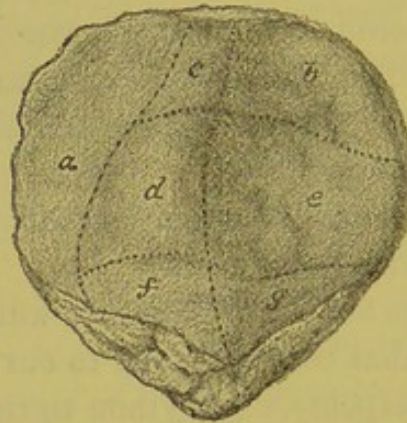
This is a flat triangular bone gliding on the trochlear surface of the femur, and with its apex pointing downwards. It presents anterior, posterior, and superior surfaces, and inner and outer borders.

Its *anterior surface* is convex, and marked by longitudinal

streaks, indicating the insertion of the fibres of the 'quadriceps extensor cruris' tendon, and also by a number of vascular foramina.

Its *posterior surface* is divisible into a smaller lower non-articular part and a larger upper articular portion. The non-articular part lies under cover of the apex of the bone. It is triangular in shape and is rough, and shows several large nutrient foramina. It attaches, by its inner and outer margin and its apex, fibres of the ligamentum patellæ, and in the rest of its extent is covered by fat underlying the synovial membrane of the knee joint. The upper, articular portion is for articulation with the trochlea. It is large and quadrilateral, rises higher up externally than

FIG. 36.



ARTICULAR SURFACE OF THE RIGHT PATELLA.

<i>a, b,</i>	in contact with femur in complete flexion.
<i>b, c</i>	„ „ rectangular flexion.
<i>d, e</i>	„ „ semi-extension.
<i>f, g</i>	„ „ complete extension.

internally, and is unequally divided into two parts by a smooth vertical ridge. The *outer* part is the larger. It is concave from side to side and is further subdivided into three facets, upper, middle, and lower, by smooth and faintly marked transverse ridges for articulation with the outer part of the trochlea in certain positions of the knee joint. The *inner* part is again subdivided into two unequal portions by a smooth vertical ridge. The smaller is the inner portion. It lies close to the inner edge of the bone, and articulates with the facet situated at the inner angle of the 'oblique surface' of the femur in extreme flexion

of the knee joint. The larger external portion is further subdivided into three facets by two faintly marked elevations of the articular surface, viz. an upper, middle, and lower for articulation with the femur in certain positions of the knee joint. (See fig. 36.)

The *upper surface* or *base* of the bone is triangular in shape and looks upward and forward. It gives attachment in front to fibres of the 'quadriceps extensor' tendon.

The *inner* and *outer borders* are convex and rough, and give attachment each to its own 'lateral patellar ligament.'

The *apex* is pointed, and gives attachment to the ligamentum patellæ.

Structure and Mechanism.—In structure the patella consists of a mass of cancellous tissue covered by a thin layer of compact bone, forming the longitudinal ridges with the intervening grooves for the attachment of the tendon of the quadriceps extensor cruris muscle.

It is the largest and best example of a sesamoid bone. It is developed in the extensor tendon of the knee, where it protects the knee joint and increases the power of the extensor muscles by enabling them to act at a greater angle. It is a principle in mechanics that the efficiency of a force which acts upon a lever is greatest when its direction is at right angles to the lever, and that the force decreases as the obliquity of its direction is increased.

The patella, thus serving a mechanical purpose in the substance of the extensor tendon, is liable to be broken by a sudden and violent action of the extensor muscles, as in making a strong effort to regain the balance of the body in danger of falling backwards. In this position—that is, when the knee is *half-bent*—the upper part of the patella is not supported by its trochlea: there is a hollow under it, and here the patella snaps transversely, like a stick broken across the knee. The broken ends separate widely, and therefore in these transverse fractures it is very difficult to obtain osseous, and not ligamentous reunion.

But even when the knee is *extended*, violent muscular contraction is able to snap the patella. Desault speaks of both patellæ being broken by convulsions in a patient after he had been cut for the stone.

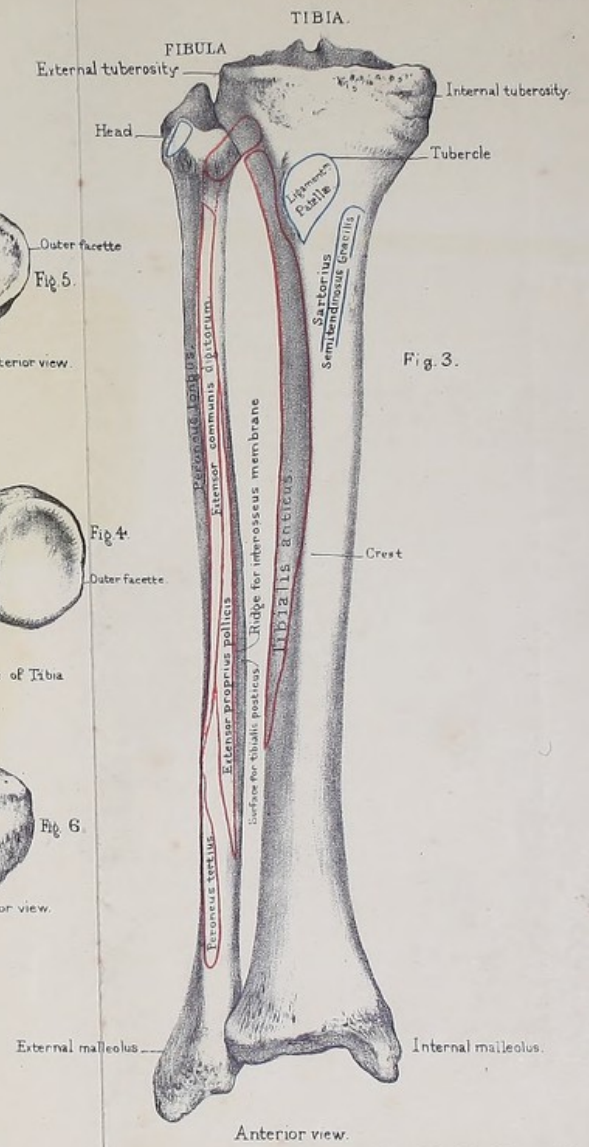
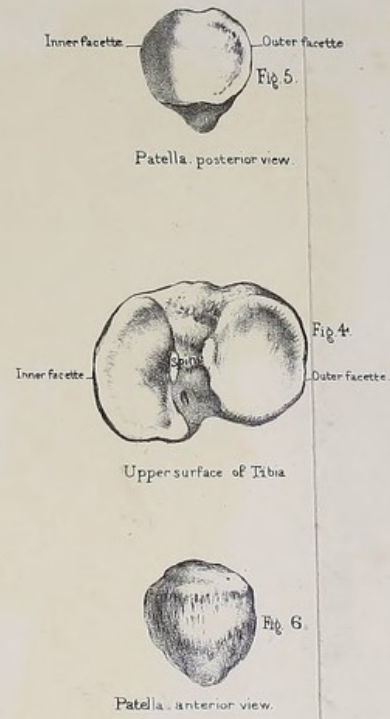
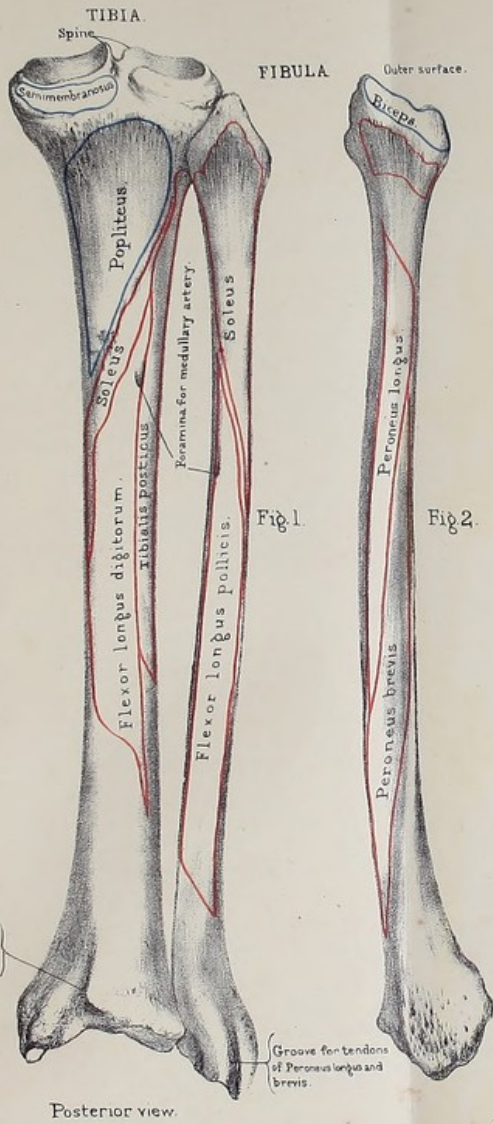
Ossification.—The patella is developed from a single centre, which appears about the third year. It is not fully ossified until the age of fourteen or fifteen.

THE TIBIA.

(PLATE XXXV.)

Situation and Direction.—The tibia is the larger of the two bones of the leg, and is placed on the inner side. It entirely supports the condyles of the femur, and transmits the weight of the body to the foot. Its direction is not oblique like the femur, but vertical; so that in well-formed legs the two tibiæ should be parallel. Let us examine in succession the upper end, the shaft, and the lower end.

Head.—The upper end is called the 'head' of the tibia. It is very broad in the transverse direction for the support of the condyles of the femur: this great breadth is another peculiarity of the human skeleton. The two articular surfaces for the condyles are very shallow in the dry bone, but slightly deepened in the recent state by discs of fibro-cartilage (termed the 'semilunar cartilages'). These cartilages convert the shallow articular surfaces of the tibia into *variable* sockets; that is, sockets which adapt themselves to the varying forms of the condyles in flexion and extension of the knee. The *outer* articular surface is more or less round, slightly concave from before backwards and from within outwards. It appears as a gradual rising up of the bone from the margin of the articular surface to the top of the 'spine'—an eminence which lies between the two articular surfaces. The *inner* is oval, with the long diameter from before backwards. It is more concave, especially internally, and narrower than the outer one. Its inner part rises up abruptly, to be continuous with the inner surface of the 'spine.' Both articular surfaces show flattened crescentic spaces at their margins, upon which rest the semilunar fibro-cartilages. The crescentic space is usually best seen upon the internal surface. The condyloid surfaces of the femur will therefore touch only the internal and external parts



From nature by L. Holden.

Drawn on Stone by T. Godart.

Printed by West, Newman & Co.



of the external and internal condyles respectively. Between the articular surfaces is the projection termed the 'spine.' It lies in the intercondyloid notch, acting like the flange of a wheel and preventing lateral displacement of the tibia from the femur at the knee joint. Its inner and outer sides are articular and continuous with the corresponding articular surfaces on the head of the bone. The front of the spine is rough and gives attachment internally to the anterior crucial ligament and externally to the anterior end of the external semilunar fibro-cartilage. The posterior surface of the spine is also rough and gives attachment to the posterior end of the external semilunar fibro-cartilage and slightly to that of the internal.

In front of the spine is a triangular, rough surface, looking upwards, and marked by a number of nutrient foramina for blood-vessels derived from the adjacent 'infra-patellar synovial pad.' On it rests too the transverse ligament connecting the anterior ends of the semilunar fibro-cartilages. It gives attachment likewise to the anterior extremity of the internal and to some fibres of the external semilunar fibro-cartilage and of the anterior crucial ligament. Behind the spine is another rough space, not so extensive as the one in front. It is rough and looks backwards as well as upwards. It gives attachment to the posterior end of the internal semilunar fibro-cartilage, the lower end of the posterior crucial ligament, and anteriorly to fibres belonging to the posterior extremity of the external semilunar fibro-cartilage.

Tuberosities, External and Internal.—The lateral masses which support the articular surfaces are called the 'tuberosities' of the tibia. The *external* tuberosity has at its back part a small nearly circular articular surface for the head of the fibula: this articular surface is on a kind of bony ledge, and its direction is obliquely downwards, backwards, and outwards. The *internal* tuberosity is much larger, and projects more than the external. It has a horizontal groove behind for the insertion of the 'semi-membranosus.' About one inch and a half below the head of the tibia, and in front of it, is the 'tubercle' for the insertion of the common extensor tendon of the leg (ligamentum patellæ).

In a few tibiæ we notice that the lower part of the tubercle

is rough for insertion of the ligament, and the upper part smooth to allow the easy play of the tendon (a bursa being interposed between the ligament and the bone). Starting from the superior internal and superior external angles of the 'tubercle' are two ridges which run upwards and then diverge to be lost on the inner and outer surfaces of the corresponding tuberosities about half an inch below the articular margin. Of the two the outer is the most prominent and gives attachment to the lateral patellar ligament, and limits superiorly the origin of the 'extensor longus digitorum' and the 'tibialis anticus.' The inner one affords attachment to the inner patellar ligament and fibres of the internal ligament of the knee joint. Both ridges are continuous with the inner and outer borders of the tubercle, and indicate the line of junction of the upper epiphysis with shaft in that region (fig. 39).

The tuberosities are separated behind by a notch, continuous with the posterior triangular rough surface on the upper end, and called the 'popliteal notch,' for the attachment of the posterior crucial ligament. The outer surface of the external tuberosity is rough and gives origin to the tibial head of the 'extensor longus digitorum' and the upper fibres of the 'tibialis anticus,' also to the 'fibrous expansion of the vastus externus.' The inner surface of the internal tuberosity is rough, shows posteriorly the fore part of the groove for the 'semimembranosus,' and gives attachment to the 'fibrous expansion' of the 'vastus internus' and 'crureus' and to the internal lateral ligament of the knee joint. About half an inch below the upper articular surfaces we notice horizontal ridges on the inner and outer and posterior surfaces of the tuberosities continuous with the divergent ridges on the anterior surfaces already described, and indicating the line of junction of the epiphysis with the shaft.

Shaft.—The shaft of the tibia is triangular on section. It is a little twisted outwards, determining the obliquity of the foot; consequently the inner malleolus advances a little more than the outer. This disposition corresponds with the obliquity of the neck of the femur, the position of its trochanters, and the oblique direction of the muscles; the result of all being to give a natural inclination

outwards to the lower extremity. The narrowest part of the shaft is about the junction of the lower fourth with the upper three-fourths. This is the part most frequently broken.

It presents *internal, external, and posterior surfaces*, separated by *anterior, external, and internal borders*.

The *internal* surface is subcutaneous. Notice on it, below the internal tuberosity, the insertions of the 'sartorius,' the 'gracilis,' and the 'semitendinosus.' Behind these is a slightly rough surface for the attachment of the internal lateral ligament of the knee.

The *external* surface is slightly hollowed in its upper half for the origin and lodgment of the 'tibialis anticus:' its lower part is turned forwards, presenting a smooth surface for the play of the tendons which run over the front of the ankle joint.

The *posterior* surface presents in its upper third a rough line ('soleal ridge'), slanting from the outer towards the inner side, and running from the articular surface for the fibula downwards and inwards to join the internal border at the junction of its upper with its middle thirds. It is ordinarily called the 'oblique line of the tibia,' and it marks part of the tibial origin of the 'soleus;' the remainder of this origin runs down the inner edge of the shaft to the extent of about three inches. This origin is important, since it concerns the operation of tying the posterior tibial artery. Above the 'oblique line' is a triangular surface, indicating the insertion of the 'popliteus.' The surface of the bone below the ridge is occupied, internally, by the origin of the 'flexor longus digitorum;' externally, by part of the origin of the 'tibialis posticus.' Just below the line is the canal for the medullary artery. It is the largest of all the like canals in the long bones, runs very obliquely from above downwards, and when divided in amputations sometimes occasions troublesome hæmorrhage. A nerve has often been traced through this canal with the artery into the medullary cavity.

With regard to the borders of the tibia, the *anterior*, called the 'crest,' or 'shin,' is very sharp, and readily felt beneath the skin, but only along the upper two-thirds of the shaft: in the lower third the front of the bone is flattened, for the passage of the extensor tendons and the anterior tibial vessels and nerve.

It begins above at the tubercle, runs a sigmoid course downwards, and terminates in front of the internal malleolus. It is convex inwards in its upper and convex outwards in its lower half.

The *external* border looks towards the fibula, and gives attachment to the interosseous membrane (represented by the dotted line in fig. 37) which connects the two bones. It begins above about half an inch in front of the articular facet for the fibula, runs downwards, and bifurcates below into two branches which enclose a rough space for the attachment of strong ligamentous fibres between the tibia and the fibula.

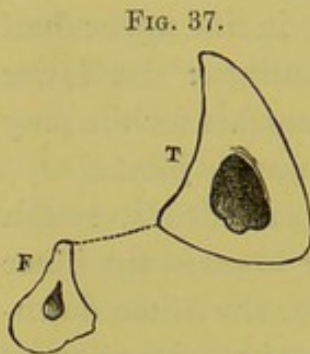


FIG. 37.
SECTION THROUGH THE TIBIA T, AND FIBULA F, TO SHOW THE THICKNESS OF THEIR WALLS.

It will be seen that the chief strain on the tibia is at the crest or anterior border—the shin. This, therefore, is by far the strongest and densest part of the bone.

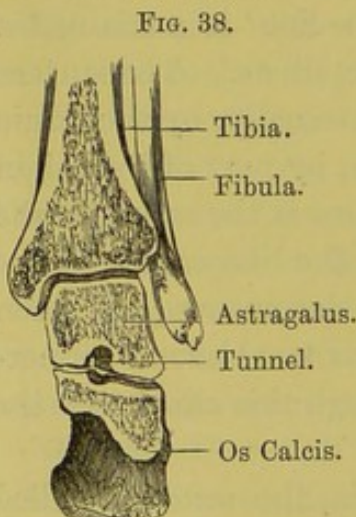


FIG. 38.
SECTION TO SHOW THAT THE PLANE OF THE ANKLE JOINT IS HORIZONTAL.

The *internal* border runs from the hinder part of the head of the tibia down to the inner malleolus. It gives attachment to fibres of the 'popliteus,' 'soleus,' and 'flexor longus digitorum' muscles (Plate XXXV.)

If the direction of the force in running, leaping, or walking be considered,

Lower End.—The lower end of the tibia is expanded transversely to form a hinge joint with the astragalus. Its articular surface is concave from before backwards; but the transverse plane of the joint is horizontal (as seen in fig. 38), like that of the knee, for the better support of the weight of the body. The joint is secured on the inner side by the projection termed the 'malleolus internus.'

The *anterior surface* of the lower end is smooth and slightly convex from side to side, for the transmission of the extensor tendons. Immediately above the anterior margin of the

terminal articular surface it shows a transverse rough groove for the attachment of the anterior ligament of the ankle joint.

The *posterior surface* is marked from within outwards by a deep oblique half-groove, made a whole one by the addition of the corresponding half on the back of the internal malleolus, and serving for the transmission of the 'tibialis posticus' tendon. Next the surface presents a slightly convex space, on which is sometimes placed a shallow oblique groove, parallel with the large one for the 'tibialis posticus,' situated about the middle of the space, and transmitting the 'flexor. longus pollicis' tendon. The edge of the surface which separates it from the articular surface on the inferior aspect of the bone is rounded and rough for the attachment of the transverse ligament of the inferior tibio-fibular joint.

The *external surface* presents a rough triangular excavation for the reception of the fibula, the anterior side of the triangle being more prominent than the posterior one. There is no sensible movement between the bones, but enough to give a slight amount of elasticity, thereby breaking the shock striking the leg from the foot below. The security of the ankle requires that the bones of the leg be firmly riveted together by a strong interosseous ligament; and their contiguous surfaces are found to be rough, marking the attachment of such a ligament.

The *inner surface* is smooth and subcutaneous, and is prolonged downwards into a transversely flattened and four-sided process, the 'malleolus internus.' The inner surface of the process is smooth, subcutaneous, and continuous with the inner surface of the lower extremity of the bone. The external surface is smooth and articular, broader in front than behind, and continuous with the articular surface on the inferior aspect of the bone. The anterior border of the process is rounded and rough, for the attachment of fibres of the anterior ligament of the ankle joint. The posterior surface forms the inner half of the oblique groove, already described, for the 'tibialis anticus.' We notice too that the internal lip of the groove projects more than the outer. The lower border of the malleolus is rough, and extends lower down in front than behind. It is bevelled at the expense

of the internal surface in front and the external surface behind. It is important to notice that the lowest point of the internal malleolus is situated in a plane anterior to the lowest point of the external malleolus.

The *inferior* or *terminal articular surface* of the lower extremity is four-sided, broader in front than behind, and outside than inside. It is concave from before backwards, and concavo-convex when traced from side to side, a smooth antero-posterior elevation rising up about the middle of the surface. It is continuous with the articular surface upon the internal aspect of the inner malleolus, and articulates with the astragalus.

The ankle joint is such a perfect hinge that in any position of the joint no lateral movement whatever is permitted.

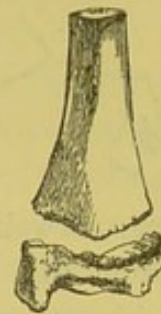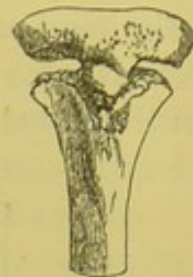Structure and Mechanism.—In structure the tibia follows the ordinary laws with reference to the arrangement of the fibres of the cancellous tissue. Its compact wall is especially developed at the most slender part of the shaft, to form the anterior border or crest. The weakest part of the bone is situated about the junction of the upper three-fourths with the lower fourth of the shaft, so that if a person fall from a great height upon the foot the bone usually breaks there. Rickets, too, usually shows itself early, by an increase of the natural curve of the bone in this situation. The shaft is sigmoid in its long axis and twisted outwards below. Elasticity and strength are thereby gained, and the foot at the same time turned outwards. The anterior border strengthens the bone very much. It terminates above in the tubercle, and is more in the line of the external tuberosity than of the internal. The weight of the body, which is mostly transmitted to the leg through the external condyle of the femur, strikes, therefore, the strongest part of the shaft, viz. the outer and anterior part. The outer tuberosity overhangs the fibula, thereby transmitting a certain amount of weight to it. It receives, too, directly all shocks coming to it from below through the fibula. The medullary canal is specially large to transmit the vessel for the chief supply of the marrow: the compact tissue of the shaft is so dense that few other nutrient blood-vessels penetrate it.

Ossification.—The tibia is ossified from three centres: one for the shaft, and one for each end. The centre for the shaft appears at the seventh week of foetal life. The one for the upper end, which (see fig. 39) includes the tubercle, appears just before or just after birth, nearly as early as the lower epiphysis of the femur. The centre of the lower end appears about the second year. The tubercle is occasionally formed from a separate centre. The upper epiphysis joins the shaft in the twenty-first or twenty-second year, while the lower one joins in the eighteenth or nineteenth year.

The tibia has been found congenitally absent, as in a case recorded by Billroth.

Comparative Osteology.—The tubercle of the tibia is very largely developed in the rhinoceros, but in the elephant there is no trace of it. The high and expanded crest in the pig, camel, and tapir are remarkable. In the higher quadrumana, as the gorilla, chimpanzee, and ourang outan, the tubercle and crest are flattened. (For all these specimens see the Separate Series.)

FIG. 39.

EPIPHYSES OF
THE TIBIA.

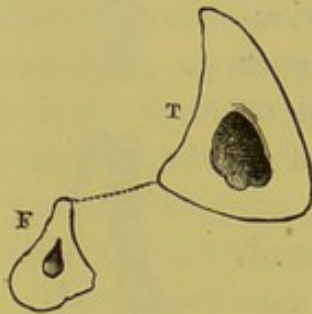
THE FIBULA.

(PLATE XXXV.)

Relations of Tibia to Fibula.—The 'fibula' (a clasp) is the outer of the two bones of the leg. Though quite as long as the tibia, it is a slender bone, and sustains hardly any of the weight of the body. The upper end is placed on a lower level than the knee joint, and forms no part of it; but the lower end projects considerably below the tibia, and constitutes the outer ankle. The bone not only secures the ankle externally, but gives additional extent of origin to the powerful muscles of progression. Look well at the relative position of the two bones of the leg in an articulated skeleton. The fibula articulates with the outer and

back part of the head of the tibia, and the shaft of the fibula arches backwards, while that of the tibia arches forwards: the result of this is, that the fibula lies very much in the background, except at its lower part, where it advances to form the malleolus externus. A knowledge of this relative bearing of the two bones is important in the adjustment of fractures, but more especially in the performance of flap amputations; and for this

FIG. 40.



reason: that the knife, introduced from the tibial side, is apt, unless properly directed, to pass between the two bones, instead of behind them: and this is the more likely since the plane of the posterior surface of the tibia slants considerably in front of the fibula. The relative position of the two bones, as well as their relative thickness, is shown by a transverse section (fig. 40). The dotted line represents the interosseous membrane.

Head.—The upper end of the fibula is called its ‘head,’ and can be felt plainly beneath the skin. On its *upper surface* is a small oval facet looking forward, upward, and inward to articulate with the tibia. Its *anterior surface* is rough, giving attachment above to fibres of the anterior tibio-fibular ligament, and below to fibres of the ‘extensor longus digitorum’ muscle. The *external surface* is much bulged outwards by an antero-posterior ridge. Above the ridge we have the ‘biceps’ tendon and the long external lateral ligament of the knee joint attached, and below the ridge the highest up fibres of the ‘peroneus longus’ muscle. The *posterior surface* is rough and flattened. Its superior and external angle rises into a short projection termed the ‘styloid process,’ for the attachment of the short external lateral ligament of the knee joint. The surface gives origin to fibres of the ‘soleus’ and internally to the posterior tibio-fibular ligament. The *internal surface* is rough, slightly hollowed, and lodges the superior interosseous ligament.

Shaft.—As we have mentioned before, the shaft, excepting at its lower end, lies in a plane posterior to that of the tibia. In its long axis it is curved backwards and outwards in its upper half

and backwards and inwards in its lower. The space between the two bones is widest about the junction of its upper and middle thirds. The surfaces and borders follow a spiral course along the bone in such a way that a surface which looks outwards above looks as near as possible backwards below. The shaft too is irregularly prismatic in its upper three-fourths and gets flattened from within outwards in its lower fourth, the most slender part being situated at the meeting of these two parts.

We describe *anterior, internal, and external borders*, separating *internal, external, and posterior surfaces*, corresponding to those of the tibia.

The *anterior border* commences superiorly at the junction of the anterior and external surfaces of the head. It is rounded and indistinct above, but is well marked in the rest of its extent. Tracing it down the bone, it gradually turns outwards, and, about three inches from the lower end, it bifurcates into branches which run to the front and back of the lower end of the bone and enclose a flattened triangular subcutaneous space facing outwards. In this space we feel for fractures of the lower part of the fibula.

The *internal border* begins above at the inside of the posterior surface of the head and terminates about an inch and a half above the lower end of the bone by dividing into an anterior and a posterior branch, enclosing a rough triangular space. This space is rough in its upper two-thirds for the attachment of strong interosseous fibres, and presents below a somewhat flattened and smooth crescentic surface for articulation with the external surface of the lower end of the tibia. In most fibulae the border is very well marked in its upper three-fourths. It takes an oblique or spiral course down the shaft, looking inwards and slightly backwards at its upper end, inwards and slightly forwards at its lower. Its upper three-fifths is ordinarily called the 'oblique line of the fibula.' It gives origin in the upper part of the middle third and lower part of the upper third to fibres of the 'tibialis posticus,' and in the rest of its extent attaches the fibrous septum which separates the 'soleus' and 'flexor longus pollicis' on the one side from the 'tibialis posticus' on the other.

The *external border* begins above at the root of the styloid process, runs down the shaft, gradually inclining towards the back, and terminates below by joining the posterior branch of the internal border at the lower end of the shaft. In some fibulæ it is sharp and distinct throughout. In others it is rounded in the upper and lower thirds, and well marked in the middle. It separates the external from the posterior surface, and gives attachment to the fibrous septum between the 'peronei' muscles on the one side from the 'soleus' and 'flexor longus pollicis' on the other.

The *surfaces* we have named *internal*, *external*, and *posterior*.

The *internal* faces the external surface of the tibia. It looks forwards and inwards above, forwards below. It is unequally divided into a smaller anterior part and a larger posterior part by a vertical ridge. This ridge is called the 'interosseous ridge' of the fibula, affording attachment to the interosseous membrane, which stretches between it and the external border of the tibia, and which separates the muscles on the front from the deep muscles on the back of the leg. In well-marked bones the ridge commences above at the inside of the head and somewhat nearer the anterior than the internal border, runs downwards, inclining backwards as it descends, and blends with the internal border at a point about an inch to two inches above its lower bifurcation. In slender fibulæ the interosseous ridge may blend with the anterior border of the shaft for a good way below its upper end. The *anterior part of the internal surface* is therefore broader below than above and more hollowed from side to side. It affords origin anteriorly in its upper three-fourths to the 'extensor longus digitorum' and in its lower fourth to the 'peroneus tertius,' and posteriorly in its middle two-fourths to the 'extensor proprius pollicis.' The *posterior part of the internal surface* is broader above than below, concave from side to side, and gives origin to the fibular fibres of the 'tibialis posticus.'

The *external surface* lies between the anterior and external borders. It looks forwards and outwards, but towards the lower end of the shaft it inclines backwards. It gives origin to the 'peroneus longus' above and the 'peroneus brevis' below. (Plate XXXV.)

The *posterior surface* lies between the external and internal borders. It looks backwards above and inwards below, and gives origin in its upper third to the 'soleus' and in its lower two-thirds to the 'flexor longus pollicis.' Near the internal border, situated somewhere in the middle third of the surface, is the medullary foramen, leading downwards. In a few rare specimens we may see, in this surface, an additional foramen directed upwards.

Lower End.—The lower end of the fibula descends below that of the tibia, and forms the 'malleolus externus.' This process we may describe as a pyramid flattened laterally, whose base is continuous with the shaft of the bone, and whose apex is free, points downwards, and is situated in a plane posterior and inferior to that of the corresponding part of the malleolus internus. The external surface of the pyramid is smooth, subcutaneous, and continuous with the triangular subcutaneous surface already described as formed by the bifurcating anterior border of the shaft. The anterior surface is narrow, slightly rough, slopes downwards and backwards, and affords attachment to fibres of the anterior inferior tibio-fibular ligament and anterior ligament of the ankle joint, and anterior fasciculus of the external ligament of the ankle joint. It is more a border than a surface. The posterior surface presents a smooth longitudinal groove, running downwards and outwards, for the passage of the 'peronei' tendons. The inner lip of the groove is rough, and attaches fibres of the posterior inferior tibio-fibular ligament and posterior fasciculus of the external ligament of the ankle joint. The internal surface is divisible into a larger anterior superior part, triangular in shape, somewhat convex from above downwards and concave from before backwards, for articulation with the astragalus, and a smaller posterior and inferior part, rough and deeply depressed, for the attachment of the middle fasciculus of the external ligament of the ankle joint. The apex is rounded and rough, and has attached to it anteriorly, posteriorly, and internally the anterior, posterior, and middle fasciculi of the external ligament of the ankle joint.

Structure and Mechanism.—In its structural formation the fibula presents the ordinary characters of a long bone. Its

function is very slight as regards helping the tibia to support the weight of the body. The outer tuberosity *does* overhang the head of the fibula, but the plane of the articulation between the two is very oblique, and the fibula can therefore act as a very weak prop to that part of the tibia. Its chief office is to give increased breadth to the leg for muscular attachment, and to support the ankle joint. We notice, also, the general bendings backwards of the shaft, throwing it into a plane which is posterior to that of the tibia. We observe too, that the shaft is farthest away from the tibia above, so as to give greater breadth to the interosseous membrane as the muscles of the leg arise from the upper part and not the lower part of the tibia. There is a certain amount of movement between the tibia and fibula, just enough to help to break shocks transmitted to the bones of the leg from below. The fact that the fibula is embedded in muscles in the greater part of its extent makes the diagnosis of fractures of its shaft somewhat difficult: hence the rule to test its natural resistance by pressing it against the tibia, and notice whether there is a slight natural rebound after having done so. The external malleolus supports the ankle joint on the outer side. The two malleoli with the terminal articular surface of the astragalus form an arch for articulation with the astragalus. The external one projects farther down and farther back than the internal one. The result of this is that the foot may receive, in the best possible way, shocks transmitted to it from above. In the ordinary act of walking, when the foot is thrown forwards and the leg gradually raised over it, the weight of the body strikes the astragalus, from above and behind, downwards, forwards, and inwards; hence the external malleolus and the facet for it on the outside of the astragalus are placed as far *back* as possible, to transmit and receive their share of the shock. On the contrary, when the leg is behind the body, with the toes touching the ground and throwing the body forward, the shock is transmitted to the astragalus from above and in front downwards, backwards, and outwards; hence the internal malleolus and corresponding facet upon the astragalus are placed as far *forward* as possible. The relative position of the two malleoli is

important in relation to Syme's amputation at the ankle joint. The weakest part of the shaft is situated about $2\frac{1}{2}$ inches from the lower end; hence we find that fractures of the bone most commonly occur here.

Ossification.—The fibula has three centres of ossification: one for the shaft, and one for each end. The centre for the shaft appears about the seventh week of foetal life. The lower end begins to ossify about the second year; the upper about the third or fourth. It is interesting to note that the lower end, the early solidity of which is so necessary, is the first to unite to the shaft, and is thus contrary to the rule laid down on p. 25. The lower epiphysis joins the shaft about the twenty-first year, the upper about the twenty-fourth.

The fibula is sometimes—rarely, however—congenitally absent. It is more common to find absence of a *part* of it than of the *whole* bone. In some cases the shaft may be represented by thickening of the interosseous membrane connecting the upper and lower ends of the bone. In other cases the upper part, and in others the lower part of the bone may be wanting. Complete or partial absence of the fibula is usually associated with an imperfect development of the bones of the tarsus and an absence of one or more of the four outer toes.

Comparative Osteology.—It is interesting to notice the gradual disappearance of the fibula in reviewing the vertebrata. In the horse it is reduced to a mere splint at the upper part of the tibia.

In the *Ornithorynchus* (No. 3964) there will be seen a broad flat process, projecting high upwards at the back of the fibula, which gives origin to enormous extensor and flexor muscles, which work the paddle-like foot (see Phys. Ser. Mus. Roy. Coll. Surg., No. 255 C). A similar process exists on the fibula of the *Echidna* (No. 3952 C). The fibula of the *Armadillo* (No. 3580) attains a great size, and is ankylosed above and below to the tibia and enters into the formation of the knee joint.

THE BONES OF THE FOOT.

(PLATES XXXVI., XXXVII.)

Number and Shape of Bones.—There are twenty-six bones in the foot (excluding the two sesamoid bones of the great toe, and two others in connection with tendons. We divide them into three sets, viz. a posterior set or ‘tarsus,’ a middle set or ‘metatarsus,’ and an anterior set or ‘phalanges,’ corresponding to similar sets described in the hand as ‘carpus,’ ‘metacarpus,’ and ‘phalanges.’ The ‘tarsus’ consists of seven more or less cubical bones arranged in an *inner* and an *outer* row. The *inner row* consists of five bones named the ‘astragalus,’ ‘scaphoid,’ and ‘inner,’ ‘middle,’ and ‘outer cuneiform,’ supporting the three inner toes; the *outer row* consists of two, viz. the ‘os calcis’ or ‘calcaneum,’ and the ‘cuboid,’ for the support of the two outer toes. From a mechanical point of view this is the best division of the tarsus, although surgically the tarsus is conveniently divided into a *posterior row*, consisting of the ‘astragalus’ and ‘os calcis,’ and an *anterior row* made up of the rest. The line of junction between these rows is called the ‘medio-tarsal joint,’ and through it Chopart’s amputation is performed.

The ‘metatarsus’ consists of five long bones named first, second, third, fourth, and fifth, counting from the inside of the foot. The posterior end of the metatarsus is firmly dovetailed into the front of the tarsus, while the anterior end supports the ‘phalanges.’ The ‘phalanges’ consist of fourteen long bones, three for each toe excepting the first one, which has only two. They are more diminutive than those of the hand, and are named

metatarsal, proximal or first, middle, and ungual, distal, or third for the four outer toes; proximal, metatarsal or first, and distal, or third for the first or great toe.

Advantage of many Bones.—The advantage of so many bones entering into the formation of the foot is the same for the foot as for the hand. With a larger number of joints motion and elasticity are increased, while the chances of fracture or dislocation are lessened.

Arches of the Foot.—The bones of the foot form two arches: one, 'longitudinal,' extends in the long axis of the foot; the other, transverse, is most marked at the instep. The longitudinal arch is supported, behind, by the os calcis, and in front by the heads of the metatarsal bones. Its height and span are greatest on the inner side of the foot, and gradually decrease towards the outer side. The marks made by wet feet show how much more the outer border of the foot comes in contact with the ground than the inner. The weight of the body falls perpendicularly on the astragalus, which is the key-stone or crown of the arch. Concerning the astragalus, two points must be borne in mind: 1. A part (the head) of it is supported below by a remarkably strong and slightly elastic ligament (calcaneo-scaphoid), which admits of its rising and falling like a spring; 2. It is articulated with the os calcis and the scaphoid in such a way as to allow the lateral motions of the foot (adduction and abduction). Flexion and extension of the foot are performed at the *ankle* joint. Further, all the bones of the foot are more or less movable on each other, thus breaking shocks and increasing elasticity; and yet their mutual connection is so well secured that dislocation of any one bone is extremely rare.

Tarso-Metatarsal Articulations.—The second row of tarsal bones consists of four: namely, the three cuneiform and the cuboid. These articulate with the metatarsal bones as follows: The internal cuneiform with two, those of the great and second toes; the middle cuneiform with one, that of the second toe; the external cuneiform with three, those of the middle, the second, and fourth toes; and the cuboid with two, those of the fourth and fifth toes. See how this exactly corresponds with the articu-

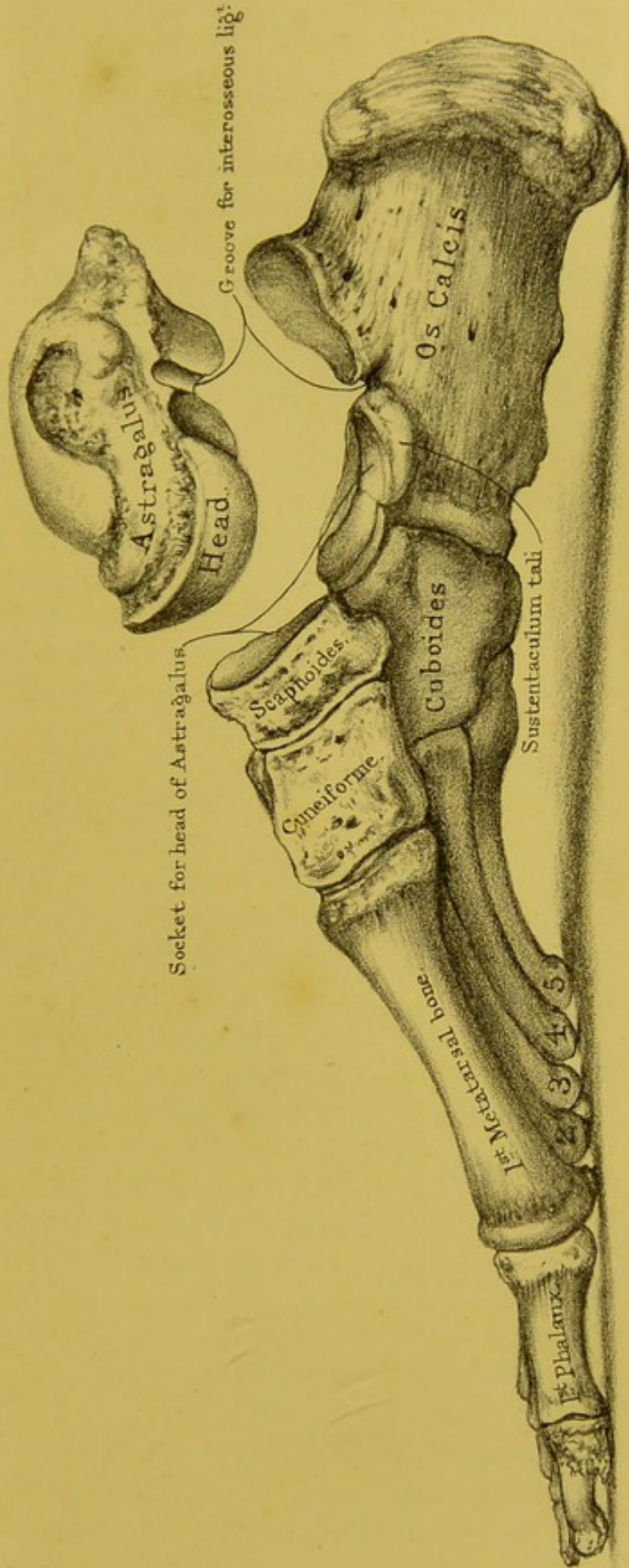
lations of the second row of carpal bones with the metacarpals. Starting from the great toe, or thumb side, these bones articulate with 2, 1, 3, and 2 metatarsal and metacarpal bones respectively.

THE ASTRAGALUS.

(PLATE XXXVI.)

The Key-Stone : its Six Aspects.—The astragalus (ἀστράγαλος, talus, the knuckle bone, with which the ancients used to play at dice) is the key-stone of the arch of the foot, and supports the whole weight of the body, which, in the erect position, falls perpendicularly upon it from the tibia. It is so much concerned in the mechanism of the spring of the foot, that the Germans call it the ‘spring bone.’ To examine it thoroughly study its six surfaces.

SUPERIOR SURFACE.—The superior surface, broad and rising up slightly at its outer border in the transverse direction, the best adapted for the erect posture, presents a pulley-like convexity in the antero-posterior direction, which articulates with the tibia, and admits of the flexion and extension of the ankle. The pulley-like surface is at least one-fifth of an inch broader in front than behind. This prevents dislocation of the astragalus backwards, which would otherwise be a more frequent occurrence, considering the direction of the force in walking, running, or leaping. The broad side of the pulley is the outer one. The inner edge of the pulley is nearly straight from behind forwards and inwards, while the outer one is more prominent and makes a sweep inwards on its way forwards. The articular surface of the pulley is continuous over the edges with the articular surfaces on the sides of the bone. In front of the trochlear surface is a rough narrow and depressed part of the bone, marked by nutrient foramina and affording attachment to the anterior ligament of the ankle joint. It is sometimes called the upper surface of the ‘neck’ of the bone.



Drawn on Stone by T. Godart.
From nature by L. Holden. Printed by West, Newman & Co.



POSTERIOR SURFACE.—The posterior surface is narrow, and presents a groove running obliquely downwards and inwards for the tendon of the flexor longus pollicis, and a projection on the outer side of it for the attachment of the posterior division of the external lateral ligament of the ankle.

INTERNAL SURFACE.—The internal surface presents above a flat or slightly concave pyriform articular facet, rounded in front and pointed behind, for articulation with the internal malleolus; the facet occupies very little of the bone, so that a large, rough, and slightly excavated surface is left below and in front, for the attachment of the deep plane of fibres of the internal lateral ligament of the ankle joint.

At the anterior and inferior angle of the internal surface is a convex articular facet, looking inwards and downwards, and continuous with the articular surface upon the front and under aspect of the bone, for articulation with the 'inferior calcaneo-scaphoid' ligament.

EXTERNAL SURFACE.—The external surface presents from behind forwards a narrow, rough groove directed from above downwards, forwards, and outwards, for the attachment of ligamentous fibres, next a large triangular articular facet, continuous by its base with the trochlear surface on the upper aspect of the bone, and for articulation with the external malleolus. The facet is concave from above downwards, slightly concave from before backwards above, but rather convex in the same direction below. In front of this facet and inferiorly the surface is deeply hollowed out to form the anterior end of the interosseous groove, which we shall see lies on the under surface, while superiorly it is narrow, rough, and prominent, and forms the outer surface of the neck.

ANTERIOR SURFACE.—The anterior surface presents a four-sided and uniformly convex articular facet, having its long axis directed downwards and inwards, and its outer side broader than its inner, for articulation with the scaphoid.

INFERIOR SURFACE.—The inferior surface rests on the os calcis by two articular surfaces, one behind the other, and separated by a deep groove directed from the inner side obliquely outwards and forwards. Of these surfaces, the posterior is by far the

larger, and placed a little more external than the anterior. It is quadrilateral in shape with its long axis running forwards, outwards, and slightly downwards. It is concave in every direction, especially so in its long axis. The facet is twisted in such a way that it looks downwards, forwards, and outwards behind, and downwards, backwards, and slightly inwards in front. The anterior facet forms an elongated oval figure with its long axis running forwards, and more outwards than the posterior one. In well-marked bones it is constricted in the middle and divided into an *anterior* and *posterior* part by a smooth transverse elevation. The *anterior part* is continuous with the two articular surfaces already described as existing: one for articulation with the scaphoid, and the other to rest on the outer and upper side of the 'inferior calcaneo-scaphoid' ligament. The facet looks downwards and rather forwards, is nearly flat from before backwards, and rather convex from within outwards for articulation with the upper surface of the greater process of the os calcis. This facet and those for the scaphoid and calcaneo-scaphoid ligament constitute what is called the articular surface of the 'head' of the astragalus. The *posterior part* is oval, broader in front than behind, and directed downwards and backwards. It is slightly concave in all directions, somewhat twisted in its long axis, and articulates with a corresponding facet on the upper surface of the 'sustentaculum tali' of the os calcis. This intricate arrangement of the facets for articulation with the os calcis allows of the oblique movements which occur at the calcaneo-astragaloid joint, viz. a combination of adduction with rotation in of the foot, or of abduction with rotation out of the same. The 'calcaneo-scaphoid' ligament articulating with the inner and under side of the head mainly supports the arch of the foot on the inside, and gives it its spring. If the ligament yield more than it should do from any reason, the arch goes down, the foot becomes flat, and the astragalus may sink low enough to touch the ground.

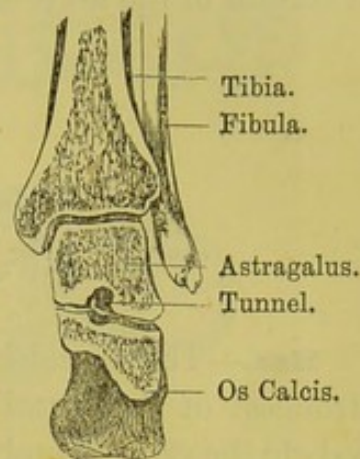
Tunnel of the Tarsus.—The rough groove just alluded to, between the articular surfaces of the astragalus, corresponds with another between those of the os calcis. When the bones are to-

gether, the grooves form a complete tunnel (*canalis tarsi*) beneath the astragalus, wide on the outside, but narrow on the inside of the foot (fig. 41). This tunnel is occupied in the recent state by fat and by the strong interosseous ligament which connects the two bones: its direction is obliquely from before backwards and inwards, and permits the movements of the foot which take place at the calcaneo-astragaloid joints.

Connections.—The astragalus articulates with four bones—namely, the tibia, the fibula, the os calcis, and the scaphoid.

Ossification.—It is ossified from a single centre, which appears about the seventh month of foetal life. Occasionally the astragalus has a second centre of ossification, situated at the meeting of its posterior with its external surface and close to the lower border. This additional centre may form a small ossicle, situated at the back of the bone and called the ‘secondary astragalus.’ It gives attachment to the posterior fasciculus of the external lateral ligament of the ankle

FIG. 41.



SECTION TO SHOW THE TUNNEL OF THE TARSUS.

FIG. 42.

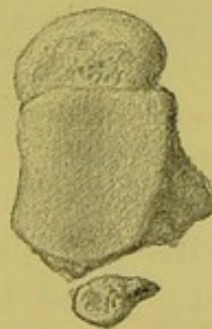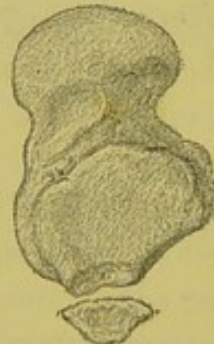RIGHT ASTRAGALUS
(Upper Surface).

FIG. 43.

LEFT ASTRAGALUS
(Under Surface).

joint. The little piece of bone, if present, will lie on the outer side of the groove for the ‘flexor longus pollicis,’ which it may or may not help to form. It may articulate with the rest of the

bone by a distinct synovial prolongation from the ankle joint above or from the calcaneo-astragaloid joint below, or it may be connected with the rest of the bone by strong fibrous tissue. Its presence, however, may only be indicated by a notch or fissure on the *surface* of the bone. By some anatomists this ossicle is considered to represent the *os intermedium tarsi* found in certain of the lower mammals (figs. 42, 43).

OS CALCIS, OR CALCANEUM.

(PLATES XXXVI., XXXVII.)

Use.—The os calcis, or ‘calcaneum,’ is the longest and strongest of the tarsal bones. It transmits the weight of the body to the ground, and forms a powerful lever for the muscles of the calf. The nearly horizontal direction of the heel is peculiar to the skeleton of man, in adaptation to his erect position. The oblique projection in the hind limb of a horse, called the ‘hock,’ is the os calcis.

There is a prevalent opinion that the negro has a longer heel than the white man; but an examination of a series of calcanea in both races proves this to be an error. Professor Flower, in his lectures on the ‘Comparative Anatomy of Man,’ states that the *apparent* lengthening in the negro is due to the smallness of his calf and the slenderness of the tendo Achillis immediately above the heel.

The os calcis is divided into a ‘body’ whose anterior end is named the ‘greater process,’ and which has projecting from its inner and upper edge a nearly horizontal shelf called the ‘lesser process,’ or ‘sustentaculum tali.’ Viewed as a whole the os calcis presents six surfaces.

SUPERIOR SURFACE.—The superior surface presents from behind forward, first, a rough surface narrower from side to side than from before backwards, convex transversely, and concave antero-posteriorly. It is marked by a number of nutrient fora-



mina and covered in the recent state by a mass of fat which lies in front of the tendo Achillis. Next we notice a quadrilateral articular surface looking forwards and upwards for articulation with the posterior facet on the under surface of the astragalus. The surface has its long axis directed forwards, outwards, and downwards. Its plane is somewhat twisted, so that it looks backwards, upwards, and inwards at its posterior extremity, and forwards, upwards, and very slightly inwards at its anterior end. It is concave from side to side and convex in the opposite direction. In front of this articular surface, and running forwards and outwards, is a rough groove for the attachment of the interosseous ligament, the groove also giving attachment, at its anterior extremity, to fibres of the 'extensor brevis digitorum' and 'anterior annular' ligament. The interosseous groove is concave upwards, broadest, shallowest, and roughest in front, and narrowest and deepest about the junction of its posterior fourth with the anterior three-fourths: it makes with the astragalus a complete tunnel, shown in fig. 41. In front of and inside this groove, and parallel with its anterior and inner lip, is an oval articular facet, lying partly on the upper surface of the sustentaculum tali, and partly on the upper surface of the greater process. The surface generally is divided into two parts corresponding to the parts of the bone upon which they rest by notches on the edges of the surface; a deep transverse groove, however, continuous with the 'interosseous' one, may completely separate the one from the other. The whole surface is concave in its long axis and slightly concave from side to side. Both the surfaces for articulation with the astragalus are adapted to the oblique movements which take place at the calcaneo-astragaloid joint.

ANTERIOR SURFACE.—This surface presents a rounded triangular smooth surface, covered by cartilage in the recent state, for articulation with the posterior surface of the cuboid. The upper edge of the surface overhangs the lower, overlapping the corresponding part of the articular surface of the cuboid. When traced vertically the surface is concave from above downwards, but when followed from above downwards and inwards it is

sinuously curved, presenting first a concavity, next a convexity, and lastly a slight concavity at its lower and inner part. The projection of the upper edge deserves notice from a surgical point of view, because it is in the way in the performance of 'Chopart's' operation, which consists in the removal of all the bones of the foot, except the os calcis and astragalus. Mechanically the hanging of the upper edge over the corresponding edge of the cuboid throws the weight of the body, coming down from above, on to the cuboid and prevents the natural tendency of the fore part of the os calcis to be displaced downwards.

POSTERIOR SURFACE.—The posterior surface is four-sided, broader below than above. Inferiorly it is marked by a number of rough vertical ridges and grooves for the attachment of the tendo Achillis. Superiorly it presents a smooth part which indicates the position of a bursa between the same tendon and the bone.

EXTERNAL SURFACE.—The external surface is broad, flat, and nearly subcutaneous. At about the junction of its anterior third with its posterior two-thirds we notice a short rough ridge directed downwards and forwards, with a smooth groove above and a smooth groove below it. The ridge is called the 'peroneal tubercle,' and serves to keep the peroneal tendons in their place, that of the 'peroneus brevis' being in the groove above the tubercle, that of the 'peroneus longus' below the tubercle. Above and behind the peroneal tubercle, and situated about half an inch below the posterior and outer angle of the articular surface for the astragalus, is another smaller rough tubercle for the attachment of the middle fasciculus of the external lateral ligament of the ankle joint; and in some bones above and in front of the smaller tubercle another little tubercle exists for the attachment of the external calcaneo-astragaloid ligament. Scattered over the outer surface are a number of nutrient foramina. These are especially numerous inferiorly.

INTERNAL SURFACE.—The internal surface presents at its anterior superior angle the '*sustentaculum tali*.' This process is flattened from above downwards and backwards, articulates with the astragalus above, and presents a smooth groove

peroneal

inferiorly, continuous with the one on the posterior surface of that bone for the passage of the 'flexor longus pollicis' tendon. Internally the process is rough and affords attachment to fibres of the internal lateral ligament of the ankle joint, to the posterior end of the inferior calcaneo-scaphoid ligament, and to fibres of the 'tibialis posticus' tendon. At the posterior and inferior angle we notice the inward projection of the greater tuberosity to be described as lying at the back of the inferior surface. Tracing the surface downwards and backwards it is very concave, and from behind downwards and forwards it is very slightly convex. The concavity of the surface safely transmits the plantar vessels and nerves. At its lower and back part it gives origin to the inner head of the 'flexor accessorius' muscle.

INFERIOR SURFACE.—The inferior surface presents posteriorly two rough 'tuberosities,' the 'inner' and the 'outer,' separated anteriorly by a rough notch. The inner is the larger, and by it the os calcis touches the ground. It gives origin to the 'abductor pollicis,' 'flexor brevis digitorum,' and 'abductor minimi digiti,' and attaches part of the plantar fascia. The external is much the smaller, and affords attachment to the abductor minimi digiti and the outer part of the plantar fascia. In front of these tuberosities is a long triangular rough surface streaked longitudinally and ending in front in a small eminence called the 'anterior tuberosity.' The triangular surface and the anterior tuberosity give attachment to the long calcaneo-cuboid ligament. In front of the anterior tuberosity is a rough transverse groove, forming the under surface of the greater process and attaching the posterior end of the short calcaneo-cuboid ligament. At the line of junction between the inferior and external surfaces, and just in front of the external tuberosity, is the point of attachment of the external head of the 'accessorius.'

Connections.—The os calcis articulates with two bones, the astragalus and cuboid.

Ossification.—The os calcis has two centres of ossification: one for the great mass of the bone, which appears about the sixth month of foetal life; and another for the great tuberosity

which is an epiphysis and appears about the tenth year. The epiphysis unites to the bone about the sixteenth year. It probably represents the pisiform bone of the carpus.

THE SCAPHOID BONE.

The scaphoid bone is so named from its boat-like form, and is situated on the inner side of the tarsus. Its long axis is directed downward and inward and *more downward than inward*.

SURFACES.—The *superior surface* is convex and rough, directed upwards and outwards, and gives attachment to ligaments connecting it with the adjacent bones.

The *inferior surface* looks downwards and inwards, is rough, and forms a blunt projection easily felt under the skin of the inner side of the foot, and called the ‘tuberosity of the scaphoid’ for the attachment of the ‘tibialis posticus’ tendon and inferior calcaneo-scaphoid ligament. This tubercle is the best guide to the joint behind it in the performance of Chopart’s operation.

The *internal surface* is nearly flat, or it may be slightly convex; it looks inwards and upwards, and is rough for the attachment of ligaments.

The *external surface* looks downwards and outwards, is slightly concave in its long axis and very rough for the attachment of a prolongation of the tendon of the ‘tibialis posticus’ and ligaments connecting it with adjoining bones. Its upper and outer part rests upon the cuboid, an interosseous ligament intervening between their contiguous surfaces. It is not uncommon to find the two bones actually *touching* one another, in which case they present two small articulating surfaces covered in the recent state with cartilage and lined by a prolongation of the scapho-cuneiform joint.

The *posterior surface* presents an oval articular facet, concave in every direction, and broader above and outside than below and inside, to articulate with the front of the head of the astragalus.

The *anterior surface* is convex in its long axis, and is marked by three facets continuous with one another for articulation with

the three cuneiform bones. The lowest and most internal one is triangular, with its base downwards, and is convex to fit the posterior surface of the internal cuneiform; the middle one, the highest of the three, triangular with the base upwards, and sinuously curved to articulate with the middle cuneiform. The external facet is the smallest of the three. It is on a somewhat lower level than the middle one, and is triangular in shape, with the base upwards and slightly concave, for articulation with the external cuneiform.

Connections.—The scaphoid articulates with the three cuneiform bones in front, the astragalus behind, and sometimes with the cuboid.

Ossification.—It has a single centre, which appears about the fourth year.

THE CUBOID BONE.

Situation.—The cuboid bone is situated on the outer side of the tarsus, and is wedged in between the os calcis and the fourth and fifth metatarsal bones. The *base* of the wedge is turned towards the cuneiform bones, so that the pressure in the arch of the foot is properly distributed. Suppose, for a moment, the base were turned the other way, would not the lateral thrust from the external cuneiform bone force the cuboid out of the arch, and falling of the arch be the consequence?

SURFACES.—The *posterior surface* is slightly concave from above downwards, and concavo-convex from without inwards, to articulate with a corresponding surface on the os calcis. Observe that the plane of this joint is the same as that between the scaphoid and astragalus. Hence partial amputation of the foot (Chopart's operation) here is easy. But it cannot be done at one stroke of the knife, because the inner corner of the cuboid projects a little beneath the os calcis, which tends to prevent it being dislocated upwards.

The *anterior surface* has two smooth facets, the inner nearly square, the outer triangular, which support the fourth and fifth metatarsal bones.

The *internal surface* is much larger than the external. It

forms the base of the wedge and looks upwards, inwards, and a little forwards. It articulates by a flat oval facet, situated in the middle of its upper half, with the external cuneiform, and occasionally by a small articular surface, placed posteriorly, with the scaphoid. The rest of the surface is rough for the attachment of interosseous ligaments.

The *superior surface* is rough for dorsal ligaments, and nearly flat.

The *external surface* represents the edge of the wedge, is rough in front and behind, and, in the middle, shows the outer extremity of the groove for the 'peroneus longus.'

The *inferior surface* is traversed by a deep groove which runs obliquely inwards and forwards and lodges the tendon of the 'peroneus longus.' The prominent ridge behind the groove gives attachment to the calcaneo-cuboid ligament. Observe near the posterior part of the ridge a small smooth facet (crusted in the recent state with cartilage), which articulates with the sesamoid bone in the tendon that plays in the groove. Posterior to the inner end of the ridge, and at the line of junction between the inferior and internal surfaces of the bone, are situated part of the origin of the 'flexor brevis pollicis' and the insertion of a prolongation of the tendon of the 'tibialis posticus.'

Connections.—The cuboid articulates with four bones—the os calcis, the outer cuneiform, and the fourth and fifth metatarsals—and sometimes with a fifth, namely the scaphoid.

The cuboid gives origin to parts of three muscles in the sole—the 'adductor pollicis,' and the 'flexor brevis pollicis' and 'flexor brevis minimi digiti.' Remember that the 'adductor pollicis' and 'flexor brevis minimi digiti' arise, not immediately from the bone, but from the fibrous sheath which bridges over the groove for the peroneus longus.

Ossification.—The single nucleus of the cuboid bone appears at birth.

THE CUNEIFORM BONES.

Position.—The cuneiform or wedge bones are placed at the front part of the tarsus, and are named the 'internal,' 'middle,'

and 'external,' according to their position. Behind, they articulate with the scaphoid; in front, with the three inner toes, respectively. The bases of the middle and external are towards the dorsum of the foot; but the base of the internal is turned towards the sole, in order to form one of the buttresses of the transverse arch of the foot.

Internal Cuneiform.—SURFACES.—The *anterior surface* is convex, articular, and kidney-shaped, with the long diameter vertical and the hollow of the kidney pointing out, for articulation with the base of the first metatarsal bone.

The *posterior surface*, much smaller than the anterior, is concave, with the broad end below, for articulation with the innermost facet on the front of the scaphoid.

The *superior surface* forms the edge of the wedge. In its anterior third it runs straight from above and behind downwards and forwards, forming the upper limit of a facet for articulation with the second metatarsal bone; in its posterior two-thirds it is narrower, runs downwards and backwards and forms the upper limit of a facet for articulation with the middle cuneiform.

The *internal surface* looks inwards and slightly upwards, and is subcutaneous in its upper part. At its anterior and inferior corner is a smooth, convex, articular facet over which the tendon of the 'tibialis anticus' plays. The surface is elsewhere rough, and somewhat elevated along its anterior, superior, and posterior margins, for the attachment of ligaments.

The *external surface* presents an L-shaped articular facet, slightly concave, and skirting the upper and posterior margins. Anteriorly this facet looks outwards and slightly forwards for articulation with the inner side of the base of the second metatarsal bone; the remainder of the facet looks inwards and slightly backwards for articulation with a corresponding facet upon the inner surface of the middle cuneiform. Sometimes the horizontal and vertical parts of the articular surface are separated from one another by a rough groove running across it from the superior and posterior angle of the bone. The rest of the external surface is rough for ligamentous attachment.

The *inferior surface* forms the base of the wedge, is rounded and rough for the attachment, posteriorly, of part of the tendon of the 'tibialis posticus' and, anteriorly, of fibres of the 'tibialis anticus.'

Thus it articulates with four bones—namely, the scaphoid, the middle cuneiform, and the two inner metatarsals.

Middle Cuneiform.—The second or middle cuneiform bone is not only the smallest of the three, but does not project so much as the others; consequently the second metatarsal bone, which it supports, is more deeply set in the tarsus than the other metatarsals. This is a point to be remembered in removing the metatarsal bones (Hey's operation).

SURFACES.—The *superior surface* is very slightly rough, and elevated at the edges, for the attachment of ligaments.

The *inferior surface* forms the edge of the wedge and is rough for plantar ligaments and for the insertion of fibres derived from the 'tibialis posticus' tendon.

The *posterior surface* is smooth, triangular, concave from above downwards, but somewhat sinuously curved, for articulation with the middle facet on the anterior surface of the scaphoid.

The *anterior surface* is smooth, triangular, larger than the posterior, and convex for articulation with the second metatarsal.

The *internal surface* presents an L-shaped, somewhat convex articular facet, skirting the upper and posterior part of the surface, for articulation with the corresponding facet on the external surface of the 'internal cuneiform.' The angle of the L may be interrupted by a rough groove separating the horizontal from the vertical parts of the articular surface. In front, the L-shaped facet is continuous with the articular surface on the anterior surface of the bone, and behind with the articular surface on the posterior surface. The rest of the internal surface is rough for ligamentous attachment.

The *external surface* presents a vertical, smooth, articular, slightly concave facet, continuous with the one on the back of the bone, for articulation with the inner surface of the external cuneiform. In front of this facet the surface is rough and depressed for the attachment of interosseous ligaments.

Connections.—The middle cuneiform articulates with four bones—the scaphoid, the outer and inner cuneiform, and the second metatarsal.

The External Cuneiform.—The external cuneiform is the second in size of the two cuneiforms. It juts forwards between the second and fourth metatarsal bones to support the third, its proper metatarsal, and at the same time partly the second and fourth. The forward projection of the external cuneiform has to be remembered in Hay's amputation.

SURFACES.—The *superior surface* is smooth, looks up and out, and is covered by the extensor muscles on the back of the foot. It is rather rough at the margins for the attachment of ligaments.

The *inferior surface* forms a rough rounded border projecting into the sole, and affords attachment to plantar ligaments, a prolongation of the tendon of the tibialis posticus, and, by means of this prolongation, to fibres of origin of the 'flexor brevis pollicis' muscle.

The *posterior surface* shows a rounded and slightly concave articular facet to articulate with the corresponding one on the scaphoid.

The *anterior surface* presents a vertically elongated triangular surface—apex below—and slightly concave for articulation with the terminal facet on the third metatarsal.

The *internal surface* has near the posterior edge a vertical, four-sided, somewhat convex articular surface, continuous with the one on the posterior surface of the bone for articulation with the middle cuneiform. Running along the anterior part of the surface is another narrow articular facet, widest above and narrowest in the middle, and continuous with the one on the front of the bone, for articulation with the second metatarsal. The rest of the surface is rough and uneven for the attachment of ligaments.

The *external surface* is more extensive than the internal. Posteriorly and superiorly it presents a round, slightly concave, and completely isolated articular facet, looking downwards and outwards and a little backwards to articulate with the cuboid. Occasionally this facet is continuous over the edge of the bone

with the facet on the posterior surface. At the anterior and superior angle of the surface is a small, flattened, articular facet for articulation with the outside of the base of the fourth metatarsal. This little facet is continuous with the articular surface on the front of the bone. The remainder of the surface, which looks outwards and slightly forwards, is rough and irregular for the attachment of ligaments.

Connections.—The external cuneiform articulates with six bones, viz. the scaphoid, the middle cuneiform, the cuboid, and the second, third, and fourth metatarsals.

Ossification of Tarsal Bones.—Each bone of the tarsus has one centre of ossification, except the os calcis, which has always two, and the astragalus, which has occasionally an additional one situated at its posterior extremity, and which we have seen may go on to develop a little bone called the ‘secondary’ or ‘supernumerary astragalus.’ The os calcis begins to ossify about the sixth month of foetal life; the astragalus about the seventh month; the cuboid about birth; the external cuneiform about the first year after birth; the middle and internal cuneiform and scaphoid about the third or fourth year.

The second centre (or epiphysis) of the os calcis is at the back part of it. It appears about the tenth year, and joins the rest of the bone about puberty.

THE METATARSUS.

General Description.—The five metatarsal bones are named the first, second, third, fourth, and fifth, counting from the inner side. The first is the shortest and by far the strongest, and supports the great toe. The second is the longest; and from this the third, fourth, and fifth gradually decrease in length. All are slightly arched from before backwards; in addition to this, the three outer incline a little sideways towards the great toe. The spaces between them are termed the ‘interosseous spaces,’ and gradually decrease in size towards the outer side. As the metatarsal bones are ‘long’ bones, we speak of their shafts and their articular ends; the upper end of each being termed the ‘base,’ ‘proximal,’

or 'tarsal extremity,' and the lower or rounded end the 'head,' 'distal,' or 'phalangeal extremity' of the bone.

Like the corresponding bones in the hand, the shafts of the metatarsal bones are more or less triangular on transverse section, being flat on the dorsal surface; and they gradually taper from their proximal ends.

BASES OR UPPER ENDS.—Their *bases* articulate with the second row of the tarsus, and, laterally, with each other; that of the first excepted. The line of the tarso-metatarsal articulations would be a tolerably even curve, but for the second metatarsal, which is jammed into a recess between the cuneiform bones. Thus the second metatarsal is firmly locked in like the second metacarpal. The bases of the outer four slope outwards and backwards.

HEADS OR LOWER ENDS.—Their *heads*, which are much smaller than those of the metacarpal bones, are convex, and fit into the cups of the first phalanges; they are grooved above for the attachment of ligaments.

The convexity of the head of each metatarsal extends downwards towards the sole of the foot—that is, in the direction of flexion—and terminates below in two points called the 'condyles.' On each side there is a tubercle for the attachment of the lateral ligament. The external condyle is always the larger and more prominent, and a well-marked ridge connects it with the shaft. Hence, when a metatarsal bone is held with the head forward, and the dorsum of the shaft upward, the more prominent condyle will be on the outer side.

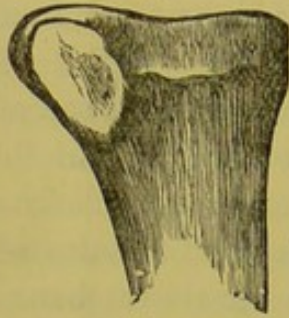
First Metatarsal.—The excessive strength and size of the first metatarsal bone, which supports the great toe, are peculiar to man. It is the chief support upon which the body is raised by the great muscles of the calf.

BASE.—The base presents, posteriorly, a concave, kidney-shaped surface, with the hilus of the kidney pointing outwards, to articulate exclusively with the internal cuneiform bone; and there is an impression on the outer side of its plantar aspect, indicating the insertion of the 'peroneus longus' (fig. 44). Superiorly, internally, and inferiorly the base is rough for the

attachment of ligaments, and below and inside for part of the tendon of the 'tibialis anticus.' Frequently we notice an elongated, flattened facet on the outer side, and

FIG. 44.

I.



BASE OF FIRST RIGHT METATARSAL. OUTER SIDE.

in front of the one for the 'peroneus' tendon, to articulate with the inner surface of the base of the second metatarsal.

HEAD.—The head is remarkably broad, and supports the ball of the great toe. It has on its under surface two deep antero-posterior articular grooves (separated by a ridge) for the play of the two sesamoid bones.

SHAFT.—The shaft is the shortest and thickest of all the five shafts. It has three borders, viz. inner, outer, and inferior, separating three surfaces, viz. superior, inner, and outer. The *inner border* begins behind at the most prominent part of the inside of the base, and terminates anteriorly at the tubercle on the inside of the head. It is smooth and rounded throughout. The *external border* begins at the upper surface of the base, runs downwards and forwards and terminates on the dorsal side of the tubercle on the outside of the head. It is also smooth and rounded, and is seen more when viewing the bone from above than from the outside. The *inferior border* starts behind at the rough prominent under surface of the base, and terminates about the junction of the anterior and middle thirds of the shaft by dividing into two very slightly marked branches running to the corresponding condyles.

The *superior surface* is smooth, looks upwards and inwards. Posteriorly, it looks more inwards than upwards. It is covered by the tendon of the 'extensor longus pollicis' and the innermost one of the 'extensor brevis digitorum.' The *internal surface* is broader and more hollowed posteriorly than anteriorly. It looks downwards and very slightly inwards at its posterior and straight downwards at its anterior extremity. It is smooth throughout. The *external surface* is also broader and more hollowed behind than in front. It looks upwards and outwards in its whole extent, and gives origin to part of the first 'dorsal interosseous' muscle. The medullary foramen is situated in the

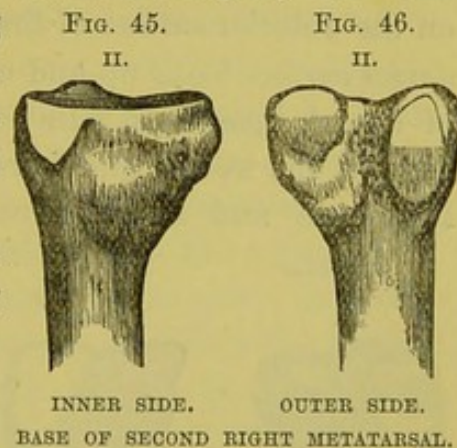
middle third of the outer surface of the shaft, close to the inferior border, and is directed obliquely forwards.

Second Metatarsal.—The second metatarsal is the longest of all.

BASE.—The base is cuneiform, with the edge of the wedge pointing downwards. Its *posterior surface* is triangular and concave to articulate with the middle cuneiform. Its *superior surface* is rough, points upwards and slightly outwards, and gives attachment to dorsal ligaments. Its *inferior surface* forms a rough ridge for the attachment of plantar ligaments. Its *internal surface* shows at its posterior and superior angle a small flat facet looking inwards for articulation with the corresponding facet upon the internal cuneiform. In front of this the internal surface is rough for the attachment of interosseous ligaments. The *external surface* of the base presents a superior and an inferior articular facet, separated by a deep rough antero-posterior groove. The articular facets are further divided into four facets by a smooth vertical elevation, viz. two anterior, looking outwards and slightly forwards for articulation with the third metatarsal bone, and two posterior, looking outwards and slightly backwards for articulation with corresponding facets upon the external cuneiform. The rough antero-posterior groove gives attachment to interosseous ligaments (figs. 45, 46).

HEAD.—The head presents the ordinary characters of the head of a metatarsal bone.

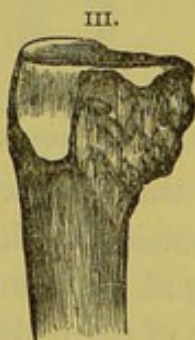SHAFT.—The shaft is flattened from side to side. Its most slender part is about the junction of the anterior third with the posterior two-thirds. The *external border* begins at the outside of the posterior surface of the base, runs forwards, arching at the same time inwards, and terminates at the external tubercle of the distal extremity. The *internal border* stretches between the inside of the back of the base and the internal tubercle. It arches outwards on its way forwards, so that the external and internal



borders almost meet in the middle of the shaft. The *inferior border* runs along the outer side of the under aspect of the bone, commencing behind at the under side of the base, and bifurcating in front to terminate in the inner and outer condyles on the under surface of the head. The *superior surface* is enclosed by the internal and external borders. It is very narrow in the middle and is covered by the extensor tendons of the corresponding toe. The *inner surface* lies between the internal and inferior borders. It is very convex from above downwards internally, occupies nearly two-thirds of the circumference of the shaft, and gives origin to part of the first 'dorsal interosseous' muscle. Frequently it presents, at its posterior end, an oval facet to articulate with a corresponding facet on the outside of the base of the first metatarsal. The *external surface* is flatter when traced vertically than the inner surface, and gives origin to part of the second 'dorsal interosseous muscle.' The 'medullary foramen' is situated in the middle third of this surface, and slants towards the proximal extremity of the bone.

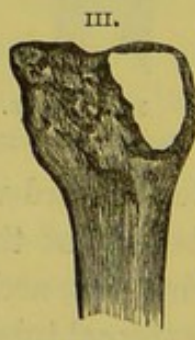Third Metatarsal.—**BASE.**—The base of the third metatarsal is wedge-shaped, like that of the second. It is supported on the anterior surface of the external cuneiform. Its *superior or dorsal surface* looks up and out, and is rough for the attachment of dorsal ligaments. Its *inferior or plantar surface* forms the edge of the wedge, and is rough for the attachment of plantar ligaments and a prolongation of the tendon of the 'tibialis

FIG. 47.



INNER SIDE.

FIG. 48.



OUTER SIDE.

BASE OF THIRD RIGHT METATARSAL.

posticus,' and for the origin of part of the 'adductor pollicis.' Its *posterior surface* is triangular and concave for articulation with the external cuneiform. Its *internal surface* presents two flattened articular facets, separated by an antero-posterior rough groove, for articulation with the corresponding facets on the second metatarsal bone. The upper facet is larger than the lower one, and both are continuous with the articular surface

on the posterior surface of the base. Its *external surface* shows a large oval, slightly concave, and isolated facet at its upper and back part for articulation with the fourth metatarsal, and below and in front a very rough space for interosseous ligaments (figs. 47, 48).

HEAD.—The head shows the ordinary features belonging to the heads of metatarsal bones.

SHAFT.—The shaft resembles that of the second, already described, with this exception, that we may describe a rounded *vertical ridge* running down the middle of the internal surface and marking off a space above for the origin of part of the second 'dorsal interosseous' and a space below for the origin of the first 'plantar interosseous.' The *external surface* looks a little more upwards than the corresponding surface on the second, and gives origin to part of the third 'dorsal interosseous' muscle. The medullary foramen is situated in the middle third of this surface and runs towards the base of the bone.

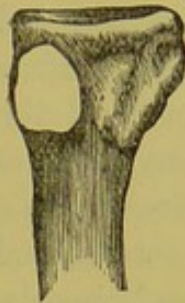
Fourth Metatarsal.—**BASE.**—The base of the fourth metatarsal is cubical in shape, and projects more above and outside than below and inside. Its *superior surface* is rough for dorsal ligaments, and frequently, at its outer border, for insertion of part of the tendon of the 'peroneus tertius.' Its *inferior surface* is somewhat less in extent than its superior, and is also rough for the attachment of plantar ligaments and a prolongation of the tendon of the 'tibialis posticus,' and for the origin of part of the 'adductor pollicis.' The *posterior surface* presents a four-sided, sinuous, articular facet to articulate with the corresponding one on the cuboid. The *internal surface* has above an oval, slightly concave, articular facet, divided by a slight ridge into a larger anterior part for articulation with the side of the base of the third metatarsal, and a smaller posterior part to articulate with the outer cuneiform. The fourth metatarsal does not always touch the outer cuneiform, which variation is seen in several specimens in the stores of the Museum of the Royal College of Surgeons. The *external surface* of the base has, at its upper and posterior angle, a large facet, rather triangular in shape, and slightly concave, for articulation with the inside of the base of the fifth metatarsal (figs. 49, 50).

HEAD.—The head shows the characters common to the heads of the four outer metatarsal bones.

SHAFT.—The shaft is much compressed laterally. It is twisted so that its *outer surface* looks outwards and upwards behind, and outwards in front. The *dorsal surface* is extremely narrow,

FIG. 49.

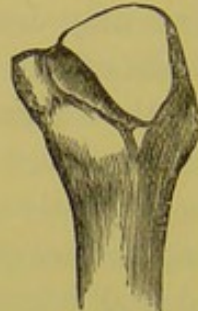IV.



INNER SIDE.

FIG. 50.

IV.



OUTER SIDE.

BASE OF FOURTH RIGHT METATARSAL.

the inner and outer borders almost touching in their whole length. The *inferior border* is thrown well out on the inferior aspect of the bone, allowing therefore a very large *internal surface*. The vertical line on the internal surface, separating the origin of the third 'dorsal interosseous' from that of the second 'plantar interosseous' muscle, is well marked. The *external surface*

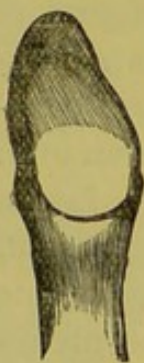gives origin to part of the fourth 'dorsal interosseous.' The medullary foramen is situated as in the third metatarsal.

Fifth Metatarsal.—**BASE.**—The *superior surface* is wide and rough, especially internally for the insertion of the 'peroneus tertius' and externally for the insertion of the 'peroneus brevis.' The

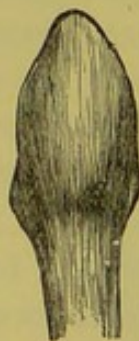FIG. 51. FIG. 52.

V.

V.



INNER SIDE.



OUTER SIDE.

BASE OF FIFTH RIGHT METATARSAL.

inferior surface of the base is broad and rough, affording attachment, posteriorly, to ligamentous fibres connecting it with the under surface of the cuboid, and, anteriorly, to the fibres of origin of the 'flexor brevis minimi digiti.' The *posterior surface* (fig. 51) presents, internally, a large triangular, concave, smooth facet, looking backwards and inwards for articulation with a corresponding one on the anterior surface of the cuboid, and, externally, a rounded, blunt, rough prominence for the attachment of the outer division of the 'plantar fascia.' The

internal surface shows a four-sided articular facet for the base of the fourth metatarsal. The *external surface* (fig. 52) forms a rounded, rough eminence projecting outwards and backwards, and

called the 'tuberosity' of the fifth metatarsal, and giving attachment superiorly to part of the 'peroneus brevis' tendon, inferiorly to fibres of the 'flexor brevis minimi digiti,' and between these two to part of the outer band of the 'plantar fascia.'

HEAD.—The head is more flattened from above downwards and turned more outwards than that of the second, of the third, and of the fourth metatarsal.

SHAFT.—The shaft is much flattened vertically and much broader posteriorly than anteriorly. The *external* and the *internal borders* are well marked. They enclose a broad *superior surface* looking upwards and inwards, and are covered by the extensor tendon of the little toe. The *inferior border* is slightly marked. It begins behind in front of the roughness for the 'extensor minimi digiti' and terminates by joining the outer condyle anteriorly. The *internal surface* is broad and lies between the internal and inferior borders. It is divided into two parts by the vertical line, which runs forwards from the inside of the inferior surface of the base and terminates at the internal condyle. The part of the surface above this line looks inwards, and gives origin to the fourth 'dorsal interosseous' muscle, while the part below looks more downwards than inwards, and gives origin to the third 'palmar interosseous' muscle. The medullary foramen is situated close to the middle of the vertical line, and runs backwards towards the base of the bone.

Agreement between Metatarsals and Metacarpals.—It may be well to remind the reader that there is a remarkable agreement, in the majority of cases, in the number of bones with which corresponding metatarsals and metacarpals articulate at their bases. Thus, the base of the first, in each case, articulates with one bone—that of the second with four—that of the third with three—that of the fourth with four—and that of the fifth with two.

Ossification.—Like the corresponding metacarpal bones, the *four* outer metatarsals have each a centre of ossification for the shaft, appearing in the eighth or ninth week, and a centre for the head or distal extremity, appearing from the third to the eighth year, and joining the shaft from the eighteenth to the

twentieth year. In the first metatarsal bone, the centre for the epiphysis appears at the proximal extremity, although there is occasionally a second epiphysis formed at the distal end. Notice that the situation of the epiphysis with regard to the direction of the medullary foramina follows the ordinary law observable in other long bones.

Phalanges of the Toes.— Each toe consists of three phalanges, named, as in the fingers, proximal, metatarsal, or first; middle or second; and distal, ungual or third, with the exception of the great toe, which has only two, viz. the proximal, metatarsal, or first; and the distal, ungual, or third. The phalanges of the toes present the characters which belong to the corresponding phalanges of the fingers (to the description of which the reader is referred), with this exception, that in the three outer toes they are much smaller, especially those of the middle row. Sometimes the middle phalanges of the three outer toes are reduced to mere flattened nodules of bone, which occasionally are ossified to the distal ones. This ossification is most often seen in the little toe. The plantar aspects of the lateral margins of the middle phalanges of the four outer toes give insertion to the tendons of the ‘flexor brevis digitorum.’ The dorsal surfaces of the bases of the same phalanges and of the distal ones afford attachment to the tendons of the ‘extensor longus digitorum.’ The tendons of the ‘extensor brevis digitorum’ are attached with the tendons of the extensor longus digitorum going to the middle and distal phalanges of the second, third, and fourth toes. (Plate XXXVII.) As the great toe is the most important digit in the foot, so it is the longest and strongest of all the toes. In the antique, the second is represented as the longest toe. The metatarsal phalanx of the great toe is thick, and, all round the margin of its base, it is rough for the attachment of ligamentous fibres of the metatarso-phalangeal articulation and dorsally for the insertion of the innermost tendon of the ‘extensor brevis digitorum.’ The inner aspect of the base, near the plantar surface, affords insertion to the ‘abductor pollicis’ and the inner head of the ‘flexor brevis pollicis,’ while the corresponding part of the external surface gives insertion to the

'adductor pollicis,' 'transversus pedis,' and the outer head of the 'flexor brevis pollicis.' The distal phalanx has, on the plantar surface of its base, a rough triangular mark for the insertion of the tendon of the 'flexor longus pollicis,' and close to the posterior margin of its dorsal surface a rough transverse ridge for the insertion of the tendon of the 'extensor proprius pollicis.'

Ossification.—The mode of ossification of the phalanges agrees with that of the corresponding bones of the hand. The nuclei of the shafts appear from the ninth to the tenth week. The epiphyses at the bases appear from the fourth and the eighth year, and unite with the shafts from the nineteenth to the twenty-first year.

Comparative Osteology.—Like the thumb, the first or great toe has only two phalanges. This is the case throughout the whole mammalian class, provided it supports a nail, a hoof, or a claw. The hind foot of the horse is the representative of the third toe.

SESAMOID BONES.

There are two sesamoid bones, which play in two grooves beneath the head of the first metatarsal bone. They act like little 'patellæ,' and increase the leverage of the muscles which work the great toe (see p. 215). Very exceptionally similar bones are met with in the corresponding joints of other toes.

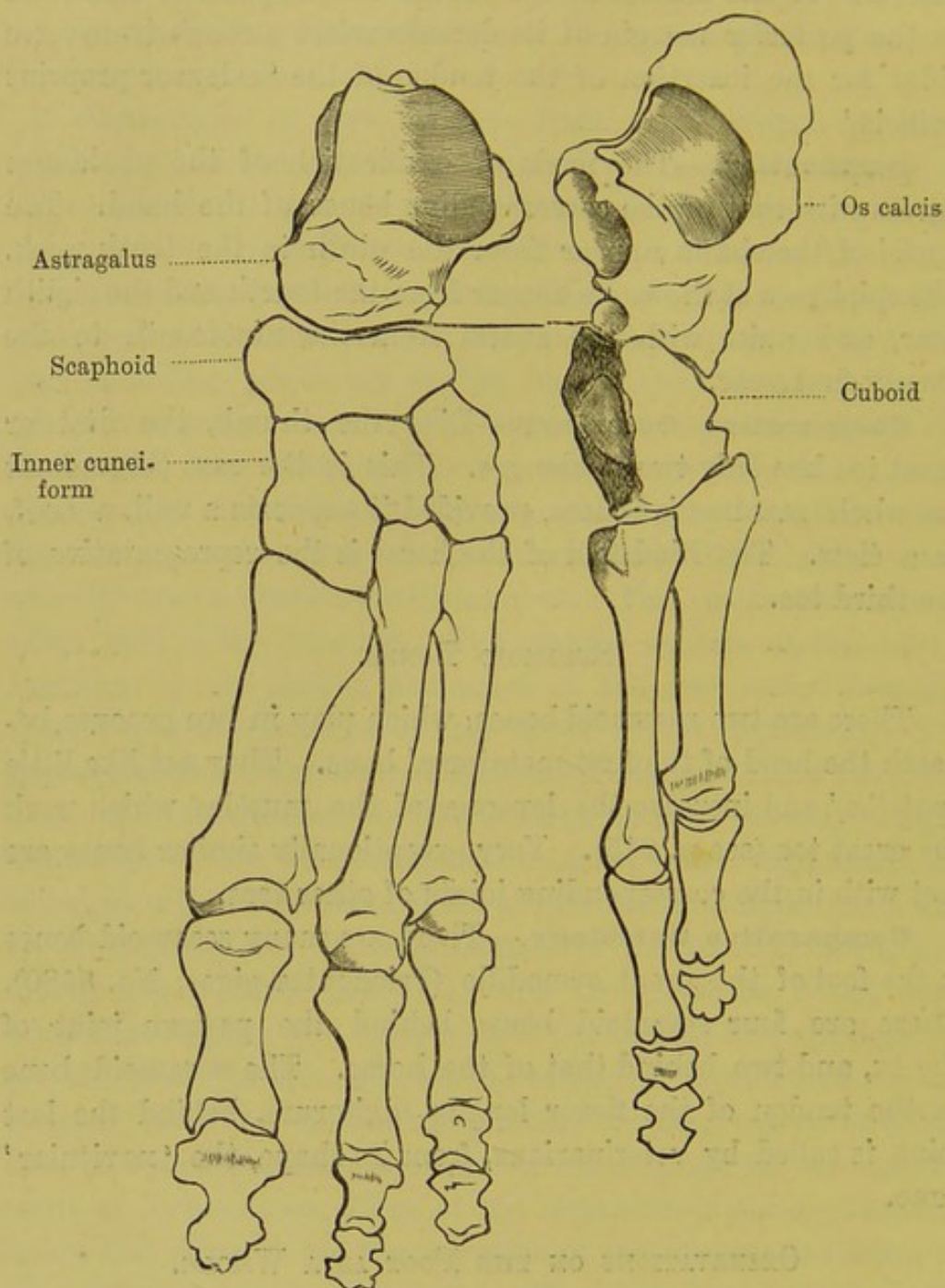
Comparative Osteology.—There are many sesamoid bones in the foot of the great armadillo (*Priodontes gigas*, No. 3580). There are four sesamoid bones behind the pastern joint of the ox, and two behind that of the horse. The sesamoid bone in the tendon of the flexor longus digitorum, behind the last joint, is called by veterinarians, from its shape, the 'navicular' bone.

OBSERVATIONS ON THE FOOT AS A WHOLE.

General Observations on the Foot.—The knowledge of the individual bones will be of little practical use, unless the skeleton of the foot be studied as a whole.

The sketch below,⁵⁹ taken from a preparation, is made to show the sequence of the bones which form the inner and the

FIG. 53



outer sides of the longitudinal arch of the foot. On the inner side are the astragalus, the scaphoid, and the three cuneiform,

bones supporting the three inner metatarsals. On the outer side are the os calcis, the cuboid, and the two outer metatarsals. By putting the two sides together, it is easy to study and recollect their relative bearings.

Arches of the Foot.—The foot is a combination of numerous small bones, so adapted and connected as to form strong and, at the same time, elastic arches.

Longitudinal Arch.—The principal arch is in the antero-posterior or long axis of the foot. The 'longitudinal arch' has to bear the weight of the body erect. It is supported, behind, by the tuberosities of the os calcis; and in front, by the distal ends of the metatarsal bones. Its inner side is much higher than the outer, and is formed by the astragalus, the scaphoid, the three cuneiform and three inner metatarsal bones. This is well seen in fig. 53. The outer side of the arch is much lower than the inner, and is formed by the os calcis, the cuboid, and the two outer metatarsal bones. It is supported mainly by a strong ligament termed the 'calcaneo-cuboid.'

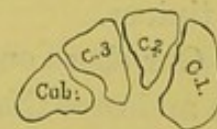
Transverse Arch.—Besides the longitudinal arch there is another in the transverse direction. This is most marked over the instep: that is, its greatest convexity is across the cuneiform and the cuboid bones. Its inner side is much thicker than the outer.

Yielding of the Arches.—When we stand, not only does the *longitudinal* arch of the foot yield, but the *transverse* arch yields also. The wedge bones and the metatarsals are connected by interosseous ligaments, which, being slightly elastic, give a little, and thereby increase the transverse breadth of the foot. A transverse section across the instep—that is, through the wedge bones—shows that they are shaped, not like the stones of a bridge, as in fig. 54, but as represented in fig. 55. Their sides are not in apposition all the way down, but gaps are left between them: now these gaps are occupied by elastic ligaments, which permit a certain

FIG. 54.

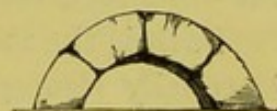

FIG. 55.



TRANSVERSE SECTION TO SHOW THE FORM OF THE CUNEIFORM BONES.

amount of separation between the bones when the arch is pressed upon.

Mechanism of Foot in Walking.—Consider the mechanism of the foot in the act of walking. In standing, the weight of the body is transferred from the astragalus both backwards and forwards; backwards to the heel bone, forwards to the ends of the metatarsals and toes. The inner side of the arch sinks a little; the outer side touches the ground, or nearly so. Thus the weight is evenly distributed; the head of the astragalus transmitting it to the inner side, the calcaneum to the outer side. The foot then forms a firm basis of support, becoming a little longer, and a little wider at the toes, owing to the widening of the transverse arch and the slight separation of the metatarsals.

When we begin to walk, the heel is first raised; the astragalus is tilted forwards and downwards, but cannot slip off the os calcis by reason of the alternately convex and concave joints between them. The astragalus in this position is almost hooked on to the calcaneum. It transmits the weight of the body through the scaphoid to the three inner toes, and through the calcaneum and cuboid to the two outer; then the weight is entirely sustained by the heads of the metatarsal bones, especially that of the great toe, which is the last to leave the ground, and propels the body on to the other foot, extended forward to receive it.⁶⁰

Such is the mechanism of the calcaneo-astragaloid joint. It is equally strong and transmits weight with the same security, whether the pressure be vertical, as in the erect position, or oblique, as in the middle of the act of walking, or when we stand on tiptoes.

Our shoes ought to be made so as to permit the natural play of the arches of the foot. It is manifest that the practice of wearing high heels alters the level of the piers of the arches. By thus raising one pier, i.e. the heel bone, we walk on an inclined plane; we alter the bearings of all the other bones; we throw the pressure on the articular surfaces of the heads of the metatarsal bones, and thus give rise to distortion, crooked toes, bunions, and corns—local troubles which disincline or prevent us from taking

necessary exercise, and set up far more serious constitutional ailments.

Ancient Egyptian and Greek art represents the second toe as longer than the great toe. This was probably copied from the negro, for in our race at the present time the great toe is certainly the longest of all the toes in the vast majority of cases.⁶¹

Comparative Osteology.—The chief variations in the digits of the vertebrata are of number and connections. In some instances—e.g. seal (No. 1062), also *Platanista gangetica* (Cetacea, No. 2932)—the digits are so bound together in a common sheath that they have little individual movement, though they form an excellent paddle. The number is reduced to four in the boar (No. 1773), to three in the rhinoceros (No. 2142), to two in the ox (No. 1143), and to one in the horse (No. 2069, *Equus caballus*). The middle digit is the most constant of all the digits in the vertebrata. The bones forming the three joints of this toe answer to those called the ‘great pastern bone,’ the ‘little pastern bone,’ and the ‘coffin bone’ in the horse, while the nail in the toe is represented by the hoof.

An inspection of the separate series of bones in the Osteol. Mus. of the Royal College of Surgeons will show that the horse walks on his third toe (i.e. our middle toe), and the pig and cow on the third and fourth. The kangaroo walks on his fourth and fifth toes, the second and third being greatly diminished in size. Birds have three toes usually developed, viz. the second, third, and fourth; but the ostrich only has two, viz. the third and the fourth.

The elephant (*Proboscidea*, No. 2359) has five toes, and the weight of the body is supported by a palmar and plantar pad under the toes.

The Hyrax *Capensis* (No. 2231) will be seen to have four toes on each fore, and three on each hind limb; those in front correspond to the second, third, fourth, and fifth; those behind to the three middle ones. The inner nail on the hind foot is much curved.

In Ungulata there are never more than three full-sized toes on each limb, and they end in hoof-like nails. They are never plantigrade, but unguligrade, or digitigrade.

A very large number of animals, as cats, dogs, tigers, and most carnivora, walk on their toes (digitigrade); but bears may be seen to have five toes of equal length, and to walk on the flat of the foot—that is, they bring the heel to the ground, which makes them bad walkers but good climbers.

Tigers and cats can at will either show or hide their claws. When their claws are hidden, the unguis phalanx with the attached claw is bent backwards and on to the outer side of the second phalanx by a strong elastic ligament.

When these animals wish to scratch or climb they set in action the flexor longus digitorum, which flexes the unguis phalanx and brings down with it the claw. Examine this beautiful arrangement in the digit of a lion, in the comparative anatomy of the soft parts in the College of Surgeons' Museum (No. 287 A).

Bears have not this power; hence their claws are always visible, and rattle on the ground as they walk.

Compare the foot of the tiger with that of the grizzly bear.

INTEROSSEOUS MUSCLES OF THE FOOT.

Plan of Arrangement.—The interosseous muscles in the foot (Plate XXXVII.) are arranged very much like those in the hand. They are seven in number; four on the dorsal surface and three on the plantar. Observe that the *dorsal* arise from the opposite sides of the metatarsal bones, and are inserted into the first phalanges of the second, third, and fourth toes, so that they draw the toes *from* a line corresponding to the axis of the *second* toe. It should be remembered that, in the case of the hand, this line corresponds to the axis of the middle finger.

The *plantar* belong to the three outer toes; each arises from one metatarsal bone, and is inserted into the first phalanx of the same toe on the inner side of its base, so that they draw *towards* the above-mentioned line.

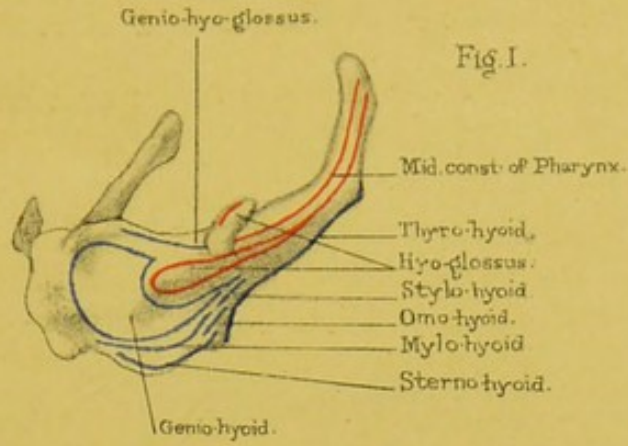
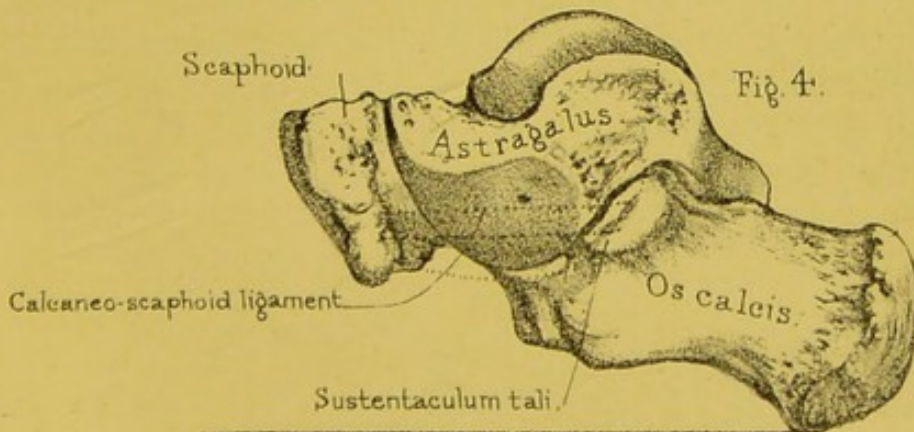
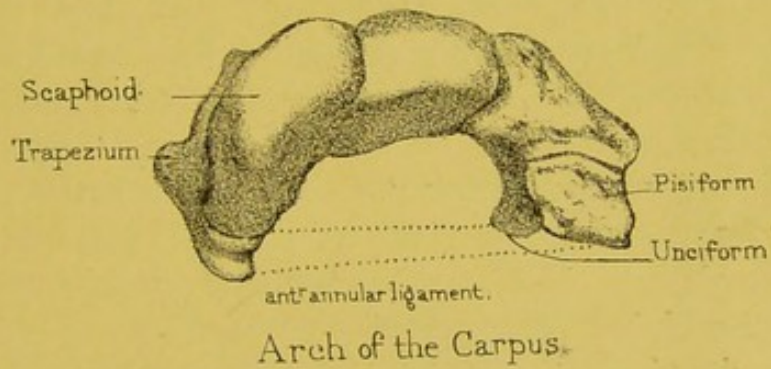


Fig. I.


Os-hyoides



Drawn on Stone by T. Godart.

From nature by L. Holden.

Printed by West, Newman & Co.



THE THORAX.

(PLATES XXXIX.-XLII.)

General Description.—The thorax is the framework which contains the heart and lungs. The ribs, with their cartilages, describe a series of arcs, successively increasing in length as far as the seventh, and form, with the spine and sternum, a barrel of a somewhat conical shape, much broader from side to side than from before backwards. The lower aperture or base of the cavity is open in the skeleton, but closed in the recent subject by a thin flat muscle, called the ‘diaphragm,’ which separates the chest from the abdomen, and has openings for the passage of the alimentary canal and the great blood-vessels. This muscular partition is not flat, but arched, so that it forms a vaulted floor for the chest. By alternately falling and rising, it increases and diminishes the capacity of the chest. The spaces between the ribs are filled by the intercostal muscles.

Such, in outline, is the framework of the chest. Its walls are made up of different structures—bones, cartilages, and muscles—which by their union answer two apparently incompatible purposes. By their solidity and elasticity they protect the important organs contained in the chest; and by alternately dilating and contracting, serve as the mechanical agents of respiration. They enlarge the cavity of the chest in three directions: in *height*, by the descent of the diaphragm; in *width*, by the turning outwards of the ribs; in *depth*, by the raising of the sternum.

THE STERNUM.

(PLATE XXXIX.)

Position.—The sternum (*στέρνον*, the breast) is a long flat bone, situated in front of the chest, and supports the ribs and the clavicles. In the adult male, it is from six to seven inches long: rather less in the female. Observe that its direction is not perpendicular, but that it slants forwards, and thus makes more room for the heart and lungs. It is much broader and thicker at the upper end (manubrium), where it supports the clavicles. The middle of its upper border is on a level with the under edge of the second dorsal vertebra, while the corresponding part of its lower edge is somewhere opposite the tenth dorsal vertebra. The sternum was compared by the ancients to a sword; the broad part was called 'manubrium,' the middle part 'mucro,' or gladiolus, and the cartilage at the end the 'xiphoid' or 'ensiform' cartilage.

Manubrium, or Presternum.—This part of the sternum presents an *anterior surface* which is somewhat convex from side to side and concave from above downwards. The surface is marked by a number of good-sized nutrient foramina, and gives attachment above to the 'sterno-mastoid' and below those to the 'pectoralis major' muscles.

The *posterior surface* is smooth, slightly concave in every direction, marked by a number of large nutrient foramina, and in the neighbourhood of its lateral borders gives origin to the 'sterno-hyoid' and 'sterno-thyroid' muscles.

The *superior border* is divisible into thirds: a middle one, smooth and rounded, called the 'suprasternal' or 'intra-clavicular notch,' and giving attachment to a ligament of the same name; two lateral ones, broad from before backwards and looking upwards and outwards. Each of the lateral ones is oval in shape, concave from above downwards and outwards, and slightly so from before backwards (in some bones it is rather convex in this direction), and articular for articulation with the sternal ex-

tremity of the clavicle. These 'clavicular facets' of the sternum present the above appearances in a much more marked degree when they are covered by their articular cartilage, and they thereby permit the clavicles to rotate upon them nearly as freely as the thumb does upon the trapezium. The end of the clavicle is much larger than the surface on which it rotates; yet dislocation of it is exceedingly rare, owing to the great strength of the ligaments. To break the clavicle is much easier than to dislocate it.

The *inferior border* is not so broad as the superior one. It presents an oval, rough surface for articulation by the intervention of a plate of cartilage with the upper border of the mesosternum. Its anterior and posterior edges are somewhat prominent for the attachment of anterior and posterior ligamentous fibres. Frequently in old age the intervening cartilage gets ossified at its circumference, the central part remaining soft and flexible.

Each lateral border, thicker above than below, presents, in its upper half, an elongated, triangular, rough, concave facet for the junction of the cartilage of the first rib, and in its lower half, from above downwards, first a smooth rounded notch, forming an inner end of the first intercostal space and next a slightly concave, somewhat triangular facet, which, with a corresponding one on the mesosternum, articulates with the cartilage of the second rib.

Gladiolus, or Mesosternum.—This presents a flattened, oval figure, with the broadest part of the oval at the level of the fifth costal cartilages. It is bent forwards, so as to present its greatest convexity in that direction at the level of the third or fourth costal cartilages or in the interval between these. *Anterior surface*: This surface is broadest at the line of junction of the fifth costal cartilages. It is marked by three transverse ridges, indicating the original formation of the gladiolus by four primary pieces, and situated opposite the junction of the third, fourth, and fifth costal cartilages. The upper ridge is usually the best marked, and the lowest one may be very indistinct. The intervening spaces between these ridges are slightly

concave both from side to side and from above downwards. They afford attachment, on each side of the middle line, to fibres of the 'pectoralis major' muscles.

The *posterior surface* is smoother than the anterior; it shows indications of the transverse ridges and is concave from above downwards and slightly so from side to side. Close to the lower half of each of its lateral margins it gives origin to part of the 'triangularis sterni.' In a few rare cases the gladiolus presents an aperture, called the 'sternal foramen,' at the junction of its third and fourth pieces, and leading from the anterior to the posterior surface of the bone. It is filled up by membrane in the recent state. In a still fewer number of cases the fourth piece and lower part of the third are split by a fissure which runs through the metasternum. This latter appearance gives rise to the term 'cleft sternum.'

The *lateral borders* are each marked by six blunt teeth supporting concave notches for the reception of the lower half of the articular extremity of the second costal cartilage, the whole of the articular extremities of the third, fourth, fifth, sixth, and the upper half of the seventh. The intervals between the costal-cartilage notches form smooth concavities, looking outwards and forming the inner ends of the 'intercostal spaces.' They decrease in size from above downwards, and in many cases the interval between the sixth and seventh cartilage facets is wanting. The notches for the third, fourth, and fifth rib-cartilages are situated where the original pieces of the gladiolus unite; the notches for the whole of the sixth and upper half of the seventh rest on the side of its fourth or last piece.

The *superior border* forms a rough oval surface, corresponding to a similar one on the lower edge of the manubrium, and to which it is united by cartilage and ligaments. The articulation between the manubrium and gladiolus forms a somewhat prominent transverse ridge on the front of the sternum, readily felt in the living person, and situated on the level of the body of the fourth dorsal vertebra.

The *inferior border* is short and irregular, and joined to the metasternum by cartilage and fibrous tissue.

Ensiform Cartilage, Xiphi-sternum, Xiphoid Cartilage, or **Metasternum**, generally remains unossified even at a great age. Its length and shape vary much in different persons. Sometimes it is bent forwards, or it may be backwards, and this especially in workmen who hold tools against the pit of their stomach. Occasionally it is forked at the lower end. It gives attachment to the 'linea alba,' a narrow aponeurotic band, which descends along the middle line of the abdomen to the symphysis pubis, and is the fibrous continuation of the sternum. To its anterior surface is attached the 'rectus abdominis,' and to its posterior the 'diaphragm' and 'transversalis abdominis' muscles.

Ossification.—The presternum has usually a single centre, appearing about the sixth month of foetal life. Sometimes there are two, and rarely several. In the mesosternum we find a centre for the first segment appearing at the seventh month, a centre for each of the second and third segments at the eighth or beginning of the ninth month, and a centre for the fourth segment appearing in the first year. In the metasternum ossification begins in the sixth year, or it may be much later. The second, third, and fourth pieces of the mesosternum unite about puberty. The first part joins the second about the twenty-fifth year. The metasternum joins the mesosternum about middle age and the mesosternum rarely unites with the presternum. If it does, it is only in advanced age, and even then, there is only a thin layer of bone externally, the cartilage in the centre still remaining. The above is the ordinary mode of ossification of the sternum, but sometimes we find each of the second, third, and fourth pieces of the mesosternum and the single piece of the metasternum developed from two centres placed on either side of the middle line of each segment. Should these centres not join one another *across the middle line*, a 'cleft sternum' will remain. Should each of the lower segments of the mesosternum possess two lateral centres of ossification, and those not join *across the middle line*, the 'sternal foramen' shall then be formed.

Two little pieces of bone, *ossa supersternalia*, are, in a very rare number of cases, situated on each side of the suprasternal

notch. If present they are joined to the presternum by ligamentous fibres. They are probably remains of the episternal bone of monotremata.

Comparative Osteology.—Contrast the broad chest of man with that of the ourang utan (No. 37) and that of the chimpanzee (Nos. 1-2). In the adult gorilla the parts of the sternum, which in us are united, are seen to remain separate.


In the Separate Series, as well as in the two complete skeletons in the Normal Human Osteological Series, examine the sternum of the Bushman, and you will see that the manubrium sterni is firmly united to the gladiolus, and there is little or no trace of the original separations between the pieces of which the sternum is composed.

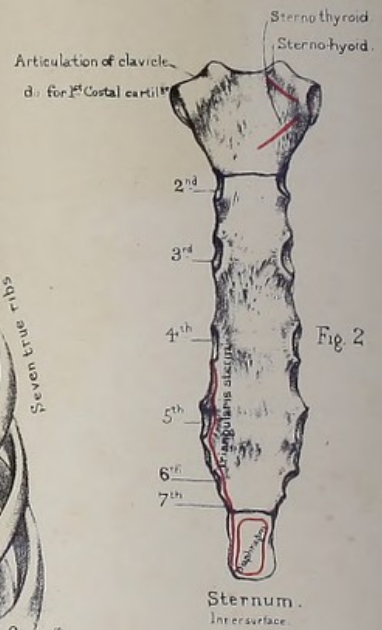
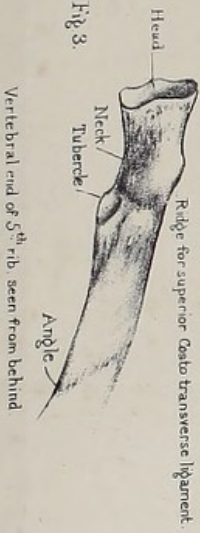
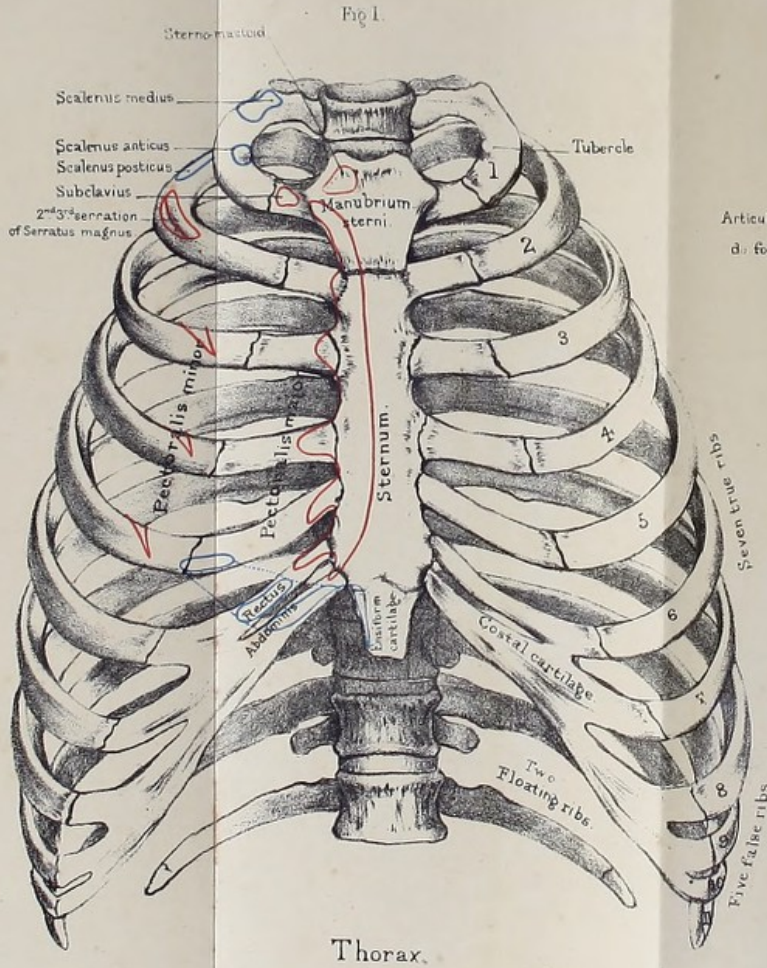
Most flying animals support themselves in the air by the action of their pectoralis major muscle on the upper extremity, and therefore this muscle is large in proportion with the flying capability. The surface of origin in such animals is increased by the development of a great keel down the middle of the sternum, which may be seen in nearly all of the flying birds (*Carinatae*)—for instance, in the great bustard (No. 1349)—as well as in the extinct flying lizards (Pterosauria, No. A 119, Pal. Ser. Mus. Roy. Coll. Surg.) This keel is absent in the non-flying birds, such as the ostrich (No. 1362), the extinct *dinornis* (No. 1588 A, Pal. Ser. Roy. Coll. Mus. Surg.), the apteryx (Nos. 1355 and 1355 E), showing that this keel exists for the function of flight, or where the pectoral muscles are from any reason large, and not as a class character of aves.

Among the variations which the sternum undergoes perhaps the most curious is that in the male wild swan and guinea fowl (see Nos. 1248 B, 1249 A, B, C), where it will be seen to be tunnelled extensively, and to contain a long tortuous trachea as well as the inferior larynx.

In snakes (*Ophidia*) there is neither a sternum nor a pectoral arch (No. 629), and there is no trace of a fore limb.

There is no sternum either in *ichthyosauria* or *plesiosauria* (Nos. 172 and 222 Palæontological Series, Mus. Roy. Coll. Surg.)





THE RIBS.

PLATE XXXIX.)

Number and Division.—There are twelve ribs on each side; the upper seven, the ‘sternal,’ or ‘true ribs,’ increase in length from the first, and are fixed to the sternum by their cartilages, and hence may be called ‘vertebro-sternal’ ribs. The lower five, or ‘false ribs,’ decrease in length from above downwards, and their cartilages fall short of the sternum. The eighth, ninth, and tenth ribs are connected behind with the spine and in front with the costal cartilages, and may therefore be called ‘vertebro-chondral’ ribs. The eleventh and twelfth are free at their anterior ends, and are therefore called ‘floating’ or ‘vertebral ribs.’ One sometimes, though rarely, meets with skeletons with thirteen ribs, the thirteenth being a cervical or a lumbar rib. This is a retrocession. The chimpanzee has thirteen ribs, but the same number of vertebræ as man.

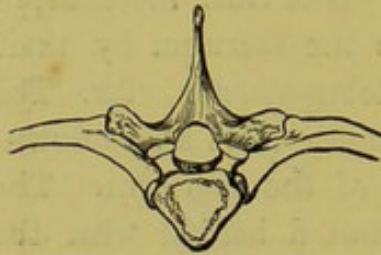
General Characters of a Rib.—As an example of the general characters of a rib, take the fifth or sixth. In the first place, observe that the curve is not uniform. It is more curved towards the vertebral end than elsewhere. Besides which, if laid on a table, the vertebral end will rise. The rib is twisted, too, in its long axis in such a way that a surface which looks backwards and inwards at the posterior end of the bone looks forwards, outwards, and slightly upwards at the anterior end. It is plain in the skeleton that the vertebral ends of the ribs are higher than the sternal ends. If both ends had been on the same level, the sternum could not have been raised *forwards* in inspiration.

VERTEBRAL END.—The vertebral end or ‘head’ (Plate XXXIX. fig. 3) has two oblique, slightly concave surfaces (with an intervening ridge, to which the interarticular ligament is attached), which articulate with the sides of the bodies of two contiguous vertebræ. The lower of these two surfaces is always the larger. The head of the rib is the fulcrum upon which the rib moves. It is wedged

in between two vertebræ, and is less liable to be dislocated than if supported by one only; and, moreover, it has the benefit of the elasticity of the intervening fibro-cartilage.

NECK.—Next to the head comes the ‘neck’ of the rib. This is flattened from before backwards. It is smooth in front, where

FIG. 56.

DORSAL VERTEBRA WITH RIBS
ATTACHED.

it is covered by pleura, but rough behind, where is attached a ligament (middle costo-transverse) connecting it to the transverse process by which the rib is supported, as seen in the adjoining figure; again, the neck has a ridge along its upper surface to which is attached a second ligament (superior costo-transverse); this con-

nects it to the transverse process *above* it.

TUBERCLE.—External to the neck is the ‘tubercle.’ It has a little facet which looks *downwards, backwards, and inwards*, and articulates with the transverse process supporting the rib; outside and above the facet is the rougher part of the tubercle which gives attachment to a third ligament connecting the rib to the transverse process (posterior costo-transverse).

ANGLE.—External to the tubercle, the rib makes a curve forwards and downwards, forming the ‘angle.’ Here there is a prominent line—‘the oblique line’—which runs downwards and forwards, and indicates the attachment of muscles, which form the outer border of the ‘erector spinæ.’ Observe that the distance between the angle and the tubercle increases as we trace the ribs downwards, and makes room for the great muscle of the spine (erector spinæ). It is near the angle that the rib breaks when the chest is compressed—for instance, in a crowd. In this kind of fracture—i.e. by *indirect* violence—the broken ends project outwards, and are therefore less liable to injure the pleura. But in *direct* violence—e.g. a kick by a horse—the rib breaks where it is struck, the broken ends are driven inwards, and consequently are more liable to injure the pleura.

SHAFT.—The part of the rib arching forwards from the angle along the side of the chest is called the ‘shaft.’ It is flattened

both from above downwards, and from without inwards, like a bow. Its *outer surface* is smooth and gives attachment to muscles, and near the anterior end presents, in some bones, a slightly marked oblique line, called the 'anterior angle.' On its *inner surface*, near the lower border, is a deep groove, called the 'subcostal groove,' for the intercostal vessels and nerve. Observe, the groove does not extend the whole length of the rib; it begins inside the angle, and is gradually lost about the junction of the anterior third with the posterior two-thirds of the shaft. The vessels and nerves are safe where they lie in the groove; but between the angle of the rib and the spine, and again in front of the chest, they are liable to be injured through the intercostal spaces. In consequence of this groove, the lower edge of the rib is much thinner than the upper, which is thick and rounded. The upper edge of the subcostal groove gives attachment to the 'internal intercostal' and the lower to the external intercostal muscle. In the groove itself are the orifices of the numerous canals, mostly directed towards the vertebral end, and which transmit blood-vessels into the interior of the rib. The ribs are the most vascular bones in the body: hence the rapidity with which they unite after a fracture.

ANTERIOR END.—Respecting the anterior end, remark that it is rough, and a little excavated to receive the costal cartilage.

Peculiarities of certain Ribs.—The first, second, tenth, eleventh, and twelfth ribs have peculiarities requiring separate notice.

First Rib.—The plane of the first rib is nearly horizontal. It is the shortest, the most curved, the flattest and broadest of all. Its head has a single articular surface which rests on the first dorsal vertebra. It has the largest tubercle, and this is well supported by the strong transverse process of the first dorsal vertebra. There is no angle. On its upper surface we may see in a well-marked bone two slight transverse grooves about the breadth of a finger; the subclavian artery lies in the posterior groove as it crosses the rib, the vein passes along the anterior. Against this surface the subclavian artery may be effectually

compressed. The grooves are separated on the inner border of the rib by a 'tubercle' denoting the insertion of the 'scalenus anticus.' Behind this are the rough surfaces for the insertion of the 'scalenus medius,' and, near the outer border, for the attachments of the first digitation of the 'serratus magnus' and the first 'levator costæ' muscle. Lastly, there is no groove for the intercostal artery.

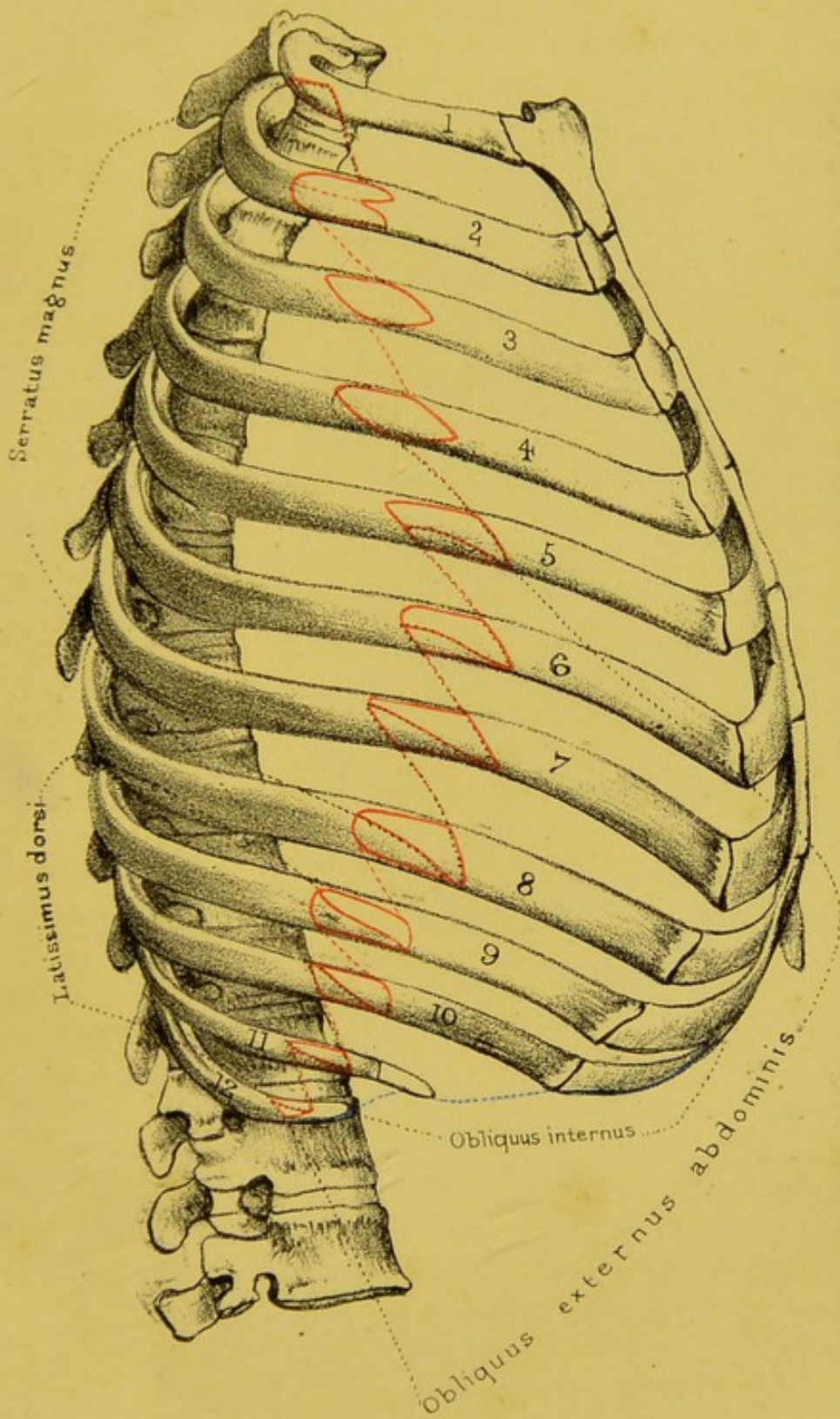
It is an interesting fact, that the compact tissue forming the *concave* margin of the first rib is very much thicker than that on the convex side. The first rib is the strongest of all: it has to support the manubrium sterni and the clavicles, and to protect all the important parts at the base of the neck. The first rib is very rarely fractured, being so well protected by the clavicle; but when it does happen it is a most serious accident, because it is the starting point of all the other ribs in respiration, and because there are so many important vessels and nerves in relation with it.

Second Rib.—The second rib has little or no angle, no twist on its axis, and has, near the middle of its outer surface, a rough eminence for the origin of the second and third digitations of the serratus magnus. It has a short groove for the intercostal artery.

Tenth Rib.—The tenth rib has a single 'facet' on the head, for the tenth dorsal vertebra.

Eleventh and Twelfth Ribs.—The *eleventh* and *twelfth* ribs being shorter and less perfectly developed, are chiefly distinguished by their negative characters. Each articulates with only one vertebra, so that the head has only one facet, does not touch the transverse process, and has no tubercle. Each is tipped with cartilage. The eleventh has a trace of an angle and a groove. In the twelfth, angle and groove are imperceptible.


Ossification—Ossification in the ribs begins about the eighth week of foetal life. There is one 'primary' centre for the body, an epiphysis for the head, and another for the tubercle. There is no epiphysis for the tubercle in the eleventh and twelfth ribs. The epiphyses appear from the fifteenth to the eighteenth year, and unite with the rest of the bone about the age of maturity.

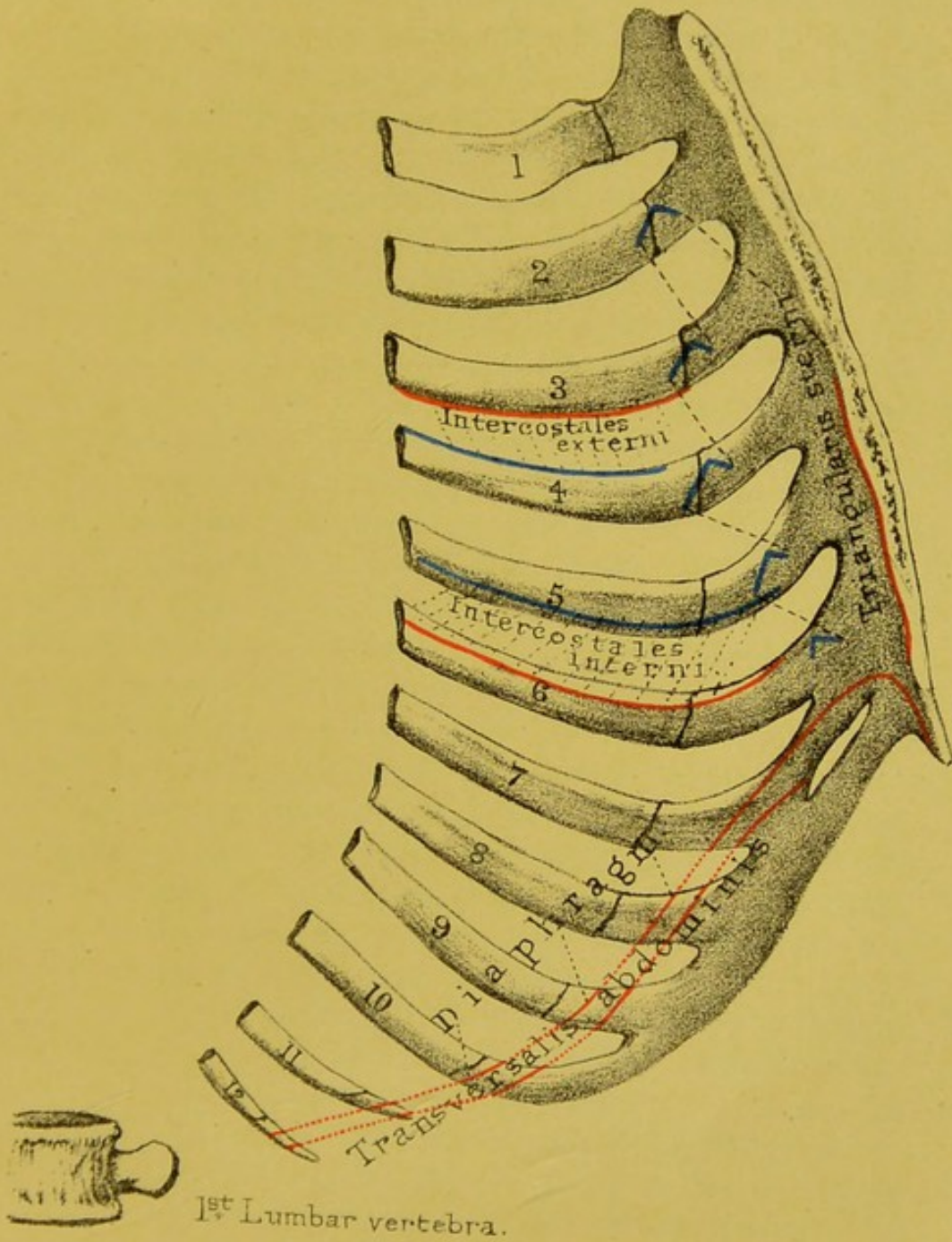


Drawn on Stone by T. Godart.

From nature by L. Holden.

Printed by West, Newman & Co.






Drawn on Stone by T. Godart.

From nature by L. Holden.

Printed by West, Newman & Co.



Costal Cartilages.—Respecting the costal cartilages, remember that the first seven are connected with the sternum. The first cartilage is united directly with the manubrium. The others, from the second to the seventh inclusive, are articulated to the sternum with the intervention of synovial membranes. The cartilages of the eighth, ninth, and tenth ribs are gradually bevelled off, and each joins the costal cartilage immediately above it. Moreover, synovial membranes exist between these last-mentioned ribs. The last two costal cartilages do not join those above, but merely cap the eleventh and twelfth ribs. These numerous little articulations, connected with the cartilages, much facilitate the respiratory movements of the thorax.

The costal cartilages increase in length and decrease in breadth from the first to the seventh; below that they decrease in length as well as in breadth from above downwards. The first descends a little on its way to the sternum, the second is nearly horizontal, the third ascends a little, while the remainder, excepting the eleventh and twelfth, which are short and free, follow the direction of the ribs they belong to for a little way, and then ascend obliquely upwards and inwards. Their upper and lower borders are smooth and rounded, completing the intercostal spaces in front; and, as the sixth, seventh, eighth, and sometimes the ninth and tenth, are in contact with one another, they present small oval articular facets. The sternal extremity of the first is joined directly to the presternum without the intervention of a synovial cavity. The same extremities of the second, third, fourth, fifth, sixth, and seventh are slightly enlarged and are jointed by ligaments, enclosing synovial cavities, to the facets already described as existing upon the presternum, mesosternum, and metasternum. The anterior extremities of the eighth, ninth, and tenth gradually taper to a point as they join their corresponding cartilages above, while those of the eleventh and twelfth are free and pointed. The rib ends of all the cartilages are received into the sockets, supported by the anterior extremities of the shafts of the ribs.

It is quite common to find the costal cartilages more or less covered by a sheath of true bony substance and calcified cartilage.

This process may be found commencing in comparatively young persons and is not confined to old age. It begins at the rib ends of the cartilages and spreads inwards towards the sternal extremities. However far the process advances no fusion ever occurs between the sheath of bone and calcified cartilage and the sternum. Even in the case of the first cartilage this holds true.

The great elasticity of the costal cartilages answers two purposes. 1. They act as mechanical agents of expiration by depressing the ribs after they have been raised by muscular action. 2. A blow on the sternum is distributed over fourteen elastic arches! One can understand, then, why the chest is able to bear such tremendous blows with impunity; more especially during a full inspiration. During expiration the bones are less able to resist injury, because the muscles are not acting. Notwithstanding these beautiful provisions, the sternum is sometimes broken, especially when the cartilages of the ribs are ossified.

Thorax as a whole.—In addition to what has been said of the thorax at p. 261, attention should be directed to one or two points which might otherwise be overlooked. 1. The great narrowness of the upper opening of the chest. In an adult of average size, it measures about 2 inches from before backwards, and $3\frac{1}{2}$ inches transversely. Yet in this seemingly narrow space there is room for the trachea, the œsophagus, the great blood-vessels and nerves at the root of the neck, besides the apex of each lung, and three muscles on each side. 2. Notice how much the ribs slope in subserviency to the mechanism of respiration. Their sternal and vertebral ends are not in the same horizontal plane; for instance, the sternal end of the third rib is not on a level with the third dorsal vertebra, but, roughly speaking, with the sixth. 3. Notice how much additional space is gained posteriorly (for the lungs) by the backward projection of the ribs. 4. Notice that the lower margin of the thorax is represented by a line sloping from the end of the sternum downwards and backwards to the last rib. 5. Notice that the intercostal spaces are widest where the ribs unite to their cartilages, and narrowest where the ribs join the spine.

Comparative Osteology.—It is curious that the gorilla and

chimpanzee have each 13 pairs of ribs. So that man in his descent from his pretended ancestors must have lost a rib, for he (like the man of the woods, orang utan) has only 12.

In mammalia the number of ribs on each side ranges from 9 in the bottle-nosed whale (*Hyperoodon*, No. 2892) to 24 in the two-toed sloth (No. 3434). The horse and tapir have 18 pairs each, and the elephant 19.

The ribs of the manatee (No. 2729) are extraordinarily thick, broad, and massive.

In whales some of the posterior ribs are attached only to the transverse processes of the vertebræ. Commonly in mammalia about 6 ribs articulate with the sternum by cartilage or bone, but in whales the number so attached is much smaller, in the whalebone whale there being only one pair of true ribs.

This freedom of action allows the great play of the respiratory apparatus in cetacea.

Some animals have the costal cartilages ossified, forming sternal ribs, as in the giraffe, crocodile, ox, porpoise, and dolphin; in many there is an intermediate rib, or shaft of bone, set in between the sternal and vertebral ribs (see Nilotic crocodile, No. 717 D, and monotremata, No. 3964).

The ribs mostly serve in respiratory movements and protection of thoracic viscera throughout the animal kingdom. In addition to this the snakes use the tips of them to walk upon, and the flying lizard (*Draco volans*, No. 673) has the 5 posterior ribs so recurvated and elongated as to form the bony skeleton of the membranous sail by which he supports himself in his flight from tree to tree.

The middle part of the ribs in birds (see griffin vulture, No. 1674) presents a long flat process which projects backwards and rests on the rib below. These are called uncinæ processes.

There are no processes in mammalia corresponding to the uncinæ processes in birds. They are, however, seen in alligators and sphenodon, &c. (No. 760 A).


Sharks and rays have no ribs. What appear to be ribs in the Porbeagle shark (No. 419 A) are simply the supports of the

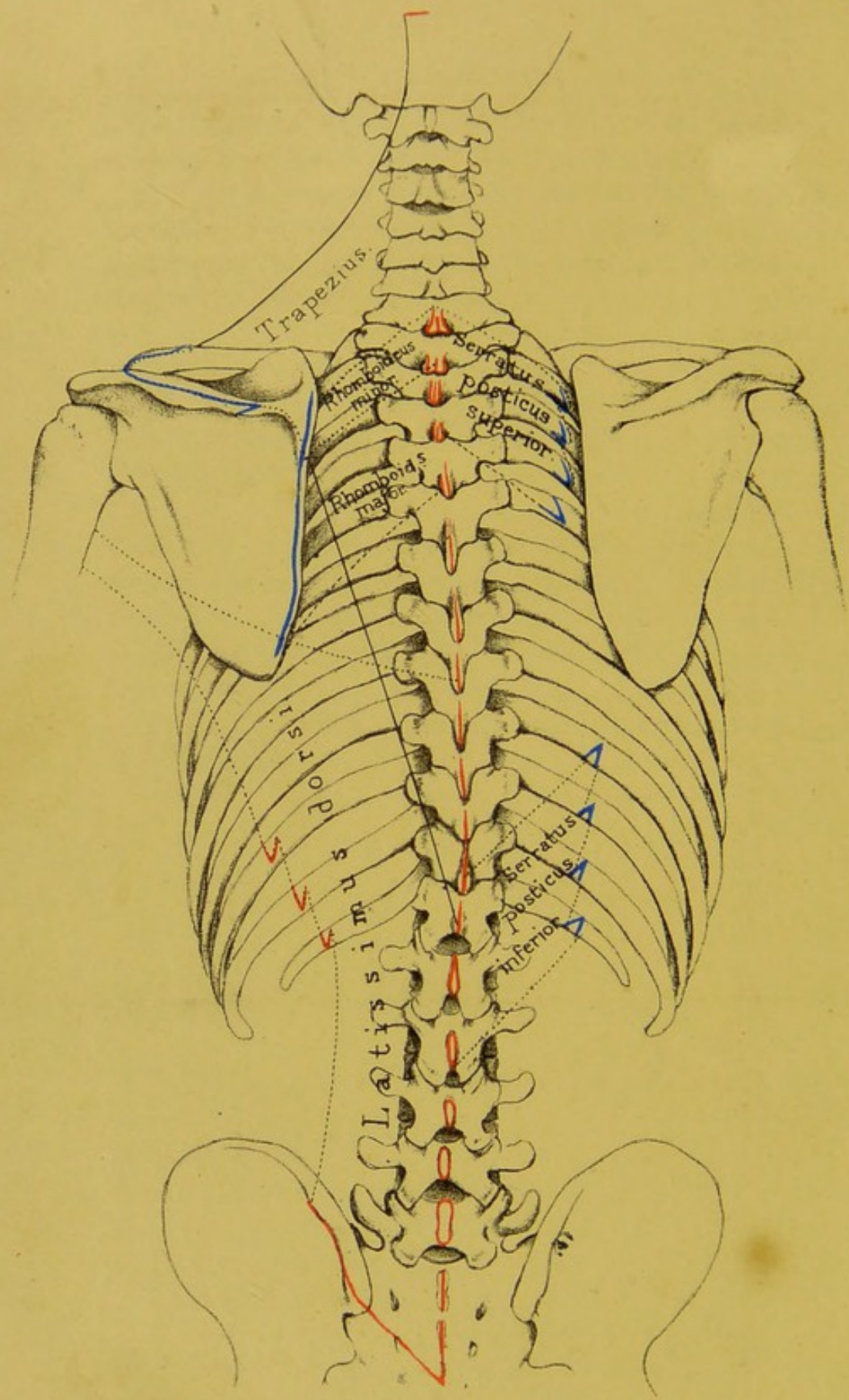
gills, as may be understood by a reference to the skeleton of the cod-fish (No. 147 A), which has 17 pairs of ribs.

Examine the great Nilotic crocodile (No. 717 D), and you will see that an anterior and a posterior bar forming the transverse processes of the cervical vertebræ correspond to the two processes which in the dorsal vertebræ support respectively the head and the tubercle of the rib. In its middle and posterior dorsal regions the end of a transverse process supports both the head and the tubercle of the rib. There will be seen also what are called intermediate ribs, i.e. a piece of bone between the end of the rib and the costal cartilage or sternal rib. Some of the ribs are furnished with uncinæ processes, as in birds; but this is better seen in the alligator (No. 760 A). Seven pairs of false ribs are developed as superficial ossifications of the lineæ transversæ in the abdominal wall (see also No. 711 A).

The extinct flying lizards, Pterosauria (No. 119 A), had splint-like sternal, as well as abdominal, ribs.

In Ophidia (No. 630) the ribs articulate only with the ends of transverse processes.





Drawn on Stone by T. Godart.

From nature by T. Holden.

Printed by West, Newman & Co.

*ATTACHMENTS OF THE MUSCLES OF
THE BACK.*

(PLATES XLII.-XLVII.)

IN the description of the attachments of the muscles of the back the more superficial muscles, connected with the arm, will be first considered. These removed, the great muscles of the spine, which fill up the vertebral grooves, and keep the body erect, are exposed. Lastly, there is the mass of muscles at the back of the neck attached to the occipital bone.

THE SUPERFICIAL MUSCLES OF THE BACK.

These are shown in Plate XLII. The most superficial is the 'trapezius,' a triangular muscle of which the limits are defined by the continuous dark line. The other wide-spreading superficial muscle is the 'latissimus dorsi.' Under the trapezius we have the 'rhomboidei' and the 'levator anguli scapulæ,' shown in Plate XLIV.

Trapezius	{	O. Occiput; ligamentum nuchæ: spines of all the dorsal vertebræ.
	{	I. Spine of scapula; acromion, acromial third of clavicle.
Latissimus dorsi	{	O. Crest of the ilium. Spines of all the lumbar, sacral, and six lower dorsal vertebræ, crest of ilium, and by digitations from the three or four lower ribs.
	{	I. Bottom of bicipital groove of humerus.
Rhomboides (major and minor)	{	O. Spines of last cervical and five upper dorsal vertebræ.
	{	I. Vertebral border of scapula.
Levator anguli scapulæ	{	O. Transverse processes (posterior tubercles) of four upper cervical vertebræ.
	{	I. Upper angle of scapula.

When the preceding muscles are removed, there still remain the 'serratus posticus superior' and 'inferior.' These belong not to the arm, but to the ribs.

- Serratus posticus superior
 - Serratus posticus inferior
- } O. Spines of last cervical and three upper dorsal vertebrae.
 } I. Second, third, fourth, and fifth ribs.
 } O. Spines of two last dorsal and two or three upper lumbar vertebrae.
 } I. Four lower ribs.

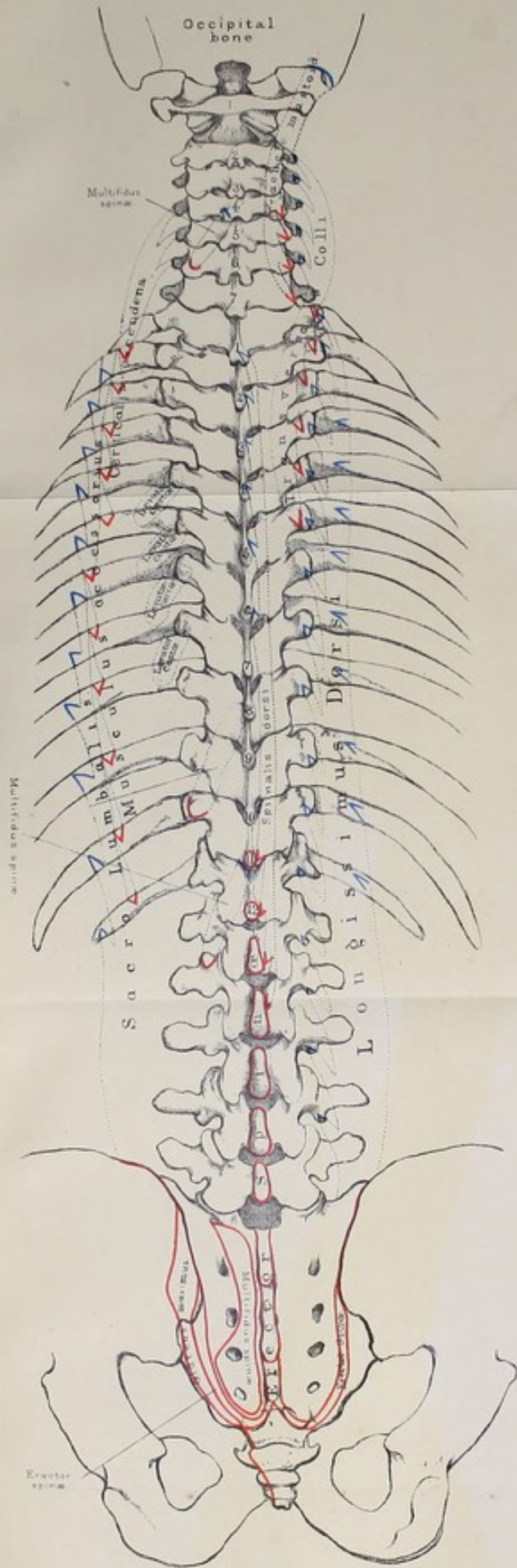
Next come the great muscles of the spine concerned in keeping the body erect. These are considered to be complicated; the truth is, they are very simple, provided the plan of their arrangement be borne in mind. An attempt has been made to bring out the plan in Plate XLIII.

The vertebral groove on each side of the spine is occupied by the 'erector spinæ' and its prolongations, and by the 'transverso-spinalis.'

The 'erector spinæ' arises by strong tendons from the crest of the ilium, the back of the sacrum, and the spines of the lumbar vertebrae, and subdivides into three masses of muscle. The outer, termed the 'sacro-lumbalis,' with its prolongations ('musculus accessorius' and 'cervicalis ascendens'), is attached to the angles of the ribs. The middle, termed the 'longissimus dorsi,' with its prolongations ('transversalis colli' and 'trachelomastoid'), is attached to the transverse processes of the vertebrae. The inner, termed the 'spinalis dorsi,' is attached to the spinous processes of the vertebrae. Subjoined, these muscles are arranged in a natural tabular form. They all run longitudinally.

PLAN OF THE LEFT ERECTOR SPINÆ.

O. Crest of ilium. Back of sacrum. Spines of lower 2 or 3 dorsal and of all lumbar and sacral vertebrae.	Outer mass Middle mass Inner mass	Angles of ribs Transverse processes of vertebrae	Sacro-lumbalis. I. 6 lower ribs.	Musculus accessorius. O. 6 lower ribs. I. 6 upper ribs.	Cervicalis ascendens. O. 4 or 5 upper ribs. I. 4th, 5th, and 6th lower cervical vertebrae.	Transverse processes of 7th cervical vertebra. Longissimus dorsi. I. All the lumbar and dorsal vertebrae.	Transversalis colli. O. 4 or 5 upper dorsal vertebrae. I. 2nd, 3rd, 4th, 5th, and 6th cervical vertebrae.	Trachelo-mastoid. O. 4 or 5 upper dorsal and 3 or 4 lower cervical vertebrae. I. Mastoid process.	Spinalis dorsi. O. Lowest 2 or 3 dorsal and upper lumbar. I. From 4th to 9th upper dorsal.
--	---	---	-------------------------------------	---	--	---	---	---	--





The 'intertransversales' pass between the transverse processes of contiguous vertebræ, the 'interspinales' between the spinous processes beginning at the axis. Both these sets are ill developed and most tendinous in the dorsal region.

The 'transverso-spinalis' is the mass which fills up the space between the transverse and spinous processes of the vertebræ. It *arises* from transverse, and is *inserted* into spinous processes. Therefore its direction is oblique. It is composed of several bundles. The more superficial pass over many vertebræ; the deeper over one or two; the deepest run from vertebra to vertebra. The 'transverso-spinalis' comprises the 'semi-spinalis dorsi,' 'semi-spinalis colli,' 'multifidus spinæ,' and 'rotatores spinæ' of systematic authors, and for the attachments of which the reader is referred to works on myology.

The 'levatoros costarum' arise from the transverse processes, and are inserted into the ribs below them.

MUSCLES OF THE BACK OF THE NECK.

(PLATE XLV.)

A separate group is made of these, because they specially maintain the head erect, and move the first upon the second vertebra. The 'trapezius' being reflected, the 'splenius' is exposed, and beneath that the 'complexus.'

Splenius capitis et colli	{ O. Spines of four cervical and six dorsal vertebræ. I. Mastoid process and occipital bone; transverse processes of two or three upper cervical vertebræ.
Complexus	
	{ O. Transverse processes of six dorsal and articular processes of four cervical vertebræ. I. Occipital bone.

The above muscles being reflected, we expose the muscles of the atlas and axis; namely, the 'rectus capitis posticus major' and 'minor,' the 'obliquus superior' and 'inferior,' and the 'rectus capitis lateralis.'

Rectus capitis posticus major	{	O. Spine of the axis.
		I. Occipital bone.
Rectus capitis posticus minor	{	O. Spine of the atlas.
		I. Occipital bone.
Rectus capitis lateralis	{	O. Transverse process of atlas.
		I. Jugular eminence of occipital bone.
Obliquus superior	{	O. Transverse process of atlas.
		I. Occipital bone.
Obliquus inferior	{	O. Spine of the axis.
		I. Transverse process of atlas.

MUSCLES IN FRONT OF THE SPINE.

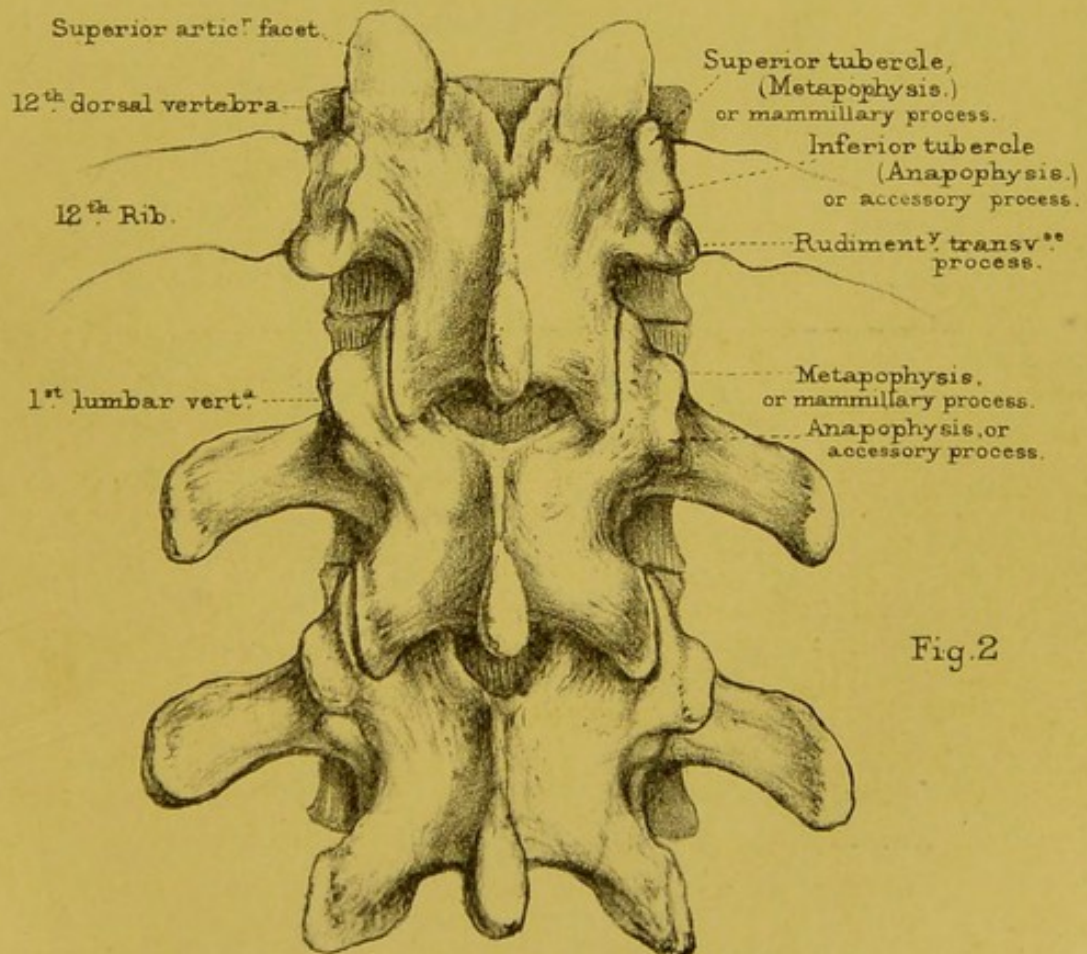
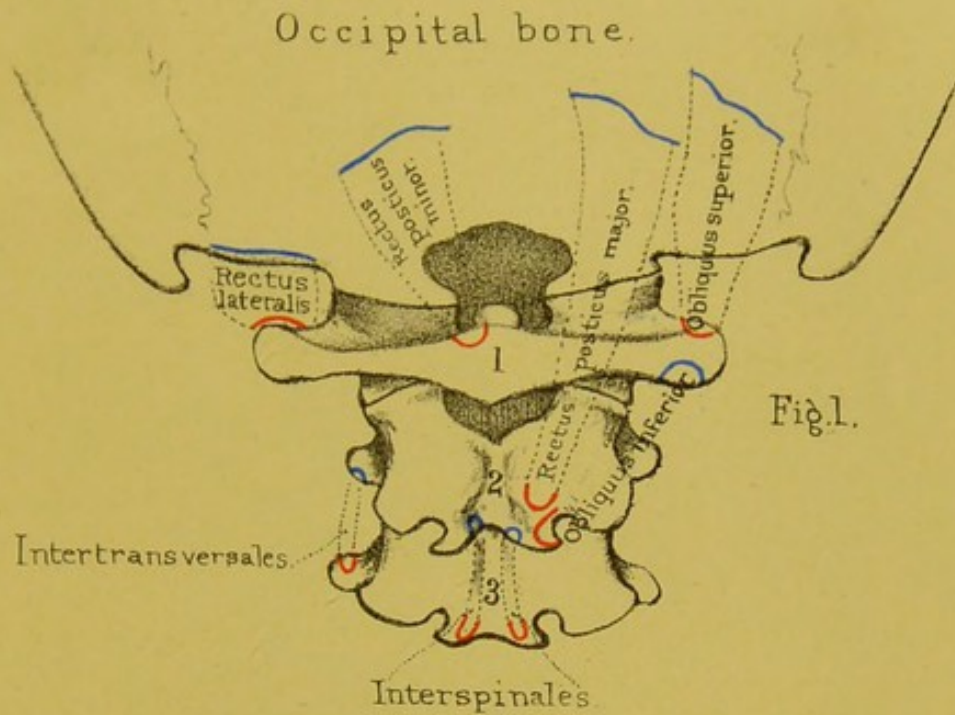
(PLATES XLVI., XLVII.)

There are three pre-vertebral muscles in the cervical region ; namely, the 'rectus capitis anticus major' and 'minor' and the 'longus colli.' In the lumbar region are the right and left crura of the 'diaphragm,' the 'psoas magnus,' and occasionally a 'psoas parvus.'

Rectus capitis anticus major	{	O. Transverse processes of third, fourth, fifth, and sixth cervical vertebræ.
		I. Basilar process.
Rectus capitis anticus minor	{	O. Transverse process of atlas.
		I. Basilar process.

The 'longus colli' consists of a *longitudinal* and two *oblique* portions. The *longitudinal* part arises from the bodies of the three upper dorsal and two lower cervical vertebræ, also from the transverse processes of the three or four lower cervical, and is inserted into the bodies of the second, third, and fourth cervical. The *lower oblique* part arises from the bodies of the upper dorsal vertebræ and is inserted into the transverse processes of the fifth and sixth cervical. The upper *oblique* part arises from the transverse processes of the third, fourth, and fifth cervical vertebræ, and is inserted into the side of the tubercle of the atlas.


Diaphragm	{	O. Right crus from three or four lumbar vertebræ, left from two or three.
		I. Central tendon.
Psoas magnus	{	O. Body of last dorsal, bodies and transverse processes of all the lumbar vertebræ.
		I. Trochanter minor.

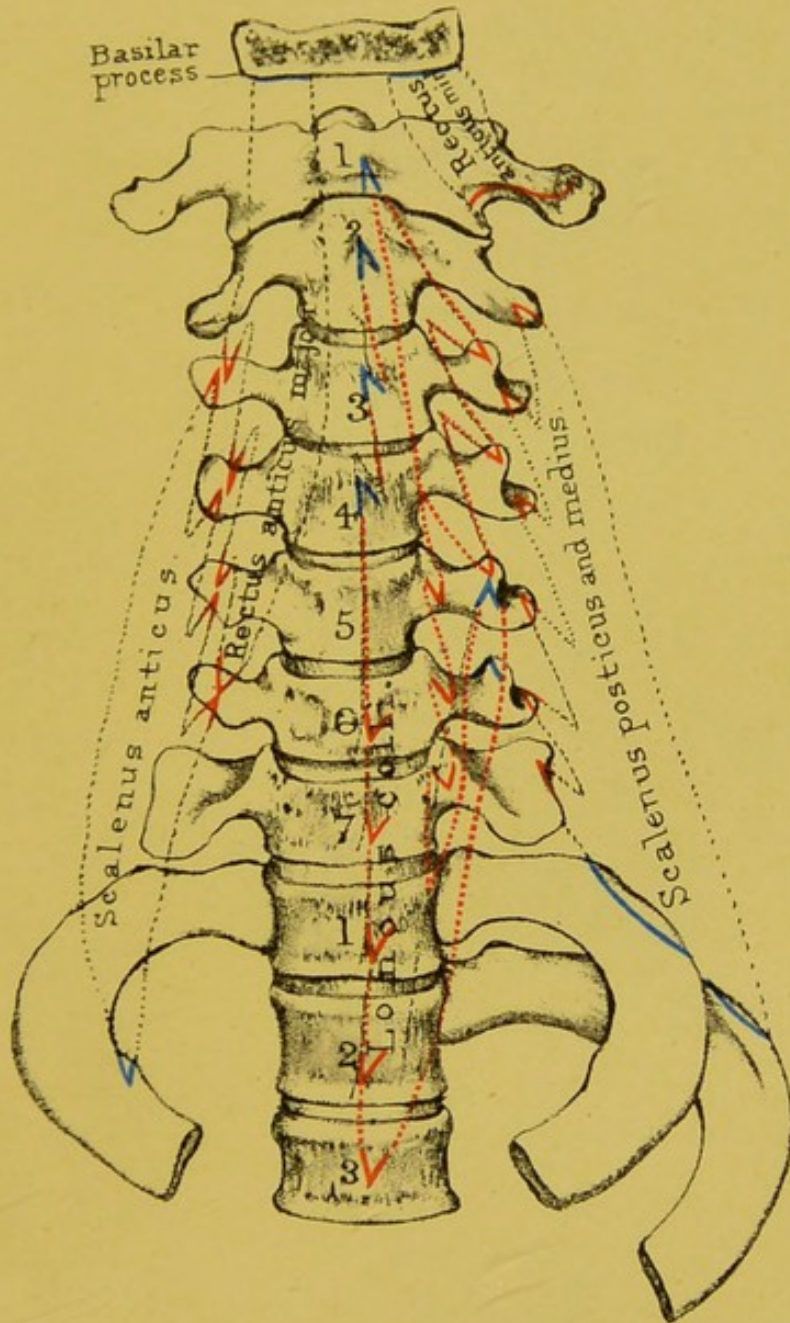


Drawn on Stone by T. Godart.

From nature by L. Holden.

Printed by West, Newman & Co.




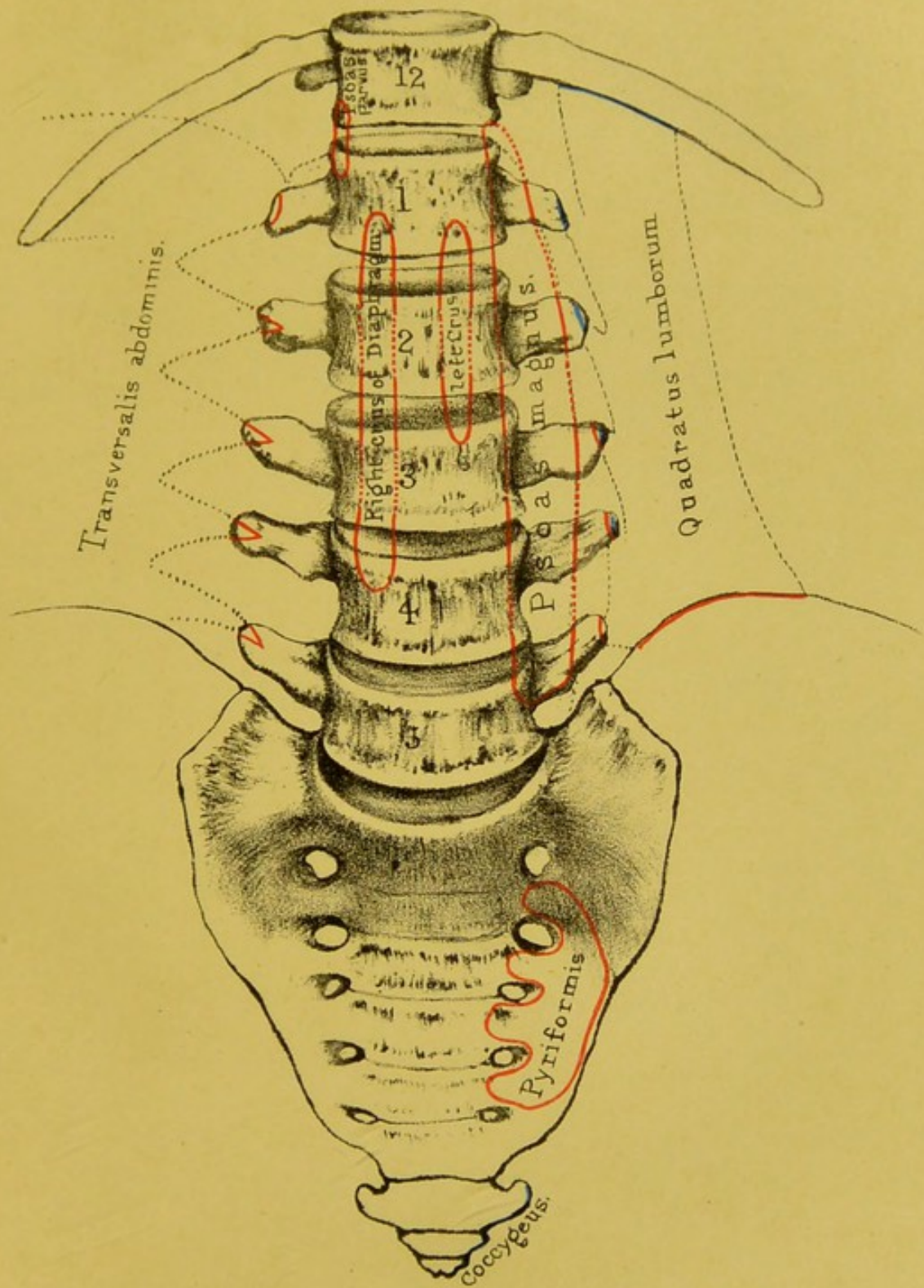


Drawn on Stone by T Godart.

From nature by L Holden.

Printed by West, Newman & Co.






Drawn on Stone by T. Godart.

From nature by L. Holden.

Printed by West, Newman & Co.



Psoas parvus { O. Body of last dorsal vertebra.
I. Brim of pelvis.

There are three deep lateral muscles in the cervical; namely, the 'scalenus anticus,' 'scalenus medius,' and the 'scalenus posticus.'

Scalenus anticus { O. Transverse processes of third, fourth, fifth, and
sixth cervical vertebræ.
I. Scalene tubercle on first rib.

Scalenus medius { O. Transverse processes of six or seven cervical
vertebræ.
I. First rib.

Scalenus posticus { O. Transverse processes of lower two or three cer-
vical vertebræ.
I. Second rib.

BONES OF THE UPPER EXTREMITY.

Component Bones.—The bones of the upper extremity consist of the ‘clavicle,’ the ‘scapula,’ the ‘humerus,’ the two bones of the fore-arm, namely, the ‘radius’ and the ‘ulna,’ the bones of the carpus, the metacarpus, and the phalanges of the fingers. The clavicles and scapulæ form the ‘shoulder girdle’ or ‘pectoral arch.’ The length of the arm should be in exact proportion to the height of the individual. If the arms are fully stretched in the same horizontal line, the space from the end of the middle finger of one hand to that of the other is about equal to the length of the body.

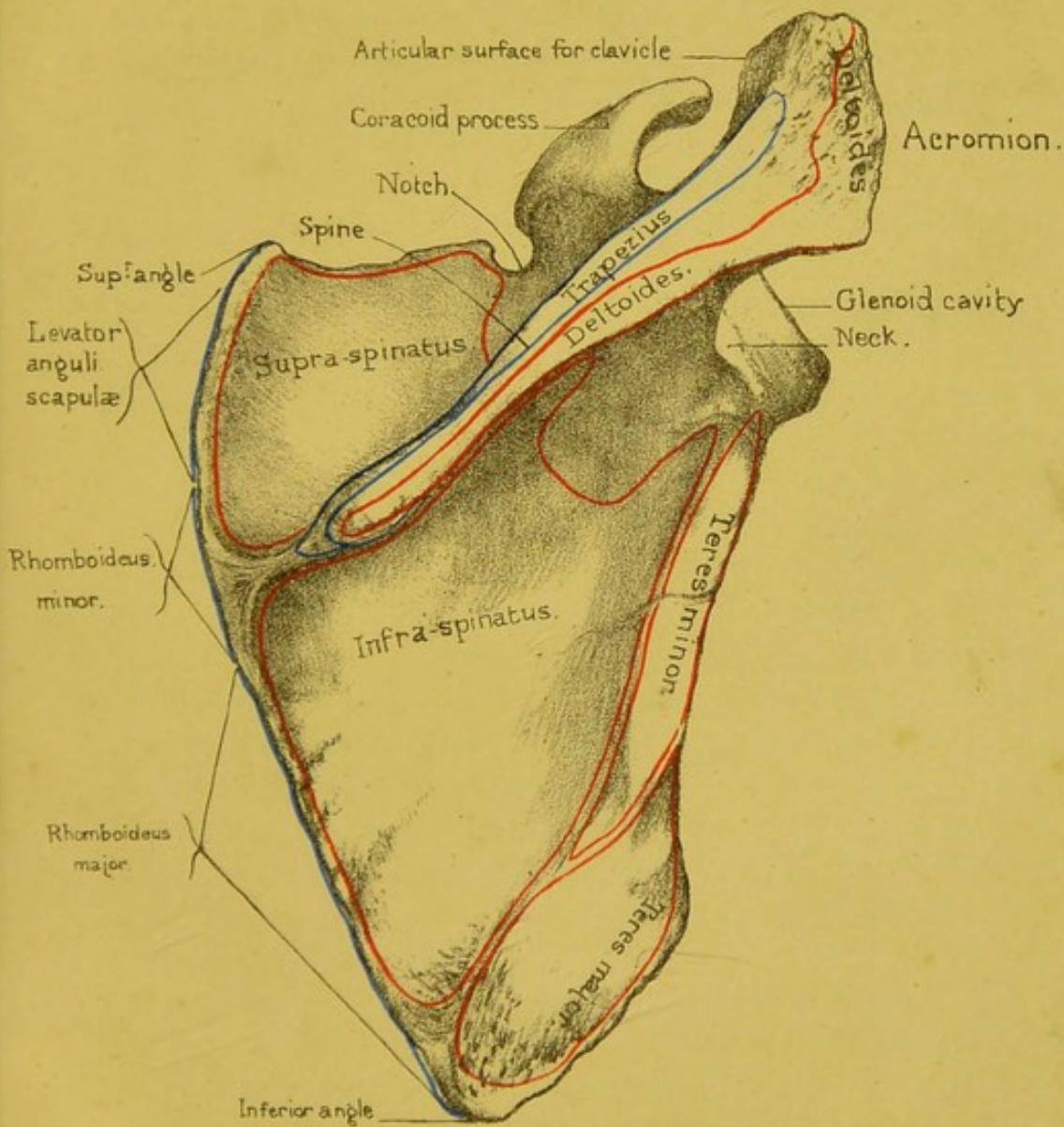
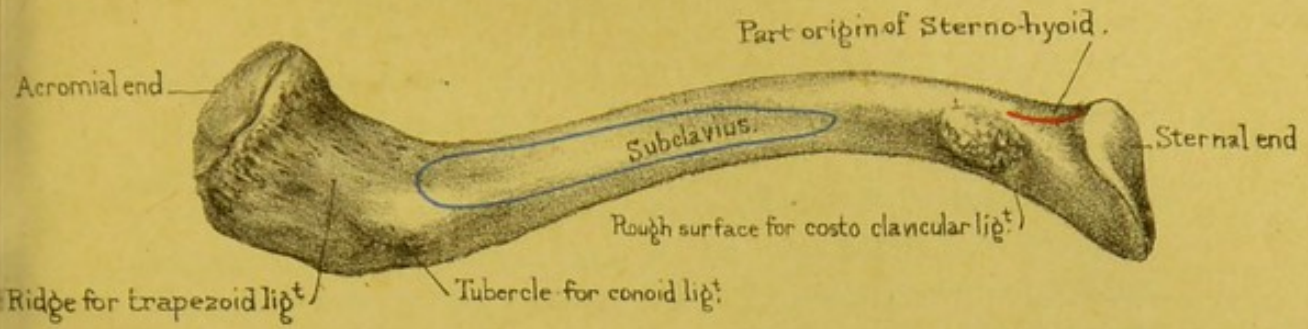
THE CLAVICLE.

(PLATES XLVIII., XLIX.)

Position and Use.—The clavicle, or collar bone, so named from its resemblance to an ancient key, extends nearly horizontally from the upper part of the sternum to the scapula. It keeps the shoulders wide apart, giving the arm a freer range of motion; affords attachment to powerful muscles; and protects the axillary vessels and nerves. By moving the shoulder, you find that the clavicle acts as a prop, the fixed end of the prop being at the sternal joint. Hence, in fractures of the clavicle, the shoulder generally falls a little *forwards*. The patient leans his head towards the injured arm so as to relax the muscles, and supports the elbow in his hand.

Advantage of its Curves.—The shape of the clavicle is like an italic *S*. It has two curves, arranged so that, when viewed

Under surface of clavicle




Outer surface of Scapula.

Drawn on Stone by T. Godart.

From nature by L. Holden.

Printed by West, Newman & Co.



from the front, the inner half is convex, and the outer half concave. The inner curve is the larger of the two. The great vessels and nerves of the arm pass under it. About the junction of the two curves the bone is most frequently broken. These curves not only make the bone stronger than if it were straight, but better able to resist shocks; since, by virtue of its elasticity, the force is partially broken at each of the curves. The strength and degree of curvature vary considerably in different bones. They are usually greater in men than in women, and most marked in those persons who do much manual labour.

Shaft.—The shaft is divided into an outer third ‘flat,’ or ‘acromial portion,’ and an inner two-thirds, ‘prismatic’ or ‘sternal portion.’

FLAT PORTION.—The flat portion presents an *anterior border*, which is concave from side to side, narrow from above downwards, and rough for the attachment of the ‘deltoid,’ and a *posterior border*, which is more a surface than a border, convex from side to side, and rough for the attachment of the ‘trapezius.’ The *superior surface* is rough anteriorly and posteriorly for the attachment of the ‘deltoid’ and trapezius respectively. The *inferior surface* presents at its posterior and internal extremity a rough tubercle—‘conoid tubercle’—for the attachment of the ‘conoid ligament,’ and, running forwards and outwards from that, a broad ridge—‘oblique line’—for the attachment of the ‘trapezoid ligament.’ Here fractures of the bone are likely to escape notice, in consequence of the ligaments preventing the separation of the fractured ends. Both surfaces are marked by a number of small nutrient foramina.

STERNAL PORTION.—The sternal or prismatic portion is triangular on cross section. It presents for examination *superior*, *anterior*, and *posterior borders*, enclosing *anterior*, *posterior*, and *inferior surfaces*.

The *superior border* runs from the superior angle of the sternal end outwards to become continuous with the upper lip of the posterior border of the flat portion. It is rough internally for the attachment of the ‘sterno-mastoid.’ The *anterior border* begins internally at the anterior angle of the sternal end and

runs outwards to become continuous with the anterior border of the flat portion. Its inner three-fourths are rough and form the lower limit of the space for the attachment of the 'pectoralis major.' Its outer fourth is smooth and forms the base of a triangle whose other sides are made, in the recent state, by the 'pectoralis major' and the 'deltoid,' and through which in the living body the apex of the 'coracoid process' may be felt. The *posterior border* commences at the posterior angle of the sternal and runs outwards to join the lower lip of the posterior border of the flat portion. Its inner third is rough and forms the posterior boundary of the facet for the 'rhomboid ligament.' Its middle part is smooth and rounded; the outer third becomes more prominent.

The *anterior surface* lies between the superior and anterior borders. It points forwards at its inner end, forwards and upwards at its outer end. Internally it presents a few small eminences near the upper border for the attachment of the sterno-mastoid, and below a large, oval, flattened, and rough space for the attachment of the 'pectoralis major.' Externally it is smooth and rounded. The *posterior surface* is concave backwards, looks backwards, upwards, and outwards at its inner end, backwards, downwards, and inwards at its outer end. It is smooth throughout. Near its middle and close to the posterior border is situated the large nutrient foramen, and internally the surface is slightly rough for the attachment of the 'sterno-hyoid.' The *inferior surface* presents at its inner end a large rough depression—'rhomboid depression'—for the attachment of a ligament of the same name, and usually a little in front and internal to that a small articular facet for articulation with the cartilage of the first rib. The rest of the surface is marked by a groove, wider externally than internally, for the insertion of the 'subclavius.'

Sternal End.—The sternal end of the clavicle is thick, strong, and expanded. It is triangular in shape, presenting a superior, an anterior, and a posterior angle—the posterior being the most prominent of the three. Its upper part is non-articular and rough for the attachment of the interarticular fibro-cartilage. Its lower part is uneven and articulates, through the

medium of the interarticular fibro-cartilage, with the sternum. In the recent state, when crusted with cartilage, the articular surface is slightly convex from above downwards, and concave from before backwards; and, moreover, its circumference projects on all sides considerably beyond the articular surface of the sternum, to which it is so firmly attached by its ligaments that dislocation is very rare, notwithstanding the small size of the articular surface of the sternum. A fracture of the clavicle is much more common than a dislocation of its sternal end.

Acromial End.—The acromial end presents an oval articular facet slightly concave from above downwards and slightly convex in the opposite direction, to articulate with a corresponding facet on the acromion. The plane of the surface is oblique, so that the upper edge projects farther out from the bone than the lower, and the general direction of the whole surface is forwards, outwards, and a little downwards. The projection of the upper border, and its thereby overhanging the upper border of the acromial facet, prevents the natural tendency to displacement upwards of the scapula from the clavicle in all shocks transmitted to the scapula from below, and the hollowing out of the articular facet in its different axes allows of the inwards and outwards, and forwards and backwards hinge-like motions, which take place at the acromio-clavicular joint. The plane of the articulation is such that it is very difficult to keep the clavicle in its proper place after a dislocation.

Like all the long bones, its structure is spongy at the extremities, but very compact in the middle of the shaft, where there is a small, irregular medullary cavity. The compact wall is much thicker on the concave side of each of its curves than elsewhere.

Connections.—The clavicle articulates with the acromion process of the scapula, and with the top of the sternum.

Ossification.—The clavicle begins to ossify about the sixth week of foetal life, that is, sooner than any other bone in the body. Its ossification begins before the appearance of cartilage in connection with it, and it goes on ossifying afterwards both in cartilage and in fibrous tissue. It has only one centre of ossification for the shaft. The sternal end has an epiphysis which

makes its appearance from the eighteenth to the twentieth year, and subsequently coalesces with the shaft.

Comparative Osteology.—All Primates have clavicles to which they owe the breadth of their shoulders. In the Carnivora the clavicles do not articulate with any bone, but are simply suspended in the muscles, and are always more or less rudimentary or absent (see *Felis leo*, No. 304). Bears seldom have clavicles.

There is no clavicle in the elephant (No. 2241), or *Hyrax capensis* (No. 2231). The three sub-orders of Ungulata have no clavicles, i.e. Pachydermata, Ruminantia, Solidungula, as the horse and ox. The same is true of all Cetacea, Sirenia, and Crocodilia.

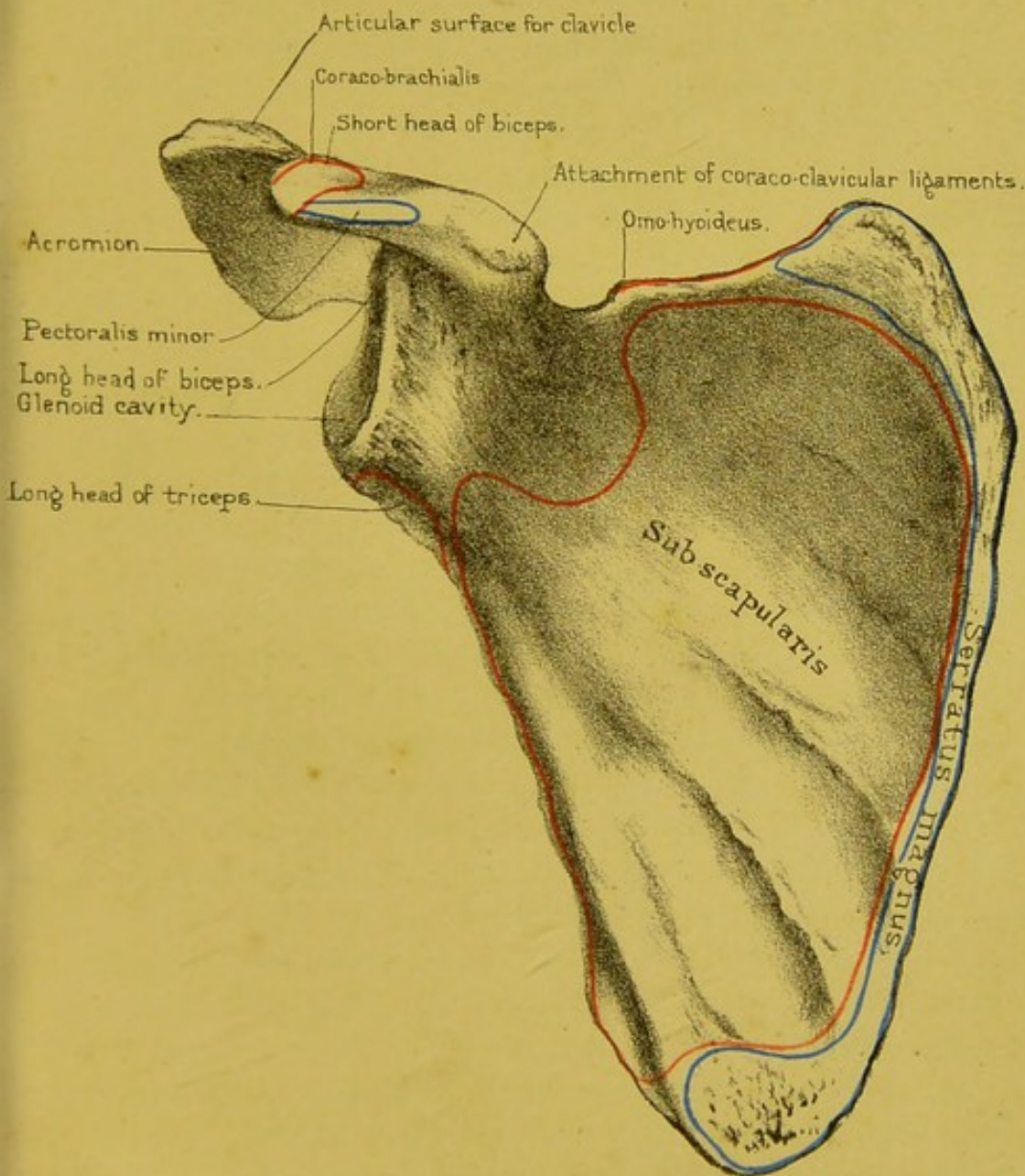
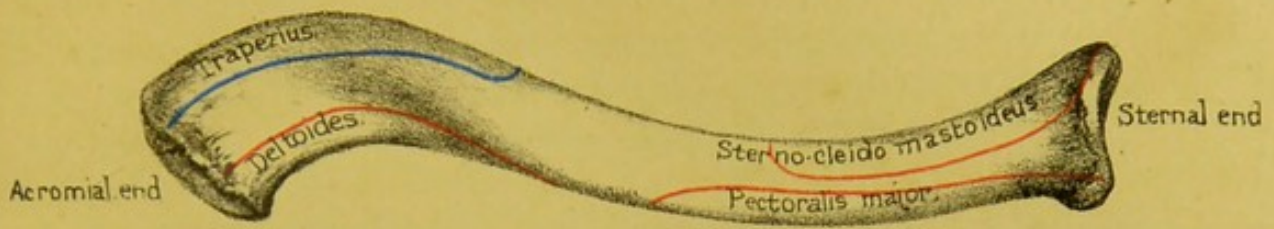
The majority of birds have clavicles the strength of which bears a direct relation to the power of the fore-limb. They are early ankylosed together in the middle line, and form a single bone called the furculum or merrythought. The chief action of this elastic arch of bone would appear to be to counteract the great pectoral muscles, which tend to press the humeri inwards during the downward stroke of the wing. The apteryx and some parrots have no clavicles.

THE SCAPULA.


(PLATES XLVIII., XLIX.)

Position and Use.—The scapula, or shoulder-blade, is placed at the back of the chest. When the arm hangs loosely by the side, the scapula ought to extend from the upper edge of the second rib to about the lower edge of the seventh, and the lower angle should be a little farther from the spine than the upper. The inferior angle of the scapula is a good guide to the seventh rib. During life this angle is held down by the upper border of the 'latissimus dorsi,' and sometimes gives origin to some of its fibres. In emaciated persons the yielding of this muscle allows the lower end of the scapula to project very perceptibly. The middle of the articular surface for the humerus is situated opposite the lower edge of the body of the fourth dorsal vertebra, when the arm is parallel with the side of the chest.

Upper surface of clavicle.



Inner surface of Scapula.



The scapula acts as a movable fulcrum in the motions of the arm, and gives extensive attachment to the muscles which effect the movement. It is a flat triangular bone, and so thin in places as to be translucent.

The scapula presents for examination a *head*, a *neck*, and a *body* or *ala*, also outstanding processes—the *spine*, the *acromion*, and the *coracoid*.

Head.—The head is the truncated external angle of the bone supporting the ‘glenoid cavity’ for articulation with the head of the humerus. This cavity is oval or pyriform in shape, broader below than above, shallow, smooth, and articular, and directed outwards, forwards, and a little upwards. The most prominent part of its circumference is the lower and inner portion. This rising up of the edge below and inside counteracts the natural tendency of the head of the humerus to slip inwards, pulled, as it is, by the strong muscles dragging it in that direction. Below the top of the cavity, and on its inner edge, we notice a notch, or small concavity, for the lodgment of some large fringes of the synovial membrane. In some bones we notice a similar notch on the corresponding part of the outer edge. The margin of the articular surface is rough and gives attachment to the ‘glenoid ligament.’ At the upper end it broadens out and gives origin to the long tendon of the ‘*biceps*’ muscle. The surface of bone immediately inside the edge of the ‘glenoid cavity,’ and which we may call the circumference of the head, is rough and uneven, and gives attachment to the capsular ligament of the shoulder joint. In it, as it merges into the neck, we notice a number of nutrient foramina, especially on its anterior and posterior aspects. We shall see that the centre of the head of the scapula is situated structurally at the strongest part of the whole bone.

Neck.—The neck is the slightly constricted part of bone which joins the head to the body. It is flattened from before backwards, and is thicker externally than internally, where it fades off into the adjacent ala. Its *anterior surface* is smooth, externally is marked by a number of large nutrient foramina, and internally is continuous with the anterior surface of the body of the bone. The ‘*subscapularis*’ overlies this part of the neck, a

bursa intervening between the two. The *posterior surface* is deeply concave from within outwards, and slightly convex from above downwards. It forms a direct communication between the 'supra-' and 'infra-spinous fossæ.' The *lower border* is the somewhat expanded upper end of the axillary border of the ala. It is rough for the origin of some fibres of the long head of the 'triceps.' The *superior border* supports in its whole length the root of the ascending part of the coracoid process.

Body.—This part of the bone is, as it were, the expanded neck. It presents for examination an *anterior surface* or *venter* or *subscapular surface*, a *posterior surface* or '*dorsum scapulæ*,' a *superior border*, an *internal* or *vertebral border*, and an *external*, *axillary*, *inferior* or *subscapular border*.

The *anterior surface*, looked at generally, is hollowed both vertically and transversely. It is usually marked by five convexities separating four concavities converging from the vertebral border to the front of the neck. The first concavity, tracing from above downwards, forms a deep groove and is situated opposite the origin of the 'spine' from the dorsum. It is known by the name of the 'subscapular angle' of the scapula. The other concavities are not so well marked. At the convergence and meeting of the first and second concavity the surface is deeply concave and is marked by a large medullary foramen. On the summits of the second, third, and fourth convexities we notice rough ridges for the attachment of 'intermuscular septæ' in the 'subscapularis' muscle. The ridges are sometimes called the 'costæ' of the scapula, and the hollows between them were mistaken, even by the great anatomist Vesalius, for the impressions of the ribs. On the anterior surface also observe a rough space near the upper angle, and a still larger and rougher space near the lower angle, and a very narrow tract along the internal border for the insertion of the 'serratus magnus.' Omitting all the part for the 'serratus magnus,' the anterior surface gives origin in its inner three-fourths to the 'subscapularis' muscle, and goes by the name of the 'subscapular fossa.' The *posterior surface* ('*dorsum scapulæ*') in its general aspect is convex from above downwards. The spinous process, rising from about the

junction of its upper fourth with its lower three-fourths, divides it into two unequal parts—the ‘supra-’ and ‘infra-spinous’ surfaces. The upper part is smooth, triangular, and somewhat concave in all directions. It is continuous with the upper surface of the spine and forms the large part of the ‘supra-spinous fossa.’ To its inner two-thirds the ‘supra-spinatus’ muscle is attached. The part below the spine forms about three-fourths of the dorsum scapulæ and the greater part of the ‘infra-spinous fossa.’ Tracing it from within outwards, it presents first a concavity, next a convexity, next a concavity, and lastly a rounded border which in its lower third becomes a flattened surface for the origin of the ‘teres major’ muscle. The rounded border gives origin to the ‘teres minor,’ and is separated from the flattened surface by the *oblique line* running downwards and inwards for the attachment of the intermuscular septum between the ‘teres major’ and ‘minor’ muscles. In the rounded border, at about the junction of the upper fourth with the lower three-fourths, we notice two or more transverse grooves for the passage of branches of the ‘dorsalis scapulæ’ artery. The ‘infra-spinatus’ muscle arises from the inner two-thirds of the rest of the infra-spinous surface. The posterior surface of the neck of the bone forms a communication between the ‘supra-’ and ‘infra-spinous’ surfaces, and in each surface, near the root, the spine, we notice one or two large nutrient foramina.

Of the three *borders* the *superior* is the shortest and thinnest. It is concave in its long axis and slightly rough. At its outer end it shows the ‘supra-scapular notch,’ which in its recent state is bridged over by a ligament and gives passage to the supra-scapular nerve. In some cases it is bridged over by a process of bone or by an arch formed partly by bone and partly by ligament. Between the notch and the superior angle the border gives attachment to the ‘omohyoid.’ The *internal* or *vertebral border* is always the longest in man, and is therefore called the ‘base’ of the scapula. In the lower animals it is generally the shortest. It is rough throughout, and thicker above and below than in the middle. Where the spine rises from it, it is rather suddenly bent backwards, forming an obtuse angle, the inner end

of the 'subscapular angle,' already described as existing on the venter of the bone. Opposite a triangular space at the root of the spine the border gives attachment to the 'rhomboideus minor,' above it to the 'levator anguli scapulæ,' and below it to the 'rhomboideus major.' The border, in the whole length of its ventral aspect, affords insertion to the 'serratus magnus.' The *external* or *axillary border* is rough and rather sharp in its lower third, where it gives origin to the 'teres major.' In its upper two-thirds it spreads out into a surface, widening towards the under surface of the neck of the bone. This surface presents the appearance of a groove looking forwards and outwards. It is bounded posteriorly and externally by a prominent lip which gives attachment dorsally, in its whole length, to the 'teres minor.' About the junction of the upper and middle thirds the lip is interrupted by one or more grooves for the dorsalis scapulæ artery. At the upper end the border forms a rough ridge continuous with the rough under surface of the neck, and affords attachment to the 'long head of the triceps.' The surface of bone for the attachment of the long head of the 'triceps' is sometimes spoken of as the 'infra-glenoid process,' and the corresponding part above the glenoid cavity giving origin to the long head of the biceps is sometimes called the 'supra-glenoid process.' The inner lip of the groove is smooth and rounded, and in well-marked bones shows a shallow transverse depression about its middle for the passage of the 'ventral branch of the dorsalis scapulæ artery.' The inner lip and the bottom of the groove give origin in their whole extent to the 'subscapularis' muscle.

Of the *angles* of the body of the bone the *external* has been already described as forming the head of the bone. The *inferior* is the thickest, and, if the sides forming it were prolonged, the most acute. Posteriorly it gives origin to the 'teres major,' occasionally to a few fibres of the 'latissimus dorsi,' and anteriorly to the 'serratus magnus.' The *superior angle* is the thinnest, forms somewhat less than a right angle, and gives attachment to the 'levator anguli scapulæ.'

Spine.—This process can be plainly felt in the living subject, as it rises into a high crest, which runs towards the neck of the

scapula, where it stands out from the rest of the bone, and suddenly altering its direction at a right angle, projects forwards so as to form a lofty arch overhanging the 'glenoid cavity.' This arch is termed the 'acromion' (*ἄκρος, ὤμος*). It protects the shoulder joint and gives great leverage to the powerful 'deltoid' which raises the arm. It is not only a defence, but prevents luxation upwards: without this the head of the humerus would not remain a moment in its socket. It is this process which gives breadth to the shoulder. On the inner border of the acromion is the surface which articulates with the clavicle; this surface slants from above inwards, so that the clavicle, once dislocated, is with difficulty kept in its place. The end of the acromion gives attachment to the coraco-acromial ligament, which bridges over the gap left in the bone between it and the coracoid process, and thus completes the arch for the shoulder. Through this coraco-acromial ligament we pass the point of the knife, in excising the head of the humerus, and thus reach the shoulder joint in a moment.

SPINOUS PROCESS.—This is a triangular plate of bone rising backwards and slightly upwards from the posterior surface of the body at about the junction of its upper fourth with its lower three-fourths. It presents an *upper* and *lower surface* with *anterior*, *posterior*, and *external borders*. The *upper surface* is smooth and hollowed in every direction, contributes to form the supraspinous fossa, and gives attachment to the 'supraspinatus' muscle. The *inferior surface* presents similar appearances, and affords origin to the 'infra-spinatus' muscle. The *anterior border* is continuous with the body of the bone. The *posterior* seems more a surface than a border. Tracing it from within outwards, we notice, first, a smooth triangular surface over which the 'trapezius' glides, next a rough constriction, next a widened rough part with a prominent tubercle on it (sometimes called the 'deltoid tubercle'), then a narrowed rough part, and finally a widened rough portion continuous with the superior surface of the acromion process. The upper lip of the posterior border gives insertion to the 'trapezius.' The lower lip affords origin to the 'deltoid,' in its whole extent, excepting the lower margin

of the triangular space at the inner extremity of the posterior border, which margin affords insertion to the lowest fibres of the 'trapezius.' The surface between the lips gives attachment to the interlacing fibres of the muscles. The *external border* is continuous above and behind with the inferior surface of the acromion process, and below and in front with the posterior surface of the neck of the bone. It is smooth, convex from above downwards, and concave from behind and above downwards and forwards. The posterior border of the spine can be plainly felt in the living subject as a crest running upwards and outwards from the vertebral border towards the back of the shoulder joint, where it becomes continuous at an obtuse angle with the subcutaneous upper surface of the acromion.

ACROMION PROCESS.—This process we may describe as a continuation and flattening out of the posterior border of the spine. Its plane is therefore at right angles to that of the spine. In its long axis, it runs at first outwards and upwards in the same direction as the posterior border of the spine. It then turns somewhat suddenly forwards, upwards, and outwards, to terminate in a flattened point, joined to the coracoid process by a ligamentous band. The acromion and coracoid processes, with the ligamentous band between them, form a bony and ligamentous arch overhanging the head of the humerus as it plays in the glenoid cavity of the scapula. We describe the process as possessing *superior* and *inferior surfaces* with *internal* and *external borders* and an *anterior extremity* or *tip*. The *superior surface* looks as much backwards as upwards. It is continuous with the posterior surface of the spine and is widest about the junction of its inner third with its outer two-thirds. It is marked by a number of nutrient foramina, and is especially rough in the neighbourhood of the internal border, where it gives insertion to the 'trapezius,' and of the external border, where it gives origin to the 'deltoid.' The intervening space between these roughnesses gives attachment to the interlacing fibres of the muscles. The *inferior surface* is smooth and slightly concave in its inner half, rough and marked by a number of nutrient foramina in its outer half. It looks forwards as well as downwards. The

internal border is concave in its long axis. Its inner two-thirds shows an impression for the insertion of the uppermost fibres of the 'trapezius.' Its outer third presents an oval articular facet directed upwards and inwards for articulation with the corresponding surface of the clavicle. This facet shows reverse appearances to those already described as belonging to the articular facet on the outer end of the flat part of the clavicle, i.e. it is slightly concave from before backwards and convex from above downwards to allow of the double hinge motion existing at the acromio-clavicular joint. The *external border* is rough throughout for the origin of the middle fibres of the 'deltoid.' It presents at the junction of its inner third and its outer two-thirds a prominent angle looking downwards, backwards, and outwards. This angle is called the 'tip of the shoulder,' and is an important landmark in the living body, as from it we measure the relative lengths of the arms. The *apex* of the acromion is rough, points slightly downwards as well as forwards, and gives attachment to the coraco-acromial ligament.

Coracoid Process.—From the upper border of the neck of the scapula stands off a projection termed the 'coracoid process,' from its fancied resemblance to the beak of a raven (*κόραξ*). Arising from a very broad base, it takes first a direction upwards, forwards, and inwards, but soon curves forwards and outwards towards the acromion, like a half-bent finger, and overhangs the glenoid cavity on the inner side. Its apex is about one inch and a half from the point of the acromion, and on a lower plane. It is necessary to be familiar with the direction of these points of bone, and their accurate bearing to the glenoid cavity and to each other, since they serve as landmarks in determining the nature of obscure injuries about the shoulder. Into the front part of the coracoid process is inserted the tendon of the 'pectoralis minor,' and from the 'apex' arises the common tendon of the 'coracobrachialis,' and the 'short head of the biceps.' At the upper part of the root of the process is a rough surface for the attachment of the 'coraco-clavicular' ('conoid' and 'trapezoid') ligaments which bind down the clavicle; and the border next to the acromion gives attachment to the 'coraco-acromial ligament,' which extends

across the interval between the coracoid and acromion, and completes the arch over the shoulder joint.

The process is conveniently divided into a vertical and a horizontal portion. The *vertical part* is flattened from before backwards. Its anterior and posterior surfaces are smooth, continuous with the anterior and posterior surfaces of the neck of the bone, below, and with the inferior and superior surfaces of the horizontal portion, above. The external border is rounded and slightly rough, affording attachment to the coraco-humeral ligament, while the internal border is smooth and narrow, forming the outer side of the suprascapular notch below and giving attachment to the suprascapular ligament above. The *horizontal portion* presents a superior surface twisted in its long axis in such a way that while it looks upwards, inwards, and a little forwards at its inner end it looks slightly upwards and inwards and mostly forwards at its outer end. At the inner extremity of this surface there is a rough eminence called the 'conoid tubercle,' because it gives attachment to the 'conoid' ligament. Leading forwards and outwards from this is a low rough ridge, joining the anterior border about half an inch inside the point of the process. The ridge is called the 'oblique ridge' and attaches the 'trapezoid' ligament. The anterior and posterior borders are rough for the attachment of the 'pectoralis minor' with the costo-coracoid membrane and coraco-acromial ligament respectively. The *apex* of the process is rough and marked by eminences and depressions for the common origin of the 'coracobrachialis' and the 'short head of the biceps.' In the living body one can feel the tip of the coracoid process by pushing one's finger backwards and outwards in the small triangular hollow situated on the front of the shoulder and bounded *above* by the outer part of the anterior border of the prismatic part of the clavicle, *inside* by the outer edge of the 'pectoralis major,' and *outside* the anterior border of the 'deltoid.' As the floor of the space is formed by a strong membrane stretching between the coracoid process and the first rib, and called the costo-coracoid membrane we may conveniently term the interval the 'costo-coracoid triangle.'

Connections.—The scapula is connected by its acromial process to the clavicle, which serves to keep well apart the shoulders. In its glenoid cavity it receives the head of the humerus.

Ossification.—The scapula has seven centres of ossification. The 'primary' centre, which appears a little behind the glenoid cavity about the seventh week of foetal life, forms all parts of the bone, except the coracoid process, the acromion, the inferior angle, and the base: these are cartilaginous at birth. There are two centres of ossification for the coracoid process. The chief centre, representing the true coracoid bone, appears soon after birth, and about the fifteenth year unites to the rest of the bone. The second centre, appearing somewhat later, is an epiphysis for the tip. About puberty, the other secondary centres appear; namely, two for the acromion (one near the summit, the other near the base); one for the inferior angle; and, lastly, one for the border of the base. They all unite to the scapula about the twenty-second year.⁶² In a practical point of view it is well to remember that the acromion is not invariably united to the spine by bone. In some rare cases it remains permanently distinct, and is united to the spine only by ligament, and may be mistaken for a fracture.

Structure and Mechanism.—The scapula is a flat bone, composed of two plates of compact tissue separated by cancellous tissue wherever the bone is thickened. The cancellous tissue is therefore especially deposited in the borders and angles of the body and in the various processes. The bone is flattened to afford attachment to the large rotators of the humerus and also to conform nicely to the shape of the chest wall, on which it glides in its different movements. The head is the most important part, all other parts of the bone being subservient to it. The spine, acromion, and coracoid arch over it, while the costæ diverge from it. The centre of the head is situated at the strongest part of the bone. It lies at the end of the line of junction of three ribs or plates of bone formed by the spine, the upper and the lower parts of the blade (fig. 57). If we look at a vertical section of the bone we notice that the angles formed by these plates are nearly equal. By this reason, therefore, the holding power of the muscles on

the head of the humerus is nearly equal above, behind, and in front. The coracoid and acromion form a secondary shoulder joint for the play of the upper extremity of the humerus.

FIG. 57.



If the area be raised above a right angle the scapula rotates forwards round the middle of its blade. Its lower angle comes forward, the movement taking place at the sterno-clavicular joint.

Comparative Osteology.—The scapula is present in all mammalia.


In ruminants the coracoid and acromion are absent.

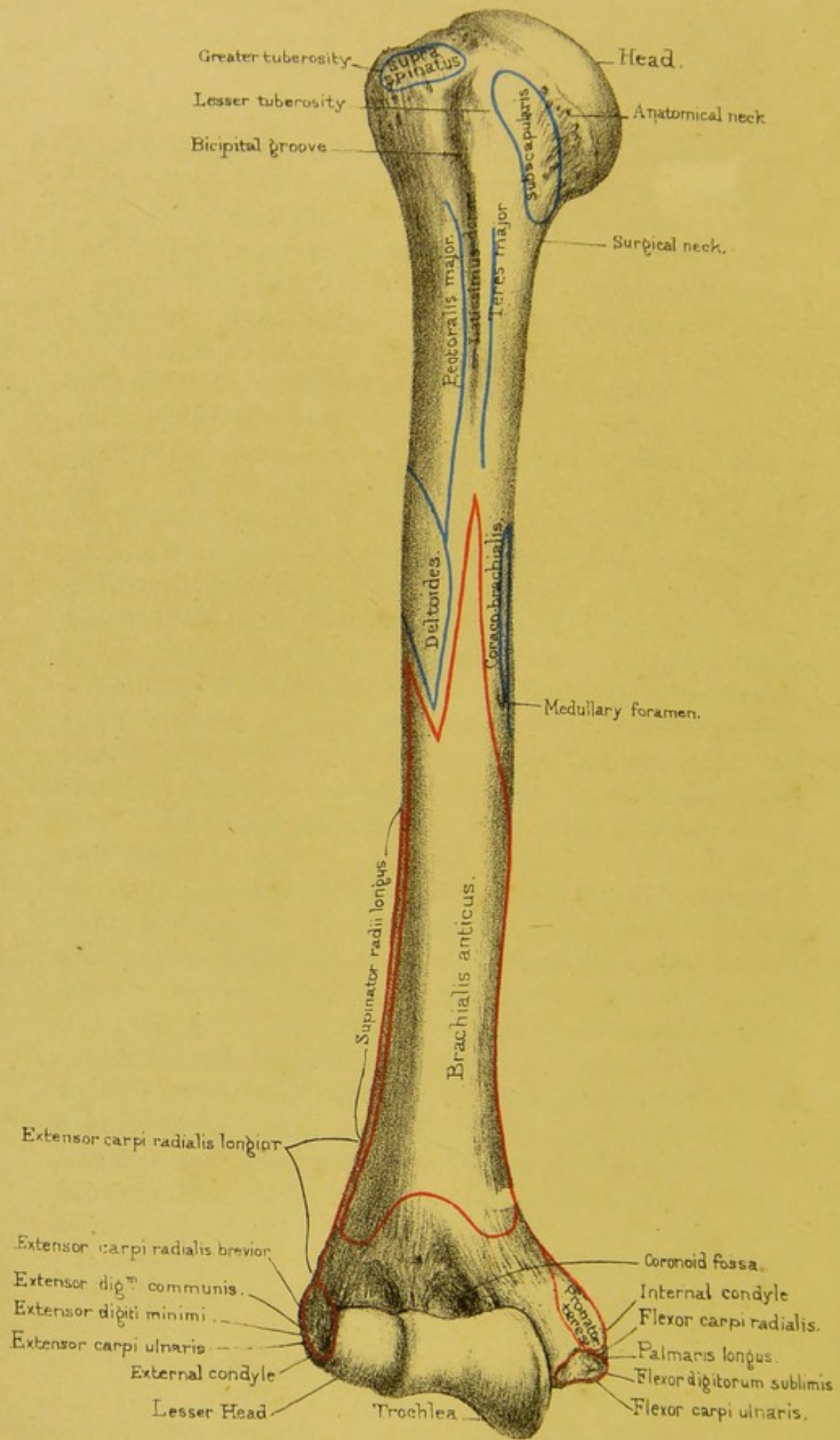
The elephant, rhinoceros, pig, and tapir have a very large process at the lower part of the spine, to which in man is attached a portion of the trapezius.

The suprascapular notch is converted into a foramen by ossification of the ligament in the two-toed sloth (No. 3434).

The coracoid process is a remarkable bone in birds. In them it is of great strength and solidity, and extends from the sternum to the scapula, where it helps to form the glenoid cavity. It forms a buttress on each side, which supports the shoulder during the downward stroke of the wing. This process never articulates with the sternum in any mammal excepting in the ornithorynchus and the echidna.

On the top of the sternum of the echidna (No. 3952) there is a T-shaped bone called the episternum. On each side of its lateral branches lies a thin plate of bone, which is the clavicle in this animal. Extending forward from the glenoid cavity towards the top of the sternum is a block of bone which corresponds to our coracoid process, and on the top of this is a second piece of bone called the epicoracoid. The coracoid being, as we may say, in two pieces is not surprising, seeing that in us the coracoid has two centres of ossification which now and then remain separate. This coracoid will be seen to enter into the formation of the glenoid cavity.





Humerus. anterior view.

Drawn on Stone by T. Godart.

From nature by L. Holden.

Printed by West, Newman & Co.

THE HUMERUS.

(PLATES L., LI.)

The humerus is the longest and strongest of the bones of the upper extremity. It is a lever of the third order, the fulcrum being at the shoulder joint, and the power at the insertions of the several muscles which move the bone. It articulates with the scapula above, and the radius and ulna below. Like all the long bones, it has a 'body' or 'shaft,' and an 'upper' or a 'lower extremity.'

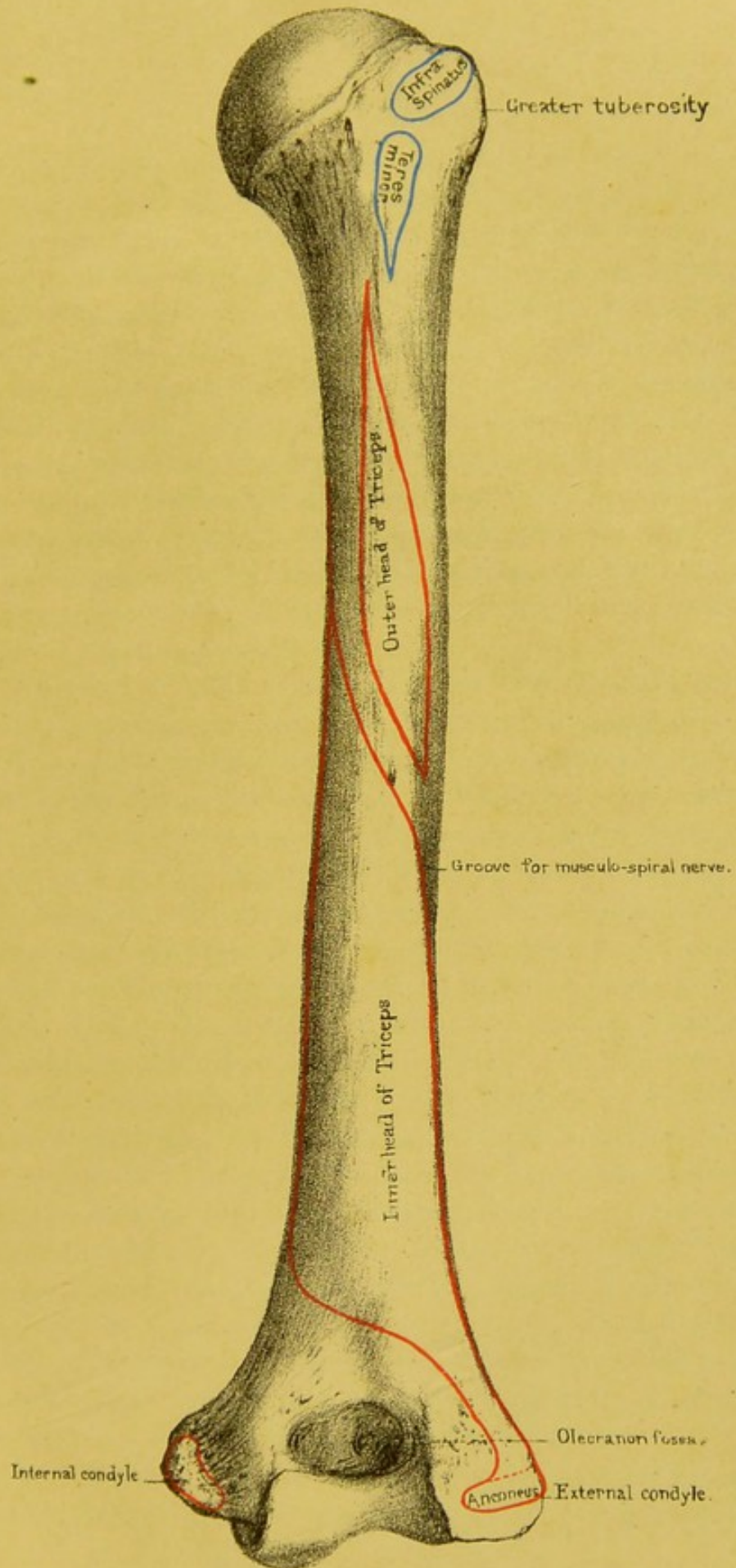
Upper Extremity.—**HEAD AND NECK.**—At the upper end is the smooth eminence termed the 'head.' It forms about one-third of a sphere, and articulates with the glenoid cavity of the scapula. The head of the humerus is much larger than the socket in which it plays. This arrangement, together with the shallowness and direction (p. 285) of the socket, explains the great range of motion which the shoulder joint enjoys. It is the freest of all the joints, and resembles what mechanics call a 'universal' joint: there is no part of the body which cannot be touched by one hand or the other. The head springs from the shaft by a slightly constricted base, called the 'anatomical neck,' to the outer margin of which the capsular ligament of the joint is attached, and which is marked by a number of large nutrient foramina in front, below, and behind. Although this part of the bone is so short and thick as hardly to deserve the name of neck, yet it serves the important purpose of removing the head a little away from the axis of the shaft. In consequence of this, the axis of the head and neck forms an obtuse angle with that of the shaft. When the arm hangs quietly by the side, with the thumb in front, the precise direction of the axis of the head and neck of the humerus is upwards, inwards, and a little backwards from the shaft—a direction which facilitates rotation inwards. In the axis of the neck of the femur, where rotation outwards is more required than rotation inwards, this direction is reversed.

Raise the arm of the skeleton to a right angle, and you observe

that much of the lower part of the head of the humerus is out of the socket. This is one of the reasons why the humerus is so liable to be dislocated when the arm is extended; the head of the bone in this position being chiefly supported, below, by the fibrous capsule of the joint. Again, when the arm is raised to a right angle, there is another point worthy of notice: that the humerus *alone* cannot be raised higher, for the reason that the articular surface of the head of the bone does not admit of elevation beyond a right angle. When we do raise the arm beyond a right angle, the additional elevation is accomplished by the movement of the scapula upon the chest, an effect chiefly due to the action of the trapezius and serratus magnus muscles.


TUBEROSITIES.—At the root of the neck, or rather at the top of the shaft, are two projections, termed the ‘tuberosities,’ which give greater leverage to the muscles moving the bone. They are separated by a perpendicular groove which runs about three inches down the shaft, and is called the ‘bicipital groove,’ because the tendon of the long head of the biceps plays in it. Of these tuberosities the ‘*greater*’ is the more external. It presents an external surface, which is free, somewhat streaked vertically by slight grooves and ridges, and presents a few rather large nutrient foramina. Its upper border is marked by three flattened impressions, of which the middle one is the largest, for the insertion from before backwards of the ‘supra-spinatus,’ ‘infra-spinatus,’ and ‘teres minor’ respectively. Its anterior border is prominent, continuous with the anterior border of the shaft, and makes the upper part of the *outer lip of the bicipital groove*. Its posterior border is flattened and rough and gives attachment to the ‘teres minor.’ In a thin person it can be plainly felt immediately below the acromion, and the centre of its outer surface is in the same vertical line as the ‘external condyle’ at the inferior extremity. It is useful to know this in determining the nature of injuries about the shoulder. The ‘*lesser tuberosity*’ is the more internal, and points straight forwards. It is a rough conical eminence and gives insertion to the ‘subscapularis.’

Shaft.—The first thing to be observed in the shaft is, that its lower part is twisted inwards, and that it is slightly curved



Humerus. posterior view.

Drawn on Stone by T. Godart.
From nature by L. Holden. Printed by West, Newman & Co.



forwards. This twist and curve make the axis of motion at the elbow such, that the forearm naturally bends towards the front of the body. The upper half of the shaft is more or less cylindrical; the lower half is prismatic, although somewhat flattened from before backwards below. Immediately below the tuberosities is the 'surgical neck' of the humerus; so called in contradistinction to the anatomical neck already described. Fracture of the surgical neck is common; of the anatomical neck rare. The muscles play an important part in causing displacement in fracture when it occurs through the surgical neck. There is often a double displacement: i.e. the upper fragment is drawn outwards by the muscles inserted into the tuberosities, and the lower fragment is drawn upwards and inwards by the muscles which go from the trunk to the arm.

The shaft presents three borders, *anterior*, *internal*, and *external*; and three surfaces, *internal*, *external*, and *posterior*.

The *anterior border* begins above as a continuation of the anterior border of the greater tuberosity, and runs down the front of the bone to terminate at the lower end by dividing into branches to enclose depressions in that situation, viz. the coracoid fossa, and the radial depression. In its upper third the border forms the outer lip of the bicipital groove and is rough for the insertion of the 'pectoralis major.' The upper part of its middle third is also rough, and forms the anterior edge of the eminence for the insertion of the 'deltoid.' In its lower third, and in the lower part of its middle third, it is smooth and rounded and gives attachment to the 'brachialis anticus.'

The *internal border* reaches from the lesser tuberosity to the internal condyle. Its upper fourth forms the inner lip of the bicipital groove for the insertion of the 'teres major.' About the middle, the border is rough for the insertion of the 'coracobrachialis,' and below that it becomes very prominent and distinct, and is called the '*internal condyloid ridge*,' for the attachment of the 'internal inter-muscular septum.' Immediately above the condyle the 'pronator radii teres' arises.

The *external border* runs from the posterior border of the greater tuberosity to the external condyle. It is indistinctly

marked above, where it gives attachment to the 'teres minor' and 'external head of the triceps.' In the middle it is hollowed by the commencing 'musculo-spiral groove,' and below it is very prominent, forming the *external condyloid ridge*, for the attachment of the 'external intermuscular septum,' 'supinator longus,' and 'extensor carpi radialis longior.'

The *internal surface* lies between the anterior and internal borders. It looks forwards at its upper end and forwards and inwards below. Its upper fourth forms about the lower two-thirds of the *bicipital groove*, for the passage of the long tendon of the 'biceps.' The surface here is rough for the attachment of the 'latissimus dorsi.' Towards the lower and back part of the middle third we notice an elongated roughness for the insertion of the 'coraco-brachialis' and immediately below that the *medullary* foramen, directed downwards. In the lower third the bone is smooth and gives origin to the brachialis anticus.

The *external surface* looks backwards and outwards above, forwards and outwards below. Its upper third is smooth and rounded. Its middle third shows in its upper part a large triangular rough eminence—the *deltoidal eminence*—for the insertion of the 'deltoid.' The base of the triangle is above, and its superior angles in well-marked bones are usually prolonged for a short distance up the bone. The lower part of the middle third presents the *musculo-spiral groove*, smooth and running downwards and forwards for the transmission of the musculo-spiral nerve and vessels. The lower third of the surface is more or less smooth and gives attachment to the 'brachialis anticus.' It is generally below the insertion of the deltoid that ununited fractures of the humerus are met with, partly on account of the injury to the nutrient artery, and partly on account of the action of the deltoid in causing a displacement of the upper fragment over the lower.

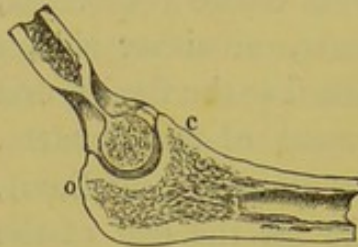
The *posterior surface*, in its upper third, is rounded transversely and gives attachment quite at its upper end to the teres minor and in the rest of its extent to the 'external head of the triceps.' In its middle third it shows the commencement of the musculo-spiral groove. The remainder of the surface is some-

what flattened, and even concave transversely below, for the attachment of the 'internal head of the triceps.'

Lower Extremity.—The lower end of the humerus curves slightly forwards, and is much flattened from before backwards, and widened from side to side. It presents, on either side, a condyle with articular surfaces between, suited to the flexion and extension, as well as the rotatory movement of the forearm. On the outer side, we observe the 'lesser head' (*capitellum*), which corresponds with the shallow cavity at the end of the radius. The chief point about this head is, that it projects directly forwards, so that when the forearm is bent there is a smooth surface ready for the rotation of the radius. On the inner side is the 'trochlea' or pulley for the ulna. This admits of flexion and extension only. The direction of this pulley is oblique; that is, it slants from behind forwards, and from without inwards, so that the forearm, in the act of bending, comes naturally in front of the chest. Observe that the inner border of the trochlea descends much lower than the outer, thus protecting the ulna from dislocation inwards. The downward projection of the inner edge of the trochlea allows also for the divergence of the upper end of the humerus, and enables the bones at the elbow joint to fall inwards and adapt themselves to the contour of the trunk in that neighbourhood. Above the trochlea there is a deep cavity in front (*coronoid fossa*) which receives the coronoid process of the ulna in flexion; and a similar but deeper one behind (*olecranon fossa*) receiving the 'olecranon,' or the point of the elbow, in extension of the forearm. External to the coronoid fossa, immediately above the lesser head, is a shallow depression (*radial depression*) for the head of the radius in extreme flexion. Between the 'olecranon and coronoid fossæ' the bone is translucent, as is well seen in fig. 58, which exhibits a section through the joint. In consequence of this thinness, a transverse fracture through the humerus in this situation is not uncommon. From the displacement produced so close to the elbow joint this accident is very liable to be mistaken for a dislocation of the radius and ulna backwards. However, the bearing of the condyles with respect to the olecranon enables us

in most cases to determine the diagnosis. If the olecranon be higher than the condyles, there is dislocation of the elbow; if not higher, the ulna is in its proper place.

FIG. 58.



SECTION TO SHOW THE TROCHLEA OF THE HUMERUS.

o. Olecranon
c. Coronoid process.

The *internal condyle* projects more than the external, and gives origin to the powerful pronator and flexors of the hand and fingers, namely, to the 'pronator radii teres,' 'flexor carpi radialis,' 'palmaris longus,' 'flexor sublimis digitorum,' and 'flexor carpi ulnaris.' The internal lateral ligament of the elbow is also attached to it.

The *external condyle* is not so prominent as the internal. It is flattened, and gives origin, in front, to the common tendon of the extensor muscles; namely, the 'extensor carpi radialis brevis,' 'extensor digitorum communis,' 'extensor minimi digiti,' and 'extensor carpi ulnaris:' behind, it gives origin to the 'anconeus.' Lastly, the external lateral ligament of the elbow is attached to it.

Connections.—The head of the humerus articulates with the glenoid cavity of the scapula at the shoulder. At the lower end on its outer side is a round convex surface which articulates with the cup on the top of the radius; while the trochlea is adapted to the form of the sigmoid cavity of the ulna.

Ossification.—The humerus has seven centres of ossification. There is one for the shaft, which appears about the seventh week of foetal life, when the foetus is about an inch long.

- 1
- 2 About the second year after birth the centre of the head appears;
- 3 and about the third year, the centre of the great tuberosity.
- 4 The centre for the lesser tuberosity appears about the fifth year, or it may be produced by an extension of the ossification of the great one. About the end of the fifth year the centres for the head and tuberosities have coalesced, and form a large epiphysis, which joins the top of the shaft about the twentieth year. It is necessary to remember that this epiphysis includes the tuberosities (see fig. 59). On the inner side, the line of junction runs
- 5

close to the cartilage on the head of the bone: therefore, in the event of separation, the shoulder joint would certainly be implicated.

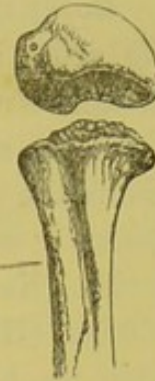5- About the beginning of the third year, ossification of the lower end commences by a fourth centre in the lesser head. About the fifth year, a fifth centre appears in the internal condyle. About the twelfth year, a sixth centre appears in the great sweep of the trochlea; and, lastly, about the thirteenth year, the seventh centre appears in the external condyle. The centres for the external condyle, capitellum, and trochlea coalesce and form an epiphysis which joins the shaft in the sixteenth or seventeenth year. The epiphysis formed by the internal condyle does not join the shaft till the eighteenth year. Therefore there may be a separation of the upper epiphysis from the shaft by violence as late as about the twentieth, but of those at the lower end not later than about the sixteenth, seventeenth, or eighteenth year. (See Nor. Hum. Ost. No. 54.)

6
7

It is interesting to remark, that the epiphysis of the upper end, though the first to ossify, yet remains separate from the shaft about two or three years longer than those of the lower end. This is in accordance with the rule, that, of the epiphyses of a long bone, those towards which the nutrient artery of the marrow runs, are always the first to unite with the shaft. Remember, that the nutrient arteries of the marrow of the bones of the upper extremity run *towards* the elbow. In the bones of the lower extremity, they run *from* the knee.

Structure and Mechanism.—The cancellous tissue follows the ordinary law, viz. that its spicules run at right angles to the plane of pressure. There is a well-developed ‘medullary cavity.’ Extensive movement at the upper end of the bone is obtained by the large size of the articular surface of the head and the small size and shallowness of the ‘glenoid cavity.’ The tuberosities are applied close to the fulcrum; therefore great play is gained at the far end of the lever. The upper end is protected by over-

FIG. 59.



EPIPHYSIS OF
THE HEAD OF
THE HUMERUS,
SHOWING THAT
IT INCLUDES
TUBEROSITIES.

hanging bony processes. The lower end is oblique, for the reasons we stated in its description (p. 289), and the motion taking place there too is limited in extent. The whole bone is twisted and curved, thereby gaining elasticity.

Comparative Osteology.—In man the legs are longer than the arms, and grow faster than the rest of the body after birth. In apes and monkeys the converse of this is true, and, after birth, the arms grow faster than the rest of the body. In most giants the great proportion of the height is due to the length of the lower extremity. It is curious that the right humerus of the gorilla (No. 20) is of the same length as that of the Irish giant O'Brien (Hum. Ost. Ser. No. 223), who stood about eight feet, while the height of the gorilla is only four feet four inches. The left humerus of O'Brien is 20 mm. shorter than the right, and there exists a similar difference in the two humeri of the gorilla. It may be well to mention that the corresponding bones of opposite sides commonly differ a little in length, without giving rise to any obvious deformity.

The olecranon and coronoid fossæ occasionally communicate by a small hole in man. This seems to be pretty constantly the case in the Bushman, gorilla, tapir, and dogs. (See Separate Series, Mus. Roy. Coll. Surg., as well as in the articulated skeletons.)

Above the inner condyle in many carnivora is a foramen (supra-condyloid) which transmits the median nerve and the brachial artery. (See Separate Series, Mus. Roy. Coll. Surg.: tiger, lion, and leopard.) A trace of this foramen occurs now and then in man by the ossification of a part of the fibrous band which passes over the median nerve and from which the pronator teres arises.⁶³

The deltoid ridge is especially prominent in the Carnivora (see that of the seal). It is extensive in the rhinoceros, the tapir, and the horse, which have heavy limbs to raise.

The tuberosities are very large in the heavy-limbed rhinoceros and the heavy-boned dugong.

Notice how extensive the supinator ridge is in the aye aye and the beaver.

In moles the clavicle articulates with the humerus (No. 3329).

There is no complete articulation between the humerus and forearm in Cetecea, nor between their carpus, forearm or digits; the upper extremity forming a flipper which has free movement only at the shoulder joint. (See the Cachalot Whale.)

In flying birds, notice the large foramen, at which the air enters the cavity in the bone immediately below the head, and feel the great lightness of their bones. The humerus of the adjutant (No. 1306) is a mere shell. A bone of this bird, thirteen inches long, weighed only half an ounce, while a corresponding one seventeen inches long of an ostrich weighed half a pound, that is, it was sixteen times as heavy.

In snakes there is no trace of fore limb, and consequently no humerus (No. 629).

Near the end of the humerus of the turtle there is a line which may appear to denote an epiphysis, but it simply marks the limit to which the cartilaginous cap extended in the recent bone (see No. 1016). These animals have no epiphyses.

THE RADIUS.

(PLATES LII., LIII.)

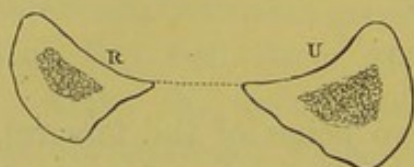
The radius is the external of the two bones of the forearm, and is so called from its resemblance to the spoke of a wheel. In learning this bone, keep in mind that both its ends move upon the ulna, and admit of the pronation and supination of the hand. It is a long bone with its inferior extremity much expanded for the support of the wrist, and its upper end small, entering but slightly into the formation of the elbow joint.

Upper Extremity.—The upper extremity of the radius presents the 'head,' 'neck,' and 'tubercle' for description. The 'head' has a shallow circular cup above, which articulates (when the forearm is bent) with the lesser head of the humerus, and in the recent state is held in its place by the strong 'orbicular' ligament which encircles it. 'The head' is surrounded by an articular surface narrower below than above to articulate with

the lesser cavity of the ulna. The broadest part of the surface (measuring vertically) rests in the lesser sigmoid cavity, when the bones are parallel. The narrowest part is situated on the opposite side of the head. The rotation of the radius can be distinctly felt in one's own person below the external condyle of the humerus; a fact of great value in determining the existence of fracture or dislocation. Below the head is the constricted part termed the 'neck,' which may be described as a truncated cone with its base upwards. It is surrounded by a continuation downwards of the orbicular ligament. The conical shape of the neck prevents the bone slipping down from its bony and ligamentous socket. Below this is the 'tubercle' which gives insertion to the tendon of the 'biceps.' The tubercle projects on the inner side of the bone, so that the biceps can *supinate*, as well as *bend*, the forearm. The posterior half of the tubercle is rough for the insertion of the tendon; the anterior half is smooth, and is the seat of a bursa which facilitates the play of the tendon.

Shaft.—The outer side of the shaft is thick and rounded; and from it the anterior and posterior surfaces gradually converge

FIG. 60.



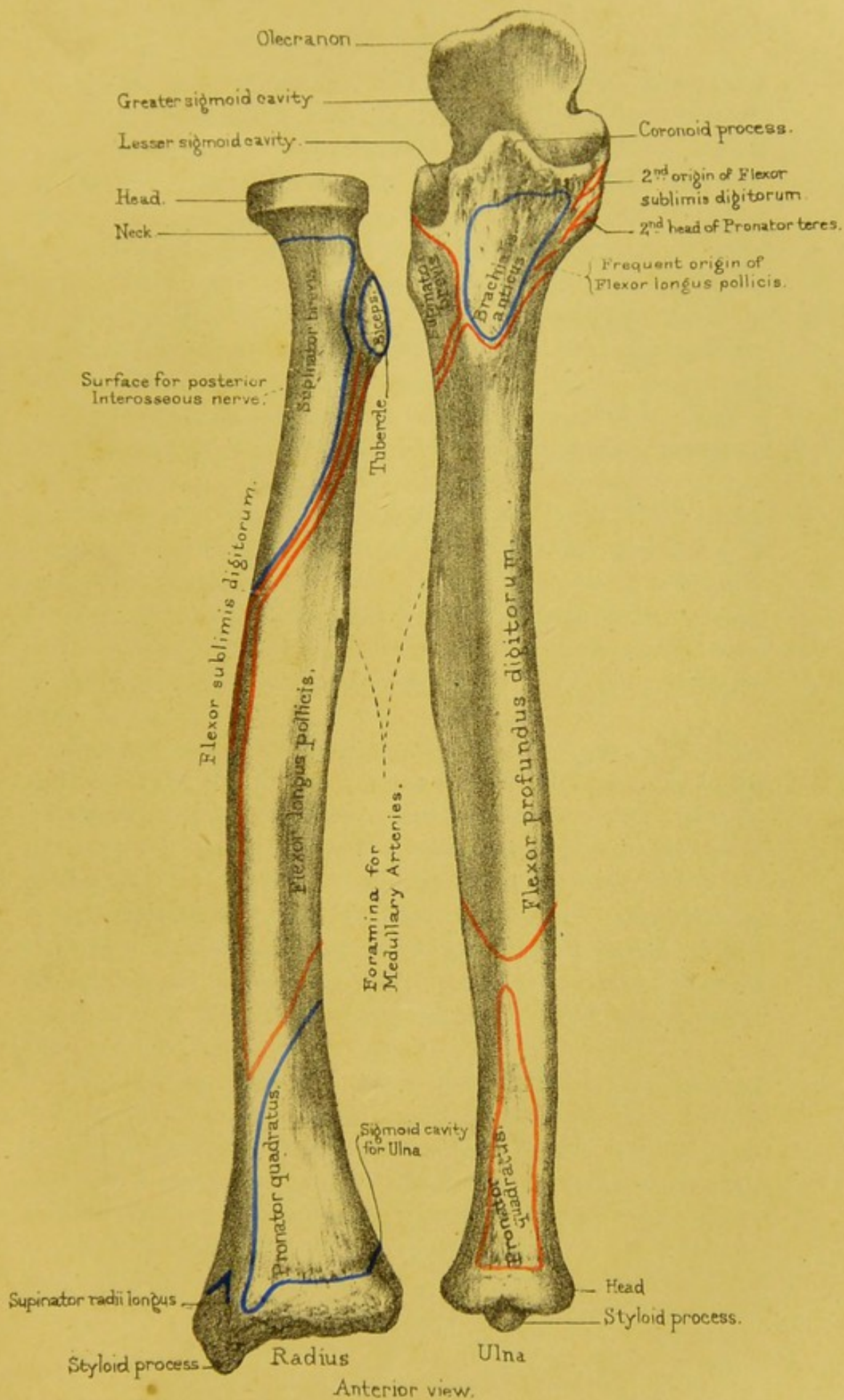
to a sharp edge, which faces a corresponding edge of the ulna (see fig. 60), and gives attachment to the interosseous membrane represented by the dotted line. The shaft is slightly arched outwards, by which

arrangement it increases the breadth of the forearm, and gives more power to the 'pronator teres.'⁶⁴ The shafts of the radius and ulna are farthest apart when the hand is placed vertically with the thumb uppermost: hence, fractures of the forearm are put up with the hand vertical, that there may be less risk of the opposite bones uniting.

The shaft increases in size, too, towards its lower end, for the support of the hand.

Looking at the bone more carefully, we notice that the shaft presents an *anterior*, *posterior*, and *internal border*, separating *anterior*, *posterior*, and *external surfaces*.


The *anterior border* is continuous above with the front of the



Drawn on Stone by T. Godart.

From nature by L. Holden.

Printed by West, Newman & Co.



tuberosity, runs downwards and outwards in its upper part, vertically downwards in the rest of its extent, and terminates in a narrow but prominent vertical ridge at the front of the outside of the lower end of the bone for the insertion of the 'supinator longus.' The upper oblique portion is called the *oblique line of the radius*, and gives insertion to the 'supinator brevis' and origin to the 'flexor sublimis.' The middle part is rather rounded, and gives attachment to the thin but variable origin of the latter muscle. The lower fourth is more prominent and affords insertion to fibres of the 'pronator quadratus.'

The *posterior border* commences at the outside of the back of the neck and terminates at the outside of the back of the lower end of the bone. It is only in the middle third that it exists as a border at all. Here it is prominent and forms the posterior boundary of the impression for the insertion of the 'pronator radii teres.' In the upper and lower thirds the border is imaginary, but for convenience of description of the surfaces we suppose the upper and lower ends of the prominent border in the middle third of the shaft to be prolonged to the upper and lower extremities of the bone.

The *internal or interosseous border* is the most prominent of the three borders. When the bones are in a position parallel to one another it faces a corresponding border upon the ulna. It commences at the back of the bicipital tuberosity and terminates below in two branches which enclose a surface at the lower end of the bone for articulation with the head of the ulna. Its upper end is smooth and rounded, its middle half or so is very sharp and prominent, and its lower fourth is somewhat flattened. It gives attachment to the interosseous membrane which stretches between the two bones.

The *anterior surface* lies between the anterior and internal borders. It is slightly hollow in its upper two-thirds, where it gives origin to the 'flexor longus pollicis,' increases in breadth and gets flattened in its lower third, where it affords insertion to the 'pronator quadratus.' Somewhere in the upper third, and near the internal border, we notice the medullary foramen, directed upwards.

The *posterior surface* is rounded and rough at its upper part for the insertion of the 'supinator brevis,' hollowed in the middle for the origin of the 'extensor ossis metacarpi pollicis' and 'extensor primi internodii pollicis.' It is convex from side to side and twisted outwards in its lower part, and shows the commencement of grooves, specially marked on the back of the lower end of the bone, for the transmission of the extensor tendons.

The *external surface* is rough and rounded in its upper third, presents a flat rough impression in its middle third (best marked towards the posterior border), for the insertion of the 'pronator radii teres,' and gets smooth and narrow below, where it shows a commencing groove for the passage of the 'extensor ossis metacarpi pollicis' and 'extensor primi internodii pollicis' tendons.

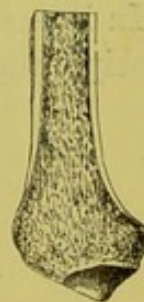The insertion of the 'pronator teres' being at the outer and *back* part of the shaft, gives the muscle greater power of pronation. In amputation of the forearm it is desirable to saw through the bones below the insertion of this muscle, that the stump may have the benefit of a pronator.

Lower Extremity.—The lower end of the radius expands into an inferior surface, slightly cupped transversely, as well as from before backwards, which articulates with the 'scaphoid' and 'semilunar' bones of the carpus. In the recent state, if not in the dry bone, this surface is divided by a slight ridge: the part for the 'scaphoid' is triangular, while that for the 'semilunar' bone is square. On its inner side is the concave articular surface ('semilunar' or 'sigmoid' cavity), which glides upon the lower end of the ulna. The direction of this surface is upwards and inwards. The radius is thereby prevented from being thrust upwards from the ulna by shocks transmitted to it from the hand below, and by means of this surface shocks also are partly distributed directly to the ulna. On its outer side is the conical projection, termed the 'styloid' process, of which the apex gives attachment to the external lateral ligament of the wrist; while the base gives insertion to the tendon of the 'supinator radii longus,' and the outer surface presents a groove directed downwards and forwards for the transmission of the 'extensor ossis

metacarpi' and 'extensor primi internodii pollicis' tendons. In front, the lower end has a rough and elevated margin for the attachment of the powerful anterior ligament of the carpus: and behind there are three grooves for the passage of the extensors of the wrist and fingers. (Plate LVI.) Beginning from the outer side, we observe: 1, a groove for the 'extensores carpi radiales, longior' and 'brevior'; 2, a very distinct and slanting groove for the 'extensor secundi internodii pollicis'; 3, a groove for the 'extensor indicis' and the 'extensor communis digitorum.' In the recent state these grooves are made complete canals by the 'posterior annular ligament.' Notice that the external lip of the groove for the 'extensor secundi internodii pollicis' is the more prominent. The tendon as it lies in the groove makes a sudden bend outwards, and this projection of the outer lip acts as a pulley for the tendon when the muscle is in action.

The lower end of the radius is composed of cancellous tissue covered by a thin layer of compact bone, as shown in the adjoining fig. (61). It falls, therefore, upon the palm of the hand; the lower end of this bone, which receives the full force of the shock, is very liable to be broken transversely about half an inch or an inch above the wrist joint. This fracture of the radius is commonly called Colles's fracture, after the Irish surgeon who first accurately described it. The lower fragment, with the hand, is thrown backwards, so as to make an unnatural swelling on the back of the forearm: the upper fragment protrudes on the palmar aspect of the forearm just above the wrist. Now a fracture with such displacement is liable to be mistaken for a dislocation of the wrist. The two injuries may be distinguished as follows: If the styloid process be in the same line with the shaft of the radius, the injury is probably a dislocation of the wrist backwards: if it be not in the same line, there is probably a fracture of the lower end of the radius, which is by far the more frequent accident of the two.

FIG. 61.



SECTION THROUGH THE LOWER END OF THE RADIUS, TO SHOW THE THINNESS OF ITS COMPACT WALL.

Connections.—The radius articulates above with the humerus,

and rotates in the lesser sigmoid cavity of the ulna. Below, it articulates with the scaphoid and semilunar bones of the wrist, and glides round the head of the ulna.

Ossification.—The radius has three centres of ossification: one for the shaft, and one for each end. The upper end begins to ossify at the fifth year, and is united at the seventeenth. The lower end begins about the second year, and is not united till the age of eighteen or twenty. (Nor. Hum. Ost. No. 54.) This is in accordance with the general law, that epiphyses unite with the shafts in the inverse order of their ossification.

Comparative Osteology.—In ruminants the ulna and radius are immovably united. The ulna is at the back of the radius, and forms a very prominent olecranon, on the top of which may be seen an epiphysis in the fore limb of the bison.

In the zebra (*Solidungula*) the ulna is represented by an olecranon adhering to the back of the radius, but in the elephant the ulna is very large and the radius is small. (See the Separate Series, Mus. Roy. Coll. Surg.)

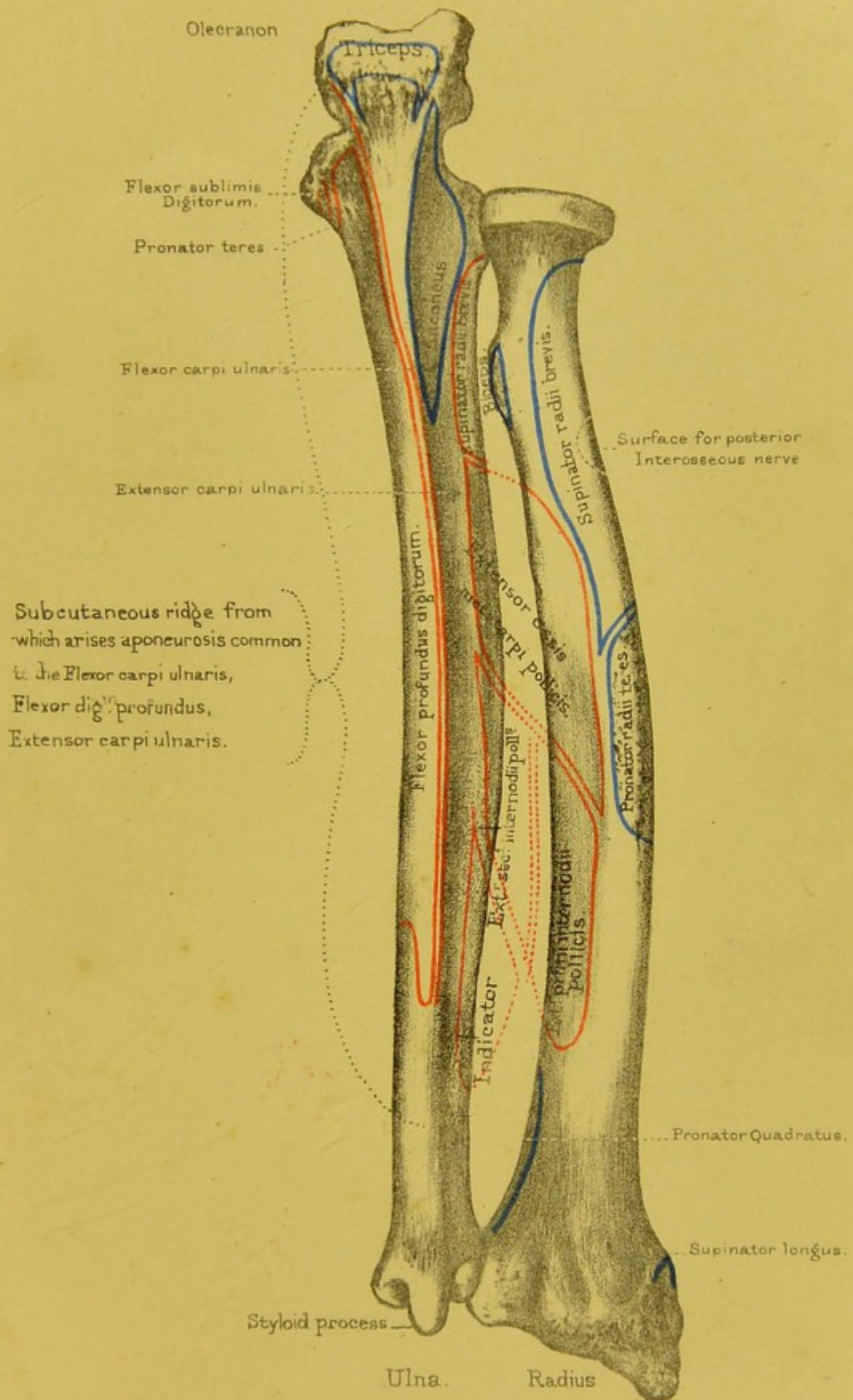
In bats and birds the radius is enormously long, forming the principal support of the wing in the former (No. 3383).

THE ULNA.

(PLATES LII., LIII.)

The ulna, so called because it forms the elbow (*ὀλένη*), is the inner of the two bones of the forearm. Looking at the bone generally, we notice that it presents the appearance of a long pyramid with the base above, in contradistinction to the radius, which has the base of the pyramid below. We notice too that it is longer than the radius by the projection upwards, at its upper end, of a process called the 'olecranon process.'

Upper End.—Its upper end presents a deep semicircular cavity, which accurately fits on the trochlea of the humerus, and forms a perfect hinge-joint admitting of flexion and extension



Posterior view

Drawn on Stone by T. Godart.

From nature by L. Holden.

Printed by West, Newman & Co.

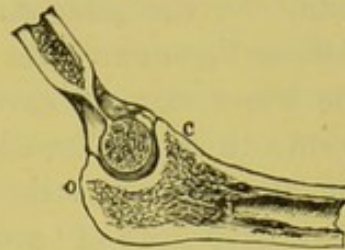


only. (See fig. 62.) This is called the 'greater sigmoid' ⁶⁵ cavity, as distinguished from a smaller one, termed the 'lesser sigmoid,' which is placed on its outer side, and forms a socket for the rotation of the head of the radius. The 'greater sigmoid cavity' is formed by the anterior surface of the olecranon and the superior surface of the coronoid process, a pyramidal eminence projecting forwards from the upper end of the bone.

It is marked by a smooth rounded elevation, running from above downwards, and dividing it into a larger internal portion, concave from side to side as well as from above downwards, and a smaller external portion, which is convex transversely at its upper and somewhat flattened at its lower extremity. The cavity is constricted from side to side, by two small notches situated rather below the middle of the inner and outer margins. These notches may be connected by a somewhat rough groove indicating the line of junction of the olecranon process with the shaft. The cavity is likewise constricted from above downwards by the projection into it of the points of the olecranon and coronoid processes. The 'lesser sigmoid cavity' lies partly on the outer side of the upper end of the bone, and partly on the outer side of the coronoid process. It is oval in shape, with the broad end backwards. The surface is smooth and articular and continuous with the articular surface of the greater sigmoid cavity. It is concave from before backwards, forming about the fourth of the circumference of a circle. It is very slightly concave from above downwards, and its lower edge is more prominent than its upper. In front, and behind, it is rough for the attachment of the orbicular ligament.

In front of the greater sigmoid cavity is a rough projection, termed the 'coronoid process' (*κορώνη*, the top of a curve). It is pyramidal in shape, with its *base* continuous with the upper end of the bone, and its *apex* free and pointing forwards and upwards. Its *upper surface* has already been described as forming the lower part of the greater sigmoid cavity. Its *inferior surface*

FIG. 62.

SECTION THROUGH THE
GREATER SIGMOID CAVITY
OF THE ULNA.

looks forwards and downwards, and is rough for the attachment of the 'brachialis anticus.' At the lower extremity of this surface we notice a rather well-marked projection—the 'tubercle of the ulna,' for the attachment of the 'brachialis anticus' and the oblique ligament. Its *outer surface* supports the fore part of the lesser sigmoid cavity, already described. Its *inner surface* is smooth and hollowed below, but rough above and in front for the attachment of the internal lateral ligament of the elbow joint, deep head of 'pronator teres,' 'flexor sublimis digitorum,' and occasionally an ulnar origin of the 'flexor longus pollicis.'⁶⁶ The coronoid process limits the flexion of the forearm. When the forearm is flexed on the arm as much as possible, the point of the process strikes against the fossa at the lower part of the humerus, and prevents further flexion. In dislocation of the ulna backwards the coronoid process is very liable to be broken: this complication makes reduction more easy, but subsequent retention of the bones in their proper place more difficult. Violent action of the 'brachialis anticus' may break off the coronoid process: but this is very rare. An instance of this happened to a boy about eight years old, in consequence of hanging with one hand from the top of a high wall.⁶⁷ When it is broken, the coronoid process unites by ligament, owing to the separation of the fragments by the 'brachialis anticus.'

Behind the sigmoid cavity is the 'olecranon' (ὀλένη, elbow, and κρᾶνον, head). It is a cubical piece of bone somewhat constricted at its *inferior surface*, where it is continuous with the upper extremity of the bone. Its *superior surface* is diamond-shaped, the anterior angle of the diamond overhanging the greater sigmoid cavity. The margins of the surface form the prominent upper lip of the same cavity. Immediately behind this lip there is a well-marked groove for the attachment of the posterior ligament of the elbow joint, and behind that the surface is marked by elevations and depressions for the insertion of the 'triceps.' The *anterior surface* is smooth and covered in the recent state by cartilage, and forms the larger part of the greater sigmoid cavity, already described. The *posterior surface* shows a smooth, triangular, and subcutaneous surface, the apex of the

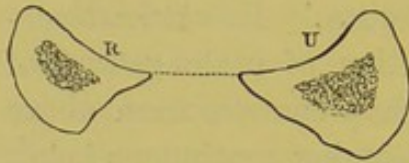
triangle being continuous with the posterior border of the shaft. The surface is somewhat streaked longitudinally in its upper part for the insertion of fibrous processes extending down from the tendon of the triceps. Its *inner surface* is rough above for the attachment of the internal lateral ligaments of the elbow joint, and smooth and rather hollowed below, where it fades into the inner surface of the shaft and gives origin to the 'flexor carpi ulnaris' and the 'flexor profundus digitorum.' Its *external surface* is rather rough above for the insertion of prolongations of the triceps tendon, and smooth and slightly concave from above downwards in the rest of its extent, becoming continuous below with the posterior surface of the shaft, and giving insertion to fibres of the 'anconeus.' We notice a number of small nutrient foramina on both inner and outer surfaces, and in the groove on the upper surface, of the process. The 'olecranon' serves many purposes and plays an important part in the perfection of the hinge of the elbow joint. It gives leverage to the 'triceps,' which is inserted into it and extends the forearm. It forms a convenient knob of bone for the protection of the joint when we lean on the elbow, and it limits the extension of the forearm. The surgical interest about it is, that it is sometimes broken by a fall upon the elbow; and the fracture generally takes place just at the slight constriction or notch where the olecranon joins the shaft: so that the joint is involved in the mischief. Fractures of the olecranon, like those of the patella and coronoid process, unite, generally, by ligament, because it is so difficult to keep the fragments in apposition. But if the tendinous expansion from the triceps be not torn, the union may take place by bone.

In almost all injuries about the elbow joint, however swollen the parts, one can always feel the olecranon and the internal condyle of the humerus. In determining, therefore, the nature of obscure injuries about this joint, it is useful to know that, when the arm is extended, the tip of the olecranon and the internal condyle are about one inch apart and in the same transverse line. When the arm is bent to a right angle, the olecranon is an inch and a half from the condyle and below it. By this test dislocation

of the ulna backwards and fracture through the lower end of the humerus can be distinguished.

Shaft.—The shaft of the ulna is triangular in cross section, and tapers gradually from the upper towards the lower end. The lower extremity inclines a little outwards towards the radius and terminates in the little ‘head’ round which the radius rolls. A

FIG. 63.



transverse section, seen in fig. 63, shows the shape of the radius and ulna about the middle. We observe that their sharp edges are turned towards each other, and that to these is

attached the interosseous membrane (represented by the dotted line) which connects the bones. Together, they form a shallow concavity in front and behind, wherein the muscles of the forearm are lodged. We notice too that the shaft is somewhat sigmoid from side to side when looked at in its long axis, presenting a convexity looking outwards in its upper third and a convexity in the opposite direction in its lower third. When viewed laterally it is pretty uniformly bowed backwards.

The body or shaft of the bone presents an *external, anterior, and posterior border*, bounding an *anterior, internal, and posterior surface*.

The *external border* begins above by two branches running to the front and back of the lesser sigmoid cavity, and enclosing a rough, hollowed, and triangular surface for the ulnar origin of the ‘supinator brevis.’ In its middle two-fourths it is very sharp and prominent, giving attachment to the interosseous membrane, and in the lower fourth it is rounded, approaches the anterior aspect of the bone, and terminates at the middle of the articular surface on the side of the lower extremity. The lower fourth affords attachment to fibres of the ‘pronator quadratus’ and to the interosseous membrane, which is thinned in this part of its extent.

The *anterior border* stretches between the ‘tubercle of the ulna’ superiorly, and the front of the root of the ‘styloid process’ inferiorly. It is smooth and rounded in its upper three-fourths, where it gives origin to the ‘flexor profundus digitorum.’

It is rough below, where it gradually twists towards the posterior aspect of the bone and gives attachment to fibres of the 'pronator quadratus.'

The *posterior border* gives attachment to a strong aponeurosis, which covers the muscles on the inner side of the forearm, and affords additional surface for the origin of the 'flexor carpi ulnaris,' the 'flexor profundus digitorum,' and the 'extensor carpi ulnaris.' The posterior edge (or ridge of the ulna, as it is generally called) deserves the more notice, because being subcutaneous it can be traced from the olecranon to the styloid process, and is therefore an important guide in cases of doubtful fracture. Before reaching the elbow the ridge becomes continuous with the posterior surface of the olecranon, which is also subcutaneous: here we feel for fractures of the olecranon.

The *anterior surface* lies between the external and anterior borders. It is concave from above downwards in its upper three-fourths, where it looks forwards and gives attachment to the 'flexor profundus digitorum.' Its lower fourth is somewhat convex from side to side, is directed inwards at its lower end, and gives origin to the 'pronator quadratus.' The lower fourth is marked off from the rest of the surface in well-developed bones by an oblique ridge running from the external border downwards, inwards, and backwards, to join the anterior border about an inch above the root of the styloid process. At the junction of the upper and middle thirds of the surface we notice the medullary foramen entering the bone obliquely upwards.

The *internal surface* lies between the anterior and posterior borders. It is continuous above with the inner surface of the olecranon process, looks backwards as well as inwards, and is somewhat flattened. It gets more and more convex, both from side to side and in its long axis as it is traced downwards, and gradually gains a direction so as to look nearly straight backwards at its lower end. It is smooth all over, and gives origin in its upper three-fourths to the 'flexor profundus digitorum.'

The *posterior surface* looks backwards and slightly outwards above, where it is continuous with the external surface of the olecranon process, but very slightly backwards and very much

outwards below, as it joins the lower extremity of the bone. It is divided into two very unequal parts by the 'oblique line of the ulna.' This is a ridge which runs obliquely from the posterior inferior angle of the lesser sigmoid cavity downwards and backwards to join the posterior border about the junction of its upper and middle thirds. The part of the surface above the line is continuous with the external surface of the olecranon, and is marked by a few low elevations, and has the 'anconeus' inserted into it. The part below the line is subdivided into two unequal parts by a vertical line or ridge, which commences in the oblique line, rather above its middle. It runs down the posterior surface in a slightly wavy manner, keeping nearly parallel to the posterior border of the bone, and gradually disappears about the junction of the lower fourth with the upper three-fourths of the posterior surface. The part of the posterior surface which is internal to this line is the broader. It is slightly hollowed from side to side in its upper part, somewhat rounded from side to side below. On it, without being attached to it, lies the 'extensor carpi ulnaris.' The part of the posterior surface external to the vertical line is somewhat broader above than below, slightly concave transversely, and rough in its upper three-fourths, and rounded and smooth in its lower fourth. The upper three-fourths is divided into three nearly equal impressions, which overlap one another from below and are marked off from one another by two oblique ridges running from the vertical line downwards and outwards to the external border of the bone. The impressions give attachment respectively, from below upwards, to the 'extensor indicis,' 'extensor secundi internodii pollicis,' and the ulnar origin of the 'extensor ossis metacarpi pollicis.'

Lower End.—The lower end of the ulna presents a rounded prominence of bone, plainly to be felt on the back of the inside of the wrist when the hand is pronated—the 'head' of the ulna and a short blunt process projecting from the inner and posterior side of the lower extremity—the 'styloid process.'

The 'head' is slightly rough in front for ligamentous attachment, concave from side to side behind, and smooth for the passage of the 'extensor carpi ulnaris' tendon. Externally it is

convex from before backwards, and slightly so from above downwards, smooth and articular, the upper edge overhanging the lower. The articular surface forms rather more than half a circle from before backwards, and on it the radius glides in pronation and supination of the forearm. The inferior surface of the head presents, externally, a semilunar, flattened, articular facet, continuous with the one on the outside of the head and articular for the triangular fibro-cartilage which separates it from the cuneiform bone of the carpus. Internally, where the lower surface joins the styloid process there is a rough depression for the attachment of the apex of the triangular fibro-cartilage.

The *styloid* process projects from the inner and back part of the lower end of the ulna, and thus does not interfere with the rotation of the radius; it gives attachment to the internal lateral ligament of the wrist. Between the process and the head there is a groove on the posterior aspect of the bone for the passage of the tendon of the 'extensor carpi ulnaris' (Plate LVI.); and externally the process is separated from the head by the depression for the attachment of the triangular fibro-cartilage of the wrist, already described.

The styloid processes of the radius and ulna can be readily felt beneath the skin, and are important guides in the determination of injuries of the wrist, whether fracture of the radius or dislocation. The relative position of the styloid processes with regard to the axis of motion at the wrist will settle the question.

Connections.—The ulna articulates, above, with the trochlea of the humerus and with the head of the radius; below, it articulates with the sigmoid notch of the radius, but is prevented from articulating with the cuneiform bone of the wrist, by the intervention of an interarticular fibro-cartilage.

Ossification.—The ulna has three centres of ossification—one for the shaft and coronoid process, one for the lower end, and a third for the olecranon. The lower end begins to ossify about the fifth year, and unites to the shaft about the twentieth. The top of the olecranon remains cartilaginous until the age of eight, about which time it begins to ossify: it coalesces with the base about puberty. (Nor. Hum. Ost. No. 54.)

Structure and Mechanism of Radius and Ulna.—Structurally the radius and ulna are typical examples of long bones. The ulna is longer than the radius by the olecranon process, and articulates to a greater extent with the humerus for steadiness. The radius is thick below and articulates to a greater extent than the ulna with the carpus. Shocks from the hand are therefore received directly by the radius, and transmitted to the ulna partly by the head of the ulna overhanging the sigmoid cavity of the radius, but chiefly by the interosseous membrane stretching between the shafts of the bones; the direction of the fibres of the membrane from the radius downwards and inwards to the ulna favours this transmission. In the act of pronation and supination the radius articulates with the ulna in a conical way. The centre of the head of the radius is the apex of the cone. The pit at the root of the styloid process is the centre of the base of the cone; that is to say, the centre of the base of the



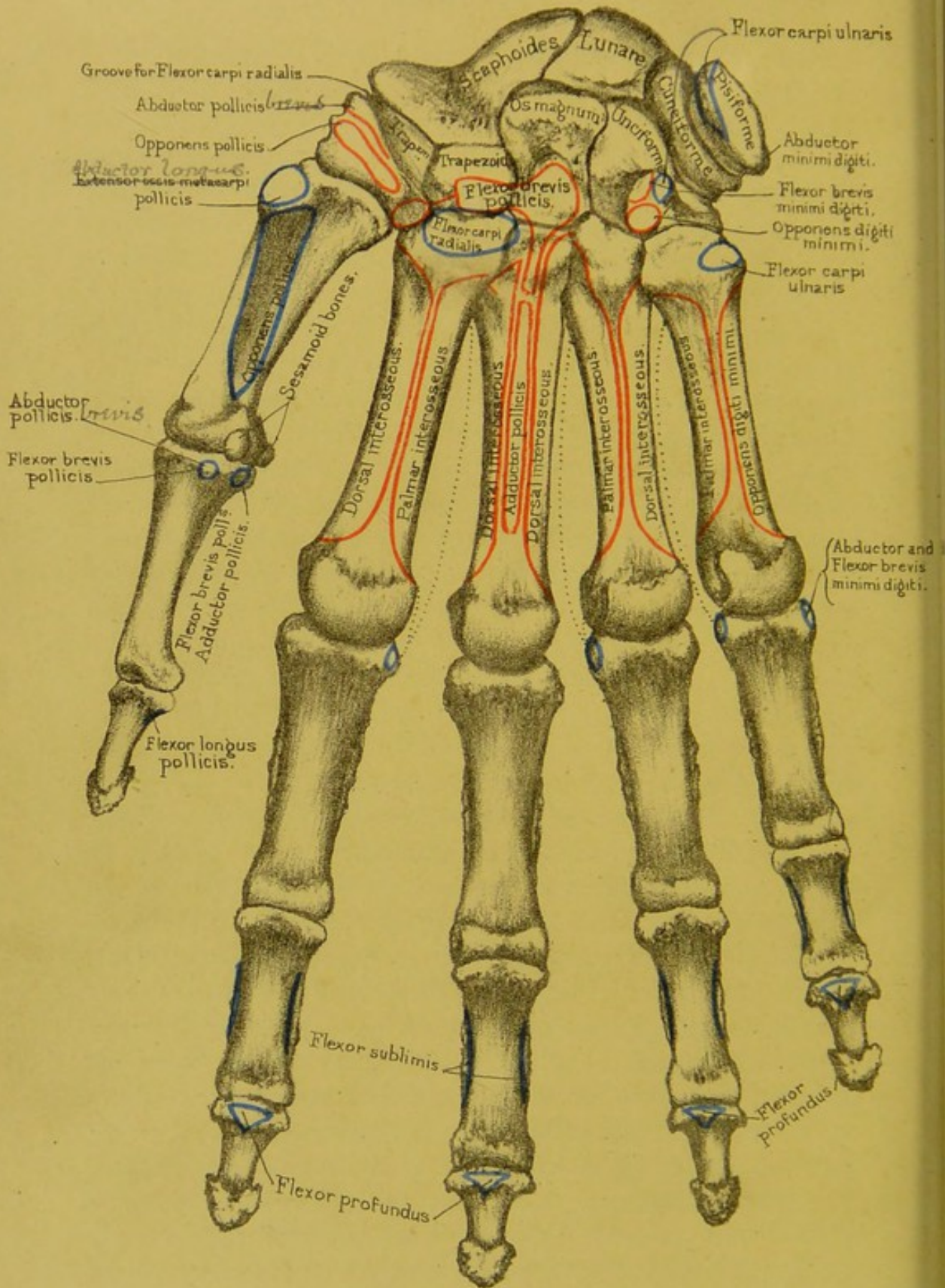


FIG. 64. cone is the centre of a circle of which the sigmoid cavity of the radius is part of the circumference. The axis of the cone therefore runs through the centre of the head and neck of the radius, leaves the shaft just below the tuberosity, crosses obliquely the interosseous space, and enters the ulna a little above its lower end and terminates at the pit at the root of its styloid process. Pure rotation consequently takes place at the superior radio-ulnar joint, and a gliding, circumductory, forward and backward motion at the inferior radio-ulnar joint. With pronation there is slight flexion of the elbow and with supination slight extension.

Comparative Osteology.—The ulna in many birds will be seen to be very long, like the radius, forming the largest part of the length of the wing, and to be dotted by a line of small tubercles along its outer surface where the winged feathers are attached. See the length of the ulna in the Frigate bird (No. 1188 A) and the prominent feather-tubercles in the Adjutant (No. 1306). Contrast the great length of the ulna and radius in the swift-flying birds, as the Frigate (No. 1188 A) and Albatross (No. 1189), with the shortness of those which do not fly, as the Great Auk (No. 1118), the Ostrich (No. 1362), and the Cassowary (No. 1357 A).





Palmar surface.

Drawn on Stone by T. Godart.

From nature by L. Holden.

Printed by West, Newman & Co.

BONES OF THE HAND.

(PLATES LIV., LV., LVI.)

THE skeleton of the hand consists of twenty-seven bones. The first eight are the little bones of the carpus; the five succeeding bones constitute the metacarpus: these support the bones of the fingers. Each finger has three bones, termed, in order from the wrist, the first, or proximal or metacarpal, the second, or middle, and the third, or distal or unguis phalanges. The thumb has only two phalanges.

THE CARPUS.

(PLATE LVI.)

Number and Names.—The carpus consists of eight little bones, arranged in two transverse rows of four bones each, thus forming a broad base for the support of the hand. What is the advantage of so many bones in the wrist? It confers strength and elasticity and permits some motion. The contiguous surfaces are crusted with cartilage and form synovial joints. Suppose there had been a single bone instead of the eight carpal bones, how much more liable it would have been to fracture and dislocation. As it is, dislocation of one or more bones of the carpal range is a rare occurrence; but it does happen sometimes. Sir C. Bell tells us that ‘the boy that played the dragon in a pantomime at Covent Garden, fell upon his hands, owing to the breaking of the wire that suspended him, and he suffered dislocation of some of the carpal bones in both hands.’

The bones of the carpus are named as follow, beginning from the radial side :

FIRST OR PROXIMAL ROW	. 'SCAPHOID,' 'SEMILUNAR,' 'CUNEIFORM,' 'PISIFORM.'
SECOND OR DISTAL ROW	. 'TRAPEZIUM,' 'TRAPEZOID,' 'OS MAGNUM,' 'UNCIFORM.'

The student will obtain a better idea of the general shape and arrangement of these bones by examining them, at first, collectively. For this purpose it is very desirable that he should have before him an articulated hand, as well as the separate bones.

Carpal Arch.—The outline of the carpus as a whole is oblong, with the broad diameter in the transverse direction. Its bones are wedged together, and so form an arch with the concavity towards the palm, which gives passage to the flexor tendons of the fingers. Fig. 3 in Plate XXXVIII. shows that the piers of the arch are formed on one side by projections from the scaphoid and trapezium ; on the other, by the pisiform and the hook of the unciform. The arch is converted into a complete tunnel by the anterior annular ligament.

Radio-carpal Joint.—To begin with the bones of the first row. Excluding the pisiform, which is only an outstanding 'sesamoid' bone, it will be seen that the scaphoid, semilunar and cuneiform bones form a convex articular surface, which, with the lower end of the bones of the forearm, forms the radio-carpal joint. This joint admits not only of the movements of flexion and extension, but also of the horizontal movements of the wrist (abduction and adduction). The upper articular surfaces of the first row of bones are prolonged farther down their dorsal than their palmar aspect : hence the free movement of extension at the wrist. The articular surfaces of the scaphoid and semilunar bones fit into the radius ; while that of the cuneiform, which is the least extensive of the three, would articulate with the ulna, but for the intervention of the triangular fibro-cartilage attached, in the recent state, to the lower end of the ulna. The bones of the first row articulate with each other by plane surfaces crusted with cartilage, but they are so firmly connected by ligaments that there is very little movement between them.

Intercarpal Joint.—Collectively, the lower ends of the first row form, with the bones of the second row, an important movable joint, which we call the ‘intercarpal.’ It is very different in form from the first joint (radio-carpal) of the wrist, since its outline is alternately convex and concave. By means of this second joint we get a great range of flexion and extension at the wrist. If there had been only a single joint for this amount of motion, it would have been comparatively insecure, and very liable to dislocation, whereas dislocation of the wrist happens very rarely indeed. By reference to Plate LVI. it is seen that the lower part of the scaphoid has a *convex* articular surface which corresponds with the trapezium and trapezoid, and also a *concave* one, which, with a concavity in the semilunar and cuneiform bones, forms a deep socket for the reception of the head of the os magnum and the unciform.

Articulations of First Row.—The ‘scaphoid’ articulates with five bones, viz. the ‘trapezium,’ ‘trapezoid,’ ‘semilunar,’ ‘os magnum,’ and ‘radius;’ the ‘semilunar’ with five, viz. the ‘scaphoid,’ ‘cuneiform,’ ‘os magnum,’ ‘unciform,’ and ‘radius;’ the ‘cuneiform’ with three, viz. the ‘semilunar,’ ‘unciform,’ and ‘pisiform;’ and the ‘pisiform’ with one, namely, the ‘cuneiform.’

In consequence of the flexors and extensors of the wrist being inserted below the second row of carpal bones, they necessarily act on the ‘intercarpal joint’ as well as on the radio-carpal. Thus a greater amount of motion is provided at the wrist than it otherwise could have possessed with safety. If such free motion had been given to one joint, the angle of flexion must have been great and the ligaments looser than would have been consistent with the security of the joint.

Bones of the Second Row.—The trapezium and trapezoid form a shallow socket for part of the scaphoid, while the os magnum and unciform form a convexity, which fits into the deep socket formed by the scaphoid, semilunar, and cuneiform in the first row. Below, the second row articulates with the metacarpal bones, as follows: The trapezium with two, that of the thumb by a concavo-convex surface, and partly with that of the index

finger; the trapezoid with one, that of the forefinger; the os magnum with three, that of the middle finger, and besides this with those of the index and ring fingers; and the unciform with two, those of the ring and little fingers. Thus the trapezium supports the metacarpal bone of the thumb; the trapezoid that of the index finger; the os magnum that of the middle finger; and the cuneiform those of the ring and little fingers. The consequence is, that the metacarpal bones present different degrees of mobility—that of the thumb being the most movable, those of the fore and middle fingers the least so.

Articulations of Second Row.—Like the bones of the first row, those of the second articulate with each other by plane surfaces firmly connected by ligaments. The trapezium articulates with four bones; the trapezoid with four; the os magnum with seven; the unciform with five.

Description of Individual Bones.—Thus far we have examined the bones of the carpus collectively; let us now look at them individually. Each bone of the carpus is more or less cubical in shape. Hence we describe six surfaces upon it—*superior, inferior, external, internal, anterior, and posterior*. In all except the ‘scaphoid’ and ‘semilunar’ the posterior or dorsal surface is larger than the anterior or palmar. Both these surfaces likewise, except in one bone, the ‘cuneiform,’ are rough all over for the attachment of ligaments.

Scaphoid Bone.—This bone is so named from its boat-shaped socket (*σκάφη*, a boat). Its *superior surface* is smooth, triangular, slightly convex, looks upwards and outwards and backwards, and articulates with the triangular part of the inferior surface of the lower end of the radius. The *inferior surface* looks downwards, outwards, and backwards, presents a four-sided articular facet much broader behind than in front, and divided by a slight antero-posterior ridge into a larger external quadrilateral surface for articulation with the ‘trapezium’ and a smaller internal quadrilateral one for articulation with the ‘trapezoid.’ Both facets are slightly convex in all directions. The *external surface* looks backwards, outwards, and downwards, is encroached upon by the superior and inferior surfaces, and is

thereby reduced to a rough groove running from behind and inside forwards, outwards, and slightly downwards. The upper lip of the groove is the most prominent, and the entire groove affords attachment to ligaments. Its *internal surface* presents from above first a narrow rough space separating the superior from the external surface and attaching an interosseous ligament, next a very slightly convex semilunar articular facet directed forwards and inwards to articulate with the semilunar, and below a deep articular concavity for articulation with the outside of the head of the 'os magnum.' This concavity is oval in outline, broader above than below, and somewhat twisted, so that, while it looks downwards, inwards, and backwards above, it looks upwards, inwards, and a little forwards below. Below this articular hollow the bone is rough for ligamentous attachment. The *posterior surface* is encroached upon by the articular facet upon the upper surface, and merely shows a narrow rough border for ligamentous attachment, from which the groove on the external surface starts. The *anterior surface* is triangular in shape, apex above, base below. It is rough and convex from side to side, concave from above downwards, and prolonged forwards at its base into a prominence for the attachment of the 'anterior annular ligament' and the 'abductor pollicis' muscle, and called the 'tuberosity of the scaphoid.'

Semilunar Bone.—The 'semilunar' bone may be told by its semilunar shape (whence the name). The *superior surface* forms a four-sided, articular, and slightly convex facet, broader externally than internally and in front than behind, for articulation with a corresponding surface on the inferior surface of the lower end of the 'radius.' The *inferior surface* shows a quadrilateral articular facet concave from before backwards and slightly so from side to side. It is divided into two very unequal parts by a smooth antero-posterior ridge. The external is much the larger and fits a corresponding surface on the head of the 'os magnum.' The internal part forms a narrow antero-posterior facet for articulation with the narrow upper surface of the 'unciform.' On the *external surface*, as it joins the superior, there is a narrow rough surface, broadening towards the front of the bone, for the attachment of an interosseous ligament. Below

and parallel with it is a semilunar surface slightly concave from above downwards and from before backwards for articulation with the 'scaphoid.' The *internal surface* forms a smooth four-sided slightly convex surface for articulation with the 'cuneiform.' The *anterior and posterior surfaces* are both rough for ligamentous attachment, the anterior being more extensive than the posterior.

Cuneiform Bone.—The *superior surface* is divisible into two parts—an external, smooth, four-sided, and looking upwards and slightly backwards for articulation with the triangular fibrocartilage between it and the ulna; and an internal, rough for the attachment of ligaments. The *inferior surface* is smooth and articular, concavo-convex from above downwards and inwards for articulation with the 'unciform.' The *external surface* is four-sided and slightly concave for articulation with the 'semilunar.' The *internal surface* forms a blunt rough point for ligamentous attachment. The *anterior* is divisible into an internal articular and an external non-articular portion. The internal portion forms a rounded, smooth, and very slightly convex surface for articulation with the 'pisiform.' In some bones this is continuous with the external articular part of the superior surface. The external portion is rough for ligaments. The *posterior surface* is convex and rough for the attachments of ligaments.

Pisiform Bone.—The 'pisiform bone may be told by its pea shape (whence its name). It is a sesamoid bone developed in the tendon of the 'flexor carpi ulnaris' and gliding on the front of the 'cuneiform.' It is a very irregularly formed bone, but if well developed presents the following features: The *superior surface* is rough and slightly hollowed anteriorly, while posteriorly it forms a smooth facet continuous with the one on the posterior surface of the bone. The *inferior surface* is rough and forms a prominence overhanging the termination of the groove which lies on the external surface. The *external surface* slopes backwards and inwards to a sharp edge which overhangs a well-marked but narrow groove running downwards and inwards immediately in front of the inner edge of the articular facet on the posterior surface. The *internal surface* is rough and slightly convex. The *anterior surface* is rough and convex,

especially below. The *posterior surface* forms a rounded and slightly concave smooth surface, continuous with the smooth part on the upper surface of the bone, and articulates with the 'cuneiform.' The 'pisiform' has the tendon of the 'flexor carpi ulnaris,' the 'abductor minimi digiti,' and the anterior annular ligament attached to it.

Trapezium.—The 'trapezium' (so named from its shape) presents on its *superior surface* a smooth four-sided facet, concave from before backwards and nearly flat from side to side, for articulation with the 'scaphoid.' The *inferior surface* forms a large saddle-shaped articular facet for the base of the 'first metacarpal bone.' The long axis of the saddle runs from before backwards and slightly inwards. The *external surface* is rough and somewhat hollowed for ligamentous attachment. The *internal surface* presents above a large, somewhat sinuous surface skirting the upper and posterior borders, and concave from above downwards for articulation with the 'trapezoid.' Below and in front of this surface is a rough non-articular part for a ligament, and occupying the posterior and inferior angle is a small oval, flat facet looking downwards and inwards for articulation with the 'second metacarpal bone.' The *anterior surface* presents a smooth groove running downwards, backwards, and a little inwards for the passage of the 'flexor carpi radialis' tendon. The outer lip of the groove is the more prominent, is ordinarily called the *oblique ridge of the trapezium*, and gives attachment to the 'anterior annular ligament,' 'opponens pollicis,' 'flexor brevis pollicis,' and occasionally 'abductor pollicis.' Below the groove the surface is rough, and tapers to a rough ridge inferiorly for ligamentous attachment. The *posterior surface* is broad and rough, and presents at each side a well-marked tubercle. Between these tubercles the surface is hollowed.

Trapezoid Bone.—The 'trapezoid' bone has a *superior surface*, four-sided, and slightly concave in all directions, for articulation with the 'scaphoid.' The *inferior surface* is much broader and more prolonged inwards behind than in front, convex from side to side, and concave from before backwards. It is smooth and articulates with the posterior surface of the base of the

'second metacarpal bone.' The *external surface* presents a somewhat L-shaped articular surface skirting the upper and posterior borders. This articular surface is twisted, so that it looks outwards and slightly forwards in front and outwards and slightly backwards behind. It articulates with the corresponding surface on the 'trapezium.' The rest of the surface is rough for ligaments. The *internal surface* about its middle makes a sudden bend inwards. The surface in front of the bend is quadrilateral, slightly concave from above downwards, nearly flat from before backwards, and looks inwards and slightly forwards. It articulates with the 'magnum.' The part behind the bend is rough, and looks forwards and slightly inwards for the attachment of a ligament. Sometimes in this rough part one notices a small oval, flattened facet for articulation with a corresponding facet on the 'magnum.' The *anterior surface* is small, quadrilateral, rough, and slightly raised. It gives attachment to part of the 'flexor brevis pollicis.' The *posterior surface* is large, convex, and rough. It is prolonged downwards and inwards into a prominence so as to overlap the 'second metacarpal' bone behind. The part of the bone which has this relation to the second metacarpal bone is sometimes called the *tuberosity or peak of the trapezoid*.

Os Magnum.—The 'os magnum' is the largest and most important of all the carpal bones. It lies directly in the axis of the hand, and articulates with seven bones. Its large round 'head' forms the ball for the socket in the scaphoid and semilunar above. Its *superior surface* is smooth, articular, and convex in all directions, but especially from before backwards. It encroaches more on the posterior than on the anterior aspect of the bone, and articulates with the 'semilunar.' The *inferior surface* presents three very unequal articular facets, continuous, however, with one another. The central facet is the largest. It is triangular in shape with the apex forwards, slightly concave from before backwards, and nearly flat from side to side. It looks directly towards the metacarpus and articulates with the 'third metacarpal bone.' The external facet is the second in size. It cuts off the border which separates the inferior from the external


surface. The facet lies, therefore, on the anterior and external angle of the lower surface. It is slightly concave in all directions and more or less triangular in shape, looking forwards and outwards for articulation with the second metacarpal bone. The internal is the smallest of the three facets. It lies on the posterior and internal angle of the lower surface. It is triangular in shape, and looks forwards and slightly inwards, articulating with the fourth metacarpal bone. The *external surface* presents above a convex, smooth, four-sided space, facing upwards and outwards and a little backwards, for articulation with the hollow of the 'scaphoid.' Below and continuous with this surface is another quadrilateral smooth space, convex from before backwards and slightly concave from above downwards, for articulation with the 'trapezoid.' Immediately behind this surface, the bone is rough for ligamentous attachment. The *internal surface* as a whole is flattened. It is divided into an anterior rough and uneven part for the attachment of ligaments, and into a posterior part, which in its upper two-thirds shows a flattened, elongated, and somewhat twisted surface for articulation with the 'unciform,' and in its lower third an irregular and rough surface prolonged backwards for the attachment of ligaments. The *anterior surface* is rough. It presents a transverse rough groove immediately below the articular surface on the summit of the head, and below it is bulged forwards and uneven for the attachment of ligaments and part of the 'flexor brevis pollicis.' The *posterior surface* is much broader than the anterior. It is concave from above downwards, especially just below the articular surface on the summit of the head. It is rough, especially externally, and shows, as do all the non-articular surfaces of carpal bones, a few well-marked nutrient foramina.

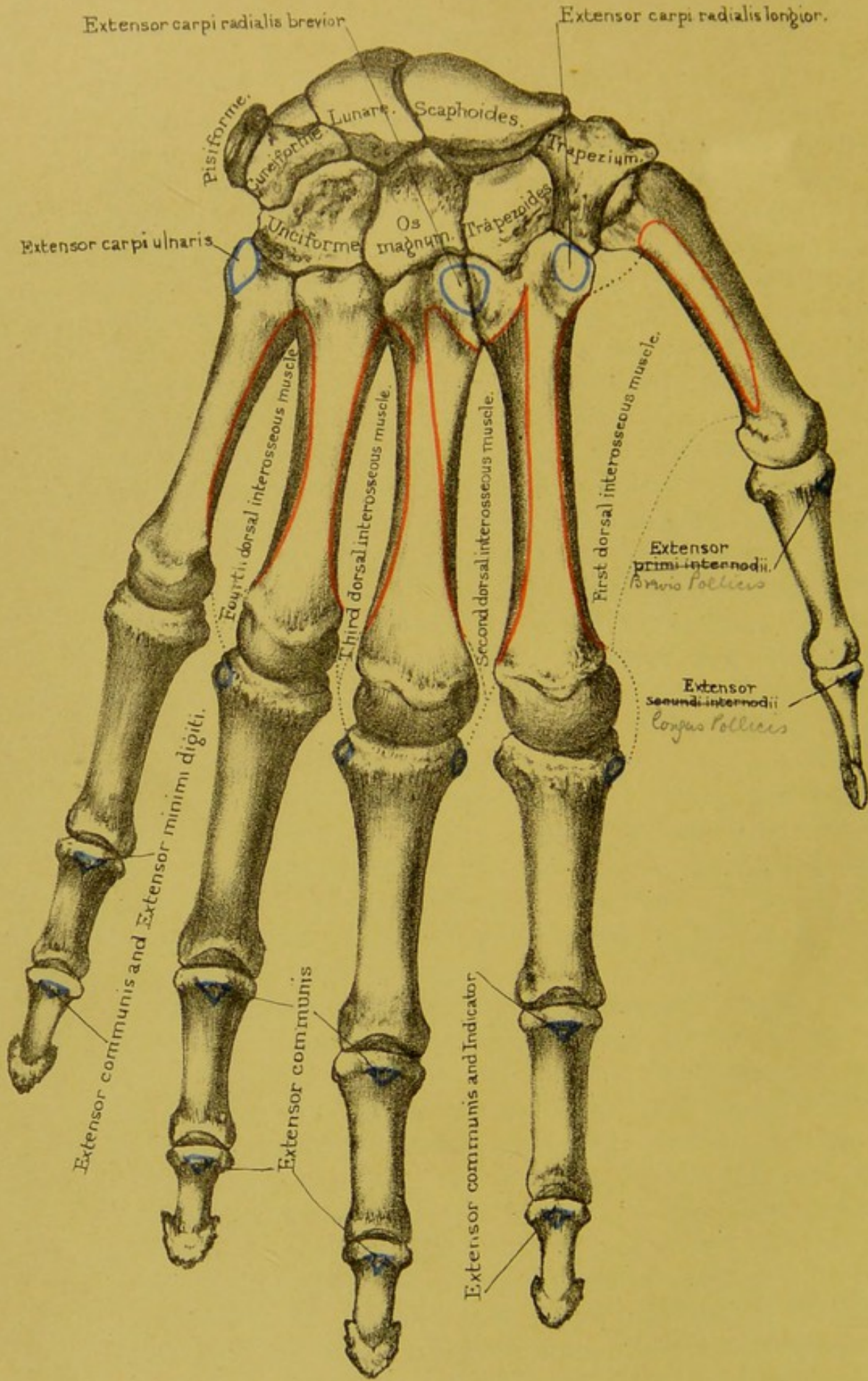
Unciform Bone.—The 'unciform' bone may be told by its remarkable hook-like process; whence its name. Its *superior surface* forms a mere articular edge, with its long axis sloping downwards, backwards, and a little inwards, for articulation with the 'semilunar.' Its *inferior surface* presents a quadrilateral articular facet, concave from before backwards and somewhat convex from side to side. It is subdivided by a low antero-posterior ridge

into an external part for articulation with the 'fourth metacarpal,' and an internal part for articulation with the 'fifth metacarpal' bone. The *external surface* presents in its upper two-thirds a quadrilateral and somewhat sinuous facet for articulation with the corresponding surface on the 'magnum.' In its lower third, and extending also to the upper edge close to the posterior border of the bone, the surface is rough for the attachment of interosseous ligamentous fibres. The *internal surface* presents a large four-sided facet, smooth, broader above than below, and twisted so that it looks inwards and slightly backwards above, inwards and slightly forwards below, for articulation with the 'cuneiform.' It is convex in all directions above, and concave both vertically and laterally below. Immediately above the lower edge of the internal surface the bone is rough and continuous with the internal surface of the unciform process. The *anterior surface* is triangular in shape and rough for ligaments. Rising from its inferior and internal angle is the '*unciform process.*' This is a hooked process flattened from side to side, concave and smooth externally for the passage of the flexor tendons. Internally it is slightly convex and rough. Anteriorly it presents a roughened edge for the attachment of the 'anterior annular ligament,' 'flexor brevis,' and 'opponens minimi digiti' muscles. The *posterior surface* is triangular in shape, and marked by slight eminences and depressions for the attachment of dorsal ligaments.

Muscles attached to the Carpal Bones.—No muscles are connected with the dorsal surface of the carpus. On the palmar aspect the pisiform gives insertion to the 'flexor carpi ulnaris,' and origin to the 'abductor minimi digiti.' The trapezium gives origin by its 'ridge' to the 'opponens pollicis,' sometimes to parts of the 'abductor pollicis,' and outer head of the 'flexor brevis pollicis;' the trapezoid and os magnum to the 'flexor brevis pollicis.' The unciform gives origin by its process to the 'flexor brevis minimi digiti' and to the 'opponens minimi digiti.'

Ossification.—The carpus is entirely cartilaginous at birth. Each bone ossifies from a single nucleus. The nucleus of the os magnum appears in the first year; that of the unciform in the





Dorsal surface

Drawn on Stone by T. Godart.
 From nature by L. Holden. Printed by West, Newman & Co.

second; that of the cuneiform in the third; those of the trapezium and semilunar in the fifth; that of the scaphoid in the sixth or seventh; that of the trapezoid in the seventh or eighth; that of the pisiform in the twelfth. This is the last bone in the body to ossify. The 'os centrale,' lying in the *typical carpus* between the bones of the first and second row, is present in man as a small cartilage, situated between the 'trapezium,' 'trapezoid,' 'magnum' and 'scaphoid' at the second month, and disappears about the fourth month of foetal life. In rare cases it persists as a separate bone in the adult. Again, a part of the 'scaphoid,' corresponding to its tuberosity, may remain separate, and represents the 'radial sesamoid' of Gegenbaur.

Comparative Osteology.—In many of the Carnivora, as the seal, walrus, tiger, and dog, the scaphoid and lunar are ankylosed into one mass. In the bat, the scaphoid, lunar, and cuneiform form only one bone. In the dugong, all the carpal bones are ankylosed into three bones, the distal row being in one piece.

In birds, as in other animals, they are diminished in number according to the disappearance of the digits which each usually supports.

The carpus of the orang utan, baboon, several other monkeys and reptiles, contains one more bone than that of man, which seems due to the division of the scaphoid into two parts: it is known as the os centrale. (See Separate Series, Mus. Roy. Coll. Surg.)

THE METACARPUS.

(PLATES LIV., LV.)

The metacarpus consists of the five bones which support the phalanges of the thumb and fingers. They are described as the first, second, third, fourth, and fifth, counting from that of the thumb, or as metacarpal bones of the thumb, index, middle, ring, and little fingers; and, regarding them as 'long bones,' which they much resemble in their general structure, we speak of their shafts and their two ends; the upper end being termed

the 'base' 'or proximal end,' the lower the 'head' or 'distal end' of the bone.

SHAFTS.—The 'shafts' are slightly concave towards the palm, forming the hollow of the hand. They are made somewhat triangular on section by the impressions of the 'interosseous' muscles, which occupy the 'interosseous spaces.' The apex of the triangle is on the palmar surface, the base on the dorsal surface forming the support of the extensor tendons of the fingers. We consequently describe *anterior*, *internal*, and *external borders* separating *internal*, *external*, and *posterior surfaces*. The *anterior border* is curved backwards in its long axis. It begins behind by two branches enclosing a rough space on the palmar surface of the base, is sharp, prominent in the middle of the shaft, and terminates anteriorly by two branches running each to its own condyle at the distal end of the bone. The *internal* and *external borders* begin behind on either side of the base of the bone, and are rather rounded posteriorly, sharp and prominent anteriorly, where they terminate in the tubercles of the distal end. The *internal* and *external surfaces* are both seen when looking at the bone in its palmar aspect. They are somewhat concave antero-posteriorly and convex from side to side. They are smooth, and give attachment to the interosseous muscles. The 'medullary foramina' of the second, third, fourth, and fifth metacarpal bones are usually situated about the middle of the external surfaces, close to the external borders, and directed obliquely towards the base. In the metacarpal bone of the thumb the 'medullary foramen' is generally seen on the internal surface near the 'internal border,' and directed obliquely towards the distal end. The *posterior surface*, enclosed by the inner and outer borders, is bowed backwards in its long axis. It is divided into three parts by three lines. A vertical line, which begins in the middle of the posterior surface of the bone, runs vertically down the middle of the posterior surface in its posterior third, and then divides into two branches which terminate in the tubercles of the distal end. Three surfaces are thus marked off—two posteriorly, which are hollowed from back to front and give origin to interosseous muscles; and one anterior, which is large, tri-

angular, flattened, and covered by the tendon of the 'extensor communis digitorum' muscle. The posterior surfaces of the *first* and *fifth* metacarpal bones are not thus mapped out, as we shall see in their description.

BASES.—The 'bases' are cubical in shape with their anterior surfaces less than their posterior ones, and both rough for ligamentous attachment. They articulate not only with the bones of the carpus by their superior surfaces, but, by articular facets on their inner and outer surfaces with each other: that of the thumb, however, stands out alone, so as to oppose all the others. It is one of the great characteristics of the hand of man, that the point of the thumb can touch with perfect ease the tips of all the fingers.

HEADS.—The lower ends or 'heads' are rounded for articulation with the first phalanges of the fingers. The articular surfaces of the heads extend chiefly towards the palm, and are broader on that aspect than on the dorsal side. They run back, too, upon the palmar surfaces of the heads as lateral projections termed the 'condyles,' which are grooved antero-posteriorly for sesamoid bones where such bones exist. They allow the fingers not only to be flexed and extended, but to be moved laterally, the latter motion being especially well seen when the metacarpophalangeal joint is extended. On each side of the heads are a tubercle and a deep pit for the attachment of the thick and strong lateral ligaments.

Let us now look at the features peculiar to the individual metacarpal bones.

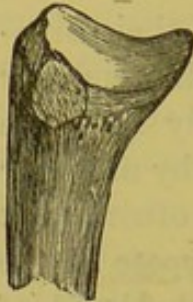
Metacarpal Bone of the Thumb.—Viewed generally it is the shortest, stoutest, and broadest of all the metacarpal bones. Its *base* presents, superiorly, a saddle-shaped surface much pointed forwards, and broader externally than internally, for articulation with the trapezium. It shows no articular facets on the sides of its base, but externally there is a rough, oval depression for the insertion of the 'extensor ossis metacarpi pollicis.'

Its *distal end* is much flattened from before backwards, and shows well-marked condyles, with an antero-posterior groove on each, for articulation with the sesamoid bones which are developed

in connection with the tendons crossing the front of the metacarpophalangeal articulation of the thumb. The *shaft* too is much

FIG. 65.

I.



BASE OF FIRST
RIGHT META-
CARPAL, OUTER
SIDE.

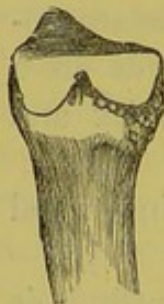flattened, so that its anterior border is ill marked. To its outer surface we have attached the 'opponens pollicis,' and to its inner the first 'dorsal interosseous' or 'abductor indicis' muscle. There are no less than nine muscles to work the thumb. Its great mobility in all directions, so essential to the power and perfection of the human hand, depends upon this saddle-shaped joint at its base; and its power of antagonising the fingers is owing to its base being set off on a plane anterior to them. But for a little buttress of bone which projects from the inner and front part of the trapezium, the thumb

would fall into the same line as the fingers, and would not possess that power of opposing them which makes the human hand such a wonderful instrument.⁶⁸

Metacarpal of Fore-finger.—The metacarpal bone of the fore-finger is the longest of all the metacarpal bones. Its *base*

FIG. 66.

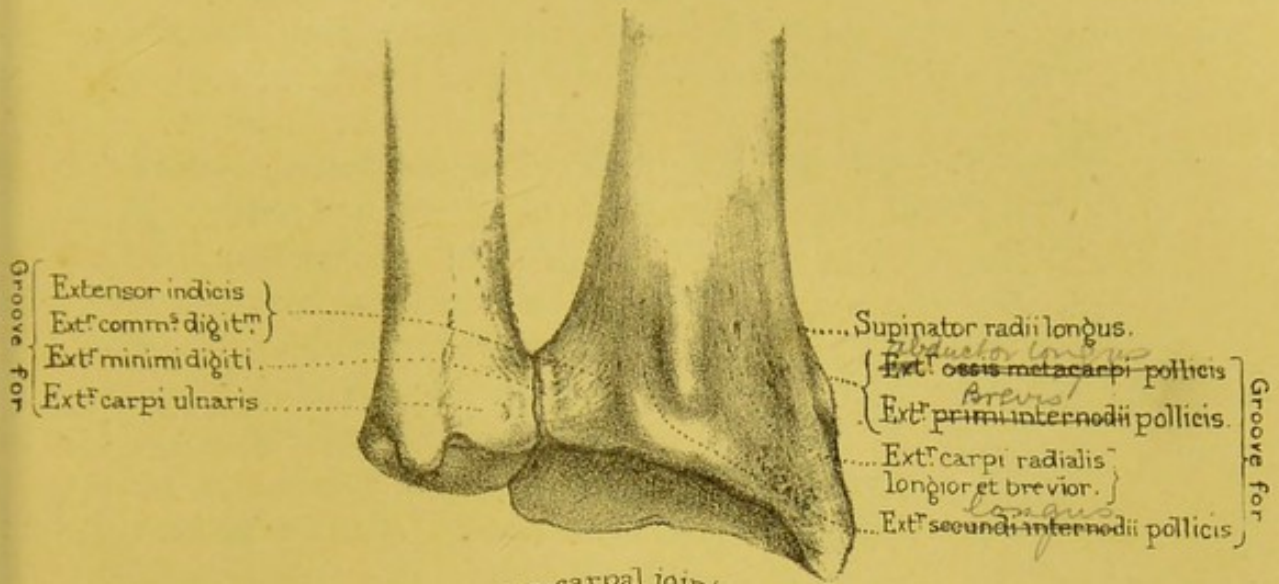
II.



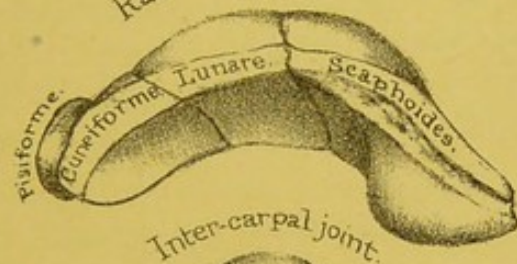
BASE OF
SECOND RIGHT
METACARPAL,
INNER SIDE.

presents superiorly an antero-posterior groove, wider behind than in front and inclining inwards posteriorly, for articulation with the 'trapezoid.' The outer lip of this groove is the lower, and is marked by a facet looking forwards and upwards for articulation with the 'trapezium.' The inner lip projects upwards and is articular along its edge, for the 'external angular facet' of the 'os magnum.' The anterior surface is rough for the insertion of the tendon of the 'flexor carpi radialis.' The posterior surface is also rough and presents externally a flattened, rough mark for the insertion of the 'extensor carpi radialis longior,' and internally a smaller rough space, looking towards the third metacarpal bone, for the insertion of part of the tendon of the 'extensor carpi radialis breviar.' Externally the base presents *no* facet for articulation with the first metacarpal, but internally it has a well-marked articular surface, notched below, for the third metacarpal.

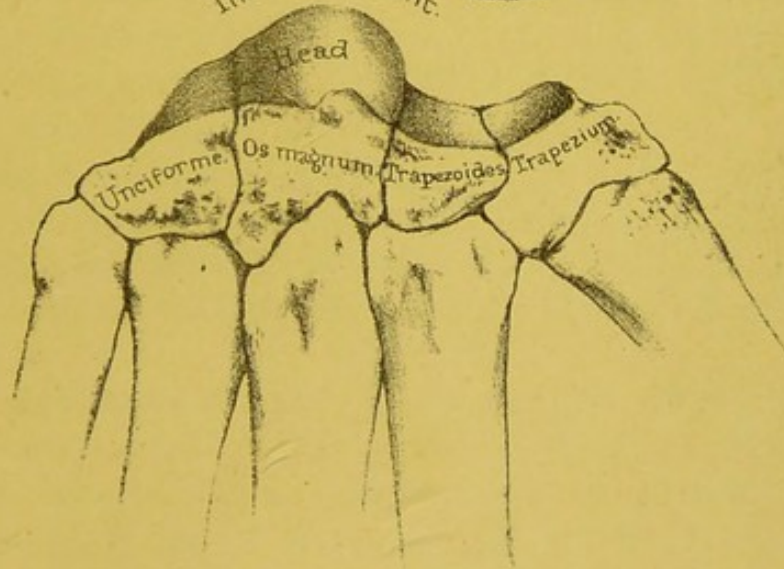
Ulna. Radius.



Radio-carpal joint



Inter-carpal joint.

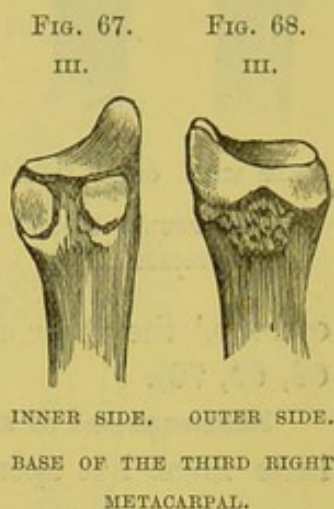


View of the intercarpal joint.



The *shaft* and *distal end* present the characters common to all metacarpal bones. The external surface of the shaft gives origin to the first 'dorsal interosseous,' and the internal surface to the second 'dorsal' and first 'palmar interosseous' muscles (figs. 73, 74).

Metacarpal of Middle Finger.—The metacarpal bone of the middle finger is second in length of all the metacarpal bones. Its *base* presents superiorly a four-sided, somewhat sinuous surface for articulation with the 'os magnum,' while its posterior and external angle rises up into a blunt projection, overlapping the posterior surface of the 'os magnum' from below, and called the 'tuberosity' or 'peak' of the third metacarpal bone. Anteriorly the base is rough and bulged forwards for the insertion of a few fibres of the tendon of the 'flexor carpi radialis' and the origin of part of the 'flexor brevis pollicis' muscle. Posteriorly the base is rough and shows externally a depressed rough surface, running upon the back of the 'peak' for the insertion of the extensor 'carpi radialis brevior.' The sides of the base present the appearances shown in figs. 67 and 68. There is nothing peculiar to notice on the *distal end* and *shaft* of the bone. The outer and inner surfaces of the shaft give origin to the second and third 'dorsal interosseous' respectively (figs. 73, 74). The anterior border gives origin in its upper fourth to the 'flexor brevis pollicis,' and in its lower three-fourths to the 'adductor pollicis.'



Metacarpal of Ring Finger.—The metacarpal bone of the ring finger presents on the superior surface of its *base* a four-sided flattened surface, for articulation with the 'unciform.' Outside this facet is a deep, rough, antero-posterior groove, and, external to it, are the upper edges of the facets upon the external surface of the base. The upper edge of the posterior facet is cut off obliquely, so as to present a small flat facet, looking backwards, upwards, and outwards for articulation with the 'os

magnum.' The outer surface of the base shows two oval flattened facets separated from one another by a deep vertical groove continuous with the horizontal one on the superior surface of the base. These isolated facets are for articulation with the third metacarpal. The inner surface presents a single large facet rather hollowed in every direction for articulation with the outside of the base of the fifth metacarpal. The rest of the base, the *shaft*, and *distal extremity* offer nothing peculiar for description. The outer surface of the shaft gives attachment to the second 'palmar' and the third 'dorsal interosseous,' the inner to the fourth 'dorsal interosseous' (figs. 65, 66, 69, 70).

FIG. 69.

IV.

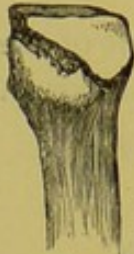
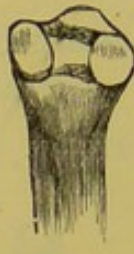
FIG. 70.

IV.



INNER SIDE. OUTER SIDE.

BASE OF FOURTH RIGHT
METACARPAL.

Metacarpal of Little Finger.—The metacarpal bone of the little finger has upon the superior surface of its *base* a saddle-shaped surface with the convexity running from before backwards and inwards for articulation with the 'unciform' bone. Externally the base has a single oblong, flattened facet for articulation with the fourth metacarpal. Internally it projects into a rough low ridge for the attachment of the 'extensor carpi ulnaris.' The only other peculiar feature noticed on the fifth metacarpal bone is that the posterior surface shows a single oblique line running from above downwards and outwards; the surface outside the line giving attachment to the fourth 'dorsal' and third 'palmar interosseous' muscles (figs. 69, 70). In well-marked bones there is a second oblique line running from near the upper end of the 'oblique line' downwards and inwards, and marking off a space internal to it for the insertion of the 'opponens minimi digiti.'

FIG. 71.

V.

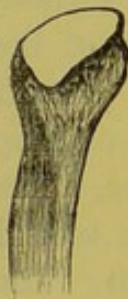

FIG. 72.

V.



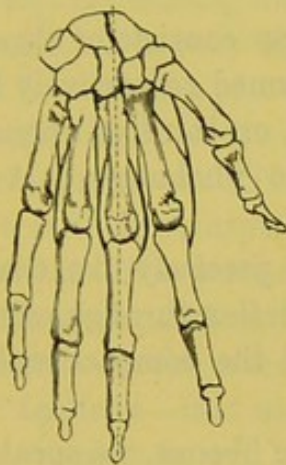OUTER SIDE. INNER SIDE.

BASE OF FIFTH RIGHT
METACARPAL.

Ossification.—Each metacarpal bone has a centre of ossification for the shaft and proximal end, which appears near the

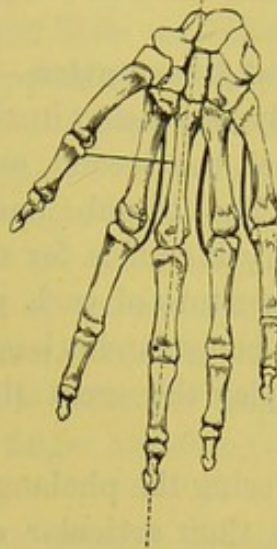
distal end about the eighth week of foetal life. Each also has an epiphysis at its distal end, of which the nucleus appears about the third to the fifth year. The metacarpal bone of the thumb, however, has its epiphysis at the proximal end, like the phalanges of the fingers. All unite to the shafts about the twentieth year.⁶⁹ (Nor. Hum. Ost. No. 54.) Very often there is a distal epiphysis appearing in the metacarpal bone of the thumb about the eighth

FIG. 73.



FOUR DORSAL INTEROSSEI
DRAWING FROM THE MIDDLE LINE.

FIG. 74.



THREE PALMAR INTEROSSEI
DRAWING TOWARDS THE MIDDLE LINE.

year, and an epiphysis at the proximal end of the second metacarpal about the same time.

Comparative Osteology.—In all birds excepting the extinct archæopteryx the metacarpal bones are anchylosed together. (See the Separate Series in the Mus. Roy. Coll. Surg.)

Contrast the short metacarpal bones of the elephant with the enormously long ones of the horse or giraffe.

THE BONES OF THE FINGERS.

(PLATE LIV.)

General Description.—Each finger consists of three bones, successively decreasing in size, and termed respectively the first, or proximal, the second, and the last, or third or ungual ‘phalanges.’ The thumb has only two phalanges. A general description will suffice for all.

The structure of each phalanx is precisely like that of the great long bones, and a longitudinal section through one of them would display the great thickness of the compact wall of the shaft.

Considering the phalanges as ‘long’ bones, we speak of their shafts and their articular ends. The shafts are convex on the dorsal surface, and flat on the palmar; on each side of this flat surface is a ridge for the attachment of the fibrous sheath (theca), which keeps the tendons in their places.

First Phalanges.—The first phalanges are distinguished by their greater length, and by the shape of their metacarpal ends, which do not form strictly hinge-joints, but have concave oval surfaces, with the long diameters transverse, adapted for lateral movement as well as flexion on the heads of the metacarpal bones. In accordance with this lateral movement, we observe, on each side, a tubercle for the insertion of the interosseous muscles which produce it. The articular surfaces of the distal ends encroach more upon the palmar than on the dorsal surface, and are divided by a shallow groove into two condyles. On each side of the distal ends are tubercles and depressions for the attachment of lateral ligaments. The base of the *metacarpal phalanx of the thumb* is rough externally for the insertion of the

'abductor indicis' and outer head of the 'flexor brevis pollicis,' and internally for the insertion of the 'adductor indicis' and inner head of the 'flexor brevis pollicis.' Posteriorly the base shows a rough triangular depression for the insertion of the tendon of the 'extensor primi internodii pollicis.'

Second Phalanges.—The second phalanges are shorter than the first, and are recognised by the shape of their proximal ends, each of which has two little concave surfaces, with an intervening ridge, encroaching more on the palmar than on the dorsal surfaces, and so forming hinges with the little condyles of the first phalanges. On each side of the palmar surfaces, close to the lateral borders and placed rather behind the middle of the shafts, are rough ridges for the insertions of the tendons of the 'flexor sublimis digitorum.' The first phalanges have only one articular surface at their proximal ends, and are thus distinguished from the second. The posterior surfaces of the second, third, fourth, and fifth present, close to the proximal articular surfaces, transverse ridges for the attachment of the 'extensor communis digitorum' tendons—that on the index finger attaching the 'extensor indicis' tendon as well.

Third Phalanges.—The last or unguis phalanges are the shortest. Each of their distal ends expands into a horse-shoe shape, smooth on one surface for the support of the nails, and rough on the other for the support of the pulp of the fingers. Anteriorly their bases are rough for the attachment, on the four outer fingers, of the 'flexor profundus digitorum,' and posteriorly the 'extensor communis digitorum,' with the 'extensor indicis' on the index finger. The base of the last phalanx of the thumb presents anteriorly a large rough depression for the insertion of the 'flexor longus pollicis,' and posteriorly a rough transverse ridge for the insertion of the 'extensor secundi internodii pollicis.'

Unequal Length of Fingers.—It has been asked, What are the advantages of the fingers being of unequal length? Close them upon the palm, and then see whether or not they correspond. This difference in the length of the fingers serves a thousand purposes, to which the works of human art and industry bear ample testimony.

Ossification.—Each phalanx has two centres of ossification : one for the shaft and distal end, appearing about the eighth week ; the other for the proximal end, appearing from the third to the fifth year, and remaining an epiphysis till about the twentieth year.⁷⁰ (Nor. Hum. Ost. No. 54.)

Comparative Osteology.—In the Separate Series in the Mus. Roy. Coll. Surg. it will be seen that the elephant has five digits ; the elk four, viz. the 2nd, 3rd, 4th, and 5th ; the ox two, the 3rd and 4th ; the rhinoceros three, the 2nd, 3rd, and 4th ; the tapir four, the 2nd, 3rd, 4th, and 5th ; the zebra and horse one, the 3rd.

The flipper of the whale, which corresponds to the front limb, has no nails ; some of the digits have more than three phalanges. (See the round-headed whale, No. 2988 B, and the lesser fin-whale.)

Bats (Cheiroptera) have their four ulnar digits very much elongated, forming the framework for the wing. At least three of these digits bear no nails. The hook at the top of the bat's wing is the thumb-nail. (See Sep. Ser. Mus. Roy. Coll. Surg., as well as Nos. 3383, 3419.)

In the digitigrade Carnivora, as the tiger and cat, the sharp claws are firmly fixed into the ungual phalanges, and these are under ordinary circumstances bent backwards on to the back and outer side of each corresponding second phalanx by an elastic ligament, and are thus held out of the way as long as the flexor profundus digitorum remains at rest.

When a cat pats you in play she only uses the flexor sublimis digitorum ; but when she claws you in anger she uses her flexor profundus digitorum, which flexes the ungual phalanx and brings down the claw.

That which is commonly called the knee in the horse, is really the wrist. From this joint down to the foot extends the greatly elongated third metacarpal bone.

In birds these fingers can be traced as forming the extremity of the wing. (See Sep. Ser. Mus. Roy. Coll. Surg.)

The phalanges were very numerous in the Ichthyosauria. (Pal. Ser. No. 222, Mus. Roy. Coll. Surg.)

SESAMOID BONES.

(PLATE LIV.)

Position and Use.—These little bones are so called from their resemblance in size and shape to the grain '*sesamum*.' They are met with in the substance of tendons in the neighbourhood of joints—the '*patella*,' or '*knee-pan*,' being the best example. Their use is to increase the leverage of the tendons. The thumb has two of these bones beneath its metacarpal joint, which increase the leverage of the '*flexor brevis pollicis*.' We rarely find any in the fingers.

Comparative Osteology.—Of all animals, the mole has the most remarkable apparatus of '*sesamoid*' bones. Its prodigiously strong digging feet are provided with many of them, which increase the leverage of the brachial muscles, and enable the animal almost to swim through the earth.

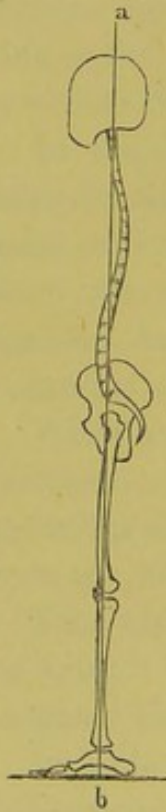GENERAL SURVEY OF THE SKELETON.

A GENERAL SURVEY of the human skeleton shows how admirably it is adapted to the erect attitude.

Adaptation of the Skeleton to the Erect Position.—

1. When a man stands erect, an imaginary vertical plane (*a b*) supposed to fall through the top of the head would pass through the occipito-atlantoid, lumbo-sacral, sacro-iliac, hip, knee, and ankle joints; in a word, through all the joints which transmit

FIG. 75.



the weight to the ground. This explains why a man can carry a weight on the top of his head easier than in any other way.

Position of Foramen Magnum and Condyles.—

2. The foramen magnum and the condyles of the occiput are nearly horizontal (when the head is held upright), and they are advanced almost to the middle of the base of the skull, and thus the head is nearly balanced on the cups of the atlas. The head has a slight tendency to drop forwards, but this is limited by the ligamentum nuchæ. Contrast the position of the condyles in the human skull with that of the orang utan, in which the condyles are not only placed near to the *back* of the head, but obliquely, making an angle of 40° with the horizon. The lower we go in the scale, the greater is the contrast. In the horse, for instance, the plane of the condyles and foramen magnum is vertical. In this, and all other her-

bivorous quadrupeds, the weight of the head is sustained by an enormously strong and elastic ligament (ligamentum nuchæ, or

pack-wax), the strength of which is in proportion to the weight of the head and its tendency to drop. It extends from the lofty spines (withers) of the anterior dorsal vertebræ to the crest of the occiput.

Direction of the Face.—3. The face is placed perpendicularly under the cranium, so that the planes of the face and forehead are parallel, and this characteristic of the human face is well adapted for the erect attitude. If man went on all-fours, he would habitually see and smell nothing but the ground. As it is, the direction of the orbits is horizontal, and therefore gives the greatest range of vision; and the direction of the nose gives the greatest range of smell. We are reminded here of the beautiful lines—

Pronaque dum spectent animalia cætera terram,
Os homini sublime dedit, cœlumque tueri
Jussit, et erectos ad sidera tollere vultus.

OVID, *Metam.* I. 84-86.

Breadth of the Thorax.—4. The thorax is much broader in the transverse than in the antero-posterior diameter. This great breadth of the chest is peculiar to man and the highest species of ape; it throws the arms farther apart, and gives them a more extensive range; besides which, it diminishes the tendency there would otherwise be in the trunk to fall forwards. Contrast this with the chest of quadrupeds, compressed laterally, and deep from sternum to spine, so that the fore legs come nearer together, and fall perpendicularly under the trunk.

Curves of the Spine.—5. The vertebral column gradually increases in size towards the base. It is curved, which makes it all the stronger, and better adapted to break and diffuse shocks: and these curves, waving alternately, distribute the weight in the line of gravity. This line passes through all the curves, and falls exactly on the centre of the base. Observe, moreover, the length and size of the spinous processes in the lumbar region for the origin of the ‘erector spinæ.’

Shape and Inclination of the Pelvis.—6. The weight of the vertebral column is supported on a sacrum broader in proportion than in any other animal. The iliac bones are widely

expanded and concave internally; they support the viscera and give powerful leverage to the muscles which balance the trunk. The whole pelvis is remarkably broad, and thus the base of support is widened; and the plane of its arch so inclines as to transmit the weight from the sacrum (or crown of the arch) vertically on to the heads of the thigh bones: lastly, the deepest and strongest part of the socket for the thigh bone is in the line of weight: consequently, the joint is never more secure than in the erect position.

With the broad and capacious pelvis of man, contrast the long and narrow pelvis of animals, which, instead of forming an angle with the spine, is almost in the same line with it.

Lower Limbs.—7. In proportion to the trunk, the lower limbs of man are longer than in any other mammal, the kangaroo not excepted. Their great length prevents their being adapted for locomotion in any but the erect attitude. The femur has a long neck, set on to the shaft at a very open angle, so that the base of support is rendered still wider. The long shaft of the femur inclines inwards, bringing the weight well under the pelvis, which is obviously of great advantage in progression: and when the leg is extended, the femur can be brought into the same line with the tibia; thus the weight is transmitted vertically on to the horizontal plane of the knee joint, while the articular surfaces of the bones are expanded and give adequate extent of support.

Contrast our long lower limbs with the short and bowed legs of the gorilla, chimpanzee, and orang utan. Watch attentively one of these three apes (the highest of the mammalia below man) in the act of walking; you will find that he supports himself alternately on the right and left knuckles as well as on his feet.

Feet.—8. The foot of man is broader, stronger, and larger in proportion to the size of the body than in any other animal; so that man can stand on one leg, which no other mammal can do. Its strong component bones form a double arch of exceeding elasticity, which touches the ground at both ends, and receives the superincumbent weight vertically on its 'crown.' The great bulk and backward prolongation of the os calcis at right angles

to the tibia support the arch behind, and form a powerful lever for the great muscles of the calf, which raise the body in progression, while the bones of the great toe are proportionately strong, and form the chief support upon which the body may be raised.

Upper Limbs.—9. We see, then, that the whole fabric of the skeleton is so adjusted as to exempt the upper limbs from taking any part in its support. These are kept wide apart by the clavicles, and their component joints admit of the freest range of motion. The twenty-seven bones at the extremity of each constitute those instruments of consummate perfection the 'HANDS, of which, even if a formal dissertation⁷¹ had not been written, one might well forbear to speak, since they have such eloquence of their own. 'Nam cæteræ partes loquentum adjuvant, hæ, prope est ut dicam, ipsæ loquuntur: his poscimus, pollicemur, vocamus, dimittimus, minamur, supplicamus, abominamur, timemus; gaudium, tristitiam, dubitationem, confessionem, pœnitentiam, modum, copiam, numerum, tempus, ostendimus.'⁷²

Comparative Osteology.—Some of the vertebrata have bones which do not exist in man as such and are only represented in him by fibrous or cartilaginous tissue. Thus there is the bone of the heart, 'os cordis,' in the bullock—*bos taurus*—(No. 4), an example of the visceral system of bones or splanchno-skeleton. Another instance is the bony sclerotic of many fishes and some birds. This is well seen in a specimen from the sun-fish (No. 5). There was a ring of bone in the sclerotic of the extinct flying lizards (*Pterosauria*), as well as in that of the *Ichthyosauria*, the life-size models of which animals are seen at the Crystal Palace, a similar ring being present in modern lizards and chelonia. In the *Phocidæ*, *Trichechus*, the walrus, and in many dogs, is found the 'os penis' (Nos. 3906, 3907, 3908, 3909, and 3910, the last showing a fracture which has been repaired). Another is the 'interclavicula' found in *Reptilia*. It is often, too, present in birds, though it is in them confluent with the clavicles. In many of the *Lacertilia* a partially ossified or cartilaginous rod runs up from the symphysis of the ischia, and supports the front

wall of the cloaca, and is called the 'os cloacæ.' In all pouched animals (Marsupialia), as in the kangaroo (*Macropus major*, Ost. Ser. Coll. Surg. Mus. 3699), and in the Monotremata (that is, in *Echidna* and *Ornithorhynchus*, Ost. Ser. Coll. Surg. Mus. 3952, 3964), are found the marsupial bones : ossifications, or often only chondrifications, of the internal pillars of the external abdominal rings.

OS HYOIDES.

(PLATE XXXVIII.)

Position and Use.—The os hyoides, so called from its resemblance to the Greek letter *upsilon*, is situated between the larynx and the root of the tongue. It is suspended from the styloid processes of the temporal bones by the stylo-hyoid ligaments, often partly ossified in man, and generally distinct bones in animals. When the neck is in its natural position the bone can be felt just below the lower border of the body of the lower jaw, and about an inch inside and behind the arch formed by that part of the bone. It supports the tongue, and gives attachment to the most powerful extrinsic muscles which move that organ.

It is divided, for the sake of description, into the *body*, or front part, and a *greater* and a *lesser cornu* on each side.

Body.—The ‘body’ (basi-hyal part) is the thickest and strongest part of the bone. In the easy position of the head and neck it is on the same level as the ‘intervertebral’ substance between the fourth and fifth cervical vertebræ. It is flattened from before backwards, and from above downwards, so as to present an anterior and a posterior surface, with superior, inferior, and two lateral borders.

The *anterior surface* presents a general convexity forwards and upwards, and shows a prominent rough transverse ridge, situated nearer the upper than the lower borders. Crossing this at right angles in the middle line is a less prominent vertical ridge, and often at the point of junction there is a little projection, which is interesting as being a rudiment of the process to which is attached the lingual bone of animals, which runs into the sub-

stance of the tongue. The spaces enclosed by these ridges are hollowed, rough, marked by a number of nutrient foramina, and give attachment to muscles, as shown in Plate XXXVIII. The *posterior surface* looks downwards and backwards, is concave in every direction, marked by small nutrient foramina, and separated from the epiglottis (one of the cartilages of the larynx) by fatty fibrous tissue and the thyro-hyoid membrane. A bursa is usually situated in the fibrous tissue immediately behind the 'body.'

The *superior border* is rough, uneven, somewhat rounded, and gives attachment anteriorly to muscles (see plate) and posteriorly to the thyro-hyoid membrane.

The *inferior border* is slightly concave downwards, and forms the lower limit of the muscular attachments on the anterior surface.

The *lateral borders* show, in their upper two-thirds, oval and slightly rough depressions, to which the greater cornua are united by fibrous tissue. This fibrous tissue usually gets ossified after middle life. Frequently the oval surface is covered, in the adult state, by smooth articular cartilages and distinct synovial cavities, existing between the body and greater horns. The lower thirds of the lateral borders are sharp and rough for muscular attachment. At the angles between the superior and lateral borders are little smooth articular half-facets, looking upwards and outwards, and which, with corresponding half-facets upon the upper borders of the greater cornua, form whole facets, covered in the recent state by cartilage and articulating by distinct synovial cavities with the lesser cornua.

Greater Cornua.—The greater cornu ('thyro-hyal' part) projects backwards about an inch and a quarter, not quite horizontally, but with a slight inclination upwards, and terminates in a smooth, blunt, enlarged end. The horn presents an *external surface* looking forwards, outwards, and slightly upwards posteriorly, upwards, forwards, and outwards anteriorly. It shows a smooth groove running from its lower border posteriorly, forwards, and slightly downwards, to become continuous with the upper part of the anterior surface of the body. The surface gives attachment to muscles (see plate), and the tendon of the 'digastric' with the 'stylo-hyoid muscle' lies against the groove in the easy position

of the head and neck. The *inner surface* is smooth, presents a sinuosity corresponding to the twist of the external surface, and is covered by the thyro-hyoid membrane. The *upper border* is sharp and attaches the thyro-hyoid membrane. The *lower border* is sharp posteriorly, broad and rough anteriorly, lies in a plane external to the upper border, and gives attachment to a muscle. The *posterior extremity* is rounded, swollen and smooth, and gives attachment to the lateral thyro-hyoid ligament. The *anterior extremity* shows a small half-facet above, for articulation with the lesser horn, and a large oval facet below for union with the similar facet already described as existing upon the lateral border of the body.

Lesser Cornua.—The lesser cornu ('cerato-hyal' part) is not much larger than a barley-corn, and projects upwards and backwards from the upper end of the junction of the body with the greater horn. It varies in size in different persons and in the same bone on opposite sides. Its apex gives attachment to the stylo-hyoid ligament, and its base articulates, by a complete synovial joint, with the body and greater horn, and is freely movable. It gives attachment to muscles as shown in the plate.

Ossification.—The bone is ossified from five centres—one for the body and one for each of the four cornua. The body and greater cornua begin to ossify in the last month of foetal life, the lesser cornua in the first year after birth.

The greater cornua are usually ossified to the body after middle age, and the lesser ones sometimes in advanced age.

Comparative Osteology.—The posterior surface of the hyoid bone is concave from side to side and from above downwards. This concavity is characteristic of the higher mammalia. In the gorilla it will lodge the tip of the finger, while in the howling monkey, *Mycetes laniger*, it develops into a sac large enough to hold a pigeon's egg.

Notice a remarkable anterior projection from the front of the body of the hyoid bone of the horse, seen also more or less in many other animals and especially in birds. (Sep. Ser. Mus. Roy. Coll. Surg.)

The first part of the history is devoted to a description of the country and its inhabitants. The author describes the various tribes and their customs, and the different parts of the country. He also mentions the various rivers and lakes, and the different kinds of animals and plants which are found there. The second part of the history is devoted to a description of the various wars and battles which have taken place in the country. The author describes the different battles and the various strategies which were used by the different tribes. The third part of the history is devoted to a description of the various customs and traditions of the different tribes. The author describes the different kinds of dances and songs, and the various customs and traditions which are still practiced today.

The fourth part of the history is devoted to a description of the various tribes and their customs. The author describes the different tribes and their customs, and the different parts of the country. He also mentions the various rivers and lakes, and the different kinds of animals and plants which are found there. The fifth part of the history is devoted to a description of the various wars and battles which have taken place in the country. The author describes the different battles and the various strategies which were used by the different tribes. The sixth part of the history is devoted to a description of the various customs and traditions of the different tribes. The author describes the different kinds of dances and songs, and the various customs and traditions which are still practiced today.

The seventh part of the history is devoted to a description of the various tribes and their customs. The author describes the different tribes and their customs, and the different parts of the country. He also mentions the various rivers and lakes, and the different kinds of animals and plants which are found there. The eighth part of the history is devoted to a description of the various wars and battles which have taken place in the country. The author describes the different battles and the various strategies which were used by the different tribes. The ninth part of the history is devoted to a description of the various customs and traditions of the different tribes. The author describes the different kinds of dances and songs, and the various customs and traditions which are still practiced today.

The tenth part of the history is devoted to a description of the various tribes and their customs. The author describes the different tribes and their customs, and the different parts of the country. He also mentions the various rivers and lakes, and the different kinds of animals and plants which are found there.

Fig. 1.

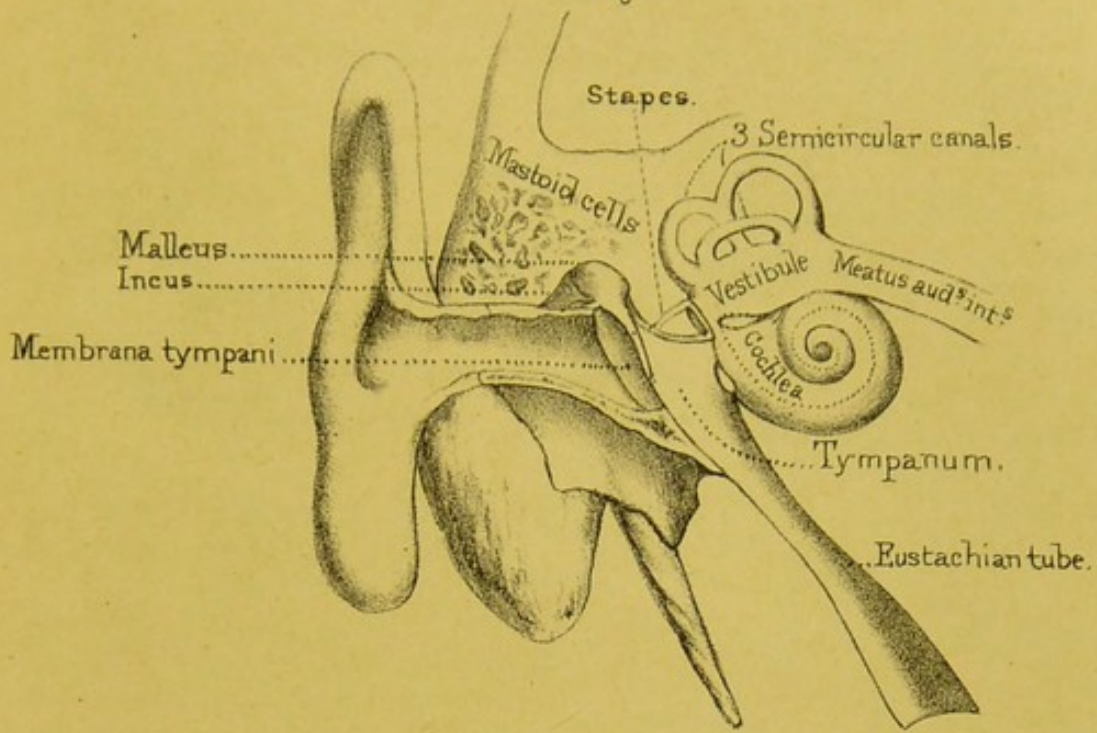
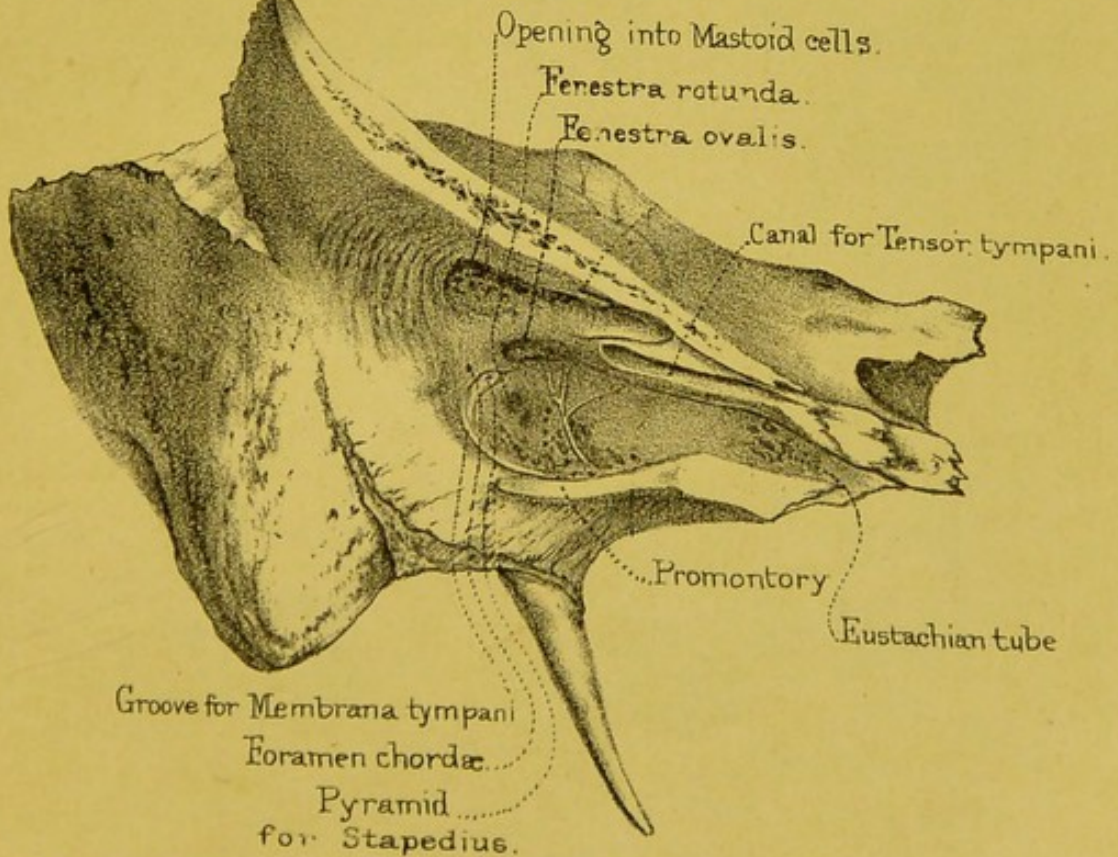


Diagram of the Ear.

Fig. 2.



Preparation to shew inner wall of tympanum.

Drawn on Stone by T. Godart.

From nature by L. Holden.

Printed by West, Newman & Co.


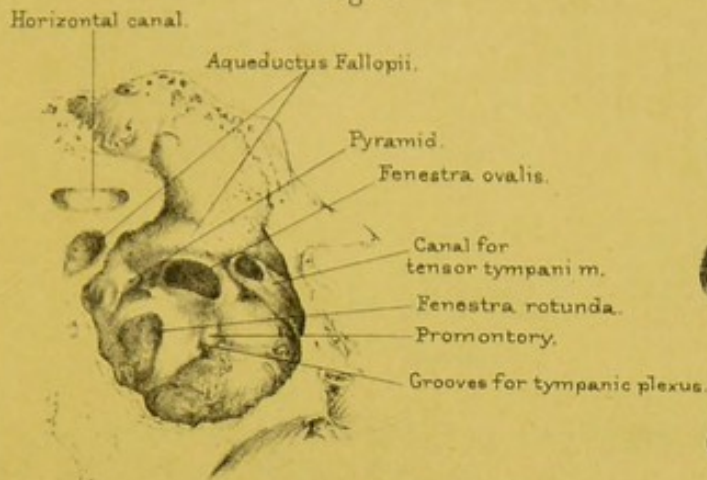
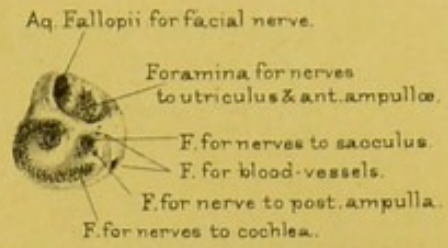


Fig. 1.



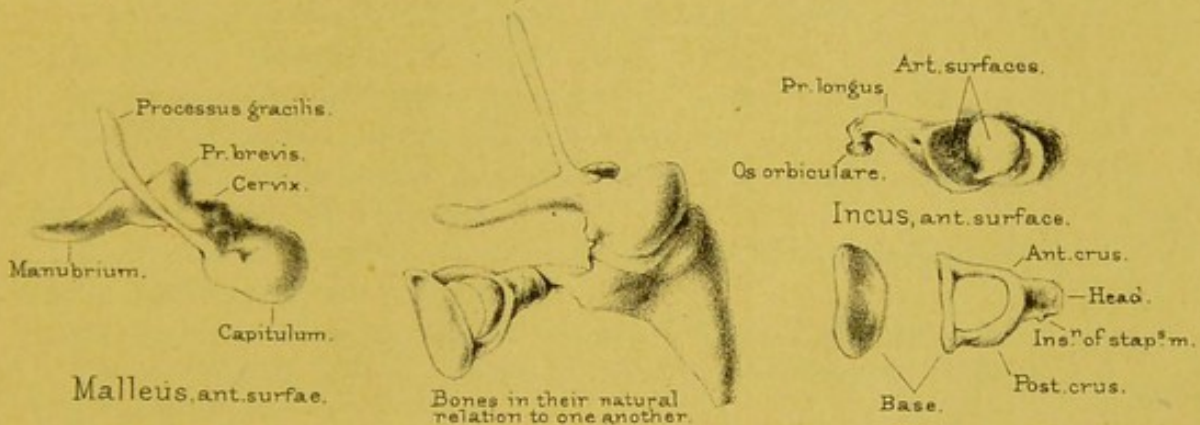
Inner wall of tympanum.
 x 2 diam.

Fig. 2.



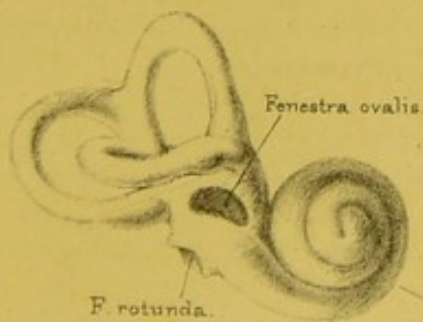
Outer wall of meatus aud. int.
 x 2 diam.

Fig. 3.



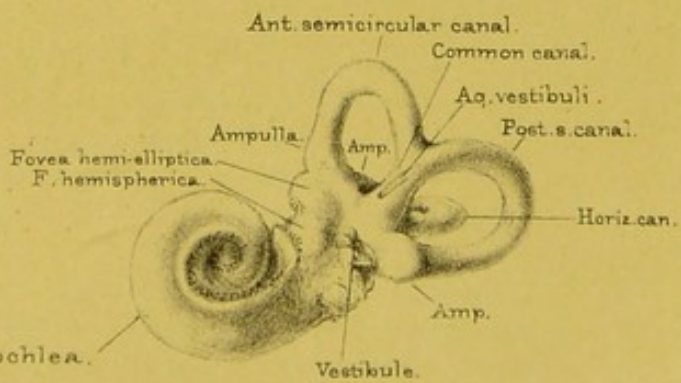
Ossicula auditûs.
 x 4 diam.

Fig. 5.



Outer surface.


Fig. 4.



Inner surface.

Bony labyrinth.
 x 2 diam.

RIGHT EAR.



NOTES.

1. Dr. Stark, 'Edin. Med. and Surg. Jour.,' April 1845; Nélaton, 'Éléments de Pathologie,' vol. i. p. 636.
2. Berzelius's 'Analysis of Bone.'
3. Dr. Bostock's 'Analysis of Rickety Bones.'
4. Liebig's 'Letters on Chemistry,' p. 522.
5. Gregory's 'Mechanics,' vol. i. c. 5.
6. Bishop 'On Deformities,' 1852, p. 14.
7. 'Outlines of Osteology,' p. 368. T. Ward.
8. 'Lectures on Surgical Pathology.' Sir J. Paget, F.R.S.
9. Curling, 'Medico-Chir. Trans.' vol. xx.
10. Cruikshank, 'Anatomy of the Absorbent Vessels,' 1790, p. 198.
11. Budge, 'Archiv f. Microsc. Anatomie,' bd. 13.
12. Dr. Clopton Havers, an English physician of the seventeenth century, was the first to describe these canals.
13. From a preparation in the museum at St. Bartholomew's Hospital.
14. Discovered by Mr. Queckett.
15. First described by Domenico Gagliardi, Professor of Medicine at Rome in the seventeenth century. *Anatomie Ossium novis inventis illustrata*, Romæ, 1689, in 8vo.
16. Mr. Queckett.
17. Mr. Bransby Cooper.
18. See 'Catalogue of Historical Series,' Mus. Roy. Coll. Surg., vol. i, plate viii. fig. 11.
19. 'Philosoph. Trans.' for 1736, vol. xxxix.
20. Stanley, 'Diseases of the Bones,' p. 108.
21. 'Callus' is the term applied by the old surgeons to the materials by which fractures are repaired.
22. Hyrtl, 'Topog. Anatomie.'
23. Guthrie, 'Commentaries on Surgery,' 6th edition, p. 374.
24. Dr. Leach and others, who have examined the immense collection of crania in the Catacombs at Paris, have remarked that the number of adult skulls in which the frontal suture remained unobliterated was about one in eleven.
25. Fallopius was a distinguished Italian anatomist, born 1523, died 1563.
26. This name was given to it by Galen, who thought that it secreted the 'pituita,' or mucus, and that this passed down into the throat through the small foramina which are often found at the bottom of the fossa ('De usu partium,' lib. ix. cap. 1). Its functions are not even yet understood; it is gene-

rally classed as a 'ductless' or 'vascular gland,' along with the spleen and thyroid body.

27. In some skulls, in which the malar bone does not enter into the composition of the sphenomaxillary fissure, the sphenoid meets the superior maxillary bone. In such exceptional skulls the sphenoid would be connected with seven bones of the face.

28. Sometimes there are two openings, separated by the thin plate (unciform process) which descends from the ethmoid bone.

29. Blandin ('Anat. Topog.' p. 44) relates a case in which a tumour, originating in the antrum, made its way into the zygomatic fossa, and caused a swelling in the temple.

30. Nathaniel Highmore was an English anatomist, born 1613, died 1684, who wrote much about the diseases of the antrum. He did not discover the antrum, for it was known to Galen as the 'sinus maxillaris.'

31. 'Commentaries,' p. 528. Guthrie.

32. See a curious case by Catlin, 'Trans. Odontolog. Soc.' vol. ii. 1857.

33. Drake's 'System of Anatomy,' 8vo. 1707.

34. 'Dental Anatomy,' p. 179. Tomes, 1876.

35. This part, in man, was first pointed out by the poet Goethe.

36. For the most recent investigations concerning the 'Formation and Early Growth of the Bones of the Human Face,' see a very interesting and elaborate paper by Mr. G. W. Callender in the 'Philosoph. Trans.' for 1869.

37. Jarjavay, 'Anatomie Chir.' t. ii. p. 61.

38. Skilful as he was, Hippocrates once mistook a natural suture of the skull for a fracture, and was afterwards so ingenuous as to leave his mistake on record. On this, Celsus observes: 'A suturis se deceptum esse Hippocrates memoriæ prodidit, more scilicet magnorum virorum, et fiduciam magnarum rerum habentium. Nam levia ingenia, quia nihil habent, nihil sibi detrahunt: magno ingenio, multa que nihilominus habituro, convenit etiam simplex veri erroris confessio; præcipueque in eo ministerio quod utilitatis causâ posteris traditur, ne qui decipiantur eadem ratione, quâ quis ante deceptus est.' (Liber viii. cap. iv.)

39. Broca, 'Ostéologie du Crane,' 1875.

40. The old anatomists call this the 'additamentum suturæ lambdoidalis.' This old name as well as others mentioned in the text, e.g. 'coronal,' 'sagittal,' and 'lambdoid,' are gradually falling into disuse, and giving place to more appropriate terms, derived from the bones connected, as 'inter-parietal,' 'fronto-parietal,' etc.

41. 'Prognathous' signifies 'with prominent jaws.'

42. These bodies are developed from the 'arachnoid' or serous membrane investing the brain, beneath the 'dura mater,' which they perforate, and thus come to press immediately on the bony vault of the skull. *Vide* Quain's 'Anatomy,' vol. ii. p. 379, 9th edition.

43. Except in cases where the sphenoid and superior maxillary come into contact and exclude the malar. (See *note*, 27.)

44. Craniology is nothing new. An Italian poet in the age of Dante writes:—

Nel Capo son tre celle,
 Et io dirò di quelle,
 Davanti è lo intelletto
 E la forza d' apprendere ;
 In mezzo è la ragione
 E la discrezione,
 Che scerne buono e male.
 Indietro stà con gloria
 La valente memoria, etc. etc.

45. The above is taken, with but slight alteration, from the Osteological Catalogue, Part I., of the Museum of the Royal College of Surgeons, by kind permission of the Council.

46. Cuvier, 'Recherches sur les ossemens fossiles,' 1822, vol. ii. p. 231.

47. See a case of this kind, with a drawing, in 'Med.-Chir. Trans.' vol. xxxi., by Sir James Paget.

48. 'Natural Theology.' Paley.

49. The inferior tubercles are alluded to by Monro, 'Anatomy of the Human Bones,' 1726; also by Soemmering, 'De Corp. Human. Fabrica,' 8vo. 1794. The superior as well as the inferior tubercles are developed as little epiphyses with distinct centres of ossification, and unite to the rest of the vertebræ about the twenty-fifth year.

50. Rollin and Magendie make it sixteen times stronger.

51. It is not easy to say why this was called the 'sacred bone' (*ἱερὸν ὀστέον*). The reason generally assigned is, that it was the part used in sacrifices. The following is another:—It appears the Jewish Rabbis entertained a notion that this part of the skeleton, which they call the 'luz,' would resist decay, and become the germ from which the body would be raised. Hence Butler has it—

'The learned Rabbins of the Jews,
 Write there's a bone, which they call "Luz,"
 I' the rump of man of such a virtue
 No force in Nature can do hurt to:
 Therefore at the last great day
 All th' other members shall, they say,
 Spring out of this, as from a seed
 All sorts of vegetals proceed;
 From whence the learned sons of art
 "Os sacrum" justly call that part.'

HUDIBRAS, part iii. cant. ii.

52. It is not uncommon to meet with six sacral vertebræ. Sometimes there are but four. The first sacral may be detached from the lower sacral vertebræ. Again, the last lumbar may be ankylosed to the sacrum by its body, or to the ilium by one or both of its transverse processes. This last condition is frequent among the higher monkeys.

53. Dr. Ramsbotham's 'Principles and Practice of Obstetric Medicine and Surgery,' 5th edition, p. 9.

54. Some authors state the reverse. But Albinus ('De Sceleto') says

truly: 'Sacrum feminis latius, per longitudinem rectius, infra non æque incurvatum in priora.'

55. In his lectures 'On the Comparative Anatomy of Man,' 1877, Professor Flower gives 61° as the mean subpubic angle in men, 80° in women.

56. The brothers Weber, 'Mechanik der mensch. Gehwerk.,' Gott. 1836.

57. See 'Medical and Surgical Landmarks,' by the Author, 3rd edition, 1881.

58. Concerning the bearing of Osteogeny on forensic medicine, see 'Médecine légale,' by M. Orfila.

59. We are indebted for this outline to Mr. Keetely, late Assistant-Demonstrator of Anatomy at St. Bartholemew's Hospital.

60. For further [practical remarks on this subject, see 'Anatomy and Surgery of the Human Foot,' by J. Hancock, 1873.

61. Professor Flower, F.R.S., 'Fashion in Deformity,' p. 67; also Professor Marshall, F.R.S., 'Anatomy for Artists,' p. 45.

62. The nucleus at the margin of the glenoid cavity is not to be regarded as an epiphysis, but only an occasionally present scale, like those sometimes found on the coracoid and having no morphological bearing, and scarcely worthy of notice. Professor Humphrey, F.R.S.

63. On the supra-condyloid foramen read Hyrtl, 'Topog. Anat.' vol. ii. p. 283; also Gruber, 'Canalis supra Condylloideus humeri,' Mém. de l'Acad. Imp. de St. Pétersbourg, 1859, p. 57; and Professor Struthers, 'Edin. Med. Jour.' 1848.

64. The radius of the skeleton of the gorilla in the Museum of the College of Surgeons is extremely arched. The power of his arms is enormous.

65. So called from its fancied resemblance to the letter Sigma, which the Greeks originally used in the form of the English C.

66. Very often the coronoid process gives origin to a second head of the flexor longus pollicis.

67. Mr. Liston, 'Practical Surgery.'

68. Mr. Lockwood, Demonstrator of Anatomy at St. Bartholomew's Hospital.

69. To the rule stated there are certainly exceptions. I have seen preparations clearly showing separate epiphyses at the bases of the metacarpal bones of the fore and middle fingers. I have also seen a separate epiphysis at the head of the metacarpal bone of the thumb. Whether these additional epiphyses be normal or exceptional, they always unite the first to the shaft, in accordance with the direction of the artery of the marrow, which in the metacarpal of the thumb runs towards the head, in those of the fingers towards the base.

70. The centre of ossification in the shaft of every long bone appears in its middle, excepting in the case of the unguis phalanges, which commence to ossify at their distal ends.

71. 'The Hand, its Mechanism and Vital Endowments, as evincing Design.' London, 1834, by Sir Charles Bell, F.R.S.

72. Quintilian.

INDEX.

ACE	PAGE	CEL	PAGE
A CETABULUM	188	Bones, properties of	5
Acromion	290	strength of	5
Air-cells in bone	8	uses of	2
Alveolar process	95	C ALCANEUM	236
Ampullæ	69	Callus	35
Analysis of bones	4	Callus provisional	35
Anatomical neck of humerus	295	Canal, anterior dental	93
Animal matter of bone	3	anterior palatine	88, 133
Anterior clinoid process.....	74	carotid	65
Antlers	56	infra-orbital	93
Antrum of Highmore.....	94	of Huguier	59
Aquæductus cochleæ	66	posterior palatine.....	91, 11
Fallopîi.....	65	pterygo-palatine	134
vestibuli	63	malar	103
Arch, carpal.....	318	semicircular.....	69
of foot	231	,, membranous	69
Arches of foot	257	vertebral	169
Articular arteries.....	10	Vidian	81
Astragalus	232	Canaliculi of bone	20
Atlas	157	Canals, accessory palatine.....	111
Axis	158	Cancellous tissue.....	9
B ASILAR process	38, 137	Canine fossa	92
Bicipital groove of humerus... 298		Carotid canal	62
Blood-supply of bones	10	Carpal arch	318
Bones, air-cells in	8	Carpus	317
classification of	6	Cartilages, costal	271
composition of.....	2	Cavity, sigmoid, of radius	306
elasticity of	6	,, of ulna.....	309
hollow shaft of	7	Cells, ethmoidal	83
microscopic structure of	13	frontal	49
naked-eye structure of	7	mastoid.....	60
nomenclature of	3	maxillary	94

CEL	PAGE	FRA	PAGE
Cells, palatine	111	Fibula	223
sphenoidal	76	First rib	269
Clavicle.....	280	Fissura Glaseri	58
curves of	280	Fissure, sphenoidal	80, 141
Coccyx	177	spheno-maxillary	141
Cochlea.....	70	Floating ribs	270
membranous	70	Fontanelles	47
Condylloid ridge of humerus, external	298	Foot, arches of	257
" " " internal	297	as a whole	255
Coracoid process.....	291	bones of	230
Cornua sphenoidalia	75	mechanism in walking	258
Coronoid fossa.....	299	Foramen cæcum	52
process of lower jaw	120	condyloid, anterior	137
" " ulna.....	309	" posterior	137
Costal cartilages.....	271	ethmoidal, anterior.....	85
Cranial fossæ	129	" posterior	85
Cribriform plate	83	infra-orbital.....	92
Cristi galli	83	magnum	38
vestibuli	96	mentale	121
Cuboid bone.....	241	obturatum	188
Cuneiform bone of carpus.....	322	occipital	137
bones of tarsus	242	opticum	77
Cupola	70	ovale	188
Cuvier on fossil bones	153	parietal.....	127
		rotundum	78
		spheno-palatine	110
		spinosum	78
		stylo-mastoid	64
		supra-orbital	49
		Vesalii	78
		Fossa, canine	92
		coronoid	299
		digastric	60
		digital	202
		iliac	190
		jugular	65
		mental	116
		olecranon	299
		pituitary	73
		pterygoid	80
		scaphoid	81
		spheno-maxillary	138
		temporal	127
		zygomatic.....	138
		Fossæ, nasal	141
		of skull.....	129
		Fovea hemielliptica	69
		hemispherica	69
		Fractures, repair of	35
DENTAL foramen	119		
Digital fossa	202		
Diploe.....	11, 106		
Diploic veins	106		
EAR, anatomy of	69		
Earthy matter of bones.....	3		
Endosteum	12		
Ensiform cartilage	265		
Epipteric bone.....	72		
Ethmoid bone	83		
Ethmoidal foramen, anterior	85		
" " posterior	85		
notch.....	53		
Eustachian tube	66		
FACE, bones of.....	90		
Falx cerebri.....	84		
Femur	198		
Fenestra ovalis	67		
rotunda.....	67		

FRO	PAGE
Frontal bone	48
sinus	49
G LASERIAN fissure	58
Glenoid cavity	57, 285
Glenoid fissure.....	58
Groove, bicipital, of humerus	296
optic	74
Growth in length of bones.....	33
Gumboil	96
H AMULAR process.....	81
Hamulus of cochlea	70
Hamulus of lachrymal bone.....	108
Hand, bones of	317
Haversian canals	13, 16
interspaces	15
lamellæ.....	14
system	14
Helicotrema	70
Hiatus Fallopii	62
Highmore, antrum of.....	94
Hollow shaft of bone	7
Horns	56
Hugnier, canal of	59
Humerus	295
Hunter's experiments with shots...	33
Hyoid bone	343
I NCUS	68
Inferior maxillary bone	116
Inferior spongy bone	112
turbinated bone	112
Infra-orbital canal	92
foramen	92
Infundibulum	50, 87
Iliac fossa.....	190
Ilium.....	180
Innominate bone.....	180
Intervertebral fibro-cartilage.....	167
Ischium	180
J AW, buttresses of upper.....	145
Jaw, joint of	124

MYE	PAGE
Jaw-bone, lower	116
" upper	90
Jugular foramen	136
fossa	65
L ABYRINTH, membranous	69
Lachrymal bone.....	107
Lachrymal fossa	54
groove.....	97, 107
process	113
sac.....	97
Lacunæ of bone	14
Lamina, spiralis ossea	70
Levers, bones act as	2
Linea aspera	205
Lower extremity, bones of.....	180
Lymphatics of bone	13
M ADDER, experiments with.....	32
Malar bone	102
Malar canals	103
Malleolus externus	227
internus	220
Malleus.....	68
Manubrium	262
Marrow, artery of	11
red.....	10
yellow	9
Mastoid process	59
Maxillary sinus	94
Meatus auditorius externus	61
internus	63
of nose	86, 142
Median crest of palate bone	109
Medullary artery.....	11
membrane	12
Membrana tympani	62
Metacarpus	327
Metatarsus	246
Microscopic structure of bone	13
Milk dentition	95
Modiolus	70
Muscles in front of the spine	278
of back	275
" superficial	275
of the back of the neck	277
Myeloid cells	10

NAS		REP	
	PAGE		PAGE
N ASAL bone	105	Pelvis, arch of	194
Nasal duct	97	axes of	195
Nasal fossæ	141	brim of the	193
process of sup. maxillary bone	96	diameters of.....	196
slit.....	84	lever of first order	193
spine, anterior.....	99	obliquity of	195
,, posterior	109	sexual differences of	197
suture	106	Periosteum	12
Neck of humerus, anatomical	295	blood-vessels of	12
,, surgical.....	297	value of	33
Necrosis	34	Perivascular lymphatics	13
Nerves in bone	12	Phalanges of fingers	334
Neuralgia of bone	13	of toes	254
Nose, meatus of	142	Phosphate of lime	4
posterior openings of	133	Pisiform bone	322
septum of.....	143	Pituitary fossa.....	73
Notch of acetabulum	188	Pre-maxillary bones	99
intercondyloid	207	suture	99
ischiatric, greater.....	184	Process, acromion	290
,, lesser	185	alveolar.....	95
sigmoid.....	309	basilar	137
Notches in sternum	264	clinoid	74
Nutrient artery of bone	11	coracoid	291
		coronoid, of lower jaw	120
		,, of ulna.....	309
O CCIPITAL bone.....	36	hamular	81
Olecranon	308	lachrymal.....	113
Olecranon fossa	299	malar	100
Optic foramen	77	mastoid.....	59
groove	74	nasal.....	96
Orbital wings of sphenoid.....	77	palatine	98
Orbits	139	post-glenoid	58
Os calcis	236	pterygoid	80
Os hyoides	343	sphenoidal	112
Os innominatum.....	180	styloid	64
Os magnum	324	,, of radius	306
Os orbiculare	68	,, of ulna	314
Os planum	86	unciform	86
Os unguis.....	107	vaginal	77
Ossification	23	Promontory of tympanum.....	68
Osteoblasts	27	Pterygoid process	80
Osteology, interest of.....	1	Pterygo-palatine canal	77
		Pubes	180
		Pyramid	67
P ACCHIONIAN bodies.....	46, 127		
Palate bone	108	R ADIUS	303
Parietal bone	44	Radius, rotation of	316
Paroccipital process	40	Repair of fractures.....	35
Patella	213		

RIB	PAGE
Ribs, general characters of	267
Rickety bones	4
Ridge, deltoid	298
Ridges, intertrochanteric	203
condyloid of humerus.....	297
Rostrum of sphenoid	76
S ABRE-cuts	34
Saccule.....	69
Sacro-iliac symphysis	176
Sacrum	174
Scala tympani.....	70
vestibuli	70
Scaphoid bone of carpus	320
,, of tarsus	240
fossa	81
Scapula.....	284
spine of.....	288
Sella Turcica	74
Semicircular canals	69
,, membranous ..	69
Semilunar bone	321
Septum of nose	143
Sesamoid bones of hand	337
,, of foot	255
Sigmoid cavity of radius	306
Sinus, frontal	50
inferior petrosal	131
lateral	131
superior petrosal.....	131
Skeleton, general survey of	338
Skull as a whole	125
base of	132
bones of	36
buttresses of.....	145
-cap	126
general observations on.....	144
lever of first order	144
locking of bones of	144
power of resisting shocks	145
sexual differences	146
tables of	144
Sphenoid bone.....	73
lesser wings of.....	77
rostrum of	76
Sphenoidal fissure	141
process	112

TOE	PAGE
Spheno-maxillary fossa.....	138
fissure	141
Spheno-palatine foramen	112
Spine.....	154
curves of	167
ethmoidal.....	74
extent of motion of.....	167
of pubes	183
of scapula.....	289
Spines of ilium, anterior and post ^r ..	182
Spongy bones	86
Squamosal bone	57
Stapes	68
Stature of individual	33
Sternum	262
Styloid process of radius	306
,, of ulna	314
Superciliary ridge	49
Superior maxillary bone	90
Surgical neck of humerus.....	297
Suture, basilar.....	74
coronal	54
zygomatic.....	71
Sutures of skull	125
Symphysis of lower jaw.....	116
pubis.....	183
sacro-iliac.....	176
T ABLES of skull	144
Tarsus, bones of.....	230
Tarsus, tunnel of	234
Teeth.....	95
fangs of.....	96
milk	95
of lower jaw	118
of upper jaw.....	95
permanent	95
sockets of.....	95
Temporal bone	56
,, mastoid portion of...	59
,, petrous portion of...	61
,, squamous portion of	57
Tendo oculi	98
Thorax as a whole	272
general description of.....	261
Tibia	216
Toes, relative length of	259

	PAGE	ZYG	PAGE
Torcular Herophili.....	41	V AGINAL processes	77
Trapezium	323	Vertebra, constituent parts of	154
Trochanters, major and minor.....	201	Vertebræ, cervical	156
Tubercle of radius	304	coccygeal	177
Tubercles of dorsal and lumbar ver-		dorsal	160
tebræ.....	164	lumbar	163
Tuberosities of femur.....	208	sacral	174
of humerus, greater	296	Vertebral canal	169
" lesser	296	column	154
of tibia	217	" shape of	168
Tuberosity of ischium	190	" strength of.....	166
Tunnel of tarsus.....	234	groove	169
Turbinated bones	86	Vestibule	69
bone, sphenoidal.....	75	Vidian canal	81
Tympanum	67	Vomer	114
U LNA	308	W ALKING, mechanism of foot in	258
Unciform bone	325	Wormian bones	88
Unciform process	86	 	
Upper extremity, bones of.....	280	Z YGOMA	57
Utricle	69	Zygomatic fossa	138

PRINTED BY

SPOTTISWOODE AND CO., NEW-STREET SQUARE

LONDON

Catalogue B]

London, 11, New Burlington Street,
March, 1890.

SELECTION

FROM

J. & A. CHURCHILL'S GENERAL CATALOGUE

COMPRISING

ALL RECENT WORKS PUBLISHED BY THEM

ON THE

ART AND SCIENCE OF MEDICINE



N.B.—As far as possible, this List is arranged in the order in
which medical study is usually pursued.

J. & A. CHURCHILL publish for the following Institutions
and Public Bodies:—

ROYAL COLLEGE OF SURGEONS.

CATALOGUES OF THE MUSEUM.

Twenty-three separate Catalogues (List and Prices can be obtained of J. & A. CHURCHILL).

GUY'S HOSPITAL.

REPORTS BY THE MEDICAL AND SURGICAL STAFF.

Vol. XXX., Third Series. 7s. 6d.

FORMULÆ USED IN THE HOSPITAL IN ADDITION TO THOSE
IN THE B.P. 1s. 6d.

LONDON HOSPITAL.

PHARMACOPŒIA OF THE HOSPITAL. 3s.

ST. BARTHOLOMEW'S HOSPITAL.

CATALOGUE OF THE ANATOMICAL AND PATHOLOGICAL
MUSEUM. Vol. I.—Pathology. 15s. Vol. II.—Teratology, Anatomy
and Physiology, Botany. 7s. 6d.

ST. GEORGE'S HOSPITAL.

REPORTS BY THE MEDICAL AND SURGICAL STAFF.

The last Volume (X.) was issued in 1880. Price 7s. 6d.

CATALOGUE OF THE PATHOLOGICAL MUSEUM. 15s.

SUPPLEMENTARY CATALOGUE (1882). 5s.

ST. THOMAS'S HOSPITAL.

REPORTS BY THE MEDICAL AND SURGICAL STAFF

Annually. Vol. XVII., New Series. 7s. 6d.

MIDDLESEX HOSPITAL.

CATALOGUE OF THE PATHOLOGICAL MUSEUM. 12s.

WESTMINSTER HOSPITAL.

REPORTS BY THE MEDICAL AND SURGICAL STAFF.

Annually. Vol. IV. 6s.

ROYAL LONDON OPHTHALMIC HOSPITAL.

REPORTS BY THE MEDICAL AND SURGICAL STAFF.

Half-yearly. Vol. XII., Part IV. 5s.

OPHTHALMOLOGICAL SOCIETY OF THE UNITED KINGDOM.

TRANSACTIONS. Vol. IX. 12s. 6d.

MEDICO-PSYCHOLOGICAL ASSOCIATION.

JOURNAL OF MENTAL SCIENCE. Quarterly. 3s. 6d.

PHARMACEUTICAL SOCIETY OF GREAT BRITAIN.

PHARMACEUTICAL JOURNAL AND TRANSACTIONS.

Every Saturday. 4d. each, or 20s. per annum, post free

BRITISH PHARMACEUTICAL CONFERENCE.

YEAR BOOK OF PHARMACY. 10s.

A SELECTION

FROM

J. & A. CHURCHILL'S GENERAL CATALOGUE,

COMPRISING

ALL RECENT WORKS PUBLISHED BY THEM ON THE
ART AND SCIENCE OF MEDICINE.

N.B.—*J. & A. Churchill's Descriptive List of Works on Chemistry, Materia Medica, Pharmacy, Botany, Photography, Zoology, the Microscope, and other Branches of Science, can be had on application.*

Practical Anatomy :

A Manual of Dissections. By CHRISTOPHER HEATH, Surgeon to University College Hospital. Seventh Edition. Revised by RICKMAN J. GODLEE, M.S. Lond., F.R.C.S., Teacher of Operative Surgery, late Demonstrator of Anatomy in University College, and Surgeon to the Hospital. Crown 8vo, with 24 Coloured Plates and 278 Engravings, 15s.

Wilson's Anatomist's Vade-

Mecum. Tenth Edition. By GEORGE BUCHANAN, Professor of Clinical Surgery in the University of Glasgow; and HENRY E. CLARK, M.R.C.S., Lecturer on Anatomy at the Glasgow Royal Infirmary School of Medicine. Crown 8vo, with 450 Engravings (including 26 Coloured Plates), 18s.

Braune's Atlas of Topographi-

cal Anatomy, after Plane Sections of Frozen Bodies. Translated by EDWARD BELLAMY, Surgeon to, and Lecturer on Anatomy, &c., at, Charing Cross Hospital. Large Imp. 8vo, with 34 Photolithographic Plates and 46 Woodcuts, 40s.

An Atlas of Human Anatomy.

By RICKMAN J. GODLEE, M.S., F.R.C.S., Assistant Surgeon and Senior Demonstrator of Anatomy, University College Hospital. With 48 Imp. 4to Plates (112 figures), and a volume of Explanatory Text. 8vo, £4 14s. 6d.

Harvey's (Wm.) Manuscript

Lectures. *Prelectiones Anatomiae Universalis*. Edited, with an Autotype reproduction of the Original, by a Committee of the Royal College of Physicians of London. Crown 4to, half bound in Persian, 52s. 6d.

Anatomy of the Joints of Man.

By HENRY MORRIS, Surgeon to, and Lecturer on Anatomy and Practical Surgery at, the Middlesex Hospital. 8vo, with 44 Lithographic Plates (several being coloured) and 13 Wood Engravings, 16s.

Manual of the Dissection of the Human Body.

By LUTHER HOLDEN, Consulting Surgeon to St. Bartholomew's Hospital. Edited by JOHN LANGTON, F.R.C.S., Surgeon to, and Lecturer on Anatomy at, St. Bartholomew's Hospital. Fifth Edition. 8vo, with 208 Engravings. 20s.

By the same Author.

Human Osteology.

Seventh Edition, edited by CHARLES STEWART, Conservator of the Museum R.C.S., and R.W. REID, M.D., F.R.C.S., Lecturer on Anatomy at St. Thomas's Hospital. 8vo, with 59 Lithographic Plates and 75 Engravings. 16s.

Also.

Landmarks, Medical and Surgical.

Fourth Edition. 8vo, 3s. 6d.

The Student's Guide to Surgical

Anatomy. By EDWARD BELLAMY, F.R.C.S. and Member of the Board of Examiners. Third Edition. Fcap. 8vo, with 81 Engravings. 7s. 6d.

Diagrams of the Nerves of the

Human Body, exhibiting their Origin, Divisions, and Connections, with their Distribution to the Various Regions of the Cutaneous Surface, and to all the Muscles. By W. H. FLOWER, C.B., F.R.S., F.R.C.S. Third Edition, with 6 Plates. Royal 4to, 12s.

Pathological Anatomy of Diseases.

Arranged according to the nomenclature of the R.C.P. Lond. (Students' Guide Series). By NORMAN MOORE, M.D., F.R.C.P., Assistant Physician and Lecturer on Pathological Anatomy to St. Bartholomew's Hospital. Fcap. 8vo, with 111 Engravings, 8s. 6d.

General Pathology :

An Introduction to. By JOHN BLAND SUTTON, F.R.C.S., Sir E. Wilson Lecturer on Pathology, R.C.S. ; Assistant Surgeon to, and Lecturer on Anatomy at, Middlesex Hospital. 8vo, with 149 Engravings, 14s.

Atlas of Pathological Anatomy.

By Dr. LANCEREAUX. Translated by W. S. GREENFIELD, M.D., Professor of Pathology in the University of Edinburgh. Imp. 8vo, with 70 Coloured Plates, £5 5s.

A Manual of Pathological Anatomy.

By C. HANDFIELD JONES, M.B., F.R.S., and E. H. SIEVEKING, M.D., F.R.C.P. Edited by J. F. PAYNE, M.D., F.R.C.P., Lecturer on General Pathology at St. Thomas's Hospital. Second Edition. Crown 8vo, with 195 Engravings, 16s.

Post-mortem Examinations :

A Description and Explanation of the Method of Performing them, with especial reference to Medico-Legal Practice. By Prof. VIRCHOW. Translated by Dr. T. P. SMITH. Second Edition. Fcap. 8vo, with 4 Plates, 3s. 6d.

The Human Brain :

Histological and Coarse Methods of Research. A Manual for Students and Asylum Medical Officers. By W. BEVAN LEWIS, L.R.C.P. Lond., Medical Superintendent, West Riding Lunatic Asylum. 8vo, with Wood Engravings and Photographs, 8s.

Manual of Physiology :

For the use of Junior Students of Medicine. By GERALD F. YEO, M.D., F.R.C.S., F.R.S., Professor of Physiology in King's College, London. Second Edition. Crown 8vo, with 318 Engravings, 14s.

Principles of Human Physiology.

By W. B. CARPENTER, C.B., M.D., F.R.S. Ninth Edition. By HENRY POWER, M.B., F.R.C.S. 8vo, with 3 Steel Plates and 377 Wood Engravings, 31s. 6d.

Elementary Practical Biology :

Vegetable. By THOMAS W. SHORE, M.D., B.Sc. Lond., Lecturer on Comparative Anatomy at St. Bartholomew's Hospital. 8vo, 6s.

Medical Jurisprudence :

Its Principles and Practice. By ALFRED S. TAYLOR, M.D., F.R.C.P., F.R.S. Third Edition, by THOMAS STEVENSON, M.D., F.R.C.P., Lecturer on Medical Jurisprudence at Guy's Hospital. 2 vols. 8vo, with 188 Engravings, 31s. 6d.

By the same Authors.

A Manual of Medical Jurisprudence.

Eleventh Edition. Crown 8vo, with 56 Engravings, 14s.

Also.

Poisons,

In Relation to Medical Jurisprudence and Medicine. Third Edition. Crown 8vo, with 104 Engravings, 16s.

Lectures on Medical Jurisprudence.

By FRANCIS OGSTON, M.D., late Professor in the University of Aberdeen. Edited by FRANCIS OGSTON, Jun., M.D. 8vo, with 12 Copper Plates, 18s.

The Student's Guide to Medical

Jurisprudence. By JOHN ABERCROMBIE, M.D., F.R.C.P., Lecturer on Forensic Medicine to Charing Cross Hospital. Fcap. 8vo, 7s. 6d.

Hospitals, Infirmaries, and Dis-

pensaries : Their Construction, Interior Arrangement, and Management; with Descriptions of existing Institutions, and 74 Illustrations. By F. OPPERT, M.D., M.R.C.P.L. Second Edition. Royal 8vo, 12s.

Hospital Construction and

Management. By F. J. MOUAT, M.D., Local Government Board Inspector, and H. SAXON SNELL, Fell. Roy. Inst. Brit. Architects. Second Edition. Half calf, with large Map, 54 Lithographic Plates, and 27 Woodcuts, 35s.

Sanitary Examinations

Of Water, Air, and Food. A Vade-Mecum for the Medical Officer of Health. By CORNELIUS B. FOX, M.D., F.R.C.P. Second Edition. Crown 8vo, with 110 Engravings, 12s. 6d.

Microscopical Examination of

Drinking Water and of Air. By J. D. MACDONALD, M.D., F.R.S., Ex-Professor of Naval Hygiene in the Army Medical School. Second Edition. 8vo, with 25 Plates, 7s. 6d.

Epidemic Influences :

Epidemiological Aspects of Yellow Fever and of Cholera. The Milroy Lectures. By ROBERT LAWSON, LL.D., Inspector-General of Hospitals. 8vo, with Maps, Diagrams, &c., 6s.

A Manual of Practical Hygiene.

By E. A. PARKES, M.D., F.R.S. Seventh Edition, by F. DE CHAUMONT, M.D., F.R.S., Professor of Military Hygiene in the Army Medical School. 8vo, with 9 Plates and 101 Engravings, 18s.

A Handbook of Hygiene and Sanitary Science. By GEO. WILSON, M.A., M.D., F.R.S.E., Medical Officer of Health for Mid-Warwickshire. Sixth Edition. Crown 8vo, with Engravings. 10s. 6d.

By the same Author.

Healthy Life and Healthy Dwellings: A Guide to Personal and Domestic Hygiene. Fcap. 8vo, 5s.**Public Health Reports.**

By Sir JOHN SIMON, C.B., F.R.S. Edited by EDWARD SEATON, M.D., F.R.C.P. 2 vols. 8vo, with Portrait, 36s.

Illustrations of the Influence of the Mind upon the Body in Health and Disease: Designed to elucidate the Action of the Imagination. By D. H. TUKE, M.D., F.R.C.P., LL.D. Second Edition. 2 vols. crown 8vo, 15s.

By the same Author.

Sleep-Walking and Hypnotism. 8vo, 5s.**A Manual of Psychological Medicine.** With an Appendix of Cases. By JOHN C. BUCKNILL, M.D., F.R.S., and D. HACK TUKE, M.D., F.R.C.P. Fourth Edition. 8vo, with 12 Plates (30 Figures) and Engravings, 25s.**Mental Affections of Childhood and Youth (Lettsomian Lectures for 1887, &c.).** By J. LANGDON DOWN, M.D., F.R.C.P., Senior Physician to the London Hospital. 8vo, 6s.**Mental Diseases:**

Clinical Lectures. By T. S. CLOUSTON, M.D., F.R.C.P. Edin., Lecturer on Mental Diseases in the University of Edinburgh. Second Edition. Crown 8vo, with 8 Plates (6 Coloured), 12s. 6d.

Intra-Uterine Death:

(Pathology of). Being the Lumleian Lectures, 1887. By WILLIAM O. PRIESTLEY, M.D., F.R.C.P., LL.D., Consulting Physician to King's College Hospital. 8vo, with 3 Coloured Plates and 17 Engravings, 7s. 6d.

A Manual of Obstetrics.

By A. F. A. KING, A.M., M.D., Professor of Obstetrics, &c., in the Columbian University, Washington, and the University of Vermont. Third Edition. Crown 8vo, with 102 Engravings, 8s.

Manual of Midwifery.

By ALFRED L. GALABIN, M.A., M.D., F.R.C.P., Obstetric Physician to, and Lecturer on Midwifery, &c. at, Guy's Hospital. Crown 8vo, with 227 Engravings, 15s.

The Student's Guide to the Practice of Midwifery. By D. LLOYD ROBERTS, M.D., F.R.C.P., Lecturer on Clinical Midwifery and Diseases of Women at the Owens College; Obstetric Physician to the Manchester Royal Infirmary. Third Edition. Fcap. 8vo, with 2 Coloured Plates and 127 Wood Engravings, 7s. 6d.**Lectures on Obstetric Operations: Including the Treatment of Hæmorrhage, and forming a Guide to the Management of Difficult Labour.** By ROBERT BARNES, M.D., F.R.C.P., Consulting Obstetric Physician to St. George's Hospital. Fourth Edition. 8vo, with 121 Engravings, 12s. 6d.

By the same Author.

A Clinical History of Medical and Surgical Diseases of Women. Second Edition. 8vo, with 181 Engravings, 28s.**Clinical Lectures on Diseases of Women: Delivered in St. Bartholomew's Hospital,** by J. MATTHEWS DUNCAN, M.D., LL.D., F.R.Ss. L. & E. Fourth Edition. 8vo, 16s.**West on the Diseases of Women.** Fourth Edition, revised by the Author, with numerous Additions by J. MATTHEWS DUNCAN, M.D., F.R.C.P., F.R.S.E., Obstetric Physician to St. Bartholomew's Hospital. 8vo, 16s.**The Female Pelvic Organs:**

Their Surgery, Surgical Pathology, and Surgical Anatomy. In a Series of Coloured Plates taken from Nature; with Commentaries, Notes, and Cases. By HENRY SAVAGE, M.D., F.R.C.S., Consulting Officer of the Samaritan Free Hospital. Fifth Edition. Roy. 4to, with 17 Lithographic Plates (15 coloured) and 52 Woodcuts, £1 15s.

Notes on Diseases of Women: Specially designed to assist the Student in preparing for Examination. By J. J. REYNOLDS, L.R.C.P., M.R.C.S. Third Edition. Fcap. 8vo, 2s. 6d.

By the same Author.

Notes on Midwifery:

Specially designed for Students preparing for Examination. Second Edition. Fcap. 8vo, with 15 Engravings, 4s.

The Student's Guide to the Diseases of Women. By ALFRED L. GALABIN, M.D., F.R.C.P., Obstetric Physician to Guy's Hospital. Fourth Edition. Fcap. 8vo, with 94 Engravings, 7s. 6d.

Obstetric Aphorisms :

For the Use of Students commencing Midwifery Practice. By JOSEPH G. SWAYNE, M.D. Ninth Edition. Fcap. 8vo, with 17 Engravings, 3s. 6d.

Handbook of Midwifery for Midwives : By J. E. BURTON, L.R.C.P. Lond., Surgeon to the Hospital for Women, Liverpool. Second Edition. With Engravings. Fcap. 8vo, 6s.

A Handbook of Uterine Therapeutics, and of Diseases of Women. By E. J. TILT, M.D., M.R.C.P. Fourth Edition. Post 8vo, 10s.

By the same Author.

The Change of Life

In Health and Disease: A Clinical Treatise on the Diseases of the Nervous System incidental to Women at the Decline of Life. Fourth Edition. 8vo, 10s. 6d.

Diseases of the Uterus, Ovaries, and Fallopian Tubes : A Practical Treatise by A. COURTY, Professor of Clinical Surgery, Montpellier. Translated from Third Edition by his Pupil, AGNES McLAREN, M.D., M.K.Q.C.P.I., with Preface by J. MATTHEWS DUNCAN, M.D., F.R.C.P. 8vo, with 424 Engravings, 24s.

Gynæcological Operations :

(Handbook of). By ALBAN H. G. DORAN, F.R.C.S., Surgeon to the Samaritan Hospital. 8vo, with 167 Engravings, 15s.

Diseases and Accidents

Incident to Women, and the Practice of Medicine and Surgery applied to them. By W. H. BYFORD, A.M., M.D., Professor of Gynæcology in Rush Medical College, and HENRY T. BYFORD, M.D., Surgeon to the Woman's Hospital, Chicago. Fourth Edition. 8vo, with 306 Engravings, 25s.

A Practical Treatise on the Diseases of Women. By T. GAILLARD THOMAS, M.D., Professor of Diseases of Women in the College of Physicians and Surgeons, New York. Fifth Edition. Roy. 8vo, with 266 Engravings, 25s.

Abdominal Surgery.

By J. GREIG SMITH, M.A., F.R.S.E., Surgeon to the Bristol Royal Infirmary and Lecturer on Surgery in the Bristol Medical School. Third Edition. 8vo, with 82 Engravings, 21s.

The Student's Guide to Diseases of Children. By JAS. F. GOODHART, M.D., F.R.C.P., Physician to Guy's Hospital, and to the Evelina Hospital for Sick Children. Third Edition. Fcap. 8vo, 10s. 6d.

Diseases of Children.

For Practitioners and Students. By W. H. DAY, M.D., Physician to the Samaritan Hospital. Second Edition. Crown 8vo, 12s. 6d.

A Practical Treatise on Disease in Children. By EUSTACE SMITH, M.D., F.R.C.P., Physician to the King of the Belgians, and to the East London Hospital for Children, &c. Second Edition. 8vo, 22s.

By the same Author.

Clinical Studies of Disease in Children. Second Edition. Post 8vo, 7s. 6d. *Also.*

The Wasting Diseases of Infants and Children. Fifth Edition. Post 8vo, 8s. 6d.

A Practical Manual of the Diseases of Children. With a Formulary. By EDWARD ELLIS, M.D. Fifth Edition. Crown 8vo, 10s.

A Manual for Hospital Nurses and others engaged in Attending on the Sick, and a Glossary. By EDWARD J. DOMVILLE, Surgeon to the Exeter Lying-in Charity. Sixth Edition. Cr. 8vo, 2s. 6d.

A Manual of Nursing, Medical and Surgical. By CHARLES J. CULLINGWORTH, M.D., F.R.C.P., Obstetric Physician to St. Thomas's Hospital. Third Edition. Fcap. 8vo, with Engravings, 2s. 6d.

By the same Author.

A Short Manual for Monthly Nurses. Second Edition. Fcap. 8vo, 1s. 6d.

Hospital Sisters and their Duties. By EVA C. E. LÜCKES, Matron to the London Hospital. Second Edition. Crown 8vo, 2s. 6d.

Diseases and their Commencement. Lectures to Trained Nurses. By DONALD W. C. HOOD, M.D., M.R.C.P., Physician to the West London Hospital. Crown 8vo, 2s. 6d.

Infant Feeding and its Influence on Life. By C. H. F. ROUTH, M.D., Physician to the Samaritan Hospital. Fourth Edition. Fcap. 8vo. [*Preparing.*]

Materia Medica.

A Manual for the use of Students. By ISAMBARD OWEN, M.D., F.R.C.P., Lecturer on Materia Medica, &c., to St. George's Hospital. Second Edition. Crown 8vo, 6s. 6d.

Manual of Botany :

Including the Structure, Classification, Properties, Uses, and Functions of Plants. By ROBERT BENTLEY, Professor of Botany in King's College and to the Pharmaceutical Society. Fifth Edition. Crown 8vo, with 1,178 Engravings, 15s.

By the same Author.

The Student's Guide to Structural, Morphological, and Physiological Botany. With 660 Engravings. Fcap. 8vo, 7s. 6d.

Also.

The Student's Guide to Systematic Botany, including the Classification of Plants and Descriptive Botany. Fcap. 8vo, with 350 Engravings, 3s. 6d.

Medicinal Plants :

Being descriptions, with original figures, of the Principal Plants employed in Medicine, and an account of their Properties and Uses. By Prof. BENTLEY and Dr. H. TRIMEN, F.R.S. In 4 vols., large 8vo, with 306 Coloured Plates, bound in Half Morocco, Gilt Edges, £11 11s.

A Companion to the British Pharmacopœia. By PETER SQUIRE, Revised by his Sons, P. W. and A. H. SQUIRE. 15th Edition. 8vo, 10s. 6d.

By the same Authors.

The Pharmacopœias of the London Hospitals, arranged in Groups for Easy Reference and Comparison. Fifth Edition. 18mo, 6s.

The Prescriber's Pharmacopœia:

The Medicines arranged in Classes according to their Action, with their Composition and Doses. By NESTOR J. C. TIRARD, M.D., F.R.C.P., Professor of Materia Medica and Therapeutics in King's College, London. Sixth Edition. 32mo, bound in leather, 3s.

Royle's Manual of Materia Medica and Therapeutics. Sixth Edition, including additions and alterations in the B.P. 1885. By JOHN HARLEY, M.D., Physician to St. Thomas's Hospital. Crown 8vo, with 139 Engravings, 15s.

The Student's Guide to Materia Medica and Therapeutics. By JOHN C. THOROWGOOD, M.D., F.R.C.P. Second Edition. Fcap. 8vo, 7s.

A Treatise on the Principles and Practice of Medicine. Sixth Edition. By AUSTIN FLINT, M.D., W. H. WELCH, M.D., and AUSTIN FLINT, jun., M.D. 8vo, with Engravings, 26s.

Climate and Fevers of India, with a series of Cases (Croonian Lectures, 1882). By Sir JOSEPH FAYRER, K.C.S.I., M.D. 8vo, with 17 Temperature Charts, 12s.

By the same Author.

The Natural History and Epidemiology of Cholera: Being the Annual Oration of the Medical Society of London, 1888. 8vo, 3s. 6d.

Family Medicine and Hygiene for India. A Manual. By Sir WILLIAM J. MOORE, M.D., K.C.I.E., late Surgeon-General with the Government of Bombay. Published under the Authority of the Government of India. Fifth Edition. Post 8vo, with 71 Engravings, 12s.

By the same Author.

A Manual of the Diseases of India: With a Compendium of Diseases generally. Second Edition. Post 8vo, 10s.

The Prevention of Disease in Tropical and Sub-Tropical Campaigns. (Parkes Memorial Prize for 1886.) By ANDREW DUNCAN, M.D., B.S. Lond., F.R.C.S., Surgeon, Bengal Army. 8vo, 12s. 6d.

Practical Therapeutics :

A Manual. By EDWARD J. WARING, C.I.E., M.D., F.R.C.P., and DUDLEY W. BUXTON, M.D., B.S. Lond. Fourth Edition. Crown 8vo, 14s.

By the same Author.

Bazaar Medicines of India,

And Common Medical Plants: With Full Index of Diseases, indicating their Treatment by these and other Agents procurable throughout India, &c. Fourth Edition. Fcap. 8vo, 5s.

A Commentary on the Diseases of India. By NORMAN CHEVERS, C.I.E., M.D., F.R.C.S., Deputy Surgeon-General H.M. Indian Army. 8vo, 24s.

Preventive Medicine.

Collected Essays. By WILLIAM SQUIRE, M.D., F.R.C.P., Physician to St. George, Hanover-square, Dispensary. 8vo, 6s. 6d.

Contributions to Clinical and Practical Medicine. By A. T. HOUGHTON WATERS, M.D., Physician to the Liverpool Royal Infirmary. 8vo, with Engravings, 7s.

Hooper's Physicians' Vademecum. A Manual of the Principles and Practice of Physic. Tenth Edition. By W. A. GUY, F.R.C.P., F.R.S., and J. HARLEY, M.D., F.R.C.P. With 118 Engravings. Fcap. 8vo, 12s. 6d.

The Principles and Practice of Medicine. By C. HILTON FAGGE, M.D. Second Edition. Edited by P. H. PYE-SMITH, M.D., F.R.S., F.R.C.P., Physician to, and Lecturer on Medicine in, Guy's Hospital. 2 vols. 8vo. Cloth, 38s. ; Half Leather, 44s.

Manual of the Practice of Medicine. By FREDERICK TAYLOR, M.D., F.R.C.P., Physician to, and Lecturer on Medicine at, Guy's Hospital. Crown 8vo, with Engravings, 15s.

The Student's Guide to the Practice of Medicine. By M. CHARTERIS, M.D., Professor of Therapeutics and Materia Medica in the University of Glasgow. Fifth Edition. Fcap. 8vo, with Engravings on Copper and Wood, 9s.

The Student's Guide to Clinical Medicine and Case-Taking. By FRANCIS WARNER, M.D., F.R.C.P., Physician to the London Hospital. Second Edition. Fcap. 8vo, 5s.

Handbook of Hospital Practice and Physical Diagnosis. By CHRISTOPHER J. NIXON, M.D., LL.D., Senior Physician to the Mater Misericordiarum Hospital, and Professor of Medicine in the Catholic University, Dublin. 8vo, with Plates and Engravings, 9s.

An Atlas of the Pathological Anatomy of the Lungs. By the late WILSON FOX, F.R.C.P., Physician to H.M. the Queen. With 45 Plates (mostly Coloured) and Engravings. 4to, half-bound in Calf, 70s.

The Bronchi and Pulmonary Blood-vessels: their Anatomy and Nomenclature. By WILLIAM EWART, M.D., F.R.C.P., Physician to St. George's Hospital. 4to, with 20 Illustrations, 21s.

The Student's Guide to Diseases of the Chest. By VINCENT D. HARRIS, M.D. Lond., F.R.C.P., Physician to the City of London Hospital for Diseases of the Chest, Victoria Park. Fcap. 8vo, with 55 Illustrations (some Coloured), 7s. 6d.

Medical Lectures and Essays. By G. JOHNSON, M.D., F.R.C.P., F.R.S., Consulting Physician to King's College Hospital. 8vo, with 46 Engravings, 25s.

By the same Author.

An Essay on Asphyxia (Apnœa). 8vo, 3s.

Fever: A Clinical Study.

By T. J. MACLAGAN, M.D. 8vo, 7s. 6d.

The Student's Guide to Medical Diagnosis. By SAMUEL FENWICK, M.D., F.R.C.P., Physician to the London Hospital, and BEDFORD FENWICK, M.D., M.R.C.P. Sixth Edition. Fcap. 8vo, with 114 Engravings, 7s.

By the same Author.

The Student's Outlines of Medical Treatment. Second Edition. Fcap. 8vo, 7s.

Also.

Clinical Lectures on Some Obscure Diseases of the Abdomen. Delivered at the London Hospital. 8vo, with Engravings, 7s. 6d.

Also.

The Saliva as a Test for Functional Diseases of the Liver. Crown 8vo, 2s.

The Microscope in Medicine. By LIONEL S. BEALE, M.B., F.R.S., Physician to King's College Hospital. Fourth Edition. 8vo, with 86 Plates, 21s.

By the same Author.

The Liver.

With 24 Plates (85 Figures). 8vo. 5s.

Also.

On Slight Ailments:

Their Nature and Treatment. Second Edition. 8vo, 5s.

Winter Cough

(Catarrh, Bronchitis, Emphysema, Asthma). By HORACE DOBELL, M.D., Consulting Physician to the Royal Hospital for Diseases of the Chest. Third Edition. 8vo, with Coloured Plates, 10s. 6d.

By the same Author.

Loss of Weight, Blood-Spitting, and Lung Disease. Second Edition. 8vo, with Chromo-lithograph, 10s. 6d.

Vaccinia and Variola:

A Study of their Life History. By JOHN B. BUIST, M.D., F.R.S.E., Teacher of Vaccination for the Local Government Board. Crown 8vo, with 24 Coloured Plates, 7s. 6d.

Treatment of Some of the Forms of Valvular Disease of the Heart. By A. E. SANSOM, M.D., F.R.C.P., Physician to the London Hospital. Second Edition. Fcap. 8vo, with 26 Engravings, 4s. 6d.

Diseases of the Heart and Aorta:

Clinical Lectures. By G. W. BALFOUR, M.D., F.R.C.P., F.R.S. Edin., late Senior Physician and Lecturer on Clinical Medicine, Royal Infirmary, Edinburgh. Second Edition. 8vo, with Chromo-lithograph and Wood Engravings, 12s. 6d.

Bronchial Asthma :

Its Pathology and Treatment. By J. B. BERKART, M.D., late Physician to the City of London Hospital for Diseases of the Chest. Second Edition, with 7 Plates (35 Figures). 8vo, 10s. 6d.

Notes on Asthma :

Its Forms and Treatment. By JOHN C. THOROWGOOD, M.D., Physician to the Hospital for Diseases of the Chest. Third Edition. Crown 8vo, 4s. 6d.

Medical Ophthalmoscopy :

A Manual and Atlas. By W. R. GOWERS, M.D., F.R.C.P., F.R.S., Physician to the National Hospital for the Paralyzed and Epileptic. Third Edition, with Coloured Plates and Woodcuts. 8vo. *[In the press.]*

By the same Author.

Diagnosis of Diseases of the Brain. Second Edition. 8vo, with Engravings, 7s. 6d.

Also.

Diagnosis of Diseases of the Spinal Cord. Fourth Edition. 8vo, with Engravings. *[In the press.]*

Also.

A Manual of Diseases of the Nervous System.

Vol. I. Diseases of the Spinal Cord and Nerves. Second Edition. Roy. 8vo, with many Engravings. *[Preparing.]*

Vol. II. Diseases of the Brain and Cranial Nerves: General and Functional Diseases of the Nervous System. 8vo, with 170 Engravings, 17s. 6d.

Diseases of the Nervous System.

Lectures delivered at Guy's Hospital. By SAMUEL WILKS, M.D., F.R.S. Second Edition. 8vo, 18s.

Secondary Degenerations of the Spinal Cord (Gulstonian Lectures, 1889). By HOWARD H. TOOTH, M.D., F.R.C.P., Assistant Physician to the National Hospital for the Paralyzed and Epileptic. With Plates and Engravings. 8vo, 3s. 6d.

Diseases of the Nervous System.

Clinical Lectures. By THOMAS BUZZARD, M.D., F.R.C.P., Physician to the National Hospital for the Paralyzed and Epileptic. With Engravings, 8vo. 15s.

By the same Author.

Some Forms of Paralysis from Peripheral Neuritis: of Gouty, Alcoholic, Diphtheritic, and other origin. Crown 8vo, 5s.

Gout in its Clinical Aspects.

By J. MORTIMER GRANVILLE, M.D. Crown 8vo, 6s.

Diseases of the Liver :

With and without Jaundice. By GEORGE HARLEY, M.D., F.R.C.P., F.R.S. 8vo, with 2 Plates and 36 Engravings, 21s.

By the same Author.

Inflammations of the Liver, and their Sequelæ. Crown 8vo, with Engravings, 5s.

Gout, Rheumatism,

And the Allied Affections; with Chapters on Longevity and Sleep. By PETER HOOD, M.D. Third Edition. Crown 8vo, 7s. 6d.

Regimen to be adopted in Cases

of Gout. By WILHELM EBSTEIN, M.D., Professor of Clinical Medicine in Göttingen. Translated by JOHN SCOTT, M.A., M.B. 8vo, 2s. 6d.

The Rheumatic Diseases (so-

called): With Original Suggestions for more clearly defining them. By HUGH LANE, L.R.C.P. Edin., M.R.C.S., Honorary Physician to the Eastern Dispensary, Bath; and CHAS. T. GRIFFITHS, L.R.C.P. Lond., M.R.C.S., Resident Medical Officer to the Royal Mineral Water Hospital, Bath. Crown 8vo, with 8 Plates, 6s.

Diseases of the Abdomen,

Comprising those of the Stomach and other parts of the Alimentary Canal, Œsophagus, Cæcum, Intestines, and Peritoneum. By S. O. HABERSHON, M.D., F.R.C.P. Fourth Edition. 8vo, with 5 Plates, 21s.

By the same Author.

Diseases of the Liver,

Their Pathology and Treatment. Lettsomian Lectures. Second Edition. Post 8vo, 4s.

On the Relief of Excessive and

Dangerous Tympanites by Puncture of the Abdomen. By JOHN W. OGLE, M.A., M.D., F.R.C.P., Consulting Physician to St. George's Hospital. 8vo, 5s. 6d.

Handbook of the Diseases of

the Nervous System. By JAMES ROSS, M.D., F.R.C.P., Assistant Physician to the Manchester Royal Infirmary. Roy. 8vo, with 184 Engravings, 18s.

Also.

Aphasia :

Being a Contribution to the Subject of the Dissolution of Speech from Cerebral Disease. 8vo, with Engravings, 4s. 6d.

Stammering :

Its Causes, Treatment, and Cure. By A. G. BERNARD, M.R.C.S., L.R.C.P. Crown 8vo, 2s.

Food and Dietetics,

Physiologically and Therapeutically Considered. By F. W. PAVY, M.D., F.R.S., Physician to Guy's Hospital. Second Edition. 8vo, 15s.

By the same Author.

Croonian Lectures on Certain Points connected with Diabetes. 8vo, 4s. 6d.

Acute Intestinal Strangulation, And Chronic Intestinal Obstruction (Mode of Death from). By THOMAS BRYANT, F.R.C.S., Senior Surgeon to Guy's Hospital. 8vo, 3s.

Headaches :

Their Nature, Causes, and Treatment. By W. H. DAY, M.D., Physician to the Samaritan Hospital. Fourth Edition. Crown 8vo, with Engravings, 7s. 6d.

Health Resorts at Home and Abroad. By M. CHARTERIS, M.D., Professor of Therapeutics and Materia Medica in the University of Glasgow. Second Edition. Crown 8vo, with Map, 5s. 6d.

Winter and Spring

On the Shores of the Mediterranean. By HENRY BENNET, M.D. Fifth Edition. Post 8vo, with numerous Plates, Maps, and Engravings, 12s. 6d.

Medical Guide to the Mineral Waters of France and its Wintering Stations. With a Special Map. By A. VINTRAS, M.D., Physician to the French Embassy, and to the French Hospital, London. Crown 8vo, 8s.

The Ocean as a Health-Resort : A Practical Handbook of the Sea, for the use of Tourists and Health-Seekers. By WILLIAM S. WILSON, L.R.C.P. Second Edition, with Chart of Ocean Routes, &c. Crown 8vo, 7s. 6d.

Ambulance Handbook for Volunteers and Others. By J. ARDAVON RAYE, L.K. & Q.C.P.I., L.R.C.S.I., late Surgeon to H.B.M. Transport No. 14, Zulu Campaign, and Surgeon E.I.R. Rifles. 8vo, with 16 Plates (50 figures), 3s. 6d.

Ambulance Lectures :

To which is added a NURSING LECTURE. By JOHN M. H. MARTIN, Honorary Surgeon to the Blackburn Infirmary. Second Edition. Crown 8vo, with 59 Engravings, 2s.

Commoner Diseases and Accidents to Life and Limb: their Prevention and Immediate Treatment. By M. M. BASIL, M.A., M.B., C.M. Crown 8vo, 2s. 6d.

How to Use a Galvanic Battery in Medicine and Surgery. By HERBERT TIBBITS, M.D., F.R.C.P.E., Senior Physician to the West London Hospital for Paralysis and Epilepsy. Third Edition. 8vo, with Engravings, 4s.

By the same Author.

A Map of Ziemssen's Motor Points of the Human Body: A Guide to Localised Electrification. Mounted on Rollers, 35 x 21. With 20 Illustrations, 5s.

Also.

Electrical and Anatomical Demonstrations. A Handbook for Trained Nurses and Masseuses. Crown 8vo, with 44 Illustrations, 5s.

Surgery: its Theory and Practice (Student's Guide). By WILLIAM J. WALSHAM, F.R.C.S., Assistant Surgeon to St. Bartholomew's Hospital. Second Edition. Fcap. 8vo, with 294 Engravings, 10s. 6d.

Surgical Emergencies :

Together with the Emergencies attendant on Parturition and the Treatment of Poisoning. By W. PAUL SWAIN, F.R.C.S., Surgeon to the South Devon and East Cornwall Hospital. Fourth Edition. Crown 8vo, with 120 Engravings, 5s.

Operative Surgery in the Calcutta Medical College Hospital. Statistics, Cases, and Comments. By KENNETH MCLEOD, A.M., M.D., F.R.C.S.E., Surgeon-Major, Indian Medical Service, Professor of Surgery in Calcutta Medical College. 8vo, with Illustrations, 12s. 6d.

A Course of Operative Surgery. By CHRISTOPHER HEATH, Surgeon to University College Hospital. Second Edition. With 20 coloured Plates (180 figures) from Nature, by M. LÉVEILLÉ, and several Woodcuts. Large 8vo, 30s.

By the same Author.

The Student's Guide to Surgical Diagnosis. Second Edition. Fcap. 8vo, 6s. 6d.

Also.

Manual of Minor Surgery and Bandaging. For the use of House-Surgeons, Dressers, and Junior Practitioners. Ninth Edition. Fcap. 8vo, with 146 Engravings, 6s.

Also.

Injuries and Diseases of the Jaws. Third Edition. 8vo, with Plate and 206 Wood Engravings, 14s.

Also.

Lectures on Certain Diseases of the Jaws. Delivered at the R.C.S., Eng., 1887. 8vo, with 64 Engravings, 2s. 6d.

The Practice of Surgery :

A Manual. By THOMAS BRYANT, Consulting Surgeon to Guy's Hospital. Fourth Edition. 2 vols. crown 8vo, with 750 Engravings (many being coloured), and including 6 chromo plates, 32s.

By the same Author.

On Tension: Inflammation of Bone, and Head Injuries. Hunterian Lectures, 1888. 8vo, 6s.**The Surgeon's Vade-Mecum :**

A Manual of Modern Surgery. By R. DRUITT, F.R.C.S. Twelfth Edition. By STANLEY BOYD, M.B., F.R.C.S. Assistant Surgeon and Pathologist to Charing Cross Hospital. Crown 8vo, with 373 Engravings 16s.

The Operations of Surgery :

Intended for Use on the Dead and Living Subject alike. By W. H. A. JACOBSON, M.A., M.B., M.Ch. Oxon., F.R.C.S., Assistant Surgeon to Guy's Hospital, and Teacher of Surgery in the Medical School. 8vo, with 200 Illustrations, 30s.

Regional Surgery :

Including Surgical Diagnosis. A Manual for the use of Students. By F. A. SOUTHAM, M.A., M.B., F.R.C.S., Assistant Surgeon to the Manchester Royal Infirmary. — Part II. The Upper Extremity and Thorax. Crown 8vo, 7s. 6d. Part III. The Abdomen and Lower Extremity. Crown 8vo, 7s.

Lectures on Orthopædic Surgery. By BERNARD E. BRODHURST, F.R.C.S., Surgeon to the Royal Orthopædic Hospital. Second Edition. 8vo, with Engravings, 12s. 6d.

By the same Author.

On Anchylosis, and the Treatment for the Removal of Deformity and the Restoration of Mobility in Various Joints. Fourth Edition. 8vo, with Engravings, 5s.

Also.

Curvatures and Disease of the Spine. Fourth Edition. 8vo, with Engravings, 7s. 6d.**Treatment of Internal Derangements of the Knee-Joint, by Operation.** By HERBERT W. ALLINGHAM, F.R.C.S., Surgeon to the Great Northern Central Hospital, &c. 8vo, with Engravings, 5s.**Spina Bifida :**

Its Treatment by a New Method. By JAS. MORTON, M.D., L.R.C.S.E., Professor of Materia Medica in Anderson's College, Glasgow. 8vo, with Plates, 7s. 6d.

Surgical Pathology and Morbid Anatomy (Student's Guide Series).

By ANTHONY A. BOWLBY, F.R.C.S., Surgical Registrar and Demonstrator of Practical Surgery and of Surgical Pathology at St. Bartholomew's Hospital. Second Edition. Fcap. 8vo, with 158 Engravings, 9s.

By the same Author.

Injuries and Diseases of Nerves and their Surgical Treatment. 8vo, with 20 Plates, 14s.**Illustrations of Clinical Surgery.**

By JONATHAN HUTCHINSON, F.R.S., Senior Surgeon to the London Hospital. In fasciculi. 6s. 6d. each. Fasc. I. to X. bound, with Appendix and Index, £3 10s. Fasc. XI. to XXIII. bound, with Index, £4 10s.

Diseases of Bones and Joints.

By CHARLES MACNAMARA, F.R.C.S., Surgeon to, and Lecturer on Surgery at, the Westminster Hospital. 8vo, with Plates and Engravings, 12s.

The Human Foot :

Its Form and Structure, Functions and Clothing. By THOMAS S. ELLIS, Consulting Surgeon to the Gloucester Infirmary. With 7 Plates and Engravings (50 Figures). 8vo, 7s. 6d.

Face and Foot Deformities.

By FREDERICK CHURCHILL, C.M., Surgeon to the Victoria Hospital for Children. 8vo, with Plates and Illustrations, 10s. 6d.

Clubfoot :

Its Causes, Pathology, and Treatment. By WM. ADAMS, F.R.C.S., Surgeon to the Great Northern Hospital. Second Edition. 8vo, with 106 Engravings and 6 Lithographic Plates, 15s.

By the same Author.

Lateral and other Forms of Curvature of the Spine: Their Pathology and Treatment. Second Edition. 8vo, with 5 Lithographic Plates and 72 Wood Engravings, 10s. 6d.**Electricity and its Manner of Working in the Treatment of Disease.** By W. E. STEAVENSON, M.D., in charge of the Electrical Department at St. Bartholomew's Hospital. 8vo, 4s. 6d.

By the same Author.

The Uses of Electrolysis in Surgery. Crown 8vo, with Engravings, 5s.**On Diseases and Injuries of the Eye: A Course of Systematic and Clinical Lectures to Students and Medical Practitioners.** By J. R. WOLFE, M.D., F.R.C.S.E., Lecturer on Ophthalmic Medicine and Surgery in Anderson's College, Glasgow. With 10 Coloured Plates and 157 Wood Engravings. 8vo, £1 1s.

Hintson Ophthalmic Out-Patient

Practice. By CHARLES HIGGENS, Ophthalmic Surgeon to Guy's Hospital. Third Edition. Fcap. 8vo, 3s.

The Student's Guide to Diseases

of the Eye. By EDWARD NETTLESHIP, F.R.C.S., Ophthalmic Surgeon to St. Thomas's Hospital. Fourth Edition. Fcap. 8vo, with 164 Engravings and a Set of Coloured Papers illustrating Colour-Blindness, 7s. 6d.

Manual of the Diseases of the

Eye. By CHARLES MACNAMARA, F.R.C.S., Surgeon to Westminster Hospital. Fourth Edition. Crown 8vo, with 4 Coloured Plates and 66 Engravings, 10s. 6d.

Normal and Pathological His-

tology of the Human Eye and Eyelids. By C. FRED. POLLOCK, M.D., F.R.C.S. and F.R.S.E., Surgeon for Diseases of the Eye to Anderson's College Dispensary, Glasgow. Crown 8vo, with 100 Plates (230 drawings), 15s.

By the same Author.

Leprosy as a Cause of Blindness.

With Notes of Forty-one Cases. Crown 8vo, 2s. 6d.

Atlas of Ophthalmoscopy.

Composed of 12 Chromo-lithographic Plates (59 Figures drawn from nature) and Explanatory Text. By RICHARD LIEBREICH, M.R.C.S. Translated by H. ROSBOROUGH SWANZY, M.B. Third edition, 4to, 40s.

Refraction of the Eye :

A Manual for Students. By GUSTAVUS HARTRIDGE, F.R.C.S., Surgeon to the Royal Westminster Ophthalmic Hospital. Fourth Edition. Crown 8vo, with 98 Illustrations, Test-types, &c., 6s.

Squint :

(Clinical Investigations on). By C. SCHWEIGGER, M.D., Professor of Ophthalmology in the University of Berlin. Edited by GUSTAVUS HARTRIDGE, F.R.C.S. 8vo, 5s.

Practitioner's Handbook of

Diseases of the Ear and Nasopharynx. By H. MACNAUGHTON JONES, M.D., late Professor of the Queen's University in Ireland, Surgeon to the Cork Ophthalmic and Aural Hospital. Third Edition of "Aural Surgery." Roy. 8vo, with 128 Engravings, 6s.

By the same Author.

Atlas of Diseases of the Mem-

brana Tympani. In Coloured Plates, containing 62 Figures, with Text. Crown 4to, 21s.

Diseases and Injuries of the

Ear. By Sir WILLIAM B. DALBY, Aural Surgeon to St. George's Hospital. Third Edition. Crown 8vo, with Engravings, 7s. 6d.

By the same Author.

Short Contributions to Aural

Surgery, between 1875 and 1889. Second Edition. 8vo, with Engravings, 3s. 6d.

Diphtheria :

Its Nature and Treatment, Varieties, and Local Expressions. By Sir MORELL MACKENZIE, M.D., Consulting Physician to the Throat Hospital. 8vo, 5s.

Sore Throat :

Its Nature, Varieties, and Treatment. By PROSSER JAMES, M.D., Physician to the Hospital for Diseases of the Throat. Fifth Edition. Post 8vo, with Coloured Plates and Engravings, 6s. 6d.

Endemic Goitre or Thyrocele :

Its Etiology, Clinical Characters, Pathology, Distribution, Relations to Cretinism, Myxœdema, &c., and Treatment. By WILLIAM ROBINSON, M.D. 8vo, 5s.

Studies in Pathological Anatomy,

Especially in Relation to Laryngeal Neoplasms. By R. NORRIS WOLFENDEN, M.D., Senior Physician to the Throat Hospital, and SIDNEY MARTIN, M.D., Pathologist to the Victoria Park Hospital. Fasc. I. and II. Roy. 8vo, with Coloured Plates, 2s. 6d. each.

A System of Dental Surgery.

By Sir JOHN TOMES, F.R.S., and C. S. TOMES, M.A., F.R.S. Third Edition. Crown 8vo, with 292 Engravings, 15s.

Dental Anatomy, Human and

Comparative: A Manual. By CHARLES S. TOMES, M.A., F.R.S. Third Edition. Crown 8vo, with 212 Engravings, 12s. 6d.

A Manual of Nitrous Oxide

Anæsthesia, for the use of Students and General Practitioners. By J. FREDERICK W. SILK, M.D. Lond., M.R.C.S., Anæsthetist to the Great Northern Central Hospital, Dental School, Guy's Hospital, and National Epileptic Hospital. 8vo, with 26 Engravings, 5s.

Mechanical Dentistry in Gold

and Vulcanite. By F. H. BALKWILL, L.D.S.R.C.S. 8vo, with 2 Lithographic Plates and 57 Engravings, 10s.

Dental Medicine :

A Manual of Dental Materia Medica and Therapeutics. By FERDINAND J. S. GORGAS, A.M., M.D., D.D.S., Professor of Dental Surgery and Science, &c., in the University of Maryland. Third Edition. 8vo, 16s.

Principles and Practice of Dentistry :

including Anatomy, Physiology, Pathology, Therapeutics, Dental Surgery, and Mechanism. By C. A. HARRIS, M.D., D.D.S. Edited by F. J. S. GORGAS, A.M., M.D., D.D.S., Professor in the Dental Department of Maryland University. Twelfth Edition. 8vo, with over 1,000 Illustrations, 33s.

A Practical Treatise on Mechanical Dentistry.

By JOSEPH RICHARDSON, M.D., D.D.S., late Emeritus Professor of Prosthetic Dentistry in the Indiana Medical College. Fourth Edition. Roy. 8vo, with 458 Engravings, 21s.

Elements of Dental Materia Medica and Therapeutics, with Pharmacopœia.

By JAMES STOCKEN, L.D.S.R.C.S., Pereira Prizeman for Materia Medica, and THOMAS GADDES, L.D.S. Eng. and Edin. Third Edition. Fcap. 8vo, 7s. 6d.

Papers on Dermatology.

By E. D. MAPOTHER, M.D., Ex-Pres. R.C.S.I. 8vo, 3s. 6d.

Atlas of Skin Diseases.

By TILBURY FOX, M.D., F.R.C.P. With 72 Coloured Plates. Royal 4to, half morocco, £6 6s.

Diseases of the Skin :

With an Analysis of 8,000 Consecutive Cases and a Formulary. By L. D. BULKLEY, M.D., Physician for Skin Diseases at the New York Hospital. Crown 8vo, 6s. 6d.

By the same Author.

Acne : its Etiology, Pathology, and Treatment : Based upon a Study of 1,500 Cases. 8vo, with Engravings, 10s.

On Certain Rare Diseases of the Skin.

By JONATHAN HUTCHINSON, F.R.S., Senior Surgeon to the London Hospital, and to the Hospital for Diseases of the Skin. 8vo, 10s. 6d.

Eczema and its Treatment :

A Practical Treatise. By M. J. RAE, M.D., late Physician to the Blackburn and East Lancashire Infirmary. Crown 8vo, 5s.

Diseases of the Skin :

A Practical Treatise for the Use of Students and Practitioners. By J. N. HYDE, A.M., M.D., Professor of Skin and Venereal Diseases, Rush Medical College, Chicago. Second Edition. 8vo, with 2 Coloured Plates and 96 Engravings, 20s.

Leprosy in British Guiana.

By JOHN D. HILLIS, F.R.C.S., M.R.I.A., Medical Superintendent of the Leper Asylum, British Guiana. Imp. 8vo, with 22 Lithographic Coloured Plates and Wood Engravings, £1 11s. 6d.

On Cancer :

Its Allies, and other Tumours; their Medical and Surgical Treatment. By F. A. PURCELL, M.D., M.C., Surgeon to the Cancer Hospital, Brompton. 8vo, with 21 Engravings, 10s. 6d.

Sarcoma and Carcinoma :

Their Pathology, Diagnosis, and Treatment. By HENRY T. BUTLIN, F.R.C.S., Assistant Surgeon to St. Bartholomew's Hospital. 8vo, with 4 Plates, 8s.

By the same Author.

Malignant Disease of the Larynx (Sarcoma and Carcinoma).

8vo, with 5 Engravings, 5s.

Also.

Operative Surgery of Malignant Disease.

8vo, 14s.

Cancerous Affections of the Skin.

(Epithelioma and Rodent Ulcer.) By GEORGE THIN, M.D. Post 8vo, with 8 Engravings, 5s.

By the same Author.

Pathology and Treatment of Ringworm.

8vo, with 21 Engravings, 5s.

Cancer of the Mouth, Tongue,

and Alimentary Tract: their Pathology, Symptoms, Diagnosis, and Treatment. By FREDERIC B. JESSETT, F.R.C.S., Surgeon to the Cancer Hospital, Brompton. 8vo, 10s.

Clinical Chemistry of Urine

(Outlines of the). By C. A. MACMUNN, M.A., M.D. 8vo, with 64 Engravings and Plate of Spectra, 9s.

Lectures on the Surgical Disorders of the Urinary Organs.

By REGINALD HARRISON, F.R.C.S., Surgeon to St. Peter's Hospital. Third Edition. 8vo, with 117 Engravings, 12s. 6d.

The Surgical Diseases of the

Genito-Urinary Organs, including Syphilis. By E. L. KEYES, M.D., Professor of Genito-Urinary Surgery, Syphiology, and Dermatology in Bellevue Hospital Medical College, New York (a revision of VAN BUREN and KEYES' Text-book). Roy. 8vo, with 114 Engravings, 21s.

Diseases of the Urinary Organs.

Clinical Lectures. By Sir HENRY THOMPSON, F.R.C.S., Emeritus Professor of Clinical Surgery and Consulting Surgeon to University College Hospital. Eighth Edition. 8vo, with 121 Engravings, 10s. 6d.

By the same Author.

Diseases of the Prostate :

Their Pathology and Treatment. Sixth Edition. 8vo, with 39 Engravings, 6s.

Also.

Surgery of the Urinary Organs.

Some Important Points connected therewith. Lectures delivered in the R.C.S. 8vo, with 44 Engravings. Students' Edition, 2s. 6d.

Also.

Practical Lithotomy and Litho-

trity; or, An Inquiry into the Best Modes of Removing Stone from the Bladder. Third Edition. 8vo, with 87 Engravings, 10s.

Also.

The Preventive Treatment of

Calculous Disease, and the Use of Solvent Remedies. Third Edition. Crown 8vo, 2s. 6d.

Also.

Tumours of the Bladder :

Their Nature, Symptoms, and Surgical Treatment. 8vo, with numerous Illustrations, 5s

Also.

Stricture of the Urethra, and Uri-

nary Fistulæ: their Pathology and Treatment. Fourth Edition. With 74 Engravings. 8vo, 6s.

Also.

The Suprapubic Operation of

Opening the Bladder for the Stone and for Tumours. 8vo, with 14 Engravings, 3s. 6d.

Electric Illumination of the

Bladder and Urethra, as a Means of Diagnosis of Obscure Vesico-Urethral Diseases. By E. HURRY FENWICK, F.R.C.S., Assistant Surgeon to the London Hospital and Surgeon to St. Peter's Hospital for Stone. Second Edition. 8vo, with 54 Engravings, 6s. 6d.

Modern Treatment of Stone in

the Bladder by Litholopaxy. By P. J. FREYER, M.A., M.D., M.Ch., Bengal Medical Service. 8vo, with Engravings 5s.

The Surgery of the Rectum.

By HENRY SMITH, Emeritus Professor of Surgery in King's College, Consulting Surgeon to the Hospital. Fifth Edition. 8vo, 6s.

Diseases of the Rectum and

Anus. By HARRISON CRIPPS, F.R.C.S., Assistant Surgeon to St. Bartholomew's Hospital, &c. Second Edition. 8vo, with 13 Lithographic Plates and numerous Wood Engravings, 12s. 6d.

By the same Author.

Cancer of the Rectum.

Especially considered with regard to its Surgical Treatment. Jacksonian Prize Essay. 8vo, with 13 Plates and several Wood Engravings, 6s.

Urinary and Renal Derange-

ments and Calculous Disorders. By LIONEL S. BEALE, F.R.C.P., F.R.S., Physician to King's College Hospital. 8vo, 5s.

The Diagnosis and Treatment

of Diseases of the Rectum. By WILLIAM ALLINGHAM, F.R.C.S., Surgeon to St. Mark's Hospital for Fistula. Fifth Edition. By HERBERT WM. ALLINGHAM, F.R.C.S., Surgeon to the Great Northern Central Hospital, Demonstrator of Anatomy at St. George's Hospital. 8vo, with 53 Engravings, 10s. 6d.

Syphilis and Pseudo-Syphilis.

By ALFRED COOPER, F.R.C.S., Surgeon to the Lock Hospital, to St. Mark's and the West London Hospitals. 8vo, 10s. 6d.

Diagnosis and Treatment of

Syphilis. By TOM ROBINSON, M.D., Physician to St. John's Hospital for Diseases of the Skin. Crown 8vo, 3s. 6d.

By the same Author.

Eczema: its Etiology, Patho-

logy, and Treatment. Crown 8vo, 3s. 6d.

The Medical Adviser in Life As-

urance. By Sir E. H. SIEVEKING, M.D., F.R.C.P. Second Edition. Crown 8vo, 6s.

A Medical Vocabulary :

An Explanation of all Terms and Phrases used in the various Departments of Medical Science and Practice, their Derivation, Meaning, Application, and Pronunciation. By R. G. MAYNE, M.D., LL.D. Sixth Edition, by W. W. WAGSTAFFE, B.A., F.R.C.S. Crown 8vo, 10s. 6d.

A Dictionary of Medical Science:

Containing a concise Explanation of the various Subjects and Terms of Medicine, &c. By ROBLEY DUNGLISON, M.D., LL.D. Royal 8vo, 28s.

A German-English Dictionary

of Medical Terms. By FREDERICK TREVES, F.R.C.S., Surgeon to the London Hospital; and HUGO LANG, B.A. Crown 8vo, half-Persian calf, 12s.

INDEX.

- Abercrombie's Medical Jurisprudence, 4
 Adams (W.) on Clubfoot, 11
 — on Curvature of the Spine, 11
 Allingham (H.) on Derangements of Knee-joint, 11
 Allingham (W.) on Diseases of the Rectum, 14
 Balfour's Diseases of the Heart and Aorta, 8
 Balkwill's Mechanical Dentistry, 12
 Barnes (R.) on Obstetric Operations, 5
 — on Diseases of Women, 5
 Basil's Commoner Diseases and Accidents, 10
 Beale on Liver, 8
 — Microscope in Medicine, 8
 — Slight Ailments, 8
 — Urinary and Renal Derangements, 14
 Bellamy's Surgical Anatomy, 3
 Bennet (J. H.) on the Mediterranean, 10
 Bentley and Trimen's Medicinal Plants, 7
 Bentley's Manual of Botany, 7
 — Structural Botany, 7
 — Systematic Botany, 7
 Berkart's Bronchial Asthma, 9
 Bernard on Stammering, 9
 Bowlby's Injuries and Diseases of Nerves, 11
 — Surgical Pathology and Morbid Anatomy, 11
 Braune's Topographical Anatomy, 3
 Brodhurst's Anchylosis, 11
 — Curvatures, &c., of the Spine, 11
 — Orthopædic Surgery, 11
 Bryant's Acute Intestinal Strangulation, 10
 — Practice of Surgery, 11
 — Tension. Inflammation of Bone, Injuries, &c. 11
 Bucknill and Tuke's Psychological Medicine, 5
 Buist's Vaccinia and Variola, 8
 Bulkley's Acne, 13
 — Diseases of the Skin, 13
 Burton's Midwifery for Midwives, 6
 Butlin's Malignant Disease of the Larynx, 13
 — Operative Surgery of Malignant Disease, 13
 — Sarcoma and Carcinoma, 13
 Buzzard's Diseases of the Nervous System, 9
 — Peripheral Neuritis, 9
 Byford's Diseases of, and Accidents to, Women, 6
 Carpenter's Human Physiology, 4
 Charteris on Health Resorts, 10
 — Practice of Medicine, 8
 Chevers' Diseases of India, 7
 Churchill's Face and Foot Deformities, 11
 Clouston's Lectures on Mental Diseases, 5
 Cooper's Syphilis and Pseudo-Syphilis, 14
 Courty's Diseases of the Uterus, Ovaries, &c., 6
 Cripps' Cancer of the Rectum, 14
 — Diseases of the Rectum and Anus, 14
 Cullingworth's Manual of Nursing, 6
 — Short Manual for Monthly Nurses, 6
 Dalby's Diseases and Injuries of the Ear, 12
 — Short Contributions, 12
 Day on Diseases of Children, 6
 — on Headaches, 10
 Dobell's Lectures on Winter Cough, 8
 — Loss of Weight, &c., 8
 Domville's Manual for Nurses, 6
 Doran's Gynæcological Operations, 6
 Down's Mental Affections of Childhood, 5
 Druitt's Surgeon's Vade-Mecum, 11
 Duncan (A.), on Prevention of Disease in Tropics, 7
 Duncan (J. M.), on Diseases of Women, 5
 Dunglison's Medical Dictionary, 14
 Ebstein on Regimen in Gout, 9
 Ellis's (E.) Diseases of Children, 6
 Ellis's (T.S.) Human Foot, 11
 Ewart's Bronchi and Pulmonary Blood Vessels, 8
 Fagge's Principles and Practice of Medicine, 8
 Fayer's Climate and Fevers of India, 7
 — Natural History, etc., of Cholera, 7
 Fenwick (E. H.), Electric Illumination of Bladder, 14
 Fenwick's (S.) Medical Diagnosis, 8
 — Obscure Diseases of the Abdomen, 8
 — Outlines of Medical Treatment, 8
 — The Saliva as a Test, 8
 Flint's Principles and Practice of Medicine, 7
 Flower's Diagrams of the Nerves, 3
 Fox's (C. B.) Examinations of Water, Air, and Food, 4
 Fox's (T.) Atlas of Skin Diseases, 13
 Fox (Wilson), Atlas of Pathological Anatomy of Lungs, 8
 Freyer's Litholopaxy, 14
 Galabin's Diseases of Women, 6
 Galabin's Manual of Midwifery, 5
 Godlee's Atlas of Human Anatomy, 3
 Goodhart's Diseases of Children, 6
 Gorgas's Dental Medicine, 12
 Gowers' Diseases of the Brain, 9
 — Diseases of the Spinal Cord, 9
 — Manual of Diseases of Nervous System,
 — Medical Ophthalmoscopy, 9
 Granville on Gout, 9
 Guy's Hospital Formulæ, 2
 — Reports, 2
 Habershon's Diseases of the Abdomen, 9
 — Liver, 9
 Harley on Diseases of the Liver, 9
 — Inflammations of the Liver, 9
 Harris's (C. A.) Dentistry, 13
 Harris's (V. D.) Diseases of Chest, 8
 Harrison's Surgical Disorders of the Urinary Organs 13
 Hartridge's Refraction of the Eye, 12
 Harvey's Manuscript Lectures, 3
 Heath's Certain Diseases of the Jaws, 10
 — Injuries and Diseases of the Jaws, 10
 — Minor Surgery and Bandaging, 10
 — Operative Surgery, 10
 — Practical Anatomy, 3
 — Surgical Diagnosis, 10
 Higgins' Ophthalmic Out-patient Practice, 12
 Hillis' Leprosy in British Guiana, 13
 Holden's Dissections, 3
 — Human Osteology, 3
 — Landmarks, 3
 Hood's (D. C.) Diseases and their Commencement, 6
 Hood (P.) on Gout, Rheumatism, &c., 9
 Hooper's Physician's Vade-Mecum, 7
 Hutchinson's Clinical Surgery, 11
 — Rare Diseases of the Skin, 13
 Hyde's Diseases of the Skin, 13
 Jacobson's Operations of Surgery, 11
 James (P.) on Sore Throat, 12
 Jessett's Cancer of the Mouth, &c., 13
 Johnson's Asphyxia, 8
 — Medical Lectures and Essays, 8
 Jones (C. H.) and Sieveking's Pathological Anatomy, 4
 Jones' (H. McN.) Diseases of the Ear and Pharynx, 12
 — Atlas of Diseases of Membrana Tympani, 12
 Journal of Mental Science, 2
 Keyes' Genito-Urinary Organs and Syphilis, 13
 King's Manual of Obstetrics, 5
 Lancereaux's Atlas of Pathological Anatomy, 4
 Lane and Griffiths' Rheumatic Diseases, 9
 Lawson's Milroy Lectures on Epidemiology, 4
 Lewis (Bevan) on the Human Brain, 4
 Liebreich's Atlas of Ophthalmoscopy, 12
 London Hospital Pharmacopœia, 2
 Lückes' Hospital Sisters and their Duties, 6
 Macdonald's (J. D.) Examination of Water and Air, 4
 Mackenzie on Diphtheria, 12
 Maclagan on Fever, 8
 McLeod's Operative Surgery, 10
 MacMunn's Clinical Chemistry of Urine, 13
 Macnamara's Diseases of the Eye, 12
 — Bones and Joints, 11
 Mapother's Papers on Dermatology, 13
 Martin's Ambulance Lectures, 10
 Mayne's Medical Vocabulary, 14
 Middlesex Hospital Reports, 2
 Moore's (N.) Pathological Anatomy of Diseases, 4
 Moore's (Sir W. J.) Family Medicine for India, 7
 — Manual of the Diseases of India, 7
 Morris' (H.) Anatomy of the Joints, 3
 Morton's Spina Bifida, 11
 Mouat and Snell on Hospitals, 4
 Nettleship's Diseases of the Eye, 12
 Nixon's Hospital Practice, 8
 Ogle on Puncturing the Abdomen, 9
 Ogston's Medical Jurisprudence, 4
 Ophthalmic (Royal London) Hospital Reports, 2
 Ophthalmological Society's Transactions, 2
 Oppert's Hospitals, Infirmarys, Dispensaries, &c., 4
 Owen's Materia Medica, 6
 Parkes' Practical Hygiene, 5
 Pavy on Diabetes, 10
 — on Food and Dietetics, 10
 Pharmaceutical Journal, 2
 Pollock's Histology of the Eye and Eyelids, 12
 — Leprosy as a Cause of Blindness, 12
 Priestley's Intra-Uterine Death, 5

[Continued on the next page.]

- Purcell on Cancer, 13
 Rae's Eczema and its Treatment, 13
 Raye's Ambulance Handbook, 10
 Reynolds' (J. J.) Diseases of Women, 5
 Notes on Midwifery, 5
 Richardson's Mechanical Dentistry, 13
 Roberts' (D. Lloyd) Practice of Midwifery, 5
 Robinson (Tom) on Eczema, 14
 on Syphilis, 14
 Robinson (W.) on Endemic Goitre or Thyreocele, 12
 Ross's Aphasia, 9
 Diseases of the Nervous System, 9
 Routh's Infant Feeding, 6
 Royal College of Surgeons Museum Catalogues, 2
 Royle and Harley's Materia Medica, 7
 St. Bartholomew's Hospital Catalogue, 2
 St. George's Hospital Reports, 2
 St. Thomas's Hospital Reports, 2
 Sansom's Valvular Disease of the Heart, 8
 Savage on the Female Pelvic Organs, 5
 Schweigger on Squint, 12
 Shore's Elementary Practical Biology, 4
 Sieveking's Life Assurance, 14
 Silk's Manual of Nitrous Oxide, 12
 Simon's Public Health Reports, 5
 Smith's (E.) Clinical Studies, 6
 Diseases in Children, 6
 Wasting Diseases of Infants and Children, 6
 Smith's (J. Greig) Abdominal Surgery, 6
 Smith's (Henry) Surgery of the Rectum, 14
 Southam's Regional Surgery, 11
 Squire's (P.) Companion to the Pharmacopœia, 7
 Pharmacopœias of London Hospitals, 7
 Squire's (W.) Essays on Preventive Medicine, 7
 Steavenson's Electricity in Disease, 11
 Uses of Electrolysis, 11
 Stocken's Dental Materia Medica and Therapeutics, 13
 Sutton's General Pathology, 4
 Swain's Surgical Emergencies, 10
 Swayne's Obstetric Aphorisms, 6
 Taylor's (A. S.) Medical Jurisprudence, 4
 Poisons in Relation to Medical Jurisprudence, 4
 Taylor's (F.) Practice of Medicine, 8
 Thin's Cancerous Affections of the Skin, 13
 Pathology and Treatment of Ringworm, 1
 Thomas's Diseases of Women, 6
 Thompson's (Sir H.) Calculous Disease, 14
 Diseases of the Prostate, 14
 Diseases of the Urinary Organs, 14
 Lithotomy and Lithotripsy, 14
 Stricture of the Urethra, 14
 Suprapubic Operation, 14
 Surgery of the Urinary Organs, 14
 Tumours of the Bladder, 14
 Thorowgood on Asthma, 9
 on Materia Medica and Therapeutics, 7
 Tibbits' Map of Motor Points, 10
 How to use a Galvanic Battery, 10
 Electrical and Anatomical Demonstrations, 10
 Tilt's Change of Life, 6
 Uterine Therapeutics, 6
 Tirard's Prescriber's Pharmacopœia, 7
 Tomes' (C. S.) Dental Anatomy, 12
 Tomes' (J. and C. S.) Dental Surgery, 12
 Tooth's Spinal Cord, 9
 Treves and Lang's German-English Dictionary, 14
 Tuke's Influence of the Mind upon the Body, 5
 Sleep-Walking and Hypnotism, 5
 Vintras on the Mineral Waters, &c., of France, 10
 Virchow's Post-mortem Examinations, 4
 Walsham's Surgery: its Theory and Practice, 10
 Waring's Indian Bazaar Medicines, 7
 Practical Therapeutics, 7
 Warner's Guide to Medical Case-Taking, 8
 Waters' (A. T. H.) Contributions to Medicine, 7
 West and Duncan's Diseases of Women, 5
 Wilks' Diseases of the Nervous System, 8
 Wilson's (Sir E.) Anatomists' Vade-Mecum, 3
 Wilson's (G.) Handbook of Hygiene, 5
 Healthy Life and Dwellings, 5
 Wilson's (W. S.) Ocean as a Health-Resort, 10
 Wolfe's Diseases and Injuries of the Eye, 11
 Wolfenden and Martin's Pathological Anatomy, 12
 Year Book of Pharmacy, 2
 Yeo's (G. F.) Manual of Physiology, 4

The following CATALOGUES issued by J. & A. CHURCHILL will be forwarded post free on application:—

A. *J. & A. Churchill's General List of about 650 works on Anatomy Physiology, Hygiene, Midwifery, Materia Medica, Medicine, Surgery, Chemistry Botany, &c., &c., with a complete Index to their Subjects, for easy reference.* N.B.—This List includes B, C, & D.

B. *Selection from J. & A. Churchill's General List, comprising all recent Works published by them on the Art and Science of Medicine.*

C. *J. & A. Churchill's Catalogue of Text Books specially arranged for Students.*

D. *A selected and descriptive List of J. & A. Churchill's Works on Chemistry, Materia Medica, Pharmacy, Botany, Photography, Zoology, the Microscope, and other branches of Science.*


E. *The Medical Intelligencer being a List of New Works and New Editions published by J. & A. Churchill.*

[Sent yearly to every Medical Practitioner in the United Kingdom whose name and address can be ascertained. A large number are also sent to the United States of America, Continental Europe, India, and the Colonies.]

AMERICA.—*J. & A. Churchill being in constant communication with various publishing houses in Boston, New York, and Philadelphia, are able, notwithstanding the absence of international copyright, to conduct negotiations favourable to English Authors.*

LONDON: 11, NEW BURLINGTON STREET.

(3)



24.2.1993



