

**Handbook of ophthalmology / by C. Schweigger ; translated from the third German edition by Porter Farley.**

**Contributors**

Farley, Porter.  
Schweigger, C., 1830-1905.  
Royal College of Physicians of Edinburgh

**Publication/Creation**

Philadelphia : J.B. Lippincott, 1878.

**Persistent URL**

<https://wellcomecollection.org/works/qntp987k>

**Provider**

Royal College of Physicians Edinburgh

**License and attribution**


This material has been provided by This material has been provided by the Royal College of Physicians of Edinburgh. The original may be consulted at the Royal College of Physicians of Edinburgh. where the originals may be consulted.

This work has been identified as being free of known restrictions under copyright law, including all related and neighbouring rights and is being made available under the Creative Commons, Public Domain Mark.

You can copy, modify, distribute and perform the work, even for commercial purposes, without asking permission.





Wellcome Collection  
183 Euston Road  
London NW1 2BE UK  
T +44 (0)20 7611 8722  
E [library@wellcomecollection.org](mailto:library@wellcomecollection.org)  
<https://wellcomecollection.org>





Ja<sup>th</sup> S. 14





6  
Fa<sup>4</sup> p. 14

R37560





Digitized by the Internet Archive  
in 2015

<https://archive.org/details/b21906713>



HANDBOOK  
OF  
OPHTHALMOLOGY.

BY  
PROF. C. SCHWEIGGER,  
OF THE UNIVERSITY OF BERLIN.

TRANSLATED FROM THE THIRD GERMAN EDITION

BY  
PORTER FARLEY, M.D.,  
ROCHESTER, NEW YORK.



---

WITH DIAGRAMS AND OTHER ILLUSTRATIONS.

---

PHILADELPHIA:  
J. B. LIPPINCOTT & CO.  
1878.



---

Copyright, 1878, by J. B. LIPPINCOTT & Co.

---




## TRANSLATOR'S PREFACE.

---

IN presenting his work to the profession, the translator wishes to acknowledge the assistance received during its preparation from his friend Dr. Charles E. Rider, of Rochester, N.Y.

During the work of translation his advice on all doubtful points was freely sought and as freely given. While the book has been passing through the press, he has, at the expense of great labor and care, assisted in the reading and revision of the entire proof.

ROCHESTER, N. Y., Feb. 15, 1878.





# CONTENTS.

---

## PART FIRST.

ANOMALIES OF REFRACTION AND ACCOMMODATION. Condition of refraction. Emmetropia. Far point. Near point. Limits of range of accommodation. Relative range of accommodation. Mechanism of accommodation. Optical determination of range of accommodation. Senile changes in eye. Presbyopia. Correction by convex lenses. Acuteness of vision . . . . .	11-30
MYOPIA. Its degree,—anatomical and ophthalmoscopical changes, causes, and course. Functional anomalies and complications. Position of absolute and relative range of accommodation. Insufficiency of internal recti. Relative divergence. Amblyopia complicating extreme myopia. Myodesopia. Cloudiness of vitreous. Posterior polar cataract. Choroiditis near equator and macula lutea. Enlargement of Mariotte's spot. Scleral staphyloma near posterior pole. Metamorphopsia. Detachment of retina. Use of eyes in myopia. Correction by concave lenses. Symptoms of irritation . . . . .	31-51
HYPERMETROPIA, absolute, relative, facultative. Range of accommodation and its relative extent. Latent tension of accommodation. Accommodative asthenopia. Causes and diagnosis. Correction by convex lenses . . . . .	52-62
ASTIGMATISM, irregular and regular. Physiological meridional asymmetry. Principal meridian. Focal lines. Focal range. Abnormal meridional asymmetry. Impairment of vision. Accommodative asthenopia in hypermetropic astigmatism. Diagnosis. Degree of astigmatism. Lens participates in the asymmetry. Directions of principal meridians. Correction by cylindrical and spherocylindrical lenses. Stokes' lenses . . . . .	63-73
DIFFERENCE OF REFRACTION. Anisometropia . . . . .	74-76
PARALYSIS OF ACCOMMODATION. Differs from presbyopia. Micropia. Paresis of accommodation a symptom of oculo-motorius paralysis. Paralysis of pupillary branches alone. Connection with facial paralysis. Paresis of accommodation after diphtheritis faucium. Traumatic mydriasis and paresis of accommodation . . . . .	76-82
SPASM OF ACCOMMODATION. Apparent myopia. Calabar myosis. Asthenopia from spasm of ciliary muscle. Nervous asthenopia. Myosis . . . . .	83-86
MONOCULAR POLYOPIA AND DIPLOPIA . . . . .	86
SPECTACLES. Spherical lenses. Concave, convex, and cylindrical lenses. Prismatic spectacles. Stenopaic apparatus. Protective spectacles . . . . .	87-94
OPHTHALMOSCOPE. Upright image in emmetropia, in myopia, in hypermetropia. Inverted image. Size of ophthalmoscopic image. Binocular ophthalmoscope. Hering's experiment. Examination by daylight . . . . .	95-115
OPHTHALMOSCOPIC DIAGNOSIS OF ANOMALIES OF REFRACTION, of astigmatism . . . . .	116-119



OPHTHALMOMETER. Corneal curvature in emmetropia, myopia, and hypermetropia. Angle $\alpha$ . Apparent strabismus divergens and convergens . . . . .	119-125
DISEASES OF THE OCULAR MUSCLES. Movements of the eyes, and laws of diplopia. Centre of revolution. Extent of ocular movements. Laws of innervation. Overcoming prisms. Physiological diplopia. Double images united by prisms . . . . .	126-134
PARALYSIS OF ABDUCENS. Diminished motion. Imperfect associated movement. Secondary deviation of healthy eye. Paralytic squint. Behavior of double images. Limit between region of single vision and diplopia. Masked diplopia. Treatment. Use of prismatic spectacles. Exercise of paralyzed muscle. Result in strabismus convergens . . . . .	134-141
PARALYSIS OF OCULO-MOTORIUS, complete and partial. Dizziness from false projection of visual field. Etiology. Treatment. Indications for tenotomy of rectus superior and inferior . . . . .	141-145
PARALYSIS OF TROCHLEARIS. Action of rectus inferior. Behavior of double images. Differential diagnosis from paralysis of rectus inferior . . . . .	145-147
SPASM OF OCULAR MUSCLES . . . . .	148
STRABISMUS. Distinction between paralytic and typical or concomitant squint . . . . .	149
STRABISMUS CONVERGENS. Its connection with hypermetropia, amblyopia, and loss of accommodation. Elasticity of muscles. Reflex impulses. Stationary monolateral squint. Invariability of squinting angle upon change of fixation, and exceptions to the rule. Alternating strabismus convergens. Periodic squint. Linear measure of squint. Simultaneous upward or downward squint. Binocular vision with strabismus. Suppression of retinal images in squinting eye. Proof that squinting eye participates in vision. Provocation of double images. Use of stereoscope. Vision in squinting eye. Amblyopia congenita. Separate exercise. Spontaneous disappearance of squint. Therapeutic use of convex lenses . . . . .	149-165
STRABISMUS DIVERGENS. Preponderance of externi. Unilateral blindness. Unilateral myopia. Relative divergence in myopia . . . . .	165-168
MUSCULAR ASTHENOPIA AND DYNAMIC SQUINT. Insufficiency of recti interni. Condition of refraction in reference to diagnosis. Use of prismatic spectacles. Indications for tenotomy of recti externi . . . . .	168-173
SQUINTING UPWARD AND DOWNWARD . . . . .	173, 174
OPERATION FOR STRABISMUS. Simple tenotomy. Mechanical effect of operation. Operation divided between both eyes. Influence upon acuteness of vision and binocular vision. Correction of the hypermetropia by lenses. Dissimilarity of squinting angle after unilateral operation. Twitching fixation movement. Bringing forward ocular muscle . . . . .	174-187
NYSTAGMUS . . . . .	187, 188

## PART SECOND.

DISEASES OF THE ORBIT. Inflammation of fat and connective tissue. Abscess. Purulent periostitis. Danger of blindness from ulceration of cornea, from neuritis, from detachment of retina, or from purulent choroiditis. Course and treatment. Caries and necrosis of orbital walls. Exophthalmus from morbus Basedowii, from obstruction of circulation. Pulsating exophthalmus. Tumors of orbit. Hemorrhage. Fractures of orbital walls. Emphysema of orbit. Foreign bodies. Exophthalmometer . . . . .	191-202
DISEASES OF LACHRYMAL ORGANS. Inflammation of lachrymal gland (dacryoadenitis). Fistula of gland. Dacryops. Tumors and extirpation of gland.	



Congenital anomalies of puncta lacrymalia. Foreign bodies and cryptogams in canaliculi. Ectropion and occlusion of canaliculi. Dacryocystitis. Strictures of canaliculi. Bowman's probes. Cutting stricture. Cauterization of lachrymal sac. Lachrymal fistula. Polypi of canaliculi . . . . .	203-217
DISEASES OF EYELIDS. Blepharitis. Phtheiriasis of cilia and eyebrows. Hordeolum. Abnormities of tarsal glands. Chalazion. Herpes zoster frontalis. Eczema, erysipelas, and abscess of lids. Syphilitic ulceration of lids and conjunctiva. Lupus. Epithelioma. Telangiectasia. Cystic tumors of lids. Epi- drosis. Seborrhœa. Chromhidrosis. Xanthelasma. Blepharospasm. Ptosis. Paralysis of orbicular muscle. Lagophthalmus. Ectropion. Entropion. Blepharophimosis. Distichiasis congenita. Epicanthus. Coloboma of upper lid. Symblepharon. Blepharoplastic operations . . . . .	218-251
DISEASES OF CONJUNCTIVA. Hyperæmia. Conjunctivitis, simple or catarrhal. Chronic conjunctivitis. Atropine conjunctivitis. Blennorrhœa of conjunctiva. Blennorrhœal corneal affections. Rules for cauterization. Chronic blennor- rhœal processes. Diphtheritic conjunctivitis. Swelling of conjunctival folli- cles. Trachoma. Ophthalmia militaris, granulosa, etc. Hemorrhage beneath the conjunctiva. Serous swelling. Lupus. Pemphigus. Foreign bodies. Burns. Pterygium. Pinguecula. Phlyctenular conjunctivitis . . . . .	252-290
DISEASES OF THE CORNEA. Examination by focal illumination. Keratitis phlyc- tænulosa, parenchymatosa, punctata. Hypopion. Keratitis. Corneal abscess. Ulcus corneæ serpens. Neuro-paralytic keratitis. Corneal ulceration with interstitial encephalitis. Corneal ulcers. Corneal opacities. Irregular astig- matism. Staphyloma. Corneal fistula. Cysts on cornea. Keratoconus. Wounds of cornea. Tumors of cornea. Arcus senilis . . . . .	291-325
DISEASES OF THE SCLERA. Scleritis and episcleritis, simple and complicated. Scleral staphyloma . . . . .	326-331
DISEASES OF THE IRIS. Iritis idiopathica. Relapsing iritis. Total adhesion of pupillary margin. Irido-choroiditis. Corelysis. Iritis syphilitica, gummosa. Hydro-meningitis. Secondary iritis. Irido-cyclitis. Sympathetic disease. Enucleatio bulbi. Membrana pupillaris perseverans. Irideremia. Disap- pearance of iris by sinking. Coloboma iridis. Tumors of iris . . . . .	332-355
DISEASES OF THE LENS. Senile changes. Soft cortical cataract. Cataracta seni- lis, congenita, diabetica. Complicated cataract. Examination of vision. Par- tial opacity of lens. Cataracta incipiens, punctata, striata. Lamellar cataract. Cataracta centralis anterior, pyramidalis, centralis, posterior. Calcification of lens. Cataract operation. Linear extraction. Iridectomy in flap operation. Peripheral linear incision. Discision. Cataracta traumatica. Capsular and secondary cataract. Luxation of lens. Aphakia . . . . .	356-392
DISEASES OF THE VITREOUS BODY. Liquefaction and detachment. Myodesopia. Opacities. Hyalitis. Cholesterin in vitreous. Recurring hemorrhages into vitreous. Development of vessels in vitreous. Arteria hyaloidea persistens. Cysticercus . . . . .	393-400

## PART THIRD.

NORMAL FUNDUS OF EYE. Optic disc. Lamina cribrosa. Differences in level about disc. Physiological excavation. Ophthalmoscopic diagnosis of differ- ences of level. Central vessels of retina. Adventitial layer visible. Venous pulsation. Arterial pulsation. Retina visible. Its physiological opacity and reflex. Macula lutea. Fovea centralis. Choroid, differences in its pigmenta- tion. Albinismus. Intervascular spaces of choroid . . . . .	403-417
---	---------




DISEASES OF CHOROID.	Hyperæmia. Cyclitis, idiopathic and as sequel of recurring fever. Purulent choroiditis. Puerperal choroiditis. Embolism. Irido-choroiditis in cerebro-spinal meningitis. Acute irido-choroiditis. Calcification and ossification. Acute choroiditis, disseminated, syphilitic. Detachment. Rupture. Miliary tubercle. Choroidal sarcoma. Coloboma of choroid .	418-438
DISEASES OF RETINA AND OPTIC NERVE.	Medullary nerve-sheaths. Hyperæmia of retina. Detachment of retina. Pigmentation of retina. Hemorrhage in retina. Retinitis. Ophthalmoscopic indications. Disturbances of vision. Different forms of retinitis. Anatomical changes. Neuro-retinitis. Choked disc. Connection with intracranial diseases. Retrobulbar neuritis. Ischæmia retinae. Anatomical changes in neuritis and neuro-retinitis. Embolism of central artery of retina. Atrophic degeneration of optic nerve. Glioma of retina .	439-500
GLAUCOMA.	Glaucoma simplex. Pressure excavation. Differential diagnosis of optic-nerve excavations. Determining increased tension by touch. Tonometer. Atrophy of nerve fibres in consequence of excavation. Contraction of visual field and diminution of vision. Inflammatory glaucoma. Symptoms of intra-ocular pressure. Clouding of refracting media. Arterial pulsation. Seeing colors of spectrum. Prodromal stage. Glaucoma chronicum, acutum, and fulminans. Glaucomatous degeneration and atrophy of eyeball with detachment of retina. Etiology. Secondary glaucoma. Iridectomy in glaucoma. Cystoid cicatrization. Cure by iridectomy . . . . .	501-523
ESSENTIAL PHTHISIS BULBI . . . . .		524, 525
AMBLYOPIA AND AMAUROSIS.	Examination of visual field. Amblyopia congenita. Color-blindness. Hemeralopia. Anæsthesia and hyperæsthesia of retina. Amblyopia with no cause to be seen ophthalmoscopically. Amblyopia potatoria and saturnina. Scotoma centrale. Progressive atrophy of optic nerve. Hemipic defect in visual field. Amaurosis from intracranial and cerebral causes. Uræmic amaurosis. Amaurosis following hæmatemesis. Amaurosis simulata . . . . .	526-546

## PART FIRST.

ANOMALIES OF REFRACTION AND ACCOMMODATION.

—SPECTACLES, OPHTHALMOSCOPE, AND OPHTHAL-  
MOMETER.—ANOMALIES OF THE OCULAR MUSCLES.



## I.

### ANOMALIES OF REFRACTION AND ACCOMMODATION.

---

THANKS to the lucid treatment of this subject by Donders, the Anomalies of Refraction and Accommodation have become one of the clearest and most complete chapters of ophthalmology. Even the first step was decisive. The sharp distinction which Donders made between Refraction and Accommodation was sufficient to banish all obscurity. By refraction we understand that optical adjustment of the eye which depends upon its anatomical structure; the accommodation includes those changes of the optical adjustment which are effected by the ciliary muscle. Hence we can say that the refraction is that optical condition of the eye which we have when the ciliary muscle is wholly relaxed.

The anatomical components which determine the optical structure of the eye are as follows: (1) the curved surfaces of the dioptric apparatus,—*i.e.*, the surface of the cornea, the surfaces of the lens, together with the distance between these surfaces; (2) the refractive index of the transparent media,—*i.e.*, of the cornea, aqueous humor, lens, and vitreous body; and (3) the length of the axis of the eye.

The great number of these components, and their liability to variations, naturally cause different conditions of refraction in different individuals. Donders, however, easily succeeded in arranging the possibilities, since he started out with the behavior of the eye toward rays of light which fall parallel upon the cornea; for such rays after refraction in the eye must be focused either upon the sensitive layer of the retina or before or behind it.

Hence there may be three different conditions of refraction, perfect rest of accommodation—that is, total relaxation of the ciliary muscle—being always assumed.

When rays of light which proceed from a point lying at an infinite distance, and which are therefore practically parallel, fall



upon the cornea, and are focused upon the retina, we have emmetropia; if focused in front of the retina, we have myopia; if behind the retina,—that is to say, if the rays after their refraction in the dioptric apparatus converge toward a point lying behind the retina,—we have hypermetropia.

Perhaps it will contribute to the elucidation of this subject if we call attention to the fact that the eye considered as an optical instrument is constructed like a camera obscura. In fact, it is just as important with the camera obscura of the photographer as with the eye that the optical image of the object be thrown with perfect distinctness upon the sensitive plate. Now, under what conditions will this requirement be satisfied?

Let us first examine the camera obscura, which in its simplest form consists merely of a convex lens and of a ground-glass plate, upon which the optical image is received. This image depends upon the fact that the rays of light which proceed from each separate point of the object are brought again to a point. We may therefore consider both the object and the image as composed of an infinite number of points, and what is true of one object-point and of its corresponding image-point is true of all.

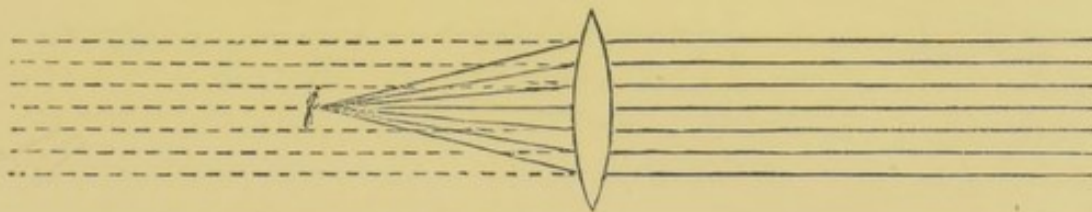
If the position of the object-point—that is, its distance from a convex lens—be given, the position of the image-point depends upon the focal length of the lens, or in other words, upon the distance at which parallel rays are brought together. The less this distance, the greater is the refractive power of the lens. Focal length and refractive power are therefore in inverse proportion. If one lens has, for instance, a focal length of 1 inch, while another lens has one of 2 inches, and a third one of 3 inches, then the refractive power of these lenses is as  $1 : \frac{1}{2} : \frac{1}{3}$ . We therefore express the optical value of a lens by a fraction whose numerator is 1 and whose denominator is the focal length of the lens. The optical value of a lens of ten inches focal length is thus expressed by  $\frac{1}{10}$ . This is ten times less than that of a lens of one inch focal length. In expressing the power of lenses any other unit of measure may of course be taken as well as the inch.

If  $f$  in Fig. 1 be the image-point belonging to an object-point infinitely distant, the point of union for parallel rays—that is, the principal focus of the convex lens—lies at  $f$ . The optical value of the lens would therefore be expressed by  $\frac{1}{f}$ .



From the above it follows that a camera obscura, in order to form images of distant objects, must be so constructed that the focus of the convex lens falls exactly upon the ground-glass plate; and conversely a camera obscura whose screen lies in the focus of the convex lens can give sharp images of only such objects as lie practically at an infinite distance from the lens. Precisely these optical conditions exist in the emmetropic eye; when its accommodation is wholly relaxed the retina lies exactly in the principal focus of the dioptric apparatus.

FIG. 1.



If the object-point is not at an infinite distance the image-point will not coincide with the principal focus, but its position will be determined, as has already been mentioned, by the distance of the object-point and by the focal length of the convex lens.

It is evident from Fig. 1 that rays of light which proceed from  $f$  are so refracted in the lens that they will be focused at an infinite distance beyond it, or what is the same thing, and is expressed by the dotted lines, they take a direction as if they had proceeded from a point at an infinite distance in front of the lens.

The farther the object-point is removed from the lens the nearer the image-point approaches it, until finally, upon infinite removal of the object-point, the image-point coincides with the principal focus. Thus rays of light which diverge from a point more distant than the principal focus, become convergent after passing through the lens and intersect each other in an image-point whose distance is likewise greater than that of the focus.

Let  $f$ , in Fig 2, be the focus of the convex lens,  $a$  the luminous point, and  $\alpha$  the image-point, then an inverted, diminished image of an object lying at  $a$  will be formed at  $\alpha$ , while if the rays diverge from  $\alpha$  their union takes place in  $a$ , and an inverted, enlarged image of  $\alpha$  would there be formed. The distances of  $a$  and  $\alpha$  are thus conjugate focal distances, each of which, just



as in the case of the principal focal distance, is expressed by a fraction whose numerator is one, and whose denominator is the distance of the points  $a$  and  $\infty$  respectively from the centre of the lens. The optical significance of the object-point is expressed by  $\frac{1}{a}$ , that of the image-point by  $\frac{1}{\alpha}$ . We obtain in this way three optical values, whose relation to each other is expressed by the formula  $\frac{1}{a} + \frac{1}{\alpha} = \frac{1}{f}$ . By this formula, when two values are given, we obtain the third.

FIG. 2.



If we have, for instance, a camera obscura with a lens of 4 inches focal length, while the screen lies not at the principal focus of the lens, but at 5 inches from the centre of the lens, we have given the values of  $f$ —*i.e.*, the principal focal length—and  $\alpha$ ,—*i.e.*, the distance at which the image is to be thrown. The formula  $\frac{1}{a} + \frac{1}{\alpha} = \frac{1}{f}$  becomes  $\frac{1}{a} + \frac{1}{5} = \frac{1}{4}$ , that is,  $\frac{1}{a} = \frac{1}{20}$ . The object must therefore be at a distance of 20 inches in order to cast its image on the screen, or in other words, the camera obscura is adjusted for a distance of 20 inches.

So it is with the eye which is adjusted for a determinate finite distance, either by the action of its accommodation or by its optical structure. The latter is the case in the short-sighted eye.

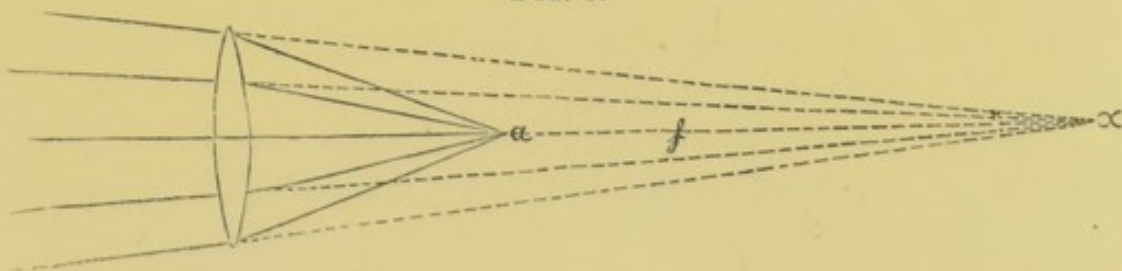
The third possibility is, that the screen of the camera obscura may lie within the focal distance of the lens. For what distance is the instrument now adjusted? where must the object be placed to cast its image on the screen?

We have seen that objects at a finite distance cast their images beyond the principal focus. The further the object is removed the nearer its image approaches the principal focus, and finally, when the object is at an infinite distance, its image is formed exactly at the principal focus of the lens. An object cannot be at a greater than an infinite distance; therefore a camera obscura, whose screen lies within the focal distance, can exhibit no distinct pictures. Since this condition actually exists in the hypermetropic



eye, we must examine it more closely, and apply to it the formula for conjugate foci.

FIG. 3.



If, for instance, the convex lens in Fig. 3 have a focal length of 3 inches, then  $\frac{1}{f} = \frac{1}{3}$ ; and if the screen be 2 inches from the lens, then  $\frac{1}{a} = \frac{1}{2}$ , and we have from the formula

$$\frac{1}{a} + \frac{1}{\alpha} = \frac{1}{f}$$

$\frac{1}{2} + \frac{1}{\alpha} = \frac{1}{3}$ , or  $\frac{1}{\alpha} = \frac{1}{3} - \frac{1}{2} = -\frac{1}{6}$ . The negative sign shows that rays of light which proceed from  $a$ , after refraction in the convex lens, diverge as if they had proceeded from  $\alpha$ ;  $\alpha$  is the image-point of  $a$ ; but since the rays do not actually intersect at  $\alpha$ , but only diverge as if they had proceeded from it, the image at  $\alpha$  is called a virtual image.

It follows further that when we can give to rays proceeding from any given point a direction such that they converge toward the point  $\alpha$ , they will after refraction in the convex lens form an optical image at the point  $a$ . Under these conditions a distinct image will be formed in spite of the faulty construction of the camera obscura; these conditions must be fulfilled in the case of the hypermetropic eye.

#### EMMETROPIA.

According to the foregoing the optical construction of the emmetropic eye is such that with absolute relaxation of accommodation it is adjusted for far-distant objects, and throws distinct retinal images of them. The ability to see near objects distinctly depends upon the accommodation.

The limits of accommodation are called respectively the far and the near point. The position of the far point depends upon the condition of refraction. It is the most distant luminous point whose rays can still be united in an image upon the retina. Assuming the accommodation to be relaxed, the far point of the emmetropic eye lies at an infinite distance, since light which proceeds



from an infinitely distant point falls upon the cornea in parallel rays. Every contraction of the muscle of accommodation causes the eye to be adjusted upon some nearer point. The nearest point upon which, with the full power of accommodation, the eye can be adjusted is called the near point.

Donders has shown that a distinction is to be made between an absolute and a binocular near point. The binocular near point is the nearest point upon which the accommodation, with simultaneous convergence of the visual axes,—that is, with binocular vision,—can be directed. The absolute near point shows the maximum power of accommodation. But this greatest possible action of accommodation by which the eye is adjusted for the absolute near point can be accomplished only with a relatively too strong convergence of the visual axes,—that is, with monocular fixation.

These relations existing between the convergence of the visual axes and the action of accommodation were first fully appreciated by Donders, and by him explained. For the emmetropic eye, he showed that in general the accommodation is adjusted for that point in which the visual axes intersect each other; and conversely, in ordinary use under normal conditions, the visual axes converge toward the point for which the eye as an optical instrument is adjusted. Nevertheless there does not exist, as was formerly thought, a constant relation between the convergence of the visual axes and the degree of accommodation. With one and the same degree of accommodation, there may be a greater or less convergence of the visual axes; and conversely, with an unchanged angle of convergence, the degree of accommodation can be either increased or diminished. We call this space through which the accommodation can be effected without change in the direction of the visual axes the relative range of accommodation. With an unchanged angle of convergence of the visual axes, the accommodation can adjust the eye for the relative near point, and relax it for the relative far point.

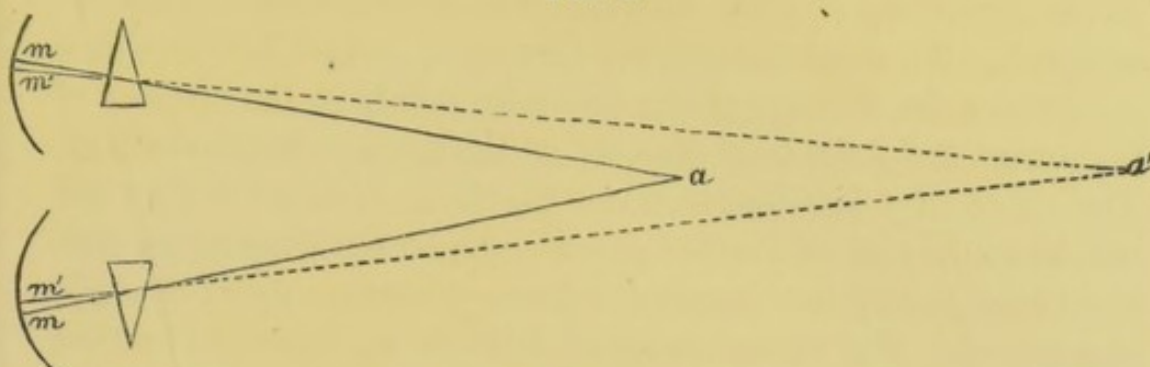
Donders has not only given the proof of the existence of relative accommodation, but has also accurately determined the position of the relative range of accommodation, and of the relative near and far points for every given convergence of the visual axes.

With the help of prisms we are able, with unchanged tension of accommodation, to alter the convergence of the visual axes.



If in Fig. 4 both eyes are fixed upon and see distinctly the point  $a$ , a distinct retinal image will be formed in both eyes upon

FIG. 4.

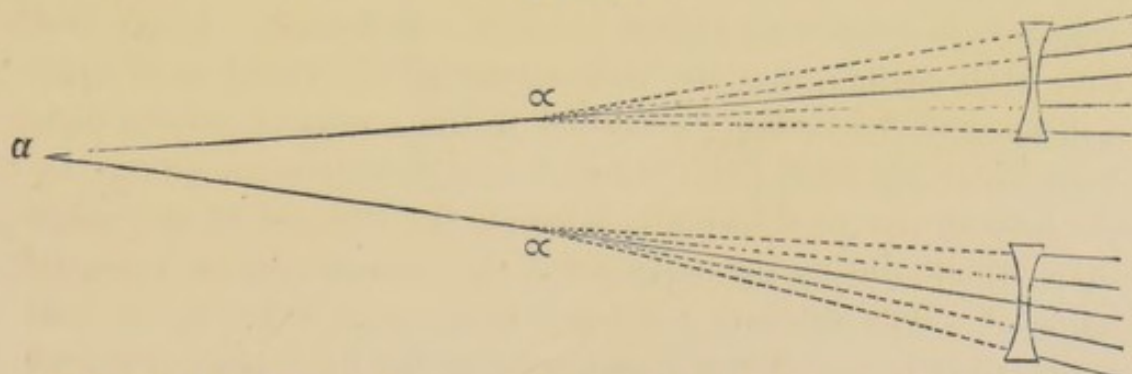


the macula lutea at  $m$ . Now, if we place before the eyes prisms with their refracting angles turned outward, the rays proceeding from  $a$  will be refracted towards  $m'$ , and the point  $a$  will be seen double. Binocular single vision will, however, be soon re-established by a lateral turning of the cornea, the macula lutea being moved from  $m$  to  $m'$ . The deviation caused by the prisms will be balanced by a compensating deviation of the visual axes, and it is easy to determine within what limits this is possible. Conversely, by the use of prisms with their bases turned outward, the visual axes may be caused to intersect at a point lying nearer to the eye than  $a$ , while the accommodation remains adjusted for that point.

The results appear even more striking in the method usually employed by Donders, which determines the limits of accommodation, while the convergence of the visual axes remains unchanged.

If, for instance, the object-point  $a$  in Fig. 5 is at a distance

FIG. 5.



of 12 inches from the eyes, it can be determined, while the visual angle remains the same, with what concave and convex



lenses the object may still be distinctly seen. If, for instance, concave 12 is the strongest concave glass with which binocular vision at a distance of 12 inches is still possible, it can easily be calculated upon what distance the accommodation must be adjusted. We employ again the formula  $\frac{1}{a} + \frac{1}{\alpha} = \pm \frac{1}{f}$ , in which  $a$  expresses the distance of the luminous point,  $\alpha$  the distance of the image, and  $f$  the focal distance of the concave or convex lens. The value of  $f$  is negative when the focal distance is a virtual one, as in the case of concave glasses. Upon our supposition that  $a=12$  and  $f=12$ , the formula  $\frac{1}{a} + \frac{1}{\alpha} = -\frac{1}{f}$  becomes  $\frac{1}{12} + \frac{1}{\alpha} = -\frac{1}{12}$ , or  $\frac{1}{\alpha} = -\frac{1}{6}$ . The virtual image of  $a$  lies at  $\alpha$ , 6 inches from the lens,—that is, after their refraction in the concave lens the rays diverge as if they had proceeded from the point  $\alpha$ , 6 inches in front of the lens. The accommodation must be adjusted for this distance in order to see distinctly the image at  $\alpha$ , while the visual axes still intersect at the point  $a$ . That is to say, if in our experiment the visual axes converge toward a point 12 inches distant, and  $-\frac{1}{12}$  is the strongest concave lens with which the fixation-object can still be distinctly seen, it follows that with the same convergence of the visual axes the accommodation can still be adjusted on a much nearer point. We find for this case the relative near point to lie 6 inches in front of the concave lens; or supposing the distance between the lens and the optical centre of the eye to be  $\frac{1}{2}$  inch, the relative near point lies  $6\frac{1}{2}$  inches distant from the latter.

We can determine in the same manner and with the same degree of convergence the strongest convex glass with which the point  $a$  can still be distinctly seen. In this case the accommodation must, of course, be relaxed and adjusted for rays of less divergence, or no distinct retinal image can be formed. If we find that while maintaining the convergence of the visual axes upon a distance of 12 inches, convex 16 is the strongest convex lens with which the fixed point can still be distinctly seen, we can, by the help of the same formula, calculate the distance of the point upon which, during the experiment, the accommodation must be adjusted. The formula  $\frac{1}{a} + \frac{1}{\alpha} = \frac{1}{f}$  becomes  $\frac{1}{12} + \frac{1}{\alpha} = \frac{1}{16}$  or  $\frac{1}{\alpha} = -\frac{1}{48}$ ; that is, the virtual image-point of the fixed point  $a$  lies 48 inches from the convex lens, or the rays of light proceeding from  $a$  diverge after their refraction by the convex lens as if they had



proceeded from a point 48 inches on the other side. In order to see a distinct and single image of the point *a*, the eyes must have adjusted themselves to such diverging rays without changing the convergence of their visual axes. We find, then, in this case, with the visual axes converging upon a point 12 inches distant, a relative near point 6 inches and a relative far point 48 inches from the eye. Now, since the ordinary adjustment of accommodation is upon the point of intersection of the visual axes, the range of relative accommodation is divided into two parts,—the one within, the other beyond, that point of intersection. That part of the relative range of accommodation which lies between the fixation-point and the relative far point is called the negative part, because, under ordinary circumstances, it is already used in accommodating upon the binocular fixation-point. The other part, extending from the point of intersection of the visual axes to the relative near point, is called the positive part of the relative range of accommodation, because, with the given degree of accommodation, it is not yet brought into use. It represents the unemployed power of accommodation. The results of a complete series of experiments made by Donders upon this subject may be stated as follows:

(1) With parallel visual axes the emmetropic eye is adjusted upon its far point. Its accommodation is fully relaxed. There can be no further relaxation, but there can be tension of the accommodation. All emmetropes having a good range of accommodation can see distinctly at a distance through concave glasses. In such cases, in spite of the parallelism of the visual axes, the accommodation must be adjusted upon the negative focal points of the concave lenses. Youthful individuals with a normal range of accommodation have, with parallel visual axes, an attainable relative near point at about 12 inches from the eye. With parallel visual axes, the relative range of accommodation is wholly positive; that is, a stronger tension but no further relaxation is possible.

(2) With convergence for the binocular near point no further tension, but only a relaxation of the accommodation, is possible; that is, the relative range of accommodation is wholly negative.

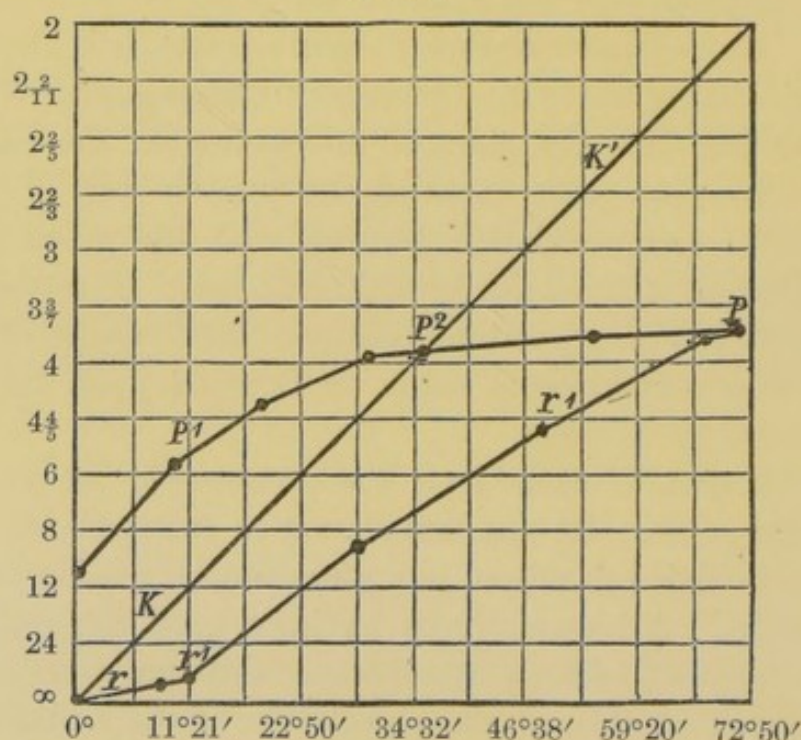
(3) With a degree of convergence for intermediate points, say at from 8 to 24 inches, as in ordinary work, the positive part of



the relative range of accommodation is greater than the negative part; that is, with this degree of convergence only the smaller part of the whole available accommodation is employed.

Donders has presented these results diagrammatically. The principle of this diagrammatic representation is, that the distance between two horizontal lines represents a definite result of accommodation, which is assumed as the unit of measure. As this unit,  $\frac{1}{24}$  is chosen,—that is, a result of accommodation equivalent to the action of a convex lens of 24 inches focal distance. We begin now, in Fig. 6, with the lowest line, marked  $\infty$ , which represents the eyes

FIG. 6.



as adjusted for parallel rays. The second horizontal line, marked 24, represents an increase of accommodation by  $\frac{1}{24}$ , or the adjustment of the eyes for a distance of 24 inches. The third horizontal line, marked 12, represents an increase of accommodation by twice  $\frac{1}{24}$ ; the third line, marked 8, by three times  $\frac{1}{24}$ ; and so on. The diagonal line,  $K K'$ , represents the convergence of the visual axes. The numbers in the column on the left express in inches the distance of the object. The numbers below the diagram express the angle of convergence. The distance between the eyes is assumed to be 64 millimetres.

The position of the relative near point for every given angle



of convergence is shown by the line  $p^1 p^2 p$ , and the position of the corresponding far point by the line  $r r^1$ . The points marked on these lines were found by direct experiment.

The diagram shows that the eye, whose relative accommodation it illustrates with parallel visual axes, has its relative near point at a distance of 11 inches: with an angle of convergence of  $22^\circ 50'$  the relative range of accommodation lies between a distance of 12 inches and about 4.5 inches from the eye. The binocular near point lies at  $p^2$ , where the near-point line intersects the diagonal  $K K'$ . If the convergence of the visual axes increases still more, for instance, to  $46^\circ 38'$ , the line  $p^2 p$  remains below the diagonal  $K K'$ ; that is, the tension of accommodation remains behind the point of convergence of the visual axes; if this point is 3 inches from the eye, the accommodation is adjusted upon a point 3.8 inches distant. The absolute near point  $p$  lies somewhat nearer, at 3.7 inches. It can, however, be reached only with an angle of convergence of about  $70^\circ$ , when the visual axes will intersect at a distance of about 2 inches. At this maximal tension the range of accommodation ends; the lines  $p^2 p^1$ , and  $r r^1$ , end here in one and the same point.

The changes which can be observed in the eye during accommodation are the following:

(1) The pupil contracts in accommodation for near objects; it dilates for distant vision.

(2) The margin of the iris and the centre of the anterior surface of the lens move forward in accommodating for near objects; simultaneously the peripheral part of the iris sinks back, as must necessarily be the case, since the volume of the aqueous humor remains unchanged.

(3) The anterior surface of the lens becomes more curved in near, and flattens again in distant, vision. This phenomenon, evidently the most important connected with accommodation, may be directly observed by studying the images reflected from the anterior and posterior surfaces of the lens. In accommodating for near objects the image reflected from the anterior surface of the lens becomes smaller, a proof that the surface becomes more curved; its position, too, is changed, which is explained by the moving forward of the reflecting surface.

(4) The image reflected from the posterior surface of the lens



also diminishes in accommodating for near objects, from which it may be concluded that during this act that surface also becomes more curved; a simultaneous change in the position of this surface does not seem to occur.\* Hensen and Völckers found, on the contrary, in the case of dogs, that the posterior surface of the lens moved backward.

Observations in cases of iridectomy and of albinos with transparent irides† have shown beyond doubt that there always exists between the ciliary processes and the equator of the lens a free space, in which the zonula is stretched. It is certain that the ciliary muscle in contracting does not compress the equator of the lens. The phenomena to be observed after iridectomy, in the region of the ciliary processes, the zonula, and the equator of the lens, have been thoroughly investigated by Coccius.‡ He established the fact that in accommodating for near objects the points of the ciliary processes move so far forward toward the iris that the processes themselves form an acute angle with the axis of the eye. The circle formed by the ciliary processes becomes smaller. Coccius saw simultaneously a swelling of the ciliary processes and, in agreement with Becker, a widening of the zonular space; according to Coccius, also, the movement of the margin of the lens toward its centre during accommodation may be directly observed.

Hensen and Völckers§ demonstrated in the case of dogs a forward movement of the choroidea, simultaneous with the contraction of the ciliary muscle. Adamiuk|| confirmed this, but does not think it true of man, whose ciliary muscle has a different structure from that of the dog. From the accommodation phosphenes, described by himself, Czermak¶ argues that there is a tension of the retina during accommodation.

At all events, the processes to be observed within the lens play the most important rôle in accommodation, and there is every

\* Helmholtz, *Physiologische Optik*, § 12.

† Becker, *Wiener medicinische Jahrbücher*, 1863 u. 1864.

‡ *Der Mechanismus der Accommodation*, Leipzig, 1868.

§ Hensen und Völckers über den Mechanismus der Accommodation, Kiel, 1868.

|| *Centralblatt f. d. med. Wissensch.*, 1870, No. 19.

¶ *Archiv für Ophth.*, vii. 1, 147.



reason to believe that they fully explain all the changes of optical adjustment. It only remains to show more exactly how the changes in the lens are caused.

We start from the assumption that with perfect relaxation of accommodation the eye is adjusted for its far point, and that with each effort of accommodation it is adjusted for some less distant point. The simple suspension of accommodation causes a return to the optical adjustment for the far point. The truth of this supposition is established by the fact that the eye may be adjusted for its far point artificially, by the use of atropine, or pathologically, by the paralysis of accommodation.

The phenomenon of accommodation is reduced accordingly to an antagonism between the elastic strength of the lens on the one side and the zonula on the other, which is excited by the action of the ciliary muscle. The lens from its elasticity has a tendency to approach a spherical shape; Helmholtz,\* who first announced this fact, also found that with absolute relaxation of accommodation for distant vision, the thickness of the lens is less than it is after death.

The zonula, which is stretched between the ciliary processes and the equator of the lens and is attached to both, tends by reason of its elasticity to flatten the lens. So soon as the zonula is relaxed the lens will follow its own elastic tendency and will assume a greater convexity.

It may with the greatest probability be assumed that both the radiating and the circular fibres of the ciliary muscle act simultaneously to relax the zonula. The elasticity of the lens then comes in play, and the above-described changes in its form occur; upon the cessation of muscular contraction the elastic tension of the zonula acquires the ascendancy, and then occurs that flattening of the lens which corresponds to the condition of relaxed accommodation.

#### OPTICAL DETERMINATION OF THE RANGE OF ACCOMMODATION.

It is advantageous in practice to possess a uniform standard of measure for the power of accommodation, in order to compare the

---


\* *Physiol. Optik*, pag. 110.



results of examinations in different individuals, or in the same individual under different circumstances. Donders provided this standard in a very simple way by comparing the result of accommodation to the optical value of a convex lens, which, if placed before the relaxed eye, would have accomplished the same as the accommodation does.

Let the lens  $L$ , in Fig. 7, be such that parallel rays striking its surface are focused at  $f$ . A screen at  $f$  would show distinct pictures of distant objects, just as a landscape camera obscura does.

FIG. 7.



If now the instrument be adjusted for some nearer point upon the axis, say at  $p$ , then, according to the rule, the distance between  $L$  and  $f$  would be increased; if, however, this distance cannot be changed, there is still a means by which a distinct image of  $p$  can be cast at  $f$ ; for this purpose it is only necessary to combine with the lens  $L$  an auxiliary meniscus,  $L'$ , which has such a focal length that rays proceeding from  $p$ , after their refraction in  $L'$ , become parallel; they then fall parallel upon  $L$ , and, according to the original supposition, are focused at  $f$ ; now if, for instance, the distance from the point  $p$  to  $L'$  is 4 inches, then the convex meniscus must evidently have a focal length of 4 inches; its optical value would be expressed by  $+\frac{1}{4}$ . The same principles can be applied to the eye. If before an emmetropic eye with relaxed accommodation we place a convex meniscus of  $+\frac{1}{4}$ , the eye is thus adjusted for a distance equal to the focal length of this lens, that is, 4 inches. If the near point of an emmetropic eye is 4 inches distant, then the accommodation does for this eye just what was done by the convex meniscus for the relaxed eye. If we represent the accommodation by the letter  $A$ , we have as the measure of the accommodation of an eye whose far point is at an infinite distance, and whose near point is at 4 inches, the expression  $\frac{1}{A} = \frac{1}{4}$ . The optical value of the accommodation is thus best expressed by the principal focal distance of that convex lens which, added to the condition of refraction in the eye, would com-



plete an apparatus adjusted for the nearest point upon which the eye could have been adjusted by its own physiological power.

The near point  $p$  corresponds always to the optical adjustment of the eye when to its anatomical condition of refraction (determined by the position of the far point  $r$ ) the result of accommodation is added. Expressed in an optical formula we have  $\frac{1}{r} + \frac{1}{A} = \frac{1}{p}$ ,—that is, refraction plus accommodation gives the near point. An immediate deduction from this is the expression  $\frac{1}{A} = \frac{1}{p} - \frac{1}{r}$ ,—that is, when we know the positions of the far and near points we can calculate the range of accommodation. The value which we obtain assumes the form of a fraction whose numerator is 1 and whose denominator expresses in inches the principal focal length of that convex lens which placed in front of the relaxed eye would have accomplished the same as the accommodation.

The same method of mathematical expression is employed for the relative range of accommodation, which is generally denoted by  $A'$ .

We found, for example (page 18), with a convergence upon a point 12 inches distant, that the relative far point lay at 48 inches, and the relative near point at 6 inches; from this we can calculate the value of the relative range of accommodation,  $\frac{1}{A'} = \frac{1}{6} - \frac{1}{48} = \frac{1}{6.8}$ . The negative part of the relative range of accommodation is in this case  $\frac{1}{16}$ , the positive  $\frac{1}{12}$ .

#### PRESBYOPIA.

Having thus obtained a common measure for the range of accommodation in different individuals, Donders further showed that the extent of the range of accommodation depends upon the age of the individual. With the increase of years the near point moves gradually from the eye, and the range of accommodation is thereby reduced. Two possibilities suggested themselves by which to explain this phenomenon: either the power of the muscle of accommodation must weaken, or there must be changes in the elasticity of the lens. The circumstance that the range of accommodation is already noticeably diminished at a time when the strength of all other parts of the muscular system is unimpaired must banish the idea of a premature loss of power in the muscle of accommodation; on the other hand, however, there are all-sufficient proofs of changes in the lens dependent upon age.



It is known that the lens becomes harder with age. From the investigations of F. J. v. Becker,\* this hardening begins at a very early age, affecting first the nucleus of the lens and spreading to the periphery. At a later age this hardening may be plainly recognized by the stronger reflection of light observable upon focal illumination of the lens. It is fair to assume that with the change in the index of refraction there occurs also a change in the elasticity of the lens, so that it gradually loses the power to respond to the contraction of the ciliary muscle by increasing the convexity of its curved surfaces.

The gradual withdrawal of the near point causes at first no inconvenience. According to Donders, the average distance of the near point in the emmetropic eye at 20 years of age is  $3\frac{3}{4}$  inches, at 35 years about 6 inches: and it is very seldom that there is occasion to use the eyes upon objects so near. When the near point recedes to 15 inches or more, inconvenience is felt in all occupations which require distinct vision of near objects, such as reading, sewing, etc. If the objects are placed within the region of distinct vision,—that is, beyond the near point,—the retinal images become too small to admit of continuous vision; upon bringing the objects within the near point the retinal images become larger, but at the same time are rendered indistinct by circles of diffusion. This indistinctness of the retinal images is less than it otherwise would be from the fact that simultaneously with the limitation of accommodation the pupil becomes smaller and the circles of diffusion are correspondingly decreased. Presbyopes seek, therefore, in every occupation the greatest possible amount of light; in the evening, for instance, when reading, they will hold the light between the book and their eyes in order by strong illumination to reduce as much as possible the size of the pupil.

The senile changes in the lens cause not only a withdrawal of the near point, but may affect the far point in the same way. The lens is known to consist of a great number of layers, whose indices of refraction increase from the periphery toward the centre, and it has been proved that by reason of this arrangement the resulting focal length is shorter than it would be if the entire lens possessed the refracting power of the nucleus. Now, we

---

\* Arch. f. Ophth., Bd. ix. 2, pag. 19.



have ground to believe that from the senile changes of the lens its cortical part becomes harder, so that its refracting power more nearly approaches that of the nucleus; an increase of focal distance is the result. Moreover, in extreme old age the lens appears to become actually flatter, a further cause for the diminution of refraction. In this way hypermetropia may develop in eyes originally emmetropic.

The diminution of the range of accommodation by a withdrawal of the near point from the eye is, then, to be called presbyopia only when it is a co-symptom of senile changes in the eye. These changes are numerous. All the refracting media of the eye become less transparent; this is noticeable when one compares ophthalmoscopically a senile eye with a youthful one; the anterior chamber becomes shallower; the iris loses its motility; the pupil becomes smaller, and often does not dilate normally upon the use of atropine; the choroid and membrane of Descemet (the last, fortunately, as a rule, only near the corneal margin) become thickened and uneven; phosphate of lime, as Donders has shown,\* is deposited in the sclera; the muscle of accommodation atrophies; the retina in its vessels and in the structure of its peripheral parts also shows changes which must be regarded as senile. Diminished clearness of vision follows all these phenomena. We thus find presbyopia to be a co-symptom of a considerable series of changes, and must, therefore, regard the withdrawal of the near point as a normal phenomenon only when it stands in due proportion to the age. Emmetropes, on an average, first experience the inconveniences of presbyopia between the forty-fifth and fiftieth years of life. Only very sharp-sighted eyes can, at a greater age, be used by the hour in reading or writing without experiencing fatigue.

Premature presbyopia occurs in connection with premature marasmus, after prostrating sicknesses, with incipient cataract and with the development of glaucoma.

The diagnosis of presbyopia is easy. It is first to be ascertained that the vision for distance is good, then that the indistinctness of near objects is corrected immediately by weak convex lenses, and, finally, that the diminution of accommodation stands

---

\* Arch. f. Ophth., ix. 2, pag. 217



in the proper relation to the age of the patient. Paralysis of accommodation is partly thus excluded, partly, also, by the behavior of the pupil. As a rule, the pupil is contracted in presbyopia and dilated in paralysis of accommodation.

The treatment consists in substituting convex lenses for the lost power of accommodation. So soon as presbyopia causes inconvenience which is relieved by the use of weak convex lenses ( $\frac{1}{60}$  to  $\frac{1}{40}$ ), such spectacles should always be used for work. It is useless, by straining the eyes, to attempt to postpone the use of glasses, and it is equally useless to adopt them so long as, in spite of the removal of the far point, continuous reading or writing causes no inconvenience.

The strength of the glasses to be prescribed depends upon the nature of the patient's occupation. The farther his near point has receded beyond the distance of the objects on which he uses his eyes, the stronger the glasses which he requires. For reading and writing it generally suffices to bring the near point up to a distance of from 12 to 15 inches. In simple, uncomplicated presbyopia, with fair acuteness of vision, the choice of proper spectacles may usually be left with the patient. From time to time, as the near point gradually recedes from the eye, somewhat stronger glasses must be chosen. For healthy eyes it is better to use uncolored glasses. The blue ones, which have become perhaps too fashionable, are at first very agreeable, but since they deprive the retina of the normal stimulus of white light, the eye becomes too sensitive; hence having once begun, it is necessary to continue wearing them.

#### DETERMINING ACUTENESS OF VISION.

We have said that in making the diagnosis of presbyopia it is necessary to determine the acuteness of vision; we must now consider the method of doing it. A sufficient judgment may be formed by trying the acuteness of vision by test type of varying sizes, such as Jaeger's. In many respects, however, Snellen's test letters are better. They are more exact, and the results are more easily compared with each other. These letters increase in size according to a definite proportion.

The most suitable objects appear to be black letters, of sizes so arranged that they are seen plainly by the normal eye under



an angle of five minutes. The thickness of the lines and smaller parts of the letters is exactly one-fifth their height, so that the different parts of the letters are included in an angle of one minute, while the whole letter is included in an angle of five minutes. The letter C, for example, in comparison with the letter O, shows an interruption with a visual angle of one minute. Accordingly this series of letters is so arranged that the test letters, No. I, one foot distant, No. II, two feet distant, No. XX, twenty feet distant, and No. C, one hundred feet distant, are all included in the same visual angle of five minutes. If, for instance, No. XX is distinctly seen at twenty feet, but not No. I at one foot, it shows normal acuteness of vision, but that probably the accommodation is insufficient to adjust the eye for a distance of one foot. This probability becomes a certainty if by the use of the proper convex lenses No. I is also plainly seen at a distance of one foot.

Again, if No. I is seen distinctly at a distance of one foot, but not No. XX at twenty feet, there is normal acuteness of vision, but there is reason to suspect the existence of myopia. This suspicion is confirmed if with the proper concave lenses No. XX is seen distinctly at twenty feet.

If after the correction of any existing anomaly of refraction the patient cannot see No. XX at a distance of twenty feet, but only at a distance of perhaps ten feet, there exists a deficiency in the acuteness of vision. The degree of this deficiency may be expressed by a fraction whose numerator is the number of feet at which the letters are seen, and whose denominator is the number of feet at which they should be seen. In the example just given there is an acuteness of vision of  $\frac{10}{20} = \frac{1}{2}$ .

The examination of the condition of vision is conducted as follows. The test letters are set up in a well-lighted position in a room twenty feet long or more. If now, for example, No. XX is read at a distance of twenty feet, the acuteness of vision is  $\frac{20}{20}$ , that is  $= 1$ . Persons who see No. XX at more than twenty, say at twenty-five feet, possess an acuteness of vision of  $\frac{25}{20}$ , or one exceeding the normal average; such cases are not uncommon among young individuals. If, on the contrary, No. XX is not seen at a distance of twenty feet, but the patient must approach nearer in order to distinguish the different letters, there is a dimi-



nution in the acuteness of vision, and it is to be expressed in the manner above described.

It is in many respects more convenient to allow the distance between the test letters and the patient's eye to remain unchanged, and to write as numerator of the fraction the number which is seen with normal vision at that distance, and as denominator the number which the patient actually sees; for instance, if not No. XX but No. LXX are the smallest letters to be seen at a distance of twenty feet, the acuteness of vision is  $\frac{20}{70}$ .

In using these test letters it should be remembered that it is by average daylight that the letters are recognized at the given distances. With intense illumination they can be seen at even a greater distance. The changes in the intensity of daylight, which are dependent upon variations in the weather, are a source of error difficult to avoid.

The proposition to abandon daylight and conduct this examination by artificial light is also objectionable, for artificial light is likewise subject to considerable variations of intensity, is difficult to control, and further, when we conduct a patient out of the daylight into a room artificially lighted in order there to try his acuteness of vision, an adaptation of the retina to the changed illumination must first take place. The laws according to which the retina adapts itself, especially in pathological conditions, to light of different degrees of intensity, are as yet imperfectly understood.

The unavoidable variations in the intensity of daylight seem the simplest to deal with. In my own private practice I have found it convenient to use a modification of the usual expression for the acuteness of vision. If, according to Snellen's plan, the denominator of the fraction be the number of the test type recognized by the patient, and the numerator the number of feet at which he sees them, then it is only the denominator which is affected by changes in the illumination; the errors from this source become less when we subject the numerator also to the same influences. I prefer, therefore, to write as numerator of the fraction that number of the test type which I can recognize simultaneously with and at the same distance as the patient; as denominator, I write the number of the type which the patient reads. In this way some but not all sources of error are avoided.



## MYOPIA.

Myopia exists when, accommodation being relaxed, parallel rays falling upon the cornea are not united to an image-point upon the retina, but intersect each other in front of it. Of course under these circumstances every distant object casts upon the retina a circle of diffusion. The retinal images of distant objects are therefore diffuse and indistinct. In order to cast a sharp image upon the retina the luminous point or object fixed must approach the eye to within a certain distance. The far point of distinct vision does not lie as with the emmetropic eye at an infinite but at a finite distance.

The position of the far point can be directly determined by ascertaining the greatest distance at which test type of the proper size can be read. If, for instance, the patient read No. I of Snellen's test type at 12 inches, but cannot read No. II at 24 inches, it may be assumed with certainty that his far point lies between 12 and 24 inches, and it remains, by further experiments, to determine more exactly its position.

It is advisable in all cases to begin the examination in this manner and then to verify and perfect the result by giving to the rays from a distant object, by the help of a concave lens, a divergence such as if they had proceeded from the far point. If, for instance, the far point lie at 16 inches, and we place immediately in front of the patient's eye a concave lens with a negative focal length of 16 inches, then will the parallel rays after their refraction in the concave lens so diverge as if they had proceeded from the negative focal point of the lens; but according to our supposition this negative focal point coincides with the far point; both lie 16 inches from the eye, the distance between the concave lens and the eye not being considered. Under these circumstances there is distinct distant vision, and upon using the test type for distance, normal acuteness of vision is found. A concave lens weaker than  $-\frac{1}{16}$  would not produce this result, for its negative focal point would lie at a greater distance from the eye than the far point; but with a stronger lens, for instance with  $-\frac{1}{14}$  or  $-\frac{1}{12}$ , distant vision is still possible; the rays falling parallel upon the lens diverge after their refraction in it, as if they had proceeded from a point 14 or 12 inches distant, and a myopic eye whose far point lies 16 inches distant, can by a slight effort of accommodation



adjust itself for these distances. Since, however, we wish to determine the optical adjustment of the eye when its accommodation is fully relaxed, we have the important rule that only the weakest concave lens with which distant vision is possible gives the proper expression for the position of the far point. One ought not to trust the subjective impressions of the patient; his simple statement that he sees better, is not sufficient unless in connection with it the reading of the test letters shows a perceptible improvement in vision. Weaker and weaker glasses should be tried till one is found which diminishes the sharpness of vision; the limit is then passed.

If acuteness of vision be diminished, as is usually the case in the high grades of myopia, then the weakest concave lens which gives the best attainable vision must be regarded as giving approximately the correct expression for the degree of myopia.

If the position of the far point requires the employment of a moderately strong concave lens, say  $-\frac{1}{12}$  or more, there is a very simple method of determining whether it is too strong or not. Move the lens, and of course at the same time its negative focal point, gradually away from the eye; if with the lens close to the eye its negative focal point coincided with the far point, then upon withdrawing the lens its focal point will be removed beyond the far point, and vision loses its distinctness; if upon withdrawing somewhat the lens vision is as distinct or even more distinct than with the lens held close to the eye, it shows that the concave lens is too strong. In the case of strong concave lenses the distance between the eye and the lens should not be neglected; if, for instance, it be  $\frac{1}{2}$  inch and the far point lie at 3 inches, then will the negative focal point of a lens  $-\frac{1}{2.5}$  coincide with the far point.

The degree of myopia is determined by the position of the far point; if it lie at 16 inches the degree of myopia is expressed by  $M_{\frac{1}{16}}$ ; if it lie at 3 inches, by  $M_{\frac{1}{3}}$ . That concave lens whose negative focal point corresponds with the far point is called the neutralizing lens. The far point of an eye provided with a neutralizing lens lies, as it does in the emmetropic eye, at an infinite distance.

#### ANATOMICAL CHANGES IN MYOPIA.

Formerly the optical cause of myopia was thought to be too great a curvature of the cornea. By ophthalmometric measure-



ments, Donders attained the unexpected result that the radius of curvature of the cornea is generally greater in the case of myopes than with emmetropes. Of course a too great curvature of the cornea, when it exists, will cause myopia. The same is true of the lens. Changes in it may cause myopia, but such cases do not often occur. A forward displacement of the lens must, for optical reasons, increase the refractive condition; this seems, however, to be an infrequent cause of myopia. Shortsightedness seems to be oftener caused by an increase of the index of refraction, particularly in the nucleus of the lens. The condition may be easily recognized ophthalmoscopically, if the pupil be large enough, or has been dilated by mydriatica. The reflection from the nucleus of the lens is generally stronger than normal, as well upon examination by daylight with the naked eye as by focal illumination; upon ophthalmoscopic illumination, especially with a weak mirror, the nucleus appears evidently differentiated from the cortical part of the lens; this can be best seen by making slight movements of the mirror. These changes occur as the prodroma of nuclear cataract, both in eyes previously healthy and in those recovered from glaucoma. They often occur, also, as one of the many complications of myopia depending upon an elongation of the axis of the eye. Under the title "Diseases of the Accommodation" it will be shown that apparent myopia may be caused by a continuous tension of the accommodation.

The most frequent and important cause of myopia is the elongation of the axis of the eye. The other diameters are not unfrequently somewhat increased. As a rule, however, the axis is most elongated, and the eye assumes therefore an ellipsoid form. The distention of the membranes occurs mostly at the posterior part of the eye, involving generally the region of the optic nerve. The greatest diameter of the eye, therefore, very nearly coincides with its axis; it may, however, deviate laterally, generally toward the median side. According to E. v. Jaeger,\* the greatest expansion may occur even on the median side of the optic nerve.

This anomaly of form was first described by Scarpa. Its designation as "staphyloma posticum" is not exactly appropriate, inas-

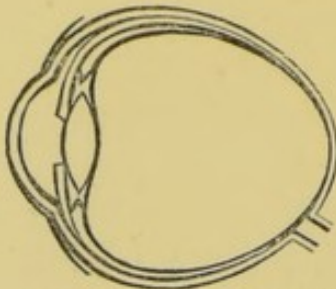
---

\* *Einstellungen des dioptrischen Apparates*, Wien, 1861, pag. 54.



much as in uncomplicated myopia the protrusion is by no means so circumscribed and prominent as in anterior scleral staphyloma. In spite of the elongation of the axis, the eye maintains, as shown

FIG. 8.

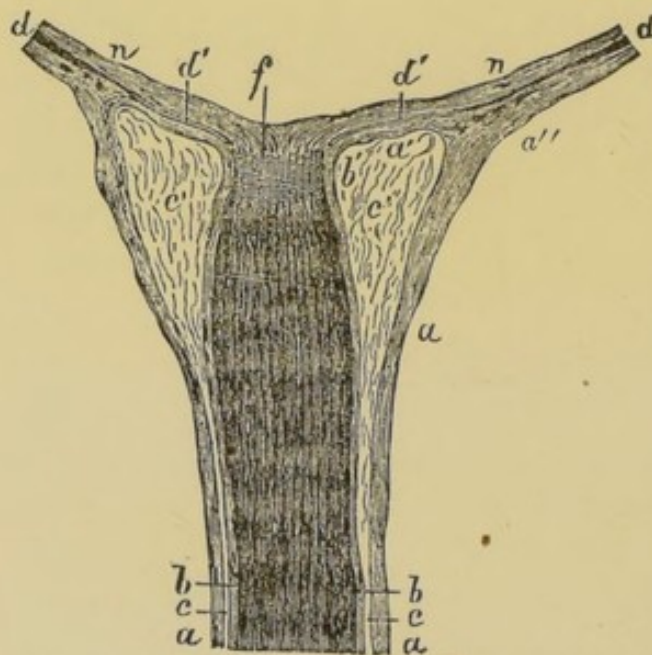


After Donders, *Anomalien der Refraction*, etc, Fig. 145.

in Fig. 8, a regular form. The sclera is expanded and thinned throughout its whole extent, on the temporal more than on the median side, and most of all in the region of the posterior pole. So thin may it become that this part upon enucleated eyes appears blue, like an anterior staphyloma, and if the cornea be turned to the light, an inverted image of outer objects will be

plainly seen cast upon the attenuated portion. Indeed, even during life the bluish color in the region of the posterior pole can

FIG. 9.



From Donders, l. c., Fig. 147. The space *c* between the inner and outer nerve-sheaths widens as it approaches the sclera; the largest part of the outer sheath *a''* blends with the sclera; a thinner membrane, *a'*, runs toward the optic nerve, and is continuous with the inner nerve-sheath *b'*. At this place the sclera consists therefore of only a thin lamella, *a'*, which is in relation posteriorly with the loose areolar tissue *c'*, and which anteriorly is covered by the atrophied and depigmented choroid *d'*; *f* is the lamina cribrosa, and the tissue *n*, above the choroid, is the retina.

causes a traction upon the external sheath, drawing it from the other and increasing the space between the two. (See Fig. 9.)

be often seen by causing the patient to turn his cornea strongly inward.

These changes exert a marked influence upon the place where the optic nerve enters the eye.

The stretching of the membrane in the region of the posterior pole pushes the optic nerve somewhat aside toward the median line.

Moreover, the two nerve-sheaths change in their relations toward each other. Since the inner nerve-sheath is adherent to the nerve itself, while the outer one is continuous with the sclera, it follows that a distention of the latter



According to Donders, the place of entrance of the optic nerve on the outer surface of the sclera may attain by this widening a diameter of 8 millimetres or more, so as to present an appearance as if the optic nerve were set upon a second terrace of the staphyloma. This widening of the space between the outer and inner sheath of the optic nerve is mentioned by Von Ammon.\*

The investigations of E. v. Jaeger† show that the same thing occurs in myopia of a low grade.

As a rule the choroid remains normal in its anterior part, but the more it approaches the expanded part the thinner, paler and more atrophied does it become. These changes are greatest close to the optic disc, so that here nothing remains of the choroid but a thin, structureless, transparent membrane, containing no trace of blood-vessels or even capillaries. Beyond this fully-atrophied part, however, the anatomical elements of the choroid are but little changed. The pigmented epithelium forms a uniform layer; the individual cells lose more or less of their pigment molecules in the greatly distended part, and may even become colorless; in places they are noticeably enlarged and flattened. The branching pigmented cells of the choroidal stroma behave in the same way; anteriorly, where the choroid retains its normal thickness, they remain entirely normal; further back they contain less pigment, and finally none at all.

A further consequence of the distention suffered by the choroid is that its anterior portions, the ciliary body, the iris and at the same time the lens, move backward; this accounts for the very frequent deepening of the anterior chamber in myopic eyes. The ciliary muscle having a tendinous attachment on the edge of the cornea, experiences from this process a traction which may induce atrophy.

In uncomplicated cases of myopia the retina shows no recognizable changes.

#### OPHTHALMOSCOPIC APPEARANCE.

In myopia, changes are almost always observable about the optic disc; as a rule there is a sharply-defined sickle-shaped or crescentic spot on the temporal side and close to the disc, where

---

\* Von Ammon, *Zeitschrift für die Ophthalmologie*, Bd. ii. pag. 250.

† *Einstellungen des dioptr. Apparates*, Taf. ii. Fig. 18 bis 29.



more or less atrophy of the choroid exists. In many cases it is only the pigmented epithelium, which is faded or degenerated so that the choroidal stroma can be distinctly seen. In most cases, however, there is an unmistakable atrophy of the stroma, and the entire choroid is transformed into a thin, structureless, transparent membrane, which does not weaken in any degree the white reflex from the sclera. In many cases one still sees a few large vessels remaining in the region of the choroidal atrophy. These various appearances are observed quite constantly. Often with a high degree of myopia, and with an atrophied part equal in width to the diameter of the disc, only the pigment-epithelium will have lost its color, while in other cases of a mild form of myopia there will be only a small but fully atrophied crescent about the margin of the disc.

The atrophied part is often separated from the adjoining choroid by a rather regular dark line. Some cases, where the atrophy has extended farther over the choroid, show traces of several such concentric curved lines. In other cases the atrophied part has a more or less irregular form.

In the majority of cases this circumscribed choroidal atrophy occurs on the temporal side of the optic nerve, and spreads from it toward the macula lutea, generally, however, without reaching it. The increase of the atrophied region does not depend alone upon an implication of the adjoining choroidal tissue in the degenerative process, but at the same time upon a further stretching of the already thin and yielding part; in this way the distance between the macula lutea and the optic nerve increases, and the latter becomes more displaced toward the median line.

In high degrees of myopia the choroidal atrophy often extends around the entire optic nerve; the disc appears surrounded by a white ring, whose breadth is generally greater on the temporal than on the median side.

In rare cases the atrophied spot is below the optic nerve; oftener its position is under and outward, or over and outward, from the optic nerve. Its rarest position is above the optic nerve, and such cases do occur.\* A beginning of the choroidal atrophy upon the median side of the optic nerve has been observed.

---

\* *Streatfeild, Ophth. Hosp. Rep., v. 1, pag. 80, and Mauthner, Lehrbuch der Ophthalmoscopie, pag. 422.*



These small atrophied spots often seem to lie at a different level from the other parts of the fundus,—at least it is often noticed that the retinal vessels in passing from the periphery upon the atrophied part experience a change of direction, which is to be regarded as the expression of a transition from one surface to another lying deeper. Donders\* and Mauthner† regard these cases as exceptional, and I have also formerly expressed myself in the same way, since in cases of a high degree of myopia, with wide-spread choroidal atrophy, I missed the ophthalmoscopic signs of the difference of level. The case is somewhat different with the crescentic spots of moderate size with a breadth less than that of the disc. Especially when they are sharply bounded and surrounded by the dark line before described, do they give the impression of a slight ectasia. The optic disc shows generally in these cases where the ectasia affects it only on one side, an oblique position, the side corresponding to the greatest diameter of the ectasia lying deepest; and besides this, we have such a change of form of the optic nerve that its transverse section forms an oval, whose shortest diameter lies in the same direction as that in which the ectasia has attained its greatest extent. This change of form of the optic nerve is, in part certainly, only an apparent one; its dislocation toward the median wall of the eyeball causes us to see it in a more oblique position than normal, and therefore foreshortened; still more must this be the case where the disc has suffered the oblique excavation above described. Where the choroidal atrophy is of slight extent, the contour of the optic nerve is generally sharply distinguishable from the adjoining white scleral region. If the atrophy involves a large part of the fundus, the demarcation of the optic disc generally becomes very indistinct.

The retinal vessels show with unusual distinctness upon the white background of the sclera; for this reason they are often visible in greater numbers; they are, moreover, less sinuous than normal.

The choroid bordering upon the atrophied spot may appear wholly unchanged, but sometimes shows traces of a slight degree of atrophy; it appears somewhat lighter and more transparent,

---

\* L. c., pag. 300.

† L. c., pag. 421.



and its intervacular spaces in consequence of its stretching are somewhat widened.

This circumscribed choroidal atrophy is almost always present in myopia, and according to Donders there is a quite uniform average relation between the extent of the atrophy on the one hand and the degree of myopia and time of life on the other. It must be mentioned, however, that in this respect there are very considerable individual variations. The consecutive atrophy may be very slight, with a quite high degree of myopia; and, on the other hand, in emmetropes, and even in hypermetropes, these white, crescentic, slight ectasias are sometimes seen upon the temporal side of the disc; they are observed oftener in old than in young persons. The condition of refraction not considered, the ophthalmoscopic appearances in many of these cases are exactly the same as in myopia. On the other hand, however, it is unmistakable that in this matter there are very gradual transitions, so that in any given case one cannot be certain whether he has before him an atrophied crescent or a rather broad "scleral stripe."

At all events, the connection between myopia and atrophy of the choroid is undoubted. It only remains to be explained why it develops so constantly on the temporal border of the optic nerve, and not on that part of the choroid lying near the visual axis. It is to be remembered that around the optic nerve the choroid is closely attached to the sclera, that often too it sends fibrous processes into the nerve itself. At this place, therefore, the choroid cannot so easily escape the strain as it can in other localities where it is more loosely connected with the sclera. Now, since the eye is most distended in its antero-posterior diameter, it is easy to see why the choroidal atrophy should begin just upon the temporal side of the optic nerve.\*

Nevertheless, the sharp demarcation which many of these cases show, proves that certain local causes limit the effect of the distention of the entire choroid to a sharply circumscribed region. So, too, the fact that the atrophy often extends entirely around the optic nerve shows that the nerve itself participates in the process. In this connection the widening of the space between the two

---

\* Comp. Schweigger, *Zur path. Anat. der Choroidea*, Arch. f. Ophth., Bd. ix. 1, pag. 195, and Donders, *Anomalien der Refraction*, pag. 320.



nerve-sheaths recurs at once to the mind. The elongation of the sagittal diameter stretches the sclera equally with the choroid, and a traction must necessarily be brought to bear upon the outer nerve-sheath, which is continuous with the sclera. The outer nerve-sheath yields to this traction, separates from the inner sheath, the lamellæ of the sclera nearest the disc (Fig. 9, *a'b'*) lose their support and become stretched and thinned in proportion as the space between the sheaths becomes greater. The same happens with the choroid, which maintains its normal attachments to the inner surface of the sclera, the border of the optic nerve and the lamina cribrosa. It is easy to understand why this exceedingly thin place should yield to the normal intraocular pressure, and thus form an ectasia, which, to be sure, is generally slight. Externally this is not perceptible, since it is too small and is covered by the external nerve-sheath. These conditions, however, are no obstacle to the ophthalmoscopic examination. For the recognition of this condition the choroid need not be fully atrophied; with a very slight atrophy of the choroid about the optic nerve the course of the retinal vessels is often sufficient to determine the existence of a slight ectasia.

If in a high degree of myopia the greatest diameter of the eye coincide nearly with the visual axis, the outer optic nerve-sheath appears to separate on all sides from the inner one, and the choroidal atrophy assumes the annular form. Donders states that such was the case in the eye whose optic nerve is represented in Fig. 9.

Of course in high degrees of myopia the diffuse atrophy of the choroid caused by the stretching of the ocular membranes may easily overstep the limits bounded by the outer nerve-sheath. Nevertheless, one often sees in these cases upon the white scleral background which has been laid bare by the choroidal atrophy, a distinct curved line, which may be regarded as probably the line of junction of the external nerve-sheath with the outer surface of the sclera.

#### CAUSES AND COURSE.

In the majority of cases myopia, or at least a predisposition to it, is to be regarded as congenital or inherited. On the other hand it is certain, and one hears it often enough confirmed by the



myopes themselves, that straining the eyes favors the development of myopia.

The clinical history of hypermetropia shows that a long-continued tension of accommodation is of itself not enough to induce an elongation of the eye. Nevertheless it might be otherwise if the sclera possessed diminished power of resistance, and if other conditions were present, particularly strong convergence of the visual axes and a bowed position of the head. The first is associated with an increased intraocular pressure, which favors a distention of the sclera; the last causes a passive hyperæmia, which tends in the same direction. All these conditions almost of necessity exist when work is undertaken in an insufficient light. The habit which children early acquire of reading long into the twilight, and the use of ill-contrived school-furniture, are both frequent causes of myopia.

Accordingly, it is no wonder that myopia is such a wide-spread abnormality. It occurs in early childhood, and shows with the increase of years a progression both in frequency and degree of development.

Although for the majority of cases we must regard a congenital weakness of the posterior part of the sclera as the primary cause of myopia, it is certain that the same condition may be an acquired one. The circumstance that myopia often develops in children shortly after measles or scarlet fever goes to prove this. Myopia often occurs also in connection with cloudiness of the cornea; this is not because the cornea becomes more convex, for in most cases there are simultaneously present the ophthalmoscopic indications of elongation of the axis; it is more probably due to the indistinctness of the retinal images, the patient seeking to compensate by increase in size for what he loses in distinctness. In order to obtain larger retinal images, the patient brings his eye as near as possible to his work; a bowing of the head, strong tension of accommodation and a corresponding convergence of the visual axes are the consequences.

If the distention of the sclera be once established, it can be easily understood how intraocular hyperæmia and conditions of slight irritation may still further lessen its capacity for resistance and render the distention progressive. On the other hand, one often sees, in cases with great distention of the sclera and high



degree of myopia, choroidal changes which must be regarded as inflammatory. This, however, does not justify us in regarding the process as an inflammatory one from the beginning, and the atrophied crescent as the result of a sclerotico-choroiditis posterior.

Myopia may remain stationary through life, or at an advanced age it may show an apparent or actual decrease. The apparent decrease is due to the contraction of the pupil, by which the circles of diffusion are made smaller and the images of distant objects more distinct. An actual decrease of myopia may be caused by the senile changes in the lens before referred to.

In other cases myopia is rapidly progressive during a certain period of life, generally up to about the twenty-fifth year, and after that remains stationary. Finally, it may happen that myopia remains progressive through life.

#### COMPLICATIONS IN MYOPIA.

The myope receives with the naked eye only indistinct, diffuse retinal images of all objects lying beyond his far point. In low degrees of myopia the indistinctness of distant vision is often not so great as to cause marked inconvenience, but the opposite is true in high degrees of myopia, where the retinal images of objects only a few feet distant are very confused. If, moreover, the objects are insufficiently illuminated, as in the twilight, vision will be very imperfect.

The size of the circles of diffusion increases with the distance of the object and the size of the pupil.

Myopes are often better able than emmetropes to recognize very small objects, even in a poor light, since the position of the near point allows a closer approach of the object.

As the far point approaches the eye, the whole range of accommodation approaches with it, so that without any lessening of the angle included by the accommodation the space covered by accommodation is greatly diminished. If, for instance, with  $M_{\frac{1}{2}}$  the action of accommodation is as great as we have above assumed it to be in the emmetropic eye, that is  $\frac{1}{A} = \frac{1}{4}$ , the position of the near point may be calculated from the formula  $\frac{1}{r} + \frac{1}{A} = \frac{1}{p}$ , which becomes  $\frac{1}{\frac{1}{2}} + \frac{1}{4} = \frac{1}{p}$ . The whole region of distinct vision lies between the points 3 inches and 4 inches distant, while the



emmetrope, with exactly the same amount of accommodative power, receives distinct retinal images from 4 inches up to an infinite distance.

The range of accommodation of myopic eyes may be determined by finding the positions of the far and near points, and reckoning from them the accommodation; or the examination may be made to resemble that of the emmetropic eye by removing the far point to an infinite distance, by the use of a neutralizing lens, and then finding the near point.

The behavior of the relative range of accommodation is of special interest. The myope learns unconsciously to converge nearly to his near point without accommodating. If, for instance, the far point lie at 8 or 10 inches, the eyes (of course without glasses) converge to nearly this distance without there being any simultaneous tension of accommodation.

Now, since myopes are much seldomer than emmetropes in a position to use their near points, it follows, by reason of the change in the relative range of accommodation, that less demand is made upon the accommodative power of the myopic than of the emmetropic eye.

In other respects, however, greater demands are often made on the myopic than on the emmetropic eye; particularly is this the case in reference to the convergence of the visual axes. If, with the naked eyes, the myope wishes to see distinctly and binocularly an object within his range of accommodation, his visual axes must converge to at least the distance of his far point. In only moderate degrees of myopia a stronger convergence is required than in emmetropic eyes. Moreover, the convergence is made difficult by two circumstances.

In emmetropic eyes the line of vision does not intersect the cornea at its centre, but somewhat toward the median side. A perpendicular let fall upon the centre of the cornea will form with the line of vision and on the external side of it an angle which we designate as the angle  $\alpha'$ . If the lines of vision are parallel, then the perpendiculars let fall upon the centre of the cornea must be divergent, and if the lines of vision intersect at any given point, the point of intersection of the perpendiculars must be at a greater distance. In myopia the deviation of the line of vision from the centre of the cornea is less than in emmetropia, and consequently



to direct the eyes upon a point at any given distance there must be a stronger convergence of the eyes, and a greater demand upon the action of the internal recti muscles, than in emmetropia.

In addition to this, the abnormal shape of the myopic eye impedes its movements. While the nearly spherical emmetropic eye plays like a ball-and-socket joint in the capsule of Tenon, the myopic eye, on account of its elliptical shape, meets with considerable resistance to all lateral rotation, restricting the movement both outward and inward. But while a slight turning of the head may take the place of a rotation of the eye outward, no such compensation is possible when it is desired to turn both eyes simultaneously toward the median line. This difficulty of convergence is the reason that in high degrees of myopia binocular vision for near objects is relinquished, especially when the myopia or the acuity of vision of the two eyes does not correspond. For reading, etc., the best eye only is then used, while the axis of vision of the other eye is not directed upon the point fixed, but has a direction relatively or absolutely divergent. The inconveniences of diplopia, which one would expect under these circumstances, do not generally occur, because the attention is directed only upon the distinct retinal images in the one eye, while the retinal images of distant objects in the other eye being diffuse and indistinct, are readily neglected.

The relinquishment of binocular vision under these circumstances is to be regarded as an advantage. These myopes do exactly what we would advise them to; they avoid all straining of accommodation and strong convergence of the visual axes, and for the most part, too, the bent-over position of the head, since they, at least when reading, are accustomed to hold the book vertically and the head erect. This insufficient movement of the eyes is to be distinguished from an insufficiency of the muscles, of which we have yet to speak.

Other and very important functional disturbances are caused by the distention of the membranes in high degrees of myopia. In the first place, the distention of the retina causes a separation of the perceptive retinal elements; this, in high degrees of myopia, causes a diminution in the acuteness of vision. Nevertheless, myopes do not generally complain of this. Since they can hold objects nearer the eye, they use a larger visual angle, and can



therefore often read fine print easily, although for distance and with concave glasses a diminution of normal vision to one-half or one-third is already evident.

This form of amblyopia is to be distinguished from a diminution of vision which, in high degrees of myopia, often occurs as one of the symptoms of a retinal irritation. The stretching which the retina and other membranes suffer in the myopic eye is probably the cause of this irritation. Aside from the diminution of vision in such cases, there are speedy fatigue in working and a feeling of fulness and tension in the eye; often too the eye is sensitive upon light pressure; besides this there is dazzling, subjective perception of light and troublesome myodesopia. The latter is often the principal inconvenience which myopes complain of; the material cause of this is always small elements in the vitreous, which are also present and visible in perfectly normal eyes. In eyes not myopic these "*mouches volantes*" are principally noticed when there are upon the retina no distinct images other than those cast by these elements of the vitreous,—that is, when the gaze is directed upon a uniform surface. Hence myopes not unfrequently find relief from this inconvenience in the use of concave glasses, which do away with the uniform indistinctness of their retinal images.

On the other hand, it is probable that in many cases of myopia the myodesopia is actually caused by microscopic opacities in the vitreous, since a cloudiness often develops there which is ophthalmoscopically visible. The presence of such opacities is the rule with those wide-spread choroidal changes which accompany high degrees of myopia in the latter half of life. The vitreous appears fluid and presents under the microscope small opacities, which, without possessing any determinate structure, present a fibrous, granular appearance. These are either fixed by threads which run off and end in the sound vitreous tissue, and in this case are situated generally not far from the disc, or they are freely movable in the fluid substance, and swim about here and there with every movement of the head. Under these circumstances there is often also a circumscribed cloudiness at the posterior pole of the lens (*cataracta polaris posterior*).

In high degrees of myopia, especially in advanced age, other changes of undoubted inflammatory nature are added to the consecutive choroidal atrophy; they are principally in the region of the



equator and about the posterior pole. In the former position they appear oftenest in the under part of the choroid, in the form of round spots which sometimes, through loss of color and atrophy, are bright red or white, sometimes are noticeable from the dark coloring of the choroidal epithelium; both appearances may be combined, presenting bright spots with black edges. On account of their peripheral position they do not cause much disturbance of vision; they are, however, symptomatic of a predisposition to serious disease.

The changes about the posterior pole of the eye are more frequent. The originally crescentic or annular choroidal atrophy surrounding the disc loses its regular boundaries and spreads irregularly, mostly in the temporal direction.

Insular atrophied spots appear in the neighborhood, and finally coalesce with the principal one. Black, irregular spots, formed evidently of groups of changed choroidal epithelium, often appear upon the white background.

The increase in size of Mariotte's blind spot, under these circumstances, ought scarcely ever to cause disturbances of vision, since the inner layer of the retina remains intact, and therefore the conducting power of the nerves from the periphery is not diminished.

On the contrary, affections of the macula lutea, occurring simultaneously with the above-mentioned changes, or even independent of them, give rise to very serious disturbances of vision. At first, even in eyes whose vision has not yet suffered, there appear a number of irregular bright lines of perhaps the breadth of the principal retinal vessel, or somewhat broader, and of various lengths. These are, perhaps, consequences of the stretching which in places separates the pigment-cells one from another, or flattens, stretches, and depigments them. If central vision is already essentially affected, we generally find changes of an inflammatory nature in the macula lutea, irregularly diffused pigment changes, collections of black pigment interspersed with bright-red or white spots; or exactly in the centre of the macula lutea there may be a black spot, of about the size of the optic disc; or there may be a larger, bluish, elevated spot, perhaps surrounded by a black ring of pigment and often accompanied by hemorrhages in the neighboring retina.



In rare cases it happens that a sharply defined, small staphyloma develops, independent of the crescentic atrophy surrounding the nerve, and separated from it by healthy choroidal tissue. In one case which I observed there was in the neighborhood of the macula lutea a bright spot with a diameter once-and-a-half or twice that of the disc, with pigment-spots sprinkled over it and surrounded by a black ring; it was evidently excavated and there was a corresponding defect in the field of vision. Streatfeild\* has described a similar case.

The disturbances of vision which accompany the above-described changes in the region of the macula lutea are dependent partly upon the stretching of the retina in this region, partly upon the mechanical insulation which the layer of rods and cones suffers by reason of changes upon the surface of the choroid, and partly from disease of the retina itself. The patients complain of a trembling of the letters when reading, of irregular curves in the lines, of an oblique position and irregular form of the individual letters, of clouds or dark spots in the centre of the field, or finally of absolute inability to see the point fixed (*scotoma centrale*).

Donders explains the trembling of the letters, by the presence in the macula lutea of a number of very small defects (*scotomata*). Now, with the movements of the eye, the image of each individual letter falls first upon some spot in the retina which is sensitive, then upon one insensitive to light, so that it alternately appears and disappears; at the same time, in consequence of the irregular displacement of the layer of rods and cones, the shape of the letters appears changed.

Förster† has carefully analyzed the phenomena of metamorphopsia (seeing objects distorted and inclined from their true position), and by the use of a system of parallel lines has shown that in a limited central part of the field of vision the curvatures of the lines are concentric. The metamorphopsia also occurs in distant vision with concave glasses, so that, for instance, the bars in the window-sash appear crooked. The sensibility of the macula lutea appears reduced, so that distinct vision is only possible by intense illumination. At the same time the bright light causes

---

\* Ophthalmic Hosp. Rep., v. 1, p. 84.

† Ophthalmologische Beiträge, 1862.



an unpleasant dazzling. The retina is quickly fatigued in reading, etc.

Upon ophthalmoscopic examination, a black spot appears near the macula lutea, often surrounded by a reddened area (hyperæmia or extravasation). Still, Förster was satisfied that the portion of the retina affected by metamorphopsia was much larger than that in which changes were ophthalmoscopically visible. From the concentric curvature of the lines Förster supposed that the sensitive elements of the retina were crowded by the pathological process toward the centre of the diseased part.\*

While the above-mentioned diseases of the macula lutea at least spare the periphery of the field of vision, it happens much oftener in myopic than in previously healthy eyes, that sight is absolutely destroyed by detachment of the retina.

The complication of myopia with glaucoma will be considered under the head of the last-named disease.

#### TREATMENT.

A cure for myopia cannot be expected. In the cases of myopes who have strained their eyes for weeks or months, one often sees that rest or the use of atropine causes some withdrawal of the far point; in such cases there has been no change in the condition of refraction, but there has been relief to a spasm of accommodation, which, when discussing hypermetropia, we shall describe as latent accommodation. There is more to be done in avoiding the development of myopia. With this in view, it is all-important to regulate the use of the eyes. Reading, etc., at twilight is to be strictly forbidden; and even with sufficient light, work upon very near objects should not be too steadily pursued. Above all, a strong bending forward of the head is to be avoided. Children with very slight myopia often, in spite of that fact, use persistently an object distance from 4 to 6 inches; this, of course, involves a strong tension of accommodation, a high degree of convergence and a bowed position of the head. It is the duty of parents and teachers to correct this. If the case is

---

\* An affection which might well cause this is the retinitis of the external layer, described by H. Müller. Saemisch (*Beiträge zur Anatomie des Auges*, 1862) has shown that it also occurs as a circumscribed affection of the macula lutea.



not one of simple bad habit, but if in connection with distinct vision there exist a high degree of myopia, for instance,  $M\frac{1}{6}$ , it is at all events advisable to remove the far point by concave glasses to about 16 or 18 inches, and then to enforce an object distance of at least 12 or 14 inches.

To insure an erect position of the head, it is advisable in reading to hold the book in the hand, and in writing to use a desk with a steeply-inclined and sufficiently high surface. In furnishing school-rooms these points deserve careful attention. It is for the interest of society to combat the development of myopia by a proper system of lighting and furnishing school-rooms.\*

If a high degree of myopia appear in early youth, it should influence the choice of an occupation. It is difficult, however, to lay down positive rules in this matter.

In most cases it is necessary to render distant vision distinct by the use of proper concave lenses. We have already seen that the concave lens whose focal point corresponds with the far point fulfils this condition, and we shall here only repeat that always only the weakest lenses with which distinct distant vision is possible should be used. The question whether the correcting lenses should also be used for near objects has been much discussed. In this matter a general rule cannot be laid down. The question must be decided for each individual case. A myopic eye, provided with the proper concave lens, behaves exactly as an emmetropic one, which indeed is a desirable condition. Nevertheless, it is only under the following circumstances that the neutralizing concave glasses ought to be worn continuously and used for near objects.

1. The myopia should not be greater than  $\frac{1}{5}$  or  $\frac{1}{6}$ . For low degrees of myopia, under  $M\frac{1}{20}$  there is scarcely ever any necessity for wearing concave glasses continuously.

2. The range of accommodation must be normal.

3. Vision must be normal.

4. The continuous use of concave glasses must have been begun in youth.

Under these circumstances, there is no objection to the contin-

---

\* Compare Dr. H. Cohn, *Untersuchung der Augen von 10,060 Schulkindern, nebst Vorschlägen zur Verbesserung der den Augen nachtheiligen Schuleinrichtungen*. Leipzig, 1867, und *Deutsche Klinik*, 1866, No. 7.



uous use of neutralizing glasses. One often sees myopes who wear their glasses continuously, and with only good effects.

If any one of these four conditions be wanting, we have a contra-indication for the continuous use of neutralizing glasses. A more exact explanation of these conditions belongs with the consideration of the above-named contra-indications. The circumstances which make the use of neutralizing concave lenses inadvisable are the following :

1. A high degree of myopia. The continuous use of neutralizing concave glasses with myopia of a greater degree than  $\frac{1}{5}$  is inadvisable, on account of the diminished acuteness of vision which generally co-exists. Even in high degrees of myopia, where circumstances make it necessary to wear spectacles continuously, the patients generally prefer those which do not completely neutralize the myopia. A continuous use of such glasses is sometimes impossible even for distant vision. This is perhaps because of the preponderating elongation of the eye in the direction of the visual axis. The sagittal diameter increases relatively more than all the others, so that lenses which correct the myopia for central vision are too strong for all objects in the periphery of the visual field. Under such circumstances it is often best to wear continuously spectacles which remove the far point to about 12 inches, and then to employ an auxiliary glass, about  $-\frac{1}{12}$ , for distant vision.

2. Diminution in the range of accommodation. We have already remarked that the myopic eye is naturally adapted to only slight efforts of accommodation, and all straining of accommodation is regarded as hurtful to it. If now by neutralizing glasses we remove the far point to an infinite distance, we at the same time remove the near point and the whole range of accommodation away from the eye, and the myope who formerly saw near objects distinctly without accommodation, can now do so only by accommodating. We demand in this case no more from the accommodation than the emmetropic eye does without difficulty ; but we ought first to satisfy ourselves that the accommodation of the myopic eye is able to respond to such a demand without injurious straining. We ought, for instance, never to compel continuous accommodation up to the region of the near point. Myopes who have worn neutralizing glasses from their youth, are compelled to use weaker ones on account of the gradual with-



drawal of the near point, dependent upon advancing age. Presbyopia develops in myopic as well as in emmetropic eyes. At the same time of life when the emmetrope begins to need convex glasses the neutralizing concave glasses become too strong for the myope to use on near objects.

3. Generally the use of concave lenses is contra-indicated if from any cause the acuteness of vision is noticeably diminished. Corneal opacities or irregular astigmatism, cloudiness of the lens or vitreous, and all the causes of amblyopia, which occur so frequently in high degrees of myopia, and are due to retinal or choroidal changes, contra-indicate the use of concave lenses. For distance, little is usually gained by the correction of the myopia, and for near objects the hurtful influence of the concave lenses is to be feared, since the patients, in spite of them, approach closely to objects in order to obtain as large retinal images as possible, and then they must employ a tension of accommodation so much the stronger. To abstain as much as possible from work is the only advice to be given under these circumstances, as the causes of the amblyopia cannot be removed.

4. Finally, with reference to the relative range of accommodation, the use of concave lenses ought not to be begun too late. Myopes not only acquire the habit of converging to the near point without accommodating, but also within the range of their distinct vision they associate with every degree of convergence of the visual axes only a relatively slight degree of accommodation. Now, upon providing the eyes with concave lenses not only is the entire range of accommodation removed farther from the eye, but the position of the relative range of accommodation is also changed. Youthful eyes can generally accommodate themselves to these changed conditions; or where this is the only difficulty, one can begin with weak lenses and proceed gradually to the neutralizing ones. At advanced age, however, myopes cannot, so easily as emmetropes, change the position of their relative range of accommodation. The greater demand upon the available accommodation in near vision with concave glasses is generally very uncomfortable, and causes quick fatigue of accommodation.

It is, moreover, probably because of the changed position in the relative range of accommodation that myopes who are accus-



tomed always to wear their neutralizing glasses feel very uncomfortable so soon as they take them off, even for near vision.

If from any cause the use of neutralizing glasses cannot be allowed, we still often have occasion to remove the far point to a given distance, in order to allow the pursuit of some particular occupation, piano-playing, for instance. The suitable lenses can be easily calculated. If we wish with myopia  $\frac{1}{6}$  to remove the far point to 18 inches, that is to reduce this  $M_{\frac{1}{6}}$  so that only  $M_{\frac{1}{18}}$  remains, then  $\frac{1}{6} - \frac{1}{x} = \frac{1}{18}$ , consequently  $\frac{1}{x} = \frac{1}{9}$ . Concave 9 is therefore the requisite lens. Of course the calculation and direct experiment should always verify each other. Here, too, the weakest lenses which will fulfil the requirement are the ones to be chosen.

Insufficient movement of the eyes in consequence of their change of form exists generally only in high degrees of myopia. It appears best that the relative divergence in near vision which results from it should not be interfered with. Under these circumstances little is to be accomplished with the prismatic spectacles which are so often employed. The optical effects of prisms will be more particularly explained hereafter.

If, on the contrary, the difficulty of binocular vision does not depend upon a limitation of the movement of the eyes but upon an elastic preponderance of the external recti muscles, and if it is evident that binocular vision can be maintained only by a strain upon the internal recti muscles, the indications are for a tenotomy of the rectus externus. This condition occurs congenitally, as does myopia; it is often a complication of slight degrees of myopia.

The symptoms of irritation which frequently appear at the period of puberty, characterized by hyperæmia of the optic nerve, quick fatigue and pain in the eyes, especially when working in the evening, demand a strict hygienic regimen. There must be good light, frequent interruption of work, the head must not be bent forward, all influences which tend to congestion of the head or eyes must be avoided, the feet must be kept warm, the bowels open, the douche must be used with closed lids and sometimes blood is to be drawn with the artificial leech. In slight degrees of myopia it is advisable under these circumstances to avoid the use of spectacles; in high degrees, if the difficulties are not



thereby increased, the far point may be removed by concave glasses to about 12 inches; all strong convergence is to be avoided. If we suspect, as is frequent in high degrees of myopia in young individuals, that the symptoms of irritation are caused by spasm of the muscle of accommodation, the spasm is first to be relieved by the use of atropine, and the true degree of the myopia is then to be determined; the use of atropine can be continued several days, during which time the eyes should be protected from dazzling light by colored glasses. Upon a recurrence of the spasm of accommodation the use of the artificial leech is advisable.

The cases of diminished acuteness of vision which develop in the course of myopia, and which depend upon diseases of the vitreous, retina, or choroid, require a derivative treatment, and such eyes must be spared as much as possible.

The prognosis in these cases is, on an average, so much the better the fewer the material changes visible with the ophthalmoscope.

#### HYPERMETROPIA.

Hypermetropia exists when, accommodation being relaxed, parallel rays falling upon the cornea of the eye are focused at a point behind the retina. Under these circumstances every luminous point casts a circle of diffusion upon the retina. It is only by an effort of accommodation, or (since we are at present not regarding accommodation, but considering only the condition of refraction) by the help of convex lenses, that the image of the luminous point can be brought forward and cast upon the surface of the retina. In a hypermetropic eye, whose accommodation is fully relaxed, it is only rays already converging which, falling upon the cornea, are united upon the retina. The point behind the eye toward which they converge is called the far point. Of course only a convex lens of a certain focal length can give to parallel rays such a convergence as is necessary to cast an image from distant objects exactly upon the retina; this can happen only when the focal point of the lens and the far point of the eye coincide. Such a lens is called the neutralizing one; it expresses the grade of the hypermetropia. Strictly speaking, the distance between the lens and the eye must be taken into account just as in myopia. If for instance the rays must converge toward a point 12 inches



behind the cornea in order to be focused upon the retina, then the far point lies 12 inches behind the eye, and hypermetropia of  $\frac{1}{12}$  exists ( $H \frac{1}{12}$ ).

The condition of refraction in the hypermetropic eye is such that it is adjusted for converging rays. Now, since we generally have to do only with diverging or parallel rays, it is evident that the hypermetropic eye possesses a useless faculty, and one which often leads to unpleasant consequences.

Absolute hypermetropia exists when with its greatest power of accommodation the eye cannot adjust itself for parallel light, but only for rays which converge toward a point behind and more or less distant from it. The whole range of its accommodation from its far to its near point lies beyond infinity. Distinct vision even for distance is consequently impossible without a convex lens.

With relative hypermetropia the eye can adjust itself for parallel or even diverging light, but it can do so only when at the same time the visual axes converge upon a distance which is less than that upon which accommodation is adjusted.

With facultative hypermetropia the binocular near point lies at a finite distance; distinct distant vision with parallel visual axes is also possible; so is near vision with a proper convergence of the visual axes; there is, however, distinct distant vision and, of course, near vision also, when convex lenses are used.

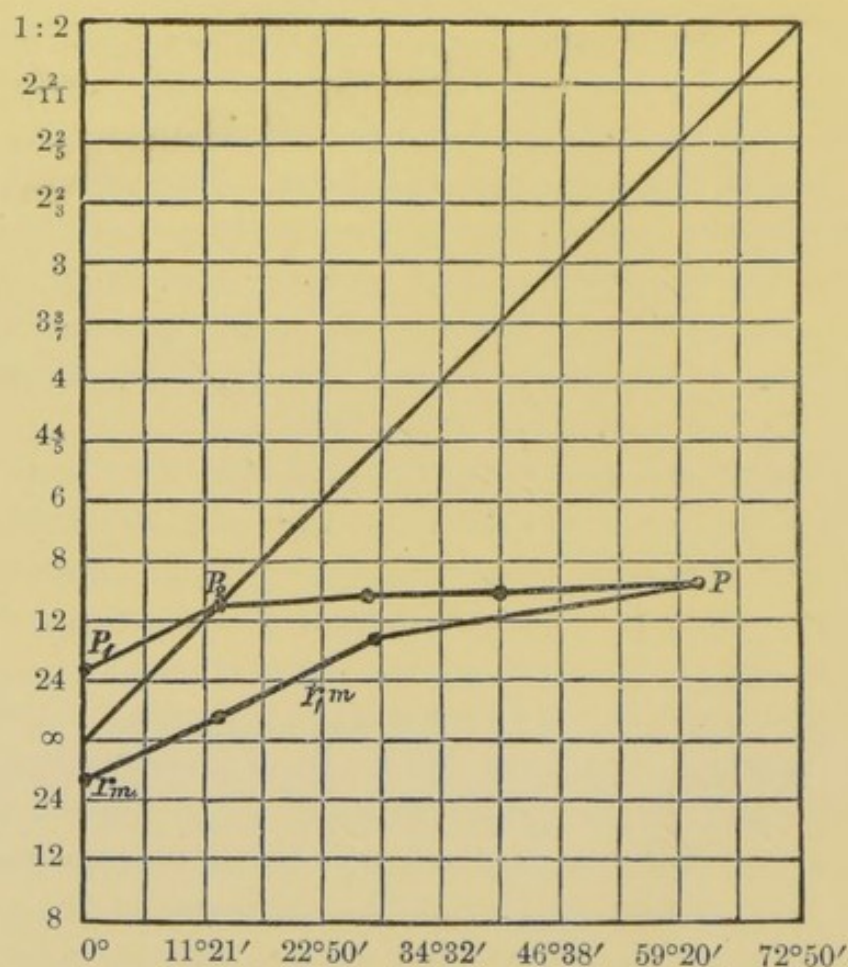
The above classification depends not only upon the grade of the hypermetropia, but upon the range of accommodation. If the degree—that is, the optical value of the hypermetropia—is higher than that of the range of accommodation, the hypermetropia will always be absolute. The gradual narrowing of the range of accommodation which occurs with increasing years makes an originally facultative hypermetropia finally an absolute one; and, on the other hand, most cases of hypermetropia at a youthful age, with ample range of accommodation, are facultative.

Donders has represented diagrammatically the relations in hypermetropia, upon the same plan as he has those of the relative range of accommodation (see page 20). To do this it is only necessary to represent that part of the range of accommodation lying beyond an infinite distance by horizontal lines whose respective distances from one another represent an optical value of  $\frac{1}{24}$ ; these follow in order under the line marked  $\infty$ .



Fig. 10 represents the facultative hypermetropia and range of accommodation of a man 28 years old, whose manifest hypermetropia is corrected by convex 30, whose far point, therefore, lies 30 inches behind his eye. The relative near point with parallel axes of vision is 20 inches in front of the eye; he sees at a distance as well with  $+\frac{1}{30}$  as with  $-\frac{1}{20}$ . The relative range of accommodation with parallel visual axes is then  $\frac{1}{20} + \frac{1}{30} = \frac{1}{12}$ .

FIG. 10.

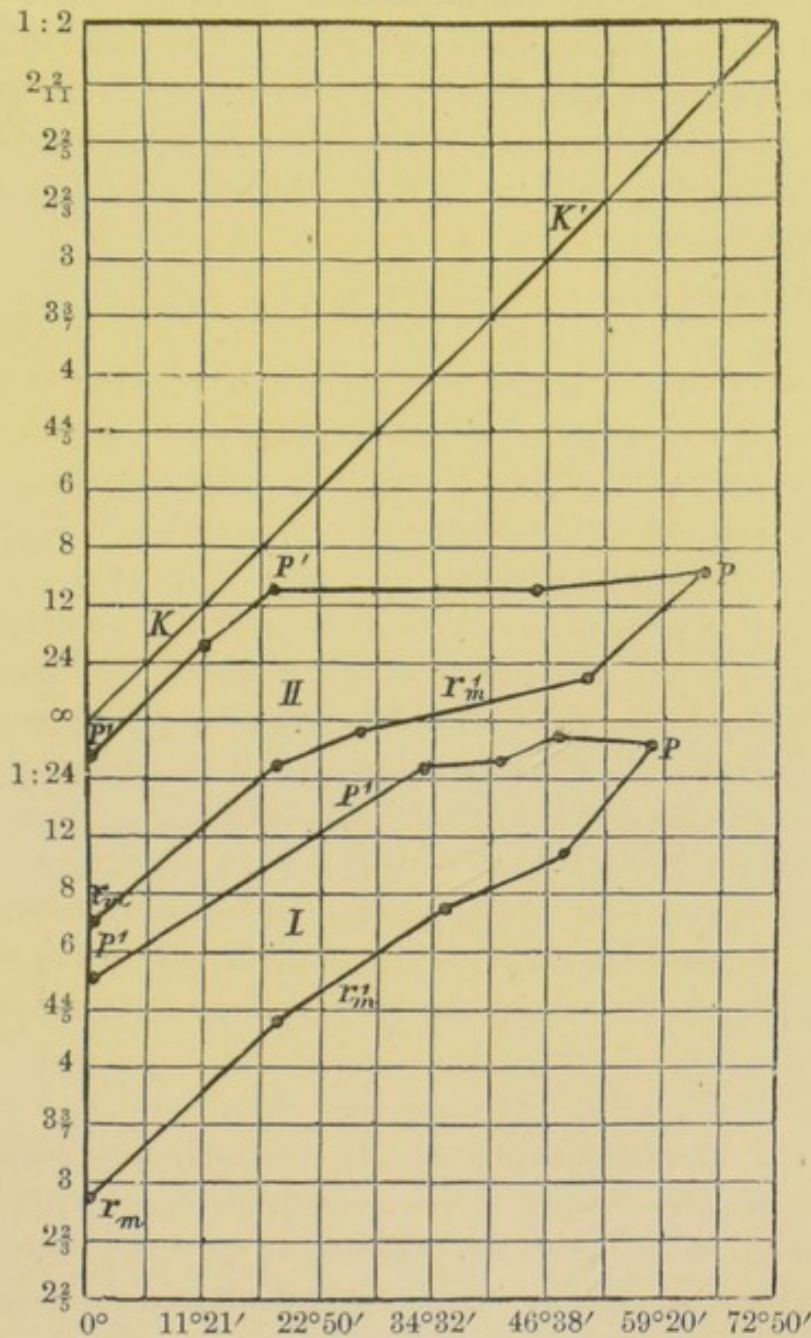


At a distance of  $10\frac{1}{2}$  inches he can for a short time see binocularly. In the course of years, however, the range of accommodation will become narrowed by the withdrawal of the near point, so that before his thirty-eighth year his facultative hypermetropia will become relative, and about his forty-fifth year absolute.

In Fig. 11, II shows the relative hypermetropia of a girl of 17 years. The manifest far point  $r_1m$  lies about 7 inches behind the eye (convex 7 corrects the hypermetropia). The absolute near point lies 10 inches from the eye; if one assumes in the calcula-

tion of the range of accommodation  $r^1m$  as the far point, we have  $\frac{1}{A} = \frac{1}{4.12}$ , and still the near-point line  $p^1 p^1 p$  never reaches the diagonal  $K K'$ , which represents the convergence of the visual axes.

FIG. 11.



This eye can accommodate for divergent light, but can do so only when the visual axes intersect at a point which is nearer the eye than the point upon which the accommodation is adjusted. The hypermetropia is not absolute, but it is so in relation to the convergence of the visual axes. For instance, accommodation can be adjusted for a distance of 16 inches, but only by con-



verging at the same time for a distance of 12 inches, or under an angle of convergence of  $10^{\circ} 21'$ . This particular patient, however, does not avail herself of this possibility, even when one eye is covered. Consequently, she does not see distinctly with the naked eye at any distance, not even monocularly; she can see well, however, with convex lenses. Perhaps at the age of 11 or 12 years, when the range of accommodation was greater, she could see distinctly even binocularly. When, with increase of years, her accommodation shall be reduced to  $\frac{1}{7}$ , her relative hypermetropia will become absolute.

The lines *I* in Fig. 11 show the limits of accommodation in a case of very high degree of hypermetropia. Nearly  $H\frac{1}{3}$  exists, and yet by the help of strong convergence the eyes can be adjusted almost for parallel rays. The range of accommodation is about  $\frac{1}{3}$ ; some years earlier it was probably greater, and the hypermetropia was then not yet absolute.

In facultative hypermetropia, with normal acuteness of vision, distant vision is possible, but only by a tension of accommodation corresponding to the grade of the hypermetropia. If for instance in hypermetropia  $\frac{1}{12}$  there be accommodation  $\frac{1}{4}$ , the patient can indeed see plainly at a distance, but only by an effort of accommodation which adjusts the eye for parallel rays. The accommodation does exactly what a convex glass of 12 inches focal distance would have done;  $\frac{1}{A} = \frac{1}{12}$  is employed; of course there remain  $\frac{2}{12} = \frac{1}{6}$ ,—that is, the near point can be brought only up to 6 inches. The entire range of accommodation is further removed from the eye.

While the emmetrope with parallel visual axes, and with full relaxation of accommodation, can see distinctly at a distance, the hypermetrope, under these circumstances, must accommodate according to the condition of his refraction; he must accommodate still more for near objects. Under all circumstances, in obtaining distinct retinal images hypermetropes make greater demands on their accommodation than do emmetropes, and for that reason there develops a permanent tension of the muscle of accommodation, independent of the will, so that accommodation can no longer be voluntarily relaxed.

This renders it difficult to determine exactly the degree of the hypermetropia. We have already said that this degree of hyper-



metropia is expressed by that convex lens which, in the relaxed eye, focuses parallel rays upon the retina. But it is only with full relaxation of the accommodation that the focal length of that convex lens which gives distinct distant vision expresses the degree of the hypermetropia. Every tension of accommodation, during the examination, acts in the same sense as a convex lens, and from this follows the rule, that the strongest convex lens with which distinct distant vision is possible is the one which expresses most correctly the degree of the hypermetropia. Now, in many cases a full relaxation of accommodation never occurs, so that distinct distant vision is possible, sometimes with a stronger, sometimes with a weaker, convex lens. The grade of the hypermetropia, which is expressed by the strongest convex lens with which distinct vision is possible, is called, under these circumstances, manifest hypermetropia (Hm); the actual or absolute degree can be discovered only by first paralyzing the accommodation. The interval between the manifest and the absolute far point is called "latent hypermetropia" (Hl), or "latent range of accommodation."

Very striking, and indicative of the force of habit, is the fact that, after complete atropine mydriasis, the latent hypermetropia returns, even when the patient wears continuously those convex glasses with which there is distinct vision during the paralysis of accommodation. In proportion as the range of accommodation, subject to the will, again develops, there occurs again the spasm of accommodation, which is directly opposed to the interests of vision, which now is less distinct with convex lenses than with the naked eye.

Another consequence of the strong tension of accommodation which hypermetropes must make in order to see distinctly, appears in the behavior of the relative range of accommodation. While with the ordinary convergence of the visual axes necessary for work the myope uses only a little, and the emmetrope perhaps half, of his available range of accommodation, the hypermetrope uses nearly all of it. This demand sometimes exceeds the strength of the muscle of accommodation; it refuses to do its duty, and in this way are developed those difficulties which are known by the name of asthenopia.

Of the troubles connected with hypermetropia, asthenopia is



the principal one. Its symptoms are very characteristic, and the disease is one long known and described under the greatest variety of names, such as *hebetudo visus*, *kopiopie*, *amblyopie presbytique*, impaired vision from overwork, etc. It was never rightly understood till Donders showed hypermetropia to be the true cause of it.

Upon external examination, the eyes show no anomaly; the acuteness of vision is generally normal; when work, such as writing, reading, sewing, etc., is undertaken, vision is at first distinct, but soon, especially by artificial or imperfect light, vision becomes indistinct and confused; a feeling of fatigue and tension is experienced, especially above the eyes; it becomes necessary to suspend work; the eyes are shut, the forehead and eyelids are rubbed with the hand, and after a short rest work can be again resumed. Soon, however, the same inconveniences recur. The interruptions become more frequent, and must be more and more prolonged; finally, the work must be entirely abandoned. If, in spite of the strain upon the eyes, work be continued, the feeling of tension above the eyes becomes one of actual pain, the eyes become red and filled with tears, and for a short time even distant vision is imperfect. Pain in the eyes themselves is rare in accommodative asthenopia.

The higher the degree of the hypermetropia the earlier the age at which accommodative asthenopia appears. In the middle grades of hypermetropia it develops later, and it may happen that the hypermetropia is completely masked, up to the limit of the far point, so that the entire hypermetropia remains latent, while the effort of accommodating to almost the near point is so great that it can be maintained only for a short time.

Slight hypermetropia may exist a long time without causing any inconvenience. The eyes gradually accustom themselves to combining with every convergence of the visual axes, a relatively strong strain of the accommodation, and to maintain the same while working. But as, in the course of years, by the gradual withdrawal of the near point, the absolute extent of the range of accommodation becomes lessened, just so, finally, does the relative available tension of accommodation, corresponding to the degree of convergence necessary for work, become too small. Fatigue comes on sooner and sooner. In this way slight hypermetropia leads to premature presbyopia, more likely to be complicated with



asthenopic difficulties, and occurring earlier in life the higher the grade of the hypermetropia. Of course, the occurrence of asthenopic difficulties is favored by all debilitating influences which weaken the energy of the muscular system in general and the ciliary muscle in particular. Indeed, after prostrating sicknesses, after severe hemorrhages, or with paresis of accommodation, asthenopic difficulties may occur without the existence of any hypermetropia.

The principal symptom of absolute hypermetropia is indistinct vision of both near and far objects, and in such a condition one of the most prominent features in asthenopia is wanting, namely, distinct vision at first.

There often exist simultaneously with hypermetropia, especially in connection with the higher grades of it, other causes for defective vision, such as astigmatism, or meridional asymmetry; not unfrequently there is amblyopia, for which there exists no discoverable cause, and which, therefore, must be considered as amblyopia congenita.

A very characteristic symptom, under these circumstances, is, that such patients hold objects which they wish to see distinctly, for instance, the book, when reading, as near as possible to the eye; they may even use an object distance of from 1 to 2 inches. When this is done, as Von Graefe\* has shown, the size of the retinal images increases more rapidly than that of the circles of diffusion. Moreover, as Donders remarks, it is probably in these cases more a question of monocular polyopia than of circles of diffusion. Some of the multiple images can be excluded by partially closing the lids, or in monocular vision, by holding the book on one side, so that the nose covers a part of the pupil; both these devices are practised with so much the happier effect the smaller the pupil. If under these circumstances even fine print, for instance, No. I of the usual test letters, can be read at a distance of 1 inch, this would indicate an acuteness of vision of only about  $\frac{1}{18}$ , for the retinal images must be very indistinct. Such patients, by practice, have learned to draw, from very imperfect retinal images, correct conclusions as to the form of objects.

The anatomical peculiarity of the hypermetropic eye is, that all

---

\* Arch. f. Ophth., ii. 1, pag. 181



its diameters, and particularly its sagittal diameter, are shorter than in emmetropic eyes. This shortness of the axis is probably the cause of the hypermetropia; at least there are no discoverable changes in the refracting media which could increase the focal distance. Ophthalmometric measurement has shown that the cornea is not flatter; but in high grades of hypermetropia, where its circumference is smaller than normal, its curvature is generally even greater than in the emmetropic eye. The reason that it appears flatter is, just as in presbyopia, because the anterior chamber is shallower and the pupil smaller. Whether in hypermetropic eyes the lens is flatter than usual is not known.

A further, and often very striking, peculiarity is, that in hypermetropia the line of vision deviates inward from the centre of the cornea much more than in emmetropia (comp. p. 42). With parallel visual axes, perpendiculars let fall upon the centre of the cornea would therefore diverge strongly, causing an apparent strabismus divergens, concerning which we have yet to speak more fully.

The hypermetropic formation of the eye occurs congenitally. E. von Jaeger,\* by ophthalmoscopic examination of the condition of refraction, found hypermetropia in 17 cases among 100 new-born infants. Hypermetropia may also develop during the growth of the eye. A hereditary influence is very evident. If parents have hypermetropia, it is generally observed in some of their children also. On the other hand, several brothers and sisters may be hypermetropic when the same anomaly did not exist in the parents.

It is only relatively seldom that hypermetropia is acquired. The removal of the lens from behind the pupil (aphakia) is the most frequent cause of acquired hypermetropia.

Glaucoma in its early stages may also perhaps cause hypermetropia. The flattening of the cornea by central facets may cause a high degree of hypermetropia complicated by irregular astigmatism. Finally, a displacement forward of the retina by choroidal exudations, or a flattening of the posterior part of the eye by orbital tumors, may cause hypermetropia.

The existence of hypermetropia is proved whenever with normal or nearly normal acuteness of vision the patient sees at a distance

---

\* *Einstellungen des dioptrischen Apparates*, pag. 20.



as well with convex lenses as with the naked eye. Where the acuteness of vision is considerably less than normal, this method of examination is unreliable, because the enlargement of the retinal images caused by the convex lenses may improve vision without the presence of hypermetropia. In such cases the ophthalmoscopic diagnosis should be made; this will be explained later.

In cases of hypermetropia complicated with amblyopia, especially when both anomalies exist in a somewhat high degree, there is often no result attained by the examination with convex lenses and test letters. The patients say they see better sometimes with, sometimes without, sometimes with weaker, sometimes with stronger, lenses. The reason for these contradictory statements is, that even hypermetropes with good vision are compelled to accommodate whenever they wish to see anything distinctly, and the necessity so to do is still greater when there is amblyopia. This acquired habit of straining the accommodation for the sake of distinct vision is not avoided during an examination with convex lenses; consequently it is impossible to attain an accurate result. In the ophthalmoscopic examination, on the contrary, the patient has no necessity, and scarcely the possibility, of distinct vision; he relaxes his accommodation, and then with the ophthalmoscope we can determine the existence of the anomaly of refraction with certainty, and generally, too, its degree with sufficient exactness. By reason of a permanent tension of the accommodation, a part of the hypermetropia may remain latent, even during the ophthalmoscopic examination.

Even with good vision a latent tension of accommodation may render the diagnosis difficult. In such cases the only method by which to ascertain the existence of hypermetropia, and determine the grade of it, is to paralyze temporarily the accommodation by atropine.

Hypermetropes generally seek treatment either on account of accommodative asthenopia or for indistinctness of vision. Both difficulties may occur very early in high degrees of hypermetropia.

The relief of asthenopia is no longer difficult, since Donders has so successfully combated the error which would forbid the use of strong convex glasses to young persons.

If in connection with accommodative asthenopia the usual manifest hypermetropia exist, it generally suffices to correct this;



that is, to order the strongest convex lenses with which, during the examination, distinct distant vision is possible. Such glasses generally relieve the asthenopic difficulties immediately. It may happen that glasses which correct simply the manifest hypermetropia nevertheless appear to the patient to be too strong; the work must be brought nearer the eye than usual, so that an unwonted convergence of the visual axes is required; the objects appear distinct, it is true, but unpleasantly magnified, etc. Chiefly is this the case with such hypermetropes as have long been accustomed to work without any or with too weak convex glasses, and have thereby acquired the habit of combining the convergence of the visual axes necessary to their pursuits with a relatively strong tension of accommodation; they cannot give up the habit even when properly-chosen convex glasses render accommodation necessary. Under these circumstances, somewhat weaker glasses generally relieve all difficulties.

On the other hand, it may happen that the correction of the manifest hypermetropia is not sufficient, and that for entire relief of the asthenopic symptoms stronger convex glasses are necessary. Of course this is always the case when the range of accommodation is diminished by the development of presbyopia.

If the difficulties of accommodative asthenopia exist while there is no manifest hypermetropia, or only a very slight degree of it, there is no course left but to paralyze accommodation by atropine, and then to determine if hypermetropia exist, and if so, in what degree. It is advisable, however, to limit the use of atropine as much as possible, since its effects, when applied in sufficient quantities to produce absolute paralysis of the muscle of accommodation, last several days, and during this time the patient is in a very uncomfortable condition. If latent hypermetropia be found, then would the neutralizing convex glass be, as a rule, too strong; it is advisable to neutralize, then, only the manifest and perhaps  $\frac{1}{4}$  of the latent hypermetropia. If, as rarely happens, the asthenopic symptoms do not yield, in spite of properly-chosen convex glasses, we must look for other co-existing affections which might cause similar troubles, for instance, astigmatism, muscular, conjunctival, or nervous asthenopia.

So long as in facultative hypermetropia the accommodation is sufficient to give distinct distant vision, it is not advisable to allow



the use of convex lenses continuously, and for distance. Otherwise the time will soon come when the correcting convex lenses, with which distant vision is good, will not be strong enough for near objects. In absolute hypermetropia, on the other hand, whether it appear in early youth or is developed in consequence of presbyopia, from hypermetropia that was originally facultative, correcting convex glasses may be worn continuously. In young people, such glasses are generally sufficient for all purposes, while later in life, for near vision, it becomes necessary to wear glasses which correct the hypermetropia and the presbyopia as well.

The relation between hypermetropia and strabismus convergens will be discussed under the title "diseases of the ocular muscles."

#### ASTIGMATISM.

We have shown that in the normal emmetropic condition of refraction, rays of light which fall parallel upon the cornea, with absolute rest of accommodation, are, after refraction, focused exactly upon the retina.

If the place of the image cast by a distant luminous point be not upon the retina, it must be either before or behind it, and looked at from this point of view there seem to be but two anomalies of refraction possible, viz., myopia and hypermetropia. There is, however, a third, dependent upon the fact that rays of light proceeding from a given point (homocentric light) do not in general, after their refraction in the eye, remain homocentric. Etymologically, the word astigmatism expresses nothing more than that condition in which homocentric rays, after their refraction in the eye, do not intersect each other again in one and the same point. The fact that to most men the stars do not appear as round dots, but star-shaped, proves the frequency of these aberrations.

In fact, the human eye shows the same defects which we seek to correct in an optical instrument, or which not being corrected we would regard as a fault. These aberrations exist too in a quite high degree. Chromatic aberration is least noticeable, although the eye is by no means free from it; under ordinary circumstances it does not affect the acuteness of vision. The monochromatic aberrations of the eye are more important, and are complicated to a high degree. For our present purpose we must distinguish between



(a) An aberration affecting those rays which are refracted in one and the same meridian, and

(b) An aberration dependent upon differences in the focal length of the various meridians of the refracting apparatus.

The first, which is called irregular astigmatism, depends, under physiological relations, partly upon the form of the cornea, but mostly upon irregularity of refraction in the lens. In the first place, its curved surfaces are not centred with those of the cornea; further, the refraction in the various sectors of the lens varies, so that each sector casts an image which does not coincide with that of the sector lying opposite and on the same meridian with it, and finally, each image of each sector possesses an aberration of its own.\*

Under pathological conditions irregular astigmatism is oftenest caused by cloudiness of the cornea and partial cloudiness of the lens.

The aberration depending upon inequality of the dioptric apparatus, in its different meridians, is called regular astigmatism, or meridional asymmetry.

It appears to be only seldom that meridional asymmetry is absent. The near point of most eyes lies nearer for horizontal than for vertical lines, and the same symptom can also be shown for the far point, if when myopia is not already present, the far point be brought nearer by means of a carefully-centred convex glass.

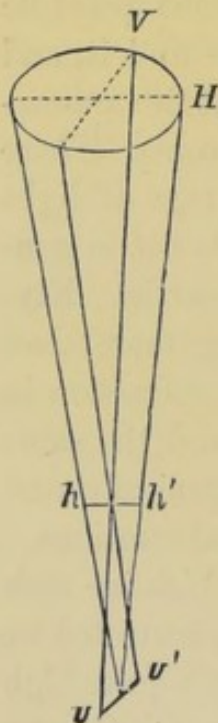


FIG. 12.

The physiological meridional asymmetry of the cornea has been demonstrated objectively by ophthalmometric measurement. In the majority of cases the vertical meridian was shown to have a shorter radius of curvature than the horizontal, although the principal meridians—that is, those having the greatest and least curvature—do not by any means stand always in a vertical and horizontal position. The manner in which light is refracted by such asymmetric surfaces was long ago investigated by Sturm. He found (comp. Fig. 12) that a homocentric beam of light, after

refraction by an asymmetric surface, is not united at a focal point,

\* Donders, *Astigmatismus und cylindrische Gläser*, Berlin, 1862, pag. 9.



but experiences its greatest concentration within a certain interval, which is called the "focal interval;" this interval is bounded by two lines, the anterior ( $h h'$ ) and posterior ( $v v'$ ) focal lines, which include all the rays.

The place of the anterior focal line is determined by the focal distance of the meridian of greatest ( $V$ ), and its direction by the direction of the meridian of least ( $H$ ), curvature. A circle of diffusion is formed at the middle of the focal interval. The posterior focal line stands at right angles with the anterior one; its place is determined by the focal distance of the meridian of least curvature; its direction is in the plane of the meridian of greatest curvature.

The greater the asymmetry, the longer the focal interval, and the longer the focal lines which bound it.

We can now easily understand the different adjustment of the eye for horizontal and vertical lines. If, for instance, the meridian of shortest focal distance be vertical, and that of longest focal distance horizontal, then will the anterior focal line have a horizontal, and the posterior a vertical, direction.

A horizontal line whose retinal image coincides with the anterior focal line will appear perfectly distinct, except at each end, for a distance equal to half the length of the diffuse image thrown from each and every individual point of the line, since the diffuse images from all its points are again horizontal lines which overlap each other. A vertical line at the same distance will, on the contrary, appear broad and indistinct; because each of its points casts a horizontal diffuse image; the vertical line can cast a distinct image only by such an effort of accommodation as is necessary to bring the posterior focal line upon the retina. Of course, in that case, the horizontal line becomes indistinct, and unless the accommodation is changed, it must be brought nearer the eye in order to be seen distinctly. This explains why, as a rule, horizontal lines can be seen at a nearer distance than vertical ones. It follows that in the higher grades of meridional asymmetry only those lines whose directions correspond with one of the principal meridians can cast distinct retinal images.

A certain degree of meridional asymmetry exists in all eyes, and cannot therefore be regarded as abnormal. It can be called abnormal only when it exists to such a degree that acuteness of



vision suffers noticeably. This is so much the more the case the larger the pupil, the length of the focal interval being the same. Indistinctness of vision is the first difficulty of which astigmatics complain. In fact, under no circumstances do they receive from any object-point a distinct image-point upon the retina, but always areas of diffusion, which are round when the retina is at the middle of the focal interval, but which at the ends of the focal interval are oval or nearly linear, in a direction corresponding with that of the principal meridians. In general they can see distinctly only such lines as are parallel with one of the principal meridians.

Astigmatics, on account of their indistinctness of vision, are seldom capable of working continuously. Now, if hypermetropia exist in connection with astigmatism, the symptoms of asthenopia are the more likely to occur, for the astigmatic is generally compelled to use short distance for working, in order to compensate by the size of the retinal images for what they lack in distinctness. Even when only one principal meridian is hypermetropic, it is sufficient cause for the occurrence of accommodative asthenopia. If, for instance, the vertical principal meridian be emmetropic and the horizontal one hypermetropic, then will a distant point appear upon the retina as a horizontal line,—that is, the anterior, in this case horizontal focal line, falls upon the retina. Horizontal lines appear distinct, vertical lines indistinct. But in order to judge accurately the form of an object it is necessary to see its vertical lines distinctly, because, with reference to the horizontal lines, the binocular parallax, that is, the angle of convergence of the visual axes, has no determined size, and therefore is of no help in judging of distance. In order to see distinctly at a distance, the astigmatic, just as the hypermetrope, is compelled to make an effort of accommodation corresponding to the hypermetropia in the horizontal meridian, in order to bring the posterior vertical focal line upon the retina, and so to see vertical lines distinctly. An effort of accommodation is necessary, even when, in order to receive from every object-point as small a circle of diffusion as possible, the middle of the focal interval, and not the posterior focal line, is brought upon the retina. The same is true for near vision; the demand upon the accommodation is always greater than in emmetropia. On account of the preponderance of vertical lines in our letters it is advantageous when reading to bring the poste-



rior focal line, when it has a vertical direction, upon the retina, although it involves a greater effort of accommodation. If hypermetropia exist in both principal meridians, but in different degrees, accommodative asthenopia is so much the more likely to occur.

The relations are more favorable when emmetropia exists in the horizontal principal meridian and myopia in the vertical one. With perfect rest of the accommodation the posterior focal line falls then upon the retina, and vertical lines are therefore distinctly seen, while by narrowing of the palpebral fissure the circles of diffusion are made smaller, and horizontal lines are also seen more distinctly. Astigmatics often avail themselves of this advantage. If the directions of the principal meridians be neither exactly vertical nor horizontal, astigmatics often assume instinctively an inclined position of the head, by which that principal meridian best suited to the purposes of vision is placed in the most advantageous position.

Astigmatics do not generally complain of other optical disturbances which are the necessary result of meridional asymmetry, such, for instance, as that a square appears elongated, and a circle elliptical.

If congenital amblyopia ( $V = \frac{1}{2}$  or  $\frac{1}{7}$  or  $\frac{1}{10}$ ) give reason to suspect the existence of astigmatism, the vision for distance is first to be determined, and it is then to be tried if any improvement can be made with concave or convex glasses; for astigmatism may exist with either myopia or hypermetropia. If spherical lenses cause no improvement, or if they cause slight improvement, but not distinct vision, it is next to be determined

- (1) If meridional asymmetry exists?
- (2) What is the direction of the principal meridians?
- (3) What is the condition of refraction in each of the principal meridians?

The first two questions can generally be determined by ophthalmoscopic examination. For the functional examination it is best to use certain systems of lines. Javal's\* optometer is a contrivance with which to determine the existence of astigmatism. Instead of this complicated instrument we may use a system of lines placed at a definite distance; the patient looks at these lines


---

\* Annales d'Oculistique, 1866.



with each eye separately, and it is determined experimentally with what lens his vision is most improved. Among these systems of lines are Becker's, and the letters of Pray and Heymann, or, perhaps the very best, those which accompany Snellen's test letters, and which are shown on a reduced scale in Fig. 13. The lines are arranged in the form of a half-star, since a figure of that shape embraces lines running in every conceivable direction. Their deviation from the perpendicular is expressed in degrees, which are marked with the positive sign on the right side of the perpendicular and with the negative sign on the left.

FIG. 13.



The lines are placed at a distance suited to the vision of the patient, and he is directed to look at them with one eye while the other is covered. If concave or convex glasses improve distant vision, the examination is to be conducted with their help. Care should be taken that the head be held erect, and that the eyes be well opened, so that the palpebral fissure does not act as a stenopaic slit. If, for instance, there be emmetropia in the horizontal and myopia in the vertical meridian, then will a distant luminous point throw its image upon the retina in the form of a vertical line, since the posterior focal line, which in this case is vertical, falls with relaxed accommodation exactly on the retina.

Consequently, only the vertical lines in the figure will be seen distinctly, the others being less sharply defined. If, on the contrary, there be hypermetropia in the horizontal and emmetropia in



the vertical meridian, then only the horizontal lines cast distinct retinal images. For the same reasons would one or the other of the inclined lines appear distinct if the direction of the principal meridians were not exactly vertical or horizontal. It is next to be experimentally ascertained what concave or convex cylindrical lens corrects the meridional asymmetry and causes all the lines to appear equally distinct.

In order to determine more exactly the condition of refraction in each of the principal meridians, a stenopaic slit with a breadth of 1 or 2 millimetres should be held before the eye in a direction corresponding with that of the line which is seen most distinctly; the condition of refraction in the principal meridian is then to be determined in the usual manner by the aid of concave or convex lenses; the slit is then to be placed at an angle of  $90^\circ$  with its former position, and the condition of refraction in the second principal meridian to be determined in the same way. The difference between the condition of refraction in the two principal meridians shows the degree of the astigmatism.

If one of the principal meridians is emmetropic, Donders calls the asymmetry "simple astigmatism." He distinguishes a simple myopic and a simple hypermetropic form; generally, in the myopic form the emmetropic principal meridian is horizontal, and in the hypermetropic form it is vertical.

Compound astigmatism is where the same anomaly of refraction exists in both principal meridians, but in a different degree; there may be myopic or hypermetropic compound astigmatism.

Mixed astigmatism is where myopia exists in one principal meridian and hypermetropia in the other.

Donders\* has made numerous ophthalmometric measurements of the curvature of the cornea in cases of regular astigmatism. He has proved that a considerable meridional asymmetry of these curvatures must be regarded as the principal cause of this anomaly of refraction. Still, he found that neither the degree of astigmatism, as calculated from the difference of curvature of the cornea in the principal meridians, nor the direction of those meridians, corresponds absolutely with the actual condition of refraction of the entire refracting apparatus of the eye, obtained experimentally.

---

\* Arch. f. Ophth., B. x. 2, pag. 83.



The degree of astigmatism for the entire eye is generally less than can be calculated from the asymmetry of the cornea, and consequently less than it would be if only the corneal asymmetry were concerned.

Carrying his calculation still further, Donders arrived at the conclusion, that up to a certain degree the asymmetry of the cornea is compensated for by a similar but opposite asymmetry in the lens. The maximum of curvature in the lens is still more constantly in the horizontal than that of the cornea is in the vertical direction. Asymmetry of the lens alone seems scarcely ever to occur. If, however, the asymmetry of the cornea exist, there is almost certain to be asymmetry of the lens also. Generally, however, that of the cornea is the greater, and the resulting refractive effect approaches, therefore, more nearly that of the cornea.

From exact statistics which Snellen\* compiled with reference to the principal meridians, he found the meridian of shortest focal length to be exactly vertical in 50.5 per cent. and to be horizontal in 9 per cent. of all cases; in 40.5 per cent. of all cases its direction was found to be about as often in one as in another of the other directions. The direction of the principal meridians in both eyes is generally symmetric. There exists no essential difference in reference to the direction of the meridian of shortest focal distance in myopic and hypermetropic astigmatism; in this respect the degree of the astigmatism seems to exert no influence.

*Correction.*—All the symptoms of regular astigmatism may be illustrated by the help of cylindrical lenses, which cause the same asymmetric refraction of light as occurs in astigmatic eyes. From this it is evident that regular astigmatism can be corrected by cylindrical lenses, which have the same degree of asymmetry, but which act in an opposite sense.

The degree of the astigmatism gives, therefore, the number of the positive or negative cylindrical lens necessary for its correction.

Theoretically, it makes no difference whether we increase the focal distance of the vertical meridian till it equals that of the horizontal meridian, by means of a concave cylindrical lens, with its axis held in a horizontal direction, or whether we equalize the

---

\* Arch. f. Ophth., B. xv. 2, pag. 199.



condition of refraction in the two principal meridians by increasing the refraction in the horizontal meridian by means of a convex lens with its axis vertical. In practice, however, each particular case will present grounds upon which to decide whether concave or convex glasses should be used.

If there be emmetropia in the vertical meridian and  $H_{\frac{1}{2}}$  in the horizontal meridian, then will a cylindrical lens of  $+\frac{1}{12}$  correct the error, if it be held with its axis vertical before the eye; since rays of light which diverge in the plane of the axis of the cylinder suffer no refraction, while rays which diverge in a plane at right angles to the axis experience a refraction proportionate to the radius of curvature. Or suppose that in the vertical meridian  $M_{\frac{1}{8}}$  be found, and in the horizontal meridian  $M_{\frac{1}{24}}$ , then, since  $\frac{1}{8} - \frac{1}{24} = \frac{1}{12}$ ,  $As_{\frac{1}{12}}$  is present, and, according to our classification, it is compound myopic astigmatism. A cylindrical lens  $-\frac{1}{12}c$  is, in this case, sufficient to correct the astigmatism; held before the eye, with its axis horizontal, it does not affect the myopia existing in that meridian; its curved surfaces, however, do reduce the myopia in the vertical meridian, but do not neutralize it, since  $M_{\frac{1}{8}} - \frac{1}{12} = \frac{1}{24}$ . The astigmatism is then corrected, since  $M_{\frac{1}{24}}$  exists in both principal meridians.

For near objects, under these circumstances, a concave cylindrical lens ( $-\frac{1}{12}c$ ) suffices, but for distinct distant vision it is necessary to correct the myopia by a spherical lens. A spherocylindrical lens  $-\frac{1}{12}c \subset -\frac{1}{24}s^*$  would neutralize at the same time the astigmatism and the myopia, and such lenses should be employed under the same restrictions as correcting concave glasses in general. In compound hypermetropic astigmatism, on the contrary, it is always necessary to correct the hypermetropia which exists after the correction of the astigmatism; this is done by convex spherocylindrical lenses. When there is not sufficient accommodative power, it may be necessary to bring the far point somewhat nearer to the eye.

Mixed astigmatism is also corrected by spherocylindrical lenses. If, for instance, there be  $M_{\frac{1}{12}}$  in the vertical and  $H_{\frac{1}{24}}$  in the

---

\* As indicates astigmatism; c = cylindrical; s = spherical;  $\subset$  indicates that a spherical curved surface is combined with a cylindrical curved surface to form a spherocylindrical lens.



horizontal meridian, we have  $As\frac{1}{8}$ ; for since the value of the hypermetropia must in our calculation be affected with the negative sign, we have  $\frac{1}{12} - (-\frac{1}{24}) = \frac{1}{12} + \frac{1}{24} = \frac{1}{8}$ . If now we place before the eye a cylindrical convex lens of 8 inches focal distance ( $\frac{1}{8}c$ ), with its axis placed vertically, the myopia in the vertical meridian remains unchanged; the hypermetropia in the horizontal meridian is, on the contrary, so much over-corrected that  $M_{\frac{1}{12}}$  is the result ( $\frac{1}{8} - \frac{1}{24} = \frac{1}{12}$ ). For distinct distant vision, therefore, there must be added to the cylindrical lens  $\frac{1}{8}c$ , a spherical curved surface of  $-\frac{1}{12}$ .

Instead of sphero-cylindrical lenses, one may, in all cases, choose bi-cylindrical lenses with their axes crossing each other at right angles, since in that case each of the cylindrical surfaces corrects the ametropia of one of the principal meridians. \*

The improvement of vision to be attained by the use of cylindrical glasses varies greatly, according to whether the defect of vision depends upon regular astigmatism alone, or whether complications exist. A very considerable degree of irregular astigmatism often complicates regular astigmatism; this appears to be especially true of those cases in which the asymmetry is principally in the lens. Moreover, it is very probable that astigmatism, like hypermetropia, is often complicated by congenital amblyopia. These two circumstances explain the fact, that often no improvement in vision is to be obtained by the use of cylindrical lenses in cases where the presence of regular astigmatism can be recognized with certainty by ophthalmoscopic examination. The same causes often make it difficult to determine exactly the degree of the astigmatism. Upon examination with the stenopaic slit, vision is equally bad or good with a series of spherical lenses, and it is impossible to say which expresses the degree of refraction correctly. One attains about the same result when he seeks empirically for that cylindrical glass with which vision is best. He will find, just as in the examination with the stenopaic slit, that cylindrical lenses with quite different focal lengths perform equal service. In the case of concave cylindrical lenses, we follow the rule for the choice of concave spherical lenses, and order the weakest, with which equally good vision can be attained. But with convex cylindrical glasses it is not important to observe the analogy of practice in hypermetropia, and choose the strongest with which



distant vision is relatively best, since on looking obliquely through the lenses, an act impossible to avoid in wearing spectacles, the cylindrical lenses lose their centring and cause distortion of the retinal images, which is so much the more disturbing the shorter the focal length of the lens.

Cylindrical lenses give great relief, even in cases where they produce no complete, but only a partial, correction of vision. Frequently, accommodative asthenopia, which cannot be overcome by spherical convex glasses, disappears after correction of the astigmatism, even where normal distinctness of vision cannot be attained.

In a very respectable minority of cases the correction of vision attainable by cylindrical lenses is entirely satisfactory.

Mention must be finally made of the Stokes lens, an ingenious instrument which may be used for the diagnosis of astigmatism. It consists of two plano-cylindrical lenses of equal focal distance, the one concave, the other convex. If these be placed with their plane surfaces in apposition and their axes parallel to each other, then the cylindrical surfaces are also parallel, and the instrument acts exactly like a glass with plane surfaces. If, however, one glass be so turned that its axis forms an angle of  $90^\circ$  with the axis of the other, there then exists an asymmetry whose value equals the entire difference of the two lenses. If for instance the two combined glasses have, the one a positive and the other a negative focal distance of 10 inches, then, with parallel axes, they will act as a plane glass; with axes crossing each other at right angles the optical value of the asymmetry is  $\frac{2}{10} = \frac{1}{5}$ . Any desired degree of asymmetry up to this maximum may be produced by the revolution of the lenses, consequently every degree may be corrected also.

In the practical use of this instrument it is to be remembered that all is not done when the meridional asymmetry is corrected. If the condition of refraction in both principal meridians be reduced to one and the same degree of myopia or hypermetropia, we must, in order to make this step of any practical value, still further determine the degree of the remaining myopia or hypermetropia.

An exact manipulation of this ingenious instrument has therefore its special difficulties, and since cylindrical glasses are so



easily obtained, their use is generally preferable to that of Stokes's lens.

#### DIFFERENCE OF REFRACTION IN THE TWO EYES (ANISOMETROPIA).

As a rule, both eyes have the same condition and degree of refraction, although slight differences of perhaps  $\frac{1}{60}$ , or even less, are quite frequent. The remarks which follow, have reference principally to cases in which the difference in refraction is considerable.

There occur all possible combinations in the refractive condition of the two eyes. For instance, with emmetropia in one eye, the other may be myopic or hypermetropic; or there may be the same anomaly of refraction in both eyes, but in a different degree; in high degrees of acquired myopia such differences are relatively frequent.

Cases occur of hypermetropia in one eye and myopia in the other. So, too, unilateral astigmatism may occur; but in such cases the rule of correspondence in the condition of refraction holds good thus far, that with myopic astigmatism in one eye there is myopia in the other, or with hypermetropic astigmatism in one eye there is hypermetropia in the other.

Loss of the lens on one side, for instance, by cataract operation, is to be mentioned in this connection; and finally the paresis of accommodation on one side has the same physiological effect on near vision that differences of refraction have upon vision in general.

Under these circumstances, only one eye can receive a distinct retinal image, while the image in the other eye is made up of circles of diffusion; this is true for every distance at which each eye alone can receive a distinct image.

This is a consequence of the fact that the accommodative apparatus of both eyes is simultaneously and equally innervated. If one eye is emmetropic with its near point at 4 inches ( $\frac{1}{A} = \frac{1}{4}$ ), while the other possesses the same power of accommodation with myopia  $\frac{1}{12}$  and a near point at 3 inches, then each eye alone may see distinctly a point 6 inches distant, but not at the same time. If the myopic eye accommodate to a distance of 6 inches, it employs an effort of accommodation equal to  $\frac{1}{12}$ , which, however, affects equally the other eye, and adjusts it upon a distance of 12 inches.



Under these circumstances it can be shown, by the help of prisms, that for such distances as lie within the range of accommodation it is always only one eye which is properly adjusted and receives distinct retinal images. The patient is to look at some suitable object, say a fine line, while a weak prism of perhaps  $4^{\circ}$  or  $5^{\circ}$  is held with its base either up or down in front of the other eye; double images will then be seen, of which only one, and that corresponding to the properly-adjusted eye, will appear distinct. In all the cases of difference of refraction with good vision on both sides, which I have examined in this manner, it could be shown that only that eye was used for near vision which received distinct retinal images with the least effort of accommodation; for instance, in unilateral myopia, always the myopic eye. Where there is difference in refraction, under all circumstances it is only one eye which receives a distinct retinal image.\*

A normal binocular vision may exist in spite of the dissimilarity of the opposite retinal images, as can be proved by Hering's experiment (see p. 113), and the circles of diffusion in the one eye are overlooked in the binocular image.

When in one eye there is emmetropia and in the other myopia of a moderate degree (at least  $\frac{1}{16}$ ), but with good vision on both sides, there is but slight demand made on the accommodation, for the myopic eye is used for near and the emmetropic for distant vision. In high degrees of unilateral myopia there often develops a characteristic form of strabismus divergens alternans.

If one eye be hypermetropic and the other emmetropic or myopic, the effort of accommodation adjusts only the latter eye. Generally, under these circumstances, the hypermetropic eye is amblyopic, but the degree of amblyopia is usually much overestimated by patients accustomed to very slight efforts of accommodation.

If on both sides there be hypermetropia, but in different degrees, it may favor the occurrence of strabismus convergens, in which, supposing there is equal distinctness of vision, the less hypermetropic eye is used for fixation. On the other hand, with bilateral

---

\* Schneller's contrary assertion (Arch. f. Ophth., Bd. xvi. pag. 176) does not agree with my observation.



myopia of high grade and different degrees, relative strabismus divergens easily develops with an inclination to employ the sharpest-sighted and, as a rule, least myopic eye.

If we have difference of refraction in the two eyes, the question often arises whether this difference is to be equalized by different lenses.

If there exist under these circumstances the mutual visual act and binocular fixation, it is first to be determined which eye possesses the better vision and at the same time the less anomaly of refraction. There follows, then, for this eye the choice of the necessary lens according to the usual rules. Generally it is advantageous to prescribe the same lens for the other eye. The patients are accustomed to the dissimilarity of their retinal images, and the equalization of their refraction they find only an inconvenience, and that so much the more, since absolute similarity of the two images as respects their size cannot be attained. If allowed to choose for themselves between spectacles with glasses alike on both sides and those with unlike glasses, such patients generally prefer the first.

There occur, however, exceptions to this rule. For instance, often in myopia, with slight difference of refraction (perhaps  $\frac{1}{36}$  or  $\frac{1}{40}$ ), an equalization of refraction gives better vision; sometimes, when the difference is greater, a partial equalization gives the same result. So too, in hypermetropia with deficient vision, the relatively best binocular vision is sometimes attained by providing each eye with its best correcting lens.

If, as is seldom the case, the eye with the best vision has at the same time the greatest degree of anomalous refraction, it is advantageous to give the other eye a proportionately weak lens.

If, as for instance with myopia on one side and emmetropia on the other, the eyes are used interchangeably, there is generally no occasion for spectacles.

#### PARALYSIS OF ACCOMMODATION.

Paralysis of accommodation causes the same optical disturbances as presbyopia. In this respect it is all the same whether the near point withdraws on account of a loss of elasticity in the lens or because the muscle refuses to perform its office. There is, however, this essential distinction, that in presbyopia the pupil is con-



tracted, while, as a rule, the sphincter iridis participates in the paralysis, and the pupil is dilated and immovable. Often the form of the pupil is more affected than its size.

There occur also cases of paralysis of accommodation without participation of the sphincter iridis; this is generally so in paresis of accommodation following diphtheritis faucium. A distinction closely allied to this last is, that presbyopia, the diminution of accommodation dependent on age, always occurs in both eyes simultaneously and to an equal degree, while paralysis of accommodation may be either unilateral or bilateral.

In presbyopia the difficulties of paralysis of accommodation are but little noticed; so too in myopia, when the far point is not more than 12 or 15 inches distant, since this distance is generally sufficient for reading, writing, etc.

Emmetropes are annoyed by indistinctness of vision for near objects; they, however, see distinctly at a distance. With the loss of accommodation hypermetropes lose also the possibility of seeing distinctly at a distance. The disturbance in vision gives the impression of serious amblyopia, and is occasionally confounded with it. Such an error in diagnosis may be easily avoided, and vision made distinct by such convex lenses as correct the hypermetropia and paralysis of accommodation.

All the annoyances of paralysis of accommodation are so much the greater the wider and more immovable the pupil, because the size of the circles of diffusion and the dazzling of light are proportionately increased.

Micropia is a characteristic phenomenon often observed in connection with paralysis of accommodation. Objects which with full tension of accommodation may be still seen plainly, appear diminished, because our judgment respecting the size of objects depends not only upon the size of the retinal images, but also upon the distance at which we project that image. Our judgment concerning the distance of objects depends mostly upon the convergence of the visual axes and the tension of accommodation.

One can very easily satisfy himself respecting the influence of the convergence of the visual axes by holding before his eyes prisms of  $4^{\circ}$  to  $6^{\circ}$ , with the refracting angle turned outward; in this way the lines of vision relatively to the point fixed are made to diverge (comp. Fig. 4, page 17). Objects at a distance of per-



haps 25 or 30 centimetres seen under an unusually small angle of convergence appear enlarged. The size of the retinal images remains, of course, unchanged, but they are referred to more distant and therefore larger objects. In looking at solid objects the apparent increase of their third dimension is very striking.

For similar reasons, in paresis of accommodation, with a strong effort at accommodation an object fixed appears nearly as small as under normal conditions an object would appear if placed at the near point and casting an equally large retinal image.

This kind of myopia was first observed and explained by Donders in cases of paralysis of accommodation by atropine. In general, atropine mydriasis affords a very good opportunity for the study of paralysis of accommodation.\*

The ciliary muscle is innervated by the nervus oculo-motorius. The course of this nerve is therefore to be examined for the cause of the paralysis of accommodation. Clinically, we should class together in one group those cases in which not only the accommodation, but also all the other muscles supplied by the oculo-motorius are either wholly or partially paralyzed,—that is, cases in which paralysis of accommodation is only one of the symptoms of a paralysis of the oculo-motorius. Even when only a few of the

---

\* Another form of micropia will be described later as a consequence of retinitis.

Micropia has, in many cases, only physical causes. I treated a physician (himself a good observer) for rheumatic paralysis of the abducens on the right side, with strabismus convergens paralyticus in the entire field of vision. He found that under certain fixed conditions the double image seen excentrically appeared much smaller than the fixed object. The double images of an object placed in the median line appeared, as usual, of similar size. There occurred, however, a very marked difference in the size of the images when the patient placed himself opposite the wall of his room and then fixed with his left eye an object lying to his left. Evidently the explanation of this micropia can be deduced neither from the character of the retina nor from the behavior of accommodation or the muscles of the eye. Von Graefe, who was also interested in the case, gave the following explanation of the phenomenon. The retinal image in the deviating eye was projected in a plane whose situation was given by the wall standing opposite to the patient. Now, since the phenomenon was observed always in reference to objects at one side, and since the double images were always homonymous, they were projected at a place on the wall the distance to which was less than to the object fixed. Consequently, the retinal image was referred to an object which at this shorter distance would have given a retinal image of the same size.



muscles innervated by the oculo-motorius are paralyzed, the accommodation is seldom unaffected. On the other hand, in absolute paralysis of accommodation, and of all the muscles supplied by the oculo-motorius, the pupil shows only moderate dilatation, so that it can be considerably more dilated by atropine.

The etiology and therapeutics of these cases coincide exactly with those of paralysis of the oculo-motorius.

Paresis of accommodation in connection with paralysis of the nervus abducens occurs very rarely. This peculiar combination may be explained, as Adamiuk\* has suggested, by assuming that exceptionally fibres supplying the sphincter of the iris may accompany the abducens. In the orbit these fibres always pass through the ciliary ganglion.

Cases occur of complete and incomplete paralysis of accommodation, as an idiopathic affection without participation of the other branches of the oculo-motorius.

In the incomplete form the near point recedes from the eye, but there is still some power of accommodation, and the pupil is often unsymmetrically dilated; in the complete form accommodation is lost, and then often the pupil is dilated ad maximum, exactly as in atropine mydriasis.

The etiology of these cases is generally obscure. A cold is often regarded as a cause, and often no cause can be found. Many cases are due to brain-disease.

The prognosis in reference to the duration and curability of the disease is always uncertain. In reference to retaining the power of vision, it is generally favorable: still, it must be remembered that the paralysis of accommodation may be the precursor of deeper-seated disturbances in the central nervous system.

*Treatment.*—At first an anti-rheumatic treatment generally seems best,—bleeding from the temple, cathartics, diaphoretics, inunction of stimulating substances on the forehead (for instance, veratrin salve), vesication behind the ears and upon the neck, and finally electricity. For internal use ergot is recommended. At the same time the use of the eyes must be limited as much as possible.

A very happy but transitory effect is produced by the extract

---

\* Centralblatt f. die med. Wissenschaften, 1870, N. 12.



of Calabar bean. It contracts the pupil, and where there is only partial paralysis of accommodation it causes the range of accommodation to approach the eye. Indeed, one can observe a temporary positive increase in the range of accommodation, which Donders\* and Hamer have shown to be the physiological effect of the Calabar bean. All the inconveniences of paralysis of accommodation may in this way be relieved for some hours. The hopes placed on extract of Calabar bean as a remedy by which to effect a radical cure have, however, not been realized.

Many cases of paresis of accommodation recover after some weeks or months, either with or without this treatment. A greater number, however, are not benefited by it. In such cases the principal thing to be done is to relieve the optical disturbances. When the affection is on one side only, these disturbances, on account of the dissimilarity of the retinal images, are at first very unpleasant, especially when reading or writing, provided the eye is not myopic. The retinal images of the affected eye are not only diffuse, but, on account of the dilatation of the pupil, they are at the same time more brightly illuminated than those of the other eye, and therefore cannot be so easily neglected. A correction by means of a convex lens, which adjusts the eye for the distance necessary for work, is therefore, at first, generally very agreeable; later, the patients become accustomed to the dissimilarity of the retinal images, just as in difference of refraction, and they then generally lay the spectacles aside.

The disturbances in bilateral paralysis of accommodation are much more important, especially when it is complete and is associated with excessive dilatation of the pupil. It is true that the defect in accommodation may be compensated for by a convex lens, but only for one particular distance. An emmetrope, for instance, with complete bilateral paralysis of accommodation, will, with convex 12, see distinctly at a distance of 12 inches, but at that distance only. Whether the object be moved toward or from him, there begin to be circles of diffusion, which are so much the greater the wider the pupil. For these cases the extract of Calabar bean gives us the means of contracting the pupil, and so making the use of convex glasses for near vision easier and

---

\* L. c., pag. 518.



pleasanter, except where the mydriasis is due to cerebral causes, and there the Calabar refuses to do its work. The solution should be of such a strength that one drop in the conjunctival sac is sufficient to hold the pupil contracted for about twelve hours. Its use may be continued a long time.

Paralysis of accommodation after diphtheritis faucium occurs as one of the symptoms of a very peculiar group of paralyses which appear as sequelæ to diphtheritis, and generally from three to six weeks after it. The severity of the diphtheritic disease has no influence upon them; paralyses may occur after even the mildest cases. A paralysis of the muscles of deglutition is always the first to appear; its symptoms are difficulty in swallowing, a nasal tone, and a disagreeable secondary tone accompanying certain consonants. According to Pagenstecher,\* this throat paralysis is generally unilateral; there is on the one side relaxation of the velum and pharynx, an oblique position of the uvula and epiglottis, imperfect closure of the glottis and anæsthesia of the parts affected. After this follows paralysis of the accommodation, and often of some of the muscles of the eye. Later, there may be paralytic symptoms in the extremities; and lastly, and this is most alarming, paralysis of the muscles of respiration, which may end in death.

As a rule, the accommodation is not absolutely paralyzed. The pupils generally are only slightly dilated, and perhaps there is no dilatation to be recognized, and only a slight diminution in their motility.

Jacobson† found in certain cases where he used atropine energetically during the paresis of accommodation, a much higher degree of hypermetropia than could be demonstrated by the atropine mydriasis after recovery from the paralysis. He drew from this the conclusion that not only the power of accommodation but also the refraction is decreased as a consequence of diphtheritis. Nevertheless, these cases may indicate that during the paresis of accommodation the latent tension is relaxed either absolutely or to a degree easily overcome by atropine, while with normal accommoda-

---

\* Pagenstecher (aus Elberfeld) klin. Monatsbl. f. Augenheilk., 1864, pag. 358.

† Arch. f. Ophth., B. x. 2, pag. 47.



tion considerable latent tension persists. It is then several days before the eye can be reduced to its true refractive condition by atropine. Probably the uninterrupted tension of accommodation induces in the eyes of most youthful hypermetropes a modification in the form of the lens, which does not yield immediately, but only very gradually, to atropine mydriasis.

The prognosis in diphtheritic paralysis is generally favorable: it is grave only in the rare cases where the muscles of respiration are affected.

The paralysis of accommodation generally recovers spontaneously in from six to eight weeks; still, the recovery may be hastened by daily dropping the Calabar-bean extract in the eye, or by the use of electricity, while the disturbances of vision may be relieved by spectacles which bring the near point up to about 12 inches. A moderate use of the muscle of accommodation is thus called into play, which also may contribute to the recovery.

The general health of the patient usually requires at the same time tonic treatment: iron, quinine, good nourishment, etc.

Finally, there is still a peculiar and quite frequent form of mydriasis, with paralysis of accommodation, namely, the traumatic. After contusions of the eye, without any apparent wound, there often appears an unsymmetrical or a complete dilatation of the pupil, with limitation or loss of accommodation.

The prognosis depends in the first place upon the nature of the traumatic cause. Even when, immediately after the injury, no great disturbances of vision occur, there may appear later not only mydriasis, but marked functional anomalies, especially when the injury has caused luxation of the lens.

Slight cases of traumatic mydriasis often pass away spontaneously.

The treatment depends upon the nature of the injury, and at first, at least, must be antiphlogistic. Without there being any paralysis of accommodation, mydriasis may occur in consequence of irritation of the cervical sympathetic. In his own person, during an attack of hemicrania, Du Bois Reymond\* observed a dilatation of the pupil on the affected side. This, and the other symptoms, he

---

\* Archiv f. Anat. und Physiologie, 1860, pag. 461.



regarded as a tetanization of the contractile tissues supplied by the cervical sympathetic (mydriasis spastica\*).

#### SPASM OF ACCOMMODATION.

In describing hypermetropia, we mentioned that in most cases, in young individuals, a part of the hypermetropia is masked by a permanent tension of the ciliary muscle, not under the control of the will. In the course of years the latent hypermetropia becomes manifest either by the limitation of accommodation (presbyopia) or by its paralysis, either pathological or toxic; for instance, by atropine mydriasis. The paralysis of accommodation and the atropine mydriasis set aside not only the voluntary but also the latent tension of accommodation, either wholly or for the greater part. When the paralysis passes away the latent hypermetropia returns. The condition is one of persistent contraction of the muscle, which makes its relaxation beyond a certain limit impossible; up to that limit, however, its action is not interfered with. This condition may be called a tonic spasm, but it must not be forgotten that it bears a physiological impress, since it was introduced, is maintained, and has become habitual in the service of the visual act, and to neutralize as much as possible the disadvantage of hypermetropia.

The case is somewhat different when anatomical emmetropia or hypermetropia is changed by a tonic contraction of the ciliary muscle into apparent myopia. The frequency of latent hypermetropia makes it probable that, in consequence of severe and continuous straining of the accommodation, especially in the evening by insufficient light, youthful individuals frequently lose the power to relax voluntarily their accommodation, and so acquire an apparent myopia. It is more difficult to understand how, in myopia also, there should arise a tonic tension of accommodation to cause an apparent increase of the refraction, especially when there exist those symptoms of irritation described on page 44.

In these cases of spasm of accommodation or apparent myopia the subjective symptoms are very similar to those of accommodative asthenopia. The patients complain of quick fatigue and pain while working, symptoms probably depending upon the

---

\* Comp. Hirschler, Wiener med. Wochenschrift, 1873, No. 17.



fact that the permanent tension of the muscle interferes with its normal movements and endurance. In fact, there is often not only an approach of the far point, but also a withdrawal of the near point.

One circumstance is useful in making the diagnosis, and we have already referred to it in connection with latent hypermetropia: it is the fluctuation of the tension of accommodation about the limit of the far point. Just as in latent hypermetropia the patients sometimes prefer stronger, sometimes weaker, convex glasses, so is the same thing noticed with reference to concave glasses in apparent myopia. A certain diagnosis can be made only by determining the optical adjustment of the eye before and after the action of atropine.

In the treatment of apparent myopia the general care of the eye is of the greatest importance. In obstinate cases atropine can be used continuously for two weeks; blood may be taken from the temple by means of the artificial leech. If hypermetropia exist, it is to be corrected.

As above intimated, this condition passes over without sharply-defined limits into normal relations. Even in eyes which, upon examination, appear emmetropic, act normally and give occasion for no complaints, there is frequently during the atropine mydriasis a condition of refraction  $\frac{1}{40}$  to  $\frac{1}{60}$  weaker. It would be hardly proper to class such cases among those of spasm of accommodation.

It is, moreover, to be observed that there are certain sources of error scarcely to be avoided in the methods of examination employed in practice for determining the acuteness of vision and the condition of refraction. This must make us careful to avoid drawing conclusions based upon slight differences observed in examinations made at different times.

Of another nature are certain hitherto little-noticed cases, in which the accommodation is narrowed down to a space very near the eye.

The Calabar myosis\* presents a typical picture of toxic spasm of accommodation, such as often develops pathologically. A few minutes after dropping into the eye a 10 per cent. solution in

---

\* Donders, l. c., p. 513; v. Graefe, Arch. f. Ophth., Bd. ix. 3, pag. 87.



glycerin of the extract of Calabar bean there begins a considerable contraction of the pupil, which in from twenty to thirty minutes attains its maximum. At the same time both the far point and the near point approach the eye, and the relative range of accommodation is so changed that too strong a tension of accommodation is associated with the convergence of the visual axes.

In about three-quarters of an hour after the instillation of the Calabar extract the far point begins gradually to recede again, and after about two hours attains its original position. The simultaneous withdrawal of the near point follows more slowly, so that for some hours there is an actual increase in the range of accommodation. The contraction of the pupil begins to give way some hours after the instillation, but remains recognizable for two or three days.

The subjective symptoms are,—

1. Pains which accompany every strong voluntary tension of the ciliary muscle when the application has been too strong, or when there is peculiar sensitiveness of the patient.

2. The entire field of vision seems strangely shaded; this is due to the diminished illumination caused by the myosis. After a time this symptom disappears as the retina accommodates itself to the fainter light.

3. There is macropia, the explanation of which is analogous to that of micropia in atropine mydriasis.

In connection with spasm of the ciliary muscle, mention must be made of those rare cases in which even slight demands upon the ciliary muscle cause immediately severe pain. This condition, according to Donders,\* occurs only in hypermetropia, but it may be in cases of the very lowest degree. The symptoms are similar to those of accommodative asthenopia, but can be distinguished from them by the fact that convex glasses have no influence upon them, since the convergence necessary for near vision is of itself sufficient to account for the painful contraction of the muscle of accommodation. That it is, however, an affection of the muscle is proved by the fact that with complete atropine mydriasis and the help of correcting convex glasses work can be continued without inconvenience.

---

\* L. c., pag. 241.



Complete recovery may be obtained by continuing for months the use of atropine.

There is an entirely different cause for certain nervous difficulties, which must here be mentioned, because they give rise to symptoms very similar to spasm of the ciliary muscle. After working a short time, disturbances are felt in the eyes, which make it necessary to lay the work aside; often it is not possible to observe attentively either a near or a far object; generally other nervous symptoms, and often hysteria, are present.

The term myosis expresses in general every continuous contraction of the pupil; usually, however, those cases are excluded which depend upon contraction of the sphincter pupillæ, caused by irritation of the ocular branches of the nervus trigeminus, as by irritating substances, foreign bodies, inflammation, etc.

Myosis is often only a symptom of disease of the nervous centres, especially of the spinal cord; or it may depend upon peripheral paralysis of the cervical filaments of the sympathetic.

In many cases there is no evident cause; especially in aged persons one often finds very small and slightly active pupils, which widen only a little under the use of atropine.

#### MONOCULAR POLYOPIA AND DIPLOPIA.

There is, finally, one symptom to be mentioned which may occur in all the anomalies of refraction and accommodation, and is then always to be explained upon the principle of Scheiner's experiment. The conditions precedent to the appearance of this symptom are an inaccurate adjustment of the eye upon the point fixed, and the existence of irregularities in the structure of the refracting media. Monocular polyopia under physiological relations may always be produced experimentally.\* Under pathological relations it is principally irregularities in the cornea, or in the iris (coloboma, or defects near the pupil), or in the lens (cataracta incipiens, or luxation), which, in connection with inaccurate optical adjustment, cause polyopia.

---

\* Comp. Helmholtz *physiol. Optik*, pag. 139.



## II.

### SPECTACLES, OPHTHALMOSCOPE, AND OPHTHALMOMETER.

#### SPECTACLES.

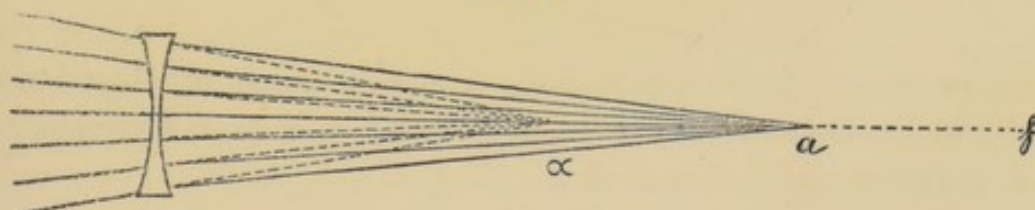
SPHERICAL lenses are those most frequently employed. Rules for their use having been already given, it remains only to note their most elementary optical laws.

#### SPHERICAL LENSES.

*a. Concave Lenses.*—Rays of light which fall parallel upon the surface of a concave lens diverge after refraction as if they came from its negative focus. Thus a virtual diminished image of distant objects is formed in the focus of the concave lens. Rays of light which, proceeding from a point at a finite distance, fall divergent upon the surface of the concave lens, after refraction diverge as if they had proceeded from a point within the focus. The conjugate focal distances are calculated by the formula  $\frac{1}{a} + \frac{1}{\alpha} = -\frac{1}{f}$ .

If, for example, in Fig. 14, the distance of the negative focus

FIG. 14.



( $f$ ) be 12 inches ( $\frac{1}{f} = -\frac{1}{12}$ ), and the distance of the point  $a$ , seen through the concave glass, be 9 inches ( $\frac{1}{a} = \frac{1}{9}$ ), then the position of the conjugate focus  $\alpha$  is determined by the calculation  $\frac{1}{\alpha} = -\frac{1}{f} - \frac{1}{a} = -(\frac{1}{9} + \frac{1}{12}) = -\frac{1}{5\frac{1}{4}}$ . That is to say, the light, after refraction in a concave lens, diverges as if it had proceeded from



a point  $5\frac{1}{7}$  inches distant,—that is, from  $\alpha$ , the virtual image of the point  $a$ .


If the far point of the myopic eye coincide with  $f$ , and the near point with  $\alpha$ , then by the use of the concave lens the far point is removed to an infinite distance, and the near point to the distance of  $a$ . The virtual images of all objects seen distinctly fall between  $\alpha$  and  $f$ . No virtual image can be formed at a greater distance than  $f$ , because the image of an object at an infinite distance is formed at  $f$ . (For convergent rays of light the dispersion-point, it is true, would lie farther distant than  $f$ . We may, however, for the present neglect this case.)

Virtual images which lie between the concave glass and  $\alpha$  give no distinct retinal images, because the accommodation is insufficient,  $a$  being the near point.

*Convex Lenses.*—Rays of light which fall parallel upon the surface of a convex lens converge, after their refraction, in such a manner that they intersect each other at its focus. Rays coming from a far-distant object may be regarded as parallel; after refraction they accordingly form at the focal distance of the lens an inverted diminished image. If a luminous point lie at a finite distance from the convex lens, the conjugate focal distance is calculated from the formula  $\frac{1}{a} + \frac{1}{\alpha} = \frac{1}{f}$ .

If, in Fig. 15, the distance of the focus  $f$  be 4 inches, and the

FIG. 15.



object  $a$  be placed 12 inches distant, then the image  $\alpha$  must be formed 6 inches beyond the lens, since  $\frac{1}{a} = \frac{1}{4} - \frac{1}{12} = \frac{1}{6}$ . The image at  $\alpha$  is inverted and diminished.

Inversely: if the rays proceed from  $\alpha$ , an enlarged inverted image will be formed at  $a$ . The size of the image is the same as that of the object when the object is placed at twice the focal distance of the lens.

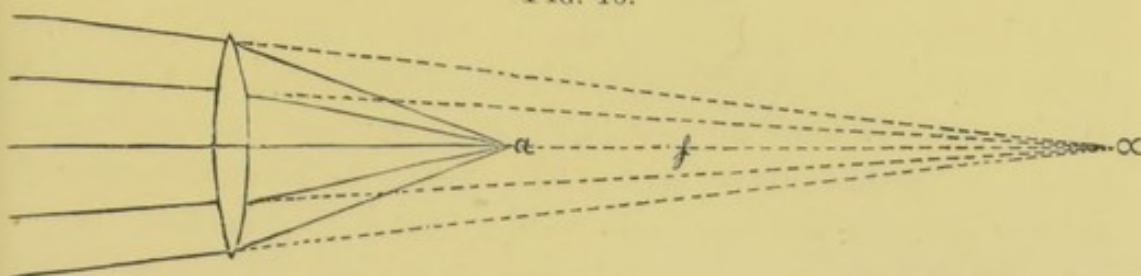
If the luminous point be at the focus, the rays, after refraction, are parallel.

If, as in Fig. 16, the luminous point  $a$  lie between the focus



and the lens, the rays, after refraction, will diverge as if they came from  $\alpha$ , a point lying beyond the focus.

FIG. 16.



In the formula  $\frac{1}{a} + \frac{1}{\alpha} = \frac{1}{f}$ ,  $\alpha$  becomes a negative quantity,—that is, a virtual image is formed. For instance, if the focal distance be 12 inches and the object be placed at a distance of 8 inches, the virtual image  $\alpha$  will be formed at a distance of 24 inches.

This relation is illustrated in emmetropic or slightly myopic eyes, which, on account of presbyopia or paresis of accommodation, require the use of convex glasses. Only such objects as lie at or within the focal distance can be distinctly seen; the rays from a more distant object converge after their refraction and intersect each other before reaching the retina.

In facultative hypermetropia, a correcting convex glass being used, objects placed within the focus can be distinctly seen up to a distance determined by the strength of the accommodation. All objects lying beyond the focus can also be distinctly seen, because such eyes can accommodate to convergent rays. In absolute hypermetropia only objects lying beyond the focal point can be seen, because such eyes are adapted only to convergent rays.

Biconcave or biconvex lenses are the ones generally used for spectacles. They should be so fixed in their frames that the centre of the lens is exactly opposite the pupil. Lenses intended for use on near objects must therefore have their optical centres somewhat nearer together than those to be used upon distant objects; they must also be so inclined to each other that their axes nearly correspond to the convergence of the visual axes.

Wollaston recommended the so-called periscopic glasses. These are positive or negative meniscuses,—that is, lenses having one concave and one convex surface of different curvature. They diminish spherical aberration. In weak glasses this advantage is of little importance, and in strong ones it is greatly overbalanced by the thickness of their edges.

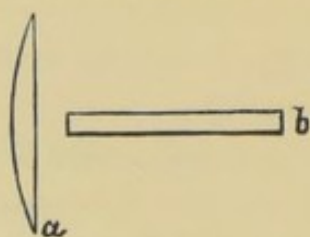


Franklin was the first to propose an arrangement for the convenience of those who require one pair of lenses for near and another for distant objects. He placed the two sets of lenses in the same frame, in such a manner that in the case of convex glasses one-half of a weak lens, for distant objects, is in the upper part of each frame, and one-half of a stronger one, for near objects, is in the lower part. For concave glasses the relative position of the stronger and weaker lenses is reversed. Still better are the glasses of double focus now in use. The upper half is so ground as to be suitable for distant objects; the lower half for near ones. Such glasses are especially adapted to presbyopic hypermetropes, since the slightest movement is enough to adjust the eye either for near or distant vision.

#### CYLINDRICAL LENSES.

In spherical lenses the curved surfaces form portions of a sphere; in cylindrical lenses they form portions of a cylinder. If from a solid glass cylinder, a piece be cut by a plane parallel with its axis, a plano-convex cylindrical lens is obtained. The figure presented by the cross-section of such a lens is the segment of a circle, bounded on one side by the arc, on the other by the

FIG. 17.



Section through a cylindrical convex glass: *a*, at right angles; *b*, parallel to the axis of the cylinder.

chord (see Fig. 17, *a*). The figure presented by the section of such a lens by a plane parallel with the axis of the cylinder, is bounded by parallel straight lines (Fig. 17, *b*).

Rays of light which diverge in the plane of the axis are therefore refracted, as in a plane glass; while rays which diverge at right angles to the axis experience a refraction corresponding to the radius of curvature.

Lenses which have two cylindrical curved surfaces, whose axes are at right angles to each other, are called bi-cylindrical lenses. If in this case the radii of the two curved surfaces be equal, and both surfaces be either concave or convex, the effect is the same as that of a spherical lens.

Sphero-cylindrical lenses have one spherical and one cylindrical curved surface. The surfaces may be both concave, or both convex, or one may be concave and the other convex.



Great care must be taken in setting cylindrical lenses in spectacle frames. They must be so placed that the axis of each cylinder lies in the plane of one of the principal meridians of the eye. Supposing the principal meridian of the shortest focal distance in an astigmatic eye to be vertical, then concave cylindrical glasses must be set with their axes horizontal, and convex glasses with their axes vertical.

If the principal meridians are neither exactly vertical nor horizontal, one may either direct the optician at what angles he must place the axes, or the glasses may be made circular and so set as to turn in their frames. The proper direction for the axes of the cylindrical lenses may then be found experimentally. If the spectacles are to be used principally for near objects, their proper position should be determined by testing them upon objects at the usual reading distance.

The refraction of light by an asymmetric system is easily demonstrated by allowing the rays from a luminous point to pass through a strong convex lens combined with either a cylindrical or a Stokes lens, and, after their refraction by this apparatus, to receive them on an opaque, ground-glass plate. The shape of the image formed at any point within the focal interval is thus beautifully shown.

Light is refracted in a similar manner in spherical lenses whose axes are placed at an inclination to the direction of the impinging rays. In cases, therefore, in which strong spherical lenses are necessary, for instance after cataract operation, a slight degree of astigmatism may be corrected by giving the lenses a proper inclination.

#### PRISMATIC SPECTACLES.

Rays of light on passing through a prism are refracted toward its base. The degree of their refraction increases with the increase of the refracting angle of the prism, and with the refrangibility of the rays themselves. A limitation of the use of prismatic spectacles is thus set, both by the diffusion of color and the weight of the prisms. There is no difficulty in correcting the diffusion of color by means of achromatic prisms; but such glasses, being a combination of two prisms, are too cumbersome to allow their use as spectacles.

Prisms with a refracting angle greater than  $6^\circ$  can hardly be

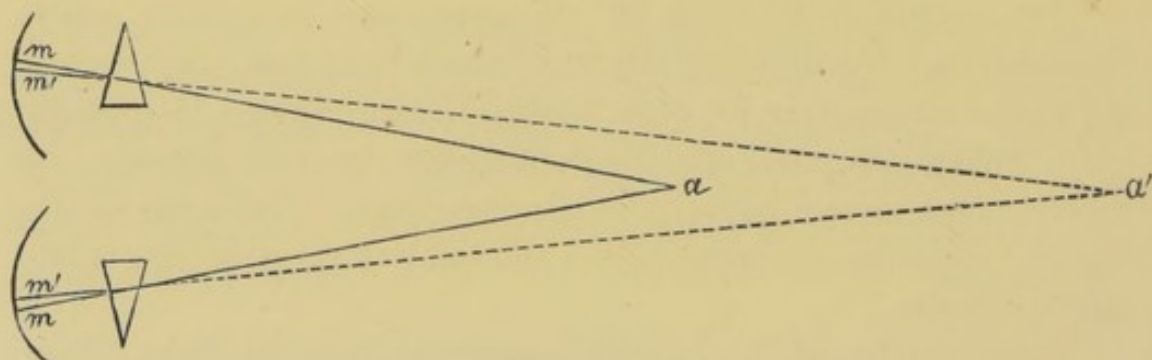


used as spectacles. At about this limit the diffusion of color and the weight of the glasses begin to cause inconvenience. Prisms with a refracting angle greater than  $4^\circ$  are seldom used.

The advantage derived from the use of prisms is, that they unite double images when not widely separated, and thus prevent the occurrence of diplopia. For example, if the axis of vision of one eye be directed exactly upon an object, and if the axis of vision of the other eye deviate outward from the object, the image in the deviating eye will fall to one side of the macula lutea. By the choice of a proper prism it can, however, be thrown directly upon it.

Prisms are oftenest used where there is insufficiency of the internal recti muscles. They unite double images and prevent diplopia.

FIG. 18.



In Fig. 18, suppose the point  $a$  to be placed in the median plane and so near the eyes that the internal recti muscles can direct the axes of vision simultaneously upon it but are unable to hold them continuously there. Now, if we place before each eye a prism with its refracting angle turned outward, the place of the retinal image  $m$  will be moved to  $m'$  on the median side of the macula lutea. Double images appear, but are almost immediately united, as the cornea turns spontaneously outward and the macula lutea inward. Meanwhile the accommodation remains unchanged, and is directed upon the distance of the point  $a$ , while the axes of vision intersect at the more distant point  $a'$ .

We have thus substituted prisms for the action of the recti interni muscles, just as convex lenses may be substituted for the action of accommodation. But while the use of convex lenses presents no difficulties, that of prisms has very narrow limits. How much now can be accomplished within these limits? The



answer to this question depends upon the situation of the far point. The nearer the point upon which the visual axes must converge, the less the effect of prisms. The minimum of deviation in the case of weak prisms, thus employed, is equal to about half their refracting angles; for stronger prisms it is somewhat more. We can calculate the place of the apparent image of any given object when seen through prisms.

A myope, without the help of concave glasses, can get no distinct image of an object lying beyond his far point. If, for instance, his far point be 100 mm., or about 4 inches distant, then  $M = \frac{1}{4}$ . If convergence upon this point cannot be maintained, the point of intersection of the axes of vision can be removed farther from the eyes by placing in front of each, a prism of  $4^\circ$ , with the refracting angle turned outward. The calculation shows that the point of intersection is thus removed 15 mm. Instead of converging upon a point 100 mm. distant, it is now necessary to converge upon a point 115 mm. distant (less than  $4\frac{1}{2}$  inches). But it is still questionable whether most myopes, under such circumstances, may not prefer, in place of so inadequate assistance, either with or without prismatic spectacles, to renounce binocular vision, and to see distinctly with relative divergence and monocular vision.

Even with stronger prisms, little more can be accomplished. Prisms of  $6^\circ$ , with their bases turned inward, placed before each eye, with an object distance of 4 inches, remove the apparent place of the image only to  $4\frac{4}{5}$  inches. The convergence necessary for binocular vision is therefore only slightly diminished.

The relations are more favorable when it is possible to employ greater distances. An object being 10 inches distant, a prism of  $4^\circ$  before each eye removes the apparent place of the image toward which the visual axes must converge to a distance of  $12\frac{1}{6}$  inches. If now it is wished to use the eyes upon work at a distance of 12 inches, these same prisms make it possible to maintain binocular fixation with a convergence of the visual axes of not more than 18 inches.

Prismatic spectacles are more useful the greater the distance of the work upon which they are employed. For this reason, in many cases of myopia, more can be accomplished with concave prismatic glasses than with simple prisms. Such glasses, it is



true, always give somewhat irregular retinal images, on account of the asymmetric refraction caused by the inclined position of the curved surfaces.

Convex lenses whose axes do not coincide with the axes of vision act as sphero-prismatic lenses. The degree of refraction which they cause depends on the focal distance of the lenses, and the degree of their eccentricity. If, for instance, a 6-inch convex lens be so placed in spectacle frames that its optical centre is  $\frac{1}{4}$  of an inch toward the median line of the visual axis, the same effect is produced as by combining a convex lens of 6 inches focal distance with a prism of  $4^\circ$ , with its refracting angle turned outward. With weaker glasses and less eccentricity the effect is naturally slighter.

#### STENOPAIC APPARATUS.

Donders's stenopaic apparatus is an arrangement by which the rays of light are admitted to the eye only through a small circular opening or a very narrow slit. It is an indispensable instrument in diagnosing anomalies of refraction. The use of this apparatus often causes a marked improvement of vision in cases of cloudiness of the cornea, lens, or any of the refracting media. But it is seldom possible to wear it in the form of spectacles, because the field of vision is made so small. It is most applicable to spectacles which are used on near objects.

Donders recommends stenopaic spectacles in cases of high degree of myopia combined with loss of distinct vision, where the proper correcting lenses cause only slight improvement of vision for distant objects, because the retinal images are rendered so small. Concave glasses, too weak to fully correct the myopia, give larger retinal images; but under these conditions the pupils are quite large, and the circles of diffusion are correspondingly annoying. A combination of these weak lenses with a stenopaic opening of about 1 mm. diameter lessens the size of the circles of diffusion without affecting that of the retinal images.

#### PROTECTIVE SPECTACLES.

Blue or smoke glasses are the best to protect the eyes against dazzling light. In order to protect the whole field of vision as uniformly as possible, the spectacles should be shaped like watch-glasses, or else be provided on the temporal side with a small



shade of silk or of colored glass. If this precaution be not observed, the light falling upon the eyes from the side becomes the more annoying the darker the glass. It is not advisable to wear such glasses when the light is not dazzling, as the practice rather tends to increase the sensitiveness to the impression of light. It must also be remembered that the darker the glasses the more heated they become when exposed to the sun, and, consequently, the more hurtful to the eyes.

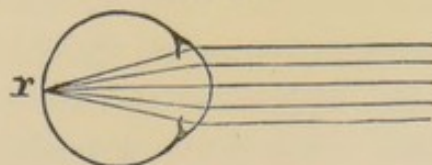
#### THE OPHTHALMOSCOPE.

In the ophthalmoscopic illumination of the eye, the first condition to be fulfilled is that light shall be thrown into it in the direction of the visual axis of the observer.

The construction of the various ophthalmoscopes by which the fundus of the eye is illuminated will be briefly explained in the latter part of this section. They have all the common object to cast upon the fundus of the eye either a distinct or a diffuse image of the light used for illumination. This being accomplished, we must next see what happens with the rays which have been united upon the fundus and have there formed an image of the light. Part of them are absorbed by the pigment in the fundus; the remainder are reflected diffusely, and a part of these thus diffusely reflected rays pass out of the eye, through the pupil, through the ophthalmoscope, and into the eye of the observer. To him, therefore, the pupil of the eye examined appears brightly illuminated.

What now is the exact direction of the rays reflected from the fundus of the eye after they emerge from the refracting media? This question can be easily answered so soon as we know the position of the fundus in relation to the focus of the refracting media. If, as in the emmetropic eye, the length of the visual axis equal the focal length of the dioptric apparatus, then will the rays from each illuminated point in the fundus, after their exit from the refracting media, form a parallel beam. Since, for example (as in Fig. 19), rays of light which fall parallel upon the schematic eye are, after their refraction, focused upon the fundus at  $r$ ; conversely, rays which proceed from  $r$ , after their exit from the eye, are parallel.

FIG. 19.





If now the observer be emmetropic, these parallel rays falling upon his cornea will be focused upon his retina. For each point of the fundus of the examined eye he will receive a distinct retinal image; that is to say, he can see the fundus without any further optical aid.

The dioptric apparatus of the eye examined, serves the observer just as a lens, by means of which he can see an object (in this case the fundus) placed at its focus. The lens gives, under these circumstances, an upright, enlarged image, and for that reason this kind of ophthalmoscopic examination is called "the examination in the upright image."

Later we will speak of the modification of this examination in cases where the observer is not emmetropic. For the present, to avoid complication, we will suppose him to be so.

The most favorable condition under which to see an object at the focal distance of a lens is to place our own eye as near as possible to the lens. Only under this condition do we have the field of vision in its greatest extent. As we increase the distance between our eye and the lens, there is only an apparent enlargement of the image; simultaneously, however, the size of the visual field is rapidly diminished.

It follows, therefore, that to examine the fundus of an emmetropic eye in the upright image the examiner must place his own eye as near as possible to it. If he place his own eye at too great a distance, the field of vision becomes so contracted that small objects, no broader than a retinal vessel, entirely fill it. It is no longer possible to obtain a complete and distinct view of the fundus.


The size of the visual field is always somewhat smaller than the pupil of the eye under examination. It is, moreover, somewhat obscured by the unavoidable corneal reflex. A second essential condition to be fulfilled is, that the observer relaxes fully his accommodation, so that his eye is adjusted for parallel rays. The same applies to the eye under examination. Their nearness to each other causes a tendency, both in the examined eye and in that of the examiner, to involuntary accommodation. This may be avoided on the part of the patient by directing his attention upon some distant object. The examiner must, however, learn without any such help to avoid all accommodation. If he cannot



do this, he is, during an ophthalmoscopic examination, in the same condition as a myope, and must make use of the same means of correction.

If the eye under examination be myopic, the relations are those shown in Fig. 20.

FIG. 20.

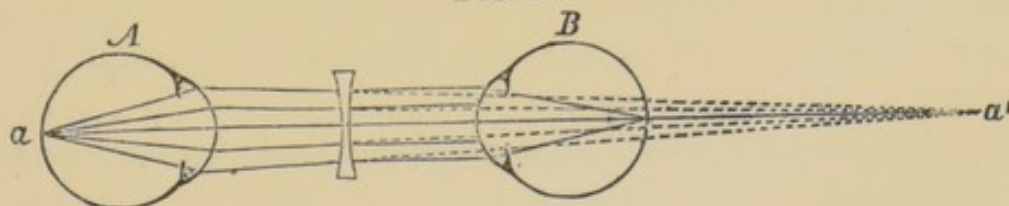


Rays which fall parallel upon the cornea are focused at  $\phi$  in front of the retina. In order to cast its image upon the retina, the luminous point must approach the eye to the point  $r$ . Then rays of light which diverge from the point  $r'$  within the eye will, after their exit from it, converge toward the point  $r$ .

Assuming entire relaxation of accommodation, the rays of light which diverge from the fundus of a myopic eye will be focused at the far point of the eye. At this distance an enlarged inverted image of the fundus is formed. In the ophthalmoscopic examination of a myopic eye, the rays emerge from it in converging beams, and they cannot be united in a distinct retinal image in the eye of an emmetropic observer. He will accordingly see the fundus of the myopic eye only in indistinct outlines. In order to get a distinct image the convergent beams must be converted into parallel ones.

In Fig. 21, let  $A$  be the myopic eye under examination, and  $B$  the emmetropic eye of the observer adjusted for parallel rays.

FIG. 21.




The rays from the point  $a$  of the eye  $A$  will intersect at the far point  $a'$ . Suppose this distance to be 10 inches ( $M = \frac{1}{10}$ ). If now there be placed in front of the eye  $B$  a concave lens of such a power that its negative focus coincides with the point  $a'$ , then the rays which fall convergently upon it will be refracted into parallel ones, and will consequently form a distinct retinal image in the eye  $B$ . If the distance between the concave glass and the



eye *A* be 2 inches, the concave lens must have a focal distance of 8 inches. The fundus is seen just as is an object through a Brücke lens. The convex glass of the instrument corresponds with the refracting apparatus of the myopic eye, while the ocular corresponds with the concave glass in front of the eye of the observer.

It follows from what has been said that in high degrees of myopia the image may be formed within a very few inches of the

FIG. 22.

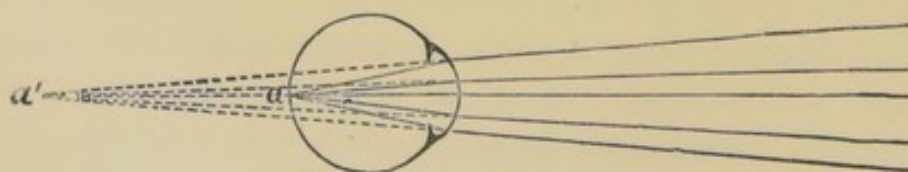


eye. If, for instance, in Fig. 22, the far point *r* of the eye be at a distance of 3 inches, an inverted enlarged image, *n'*, will be formed at that distance. The observer, whose axis of vision is directed upon *n*, needs, in order to see the image at *n'*, only to withdraw so far from it that he can accommodate his eye upon it, or he may use a weak convex lens, say  $+\frac{1}{10}$ . He can thus get an inverted enlarged view of any part of the fundus. If the observer approaches the observed eye, the inverted image becomes indistinct so soon as it comes to lie between the observer's eye and his near point. As he approaches still nearer it becomes unrecognizable.

The extent of the visual field depends upon the size of the pupil of the eye observed. But even with the pupil fully dilated it must always be rather small, since the distance between the examiner's and the examined eye must necessarily be from 8 to 12 inches.

If the examined eye is hypermetropic,—that is, if the fundus lie

FIG. 23.



in front of the focus of the dioptric apparatus,—then will the light reflected from *a* (Fig. 23) diverge, after its exit from the eye, as if



it had proceeded from the point  $a'$ . In this examination the relations are the same as if we were examining the fundus with a lens which relatively to its focal distance had approached too near the eye, or, in other words, as if we were examining with too weak a lens. Under these conditions the enlargement diminishes, while the extent of the field increases. In emmetropia we were always compelled to approach as near as possible in making our examination, because upon withdrawing from the eye the field of vision diminished so rapidly that soon even the smallest objects could not be seen. This disadvantage becomes less in hypermetropia, and this is the reason for the easily observed and characteristic phenomenon, that immediately upon making the ophthalmoscopic examination the observer sees the various parts of the fundus in an upright enlarged image. Since the place of this image is behind the eye under examination, the observer must regulate his accommodation accordingly. Upon approaching the eye the size of the visual field increases, but it can happen only in cases of the highest degree of hypermetropia, in which the far point lies only a few inches behind the eye, that the image becomes indistinct, by reason of its lying within the near point of the observer.

Instead of employing his accommodation, it is in general better for the observer to use a convex lens. The lens should be so chosen that its focus coincides with the far point of the examined eye. If with his own eye placed as near as possible to the examined eye the observer can still see the details of the fundus through a convex lens, hypermetropia exists.

All the rules which have been given are equally applicable to the case of an examiner who is not emmetropic, provided he first correct his ametropia by a suitable lens.

To examine an emmetropic eye in the upright image, a myope must use a concave lens which fully neutralizes his myopia, which places his far point at an infinite distance, in short, which makes the relations the same as in emmetropia. A fact may here be mentioned which Helmholtz\* first called attention to. It is this, that an emmetrope requires a somewhat stronger concave lens to see the fundus of a myopic eye than does a myope to see the fundus of an emmetropic eye. As already shown in Fig. 21, the

---

\* Beschreibung eines Augenspiegels, 1851, pag. 24.



focal distance of the lens used by the emmetropic observer must be shorter than that used by a myopic observer by a distance equal to that at which the eyes are held from each other during the examination.

In examining a myopic eye, a myope must correct by the use of a concave lens not only his own myopia but that of the patient.


A myope may examine a hypermetropic eye without concave glasses, provided the hypermetropia be somewhat greater than his own myopia. If the hypermetropia be less, the myope will require a concave lens which will remove his far point till it coincides with that of the hypermetropic eye.

A hypermetrope can examine an emmetropic eye with his own correcting glasses. For a degree of myopia somewhat less than his own hypermetropia, he requires no correcting glasses. If the myopia is greater than his own hypermetropia, he must by the use of a concave lens so change the direction of the convergent rays from the myopic eye that they shall converge toward his own far point. For a hypermetrope to examine a hypermetropic eye in the upright image, he must either accommodate strongly or use convex glasses.

#### EXAMINATION IN THE INVERTED IMAGE.

We will suppose the fundus of the eye in Fig. 24 to be illuminated, and that the rays emerging from the pupil are received by the convex lens  $c$ ; then, according to known laws, will the rays proceeding from  $a$  be again united at the point  $a'$ . If the eye under

FIG. 24.



examination be emmetropic, so that the rays of light upon emerging from the pupil are parallel, then will the point  $a'$  coincide with the principal focus of the convex lens. If the eye be myopic, the rays fall converging upon the convex lens, and the point  $a'$  will lie nearer to it than its principal focus; in hypermetropia, where the light diverges from the eye, the point  $a'$  will lie beyond the principal focus. The position of the point  $b'$  is found in the same



way. The direction of the rays proceeding from  $b$  is determined by a line which, proceeding from the point  $b$ , intersects the line  $a a'$  at the nodal point of the eye. One of the rays belonging to this beam will pass through the nodal point of the lens  $c$ , and is therefore the axial ray upon which all the rays belonging to this beam, which are refracted in the lens, are united (for instance, at  $b'$ ).

It is evident that the inverted image is so much the greater the greater its distance from the convex lens, since the farther  $a'$  is removed the greater will be the distance between  $a'$  and  $b'$ .

Now, in order to see distinctly the inverted image cast in this manner, the observer has only to take care that his line of vision coincides with the line  $a a'$  and that his accommodation is adjusted upon the image  $a' b'$ .

The size of the field of vision in the examination in the inverted image depends on the size of the pupil in the eye under examination and on the focal length of the convex lens; the shorter its focal distance, the less the enlargement and the greater the field of vision. A proper holding of the convex lens is of great importance. Its distance from the eye under examination should be about that of its focal length. If the convex lens be so held that rays of light which fall parallel upon it are, after their refraction, united exactly at the plane of the pupil of the eye under examination, then, conversely, will rays of light diverging from every point in the plane of the pupil, after their refraction in the convex lens, become parallel. In this case the image of the pupil cast from the convex lens attains its greatest dimensions; since it lies at an infinite distance it will be infinitely large. If the convex lens be held too near the eye, it casts a virtual image of the iris; if too far, a real image. In both cases the field of vision is diminished.

#### SIZE OF THE OPHTHALMOSCOPIC IMAGE.

We base our discussion of the size of the ophthalmoscopic image upon Listing's schematic eye as reduced by Donders.\* The entire dioptric apparatus is here represented by one curved surface bounded in front by atmospheric air, behind by the aqueous humor, and whose radius of curvature is 5 millimetres.

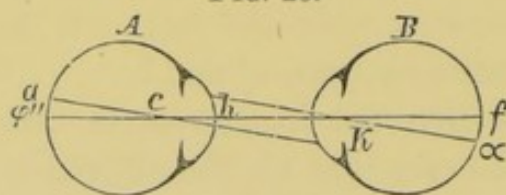
---

\* L. c., pag. 149.



The point  $c$ , Fig. 25, lying 5 millimetres behind the point  $h$  of the curved surface, is the optical centre. The index of refraction is  $=\frac{4}{3}$ . Rays of light which fall parallel upon the anterior curved surface are united in the second medium at  $\phi''$ , 20 millimetres behind  $h$ ; the length of the axis of vision is 20 millimetres, and the distance  $c \phi''$  must consequently be 15 millimetres. In making the ophthalmoscopic examination, we place, as in Fig. 25, two emmetropic eyes

FIG. 25.



opposite each other. It is plain that all the rays of light proceeding from the point  $a$  in the eye  $A$  will, after emerging from it, form a beam whose direction is determined by the axial ray  $a c$ . One

of the rays belonging to this beam striking the eye  $B$  will be directed upon the nodal point  $k$  of this eye, and will consequently pass through it unrefracted, forming the axial ray, upon which all the rays proceeding from  $a$  will intersect;  $\phi$  will consequently be the optical image of the point  $a$ . Since upon our supposition the lines  $a c$  and  $\phi k$  are parallel, the angles  $a c \phi''$  and  $\phi k f$  will be equal.

An immediate consequence of our supposition is that the image and the object have the same size; or in this particular case the optic disc of the eye  $A$  casts in  $B$  a retinal image exactly as large as itself. The distance between the two eyes has no effect on the size of the image: it is plain, however, that the field of vision becomes smaller the more  $A$  and  $B$  are removed from each other.

Under what angle now does the optic disc of the eye  $A$  appear to the eye  $B$ ? Evidently it is the angle  $f k \phi$ , which we call the angle of vision. Its size is easily calculated. If  $k f = c \phi'' = 15$  millimetres, and if, for simplicity, we call the diameter of the optic disc 1.5 millimetres, then the angle of vision expressed in terms of the arc of a circle  $= \frac{1.5}{15}$ , or in degrees  $\frac{1.5}{15 \times 3.14} \times 180^\circ = 5.73^\circ$ .

What now are the relations when the eye  $A$  is not emmetropic?

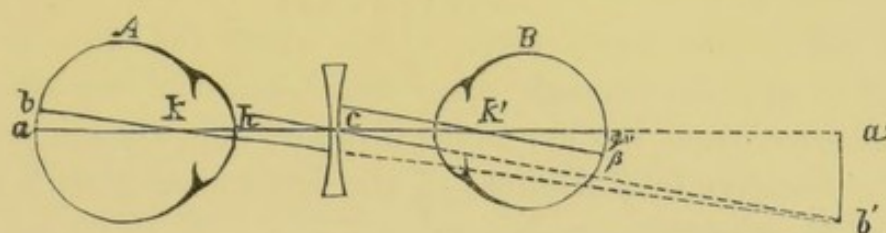
If  $A$  be myopic in consequence of elongation of its axis, and if its far point lie, for instance, 139.5 mm. in front of  $k$  (that is, myopia of about  $\frac{1}{5}$ ), we can find the length of its axis by calculating, with reference to such a far point, the conjugate focus in the eye  $B$ , whose curved surfaces of course remain unchanged.



The formula for the calculation is  $\frac{1}{F} = \frac{1}{\varphi''n} - \frac{1}{na}$ ,\* in which  $F$  is the conjugate focal distance sought,  $\varphi''$  the principal focal distance = 20 mm.,  $n$  the index of refraction =  $\frac{4}{3}$ , and  $a$  the distance of the object from the anterior curved surface  $h = 134.5$  mm. This calculation shows an increase in the axis of 2.5 mm.

In Fig. 26 the eye  $A$  has an axis of 22.5 mm., and did not the emmetropic eye of the observer intervene, the object  $a b$  would cast its enlarged inverted image  $a' b'$  at a distance of 139.5 mm. from  $k$ .

FIG. 26.



All the rays converging toward  $a$  become parallel after passing through the concave glass  $c$ , provided the negative focal point of  $c$  coincide with  $a'$ . Further, one of the rays converging toward  $b'$  will pass through the optical centre of the concave lens  $c$ , and will indicate the direction of the parallel beam, into which all the rays converging toward  $b'$  have been converted.

We need only draw through  $k'$ , the optical centre of the eye  $B$ , a line parallel to the line  $c b'$  to obtain the axial ray, upon which the image of  $b'$  ( $\beta$ ) is formed.

The angle  $\varphi'' k' \beta$  is therefore the visual angle under which the object  $a b$  is seen ophthalmoscopically, and we will in future designate it by the letter  $d$ . It is evident from the figure that the size of this angle depends on the distance of the concave glass  $c$  from the eye  $A$ . The more the concave glass approaches the image  $a' b'$ , so much the shorter is its conjugate focal distance, so much the greater becomes the angle  $b' c a'$ , which, as a parallel angle, is equal to the angle  $d$ , so much the greater is the image, but so much the smaller is the field of vision. The conditions are similar to those in a Brücke lens or a Galilean telescope. It is only necessary in Fig. 26 to substitute a convex lens for the eye  $A$ . In the Galilean telescope the principal focus, and in Brücke's lens

\* Comp. Wüllner, Einleitung in die Dioptrik des Auges, pag. 12.



the conjugate focus, with reference to the object distance, coincide with  $a'$ : the rest is unchanged.

The value of the angle  $d$  is determined by the following calculation. As already said,  $d = \text{angle } a' c b'$ ; consequently, expressed in terms of the arc of a circle,  $d = \frac{a' b'}{a' c}$ .

The value of  $a' b'$  is determined from the proportion  $a' b' : a b :: a' k : a k$ . Now,  $a k = h a - h k$ ,—that is,  $= 22.5 - 5 = 17.5$  mm.  $a' k = 139.5$  mm. Then, taking from the above  $a b = 1.5$  mm., we have  $a' b' = \frac{1.5 \times 139.5}{17.5}$ , consequently  $d = \frac{1.5 \times 139.5}{a' c \times 17.5}$ , or expressed in degrees,  $d = \frac{1.5 \times 139.5}{a' c \times 17.5 \times 3.14} \times 180^\circ$ .

The size of the visual angle under which the optic nerve of the eye  $A$  appears depends upon the distance of the correcting concave glass from the eye under examination, always provided that the negative focal distance of the lens coincides with the far point of the eye.

If we hold a concave lens of 124.5 mm. focal length in front of the mirror at the same distance as that at which a spectacle-glass is generally worn, that is, 15 mm. from  $k$ , the value of the angle  $d = 5.4^\circ$ . But if we place the concave lens behind the mirror so that its distance is 50 mm. from  $k$ , the optical centre of the examined eye  $A$ , its focal distance must be 89.5 mm., and the angle  $d$  is then  $= 7.4^\circ$ .

If the diagrammatic eye, while retaining an axis of 20 mm., be adjusted for a distance of 139.5 mm. by a change of curvature, it will have, according to Donders,\* a radius of curvature of 4.5 mm., consequently  $a k$  will equal 15.5 mm.

Substituting this value in the above formula, in an ophthalmoscopic examination with a concave lens of 164.5 mm. focal length, held at a distance of 15 mm. from  $k$ , the optic nerve would appear under an angle of  $5.7^\circ$ ; if, however, we use a concave lens of 89.5 mm. focal length at 50 mm. from  $k$ , the visual angle  $= 8.59^\circ$ .

The angle under which the optic disc appears in hypermetropia may be calculated in an analogous manner. We will suppose the axis of our diagrammatic eye to be shortened by 2 mm. Then the distance  $a k = 13$  mm. We have first to calculate toward what point behind  $k$  rays of light must converge in order to be

\* L. c., pag. 152.



focused at  $a$ . We employ in this calculation the same formula as we have used above in computing the increase of the axis of vision in myopia, namely,  $\frac{1}{F} + \frac{1}{\varphi n} = \frac{1}{na}$ , in which  $a$  represents the distance of the illuminated point from  $h$ ;  $F$  its conjugate focal distance ( $h\ a = 18$  mm.);  $\varphi''$  the focal distance for parallel rays ( $h\ \varphi'' = 20$  mm.); and  $n$  the index of refraction  $= \frac{4}{3}$ . Since we know the value of all the quantities except  $a$ , the formula becomes

$$\frac{1}{a} = \frac{n}{\varphi n} - \frac{n}{F}.$$

From the calculation we find  $a = 135.4$  behind  $h$ , or 130.4 behind  $k$ ; we have very nearly  $H\frac{1}{5}$ .

The relations are analogous to those in myopia, only reversed. The image of the optic disc cast from the refracting media is a virtual one, and lies 130.4 mm. behind  $h$ . In order to convert the rays proceeding from this virtual image into parallel ones we need a convex lens whose focal distance must be shorter the nearer we bring it to the eye under examination, and consequently, also, the visual angle becomes smaller the farther we remove the correcting convex lens from the eye examined. If we hold it in front of the mirror 15 mm. from the optical centre of the eye examined, we have for the optic disc, whose diameter as above  $= 15$  mm., a visual angle of  $7.73^\circ$ . If, on the contrary, we place the correcting convex lens behind the mirror, 50 mm. from the optical centre of the eye examined, the visual angle diminishes to  $4.76^\circ$ .

But if, on the contrary, a diagrammatic eye with an axial length of 18 mm. accommodate itself for parallel rays, this involves a shortening of the radius of curvature to 4.5 mm. If now we examine the eye ophthalmoscopically in this condition,—that is, when the hypermetropia of  $\frac{1}{5}$  has been neutralized by an effort of accommodation,—we of course need no correcting lens, since the rays of light reflected from the fundus already emerge parallel from the refracting media. The optic disc appears therefore under a visual angle of  $6.3^\circ$ .

Accordingly, an optic disc having a diameter of 1.5 mm. appears as follows:

- a. In emmetropia under a visual angle  $d$  of  $5.7^\circ$ .
- b. In myopia with a far point 139.5 mm. distant,—that is, about  $M\frac{1}{5}$ ,—
  - 1, with concave 124.5 mm. at a distance of 15 mm.,  $d = 5.4^\circ$ ;
  - 2, with concave 89.5 mm. at a distance of 50 mm.,  $d = 7.4^\circ$ .



*b'*. With the same degree of apparent myopia,

1, with concave 124.5 mm. at 15 mm.,  $d = 5.7^\circ$ ;

2, with concave 89.5 mm. at 50 mm.,  $d = 8.59^\circ$ .

*c*. In hypermetropia with a negative far point 130.4 mm. distant,—that is, about  $H\frac{1}{5}$ ,—

1, with convex 145.4 mm. at a distance of 15 mm.,  $d = 5.7^\circ$ ;

2, with convex 186.4 mm. at a distance of 50 mm.,  $d = 4.76^\circ$ .

*c'*. In the same degree of hypermetropia, which, however, is latent through tension of accommodation,  $d = 6.3^\circ$ .

These results agree with those of Mauthner.\* Still, I am inclined to doubt the conclusions which others have drawn from these calculations. It would certainly be an interesting fact if we could determine from the size of the ophthalmoscopic image whether we had to do with actual or with only apparent emmetropia,—that is, with latent hypermetropia; and so, too, whether we had to do with actual or with apparent myopia,—that is, spasm of accommodation.

In the first place, the question must be answered whether the optic disc may be regarded as of an invariable size, since, of course, the size of the ophthalmoscopic image depends upon the actual size of the disc. In this matter, however, it is certain that there are individual variations. According to Henle,† for instance, the optic nerve in the plane of the choroid has a diameter varying from 1.2 to 1.6 mm. If we substitute these values for the 1.5 mm. assumed in the original calculation, the optic disc would be seen in the diagrammatic eye under an angle varying from  $4.5^\circ$  to  $6^\circ$ . The difference is  $1.5^\circ$ ,—that is, nearly as great as the difference between the visual angles in manifest  $H\frac{1}{5}$ , examined with convex  $\frac{1}{7}$  at 2 inches from the eye, and the same degree of hypermetropia masked by the accommodation. In such a case we should be doubtful whether we had before us an anatomically large or small optic disc, or one more or less magnified for optical reasons. This must still more be the case in slight degrees of hypermetropia. Cases where hypermetropia of  $\frac{1}{5}$  remains wholly latent are very infrequent.

In myopia, moreover, the enlargement increases in very rapid

\* Lehrbuch der Ophthalmoscopie, pag. 186.

† Anatomie, ii. pag. 586.



progression as the correcting lens is withdrawn from the eye. The most certain method, that of Coccious, is to hold the correcting lens close to the eye under examination; but just in that case the difference between the images in apparent myopia and in actual myopia, caused by elongation of the eye, is least apparent.

Still more important is the fact that we possess no means of measuring the size of the upright image, but can only estimate it approximately. The errors likely to be made under such circumstances may be shown by a simple experiment. Any object, say the smallest size of ordinary print, is placed at the focus of a convex lens, provided with a diaphragm, which must not be too small. If now the observer place his eye close to the lens, he perceives a visual field of a certain extent, and the objects in it magnified to a certain size. If now he withdraw his eye from the lens, he can scarcely avoid the impression that the objects become more magnified. Evidently this is an optical illusion, based upon the fact that the relations between the enlargement of the objects and the size of the visual field change to the disadvantage of the latter. The object portrayed upon the retina of the observer is, however, the virtual image of the test letters at the focus of the convex lens; but this image lies already at an infinite distance behind the convex lens, and accordingly, as regards the size of the retinal image, the withdrawal of the eye a few inches from the lens has no effect. If we prefer to assume, with Mauthner,\* a common optical centre for the eye and the convex lens, it is of course true that this point recedes from the retina the more the distance between the eye and the convex lens is increased; but at the same time the distance between this point and the test type behind the lens increases in the same proportion, so that the size of the retinal image is unaffected. That this last must be the case we have already proved by Fig. 25.

We have hitherto spoken only of the size of the retinal image. Generally the process has been another one, and the attempt has been to determine not the visual angle, but the enlargement, assuming a so-called "distance of distinct vision," of 8 inches. From the present stand-point of ophthalmology it seems very desirable to dispense altogether with such an antiquated idea as that

---

\* L. c., pag. 179.



of "a distance of distinct vision." There is no more reason for assuming it to be 8 inches than 80 or 800 inches. We measure the magnifying power of a telescope, for instance, by superposing the enlarged image of a distant scale, as seen by the one eye through the instrument, upon the image of the same scale as seen by the other and naked eye. We compare, in fact, the size of the retinal images, or, what is the same thing, we ascertain by how much the visual angle for the scale in question is increased by the telescope. Surely no one will assert that the moon viewed through an opera-glass which magnifies two or three times appears two or three times larger than this celestial body would, could we observe it at the distance of 8 inches, the so-called distance of distinct vision. Now, whether we observe a distant object through a Galilean telescope, or a near object through a Brücke lens, or the fundus of a myopic eye in the upright image, with the help of a concave glass, each case is governed by exactly the same optical laws, and it is impossible to measure processes which are the same by standards which are different.

Moreover, it is plain that calculations of the ophthalmoscopic enlargement, based upon an assumed distance of distinct vision of 8 inches, furnish inaccurate results. To me at least, the optic disc in the upright image appears about as large as E. v. Jaeger has delineated it in his ophthalmoscopic hand atlas. The most of these figures, as the author expressly states, and as one may satisfy himself by measurement, are drawn as if magnified 7-fold; how does that agree with the 15- to 24-fold enlargement which has been calculated for the upright image? It of course is undoubtedly true that a virtual image included in a visual angle of  $5.73^\circ$ , projected at a distance of 200 mm. (about 8 inches), would have a length of 20 mm.; but to me at least the optic disc never appears so large. This question, moreover, is of no practical importance, since we possess no means of measuring the size of the image, but are simply left dependent upon a method of estimation full of sources of error. The case is exactly the same as in magnifying with a lens. If we are not contented with reckoning the size of the visual angle, but insist on knowing the degree of the so-called enlargement, we can proceed only in the method above described for measuring the telescopic enlargement. We designate the visual angle under which we see the object with



the naked eye by the letter  $d$ , and the angle under which it appears at the same distance, but with the help of the magnifying instrument, by the letter  $D$ ; then evidently the enlargement is expressed by the relation of  $d$  to  $D$ . But in magnifying with a lens, the relation of  $d$  to  $D$  depends essentially upon the distance between the eye and the object observed through the lens. If the object be at the focus of the lens we cannot estimate the size of the image, since it lies at an infinite distance and is therefore infinitely large; but the visual angle under which, in this case, the object appears, is simply dependent upon the focal length of the lens. We designate the size of the object by  $a$ , and its distance from the convex lens by  $c$ , then will the visual angle  $D = \frac{a}{c}$ , no matter how great the distance of the lens from our eye. The visual angle of the same object observed from the same distance with the naked eye would be  $d = \frac{a}{k}$ , where  $a$  again represents the size of the object, and  $k$  its distance from the optical centre of our eye. The quotient  $\frac{D}{d}$  becomes of course smaller the more the lens, with the object always at its focus, approaches the eye, and it becomes  $=1$  when  $k$  and  $c$  coincide, since, seen from the middle of the convex lens, the object and image always appear under the same visual angle. In this case it is simply the very near approach made possible by the lens, which causes the increase of the visual angle, and the retinal image cast by it would be no larger than without the lens, provided we could accommodate upon so short a distance. Since, however,  $k$  and  $c$  never actually coincide, the retinal image cast by the lens will always be somewhat larger than can be obtained from the same object at the same distance, by accommodation alone.

If the object lie not at the focus, but somewhat nearer the convex lens, the size of the virtual image may be easily calculated from the well-known optical formula. In order to see the image distinctly, the observer's eye must either be myopic, so that its far point coincides with the place of the image, or it must make an effort of accommodation, to adjust it upon the place of the image. The visual angle, however, under which the object appears, is not necessarily smaller than it would be if the object were at the focus of the convex lens: it may even be larger. If we place in front of our eye a convex lens with a focal distance of 10 inches, and if we now place a small object in the focus of the lens, it will



evidently appear under a considerably smaller visual angle than when we bring the object so near that its virtual image coincides with our near point.

If the object lie beyond the focus of the convex lens, the case is the same as that when we make the ophthalmoscopic examination in the inverted image. The size of the inverted real image is easily calculated, since, from the optical centre of the convex lens, both object and image are included in the same angle. Their sizes are proportional to their respective distances from the convex lens. The calculation is only slightly more complicated when, as in the case of the ophthalmoscopic examination in the inverted image, the image is not cast directly from the eye, but with the help of a convex lens. When using a convex lens of 80 mm. (3 inches) focal distance, and held at that distance from the eye, the relation of the size of the optic disc to its inverted image is found, upon calculation, to be as follows:

1. In emmetropia, as 1 : 5.3.
2. In  $M_{\frac{1}{5}}$  (more exactly  $M_{\frac{1}{130.4}}$  mm.), as 1 : 4.6.
3. In apparent myopia  $\frac{1}{5}$ ,—that is, when the accommodation of the emmetropic eye under examination is adjusted for that distance, —as 1 : 5.2.
4. In  $H_{\frac{1}{5}}$  ( $=\frac{1}{130.4}$  mm.), as 1 : 6.1.
5. In the same grade of latent hypermetropia, as 1 : 5.9.

These relations, however, are true only for the case in which the convex lens is held at its focal distance from the examined eye. In emmetropia, to be sure, the distance of the lens from the eye has no influence upon the size of the image, since the rays proceeding from the fundus always fall parallel upon the lens, and will consequently always intersect at its focus. But in hypermetropia the size of the image increases with the distance of the convex lens from the eye. The far point of the hypermetropic eye and the place of the inverted image are conjugate foci. The nearer the convex lens is brought to the examined eye the larger the image, and, inversely, the more it is withdrawn the smaller the image. For the same reasons, the size of the image increases in myopia with the distance of the lens from the eye. But the inverted image is always greater in hypermetropia and less in myopia than it is in emmetropia.

If an extreme case of myopia, say  $M_{\frac{1}{2.5}}$ , be examined with a



convex lens which is not too strong, say  $+\frac{1}{3}$ , the inverted image of the fundus, cast from the eye itself, may lie between the examined eye and the convex lens. The inverted image, cast from the myopic eye, will be enlarged very little by the convex lens, because it lies too near it, but a great advantage is gained for the field of vision. When the glass is correctly held (compare page 96), the iris disappears out of the field of vision, and the field itself becomes considerably larger than it appears without the convex lens.

Hitherto we have supposed the fundus of the eye to be illuminated, and we must, therefore, now describe the means by which it is possible to throw a beam of light in the direction of our line of vision, into the eye under examination. This is done by means of a transparent or perforated mirror. The ophthalmoscope, as originally constructed by Helmholtz,\* has, as reflectors, three plates of glass with parallel plane surfaces, placed one over the other. In order to increase as much as possible the intensity of the reflected light, they are placed at an angle of  $36^\circ$  with the optical axis of the instrument. Perforated mirrors, however, soon came to be preferred, on account of the better illumination which they give. Rute† introduced the use of the concave mirror. Coccius‡ preferred to produce the same effect by the combination of a plane mirror with a convex illuminating lens.

It is desirable in practice to be able to vary the intensity of the light, especially in the examination in the upright image. In this respect the mirror of Coccius possesses an advantage over the concave mirror, for one can use the plane mirror either alone or in combination with the convex illuminating lens. Jaeger's ophthalmoscope is so contrived that either a concave or a plane mirror, or Helmholtz's reflecting glass plates, can be set in it at pleasure. Another advantage possessed by this instrument is, that the correcting lenses, which are placed as oculars behind the mirror, can always be held perpendicular to the observer's line of vision,—an important point in cases in which somewhat strong lenses are used.

Giraud-Teulon's binocular ophthalmoscope deserves a particular

---

\* Beschreibung eines Augenspiegels, 1851.

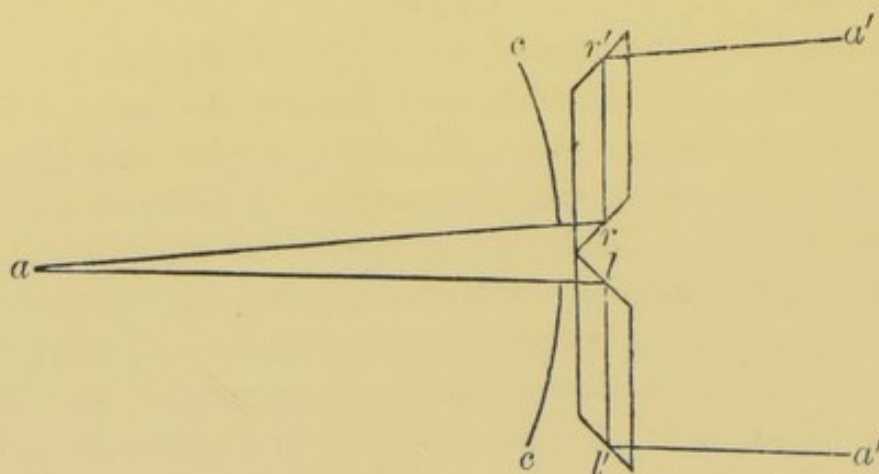
† Der Augenspiegel und das Optometer, 1852.

‡ Ueber die Anwendung des Augenspiegels, etc., 1853.



mention. Its principle may be thus explained. Behind the opening in the concave mirror, Fig. 27, are two rhomboidal glass prisms, whose end surfaces stand at an angle of  $45^\circ$  with the longitudinal axes of the prisms. The rays  $ar$  and  $al$  proceeding from the point  $a$  are reflected on the surfaces  $r$  and  $l$  towards  $r'$  and  $l'$ , where they experience another reflection in the direction  $r'a'$  and  $l'a'$ ,

FIG. 27.



parallel to  $ra$  and  $la$ . If instead of the point  $a$  we have a solid object, its retinal images will be so related as if the object were seen under a very slight angle of convergence, equal to the angle  $lar$ .

As seen in Fig. 27, the lines of vision intersect each other in a point much farther from the eye than the point  $a$ , upon which the accommodation must be adjusted. This difficulty can be overcome either by adjusting the accommodation by convex glasses upon the point  $a$  without making any greater demand on the accommodation than is natural with a slight angle of convergence; or by means of prisms with their refracting angles turned inward, a convergence of the visual axes may be induced, more nearly corresponding to the distance of the point  $a$ ; or, finally, both methods may be combined by the use of convex prismatic glasses with the refracting angle turned inward.

If the perception of the third dimension depend upon the fact that the retinal images in the two eyes are not identical, but show certain perspective differences, these differences can be but very small when, as is the case in the binocular ophthalmoscope, the lines of vision include so acute an angle. Hering's experiment gives, therefore, by means of this instrument, only a very uncertain perception of the third dimension. When practising it, one



is mistaken just about as often as in monocular vision. We shall have repeated occasion to mention this experiment; it is the only one which in a simple way shows whether there is a normal binocular act of vision. It is conducted in the following manner:

A cylindrical tube about 25 centimetres in length, and wide enough to be looked through with both eyes, has at one end, and fastened on its outside, two long needles, which must be so bent outward that they cannot be seen on looking through the tube. A fine silken thread connects the point of one needle with that of the other. Midway between the needles is a knot in the thread, or, better still, a small bead, which then lies in the centre of the field of vision, when one looks through the tube.\* The tube is held close before the face, with the thread horizontal, and so that both eyes look through the tube; the bead in the middle of the field of vision serves as a fixation-point. Small balls, of different sizes, are allowed to fall about twelve times, one after the other, some before and some behind the bead. One who sees binocularly can tell with certainty whether a ball falls within or beyond the fixation-point, while one who perceives the retinal image of one eye only, is frequently deceived; he can, when the experiment is carefully conducted, only guess the place of the ball, and therefore is mistaken in half the cases.

It is the same when one makes this experiment with the binocular ophthalmoscope. Such binocular vision as is made possible by that instrument is, for the reasons just given, insufficient to give a proper perception of the third dimension.

Although there is a wide-spread prejudice in favor of the binocular ophthalmoscope, we should remember that in monocular vision, also, we have a means at our disposal by which to judge of the third dimension, and, further, that absolutely identical retinal images may produce a stereoscopic effect. One receives, for instance, an undeniable impression of solidity when one unites, stereoscopically, two photographs taken from one and the same negative. In such a case there is, of course, simply an optical illusion, to be explained by the fact that the visual impression of solidity does not depend exclusively upon certain differences

---

\* The description here given varies somewhat from the original of Hering; it is, however, more convenient. Comp. Hering, *Arch. für Ophth.*, B. xiv. 1, pag. 3.



between the retinal images in the two eyes, but it is caused by the perspective, the illumination, etc., even with identical retinal images, or in monocular vision. Whoever wishes to repeat the simple experiment of uniting, stereoscopically, two identical photographs, can satisfy himself that such an optical illusion of necessity occurs. The same principle is employed in Coccius' binocular mirror. Behind a perforated concave mirror is placed a plane mirror, also perforated, with its reflecting surface directed forward toward the eye to be examined, and forming with the line of vision of the examiner an angle of about  $45^{\circ}$ . Suppose these two perforated mirrors to be held in front of the left eye of the examiner, and that before the right eye be held an imperforate plane mirror with its reflecting surface turned toward the others. The ophthalmoscopic image is reflected from the first plane mirror to the second, and from that to the right eye of the examiner. He receives, therefore, from the ophthalmoscopic object, it is true, two retinal images, but they are alike in the strictest mathematical sense. One of these images is always somewhat smaller than the other, and in this case it is that in the right eye, because that eye is farther from the object than the left. The difference of the two retinal images, upon which the perception of depth depends, in so far as it involves a relation of correspondence of the retinae, is here wanting entirely.

In spite, however, of the negative result of Hering's experiment, we do, with the aid of the binocular instrument, form a better judgment of the third dimension in the fundus of the eye. This is due to the fact that in using this instrument we have the convergence of the visual axes to assist in forming a judgment of the third dimension. The same is true of the convergence of the visual axes as of the retinal images. If the images be identical, the convergence of the visual axes will remain the same while scrutinizing them. But with Giraud-Teulon's binocular mirror, at least, the retinal images are not absolutely identical, and even if their differences be too slight to be proved by Hering's experiment, the change in the convergence of the visual axes is, perhaps, a more delicate means of judging of distances. Finally, the binocular mirror makes it possible to observe the image for a considerable time.

For many cases it is simplest and most advantageous, in making



a binocular examination, to employ two concave mirrors; these are placed in a frame provided with a handle, and are separated from each other by a distance corresponding to the distance between the two eyes; each mirror revolves about both a vertical and a horizontal axis. It is only necessary, then, to so arrange the mirrors that the two images of the light cast by them fall upon each other, in order to be able to see ophthalmoscopically with both eyes. Cloudiness of the lens or vitreous, and many cases of detachment of the retina, may be observed binocularly in this manner under the most favorable circumstances. This method is not available for objects lying deeper in the eye, nor for examination in the inverted image.

The source of light for the ophthalmoscopic examination may be either a bright oil- or gas-flame, or daylight. The last, as has been shown by Helmholtz,\* is the best light for all cases where it is desirable to judge of the true color of the fundus, or to detect slight cloudiness in the retina. Moreover, it has the advantage of dazzling the patient less than lamp-light.

Since, in general, daylight is preferred to artificial illumination in cases where it is wished to recognize fine shades of color, it of course suggested itself to make use of this advantage in ophthalmoscopic examination. It is noticed that by daylight the ophthalmoscopic image has a yellow shade, which disappears entirely by artificial illumination. Under normal relations, this effect is seen most distinctly upon the optic nerve.

The more exact recognition of shades of color and differences in illumination possible by daylight, is probably the reason why slight cloudiness, especially in the retinal substance, which cannot be seen by artificial illumination, becomes visible by daylight. Eyes absolutely physiological often furnish proof of this fact.

The illumination by daylight is best arranged by allowing it to enter a dark room through an opening 3 or 4 centimetres in diameter, cut in the window-shutter. The ophthalmoscope may then be directed toward the sky just as is the mirror of the microscope. Direct sunlight ought, of course, not to be used except in eyes absolutely blind.

The use of daylight is particularly applicable to examinations

---

\* Beschreibung eines Augenspiegels, Berlin, 1851, pag. 19.



of the optic nerve and retina; for all other cases a good lamp-flame is all-sufficient, and in many cases more convenient.

#### OPHTHALMOSCOPIC DIAGNOSIS OF THE CONDITION OF REFRACTION.

The use of the ophthalmoscope for the diagnosis of the condition of refraction is as old as the use of this instrument in general. Helmholtz\* mentions a case in which, in a perfectly blind eye, by the help of the ophthalmoscope, he could decide the important question whether certain former difficulties of vision, which the patient complained of, depended upon myopia or incipient amblyopia. He pointed out as an advantage of this method that it makes the examiner entirely independent of the statements of the patient, since he himself sees with the patient's eye, at least with the refracting part of it. Cases in which it is desirable to be entirely independent of the statements of the patient are, in fact, frequent. Indeed, it happens often that the ophthalmoscopic examination first gives a proper direction to the functional examination.

We have already explained the manner in which the condition of refraction is disclosed by the ophthalmoscopic examination. The degree of the anomaly may be determined by the same method. Above all things the observer must be certain that both he and the patient have fully relaxed their accommodation. He can then, observing the distance from the eye under examination, determine the degree of the refraction from the number of the lens with which the fundus can be distinctly seen in the upright image. If one wish to determine exactly the condition of refraction by the ophthalmoscopic examination, it is best to paralyze the accommodation by atropine, and to use as a test-object, not the optic disc, but one of the fine retinal vessels running from it toward the macula lutea. In such a case it is well, as Coccius† has proposed, to place the correcting lens close in front of the eye under examination, between it and the mirror, and to avoid the annoying reflex by slight movements of the lens. The correcting lens is then at the same distance from the eye as it would be if used as a spectacle-glass.

---

\* Beschreibung eines Augenspiegels, pag. 38.

† Ueber die Anwendung des Augenspiegels, Leipzig, 1853, pag. 28.



The ophthalmoscopic diagnosis of the condition of refraction furnishes an excellent check upon the results derived from the examination with test letters; especially is this true in all those cases in which an anomaly of refraction is complicated by amblyopia. In myopia, under these circumstances, there are generally other changes in the fundus which immediately attract attention. Hypermetropia and astigmatism, on the contrary, often exist in connection with a form of amblyopia in which there are no material changes in the fundus, while the poor vision makes it difficult or impossible to determine the condition of refraction by testing the power of vision. These cases would be enigmatical if we had not the ophthalmoscope to aid us.

The ophthalmoscopic diagnosis of meridional asymmetry depends upon the optical nature of this anomaly. We have above explained that we see the fundus of the eye in the upright image as if through a lens. Under these circumstances, the shorter the focal distance the greater the enlargement,—that is, it is greatest in the direction of the meridian which possesses the highest refraction, generally in the vertical. The image of a round object, for instance of the optic disc, will not appear round, but oval and elongated, in the direction of the meridian of shortest focal distance,—that is, generally in the vertical direction. The appearance is exactly reversed in the examination in the inverted image. In the meridian of shortest focal distance the image lies nearer the convex glass than in the other principal meridians: it is therefore less enlarged than in the meridian of longest focal distance. A round optic disc appears, therefore, not round, but elongated, in the direction of the meridian of longest focal distance.

We ought not to forget that in the ophthalmoscopic examination we do not see the fundus as if with the naked eye, but always only an optical image of the fundus, an image depending upon the nature of the apparatus producing it. If now in the upright image the optic disc appear oval in the vertical direction, and in the inverted image oval in the horizontal direction, it is plain that it can anatomically be neither the one nor the other, but that this change of form in the ophthalmoscopic image rests upon optical grounds. Frequently the optic disc is actually oval, and oftener elongated in the vertical than in the horizontal direction, as may be ascertained by the comparative examinations in the up-



right and inverted images. This, however, does not hinder in the least the ophthalmoscopic diagnosis of astigmatism, since neither the examination in the upright nor in the inverted image is by itself sufficient, but the diagnosis is always based upon a comparison of the two images. The change of form in both the upright and inverted image, caused by astigmatism, is always present, be the anatomical form of the optic disc what it may. A vertically elongated disc would then in the upright image appear much more elongated in the vertical direction; in the inverted image, it would appear nearly round. A horizontally elongated disc would, on the contrary, appear nearly round in the upright image, and in the inverted image still more horizontally elongated. To compare more easily the two images, it is important that they should be as nearly as possible the same size. This condition is sufficiently fulfilled if one use a convex lens of 3 inches focal length when examining in the inverted image. It is still more important that the convex glass be not held obliquely, so as to cause asymmetry and change of form in the inverted image. Care must also be taken that the convex glass be so centred that the images of the flame reflected from its anterior and posterior surfaces cover each other, and, when possible, are nearly in line with the optic disc.

Finally, it is to be mentioned that when examining astigmatic eyes in the inverted image the apparent form of the optic disc is also dependent upon the distance of the convex glass. If, for instance, there be emmetropia in the vertical meridian, and hypermetropia in the horizontal meridian, then, as before said, an anatomically round optic disc would appear horizontally elongated. Since, however, in hypermetropia (comp. page 110) the size of the image increases as the convex lens approaches the eye, the difference between the horizontal and vertical extent of the image will be the more striking the less the distance between the convex lens and the eye. The case is reversed when there is emmetropia in the horizontal meridian and myopia in the vertical. In myopia the size of the inverted image increases with the distance of the convex lens from the eye. The preponderating enlargement in the horizontal meridian is least when the lens is nearest the eye, and becomes more distinct the farther the lens is withdrawn.



In astigmatism the optic disc often appears irregularly and incompletely surrounded by a bright space, which anatomically is the sclera shining through the choroid. Under these circumstances one must be careful to observe the proper boundary of the nerve itself. If, however, the nerve and the scleral stripe surrounding it present a regularly bounded and nearly round figure, it may be more advantageous to direct the attention upon this distinctly bounded surface.

Coccius\* proposes for the diagnosis of astigmatism the following method of examination. From the distance of from 20 to 24 inches the image of a broad bright flame is cast by a plane steel mirror into the fundus of the eye; a small rod, for instance a lead-pencil, is now to be held immediately before the flame, and the observer is to notice whether the image of this rod, when held in all positions, vertical, horizontal, or inclined, appears of uniform distinctness and size. If such be the case, the rays are focused homocentrically. If, on the contrary, the rod when held vertically appears in the fundus undefined, dull, and broad, but when held horizontally appears sharp, black, and narrow, then will this phenomenon agree always with the subjective observation,—that is, the astigmatic sees vertical lines indistinctly, but horizontal ones distinctly.

#### THE OPHTHALMOMETER.

The ophthalmometer was constructed by Helmholtz for the purpose of measuring exactly the curved surfaces participating in accommodation.

The images cast from a convex reflecting surface are so much the smaller the shorter the radius of curvature. Consequently we may use the size of an image to reckon the radius of curvature. The great difficulty, however, in measuring the images reflected from the cornea is, that it is impossible to hold the living eye immovable. The images from a spherical reflecting surface or from the cornea can be distinct only when all the rays from the object fall nearly perpendicularly upon the reflecting surface. It follows that for the purpose of this measurement only such images can be used as are considerably shorter than the radius of curvature; they should not exceed one-fourth its length. Even then, an error in

---


\* Ueber den Mechanismus der Accommodation, pag. 142.



the measurement of the image is multiplied by 4 in calculating the radius of the cornea. The size of the image must therefore be determined to within the hundredth part of a millimetre, in order to calculate the radius of the cornea within a hundredth part of its length, that length being on an average about 8 millimetres.

Of course there is no means of fastening the head in such a way as to prevent movements of  $\frac{1}{100}$  of a millimetre. It is impossible by applying a graduated scale directly to the cornea to make any measurements of the necessary exactitude. The problem, then, was to measure the movable corneal image while in motion. Helmholtz\* solved this problem by the construction of his ophthalmometer. This instrument depends upon the principle that objects seen through glass plates with plane parallel surfaces, placed at an angle with the line of vision, seem displaced, and that this displacement is greater the greater the angle of incidence of the rays upon the plate.

FIG. 28.



In Fig. 28, let  $A$  be a telescope before whose objective glass, and inclined to its axis, are placed the two glass plates  $a^1 b^1$  and  $a^2 b^2$ ; the plate  $a^1 b^1$  covers the right half and the plate  $a^2 b^2$  the left half of the objective. The telescope is directed upon the object  $c d$ ; then to the observer the image seen through the plate  $a^1 b^1$  does not appear to be at  $c d$ , but at  $c^1 d^1$ , and that seen through the plate  $a^2 b^2$  at  $c^2 d^2$ . Both images appear simultaneously side by side in the field of the telescope. If now the glass plates be so turned that the end  $c^1$  of the first image correspond with the end  $d^2$  of the second image, and if the angle be known through which the plates have been revolved, then the length of  $c d$  can be calculated. The adjustment of the edges of the images against each other can be very exact, even when the field of vision is in motion, since the two images  $c^1 d^1$  and  $c^2 d^2$  always move together, and their apposition is not disturbed.

\* Arch. f. Opth., Bd. i. 2, pag. 1-74.



The instrument is so contrived that the two glass plates always revolve through the same angle, and their revolution can be observed on a vernier scale. In order to calculate the size of the image it is necessary to know the angle through which the plates revolve, their thickness, and the index of refraction of the glass from which they are ground. According to Donders,\* it is well to determine experimentally, for each ophthalmometer, by what angular position of the glass plates known dimensions are measured. A fine scale, divided into tenths of millimetres, is observed through the ophthalmometer, and it is determined through what angle the plates must revolve to measure 0.1, 0.2, 0.3 millimetres, and so forth. A tabulated statement of the results thus obtained enables one to see at a glance the size of a corneal image as soon as one has read from the instrument the angle through which the glass plates have been revolved in order to bring the ophthalmometric double images in apposition.

The radius of curvature of the cornea measured in the line of vision has, according to Donders, an average length of 7.7 millimetres. It appears that it grows shorter with increasing years. At all events, the former prevailing opinion that presbyopia depends upon a flattening of the cornea must be regarded as fully disproved.

So, too, contrary to the old idea that myopia depended upon excessive curvature of the cornea, it has been found that with that condition of refraction the radius of curvature is generally greater than in emmetropia; in fact, that it increases with the degree of the myopia. The reason for this is, that in myopia not only the visual axis, but all the diameters of the eye, are increased.

In hypermetropia, also, Donders found the cornea on an average less curved than in emmetropia; still, he discovered no relation between the degree of the hypermetropia and the length of the radius of curvature.

Numerous measurements have proved that the different meridians of the cornea possess radii of different lengths, and that the vertical meridian generally has the greatest curvature. The curvature of each individual meridian is nearly elliptical.

Under normal relations the line of vision always deviates inward

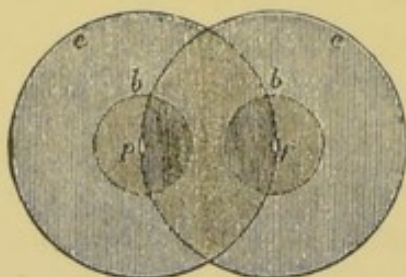
---

\* L. c., pag. 17.



from the centre of the cornea. The angle which it forms with the axis of the cornea is called the angle  $\alpha$ . Donders\* measured the size of this angle in the following manner. A flame was placed vertically and immediately over the ophthalmometer, and its image reflected in the cornea was observed ophthalmometrically. In front of the eye under examination was placed a horizontal graduated arc, with its centre opposite the centre of rotation of the eye. Upon this was placed a movable object, which served as a

FIG. 29.



*c* is the cornea, *p* the pupil, *b* the corneal reflex. In order to see the eye under examination with sufficient exactness it must be illuminated by a lamp.

fixation-point for the eye under examination, and made it possible so to direct it that the image of the flame should be reflected exactly from the centre of the cornea. This was the case when, upon revolving the glass plates of the ophthalmometer, the double images of the corneal reflex reached simultaneously on both sides the border of the double images of the cornea, then half covering each other. Comp. Fig. 29.

The position of the object upon the scale gives the angle which the line of vision forms with the axis of the ophthalmometer, which is directed upon the centre of the cornea.

The axis of the ophthalmometer will coincide with the axis of the cornea provided the latter passes through the centre of the cornea. This provision is, however, fulfilled; for, according to Helmholtz,† the summit of the ellipse formed by the curvature of the cornea coincides with the central point of the cornea. This was proved by Donders from ophthalmometric measurements made for the purpose. These results are contradicted by Woinow,‡ according to whose measurements the corneal axes do not pass through the middle of the cornea. According to the same observer the angle between the visual line and the corneal axis may vary greatly in the two eyes of the same individual, the distance of the visual line from the centre of the cornea being, however, the same in the two eyes. Woinow maintained that Donders' method did not measure the angle between the corneal axis and the line of vision, but the

\* L. c., pag. 157.

† Arch. f. Ophth., B. i. 2, pag. 23.

‡ Ibid., B. xvi. pag. 225.



angle included between the line of vision and the perpendicular erected upon the middle of the horizontal diameter of the base of the cornea. Until this question is decided it will be well to indicate the angle measured by Donders by the letter  $\alpha'$ .

The investigations conducted by Donders and Doyér upon this method show that the size of the angle  $\alpha'$  depends upon the condition of refraction. In emmetropia the angle  $\alpha'$  averages  $5^\circ$ ; in myopia it is smaller, and may indeed be negative, so that the line of vision deviates outward from the centre of the cornea. In hypermetropia the angle  $\alpha'$  is greater than in emmetropia; in 16 cases examined by Donders the minimum of the angle  $\alpha'$  was  $6^\circ$ , the maximum  $9^\circ$ , the average  $7.3^\circ$ . In meridional asymmetry, also, especially when complicated with hypermetropia, the deviation of the line of vision from the centre of the cornea is generally greater than normal. Figs. 30, 31, and 32 show these relations.\* Fig. 30 is an emmetropic, Fig. 31 a myopic, and Fig. 32 a hypermetropic eye. In all of them the horizontal section passes through the optic nerve  $n$ .  $I$  is therefore the inner (median),  $E$  the outer (temporal), part of the eye. The axis of the cornea  $ga$  is not directed upon the object fixed, which casts its image in the fovea centralis at  $l$ . A straight line drawn from the object fixed

FIG. 30.

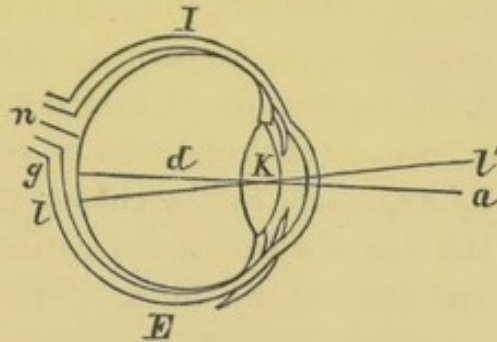


FIG. 31.

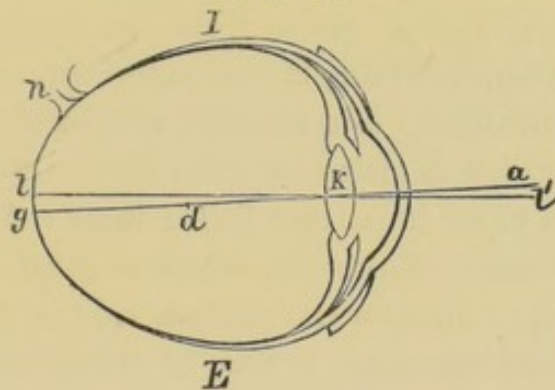
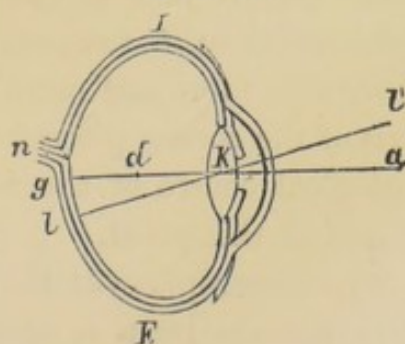


FIG. 32.



\* From Donders, l. c., pag. 155.



to its retinal image in the fovea centralis is the line of vision  $l\ l'$ , and we will assume that this intersects the line drawn through the centre of the base of the cornea and perpendicular to it, at the optical centre of the eye. The angle  $l' K a$  is the angle between that perpendicular and the line of vision in the horizontal meridian. In the vertical it is generally much smaller, and has no special clinical interest. The point  $d$  indicates the position of the centre of rotation.

The most striking difference which these figures present is in reference to the length of the axes of the eyes. The angle  $l' K a$  is greater in the hypermetropic eye than in the emmetropic. In Fig. 31, representing a very myopic eye, it is negative. The relation between the condition of refraction and the angle  $\alpha'$  is partially explained by the change of form of the eye. The direction of the line of vision is determined by two points, the optical centre  $K$  and the macula lutea. The higher the degree of the myopia the greater the distance between  $K$  and  $l$ , and this alone, if the distance  $g l$  remained constant, would diminish the deviation of the line of vision from the centre of the cornea. This explanation, however, is not sufficient, since the deviation may not only diminish, but become absolutely negative, so that the line of vision deviates outward from the centre of the cornea. There is a more important factor involved, namely, an unsymmetrical distention of the eye, which is greatest upon the temporal side. The optic disc on the median side is thereby forced still more inward, and the same is true of the macula lutea, although the distance between it and the optic disc increases, and the choroidal atrophy generally begins just at this place. Since the eye is relatively more distended in its temporal than in its median part, the macula lutea becomes more and more displaced toward the point in which the axis of the cornea pierces the posterior wall of the eye, and the physiological centre of the retina may even be displaced to the inner side of this point.

In hypermetropic eyes the distance between the optical centre and the macula lutea is shorter, but if the distance  $g l$  be the ordinary normal one, the angle  $\alpha'$  must of course be increased. This explanation again does not seem sufficient, and an abnormal displacement outward of the yellow spot must be assumed.

The varying deviation of the line of vision from the centre of



the cornea is the reason for the peculiar appearance presented by myopic and hypermetropic eyes. Our judgment respecting the position of the eyes depends upon the position of the cornea. In emmetropic eyes, when the lines of vision are parallel the axes of the cornea deviate outward by  $2 \times 5^\circ = 10^\circ$ . We regard this as the normal position. If now the angle  $\alpha'$  increase as in hypermetropia to  $9^\circ$ , then when the lines of vision are parallel the corneal axes will intersect each other behind the eye at an angle of  $2 \times 9^\circ = 18^\circ$ , and this gives the impression of divergence. An apparent strabismus divergens is therefore one of the peculiarities of hypermetropic eyes, and this appearance is often so deceptive that one can satisfy himself of the actual direction of the lines of vision only by experiment.

The simplest manner of conducting the experiment is as follows. The patient is directed to fix an object about 25 cm. distant. The examiner covers first one eye with his hand, and then moves it so as to cover the other eye, observing at the same time whether the eye thus uncovered changes its position before it can be used for fixation; if it does, then there was an abnormal position,—that is, strabismus. If during the experiment the eye does not change its position, there is no true, but only apparent strabismus.

The case is reversed in myopia. The smallness of the angle  $\alpha'$  causes an apparent strabismus convergens. Often, upon trying the experiment just described, it is found that there is apparent strabismus convergens, but at the same time actual divergence of the visual axes.



## AFFECTIONS OF THE OCULAR MUSCLES.

---

### THE MOVEMENTS OF THE EYES, AND THE LAWS OF DIPLOPIA.

THE movements of the eyes take place about axes which are assumed all to intersect each other at a point called the centre of rotation. Many investigations have been made with reference to the situation of this point, but they have led to somewhat contradictory conclusions. This disagreement is due partly to the different methods of examination and partly to differences in the eyes examined. Starting with the fact that ametropia depends principally upon the length of the visual axis, Donders and Doyer made a series of experiments to determine the position of the centre of rotation in the various conditions of refraction. Their method of examination was as follows:

The horizontal diameter of the cornea and the angle formed by the line of vision and the axis of the cornea were first measured with the ophthalmometer. A fine thread was then stretched perpendicularly before the eye, and it was observed how far the eye had to move toward the right and left in order to bring first one margin of the cornea and then the other exactly behind the thread. From this angle and from the known length of the rotation, the position of the centre of rotation was calculated.\* The results at which they arrived were as follows:

1. In emmetropic eyes the centre of motion is, on an average, 1.77 millimetres behind the middle of the axis of vision.

2. In myopia the centre of motion lies deeper in the eye, but at the same time, on account of the length of the sagittal diameter, it lies also farther from the posterior wall. The proportion between that part of the visual axis lying in front and that behind the centre of motion is nearly the same as in emmetropic eyes.

---

\* Comp. Donders, *Die Anomalien der Refraction und Accommodation*, § 16.



3. In hypermetropic eyes the centre of motion does not lie so far behind the cornea, but at the same time it is considerably nearer than normal to the posterior wall of the eye.

In Figs. 30, 31, and 32 the position of the centre of motion is indicated by the letter *d*. Donders expressly stated that these results affect only movements in the horizontal plane, and left the question still open whether the movements in the other directions have the same centre of rotation. Later investigations have not settled this question. In the case of his own eyes, J. J. Müller\* found that the centre of motion was farther back from the centre of the cornea the higher the plane of vision relatively to the position of the head. Experiments which Dr. Berlin† made, by a method altogether different, led to the same result. On the contrary, A. W. Volkmann‡ and Woinow§ found one and the same centre of rotation for all the movements of the eye.

The movements of the eye in a vertical direction extend through an angle of about  $90^\circ$ , in such a way, however, that the movement downward is greater than the movement upward. In youth, the emmetropic eye can move in the horizontal direction inward from  $42^\circ$  to  $51^\circ$ , and outward from  $44^\circ$  to  $49^\circ$ .

The movement of both eyes is generally equal. With increase of age the motility diminishes. It is, moreover, to be noticed that practice exercises a marked influence in the extent of the movements of the eyes.

The movement inward is greater when both eyes are turned simultaneously toward the same side (associated movement) than when both eyes are simultaneously directed inward (convergent or accommodative movement). From this it follows that during the movement of convergence not only the recti interni muscles, but also the recti externi, are innervated. The tension of the muscles of the eye is greater during convergence than it would be were one eye to be held in the same position and the other turned in a direction parallel to it. The point of intersection of the visual axes during the strongest convergence in emmetropia lies at a

---

\* Arch. f. Ophth., B. xiv. 3, pag. 183.

† Dr. E. Berlin in Palermo, Arch. f. Ophth., B. xvii. 2, pag. 154.

‡ Berichte der Königl. sächs. Gesellschaft der Wissenschaften, 6 Feb. 1869.

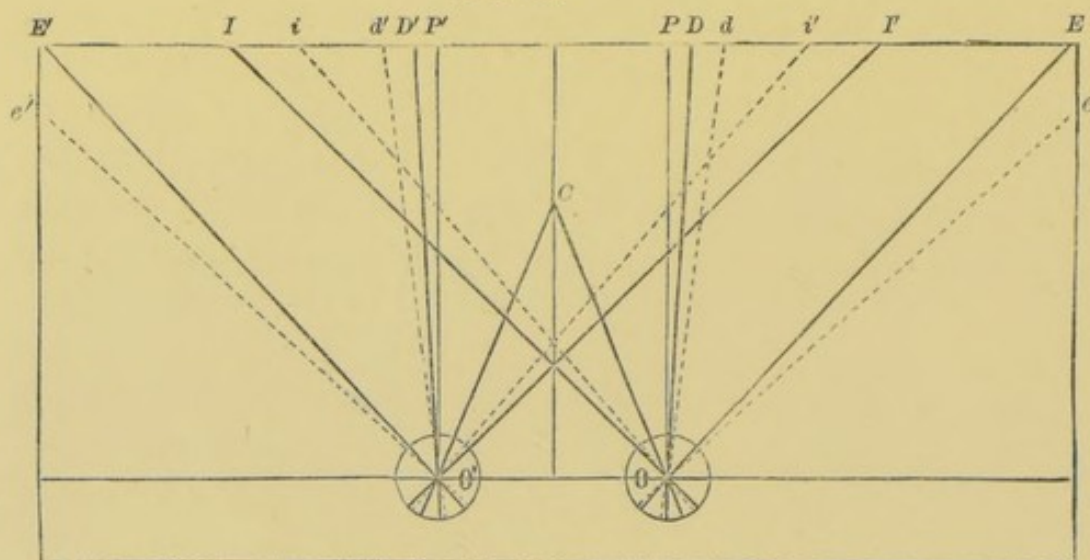
§ Arch. f. Ophth., B. xvi. 1, pag. 243.



distance of from 6 to 8 centimetres. Fig. 33 shows the average results of experiments upon the movements of emmetropic eyes; it is reduced to one-third the natural size.

The continuous lines indicate the direction of the lines of vision; the dotted lines are drawn perpendicularly to the centre of the cornea.  $OP$  and  $O'P'$  represent parallel lines of vision. The maximum of divergence caused by prisms with their refract-

FIG. 33.\*



ing angles turned outward is indicated by the lines  $OD$  and  $O'D'$  for the visual axes, and  $Od$  and  $O'd'$  for the axes of the cornea. The direction of the lines of vision during the greatest movement outward is indicated by the lines  $OE$ ,  $O'E'$ , and during the greatest movement inward by the lines  $OI$  and  $O'I'$ .  $Oe$ ,  $O'e'$  and  $Oi$ ,  $O'i'$  show the corresponding positions of the corneal axes.  $C$  is the nearest point attained during the maximum of convergence; it lies considerably farther from the eyes than the point at which the lines  $OI$  and  $O'I'$  intersect.

In full accord with the above are the facts shown by Hering,† that the movement of the right eye to the right and the left eye to the left is less in near than in far vision, and that the field of vision becomes smaller the nearer it lies to the eye.

The position of the eye is not absolutely determined by the direction of the line of vision,—that is, the line which connects the

\* Nach Schuurmann, *Vifde Verslag*, pag. 44.

† *Die Lehre vom binocularen Sehen*, pag. 11, Leipzig, 1868.



point fixed and the centre of rotation of the eye,—for the eye may revolve about this axis and the position of the axis be unchanged. Such movements of the eye are called wheel rotations (*Raddrehungen*), because the iris revolves like a wheel. Investigations upon this subject have established the law, first laid down by Donders, that for every position of the axis of vision relatively to the head there is a determined and unchangeable limit to the degree of revolution of the eye upon this axis. The inclination of the meridians, under normal relations, is never so great as occurs in consequence of pathological conditions of the ocular muscles.

Under physiological relations the innervation of the eye is always so regulated as to insure binocular single vision. If we wish to look directly at an object, to which our attention is called, we turn our eyes in such a direction that the image will be cast upon the fovea centralis, physiologically the most sensitive part of the retina. The symmetrical position of the physiological centres of the retina is the anatomical ground for binocular vision. If a distant object be fixed with parallel lines of vision, and the attention be then directed to a second object lying to one side of the first, the retinal image of this second object will be thrown in both eyes at an equal distance from the macula lutea, and in order to fix this object both eyes must move through an equal angle. Consequently, equal innervation on both sides is necessary for the symmetrical movements of the eyes. The case is, of course, the same when the object fixed approaches the median line.

But Hering\* has further shown that an equal innervation of the two eyes is required to direct them upon a near as well as a far object lying to one side of the median line. To illustrate: let the eyes at first be directed upon a far point, so that the lines of vision are parallel. If now the sight be directed upon a nearer point, one lying to the left of the median plane and upon the line of vision of the left eye, then will the left eye have to change its accommodation, but not the direction of its line of vision, while the right eye in order to adjust itself upon the fixed point must execute a movement of convergence. But even in such a case the impulse of innervation imparted to the ocular muscles is divided equally between both eyes. Both receive an equally strong im-

---

\* Hering, *Die Lehre vom binocularen Sehen*, § 4, Leipzig, 1868.



pulse toward an accommodative (converging) movement, and at the same time toward an associated movement, to the left. The left eye receives at the same time two opposite and equally strong impulses; consequently it yields to neither of them. In the right eye the equally strong impulses both act in the same direction and move it to the left.

Now, that it is actually true in the case just described that two antagonistic muscles are called into activity, is shown by a slight twitching to and fro of the eye, which can be observed by a second person. The two concurring innervations acting upon the left eye, during this movement, are not so exactly balanced but that an interchangeable momentary preponderance of the one muscle over the other may occur. This twitching becomes gradually less perceptible if one practise such experiments. That such twitchings do occur at all, is proof that the innervation affects not only the right eye, but the left eye as well, although the left eye is already directed upon the point fixed.

The laws of the associated action of muscles, which become established in individuals through practice and habit, gradually by hereditary transmission become congenital characteristics. It may indeed be said that the laws which in general govern the movements of the eyes, prevail for the most part as congenital compulsions, just as pathological relations of the ocular muscles and their innervation may be transmitted to offspring. On the other hand, it can be proved that in the interest of binocular vision movements of the eyes can be caused which never occur under normal relations, particularly divergence and differences in level of the visual axes. If when viewing a distant object a prism of from 6 to 8 degrees be placed before the eye, with the refracting angle turned outward, the retinal image will be thrown to the median side of the macula lutea. Diplopia occurs, but it gradually disappears, because the eye performs a partial revolution, by which the macula lutea is moved inward and the cornea outward. The divergence which can be effected in this way is in emmetropia on an average  $4^{\circ}$ . It has no influence upon the maximum of divergence attainable, whether a prism of  $8^{\circ}$  (which causes a refraction of about  $4^{\circ}$ ) be placed before only one eye, or whether the effect of the prisms be divided upon both eyes by placing in front of each a prism of perhaps  $4^{\circ}$ , with the refracting angle turned outward. This fact



also proves that the impulse of innervation is equally divided between the two eyes, so that when the prism is applied to only one eye, although only that eye deviates outward, still the impulse of innervation extends to both eyes.

The act by which the compensating revolution of the eye does away with the diplopia produced by prisms is generally called the "overcoming of prisms." Starting from a parallel position of the visual axes, emmetropes are, on an average, able to overcome prisms of  $8^{\circ}$ , which is equivalent to a divergence of the visual axes of  $4^{\circ}$ . The axes of the cornea, which in emmetropic eyes form an angle of  $5^{\circ}$  with the line of vision, diverge at an angle of  $10^{\circ}$  when the visual axes are parallel, and at an angle of about  $14^{\circ}$  when the maximum of divergence is reached. In hypermetropia, according to Schuurmann, the divergence of the visual lines attainable by prisms is less (on an average  $2.8^{\circ}$ ); but since at the same time the deviation of the line of vision from the centre of the cornea is greater (on an average  $7.5^{\circ}$ ), the divergence of the corneal axes is greater than in emmetropic eyes (on an average  $17.8^{\circ}$ ). In myopia, stronger prisms can be overcome than in emmetropia. The maximum attainable divergence of the visual axes is on an average  $5.8^{\circ}$ . Although in myopia the line of vision intersects the cornea nearer its middle than in emmetropia, the possible divergence attainable by the corneal axes is greater than in emmetropia. In some cases the deviation of the line of vision from the centre of the cornea may be actually negative,—that is, the line of vision intersects the cornea to the outer side of its middle point, so that with divergence of the visual lines there is still convergence of the corneal axes. For this reason, in the cases examined by Schuurmann, the average attainable divergence of the corneal axes was about  $9^{\circ}$ , or something less than for emmetropic eyes.

Prisms with their refracting angles turned inward are overcome by convergence in a similar manner; a contraction of the pupil and a tension of accommodation occur at the same time. The indistinctness of vision, caused by this tension of accommodation, may be relieved up to a certain degree by the accommodation adjusting itself for the relative far point corresponding to the given degree of convergence. The limits within which this can be done are determined by the laws governing the relative range of



accommodation (see p. 19). Upon abandoning distinct retinal images, and after some practice, one can overcome very strong prisms with their refracting angles turned inward, even up to the greatest degree of convergence attainable under any circumstances.

These are movements of the eyes with which we are more or less familiar. We make the movement of convergence so often in our daily occupations, that we find no difficulty in doing it under the influence of prisms. Divergence of the visual axes never occurs under normal relations; but we have learned as often as we pass from convergence to parallelism to call both externi muscles simultaneously into action, and this action will extend somewhat beyond the normal limit if a demand is made upon it in the interest of binocular single vision. The case is altogether different when we provoke double images, standing in different horizontal planes, by means of prisms with the refracting angle turned upward or downward, and which are united by change of level of the visual lines. The ordinary motions of the eye present no analogy for this case, and under physiological relations one line of vision cannot deviate perpendicularly more than  $1\frac{1}{2}$  or 2 degrees from the direction of the other,—that is, prisms of from  $3^{\circ}$  to  $4^{\circ}$  are the strongest which can be overcome by deviations in a perpendicular direction. One can learn by practice, and by beginning with prisms in a horizontal and gradually turning them to a vertical position, to overcome prisms of from  $6^{\circ}$  to  $8^{\circ}$ . Under pathological conditions, especially with insufficiency of the internal recti muscles, much stronger prisms acting in a vertical direction are often overcome.

The diplopia, which we can provoke by physiological experiments, serves to explain almost all cases of pathological diplopia, upon the basis of the so-called empirical theory of vision. If we fix a certain object with the right eye, then a second object lying to the right of the first will cast its image on the median half of the retina. Impressions made upon the median half of the right retina are referred to objects lying to the right of the fixation-point. For the same reason, retinal images on the temporal half of the right eye are referred to objects to the left of the fixation-point. For the left eye the relations are of course exactly symmetrical.

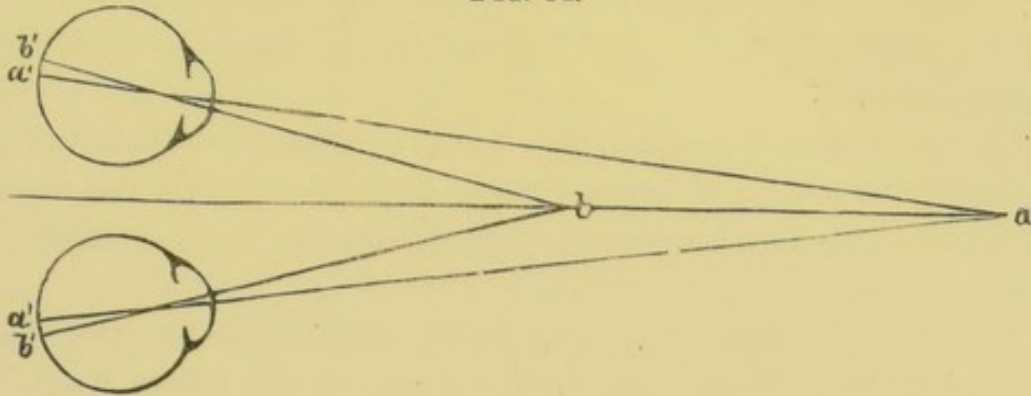
Applying this principle at the same time to both eyes, we have



the laws for the occurrence of homonymous and of crossed double images.

In Fig. 34, suppose both eyes to be directed upon the point  $b$ , then will the image  $a'$  of the point  $a$  be cast in both eyes upon the median half of the retina, and from what has been said it follows that the image  $a'$ , in the left eye, will be referred to an object

FIG. 34.



to the left of the point  $b$ , and the image  $a'$ , in the right eye, to an object to the right of  $b$ . The point  $a$  appears in double homonymous images. Relatively to the point  $a$  the visual axes converge, since they intersect at  $b$ . Convergence of the visual axes causes homonymous double images, and conversely we can, as a rule, diagnose convergence of the visual axes from homonymous double images. On the contrary, impressions made on the temporal half of the retina are projected by the right eye to the left, and by the left eye to the right of the fixation-point. If  $a$  is the point fixed, then  $b$  casts its image  $b'$  in both eyes upon the temporal half of the retina; the point  $b$  appears double, and the image in the right eye will be seen to the left, and the image in the left eye to the right, of the point  $a$ . There is crossed diplopia. Relatively to the point  $b$  the visual axes are divergent; consequently divergence of the visual axes causes crossed double images, and conversely divergence of the visual axes may be inferred from diplopia.

The results of this easy experiment may be still further confirmed by prisms. If we place before the right eye a prism with the refracting angle turned outward, then will the image be so displaced that the point fixed with the left eye will cast its image in the right eye to the median side of the macula lutea, and homonymous diplopia occurs. If, on the contrary, there exist



homonymous diplopia in consequence of a false position of the right eye (converging squint), we can, by the use of the proper prisms with their refracting angles turned inward, move the image so far toward the temporal side that it will fall upon the macula lutea. In this way we again establish the possibility of binocular single vision, and this possibility is realized whenever the normal binocular act takes place. From what has been said, it follows that we can correct homonymous diplopia by prisms with their bases turned outward, and crossed diplopia by prisms with their bases turned inward.

In accordance with what has been said above, concerning the action of prisms, it is not necessary to place the correcting prism before the deviating eye: it is generally better to place prisms of equal strength before both eyes.

The same is true when the double images are on a different level. If, for instance, the retinal image of the object fixed, fall in one eye below the macula lutea, it will be seen by that eye above the object. We can cause it to approach the macula lutea, and can restore binocular single vision by means of a prism with its base turned upward. If one wishes to divide the action of the prisms upon both eyes, the other eye is to be provided with a prism with its base turned downward.

#### PARALYSIS OF THE OCULAR MUSCLES.

The nerves which control the movements of the eyes are distributed very un-uniformly to the muscles. While the *nervus abducens* and the *nervus trochlearis* innervate only a single muscle each, all the other muscles of the eye, together with the *levator palpebræ superioris*, depend upon the *nervus oculo-motorius*. Moreover, the sympathetic exercises an influence upon the muscles of the iris, and upon those smooth muscular fibres of the lids which H. Müller discovered.

A special consideration of the paralysees of the ocular muscles will be conducted with reference to the nervous distribution.

#### PARALYSIS OF THE ABDUCENS.

The paralysis of the *rectus externus* muscle causes a limitation in the outward movement of the eye, which varies greatly in



proportion to the degree of the paralysis. In complete paralysis the eye can be turned outward scarcely beyond the middle of the palpebral fissure, while with incomplete paralysis movement is often so well maintained that the eye can be turned outward almost to the normal limit, but only for a short time, and with a twitching movement. The estimation of the loss of motility is made easy by observing that portion of the sclera between the cornea and the external canthus, which remains visible when the eye turns outward to its farthest limit; this free scleral space is of a size easily recognizable. More important, however, is it to compare the motility of the two eyes, since the degree of movement in general and under normal conditions, varies greatly in different individuals. While many persons can move their eyes through so great an arc that the limbus of the cornea disappears behind the external canthus, there always remains visible, in the case of others, a segment of the sclera more than a millimetre in breadth. Nevertheless, aside from exceptional cases which are explained by striking differences in the anatomical structure of the eye (for instance, a high degree of unilateral myopia), the movements of the two eyes are equal, so that a difference in the movements, as a rule, should be referred to a muscular paralysis of that eye which falls behind in associated movements.

Even when the defect of absolute motion is too slight to be observed with certainty, the disturbances in associated movements are apparent. We will suppose a case of paralysis of the abducens on the right side, then in the associated movement toward the left, the *musculus rectus externus* of the left and the *rectus internus* of the right eye will act equally and together; in the movement toward the right, on the contrary, the impulse of innervation divided equally between the two eyes is sufficient for the healthy *rectus internus* of the left, but not for the paralytic *rectus externus* of the right eye. The left eye can follow the movement toward the right of the object fixed, but the right eye falls behind in its movement, even before it attains the limit of its absolute motility; it surrenders fixation, and an abnormal convergence of the visual axes and consequent homonymous diplopia occur. If now the unaffected left eye be covered, the right eye, before it reaches the limit of its absolute motility, can direct itself upon the object fixed, but of course only by a greater effort than



under normal conditions. Since, however, the impulse of innervation acts equally upon both eyes, the healthy rectus internus of the left eye will be just as strongly innervated as is the paralytic rectus externus of the right eye, consequently the associated movement of the left eye is relatively too great, and there occurs a still stronger convergence than when the healthy eye is used for fixation.

Often the antagonist of the paralyzed muscle becomes shortened, and the effect is an abnormal convergence for every part of the field of vision. This is due to the fact that the antagonist is always in action. So, for instance, in paralysis of the abducens on the right side, the rectus internus of the eye affected is called into activity, both in the associated movement toward the left and during convergence, without the occurrence of any counterbalancing tension on the part of the abducens. In many cases this paralytic squint often develops at a very early stage of the disease; it occurs in the majority of cases of paralysis of the abducens. Still, there are cases in which, during the whole course of the paralysis, a true paralytic squint does not develop, but convergence occurs only in those positions which call for the activity of the paralyzed muscle. It is highly probable that the occurrence or non-occurrence of paralytic squint depends upon the pre-existing relative elasticity of the ocular muscles.

The recognition of paralysis of the abducens presents no difficulties. The limitation of motion is often so apparent that it alone assures the diagnosis. If this limitation be so slight that there is still some doubt, the test by double images is a very reliable one. Diplopia occurs whenever vision is turned in a direction for which the action of the abducens is insufficient, and the distance between the double images is increased, the greater the demand made upon the paralyzed muscle. The best method of conducting the test by double images is as follows. A sharply defined, easily perceived fixation-object is employed, the flame of a candle is the best; one eye is covered with a colored glass, say a bright red. The difference in color of the two images makes it easy for the patient to see them both, and enables the examiner to determine at once to which eye the respective images belong. We will suppose, again, a paresis of the abducens on the right side, in the first place without any contraction of its antag-



onist; then there will be single vision in the left half of the visual field, up to the median line or even beyond it, till the object fixed comes opposite the right eye. The more vision is directed toward the right, so much the more does the right eye fall relatively behind the left: homonymous double images appear, whose distance from each other increases the more the candle is moved toward the right.

The boundary-line which separates the region of single vision from that of diplopia may lie upon the same side of the median plane if the degree of paresis is slight, or it will lie beyond it if secondary contraction of the antagonist has occurred. This boundary-line, moreover, is generally not vertical, but so inclined that the region of diplopia is more extensive below than above. Since nearly all objects in the upper half of the visual field are seen with parallel axes of vision, while downward vision is generally associated with convergence, we accordingly often find under pathological conditions an inclination to parallelism or divergence while looking upward, and to convergence when looking downward.

Finally, the line of demarcation between single and double vision is no fixed and unchangeable one, for its position varies according to whether, in making the examination, one starts from the region of single or of double vision. In the first case, binocular single vision is maintained as long as the relations of innervation permit, while conversely, if the object fixed be moved gradually from the region of double vision toward the other side, the double images still persist when the position has come to be that in which single vision can be perfectly well maintained. The impulse toward binocular single vision resists the separation of the double images as long as possible, but its effect is not so great when called upon to unite double images already existing. The influence which the requirements of binocular vision exercise upon the maintenance of a proper position of the eyes, is early seen in those cases of receding muscular paralysis in which, in the greater part of the field, single vision has been restored. If, for instance, in such a case of paresis of the abducens, double images, standing one higher than the other, are produced by prisms acting vertically, the images will show near the boundary of binocular single vision not only a difference in level but a homonymous lateral separation. This proves that under these circumstances single vision



can be maintained only by an unusually strong impulse of innervation. The occasion for this impulse no longer exists when vertically refracting prisms render the uniting of the double retinal images impossible.

If paralytic strabismus convergens has developed, diplopia extends over all or nearly all the field of vision. The diagnosis between paralytic and typical strabismus convergens is not difficult, although a squint originally paralytic may become a typical one,—that is, when strabismus convergens remains after recovery from the paralysis. We class as paralytic squint all those cases in which there are signs of paralysis of the ocular muscles, recognizable by a limitation of movement and the behavior of the double images. If diplopia exist in typical strabismus, the distance between the two images remains nearly the same in every part of the field, while in paralytic strabismus there is, it is true, diplopia in the entire field of vision, but the distance between the images increases the greater the demand made upon the paralyzed muscle.

It should be mentioned that in some cases the patients do not complain of diplopia, but only of indistinct vision. The impression is that they see one object through another, since each eye sees a different portion of the field of vision, while it is a matter of observation to find out which position of the field of vision belongs to each one of the double images.

This form of indistinct vision is generally called masked double vision (*verkapptes Doppeltsehen*). It is characterized by the fact that each eye separately sees distinctly, and the disturbance occurs only in binocular vision. In most cases of this kind the diplopia, as such, may be brought to the attention of the patient by placing in front of one eye a red glass and using as a fixation-object the flame of a candle. The same symptoms can, of course, occur in all the paralyses of the ocular muscles.

A very curious condition is presented by those cases in which, on account of defective vision in the other eye, the one affected with paralysis is used for fixation. Let us suppose again a case of paralysis of the abducens on the right side, but with defective vision in the left eye,—then, for the reasons set forth on page 136, the left eye will experience a strong secondary deviation. The patient presents himself to us with strong strabismus convergens on the left side, with free movement of that eye, which, at first,



will therefore appear to be the affected one. Nevertheless, a critical comparison of the movements of the two eyes and the behavior of the double images (when the weak-sighted eye has sufficient power of vision) enables one to locate the seat of the paralysis on the right side.

One symptom occurring with other paralyzes of the ocular muscles is generally very marked in these cases. The face is turned toward the side of the paralyzed muscle, partly by that position to compensate for the loss of its action, and partly to move the field of single vision as much as possible to the front.

Most cases of paresis of the abducens may be ascribed to rheumatic causes; these cases are often preceded by rheumatic pains in the head on the side affected, especially in the temporal region; or they may persist after the occurrence of the paralysis. A less frequent cause is syphilis. In many cases there are local causes in the orbit, and finally paralysis of the abducens, as of the ocular muscles in general, may occur as a symptom of cerebral or spinal disease; it is often indeed the first symptom of such a condition. Some cases are congenital, or they develop without any known cause during childhood.

The prognosis is generally favorable provided the patient be subjected to proper treatment. In cases which recover spontaneously the condition generally lasts two months. The secondary contraction of the antagonistic muscle generally disappears simultaneously with the paralysis; if the paralysis does not entirely recover, there is more probability of permanent convergent squint. In such cases the diplopia does not generally entirely disappear, but it becomes less annoying.

The treatment is to be directed principally against the cause of the disease. Rheumatic paralyzes require, in the first place, protection from all injurious influences. The patient should remain in a warm room; should avoid changes of temperature, keeping the affected side of the head covered with cloths or wadding; diaphoretics, and even emetics, are recommended in the earliest stages of the disease. The rheumatic pains in the temple, or anywhere in the affected half of the head, which are, at first, often present, are relieved in the most satisfactory manner by local blood-letting. In the further course of the disease derivative remedies are indicated,—vesications on the neck, painting the



forehead and temple with tincture of iodine, etc. Electricity also does good service in the later periods of the disease, and although the electric treatment, on account of the deep position of the muscle, cannot act in so direct a manner as in the case of other muscles, still, some part of the electric current seems to be able to reach it.

The indications suggested by the presence of syphilitic, cerebral, or spinal disease, belong in the province of special pathology, and need not here be discussed.

To relieve the annoyance of diplopia, a pair of spectacles may be worn which cover the affected eye with a ground glass. The idea suggests itself of uniting the double images by means of prisms, but it is seldom practicable. The principal reason for this is that, even in a case of slight paralysis, the distance between the double images is too great to admit of their being united by prisms which could be worn as spectacles. Prisms of more than  $6^{\circ}$  or  $7^{\circ}$  can scarcely be worn for this purpose, partly because of their weight, partly because of their chromatic aberration. Even if both eyes were provided symmetrically with such prisms, the effect would be that of a prism of  $12^{\circ}$  or  $14^{\circ}$ , which would generally be insufficient.

Another essential reason against their use is, that the distance between the double images varies greatly with every change in the direction of vision. If, for instance, with paresis of the abducens on the right side there be single vision in the left half of the visual field, while during vision directed in the median plane diplopia is present, which could be corrected by a prism of  $12^{\circ}$  or  $14^{\circ}$ , it would still not be well to allow such prismatic spectacles to be worn. On account of the increased distance between the images in the right half of the field, they would not be sufficient to unite the double images during vision in this direction; while in the left half of the field, where there was normal single vision, the prisms would provoke crossed double images, and a compensating convergence of the visual axes. Under these circumstances a secondary contraction of the antagonistic muscle is induced, and the development of strabismus convergens is favored.

The correction of the diplopia by prisms is, then, indicated only when there exists secondary contraction of the antagonistic muscle, and, as a consequence of that, diplopia throughout the



entire field of vision. The prisms should be chosen of such a strength as to correct only that part of the diplopia which is due to this contraction of the antagonist,—that is, they are to be chosen with reference to a position of the eyes in which no demand is made upon the paralyzed muscle. Since, however, as already remarked, only very weak prisms can, under any circumstances, be used, it follows that they can be resorted to only in cases which are very nearly recovered. Under such circumstances the use of prismatic spectacles with their refracting angles turned inward is, in many cases, to be recommended, because as the region of single binocular vision is increased the impulses of innervation, which affect the paralyzed muscles in favor of binocular single vision, increase also.

A similar result—that is, the exercise of the paralyzed muscles in the service of binocular single vision—may be obtained in another manner. The patient is directed to look at an object held within the region of binocular single vision, and it is then moved slowly over into the region of double vision, or, what has the same effect, the object remains stationary while the position of the head is changed.

Convergent squint may exceptionally follow, in spite of complete recovery from the paralysis. If, in such cases, both eyes are alike in reference to refraction and acuteness of vision, strabismus convergens alternans generally develops, which is to be relieved by the tenotomy of one or both recti interni muscles. But convergent squint is more frequent in cases of incomplete recovery from the paralysis. Besides the tenotomy of the rectus internus it may be necessary to bring the externus forward.

All such operations should, however, be postponed until the paralysis is either completely cured or has become so chronic that no improvement is to be expected. Too early an operation, although its effect is at first satisfactory, may cause a deviation in the opposite direction after recovery from the paralysis takes place.

#### PARALYSIS OF THE OCULO-MOTORIUS.

Complete paralysis of the oculo-motorius presents a very striking picture. The upper lid droops and covers the cornea; the external canthus is generally lower than on the other side. If we raise the upper lid we see the eye generally turned outward,



and it can be only partially turned inward,—scarcely to the middle of the palpebral fissure. There is no upward motion whatever, for both muscles acting in that direction, the rectus superior and obliquus inferior, are paralyzed; the downward movement is effected only by the obliquus superior, and is therefore incomplete, and is accompanied, especially when the cornea is turned outward, by a perceptible rotation, which causes the upper end of the vertical meridian to incline inward. The pupil is moderately dilated and accommodation is lost. There is often a slight protrusion of the eyeball noticeable (*exophthalmus paralyticus*); this is due to the diminished elastic tension of the three muscles, innervated by the oculo-motorius, and which draw the eyeball backward.

The picture of a complete paralysis of the oculo-motorius is so striking that it seems hardly necessary to confirm the diagnosis by the test of double images; still, in certain cases it may be desirable to do so. We will suppose again a paralysis on the right side, by which all the branches of the oculo-motorius are more or less affected; then will there be, either in the entire visual field or when vision is directed to the left, double crossed images, whose distance from each other increases the more the object fixed is moved to the left. When vision is directed upward the right eye falls behind, the crossed double images separate from each other in a vertical direction, the distance between them increasing the more vision is directed upward. In looking downward, also, the same differences in the level of the double images will appear, only the relations will be reversed, and the image in the right eye will appear to stand the lower.

If there be only partial paralysis of the oculo-motorius, affecting only certain muscles, while others are free, the diagnosis may become very complicated, especially if incomplete paralysis affect both eyes at the same time. On the other hand, the diagnosis is the more easily arrived at, from the fact that the levator palpebræ superioris is seldom unaffected, and its condition is easily recognized; the iris and the accommodation are often simultaneously affected.

Moreover, every limitation of movement upward, if it depend upon muscular paralysis, must be referred to the oculo-motorius, from which both the muscles acting upward, the rectus superior and obliquus inferior, are innervated. The only diagnostic diffi-



culty is in connection with that antagonistic pair of muscles,—the rectus inferior and the obliquus superior,—the first being innervated from the oculo-motorius, while the second has its own nerve. The differential diagnosis between the paralyses of these two nerves will be discussed under the head of “paralysis of the trochlearis.”

The inconveniences experienced by the patients are diplopia and paralysis of accommodation, except when, as is generally the case, the eye is absolutely excluded from the visual act by the drooping of the lid (ptosis).

If the affected eye, on account of the poorness of the other, must be used for fixation, the patients are in a very unfortunate position. Not only the strong secondary deviation of the other eye, which we have mentioned as occurring under analogous conditions in paralysis of the abducens, but other more serious difficulties appear, which indeed exist and are evident in paralysis of the abducens, but are there less annoying.

In all paralyses of the ocular muscles, with fixation by the affected eye, the field of vision is falsely projected whenever a demand is made upon the action of the paralyzed muscle.\* This is most easily demonstrated in the case of paralysis of the abducens. The patient is directed to shut the healthy eye, and then to fix with the other eye some object lying on the same side with the paralyzed muscle; he is then directed to touch quickly with his finger the object fixed. In doing so he will project his hand too far on the paralyzed side, provided he do not make the movement so slowly that it is controlled and corrected by vision instead of the original impulse. In order to give the eye the necessary position, the paralyzed abducens must receive a stronger impulse of innervation, which, under normal conditions, would cause much too strong a contraction of the muscle. This gives to the patient the impression that he is directing his eye farther outward than is really the case, and accordingly he displaces his entire field of vision too far toward the same side.

Although this false projection of the field of vision is easily demonstrable in paralysis of the abducens, still it seldom causes inconvenience, even when the affected eye has to be used for fixation;

---

\* V. Graefe, Arch. f. Ophth., B. i. 1, pag. 18.



but the reverse obtains in the case of paralysis of the oculo-motorius on account of the number of muscles affected. The field of vision is in rapid succession falsely projected in various directions, according to the changes in the direction of vision; it is first too far on one side, then too high, then too low. The want of correspondence between the strain made upon the ocular muscles and the actual movements of the eye thereby accomplished, causes an impression upon the patient as if the surrounding objects were in motion; this gives him the sensation of dizziness, causes his gait to be very unsteady, and induces total loss of co-ordination in rapid movements.

In reference to the etiology, it should be noted that syphilis is a relatively frequent cause of paralysis of the oculo-motorius. Aside from this it may be caused, as may paralyse in general, by rheumatism, diseases of the central nervous system, changes at the base of the brain, in the orbit, etc.

The treatment is in the first place to be directed against the cause; for instance, syphilis. In other respects the treatment recommended for paralysis of the abducens is applicable.

If, after recovery from paralysis, strabismus remain, it is to be relieved by tenotomy of the rectus externus, and if there be very great loss of motion on the side of the rectus internus, it may be necessary simultaneously to bring the insertion of that muscle forward. The question of treatment is more complicated in cases where the upward and downward movements are only partially restored. Only where the vertical deviation of the eyes is very considerable do we have the indication for bringing forward the insertion of the rectus inferior or superior. Von Graefe\* recommended that slight defects of vertical motion be compensated for by tenotomy in the other eye of the muscle acting in the same direction, be it the rectus inferior or superior. If, for instance, the right eye squints upward and has but limited movement downward, then a tenotomy of the rectus inferior in the left eye will cause that to turn upward and limit its movement downward. If a harmonious action of the ocular muscles is thus partially, but not sufficiently established, the insertion of the rectus superior of the right eye may be set backward.

---

\* Klin. Monatsbl. für Augenheilk., 1864, pag. 1.



The objection is made to this procedure, that in movements either upward or downward one rectus muscle always acts in connection with one obliquus, while it is possible to reach only the recti muscles by a regular operation; still, experience teaches that after tenotomy of the rectus inferior or superior, the inconveniences dependent upon the action of the corresponding obliquus soon pass away under the influence of binocular single vision.

#### PARALYSIS OF THE TROCHLEARIS.

Under physiological conditions the musculus obliquus superior and the rectus inferior always act together; both turn the eye downward, acting under the influence of the will as a single muscle. If now the action of the obliquus fail, so that in looking downward the rectus inferior alone acts, then, starting from a position in which the visual axes are parallel to the median plane, the movement will not be simply downward, but at the same time somewhat inward. The effect of the rectus inferior in moving the cornea downward is greatest when the muscle is nearest to lying in the plane of the meridian of its insertion, and this is the case when vision is directed outward, thus bringing the line of vision and a line connecting the origin and insertion of the muscle into the same vertical plane. The more, on the contrary, the eye turns inward, the greater the angle between the line of vision and the direction of the traction of the muscle. Only a part of the force of the muscle can then be expended in turning the cornea downward; the other part acts to revolve the eye about the axis of vision. If in paralysis of the trochlearis the rectus inferior has to act alone in directing vision downward, then the defect in downward movement will be least in looking downward and outward, and greatest when looking downward and inward.

In paralysis of the obliquus superior, not only is the muscular force which rotates the eye downward diminished, but we must take into consideration the elastic resistance which the antagonistic group of muscles opposes to this rotation. There is, of course, no change in the antagonistic relations between the rectus inferior and superior, but the paralyzed trochlearis no longer counterbalances the obliquus inferior. The effect of this is different in the different directions of vision. When vision is directed inward, the curve by which the two obliqui muscles embrace the posterior



part of the eyeball very nearly approaches the form of a part of a great circle. It is then in this position that the elastic resistance of the obliquus inferior acts most strongly to prevent downward vision. The direction of the obliquus inferior does not, however, lie exactly in the plane of a great circle; it therefore not only opposes the downward rotation, but simultaneously causes a rotation of the eye about the axis of vision, by which the vertical meridian is abnormally inclined outward. This revolution is the greater the farther vision is directed toward the temporal side. But even when vision is directed toward the median plane this pathological inclination of the meridian persists, since in this position of the eye the rectus inferior contributes in causing this same rotation about the axis of vision.

For the objective recognition of the pathological condition it is important to notice that the eye affected falls behind when vision is directed downward. Since in the median direction of the lines of vision the rectus inferior acts least and the trochlearis most on the downward movement of the cornea, it follows that the consequence of, for instance, a paralysis of the obliquus superior of the right eye will be that an object lying to the left and downward can be properly fixed only by the left eye, while the right eye falls behind in the movement, and its cornea, relatively to the fixed object, stands too high. Often, however, with incomplete paralysis of the trochlearis, the defect in movement is so slight that it is not easy to recognize it. Upon causing the patient to direct his two eyes alternately downward and inward, it will be seen that when the affected eye is used for fixation the healthy eye, for the reason already explained, suffers an associated deviation downward.

By reason of the relations just stated, diplopia appears as follows. In the upper half of the field there is single vision. Upon looking downward, homonymous double images appear, which at the same time are projected at different levels. We will suppose a case of paralysis of the trochlearis on the right side, then will the image of the right eye stand the lower, and the distance between the images will increase on looking to the left, while it will decrease on looking to the right. At the same time it is noticed that the upper ends of the images incline toward each other. It generally appears to the patient as if the lower image were the



nearer. This is an error in judging of distance, which certainly is not to be wondered at, since its proper estimation depends essentially on binocular single vision. It is not in paralysis of the trochlearis alone that the lower image appears the nearer,—the same thing occurs almost invariably in all forms of diplopia in which the images are on different levels. Förster\* first explained this optical illusion as follows. When several objects lie at different distances but in the same horizontal plane, the images from the nearer objects are cast upon the upper part of the retina. This develops the habit of referring images in the upper part of the retina to relatively near objects.

The most important diagnostic points are, that the diplopia occurs only in the lower half of the field, and that the images separate more and more in a vertical direction as vision is directed toward the median plane. In some cases the images may not be homonymous, but slightly crossed. This is due to a pre-existing elastic preponderance of the recti externi muscles, which, however, in the interest of binocular single vision, is overcome by a stronger tension of the interni. If under these circumstances diplopia occur, the stimulus to a strong innervation of the interni muscles fails, and the elastic preponderance of the externi muscles asserts itself. The disturbances consist principally in diplopia when looking downward. This is especially annoying when going upstairs.

Finally, we must consider the differential diagnosis between paralysis of the obliquus superior and of the rectus inferior. In the case of the last, downward movement is limited, and there is diplopia in the lower part of the visual field, the images showing a lateral deviation and a difference of height. But the images are crossed, because, since the downward movement is now effected by the trochlearis alone, the cornea is at the same time directed outward. The difference in the level of the images increases as the affected eye moves outward. Moreover, the images are inclined in the opposite direction, being wider from each other at the top.

The etiology and treatment are the same as in the other ocular paralyses.

---

\* Verhandlungen der Breslauer medicin. Section, 1859-60.



## SPASM OF THE OCULAR MUSCLES.

Spasm of the ocular muscles occurs frequently as a symptom of cerebral disease. It cannot be doubted that a similar condition may also occur idiopathically. Observations on this subject have, however, been few and not decisive. At all events, it may be affirmed that, if spasm of the ocular muscles occurs at all as an idiopathic disease, it is only very exceptionally.



## STRABISMUS.

---

STRABISMUS, in the most general sense of the word, exists whenever the visual axes do not intersect at the point fixed, or in other words, whenever the point fixed casts its image upon the macula lutea of only one eye, while in the other it falls upon some eccentric part of the retina. We have seen, in the preceding chapter, that this condition occurs as a constant symptom of paralysis of the ocular muscles, and we have frequently used the expression "paralytic squint."

It follows, from the law of the symmetrical innervation of both eyes, that in paralytic squint the degree of deviation varies greatly in the different positions of the eyes. It is greatest in that position where the greatest demand is made upon the paralyzed muscle. Another consequence of the same law is the strong secondary deviation which affects the healthy eye, whenever the affected eye is used for fixation in a direction in which a demand is made upon the paralyzed muscle.

From the same law of symmetrical innervation of the two eyes, it follows that in typical so-called concomitant squint the movements of the squinting eye accompany those of the normal one, and that upon using the affected eye for fixation the associated deviation of the eye generally used for fixation is equal to the usual deviation of the squinting eye. The exceptions to this rule, due to special circumstances, will be considered later. In general, the principle just stated is sufficient to distinguish the paralytic from the typical squint.

### STRABISMUS CONVERGENS.

Donders has shown that in the great majority of cases strabismus convergens exists in connection with hypermetropia. The hypermetropia is often manifest; but even when convex glasses do not improve distant vision, even when the patients affirm that they do not see at a distance as well with weak convex glasses as



with the naked eye, hypermetropia is not absolutely excluded. Frequently there is associated with strabismus convergens, a high degree of latent tension of accommodation, which yields only slowly under the energetic use of atropine. Donders' investigations also showed that not the highest degrees of hypermetropia oftenest induce strabismus, but rather the medium and slight degrees.

The physiological ground for the relation between hypermetropia and strabismus convergens lies in the very nature of this anomaly of refraction. It is known that for distinct vision hypermetropic eyes require a relatively strong tension of accommodation. It is further known that a physiological connection exists between the movement of convergence and accommodation,—that is, that with the increase of convergence the relative range of accommodation approaches the eye. It is accordingly easy to understand why, in order to bring the relative range of accommodation nearer to the eye, hypermetropes should converge too strongly. While they are often compelled in near vision to exhaust their available power of accommodation, and to work with the relative near point, they gain by a relatively too strong convergence the advantage of bringing the entire range of accommodation nearer the eye. They do not then need, when working, to employ their entire available accommodation, but only a small part of it: they work with a relatively small tension of accommodation. If then hypermetropia, from its very nature, can induce the habit of associating each action of accommodation with a relatively too strong convergence of the visual axes, the question arises, why all hypermetropes do not squint. It is plain that the advantage just referred to, of working with a relatively slight tension of accommodation, is purchased at the expense of binocular vision. Under what circumstances now will the necessity for sparing accommodation prevail, and when will binocular single vision prevail? In the first place, there will be but slight cause for sacrificing binocular vision when, in spite of relatively too strong convergence, no distinct retinal images are obtained, as is the case in the highest degrees of hypermetropia. In the medium and lower grades of hypermetropia there will exist the inclination to exchange binocular single vision for a convenient monocular fixation when any cause whatever makes binocular fixation less valuable. As such causes, differences in refraction, or in the acuity of vision of the



two eyes, is first to be named. It was explained on page 74 that where there is difference of refraction a distinct retinal image is formed in only one eye. The same is the case in astigmatism, corneal opacities, etc., affecting only one side. But, even with faultless retinal images, differences in the acuteness of vision will exert the same effect upon binocular vision. In this connection is especially to be remembered that form of amblyopia congenita which occurs oftener associated with hypermetropia than with any other condition of refraction. If there be in both eyes faultless and distinctly perceived retinal images, the incentive to unite them binocularly is much greater than when there is an ill-defined or indistinctly perceived retinal image in one eye and a clear retinal image and better vision in the other.

Although these causes for convergent squint, as pointed out by Donders, often enough exist, still, it must be remembered that they alone do not necessarily induce it. We frequently see cases of bilateral hypermetropia with considerable differences in refraction or in vision, or in both, without there being any squint, and with the persistence of the normal binocular visual act.

Other favoring circumstances must contribute to the development of strabismus convergens. Perhaps it is in this respect not without influence, that, according to my observations at least, in a very considerable number of these cases even the non-squinting eye does not possess full sharpness of vision; this induces the effort to get as large retinal images as possible by approaching very near the object, which in turn demands strong tension of accommodation, and increases the tendency to convergence of the visual axes. All influences which diminish even temporarily the strength of the muscle of accommodation tend in the same direction. Contraction of the range of accommodation may, not only with hypermetropia but even with emmetropia, become a cause for strabismus convergens in young persons.\*

There are still other causes which favor convergence, or which render it difficult to maintain parallelism of the visual axes. In this connection Donders† has shown that the deviation of the line of vision from the centre of the cornea is not only generally greater

---

\* Donders, *Het tienjarig bestaan*, etc., pag. 115.

† *Arch. f. Opth.*, B. ix. 1, pag. 121.



in hypermetropia than in emmetropia, but is greater in hypermetropia complicated with strabismus convergens than in the same degree of hypermetropia not so complicated. The more the line of vision deviates inward, the more the cornea must diverge when the lines of vision are parallel, and we have seen (p. 124) that the apparent strabismus divergens of hypermetropes is explained by this divergent position of the cornea. A greater demand is made upon the recti externi in maintaining parallelism of the visual axes with hypermetropia than with either emmetropia or myopia. This is the reason for the fact mentioned on page 131, that in hypermetropia only a slight degree of divergence of the visual axes can be produced by prisms. In this condition of refraction the recti externi muscles are all the time taxed nearly to the limit of their capacity. The subject may be thus formulated: the great deviation of the lines of vision from the corneal centres, in hypermetropia, causes a relative insufficiency of the recti externi, which favors the occurrence of strabismus convergens.

It is certain also that in many cases the relations of muscular elasticity induce the occurrence of strabismus. This is seen most plainly in cases of one-sided blindness. Frequently the blind eye maintains, at least at first, its normal position, the muscles remaining in equilibrium without the regulating influence of binocular single vision. If squint develop, it is generally strabismus divergens; the reasons for this will be explained later. But cases do occur in which the blind eye acquires a pathological convergence, which indicates a pre-existing preponderance of the recti interni muscles. An elastic preponderance of the recti interni, or what amounts to the same thing, an insufficiency of the recti externi, may be overcome just as may the hypermetropia in the service of binocular single vision; but this will be the more difficult when both causes act together, and the strong tension of the interni may induce strabismus convergens when acting simultaneously with causes which lessen the value of binocular vision. In this way strabismus convergens may occur as well with emmetropia as with myopia. Cases in which strabismus convergens remains after paralysis of the abducens belong to this class.

It is finally to be mentioned that irritation of the sensitive ocular nerves may cause reflex, pathological contraction of the recti interni. I observed this unmistakably in the case of a child two



years old, whom I treated with nitrate of silver for purulent conjunctivitis. After each application to the conjunctiva there occurred a strong converging squint, which disappeared spontaneously after a few hours. This reflex contraction of the recti interni may explain some of the cases in which corneal opacities exist in connection with strabismus convergens. On the one hand the inflammatory process, which leaves the opacity behind it, may by reflex irritation have induced the strabismus convergens; on the other hand, however, the diminution of vision, caused by the opacities, acting with other favoring causes, such as hypermetropia or preponderance of the recti interni, is sufficient to produce the strabismus.

In most cases strabismus convergens develops in early childhood, between the ages of two and seven years. It is possible that it occurs congenitally. There is no doubt that the conditions inducing hypermetropia and abnormal relations of elasticity in the ocular muscles are hereditary.

After the period of childhood has passed, strabismus convergens very seldom occurs. It may happen in connection with myopia. Myopia generally causes strabismus divergens; still, it may sometimes happen, even in high degrees of myopia, that the lines of vision can be properly converged for near vision, and can be held in that position without straining. This may be due to a more favorable change of form, or to a congenital or acquired preponderance of the interni recti muscles. This happens mostly at the expense of movement outward, which is always more or less limited. This limitation may become such that it is impossible to give the visual lines a parallel position for distant vision. Convergent squint then exists. According to Von Graefe, the occurrence of this form of strabismus convergens, in the middle grades of myopia ( $\frac{1}{6}$  to  $\frac{1}{4}$ ), is favored by continuous work with strong convergence of the visual axes. Under these circumstances there is developed a preponderance of the recti interni, which finally cannot be relaxed sufficiently to admit of parallelism of the visual axes.\*

Strabismus convergens, as a consequence of paralysis of the abducens, may occur at any time of life, the paralytic strabismus

---

\* Comp. Donders, Arch. f. Ophth., B. ix. 1, pag. 142, and V. Graefe, Arch. f. Ophth., B. x. 1, pag. 156.



gradually, during recovery from the paralysis, passing into concomitant strabismus. Diplopia is generally present in all cases of strabismus convergens which develop later than childhood.

The most frequent form of strabismus convergens is the stationary monolateral squint. One and the same eye is always used for fixation, while the other remains turned inward.

We have before said that in general the angle between the visual axis of the squinting eye and its normal direction remains constant as well during associated movements as during the secondary squint, which affects the eye usually employed for fixation when the other is so employed. This rule must not be regarded as absolute; for aside from certain fluctuations which it exhibits in the same individual within short periods of time, it generally increases during fixation of near objects and when the squinting eye is turned outward. The mobility of the eyes does not by any means remain unchanged in strabismus convergens; as a rule, the movement outward is less and that inward greater than normal. This limitation of movement may be divided symmetrically between the two eyes, but oftener the lateral movement of the squinting eye is noticeably less than that of the eye used for fixation; this causes an increase of the squinting angle when looking toward the side of the squinting eye.

Often, too, the associated deviation occurring upon change of fixation is observed to be stronger than the primary squint. Particularly if there be hypermetropia on both sides, but with difference in refraction, the squinting angle is always greater when the eye with the higher degree of hypermetropia is used for fixation than when the other is used. The stronger tension of accommodation which the more hypermetropic eye requires, causes immediately an increase of convergence. This symptom is so characteristic that one may diagnose from it, both the existence of different refraction in the two eyes and which eye is the more hypermetropic, even when the hypermetropia is latent in both eyes.

Alternating strabismus convergens is comparatively rare. Even when vision is so good in both eyes that either may be used for fixation, the eyes are but seldom used alternately. Slight differences in the acuity of vision generally determine the habitual use of one particular eye.



Periodic strabismus convergens is a special form which deserves mention. Most cases of squint are not permanent from the beginning, but become so after a short time. For this reason only those cases are called periodic squint in which during a long period the squinting appears only occasionally. These are generally cases of accommodative squint dependent on hypermetropia. When the eyes are not fixed on some object there is either no apparent or only a slight convergence; it becomes considerable, however, when the effort of accommodation is made in order to see distinctly a near or far object.

I have observed in emmetropic eyes another form of periodic squint, dependent upon an elastic preponderance of the interni. Convergence occurs immediately whenever binocular single vision is interrupted by prisms refracting vertically, and it remains a short time after removal of the prisms. Squinting followed spontaneously, generally under the influence of some slight disturbance of the general condition, and was connected with diplopia.

The degree of strabismus can be determined exactly only by ophthalmometric measurement, but for the purposes of practice an approximative estimate is sufficient.

According to Von Graefe,\* the patient is directed to fix an object lying in the median plane and at a level with the eye; a mark is then made on the under lid of that eye exactly below the centre of the cornea. Then the symmetrical point under the second squinting eye is determined, as well as the point upon the lid lying directly under the centre of the deviating cornea. The distance between these two last-named points gives the linear measure of the deviation in this position. An accurate marking of the lid is in practice impossible, on account of the movement caused whenever the lid is touched, and the difficulty in applying any ink or coloring-matter to a surface covered with such oily secretions. One must content himself with merely noting the point in question on the first lid, and compare it with the symmetrical point on the second eye; in fact, it amounts to a superficial estimation of the linear deviation.

A somewhat more exact result is obtained when this measurement is made by the help of a scale, used in the following manner.

---

\* Arch. f. Ophth., B. iii. 1, pag. 195.



The eye generally used for fixation is covered, and an object is fixed with the squinting eye; a scale divided into millimetres is then held immediately under the edge of the lid, and it is noted what division of the scale comes immediately under the centre of the pupil; the other eye is then uncovered, and the first allowed to resume its ordinary squinting position, and it is then again noted what division is exactly under the middle of the pupil; in this way the linear measure of the deviation is found. The secondary deviation of the other eye is, of course, found in the same manner. If, in consequence of poor vision, the squinting eye cannot be steadily fixed, the graduated scale may be held in such a way that its end is exactly under the punctum lachrymalis, and while fixation remains unchanged, the distance between that point and the centre of the pupil is determined, first for the normal and then for the squinting eye. The difference between these two measurements is the linear deviation. Instead of the ordinary millimetre measure, one may use a scale made of ivory, of a shape to fit the lower lid, and provided with a handle. The scale is so graduated on its free edge that 0 is at the middle, and the millimetres are counted from that point in both directions.\* Another "strabometer"† consists of two small scales, one for each eye, fitting closely to the under lid, each provided with a movable indicator, and both fastened on the same handle. By means of a screw the indicators may be adjusted on either side to the point exactly under the centre of the pupil.

It is advisable in every case to make this measurement, even though it cannot be done with strict accuracy. It is to be remembered that for the purposes of operative treatment the exact measurement of the deviation is not so important as was formerly thought.

Often the squinting eye turns upward as well as inward; in such a case, upon changing fixation the eye generally used turns usually upward, seldom downward. Where there is vertical deviation it generally persists after change of fixation. I have often observed a rotation of the eye in connection with these differences in level; generally, simultaneously with the deviation

---

\* Laurence, *The Optical Defects of the Eye*.

† Eduard Meyer, *Du Strabisme et de la Strabotomie*, Paris, 1863.



upward there is an inclination outward of the vertical meridian, and inversely, upon returning to fixation, it inclines inward. Generally the other eye rolls in a corresponding manner, that is, the meridians of both eyes incline simultaneously either to the right or to the left, but they do not always stand at the same level.

Typical concomitant squint is very seldom accompanied by diplopia. So long as the theory of an anatomically preformed and uniformly acting symmetrical correspondence of the retinae was entertained, this fact could be explained only upon one of two assumptions,—either that in consequence of asymmetry of the retinae, in spite of the strabismus, a binocular union of the two fields of vision takes place, or that the retinal image in the squinting eye is excluded from perception by some psychical process, or, as is generally said, “is suppressed.” Now, there cannot be an asymmetry of the retinae in the sense above indicated; if there were, diplopia would always occur when a proper direction is given to the lines of vision by an operation, but it is well known that such is not the case. For this reason the other view, which assumes a suppression of the retinal images, has been generally accepted, since it seems to relieve the subject of all difficulty.

It was thought that when the attention was concentrated upon the central image in the eye used for fixation, the ease with which the image in the squinting eye could be suppressed, depended upon its eccentricity, that is, its position on a less sensitive part of the retina. But in paralytic squint exactly these conditions do not prevent the occurrence of diplopia.

But supposing the double vision of one and the same object may be avoided by a considerable eccentricity of one of the retinal images, what becomes then of the image which is cast upon the macula lutea of the squinting eye? According to the theory of corresponding points, the images at both retinal centres are projected upon each other in space, from which would result about as much trouble as from diplopia.

A careful analysis of binocular vision with strabismus, shows that the hypothesis of the suppression of the retinal image in the squinting eye does not sufficiently explain all the facts.

The well-known fact that the squinting eye contributes toward widening the field of vision, compels the admission that its function is not absolutely suspended. Accordingly, a participation in



the act of vision must be admitted for the median part of the retina, which serves for eccentric vision outward, but it was thought that the theory of the suppression of retinal impressions could still be retained with reference to the other parts of the retina. One can, however, easily satisfy himself that even that part of the field of vision of the squinting eye which coincides with that of the eye used for fixation is not excluded. Of course it is only cases in which the squinting eye has moderately good vision which can be the subjects of such experiments.

The following experiment is very simple. The patient directs the eye generally used for fixation upon an object in the median plane, and on the same level with itself; a small mirror, or, still better, a transparent, reflecting plane glass, is then placed before the squinting eye, its edge supported on the nose, and its surface so held that objects behind the patient are reflected in it. A light is best used for this purpose which is placed behind and to the side of the head, and at a level with the eye. Patients with a little skill soon learn to receive the image of the light with the squinting eye, and to throw it at will upon any part of the retina. It can be proved in this way that in binocular vision there is consciousness of the retinal impressions made in the squinting eye. Now, if the retinal images of the squinting eye are not suppressed, but are perceived in about the same way as are objects in the periphery of the field of vision, the relations of the two retinæ cannot be the same as in the normal condition. In fact, the relations are so complicated that it is difficult to formulate them. At all events, the facts above stated cannot be explained upon the theory of a preformed and therefore unchanging symmetrical correspondence of the retinæ.

If now we find, on the other hand, that diplopia, such as we can provoke during the normal binocular visual act, and as it occurs in cases of paralysis of the ocular muscles, agrees fully with the theory of retinal symmetrical correspondence, all the facts may be reconciled by assuming that the relations of the corresponding retinal parts are not congenital but acquired.

We bring the macula lutea exactly opposite those objects upon which the attention is directed, as a consequence of that physiological preference, in respect of acuteness of vision, which has made this place the centre of the retina; and that we see singly



an object fixed with both retinal centres must be regarded as a habit acquired from experience. When binocular fixation is once established, then the symmetrical points of the retinæ first acquire the significance of correspondence. If now, for any of the reasons above stated, binocular fixation be relinquished in early childhood, no habit is developed of uniting the two retinal images, but each eye projects its field of vision in the proper manner. Each eye for itself sees the objects in the direction toward which it is turned. Diplopia does not occur in these cases because that depends upon a previous habit of uniting the two fields of vision. If a binocular union of the two retinal images never occurs, then there will be no diplopia when the field of vision of one eye is moved up or down by a prism refracting vertically, and such is the fact in many cases of strabismus.

There is not always the absolute impossibility of perceiving double images. Often an inconsiderable remainder of binocular single vision is retained. In such cases double images do not occur spontaneously, but they may be made perceptible by means of a colored glass and a vertically refracting prism. Nevertheless, the results are very inconstant; the double images appear and disappear again without the patient being able every time to perceive them with certainty. Their positions do not generally agree with the theory of the correspondence of symmetrical points. For instance, they show only slight horizontal separation, in spite of considerable convergence, or they are crossed when they should be homonymous, or the double images may always stand one above the other, and never side by side. It sometimes happens that, with the help of a red glass before one eye and a vertically refracting prism before the other, double images are seen; but when by a slow revolution of the prism the vertical distance between the double images is decreased, they suddenly disappear, even before the refracting angle has revolved through  $45^\circ$ , and they cannot be again called up.

For many cases the stereoscope is an excellent instrument for examining the relations of binocular vision in squint. Du Bois-Reymond\* first called attention to this. Shortly after the dis-

---

\* Ueber eine orthopädische Heilmethode des Schielens, Arch. f. Anat. u. Physiol., 1852, pag. 541.



covery of the instrument, he made the remark that for an orthopedic treatment of squint, no plan promised more than that of methodical practice with the stereoscope. Javal\* arrived later at the same opinion.

The stereoscope presents the advantage that each eye has its own separate field of vision, into which suitable objects may be introduced. The only difficulty is, that in many cases the patient is not able to see in the stereoscope the two fields of vision at the same time, but always perceives only that of the eye used for fixation. This may be regarded as a "suppression" of the retinal image in the squinting eye; but it is remarkable that the retinal image of the normal eye can be suppressed with the same readiness so soon as the generally squinting eye is used for fixation. But another interpretation of this phenomenon is possible. One who is generally accustomed to binocular fixation will endeavor to fix binocularly in the stereoscope, but the squinting patient, accustomed to monocular fixation, will endeavor to fix monocularly in the stereoscope. The entire retina of the squinting eye serves in this case only for eccentric vision, and just such stereoscopic experiments are well calculated to demonstrate how difficult it is to perceive distinctly eccentric retinal images even with the normal visual act.

In other cases, after some effort, the patient succeeds in seeing the two stereoscopic fields of vision simultaneously; when this is accomplished, he may proceed to practice in uniting the two retinal images. For this purpose, Javal proposes to place in each of the two stereoscopic fields of vision, a wafer contrasting in color with the background. The distance between the two wafers corresponds to the distance between the lines of vision where they pierce the fields. In order to know from the statements of the patient whether binocular union or only monocular vision takes place, a wafer of another color is placed above one of the first wafers and another below the other. In the binocular image there must appear to be three wafers one above the other.

One must be very careful in drawing conclusions from the statements of the patients. Even when the three wafers are seen to stand perpendicularly over each other, there need be no binoc-

---

\* *Klin. Monatsbl. für Augenheilk.*, 1864, pag. 404.



ular fixation of the two middle wafers intended for binocular union. In spite of an abnormal direction of the axis of the squinting eye, the images may appear perpendicularly, one above the other, just as in squint double images standing one above the other may be provoked by prisms refracting vertically. On the other hand, it may happen that after an operation has established a normal direction of the visual axes, the three wafers may be seen one above the other, and still the middle one not be a binocular image. This can be detected by marking one wafer with a horizontal and the other with a vertical line; the binocular image would then appear as if marked with a cross; but, although all the wafers appeared to stand vertically over each other, the middle one in these cases was generally marked with either a horizontal or a vertical line, and the binocular image, marked with a cross, appeared during the experiments only momentarily or not at all.

In the great majority of squinting patients the normal relations between the two retinal images do not exist.

Generally they see with both eyes at the same time, but, so to speak, monocularly. In many cases a new relation of correspondence appears to develop between the macula lutea of the eye used for fixation and that retinal region in the squinting eye on which the image of the object fixed is usually cast; and finally it may happen, especially in those cases of squint which develop at a later period of life, that double images appear in a manner very annoying to the patients; this is, however, by no means always the case. For instance, in the relative strabismus divergens of myopes, it may happen that distant objects are properly fixed by a normal visual act; double images may be easily provoked by prisms, and are united in the physiological manner, and nevertheless it is in many of these cases impossible to provoke double images for near objects, although there is evident divergence of the visual axes when they are fixed. We see in these cases the normal binocular visual act associated with a normal direction of the visual lines, but with an abnormal position of the eyes the relations of binocular vision assume an abnormal character also.

We have already learned that defective vision of one eye favors the occurrence of squint; it would be reasoning in a circle to argue from the fact that a considerable number of squinting eyes are amblyopic, that consequently squint is the cause of amblyopia.



So long as the theory was entertained that the retinal impressions in the squinting eye, in order not to cause diplopia, were forcibly suppressed by a kind of psychical process, it was but one step further to conclude that in this way the power of vision in the squinting eye diminished; that is, in consequence of the suppression of the physiological retinal excitation the excitability itself finally became blunted. So soon as we declare that theory to be insufficient, we must examine more carefully the effect of strabismus in the deviating eye.

In the first place, it is to be remarked that cases occur in which, with strong monolateral squint, double images neither exist nor can be provoked, but that nevertheless the squinting eye possesses good vision. The theory that amblyopia with strabismus is caused by the suppression of the retinal impressions is not supported by these cases.

Secondly, there are no observations which prove that an eye which once possessed good vision has become amblyopic in consequence of strabismus.

Thirdly, attention has been called to the nature of the amblyopia, particularly to a certain group of cases in which central vision is more or less diminished, while the rest of the field is unaffected. In cases showing the highest degree of this form of amblyopia, central vision is so weak that an eccentric part of the retina, on the nasal side, possesses better vision than the macula lutea. In consequence of this, such objects as can still be seen, are fixed by turning the visual axis inward; eccentric fixation inward takes place. The amblyopia, under these circumstances, is generally so great that fingers can be counted only at the distance of a few feet. No changes can be observed by the ophthalmoscope. Particularly the optic nerve and retina appear to be in every respect normal. This is certainly a well-marked form of amblyopia, but it is absolutely identical with that frequent form of amblyopia congenita which, in extreme cases, is generally unilateral, and which often occurs in eyes which do not squint.

Only one circumstance remains which would seem to indicate that squint exercises an injurious influence upon the vision of the eye affected. In a certain class of cases the vision is improved by the separate practice of the squinting eye. In reference to this fact, we should first examine whether the defect of vision in these



cases depends upon amblyopia or some other cause; for an eye possessing normal sensitiveness of the retina may still not be able to see distinctly; for instance, in case of hypermetropia with paralysis of the accommodation. For each individual case it is, of course, of diagnostic and prognostic importance to decide whether the defect in vision depends upon amblyopia congenita or some other cause. In a series of such cases, in spite of normal distinctness of vision, there is nevertheless such functional inability of the squinting eye that, for instance, after reading a few lines, the letters lose their sharpness and become confused; pain is soon felt in the eye, so as to make reading impossible. That weakness of the accommodation is one of the elements in this condition is shown by the fact that, generally, vision is better with convex glasses than with the naked eye; but this explanation is not sufficient, since even with convex glasses fatigue is soon experienced. We must therefore conclude that these cases consist essentially in a rapid exhaustion of the functional power of the retina. Most of the patients are perfectly conscious of the inability of the squinting eye; they affirm that they cannot see anything with it; they read, for instance, some words from No. 16 or 14 of Jaeger's test letters, and then put the book aside, fatigued. If one insist, however, that they shall continue the experiment, they read still further, with the same difficulty perhaps, No. 8 or 6, or even No. 4 or No. 3. The extract of Calabar bean is generally of more assistance to them than convex glasses.

The rule may be now laid down that the degree of vision apparent upon making the first experiment can be best improved by the use of Calabar extract, by separate practice and persistent use of the squinting eye. And though this practice does not succeed in all cases, still, the good influence exercised by separate practice has been sufficiently shown. The evil influence of squint depends not so much upon the diminution of the acuteness of vision as upon functional incapacity of the retina, affecting it just as other organs are affected by the want of exercise. The entire attention of the squinting patient is concentrated upon the eye used for fixation, often so intensely that it is very difficult for him to divide his attention upon his two eyes and perceive the retinal images in the squinting one. For these cases physiological analogies are not wanting; many retinal images move across the peripheral parts of



our retina without our seeing them. The entire retina of the squinting eye, including its macula lutea, serves only for eccentric vision, since every object in the periphery of the visual field to which the attention is called is fixed with the normal eye. There is, in fact, neglect on the part of the squinting eye, and particularly of its macula lutea, which does not get the necessary exercise. Its retinal images have the same claim for recognition as those of the macula lutea of the fixing eye, and still the attention is not directed to them any more than to any peripheral retinal image. The consequence of this insufficient practice appears to be not so much loss of distinct vision as of the ability to maintain vision continuously.

We often hear it asserted by persons in whom no abnormal position of the eyes is perceptible, that their former squint has disappeared spontaneously. Aside from such cases as depend upon paralysis of the ocular muscles, it is not improbable that even typical concomitant squint may disappear spontaneously ; at least, I have been able, in the cases of several persons who have made such assertions, to detect both defective vision in the eye formerly said to squint and an absence of the binocular visual act. Such cases are rare, and the conditions under which this spontaneous recovery occurs are not known.

The influence exerted by hypermetropia upon the development of squint suggested the idea that the correction of this anomaly of refraction might prevent, or might even relieve a squint when once established. And, in fact, one often has the opportunity to demonstrate the favorable influence which correction of hypermetropia exerts upon incipient strabismus convergens. Generally, however, the extreme youth of the patients renders this treatment unavailable. In children between the ages of two and seven years it is generally possible to demonstrate the existence of hypermetropia only by ophthalmoscopic examination, and even this presents its difficulties.

But to correct fully the hypermetropia and to cause spectacles to be worn is at this age impracticable and indeed dangerous. How likely such a child is to fall and wound itself seriously with the splinters of the broken glasses ! With older children, who can be trusted with spectacles, the time is generally past for any hope of influencing the strabismus by correcting the hyper-



metropia. The rectus internus is already shortened and the externus lengthened. That actual structural changes have occurred in the muscles implicated is evident during the operation for squint. This is perceived, upon cutting through the shortened muscle, by the resistance it offers and the way it creaks under the scissors, while on bringing forward its antagonist one can see that it is very weakly developed.

Although as a rule the operative treatment is the only effectual one, we ought in every case before resorting to it to do all that we can to improve binocular and monocular vision.

It has been mentioned that the usefulness of the squinting eye may, in many cases, be increased by separate practice, assisted when necessary by convex glasses or Calabar extract. In some rare cases it is even possible to restore the lost binocular vision. These results are, however, attained only by long practice, and are not to be expected as the immediate consequences of an operation.

#### STRABISMUS DIVERGENS.

Strabismus divergens is caused, as is strabismus convergens, sometimes by anomalies of the muscles and sometimes by the condition of refraction.

Many cases of the most extreme divergence are caused simply by an elastic preponderance of the externi. At first the visual axes can be converged, but the necessary tension cannot long be sustained, and while one eye remains fixed the other deviates outward. Most patients in this condition relinquish binocular fixation for near objects. Convergence is soon entirely forgotten; even parallelism of the visual lines is attained with difficulty; in place of accommodative movements only associated ones are made, and the insufficiency of the interni muscles finally becomes so great that even in associated movement inward, the squinting eye falls behind the other.

In many cases the gradual development of this insufficiency of the interni muscles is due to some peculiarity of the visual act. Among these are those cases in which strabismus divergens occurs in consequence of blindness on one side. At first the movements of the eyes appear normal; gradually, during near vision, the convergence becomes insufficient; later, the blind eye makes associated instead of accommodative movements; the recti interni



are not sufficiently exercised, and no longer counterbalance the recti externi. Finally there comes to be divergence in every position.

A similar process may be developed when there is good vision on both sides, but with emmetropia in one eye and a high degree of myopia in the other. Generally, under these circumstances, the myopic eye is used for near vision, since without accommodation it receives larger retinal images than the emmetropic one, which in its turn is used only for distant vision. The absence of accommodation during near vision is sufficient to give to the emmetropic eye a relatively divergent position. In such a case annoying diplopia does not generally exist, because the attention is directed exclusively upon the sharp retinal image in the myopic eye, the blurred image in the emmetropic one being neglected. For distant vision the relations are reversed; here the image in the myopic eye is neglected, and the attention is directed exclusively upon that in the emmetropic eye. This strictly separate use of the two eyes excludes the exercise of accommodation and of convergence. The emmetropic eye experiences generally a diminution in its range of accommodation, while the circumstance, that in near vision, associated instead of accommodative movement takes place, leads to a relative preponderance of the recti externi and to strabismus divergens.

With unilateral myopia of a slight degree, the maintenance of the normal visual act is quite possible.

The influence of the condition of refraction in causing strabismus divergens becomes apparent when one includes in his investigations all those cases of relative divergence in which during distant vision there is no abnormal position, but insufficient convergence during near vision. In at least ninety per cent. of these cases myopia exists. The connection between the two conditions depends upon the change of form, and the peculiarity of movement due to it, in myopic eyes.

In his investigations on this subject, Schuurmann\* arrived at the following results with reference to the movements of myopic eyes. Movements in the horizontal plane, as Donders and Doyer† had already found, are less in myopia than in emmetropia. As a rule, movement decreases as the myopia increases. Moreover, myopic

\* Vijfde Verslag, etc., 1864.

† Donders, l. c., pag. 159.



as well as emmetropic eyes show a decrease of movement dependent upon advancing age. The relation between inward and outward movement, relatively to the line of vision, is the same in myopia as in emmetropia,—that is, the movement inward is generally greater than the movement outward. The degree of convergence attainable by different myopes varies greatly. The maximum of convergence is greater than normal with some myopes, and less with others. The divergence to be produced by prisms is on an average greater in myopia than in emmetropia, for which reason, as remarked on page 131, in spite of less deviation of the visual lines from the centres of the corneas, they can, nevertheless, be directed farther outward than in emmetropia,—that is, greater divergence can be attained.

The movements of myopic eyes are restricted, because in myopia all the diameters of the eye, but especially the sagittal diameter, are increased. The ellipsoidal form which the eye thereby acquires prevents its playing, as before, like a ball in the capsule of Tenon. Movement becomes possible only with a simultaneous displacement of the orbital tissues, which, of course, present a resistance not met with when the eye more nearly approaches the form of a sphere.

The defect in associated ocular movements can be compensated for by movements of the head, but no such substitution can be made for insufficient convergence. Divergence is the more likely to occur, for the reason that the change in the form of the eye causes greater resistance on the part of the external muscles.

Myopic eyes generally appear more prominent than emmetropic ones. The elongation of the axes appears to cause a displacement forward. Since the distance between the margin of the cornea and the insertion of the muscles is not changed, the increase in the volume of the eye must cause increased tension of the recti muscles. The rectus externus is the muscle which experiences this tension most. While the expansion of the eye displaces the insertion of the rectus internus only forward, that of the rectus externus is displaced outward as well as forward. On account of the median position of its origin this last-named muscle is thus subjected to a very considerable tension. Moreover, that part of the externus in contact with the eyeball is greater than is the case with the other muscles, and it must neces-



sarily participate in the expansion of the eye. All these circumstances result in an increased elastic tension of the external muscles and a consequent increased resistance to the action of their antagonists.

Finally, the deviation of the line of vision from the centre of the cornea must be considered. Since this deviation is less in myopia than in emmetropia, the lines of vision will intersect at a greater distance in myopia than in emmetropia, supposing the position of the cornea to be the same in both cases. In order to attain the same convergence there must be, on the part of the interni muscles, a stronger action in myopia than in emmetropia. This fact explains both the relative divergence of the visual lines during near vision and the very considerable absolute divergence which may be caused by prisms with their refracting angles turned outward.

It is remarkable that in many cases, in spite of a considerable inclination to absolute divergence, quite a respectable movement of convergence is still possible. It is only exceptionally that absolute strabismus divergens develops from the relative divergence of myopia. The reason for this is, that the limitation in the movements of the eyes prevents any very great divergence, and in spite of relative divergence for near vision, still, for distant vision the binocular visual act is maintained.

Strabismus divergens generally develops later than convergent squint, as a rule, after childhood has passed.

The therapeutic indications in cases of relative divergence depending upon myopia have been already mentioned, on page 51. Absolute divergence demands relief by operation.

#### MUSCULAR ASTHENOPIA AND DYNAMIC STRABISMUS.

We have already learned that an elastic preponderance of the external, or, what amounts to the same thing, an insufficiency of the internal muscles, is the principal cause of absolute strabismus divergens, and, in connection with myopia, the cause of relative divergence also. Nevertheless, insufficiency of the interni does not always lead to divergence; although the equilibrium of the muscles is destroyed, binocular vision may be maintained.

The occurrence of this condition after recovery from paralysis of the ocular muscles has been already mentioned, page 137. For



instance, if in a nearly recovered case of paralysis of the abducens, in a part of the field in which binocular single vision has been restored, it be disturbed by prisms refracting vertically, the double images often show a lateral deviation not dependent on the action of the prisms, since with the interruption of binocular single vision there remains no incentive to oppose the elastic tendency of the muscles by an unusually strong innervation. In a similar manner one can detect in many cases, by the help of vertically refracting prisms, during fixation on far or near objects, an inclination to convergence or divergence, which, under ordinary circumstances, is overcome in the interest of binocular single vision. Von Graefe designated this condition as dynamic squint.

Insufficiency of the recti interni can accordingly cause absolute, relative, or dynamic strabismus. In the last case the strain upon the recti interni, which must be made to maintain the convergence necessary while working, causes fatigue in those muscles, with the same painful symptoms as occur in accommodative asthenopia, depending there upon fatigue of the ciliary muscle.

In making the diagnosis of this muscular asthenopia, we must determine first the maximum attainable convergence, while the eyes are looking slightly downward. If a convergence to a distance of from 6 to 8 cm. cannot be reached, but if one eye before reaching such a point deviates outward, then there is insufficiency of the recti interni.

In order to relieve the ocular muscles from the controlling influence of binocular single vision one eye may be covered during convergence at the distance usual for work. This is best done with a ground glass, which, when held close to the eye, still allows observation of its position. When this is done the covered eye deviates outward, and returns again to fixation whenever the glass is removed.

Binocular single vision may also be interrupted by holding in front of one eye, a prism with its refracting angle turned upward or downward. If the tension upon the inner muscles be excessive, the visual axes will diverge somewhat upon interruption of binocular single vision. The double images will not stand directly one above the other, but will be crossed, and at different levels.



According to Von Graefe,\* the experiment is made as follows. A large dot is made on a sheet of white paper and a fine vertical line drawn through it. This is laid before the patient in the position and at the distance usual in reading. If then, upon placing a vertically refracting prism before one eye, the double images do not stand one above the other, but are crossed, divergence of the visual axes is indicated. The measure of this divergence, or of the insufficiency of the interni, is given by that prism which, placed before the other eye with its angle turned outward, causes the two images to appear exactly one above the other. According to Von Graefe, the same distance and fixation-object should be used to determine what prisms may be overcome by convergence and divergence.

This method of examination should not be relied on in determining the condition of the muscles, without investigating at the same time the condition of refraction. For instance, if a hypermetrope sees through a vertically refracting prism the double images of a distant object not exactly one above the other, but separated laterally and homonymous, this may be due to insufficiency of the recti externi; it may, however, occur without that, simply in consequence of a certain degree of convergence attending the accommodation necessary even for distance, just as happens under the same circumstances to emmetropes when they put on concave glasses.

If in myopia of a medium grade (say  $\frac{1}{6}$  to  $\frac{1}{10}$ ) the fixation-object be placed near the far point and double images be provoked by a prism refracting vertically, there no longer exists any incentive for maintaining the proper convergence. If the double images cannot possibly be united, it is all the same to the myopes whether they stand exactly one above the other or at the same time show a lateral deviation. The retinal images remain distinct, except as their clearness is diminished by the prisms, even with a parallel direction of the visual axes.

Of course, when vision is directed upon an object in the neighborhood of the far point, the greatest possible degree of divergence may be given to the visual lines by means of prisms with their refracting angles turned outward. To determine the maximum

---

\* Arch. f. Ophth., B. viii. 2, pag. 314.



degree of convergence by means of prisms with their refracting angles turned inward is useless trouble, since it may be done in a more direct and simpler way by merely bringing the object fixed nearer to the eye.

Under all circumstances, but particularly in myopia, convergence is maintained by a muscular effort, which is gladly relinquished as soon as it is no longer necessary in the service of binocular vision. This is especially apt to happen when other causes for fatigue co-exist, for instance, conjunctival irritation or those symptoms of irritation so common in myopia. Upon examining these cases with prisms refracting vertically, an inclination to parallelism of the visual axes is almost always found, but from this it does not follow that muscular asthenopia is the cause of all symptoms of irritation. These symptoms occur, as a rule, in myopia of a middle grade, even when there is no asthenopia. Generally, and especially when any symptoms of irritation exist, as, for instance, in conjunctival hyperæmia, myopes prefer a parallel position of the visual axes, and make the movement of convergence only when it is necessary for binocular vision.

The examination with prisms gives altogether different results when it is conducted with the help of correcting concave lenses. The effort of accommodation then affects the convergence exactly as in emmetropia. In this case, too, when binocular fixation is interrupted, the inclination to diminish convergence is perceptible. At the same time, however, the accommodation relaxes, and as soon as the indistinctness of the retinal images, caused by this, becomes annoying to the patient, there follows with the renewal of the accommodative effort an increased innervation of the interni, which in its turn is often excessive, and causes a slight temporary convergence.

If, on the contrary, there follow under these circumstances a considerable and permanent diminution of convergence as soon as binocular fixation is interrupted by prisms, it proves that there is some disturbance in the normal relations between the convergence of the visual lines and the tension of accommodation.

In most of these cases the preponderance of the recti externi can be demonstrated when the patient is directed to fix a distant object. If, for instance, one choose as the fixation-object the flame of a candle, twenty feet distant, double crossed images often appear



as soon as the two fields of vision are differentiated by placing a red glass in front of one eye. This is much more certain to happen when binocular fixation is made impossible by a weak prism refracting vertically.

Moreover, a much greater divergence of the visual axes may be caused in cases of myopia by prisms with their refracting angles turned outward than is possible under normal relations; or, in other words, much stronger prisms, even up to  $20^{\circ}$  or more, can be overcome by divergence.

It is remarkable that in marked cases of elastic preponderance of the externi the nearest point to be attained by convergence is by no means always at a greater distance than normal from the eyes.

Muscular asthenopia is not near so frequent as accommodative asthenopia. It may occur in every condition of refraction,—in emmetropia, hypermetropia, or astigmatism. Cases of but slight myopia are those generally associated with muscular asthenopia. In the higher grades of myopia the fatigue of the recti interni is avoided by the occurrence of relative divergence. The patient, for instance in reading, begins binocularly; soon, however, one eye deviates outward involuntarily and unnoticed. The patients do not in such cases complain of fatigue, but simply notice that one page seems to project over the other. They generally learn to escape the annoyances of diplopia.

In the treatment of muscular asthenopia we may palliate the condition by the help of prismatic glasses, or it may be cured by operation.

It follows from what has been said on page 93, concerning the use of prismatic spectacles, that they may be used with special advantage when it is possible to employ a working distance of at least 10 or 12 inches.

It is generally advisable to begin the treatment by these palliative means, since the abnormal relations in the tension of the muscles may disappear in time. I have observed this especially in those cases in which, in spite of a decided inclination to divergence, the normal near point for convergence could still be reached without much difficulty.

Prisms of perhaps 3 and at most 6 degrees are set in spectacle frames with their refracting angles turned outward. They are of course to be used only for near, and never for distant objects, since



there is no occasion for inducing absolute divergence of the visual lines.

The operative treatment consists in the tenotomy of the recti externi. Under certain circumstances a radical cure may be thus accomplished. The greatest care must, however, be taken that by this operation a simple dynamic divergence be not converted into a real converging squint. The tenotomy may be resorted to without fear of this result, in cases where the existence of an elastic preponderance of the externi is demonstrated. If during distant vision an inclination to divergence be apparent, and if at the same time unusually strong prisms can be overcome by divergence of the visual lines, it is certain that after tenotomy of the externi there will be no annoying convergence.

As a rule, the tenotomy is to be performed on that eye which, during the maintenance of convergence, shows the greater inclination to deviate outward. In many cases the tenotomy of both externi seems to be necessary.

If insufficiency of the interni occur without elastic preponderance of the externi, the tenotomy is to be avoided, and only the use of prismatic glasses can be resorted to.

#### UPWARD AND DOWNWARD SQUINT.

Associated with a high degree of convergence there often occurs, as already mentioned, a vertical deviation, generally simply as an accompanying symptom which demands no special correction, and disappears when the convergence is relieved.

Another much rarer group of cases are those in which the vertical deviation exists without any marked, or with only very slight, lateral squint, and shows a decidedly concomitant character. For instance, if the eye which squints upward be used for fixation, the other makes an accompanying movement downward.

The vertical deviation under these circumstances does not remain the same in all directions of vision. As a rule, the upward deviation is greatest when vision is directed toward the median plane, and least when directed outward; while, on the contrary, in downward squint, the deviation is greatest when looking outward, and disappears in looking inward. While the cornea of the unaffected eye moves through a horizontal course, that of the squinting eye is in a plane whose direction is downward and outward.



It is not possible to refer this peculiar movement to the action of any particular muscle. It is very seldom that the vertical deviation is the same in all directions of vision, and when such is the case it must be regarded as due to an increased tension of the two muscles acting upward or downward as the case may be.

Double images exist in most cases of vertical deviation.

In respect to operative treatment, the same principles are applicable as were laid down with reference to vertical deviation remaining after paralysis of the ocular muscles.

#### OPERATION FOR STRABISMUS.

The operative treatment of strabismus was first introduced by Stromeyer, in 1838, and in 1839 was practised methodically by Dieffenbach.

The first object of the operation for squint, as now performed, is to divide the tendon of the shortened muscle close to its insertion upon the sclera. The direct attachment of the muscle to the eyeball is thus destroyed, but indirect attachments remain, by means of the connections of the muscle with the capsule of Tenon and with the conjunctiva. The effect of the operation is greater or less, according as these indirect attachments are more or less divided.

The following method of operation is generally the best. The patient is laid in a suitable position and anæsthetized. The lids are held apart by an assistant or by a speculum. With the fixation forceps the eyeball is seized at a point near the cornea and diametrically opposite the muscle to be divided. The eyeball is rolled over into a position which leaves the field of operation free. Exactly above the tendon of the muscle, or a little in front of it, the conjunctiva is seized with a pair of forceps, lifted into a fold, and an incision made. This incision may be made either parallel with the direction of the muscle,—the advantage in that method being that the wound gapes less after the operation,—or may be parallel to the line of insertion of the muscle, in which case the latter is somewhat better exposed. The conjunctiva is now loosened toward the periphery with the scissors, in case of strabismus convergens, as far as the caruncle. Then the muscle is grasped by the forceps close behind its insertion; when possible the whole breadth of the muscle should be seized. The insertion of the muscle is



first pierced in the middle with the scissors, one blade being thrust between the muscle and the sclera, first to the one side and then to the other, and the tendon is divided close to the sclera. By passing in a strabismus-hook the operator satisfies himself that no tendinous threads remain in the neighborhood of the insertion. It is important to know the position of the insertions of the various ocular muscles. That of the rectus internus, measured in the horizontal meridian, is 6 mm. from the margin of the cornea, that of the externus about 8 mm., and those of the superior and inferior from 7 to 8 mm.

I cannot agree with Von Graefe in his oft-repeated advice to make the conjunctival wound as near as possible to the margin of the cornea. If one does so, he finds himself so far from the insertion of the tendon that the blunt hook which he must insert under it before he can cut it must be thrust a relatively long distance under the conjunctiva. In doing this the conjunctival wound is generally torn larger, and still more when, according to directions, the handle of the hook is turned so as to draw the tendon tense.

The scissors used in the operation should be blunt-pointed and slightly curved on the flat.

After the operation, the absolute separation of the tendon from the sclera is shown by a marked limitation of the movement of the eyeball toward that side. There should be only a limitation, and not abolition of movement, because the muscle still remains in indirect connection with the sclera. If, on the contrary, there be no limitation of movement, or if it be too slight, there is reason to suspect that some tendinous threads about the margin of the insertion remain uncut. These are to be found with the strabismus-hook and divided. It is very seldom that the muscle is attached by strong connective tissue to the sclera behind its insertion. In these cases a careful detachment of the muscle back to the posterior end of this insertion is indicated, but it is not always practicable.\*

Except in these few cases, the operation should not be regarded as completed until marked limitation of movement is perceptible.

---

\* Von Graefe, *Arch. f. Ophthal.*, B. ix. 2, pag. 32.



If, after the operation, the conjunctival wound gapes too widely, it may be closed with a fine silken suture. If it be intended only to unite the conjunctival wound with the suture, it is well to place it parallel to the insertion of the muscle, and pass it simply through the conjunctiva so as to include as little of the subconjunctival tissue as possible, because when so done it will cut through of itself in a few days and not require to be removed.

The after-treatment consists in cold dressings or the immediate application of a light bandage.

The mechanical effect of the operation for squint may be explained in the following manner. After the detachment of the tendon from its insertion, the muscle retracts as far as its elastic tension demands and its connections with the capsule of Tenon and the conjunctiva allow. Simultaneously the antagonistic muscle draws the eye around until the equilibrium is reached.

After some days union takes place between the muscle and the sclera in a line parallel with the original insertion, but farther back. The influence of the muscle upon the eyeball then becomes direct and stronger, the movement increases, but generally at the same time diminishes somewhat the effect upon the position of the cornea which was perceptible immediately after the operation. Probably the anterior end of the detached muscle is drawn somewhat forward by the contraction of cicatricial tissue which develops in the wound. This effect is greater the weaker the antagonistic muscle. It may happen in this way that an effect which immediately after the operation was satisfactory, becomes insufficient.

It is evident from what has been said that the ultimate results in respect to the position of the cornea, obtained by the operation for squint, vary greatly in different cases. If tenotomy of the rectus externus be performed on account of muscular asthenopia, it is an error and an over-effect of the operation to cause a permanent change in the position of the eyes. In these cases we have to thank the pre-existing elastic relations of the ocular muscles, and the regulating influence of binocular fixation, that the convergence generally existing immediately after operation does not remain permanent. But it may happen without the influence of binocular vision that the ultimate effect of the operation is very slight. The operation for squint has been mistakenly regarded as if it consisted essentially in setting back the insertion of the



shortened muscle; but it is perfectly clear that this alone would exert no influence upon the position of the eye if there were not an antagonistic force drawing it over to the other side. In the operation of tenotomy we count upon a sufficient elastic strength in the antagonist, and this is the element which cannot always be relied upon with certainty, since it is probable that elastic tension and muscular contractibility are two different properties, and the result of an operation is essentially influenced by the elastic tension of the antagonist.

In many cases of hypermetropia with strabismus convergens, the correction of the hypermetropia is absolutely necessary after an operation, even when there is no binocular fixation. An annoying strabismus convergens returns whenever the use of convex glasses is discontinued. This may be well understood from the relation which has been shown to exist between hypermetropia and strabismus convergens; it is only remarkable that it does not occur oftener.

Finally, the effect of tenotomy is somewhat different on the different muscles; it is less for divergent than for convergent squint. In those disfiguring cases of strabismus divergens in which the movement of convergence is so far lost that parallelism of the visual lines cannot be attained, the effect of simple tenotomy of the externus of the squinting eye is likely to be very slight. The explanation of this fact is not so simple. The rectus internus is in these cases lengthened and weakened, it is true, by continuous stretching, but still scarcely more than the rectus externus in extreme cases of strabismus convergens. It is true that a longer portion of the rectus externus lies in contact with the eyeball than is the case with the rectus internus, but that does not prevent very considerable strabismus convergens in cases where simple tenotomy of the externus has been performed when the proper indications for the operation did not exist. Although experience shows that simple tenotomy of the externus of the squinting eye in cases of high degree of divergence is almost without result, the explanation of this fact ought not to be sought for wholly in the rectus externus and its antagonist. It is probable that the obliqui muscles play a part in this matter which has not yet been recognized. Aside from their muscular contractibility and regarding only the elastic tension of the obliqui, this will be greatest when the mus-



cles embrace the eye in the direction of a great circle, as is the case when vision is directed strongly inward. The elastic tension of the obliqui muscles has in that position only the effect to draw the eye forward in the plane of the muscles. On the contrary, when vision is directed more outward, the obliqui no longer embrace the posterior part of the eye in the direction of a great circle; accordingly they are less stretched, and, moreover, only a part of their elastic tension is expended in drawing the eye forward; the other part will be exerted in turning the posterior pole of the eye inward and the cornea outward.

The consequences of this are the following. In high degrees of strabismus divergens the squinting eye is seldom or never turned so far inward that the obliqui assume the direction of a great circle, or experience so great a strain as they do under physiological relations; since, though the power of turning the eye inward may still remain, it is in fact but little exercised. The obliqui of the diverging eye are thus less stretched than under normal relations, and it is possible that their extensibility for this reason becomes so diminished that they finally oppose a greater elastic resistance to motion in the median direction than they do under physiological conditions. Now, since the tension of the obliqui is not affected by the operation, it is plain that when in old cases of extreme strabismus divergens they have lost their extensibility they will act after, just as before the operation, to turn the cornea outward and to lessen the effect. In strabismus convergens, moreover, the superior and inferior recti muscles play a similar though less effectual part.

Where there is sufficient elastic tension of the antagonistic muscle, a correction of 3 or 4 mm. in the position of the eye may be accomplished by the tenotomy of the rectus internus, and still the movements of the eye be not unduly interfered with by too extensive loosening of the indirect connections between the muscle and the eyeball.

The farther the insertion of the muscle is set back upon the sclera, the sooner will the muscle in its contraction attain the limit beyond which it can exercise no further influence upon the position of the eye. There will remain a limitation of movement in the same direction in which the eye formerly squinted. This limitation of movement is more noticeable in converging than in



associated movements. For a somewhat similar phenomenon and one depending on the same reasons, see page 128.

A correction of from 3 to 4 mm., which may be accomplished without any annoying limitation of movement, is certainly for most cases of squint not sufficient, but there is a very simple method by which we may double the effect of the correction without too great a sacrifice of movement; this is by dividing the operation symmetrically between the two eyes. If, for instance, in strabismus convergens we divide the two interni, or in strabismus divergens the two externi, the result as affecting the correction of position will be cumulative, while the defect in movement toward either side of the visual field is very slight.

If it can be foreseen with certainty that at least two operations are necessary, both eyes may be operated on at the same sitting in order to economize time. If the greatest possible effect is aimed at, it is well to fix the visual axes for 24 or 36 hours in a position slightly beyond the one desired. The method is as follows. Near the outer margin of the cornea a threaded needle is passed through the conjunctiva just above the horizontal meridian, and is brought out about  $2\frac{1}{2}$  mm. lower down; it is then again inserted about  $2\frac{1}{2}$  mm. above the first point and brought out just below the horizontal meridian. The conjunctiva through an extent of about 5 mm. is thus embraced very securely. The ends of the thread are then drawn upon, but not tied in a knot, and in case of strabismus convergens are carried over upon the temple, there to be fastened with adhesive plaster and collodium. In strabismus divergens the threads are fastened on the bridge of the nose, and in cases where the nose is so low as to allow the threads to rub upon the cornea, they must be raised by a roll of adhesive plaster. To remove the thread, cut one end close to the conjunctiva, and the stitch can then be easily withdrawn. So long as the thread is in position it is well to hold both eyes closed by a bandage.

If the bilateral operation does not prove to be sufficient, a repetition on the originally squinting eye or on both may be undertaken.

In order to increase the effect of the operation, one often hears the advice given, to hold the eye, after the operation, continuously in the direction opposite to the squint. It is evident that little can be expected from such an effort. Let any one try how long he



himself can hold his eyes turned to one side; in a few minutes fatigue is experienced, and involuntarily the head instead of the eye is turned in that direction. Little more can be accomplished by the so-called strabismus spectacles, which entirely cover one eye and leave for the other only an eccentric opening on the side opposite to the direction of the squint. More is accomplished by subjecting the antagonistic muscle to methodical orthopedic exercise, either before or some days after the operation. Very considerable defects of movement often disappear in a short time under this treatment.

The immediate effect of an operation for squint may be diminished as well as increased, though it is not so often necessary to do so. The method is by placing a suture in the conjunctival wound parallel with the direction of the muscle, and including some of the subconjunctival tissue, especially near the anterior end of the divided muscle. The muscle is by this means drawn forward, or at least prevented from retracting too far.

A satisfactory cosmetic effect may be almost always attained by the operation for squint. Its influence upon the sight in the squinting eye and upon binocular vision has, on the contrary, been over-estimated. The oft-repeated assertion that immediately after dividing one of the ocular muscles a considerable improvement in vision may occur, is so contrary to all known physiological laws that it can be accepted only after further observations, which must be invested with every guarantee of accuracy. Only repeated tests of vision, made before the operation, and conducted both with reference to far and near vision, and in respect to the latter made with the help of convex glasses or Calabar extract, can be recognized as proving the truth of so improbable a statement. In my investigations on this subject I have found no immediate effect on the acuteness of vision from tenotomy.

So, too, the operation for squint exercises no direct influence upon the re-establishment of normal binocular vision, except in those relatively rare cases in which there existed before the operation a normal correspondence between the two retinae, made evident by the existing diplopia.

Von Graefe,\* indeed, asserted that only about one-half of all

---

\* Arch. f. Ophth., B. iii. 1, pag. 235.



squinting patients remained after operation incapable of the binocular visual act, nevertheless he admitted that with reference to the other half nothing more could be asserted than the possibility, in some way or other, of bringing double images to their notice. That, however, is far from being the re-establishment of the normal binocular visual act.

Knapp,\* too, asserts that he has attained the re-establishment of binocular fixation in fifty per cent. of his cases, but he goes on immediately to say that binocular fixation is not identical with binocular single vision or with stereoscopic vision, and that in many of these patients—capable of binocular fixation—double images could in no way be provoked by prisms. Of course this kind of binocular fixation has nothing in common with normal binocular single vision.

In the majority of cases it can be proved, before operation, by examining binocular vision with prisms or with the stereoscope, that no disposition exists to unite the two retinal images; and, judging from my experience, I hold it far more probable that in this respect nothing is changed by the operation. Even in cases in which there was, before operation, good vision on both sides, and evident traces of a former normal binocular visual act, and in which, by the operation, apparently absolutely correct fixation was attained and retained for several months, still no normal binocular vision returned. It is true that, with the help of prisms, double images were easily provoked and their positions rightly stated; with the stereoscope, too, an undoubted union of the two retinal images could be attained, even when this did not always occur spontaneously, and, nevertheless, Hering's experiment gave negative results. The operation had restored the possibility of the normal binocular visual act, but as a general thing this possibility was not taken advantage of.

These results are not without practical consequences. In many cases of strabismus convergens with hypermetropia, the line of vision deviates inward from the centre of the cornea more than usual. Just as with proper binocular fixation this condition causes an apparent strabismus divergens, so in the case of strabismus convergens it has as a consequence, that a satisfactory position

---

\* *Klin. Monatsbl.*, 1863, pag. 472.



as regards cosmetic effect may be obtained in spite of a persistent convergence of the visual lines, which is perfectly apparent when the eyes are used alternately for fixation. The removal of this slight convergence, when there is no prospect of restoring normal binocular vision, would be no advantage to the patient, but an apparent strabismus divergens would be caused where before the cosmetic effect was satisfactory.

The fact that in many cases of hypermetropia the lines of vision deviate unusually far inward from the centre of the cornea, may favor the occurrence of strabismus convergens; at all events, it makes the operation easier.

But after operation, even if a slight remaining convergence of the visual axes be not hidden by a deviation outward of the corneal axes, it is better, in the operation for convergent squint, rather to do too little than too much. It does no harm if a slight degree of convergence does remain, for a gradual improvement in position may be hoped for. On the other hand, it is to be feared that a slight divergence remaining after operation will increase, and in time become a deformity.

It is not necessary in all cases of strabismus convergens with hypermetropia, to correct this with convex glasses, after operation; still, cases occur in which the correction of the hypermetropia is necessary in order to overcome the squint. The necessity of this is always to be suspected in cases where the result is at first satisfactory, but where a few weeks after the operation convergence reappears.

Finally, mention should be made of certain peculiarities in the movements of the eyes, which may occur after the operation for squint. After the rectus internus has been set back on one side there often appears a remarkable inequality in the squinting angle upon change of fixation. If, for instance, there was strabismus convergens on the right side of from 6 to 7 mm., which, by setting back the right rectus internus, has been reduced to 3 or 4 mm., it may happen that during fixation with the right eye the left eye will deviate inward, not 3 or 4 mm., but 6 or 7 mm. While the rectus externus of the right eye turns that eye 3 or 4 mm. to the right, the rectus internus of the left eye turns it simultaneously 6 or 7 mm. in the same direction; there appears, accordingly, to be a striking inequality in the associated movements.



This phenomenon is more explicable when one remembers that in such cases not only an associated but at the same time an accommodative movement is involved. Generally, the object fixed is near enough to require, even in emmetropia, an effort of accommodation. If there be hypermetropia of different degrees in the two eyes, no other explanation need be sought, as under these circumstances alone, even before the operation, there will be evident inequality of the squinting angles upon change of fixation. But even when there is no difference in refraction, the innervation of the recti interni muscles, associated with the accommodation, may cause greater convergence in the eye not operated on than in the other, the insertion of whose internus has been set back, and whose movement has thereby been limited. The limitation in movement is more apparent during accommodation than during associated movements.

It is often observed, after operation for squint, that the squinting eye, when the effort is made to use it for fixation, shoots with a twitching movement beyond its mark before it settles in steady fixation. This phenomenon, when it occurs, is generally observable only for some few days after the operation, and then gradually disappears. Evidently in these cases the normal relation between the eccentric position of the retinal image and the ocular movement which must be made in order that the image be cast upon the macula lutea, is broken up and a new relation gradually established.

Since many cases of strabismus convergens occur in the first years of childhood, the question often arises whether the operation for squint may properly be undertaken at that period of life. In general, the question may be answered affirmatively; it is indeed possible that the restoration of the normal visual act is more likely to happen at such an age than later. But, on the other hand, it is to be remembered that the assistance to be obtained in many cases of strabismus convergens, by correcting the hypermetropia, can be taken advantage of only at a more advanced age. It is generally best to wait until the mental development of the child is such that at least an exact examination is practicable. Up to this time separate exercise of the squinting eye, both in movement and in vision, should be practised. This is best accomplished by causing the patient to wear during several



hours of each day a pair of strabismus spectacles, so made as to cover, with an opaque glass, the normal eye, and with an eccentric opening for the other, on the side opposite to the direction of the squint.

It is often beneficial to practise methodically, looking to one side. It is frequently the case that the outward movement of the eye used for fixation, as well as the squinting one, is defective, and is improved by practice. The strength thus given to the abducens is useful when, somewhat later, an operation for squint is performed.

Bringing forward the insertion of an ocular muscle has hitherto been practised principally with the object of relieving deformities which remain as the result of excessive effect produced by the operation for squint. It is not proposed in this place to enter upon the history of this operation, but simply to describe a method which I think combines all the good points of the various operations practised by J. Guérin, Von Graefe, Critchett, Knapp, Liebreich, and Snellen.

In the first place the shortened muscle is divided, as above described, and the antagonist is then brought forward in the following manner. An incision is made in the conjunctiva directly above and over the whole extent of the insertion of the muscle. The conjunctiva and subconjunctival tissue are then loosened from the sclera by the scissors, as far as the margin of the cornea, and over a vertical extent corresponding to the width of the insertion of the muscle (10 to 12 mm.). The attachments between the anterior surface of the muscle and the conjunctiva are also divided back to a distance of about 5 mm.

Since in this operation the conjunctiva, especially near the corneal margin, should not be punctured, it is best to use round-pointed scissors.

At one end of the insertion of the muscle an incision is made in the capsule of Tenon, through which a flat, blunt hook is thrust between the muscle and the sclera. The point of the hook is brought out through another incision made at the other end of the insertion. The sutures are now to be inserted in the muscle.

A fine waxed silk thread, provided with a needle at each end,



is passed along the hook under the muscle, and the needles passed through it from the scleral surface outward, in such a manner that the loop includes a portion of the middle of the tendon, 2 or 3 mm. in breadth. A thread is then placed in a similar manner near each end of the insertion.

The insertion is then divided from the sclera, leaving the three threads in the end of the severed tendon. The threads are then brought from the scleral surface outward, through the conjunctival flap, near the margin of the cornea, and tied fast. To assist in their recognition it is well to have the sutures of different colors.

One end of each suture is cut off closely, while the other is left sufficiently long to make its removal on the second or third day easy. To avoid altogether the difficult task of removing the sutures, fine catgut may be used instead of silk, and in that case both ends of the suture are cut off close to the knot. The conjunctival wounds, when it appears necessary, may be closed by sutures.

As after-treatment, it appears best to use ice-dressings for twenty-four or thirty-six hours, and then apply a pressure-bandage.

The method here recommended, of inserting the sutures in the muscle before it is detached from the sclera, greatly facilitates the operation. If, according to the hitherto usual method, the muscle be detached before securing it with the sutures, it retracts by virtue of its elasticity; to draw it forward, it must be searched for in the wound with the forceps, which each time draw out little more than the few bundles of fibres which they grasp. This unpleasant manœuvre has to be repeated for each suture which is inserted.

The indications for this procedure I consider more frequent than has generally been thought. It is advisable for all cases of high degrees of strabismus with marked amblyopia in the squinting eye.

If under these circumstances the operation for squint be divided in the usual manner between the two eyes, the effect upon the squinting eye is generally much less than upon the other, because its externus has become stretched and has lost its elasticity. The greater part of the correction, under these circum-



stances, is generally from the effect of the operation on the normal eye, in which the elastic tension of the antagonistic muscle is normal. The operation of bringing forward the insertion of this muscle, gives us a very simple means of increasing its elastic tension, and so attaining a satisfactory degree of correction. Even in extreme cases of strabismus convergens, one may almost always expect by the operation above described to obtain a satisfactory cosmetic effect.

Many patients with very defective vision in the squinting eye shrink from submitting their single good eye to an operation from which only a cosmetic effect is to be obtained.

The objection raised by Von Graefe,\* that after bringing forward the rectus externus the caruncle remains too deeply sunken and motion is too much limited, has not been confirmed by my experience. Cases of extreme strabismus convergens, with amblyopia of the squinting eye, require, when simple tenotomy is performed, generally no less than three operations,—two on the squinting and one on the normal eye. In such cases the caruncle of both eyes is sunken, and on the squinting eye certainly not less than after bringing forward the externus. As to the limitation of movement following this operation, it is not of much importance, provided the squinting eye is highly amblyopic.

If in strabismus convergens both eyes possess a fair degree of vision, the tenotomy of both recti interni is to be preferred as a rule, but the operation for bringing forward the insertion of the antagonist may still be indicated by defect of motion toward that side.

The operation of bringing forward the internus is the treatment principally relied on in disfiguring strabismus divergens. In cases of extreme divergence, with loss of the power of convergence, the effect of a simple tenotomy of the externus is too slight, but the effect also of bringing forward the internus is somewhat less than that of the operation on the externus in converging squint. Since the insertion of the rectus externus is 8 mm. and that of the rectus internus only 6 mm. behind the margin of the cornea, the muscles can be brought forward only corresponding distances, unless a piece be cut from their anterior ends. Nevertheless, as much

---

\* Arch. f. Ophth., B. ix. 2, pag. 48.



may be expected from tenotomy of the externus and bringing forward the internus of the squinting eye as from three operations of simple tenotomy distributed between the two eyes.

For extreme cases of strabismus divergens it is advisable to divide the externi and bring forward the interni on both sides.

The red color of the muscle which has been brought forward is perceptible for some time through the conjunctiva. After some months, however, this slight cosmetic defect disappears.

#### NYSTAGMUS.

By nystagmus is understood a continuous oscillating movement of the eyes. The movement is generally in a horizontal direction, often with a simultaneous rotation about the visual axis, and very seldom in a vertical direction. Often the nystagmus is greater in certain positions of the eyes than in others, so that such patients see with the eyes directed to one side better than when vision is directed straight forward.

Some cases are complicated by a similar oscillation of the head, but in an opposite direction about the vertical axis.

In most cases nystagmus occurs in early childhood, perhaps even congenitally, and it appears that amblyopia exercises the greatest influence upon the development of this anomaly. Bilateral amblyopia congenita, corneal opacities following blennorrhœa neonatorum or from other causes, cataracta congenita, or total blindness in childhood, often lead to nystagmus. Cases of high degrees of albinismus always present this complication. In many cases one eye is amblyopic in a higher degree than the other. Although the influence which amblyopia, existing in early childhood, exerts upon the occurrence of nystagmus, is so great, it appears that there must simultaneously be other essential concurrent causes, since there are frequent cases of amblyopia, either congenital or acquired in early childhood, with absolutely steady fixation. Normal acuity of vision, at all events, does not appear to exist in connection with nystagmus, but vision is often sufficient for ordinary occupations, reading, etc., though it is difficult to understand how, during the continual oscillations, so distinct a recognition of the retinal images is possible. The apparent movements of the objects which would be expected under the circumstances are scarcely ever noticed by the patients.



In many cases, strabismus convergens co-exists, but the operation for its relief is not contra-indicated by the nystagmus.

A very peculiar form of nystagmus is that which occurs principally among miners.\* The nystagmus comes on first while working in the darkness of the mines. As it progresses, it lasts throughout the day, but greatly increases as twilight comes on. In this condition, also, the nystagmus is generally less in certain directions of vision. By bright daylight, vision and the ocular movements are normal, but as the light decreases, not only is the nystagmus increased, but a disproportionate decrease in the sensibility of the retina is apparent (hemeralopia from torpor retinae).

It is noticeable that these patients are greatly annoyed and made dizzy by the apparent movement of objects, due to the nystagmus. We recognize here again a confirmation of the empirical theory of vision. Individuals who, since their earliest childhood, have been the subjects of nystagmus, learn that the movement of the image which it causes upon the retina does not correspond to a movement of the object; if, on the contrary, the normal visual act has once become habitual, the movements of the image will be referred to movements of the object.

This affection is probably due to the work done by the insufficient light of the miners' lamps, and with the eyes turned in a very inconvenient position. Frequently the miners work lying in a prone position, with a strained upward direction of the eyes.

A tonic treatment, absolute rest of the eyes, the use of the induction current and the alcoholic extract of *nux vomica* (pill 0.02 grammes per dose =  $\frac{1}{3}$  grain) have been found useful.

Unilateral nystagmus has been observed. Zehender† has described a remarkable case of this sort; one eye possessed normal vision, the other, blind without any cause which could be detected by the ophthalmoscope, oscillated in a vertical direction.

Nystagmus often becomes less in advanced life; treatment is of no benefit.

---

\* P. Schröter, *Acquirirter Nystagmus bei Bergleuten*, *Klin. Monatsbl. für Augenheilk.*, 1871, pag. 135; und Dr. Nieden, *Ueber Nystagmus als Folgezustand von Hemeralopie*, *Berliner klin. Wochenschrift*, 1874, No. 47.


† *Klin. Monatsbl. f. Augenheilk.*, 1870, pag. 112.



## PART SECOND.

DISEASES OF THE ORBIT, LACHRYMAL APPARATUS,  
LIDS, CONJUNCTIVA, CORNEA, SCLERA, IRIS, LENS,  
AND VITREOUS BODY.







## AFFECTIONS OF THE ORBIT.

---

### INFLAMMATION OF THE TISSUES, AND CARIES OR NECROSIS OF THE ORBITAL WALLS.

INFLAMMATION of the orbital adipose and connective tissue occurs rarely as an independent affection; it is more frequent in connection with periostitis. Diseases of the neighboring bones, of the base of the skull, of the zygomatic or pterygo-palatine fossa, may cause an inflammatory infiltration of the orbital tissue, with protrusion and loss of movement of the eye. Pathological processes in the neighboring bony cavities, in the frontal and ethmoidal sinuses, and in the antrum of Highmore, cause like effects, especially when collections of pus or morbid growths in these localities break through the orbital walls. The cause is often a traumatic one, such as a contusion or wound in this region, the penetration of a foreign body into the orbit, or an operation, for instance, that for squint\* or for extirpation of the lachrymal gland. Other cases occur as puerperal metastases, as one of the symptoms of glanders, or in connection with facial erysipelas. Typhoid, scarlet fever, and smallpox have been suggested as causes, and Leyden† has called attention to the fact that a hemorrhagic purulent inflammation of the orbital tissue may result from purulent meningitis. The etiological relation between the two affections is to be explained by the anatomical connection which Schwalbe‡ has shown to exist between the arachnoidal space and the lymph-spaces which surround the external sheath of the optic nerve and pass over into Tenon's space.

The symptoms vary according to whether all the fatty tissue of the orbit is diffusely inflamed or the affection is a more localized one.

---

\* Desmarres, *Maladies des Yeux*, tome i. pag. 170, Paris, 1854.

† Virchow's *Archiv für path. Anat.*, 1864, B. 29, pag. 197.

‡ *Archiv für microscop. Anatomie*, B. vi.



Cases of the latter kind are generally due to traumatic causes or to circumscribed periostitis of the orbit. Cases of diffuse inflammation of the orbital fat develop with deep-seated pain and with inflammatory swelling, by which the eyeball is forced forward in the direction of the axis of the orbit; at the same time all its movements are quite uniformly interfered with, since the ocular muscles participate in the hemorrhagic purulent inflammation. Swelling and hyperæmia of the lids and conjunctiva soon follow.

Chemosis is not always present, but it may become so considerable that the fornix conjunctivæ protrudes and the cornea is surrounded by a wall-like swelling. If the protrusion of the eyeball be but slight, it may be entirely masked by the chemosis, and under these circumstances, especially if the development of the disease has not been followed from the beginning, there is danger of mistaking it for blennorrhœa, if that error be not guarded against by observing the absence of the characteristic secretion. The swelling of the lids, especially of the upper one, is generally considerable; the skin is dark red, smooth, and shining; disturbances of the general condition, fever, etc., usually are present.

Resolution does not often occur; the inflammation generally goes on to suppuration. The skin becomes a darker red; upon everting the lids the fornix conjunctivæ appears swollen and often yellow from the pus beneath. Fluctuation may be detected between the eyeball and the orbital wall. Finally the abscess breaks.

Purulent periostitis of the orbit may cause nearly the same symptoms as genuine inflammation of the orbital fatty tissues, and may with the greatest probability be assumed to exist when the margin of the orbit is sensitive to pressure. According to Von Graefe,\* the skin and the subcutaneous connective tissue do not so soon become involved in periostitis as in inflammation of the fatty tissue.

Moreover, the secondary participation of the connective tissue is apt in periostitis to concentrate in the neighborhood of the affected spot, and the eyeball is therefore more frequently forced to one side; the limitation of movement, too, is greater in some directions than in others. Nevertheless, the diagnosis is often

---

\* Klin. Monatsbl. für Augenheilk., 1863, pag. 51.



uncertain till the opening of the abscess; it may then be made positive by examination with the sound and by the character of the pus, which, if the bony walls of the orbit be diseased, has the fetid smell and other peculiarities of bone pus.

In making the prognosis, various possibilities are to be remembered. An acute caries or necrosis of the superior orbital wall may cause a fatal brain affection; moreover, vision is greatly endangered.

The exophthalmus may become so extreme that the eye can no longer be covered by the lids. In consequence of this the cornea becomes cloudy and finally ulcerates.

Oftener the eye is endangered, not so much by the exophthalmus as by the inflammatory process in the orbit. Blindness is generally caused by neuritis optica, in many cases, too, by retro-ocular neuritis, which can be recognized ophthalmoscopically only by its final result,—that is, the atrophic degeneration of the intraocular termination of the optic nerve.

Less frequently, blindness is caused by detachment of the retina, or purulent irido-choroiditis. Both complications may be explained by the communication which Schwalbe has shown to exist between the space of Tenon and the supra-choroidal lymph-space described by him.

The course is generally acute, and, unless due to bone disease, is ended in a few weeks; still, cases do occur of chronic inflammation of the orbital connective tissue, which go on finally to suppuration, and which, extending through several months, may present the greatest diagnostic difficulties. In these cases, after the opening of the abscess, there often remains a long-persisting purulent discharge, even when no disease of the bone exists.

A milder non-purulent form of inflammation of the orbital connective tissue has been described under the name of inflammation of the capsule of Tenon; this definition ought not to be taken too literally, since it is not likely that an inflammatory process which manifests itself by distinct symptoms could be limited to the capsule of Tenon alone without involving the orbital connective tissue. The symptoms are the same as those given above, only less severe.

The lids are either normal or œdematous, the conjunctiva, especially in the fornix and upon the sclera, is hyperæmic and much



swelled; there is some exophthalmus and slight limitation of movement.

The prognosis in the milder cases is generally good; still, they may cause retinal detachment.

The course is generally acute, but it may become chronic.

*Treatment.*—In mild cases of inflammation of the orbital areolar tissue it is sufficient, after a proper antiphlogistic treatment, to use merely warm fomentations and the pressure-bandage.

If the inflammation be severe from the beginning, decided antiphlogistic treatment is indicated. When it becomes probable that the process will go on to suppuration, that result is to be hastened by the use of warm poultices, and the abscess should be opened as soon as fluctuation can be perceived. Especially in those cases where periostitis of the orbit is suspected must the puncture be made as soon as possible, in order to prevent widespread exposure of the bone.

The abscess is to be kept open by a charpie tent, and, according to circumstances, is to be examined either immediately or somewhat later with the probe. In that way the depth and character of the abscess and the condition of the bony walls are determined.

It must, at the same time, be remembered that a foreign body may remain a long time in the orbit, and there cause the formation of an abscess, without the patient being able to give any certain information respecting its presence.

If the cavity of the abscess be large, if it has pockets, and penetrates behind the eyeball, it must be cleansed by frequent syringing, and must be kept open till it heals from the bottom. It is advisable in these cases to insert a drainage-tube and thus insure an easy escape for the pus. The same practice is to be recommended when the bone is diseased. Care must be taken to remove all loose pieces of bone.

Caries and necrosis of the orbital margin are most frequent on the outer under portion, generally in scrofulous children, and in the majority of cases are due to traumatic causes. The portion of the orbital margin in the neighborhood of the lachrymal gland is the one next likely to be diseased.

Generally, but not always, a swelling develops above or below the external canthus, with reddening of the skin and pain; this gradually becomes fluctuating. The eyelids become swollen and



œdematous; the conjunctiva becomes inflamed; slight fever begins; the abscess points, and finally breaks. Nevertheless, the inflammatory symptoms of the skin and conjunctiva persist; the secretion of pus in the cavity of the abscess continues, the opening becomes fistulous, its edges uniting with the periosteum, while the denuded bone can be felt with the probe. When the swelling of the lids has disappeared, and the skin is closely united with the periosteum, portions of the carious margin of the bone may lie exposed to sight.

Finally, the fascia tarso-orbitalis, by attachment to the diseased bony spot and by ulceration, becomes shortened, and ectropion of the lid is caused.

A similar form of caries or necrosis occurs in aged individuals, generally on the upper orbital roof. The cause can seldom be recognized. It runs the same course as disease of the margin of the orbit.

If such cases come under treatment early enough, the abscess is to be opened as soon as possible, and as far back from the orbital margin as circumstances allow.

#### EXOPHTHALMUS FROM MORBUS BASEDOWII.

Basedow's disease presents a group of symptoms, the principal of which are palpitation of the heart, abnormal frequency of the pulse (100 beats and more per minute), swelling of the thyroid gland, and exophthalmus. Often, especially in the beginning of the disease, there are disturbances of digestion, manifested by frequent vomiting.

In almost all cases the heart is found to be enlarged and generally dilated, the dilatation being greatest in the left ventricle. Abnormal conditions of the valves have been found in only a few cases. The hypertrophy of the heart appears to develop in the course of the disease.

The condition of the thyroid gland varies greatly during life. As a rule, it is not so much enlarged as in ordinary goitre, and still its size is considerably increased. The most striking change observed in it is a great development of the vessels, in which a diastolic pulsation and murmur are frequently perceptible.

At first there is a simple swelling of the thyroid gland. In time it may develop into true goitre, passing through the various



stages of, first, a uniform hyperplasia, then colloid and cystic degeneration or irregular fibroid induration.

The cause of the exophthalmus is sometimes a hypertrophy of the fatty tissues of the orbit, but more frequently it is a hyperæmia of these tissues, which can easily be overcome by pressure during life, and disappears after death.\* An observation made by Snellen† shows enlargement of the orbital vessels. He observed in a case of morbus Basedowii, while examining the eye with the stethoscope, a distinct vascular murmur, analogous to the placental murmur, but with a slighter systolic augmentation. Such murmurs occur only in places where the blood-channels expand, and, occurring in connection with exophthalmus, they argue a distention of the orbital vessels.

The exophthalmus is generally bilateral and symmetrical; still, it sometimes happens that it occurs first on one side, or, at least, is greater on one side than on the other. It may be very slight, or it may be so great that the lids can no longer be brought together.

A valuable diagnostic sign, especially at the beginning of the disease, is a peculiar disturbance of innervation in the upper lid, to which attention was first directed by Von Graefe.‡

While normally the upper lid accompanies the rising and falling of the plane of vision, in Basedow's disease this movement is lost or reduced to a minimum. Particularly when the cornea sinks, the upper lid fails to follow it. This is not a direct consequence of the exophthalmus, for with tumors of the orbit, or other causes for protrusion, this symptom is often entirely absent, although in extreme cases the movements of the lids are naturally interfered with. But it is present in the slightest cases of exophthalmus from Basedow's disease, where the normal position of the eyeball has been but slightly altered. This symptom may disappear in the course of the disease, while the exophthalmus continues. In one case Von Graefe saw a sudden disappearance of the symptom after an injection of morphine.

Von Stellwag§ calls attention to the unusual distention of the

---

\* Comp. Virchow, Die krankhaften Geschwülste, B. iii. 1, pag. 73-86.

† Arch. f. Ophth., B. xvii. 1, pag. 102.

‡ Deutsche Klinik, 1864, No. 16.

§ Wiener med. Jahrbücher, ii. Heft, 1869.



palpebral fissure, and to the infrequency and only partial execution of the involuntary act of winking, stating that these belong to the most frequent symptoms, and referring them, as well as the defective associated movement of the lid, above described, to disturbed innervation in the orbicularis muscle.

In favor of this view we have the circumstance that cases occur in which, with loss of the associated movement of the upper lid, but with scarcely any perceptible protrusion of the eye, the voluntary closure of the lids is accomplished only with the greatest effort: a simple spastic contraction of H. Müller's smooth muscular fibres of the upper lid could oppose no very great resistance to the normal action of the orbicularis.

The movements of the eye are generally unobstructed; yet in high degrees of exophthalmus they may be interfered with by the stretching of the muscles. Paralysis and fatty degeneration\* of the ocular muscles have been observed.

If the exophthalmus be so excessive that the cornea is not covered during sleep, there is danger of blindness being caused by ulceration of the cornea. This serious result seems somewhat more frequent in Basedow's disease than in other cases of chronic exophthalmus. Accordingly, Von Graefe is inclined to regard the corneal affection as possessing a neuro-paralytic character, and all the more since, in the advanced stages of the disease, a diminished sensibility of the cornea is often observed.

The general cause of all these symptoms must lie in the nervous system; but it cannot be said that it has as yet been certainly discovered.

The majority of cases occur in the female sex, and develop generally at the time of puberty, or after confinement. Prostrating sicknesses have been regarded as causes; for instance, typhus, colds in the throat, and oftenest chlorosis. According to Von Graefe, the disease occurs in men not only less frequently, but later in life, than in women; it also seems to be more dangerous. Both blindness from corneal destruction and fatal terminations of the disease have been observed much more frequently in men, although the disease is much less frequent with them than with women.

---

\* Recklinghausen, *Deutsche Klinik*, 1863, No. 29, pag. 286.



Death follows upon the increase of all the symptoms, sometimes very rapidly, with great anxiety and cerebral disturbances, but generally gradually, with decline of nutrition and of the strength. Copious and frequently dysenteric diarrhœa and hemorrhage from the lungs are apt to hasten the end.

In other cases, sometimes after very short duration of the disease, recovery occurs, or, at least, there is such a mitigation of the symptoms that they cause little inconvenience.

Iodine has seldom, but digitalis has often, proved useful. Tinct. veratri viridis is recommended, beginning with one drop daily, and gradually increasing; best given in combination with tinct. opii, since the veratrum easily provokes diarrhœa and vomiting. Preparations of iron, cold-water treatment, sea-bathing, and nutritious diet appear of the greatest use. The galvanization of the sympathetic nerve has also in some cases appeared to be beneficial.\*

Corneal affections occurring in the course of the disease require atropine and the pressure-bandage.

In order to diminish the gaping of the lids, Von Graefe† at first recommended the operation of tarsorrhaphy; later, the partial division of the tendon of the levator palpebræ superioris.

#### EXOPHTHALMUS FROM VENOUS HYPERÆMIA.

A similar form of exophthalmus is due to causes which obstruct the flow of venous blood out of the orbit; for instance, thrombus of the ophthalmic vein, or its compression by a tumor.

The causes of this rare form of exophthalmus cannot always be determined. They are often of a transitory nature, since the affection sometimes disappears in the course of a few months, either spontaneously or under a nearly indifferent treatment.

Another group of these cases presents the peculiar phenomenon of a pulsating exophthalmus.

The pulsation in the eye, the orbit, and even in the forehead and temple, and the sound of the accompanying murmur, are perceptible to the patient, and very annoying to him. The protruding eyeball may often be gradually pushed back in the

---

\* M. Meyer, Berliner Klinische Wochenschrift, 1872, pag. 469.

† Arch. f. Ophth., B. iii. 2, pag. 302, und Klin. Monatsbl., 1867, pag. 272.



orbit, but immediately comes forward again when the pressure is removed.

The anatomical causes of this pulsating exophthalmus may have their seat either within the orbit, or still deeper, within the cavity of the skull.

Aneurism of the ophthalmic artery or of its branches, or of the carotis interna near the sinus cavernosus, varicosity of the orbital veins, thrombus of the vena ophthalmica or its compression by tumors, have been observed as causes. It is often due to injuries or to violent exertion; often no cause whatever is to be discovered.

Upon the assumption that the pulsation was caused by an aneurism, the common carotid has been tied a number of times. Zehender\* has collected 31 such cases, in which 23 of the operations were followed by good results and 2 by death. The digital compression of the carotid has been made, sometimes with and sometimes without effect.

#### TUMORS IN THE ORBIT.

Tumors which develop in the bottom of the orbit push the eyeball forward, and often at the same time, according to the form and manner of growth of the tumor, push it to one side. Since the exophthalmus generally develops slowly, the danger to vision is somewhat less than in the rapidly-developing inflammatory forms; at least, the cornea is not so much exposed to the danger of losing the protection of the lids, since they frequently experience a very considerable distention. A useful degree of vision may therefore long be retained; but generally neuritis or atrophic degeneration of the optic nerve is finally caused by the irritation, compression, or distention to which it is subjected.

The optic nerve itself may be the seat of the tumor, in which case there is absolute blindness.

The movements of the eye are generally interfered with, for the muscles and nerves may be compressed by the tumor, or may have grown to it. The eyeball may even be adherent to it, or the tumor may have grown into the eyeball; although the reverse process is more frequent,—that is, the intraocular tumor breaks through the eyeball and extends into the orbit.

---

\* Klin. Monatsbl., 1868, pag. 99.



It is seldom possible by a clinical examination to satisfy one's self of the nature of these tumors, since from their position they are not accessible to direct examination. Often the only way in which the tumor can be palpated is to thrust the little finger into the conjunctival sac, between the lid and the eyeball; but even then only a small portion can be reached.

No symptoms can be named from which the nature of the tumor can be determined with certainty. As the nearest approach to a pathognomonic symptom, it may be mentioned that sometimes, but not always, an increase and decrease of the exophthalmus have been observed depending upon mechanical causes regulating the hyperæmia of the orbit.

The same symptoms as those caused by tumors, in the strict sense of the word, may be caused by echinococci or cysticerci in the orbit.

The diagnosis of tumors which develop in the anterior part of the orbit is somewhat easier. If they extend behind the eyeball and cause exophthalmus, it is often impossible to determine how far backward the tumor extends.

Orbital tumors which grow rapidly should be extirpated, and this course is the more readily decided on when sight has already been considerably affected. If the tumor be situated outside the ocular muscles, the attempt should at least be made to retain the eyeball. With this object in view, several of the ocular muscles may be divided, the tumor enucleated, and the ball replaced, the muscles being again attached with sutures. If the tumor has originally developed behind the eyeball, or if adhesions have been formed between the eyeball and it, it may be necessary to begin the operation by the enucleation of the eye.

If the malignity of the tumor be ascertained, or if, as is often the case with sarcomatous growths, it has become adherent to the orbital fasciæ and periosteum, it may be necessary to remove even the periosteum of the orbit, either as the last act of the operation, or the tumor and periosteum may be removed at the same time.

In general, after the removal of these tumors, only a little tissue remains in the orbit, and there is no difficulty in pushing the periosteum back toward the foramen opticum, there as deep as possible to cut away it and all the tissues included in it.

If the removal of the periosteum has been decided on before



beginning the operation, the following is the method. An incision is made through the skin around the margin of the orbit, except for a space of about 20 mm. at the inner angle of the eye, where a bridge of skin is left. A small gouge is then used to detach the periosteum from the margin of the orbit, where it is firmly adherent. Farther back, where the attachment to the bone is looser, the handle of the scalpel may be used for that purpose. The entire mass enclosed by the periosteum is then cut through at the apex of the orbit with a pair of scissors curved on the flat; the mass thus loosened is drawn up out of the orbit and reflected inward over the nose, and then detached from the inner surface of the lids. Finally, the cutaneous flap is turned back to its place and there fastened with sutures.\*

Bony tumors may grow from any part of the orbital walls, but are most frequent on the upper and inner portion. These tumors are often connected with diseased conditions, such as polypi or granulations of the nasal cavity or frontal sinus, or they may extend even into the cavity of the skull.† This latter possibility is to be particularly considered with reference to the prognosis. The use of iodide of potassium has proved beneficial in many cases. The resection of these bony tumors has not generally proved a satisfactory operation, on account of the uncertainty in the diagnosis of their nature and extent and their inaccessible position in the orbit.

Hemorrhages in the orbit following contusions, cause exophthalmus and loss of motion, and in consequence of these diplopia. Diminution of vision also occurs. The ecchymosis of the lids and conjunctiva confirms the diagnosis.

The treatment consists in local blood-letting, cold dressings, and the pressure-bandage.

Fractures involving the roof of the orbit may cause fatal brain affections. If by a fracture of the inner wall a communication be established between the orbit and the nasal cavity, emphysema of the orbit may follow.

Foreign bodies may remain a long time in the orbit without causing noticeable symptoms. Cases of this sort have occurred

---

\* Snellen nach V. Langenbeck, Zevende Verslag, 1866, pag. 51.

† Comp. Virchow, Geschwülste, B. i. 1, pag. 43.



in which the foreign body has been relatively large, such as pieces of wood, of pipe-stem, etc. The manner in which these injuries have occurred is often such that the patients are unable to say whether the foreign body which penetrated the orbit, left it again or remained there. The penetrating substance may break within the orbit, so that fragments remain within which are not visible from without.

The wound in the skin or conjunctiva may close completely, or it may remain open and be covered with granulations. In other cases the injury is followed by purulent inflammation of the orbital tissues and the discharge of pus.

From what has been said it appears that exophthalmus is a symptom which may occur in consequence of the most diverse diseased conditions of the orbit, and consequently may be of all degrees.

Recent investigations have shown that even physiologically the position of the eyeball in the orbit is not always the same upon the two sides. Frequently one eye lies some millimetres deeper than the other. Small differences of position can be determined only by measurement, while greater ones cause a striking asymmetry of the countenance.

Measurements to determine the position of the apex of the cornea relatively to the margin of the orbit with instruments constructed for this purpose and called exophthalmometers, were first made by Cohn,\* and later by Hasner,† Emmert,‡ and Zehender.§

---

\* Klin. Monatsbl., 1867, pag. 339.

† Die Statopathien des Auges, Prag, 1869

‡ Klin. Monatsbl., 1870, pag. 33.

§ Ibid., pag. 42.



## DISEASES OF THE LACHRYMAL APPARATUS.

---

ACUTE inflammation of the lachrymal gland (dacryoadenitis) occurs as an inflammation which is localized in the region of the lachrymal gland, and from there spreads to the lids and conjunctiva. The lids are red and infiltrated, so that they can be only partially opened; the conjunctiva is hyperæmic and swollen; often there is an exudation under the conjunctiva oculi; generally, too, there is an increased muco-purulent secretion.

We have, accordingly, a group of symptoms which occur also in blennorrhœa, namely, a quickly developing inflammatory swelling of the lids and conjunctiva, with muco-purulent secretion. It is, however, easy to avoid mistaking it for blennorrhœa, since in the latter disease the mucous membrane is uniformly affected throughout its whole extent, while in dacryoadenitis the inflammation is greatest in the region of the lachrymal gland and diminishes toward the nasal side. The pathognomonic symptom, however, is this, that the swollen lachrymal gland pressed downward and outward can be seen between the lid and eyeball when the patient looks downward and inward, while the examiner at the same time raises the upper lid as much as possible. The swelling of the lachrymal gland may be so great that the eyeball is displaced downward and inward.

The usual result is in resolution; still, the connective tissue supporting the gland, which is the tissue essentially involved in the inflammation, may suppurate and a small abscess be formed, which appears to have more tendency to break into the conjunctival sac than through the skin.

The process appears also to end sometimes in induration and hypertrophy of the gland.

The occurrence of acute dacryoadenitis is not very rare. Cold has been regarded as the usual cause. Operations upon the eyes may cause it.\*

---

\* A. v. Graefe, Arch. f. Ophth., B. iv. 2, pag. 258.



As to treatment, warm applications and protection from injurious influences are generally sufficient. Under this treatment recovery usually occurs in the course of a few weeks.

More seldom than the acute form is that which is chronic from the beginning, which goes on without external signs of inflammation, and which often occurs on both sides. Iodide of potassium internally, or as a salve applied in the region of the lachrymal gland, has proved useful in such cases.

Fistulas of the lachrymal gland are but rarely seen. They may remain after accidental wounds, or after operations in that region, or may be caused by ulceration, as in cases of lupus.

So long as the fistula remains open, the annoyances are slight, and consist principally in the flow of tears from the fistulous opening. This condition may remain a long time unchanged, but it may happen that the external opening closes without the healing of the fistulous canal. The secretion of the gland is then retained, and infiltrates the surrounding tissues, causing inflammation there, with swelling of the lids and inflammatory exudation beneath the conjunctiva palpebrarum and oculi, often ending in small abscesses of the lids.

Generally in the course of the disease the fistula breaks open again, the inflammatory symptoms disappear, but return again if the fistula closes.

According to Bowman,\* these fistulas are healed in the following manner. A strong silk thread is provided with two needles; one needle is passed into the fistulous opening and through the wall of the fistula and the conjunctiva above the tarsus; the second needle is passed through in the same way, but brought through the conjunctiva at a distance of about 5 mm. from the first; both ends of the thread are then carried outward upon the cheek and there fastened with adhesive plaster. In this way a communication is established between the fistula and the conjunctival sac, and as soon as the danger of inflammatory reaction seems to be past, say after from 8 to 14 days, the edges of the external fistulous opening are to be freshened and carefully united.

If the closure of the external fistulous opening be effected in

---

\* Ophthalmic Hospital Reports, i. pag. 286.



this manner, the thread will finally cut its own way through the tissue included by it.

If an old fistulous opening has become closed and cannot be found, while the patient is annoyed by oft-returning inflammations, the only relief is by extirpation of the lachrymal gland.\*

Dacryops is the name given to a rare tumor on the upper lid near the outer canthus, which is due to the retention of the tears in one of the excretory ducts of the lachrymal gland. It may occur without the actual closing of the conjunctival opening of the duct, so that the tumor may be emptied by pressure.†

The tumor is distinctly circumscribed, very elastic, and painless; the skin above it is normal. Upon everting the upper lid the tumor protrudes in the form of a thin-walled cyst. What characterizes it most is that its size increases whenever increased secretion of the lachrymal gland occurs.

The treatment of these tumors consists in making an opening into them on the inner surface of the lid large enough to insure the easy flow of the tears into the conjunctival sac. This is best done by passing a thread through the conjunctival wall of the tumor in such a way that the puncture and counter-puncture are about 5 mm. from each other. The thread is then lightly tied, and the two ends carried over upon the cheek and there fastened, and allowed to remain from 8 to 14 days, till the edges of the wound in the cyst are healed.

Tumors of the lachrymal gland—simple hypertrophy, cystic growths, cancrioid, adenomata, etc.—cause in the first place a protrusion of the enlarged gland between the eyeball and the orbital wall. As the tumor grows and extends backward into the orbit the eyeball is pressed forward and inward, and at the same time, according to circumstances, either upward or downward. With this variety of exophthalmus vision may remain unaffected a long time, or it may in various ways be interfered with. If the cornea be no longer covered by the lids, the consequence will be inflammatory clouding, and at last ulceration and rupture, ending in atrophy of the eye. Further, the mechanical irritation of the optic nerve may cause neuritis. Finally, adhesions may form

---

\* Alfr. Graefe, Arch. f. Ophth., B. viii. 1, pag. 279.

† A. v. Graefe, Arch. f. Ophth., B. vii. 2, pag. 1.



between the tumor and the eyeball, and direct communications between cysts of the lachrymal gland and the interior of the eye have been observed.

The extirpation of the lachrymal gland with retention of the eyeball is best accomplished by an incision on the external upper margin of the orbit, passing through the skin, the muscle, and the fascia tarso-orbitalis. The length of the incision is determined by the size of the tumor, and for the normal gland should be about 25 mm. The eyeball, when necessary, should be protected by a horn spatula thrust under the upper lid, the gland seized with the toothed forceps, and then detached first from the periosteum and then from the surrounding soft parts. The last act, especially in the case of the normal gland, is difficult, by reason of the toughness of the tissues and the copious hemorrhage.

The wound under the use of ice-dressings may heal quickly, but suppuration as well as erysipelatous inflammation, with great swelling of the lids, fever, and symptoms of cerebral hyperæmia, may follow.

The function of the eye is not essentially interfered with by the extirpation of the lachrymal gland.

#### ANOMALIES OF THE PUNCTA LACRYMALIA AND CANALICULI.

The congenital anomalies of these organs are their occlusion and their presence in superfluous number.

Foreign bodies which accidentally enter them, such as hairs, eyelashes, etc., may close the canals, and at the same time provoke inflammatory symptoms.

Cryptogamous growths (leptothrix) must be included among the foreign bodies found in the canaliculi. They have been observed oftener in the lower than in the upper canaliculus, and may fill it so completely as to cause a perceptible tumor. The neighboring tissues become inflamed, the caruncle and adjacent conjunctiva are reddened, the edges of the lids corresponding to these parts are swollen, the lower punctum is enlarged, and often discharges a white secretion, especially on pressure. In this condition a troublesome dripping of the tears occurs. In the further course of the affection the local inflammation and swelling increase, exciting from time to time diffuse catarrh of the conjunctiva. After splitting up the canaliculus the concretions may be



pressed out, and consist of leptothrix-elements often mixed with the salts of lime. The treatment consists in splitting and carefully cleansing the canaliculi.

An abnormal position of the lower punctum occurs in consequence of chronic inflammatory swelling of the conjunctiva, or of those superficial contractions of the skin which result from chronic blepharitis. It is in fact a slight ectropion, which is most apparent when the patient looks upward, since in that position the lower lid is raised slightly away from the eye. In consequence of its abnormal position the lower punctum cannot receive the tears, but they collect at the inner angle of the lids and trickle down the cheek. In this condition the puncta themselves may be unchanged, or, especially in chronic blepharitis, they may become obliterated and entirely disappear. The small prominences on which they stand become levelled down, that part of the edge of the lid rounded off, the puncta greatly contracted, so that it becomes difficult or impossible to find them. To cure these cases, Bowman has proposed the splitting of the canaliculi, thus converting them into open furrows upon the conjunctival surface. To do this the punctum is first dilated by a probe whose fine point thickens rapidly, and room is thus made in which to introduce Weber's knife; this consists of a probe-pointed sound, which about 2 mm. back from its blunt point passes over into a small convex blade, about  $1\frac{1}{2}$  or 2 mm. wide. The point is thrust into the lachrymal sac, and the canaliculus is split by lifting the handle in the case of the lower, or depressing it in the case of the upper canaliculus. To avoid reunion of the edges of the wound, it is well to keep the patient several days under observation, and to break up with a fine sound any adhesions which may occur. This practice is generally successful, and yet in cases of chronic blepharitis it sometimes fails in spite of all pains taken; and even without this complication it sometimes happens that the canaliculi, which have been split and kept open for months, finally reunite throughout their entire length.

Wounds which have divided the canaliculi should be carefully united by sutures and then kept in perfect rest. If cicatrization destroy the continuity of the canal, it generally is not possible to re-establish it again.

In consequence of such wounds, or of ruptures of the lachrymal



sac by contusions, air may be driven from the nasal cavity through the canaliculus into the subcutaneous connective tissue, for instance, during forced expiration, sneezing, etc. Its presence there is detected by a crepitating, emphysematous tumor. At the same time infiltration of the tears into the tissues of the lids may take place.

#### DISEASES OF THE LACHRYMAL SAC.

The first symptom of acute dacryocystitis is generally a considerable swelling of the mucous membrane of the lachrymal sac, both painful and tender, and causing a low, rounded, circumscribed tumor. The skin lying over it is generally red and swollen from the first. The inflammation involves the inner angle of the eye, so that the lids, the caruncle, and often, too, the conjunctiva palpebrarum, are oedematous. The swelling and redness frequently spread out upon the nose and cheek. Generally the inflammation goes on to suppuration within the sac, and rupture outwards; still, resolution may occur, or the dacryocystitis become chronic.

It is generally due to strictures in the nasal duct, which cause retention of the secretion, and consequent inflammatory changes in the mucous membrane. Under these circumstances accidental causes, such as cold, may excite acute inflammation, or an inflammation which was at first slight, may cause such a rapid accumulation of the secretions that the distention of the sac excites inflammation in the adjoining tissues.

It is best from the beginning to use warm cataplasms: the tension of the tissues is thereby diminished, the pain soothed, and resolution, if possible for it to occur, is favored. If the inflammation go on to suppuration the tumor points, becomes soft and fluctuating, and the pus can be seen through the skin. Under these circumstances the cataplasms may be continued, and the spontaneous opening of the tumor awaited, or it may be incised,—and this is generally most advantageous, since in this way the sac is more freely evacuated. After opening the sac it is advisable, in order to avoid too speedy closure, to place charpie in the wound; and under all circumstances the free discharge of the secretions must be insured by the use of cataplasms and frequent syringing with warm water. The opening must not be allowed to heal till the swelling of the mucous membrane is so far reduced that the secretions can be discharged through the normal channels,—that



is, through the nasal duct and canaliculi. Exceptionally the opening shows no tendency to heal, so that a lachrymal fistula is formed. But no matter what course the dacryocystitis takes, whether it end in resolution, suppuration, chronic inflammation, or fistula, the second step always consists in determining whether there are strictures in the nasal duct, and, if they are found, proceeding to their treatment.

Chronic inflammation of the mucous membrane of the lachrymal sac (*blennorrhœa sacci lacrymalis*) develops, as does the acute form, almost always from the presence of strictures.

Since the normal force which impels the tears through the nasal duct is but very slight, a moderate contraction of this passage suffices to cause above the stricture an accumulation of the secretions; this decomposes and irritates the mucous membrane. The irritated membrane contributes now, on its part, to the increase of the secretion, that portion of the canal above the stricture becomes filled, and the membranous walls of the lachrymal sac, which, from the chronic inflammation and infiltration of the mucous membrane and adjacent tissues, have become relaxed, yield gradually to the pressure of the accumulating secretion.

The distended sac now causes at the nasal angle a small tumor, whose muco-purulent contents may be discharged by pressure of the finger either downward into the nasal cavity or upward through the canaliculi. This condition may remain for a long time unchanged, without any external visible signs of inflammation: or the relaxation and distention of the sac may increase, and the tumor enlarge till it attains the size of a cherry-stone or hazel-nut; it may even become larger, and in such cases the contents generally lose their purulent character, changing to an almost colorless, clear, thin mucus (*atonía* or *hydrops sacci lacrymalis*). In other cases external signs of inflammation are superadded, and these run a course similar to that of acute dacryocystitis, or they may continue for a long time in a subacute course, and may even finally lead to rupture of the sac. In such cases the contents do not always reach the surface by the shortest way; the pus breaks from the sac into the adjoining tissue and there spreads out irregularly, often in several channels, before it penetrates the skin.

The etiology is generally the same as in acute dacryocystitis. Strictures are almost always present. Still, it may be caused by



foreign bodies in the nose, nasal polypi, or by the necrosis of the surrounding bones, due to scrofula or syphilis.

The treatment as regards acute exacerbations is the same as in the acute form. In most of these chronic cases the cure of the stricture is the first indication.

Strictures of the nasal duct are most frequent at its lower extremity, and just below the sac, at the boundary between the orbital and maxillary parts. These strictures are often due to chronic catarrhal inflammation, which is frequently connected with diseases of the nasal mucous membrane.

In consequence of this connection, scrofula may be classed among the causes. Acute blennorrhœal inflammation of the conjunctiva causes frequently a similar inflammation of the mucous membrane of the tear-passages, probably because the resorption of the tears is prevented at the most infectious period of the blennorrhœa, by the swelling of the conjunctiva. Chronic conjunctival inflammations appear more likely to cause strictures. In many cases it is not possible to discover any cause.

The contraction of the duct, of course, presents a hindrance to the passage of the tears, but this does not always cause permanent epiphora. It is not rare to see persons whose nasal ducts are almost closed, and who yet are but little discommoded by the tears,—never, indeed, except under circumstances which cause increased secretion, as, for instance, slight conjunctivitis. In such cases, without touching the stricture, the difficulty may often be relieved by the use of some mild astringent eye-water,—for instance, a  $\frac{1}{4}$  per cent. solution of sulphate of zinc.

In most cases, however, the strictures appear to lead to the above-described blennorrhœal condition of the tear-passages.

The treatment of the strictures is best accomplished by the introduction of Bowman's probes, which may be curved so as to adapt themselves to the anatomical relations of the special cases. Generally a circular curvature, with a radius of from 40 to 50 mm., is most suitable.

After one of the canaliculi—for instance, the lower one—has been split up in the manner above described, and the bleeding has stopped, the sound is slipped along the lower anterior wall of the canal into the sac. While doing this, the punctum lacrymale must be drawn somewhat outward and downward, and the



canaliculus held tense in that direction, while the patient is told to look upward. The probe is carefully thrust forward, in a nearly horizontal direction, until its end strikes the median wall of the sac, resting against the lachrymal bone. Then the probe is brought into a nearly vertical position. If during the passage of the probe through the canal, or the attempt to turn it up in the vertical position, its end is seen to cause tension on the lid, that is proof that it has not yet entered the sac, but that it has caught in the canaliculus.

In introducing the probe through the upper canaliculus, it is to be slid along the median wall down into the lachrymal sac.

In general, while introducing the probe, its direction at any given time should correspond with the direction of that portion of the tear-passage through which the point of the probe is then passing. While the sound is gliding down the nasal duct the upper part of the sound should lie in contact with the upper eyebrow, from 4 to 6 mm. to the median side of the incisura supra-orbitalis. Under all circumstances, the operator must proceed carefully, without the use of force, and find his way through the stricture by a rotary motion of the probe. Sometimes there are pockets above the stricture, especially in the outer anterior wall of the sac; the probe may easily be passed into one of these, and its farther progress absolutely prevented. When this occurs, instead of using force, the probe must be withdrawn a little distance, and the normal passage sought, while avoiding the diverticulum. By proper manipulation of the probe the stricture may almost always be passed, and I recall but few cases in which an absolutely impermeable stricture seemed to exist. I have satisfied myself by anatomical examination that such complete strictures do, however, occur. In one case,\* for instance, I found the lachrymal sac considerably distended, filled with viscid mucus, the mucous membrane smooth, and the lower end of the sac absolutely closed by cicatricial tissue: the lower end of the nasal duct was also closed by the same tough tissue. Within the duct thus closed on every side I found a transparent viscid secretion, which was mixed with numerous epithelial cells (perhaps a post-mortem occurrence), and was coagulable with acetic acid.

---

\* Verhandl. der physical.-med. Gesellschaft zu Würzburg, B. x. pag. 12.



Complete stricture ought not to be assumed simply because the probe cannot be passed at the first sitting. The splitting of the canaliculi, the easier and more frequent discharge of the secretion, and the syringing with some astringent solution, in many cases cause, in the course of some days, a diminution in the swelling of the mucous membrane, so that the probe can be passed without any trouble. The probe is allowed to remain in the canal for a quarter or half an hour, and is then carefully and slowly withdrawn. The probing is generally repeated every day; but if it be very painful, or if, after the withdrawal of the probe, there be hemorrhage from the nose, it is well to wait some days before repeating the operation.

It is best to begin with a probe having a diameter of about 1 mm., and increase gradually to those with a diameter of 1.5 or 1.75 mm. The probes first introduced by Bowman have as their highest numbers some of greater thickness, but Arlt very properly warns against the use of too thick a probe.\* The observation that stricture of the canaliculi at their place of opening into the lachrymal sac may be a consequence of probing, has been often enough made, and Arlt explains it by saying that in these cases this place has been wounded by too thick a probe. This reason applies with still greater force against the use of A. Weber's probes, which at the point corresponding with the openings of the canaliculi into the sac have a diameter of at least 2 mm., and the highest a diameter of 3 or 4 mm. Weber, indeed, recommends that the canaliculi be split through their whole extent down to the sac, involving the incision of the ligamentum mediale; but it is very doubtful if by this method the mechanical irritation is lessened. Arlt suggests further that similar contractions may occur also at the lower end of the nasal duct in consequence of using too thick a probe. Certainly it is as likely to occur here as in the canaliculi, for the anatomical relations at this point present the greatest variations. "In many cases the mucous membrane forms here simply a covering for the bony walls; the nasal opening will then be wide and round, with sharp margins. If the canal continue a distance within the

---

\* Behandlung der Thränenschlauchkrankheiten, Arch. f. Opth., B. xiv. 3, pag. 270.



mucous membrane on the side of the nasal cavity, its opening is sometimes narrow, sometimes wide, sometimes round, sometimes a mere slit, which is sometimes horizontal, sometimes vertical. In general, the deeper the opening the narrower it is. Frequently one seeks in vain for it, even after removal of the palate, when the light is allowed to fall into the space covered by the turbinated bone, and it can be found only by passing a fine bristle, or making an injection from the lachrymal sac downward.”\*

In undertaking the treatment by probing, it is impossible to tell which of these anatomical variations exists, but it will do no harm to assume in every case that the most unfavorable condition exists, and therefore proceed to probing in the most careful manner.

It is well from time to time, during the treatment by probing, to try whether the duct is permeable also for injections. Cases occur in which the probe passes easily, while an injection will not; the point of the canula must first be passed through the stricture. The canula must, of course, have the size and curvature of a Bowman's probe. It is not strange that in such cases the epiphora continues, although the probe passes easily.

But even when both probes and injections pass easily, the epiphora may continue in consequence of the distention and relaxation of the lachrymal sac, since, probably, an elastic tension of its walls is necessary to cause a normal discharge of the tears. One often sees, in persons with a loose texture of the entire lids, an already existing slight epiphora increase under the influence of a mild conjunctivitis, in spite of the permeability of the nasal duct. In such cases less is accomplished by continuous probing than by the local treatment of the conjunctiva and mucous membrane of the sac. In a series of similar cases Alfr. Graefe† has shown the cause of the epiphora to be a hypertrophy of the lachrymal caruncle, and by its extirpation he removed the difficulty. Nasal polypi may cause epiphora in a similar manner.

While the strictures are being probed, attention is to be di-

---

\* Henle, *Anatomie*, B. ii. pag. 712. Comp. R. Maier, *Ueber den Bau der Thränenorgane*, pag. 20, Freiburg, 1869.

† *Klinische Monatsblätter f. Augenheilk.*, 1868, pag. 223.



rected at the same time to the secondary inflammatory processes caused by them. Chronic conjunctivitis and blepharitis are here first to be mentioned. The first requires the use of a strong astringent solution of nitrate of silver (1 or 2 per cent.), or of sulphate of zinc (2 or 3 per cent.), which is to be pencilled on the lids, and then immediately washed away with water. To cure the blepharitis, which is maintained by the presence of small ulcers on the edges of the lids, it is necessary in the first place carefully to remove the crusts which cover these ulcers, and then pencil them with some solution which will cause a slight eschar; for instance, nitrate of silver (3 per cent.) or acetate of lead, or a concentrated solution of sulphate of copper, or, finally, a salve of precipitate of mercury, 1 to 2 per cent., in ung. glycerini.

More important still is the treatment of the mucous membrane of the lachrymal sac, when that throws off a blennorrhœal secretion; indeed, in many cases, upon this depends the relief of the principal annoyances of which the patients complain. In mild cases it often suffices to press out the secretion and inject an astringent solution of  $\frac{1}{4}$  per cent. nitrate of silver, or sulphate of copper or of zinc, etc. The injections must always be very carefully made, since, if the mucous membrane of the canal be wounded, the fluid may be driven into the subcutaneous tissue of the lids, and even into the orbit, and there excite violent inflammation. If the secretion be copious and the sac greatly distended, it is best to make an incision into it, and in this way open a direct passage into the mucous membrane. The opening must be made large enough to allow the introduction of a pencil of pure or mitigated ( $\frac{1}{2}$  or  $\frac{1}{3}$  nitrate of potassium) nitrate of silver, with which to cauterize the interior of the sac. To neutralize the superfluous nitrate of silver, a solution of common salt is to be applied with a camel-hair pencil. The wound is to be kept open by a piece of catgut so long as it is wished to continue the cauterization of the mucous membrane.

When the sac is very greatly distended, Bowman has recommended to excise a portion of its anterior wall.

The undeniable fact that strictures of the lachrymal duct, after satisfactory treatment by probing, often return, has led to many attempts to modify that method.

In the first place it was undertaken by using the thickest pos-



sible probes, or expansible laminaria bougies, to dilate the stricture as far as the diameter of the lachrymal duct would allow. We have already stated the objections to this practice.

In order to avoid the daily introduction of the probe, Walton\* proposed to use a style which could be allowed to remain a longer time. Williams† also favors this method. So soon as Bowman's probe can be allowed to remain inserted for say half an hour without annoyance, it may generally be assumed that a style made for the purpose can be worn for a still longer time. This practice commends itself for such patients as are unable to present themselves for treatment by probing as often as is desirable.

Finally, Jaesche‡ and Stilling§ have proposed to cut through the strictures. According to both their methods the cutting instrument is to be introduced through one of the canaliculi, which can hardly be done without at the same time wounding its walls.

I have therefore preferred, in some cases which I have treated in this manner, to open the lachrymal sac, since a simple incision in its walls can always be made to heal, while the introduction of the instrument through the canaliculi causes injuries which may lead to their entire obliteration. After opening the sac, Weber's knife, either alone or upon a director, was passed through the stricture, which was incised in several different places by up-and-down cuts with the knife.

Whether strictures return less frequently after incision than after probing, remains yet to be determined.

The former much-employed practice of obliterating the lachrymal sac is not often indicated. It is called for only where an incurable blennorrhœa exists above an impermeable stricture of the canal. To do the operation, the wall of the sac is split as widely as possible, the wound still further enlarged by sponge tents, and the attempt made to destroy the mucous membrane by caustics or the actual cautery. Various caustics have been recommended, the concentrated mineral acids, chloride of zinc, etc. But the

\* British Medical Journal, 1863, April.

† Annales d'Oculistique, 9. sér., iii. pag. 86, and Arch. f. Augen- und Ohrenheilkunde von Knapp und Moos, B. i. pag. 78.

‡ Arch. f. Ophth., 1864, B. x. 2, pag. 166.

§ Ueber die Heilung der Verengerung der Thränenwege mittelst der inneren Incision, Cassel, 1868.



best method is the use of nitrate of silver, to be neutralized immediately after with a solution of common salt. By this method one can be certain that the cauterization is localized and is not infiltrated in the adjoining tissues. Energetic cauterizations must be made daily for some time in order gradually to destroy the mucous membrane. Care must be taken, too, that the concentrated solution of silver which forms in the sac during the cauterization does not run through the canaliculi into the conjunctival sac.

If one wish to employ the actual cautery for the obliteration of the lachrymal sac, the galvano-caustic is the best.

An annoying epiphora does not always remain after obliteration of the sac, just as strictures may exist without giving rise to any great inconvenience, provided they do not cause a blennorrhœal inflammation of the mucous membrane.

If rupture of the lachrymal sac occur in chronic dacryocystitis, the opening generally closes under proper treatment, or perhaps spontaneously. Often, however, it shows no tendency to heal; it contracts only slightly, the edges become callous, and a lachrymal fistula is established, out of which pus and tears flow. Especially is this the case when from syphilis, scrofula, or any other cause there is caries of the bony walls of the lachrymal canal. But fistulas of the lachrymal sac occur also without any disease of the bone. In many cases the opening becomes exceedingly small, and if at the same time no blennorrhœa of the sac exist, or very little, the annoyance is very slight.

The first object of treatment is to re-establish the normal passage through the nasal duct. The presence of bone disease demands, besides the local treatment of the diseased bone, of the mucous membrane, and of the strictures, treatment of the existing dyscrasia. Especially is the use of iodide of potassium often indicated in these cases.

If there be no bone disease, it is well, in addition to the probing, to touch the walls of the fistula with nitrate of silver. If the duct below the fistula be obliterated, and if there be considerable blennorrhœa of the mucous membrane, the question of the cauterization of the sac arises. Capillary fistulas are best left untouched, since when there is absolute impermeability of the lachrymal canal the closure of the fistula will probably not improve the condition.

Spontaneous obliteration of the lachrymal sac occurs quite rarely



in consequence of dacryocystitis. Sometimes when this occurs the fossa lacrymalis may be seen externally.

Polypi of the lachrymal sac occur simultaneously with the blennorrhœa of its mucous membrane. Their presence may, in many cases, be recognized by the fact that after pressing out the blennorrhœal secretion through the puncta, the sac is not emptied, but still offers an elastic resistance. There is no difficulty in extirpating these polypi after opening the sac. But such growths sometimes occur also in the lower part of the nasal duct. I have at least once during an anatomical examination found a pediculated villous growth of the mucous membrane in the lower third of the duct.\* In such cases both the diagnosis and the treatment would be very difficult.

---

\* Verhandlungen der medicinisch-physikalischen Gesellschaft zu Würzburg, B. 10, pag. xii.



## DISEASES OF THE EYELIDS.

---

### INFLAMMATION OF THE EDGE OF THE LIDS. BLEPHARITIS.

MANY individuals, especially those with a scrofulous disposition and tender skin, are affected with a slight redness and exfoliation along the outer angle of the lids.

The skin on those parts is generally in an irritated condition, which upon the slightest cause assumes an inflammatory character, often connected with conjunctivitis. Protection from injurious influences, and, where there is great irritability, the use of mild astringents, for instance, lead-water, is the proper treatment.

Severe inflammation of the edge of the lids may occur as a consequence of other diseases which have caused long-continued hyperæmia of the conjunctiva and abnormal retention of the lachrymal secretions, such, for instance, as chronic inflammation of the conjunctiva or cornea, or stricture of the nasal duct. Blepharitis, however, occurs just as often as an idiopathic disease, and gives rise during its course to secondary diseases of other parts of the eye.

The mildest form of blepharitis is that in which the inflammation occurs at circumscribed points along the edge of the lids while the intervening spaces remain normal.

At one or more places on the edge of the lids occur circumscribed redness and swelling. The cilia are glued together by scabs, whose removal leaves raw bleeding places, or deep, crater-like ulcers between the cilia. If the eyes, as when sleeping, are kept for a long time closed, the edges of the lids become glued together by the dried secretions.

These ulcers are best cured by carefully removing the scabs and causing an eschar upon the raw surfaces by the application of some metallic caustic. Pencillings with acetate of lead or nitrate of silver in 2 or 3 per cent. solution, or with a concentrated solution of sulphate of copper, or finally with the red oxide of mercury,



are the best applications. In many cases, especially where considerable thickness is associated with moderate excoriation of the edges of the lids, I have seen very good results from the penciling with tincture of iodine along the line of the cilia.

If the local treatment must be intrusted to the patient himself, prescribe a wash of acetate of lead, 10 drops liq. plumb. acet. to a teacup of water, and a salve of nitrate of silver, 1 to 2 per cent., or the red oxide or ammonio-chloride of mercury, 1 to 2 per cent., generally in combination with the oxide of zinc and the addition of a solution of lead, for instance :

R White precipitate of mercury,	0.2-0.3 =	about gr. iii-ivss ;
Oxide of zinc,	0.3-0.5 =	" " ivss-viiss ;
Glycerine ointment,	10.0 =	" 3 iiss ;
Sol. acetate of lead,	gtt. 4-6.	

These applications are none of them of any use until the dried secretions about the cilia have been removed and the ulcers exposed. The crusts generally cling very tenaciously, so that their removal is painful, and is gladly neglected by the patients. The process is made easier by previously softening them with oil or warm cataplasms. When the crusts are removed, the salve must be well rubbed upon the ulcers so as to cause a burning sensation.

Another form of blepharitis is that in which the inflammation, ulceration, suppuration, formation of crusts, and thickening of the edges extend along the whole length of the lids. After long continuance of the disease the cilia become straggling and irregular. They are either entirely destroyed by the deep ulcers at their bases or they are replaced by ill-developed after-growths.

The most dangerous and obstinate form of blepharitis is that in which there is at the same time a wide-spread disease of the integument of the lids. Besides the excoriations on the edges of the lids, others occur, first near, then farther from the edges ; they are covered with flat crusts, which upon removal expose raw, bleeding surfaces. The skin loses its softness and elasticity, and becomes shrunken. The first consequence of this is an ectropion, which generally very early turns the puncta lacrymalia outward and interferes with their function. Later, the edge of the lid becomes more and more rounded off ; the inner angle, as well as the intermarginal part, gradually disappears ; no trace can be seen of the openings of the Meibomian tarsal glands, or the puncta



lacrymalia; the position of the outer angle of the lid can be recognized only with difficulty by the few remaining cilia, or rather by the poorly developed, pale hairs which have taken the place of them.

These changes stand in such close causal relations that the disease runs in a vicious circle. The lachrymal secretion is increased by the inflammatory irritation; the absence of the normal lubrication of the lids by the secretion of the Meibomian tarsal glands, and the impossibility of conducting away the tears through the canaliculi, cause them to drip continually over the edge of the lid. The irritation and shrinking of the skin and the already existing ectropion are thereby increased; the everted conjunctiva causes the lids to appear as if bordered by a red seam; they close only imperfectly upon the eyeball; and finally, the combined effect of the shortening of the skin of the lids and of the ectropion is that the palpebral fissure can no longer be sufficiently closed. The eye is deprived of the greater part of its natural protection, and, as a consequence, corneal ulcers are very apt to appear, especially on its lower margin.

The disease does not always proceed so far as this, but at an even earlier stage it has passed the possibility of recovery. If ectropion exist, if the angle of the lids be rounded down, and if the openings of the tarsal glands and the puncta lacrymalia be obliterated, a *restitutio ad integrum* is not possible. Proper treatment in the early stages is therefore not to be neglected. Especially is the tear-passage to be kept open, since a perpetual dripping of the tears has a most hurtful influence. Whenever the punctum lacrymale is drawn outward from its normal position, the canaliculus is to be split and kept open. It is well also to ascertain the permeability of the nasal duct. If ectropion develop, its effect should be resisted by proper operative treatment. Snellen's ectropion stitch, to be described later, is often a very suitable method. Among the above-named external applications, the white precipitate of mercury, alone or in combination with the oxide of zinc, is especially recommended. Quite celebrated is its combination with tar:

R White precipitate of mercury,	0.5-0.75	= about gr.	$7\frac{1}{2}$ - $11\frac{3}{4}$ ;
Liquid tar,	2.0	=	" 3 $\frac{1}{2}$ ;
Simple ointment,	7.5	=	" 3 2.



Somewhat rarely, lice are found upon the cilia and eyebrows. They cause chronic inflammation and great itching. They are so small as to be easily overlooked, if not examined with a lens. The nits fastened on the cilia cause them to appear as if sprinkled with a black powder.\* The evil is removed by cleanliness and the use of mercurial ointment, or pencilling with a  $\frac{1}{2}$  per cent. solution of corrosive sublimate, being careful to allow none to get into the eye.

There often develop on the skin of the lids, either with or without other simultaneous conjunctival affections, hyaline cysts, which are very small, at most not larger than a poppy-seed, and which cause sensitiveness of the eye. It is sufficient, simply to break them with the finger-nail, or some other instrument.

The hordeolum or styne occurs in the form of a small, inflamed, tender swelling on the edge of the lid. It increases in size for several days, when resolution or, more frequently, suppuration occurs. In the latter case the tumor points and breaks at the outer edge of the lid. Since the place of the rupture is always near the cilia, the hordeolum is generally regarded as an inflammation of the hair follicles.

In many cases the hordeolum is associated with great swelling of the lids, and, when near the outer canthus, with swelling and reddening of both lids. The swelling of the lids may be so great that, at first glance, the existence of blennorrhœal conjunctivitis may suggest itself. Such a diagnostic error may, however, be easily avoided. Aside from the fact that the signs of blennorrhœa are absent from the conjunctiva, the swelling of the lids is always localized, being greatest near the hordeolum. Moreover, the circumscribed inflammatory tumor may be easily recognized by the touch.

Frequently several hordeola follow rapidly one after the other, or they develop with pauses of some weeks between, just as is the case with furuncles.

The treatment may be limited to the use of warm fomentations. The spontaneous rupture occurs generally without any difficulty, but if it be unduly delayed the process may be hastened by puncture. Where there is a persistent tendency to the development of

---

\* Mackenzie, Practical Treatise, London, 1854, pag. 228.



hordeola, especially in scrofulous individuals, the ordinary saline remedies, salt-baths, etc., are recommended.

Anomalies of the Meibomian tarsal glands are generally due to retention of their secretion. It collects often in the excretory ducts, and forms small round prominences upon the tarsal part of the conjunctiva, near the edge of the lid; they cause to the patient a sensation of pressure. For their relief it is sufficient to split the little tumors in the direction of the excretory ducts: the contents, a mass resembling stearine, are then easily pressed out.

Oftener, especially in old people, the retention occurs in the deeper parts of the glands. At their posterior ends they become distended by hardened secretions, forming small yellow tumors above the surface of the conjunctiva. In some cases deposits of lime, forming stony concretions, are found in the retained glandular secretions (*lithiasis conjunctivæ*). If this condition cause local irritation of the conjunctiva, chronic conjunctivitis, or other annoyances, the glands may be opened with a cataract-needle and the contents evacuated.

Chalazion is the name given to a circumscribed tumor in the tarsal cartilage. There develops generally without any annoyances a swelling in the cartilage of the lids. In some cases it remains for a long time small and stationary, in others it grows gradually and forms a tumor, projecting on the outer surface of the lid. Since it develops in the tarsus itself, the tumor can be moved only with the cartilage, and not upon it. If the eyelid be everted, the corresponding part of the tarsus appears slightly yellow, and often somewhat elevated.

The contents of a chalazion are at first a soft, light-gray mass, consisting of round or oval, slightly granular cells of various sizes. Fine blood-vessels ramify within the tumor. Large chalazia, which have existed a long time, often have light-yellow fluid contents.

The swelling may vary in size from that of a pea to that of a hazel-nut. Its spontaneous rupture occurs but seldom, but when it does, is always on the conjunctival surface of the tarsus. Granulations may grow out from the interior of the tumor, and, becoming flattened by pressure against the eyeball, spread out on all sides about the place of rupture.

In the beginning, and while the chalazia are still small, their



resolution may often be brought about by external applications. Iodide of potassium, in the form either of an ointment or of a strong solution in glycerine, is the best to employ for this purpose.

If the attempt to cause resolution does not succeed, it is advisable to leave very small hard chalazia to themselves; but when the tumors attain such a size that they become noticeable and may be regarded as a deformity, they should be removed by operation. The lid is to be everted, and the tumor split upon the conjunctival surface in a direction perpendicular to the edge of the lid. The contents are then evacuated, partly by pressure on the outer surface of the lid, partly by a Daviel spoon, or some such suitable instrument introduced into the cavity of the tumor.

Subsequently the cavity may be cauterized with nitrate of silver, to be followed by careful neutralization by a solution of salt. Still, in most cases this cauterization appears unnecessary. The external prominence is not immediately removed by the incision, since the tough tissue of the tarsus only gradually resumes its normal shape. The final result of this method is a return to the normal relations, and I have never found it necessary to remove a chalazion from the outer surface of the lid.

If after spontaneous rupture of the chalazion granulations have formed in the cavity of the tumor, they are to be clipped off with the shears and the wall of the cavity cauterized with nitrate of silver.

Occasionally there occur circumscribed acute inflammations in the tarsal cartilages, which, proceeding probably from the Meibomian glands, cause the same symptoms as a hordeolum. The difference between the two is, that these tumors are farther from the edge of the lid than the hordeolum, and that when suppuration occurs they break not at the outer edge of the lid, but always on the inner surface. The treatment at the beginning is by warm poultices: still, it is not advisable to wait for their spontaneous rupture, which is generally delayed by the resistance of the tarsus. So soon as the tumor is perceptible above the general conjunctival surface of the lid and begins to grow yellow, it should be split through the conjunctiva in a direction perpendicular to the edge of the lid.



## HERPES ZOSTER FRONTALIS SIVE OPHTHALMICUS.

Herpes zoster in the region of the ramifications of the first branch of the fifth nerve is a rather rare affection. The herpetic eruption is most frequent in the region of the nervus frontalis; it may, however, correspond with the distribution of the nervus naso-ciliaris upon the nose, even to its extremity. Exceptionally, the eruption occurs in the region of the second branch of the fifth nerve. Hutchinson\* states that the participation of the eye in the process is most frequent when the presence of vesicles along the side of the nose shows that the naso-ciliary branch is affected, explaining this tendency by the fact that the long root of the ciliary ganglion and the long ciliary nerves spring from the naso-ciliary branch of the fifth pair. Bowman,† however, could not satisfy himself of this coincidence, and Horner‡ describes a case of zoster with iritis, in which the eruption upon the side of the nose entirely failed.

The affection begins generally with severe neuralgia of the fifth nerve. After some days there appear swelling and redness of the skin and an eruption of groups of herpetic vesicles, which gradually dry and become converted into hard crusts, which generally leave deep, permanent scars when they fall off. Almost always the part of the skin affected remains a long time anæsthetic, but it may be the seat of severe neuralgia. This subsequent neuralgia appears to be particularly obstinate in old people, and it may be so severe as seriously to reduce their strength. Joy Jeffries relates a case in which a patient 80 years of age died in this way in consequence of herpes ophthalmicus. Horner observed, too, a remarkable elevation of temperature upon the affected half of the forehead, which continued for a month and a half after its first appearance.§

The affection of the eyes may precede the eruption on the skin, but generally follows some days after it. According to Horner, the corneal affection always begins with the appearance of a series

---

\* Ophthalmic Hospital Reports, 1866, vol. v. 3, pag. 214.

† Ibid., 1867, vol. vi. 1, pag. 3.

‡ Klin. Monatsbl. f. Augenheilk., 1868, pag. 371.

§ Ibid., 1871, pag. 321.



of transparent vesicles, grouped oftener upon the margin than at the centre of the cornea. These vesicles burst, leaving an irregular loss of substance, while the cornea becomes cloudy over a considerable extent of its surface. Simultaneously an anæsthesia over nearly the whole surface of the cornea is observable. Very interesting, too, is the simultaneous occurrence of marked diminution of the intraocular pressure, which, in the cases observed by Horner, disappeared only slowly and simultaneously with the recovery of the cornea and the return of a normal temperature on the side affected. Recovery from the corneal affection is generally slow, leaving opacities behind it. An iritis is often associated with the keratitis; still, it may occur independent of the corneal affection.

In severe cases irritability of the eyes may remain for months.

Paralysis of the oculo-motorius has been observed by Hutchinson\* as a rare complication of herpes frontalis. I also have observed one case in which mydriasis and paresis of accommodation remained in the affected eye.

In reference to diagnosis, it is likely to be confounded with erysipelas. The pains which precede the eruption, and the limitation of the disease to one-half of the face, are at the beginning the essential points to be observed in the diagnosis. Herpes frontalis never extends beyond the median line, while erysipelas observes no such law. The swelling of the skin is less than in erysipelas, and in many cases is quite slight; the herpetic vesicles are smaller, more sharply circumscribed, and more numerous than are those in erysipelas. In the further course of the disease the anæsthesia of the parts affected and the formation of scars are characteristic of herpes.

The treatment of the affection of the eyes consists in rest and in the use of atropine. On account of the severe subsequent neuralgia, Bowman has performed subcutaneous neurotomy in several cases, partly with temporary and partly with permanent good results.

According to Horner, an eruption of transparent vesicles grouped upon the cornea occurs in connection with herpes labialis

---

\* Ophthalmic Hospital Reports, vol. vi. 3, pag. 183.



following pneumonia or severe catarrhal affections of the respiratory organs.

Eczema of the palpebral skin occurs quite frequently in children in connection with eczema of the face. The hyperæmia generally extends from the skin through the entire thickness of the lid to the conjunctiva, there causing catarrhal, blennorrhœal, or even diphtheritic inflammation, by which the swelling of the lids is still further increased. Keratitis phlyctænulosa, and its consequences, ulceration or pannus of the cornea, are frequent complications.

Long-continued eczema of the lids, especially with co-existing conjunctival swelling and blepharitis, favors the occurrence of ectropion by the shrinking of the skin.

Erysipelas of the eyelids in cases of facial erysipelas is not infrequently seen. If the inflammation be principally upon the eyelids, one must be careful in the diagnosis to distinguish it from conjunctival blennorrhœa and from acute dacryocystitis.

The inflammation often extends from the eyelids into the orbital connective tissue, and by involving the optic nerve may cause blindness. Severe inflammations may go on to suppuration of the subcutaneous connective tissue of the lids and wide-spread destruction of their skin. If there be reason to fear such results, incisions should be made in the direction of the fibres of the orbicularis.

After erysipelas there often remains a pale, painless, œdematous swelling of the lids, sometimes so great that they can scarcely be opened. In such cases the use of iodide of potassium, either as a salve or in a strong solution in glycerine applied with a pencil, or pure tincture of iodine, is indicated.

It is only seldom in the course of erysipelas that extensive gangrene occurs upon the lids or within the orbit.

Exceptionally, erysipelas of the lids occurs, of an exceedingly severe and gangrenous character from the very first. Cases of this sort may prove quickly fatal, and are generally regarded as the consequence of an infection with animal poison. Malignant pustule upon the eyelid has been observed.

Abscesses of the eyelids occur oftener in children than in adults. They are generally in the upper lid, and cause there a noticeable swelling. The treatment is by warm poultices and opening of



the abscesses so soon as fluctuation is felt or pus can be seen through the skin.

Syphilitic ulcers occur on the skin of the eyelids, and may be either primary or secondary. They generally show a great tendency to extend upon the surface, and often penetrate also to a considerable depth. If they be situated near the edge of the lid they are very apt to involve the conjunctiva. This appears to occur oftenest near the inner canthus. But syphilitic ulcers occur on other parts of the conjunctiva, such as the tarsus and fornix, and persist with great obstinacy.

The treatment demands local cauterization with nitrate of silver or the application of the red oxide of mercury to the outer surface of the lid, and in addition to this suitable constitutional treatment.

Lupus of the lids generally extends from the face; it may, however, appear primarily on the lids. When it involves the conjunctiva it causes it to shrink. Symblepharon, corneal opacities, and absolute blindness follow.

Circumscribed isolated lupus ulcers also occur upon the ocular conjunctiva.

Epithelioma often develops upon the edges of the lids, and in time destroys them. Its earliest possible extirpation, combined when practicable with a blepharoplastic operation by which to replace the lost tissue, is the proper treatment.

Telangiectasia of the lids is not uncommon, and may be situated either in the skin alone or in the subcutaneous connective tissue, or in both at the same time. These tumors often extend deep into the orbit.

The treatment is not essentially different from that of telangiectasia in other parts of the body. Superficial cauterization with fuming nitric acid, inoculation with vaccine virus, or puncture with the hot iron, or, still better, the galvano-caustic puncture, is suitable treatment for most cases. The attempt must always be made to cause as little loss of skin as possible.

Congenital cysts of the eyelids are generally situated on the temporal side near the eyebrow. They contain a serous, often atheromatous, fluid, and often, too, hairs, which grow from the inner walls of the cyst. They often lie beneath the orbicularis, may penetrate to a considerable depth, and may be connected with the periosteum.



Their extirpation demands a free incision of the skin and a careful dissection of the external wall to its posterior part. If during the operation the cyst be wounded, it must nevertheless be carefully extirpated, since if any part be left behind it is apt to delay the healing of the wound or cause it to break open anew.

Abnormal secretion of the skin of the eyelids occurs as a local hypersecretion of the sweat glands (ephidrosis). It causes a sensation of itching and biting upon the lids, a high degree of irritation of the conjunctiva and of the edges of the lids, and excoriation of the skin.

Seborrhœa is an abnormal secretion from the sebaceous glands of the lids.

Chromhidrosis is the name given to an abnormal, generally dark-blue or black discoloration of certain portions of the eyelids. It appears suddenly, and may easily be washed off with water or glycerine, but appears again in a wholly irregular manner. Respecting the nature of this affection nothing is absolutely known, but it is certain that such cases are not all simulated.

Xanthelasma or vitiligoidea are names given to a peculiar disease of the skin which, from anatomical investigations,\* appears to be due to the fact that the connective-tissue cells in the parts affected are filled with yellow fat. It appears as dark, straw-colored spots slightly elevated above the general surface of the skin, which develop very slowly and are almost always situated on the eyelids. Similar spots have in rare cases been observed upon the ears, the elbows, and the hands.

#### BLEPHAROSPASM.

Spasm of the orbicularis occurs in very different forms. The mildest consists in short twitchings of some few fibres of the orbicularis, generally in the lower lid, near the outer canthus, which last only a few minutes, are due to no known cause, and disappear again, causing only a temporary uncomfortable sensation.

Generally only those cases are called blepharospasm in which the palpebral fissure is absolutely closed. There may be but a

---

\* Von Baerensprung, *Deutsche Klinik*, 1855, pag. 17; Waldeyer, *Virchow's Arch.*, 1871, pag. 318; Virchow, *Arch. f. Path. Anat.*, 1871, pag. 504; Manz, *Klin. Monatsbl. f. Augenheilk.*, 1871, pag. 251.



single spasm or they may be repeated. The eyelids are suddenly closed during some seconds or minutes by spasmodic twitchings and then opened again. The spasms occur without any apparent cause or warning, in different cases with different degrees of severity and frequency, often with such short intervals as to make it dangerous for the patients to walk upon frequented streets. The usual complications are hyperæmia of the connective tissue, dilatation of the veins of the lids, and more or less photophobia.

Besides the cases of spasmodic twitching of the orbicularis, there is another class of cases in which there is a tonic spasmodic closure of the eye. For this very reason the patients are exceedingly sensitive to light, generally carry the head bent forward, and are not able, with the greatest effort, to open their eyes. They resist also, with all their power, the forcible opening of the lids, on account of the painful dazzling sensation thereby caused, while the eye itself rolls spasmodically upward and is hidden under the upper lid.

Scrofulous blepharospasm is the most frequent of these forms. Keratitis, in scrofulous individuals, is generally connected with a much more irritable condition than in those otherwise healthy. So long, however, as an acute inflammatory process is evident in the cornea, the closure of the lids, the contraction of the pupil, and the increased flow of tears will be regarded as reflex symptoms. But if the inflammatory process be ended, and if the lids are still spasmodically closed, the blepharospasm loses the character of a simple reflex affection.

The constitutional nature both of the keratitis and of the scrofulous blepharospasm is shown by the fact that, in the great majority of cases, they occur bilaterally. It is advisable to resort to the chloroform narcosis in order to make a more thorough examination of the cornea. The lids can be then easily separated, and it is only in this way that the eye can be seen in its natural condition, while if, without the anæsthetic, the lids be forcibly opened, the pain and dazzling cause such injection of the conjunctiva, and under certain circumstances of the cornea also, such a flow of tears, etc., that it is impossible to decide whether inflammation exist or not. As regards treatment, this question is very important. If in scrofulous blepharospasm there be no inflammation of the cornea, the ordinary local applications employed in



keratitis (atropine, ointment of suboxide of mercury, calomel, etc.) are not indicated, on the contrary, are hurtful.

Often the corneal affection is healed, or nearly so, but there is an inflammatory swelling and secretion of the conjunctiva, by which the irritability is maintained. In such cases the blepharospasm often disappears under local treatment of the conjunctiva, best done with a 1 or 2 per cent. solution of nitrate of silver.

A proper constitutional treatment is, however, generally of the greatest importance. Salt-baths are excellent, and when, as is frequently the case, the eyelids or the entire face appear abnormally warm, washing or dipping the face in ice-water gives relief.

Just as reflex symptoms which have been excited by keratitis may continue after the inflammation has run its course, so, too, can blepharospasm be caused by foreign bodies which wound the surface of the cornea. In such cases a spasmodic closure of the lids often continues long after the foreign body has been removed. In the course of time the spasm may pass over from the eye first injured to the other one.

All these cases are due to a primary irritation of the sensitive nerves of the cornea or conjunctiva, but the reflex spasm lasts much longer than the primary irritation.

Irritation of other branches of the fifth nerve, especially in the region of the supra-orbitalis and dental nerves, is mentioned as a cause of blepharospasm. Compression of the trunk of the nerve affected, especially where it lies against a bone, interrupts the reflex current, and for the moment relieves the spasm.

A very peculiar form of blepharospasm has been pointed out by Donders\* as "sympathetic neurosis." After one eye had been lost by irido-cyclitis, following an injury, blepharospasm appeared in the other, otherwise healthy eye. It was persistent, closed the lids absolutely, and disappeared immediately after the extirpation of the primarily diseased eye. There was in that case evidently a reflex spasm, whose source was in the eye first injured.

Blepharospasm may appear in connection with spasms over the entire region of the facialis, or, after having continued a long time, it may cause such spasms. Other nervous tracts may become gradually involved.

---

\* Klin. Monatsbl., 1863, pag. 448.



Mackenzie\* mentions unilateral blepharospasm after injuries of the head, and warns against confounding it with paralysis of the levator palpebræ superioris. The twitching at the angle of the lids, and the resistance when the attempt is made to lift the lids with the fingers, confirm the diagnosis.

Finally, hysteria should be named as a cause of blepharospasm.

The treatment of blepharospasm is generally not very satisfactory. The usual means employed are the cold douche, cold face-baths, and counter-irritation on the forehead, the temporal region, or the mastoid process. Treatment is most successful in those cases of reflex spasm in which it is possible to discover the place of the primary irritation. In such cases Von Graefe† recommended subcutaneous injections of morphine. He also practised the division of the nervous trunk which conducts the reflex current, as first proposed by Romberg. Good results may be expected from this operation in those cases in which the spasm can be interrupted by pressure on the trunk of the nerve. The supra-orbital nerve presents oftenest the indications for this operation.

It is, however, in this connection to be remembered that in many cases the spasm may be interrupted by pressure upon quite distant points, as, for instance, in a case observed by Charles Bell, by pressure upon the cartilages of the ribs in the left hypochondriac region.‡ In hysterical patients, also, one often sees the spasm temporarily interrupted by pressure on any indifferent part of the body.

#### PTOSIS.

The inability to raise the upper lid may be due to imperfect action of the levator palpebræ muscle, for instance, after injuries. It may be due to paralysis of the oculo-motorius, or it may be that, in consequence of pathological changes, the lid has become too heavy, as may be the case in chronic conjunctival inflammations, such as trachoma, blennorrhœa, etc., or in phlegmonous inflammation. Finally, abnormal adhesions may hinder the raising of the lids.

---

\* Practical Treatise on the Diseases of the Eye, London, 1854, pag. 181.

† Arch. f. Ophth., B. ix. 2, pag. 73, und B. iv. 2, pag. 184.

‡ Mackenzie, l. c., pag. 184.



In many individuals there is such a superfluity of skin on the upper lid that it forms a fold, which may hang even below the edge of the lid. This annoyance may be relieved by excision of the superfluous fold parallel to the course of the orbicularis fibres. The same operative method is applicable in cases where there is similar relaxation and lengthening of the skin, caused by repeated facial erysipelas or local infiltration of the lids.

To be distinguished from the class of cases just described is another, in which, as, for instance, in partial congenital ptosis, there is neither a mechanical hindrance to motion nor an elongation of the lid. If, in these cases, the patient be directed to look downward, the difference between the two lids disappears, and accordingly an incision of the skin would cause a shortening of the upper lid, would make the closure of the eye difficult, and, upon looking downward, would cause the upper lid to fall behind the other. Von Graefe, therefore, recommended in such cases to excise not the skin, but the orbicularis of the upper lid for a breadth of from 7 to 10 mm., in order that there may be less resistance to be overcome by the weakened levator. The skin of the lid is incised parallel to, and about 5 mm. from, the edge, and is dissected up on both sides of the incision. The orbicularis is then raised with the forceps, and a piece of the proper size excised. The wound is closed in such a manner that the upper and lower remaining portions of the orbicularis are included in the sutures.\*

A peculiar form of ptosis sometimes occurs in connection with contraction of the pupil. In a case described by Horner,† a simultaneously occurring turgescence of the vessels on the affected half of the face was observed, which confirmed the suspicion that the primary difficulty was a paresis of the cervical filament of the sympathetic nerve. It is well known that irritation of this nerve causes dilatation of the pupil and elevation of the upper lid, due to contraction of the smooth muscular fibres in it.

Paresis of the orbicularis generally occurs as one of the symptoms of facial paresis. The slightest degree of weakness in the action of the orbicularis is manifest by the dripping of the tears.

---

\* Arch. f. Ophth., B. ix. 2, pag. 57.

† Klin. Monatsbl. f. Augenheilk., 1869, pag. 193.



As the paresis increases, the lids can be only imperfectly closed. In extreme cases the upper lid is drawn up by the levator, while the under one sinks of its own weight, its edge turned away from the eye, so that finally there may be absolute ectropion.

The continual gaping of the lids (*lagophthalmus*) exposes the eye to all those injurious influences against which it should be protected by the movements of the lids. Under these circumstances, therefore, inflammation of the conjunctiva and cornea develops very easily.

Relaxation of the orbicularis, independent of facial paresis, often occurs in old people, and causes likewise dripping of the tears, chronic conjunctivitis, and finally ectropion of the under lid.

#### ECTROPION.

In acute blennorrhœa, especially in new-born infants, it often happens that the lids are everted accidentally, or by the strong contractions of the orbicularis, and that they cannot be replaced by the persons present. The swollen mucous membrane is strangulated by that portion of the orbicularis running along the edge of the lid, and becomes in consequence very œdematous. Generally, however, the everted lids may be replaced without difficulty, and held in position by a pressure-bandage. If the swelling be so great that this cannot be done, the conjunctiva should be slightly scarified. As soon as the reposition of the lids seems permanent, the local treatment of the blennorrhœa is to be begun.

Ectropion occurs oftener associated with chronic blennorrhœa of the conjunctiva, by which the tarsus gradually becomes softened and the lid covering it becomes not only thicker but broader and longer. So, too, the fibres of the orbicularis lying along the edge of the lid participate in the relaxation of the tissues, so that a somewhat stronger action of the other part of the muscle from an accidental irritation or from photophobia, causes an eversion of the edges of the lid. This occurs more easily, and therefore oftener, on the under than on the upper lid. This form has been called sarcomatous ectropion, since the everted part of the conjunctiva, which is continually exposed to the air and all the injurious substances floating in it, becomes much thickened, and appears like a cushion-shaped swelling. In such a condition the inner edge of the lid is generally obliterated, and the outer one is indicated only

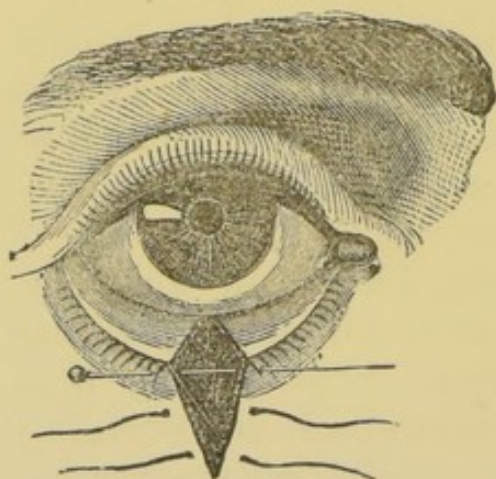


by a row of poorly developed cilia, while the posterior angle of the swelling, where it lies against the eyeball, is separated by a distinct line from the non-everted part of the conjunctiva.

In recent cases it is often sufficient, as in acute blennorrhœa, to make the reposition and apply the pressure-bandage. If the ectropion has developed gradually, and has already existed some time, the reposition of the lid is generally quite easy, but it quickly falls back into its abnormal position. Still, in many of these cases a cure may be effected by proper local treatment of the conjunctiva and by the pressure-bandage.

If there be perceptible elongation of the cartilage and lid, its normal tension must be restored by operation. According to

FIG. 35.



Adams, this is done by the excision of a wedge-shaped piece from the entire thickness of the lid. The breadth of the piece to be excised from the edge of the lid is determined by measuring its length from the caruncle to the external canthus by means of a lead wire adapted to its surface and then comparing this with the normal lid. Two incisions are now made with the knife through the skin, as shown in Fig. 35.

Their distance from each other at the edge of the lid is determined by the width of the piece necessary to be excised; they converge as they descend on the cheek to a point about 10 mm. below. The piece to be excised is then grasped by the forceps, one blade being placed on the skin, the other on the conjunctiva. One blade of the straight scissors is then placed in the wound and the other blade in the conjunctival sac, and the tissues included by them are cut through first on one side of the forceps and then on the other. Thus there is cut from the conjunctiva also a triangular piece, whose apex extends beyond the thickened portion, nearly back to the fornix. In order accurately to unite the edges of the wound, a straight pin is thrust through both of them close to the margin of the lid and just in front of the cartilage. The edges are then brought in apposition, and held there by a thread, wound like a



figure 8 about the two ends of the pin. The lower part of the cutaneous wound is united with sutures.

That place is chosen for the operation at which the ectropion is greatest; but if it be uniform along the whole edge of the lid, the excision is made from the middle. If the ectropion be principally at the outer canthus, the operation should be tarsorrhaphy after Walther's method. A strip from 4 to 5 mm. long and 2 mm. broad is cut from both the upper and the lower lid, by incisions converging toward the temple, care being taken that the hair follicles belonging in the parts excised be entirely removed. The freshened edges of the lids are then united by the pin and figure 8 ligature, and thus the palpebral fissure is shortened, the lids made more tense and caused to press upon the eyeball.

Quite similar is that form of ectropion which occurs in consequence of atonia of the orbicularis muscle of the under lid (ectropium senile sive paralyticum). The operations above described or Dieffenbach's\* method may be resorted to in these cases. Dieffenbach made, somewhat above the lower margin of the orbit and parallel to it, an incision through the entire thickness of the lid, extending it by a probe-pointed knife through the conjunctiva. The conjunctiva palpebrarum was then drawn with a hook into the wound, and there so fastened with sutures that by means of it the edge of the lid was drawn upward.

A similar effect is obtained by the application of Snellen's ectropion stitch.† A silk thread is provided with two needles, which are thrust into the conjunctiva behind the edge of the lid at about 3 mm. from each other; they are thrust downward and brought out through the skin about 20 mm. below the edge of the lid. The loop of the thread lies upon the conjunctiva parallel to the edge of the lid, and the two ends of the thread run parallel to each other under the skin. A washer of soft glove leather is then placed on each end, and moderately strong tension being made, they are tied together. The washers prevent the threads from cutting into the skin, and facilitate their removal if excessive swelling render it necessary. In this way three stitches are in-

---

\* Staub, Dissert. de Blepharoplastice, Berlin, 1835; Casper's Wochenschr. für die gesammte Heilkunde, i.

† Jahresbericht der Utrechter Augenklinik, 1870, pag. 120.



sented, one of which it is well to place directly behind the punctum lacrymale. If the effect be at first too great, so as to cause entropion, the irritation so excited may be relieved by a few drops of olive oil and a pressure-bandage. After about three days the threads are removed, or when they cause no very great irritation they may be allowed to cut through of themselves.

Ectropion caused by shrinking of the skin of the lid following blepharitis, is generally curable. Von Graefe recommended in these cases that the rounded ulcerated part of the lid belonging to the conjunctiva be removed from one canthus to the other, thus separating the cutaneous and conjunctival surfaces of the lid for a distance of from 13 to 20 mm. In order now to change the position of the cutaneous surface, sutures are placed through the superficial fold of the skin near the edge of the lid, and these are connected with similar sutures passed through folds of more distant parts of the skin upon the forehead or cheek, according to the direction in which traction is to be made. If the parts be strongly drawn together by such sutures, a very considerable change in the position of the edge of the lid can be effected.

Ectropion caused by extensive and deep penetrating destruction of the skin of the lids, burns, lupus, etc., and continuing after complete healing of the ulceration, may often be relieved by the methods of operation above described; more frequently they require a blepharoplastic operation. The same is true of ectropion remaining after caries of the edge of the orbit, by which the fascia tarso-orbitalis is shortened and the skin of the lid becomes adherent to the bone.

#### ENTROPION.

The turning inward of the margin of the lid occurs in two different forms: the one is caused by the abnormal action of the orbicularis, the other by the shrinkage of the conjunctiva and tarsus.

The first form occurs only upon the lower lid, and generally only in old people, with relaxed and wrinkled skin. If the entire orbicularis be relaxed, and yet in such a way that the muscular fibres lying immediately along the edge of the lid are relatively the most tense, it may happen that every irritation which causes the patient to shut his eyes tightly causes also a rolling inward of



the margin of the lid. The entire margin of the lid is not always turned in, but frequently only the temporal half.

Foreign bodies, all kinds of inflammation of the eyes, and slight irritation after operations are the principal causes of this kind of entropion. The irritation which the cilia cause upon the conjunctiva and cornea contributes of course to perpetuate the irregular action of the orbicularis and to increase the entropion.

A slight traction upon the lid is generally sufficient to bring the margin into its normal position, but after winking a few times it again rolls inward. Since the causes of this form of entropion are generally transitory, the indication in most cases is to retain the lower lid in its normal position by a pressure-bandage until the cause of irritation (inflammation, etc.) is removed.

In many cases it is sufficient to paint the under lid with collodion, which, by shrinking, furnishes sufficient traction. Generally, however, the skin of the lid is so moist, from the continual flow of tears, that the collodion will not hold. In such cases an adhesive plaster bandage is more effective.

The skin of the lid is first made tense by strong traction, made at the same time both outward and inward; a strip of adhesive plaster about 1 cm. broad and from 4 to 10 cm. long is then fastened close under the edge of the lid and parallel to it, and so placed that being fastened first over the region of the lachrymal sac and then strongly stretched, its other end is fastened over the zygomatic process upon the skin, which has been slid inward toward the outer angle of the eye. The strip of adhesive plaster is then painted with collodion in order to make it impermeable to fluids, and still further to increase its tension. If the effect be not yet sufficient, a second strip of plaster may be placed upon the first in a direction nearly perpendicular to it, and fastened on the lower jaw so as to make traction downward.

If after the removal of the original irritation the entropion still persist, it then becomes necessary to oppose a continuous counter-tension to the abnormally increased tension of the marginal portion of the orbicularis. This is done by an operation. The operation for the subcutaneous formation of cicatricial tissue may be resorted to as follows:

A fold of skin in the middle of the lid and just below its edge is seized between the thumb and first finger. Through the base of

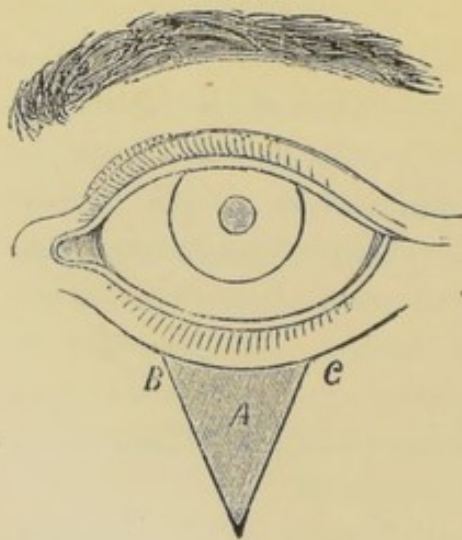


the fold, to the median side of the thumb and finger, a thread is passed by a curved needle thrust from below upward, and then again at a distance of from 2 to 4 mm. from above downward. A second thread is placed in the same manner on the temporal side of the finger. The ends of each suture separately are then brought together and tied. The fold is thus fixed and partially strangulated at two points about 1 cm. distant from each other. After from 48 to 60 hours the ligatures are removed.

The threads should not be too fine, lest they cut through too soon, and they should not be cut off too short, lest their removal should be made difficult by the swelling of the skin. After some days the swelling disappears, and gradually also the fold in the skin, and the cure is effected.\*

There are other methods intended to effect the same object, by shortening the skin of the lid either by the excision of an oval piece, or according to the following method by Von Graefe.† Three mm. under the edge of the lid, and parallel to it, an incision is made through the skin, and corresponding in length with the palpebral fissure. A triangular piece of skin,—Fig. 36,—*A*, is

FIG. 36.



then removed; the two lateral flaps, *B* and *C*, are loosened somewhat, and are united to each other by two or three sutures. The horizontal wound, which gapes but little, is left to cicatrize.

Entropion from the shrinkage of the conjunctiva and tarsal cartilage, occurs in the majority of cases as the result of trachoma. The entropion generally develops in such a manner that in the first place the inner edge of the lid disappears in consequence of the conjunctival shrinkage, and thereby the outer edge, together with the cilia, is turned toward the eyeball. In most cases there is, especially upon the upper lid, at the same time, a shrinkage and bowl-shaped curvature of the cartilage,

\* Arlt (nach Gaillard und Rau), *Augenheilkunde*, iii. pag. 368.

† *Arch. f. Ophth.*, B. x. 2, pag. 223.



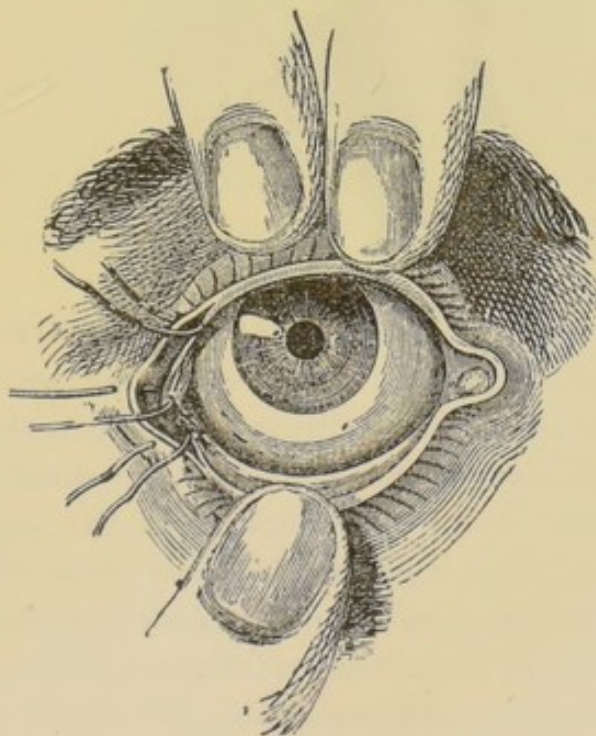
involving either a part or the whole of the margin of the lid. This causes the margin of the lid and the cilia to turn still more inward. The shrinkage occurring about the roots of the cilia interferes with their nutrition, and, moreover, gives a false direction to some of them, so that thin, pale, poorly developed hairs penetrate the margin of the lid in an abnormal direction, sprouting more toward the inner angle (trichiasis and distichiasis). This evil is still further increased by the fact that, in consequence of the deformity of the cartilage, the marginal fibres of the orbicularis rest upon a plane inclining downward upon the eyeball, and, moreover, they are constantly contracted by the irritation always existing in such eyes.

Simultaneously there is often a contraction of the palpebral fissure at the outer canthus (blepharophimosis), caused for the greater part by excoriations and subsequent union of the edges of the two lids at this place. Together with the occurrence of the blepharophimosis there is often a shrinkage of the tarsal portion of the conjunctiva, and as a consequence of this the outer angle of the eye seems bridged over by a fold of mucous membrane, extending several millimetres toward the median plane.

If the blepharophimosis be extreme, its relief is often a prerequisite to the performance of an entropion operation. The external canthus is split in a horizontal direction with a strong pair of scissors, one blunt point of which is thrust behind the external commissure as far as possible into the conjunctival sac. To prevent the lids growing together again, the conjunctival and cutaneous edges of the wound should be united by sutures, as shown in Fig. 37.

In the operative treatment of entropion with trichiasis and dis-

FIG. 37.





trichiasis, the result to be aimed at is while retaining the cilia to give them a proper direction.

Upon the under lid this may generally be done by one of the methods of operation above described. They are, however, not applicable to the upper lid. The operation there is as follows. A horn spatula is thrust under the upper lid, which is then rolled upward upon it until the margin of the lid is somewhat raised. Then with a small pointed knife an incision is made, from a point near the punctum lacrymale along the line of the mouths of the Meibomian glands, the whole length of the lid, and about 3 or 4 mm. deep, thus dividing the lid into two leaves (Fig. 38), the

FIG. 38.

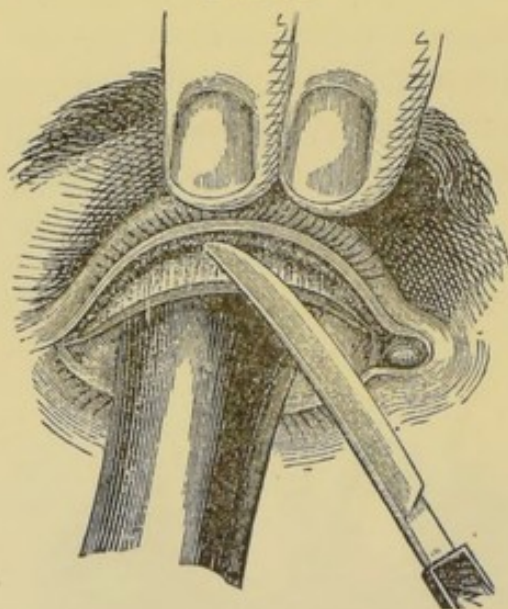
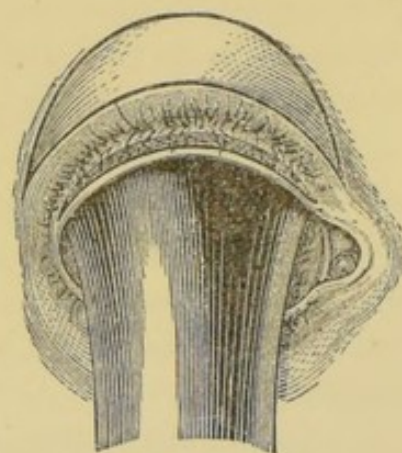


FIG. 39.



inner one containing the conjunctiva and tarsal cartilage, with the tarsal glands, and the outer one the skin, the fibres of the orbicularis and the cilia, together with their bulbs. The skin of the lid being now held tense, an incision is made through the outer leaf about 3 or 4 mm. from the edge of the lid, and parallel to it. This incision must be some millimetres longer at each end than the incision made upon the edge of the lid. The outer leaf of the lid is thus transformed into a kind of bridge, entirely free except at the two ends. If this be not the case, if the bridge, at least in its middle, be not free, the knife is to be introduced in the upper wound, and its point made to appear in the lower one; the communication between the two is then to be enlarged to correspond to the lower wound. This being done, a crescent-shaped



piece of skin is to be excised (Fig. 39). Its size is to be determined by the degree of the entropion and the amount of superfluous skin. To remove this piece a third incision is made with the knife, as shown in Fig. 39. The skin included between the two incisions is then grasped with the forceps, and dissected up from the orbicularis with the knife or curved scissors. If the orbicularis, in consequence of the habitual contraction by which it has contributed toward maintaining the entropion, be too strongly developed, its marginal fibres may be cut away. The wound in the surface of the lid is then closed with sutures, beginning in the middle. When this is done, the wound on the margin of the lid gapes widely, the outer leaf being drawn up, and in such a position that the cilia are horizontal, or perhaps directed somewhat upward.

The after-treatment consists simply in cold-water dressings. The sutures are removed in from 30 to 36 hours. The wound at the edge of the lid becomes covered with a plastic, yellowish-red substance, and heals in from 3 to 6 days, without suppuration. The worst accident which can happen is the destruction of the cutaneous bridge in one or more places by suppuration.\* In order to reduce this danger as much as possible, Von Graefe† has proposed so to modify the operation that it is begun by two vertical incisions running down to the two angles of the eye, through the skin and orbicularis, forming side boundaries to the part to be transplanted. The intermarginal incision is then made just as in Arlt's method. The outer leaf is then pushed up 3 or 4 mm., and sewed along the vertical incisions. If there be any superfluous skin, an oval piece may be excised from the lid. This method presents no essential advantages. As a general rule, perpendicular incisions upon the eyelids should be avoided as much as possible.

The results obtained by Arlt's method are generally so satisfactory, and the operation is so simple, that for the ordinary demands of practice it may be regarded as sufficient. However, there is one essential element in these forms of entropion which this operation does not affect, namely, the bowl-shaped deformity of the

---

\* Arlt (nach Jäsche), *Augenheilkunde*, i. pag. 146.

† Arch. f. Ophth., B. x. 2, pag. 226.



tarsal cartilages. Other operations have therefore been proposed, with a view of improving the shape of the tarsal cartilages, and in that way healing the entropion. By the Crampton-Adams method, the tarsus is divided by two vertical incisions made near the angles of the eye. These incisions are about 5 mm. in length, and their upper ends are united by a third incision, in the cartilage, made from the inner surface of the lid and parallel to its edge. The margin of the lid is now everted, and held in that position by excising an oval piece of the skin and closing the wound with sutures. Care is to be taken that the vertical incisions in the cartilage do not reunite too quickly. The objections to be made to this method are with reference to the vertical incisions in the margin of the lid and the incision of the tarsus on the conjunctival side. Among the operations intended to improve the form of the cartilage, that of Snellen deserves the preference. It is as follows. In order to control the bleeding, the upper lid is strongly stretched by a horn spatula thrust under it, or it is compressed by means of Snellen's blepharospast.\* An incision is then made through the skin the whole length of the lid, 2 or 3 mm. above its edge, and parallel to it; the skin of the lower lip of the wound is then somewhat loosened and a strip from the marginal portion of the orbicularis taken away with the scissors; nearly the whole of the tarsus is thus exposed. With a small, very sharp knife two horizontal incisions are made along the whole length of the tarsus; they converge downward toward the conjunctival surface of the tarsus, and thus a wedge-formed strip is cut away from it. These incisions do not pass through the entire thickness of the tarsus. Its conjunctival surface is not cut. A furrow being thus made upon the surface of the tarsus, it, together with the edge of the lid, is then turned outward in the following manner. The skin of the lid is, in the first place, slid upward, and in that way the upper margin of the tarsus is exposed. A silk thread, provided with two needles, is then

---

\* A kind of forceps, one arm of which is a metal plate, corresponding in size and shape to the upper lid, under which it is thrust. The other arm of the forceps is roundish, and so curved that it covers the edge of the plate, with the exception of that part which corresponds with the edge of the lid. The forceps may be clamped together by a screw, and in that way all annoying hemorrhage prevented.



passed by means of one of the needles through the upper margin of the tarsus; the two ends of the thread are then brought down over the anterior surface of the tarsus, are passed through the lower lip of the wound, and are brought out just above the roots of the cilia, at a distance of about 3 or 4 mm. from each other. In order to bend the tarsus outward and to turn the edge of the lid upward, it is necessary to draw upon these threads quite strongly and tie them together; this may easily cause them to cut through the skin. In order to avoid this evil, it is well to place a washer of glove leather upon each end of the thread, just as in the ectropion operation (see page 235.) Nevertheless, necrosis of the skin of the lid is often caused by the pressure. The presence of the washers facilitates the removal of the threads on about the second day.

Three sutures are placed in this manner. It is unnecessary to close the wound in the skin by sutures. The ends of the three sutures before mentioned are fastened with adhesive plaster above the eyebrow upon the forehead, and in this way the two lips of the wound are held in apposition. Since there is no excision of the skin connected with this operation, it may without any injury be repeated if the effect be insufficient or if relapses occur in the further course of the trachoma.

If not the entire margin of the lid but only a part of the cilia be turned inward, or if the condition in general be so slight that a serious operation does not seem to be indicated, the affected place upon the margin of the lid may be cauterized with concentrated sulphuric acid.

If upon an otherwise normal lid only a single cilium, or a very small number of them, turn inward and irritate the cornea, they may be restored to their normal position in the following manner. Both ends of a very fine thread or a sufficiently long hair are placed together and passed through the eye of a needle so as to form a loop. The needle is then inserted just at the root of the falsely placed cilium, and is brought out exactly in the line of the normal cilia. The thread is then drawn so far through that only a small loop protrudes at the place of entrance, and in this the abnormal cilium is placed with the forceps. The loop is then drawn through so that the point of the cilium is brought to view between the normal cilia. If the cilium do not fall out too soon,



the position and direction of its follicle may be in this way permanently changed. This method was described by Celsus as "illaqueatio."

Occasionally, in patients who are annoyed by a sensation as of a foreign body in the eye, there may be found, either with the naked eye or by the help of a lens, a number of very fine cilia (strongly developed lanugo), which, with their points, touch the caruncula lacrymalis. Epilation is the only remedy.

Distichiasis congenita is very rare. In this condition the cilia at the outer edge of the lid are normally developed, but from the intermarginal part, near the mouths of the tarsal glands, there springs a second row of cilia which lean against the eyeball. In many cases there exist still other congenital anomalies; for instance, in one case which I observed there was epicanthus and bilateral ptosis congenita; in another case I found a cleft in the soft palate.

Ammon has given the name epicanthus to that condition in which there is a redundancy of skin upon the bridge of the nose, and as a consequence the inner canthus is covered by a vertical fold. It occurs only when the bridge of the nose is very flat, and in its highest grades is generally associated with congenital ptosis. If it seem desirable to relieve the condition by operation, it may be done by the excision of an elliptical piece from the superfluous skin on the bridge of the nose.

Congenital cleft (coloboma) of the upper lid has been observed generally associated with other congenital anomalies. If the cleft be so deep that it requires to be closed by an operation, its edges are to be freshened and then united with sutures.

#### SYMBLEPHARON.

Symblepharon is the union of the inner surface of the lid with the eyeball, following destruction of the conjunctiva. Burns with hot metal, concentrated mineral acids, lime, and unskilful cauterizations with nitrate of silver are the usual causes. It very seldom follows wounds made with sharp instruments.

Since it is almost always due to an accidental spurting of the caustic into the eye, the scleral and palpebral conjunctiva are generally simultaneously destroyed and the cornea involved in the injury



The immediate consequence of the injury is generally a severe traumatic keratitis and conjunctivitis, in which, during the acute stage, the palpebral fissure is kept closed either by the swelling of the lids or by the irritation. During this time adhesions form between the two raw surfaces of the conjunctiva or between the inner surface of the lid and the injured cornea. These adhesions remain, although they become somewhat stretched when motion is restored.

The form and extent of the adhesions vary according to the injury to the conjunctiva. The destruction generally extends back to the fornix, so that the lids adhere to the eyeball throughout a great extent of surface. Often in such cases, when both lids are involved, the palpebral fissure becomes shortened, and the mobility of the lids, as well as of the eyeball, is limited.

In other cases the adhesion of the two conjunctival surfaces extends forward from the fornix to the edge of the lid in an oblique direction; a probe can then be thrust for a greater or less distance under the adhesion till its point reaches the end of the pocket thus formed by the symblepharon.

Finally, it sometimes happens that the adhesions do not extend back quite to the fornix, but bridge it over, so that a probe can be passed under it.

In consequence of these adhesions the movements of both the lids and eyeball are impeded. This gives to the patient a sensation of traction, and where the eye still possesses vision it causes diplopia corresponding to the defect of motion.

The removal of the symblepharon may be indicated either to restore the function of the eye, or, where that cannot be done, to render possible the use of an artificial one.

If the cornea be entirely destroyed by the injury which caused the symblepharon and there be no desire to wear an artificial eye, there is no indication for an operation. If a useful degree of vision still remain, or if in case of extensive corneal opacities it may be re-established, for instance, by an iridectomy, the removal of the symblepharon should be undertaken when the adhesions do not involve more than half the upper or lower lid. More extensive adhesions cannot be relieved, not from any difficulty in dividing them, but because of the impossibility of preventing their reunion. After the division of the adhesions the two wounded



surfaces—that of the lid and that of the sclera—lie in apposition, and they are, moreover, continuous with each other when, as is usually the case, the adhesions extend back to the fornix instead of bridging it over, as we have said occasionally happens.

The simple contact of the two wounded surfaces would cause no difficulty. The natural movements of the eye, or a frequent lifting of the lid from the eyeball, are sufficient to prevent reunion. But if the wounded surfaces are continuous with each other across the fornix, a cicatricial process begins there which gradually but surely brings the eye back to its old condition. The important thing is to prevent the two surfaces from being united by cicatricial tissue at the fornix. An effort should be made to bridge over the fornix. This is done by passing a lead wire, by means of a curved needle, through the deepest part of the symblepharon and allowing it to lie there till a cicatrix has formed about it. This always requires several weeks or months, and occasionally nothing more is accomplished than that the wire gradually cuts through, and the cicatricial tissue closes up after it.

Arlt has proposed a good method by which the conjunctiva is united by sutures at the fornix. If the adhesions be not too wide, it is easy after dividing them to sew up the wound upon the eyeball by passing sutures, by means of a curved needle, through the connective tissue and subconjunctival fascia from one lip of the wound to the other.\* If in doing this the conjunctiva be drawn too tense, so that the sutures threaten to cut through, it is well to relieve the tension by lateral incisions, such as are made in plastic operations.

In those cases in which an adhesion has formed in a slanting direction from the fornix up to the margin of the lid, it is well, after separating the adhesion, to close the wound at the fornix, since it is from that point that the cicatrix re-forms.

A bridge-like symblepharon, which does not extend down into the fornix, may be divided upon a director which has been passed under it. A suture is, under these circumstances, not absolutely necessary, but for safety the wound in the conjunctiva scleræ may be closed with stitches.

After extensive burns upon the face in the neighborhood of the

---

\* Prager Vierteljahrsschrift, 1854, und Augenkrankheiten, iii. pag. 375.



eyelids, and often, too, after ulceration by lupus in this region, there may be a total occlusion of the palpebral fissure (ancho-blepharon). No trace of the eyelids is left; the eyeball is covered by tightly stretched cicatricial tissue, through which it can sometimes be recognized by its movements, and through which, too, it may receive a sensation of light. No improvement can be made by an operation, since in such cases the cornea is either destroyed or united with the cicatricial tissue.

#### BLEPHAROPLASTIC OPERATIONS.

The indication for a blepharoplastic operation is given by an extensive loss of substance from the eyelids. In most cases its object is to cover the loss of substance remaining after the extirpation of tumors upon the lids, or to relieve an ectropion which is due to cicatricial contraction after ulcerations or other loss of substance.

The most important points to be observed in doing blepharoplastic operations are the following :

1. A normal part of the defective lid ought never to be sacrificed, because the new-formed part of the lid can be moved only by what remains of the original one.

2. Healthy conjunctiva, even when in a state of inflammatory irritation, ought never to be cut away. Where possible, it is to be used for lining the edge of the new-formed lid.

3. The piece of skin to be transplanted must not be taken from too distant a part. It must be so cut that the flap is neither too scant nor too long, in which latter case it will roll together.

4. Finally, it is advisable so to plan the operation that the defect caused by cutting out the flap does not need to heal by granulation, since otherwise, in consequence of the cicatricial contraction near the transplanted flap and upon its posterior surface, a deformity is caused in the new lid. The hope expressed by Dieffenbach, that the cicatricial contractions under and near the flap would neutralize each other, has not been realized.

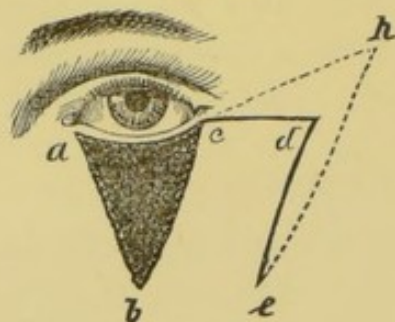
With these rules in mind, the plan for each separate operation is to be made, since the individual variations are so great that almost every case requires some peculiar arrangement of the incisions. It would be exceeding the limits prescribed in this work to take up this subject exhaustively. It will suffice to describe



the original method of Dieffenbach, since with slight modifications it is suitable for the majority of cases.

In the case of the under lid, the extirpation of the scar or tumor is so made that a triangular loss of substance remains. Its base

FIG. 40.



base *a c* (Fig. 40) is turned toward the lid, its apex, *b*, is directed downward. To replace the defect *a b c*, Dieffenbach made the flap *c d e*, which he dissected up, leaving the fatty tissue; and after stopping the hemorrhage and cleansing the previously exposed triangular space, he moved the flap over, so that its upper border occupied the place of

the margin of the lid, or was joined to it in case the margin still remained; the median margin of the flap was thus brought over to the line *a b*. The flap is stitched first at the inner angle of the eye. Its upper margin is then stitched to the conjunctiva, or to the margin of the lid, if that be still present; the wound at *a b* is closed in the same way after its median lip has been dissected upward somewhat from the subcutaneous tissue.

There remains now on the temporal side of the transplanted flap a defect which is left to cicatrize, but which, without any injury, and indeed with advantage to the flap, may be somewhat reduced by sutures placed at the angle *d*.

Szymanowski\* proposed to give to the transplanted flap the form *e h e*. The advantages are: 1, that the flap *b c h e* is longer, and even after its contraction fills the space *a b c* without causing tension; 2, that its upper, broader margin may be stitched out beyond the outer angle of the eye, thus making the best possible provision against its sinking downward; and, 3, that the defect may be more easily closed from the acute angle *h*.

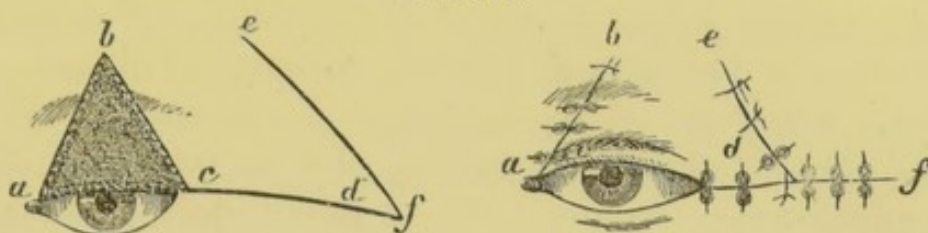Blepharoplastic operations are much more difficult upon the upper lid. The simplest and best method is that of Dieffenbach, for which Szymanowski also recommended his modification of the acute-angled flap. The defect *a b c* (Fig. 41) is covered by a flap, *b c d e*, borrowed from the temple. Since this is considerably broader than the defect, its union may be insured by sutures, not

\* Handbuch der operativen Chirurgie, i. pag. 220 u. folg.



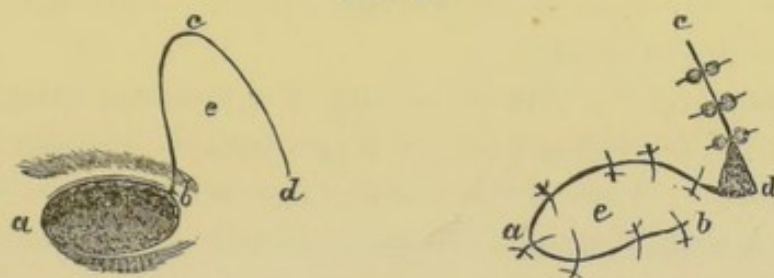
only along the line *ab* but also at *d*. Moreover, the whole defect may be covered by sutures from *f* to *d* and from *e* to *d*. The

FIG. 41.



hurtful influence which the cicatricial contraction at this place may exert upon the form of the new lid is thereby diminished, and at the same time the sutures at *d* act to prevent both the transplanted flap from drawing upward and the lower lid from sinking downward.

FIG. 42.



When this method is not practicable, the transplantation of an oval or tongue-shaped flap from the temple or forehead may be undertaken, as shown in Fig. 42. This method, first proposed by Fricke, has the disadvantage that the newly made defect cannot, on account of its oval shape, be entirely closed. Moreover, the oval flap has a special tendency, on account of the cicatricial contraction on its under surface, to draw itself concentrically together into a spherical mass. If the flap be very long and tongue-shaped, there is danger of gangrene occurring at its point.

Loss of substance at the inner angle of the eye may be replaced by transplantation from the skin of the nose, or, if that be not practicable, from the forehead. With loss of substance at the outer angle of the eye the closure of the wound is not difficult, as the skin in this region is so loosely attached.

In many cases the blepharoplastic methods above described may be dispensed with, and small pieces of skin transplanted from distant parts of the body, or, indeed, taken from other persons. This method has before been practised in surgery for healing



ulcers, closing losses of substance after burns, etc. For replacing lost tissue upon the eyelid one may proceed as follows.\* A small fold of skin is raised upon the forearm with the thumb and forefinger; its base is then transfixed with a knife, and separated at one end; it is then grasped with the forceps, and the whole fold cut away with a pair of scissors curved on the flat. In this way a small piece is obtained, measuring, after its contraction, from 3 to 8 mm. in every direction. This is placed upon the raw surface and carefully spread out with the probe. The wound is covered as fully as possible with a thick mosaic of such little pieces, 10 to 20 in number, according to the size of the defect.

The entire wound is then covered with gold-beater's skin, which is sufficiently transparent to allow the observation of the transplanted pieces. Finally, to insure perfect rest, both eyes are closed with a pressure-bandage, which is allowed to remain unchanged for 24 hours.

The result of the operation may be predicted after the very first day, by the changes in color perceptible through the gold-beater's skin. Those little pieces which adhere show, after 36 to 48 hours, a bright redness, which gradually grows darker. Even if some of them retain their pale-yellow color, become surrounded by a brownish-black zone, and finally mummify, it may still be the case that only the epidermis has died, while the cutis has adhered. There is nothing to prevent substituting new pieces for those which have died, and this is advisable in order to avoid the hurtful influence which continual suppuration may exert upon the living pieces.

If this method be determined on, for instance, in a cicatricial ectropion which otherwise would require a blepharoplastic operation, the first step is to detach the lid from the cicatrix by an incision, if possible,  $1\frac{1}{2}$  or 2 cm. from the edge of the lid. The cicatrix is to be dissected up till the ectropion is fully relieved and the palpebral fissure can be closed without any difficulty. This last is the most important point in the operation, and, no matter how large the wound, the lids must be allowed to close perfectly.

---

\* L. de Wecker, De la Greffe dermique en Chirurgie oculaire, Annales d'Oculistique, Juillet et Août, 1872.



The margins of the two lids are then freshened at several points and united with sutures. The covering of the wounded surface is not to be undertaken until its edges have flattened down and free suppuration is established, on the seventh or eighth day. The transplantation effects an absolute cure of the extensive wounded surface, which otherwise, by its cicatricial contraction, would have been sure to cause ectropion again. When the cure is finally made sure, the last step is to re-open the palpebral fissure which had been closed by the tarsorrhaphy.

Transplantation is resorted to in a similar manner in cases in which there has been extensive loss of substance on the lids, in consequence of wounds, burns, or operations.



## DISEASES OF THE CONJUNCTIVA.

---

ALTHOUGH in describing the diseases of the conjunctiva they are divided into certain groups, it must be remembered that in practice the boundaries of these groups are very indistinct. Cases often occur which may properly enough be classed in either one group or another. For instance, what was originally a simple catarrhal conjunctivitis may, by neglect and continual irritation, pass into a chronic blennorrhœal or trachomatous state. Phlyctenular conjunctivitis about the margin of the cornea presents another example of this kind. One often sees an acute catarrhal or mild blennorrhœal swelling occur simultaneously with, or somewhat later than, the phlyctenules. Conjunctival diseases of various kinds often present a peculiar appearance, differing from their typical forms in the fact that the conjunctival follicles are abnormally prominent.

These various encroachments of one form of disease upon the other, only prove that no classification must be too dogmatically adhered to, as it cannot hold good for all cases.

### HYPERÆMIA OF THE CONJUNCTIVA.

Acute hyperæmia of the conjunctiva either passes quickly away or is the precursor of an inflammatory condition. A slowly developed chronic hyperæmia, or one remaining after a previous conjunctivitis, may, on the contrary, remain unchanged a long time. It is characterized by a stronger injection of the visible vessels, especially those of the conjunctiva palpebrarum; a hyperæmia of the conjunctiva scleræ and a redness of the margins of the lids generally exist at the same time. There is frequently a slight swelling of the conjunctival follicles, especially on the temporal half of the lower lid. Anomalies of secretion are absent, or there may be slightly increased lachrymation and secretion of mucus, which, during the night, glues the cilia together in bundles.



The annoyances consist in sensations of burning, itching, pricking, etc., which increase the more the eyes are used, especially by artificial light. The heat from the lamp aggravates these symptoms.

In many cases the feeling of pressure, pricking in the eyes, etc., which comes on during work, is so annoying that the condition resembles asthenopia; consequently we may speak of conjunctival as well as of accommodative or muscular asthenopia. The diagnosis is generally made certain by the objective symptoms. Nevertheless, I have seen some cases in which the conjunctiva showed no abnormality, but in which there was asthenopia, which was certainly of neither an accommodative nor a muscular nature, while the absence of all other nervous disturbances excluded the idea of nervous asthenopia; moreover, the symptoms of irritation were not those so often occurring in connection with myopia. The evidence that in these cases a conjunctival affection was the primary one, lay in the fact that after reading a few minutes, pain occurred, with evident hyperæmia of the conjunctiva and copious secretion of tears, which made work impossible.

The treatment based upon this idea consisted at first in pencilling with a 3 per cent. solution of sulphate of zinc, and later with dilute tincture of opium. It proved efficacious, thus confirming the diagnosis.

The causes of chronic conjunctival hyperæmia often lie in a continuous exposure to hurtful influences, such as confined impure air, smoke, dust, etc., or in straining the eyes by working with insufficient illumination.

The treatment consists in the first place in removing as much as possible the causes, not forgetting the possible co-existence of accommodative or muscular asthenopia. The local treatment consists in the use of cooling and slightly astringent applications, cold baths for the eyes, cold dressings, or the eye-douche. Among the astringent eye-waters, the best are  $\frac{1}{4}$  per cent. solutions of either sulphate of zinc or neutral acetate of lead. In cases of very marked hyperæmia it is often well to apply a 2 or 3 per cent. solution of either of these remedies to the conjunctiva with a pencil, and immediately wash away the surplus with water. In conjunctival asthenopia it is often well, toward the end of the treatment, to employ dilute tincture of opium.



## SIMPLE CONJUNCTIVITIS.

Conjunctivitis exists whenever, in addition to swelling and redness, there is a copious abnormal secretion from the conjunctiva. The redness is characterized by a dilatation both of the larger vessels and the capillaries, and appears therefore as a net-work in the fornix, where the larger vessels and their first branches lie, but in the tarsal part it is a more uniform bright red. The vessels of the conjunctiva scleræ are often also dilated. These vessels run from the fornix toward the cornea, and form with their branches a coarse net-work, distinctly visible against the white background of the sclera. In more severe cases the anterior ciliary vessels may also be injected; they form then a rosy-red border of short, thickly-set vessels radiating about the cornea. Often there are also slight ecchymoses upon the scleral conjunctiva. After it has continued a long time, the redness shows a tendency to concentrate at the angles of the eyes and along the edges of the lids.

The swelling is generally not very great, is mostly limited to the conjunctiva of the lids, is greatest near the fornix, and less upon the tarsal part. In very acute cases, or in very old people with relaxed conjunctivæ, a serous infiltration occurs in the subconjunctival tissue of the sclera, making it still more easy to slide the vessels upon the sclera than in the normal condition.

When the process is long continued, a hypertrophy of the papillary layer of the mucous membrane may take place, giving to the surface a velvety, dark-red appearance.

It is only in very acute cases that the subcutaneous connective tissue of the lids participates in the process. There is then great swelling of the fornix and conjunctiva scleræ with copious mucopurulent secretion, a condition closely resembling the blennorrhœal affection.

The abnormal secretion appears first as a copious flow of tears containing formed elements, such as epithelial cells, mucus, and fat-corpuscles, partly to be seen only microscopically, partly occurring in the form of grayish-yellow flakes or threads; these last are found principally in the fornix, where the secretions are rolled together by the movements of the eye. The secretion dries and forms crusts upon the lachrymal caruncle and cilia; it often so accumulates during sleep as to glue the eyelids together. If the



secretion be so copious that the tears drip continually over the lid, an excoriation of the skin may result.

The secretion becomes infectious as soon as it assumes a mucopurulent character; but even in the less severe forms it is advisable to regard it as possibly infectious, and to observe the proper precautions.

The subjective symptoms consist principally in a sensation of pressure and pricking, as if sand or a foreign body were in the eye, or in itching, burning, and heaviness of the eyelids, as when drowsy, etc. Associated with these symptoms there is often a sensitiveness to light, especially to artificial illumination, with inability to use the eyes for work, and occasional indistinctness of vision. These disturbances of vision are evidently caused by thin films of mucus which occasionally form over the cornea; after their removal vision is as good as ever. It is probable, too, that still another symptom, which is especially frequent in chronic cases, namely, the appearance of colored rings about the flame of a lamp, is likewise due to the refraction caused by a thin film of abnormal secretion upon the cornea.

Often, after all the actual symptoms of conjunctivitis have disappeared, this single annoyance remains,—that the patient upon waking finds it is only with an unpleasant sensation of pain that he can open his eyes; this is probably because during sleep, and favored by the perfect rest in that condition, and on account of some anomaly in the secretions of the mucous membrane, a relatively too strong adhesion between the lid and the eyeball occurs.

The causes of conjunctivitis are partly general and partly local. Often it is associated with other catarrhal processes, as, for instance, with nasal catarrh, or as a part of a general catarrhal affection, as in the exanthematous diseases, measles, scarlatina, etc.; or it may occur as an independent disease following colds or injuries. Traumatic conjunctivitis, for instance, when it is neglected or exposed to injurious influences, may pass over into a catarrhal or even a blennorrhœal conjunctivitis. Confinement in dusty, smoky rooms, or in those filled with animal exhalations, is likewise a frequent cause of conjunctivitis.

Among the local causes which induce or maintain conjunctivitis are strictures of the nasal duct, diseases of the margins or of the glands of the lids, as, for instance, distention of the tarsal glands



by retained secretions, distichiasis, etc. Straining the eyes at work, especially by insufficient light, tends to maintain an already existing conjunctivitis.

The course of the disease varies with the cause exciting it. Simple cases may pass away in a few days, but other cases, especially where the exciting causes cannot be fully removed, may be very protracted.

Chronic conjunctivitis generally causes relaxation of the conjunctiva, with hyperæmia either of the larger vessels alone or of the capillaries also. This relaxation becomes more noticeable when, as in old people, the skin and muscle are already relaxed. In such cases an ectropion or sinking of the lid is likely to occur.

In other cases there develop gradually a swelling of the mucous membrane and a gradual transition into a chronic blennorrhœal or granular process. The danger of consecutive corneal affections then becomes greater than is the case in simple chronic conjunctivitis.

The treatment must, of course, in the first place, be directed toward removing all hurtful influences. The condition of the mucous membrane determines what further remedies are to be employed. So long as the inflammation is still progressive, only antiphlogistic and derivative treatment is indicated, perhaps simple applications of cold water or a dilute solution of lead, say 10 drops of liquor plumbi acetatis to a teacup of water. So soon as a relaxation of the mucous membrane is apparent, astringent eye-waters are to be used, say a  $\frac{1}{4}$  per cent. solution of sulphate of zinc or neutral acetate of lead dropped in the eye three times daily, or, where there is greater swelling or more copious muco-purulent secretion, a solution of nitrate of silver also  $\frac{1}{4}$  per cent.

If the patient can be seen daily, a cure may be effected sooner, by pencilling upon the conjunctiva of the lids a 2 to 4 per cent. solution of sulphate of zinc, or 1 to 3 per cent. acetate of lead, or 1 to 2 per cent. nitrate of silver. In all cases the superfluous solution remaining after the application, should be immediately washed away with pure water. Cold-water dressings are to be made afterward, so long as pain remains in the eye.

If the conjunctivitis be complicated by a diseased condition of the tarsal glands, made evident by a redness of the margins of the lids and an accumulation of the glandular secretions between



the roots of the cilia, eye-washes are often not well borne, or at least do not accomplish the desired result. In such cases it is well to try a salve  $\frac{1}{4}$  to 1 per cent. red or white precipitate of mercury, perhaps with the addition of some oxide of zinc or a few drops of the solution of acetate of lead, causing it to be rubbed each evening along the margin of the lids.

Other means recommended in conjunctivitis, especially in the chronic or oft-recurring forms, are washes of corrosive sublimate (1 or 2 parts in a thousand), solutions of alum, aluminate of copper, borax, etc.

Atropine conjunctivitis, which sometimes develops after the long use of atropine, deserves a special mention. It occurs sometimes in the form of a simple inflammatory swelling of the mucous membrane with a muco-purulent secretion, often, too, in connection with the swelling of the conjunctival follicles, or there may be only slight swelling but great hyperæmia and a copious secretion of tears. In connection with this condition, redness and exco-riation of the skin of the lid often appear.

Preparations of atropine, which irritate and immediately cause pain and redness after being dropped in the eye, ought of course not to be used. But even perfectly neutral sulphate of atropine has the above-named unpleasant property. Individual predisposition is certainly one of the elements involved, since only a few of the patients treated with atropine are affected with this kind of conjunctivitis.

The muco-purulent secretion of this conjunctivitis is of course as infectious as all other secretions of this kind. It is well, therefore, especially in clinical practice, never to drop atropine in the eyes with a camel-hair pencil, but always with a small glass pipette, —a thin glass tube, its lower end somewhat narrowed and its upper end provided with a short piece of rubber tube closed at the top. In the clinic, each patient requiring atropine treatment should be provided with his individual pipette. In this way the danger of spreading the disease by contagion is diminished. The only way to render the occurrence of this complication less frequent is to use as little atropine as possible in all cases where its application must be continued a long time.

The treatment is the same as in other forms of conjunctivitis; beginning with cold- or lead-water dressings, following later with



astringents, or pencilling with a 1 or 2 per cent. solution of nitrate of silver. My experience has not confirmed the oft-repeated assertion that preparations of lead have a specific action in the cure of atropine conjunctivitis.

If possible, it is well to dispense with the use of atropine; if mydriasis must be maintained, a solution of extract of belladonna may be substituted for the sulphate of atropine, and the conjunctivitis treated at the same time. After the conjunctivitis has been fully cured, the use of atropine ought not to be begun again, since a few drops are sufficient to cause a relapse.

Distinct from this atropine conjunctivitis, is a very rare atropine idiosyncrasy of the conjunctiva. Cases occasionally occur in which immediately after instilling atropine, pains ensue, and following quickly on these are acute erysipelatous inflammation of the conjunctiva and great swelling both of it and of the eyelids. In milder forms of this idiosyncrasy the atropine causes only a feeling of burning and pricking, with redness of the eyes and a copious secretion of tears. Many such patients bear extract of belladonna very well.

#### BLENNORRHOËAL CONJUNCTIVITIS.

Acute blennorrhœa develops in an eye previously healthy or one already suffering from some conjunctival disease, with the symptoms of a rapid inflammation of the conjunctiva. The whole surface of the mucous membrane is reddened by an excessive hyperæmia, and often, especially upon the sclera, is infiltrated with hemorrhages. The looser the subconjunctival tissue the greater the swelling. It is therefore least near the margin of the lid, on account of the close connection of the conjunctiva with the tarsus at this point; the swelling increases toward the fornix, and finally attains such a volume that when the lids are everted and the patient is told to look downward, or upward, it puffs forward like a broad, ring-shaped cushion. The surface of the mucous membrane is generally smooth, glistening, tense, and bright red; in severe cases it may present a grayish appearance which, by touching lightly with a brush, will be seen to be caused by an exudate not upon but in the mucous membrane itself.

The scleral conjunctiva is likewise very red and infiltrated with



an inflammatory exudate. In mild cases this exudate is of a serous character, of a yellow or reddish color; in more severe cases it assumes a dense, so-called fleshy character, so that the greatly swollen conjunctiva surrounds the cornea like a wall. Under these circumstances the cornea generally appears small, because the *limbus conjunctivæ corneæ* participates in the vascularization and swelling, and the thickened conjunctiva *scleræ* presses over the edge of the cornea on every side. The swelling of the conjunctiva is generally called "chemosis" or "chemotic swelling."

The eyelids, too, particularly near their margins, or perhaps throughout their whole extent, are of a bright or livid red, in consequence of excessive hyperæmia. The upper lid, owing to its increased volume, hangs heavily downward, and can be only partially raised by the action of the levator. In very acute cases the infiltration extends downward upon the cheek and upward above the eyebrows. A decided increase in the temperature of the lids is perceptible.

The secretion is at first thin, serous, of a yellowish tinge, due to blood coloring matter, and is mixed with gray flakes. Since the *puncta lacrymalia* are forced away from the eyeball by the swelling of the lids, the secretion runs continually over their margins and causes excoriation of the cheek. Often, especially at first, the secretion is so coagulable that one finds upon the surface of the everted lids a membranous coagulated layer of exudation, which can generally be easily removed, and sometimes but not always leaves a slightly bleeding mucous surface. This so-called croupous form possesses no prognostic importance. After a few days the secretion becomes decidedly purulent, of a creamy consistency, yellowish and often greenish, and more or less profuse in quantity.

In the course of a few days the mucous membrane assumes a somewhat different appearance. It no longer appears smooth and glistening, but more velvety; its folds become more relaxed, more numerous and smaller, and are traversed by cross-folds, so that the surface of the mucous membrane appears more and more uneven. Simultaneously, a hypertrophy begins in the tissue of the mucous membrane itself, which furnishes to these irregularities of the surface a more solid substratum.



The great danger in these severe cases of blennorrhœa is that the cornea will participate in the process. During the first few days, while the conjunctival swelling is still increasing, the cornea generally remains intact; but, unfortunately, it is not safe to base a favorable prognosis upon the fact that the cornea remains free during the progressive stage of the disease; that cannot be done till the disease has passed its acme and has entered upon an evidently regressive stadium. The period of the disease in which the cornea is most endangered is that at which the conjunctival swelling has attained its maximum, and the danger is the more threatening the more the conjunctiva scleræ is involved in the process, and particularly where chemotic swelling is protracted into the later stages of the disease. The following are the most usual forms of corneal affections:

Among the most dangerous of the blennorrhœal affections of the cornea is the annular marginal ulcer. It may occur in the form of a narrow furrow close to and parallel with the margin of the cornea. At first it seems an unimportant loss of substance, hardly wider than a hair, with a smooth and glistening floor, but it creeps gradually farther around the margin of the cornea, and at the same time becomes broader and deeper.

In other cases there develops at some one point upon the margin of the cornea, generally upon its upper part, a purulent infiltration, which spreads rapidly in a direction parallel to the margin of the cornea.

At first the centre of the cornea seems relatively little changed. So soon, however, as the ulcer spreads more than half-way around the cornea, there ensue a deep-gray color and necrotic destruction of the central part of the cornea.

In other cases the cornea appears misty. Necrotic softening takes place; one layer after another of the corneal substance is cast off in quick succession. This process may run a somewhat more favorable course when it affects only a small portion of the cornea, and perforation occurs quickly.

A very frequent form of blennorrhœal corneal affection is the circumscribed purulent infiltration. Its prognosis depends upon the course of the blennorrhœa. If it occur very early in the first stages of an acute blennorrhœa, it inclines to increase rapidly, both in depth and in surface, quickly causing perforation and de-



- struction of the cornea. Where the course of the blennorrhœa is less acute, there is more chance that the process will be arrested and healing occur before the entire cornea is destroyed. Frequently there are in the cornea at the same time several such points of purulent infiltration, in which case the danger to the cornea is, of course, increased.

The suppurative process which occurs in the cornea during the course of an acute conjunctival blennorrhœa has this peculiarity, that the pus never sinks downward in the substance of the cornea, nor is hypopion ever formed. But, as in other suppurations of the cornea, iritis is a frequent complication.

In blennorrhœal conjunctivitis of the milder forms, small, circumscribed corneal infiltrations are most apt to occur, with perhaps extensive loss of epithelium and diffuse clouding of the corneal tissue thus exposed, and shallow ulcers with smooth, reflecting floors.

Blennorrhœa may occur idiopathically, or in consequence of some external hurtful cause, especially in cases where the conjunctiva was previously quite normal. But very severe cases not infrequently occur for which no cause can be with certainty determined. In the great majority of cases, however, the disease is acquired by infection with the purulent blennorrhœal secretion. The most frequent source is the blennorrhœal disease of the conjunctiva itself.

Among the inoculated forms, the first to be mentioned is the blennorrhœa neonatorum. The circumstance that this affection occurs always within a few days, generally three or four, after birth, points very decidedly to an infection occurring either at that time or very soon after it. It is, however, by no means necessary that the mother should have had a virulent vaginal blennorrhœa. It is probable that any muco-purulent secretion which during delivery accidentally gets into the conjunctival sac, is sufficient to produce this condition. It is possible that some days later, through carelessness, an infection may be caused by the lochial discharges. Frequently only one eye is at first affected; still, it is seldom possible to protect the second from infection by the first. The intensity with which blennorrhœa neonatorum occurs, varies greatly, probably on account of differences in the infecting secretion. Accordingly, the symptoms presented by the swelling of the



conjunctiva and the purulent secretion are sometimes more and sometimes less threatening. Frequently the exudation from the mucous membrane is so copious that, upon everting the lids, one can see it collect upon the surfaces while under observation. Frequently the exudate is at the same time so coagulable that it immediately forms a membrane which covers the mucous surface, and, when the lids are closed, may extend unbroken from the inner surface of one to the other. Frequently the mucous membrane shows also a great inclination to bleed, so that the eversion of the lids or the least touch suffices to provoke a hemorrhage, which, however, when the lids are returned to their normal position, generally ceases again spontaneously. This symptom has no special prognostic or therapeutic importance.

During the first days of a severe blennorrhœa neonatorum the cornea often shows a slight diffuse cloudiness throughout its whole extent; this, however, disappears entirely under suitable treatment. Any corneal affection which occurs is generally in the form of a circumscribed purulent infiltration.

Gonorrhœal blennorrhœa is caused by inoculation of the gonorrhœal secretion upon the conjunctiva, and often proves one of the severest and most dangerous forms. The inflammation may, however, assume a milder type in cases where the inoculating secretion has been diluted.

There are no special symptoms by which a gonorrhœal blennorrhœa can be recognized as such in cases where it is not possible to discover the gonorrhœa as a cause. Moreover, this etiological fact has no influence upon the prognosis or treatment of the blennorrhœa.

Blennorrhœas in which the infection is caused by inoculation with conjunctival secretions are very frequent, since all conjunctival affections accompanied by a muco-purulent secretion may be regarded as infectious. As a general thing, there is a certain agreement in type between the original and the inoculated disease. But one often sees very malignant blennorrhœas resulting by inoculation from slight conjunctival affections.

The course and prognosis of acute conjunctival blennorrhœas depend in the first place upon the degree of the inflammation. Mild cases may be cured by proper treatment in from one to two weeks; severe ones in from six to eight weeks. The most impor-



tant point is the behavior of the cornea. The danger to that is in direct relation to the participation in the process on the part of the conjunctiva scleræ. The greater the chemotic swelling, and the longer it continues, the greater the danger to the cornea.

Even in the severest forms of blennorrhœa, pathological corneal processes do not generally appear at the very first, but upon the third or fourth day of the affection, after it has reached or already passed its highest point. As a general rule, the later in the course of a blennorrhœa a corneal affection appears, the more amenable is it to treatment.

The treatment in a case of unilateral blennorrhœa must, in the first place, be directed toward preventing an infection of the second eye. This is most surely done by a properly applied protective bandage. The healthy eye is covered by a pad of charpie and covered with linen made impermeable by collodion.

The treatment of the eye attacked with blennorrhœa must at first be antiphlogistic. The most important means to be employed during the first days are cold-water dressings, whose temperature is to be regulated by that of the eyelids. Where the temperature is very high it is best to lay the compresses on ice, and from that directly upon the eye. For a lower degree of temperature it suffices to use ice-water for wetting the compresses. In every case the dressing must be changed very frequently, say every two or three minutes, so that they may not become warm. So soon as the swelling of the lids begins to diminish, or, in mild cases, at the very beginning, it is well to add to the water used, a few drops of the solution of acetate of lead. Frequently the application of cold diminishes greatly the pain and burning in the eyelids. Simultaneously the lids must be occasionally carefully separated and the secretion removed by washing out the conjunctival sac with a soft camel-hair pencil.

If, in spite of this, severe pain continue, a few drops of sulphate of atropine in a 1 per cent. solution often do good service. Leeches, placed on the temple about midway between the outer canthus and the ear, exert often an inexplicable influence in allaying the pain. If during the first days of the disease the conjunctiva scleræ be infiltrated by a bloody serous exudation, escape may be given it by a few incisions with the points of the scissors. Scarification is not so efficacious in the flesh-like chemotic swelling



which occurs later, in which the exudation has more consistency. Excision of any portions of the mucous membrane is to be absolutely avoided.

The local treatment of the conjunctiva is first indicated when the disease has evidently passed into a regressive stadium. If the lids were greatly swollen and their skin very red and glistening, they now begin to grow paler, and fine wrinkles appear. The mucous membrane, too, no longer seems so tense and glistening, but is more relaxed, and is traversed by several folds parallel to the edge of the lid. The nature of the secretion is also to be noticed. So long as it is still serous, with only an occasional flake of pus, caustics must be used very carefully; but when the secretion becomes decidedly purulent they may be used more boldly.

In general it is advisable not to be too hasty in beginning the use of caustics. If in a recent case of blennorrhœa one is doubtful whether the use of caustics is yet indicated, it is better to wait than to cauterize too early, since a premature use of caustics may be followed by the most serious consequences. For instance, by such mistaken treatment what would have been a mild process may be excited to an inflammatory condition, which it would never have reached under a simple antiphlogistic treatment; and just these inflammatory conditions which have been induced by too early cauterization show a great inclination to associate themselves with destructive corneal processes. The rule is different in old neglected cases. Here the last possibility of salvation may be lost by postponing the cauterization, which when properly conducted is the surest means by which to check the blennorrhœal process.

Generally it is advisable to use, for the first cauterization, a dilute solution of nitrate of silver, say from  $\frac{1}{2}$  to 2 per cent., and, if that be well borne, to proceed gradually to the use of stronger solutions, say 2 to 3 per cent. The use of the mitigated pencil of nitrate of silver (nitrate of silver with nitrate of potassium) is not near so well, for when long continued it is very apt to cause a superficial cicatrization of the mucous membrane.

In order to cauterize the lids, each is everted separately, as in this way the fornix conjunctivæ, the part most important to be reached, is best exposed. In using the solution of nitrate of silver,



its action upon the conjunctiva may be regulated by allowing it to remain a greater or less time before washing it away with water.

In the treatment by caustics, it is always to be remembered that under no circumstances should any destruction of the tissue of the mucous membrane be caused. Only its epithelial layer should be converted into a thin eschar, and the cauterization ought never to be repeated until this eschar has been cast off and the epithelial layer regenerated. If the applications have been properly made, the average time required for this is about 24 hours. The cauterization should therefore be repeated daily at the same hour. If one finds any remains of the eschar, it shows that the last cauterization was too strong for the condition of the mucous membrane, and it is then well to postpone a new application, or else carefully limit it to those portions of the surface where the epithelium has been renewed.

The curative effect of the cauterization is first manifested by a decrease of the purulent secretion. It is only very seldom that a profuse purulent secretion obstinately persists in spite of a systematic cauterization. In these exceptional cases the applications must be made stronger or repeated oftener, perhaps twice in 24 hours. Generally the latter course is preferable.

After each cauterization cold-water dressings should be applied, to soothe the pain and prevent too great a reaction.

When during this treatment the purulent secretion and the swelling of the mucous membrane diminish, it is well to pass gradually to the use of weaker solutions.

The above rules are not altered by the appearance of pathological processes in the cornea. If the cauterization be indicated by the condition of the mucous membrane, its effect can be only favorable upon the co-existing corneal affection.

On the other hand, corneal affections which occur early in the course of a severe blennorrhœa, in general furnish ground for an unfavorable prognosis, and are not likely to be improved by early cauterization. In all these corneal affections the use of sulphate of atropine in at least a 1 per cent. solution is specially indicated. It must be dropped into the eye as often as is necessary to induce and maintain mydriasis.

The early use of atropine tends also to prevent the occurrence



of iritis, which is so apt to be a complication of these corneal affections.

If the corneal ulcer penetrate so deeply that its floor is evidently forced outward by the intraocular pressure, it is often well to puncture it, and where possible to establish for some time a fistulous opening into the anterior chamber. In this way there is the greatest chance of limiting the ulceration and retaining that part of the cornea still intact.

If after spontaneous or artificial perforation of the cornea, a prolapse of the iris occur, it may be left to itself so long as it remains small, but if an increase and expansion of the prolapse occur, it should be removed with the scissors.

Chronic blennorrhœal processes for the most part remain after an acute inflammation of the conjunctiva. They often follow inflammations which were originally slight and perhaps for that very reason were neglected. Other influences often play an important rôle, for instance, unhealthy dwellings, and the continual action of irritating substances.

The condition of the mucous membrane is nearly the same as in the later stages of the acute blennorrhœal inflammation. The conjunctiva is reddened, swollen, wrinkled, and discharges a more or less copious muco-purulent secretion. Frequently, however, there are still other changes. The surface of the mucous membrane presents a greater or less number of slight round prominences, due partly to swelling of the conjunctival lymph follicles, and partly, when the process has been very protracted and subject to frequent exacerbations, to proliferations in the mucous membrane itself.

The mucous membrane is often so tender that it bleeds when the lids are everted or lightly touched. Probably it is at places, especially in the tarsal part, actually raw, which gives rise to the development of excrescences closely resembling the granulations which form on a wound. The surface of the conjunctiva is in such cases uneven, studded with round or cockscomb-like prominences, projecting above the general level of the conjunctiva, especially on the tarsal part of the upper lid.

Now, since it is usual to call all irregularities upon the conjunctiva "granulations," these cases are called "granular conjunctivitis." Other cases of the same kind may, on account of the



decided roughness of the surface of the mucous membrane, be as properly called "trachoma" as "chronic blennorrhœa."

Chronic blennorrhœal conjunctivitis is frequently associated with corneal affections. Sometimes there is a superficial loss of substance with a transparent floor; sometimes extensive superficial exfoliation with diffuse clouding of the exposed and neighboring corneal tissue; sometimes small, circumscribed infiltrations, which at first produce great irritation, and, notwithstanding their smallness, frequently cause perforation of the cornea. After existing some time, these infiltrations usually become vascularized from the margin of the cornea.

In the course of the disease many acute exacerbations occur, which may proceed as well from the cornea as from the conjunctiva; they assume, therefore, more or less the character of a decided acute blennorrhœa. In any such case the cornea is exposed to new danger.

The treatment must, in the first place, be directed toward improving the hygienic surroundings of the patient and removing all hurtful influences. In other respects it scarcely varies from that of acute blennorrhœa. The cauterizations must be begun very carefully, since the mucous membrane does not bear them well in all cases. If a weak solution of nitrate of silver cause only an increase of the irritability, a 1 or 2 per cent. solution of acetate of lead, sulphate of zinc, or tannic acid should be tried. Generally, however, a 2 or 3 per cent. solution of nitrate of silver is well borne, and reduces gradually the swelling of the mucous membrane.

Even considerable excrescences of the mucous membrane generally shrink up under this treatment in the course of a few weeks; this being so, the experiment of cutting off the cockscomb growths to the level of the mucous membrane should be avoided. This proceeding is superfluous and injurious, for it causes an unnecessary loss of substance. Nevertheless, in many of these cases healing occurs with formation of cicatricial tissue, which gives the mucous membrane a marmorated appearance.

If acute exacerbations occur, the cauterizations should be stopped and antiphlogistic treatment substituted. The complication of keratitis, which usually is present, gives the indication for the use of atropine.



## DIPHTHERITIC CONJUNCTIVITIS.

Diphtheritic conjunctivitis is characterized by the same changes as diphtheritis on any other mucous membrane. A coagulable exudate is deposited within the tissue of the mucous membrane itself. The diphtheritic infiltration may affect the conjunctiva only at certain places, and then it is mostly on the tarsal part of the upper lid, or it may involve the entire membrane.

Often there is simultaneously a more or less adherent coagulated membrane upon the mucous surface, without its presence or absence, however, being of any particular diagnostic importance.

Diphtheritic conjunctivitis generally occurs at the very first in the form of a severe inflammation; the lids are greatly swollen, are of a bright or livid red, hard and hot to the touch. The higher the temperature, the greater the swelling, and the harder the lids, the more difficult is it generally to evert them or to open the eyes, and the more extensive is the diphtheritic infiltration.

In partial diphtheritis, in which the infiltration and the symptoms depending on it have not attained their full development, there is generally less difficulty in everting the lids.

The tarsal part of the upper lid is then found to be of a bright yellowish-gray color, due to an exudation not on, but in, the mucous membrane. The spot occupied by the diphtheritic exudate appears generally somewhat depressed, as the rigidity of the exudate prevents the swelling of the conjunctiva, which is very great at other places, and is accompanied by such hyperæmia that ecchymoses are often visible within the tissues, especially upon the sclera. Hemorrhages from the conjunctiva palpebrarum may be caused by simply everting the lids. In some cases superficial ulcerations of the diphtheritic mucous membrane may be the source of such hemorrhages. Frequently the diphtheritis of the tarsal part extends to the intermarginal part of the lids, and in many cases there occur excoriations on the outer skin which assume the character of diphtheritic ulcers. This is especially the case with the under lid, over which the swollen upper lid hangs, thus placing the skin in immediate contact with the diphtheritic secretions.

Diphtheritic excoriations occur also not unfrequently in the nasal cavities, perhaps by the direct action of the conjunctival



secretions which pass through the lachrymal duct. In rare cases it goes on to diphtheritis faucium with fatal result.

The diphtheritic process may be limited to the tarsal part of the lid, or, without passing over into total diphtheritis, it may extend somewhat upon the fornix and conjunctiva scleræ. The danger to the cornea is thereby greatly increased. Even where there are small, circumscribed diphtheritic spots upon the conjunctiva scleræ the cornea almost always participates in the process, the result even in the most favorable cases being a partial ulceration.

Total diphtheritis of the conjunctiva occurs generally with very severe symptoms. The lids are greatly swollen, glistening, livid red, hard, burning hot to the touch, and very painful when everted. The diphtheritic infiltration extends through the entire mucous membrane, and generally the cornea is destroyed during the first few days. Either it becomes clouded throughout its entire extent and sloughs away, or without any noticeable clouding one layer of tissue after another is thrown off.

The secretion is often mixed with blood or with flaky, ragged clots.

This first stage, that of the diphtheritic infiltration, lasts from 8 to 10 days, after which the resorption of the diphtheritic exudate begins. Small spots begin to diminish from their peripheries; wide-spread infiltrations begin to show island-like surfaces of beginning resolution. In these last-named spots the tissues become more expansible, and therefore swell above the surface of the adjoining mucous membrane, which is still infiltrated with the diphtheritic exudate. In this way occur the diphtheritic nodules (Knöpfe) described by Von Graefe.\*

Upon the resorption of the diphtheritic infiltration the disease, especially the partial forms, may go on to absolute recovery. Generally, however, after severe attacks the mucous membrane does not return immediately to its normal condition, but remains in a condition of relaxation, swelling, and purulent secretion. These last two symptoms may be quite prominent. When the disease assumed this form Von Graefe described it as in the blennorrhœal stage.

---

\* Arch. f. Opth., B. i. pag. 180.



During this stage the danger to the cornea has not yet passed. The occurrence of circumscribed purulent infiltrations, marginal ulcers, etc., may still greatly endanger it.

In very unfortunate cases there follows upon this second stage still a third, namely, that of shrinking. The mucous membrane appears thin, abnormally smooth, and shortened in its whole extent. The tarsal cartilages are bent and shrunk; there is trichiasis and entropion; in short, exactly the same appearances most frequently presented as the result of trachoma. Probably in these cases the diphtheritic infiltration had extended into the cartilages and there caused such changes as finally led to their atrophy and shrinkage.

The prognosis depends most upon whether the diphtheritis is partial or total. Total diphtheritis always involves the greatest danger to vision. In partial diphtheritis, limited to the tarsal part, the prognosis is no more unfavorable than in blennorrhœa. The more the diphtheritis extends upon the conjunctiva of the sclera the greater the danger to the cornea. If the disease has passed into the second stage and the cornea has not been affected, or only slightly so, it may generally be hoped that sight will be saved.

Diphtheritic conjunctivitis occurs both epidemically and sporadically. Infants are seldom attacked. The greatest number of cases are between the ages of 2 and 3 years. Poorly nourished children, who suffer from facial eczema, appear to be specially predisposed. After the third year the predisposition becomes less, decreasing gradually as time goes on.

There is no doubt that the disease is contagious. It is probable that a direct inoculation of the infectious secretion into the conjunctiva is not absolutely a condition for the spread of the disease. If such an inoculation occur, a diphtheritis is not always the consequence, just as infection with blennorrhœal secretion does not always cause blennorrhœa, but may lead to diphtheritis. Climate has a decided influence upon the frequency of diphtheritis. In North Germany it is quite frequently seen, while in Vienna\* it is one of the rarest of all diseases of the eye.

In cases where the affection is at first unilateral, the first step

\*

\* Bericht über die Wiener Augenklinik, Wien, 1867, pag. 44.



in the treatment, just as in acute blennorrhœa, is to cover the healthy eye by a protective bandage. It is true this does not always succeed.

In the beginning of the disease the treatment is strictly anti-phlogistic, the principal reliance being placed on ice-water dressings. Still, cases do occur in which these applications are not well borne, but where warm fomentations act more favorably.

Among other remedies recommended are copious bleeding by means of leeches, the splitting of the outer canthus,\* deep incisions in that part of the conjunctiva infiltrated by the diphtheritic exudate,† and rapid mercurialization by calomel and the inunction of gray ointment.

There is no doubt whatever that cauterization of the conjunctiva during the diphtheritic stage should be absolutely avoided. And in general the indications for the use of caustics in this disease must be more carefully considered than in blennorrhœa. No local treatment is indicated till the diphtheritic exudate is completely absorbed, the mucous membrane swollen, but relaxed and yielding a purulent secretion; then the application of a  $\frac{1}{2}$  to 1 per cent. solution of nitrate of silver may be begun, increasing gradually to a 2 or 3 per cent. solution. In other respects the general rules for the treatment of blennorrhœa are applicable.

In those cases in which the disease passes immediately over from the first stage to recovery, no local treatment whatever of the conjunctiva is indicated.

The treatment of corneal affections is the same as in blennorrhœa.

#### SWELLING OF THE CONJUNCTIVAL FOLLICLES.

One often sees upon the conjunctiva, especially on the temporal half of the fornix of the under lid, small, bright, semi-transparent, superficial and slightly prominent vesicles. Their number may be very small and limited to the under lid; when more numerous they occur also on the upper lid, and in that case first near the median angle, or they may become so numerous as to occupy the entire conjunctiva palpebrarum. They are then generally sparse and small on the tarsal part and more numerous at the fornix, so

\* Von Graefe, Arch. f. Ophth., B. vi. 2, pag. 123.

† Jacobson, Arch. f. Ophth., B. vi. 2, pag. 203.



that they appear like several strings of pearls one behind the other. The largest of these bodies are oval, their longest axis parallel to the palpebral fissure, and measuring something more than 1 mm. Frequently, where their numbers are very great, similar vesicles are found on the scleral conjunctiva near the fornix.

The pathological anatomy of these so-called "vesicular granulations" was asserted by Stromeyer\* to consist in obstruction of the follicles of the conjunctiva. As this, however, has lately appeared to be doubted, I have repeatedly taken occasion to examine freshly excised portions of the conjunctiva with special reference to it. Prof. W. Krause, whose accurate investigations on this subject have contributed much to our understanding of it, had the kindness to examine at the same time most of these preparations, and we can both say that in these cases the objects in question were swollen conjunctival follicles. These follicles appear under the microscope as oval or spherical bodies, having a capsule of connective tissue, with a diameter seldom greater than 0.5 mm. As components of the follicle one may recognize, besides the indistinct fibrous capsule, a delicate reticulation of connective-tissue fibres, in whose meshes lie lymph corpuscles and free nuclei. The lymph follicles are, moreover, permeated by fine capillaries, which are continuous with the vascular net surrounding the capsule. There is also a small number of nerve fibres. Finally, Frey demonstrated between and upon the follicles, an intricate lymphatic net-work, so that it can no longer be doubted that these bodies belong to the lymphatic system.

This circumstance deserves special mention, that, upon anatomical examination, generally only a small number of conjunctival follicles are found, while during life we often see the whole conjunctiva covered with them. Still, from this fact there is no certainty that new follicles are formed, since all the follicles which exist are not necessarily anatomically demonstrable. It is evident that the development of these structures in general, not only on the conjunctiva but, for instance, upon the walls of the intestines, even under physiological relations, depends upon conditions not fully understood. The theory that the lymph follicles are not physiological organs but pathological products, depends partly

---

\* Deutsche Klinik, 1859, pag. 247.



upon this change in their appearance. There is no direct proof to substantiate this theory. To call all conjunctival follicles trachoma and to assume the existence of trachoma from the presence of follicles may be very convenient, but it does not advance our knowledge either of the conjunctival follicles or of the nature of trachoma. Clinical observation has at least determined this much with certainty, that swelling of the conjunctival follicles may exist and continue a long time without the development of the slightest trace of trachoma.

Unfavorable hygienic surroundings seem the most frequent cause of this follicular swelling. It occurs also frequently in individuals whose general surroundings are good, but who periodically occupy overcrowded apartments, badly ventilated school- or sleeping-rooms, etc. The same circumstances, of course, favor the contagious spread of a muco-purulent conjunctivitis occurring in one of these individuals, either accidentally or from these very causes. It is frequently the case, though it should not be so, that the common use of wash-basins, towels, etc., gives sufficient opportunity for direct inoculation. But even where this is not the case the disease may spread, as an endemic, in a manner only to be explained by assuming an atmospheric infection.

Its course varies considerably. Simple swelling of the conjunctival follicles may persist a long time in spite of the most careful treatment. It often disappears under the use of an astringent eye-water, for instance, a  $\frac{1}{4}$  per cent. solution of sulphate of zinc.

The other symptoms connected with this condition depend for the most part upon the behavior of the mucous membrane. The patients often experience no annoyance, and the discovery of the follicles is accidental. In other cases the mucous membrane presents the symptoms of a simple hyperæmia, and the patients complain of burning and pricking in the eyes, especially during work, and perhaps that upon waking in the morning the lids are glued together. Even when the entire conjunctiva of the lids is covered with swollen follicles, there may be no further symptoms than those named. Swelling of the follicles, however, appears to make the conjunctiva more susceptible to inflammation; and this much is certain, that all conjunctival inflammations, under these circumstances, are very obstinate. Moreover, all forms of con-



conjunctivitis, chronic hyperæmia, simple, blennorrhœal, or phlyctenular conjunctivitis, may be complicated with swelling of the conjunctival follicles.

A very peculiar condition develops when swelling of the follicles becomes complicated by severe inflammation and a mucopurulent secretion. The clear, transparent color of the follicles then disappears, principally because the mucous membrane covering them becomes more opaque; moreover, their sharp outlines are lost in the swelling of the mucous membrane; still, we can detect upon the folds of the thickened conjunctiva, traces of the follicles. Especially in those cases in which the conjunctivitis is unilateral, while the swelling of the follicles exists on both sides, is the comparison of the two eyes very instructive.

Cases of follicular swelling which become complicated with mild conjunctivitis are difficult to distinguish from those which are generally described as "acute granulations." Besides the symptoms of an acute inflammation, the mucous membrane is found covered with small spherical prominences, smaller and fewer upon the tarsal part, larger and more numerous in the fornix. In more severe cases the margins of the lids are red and swollen. The hyperæmia of the mucous membrane is frequently so excessive that, upon everting the lids or lightly touching them, bleeding follows. The conjunctiva scleræ is often infiltrated with a serous exudation, and, as a special peculiarity, the cornea is often surrounded by a zone of injected, radiating, fine, deep-lying vessels. The secretion is at first a thin fluid, consisting of copious tears with some coagulated mucus; later, it becomes muco-purulent and less profuse. There is the same tendency to severe corneal affections as in the blennorrhœal process.

It need scarcely be remarked that the conjunctival follicles ought never to be destroyed by cauterization. The local treatment should be regulated by the condition of the mucous membrane. If the latter be simply hyperæmic, fresh air, frequent washing of the eyes in cold water, the eye-douche, etc., should be prescribed. If there be at the same time an abnormal secretion, mild astringent eye-washes should be used, for instance, a  $\frac{1}{4}$  per cent. solution of sulphate of zinc or neutral acetate of lead.

Swelling of the conjunctival follicles complicated with considerable blennorrhœal swelling of the mucous membrane demands



at first, antiphlogistic treatment, and, later, cauterization with a 1 to 3 per cent. solution of nitrate of silver. Still, the caustic treatment must be undertaken with great caution, since premature and severe cauterizations are likely to cause dangerous exacerbations. So, too, the cauterizations should be stopped, and an antiphlogistic treatment substituted, so soon as any intercurrent inflammation appears. After it has passed, the caustic treatment may be again carefully begun.

If the above described conjunctival affections spread epidemically in schools, barracks, etc., the diseased should be separated from the well, and the unfavorable hygienic surroundings which usually exist should be improved as much as possible.

#### TRACHOMA.

At first glance, it would seem strange that a general understanding of so frequent a disease as trachoma has not yet been reached. But it is true, for the same reasons that confusion of ideas prevails in other branches of medicine. How different, for instance, would be the understanding of syphilis if it were possible to follow each case through its entire course! In the same way we may account for the many deficiencies and obscurities existing in our understanding of trachoma. Not only are the opportunities for anatomical examinations in recent cases very rare, but, what is still more unfortunate, the clinical observations remain often very imperfect. On account of the exceedingly chronic nature of the disease, it is very seldom possible to follow any individual case from beginning to end. The difficulties are still further increased by the fact that processes which at first appear very different may lead to the same results, namely, shrinking of the conjunctiva and tarsus, and pannus of the cornea. In general, we must class as trachoma all cases which begin insidiously, whose course is chronic, and which finally lead to shrinking of the conjunctiva.

In many cases trachoma develops in the following manner. The entire surface of the conjunctiva is at first observed to be strewed with spherical, yellow, opalescent granulations, standing so near together that they have been compared to frog's spawn. Upon everting the lid the fornix comes prominently to view, swollen into thick folds, and covered with trachomatous granulations.



These changes may cause a very considerable hypertrophy of the plica semilunaris, which then projects over the lachrymal caruncle in the form of a yellow fold. Scattered granulations also generally appear upon the conjunctiva scleræ, near the fornix.

If one of the spherical granulations be removed with the scissors for the purpose of microscopic examination, there is found immediately under the epithelium an accumulation of cells having exactly the character of lymph- or white blood-corpuscles. Among these cells run very delicate blood-vessels, and upon the surface, immediately under the epithelium, are generally a number of fatty degenerated cells, which possibly cause the yellow appearance of the trachomatous granulations. Smaller bodies of this sort, of perhaps 1 mm. diameter, which I have occasionally examined, appear to be enveloped by a closed capsule of connective tissue, and should therefore be regarded as lymph follicles, but as a general thing the larger of these bodies do not possess the most essential characteristic of a lymph follicle, namely a connective-tissue capsule separating it from the surrounding tissues. The accumulated lymphoid cells which give the yellow color to the granulations are by no means strictly limited to them. Their limits are gradually lost in the adjoining conjunctival tissue, where they are more sparsely scattered. This is why frequently extensive portions of the conjunctival tissue are found infiltrated with these yellow-gray masses, and still, none of the above described trachomatous granulations are present.

This condition may exist without any subjective symptoms by which the patient becomes aware of it. Generally, however, inflammatory attacks occur sooner or later, in the course of which corneal disease (*Pannus trachomatosus*) develops. Still, this condition is one from which there may be full recovery. I have seen cases in which the conjunctiva presented the above described macroscopic and microscopic appearances and the cornea a considerable trachomatous pannus, and yet recovery was so complete that no changes could be seen in the conjunctiva, and in the cornea only a superficial, diffuse clouding. Still, such a favorable course is comparatively rare.

The intercurrent inflammations are often very severe. Great swelling of the lids comes on suddenly; they are red, glistening, and hot; the conjunctiva is swollen, smooth, glistening, and very red;



the secretion is very profuse, consisting of tears mixed with mucus. Keratitis is frequently present. The eyes are very sensitive to light; the head is held bent forward; the attempt to separate the lids forcibly is exceedingly painful, and causes violent spasmodic contractions in them. If the conjunctiva be carefully examined after the severe inflammatory symptoms have abated, it will be found, especially on the tarsal part of the upper lid, in a condition resembling the granulating surface of a wound. It is covered with growing nodules, which are exceedingly hyperæmic and painful, and which bleed if lightly touched.

It cannot be determined whether this condition is always preceded by the above mentioned frog-spawn granulations or the diffuse infiltration of the mucous membrane, since many patients do not present themselves for treatment till the disease has reached this stage.

If the disease has once reached this condition, the formation of cicatricial tissue and more or less shrinkage of the conjunctiva always follow. The conjunctiva then appears smooth, presenting no longer the soft, velvety surface of a normal mucous membrane, but is changed as is the skin by the formation of an extensive cicatrix. There are generally strong strings of cicatricial tissue on the tarsal part of the upper lid, parallel to its margin, and about 2 mm. from it. The fornix also is smooth and shortened, so that when the lower lid is everted and the patient looks upward a number of vertical folds are seen to stretch from the scleral to the palpebral conjunctiva. The same can be seen on the upper lid when the patient looks downward. The margin of the lids and the cilia may remain normal, but as a rule the shrinking is not limited to the conjunctiva, but extends to the tarsus. The effect of this is to obliterate the inner angle of the lid, and an abnormal direction is given to the cilia. The tarsus becomes too much curved, both in the vertical and in the horizontal direction, and its anterior convex aspect causes the lid to appear swollen; an examination of the inner surface suffices to clear up this error. The nutrition of the cilia suffers from the disease of the tissues about their roots. They become replaced by poorly developed, thin hairs, which are often abnormal in position and direction, resting upon the cornea and keeping up a continual mechanical irritation. The consequence may be a spasmodic contraction of the marginal



portion of the orbicularis, which causes the cilia to turn absolutely inward (trichiasis, distichiasis, and entropion).

Whether a condition of proliferation always precedes this shrinkage of the conjunctiva cannot be absolutely asserted.

In the worst cases the shrinkage of the conjunctiva finally becomes so great that it loses the character of a mucous membrane. The excretory ducts of the lachrymal, tarsal, and conjunctival glands, and the hair follicles, become obliterated, and thus all those organs are destroyed which serve to moisten the mucous membrane. Its epithelium becomes dry, and therefore appears gray like the epidermis. The same condition exists on the cornea, which is of course absolutely opaque. The shrinkage of the mucous membrane is often so great that the margins of the lids are drawn close about the margin of the cornea, so that a conjunctival sac no longer exists. This condition of atrophy and dryness of the conjunctiva is called xerosis.

The disease of the cornea which so often accompanies trachoma deserves special mention. Daily experience contradicts the view here and there expressed that the implication of the cornea is simply the mechanical consequence of the trichiasis, or of the roughness of the inner surface of the lids. Pannus trachomatous occurs, and that, too, not infrequently, where the margins of the lids are normal, and where there is no unevenness of the inner surface of the lids.

Frequently a cloudiness and vascularization develop, beginning at the upper corneal margin. Large vessels pass from the conjunctiva scleræ over into the superficial layers of the cornea and there ramify, while the corneal tissue within the region of this vascularization, and generally somewhat beyond it, appears clouded and frequently filled with a great number of somewhat brighter gray dots. Upon focal illumination the surface appears uneven as if stippled, or as if there had been extensive superficial loss of substance. The longer the process the more the clouding extends downward, till finally in this way the whole cornea loses its transparency. In this form of pannus, too much importance has been attached to the fact that the development of vessels takes place from above downward. Pannus and vascularization of the upper portion of the cornea occur without trachoma, and even with trachoma it is characteristic only as it involves a very small



portion of the cornea. The more, however, the vascularization extends over the cornea, the more this peculiar characteristic disappears, since these vessels may encroach upon the cornea from every part of the margin.

This is still more the case with pannus occurring in a different manner. There occur very often with trachoma, either with or without pre-existing pannus, circumscribed corneal infiltrations which present fully the character of a keratitis phlyctenulosa. They are at first greatly distended, elevated above the general surface of the cornea, of a gray color, and surrounded by a diffuse clouded zone. Somewhat later the more prominent part of the infiltration breaks down, and a small corneal ulcer is formed, which may perforate the cornea and cause anterior synechia of the iris. Extensive ulceration of the cornea with great prolapsus iridis is less frequent. Often these infiltrations and ulcers cause a chronic irritable condition. They become vascularized from the corneal margin, and in this manner, by a repetition of the process, pannus is produced.

Simultaneously, the protracted hyperæmia of the cornea may extend to the iris and cause an iritis, which in such a case is hard to recognize on account of the cloudiness of the cornea. Generally, however, upon using atropine and by focal illumination, the cornea is still transparent enough to admit of seeing adhesions which may have formed between the margin of the pupil and the capsule of the lens.

The pathological changes in the cornea in pannus trachomatosis consist in the development of blood-vessels and the proliferation of countless spindle-shaped cells. Ritter\* found this proliferation of cells beneath the anterior layers of the cornea, and in the neighborhood of the sclerotic, penetrating as far as the membrane of Descemet, while in the centre the clouded portion of the cornea occupied only about one-eighth its entire thickness and was sharply differentiated from the apparent normal portion below. In one case which I examined, where the pannus had been of a high degree and long protracted, the anterior elastic membrane was nearly entirely destroyed by numerous superficial ulcers, some of which had been already covered with new epithelium. The clouded

---

\* Arch. f. Ophth., B. vi. 1, pag. 355.



portion occupied about one-third the thickness of the cornea, and consisted, just as in the case described by Ritter, of crowded spindle-shaped cells, among which could be seen but very little transparent intercellular substance.

This thinning of the intercellular substance explains why in many cases of pannus the cornea assumes an abnormal curvature.

The causes of trachoma are to be sought for principally in unfavorable hygienic surroundings. Badly ventilated and over-filled dwelling-rooms, barracks, schools, factories, etc., can either cause trachoma in a conjunctiva previously healthy, or can give to a somewhat protracted conjunctival inflammation a trachomatous character. But certain forms of keratitis, especially those which depend, as do most phlyctenular processes, upon unfavorable hygienic surroundings, may, under the above named deleterious influences, become complicated with trachoma. The contagious character of the secretions in acute inflammatory attacks is undoubted. Inoculated conjunctivitis may vary greatly in severity, and may even assume a blennorrhœal character. Generally, however, at the time of the inoculation the patient is subjected also to the above named hurtful influences, and a trachomatous character is thereby conditioned.

Trachoma is less frequent in children than in adults, but there is no truth in the asserted immunity of childhood from the disease.

It is noticeable, further, that geographical causes affect the disease. Low, damp lands appear favorable to trachoma, while in mountainous regions it is much less frequent. Switzerland, for instance, is said to be entirely free from trachoma.

The course and result in many mild cases of trachomatous disease are quite favorable. Recovery takes place either spontaneously or under proper treatment before cicatricial contraction of the conjunctiva or pannus has developed. In other cases the process does not cease till the conjunctiva has shrunk to somewhat less than its normal extent and has assumed a peculiar smooth appearance. If the position of the margin of the lids and the direction of the cilia remain normal, there may be no annoyances connected with this condition; but in some cases such patients suffer from frequent relapses of conjunctival hyperæmia. If, however, trichiasis and entropion have developed, the continual mechanical irritation of the cornea and conjunctiva thereby caused



excites constant inflammation. Fortunately, most of these cases may be greatly benefited by an operation.

Finally, in many cases not even relative recovery is attained. The patients, even after cicatricial contraction of the conjunctiva, are exposed throughout their lives to attacks of inflammation, beginning sometimes on the conjunctiva, sometimes on the cornea. Generally, incurable blindness follows, due to the clouding or ulceration of the cornea, or to xerotic shrinkage of the entire conjunctival sac.

*Treatment.*—In the first place the hygienic relations are to be improved as much as possible, and all means employed to prevent the spread of the disease.

The local treatment of the mucous membrane is modified by its condition, and accordingly all the remedies ever employed in conjunctival inflammations may be used in their proper place in the treatment of trachoma. Above all things one must rid himself of the idea that it is desirable to destroy by caustics the excrescences upon the surface of the conjunctiva. The use of all local means should be with the object of altering the nutrition of the mucous membrane; all destructive effects must carefully be avoided.

In those cases of trachoma which present the above described peculiar yellow-gray exudation in the mucous membrane, or in which the conjunctiva has upon its surface hyperæmic excrescences, which incline to bleed easily, sulphate of copper is the sovereign remedy. The conjunctiva may be touched with a pencil of the pure crystal, or solutions of varying strength up to 10 per cent. may be used. These are applied with a camel-hair brush, and then immediately washed off again. In most cases, rapid improvement takes place under this treatment. It is generally advisable to prescribe the continual use, for some time, of a salve consisting of 1 to  $1\frac{1}{2}$  parts sulphate of copper to 100 parts unguentum glycerini. If the sulphate of copper be not well borne, or if it do not produce the wished-for results, a 1 or 2 per cent. solution of nitrate of silver should next be tried. A still milder effect may be had by using a 1 or 2 per cent. solution of acetate of lead or tannic acid. Frequently the conjunctiva is so sensitive that local applications are not well borne, but always cause an aggravation of the irritable condition. In such cases it is well to



use warm fomentations, either cataplasms or warm vapor directed against the eye. When under this treatment a copious mucopurulent secretion occurs, the use of mild local applications may be begun.

If in the later stages of trachoma, when the conjunctiva has become smooth and shrunken, there be still hyperæmia and a mucopurulent secretion, only mild local applications are suitable, say a 1 per cent. solution of nitrate of silver, or a 1 to 2 per cent. solution of acetate of lead, or an eye-water containing  $\frac{1}{4}$  per cent. acetate of lead.

As already said, trichiasis and entropion are to be relieved by operation. If only a few small cilia have an abnormal direction, and rest against the cornea, it is better to pull them out as often as necessary.

The pannus trachomatosus appears generally directly dependent upon the behavior of the conjunctiva, and improves at the same time that it does. On the other hand, it sometimes happens that the conjunctiva becomes shrunken, but is entirely free from inflammatory irritation, while the pannus persists unchanged. It is useless in these cases to continue the usual local treatment of the conjunctiva. The treatment is to be applied directly to the cornea. In such cases the use of spray is greatly to be recommended. The spray of a 1 per cent. solution of sulphate of copper should be thrown for some minutes directly against the cornea. A dilute solution of tincture of opium (one part to three of distilled water) often does good service.\* Frequently the keratitis maintains an irritable condition, which demands the use of atropine. If in the later stages, when the cicatrized conjunctiva has already shrunken, the keratitis excite irritability, a salve of red precipitate, 1 part to 100 parts ung. glycerini, is often serviceable.

As a last resort in the most severe cases of trachoma, the inoculation of blennorrhœal or gonorrhœal secretion in the conjunctival sac is recommended. There follows then a blennorrhœal inflammation, whose acute stage lasts from 2 to 6 weeks, while a chronic

---

\* Schenkl, Anwendung des Pulverisateurs bei Augenkrankungen, Prager Vierteljahrschrift, 1871, pag. 149; Jules Cyr, Note sur la Pulverisation appliquée aux Maladies des Yeux, Annales d'Oculistique, 1866, pag. 232.



blennorrhœal condition may last from 2 to 20 months longer. There should be no treatment other than cleanliness and careful bathing of the eyes, since the destruction of the trachomatous growths and the cure of the pannus depend upon the undisturbed course of the blennorrhœal process. The clearing up of the pannus, moreover, occurs very slowly, so that one or two years may elapse before a definite effect is reached. This treatment is recommended for cases in which the lids are covered with thick trachomatous growths, and the pannus of the cornea is such that the patient is able only to perceive light or to count fingers. If a part of the cornea be still clear, its ulceration is to be feared. This treatment, therefore, is scarcely to be employed in cases in which there is blindness in one eye but still useful vision in the other. For in the progress of the inoculated blennorrhœa an accidental infection of the other better eye may easily occur, and the danger here on account of the relatively good or absolutely normal condition of the cornea is much greater than in the eye whose cornea is already highly vascularized. But, after all, I cannot recommend this practice. No more seems to be accomplished by it than may be done in a less dangerous way by skilful local treatment of the conjunctiva.

The conjunctival diseases which occur as epidemics or endemics in the army, and which are called by the names *Ophthalmia militaris*, *O. Egyptiaca*, or *O. granulosa*, should be classed in one or the other of the groups here described. A proper understanding of this subject is difficult to attain, for the reason that it has been usual to include under the term granulations, all inequalities upon the surface of the conjunctiva. Indeed, upon clinical examination, there is often doubt whether one has before him swollen follicles, infiltrated folds of the mucous membrane, or excrescences from the tissue of the conjunctiva; even the microscopic results fail to agree.

While Stromeyer\* has correctly shown that anatomically the so-called vesicular granulations are the closed follicles of the conjunctiva, Preuss† regards them as the products of inflammation, and compares them with condylomata of the external

---

\* Deutsche Klinik, 1859, pag. 247.

† Berliner klinische Wochenschrift, 1869, pag. 438.



skin, the granulation tissue, "*caro luxurians*" of Virchow. The statements of Preuss respecting the microscopic appearances assert nothing which cannot be referred to the lymph follicles, and his remark that "often when such a granulation is seized with the scissors, a thick pulp issues from it as from a ruptured capsule," makes it probable that they are actually swollen lymph follicles. When now Preuss goes on to describe a proliferation of connective tissue and subsequent shrinkage as a metamorphosis of the granulations, it is certainly not to be doubted that such processes frequently occur upon the conjunctiva, but it is not probable that the lymph follicles alone experience this transformation.

The difficulty connected with the subject is that the various formations which are called conjunctival granulations may some of them have been originally anatomically identical, but by internal metamorphosis have come to be different, while others which seem similar were originally anatomically different. That this last often happens has been frequently shown in our discussion of conjunctival diseases.

Hemorrhages beneath the conjunctiva scleræ occur sometimes in consequence of injuries, sometimes from violent straining,—for instance, frequently during whooping-cough,—sometimes without any perceptible cause. They disappear spontaneously in a few days.

Œdema of the conjunctiva scleræ is generally only a symptom of some other disease. Acute conjunctival inflammation, severe iritis or choroiditis, inflammation of the orbital fat, etc., may be accompanied by excessive chemotic swelling. Often, however, without any apparent cause, there occur great swelling and hyperæmia of the conjunctiva scleræ, which protrudes from the palpebral fissure as a tensely stretched dark-red tumor. In the course of one or two weeks, if the eye be kept quiet and protected from external irritation, this erysipelatous inflammation—if one wish to call it so—may disappear.

In the course of variola the characteristic pustules may develop upon the conjunctiva. After they are healed they generally leave pigmented spots.

The occurrence of lupus has already been mentioned on page 227.



Pemphigus of the conjunctiva is very rare. Only two cases\* are known in which pemphigus occurred upon the conjunctiva in connection with the eruption on other parts of the body. It always leaves a scar, just as if the surface had been destroyed by a strong caustic. Repeated eruptions of pemphigus, therefore, greatly endanger vision, by shrinkage of the conjunctiva and opacity of the cornea depending upon it.

Foreign bodies in the conjunctival sac generally fix themselves upon the tarsal part of the upper lid, and cause an easily recognizable traumatic conjunctivitis. Their removal is not difficult.

Splinters of straw, wood, etc., often hide in the fornix of the upper lid, and may remain there a long time. They cause a circumscribed proliferation of the connective tissue, which disappears after the foreign body has been removed.

Burns of the conjunctiva, by molten substances or chemical caustics, cause a traumatic conjunctivitis, which in mild cases yields to simple antiphlogistic treatment, or may pass over into some one of the above described forms of conjunctivitis. Deep burns, destroying the mucous membrane, cause cicatricial adhesions and symblepharon.

By pterygium is understood a thickening of the conjunctiva, of triangular form, its base generally turned toward the inner canthus, while its white, glistening, blunt point lies upon the cornea. A number of vessels converging toward the point can generally be seen in the pterygium.

The base of the pterygium is sometimes only a few millimetres from the margin of the cornea. Where it has existed a long time, and has reached a high degree of development, it may extend to the plica semilunaris or to the fornix, and this, on account of the non-yielding nature of the pterygium, causes a limitation of the movement of the eye.

Near its point the borders of the pterygium are sharply defined, and in the neighborhood of the limbus conjunctivæ corneæ they are often reflected under, so that a fine probe may be inserted for a short distance between the pterygium and the cornea. Toward its base the pterygium gradually loses its sharp boundaries.

---

\* White Cooper, Ophth. Hosp. Rep., 1858, No. 4, pag. 155; Wecker, Klin. Monatsbl. f. Augenheilk., 1868, pag. 232.



The connection between the pterygium and the tissue under it is quite loose, and it may be removed with the forceps and scissors from the sclera and cornea without causing pain to the patient, especially when he is told to look toward the side on which the pterygium grows.

In the great majority of cases the base of the pterygium is directed toward the inner canthus, seldomer outward, and only very rarely upward or downward. The point gradually grows from the margin of the cornea toward the centre, but without actually reaching it, except in rare cases.

Under the influence of conjunctival inflammations the pterygium may swell greatly and assume a fleshy, uneven appearance.

Pterygium occurs most frequently in aged persons who by the nature of their daily occupations are exposed to the effect of mechanical or chemical irritants, for instance, dust, and particularly lime-dust, or the irritating fumes of stables, etc. Chronic conjunctivitis often exists simultaneously with the pterygium.

Microscopic examination\* has shown that the pterygium anatomically is a mass of connective tissue, which is to be regarded as continuous with the conjunctiva scleræ. Upon longitudinal section the bundles of connective-tissue fibres are seen converging toward the point of the pterygium; parallel with them run many very thin-walled blood-vessels, which are more numerous just below the epithelium than in the deeper parts, where only a few large vascular stems are to be found.

The connective tissue composing the inner part of the pterygium is of two kinds, colloid or mucous, and fibrillar. There is, however, no sharp demarcation between the two kinds of tissue, but the transition from one to the other is gradual. The fibrillar tissue lies mostly in the central part, and consists of fibres running longitudinally, having few nuclei, and arranged in bundles. Its structure is most dense at the point and at the outer sides of the pterygium, while in the inner part it lies only along the course of the blood-vessels. The nearer its cells lie to the vessels the closer and more regularly are they disposed; the farther they are from the vessels the sparser and longer they become, and the more

---

\* Schreiter, Untersuchungen über das Flügelfell, Inaugural-Dissertation, Leipzig, 1872.



apparent their arrangement in parallel bundles. It is especially noticeable that not only the anterior surface of the pterygium, but also that part of its posterior surface which lies upon the cornea is covered with epithelium. This gives to the pterygium the appearance of being a growth of that layer of the conjunctiva scleræ which lies between the epithelium and the sclera. The growth and progress as well as the triangular form of the pterygium would then depend principally upon the growth of the vessels and their arrangement.

These formations are really different from the somewhat similar ones which are caused by loss of substance and cicatrization at the margin of the cornea, and which have therefore been called "cicatricial pterygium." Ulcerative processes at the margin of the cornea, involving both it and the conjunctiva, may, from the resulting cicatricial contraction, end in this kind of pterygium. The easily displaced conjunctiva is drawn over upon the cornea, and thus a triangular, folded, thickened mass is formed, whose point lies upon the cornea, and whose base extends to the fornix conjunctivæ. Wounds upon the margin of the cornea by foreign bodies, gunpowder blown into the eye, burns from mineral acids or from molten metals, have been observed as causes. It is only exceptionally, but in such cases quite rapidly, that cicatricial pterygium occurs in consequence of acute conjunctival blennorrhœa or of phlyctenular keratitis. When it does occur it differs from the typical, slowly developing form, by being more frequently directed upward than toward the inner canthus.

Pterygium generally causes no inconvenience. It is only very seldom that it attains such a development as to interfere with vision, or to cause diplopia by limiting the movement of the eye. For this reason the indication for an operation seldom exists. Moreover, the patients generally affected by pterygium are of a class very indifferent to the cosmetic effects of an operation.

If the pupillary region of the cornea be covered by the pterygium, the operation of iridectomy affords a good prospect for improving vision.

If the removal of the pterygium be indicated, it may, according to Arlt's\* method, be performed by making a rhomboidal incision.

---

\* Augenheilk., B. i. pag. 163.



The pterygium is to be grasped above the margin of the cornea with the toothed forceps; its point is then to be dissected with the cataract knife as cleanly as possible from the cornea. The pterygium is then loosened from the sclera by the scissors along the line of its edges to a distance of from 2 to 4 mm. beyond the corneal margin, and dissected up as closely to the sclera as possible. The two diverging incisions along the edges are then united by two converging ones, thus giving to the exposed surface the shape of a rhomboid, with one acute angle directed toward the middle of the cornea and the other toward the equator of the eye.

If the pterygium be large, and especially if of the cicatricial variety, the operation by transplantation is to be recommended, since where there is already loss of substance it is not advisable to increase it by further incisions. The method is as follows. The point of the pterygium is dissected up from the cornea and from the anterior part of the sclera, so that the pterygium can be pushed back to the fornix conjunctivæ. The conjunctiva, above and below the wound thus made, is then loosened from the sclera so that the two lips can be slid together across the exposed sclera and fastened together in that position by sutures.

Pinguecula is the name given to a small yellow elevation, having its seat in the conjunctiva and subconjunctival tissue, near the margin of the cornea, sometimes on the temporal and sometimes on the median side. It causes no annoyances.

Tumors, generally speaking, do not often develop upon the conjunctiva. Among the growths which occur upon the conjunctiva itself are first to be mentioned certain proliferations of the connective tissue, which are generally situated at the inner angle of the eye, near the lachrymal caruncle, or even on it. They are round, varying from the size of a small pea to that of a hazel-nut, often easily inclined to bleed, and generally attached to the conjunctiva by a thin pedicle. They may be easily removed and subsequently cauterized, if necessary. In exceptional cases these growths show a tendency to return.\* Similar connective-tissue growths, which occur in the conjunctival wound made during the operation for squint, have already been mentioned on page 176.

---

\* Arlt, *Krankheiten des Auges*, B. i. pag. 166; A. v. Graefe, *Arch. f. Ophth.*, B. i. 1, pag. 293.



More frequently tumors develop upon the margin of the conjunctiva, and spread from thence upon the general conjunctival surface, for instance, epithelioma, from the margin of the lids (comp. page 227), or the melanoma, the melanosarcoma, and the dermoid tumors, which generally originate on the corneo-scleral boundary, and which will be mentioned among the diseases of the cornea.

#### PHLYCTENULAR CONJUNCTIVITIS.

A very sharply defined group of conjunctival inflammations is characterized by the fact that the inflammatory process localizes itself upon the conjunctiva scleræ.

There generally appears close to the corneal margin a circumscribed papular swelling, which is commonly called a phlyctenule. It forms the point toward which converge a number of conjunctival and subconjunctival vessels, which can frequently be traced back nearly to the fornix.

As a rule, the phlyctenules appear first as papules, having a diameter of from 1 to 2 mm., with turbid contents. After a short time they burst, and leave a shallow loss of substance. Frequently several such phlyctenules appear simultaneously upon the margin of the cornea. In many cases the eruption of this inflammation is accompanied by an acute swelling of the conjunctiva palpebrarum, with muco-purulent secretion. This inflammation may be so severe as to form the most prominent symptom of the disease, and the first to demand treatment.

Occasionally in the course of a simple conjunctivitis there occur a circumscribed redness and swelling of the conjunctiva scleræ, of the size of a pin-head, and situated not exactly at the corneal margin, but at a little distance from it. Strictly speaking, this does not belong to the conjunctivitis phlyctænulosa here described.

Another form, the broad phlyctenular conjunctivitis, occurs in the form of flat infiltrations, 3 to 4 mm. in breadth, crowded closely about the cornea, and likely to cause purulent infiltration in it.

Lastly, the small phlyctenules, which occur in the form of numerous small papules upon the limbus conjunctivæ corneæ, may just as properly be called marginal keratitis.



In many cases the process does not go on to the development of actual phlyctenules, but is limited to a phlyctenular injection at the margin of the cornea.

The subjective symptoms of phlyctenular conjunctivitis are mild, so long as the inflammation is limited to the conjunctiva scleræ, but so soon as it invades the cornea there occur those violent irritative symptoms so characteristic of keratitis.

In simple cases of this kind the causes are the same as in other forms of conjunctivitis. Recurring phlyctenular conjunctivitis generally exists in connection with scrofula, and is frequently complicated with keratitis.

The treatment must, in the first place, be directed toward allaying the existing irritation. If the inflammation be acute, an antiphlogistic and mildly derivative treatment is to be employed. Cold dressings of fresh water or of lead-water, and, if necessary, mild cathartics, are generally sufficient. If in consequence of corneal irritation there be excessive lachrymation, photophobia, etc., atropine mydriasis is to be established and maintained.

After the irritation has been allayed, the mercurial preparations are most relied on in the local treatment. The yellow oxide, 1 to 1.5 per cent., in the form of salve, is most frequently employed; it is to be placed in the conjunctival sac once or twice daily. If, as rarely happens, it be not well borne, lukewarm drops of a weak solution of corrosive sublimate should next be tried:

R Hydrarg. chlorid. corrosiv.,	0.06 = about gr. i;
Aquæ,	200.00 = "    ℥ vi.

In mild cases, in which it is wished to continue the treatment a long time, in order to guard against relapses or to remove all traces of the disease, calomel is a very useful remedy. It is used in the form of a very fine powder, and is dusted into the eye with a dry camel-hair brush.

Relapsing phlyctenular conjunctivitis depending upon scrofula demands the appropriate general treatment.



## DISEASES OF THE CORNEA.

---

THE recognition of corneal diseases, as well as of all pathological products in the anterior chamber, the iris, or the pupillary region, is greatly facilitated by the method of focal illumination, the introduction of which into ophthalmology we owe to Helmholtz.\* It consists, essentially, in concentrating the flame of a lamp, in a darkened room, by means of a convex lens of about 2 inches focal distance, upon the point which is the special object of examination.

This point is thus intensely illuminated, and all the more distinctly from the fact that the surrounding tissues lie in the shadow of the convex lens.

By means of the convex lens the inverted image of the flame is cast upon the cornea, and moved gradually over its entire surface. Then, by holding the lens a little nearer the eye, the image of the flame may be cast upon the iris, upon the anterior capsule of the lens, into the lens itself, and, when the pupil is dilated, even into the vitreous body.

If it be desired at the same time to magnify the objects under observation, it is best done by a simple binocular lens, such a one as, having an opening of  $2\frac{1}{2}$  to 3 inches and provided with a suitable handle, is used by old people as a reading glass. The observer holds the glass at such a distance as allows him to look through it with both eyes, while the distance to the object examined is that at which it is most magnified. In this way not only the dimensions of surface but those of depth also are magnified, and, in examining corneal diseases, this has the advantage that it enables one to determine whether only the superficial layers, or the deeper ones as well, are affected.

The diseases of the cornea, like those of the conjunctiva, can be divided only into certain great groups, but even then it by no

---

\* Arch. f. Ophth., B. i. 2, pag. 44.



means follows that every case as it occurs in practice may be referred immediately to one of these divisions.

#### PHLYCTENULAR KERATITIS.

This is a very frequent and varied form of disease. It is characterized by the appearance upon some part of the cornea of small, sharply defined centres of inflammation, which, when they first appear, are elevated above the general surface of the cornea in the form of small gray prominences, varying from the size of a poppy-seed to that of a millet. In its further course this infiltration breaks down, leaving a loss of substance whose various forms shall be described later. The eruption, and frequently, too, the further course of phlyctenular keratitis, is generally accompanied by severe irritation.

Either the entire margin of the cornea or that part near the centre of inflammation is surrounded by a redness due to the injection of the thickly crowded, radiating, episcleral vessels. The scleral and palpebral conjunctiva participate more or less in the hyperæmia. It is often inflamed and swollen, and yields a mucopurulent secretion.

The photophobia which is caused by this process is in children often so great that they cannot be induced to open their eyes, but seek the darkest corner of the room and bury their faces away from the light. The skin is drawn into a fold at the outer angle of the eye, in consequence of the spasmodic closure of the lids, and is excoriated by being constantly wet with tears. An examination under these circumstances is often very difficult; a voluntary opening of the lids cannot be obtained, and the most careful efforts on the part of the physician to open them excite the most violent movements of the head and of the entire body. In these cases it is therefore necessary, both with reference to the prognosis and treatment, so to conduct the examination that its results may be certain. It is best to lay small children upon the back on the lap of the nurse, who at the same time holds the hands while the examiner takes the head of the child between his knees, and then carefully separates the lids, without, however, everting them.

The cornea generally at first rolls upward, but generally, too, after a few moments, turns downward again, and becomes visible in the palpebral fissure. If the cornea, however, remain hidden



under the upper lid, the eye may be rolled downward with the fixation forceps. The examination under chloroform narcosis is the best method, and very slight narcosis answers the purpose.

The excessive blepharospasm which accompanies phlyctenular keratitis depends probably upon a direct irritation of the corneal nerves. Iwanoff\* found, in certain of these cases of keratitis, an accumulation of cells between the epithelium and Bowman's membrane; the epithelium covering the phlyctenule was quite normal, and but slightly raised; the corneal tissue below showed no changes, and in certain cross sections the communication between the phlyctenule and the corneal tissue could be detected. Within the corneal substance the cellular infiltration was more or less crowded along the course of the fine nerves, surrounding them as they penetrated Bowman's membrane, and then collecting in little heaps beneath the elevated epithelium.

Aside from the typical phlyctenular corneal infiltration, there are still to be mentioned, as special forms of this disease, the marginal keratitis, and the so-called fascicular keratitis.

The phlyctenular marginal keratitis begins with a partial or total hyperæmia of the limbus conjunctivæ corneæ; it appears thickened and covered by a row of closely crowded little prominences. The process may go no farther, or, if it last some time, may invade the surface of the cornea proper. The neighboring marginal part of the cornea appears, then, diffusely clouded, uneven, and often strewed with numerous small phlyctenules. Later, fine blood-vessels run across the limbus conjunctivæ corneæ.

The fascicular keratitis generally develops from a phlyctenular marginal infiltration, which gradually advances toward the centre of the cornea, the thickly crowded blood-vessels following it in a ribbon-like stripe. At first this infiltration advances quite regularly, by lines radiating toward the centre of the cornea, but after having passed the centre it often bends about like a horseshoe. Finally the process ceases, leaving behind a ribbon-shaped cicatricial stripe.

More rarely it happens that, instead of an infiltration, a moderately deep ulcer, with a purulent surface and followed by a broad bundle of vessels, creeps from the margin of the cornea toward

---

\* Klin. Monatsbl. f. Augenheilk., 1869, pag. 462.



its centre. The opacities remaining after this process are still greater.

Phlyctenular keratitis stands in very close etiological relation with scrofula. Corneal diseases in general, but this one in particular, are not only much more frequent in scrofulous individuals, but are also more obstinate and dangerous than in healthy constitutions.

Not only do the reflex symptoms, photophobia, etc., occur in scrofulous children in their most intense form and accompanying very slight objective changes, but the course of the disease is, under these circumstances, slower and more obstinate, more severe forms occur, and relapses are more frequent.

The recurring inflammations, moreover, do not always have their seat in the hitherto intact portions of the cornea. Frequently new inflammation, softening, infiltration, and vascularization occur in old scars which have remained from former inflammations.

In many cases the cornea becomes very vascular. Its whole surface is thus covered with a net-work; it appears uneven in consequence of loss of epithelium, and looks as if stippled. In the diffusely clouded corneal substance can be seen a number of small flakes, which are partly scar tissue and partly fresh infiltration.

This condition of cloudiness and vascularization of the cornea, which occurs in just the same way as with trachoma, is called pannus. Formerly, according to the degree of the opacity a distinction was made between a pannus crassus sive carnosus and a pannus tenuis; but this distinction rests only on a quantitative difference, and during the course of the disease the one form may pass into the other. More important, because resting on etiological grounds, is the distinction between pannus trachomatosis and pannus phlyctænulosus, but in this connection it is to be mentioned that superficial, pannous keratitis may develop without any preceding keratitis phlyctænulosa, and independent of conjunctival disease.

The course varies greatly. In favorable cases the corneal phlyctenule breaks down, leaving a small superficial loss of substance, which is replaced by new tissue. The traces of the disease can then generally be detected only by focal illumination. In other cases the loss of substance is somewhat greater, its margins



flatten down, the ulcer becomes clean and smooth, and is finally covered with new epithelium; in these cases, too, a slight clouding of the tissues is to be observed only by focal illumination. These so-called corneal facets represent a peculiar reparative process, which may occur in the same way in other corneal diseases.

Finally, it may happen that the loss of substance assumes the character of a corneal ulcer. There frequently follows, then, a vascularization of the ulcer from the margin of the cornea, which facilitates its healing, but which generally disappears very slowly after cicatrization.

A rather rare but very dangerous complication of the superficial phlyctenular process is the development of a gray or gray-yellow infiltration, which appears first in the deep layers of the cornea, and which shows a decided tendency to go on to suppuration, formation of hypopion, and ulceration of the cornea. The condition in fact is that of a complication by hypopion-keratitis, generally with great irritation.

Quite as rare is another form of infiltration, not inclined to suppuration, but involving a considerable extent and depth of the corneal tissue, and resembling keratitis parenchymatosa, but differing from it by running a decidedly more rapid course.

With unfavorable hygienic surroundings, or in scrofulous individuals, phlyctenular keratitis may persist with the greatest obstinacy, and may recur so often as greatly to endanger vision by the opacities which it leaves behind.

*Treatment.*—On account of the close connection between scrofula and phlyctenular keratitis, constitutional treatment is in many of these cases very essential. Preparations of iron, salt-baths, etc., are frequently employed. But aside from the fact that circumstances generally make it impossible to regulate the hygienic surroundings, the results to be expected from anti-scrofulous treatment are so tardy that they cannot be relied on to avert the pressing danger always threatened by diseases of the cornea. The most reliance must be placed upon the local treatment. The first indication is to allay the irritability. This is generally best done at first by cold-water or lead-water dressings and atropine. The atropine must from the first be so employed that a sufficient mydriasis is caused and maintained, a thing difficult to do on account of the irritability. Frequently the action of the atropine proves



insufficient and very transitory. In the later stages of the disease, where the irritability has lasted a long time, lukewarm applications are better than cold. When the irritability is lessened, the local use of mercurials is indicated just as in phlyctenular conjunctivitis. The principal remedies used are the yellow oxide of mercury, 1 or 2 per cent., in salve form, and calomel, which is dusted into the eye as a fine powder. If these remedies do not prove useful, pencilling with a 1 or 2 per cent. solution of nitrate of silver often causes rapid improvement. This treatment is particularly indicated in those cases in which the disease has lasted a long time, and hyperæmia and swelling of the conjunctiva have developed. Under such circumstances mercurials generally prove more or less inefficacious, while the best results are obtained by the local treatment of the conjunctiva, particularly in the superior fornix.

Mercurials are also not generally well borne when the disease is complicated by the above described purulent inflammation of the deeper layers, and still on account of the dangerous nature of this complication some promptly acting treatment is necessary. It seems best in these cases to use atropine liberally, and warm fomentations, alternating with a pressure-bandage. If this do not prove sufficient, chlorine water or a 1 per cent. solution of the muriate of quinia may be dropped into the eye three or four times during the day.

The deep infiltration resembling keratitis parenchymatosa generally disappears rapidly under the use of atropine and the pressure-bandage.

The treatment above described is also suitable for pannus phlyctænulosus. The improvement of the general health is often very important. The fresh country air often exercises a surprisingly good influence. Among the local remedies are calomel, red precipitate salve, and lukewarm washes of corrosive sublimate (solution, 1 part to 3000 or 4000). Swelling of the conjunctiva, especially at the fornix, demands generally the use of nitrate of silver. Chlorine water may also often be used to advantage. Under this treatment the vascularization may disappear entirely, and the cornea again become so clear that by ordinary daylight no abnormality can be seen in it. But nevertheless there remains over the whole surface a delicate clouding, visible by focal illumination.



For very obstinate cases of pannus the operation of periotomy or syndectomy is recommended. It consists in the removal of a circular strip, 3 to 5 mm. wide, from about the cornea. In the course of a few months the cornea becomes surrounded by a ring of dense cicatricial tissue, which cuts off the blood-supply from the vessels ramifying on it.

Obstinate and relapsing cases are frequently checked by a derivative treatment. The practice so often resorted to by the English ophthalmologists, of inserting in the temple a small seton consisting of 4 or 5 cotton threads, is a good one.

#### PARENCHYMATOUS KERATITIS.

Keratitis profunda, interstitialis, or parenchymatosa, is a very well defined form of disease which in the majority of cases is bilateral. As a rule, both eyes are not attacked at the same time, but first one and then, after an interval of some weeks or months, the other. There is often, therefore, the opportunity to observe the development of the disease in the second eye. After an increased irritability has been observed for some time in the eye, a bright-red injection of the episcleral vessels appears in the neighborhood of the ciliary body; this gradually approaches the margin of the cornea, and there attains its greatest intensity. Simultaneously appears a clouding of the corneal substance, which begins either in the centre of the cornea, and from there spreads out in the course of a few days or weeks toward the periphery, where it often leaves a small marginal part of the cornea free, or beginning at any point of the margin, it spreads from there over the entire cornea.

At first the cornea appears semi-transparent, somewhat like ground glass. Later, bright gray or gray-yellow indistinctly defined spots appear, mostly near the centre of the cornea, often uniting together to form an annular figure. These opacities lie in the deep layers of the cornea, while the surface, when examined through a convex lens and by focal illumination, appears uneven.

At first there is no vascularization of the cornea, and as a general thing mild cases of keratitis profunda run their course without the development of blood-vessels in the cornea. Frequently a fine vascular net with large meshes appears upon the surface of the cornea, just as in other forms of keratitis. There is, however, a certain kind of vascularization which is especially characteristic



of this form. The entire margin of the cornea is encroached upon by closely crowded, short vessels radiating toward the centre. Without advancing any farther they may remain a long time stationary. But in the worst cases these vessels creep steadily on toward the centre of the cornea. The opacity of the cornea becomes so great that it assumes a dirty-red flesh color, while its middle, so long as it is not vascularized, is by its bright gray color sharply defined from the surrounding vascularized part.

Gradually the vessels reach the middle of the corneal surface, and not till then does the retrogressive process begin in the vascularization. By this process the cornea becomes clearer. This affection does not cause ulcerations of the cornea.

Even in a few weeks after the appearance of the disease the cornea may become so opaque that the condition of the iris cannot be accurately observed. Generally when the cornea clears up again, the iris is found unchanged and acting normally, but sometimes the existence of adhesions shows that there has been iritis.

The subjective symptoms vary in intensity. In mild cases, in which there is no vascularization of the cornea, and where the development of vessels about its margin is only slight, the patients generally complain only of indistinctness of vision and an inclination of the eyes to redness and weeping. Where there is greater opacity and vascularization there is more irritability, photophobia, lachrymation, pain, etc.

The course of the disease is always slow, extending over several months. As a rule, vision, after recovery, is more or less injured according to the severity of the case. There remain diffuse or punctated opacities, frequently to be seen only by focal illumination. Still, the final result is generally more favorable than one would expect from the appearance of the disease at its height.

The causes are frequently of a constitutional nature; at least the circumstance that it generally affects both eyes would so indicate. It occurs most frequently in children and young persons whose health and general nutrition are bad; but quite healthy persons with good hygienic surroundings are sometimes attacked. Hutchinson's\* view, that this form of keratitis is to be regarded as the direct consequence of congenital syphilis, has not been

---

\* Ophth. Hosp. Rep., 1858, No. 5, pag. 229.



generally accepted in Germany. The disease undoubtedly occurs in individuals absolutely free from syphilis.

Hutchinson refers to a certain abnormal development of the teeth as nearly constantly associated with the disease, but this, too, is absent in many cases. The peculiarity of this abnormality is that the middle of the cutting edge of the incisors, which should be the most prominent part, crumbles down and assumes, especially in the two upper front teeth, a concave form.

Keratitis parenchymatosa is most frequent from the sixth to the twentieth year. After that it is rarer, and its course, when it occurs, is milder.

In making the prognosis, we have to consider the length of the process and the remaining opacities. These last are generally so much the greater the higher the inflammation and the more extensive the vascularization of the cornea has been.

The treatment of this form of keratitis cannot be a very active one. Improvement of the hygienic surroundings, attention to constitutional disturbances, protection of the eyes from injurious influences of all kinds, and patience on the part of the physician and patient, are the principal points in the therapeutic programme. Iodide of potassium and preparations of iron are generally to be recommended. The local treatment should be such as to diminish as much as possible the irritability. For this purpose warm fomentations and atropine are best. All irritants are to be avoided. Hasner\* recommends the paracentesis of the cornea for all cases which are free from complications, and in which the cornea, although considerably clouded, is but little or not at all vascularized, while the hyperæmia of the sclera and the ciliary neuralgia are but slight. It is especially in recent cases of this kind, in which the affection has lasted but a few weeks, that favorable results have been observed to follow paracentesis.

Keratitis punctata is a quite rare affection, and one always complicated with iritis; it ought not, however, for that reason to be confounded with certain cases of iritis, which are characterized by a precipitate upon the membrane of Descemet. With inflammatory symptoms, and the corresponding irritability, there develop in the parenchyma of the cornea, isolated, circumscribed, white

---

\* Klinische Vorträge über Augenheilkunde, pag. 163.



specks about the size of a hemp-seed, and surrounded by a diffuse clouding. After a few days the adhesion of the margin of the pupil with the capsule of the lens, shows the existence of iritis. As the process advances, these specks multiply; they run together at places, forming irregular lines, the diffuse clouding becomes denser, and the adhesions of the iris more numerous.

The disease is most frequent in children before the time of puberty, and appears frequently to be of a syphilitic nature. It is not near so frequent as keratitis profunda, runs a less typical course, and appears, at least at first, to be more amenable to treatment. Continued and extreme mydriasis, by the use of sulphate of atropia, is indicated, and so is iodide of potassium in cases which are suspected to be caused by syphilis or scrofula. Some cases which I have been able to treat from the first in this manner, I have seen heal, leaving only small peripheral spots in the cornea and with vision unimpaired, while, if the disease be neglected,—as it is very apt to be, as its symptoms are at first not severe,—the corneal opacities become more numerous and denser, and interfere greatly with vision, while simultaneously the danger from the persistence of the iritis is very great.

Aside from atropine and the continued use of derivatives and attention to existing constitutional anomalies, the question of iridectomy may often arise, partly for optical reasons, partly to check the progress and avoid the ruinous consequences of chronic iritis.

#### PURULENT KERATITIS.

A purulent process in the cornea may occur as a symptom of very different diseases. In the strictest sense, however, by purulent keratitis are understood those cases which occur as an independent disease. If the case be one in which there is a circumscribed collection of pus in the tissue of the cornea, it is generally called a corneal abscess.\* Since in many cases of purulent keratitis there is at the same time a collection of pus in the anterior

---

\* A corneal abscess was generally designated by the term *Onyx* or *Unguis* by the older ophthalmological writers. Jüngken discriminated between *abscessus corneæ* and *onyx*, meaning by the latter a congestion abscess,—that is, a collection of pus in the tissue of the cornea at its lower margin, formed by the sinking of the pus from an abscess, ulcer, or wound in the upper part of the cornea.



chamber, Roser\* has proposed for this condition the very suitable name of "hypopion keratitis."

The beginning of this affection is always near the centre and in the deeper layers of the cornea. At that place there appears a round, circumscribed, gray opacity, in which, when examined with a magnifying lens and by focal illumination, a number of short gray striæ may be detected. They may be either parallel with one another or radiating. The superficial layers of the cornea are at the same time diffusely clouded, and there are many small defects and irregularities in the epithelial covering.

The infiltration of the deeper layers now assumes gradually a yellowish purulent color, while a loss of substance occurs upon the surface. The appearance of these superficial ulcers is very varied. Often the ulcer is no larger than the purulent infiltration, has the appearance of a so-called corneal facet, with a smooth, glistening floor, clean margins, and no steep walls, exactly as if a piece had been sliced from the cornea by a single cut with a sharp knife. It is very easy to conceive, under these circumstances, that by the collapse of an abscess the anterior surface of the cornea has sunk in. The possibility of such a process, as described by Arlt,† cannot be questioned, but, as a general rule, this change of form seems to be due to a superficial disintegration of tissue.

In other cases the superficial ulcer attains soon a greater size than the purulent infiltration behind it; its margins are sometimes flat, sometimes steep, and are often quite clean, that is, free from any purulent infiltration; it is then sometimes not easy to recognize the full extent of the loss of substance.

Frequently there is some punctated purulent infiltration in the corneal substance surrounding the margin of the ulcer.

The further course and the entire type of the disease depend essentially upon whether the deep purulent infiltration or the superficial ulcer becomes more extensive. Cases of the first kind are called corneal abscesses, on account of the circumscribed accumulation of pus in the tissue of the cornea. Unless recovery is rapid, the enlargement of the abscess and of the superficial ulcer causes extensive destruction of tissue.

Other cases assume a dangerous character, less from the puru-

---

\* Arch. f. Ophth., B. ii. 2, pag. 151.

† Ibid., B. xvi. 1.



lent process in the deeper parts of the cornea than from the purulent infiltration of the edges of the ulcer. The floor of the ulcer is often also purulently infiltrated, and this is especially true of small ulcers; or it may be quite clean and smooth; or finally, by the help of focal illumination and a magnifying lens, it may be seen to be gray and clouded, and to contain numerous gray-white, punctated, purulent infiltrations. This purulent infiltration of the margin of the ulcer is generally only at one part of its circumference, and shows itself in the form of a dirty, yellowish-white line, while the remaining part of the circumference is clean and smooth, and therefore more difficult to see. The ulcer spreads toward the side of the infiltrated margin, and after a time comes to a stand-still at this point, but the process is renewed at some other portion of the circumference, and the tissue in its neighborhood is destroyed.

Since this destructive process gradually creeps over the surface of the cornea, Sämisch\* has designated this form of disease as *ulcus corneæ serpens*. These ulcers frequently appear flatter than they really are, since the thinned floor yields to the pressure of the aqueous humor and is pressed forward. Between the corneal abscess and the *ulcus serpens* there are many intermediate forms.

In the great majority of cases of purulent keratitis pus collects in the anterior chamber. In such cases iritis generally exists at the same time; but cases do undoubtedly occur in which hypopion exists, while the iris still reacts promptly under atropine and there are no adhesions with the capsule, nor any other traces of inflammation.

The belief formerly generally accepted, that the hypopion was due to a participation in the purulent process by the epithelium of the membrane of Descemet, seems no longer plausible, since we have come to regard the pus-cells as identical with the white blood-corpuscles. The process of a direct rupture of the abscess into the anterior chamber, as described by A. Weber,† I have never been able satisfactorily to observe. But one very often sees a yellowish-white thread of pus, of greater or less thickness, lying close to the membrane of Descemet, and extending from the ulcer

---

\* *Das ulcus corneæ serpens*, Bonn, 1870.

† *Arch. f. Ophth.*, B. viii. 1, pag. 322.



down to the lower margin of the cornea. But upon examination with focal illumination, it is impossible to say whether it lies before or behind the membrane. The structure of the deeper layers of the cornea is so loose, and their connection with the membrane of Descemet is so slight, that the wandering downward of the pus-cells, assisted by gravity, meets with but little obstruction. But when the pus has once reached the membrane of Descemet, it can easily pass through the openings of the ligamentum pectinatum into the anterior chamber. It is possible that the pus may settle in this manner, but the question is, does it actually do so? According to Horner's\* observations, this process takes place on the posterior surface of the membrane of Descemet. The pus-cells from the corneal ulcer penetrate the membrane of Descemet, accumulate upon its posterior surface, and finally sink downward. Evidently an accumulation of pus in the corneal substance could not immediately rise and discharge itself with the aqueous humor when a puncture is made in the cornea at some distance from it in the horizontal direction. At least the walls of the channels through which it had sunk would remain infiltrated and would show a distinct cloudiness. If now, after paracentesis of the cornea, nothing remain but the diffuse clouding of the anterior layers, we are forced to the conclusion that the appearances which seemed to be in the corneal substance, really were in the anterior chamber. Experiments upon the eyes of guinea-pigs and rabbits have furnished results which confirm this view.

Iritis is a complication which generally occurs quite early and is seldom absent. The change in the color of the iris, caused by it, cannot always be well seen, on account of the clouding of the cornea, but can generally be detected, at least at the margin of the pupil. The diagnosis is confirmed by the posterior synechiæ, which are made to appear by the action of atropine. Often there are, simultaneously, especially near the lower margin of the pupil, semi-transparent flakes floating in the aqueous humor, which present exactly the appearance of coagulated fibrin. Frequently, in consequence of the purulent infiltration, the tissue of the iris, as appears in the operation of iridectomy, is exceedingly weak and brittle.

---

\* Comp. Marie Bukowa, Inaugural-Dissertation, Zürich, 1871.



The conjunctiva, especially on the sclera, is strongly injected and often swollen. Pain, lachrymation, etc., are sometimes slight and sometimes severe.

The causes of purulent keratitis are in the majority of cases traumatic. It is often caused by slight contusions and wounds of the cornea by little pieces of stone or other splinters, and in country-people most frequently by wounds from the beards of grain during harvest. Neglect is often the reason why such slight injuries assume so dangerous a character; still, an individual predisposition, which causes such insignificant wounds to run so unfavorable a course, cannot be denied. Generally, the cases are in poorly-nourished, hard-working individuals.

Colds are considered also as causing purulent keratitis. In many cases no determinate cause can be ascertained.

Among the non-traumatic cases should be mentioned the non-irritating form of corneal infiltration described by Von Graefe.\* It occurs in children under eight years of age, and presents the pure type of a corneal abscess with remarkably slight subjective symptoms.

The course is very tedious and without any tendency to spontaneous healing. Left to itself, the ulceration spreads over the entire cornea, ending generally rather late in perforation, which is followed by prolapse of the iris, development of staphyloma, etc. The already existing purulent iritis favors a transition into choroiditis and ultimate atrophy of the eye.

*Treatment.*—Atropine, lukewarm fomentations, and the pressure-bandage are generally the means first resorted to, and in mild cases are sufficient. In the first place the hypopion generally disappears, and gradually also the purulent infiltration in the cornea. The ulcer becomes clean, and heals, leaving a superficial opacity. If the clearing-up of the ulcer be delayed, a drop of chlorine water† three or four times daily, in the eye, is to be recommended. I have also seen good results follow the use of a 1 or 2 per cent. solution of the muriate of quinia. Dilute tincture of opium is also recommended under these circumstances.

If there be great irritability, subcutaneous injections of mor-

---

\* Arch. f. Ophth., B. vi. 2, pag. 135.

† Ibid., B. x. 2, pag. 204.



phine are to be made in the temporal or supraorbital region, and in every case, quiet sleep is to be secured by morphine or chloral, if necessary.

In many cases an improvement occurs at first, the hypopion diminishes, but soon without any apparent cause the purulent infiltration begins to increase, and the hypopion becomes larger. If these relapses gradually make the condition worse; if in spite of suitable treatment the hypopion increase and the corneal ulcer spread, the reason generally is that the iritis, which is very apt to assume a purulent character, has gained the upper hand. Atropine is then insufficient to meet the case, the pressure-bandage is no longer well borne, and all irritants, such as chlorine water, tincture of opium, etc., seem to be actually hurtful. The discharge of the hypopion by puncture of the cornea is often resorted to in these cases, but is not always sufficient. Frequently on account of its viscidness the hypopion cannot escape from a small corneal wound, but even if entirely discharged through a larger wound, it often soon collects again, since the corneal suppuration and the iritis continue. In many cases, escape from this dilemma is offered by iridectomy, as proposed by Von Graefe.\* The wound for this purpose is best made with a small cataract knife, in the periphery of the upper corneal margin, and should be large. The operation promises no optical advantages, in view of the later cicatrization of the ulcer, since on account of the severe iritis the coloboma of the iris always closes again. Iridectomy is often of decided use, and checks malignant cases which would yield to no other treatment. Its effect is uncertain when it is resorted to at too late a period of the disease, after more than half the cornea is destroyed. Frequently, too, iridectomy cannot well be performed, because the iris is so rotten that it crumbles when grasped with the forceps.

The artificial opening of the corneal abscess is not absolutely reliable. Authorities have been much divided as to the results of this practice. Mackenzie† asserts emphatically that he has always seen it followed by extensive destruction of the cornea, with subsequent partial or total staphyloma; while other authors regard the incision of the anterior abscess wall, or even the entire

---

\* Arch. f. Ophth., B. ii., pag. 241; B. vi. 2, pag. 139; B. x. 2, pag. 205.

† Practical Treatise, etc., London, 1854, pag. 627.



thickness of the cornea throughout the whole extent of the abscess, as advisable.

In *ulcus corneæ serpens*, also, Sämisch recommends the splitting as early as possible of the floor of the ulcer over its whole breadth, and even the extending of the incision beyond the margins into the sound tissue on both sides. Until the beginning of cicatrization the wound should be kept open by probing once or twice daily with a blunt-pointed stilet.

Finally, one of the worst forms of purulent keratitis occurs with variola. There are generally deep infiltrations, connected with great irritability, and leading to slowly progressive destruction of the cornea. The ulcer shows more inclination to extend superficially than to penetrate, so that perforation seldom happens before a large portion of the cornea is destroyed. Hypopion and iritis are seldom absent in this form of purulent keratitis. The affection is very obstinate, and cannot generally be successfully treated by atropine, lukewarm fomentations, the pressure-bandage, etc. I have found a 1 or 2 per cent. solution of the nitrate of quinia useful in some of the cases. Iridectomy was generally necessary, and in many cases was of decided benefit.

Those cases in which the purulent infiltration and ulceration begin at the corneal margin are to be classed as purulent keratitis. There generally also develops soon, an extensive conjunctival swelling with muco-purulent secretion. Atropine and the pressure-bandage if necessary, chlorine water or a 1 to 2 per cent. solution of nitrate of silver where there is great conjunctival swelling, are the suitable remedies.

Still more rarely there occur near the margin of the cornea, but separated from it by a zone of healthy tissue, small purulent infiltrations, which form an ulcer parallel to the corneal margin. If they are early and suitably treated with the remedies above mentioned, these ulcers heal well. If, however, they have once crept around more than half the circumference of the cornea, they threaten great danger to the nutrition of its centre. It becomes gray and clouded, and finally necrotic.

Neuro-paralytic keratitis, in consequence of paralysis of the fifth nerve, is a rather rare disease. The sensibility of the cornea, conjunctiva, and lids, and frequently also of the greater part of the corresponding half of the face, is lost. There occur upon



the cornea, generally at its centre, a gray clouding, and soon a loss of substance by ulceration. Frequently there is at the same time a noticeable dryness of the epithelial covering of the conjunctiva and cornea.

The neuro-paralytic inflammation of the eyes cannot be regarded as a direct consequence of the paralysis of sensation, since the experiments of Meissner and Büttner\* have proved that complete anæsthesia may exist without being followed by keratitis. The anatomical examination in these cases showed that the ophthalmic branch at the Casserian ganglion was not cut entirely through, but that a few of its lower fibres were not divided. On the other hand, Snellen has shown that the inflammation of the eyes can be postponed or entirely prevented by protecting them from external irritation. The influence of the division of the nerve may be regarded as diminishing the eyes' capacity for resistance, so that external irritations, which under normal relations were harmless, now cause traumatic inflammation.

In the human subject the course of these cases depends upon the nature of the cause of the paralysis of the fifth nerve. Generally there are extensive central lesions, which are noticeable in the course of the other nerves, the facialis, abducens, etc.

Von Graefe† has described a peculiar form of corneal ulceration as the result of interstitial encephalitis.‡ The condition is generally bilateral, but the second eye is attacked some weeks after the first. There is photophobia in the diseased eye; it begins to weep; conjunctival veins and episcleral vessels develop upon it, without however there being decided injection. A small part of the cornea, generally central or slightly eccentric, becomes a cloudy gray yellow, while the epithelium covering it becomes dull and loses its mirror-like surface. The infiltration increases in thickness and circumference, and leads to ulcerative destruction of the cornea. Finally there follow purulent iritis and panophthalmia.

At the very beginning there is a very peculiar behavior of the conjunctiva oculi. Below and at the sides of the cornea it becomes dull, dry, and dotted, and when relaxed by rolling of the eye, it

---

\* Henle und Pfeufer's Zeitschrift, 3 R., B. xvi.

† Arch. f. Ophth., B. xii. 2, pag. 250.

‡ Virchow, Ueber interstitielle Encephalitis, Arch. f. path. Anat., B. 44, pag. 472.



gathers up into small perpendicular folds. It loses its natural moisture and elasticity, and its epithelium is not reproduced. The condition may be called acute xerosis.

The cases were those of children from two to six months old, and ended fatally in consequence of encephalitis.

Corneal ulcerations, which could not be arrested, have been observed in the course of severe constitutional diseases, such as typhoid fever, complicated scarlatina, etc.

#### CORNEAL ULCERS.

Corneal ulcers may occur in various ways. The most frequent causes are injuries of all kinds, corneal diseases in consequence of conjunctival affections, for instance, severe catarrhal conjunctivitis, acute and chronic blennorrhoeal processes, diphtheritis, trachoma, etc., and finally phlyctenular and purulent keratitis in their various forms. The treatment of the ulcer depends upon the process which caused it, and therefore need not here be repeated. If the ulceration stop before a large portion of the cornea be destroyed or perforation have occurred, the loss of substance is generally replaced by new-formed tissue, which, under favorable circumstances, may be so clear as not to be detected by ordinary daylight. By focal illumination, however, one can always see that the layers of new-formed tissue are not so transparent as those of the normal corneal substance; indeed, a very considerable diminution of vision may be caused by these opacities which can be seen only by focal illumination. Frequently the scar tissue is so thick that it is noticeable by its bright color.

The new-formed tissue does not always correspond to the size of the defect; it may be too small, as in the case of corneal facets, or it may be too large, forming a prominence; even its superficial extent may be greater than that of the original loss of substance. The mass of tissue which grows up from the bottom of the ulcer often finds the anterior elastic lamella upon the margin of the ulcer still deprived of its protecting epithelium, and may spread out upon it beyond the limits of the original ulcer, till it reaches the epithelium. If now the epithelial layer be renewed, the new-formed tissue will be covered by it. In this manner occur many of those cases in which, upon anatomical examination, a layer of new-formed tissue is found between the epithelium and the ante-



rior elastic membrane. Large, thick corneal scars are frequently penetrated by permanent blood-vessels.

If perforation occur in a corneal ulcer, the further course depends principally upon the size and position of the opening. In the first place, the aqueous humor flows out, allowing the iris and lens to come in apposition with the posterior surface of the cornea. In small perforating ulcers the opening may close again in a few days, the anterior chamber refill, and the ulcer heal, leaving a scar more or less visible.

An adhesion of the iris with the inner opening of the ulcer often occurs (anterior synechia). When the anterior chamber refills, that part of the iris which is attached to the cornea is lifted forward, or, if the adhesion be very small, only a part of the stroma of the iris is drawn forward like a thread, while the rest of the iris remains in its normal position. In fresh cases it is sometimes possible by maintaining atropine mydriasis to cause the complete detachment of the anterior synechia.

In somewhat larger perforations the iris generally falls forward and adheres to the margins of the opening. The prolapsed part of the iris, which is exposed to all kinds of external irritations, may now swell or even become purulently inflamed and be the starting-point of a purulent irido-choroiditis.

The prolapsed iris is generally driven forward like a cyst, by the accumulation of the aqueous humor, and thus new parts of the iris may be drawn into the prolapse. In the further course of the cicatrization the distended prolapsed iris may become flattened again; but frequently the cicatricial tissue does not prove strong enough for this, and a staphylomatous cicatrix is formed (staphyloma partiale).

The course is similar when the entire cornea is destroyed. The iris, which is laid bare, is covered with a new-formed layer of tissue, and becomes distended forward. Later, the cicatrix may flatten or may remain staphylomatous (staphyloma totale).

The treatment indicated by these processes must be such as to avert as much as possible the dangers connected with a rupture of the ulcer. If the floor of a large ulcer be bulged forward, perforation may certainly be expected, and accordingly care is to be taken, first, that the perforation shall be as small as possible, in order to avoid anterior synechia and prolapsus iridis, and, second,



that the escape of the aqueous humor be as gradual as possible. If there be a sudden and extensive rupture of the floor of the ulcer, the aqueous humor will be forcibly discharged, the iris driven forward, and even luxation of the lens, with rupture of its capsule, may follow.

Both indications may be fulfilled by the artificial perforation of the floor of the ulcer, allowing the gradual escape of the aqueous humor. The after-treatment consists in keeping the patient quiet in bed, and using atropine and the pressure-bandage. The same treatment is indicated after spontaneous perforation. Distended prolapses of the iris may at first be left to themselves; if, however, in the course of a week or two they do not flatten down by cicatricial contraction, their removal is necessary in order to guard against the development of a partial staphyloma. Very prominent, distended prolapses are most easily removed by the scissors. If, however, the prolapse rise very gradually above the general surface of the cornea, its base is to be transfixed with a small knife, and one-half or more of the prolapse is to be separated by to-and-fro cuts as the knife is withdrawn. The flap thus formed is to be seized with the toothed forceps, and the excision of the other half completed by one or two cuts with the scissors.

The practice, here and there recommended, of touching the prolapse of the iris with nitrate of silver or other substances, is a very uncertain one, and in no way to be preferred to its excision.

A certain rare form of corneal ulceration, which occurs generally in aged, poorly nourished individuals, deserves a special mention. It begins insidiously, and goes on, at first, with scarcely any reaction, but if unchecked, ends in the destruction of the cornea. A loss of substance is first noticed at the margin of the cornea. It increases slowly, and either extends along the margin of the cornea in the form of a furrow, finally, however, destroying the centre, or gradually extends over the surface of the cornea from the very first.

The upper layers of the cornea break down without there being any purulent infiltration to be seen, either about the margin or at the bottom of the ulcer. The deeper layers generally remain intact and transparent; still, perforation may occur. Cicatrization gradually extends from the margin till the entire surface of the cornea is changed into a smooth, vascularized scar.



## CORNEAL OPACITIES.

Corneal opacities are the permanent traces left by an ulceration or infiltration of the cornea.

The influence which they exert upon vision depends, in the first place, upon their position, whether within or without the pupillar region. It must be remembered that the pupillar region of the cornea—that is, that portion of its surface through which rays of light can enter the pupil—is somewhat larger than the pupil itself, because the rays of light proceeding from a fixed point are made to assume a convergent direction by the refraction of the cornea. Corneal opacities which lie external to the pupillar region cause, therefore, no disturbance, while, when all that part of the pupillar region which serves for central vision becomes opaque, it is evident that objects lying upon the visual axis can cast no retinal image. Direct vision is prevented. If under these conditions a part of the periphery of the cornea remain transparent, eccentric vision is still possible. During monocular vision, with the affected eye, eccentric fixation takes place, its direction being determined by the position of the still transparent portion of the cornea; if, for instance, it be above, then will an object which is directly in front be seen with the axis of vision directed downward. During binocular vision that particular object will not be seen with the affected eye; still less does this condition ever cause strabismus, as it was formerly thought to do.

Corneal opacities which are smaller than the pupillar region and absolutely opaque, and not complicated with anomalies of curvature, exercise only a very slight influence over vision. A simple diminution of the pupillar region, as, for instance, by looking through a small opening, does not diminish the acuteness of vision. But if these corneal opacities be not absolutely opaque, the rays penetrate them in all directions; a flood of diffuse light is thrown upon the retina, and the distinctness of vision is thus interfered with.

Nevertheless, it appears that this is less important than irregularities in curvature and refraction, which distort the retinal images. Corneal opacities have been already mentioned as a frequent cause of irregular astigmatism (page 64).



If we suppose the cornea to be composed of a number of small parts, having each a different curvature and refractive power, their focal distances will, of course, vary. Each part will cast its own image, which will interfere with those cast by the other parts, and this irregularity becomes so much the greater when not only the focal distances but also the optical axes of these different parts do not correspond with each other. Both these conditions exist in irregular astigmatism, caused by corneal opacities, as may be demonstrated ophthalmoscopically.

If in the examination in the upright image the examiner fixes some sharply defined object in the fundus, a retinal vessel, for instance, and if he then makes slight movements of his head, so that his line of vision successively penetrates various neighboring portions of the cornea, which vary in refraction and in centring, a remarkable apparent movement of the ophthalmoscopic image is the necessary consequence. This is still more evident in the examination in the inverted image, if, for instance, when fixing upon a retinal vessel the convex lens be moved slightly to and fro in a direction perpendicular to the course of the vessel.

In irregular astigmatism the ophthalmoscopic image of the fundus, as well as the retinal image, is composed of several images inaccurately superimposed, and the relative position of these various images varies with the movements of the convex lens. Moreover, when the optic disc is fixed and these movements are made, there appears to be a remarkable change in its form.

The hurtful influence of corneal opacities upon vision may be shown in a very simple manner by the ophthalmoscopic illumination with a weak reflecting mirror,—that is, with a silvered plane mirror, or Helmholtz's reflecting glass plates. Irregular astigmatism is then made apparent by the fact that during slight movements of the mirror one and the same place upon the cornea appears alternately dark and bright. In this experiment we examine the corneal opacities by transmitted light, the source of the light which causes the pupil to seem illuminated being the image of the flame cast in the fundus of the eye by the mirror, which image of course changes its place with every movement of the mirror. If now the curvature and transparency of the cornea be normal, slight changes in the position of the source of light would not affect the amount of light which passes through the



pupillar region of the eye examined to that of the examiner; if, on the contrary, irregularities exist, the consequence of a slight change in the position of the source of light would be, that in one and the same place in the cornea sometimes more and sometimes less rays of light would be so refracted as to correspond with the line of sight of the observer; the irregularly curved places will therefore appear during the movements of the mirror alternately brighter and darker.

The disturbances of vision caused by corneal opacities may generally be diminished by Donders'\* stenopaic apparatus, which covers the entire eye, leaving only a small round or slit-shaped opening. By diminishing the light falling on the eye, the pupil dilates, and this enables the patient so to hold the diopter that he may use the clearest portion of his pupillar region.

In spite of the very considerable improvement in vision which may be caused by the stenopaic apparatus, it is seldom practicable to allow it to be worn as spectacles, for it makes the field of vision too small, and its position can be altered only by movements of the head and not by rolling the eyes. It may be best employed for reading.

*Treatment.*—So long as the inflammatory process which causes the opacity still lasts, the proper treatment of the inflammation is the best means by which to prevent the occurrence of opacities. But if the opacities remain as the effect of a process which has already run its course, their disappearance cannot be hoped for. In many cases in which the entire pupillar region is occupied by thick opacities while the periphery of the cornea is still clear, the formation of an artificial pupil is indicated. If the iris has retained its normal motility, the atropine mydriasis shows us about how much may be expected from an artificial pupil: indeed, in many cases the question arises whether continuous and suitably graduated atropine mydriasis is not to be preferred to an operation.

If an operation has been decided on, a choice is to be made between iridectomy and iridotomy. Under all circumstances the artificial pupil must be made as small as possible, and its position carefully chosen, opposite that part of the cornea which is clearest. It often happens that against the black background of the new-

---

\* Arch. f. Ophth., B. i. 1, pag. 291.



formed pupil, opacities become visible which could not before be seen over the lighter-colored iris. The objection to be made to iridectomy in corneal opacities is, that the artificial pupil generally proves larger than is desirable for optical purposes; moreover, in doing the operation the wound must be made at the margin of the cornea close to the new pupillary region, and there is danger of its causing cicatrices, opacities, and anomalies of curvature which cause optical disturbances.

The operation of iridotomy consists in making a straight incision in the iris from its pupillar margin toward its periphery. For this purpose a puncture is made with the lance knife in the margin of the cornea on the side opposite to that on which the iris is to be incised, and thus it happens that the wound is almost always in a part of the cornea already clouded. It is well, after the lance knife has been slowly inserted until a wound is made 3 or 4 mm. in length, to withdraw it quickly, in order to retain some of the aqueous humor in the anterior chamber. Wecker's\* forceps-like scissors, made for this purpose, are then passed into the anterior chamber with one blade before and the other behind the iris, which is then cut through by quickly closing the scissors. Great care must be taken when inserting the blade to avoid wounding the capsule or causing luxation of the lens. The contraction of the sphincter of the iris causes the wound to gape, so as to open an artificial pupil of sufficient size.

The removal of a corneal opacity by an operation is very rarely possible. In a case described by Bowman,† a deposit of phosphate and carbonate of lime had, in the course of several years, and apparently without symptoms of inflammation, accumulated beneath the unchanged epithelium, and it was scaled off the cornea, to the great improvement of vision.

A very peculiar form of corneal opacity remains to be mentioned. It is a band-like stripe, 3 or 4 mm. in breadth, which crosses the cornea in the direction of the palpebral fissure. The opacity always begins at the extremities of the horizontal diameter of the cornea, and extends gradually toward the centre. Its

---

\* *Annales d'Oculistique*, tome lxx. pag. 123, and *Klin. Monatsbl. für Augenheilk.*, 1873, pag. 377.

† *Lectures*, pag. 119.



color is so slight that it can be more easily seen by focal illumination than by daylight, and it appears to be composed of fine and coarse dots and flakes immediately under the epithelium. It always appears upon both corneæ, although not always in the same degree.

The condition is a rare one. It often occurs without any complications, and is accompanied only by those disturbances of vision which are due to the optical relations, as may be demonstrated by the stenopaic apparatus or by atropine mydriasis. These corneal opacities are oftener seen in the later stages of irido-chôroiditis, and are then generally noticeable by their bright color. They also occur in connection with glaucoma.\*

#### CORNEAL STAPHYLOMA.

The name staphyloma designates a distention of the corneal cicatrix to whose inner surface the iris has become adherent. The staphyloma is called total when it involves the whole, and partial when it involves only a part of the cornea.

When the entire cornea, or the greater part of it, is destroyed by ulceration and the iris exposed, a membranous cicatrix forms over it, and this is driven forward by the accumulation of aqueous humor behind it. Later, the cicatricial tissue may flatten down and heal fast, or it may soften under the influence of new inflammatory irritation and again bulge forward. This process may be repeated several times.

But even small corneal ulcers, which have destroyed only the central part of the cornea, may lead to staphyloma by the adhesion of the entire pupillar margin of the iris to the cicatrix. A restoration of the anterior chamber under these circumstances is impossible. The iris remains in apposition with the posterior surface of the cornea, the aqueous humor accumulates behind it, and causes a stretching and protrusion both of the cornea and of the iris.

In both cases there finally develops a tumor, which protrudes from the palpebral fissure, and which the lids can cover only by a certain tension. Both the deformity and the continual irritation kept up by the staphyloma indicate its removal by operation.

The staphyloma is transfixed at its base with a cataract knife,

---

\* Von Graefe, Arch. f. Ophth., B. xv. 3, pag. 139.



and one-half of it detached; the flap is then seized with the toothed forceps, and the removal completed with the scissors curved on the flat.

The loss of substance caused by this operation is of course as large as the base of the excised staphyloma, and it may be left to heal spontaneously under a pressure-bandage.

In order to hasten healing, Critchett\* has proposed to close the wound with sutures, which should be inserted before the staphyloma is removed. Critchett passed five curved needles through under the base of the staphyloma, which was then removed and the sutures united. Since in most cases of staphyloma the base corresponds nearly to the corneo-scleral boundary, the sutures must be passed through the ciliary body. The great danger attending all wounds in this region must be remembered, and this danger is increased by the fact that the threads which act as a foreign body must be allowed to remain a long time. Knapp† has proposed, therefore, to include only the conjunctiva in the sutures. The simplest method is to insert about four threads in the conjunctiva above and below the staphyloma. The portions of the threads extending across the staphyloma in a vertical direction are then pushed aside, the staphyloma is removed, the sutures tied, and a pressure-bandage applied. In most cases, however, the sutures cut through the conjunctiva after two or three days, and the wound then remains open, till after four to six weeks it closes by cicatrization. The matter is not improved by previously detaching the conjunctiva from the sclera about the cornea and inserting the threads so that the edges of the conjunctiva come in apposition. Even then the conjunctival wound does not heal before the sutures cut through.

The object of placing the sutures before removing the staphyloma is to make it possible to close the wound immediately and without any escape of the vitreous. But if the operation be done during deep narcosis, the wound may be closed by stitches after the removal of the staphyloma without any escape of the vitreous. In some cases I have therefore operated by excising from the staphyloma a sufficiently large elliptical piece whose longest

---

\* Ophth. Hosp. Rep., iv. 1.

† Arch. f. Ophth., B. xiv. 1, pag. 273.



diameter corresponded with the direction of the palpebral fissure. The wound is made with an acute angle at either end, giving it thus a form suitable for direct union. The upper and lower margins of the corneal wound are then brought in apposition by catgut sutures. I generally neglect the enucleation of the lens in the removal of total staphyloma. The catgut sutures are cut off closely, since their removal is unnecessary.

Before every operation for staphyloma, it is advisable to ascertain whether there is good perception of light. If there be not, there exists some serious intraocular disease, generally excavation of the optic disc. Under such circumstances the removal of the staphyloma by suddenly relieving the intraocular pressure may easily cause choroidal hemorrhage, which may be so severe as to force out the entire contents of the eye. At all events, panophthalmitis follows, with a tedious, painful healing process, and eventual shrinkage of the stump. In such cases the question may arise whether it is not preferable to enucleate the eye in the first place. Even when there is good perception of light, and when the existence of intraocular complication is therefore not probable, the operation for staphyloma may lead to purulent chorooiditis and atrophy.

Anatomical examination shows a staphyloma to consist of cicatricial tissue, which on its anterior surface is covered by epithelium arranged in several layers, while its intraocular surface is covered by the remains of the iris, generally, however, only by the uveal layer. The stroma of the iris disappears in the adhesions formed with the new scar tissue, leaving only a slight trace of pigment. There is no trace of either an anterior or a posterior elastic lamina upon the staphyloma. The anterior elastic membrane is seen broken abruptly off at the margin of that portion of the corneal tissue which still remains, while the posterior elastic membrane is folded, rolled together, and included in the cicatricial tissue. Flat, non-staphylomatous scars in the cornea present exactly the same appearances.

Staphylomatous scars vary in thickness. They are generally thin, but sometimes have a thickness of 2 or 3 mm.

The way in which partial staphyloma occurs is as follows. After a perforation of the cornea the iris falls forward, is bulged outward by the accumulation of the aqueous humor, and fails to



be drawn backward to its normal level by the subsequent cicatricial contraction.

Where there has been extensive loss of corneal substance the occurrence of total corneal staphyloma cannot always be avoided, but where there is a small ulcer, with the destruction of not more than one-third of the cornea, a staphylomatous cicatrization should be prevented by a prompt excision of the prolapse. If this be not done, and a permanent staphylomatous scar be allowed to develop, the normal curvature of the portion of the cornea still remaining transparent is soon destroyed, to the detriment of vision.

A partial staphyloma is removed in the same way as a larger prolapse of the iris or a total staphyloma. If the partial staphyloma develop again after its removal, it is often due to the fact that the lens is luxated and presses with its edge against the scar. If this condition can be recognized during the operation for removing the staphyloma, it is best to open the capsule and extract the lens. Partial staphyloma is often observed to decrease after iridectomy.

Corneal fistula is a small opening in the anterior chamber, through which the aqueous humor continually flows. This exceptionally happens after wounds or operations at the corneo-scleral boundary, over which the conjunctiva heals, while a small portion of the corneal wound remains open. The aqueous humor then accumulates beneath the conjunctiva.

Fistula of the anterior chamber more frequently follows corneal ulcers.

Even when the perforation caused by a corneal ulcer is very small, the refilling of the anterior chamber is often long delayed; the aqueous humor trickles away constantly, and the iris and lens lie against the posterior surface of the cornea. Now and then the fistula closes superficially, some aqueous humor accumulates, but before the anterior chamber becomes normally filled the fistula opens anew. Even after complete closure of the fistula, a slight irritation may cause it to reopen.

This condition appears to develop principally when the iris has become adherent to the perforation of the ulcer.

The treatment consists in a continuance of the means indicated in the treatment of the ulcer. Often the fistula does not close till the atropine, which up to that time had been in use, is withheld.



A certain degree of tension upon the iris attached to the fistulous opening appears to favor the healing. The curative effect of Calabar bean, which Zehender\* observed in one case, probably depends upon this. In one case of corneal fistula, which had persisted a long time and had resisted all other means, I was able to close it permanently by introducing a fine hook in the fistulous opening, raising it up and excising its walls with the scissors.

Corneal fistulas may persist a long time without doing any great harm. But while they last, the degree of vision and the extent of the visual field should be carefully watched, since, in many cases, rapid glaucomatous blindness, due to excavation of the optic nerve, comes on without any noticeable external changes.

Vesicles sometimes occur upon the cornea in eyes otherwise quite normal, and without any previous inflammatory symptoms, but they are more frequent in eyes which have a long time been diseased. They have been most frequently observed during the course of interstitial keratitis, chronic iritis, and glaucoma. The vesicles consist simply of the epithelium raised from the anterior elastic lamina, and are sometimes quite tense and sometimes so relaxed that their form can be changed by pressure on the epithelial covering.

The annoyances which they cause are nearly the same as those of a foreign body irritating the cornea. They may generally be cured by simple puncture. Exceptionally, however, the process is obstinately persistent. Von Hasner† was able to cure one such case, only by removing the anterior lamellæ of the cornea, corresponding to the part upon which the vesicles persistently recurred.

#### KERATOCONUS.

Keratoconus is a change in the form of the cornea, by which it loses its normal curvature and becomes more or less pointed in its centre. The cornea at this point is considerably thinned, frequently to one-third its marginal thickness. In one case examined by Hulke‡ the anterior elastic lamina participated in this thinning, while the membrane of Descemet was unchanged.

---

\* Klin. Monatsbl., vi. pag. 35.

† Klinische Vorträge, pag. 196.

‡ Ophth. Hosp. Rep., ii. pag. 155.



The thinning and pointing of the centre of the cornea occur quite gradually, and at first the cornea is absolutely clear. Later, a slight gray opacity appears at the apex of the cone, which Hulke found to be due to a layer of elongated nuclei immediately beneath the anterior elastic membrane, and a transformation of the corneal tissue into a net-work of nucleated fibres surrounding clusters of large spindle-shaped cells.

The beginning of the disease is generally at a time between the fifteenth and the twenty-fifth year, but it may be either earlier or later. As a rule, both eyes are successively affected, and generally to a different degree. This stretching of the centre of the cornea may become stationary at any stage. It may also, though it rarely does, begin again after having been a long time stationary. Even in the most extreme cases, bursting or ulceration of the cornea never occurs. There is no increase of hardness of the eyeball.

The optical consequence of the increased prominence and shorter curvature of the centre of the cornea is myopia. But at the same time the irregularity of the corneal curvature makes the retinal images likewise so irregular that the distinctness of vision is greatly interfered with. The annoyances are, in general, those of myopia complicated with amblyopia.

Such patients are often able to read ordinary print, since they hold it close to the eye and so receive large retinal images. Only a slight improvement of vision for distance can be obtained by concave glasses.

The diagnosis is very easy after the condition has passed a certain stage. The characteristic change in the form of the cornea can then scarcely be mistaken. Slight degrees, on account of the irregular astigmatism connected with them, are easily recognized with the ophthalmoscope.

It is plain that no kind of medication can be expected to restore the normal curvature of the cornea. Operative relief, too, is quite limited.

Iridectomy, originally proposed by Von Graefe,\* would in most cases do more harm than good, since the circles of diffusion upon the retina increase with the size of the pupil.

---

\* Arch. f. Ophth., B. iv. 2, pag. 271.



Bowman,\* therefore, proposed, by the operation of iridodesis,† to lengthen the pupil or to change it into a narrow, vertical slit by two such operations at diametrically opposite points at the margin of the cornea. Still, this operation does not relieve the optical disturbances caused by the irregular curvature of the cornea. It simply diminishes the size of the circles of diffusion.

Finally, Von Graefe‡ tried the plan of provoking an ulcer upon the middle of the cornea, with the hope that the contraction of the resulting cicatrix would cause an improvement in the curvature. For this purpose a slight superficial loss of substance is caused at the apex of the cone. A small knife is inserted to the depth of the middle layers, and its point brought out at a distance of from 1 to 2 mm. The flap thus formed is seized with the fine-toothed forceps, and cut off close to its base with the scissors. The small defect thus caused is cauterized a day or two later with mitigated nitrate of silver, and this is repeated every two or three days till a sufficiently intense infiltration process is set up. The ulcer heals finally with a scar, by the contraction of which the abnormal curvature of the cornea is diminished.

An improvement of vision cannot be expected till the traumatic keratitis has run its course; and this requires from two to three months.

In rare cases the cornea at birth is much too large, although perfectly transparent.

#### WOUNDS OF THE CORNEA.

Foreign bodies which lodge upon the cornea, without becoming imbedded in it, are generally soon removed, on account of the irritation which they set up. Sometimes, however, these objects

---

\* Ophth. Hosp. Rep., ii. pag. 166.

† The operation of iridodesis was proposed by Critchett (Ophth. Hosp. Rep., i. pag. 220), with the object of lengthening and at the same time retaining the motility of the pupil. The sphincter iridis must be spared, and not excised, as in iridectomy. With this object a small opening is made in the extreme margin of the cornea, the iris is grasped with the forceps not far from its ciliary insertion, is drawn outward, and included in a loop of thread, in order to prevent the spontaneous retraction of the small prolapsus. This operation would fulfil many therapeutic indications if it did not involve the danger of irido-cyclitis and sympathetic disease of the other eye.

‡ Arch. f. Ophth., B. xii. pag. 215.



remain a longer time and maintain a chronic inflammation. This seems oftenest to happen with the husks of small seeds, but insects' wings, small pieces of vegetable membranes, etc., have also been observed to remain a long time upon the cornea.

The removal of all such objects is most easily accomplished with a Daviel spoon.

It much oftener happens that small splinters of iron (frequently red-hot), pieces of glass or stone, grains of powder, etc., strike upon the cornea and imbed themselves in its substance.

It is generally very easy to see the foreign body. It is difficult only when very small dark bodies are lodged near the centre of the cornea against the dark background of the pupil. But even then the diagnosis is easy with the help of focal illumination.

The removal of foreign bodies which have penetrated the cornea is best done with a flat curved cataract needle, while the lids are kept apart with the thumb and first finger of the left hand. With very restless patients it may be necessary to introduce a lid speculum and hold the eyeball with the toothed forceps.

If there be great irritation, it is well to drop a solution of atropine in the eye after the removal of the foreign body.

When foreign bodies penetrate the cornea and pass into the anterior chamber they cause iritis, and if they wound the lens, traumatic cataract also.

The best method then is to open the anterior chamber with a lance or small cataract knife at the margin of the cornea as near the foreign body as possible, and attempt its removal with a hook or forceps. If the foreign body be lodged in the iris, iridectomy is generally unavoidable.

As a rule, however, foreign bodies which have penetrated the cornea do not lodge in the iris or lens, but find their way to the fundus of the eye.

Superficial injuries of the cornea with blunt instruments, cause often only a circumscribed loss of epithelium, which is best recognized by showing the reflection of the window-frame as it passes over the edge of the defect.

These injuries generally cause great irritation. Atropine, cold-water dressings, or, when these are not enough, the pressure-bandage, are the proper remedies.

Small superficial losses of substance of the cornea generally



assume very soon a bright-gray color, and appear upon focal illumination to be surrounded by a superficial, diffuse, dull-gray clouding. The process may go on to healing, or the spot may assume a more yellowish-white color, and there generally appear in the deeper parts of the cornea peculiar, striated, gray opacities, 2 or 3 mm. in length, which are very apparent on focal illumination.\* If properly treated from the very first, these injuries almost invariably run a favorable course. Quiet, anti-phlogistic diet, cold-water dressings, and atropine are generally sufficient. Neglect of these cases is very apt to lead to purulent keratitis.

Very slight wounds of the cornea often leave behind them a peculiar form of relapsing keratitis. After slight, even imperceptible causes, there occur the same complex symptoms as with traumatic keratitis, namely, swelling of the lids, lachrymation, pains in the eyes, often streaming through the whole distribution of the fifth nerve, photophobia, contraction of the pupil, injection of the conjunctiva scleræ, and hyperæmia of the crowded, radiating, fine conjunctival vessels about the margin of the cornea. Upon the cornea is a small, gray, often swollen opacity, with or without loss of its epithelium. It is often remarkable how very slight are the changes visible in the cornea in comparison with the intensity of the inflammatory symptoms. The treatment at first is the same as that of traumatic keratitis. If the irritable condition has lasted a long time, warm fomentations are better than cold. As after-treatment it is well to continue for some time dusting calomel into the eye.

Similar cases of cicatricial keratitis also occur in non-traumatic scars.

Perforating wounds of the cornea vary greatly according to their nature. Accidental wounds of course vary in size, and are generally more or less bruised. In most cases the aqueous humor flows away immediately, and if the wound be not too small there is prolapse of the iris. Frequently there is at the same time a wound of the lens and traumatic cataract.

---

\* These deep-gray, striated opacities occur not only in traumatic keratitis, as, for instance, in all wounds caused by operations upon the cornea, but also very often in keratitis of any form, and cannot therefore be regarded as an independent form of disease. They generally disappear entirely.



Absolute rest, atropine, and the pressure-bandage are generally the first indications to be fulfilled in perforating corneal wounds. If prolapse of the iris has occurred, it is but seldom, and then only during the first few hours after the injury, that its reposition is possible. The reposition is best attempted during chloroform narcosis, by rubbing lightly with the upper lid, or having attempted this, the aqueous humor contained in the prolapse may be emptied into the anterior chamber by suitable direct pressure, made with a Daviel spoon, and then the attempt at reposition begun anew; if it be not successful, the prolapse should be cut away with the scissors.

The inflammation excited by wounds in the cornea may cause its destruction to a greater or less extent, or may set up inflammation in the deeper parts (*irido-choroiditis traumatica*) ending in suppuration and atrophy of the eye, or in blindness with the development of scleral staphyloma.

Those wounds which occur at the junction of the sclera with the cornea, involving at the same time the ciliary body, are most dangerous, for the reason that they much oftener than any others cause sympathetic disease of the other eye.

Injuries to the cornea from substances which act chemically, as, for instance, burns from melted metals, mineral acids, lime, etc., are generally of a very dangerous character. They are often very extensive, not only involving the greater part of the cornea but also extending into the conjunctiva, and therefore generally cause symblepharon. There often develops about the wound in the cornea a purulent inflammation, which may extend over the whole cornea, or even into the iris and choroid, thereby causing panophthalmitis. Even where the course is more favorable, there often remains, as a consequence of the intense traumatic keratitis, a clouding of parts of the cornea not directly injured.

Tumors of the cornea are generally situated upon its margin, and often extend over upon the conjunctiva or down into the sclera.

The first to be mentioned are the congenital dermoid tumors, which vary from the size of a hemp-seed to that of a pea, and are frequently covered with hair. If they become annoying they should be seized with the toothed forceps and removed with the cataract knife.



Canceroid in this region may begin upon either the cornea or the conjunctiva.

Melanoma and melano-sarcoma\* of the eye develop usually upon the margin of the cornea, and it is generally only at this place that they are firmly attached to the wall of the eye; posteriorly they are continuous with the conjunctiva, and movable with it upon the sclera; anteriorly they grow over the cornea, and may thus entirely destroy vision, while the eyeball presents only the appearance of a tumor projecting from the palpebral fissure. Nevertheless, the extirpation of the eye should not be immediately resorted to, since the removal of these tumors from the sclera is not difficult, and they do not penetrate into the substantia propria of the cornea. They may, therefore, be easily peeled off, leaving only an unevenness of the epithelium, which soon becomes smooth. At the corneo-scleral boundary, the place of origin of these morbid growths, the extirpation must be made with great care and thoroughness.

The arcus senilis, or gerontoxon, is scarcely to be classed among the pathological affections of the eye, since it invariably occurs in old age. The brighter color seen about the margin of the cornea is due to a fatty degeneration, both of the intercellular substance and of the corneal corpuscles.

---

\* Virchow, *Geschwülste*, B. ii. pag. 122 and 279.



## DISEASES OF THE SCLERA.

---

**SCLERITIS AND EPISCLERITIS.**—The inflammation of the episcleral and scleral tissue is characterized by circumscribed hyperæmia and swelling of a region generally some millimetres distant from the margin of the cornea.

The hyperæmia, which is at first bright red, becomes darker in time, assuming a violet shade, while the swelling is sometimes flat, gradually disappearing in the general surface of the sclera, sometimes circumscribed, forming a hemispherical prominence of perhaps the size of a pea. In the latter case the affection very much resembles the broad phlyctenular conjunctivitis, but differs from it in the fact that the infiltration is not in, but under the conjunctiva.

In cases where the course is favorable, the swelling, in the course of several weeks or months, gradually disappears, the violet shade passing into a slate-gray and then into a lead-colored spot, which may finally fully disappear, or may remain as a slight discoloration.

We may distinguish a simple scleritis from that form complicated with keratitis and iritis. In simple scleritis the annoyances are generally not very great; still, the acute stage may be accompanied by quite severe pain. The course of the disease in each centre of inflammation requires generally from four to six weeks; still, the entire process may be very much prolonged, from the fact that several attacks of episcleritis, affecting different localities, follow one after the other.

Frequently there seem to be a predisposition to the disease and a tendency to relapses.

At first a derivative treatment, by mild cathartics, etc., is indicated. Where there is severe pain, and in general during the progressive stage of the inflammation, good results often follow the use of atropine. If this do not prove sufficient, lukewarm fomentations, or dry warmth, or morphine injections in the supra-



orbital region, or, if necessary, leeches on the temple, should be tried. In the later stage, calomel dusted into the eye, hastens the resorption of the exudate.

Simple non-complicated scleritis may, however, become annoying, partly by pain, partly by its tedious course and frequent relapses. As a general thing, however, a good prognosis may be made. On the contrary, the form which is complicated with keratitis and iritis is a very dangerous disease.

In these latter cases the scleritis generally begins with very severe symptoms. After there have existed for some days the symptoms of a severe inflammation of the eye, with excessive injection of the conjunctiva throughout its whole extent, lachrymation, pain, etc., but still without special localization, there appears a distinct swelling of the sclera, either occupying a greater or less space about the cornea, or forming a livid gray-red hemispherical elevation. Several such swellings may appear at the same time. After some days there develops in the neighboring portion of the cornea a grayish-white, opaque infiltration, which may extend to or even beyond the centre of the cornea, while its neighboring parts show a smoky clouding. These centres of inflammation in the sclera and cornea are both painful and tender under the slightest touch.

The participation of the iris is shown by adhesions of its pupillar margin with the capsule of the lens.

This complicated form of scleritis is in every respect a more severe disease than the simple one. The inflammatory attacks are more painful and tedious, the relapses are more frequent, and may finally cause blindness. The intensity of the inflammatory process in the sclera frequently causes a thinning of the place affected; it becomes more yielding, and a staphyloma scleræ is the result. In this way the entire anterior portion of the sclera may become distended and covered with a number of dark prominences about the size of a pea. Frequently the cornea, too, participates in this process of stretching and enlargement.

In other cases, in which the thinning of the anterior portion of the sclera is more uniform, the eye assumes the form of a pear, so that its cornea projects farther forward than that of the other eye.

The grayish-white infiltrated portions of the cornea do not clear up again; thick bright spots remain, so that when the re-



lapses have been frequent, scarcely a perfectly clear place in the cornea remains. Finally, the adhesion of the entire margin of the iris to the capsule of the lens brings with it all the dangers connected with chronic iritis.

The treatment during the progressive stage should be derivative and antiphlogistic, including local blood-letting, cold-water dressings, cathartics, etc. Atropine is to be used from the very first, and continued as long as the inflammation lasts. In the later stages of the disease, after the irritability has passed away, calomel dusted into the eye, or weak mercurial precipitate salve (1 per cent.), does good service.

If the whole, or nearly the whole, margin of the iris have become adherent to the capsule of the lens, the operation of iridectomy is indicated in order to avert the dangers threatened by this condition.

#### STAPHYLOMA OF THE SCLERA.

The so-called "staphyloma posticum Scarpæ," and the circumscribed scleral ectasiæ which occur in the posterior part of the eye, have already been mentioned on pages 33 and 45. We have here to consider the staphylomas which occur in the equatorial and anterior part of the sclera.

They consist of more or less sharply defined, dark-bluish prominences projecting above the general surface of the sclera, either isolated or in considerable numbers near one another. The last, for instance, may be the case near the cornea, which may be surrounded by a more or less complete circle of such prominences, or the same appearance may be presented at the equatorial part of the eye.

Among the diseases which may lead to the development of such staphylomas, we have already mentioned that form of scleritis which is connected with infiltration of the cornea and with iritis.

Cicatricial staphyloma of the cornea may extend to the adjoining portion of the sclera. Under these circumstances the usual demarcation at the base of the staphyloma is absolutely wanting; the anterior portion of the eye assumes a conical shape, and the staphyloma without any sharply defined limits extends back to the equatorial part of the sclera. These are always cases of deeply disorganized eyes, in which generally there is excavation of the optic nerve, in consequence of increased intraocular pressure.



Choroiditis is the most frequent cause of scleral staphyloma, especially those forms of choroiditis which follow upon iritis with absolute closure of the pupil, upon traumatic irido-choroiditis, and upon the later stages of glaucoma.

In almost all these cases there is blindness from excavation of the optic nerve in addition to the scleral staphyloma.

Intraocular tumors may likewise cause staphyloma; sometimes by consecutive choroiditis, sometimes by the sclera being directly forced out by the tumor.

Finally, cases occur both congenitally and later in connection with some of the above named diseases, in which the size of the eye increases nearly uniformly in all its diameters, and to which is given the name *hydrophthalmus* or *buphthalmus*. The cornea, too, generally participates in the general distention, and becomes therefore flatter. In this condition there is generally absolute blindness, though exceptionally there is some remnant of vision in connection with a high degree of myopia.

In the region of the staphyloma the sclera, choroid, and retina are generally closely adherent to one another. Some cases, it is true, have been observed in which the sclera has been raised from the internal membranes, but, as a rule, the distention and atrophy affect all three of the coats. By this process the retina is transformed into a net-work of indifferent connective tissue, and at the same time is often infiltrated with pigment.

The consecutive atrophy of the choroid generally begins with changes in the pigment-cells of its stroma; they lose their color and disappear gradually. Soon the choroidal capillaries begin to atrophy, while simultaneously the pigment epithelium loses its pigment and its regular disposition is disturbed. Even the large vessels become obliterated, and at last nothing remains of the choroid but the delicate fibres forming the so-called elastic network of the choroidal stroma, the lamina vitrea, and an incomplete and irregular covering of epithelium. Even these remains of tissue may so disappear that nothing is left but a thin structureless transparent membrane. On the other hand, cases occur in which simultaneously with the distention of the choroid the formation of new tissue seems to take place in it. One would expect, and as a rule it is generally found, that the consequences of the distention of the choroid are a diminution of the calibre



of its capillaries, an extension of its intervascular spaces, and a separation from each other and a flattening of its individual epithelial cells; but cases occur in which the appearances are directly the opposite. The vessels of the choroid are of normal or more than normal breadth, the intervascular spaces are smaller, the pigment epithelium small and regularly disposed.

Staphyloma in the region of the ciliary body, and extending to the margin of the cornea, generally leads to destruction of the zonula and luxation of the lens.

Frequently there is a detachment of the iris from the ciliary body, so that the staphylomatous distention takes place between the two. In other cases the normal connection between the iris and the ciliary body is maintained, and the ridges of the ciliary processes are found in front of the staphyloma.

The therapeutic indications are very limited. Vision is generally destroyed, and even if it be not entirely lost, that fact offers no promise for an improvement.

Operative interference may be indicated from fear of sympathetic disease in the other eye, especially when the staphyloma is of traumatic origin and when the eye continues painful. Under such circumstances enucleation of the eye is the only operation from which any good result can be expected.

Frequently it is desirable in the case of an absolutely blind eye to effect a cosmetic improvement by making it possible to wear an artificial one. This indication is not an easy one to fulfil. In these seriously disorganized eyes an operation by the method described for corneal staphyloma, is very likely to lead to intraocular hemorrhages and panophthalmitis, which, after running a painful, tedious course, generally leave a very small stump.

On the other hand, enucleation under these circumstances is apt to leave a condition very unfavorable for the use of an artificial eye. If the staphyloma of the eyeball has been considerable, the orbital fat is much reduced, and as a consequence the conjunctival sac drops farther back in the orbit than otherwise. The artificial eye has then only slight movement, and, moreover, feels so uncomfortable that many such patients finally prefer to dispense with it entirely.

For these reasons Von Graefe\* made the attempt to cause a

---

\* Arch. f. Ophth., B. ix. 2, pag. 105.



moderate degree of atrophy in the eye by an artificially induced choroiditis. An ordinary double silk thread is passed through the vitreous body in such a way as to include in the suture a scleral bridge 8 or 10 mm. in breadth. The ends of the thread are to be simply tied in a loose knot to keep them in position. The thread should not be passed through too thin a portion of the sclera, as the inflammation there set up might be too severe. So soon as an evident swelling of the scleral conjunctiva and a limitation in the movements of the eyeball announce the beginning of a purulent choroiditis, the threads should be removed and warm fomentations or cataplasms applied.

If there be any symptoms which suggest the danger of a sympathetic affection of the other eye, this method should not be resorted to, and enucleation is the only course left.



## DISEASES OF THE IRIS.

---

IRITIS is one of the most important diseases of the eye, both on account of its sad termination in many cases, and on account of the certainty with which in the great majority of cases it yields to prompt treatment.

The typical form of this disease, and also the most frequent, is that which may be called "Idiopathic Iritis."

During its first stage the inflammatory symptoms are often so slight as to escape the observation of the patient. His attention is first arrested by an indistinctness of vision and an inability to use the eyes continuously.

Soon, however, there appears a deep-seated injection surrounding the cornea, due to a hyperæmia of the radiating vessels occupying this zone. This hyperæmia gradually extends to the superficial conjunctival vessels. There is generally no pain at first, but it becomes very severe when the inflammation reaches its highest point; in idiopathic iritis the pain stands in quite uniform relation to the severity of the inflammation.

The pains are not generally limited to the eye, but extend upon the supraorbital region or over the distribution of the sensitive branches of the fifth nerve. They generally increase at night, and may become insufferable. A copious flow of tears generally accompanies the attacks of pain.

The clouding of the cornea, too, stands in close relation to the degree of the inflammation. At first and in mild cases it merely dulls the appearance of the eye, and the patient experiences only a slight dimness of vision. Even by focal illumination it can often be detected only by comparison with the other eye. When the inflammation is more severe, the smoky-gray opacity of the cornea may be seen with the naked eye. The epithelial surface, seen through a magnifying glass and by focal illumination, appears punctated and uneven, while in the deeper layers, short, gray striations are often visible.



A change of color is noticeable in the iris, appearing first in the *circulus minor*, which assumes a darker color, then in the *circulus major*, which in blue eyes becomes green and in darker eyes assumes a reddish tinge. The change in color is probably due to a saturation with blood-coloring matter; at least that is indicated by the fact that the same changes occur without any trace of iritis simply in consequence of a subconjunctival hemorrhage. This observation is most frequently made after operations for squint. The same greenish discoloration of the iris may, however, be due, especially where there is choroiditis with hemorrhage in the vitreous, to a yellow color of the aqueous humor, for under these circumstances, when the cornea is punctured and the aqueous humor allowed to flow away, the greenish discoloration of the iris is not unfrequently seen to disappear and the normal color to return.

The most important symptom of iritis is the adhesion of the pupillary margin of the iris with the capsule of the lens. This can be easily recognized by focal illumination, and where there is any doubt it can be made perfectly evident by atropine. The pupillary margin can retract toward its periphery only in those portions where it is freely movable; the portions which are adherent to the capsule are held fast, and the pupillary opening assumes in consequence a very irregular form.

Recent adhesions can generally be torn through by atropine, leaving behind pigment upon the capsule, while if the adhesions have existed some time this seldom occurs. Although posterior synechiæ are caused only by iritis, still, in any given case, when the diagnosis of iritis cannot be made out from other signs, there may be doubt whether the synechia is a symptom of an existing affection or whether it is the residuum of a process which has long since run its course.

The limitations in the movements of the iris which are connected with iritis appear to depend principally upon the presence of these synechiæ. At first and so long as no synechiæ are present the iris remains movable, and at a later stage it still moves as much as these adhesions will allow.

It is only in the most severe forms of idiopathic iritis that hypopion or an exudate having a fibro-gelatinous appearance is seen in the anterior chamber.



The causes of this form of iritis are often of a rheumatic nature, and for such cases the name "rheumatic iritis" is very suitable. Frequently, however, no cause can be determined with certainty.

In the majority of cases, if there be proper treatment from the beginning, recovery is reached in the course of from 4 to 6 weeks. In mild cases the course may be shorter, but, on the other hand, relapses may greatly delay the entire disappearance of the inflammation.

The treatment of idiopathic iritis is very simple. The eyes must not be used; they must be protected from all harmful influences, such as dazzling light, smoke, etc.; there must be mild antiphlogistic treatment, and still more important and indispensable is the use of a 1 per cent. solution of the sulphate of atropia. A drop of this must at first be placed in the conjunctival sac, say every five minutes, till the greatest possible mydriasis is obtained; after this only so much atropine is to be used as is necessary to keep the pupil dilated.

Under this treatment adhesions between the capsule of the lens and the margin of the pupil, if they have not existed longer than a week, are generally broken up; older adhesions are somewhat stretched, but generally not torn through.

Frequently there is an evident remission of the inflammation so soon as a sufficient action of the atropine is once obtained, and the disease then goes on uninterruptedly to recovery. In severe cases exacerbations of pain recur in spite of complete mydriasis, especially at night, and often with a simultaneous exacerbation of all the inflammatory symptoms, such as increased vascular hyperæmia, copious lachrymation, dense clouding of the cornea, and a recontraction of the previously dilated pupil.

Warmth should be employed during the attacks of pain; the eye and the entire half of the face should be covered with wadding, or, when the pain is very severe, subcutaneous injections of morphine may be made in the supraorbital region. The application of leeches upon the temple is also often useful in allaying the pain.

There is a form of iritis nearly allied to the idiopathic. Its single attacks are exactly like it, and in its whole course it differs from it only by its frequent relapses. Such patients are, for an



indeterminate length of time, at intervals of a month, or longer, attacked more or less severely with iritis. It is not strange that such persons generally have a number of iritic adhesions; and still this fact is the only ground upon which is based the generally accepted assertion that these adhesions are the cause of the relapses.

The possibility of such a causal connection of course cannot be denied, but the number of persons who, in spite of numerous posterior synechiæ, do not suffer from relapsing iritis is too great for us to admit, without hesitation, that the synechiæ are the cause of the relapses, and, moreover, cases occur in which the relapses appear to be entirely independent of any adhesions. I have seen patients with numerous synechiæ in both eyes, who for a long time were affected with relapsing iritis only in one eye, and then suddenly, without any apparent cause, the disease left the hitherto affected eye and appeared with the same obstinacy in the other. Finally, I have known cases which from the beginning were properly treated with atropine, in which no synechiæ remained, and which still were not protected from frequent relapses which occurred without any apparent cause.

Often the causes for relapses of iritis cannot be certainly determined. They may be due to syphilis, but, as a rule, relapses due to that cause follow, with very short intervals, one after the other. Colds are often regarded by the patients as the cause. In many cases anomalies in the circulation of the nasal mucous membrane appear to precede, and stand in connection with, the attacks of iritis.

In all these cases each relapse should be treated according to the above rules, unless the etiology of the particular case should suggest special indications.

So long as there remains a freely movable portion of the pupillary margin between the adhesions, relapsing iritis does not involve the danger of blindness; but the condition is a very serious one so soon as the adhesion of the entire pupillary margin with the capsule has formed. This condition is liable to occur with any neglected or badly treated acute iritis. When it does occur, the inflammatory symptoms are generally very severe, and in addition to those mentioned above, there is a gray, fibrinous, coagulated exudate in the pupil. Simultaneously the periphery of the iris



is driven forward. It may still be possible, by the energetic use of a 1 or 2 per cent. solution of atropine, to rupture the adhesions, and so avert the dangers connected with them.

These annular adhesions of the pupillary margin occur most frequently in consequence of chronic relapsing iritis. The margin of the pupil appears attached to the capsule of the lens by a gray band of new-formed tissue, of a greater or less breadth. The pupil is considerably contracted, and either has no further deposit within it, or may be covered with a new-formed tissue, in which, upon microscopic examination, numerous pigment-cells and often blood-vessels are found.

So long as a small portion of the pupillary margin remains free and a communication exists between the anterior and posterior chambers, the iris remains in its normal position; but so soon as the annular adhesion of the margin of the pupil becomes complete, the eye is in great danger. The periphery of the iris is driven forward by the accumulation of fluid in the posterior chamber, so that the margin of the pupil appears sunken like a crater. The different portions of the periphery of the iris are generally not uniformly driven forward, but are somewhat irregularly prominent,—partly because some portions of the tissue of the iris are more distensible than others, and partly because the adhesion in every place is not confined simply to the margin of the iris, but extends, at certain points, more or less outward toward the periphery of the uveal layer.

The fluid accumulated in the posterior chamber consists probably of aqueous humor mixed with exudates; at all events, it appears of a yellow color when it flows out during the operation of iridectomy. The attacks of iritis now follow very rapidly one after the other, or, in consequence of these frequent exacerbations, there develops a chronic inflammatory condition, which generally extends to the choroid. In this manner there generally comes on a clouding of all the refracting media. The acute inflammatory attacks are accompanied by clouding of the cornea, the disease extends to the choroid, and then appears a diffuse clouding of the vitreous body, and at a later stage, opacity of the lens.

The loss of vision does not, however, depend simply upon the clouding of the refracting media. Where the disease lasts a long time, severe intraocular complications are sure to occur. In



most cases these eyes become abnormally soft, and finally atrophic, but, on the other hand, increased intraocular pressure and excavation of the optic disc also occur, and not infrequently end in staphyloma of the sclera.

When these complications begin to develop, the consequence is that vision becomes much poorer than can be explained from the condition of the pupil, which may be distinctly seen by focal illumination. The field of vision should be tested with great care, since any defects in it always indicate some serious intraocular complication, generally excavation of the optic nerve or detachment of the retina.

Among the objective symptoms, the resistance of the eyeball is to be particularly observed. Increased hardness indicates optic-nerve excavation, decreased hardness indicates detachment of the retina, or a slight atrophy of the vitreous body, due to an inflammatory degeneration of the retina dependent on a chronic choroiditis.

It is generally difficult or impossible to make an exact ophthalmoscopic diagnosis of the complication, on account of the contraction of the pupil and the opacities in the refracting media.

It is noticeable that this form of iritis in the majority of cases exists in both eyes at the same time, although in different stages of development. It is therefore not improbable that it is due to some unknown anomaly in the constitution or perhaps in the eyes of the patient.

When adhesions have formed around the entire pupillary margin, and the iris is driven forward, the disease if neglected leads to incurable blindness.

The annular adhesion of the margin of the iris cannot be broken up by the use of atropine, and all internal medication, including mercurials which were formerly often employed, has proved wholly inefficacious against this disease. Iridectomy is the only means by which to check this destructive process.

It was formerly thought that the operation should be restricted to those cases in which the pupil is entirely closed, and that its only benefit was to provide a new opening for the admission of light. Von Graefe,\* however, demonstrated the great value of

---

\* Arch. f. Ophth., B. ii. 2, pag., 202.



the operation in those cases also in which the pupil remains transparent, and proved that it is the only means by which to check the ruinous course of the disease. Iridectomy is always urgently indicated so soon as the margin of the pupil becomes completely adherent to the lens, even though good vision may still remain. Nothing is gained by waiting, for the operation will have to be performed later and under less favorable circumstances. In general, with irido-choroiditis, the longer the disease has lasted the less is to be expected from iridectomy. If it has lasted but a short time, a good result may be expected from the operation, even though vision has already become quite poor, especially when the loss of vision can be sufficiently explained from the condition of the pupil and the clouding of the cornea.

But if a disproportion exist between the transparency of the refracting media and the degree of vision, so that there is, for instance, a distinct red reflex from the fundus upon ophthalmoscopic illumination, while the patient is unable to count fingers, or if defects exist in the visual field, no essential improvement can be expected from an iridectomy. A very guarded prognosis should also be given in those cases in which cataract has developed. In such there is generally at the same time an abnormal softness of the eye, indicating a slight degree of atrophy. Under these circumstances, even though there may be good perception of light, there can usually be but very little done, since generally there is opacity of the vitreous body, as well as of the lens, and the retina too is probably somewhat affected.

Calcification of the lens frequently happens in very old cases of irido-choroiditis. The pupil then appears of a chalky-white or of a bright-gray color when, as is often the case, there is some fluid within the capsule in front of the chalky concretment. In such cases the iris is much atrophied and closely adherent to the calcified lens. This being so, even when there is good perception of light, there can be very little hope of improvement from an operation.

The great danger connected with complete adhesion of the margin of the pupil often makes it advisable to perform an operation in cases where a very small portion of the margin still remains free. This free portion is generally that vertically above the pupil, and it is best to perform the iridectomy just here. If at



the same time the pupillary region be clouded by the products of iritis, or be optically useless from other causes, as, for instance, from corneal opacities, and it be consequently desirable to obtain at the same time some optical advantage from an iridectomy performed above, it must be determined with certainty whether the upper lid is generally sufficiently raised to allow the new-formed pupil to be of any use.

Where the annular adhesions are strong and have existed a long time, it is best in the operation of iridectomy to forego the attempt to break through them, for there is great danger, during the effort, of rupturing the capsule of the lens. After opening the anterior chamber with the lance knife, the iris should be grasped with the forceps at a little distance from its pupillary margin, and then torn through in its continuity by traction, while the pupillary margin which has grown fast with the capsule of the lens is left behind.

When the periphery of the iris is irregularly driven forward, a point should be chosen for the iridectomy where there is the most room for the lance between the cornea and iris. But in all cases, even where the anterior chamber is very shallow, it is better to make the incision with the lance than with the ordinary narrow cataract knife. The wound made by the cataract knife, on account of the steepness of its walls, shows much less tendency to close like a valve, from the simple pressure of its edges, than does the flat wound made by the lance. This fact may be very important in the not infrequent cases in which liquefaction of the vitreous and defect in the zonula co-exist. In such cases a slow escape of the vitreous, complete collapse and final atrophy of the eye must necessarily follow a wound so made as to gape too easily.

Various methods of operation, under the name of "corelysis," have been proposed, all with the object of tearing through the adhesions between the iris and the capsule of the lens. The great objection to this operation is that there are no sufficient indications for its performance. Isolated synechiæ furnish no ground for operation. Their influence in causing relapses has been greatly over-estimated. In rare cases, isolated synechiæ cause annoyances which have been called "Iridalgia," and which, as shown by a case published by Hasner,\* may be relieved by corelysis. If

---

\* Prager Vierteljahrschrift, 1862.



annular adhesion of the pupillary margin have formed, and the periphery of the iris be driven forward, an iridectomy is the most certain operation. There remain only those cases in which there are numerous synechiæ with only a small portion of the pupillary margin left free. Now, this condition may continue for years without leading to any bad consequences. But in the case of such patients as cannot at any desired time obtain operative help it is greatly for their interest to avert any possible danger. Of course, under these circumstances, an operation having for its object to establish a circular movable pupil is to be preferred to iridectomy, but in just these cases very imperfect results are often obtained from corelysis.

Streatfeild,\* who was the first to practise the operation methodically, opened the anterior chamber by a wound just large enough to admit a flat, blunt hook, which he pushed under the margin of the pupil. Weber† tore the adhesions in a similar way by means of a blunt hook. Passavant‡ advised to make a puncture at the margin of the cornea, to grasp the iris with the forceps at the margin, where it is attached to the lens, and to detach it by gentle traction. In order to avoid the occurrence of anterior synechiæ as a result of the operation, it is best to make the puncture in the transparent portion of the cornea, and not too near the margin.

Iritis syphilitica is one of the earliest symptoms of secondary syphilis, and is generally observed simultaneously with condylomata or with syphilitic roseola.

The great majority of cases of iritis which are observed simultaneously with other syphilitic symptoms are distinguished by no anatomical characteristics from idiopathic iritis. It is only exceptionally that certain formations appear in the iris which must be regarded as the specific results of syphilis. Formerly they were generally called condylomata, till Virchow§ decided, from the clinical history of these formations, that they ought to be regarded as gummy tumors. A case examined anatomically by Colberg||

---

\* Ophth. Hosp. Rep., i. pag. 6, and ii. pag. 309.

† Arch. f. Ophth., B. vii. 1.

‡ Ibid., B. xv. 1, pag. 259.

§ Arch. f. path. Anat., B. xv. pag. 306.

|| Arch. f. Ophth., B. viii. 1, pag. 292.



fully confirmed this view. These formations grow from the tissue of the iris, generally near the margin of the pupil, and appear at first simply as a swelling of the parenchyma itself. Gradually the small tumor rounds up in the form of a pale-yellow or yellowish-red, translucent nodule, more or less distinctly permeated by blood-vessels. Simultaneously the signs of iritis are present (iritis gummosa). Under proper treatment these gummata shrink away rapidly, drawing themselves back into the tissue of the iris, leaving no trace, or a merely discolored spot.

Often, however, these tumors grow unchecked, so that they almost or entirely fill the anterior chamber. The cornea and neighboring sclera are pushed forward, and finally break through. Simultaneously the iritis becomes very severe, assumes a purulent character, so that hypopion occurs, and the final result is generally atrophy of the eye. It is only very seldom that gummata of the iris occur without syphilis.

Those cases of syphilitic iritis in which no gummata are present often differ in their clinical history from the idiopathic form. Both eyes are more frequently affected, although they are not always attacked at exactly the same time; the inflammation is more subject to relapses, and finally there come on more frequently, especially at night, severe ciliary pains, which differ from those of idiopathic iritis in the fact that they do not correspond to the intensity of the inflammatory symptoms.

The prognosis in syphilitic iritis is generally scarcely less favorable than in the idiopathic form; still, it is to be remembered that complications with a peculiar kind of faint clouding of the vitreous or with retinitis or choroiditis occur. The gummata of the iris, so long as they remain small, are not really dangerous, but where their growth is rapid they become very alarming.

In the treatment, atropine mydriasis is under all circumstances absolutely necessary. In iritis gummosa, an energetic general mercurial treatment should in most cases be resorted to, though in cases where neither the iritis itself nor the other syphilitic symptoms are of a very threatening character the indications for general treatment are less decided.

Variola and recurring fever are also constitutional diseases which stand in evident relation with iritis.

In both cases, however, the condition is generally that of an



inflammatory process affecting the entire uveal tract and participated in by the iris. In these cases, therefore, opacities of the vitreous are generally simultaneously present. Iritis also occurs in connection with articular rheumatism, especially in those forms which appear to stand in connection with gonorrhœa.

Iritis serosa, or hydromeningitis, are names usually given to that form of iritis in which there is a very peculiar participation on the part of the membrane of Descemet. In addition to the symptoms of iritis already mentioned, which, moreover, are as apt to be present with a moderate as with a violent inflammation, there appear on the posterior surface of the cornea a greater or less number of fine gray punctations, the largest being of a dirty-white color. Microscopic examination shows that they are due to changes in the epithelium of the membrane of Descemet. In an eye enucleated on account of irido-choroiditis I found upon the epithelial surface of the membrane of Descemet numerous gray-white prominences so loosely attached that a drop of water allowed to flow over it was sufficient to float away many of them. The particles which floated off consisted of detritus and fat, while the spots remaining on the membrane consisted of cells, proliferating and undergoing decomposition. Similar changes were going on in the epithelium about these specks, the process extending even to the cellular elements upon the ligamentum pectinatum. Now, since this structure sinks into the anterior part of the ciliary body, it may be easily understood how the epithelium upon the membrane of Descemet may become affected by an extension of disease from the choroid, without any participation by the iris. For instance, in a case of recent choroiditis and retinitis in the region of the macula lutea, with slight opacity of the vitreous, I saw at the same time a distinct though slight punctated appearance upon the membrane of Descemet. It disappeared under atropine treatment, after about eight days, no signs of iritis having developed.

Cases of iritis which present these changes upon the membrane of Descemet are generally very obstinate, greatly inclined to relapses, and frequently exist in both eyes at the same time.

The treatment is the same as in other forms of iritis. Attention must be paid to the general condition, and, above all things,



atropine is necessary. Derivatives are specially suitable, such as vesications upon the neck, or small setons upon the temple.

Secondary iritis not infrequently occurs as a consequence of inflammatory processes in the collateral vascular channels.

Frequently both the primary inflammation and the secondary iritis are so severe that hypopion occurs just as in idiopathic iritis.

In this class belong many cases of keratitis. Purulent keratitis, for instance, with hypopion, is generally accompanied by iritis, which may assume a purulent character. Atropine and luke-warm fomentations are the first remedies to be resorted to in these cases. If they prove insufficient, it is often possible to check the process by an iridectomy. The tissue of the iris is generally found very brittle, and its surface covered with a layer of exudation.

Nearly all cases of acute choroiditis cause secondary iritis. This is true both where the disease is acute and violent, leading rapidly to blindness, and in those more chronic cases during which acute exacerbations occur.

Iritis also generally follows sooner or later after detachments of the retina.

Frequently iritis is caused by the development of cataract, which in its turn is due to choroidal disease. In such cataracts, even in old people, there is considerable swelling of the cortical substance. The iris is driven forward, moves sluggishly upon the surface of the lens, and soon the symptoms of iritis appear. It is best, therefore, when the lens swells in this manner, to use atropine as soon as the iris appears to be driven forward.

Those forms of iritis in which the posterior synechiæ are not limited to the pupillary margin, but where the adhesions between the iris and the capsule of the lens extend far back toward the periphery, are all of a very dangerous nature.

The existence of extensive adhesions between the lens and the posterior surface of the iris may be assumed when, in the absence of atropine mydriasis, the entire pupillary margin is adherent, and yet the periphery of the iris is not driven forward, or the pupillary margin not sunken like a crater. Under such circumstances there occurs generally a disturbance in the nutrition of the vitreous, which is manifested by a diffuse or flocculent clouding



and liquefaction within it, as well as by an abnormal softness of the eye. Opacity of the lens generally follows.

This form of iritis, with extensive superficial adhesions, may develop from the above named cases of annular adhesion of the pupillary margin, by an absorption of the fluid collected behind the iris; but cases also occur which run a rapid course, and in which, without any preceding accumulation of fluid, the adhesions form immediately from the margin of the pupil to the periphery of the iris.

In many cases the process is not limited to a simple adhesion between the capsule of the lens and the uveal layer, but the cellular elements participate in an active process of proliferation, forming a new, thick, vascularized membrane, which extends from the uveal layer of the iris over upon the ciliary body, where the same inflammatory process develops. As soon as the ciliary body is involved in the process the disease is called irido-cyclitis.

Spontaneous irido-cyclitis occurs very rarely, but when it does the danger to the eye affected, and to the other from sympathetic disease, is just as great as in the traumatic form, yet to be described. The pupil is either contracted or closed by an exudate. If the iris be naturally of a bright color, its surface is frequently dotted with a number of dark-brown specks, which upon anatomical examination I have found to be due to a circumscribed atrophy of the stroma, which allows the pigment of the uveal layer to be seen through it.

The cornea appears small and flat, less transparent than normal, the anterior chamber shallow, the iris and lens driven forward. At a later stage the new membrane, which forms upon the uveal layer of the iris, extends directly over upon the ciliary body. Certain portions of the periphery of the iris may be drawn back toward the ciliary body by the shrinkage of the new-formed tissue, although the pupillary part is driven forward. Frequently at the same time blood-vessels may be recognized upon the iris. Probably they are small veins which are distended in consequence of the obstructed flow of blood through the ciliary part, or they may be more distinct by reason of the atrophy of tissue upon the surface of the iris.

The most important symptom of disease of the ciliary body is pain upon pressure made over it, especially at its upper portion.



In connection with the symptoms above described and the abnormal softness of the eye, yet to be referred to, this tenderness of the ciliary body is a very important symptom for the diagnosis of irido-cyclitis; but by itself no importance is to be attached to it, since the same symptom frequently occurs in connection with acute inflammation of the cornea, of the iris, or even of the choroid.

With irido-cyclitis there never fails to be a disturbance in the nutrition of the vitreous body. It frequently occurs at a very early stage of the disease, and is manifested by an abnormal softness of the eyeball. At a later stage, opacities of the lens generally develop.

Vision is, of course, always greatly diminished, and may finally be lost when atrophy of the eye begins.

Irido-cyclitis may develop without any apparent cause, or it may follow upon other forms of iritis. It is most frequently caused by wounds of the eyeball. In such cases, however, the appearances in the disease are somewhat modified by the immediate consequences of the injury.

In these cases the proper diagnosis is of the greatest importance on account of the great inclination to sympathetic affection of the other eye. Under these circumstances the most important prognostic symptom is a tenderness of the ciliary body, out of proportion to the external inflammatory signs, while at the same time it is associated with a diminished tension of the eyeball.

The conditions for the occurrence and course of sympathetic irido-cyclitis were first faithfully described by Mackenzie.\*

After one eye has become seriously diseased, or is already blinded, generally from some traumatic cause, the signs of sympathetic affection of the second eye are, as a rule, first manifested by indistinct vision. Soon the signs of iritis appear, namely, pericorneal injection, diffuse clouding of the cornea, discoloration of the iris, and adhesions with the capsule of the lens. The periphery of the iris may at first be driven forward by the accumulation of fluid behind it. Generally, however, extensive adhesions of its posterior surface occur. There is contraction or absolute closure of the pupil, with shallowness of the anterior chamber, and all the signs of irido-cyclitis. A diffuse clouding

---

\* Practical Treatise on the Diseases of the Eye, London, 1854, pag. 64.



of the vitreous is frequently present from the very first, which explains why in these cases it is that at the beginning of the inflammation, vision is much poorer and the ophthalmoscopic image much less distinct than would be supposed from the condition of the refracting media, as examined by focal illumination. Later, the lens generally becomes opaque.

The tension of the eyeball may increase somewhat at first, but later there ensues a distinct and permanent diminution of tension.

The subjective symptoms, such as pain and photophobia, are in some cases severe, but generally are slight.

Under all circumstances the course of the disease is very slow, with perhaps many exacerbations. Finally, the process ends with more or less diminished vision, or the tension of the eyeball may continue growing constantly less till there is complete atrophy.

The wounds which are followed by irido-cyclitis of the injured eye and by sympathetic disease of the other, are generally lacerating or penetrating wounds. A foreign body, such as a splinter of iron or piece of percussion-cap, may or may not have been left in the eye. Simply a severe blow may be followed by like results. Mackenzie has called attention to the fact that wounds at the junction of the sclera with the cornea involving the ciliary body are the most dangerous, especially when at the same time a prolapse of the iris occurs, which, healing in the wound, is subjected to continuous irritation by the subsequent contraction of the cicatrix.

Operations on the eye rarely cause sympathetic inflammation: still, Critchett\* mentions two cases in which it followed the extraction of cataract by the flap incision, and I, too, have seen one such case occur in Von Graefe's practice.

This sad result has been more frequent after iridodesis, an operation which involves all those conditions which Mackenzie has described as particularly dangerous. The wound is at the corneo-scleral boundary, there is prolapse of the iris, and scar tissue forms in such a way that the portion of iris within the eye is subjected to continuous traction.

As a rule, the injured eye is already blind before it causes sympathetic disease in the other, but Mackenzie mentions one case in

---

\* Klin. Monatsbl., i. pag. 445.



which the eye first affected still retained some power of vision, while the one affected by sympathetic disease was absolutely lost.

Between the primary injury and the appearance of the sympathetic inflammation there is generally, as Mackenzie stated, an interval of from four to six weeks. This appears to be the earliest time at which sympathetic disease can occur, but by no means the latest. So long as there remains any trace of irido-cyclitis, with tenderness of the ciliary body in the injured eye, there is reason to fear sympathetic disease of the other. Moreover, the traumatic inflammation may run its course without affecting the other eye; the injured eye may become atrophic and remain for years unchanged, when suddenly, without any apparent cause, there appears new inflammation, and with it the renewed danger of sympathetic disease.

This is most to be feared when a foreign body has remained in the eye, or when ossification of the choroid or calcification of the lens has occurred.

That the propagation of the disease from one eye to the other takes place through the medium of the nerves cannot be doubted. Formerly this was thought to occur in the course of the optic nerve, but Arlt,\* in 1855, showed that the ciliary nerves are more probably the ones concerned. Somewhat later H. Müller† expressed the same view, which was greatly strengthened by the anatomical investigations of De Maats.‡ Moreover, Bowman§ has pointed out the very frequent beginning of the sympathetic inflammation at a point exactly symmetrical with that of the injury in the first eye. This goes to show a participation of the ciliary nerves in the process.

It may then be regarded as certain that the disease is propagated along the course of the ciliary nerves, but since these nerves contain fibres having different functions, it remains doubtful which set of fibres is concerned; there appears reason to suspect the sensitive fibres of the fifth pair. It should be noticed, however, that this sympathetic disease is not propagated with the same rapidity along the course of the nerves as are ordinary irritations.

\* *Krankheiten des Auges*, 1855, i. pag. 51.

† *Arch. f. Ophth.*, B. iv. 1, pag. 368.

‡ *Utrecht*, 1865.

§ Cf. *De Maats*, l. c., pag. 53.



*Treatment.*—When the occurrence of sympathetic disease first attracted the general attention of ophthalmologists, it was natural that the limits of the subject should have been too widely extended, and this fact may explain the brilliant results described as having followed the extirpation of the primarily diseased eye. In the course of time, however, as the nature of sympathetic irido-cyclitis became better understood, the conviction grew more general that the extirpation of the primarily diseased eye cannot allay a sympathetic inflammation once excited in the other. Critchett\* was the first to make the valuable suggestion that the injured eye be extirpated before any signs of inflammation appear in the other. Undoubtedly the enucleation should be performed as soon as an eye, whether injured or not, becomes blind, with the symptoms of irido-choroiditis, loses its normal consistency, and remains painful upon light pressure in the region of the ciliary body. By following this rule it is possible that many eyes may be unnecessarily extirpated, since all the recognizable conditions for the occurrence of sympathetic inflammation may be present without its following. Nevertheless, the sacrifice of a blind, shrunken, and disfigured eye is of no importance as compared with the danger of complete blindness, which will be caused by the appearance of sympathetic irido-cyclitis in the other eye.

On the other hand, however, the enucleation must be resorted to with more hesitation when irido-cyclitis does not exist. The depressing influence which the extirpation, even of a blind eye, has upon the patient is generally very considerable, and under these circumstances an artificial eye does not always effect a cosmetic improvement.

When irido-cyclitis has once appeared, the question arises whether at this late period it is still advisable to remove the eye first diseased. The hope formerly cherished, of being able by this operation to arrest the sympathetic inflammation, must be relinquished; nevertheless there is always the possibility that, after the removal of the cause of the disease, the sympathetic process may run a more favorable course than if the cause remained. If under these circumstances there still remain in the injured eye some degree of vision, which of course it is desirable

---

\* Klin. Monatsbl., i. pag. 447.



to retain, the enucleation must be postponed, as the benefit of the operation is very problematical, and there is no justification for sacrificing an actual though slight degree of vision.

Nor can any more benefit be expected from the operation for the eye affected with sympathetic inflammation. Iridectomy, which for a long time was greatly over-estimated as a cure for all kinds of iritis and irido-choroiditis, proves wholly useless in irido-cyclitis.

Critchett\* was the first to assert that in irido-cyclitis all operative interference so long as any inflammation remains is absolutely hurtful. He therefore advised to limit the treatment to protection from all injurious influences, and to await the disappearance of all inflammatory symptoms. This may require a number of months, and meanwhile absolute atrophy of the eye may occur; but nevertheless no better result is obtained by too early operative interference.

Even when all irritability and tenderness has disappeared from the eye an iridectomy does not generally prove sufficient, since the adhesion of the uveal layer with the capsule of the lens is too strong. Only that part of the stroma which is grasped by the forceps can be torn away. The uveal layer and the false membrane connected with it remain behind, a hemorrhage in the anterior chamber generally follows, and the result is that no improvement is obtained. Critchett therefore adopted the advice previously given by Von Graefe,† to extract the lens at the same time when making the iridectomy, in those cases of irido-cyclitis in which the pupil is closed by false membrane or in which there is opacity of the lens.

The best method for these cases is the peripheral linear incision, to be made just as long as for cataract extraction.

If the anterior chamber be shallow, the narrow knife is passed through the iris and false membrane, and behind them, till the counter-punction is made. A pair of straight forceps is then inserted in such a way that one branch is before and the other behind the iris; but even then, on account of the strength of the adhesions, it is generally not possible to draw out of the wound that portion of the iris which is grasped by the forceps, but it is

---

\* Klin. Monatsbl., i. pag. 440.

† Arch. f. Ophth., B. vi. 2, pag. 97.



necessary to introduce a fine pair of scissors, just as were the forceps, with one point before and the other behind the iris, in order to cut through it, in the direction of a radius, to the pupil. The flap of iris so formed may then generally be drawn out of the wound and completely removed.

During this procedure a portion of the cortical substance of the lens generally flows out. The remainder of the lens is then to be removed, either by rubbing and pressing on the cornea or by introducing a spoon.

It cannot be doubted that less destructive cases of iritis may occur as sympathetic inflammation, and if properly treated may run a favorable course. Still, upon critically examining such cases, it is often very difficult to determine whether there really is any causal connection between the diseases in the two eyes, or whether their simultaneous occurrence is merely accidental.

The most convincing proof of the sympathetic nature of a disease of the eye is given when, immediately after the extirpation of the eye first diseased, the affection disappears from the other, as, for instance, in the form of blepharospasm mentioned on page 230, which was proved by Donders to be sympathetic. It is only exceptionally that these reflex neuroses attain such a grade as that there described, where the blepharospasm destroyed the usefulness of an otherwise normal eye. In the majority of cases there exists only a painful irritation of the eye. Photophobia, subjective sensations of light, slight lachrymation and reddening of the eyes upon slight use, inability to work continuously, transitory darkness of the visual field, etc., may exist a long time without the occurrence of actual inflammation. The rapid disappearance of these symptoms after the extirpation is proof of their sympathetic character.

If the effect of the operation be slower, appearing only after several weeks, as, for instance, in certain cases where there is contraction of the visual field, which may be regarded as due to sympathetic disease, the proof that it is so can be furnished only by the accumulation of numerous observations. If, however, the enucleation have no effect upon the disease in the other eye, we must look about for other proofs of the sympathetic nature of the disease.

The view frequently expressed, that the condition of the eye affected with sympathetic disease is directly dependent upon the



condition at that particular time of the eye primarily affected, that every exacerbation in the last is responded to by an exacerbation in the first, is by no means confirmed by observation.

If, however, following certain determined changes in one eye, we see a distinctly characterized disease of the other eye, which without some such cause occurs very rarely, the cumulative evidence of such cases proves their sympathetic character. This, for instance, is the case in irido-cyclitis sympathetica.

It is very difficult in observing any particular case to be convinced of its sympathetic character. For instance, the case of choroideo-retinitis described by Von Graefe,\* which I know perfectly well, since I observed it with him, presented such a peculiar appearance that Von Graefe regarded its sympathetic nature as probable. But it requires a number of such cases to furnish satisfactory proof of the correctness of such an opinion.

If, on the other hand, the disease of the second eye be attended with symptoms by no means peculiar, and if the condition be one which we see occur under the most varied circumstances, only very careful investigation and a great number of cases could establish the sympathetic nature of the affection.

The only disease which can positively be said to cause sympathetic inflammation is irido-cyclitis. All other statements on the subject, as, for instance, that after operation for glaucoma in one eye sympathetic glaucomatous inflammation may occur in the other, must be regarded as based on little more than assumptions.

If a few days after iridectomy in one eye an acute glaucomatous inflammation appear in the other, this accident certainly may be a very unpleasant surprise; but the circumstance that the operation in the first eye and the inflammation in the second occur only a few days apart argues against the suspicion of a sympathetic connection. For in ocular inflammations whose sympathetic origin is demonstrated, it is not days but weeks before the inflammatory process proceeding from one eye, and following the course of the ciliary nerves, reaches the second.

Furthermore, glaucoma is a bilateral disease in so great a majority of cases that it is no wonder if, after iridectomy in one eye, glaucomatous inflammation appear in the other. It is to be

---

\* Arch. f. Ophth., B. xii. 2, pag. 171.



remembered, too, that attacks of glaucoma are greatly favored by loss of sleep, mental anxiety, etc., and that the operation furnishes cause for just these conditions in very many patients.

It is finally to be mentioned that some cases have been observed in which the use of an artificial eye caused sympathetic disease. Lawson\* mentions a case in which, five years previously, an eye had become blind and atrophic, in consequence of ulceration of the cornea. During all this time it had shown no annoying symptoms, but by using an artificial eye it became inflamed and painful, and finally caused sympathetic irido-cyclitis. Lawson explained this intolerance of an artificial eye by the fact that a portion of the corneal tissue, too sensitive to endure the friction of a foreign body, still remained upon the shrunken stump.

Salomon† reports a case in which symptoms of sympathetic irritation, which were the occasion for the enucleation of an eye, reappeared when an artificial eye was inserted. Such a case may be explained by supposing that the disease excited along the course of the ciliary nerves still persisted after the enucleation of the eye, and that the portions of the ciliary nerves remaining in the orbit being irritated by the presence of the artificial eye, the sympathetic disease reappeared in the other eye.

Enucleation is performed in the following manner. The lids are held apart by the speculum; the conjunctiva is grasped at the upper part of the eye with the fixation forceps, is cut close about the cornea and immediately loosened from the sclera by strokes of the scissors, carried far back toward the equator; the rectus superior is then caught with the strabismus hook and its scleral insertion divided; the same is done with the other recti muscles. When these four muscles are divided, it is best to remove the speculum and by pressure directed backward upon the margin of the lids to dislocate the eyeball forward. Should the conjunctival wound prove too small to allow the eyeball to pass through, it must be somewhat enlarged. When the eyeball has passed through the conjunctival wound and is pressed forward between the margins of the lid, a pair of curved scissors is to be introduced at the inner angle of the eye and the optic nerve divided. The eye may

---

\* Ophth. Hosp. Rep., vi. 2, pag. 123.

† Dublin Quarterly Journal, xxxv., pag. 58.



then be easily drawn out of the orbit, the two oblique muscles cut off at their insertion, and the enucleation ended. It is well after the bleeding ceases to close the conjunctival wound with a suture, passing the thread alternately in and out near the margin of the conjunctiva around the entire wound, and then drawing it up, like a tobacco-pouch, and tying it.

Remnants of the foetal pupillary membrane (*membrana pupillaris perseverans*) are frequently observed in the form of a greater or less number of isolated or anastomosing threads, springing from the *circulus minor iridis*, extending across the margin of the pupil, and ending either upon the capsule of the lens or upon a pigmented disc occupying the centre of the pupil, or they may pass uninterruptedly across the pupil. Under these circumstances the margin of the pupil retains its motility.

Irideremia, or absence of the iris, occurs very rarely as a congenital defect, either with or without other congenital anomalies.

Traumatic irideremia, the tearing of the iris from the ciliary body, happens only in consequence of some severe injury, and is therefore generally complicated with loss of vision, due to hemorrhages in the vitreous, etc. It is only exceptionally that these complicating injuries are unimportant, but when they are, recovery with good vision is possible. It is noticeable that the secretion of the aqueous humor is not affected by the total loss of the iris, and that a normal power of accommodation may remain.

Ammon describes a case in which, in consequence of a severe shock to the head, in a case of suicide by shooting, the lens was displaced and the iris reflected behind the ciliary body.

A congenital opening in the iris (*coloboma iridis*) occurs either in only one eye, more frequently the left, or in both eyes at the same time. The fissure is generally below or directed inward and downward. It generally causes no particular disturbance of vision if not connected with other abnormalities. Frequently there are simultaneously corresponding defects in the choroid.

Tumors of the iris, aside from the gummy tumors already mentioned, occur but rarely. Among the different varieties which have been observed are congenital pigment tumors, granulation tumors, *telangiectasiæ* and *melanosarcoma* of the iris.



Cysts of the iris are generally caused by wounds. In 37 cases collected by Rothmund,\* 28 had been preceded by wounds, and in most of these there had been perforation of the cornea. The contents of these cysts may be either serous or colloid, or even of a more solid consistency. Their walls are sometimes very delicate and transparent, in other cases they are thicker and more opaque. These cysts are situated either in the tissue proper of the iris or they appear as a new growth upon its surface. In a case observed by White Cooper, the cyst was connected with the ciliary body.

The removal of a cyst is indicated so soon as the diagnosis is certain, for its continued presence and constant growth may cause consecutive iritis, ulceration of the cornea, and possibly, as in a case observed by Hulke,† sympathetic irritation of the other eye. The best method is to open the anterior chamber with the lance knife, near the cyst, and, if possible, without wounding its walls. The cyst then often protrudes of itself through the wound in the cornea, or it may be drawn out with a spoon or hook. If any portion of the cyst wall be left in the eye, or if the cyst be merely punctured, it will often reappear.

A peculiar tumor of the iris is sometimes caused by eyelashes, which penetrate the anterior chamber at the time of a wound in the cornea. After remaining there some time, they cause the development of growths which greatly resemble atheroma, being whitish in color, circumscribed in form, and filled with a pasty substance containing fat and cholesterin. I observed one such case in which about six cilia penetrated the anterior chamber through a perforating wound. Three months later, two white dots were noticed, for the first time, upon the iris. After the removal of the cilia from the anterior chamber the little tumors continued to grow, and six months after the injury, their extirpation seemed advisable. The larger tumor had now attained a diameter of  $1\frac{1}{2}$  mm. It was spherical, and sat upon the iris like a ball attached by only a small pedicle. Its surface had a pearly, glistening, semi-transparent appearance, and within it was an opaque, white nucleus, from  $\frac{1}{2}$  to  $\frac{3}{4}$  mm. in diameter. The smaller tumor was of a similar character. Both were removed

---

\* Klin. Monatsbl. f. Augenheilk., 1872, pag. 189.

† On Cysts in the Iris, Ophth. Hosp. Rep., vi. pag. 12.



by an iridectomy. Prof. W. Krause, of Göttingen, kindly made a microscopic examination, and gave me the following report: "The central white nucleus contained free fat in larger and smaller drops, numerous crystals, mostly cholesterin, and polygonal cells. The transparent, peripheral part, aside from a few cholesterin crystals, consisted of long, hexagonal, slightly flattened, epidermis cells, destitute of nuclei. A thick layer of similar cells formed the cortical part. This layer at the base of the tumor is covered with a thin, indistinct, fibrous, connective-tissue membrane, which, however, does not completely envelop the tumor, but leaves the layer of cells exposed at several places. An epithelial covering can nowhere be discovered upon this connective-tissue membrane, which, moreover, at the base of the tumor, is continuous with the tissue of the anterior surface of the iris. As explaining these remarkable growths, we may suppose that, at the time of the injury, fat-producing cells, probably from the hair follicles, were carried with the cilia into the iris, and that their growth was continued there. The mass of new-formed cells resemble those found in atheroma."



## DISEASES OF THE LENS.

---

WE have already had occasion, on page 26, to mention that the physiological growth and nutrition of the lens cause changes whose dioptrical consequences affect refraction and accommodation. In this place we have to do principally with the catoptric phenomena caused by the senile changes of the lens. The greater density assumed by the lens causes the difference between the index of refraction of the lens on the one hand, and of the aqueous humor and vitreous body on the other, to become greater. At the limits of these media, accordingly, a greater reflection of light takes place, which causes a noticeable gray shimmer in the pupil. This gray reflex from the pupil becomes still more striking from the fact that frequently the fibres of the lens assume an index of refraction somewhat different from that of its amorphous substance. The structure of the anterior cortical layer becomes, therefore, more distinctly visible by focal illumination than in the normal condition; certain sectors appear of a dull-gray color, so that one may think he has before him a cataractous opacity, while a single glance with the ophthalmoscope suffices to prove the transparency of the lens.

No annoyances are connected with this condition aside from the contraction of the range of accommodation, and a slight diminution of vision.

With reference to the prognosis, it is to be remarked that this senile condition of the lens may remain unchanged many years without the development of cataract.

The many forms of cataract may be most simply divided into progressive, or such as eventually cause opacity of the entire lens, and partial or stationary opacities. This indeed does not give an absolutely sharp division, since the total opacities of the lens are at first partial, and, moreover, there are partial opacities respecting which it cannot be foretold whether they will develop to total opacities or not, or which go on in this process of development with extreme slowness.



The physiological relations of the lens exercise a great influence upon the form of the cataract. In total opacities of the lens in young individuals, the tendency to soften and liquefy preponderates, while in more advanced age these processes, it is true, may occur, but they are always limited to the cortical part, while the nucleus of the lens has already become hard and resists the softening process.

The softening of the cortical substance manifests itself by the appearance of a number of light-gray, radiating, transparent stripes, perhaps 0.5 to 0.75 mm. in breadth, dividing the cortical substance into several pearly, glistening sectors. The cortical substance, however, still remains transparent, so that, with the pupil dilated and by focal illumination, one may look deep into the lens, in order to satisfy himself whether its whole substance be softened, or whether a hard nucleus still exist. The fact, already mentioned, that the physiological growth and nutrition of the lens cause a gradual hardening of the nucleus, furnishes the ground upon which to suspect the existence of a hard nucleus in all cataracts which develop after the thirtieth year of life, even although, when examined by focal illumination, the differences in color between the hard and the soft forms may be so slight as to leave the matter doubtful. In old age the color of the nucleus of the lens generally makes it distinctly visible.

The soft cortical cataract generally develops so much the more rapidly the broader the sectors into which the corticalis is divided; there is generally at the same time a swelling of the clouded lens; the anterior capsule appears very convex; the iris is pressed forward, and impeded in its movements.

The swelling of the lens gradually recedes, by the absorption on the part of the aqueous humor of a portion of the fluid enclosed in the capsule.

In the further course of the process there may be either a thickening or a complete liquefaction of the softened corticalis.

In the latter case the cataract assumes a uniform milky appearance, and only here and there can fine white spots and flakes be seen attached to the capsule.

If this liquefaction occur in childhood, and if the cataract remain a long time uninterfered with, a very considerable reduction in the volume of the lens may occur, so that the cataract recedes from the plane of the pupil.



It may even happen that the lens shrinks to a thin layer of precipitates upon the inner surface of the capsule, and so assumes exactly the appearance of a secondary cataract.

Even in old age an absolute liquefaction of the corticalis is possible; still, there is accompanying it no reduction in the size of the lens, or one exceeding very little the physiological reduction. Moreover, there always remains the hard nucleus of the lens, which sinks to the bottom of the fluid with which the capsule is filled, whatever may be the position in which the patient holds his head (*cataracta Morgagniana*). The diagnosis of this form of cataract is easy if the capsule has remained transparent. By the help of focal illumination, with the pupil moderately dilated, one can see the yellowish nucleus of the lens whose sinking proves the liquefaction of the corticalis. On the contrary, if the capsule has become opaque by deposits upon its inner surface (*capsular cataract*), and if the pupil can be only partially dilated by atropine, as is so often the case in old people, the diagnosis may be exceedingly difficult.

It still remains to be mentioned that the prognosis of an operation in *cataracta Morgagniana* is generally regarded—though perhaps erroneously—as less favorable than in the usual forms of senile cataract.

Relatively less frequent than the soft cortical cataract are those cloudings of the lens which begin by a hardening and a distinct demarcation of the nucleus from the cortical substance. The nuclear cataract never develops until an age in which the nucleus has become markedly differentiated from the cortical substance,—that is, seldom before the thirtieth, and generally about the fiftieth year. In their mildest grades, these changes present a process similar to that which we have already described as the senile change of the lens, only they are limited to the nucleus. By diffuse daylight the pupil shows a striking gray reflex, which, however, as appears immediately by focal illumination, has its seat not in the superficial layers, but in the deeper part of the lens. The nucleus is distinctly differentiated from the cortical substance, upon ophthalmoscopic illumination, by means of a weak reflecting mirror. According to the position in which the mirror is held, one sees the nucleus bounded upon the one side by



a bright reflex and on the other by a dark shadow of the corticalis, and by slight movements of the instrument this phenomenon of refraction may be caused to appear at different points successively all around the nucleus. The nucleus, however, may remain a long time transparent. These changes in the lens cause, in the first place, an increase of refraction; still, the degree of the myopia cannot always be exactly determined, because there is simultaneously a diminution of vision, due partly to irregularity of refraction and partly to a decrease of transparency.

This condition may remain stationary a long time, or may lead finally to actual cataract of the nucleus, and of the entire lens. The lens assumes more and more a gray color, becomes gradually opaque, and finally opacity of the cortical substance develops.

The above described form of cataract occurs both idiopathically, without known causes, and also in connection with other ocular diseases; it is especially frequent in eyes which have suffered from glaucoma, in high degrees of myopia, and where there have been extensive choroidal changes, for instance in connection with staphyloma posticum.

The most frequent form of opacity in the lens is the so-called senile cataract. It generally begins near the equator of the lens, and, according to Förster,\* with a clouding of that layer of the corticalis which lies immediately upon the nucleus. There occur then a number of short linear opacities or irregular cloudy specks, which appear dark by ophthalmoscopic illumination and gray by focal illumination. They gradually increase both in size and in number. Simultaneously the nucleus becomes more distinctly differentiated from the corticalis, by a more or less decided yellowish-brown color; its transparency, however, does not suffer to the same degree as that of the corticalis.

The anatomical changes occurring in the corticalis are somewhat different from those in the nucleus. The fibres of the corticalis appear finely punctated, and run more or less together, so that in the layers which can be scaled off from the corticalis one can only indistinctly recognize the individual fibres. Besides this fine granular punctation, there occurs an exudation of myeline and

---

\* Arch. f. Ophth., B. iii. 2, pag. 187.



other drops, which appear red under the microscope; and, finally, cholesterin crystals appear in cataracts which have existed a long time, especially when the process has been that of softening of the corticalis.

This chemical decomposition appears less prominent in the nucleus. On the contrary, the individual fibres appear more consistent, shrunken, uneven on the surface, dry and brittle, and, on account of their increased opacity, easier to recognize than in the normal condition. The nucleus is generally so much the harder and larger the darker it is; indeed, cases occur in which the nucleus is so large and dark that, when examined with the naked eye, the pupil appears black, since the large dark nucleus leaves but little space for the semi-transparent corticalis. These cases have been called *cataracta nigra*. Their diagnosis was difficult before the time of the ophthalmoscope, but a single glance with that instrument, or by focal illumination, suffices to make the relations clear. In some such cases, upon anatomical examination, I found the nucleus of a transparent dark red. Microscopic examination shows that the dark color is due simply to a delicate red tinge of each individual fibre, and that the dark tinge was caused by many of these lying in apposition. Pigment molecules were not present, either in or about the fibres of the lens. The yellowish or brownish color of the lens, so frequent in senile cataract, is caused in exactly the same way.

Senile cataract is called "ripe" when the opacity has extended to the external cortical layers. This condition is in general desirable, but by no means necessary for operation. In old, so-called over-ripe senile cataracts the lens is generally somewhat flattened by the shrinking of its fibres. They experience simultaneously in the anterior cortical substance, changes which will be more particularly described under the head of capsular cataract.

Cataract may develop at any age, even during foetal life. Both partial and total cataract occur congenitally. In one case I found an emulsive detritus of fibres which had been already formed, and a great number of fatty granular cells, which probably consisted of a detritus of the embryonal cells destined for the formation of the lens fibres. Frequently there is congenital amblyopia in connection with congenital cataract; this cannot be



detected for some years, until the child has attained a certain degree of mental development. The hereditary nature of congenital cataract is often observed; but even when both parents have normal eyes it frequently happens that several of their children are born with cataract, while other brothers and sisters remain free. Once, indeed, at a twin birth, I have seen one twin affected with cataract while the other had healthy eyes.

Furthermore, the various forms of cataract may develop during childhood, and in view of the possibility of co-existing amblyopia, may present the greatest diagnostic difficulties. If nystagmus be also present, one may conclude that amblyopia exists with the cataract. The hereditary nature of cataract developed later in life has been proved.

In diabetes mellitus a relation is known to exist between the general condition and the development of cataract. In a case which was chemically examined by L. Carius,\* a great quantity of sugar was detected in the aqueous humor, and it probably existed in the lens and vitreous body. Further investigations must determine whether this is the real cause of the cataract. The oft-repeated statement that *cataracta diabetica* generally develops very rapidly, I have not found true in cases where it occurred in aged persons.

J. Meier† has recently observed cataract as a consequence of ergotism, and Rothmund,‡ a case in connection with a very peculiar degeneration of the skin. In most cases of uncomplicated cataract a determinate cause cannot be ascertained. It can only be asserted as a general rule that the frequency of cataract is in direct relation with the increase of age.

As a direct and immediate cause of cataract all wounds of the lens are to be named (*cataracta traumatica*). The presence of entozoa in the human lens is one of the greatest rarities.

Among those causes of cataract which have their seat in the eye itself, we know accurately only those which at the same time are deleterious to vision. Among these belong, for instance, certain cases of iritis, especially those complicated with cyclitis or choroiditis, also certain forms of choroiditis, either with or without disease of the vitreous, and especially retinal detachment and glaucoma.

---

\* Klin. Monatsbl., 1863, pag. 172.

† Arch. f. Ophth., B. viii. 2, pag. 120.

‡ Ibid., B. xiv. 1, pag. 157.



The diagnosis of complicated cataract is generally not difficult. There are either evident changes in the iris or in the cornea, or the cataract itself shows certain peculiarities. But even when all other evident changes are absent, the presence of a complicating disturbance of vision can generally be determined by carefully testing the perception of light.

In order to determine accurately the degree of vision in cataract, care should be taken that no diffuse light, but only that from a flame, reaches the eye. If the examination be made by daylight, the patient is to be placed with his back toward the window and the light not allowed to fall into his eyes from the side. Even when there is total clouding of the lens, fingers can often be counted at the distance of some inches from the eyes, and movements of the hand recognized at the distance of one or two feet. If the field of vision be free, so that movements of the hand can be recognized from the side of the eye, the perception of light may be regarded as sufficient. If one wish to make a very exact examination, it is best to do it in a dark room, with only a single lamp, and to proceed as above described, and further, by lessening the flame, or increasing its distance from the eye, to determine the smallest quantity of light which the patient is able to recognize. It is a very good plan to place the lamp behind the patient and then cast the flame from in front into his eye by means of a plane mirror. The least intensity of light perceptible to the patient may be determined by holding the mirror at a greater distance from the eye, and more easily than when the lamp is used directly as the source of light, while the slightest movement of the mirror suffices to deflect from the eye the reflected rays.

The field of vision is tested by quickly changing the position of the lamp or by reflecting its flame, with the mirror, into the eye from various points in the periphery of the field. In both cases the patient should be able quickly and accurately to state the position of the light. The method of testing vision by artificial illumination has the advantage that we can modify the intensity of the light, and is therefore the one to be employed for those cases in which there is reason to suspect some complicating disease of the eye.

Especial care and attention should be had in testing the perception of light in the soft cortical cataracts of young individuals,



particularly when they are unilateral. Complications with intra-ocular diseases, such as detachment of the retina and clouding of the vitreous, are relatively much more frequent under these circumstances than in senile cataract, and even by the most careful examination it is not always possible absolutely to exclude the existence of complications. Even where there is partial opacity of the lens it may under certain circumstances be very difficult to determine whether vision stands in the proper relation to the degree of opacity in the lens, as determined ophthalmoscopically. It is of great importance in all these cases to test the field of vision.

Among the partial opacities of the lens, the first to be mentioned is the *cataracta incipiens*,—that is, the beginning of cortical or nuclear cataract. One frequently finds, as an accidental ophthalmoscopic discovery, linear opacities in the equatorial part of the corticalis, with no disturbance of vision; the latter does not occur until these opacities invade the region of the pupil. Under these circumstances, so long as vision is sufficient for the purposes of the individual, it is best not to inform him of the nature of his disease, because such opacities may remain for years without making any further progress, and it is certainly not right, if their sight is at present good, to cause anxiety in the minds of patients with reference to a blindness which perhaps may never occur, or at least not for many years. Of course one would not hesitate to explain the nature of the disease to patients whose vision is no longer sufficient for the demands of their occupation.

More rarely *cataracta incipiens* occurs with a quite irregular flaky clouding of the anterior corticalis, immediately below the capsule. In such cases its progress is generally very slow. Complications with choroiditis, detachment of the retina, etc., exist in many but by no means all of these cases.

Frequently there develops in the lens a great number of fine points or irregular lines, between which, transparent lens-substance remains (*cataracta punctata* and *striata*). The course of these cases is generally very slowly progressive, or they may even remain a long time unchanged in a condition which reduces the patient to a very insufficient degree of vision. In such cases, just as in the very slowly progressive nuclear cataracts, it would be very unwise to postpone operation until the so-called "ripeness" of the cataract,—that is, until the entire lens becomes opaque. Generally



these cataracts are ready for operation much earlier. The age of the patients generally makes it impossible to cause resorption of the cataract by discision, while, on the other hand, in the operation by extraction, there is the fear of leaving behind transparent cortical masses. Frequently, however, the unclouded, or, more properly speaking, the ophthalmoscopically transparent corticalis, gradually becomes hard and horn-like; in the operation it comes away easily and completely from the capsule.

It has been recommended, when the corticalis appears to have retained its normal consistence, to perform discision some days before extraction, in order to soften the corticalis and so make the extraction easier.

A particularly interesting form of partial lens opacity is the lamellar cataract. Its peculiarity is, that between a transparent corticalis and a likewise transparent nucleus there is a clouded layer of lens-substance. Frequently this layer has upon its anterior surface, and sometimes too on its posterior surface, a number of white points; in other cases the entire clouded portion is filled with radiating lines. Sometimes similar figures or irregular processes extend from the limits of the opacity into the transparent cortical substance, or this substance itself may likewise be clouded in a diffuse, punctated, or linear manner. Very rarely cases occur in which several layers become clouded, while between them is transparent lens-substance.

There is no difficulty in the diagnosis. Upon dilating the pupil, and by focal illumination, one sees behind the pupil a uniform opacity whose convex surface lies perceptibly at some distance from the plane of the pupil, and is separated from the periphery of the lens by a sharply defined boundary-line. Generally the posterior limit of the lamellar cataract can be recognized through the opacity and the transparency of the nucleus at the same time be observed. Upon ophthalmoscopic illumination the entire disc appears dark and sharply defined. But when illuminated by light falling perpendicularly upon it, and when the opacity is not too dense, the central part often shows the red reflex from the fundus, which also proves the transparency of the nucleus.

E. von Jaeger,\* who first described this form of cataract and

---

\* Ueber Staar- und Staaroperationen, Wien, 1854, pag. 17 und 22.



examined it anatomically, explains its mode of occurrence as follows. At an early period of life, when the lens is still in the process of rapid growth, from some cause or other an opacity forms in the external cortical layers, which, however, by the growth of new lens fibres, gradually are pushed away from the capsule. When these new lens fibres are quite normal, the corticalis will be transparent; when they are somewhat diseased, it will be clouded, in the manner above described.

Lamellar cataract, in the great majority of cases, occurs in both eyes at the same time. Whether it often occurs congenitally cannot with certainty be stated, since, in the narrow pupils of new-born children, such a cataract may be easily overlooked. The development of lamellar cataract in childhood has been proved beyond doubt. Arlt and Horner regard it as connected with convulsive brain disturbances. Horner,\* moreover, calls attention to the coincidence of a peculiar abnormality of the teeth, which depends upon an imperfect development of the enamel fibres (the so-called rachitic teeth). Von Graefe† observed the occurrence of lamellar opacities three times, in lenses dislocated by injury, and once with iritis.

Finally, we must mention certain rare cases of partial opacities which penetrate the lens in the direction of its axis, either with or without simultaneous lamellar opacities.‡ Moreover, opacities of the nucleus in the form of a triangular radiating figure are occasionally observed.

Lamellar cataracts generally remain absolutely stationary. Cases in which they have been followed by a shrinkage of the entire lens, or where calcification of the clouded layer has occurred, are among the greatest rarities.§

With lamellar cataract, vision is in inverse relation to the extent and degree of opacity, provided there be no congenital amblyopia or nystagmus. Myopia, as Donders remarks, frequently exists with lamellar cataract.

In the treatment of lamellar cataract, the first step is to deter-

\* *Klin. Monatsbl.*, 1865, pag. 181.

† *Arch. f. Ophth.*, B. ii. 1, pag. 273; B. iii. 2, pag. 373.

‡ Pilz, *Prager Vierteljahrsschrift*, B. xxv.; Von Ammon, *Zeitschrift für Ophthalmologie*, B. iii. pag. 86, und *klinische Darstellung*, etc., B. iii. pag. 67; E. Müller, *Arch. f. Ophth.*, B. ii. 2, pag. 169; O. Becker, *Bericht über die Wiener Augenklinik*, Wien, 1867, pag. 99.

§ V. Graefe, *Arch. f. Ophth.*, B. iii. 2, pag. 379.



mine the degree of vision. Opacities of this kind occur which indeed have considerable superficial extent, but are at the same time so thin that vision is not greatly reduced, perhaps not more than by one-third or one-fourth. Under such circumstances it would not be well to resort to operation. If the lamellar cataract be so small that it encroaches only a little upon the region of the pupil, many of these patients learn in the interest of distinct vision to shade their best eye in such a manner, with the hand, that the pupil dilates and a part of the unclouded peripheral zone is exposed. In such cases, too, atropine mydriasis causes a very considerable improvement in vision. The continuous use of atropine may be allowed in a solution so graduated that the pupil is not dilated ad maximum, but only so widely as is necessary to carry it beyond the border of the cataract. The objection made in this connection, that the atropine mydriasis involves a paralysis of accommodation, does not amount to much, since if the solution be properly graduated, paralysis of accommodation above a certain grade may be avoided, and in any event the accommodation may be replaced by convex lenses. The operation of iridectomy can scarcely be expected to cause a greater improvement in vision than does the use of atropine. The artificial pupil may easily prove too large and cause dazzling and indistinct vision by enlarging the circles of diffusion. At any rate, the operation of iridotomy (comp. page 314) is a better one.

The most favorable optical conditions could be obtained by the operation of iridodesis (comp. page 321) if it were not for the danger of irido-cyclitis connected with it.

Lamellar cataract is generally so large that only a narrow, transparent, marginal zone exists, or even this may be diffusely clouded. In such cases, when vision is greatly reduced, and no improvement can be attained by atropine, the removal of the lens, either by discision or by extraction, is indicated.

Among the partial opacities of the lens belong, still further, small cataractous spots at the anterior or posterior pole of the lens.

Cataracta centralis anterior sometimes occurs congenitally, and in such cases almost always in both eyes. It develops more frequently in children, and somewhat rarely in adults, in consequence of ulcers which cause perforation of the cornea. Arlt's\* view,

---

\* Die Krankheiten des Auges, B. i. pag. 232, Prag, 1835.



agreeing with the then existing opinion that a portion of the exudate from the corneal ulcer remained attached to the capsule, does not explain the connection. I have satisfied myself that corneal ulcers, which do not perforate at the centre, but near the margin of the cornea, may cause cataracta centralis.

The contraction of the pupil after the escape of the aqueous humor allows only the centre of the anterior capsule to come in contact with the posterior surface of the cornea, and this alone seems sufficient to induce a disturbance of nutrition at this place on the lens.

Frequently the central opacity is elevated in the form of a pyramid above the surface of the capsule; indeed, cases have been observed in which a thread-like connection existed between the posterior surface of the cornea and the capsular cataract. Cataracta pyramidalis also occurs congenitally, but it generally develops during childhood.

H. Müller\* was the first who showed that in cataracta pyramidalis the entire opacity is situated within the capsule. In the case which he examined, a conical elevation sat upon the anterior surface of the lens, at about its middle; its base was nearly round, and had a diameter of about 3 mm., while its height was about 1 mm. The surface of the elevation was uneven, and its color an intense white. It consisted internally of a chalky mass. The capsule extended over it, following the irregularities of its surface.

For a case of pyramidal cataract, which I examined anatomically, I must thank the kindness of Dr. Samelson, of Manchester. It† occurred in the left eye of an individual twenty-three years old, who in his third year had the smallpox, and after that a central corneal opacity and this cataract. The apex of the pyramid appeared nearly to touch the posterior surface of the cornea, its base rested upon a sort of broad pedestal, which had an uneven, wrinkled surface and an irregular boundary.

The cataract was removed by linear extraction, preserved in spirits, and given to me for examination. I found the pyramid about 2 mm. high, and its base about 1.5 mm. in diameter. Under a weak magnifying power it appeared striped by a great

---

\* Verhandl. der physik. med. Gesellschaft zu Würzburg, B. vii. pag. 288.

† Ophth. Hosp. Rep., v. 1, pag. 48.



number of fine longitudinal folds; at its base it was continuous with a wrinkled, hyaloid membrane, which, although very much thinned, could still, by the evident remains of the intra-capsular cells, be recognized as the anterior capsule. In connection with it there was a thick mass, which, under a strong magnifying power, appeared striated and punctated. It cleared up with dilute acid, and contained distinct traces of a delicate, hyaloid, membranous growth, together with cholesterin, and other lance-shaped crystals, which are frequently found in the secondary altered cataractous lens-substance. Upon perpendicular section through the dried preparation, the pyramid, from base to apex, appeared to be formed of delicate lamellæ, arranged parallel to the surface of the lens, showing the same structure as capsular cataract. The lamellæ could easily be torn apart, except upon the smooth surface of the pyramid, where they seemed as if closely united, to form a delicate membrane, without, however, its being possible to isolate such a structure. At the base of the pyramid was a fatty or calcified mass, deeper still a striated tissue, and lastly amorphous masses, the detritus of the cataractous lens-substance.

The capsule could not be recognized upon sections of the dried preparation; it must have become torn and lost. It is highly probable that the pyramid was covered by the very much thinned anterior capsule. If the pyramid had been external to the capsule, a section of the capsule would have been found between the base of the pyramid and the remains of the cataractous lens-substance, since at this place it could not have been accidentally lost either before or during preparation.

The occurrence of pyramidal cataract may be explained by supposing that at an early period of life, during the existence of a corneal fistula, an adhesion forms between the inner surface of the cornea and the capsule of the lens, which, when the cornea becomes again gradually removed from the lens, is drawn out to a point.

At present no one would attempt the experiment, formerly much practised, of detaching the pyramidal cataract from the anterior surface of the lens, unless he meant purposely to open the capsule and cause the absorption of the lens.

In general, operative interference is seldom indicated in cataracta centralis, since there is generally an absolutely transparent



portion of the lens between the opacity and the margin of the pupil. If, under such circumstances, vision do not seem proportionate to the transparency of the refracting media, no improvement can be expected from a cataract operation.

Circumscribed opacities of the posterior corticalis always awaken a suspicion of a complicating disease of the internal membranes of the eye. For instance, in choroiditis or in pigmentation of the retina, radiating and often feathered striæ are seen converging toward the posterior pole, upon the posterior surface of the lens. With dilatation of the pupil and focal illumination the opacity in the posterior corticalis and the transparency of the anterior portion of the lens can be easily demonstrated.

Still more frequent than this form are certain small, circumscribed opacities, which develop in chronic diseases of the internal ocular membranes, in the region of the posterior pole of the lens, and therefore are called *cataracta polaris posterior*. They are quite frequent, for instance, in *staphyloma posticum* with secondary choroiditis. In many cases their anatomical position is rather within the vitreous than in the lens.

Calcification of the lens occurs most frequently in complicated cataract, and begins often as capsular cataract, which, under these conditions, may attain a very considerable development. The chalky deposits (mostly carbonate of lime) appear generally as a great number of isolated granules, or in spherical formations composed of concentric layers. When the lime is dissolved by acid, an organic substance is left behind. The chalky deposit generally takes place immediately upon the superficial cataractous layers of the lens. A shell of chalk varying in thickness is formed beneath the capsule, and if at the time of the chalky deposit the fibres of the lens were not fully dissolved, their form may be preserved by petrification in the living eye. The entire lens may become so calcified that it is transformed into a stony concretion, which is still enclosed in an atrophied capsule.

In such cases there is generally a loosening of the normal attachments of the lens, due to the liquefaction of the vitreous body and the atrophy of the zonula.

Striking oscillations of the lens can be seen during movements of the eye, or it may have sunk entirely away from its normal position. If the lens sink into the anterior chamber, it causes a



very irritable condition, which after a time passes over into inflammation. When the lens has only very recently fallen into the anterior chamber, it is generally sufficient to dilate the pupil with atropine, and, by throwing the head backward, allow the chalk concrement to sink back into the vitreous body. If this do not succeed, the extraction of the calcified lens is necessary.

In such cases the lens must be fixed by a needle thrust into its posterior surface, before the chamber is opened. If this precaution be omitted, the escape of the aqueous humor allows the lens to come in contact with the cornea, and it is immediately pushed back through the pupil and disappears in the vitreous body.

#### OPERATION FOR CATARACT.

The different methods of operating on cataract have for their object either to remove the entire lens, through a suitable opening (extraction), or, by splitting the anterior capsule, to expose the lens to the action of the aqueous humor, and so cause its absorption (discision).

The methods by which the lens was pushed away from behind the pupil (reclination) are no longer practised.

Soft cortical cataracts, in which the entire lens has become converted into a thick fluid mass, and which contain no hard nucleus, may often, with advantage, be extracted through a linear corneal wound.

This method of extraction by the linear incision was first methodically practised by Gibson, in 1811, and by Travers, in 1814. In Germany it was principally practised by Friedrich von Jaeger for capsular cataract. Von Graefe preferred it to all others. He opened the anterior chamber by a puncture at the temporal side of the cornea. It is advisable to make the wound upward, in view of the possibility that a prolapse of the iris may occur, which it will be necessary to remove. The lance knife, held at a considerable angle with the cornea, and still in such a way that the capsule of the lens will not be wounded, is introduced at 2 or 2.5 mm. from the margin of the sclera, and the wound so made that its outer aspect measures about 5 mm. and its inner aspect 4 mm. The capsule is then freely opened with a sharp hook or cystotome. The soft lens-substance then presses forward into the pupil, and its complete discharge from the eye is assisted by causing the wound to



gape by means of a Daviel spoon, while slight pressure is made with the finger on the margin of the cornea opposite the spoon. After the complete discharge of the lens, the eye is closed with a bandage, and the patient kept for a day or two quiet in bed. The after-treatment, when the course is normal, is simply the use of atropine.

The indications for this treatment are quite limited. Discision with a broad needle is to be preferred in cataracts which are wholly fluid, such as often occur in childhood. The small wound made by this method in the cornea is sufficient to admit the escape of the fluid lens-substance without the danger of prolapse of the iris.

If a shrinkage has already taken place in a soft cortical cataract of some standing, it has no longer the consistence desirable for the linear extraction, and generally discision is indicated. In cases in which posterior synechiæ exist, or in which the presence of a hard nucleus is probable, the best method is that by the peripheral linear incision, which is yet to be described.

Until late years, the method by the flap incision, suggested by Daviel in 1748, was the only one practised for cataracts with a hard nucleus.

This method was as follows. The cataract knife was inserted in the cornea about 1 mm. from its margin, carried forward with its surface parallel to the iris, and the counter-puncture made at the opposite and symmetrical point of the cornea. The incision is ended by pushing the knife still farther toward the median line, directing it in such a way that the entire wound will be parallel with the margin of the cornea.

The flap may be made in any convenient direction, and this is generally downward. By reason of its shape, the cataract knife, so long as it is pushed forward, completely fills the corneal wound, and accordingly the aqueous humor is retained until nearly the completion of the incision.

The escape of the aqueous humor is followed by a corresponding concentric diminution of the volume of the entire eyeball. The lens and iris are pushed forward, and come in apposition with the posterior surface of the cornea. In many cases, however, especially in old persons, the sclera is so rigid that after the escape of the aqueous humor it prevents the necessary compensating change in the form of the eyeball. The lens and iris cannot then



come forward sufficiently, and consequently the cornea sinks in and becomes wrinkled. After the removal of the lens, this so-called collapse of the cornea is still greater.

The second act of the operation consists in opening the capsule of the lens by splitting it freely in several directions with a cystotome or cataract needle.

The third act is the removal of the lens. Its normal position, parallel with the base of the cornea, must be changed so that, for instance, with a flap incision made downward the lower edge of the lens comes forward and presents in the wound. To accomplish this it is often sufficient to direct the patient to look upward. The muscular contraction involved in this effort exercises a compression of the entire contents of the eyeball, and as this pressure meets with no resistance opposite the wound, the margin of the lens, which lies just here, is forced forward. If this physiological pressure prove insufficient, it must be supplemented by external pressure acting in the same direction. To this end slight pressure is made upon the margin of the cornea in the direction of the centre of the eyeball, by means of the Daviel spoon, or, better still, with the margin of the upper lid; the edge of the lens being thus forced up into the wound, its escape is assisted by a slight pushing movement. The lens first pushes before it that portion of the iris lying behind the wound, and then appears in the pupillary opening. As soon as its greatest diameter is engaged in the pupil, the pressure must be lessened or entirely removed. If necessary, it is better to work directly upon the now exposed lens with the Daviel spoon, or hook it with the cystotome.

After removing the lens, the iris is to be replaced in its normal position, and the discharge of any remaining portions of cortical substance effected. If possible, both should be accomplished simply by manipulation of the eyelids. Soft circular rubbing movements, made by the upper lid upon the cornea, restore the normal shape of the cornea, and roll the remaining cortical substance together in the pupillary space, whence it can be discharged through the wound by gliding movements of the upper lid. As the last act of the operation, Von Hasner\* recommends a slight puncture of the vitreous body in the depression left by the lens.

---

\* *Klinische Vorträge*, pag. 305.



A well-healed flap extraction is certainly one of the most satisfactory operative results. There remains in the cornea a scarcely visible peripheral scar, the pupil retains its normal size and movement, only the flatness and deep position of the iris and its oscillation during movements of the head betray the absence of the lens. But so satisfactory a result is by no means certain; indeed, it is attained in scarcely half the cases.

The healing is often interfered with or delayed by some cause or other, and the result is very imperfect vision, or even absolute blindness.

It is evident that the operation, even when skilfully performed, must be regarded as a very serious one.

Nearly one-half the cornea is cut off from its natural source of nutrition, and it is difficult to see how a compensating collateral supply is possible. That this defective nutrition is frequently the cause of necrosis of the cornea cannot be doubted. The extensive semicircular wound never closes accurately, and, instead of healing by first intention, a suppurative process may occur which, by destruction of the cornea or by consecutive iritis, may prove ruinous. The form of the wound inclines it so little to spontaneous closure that any traction or pressure on the eye, or any sudden movement, may cause it to reopen. The escaping aqueous humor will in that case float the iris forward, and its prolapse, with all its unfortunate consequences, the distortion of the wound, the inflation of the prolapsed part, severe irritation, etc., may be the result of this accident. It is advisable to remove promptly any prolapse of the iris which may occur after an operation.

Even when the iris is not injured in the least by the instruments during the operation, it is always forcibly stretched and pressed during the passage of the cataract through the pupil, especially in old persons, in whom frequently the tissue of the iris has become so rigid that only a slight dilatation of the pupil can be effected by the atropine. The injury thus caused to the iris is frequently proved by the pigment from the uveal layer found on the lens after its removal. At all events, this method of operation is very likely to induce iritis.

This being true, it was natural that attempts should be made toward improving the method of operation. Supported by the experience of most observers, that cases in which a portion of the



iris had been accidentally excised, proved quite as successful as others, Von Graefe\* recommended the combination of iridectomy with the flap incision in all cases in which any difficulty was experienced in performing the operation by the old method,—for instance, when the flap incision or the opening in the capsule has not been made large enough, or when the corticalis appears so strongly adherent as to prevent the lens from slipping out easily. He recommended iridectomy also in cases where there is imperfect closure of the wound, and consequently reason to expect prolapse of the iris; and further, in cases where there is a small and rigid pupil, with a hard cataract, or where, on account of unripeness, portions of the cortical substance are left behind, or where, in ripe cataracts, the same thing happens in consequence of excessive visciduity and adherence of the cortical substance; further, in all cases where, on account of general marasmus, a deep position of the eyeball, due to atrophy of the orbital fat, limitation in the movements of the eye, collapse of the cornea from loss of elasticity in the sclera, or concentric shrinkage of the corneal flap, there is the probability that the wound will heal badly. In some cases Von Graefe performed iridectomy at the same time, and in others some weeks before the cataract operation. With reference to the effect of the iridectomy, Von Graefe† came to the conclusion that it could neither avert total necrosis of the cornea nor partial suppuration of the wound, but simply that the course of this last process is to some extent favorably modified by it.

The danger of circumscribed suppuration, aside from the possibility of its becoming diffuse, lies not so much in the destruction of the cornea as in iritis, propagated from the wound. Pus appears in the anterior chamber, and the iris is swelled by a purulent infiltration. This particular form of iritis seems much inclined to cause irreparable loss of vision by atrophy of the eyeball. The combination of the extraction with an iridectomy does not, it is true, do away with the possibility of such a propagation, but it surely acts to a certain extent against it. The process is not so often developed and is not so severe. Adhesions of the iris to the lens do not form so rapidly. Iridectomy, moreover, does not

---

\* Arch. f. Ophth., 1856, B. ii. 2, pag. 247-248.

† Klin. Monatsbl., 1863, pag. 141.



preclude the occurrence of iritis due to violence done the iris during an operation or to cortical substance left behind.

At the same time Von Graefe's experiments took another direction. The good results following linear extraction of soft cataract suggested the idea that the method could be employed also in cataracts having a hard nucleus. His first experiment\* was to make an incision equal to one-fourth the circumference of the cornea with a broad lance knife, on the temporal side, and exactly at the corneo-scleral boundary; the iris was then seized in the usual manner with the forceps and excised, and the capsule freely opened with the cystotome. Lastly, a spoon spatula was introduced behind the nucleus and its fragments thus brought out through the wound.

No good fortune attended this practice, and it was in no way improved by the use of Waldau's spoon.† But somewhat later, Critchett and Bowman‡ took it up and introduced very important modifications. The incision was made at the upper part of the cornea; a broader lance was used, and the wound made larger, so as to occupy from one-fourth to one-third the margin of the cornea, and the extraction spoon used was much smaller.

The principal difference between their two methods of operation was that Critchett made the puncture in the cornea about 1 mm. from its margin, while Bowman made it exactly at the corneo-scleral boundary.

Shortly previous to this, Jacobson§ had recommended a similar peripheral incision, laying great importance upon making the flap as large as possible, so that the largest nucleus with the corticalis about it could pass through easily. Jacobson therefore made his incision in the limbus conjunctivæ corneæ. After the lens was removed, a broad piece from that portion of the iris which had been bruised by the lens was excised as far back as its ciliary margin.

The method by the peripheral linear extraction, which Von Graefe finally practised, followed upon Bowman's and Critchett's

---

\* Arch. f. Ophth., 1859, B. v. 1, pag. 158.

† Die Auslöfflung des Staares, Berlin, 1860.

‡ Ophth. Hosp. Rep., 1865, vol. iv. part 4, pag. 315 and 332.

§ Ein neues und gefahrloses Operationsverfahren zur Heilung des grauen Staars, Berlin, 1863.



methods. Proceeding on the principle that upon a spherical surface the shortest distance between two points must be upon the line of a great circle, Von Graefe arrived at the conclusion that it was impossible with a lance knife to make a linear incision long enough, since to do it the point of the knife must be directed toward the centre of the eye, in which case the iris and lens would certainly be injured. But if the incision be begun by puncture and counter-puncture, there is no difficulty in so completing the incision which shall unite these two points that it shall form a portion of a great circle. The length of the wound should equal the horizontal diameter of the cornea,—about 11 mm.,—and should be made at the upper corneal margin in order to obviate as much as possible the optical disadvantages connected with an iridectomy. The points for puncture and counter-puncture are determined by imagining a tangent to be drawn from each extremity of the horizontal diameter of the cornea, then a line parallel with this diameter and 2 mm. below the upper margin of the cornea. The points where this last line intersects the tangents are the ones desired; they lie about 1 mm. from the margin of the cornea. If now the incision were made exactly in the line of the great circle connecting these points of puncture and counter-puncture, a portion of the external wound would pass through the cornea. But to insure its uniformity the incision should be made entirely outside the external corneal surface; and still, since the inner surface of the cornea is larger than its outer surface, the inner wound will be entirely in the cornea, its ends slightly, but its middle more decidedly, removed from the scleral boundary. Scarcely more than one-fourth of the whole wound is in the scleral tissue, the rest being in the peripheral zone of the cornea.

Some difficulty attends the execution of the incision. If the blade be carried up, parallel to the plane of the iris, the middle portion of the incision will be too far in the periphery, involving the danger of prolapse of the vitreous. If, trying to avoid this fault, the edge of the knife be turned somewhat forward when the incision is about half completed, an abrupt angle is made in the line of the incision, which is very unfavorable for the exact apposition of the edges of the wound.

It is best from the moment of the puncture to give the blade of the knife the direction which it is to follow till the completion



of the incision,—that is, the flat of the blade not parallel with the iris, but its edge directed somewhat forward. At the same time this inclined position of the blade must not be too great when the aqueous humor escapes, which generally happens as soon as the counter-puncture is made, for the back of the blade, if it be held too much inclined, rubs across the lens and may tear the zonula and displace the lens itself. For this same reason the knife should be as narrow as possible.

The point of the knife should not immediately be directed toward the point of counter-puncture, but in order to make the inner aspect of the wound as large as possible it should at first be directed somewhat downward and toward the centre of the pupil. As soon as the knife-point, in making the counter-puncture, has passed through the sclera, the aqueous humor escapes under the conjunctiva and distends it for a greater or less extent. No attention should be paid to this, but the incision should be continued in the direction chosen, till the sclera is entirely cut through. The knife is then freely movable under the loosened conjunctiva, which now, in order to avoid making the flap too long, is to be cut through by directing the edge of the knife forward. If the conjunctiva be very distensible, the point of the knife may not come through it at a point corresponding with the counter-puncture in the sclera, but somewhat higher up and later in the progress of the incision. If this happen, the conjunctival wound should be enlarged with the scissors, so that the conjunctival flap may retract well from the prolapsed iris. Immediately upon the completion of the corneal flap the iris generally prolapses spontaneously, and must then be excised.

The fixation forceps are given to the assistant, and with the straight iris forceps the conjunctival flap is lifted away from the prolapsed iris and reflected upon the cornea. The iris is then grasped with the same forceps near the temporal angle of the wound, and carefully cut away by three or four strokes with the scissors, gradually carried toward the median angle of the wound, slight traction being meanwhile made with the forceps. A very careful excision of the iris is necessary, for by its prolapse and incarceration in the wound, healing is interfered with; and, furthermore, the prolapsed portion may at a later stage become a permanent centre of irritation, or, giving rise to staphyloma, may



destroy the normal curvature of the cornea. After the excision of the iris, care should be taken that its cut edges are returned to their proper position. If the iris appear to be caught in the angles of the wound, the attempt may be made to replace it by lightly rubbing the cornea with the convex surface of the cataract spoon. If only the median angle of the iris remain in the wound, it may frequently be released by a delicate pressure with the back of the cystotome, when introducing that for the purpose of opening the capsule. The opening of the capsule should be by free incisions, extending quite across the lens at both sides of the pupil, and the cystotome should be bent in a suitable manner. This manoeuvre, however, must be performed carefully, to avoid displacing the lens, either by pressure or by traction, an accident which may easily occur, especially with hard cataract.

When the way for the exit of the lens is thus made ready, its removal is accomplished in essentially the same manner as in the flap incision.

In the normal course of the operation the extraction of the lens does not require the introduction of a spoon, hook, or any other instrument. Just as in the flap incision, the discharge of the lens may be effected by manipulations with the eyelids. Since, however, for making the incision at the upper portion of the cornea, it is more convenient, and involves less danger of gaping of the wound, to allow the lid speculum and fixation forceps to remain in position till the escape of the lens, it is best to dispense with the use of the lids, and to use the Daviel spoon, just as many operators do in the flap operation, making with it the necessary pressure on the surface of the cornea.

Von Graefe recommended for this purpose a spoon-shaped instrument of hard rubber. A properly bent Daviel spoon serves the purpose very well. The convexity of the spoon is laid upon the lower margin of the cornea, and while a constant pressure is exercised, a slight upward movement is made, causing the upper edge of the lens to appear in the wound, which opens spontaneously. Pressure is then made with the spoon, almost in the direction of the centre of the eye, in order to rotate the lens about its transverse axis and to force it bodily into the wound. When this is accomplished, the pressure is to be gradually directed upward, the spoon thus forcing the lens before it, out of the wound.



Prolapse of the vitreous is the principal accident likely to happen during the operation. It may be caused by the incision being made too far in the periphery, or by luxation of the lens either before or during the opening of the capsule, or by too strong a pressure with the spoon, especially when the incision has been made too small or too far in the periphery. Finally, it may be caused before the escape of the lens by too strong a pressure on the part of the patient, or by a pre-existing looseness or partial atrophy of the zonula, which is especially to be feared in over-ripe, shrunken cataracts.

If prolapse of the vitreous occur after the nucleus and the greater part of the cortical substance have escaped, the speculum and fixation forceps should be removed, and the attempt made by manipulating the lids to expel the remaining fragments of the cortical substance. A repeated introduction of the spoon is not advisable, and generally does not accomplish its object, for, the hollow of the spoon being filled with the viscid vitreous substance, no sufficient hold can be obtained upon the cortical fragments. If prolapse of the vitreous occur before the escape of the lens, it may nevertheless often be expelled without the introduction of an instrument. If this be found impossible, and if the nucleus be small and the corticalis soft, it is best to open the capsule and extract the nucleus with a broad but very thin spoon. Still, against the extraction with the spoon there is the objection that the nucleus lying in the spoon is always pressed forward against the uveal layer of the iris. In the case of large hard cataracts, therefore, I prefer, by means of a small, sharp hook inserted into its posterior surface, to draw out the nucleus, or even the entire lens, without previously opening the capsule.

Hemorrhage into the anterior chamber during the course of the operation is, to a certain extent, embarrassing. This occurs most frequently in eyes in which, on account of the rigidity of the sclera, the cornea collapses under the atmospheric pressure, immediately after the escape of the aqueous humor; the blood from the conjunctival wound may then be said to be forced "ex vacuo" into the anterior chamber. If the tension of the muscles be relieved by deep chloroform narcosis, considerable difficulty is, under these circumstances, often experienced in expelling the blood from the anterior chamber. The operation is thus made more difficult, but its results are not interfered with.



In the course of healing, all those unfavorable conditions may occur which have been mentioned as occurring in the flap operation, but statistics abundantly prove that they are much less likely to. Prolapse of the iris may be avoided by the proper performance of the operation; it may, however, happen if the iris be not excised up to the angles of the wound, or if it remain caught in them. Complete necrosis of the cornea and partial suppuration of the wound are both of them less frequent with this operation than with the flap incision. A mild iritis, during which a few small posterior synechiæ form, but involving no further optical disadvantages, is very frequent. Severe forms of purulent iritis or irido-choroiditis, in the normal course of recovery from the operation, are rare.

Under ordinary circumstances the after-treatment is very simple. After removal of the coagulated blood from the conjunctival sac a bandage is applied, which, if necessary, may be renewed twice daily. Atropine should be used from the first, in view of the tendency to iritis. For some days the patient should lie quiet, though after the third day he may be allowed to sit upright in the bed for a short time at first, increasing the time gradually from day to day. Generally he can leave the bed at the end of the first week. The period elapsing before complete recovery averages from two to three weeks.

The operation may be performed either with or without chloroform. If the first method be chosen, the narcosis must be profound before the operation is begun. But, even though it be carried so far that the orbicularis is fully relaxed, and the speculum and fixation forceps are applied without causing the slightest spasm of the lids, it is by no means certain that the operation can be carried on uninterruptedly to the end. There are patients who, during the operation, do not awake from the narcosis, but, while wholly unconscious, fall into a sort of combined asphyxia and delirium, which interrupts the operation very annoyingly.

If a subcutaneous injection of morphine be given about a quarter of an hour before the operation, a quiet narcosis is more likely, but not absolutely certain, to be had.

Vomiting may very seriously disturb the course of the operation, even though for a day previous the patient has eaten but very little, and for several hours nothing at all. Another dis-



advantage attending narcosis is, that in many cases, for the success of the operation, the complete relaxation of the ocular muscles is undesirable.

With a patient who possesses the necessary nerve, it is pleasanter to operate without chloroform, and although the behavior of the patient cannot with certainty be foretold, the same uncertainty exists with reference to his behavior during narcosis.

If there be cataract in both eyes, both may be operated on at the same time. It is advisable, however, to allow an interval between the two of about four days. If the course of healing up to that time be normal, an unfavorable change is hardly to be feared.

If there be cataract in but one eye, the decision of the much-mooted question, whether an operation is desirable or not, may be left to the patient. If the usefulness of the second eye be already somewhat impaired by incipient cataract, the operation upon the eye first affected is always advisable. So, too, when the eye not affected by cataract is very near-sighted. He can use this eye for near vision, reading, etc., and by the operation on the other eye he obtains distinct distant vision.

Finally, mention must be made of a modification of the method of extraction,—that is, extraction of the lens with the capsule. Where there is pre-existing relaxation of the zonula, this practice can often be adopted without any difficulty; if, however, the zonula retain its normal strength, this method must be regarded as too severe, for it cannot be carried out without introducing into the eye some powerfully acting tractive instrument. On the whole, the general results of the operation have not been encouraging.

Peripheral linear extraction cannot be performed without an iridectomy, for, owing to the peripheral position of the incision, the iris, if it were not excised, would prolapse without there being any possibility, during the course of healing, of replacing and retaining it in its normal position.

In order to avoid the excision of the iris without resorting to the flap incision, Weber's\* method may be employed. In this operation the incision is made with a curved lance, 10 to 12 mm.

---

\* Arch. f. Ophth., B. xiii. 1, pag. 187.



broad, whose concave under surface is curved on a radius of 10.7 mm. The lance is introduced exactly in the plane of the base of the cornea, and is carried forward till it almost touches the point in the corneal margin diametrically opposite the place of puncture. This gives an incision of sufficient size. The capsule is then freely opened, and the expulsion of the lens accomplished by slight continuous pressure made on the one side opposite the wound, by the fixation forceps applied there, and on the other side by a hollow spatula, 9 or 10 mm. broad, whose margin is laid along the peripheral lip of the wound. Of course this method may also be combined with iridectomy, in which case it is merely a matter of choice whether this method or the peripheral linear incision be employed. For senile cataract I decidedly prefer the latter method, but for the soft cataracts of young individuals I prefer Weber's method, without iridectomy.

To operate successfully on cataract by discision, the patient must be young, and his pupil freely dilatable by atropine. The cornea is punctured with the discision needle at a point opposite the margin of the dilated pupil, and a small crucial incision is made in the middle of the capsule. The lens imbibes the aqueous humor; its cortical part becomes clouded and swollen; flakes from it protrude from the wound in the capsule and become slowly absorbed. Gradually the swelling extends to the posterior corticalis, which presses forward the nucleus, so that finally it may fall out of the capsule into the anterior chamber. If the absorption of the lens cease, as it may, owing to closure of the wound in the capsule, the discision should be repeated, the opening being made more extensive, till a perfectly clear central pupil is obtained.

The time necessary for this, during the first year of life, is from one to two months, in older persons, from six to eight months. During all this time the pupil must be kept widely distended by atropine; for the danger attending discision does not lie in the slight wound, but in the hurtful effect which the swelling lens may exercise upon the iris. The iritis, excited by the fragments of the corticalis, or by the lens falling forward into the anterior chamber, may assume a purulent character, and the eye be destroyed by panophthalmitis; or a membranous growth may develop from the uveal layer of the iris, proving finally a complete optical barrier to vision, or leading to atrophy of the eye from



irido-cyclitis; or a glaucomatous increase of intraocular pressure may develop, which increases steadily, with corresponding contraction of the visual field, and excavation of the optic nerve, ending in complete blindness.

This last-named complication is particularly to be feared in cases where the swelling lens, pressing against the posterior surface of the iris, forces it forward. If symptoms of iritis appear which do not yield to atropine mydriasis, or if a severe inflammation develop, or if, without any external signs of inflammation, vision become defective in the periphery of the visual field, while the tension of the eyeball increases, the puncture of the anterior chamber should not be delayed. If, however, the tension persist, or if after a short time it return, the removal of the swollen lens-substance, either with or without iridectomy, is indicated. Iridectomy, however, is generally unavoidable.

The irritability of the iris in the presence of the swollen lens-substance is very varied, and depends mostly upon the age of the patient. Children bear the swelling even of the entire lens very well, but the toleration on the part of the iris decreases with increasing years. Moreover, the irritability of the iris in patients of the same age varies. The more easily atropine mydriasis can be produced and maintained, the better does the iris resist the irritation excited by the swelling of the lens.

Von Graefe\* therefore advised in all cases in which discision is to be performed on a patient above the age of say 15 years, or in cases in which the pupil does not dilate readily under atropine, to do an iridectomy some three weeks before the discision. In fact, in such cases as these, choice will have to be made between this procedure and the extraction by the peripheral linear incision.

The general rules and conditions under which discision is to be practised are, accordingly, as follows :

1. Total opacity of the lens in childhood. If the substance of the lens have at the same time become liquefied, Von Graefe recommends the use of a rather broad needle in order to allow the escape of the cataract fluid together with the aqueous humor.

2. Discision is the principal method for those partial opacities of the lens in childhood which require operation.

---

\* Arch. f. Ophth., B. v. 1, pag. 173.



3. The operation must be resorted to with great caution at a period later than the fifteenth year. Later than the twenty-fifth to the thirtieth year the indications for the operation are limited to cases in which the size of the cataract is already diminished by shrinkage. Secondary cataract furnishes the principal indication for the performance of discision at an advanced age.

TRAUMATIC CATARACT.—The immediate consequence of wounds by which the capsule of the lens is opened, is an absorption by the lens-substance of the aqueous humor, to whose influence it is exposed. The lens swells, becomes white, protrudes from the wound in the capsule, and, according to the size of this wound, fills more or less completely the anterior chamber. During this process the entire lens, or the greater part of it, may be absorbed. If the wound in the capsule be very small, the opacity may extend only about the immediate neighborhood of the injury and then remain stationary; especially is this likely to happen in old persons in whom the lens has become hard.

The dangers attending traumatic cataract depend upon a series of various circumstances. Much depends upon the time of life and the irritability of the iris, as already stated, in connection with the operation of discision, which indeed is nothing more than a traumatic cataract methodically produced.

Traumatic cataract is frequently only a part of a complicated injury. In many cases the cornea, sclera, iris, or ciliary body is also wounded. These complications may cause immediate loss of vision by intraocular hemorrhage, detachment of the retina, or a destructive irido-cyclitis or choroiditis.

In recent and slightly complicated cases, atropine is to be used to cause and maintain a complete dilatation of the pupil in order to withdraw the iris from irritating contact with the swollen lens-substance. If this complete mydriasis can be maintained, no other treatment is necessary in the majority of cases, especially in children. If, however, the mydriasis be only partial, if iritis have already appeared, and do not yield to atropine, or if symptoms of glaucoma appear, then, according to the circumstances of the case, the indication exists for either puncture of the cornea, iridectomy, the linear extraction of the swollen lens either with or without iridectomy, or the peripheral linear extraction.

The worst cases of traumatic cataract are those which are caused



by a foreign body, such as a piece of percussion-cap, or a splinter of glass or stone. It is only exceptionally that the foreign body remains imbedded in the lens. When a fragment of iron lodges in the lens, its oxidation generally imparts a peculiar rust color to the surrounding lens-substance. The arrest of the foreign body in the lens is always a fortunate circumstance, for in that case, as a rule, the sad consequences attending the lodgment of a foreign body in the deeper parts of the eye are avoided. The operation for cataract extraction indicated under these circumstances must be so performed that the foreign body is removed with the lens.

If a foreign body penetrate deeply into the eye, it is very seldom that a useful degree of vision is retained. As a rule, blindness follows from detachment of the retina, chronic relapsing irido-choroiditis, or irido-cyclitis. Frequently, too, there is danger of sympathetic affection of the second eye. If, under these circumstances, the injured eye be blind, and show symptoms of irido-cyclitis, its enucleation is the best practice by which to insure the safety of the other eye.

By capsular cataract is understood an opacity of that portion of the lens immediately beneath the capsule. Opacities upon the external surface of the capsule, as, for instance, those left by iritis, are therefore not designated as capsular cataracts.

The conditions for the development of capsular cataract always exist when disorganized and softened lens-substance is separated from the aqueous humor simply by the anterior capsule. The fluid components of the external cortical layers filter through the capsule, leaving behind on its inner surface a precipitate consisting of the detritus of disorganized lens-substance.

This interchange between the aqueous humor and the lens-substance is naturally most active in the pupillary region, and just this place is therefore most predisposed to the formation of capsular cataract. In simple senile, over-ripe cataract, the capsular cataract does not generally extend far beyond the boundaries of the pupillary region. It is characterized by its chalk-white color, its frequently somewhat uneven surface, its irregularly serrated boundary, and its position in the pupillary region immediately upon the inner surface of the anterior capsule.

Upon microscopic examination, the capsular cataract appears to



be an amorphous, striated, or punctated mass, thickest at its centre, thinning toward its periphery, from which run out irregular projections; the thinner the layers of this substance the more transparent are they, and the above named irregular thin projections, which run out to points, or interlace among one another, appear, therefore, frequently almost hyaline. Isolated, punctated deposits are frequently found on the inner surface of the capsule, beyond the limits of the principal opacity.

At the part where this precipitate adheres to the surface of the capsule, the intra-capsular cells generally break down, and the surrounding cells, even in uncomplicated cataract, frequently show slight signs of irritation. The capsule itself always remains transparent; at the place of the deposit it is frequently somewhat thinned, and is always more or less wrinkled. This wrinkling of the capsule is exactly what would be expected from the nature of the process above described. If the cortical substance lose its fluid constituents by filtration through the capsule, of course there will be a loss of volume, which will be expressed by a wrinkling of the capsule.

Where capsular cataract exists, the operation for cataract must be somewhat modified. The capsule must be opened at one side of the capsular cataract, which, if possible, must be extracted with the forceps or hook in order to avoid leaving a thick secondary cataract.

With cataract complicated by irido-choroiditis, capsular cataract is not only very frequent, but generally covers a considerable surface, and attains an unusual thickness.

The participation of the intra-capsular cells in the development of capsular cataract is another very important factor in the process above described. They may take on an active proliferation, lose their hexagonal or roundish form, become flat, elongated, spindle-shaped, or stellate, and detach themselves from their normal support upon the inner surface of the anterior capsule. This condition may indeed extend to the posterior capsule, penetrating in broad curved lines the disorganized substance precipitated on the surface of the capsule. As this process goes on, these proliferated cells appear to undergo gradual atrophy, though meanwhile the proliferation is taking place in the more peripheral parts. This proliferation of the intra-capsular cells, since it occurs only in



connection with irido-choroiditis, may well be regarded as an inflammatory process.

Finally, capsular cataract is a frequent occurrence in all those forms of cataract which develop from the very first in the most superficial layers of the lens,—for instance, in *cataracta centralis anterior*, *cataracta traumatica*, and certain irregular forms of incipient cataract.

There is no cataract operation, except the extraction with the capsule, in which the entire lens is removed from the eye. The capsule, the intra-capsular cells, and generally also some of the lens-substance remain in the eye. These constitute the starting-point for a membranous formation which is designated as secondary cataract. The lacerated capsule rolls together, but does not, however, withdraw entirely from the pupillary region. Moreover, immediately after the operation, a proliferation of the intra-capsular cells begins; they spread out behind the iris, forming, in some cases, a new hyaline membrane. It is often several months before these delicate, membranous, secondary cataracts attain such a thickness as to cause disturbance of vision.

If a large quantity of the cortical substance remain after the operation, or if the course of healing be disturbed by iritis, the growth of the intra-capsular cells increases, and the secondary cataract, under these circumstances, attains a considerable thickness.

In its thinnest form the secondary cataract appears, upon focal illumination, like a delicate spider-web membrane, stretched behind the iris. Focal illumination often reveals upon it bright opaque lines or spots, caused by remaining lens-substance, by the products of iritis, or by folds in the capsule.

The disturbance of vision caused by secondary cataract may be best determined by observing first the degree of opacity by examination with focal illumination and the plane mirror, and then testing vision with correcting glasses and the stenopaic apparatus, combined, perhaps, with atropine mydriasis. The improvement of vision caused by the stenopaic apparatus is in many cases so great that it is sufficient to provide cataract spectacles, especially such as are intended for near vision, with such a stenopaic arrangement. If such a correction do not prove sufficient, an operation is to be resorted to.

It would seem most rational at first sight to extract the second-



ary cataract; for which purpose only a very slight linear wound at the margin of the cornea is sufficient. In this way a perfectly clear pupillary region is obtained. But this slight operation is more dangerous than it appears, and may cause purulent choroiditis. Perhaps this is because the traction made upon the cataract is easily transferred to the ciliary body, either through the zonula or by the direct adherence of the cataract. Discision is a more certain method; but even in this, the thicker portions of the membrane should not be invaded unless necessity compel it. For instance, if the natural pupillary region be occupied by a thick mass, while by the use of atropine a thinner portion of the secondary cataract can be uncovered, it is best to enlarge the pupil by iridectomy or iridotomy so as to include this space, and there perform discision.

Frequently these thin membranes are so elastic and distensible that it is indeed easy to penetrate them with the discision needle, but impossible to tear or cut them. For such cases, as also for very thick secondary cataracts, Bowman's operation with two needles is appropriate. The needles are to be inserted at two points in the periphery of the cornea diametrically opposite each other, and so directed that their points meet in the cataract. If now the handles of the needles be moved toward each other their points will be separated, and by their opposite action the cataract can be freely torn without violence to the zonula.

Reclination may be appropriate for many cases of secondary cataract.

#### LUXATION OF THE LENS.

A dislocation of the lens from its natural position necessarily involves a series of changes which furnish the data for a certain diagnosis. In the first place, the lens itself shows an abnormal movement; its oscillations during movements of the eyeball are distinctly visible, and this symptom alone suffices to show that its normal attachments have become loosened, even though the displacement be but very slight. That part of the iris from which the lens is removed loses its support, and a tremulousness can be seen in it with every movement of the eye. Often, too, it lies deeper in the anterior chamber, at this part, while on the opposite side it is pressed forward by the revolution of the lens on its transverse axis. If the dislocation of the lens be so great that



its margin appears opposite the pupil, either in its normal condition or when dilated with atropine, the position of the equator of the lens can be determined with the greatest exactitude. Upon ophthalmoscopic illumination it appears as a dark zone, and upon focal illumination as a bright one.

Luxation of the lens occurs congenitally, and not infrequently is inherited. In such cases the lens is generally transparent, but abnormally small, and often so movable that when the head is thrown forward it drops through the pupil into the anterior chamber, and upon bending the head backward it slips behind the iris again. There is generally also in these cases a certain degree of congenital amblyopia, so that perfect vision cannot be obtained by correcting with lenses the aphakia existing in part of the pupil.

Traumatic luxation of the lens may be caused by a contusion of the eye or by a violent jar of the entire body, and may occur either with or without any other injuries.

It is not improbable that in many cases there is a predisposition to traumatic luxation of the lens, owing to an abnormal weakness of its attachments, for occasionally, acquired luxation of the lens occurs without any apparent cause. This individual predisposition may explain the fact that luxation of the lens from non-traumatic as well as traumatic causes frequently occurs in both eyes. If a part of the pupil be occupied by a luxated but transparent lens, while there is aphakia in the remaining part, there may still be monocular diplopia, in spite of the great difference of refraction in the two parts of the pupil, and this generally disappears when the aphakia is corrected by convex lenses. The rays refracted in the luxated lens then form upon the retina large circles of diffusion, which cannot concur with the distinct retinal image cast through the free portion of the pupil.

If a portion of the equator of the lens fill the pupil completely when contracted, there is generally considerable disturbance of vision from the regular and irregular astigmatism, due to the inclined position of the lens and the irregular refraction of light through its margin. Vision is, of course, still poorer when the luxated lens is at the same time clouded. If, under these circumstances, aphakia can be produced in a portion of the pupil by atropine mydriasis, it is generally possible to obtain a considerable



improvement of vision by the correcting convex glasses, and for such cases the continued use of atropine is advisable.

Iridectomy or iridotomy is necessary in these cases, when, from adhesions due to iritis, or from any other cause, mydriasis cannot be produced or maintained.

The luxated lens may remain a long time transparent, or may grow gradually opaque.

The influence of the luxation upon the other parts of the eye varies. In one class of cases no further accidents follow, while in others a glaucomatous process comes on which ends in blindness unless checked by iridectomy or the extraction of the luxated lens in its capsule.

The luxated lens may drop forward into the anterior chamber and become adherent to the cornea. Iritis or irido-choroiditis generally then develops either with or without glaucomatous symptoms. Under these circumstances it is sometimes possible to extract the adherent lens by the linear incision.

Cases in which luxation of a calcified lens occurs as a consequence of irido-choroiditis have been already referred to on pages 338 and 369.

It sometimes happens with severe contusions of the eyes that the sclera is torn through at a point anterior to the insertion of the recti muscles, generally upward, and the lens, escaping through the opening, comes to lie beneath the conjunctiva. In such cases it is very seldom that the uninjured capsule still envelops the lens as it lies beneath the conjunctiva, but when such is the case the lens may remain for a long time transparent. As a rule, the capsule is ruptured, and its fragments, with some of the lens-substance adhering to them, remain behind in the eye, while the lens beneath the conjunctiva in a short time becomes opaque. In either case a simple incision of the conjunctiva is sufficient for the removal of the lens. In spite of the severity of this injury, many of these cases recover surprisingly well.

Aphakia is that condition of refraction which exists when the lens is absent.

When the lens is removed, the dioptric structure of the eye is exceedingly simple. In calculating its refraction there remain then but three factors: 1, the length of its axis, 2, a single refracting surface, the cornea, and 3, the index of refraction, of the intra-



ocular fluids. With an axis of vision of normal length there is always a high degree of hypermetropia in connection with aphakia, so that it is necessary to use convex glasses of about 4 inches focal length for distance, and of about  $2\frac{1}{2}$  inches for near vision. Of course, if the axis of the eye be abnormally long or short, the convex glasses must be correspondingly weaker or stronger.

In many cases cataract extraction produces both aphakia and astigmatism. In this acquired form of astigmatism the meridian of greatest curvature generally lies in the horizontal direction, exactly the opposite to the usual congenital meridional asymmetry.\* This statement has been confirmed by the results of ophthalmometric measurements made by Reuss and Woinow,† and as their observations, in a number of cases, were made upon eyes both before and after the operation, they proved conclusively that the astigmatism was caused directly by it. In twenty-three cases which were measured, both before and after the operation, there were ten in which the radius of curvature in the cornea had become less in the horizontal and greater in the vertical meridian. The exact contact of the edges of the wound is prevented by the new connective tissue which forms between them, and the cornea consequently becomes flattened in the vertical meridian in which the middle of the wound lies, while the curvature in the horizontal meridian is increased. Any abnormality in the healing, such, for instance, as incarceration of the iris, causes of course a higher degree and more irregularity of the astigmatism. As the scar contracts there is a corresponding decrease in the astigmatism, but it never entirely disappears. Under these circumstances, therefore, better vision can be obtained by sphero-cylindrical than by simple spherical lenses.

Under physiological relations the processes to be observed in the lens certainly play the most important part in the function of accommodation, and the conclusion seems therefore unavoidable that aphakia must be accompanied by a total loss of the power of accommodation. Still, assertions are constantly being met with which assume a power of accommodation in an eye where there

---

\* Haase, in Pagenstecher's *klinischen Beobachtungen*, iii. pag. 116, 1866.

† *Ophthalmometrische Studien*, Wien, 1869.



is aphakia.\* Coccius lays emphasis upon the fact that in many persons the eyes move forward during near vision and recede somewhat for far vision, and since he observed the same in the case where he found accommodation to co-exist with aphakia, he regarded it as probable that the eye, by being drawn backward by the recti muscles and by pressure from behind, is made more far-sighted, and that when drawn forward by the obliqui muscles and the pressure from behind is relieved, the axis is slightly lengthened, and the eye is better adapted for near vision.

---

\* Arlt, *Krankheiten des Auges*, B. ii. pag. 347; Coccius, *Der Mechanismus der Accommodation*, pag. 55; Förster, *Accommodationsvermögen bei Aphakie*, *Klin. Monatsbl. für Augenheilk.*, 1872, pag. 39.



## DISEASES OF THE VITREOUS BODY.

---

LIQUEFACTION of the vitreous body occurs under normal relations as a senile change; it occurs also frequently in myopic eyes with elongated visual axes, and also as a consequence of chronic choroiditis. The pathology underlying all these cases is probably a fatty degeneration of the cells of the vitreous body.

If there be at the same time opacities of the vitreous, their great mobility will give evidence of the liquefaction; but if the vitreous remain clear, there may be absolutely no symptoms of the condition, unless, perhaps, the attachments of the lens have become loosened.

A slight oscillation of the margin of the lens, occurring during movements of the eye, often betrays this condition of senile liquefaction of the vitreous, and in cases of cataract is a symptom to be carefully looked for, as its appearance prognosticates a prolapse of the vitreous during the operation of extraction.

Iwanoff\* has shown that detachment of the vitreous from the retina is a frequent occurrence. In the majority of cases it is generally a condition following injuries, choroiditis, etc. Still, it has been observed to occur in myopic eyes.

Accordingly, either with the symptoms of an acute inflammation or by a process of gradual transudation, a fluid may accumulate between the vitreous body and the retina, by which the vitreous is pressed forward; or a shrinkage of the vitreous, caused by disease of that part itself, may be the cause of the detachment. In both cases there is reason to fear that the same causes may induce detachment of the retina.

As yet there is no certain method by which to make the ophthalmoscopic diagnosis of this condition.

Mouches volantes, or myodesopia, is the name given to the sub-

---

\* Arch. f. Opth., B. xv. 2, pag. 1.



jective perception of the elements of the vitreous body. They may be observed in any healthy eye by the method of entoptic examination, by which their shadows are made to fall upon the retina. They appear as isolated rings, with a bright centre and a dark contour, or the objects may be somewhat darker, with long branches or outrunners, or they may seem like a string of bright beads, or like a folded membrane, and so on. Under circumstances which cause hyperæmia in the head or eyes, as, for instance, very often in myopia (page 44), these shadows upon the retina often become so distinct as to attract the attention of the patient and cause him anxiety. These fears may be pronounced groundless, provided vision is normal and the ophthalmoscopic examination reveals no opacities in the vitreous.

Opacities of the vitreous occur in very varied forms; often as a number of small, sharply defined bodies, frequently having several sharp, radiating points. They are surrounded on all sides by transparent vitreous substance, and, on account of their connection with this surrounding substance, are immovable, or nearly so. These small fixed opacities of the vitreous are frequently not easy to be seen, as they are distinct only when the accommodation is exactly adjusted on them.

Generally they are most easily found by the examination in the inverted image. After observing the fundus, the convex glass, without altering its centring, is to be withdrawn gradually from the eye, until it casts the inverted image of the iris and pupillary region. Every portion of the vitreous lying upon the line of vision of the observer comes thus in a position to cast its inverted image at a distance for which the examiner's eye can accommodate.

These opacities are generally situated not far from the optic nerve; there are often several of them present, which may be connected with one another by delicate processes. They occur as the consequences of choroiditis or retinal disease, also in myopia with staphyloma posticum, and finally under otherwise normal relations, but, in such cases, generally late in life.

The delicate, veil-like, broad, immovable, or slightly waving membranes which sometimes form, are likewise not always easy to be seen. The hazy appearance of the fundus noticeable in such cases, particularly about the optic disc, may suggest the erroneous



idea of a retinal opacity, and it is only by an accurate adjustment of the accommodation, generally also when the pupil is dilated, that the uniformly clouded veil, stretched through the vitreous body, can be recognized. If such membranes lie immediately behind the lens, they can generally best be recognized in the upright image by the help of a weak convex lens, say  $\frac{1}{10}$ , placed behind the mirror. Dust-like opacities occur, often accompanying chronic choroiditis, but more frequently with syphilitic retinitis, or even without any other visible changes, and in such cases appear not infrequently to stand in connection with syphilis.

The vitreous opacities most frequent and easiest to be seen are dark, movable, thread-like, flocculent, or membranous bodies, which are set in motion by the movements of the eye. Their great mobility is symptomatic of liquefaction of the vitreous. Still, such bodies may be situated in fluid which has accumulated between the detached vitreous body and the retina.

It is certain that a great part of these opacities are due to changes in the cell elements of the vitreous. Both the nature of these changes and their occurrence simultaneously with other inflammatory processes fully justify the designation of the condition as inflammation of the vitreous, or hyalitis. In fact, important changes in the cell elements of the vitreous are always found upon anatomical examination of any eye which has become fluid from disease of its internal membranes, especially from disease of the choroidal tract. Frequently we find great numbers of roundish cells whose nuclei are undergoing division, often, too, containing dark pigment granules. Frequently these cells have numerous delicate anastomosing processes, permeating the vitreous in the form of a reticulated membrane.

The essential symptom of an inflammation of the vitreous is, therefore, its opacity. Its transparency is diminished during an acute choroiditis, and also by the presence of easily coagulable exudative fluid. In those cases of irido-choroiditis which go on to complete detachment of the retina and atrophy of the eyeball, a dense, fibrous, shrunken mass is found lying in the vitreous body immediately behind the lens. It appears to be particularly in such cases that osteoma develops in the vitreous body.\* The

---

\* Virchow, *Geschwülste*, B. ii. pag. 109.



cases described as ossification of the lens may have been confounded with this process in the vitreous body.

But of course all opacities in the vitreous body are not of an inflammatory nature. This can scarcely be assumed, for instance, with reference to those small, fixed specks which are occasionally found in a vitreous otherwise transparent and in an eye otherwise normal. Some such small opacities, from a transparent vitreous which I have been able to subject to microscopic examination, consisted only of numerous fine pigment granules, which appeared to be contained in ramifying canals.

Very dense vitreous opacities sometimes occur so suddenly that they must in all probability be regarded as of hemorrhagic origin.

The disturbances of vision are caused by the shadows which the opacities cast upon the retina. Small fixed opacities may therefore occur in an otherwise transparent vitreous and while vision is unimpaired. They appear to the patient as dark specks, which do not greatly change their position in the visual field. Delicate clouded membranes or diffuse opacities obscure vision more or less, while the large movable flakes cause a diffuse cloudiness, and in addition cast upon the retina movable shadows, perceptible to the patient.

Diseases of the choroid and retina are generally the causes of vitreous opacities. This is perhaps the reason why it is customary to speak of choroiditis as soon as any vitreous opacity appears, even though no choroidal changes can be detected by the ophthalmoscope; or cyclitis is assumed when the opacity lies in the anterior portion of the vitreous. As opposed to this view, it may be remarked that no reason can be given why the cellular elements of the vitreous may not become independently diseased as well as those of the cornea.

The prognosis is generally unfavorable. In some cases of inflammatory or hemorrhagic origin, it is true, the opacities may entirely disappear, but as a rule they are permanent.

The fact has been observed, especially in myopic eyes, that disease of the vitreous may be the precursor of retinal disease.

In the treatment it is first to be ascertained whether the existence of syphilis, hemorrhagic diseases, etc., indicate the propriety of any special therapeutics.

In most cases the indications exist for the usual derivative



therapeutic means employed for intraocular diseases in general, such as bleeding by the artificial leech, foot-baths, cathartics, diaphoretics, mercurials, or iodide of potassium.

The case reported by Von Graefe, in which complete restoration of vision was obtained by discision of a membrane stretched transversely across through the vitreous, appears as yet to be the only such on record.\*

Cholesterin crystals are frequently observed in the vitreous body. They occur sometimes in connection with other opacities of the vitreous, or as the residuum of such opacities, sometimes in a vitreous otherwise clear, presenting no other changes and where vision is nearly perfect. Ophthalmoscopically they appear as fine, glittering, trembling points, much brighter when illuminated by the concave mirror than when the plane mirror is used. In the anterior part of the vitreous they can be well seen by focal illumination. In the course of some months they may disappear spontaneously.

Recurring hemorrhages into the vitreous are rare, but the condition generally resists treatment obstinately, and is a very serious one.

Immediately after a hemorrhage vision is generally much diminished. In the course of one or two months the effusion is resorbed, but only to be followed soon by a repetition of the process. Small hemorrhages do not necessarily cause disintegration of the vitreous tissue, but may simply indent the retinal surface of the vitreous, and in such cases are often enclosed by layers of clouded vitreous substance. Frequently there exist simultaneously hemorrhages in the equatorial part of the retina, and these may with greater probability be regarded as the source of the vitreous hemorrhages than can those choroidal hemorrhages to which Von Graefe† ascribed them. These last, if they should break through the hyaloid membrane of the choroid, would be much more likely to detach the retina than to penetrate it through a small, sharply defined opening.

Nothing is known respecting the causes of recurring vitreous

\* Arch. f. Ophth., B. ix. 2, pag. 102.

† Ibid., B. i. 1, pag. 358.



hemorrhages. It is noticeable that they occur principally in persons between twenty and forty years of age.

The development of blood-vessels in the vitreous of eyes which are already blind, in consequence of choroiditis, is no great rarity. The new vessels appear to spring mostly from the retina. But since in these cases both the vitreous and the lens are generally opaque, there is very seldom an opportunity for recognizing these new vessels upon clinical examination. If, however, the refracting media before the vitreous remain transparent, and if the vessels ramify in the hollow formed by the lens, they may be easily seen with the naked eye.

Those cases in which the development of vessels must probably be regarded as a consequence of a retinitis, as evinced by an opacity and excessive hyperæmia of the retina, are of an entirely different nature. There are on record\* but two observations of this kind. In both the vitreous was clouded, but still sufficiently transparent to admit of the examination of the fundus. The vessels sprang from the optic disc itself, or from its neighborhood, and spread through the posterior part of the eye, the longest branches reaching its centre.

In one case one of these branches was the source of a hemorrhage. The vitreous opacity and the affection of the retina were bilateral, but the development of vessels was, in one case, confined to one eye. In both cases, at the height of the disease, vision improved greatly as the vitreous cleared up.

As a very rare cause of vascularization of the vitreous, it should be mentioned that in one case of choroidal abscess, probably a suppurated tubercle which penetrated the vitreous body, Becker† saw the development of vessels in the vitreous. A subsequent anatomical examination showed that they were connected with the retinal vessels. The same observer reports a case in which a vascularized morbid growth developed in the vitreous.‡

In the foetus the hyaloid artery runs through the hyaloid canal from the optic disc to the posterior pole of the lens. Stilling§ has

\* Cœcius, Ueber Glaucom, Entzündung, etc., Leipzig, 1859, pag. 47; E. von Jaeger, Ophthalm. Handatlas, pag. 117, Taf. xv., Fig. 72.

† Bericht der Wiener Augenklinik, 1867, pag. 114.

‡ L. c., pag. 106.

§ Arch. f. Ophth., B. xv. 3, pag. 299.



recently re-demonstrated that the hyaloid canal persists during life, and it appears that in rare cases, in consequence of a slight opacity or vascularization of its walls, it may remain visible by the ophthalmoscope.\* Somewhat more frequently a thread is observed connecting the optic nerve with the posterior pole. This must be regarded as the atrophied remnant of the hyaloid artery.

Cysticercus within the eye was first observed in the anterior chamber. Ophthalmoscopic examination has shown that it is relatively more frequent in the deeper parts of the eye.

The cysticercus appears as a semi-transparent, bluish-white, distinctly defined cyst, upon which it is often possible to see the movements of the outstretched neck and head, with its sucking apparatus. When the ophthalmoscopic image is as distinct as this, there is no danger of an error in diagnosis. Frequently, however, the head and neck are drawn in, and the place upon the cyst occupied by the neck appears simply as a brighter spot. If, under these circumstances, the examiner fix his gaze for, say a minute, on one particular point of the cyst, he may frequently detect its movements. Still, in most cases I have not been able to determine whether the movements observed were spontaneous on the part of the cyst or were slight movements of the eye itself.

In the majority of cases the cysticercus lies originally between the retina and the choroid, and therefore causes extensive detachment of the retina. At a later period the cysticercus may break through the retina and penetrate the vitreous, or it may remain lying between the retina and the vitreous.

When first observed, the cysticercus is in the vitreous body in only about half the cases.

As might be expected, aside from the cysticercus, there almost always exist important pathological changes. Opacities of the vitreous sometimes precede the appearance of the cysticercus or appear at a later stage. The mechanical irritation caused by the presence of the entozoon frequently induces inflammatory changes in the retina or choroid. In consequence of this, both membranes, and often, too, a portion of the neighboring vitreous, may grow

---

\* Saemisch, *Klin. Monatsbl.*, 1869, pag. 304.



together, forming a compact mass. Under these circumstances there is frequently seen simultaneously with the cysticercus a dirty-white, strongly reflecting, circumscribed place in the interior of the eye, which does not, however, for the moment necessarily correspond with the position of the cysticercus, which can change its place by its own spontaneous movements.

These changes, in the course of time, make the ophthalmoscopic examination impossible. The vitreous and frequently the lens become opaque; iritis and choroiditis appear, and complete blindness, with atrophy of the eye, is the most frequent termination.

It is noticed that cysticercus is found in those regions where the *tænia solium* most prevails, while in those regions infested by the *tænia mediocanellata*, cysticercus is almost never found in the eye.

The extraction of the cysticercus from the anterior chamber is generally not difficult. If it be situated deep in the eye, it may still be possible to remove it by means of the peripheral linear incision, having first removed the lens. But it is seldom that vision can be saved. The form of the eye is, however, often preserved by this operation.



### PART THIRD.

NORMAL FUNDUS; DISEASES OF THE CHOROID, OF THE  
RETINA, AND OF THE OPTIC NERVE; GLAUCOMA AND  
AMBLYOPIA.







## OPHTHALMOSCOPIC IMAGE OF THE NORMAL FUNDUS OF THE EYE.

---

THE normal optic nerve is distinguished from the surrounding fundus by a brighter color, which by daylight appears as a bright yellowish-red. By artificial light the yellow tinge is lost, while the red still remains. The optic nerve therefore appears white, tinged with red. This red tinge is caused by the numerous capillary blood-vessels at the intraocular extremity of the optic nerve.

The optic nerve is generally bounded by a white line varying in breadth, generally most distinct upon the temporal side, and often surrounding the optic nerve like a ring. The anatomical cause for this appearance is that between the inner nerve-sheath and the margin of the foramen choroideæ a stripe of scleral tissue shines through the retina. The breadth of this scleral stripe varies greatly in different individuals. Generally it is just recognizable; when it equals the breadth of a retinal vessel it is relatively broad. As these scleral stripes increase in width they gradually begin to present the same ophthalmoscopic image as do the white crescents surrounding the optic nerve in myopia (comp. p. 38).

The margin of the foramen choroideæ often forms a dark pigmented ring surrounding the optic nerve. Often, however, this ring remains incomplete, and at times is only indicated by small specks of pigment, generally most numerous on the temporal side of the optic nerve.

The optic disc usually presents at its centre a slight depression, which sometimes attains a considerable size.

The bundles of nerve fibres contained in the trunk of the optic nerve, having arrived at its intraocular end, must necessarily bend in order to pass into the nerve-fibre layer of the retina. This causes a slight funnel-shaped depression, which is always close to the central vascular canal, and on the temporal side of it. This



depression appears ophthalmoscopically as a brighter spot, varying in size in different individuals, but nearly always large enough to admit the recognition of the characteristic appearances of the lamina cribrosa at its bottom. When sufficiently magnified, and that best in the upright image, or in the inverted image with convex 3 or  $3\frac{1}{2}$ , the net-work of interwoven connective tissue can be recognized by its brilliant white color, while the bundles of nerve fibres filling its meshes appear as bright-gray dots. These dots are round when the bundles turn at right angles, and are oval when the bundles pass into the retina in a more oblique direction.

With reference to the ophthalmoscopic image of the lamina cribrosa, it is to be remembered that every cross-section of the optic nerve, and not simply the natural one at its intraocular extremity, presents the appearance of a cribriform disc. Accordingly, at whatever depth we are able ophthalmoscopically to penetrate the optic nerve, everywhere will we find the image of the lamina cribrosa repeated.

Anatomically, however,—and this is the point to be here particularly observed,—only that part of the optic nerve in which the tissue is intimately interwoven with that of the sclera is designated as the lamina cribrosa. Fibres of the scleral tissue pass transversely through the optic nerve, and shreds of connective tissue bend out of the optic nerve into the sclera. Anteriorly, this place is bounded by a slightly concave line in the plane of the choroid; posteriorly, it extends as far as the middle of the thickness of the sclera. In longitudinal section, this portion is exceedingly distinct, for the reason that at its posterior limit the optic-nerve fibres lose their myelin sheaths, in order, as fine pale fasciculi, to pass through the connective-tissue meshes of the lamina cribrosa.

Differences of level at the intraocular extremity of the optic nerve may be caused, as H. Müller\* has shown, by the behavior of the external layers of the retina, that is, of all those layers which lie external to the nerve fibres. If they extend close up to the optic nerve, the nerve fibres must ascend vertically along the external layers, and then curve suddenly. This narrows the central depression. If, on the contrary, the external layers, be-

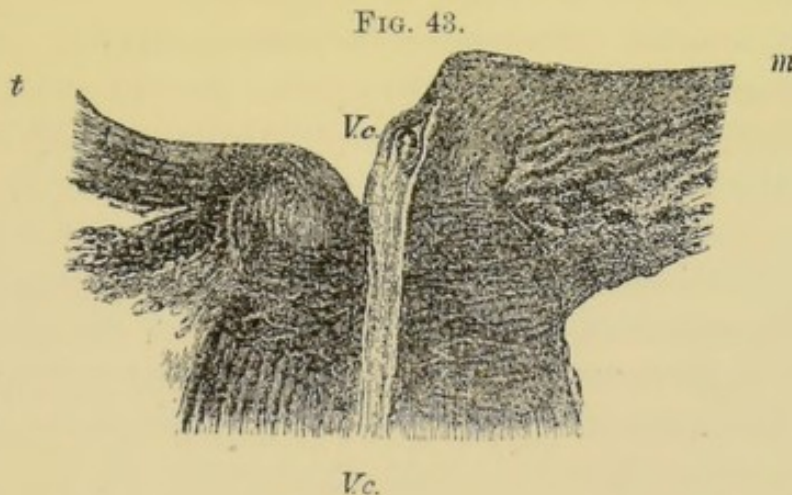
---

\* Arch. f. Ophth., B. iv. 2.



ginning at the optic nerve, increase in thickness only gradually, the curves made by the nerve fibres are less abrupt, the central depression is broader and deeper, so that the lamina cribrosa is seen at its bottom. This slight depression, as already mentioned, is always on the temporal side of the vessels of the nerve, and therefore is nearer to the temporal than to the median side of the optic nerve.

H. Müller pointed out the fact that very often the mass of nerve fibres which passes over the margin of the place of entrance of the optic nerve is not equal at all parts, but is less upon the side toward the yellow spot than in the other portions. These differences of level are distinctly shown in the longitudinal section of an optic nerve represented in Fig. 43.



The thickness of the intraocular portion of the optic nerve is greater on the median side at *m* than on the temporal side at *t*. The trunks of the retinal vessels ascend along the median side, but leave the plane of the section before they reach the surface of the retina.

This distribution of the optic nerve fibres is probably to be explained by an anatomical peculiarity of the macula lutea. The fibrous nerve layer is at that place considerably thinner than at any other point equally distant from the optic nerve, because at that place are found only those fibres whose extremities belong to the macula lutea itself, while those fibres destined for the periphery of the retina avoid this spot by curving around it. It is very likely that in some cases those nerve fibres destined for the temporal half of the retina are arranged, even in the optic nerve itself,



with reference to this peculiar distribution about the region of the macula lutea.

The temporal margin of the optic nerve is there principally crossed by those nerve fibres which end in the macula lutea, while the remaining fibres are crowded together upon the median, upper, and lower parts of the optic nerve.

The nerve fibres which belong to the temporal periphery of the retina, and which serve for eccentric vision in the median portion of the visual field, will then be found at the upper and lower portions of the optic nerve.

The above described difference of level in the optic nerve is called a physiological excavation when the floor of the central depression lies below the plane of the choroid.

Upon anatomical examination the anterior limit of the lamina cribrosa is generally found on the level of the choroid, but where there is physiological excavation the ophthalmoscope shows us the characteristic picture of the lamina cribrosa at a much deeper level, for every cross-section of the optic nerve, at whatever distance from the retina, shows this same picture. A physiological excavation more than half a millimetre deeper than the plane of the choroid is no great rarity.

The ophthalmoscopic picture of the physiological optic-nerve excavation is as follows :

One sees upon the optic disc a bright spot, in which can be recognized the central vessels and the characteristic signs of the lamina cribrosa, and upon whose bright background the delicate vessels running toward the macula lutea are sharply defined.

At the median, upper, and lower portions of the optic disc, the bright spot is more or less sharply bounded by the gray-red mass of the optic nerve. The greater part of the nerve fibres are crowded together in the form of a crescent, whose convexity is turned toward the median side, while its two horns, above and below, are directed toward the macula lutea. The nerve fibres forming this crescentic mass are seen ascending steeply from the floor of the lamina cribrosa and curving sharply into the plane of the retina.

The vascular trunks follow the same course as the nerve fibres surrounding them. They always ascend upon the median wall of the nerve-fibre layer, simply because at the intraocular extremity



of the optic nerve they retain the same relative position that they do in its orbital part, and because their principal branches for the most part run to the median half of the retina.

If one follow the retinal vessels from the periphery to the optic nerve, they are seen at the margin of the excavation to bend over hook-shaped. That part of the vessel which descends upon the median wall of the excavation is foreshortened in perspective, or else is not visible down to the point where it sinks into the lamina cribrosa.

The descent into the physiological excavation is often quite gradual; in other cases the margin, especially in its median, upper, and lower portions, is very sharp, often indeed overhanging, and the walls steep. But it is of great diagnostic importance to observe that the margin of the physiological excavation never coincides with that of the optic disc itself. At the median side this is easily seen by reason of the breadth and distinctness of the nerve-fibre layer; but this is more difficult upon the side toward the macula lutea, because here there is often really no sharply defined margin of the excavation. Upon this side the slope of the wall is quite gradual; the surface of the optic nerve rises gradually to the level of the retina, but always reaches it before passing the margin of the optic disc.

The diagnosis of physiological excavation is made by the help of those ophthalmoscopical experiments by which both in the inverted and in the upright image we are enabled to detect differences of level in the fundus of the eye.

In the examination in the upright image the diagnosis depends upon those laws which have been given on page 96. If, for instance, the eye be emmetropic, so that the plane of the retina can be distinctly seen in the upright image, without a correcting lens, then, in order to see distinctly the bottom of an excavation, a concave lens is necessary whose focal distance must be so much the shorter the deeper the excavation.

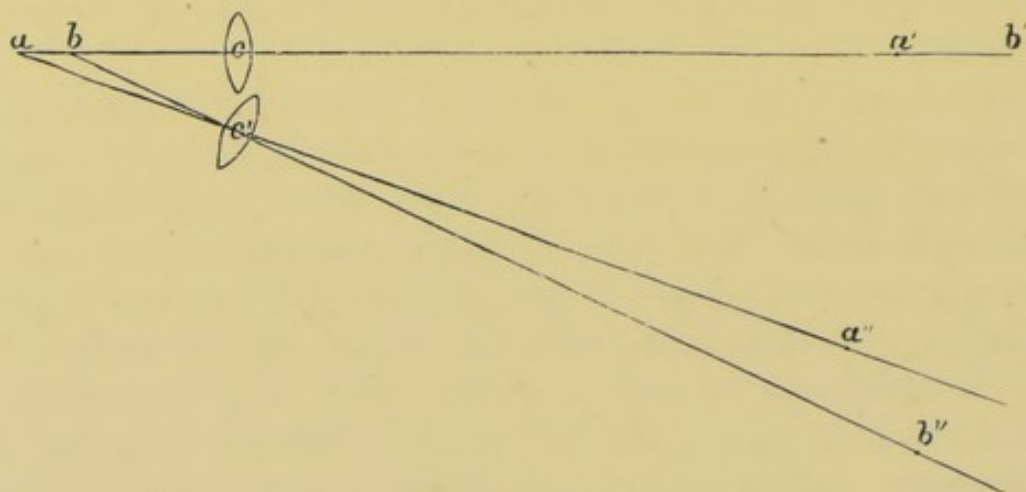
Assuming complete relaxation of accommodation for both the examined and the examining eye, a different correcting lens is necessary for seeing the plane of the retina than for seeing the floor of the excavation, and the depth of the excavation may be calculated from the difference between these two glasses. This calculation may be made by the method which we have employed



on page 104, but in view of all the unavoidable sources of error the practical application of this method is quite limited.

In the examination in the inverted image the greatest reliance is placed upon the change in the parallax of the ophthalmoscopic image, caused by movements of the convex lens. The optical principle involved is explained by Fig. 44.

FIG. 44.



Suppose the points *a* and *b* to lie upon the line of vision of the observer, *c* to be the optical centre of the convex lens, and the points *a* and *b* to lie beyond its principal focus, then will *a'* and *b'* represent the real, inverted images of these points. If now, without changing the direction of the line of vision, we move the convex lens so that its optical centre comes to *c'*, then will the image of the point *a* be formed upon the line *ac'*, for instance, at *a''*, and the image of the point *b* upon the line *bc'* at *b''*.

The image of the point *b* has moved farther from our line of vision than has that of the point *a*. Accordingly the movement of the convex lens displaces the image of a more distant point less than it does that of a nearer one.

If now, during the examination in the inverted image, slight movements of the convex lens be made, the entire sharp margin of the physiological excavation will be seen to move over the lamina cribrosa. It is still better when the examiner fixes his attention upon that portion of a retinal vessel which bends over the margin of the excavation, and then makes movements of the convex lens at right angles to the course of the vessel. The part of the vessel fixed, appears then to move more at the margin of the excavation than does that part lying upon the lamina cribrosa.



The starting-point of the central vessels generally lies slightly to the inner side of the centre of the optic disc. The principal branches of the retinal vessels run mostly upward and downward; only two delicate vessels start out in the direction of the macula lutea. Frequently the vessels branch off deeper in the optic nerve, and make their first appearance at the temporal margin of the disc. In general the individual differences in the arrangement of the vessels depend for the most part upon whether the point at which they are given off is visible or not.

In the case of the larger retinal vessels it is easy to distinguish the arteries from the veins. The arteries are of a bright-red color; the veins are darker and often somewhat wider. The arteries, moreover, generally run much straighter than the veins, which latter, even under physiological relations, are often remarkably sinuous. Along the centre of the larger retinal vessels is seen a bright stripe, the reflex from the cylindrical wall, more apparent on the arteries than on the veins. In many cases, even under physiological conditions, the adventitial coat of the vessels can be seen as a dull white line, accompanying the principal trunks, both of the arteries and the veins. It can generally be seen most distinctly in the upright image, but it is very seldom that it can be traced upon the retina beyond the limits of the optic disc.

The venous pulsation is a remarkable physiological phenomenon, frequently present, but not always easily seen. Upon one or another of the larger veins at a place where it curves to sink into the optic nerve, or in general at places where it experiences a sudden curvature, for instance, on the margin of a physiological excavation, a short portion of the vein can be seen in regular rhythm alternately to collapse and then become distended with blood. The collapse begins at the central part of the vein, in advance of the radial pulse, very seldom extends to the limit of the optic disc, and never beyond it into the region of the retina. The dilatation proceeds quickly from the periphery toward the centre, and follows immediately after the radial pulse. There is a short pause at the maximum of dilatation, when the phenomenon repeats itself anew.

This symptom was explained by Donders\* in the following

---

\* Arch. f. Ophth., B. i. 2, pag. 75.



manner. The augmented pressure with which the blood streams into the arteries is partially propagated to the vitreous body before it has had time to extend through the capillaries into the veins. The pressure of the blood in the veins decreases from the capillaries toward the heart, and accordingly the augmented pressure in the vitreous body meets with the least resistance from the principal venous trunks just at the point where they leave the interior of the eye. This portion of the vein is therefore compressed, and its contents quickly forced out, while the blood streaming from the capillaries is dammed up on the distal side of the compressed portion. After the ending of the heart's systole the augmented pressure in the arteries and that in the vitreous body dependent upon it intermit, the compression of the veins ceases, and the obstructed blood flows rapidly away. If the intraocular pressure be increased by lightly laying the finger on the eye, the venous pulsation may be produced where it was not formerly seen, or if it was seen, is thus made more apparent.

Pulsations may also be observed in the arteries, as was first demonstrated by E. v. Jaeger.\* The most striking and longest known phenomenon of this sort is the so-called arterial pulsation of the central artery of the retina. An impulse in the red column of blood in the trunk of the artery is seen at the time of the heart's systole, while during the heart's diastole the pulsating artery appears empty. This phenomenon is never noticed beyond the limits of the optic disc, and very seldom extends to the first division of the arterial branches.

This arterial pulsation never occurs except when the pressure in the vitreous body is greater than the lateral pressure in the arteries, so that it is only by the sudden increase of the arterial pressure during the heart's systole that the blood can penetrate the arteries.

This phenomenon can be observed at any time in the normal eye, since the arterial pulsation may always be produced by a steady, increasing pressure of the finger upon the eye. During this experiment the vessels will at first be seen to contract gradually, and soon, without the pressure being at all unpleasant, the pulsations appear. The arteries become empty during the heart's

---

\* Wiener med. Wochenschrift, 1854, No. 3 bis 5.



diastole, and during each systole the blood is seen to stream swiftly in again. Under this moderate pressure the emptying of the vessels occupies about one-third and their filling about two-thirds of the entire rhythm. Meanwhile the veins, especially upon the optic disc, are relatively empty, and only seldom show pulsations. If exceptionally a simultaneous venous pulsation be visible, the distention of the veins coincides in time with the contraction of the artery.

As the pressure increases, the diastole of the arteries grows shorter. Immediately after follows the distention of the veins. It appears as if the positive wave, when the pressure is so great, were propagated more rapidly into the veins, so that the blood streams almost simultaneously in through the arteries and out through the veins.

Finally, during the greatest pressure, which, however, is scarcely painful, all movement of the blood ceases; the positive circulatory wave can no longer overcome the pressure on the external surfaces of the arteries.

Simultaneously with these changes in the circulation there comes on, while the pressure of the finger upon the outer side of the eyeball is gradually increased, a darkening of the visual field. Objects appear at first obscured, and as the pressure increases they disappear entirely. This darkening follows a few seconds after the appearance of the arterial pulse, and is due to the obstructed circulation and to the arrested chemical metamorphosis dependent upon it, from which, as Donders\* remarks, it seems plainly enough to follow that, even in the retina, the physical effect of light becomes a chemical one. Upon removing the pressure the disturbance of vision ceases almost immediately, so that after a few seconds it is no longer noticed.

Arterial pulsation, appearing spontaneously, always shows an abnormal relation between the blood pressure in the arteries and the intraocular pressure. In most cases it is due to the increase of pressure which characterizes glaucoma. It is only seldom that the opposite condition obtains,—that is, an arterial pressure so decreased that it is too weak to overcome the normal intraocular pressure.

---

\* Arch. f. Ophth., B. i. 2, pag. 101.



Arterial pulsation may be caused by a mechanical obstruction in the circulation, by which the current in the central artery of the retina is retarded. Among such obstructions are intraorbital tumors, inflammatory swelling of the optic nerve,\* or too weak an action of the heart, like that preceding a fainting-fit.†

The rhythmical streaming in of the blood, and the change in the condition of the artery, which is alternately empty or nearly so, and then distended with blood, give to the arterial pulse a thoroughly pathological character; still, there occur in the central retinal artery other phenomena of pulsation more physiological in their nature. Quincke‡ first pointed out the fact that with insufficiency of the aortic valves a strong distention of the retinal arteries simultaneously with the heart's systole is seen, far beyond the limits of the optic disc. One sees not only a lateral distention of the vessels, but at the same time an elongation of the arteries, which is expressed by an increase of all their curvatures. O. Becker,§ who confirmed this fact in a series of cases of aortic insufficiency, observed, at the same time, in a perfectly normal eye of a person not affected with heart disease, an unmistakable rhythmical swelling and movement of the arteries upon the disc and retina. Becker, moreover, confirmed the observation made by Quincke, that in aortic insufficiency a uniform systolic blush and diastolic paling of the optic disc analogous to the capillary pulsation to be seen in the finger-nails can be observed in the upright image.

In its normal condition the retina is exceedingly transparent, and reflects but little light. The brighter the color of the choroid, the more light is reflected from it and from the sclera, and so much the less visible is the weak reflex from the retina. If, however, the choroid be darkly pigmented, the light reflected from the retina is plainly visible against this dull, dark background, and this, of course, most at the place where the retina is thickest, that is, at the place of entrance of the optic nerve. With proper

---

\* Only three cases of this kind are reported. See V. Graefe, *Arch. f. Ophth.*, B. xii. 2, pag. 131.

† An observation by Wordsworth, *Ophth. Hosp. Rep.*, iv. pag. 111.

‡ *Berl. klin. Wochenschrift*, 1868, No. 34, and 1870, No. 21.

§ *Arch. f. Ophth.*, B. xviii. 1, pag. 206.



illumination,—that is, in the examination in the upright image with a weak mirror, or in the inverted image using diffuse daylight,—the retina can generally be seen near the optic disc, as a thin, light-gray membrane. This physiological opacity of the retina may be so great as to become evident by artificial illumination, and to hide the boundary-line of the optic disc, especially on its median side. Occasionally in such cases certain of the retinal vessels, where they run for a distance behind the nerve-fibre layer, appear lightly veiled.

That margin of the optic disc which is turned toward the yellow spot always remains free from this clouding.

This appearance in the retinal substance is different from a peculiar reflection from the inner surface of the retina, which is often seen in the inverted image in children, and more rarely in adults, and which is generally visible over a great part of the retina. This is a diffuse, glistening reflex, which changes its position as the mirror is moved, and which generally can be followed farthest toward the periphery along the course of the retinal vessels. This reflection from the retina, when present, shows a very peculiar and characteristic behavior in the region of the macula lutea; it ends here abruptly, with a sharply defined boundary; it is wholly absent or is very weak at the macula lutea, which thus appears as if surrounded by a glittering ring, whose diameter is somewhat greater than that of the optic disc, and which, by a slight movement of the mirror, may be distinctly traced in its entire circumference.

It appears most natural to refer this reflex to the connective tissue of the retina, particularly of the nerve-fibre layer. This is known to be very thin in the region of the yellow spot, and, moreover, Müller's radiating fibres, which are attached by broad extremities to the internal limiting membrane, though not absolutely wanting at the macula lutea, are so thin that they can be microscopically demonstrated only with great difficulty. Of course there must be certain individual peculiarities which cause this reflex to be only occasionally visible. Mauthner directed attention to the remarkable fact that this reflex is wholly absent in the upright image.

In many cases, and even in such as do not show the above described reflex, the centre of the macula lutea is prominent by



reason of its red color. The fovea centralis is recognized as a small red disc, whose centre often appears as a whitish, round, or sometimes hook-shaped spot. This spot is perhaps only to be regarded as a reflex, since the centre of the fovea centralis is better adapted than are its steep walls to reflect light in the direction of the visual axis. The red color of the fovea centralis, as well as that of the fundus in general, can be due only to the blood of the choroid; and the fact that this color is a darker red in the region of the fovea centralis may be partly explained by the darker pigmentation which always exists in the choroidal epithelium in the region of the macula lutea, on account of which, especially in a light-colored stroma, this portion presents a deep-red color. Moreover, this color is so much the more distinct for the reason that the fovea centralis is a circumscribed depression, upon whose floor the retina is much thinner than upon the immediately adjoining portions of the yellow spot. Generally, in the cases in which the fovea centralis is ophthalmoscopically distinct, the above described slight physiological opacity of the retina can be seen in the inverted image, and by daylight extending up to the fovea centralis, but wanting within it. This also proves that the red color of the choroid is somewhat softened by the retina, and that it is only because the retina at this place is thinner that the fovea centralis appears so distinctly.

The examination by daylight shows, moreover, that the yellow color of the macula lutea is only a post-mortem appearance; if the retina surrounding the fovea centralis exhibit any color, it is always a light gray, and never a bright yellow. Such a bright yellow, if it were present during life, could not possibly escape observation during the ophthalmoscopic examination by daylight, which admits of so distinct a recognition of all colors.

Frequently the macula lutea presents none of the above described appearances. Only its position is then indicated, and that, by the manner in which the retinal vessels taper to a point and appear to end about it.

The examination of the macula lutea is more difficult than that of any other portion of the fundus, since, in the first place, the pupil contracts very suddenly when the light is directed upon this most sensitive part of the retina; and, secondly, the unavoidable corneal reflex covers a part of the already contracted pupil.



When these optical difficulties are overcome by the use of atropine, the macula lutea is most easily found, both in the upright and in the inverted image, by finding first the optic disc, and then proceeding outward from its temporal margin.

In cases in which the fovea centralis is not especially distinct, and where it is desired to examine this region carefully, it is best to examine in the upright image with a weak mirror, and to cause the patient to look directly at the flame reflected from the mirror.

At the periphery, the retina is so thin and transparent that it can be recognized by the presence of its vessels only.

Under pathological conditions, however, and most frequently from detachment of the retina, its peripheral part may become so opaque as to be distinctly seen.

The choroid in its natural condition, on account both of its pigment and of its great vascularity, exercises an important influence upon the ophthalmoscopic image, and upon the color of the fundus.

The retina is almost absolutely transparent, the sclera is covered by the choroid, and can be illuminated and seen only through it. The more pigment the choroid contains, the less noticeable in the ophthalmoscopic image is the white sclera shining through it.

But the appearance of the choroid itself varies according to the amount of pigment contained in it.

The character of the pigment epithelium is of great influence. Although it consists of but a single layer of cells, it is still very opaque, and when possessing its normal quantity of pigment it almost wholly hides the choroidal stroma lying behind it. This can be easily demonstrated anatomically by comparing, under a weak magnifying glass, a portion of the choroid still covered by its epithelium with another portion from which the epithelium has been removed.

The great absorption of light in the choroidal epithelium is the cause why, when the pigment is very dense, so little can be seen of the choroidal stroma. In such a case the retinal vessels are seen to branch over a quite uniformly colored red background.

Nevertheless, the amount of pigment in the choroidal epithelium varies considerably in different individuals, but the color of this epithelial layer over the entire fundus, so far as can be



seen, is in any given case uniform, except that in the region of the macula lutea the epithelium is always darker.

In new-born infants the pigment epithelium is always very dark, while the stroma is of a lighter color.

In many cases, especially with relatively slight pigmentation of the choroidal stroma, the fundus presents a granular, shagreen appearance, generally most distinct at the equatorial part. It is certain that this punctation, which has no pathological significance, must be referred to the epithelial layer of the choroid. But the possibility asserted by Liebreich,\* of recognizing ophthalmoscopically the individual cells of the choroidal epithelium, is doubtful. The superficial diameter of a single cell is 0.013 to 0.016 mm. Substituting these figures in the calculation made on page 102, each cell in the upright image would appear included within a visual angle of about 3 minutes.

Now, it is true, according to Tob. Mayer,† that checker-board-like figures can be recognized under a visual angle of only a little more than 2 minutes; but the uniform, closely placed epithelial cells of the choroid are, even with ophthalmoscopic illumination, far less favorable objects.

If the choroid, both in its epithelium and in its stroma, be weakly pigmented, its vascular net-work is the more apparent. The choroidal vessels, even to their finest ramifications, are distinctly visible against the background formed by the sclera. The vascular trunks of the *venæ vorticosæ* which penetrate the sclera, also appear with equal distinctness, and of surprising size. Eyes affected with this slight degree of albinismus are generally myopic, and not sharp-sighted. Higher grades of albinismus, with complete absence of pigment in the epithelium and in the stroma cells, are always connected with nystagmus.

The image of the fundus of the eye is very different when the choroidal stroma is rich in pigment, while the epithelium has but little and is therefore transparent. Here the large vascular trunks lying in the outermost layers, and their finest branches as well, are hidden by the pigment of the stroma, while the vessels of medium size remain visible, forming a distinct red net-work,

---

\* Arch. f. Ophth., B. iv. 2, pag. 486.

† Helmholtz, Physiologische Optik, pag. 218.



whose meshes, the so-called intervacular spaces, appear almost black on account of the darkness of the stromal pigment.

The form of these intervacular spaces varies according to their locality. In the deeper parts of the fundus, in the region of the optic disc and macula lutea, the net-work of the choroidal vessels is closer, and the intervacular spaces therefore more rounded at the corners. In the equatorial part the choroidal vessels run more in a meridional direction, and with fewer anastomoses; consequently the intervacular spaces are elongated.

Frequently the consequences above explained, of a very dark pigmentation of the choroidal stroma with a relatively light pigmentation of the epithelium, are so marked, and produce an ophthalmoscopic image so different from the usual one, that the beginner is often inclined to regard the dark intervacular spaces upon the red background as pathological. Such an error may be guarded against by observing the differences of form of these dark intervacular spaces dependent upon their position in the fundus, and the uniformity with which this peculiar pigmentation is diffused over the fundus.

If, on the contrary, the vessels and intervacular spaces of the choroid be much more distinct at certain places than at others, there is reason to assume that there is a local loss of pigment in the epithelium at those places where the choroidal stroma is most apparent.

Of course, from pathological causes, the epithelium over a large portion of the choroid may lose its pigment, and present thereby the above mentioned ophthalmoscopic picture. If simultaneously there exist other changes, for instance, pigmentation of the retina, there can be no doubt concerning the process. In the absence of other visible choroidal changes, the only circumstance to indicate that this is a pathological discoloration of the choroidal epithelium is that this ophthalmoscopic picture is relatively frequently observed in connection with certain pathological processes, for instance, with a protracted increase of the intraocular pressure in darkly pigmented eyes.



## DISEASES OF THE CHOROID.

---

**HYPERÆMIA** of the choroid frequently occurs in connection with inflammatory processes in the vascular coat of the eye, and probably also as an independent chronic condition. This condition, however, cannot be diagnosticated with any certainty. The distinctness with which the choroidal vessels are seen ophthalmoscopically, as well as the color of the fundus of the eye in general, depends upon the color and quantity of the pigment both in the choroidal epithelium and in its stroma, and aside from this, upon the intensity of the ophthalmoscopic illumination, which, assuming an unvarying source of light and complete transparency of the refracting media, depends principally upon the size of the pupil. The possible combinations of all these factors are too numerous to admit the possibility of determining from the ophthalmoscopic appearance of the choroid whether it contains more or less than the normal quantity of blood. The appearance of the optic disc furnishes a more reliable criterion, its increased redness indicating a collateral hyperæmia, but even from this appearance no certain conclusion can be drawn.

Hyperæmia of the choroid, therefore, is a condition which cannot be absolutely demonstrated, but whose existence or absence is rather to be inferred from the circumstances of each particular case.

### CYCLITIS.

It can be easily understood from the continuity of tissue in the iris, ciliary body, and choroid that the inflammatory processes in these three portions of the vascular coat cannot be sharply defined one from another. Opacities of the vitreous frequently remain after iritis, proving that the inflammation was by no means limited to the iris. On the other hand, we observe ophthalmoscopically acute choroiditis in connection with iritis; or an iritis is gradually developed in the course of a chronic choroiditis.

We must certainly assume that the extension of such an in-



flammatory process is through the ciliary body, but it is only seldom that the changes within this part are so considerable, and the symptoms to be referred to this complication so decided, as those described upon page 344 as characteristic of irido-cyclitis.

There is still greater difficulty in recognizing an inflammation which begins in the ciliary body, for this part can neither be seen directly nor with the ophthalmoscope, and the tenderness upon pressure is not an absolutely reliable symptom. If, however, we observe severe pain, with decided hyperæmia of the subconjunctival vessels at the margin of the cornea, without any visible corresponding changes in the iris, while after the lapse of an acute inflammatory period, opacities are visible in the anterior portion of the vitreous body, we are certainly justified in regarding the process as cyclitis. Frequently iritis comes on at a later stage.

In another class of cases, after there have been for some days moderate photophobia, pain when using the eyes, an inclination to deep subconjunctival hyperæmia, and disturbance of vision, due to slight opacity of the vitreous, there develops a small hypopion, which must be regarded as coming from the ciliary body, since there is no apparent disease of the cornea or iris. In its further course this hypopion generally disappears and reappears repeatedly, while the opacities of the vitreous increase and vision greatly diminishes.

Both forms of cyclitis are very rare. They may occur without any apparent cause.

The fact that the diseases of the uveal tract are not sharply defined, but pass one into another, is well illustrated by those inflammations of the eye which occur as sequelæ of recurrent fever. The most recent observers agree as to their essential nature, but some describe them as irido-choroiditis, some as cyclitis.

The cases which were observed during an epidemic of recurrent fever in the Charité Hospital in Berlin, occurred mostly after the second or third attack of fever, which then generally proved the last. Nearly half the cases were simple unilateral iritis of a moderate grade. About one-third of the patients presented diffuse punctiform or flocculent floating opacities of the vitreous, without any trace of iritis, and without any external symptoms of disease, while the remainder of the cases presented iritis with opacities of the vitreous. In the great majority of cases only one eye was



affected. On the whole, the disease ran a very mild course. The external symptoms of inflammation were moderate, and only exceptionally was there any chemotic swelling of the conjunctiva. The treatment was limited to the use of atropine, except in the cases where dense opacities of the vitreous existed, when iodide of potassium and diuretics were resorted to. Of course, as the patients were greatly reduced, a nutritious diet was provided.

Other epidemics of recurrent fever appear to be followed by more severe disease of the eyes. The objective symptoms are great hyperæmia at the margin of the cornea, chemotic swelling of the conjunctiva, fine punctiform deposits upon the posterior wall of the cornea, hypopion, dense opacity of the vitreous, and frequently an abnormal softness of the eye. Slight amblyopia, with posterior polar cataract or opacities of the vitreous, or with changes in the pigment of the anterior portion of the choroid, has been observed to remain behind. Blindness rarely ensues, and when it does, is a consequence of iritis with annular adhesion of the margin of the pupil or of detachment of the retina, or exceptionally of suppuration of the cornea.

We have here a form of disease whose etiology is very clearly defined, and which affects the uveal tract, but it localizes itself sometimes on one portion and sometimes on another, and the degree of its intensity varies greatly.

#### CHOROIDITIS.

Purulent choroiditis is the most severe form of choroidal inflammation. It generally involves the entire eye, and the name panophthalmitis, therefore, well describes this condition.

The lids are swollen and reddened, the entire conjunctiva is infiltrated, there is a purulent secretion in the conjunctival sac, the cornea is clouded, the iris discolored and adherent to the capsule of the lens, the aqueous humor is clouded, and often contains flocculent coagula or a copious purulent sediment. In consequence of the swelling of the orbital tissues, the eye is prominent and its movements are difficult. Vision is in a short time completely lost or reduced to a slight perception of light. From the very first there are generally severe pains, which may last during the whole course of the disease; in some cases, however, the pain is very slight.



The disease is frequently accompanied by vomiting, and in severe cases by fever.

The pus accumulated within the eyeball generally breaks through. This occurs in the cornea when that has likewise been destroyed by suppuration, or when the cornea remains intact the rupture is in the sclera. In milder cases, in which the pus does not break through, there follow, with all the signs of chronic irido-choroiditis, an opacity of the lens and more or less atrophy of the eyeball.

The disease is most frequently of traumatic origin, being caused by wounds, unfortunate operations, foreign bodies in the eye, etc. The same result may be caused by ulceration of the cornea, with prolapse and purulent inflammation of the iris.

A very slight provocation may excite a purulent choroiditis in an eye already suffering from a chronic internal inflammatory trouble, such as choroiditis or retinal detachment, or the presence of a cysticercus.

Embolism is another very noticeable cause. It occurs most frequently in puerperal diseases, but anything which causes embolism may also induce purulent choroiditis. It is remarkable that in the choroiditis caused by embolism, at least in the puerperal form, it sometimes happens that both eyes are affected, one shortly after the other.

Anatomically, the condition is one of hemorrhagic purulent inflammation.

The pus-corpuscles in the stroma of the choroid are at first always most numerous in the immediate neighborhood of the chorio-capillaris; if the suppuration be more profuse, the entire stroma becomes filled with corpuscles, between which the branching pigment cells are crowded together in parallel anastomosing lines. In many cases the choroidal stroma is greatly thickened by the inflammatory exudate and its inner surface thrown into irregular prominences.

The pigmented stroma cells mostly remain unchanged; still, they sometimes undergo fatty degeneration and loss of color.

The pigment epithelium may remain normal, or may suffer changes in spots or in its entire extent. These changes affect partly the form and partly the pigment of the cells. In consequence of their growth and segmentation, the cells assume an



irregular form, and their proliferation may become excessive. Fatty degeneration of the pigment epithelium and its detachment from the surface of the choroid may also occur.

The ciliary body and iris participate early in the inflammatory process, which at a later stage assumes a purulent character.

The retina soon becomes involved. H. Meckel\* diagnosed on the second day of the inflammation a complete softening of the retina in those portions lying over the inflamed parts of the choroid. Later there was hemorrhagic purulent retinitis near the optic nerve and macula lutea, with here and there fast adhesions between the retina and the choroid, caused by a fibrinous exudate, and at other places circumscribed detachments of the retina, caused by a bloody serous fluid. From my own investigations, I can also affirm the occurrence of hemorrhagic purulent retinitis as a consequence of purulent choroiditis. Still, it should be remarked that in the puerperal forms which were examined by Meckel the retinitis may be caused by simultaneous embolism of the retinal vessels, as some cases of Virchow's have proved.†

At a later stage, total detachment of the retina generally follows, and the exudate collected between the retina and the choroid is then frequently also of a purulent character.

H. Meckel found in the vitreous, pus-corpuscles and proliferation of the cells. The cloudiness of the vitreous observed when the disease has been of a few days' duration, and which appears to consist of fine granules and countless interlacing fibres, he regarded as post-mortem coagula; and probably he is right.

The sclerotic, aside from slight hemorrhages upon its inner or its outer surface, is at first unchanged; later, however, it becomes thickened. H. Meckel observed a thickening as early as the eleventh day of the choroiditis.

When panophthalmitis is once established, its course cannot be checked. The object of the treatment, therefore, is simply to make the condition endurable, and to soothe the pain. Opiates, injections of morphine into the temple, and warm cataplasms upon the eye are the most useful remedies.

There is a special interest attached to a certain form of irido-

---

\* *Annalen der Charité-Krankenhäuses*, B. v. pag. 276.

† *Arch. f. path. Anat.*, B. x. pag. 181; *Gesammelte Abhandl.*, pag. 719.



choroiditis on account of its connection with meningitis. It generally occurs during the first days or weeks of that disease. It is in connection with cerebro-spinal meningitis\* that this sad complication most frequently occurs. Iritis develops with symptoms of irritation, which sometimes are at first slight, but often are severe from the beginning. Adhesion of the margin of the pupil to the lens immediately occurs, with its usual consequences, such as the driving forward of the periphery of the iris, etc. There is frequently an exudate in the pupil, or there is hypopion. An early infiltration of the vitreous body causes, when the pupil is still transparent, a bright reflex from the fundus. Detachment of the retina and atrophy of the eyeball are the usual results. It is very seldom that the disease runs its course without decided injury to vision, and without leaving slight adhesions.

Neuro-retinitis, paralysis of the ocular muscles, and amblyopia may also be mentioned as consequences of meningitis.

The connection between meningitis and the diseases of the eye may, with the greatest probability, be explained by the direct connection which Schwalbe† has shown to exist between the arachnoidal lymph-space and the lymph-spaces of the eye.

Acute irido-choroiditis is often the consequence of an injury. Traumatic choroiditis, sooner or later, generally assumes the character of panophthalmitis; but frequently, with all the symptoms of a severe iritis, there follow dense opacity of the vitreous, detachment of the retina, and atrophy of the eyeball.

Acute irido-choroiditis, occurring without any apparent cause in hitherto healthy eyes, is exceedingly rare. In addition to the signs of a severe acute iritis, with or without purulent and fibrinous exudations in the anterior chamber, there appears a diffuse or flocculent clouding of the vitreous, with considerable diminution of vision. The usual treatment is by strong antiphlogistics and rapid mercurialization. Dobrowolski‡ observed in two

---

\* Salomon, Berl. klin. Wochenschrift, 1864, No. 33; Knapp, Centralblatt für die med. Wissensch., 1865, No. 33; Kreitmeyer, Aertzliches Intelligenzblatt für Bayern, 1865, Nos. 21 und 22; Jos. Jacobi, Arch. f. Ophth., B. xi. 3, pag. 157; Schirmer, Klin. Monatsbl. f. Augenheilk., 1865, pag. 275.

† Untersuchungen über die Lymphbahnen des Auges, M. Schultze's Arch., B. vi. 1870.

‡ Klin. Monatsbl., 1868, pag. 239.



such cases a good effect from repeated puncture of the anterior chamber.

Just as chronic irido-choroiditis may follow iritis with annular adhesion of the margin of the pupil, so, too, the opposite process may take place,—that is, iritis may supervene upon chronic choroiditis.

If such blind or nearly blind eyes be the seat of severe pain, a  $\frac{1}{2}$  to 1 per cent. solution of morphine dropped into them gives often great relief. The immediate local effect of morphine is, it is true, irritating; but this soon passes away.

Long-persisting irido-choroiditis may cause calcification of the lens, or extensive calcareous deposits on the surface of the choroid, or an irregular thickening or ossification of the lamina vitrea. The new-formed osseous tissue generally develops between the choroid and the retina. It is only exceptionally that the formation of bone occurs in the stroma of the choroid.

These new-formed bony shells are generally thickest at the posterior part of the choroid, where they surround the optic disc, and are penetrated by the detached, stretched, and distorted retina. There is always total detachment of the retina, and generally also atrophy of the eyeball. Frequently the bony shell extends so far forward that it may be recognized by palpation.

The ossification generally excites a continual irritation, with very painful exacerbations; indeed, it may even give rise to sympathetic affection of the other eye. The enucleation of the eye is therefore indicated as soon as symptoms occur which give reason to fear this complication.

Another class of cases, partly on account of the very slight external visible changes, and partly on account of the ophthalmoscopic appearances, are characterized as acute choroiditis. There are deep pericorneal injection, hyperæmia of the iris or slight iritis, frequently also punctated opacities on the inner surface of the membrane of Descemet, and in some cases deep-seated pain in the eye; all indicating that the entire vascular coat participates in the inflammatory process.

The actual centre of inflammation is generally in the posterior part of the choroid. Frequently, circumscribed, whitish masses of exudate may be observed there, hiding the choroid, and elevating slightly above the surface of the surrounding parts the



retinal vessels which run over them. At a later period black pigment spots frequently develop upon this exudate. Generally there is a dense clouding of the vitreous from the very beginning. This may diminish in the course of time, or the condition may become one of chronic inflammation, even becoming complicated with cataract.

In another class of cases the choroidal exudate seems rather to be of a serous character, and to cause an infiltration of the retina.

At first a somewhat distinct whitish opacity of the retina is observed. It appears to be mostly in the external layers, since the fine retinal vessels can be seen sharply defined against this bright background, although at places the larger vessels also appear to be hidden by slightly clouded retinal substance. A swelling of the intraocular extremity of the optic nerve may at the same time occur, and is all the more likely to give rise to an error in diagnosis from the fact that at this stage the opacity of the retina prevents the examination of the choroid. But in the course of a few weeks, as the retina clears up, the choroidal changes, which consist partly in discoloration of the pigment epithelium and partly in the formation of dark pigment patches, become visible. The principal seat of these changes is in the neighborhood of the optic nerve and macula lutea; still, they appear also in the equatorial parts of the choroid. Opacities of the vitreous generally do not exist, or are very slight.

This serous infiltration always causes a decided *torpor retinæ*; that is, retinal images can be perceived only by very intense illumination, while as the illumination is diminished there occurs a disproportionate diminution of retinal sensitiveness. This *torpor* is generally most decided in the periphery of the retina, so that as the illumination diminishes a rapid contraction of the visual field occurs.

Serous infiltration of the macula lutea always causes a considerable diminution of vision.

Many cases of choroiditis run their course without giving rise to any external symptoms of inflammation, and can therefore be recognized only by ophthalmoscopic examination. The diagnosis is based in all cases upon the changes visible in the choroidal pigment; but it must be remembered, on the one hand, that by no



means all visible choroidal changes are of inflammatory origin, and, on the other, that choroiditis may run its course without leaving noticeable traces in this membrane.

In one class of cases these pigment changes are uniformly disseminated over the entire choroid, or over a large region of it; another class presents the peculiarity that a number of variously shaped and very variously colored spots lie scattered, island-like, upon an otherwise normally appearing choroid (*choroiditis disseminata*).

The form of these spots is generally roundish or oval. They are generally considerably smaller than the optic disc; still, larger ones do occur, or several such spots may run together, forming large, irregular figures.

The colors presented by these patches are principally black, white, and light red. The black is due to a hypertrophy of the pigmented epithelial cells. The cells may retain their normal form, or may assume a roundish shape; they may accumulate in great numbers, forming dark hillocks; the epithelium surrounding them is often quite normal, in other cases poor in pigment. The pigment may gradually disappear from the centre of these dark hillocks, so that they present a bright spot surrounded by a black margin. Lastly, the proliferating epithelial cells may assume a spindle-shaped form, and often show a tendency to a reticulated arrangement, by which process a delicate black net-work is formed. It is noticeable, moreover, that wherever the choroidal epithelium bounds a sharply defined change of level in the choroid it shows a great tendency to become blacker. Accordingly, both circumscribed elevations, such as the irregular thickenings of the lamina vitrea, and sharply defined depressions, such as small posterior ectasiæ in myopia, frequently appear surrounded by a circle of coal-black epithelium.

Within the limits of the bright-red spots the choroidal stroma can sometimes be recognized as unchanged, and sometimes more or less atrophied. These spots, therefore, are probably caused by a loss of color in the pigment epithelium. The more advanced the atrophy of the choroid, the brighter do these spots become, so that often only a few choroidal vessels can be seen running across the white background of the sclera. Such spots, caused by a circumscribed atrophy of the choroid, can generally be recognized as depressions in its surface, and may either be sharply bounded by the



normal choroid, or, at certain parts of their circumference, pass over gradually into normal tissue.

Such bright spots, whether caused by atrophy or by other changes, are frequently surrounded by a border of black pigment, or their surfaces present black, pigmented, irregular figures.

The anatomical changes which appear as white spots in the choroid are, however, the most diverse. They are sometimes due to the above described atrophy of the choroidal stroma, sometimes to flat, bright-colored layers of exudate upon the inner surface of the choroid, sometimes to circumscribed growths of cell elements in the choroidal stroma, and sometimes to fatty degeneration of the pigment epithelial cells or of the cells of the stroma.

Frequently very peculiar changes of the choroidal epithelium occur in a disseminated form. For instance, in a case of total detachment of the retina, caused by a sarcomatous choroidal tumor at the equator of the eyeball, I found a punctated condition of the choroid, which depended upon the fact that the choroidal epithelium, forced by an amorphous molecular mass above the plane of the hyaline membrane, formed numerous flat prominences. Over the entire extent of those parts of the choroid thus changed, and above the pigmented epithelium, was a hyaline, structureless mass, which in many places projected in irregular shapes above the plane of the epithelial layer, and, when observed from its surface, presented a peculiar glistening appearance.

The pathological processes to which this disseminated choroiditis is due are only imperfectly known, as the opportunity very rarely occurs to examine such eyes anatomically. As yet, only the following anatomical appearances have been observed:

There develop in the choroidal stroma disseminated nodules, composed of small non-pigmented cells or nucleated fibres, which at a later stage undergo cicatricial contraction. The surface of the nodules is, at first, covered with coal-black epithelium. The pigmented epithelium gradually disappears from the centre of these black spots, leaving thus a bright spot surrounded by a black border. The retina at these places is adherent and atrophied.\*

At circumscribed points there occurs a proliferation of the

---

\* Wedl, Atlas der pathol. Anat. des Auges, Iris und Choroidea v., Fig. 54 und 55; Förster, Ophthalmol. Beiträge, Berlin, 1862, Choroiditis areolaris.



pigment epithelium, which penetrates the external and sometimes even the internal granular layer. The new-formed cells are non-pigmented. The retinal elements in the affected places are completely destroyed, though they may remain normal in the immediate neighborhood.\*

An inflammatory process in the external layers of the retina may likewise produce the ophthalmoscopic appearances of a disseminated choroiditis.†

The peripheral extremities of the radial fibres of the retina are thickened and lengthened, are crowded against the inner surface of the choroid, become bent upon themselves, and to some extent adherent to each other. The pigment epithelium of the choroid partly breaks down, while countless pigment molecules or even entire cells penetrate the substance of the retina.

Finally, mention should be made of an anatomical process which may furnish a similar ophthalmoscopic picture, namely, the thickening of the hyaline membrane. Flat or hemispherical elevations are found upon it analogous to those hyaline growths which occur upon the membrane of Descemet, and which, like those, are most frequent as senile changes. But they occur also in young persons, and in such cases generally in connection with inflammatory processes. The size which they may attain, and the changes of the pigmented choroidal epithelium connected with them, render them visible to the naked eye, or with the help of a lens, and accordingly they must be ophthalmoscopically visible. H. Müller‡ has found deposits of chalk in the eyes of old people, partly in the thickened hyaline membrane and partly in the tissue of the choroid itself, external to the capillary layer. Some of these deposits have a diameter of 0.5 mm., and accordingly must be ophthalmoscopically visible.

It is only seldom that the nature of these different processes and the changes caused by them can be determined by their ophthalmoscopic appearances or clinical history. In determining these questions an examination of the other parts of the eye is of the greatest importance.

---

\* Iwanoff, *Klin. Monatsbl.*, 1869, pag. 470.

† Rudnew, *Virchow's Arch.*, 1869, B. xlviii. pag. 494; Iwanoff, *l. c.*

‡ *Arch. f. Ophth.*, B. ii. 2, pag. 1.



The vitreous generally remains clear; still, there may be opacities in it. The retina and optic disc generally show no ophthalmoscopic changes. In many cases, however, the participation of the retina in the pathological process is shown in various ways, partly by pigmentation along the course of the retinal vessels, partly by contraction of those vessels, especially of the arteries. A change in the optic nerve may proceed from the same causes. It loses its normal reddish tinge as the numerous delicate vessels which ramify in its intraocular extremity become bloodless. In this condition it presents exactly the appearance of atrophic degeneration.

The disturbances of vision depend principally upon the location of the disseminated points of inflammation. They always exercise a hurtful influence upon the retina, but so long as only a small eccentric part of the visual field is affected the disturbances are not great, and accordingly there may be very considerable choroidal changes with relatively good vision. On the contrary, very slight changes in the region of the macula lutea injure direct vision very seriously. Although these forms are so destructive to the usefulness of the eye, they seldom lead to complete blindness, as eccentric vision generally remains good enough to enable the patients to recognize their surroundings.

Vision is affected in a much higher degree in those cases in which the retina or the optic nerve is essentially involved in the pathological process.

Choroiditis syphilitica is a special clinical form which should be mentioned in this place. It is characterized by exceedingly small black, white, and red spots scattered in the fundus. It is always well not to base the diagnosis upon the ophthalmoscopic appearances alone, but to determine the existence of syphilis from other symptoms.

In choroiditis disseminata the diseased portions are always scattered and separated from one another by normal tissue. But there is another form of choroiditis which spreads uninterruptedly over great regions of the choroid. The posterior portion of the choroid is generally the part diseased, while about the periphery there remains a border of normal tissue. Frequently throughout the entire fundus, as visible by the ophthalmoscope, no normal region can be seen.



The epithelium over a great extent has lost its color or has absolutely broken down, and accordingly the stroma with its vessels and intervascular spaces is very distinct, appearing either unchanged or more or less atrophied.

Frequently there are in the epithelial layer, atrophy, circumscribed proliferation, and pigment changes of the cells, and the result is a greater or less number of black, punctated, or irregular spots, dark lines, and reticulated figures. Frequently there are accumulations of pigment upon the retinal vessels, with contraction of the larger vascular trunks, and atrophy of the optic nerve.

The vitreous may remain clear, but there are more frequently opacities in it, which, by their great mobility, show its complete liquefaction. This same degenerative process may cause relaxation of the zonula and luxation of the lens.

As the macula lutea is generally involved, vision is greatly interfered with. In many cases all sensation of light is lost.

In the treatment of choroiditis, especially of those forms in which the diagnosis is based simply upon the ophthalmoscopic appearances, the first thing to be determined is whether the inflammatory process is still going on or has run its course. If the disturbances of vision be but recent, or if there be signs of an active inflammation, such as hyperæmia of the ciliary vessels about the margin of the cornea, or an abnormal redness of the intraocular extremity of the optic nerve, an antiphlogistic treatment is indicated. Bleeding from the temple by means of the artificial leech, so much employed in these cases, should be so performed that within a few minutes from 30 to 50 grammes are drawn; the patient should then be kept for at least 24 hours in a darkened room. If there be no special contra-indications, an energetic mercurial treatment should be resorted to, the method by inunction being employed in cases where very threatening symptoms render a rapid effect desirable. If a slower action be wished, corrosive sublimate may be employed.

The same treatment should be employed during the inflammatory exacerbations in chronic cases.

If it be impossible to determine with certainty that the inflammatory process is yet going on, it is still best to try once or twice the effect of bleeding; but it should not be repeated oftener if it do not appear to improve vision.



In suitable cases energetic cathartics, diaphoretics, or iodide of potassium may be employed instead of the mercurial treatment.

According to Von Graefe,\* repeated puncture of the anterior chamber is also beneficial in cases of chronic choroiditis with disease of the vitreous.

In all cases, even in those where no special treatment is indicated, suitable dietetic rules should be observed, and to guard against relapses vision should be spared as much as possible, and the eyes protected from all external irritation, from dazzling light, etc.

#### DETACHMENT OF THE CHOROID.

In a few cases† the ophthalmoscope has revealed in the fundus of the eye a number of circumscribed prominences, upon whose surface the choroid as well as the retina could be seen. Both membranes had been raised together from the sclera. The color and outlines of the ophthalmoscopic image are determined by the character of the pigment in the individual cases, and also by the hemorrhages, which are seen partly in the tissue of the choroid and partly in the retina. In a case which I observed, the retina itself upon the prominences was slightly pigmented.‡

In many cases the patients state that the disturbances of vision connected with the condition came on suddenly. Generally, however, they develop gradually, and are always very considerable.

At a later stage a partial or total detachment of the retina generally occurs.

The recognition of this condition ophthalmoscopically is a great rarity, but a separation of the choroid from the sclera is quite frequently found on anatomical examination. Von Ammon,§ for instance, describes a case of hydrophthalmus, in which the sclera was separated from the choroid throughout the limits of a circumscribed scleral staphyloma; a thin layer of exudate covered a great extent of the remaining portion of the scleral surface of the choroid. In the retina there were no changes visible to the naked

---

\* Arch. f. Ophth., B. xv. 3, pag. 169.

† V. Graefe, Arch. f. Ophth., B. iv. 2, pag. 226; Liebreich, Arch. f. Ophth., B. v. 2, pag. 259; Liebreich, Atlas der Ophthalmoscopie, Taf. vii., Fig. 4.

‡ Vorlesungen über den Gebrauch des Augenspiegels, pag. 122.

§ Zeitschrift f. Ophthalmologie, 1832, B. ii. pag. 252.



eye. In a case of intraocular tumor in the region of the ciliary body, Von Stellwag\* found a circumscribed staphylomatous upheaval of the sclera from the choroid. In another case, in which there was atrophy of the eye in consequence of irido-choroiditis and detachment of the retina, the posterior part of the choroid was raised from the sclera by a yellow fluid mixed with pigment granules, and the inner surface of this part of the choroid was covered with a bony growth.

Virchow† found in an eye which had been destroyed by neuro-paralytic suppuration of the cornea, the choroid detached from the sclera by an accumulation of thin purulent fluid. There was purulent infiltration of the choroid, the retina, and the vitreous.

In a case of purulent choroiditis which I examined, the stroma of the choroid was so infiltrated that at places its inner surface projected in hemispherical nodules from 3 to 5 mm. into the cavity of the eyeball. There was total detachment of the retina.‡

In a case in which there were a high degree of amblyopia, liquefaction of the vitreous, luxation and opacity of the lens, Knapp§ performed cataract extraction. Five weeks later he enucleated the eye, because in the ciliary region three brownish, hemispherical prominences projecting into the vitreous could be seen, which awakened the suspicion of a choroidal melanosarcoma. The anatomical examination revealed an annular detachment of the ciliary body and the anterior portion of the choroid by a clear fluid. There was no retinal detachment.

In irido-choroiditis Iwanoff|| has repeatedly found detachment of the choroid from the sclera. In general such anatomical observations are so frequent that it seems scarcely necessary to cite particular cases.

In the course of acute or chronic choroiditis exudations not unfrequently occur by which the choroid is wholly or partially detached from the sclera. It is possible that the ophthalmoscopic picture of choroidal detachment is due to a similar process; still, this involves the assumption that copious and circumscribed effu-

---

\* Ophthalmologie, 1856, B. ii. 1, pag. 427 bis 432.

† Arch. f. Ophth., B. iii. 2, pag. 430.

‡ Ibid., B. vi. 2, pag. 265.

§ Intraoculare Geschwülste, pag. 194 bis 200.

|| Arch. f. Ophth., B. xi. 1, pag. 191, und B. xv. 2, pag. 15 bis 46.



sions can take place in the choroidal stroma without any apparent inflammatory symptoms, just as is frequently the case in detachment of the retina.

Hemorrhages in the tissue of the choroid occur rather rarely. They appear as red spots, whose extent, form, and color depend principally upon the quantity of the effused blood. If, as is usual, the hemorrhages be not profuse, their ophthalmoscopic appearance will be somewhat modified by the stroma pigment scattered through them, and by the epithelial layer covering them. Sometimes they are sharply defined, sometimes they lose themselves without any distinct limits in the choroidal stroma. Specially characteristic is the fact that the retinal vessels run over them.

Wounds, bruises, or severe jars of the eye are the most frequent causes. Thus, for instance, a gunshot wound which grazes the wall of the orbit may cause copious hemorrhage in the tissue of the choroid without any external visible changes in the eye.

Aside from traumatic causes, choroidal hemorrhage occurs principally with acute choroiditis. Ophthalmoscopically, it is observed frequently with high degrees of myopia, frequently, too, in eyes previously absolutely healthy, and without any known cause.

The effect upon vision depends less upon the effusion in the choroidal stroma than upon the concomitant changes, such as retinal hemorrhages, opacities, or hemorrhages into the vitreous, etc.

The complications, too, modify the therapeutic indications.

Ruptures of the choroid are caused by external violence, such as a blow, thrust, or shot wound, which either affects the eye alone or at the same time fractures the bony walls of the orbit. The rupture almost always occurs near the optic disc, and generally in the form of a curve, with its concavity turned toward the disc. The color within the rupture is at first not a clear white, but somewhat yellow, probably because the lamina fusca remains attached to the sclerotic. Later the color generally grows brighter, while the margins of the rupture often grow dark. Near by are generally small choroidal or retinal hemorrhages, which in time disappear. There is no apparent rupture of the retina or sclera. Frequently there is at first traumatic mydriasis.

The result, as affects vision, depends upon the severity of the



injury. In many cases there is at the same time considerable blood in the anterior chamber or in the vitreous, in consequence of the contusion. In other cases there develop in the choroid inflammatory processes, which in the acute stage are accompanied by opacities of the retina and vitreous. Some of the consequences of the contusion are transitory and admit of a complete recovery of sight; generally, however, the disturbances of vision are very great, and though there may be some improvement at first, it may be but temporary, and the condition may be made still worse by persisting choroiditis or detachment of the retina, in consequence of contraction of the choroidal cicatrix.\*

The treatment of recent cases is antiphlogistic in proportion to the intensity of the symptoms. There is generally no treatment which can benefit old cases.

Tubercle of the choroid was first demonstrated anatomically by Manz.† Later, a case was reported by Busch.‡ Finally, Cohnheim§ showed that tubercle of the choroid occurs almost constantly with acute miliary tuberculosis. Shortly afterward the subject was discussed by Von Graefe and Leber from both a clinical and an anatomical stand-point.||

Generally both eyes are affected, but such is not always the case. Frequently there is only a single tubercle in the choroid, but generally there are several, and in some cases Cohnheim counted more than fifty. If only a few tubercles be present, they are always in the neighborhood of the optic disc and macula lutea; if their number be great, they are found even on the periphery of the choroid. They appear as uniform spherical nodules, sometimes scarcely visible to the naked eye, but having an average size of from 0.5 to 1 mm. They may even attain a diameter of 2.5 mm. The smaller ones are covered by unchanged choroidal epithelium, and therefore cannot be seen until after its removal.

But in the case of those having a diameter of 1 mm. or more

---

\* Saemisch, *Klin. Monatsbl.*, 1866, pag. 111.

† *Arch. f. Ophth.*, B. iv. 2, pag. 120, und B. ix. 3, pag. 133.

‡ *Virchow's Arch. f. path. Anat.*, B. xxxvi. pag. 448.

§ *Ibid.*, B. xxxix.

|| *Arch. f. Ophth.*, B. xiv. 1, pag. 183.



the pigment is always lighter, and the nodule beneath it shimmers through, all the more distinctly as the tubercle at this time loses its gray transparent appearance in consequence of a caseous metamorphosis beginning at its centre. The growth of the nodules is always forward toward the retina, so that they very soon cause slight protuberances above the surface of the fundus. The largest of these appear, therefore, as prominent elevations with non-pigmented surface.

Ophthalmoscopically, they appear as bright, generally rose-tinted spots, which shade off without sharp boundaries into the normal color of the surrounding fundus. The black pigmented border, so constant in other similar choroidal changes, is wanting, and was observed by Cohnheim in only a single case, in which the tubercle had attained the unusual size of 2.5 mm. For such cases the well-marked caseous degeneration and the distinct prominence of the nodules furnish diagnostic points. Simultaneously with tubercle of the choroid I have several times observed inflammatory changes in the neighboring parts of the retina.

Tubercle of the choroid occurs oftenest in connection with acute miliary tuberculosis, and this fact is of great importance in the diagnosis of this disease. Exceptionally, the choroid is affected in forms other than the acute miliary tuberculosis in cases where a great number of different organs are affected. In the ordinary chronic pulmonary, or pulmonary and intestinal tuberculosis, or in general where only a few organs are affected, the choroid remains free.

Choroidal tumors are all sarcomatous, and with few exceptions pigmented. They are of all degrees of consistency, from the dense fibrous forms to pap-like, almost fluid masses. As yet they have not been observed during childhood. Between the ages of 15 and 30 years they are rare, becoming frequent only at a more advanced age.

The appearances at an early period depend, in the first place, upon the situation of the tumor. If it be upon the ciliary body or the anterior portion of the choroid, it appears as a brownish reflecting prominence, projecting into the vitreous behind the lens. The possible error under these circumstances of mistaking it for a choroidal detachment is avoided by observing that the color is



different from that of the normal choroid, and in very vascular sarcomas, by the fact that an irregular vascular system can be recognized in the tumor itself. During its further development the tumor may dislodge the lens and become visible in the periphery of the anterior chamber.

If the tumor develop deep in the fundus it can seldom be seen ophthalmoscopically, for it is generally hidden by an extensive retinal detachment. Some cases, it is true, have been observed in which the tumor developed in the region of the macula lutea or in the upper or lateral portion of the choroid without any retinal detachment; or the detachment remained circumscribed, and by its peculiar appearance awakened the suspicion of its real nature; sometimes it was possible to recognize the tumor and its peculiar vascular system through the detached retina.\* But such cases are exceptions. In the great majority of cases there occurs an early detachment of the retina.

The diagnosis is generally not possible until either the growing tumor again reaches the posterior surface of the retina and becomes visible through it, or till glaucomatous symptoms appear. The tension of the eye increases, the pupil is dilated and rigid, the cornea anæsthetic, the anterior chamber shallow, the subconjunctival veins dilated, and scleral staphyloma and optic-nerve excavation developed. In many cases glaucomatous inflammation appears. At last cataract comes on, and the appearance as of glaucomatous blinding is then so decided that even in this stage the diagnosis would be impossible if the course of the disease had not been observed from the beginning.

Sooner or later the tumor grows beyond the limits of the eyeball, and, according to circumstances, in one of three different ways. Often at an early period it creeps along the optic nerve. Black pigment is infiltrated into the perineurium posterior to the lamina cribrosa. Its quantity increases, and it gradually extends backward between the nerve fibres, distending the nerve and propagating the disease into the orbit or even into the cranial cavity.

Or an actual perforation occurs, generally through the margin of the cornea, sometimes through the sclerotic. The dark mass

---

\* Becker, Arch. f. Augen- und Ohrenheilk., B. i. 2, pag. 214.



presses forward through the opening and spreads out as a black fungoid growth, inclined to hemorrhage and ulceration.

Or finally, black nodules appear on the outer surface of the sclerotic, seldom in distinct connection with the intraocular tumor, but apparently independent growths. Microscopic examination, however, generally shows that there is a progressive disease of the sclerotic elements. When these nodules have once appeared, the increase of the tumor within the orbit goes on very rapidly.

This course is only occasionally varied by the occurrence of corneal ulceration with consecutive atrophy of the eye before the ball has become completely filled with the tumor.

The presence of this form of atrophy may embarrass the diagnosis. The signs of an intraocular tumor are severe spontaneous paroxysms of pain and a peculiar form of the atrophied eye. It is not, as under ordinary circumstances, contracted in a quite uniform concentric manner, but more in a direction from before backward, as the atrophy begins at a time when the posterior portion of the ball is already filled by the tumor. In these cases, as a rule, there is generally at last a growth of the tumor into the orbit, and the atrophied eye appears, therefore, less sunken than in ordinary cases of atrophy.

As soon as the diagnosis of choroidal sarcoma is made, or when, in the case of an already blinded eye, it can be assumed as highly probable, the enucleation of the eye is indicated. If there be a morbid growth in the orbit, the method by periosteal extirpation is preferable (see page 200). It is always a matter of doubt up to how late a time the operation will be useful in prolonging the patient's life, for at any stage of its development the choroidal sarcoma may be complicated by deposits in the liver, in the nervous centres, etc. Respecting the relation of these deposits to the primary tumor, it cannot be determined upon existing data whether they actually depend upon it or are simply due to a common cause (dyscrasia).\*

Coloboma of the choroid occurs in connection with congenital coloboma iridis. It is very rare without this defect of development.

The defect is always in the lower portion of the choroid, and

---

\* Von Graefe, Arch. f. Ophth., B. xiv. 2, pag. 103.



may begin at the optic disc, or somewhat above it, and extend so far downward that its anterior limit, that turned toward the iris, cannot be seen by ophthalmoscopic examination. As a rule, however, the anterior limit is so far behind the ora serrata that it is distinctly visible. The place of the choroidal defect appears white, because here the sclera, being covered only by transparent retinal tissue and slight traces of the choroid, is exposed to the ophthalmoscopic illumination. In some cases remnants of pigmented tissue are strewn upon the white surface. More frequently there is no trace of choroidal tissue. The vessels branching upon the bright surface of the choroid, and the shadows visible upon it, prove that the surface of this portion of the sclera is irregularly undulating. The margins of the ectasia are generally characterized by a very dark pigmentation of the choroid. In other cases this pigmentation occurs only at places about the margin, or it forms a very slight line about the defect.

The optic disc may be normal, or be more or less changed. For instance, it may present irregular depressions, or an unusual shape, in consequence of a distortion of the optic-nerve sheath. If the optic disc be surrounded by the coloboma, it may be either normal and distinctly defined, or it may be irregular in shape and shade off imperceptibly into the surrounding sclera.

Not infrequently the retinal vessels spring in an irregular manner from the nerve. In cases where they reach the coloboma, and where the coloboma itself does not extend to the disc, the retinal vessels may either pass around the defect, coursing along its border, or they or their branches may pass into the defect. In many cases the parallax shows that the retina, with its vessels, is stretched like a bridge over the scleral ectasia. In other cases the retina follows all the changes of level in the coloboma. Besides the retinal vessels, there can often be seen within the defect a number of sinuous vessels belonging to the choroid, the trunks of some of them penetrating the sclera.

Coloboma of the choroid occurs both bilaterally and unilaterally, and in the latter case generally on the left side. Frequently the eye affected is somewhat smaller than normal; often there is decided microphthalmus. Central vision may be normal, or more or less affected. Eccentric vision generally shows a defect corresponding to the position of the coloboma.



## DISEASES OF THE RETINA AND OF THE OPTIC NERVE.

---

A RARE anomaly of the retina, which probably should hardly be regarded as a pathological condition, is that in which there is persistence of the medullary sheaths of the nerve fibres. The ophthalmoscopic picture in such cases is very striking.

A bright white spot is seen, generally close about the margin of the optic disc, and in rare cases extending upon it. Otherwise the retina is normal, and vision is perfect. The spot sends out radiating stripes from its periphery. A similarly arranged striation can be detected upon the surface of the spot when examined in the upright image. Sometimes this portion is slightly elevated above the general surface of the retina. This spot completely hides the choroid; showing that the changes are in the retina; while the fact that it veils or completely hides the retinal vessels at places, shows that the changes must be in the nerve-fibre layer.

As a rule, these changes occupy only a portion of the median, upper, or under margin of the optic disc, extending upon the retina about one diameter of the disc. Frequently their extent is smaller, and only seldom is it much larger, and when such is the case the white fibres, as they spread out in the periphery, avoid the macula lutea by curving about it.

This ophthalmoscopic appearance is very similar to that seen to the right and left of the optic disc in the rabbit's eye, and which there can be demonstrated to be due to the persistence of the myelin sheaths upon the fibres of the retina.

Furthermore, Virchow,\* Beckmann,† and Von Recklinghausen‡ have observed white spots in the retina, which, upon microscopic examination, proved to be caused by the myelin sheaths with which the fibres are covered at these places. Vir-

---

\* Arch. f. path. Anat., B. x. pag. 190.

† Ibid., B. xiii. pag. 97.

‡ Ibid., B. xxx. pag. 375.



chow at the same time found in these cases that the optic-nerve fibres lost their myelin sheaths in the ordinary manner at the lamina cribrosa, but that after a short interval, through which the nerve runs as a simple axis cylinder, the sheath reappears, and finally is again lost. This reappearance of the myelin sheath may occur at some distance from the optic disc; for instance, in Von Recklinghausen's case it was 4 mm. from its margin. This condition is of course more frequently observed by ophthalmoscopic than by anatomical examination.

In the case of a post-mortem examination made in the Berlin Charité Hospital of a subject who during life had presented the above described ophthalmoscopic appearance, Prof. Virchow had the kindness to examine the preparation, and demonstrated anatomically the persistence of the medullary sheaths. H. Schmidt\* also reports a case in which the ophthalmoscopic diagnosis was confirmed by post-mortem examination.

The capacity of the fibres to conduct impressions appears to be in no way affected. But the consequence of their opacity is a circumscribed defect in the visual field corresponding to the position of the white spot seen by the ophthalmoscope. It is generally continuous with Mariotte's blind spot, and, like that, is not subjectively perceived as a defect in the visual field.

In connection with this anomaly, especially when of a high degree, there is often very poor vision, which, however, according to Mauthner,† appears to depend rather upon co-existing hypermetropia with amblyopia congenita.

This anomaly occurs upon one or both sides. Most probably it is congenital.

Hyperæmia of the retina is characterized by a reddening of the intraocular extremity of the optic nerve and a dilatation and sinuosity of the retinal veins. It occurs as a collateral fluxion in connection with inflammation of other parts of the eye, or as one of the symptoms of retinitis, or as a venous obstruction of the retinal veins, caused by compression at some part of their course, or as a part of an extensive venous stagnation, as, for instance, is often seen in cyanosis congenita.

---

\* Klin. Monatsbl. f. Augenheilk., 1874, pag. 186.

† Lehrbuch der Ophthalmoscopie, pag. 266.



Hyperæmia of the retina, accordingly, is not to be regarded clinically as an independent form of disease.

## DETACHMENT OF THE RETINA.

Detachment of the retina from the choroid by an effusion of fluid between the two membranes causes two changes of great importance in the diagnosis. The detached retina is brought nearer the middle point of the eye, and it becomes wrinkled. Even in very myopic eyes the detached retina generally lies in front of the principal focus of the dioptric apparatus. It can therefore be seen very easily in the upright image. It is wrinkled because the spherically stretched membrane, when forced toward the centre of the eyeball, presents a smaller superficies.

Frequently the detached portion is so relaxed that the movements of the eye impart to it wave-like undulations. This floating of the detached retina is a very characteristic and important diagnostic symptom, but it is not always present. The condition upon which it depends is the presence both before and behind the detached retina of a thin fluid,—that is, there must be either a liquefaction or a detachment of the vitreous with a serous effusion between it and the retina.

The detached retina is recognized in the same manner as under normal conditions,—by its vessels and by the appearance of the membrane itself.

The appearance of the vessels is very characteristic. They follow all the wrinkles and folds of the detached portion; their course, therefore, is exceedingly irregular, and certain portions of the vessels which lie in the depths of the folds are invisible.

The boundary-line between the normal and the detached portion of the retina can generally be recognized by the change of direction which the retinal vessels experience in crossing it. Often the distinction in color between the two portions is very marked.

The detached retina in most cases is of a bright-gray color, interspersed at places with a brownish-green or yellow tinge, and its vessels seen against the lighter colored background appear darker than normal.

This difference in color depends on several causes. The tension of the detached portion is diminished, and this diminishes its transparency. It seems more opaque than normal, for the reason



that we do not view it in a direction perpendicular to its surface, but, on account of its detachment and foldings, always under an angle. Still further, there are those secondary inflammatory changes which generally develop in consequence of detachment. The layer of the rods and cones is the first to suffer; its elements swell and break down under the action of the subretinal fluid. Somewhat later, inflammatory processes begin, especially in the outer layers. Proliferation of the connective-tissue elements is set up, and finally, after total detachment has existed for some time, the retina loses all its specific elements and is transformed into a funnel-shaped fibrous membrane, its posterior end attached at the optic nerve and its anterior end at the ora serrata, enclosing the residuum of the vitreous, which has likewise undergone a fibrous degeneration. At this advanced stage the opacity of the lens and the irido-choroiditis render the ophthalmoscopic examination no longer possible.

The character of the fluid behind the detached retina has also an influence upon its color. It has generally a different refractive power, another color, and less transparency than the vitreous. It is generally very coagulable by heat, and contains some blood-corpuscles and nucleated cells of various sizes; cholesterin crystals are also sometimes found in it. It may be the presence of these crystals which, in rare cases, causes the detached retina to appear as if strewed with a great number of small, bright specks, whose reflexes change according to the position of the mirror.

The retinal detachment is generally betrayed by the absence of the normal red color of the pupil, when illuminated by the ophthalmoscope.

Recent detachments, and sometimes older ones, are more difficult to recognize, for the reason that the retina and the fluid behind it remain unusually transparent. Still, in such cases the diagnosis may be made certain by the irregularity in the course of the vessels, and by the reflex from the retina itself. This reflex is most distinct in the folds of the membrane, but can also be plainly seen in the examination in the upright image, if the retina be brightly illuminated and slight movements of the mirror be made, by which the inverted image of the flame is caused to pass over the detachment. One may thus satisfy himself that it lies far in front of the choroid.



Frequently the retina is detached only in the form of a few small folds, which may be recognized by their brighter color, but more surely by the behavior of the retinal vessels running over them.

In the great majority of cases the detachment is at the lower part of the retina, for the fluid, even if the detachment began above, naturally sinks downward. The upper part, originally detached, may under such circumstances sink back into its normal position, and even resume its function.

In recent, extensive detachments the retina is frequently seen to be torn. The rent presents sharp edges, somewhat rolled away from each other, so that the choroid can be seen between them with great distinctness. In old detachments these rents are less frequent, which may be explained by the sinking of the subretinal fluid. At least, I have satisfied myself that rents in the upper portion of the retina, which at first were very distinct, could no longer be seen after the lower part had become detached by the sinking of the fluid, and the upper part had settled back into its normal position.

The disturbances of vision are due to the fact that the abnormal position and the folds in the retina prevent the formation of any distinct images upon it. The subjective sensation caused by this condition is that of a cloud in the field of vision. In recent cases the detached retina is often still sensitive to light. At the margin of the visual field the patient can often count fingers. This is sometimes the case even in old detachments, at least by bright illumination. When the above described inflammatory changes appear, sensitiveness to light is generally entirely lost.

Central vision, too, appears to suffer from the very first, perhaps for the reason that by the detachment of a portion of the retina the remaining part loses its normal tension.

As the margin of the detachment approaches the macula lutea, metamorphopsia occurs, so that objects appear slanting and crooked. Even a detached macula lutea, if it be not wrinkled, may retain some degree of vision, so that large letters (No. 12 to 14 Jaeger) can be read. When the perception of light is lost at this place, the result is eccentric fixation, a neighboring portion of the retina being used for this purpose, and generally the axis of vision deviates upward.



Opacity of the vitreous very often exists at the same time with detachment of the retina.

The disturbances of vision generally come on suddenly, and increase rapidly in degree. In recent cases the time of the beginning of the trouble can generally be accurately determined, and still it is seldom possible to trace it back to any particular cause. The patients most frequently refer it to colds or to straining the eyes. I have repeatedly been able to satisfy myself that there may for years be small retinal detachments in the peripheral part of the fundus without the patient being aware of their existence.

Retinal detachments may occur in eyes hitherto sound, as well as in those which have been diseased. Retinitis hæmorrhagica, syphilitica, or that of Bright's disease seldom causes it. Choroiditis is a more frequent cause. It almost always occurs with acute irido-choroiditis, though it may not be a prominent symptom in these cases. Chronic choroiditis generally leads either to abnormal adhesions between the retina and the choroid or to detachment of the retina. In rare cases both these processes take place at different portions of the fundus.

Detachment of the retina most frequently occurs in connection with a high degree of myopia. This is true in so great a majority of cases that there must be some causative relation between the two conditions. It has been usual to explain this connection on purely mechanical grounds. It is said that during the progressive distention of the sclera the choroid yields with it. But the retina being only loosely attached to the choroid, shows a tendency to become detached rather than to suffer a distention corresponding with that of the other membranes. It is plain that this view is based upon an error. It could apply only to a distention of the sclera by a force acting from without, since it is impossible for a pressure acting first upon the inner surface of the retina to cause its detachment. Perhaps at present no better explanation can be given than that myopic eyes in general are especially predisposed to intraocular diseases.

Opacities of the vitreous precede, accompany, or follow detachment of the retina. There must necessarily be a disturbance in the nutrition of the vitreous, for its volume is reduced with the same rapidity and in the same proportion as the effusion accumulates behind the retina. I have been able to confirm by anatom-



ical\* examination the assertion made by H. Müller,† that in a class of cases detachment of the retina is caused by shrinking of the vitreous; but such cases appear to be rather rare exceptions. Clinical experience forces us to this conclusion. The freely movable opacities of the vitreous, which are so frequent, when they shrink, of course cannot cause detachment of the retina. Only such stringy opacities, fastened at both ends, as those existing in a case which I reported, can exercise traction on the retina, while contraction of the vitreous as a whole appears rather to cause an effusion between it and the retina.

Von Graefe has called attention to the fact that the contraction following perforating wounds of the sclera may lead to detachment of the retina. Saemisch refers choroidal ruptures to the same cause.

In many cases detachment of the retina occurs as the immediate consequence of a contusion of the eye. Often in such cases a hemorrhage may have taken place between the retina and the choroid. In other cases, even very shortly after the injury, the fluid shows no bloody color.

Among the rarer causes are inflammation of the orbital tissue,‡ intraocular cysticercus, and choroidal and retinal tumors.

According to Iwanoff,§ detachment of the retina may be caused by that peculiar condition which he describes as œdema of the retina. A peculiar change is generally found in the peripheral portion of the retina in the eyes of old persons, visible to the naked eye upon anatomical examination. In a meridional section, at a distance of from 0.5 to 2.0 mm. from the ora serrata, the thickness of the retina suddenly increases, and again as suddenly decreases at the ora serrata. The corresponding zone of the retina, seen from the surface, appears traversed by zigzag stripes. These bright stripes are conduits filled with a homogeneous, transparent, probably fluid substance; they run between fibrous bundles placed at right angles to the surface of the retina. The fibres constituting these bundles radiate at both extremities in the plane of

---

\* Arch. f. Ophth., B. ix. 1, pag. 199.

† Ibid., B. iv. 1, pag. 372.

‡ Von Graefe, Klin. Monatsbl., 1863, pag. 49; Berlin, *ibid.*, 1866, pag. 77; Becker und Rydel, Wiener med. Wochenschrift, 1866, No. 65.

§ Arch. f. Ophth., B. xv. 2, pag. 88.



the surface of the retina. Upon a section made perpendicularly through the retina these conduits present a series of openings, either circular or elliptical in shape, their longest diameter being at right angles to the surfaces of the retina. The average diameter of these openings is 0.13 mm. If the section be thick enough, a second series of bundles and openings can be seen below the first. The bundles contain blood-vessels, and are composed of nucleated fibres. Enclosed in the openings nearest the ora serrata are a greater or less number of cystoid corpuscles.\*

According to Iwanoff, this condition obtains not exclusively in old age, but also as an undoubted pathological process in young persons, and that, too, quite frequently. The changes may extend from the ora serrata 7 or 8 mm. toward the equator, or may occur isolated in any part of the retina.

The cysts may attain such a size that they can be seen with the naked eye. Merkel† states that their inner walls consist of a membrane lined with cells. The height of the cysts is, as a rule, from 2 to 6 mm., their diameter from 4 to 8 mm. In one case Iwanoff saw a cyst which occupied one-half the retina and filled two-thirds of the eye. In fact, as I have already stated,‡ the ophthalmoscopic examination not infrequently reveals circumscribed detachments of the retina protruding like a tense cyst into the vitreous space.

When detachment of the retina has once begun, its course is generally unfavorable, and it may be regarded as very fortunate if only the *status quo* be preserved. At a later stage iritis is very likely to come on, and under these circumstances is particularly liable to be associated with choroiditis. With this condition of affairs the lens always becomes opaque; but, on the other hand, the process may be reversed; the opacity of the lens may develop first, and its swelling and pressure upon the iris be the exciting cause for an acute iritis.

In reference to prognosis, it is to be remembered that the conditions which favor a detachment of the retina, such, for instance,

\* Comp. Henle, Anatomie, B. ii. pag. 670.

† Ueber die macula lutea des Menschen und die ora serrata einiger Säugthiere, Leipzig, 1870.

‡ Vorlesungen über den Gebrauch des Augenspiegels, Berlin, 1863, pag. 121.



as a high degree of myopia, frequently exist simultaneously in both eyes, and that consequently there is great danger of complete blindness. Bilateral detachment of the retina seldom occurs unless with myopia; still, it has been observed.

Spontaneous recovery with the reposition and resumption of function on the part of the detached retina sometimes occurs, but only as a rare exception. The usual treatment by cathartics has proved to be of but little benefit.

Von Graefe and Bowman undertook to introduce the practice of incising the detached retina. Von Graefe used two broad needles and Bowman two fine needles, in the same way as for the discision of secondary cataract. In some few cases the operation has proved useful, but generally only a slight and temporary improvement is obtained. Bad consequences, too, have been seen to follow the operation. Upon the whole, the practice cannot be recommended; for the cases of spontaneous rupture of the retina, in which there is a larger perforation than can be obtained by an operation, are seldom followed by the reposition of the membrane. Moreover, no statistics have ever been presented to prove the oft-repeated assertion, that those cases in which spontaneous rupture of the retina occurs, run a more favorable course than others.

#### PIGMENTATION OF THE RETINA.

The subjective symptoms of the pigment degeneration of the retina are so characteristic that in most cases the ophthalmoscopic appearances can be predicted from them.

Hemeralopia is generally the first symptom of the disease. During daylight vision is sufficiently good, but toward evening, and at night, it is so poor that even large objects can no longer be recognized, and the patients generally cannot move about alone.

The investigations made by Maes,\* under Donders' supervision, have demonstrated that the hemeralopia is simply due to a condition which he very appropriately described as *torpor retinæ*. The retina reacts only under the stimulus of a strong light, and very slightly, or not at all, under a weak illumination. The symptoms of hemeralopia may be produced at any time by bring-

---

\* Over *torpor retinæ*, Utrecht, 1861.



ing the patient into a closed room where the artificial illumination can be regulated at will. The influence of the intensity of the light, upon both direct and indirect vision, can thus be easily shown. It is generally most evident as affecting indirect vision. The field of vision is contracted, its boundary-line being very irregularly traced around the fixation-point. As a rule, central vision is also affected, and in cases in which, by full daylight, vision is still nearly normal, it diminishes with disproportionate rapidity as the illumination grows fainter.

Gradually, as the process goes on, the visual field contracts, so that defects appear on its periphery even by bright illumination. Central vision also soon begins to suffer, and absolute blindness comes on.

Ophthalmoscopic examination reveals a pigmentation of the retina, beginning at the periphery, and extending inward toward the macula lutea. The pigment is of a deep-black color, in the form of irregular, radiating specks, much resembling highly magnified bone-corpuscles. The location of the pigment in the retina is made evident by an unmistakable relation which it presents to the retinal vessels, whose walls, at places, are accompanied by pigment stripes.

At first the pigmentation is very sparse, and to be found only by a careful examination of the periphery of the fundus. Later, the deposit of pigment goes on more rapidly, and the net-work of anastomosing, dark, irregular figures surrounds the macula lutea in a steadily contracting circle.

At an early period of the disease there begins a remarkable change in the retinal vessels. Their calibre is greatly reduced by a peculiar hyaline thickening of their walls, so that the red column of blood in them, especially in the arteries, appears very thin.

At a later stage the optic disc and the surrounding retina present a light-gray opacity. Perhaps this is due rather to a change in the vitreous; at least I have several times found in cases of pigmentation of the retina a rich development of cells in the peripheral part of the vitreous.\* These cells represent the beginning of membranous and fibrous growths.

---

\* Arch. f. Ophth., B. v. 1, pag. 103.



The choroid may remain unaltered, or slight changes may be visible in it. Frequently in children a distinct punctation of the equatorial part of the choroid is seen to precede by years the deposition of pigment along the retinal vessels. In other cases, on the contrary, I have observed in connection with hemeralopia in children, decided contraction of the large retinal arteries, but only very slight pigment deposits along some of the peripheral retinal vessels, and no perceptible choroidal changes.

In old cases, in addition to the pigmentation of the retina, bright spots of various sizes are sometimes seen. As the choroidal stroma is very distinct within their limits, the impression which they convey is that the epithelial layer has lost its pigment.

Those cases, however, in which the choroidal changes are very apparent, even though the participation of the retina is evident from the pigmentation of its vessels, ought rather to be referred to choroiditis.

Frequently in the later stages of the disease very peculiar forms of opacities in the lens and vitreous develop. As regards the lens, there is generally a punctated posterior polar cataract, with occasionally a few radiating opacities. The somewhat rarer opacities of the vitreous consist mostly of small, gray, rounded, movable flakes occasionally provided with thread-like processes.

It has been shown that pigmentation of the retina very often occurs in connection with diseases whose history is very different from that of the typical pigment degeneration of the retina. Let us first consider how pigmentation of the retina in general can take place. Choroiditis is a frequent cause by which the retina becomes adherent to the choroid and saturated and swollen by the fluid exudates. The immediate effect is the destruction of the layer of rods and cones within the limits of the adhesions. The other nervous elements gradually break down, while the connective tissue experiences a hypertrophic growth.

The radial fibres are thickened and lengthened and their outer halves frequently curved upon themselves, thus forming an intricate net-work. When this degeneration of the retina has taken place, the pigment from the choroid can very easily penetrate it. The proliferating choroidal epithelium penetrates the pervious substance of the atrophied retina, and it will be accordingly found filled with round black cells. Or the choroidal epithelium breaks



down, its pigment molecules become free, and are carried into the retina by the inflammatory exudations. This process may be described as a pigment infiltration of the retina. The pigment may also be deposited in the exudate between the choroid and the retina.

H. Müller\* has called attention to the mechanical influence which the above mentioned growth of the radial fibres may exercise upon the choroidal epithelium. The epithelium is displaced and the furrows in the granular layer become crowded together.

The fact being established that pigment does penetrate the retina, the questions arise: does all the pigment found in the retina come from sources external to itself? and, how does the pigmentation of the retinal vessels occur? The two questions are intimately connected. H. Müller has repeatedly and explicitly answered the first in the affirmative, and seems disposed to regard the coloring matter of the blood as the only source, aside from the choroidal pigment, from which the pigment found in the retina can come. From this point of view the pigmentation of the retinal vessels must be regarded rather as an accident, due, perhaps, to the fact that the pigment adheres to the walls of the vessels more easily than to other parts. In fact, in most of the cases examined anatomically the pigment was found deposited in all the layers of the retina and not limited to the vessels.

But, in view of the ophthalmoscopic appearances, the theory that all the pigment found in the retina originally belonged to the choroid is not tenable. If that were true, the choroidal changes would be greater than is really the case. Moreover, it would be difficult to understand why the above described contraction of the retinal vessels always precedes the pigment degeneration of the retina.

Anatomical examination also shows that together with the pigmentation of the vessels there is always a very peculiar change in their walls. They undergo a hyaline thickening, which causes a contraction of their calibre and finally an obliteration of their finer branches. The same effect may be caused by a hypertrophy of the connective tissue of the vessels. They become reduced to mere fibrous strings, and disappear in the tissue of the retina.

On the one hand, it is shown that choroiditis may cause pig-

---

\* Würzburger med. Zeitschrift, B. iii. pag. 252.



mentation of the retina; on the other hand, however, the reports of all the anatomical examinations of cases which during life had presented the ophthalmoscopic and clinical symptoms of retinitis pigmentosa, agree in this, that there existed greater or less changes in the choroidal epithelium. It appears, therefore, that the answer respecting the source of the pigment in the retina is that in some way it must come from the pigment epithelium of the uvea. If the growing choroidal epithelium has once penetrated the retina, it is likely that the growth may continue within that membrane until it contains more pigment than has been lost by the choroidal epithelium.

Certain conditions which I have previously described,\* in which it was evident that the pigmentation of the retinal vessels could not have proceeded from the choroid, are probably to be explained by assuming some portion of the uvea other than the choroid as the source of the pigment. The case, as is true of most anatomical examinations, was not one of typical torpor retinæ with pigmentation of the retina. There existed iritis, atrophy of the nervous elements, excavation of the optic nerve, and besides all this there were in the region of the ciliary body peculiar changes which I did not then particularly describe, for the reason that I was in doubt as to their nature. But now, after repeated examination of the preparation which I still possess, I think these changes in the ciliary body should be particularly described, as it is possible that just here was the source from which emanated the pigment found in the retinal vessels.

There remained upon the vitreous, after it was drawn away from the corpus ciliare, a pigmentation which, magnified about 100 times, showed a net-work having long meshes, and appeared as if made up of delicate pigmented vessels, whose larger trunks were directed toward the ora serrata. In fact, in this pigmented net-work some fine capillary, non-pigmented vessels could be seen.

It appeared to me as if a new vascular net-work connected with the retina had developed in the pars ciliaris. If this interpretation of the condition be the true one, the pigment epithelium of the ciliary body must have been the source of the pigment found on the retinal vessels.

---

\* Arch. f. Ophth., B. ix. 1, pag. 205.



The deposition of pigment along the vessels does not always appear to be continuously progressive, but the deposit takes place at intervals with free spaces between. This peculiar disposition of the pigment is occasionally observed during ophthalmoscopic examination of the vessels upon the surface of the optic disc. It has also been demonstrated anatomically, and first by Donders.\*

Since as yet but few eyes in which retinitis pigmentosa has been recognized during life have been examined anatomically, it is perhaps well to describe here briefly the results of such examinations.

In a case which had long been under observation, Donders† found the retina adherent to the choroid at three or four places where it was most pigmented, so that it was difficult to separate the two. It appeared as if there were in these places an exudate filled with pigment, which tore apart when the two membranes were separated, so that one part remained on the retina and the other on the choroid. In these places the pigment which permeated the retina was continuous with that in the choroid. But over a surface of more than a square centimetre no such connection could be found. It was incredible that all the pigment could have infiltrated the retina from these adherent spots, for in the immediate neighborhood of these exudations the choroidal pigment epithelium was quite uniform and normal.

The second case was examined by Leber‡ ophthalmoscopically shortly before the death of the patient. The subsequent anatomical appearances were as follows: there were atrophy of the nervous elements, hyperplasia of the connective tissue, thickening and sclerosis of the walls of the vessels, reticulated pigmentation of all the layers following principally the vessels, great changes in the pigment epithelium, numerous excrescences of the hyaline membrane, and small circumscribed deposits of fatty, degenerated exudate between the choroid and the retina.

Lastly, Landolt§ reports two cases in which repeated previous ophthalmoscopic examination had revealed the typical appearances.

---

\* Arch. f. Ophth., B. iii. 1, pag. 141.

† Maes, Over torpor retinæ, Zweiter Jahresbericht der Utrechter Augenklinik, 1861, pag. 263.

‡ Arch. f. Ophth., B. xv. 3.

§ Ibid., B. xviii. 1, pag. 325.



The principal anatomical changes were an almost complete absence of the nervous elements, including the rods and cones, and hyperplasia of both the general connective tissue and that of the vessels, which accordingly were much thickened, their calibre reduced, and their finest branches completely obliterated. In the walls were great quantities of pigment, which probably had partly wandered and partly been formed there, part contained in cells and part free. The pigment of the epithelial layer had, for the most part, wandered away from it, and was collected at places in the retina in the typical manner, as determined by the course of the vessels.

The anatomical conditions, considered in connection with the functional disturbances and the course of the disease, show the correctness of Donders'\* early opinion, that the pigmentation of the retina is a secondary matter, and not the essential element of the process. Donders arrived at this conclusion from the circumstance that it is sometimes possible to demonstrate a loss of perception beyond the limits of the pigmented portion of the retina in the direction of the macula lutea. His method of doing this was a very ingenious one, and consisted in throwing with the ophthalmoscope a very small image of a flame upon the various parts of the retina, and directing the patient to tell at what places he could see it.

Transmission from parents is an important element in the etiology of the disease. But several children in the same family may suffer from it without the parents having been so affected. Under these circumstances, deafness frequently exists as a complication.

The disease appears to be more frequent with deaf-mutes and idiots than with any other class of persons. Frequently other anomalies of development co-exist, such, for instance, as supernumerary fingers and toes.† Liebreich has called attention to the fact that in many cases the parents were blood relations.‡ More comprehensive statistics with reference to the matter of consanguinity are certainly desirable.

The disease frequently occurs congenitally. Children are born

---

\* Arch. f. Ophth., B. iii. 1, pag. 148.

† Höring, Klin. Monatsbl., 1864, pag. 233, und 1865, pag. 236; Stör, ibid., 1865, pag. 23.

‡ Deutsche Klinik, 1861, No. 6.



with pigmented retinas, and at the same time frequently with eyes that are too small, and either absolutely blind or with only a feeble perception of light. Under such circumstances, nystagmus generally develops.

Hemeralopia generally dates from childhood or about the time of puberty. Both eyes are affected, almost without exception.\*

The course of the disease is exceedingly slow. From 20 to 40 years may intervene between the appearance of hemeralopia and eventual blindness. It is not certain whether all cases go on to complete blindness or remain stationary at some stage of their development.

As supplemental to the above description of typical pigmentation of the retina, it should be mentioned that cases occur which agree with it in many points, but vary from it in other essential respects.

In the first place, hemeralopia may occur under various conditions without pigmentation of the retina. Aside from those cases in which hemeralopia is observed as a symptom of some acute pathological process in persons hitherto healthy, and which represent a peculiar form not belonging in this place, we must mention, first, those rather rare cases in which congenital amblyopia exists without any ophthalmoscopic changes. By good illumination central vision may be perfect or slightly defective, while by a weaker illumination the torpor retinæ is manifested by a very considerable diminution of central vision, and generally also by a contraction of the visual field. Exceptionally, the torpor is greater for central than for slightly eccentric vision. This condition appears generally to remain stationary, and the prognosis is better than when pigmentation exists. The relationship between this form and that accompanied by pigmentation is shown by the fact that, among several children of the same parents, some will have the one form of hemeralopia and some the other.

There occur rare cases in which hemeralopia, due to torpor retinæ, with defective eccentric vision, or contraction of the visual

---

\* In a case described by Pedraglia (Klin. Monatsbl., 1865, pag. 114), there was complete choroidal atrophy at several places, and for this reason it should be regarded as one of choroiditis with pigmentation of the retina. In a case observed by Donders (E. Baumeister, Arch. f. Ophth., B. xix. 2, pag. 261), there was at least a trace of pigment development upon the other healthy eye.



field, develops at a later period of life, without any traces of pigmentation of the retina or any other apparent changes, such as contraction of the arteries and gray discoloration of the optic nerve. In similar cases Von Graefe observed a development of pigment in the retina after the lapse of several years.

As a result of syphilitic retinitis I have observed marked torpor retinæ, in connection with diffuse opacities of the vitreous, a whitish discoloration of the optic disc, and slight changes in the periphery of the choroid (white punctiform, but never black spots), but without a trace of pigmentation in the retina. Förster's\* observations, however, indicate that in these cases pigmentation of the retina may occur at a later period of the disease.

But even with evident pigmentation of the retina some cases deviate essentially from the usual type of the disease. This is true of the cases described by Von Graefe,† in which there existed an annular defect in the visual field, and beyond the peripheral margin of this ring eccentric vision was still retained. The pigmented portion of the retina had lost its power of perception, but the conducting function of the nerve fibres running to the periphery was retained. This condition can be explained on the assumption that the pathological process first destroys the external perceptive retinal layers.

In other cases of unusual forms of retinitis pigmentosa, amblyopia may be caused at an early period of the disease by irregular, roundish, black masses of pigment which occupy the position of the macula lutea.

#### HEMORRHAGES IN THE RETINA.

Hemorrhages in the retina are frequently seen ophthalmoscopically, for they occur both as an independent disease, and accompanying various inflammatory processes.

The hemorrhages are most frequent in that part of the retina lying posterior to the equator. Frequently they are numerous, large, and crowded together, and in such cases the macula lutea is seldom spared. It may, however, happen that the entire hemor-

---

\* Arch. f. Ophth., B. xx. 1, pag. 33, und H. Magnus, Ophthalmoscopischer Atlas, Taf. xiii. Fig. 1, pag. 76.

† Arch. f. Ophth., B. iv. 2, pag. 250.



rhage consists of only some few punctiform extravasations, which, however, unluckily occupy exactly the position of the macula lutea. The form of the extravasations varies with the place in which they occur. Near the optic disc, where the nerve-fibre layer is relatively thick, they assume an elongated shape, radiating in the direction of the fibres. They spread more in the middle layers of the retina, and for that reason appear as circular patches. A rupture of the hemorrhage may occur on either surface of the retina. If it happen on the outer surface, a layer of blood spreads out between the retina and the choroid. If the rupture be through the internal limiting membrane, the effusion of blood is into the vitreous body.

Exceptionally it happens, and principally in the neighborhood of the macula lutea, that the blood spreads out between the retina and the vitreous. In such cases the large retinal vessels are seen to disappear behind the sharply defined margin of the extravasation which covers them.

The color of the retinal hemorrhages appears to be modified to some degree by that of the fundus. Against the lighter background of a weakly pigmented choroid the blood-patches appear of a brighter red, while against a darker choroid they are likewise darker.

Retinal hemorrhages are always very slowly absorbed, requiring from 4 to 6 weeks, even under the most favorable conditions, as, for instance, when they have occurred after an iridectomy in glaucoma. More extensive hemorrhages may remain from 6 to 8 months, or even longer. As a rule, the blood-patches grow gradually paler, contract, or break up into several parts.

The extravasations somewhere between the third and the sixth week frequently show a remarkable alteration, becoming changed to glistening white patches. The anatomical process by which this is brought about is not well understood. It may be due to a varicose hypertrophy of the nerve fibres, or to fatty degeneration of the broken-down nerve elements, or to a metamorphosis of the effused blood-corpuscles. Occasionally these same changes are observed to take place in the optic nerve itself.

It is very seldom that dark, pigmented spots remain after retinal hemorrhages. In the course of time they generally disappear without leaving any trace, but exceptionally choroidal



changes appear as the hemorrhages are absorbed. These changes may be caused by the rupture of small hemorrhages through the external limiting membrane and the effusion of a small quantity of blood upon the choroidal epithelium. It seems likewise probable that retinal hemorrhages may cause inflammatory processes in the external layers, followed by hypertrophy of the radial fibres, and subsequent choroidal changes.

The disturbances of vision depend, for the most part, upon the fact that the rays of light are absorbed by the effusion before they reach the sensitive layer. The destruction of tissue caused by the hemorrhages is still more important, and it almost of necessity takes place when such an accident occurs in so delicate a membrane as the retina. Less damage seems to be done by hemorrhages occurring near the optic nerve, where the blood can spread out in a direction parallel to the nerve fibres. In the deeper layers of the retina, however, a hemorrhage can scarcely occur without tearing the delicate nerve fibres which connect the ganglion cells with the external layers.

For every hemorrhage there is therefore a loss of eccentric vision, or a defect in the visual field, which, if in the region of the macula lutea, is very annoying. If the hemorrhages be in the periphery, they can be discovered only by careful examination, and must be very extensive to cause any annoyance. A slight hemorrhage, if it occur at the macula lutea, may therefore interfere greatly with vision, while if that part be spared, very extensive hemorrhages in the equatorial part may cause no great annoyances. But it is unfortunate that retinal hemorrhages are most frequent just in the region of the macula lutea.

Diseases of the optic nerve frequently develop in consequence of numerous and extensive hemorrhages. A remarkable sinuosity of the small vessels visible upon the optic disc often remains, with signs of an atrophic degeneration in the nerve, such as a whitish color, and slight excavation. This may happen without vision growing any poorer. If numerous hemorrhages have broken up a great number of the delicate fibres of the retina, a secondary atrophy may extend back to the optic nerve without causing any new symptoms of loss of vision.

In another class of cases, a glaucomatous condition develops after extensive retinal hemorrhages. The eyeball becomes hard,



and there is excavation of the optic nerve. The course of the disease may be either with or without severe pains.

Retinal hemorrhages, as an independent disease, generally do not occur till late in life. They are most frequent after the fiftieth year. They may occur at any time of life as a symptom of retinitis, or from traumatic causes. Diseases of the heart or vascular system, such, for instance, as hypertrophy of the left ventricle or rigidity of the arteries, may cause them. In many cases congestion of the head is the exciting cause. Atheromatous degeneration of the retinal arteries has been described and represented by Wedl.\* Manz† also found, in a case of hemorrhage in the retina, a sclerosis and atheromatous degeneration of its arteries. It is remarkable that the ophthalmoscopic appearances give no hint for the diagnosis of this probably not uncommon condition. Exceptionally, retinal hemorrhages occur as one of the symptoms in purpura hæmorrhagica. It should be mentioned finally that they frequently occur after iridectomy in inflammatory glaucoma. These hemorrhages, however, seldom interfere with direct vision.

The prognosis depends upon the degree and the cause of the disturbances of vision.

Peripheral hemorrhages, which leave the macula lutea intact, cause slight loss of vision, and admit of complete recovery. If the macula lutea be actually involved, no great improvement can be expected, even after the resorption of the effused blood. Those rare effusions, however, which spread out in front of the macula lutea, between it and the vitreous body, interfere greatly with vision, but admit of complete recovery.

It is to be remembered that retinal hemorrhages not infrequently recur.

The prognosis is unfavorable in those cases in which glaucomatous symptoms develop. Vision is generally already greatly damaged by the hemorrhages, and the secondary glaucoma is usually of a malignant type, which is not benefited by iridectomy.

Rest and derivative treatment are the principal indications. All straining of the eyes, all violent bodily exertion, everything which

---

\* Atlas der path. Anat. des Auges, Retina und Opticus, Taf. i. Fig. 5.

† Bericht der naturforschenden Gesellschaft zu Freiburg, 1866.



accelerates the circulation or causes congestion of the head, must be avoided.

The usual means employed to assist the resorption of the effusions are the elixir acid. Halleri,\* local bleeding from the temple, cathartics, etc.

The proposition to diminish the blood pressure by digitalis, or to excite a contraction of the small vessels by ergot, cannot be regarded as of practical value.

#### RETINITIS.

The diagnosis of retinitis can be made only with the ophthalmoscope. The subjective symptoms are not so characteristic that the diagnosis can be made from them. There are no external visible changes.

The general ophthalmoscopic signs of retinitis are clouding of the retina and hyperæmia of its vessels. The clouding is generally most intense at the intraocular extremity of the optic nerve, and hides, therefore, the boundary-line of its place of entrance. The inner optic-nerve sheath, the dark choroidal ring, and the white scleral stripe which is often visible between them, lie behind the retina, and are therefore hidden when it becomes opaque. If this clouding be limited principally to the inner layers, fine radiating striæ may often be seen about the optic nerve.

The hyperæmia is likewise greatest at the intraocular extremity of the optic nerve. The numerous fine vessels which in the normal condition give a rosy tint to the optic disc, cause, when fully distended, an intense redness of the spot; but the hyperæmia is most noticeable in the large vessels of the retina, especially its veins. Since the vessels are more distensible in the longitudinal than in the transverse direction, they become not only dilated but also elongated. Ophthalmoscopically, therefore, they appear thicker, and at the same time exceedingly sinuous, their curves being both in the plane of the retina and perpendicular to it. The deeper-lying ones, when there is at the same time a dense clouding of the retinal substance, are veiled by it or absolutely hidden, so that the vessels appear as if interrupted, while the

---

\* This preparation consists of 1 part sulphuric acid and 3 parts spirits of wine. Dose, 5 to 20 drops.—*Translator.*



superficial curves, which are covered by very little retinal substance, are sharply defined and intensely red.

These sinuosities may also occur while the retina is absolutely transparent, in which case they indicate œdema of the retina.

The arteries are generally not dilated; indeed, they are often smaller than in the normal condition, which may be due to the fact that the swelling and hyperæmia of the tissues extend into the intraocular end of the optic nerve as far as the lamina cribrosa. If a swelling of the tissues occur at this point, surrounded as it is by the unyielding scleral ring, a compression of the central vessels may be caused, the immediate consequence of which will be both anæmia of the arteries and hyperæmia of the veins.

Venous hyperæmia and cloudy swelling are the essential characteristics of retinitis, but the ophthalmoscopic picture is often varied by a series of other changes.

Hemorrhages are here to be mentioned as a frequent symptom in retinitis, and yet in many cases they are absolutely wanting.

Next should be mentioned certain white spots, which sometimes occur in the form of dots, sometimes have nearly the diameter of the optic disc, or, by the coalescence of several such, may form large irregular figures. These changes often present a very peculiar appearance in the region of the macula lutea.

Fine white points are there often arranged in peculiar stellate groups, appearing as if placed upon lines radiating from the fovea centralis. More rarely there are broad bright stripes, which converge toward the same point.

Probably this singular grouping is due to the peculiar arrangement of the radiating fibres, which in the macula lutea do not run perpendicularly through the thickness of the retina, but in such a manner that upon their way from the inner to the outer layers they all converge toward the centre of the macula lutea. Upon a flat section of the macula lutea this radiating arrangement of the external fibrous layer may be distinctly seen.\*

This stellate punctation is most frequently seen in retinitis albuminurica, but frequently also in other forms of retinitis not dependent upon albuminuria.

---

\* Fr. Merkel, Ueber die macula lutea des Menschen, Leipzig, 1870, Taf. i. Fig. 11.



Quite rarely there occur very distinct cloudings, radiating in the direction of the nerve fibres, and probably due to changes occurring at the inner extremities of these fibres.

The observations which have been made in this matter have been mostly in connection with retinitis due to albuminuria; still, two cases described by E. v. Jaeger\* and Mauthner† as "retinitis with greenish stripes" show that ophthalmoscopic changes dependent upon morbid processes in the extremities of the radiating fibres may occur without this complication.

The retinal vessels, especially the arteries, in many cases of retinitis, and most frequently in the albuminuric form, appear to be accompanied by bright white stripes close to and on both sides of the red blood-vessels, causing them to appear smaller and less distinct. Evidently this appearance is due to a thickening of the adventitial coat of the vessels.

The disturbances of vision in retinitis vary greatly, and often stand in no evident relation to the ophthalmoscopic appearances. Two cases presenting the appearance of very similar changes may be accompanied, the one with great diminution of vision, the other with but very little; so, too, in one case the visual field remains free, in another it shows a greater or less defect, without its being possible in all cases to find ophthalmoscopically an explanation for this behavior. We can only conclude that very striking ophthalmoscopic changes may occur in the retina without essentially affecting the nervous elements, while, inversely, considerable disturbances of the function of the nerves may be induced by changes not to be seen with the ophthalmoscope.

The complaints of the patients refer mostly to indistinctness of vision. Often, but not always, there is photophobia, so that dazzling is caused by full daylight.

Micropsia is a very remarkable symptom, which not infrequently develops in the later stages of retinitis. Von Graefe‡ observed this phenomenon first in syphilitic retinitis, but it also occurs in other forms. The micropsia often varies in degree on different portions of the retina, and is therefore connected with

---

\* Ophthalmoscopischer Handatlas, Taf. xv. Fig. 71.

† Lehrbuch der Ophthalmoscopie, pag. 361.

‡ Arch. f. Ophth., B. xii. 2, pag. 215.



metamorphopsia, so that objects appear not only diminished, but at the same time distorted, slanting, and crooked.

The degree of the micropsia may be easily determined by provoking double images of Snellen's test letters, standing one above the other, by means of a prism refracting vertically. In some cases I have been able in this way to demonstrate a diminution of the micropsia simultaneously with a gradual improvement of vision.

Since we cannot assume as an explanation for this form of micropsia either an actual diminution of the retinal images or a false estimation of their size, nothing remains but to refer the phenomenon to the loss of a certain proportion of the sensitive elements in the macula lutea.

Retinitis occurs most frequently as the consequence of some constitutional disease. The ophthalmoscope has shown that Bright's disease and syphilis are the most frequent causes; leucæmia should also be mentioned. Anatomical examinations\* have likewise shown it to be due to septic processes in the soft parts, to gangrenous bronchitis, purulent pericarditis, pleuritis, or peritonitis, and to senile gangrene. The anatomical changes in retinitis septica consist in hemorrhages, and small white spots formed by thickened nerve fibres and fatty degenerated connective-tissue corpuscles.

For the most part, the etiology of retinitis is distinctly indicated by the form of the disease, and, as the disease has very varied clinical histories, it is desirable to distinguish clearly these different forms.

The simplest form is that in which the retina, near the optic nerve, is moderately clouded and swollen, while only slight changes, such as redness, clouding, etc., can be recognized upon the optic disc. The retinal veins are more sinuous. Hemorrhages very rarely occur. Exposure is not infrequently the cause of such cases,—for instance, sudden wetting when the body is warm, cooling the head, etc. It also occurs simultaneously with other rheumatic symptoms. With proper treatment it may run a favorable course in a few months. Leeches upon the temple, a mild depurative and diaphoretic treatment, protection from

---

\* Dr. M. Roth, Virchow's Arch., B. lv., und Deutsche Zeitsch. f. Chirurgie, B. i. 5, pag. 471.



exposure to cold, and complete rest for the eyes, generally prove sufficient.

Another group of cases is characterized by frequent hemorrhages, which accompany the other symptoms of retinitis. The individuals affected are generally those suffering from some anomalies of the circulation. Plethora abdominalis and habitual congestion of the head are, therefore, the most frequent causes of this form of disease, which, on account of the frequency of the hemorrhages, may be called Retinitis hæmorrhagica. The appearances in this form are modified in a very peculiar manner by the preponderance of the hemorrhages. All that has been said in reference to the course and prognosis of retinal hemorrhages is also applicable here. The prognosis of retinitis hæmorrhagica is, therefore, generally quite favorable. Above all things, the behavior of the macula lutea is to be observed, as it seldom escapes when the hemorrhages become frequent.

The disorganization of retinal tissue caused by the hemorrhages is irreparable; moreover, the inflammatory process appears to be much protracted by the presence of the extravasated blood. I have seen cases in which, after one and a half or two years, there were still opacity of the retina and hyperæmia of the veins.

The treatment should be derivative, with especial attention to any existing disturbances of the circulation in distant organs.

Syphilitic retinitis generally occurs simultaneously with other local symptoms of constitutional syphilis, or follows shortly after them. Often, but not always, it occurs in both eyes.

It is characterized ophthalmoscopically principally by a diffuse gray clouding, which extends from the optic disc over a considerable portion of the retina, and particularly along the larger vessels. The veins are only moderately dilated and curved; the optic disc, too, generally appears but slightly clouded; it is only seldom that it shows any considerable swelling. Hemorrhages are not generally present, but may exceptionally occur. Irregularly shaped dull patches are often observed in the retina.

A very frequent complication is a delicate clouding of the vitreous body, when iritis or choroiditis syphilitica is present, or even without these. It is at first often so fine that its ophthalmoscopic



diagnosis without atropine mydriasis is scarcely possible ; at a later stage it becomes very distinct.

Aside from the difficulty of recognizing this condition of the vitreous body, its existence, when established, raises further questions.

The changes in the retina, as Mauthner\* correctly remarks, are frequently so slight as to appear like delicate vitreous membranes projecting from the retina. If now one has satisfied himself of the existence of such a clouding, he may still remain in doubt as to whether retinitis exists. The hyperæmia of the retinal veins, and the possible presence of hemorrhages, or other changes, furnish, then, the points upon which to rely in making the diagnosis.

Occasionally one sees also in syphilitic retinitis a swelling surrounding the optic nerve, like a wall elevated above the surface of the optic disc, and therefore due to a thickening of the external layers of the retina. The same appearance, however, also occurs independent of syphilis.

The course of this form of retinitis is quite varied. With proper treatment, the majority of cases recover in from six to eight weeks, but other cases prove very obstinate. Atrophy of the retina and of the optic nerve may occur from a slow thinning and increasing anæmia of the arteries.

Von Graefe† describes a recurring central retinitis as a peculiar and quite rare form. Its connection with syphilis was probable, from the fact that in the seven cases which were observed, syphilis had formerly existed.

The disease is characterized by a sudden disturbance of vision, which at first after a few days disappears spontaneously, to return again after some weeks or months. The intervals are at first free from all disturbances of vision, but later the attacks last longer and vision is not fully restored during the intervals. As a rule, the disease appears to occur on both sides, and may cause temporary blindness when the attacks affect both eyes at the same time. The ophthalmoscopic examination shows as cause for the disturbance of vision a delicate clouding in the region of the macula

---

\* Lehrbuch der Ophthalmoscopie, pag. 369.

† Arch. f. Ophth., B. xii. 2, pag. 211.



lutea; it is greatest at the fovea centralis, and from that point diminishes gradually in all directions. The neighborhood of the optic disc remains free, or at most shows a slight clouding on the outer side.

During the intervals which are free from inflammation the affected portion of the fundus in recent cases appears quite normal; later there remains a slight gray clouding in the neighborhood of the fovea centralis; finally, there may be a deposit of black pigment patches.

The treatment of syphilitic retinitis is exactly that of secondary syphilis in general.

A very characteristic form of retinitis is that which occurs in connection with albuminuria. It always affects both eyes, although not always in the same degree. The characteristic features of the ophthalmoscopic image, aside from the ordinary signs of retinitis, such as hyperæmia of the veins and clouding of the optic disc and surrounding retina, are hemorrhages and a number of white, bright, glistening patches in the fundus.

The hemorrhages generally appear in the form of large round blood-red patches, or they may be striated if they occur in the thicker portions of the nerve-fibre layer; moreover, they, like other hemorrhages, may break through into the vitreous body. Only seldom are they very copious, and still more seldom are they entirely absent.

The bright spots occupy principally the posterior portion of the retina, and extend forward scarcely as far as the equator. They may approach so near the optic nerve as to touch its margin, but generally there is a slight distance between it and them. At a later stage they crowd closer together, especially near the optic nerve; they increase in extent, and several of them joining together assume very irregular forms, having a white, fatty appearance, and running out toward the periphery, especially along the course of the retinal vessels, in ragged points, or ending in a great number of fine white dots. It is only occasionally that these white spots are so large that they surround the optic disc completely.

The immediate neighborhood of the optic disc generally shows a gray, red, uniform or finely striated opacity, which hides the boundary-line of the optic disc. The tissue of the optic nerve



itself appears somewhat clouded, but it is only exceptionally that the existence of an actual neuritis is shown by an evident swelling.

At a later stage the retinal vessels, especially those near the optic nerve, appear to be accompanied by white lines, which are to be referred to a thickening of their adventitial coats.

In this form of retinitis there is relatively often seen the above mentioned stellate grouping of fine white dots or lines.

The peripheral portion of the retina in front of the equator generally remains unchanged.

Choroidal changes frequently occur simultaneously. They appear as brighter or darker patches in the layer of pigment epithelium. In many cases slight diffuse opacities of the vitreous body are also observed.

Vision varies greatly in degree. It may be so good that ordinary print can still be read, or it may have become so diminished that only fingers can be counted at a short distance. The visual field remains free except when detachment of the retina has occurred, as it exceptionally does in the later stages. Retinitis albuminurica appears but very seldom to lead to complete blindness.\*

Probably in a considerable number of cases the retinal disease would disappear if life were prolonged. In those cases in which the general condition allows of a better prognosis, as, for instance, in albuminuria following scarlet fever, or during pregnancy, observation has proved that the retinitis may disappear entirely, or nearly so, while at the same time there is an improvement in vision. For instance, in a case which occurred during confinement, I saw recovery from the retinal disease and complete restoration of vision; both affections recurred at a later confinement, and again there was recovery. In the second attack both eyes had at the height of the disease a vision of only about  $\frac{1}{100}$ . Five months later one eye had a vision of  $\frac{1}{2}$ , the other of only about  $\frac{1}{4}$ , as in its macula lutea a dark, somewhat prominent spot had remained.

This form of retinitis may be developed in all cases in which albuminuria has continued for some time. This is most frequently the case in chronic Bright's disease; still, the existence of retinal

---

\* Only two such cases are known. See V. Graefe (Arch. f. Ophth., B. vi. 2, pag. 285), and Donders (Van der Laan, Over gezichtsstoornissen bij albuminurie, Utrecht, 1865, pag. 216).



disease has also been demonstrated in connection with croupous nephritis, with amyloid degeneration of the kidneys, and in the passive hyperæmia of the kidneys caused by pregnancy.\*

Only very few statements have been made respecting the relative frequency of its occurrence in Bright's disease. Among 41 patients, Frerichs† found six with more or less disturbance of vision. Lebert‡ states that in one-fifth of his cases there were amblyopic symptoms. Both statements are probably somewhat exaggerated, since all the disturbances of vision there observed ought not to be attributed to retinitis. Among 157 cases of Bright's disease, Wagner§ found 18 in which there were visible changes in the eye, but only 10 of these cases could with certainty be considered as retinitis albuminurica.

Retinal disease probably occurs in about six or seven per cent. of all cases of Bright's disease. The circumstance that the existence of albuminuria is frequently first discovered by an ophthalmoscopic examination, would perhaps indicate that this retinal affection is relatively most frequent in those cases which run an irregular course.

The treatment is directed toward the general disease. The usual antiphlogistic treatment of retinitis, by bleeding and so forth, is seldom indicated. Rest and protection of the eyes from all hurtful influences is therefore frequently the only additional treatment made necessary by the retinitis.

The uræmic amaurosis, which likewise occurs in Bright's disease, is of a different nature, and has nothing in common with retinitis.

Leucæmia is likewise one of the general diseases which may cause retinitis. It is noticed that in many cases of leucæmia the ophthalmoscopic picture of the fundus is of a remarkable orange-yellow color,|| due perhaps to the lighter color of the blood, caused by the preponderance of the white blood-corpuscles. It is, how-

---

\* Traube, *Deutsche Klinik*, 1859, pag. 67.

† *Die Brightsche Nierenkrankheit*, pag. 93.

‡ *Handbuch der practischen Medicin*, 1859, B. 2, pag. 608.

§ *Virchow's Archiv*, 1867, B. xii.

|| Liebreich, *Deutsche Klinik*, 1861, No. 50; O. Becker, *Arch. f. Augen- und Ohrenheilk.*, 1869, B. i. pag. 95.



ever, noticeable that this orange-yellow color of the ophthalmoscopic picture is wanting in other cases of decided leucæmia,\* and that it may even be wanting in cases of decided retinitis due to this disease.†

The ophthalmoscopic signs of retinitis leucæmica are opacity of the retina about the optic disc, more or less numerous hemorrhages, and small white round spots, the largest of which do not equal the size of the optic disc.

Frequently hemorrhages appear upon these spots, the largest of them evidently forming a prominence above the inner surface of the retina.

These spots do not occur in the neighborhood of the optic disc and macula lutea alone, but may be found in the more peripheral portions of the fundus. In many cases white lines are seen along the course of the retinal vessels. Sämisch observed simultaneously choroidal hemorrhages. Leber‡ found, upon anatomical examination, that the white spots consisted simply of accumulations of lymph-corpuscles. He is inclined to regard them as small leucæmic tumors, such as Virchow has pointed out in various organs, and such as Engel-Reimers§ saw in the choroid. The white lines along the course of the vessels appear also to be caused by lymph-corpuscles.

Recklinghausen found the bright spots in one case to be composed of thickened nerve fibres.

The disturbances of vision appear generally to be very slight, unless the macula lutea is considerably affected or a hemorrhage into the vitreous has occurred. Sämisch, in a case which he had under observation for a year and a half, saw the hemorrhages and the white spots disappear; after 4 or 5 months they appeared anew, and later disappeared again; still, the posterior portion of the retina remained all the time slightly clouded.

Under the name of "retinitis nyctalopica" Arlt|| describes a form of retinitis characterized less by the ophthalmoscopic appear-

\* Knapp, *Klin. Monatsbl.*, 1868, pag. 355; O. Becker, *a. a. O.*, pag. 105.

† Sämisch, *Klin. Monatsbl.*, 1869, pag. 305.

‡ *Klin. Monatsbl.*, 1869, pag. 312.

§ *Centralblatt der med. Wissenschaft.*, 1868, pag. 836.

|| *Bericht über die Wiener Augenklinik*, Wien, 1867, pag. 123.



ances than by its clinical history. Its most prominent symptoms are the dazzling caused by full daylight, and diminution of vision. This last symptom is observed when looking at distant objects, which appear to the patients as if veiled by a light cloud, or as if the intervening air were in vibration. The diminution of vision is generally not very great, and the visual field remains free. Both eyes are always attacked at the same time, and in the same or nearly the same degree. The ophthalmoscopic changes are said to be a slight uniform or perhaps striated opacity of the retina near the optic disc, or extending outward toward the equator. The limits of the optic disc are more or less indistinct; its surface in most cases is decidedly redder than normal, in other cases it shows no changes.

Arlt is of the opinion that hyperæmia and inflammatory changes exist at the beginning in all cases, but that they frequently escape observation because they are so slight as to be overlooked in the examination in the upright image, or because at the time of the examination they have already partly disappeared.

The disturbances of vision generally come on suddenly, and either remain a long time the same or increase gradually to a degree where they may remain months or years stationary, without going on to complete blindness. Arlt regards dazzling by bright reflected or diffuse sunlight as the principal cause of this affection. The treatment requires rest for the eyes and protection from the light, the patient remaining in a moderately dark room or using blue or smoked-gray spectacles. Simultaneously, mild, cooling cathartics, moderate bleeding, and, as a special treatment, a methodical use of mercury, either by inunction or in pills of corrosive sublimate in increasing doses, should be resorted to.

It may finally be mentioned that in many cases besides those of the above named syphilitic form the retinitis is localized in the region of the macula lutea. The fovea centralis never participates in this opacity, and for that reason appears as a bright-red spot, whose boundaries are all the more distinct for the reason that just here the white discoloration of the retina is greatest. Toward the periphery the opacity gradually disappears, extending often scarcely beyond the region of the macula lutea. It may, however, reach the margin of the optic disc, or at certain points extend still farther outward. Hemorrhages often exist at the margins of these



opacities. In the course of a few weeks the opacity begins to clear up at its periphery, and may finally absolutely disappear; meanwhile a whitish discoloration of the optic disc develops.

In many cases, as the retina clears up, noticeable changes become apparent in the pigment epithelium layer of the choroid. In some of these cases I have also observed severe pain at the beginning of the disease, so that the entire process ought to be regarded as a choroiditis with infiltration of the retina, while those cases which recover without leaving any choroidal changes should be regarded simply as a retinitis of the macula lutea. Another ophthalmoscopic change, however, frequently remains after these cases, namely, a whitish discoloration of the optic disc, with contraction of the retinal arteries.

The disturbances of vision are always very great, the subjective symptom being that of a dark spot covering the object fixed. It can often be proved experimentally by the ophthalmoscope, or by some other method, that there is no sensation of light in the macula lutea. Eccentric vision, however, remains unaffected. With the disappearance of the opacity, vision may likewise improve, but generally remains somewhat defective.

The anatomical changes in retinitis are best known in that form caused by Bright's disease, for the reason that, in consequence of the fatal result of the general disease, it is just such cases in which the opportunity for examination is most frequent. It appears, however, that this form of retinitis presents no anatomical peculiarities specially differing from the others.

We will here consider the anatomical changes specially as accounting for the ophthalmoscopic appearances and the functional disturbances.

The opacity of the retina is to be explained by quite a number of anatomical changes. And first, it is here to be mentioned that in many cases of retinitis albuminurica Virchow\* and H. Müller† found a very unusual toughness of the retina, and Müller thought it probable that this might in some way be a cause of the diffuse opacity.

---

\* Verhandlungen der phys. med. Gesellsch. zu Würzburg, B. ix. pag. 35.

† Würzburger med. Zeitschrift, i. 1860, pag. 50.



The more dense opacities may depend upon inflammatory infiltration of the retina. Coagula which are found in the retina, partly as compact, tough masses, and partly in fibrous form, may to some extent have been present during life, but, for the most part, these appearances seem to be due to the action of the hardening fluid upon the coagulable substances.

An important part, too, is played by the hypertrophy of the connective tissue, which may occur in all the layers of the retina. The process is one of thickening, with proliferation, hypertrophy, and often fatty degeneration of the normal connective-tissue nuclei and cells. The nuclei of the radial fibres, too, are found enlarged and proliferated in cases of acute retinitis.

In the granular layer of the retina the hypertrophy of the connective tissue causes an elongation of the radial fibres and an unevenness in the surface of this layer. But this change is not uniform throughout the entire retina, some small portions remaining unchanged, or nearly so. The external surface of the retina is thus made uneven. A perpendicular section is seen to be full of furrows, all lined by the delicate *membrana limitans externa*, and filled with broken-down rods or choroidal epithelium.

This growth of the outer ends of the radial fibres may cause disturbances of vision by destruction of the layer of the rods and cones, and may also leave visible choroidal changes.

The bright spots which are seen in retinitis are mostly due to two changes, namely, a fatty degeneration of the retina and a peculiar metamorphosis of the nerve fibres.

Fatty degeneration is most frequent in retinitis albuminurica, and principally in the external granular layer, but may occur in all the layers. It also occurs in other forms of retinitis, and has, for instance, been several times demonstrated anatomically in neuro-retinitis caused by cerebral disease.\*

In the ophthalmoscopic image the fatty degenerations generally appear as round spots, seldom as striated opacities. Still, in one case of Bright's disease Virchow† found a radiating, striated

---

\* Nagel, Arch. f. Ophth., B. vi. 1, pag. 196; Koster, Twee gevallen van tumor cerebri, Utrecht, 1865, pag. 13; H. Schmidt und Wegner, Arch. f. Ophth., B. xv. 3, pag. 253.

† Verhandl. der phys. med. Gesellschaft zu Würzburg, B. x. pag. 36.



opacity of the retina, caused by a fatty degeneration of the inner ends of the radial fibres, close to the *membrana limitans interna*. In a case which I examined,\* a stiffness of the retina was caused by a sclerotic thickening of the ends of these fibres.

Some of the most striking changes seen in retinitis are found in the nerve elements of the internal layers. Heyman and Zenker† and Virchow‡ observed this degeneration in Bright's disease, first in the inner layers of the retina, and referred it to an affection of the ganglion cells, which Virchow designated as sclerosis. The resemblance of these sclerosed elements to ganglion cells is very great; but H. Müller§ showed that in the case examined by him these form elements were the result of changes in the nerve fibres.

The sclerotic thickening affected principally the varicosities of the nerve fibres. Several successive varicosities are seen to increase in thickness, till suddenly one such swelling attains an enormous size. The fibre in the immediate neighborhood is also thickened, but soon returns to its normal size. The individual swellings appear as sharply defined, roundish, club- or retort-shaped bodies, are generally finely granulated, and not infrequently show a nucleus in their interior.

In spite of the remarkable similarity of these bodies to ganglion cells, it seemed, in a case which I examined, that Müller's view as to their nature is the correct one, from the fact that by far the most of them showed no signs of a nucleus, and, moreover, the same changes in less advanced stages were visible on the nerve fibres.

In another form of sclerotic degeneration of the nerve fibres there is a uniform thickening along a considerable extent of the fibres, but no club-shaped swellings. The nerve fibres increase gradually in thickness, retain for a shorter or longer distance their abnormal size with but slight variations, and generally present a peculiar opalescent appearance.

Lastly, cases occur in which this opalescence is wanting. The fibres then appear simply hypertrophied, usually presenting in

---

\* Arch. f. Ophth., B. vi. 2, pag. 290.

† Ibid., B. ii. 2, pag. 142.

‡ Arch. f. path. Anat., B. x. pag. 170.

§ Arch. f. Ophth., B. iv. 2, pag. 41.



their course or in their varicosities dark points, which probably are fat drops.

As a rule, the sclerosed nerve fibres lie in groups, causing swellings, which protrude inward above the surface of the retina, and also encroach on the external layers.

It may, however, happen, and that principally at the intraocular extremity of the optic nerve, that the hypertrophy of the nerve fibres does not occur at circumscribed points, but more diffusely over the surface of the disc and the adjoining retina, thereby contributing to a swelling of the disc and retina.

The sclerosed portions appear ophthalmoscopically as bright, glistening, white spots. It is doubtful whether in all cases they can be distinguished from circumscribed fatty degeneration; still, small bright spots lying in front of the retinal vessels—that is, belonging to the inner retinal layers—may with great probability be regarded as composed of sclerosed fibres. It is also of diagnostic importance that hemorrhages frequently occur among these degenerated, sclerotic nerve elements.

Such spots are as likely to occur in the optic disc as in the retina.

These peculiar changes were first observed in retinitis albuminurica, but later investigations have shown that they may be absent in this and present in other forms of retinitis.

Wounds of the retina may cause a varicose hypertrophy of its nerve fibres.\*

Virchow† was also the first to observe in Bright's disease a sclerotic infiltration of the walls of the retinal vessels. They are also frequently found to be undergoing fatty degeneration.

Choroidal changes occur in connection with retinitis. Virchow‡ found in Bright's disease round masses of sclerosed substance in the choroid, corresponding to the degenerated portions of the retina. H. Müller§ demonstrated a thickening of the walls of the vessels by a homogeneous strongly refracting substance. In some cases which I examined there was likewise sclerosis of various

\* Roth, Beiträge zur varicösen Hypertrophie der Nervenfasern, Virchow's Arch., B. lv.

† Arch. f. path. Anat., B. x. pag. 178.

‡ Verhandlungen der physic. Gesellschaft zu Würzburg, B. x. pag. 36.

§ Würzburger med. Zeitschrift, B. i.



vascular regions in certain parts of the choroid. The pigment epithelium covering these places had generally lost its color. I could not satisfy myself that there was any direct relation with the retinal changes. This co-affection of the choroid has been shown to be most frequent in Bright's disease. Schmidt and Wegner,\* however, observed sclerosis of the choroidal vessels in connection with neuro-retinitis.

In one case of retinitis albuminurica, H. Müller† demonstrated a peculiar embolism of the fine ciliary arteries. A hypertrophy and fatty degeneration of the lining epithelium of these arteries was the cause of the formation of emboli composed of detached and degenerated epithelium, young cells, and free fat, which were found here and there wedged in the smaller branches.

In the vitreous were found opacities consisting of a countless number of interwoven threads. Possibly there may be often a peculiar post-mortem form of fibrin coagulation; still, in the cases which I examined, a diffuse vitreous opacity had been already observed ophthalmoscopically.‡

It has been already mentioned that a proliferation of the connective tissue of the adventitial coat of the retinal vessels often occurs, and that it is recognized ophthalmoscopically by bright stripes accompanying the vessels.

In rare cases this disease extends over a large part of the retina, and is of so high a degree that the vessels appear transformed into white strings, which still often betray the blood within them by a thin red line.§

Iwanoff,|| who found a similar condition upon anatomical examination, designated the disease as "perivascular neuritis." In an eye blinded by a severe injury, besides swelling and oedematous saturation of the intraocular extremity of the optic nerve and the retina, there was found a very great thickening of the retinal vessels, which appeared as white, slightly prominent stripes.

The thickening was caused by a change in the adventitial coat,

\* L. c., pag. 263.

† Würzburger med. Zeitschrift, B. i.

‡ Arch. f. Ophth., B. vi. 3, pag. 279 und 290.

§ Nagel, Klin. Monatsbl. f. Augenheilk., 1864, pag. 394; E. v. Jaeger, Ophthalmoscopischer Handatlas, Fig. 50, 51, und 75.

|| Klin. Monatsbl. f. Augenheilk., 1865, pag. 328.



which generally was more developed on the arteries than on the veins. These changes extended into the optic nerve itself, and consisted essentially in a very considerable increase in the connective-tissue nuclei. The ganglion cells and nerve fibres of the retina were well preserved.

## NEURO-RETINITIS.

Neuro-retinitis or neuritis is the name given to those cases in which the ophthalmoscopic changes are confined to the optic disc or its immediate neighborhood. The principal features in the ophthalmoscopic image are hyperæmia, clouding, and swelling of the tissues.

The hyperæmia is most apparent in the retinal veins, which are greatly dilated and very sinuous. The arteries are generally somewhat contracted, in some cases remarkably so. Spontaneous arterial pulsation occurs in only very rare cases.\*

In consequence of the dilatation of the numerous small vessels of the optic nerve, the disc is noticeably reddened, the color being sometimes modified by a bluish tinge, the result being a lilac shade, which in such cases generally extends somewhat upon the retina.

The clouding of the nerve and neighboring retinal tissue causes the deeper parts, such as the lamina cribrosa, the boundary-line of the optic disc, and some of the deeper curves of the retinal vessels, to be obscured or absolutely hidden.

The swelling of the optic nerve may be relatively less than that of the retina, which consequently rises up about the disc like a wall. But, as a rule, the nerve is at least as much swollen as the retina, often, indeed, more, so that its intraocular extremity rises above the general surface of the retina.

The swelling of the optic nerve is recognized ophthalmoscopically in the same manner as are other variations of level in the fundus of the eye. It is most easily seen by observing the course of the retinal vessels, which rise up over the prominence and then sink to the level of the retina. Those portions of the vessels which are driven forward are distinctly visible in the upright image; they present a greater parallax than the neighboring portions lying in the plane of the retina.

---

\* Von Graefe saw it in three cases, *Arch. f. Ophth.*, B. xii. 3, pag. 131.



The retina, so far as it is involved in the process, presents the appearances described under the head of retinitis. But in many cases the opacity is but slight, and is confined to the neighborhood of the optic disc, or extends somewhat farther along the course of the vessels. The sinuosities of the retinal veins frequently extend far into the transparent portion of the retina, and when their curves are in a plane perpendicular to that of the retina, it is possible to recognize an œdema of that membrane.

Striated hemorrhages in the neighborhood of the optic disc, or circular ones in the more peripheral portions, are sometimes seen. White spots appear partly in consequence of circumscribed sclerotic degeneration of the retinal nerve fibres or of the optic nerve itself, partly as the expression of a fatty degeneration. There is often also a peculiar stellate punctation about the macula lutea.

In the course of time the swelling of the optic nerve diminishes, the redness disappears, but the disc remains clouded with a gray or whitish discoloration. The same is true to a less degree of the neighboring parts of the retina. In some cases I have noticed at this stage a remarkable sinuosity of the retinal veins on the surface and in the neighborhood of the optic nerve. Frequently after the subsidence of the swelling of the nerve and the clearing up of the retina, slight choroidal changes are seen about the optic nerve, which are to be accounted for by the spreading of its intraocular extremity and the growth of the outer retinal layers, processes yet to be explained.

Vision is generally much interfered with, and there are usually noticeable defects in the visual field. Still, just as in retinitis, and for the same reasons, there is no correspondence between the ophthalmoscopic appearances and the degree of vision.

Frequently during the course of the disease very considerable changes in the degree of vision occur without any corresponding ophthalmoscopic changes; or, on the other hand, during a long persistence of the disease, very great ophthalmoscopic changes may take place with but slight additional loss of vision.

It is a remarkable phenomenon that in such cases, when good vision has been retained, there may occur a sudden transitory darkening of the entire visual field.

Loss of vision generally follows gradually, but in some cases comes on with surprising rapidity, so that, vision being good,



complete blindness may occur in the course of a few hours. (Neuritis fulminans, Von Graefe.)

Neuritis may occur as an independent form of disease. Cases occur in which no other disease can be regarded as the exciting cause, and in which indeed no cause whatever can be discovered. Contusions of the eyeball or of the orbital walls are seldom to be regarded as the exciting cause. Many cases depend upon constitutional causes,—such as disturbances of the circulation in distant organs, anomalies of menstruation, etc. Syphilis and lead poisoning are also named as causes.

In another class of cases the direct effect of hurtful influences upon the orbital or intracranial course of the nerve is evident. The growth of tumors or inflammatory processes in the orbit as causes of neuritis have already been mentioned on pages 193 and 194. Such causes may remain localized in the depth of the orbit, and their existence be betrayed by disturbances of vision and subsequent atrophic degeneration, or they may extend to the intra-ocular extremity of the optic nerve.

Finally, various intracranial diseases, such as meningitis, inflammatory softening, tumors of the brain, etc., may be complicated with neuro-retinitis. Experience, however, is more and more against the idea that the nature of the intracranial disease, or its connection with the neuro-retinitis, can be determined by any peculiarities in the ophthalmoscopic appearances.

In this matter the occurrence of neuro-retinitis in connection with brain tumors has played an important part. A very exact analysis of cases of brain tumor complicated with retinal disease, made by Türek\* in 1853, developed the view that an increase of intracranial pressure rendered difficult the emptying of the ophthalmic vein into the cavernous sinus, and that thus disturbances of circulation were caused which extended to the retina. In 1860, Von Graefe† sought by this same theory to explain the fact, which

---

\* Zeitschrift der Gesellschaft der Aerzte zu Wien, pag. 218. Türek found no other changes than retinal ecchymoses, which is accounted for by the fact that the retinas were not examined till the fifth day after death.

† Arch. f. Ophth., B. vii. 2, pag. 58; Comp. Annuske, Arch. f. Ophth., B. xix. 3, pag. 165; Reich, Klin. Monatsbl. f. Augenheilk., 1874, pag. 274; Heinzel, Über den diagnostischen Werth des Augenspiegelbefundes bei intracranialen Erkrankungen der Kinder, Jahrbuch für Kinderheilkunde, 1875, B. viii. 3, pag. 331.



his observations render undoubted, that there occurs in connection with brain tumors a characteristic swelling of the nerve, which since that time has generally been called "Stauungspapille."\* The peculiarity of the condition consists in a considerable and often irregular swelling and redness of the optic nerve, in consequence of the dilatation of the delicate vessels which ramify in its intraocular extremity. The veins of the retina are likewise dilated and abnormally curved, while the contents of the arteries are diminished. If the condition be due to cerebral causes, both eyes are always affected.

Under such circumstances, vision is generally greatly diminished; still, several cases of this form of neuritis have been observed in which good vision was retained. In one case, for instance, in which the other symptoms indicated the existence of a cerebral tumor, I found in one eye a high degree of amblyopia, with a large defect in the visual field, and in the other perfect vision and a free visual field. Still, the ophthalmoscopic appearances in both eyes were the same, except that the optic disc of the poorer eye was not so red and was of a brighter gray than the other. In another case, in which besides decided "Stauungspapille" there were corneal opacities, vision was much better than was to be expected from the optical relations. Unfortunately, neither case remained long under observation.

Blessig† reports similar histories. Mauthner‡ publishes a case in which there was normal vision with decided neuritis. It possesses special interest from the fact that the report includes the results of the anatomical examination of the optic nerve. This case will be again alluded to.

Cases of neuritis in which there is considerable swelling of the intraocular extremity of the optic nerve, sinuosity of the retinal veins, but no extensive opacity of the retina, and which, therefore, may be described as "Stauungspapille," occur as an independent disease, and under circumstances which furnish no grounds for suspecting the co-existence of an intracranial disease.

It cannot be denied that the hyperæmia of the optic nerve and

---

\* "Choked disc" is the corresponding English expression.—*Translator*.

† Petersburger med. Zeitschr., 1866.

‡ Lehrbuch der Ophthalmoscopie, pag. 293.



retina which characterized the "Stauungspapille" depends upon a stasis of blood; but what causes this stasis? A swelling of the nerve itself, especially if participated in by the lamina cribrosa, would be sufficient cause for such a stasis. It is doubtful whether a deeper-lying obstruction to circulation within the cranial cavity plays any important part. It is denied on anatomical grounds.

Sesemann,\* basing his views upon very careful studies of the anatomy of the orbital veins, opposes the theory that a stasis can be caused in the ophthalmic vein by a simple increase of intracranial pressure, and sets forth the anatomical relations as follows:

The vena centralis retinae emerges from the optic nerve at about its middle, runs for a short distance on its outer side, then perforates the external sheath of the nerve, and finally empties into the cavernous sinus or into the ophthalmic vein.

In most cases, where the vena centralis empties into the cavernous sinus, and this is the most frequent arrangement, it anastomoses freely with the vena ophthalmica superior, so freely, indeed, that it is doubtful in some cases if it should not rather be said to empty into this vein. Zinn describes a case in which the vena centralis emptied only into the vena ophthalmica. Sesemann observed a simple discharge into the vena ophth. inf.

Finally, it sometimes happens that the optic-nerve sheath is surrounded by a delicate venous plexus, into which empty the vena centralis and some small veins from the substance of the nerve. The blood from this plexus is conducted by a number of small veins, partly into the vena ophthalmica sup., partly into the inferior, and partly, also, into the cavernous sinus. If the vena centralis retinae be connected with the vena ophthalmica, it becomes thereby wholly independent of the cavernous sinus, for the vena ophthalmica sup. is always connected by numerous anastomoses with the vena facialis and the vena ophthalmica inf., and this last communicates again with the vena facialis anterior and with the pterygoid plexus, so that the return of the blood is amply provided for.

Aside, however, from these anastomoses, Sesemann explains it as indifferent whether the vena cent. retinae empties into the vena

---

\* Du Bois-Reymond's und Reichert's Arch. für Anat. und Physiol., 1869, No. 2.



ophthalmica or into the sinus, since the two last are continuous the one with the other, and there can be no obstruction to the return of the blood so long as the way through the facialis is free. Sesemann regarded the vena ophthalmica as a waste weir, a so-called emissarium Santorini for the cavernous sinus. If from any cause the pressure in the sinus increase, the vena ophthalmica empties not only its contents into the facialis, but conducts into it also blood from the sinus, and it is the better adapted to play this part for the reason that throughout its whole course it possesses no valves. Finally, a compression of the cavernous sinus by a simple increase of the intracranial pressure is not so easy as one might think. In making injections, we have often tried to compress the cavernous sinus in order to prevent the escape of the mass through the sigmoid sinus, but have never succeeded in doing it.

On pathological grounds, too, the undoubted connection between cerebral tumors and neuritis cannot be regarded as a simple mechanical consequence of the increase of intracranial pressure.

It is remarkable that with "Stauungspapille" the stasis takes place only in the vena centralis retinae, and not in the other branches of the vena ophthalmica. Moreover, venous congestion of the retina is wanting in very many cases where there is undoubtedly increase of intracranial pressure, and it exists in many other cases without causing "Stauungspapille."

It is regarded as undoubted that in general a connection exists between "Stauungspapille" and cerebral tumors, but this peculiar form of neuritis may occur independent of such tumors in consequence of orbital or intracranial processes, and furthermore it may be absent in spite of the existence of cerebral tumors. Cerebral tumors may even cause blindness without "Stauungspapille," partly by a form of neuritis which runs its course without any marked swelling of the optic disc, partly by atrophy of the optic nerve.

Cerebral tumors may cause a compression of the optic nerve. Ludwig Türek\* has shown that hydrocephalus ventriculorum due to tumor or any other cause may produce blindness by the pressure of the floor of the third ventricle upon the chiasm.

In such cases a cyst-like distention of the tuber cinereum is

---

\* Zeitschrift der Gesellschaft der Aerzte zu Wien, 1852, B. ii. pag. 299.



found at the base of the brain; the inner surfaces of the optic thalami are more widely separated, and the crura cerebri more divergent, than in the normal state. The optic tracts crossing the crura are thus stretched and the chiasm somewhat flattened. In three such cases of very decided hydrocephalus, in consequence of cancer of the cerebellum, and in which death ensued in from seven to nine months after the appearance of amblyopia, which increased to complete amaurosis, Türk found in the chiasm a great number of nucleated cells and fat globules extending some distance into the optic nerve, and in one case even into the retina.

Much light has been thrown upon the connection between cerebral and optic-nerve diseases by Schwalbe's\* investigations with reference to the lymph passages of the eye. He has shown that the space between the outer and the inner optic-nerve sheath is in direct communication with the arachnoidal space, and that an injection will pass from one into the other. Manz† has confirmed by experiment and anatomical examinations the view first expressed by Schmidt,‡ that pathological processes may be propagated through this channel. It was found that a pathological fluid effusion in the arachnoidal space and the signs of increased intracranial pressure were almost always associated with an accumulation of fluid between the optic-nerve sheaths. A persistence of this condition may certainly cause an oedema of the inner nerve sheath and of the connective-tissue processes which it sends into the optic nerve. These processes are particularly numerous at the place where the nerve enters the eyeball. This oedema will cause a swelling of the optic disc, which may be of different degrees in its central and peripheral parts, or may vary in its different sectors. In the lamina cribrosa, however, where the optic nerve is surrounded by the sclera, the swelling of the nerve compresses its vessels, affecting principally the venous current. The theory that the "Stauungspapille" is caused by the pressure of the fluid collected in the intravaginal space, has little in its favor. In the first place, this pressure must be so great that

---

\* M. Schultze's Arch., B. vi., 1870, pag. 1.

† Arch. f. Ophth., B. xvi. 1, pag. 265, und Deutsches Arch. f. klin. Medicin, B. ix. pag. 339.

‡ Arch. f. Ophth., B. xv. 2, pag. 193.



the very distensible external sheath can no longer yield to it, and, in the next place, the intracranial pressure must be equally great, otherwise the fluid between the sheaths would be forced back into the arachnoidal space.

A direct propagation of an inflammatory process of the meninges of the brain through the foramen opticum is quite possible.

Retrobulbar neuritis is a name applied by Von Graefe\* to a certain condition in which sudden blindness occurs. After various constitutional diseases, among which Von Graefe mentions measles and febrile gastric catarrh, and sometimes also without any serious disturbances of the general health, the field of vision grows obscure. There may or may not be subjective light and color symptoms. In a few hours or days there is absolute blindness, generally in both eyes. The pupil is usually widely dilated, and does not react to light.

Upon ophthalmoscopic examination decided though not very great changes are seen at the optic disc. They are, moreover, very transitory. There is a slight opacity over the disc and the adjoining retina, but there is little or no elevation of the surface. The arteries are small, the veins distended and sinuous. These slight ophthalmoscopic changes are entirely disproportionate to the disturbances of vision, which sometimes reach the extreme of complete blindness. These symptoms are due to changes which escape observation.

There is great probability of the correctness of Von Graefe's view, that in such cases the principal changes are in the optic nerve, behind the eyeball. The disease is generally bilateral.

It is quite probable, as Von Graefe suspected, that certain cases described as "ischæmia retinæ" were really cases of retrobulbar neuritis. The three cases of this kind which have been described† were characterized by blindness, which came on rapidly in both eyes, but without any important visible changes other than a slight contraction of the retinal arteries. In one of these cases the veins were greatly dilated and sinuous. In the other two there was no venous hyperæmia.

---

\* Arch. f. Ophth., B. xii. 2, pag. 114.

† One by Alfred Graefe, Arch. f. Ophth., B. viii. 1, pag. 143; two by Rothmund, Klin. Monatsbl., 1866, pag. 106.



In these cases there was only a partial obstruction to the normal blood supply, and it is accordingly difficult to understand why the function of the retina should have been so completely interfered with; all the more difficult, too, from the fact that Von Graefe found vision scarcely less than normal in the extreme degree of ischæmia which exists in the asphyxiated stage of cholera.

It has, however, been demonstrated that a bilateral retrobulbar neuritis, which in a few hours may destroy the sensation of light, does occur, and manifests itself by slight and very transitory changes at the intraocular extremity of the optic nerve. It is not strange that these changes in the nerve or retina were not observed in the three cases above referred to, for they might either have already disappeared, as two of the cases were not examined till after the sixth and the other till after the fourth day, or the changes may not have existed to a perceptible degree.

At all events, it must be admitted as a possibility that the cases described as ischæmia were really cases of retrobulbar neuritis. This may be assumed with the greatest probability for the case of atrophic degeneration of the optic nerve, with contraction of the retinal arteries, described by Heddaeus as ischæmia.\*

Besides these acute forms of retrobulbar neuritis, there are others which run a chronic course. The intraocular extremity of the optic nerve appears clouded, whitish, and often slightly swelled. The cloudiness generally extends beyond the margin of the optic disc, whose boundary-line is therefore somewhat indistinct. The retina remains unchanged. The large arteries are generally contracted, the veins are normal, or only slightly dilated. As in all these processes, the disturbances of vision vary greatly. They may be limited to a moderate diminution of central vision, or they may amount to almost complete blindness, with great defects in the visual field. This chronic form of neuritis leads to atrophic degeneration of the optic nerve, a subject yet to be discussed.

The prognosis in neuro-retinitis and neuritis is generally unfavorable. Cases do occur in which there is recovery of vision, even when there has been complete blindness; still, it is impossible to state the conditions under which so favorable a result may be hoped

---

\* Klin. Monatsbl., 1865, pag. 285.



for. It is to be remembered that the prognosis, with reference to the primary intracranial processes, is frequently very unfavorable.

There is, accordingly, little encouragement for treatment. Derivatives, bleeding from the temple or behind the ear, setons in the neck, etc., are generally recommended, so, too, the use of mercurials or iodide of potassium, in so far as they are not forbidden by special etiological indications. Alfred Graefe saw a return of vision, after iridectomy in both eyes, in the case described as *ischæmia retinae*. Rothmund, in his two cases above referred to, performed paracentesis of the anterior chamber, with a similar good result. But the number of these cases is too small to draw from them any certain conclusions as to their proper treatment, for in neuritis, even after protracted blindness, a spontaneous restoration of vision has been observed.

The anatomical condition of the nerve trunk in neuritis has been examined often enough to prove that changes not visible by the ophthalmoscope may play an important part in causing the disturbances of vision.

Türk\* observed inflammatory processes in the optic nerves and chiasm in various brain diseases. Stellwag† described the anatomical changes in neuritis, and reports also some cases in which a dropsical swelling of the optic nerve within the cranial cavity was the cause of blindness.

Effusions between the two optic-nerve sheaths, simultaneously with meningitis, may be explained by the anatomical relations set forth on page 481, but it has also been demonstrated that an actual propagation of an inflammation may take place along the nerve itself.

Virchow‡ observed in a case of basilar meningitis a very marked thickening and detachment of the neurilemma along the whole course of the nerve. Besides this "perineuritis," he found an "interstitial neuritis," likewise, throughout the whole nerve, whose neurilemma was found full of nuclei and young cells.

---

\* Zeitschrift der Gesellschaft der Aerzte zu Wien, B. v. 2, pag. 582; B. viii. 2, pag. 299; B. ix. 2, pag. 214.

† Ophthalmologie, B. ii. pag. 564 und 620.

‡ Arch. f. Ophth., B. xii. 2, pag. 118.



Hulke\* reports a case of "Stauungspapille" which had developed in connection with extensive syphilitic brain disease. He called special attention to the fact that there was an evident swelling of both the orbital and intracranial portions of the optic nerve. Von Graefe believed that this so-called Neuritis descendens could be recognized by the ophthalmoscopic appearances, which he regarded as consisting in moderate swelling and redness of the optic disc, with extreme clouding of its tissue, these appearances extending somewhat upon the neighboring retina. In "Stauungspapille" the changes are limited to the optic disc, the extraocular portion of the nerve being unaffected.

It has been usual in the examination of cases of neuro-retinitis, associated with brain disease, to regard the optic nerve as unchanged when no abnormalities can be seen in it with the naked eye. But Leber† has shown that though the external appearance of the nerve be normal, that is not enough to exclude very important pathological changes. Among the changes which are to be seen in such cases on microscopical examination are interstitial neuritis and perineuritis, fatty degeneration of the nerve fibres, an infiltration with nucleated cells and simultaneous atrophy of the nerve fibres. In no case in which neuritis has been diagnosed ophthalmoscopically, and in which the macroscopic appearance of the optic-nerve trunk is normal, are delicate changes of some kind or other wanting.

The intraocular anatomical appearances do not vary greatly from those of retinitis. The swelling of the disc is due mostly to a hypertrophy of the nerve fibres, some of which are uniformly thickened, while others present fusiform or club-shaped swellings. An œdematous saturation of the disc and the development of numerous vessels may also contribute to the swelling.

A considerable swelling may be caused by a proliferation of the connective-tissue elements. The lamina cribrosa swells, is driven forward, and projects above the inner surface of the sclera, or its tissues are so separated that both its interior and its exterior limits disappear. By this swelling and hypertrophy of the connective-tissue elements the intraocular extremity of the optic nerve becomes

---

\* Ophth. Hosp. Rep., 1868, vol. vi. pag. 100.

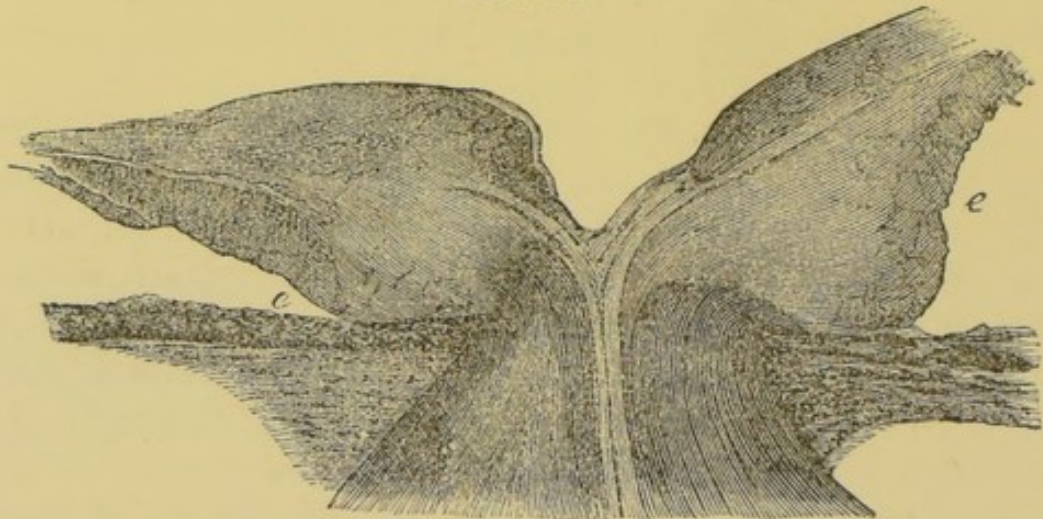
† Arch. f. Ophth., B. xiv. 2, pag. 333.



not only higher but broader, so that it projects on all sides beyond the foramen choroideæ.

Fig. 45 represents a considerable swelling of the intraocular extremity of the optic nerve and the lamina cribrosa in a case of retinitis caused by Bright's disease. The central vessels of the retina, which have been driven forward by the swelling, have by their elastic resistance caused a depression in the anterior surface of the swollen disc.

FIG. 45.



The lamina cribrosa, together with the vessels, is driven forward and elevated above the surface of the choroid. The connective-tissue fibres running from the nerve into the retina can yet be recognized. The intraocular extremity of the optic nerve is greatly swollen and extended on all sides, not only pressing forward into the vitreous, but spreading also in a lateral direction. The external layers of the retina are therefore pushed aside as far as *e*. The separation between the choroid and the retina which appears in the preparation, is artificially produced; but supposing it not to exist, it will be seen that there must have been during life a very considerable swelling of the optic disc.

Sämisch\* gives a similar representation in a case of neuroretinitis caused by brain tumor.

Most cases of decided swelling of the optic disc present upon anatomical examination undoubted inflammatory changes. In the neighboring retina there is frequently a hypertrophic development of the connective tissue in all the layers, and often the adventitial

\* Beiträge zur Anatomie des Auges, 1862, Taf. iii. Fig. 2.



coat of the vessels is also thickened. The nerve fibres, both in the retina and on the disc, frequently present either the above-described ganglion-like swellings or a simple hypertrophy. Atrophy of the ganglion cells and nerve fibres appears always to occur in those cases which go on to blindness. The appearance in the nerve-fibre layer of small, round, homogeneous bodies, having an average size somewhat greater than the blood-corpuscles, which I observed in one case,\* has been confirmed by Blessig.†

We have also a description of the anatomical appearances in one of those rare cases in which, with a high degree of intraocular swelling of the nerve, good vision was retained. Iwanoff‡ having had an opportunity to make an examination in such a case of so-called "Stauungspapille," the most striking microscopic appearance was a great hyperæmia of all the vessels and a dilatation of the capillaries, so that the great mass of the disc was composed of vessels resembling a telangiectasis. The connective tissue was slightly hypertrophied in consequence of a serous saturation. The nerve fibres had not suffered any change. There was no trace of new cellular growths. In the retina were no changes except a hyperæmia. Mauthner's§ report, which evidently refers to the same case, states that there were signs of an interstitial neuritis, consisting in a proliferation of the connective tissue in a portion of the optic-nerve trunk, which remained attached to the eyeball.

#### EMBOLISM OF THE CENTRAL RETINAL ARTERY.

Embolism of the central retinal artery as a cause of sudden blindness was first observed by Von Graefe.|| The ophthalmoscopic appearance when the patient first presented himself, about a week after the blinding, was essentially as follows. The refracting media were clear, the optic nerve quite white, but not opaque, as in atrophy, but normally translucent. All the vascular trunks upon the optic disc were greatly contracted. The principal arteries upon the retina appeared like delicate lines, and their branches were correspondingly small. The veins, too, were in all places

\* Arch. f. Ophth., B. vii. 2, pag. 63.

† Petersburger med. Zeitung, 1866, pag. 76.

‡ Klin. Monatsbl. f. Augenheilk., 1868, pag. 421.

§ Lehrbuch der Ophthalmoscopie, pag. 293.

|| Arch. f. Ophth., B. v. 1, pag. 136.



thinner than normal, but largest near the equator. After a few days a very peculiar phenomenon of circulation was observed in the retinal veins. There appeared to be an uneven filling of the veins,—that is, a portion of the vein would be well filled and an adjoining portion comparatively empty. Upon fixing the attention sharply upon one particular part of a vessel, it could be seen that the blood moved by arhythmic impulses toward the optic disc, now moving forward, and again standing quite still.

Toward the end of the second week the retina in the region of the macula lutea began to grow opaque. A gray-white infiltration appeared, which extended to the temporal margin of the optic disc, and shaded off about its periphery imperceptibly into healthy tissue.

The position of the fovea centralis was occupied by a dark cherry-red spot about one-quarter the size of the optic disc. The color of this spot was so intense as to suggest at once the suspicion of a hemorrhage. Still, it appeared more proper to regard the effect as due to a contrast in color, for while the surrounding infiltrated retina by its opacity hid the choroid, that portion in the immediate neighborhood of the fovea centralis remained free from infiltration and allowed the choroid more distinctly to shine through. In the course of two or three weeks the infiltration disappeared, and with its disappearance the intense cherry-red color of the macula lutea passed imperceptibly into a light-brown color not differing essentially from that of the neighboring parts. There was and continued to be only the slightest perception of light. Gradually there came on atrophy of the optic nerve.

The examination of the heart showed with certainty a stenosis of the aortic valves, probably in connection with a still active endocarditis.

About a year later the patient succumbed to his heart disease, and through the kindness of the attending physician I came into possession of the blinded eye. Anatomical examination fully confirmed the diagnosis. The arteria centralis retinae, at the lamina cribrosa, was completely occluded by an embolus which had forced its way up to this point, but here in the lamina cribrosa, where no more room was to be gained, it remained fast. On the cardiac side of the embolus the artery was filled by a thrombus.

Atrophy of the retina about the optic disc could be distinctly



recognized; the lamina cribrosa was covered only with atrophied tissue.\*

Since this first publication by Von Graefe a great number of cases have been described as embolism of the central artery. Indeed, for a long time it appeared to be fashionable to reckon as such all cases of sudden blindness in one eye, even though the blindness may have existed for years before coming under observation, or even cases in which both eyes have been similarly affected, the one after the other, whether the source of the embolus could be discovered or not. In this connection it should be remembered that none of the above mentioned symptoms have any pathognomonic value.

Sudden blindness with noticeable contraction of the arteries occurs also in neuritis, and under other circumstances which do not admit the idea of embolus as the cause. Though we cannot in all cases account for these sudden obstructions of circulation with simultaneous loss of vision, this much is certain, that we cannot diagnose embolus from these symptoms alone.

The peculiarity of the circulation in the retinal veins was first observed by E. v. Jaeger† in a man 72 years of age, who had become blind during the previous night. Von Graefe‡ observed it, too, in a case in which blindness had come on within a few days, but in which no embolus could be detected, and in a marked degree, too, in the asphyxiated stage of cholera. This symptom depends simply upon a diminished *vis a tergo*, a condition which obtains when the arteries are contracted and the veins consequently only partially filled. But even when an embolus has completely closed the central retinal artery, it is still possible for a small quantity of blood to reach the retina, for, as Leber§ has shown, a communication exists, by means of the vascular circle immediately surrounding the optic nerve, between the vascular system of the retina and the ciliary arteries. Unfortunately, however, this connection is only of a capillary nature, and not suitable

---

\* The preparation here referred to is still in my possession, and has been pronounced fully satisfactory by all experts who have seen it. Among others, Profs. Virchow and Cohnheim were kind enough to examine it.

† Ueber Staar und Staaroperationen, 1853, pag. 104 bis 109.

‡ Arch. f. Ophth., B. ii. 2, pag. 142 und 210.

§ Ibid., B. xi. 1, und B. xviii. pag. 31.



for the establishment of a compensating collateral circulation. Even anastomoses of more than capillary size, if they existed, would be prevented from developing by the unyielding nature of the scleral tissue through which they must pass.

The peculiar changes about the macula lutea are likewise not specially characteristic of embolus. They may occur without embolus, and in many cases of embolus they are not observed.

The interpretations of the ophthalmoscopic appearances, moreover, are at variance, some authorities regarding them as hemorrhages.

At all events, hemorrhages have been stated to exist in a large number of cases which have been described as embolisms. They were always few and small, and occupied the surface of the optic disc or its immediate neighborhood, especially on the side toward the macula lutea. These considerations bring us to the conclusion that a different interpretation must be put on at least a part of the many cases which have been described as embolism of the central artery. Thus, for instance, sudden blindness in one eye may be caused by an effusion of blood in the orbital portions of the optic nerve, and present a condition much resembling embolism.\* There occur, moreover, cases of sudden blindness in both eyes, with ophthalmoscopic appearances very like embolism, and yet no one would be inclined to believe in a simultaneous occlusion of both central arteries by embolism. If this be so, why should the same symptoms and the same ophthalmoscopic appearances, when they occur in only one eye, be assumed in all cases to indicate embolism?

If the case be as clear as that first published by Von Graefe, or that confirmed by my dissection, if a period be observed in which there is no infiltration, and the only symptoms in the eye are those which may be due to an arrest of the arterial supply, if an arterial or cardiac disease furnish the source for an embolus, the diagnosis need not be doubtful. If the last named symptom be wanting, it would awaken the suspicion that the contraction of the arteries might be a consecutive condition caused, for instance, by a retrobulbar neuritis. The occurrence of embolism in the brain, with a perfectly healthy condition of the circulatory apparatus, has, it is true, been observed, and the breaking down of clots in

---

\* Comp. Magnus, *Die Sehnervenblutungen*, Leipzig, 1874.



the heart has been demonstrated as the cause of such an occurrence. Admitting the possibility of an analogous process for the cases under consideration, it must still be remembered that processes of quite a different nature may cause an apparently similar effect upon the retinal arteries.

Embolism of a single branch of the central retinal artery was first demonstrated by Virchow,\* and the condition has been recognized several times ophthalmoscopically.

Aside from the cases above referred to, there have been but two others in which an anatomical examination confirmed the diagnosis of embolism of the central artery made during life.†

#### ATROPHY OF THE OPTIC NERVE.

The symptoms of this pathological condition consist partly in disturbances of vision and partly in changes ophthalmoscopically visible at the intraocular extremity of the optic nerve. The disturbances of vision will be discussed under the head of amblyopia and amaurosis. The ophthalmoscopic changes may be comprehended by the term atrophic degeneration of the optic nerve, since they are the consequences of some one of the various diseases which involve a partial or total degeneration of the optic-nerve fibres.

The principal sign of an atrophic degeneration is a change in color, by which the optic disc grows brighter.

Simultaneously the lamina cribrosa may be hidden by an opacity of the nerve tissue, or it may remain visible and indeed be more distinct than normal. Frequently the optic nerve assumes a peculiar bluish or more rarely a greenish-blue color.

The ophthalmoscopic examination by daylight, as described on page 115, may be employed to great advantage in these cases, as indeed it may for all diseases of the optic nerve and retina, where it is desirable to recognize slight opacities or delicate changes of color.

In the centre of the disc, or over that portion of it in which the lamina cribrosa is visible, its white net-work of connective tissue will be seen filled with bluish dots and lines, which are the bun-

---

\* Arch. f. path. Anat., B. x. p. 181, und Gesammelte Abhand., pag. 719.

† Sichel, Arch. de Physiologie, t. iv., 1871-1872, pag. 83; H. Schmidt, Arch. f. Ophth., B. xx. 2, pag. 286.



dles of nerve fibres passing through it. The bluish color must be caused by a change in the fibres themselves. The whitish discoloration may be due to various causes.

In the first place, the lamina cribrosa may be laid bare by an atrophy of the nerve fibres just as is the floor of a physiological excavation; or it may be covered by a proliferation of the connective tissue, accompanying the degeneration of the nerve fibres, thus furnishing a surface from which the light is strongly reflected.

Finally, as Von Graefe\* suggests, it may safely be assumed that an obliteration of the numerous delicate vessels of the optic nerve occurs simultaneously with or may precede the atrophy of the nerve fibres. The quantity of blood in the optic nerve being diminished, the normal rosy tinge of its disc is of course proportionately paler.

The discoloration of the optic disc, and the more distinct appearance of the lamina cribrosa, is always first apparent on the temporal half, and may there have reached a development to be regarded as pathological, while the median half still retains its normal color. This is as might be expected, for both the bright spot and the physiological excavation seen in the normal nerve always occupy the lateral half of the disc, while the great mass of the nerve fibres passes up over the median side. A beginning atrophy of the nerves would therefore first manifest itself on the temporal side of the disc where the nerve fibres are fewest.

The retinal vessels may remain unchanged or be more or less contracted. In many cases this may be due to the fact that there is simultaneous disease of the retina; or the central artery of the retina in consequence of neurotic changes may have been compressed in the optic nerve before it reaches the retina.

H. Müller† pointed out still another consequence of the atrophy, and described it as atrophic excavation.

Normally, the nerve fibres at their place of entrance form a thick layer, which at the margin of the disc exceeds the thickness of all the other layers of the retina. If now the loss of substance caused by the atrophy of the nerve fibres be not replaced by a proliferation of the connective tissue, the place of entrance of the

---

\* *Klin. Monatsbl.*, 1865, pag. 131 et seq.

† *Arch. f. Ophth.*, B. iii. 1, pag. 92.



optic disc assumes the form of a flat depression, whose floor is formed by the lamina cribrosa.

FIG. 46.

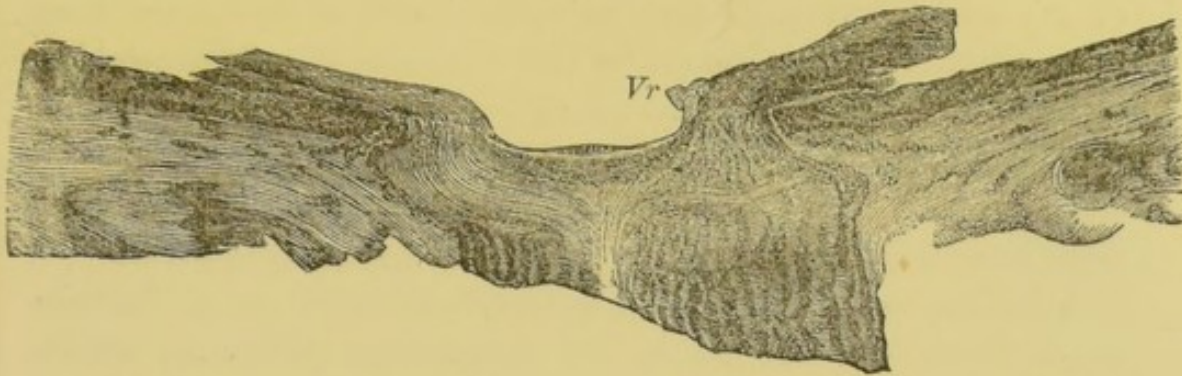


Fig. 46 represents such a case in longitudinal section of the nerve. The preparation is from a case of a high degree of atrophy of the optic nerve, and presents the appearance of an excavation. The atrophied nerve fibres, forming a thin, striated membrane, cover the lamina cribrosa. The central vessels *Vr*, at the point where they bend over upon the retina, form a prominence above its surface, for in the retina, too, the nerve-fibre layer is atrophied. Remembering that in such cases the retina generally remains perfectly transparent, and that in the case here represented the lamina cribrosa and the tissue covering it lie exactly in the plane of the choroid, it seems probable that upon ophthalmoscopic examination this case would not have presented the appearance of an excavation. Perhaps it could have been seen in the upright image that the retinal vessels upon the surface of the disc were at a deeper level than those on the adjoining retina.

Of course the relations would be different in case of atrophy of the optic nerve ensuing where there was previous physiological excavation. Under such circumstances the excavation may reach a great size and depth, so that extreme cases can no longer be distinguished from pressure excavation by the ophthalmoscopic examination alone, a consideration of all the clinical symptoms being necessary in making the diagnosis.

In some few cases of atrophy of the optic nerve more or less dark pigment has been seen upon the surface of the disc.\*

\* E. v. Jaeger, Ueber Staar und Staaroperationen, pag. 103, Fig. 31; Liebreich, Klin. Monatsbl., 1864, pag. 229; Knapp, Arch. f. Ophth., B. xiv. 1, pag. 252.



It is to be remembered that even under physiological relations, and with normal vision, pigment is found in the optic nerve.\*

The anatomical changes which occur in atrophic degeneration of the optic nerve have been partially described under the head of neuritis. Both anatomically and clinically it is impossible to separate by a sharply defined line a retrobulbar neuritis from an atrophic process. At this place, therefore, are described only those changes which both from a clinical and an anatomical stand-point must be considered as belonging to the atrophic degeneration.

According to Virchow,† the process consists in atrophy of the nerve fibres and changes in the interfibrous substance, which either becomes œdematous, or corpora amylacea or nucleated cells develop in it. The disappearance of the nerve fibres causes a gray transparent appearance. The atrophy may not essentially affect the retina, and may be limited to only a small portion of the nerve.

Virchow distinguishes two kinds of gray atrophy, or degeneration of the optic nerve,—a total and a partial or mottled,—and he commends the latter specially to the attention of ophthalmologists, as it frequently occurs in connection with affections of the brain or spinal cord. “The mottled gray atrophy of the opticus appears to be connected especially with the mottled atrophy of the spinal cord, and under these circumstances amaurosis is associated with paralysis and anæsthesia of the extremities.”

Leber‡ calls attention to the advantages of the chloride of gold reaction as a method by which to detect optic-nerve atrophy when making an anatomical examination. The failure of this reaction at certain parts of the nerve shows the existence of atrophy.

The atrophy of the optic nerve may end at the chiasm, or may exist behind it, and may correspond with similar changes in the thalami optici and corpora quadrigemina.

#### GLIOMA OF THE RETINA.

The tumors which Virchow§ designates as glioma of the retina

\* Liebreich, Atlas der Ophthalmoscopie, Taf. xii. Fig. 3; E. v. Jaeger, Ophthalmoscopischer Handatlas, Taf. xvi. Fig. 76.

† Arch. f. path. Anat., B. x. pag. 192.

‡ Arch. f. Ophth., B. xiv. 1, pag. 164.

§ Geschwülste, ii. pag. 151 bis 167.



resemble macroscopically the white substance of the brain, and are in fact identical with that form of tumor formerly described as encephaloid, or medullary sarcoma of the retina.

The principal mass of the tumor, according to Virchow, consists of countless nuclei and cells. The first correspond often with the small, round, glistening nuclei of the granular layer; at other times they are larger and more granulated. The cells are likewise small, and are generally round, though sometimes of irregular shape, and provided with delicate processes. Here and there can be seen fibre cells with very long processes, and very short, thin cell bodies. They are sometimes isolated, and sometimes several are connected together.

The development of these cellular elements takes place mostly in the external granular layer, as appeared from a case which I examined,\* and as was confirmed later by Hirschberg.† Iwanoff‡ has further shown that glioma may be developed from the connective-tissue cells in the nerve-fibre layer, and, moreover, that the cells of the adventitial coat of the vessels may participate in the process. But little intercellular substance can be seen. The tumor, when fresh, appears as an amorphous, finely granulated mass, and when hardened shows a fine reticulated character. The tissue is traversed in all directions by vessels, some of which are widely dilated. When the tumor, at last, breaks through the eye and assumes an external growth, the vessels multiply greatly, and from this circumstance comes the name "*fungus hæmatodes*" formerly applied to such growths.

In glioma of long standing are found many signs of degeneration, particularly fatty and calcareous masses. In rare instances tumors occur of a form intermediate between glioma and sarcoma. Virchow has designated them as "*gliosarcoma*."

Von Graefes§ has described the clinical course of glioma in his usual masterly style.

The first stages of its development seldom come under observation, for the patients are generally small children, who do not complain of any disturbances of vision, and the attention of the

---

\* Arch. f. Ophth., B. vi. 2, pag. 324.

† Ibid., B. xiv. 2, pag. 30.

‡ Ibid., B. xv. 2, pag. 69.

§ Ibid., B. xiv. 2, pag. 103.



parents is first called to the condition by the peculiar reflex from the fundus of the eye, which is seen by feeble illumination when the pupil is dilated.

It is easier to observe the first stage when the disease affects somewhat older children or adults. Ophthalmoscopic examination reveals peculiar and generally very numerous white spots of various sizes upon the retina, differing essentially in their opacity, form, and grouping from other retinal infiltrations. These spots at places lie immediately behind the vessels of the retina, while at other places they extend through its whole thickness, hiding portions of the vessels, and very early becoming elevated above the general surface.

These changes are always soon followed by detachment of the retina. The retina and the tumor growing from it are gradually pressed forward, causing the peculiar reflex from the tumor and the details of the anomalous surface to become still more apparent. By ophthalmoscopic or, still better, by focal illumination the tumor can now be seen as a brilliant white prominence, or at certain points it may be covered with newly developed vessels, essentially different in appearance and arrangement from those of the retinal system. The reflex will accordingly be either a chalky white or a yellowish red, with an interplay of colors if the anterior surface be smooth. This peculiar reflex from the fundus of a blind eye was first described by Beer under the name of "amaurotic cat's eye."

The optical conditions for such a reflex exist when a bright-colored body lies immediately behind a transparent lens. Such a pupillary reflex may therefore be caused by pus or new-formed layers of tissue in the vitreous or by secondary metamorphoses in a detached retina. But the best example of this reflex is furnished by a glioma of the retina. A very bright white reflex from the fundus can be caused by scarcely anything else.

There may be pigment in the tumor as the result of hemorrhage, but except as caused in this way it is absent. This and the absolute transparency of the vitreous in front of the tumor furnish the conditions which make possible such a striking illumination of the pupil as is not seen in any other affection.

The steady growth of the tumor is generally accompanied by an increase of intraocular pressure. There ensues a glaucomatous



condition, characterized by diffuse clouding of the cornea, dilatation of the pupil, hyperæmia of the large veins, running in and beneath the conjunctiva, often, too, by cataract. The diagnosis is based upon the facts that even where cataract exists the reflex can be recognized as coming from the depth of the eye, and further, that in children glaucoma is almost never a primary disease, but generally a secondary one.

Frequently in the course of glioma there occurs an intraocular inflammation of a decidedly purulent character, which ends in atrophy of the eyeball. Von Graefe thought the cause of this purulent choroiditis to be the above mentioned peculiar degeneration of the glioma, by which the tumor becomes filled with fatty and calcareous masses, and thus breaks down into a granular, flocculent pap. Suppuration of the cornea is a rarer cause of choroiditis.

The course of the disease is generally not checked by this intercurrent shrinking.

The extraocular growth of the tumor is always along the course of the optic nerve, and this process may begin at a time when the intraocular tumor has attained but a moderate size.

The beginnings of the degenerative process in the opticus can be demonstrated only microscopically. Later, there occurs a swelling of the nerve substance proper, while the sheath becomes thickened by an indifferent hyperplasia. At last the condition becomes such that the swollen or degenerated optic nerve cannot be recognized in the morbid growth which fills the orbit.

The development of the tumor in the eye is generally continuous, but it may be characterized by the appearance of new centres of development. Thus, in a case described by Rindfleisch\* there was besides the retinal glioma filling all the interior of the eye a circumscribed gliomatous growth separated from it, between the choroid and the sclera.

If the entire interior of the eye be filled, there ensues at last a rupture forward, generally at the margin of the cornea, or through it, or, more rarely, through the sclera. When thus exposed to the air, the tumor assumes a dark-red appearance, bleeds copiously on slight provocation, and grows with great rapidity.

---

\* Klin. Monatsbl. f. Augenheilk., 1863, pag. 347.



It is exceedingly difficult to determine from the symptoms, the time when the optic nerve becomes involved. As the nerve increases more in a transverse than in a longitudinal direction, the eye is not perceptibly crowded forward, as happens when large tumors develop in the orbital tissues. According to Von Graefe, the signs by which to recognize a degeneration, swelling, and rigidity of the optic nerve are that the eye is driven from 1 to 2 mm. forward, and at the same time there is a slight stiffness of movement, so that the eye affected falls slightly behind the other in concomitant movements.

Moreover, upon pressure made on the eye in a direction toward the bottom of the orbit the resistance is greater than normal, and the natural depression between the eye and the orbital wall is obliterated.

Of course these symptoms can be expected only when the disease of the nerve is somewhat advanced. Its beginning cannot be recognized, but there is always reason to fear it when the tumor within the eye has attained a considerable size and has existed a long time. If rupture occur at the anterior part of the eye, or if the eye be forced forward by growths in the orbit, it is certain that disease of the nerve has long existed.

After the fatty tissue of the orbit is once affected, the growth increases very rapidly. The same is the case when the tumor breaks through the anterior part of the eye, and, aside from the mere growth, inflammatory and hemorrhagic processes are set up.

The bony walls of the orbit remain long unaffected, but the pathological process reaches the cranial cavity along the optic nerve, generally by a steady progression, but sometimes, particularly at a late stage, as if by sudden leaps. Metastases have been observed in distant organs, for instance, in the diploë of the skull, the liver, the ovaries, and the retro-peritoneal tissue.\*

Retinal glioma is almost exclusively a disease of childhood, and probably also occurs congenitally. Only very exceptionally does it develop in adults.

That hereditary causes have something to do with it, is shown by the fact that it has been observed in several cases to occur in

---

\* Knapp, *Die intraocularen Geschwülste*, 1868, pag. 5; Schiess-Gemuseus, *Virchow's Arch.*, B. xlv. Heft 3; Heymann und Fiedler, *Arch. f. Ophth.*, B. xv. 2, pag. 173.



different members of the same family. Von Graefe reports two such cases. In one family, among six or seven brothers and sisters, two were affected in childhood with glioma. In the other, the mother of a child affected with glioma had lost several brothers and sisters during infancy by "cancer of the eye."

The assertion made by some authors that glioma of the retina must have an inflammatory origin, Von Graefe regards as undoubtedly erroneous. Inflammatory processes occur in the course of glioma after the tumor has attained a considerable development, but they are not the occasion for its beginning.

According to Von Graefe, the course of the disease is uninterruptedly progressive. He does not admit the occurrence of pauses, as described by Mackenzie and others. Between the time of the first observation of the disease—that is, from that stage when only a small portion of the interior of the eye is filled with the tumor until it attains a perceptible extraocular development—there intervenes a period of from one to three years.

The absorption of a retinal glioma is, according to Von Graefe, not conceivable. The observations which have been thought to show the possibility of such a thing must be interpreted as mere shrinkages of the eye, and of a transitory character.

It is finally to be mentioned that glioma not infrequently occurs in both eyes. Generally the second eye is attacked after the disease is already far advanced in the first. Anatomical examination has shown that this does not occur by simple extension through the chiasm. This bilateral disease may perhaps be regarded as a metastasis, if it be not sufficient to regard this as parallel with those frequent cases in which diseases occur simultaneously in both eyes without any known causes.

Treatment furnishes no very satisfactory results. The indication surely exists for as early an extirpation as possible, and offers at least the hope of saving the life, when the intraocular tumor is small and the optic nerve is not yet affected. If, however, the intraocular tumor be already far developed, and the disease have extended to the nerve, extirpation seems only to hasten the fatal result.

It has already been remarked that the beginning of degeneration in the optic nerve cannot be diagnosed; but its existence is always to be assumed when the disease has lasted a long time, and



when the interior of the eye is entirely filled with the tumor. Von Graefe, therefore, advises in these cases, in making the extirpation, to divide the optic nerve, not as usual with the scissors, but with a neurotome, and as far back in the orbit as possible.

After decided degeneration of the optic nerve is once established, the local reappearance of the disease in the orbit generally occurs within a few months after the extirpation. Even in cases where the cross-section of the optic nerve made during the operation appeared, both macroscopically and microscopically, to be perfectly normal, reappearance of the disease in the orbit has been observed within a year.

Further experience must decide the question whether better results are to be obtained by a periosteal extirpation of the entire contents of the orbit (see page 200).



## GLAUCOMA.

---

THE real nature of glaucoma was first understood when an abnormal increase in the intraocular pressure came to be regarded as the essential element in the disease. It was known to the older ophthalmologists that in glaucoma the eye becomes abnormally hard, but the fundamental importance of this increase in intraocular pressure was first appreciated and pointed out by Von Graefe.

Von Graefe regarded glaucoma as essentially an inflammatory disease which might be called a secreting choroiditis, but Donders showed that an intraocular pressure might exercise its deleterious influence upon vision, entirely independent of inflammation.

Donders, therefore, regarded the increased pressure as in itself the essential cause of glaucoma, and the occurrence of the inflammation as an exceedingly frequent complication.

Since the increase of intraocular pressure may reach a very high degree without the occurrence of any inflammatory symptoms, an inflammation cannot, at least for these cases, be regarded as the cause of the increased pressure. It in no way relieves the difficulty to regard the increased pressure as the consequence of an inflammatory process. No inflammation of the eye, not even acute choroiditis, causes by itself an actual and permanent increase of the intraocular pressure. Even copious inflammatory exudations, for instance, in detachment of the retina, generally do not cause an increase of pressure, but rather a compensating resorption of the vitreous body. The question then always recurs, why it is that in secreting choroiditis there is an increase of pressure, and we are driven to the conclusion that, in the inflammatory as well as in the non-inflammatory cases, there must be some modification of the physiological laws which govern the secretion of the ocular fluids.

Ludwig showed that the secretion of the submaxillary gland was regulated by the nerves. Donders assumed a similar relation as regulating the secretion of the ocular fluids, and regarded the



fifth nerve as the one which controlled these secretions, since after its division and in certain cases of its paralysis, an evident decrease in tension was observed.\*

Grünhagen and Hippel† found, also, that by electric irritation of the root of the fifth nerve an immediate and very remarkable increased intraocular pressure was caused.

According to Donders, the primitive form of glaucoma (glaucoma simplex) is represented by those cases in which there is simply increased pressure, but no apparent inflammation, while those cases which are complicated by inflammation are classified as glaucoma cum ophthalmia, or as inflammatory glaucoma.

In defining the two forms, it is to be noticed that cases of inflammatory glaucoma may gradually pass over into a non-inflammatory condition. Still, my experience satisfies me that all cases in which, during the course of the disease, there has been glaucomatous inflammation, even though transitory, must be regarded as inflammatory glaucoma.

#### GLAUCOMA SIMPLEX.

All the symptoms of glaucoma simplex may be traced back to a very gradual increase in the intraocular pressure. At first this increase in pressure is often very slight and difficult to recognize by the sense of touch, even though excavation of the optic disc due to pressure be already taking place. In the later stages the eye offers greater resistance to touch, and often becomes stone hard.

The consequences of this gradual increase of pressure appear first in a change of form of the optic disc. According to hydrostatic laws, the intraocular pressure acts uniformly upon every part of the membranous envelope of the vitreous body. The place of entrance of the optic nerve is, however, a weak point, because just here the sclera is penetrated by the nervous fascicles, and it is therefore plain that just at this place it will first yield to the increased pressure.

The essential anatomical character of this excavation consists in this, that the lamina cribrosa is compressed and forced back-

---

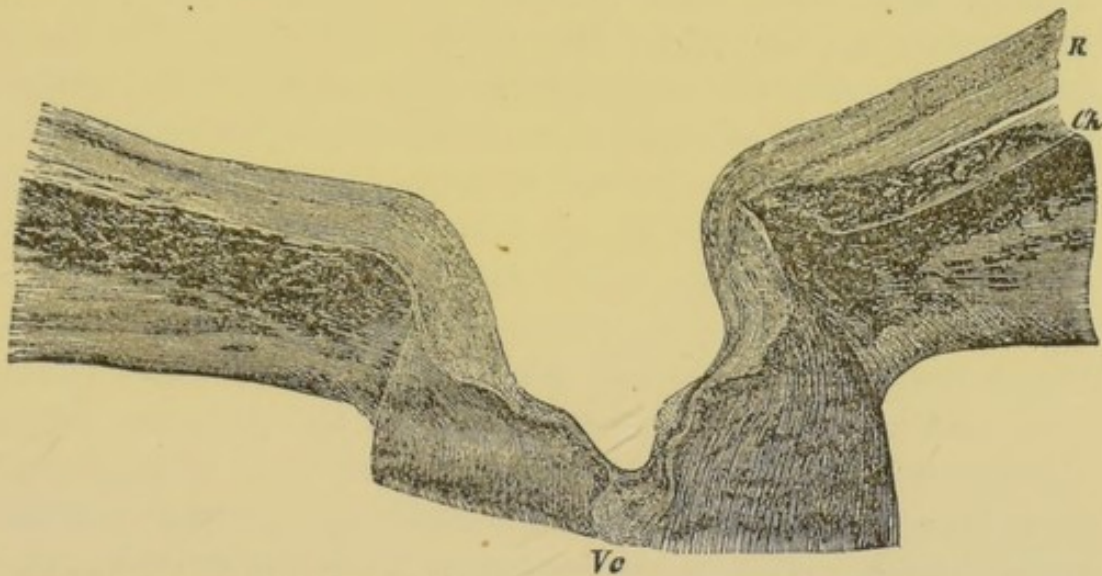
\* Arch. f. Ophth., B. ix. 2, pag. 216; Klin. Monatsblatt für Augenheilkunde, 1864, pag. 434.

† Arch. f. Ophth., B. xiv. 3, pag. 219, und B. xv. 1, pag. 265.



ward behind the general inner surface of the sclera, often so far that the floor of the excavation lies posterior to the outer surface of the sclera. The place of entrance of the optic nerve is now occupied by a hollow, its floor formed by the lamina cribrosa and its walls by the sclera. It is filled partly by the vitreous body, and partly by the degenerated tissue of the optic nerve, lying above the lamina cribrosa.

FIG. 47.



*R*, retina; *Ch*, choroid; *Vc*, central vessels. The walls of the excavation are covered with an ill-defined tissue, consisting of the remains of the terminal fibres of the optic nerve and of the vitreous body. Its floor is funnel-shaped, due to the dilatation of the central canal of the retinal vessels.

The excavation is often kettle-shaped, which may be explained partly by the anatomical structure of the lamina cribrosa. That part of the optic nerve which penetrates the sclera is often not a simple cylinder, but is enlarged at certain places in such a way that the greatest diameter of the lamina cribrosa is greater than the foramen choroideæ, and lies posterior to it. When an optic nerve so formed becomes excavated, a kettle-shaped depression must necessarily result. Moreover, the same pressure which forced the lamina cribrosa backward acts upon the lateral walls of the excavation itself, tending thus to bulge them outward.

The retinal vessels, together with the remnants of the nervous elements, lying upon the lamina cribrosa, are naturally at the same time forced against the walls of the excavation, and since the greater part of them pass over to the median side of the optic nerve, they mount also up the median lateral wall of the



excavation. When, after a protracted glaucomatous process, the excavation has become very deep, it may happen that the vascular canal in the centre of the optic nerve becomes distended. The vessels are thereby forced against the median lateral wall of the excavation, and it may happen that upon ophthalmoscopic examination the floor of the excavation appears destitute of vessels.

In the ophthalmoscopic view of the pressure excavation special notice is to be taken of the sharp border lying in the plane of the choroid, and also of the floor of the excavation. The latter presents generally the characteristic appearance of the lamina cribrosa,—that is, a net-work of connective tissue, having rounded or oval meshes, penetrated and filled by the fascicles of nerve fibres, which are of a bright-gray color.

At the point where the retinal vessels pass over the sharp edge of the excavation they experience a compression, which, when the increased pressure is very great, and especially when it has developed very rapidly, causes a stasis of blood in the veins. Oftener, and generally most striking in the case of the veins, there is another change in the ophthalmoscopic appearance of the retinal vessels. They appear to end in hook-shaped extremities at the point where they bend over the edge of the excavation to descend upon its lateral wall, while the portions of vessels visible upon the floor of the excavation appear to be sharply cut off at the point where they are hidden by the overhanging edge.

These vessels also, although actually continuous by a portion of their trunks not visible, appear as if displaced from one another laterally. This may be understood by remembering that during the ophthalmoscopic examination we cannot see the excavation from various points of view, but only through the pupil of the eye under examination.

Generally the entire median wall of the excavation is invisible, which explains fully the above described appearance of the vessels.

More frequently it is possible to see the wall on the temporal side of the excavation in its whole extent from the choroidal margin to the lamina cribrosa, and to appreciate the angle which it forms with the latter. One can follow the curves of the fine retinal vessels as they pass from the floor to the wall of the excavation, and again when they leave the wall to spread out upon



the plane of the retina. In such cases the lateral wall often appears of a light-brown color, on account of the pigment contained in this part of the sclera.

The depth of the excavation may be calculated from the optical difference of the correcting lenses needed to see distinctly in the upright image, first the plane of the retina, and then the floor of the excavation. In the inverted image the difference in parallax, produced by moving the convex lens, is directly dependent upon the difference of level. One must notice also that in slight movements of the convex lens the entire margin of the excavation moves over the floor. If the movements of the convex lens be made at right angles to the course of some particular retinal vessel, one can see distinctly that the portion of the vessel lying in the plane of the retina appears to move farther than that portion upon the floor of the excavation. The greater the parallax the deeper the excavation.

The margin of the excavation is often surrounded by a narrow bright ring. I have satisfied myself from anatomical examination that this is due to an atrophy of the choroid surrounding the optic disc. I found the choroid to be changed in this place to a very thin, absolutely transparent membrane, just as in a high degree of atrophy caused by elongation of the axis of the eye, except with this difference, that in myopia the absolutely atrophied portion merges gradually into the normal choroid, while the atrophied part of the choroid surrounding an excavation is sharply bounded by the normal choroidal tissue. The cause of the atrophy is probably this, that often very considerable bundles of fibres run from the choroidal ring into the lamina cribrosa, and when this last is forced backward the tension is extended to the choroidal ring, causing its atrophy. It is only seldom that the form of the atrophied portion is serrated instead of annular.

It often happens also that the atrophied choroidal ring is staphylomatous. In these cases the excavated optic disc is surrounded by a small annular scleral ectasia, which of course supports a part of the pressure, which otherwise would have caused more rapid destruction of vision.

With slight practice in ophthalmoscopic examination a fully developed pressure excavation can scarcely be overlooked, and still under certain circumstances there may be considerable diffi-



culty in diagnosis, since physiological excavations due to senile changes, or still more to atrophy of the optic nerve, may assume forms scarcely to be distinguished from pressure excavations.

The physiological excavation is in its typical form not less characteristic than the glaucomatous. Nevertheless it is probable that in advanced age, perhaps from senile atrophy of the connective tissue, a physiological excavation may become unusually deep and broad, so that it approaches upon all sides the border of the optic disc. Moreover, the sharpness of the margin and the steep walls of the excavation furnish no certain diagnostic criteria, since the margin of the physiological excavation may also be very sharp and its walls very steep.

One must pronounce for the existence of a pressure excavation when a sharp margin and steep wall coincide with the margin of the optic disc,—that is, with the inner nerve sheath,—and so, too, in cases where the excavation is only partial, so that a part of the optic disc lies in its normal plane.

The greatest diagnostic difficulty is when atrophy of the optic nerve develops where there was previously a deep physiological excavation.

The excavation becomes by the degeneration of the nervous elements deeper and broader, its border approaches that of the optic disc, and the ophthalmoscopic appearance is scarcely to be distinguished from that which is seen when pressure excavation causes atrophy of the optic nerve.

Under these circumstances the other diagnostic signs are often wanting. The evidence of an increased tension of the eye may be doubtful, and the other symptoms due to increased pressure are then frequently absent. Spontaneous arterial pulsation, for instance, occurs where the increase of pressure is considerable and rapid; in glaucoma simplex this generally fails, and the fact that this phenomenon can easily be produced by slight pressure of the finger upon the eye cannot confirm a doubtful diagnosis, because in this respect very considerable physiological differences exist. Very frequently under absolutely physiological relations a slight pressure of the finger suffices to produce the arterial pulsation.

Frequently the functional examination clears up the difficulty, since under these circumstances a defect appearing first in the outer half of the visual field speaks more for atrophy of the optic



nerve. In other cases the further course of the disease furnishes the first clue to the real nature of the excavation, since either the progressive atrophy or the increase of intraocular pressure will become plainly apparent.

These diagnostic difficulties are increased by the circumstance that pressure excavations may occur in eyes in which an increase of tension is not perceptible to touch.

The diagnosis of glaucoma simplex is made almost alone upon the evidence of increased intraocular pressure and the excavation of the optic disc dependent upon it. If the increase of tension be doubtful, we must remember that for the reasons above stated the ophthalmoscopic examination alone does not always furnish decisive results.

It is of great importance in such cases to compare the two eyes. Decided physiological excavation is almost always bilateral. Accordingly, if in one eye the optic disc present a flat surface, while in the other it is excavated, it must be due to pressure; but in such a case one would not fail to notice a difference in tension between the two eyes.

For the evidence of increased tension we rely principally on the sense of touch. According to Coccious, this examination is best made as follows. The patient is directed to look upward while the examiner places his two index fingers upon the sclera below the cornea, and then tests the resistance which the eye offers to a slight pressure. Or one may press the margin of the under lid upon the sclera and estimate the size of the depression thereby caused. In both cases we endeavor to determine the degree of force necessary in order to produce a given impression upon the eye.

There are instruments called tonometers, designed to measure exactly the force necessary to produce on the eyeball a depression of known and measurable depth; but they have not yet been generally adopted in practice, for reasons not necessary here to enumerate.

Bowman\* has proposed to indicate the normal tension of the eye as determined by the sense of touch by the letter T, and the degrees of increased tension by + T<sub>1</sub>, T<sub>2</sub>, T<sub>3</sub>, and the degrees

---

\* Ophth. Hosp. Rep., vol. v. 1, pag. 1.



of decreased tension by  $-T_1, T_2, T_3$ . This whole scale is of course simply a system of abbreviations which in economy of time is of slight value. It requires only a little more time and space, but is much more comprehensible to the general understanding, for instance, instead of " $+T_3$ ," to write "stone hard," or instead of " $+T_1$ ?" to write "doubtful increase of tension."

If, as is generally the case in glaucoma simplex, the increase of intraocular pressure develop only gradually, and if in consequence of this the optic disc be only slowly excavated, the pressure excavation, when physiological excavation pre-existed, may reach a considerable depth without disturbing vision.

Finally, however, a destruction of nervous elements is sure to occur. For the nerve fibres which pass through the lamina cribrosa are compressed simultaneously with it; but even if they escape this danger, they are pressed against the sharp edge of the excavation at the point where they pass over into the retina. The consequence is a gradual atrophy of the nerve fibres, most apparent at the margin of the excavation. Just here, where the layer of nerve fibres should be thickest, it is often reduced to a minimum.

Excavated optic discs often assume for this reason the opaque white color characteristic of atrophic degeneration. In the retina there follows, as the invariable consequence of this condition, an atrophy of the nerve fibres and ganglion cells, while the other retinal elements remain unchanged.

The first noticeable effect of this process upon the sight is a limitation of the field of vision, which generally begins in the inner upper or inner lower quadrant, and extends from there toward both the periphery and the centre. It may thus gradually assume a concentric form, involving the inner rather more than the outer half of the field of vision, so that by a simultaneous reduction from above and below the visual field is reduced to a small horizontal or inclined stripe whose inner limit approaches the fixation-point. Central vision is often for a long time not interfered with; indeed, it may happen that with a high degree of concentric limitation of the field of vision a small visual field with a fair degree of central vision remains. Generally, however, the defect spreads from the inner half of the field of vision as far as the fixation-point, causing then serious disturbance of vision.



Glaucoma simplex may in this way cause absolute blindness without the occurrence of inflammatory symptoms or any inconvenience other than the loss of vision. The eye becomes stone hard, the optic disc deeply excavated, and generally the branches of the anterior perforating veins running in the conjunctiva are dilated by mechanical hyperæmia. Contraction of the anterior chamber and sluggishness of the iris also occur. Other externally visible changes, which are so noticeable in inflammatory glaucoma, for instance, clouding of the cornea and dilatation of the pupil, do not occur in glaucoma simplex. I am satisfied that all cases of glaucoma which present either of the two last-named symptoms should be regarded as belonging to the inflammatory form, even although there is at the time of the examination no pericorneal injection.

The course of the disease is generally very tedious, and extends over several years; it is only exceptionally that glaucoma simplex causes blindness in a shorter time. Both eyes are generally affected.

#### INFLAMMATORY GLAUCOMA.

Under this head are included all those cases in the course of which inflammatory symptoms occur. They form the great majority of cases. The relative frequency of the two forms cannot be exactly stated. Aside from the possibility above referred to, of confounding glaucoma simplex with certain changes in the form of the optic disc, the existing statistical examinations disagree considerably. Statistics\* showing simply the condition in which the patients presented themselves for treatment, give for glaucoma without inflammatory symptoms about one-third of all cases, while Haffmans,† among 82 eyes which were absolutely blinded by glaucoma, recognized inflammatory symptoms 73 times. One may assume that generally an increase of pressure precedes the appearance of inflammatory symptoms; indeed, it is doubtful whether glaucomatous inflammation ever occurs without previous increase of pressure.

---

\* Becker, Bericht der Wiener Augenlinik, 1867, pag. 9; Lucian Rydel, Ueber Glaucom, *ibid.*, pag. 135; Laquer, Etudes cliniques sur le Glaucom, Annales d'Oculistique, 1869, Janvier et Février, pag. 33.

† Arch. f. Ophth., B. viii. 2, pag. 145.



The fact that in glaucoma simplex the eye may become stone hard without inflammation, shows that excessive pressure does not of necessity cause inflammation; still, it is very probable that it will do so if the increase of pressure be rapid. A case reported by L. Rydel\* is very interesting in this connection. In it, rapid and very considerable increase of pressure was observed as the precursor of very severe glaucomatous inflammation.

Nearly all the symptoms which give to glaucomatous inflammation its peculiar character may be referred to the influence of a rapid increase of intraocular pressure. It causes a peculiar appearance in the pericorneal injection. Not only is there hyperæmia of the numerous fine arterial vessels which radiate about the margin of the cornea, but there is at the same time, and in a still higher degree, a decided venous hyperæmia. The fine venous net-work surrounding the cornea, which in the normal eye is scarcely visible, and the larger branches, part of which, as perforating vessels, emerge from the sclera, are excessively and uniformly dilated. They are over-filled, since from the sudden increase of pressure the flow of blood through the *venæ vorticosæ* is made difficult.

We observe similar processes in the ciliary nerves. They can accommodate themselves to a gradual increase of pressure, but a sudden increase causes disturbances in both the sensitive and the motor fibres.

Among these are, first, those severe ciliary neuralgias which affect not only the eye, but principally the supra-orbital region, and often the entire half of the head. Frequently these pains are the symptom of which the patients complain most, and this fact may lead to serious diagnostic errors. A false diagnosis may still more easily be made when simultaneously severe vomiting occurs, which distracts the attention from the eyes to the gastric organs.

Aside from these pains, symptoms of paralysis appear in the sensitive nerves of the eye itself. A part or the whole of the cornea loses its sensibility, so that it may be touched with the finger without any symptoms of reaction. That in these cases the conduction is actually interfered with by the pressure, is proved by the observation of Von Graefe,† that immediately after the puncture of the anterior chamber sensation may again appear in the cornea.

---

\* L. c., pag. 140.

† Arch. f. Ophth., B. i. 2, pag. 305.



The paralysis of the motor fibres of the ciliary nerves is made evident by the dilatation and rigidity of the pupil, and the limitation of the range of accommodation. Mydriasis is a very important diagnostic sign of inflammatory glaucoma. No other inflammation of the eye causes such a striking spontaneous dilatation of the pupil.

The shallowness of the anterior chamber also shows the rapid progress of the intraocular pressure which characterizes inflammatory glaucoma. While in glaucoma simplex there is generally an equilibrium established between the pressure behind and that in front of the lens, in inflammatory glaucoma the lens, together with the iris, is forced forward, and the depth of the anterior chamber is thereby considerably diminished.

There develops simultaneously a cloudiness of the refracting media. The most striking and important is the diffuse cloudiness of the cornea, which may be easily recognized by focal illumination. At first it is uniformly disseminated over the entire cornea, but if the glaucomatous inflammation continue uninterruptedly several days, dull opacities may develop, especially in the deeper layers of the cornea, while, if the inflammation be very severe, numerous small irregularities may appear upon the surface. On the contrary, the oft-reported clouding of the aqueous humor appears to me very doubtful. If the cornea be clouded, it is scarcely possible to form an opinion whether a diffuse cloudiness exists either in the aqueous humor or in the deeper media. Coccia\* found the aqueous humor, which was received in a watch-crystal during paracentesis, frequently of a yellow color but not clouded.

The case is the same with the diffuse cloudiness which is said to occur in the vitreous body. Only when examined through a perfectly clear cornea is it possible to determine the existence of cloudiness in the vitreous body. But the clouding of the cornea is, according to my experience, so constant and so early an occurrence in inflammatory glaucoma that I have never been able to demonstrate the simultaneous presence of cloudiness in the vitreous body.

If the general fundus of the eye be visible, one frequently observes spontaneous arterial pulsation during the inflammatory

---

\* Arch. f. Ophth., B. ix. 1, pag. 19.



attack, whether pressure excavation has already been caused or not. It may disappear in the course of a few hours, and then reappear.

The disturbance of vision associated with the glaucomatous inflammatory attacks is caused partly by the increase of the intraocular pressure paralyzing the optic-nerve fibres, either in the retina itself or in the lamina cribrosa, and partly by the clouding of the cornea. Finally, it may to some extent be due to interference with retinal circulation, since Donders has shown that simultaneously with the appearance of the arterial pulse produced in the normal eye by pressure of the finger on the side of the eyeball, the field of vision is always obscured.

All these causes together may induce a very considerable diminution of central vision without any simultaneous contraction of the visual field, in cases where the glaucomatous inflammation sets in without the previous existence of a pressure excavation.

Later, of course, defects in the visual field develop in these cases, beginning generally in the upper or lower median quadrant.

The blindness which sooner or later is caused by inflammatory glaucoma is generally attributed to the optic-nerve excavation; but this cannot be the only cause. Cases occur in which inflammatory glaucoma causes blindness without the development of any excavation, and in which accordingly the lamina cribrosa appears to possess an abnormal capacity for resisting the increase of intraocular pressure.\* In such cases the optic nerve generally shows signs of atrophic degeneration. We may assume that in these cases the increase of intraocular pressure exerts a hurtful influence upon the circulation and nutrition of the inner coats of the eye, and that blindness is caused by the ischaemic paralysis of the retina or by a simultaneous disturbance of its nutrition (softening?).

Among the subjective symptoms which frequently occur in inflammatory glaucoma is first to be mentioned the appearance of a halo surrounding the flame of a light. The outer margin of this halo is red, the inner margin blue-green, and between are the ordinary prismatic colors. Donders† explained this phenom-

---

\* Comp. Mauthner, *Lehrbuch der Ophthalmoscopie*, pag. 281; A. v. Graefe, *Arch. f. Ophth.*, B. xv. 3, pag. 232; L. Rydel, *Arch. f. Ophth.*, B. xviii. 1, pag. 1.

† *Arch. f. Ophth.*, B. viii. 2, pag. 165.



enon as a refraction in the lens, which can occur entirely independent of glaucoma whenever the pupil is somewhat wider than usual. The phenomenon does not occur in glaucoma simplex where the refracting media remain unchanged and the pupil is not dilated. That it occurs more frequently in inflammatory glaucoma appears to depend partly upon the dilatation of the pupil, partly also perhaps upon a change in the lens, but principally upon the clouding of the cornea, which accompanies the attacks of glaucoma. This phenomenon can be very easily illustrated by observing the flame of a candle through a glass strewed with lycopodium powder.

The prominent subjective light and color symptoms which accompany severe inflammatory attacks are probably to be regarded as the consequences of the rapid increase of the intraocular pressure.

In the majority of cases the glaucomatous attacks are at first very mild, pass quickly away, and are separated by an interval, during which a reduction of the range of accommodation and an evident increase of tension are the only abnormal symptoms. The individual attacks are characterized in their mild forms by increase of tension, paresis of accommodation, slight sluggishness and dilatation of the pupil, diffuse clouding of the cornea, hyperæmia of the retinal veins, the perception of halos, and an irregular obscurity of vision, so that everything appears to the patient as if in a cloud or as if thick smoke swept before the eyes. In more severe attacks there are added to these symptoms flattening of the anterior chamber, indistinctness of eccentric vision, arterial pulsation, and even peripheral defect in the field of vision, especially by weak illumination.

Von Graefe called this condition the prodromal stage of glaucoma. Evidently the condition is one of periodically occurring rapid increase of intraocular pressure already complicated with inflammatory symptoms.

Later, the inflammatory attacks become more frequent, often occurring in a distinctly intermittent manner. The inflammatory symptoms also assume a more acute character, are protracted after the remission of the most severe symptoms, so that there develops a condition of chronic inflammation (glaucoma chronicum) with more or less severe exacerbations, which finally, by increasing



excavation of the optic nerve and loss of central vision, causes blindness.

Severe glaucomatous inflammation may run this course in a very few weeks (glaucoma acutum); indeed, it sometimes happens that absolute blindness occurs in the course of a few days or even hours. Such cases, already mentioned by Mackenzie,\* have been designated by Von Graefe as glaucoma fulminans.

The glaucomatous process may continue and cause great pathological changes, even after absolute destruction of vision. The iris becomes reduced to a narrow band, the pupillary margin is everted forward, so that a black ring of the uveal surface becomes visible, the lens becomes cataractous and swollen, the cornea is greatly clouded, and often partially breaks down, hemorrhages occur into the anterior chamber, into the vitreous body, and in the parenchyma of the inner membranes. The sclera finally yields to the steadily increasing intraocular pressure, so that staphylomas develop especially upon the anterior part of the eyeball. Even purulent inflammation may occur and cause atrophy of the eyeball.

It should, however, be specially mentioned that this is not the only way in which a glaucomatous eye may finally become atrophied. In a certain class of cases the eye after repeated inflammatory attacks becomes gradually softer, and, yielding to the pressure of the recti muscles, assumes a roundish, cuboidal form. All painful attacks then generally cease, and finally the eye shrinks to a very small stump. This process depends upon inflammatory detachment of the retina. Arlt† was the first to demonstrate anatomically that as a general thing detachment of the retina finally occurs in glaucomatous eyes. This statement has been very unreasonably doubted; but its truth has been fully confirmed by later investigations. Arn. Pagenstecher‡ found detachment of the retina, together with considerable excavation of the optic nerve, in a subject who two years before death had been blinded by glaucoma. I examined§ a case in which an eye had been blinded by repeated glaucomatous inflammations, and which, during a new and severe attack, was extirpated by Von Graefe.

---

\* Practical Treatise, London, 1854, pag. 570.

† Augenheilkunde, 1856, B. ii. pag. 161.

‡ Arch. f. Ophth., B. vii. 1, pag. 92.

§ Ibid., B. ix. 1, pag. 199.



The dissection showed a recent detachment of the retina, together with a deep pressure excavation.

It has been shown that detachment of the retina may occur during the later inflammatory attacks, and may then be the cause of atrophy of the eye.

The time of life is the most important element in the etiology of glaucoma. It occurs very rarely before the thirtieth year. From this limit the predisposition is in direct proportion to the age. It is more frequent in the female than in the male sex. A predisposition to the disease may be inherited, and, according to Von Graefe,\* this is especially true of the inflammatory forms.

The condition of refraction exercises a decided influence. Glaucoma rarely occurs in myopic eyes, and in these rare cases it is generally of the simple form. Hypermetropia exists in the majority of cases, and the question naturally arises, whether this is to be regarded as a cause or as a consequence of the disease. It may be that the influence which the increased intraocular pressure exercises upon the form of the eye flattens the cornea and thereby causes hypermetropia. But neither Donders† nor Coccius‡ could by ophthalmometric measurement demonstrate any such effect upon the curvature of the cornea, and we may therefore assume that the attenuated sclera of myopic eyes yields more easily to an intraocular pressure, while in emmetropic and hypermetropic eyes this pressure affects rather the optic nerve than the sclera.

It is probable that the rigidity of the sclera, which so often occurs in old age, favors the occurrence of glaucoma. Whether fatty degeneration of the sclera, which was observed by Coccius§ in one case, can be regarded as a cause of glaucoma, is doubtful. Instead of being more resisting, fatty degenerated organs are generally more yielding. Moreover, a deposit of the phosphate of lime in the sclera is, according to Donders,|| a frequent occurrence in old age, and may easily be mistaken for fatty degeneration.

\* Arch. f. Ophth., B. xv. 3, pag. 228.

† Ibid., B. viii. 2, pag. 163.

‡ Die Heilanstalt für Augenkranke zu Leipzig, 1870, pag. 56, und Ophthalmometrie und Spannungsmessung am kranken Auge, Leipzig, 1872, pag. 44.

§ Arch. f. Ophth., B. ix. 1, pag. 21.

|| Ibid., B. ix. 2, pag. 217.



The attack of glaucomatous inflammation is favored principally by mental emotion and loss of sleep.

Nearly all ophthalmologists have observed cases in which glaucoma came on soon after the use of atropine. It is possible that this is due to something more than accident; still, in a somewhat limited series of experiments which I have made in the use of atropine in glaucoma simplex, the result has been negative; no inflammatory symptoms were produced.

#### SECONDARY GLAUCOMA.

Certain other pathological processes may become complicated with glaucomatous intraocular pressure and its consequences. Among the diseases of the cornea are first to be mentioned those staphylomatous cicatrices with which the iris has formed adhesions (staphyloma partiale and totale). Iritis, with complete annular attachment of the pupillary margin, may also cause glaucomatous blindness.

Moreover, the luxation of the lens, or its expansion in traumatic cataract or in discision, may produce glaucomatous intraocular pressure.

Moreover, retinal hemorrhages, which at first differ in no way from other forms of this disease, play an important rôle. Gradually, however, in the course of some months, an increase of tension occurs; glaucomatous inflammation develops, generally with severe ciliary neuralgia, and vision which had already been seriously affected is absolutely destroyed.

Finally, certain cases should here be mentioned in which Horner\* demonstrated a severe neuralgia of the fifth nerve to be the cause of a somewhat abnormally progressing glaucoma.

These cases of secondary glaucoma are, however, frequent enough, or are sufficiently characterized by their anomalous course, to justify the assumption of a connection between the glaucoma and the pre-existing disease. In other cases, on the contrary, the occurrence of glaucoma with other affections of the eye is to be regarded simply as an accidental complication. Among such cases belongs, for instance, glaucoma with senile cataract or with aphakia. Glaucoma may also occur as an accidental complication simultaneously with

---

\* Arch. f. Ophth., B. xii. 2, pag. 1.



amblyopia, due to extraocular causes, or together with choroiditis, retinitis, etc. It is especially interesting, too, that glaucoma may develop with pre-existing detachment of the retina.\*

#### TREATMENT.

To Von Graefe undying gratitude is due for introducing iridectomy in the treatment of glaucoma, and thus greatly diminishing the number of those who formerly fell victims to this disease.

Besides iridectomy, scarcely any other treatment is of the least avail. Opiates or morphine injections may perhaps modify an existing nervous excitement, or even help to relieve slight inflammatory attacks; their effects, however, are only palliative.

Paracentesis of the anterior chamber causes a temporary diminution of the pressure, but, even though frequently repeated, does not prevent the further development of the disease.

Only iridectomy causes a permanent diminution of the glaucomatous pressure. To accomplish this object it must be broad and peripheral: the original idea, however, that by this method the iris was excised up to its ciliary margin has been proved to be an error. Be the iridectomy as peripheral as possible, the inner wound will still always be in the cornea,—that is, anterior to the circumference of the membrane of Descemet,—and even when the iris is excised close to the exterior wound, a narrow border will always remain attached to the ciliary body. Nevertheless, the iridectomy should be made so far in the periphery that, upon ophthalmoscopic examination, the equator of the lens and the zonular space, exterior to it, can be distinctly seen.

The place of the iridectomy is so to be chosen that the diffusion of light dependent upon the enlargement of the pupil may be reduced as much as possible. Bowman recommends to make the iridectomy above, in order that it may be covered by the upper lid. Arlt is in favor of the iridectomy below, because patients very soon learn, by raising the lower lid, to cover the coloboma, especially in the downward direction of vision usual when working. Both methods possess the advantage of enabling the operator more easily to excise the iris. Certainly the iridectomy either outward or inward is least to be recommended.

---

\* Haffmans, *Bijdrage tot de kennis van het glaucoma*, Utrecht, 1861, Fall iv.



The curative effect of the operation is best shown in recent acute cases of inflammatory glaucoma which have occurred in individuals whose vision was previously good. The obstruction of the circulation in the retina, the paralysis of the nerve fibres, and all the disturbances of vision depending upon it, generally disappear immediately after the iridectomy. The clouding of the cornea disappears either immediately or in the course of a few days, according to its intensity. Ecchymoses of the retina often occur after iridectomy in inflammatory glaucoma, but unless, unfortunately, they occupy the region of the macula lutea, they do not greatly disturb vision, and in the course of a few weeks they are re-absorbed.

In reference to the prognosis, the earlier the operation and the fewer the permanent changes which have already taken place the better the result which may be expected. In recent cases, even with great diminution of vision, but with normal or only slightly contracted field of vision, a perfect recovery may be predicted as the result of the operation; but in the later stages, where a pressure excavation has already been formed and the visual field has become considerably contracted, no more can be expected than to preserve the *status quo*. Occasionally, however, even under such circumstances, unexpectedly good results follow iridectomy.

If sight be already lost, or reduced to a very small eccentric field of vision, nothing can be expected from an operation. The only exceptions to this are those rare cases of acute inflammatory glaucoma which in the course of a few hours cause blindness. In one such case, in which only a very slight perception of light remained, but in which iridectomy was performed on the day when the blindness occurred, Von Graefe obtained distinct vision and a normal field.\*

If absolute blindness have already existed for a considerable time, or if it have come on gradually, the operation can be indicated only by the persistence of the severe ciliary pains; still, in the later stages of the disease their relief by an operation cannot be certainly relied on.

In glaucoma simplex the results of iridectomy are, on the whole, less satisfactory. The disturbances of vision are here principally

---

\* Arch. f. Ophth., B. viii. 2, pag. 246.



to be referred to the atrophy of the nerve fibres caused by the excavation. The iridectomy, of course, cannot improve their condition, and in the best cases the most that can be expected from it is to preserve the *status quo*. The value of iridectomy in glaucoma simplex is, of course, essentially influenced by the circumstances of the particular case. In any affection of the optic nerve in which a pre-existing physiological excavation becomes so widened and deepened that it is liable to be confounded with a pressure excavation, the iridectomy at least does no harm. It, moreover, sometimes happens that cases of inflammatory glaucoma at the time when the iridectomy is undertaken present no longer any evidence of existing inflammation, and the operation may then give an unexpectedly good result. But such cases are not glaucoma simplex. Most of those cases in which iridectomy does harm or is immediately destructive are those with undoubted increased tension and pressure excavation, with dilatation of the anterior perforating veins, but without clouding of the cornea, dilatation of the pupil, or pain, and without occasional obscurity or clouding of the field of vision, having a slow, uninterrupted, uniform course, and which, beginning with a limitation upon the median periphery, go on to blindness. Such cases we call glaucoma simplex.

There is no objection to calling these cases glaucoma malignum, but it should not be forgotten that we are not able to predict this malignity with that certainty which is desirable.

After the iridectomy the position of affairs soon becomes clear. The eye remains stone hard, and in the course of the first twenty-four hours pains occur, with copious lachrymation, pericorneal injection, and clouding of the cornea. One often sees, also, slight hemorrhages in the iris. The iris and the lens appear forcibly pressed against the inner surface of the cornea; the anterior chamber remains empty, and vision is soon lost. One or two months generally pass away before the inflammation runs its full course, but even then the anterior chamber does not fill, or at least only partially. This delayed refilling of the anterior chamber is, moreover, not the cause of the inflammatory symptoms, for in glaucoma simplex, and often also in inflammatory glaucoma, one sees the anterior chamber remain empty without the appearance of inflammation or any other bad symptoms.

The female sex appears much more disposed to malignant glau-



coma than the male. The cases which I have observed have been those of patients in whom, shortly before or in the beginning of the climacteric years, glaucoma simplex had developed in one eye, while in the other there was no apparent increase of pressure. In general, when the disposition to malignant glaucoma exists, it is for both eyes. Von Graefe's\* statement that, at most, two per cent. of the cases operated on for glaucoma simplex run a malignant course, is surely based upon too low an estimate.

The result of iridectomy is generally unfavorable in those cases of secondary glaucoma which have developed after retinal hemorrhages. In such cases vision is frequently greatly impaired by the hemorrhages, and is irrevocably lost by the glaucomatous disease. But if severe and continuous pains remain which yield to no other treatment, nothing can be expected from iridectomy, and it only remains to enucleate the eye. Still, these cases may end in atrophy and entire rest of the eye.

In the great majority of cases the cure caused by iridectomy is permanent. It is only exceptionally that an increase of pressure gradually returns and detracts from the good result which had been obtained. This appears especially to happen in cases which have run a chronic course, or where the operation has not been skilfully performed, for instance, where the iridectomy has not been made near enough to the periphery or is too small, or where the iris has not been properly replaced, but has remained fastened to the wound. Under these circumstances a second iridectomy, diametrically opposite the first, is indicated.

In the later stages of glaucoma, and very seldom also in cases which are operated upon early and under otherwise favorable circumstances, the effect of the iridectomy is gradually diminished by the fact that the process of atrophy of the nerve fibres in the excavation makes still further progress. This is partly the reason why operations which have been delayed until the field of vision is greatly reduced and central vision diminished, cannot always with certainty be relied upon to preserve the *status quo*.

In a considerable number of cases there forms upon the place of the operation a peculiar cicatrix, which Von Graefe† has described

---

\* Arch. f. Ophth., B. xv. 3, pag. 205.

† Ibid., B. viii. 2, pag. 263.



as cystoid cicatrization. The lips of the wound separate from each other, bands of tough cicatricial tissue stretch across the wound, and the space between them is closed by a transparent membranous substance. Occasionally this thin membrane is broken, and the aqueous humor, exuding under the conjunctiva, forms there a vesicular prominence. In slight cases of cystoid cicatrization there generally occurs a thickening of this membranous tissue, and the wound assumes nearly its proper appearance. In extreme cases the condition remains a long time unchanged, and may become the starting-point of irritations, which, when neglected, may, by purulent inflammation, hypopion, and secondary iritis, bring the eye into great danger or even destroy it by panophthalmia. This peculiar form of cicatrization appears to be caused by the anatomical relations of the sclera. It is occasionally also seen after peripheral linear extraction, while it does not occur in clean corneal wounds. On the other hand, it is certain that the increase of pressure has a causative effect, since in other non-glaucomatous cases this kind of cicatrization after iridectomy occurs only very exceptionally.

The theory of the operation of iridectomy cannot as yet be explained. Even in normal eyes it is said to cause a permanent diminution of the intraocular pressure. At least Von Hippel and Grünhagen\* were able to demonstrate, by manometric measurement, a diminution of the intraocular pressure in rabbits, cats, and dogs, from whom, in the course of several months, by repeated operations, a considerable part of the iris had been removed. But the explanation of this as well as of the therapeutic effect of iridectomy in glaucoma is still wanting. There seems to be the necessity for assuming that it exercises some mechanical influence, and yet the proof of this has thus far never been adduced. That the coloboma of the iris is of itself not essential is self-evident, and it would be superfluous to cite a case reported by Haffmans of glaucoma with congenital coloboma iridis. Von Graefe also saw glaucoma with congenital irideremia.

Von Graefe seemed inclined at first to lay weight upon the diminution of the secreting surface; but it is not so much a ques-

---

\* Arch. f. Opth., B. xvi. pag. 43.



tion of the extent of the secreting surface as of the pressure which determines the secretion.

Bowman entertained the idea that the vitreous fluid could pass through the zonula Zinnii into the anterior chamber, and thence escape through the cornea. On this theory the zonula should be exposed by a peripheral iridectomy, and thus this escape of vitreous substance made easy. But the occurrence of glaucoma in connection with aphakia proves that the freest possible communication between the vitreous and the anterior chamber guarantees no protection.

According to Donders,\* glaucoma is to be regarded as a neurosis of the nerves governing the secretion of the eye, generally excited as a reflex neurosis of the iris, or at least maintained and aggravated by consequent tension upon it. The iridectomy cures the glaucoma, because it relieves the irritation of the overstrained nerves of the iris. This theory, however, does not hold good for all cases. With aphakia, for instance, or even in glaucoma simplex, a tension of the iris cannot be regarded as the cause for the continuance of the glaucoma, and even in the inflammatory form no such tension can be demonstrated. When in such a condition the depth of the anterior chamber is diminished, and the iris is driven forward, it is also always paralyzed, and the pupil in consequence of this is dilated.

Stellwag finally has advanced the view that not the iridectomy, but the wound necessarily made in performing it, is the essential element. He asserts that the wound heals not by direct adhesion of its edges, but by the formation of a connective-tissue cicatrix, and thereby it becomes possible for the sclerotic to yield somewhat to an increase of intraocular pressure. These suppositions are certainly, to some extent, open to criticism. Even when the incision is made as far as possible in the periphery, only a very small part of the wound lies in the sclera. The greater part is in the cornea, and in the normal course of healing there is in these wounds, as I have satisfied myself by anatomical examination, no deposit of new-formed tissue, but immediate union. Moreover, scar tissue is generally regarded not as more yielding, but, on the contrary, as less so than normal tissue.

---

\* *Klin. Monatsbl. f. Augenheilk.*, 1863, pag. 503.



Exner\* has satisfied himself by the examination of injected albino eyes of dogs and rabbits, on which iridectomy had been performed from two to four weeks previously, that almost always anastomoses could be demonstrated, which, at the place of the operation in the iris, connected the arteries with the veins, so that arterial blood, without having to pass through a capillary system, streamed immediately into the veins. The substitution of these wide anastomoses for the narrow capillary vessels diminishes not only the pressure in the stump of the artery which had supplied the excised portion of the iris with blood, but also the pressure in the entire circ. art. iridis major and in the arterial vessels of the choroid in general. Exner lays weight upon the fact that the margin of the iris remaining after iridectomy is broader than seems to be generally supposed, and that room is thus given for the formation of anastomoses in the iris tissue. This cannot take place when, during the operation, as often accidentally happens, the iris is torn away from the ciliary body (iridodialysis), without lessening the effect of the iridectomy as regards the reduction of intraocular pressure.

---

\* 65. Band der Sitzungsberichte der k. k. Akademie der Wissenschaften, Mai, 1872, und Medic. Jahrbücher der Gesellsch. der Wiener Aerzte, 1873, Heft i. pag. 52.



## ESSENTIAL PHTHISIS OF THE EYEBALL.

---

QUITE as mysterious as the glaucomatous increase of intraocular pressure are certain cases where the pressure decreases. Von Graefe,\* in order to distinguish this from the ordinary form of atrophy of the eyeball, caused by irido-cyclitis or irido-choroiditis, has called it essential phthisis.

Only very few cases have been observed, but all of these had been preceded by injuries.

In the case described by Von Graefe, the patient, ten years previously, had received an injury at the inner angle of the eye, and had suffered since then by occasional irritability of the eye from the effect of light, with excessive lachrymation, and severe pain in the eye and in its neighborhood. The eye was exceedingly soft, and its form altered apparently by the pressure of the recti muscles. The cornea, especially when the patient was exposed for a long time to the light, was surrounded by a slightly injected zone; and, moreover, in its deeper parts a number of fine gray, irregular, sinuous opacities could be seen, which Von Graefe regarded as the optical expression of folds or wrinkles in the membrane of Descemet. During the attacks, vision was reduced to  $\frac{1}{8}$ , and by means of the stenopaic apparatus could be improved to  $\frac{1}{5}$ . The attacks lasted several hours, and in the free intervals the eye was normal, showing only a very slight diminution of vision and tension.

Swanzy† observed similar variations in the resistance of the eye, with greater or less diminution of the intraocular pressure, developed after a prolapse of the vitreous body accompanying a peripheral linear extraction. The irritability, lachrymation, pericorneal injection, ciliary neuralgia, subjective light symptoms, etc., which accompanied the diminution of pressure, were sometimes

---

\* Arch. f. Ophth., B. xii. 2, pag. 256.

† Dublin Quarterly Journal, 1869, Nov., pag. 531; Annales d'Oculistique, 1870, Nov. et Déc., pag. 212.



slight and sometimes excessive. The cornea showed no changes. In the beginning of the affection a slight hemorrhage was observed in the anterior chamber, together with clouding of the vitreous, which was likewise probably of a hemorrhagic nature.

In a case observed by Nagel\* there developed, after an operation for strabismus convergens, a diminution of the consistency of the eye, with great photophobia and hypersecretion of tears. After this condition had continued some time, the normal tension gradually reappeared. The cornea showed changes similar to those in Von Graefe's case: still, Nagel regarded the anterior corneal surface as the seat of the affection. The eye had been previously amblyopic.

Finally, in a case observed by me, a contusion of the right eye by a small fire-work (a so-called "frog") caused severe pain, which gradually increased, and spread over the corresponding half of the head. There were excessive lachrymation and photophobia. Three weeks later, Dr. v. Blödau observed a marked decrease in the resistance of the eye, and a reduction of its volume. Simultaneously there was a slight adhesion of the iris with the capsule of the lens in the outer lower quadrant, but the iris still reacted under the influence of light. Seven weeks after the injury, when the patient came under my treatment, the eye was still very soft and somewhat smaller than the other, the cornea unchanged, and surrounded by a slight injection. Upon the iris was the small synechia above referred to; the lens and the vitreous body were absolutely transparent. In the equatorial region there were slight changes in the choroidal pigment, the retinal veins were wide, the retina was absolutely transparent, the optic nerve unchanged. The eye and the upper margin of the orbit were very sensitive to pressure; the temple and forehead were likewise sensitive, but in a less degree. Vision was greatly impaired, so that fingers could be counted at a distance of only about a foot; the field of vision was free. Two years later, Dr. v. Blödau found the tension of the right eye nearly the same as that of the left, but it lay somewhat deeper, and was sensitive to pressure. Vision had improved so much that the patient, with the right eye, with convex 10, could read No. II. of Snellen's test letters at a distance of twelve inches.

---

\* Arch. f. Ophth., B. xiii. 2, pag. 407.



## AMBLYOPIA AND AMAUROSIS.

---

UNDER this head we include all those disturbances of vision which we have not already discussed, and which are caused neither by anomalies of refraction or of accommodation, nor by visible changes in the refracting media or in the inner tunics of the eyes.

The test of vision in amblyopia demands therefore, in the first place, the determination of the condition of refraction, the range of accommodation, and the distinctness of vision. An exact determination of the condition of refraction by the usual method is difficult by reason of the indistinctness of vision, and accordingly the examination by means of the ophthalmoscope is in these cases a great help in diagnosis.

That accommodation also suffers in many cases of amblyopia is shown by the fact that for short distances, for instance, when reading, better vision is frequently obtained through convex lenses of 6 to 12 inches focal distance. This cannot be accounted for by the enlargement of the images. Where vision is diminished, an exact determination of the near point is of course still more difficult than the diagnosis of the condition of refraction.

In testing vision, it is well to employ as many different methods as possible. If we wish to determine the degree of usefulness of an eye, it is not sufficient simply to ascertain the smallest visual angle under which single letters can be recognized, but it is quite as important to test the facility with which print of different sizes can be read.

Furthermore, the examination of the field of vision is of great importance. The simplest method by which to determine at the same time both the limitation of the visual field and the distinctness of indirect vision is that given by Donders,\* the principle of which is that the observer institutes at the same time a parallel experiment with his own eyes. The observer places his eye in

---

\* Arch. f. Ophth., B. iii. 1, pag. 147.



the same horizontal plane with that of the patient's eye, and while the left eye of the patient is directed upon the right eye of the observer, or *vice versa*, the other eye of both being closed, the hand or some other suitable object is moved in the middle, between the examiner's and the examined eye. In this way not only the limits but also the distinctness of indirect vision are easily determined. Moreover, the examiner has the advantage of being able to observe that the examined eye maintains continually the proper fixation, an important point, as the inclination of the patient always is to direct the axis of vision upon the object. In order to test the extreme limits of the visual field, the test object of course must be removed farther from the observer, and the parallel test then ceases.

In order to sketch the limits of the visual field, a perpendicular table is employed, upon which a large paper of a dark-blue color is fastened; a distinct fixation object is placed at the middle. One eye is now closed, and the other is placed opposite the fixation object, which may be a piece of chalk or a small white ball fastened upon a long, thin, dark rod, and which is then moved from the centre of the visual field toward the periphery. The points upon the periphery of the visual field, at which slight movements of the object can still be seen, are now marked upon the paper. When in this manner numerous boundary-points of indirect vision are determined, we have by uniting them the boundary-line of the field of vision. If the test object be moved in the opposite direction, that is, from the periphery toward the centre, the limits of the visual field are often somewhat smaller. Instead of copying the sketch upon a smaller scale, it is better to preserve it as it is. Of course, not only must the distance between the eye and the paper remain unchanged during the examination, but also, in order to get sketches which can be compared with each other, different examinations must always be made at one and the same distance. The simplest way to do this is to direct the patient to hold a rod, some 30 cm. long, by pressing one end of it with his forehead, while its other end rests against the paper.

This method is quite sufficient for defects in the neighborhood of the fixation-point, but is not suitable for determining the functional activity of the retina at its periphery. For instance, if the board upon which we wish to sketch the visual field be at



a distance of 30 cm. from the eye, a retinal point  $45^\circ$  from the macula lutea would be projected upon the board at a distance of about 30 cm. from the fixation-point, and in order to sketch the visual field corresponding to a breadth of  $75^\circ$  of the retina, the board must measure more than two metres in every diameter.

These difficulties are overcome by projecting the visual field upon the inner surface of a hemisphere, as Förster\* first suggested. An instrument constructed on this principle, and called a perimenter, is indispensable for examining the periphery of the visual field.

From what has been said, it appears that the definition of amblyopia is, for the most part, a negative one. From this it follows that it is impossible to classify its various forms upon any anatomical principles, and even clinically only certain indistinctly defined forms can be described.

In the first place, there is one form which is called amblyopia congenita. Its characteristic is that, without any external or ophthalmoscopic anomalies, and with a full visual field, there is a congenital, permanent, and more or less considerable imperfection of vision. Those forms of congenital amblyopia or amaurosis which are connected with an abnormal smallness of the eye, or which depend upon pigmentation of the retina, or cases where these anomalies appear during the first year of life, do not belong in this class.

This form of amblyopia may occur in both eyes simultaneously, or in one eye alone. Slight degrees of it, with vision of, say from  $\frac{1}{3}$  to  $\frac{1}{7}$ , occur as a binocular condition in high grades of hypermetropia, and with meridional asymmetry, less frequently with emmetropia or myopia. The highest degrees do not appear to occur in both eyes at once. With a free visual field and an absolutely normal fundus, fingers can still be counted only at a distance of a few feet, and this condition may last life-long. Frequently, too, fixation is uncertain and eccentric,—that is, a retinal point is used lying to one side of the fovea centralis. Strabismus exists in many of these cases, and for this reason the amblyopia has been regarded as the consequence of the squint, and has therefore been called amblyopia ex anopsia.

---

\* Klin. Monatsbl., 1869, pag. 412.



The arguments against this view have been already given (see pages 161 to 163). A high degree of this form of amblyopia also occurs in one eye, and, since it has been observed in eyes which have corneal opacities, it has been thought that the amblyopia in these cases, just as in those with strabismus, depended upon non-use. The proof, however, that the amblyopia was caused by the corneal opacities has never been offered. This, of course, is independent of the indistinctness of the retinal images caused by the opacities. The simple occurrence of this form of amblyopia in eyes having at the same time corneal opacities proves nothing, since there is no reason why eyes affected with amblyopia congenita should not be attacked by keratitis.

\*

In concluding the subject of amblyopia congenita, color-blindness should be mentioned. Vision may be quite normal, but the capacity to distinguish colors is either entirely wanting or very imperfect. If, as according to the hypothesis of Thomas Young,\* the perception of colors depends upon the three fundamental perceptions of red, green, and violet, then there would be color-blindness whenever any one of these fundamental perceptions is wanting. All colors which the color-blind patient recognizes may be formed by the union of two fundamental colors. The perception of red seems to be the one that is oftenest wanting. Red-blindness (anerythroptia, according to Goethe) is, therefore, the commonest form of color-blindness; but it appears that either of the other two fundamental perceptions may be wanting.

Acquired color-blindness, without considerable diminution of vision, is a very rare occurrence, while as a symptom of amblyopic disease it is quite frequent.

Among the disturbances of vision which occur without any perceptible ophthalmoscopic changes is that form of hemeralopia which appears as an acute pathological process.

The essential symptoms of the disease are that distinct vision is possible only by intense illumination, while slightly illuminated retinal images cannot be perceived. The condition is that of *torpor retinæ*.

---

\* Helmholtz, *Physiologische Optik*, pag. 291.



By daylight, and in general by bright illumination, vision is quite good. Only exceptionally, and in old cases, is there also a partial loss of central vision. Examined by bright daylight, the visual field is generally free; still, in extreme cases, even by bright daylight, there may be peripheral defects. Upon diminishing the intensity of the illumination there occurs a disproportionate weakening both of central and of eccentric vision; so that, in general terms, the visual field becomes more contracted the weaker the illumination.

Förster\* found, in most of his cases, the *torpor retinæ* greatest in the region of the macula lutea,—that is, eccentric vision was better than central. The reverse seems oftener to be the case, so that as the illumination diminishes the macula lutea longest retains its sensitiveness, while the visual field contracts from the periphery inward.

So soon as the illumination becomes so weak that the sensitiveness of the retina is considerably diminished, the pupils generally dilate strongly.

Förster, moreover, observed a simultaneous decrease of the ability to recognize colors. With an illumination which, for healthy eyes, was quite sufficient for the recognition of colors, carmine-red and indigo-blue were mistaken for black. Yellow and green were best recognized, but the first was sometimes mistaken for white.

Alfred Graefe† observed a difficulty in the movement of convergence and a decrease of the ability to overcome prisms,—that is, to unite double images by the action of certain muscles. Moreover, in most of the cases observed by him, with decreased illumination a limitation of the range of accommodation appeared to exist before the *torpor retinæ* became very decided.

Hemeralopia is not, as was formerly supposed, dependent upon the time of day. Its apparent periodicity is owing simply to the fact that the darkness of night comes on regularly, and all its symptoms may be caused at any time of day by any arrangement which diminishes the illumination. If the patient be led from the bright daylight, he sees at first very poorly, and it is only after some time

---

\* Ueber Hemeralopie, Breslau, 1857.

† Arch. f. Ophth., B. v. 1, pag. 112.



that he begins gradually to recognize objects. The same is the case with normal eyes, except that with hemeralopia the indistinctness of vision is at first much greater, more time is needed to adapt the retina to the diminished intensity of light, and, at best, vision remains far below that of normal eyes.

Both eyes are always affected, but not always in the same degree.

The changes in the conjunctiva, which some authors have observed simultaneously with hemeralopia,—for instance, dryness, with fatty degeneration of its epithelium, or the appearance of bright spots upon it,—have probably nothing to do with the hemeralopia, but are to be regarded only as accidental complications, or as the co-effects of the same causes.

The causes of hemeralopia have been by no means fully explained, but this much may be said with certainty, that insufficient nutrition and the influence of dazzling light are the principal factors. Where the disease occurs as an epidemic, it generally seems to be due to the simultaneous influence of these causes upon a great number of individuals, for instance, among troops, sailors, prisoners, etc. Especially upon shipboard a connection has been observed between it and scorbutus. The disease occurs mostly in the tropics, where the sunshine is most dazzling. It is often described by sailors as “moon-blindness.” The influence of insufficient nutrition is shown by the fact that the disease scarcely ever occurs in well-nourished persons; for instance, on shipboard the officers, who are better fed, are exempt from it, although they equally with the crew are exposed to the dazzling light. In some of the cases observed by Förster the dazzling by light could scarcely be regarded as the cause, while it probably was in certain other cases in which he found the greatest torpor in the region of the macula lutea. The so-called snow-blindness appears to be due to similar causes.

The treatment consists principally in suitable nutrition and in protection against dazzling light. Cod-liver oil, as recommended by Despont,\* appears to act simply as nutritious food. Förster recommended that the patients be kept for some time in an absolutely dark room. Where this is not practicable, dark-blue protective spectacles should be worn.

---

\* *Traitement de l'Héméralopie, etc.*, Paris, 1863.



A form of amblyopia well characterized by its clinical peculiarities consists in a diminished sensibility of the retina, usually described as "anæsthesia of the retina." In most of these cases a greater or less loss of acuity of vision is generally associated with an intolerance of light.

This affection is often connected with other nervous diseases,—with hysteria, anæsthesia, or hyperæsthesia of the sensitive cutaneous nerves, or with spasmodic affections, frequently, too, with paralyzes of certain motor nerves. It occurs also in perfectly healthy persons. It is relatively most frequent in women and children. In many cases, especially where the disease is unilateral, wounds, contusions of the eye, etc., or reflex irritations proceeding from carious teeth, are stated as causes. That reflex action really plays an important part is proved by the fact that diminution of central vision, with concentric contraction of the visual field and without any ophthalmoscopic changes, occurs as a sympathetic affection, and disappears in the course of some weeks after the enucleation of the other eye, which of course is already blinded by irido-cyclitis or irido-choroiditis.

The essential characteristics of this form of disease are the following:

Central vision is generally only moderately diminished; it is seldom less than  $\frac{1}{4}$  or  $\frac{1}{3}$  normal; still, exceptionally, there may be a very considerable loss of central vision.

There is always a great contraction of the visual field, generally concentric, but often with very striking variations in its form. The visual field often shows great variations in its extent when examined according to different methods. In general, however, the statements of the patients, especially in the hysterical form of the affection, are decidedly irrational and uncertain.

Simultaneously there is often hyperæsthesia of the retina, which manifests itself by a moderate sensation of dazzling, or it may be very marked, especially with hysteria. By a moderated light, or by means of colored (dark-blue) glasses, vision is not diminished as it normally would be; it may even be improved; so, too, with reference to the limitation of the visual field. Such patients frequently affirm that they see better through any ordinary piece of glass, or through a weak prism, than with the naked eye.

The disease almost always occurs on both sides, although it



may be of different degrees; exceptionally, it occurs only on one side.

The optic nerve remains normal even when the disease lasts a long time.

The disturbances of vision often appear in the course of a few days. In other cases, on the contrary, the amblyopia and the contraction of the visual field come on very gradually, being preceded for weeks by asthenopia, vision being still good, or but slightly diminished. The contraction of the visual field and the diminution of vision, moreover, do not always stand in corresponding relation. I have repeatedly observed the central vision very nearly restored while there was still a very considerable contraction of the visual field.

The prognosis is generally favorable. Recovery often occurs in the course of a few weeks, but in other cases it is months—even more than a year—before vision and the visual field become again normal. Peripheral contraction of the visual field and hyperæsthesia seldom remain. Amaurotic blindness does not appear to be caused.

Von Graefe recommended that the patient be kept in a darkened room, in which the light should be gradually increased after about the sixth day. Later, it is sufficient to protect the eyes from the light by dark-blue or gray spectacles. Von Graefe recommended for internal administration principally the preparations of zinc, in increasing doses (zinc. lact. 0.1 to 0.3 daily = gr. jss. to gr. ivss.).

Of course, during treatment all straining of the eyes must be sedulously avoided.

The designation of this form of amblyopia as anæsthesia retinæ is not very appropriate. This name would be equally suitable for many other forms of amblyopia. The choice of this name was founded upon the idea that the condition consisted essentially in an interruption of nervous communication between the layer of the rods and cones and that of the nerve fibres in the retina; at least Von Graefe\* drew this conclusion from the fact that the patients stated that the well-known fire circles could be produced in the eye by pressure upon that part of the retina corresponding to the

---

\* Klin. Monatsbl., 1865, pag. 263.



defect in the visual field. Now, one can by no means always be certain that external pressure on the eye always is exactly upon that point in the retina corresponding to a defect in the visual field, and not upon some neighboring point. I have not been able in all cases to produce the phenomenon; the fire circles often absolutely fail. Moreover, how do we know that the fire circles depend upon an excitation of the nerve fibres? The circumstance that the centres of the fire circles correspond with the points of pressure makes it probable that the phenomenon is due to an excitation of the rods and cones. If it depended upon an irritation of the layer of nerve fibres, the appearances would not assume the form of fire circles, but would be flame-shaped, streaming toward the periphery, corresponding to the anatomical arrangement of the terminal apparatus of the nerve fibres pressed upon.

Considering the important rôle which the contraction of the visual field plays in this disease, the most expressive name for it would be "visual-field amblyopia."

It may here be mentioned that this is the only form of amblyopia which prevails most in women and children. All other forms are more frequent in men than in women, which may be explained by the nature of the exciting causes of the disease.

A pure hyperæsthesia of the retina—that is, without diminution of central or peripheral vision—also occurs, and may continue a long time without ever causing amblyopia, or contraction of the visual field. Often there is a great susceptibility to after-images, and long continuance of the same, as well as subjective light and color symptoms.

Quite a large group of amblyopiæ are characterized by a diminution of vision without limitation of the visual field, and without a trace of central scotoma. The perception of color is generally unchanged; still, color-blindness does simultaneously occur. The fundus appears perfectly normal, aside from a hyperæmia of the retina which is often present, but even then not very marked. Even after the amblyopia has existed a long time, the optic nerve may remain normal or it may atrophy. Both eyes are always affected at the same time, and generally to an equal degree.

The causes generally appear to lie in the dietetic relations and mode of life of the patient. The following causes have been observed: constipation, irregularity of the circulation, with coldness



of the extremities, especially of the feet, the suppression of habitual hemorrhages, or of pathological or physiological secretions, irregular sleep, undue straining of the eyes, excess in venery, immoderate smoking, but above all, the abuse of spirituous liquors. All these causes are operative alone, but several are more frequently combined. The effect of the abuse of alcoholic drink may explain the fact that this form of amblyopia is much more frequent in men than in women. The so-called "amblyopia potatoria," which is simple amblyopia not affecting the extent of the visual field, and without central scotoma, may be regarded as the representative of the entire group. Indeed, central scotoma is not infrequently due to the abuse of alcoholic stimulants.

The prognosis depends principally upon whether it is possible or not to remove the exciting cause, as, for instance, the use of alcohol. If the optic nerve has already become pale, no great improvement can be expected.

The first object of the treatment must, of course, be to remove the exciting cause; next, there should be a derivative treatment proportionate to the condition of the strength. Generally, in persons otherwise healthy, blood is drawn from the temple, and afterwards diaphoretics and cathartics are employed.

To complete this subject, mention should be made of amblyopia caused by lead poisoning, which likewise attacks both eyes at the same time. The amblyopia may develop rapidly, and in a few days lead to almost complete loss of the perception of light. The pupils are at the same time generally dilated. The prognosis appears to be generally favorable, since the blindness may pass away as rapidly as it has come on. Color-blindness may remain.\* In the treatment the use of opiates is specially indicated, as indeed is the case in all lead poisoning.

Under the name "scotoma centrale" are included all those forms of amblyopia in which a diminution of central vision is more or less sharply defined in a free visual field. This symptom is so characteristic as to form the most prominent feature of the disease. But it should be remarked that various pathological processes may cause this same symptom. It may be positively asserted,

---

\* Dr. Haase, *Klin. Monatsbl.*, 1867, pag. 225.



for instance, that there are forms of neuritis or neuro-retinitis which may cause scotoma centrale, but from that it does not follow that this symptom is always caused by neuritis. Central vision may become so poor that the patients prefer to use, instead of the macula lutea, some retinal point lying near it, so that eccentric fixation occurs. Indeed, it may happen that a flame in the direction of the line of vision cannot be seen; it disappears so soon as its image reflected on the cornea corresponds with the centre of the pupil. Generally, however, the vision of the macula lutea is nearly the same as that of the neighboring retinal zone, or it may remain somewhat better than that.

The existence of central scotoma is often demonstrated while practising one of the above methods for testing the visual field by daylight, or more easily in other cases by dim lamplight. Nevertheless there are frequently cases in which these methods do not prove sufficient, and in which, as Leber\* has shown, the test of the perception of colors is a very convenient and sure method by which to recognize the nature of the lesion. One proceeds exactly in the manner above described, except that small pieces of colored paper are used instead of a piece of chalk or a white ball, and the boundary is noted at which the patient begins to lose the proper perception of color.

There is always an abnormal perception of color within the region of the central scotoma.

The affection is generally bilateral. It is seldom that it occurs only in one eye. Frequently, however, the degree of amblyopia in the two eyes differs. The form of the scotoma generally corresponds in the two eyes. Its greatest diameter may lie either in the vertical or in the horizontal direction. Förster's† investigations have shown that in most cases the scotoma extends to Mariotte's blind spot, so that the part of the retina in which perception is diminished includes the optic disc.

Central scotoma appears either suddenly or it develops in the course of a few weeks in one eye after the other, or simultaneously in both, by the enlargement of a defect which at first does not always correspond with the fixation-point. The degree of am-

---

\* Arch. f. Ophth., B. xv. 3, pag. 26.

† Annales d'Oculistique, 1868, pag. 11.



blyopia is varied; generally the large letters of the test type are still recognized.

Frequently there are at first no ophthalmoscopic changes either in the optic nerve or in the macula lutea; in other cases there appears to be an opacity of the retina, not, however, in the region of the macula lutea, as one would suppose, but in the periphery of the optic disc. Slight, mostly striated, white opacities are situated, some upon the surface of the optic disc and some radiating a distance into the retina; they cover the place of exit of the vessels, and frequently extend farther into the retina along the course of the vessels.

Hyperæmia of the retina and of the optic nerve, and small ecchymoses close to the nerve, also occur. In the later stages, but quite early, too, in many cases, there occurs a whitish or bluish discoloration of the optic disc, which, however, is almost invariably confined to its temporal half, while the color of the other half remains normal or nearly so.

On these grounds Von Graefe\* regarded central scotoma as caused by a disease of the optic nerve, and Leber regards the changes caused by a retro-ocular neuritis as the essential element of the disease.

Concerning the causes nothing is certainly known. The circumstance that this form of amblyopia as well as most others occurs almost exclusively in men and only exceptionally in women, may give some clue to its etiology. The abuse of alcohol and tobacco, repeated wetting, and colds, appear to exercise an influence upon it. The disease also appears to be hereditary.

The prognosis is essentially influenced by the behavior of the peripheral visual field. So long as eccentric vision remains normal, eventual blindness is not to be feared. But if, on the contrary, eccentric vision fail, if the field of vision contract at its periphery, or if sector-shaped defects radiating from the scotoma appear in it, blindness from atrophy of the optic nerve may be regarded as coming on.

In recent cases a derivative treatment is to be pursued,—bleeding, foot-baths, diaphoretics, cathartics, etc. In many cases the iodide of potassium does good service.

---

\* Klin. Monatsbl., 1865, pag. 209.



If the optic nerve have already become pale, no great improvement can be expected.

Progressive atrophy of the optic nerve generally first manifests itself by contraction of the visual field, which occurs either in both eyes at once or, more generally, first in one eye and then in the other. In either case, even when there is a very long interval, of perhaps several years, between the appearance of the disease in the two eyes, it generally affects them both symmetrically, so that the beginning of the disease is observed in both eyes in a corresponding part of the visual field, be it on its median or its temporal periphery.

The upper temporal part of the visual field appears oftenest to be the first affected; the contraction begins less frequently in the median periphery. The defect in the visual field in these cases appears never to be sharply defined, but is divided from the part whose function is still normal by a zone in which vision is more or less diminished. Central vision, too, begins early to fail; the normal perception of color is at the same time often interfered with.

If the defect in the visual field have already attained a certain dimension, eccentric vision in the entire periphery is generally diminished. The defect gradually approaches the fixation-point, so that frequently at a certain period of the disease eccentric vision is better than central, and absolute blindness generally follows.

The optic nerve always presents the appearances of atrophic degeneration, described on page 491, which appearances may either precede or follow the disturbances of vision. Of course the opportunity of making such observations is most frequent in the eye which is attacked last.

The course of the disease varies as to the time which ensues before absolute blindness of the eye affected, which varies from some months to some years, and further, in reference to the time when the affection appears in the second eye, which may be very soon after the beginning of the disease in the first eye, or even years later.

In a great number of these cases the pathological process is limited to the fibres of the optic nerve without there being any more central disease. In many cases blindness occurs as the precursor of mental diseases. Quite frequently the disease of the



optic nerve is connected with spinal disease, which, before vision was affected, manifested itself by other symptoms, such as loss of sensation, uncertainty of the gait, contraction of the pupil, etc. According to Virchow,\* it is especially with the spotted atrophy of the spinal cord that the spotted-gray atrophy of the optic nerve is connected, and accordingly the anatomical causes of the disturbances of vision are to be looked for in the optic nerve itself rather than in the central organ.

The prognosis is always very unfavorable; the treatment is limited to tonics. Energetic derivative remedies always do harm.

The hemiopic defects of the visual field deserve special mention. Hemiopia, in the exact sense of the word, includes those cases in which the visual field is contracted upon the same side in both eyes; that is, the defect is in the right half or left half in both eyes. The defect may involve the entire half of the visual field, or only a corresponding fractional part of it on both sides.

This homonymous hemiopia is always to be referred to some interruption in the optic tract before its entrance into the chiasm. Numerous physiological and pathological facts† show that a crossing (semidecussation) of both optic tracts occurs in the chiasm in such a manner that the right optic tract supplies the temporal portion of the right retina and the median portion of the left retina. An interruption in its course would accordingly blot out both left halves of the visual field. Generally, but not always, these hemiopic defects are separated from the normal visual field by a sharply defined line, which may either pass through the fixation-point or remain at some distance from it.

Cerebral hemorrhage is the most frequent cause of this hemiopia, and of course, under these circumstances, hemiopia and hemiplegia exist on one and the same side. Hemiopic defects, when not due to apoplexy or encephalitis, may be caused by transitory idiopathic affections of the optic nervous tract. It often appears to depend upon syphilis. Tubercle in the chiasm was found as

---

\* Arch. f. path. Anat., B. x. pag. 192.

† The semidecussation of the optic nerve in the chiasm, which has recently been again doubted, may be regarded as demonstrated by Gudden's investigations (Arch. f. Ophth., B. xx. 2, pag. 249).



the cause of hemiopia.\* Some cases are due to mysterious causes in the nervous system, which during the course of the affection, and after recovery, remain unknown. A disease in the substance of the brain is probably the cause of those hemiopic defects which do not involve the entire half of the visual field, but only a corresponding fractional part of it on both sides, while an affection of the optic tract is more probable in those cases in which the defect on both sides extends to a vertical line dividing the visual field. Especially is this true when a symptom is added to which attention has been called by recent physiological investigations.† After division of one optic tract between the chiasm and the brain there occurs a dilatation of the pupil upon the opposite side; and, in fact, I have seen many cases in which simultaneously with hemiopic defect of the left half of the visual field the pupil of the left eye was evidently dilated, though its movement remained normal.

In homonymous hemiopic defects which are limited by a sharp boundary-line the prognosis is favorable in this sense, that absolute blindness is not to be feared so long as the cerebral disease causing it does not extend to the other hemisphere. Moreover, an absolute disappearance of this symptom is within the range of possibility.

In cases of pure hemiopia the ophthalmoscopic appearance of the optic disc is at first, or during a long time, normal. Only very exceptionally, as Von Graefe‡ once observed, does a homonymous partial atrophy corresponding to the defect in the visual field develop in the course of a few years.

Among the hemiopic disturbances of vision belongs also a symptom which generally manifests itself by a sparkling in one half of the visual field. Frequently there is connected with it a simultaneous hemiopic defect of the visual field of greater or less extent, though the affection appears also to occur unilaterally. The sparkling occurs at intervals with longer or shorter pauses, in many persons almost daily, and lasts each time from a quarter to half an hour. The attacks are often connected with hemicrania, but may occur without it.

---

\* Dr. Hjort, *Klin. Monatsbl. f. Augenheilk.*, 1867, pag. 166.

† Knoll, *Beiträge zur Physiologie der Vierhügel*, *Centralblatt der med. Wissenschaften*, 1872, No. 17.

‡ *Klin. Monatsbl.*, 1865, pag. 218.



Listing\* designated the symptom as "sichelförmiges Flimmerscptom." Förster† proposed the name amaurosis partialis fugax.

It should be mentioned, in concluding the subject of homonymous hemiopia, that in very rare cases bilateral symmetrical limitations of the visual field, above and below, have been observed, for which an anatomical explanation is yet wanting.

If these defects be sharply defined from the normal visual field, and there be no great diminution of central vision, a prognosis may be made similar to that in typical hemiopia.

Temporal hemiopic defect is the name given to those limitations of the visual field which involve only its outer half on both sides. Still, we do not reckon as such, cases where, as in progressive atrophy of the optic nerve, the defect begins on the temporal side and from there spreads over the entire visual field, but only those which involve simply the temporal half on both sides, and which remain, for some time at least, stationary in this condition. Von Graefe‡ remarked that under these relations there are generally symptoms pointing to the existence of a tumor or some cause of pressure at the base of the brain, and the correctness of this view has been confirmed by numerous observations.§

Moreover, there occur cases in which the entire course of the disease, or its complete recovery, renders the existence of a tumor exceedingly improbable, and suggests the idea that simple inflammatory processes at the base of the brain may produce the same effect. Every such cause of disease acting at the median line will, of course, affect most the fasciculi cruciati lying near the median line, both before and behind the chiasm, and accordingly the inner halves of the retinae will suffer most. Such processes will not be strictly limited to certain fibrous bundles, but only the median bundles will be first and most seriously affected, while the more lateral fasciculi will be proportionately less affected, so that the defect in the visual field is not sharply defined.

The prognosis in temporal defects is generally more unfavorable

---

\* Klin. Monatsbl. f. Augenheilk., 1867, pag. 334.

† Ibid., 1869, pag. 422.

‡ Arch. f. Ophth., B. ii. 2, pag. 287.

§ Dr. D. E. Müller, Arch. f. Ophth., B. viii. 1, pag. 160; Sämisch, Klin. Monatsbl., 1865, pag. 51.



than in homonymous hemiopia. In the last-named disease the persistent action of its cause only completes the hemiopia, but never can cause blindness of one or both eyes; but where there are temporal defects there is the possibility that the cause acting at the base of the brain may extend its effects constantly upon both optic nerves beyond the limits of the fasciculi cruciati and lead to total obliteration of the visual field. On the other hand, the disease may halt at any stage, or may even entirely disappear. This depends essentially upon the nature of its cause.

Amaurosis is sometimes due to intracranial causes.

The symptomatology of these cases varies, of course, according to the nature of the disease causing them. Both eyes may be affected in a similar or dissimilar manner, or the disturbance of vision may be unilateral. In the latter case it must be assumed that the cause lies, if not in the orbit, at any rate in the nerve between the foramen opticum and the chiasm.

The prognosis depends upon the nature of the intracranial process. It sometimes happens, after the absence for several weeks, or even months, of all perception of light, that some degree of vision returns; or some remnant of vision may be retained, although atrophic degeneration of the nerve has begun.

The treatment of these cases is directed against the primary cerebral disease. Among the remedies indicated are setons in the neck, iodide of potassium, corrosive sublimate, cathartics, etc.

We may here mention a group of rather rare cerebral amauroses, in which, in both eyes, there occur sudden disturbances of vision which in the course of a few hours or days become so great that there is often absolute loss of the perception of light, and still no ophthalmoscopic changes are visible. This blindness may disappear as quickly as it came on.

The best example of this group is the uræmic amaurosis. In connection with other uræmic symptoms, such as headache, a sensation of heat, languor, shortness of breath, faintness, or convulsions, there occurs a sudden loss of vision, which in the course of one or two days may amount to absolute blindness. There generally follows an equally rapid return of vision, though not always in a uniform manner, so that during this period defects may appear in



the visual field. As a rule, ophthalmoscopic changes do not exist; but sometimes there is a slight swelling or inflammatory clouding of the optic nerve and the surrounding\* retina. Since albuminuria exists in all these cases, the simultaneous occurrence of uræmic amaurosis and of retinitis albuminurica is occasionally observed.

In a similar manner, and perhaps likewise dependent upon uræmia, sudden blindness occurs after typhoid fever, scarlatina, etc.†

Hughlings Jackson‡ observed in many cases of epilepsy that absolute blindness preceded the loss of consciousness. But such cases occur accompanied by indeterminate symptoms, and when the general condition is apparently good.

The blindness is often so absolute that there is not the slightest perception of light, and still vision may return within a few days. Or there may be only a partial improvement, or none at all, and then begins gradually an atrophic degeneration of the optic nerve.

Often in these cases the noticeable fact is observed that, in spite of the absolute loss of perception of light, the reaction of the pupil under its influence remains. Von Graefe explained this by the theory that the interruption in the central course of the optic-nerve fibres occurs at a point posterior to that at which is received the branch of the oculo-motorius, which supplies the iris, and upon whose function its reflex action depends.

This fact is important in reference to the prognosis, since, when the reaction of the pupil is retained, a restoration of vision may be expected; but even where the reaction is lost, recovery is not absolutely excluded. The normal appearance of the optic disc during the first days of the blindness furnishes no ground for a favorable prognosis, for the atrophic degeneration does not begin for some weeks or months.

Mention should be made of those cases of sudden blindness which occur in connection with hemorrhage of the stomach or bowels and which are therefore designated as amaurosis after hæmatemesis. Some days after a copious hæmatemesis, or after bloody diarrhœa, there follows a rapidly increasing amblyopia.

---

\* Dr. Herm. Schmidt, Berl. klin. Wochenschrift, 1870, No. 48 und 49.

† Ebert, Berl. klin. Wochenschrift, 1868, No. 2.

‡ Ophth. Hosp. Rep., iv. 2, pag. 14.



As a rule, all perception of light is lost after one or two days, though sometimes a remnant of vision remains. In a short time atrophic degeneration of the optic nerve begins: still, the suspicion first expressed by Von Graefe,\* that this is due to primary irritative processes in the optic nerve, has much in its favor.

In one case, which I examined on the eighth day of blindness, the boundary-line of both optic discs was marked by a clouding which extended into the retina for a distance equal to the diameter of the disc. In one eye there was a small retinal hemorrhage close to the disc. The large vessels presented no marked changes; the optic disc was somewhat pale. Later, the usual appearances of atrophic degeneration developed. The optic disc appeared, by daylight, a bright yellowish green, sharply defined, and from its surface and the surrounding retina had disappeared all traces of the original clouding. The small hemorrhage disappeared, the arteries were somewhat contracted, the veins remained of normal width. In another case, which did not lead to blindness, but which reduced vision to about  $\frac{2}{3}$ , with contraction of the visual field, there was from the beginning a very evident neuritis. In one eye it was only partial, and limited to the upper half of the optic nerve, and, corresponding to this, the defect in the visual field was below.

The relation between the loss of blood and the disease of the optic nerve is wholly unexplained. It cannot be due to simple anæmia, since not only does copious loss of blood occur without causing atrophy of the optic nerve, and even after hæmatemesis this sad complication is rare, but anæmia did not exist among any of those who were blinded under these circumstances.†

Amauroses due to orbital causes, such as tumors, periostitis, inflammation of the connective tissue, fractures of the bony orbital walls, etc., may be caused by compression of the nerve or by retro-ocular or ophthalmoscopically visible neuritis.

Certain cases in which a slight contusion or compression of the eye has immediately caused great disturbance of vision with or without defect in the visual field, or even complete blindness, remain wholly unexplained. The objective appearance in such

---

\* Arch. f. Ophth., B. xii. 2, pag. 149.

† Von Graefe, Arch. f. Ophth., B. vii. 1, pag. 150.



cases is at first wholly negative. Later, atrophic degeneration of the optic nerve may develop.\*

The occurrence of reflex amauroses is also asserted, and is referred to the irritation of dental nerves in carious teeth.† According to Hutchinson,‡ these reflex effects may occur when the carious teeth are not painful.

The hypodermic injection of strychnine in all forms of amblyopia has lately been recommended.§ I have seen a number of cases improve under this treatment, just as might happen with any treatment, or without any treatment whatever; but the majority of the absolutely negative results is so great that I have not been able to satisfy myself of the action of strychnine upon the optic nerve. I have never seen such immediate improvement of vision after the injection of strychnine as is asserted by Nagel to occur.

Here is the place to discuss the methods for detecting simulated amblyopia. If, as is generally the case, absolute amaurosis on one side be simulated, the best and shortest method is that proposed by Von Graefe.|| Only the healthy eye is experimented with, and a prism of from  $6^{\circ}$  to  $12^{\circ}$ , with its base turned upward or downward, is placed before it. If now a candle flame or a dot or fine line upon a white paper be seen double, the simulation is at once proved, and at the same time the degree of vision in the pretended blind eye can be determined with sufficient exactness. As a further confirmation, it may be tried whether the double image moves during rotation of the prism, or whether the diplopia disappears upon the re-establishment of binocular single vision when the base of the prism is turned outward.

It sometimes happens that the simulators deny the diplopia,

\* Testelin, *Klin. Monatsbl.*, 1865, pag. 358.

† Wecker, *Klin. Monatsbl.*, 1865, pag. 269; Alexander, *ibid.*, 1868, pag. 42.

‡ *Ophth. Hosp. Rep.*, iv. 4, pag. 381.

§ Frémineau, *Gaz. des Hôp.*, 49, 1863; Sämann, *Deutsche Klinik*, 1864, No. 44 und 45; Talko, *Klin. Monatsbl. f. Augenheilk.*, 1868, pag. 79, und 1869, pag. 145; Nagel, *Die Behandlung der Amaurosen mit Strychnin*, Tübingen, 1871.

|| *Arch. f. Ophth.*, B. ii. 1, pag. 266.



because they happen to know that one of the images belongs to the pretended blind eye. For such cases Von Graefe\* has proposed a modification of his other method. The pretended blind eye is covered, and a prism refracting vertically is so held before the normal eye that its refracting angle bisects the pupillary space. If this angle be sharp enough, and the pupil be not too small, monocular diplopia will be produced. If now the simulator deny the existence of the monocular diplopia, there is good ground to doubt the truth of his statements. If, however, the monocular diplopia be admitted, it can be very easily converted into binocular diplopia by uncovering the pretended blind eye and so moving the prism that it shall cover the entire pupillary region.

The stereoscope, too, may be employed for the diagnosis of simulated blindness. Each eye is known to have its own visual field. Both visual fields are united in a common one, and it is impossible for one to tell the part performed by each eye separately in this common visual field. Having now observed that a union of the two visual fields actually takes place, we can present an object to one eye which appears in the common visual field without the patient's knowing with which eye he sees it. There is no difficulty in thus leading his judgment astray. If union of the visual fields take place, an object, for instance, in the right half of the left visual field, lies upon the right side in the common visual field, thus conveying the impression that it is seen with the right eye, while in fact the retinal image belongs only to the left eye.

Under certain circumstances Hering's dropping experiment (p. 113) is also applicable for this purpose.

Where there is simulation of unilateral amblyopia, an exact determination of the acuity of vision at different distances easily exposes the falsity of the statements. Simulated defects in the visual field may be best detected by repeatedly sketching the visual field at different distances; or, where the boundaries of the defect in any direction lie near the fixation-point, the retinal image may be thrown by a prism upon the pretended non-sensitive portion of the retina, and its functional activity proved by the diplopia provoked in this way.†

---

\* Klin. Monatsbl., 1867, pag. 53.

† Alfred Graefe, Arch. f. Ophth., B. v. 1, pag. 124.



# INDEX.

---

## A.

Abscess in cornea, 301, 304.  
    in lids, 226.  
    in orbit, 192.  
Accommodation, 16, 21.  
    anomalies of, 11.  
    changes during, 21.  
    formula for, 25.  
    latent, 47, 57.  
    mechanism of, 23.  
    paralysis of, 76.  
        by atropine, 61.  
    phosphenes, 22.  
    range of, 16, 23.  
    relative range, 16.  
    spasm of, 83.  
    with aphakia, 391.  
Acuity of vision, how determined, 28.  
Albinismus, 416.  
Albuminuria a cause of retinitis, 465.  
Amaurosis, 526.  
    after hæmatemesis, 543.  
    from intracranial causes, 542.  
    partialis fugax, 541.  
    simulata, 545.  
    uræmic, 542.  
Amaurotic cat's eye, 496.  
Amblyopia, 526.  
    congenita, 528.  
    ex anopsia, 528.  
    from lead poison, 535.  
    potatoria, 535.  
Anæsthesia retinæ, 532.  
Anchyloblepharon, 247.  
Anerythroptia, 529.  
Aneurism of arteries, 199.  
Angle  $\alpha$ , 122.  
Angle  $\alpha'$ , 42, 123.

Angle of vision, 102.  
Anisometropia, 74.  
Annular adhesions, 336.  
Aortic insufficiency, 412.  
Aphakia, 60, 390.  
    and accommodation, 391.  
Apparent myopia, 83.  
Apparent strabismus divergens, 125.  
Arcus senilis, 325.  
Arteria hyaloidea persistens, 399.  
Arterial pulsation, 410.  
Artificial leech, 51, 52, 430.  
Asthenopia, accommodative, 57, 62.  
    astigmatic, 66.  
    conjunctival, 62, 253.  
    muscular, 168.  
    nervous, 62, 86.  
    spasm of accommodation, 83.  
Astigmatism, 63.  
    after cataract operation, 391.  
    compound, 69.  
    correction of, 70.  
    irregular, 64, 312.  
    mixed, 69.  
    ophthalmoscopic diagnosis, 118.  
    regular, 64.  
    simple, 69.  
    test objects, 68.  
Atheroma of retinal arteries, 458.  
Atrophy of choroid, 35.  
    of eye, 341, 514.  
    of optic nerve, 491, 538.  
Atropine conjunctivitis, 257.

## B.

Basedow's disease, 195.  
Bicylindrical lenses, 90.  
Bifocal lenses, 90.



Bleeding by artificial leech, 430.

Blennorrhœa :

conjunctival, 258.

gonorrhœal, 262.

neonatorum, 261.

of lachrymal sac, 209.

Blepharitis, 218.

Blepharophimosis, 239.

Blepharoplastic operations, 247.

Blepharospasm, 228.

Blepharospasm, 242.

Blindness in epilepsy, 543.

from compression of nerve, 544.

in scarlatina, 543.

in typhoid fever, 543.

simulated, 545.

Blue spectacles, 28.

Bougies of laminaria, 215.

Bowman's probes, 210, 212.

Brain disease, neuro-retinitis, 480.

Bright's disease and retinitis, 462.

Buphthalmus, 329.

Burns on conjunctiva, 285.

### C.

Calabar bean, 80, 163, 319.

Calcification of choroid, 428.

of lens, 338, 369.

Camera obscura, 12.

Canaliculi lacrymales, occlusion of, 206.

Cancroid of cornea, 325.

Capillary pulsation in optic nerve, 412.

Capsule of Tenon, 193.

Caries of orbit, 193.

Caruncle, lachrymal, hypertrophy and extirpation of, 213.

Cataract, 356.

anterior central, 366.

black, 360.

capsular, 385.

complicated, 360.

congenital, 360.

cortical, 357.

diabetic, 361.

incipient, 363.

Cataract, lamellar, 364.

Morgagnian, 358.

nuclear, 358.

operation for, 370.

posterior polar, 44, 369.

punctated, 363.

pyramidal, 367.

secondary, 387.

senile, 359.

striated, 363.

traumatic, 361, 384.

Caustics in blennorrhœa, 264, 274.

Centre of rotation of eye, 126.

Chalazion, 222.

Changes during accommodation, 21.

senile, in lens, 25.

Chemosis, 259.

Choked disc, 478.

Cholera and blindness, 489.

Cholesterin in vitreous, 397.

Choroid appearance, 415.

atrophy, 35.

coloboma, 437.

detachment, 431.

embolism, 421.

hemorrhages in, 433.

hyperæmia, 418.

intervascular spaces, 416.

ossification, 347, 424.

pigment epithelium, 415.

rupture, 433.

sarcoma, 435.

tubercle, 434.

tumors, 435.

Choroiditis, 420.

acute, 424.

disseminata, 426.

due to embolism, 421.

in meningitis, 423.

in myopia, 44.

in recurrent fever, 419.

puerperal, 421.

purulent, 420.

syphilitic, 429.

Chromhidrosis, 228.

Ciliary nerves, neuralgia of, 510.

paralysis of, 511.

Coloboma of choroid, 437.



Coloboma of iris, 86, 353.  
 of lid, 244.  
 Color-blindness, 529.  
 Concomitant squint, 149.  
 Condylomata iridis, 340.  
 Conjugate foci, 13.  
 Conjunctiva, burns, 285.  
 foreign bodies, 285.  
 hyperæmia of, 252.  
 tumors of, 288.  
 Conjunctivitis, atropine, 257.  
 blennorrhœal, 258.  
 diphtheritic, 268.  
 follicular, 271.  
 granular, 266.  
 inoculated, 280, 282.  
 phlyctenular, 289.  
 simple, 254.  
 trachomatous, 275.  
 Corelipsis, 339.  
 Cornea, abscess in, 301, 304.  
 cicatrices, 294.  
 curvatures, 69, 121.  
 facets, 295.  
 fistula, 318.  
 foreign bodies, 321.  
 opacities, 311.  
 staphyloma, 315.  
 tumors, 324.  
 ulcers, 197, 260, 308.  
 vesicles on, 319.  
 wounds, 321.  
 Crossed images, 133.  
 Cryptogams in canaliculi, 206.  
 Cyclitis, 418.  
 Cylindrical lenses, 69, 90.  
 Cysticercus, 399.  
 Cystoid cicatrization, 521.  
 Cysts on iris, 354.  
 on lids, 221, 227.

## D.

Dacryoadenitis, 203.  
 Dacryocystitis, 208.  
 Dacryops, 205.  
 Decussation of optic nerve, 539.  
 Dermoid of cornea, 324.

Diabetes and cataract, 361.  
 Different refraction in eyes, 74.  
 Diphtheritis conjunctivæ, 268.  
 and paralysis, 81.  
 Diplopia, 126, 130, 132.  
 masked, 138.  
 monocular, 86.  
 Discision, 370, 371, 382.  
 Distichiasis congenita, 244.  
 shrinkage of conjunctiva, 239.  
 Divergence of visual axes, 128.  
 Double images, test, 136.  
 Double masked images, 138.  
 Dropping experiment, 75, 113.  
 Dynamic squint, 169.

## E.

Ectropion, 219, 233.  
 Eczema of lids, 226.  
 Elasticity of muscles, 155.  
 Electricity, 82.  
 Embolism of central retinal artery,  
 487; of its branches, 422.  
 of choroid, 421.  
 Emmetropia, 12, 15.  
 Emphysema of lids, 208.  
 of orbit, 201.  
 Encephalitis interstitialis, corneal  
 ulcer, 307.  
 Entropion, 236.  
 Enucleation, 348-352.  
 Ephidrosis, 228.  
 Epicanthus, 244.  
 Epiphora, 210.  
 Episcleritis, 326.  
 Epithelioma of lids, 227.  
 Ergotism and cataract, 361.  
 Erysipelas, 191, 226.  
 Examination, range of accommoda-  
 tion, 23.  
 acuity of vision, 28.  
 in inverted image, 100.  
 in upright image, 96.  
 Excavation of optic nerve, atrophic,  
 492.  
 glaucomatous, 502.  
 physiological, 406, 506.



Exercise, paralyzed muscles, 141.  
 Exophthalmometers, 202.  
 Exophthalmus, obstructed circulation, 198.  
     inflamed orbital tissues, 193.  
     morbus Basedowii, 195.  
     paralytic, 142.  
     pulsating, 198.  
     venous hyperæmia, 198.  
 Exostoses of orbit, 201.  
 Extirpation of eye, 348, 352.  
     of lachrymal gland, 206.  
     of lachrymal sac, 215.  
     of orbital contents, 201.  
 Extraction, 370.  
     flap, 371.  
     linear, 370.  
     with capsule, 381.  
 Extravasation in retina, 47, 463.

## F.

Facets of cornea, 295.  
 Facultative hypermetropia, 53.  
 Far point, 15.  
 Fatty degeneration of muscles, 197.  
 Febris recurrens and choroiditis, 419.  
 Field of vision tested, 526.  
 Fistula:  
     lachrymal, 216.  
     of cornea, 318.  
 Flimmerscotum, 541.  
 Focal illumination, 291.  
     interval, 65.  
     lines, 65.  
 Follicles of conjunctiva, 271.  
 Foreign bodies in cornea, 321.  
     in anterior chamber, 322.  
     in conjunctiva, 285.  
     in lens and vitreous, 385.  
     in orbit, 201.  
 Formula for accommodation, 25.  
     for conjugate foci, 14.  
 Fovea centralis, 414.  
 Fracture of orbital walls, 201.  
 Fundus, ophthalmoscopic appearance, 403.  
 Fungus hæmatodes, 495.

## G.

Gerontoxon, 325.  
 Glaucoma, 501.  
     acutum, 514.  
     chronicum, 513.  
     fulminans, 514.  
     hypermetropia in, 515.  
     inflammatory, 509.  
     iridectomy in, 517.  
     malignum, 519.  
     neuralgia in, 516.  
     secondary, 516.  
     simplex, 502.  
 Glioma of retina, 494.  
 Glio-sarcoma, 495.  
 Gonorrhœal blennorrhœa, 262.  
 Granular lids, 266.  
 Granulations, acute, 274.  
 Gummata iridis, 341.

## H.

Habit, force of, in hypermetropia, 57.  
 Heart disease and retinal hemorrhage, 458.  
 Hemeralopia, 188, 447, 529.  
 Hemiopia, 539.  
     homonymous, 540.  
     temporal, 541.  
 Hemorrhage beneath conjunctiva, 284.  
     in choroid, 433.  
     in orbit, 201.  
     in retina, 47, 463.  
     into vitreous, 397.  
 Hering's experiment, 75, 113.  
 Herpes frontalis, 224.  
 Homonymous images, 133.  
 Hordeolum, 221.  
 Hyaline membrane thickened, 428.  
 Hyalitis, 395.  
 Hyaloid artery, 399.  
 Hydrocephalus a cause of blindness, 481.  
 Hydromeningitis, 342.  
 Hydrophthalmus, 329.  
 Hydrops sacci lacrymalis, 209.



Hyperæsthesia of retina, 534.  
 Hypermetropia, 12, 52.  
   absolute, 53.  
   anatomical condition, 59.  
   and strabismus convergens, 149.  
   congenital, 60.  
   convex lenses in, 61.  
   degree, how found, 57.  
   facultative, 53.  
   latent, 57, 61.  
   manifest, 57.  
   relative, 53.  
 Hypopion, 295.  
 Hypopion-keratitis, 295, 301.  
 Hysteria, 231.

## I.

Ice in blennorrhœa, 263.  
 Illaqueatio, 244.  
 Image, ophthalmoscopic, 101.  
 Incongruence of retina, 157.  
 Infiltration of cornea, 279.  
 Innervation of ocular muscles, 129.  
 Inoculation, gonorrhœal, 282.  
 Insufficiency of ocular muscles, 51, 169.  
 Intervascular spaces, 416.  
 Intraocular pressure, 410, 501, 507.  
 Intraocular tumors, 329, 435, 494.  
 Inverted image, 100.  
 Iridalgia, 339.  
 Iridectomy in cataract operations, 374.  
   in cloudiness of cornea, 313.  
   in discision, 383.  
   in glaucoma, 517.  
   in irido-cyclitis, 349.  
   in iritis and irido-choroiditis, 338.  
   in lamellar cataract, 366.  
   in luxation of lens, 390.  
   in suppuration of cornea, 305.  
   theory of, 521.  
 Irideremia, 353.  
 Irido-choroiditis, 324, 336, 423.  
 Irido-cyclitis, 344.  
 Iridodesis, 321.  
 Iridodialysis, 523.

Iridotomy, 314.  
 Iris, innervation of, 543.  
 Iritis, 332.  
   chronic, 336.  
   gummosa, 341.  
   idiopathic, 332.  
   relapsing, 334.  
   rheumatic, 334.  
   secondary, 343.  
   serosa, 342.  
   syphilitic, 340.  
   variola, 341.  
   with febris recurrens, 341.  
   with gonorrhœa, 342.  
   with pannus trachoma, 279.  
 Irritation in myopia, 44.  
 Ischæmia retina, 482.

## K.

Keratitis:  
   fascicular, 293.  
   hypopion, 295, 301.  
   interstitial, 297.  
   marginal, 289.  
   neuro-paralytic, 306.  
   parenchymatous, 297.  
   phlyctenular, 292.  
   profunda, 297.  
   punctated, 299.  
   purulent, 300.  
   relapsing, 323.  
   syphilitica, 298, 300.  
   variola, 306.  
   with interstitial encephalitis, 307.  
 Keratoconus, 319.

## L.

Lachrymal canals, obliteration, 207.  
 Lachrymal fistula, 216.  
 Lachrymal gland, extirpation, 206.  
   inflammation, 203.  
 Lachrymal sac, inflammation, 208.  
   obliteration, 215.  
 Lagophthalmus, 233.  
 Lamina cribrosa, 404.  
 Laminaria bougies, 215.  
 Latent range of accommodation, 57.



Leech, artificial, 51, 52, 430.  
 Lens, calcification, 338, 369.  
     changes in accommodation, 21.  
     luxation, 388, 430.  
     opacities of, 356.  
     neutralizing, 52.  
     senile changes, 26.  
     Stokes', 73.  
 Lenses, bifocal, 90.  
     cylindrical, 90.  
     properties of, 12, 87.  
 Leptothrix, 206.  
 Leucæmia, 462.  
 Lice, 221.  
 Lids, diseases of, 218.  
 Linear extraction, 370.  
 Liquefaction of vitreous, 393.  
 Lithiasis conjunctivæ, 222.  
 Lupus of lids, 227.  
 Lymph spaces, 191, 423, 481.

### M.

Macropia, 85.  
 Macula lutea, 405, 413.  
     diseased in myopia, 45.  
     physiological behavior, 414.  
     retinitis of macula lutea, 463, 469.  
 Malignant pustule on lid, 226.  
 Mariotte's blind spot, 45.  
 Masked double vision, 138.  
 Medullary sheaths, retina, 439.  
 Meibomian glands, 219, 222.  
 Melanoma of cornea, 325.  
 Membrana pupillaris perseverans, 353.  
 Meningitis, irido-choroiditis, 423.  
 Meridian, principal, 64.  
 Meridional asymmetry, 64, 117.  
 Metamorphopsia, 46, 443, 462.  
 Micropia, 77, 461.  
 Miners' nystagmus, 188.  
 Moon-blindness, 531.  
 Mouches volantes, 44, 393.  
 Movements of eyes, 126.  
     in myopia, 43, 51, 167.  
 Muscles, fatty degeneration, 197.  
     innervation of ocular, 129.

Mydriasis, 77, 78.  
 Myodesopia, 44, 393.  
 Myopia, 12, 31.  
     anatomical changes, 32.  
     apparent, 83.  
     causes of, 39.  
     complications in, 41, 153.  
     irritation in, 44.  
     ophthalmoscopic appearances, 35.  
     spectacles indicated, 48.  
     spectacles contra-indicated, 49.  
     treatment, 47.  
 Myosis, 84, 86.

### N.

Narcosis during extraction, 380.  
 Nasal duct:  
     probing, 210.  
     stricture, 208.  
 Near point, 15, 16.  
     absolute, 16.  
     binocular, 16.  
 Negative, relative range of accommodation, 19.  
 Nerve-sheaths, medul. of ret., 439.  
 Nerve-sheaths, separation of, 34.  
 Neuritis and neuro-retinitis, 475.  
     descendens, 485.  
     fulminans, 477.  
     interstitialis, 484.  
     retrobulbar, 193, 482.  
     with orbital inflammation, 193.  
 Nystagmus, 187, 454.

### O.

Œdema conjunctiva scleræ, 284.  
     retinæ, 425.  
 Onyx, 300.  
 Ophthalmia militaris, 283.  
 Ophthalmometer, 119.  
 Ophthalmoscope, 95.  
     binocular, 111.  
 Ophthalmoscopic diagnosis of refraction, 116.  
     examination by daylight, 115.  
     image, size of, 101.



- Optic disc, appearance, 403.  
     excavation, 404.  
     in myopia, 37.  
 Optic nerve, atrophy, 491.  
     decussation, 539.  
     distribution of fibres, 405.  
     excavation, 404.  
     inflammation of, 475.  
     ophthalmoscopic appearance, 403.  
 Optometer, 67.  
 Orbit, affections of, 191.  
 Orthopedic treatment of strabismus, 180.  
 Ossification of choroid, 347, 424.  
     of vitreous, 395.

## P.

- Pannus phlyctænuosus, 294.  
 Pannus trachomatous, 276, 294.  
 Panophthalmitis, 420, 422.  
 Paracentesis of cornea, 299, 310.  
     with abscess, 306.  
     with ischæmia retinæ, 483.  
     with ulcer, 309.  
 Parallax, binocular, 66.  
     ophthalmoscopic, 408, 505.  
 Paralysis of accommodation, 76.  
     causes of, 139.  
     diphtheritic, 81.  
     of abducens, 134.  
     of ocular muscles, 134, 197.  
     of oculo-motorius, 141.  
     of orbicularis, 232.  
     of trochlearis, 145.  
     rheumatic, 139.  
     syphilitic, 139.  
 Pediculi, 221.  
 Pemphigus of conjunctiva, 285.  
 Perimeter, 528.  
 Perineuritis, 484.  
 Periosteal extirpation of orbital contents, 201.  
 Periotomy, 297.  
 Peripheral linear incision, 375.  
 Periscopic glasses, 89.  
 Perivascular neuritis, 474.  
 Phlyctænulæ conjunctivæ, 289.  
     corneæ, 292.

- Phosphenes, 22.  
 Photophobia, syn. blepharospasm, 228, 292.  
 Phthisis bulbi, 524.  
 Pigmentation of disc, 493.  
 Pigmentation of retina, 447.  
 Pinguecula, 288.  
 Polyopia, monocular, 86.  
 Polypi, nasal, 213.  
     of lachrymal sac, 217.  
     of nasal duct, 217.  
 Positive relative range of accommodation, 19.  
 Presbyopia, 25.  
     correct by lenses, 28.  
 Principal focus, 12.  
 Principal meridian, 64.  
 Prisms, 91.  
     in diplopia, 140.  
     in strabismus, 172.  
     overcoming, 131, 172.  
 Probes, Bowman's, 210, 212.  
 Probing nasal duct, 210.  
 Projection, false, in paralysis of ocular muscles, 143.  
 Prolapsus iridis, 309.  
 Protective spectacles, 94.  
 Pterygium, 285.  
     cicatricial, 287.  
 Ptosis, 143, 231.  
 Pulsating exophthalmus, 198.  
 Pulsation in retina:  
     arterial, 410, 506, 512.  
     venous, 409.  
 Puncta lacrymalia, anomalies, 206.  
 Pupil, occlusion, 335.  
 Pupillary membrane, 353.  
 Purpura hæmorrhagica, 458.  
 Pustule, malignant, on lid, 226.

## R.

- Range of accommodation, 16.  
     determining, 23.  
 Reclination, 370.  
 Reflex from retina, 412.  
 Refraction, anomalies of, 11.  
     different in two eyes, 74.  
     ophthalmoscopic diagnosis, 116.



- Relative range of accommodation, 16.  
     in myopia, 42.  
 Retina, cystoid bodies in, 446.  
     detachment, 47, 441, 515, 517.  
     embolism, 422.  
     hemorrhage in, 455.  
     hyperæmia, 440.  
     inflammation, 459.  
     medullary sheaths, 439.  
     œdema of, 425, 445.  
     opacity of, 412.  
     pigmentation of, 447.  
     reflex from, 413.  
     rupture of, 443.  
     vessels of, 409, 489.  
 Retinal image suppressed, 43, 157.  
 Retinitis, 459.  
     albuminurica, 465.  
     anatomical changes, 470.  
     hæmorrhagica, 463.  
     leucæmica, 467.  
     nyctalopica, 468.  
     of Bright's disease, 470.  
     of macula lutea, 469.  
     pigmentosa, 447.  
     septica, 462.  
     syphilitica, 463.  
 Retrobulbar neuritis, 193, 482.  
 Rheumatic paralysis, 139.
- S.**
- Sarcoma of choroid, 435.  
 School furniture, 40, 48.  
 Sclera, rupture, 390.  
 Scleral stripe, 119.  
 Scleritis, 326.  
 Sclerotico-choroiditis, 41.  
 Scorbutus and hemeralopia, 531.  
 Scotoma, 46, 535.  
 Scrofula and keratitis, 294.  
 Seborrhœa, 228.  
 Snellen's types, 28.  
 Snow-blindness, 531.  
 Spasm :  
     of accommodation, 52.  
     of ocular muscles, 148.  
 Spectacles, 28, 87.  
     Spectacles, bifocal, 90.  
         blue, 28.  
         protective, 94.  
     Spherical lenses, 87.  
     Spinal disease and blindness, 538.  
     Squinting angle, 154.  
     Staphyloma corneæ, 309, 315.  
         posticum, 33, 46, 328.  
         scleræ, 328.  
     Staphylomatous cicatrices, 309.  
     Stauungspapille, 478.  
     Stenopaic apparatus, 69, 94, 313.  
     Stereoscope in amaurosis simulata, 546.  
         in strabismus, 159.  
     Stereoscopic image, 113.  
     Stokes' lens, 73.  
     Strabismus, 149.  
         apparent, 125.  
         causes of, 150.  
         convergens, 149.  
         convergens alternans, 154.  
         convergens, periodic, 155.  
         divergens, 76, 165.  
         divergens alternans, 75.  
         divergens, relative, 76.  
         dynamic, 169.  
         operation for, 144, 174.  
         paralytic, 138, 153.  
         upward or downward, 173.  
     Strabometer, 156.  
     Stricture of nasal duct, 208.  
     Strychnine in amaurosis, 545.  
     Stye, 221.  
     Style for nasal duct, 215.  
     Suppression of retinal images, 43, 157.  
     Symblepharon, 244, 285.  
     Symmetry of retina, 157.  
     Sympathetic affections, 230, 345.  
     Syndectomy, 297.  
     Synechiæ, anterior, 309.  
         posterior, 333.
- T.**
- Tarsal glands, 219, 222.  
 Tarsorrhaphy, 235.  
 Telangiectasia of lids, 227.  
 Temporal hemiopic defects, 541.




- Tenon's capsule, inflammation of, 193.  
 Tenotomy, 51, 144, 174.  
 Tension, intraocular, 507.  
 Test letters, 28.  
     lines, astigmatism, 68.  
 Testing vision, 362.  
 Thrombus of vena ophthalmica, 199.  
 Tonometer, 507.  
 Torpor retinae, 447, 529.  
 Trachoma, 267, 275.  
 Transplanted skin, 249.  
 Trichiasis, 239, 278.  
 Tubercle in chiasm, 539.  
 Tumors, conjunctival, 288.  
     corneal, 324.  
     gummy, 340.  
     intraocular, 329, 435, 494.  
     intraorbital, 199, 412.  
     of iris, 353.
- U.**
- Ulcers of cornea, 197, 260, 308.  
     of lids, 218, 227.  
 Ulcus corneae serpens, 302.  
 Unguis, 300.  
 Upright image, 96.  
 Uræmic amaurosis, 467.
- V.**
- Varicosity of orbital veins, 199.  
 Vascularization of cornea, 297.
- Vesicles of cornea, 319.  
 Vesicular granulations, 272.  
 Virtual image, 15.  
 Vision, acuity of, 28.  
     angle of, 102.  
     empirical theory, 158, 188.  
     line of, 42.  
     testing, 28, 362.  
 Visual field, 526.  
 Visual-field amblyopia, 534.  
 Vitiligoidea of lids, 228.  
 Vitreous, detachment, 393.  
     hemorrhage into, 397.  
     liquefaction, 393.  
     opacity, 394.  
     ossification, 395.  
     vascularization, 398.
- W.**
- Weber's knife, 207.  
 Wecker's scissors, 314.  
 Wounds of cornea, 321.
- X.**
- Xanthelasma of lids, 228.  
 Xerosis, 278, 308.
- Z.**
- Zoster ophthalmicus, 224.

---

### ERRATA.

- Page 78, line 10, for "myopia" read "micropia."  
 Page 78, line 3 of the foot-note, for "physical" read "psychical."  
 Page 137, line 32, for "early" read "clearly."  
 Page 156, line 12, for "lachrymalis" read "lacrymale."  
 Page 269, line 1, for "lachrymal" read "nasal."  
 Page 318, line 19, for "in" read "into."  
 Page 477, line 15, for "194" read "199."















7



