

A handbook of gynaecological operations / by Alban H.G. Doran.

Contributors

Doran, Alban H. G. 1849-1927.
Royal College of Physicians of Edinburgh

Publication/Creation

London : J. & A. Churchill, 1887.

Persistent URL

<https://wellcomecollection.org/works/x656cfyq>

Provider

Royal College of Physicians Edinburgh

License and attribution


This material has been provided by This material has been provided by the Royal College of Physicians of Edinburgh. The original may be consulted at the Royal College of Physicians of Edinburgh. where the originals may be consulted.

This work has been identified as being free of known restrictions under copyright law, including all related and neighbouring rights and is being made available under the Creative Commons, Public Domain Mark.

You can copy, modify, distribute and perform the work, even for commercial purposes, without asking permission.



Wellcome Collection
183 Euston Road
London NW1 2BE UK
T +44 (0)20 7611 8722
E library@wellcomecollection.org
<https://wellcomecollection.org>







* Feb. 6. 22

R38015

HANDBOOK
OF
GYNÆCOLOGICAL OPERATIONS

BY
ALBAN H. G. DORAN, F.R.C.S.

SURGEON TO OUT-PATIENTS, SAMARITAN FREE HOSPITAL FOR WOMEN AND CHILDREN,
LONDON


*Author of "Clinical and Pathological Observations on Tumour of the Ovary,
Fallopian Tube, and Broad Ligament"*



WITH ILLUSTRATIONS

LONDON
J. & A. CHURCHILL
11, NEW BURLINGTON STREET

1887



PREFACE.

IN this handbook I have endeavoured to draw a line between surgical operations on the female organs and proceedings of a more or less purely obstetrical or therapeutical character fully described in current works on midwifery and diseases of women. This manual is devoted to true surgery, according to the usual signification of the term, although for given reasons certain operations mainly obstetrical in nature have been introduced. Much importance is attached to the anatomy and methods of examination of the pelvic organs and to a proper selection of instruments. A sound knowledge of these subjects will greatly lighten the task of the operator.

Ovariectomy has been chosen as the type of abdominal section, and several chapters are devoted to the steps of that operation and to after-treatment. In preparing those chapters, I have availed myself of a long series of notes of nearly nine hundred abdominal operations at which I have assisted, including cases under my own care. The success of surgery of this class depends largely upon matters of detail readily recorded by the experienced, and thus transmissible through literary channels to those who seek for instruction. On the other hand, the steps of plastic procedures cannot be easily taught by printed directions; they may, however, be fairly explained by diagrams, and the success of operations of this kind depends upon other factors besides manual dexterity. I have said little about the results of major operations, since long tables of statistics prepared by experienced operators are unreliable guides to those who have few opportunities of performing abdominal section. My friend Dr.

Steavenson has kindly written a chapter on electrical apparatus, and added passages on the same subject to other chapters. We have excluded any mention of the employment of electrolysis for the cure of fibroid disease, as this important method, though apparently full of promise, has not been as yet completely established; nor is the method of its application strictly within the limits of what is understood by a surgical operation.

Many of the illustrations are original, and have been drawn by Mr. Lewin from fresh specimens and from preparations in the museum of the Royal College of Surgeons. Figs. 92, 94, 98, 99, 102 to 107, 109, 114, 115, 117, 118, 127, and 150 are taken from my own sketches, and several illustrations originally appeared in my *Clinical and Pathological Observations on Tumours of the Ovary, Fallopian Tube, and Broad Ligament*. Figs. 70, 71, and 72 were drawn by Mr. Leonard Marks, late of St. Bartholomew's Hospital. My thanks are due to Sir Spencer Wells, Drs. Emmet, Matthews Duncan, Savage, and Bantock, and Mr. Mayo Robson for permission to reproduce some woodcuts from their own works. The sketches of instruments were kindly lent by Messrs. Krohne & Sesemann, the drawings of galvanic apparatus by Messrs. Coxeter & Son and Arnold & Sons.


The absence of a satisfactory system of nomenclature has given me great trouble, and I have been compelled, by custom, to employ many words and phrases to which I object. As regards proper names applied to operations and instruments, I cannot guarantee priority to any particular operator or inventor. Certain grammatical questions relating to terms used by surgeons and gynecologists are briefly discussed in footnotes. For the orthography of many words, such as *Cæsarean*, *hilum*, *aneurysm*, *siphon*, and *perineorrhaphy*, I have relied upon Hyrtl's *Onomatologia Anatomica*, and on the authority of my friend and former colleague Dr. Alexander Henry, and other classical scholars.

Classification of the subjects of this work has proved difficult, as every surgical operation depends more or less on anatomy and also on pathology. An arrangement based on purely surgical grounds thereby becomes an impossibility, nor can any system be simultaneously consistent with anatomical and

with pathological requirements. Practical considerations being here of the first importance, many details have been repeated in chapters on different operations. Owing to the impossibility of this kind of repetition beyond a certain point, and to the impediments in the way of a system of classification allowing every facility of reference, I have made the index as copious as possible.

I here take the opportunity of thanking my colleagues, especially Drs. Bantock and Percy Boulton for kindly revising certain descriptive portions of the handbook, relating to abdominal sections and plastic operations.

9, GRANVILLE PLACE, PORTMAN SQUARE,
July, 1887.



LIST OF ILLUSTRATIONS.

FIG.	PAGE
1. The External Parts of an Adult Virgin	2
2. The Vulva in Childhood	3
3. I. Labieform Hymen (<i>Tardieu</i>). II. Lingulate Hymen (<i>Dohrn</i>) ...	5
4. Hymen Bisectus	7
5. Vulva laid open to display the Vestibule... ..	10
6. Vertical Section of the Pelvic Viscera (<i>after Foster</i>)	14
7. Broad Ligament Cyst above the Tube	22
8. Diagram of the Uterine Appendages (<i>Henle</i>)	23
9. Accessory Fimbriae and Ostium on a Fallopian Tube (<i>Author</i>) ...	25
10. Right Half of the Bladder and Uterus, with Part of Vagina ...	29
11. Normal Relations of Cervix, Ureters, and Urethra (<i>Hegar and Kaltenbach</i>)	32
12. Arteries of Internal Female Organs (<i>after Hyrtl</i>)	42
13. Bimanual Examination (<i>Sims</i>)	55
14. Fergusson's Speculum	58
15, 16. Speculum-Forceps	60
17. Playfair's Probe	61
18. Sims' Speculum	62
19. Neugebauer's Speculum	65
20. Barnes' Crescent Speculum... ..	66
21. Cusco's Bivalve Speculum	67
22. Sound... ..	73
23. Volsella	78
24. Tent Introducer	80
25. Wristlets or Handcuffs	86
26. Thigh-Belt	86
27. Scissors for Ovariectomy, bent on the Flat	92
28. Koeberlé's Pressure-Forceps	95
29. Wells' Pressure-Forceps (<i>old form</i>)	96
30. Wells' Pressure-Forceps (<i>new form</i>)	97
31. Tait's Pressure-Forceps	99
32. T-bladed Pressure-Forceps	100
33. Adams' Peritoneum-Hook	101
34. Stanley's Director	102
35. Wells' Ovariectomy-Trocar	102
36. Tait's Ovariectomy-Trocar	104
37. Wells' Tapping-Trocar	105
38. Volsella for Ovariectomy	106
39. Nélaton's Volsella	107

FIG.	PAGE
40. Large Pressure-Forceps	109
41. T-bladed and Angle-Bladed Large Pressure-Forceps	111
42. Wells' Large Clamp-Forceps	112
43. Wells' Small Clamp-Forceps	112
44. Pedicle-Needle	113
45. Wells' Blunt-ended Pedicle-Needle	114
46. Long Pedicle-Needle	114
47. Needle-holder	115
48. Needle for Ovariectomy	116
49. Hagedorn's Needles	117
50. Effects of Suture made by Ordinary and by Hagedorn's Needles	118
51. Hagedorn's Needle-holder	119
52. Koeberlé's Serre-Nœud	123
53. Pedicle-Pins	124
54. Koeberlé's Drainage-Tube	125
55. Keith's Drainage-Tube	126
56. Clover's Crutch	132
57. Thornton's Ice-cap	133
58. Leiter's Cap	135
59. Leiter's Temperature Regulator	136
60. Leiter's Temperature Regulator: How to Bend it	137
61. Leiter's Temperature Regulator: How to Straighten it	137
62. Clay's Insufflator	138
63. Kabiersky's Insufflator	139
64. Nozzles for Kabiersky's Insufflator	139
65. Bichromate of Potash Galvano-cautery Battery	144
66. Bunsen's Battery	147
67. Grove's Battery with Wire Écraseur	148
68. Cauters and Écraseur	151
69. Firm Platinum Knife	151
70. Galvanic Écraseur	152
71. Side View of same	153
72. Two Clip-Handles	153
73. Small Electric Lamp	156
74. Electric Lamp fitted to a Fergusson's Speculum	157
75. Structures in and adjacent to the Broad Ligament (<i>Author</i>)	159
76. A Small Multilocular Cyst (<i>Author</i>)	159
77. Dermoid Ovarian Tumour, bearing Teeth and Bone (<i>Author</i>)	160
78. Dermoid Ovarian Tumour, consisting of Three Loculi of Irregular Form	160
79. Papillomatous Cystic Tumour of Ovary (<i>Author</i>)	161
80. Papillomatous Disease of the Broad Ligaments	162
81. Ovary covered with Papillomata	162
82. Simple Broad Ligament, or "Parovarian Cyst"	163
83. Dissection of Broad Ligament, to show its relations to two cysts	164
84. Papilloma of the Fallopian Tube (<i>Author</i>)	165
85. A small Sarcomatous Ovary (<i>Author</i>)	165
86. A Twisted Pedicle	176
87. Dilated Vein from a Twisted Pedicle	177
88. Ovarian Cyst suppurating after Prolonged Drainage	179

FIG.	PAGE
89. Ovarian Cyst unaffected by Prolonged Drainage	180
90. Ovarian Disease in a Still-born Child	183
91. Stump of an Ovarian Pedicle One Week after Operation	186
92. Mechanism of Splitting of the Pedicle	187
93. Ovariectomy: The Waterproof Sheet applied to the Abdomen (<i>Wells</i>)	198
94. Position of Tables, Operator, etc., during Ovariectomy	200
95. Ovariectomy: The Trocar plunged into the Cyst (<i>Wells</i>)	208
96. Ovariectomy: Extraction of the Cyst through the Abdominal Wound (<i>Wells</i>)	208
97. Ovariectomy: Breaking down Solid Matter (<i>after Savage</i>)	210
98. A Long Pedicle	215
99. A Short, Broad Pedicle	216
100. Dermoid Cyst separated from its Pedicle (<i>Author</i>)	218
101. Stump of the Pedicle from the same case	218
102. Ligature of the Pedicle: Transfixion with the Needle	220
103. Ligature of the Pedicle: Thread Passed through Loop	220
104. Ligature of the Pedicle: Threads Crossed	221
105. Ligature of the Pedicle: Double Transfixion	223
106. Ligature of the Pedicle: Double Transfixion, threads tied	223
107. Cyst secured by Sutures to Abdominal Wound	229
108. Ovariectomy: Introduction of Sutures (<i>after Savage</i>)	234
109. The Sutures in the Abdominal Wound	235
110. Hernia of the Cicatrix of an Abdominal Wound	254
111. An Obstructed Fallopian Tube	274
112. Fallopian Tube forming a Large Cystic Tumour	275
113. Ovary adherent to the Great Omentum	279
114. Oöphorectomy: Transfixion of the Pedicle	281
115. Fibroid Uterus: Altered Relations of Appendages	291
116. Fibroid Uterus with Interstitial Growths	293
117. Fibroid Uterus: Pedicle very broad	294
118. Pedicle of Uterine Fibroid secured by Serre-nœud and Pins	296
119. Uterus with Large Fibroid Outgrowth	303
120. Kidd's Volsella	309
121. Sims' Guarded Tumour-Hook	309
122. Sims' Tampon-Screw	310
123. Uterine Polypus-Forceps	314
124. Curved Écraseur	329
125. Zinc Electrode for the Decomposition of Cancerous Tissue	333
126. Short Speculum for Trachelorrhaphy (<i>Boulton</i>)	341
127. Lacerated Cervix after Denudation	342
128. Lacerated Cervix after Denudation (<i>Emmet</i>)	343
129. Cicatricial Hypertrophy after Laceration (<i>Emmet</i>)	347
130. Horizontal Plane of Cervix from same case as Fig. 129 (<i>Emmet</i>)	347
131. Cicatricial Plug in a Lacerated Cervix (<i>Emmet</i>)	348
132. Bifid Laceration of the Cervix (<i>Emmet</i>)	349
133. Gestation in Outer Portion of Left Fallopian Tube	351
134. Tubal Gestation, Sac in Douglas's Pouch	355
135. Tubal Pregnancy	360
136. Tubo-Uterine, or "Interstitial" Pregnancy	361
137. Diagram of Uterine Wound in Säger's Cæsarean Section	373

FIG.	PAGE
138. Diagram representing Application of Sutures in same Operation ...	374
139. Operation for Ruptured Perineum: The Raw Surface (<i>Bantock</i>) ...	393
140. Operation for Ruptured Perineum: The Anal Sutures (<i>Bantock</i>) ...	395
141. Operation for Ruptured Perineum: The Perineal Sutures (<i>Bantock</i>)...	397
142. Operation for Ruptured Perineum: Sutures applied to Vaginal Mucous Membrane (<i>Bantock</i>)	397
143. Operation for Ruptured Perineum: Purse-string Operation (<i>Boulton</i>)	401
144. Emmet's Elytrorrhaphy: The Three Freshened Surfaces ...	410
145. Emmet's Elytrorrhaphy: The Folds in the Vaginal Wall Vivified and Sutured	410
146. Elastic Gum Vaginal Dilator	425
147. Sponge-holder	427
148. Vesico-Vaginal Fistula Knives	427
149. Vesico-Vaginal Fistula Needle (<i>Boulton</i>)	429
150. Operation for Vesico-Vaginal Fistula: Introduction of Suture ...	430
151. Blunt-Hook for same Operation (<i>Boulton</i>)	430
152. The Sutures after Introduction (<i>Simon</i>)...	431
153. S-headed Suture-Twister	432
154. The same in use	432
155. The Wires Twisted and Secured	432
156. Self-Retaining Catheter (<i>Boulton</i>)	433
157. Atresia of Urethra between two Fistulæ (<i>Simon</i>)	438
158. The same: First Operation for its Relief (<i>Simon</i>)	439
159. Vesico-Uterine Fistula (<i>Thomas</i>)	441
160. Colpocleisis (<i>Simon</i>)	444
161. Wood's Operation for Ectopia Vesicæ: Flaps Marked Out (<i>Mayo</i> <i>Robson</i>)	452
162. Wood's Operation for Ectopia Vesicæ: Flaps Stitched (<i>id.</i>) ...	454
163. Wood's Operation for Ectopia Vesicæ: Retraction of Flaps (<i>id.</i>) ...	455
164. Wood's Operation for Ectopia Vesicæ: Result of Second Operation(<i>id.</i>)	456
165. Atresia Vaginæ, with Patulous Hymen (<i>Matthews Duncan</i>) ...	461
166. Cauters for Treatment of Urethral Caruncle	471
167. Simon's Dilator	472

ERRATA, ETC.

Page 27, line 15.—For “a little over two inches” substitute “a little under two inches.”

„ 106, note.—For “page 78” substitute “page 76.”

„ 132, line 10, add “In some cases it will be found more convenient to adjust the bands below the knee.”

A HANDBOOK OF GYNÆCOLOGICAL OPERATIONS.

CHAPTER I.

THE SURGICAL ANATOMY OF THE FEMALE ORGANS.

A CONSIDERABLE portion of the earlier pages of this work will, from motives of principle and convenience, be devoted to surgical anatomy. The principle that the operator should be acquainted with anatomy needs no support from argument. Every operation involves anatomical considerations. The scope of this work is confined to a limited anatomical area, but includes descriptions of a relatively large number of operations. Hence a preliminary sketch of the anatomy of that area will save much unnecessary repetition. The term "surgical anatomy" is here employed in its conventional sense. It is an ill-defined but useful expression, intended to designate as much anatomical knowledge as is likely to prove of practical service to the surgeon. I shall at once proceed to describe the organs and structures in the order adopted by most contemporary writers.

Labia Majora.—The labia majora are a pair of large folds of skin, including the dartos, fat, and connective tissue. They are externally and, to a less extent, internally covered with hair. The labia unite at the symphysis pubis, but it is a mistake to suppose that they meet posteriorly. Fig. 1 shows that they are separate in the adult; in Fig. 2 they are seen to end behind the deeper structures of the vulva as two elevated pads of integument. This is the normal condition in very young subjects. Dubois and Pajot, and Matthews Duncan have exposed the prevalent fallacy about the posterior portions of the

labia. In plastic operations in their vicinity, there is no necessity to attempt to unite them. In the space between the ends of the labia and the hymen lies the anterior part of the perineum; its prominent anterior limit forms the "posterior fourchette"

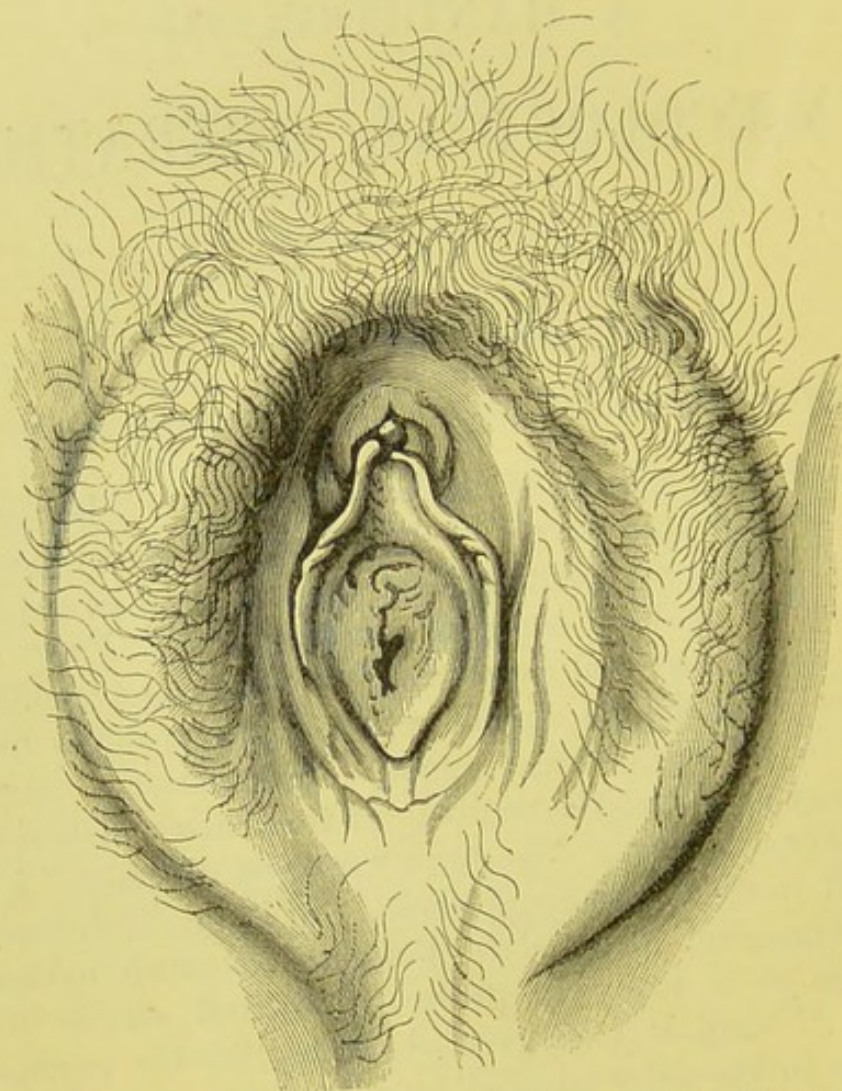


FIG. 1.—THE EXTERNAL PARTS OF AN ADULT VIRGIN.

The labia majora are seen to end posteriorly without uniting. The posterior fourchette is but slightly marked; the integument which forms it is wrinkled. The true relations of the labia minora to the clitoris and hymen are indicated. The meatus urinarius forms a narrow slit curved with its convexity forwards. The parts are displayed as seen in life when the labia are artificially separated. (*Museum R.C.S., Physiological Series, No. 2,844.*)

or "frænulum." On everting the structures on each side, a crescentic depression, with its cornua pointing forwards, will appear between the fourchette and the hymen. This depression

is the "fossa navicularis." It is the integument in the middle line of the fossa, and not the posterior fourchette, that is so frequently torn at the first labour. After that event, the posterior extremities of the labia majora undergo more or less atrophy, and the relations of the fourchette and the structures in front of it can no longer be defined with precision.

Labia Minora or Nymphæ.—These terms are given to two thin, hairless, cutaneous folds, bright red in colour, and concealed by the labia majora in most virgins. In multiparæ they become flaccid and elongated, and project beyond the greater labia. Their outer surfaces then assume the characters of dark, dry skin. The free border of each nymphæ terminates anteriorly, not in the prepuce as generally supposed, but in the frænum of the clitoris (Figs. 1, 2, 5). On the other hand,

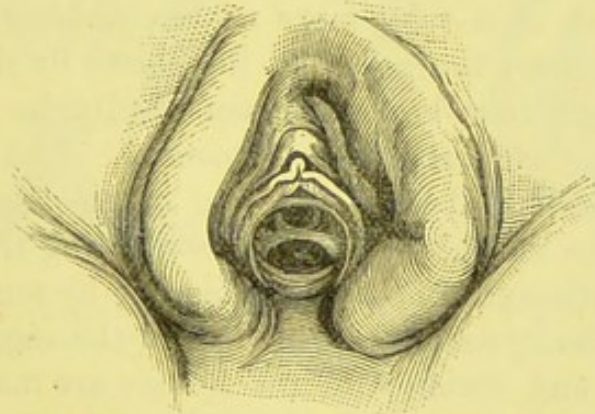


FIG. 2.—THE VULVA IN CHILDHOOD.

The true posterior relations of the external labia and the relations of the nymphæ to the clitoris are demonstrated, as in Fig. 1. The urethra has been dilated artificially. (*Museum R.C.S., Physiological Series, No. 2,841a.*)

the prepuce is continued laterally on to the outer surfaces of the labia minora, with which it blends. I have repeatedly verified the above relations by examination of live subjects. Posteriorly, the labia minora are lost on the integuments of the vulva, rather than on the inner side of the greater labia, as sometimes described. The inner surfaces of the labia minora are well supplied with sebaceous glands, and generally undergo during pregnancy a purple or lilac discoloration, in which the vaginal mucous membrane shares. A second labium minus sometimes exists; it lies external to the nymphæ, and is lost

anteriorly on the corresponding labium majus. It is not connected with the clitoris or its prepuce.

The labia minora are very sensitive, and are among the last structures to yield to the effects of anæsthetics. They are histologically skin, and not mucous membrane; their deeper substance is erectile tissue. They bleed freely when wounded, but the hæmorrhage is not always difficult to arrest.

The Clitoris.—In the anterior angle of the vulva lies the clitoris, enveloped in its prepuce. When it appears enlarged, careful examination will generally show that in reality the other parts of the vulva are small and ill-developed. This condition is seen in sickly young adults who have been laid up with some chronic illness during puberty, and in sterile women with small uteri, subject to dysmenorrhœa.

The Hymen.—This is a cutaneous fold, most developed posteriorly, and, as a rule, more or less crescentic in outline. It is separated from the posterior fourchette by the fossa navicularis, although this depression can hardly be said to exist until the parts are artificially separated. The hymen may conveniently be described as the end of the vagina and the beginning of the vulva, the fourchette marking the outer limits of the vulva, although this point is disputed by some authorities, who speak of the hymen as entirely below the vagina.

The nature and varieties of the hymen are matters of some importance to the surgeon. In operations about the vulva and vagina, and in any examination by inspection or digital exploration, certain peculiarities in this structure may be mistaken for tumours, or for evidence of some other form of disease, and the patient may, in consequence, be subjected to needless, if not absolutely objectionable, operative or therapeutic measures. I shall, therefore, proceed to describe the principal varieties of hymen, taking for my guide, where personal experience may be wanting, R. Dohrn's valuable monograph, "*Die Bildungsfehler des Hymens*" (*Zeitschrift für Geburtshülfe und Gynäkologie*, vol. xi., 1885).

In *infancy* the hymen bears the appearance of a pair of labia (*labieform hymen*), Fig. 3, I. Instead of forming a horizontal diaphragm, it is folded in two parts, the inner surfaces of which lie in contact, whilst the edges of the aperture point

downwards. As the external labia are flattened they may be overlooked by an inexperienced observer, the internal labia being taken for the external, whilst the hymen is mistaken for the internal labia. I have heard it suggested, in the course of an examination of an infant with vulvitis, that the hymen, in reality unaffected, was "absent" or "evidently torn." In some infants the posterior part of the hymen is thick and fleshy, forming a prominence closely resembling a small polypus (*hymen linguliformis*, Fig. 3, II.). This condition always disappears as the subject grows older.

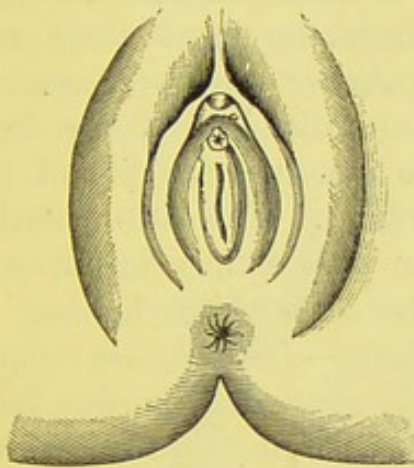


FIG. 3, I.—LABIEFORM HYMEN.
(Tardieu.)

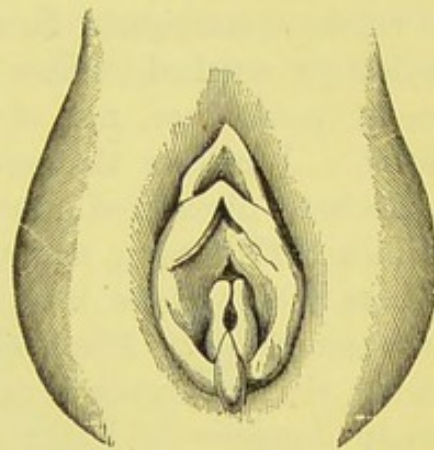


FIG. 3, II.—LINGULATE HYMEN.
(Dohrn.)

In *childhood*, as the neighbouring parts widen, the hymen becomes more and more horizontal in position, the opposite sides gradually unfolding. Lastly, later on, the edges of the orifice come to lie apart.

In the *adult virgin* the hymen forms a ring, generally broadest posteriorly. This, the commonest type, is the *hymen annularis*. In the *hymen circularis* the orifice is precisely central, the anterior part of the membrane being as broad as the posterior. This is not a rare form; it may puzzle the surgeon, before careful examination. The clitoris and meatus urinarius are safe landmarks for the explorer. The orifice is long and narrow, and the posterior part of the membrane is broad, in the *hymen semilunaris*; whilst in the *hymen falciformis* the orifice is long and somewhat wide, the membrane being narrow. The posterior attachment of the hymen is on a lower plane than the anterior.

Abnormalities in the Free Edge of the Hymen constitute several distinct varieties. In the *hymen denticulatus* the edges are, in part, thick and fleshy, and elsewhere thin, forming irregular folds. It is a persistent form of the infantile type. It is observed, not rarely, in elderly subjects. This denticulate hymen is the form most readily liable to be mistaken for a ruptured hymen, where the edges, after a few weeks of cohabitation, tend to thicken. In the denticulate hymen, however, the folds, when pressed upon, disappear, as they involve the edge only of the membrane. In the ruptured form the edge of one fold at least may be traced through the membrane, often as deep as its vulvar attachment. In a rare form, the edge of the hymen is delicately notched. This is the *hymen fimbriatus*, said to represent persistence, not of the infantile, but of the foetal condition. I believe that only one genuine example of this type has been discovered (Luschka's case). The cases described by Winckel, Hoffmann, and Guénier were simply instances of papilloma of the vulva involving the edge of the hymen.

Abnormalities in the Plane of the Hymen.—In the *hymen infundibuliformis* the membrane is completely everted. Its edge looks not only downwards, but outwards, the inner surface of the membrane being fully displayed. Thus, the line of attachment of the hymen to the vagina, at first sight, looks like the free border of a normal hymen. This form is a persistence of the infantile type. When very exaggerated it is termed *hymen hypertrophicus*. It is generally associated with imperfect development of some part of the reproductive organs.

Alleged "Multiple Hymen."—The terms "*hymen duplex*" or "*hymen multipler*" are often, I believe, of questionable accuracy, anatomically speaking. For the surgeon, however, the fact is of some importance, that folds resembling valvulae conniventes are sometimes developed in the vagina; they may be mistaken by the obstetrician for cicatrices from injuries during labour. I shall presently refer to certain precautions against mistaking a true hymen for one of these folds. In rare cases the fold lies immediately above the hymen, and may really have been derived from that membrane in the course of its development. Dr. Friso, of Metz, described in the *Gazette des Hôpitaux*, 1861, No. 96, a case where labour was obstructed in a single woman,

aged twenty-two, by four circular vaginal septa, with orifices barely admitting the point of the little finger. They were so tough that a bistoury was required for their division. The child, already dead, was turned and delivered. Dr. Friso then found out that a surgeon had divided the hymen (or more probably a fifth vaginal septum) for retained menstruation at puberty. The catamenia afterwards flowed regularly without obstruction, but complete coitus was found to be impossible. The same surgeon examined the patient again, and informed her that the vagina was incurably obstructed. She relied upon this malformation, and was greatly surprised when she became pregnant. Here I may observe that impregnation has repeatedly been known to occur whenever the normal hymen is even to the least extent perforate.

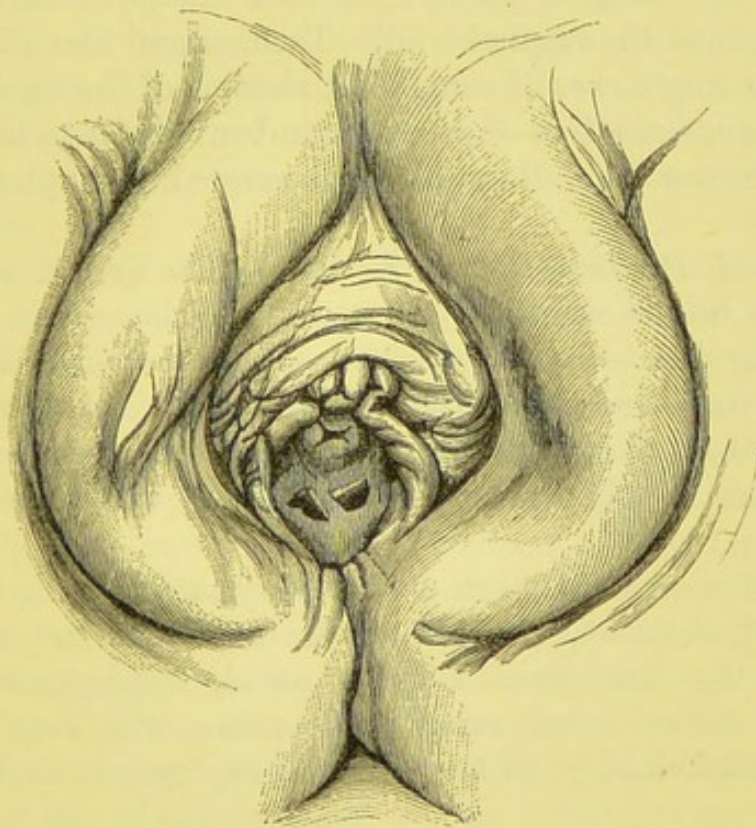


FIG. 4.—HYMEN BISEPTUS.

(Museum R.C.S., Physiological Series, No. 2,841.)

Abnormalities in the Character of the Orifice of the Hymen.—In the *hymen septus* or *biseptus* there are two orifices divided by a thin strip of membrane, generally broadest posteriorly. This

strip is said to be prolonged from the middle part of the posterior column of the vagina. The orifices are believed to represent the terminations of the ducts of Müller, whence the Fallopian tubes, uterus, and, at least, part of the vagina are developed; just as the more constant Skene's tubes, in the urethra, appear to represent the ends of Gartner's ducts. On the other hand, Breisky has observed a trace of the original septum between Müller's ducts, in the vagina, quite distinct from the hymen.

Sometimes there are two irregularly-placed orifices in the hymen (*hymen bifenestratus* of some authors); whilst in others three, four, or even as many as eleven apertures have been observed (*hymen cribriformis*).

Absence of the Hymen.—I shall presently refer to precautions against overlooking a lax hymen with its upper surface compressed against the vaginal wall. Tardieu and Devilliers failed to detect a single case of congenital absence of the hymen after systematic examination of a large number of infants, but several writers declare that they have discovered examples of this condition.

Abnormal Position of the Hymen.—The hymen sometimes appears to be abnormally high in the vagina. This, however, is generally due to great depth or peculiar development of the vulva, as in negresses. The alleged cases of abnormally low position, where the hymen has been reported as covering the urethra, are simply examples of abnormal coalescence of the labia.

Persistence of the Hymen during Pregnancy.—This has been repeatedly observed, even when the orifice of the hymen is narrow. As has been already noted, impregnation after imperfect coitus is not rare. The orifice will even allow a sixth months' child to be born without rupture, as in Tolberg's case.

Laceration of the Hymen.—Schröder has shown that in laceration of the hymen from coitus only the free border of the membrane is torn, the rent seldom extending down to the line of attachment to the vagina. The latter condition occurs at the first labour at term, and it is on that occasion, also, that the carunculæ myrtiformes are first developed. A history

of laceration of the hymen from a fall or from a blow must always be received with extreme caution. Most authorities admit that the membrane can only be torn by a force exerted directly against it, or by the continuation into its substance of a laceration of neighbouring structures. The common annular hymen is generally torn in four places, whilst a semilunar or a very tense hymen of any form tears at one point along the median line of its posterior portion.

The Hymen in Atresia Vaginae.—Dr. Matthews Duncan, who has had the advantage of a wide experience in such cases, has repeatedly found a perfect hymen associated with atresia of the vagina.* In one case the vagina was opened up by a thermocautery knife, and retained menses let out. After recovery, the true hymen was seen to be perfectly distinct from the vaginal septum which had been cut through. Dr. Duncan believes that the blue, thin-walled structure detected between the labia is generally, but often erroneously, called imperforate hymen, whereas in many cases, and often where there is even total absence of the vagina and uterus, a hymen can be distinctly seen.

General Considerations on the Hymen.—Some of the forms of hymen above described are not always easy to detect, either by sight or digital exploration. When lax the hymen may lie against the vaginal walls with its free border upwards, so as to escape a superficial examination. The exploring finger will then detect a constriction higher up the genital canal than the level of the hymen, so that a contraction of the vagina may be suspected. In the case of a cribriform hymen this error is very frequent. Sometimes the finger pulls down the hymen as it is withdrawn, then, on inspection, that structure will be discovered. The free margin of the hymen lies naturally on a higher plane than that of its posterior attachments.

Carunculæ Myrtiformes.—These structures are correctly described in most text-books, for it is the subjects that possess them who are the most frequently examined by medical attendants. In women who have had very few children they form a more or less complete circle of thin, flaccid folds; in

* "Case of so-called Imperforate Hymen" (*Trans. Obstet. Soc.*, vol. xxiv., 1882).

multiparæ they are often reduced to two or three prominent fleshy wattles. In nulliparæ who are not virgins the hymen is generally reduced to two unsymmetrical portions divided by

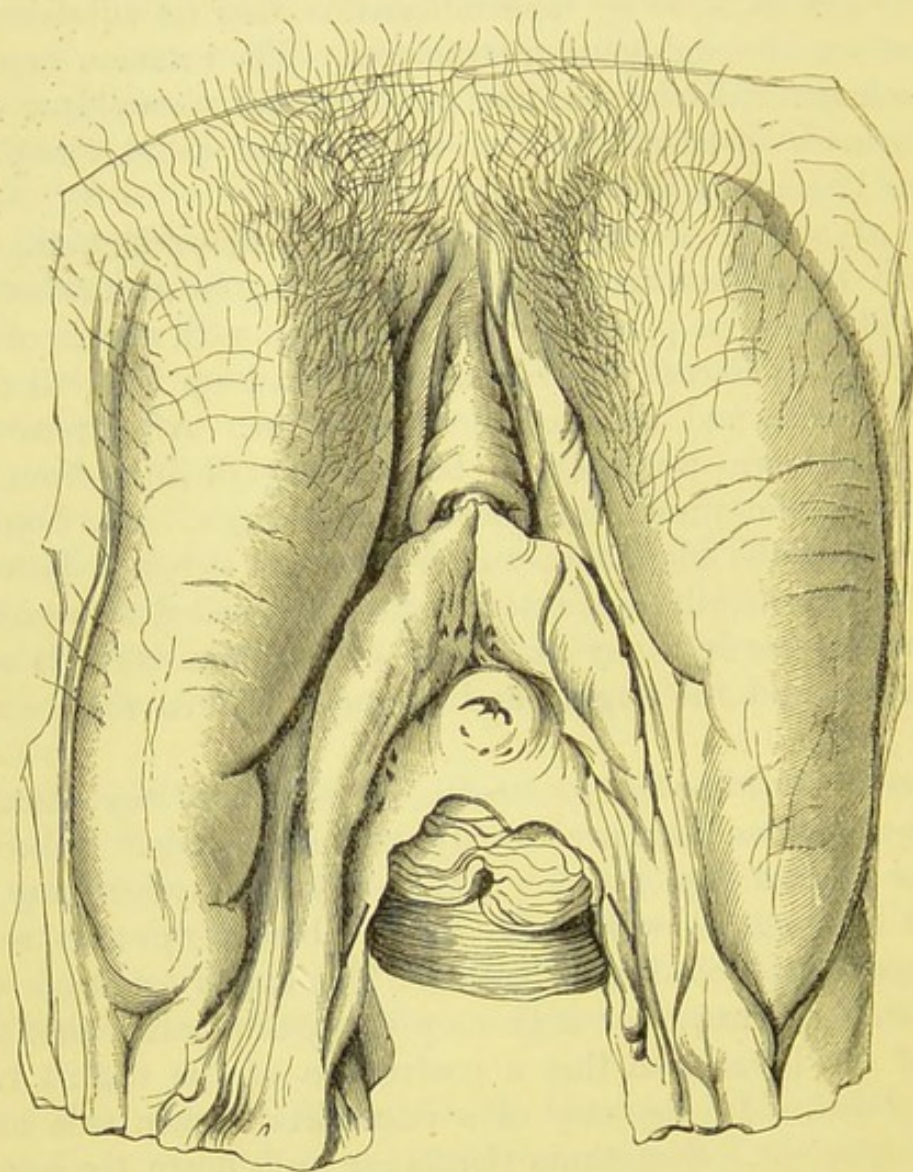


FIG. 5.—VULVA OF AN ADULT LAID OPEN BY DIVISION OF THE POSTERIOR COMMISSURE.

The vestibule is well displayed, but its posterior margin has become irregular through the action of spirit. The orifices of the vestibular follicles appear above and below the meatus urinarius. A bristle lies in each orifice of Cowper's ducts. The relations of the labia minora to the clitoris are well shown. Posteriorly the normal relations have been completely effaced. (*Museum R.C.S., Physiological Series, No. 2,830.*)

the laceration, the edges of which, as well as the free border of the hymen itself, are always more or less thickened, but the two portions can hardly be called caruncles. The orifice of

Cowper's duct may often be detected immediately outside a large caruncle a little posterior to the mid-line between the clitoris and the posterior limits of the vulvar aperture. Most writers seem to consider that it lies much farther back.

When the hymen has been torn and the carunculæ have formed, the vaginal outlet at the most posterior point of attachment of the hymen has almost invariably shared in the laceration, so that the tissues of the fossa navicularis become more or less involved towards or as far as the posterior fourchette. These lacerations totally alter the appearance of the vulva as seen in virginity, the alteration likewise involving atrophy of the prominent posterior extremities of the labia majora. Hence the structures at the posterior extremity of the vulva become hard to distinguish. When the fourchette itself is torn, the perineum is, by definition, involved in the laceration, since the fourchette is its anterior extremity.

Vestibule.—Below the clitoris is a smooth, triangular surface, with its plane almost level with the horizon (Fig. 5). It is prolonged to each side of the vulva, as the woodcut shows. This is the vestibule, and neither the anterior nor the posterior vaginal walls should be visible behind it, excepting in multiparæ, where a trifling amount of descent appears to be natural. The vestibule is much wider in some subjects than in others. Conspicuous on the surface of the vestibule is the meatus urinarius. Thanks to the characteristic smooth surface of the vestibule, well supported by the triangular ligament, the orifice of the meatus is not hard to detect for purposes of catheterism. Here too I may observe that the vestibule is not stretched in the second stage of labour; though, according to Matthews Duncan, its mucous membrane may be pushed forwards and torn longitudinally. Two clusters of large mucous follicles open by ducts on the surface of the vestibule; one group lies immediately behind the clitoris,* the other behind and at the sides of the meatus. Similar groups are found on the inner aspect of the nymphæ, and in the fossa navicularis. These follicles secrete mucus very freely, when any source of persistent local irritation exists. Their arrangement is well figured in Dr. Henry Savage's atlas.

* Hence the origin of the small cyst occasionally found in this situation.

The meatus urinarius varies considerably in appearance in healthy subjects. The urethral mucous membrane often bulges from its ring-like margin. Most remarkable is the presence of caruncles, sometimes of considerable size, and intensely red, in cases where they cause no pain during micturition, nor any other subjective symptom. On each side of the elevated margin of the meatus, somewhat posteriorly, is a minute pore. I cannot admit that it is easy to detect in healthy subjects, for I have searched for it in hundreds of patients. In chronic gonorrhœa, or leucorrhœa, the pair of pores are often discovered without difficulty. They are the orifices of Skene's tubes. The surgeon must remember that they are certainly gland-ducts, liable to morbid changes, especially in chronic gonorrhœa. Their precise significance is a purely scientific question.

Orifice of Cowper's Ducts.—On everting one of the labia minora, and pressing the hymen inwards, a small red depression may generally be seen on the vulva, somewhat posteriorly. This depression, seldom very distinct, leads to the orifice of Cowper's duct. It is most conspicuous when the hymen is replaced by carunculæ. I must here remark, that in searching for this duct, for Skene's tubes, or for similar structures in the live subject, without anæsthetics, it is not advisable to try to pass a bristle or a fine probe. Such an attempt is certain to produce great irritation.

Cowper's gland itself is a simple collection of tubules, forming an oval body about half an inch in its long diameter; it lies against the posterior part of the vaginal orifice, under the superficial perineal fascia, and covered by the fibres of the sphincter vaginæ. After the twenty-fifth year it becomes smaller, and ultimately atrophies. In emaciated subjects, such as are seen in dissecting rooms, this gland is extremely difficult to find. Abscess of this gland and cystic dilatation of its duct are two well-known diseases. Suppuration of the duct, and cystic degeneration of the gland are, on the other hand, rare.

The Vagina.—Many erroneous notions are prevalent about the anatomy of the vagina. It is often represented as a constantly open tube, bent upon itself at a somewhat indefinite angle, apparently so as to fit into the concavity of the sacrum, which, in reality, lies far above and behind it. I have heard

surgeons and obstetricians ask how a "tube like the vagina" could have an anterior and posterior wall? Great errors appear likewise to prevail on the subject of the length of the vagina.

The vagina is a structure with distinct coats, but it chiefly consists of a wide mucous surface, which is lax, so that a canal can be formed for the passage of the intromittent organ, the foetus, surgical instruments, or fluids passing outwards or inwards. In fact, the vaginal canal is only "potential."* It never forms a cavity in any natural position of the body. I shall return to this subject when speaking of the genu-pectoral and semi-prone positions in the examination of patients.

The mucous surface of the vagina is folded on itself, with a slight puckering at each side, so that a true anterior and posterior wall are formed. The anterior wall is broad above, where it is reflected on to the anterior lip of the cervix uteri, forming a slight depression—the *anterior fornix*. Below, this wall ends at the hymen, here it is very narrow. The mucous membrane of this wall forms transverse rugæ, well marked in virgins, but almost effaced in multiparæ. A vertical fold, bounded by thickened mucous membrane, and nearly an inch long, lies close above the urinary meatus. This fold is termed the *anterior column* of the vagina. When very well marked, it may be taken for a morbid condition. The urethra is in intimate relation with the lower part of the anterior vaginal wall. The bladder is separated from that wall, higher up, by connective tissue, which probably becomes more abundant during pregnancy.

In many women, especially in multiparæ over thirty years of age, the lower part of this wall descends considerably towards the vulva, without necessarily causing inconvenience. When this condition increases, however, the bladder always follows the vaginal wall in its descent, as the catheter will prove. At first, the base only descends, and then the catheter can be passed through the meatus either downwards, so that it can be felt through the prolapsed vaginal wall, or

* "The vault of the vagina" is also a mere expression, though very convenient. The reflection of the vagina on to the cervix is in no way a "vault" in a mechanical or architectural sense.

upwards into the undescended part of the bladder. When the descent of the wall is extreme, the greater part of the vesical cavity lies in the pouch formed by the prolapsed wall.

The anterior vaginal wall, from the hymen to the anterior vaginal fornix, measures, on an average, a little over two inches. Its course is almost in a straight line.

The posterior vaginal wall is also triangular, and its base likewise lies above. It measures, on an average, three inches.

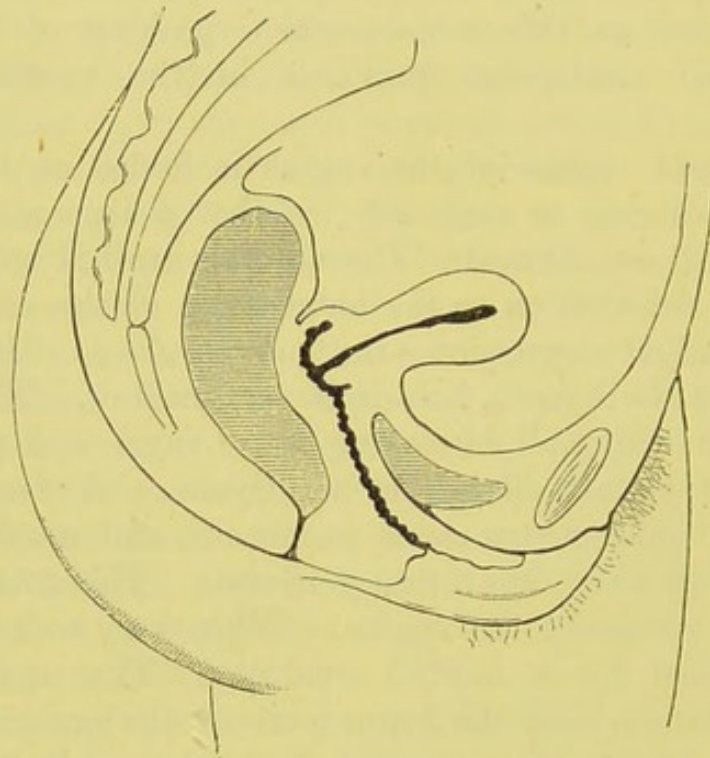


FIG. 6.—VERTICAL SECTION OF THE PELVIC VISCERA OF AN ADULT VIRGIN.

Showing the outline of the anterior and posterior vaginal walls, the position of the uterus, and the shape of the bladder when nearly empty. (*After Foster.*)

It commences at the vulva, and ends above by a reflection on to the back of the cervix uteri, forming here a deep and very distinct pouch—the *posterior fornix*, or *cul-de-sac*. Its mucous lining bears transverse rugæ and, below, an ill-marked posterior column. Successively, from below upwards, the perineal body, rectum, and the peritoneal fold known as Douglas's pouch, lie behind it. This wall is separated from the rectum superiorly by much loose connective tissue, which is continuous on each side of the vagina, with the connective tissue

between the vagina and bladder. This tissue appears to increase during pregnancy, and sometimes becomes subject to a kind of subinvolution. However this abnormal looseness of the tissue may be produced, it certainly sometimes exists, and plays an important share in the mechanism of prolapse of the uterus, vagina, or bladder.

The posterior vaginal wall makes a sigmoid curve, which varies according to the condition of neighbouring organs.

Hart and Barbour, and many other living authorities, maintain that the vaginal walls lie in apposition, excepting around the vaginal part of the cervix, in any natural position which the patient may assume.

The vagina being naturally closed, it is evident that any instrument or appliance which keeps its walls apart must be, so far, unnatural. Diseased mucous surfaces, however, are best kept apart, and certain mechanical supports have proved to be of, at least, empirical value, in some cases, possibly, on this principle alone.

When the subject stands straight up, the long axis of the vagina makes an angle of about 60° with the horizon, so that, as Hart and others have noted, it is almost parallel to the pelvic brim.

The surgeon can understand from the above description that the long axis of the vagina above is at right angles to that of the vulva below, the former being transverse, the latter running from before backwards. This fact must especially be remembered during the introduction of a pessary.

One of the most important structures to be found on the outer side of the vagina is the anterior part of the levator ani muscle. When in a state of contraction, the pair of levatores compress the vagina considerably.

The mucous membrane of the vagina is lined with stratified epithelium, squamous superficially. It appears to possess glandular structures, but not in abundance, and their precise nature and structure are disputed.

The vagina possesses a distinct muscular coat, composed of plain muscular fibres. Strange to say, their direction is differently described by different authorities; at least, there is a layer of longitudinal and a layer of circular fibres, but autho-

rities are divided as to which of the two is external. The sphincter vaginæ surrounds the lower portion of the vagina; it is a weak muscle, the levator ani being the true constrictor of the vagina. External to the muscular coat is the connective tissue already described, and a rich plexus of veins.

The Uterus.—The general aspect of this organ must be familiar to every anatomist and surgeon. The relations and minute anatomy of the uterus, the nature of its walls, its mucous membrane, and its supports have been studied and discussed for three centuries at least by anatomists, physiologists, and obstetricians. Notwithstanding this fact, there is hardly one single point respecting its structure and relations that remains undisputed.

The lower part of the cervix with the os externum lie in the vagina, accessible to the finger and visible to the eye, aided by mechanical contrivances. The fundus and body are exposed in abdominal section. The appearance of the body of the uterus, when no abnormality or no alteration due to adhesions exists, is very characteristic. Hence there is no better landmark for the operator. When he can see or touch the uterus, he knows where the bladder should be. By guiding a finger or sponge down the back of the uterus, he will find the way to Douglas's pouch, or, at least, can discover anything which may occupy that fold of the peritoneum. Most important of all are its lateral relations to the tubes and ovaries. These structures are rapidly altered by disease. By searching along the fundus and the uterine end of the tube, which is rarely hard to find or recognize, however much the remainder of the tube may be altered or concealed, the surgeon can at least discover where the appendages lie and how far they are movable or fixed by adhesions, even though he may fail to detect their component parts. The pregnant uterus is a very conspicuous object, rising above the pubes, soft and vascular. Its appendages, turgid with blood, run downwards from its sides.

When the uterus is malformed or concealed by intimate adhesions to a tumour or to a normal structure, the best landmark is lost, and the surgeon will have to rely on far less certain guides. In such cases, the bladder especially will have to be sought

with care, and with the aid of the catheter; and the difficulty of distinguishing collapsed intestine from diseased appendages must be borne in mind. In the case of a tumour strongly adherent to the pelvic viscera, the walls of its pelvic portion are often, unfortunately, so thick that the outline of the body of the uterus cannot be felt through them.

Uterine tissue bleeds very freely when wounded, whether by incision or by the tearing off of its serous coat in detaching adhesions. Of all structures in the body, it is, I believe, the most untrustworthy for treatment by ligature and for the application of sutures. The muscular walls of the uterus undergo certain contractions and relaxations in relation, it would appear, to menstruation as well as to pregnancy and parturition.* These changes, or rather movements, must be, to a great extent tidal, regular, and hence possibly calculable; still the amount of precise knowledge on the subject remains limited. As to the effects of disease and injury on the uterine muscular tissue, we are aware that there are such effects, but we know nothing precise and reliable about them. A stout ligature, tied tightly round the stump of a fibroid, may become perfectly loose in a few minutes. I am now speaking in general terms; in the chapters on Uterine Surgery I shall discuss the subject of ligature at greater length. At present it may be understood that the clamp, which can be tightened at will, is more reliable for the securing of uterine tissue than the ligature, which does not allow of similar control.

Dimensions and Weight.—In a well-formed adult, the unimpregnated uterus measures, on an average, about three inches in length, two-and-a-quarter in breadth at the fundus, and not quite an inch in thickness. The uterine cavity and the cervical canal together measure about two-and-a-half inches. The uterus weighs about one ounce, but in nearly all morbid conditions its weight is increased.

Communication between the Peritoneal Cavity and the Genital Tract.—In respect to the cavity of the uterus, the surgeon must not forget that it bears an absorbent mucous surface,

* See Matthews Duncan "On Contraction, Inhibition, and Expansion of the Uterus," and "On Elasticity, Retraction, and Polarity of the Uterus" (*Transactions of the Obstetrical Society of London*, vol. xxviii., 1886).

and that it communicates with the vagina on the one hand, and with the peritoneal cavity through the tubes on the other. Hence there is a highway into the peritoneum from the exterior of the body. The danger of neglecting vaginal discharges, and of introducing dirty sounds, or of wounding the uterine mucous membrane with stems, sounds, or cutting instruments can thus be readily understood. Fortunately, the irritation set up by septic material generally produces inflammatory changes, which cause the fimbriated extremities of the tube to become closed. This condition saves the peritoneum from sources of irritation which otherwise would be more frequent. Closure of the tubes, however, is in itself a cause of suffering and risk.

Body of the Uterus.—The body of the uterus is triangular, with its base or fundus markedly convex; the sides are also convex. The anterior surface is flat, the posterior is somewhat convex, especially in its upper third; this is often well marked when the uterus is hypertrophied from various causes.

In sterile subjects with ill-developed uteri, the body is flat on both sides and short, and the fundus looks unusually broad. The cervix, on account of the arrested development of the body, appears very long, as in infancy.

From each extremity of the fundus arise the *Fallopian tubes*, presently to be described. The peritoneum reflected over the uterus is also reflected over the tubes and the parovarium, forming the *broad ligament*. Close below and posterior to the uterine extremity of each tube, a short cord-like prolongation of uterine muscular tissue springs from the body of the uterus. This is the *ovarian ligament*, and it is conspicuous from behind, as it lies in a shallow peritoneal fold.

Round Ligament.—From each side of the uterus, in front, springs the *round ligament*. It runs upwards, outwards, and forwards, enters the inguinal canal, and ends partly in the connective tissue of the mons Veneris, but its fibres have a complicated relation anteriorly to the aponeurotic and tendinous structures which surround it—a relation differently described by different anatomists. It chiefly consists of unstriated muscular fibres; in fact, it is a prolongation of the muscular wall of the uterus. In its more anterior portion, striped

fibres are found. The round ligament receives a branch from the ovarian artery, and bears lymphatic vessels which maintain a free communication between the lymphatics of the uterus and the inguinal glands. In the inguinal canal, it has the same relations as the spermatic cord in the male. The round ligament is the part essentially concerned in Alexander's operation.

Peritoneal Fossæ around the Uterus.—Besides the broad ligament, there is another reflection of the peritoneum, on to the bladder; this forms the *utero-vesical ligament*. Posteriorly there is yet another reflection from each side of the body of the uterus reaching the second sacral vertebra. The pair form two sharp folds, which contain unstriped muscular fibre prolonged from the uterine walls, but not so much of that tissue as is found in the round ligaments. These are the *utero-sacral ligaments*. Between them lies *Douglas's pouch*, which dips deeply between the uterus and rectum, extending as far as the posterior fornix of the vagina. The sharp edges of the utero-sacral folds are readily detected on rectal examination.

Cavity of the Uterus.—The body of the uterus contains a triangular cavity with the base towards the fundus, and the apex below, where the cavity becomes continuous with the canal of the cervix at the *os internum*. It has an anterior and a posterior wall; its sides are convex. A Fallopian tube opens into each of the upper angles.

Uterine Mucous Membrane: Endometrium.—The cavity is lined with a mucous membrane bearing ciliated epithelium and special glands; it appears to be very thin, unless the theory be true that a part of the muscular wall beneath it must be considered as partly mucous and submucous tissue. This membrane (the endometrium) undergoes special changes in pregnancy, forming the uterine decidua. A question of more importance, perhaps, to operators, but still very unsettled, is the precise nature of the changes, if any, which the mucous membrane undergoes in relation to menstruation. The researches of Drs. Jacoby and Arthur Johnstone and Mr. Sutton may throw light on this question, and on the disputed nature of the form of uterine disease known as endometritis. At present nothing more can be said, except that the uterine mucous membrane is easily damaged by instruments. Such injury may set up peritonitis,

in the manner indicated at page 18, or may cause inflammatory changes to extend to the connective tissue outside the uterus, so as to develop pelvic cellulitis.

Muscular Walls of the Uterus.—The body of the uterus consists of a thick muscular wall lined with the mucous membrane just described, and covered with peritoneum, forming its serous coat.

The muscular wall is chiefly made up of plain muscular fibres arranged, it is generally admitted, in three layers. The middle layer contains numerous venous sinuses. The minute anatomy of the muscular wall of the uterus, and the changes which it undergoes during pregnancy, are not pertinent to the subject of this work. The muscular wall is tough, but easily wounded; it is then liable to bleed freely.

The serous or peritoneal coat of the uterus closely invests the entire fundus and body before and behind, and reaches as low as the supra-vaginal part of the cervix posteriorly.* It is continuous in front with the utero-vesical fold, behind with the anterior part of the fold which forms Douglas's pouch, and laterally with the broad ligaments, but more will be said on these relations presently. The peritoneum is not difficult to strip off from the muscular wall; in some operations this process has been done purposely.

The vascular supply of the uterus will presently be described.

The Cervix Uteri.—This structure is a very distinct segment of the uterus, and many authorities teach that it is practically a different organ from the body. A large portion of the cervix lies in the upper part of the vagina, where it is accessible to the finger, and can be seen by the aid of several methods which the surgeon must learn to practise skilfully. In pregnancy it becomes very soft, and is gradually drawn up, till it is lost in the body of the uterus. It is particularly important that the surgeon should learn to recognise the feeling of the cervix during pregnancy. If he attempt to practise what is understood as pure gynæcology without some previous knowledge

* Discrepancies as to the precise position of the os internum account for the difference in descriptions of the relation of the peritoneum to the lower portion of the front of the body of the uterus. Whether the peritoneum here dips down as far as the supra-vaginal part of the cervix is a matter of little real importance.

of obstetrics, he will assuredly fall into grievous errors. The cervix is very insensitive. Some patients can even bear the application of the cautery to its tissues, and few complain of pain when it is grasped by the volsella. Many practitioners speak in clinical reports of a cervix being "exquisitely tender." In an overwhelming majority of such cases the pain is due to some other part being moved when the cervix is touched. In digital exploration, many practitioners hook the cervix forcibly back with the fore-finger. This moves the whole uterus, and causes pain even in health.

The cervix lies partly above the vagina. The portion in this position is therefore called supra-vaginal; it is invested by peritoneum behind, and by loose cellular tissue, which connects it to the bladder in front. The broad ligaments lie on each side. These relations are important to remember in the course of any operation on the uterus or cervix. The body of the uterus is naturally bent forwards on this part of the cervix. The back of the supra-vaginal portion of the cervix is easily felt through the walls of the rectum. It feels very resistant, and must not be taken for a fibroid growth in the posterior wall of the uterus.

The infra-vaginal portion of the cervix (*portio vaginalis*, *pars vaginalis*) projects into the vagina. In virgins it forms a small cone, pointing somewhat forwards and feeling flattened anteriorly, and the *os externum* is a small circular depression. These peculiarities are retained more or less in all nulliparous women who are not virgins. In multiparous women the cervix becomes thick and blunt, and the *os* forms a transverse slit, admitting the tip of the finger, or it may be fissured in one or more places.

Canal of the Cervix.—This is continuous above with the uterine cavity, with which it communicates at a narrow part termed the *os internum*. It then dilates, but again becomes narrow close above its opening into the vagina known as the *os externum*. Its mucous membrane bears a longitudinal ridge anteriorly and posteriorly, and secondary elevations slope off from them obliquely. This forms the "*arbor vitæ*." The epithelial layer is single and ciliated upon the ridges, but columnar without cilia between them. At the *os internum* it

ceases, and the mucous membrane of the uterus begins. At the os externum it also ceases, and squamous stratified epithelium covering papillæ, invests the vaginal aspect of the cervix. Racemose glands abound in this mucous membrane, and secrete a clear glairy alkaline mucus. This escapes freely from the os externum in many healthy subjects, and was once taken, under these circumstances, for evidence of disease. The firm spherical bodies known as the *ovula Nabothi*, and often found on the cervix outside the os externum, are generally admitted to be retention-cysts. They do not in themselves, however, represent a severe morbid condition.

In the description of the ureters, the blood-vessels, and lastly, the relations of the pelvic viscera, as detected by different methods of examination, more will be said concerning the anatomy of the uterus.

The Fallopian Tubes.—These structures must be described together with the uterus, because they are really a part of that organ. Moreover, recent clinical and surgical experience have

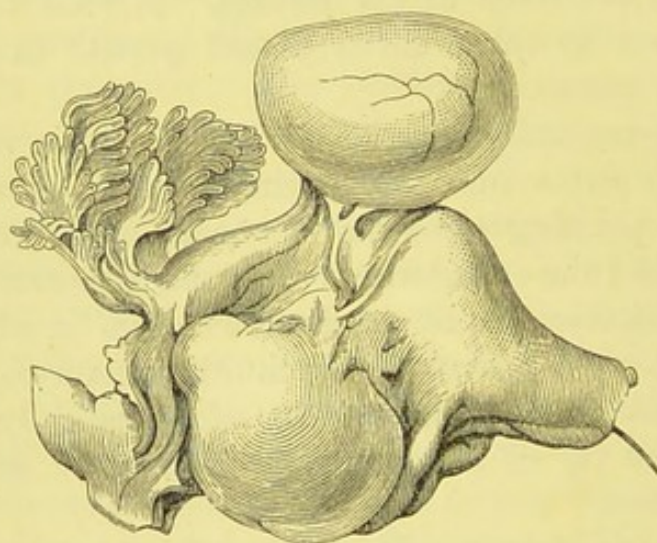


FIG. 7.—BROAD LIGAMENT CYST ABOVE THE TUBE. (*Author.*)

A similar cyst lies below the tube. (*Museum R.C.S., No. 4,583.*)

proved that the Fallopian tubes play no mean part in the physiology and pathology of the female organs, and therefore they must not be placed last in the list of these organs and dismissed in a few words.

Peritoneal Investment.—Each tube lies between the layers of the broad ligament, which are reflected over its upper surface

and meet along its lower surface, whence they are continued downwards towards the ovary. The serous membrane is held on to the tube by connective tissue, generally a little tenser and firmer than that which lies between the layers of the broad ligament lower down. Still, it is easily stripped off from the tube, whether by design or accident. The thin-walled cysts, so common in the folds of the broad ligament, are rare along this line of reflection over the tube, and when they develop there they seldom, if ever, grow large (Fig. 7). The ostium of the tube opens into the peritoneal cavity. Hence, as has already been explained, there is a free passage from the exterior of the body through the vulva, vagina, uterus, and tube into the peritoneum. The surgeon and obstetrician must never forget this fact. Fortunately, inflammatory processes tend to close the ostium, and thus protect the peritoneum.

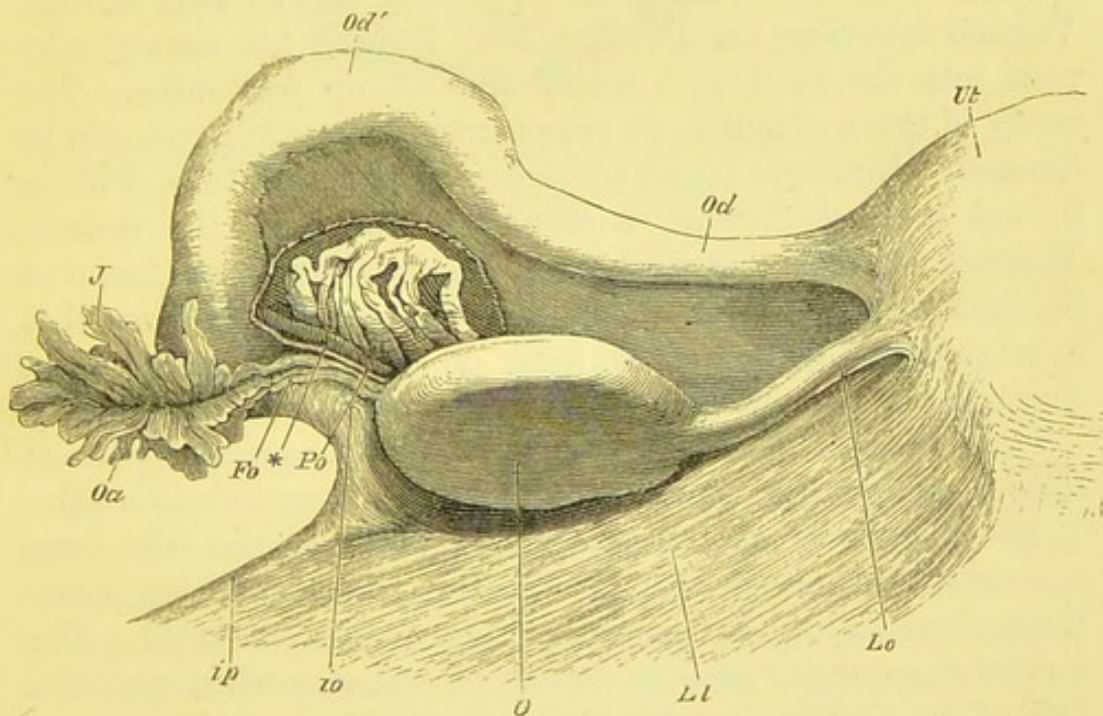


FIG. 8.—DIAGRAM OF THE UTERINE APPENDAGES. (Henle.)

Ut, uterus. *O*, ovary. *J*, fimbria. *Fo*, ovarian fimbria of the tube. *Po*, parovarium. *ip*, *io*, infundibulo-pelvic ligament. *Oa*, ostium of tube. *Od*, isthmus of tube. *Od'*, ampulla. *Lo*, ovarian ligament. *Ll*, posterior layer, cf. broad ligament.

Parts of the Fallopian Tube.—The Fallopian tube measures about four inches in length, when not stretched artificially. It

is seldom or ever of the same length as its fellow. It becomes extended to an extreme degree in cases of simple broad ligament cysts which press against it. The first inch, from the fissures of the uterus outwards, is straight and narrow; this is known as the *isthmus*. The remainder, is dilated and is called the *ampulla*. This terminates externally in the conspicuous and characteristic *fimbriated extremity*, which surrounds the *ostium*, or opening of the tube into the peritoneal cavity.

The canal of the tube is very narrow in the isthmus, barely admitting a bristle, and is narrowest at its junction with the uterine cavity. Along the ampulla the canal is wider.

Natural Patency of the Canal of the Tube.—There can be no doubt that the Fallopian tube is naturally patent. The ovum must pass along it. In menorrhagia, clots are sometimes passed, which form perfect casts of the uterine cavity and the canal of both tubes, the latter appearing as two long strings. Vaginal injections (as Dr. Matthews Duncan has shown) may pass into the peritoneal cavity and set up peritonitis. The rarity of this accident is no reason why its possibility should be ignored. Bizzozero found an *ascaris* in the right tube, whence it had escaped through a fistulous passage in the rectum. Winckel describes a case where a calcified *ascaris* was found at the back of the uterus and left appendages. He believes that it might have passed as an egg, or as a very young worm, through the tube, in the current of an injection of dirty water.

In some cases, where the sound has been apparently thrust through the uterine wall, it has in reality passed along a tube.

The Fimbriated Extremity.—The fimbriæ of the tube form a characteristic cluster of light-red laminated wattles, sometimes short and thick, sometimes ragged and elongated. The former is generally seen in robust or well-nourished patients. One of the fimbriæ is much longer and thinner than the rest. This is the *ovarian fimbria*, and it runs on to the tissue of the ovary. It is a good guide when the parts are altered by new growths—indeed, the fimbriæ altogether are excellent landmarks. Unfortunately, they are rapidly obliterated in inflammatory diseases of the tube itself, and this may cause great confusion to the operator. The ovarian fimbria is extremely elongated in cases of simple broad ligament cyst.

Accessory Fimbriae are not rare. They sometimes appear as small reddish tags, like adhesions, springing from the tube. In other cases, as in the specimen here figured (Fig. 9), they

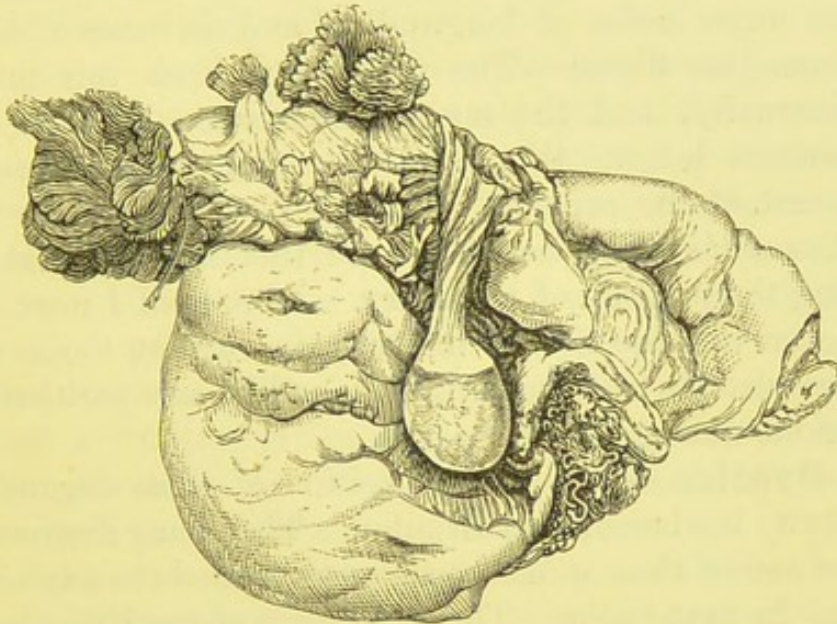


FIG. 9.—ACCESSORY FIMBRIE SURROUNDING AN ACCESSORY OSTIUM ON A FALLOPIAN TUBE. (*Author.*)

are stout and abundant, surrounding an *accessory ostium*, which may be perfectly patent. This condition is teratological, not pathological, and when, for example, it is discovered on the opposite side to an ovarian tumour, it does not in itself demand any surgical interference on that side.

The Canal of the Tube.—This is lined with mucous membrane, which bears ciliated epithelium, and is said by most histologists to possess no glands. In the ampulla, towards the ostium, it is elevated into a complicated series of longitudinal folds, which are permanent, like the *valvulae conniventes* of the intestine, and not to be effaced by simple distension, as Dr. Savage has shown. When the tube is cut across during an abdominal section, the surgeon must remember that its mucous membrane, which communicates with the exterior through the utero-vaginal canal, and may be in an unhealthy condition, is brought into immediate contact with the peritoneal cavity. This must especially be borne in mind when the fimbriated extremity is closed by adhesions, so that the peritoneum is

preserved from any morbid influx from the tube till the latter is cut through by the operator.

Structure of the Tube.—The tube essentially consists of muscular walls prolonged from the uterine tissue, and made up of an outer series of longitudinal and an inner of circular, plain, muscular fibres. The peritoneum lines this muscular tube externally, and the mucous membrane lines its canal. Some writers believe that a special sphincter surrounds the uterine end of the canal.

Position of the Fallopian Tube.—Of this I shall speak when discussing the position of the ovary. At present I need simply observe that the direction of the tubes in relation to the uterus, as represented in diagrams, is quite unlike any position which they assume during life.

The Ovaries.—The precise position of these organs in the pelvic cavity has been much disputed. They hang downwards to a greater extent than would be supposed were we to rely on stock diagrams in text-books. The outer part of the Fallopian tube turns downwards external to the ovary, so that its fimbriæ embrace to a certain extent the outer part of that organ. The ovarian fimbria runs upwards on the ovary, not downwards to the ovary, as usually represented. This relation of the tube to the ovary accounts for the singular shape of a dropsical tube, which curves outside, and a little below the ovary, and also for the position of the foetal sac in cases of gestation in the outer part of the Fallopian tube, the sac lying not above the ovary, but outside, and often partly below it. As the uterus always leans a little to one side, the ovary on that side hangs more than its fellow, which is held almost horizontally between the ovarian and the infundibulo-pelvic ligaments.

The ovary is connected with the back of the broad ligament by its dense and tough *hilum*, which is invested by a plexus of veins, the *bulb of the ovary*. As the tissue of the hilum is continuous with the connective tissue between the folds of the broad ligament, morbid growths, developed in its substance, tend to burrow into these folds. The *parenchyma* or ovum-bearing part of the ovary, hangs behind the broad ligament. It is connected with the uterus by a prolongation of the muscular tissue of the latter, called the *ovarian ligament*, and

invested by an elevation of the peritoneum. This ligament is an important landmark when the surgeon is engaged in exploring the appendages during an operation; it is much stretched in cystic disease of the ovary, and generally hypertrophied in fibroid disease of the uterus.

The ovary varies greatly in appearance according to age, health, and the stage of the menstrual cycle at the moment that it happens to be examined. The shrivelled ovaries seen in typical dissecting-room subjects, must not be considered as types of the ovary of a child-bearing woman. The surgeon must not take a ripe follicle full of blood, or a plump succulent ovary of the kind generally found in robust young women, for a morbid structure. The average weight of the normal ovary is at least a hundred grains; I believe it to be higher in young subjects. Its long axis is a little over two inches, its short axis one inch, its thickness quite half an inch.

The blood-vessels of the ovary will presently be described. The main ovarian vessels lie close to the outer part of the organ, after passing along a short fold of peritoneum, which runs from the brim of the pelvis to the ovary, and is termed the *infundibulo-pelvic ligament*. Drs. Hart and Barbour rightly describe it as that part of the upper margin of the broad ligament unoccupied by the Fallopian tube. It is a most important structure for the surgeon to study, as it forms the outer border of the ovarian pedicle.

The Parovarium.—This is a structure of high scientific, but of little practical, interest, except when the seat of disease. It appears as a group of eight or ten tortuous vertical white lines, in the broad ligament, joining a horizontal line above, and converging as they run into the hilum of the ovary below. The parovarium can only be clearly distinguished by holding the appendages up to the light after their removal.

The Female Bladder.—There can be little doubt that a great many incorrect notions prevail about the female bladder. Students usually endeavour to dissect a male subject, and, as a rule, take more pains to learn the anatomy of the male bladder and urethra than that of the corresponding parts in the female. Hence, throughout their future career, their knowledge of the latter may remain too limited to be of any practical service.

The female bladder is generally described as being more capacious than the male bladder; it certainly appears to allow of more distension transversely and antero-posteriorly, hence it does not rise out of the roomy female pelvis until very full. An over-distended bladder forms a conspicuous object when seen from the abdominal side, in the course of an ovariectomy, or any similar operation. It appears as an oval, almost perfectly central cyst, with its base upwards, projecting from the most anterior part of the pelvic cavity. Although so characteristic, it may be mistaken for part of a tumour, if a number of spherical secondary cysts lie in its vicinity; whilst if it be displaced, or its peritoneal coat altered in appearance by the results of adhesive inflammation, it will be much exposed to injury. Hence the necessity for catheterism before abdominal section; yet some operators prefer to leave the bladder distended, as a landmark.

The flaccid bladder may also be seen in the course of an abdominal section. When visible under these circumstances, it must either have been greatly displaced by the tumour, or else dragged upwards by the operator. Its outline and its thick walls are seen through the peritoneum. When the serous investment is torn, its characteristic muscular coat is exposed.

It is probably on account of its great capacity for transverse and antero-posterior, rather than for vertical distension, that the female bladder suffers, relatively, little disturbance of function after the clamping of a thick uterine pedicle close to the pubes. It is true, that at first, there is often great vesical irritation, but this may be due to other causes than the obstacles in the way of upward distension. The cervix being drawn up, the bladder can readily distend backwards as it fills with urine. I have noted this condition after hysterectomy. The patients do not appear to become subject to prolapse of the bladder.

From the vaginal aspect, the female bladder becomes conspicuous in cystocele, when it forms a globular projection distending the vulva and covered by the anterior vaginal wall. In the great majority of cases, this condition, pathologically speaking, means primary hernial displacement of the vaginal wall, the bladder following simply because it has lost its natural support behind. I have traced strong family histories of

inguinal and femoral hernia in several cases of this affection. Were cystocele due primarily to chronic over-distension of the bladder, it would, I believe, be far more frequent. In prolapsus and procidentia uteri the bladder undergoes great displacement, as will shortly be explained.

Position and Relations of the Bladder.—The female bladder lies behind the pubes (Fig. 6), except when considerably distended. Its lower portion, as well as the upper

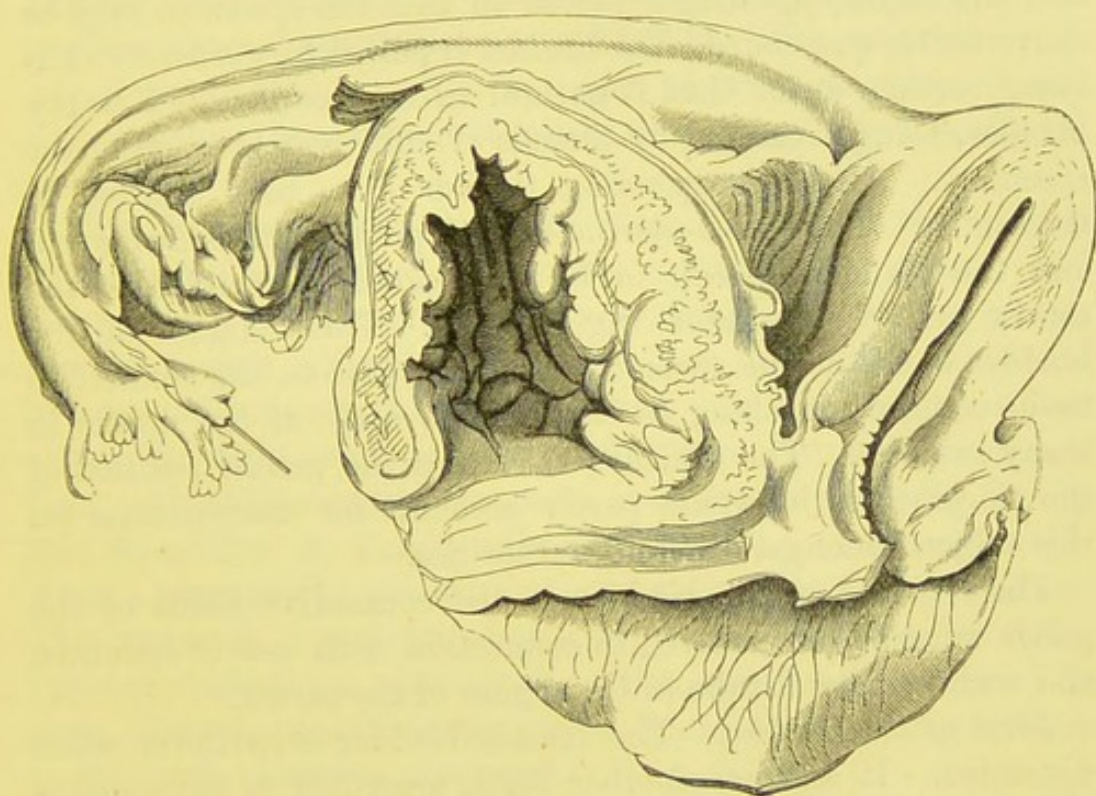


FIG. 10.—THE RIGHT HALF OF THE BLADDER AND UTERUS, WITH A SMALL PART OF THE VAGINA.

The natural relations have been displaced to show the connections of the bladder with the uterus and anterior vaginal wall. (*Museum R.C.S., Physiological Series*, No. 2,822.)

part of the urethra, is separated from the pubes by loose connective tissue containing much fat. This is the *retropubic fat* of Hart and Barbour. This loose connective tissue allows of a considerable range of motion. The fundus is invested with peritoneum; the relations of that serous membrane to the bladder will be described later on. Laterally, the bladder lies in relation with the recto-vesical fascia, some loose connective tissue intervening. Posteriorly, the bladder is connected with

the lowest part of the body of the uterus, the cervix, and the vagina. It is separated from these structures by abundant connective tissue. This connection of the bladder with the uterus and vagina is well displayed in Fig. 10, which is taken from a specimen of the right half of the anterior pelvic viscera in the Museum of the Royal College of Surgeons (*Physiological Series*, No. 2,822). The true relations have been entirely displaced. The half-uterus is bent backwards, and the right appendages placed so that the specimen may be conveniently suspended. The bladder is pulled forwards, its walls lying farther apart than is natural in an uncontracted empty bladder, being separated by threads of silk used to suspend the specimen. All the suspending threads have been omitted in the sketch. The vesico-uterine fold of peritoneum is displayed, and the bladder is seen to be very closely connected to the cervix and the anterior vaginal wall. This relation of the bladder to the uterus varies in different subjects, the connective tissue certainly reaching as high as the body of the uterus in many subjects. The difficulty of fixing the precise position of the so-called os internum partly accounts for discrepancies on this subject amongst different authorities.

The relations of the bladder to the connective tissue of the pelvis must be remembered in connection with pelvic cellulitis, and with urinary fistulæ in the region of the cervix.

Form of the Bladder.—The female bladder is pyriform when distended. It assumes another form, according to some authorities, when in the act of contracting, and yet another when it is flaccid and empty.

When contracting, the bladder remains convex at the fundus at first, and the anterior and posterior walls gradually approximate.*

As the bladder empties, the fundus tends to fall in so as to become concave externally (Fig. 6). It is received in the cup-shaped dilatation of the lower part of the bladder, formed by the falling apart of the anterior and posterior walls during relaxation. When viewed in vertical section the relaxed

* Dr. Matthews Duncan and other authorities dispute this assertion, and consider that vesical systole is a far more passive process than is generally supposed.

bladder forms with the urethra a Y. One arm of the Y lies anteriorly, the other, generally much shorter, lies posteriorly. The lower part of the Y, representing the lowest part of the bladder, and the urethra, is bent forwards, so as to form with the anterior arm an angle in which the retro-pubic fat is lodged.

In prolapsus uteri the lower and posterior part of the bladder comes down with the anterior vaginal wall. The upper and anterior part remains in place behind the pubes, whilst the urethra passes downwards and backwards. The catheter being introduced in that direction in a case of prolapsus uteri, it will be found that the instrument can be passed both downwards and upwards.

The Ureters.—The course of these ducts from the kidneys to the pelvis is described in systematic works on anatomy. At the pelvic brim the left ureter, according to Garrigues, crosses the iliac vessels somewhat higher up than the right. Thus the left generally lies in front of the lowest part of the common iliac artery, the right passing in front of the beginning of the external iliac. About this region the ureter is in danger of injury during the separation of strong adhesions in ovariectomy, especially when a large sessile tumour has burrowed under the peritoneum. The ureter is a structure not always easy to recognize when exposed during an abdominal section, and such exposure is most likely to occur in cases where the relations of the tumour to the peritoneum are abnormal.

The course of the ureter in the pelvis has been minutely described by many living writers, especially in German and American works. Each ureter runs downwards and somewhat backwards along the pelvic wall, till about half an inch above the spine of the ischium. In this part of its course it lies behind the outermost part of the broad ligament, quite out of danger during oöphorectomy. Close above the spine of the ischium the ureter turns inwards, and passes downwards and forwards. Here it passes under the base of the broad ligament, through the connective tissue of the pelvis, and is crossed by the uterine artery, which runs inwards towards the uterus. It is separated from the artery by some of the veins of the plexus in this neighbourhood. In this forward course the ureter runs about half or

three-fifths of an inch outside the cervix, passing to the front of that structure. Thence the ureter descends along the side of the upper part of the vagina, turns inwards and enters the bladder. It runs obliquely downwards and inwards for at least half an inch through the vesical walls, opening at one extremity of the base of the trigone.

These relations are of high importance; unfortunately they are often disturbed by various abnormal influences. Hence the minute details found in the works of several writers are not implicitly trusted by practical authorities. The ureter, as it runs through the healthy pelvic connective tissue, is easily displaced, so that in some operations the fingers may push it out of or into danger, and in others it may be dragged into the jaws of forceps, or into the loops of ligatures and *écraseurs*. When cancerous or inflammatory infiltrations exist, the ureter becomes fixed, grave complications may result, and its relations are liable to become deranged.

This diagram illustrates the normal relations of the cervix, the urethra, and the ureters. The measurements are given in

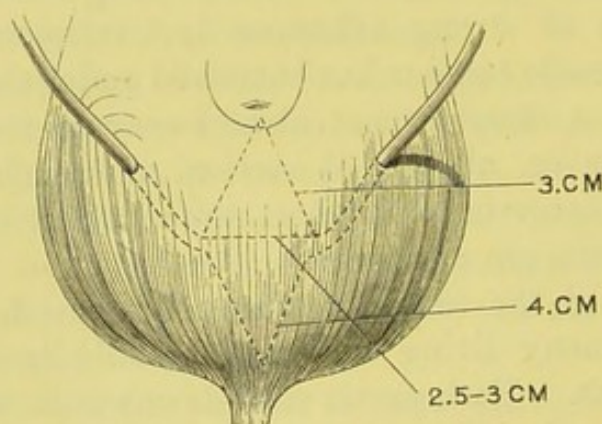


FIG. 11.—THE NORMAL RELATIONS OF THE CERVIX, THE URETERS, AND THE URETHRA. (*Hegar and Kaltenbach.*)

The distance from the cervix to the orifice of the ureter is 3 centimètres; from the orifice of the ureter to the vesical orifice of the urethra, 4 cm.; between the orifices of the ureters, 2.5 to 3 cm. The course of the ureters through the vesical walls is indicated.

centimètres (one centimètre is nearly two-fifths of an inch, four centimètres a little over one inch and a half).

The proximity of the ureter to the cervix must especially be borne in mind during supra-vaginal hysterectomy and Porro's

operation, laparo-elytrotomy, supra-vaginal amputation of the cervix, and any form of total extirpation of the uterus. Its course along the upper part of the side of the vagina and through the walls of the bladder must be remembered in association with urinary fistulæ high up the vagina, especially if laterally placed. Morison Watson asserts that the ureters reach as low as the middle of the anterior vaginal wall. It is evident that, in operations for fistulæ, a suture may obstruct the portion of one ureter which runs through the vesical walls.

The Pelvic Peritoneum.—The arrangement of the peritoneal folds in the female pelvis is described with great minuteness in most of the larger text-books of regional anatomy, and in several standard works on the diseases of women.

The parietal layer of peritoneum is reflected, a little above the symphysis pubis, on to the fundus of the bladder, when that organ is empty. When much distended, the fundus pushes up the peritoneum, leaving a distinct space uncovered by serous membrane between the reflection of the peritoneum on to the parietes and the symphysis. This fact is of great importance in relation to supra-pubic lithotomy.

The peritoneum passes from the fundus to the posterior surface of the bladder. It is thence reflected on to the anterior surface of the uterus, at about the level of the os internum, passing over the connective tissue which separates the cervix from the bladder. This arrangement of peritoneum forms the *vesico-uterine pouch*. The pouch is deep, and runs almost vertically downwards when the bladder is in systole or much distended. Most diagrams, in dissecting-room manuals, represent this pouch as though it were constantly deep. This error may cause difficulty to the operator during an abdominal section. When he recognizes a distended bladder, there is no necessity for him to trouble about the pouch. The bladder will, however, be most probably empty. Then the pouch, in many cases of tumour, will be difficult to recognize. It is quite effaced by pushing the uterus backwards. When the uterus lies naturally, with its fundus bent forwards, the pouch will form a simple reflection of peritoneum running almost directly backwards, and not downwards as in Douglas's pouch. The vesico-uterine pouch does not lodge small intestine.

All the peritoneal folds above described are loosely connected with the parts which they invest; hence they are very liable to be torn away in separating adhesions from the front of a pelvic abdominal tumour, or to be so displaced as to confuse anatomical relations. The muscular coat of the bladder is, fortunately, easy to recognize, so that when it is exposed the surgeon at least may see what he has done and where he is. Unfortunately, in many of these perilous cases of anterior pelvic adhesions, the serous coat of the bladder, already adherent to the tumour, is likewise adherent to the muscular coat, so that during any kind of traction on the former coat the latter is pulled up with it and possibly lacerated, as I have witnessed, or else dragged up into the wire loop of a *serre-nœud*.

The above important facts teach that the surgeon should faithfully study the anatomy of the anterior part of the pelvic peritoneum, and remember that it presents quite other characters than those of a Douglas's pouch on a small scale.

The Uterine Peritoneum.—The peritoneum, passing upwards from its reflection on to the uterus at the level of the os internum, invests the anterior part of the body, the fundus, the posterior part of the body, the supra-vaginal part of the cervix, and, lastly, the upper part of the back of the vagina. Thence it passes upwards over the rectum and sacrum.

The uterine peritoneum or serous coat of the uterus is closely and firmly adherent to the muscular coat, yet it is occasionally detached during the separation of adhesions. In one case, at least, of an ovarian cyst which had forced its way between the layers of the broad ligament, I observed, during the operation, that the cyst had detached the peritoneum from the back of the uterus as far as the fundus.

Douglas's Pouch.—The reflection from the vagina on to the back of the pelvis forms the well-known *Douglas's pouch*. The lower limit of the line of reflection is variable. It is greatest towards the left, and generally invests a little over one inch of the vagina, but may descend much lower. Laterally, the pouch is bounded above by the utero-sacral ligaments. These structures, it must be remembered, can be distinguished by digital exploration of the rectum.

Douglas's pouch cannot be effaced by any natural alteration of position of the surrounding structures. It is easily explored during an abdominal section, provided that it be not closed in by adhesions of any kind. In a simple ovariectomy its characteristics may readily be distinguished by digital exploration, which the operator must never omit even in the simplest operation of this kind. Owing to the dependent position of the lower limit of the pouch, blood, serum, or any other fluid escaping from adjacent structures is apt to collect there. Hence it is into the bottom of the pouch that the drainage-tube is generally inserted. In more complicated operations, when the surface of the peritoneum is altered by morbid changes, the exploration becomes a matter of difficulty. Intestine lying, free or adherent, deep down in this pouch cannot always be distinguished from peritoneum by touch alone. The peritoneum constituting Douglas's pouch is not very firmly connected with the structures which it invests below and behind the uterus, and may be damaged during the separation of deep adhesions.

Lateral Disposition of the Pelvic Peritoneum.—The Broad Ligament.—The reflection over the fundus extends along each Fallopian tube, and outwards and backwards over the ovarian vessels. The layers of peritoneum meet, after investing the tube, to form the *broad ligament*. The fold over the ovarian vessels is slight, yet well marked, and is known as the *infundibulo-pelvic ligament* (page 27). A knowledge of this structure is of great importance for the ovariectomist, especially in relation to ligature of the pedicle. It is extremely easy to recognize, on account of the pampiniform plexus of veins, which is conspicuous even in the normal condition.

The layers of the broad ligament enclose the parovarium, and several arteries, veins, and nerves; the precise nature of its lymphatic supply is disputed. The folds are closely applied between the tube and the ovary. This part of the broad ligament has been termed the *meso-salpinx*. The surgeon must remember that it is not the whole of the ligament as understood by most authorities. Below the level of the ovary, the layers separate and pass to the sides of the pelvis. The pelvic connective

tissue fills the space formed by the parting of the layers. This tissue can be felt as a tense band, running from the uterus to the side of the pelvis, on digital exploration of the vagina. When the rectum is explored, the back of the broad ligament can be reached. This is an impossibility in vaginal examination.

The lower limits of the broad ligament are not easy to define from the abdominal aspect; the separation of the layers immediately below the ovary, which projects behind the posterior layer, is, however, evident. The precise position of the upper part of the broad ligament is very hard to define. It depends entirely on the position of the tube. I have referred to this subject at page 26.

The layers of the broad ligament are often separated by tumours which push in between them, either from the direction of the ovary, as in many papillomatous ovarian tumours, or from the uterus, as in fibroid tumours. In the former case there will be difficulty in making a good pedicle. In the latter, oöphorectomy may be dangerous, as the broad ligament no longer forms a sheet-like structure, but often becomes a pyramidal body with its base towards the uterus, highly unsuited for the safe application of the ligature.

Pelvic Fascia, Connective Tissue, Muscles, and Nerves.—The anatomy of these important structures bears more upon science and clinical medicine than on operative surgery. Any direct relations between surgical proceedings and special peculiarities in the disposal of the fascia and connective tissue will presently be noted in the description of such proceedings. It would be impossible for me to describe in detail the arrangement of the pelvic fascia and connective tissue without mentioning numerous conflicting opinions of different writers, and this I could not do without wandering from the object of this work. The *perineum* will be described in association with operations for its repair when lacerated.

Muscles.—The vulvar and perineal muscles are described with quite sufficient accuracy for all practical purposes in general text-books on anatomy. The peculiarities of the anterior part of the levator ani muscle in the female will be noted in the chapter on the Methods of Pelvic Exploration. The muscular

apparatus of the pelvis is of great importance in relation to several clinical problems.

Nerves.—The observations which I have just made with regard to the muscles, apply to the pelvic nerves. The external organs are almost exclusively supplied by branches of the pudic nerve, the internal by branches of the sympathetic, mostly from the hypogastric plexus.

Pressure on a healthy nerve during exploration of the pelvis of course produces pain, which may be mistaken for evidence of disease. This kind of error is most likely to occur when the finger is pressed against the posterior vaginal fornix in a patient with a small or shallow pelvis, so that one of the cords of the sacral plexus is squeezed between the sacrum and the finger. Schultze was, I believe, the first to indicate this fact. I have verified it repeatedly.

Vessels of the Pelvis.—The distribution of the vessels of the pelvis involves many subjects of direct interest to the surgeon.

Arteries of the Pelvis.—The *common and external iliac arteries* are covered by peritoneum. The operator may come dangerously near them when separating adhesions between an ovarian tumour and the brim of the pelvis. I have known the external iliac to be wounded under these circumstances. The ureter lies under the peritoneum, close to the division of the common iliac artery (page 31); thus, care must be taken not to mistake it for a blood-vessel when pelvic adhesions are separated.

The Ovarian Artery.—This long vessel arises from the aorta high above the pelvis, descends behind the peritoneum, and enters the broad ligament in company with its vein. Before reaching the ovary it lies in the free border of the broad ligament, external to the Fallopian tube; this portion being the infundibulo-pelvic ligament (see pages 27, 35). In ovarian cystic disease this ligament becomes much hypertrophied and its vessels enlarged. It then appears as a conspicuous fold, running from the brim of the pelvis on to the pedicle. The pampiniform plexus of veins can be seen through the peritoneum, and strong pulsations of the artery can, as a rule, be distinctly felt. It is here that the vessels are secured when the outer border of the pedicle is tied separately, as will presently be described.

The nature of this infundibulo-pelvic ligament renders ligature of the ovarian artery comparatively easy at this point. Should the divided artery slip, as may readily occur when the outer border of the pedicle is not secured, the proximal end retracts, and will be found, after death, high up in the connective tissue behind the peritoneum, surrounded by clots and fluid blood. In pyæmic affections of the pelvic organs, the connective tissue, to which I have just referred, is liable to suppurate. I have seen this condition in a case where a patient with a large fibroid tumour of the uterus died after avulsion of a mucous polypus. There was a suppurating track along almost the entire course of the ovarian vessels above and below the pelvis.

The distribution of the ovarian arteries will be described in speaking of the arterial supply of the internal organs. The branches of the internal iliac pursue a course which is described in text-books on anatomy. Only such as directly bear on the subject of the manual need here be noted.

The Arteries of the Vagina and Internal Organs.—

The *vaginal arteries*, two or three in number, are given off from the anterior division of the internal iliac, or one or more of them may be branches of the uterine or middle hæmorrhoidal. They run, in the pelvic connective tissue, to the side of the vagina, where their branches inosculate freely with each other, with their fellows on the opposite side, and with perineal vessels below. From above, tortuous branches from the artery of the cervix, a branch of the uterine artery, communicate with the vaginal arteries, often on both vaginal walls, so as to form a vertical *azygos artery of the vagina* (Fig. 12, *h*, p. 42), anterior and posterior. Thus the vagina is well supplied with blood-vessels.

The *ovarian artery* (Fig. 12) becomes very tortuous when it reaches the infundibulo-pelvic ligament (see pages 27, 35, 37), and this tortuousness increases as it passes between the layers of the broad ligament, below the level of the ovary, upwards and inwards to the upper part of the body of the uterus. Before reaching the uterus it divides into two branches; the upper supplies the fundus, the lower anastomoses with the uterine artery, which passes vertically upwards to meet it.

The branches of this artery are numerous. Several small arteries run to the dilated outer part of the Fallopian tube,

supplying the fimbriæ. Half-a-dozen short, tortuous branches of wide calibre supply the ovary itself, entering that organ through the hilum. Two or three branches run across the broad ligament to the inner two-thirds of the Fallopian tube, and the round ligament receives a special branch.

In ovariectomy and allied operations on the uterine appendages, the ovarian artery is divided in two places. It must be cut through at the outer border of the pedicle, where it lies in the infundibulo-pelvic ligament, and also at the point where it crosses the line of ligature of the pedicle—that is, in the middle of its course towards the uterus, between the layers of the broad ligament. Hence a complete segment of the artery is cut away, and may be easily detected on examining the tumour after operation. It will be found between the layers of the broad ligament, running to the cut border of that peritoneal fold from the stump of the infundibulo-pelvic ligament, which must be looked for on the surface of the tumour close to the ovarian fimbria of the Fallopian tube.

This free supply of arteries to the broad ligament, and the shortness of secondary branches, account for the free hæmorrhage which occurs when the ligament is wounded or split in an operation on the internal organs, especially through faulty tying of the ligature. It is evident that the main trunk of the ovarian artery will bleed as much from its distal as from its proximal end, if not secured. The ligature applied to the outer border of the pedicle secures the ovarian artery as it lies in the infundibulo-pelvic ligament. The ligature which secures the inner half of the pedicle will, or should, hold firm the distal part of the ovarian artery, which communicates freely with the uterine. It is self-evident that, if either of the above-named ligatures be inefficient, the consequent hæmorrhage must needs be perilous in the extreme. The division of the ovarian artery into two large branches, between the layers of the broad ligament, close to the uterus, is a source of peril when the pedicle of an ovarian tumour is very short. The inner ligature may directly surround uterine tissue (see page 17).

The *uterine artery* arises from the anterior division of the internal iliac, and runs downwards and inwards in the pelvic connective tissue till it nearly reaches the cervix, when it crosses

the ureter (see page 31), and ascends between the layers of the broad ligament along the side of the uterus; in this part of its course it gives off the artery of the cervix, which is very short, rapidly dividing into smaller twigs. The uterine artery then becomes exceedingly tortuous, and, after giving off to the substance of the uterus a great number of small tortuous branches, which run very horizontally, it finally anastomoses with the lower branch of the ovarian artery (see Fig. 12).

The ultimate distribution of the branches of the uterine artery have recently been described with great minuteness of detail in the twenty-seventh volume of the *Transactions of the Obstetrical Society of London*, by Dr. John Williams. Owing to the direction of the vessels which traverse the muscular wall, the blood-current runs transversely to the length of the uterus, and perpendicularly to its surfaces; so that a ligature may be placed completely around the uterus without affecting the circulation above and below. Both broad ligaments and a portion of the uterus itself must be ligatured before the blood-supply can be materially checked. This condition is simulated in inguinal hernia of the uterus, and in extreme retroflexion and retroversion, which represents a true hernia, the utero-sacral ligaments constricting the neck of the sac. In procidentia, a similar obstruction to the circulation takes place. According to Dr. Williams, the most acute ante flexion fails to cause any impediment to the uterine circulation.

In supra-vaginal amputation of the uterus, the broad ligaments being secured and removed and the cervix held firmly by the wire of a Koeberlé's serre-nœud, arterial hæmorrhage is well checked (Fig. 12, A A). The divided uterine arteries, often much dilated in fibroid disease, are generally seen gaping on each side of the cut surface of the cervix. On the other hand, when we remember how uterine tissue is liable to contraction and relaxation, and how impossible it is to stop the uterine arterial circulation effectually without securing thoroughly both broad ligaments and also the uterus itself, the dangers of the intra-peritoneal treatment of the pedicle of an amputated uterus become evident. Hæmorrhage from a wound of the uterus or from avulsion of the pedicle of a subperitoneal fibroid growth is exceedingly hard to check.

Lastly, in conditions already noted (page 36), it may happen that in removal of the appendages for the relief of menorrhagia from uterine fibroid disease, the arteries in one or both of the appendages cannot be effectually secured; so that removal of the entire uterus above the cervix is necessary to save the patient from death from hæmorrhage. These matters will again be considered in the chapters upon the Surgery of the Uterus.

The course, position, and branches of the uterine artery just before it reaches the cervix should be borne in mind in relation to operations high in the vagina, especially vaginal extirpation of the uterus, and supra-vaginal amputation of the cervix. From a glance at Fig. 12, B B, it will be evident that when the broad ligaments are secured by pressure-forceps or ligatures passed through the vaginal wound, hæmorrhage during removal of the uterus will be as entirely controlled as when the ligaments and the cervix are secured by ligatures and the *serre-nœud* in supra-vaginal amputation.

Artery of the Cervix.—This vessel (Fig. 12, *c'*) forms a short branch of the uterine artery, given off at the point where the main vessel rises, after crossing the ureter, to meet the uterus at an acute angle. The artery of the cervix runs inwards almost horizontally, and its branches, three or four in number, proceed in the same direction to enter the cervix at right angles. One branch inosculates by two twigs with its fellow to form the *coronary artery of the cervix*; this lies high in the vaginal part of the cervix, and is in danger of injury during Emmet's operation and other procedures in the neighbourhood. Another branch, anteriorly and posteriorly, forms, with branches of the vaginal artery, the azygos arteries of the vagina, already noted.

Veins of the Internal Organs.—For full information concerning the venous supply of these parts I must refer the reader to Savage's and Hart's Atlases. Veins accompany the arteries, and also form plexuses. Among these plexuses, the pampiniform plexus and the bulb of the ovary are of the most direct practical import. *Phlebolithes* are frequent in the large pelvic veins. They sometimes escape by ulceration into adjacent tissues and organs.

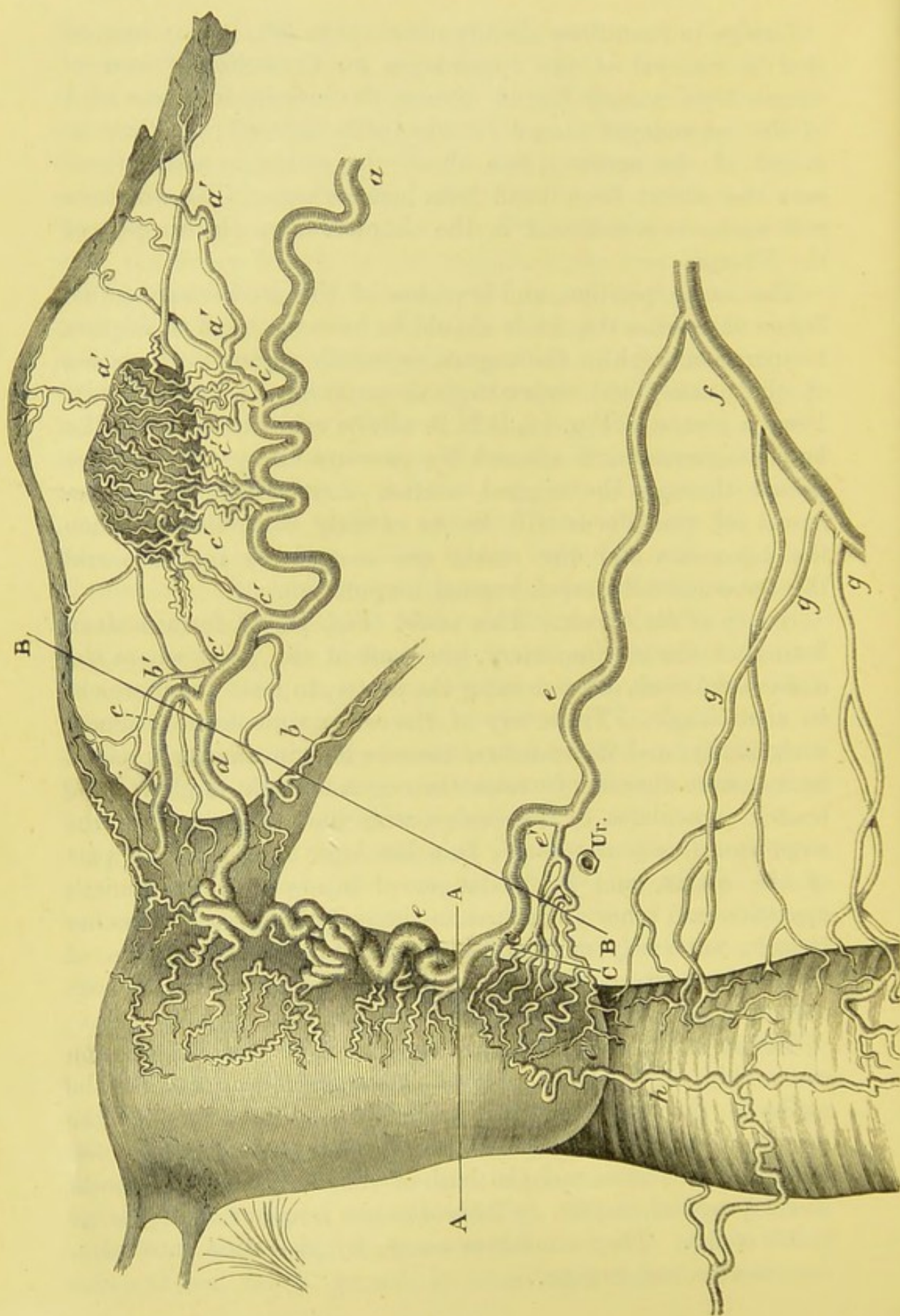


FIG. 12.

FIG. 12.—THE ARTERIES OF THE INTERNAL FEMALE ORGANS, SEEN FROM BEHIND. (After Hyrtl: "*Die Corrosions Anatomie und ihre Ergebnisse*," plate xii.)

a, Ovarian artery. *a' a' a'*, branches to the ampulla or dilated portion of the Fallopian tube. *b'*, branch to the isthmus of the tube. *c' c' c' c' c'*, branches to the ovary. *b*, branch of ovarian artery to round ligament. *c*, superior, and *d*, inferior, divisions of the ovarian artery: *c* is distributed to the fundus uteri; *d* anastomoses on the side of the uterus with *e*, the strongly twisted uterine artery. *e'*, artery of the cervix (I have often seen two distinct branches, the lower passing beneath the ureter). *Ur*, ureter crossed by the uterine artery below the broad ligament; it here lies about three-fifths of an inch from the cervix, and at the level of the os externum. *e''*, the branches of the artery to the cervix; one of the largest of these branches, anastomosing with its fellow, forms the circular or coronary artery of the cervix, sometimes wounded in Emmet's operation. *f*, internal iliac artery, giving off *g g g*, three vaginal arteries (variable; one is often given off from the uterine artery). *h*, azygos artery of vagina, formed from the artery of the cervix and branches from the vaginal arteries on both sides.

A A, average level of line of amputation in supra-vaginal hysterectomy. The trunks of the right and left uterine arteries will lie to the right and left of the uterine stump. B B shows line of structures secured during the operation for removal of the entire uterus through the vagina. It may pass through the undivided trunk of the ovarian artery. When both broad ligaments are thus secured, and the cervix separated from its lower connections, hæmorrhage from the uterus will be entirely checked. C C, line of structures divided in supra-vaginal amputation of the cervix, when the lateral connections of the cervix are detached. The branches of the artery to the cervix cannot escape division; the trunk of the uterine artery is generally pushed out of danger and seldom divided.

The *pampiniform plexus* accompanies the ovarian artery. It is always more or less conspicuous in the undivided pedicle of an ordinary multilocular ovarian cyst. The ovarian artery can be felt, or even seen, pulsating amidst the turgid mass of veins. After ligature, a large thrombus often forms on the proximal side of the threads. The plexus is surrounded by much loose connective tissue, which may inflame and even suppurate if damaged by careless handling in abdominal operations (see also pages 37, 38).

The *bulb of the ovary* is a venous plexus surrounding the hilum and extending to the ovarian ligament. It communicates with the pampiniform and uterine plexuses. It is very plainly seen in cases of oöphorectomy, when the ligature is tightened above a diseased ovary.

The practical surgeon need hardly be reminded that in

operations about the uterus and its appendages he must be careful not to transfix any veins with the ligature.

The *bulb of the vagina* is not a mere plexus of veins, but a structure composed of erectile tissue situated on one side of the vulvar orifice of the vagina. Each bulb extends from the clitoris to the posterior third of the margin of the vagina, ceasing about the point where the internal labium is lost on the vulva. The bulbo-cavernosus (accelerator urinæ of the male) muscle covers it, except internally, and Cowper's gland lies behind it. Excepting in front, it corresponds, practically speaking, with the labium minus. Extensive and serious extravasations may follow operation-wounds of the veins in the vulva.

The **Lymphatics** of the pelvis are of great importance in the clinical study of diseases of women, but want of space and other circumstances forbid any description of their distribution in this manual.

CHAPTER II.

METHODS OF PELVIC EXPLORATION.

THE physical examination of the female organs is conducted by particular methods which the surgeon must carefully practise, as they are intimately associated with some of the most important steps of certain operations. The methods in question are—simple inspection; digital exploration, single-handed or bimanual; inspection aided by posture; inspection aided by instruments, such as the speculum and volsella; and the measurement of the uterus and determination of its degree of mobility and relation to adjacent parts by the sound. Some writers add the dilatation of the cervical canal by sponge-tents to the above methods.

Inspection.—Only the external organs can be satisfactorily examined by simple inspection, which may be most readily conducted when the patient is placed on her left side, on a special couch, or on a table about three feet in height. The knees must be well drawn up, and the clothes withdrawn above the nates. The lithotomy position is not essentially necessary for simple inspection. The labia cannot be parted, to any extent serviceable to the examiner, by abduction of the thighs. Certain legal safeguards must not be overlooked by the surgeon, particularly when the patient seeks advice more or less at the behest of others. In a case of amenorrhœa with marked anæmia in a reputed virgin, it is best not to inspect at the first visit. Should the amenorrhœa have lasted for three or four months, abdominal palpation will be sufficient to detect the presence or absence of an enlarged uterus above the pubes. In cases of suspected ovarian tumour in virgins, abdominal palpation and digital exploration through the rectum, or, in obscure cases,

through the vagina, will be quite sufficient, without any recourse to inspection.

During inspection the surgeon must pay attention to the anatomical points noted in the first chapter. He must be careful not to make mistakes about the hymen; to aid in the avoidance of such errors, I have already described the anatomy and varieties of the hymen and carunculæ at some length. The labia and all the other vulvar structures may be well developed when some of the most important internal organs are malformed or absent. Discoloration of the vulva (see page 3), discharges of blood, mucus, or pus, ulcers, damage to the perineum, piles, fistulæ, and fissures must not be overlooked. Anal or rectal disease, thus discovered, may prove to be the cause of all the patient's symptoms. Among the more marked or serious morbid conditions which may be detected on inspection are—procidentia uteri, inverted uterus, prolapse of the vaginal walls, extreme elongation of the cervix, and uterine polypi with unusually long pedicles.

Digital Exploration* of the Vagina.—The surgeon must learn how to conduct this kind of exploration. Bimanual examination is a method of greater diagnostic value, but it cannot be learnt without a sound practical knowledge of digital exploration. The patient should, whenever possible, be placed on a table or couch, as during inspection (see page 45), and she should also be prepared as for bimanual palpation, in the manner shortly to be described; in any case, care must be taken that the clothes are kept out of the way. The patient lies on her left side with her left shoulder well down, and not supported by the left elbow. Her body must be bent and her knees drawn up. The stays must always be loosened, the drawers removed, and the skirts of the dress kept backwards and above the nates. The lower extremities and hips are covered by bedclothes, or a shawl, or other suitable covering. The patient's confidence is necessary in every stage of this process, for, even when she is tractable, the surgeon will often find

* After some consideration, I have come to the conclusion that "exploration" is the best term to employ in this case. I have discarded all italic Latin expressions, such as "*per vaginam*" and "*per anum*." They serve no purpose, either in respect to science, medicine, or delicacy.

himself much impeded by her constant tendency to straighten the knees and draw the pelvis away from the part of the couch on which it should lie. The surgeon must not lose her confidence by declaring that he is not hurting her when she complains of pain, or by displaying hurry, roughness, or loss of temper.

The surgeon's finger-nails must be well trimmed, for a long nail is in any case liable to scratch the vaginal mucous membrane, so as to cause great pain, which is not always transient. Care, of course, must be taken that the nails do not carry infection from a previous case; and it must be remembered, especially in hospital practice, that chaps or agnails on the fingers may expose the surgeon himself to danger. The fingers must be warm; if cold they are apt to cause great irritation.

The fore and middle fingers of the right hand, or the forefinger alone in case the vagina be evidently very narrow,* are dipped into carbolized oil or vaseline, any superfluity of which must be shaken off so as not to soil the patient's clothes. The left hand is then placed on the patient's right hip, to steady her, and the two fingers of the right hand are introduced. Here I must note, before proceeding further, that the practice of pressing the left hand on the abdomen, at this stage at least, is objectionable. In order to ascertain the actual position of the pelvic organs, the surgeon must not attempt to push them down.

The two fingers should be directed to the perineum, and then slipped into the posterior part of the vulva. The anus, which every surgeon should be able to detect by touch, must be avoided, but it may be used as a guide to the parts anterior to it in position. If the hairs of the vulva be touched, the fingers must be raised and drawn back, so as to search for the perineum, for any attempt to introduce the fingers between the labia anteriorly will probably cause some of the hairs to

* I am firmly of opinion that, in the systematic examination of patients in the out-patient room, two fingers should be employed for digital exploration. The beginner, however, will find it more convenient to introduce the forefinger only. Likewise, in defining any swelling or structure already discovered by the two fingers, it is advisable to slip the middle finger out of the vagina, and to rely on the forefinger alone.

be pushed upwards against the tender structures within the vulvar orifice. When the fingers enter the vagina, they are slipped upwards till the posterior fornix is reached. As they go higher, more and more care must be taken lest the nails scratch the mucous membrane, and lest the knuckles of the other fingers of the right hand bruise the vulva.

The surgeon now notes what the fingers can detect. They can be felt to part the anterior from the posterior wall of the vagina; in fact, they enter no true cavity.* Posteriorly, the tissues of the perineum, the coccyx, and the lowest part of the concavity of the sacrum can be felt; also, a little laterally, the limits of the rectum, which must not be mistaken for the edge of a collapsed cyst or for a prolapsed and diseased Fallopian tube. Scybala in the rectum are readily detected when low down, and then can be recognized, if not very hard, by their property of pitting on pressure. Of course they cannot in themselves be tender, but when the finger presses the recto-vaginal septum roughly against a scybalous mass, pain will be felt by the patient, and the surgeon may fall into the error of mistaking the mass for a sensitive living structure, normal or pathological. When scybala lie high in the rectum they cannot be diagnosed, with surety, by the finger in the vagina. Whenever scybala are found, the exploration should be repeated after the rectum has been cleared by an enema.

Laterally the border of the sphincter vaginæ may be detected, especially when there is some soreness about the vulva, causing it to contract. The sphincter is by no means a powerful muscle. A cleft, often easily distinguished, separates it partially from the levator ani. The well-known tendinous arch, whence part of the fibres of this latter muscle arise, is readily felt by the finger, and is an excellent landmark. The contractions of the anterior fibres of the levatores ani, which form the pubo-coccygæi, or homologues of the levatores prostatae in the male, are not difficult to detect, and sometimes resist the introduction of the fingers, especially when there is inflammatory pelvic disease or fissure of the anus. It will be observed that they press with considerable force on the vagina laterally. After the fingers

* The surgeon must remember that the posterior wall of the vagina lies far below and anterior to the concavity of the sacrum.

have passed above their level, their resistance becomes inappreciable.

Not only can the levator ani be detected, but the obturator internus is also by no means difficult to distinguish. Dr. Schultze, of Jena, was among the first to note this fact, which I have carefully investigated, and can fully confirm. By pressing the fingers against the vagina laterally, above the level of the tendinous arch of the levator ani, the muscular origin of the obturator internus can be felt, and the muscle on the right side can be made to contract by directing the patient to rotate the right thigh a little outwards; it can also be well distinguished during extension and adduction. Further backwards and upwards the pyriformis may be reached, in cases where the pelvis is not deep, and if a large branch of the sacral plexus in the neighbourhood of this muscle be pressed, considerable pain will ensue. Pressure towards the pelvic brim laterally and somewhat forwards may also cause severe pain, the obturator nerve being touched in this case.

These facts are of practical importance, and are no mere anatomical curiosities; for I have repeatedly found that where sources of pain or nerve-irritation are present these muscles are most readily detected. The reader will be best able to verify this for himself by careful and gentle exploration in cases where pelvic inflammation or fissure of the anus exists. The contractions of the pelvic muscles may, on the other hand, be marked during the first vaginal exploration in a timid patient not subject to any painful local disease. The hard contracted muscles, especially the obturator internus, may, in this case, be taken for an inflammatory deposit. At a subsequent examination there may be more confidence, hence less muscular spasm. The muscular contraction will then be absent, but the surgeon may misinterpret the case and believe that an inflammatory deposit which, as he believed, existed before, has disappeared.

I have likewise little doubt that the pain caused by pressure of the fingers on large nerves is not unfrequently taken for evidence of disease. The surgeon must never forget that many healthy structures, especially nerves, are painful on pressure; nor when he causes pain in this way must he hurt the patient's feelings by saying that "it is nothing." Lastly, the position of

the pelvic nerves explains how they may be affected when surrounded by inflamed connective tissue or pressed upon by new growths, and the direction of the radiation of pain in any case will thus become comprehensible.

In the front of the vagina the fingers will detect the urethra, like a cord in the anterior vaginal wall; the bladder, if fairly distended;* and the anterior fornix, or reflection of the anterior wall of the vagina on to the cervix. The presence of hard deposit, or a tumour pressing downwards, or an enlarged uterus, may be noted, but bimanual examination will be required in these cases.

Most important of all, as a rule, is the evidence obtained by the fingers as to the condition of the structures in the neighbourhood of the upper limits of the vagina. First, there will be the vaginal portion of the cervix uteri. The os externum at least can easily be reached unless the uterus be greatly displaced, as in some cases of fibroid disease, where a depression in front of the morbid growth, close under the pubes, is sometimes all that can be felt.

The cervix forms a truncated cone, covered with soft mucous membrane. During health it is never tender to the touch, and when pain is produced as the surgeon's fingers reach it, the cause generally lies higher up, in the uterus or its appendages which are disturbed when it is touched. The cervix is short and slightly flattened antero-posteriorly in nulliparæ, but thick, tough, and cylindrical in most multiparæ. In pregnancy it is expanded, so as to be, as it were, more or less lost† in the body of the uterus as gestation advances; the fingers can ascertain this condition. At the same time its tissues feel very soft. • When the uterus is

* Säger has detected the ureters by digital exploration of the vagina in various urinary disorders. He says that they cannot be felt in every woman, but are frequently to be made out during pregnancy, when they are hypertrophied. Dr. Säger detected the ureters in eight out of ten cases of pregnancy, but has never felt them during the lying-in period. They feel about as thick as a goose-quill, and lie in front of the upper third of the anterior vaginal wall, about three-quarters of an inch below the cervix. In the later months of pregnancy they can be pressed against the foetal head. (See *The Year-Book of Treatment for 1886*, page 222.)

† For the precise nature of the changes of the cervix during pregnancy, the surgeon must consult standard text-books on midwifery. (See Matthews Duncan, *Edinburgh Medical Journal*, March, 1859.)

healthy, the cervix can be gently moved backwards and forwards without causing pain.

The os externum feels like a small circular dimple in nulliparæ. In women who have borne children it generally forms a transverse slit, often wide enough to admit the tip of the forefinger. Its borders then appear to form a sharp rim surrounding the finger. Fissures are very frequent in women who have borne children, and are often associated with eversion of the tissues of the cervix. The lips of the os may be hypertrophied, even to an extreme extent. It is important that the presence or absence of any structure protruding from the os, or of any sign of cancerous ulceration, should be ascertained by the finger.

In normal conditions the fingers can always be passed completely round the cervix; but cicatrices may exist, causing an adhesion between its surface and the vaginal mucous membrane.

When there is difficulty in detecting the cervix, so as to lead to a suspicion of its absence, especially when a small dimple only can be detected at the upper extremity of a short, wide vagina, further evidence of absence or imperfect development of the uterus can only be satisfactorily gained by bimanual examination. An abnormality of this kind is sometimes wrongly diagnosed. Thus, an inexperienced practitioner may pass a finger into the rectum by mistake, and, feeling the cervix through its walls, may take it for an atrophied uterus not communicating with the vagina; or may recognize it as the cervix, yet believe that the vagina is occluded. In some women the hymen remains after repeated coitus; its borders may firmly surround the fingers, so that as they pass high up it is drawn upwards with them. I have already spoken of this condition in describing the hymen.

When the surgeon has examined the cervix in the manner just described, he must on no account be in a hurry to introduce the sound. In many cases it may be dispensed with altogether, and it should never be used till after bimanual examination. I shall, however, return to this subject when speaking of the use of the sound.

The fingers must now, after careful exploration of the cervix, be passed into the posterior *cul-de-sac* or posterior fornix. In ascertaining its depth, the fingers being necessarily stretched to

their utmost extent, especial care must be taken lest the nails touch the mucous membrane, else the pain so caused may entirely mislead the surgeon. In health, no structure can be distinctly felt in the posterior fornix. Scybala, or the border of the rectum, may be taken for different morbid conditions, in a healthy subject. Cysts, solid uncircumscribed deposits, well-defined tumours, and many other morbid conditions, may here be detected, but bimanual examination will always be necessary to confirm diagnosis.

On each side of the cervix, the base of the broad ligament can be felt by pushing the vault of the vagina gently upwards, taking care, once more, lest the nail touches the mucous membrane. It feels like a thin, resistant band, but is never markedly tense in health. Morbid thickening is very frequent, especially on one side. A healthy ovary can never be detected in this manner.

The surgeon's fingers will also detect any foreign body lying in the vagina, such as stems, pessaries, or plugs, introduced by other practitioners, or substances slipped in by the patient herself. The condition of the vaginal mucous membrane must also be noted. It feels abnormally hot in some local inflammatory diseases, and in many cases where the temperature of the body is high. Fistulous communications with the bladder and rectum may be explored in this manner, but they always need the use of the speculum.

Precautions in Digital Exploration.—The surgeon must not hook his finger forcibly round the front of the cervix to ascertain the degree of mobility of the uterus. Should any inflammatory deposit exist, this practice is certain to cause great pain, and may set up fresh inflammatory changes. Moreover, the pain may be mistaken for evidence of disease of the cervix, whilst in reality the morbid condition lies much higher. What is generally described as a tender cervix really signifies pain in some deep pelvic structure set up by forcible pressure on the cervix, which is itself a structure possessing a very low degree of sensitiveness.

Simple digital exploration of the pelvis through the rectum will be considered after some of the more direct methods of examining the condition of the female organs.

Bimanual Examination.—This is a method of perfecting diagnosis widely in use at the present day, and of the highest value. It only serves its purpose when properly conducted, and, as it is indispensable, every surgeon must learn how to practise it skilfully and on correct principles.

Some practitioners content themselves with passing the left hand over the hypogastrium as the patient lies on her side, and pressing downwards, whilst the right fore and middle fingers are engaged in exploration of the vagina. This kind of manipulation is often necessary, especially when the relations of an abdominal tumour to the pelvic viscera have to be ascertained, but it is not what is understood by authorities as bimanual palpation. The state of the uterine appendages and the lateral parts of the pelvic cavity can never be properly explored in this way. In cases, however, where pelvic tumours, especially if small, are suspected, much may be found out by this lateral method of bimanual examination, if carried out when the patient is placed first on her left and then on her right side.

Bimanual examination properly signifies simultaneous exploration of the vagina with one or two fingers of the right hand, and pressure on the lower part of the abdominal walls with the left, the patient lying on her back. The surgeon must ascertain what can be felt between his hands.

The patient must be placed in the position which is also most convenient for examination of the abdomen alone. She must lie evenly on the couch or bed, and on her back. A pillow should be placed under the head and shoulders, and the knees must be drawn up. Care must be taken, if the patient be examined out of bed, that the clothes are drawn well above the epigastrium, the stays taken off altogether, the upper border of the petticoat kept as low as the pubes, and the dress which covers the knees arranged so as not to interfere with the surgeon's right hand engaged in exploring the vagina. It is far better that the patient should be in bed, wearing only a night-dress; then she will be most at her ease, and there will be less trouble through contractions of the abdominal muscles. Hence the same medical attendant may discover, when examining the patient as she lies in bed, what he has failed to detect when exploring under less favourable conditions. In some

cases an anæsthetic will be required, as when great pain must otherwise be produced, or when the absence of any local disease is suspected, yet a very close scrutiny of the pelvic organs is necessary for the final justification of that suspicion.

The right hand is passed towards the vulva with the ulnar border downwards and the thumb extended. The fore and middle fingers are introduced into the vagina, the others are flexed, whilst the thumb is kept against the symphysis pubis. I am strongly of opinion, after considerable experience, that two fingers should be introduced whenever possible. The middle finger is pushed against the os uteri, the forefinger is pressed against the anterior fornix in front of the cervix. This manœuvre tilts the body of the uterus forwards—in fact, it causes anteversion, so that the fundus is brought nearer to the abdominal walls, and more within reach of the other hand. The aim of this part of the process is not to push the uterus somewhere for the feat of getting it within reach of the hand, nor to find out where it lies by forcing it into a situation where it did not lie before the hand disturbed it. What is intended is the manual examination of the body of the uterus through the abdomen, so that its consistence, its bulk, and the regularity of its surface can be detected.

The left hand must be warm, else troublesome contractions of the abdominal muscles and much discomfort to the patient will be occasioned. The surgeon must see that no clothes get in the way of this hand, and must also take care that the patient does not keep her hands so placed as to be able to seize his left wrist suddenly and unexpectedly, as timid subjects are wont to do. All the inconveniences to which I have referred must be borne in mind, for bimanual examination is worthless unless and until the surgeon can conduct it without let or hindrance. The palm of the left hand should be gently placed on the epigastrium, and passed, with steadily increasing pressure, over the hypochondria, the lumbar and umbilical regions, and, lastly, the hypogastrium. In this way some unsuspected morbid condition above the pelvis may be detected. The bulbs of the finger-ends, and not the nails, are pressed gently, firmly, and steadily against the hypogastrium, so that the abdominal walls are depressed. Hart and Barbour rightly recommend that the

inner edge of the hand should be brought to bear against the abdomen, for pressure with the whole palm may retrovert the uterus.

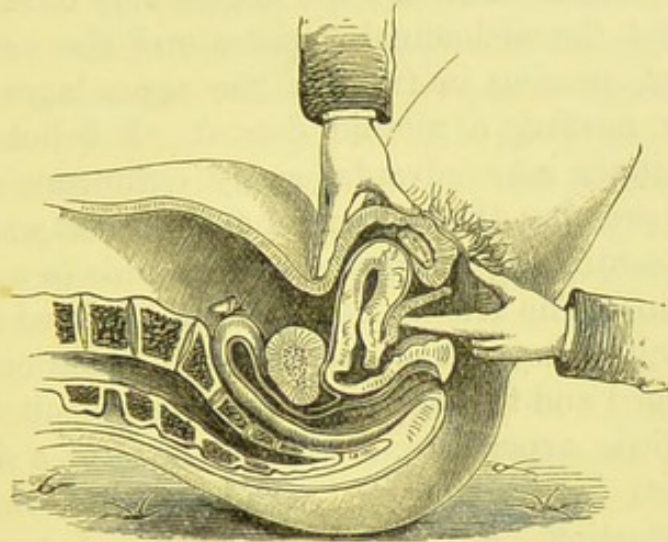


FIG. 13.—BIMANUAL EXAMINATION.

In this sketch, only one finger of the right hand has been introduced, and it is being pressed against the anterior vaginal wall, so that the body of the uterus may be felt between it and the left hand, which presses on the hypogastrium. (*Sims.*)

The right and left hands being thus placed, the fingers of each are pressed towards each other. The surgeon must note what can then be felt between them. The fundus uteri is characteristic, and not difficult to recognize, except in a stout patient. It is easiest to explore in cases of subinvolution—that is to say, in patients who come for relief from bearing-down pains, etc., shortly after recovery from confinement. The body of the uterus will feel bulky, and the beginner may believe that it is abnormally enlarged, when it is of its natural dimensions under the circumstances. The surgeon tests the mobility of the body of the uterus, and may be able to detect great irregularities on its surface, denoting fibroid growths; or he may find a tumour or an ill-defined solid deposit before or behind it. He then explores the posterior fornix of the vagina with the two fingers of the right hand, pressing over the uterus with the left hand. No solid body is to be detected in this way, if the parts be free from disease.

Lastly, the uterine appendages are examined in the same

manner, the right fingers being pressed against the vault of the vagina to the right of the cervix uteri, and the left against the abdominal walls in the right iliac fossa. Both hands must press somewhat backwards, else the fingers may be made to meet with little but the abdominal parietes and the vaginal walls between them, passing in front of the appendages altogether, and possibly missing a morbid deposit. I believe, however, that the beginner may advantageously commence a bimanual palpation by pressing the abdominal and vaginal walls together in this way, continuing the pressure afterwards in a more backward direction. The left appendages are explored in the same way. In health, they cannot be distinctly made out on either side. Enlarged and tender ovaries are not difficult to discover, and, with a little experience, even the course of a dilated tube may be traced by the fingers. Solid deposits, the result of pelvic inflammations, are readily detected. I must observe, however, that in chronic cases of such inflammations even the most experienced may fail to detect the precise extent of disease by bimanual examination.

Once more, I must insist upon declaring that bimanual examination must be learnt by those who undertake to cure the diseases of women. The surgeon must teach himself what can be discovered, and must be aware of what cannot be detected, by this invaluable aid to diagnosis. He must always learn to explore by two fingers of the right hand in this method of examination. The forefinger alone should only be used when the vagina is very narrow.

Bimanual examination should entirely replace the use of the sound in cases where pregnancy may exist, and where there is evidence of acute or subacute pelvic inflammation or malignant disease. Emmet and others reject the sound altogether, in its favour, in all cases of diseases of women. Bimanual examination must, however, be very gently and carefully conducted in acute inflammatory disease, and always preceded by vaginal exploration. If, during such exploration, great heat of the vagina, solid but ill-circumscribed deposit, or evidence of impaired mobility of the cervix be ascertained, no further kind of manual examination is advisable for the time. In cases of cancer of the cervix, the uterus may be gently explored

bimanually, but no attempt must be made to test its mobility. I have seen such an attempt set up hæmorrhage as severe as when the forefinger is roughly thrust into the canal of the diseased cervix, and dangerous pelvic inflammation may follow.

The hands must be thoroughly washed after vaginal exploration or bimanual examination, and the nails carefully cleaned. Carbolic and "Sanitas" soap are both good for the purpose. Foulis, Hart, and Barbour recommend the addition of a few drops of turpentine. This aids in dispelling the offensive odour which sometimes clings to the fingers, as well as acting antiseptically. A final washing in water containing a little glycerine, and thorough drying of the hands, will guard against chaps, a source of actual danger, or, at the least, very disagreeable, especially if many patients have to be examined when cold weather prevails.

The Genupectoral and Semi-prone Positions.—These positions allow of the inspection of the vagina and cervix. If the patient be placed on her knees, with the nates elevated, the chest and face downwards resting on the couch, and the face turned to one side, atmospheric pressure will separate the vaginal walls when the surgeon opens the vulvar aperture. When the posterior wall is elevated by the forefinger a good view can be obtained of the vagina, and often of the cervix also. The physical mechanism of this, the *genupectoral posture*, has been well described by Drs. Hart and Barbour.

The same physical conditions, whereby the vagina no longer remains a closed canal, can be produced by placing the patient in a less objectionable posture, the *semi-prone position*, which often bears the name of Marion Sims. The patient is placed on her left side, with the knees drawn up; the right must be the more flexed, not resting on the left, but on the couch itself. The left arm is drawn gently backwards and allowed to rest as comfortably as possible on that side of the couch towards which the patient's back is turned. The patient must turn her chest and face downwards towards the left side of the couch. Care must be taken that the chest does not lie flat against the couch. The aim of placing the patient in this position is to keep the anterior part of the abdominal walls unsupported, so that they slide forwards and cause the vaginal walls to part when the

vulva is opened by the finger. The nates should lie well towards the right side of the couch; the right or uppermost side of the pelvis must be rotated a little forwards towards the left of the couch.

Provided that there be plenty of light, this is an excellent position for examining the vagina. The cervix may be thoroughly inspected by drawing it down with a volsella. The skirts are simply raised above the nates, and a covering is passed over the lower extremities, so that the region of the vulva alone need be uncovered. When the patient is in bed this position is particularly convenient.

The Speculum.—This instrument must be used intelligently, and the surgeon must not conclude that everything which it displays is in a morbid condition. Its uses are limited; still it is indispensable. A very large assortment of specula of all shapes and sizes may be seen at any instrument-maker's shop. Three chief varieties, based upon different principles, may be made to include all the specula in common use.

The first variety is the cylindrical speculum, made to be directed straight to the cervix, which it brings into view. This is the Fergusson type.

The second variety is the speculum which effects its objects by the assistance of the physical conditions associated, as has already been described, with the semi-prone position of the patient. This is the Sims type.

The third variety includes all specula which essentially work by any kind of valvular mechanism, as in Neugebauer's and Cusco's instruments.

Fergusson's Speculum.—This is the most widely used; in some respects the most serviceable, and in others the least



FIG. 14.—FERGUSSON'S SPECULUM.

convenient, of all specula (Fig. 14). It is a hollow cylinder of stout glass, silvered like a mirror, and coated with black

rubber.* Three or four different sizes are constructed. Its orifice is everted; its extremity bevelled. The surgeon should always pass his finger over the edges of this extremity before use, as it is apt to get chipped, so as to cut or scratch the soft parts when the speculum is carelessly introduced. Though said to be self-retaining, Fergusson's speculum can never be trusted to remain in place without support from a hand or finger. Too much stress is laid on this "self-retaining" quality, which really means the quality of not slipping out quite so readily as other specula. In hospitals, and wherever help is at hand, there is no necessity for employing a "self-retaining" speculum, even if that term were deserved by the instrument.

Fergusson's speculum is not difficult to introduce, and is very handy for inspection of the os externum and adjacent part of the cervix. Straight probes, used for the application of medicated preparations to the cervix and endometrium, can be readily employed with the aid of this speculum, which is also valuable in emergencies, when the vagina requires plugging for hæmorrhage. On the other hand, Fergusson's speculum is unfitted for cases where the whole of the vagina and the sides of the cervix have to be explored. The narrow calibre and the straight cylindrical walls of the instrument interfere with the handling of the sound, volsella, or any other long-shanked instrument.

This speculum can be readily introduced when the patient has been placed on her left side, as during digital exploration of the vagina. When cancer of the cervix is suspected, and in some syphilitic cases, the speculum may precede or entirely replace digital research. It must be warmed, and greased externally with carbolized oil or vaseline. The vulva is then parted by the fingers, and the speculum is introduced with the longer side of the bevelled end backwards. It is slipped upwards till the cervix comes into view. As it passes upwards it should be gently pressed against the perineum and posterior vaginal wall, so as to avoid damage to anterior structures. The name of the maker is generally stamped on the outside of the

* This silvered glass answers better than white porcelain or bright metal, and resists the action of chemicals.

everted orifice of the speculum, at a point in a line with the shorter side of the bevelled extremity. When the speculum is rightly fixed, the name lies towards the pubes, not towards the thighs or the anus. By a little manipulation, only to be learnt by practice, the cervix can be placed in a convenient position for inspection. The speculum must never be screwed round and round, especially when it touches the cervix; its extremity should simply be worked into the posterior fornix of the vagina. A volsella is more useful than a sound for bringing the cervix into view when manipulations are insufficient.

Fergusson's speculum can also be passed when the patient lies in the lithotomy position. In whatever posture she has been placed, a little cleaning will be necessary when the cervix

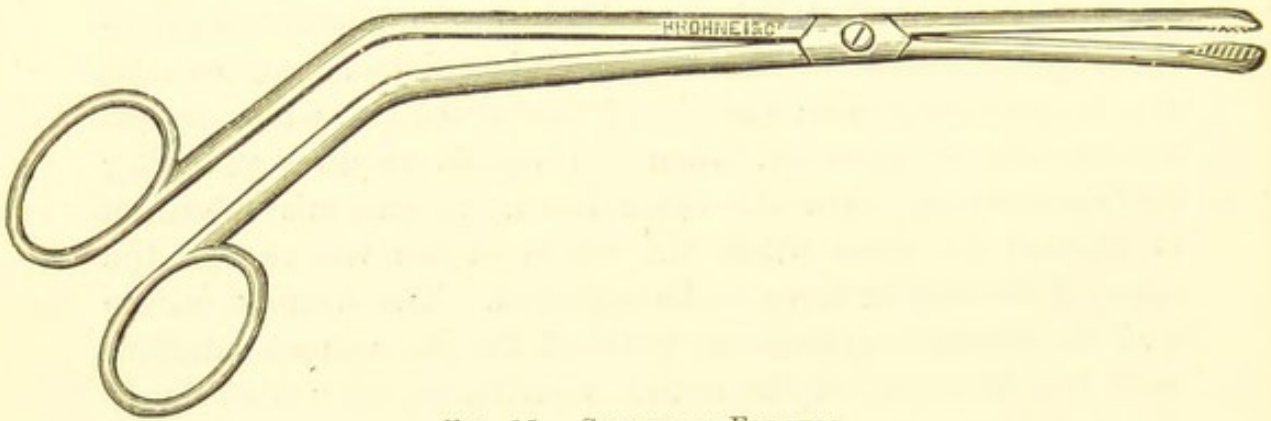


FIG. 15.—SPECULUM-FORCEPS.

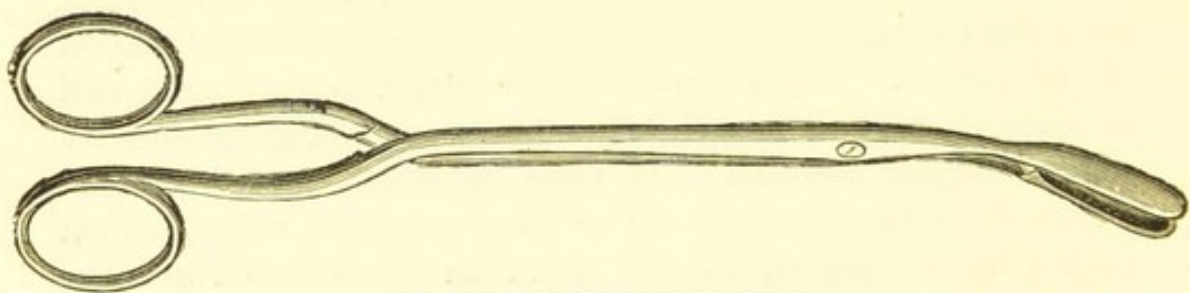


FIG. 16.—SPECULUM-FORCEPS.

has been brought into sight. This is managed by pledgets of wool held by the speculum-forceps (Figs. 15, 16) and brushed against the os. There is generally some glairy fluid to remove, but often the secretion is curdy, muco-purulent, or sanguineous. To clean the cervical canal, some wool may be neatly wrapped

around the end of a Playfair's probe (Fig. 17), which is sometimes roughened at the point so as to hold the wool.* The end of the probe is passed up the canal, gently rotated, and then



FIG. 17.—PLAYFAIR'S PROBE.

removed; much glairy mucus, at least, is thus withdrawn. Both the speculum forceps and the probe should always be used before any caustic or other medicament is applied to the cervix or to its canal.

Plugging the Vagina.—Fergusson's speculum is certainly useful for the application of plugs to the vagina, especially when the surgeon is suddenly called upon to check uterine hæmorrhage, and believes that this may be effected, at least temporarily, if not permanently, by means of vaginal plugging alone. The speculum is first introduced so as to bring the cervix and os well into sight. Probably a tent will be required for the cervical canal, and instruments have been devised for its introduction; but I am speaking now of cases of emergency where only the familiar speculum may be at hand. A piece of lint, folded several times, with several inches of stout pack-thread or twine attached to it, is passed up the speculum and well pressed over the os, and tucked into the vaginal vault around the cervix. Pledgets of absorbent wool or tenax are now passed up the speculum by means of speculum forceps, and pressed against the lint; the string is held gently, and as the pledgets are passed the speculum is gradually retracted, so that each pledget is packed into the vagina, and not left in the canal of the speculum. In this way the vagina may readily be packed. Too great traction on the string must be avoided, especially at first, or else the plug of lint will be displaced, and in consequence there will be least pressure where there should be most. This precaution being taken, the hæmorrhage will be checked, and the plugs will not come away when the speculum is withdrawn. The lint

* Some writers, such as Galabin, object to notches and to bulbous extremities in probes of this kind. They prevent the ready removal of the wool. Simple roughening is quite sufficient.

should be steeped, if possible, in glycerine of tannic acid. The plug should not be left in longer than twenty-four hours. To remove it, the wool is taken away piece by piece with the aid of speculum forceps, the string being held firmly. The last pledgets will come away with the lint on pulling gently at the string, the vagina being afterwards well washed with an antiseptic solution. Sometimes a piece of rag, and long strips of the same material, are alone available for plugging. I have been speaking of emergencies alone. More complicated methods of plugging for the arrest of hæmorrhage are in vogue amongst specialists.

Sims' Speculum.—This instrument is devised so that the vagina and cervix may be explored by its aid, assisted by the physical conditions of the semi-prone posture (page 57). If the principle of this posture be understood, there will be little difficulty and great advantage in the use of Sims' speculum.

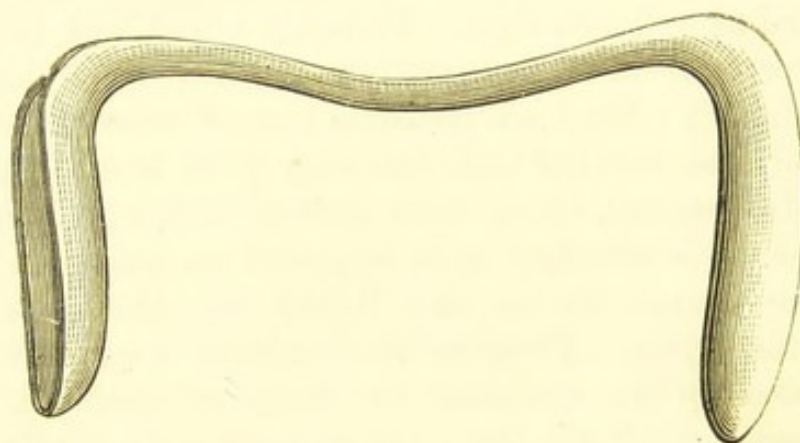


FIG. 18.—SIMS' SPECULUM.

Sims' speculum (Fig. 18) is a solid piece of metal, bent at right angles on itself at each end. The bent portions are about four inches long, and concave on one side, each forming a speculum blade, one stouter and wider than the other. A very large number of modifications of this instrument have been devised. In some the blades are bent back, so as to form acute angles with the connecting bar or handle. Sometimes, as in Bozeman's modification, this arrangement exists, and the entire instrument is also made heavier than in the original form. Increased weight is of advantage when the

speculum is employed to depress the perineum whilst operations are being performed when the patient lies in the supine position, as in vesico-vaginal fistula. The chief modifications, however, aim at making Sims' speculum an instrument which can be used without the aid of an assistant, even when the patient is placed on her back. This, however, is hardly possible. I must admit, however, the value of that modification of Sims' speculum which bears a metal bar bent so as to form a kind of loop. The bar acts like a lever, and pushes upwards the anterior vaginal wall when its extremity is pressed against the handle by the thumb of the same hand which holds the instrument. This variety may prove useful when no assistance is at hand, and it is very suitable when the patient is placed in the lithotomy position. Nevertheless, Sims' speculum is essentially intended for use in hospitals and in places where skilled assistance is at hand.

Before Sims' speculum is employed, the patient, who should lie on a high couch or operating-table in a good light, must be carefully placed in the semi-prone position, as described at page 57. Unless she lies accurately in that position, the speculum cannot be used properly, for the vaginal walls will not fall apart, as they are intended to do.

The semi-prone position being assumed, that blade of the Sims' speculum which is most adapted to the dimensions of the patient's vagina is introduced after it has been warmed and greased. The bar between the blades, and the blade which is not to be introduced, are grasped in the left hand, the thumb pressing firmly against the bar. The labia are parted by the introduction of two fingers into the vagina, which should dilate of itself directly they enter; if it does not dilate, the patient is not lying exactly in the semi-prone position. Then the blade is passed sideways into the vulvar cleft, rotated backwards as it enters the vagina, and slipped along the posterior wall till it reaches the posterior vaginal fornix. By drawing the instrument backwards and tilting its point forwards, keeping up a little gentle pressure on the perineum, the cervix and os will come in sight. The cervix may, if necessary, be drawn down with the volsella. A depressor is hardly needed when the patient is accurately placed. The uterine sound and other

long-handled instruments can readily be used while this speculum lies in the vagina.

For vesico-vaginal fistula, trachelorrhaphy, operations for the removal of vascular urethral growths, etc., this speculum is used with the patient lying on her back. It is grasped in the same manner, and one blade is slipped along the posterior vaginal wall, the labia being parted with the fingers. The cervix may be tilted into a convenient position by the beak of the blade; an assistant then presses the blade gently but firmly against the perineum, and holds it in that position during the operation. When so engaged, the connecting bar should be grasped by one hand, right or left as best suits his position in respect to the operator, the thumb being pressed into the extremity of the concavity of the blade which is in use. The assistant's hand may, however, be in the way; if so, he must grasp the lower blade, the thumb lying in its concavity close to the connecting bar. These directions will not be difficult to understand if the surgeon takes a Sims' speculum in his hand as he reads them. With regard to the concavity of each blade prolonged over the angle on to the connecting-bar, it serves several purposes. Thus, as just described, it acts as a thumb-rest. It also allows depression of the handle of any instrument used during examination, and facilitates the escape of fluids or coagula.

Valvular Specula.—Some specula have a valvular action complete in themselves, the Sims type acting only as part of a valve.

The valvular specula include two varieties. In the first, the instrument consists of two separate pieces, which slide upon each other after introduction, and thus form a valve. Neugebauer's and Barnes' specula are of this type. In the second, the instrument is made in one piece, consisting of two valves, which open by a special mechanism. This is the case in Cusco's speculum.

Neugebauer's Speculum.—This instrument (Fig. 19) consists of two deeply-hollowed pieces of metal, everted at the extremity to be introduced into the vagina, and furnished with a short, straight handle. A graduated set of blades must be kept in hand, and the speculum consists, as just

observed, of two such blades, one able to slide in the other. The broader blade is warmed, greased on its convex aspect, and passed along the posterior vaginal wall. The patient may lie either on her side or on her back. The everted extremity of the blade must be made to push back the posterior vaginal fornix, against which it rests. Then the narrower blade is warmed and greased in the same manner, and slipped along the anterior vaginal wall, its edges sliding within those of the other blade. The extremity is pushed into the anterior

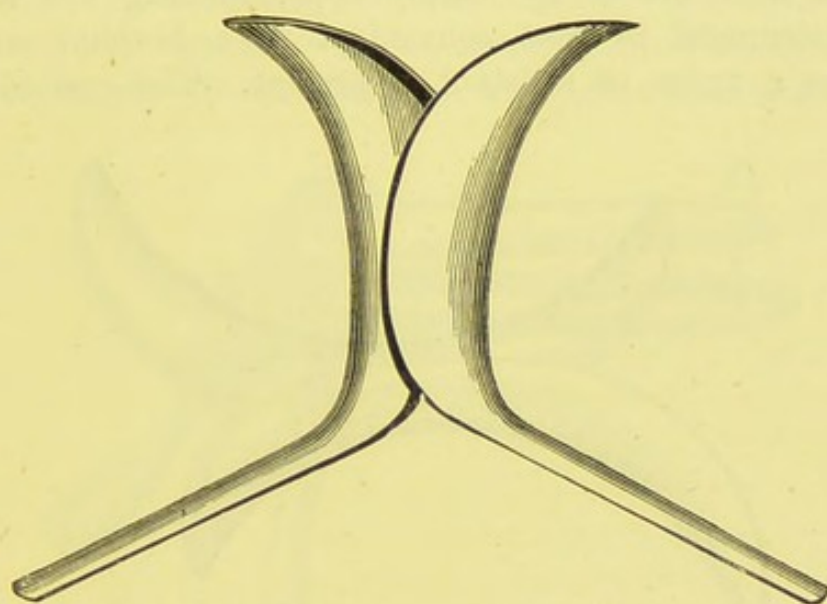


FIG. 19.—NEUGEBAUER'S SPECULUM.

fornix. By approximating the handles, the extremities are parted, so that they press against the vaginal vault in opposite directions, and expose the cervix, everting its canal more or less, as may be desired.

Barnes' Crescent Speculum (Fig. 20) is a modification of Neugebauer's. "Finding," Dr. Barnes writes in his *Clinical History of the Medical and Surgical Diseases of Women*, "that when dealing with stout patients the handles of Neugebauer's instrument were too short to be easily commanded, I have made what I find in practice a very convenient modification. I have substituted for the handle another blade. Two pieces make a series—three different sizes of speculum. The gradation is effected by having Nos. 1 and 3 in one piece, and Nos. 2 and 4 in the other. By using No. 1 with No. 2 we get the

largest size; by using No. 2 with No. 3 we get the next size; by using No. 3 with No. 4 we get the smallest size. The ends outside the vagina form excellent handles." Dr. Barnes' instrument is very portable.

This form of speculum is of high value. It is particularly needed when the cervix requires special attention. I have found Neugebauer's speculum very useful for the application of medicated fluids to the os and cervical canal when the patient lies in bed on the left side. The cervical canal is readily widened near the os by simply approximating the handles. The instrument is most convenient in a hospital ward or wherever a nurse or assistant is present. The everted canal

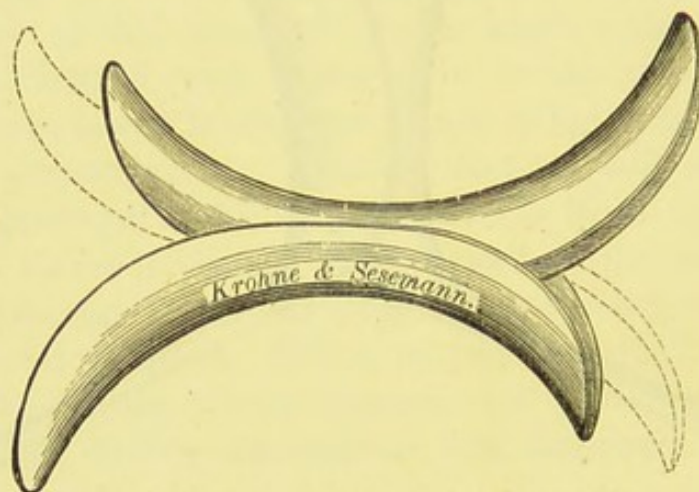


FIG. 20.—BARNES' CRESCENT SPECULUM.

of the blade allows far freer movements of any long-handled instrument than does Fergusson's speculum, and the uterine sound can be used with facility without disturbing the cervix. As to the argument that this speculum requires an assistant, I have replied to it in the case of Sims' instrument.

Cusco's, or the Bivalve Speculum.—There are a very large number of varieties of hinged, bivalve specula, and many works on diseases of women, by standard authors, are adorned by a long series of woodcuts of ingenious contrivances of this kind, bearing, of course, the names of the inventors. Multiplicity of varieties of an instrument generally implies either defects difficult to avoid, or attempts to combine qualities which cannot readily be combined. The defects, in the case of many bivalve specula, are a want of that self-retaining property which

has been claimed for them, an awkward arrangement of the mechanism which works the valves, and the absence of some contrivance to display a large surface of the vaginal wall. To combine the best self-retaining contrivance with the best mechanism for opening and closing the valves and at the same time to ensure a good view of the vaginal wall when the speculum is fixed, the instrument remaining workable for any person a little versed in the treatment of diseases of women, is probably an impossible task.

Cusco's (Fig. 21) is the best form of bivalve speculum. There are several sub-varieties. In the best type there are two blades of equal length broad, flattened, and concave internally. A

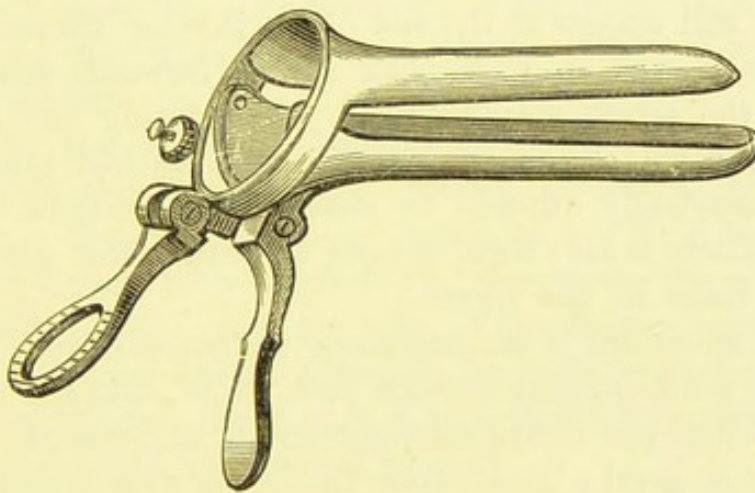


FIG. 21.—CUSCO'S BIVALVE SPECULUM.

thumb-piece is attached to one blade, and a screw passes through the thumb-piece, to be fixed to a projection from the other blade. The two blades are connected by a hinge, and can be parted by pressure on the thumb-piece; a metallic button fixes the screw at any desired point, so as to regulate the gape of the blades. Some instruments sold under the name of Cusco have a different mechanism for working the blades. Others have fenestrated blades, designed to allow a view of the vagina, but they effect their purpose very imperfectly, and increase the unfortunate tendency of this kind of speculum to hurt the vaginal walls. Lastly, some "Cusco's" have blades of unequal length. Those who hold that one blade should act as a mere repressor, of the kind often employed with Sims' instrument,

prefer that one blade should be short. Other authorities, such as Galabin, contend that both should be of equal length, so that the axis of the uterus may be brought as nearly as possible into a line with that of the vagina. Altogether, the latter opinion coincides the most with the utility of the instrument.

When Cusco's speculum is used, the outer sides of the blades are warmed and oiled, and the patient being placed on her side or back, according to circumstances, the blades are passed with their outer surfaces facing the corresponding labia. When well introduced the instrument is rotated so that the outer surface of the blade bearing the thumb-piece lies against the anterior vaginal wall. On working the screw by pressing the thumb-piece, the other blade will depress the posterior wall, and the cervix will appear at the end of the parting blades. When the cervix is well in view, with the os forwards towards the operator, the screw may be fixed. In rotating and in withdrawing the blades the vagina may get pinched, especially if they are carelessly allowed to close as the speculum is being moved. There is also some danger of entangling some of the pudendal hairs in the screw.

Cusco's speculum is an ingenious instrument, very portable and easier for beginners to work than Sims', but not nearly so valuable when the semi-prone posture is understood. It does not throw so good a light upon the cervix as does Fergusson's, but is more convenient for the application of medicated preparations to the cervix and its canal, and for the introduction of the sound. It cannot be well used without an assistant to keep a finger against the thumb-piece whilst the surgeon is inspecting or operating on the cervix. It is almost as useless as Fergusson's for inspecting the vagina, and far inferior to Sims' for operations on the vagina or cervix.

Every surgeon should possess a set of Fergusson's and Sims' specula, and should learn how to use them as directed. He may dispense with any bivalvular form, or at least keep either Neugebauer's or Cusco's instrument, but to keep both would be superfluous. Fergusson's can be put to its limited uses almost anywhere. Sims' will be of great service in the operating-room, the consulting-room, or wherever skilled assistance and a good couch are at hand. A bivalve speculum is useful for

applications to the cervix or endometrium when the patient lies in bed, especially in a private house.

Lastly, Drs. Hart and Barbour's words should be remembered by all: "If the patient be placed in the genupectoral or semi-prone posture, the posterior vaginal wall hooked back with the fingers, and the cervix drawn down with a volsella, a useful view can be obtained without the aid of any speculum." This is the best way to examine the vaginal walls.

The speculum is not a dangerous instrument to introduce in suspected pregnancy, if used very gently. When there is much probability that advanced cancer of the uterus exists, the finger should first be introduced; and if the vaginal walls or recto-vaginal septum be involved, it is best not to pass the speculum, which may bruise the cancerous tissues and cause serious hæmorrhage. At this stage local applications will be almost, if not entirely, useless.

For the inspection of lacerations of the cervix, Sims' instrument is alone thoroughly reliable, for the bivalve specula will part a fissure to such an extent as to efface it, making it appear as a wide plane surface, and Fergusson's speculum will, on the other hand, press the sides of the fissure together.

Any speculum should after use be well washed in a strong solution of Condyl's fluid, or in a 1-in-10 solution of sulphurous acid or a 1-in-40 solution of phenol.

Before speaking of the sound, I will describe the different methods of exploring the pelvic organs through the rectum and bladder. These methods are, to a certain extent, homologous to simple and bimanual exploration through the vagina.

Rectal Examination.—This method of examination must be conducted properly and on special principles, like any other method. It does not signify a perfunctory search with one finger of either hand introduced anyhow into the rectum. When carried out on scientific principles, it may prove an important guide to ascertain the condition of the internal organs. The surgeon must not forget that many patients object strongly

to this form of examination. Vaginal exploration is probably expected beforehand, so that the patient is prepared for it, but the introduction of the finger into the rectum, if unexpected, may cause great alarm. The dilatation of the sphincter, however gently performed, generally produces pain—severe if a fissure exist, as is not rare in women. The patient is also apt to think that the surgeon is making a mistake in exploring the rectum. Hence a little explanation on his part is advisable, for, as I have already observed, loss of confidence is a great bar to a free examination of the pelvic organs, unobstructed by muscular contractions or by the patient's own restlessness. Above all, the surgeon must never introduce the finger, after employing it in this way, into the vagina without first washing it.

Introduction of the Entire Hand into the Rectum.

—This process, introduced by Simon, is difficult and dangerous. It is wrong to speak triumphantly about being able to reach the kidney, without noting that the peritoneum is frequently torn in the attempt, and that the sphincter may be irremediably damaged. Dr. Thorburn has rightly observed that we must not let enthusiasm for diagnosis endanger a patient; and Dr. Gaillard Thomas maintains that, "except in a very few rare cases, it should be expunged from the list of exploratory measures in gynecology." Even the above qualification may be rejected.

Simple Rectal Examination is often required as a substitute for vaginal exploration in virgins, and for bimanual exploration in bad cases of pelvic inflammation. It is also necessary in thorough exploration of the appendages; in which case the patient should be put under the influence of an anæsthetic. Before rectal examination the surgeon should rub soap well under the nail of the right forefinger and over its root. The patient can be most conveniently examined if placed on her back. The lateral position is inconvenient, especially if the right forefinger be used, as it obliges the surgeon to stand in awkward positions; nor is the necessary pronation and supination of the engaged hand easy under these circumstances. When the patient is in the supine position the wrist can be moved with ease and freedom.

The finger first overcomes the sphincter ani externus, and then it passes forwards. It enters the dilated lower third of the rectum, generally meeting scybala. Internal hæmorrhoids or some other local disease may also be detected. On feeling through the anterior part of the rectal wall, the cervix is to be distinguished. The whole of that part of the uterus can be felt,—not only the vaginal portion, as in digital exploration of the vagina. Hence the cervix feels much larger in rectal examination, and it must not be taken for the body of the uterus, or for a morbid growth. When the uterus is retroflexed, the fundus can be felt through the rectum, above the cervix. Hart and Barbour have shown that a uterus anteflexed, but drawn backwards by cellulitis of the utero-sacral ligaments, simulates retroflexion when the vagina is explored, whilst on rectal examination the finger can detect the fundus going forward above the cervix.

Thus the chief advantage of rectal examination is the facility with which the finger can be slipped along the back of the entire cervix and the body of the uterus, an impossibility in vaginal exploration, as the finger is arrested in the posterior fornix. When the uterus lies high, it may be pulled down by means of a volsella. Rectal examination is also of great value when there is a uterine tumour in the vagina, of uncertain nature, too bulky to allow a proper exploration of the cervix through the vagina. This can readily be done through the rectum, and in this manner a fibroid polypus may be distinguished from an inverted uterus—a diagnosis often particularly important when a large polypus is in process of extraction piecemeal through the vagina, and the operator knows that he has been keeping up prolonged traction on the uterus.

The appendages can also be explored in this manner. Indeed, it is only through the rectum that the back of the broad ligaments can be explored. This exploration is absolutely necessary in cases of cancer of the uterus, as the surgeon is bound to ascertain whether the disease has extended to the appendages. It is also required in cases of extra-uterine pregnancy, hæmatocele, and pelvic inflammation.

Recto-abdominal Examination.—Bimanual examination may be conducted with one finger in the rectum and the opposite

hand on the abdomen, as in the more usual method, but the cervix cannot be so well steadied as when the finger is in the vagina. When, however, rectal examination is made as above directed, it is always advisable to conclude by making the patient lie on her back and pressing with the disengaged hand on the hypogastrium,—that is, by making the exploration bimanual. This recto-abdominal examination, as it has been termed, is often useful in the case of virgins. It is still more valuable in cases of atresia vaginæ, with or without retention of menses, and in other malformations of the genitals, as, for instance, when absence of the uterus is suspected.

Recto-vaginal Examination.—Dr. Tilt's double touch, or *toucher*, by introduction of the thumb into the vagina and the forefinger into the rectum, is chiefly useful when the recto-vaginal septum requires special examination, or when the surgeon meets with some apparent discrepancies as the result of separate exploration through the vagina and through the rectum. Some authorities prefer to use the two forefingers for this purpose.

Abdomino-recto-vaginal Examination, as recommended by Hart and Barbour, is performed in precisely the same manner as the ordinary bimanual examination described at page 53, excepting that the right forefinger is passed into the vagina and pressed against the os, and the right middle finger is introduced into the rectum. This method may prove valuable in the exploration of cases of suspected tubal disease.

Vesico-rectal Examination.—Dilatation of the urethra for the purpose of introducing a finger is only justifiable in some cases of suspected disease in the bladder itself. To adopt this method for the exploration of the uterus and its appendages is to sacrifice the patient to diagnosis; in fact, it is open to the same objection which applies to Simon's manual exploration of the rectum.

In cases of atresia vaginæ and suspected absence or malformation of the uterus, a catheter or sound may be passed into the bladder and held firm whilst the rectum is explored with the finger. The catheter is pressed gently backwards, and then the finger can detect the presence or absence of the uterus between itself and the catheter. Even when the vagina exists,

it is better to explore from the rectum, as the site of the body of the uterus is most easily reached in that way. Vesico-rectal examination is sometimes of use in very fat patients where the body of the uterus cannot be readily explored by the ordinary bimanual method.

The Sound.—This is an indispensable instrument, which, however, must be employed with caution, and the surgeon must never forget that its passage is a minor surgical operation. Authorities are much divided about the best form of sound. It must not be too long, nor deeply notched; sounds made to fold in two by means of a hinge are objectionable, as are sounds made to serve other purposes besides that for which the instrument in question is designed.

The most useful form of sound for surgical purposes is about nine and a half inches in length (Fig. 22). It should be made



FIG. 22.—UTERINE SOUND.

of silver or plated copper, and must be thoroughly flexible, yet not too soft. The handle should be about an inch and a half long, and about half an inch broad at its lower or wider portion. When the handle is too small, it is not so convenient for the fingers, unless the surgeon be very experienced in the use of the sound. The front of the handle should be well roughened, and its back need not be covered with a layer of wood. An entirely metallic instrument is the easiest to clean thoroughly without damage to itself.

The shank should be about six inches in length, and equal in calibre to a No. 6 English catheter. At its upper limit it forms an obtuse angle with what may be termed the uterine portion of the instrument. This portion must be two and a half inches long and slightly curved. Close to its extremity its calibre must be narrowed so that the end of the sound forms a bulb, of the calibre of the greater part of the uterine portion. There should be a small notch at the angle formed by this portion and the shank.

The Use of the Sound.—The manner of passing the sound is only to be properly acquired by practice, after watching how that instrument is employed by those who are experienced in its use. There is little difficulty, in these days, in gaining the requisite instruction.

The instrument may be passed whilst the patient is lying on her back, but it is far better to introduce it as she lies on her left side, with her knees drawn up and her head and shoulders bent down, as in ordinary digital exploration of the vagina. There is no objection to changing the patient's position while the sound is lying in the uterus; indeed, this is generally necessary in the course of diagnosis, but the handle of the instrument must be guarded as the patient moves, else it may slip out, or catch in the clothing, so as to get pushed upwards with some violence.

The right forefinger is placed against the anterior lip of the os externum. The handle of the sound is taken between the left finger and thumb, the point having been warmed, and greased with oil or vaseline. The point is then guided along the right forefinger to the os; this can best be done with the convexity of the curved extremity of the sound forwards. The point is now introduced into the os—an easy manœuvre unless that orifice is extremely narrow. When it is lacerated there will be some difficulty in getting the point of the sound into the cervical canal. Should the fundus be evidently retroflexed, the handle of the sound must be swung towards the pubes; then with a little gentle pressure the point will slide into the uterine cavity. If there be no retroflexion, the point of the sound is pressed upwards till it comes to a check, in the cervical canal, generally at the os internum. Then the handle is swung from behind forwards, describing a semicircle in the direction of the right or uppermost side of the patient. The concavity of the curved end of the sound will now lie forwards, and with gentle pressure the point will slip into the uterine cavity.

When there is evidence of extreme retroflexion, the point of the sound should be bent, so as to make its curve stronger than usual. When the fundus is much anteflexed or pushed down by a tumour, the sound should be bent in the same manner, and introduced into the os with the concavity of the curve forwards.

In this case, it is best to hold the sound in the right hand; the patient must then lie almost horizontally.

Two precautions must be observed during the act of introducing the sound. The cervix must never be pressed forcibly by the right forefinger in the direction of the point of the sound; the finger is simply a guide to the os. The sound must be *swung* round, when necessary, in the manner just described, and never *twirled* round—that is, rotated on its long axis. This rule must also be observed in reducing a retroflexion after introduction of the sound. Twirling the handle may succeed in forcing the sound into the uterine cavity, but it is liable to cause the point to scratch the endometrium, and is otherwise objectionable.

Two conditions are especially to be sought by the aid of the sound: these are, the length of the uterine cavity, and the mobility of the uterus in relation to a suspected tumour.

Length of the Uterine Cavity.—The surgeon can always detect an elongation of that cavity by the manner in which the sound can be passed far upwards, but he must be precise and never neglect the rule of taking the measurement. This is done by pressing the right forefinger against the sound at the point where that instrument enters the os externum. Then the sound is removed, the finger being kept against the point just mentioned. The distance from the finger to the point of the sound will represent the length of the cavity of the uterus and the cervical canal. This manœuvre must be observed, as routine practice, at the end of every examination with the sound, and the measurements accurately recorded. The direction of the cavity must be noted. Subinvolution and various forms of fibroid disease of the uterus are especially denoted by increased length of the uterine cavity.

The sound may perforate the uterine walls, or may pass along a patent Fallopian tube. Strange to say, accidents of this kind do not seem to cause grave symptoms. I have spoken of patent Fallopian tube at page 24.

Mobility of the Uterus in relation to a Suspected Tumour.—The surgeon should prefer bimanual palpation for the purpose of ascertaining whether the uterus be movable or fixed. There will then be less risk of injury than when the sound, a powerful lever, is employed. On the other hand, the sound is

absolutely necessary when a tumour exists, and the surgeon wishes to ascertain whether it moves with or is free from the uterus. The sound being introduced into the uterus, the surgeon lays his hand on the abdomen and moves the tumour in all possible directions; then he has the opportunity of finding out if the uterus move as well. The sound may also be very gently rotated, laterally and backwards and forwards, so that the amount of independent mobility of the uterus can be detected. It is self-evident that, in cases of abdomino-pelvic tumour, bimanual palpation can but imperfectly be carried out.

The relations of polypi, and the diagnosis between pedunculated polypus and inverted uterus, require the aid of the sound for their accurate determination.

Precautions in using the Sound.—I have already noted the danger of testing the amount of mobility of the uterus. Should there be evidence, through symptoms and digital or bimanual examination, of either pelvic cellulitis or perimetritis, the instrument should not be used, or at the most only passed in for measurement of the uterine cavity. When the sound is turned, it must not be rotated on its long axis—that is, simply twisted round like a screw; the handle must be rotated from before backwards, or in the opposite direction, sweeping round by the right thigh when the patient is lying on her left side. The point of the sound must be slipped gently along the uterine cavity, as a wound of the endometrium may cause serious pelvic inflammation.

To avoid the risk of abortion, the patient must be asked, before the sound is introduced, the date of her last period, and the uterus must also be carefully explored. The surgeon must never forget that a single patient may make mendacious statements about her periods, and that married women often make mistakes about their condition in the early stages of pregnancy.

The Volsella* in Diagnosis.—The speculum enables us to see the vagina and the cervix. The different methods of exploring by means of the hands and fingers afford evidence of the condition of the uterus and its appendages, as far as

* *Vulsellum* is not classical. In Dr. Smith's Dictionary I find "VOLSELLA, æ f. as a surgical instrument, *forceps*, Cels. 7, 12, 1"; and under VULSELLA, "*vide Volsella*." Strictly speaking, "*volsella forceps*" is a pleonasm.

the sense of touch will allow. The volsella is a great aid to diagnosis. The uterus is very movable and can readily be drawn downwards. When drawn downwards, the cervix is brought close to the vulva, and may then be examined more satisfactorily, at least as regards certain conditions, than through a speculum. Again, when drawn downwards, the fundus lies lower than usual in the pelvis, and thus becomes easier to explore by rectal examination (page 71). Hence, the volsella is, by itself, an important aid to diagnosis, and is likewise serviceable when employed in conjunction with other methods.

The volsella is used because it can draw down the uterus when made to grasp the cervix, and can do so without inflicting pain, owing to the relative insensibility of the tissues of the cervix. The teeth must grasp the vaginal aspect of the cervix, and must hold it well, else they will tear away when the surgeon tries to draw down the uterus.

Many varieties of volsella have been devised. A strong instrument is needed for the present purpose, and it must be long in the shanks or handle. The ovariectomy volsella, described further on, is too weak for drawing down the cervix; on the other hand, the massive instruments designed to grasp uterine fibroids during enucleation are equally unsuited for purely diagnostic purposes.

The volsella should not be used before a careful study of the history of the case, followed by digital exploration of the vagina and cervix, for serious injuries may be inflicted by attempting to draw down a uterus when it is fixed by pelvic inflammatory products, or when cancer of the cervix exists. If employed for the diagnosis of displacements, the surgeon must remember that it is in itself a displacing agent.

On the other hand, the volsella is very valuable in exploring a laceration of the cervix. The speculum is apt to give rise to fallacies with regard to the extent of this kind of injury, as already explained. The volsella affords much assistance in the diagnosis of the relations of an abdominal tumour to the uterus.

Diagnosis by aid of the volsella is no mere refinement of specialism. The surgeon must learn how to use the volsella as a diagnostic instrument. If he fail to bear this in mind,

he will probably fail in attempting its application to other purposes. Thus the volsella is indispensable in the operation of removing the cancerous uterus through the vagina. In the course of that operation, much will depend upon the dexterity with which the volsella is handled, and such dexterity must be learnt beforehand.

How to use the Volsella in Diagnosis.—A volsella like that represented in Fig. 23 will be found convenient for use in diagnosis. It bears long strong teeth which grasp well. Small fine teeth are not so readily cleansed after operation. It is self-evident that any instrument which inflicts punctured wounds must be kept scrupulously clean. When the surgeon desires to ascertain the conditions and connections of the uterus, and not merely to explore the cervix, the patient is placed on her left side, and the ordinary digital exploration is made.

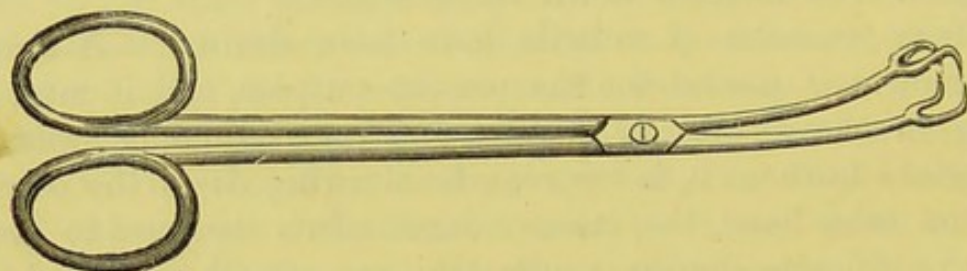


FIG. 23.—VOLSELLA.

The anterior lip of the cervix is touched and steadied by the right forefinger; it is best to keep the middle finger also in the vagina, touching the os. Guided by one or both fingers, the volsella, held in the left hand, is passed up to the anterior lip and made to grasp it antero-posteriorly. The tissues must be grasped higher up in front—that is, on the vaginal aspect—than behind, towards the cervical canal, else pain will be inflicted on the patient. The volsella is now drawn down, pulling the uterus with it.

Should the examination be made to ascertain the connections of an abdominal tumour, the right hand is placed on the abdomen over the tumour. The surgeon then attempts to draw down the uterus by means of the volsella. He will find that the tumour moves as the uterus is drawn down, or else remains fixed whilst the uterus resists traction, or perhaps remains fixed whilst the uterus descends freely during moderate traction.

When the surgeon wishes to explore the uterus and appendages, he keeps up traction with the volsella held in the right hand, and passes the left forefinger up the rectum. The fundus may be felt in that manner, the cervix being drawn a little forwards as well as downwards. As the cervix descends, the surgeon, examining through the rectum, must avoid taking the supra-vaginal portion for a tumour or a "little cellulitis."

For exploring a suspected fissure of the os, the volsella is absolutely required, but a Sims' speculum should be used, the patient being placed in the semi-prone position. In that position, it is true, the cervix can be explored, without the aid of the speculum, by drawing it down with the volsella and hooking back the posterior wall with the left forefinger. The os can then be brought close to the vulva. This simpler method, however, is good for gaining a general view of the cervix, but it is hardly sufficient for exploring a fissure.

Tents.—A tent is a rod or cone made of some material which swells under the influence of moisture. When introduced into the cervix uteri, the tent slowly expands the cervical canal. In this manner the uterine cavity becomes accessible to the finger for diagnostic purposes.

The use of the tent involves evident risks, so that it should never be employed without extreme caution. The surgeon must not attempt to dilate a stenosed cervix or to straighten a flexion by means of tents, nor to introduce a tent where there are evidences of pelvic inflammation. The chief use of the tent is in the management of some of the after-consequences of abortion, or of the retention, after natural labour, of products of conception. The tent is largely employed by some specialists for facilitating the application of local remedies to the endometrium, or for allowing of the scraping of diseased endometrium by the curette. In more essentially surgical cases it is rarely required, but it may aid the surgeon in exploring polypi and other intra-uterine tumours.

Tents are made of sponge, of a seaweed known as tangle (*Laminaria*), and of a wood which expands under the influence of moisture, called tupelo (*Nyssa*). Sponge tents are probably the best for general use. Tupelo tents are serviceable when the os externum is very narrow. A tent must always be fur-

nished with a loop of tape or string to allow of its withdrawal, and the surgeon should make sure that the loop is strong.

Introduction of a Tent.—This must never be done in a consulting or out-patient room, but always in a hospital ward or in a private patient's bedroom. The patient must be kept in bed whilst the tent is in the cervix, and for some time after its extraction. The tent must not be introduced during a monthly period. Before introduction, the vagina must be purified by a weak carbolic solution.

The tent is fixed on a special introducer which resembles a sound, and when lodged in the cervix it is detached from the introducer, which is then withdrawn. Many ingenious contrivances have been devised for the mechanical detachment of the tent. In Barnes' instrument a wire runs in a sheath; the tent is fixed on the point of the wire, introduced into the cervix, and then, by pulling the handle and keeping a finger pressed on the lower part of the sheath, the wire is




FIG. 24.—TENT INTRODUCER OR TENT CARRIER.

retracted so that the tent is disengaged from the latter, the upper end of the sheath steadying it as the wire slips back. In a simpler introducer (Fig. 24) the tent is held in place by the forefinger as the instrument is being withdrawn. Some specialists dispense with any special apparatus, and introduce the tent by placing the patient in the semi-prone position, drawing down the cervix with a volsella (see pages 69, 78), and slipping in the tent, which is held with forceps; as the cervix has been drawn down close to the vulva, the surgeon can make sure that the forceps does not displace the tent as its blades are being disengaged, and, indeed, the tent can be kept in place by the forefinger if the volsella be held by an assistant. The objection to special introducers is the difficulty of insuring their cleanliness. The inexperienced, however, will find that the introduction of a tent by aid of the semi-prone posture and the volsella is not an easy task. I believe, however, that it is the best method.

Disinfection of Tents.—Many samples of tents may be badly made, or insufficiently impregnated with antiseptic media. The surface of a tent may be fissured, so that septic dust or vaginal mucus may lie outside the substance of the tent, and be introduced into the cervical tissues lacerated during the process of dilatation. To remedy the pushing forward of vaginal secretions, the vagina must be syringed out before the tent is introduced, and the cervix must also be cleaned by wool fastened on to a Playfair's probe and soaked in a weak carbolic solution.

To ensure purity of the tent itself, Dr. Dirner, of Budapesth, keeps laminaria tents immersed in a 1 per cent. solution of corrosive sublimate in absolute alcohol. Provided the alcohol be absolute, the expansive property of the tent is not impaired. The tent is taken straight out of the solution and introduced into the cervix after the latter and the vagina have been cleansed. In the case of a hollow tent, should any crystals of sublimate lie in its canal, they must be washed away by immersion in fresh water.

Removal of the Tent.—The tent should be withdrawn in about twelve hours, then the vagina must be freely washed out with a weak carbolized or other antiseptic solution. If the cervix be not sufficiently dilated for the desired object, another tent will be needed. There is always more risk attendant on the introduction of a second or third tent, as the structures have already been injured.

Rapid dilators of the cervix should never be used except by those who have had the opportunity of seeing them employed by experienced specialists, and noting the results of their employment.

CHAPTER III.

INSTRUMENTS AND APPLIANCES.

Objects of this Chapter.—The surgeon must not only remember what instruments he may need for operative purposes, but he must acquire an intelligent knowledge of the precise use and mechanism of every knife, forceps, or other appliance which he may be called upon to handle. The technical terms applied to the different parts of an instrument should not be overlooked. Since there is so much to be said about instruments, many will be described in this chapter, and chiefly such as are needed in ovariectomy, hysterectomy, and to a less extent in other abdominal sections. The description of the steps of these operations must in any case be lengthy. It will therefore prove highly convenient to describe the instruments first, so as to avoid repeated digressions, which would greatly extend the chapters on Ovariectomy and Hysterectomy, and complicate essential details of another kind.

In the course of operations of a different class, especially plastic procedures, certain instruments are required which are more essentially special and limited in utility. As the descriptions of such operations are, as a rule, relatively brief, these instruments will be described together with the surgical proceedings in the course of which they are employed.

Practical Importance of Uniformity in Nomenclature.—I am aware that many standard English authorities trouble very little about the names of instruments. Fergusson, in his admirable *System of Practical Surgery*, often speaks of “an instrument such as here represented,” or “such an instrument as this.” I have reason to believe that

this practice is to be regretted. In the country or in the colonies it is highly important for the surgeon to know the name of an instrument which he desires to order from a dealer in this or any other country. Besides, it is very objectionable to have to ask assistants during an operation for the "what you may call it," or for the "bull-dog forceps," the latter term being understood by some to imply the full-sized "Liston's artery forceps," and by others to signify Dieffenbach's stout, dwarf "cross-action artery-forceps." The indifference to nomenclature displayed, as above noted, by some hospital surgeons is the cause of the multiplicity of names amongst dealers. Whilst upholding an intelligible nomenclature for practical purposes, I think that terms like "Brown's modification of Jones' pessary with Robinson's patent stem" deserve nothing but suppression.

Trays for Instruments.—The instruments employed in ovariectomy should always be kept immersed in fluid during the course of the operation. If the operator be in favour of Listerian precautions, the fluid will be a 1 in 40 solution of carbolic acid. If he be no believer in Listerism, pure water will, according to his views, be sufficient. The solution or water must be warm, and should be poured on the instruments about a quarter of an hour before the commencement of the operation. The surgeon must never neglect to replace every instrument in the fluid when he has done with it. It is not advisable to allow scalpels, needles, and forceps to collect on the waterproof sheet below the seat of operation. In this case some of the instruments may fall, unobserved, on the floor, or may drop into the receptacle for the fluid under the table. The loss of a pair of forceps in this manner will cause trouble and anxiety to the operator and perhaps risk to the patient. The nurses will be obliged to search with their hands over the floor around the table. They may also be compelled to thrust their arms deeply into the fluid in the receptacle. A pair of forceps is not easily found when it lies at the bottom of several gallons of dense fluid mixed with solid matter. The operator may think that the missing instrument is in the abdominal cavity, and even go so far as to open the wound afresh and disturb the viscera. Again, instruments left on the waterproof sheet are never so

readily at hand as when they are carefully replaced in the trays towards which the operator's hand is instinctively directed when they are required. Lastly, if the instruments be kept out of the fluid after use, blood and morbid products will dry on them, rendering them dangerous to use during the operation and difficult to clean afterwards.

Basins are not good receptacles for the instruments. If small, the longer forceps and mounted needles cannot be completely immersed, nor can the pressure-forceps be readily placed in regular order. A bunch or mass, rather than a row, of forceps with shanks caught in bows, or with bows interlocking, fouling ligatures and mixed up with threaded needles, will give the operator great trouble. On the other hand, the high sides and everted rims of a big basin will be in everybody's way. In any case, however, a basin full of fluid is better for the instruments than a dry towel or a bare table.

Thick gutta-percha trays employed by some operators are clean, durable, and in many ways convenient. Their dark colour, however, prevents the smaller instruments, especially suture needles, from being readily seen. In hot weather and in hot rooms they become soft so as to bend when grasped at both ends. This may cause their fluid contents to be suddenly spilt at some inconvenient moment. Porcelain dishes are good for hospital use, but are heavy and liable to break.

A tray made of block tin, about two inches deep, over a foot in length and half a foot in breadth, is a most convenient receptacle for the instruments and the fluid in which they are immersed. Two such trays should be employed. One will hold the pressure-forceps, scattered as widely and arranged as neatly as possible. All the forceps must be entirely immersed.

One of the trays should bear a longitudinal partition, cutting off a small space for the ready-threaded pedicle-needles. Near the top of the same tray there should be a transverse partition, which will cut off two small compartments. In the larger the reels containing three or four different thicknesses of silk should be placed. They must revolve on a thin bar of metal fitted to the sides of the space. This arrangement will enable the operator to dispense with a special contrivance for the reels like Lister's carbolized catgut holder. The smaller space, cut

off by the longitudinal and transverse partitions, will conveniently hold the needles for the abdominal sutures, ready threaded and fastened to a strip of gauze neatly rolled up. The largest space formed by the longitudinal partition will hold the volsellæ, the trocar, and other large instruments. The tubing, fitted to the trocar, may be rolled up in the tray. It is better, however, to place the tubing in a basin.

Some operators employ for the pressure-forceps a contrivance resembling a square tin money-box with a great many slits on the lid. This box is filled with fluid, and the blades of the forceps are pushed through the lids. This arrangement is convenient and looks neat, but I do not like to see the handles standing out high and dry, perhaps stained by the operator's fingers or by ovarian fluid. These soiled forceps, if used again and possibly kept for a time in the abdominal cavity, are not conducive to the patient's welfare. The tray is far better for the pressure-forceps; it permits total immersion.

Directly the patient has been seen into bed, the instruments should be carried in the trays into the next room, where a pan, a basin full of hot water, and some towels should be at hand. The fluid must be poured out of the trays into the pan, and the instruments are then dropped into the basin. The trays are then dried by careful rubbing with towels. The instruments must next be rubbed dry. Particular care must be taken to clean the teeth and the hinges of the pressure-forceps. Then trays and instruments should be packed up.

Receptacle for Ovarian Fluid.—A large hip-bath is the most convenient receptacle for the fluid removed from an ovarian tumour. It can easily be kept under the operating table in a suitable position. When the trocar is thrust into the cyst, care must be taken that the bath stands out a little towards the operator's side of the table, so that the tubing may not guide the stream of fluid over the floor. The bath must be so placed as to receive all solid matter, which is removed from the cyst by the operator's hand and allowed to slip down one side of the waterproof sheet. The tumour, when severed from its connections, should never be thrown into the bath. This precaution is necessary because the operator often leaves pressure-forceps and volsellæ attached to its walls. These instruments

are easily found in a basin, but are only to be recovered with great trouble in a bath.

Objectionable as it may be to search the bath for fluid, this must be done when instruments are missing. Now and again forceps will slip down unobserved, so that when missing after the abdominal wound has been sewn up, they must be looked for in the bath and elsewhere before the operator resorts to the painful alternative of opening the wound afresh.

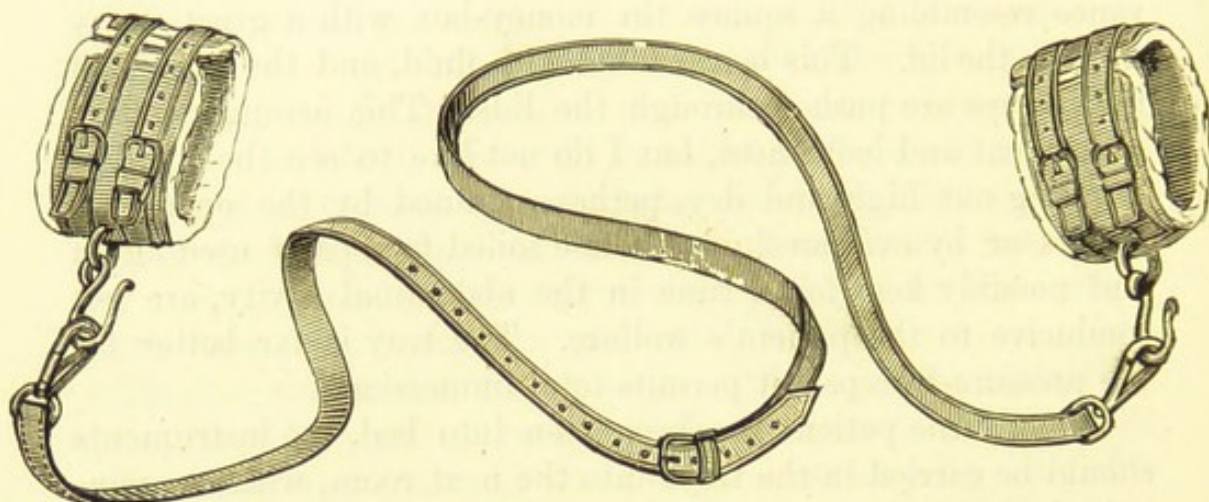


FIG. 25.—WRISTLETS OR HANDCUFFS, WITH STRAP FOR PASSING UNDER THE OPERATION TABLE.

Wristlets and Straps.—Some operators, as Sir Spencer Wells, prefer to fix the wrists of the patient, before an abdominal section, by bandages, passed in clove-hitch knots around the wrists and made fast to the legs of the table. A

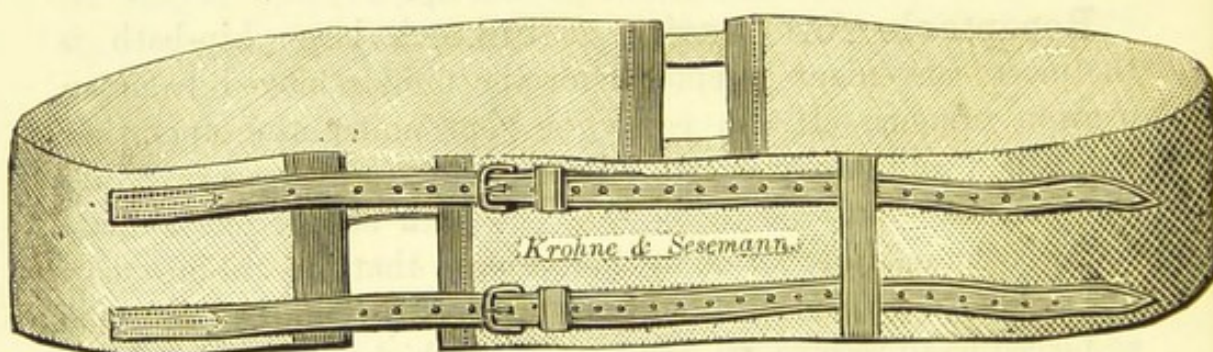


FIG. 26.—THIGH-BELT.

jack-towel may be made to serve as a strap to keep down the knees. However, the wristlets represented in Fig. 25 are very convenient. The strap is passed under the table and lengthened or shortened so that the wrists are held well down.

Fig. 26 represents a good thigh-belt, passed above the patient's knees and made fast under the table by the two straps. It is important that these straps be examined from time to time, else one or both may snap in the middle of an operation.

Mirror.—A hand-glass is very useful for throwing artificial light into the abdominal cavity on a dark day, or for reflecting the light of the sun, when that luminary is shining, into dark recesses.

The Waterproof Sheet.—This contrivance is necessary in order to protect the patient and her clothes from ovarian and other fluids, which escape through the abdominal wound in the course of the operation. When it is evident, before the abdominal incision is made, that there is much fluid, or that a large semi-solid tumour has to be removed, the sheet is almost indispensable. On the other hand, when the abdomen is not distended, and nothing but a small pelvic tumour or a cyst containing barely a pint of fluid, or a bulky but perfectly solid tumour, is likely to be found, the sheet is in the way. I shall refer to this matter in the chapters on Oöphorectomy and Hysterectomy.

The waterproof sheet should consist of a large piece of mackintosh, measuring about two square yards. An oval hole, about eight inches in length and six in breadth, is cut in this sheet, so as to leave about one foot of sheeting between its upper extremity and the upper border of the sheet. In other words, it must be near one end of the sheet, and that end is to be placed uppermost, protecting the epigastrium, and the dress over the thorax. The longer part of the sheet, below the hole, covers the thighs and knees, extending nearly to the feet; the sides of the sheet hang over the sides of the table. The under or rough side of the edge of the hole is smeared with carbolized adhesive plaster in a layer about an inch wide.

This plaster is the *emplastrum resinae* B.P. Sixteen parts of lead plaster, melted at a low temperature, are mixed with two parts of resin and one part of curd soap. The mass is stirred until the ingredients are thoroughly mixed, and 2 per cent. of melted carbolic acid crystals is added as this is

being done. Amateur and inexperienced dispensers sometimes neglect the direction about the lead plaster, and make it too hot; the compound will then be of insufficiently firm consistence, and very unsuitable for the waterproof sheet.

The hair of the pubes should be cut short or shaved before the application of the sheet. The nurse must take the two upper ends of the sheet in her hands, holding them across the patient's chest or epigastrium. The operator then guides the sheet so that the lower end of the hole lies on the abdomen just above the pubes, the margins of the hole being carefully approximated to the sides of the abdomen, and the upper limit carefully fixed to the abdomen above the umbilicus. In fact, the concavity of the prominent abdomen must fit the hole. This must be done carefully, else the plaster will smear the integuments unnecessarily, especially towards the flanks. To adjust the edges accurately to the integuments, without getting his fingers sticky with plaster, the surgeon should hold a corner of the sheet and press it gently against the edge of the hole, wherever the adhesion appears to be faulty. This precaution is most necessary in the hypogastric region. Should the apron adhere imperfectly in that region, it may come undone for an inch or two as the cyst collapses, and then several pints of fluid may escape under the sheet and drench the patient's thighs and nates. A similar accident may occur when the peritoneal cavity is flushed with warm water.

It is advisable that the long diameter of the hole be not too short. Otherwise, should the tumour be much larger than expected, the operator will have to cut through integuments soiled with adhesive plaster. In some cases, however, this must be done. Great care must be taken lest a dirty sheet be used. The sheet must be well washed, after every operation, with some antiseptic fluid, and all trace of blood-stains must be scrubbed away; the under surface will especially require attention.

During the operation, since a large surface of the sheet hangs over each side of the table, the operator may freely let fluid and semi-solid matter escape from the abdominal cavity and fall into the receptacle under the table. The assistant

must guard against any overflow on his side, or below the pubes, by raising the edge of the sheet, so as to direct the current of escaping material towards the operator's side, in such a manner that the fluid crosses the sheet below the hole, else it will get into the abdomen again. This manœuvre is especially necessary when, for any reason, much fluid is allowed to escape without the aid of the trocar and cannula.

The Sponges.—A good set of sponges must always be at hand when an ovariectomy is about to be performed. Although a large number is liable to give trouble when the sponges are counted, the difficulties when they are too few will be greater. Towards the end of any operation most of the sponges will be out of use, and should be placed in a basin, the nurse counting them carefully. The remainder will be in the operator's and assistant's hands, or in the abdominal cavity, and possibly a sponge may lie somewhere where it should not be—on the floor, or in the receptacle for ovarian fluid, for example. As the missing sponges will be few in number, the search for them will seldom be very difficult. Other precautions will be noted when the operation of ovariectomy is described.

An insufficient supply of sponges will give great trouble if the operation be long, or if sudden hæmorrhage or effusion of ovarian fluid into the peritoneal cavity occur. The nurses will then have difficulty in washing out the sponges quickly enough, and the cleansing, done in haste, will most probably be imperfect.

Hence the operator must be well supplied with sponges. Twenty is a good number. Of these, four should be broad and thin, and in two pairs of different sizes. They should be known to the operator, assistants, and nurses as "the large flat sponges," and "the small flat sponges." Ten should be large toilet sponges, never so big as to approach a bath sponge in size, but sufficiently bulky to soak up blood and fluid well. The remaining six should be somewhat smaller, and distinctly conical. These may be used as "stick-sponges"—that is, they may be mounted on holders, if necessary, when distant recesses of the peritoneum require cleansing. They must never be as small as the sponges often used in plastic operations.

Preparation of New Sponges.—The operator must always inspect newly-purchased sponges. They must not be boiled,

since that causes them to become rough and irritating to the peritoneum. To rid them of sand, they should be packed in calico bags, and well beaten about and shaken. Then they must be put into a basin of warm water, and allowed to soak all day. They can then be taken out and dried, and kneaded in the nurse's hands, so that it can be made sure that all sand and grit has been expelled. Should any such material remain, the sponge which is found to contain it must be put into warm water again. After this process is completed, the sponges must be immersed for twelve hours in a 1 in 5 solution of sulphurous acid. This will make them look very clean, and will in reality free them from all organic impurities.

Management of Sponges after Operation.—It is dangerous to have a double set of sponges in use when two operations are performed consecutively in a hospital. In such a case it is advisable to set aside any sponge which has been fouled in the course of the first operation, and to employ the remainder of the same set for the second, the rejected sponge being remembered when the others are once more counted.

All sponges which have only been stained by ordinary ovarian fluid or blood can be thoroughly cleansed by immediate immersion in hot water, with free squeezing. When a sponge has been fouled by contact with pus, fæces, gangrenous tissue, or any other deleterious fluid or solid material, it must be at once placed in the sulphurous acid solution mentioned above, and left there for twelve hours.

The greasy contents of dermoid cysts render sponges very difficult to clean. In this case the best cleansing material is a drachm of carbonate of soda dissolved in a quart of warm water; the sponges must be well squeezed out after immersion for half-an-hour in this solution.

Under no circumstances must sponges be boiled, or even dropped into boiling water, or washed in soap, or left, for however short a time, out of warm water, or any other necessary cleansing fluid, after the operator or assistant has handed them to the nurse. The water need never be heated much over 100°. This temperature is sufficient for mechanical cleansing, and does not injure the tissue of the sponges. Very hot water irritates the hands of the nurses; sometimes, as I have seen, it

may cause severe eczema, rendering a nurse totally unfit to attend a patient for weeks.

Nurses and Sponges.—That inexperienced and unintelligent nurses may not only be careless, but even unable to count properly, there can be no doubt, for facts have proved this supposition. Many persons, in counting a set of objects, hold a sample in their hands, and neglect to count it, or begin with it as "number one," and count it again at the end. The fact that the unintelligent count badly, has been recognized in European folk-lore. The Germans tell a tale of seven peasants who forded a river in a dense fog. When they had reached the further side each began to count his companions, neglecting to include himself in the muster. Hence they all concluded that as only six could be counted one must have been drowned, but to the day of their deaths could never make out which of their number perished in the stream. They had fallen into a mathematical error, much more frequently committed by nurses counting sponges. I have, on more than one occasion, observed a nurse uncertain whether she had or had not counted a sponge which she had pertinaciously held in her fingers. To avoid this accident, the counter should never hold any one sponge. The best method of counting will be presently described.

The Scalpel.—A good stout scalpel is the most suitable knife for making the abdominal incision. If too small and narrow-bladed, the incisions which it makes are apt to be tailed or jagged, the point penetrates too deeply, and the edge does not cut deep enough. The want of weight in the instrument renders it difficult for guidance by the hand. In opposite respects, a breast-knife is not advisable. That instrument is made for free-handed sweeping incisions over wide planes of firm tissue, and the cutaneous wounds, in the operations for which it is designed, are meant to be made freely and deeply, nor do they require such precise delicacy of manipulation as do incisions through the linea alba. Its heavy blade may cut through two layers of the abdominal wall when the operator intends only to divide one. There is a great difference between cutting over the pectoralis major muscle and the ribs, and making incisions over peritoneum, cysts, and viscera. In short, a scalpel, the size of a large dissecting knife, but a

little heavier, will prove a happy medium between a cutting instrument too small and another too large, for the purpose of laying open the abdominal wall. Yet individual hands have their idiosyncrasies, and there are surgeons who prefer unusually heavy or light knives for this kind of work.

The Scissors. — The best form of scissors for the ovariologist is a very strong pair, bent and not curved on the flat (Fig. 27). The ends must be quite blunt and well rounded, the edges should be kept sharp. This instrument is indispensable at the simplest ovariectomy. There is an idea still prevalent that scissor wounds do not heal by first intention, and that the margins tend to become sloughy, but the free borders of ovarian pedicles do not slough, though, at the Samaritan Hospital at least, the pedicle is always divided with scissors; and I have seen over a hundred abdominal wounds




FIG. 27.—SCISSORS FOR OVARIOTOMY, BENT ON THE FLAT.

enlarged upwards by scissors, and they never appear to unite badly in consequence.

The stoutness and size of the scissors make them manageable, and the bent blades allow them to be freely plied, whilst the operator's hand is kept out of the way of the structures which they divide. The blades must not be curved, for if they be so, it will be difficult to enlarge the wound properly, and in dividing the pedicle too much or too little of the stump may be cut away. The bluntness and thickness of the ends avoid damage to the intestines and other delicate structures—they push things away instead of catching them. Nevertheless, of course, the surgeon must take care lest certain structures get between the blades.

It is in the division of the pedicle that the scissors are most needed. They are far less liable to cause accidents than are scalpels and other knives, however blunt-pointed. As

the assistant holds the two pressure-forceps, which are fixed to each border of the pedicle in the manner directed in the account of the operation, the surgeon cuts straight between the forceps. The very act of cutting properly will be much easier with the scissors than with a scalpel. In enlarging the abdominal wound upwards the scissors should always be preferred to the knife; they cut straight and involve less danger to deep structures. Omental and other adhesions are far better divided by scissors. A piece of cyst-wall which has to be left on a portion of intestine, liver, or other structure, to which it is too firmly adherent to be detached with safety, should also be cut away by scissors from the removable part of the cyst. The same instrument should be used in enlarging the trocar wound in the cyst-wall, or in cutting through tough loculi.

The Forceps.*—An artery-forceps of the familiar Liston-Coxeter, or fenestrated variety, should be at hand when an abdominal section is performed. It is required when a large vessel needs ligature. For ordinary purposes, forcipressure is far preferable to ligature, in the course of operations on the female organs. Forcipressure generally avoids the necessity of leaving ligatures in the abdominal wound, and the pressure-forceps, by means of which it is effected, is particularly suited for application to the wound.

Sir Spencer Wells appears to have been the first to secure, as a matter of routine, bleeding vessels in the abdominal cavity by simply seizing them with artery-forceps, and taking the forceps off towards the end of the operation, without applying ligatures.† He had found that ligature was needless after temporary application of the small but strong bull-dog forceps. In 1865, Verneuil adopted the system, and gave it its name, forcipressure, but Koeberlé had, a few years previously, first

* "Forceps" is often used as though it were invariably plural, like "scissors." This is incorrect. In Smith's Latin dictionary I find "FORCEPS, CĪPIS, m. & f., a pair of tongs, pincers, forceps." Donaldson derives it from *foris* and *capio*, the first syllable referring to the "opening," or "door," which this instrument makes to grasp the object. There appears to be no authority for using a spurious singular form, "forcep."

† "Remarks on Forcipressure and the Use of Pressure-Forceps in Surgery" (*British Medical Journal*, vols. i. and ii., 1879).

employed the earliest special pressure-forceps, made with long handles, so that it could not readily be lost in the abdominal cavity. He soon dispensed entirely with the ligature. Péan was another of the principal introducers of forcipressure. The fact is now well established that, when the end of a small artery, of the kind so frequently divided in the course of an abdominal section, is seized by the forceps, hæmorrhage will be definitely checked, provided that the instrument be left on for five minutes, or longer if desired.

Several different patterns of pressure-forceps are in use and are often confounded. I shall therefore describe the principal varieties. Instrument makers do not, I find, employ a uniform system of nomenclature for the parts of a forceps. It may be said to consist of two "blades," bearing "teeth" and terminating in a "nozzle" or "point"; of two "shanks" continuous with the blades, connected by a "pivot" or "axis," and made fast when closed by a "ratchet" or catch, bearing "teeth"; and of a pair of "bows" or "rings." The term "handle" is confusing. I have heard it applied indifferently to the shanks and to the bows.

Koeberlé's Pressure-Forceps.—The oldest form of pressure-forceps is Koeberlé's (Fig. 28). This instrument has not such a finished look as the later forms, and is the longest, measuring about five and a half inches. The blades have regular teeth, interrupted by two deep grooves and two depressions.* The shanks are broad and very flat, and run for nearly an inch below the pivot. Instead of a ratchet there is a short pin or projecting point on one shank close below the ring; this pin has two corresponding holes on the opposite shank. When the instrument is closed at the first hole there is a gap half an inch long between the shanks. The rings are small and not bevelled, as now, though not I believe as at first, constructed;

* Many surgeons appear to be unaware that, as Mr. Hawksley, the surgical instrument maker, has pointed out to me, the grooves and depressions often found on the blades of dressing-forceps were originally intended to adapt the blades to hare-lip pins or suture-needles held cross-ways or longitudinally, so that the forceps might be used as a needle-holder if desired. The pressure-forceps was evolved from the dressing-forceps, so that the grooves in Koeberlé's variety are, as it were, Darwinian relics. I find that this variety of pressure-forceps is sometimes described as a "needle-holding forceps with spring catch."

the shanks can be unfastened at the pivot for cleaning. Though the gap between the shanks is so small as not to be of any serious import, this form of pressure-forceps is not satisfactory, as the pin and holes are not nearly so trustworthy as the ratchets of the later forms. Its designer, however, deserves

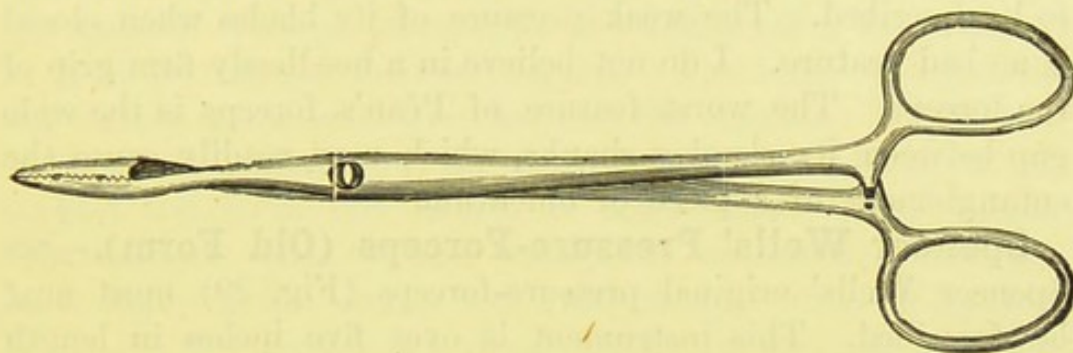


FIG. 28.—KOEBERLÉ'S PRESSURE-FORCEPS.

honour for being first in the field, though the method had been already employed before any special instrument was invented.

Péan's Forceps.—This instrument was first constructed, under M. Péan's directions, by M. Guéride in the year 1868. Its chief feature is its extreme lightness. The blades have even teeth, and are not flattened on the planes of the ends of the pivot. Their outer surface is not very convex, but the point is fairly sharp. The grip of the blades is weak. The shanks are nearly one inch long between the blades and the pivot, but comparatively short, in relation to Wells' and Tait's forceps, above the pivot, where they are very slender and separated by a wide elliptical space even when they are closed by the second catch of the ratchet. The shanks can be unfastened at the pivot. This is important for ensuring cleanliness when the instrument is not immersed in carbolic solutions or in pure water, after the custom of ovariologists. In the latter case this arrangement is not necessary. The rings of Péan's forceps are wide and thin, and the ratchet, which is double-toothed, lies immediately below them. This instrument was one of the first of the kind in the field, and M. Péan deserves well of surgery for designing and employing it and advocating its use. It is, however, more suited for general surgery than for ovariectomy. Its blades and rings are too thin and sharp, and may readily tear omentum. It is too

light, so that it easily gets pushed about when the surgeon sponges the peritoneum, or displaced when he flushes its cavity with hot water. Then, when it cannot be found without search, it is not so easy to detect rolled up in omentum or buried under viscera, as the blunt, heavy instruments presently to be described. The weak pressure of its blades when closed is no bad feature. I do not believe in a needlessly firm grip of the forceps. The worst feature of Péan's forceps is the wide gap between its slender shanks, which may readily cause the entanglement of a piece of omentum.

Spencer Wells' Pressure-Forceps (Old Form).—Sir Spencer Wells' original pressure-forceps (Fig. 29) must next be described. This instrument is over five inches in length and very heavy. The blades, nearly an inch long, begin

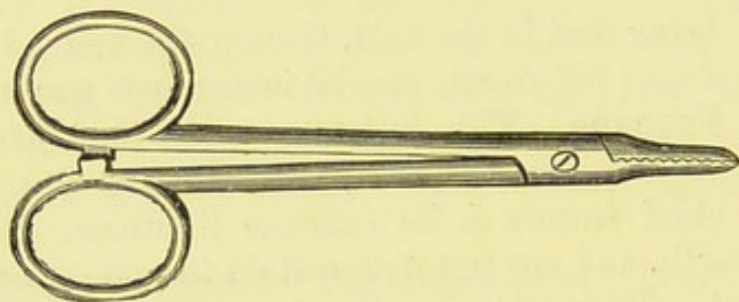


FIG. 29.—SPENCER WELLS' PRESSURE-FORCEPS (*old form*).

immediately below the pivot. They are flattened abruptly below the pivot on the anterior and posterior aspects, whilst laterally they are only slightly convex. The point is blunt and the grip very firm. The shanks are long and differ from those of all the other forms in that, owing to the construction of the hinge, where one shank passes through a slit in the other, they appear to lie almost parallel to each other when the instrument is closed, and their opposite surfaces are perfectly flat and about an eighth of an inch in breadth. The shanks, too, are exceedingly stout. The ratchet is of the kind known to instrument makers as Matthieu's catch. It has only one tooth, and lies between the rings, which are not bevelled. When the instrument is closed, a slit about three inches long and an eighth of an inch at the widest lies between the wide flat inner surfaces of the blades.

This is a highly finished instrument, and when it is placed

entirely within the peritoneal cavity its weight prevents it from being easily pushed about during subsequent manipulations. The stoutness and bluntness of its shanks are designed to avoid any tearing or bruising of delicate structures. Of course, heavy though this instrument may be, the weight of any pair of forceps of similar size could never be sufficient in itself to damage internal organs. The chief objection to this variety is the wide gap between the shanks. The flatness of the inner surfaces of the shanks renders accidents to entangled structures less likely, no doubt, than under similar circumstances when Péan's forceps is employed, where the inner edges of the shanks feel quite sharp. Still, Sir Spencer Wells has recognized this disadvantage of the gap, and discarded this variety for a new form.

Spencer Wells' Pressure-Forceps (New Form).—Wells' new pressure-forceps (Fig. 30) is lighter and slightly

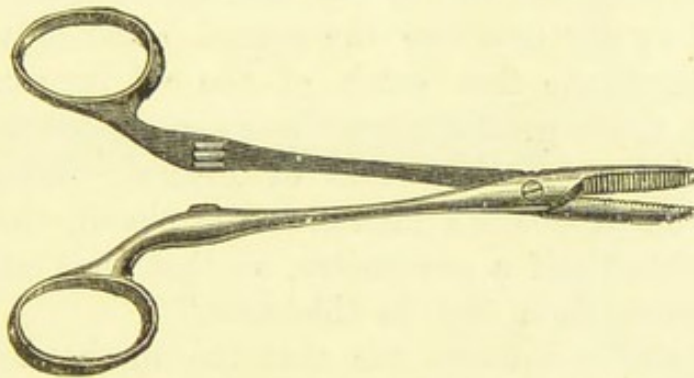


FIG. 30.—WELLS' PRESSURE-FORCEPS (*new form*).

shorter than the former kind also employed by that ovariologist. It is also more like the varieties designed by other surgeons in general construction, but is much heavier than Koeberlé's. The blades are slender and flattened but not abruptly on the aspects of the ends of the pivot; the lateral aspects are distinctly convex. The shanks are slender, and so constructed that the upper entirely and accurately covers the lower when the catch or ratchet is closed at the second tooth. The ratchet lies half an inch below the rings, and has two strong teeth. The rings are small, stout, and well bevelled. This is an excellent instrument; it is not too light, and there is no space between the shanks. Sir Spencer Wells

states that this latter defect has been completely corrected without at all lessening the compressing power exerted on the vessel. He adds:—"In October, 1878, Mr. Hawksley carefully tested the compressing power of different forceps when opened by a piece of leather one millimètre thick between the jaws of the forceps, and covering about four teeth from the points. The following table gives the result:—

"Pounds avoirdupois exerted by four teeth of the end of forceps when one millimètre apart."

FORCEPS.	FIRST CATCH.	SECOND CATCH.
Koeberlé.	—	3 $\frac{1}{4}$
Péan	8	12
S. Wells (old)	18	—
„ (new)	5—7	15—17

"It may be seen that in my old instrument there is only one catch, and in my new one the second catch only exerts the same power as the first catch of the old instrument. But this is five times greater than the second catch in Koeberlé's, and one-third more than that of Péan's. When only the first catch in Koeberlé's instrument is closed, the points are separated about half a centimètre, so that they only compress anything more than that in thickness."

Mr. Hawksley informs me that the mechanism by which the shanks accurately overlap when closed at the second tooth of the ratchet was designed entirely for the purpose of attaining the strongest possible amount of pressure, and not for obliterating the space between the shanks. It must be remembered that it is not when the vessel is being seized and the forceps closed that there is any danger from structures falling between the shanks. That accident occurs when the instrument is lying in the abdomen. Hence in this respect the method of closing is of little importance as long as no such space is left when the shanks are closed.

The blades are furnished, in all properly made samples, with U-teeth; that is, the elevated ridges are blunt-edged, and the margin of the inner surface of each blade is carefully bevelled. The object of this arrangement is to ensure a firm

grip and the crushing of the included tissues without any cutting. The older instruments generally had V-teeth, and the edges of the toothed surface of the blade were not well finished, but sharp. This involved the cutting of portions of compressed tissues, especially along the edges of the blade, and the consequent giving way of the instrument before the pressure had been maintained for sufficiently long a period. As the grip was, at the same time, not strong, the dangers of hæmorrhage were increased.

Tait's Pressure-Forceps.—A slightly different form of pressure-forceps (Fig. 31) is figured, described, and recommended in Mr. Lawson Tait's *Pathology and Treatment of Diseases of the Ovaries*, fourth edition, p. 258. I am uncertain by whom it was invented, but, provided that an instrument

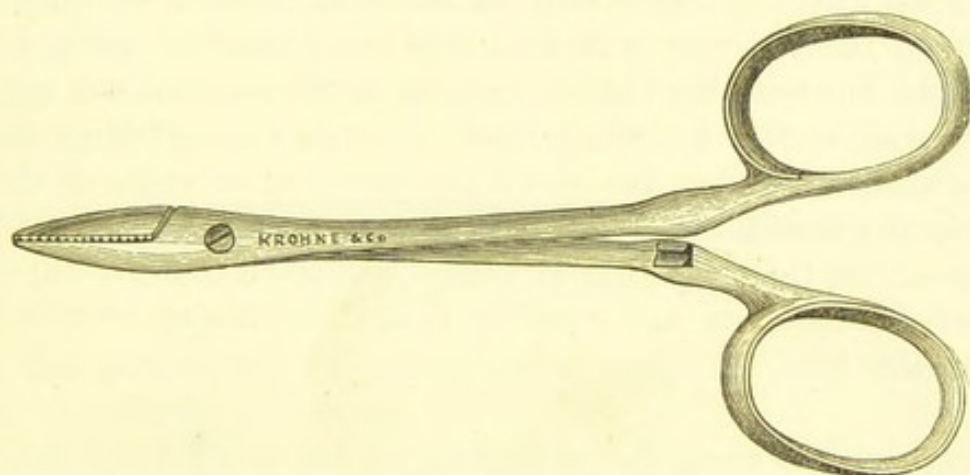


FIG. 31.—TAIT'S PRESSURE-FORCEPS.

be good, the name of the inventor is of secondary consideration. The outer surface of each blade is exceedingly convex, the curve passing on to the shank above the level of the pivot. On the other hand, the point is not so blunt as in the other varieties. In this respect it resembles, to a certain extent, the familiar Liston's artery-forceps, and the inventor devised this form of the point so that the loop of the ligature should be the less liable to catch in the blades. The grip of this forceps is very strong. As in both of the forms employed by Sir Spencer Wells, the blades are much flattened on the plane of the ends of the pivot, which is not the case in the two oldest varieties. In Tait's forceps, however, the pivot and the crossing of the shanks are mechanically the

same as in Koeberlé's and Péan's, and in Wells' new form. The ratchet has two teeth, as in Wells' new forceps, and closes the shanks in the same manner. This forceps is under five inches in length and much lighter than Wells' older variety, but a little heavier than the older kinds, as generally constructed. The bows are wide, stout, and well bevelled, and thus very convenient for manipulation.

This and the last form of forceps are valuable instruments, and one or other will be absolutely needed by the ovariologist.

Curved Pressure - Forceps. — Recently an excellent forceps has been constructed, on Wells' newer pattern, and with the blades curved. This forceps is a miniature of the large instrument presently to be described. It has the advantage of lying less in the way than the ordinary form. After securing bleeding vessels in the abdominal wound, with the old forceps, the surgeon will find that the handles, being in a straight line with the blades, stick up in the air, and are apt to be pushed by the operator's hand, or even torn off from their attachments. When the blades are curved at an angle of about 120° , the handles will lie in a more convenient position. I believe that this new form of forceps will come into general use. Nevertheless, I do not consider that it is in any way indispensable.

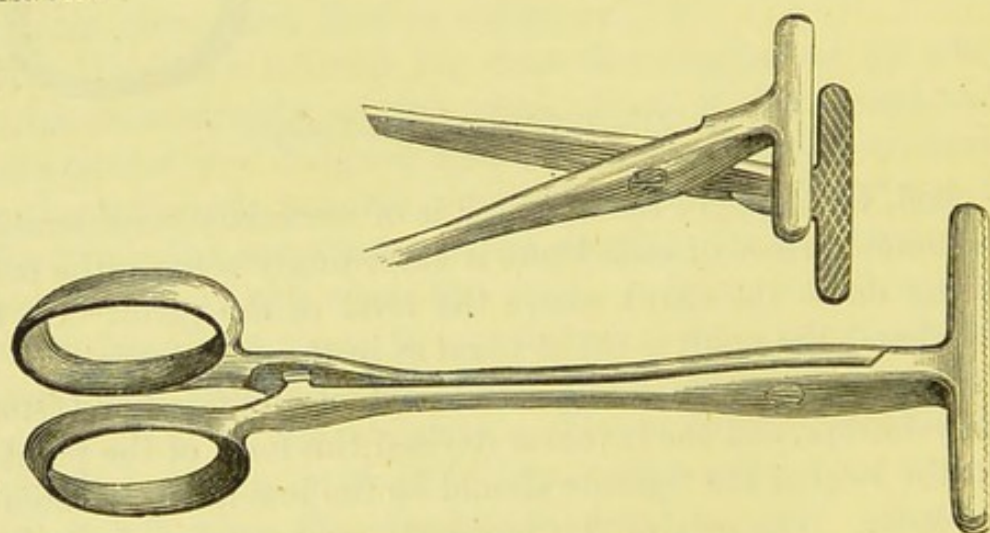


FIG. 32.—T-BLADED PRESSURE-FORCEPS.

T-bladed Pressure-Forceps.—This instrument (Fig. 32) is also a miniature of a larger forceps presently to be described.

Mr. Thornton employs it for temporarily securing broad bleeding surfaces of adhesions, omentum, etc. He also uses it to seize and compress the edges of the divided uterine tissues in flap operations for the removal of fibroids.*

Before dismissing the subject of pressure-forceps, I must observe that the surgeon must never forget that no form of the instrument can be expected to control hæmorrhage by simple momentary pressure. On the contrary, the pressure must be continuous for five minutes at least. When, through any circumstance, a pressure-forceps has to be taken off directly after its application to a bleeding point, it must first be made to twist the end of the vessel, or else the vessel must be ligatured.

Adams' Peritoneum-Hook.—This instrument (Fig. 33) consists of a steel bar mounted on a handle. The extremity of the bar bears two teeth, bent backwards. When the peritoneum is reached, it is caught in the teeth and raised, the instrument being held in the left hand. A hole is then made



FIG. 33.—ADAMS' PERITONEUM-HOOK.

in the peritoneum by means of a scalpel. Into this hole the director is introduced.

Adams' hook is not indispensable. When there is no complication the peritoneum may be raised with forceps, or simply scratched through by the point of the scalpel. When, on the other hand, the peritoneum is difficult to recognize or closely adherent to the cyst, the hook is useless. It was introduced at a time when operators were less certain of what they might be likely to encounter than they are in these days. Thanks to Sir Spencer Wells and others who have presented us, as we may say, with their experience as pioneers in ovariectomy, we are learning not only what is required, but also what is superfluous.

The hook is most likely to be of service in cases where, on reaching the transversalis fascia or in dividing it, there is evidence of either a very thin-walled cyst, or of intestine or

* See "Thornton's T-shaped Compressing Forceps" (*British Medical Journal*, vol. i., 1881, p. 55).

ascitic fluid lying between the cyst-wall and the peritoneum. The hook will then be useful in dividing the peritoneum safely, and allowing the operator to see thoroughly what he is cutting through.

The Director.—Stanley's (often incorrectly termed Key's, a name originally given to a strongly curved instrument) is the most convenient form of director (Fig. 34). It is well known



FIG. 34.—STANLEY'S DIRECTOR.

to the general surgeon. It is pushed under the peritoneum, upwards and downwards, after a hole has been made for its introduction, and then the peritoneum is divided with a scalpel or scissors, slid along the groove. On no account must the director be employed to detach adherent peritoneum from the cyst-wall.

Ovariectomy-Trocar.—The ovariectomy-trocar most generally used is that known to dealers as Sir Spencer Wells' improved siphon trocar (Fig. 35). It must be ordered "with

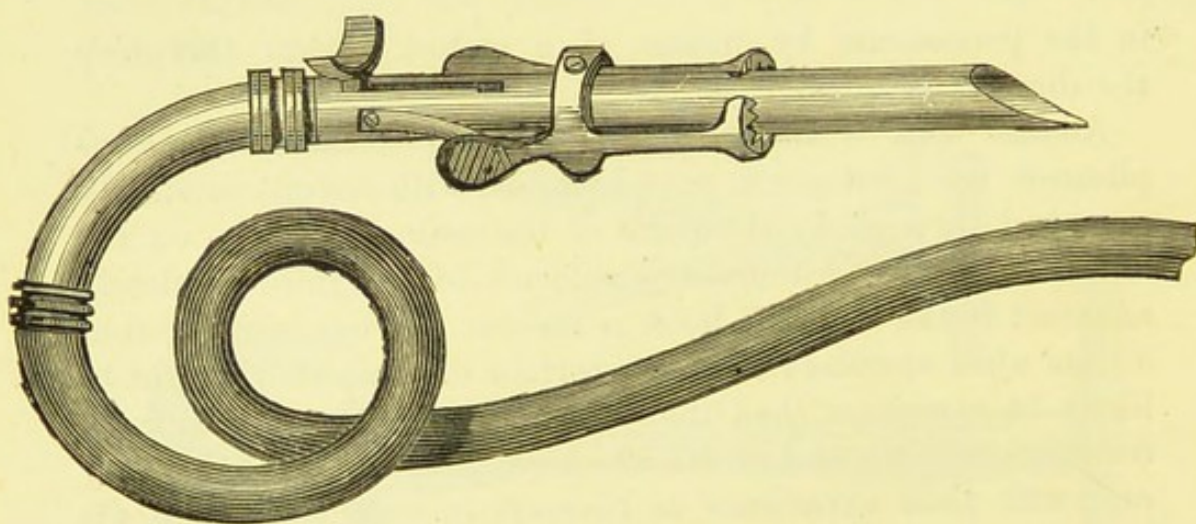


FIG. 35.—SPENCER WELLS' OVARIOTOMY-TROCAR.

india-rubber tubing and siphon end." It is a formidable looking instrument nearly one foot in length. Like other implements, it is simple to those who are used to it, or who have often seen it employed; but the inexperienced must study its

mechanism thoroughly before employing it at an operation. The entire instrument, generally spoken of as a "trocar,"* really consists of three parts. There is, first, the cannula,† a cylindrical inner tube nearly seven inches in length and half an inch in diameter. This bears a curved and roughened thumb-piece mounted on a short stem. The end is cut straight, not obliquely. It is not necessary that this end should be dome-shaped, as in the tapping trocar presently to be described. The second part of the instrument is the trocar proper. It is a stout tube, into which the cannula fits with great accuracy. Its extremity is cut obliquely, like a quill-pen, being pointed and sharp-edged.‡ The trocar is furnished with a pair of spring hooks. By pressing the thumb and outer side of the forefinger simultaneously on the bars or handles of the hooks, they are raised by a mechanical contrivance, so that the cyst-wall can be drawn up by aid of a volsella above the line of the hooks. On letting go the handles, the fine hooks or teeth catch the cyst-wall firmly, generally perforating it with their points, which fit into holes on the trocar.§ At the upper end of the trocar is a slit on the bayonet-joint principle; the stem of the thumb-piece of the cannula slides up and down in this slit. Before use, the thumb-piece is drawn up to the top of the slit. After the cyst has been perforated and the fluid has begun to run well out of the india-rubber tube, the thumb-piece is pushed down by the thumb, so that the cannula projects beyond the sharp

* This term is not of Greek but of French origin: "TROIS-QUARTS OU TRO-CART, instrument de chirurgie dont on se sert pour faire des ponctions: c'est un poinçon d'acier, monté sur un manche en poire, terminé par une pointe pyramidale triangulaire à bords tranchants, d'un surnom, à trois carres" (Bouillet: *Dictionnaire Universelle des Sciences, des Lettres, et des Arts*). The English form "trocar" is phonetic. There is no authority for spelling the word "trochar."

† This word is generally spelt "canula." In Smith's *Dictionary* I find "CAN-NULA, æ, f. dim [canna], a small, low reed: Appuleius. Cannula pulmonis, the windpipe: Cælius Aurelianus." The latter author was a physician. It is evident that a *real* Latin medical word should be spelt as it is written in the works of *real* Roman medical writers.

‡ For a good account of the history of this instrument, see "The Dome Trocar and Associated Instruments in Paracentesis, etc.," by Simon Fitch, M.D., Halifax, Nova Scotia (*British Medical Journal*, vol i., 1887, p. 263).

§ In Mr. Bryant's modification the hooks slide along the cannula, so that the volsella is not needed.

point of the trocar, and thus preserves the tumour from further wounding. The thumb-piece must be made fast by pushing it into the side slit at the end of the longitudinal slit. The third part of the entire instrument is the stout siphon end which screws on, at one end to the trocar, and at the other to a metal ring at the upper extremity of the gutta-percha tube. This tube should be about three feet in length, and half an inch in diameter.

Sometimes the cannula is made on Dr. Fitch's dome-shaped pattern, to be described under the head of Wells' Tapping Trocar.

The precise manner of using this instrument will be stated in the chapter upon the operation of Ovariectomy.

Tait's Trocar.—Mr. Lawson Tait uses a trocar apparatus of a different form (Fig. 36). It is straight and about nine inches in length. The cannula is outside, and the spring

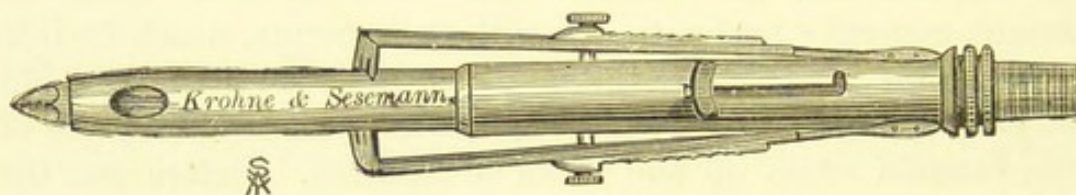


FIG. 36.—TAIT'S OVARIOTOMY-TROCAR.

hooks, which are fitted on to it, have very long handles. The end of the trocar is flattened and terminates in a blunt point, truncated by an elliptical opening. On each of the flattened surfaces, close to the point, is a wide oval hole, about three-quarters of an inch in length. Inside the cannula moves a small, stout lancet-blade, which is fitted to a short cylinder bearing a thumb-piece on a stem. This stem slides along a bayonet-joint in the cannula, and when pushed down, the lancet is thrust out of the elliptical opening at the end of the cannula. The cyst being perforated, the lancet is withdrawn into the cannula by pulling on the thumb-piece, then the cyst-wall can be drawn up into the clutches of the hooks, which act by a contrivance slightly different to that adapted to Wells' trocar. The cannula screws on to a siphon end. Mr. Tait claims for his instrument the advantages that, being perfectly solid, it never admits air, and having no inside mechanism, it

never gets out of order. The form of its point enables the operator to puncture secondary cysts without any alteration of the mechanism; it is not sharp, and therefore can do no harm. It is an ingenious instrument and, I am informed, works admirably. It seems, however, to have a good deal of inside mechanism. Mr. Tait has recently, as I understand, employed a trocar of the simplest construction. It is a plain curved tube with a very blunt point and no hooks: there are two holes a little above the point. Thus it forms a trocar and cannula in one piece of metal.

Tapping - Trocar.—For tapping ovarian cysts whenever necessary—and that should be very seldom—and for the puncture of cysts discovered deep in the pelvic cavity, or recesses

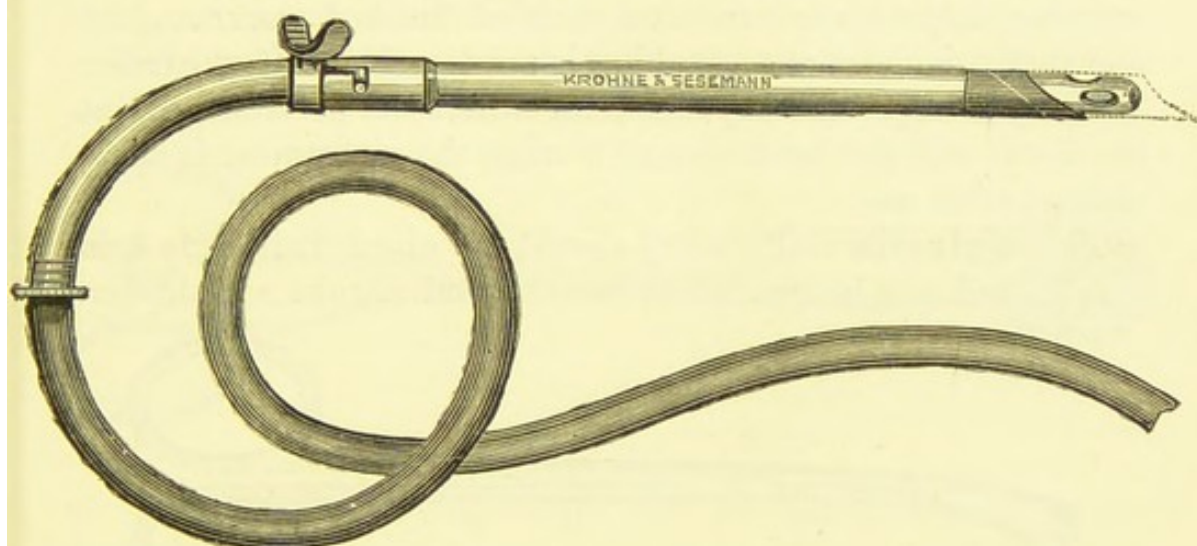


FIG. 37.—WELLS' TAPPING-TROCAR, SHOWING THE DOME-SHAPED EXTREMITY OF THE INNER TUBE, CONTRIVED BY DR. SIMON FITCH.

of the abdomen during the course of an operation, a Wells' tapping-trocar (Fig. 37) will be found useful. It is a kind of miniature ovariectomy-trocar. The cannula and the curved siphon-end are in one piece. The open extremity of the cannula is blunt-edged and slightly narrowed; close to it are three oval apertures. This contrivance, invented by Dr. Fitch,* prevents injury to deep structures, and at the same time allows

* See footnote, p. 103. Dr. Fitch appears to have been the first to contrive that the perforation should be done by the outer tube, contrary to the principle in the old hydrocele-trocar, and also the first to introduce a trocar with a rounded extremity to its inner tube.

fluid to run freely. The trocar is pointed and sharp-edged at its oblique extremity. It bears a thumb-piece, or (what I think is better) an opposed pair; on pressing upon them the cannula can be worked, a small projection on its surface sliding in a bayonet-joint slit in the upper extremity of the trocar. The whole instrument measures about nine inches, and can be fitted on to an india-rubber tube. It should always be at hand during any abdominal section. When a thin-walled broad-ligament cyst is to be removed, this trocar is far more handy than the larger instrument. It removes the fluid contents of the cyst with great expedition, and the collapsing cyst-walls can be taken up in the operator's hand, needing no spring hooks.

The intending purchaser of a sample of this instrument must examine it, to make sure that it is of finished workmanship, and that the metal of the tubing is not too thin. If the trocar is badly made, the bayonet-joint will soon be damaged, as the metal will get bent around it when the instrument is being cleaned after use.

The **Volsella** * (Fig. 38) should be about half a foot in length, and not longer. The handles and shanks are slender.

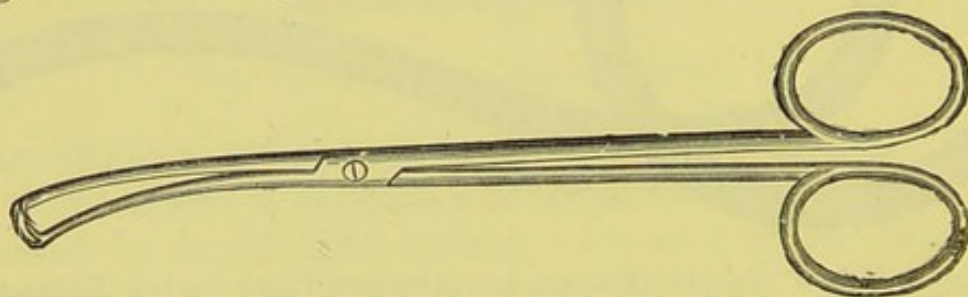


FIG. 38.—VOLSELLA FOR OVARIOTOMY.

Beyond the pivot, the shanks are continued for about two inches, and are bent at a wide curve. They terminate in strongly-bent prongs about a quarter of an inch long, two on the lower and three on the upper shank, where the middle prong is more strongly curved than the others. The forceps is held with the left thumb in the upper bow, and the fore- or middle-finger in the lower; in this position then the prongs are directed downwards, the triple prongs lying uppermost.

This volsella is, I consider, indispensable, excepting to operators who prefer Bryant's ovariotomy trocar to other similar

* See note on "Volsella," p. 78.

instruments. The prongs readily grasp the cyst-wall close to the point where it has just been perforated by the trocar. The wall is then pulled up under the spring hooks on the trocar, which are kept apart by the pressure of the operator's right thumb and fingers (page 103). This manœuvre is perfectly simple, and is the best way to prevent the collapsing cyst from slipping off the cannula, and to avoid escape of fluid into the peritoneal cavity.

This instrument is too delicately made for grasping uterine or very firm solid ovarian tumours. On the other hand, the powerful volsella used in operations for the removal of such tumours is not suited for application to the soft walls of ovarian cysts, which they crush or tear, rather than grasp, to the great inconvenience of the operator and his assistant.

Nélaton's Volsella, or Cyst-Forceps (Fig. 39), is a strong and valuable instrument that should always be at hand



FIG. 39.—NÉLATON'S VOLSELLA.

in the course of an ovariectomy, but the assistant must know how to use it. It measures nine inches in length. The blades form two stout, laterally-flattened, almost circular discs. The inner surface of each blade is deeply grooved, and bears four spikes and four holes, which fit similar holes and spikes on the opposite blade. The blades have also a large central perforation. This aperture is bevelled on the outer aspect of the blade. The object of the perforation is to allow the compressed tissue to bulge through it, so as to form a convex prominence, which acts like a pivot-head, and aids in making the grip as firm as possible. The bevelling prevents the bulging tissues from being cut. A similar arrangement is seen in tongue-forceps. The shanks can be unfastened at the pivot, and they bear a Matthieu's catch opposite the handles. This instrument is very useful for holding the cyst in the stage of the operation

between its puncture by the trocar and the ligature of its pedicle. Two are needed and should thus be employed, when solid contents or the septa within multilocular cysts are broken up. After the trocar is withdrawn, the opposite edges of the aperture in the cyst-wall made by that instrument are seized by the operator by means of the volsella.* The assistant takes the volsella in his hands, and holds the cyst-wall apart at the trocar-wound; then the operator can enlarge the wound, and plunge his hand into the cavity of the cyst. When adhesions are being broken down, the cyst-wall, doubled up if possible, may conveniently be held steady by the assistant.

There are certain precautions necessary to observe when Nélaton's volsella is used. A good broad piece of cyst-wall, broader than the blades themselves, must be seized. The operator and assistant should ascertain if the cyst-wall be firm, as is the rule in an ordinary multilocular cyst; or soft, as in most malignant tumours and in cysts filled with glandular material; or brittle, as in some dermoid cysts, or in cysts that have frequently become inflamed. If soft or brittle, traction must be effected with care by the assistant, else whilst the operator is groping in the interior of the cyst one volsella may tear away the piece of wall which it holds, and the cyst will recede into the abdominal cavity, into which some of its contents will escape. Again, if the cyst-wall be held too tightly by the assistant, it may be rendered so tense that should it be softened by some pathological change behind, the operator will be more likely to thrust his hand through the back of the tumour; besides, the volsella may itself tear away a large piece of the tumour if carelessly handled. Again, whilst the operator is separating adhesions, firm traction on the cyst-wall is dangerous; it must be merely steadied by the volsella. The assistant must not pull hard with this instrument when the tumour is coming out of the abdomen, or the latter may slip out suddenly, allowing escape of in-

* Directions of this kind will be more or less repeated when I come to the details of the operation. I consider that such repetition is necessary, as I cannot very well describe an instrument without noting how it should be employed, nor can I describe an operation without referring to the use of each instrument.

testine and omentum, and perhaps lacerating its pedicle. These are no remote nor even very unusual contingencies.

It is therefore necessary, when using Nélaton's volsella, to ascertain the stoutness of the cyst-wall; and if it be found firm, to seize a good piece between the blades of the instrument, and to hold it tightly, but without violent traction. If the wall be soft or brittle, it is best to seize a piece between the blades, and to let the instrument hang over the sides of the abdomen, as it is not safe for the assistant to drag on its handles. When, however, the walls are very soft, and, above all, if there be fear of their tearing near the pedicle, the instrument should be discarded, and a large piece of cyst-wall may be held in the assistant's hands. This I have often seen performed with advantage.

Dr. Atlee employed a forceps designed by Dr. Fitch, where the blades formed a pair of rings, with their opposing surfaces deeply grooved. This instrument rendered the teeth on the trocar and the simple volsella both unnecessary.*

Cyst-Forceps: Large Pressure-Forceps.—One of the most indispensable instruments for the ovariologist is the cyst- or large pressure-forceps. The latter term is employed by Sir Spencer Wells (Fig. 40). It is a large and powerful forceps,

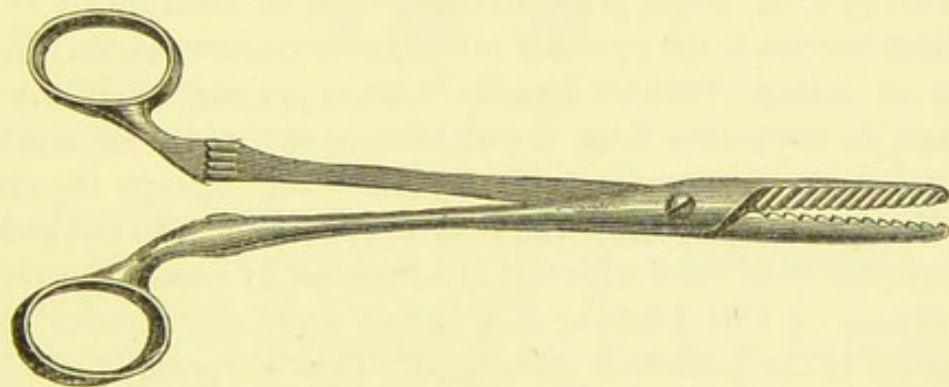


FIG. 40.—CYST-FORCEPS OR LARGE PRESSURE-FORCEPS (*straight blades*).

the handles and shanks up to the pivot measuring together over seven inches in length, the blades and the remainder of the instrument below the pivot about two and a half. In the typical and best form the blades are bent at an angle of 120° to the shanks, on the plane of the extremities of

* Fitch, *loc. cit.*, p. 103, footnote.

the pivot (Fig. 41). On this plane the blades are comparatively flat, whilst laterally they are very blunt-edged, but only slightly convex from above downwards. The point is quite blunt, but not bulbous. The teeth of the blades are of uniform size, large, blunt and oblique. They are fine examples of U-teeth, the signification of which term has been already explained. Owing to the long leverage of the shanks and the four catches, the grip of the handles is exceedingly powerful. The shanks cross each other precisely as in Wells' new forceps (page 97); when the instrument is closed at the fourth catch they almost cover each other; when closed at the first there is still no gap between the shanks. It is evident that a space of this kind would be a more serious defect in this than in the smaller forceps. Omentum, or even a piece of intestine, might easily get caught in the gap, and if the operator raised the handles without seeing the complication, a very gentle movement would be sufficient to tear the entangled structure, owing to the powerful leverage of the instrument. As it is constructed, such an accident is impossible. There are four teeth on the ratchet, which is placed half an inch below the bows or rings. These latter are more than an inch long in diameter, stout and bevelled.

The cyst or large pressure-forceps is an instrument of the highest service to the operator under many circumstances. Should part of a large tumour tear itself away, or rupture in the process of its extraction from the abdominal cavity, the hæmorrhage may be very severe, and in any case the forceps should be applied to the cyst below the rent or, if possible, to the pedicle. There are also cases where it is advisable to secure the pedicle by means of this forceps, and to cut away the tumour before ligature of the pedicle is attempted. This is especially necessary when no true pedicle exists. The tumour may have to be shelled out of its capsule or separated from its adhesions, a process which takes up much time. Then the forceps may be applied to the deepest part of the capsule or tumour, which can thus be safely grasped. The whole, or as much as possible, of the tumour is cut away, and the pedicle can be then attended to; on the other hand, this instrument is not generally used when a good long pedicle is discovered, without any trouble, as

the tapped cyst collapses. Such a pedicle is thin and delicate, and the blades of the forceps will merely crush its tissues needlessly.* Besides, it is easier to apply the ligature before cutting away the cyst, and this can be done with perfect safety. If, however, the cyst be bulky and loaded with glandular or malignant growths, and if on extraction through the abdominal wound, its pedicle be found to be thin and tender, the forceps may conveniently and safely be fixed on the pedicle, very close to its attachment to the cyst, or to the base of the cyst itself. The bulky tumour, which is then much in the way, may be cut off, and the pedicle secured afterwards. In separating adhesions to the liver and omentum some operators apply it to the adhesion and cut away the cyst, attending to the possible hæmorrhage afterwards. For this purpose, however, the cyst-forceps is too large. Most operators find that it is sufficient to tear through the adhesion and secure the bleeding vessels with small pressure-forceps. This is my own practice. In oöphorec-

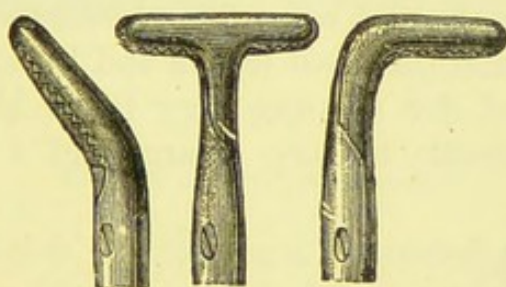


FIG. 41.—LARGE PRESSURE-FORCEPS. VARIETIES WITH T-BLADES AND WITH BLADES BENT AT A RIGHT AND AT AN OBTUSE ANGLE.

tomy the cyst-forceps is often needed in order to keep the tube and ovary steady whilst the ligature is being applied. An assistant's hand is less trustworthy for the purpose.

There are two other varieties of cyst-forceps in frequent use, the straight-bladed and the T-bladed forceps.

The straight-bladed cyst-forceps (Fig. 40) is simply a magnified or enlarged form of Wells' new pressure-forceps. The U-teeth of the blades are, however, placed obliquely in the larger forceps. The T-bladed cyst-forceps is a large form of the T-bladed pressure-forceps described and figured at page 100.

* Some operators, however, especially Dr. Bantock, prefer to employ this instrument even when the simplest pedicle is secured.

Wells' Large and Small Clamp-Forceps.—These instruments (Figs. 42 and 43) were once largely employed, but

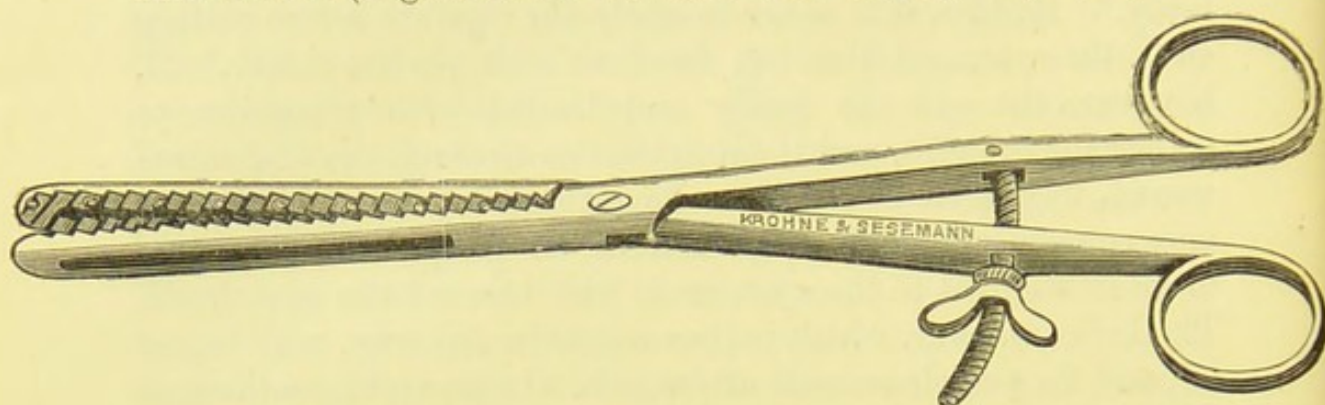


FIG. 42.—WELLS' LARGE CLAMP-FORCEPS.

are now seldom used, as the large pressure-forceps answer their purpose and are of more general application. Some operators, indeed, never use them. The chief advantage of this kind of clamp-forceps over the large pressure-forceps is the shortness of the handles of the former, which therefore do not get in the way of the operator, and the great length and breadth of the blades, which are suited for securing very broad bleeding surfaces; hence, it is advisable to keep a large and a small forceps of

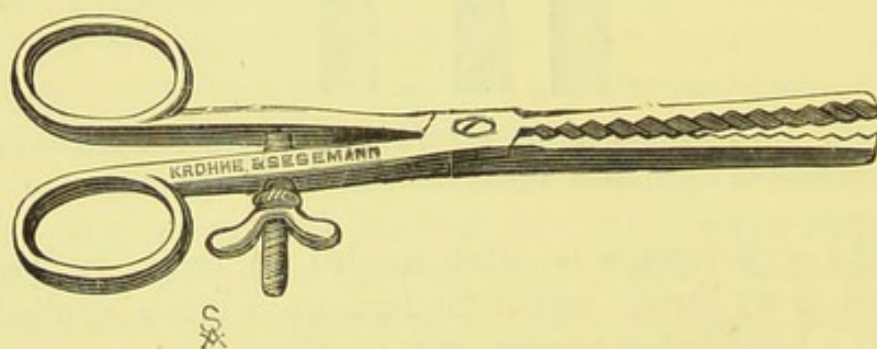


FIG. 43.—WELLS' SMALL CLAMP-FORCEPS.

this kind in hand at a general or special hospital, but they need not be added to the armoury of private operating practice. The screw mechanism on the handles for fixing the blades, explained by the woodcuts, is neither so easy to work, nor so clean, nor to keep in order, as the simple catches in the handles of the newer large pressure-forceps.

Pedicle-Needles.—These instruments are necessary for transfixing, and thus carrying the ligature through the pedicle.

For the purpose of securing the vessels in the outer border of the pedicle a stout curved suture-needle is sufficient; it should not be sharp-edged, and may be used with or without the aid of a needle-holder. An ordinary needle would involve clumsy and dangerous manipulations, if employed for the transfixion of the pedicle.

Many different forms of pedicle-needles have been devised. The most convenient type is a long curved needle mounted on a handle and bearing an eye near the point. This "Liston's needle" must be very well known to every surgeon, as it is constantly employed for plastic operations and for any procedure where ligatures and sutures have to be passed through parts not convenient for the play of the fingers necessary when a common suture-needle is used.

The pedicle-needle employed by the surgeons at the Samaritan Hospital (Fig. 44) is made in several sizes. The best for

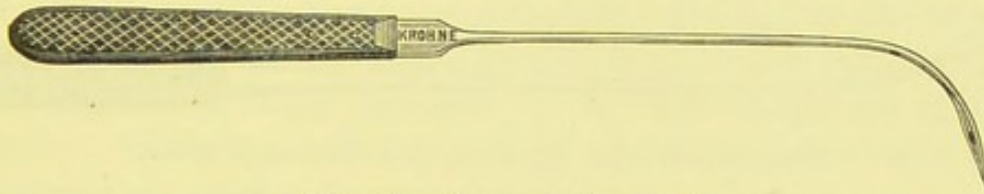


FIG. 44.—PEDICLE-NEEDLE.*

ordinary use—that is, for passing a ligature through a pedicle of the common type—is six inches in length, measured from hilt to point along the curve, and is mounted on a roughened ebony handle four inches long. The eye should be wide enough to admit No. 4 China silk ligature.† The form of this needle allows facility of movement and command of the point. The operator must remember that it may act as a powerful lever, and therefore he must hold the handle lightly as the shank of the needle passes through the tissues, else the pedicle may be split. The point must be just sharp enough to push its way through a thick pedicle, but the edges of the flattened, curved part of the needle must be very thick and blunt. The surgeon must see to this when he purchases the instrument. Bluntness of the point may bruise the tissues needlessly and even split

* Mr. Thornton employs a more strongly curved instrument.

† When the eye is too narrow, threading in the middle of an operation will be very troublesome.

them. Sharpness of the edges near the point may be the cause of large vessels being wounded.

This pedicle-needle must be threaded before the operation. The passing through of the threads with the needle never appears to me to do the least harm. On the other hand, if the needle be threaded after the point has passed through the pedicle, the process may be troublesome; the shank of the needle may have to be pushed through the pedicle to an unnecessary extent, and the surgeon, pressing on the handle, may cause the pedicle to be split rather than simply perforated.

A shorter and smaller pedicle-needle of this kind should always be at hand.

Sir Spencer Wells advocates a larger and still blunter needle (Fig. 45) with a shank nearly nine inches long, and a very




FIG. 45.—WELLS' BLUNT-ENDED PEDICLE-NEEDLE.

stout roughened ebony handle a little shorter than in the kind just described. On account of the length of the shank, it becomes necessary that the handle should be made stout in order that the surgeon may control its movements thoroughly. The point is exceedingly blunt, the sides of the needle near the point still blunter, and the eye is a large oval hole nearly a quarter of an inch in its long diameter.

Long Pedicle-Needle.—This instrument (Fig. 46) is not




FIG. 46.—LONG PEDICLE-NEEDLE.

indispensable, indeed some operators seldom, if ever, employ it; but under one condition, at least, it may prove of high service. It is a free needle—that is to say, it is not mounted upon a handle. In length it measures over six inches, and is made of well-tempered steel. In form it is cylindrical, tapering gradually to a point which is moderately sharp. The eye is

a quarter of an inch long and about one-eighth of an inch wide—that is, as wide as it can be made without weakening the head of the needle or rendering any bulging of its borders necessary; this latter arrangement would cause the wound, which the needle makes in transfixing the pedicle, to be needlessly wide.

The chief advantage of the long pedicle-needle is its large eye. Such an eye could not be safely made near the point of a handled pedicle-needle. The position as well as the size of the eye renders this needle very useful when a broad pedicle requires a second transfixion. In describing the operation, I shall explain how it is necessary, under these circumstances, to re-thread the needle with one of the ligature silks, together with another silk, after the first transfixion. Threading needles in the midst of an operation is a troublesome proceeding, especially when, as in this case, the threading must be done by the operator or his senior assistant, the position of the needle at the time preventing anybody else from doing that service. The difficulty is much lessened by the size of the eye of this needle. With an ordinary curved and handled needle this re-threading process is very troublesome.

The Needle-holder (Fig. 47) should be stout, as it has to

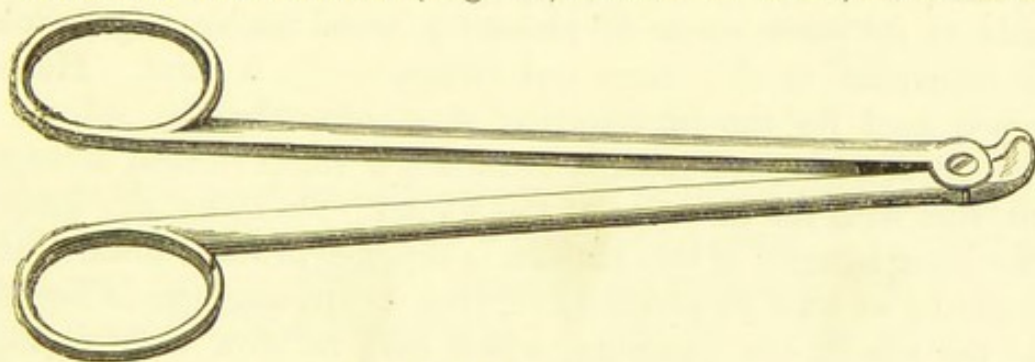


FIG. 47.—NEEDLE-HOLDER.

be employed in passing needles through the integument in the abdominal walls. The shank should be about five inches long, between the bows and the pivot. The blades are exceedingly stout, short and curved, and terminate in a very blunt nozzle. Their inner surfaces are roughened. The instrument should be held so that when the thumb lies in the upper bow, the blades, holding the needle, turn towards the part to be transfixed. For general use, this instrument is excellent.

The Needles.—The needles employed by ovariologists are generally stout and straight (Fig. 48). They are triangular,




FIG. 48.—NEEDLE FOR OVARIOTOMY.

with sharp angles, near the point. An ordinary curved suture-needle, such as is carried in a surgeon's pocket-case, is best for the purpose of passing a silk ligature through the outer border of the pedicle in order to secure the ovarian vessels.

Hagedorn's Needle and Needle-holder.—Dr. Hagedorn, of Magdeburg, is the inventor of a special form of needle much used by British and Continental surgeons, particularly for plastic operations. It is very serviceable in operations for ruptured perineum, and in the application of a suture to the edges of the stump of the pedicle of the uterus after the removal of a fibroid tumour, as will be described in the chapter on Hysterectomy. In sewing up wounds of intestine, damaged during the separation of adhesions in ovariectomy and hysterectomy it is in some respects superior to the ordinary needle.

The kind of needle in general use has a stem, the section of which forms either a circle or an oval. It is flattened at the inner side of its curve, so as to present a broad double edge, which is transverse to the curve and terminates in a point. Hence, when used for the introduction of a suture by the side of a wound, it makes a puncture, or rather, a small vertical incision, parallel with the direction of the wound. On tying the suture, the inner margin of this incision is dragged inwards towards the wound; so that an elliptical, or even triangular, gap is formed at the site of the puncture, which may be slow to heal (Fig. 50, *a*, *b*). A small fistula or abscess may form through the nature of the puncture. The point of the old kind of needle, flattened on its concave side, is weak and apt to deviate from its intended direction in tough or hardened tissues. In short, this older kind of needle has at least two serious disadvantages, especially when employed for plastic operations. In such proceedings it is particularly important that the needle should run easily through the tough integument, and that the wound should heal as quickly as possible, the punctures being of such

a nature as to offer no chance of any complication interfering with union by first intention. The presence of fistulous tracks and small abscesses near the wound is, of necessity, liable to defeat the object of any plastic operation.

The stem of Dr. Hagedorn's needle forms an oblong parallelogram on section. It is of equal width and thickness throughout its entire length, and is curved on its axis, with its short cutting edge on its convex side near the point. This edge is about three times the width of the needle. The curve of the needle forms a semi-circle.

Being curved on the edge, this needle is more resistant than the older form, and the point follows, without deviation, the intended direction of the puncture. The eye perforates the flat

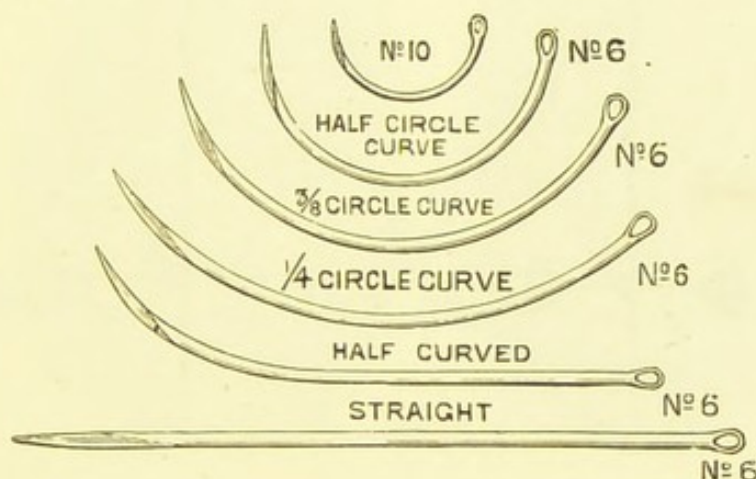


FIG. 49.—HAGEDORN'S NEEDLES (*natural size*).

side, so that it can be made larger and more tapering at the terminal end, in consequence of which even a stout double thread will pass without difficulty through the puncture. The needle is of equal thickness throughout. Hence, when under different circumstances it may be thought advisable to grasp the needle in the holder at different parts of its length, so as to facilitate its passage through the tissues, this may be done without any risk of breaking or bending. The cutting edge of Hagedorn's needle is on the convex side, and is as short as possible, consistent with efficiency. It cannot be injured or blunted by the needle-holder, and may readily be sharpened when required. Owing to the form of the needle, the incision which it makes is not vertical, but horizontal as in a button-hole, and, therefore, at

a right angle to the edge of the wound, so that the two edges of the stitch-wound, on tying the suture, are drawn into close apposition (Fig. 50). These needles cause less injury to the tissues than the older form, which is of high importance, especially in sutures of nerves and tendons, as well as in plastic operations.

As there are operations where a shallow-curved, or even a straight needle, is required, five different forms (see Fig. 49) are made. In Fig. 49, Nos. 6 and 10 (the smallest) are represented. Dr. Hagedorn has contrived a needle, with a round point, for intestinal sutures. A thinner form of needle, useful in plastic operations on the female organs, has been invented.

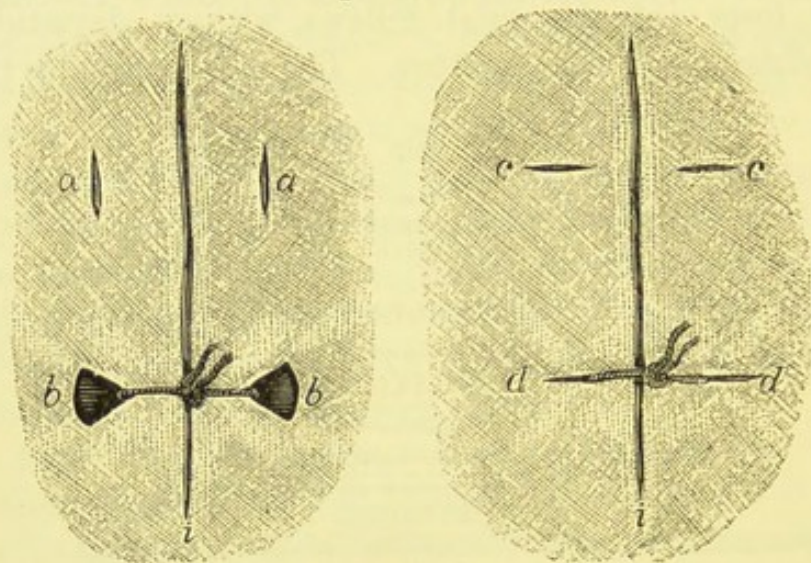


FIG. 50.—DIAGRAM SHOWING EFFECTS OF SUTURE ON WOUND MADE BY (a, b) ORDINARY AND (c, d) HAGEDORN'S NEEDLES.

Dr. Hagedorn has also invented a needle-holder which can grasp the needle firmly without any risk of breaking it. The needle can be seized or disengaged with equal readiness; and its point, after having passed through the tissues, can be taken hold of without injury to itself or to the surrounding soft parts, being guarded by the jaws of the needle-holder.

The needle-holder (Fig. 51) consists of a steel rod, ending in a handle, upon which a similar shorter rod is made to glide up and down. Both rods form, at a right angle to their anterior termination, the jaw, which is lined with copper. The up-and-down movement of the rods is effected by a lever handle, held in position by a moveable screw. A ratchet on the lower part of the handle serves for fixing the needle. When the handle is

fixed to the first tooth on the ratchet, a stout needle can be held in the jaw; the second and third teeth are intended for fixing the handle when finer needles are used. A slight pressure with the little finger on the ratchet will easily release the stop, and set the needle free. In using it, the needle-holder is held in such a position that the little finger is near the ratchet, ready for releasing its hold by slightly pressing against it. Care must be taken that the needle is placed in the longest diameter of the jaw, with the inner curve close to the stem of the fixed rod. Only when the needle has been grasped in this manner will its perfectly firm position be secured. The surgeon must never attempt to pass a needle through tissues, by the aid of this holder, without having fixed the lever handle in the ratchet.

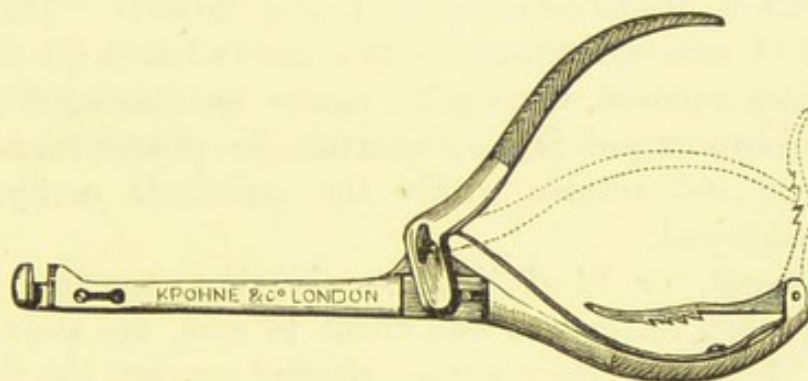


FIG. 51.—HAGEDORN'S NEEDLE-HOLDER.

Otherwise the handle will press inconveniently on the palm of his hand, and the needle will probably slip out, or become deflected from its right course.

Two varieties of the holder are especially made for operations on women. One kind has a rectangular, and the other an oblique jaw.

Hagedorn's needle-holder is easy to work after a little practice. If the surgeon attempts to use it in the course of an operation without having mastered its mechanism, which is no difficult task, he may get into difficulties, and throw unfair discredit on the instrument. It cannot be denied that new inventions are sometimes discredited in this manner.

Sutures.—These may be either of silk, composed of No. 2 Chinese twist, or else of silkworm-gut. They should be cut about a foot and a half long. If too short, they are incon-

venient for the assistant to hold firmly, whilst the surgeon is sponging the peritoneal cavity previous to closing the wound.

Each end of a suture is threaded on to a needle of the kind described at page 116. A set of six or eight pairs of needles are thus treated before operation, and fastened on to a strip of carbolic or thymol gauze, each pair being held close together, and then made to transfix the gauze. The strip of gauze is then rolled up, and placed in a convenient position in the tray.

Silkworm-Gut.—This material has been much used, and greatly recommended by Dr. Bantock and other operators. I believe that it is the best material for closing the abdominal wound, being easy to introduce, and particularly easy to remove. I do not say that if left in the tissues it can never excite irritation, nor cause abscess. It may do both. Like any other kind of suture, however, it must not be left in the tissues. Being readily removed, there is no excuse for leaving it in the tissues. Silkworm gut is also valuable for plastic operations. For ligature and sutures within the peritoneal cavity, silk must be employed.

Silkworm-gut, or *fil de Florence*, is thus prepared. The silkworms, when full-grown and about to spin, are steeped in vinegar. This makes their bodies soft, and converts the fluid in the silk-glands into a pulpy mass. After soaking in vinegar for two hours, the skins are removed from the worms, and the silk-glands are extracted. The glands are then rolled between the finger and thumb, stretched to the necessary length and thickness, and fixed till dry.*

This material is much used by anglers. When employed by the surgeon, the red-stained samples are the best. It must be soaked in water, pure, or carbolized for at least ten minutes or more before use. If not sufficiently soaked, it remains stiff and slippery, and is very apt to slip out of the needle-hole when it is being passed through the abdominal wound. This causes the operator much trouble, as I know from the experience of one of my own cases, where the gut had not been properly prepared by the nurse. It is as smooth as spun-glass or metallic suture,

* *The Colonies*, 1878. Dr. Bantock quotes the original in "First Series of Twenty-five Cases of Completed Ovariectomy" (*British Medical Journal*, vol. i., 1879, p. 770).

and not being composed of strands or fibres, it cannot lodge fluids or minute particles of solid organic matter, like silk sutures. Being very pliable, it flies apart when cut on one side of the knot. This property greatly facilitates the removal of the sutures from the abdominal wound.

Care must be taken, after the complete set of silkworm-gut sutures have been introduced into the abdominal wound, that they are not jerked out of the assistant's hands whilst the operator is introducing or withdrawing the sponges employed for cleansing the peritoneum. This may happen, as the gut becomes slippery when wet. To avoid the accident, the ends of the gut threads should be collected on each side and held together by compression-forceps. As the cut ends of the gut become stiff when it dries, the operator must be careful that they do not turn directly upwards or downwards, so as to sink between the cut surfaces of integument into the wound. The cut end need never be over a quarter of an inch in length.

CHAPTER IV.

INSTRUMENTS AND APPLIANCES

(Continued).

Instruments used in Hysterectomy.—I shall now proceed to describe certain instruments which are required for hysterectomy. They should be at hand whenever the surgeon operates in a case of doubtful pelvic tumour, and particularly when oöphorectomy for the cure of uterine fibroid is contemplated. It may very probably be found that the pedicle of one or both appendages cannot be safely secured and that hæmorrhage can only be checked by amputation of the uterus above the cervix.

Koeberlé's Serre-Nœud.—This instrument is sometimes termed an écraseur and sometimes a wire clamp, but serre-nœud appears to be the name by which it is generally known. I therefore retain that name, but to all intents and purposes it is a clamp, and was originally used as such by Professor Koeberlé, of Strasburg, in ovariectomy. In his *Manuel Opératoire de l'Ovariectomie* (1870), with notes by Dr. Taule, he states that it was then his custom to secure the pedicle of an ovarian tumour with this serre-nœud, which he considered as superior to the clamps then in use; it could be applied in all cases, and this fact alone made the instrument incontestably superior to any other. By this assertion, he signified that the wire of the serre-nœud could be applied to a very broad, short pedicle, or even around the deepest part of a cyst when no pedicle existed; this could not be done satisfactorily by Wells' or Hutchinson's instruments. In those days the clamp was always preferred, and therefore always employed excepting when the pedicle was too short to allow of its use. Koeberlé's instrument met these

exceptional cases, and therefore was perhaps the best according to the ideas then current. Our practice with regard to securing the ovarian pedicle has entirely changed since 1870, nor, indeed, was the serre-nœud ever popular amongst British ovariologists. It is in supra-vaginal hysterectomy and allied operations that this instrument has since proved to be of high value.

Fig. 52 represents the variety of Koeberlé's serre-nœud which is employed by Dr. Bantock. It consists of a steel cylinder, which should measure about four inches in length, and is hollowed to allow a long screw to revolve within it. At one extremity it is flattened and bridged for the passage of a loop of wire. This extremity must be well finished, as it comes close in contact with the stump of the uterine pedicle. At the opposite

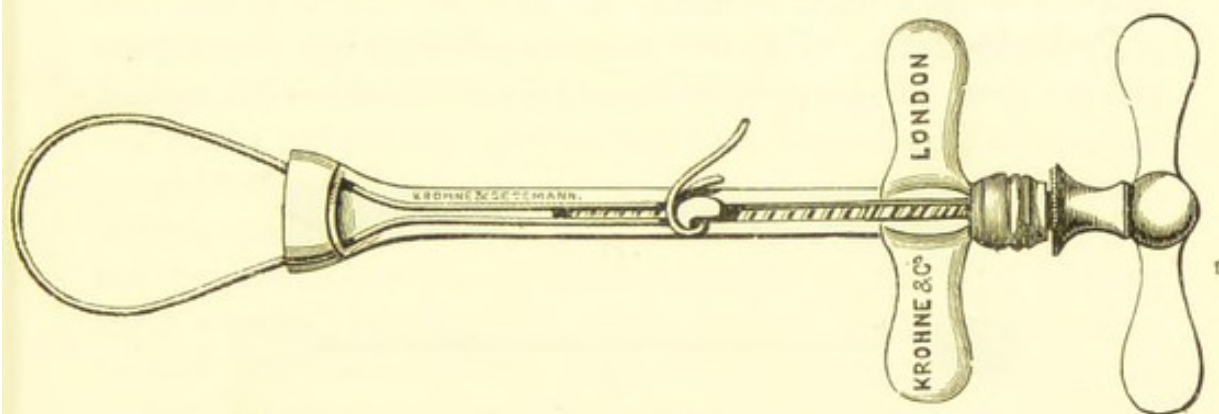


FIG. 52.—KOEBERLÉ'S SERRE-NŒUD.

extremity is a contrivance whereby a key or handle may be fitted on so as to work the screw. A button, with a short shank constructed so that it moves along the thread of the screw, slides along a slit on the upper surface of the cylinder. Just below the handle the instrument is furnished with a pair of wings, which are very convenient for the purpose of steadying it when the wire is being tightened.

When the serre-nœud is required a stout piece of soft, flexible iron wire, about one foot long and bearing at one end a small ready-prepared loop, is taken, and the loop is slipped over the button, whilst the other end of the wire is passed under the bridge at the flattened extremity of the instrument and then round the pedicle. When this has been done—and more will be said about this subject presently—the end of the wire is passed

back through the hole and twisted round the shank of the button. Care must be taken to keep the button uppermost. Special pliers or nippers are generally necessary for pulling the loop tight previous to coiling it round the button. Then, by means of the key, the loop of wire is drawn as tight as the operator may deem desirable.

Koeberlé's *serre-nœud* is far superior to Cintrat's, as it allows the wire to be tightened at any moment when required, whilst, when the latter instrument is used, the wire is twisted once for good. The *serre-nœud* is then removed. It frequently happens that the wire very soon requires tightening, so that after the use of Cintrat's *serre-nœud* the wire, should this accident occur, will have to be readjusted. The *serre-nœud* itself may not be at hand at the critical moment.

Pedicle-Pins.—For the purpose of keeping the uterine pedicle from slipping back into the peritoneal cavity, special




FIG. 53.—PEDICLE-PINS FOR HYSTERECTOMY.

pins have been devised. The pin should be over four inches in length, stout, and made of steel. The point must be sharp, as it has to penetrate very tough tissues. The handle is oval and flattened, and rough on one side so as not to slip from between the finger and thumb when it is held. The smooth side must be kept downwards towards the integuments. After transfixion the point is slipped into a channel in a metal guard, shaped precisely like the handle.

Two of these pins are generally needed. A great many precautions will be required during their use, and these will be noted in the chapter on Hysterectomy for Uterine Fibroids, and explained by a drawing.

Drainage.—I shall now describe the appliances which are necessary for the purpose.

Drainage-Tubes.*—These contrivances are widely used by some specialists, and but little employed by others. They are, however, never entirely rejected. They consist in drainage-tubes, a glass syringe with india-rubber tubing, and a square of india-rubber sheeting.

Glass Drainage-Tubes.—Glass instruments are always employed at first when drainage is resorted to in abdominal operations, excepting in some cases where a shallow or very irregular cavity requires drainage or where lumbar incisions are made, such as in removal or incision of a diseased kidney. India-rubber tubing is, owing to its physical characters, unsuited for drainage through an abdominal wound. It is Douglas's pouch, or, in rare instances, the depths of the lumbar region, that has to be drained, and for such a purpose a firm material is necessary, for the intestines and the uterus will probably press against the tube. Glass is particularly suited for the purpose, and as the patient lies quiet on her back, there is no internal nor external force that can break a stout glass drainage-tube. During attacks of violent delirium or nervous agitation, when the patient tosses about, throws herself on her side, or even turns completely round or jumps out of bed, the tube may become displaced or may fall out, but it cannot readily be broken within the abdominal cavity. These tubes are made of three or four different lengths.

Koeberlé's Drainage-Tube (Fig. 54) tapers to a point, which is blunt and closed, and the sides are perforated for more than



FIG. 54.—KOEBERLÉ'S DRAINAGE-TUBE.

two inches above the extremity. The upper orifice is everted. The rounded end was probably designed to lie against the peritoneum in Douglas's pouch without hurting it, and the holes in the side of the tube let in fluid as it collects in the peritoneal cavity.

* For the study of this question, as treated by its special exponents, I refer the reader to Dr. Keith's works and to Dr. Bantock *On Drainage in Ovariectomy*.

Dr. Keith's Drainage-Tube (Fig. 55) is preferable to the form just described. It does not taper to a point, but its lower orifice is nearly as wide as its general calibre, being very slightly inverted so that the edge should not be sharp enough to irritate the peritoneum. The perforations do not extend for more than a little over an inch above the extremity. The mouth or upper orifice is not everted, but half an inch below it is a broad rim, which not only prevents the tube from slipping into the abdominal cavity, but is also extremely convenient for the application of the india-rubber sheeting.

This tube is constructed according to sound principles. The fluid which has to be removed tends to collect at the bottom of Douglas's pouch, and the tube accordingly is open at its lowest part, which is pressed into that pouch. The perforations counteract atmospheric pressure above sufficiently to allow the fluid to rise as it collects in the pouch, whilst Koeberlé's tube is



FIG. 55.—KEITH'S DRAINAGE-TUBE.

perforated too high up, so as to interfere with the retention of fluid in and around the orifice of the tube. Hence, when the syringe is used, the fluid is more at hand and easier to withdraw when Keith's tube is employed.

Primary Drainage.—Before the tube is introduced in the course of an operation, Douglas's pouch must be well cleaned with small sponges mounted on holders, if not flushed out with warm water as well. This must be done after the sutures have been inserted into the tissues of the abdominal wall. In the chapters on Ovariectomy the manner of securing the ends of the sutures, lest they should be dragged out of their tracks during the sponging process, will be described. The operator must pass the tube into Douglas's pouch with his right hand, keeping the intestines back with his left. The tube should be passed between the two lowest sutures. It must be of such a length that when its extremity touches the bottom of Douglas's pouch, the rim or shoulder near the upper orifice lies nearly level with

the abdominal wound, and not high above it. In testing this question of measurement the operator must make allowance for the condition of the abdominal walls at the moment of introduction, as they may be distended above their usual level. For at this late stage of the operation the patient is not always thoroughly under the influence of the anæsthetic, the administrator being apt to relax his exertions, which, however, he should be strictly forbidden to do. The tube must be kept perfectly straight.

The sutures are then tied by the operator, whilst the assistant keeps his left forefinger on the orifice of the tube, pressing it very gently. Without this precaution, he or the operator may inadvertently pull the tube out of Douglas's pouch whilst sponging the edges of the wound or tying the sutures. If this occur and be not noticed, a coil of intestine may get between the end of the tube and the deepest part of Douglas's pouch. The tube will thus be in a position unsuited for perfect drainage.

The sutures having been tied and cut short, a piece of india-rubber cloth (presently to be described), perforated in the centre, is slipped over the tube, so that the hole in the sheeting embraces the tube tightly immediately below the rim. This cloth is a clean and valuable appliance, superior to any other which I have seen employed for the same purpose. The cloth is thin but strong, and the physical characters of the material allow it to be held well on to the tube, and prevent the wide escape of fluid issuing from the mouth of the tube.

The four corners of the sheeting are then folded over the orifice of the tube, after the latter has been covered by a small conical sponge. A few pieces of absorbent gauze, folded six or eight times, and cut about three inches square, are placed on each side of, and above and below, the protruding tube. Then the lower part of the abdominal binder is pinned over the tube and its covering. Once more the assistant must see that the tube is not dragged up in the course of these manipulations.

In order to empty the tube, a common glass syringe with a piece of india-rubber tubing is sufficient. The tubing must be about an inch longer than the drainage-tube, and much

narrower in calibre, else it may pull the tube up when being retracted. Care must be taken lest the tubing split whilst being slipped over the broad part of the nozzle of the syringe. The tubing being passed to the bottom of the glass tube, the fluid is drawn gently into the syringe. When antiseptic injections are employed after the withdrawal of all the fluid that will come away, a syringe-ful must be injected, and a little less withdrawn a few seconds later. The operator should clean the tubing himself after use.

Secondary Drainage.—Attempts to establish drainage after the close of the operation, when bad symptoms have appeared, are not attended with such good results as in the case of primary drainage. The intestines and omentum often become matted together, so that a collection of noxious fluid cannot always be reached. Secondary drainage is very satisfactory when pus or serum lies close under the wound or oozes through its lips. In this case, however, a rubber and not a glass tube is generally the more suitable.

India-rubber Cloth for Drainage-Tube.—I have just alluded to this appliance. Whenever the drainage-tube is employed, it is advisable to protect the parts and the dressings by means of a piece of india-rubber cloth, about one foot and a half square. A small hole is cut in the centre of the cloth. After the tube has been inserted into the wound, the edge of the hole in the cloth is slipped over the rim below its orifice, so that the cloth can be made to grip the neck of the tube, which, through its elasticity, it can do in a very effectual manner, provided that the hole has not been made too large. If properly adjusted in the manner already described, the cloth will catch any fluid which may escape in such quantities as to soak through the sponge or other covering placed over the orifice of the tube. At each dressing the surgeon has merely to turn down the corners of the cloth, and the tube will at once become accessible.

The chief feature in the proper application of the india-rubber cloth is the size of the hole, for if it be too large, its edges will not grasp the neck of the tube with sufficient firmness, and a space may be left through which fluid will run under the level of the cloth. After application, the advantage

of the cloth will be evident. It is light, readily folded, and perfectly waterproof. India-rubber tissue is too thin and not sufficiently elastic, whilst mackintosh is too heavy and is otherwise objectionable for the purpose which india-rubber cloth fulfils so well.

India-rubber Drainage-Tubes.—These may be required when a shallow cavity needs drainage, or when a collapsed sac, or natural space which has been opened up, lies much away to one side of the abdominal wound, or in any other case where a glass tube cannot be readily introduced or safely kept in place. Red rubber should be used, and tubing of several calibres will be needed. Small holes must always be cut in the sides of the tube before its introduction, else it may fail to work altogether. After the removal of the glass tube, it is in some cases advisable to introduce immediately a rubber tube of small calibre and retain it for a day or two.

The best way to secure the outer end of a rubber-tube is by simple transfixion with a safety-pin, passed through so as to lie transversely to the abdominal wound; the pin should pass through about a quarter of an inch below the cut end of the rubber. Squares of carbolized or absorbent gauze, about six or eight layers thick, are then arranged above, below, and on each side of the tube, as when glass is used.

The Many-tailed Abdominal Binder.—Surgeons differ in opinion as to the best kind of bandage to apply to the abdomen of a patient after ovariectomy or any other form of abdominal section. In every case the operator must not only decide beforehand what description of bandage he will use, but must also make sure that the nurse has made the bandage wide enough. It is very vexatious to find, at the conclusion of an operation on a stout or large-framed woman, that the ends of the binder will not meet properly in front of the abdomen.

Sir Spencer Wells simply recommends "a flannel belt," which is to be fastened around the abdomen by pins. Mr. Tait employs "a cotton binder" fastened with safety-pins. Mr. Thornton gives more elaborate rules concerning the binder. He prefers a bandage made of fine flannel and lined with soft calico. He directs that the calico should be sewn over

the edges of the flannel all round. A free edge of flannel under the patient's back is certain to cause great irritation. The bandage is fixed with three safety-pins.

The binder made on the "many-tailed" principle, though it has but four or five tails, is extremely convenient. It is constantly to be seen in Dr. Bantock's wards, and I always employ it for my own cases. When used, strapping is unnecessary.

To make a many-tailed binder, a yard and a quarter of flannel, properly shrunk, is cut into strips about three inches in width. Then a square piece of calico is prepared. It must be wide enough for its edges to come well forwards on both sides, when it is placed evenly behind the patient's loins, so that no flannel may touch the skin beyond the dressings. The four strips of flannel are now sewn on to the calico, each strip overlapping nearly half of that sewn on before it. The calico must be sewn over the edges of the highest and lowest strip, for reasons already given. The breadth of the calico, as just explained, will prevent the flannel from touching the skin of the flanks.

When the bandage is put on, after the dressings have been applied to the front of the abdomen, the calico and not the flannel must be placed next to the skin of the loins. In an uncomplicated case of ovariectomy, where no drainage-tube has been inserted, and where there is little fear that the dressings will have to be frequently disturbed, an overlapped and not overlapping strip of flannel must lie lowest, across the pubes. The two ends of that strip are drawn, very obliquely, below the anterior spines of the ilia and across the iliac fossæ over the dressings, as firmly as is deemed necessary. The ends must overlap each other to the extent of over two inches. Then the two ends of the second strip are drawn over the abdomen higher up, but partly overlapping the first strip: a safety-pin should now be fixed into the strips on one side at least. The remaining strips are folded over the abdomen in the same way, and two or more pins will be needed. They must be so placed as to overlap each other evenly, else the main object of this bandage—the undoing of one part without disturbing the remainder—will be defeated. It is im-

portant that the lower edge of the calico should come low down towards the hips, else, as the strips are applied obliquely, the lowest may pass above the hypogastrium, so that air will get under the dressings.

In the case of a patient of large proportions, the flannel must be longer, and the square of calico greater, so that the necessary conditions, to which I have already alluded, may be satisfied.

In cases where the drainage tube is used after ovariectomy, or where, for any other reason, the dressings will need frequent changing, and in all cases of supra-vaginal hysterectomy, the many-tailed binder must not be applied as above directed, but in the reverse position. That is to say, an overlapping strip of flannel must lie lowest when the bandage is placed in position, and the other strips must be adjusted in the manner described above, but from above downwards.

After the bandage has been applied according to the second method above described, the lower part of the abdominal wound, the drainage-tube, or the stump of the uterine pedicle, as the case may be, can be inspected by removing one or two of the lower safety pins, and undoing the lower strips of flannel. The upper strips will support the abdominal walls during the dressing of the lower part of the wound. The absence of strapping renders this step quite simple: when the dressing is completed the surgeon has merely to readjust the lower strips of flannel.

Two bandages should always be made for any case. At the end of a week, or sooner if it be soiled, the first bandage should be removed and washed. When the patient has recovered it is advisable that she should wear an abdominal belt in the day time, but should put on a many-tailed bandage at night for at least six months.

Absorbent Wool.—This well-known material is of great service in dressing after many gynæcological operations. The best quality should always be ordered. In order to test it, for samples must be tested from time to time, a pellet should be dropped on the surface of fresh water in a tumbler. When the pellet soaks in a few seconds and sinks, it is a proof that the wool is really absorbent. If, on the other hand, the pellet should float about, high out of the water, for a minute or

longer, the wool will be useless as an absorbent medium. The same test will be required for absorbent gauze.

Clover's Crutch.—This apparatus is exceedingly serviceable in all operations where the patient is placed in the lithotomy position. The lower extremities being kept apart artificially, there will be no necessity to employ one or two assistants for the purpose of holding them steady.

The crutch (Fig. 56) consists of two stout leather bands,

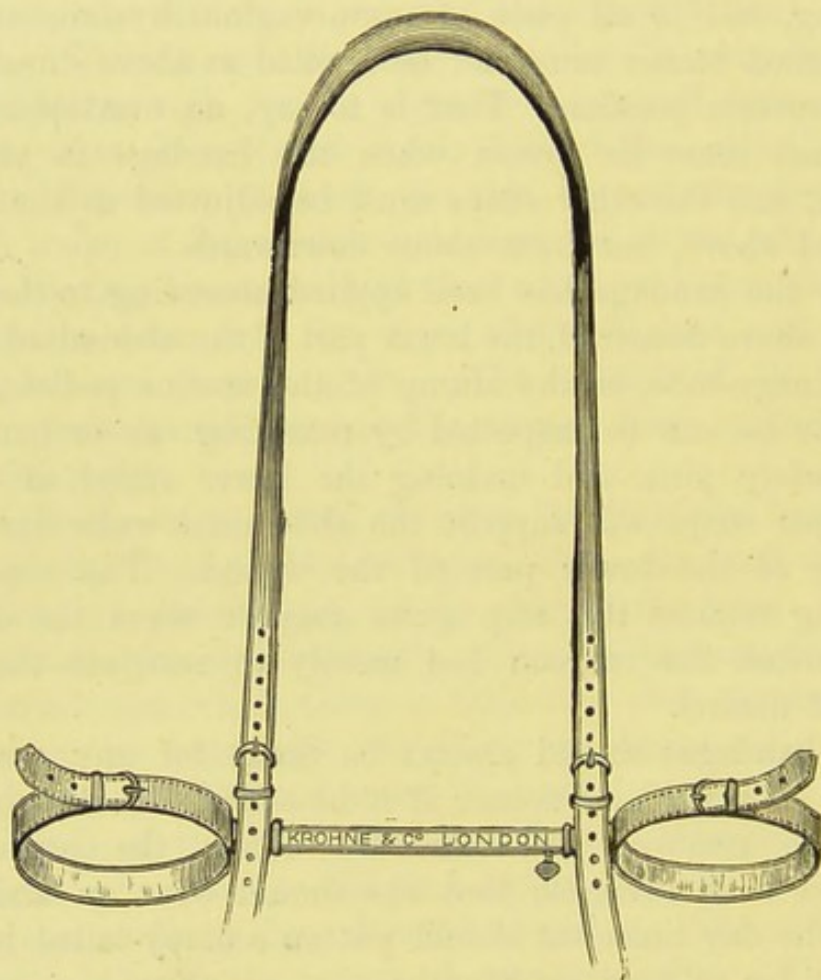


FIG. 56.—CLOVER'S CRUTCH (*the Inner Bar completely slid into the Outer*).

which are each secured, by two straps, to one of the patient's thighs immediately above the knee. One band is attached to a solid bar, deeply notched, the other to a hollow bar. The former bar is slid, between the patient's lower extremities, within the latter, and when the knees are sufficiently far apart, they can be fixed by turning a screw on the hollow bar,

which thus catches in one of the notches on the solid bar. A strap is attached to the right side of the crutch and is passed behind the right shoulder and under the left axilla, being made fast to the other end of the crutch, after having been pulled firmly so as to flex the thighs sufficiently on the abdomen. This strap must not be pulled too tight, else it will cause severe attacks of cramp in the lower extremities after the operation. Care must be taken that no nurse or assistant presses on the bar of the crutch or against the patient's knee during an operation, else the patient's body will be tilted sideways, to the great inconvenience of the operator.

A long piece of towelling makes a good substitute for the crutch. One end is made fast round the right thigh just above the knee, tied, and the knot secured by a safety-pin. The towelling is then passed behind the right shoulder and under the left axilla, the other end being secured to the left thigh, after both thighs have been flexed and sufficiently abducted. The practice of trusting to an assistant or nurse to hold the thighs in position is open to many objections.

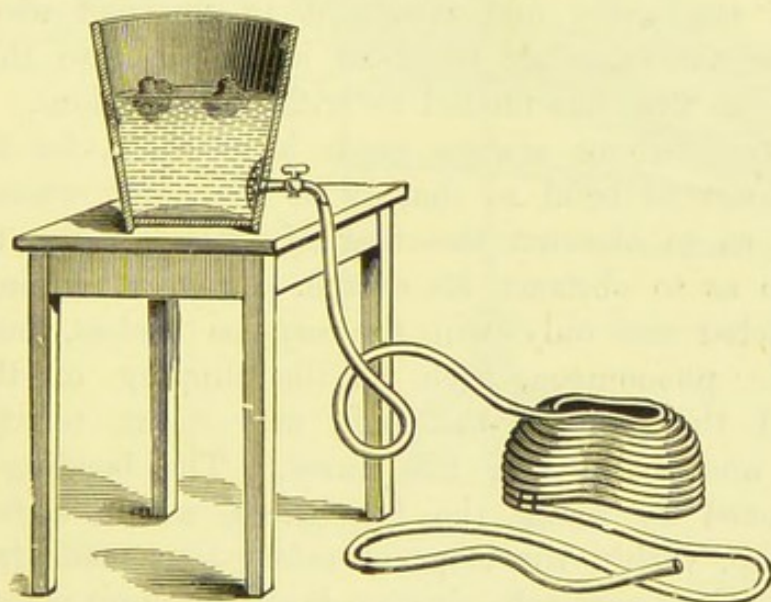


FIG. 57.—THORNTON'S ICE-CAP.

Thornton's Ice-cap.*—This appliance (Fig. 57) is modified from a form invented by a working-man employed

* Originally described by Mr. Thornton in *Medical Times and Gazette*, May 27, 1876, and *Medico-Chirurgical Transactions*, vol. lx. p. 301.

at an india-rubber factory in Glasgow. It consists of a series of coils of stout gutta-percha tubing, joined together so as to form a cap. The tubing is flat on the inner side, so that a uniformly cool, smooth surface touches the patient's head. Before this improvement was introduced, the spaces which necessarily existed between the perfectly cylindrical tubes lodged warm air and defeated the object of the appliance.

At the top of the cap the tubing is continued as a free piece, which is to be fitted on to a tap connected with a pail. The tubing at the lower border of the cap is also continued as a free piece, several feet in length.

The pail is filled with water containing ice—one large block answers the purpose best. It is placed on a stand by the side of the bed, about two feet above the level of the patient's head. The upper free piece of tubing is fitted to the tap and the water is turned on, the cap being placed on the patient's head. The lower free piece of tubing passes from the side of the patient's head into a pan beside the bed. The tap may be regulated so as to allow the water to flow slowly. As the pan fills the nurse can bale out some of the water and return it to the pail above. She must see that another block of ice is put into the pail as soon as the first has melted to trifling dimensions.

The free tubing always needs adjustment, for the upper piece is apt to bend so sharply at the point where it joins the cap as to obstruct the flow of water, whilst the lower bends so as to obstruct its escape. If this bending be not counteracted not only will the cap be useless, but various hydraulic phenomena, such as the slipping of the upper piece off the tap on the pail, may occur, terrifying the patient and perplexing the nurse. The bending may be counteracted by fixing the free tubes, within a few inches of the cap, within the loops of safety pins made fast to the pillow, so that each tube rises up from the point where it joins the cap and describes a short curve, which does not obstruct the flow of water.

Leiter's Tube, Cap, and Temperature Regulator.—

In many respects the ice-cap just described is the best apparatus for lowering high temperatures after operation. Ice, however,

is not always easy to obtain, and then Leiter's pliable metal coils, or "temperature regulators," are very convenient for the same purpose, although it is always best that the water should be ice-cold. By means of these coils, cold water may be made to circulate continuously through a length of pliable metal tubing. Leiter's contrivance is employed for the application of continuous cold, or heat, to any part of the body.

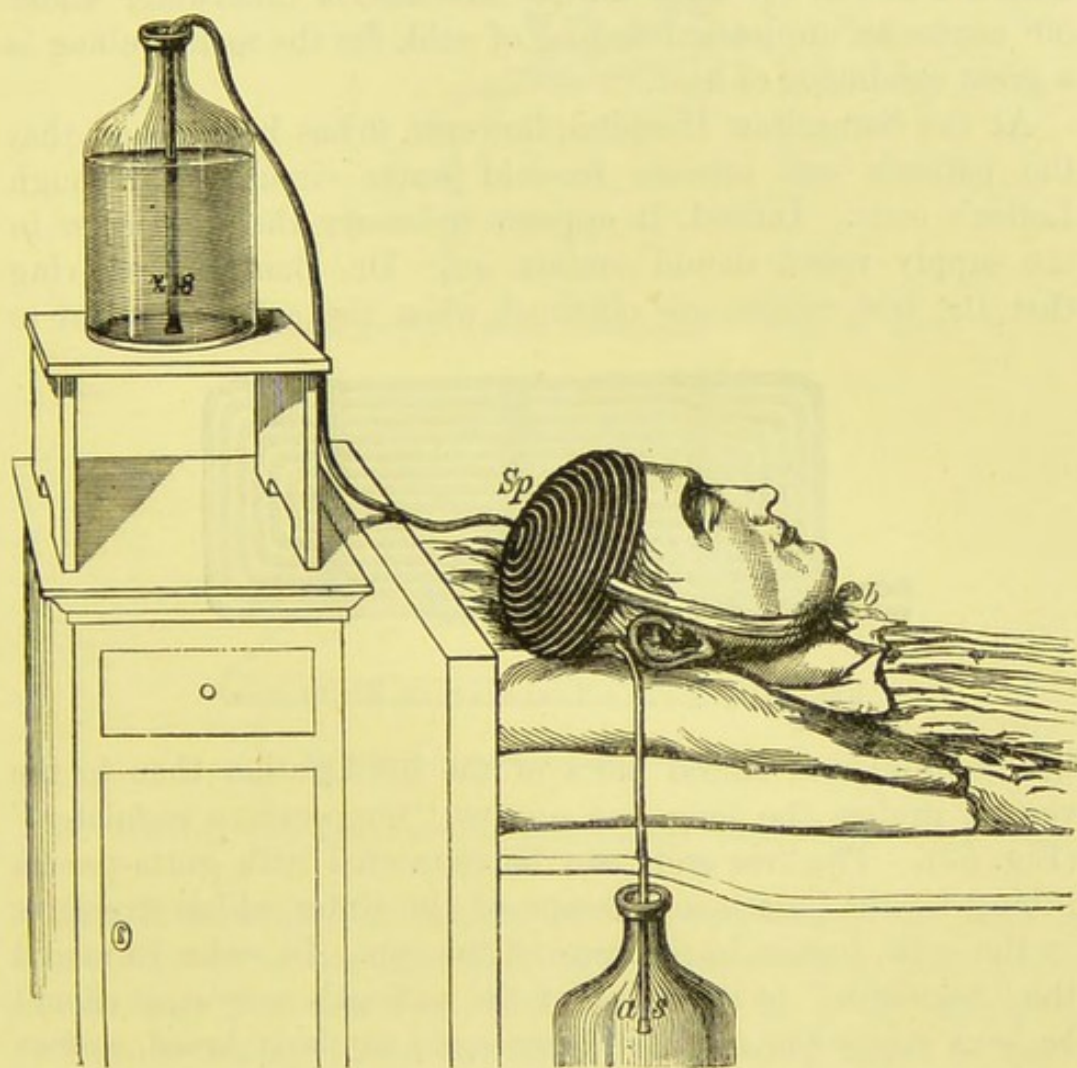


FIG. 58.—LEITER'S CAP.

For the present purpose, the special circular cap for the head is sometimes employed. It may be seen that it is arranged like Thornton's cap. A broad tape (*b*, Fig. 58) holds the cap (*Sp*) in position. A supply vessel is placed above the level of the patient's head, and a piece of gutta-percha tubing (*z s*), connected with the coils, is passed into it, whilst a similar

tube (*a s*), also connected with the coils, is placed in a receiving vessel on the floor. By slight suction in the lower tube, siphon action is at once established. When the lower vessel is nearly full, the position of the two vessels may be reversed, and by this repeated changing, a continuous flow of water through the spiral cap is maintained for any length of time. According to Leiter, the water will not require changing, provided that it does not rise to 60° Fahrenheit. He asserts that water under 50° causes an unpleasant feeling of cold, for the metal tubing is a great conductor of heat.

At the Samaritan Hospital, however, it has been found that the patients can tolerate ice-cold water circulating through Leiter's coils. Indeed, it appears necessary that the water in the supply vessel should contain ice. Dr. Bantock, believing that the best results are obtained when the cold is applied to




FIG. 59.—LEITER'S TEMPERATURE REGULATOR.

the occipital and lateral parts of the head, rather than to the vertex, prefers the long and narrow "temperature regulator" (Fig. 59). The free ends can be connected with gutta-percha tubing for the ingress and escape of the water which circulates in the coils, just as in the case of the cap. In order to mould the "regulator" to the shape of the patient's occiput, it should be bent across the thigh, or over some similarly broad, convex surface, as shown in Fig. 60. If bent by the hands without support of this kind the instrument will soon be spoilt, for the coils will no longer lie parallel, so as to touch the surface of the scalp evenly, and they will also become leaky. If the regulator be bent too much, it should be straightened as in Fig. 61—the palm must be gently pressed on the prominent surface of the regulator. When properly bent into shape, the regulator is placed behind the patient's head, the sides being pressed towards

the temples, then the supply and receiving vessels and their tubes are adjusted.

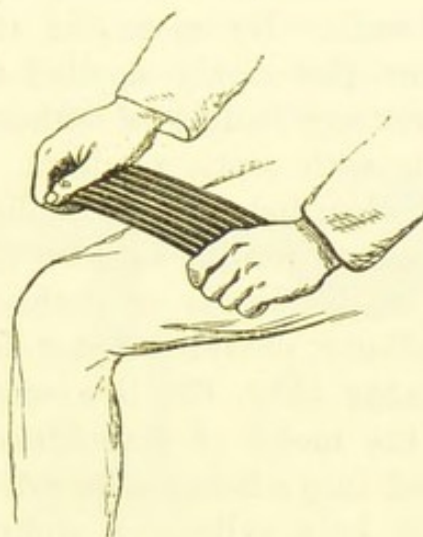


FIG. 60.—LEITER'S TEMPERATURE REGULATOR : HOW TO BEND IT.

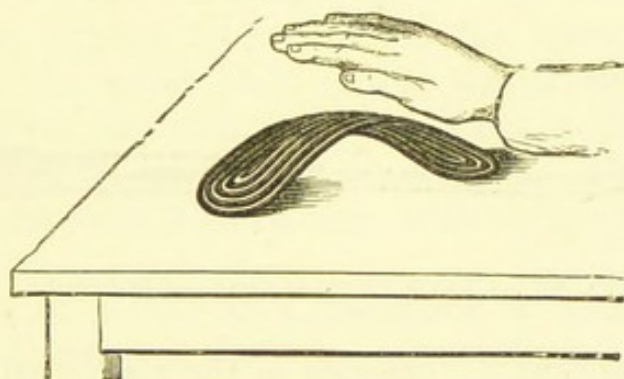


FIG. 61.—LEITER'S TEMPERATURE REGULATOR : HOW TO STRAIGHTEN IT.

Ice Bladders.—A bladder of ice placed upon the head is more difficult to manage, and far less satisfactory, than either of the caps just described, yet if ice can be freely procured, and no better appliance be at hand, the bladder must be used. Great precautions will then be necessary to renew the ice before that which is already in the bag has thawed completely, and to prevent damping of the pillow from soakage through the bladder. A piece of mackintosh, carefully folded, is better than a bladder as a receptacle for the ice.

Uterine Insufflator.—This instrument is not only useful for the application of powders to the cervix through a speculum, it is also very serviceable for blowing pulverized preparations

over the surface of cavities which require to be kept dry and antiseptic, as when an extra-uterine foetal sac has been stitched to the abdominal walls. By means of this instrument, the powder can be more thoroughly applied than by any other method, and without any fouling of either the instrument or the surgeon's hands with septic products. The insufflator is especially desirable when iodoform is applied, as, owing to its odour, it is not pleasant for the surgeon if any of that compound should fall on his hands or clothes. This accident is avoided by the insufflator, provided that it be properly used.

Clay's Insufflator (Fig. 62) is a convenient form, constructed much on the model of Rauchfuss's insufflator. The powder is introduced into a hole in the side of the tube, which is then covered over by a cylindrical sliding contrivance, and




FIG. 62.—CLAY'S INSUFFLATOR. (*In action*).

the powder is ejected by pressure on the elastic ball. The ball also moves a kind of stilette, which is dilated so as to form a knob or stopper to the open end of the tube when at rest. Pressure on the ball pushes the knob forwards, and the powder is scattered. The knob protects the powder from getting damp and clogging the tube when it is being passed up the vagina. The disadvantage of any insufflator worked in this manner is the contrivance by which the powder is introduced. This contrivance does not protect the surgeon from soiling of the fingers, which in the case of foetid, deliquescent, caustic, or dye-yielding powders may be very undesirable. The contrivance which covers in the aperture in the tube for the introduction of the powder is apt to get out of order, and to slip off the aperture when the ball is being worked.

Kabiersky's Insufflator.—In this instrument (Fig. 63)

the tube communicates with a bottle in which the powder is placed. The bottle is made flat-bottomed, so as to stand upright on a table. It is generally rounded off at its extremity. Instead of the ball, the handle of the insufflator is sometimes provided with a spring stopcock and Richardson's

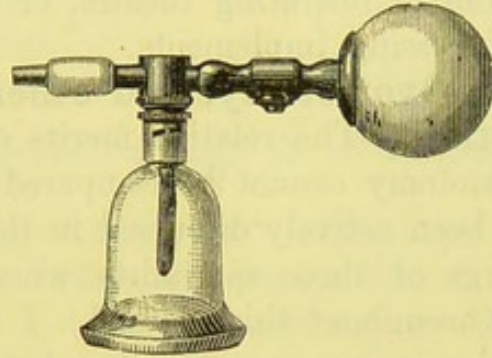


FIG. 63.—KABISKY'S INSUFFLATOR, WITH FLAT-BOTTOMED GLASS RESERVOIR
(Nozzle not Attached).

ether-spray bellows. During use, the ball covered with network is first inflated by pressure on the lower ball, then, by pressure on the metal plate of the spring stopcock, the air is released from the ball, and the powder is blown on to the surface towards which the nozzle is directed. The simple india-rubber ball, however, answers very well, so that the bellows are hardly needed.

The tube of Kabisky's insufflator is made of vulcanite, and nozzles of different shapes are made (Fig. 64, *m*, *l*, and *k*); of




FIG. 64.—NOZZLES FOR KABISKY'S INSUFFLATOR.

these, *l*, designed originally for the pharynx, is best for applying powders to the vagina, or cervix, or uterine canal; *m* for blowing into the cavity of a tumour or extra-uterine foetal sac undergoing desiccation after drainage.

The glass bottle is fixed to the tube by means of a bayonet-joint. It must be kept pointing downwards when it is advisable to apply the powder in the finest state of division possible, but upwards when a thick layer of powder is desired.

This is an excellent instrument, and the glass bottle is readily taken off and put on when required. In the case of a powder often applied, especially iodoform, it is convenient in hospital practice to keep the bottle constantly filled and fixed to the insufflator, which, thus charged, may be kept in the out-patient room or operating theatre, or taken round the wards with other dressing implements.

Antiseptics in Ovariectomy, and other Varieties of Abdominal Section.—The relative merits of Listerian and non-Listerian ovariectomy cannot be compared in these pages. The question has been actively discussed in the medical press, and in the writings of those specialists whose names I frequently mention throughout this manual. I have not as yet discarded antiseptics in my own practice, but I am ready to admit that those who have performed abdominal section many hundreds of times appear to be in a position to dispense at least with the spray.

When the spray and a 1-in-40 carbolic solution are both discarded, the instruments must be kept in warm water, when not actually in hand. For full particulars of the principles of antiseptic ovariectomy, I must refer the reader to Mr. Thornton's article on that operation in Heath's *Dictionary of Practical Surgery*, for that author is the principal authority on the subject.

The spray-apparatus, when it is used, should be placed about eight feet from the seat of operation. If too near, the jet of steam will not be diffused over a sufficiently wide area of the parts subjected to operation; it will also cause needless irritation, and will make the operator's hands numb, greatly impairing their tactile sensibility, which is so necessary for exploration of the viscera.

CHAPTER V.

ELECTRICAL APPARATUS USED IN GYNÆCOLOGICAL SURGERY

Introduction.—Electrical contrivances are extensively used both in operations on women and in the treatment of their diseases. I have endeavoured to avoid the error of taking for granted that the reader is acquainted with the batteries employed for these purposes, and that he understands the technical terms used by electricians. Therefore, I have availed myself of the services of Dr. Steavenson, physician in charge of the Electrical Department of St. Bartholomew's Hospital, who has kindly written this chapter which may, I believe, help to instruct the reader so that he may know what instruments to procure, how to use them, and how to teach their use to his assistants.

Galvano-cautery and Electrolysis.—Electricity is employed in operative surgery in two ways. Firstly, it is used for its power of producing heat; and secondly, for its property of splitting up all chemical compounds, that are conductors, into their constituent elements. These two properties of electricity go under the relative names of *galvano-cautery* and *electrolysis*. For the employment of either in surgery, batteries of different construction and different instruments are required.

In galvano-cautery the circuit is completed through the instrument that is used (see Figs. 68, 69, 70), and therefore the resistance offered to the current is very low, and every endeavour is made to further reduce it. In electrolysis each pole is attached to a separate electrode, and the circuit completed through the body of the patient, which offers a very high resistance to the current; therefore, means have to be adopted for overcoming this resistance.

The constant current, as it is called, is the kind of electricity which is used for accomplishing both objects.

In galvano-cautery the battery is arranged so as to give a large *quantity* of electricity in a short space of time, and in electrolysis the battery is so arranged as to enable it to overcome a high *external resistance*. Although both the batteries which are used produce a constant current, they are, on account of the different arrangement of the cells, usually called by distinctive names. One is called a *galvano-cautery battery*, and the other a *galvanic* or *constant current battery*.

Initial Force: Electro-motive Force.—The initial force by which electrical separation takes place in a cell depends upon the elements of which the cell is composed, and the activity with which the exciting fluid attacks the positive element (usually zinc) when the circuit is closed. Again, the amount of this chemical decomposition of the positive element is regulated by the strength of the current. This initial force is called *potential*. The difference of potential thus established in the elements of a cell produces *electro-motive force*, and electro-motive force is that force which tends to move electricity in a circuit when the current is closed. It therefore follows that whatever the size of the cell or of the elements contained in the cell, if composed of similar materials, the same electro-motive force is produced. Therefore, the electro-motive force (E. M. F.) of cells of like construction is the same, no matter what their size.

The Volt.—The Volt is the standard of electro-motive force, and is very nearly the electro-motive force produced in one Daniell's cell.

The most common cells used in medicine are:—

Daniell's; electro-motive force..	..	1.079 volts.
Smee's	..	1.62 „
Leclanché's	..	1.5 „
Chloride of silver; electro-motive force	..	.915 „
Stöhrer's	..	1.825 „
Grove's	..	1.956 „
Bunsen's	..	1.964 „
Bichromate of potash	..	2.000 „

The last three, with a high electro-motive force, are employed chiefly for galvano-cautery.

The Ohm.—The unit of *resistance* is the *ohm*. An ohm is the amount of resistance offered by $48\frac{1}{2}$ mètres of copper wire of one millimètre diameter. Dr. Stone, of St. Thomas's Hospital, has shown* that the human body offers a resistance of from 900 to 1,000 ohms.

Strength of Current.—The strength of current of a battery is determined by the accumulated electro-motive force of the cells divided by the resistance. This is what is called Ohm's law, and may be expressed by the formula:—

$$C. S. = \frac{E}{R_1 + R_2},$$

in which, C. S. = current strength; E = electro-motive force; R_1 = external resistance; and R_2 = internal resistance. It is therefore evident that the current strength will greatly depend upon the amount of resistance. The internal resistance R_2 is always low; therefore, if R_1 be relatively great, means must be taken to increase the value of our numerator, the electro-motive force. This is done by multiplying the number of cells. But if R_1 be small, the current strength can be greatly increased by reducing R_2 (making our denominator low, and therefore our quotient high). This is done by increasing the size of the cells and surfaces of the elements. "By reference to these facts we determine the form of battery to be used in the different applications of electricity to medicine and surgery."†

For instance, if $R_1 = 1,000$ ohms and $R_2 = 1$ ohm, to reduce R_2 to $\frac{1}{2}$ an ohm would leave the whole resistance at $1,000\frac{1}{2}$ ohms. This would not materially affect the strength of the current: it would only increase the current strength by about $\frac{1}{2000}$ part. But if $R_1 = 1$ ohm and $R_2 = 1$ ohm, then to reduce R_2 to $\frac{1}{2}$ an ohm, by doubling the size of the plates in the cell, the current strength would be increased by $\frac{1}{4}$. This is the object attained by a galvano-cautery battery.

* "Lumleian Lectures before the Royal College of Physicians of London" (*British Medical Journal*, vol. i., 1886, pp. 728, 812, 863).

† John Duncan: *Heath's Dictionary of Practical Surgery*, article "Electrolysis."

The Ampère.—An ampère is the unit of *current strength*, and is produced by one volt through the resistance of one ohm. In medicine, $\frac{1}{1000}$ of an ampère or a milliampère is used.

The Coulomb.—The coulomb is the unit of *quantity*, and is the quantity of electricity that will pass through a circuit in *one second* when the current strength is one ampère.

The current strength of one volt through one ohm for three seconds is still one ampère, but the quantity is three coulombs.

The Galvano-cautery Battery.—This kind of battery (Fig. 65) has to overcome a relatively low external resistance,

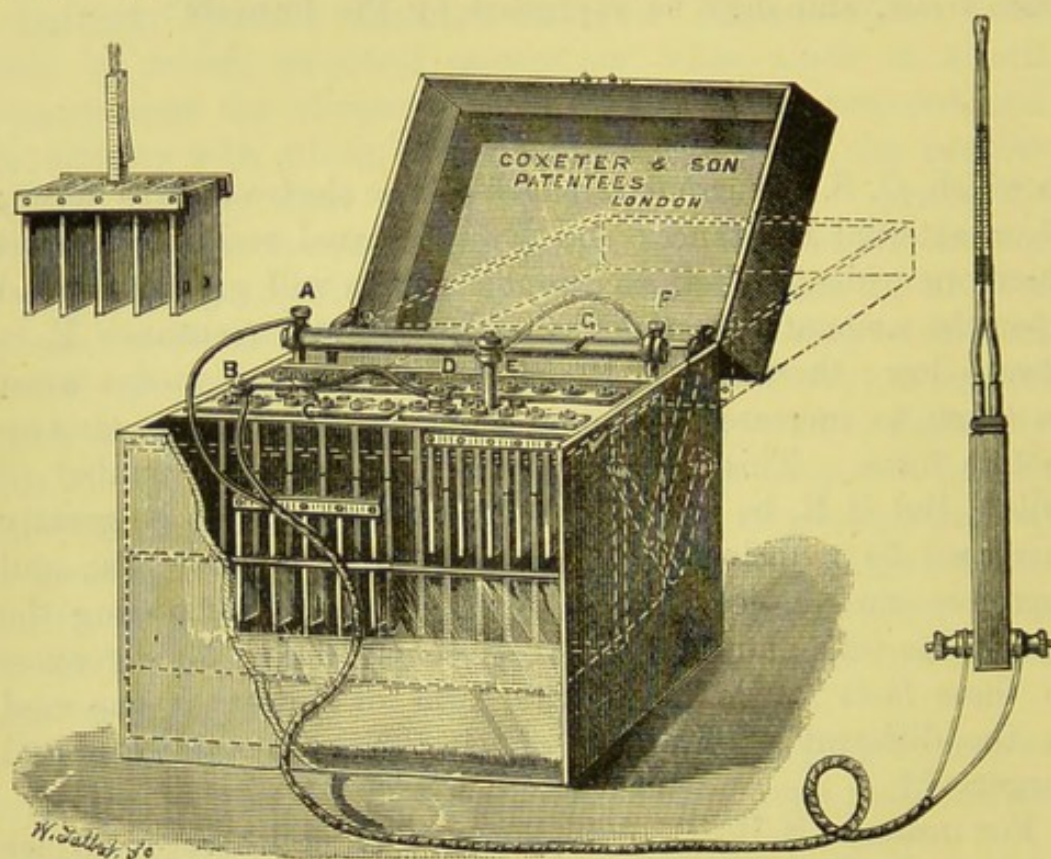


FIG. 65.—BICHROMATE OF POTASH GALVANO-CAUTERY BATTERY, WITH ELECTRODE.

A, B, terminals for attaching the conducting cords to the rheostat and carbon pole of the battery. *C, D*, connection between the two sets of plates. *E, F*, connection between the second group of zincs and the rheostat, thus completing the circuit. *A, F*, rheostat worked by a sliding button, *G*, between the terminals.

and therefore the current strength is greatly increased by reducing the internal resistance to a minimum. This is done by having large cells with elements exposing wide surfaces to the exciting fluid, and closely approximated to each other.

The current strength is therefore great, and the quantity of electricity passing in a given time is also great. A few such large cells are found sufficient to heat a platinum wire. One of the best forms of galvano-cautery batteries (Fig. 65) is composed of four or six cells (two in the diagram); each cell is composed of four or five broad plates of zinc about half an inch apart, and on either side of these plates is a similar-sized plate of carbon. By this arrangement in each cell there is one more carbon plate than zinc. This is found to be an advantage. The carbon plates are not allowed actually to touch the zinc. All the zinc plates composing each cell are joined together usually on an iron frame, and virtually form one element of considerable surface. They can be removed together for the purpose of cleansing and re-amalgamation, and in some cases for lifting from the exciting fluid when the battery is not in use. All the carbon plates of each cell are also joined together, and make one large negative element. They are usually fixed to the element board, for it does not matter if the carbons be left in the fluid, as they are not affected by it. The exciting fluid is composed of a saturated solution of bi-chromate of potash, with one ounce of pure sulphuric acid added to every seven ounces of the solution. Both elements are immersed in this fluid when the battery is at work. The fluid is contained in glass or vulcanite cells. The best method for bringing the battery into play is to have these cells containing the fluid on a stage which, by a mechanical arrangement attached to the lid, can be brought up to the elements by turning the lid back from the perpendicular (Fig. 65). This arrangement also obviates the necessity of a *rheostat*, for the current can be regulated by the amount of the plates which the fluid is allowed to cover. In this way an assistant, with his hand on the lid, can so control the current that the cauter or wire is kept at a dull or bright red heat.

The Rheostat.—A rheostat is an arrangement for regulating the current by interposing more resistance, and is generally made of a coil of German silver wire. The current is made to traverse more or less of this coil, according to the amount of heat required.

Amalgamation. — Another advantage of the lifting

arrangement attached to the lid is, that at any time during the operation, when the current is not required, the fluid can be lowered and the zincs left clear. Although theoretically no action ought to go on in a cell when the circuit is open, yet, as a matter of fact, local action does take place in the zinc, owing to certain metallic impurities which it always contains. To obviate this local action as much as possible, it is advisable to have the zinc plates well amalgamated. After every second or third operation the plates should be re-amalgamated. This process of amalgamation can be easily accomplished. The surface of the zinc is cleaned with a little dilute sulphuric acid and water, and then some crude mercury is poured upon each surface and rubbed into it by a piece of linen rag tied over the end of a stick. The mercury unites with the zinc, and forms a bright metallic layer.

Polarization.—Another action which impedes and weakens a current is called polarization. This takes place on the negative element, the carbon. Hydrogen is displaced by the action of sulphuric acid on zinc, and appears at, and adheres to, the carbon, forming a film of minute bubbles, which materially increases the internal resistance of the cell and weakens the current.

To obviate polarization, many devices are followed. 1. Bi-chromate of potash is used in the exciting fluid, as it easily parts with its oxygen, which combines with the nascent hydrogen. 2. The cell is rocked to and fro to mechanically disengage the bubbles of hydrogen. 3. A piece of vulcanite is made to pull up and down over the carbons, so as to sweep their surfaces. 4. The lifting arrangement, before described, is also useful in disengaging this layer of hydrogen. The strength of a current can often be increased by bending the lid sharply once or twice backwards and forwards, thus washing the hydrogen off the carbons by the movement of the fluid. But the chief cause of weakness in a bi-chromate of potash battery, and the reason why it runs down far more rapidly than a Bunsen's or a Grove's battery, is that the exciting fluid soon becomes what the electricians call "killed." In other words, the sulphuric acid is gradually used up and turned into a solution of sulphate of zinc. It is, therefore,

necessary to change the fluid frequently. The same fluid will not do for more than two or three operations; it then has to be thrown away and fresh fluid used. It is best, when a long operation is anticipated, always to begin with fresh fluid. A bi-chromate of potash galvano-cautery battery will work very well for most operations, which do not take more than twenty minutes or half an hour; but towards the end of that time the strength of the current is considerably reduced. The exhaustion of the fluid can be retarded by attention to the direction before given; that is, by lowering the fluid away from the elements at every opportunity during the operation when the current is not actually required—at such intervals, for example, as those caused by the necessity for readjusting the wire or changing the cauter. The bi-chromate of potash battery has an advantage over the Bunsen's or Grove's in that the operator and bystanders are spared the annoyance of the nitric acid fumes which are always given off from these batteries.

Bunsen's Battery for Galvano-cautery.—This consists of four to six cells, composed of zinc and carbon, but the elements are contained in separate cells, and immersed in different fluids. The carbon is placed in a porous earthenware inner



FIG. 66.

pot, containing concentrated nitric acid; around the pot is a circular sheet of zinc immersed in sulphuric acid and water (1 to 8), and all contained in an outside glazed earthenware or glass pot (Fig. 66). The electro-motive force of a Bunsen battery is rather higher than that of a Grove's, and carbon is much cheaper than the platinum used in the latter cell; but in the Bunsen cell it is somewhat difficult to get a good connection

between the strip of copper which unites the zinc plates to the carbon, on account of the rough surface of the carbon.

Grove's Battery (Fig. 67) is similar to Bunsen's, except that in the inner pot platinum takes the place of carbon. Although in both the cells a porous pot is introduced between the positive and the negative element, yet the internal resistance is low, on account of the good conducting power of the nitric acid. In neither of these cells does polarization take place, because the hydrogen which is liberated by the decomposition of

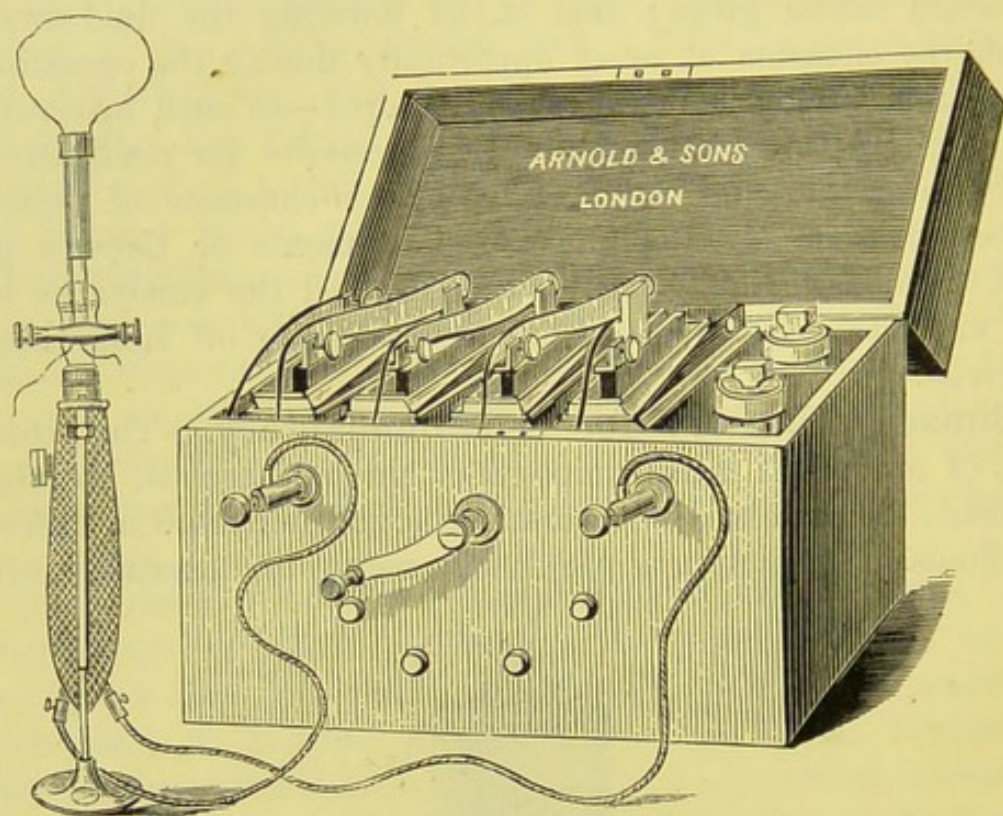


FIG. 67.—GROVE'S BATTERY, WITH ÉCRASEUR.

zinc in dilute sulphuric acid has to pass through nitric acid before it can be deposited on the negative element (carbon or platinum). In passing through the nitric acid the hydrogen becomes oxidized, and red fumes of peroxide of nitrogen escape from the battery. These red fumes make the Grove's and Bunsen's batteries objectionable for surgical work. In hospitals and large institutions, where space can be given for a regularly organized electrical department, these batteries can be kept in a dry cellar beneath the operating-room, and are far cheaper and more effectual than any other form, as a current capable of heating a

platinum wire and performing an operation can be maintained for several hours. They cannot be kept charged, because the acid fumes which arise from them destroy the connections. It is therefore almost necessary to have an electrician, whose duty it is to prepare the battery when it is required, to decant the fluid and wash the elements directly the operation is over, and to keep all the connections dry and bright. A Grove's battery can be made in a more portable form (Fig. 67) than a Bunsen's, on account of the smaller space required by the platinum, which can also be placed in a flat porous cell, and the zinc can be bent up so as to embrace the flat porous cell on both sides; this helps to reduce the internal resistance.

Rheophores.—The rheophores are the conducting cords between the battery and the instrument with which the operation is performed, and are usually composed of thick copper wire, or many strands of fine copper wire. For galvano-cautery purposes the rheophores are made thick—that is, of as large a transverse sectional area as is possible, so as to offer very slight resistance to the transit of the current. One rheophore is attached by a binding-screw to the first carbon or platinum element of the battery, forming the positive pole, and the other is attached to the last zinc, forming the negative pole. The circuit outside the battery is from the carbon to the zinc; inside each cell, from the zinc to the carbon. Each rheophore is attached by a separate binding-screw to the handle of the instrument.

Instruments: Cauters.—The instruments vary in shape and construction according to the operation for which they are required. In most of them the current passes to and from the cauter through the same handle, by means of two metal rods, frequently made of brass. The rods are insulated from each other up to the point of the instrument, where connection is made between them by some comparatively badly conducting metal, of small sectional area, usually platinum. Owing to the increased resistance and greater density of the current thus produced in this terminal part of the instrument, heat is evolved in sufficient quantity to raise the temperature of the platinum to any required degree. In the handle, the conducting rods are insulated by being each separately embedded in ebonite; and beyond the handles, up to the uniting piece of platinum, each

stem is covered with shellac, or other insulating substance, and bound round with cotton, also covered with shellac. No metallic connection takes place by which the current, after leaving the battery by the positive pole, can return to the negative pole, except through the piece of platinum which it is required to heat. If the current does find its way back to the battery, through any imperfect insulation in the instruments, or by carelessness on the part of the operator in letting his instruments touch some metal part of the battery, the current is said to be "short circuited," and does not reach the platinum at all. Platinum is generally used to form the actual burning part of the instrument, and is selected because of the great resistance it offers to the transit of electricity, being a very bad conductor, and because of its high fusing point. Platinum is, of all malleable metals, the worst conductor of both heat and electricity, and is also the least oxidizable. The shortest piece of platinum or the finest wire, compatible with the operation which it is intended to perform, is selected, because the finer the wire the greater the density of the electricity which passes in a given time.

Whereas, in every other part of the circuit, every endeavour is made to allow the current to flow along broad conducting routes as easily as possible, at the point where heat is to be evolved every obstacle is placed in the way of the current, so as to have the largest amount of electricity passing through a point of high resistance. The transverse sectional area of this part of the circuit which offers high resistance is also made as small as possible, so that the density of the current may be increased. If the transverse sectional area of a platinum wire used to complete the circuit be too small for the strength of current, the heat evolved will be so great that the wire will fuse, although platinum has the highest fusing point (1775° C.) of any known metal. By electricity we are able to produce the highest degree of heat hitherto known, and we are also able to regulate and control its production in a manner perfectly impossible in the case of any other heat-generating force.

The terminal ends of platinum are made of different sizes and shapes, so as to be suitable for very different purposes. Some are made with a small loop which can be used for the removal of urethral caruncles; others are brought to a fine

point with which sinuous passages can be cauterized ; while others again are made of flat pieces of platinum to which the name of "platinum knives" has been given. For the purpose of arresting hæmorrhage or destroying unhealthy surfaces, broad nodular ends are made of porcelain, round which platinum wire

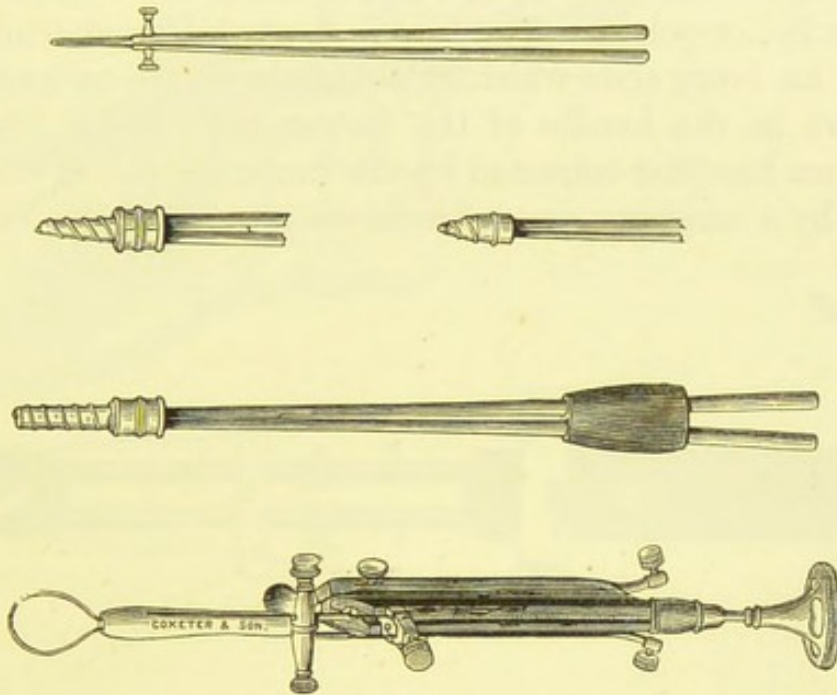


FIG. 68.—CAUTERS AND ÉCRASEUR.

is coiled (Fig. 68). The wire when red-hot heats the porcelain, which also becomes red-hot, and retains the heat for some time ; thus a more permanent cautery is obtained, and one not so likely to be damped and cooled by the moist tissues and blood as a smaller cauter composed only of a thin piece of platinum.

Platinum Knife.—The so-called platinum knives are too weak and yielding to be used in the same way as a Paquelin's thermo-cautery knife. To supply this want, a platinum knife



FIG. 69.—FIRM PLATINUM KNIFE.

It consists of a porcelain knife, of which the edge is of platinum.

has been made which consists of a stout piece of platinum wire stretched round the edge of a tongue-shaped piece of porcelain (Fig. 69). When employed with the battery, the wire becomes

red-hot, and will cut in the same way as a benzoline cautery, the wire being kept firm and in position by the porcelain.

Galvanic Écraseur.—The galvanic écraseur is an instrument in which a loop of heated platinum or steel wire can be gradually contracted. It is used for the removal of pedunculated growths, the cancerous cervix uteri, hypertrophied anterior lip, or polypi. The loop is shortened by attaching the wire to an ivory slide which is able to be moved up and down a groove in the handle of the instrument. Slides are made which can be either retracted by the finger or moved down the groove by a screwing arrangement as in an ordinary écraseur.

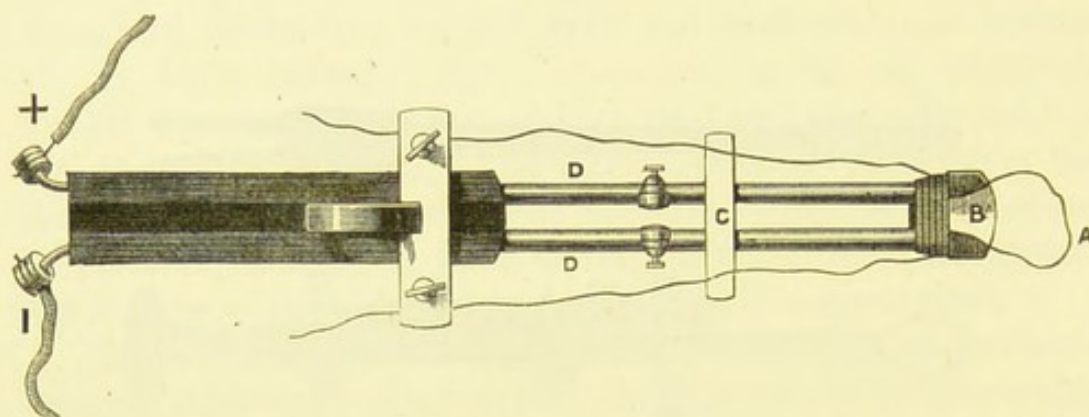


FIG. 70.—GALVANIC ÉCRASEUR.

A, platinum loop. B, piece of porcelain, a non-conductor. C, piece of ivory. The current runs along the metal rods, D D, until it comes to the place where they are separated by the porcelain; thence it completes the circuit through the small loop of platinum wire, which becomes red-hot.

The wire passes through little holes in the ends of the brass rods which convey the current through the handle. The ends of the rods are kept apart and insulated from each other by a small piece of porcelain. The eyes through which the platinum wire is threaded must not be too large, as good contact between the brass carriers and the wire is necessary to complete the circuit, the current being conveyed from the brass rods to the wire. At the other ends of the brass or steel rods, where they emerge from the handles, are binding-screws, to one of which is attached the rheophore from the positive pole, and to the other the rheophore from the negative pole. The circuit is closed by a spring arrangement, which is moved from the under surface

of the handle, and is generally pressed by the ring finger as shown in Fig. 71.

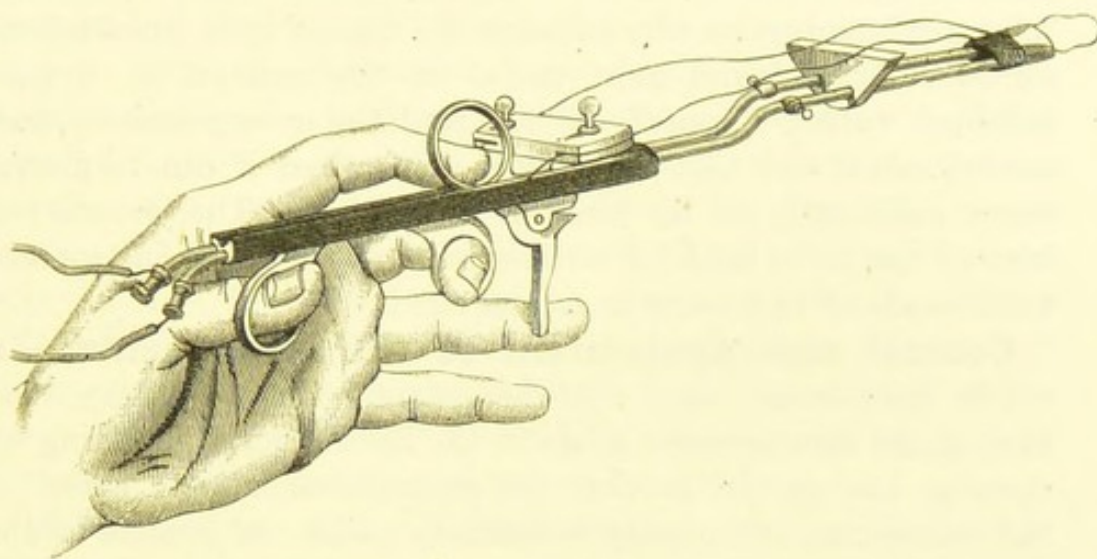


FIG. 71.—SIDE VIEW OF THE SAME GALVANIC ÉCRASEUR (see Fig. 70).
Showing the manner in which the instrument should be held.

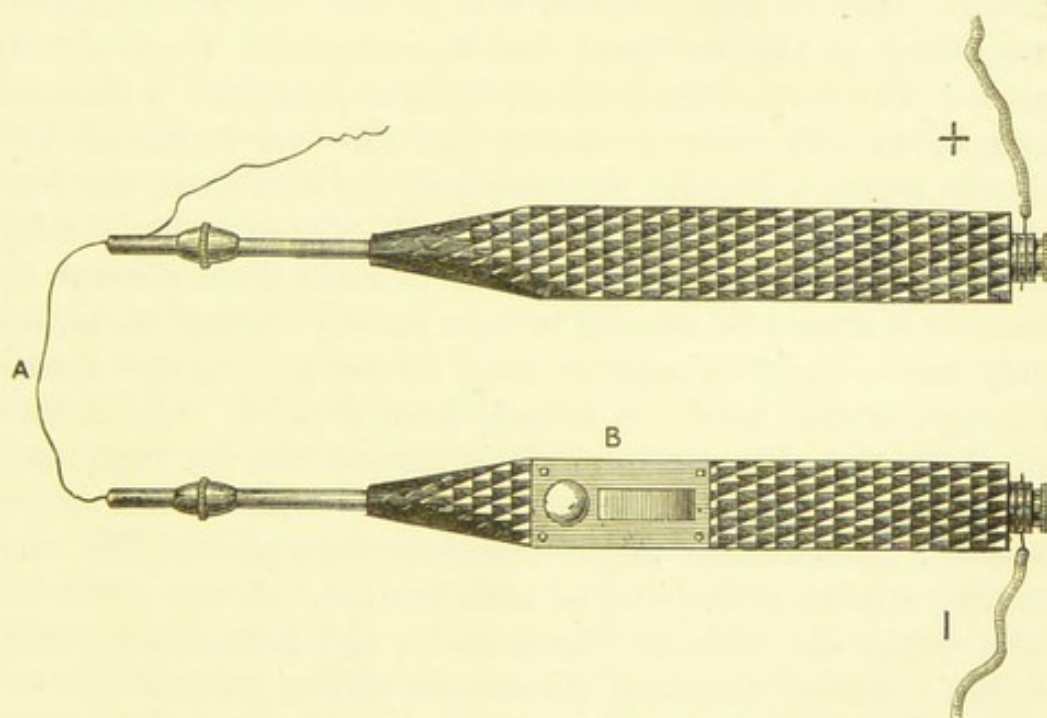


FIG. 72.—TWO CLIP-HANDLES.

A, platinum loop. B, shunt for interrupting or completing current.

Some operators prefer that the platinum wire should be connected with two conducting handles (Fig. 72), one handle

connected with the positive pole, and the other with the negative pole of the battery. The wire connected in this way gives the operator great power in directing the course that it should follow in burning its way through the tissues it is intended to remove. It is found most useful in the removal of hypertrophied vulvæ, diseased clitoris, cauliflower excrescences and condylomata, and also the cervix uteri when it can be drawn down sufficiently to be brought into view. The growth or tumour has to be held by an assistant, as with this instrument both hands of the operator are required.

Control and Application of the Instruments.—In all the instruments used with the galvano-cautery battery some mechanical arrangement exists in the handle for completing or opening the circuit, so that the commencement and arrest of the cauterizing action may be entirely under the control of the operator. With some batteries an arrangement exists by which the continuity of the current can be made or broken by the foot; the strength of the current can also be regulated by this means. The mode of application of the instruments above-mentioned is obvious from the description of them already given. The wire of the galvanic *écraseur* is applied in the same manner as with other *écraseurs*, and the wire tightened by a similar action. But the tightening of the wire is not the force with which the operation is performed. Care should be taken not to tighten it too rapidly, so as to make it cut through the tissues; it should be allowed to burn its way through them, and only drawn tight enough to keep its red-hot surface against those parts that have not already been divided. If tightened too fast, the wire itself cuts the tissues, and its hæmostatic action has not time enough to seal the divided ends of the vessels; hæmorrhage might therefore take place. The same remark applies if the wire be used too hot. A wire at a white heat would cut through like a knife, and hæmorrhage would follow. One of the chief advantages of the galvanic *écraseur* would thereby be lost. The wire ought to be kept at a dull red heat. The assistant, therefore, who has charge of the battery and who has to regulate the current ought to be experienced, for on him depends to a great extent the success of the operation. He ought to be constantly using a galvano-cautery

battery, and know the particular battery which he may be called upon to work. When acting well, a slight hissing sound is heard during the operation. If the wire were kept too long, each end of the loop not embedded in the tissues would become hotter than the remainder, and might possibly burn the surrounding parts; and if a very strong current were being employed, the wire might be fused at either of these points, and thereby interrupt the operation. When the two handles are used, and the wire cannot be shortened, those portions of it not embedded in the tissues should be carefully watched, and not allowed to become too heated. Their temperature may be kept down and the operation expedited by a gradual sawing movement—that is, alternately embedding the overlapping part of the wire in the growth undergoing removal.

Advantages and Disadvantages of the Galvano-cautery.—The galvanic has several advantages over Paquelin's and all other forms of cautery. The instrument can, in any case, be introduced into the cavity or organ or along the passage leading to the diseased part to be destroyed or removed, and placed against that part, before it is made hot. If a wire loop be used, it can be adjusted round the growth or other structure deliberately and carefully before the circuit is closed. It is therefore particularly applicable for the destruction of unhealthy tissues or removal of growths in parts difficult of access. Secondly, the amount of heat can be regulated and its action commenced and arrested at the will of the operator or by direction to his assistant. These details are under his control in a manner more thoroughly and completely than with any other form of cautery known to surgery. Thirdly, with the galvano-cautery there is no bleeding, for, if the cauter be kept at a dull red heat (about 600° C.), hæmostasis is produced at the same time, in the case of a heated wire, as the incision proceeds. Fourthly, there is a singular freedom from pain after the use of the galvano-cautery when compared with operations performed with the ordinary *écraseur* or the knife. The extremities of the severed nerves are destroyed by the burning action, and the trunks are protected by an impervious eschar. Lastly, the operation is itself antiseptic, and the eschar which covers the wound protects it and renders it less liable to

purulent infection than when a moist and granulating surface is left.

The disadvantages of galvano-cautery are that the batteries and apparatus are expensive and require frequent attention, otherwise, when wanted, it is often found that they will not work. An assistant possessed of special knowledge and skill is almost a necessity, whereas with the actual cautery and Paquelin's thermo-cautery the help of any intelligent individual is almost sufficient. When electrolysis can be used instead of galvano-cautery a second person is not always required, and the objectionable smell of burnt animal tissue is avoided. This is a consideration when an operation takes place in a private house. But electrolysis can only be employed for the destruction of unhealthy surfaces or the treatment of tumours by interfering with their nutrition; it cannot be used for the direct removal of growths: hence it is not employed so much in definite surgical operations—the subject of this manual—as in the treatment of diseases of women.

The Electric Lamp.—A small electric lamp is often found most useful in gynaecological surgery when it is necessary to employ artificial light. The electric light can be held upside down or in any position that will prevent it from casting a shadow. This is impossible with other methods of lighting when the light is derived from a flame. The electric light



FIG. 73.—SMALL ELECTRIC LAMP.

(It bears a mirror, but this is seldom required for uterine and vaginal surgery.)

can also be introduced into the vagina; and, if necessary, the interior of the uterus itself, after dilatation by tents, can be lighted up, and by this means its surface may be examined. The heat evolved is very trifling and not sufficient to cause inconvenience. The lamp (Fig. 73) has a rheostat concealed in the handle, which is cylindrical and fluted so as to facilitate manipulation. The sliding button (A) regulates the intensity of the light; by this means also the circuit can be made and

broken—that is, the lamp rendered incandescent and extinguished. The mirror at the end is not required when the lamp is used for the vagina or uterus. An independent battery

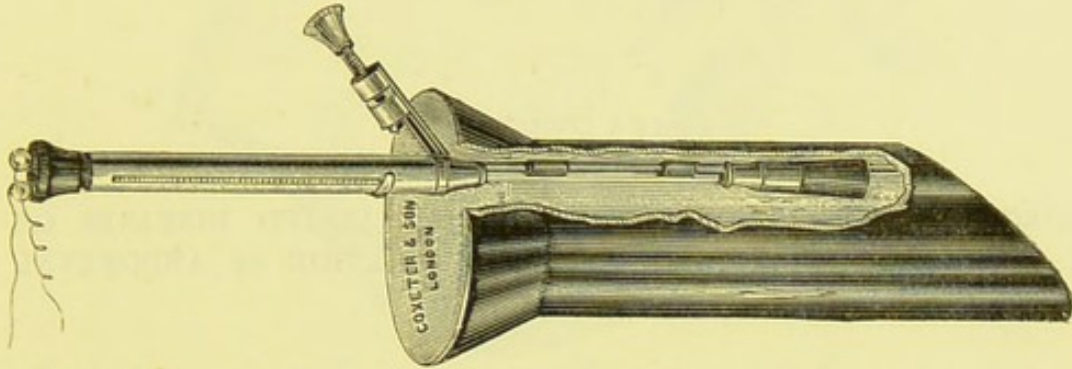


FIG. 74.—ELECTRIC LAMP FITTED TO A FERGUSSON'S SPECULUM.

composed of a few large cells is used to work the lamp, which can be kept incandescent for any length of time that it is likely to be wanted for a uterine examination or operation.

CHAPTER VI.

SURGICAL PATHOLOGY OF CYSTIC AND ALLIED DISEASES OF THE UTERINE APPENDAGES.—EXAMINATION OF ABDOMINAL TUMOURS.

Cystic and Allied Diseases of the Uterine Appendages.—This wide subject cannot be discussed at length in these pages. My own views are expressed in another work,* where I have recorded a large number of cases of disease of this kind, occurring in the practice of myself and my colleagues at the Samaritan Hospital, between 1877 and 1884. I shall simply restrict myself to an enumeration of the varieties of cystic and allied diseases of the ovary, tube, and broad ligament, noting the chief points of surgical interest. Of these, the presence or absence of a pedicle and of solid matter is the most important. The drawings may, I trust, aid the operator in identifying the tumour which he discovers in the course of an operation, and in understanding its nature and relations.

The diagram (Fig. 75) will demonstrate the seat of origin of each variety of tumour, as well as the position and relations of the different parts of the appendages when the Fallopian tube is pulled out straight (see page 26).

The varieties of cystic and allied diseases of the appendages likely to be removed by abdominal section will now be briefly tabulated.

1. Multilocular Cystic Tumour of the Ovary.—

Cystic disease of the ovary proper, common ovarian cyst. Forms a multilocular tumour, one cavity generally predominating (Fig. 76). The loculi may contain adenomatous growths

* *Clinical and Pathological Observations on Tumours of the Ovary, Fallopian Tube, and Broad Ligament.* 1884.

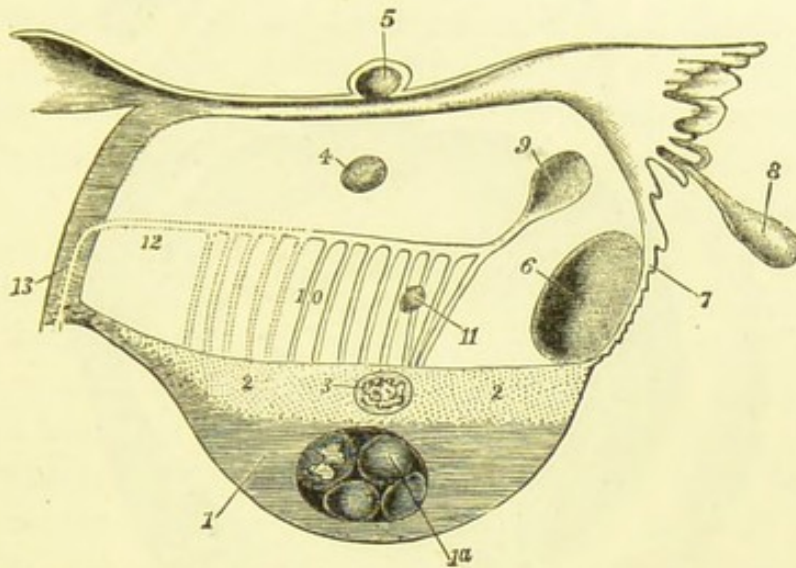


FIG. 75.—DIAGRAM OF THE STRUCTURES IN AND ADJACENT TO THE BROAD LIGAMENT. (*Author.*)

1. 1a, multilocular cystic tumour, developed in 1, parenchyma of the ovary. 3, papillomatous cystic tumour of ovary in 2, tissue of hilum of ovary. 4, simple broad ligament cyst, independent of parovarium, 10, and Fallopian tube. 5, a similar cyst in broad ligament above tube, but not connected with it. 6, a similar cyst close to 7, ovarian fimbria of tube. 8, hydatid of Morgagni; this never appears to form a large cyst. 9, cyst developed from horizontal tube of parovarium. 11, cyst developed from a vertical tube; cysts of this kind form the papillomatous tumours of the broad ligament. 12, 13, track of obliterated duct of Gartner; papillomatous cysts are said to be developed along this track.

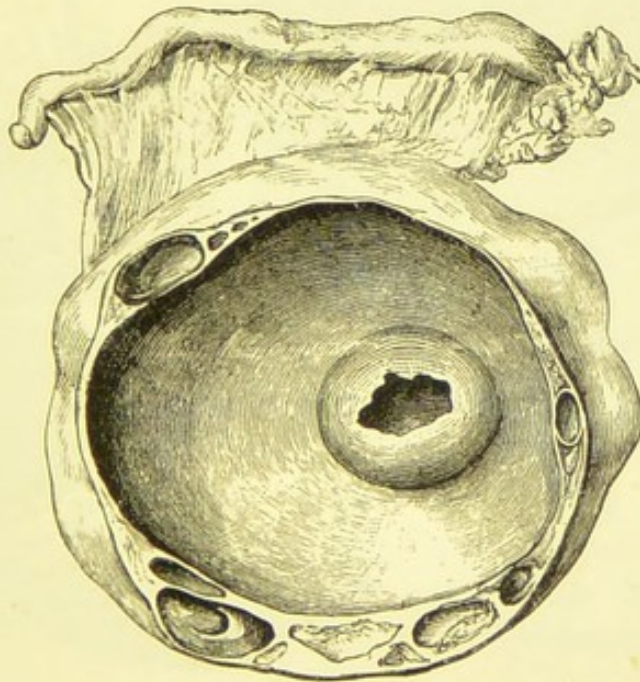


FIG. 76.—A SMALL MULTILOCULAR OVARIAN CYST. (*Author.*)

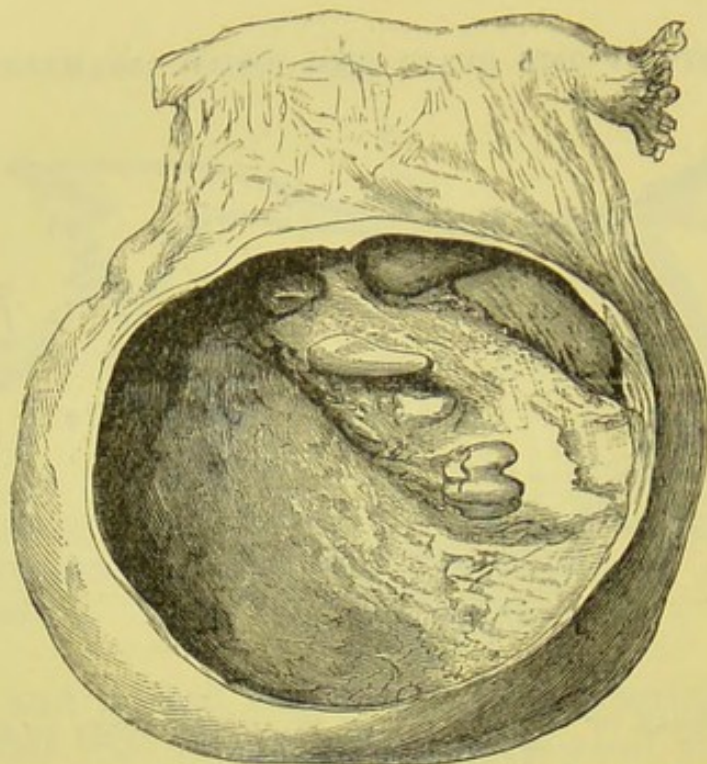


FIG 77.—DERMOID OVARIAN TUMOUR, BEARING TEETH AND BONE. (*Author.*)

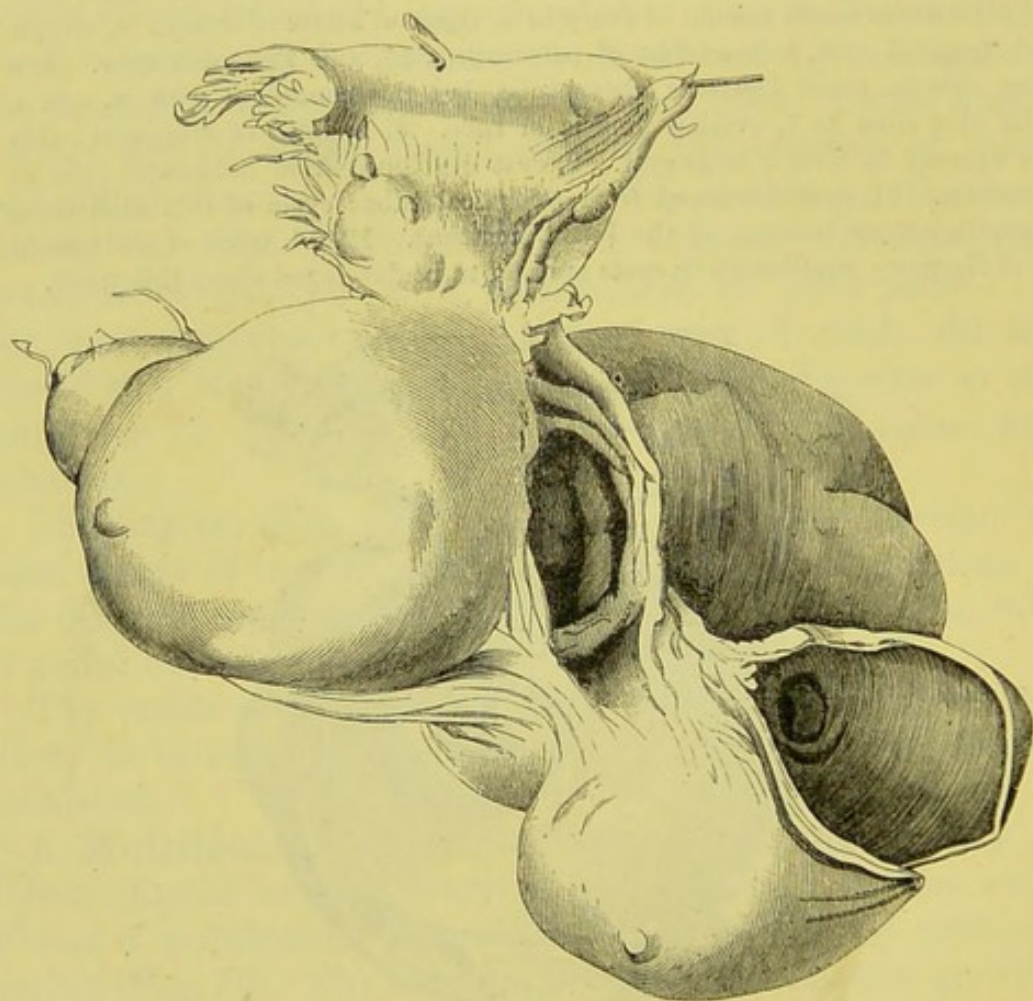


FIG. 78.—DERMOID OVARIAN TUMOUR, CONSISTING OF THREE LOCULI OF VERY IRREGULAR FORM.

They originally contained sebaceous matter. (*Museum R. C. S., No. 4,516.*)

Fluid contents glairy and albuminous, of high specific gravity, yellow or greyish in colour, often stained with altered blood-pigment. Generally well pedunculated.* Seldom malignant.

2. Dermoid Ovarian Tumour.—Same seat as the last variety. Forms a tumour with few loculi, filled with hair, bone, teeth (Fig. 77), sebaceous matter, liquid fat, etc., loculi lined with skin or anomalous mucous membrane. Any one of the contents named may be absent; hair is the most frequent. Sarcomatous elements frequent. Generally pedunculated. Dermoid tumours may assume very irregular forms (Fig. 78).

3. Papillomatous Cystic Tumour of the Ovary.—Arises in the tissue of the hilum (Fig. 75, 2, 3). Almost unilocular, cavity containing masses of papillomatous or cauliflower growths, sometimes scanty (Fig. 79), sometimes

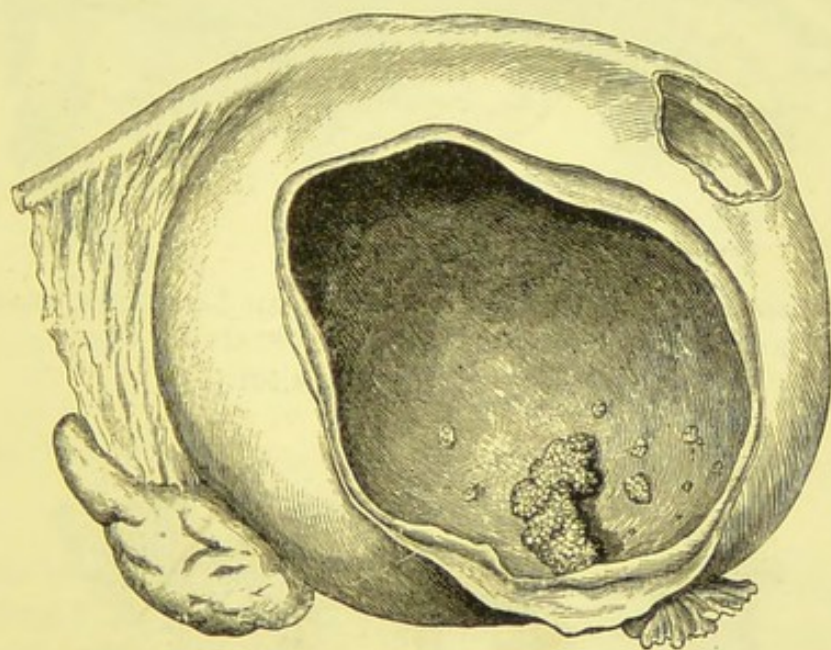


FIG. 79.—PAPILLOMATOUS CYSTIC TUMOUR OF OVARY. (*Author.*)

abundant. Fluid contents generally clear and watery, of low specific gravity and free from albumen. Pedicle short, or the tumour may burrow deeply between the folds of the broad ligament (Fig. 79), so as to be, in some cases, absolutely sessile. Papillomatous growths are sometimes found in the common multilocular form, mixed with adenomatous masses.

* By the term pedunculated, it is implied that a pedicle or connecting band, suitable for ligature, clamp, or cauterization, exists between the uterus and the tumour.

4. Papillomatous Cystic Disease of Broad Ligament.—Always sessile. Great tendency to infect peritoneum. May be multilocular. Cavities contain growths and fluid as in last variety.

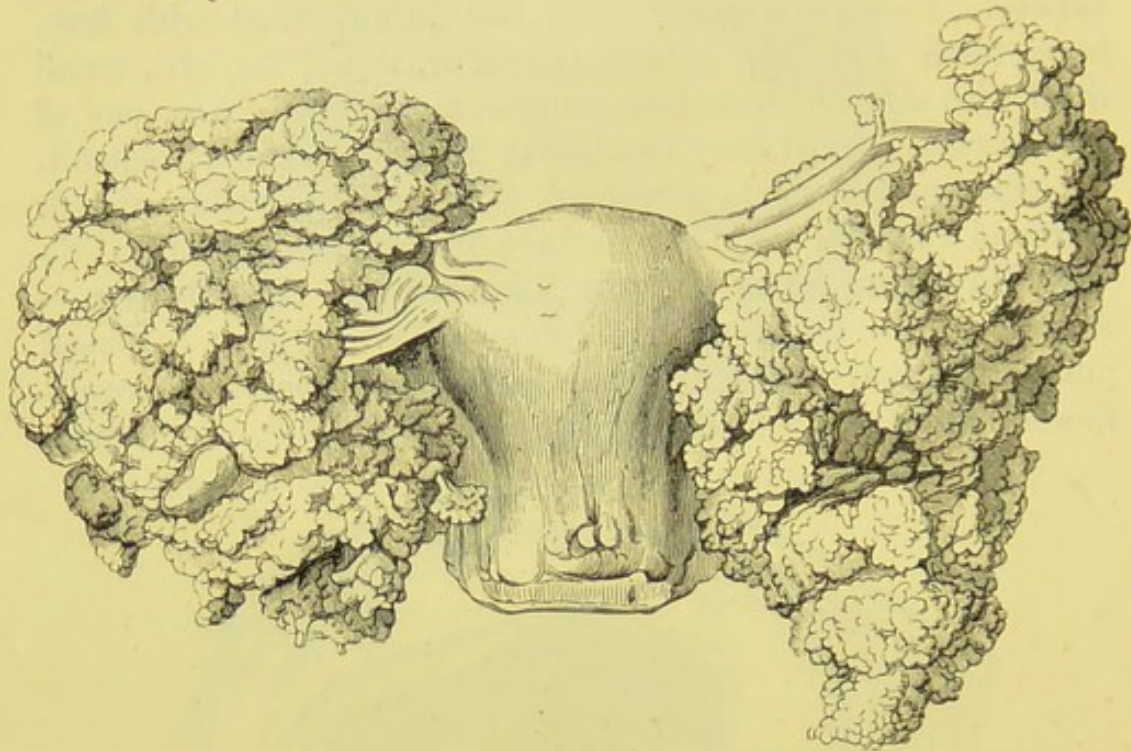


FIG. 80.—PAPILLOMATOUS DISEASE OF THE BROAD LIGAMENTS, COMPLETELY HIDING THE APPENDAGES, WHICH CONTAIN NO CYSTS.

(*Museum R. C. S.*, No. 4,501.)

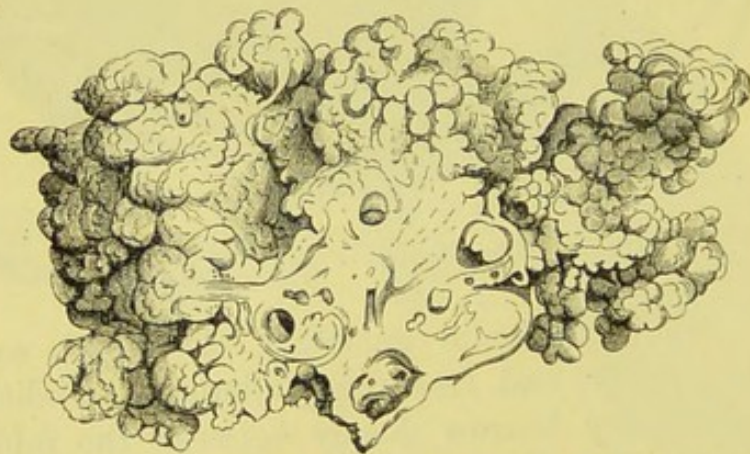


FIG. 81.—SECTION OF AN OVARY, SHOWING ITS SURFACE COVERED WITH PAPILLOMATA.

It contains a few follicles. (*Museum R. C. S.*, No. 4,502.)

5. Free Papillomatous Disease of the Broad Ligament.—Masses of papillomata infesting the uterine append-

ages (Fig. 80), often covering the surface of the ovary (Fig. 81). Always accompanied with abundant peritoneal effusion.

Varieties 3, 4, and 5 are probably developed from the tubes of the Wolffian body in the hilum and parovarium.

6. Simple Broad Ligament Cyst: "Parovarian Cyst" (Fig. 82).—Thin-walled cyst, almost invariably unilocular. Fluid contents clear, watery, of low specific gravity, and non-albuminous. Always lies between the layers of the broad ligament (Fig. 83), with the Fallopian tube and its fimbriæ greatly stretched over its surface. It is generally

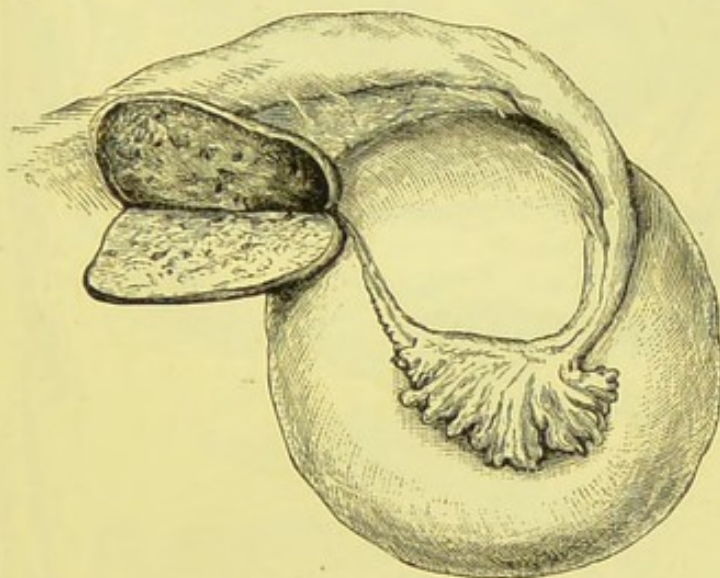


FIG. 82.—SIMPLE BROAD LIGAMENT, OR "PAROVARIAN CYST."
The Ovary has been laid open. (Author.)

pedunculated, as it does not usually burrow between the folds of the broad ligament as far as the uterus. The true parovarian origin of this kind of cyst is questionable.

7. Papilloma of the Fallopian Tube (Fig. 84).—Very rare; may be pedunculated. Fluid contents mucoid; may escape from the ostium of the tube and cause peritoneal effusion.*

8. Enlargement of the Hydatid of Morgagni.—This little cyst-like body (Fig. 75, 8) never appears to reach such an extent of development as to demand operative interference. The same is the case, except, possibly, in a few rare instances,

* See Author, *Transactions of the Obstetrical Society of London*, vol. xxviii., 1886.

with simple broad ligament cysts developed above the tube (Fig. 7, page 22).

Solid Tumours of the Ovary.—These growths are developed in the same anatomical region as the common

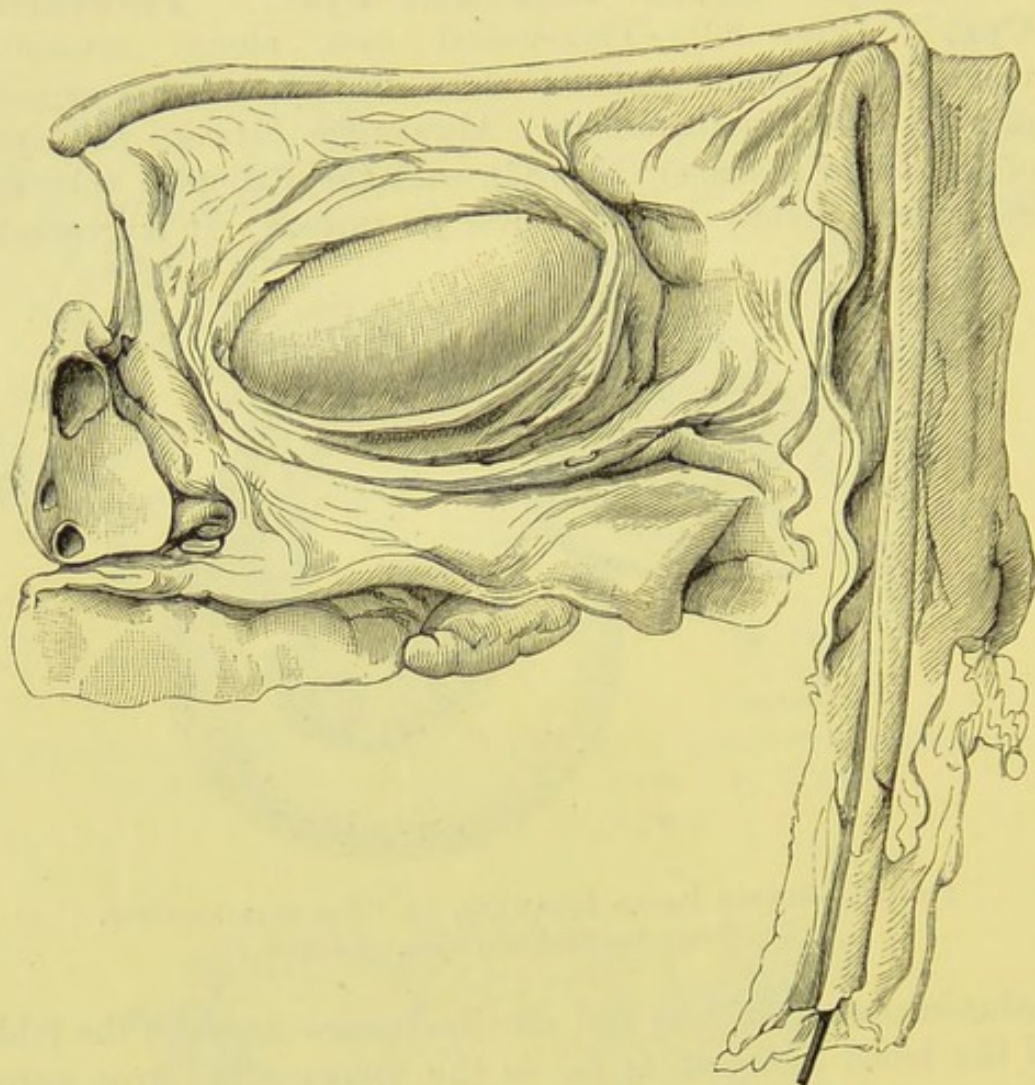


FIG. 83.—DISSECTION OF BROAD LIGAMENT, TO SHOW ITS RELATIONS TO TWO CYSTS.

The ovary lies to the left. One layer of the broad ligament is partly divided to show the smaller cyst, and is turned up below to expose part of the wall of a large cyst, which has been almost entirely cut away. The Fallopian tube (the outer part of which has a black rod inserted into its cut extremity, and hangs at a right angle to the inner part) had been stretched over the surface of the large cyst. (*Museum R. C. S.*, No. 4,588.)

multilocular cyst, and hence are generally pedunculated. The commonest forms are fibroma, sarcoma, and carcinoma. The

more malignant types grow very rapidly, and ascites and anasarca tend to develop early.

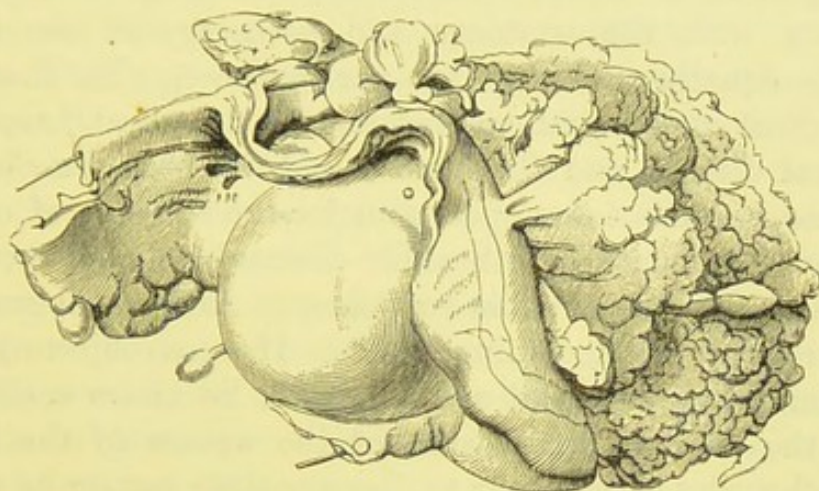
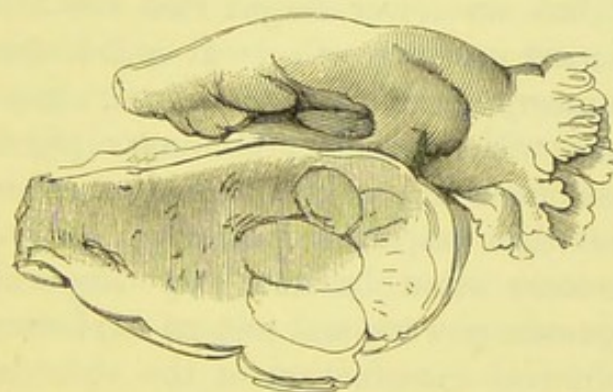


FIG. 84.—PAPILLOMA OF THE FALLOPIAN TUBE.

The tube has been laid open, showing the papillomata. A bristle passes into the tube, through the growths and out at the ostium below. The ovary, small and flattened, lies to the left. (*Museum R. C. S.*, No. 4,584.)



G. 85.—A SMALL SARCOMATOUS OVARY (*natural size*), REMOVED WITH ITS FELLOW, WHICH FORMED A LARGE SOLID TUMOUR, DURING LIFE.

(*Museum R. C. S.*, No. 4,533.)

EXAMINATION OF ABDOMINAL TUMOURS.

Diagnosis.—The general rules for diagnosis of abdominal tumours are given in all the standard text-books on medicine and surgery. Perhaps the most systematic treatise on exploration of the abdomen is the late Dr. Murchison's *Clinical Lectures on Diseases of the Liver, Jaundice, and Abdominal*

Dropsy. Every surgeon who desires to perform abdominal section should study it. Whilst what is technically known in our profession as sound "medical" knowledge is needed, a familiarity with the anatomy and pathology of the female organs is equally necessary for our purpose. In short, the surgeon must understand case-taking, the "medical" aspects of abdominal disease, and the science and art of gynæcology as well, when he undertakes operations for the removal of ovarian and uterine tumours, or otherwise diseased pelvic structures.

Diagnosis is always liable to fallacy. Abdominal swellings are covered by the abdominal walls. If some objects looking like a knife, a watch, and a small book, lie under a cloth, we lift up the cloth to make sure of the nature of the hidden objects, though to endeavour to discover their nature by placing the hand on the cloth may exercise our sense of touch. In the above facts lie some of the first principles of abdominal surgery.

Thus we feel the abdominal walls to ascertain the nature of a tumour, but we never forget that the evidence of our hands may be most untrustworthy. It is not always advisable to make exploratory incisions, nor, indeed, does any surgeon ever make them without some preliminary physical examination of the abdomen and pelvis. On the other hand, these incisions prove what palpation may never prove. Hence, experienced operators often become very sceptical about even their own diagnostic powers, and rely on exploratory operations rather than physical examination of the abdomen.

Many surgeons object to such expressions as a "minor operation," or "just a whiff of chloroform." They are right, for self-evident reasons. I believe that it is equally wrong to say that we are "*only* going to examine the case." Sounds may be necessary evils, but evils they certainly are. Simple percussion and digital exploration of the vagina are not always unattended with risk. Experienced operators at special hospitals certainly owe some of their triumphs to the freedom of patients from repeated examinations. I will conclude these preliminary observations by briefly summarizing them. The surgeon must diagnose carefully, but must not consider that the process of diagnosis is certain or void of danger to the

patient. He may teach, but not at the patient's expense. He must not have recourse too frequently to exploratory incisions, but must not fear to make them when diagnosis is obscure, yet the existence of tumours evident.

Case Taking.—The surgeon should always take his own case, though an assistant may write down the patient's name, address, and other details of the kind. A set of case books, ready printed, should be kept in the ward. Sir Spencer Wells' case book is well known. Case books may be printed at a small expense, each forming a small octavo pamphlet, with headings on each page, as follows:—

1. Number—Date of first visit—Name—Age—Condition—Occupation—Residence—Number of children—Last confinement—Abortions—Mammary Areolæ—General appearance—Medical attendant (before admission).

2. General examination of abdomen: Inspection, palpation, percussion, and auscultation.

3. Outline sketch of abdomen. Below spaces to fill in measurements (three columns will be sufficient,)* under headings: Girth at umbilical level—Ensiform cartilage to umbilicus—umbilicus to symphysis pubis—Right anterior superior spine of ilium to umbilicus—Left ditto to umbilicus.

4. Pelvic examination—Outline sketch of vertical section of pelvis, showing sacrum, symphysis pubis, anus, perineum, lower part of vagina, and urethra (the internal organs should not be drawn)—Generative system (catamenial history)—Urinary system.

5. Digestive system—Respiratory ditto (including temperature)—Circulatory ditto—Nervous ditto—History before appearance of tumour.

6. History of patient and disease.

7. Tapping or exploratory puncture—Diagnosis.

8. OPERATION. Date—Place—Nurse's name—Assistants and visitors—Anæsthetic—Antiseptic employed—Details of operation.

9. Details, continued.

* Thus, in the case of a slow-growing tumour, the abdomen may be measured at least twice, first at the patient's residence or in the out-patient department of a hospital, and afterwards a few days before operation is contemplated.

10. Details, continued—Description of tumour; its weight, fluid removed.

11—18 or 20. Tables for "After Treatment and Progress," with headings—Date—Hour—Condition, diet, and prescriptions—Temperature—Pulse—Respiration.

Lastly, three or four pages for "Subsequent History."

The above may be printed, so as to be bound up with ward registrar books, or carried about separately, after use, as may be required.

Treatment of Patient during Physical Examination of Abdomen.—The patient must remove her drawers, let down the upper border of the skirt and petticoats as low as the pubes, and raise her underclothing, so that the surface of the abdomen may be exposed thoroughly, and exploration of the pelvic organs may be facilitated at the same time. The stays had better be taken off entirely. Then the patient is placed upon her back on a couch, with her knees drawn up, and her head and shoulders raised, so that she may lie at perfect ease. The least discomfort may cause contractions of the recti, so that care must be taken that the pillows or cushions supporting the shoulders and knees are well-arranged and do not slip away. It is always best if the patient's bowels have been cleared, as scybala seriously interfere with examination of the pelvic viscera. When scybala are detected, it is advisable to repeat the examination after they have been removed by enemata.

The room in which the patient is examined should be warm, and not adjacent to a noisy street or to a room full of people engaged in conversation. A draught causes real danger to the patient; cold is the source of, not only discomfort, but also great physical irritability, impeding diagnostic manipulations. Noise is disturbing to the surgeon, and a grave impediment when pregnancy is suspected, for then auscultation must be practised, in order to find out if the foetal heart-sounds be audible, and, therefore, perfect silence is essentially requisite. The surgeon must be particularly careful that his hands are warm and his nails short. Cold fingers cause contractions of the patient's abdominal muscles, and do not possess so perfect a degree of tactile sensibility

as when warm. Tight-fitting gloves should not be worn by a surgeon about to examine an abdominal case; they greatly impair the sensibility of the fingers. The best way to restore warmth to cold hands, when it is too late to take exercise, is to wait in a warm room a few minutes before examining the case. The surgeon will find his pockets to be good receptacles of caloric for use on such occasions.

The examination must be carried on with great gentleness. The process is often fatiguing, and is apt to try short tempers. The patient, it must never be forgotten, is a patient as well as a case. Some patients will display fear, ill-temper, or signs of want of confidence in the surgeon. The word "only," or any synonymous word or expression, must never be used with regard to the examination as such, just as it is inadvisable in speaking of many other matters relating to medical subjects. I have heard a patient complain seriously of a surgeon who said to her, "This is only the *examination*, not the *operation*." Such a speech is the height of bad taste, and betrays great ignorance of human nature, and disregard of a patient's feelings. It is thus read by the patient: "I am suspected to be the subject of a serious disease, and the doctor is 'only,' as he calls it, subjecting me to a disagreeable process in order to find out if he cannot cure me by performing a dangerous operation." To understand this interpretation in full, the surgeon must bear in mind what sense the words "disease," "examination," and "operations" convey to persons outside our profession—above all, when they are patients. The objectionable expression which is quoted above is meant to be reassuring, but many well-meant words hurt people's feelings. What should be said is, "I am not going to perform any operation at present, but it is necessary that I should examine you." The patient must never be contradicted when she complains that the manipulations give pain.

Next to the patient's feelings in general, the particular state of her mind at the moment of examination must be taken into account. She is thinking of nothing but her case, of course, and is apprehending pain from the manipulations of the surgeon. This apprehension causes a characteristic expression. The teeth are usually clenched, and the limbs more or

less rigid. The patient has a tendency to stretch her hands towards those of the surgeon, to place them over a tender spot as if to keep him from touching it, and perhaps to catch hold of his wrists. This is very trying to the surgeon, and it must be remembered that all the above signs of mental perturbation are most frequent in the more obscure cases of abdominal tumour, especially when there have been inflammatory complications.

To counteract these inconveniences, the surgeon must reassure the patient, and it is quite allowable for him to divert her attention by talking of some subject not relating to her case. The effect of this judicious measure must be familiar to most surgeons and physicians. Thus the surgeon may lay his right hand upon an abdomen where the recti are so tense that he feels almost inclined to believe that there must be a solid tumour, with intestines adherent in front to account for the resonance. He inquires about the appetite, the catamenia, and other professional matters, and the tenseness will probably persist. Yet if he suddenly should ask the patient if the weather agree with her, or if the place she comes from be cold in winter, it is highly probable that the recti will immediately collapse, and the surgeon's hand may even be brought in contact with the promontory of the sacrum, or the lumbar vertebræ.

The clenching of the teeth, associated as it is with irregular respiration, is to be counteracted by asking the patient to keep her teeth apart, and not to hold her breath. Her hands should be folded across her chest.

Among other general considerations, the surgeon must remember that healthy structures may be tender as well as regions which are the seat of disease, that hard pressure on any structure causes pain,* and that rapid manipulations, even if gentle, frighten a patient. The nails are often the cause of trouble in these examinations. I have seen a surgeon with

* The reader must have met with members of the profession who seem to think that a part must be diseased because squeezing or pressing it hard causes pain. A boy's ear is not diseased because it smarts when it is boxed. See also my observations on pressure of the sacral nerves in pelvic exploration, page 49. I have already spoken against the practice of contradicting patients who complain of pain during examination (pages 47, 169).

his left hand on a patient's abdomen and his right forefinger in the vagina, wondering why a small tumour was "so painful." The pain was really caused by the nail of the forefinger pressing against the vaginal mucous membrane, and the nails of the left fingers pressing into the abdominal integuments. This latter bit of clumsiness, annoying to patient and surgeon, even if not misleading, is very likely to occur when deep pressure is made on lax abdominal walls, for the integuments bulge beyond the fingers and press against the nails. Though the nails must not be turned down, the opposite extreme of holding the fingers too stiffly must be avoided.

During inspection, *lineæ albicantes* and hernial protrusions must be taken into account, as well as other appearances which force themselves on the surgeon's observation, such as œdema, enlarged veins, and prominence in the flanks or front of the abdomen. The experienced may learn a great deal from inspection alone. Percussion should be commenced below the umbilical region, and not over the transverse colon or stomach, for the tympanitic resonance there may dull the ear for less marked resonance elsewhere. The left hand must be kept perfectly yet gently applied to the abdominal walls during the process, for if the knuckles go up and the points of the fingers press unduly, there may be a space between the fingers and the abdomen at the point where the former are tapped, and this will affect the resonance; moreover, there will be danger of running the nails into the integuments. In percussing each flank, the surgeon should stand on the opposite side, as it is not easy to keep the hand properly applied to the flank on the same side.

Lastly, vaginal digital exploration (or rectal, as a rule, in virgins) must never be omitted as part of the process. Without bimanual examination it is often impossible to tell the relations of a tumour to the pelvic viscera. Careful exploration of the cervix should be made before the sound is introduced, independently of all other precautions. Surgeons are liable to be misled by assuming that only young and attractive women can become pregnant when single, and can tell falsehoods about the catamenia. I know of a remarkable case where a surgeon,

after examining the abdomen of a single woman about forty-seven years old, who declared that she was regular, passed a sound into her uterus, remarking at the time how soft the cervix felt. A gush of fluid followed, and then it struck the surgeon that there might be a foetus in the uterus, which proved to be the case. The patient confessed that she had lied about her catamenia. I once assisted at an operation where the patient, a very plain single woman, aged thirty-five, had been bedridden for a year with a large fibroid tumour of the uterus. In removing the tumour, a foetus of about the sixth week was discovered. No sound had been passed nor had the cervix been examined for a long time.

Erroneous Diagnosis after Abdominal Examination.—I have already noted some of the chief sources of fallacy. The surgeon is not likely to forget that he may err, that a leading authority whom he consults may be wrong whilst he himself is in the right, and that the youngest student may diagnose what his elders have overlooked or failed to understand. Putting aside any further considerations of this kind, I will now classify the chief sources of error in diagnosis of suspected abdominal tumours.

1. *Preconceived Ideas.*—The surgeon, examining with the fixed idea that there must be a tumour of some kind or other, is apt to mistake rigid abdominal walls, tympanitic intestines, or a distended bladder for a tumour. He may dwell too much on the probability that a tumour, which really exists, is ovarian.

2. *Over-confidence in a Patient's History.*—This is the most frequent source of the awkward or even perilous error of mistaking a pregnant uterus for a tumour (see page 171). Not only must all cases of abdominal swelling in young single women be considered independently of the history, but the surgeon must also distrust the opinion of married women who have had many children. Experience causes these respectable members of society to believe in themselves too much. When a patient of this class says that she cannot be pregnant, the surgeon must ask her why she holds that opinion. One reply will be that she knows when she is pregnant by her bodily feelings. As the prime of life advances, however, these general sensations

tend to disappear, and the patient may be thrown off her guard. I have known a case of pregnancy mistaken for ovarian disease through neglect of this fact. Again, scanty menstruation may be overlooked, or amenorrhœa may precede conception; then the patient or surgeon may overlook pregnancy *because* there has been amenorrhœa for over nine months. In this way I have known cases of normal and of extra-uterine pregnancy to be attributed to ovarian tumour. On the other hand, a swelling said to have been detected ten months, a year, two years, or even longer, before the date of examination, may have been originally simple obesity or flatulence. Pregnancy supervening, the enlarged uterus may naturally be mistaken for a morbid growth.

3. *Omission of Precautions.*—Certain measures are of diagnostic value as well as being necessary steps in preparation for an operation. Thus neglect of the use of the catheter, on one occasion, nearly led to a distended bladder being tapped. A loaded rectum should always be emptied before a thorough examination is made. I once examined a case where a sigmoid flexure, loaded with scybala, had been taken for a dermoid ovarian tumour.

4. *Faulty Palpation and Percussion.*—The art of palpation and percussion is never thoroughly learnt or understood by many medical practitioners of fair experience. The tips only of the fingers may be applied to the abdominal walls; this causes the recti to contract, as the nails irritate the integuments, thus a solid or cystic tumour may be diagnosed. On percussing, if the fingers be not applied to the abdomen along their entire length, a dull sound may be produced. This fact can be proved at once by pressing the ends of the fingers only against a resonant part of the abdomen and percussing them high up, where they do not touch the integument; no resonance can then be elicited.

5. *Real Difficulties.*—There remain difficulties which depend entirely on the nature of the case. A complicating or coincident malady may mask the presence or nature of a tumour. A cyst already detected may burst before a second examination. Skill, care, and experience can alone guard the surgeon from errors which these difficulties may cause.

Diagnosis of Tumours and Abdominal Distensions.

—It is not possible for me to describe at length the principal conditions which more or less resemble ovarian tumours or other diseases of the female organs, which may be cured by operations allied to ovariectomy. I shall simply tabulate these conditions, for by so doing I may possibly aid the surgeon who has a case in hand which is likely to require abdominal section.

CLASS I.—A TUMOUR OR TUMOURS MORE OR LESS DISTINCT.

1. A Central Tumour, distending lower part of Abdomen.

A. *Freely fluctuating.*

Ovarian cyst, with one cavity greatly predominating over the others.

Broad ligament cyst.

Encysted dropsy of peritoneum.

Distended bladder.

Hydramnios.

B. *Fluctuating in parts.*

Ovarian cyst, multilocular.

Ovarian cyst with much solid matter.

Fibro-cystic uterine tumour.

Pregnancy (later stages).

C. *Solid, no fluctuation.*

Solid ovarian tumour.

Fibroid uterine tumour.

Pregnancy (earlier stages).

2. A Tumour distending lower part of Abdomen, not central in position.

A. *Fluctuating.*

Renal cyst or retro-peritoneal cyst in the neighbourhood of the kidney.

Cyst of omentum or mesentery.

Hydrosalpinx (extreme cases).

Ovarian cyst (rare).

Cyst in abdominal walls.

B. Solid.

Extra-uterine pregnancy (tumour may be central).

Sceyala in cæcum or sigmoid flexure.

Enlarged spleen (extreme cases).

3. **Two or more Tumours distending lower part of Abdomen.**

Bilateral ovarian tumours (especially small dermoid cysts).

Multiple subperitoneal uterine fibroids.

Hydatid disease of peritoneum.

CLASS II.—ABDOMEN DISTENDED ; NO DISTINCT TUMOUR.

1. **Fluctuation distinct.**

Ascites (all cases, including those where an ovarian or other tumour may exist).

2. **No Fluctuation.**

Tympanites and phantom tumour.

Obesity.

Pendulous abdomen.

The above table does not include tumours purely pelvic, tumours evidently confined to the upper part of the abdomen, and tumours, cysts, and abscesses in the inguinal and lumbar regions.

Physical and Clinical Characters of Ovarian Cystic Tumours.—This subject is treated at length in the standard works of Spencer Wells, Olshausen, Tait, Peaslee, Atlee, and other writers, and does not come within the immediate scope of this work. At the same time, it should be understood that the surgeon must not think of operating unless he feels that he possesses a fair knowledge of the main distinctions between ovarian tumours, uterine tumours, and other diseases which cause distension of the abdomen, and may prompt him to perform abdominal section. The use of the sound, with every precaution (page 74), is especially necessary for diagnosis between ovarian cysts and soft uterine myomata, but this diagnosis cannot be confirmed by rough and ready rules,

since the sound may move when the tumour is moved in some cases of ovarian cyst with a short pedicle; and there are other sources of fallacy attendant on the use of that instrument. The inexperienced are recommended to study, at least, any standard British text-book on diseases of women before undertaking ovariectomy.

There is seldom any difficulty in diagnosing a case of multilocular cystic tumour of the ovary, free from certain complications; on the other hand, there remain complications not at all easy to discover without opening the abdominal cavity, and some of these complications may obscure diagnosis, and cause the wisest, most experienced, and most practical surgeon to err. In the chapters on the Operation of Ovariectomy, I shall speak of what some may term unexpected conditions discovered during an abdominal section, though, strictly speaking, the operator should be careful not to be taken by surprise, and should be ready to expect any possible, though improbable, morbid condition, other than cystic ovarian disease.

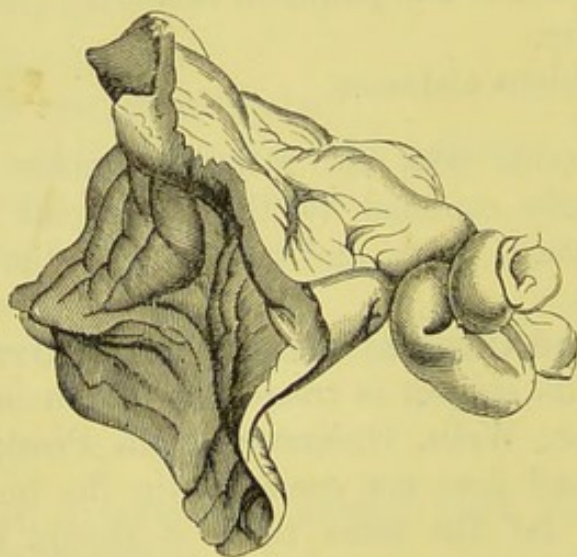


FIG. 86.—A TWISTED PEDICLE, ATTACHED TO A SMALL PORTION OF VERY THICK CYST-WALL. (*Museum R. C. S.*, No. 4,550A.)

The surgeon must note the purely clinical features of the case, especially high temperature, and histories of sudden attacks of pain, or constant local suffering, or of sudden diminution in the size of the tumour. Lives have been saved by removing suppurating cysts, and by operating in cases of gangrene of an

ovarian tumour, from twisting of the pedicle. As a rule, however, this peculiar condition simply causes dull constant pain, with a cessation of the growth of the tumour. At operation, the pedicle is often found twisted spirally, two or three turns, as in Fig. 86. The vessels are generally blocked; sometimes they are dilated as in Fig. 87, when they present a remarkable appearance, as though a large marble lay in the pedicle. When the pedicle is completely atrophied, and the cyst has become detached and receives its nourishment from adhesions, as will be noted in the chapters on Ovariectomy, the case will puzzle the

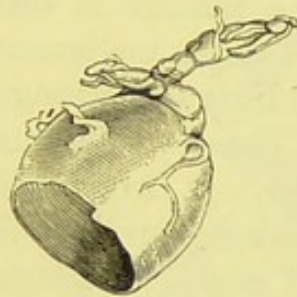


FIG. 87.—DILATED VEIN FROM A TWISTED PEDICLE.

The dilatation has been laid open. An artery, perfectly impervious, adheres to the vein posteriorly.

operator. On the other hand, when the pedicle is twisted, and no adhesions exist, the operation is, as a rule, particularly easy and safe. Twisted pedicle is very common in dermoid ovarian disease.

Tapping for Diagnosis.—Some authorities strongly advocate tapping for diagnostic purposes. They assert that the fluid thus withdrawn can be examined; that the tumour may be “parovarian”—that is, a simple broad ligament cyst curable by tapping; that it can be proved by tapping whether the tumour be suitable for operation; and lastly, that tapping can do no harm, and is safer than operation.

Long experience has led me to consider that these ideas are more or less fallacies, even when aspiration is meant, rather than simple tapping with a trocar. The fluid may be examined, certainly, but in doubtful cases little, if anything, may be proved by examination of the fluid. The thick, greasy fluid contents

of dermoid and old cystic tumours will often fail to pass through an aspirating needle. In dermoid, malignant, and papillomatous tumours, some of the secondary cysts may contain common ovarian fluid, others the clear fluid of broad ligament cysts: the puncture of one cyst would thus lead to false conclusions. Tapping cannot prove that the tumour is a simple broad ligament cyst. I have seen clear, watery fluid in the most malignant papillomatous cysts. Aspiration of such cysts may cause severe hæmorrhage from the vascular villous masses which fill them. The argument that tapping may *cure* a broad ligament cyst will receive further comment. Tapping can never prove that a tumour is suitable or unsuitable for operation, it can seldom verify malignancy, which it may often overlook, and can settle little or nothing about adhesions or the nature of the pedicle. The worst doctrine, in regard to tapping, is that it can do no harm. It involves the risk of hæmorrhage, and the escape of fœtid or purulent fluid, sarcoma or cancer cells into the peritoneal cavity. Metastatic deposits of common glandular intracystic growths are well-known and very serious complications; they can certainly be set up by exploratory punctures. In cases where there is a suspicion that the tumour may be a cystic fibroid of the uterus, should that suspicion be correct, tapping would involve great danger, as wounded uterine tissue often bleeds uncontrollably.

Tapping is, however, allowable in cases where the patient is suffering from some inter-current malady, such as bronchitis, which must be cured before operation; the presence of a bulky tumour adds to the patient's sufferings, and retards recovery. When the patient is subject to great anasarca of the legs, with ascites, and the presence of an ovarian tumour is strongly suspected, tapping will relieve the complications just mentioned; then manual exploration of the abdomen and pelvis will be facilitated, and it may be discovered that a freely movable tumour exists, perfectly suitable for operation. The anasarca in such cases is due to pressure on large veins. Tapping under these conditions is particularly indicated when there is little cachexia. Still, many specialists would object, and say that an exploratory operation is safer than tapping in such a case, as the former will show with certainty whether the tumour be

simple, or malignant and removable, or malignant and irremovable.

For tapping an ovarian cyst, a tapping trocar (Fig. 37) is employed. The patient must lie on her side, near the edge of the bed, the bladder having been emptied; then an incision is made through the middle line, over the most prominent part of the cyst below the umbilicus. A lancet is best suited for the purpose, and only the skin must be cut. Then the tapping trocar is thrust into the cyst; as the fluid empties out, the

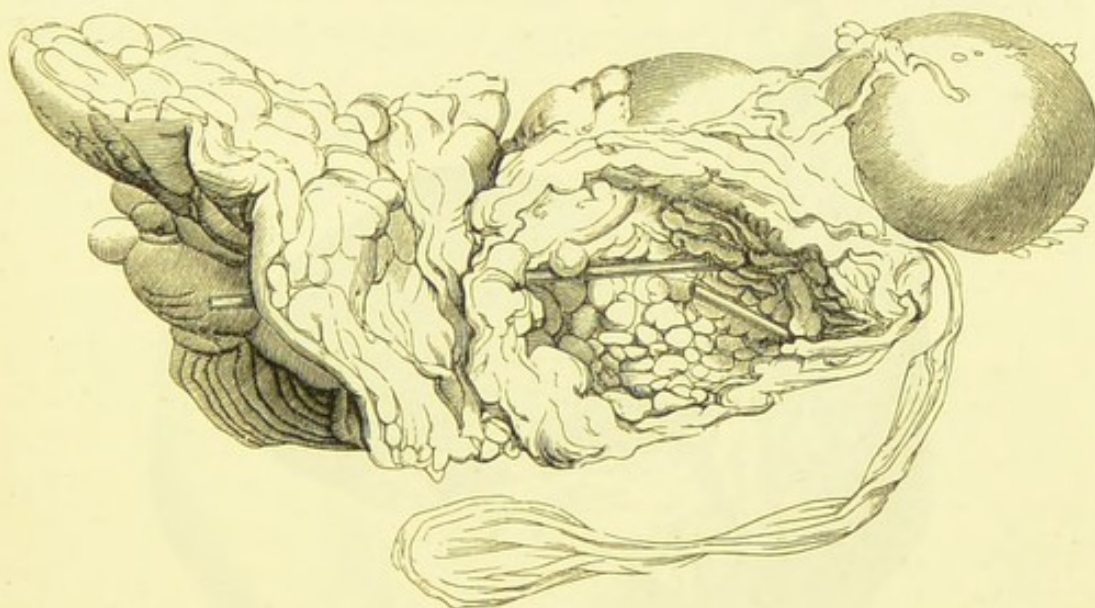


FIG. 88.—AN OVARIAN CYST REMOVED DURING LIFE, WITH A PORTION OF THE ABDOMINAL WALLS.

The cyst has become an abscess cavity, discharging pus through a fistulous passage in the integuments, through which a glass rod has been passed. It had been treated by incision and drainage. (*Museum R. C. S.*, No. 4,553.)

dome-shaped end of the cannula is pushed forwards, and fixed by the mechanism already described. A pad of antiseptic lint, secured by strapping, is placed over the puncture when the fluid has been removed; then a towel, fixed by a many-tailed binder (page 129), is applied to the abdomen, the patient being placed on her back. She should remain about two days in that position. The aspirator may be employed for tapping a cyst.

The Listerians strongly recommend full "precautions"

during tapping. In any case, the surgeon must be sure about his trocar, and the lubricant which he applies to it. "The most rapidly fatal septicæmia has been known to follow the use of a dirty trocar in tapping an ovarian cyst" (Thornton).

Tapping Parovarian Cysts.—Some specialists, more particularly the Keiths, of Edinburgh, recommend the cure of

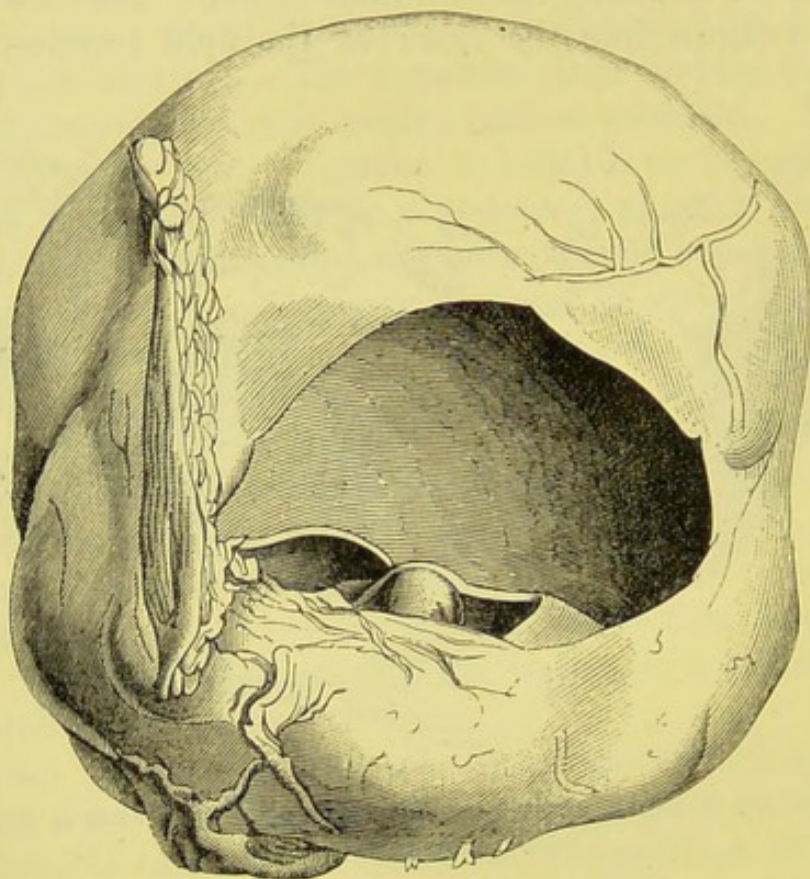


FIG. 89.—A MULTILOCULAR OVARIAN CYST REMOVED DURING LIFE, WITH A PORTION OF THE ABDOMINAL WALLS.

It had been treated as in the case of the specimen represented in Fig. 88, without any effect. (*Museum R. C. S.*, No. 4,554.)

simple broad ligament cysts, the so-called "parovarian" cysts, by tapping, and claim constantly successful results. Nevertheless, I have seen such a cyst require removal after repeated tapping, and I have known cases where other cysts, bearing all the characters of the same variety, as far as can be ascertained by examination of the fluid contents, proved to be papillomatous.

The danger of removing a "parovarian" cyst by abdominal section is very slight, the risk attending the tapping of a semi-malignant papillomatous cyst is considerable.

Incision and Drainage.—This method of "curing" an ovarian cyst is absolutely futile. Figs. 88, 89 represent two cases where this treatment proved a failure; the cysts were removed by Mr. Thornton, to the immediate benefit of the patient. In both cases the drainage had been commenced over two years before operation.

In the first, the cyst became an abscess and discharged much pus; in the second, the drainage could not be maintained, and the tumour remained almost unaffected till its removal.

CHAPTER VII.

THE OPERATION OF OVARIOTOMY.

I.—PRELIMINARY CONSIDERATIONS.

When should Ovariectomy be Performed?—Ovariectomy should be performed as soon as the ovarian tumour is diagnosed. The only exceptions to this rule, putting aside instances where the patient is subject to some other disease prejudicial to the recovery of the patient after operation, are cases where the cyst is exceedingly small and gives no pain. The most experienced specialists cannot always diagnose incipient cystic disease; an enlarged ovary easily detected in Douglas's pouch on bimanual palpation does not demand immediate operation. When once the tumour has risen above the pelvis, everything is to be gained and nothing lost by operating at once. The larger the tumour grows, the greater will be the risk of rupture, inflammation, suppuration, adhesions, and impaired health. In two of my own cases the operation was rendered very troublesome and dangerous because the patients had been "advised to wait."

Authorities are divided as to the particular day to be fixed, in relation, I need hardly say, to the question of menstruation. I have found it most satisfactory to operate a few days after the disappearance of the "show." Some operators fix a day shortly before the period is expected. The question is of far less serious import than was formerly supposed.

Age of the Patient.—Infancy and healthy old age are no bar to ovariectomy. Dr. Küster, of Berlin, successfully operated on a child aged one year and eight months. Dr. J. F. Hooks, of Texas, removed an ovarian tumour from a child thirty months old in July, 1886.* The patient died in twenty-

* *American Journal of Obstetrics*, vol. xix., p. 1,022.

four hours, but the tumour had been tapped and there were numerous parietal and omental adhesions. Spencer Wells, Thornton, Barker, and Chenowetts have all successfully operated on children eight or nine years old. In infancy the relations of the structures forming the pedicle are not likely to be obscure. The ovarian ligament, a most important landmark, is hypertrophied and prominent (Fig. 90). These ovarian tumours in infants and children are nearly always dermoid.

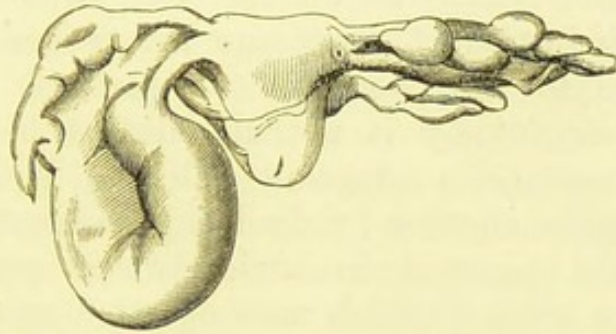


FIG. 90.—OVIARTOTOMY IN A STILL-BORN CHILD.

The left ovary forms a cyst, which is collapsed. The ovarian ligament, much hypertrophied, indicates the true seat of the cyst. (*Museum R. C. S.*, No. 4,485.)

Young girls are good subjects for ovariectomy, provided, of course, that the disease be not greatly complicated, and in bad cases they appear to stand shock very well. They must be carefully watched during convalescence as they are apt to move about too soon, to eat on the sly any unwholesome luxury which their friends may choose to bring them, and to disobey the nurse's orders in many other respects.

In old age the operation is quite justifiable when neither organic disease is present, nor great decrepitude manifest. Amongst my own patients one of the most rapid recoveries was made by a widow aged sixty-three. I assisted Dr. Bantock several years ago in the removal of dermoid cysts of both ovaries from a woman also sixty-three years old. There were strong pelvic adhesions, and the operation was prolonged and troublesome. Janvrin and Wilcke both operated successfully on a patient aged seventy-seven, Atlee on a patient aged seventy-eight, Schröder on a patient aged seventy-nine, and on another aged eighty. Dr. Miner performed ovariectomy on a

patient eighty-two years old, but she died on the fourteenth day.*

Elderly patients are apt to take bronchitis, from the exposure during operation and various influences afterwards. The possibility of hypostatic congestion of the lungs must not be overlooked.

Ovariectomy in Pregnancy.—Not many years ago it was considered hardly justifiable to perform ovariectomy during pregnancy, and when the tumour was large and growing rapidly the induction of premature labour was recommended in preference to the operation. Experience, however, has shown that ovariectomy is not attended with great danger when performed on a pregnant subject. It by no means necessarily causes abortion ; indeed, this accident, according to Olshausen, has occurred in under twenty per cent. of all recorded cases, some of which were operated upon many years ago, before ovariectomy had reached its present stage of perfection. Olshausen, quoting from the statistical results of some of the operators who have had the widest experience in ovariectomy up to the end of 1885, states that Schröder has performed ovariectomy during pregnancy in 12 cases, Sir Spencer Wells in 10, Olshausen in 8, and Tait in 6. In only one of these 36 cases did the patient die.

The same authority shows that out of 21 cases which were operated upon later than the fourth month of pregnancy only 2 died, and Pippingsköld operated at the beginning of labour, the child was born seven hours after the end of the operation, and the patient recovered. Still it is best to operate, if possible, before the fourth month, as the structures forming the pedicle become very turgid with blood at a later period of pregnancy, and this will prove serious should there be adhesions. Double ovariectomy has been successfully performed during pregnancy, as in a case under Mr. Thornton's care where the tumours were dermoid.

Before describing the operation in full, I shall dwell on some

* See also Sir Spencer Wells' statistics, *Diagnosis and Surgical Treatment of Abdominal Tumours*, 1885, p. 71.

of its essential features, more especially the abdominal incision and ligature of the pedicle.

The Abdominal Incision.—A large multilocular cyst can, after its septa have been properly broken down, be extracted without much difficulty through an incision but little over two inches in length. At the same time, when the incision is short there will be more trouble should the cyst burst during extraction, nor will it be easy to secure bleeding points on the parietal peritoneum after the breaking-down of adhesions. When the abdominal walls are loaded with fat, the application of sutures to the edges of a very short incision may prove difficult. The operator need never scruple to prolong the incision upwards in the course of the operation whenever he wishes to get well within reach of adhesions high up in the abdomen, or to make room for the extraction of a solid tumour. The umbilicus may safely be cut through, and it is advisable to remove the tissues which compose it, so as to facilitate union of the wound. As a rule, the abdominal incision should be made about three inches long. The lower end should be brought to about two inches above the pubes, else the securing of the pedicle and the cleaning of the pelvic cavity may become difficult to effect properly. The extraction of the cyst, the contact with the shanks of pressure-forceps, and the prolonged manipulations involved in ovariectomy, do not seem to cause serious bruising of the edges of the abdominal wound. Delayed union, of which I have only seen two marked cases, is due to other agencies, such as cachexia. The best material for suture is silk-worm-gut or No. 2 Chinese silk; I usually employ the former.

Ligature of the Pedicle.—The clamp, once a highly serviceable instrument, is now discarded, and I do not advise the beginner to rely on the cautery. Ligature by transfixion is the easiest and safest manner of securing the pedicle. The history and principles of this practice are fully recorded in the works of Spencer Wells, of several American and Continental authors, and in my own former writings.

After ligature and removal of the tumour, the pedicle, or more correctly speaking, the distal part of the stump of the pedicle, is kept from sloughing by the uniform heat of the interior of the body and by the bulging of the tissues over each side of the

ligature-groove. This brings the distal portion at once into close contact with the proximal part, plastic lymph is rapidly thrown out, and soon becomes vascular, so that the pedicle receives blood. The changes above described are well shown in Fig. 91. It represents a portion of the uterus and the stump of an ovarian pedicle from a patient who died of tetanus on the eighth day after operation. The silk ligatures are completely concealed. A glass rod is passed between them and the deposit of lymph which connects the bulging tissues on the distal and proximal side, as just explained. Within a year the pedicle is reduced to a small fleshy knob.

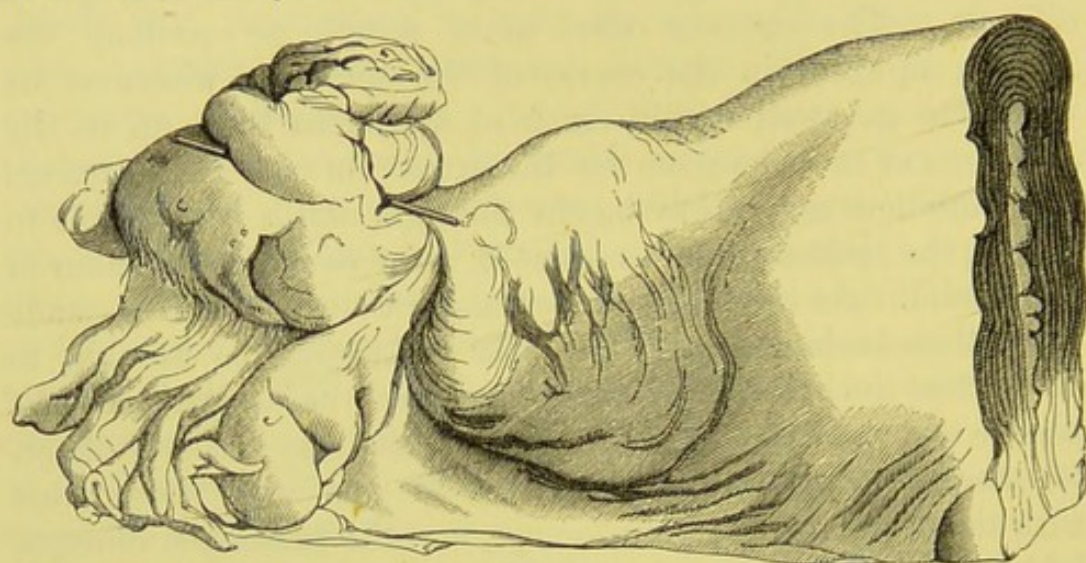


FIG. 91.—STUMP OF AN OVARIAN PEDICLE ONE WEEK AFTER OPERATION.
(*Museum R. C. S.*, No. 4,559.)

It is always advisable that solid malignant or glandular material should be carefully scraped out of the cut surface of a ligatured pedicle; otherwise the solid matter may become the starting-point for a recurrence of the disease, or more probably it may slough or undergo septic changes. The latter complication I have detected at a necropsy.

The passage of a ligature through a vein is an accident always to be avoided, as it may cause dangerous complications. The surgeon must see that the point of the pedicle-needle pushes forward and pierces a part of the broad ligament free from visible blood-vessels.

The splitting of the pedicle during the process of ligature is a yet more serious accident. It is especially liable to occur if

the threads be not interlocked, in the manner presently to be described. In Fig. 92 the mechanism of splitting is explained. The hole in the pedicle over *a* represents the point of transfixion. The unlocked threads, pulling in the direction of the arrows, tear the tissues asunder around that point. When they are interlocked, they cannot tear the pedicle at *a*, and all their constricting force is spent on the borders of the pedicle at *b* and *c*.

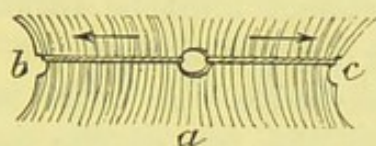


FIG. 92.—DIAGRAM ILLUSTRATING THE DANGER OF LIGATURE OF THE PEDICLE AFTER TRANSFIXION, WITHOUT CROSSING THE THREADS.

After the pedicle has been secured and some time expended in carrying out other details of the operation, the surgeon may be surprised to find, on taking a last look at the stump, that a large globular distension has formed on the proximal side of the ligature. This is a varix or, as some would say, a hæmatocele of the pedicle. It is a frequent occurrence of little importance, and must be left alone. A hæmatocele is apt to form during the first menstrual period after operation.

The Patient's Apartment.—The selection of a suitable room for ovariectomy is not an easy matter in hospital management. In private practice it is often a source of great anxiety to the surgeon. The apartment, I may say, speaking in general terms, should be large enough for two people to live and sleep in for several weeks, according to current authorities in hygiene. The probability that the operator may have to sit up and watch the patient for a night, or longer, must never be overlooked. In this case arrangements should be made for accommodating him with an apartment close, if possible, to the sick chamber. This is in accordance with that attention to matters of detail which Sir Spencer Wells has shown to be of such importance in undertaking ovariectomy. If the surgeon live near the case, he must be sent for should alarming symptoms arise in the night. In this way much time may be lost, and the surgeon may possibly be in a less suitable condition

to encounter a serious complication than if he be in a room close to the patient. Indeed, it is not at all rare for the case to be of such a nature as to make the proximity of the surgeon highly advisable after the operation, whilst at the same time it would not be beneficial for him to stay constantly in the room. These remarks apply, with even greater force, to a skilled assistant. This supplementary apartment is very useful for cleaning the instruments after operation.

The patient's apartment must be furnished with two iron bedsteads, one being for the nurse. An oil cloth, but not a woollen carpet, is advisable. A table is necessary, for the nurse's meals and for the use of the surgeon when taking notes. A cupboard is of considerable service, if well provided with shelves, as it can hold drugs and other necessities, and thus save the nurse from the needless trouble of having to leave the patient to seek for them in other rooms. The surgeon must never fail to search the cupboard himself not only before the admission of the patient, but frequently during her stay in the room. Some nurses, such as I have myself employed, appear perfectly capable of watching and caring for the patient, yet imperfectly conversant with the proper way of storing things in cupboards, so that just what is needed may be found directly it is wanted and taken out without any rumbling or clattering. A nurse may, unfortunately, prove inferior to expectations, and old experienced hands tend to grow careless and untrustworthy ; assistant nurses, also, may make use of the cupboard directly after the operation, unknown to their superior. Hence the cupboard may become a receptacle for candle-ends and edifying little books heaped artlessly over or under sounds and pots of vaseline. Urinometers, and other perishable yet more or less costly instruments and appliances, may be put on the shelves in positions almost inviting destruction, so that just when they are wanted they may be found broken or otherwise damaged. By a far more serious oversight, pans containing tumours, the contents of cysts, and vessels filled with cystic fluid or stale urine, are sometimes stowed away in a cupboard and forgotten. The operator may have much to occupy his mind after he has seen his patient safely put to bed, and if he orders the tumour to be preserved, he may neglect to forbid it

from being kept in the patient's room. In hospital practice, where an order of this kind may be systematically carried out, the surgeon must also make sure that a succession of cysts are not accumulating and decomposing in another room.

It is self-evident that drainage and ventilation must be duly considered. In ordinary houses we know how defective the hygienic conditions may be. Nor can the surgeon always get a plan of the drains and examine every pipe and see how it is ventilated. He certainly ought to inspect the water-closet nearest the apartment and see to sinks in upper stories, the waste-pipes of which may communicate with soil-pipes. This evil is, of course, very possible in hospitals and other public institutions where many sinks exist, and when the odour from the sink does not reach the surgeon's nose his suspicions may be aroused by the sight of sickly ward-maids with sore throats or pale faces. It is clearly impossible for me to enter into scientific details of hygiene in these pages, even were I an authority on that science. A study of Mr. Pridgin Teale's excellent little illustrated work* will prove of great service to the surgeon. A little knowledge may be a dangerous thing, but inquisitiveness about bad smells and inquiries as to where slops are thrown down will make nurses wonderfully circumspect.

As Sir Spencer Wells has recommended, a horse-hair mattress and an open iron spring bedstead are advisable for the patient, and the bed must not be too wide, else the patient cannot be reached equally well from either side, nor lifted with facility. Three feet and a half is the most convenient width. The castors must act well, as it may be convenient to shift the bed after a time, especially when the patient is convalescent. At first, the bed should never be shifted, and it is not a good plan to wheel it alongside the operating table for the transference of the patient at the conclusion of the operation, as the castors may roll over clots and cystic fluid inadvertently spilt on the floor and thus become fouled. At the Samaritan Hospital it has always been the practice to carry the patient gently, in a perfectly horizontal position, from the table to the bed.

The Operating Table.—The table, or rather tables, may

* *Dangers to Health: a Pictorial Guide to Domestic Sanitary Defects.*

be of the simplest construction possible, but the surgeon must make sure in due time before the operation that such tables are at hand. One, on which the patient's body will rest, is placed lengthways, and the other across the first, so that the two form a T: the second table will support the patient's head. The position of the tables is indicated further on, in a diagram. The tables should be about three feet in height and of plain deal, not too broad and without folding leaves. A horse-hair mattress must be laid on the table intended for the patient's body, passing on to the other table, which must be furnished with pillows and, if possible, with a back-rest for the support of the shoulders.* The mattress is covered with a mackintosh sheet, over which is laid an ordinary bed-sheeting. An india-rubber hot-water bottle is placed under the sheeting; it should be half filled with hot water, so that the patient can lie comfortably upon it.

The Ovariectomy Nurse.—Every woman who strives to earn her living as an ovariectomy nurse must, of course, begin from the beginning, nor can she be experienced before gaining experience. To relatively inexperienced nurses, unfortunately, an operator must sometimes entrust a patient. The true and only good school for her purpose is a hospital where ovariectomy and allied operations are very frequently performed. There she may watch her more experienced colleagues, assist them in various duties, and relieve guard when a patient is convalescent and not in need of close attention. Then, in due time, she will be entrusted with the charge of cases from the first. After a little experience, she will, if possessed with sufficient physical and moral strength, become an ideal ovariectomy nurse. When such an education is impossible, the surgeon will have to assist in training his nurse up to the ideal, a task more difficult than the operation of ovariectomy and far more tedious.

The ovariectomy nurse must be not only at hand, but also handy, when the surgeon examines and takes notes of the case before operation. She should know how to assist the patient to lie in the proper positions for examination. It is very advisable, if her services are to be retained, to teach her to take

* The back-rest is valuable, as it enables the chloroformist to raise or lower the patient's head and shoulders rapidly, whenever advisable.

the abdominal measurements. At the Samaritan Hospital some of the nurses do this office with great accuracy, but of course they must be taught, and the surgeon should always be present, if possible, when the measuring tape is being used. The nurse must see that the patient, if unclean, is well washed without risk of chill, about twelve hours before operation. She must scrupulously attend to the surgeon's directions as to the management of the bowels, and care must be taken to make sure that an enema which has been ordered has really been given. Above all, the surgeon must impress upon her the necessity of drawing off the patient's urine immediately before operation, and must ascertain that she never omits the precaution. It is exceedingly unadvisable for the surgeon or his assistant to have to pass the catheter during operation, and therefore they must rely upon the nurse in this matter.

The nurse must introduce the catheter every six hours, at least, after operation, without uncovering the patient, thrusting the instrument firmly against the fundus, or letting urine escape on to the bed-clothes. She must sometimes empty the bladder more frequently. She must keep the urine in a graduated glass vessel, till seen by the surgeon; then she should ask him if it is to be kept or thrown away, and she must have the testing apparatus ready. She must clean the catheter every time after use, so as to free its eye from vesical mucus, and must keep it immersed in a 1 in 40 solution of carbolic acid, or any other antiseptic preparation, as the surgeon may direct. She must thoroughly understand how to introduce nutrient enemata, taking care that the beef-tea is never too hot, and never neglecting to pass the rectal tube first. Here it should be noted that the surgeon must be able to demonstrate whatever he may have to direct, for sometimes he must teach his nurse, and then it is necessary for him to know what he has to teach. The use of the rectal tube requires a little delicacy of manipulation. As remarked elsewhere, the vaginal tube of a Higginson's syringe will answer very well for the purpose. Care must be taken to make sure that the nurse places a small pan or soap-dish under the tube to catch any refuse that may escape. In one of my cases, the nurse, willing and

intelligent, but inexperienced, showed me a foetid rag freely stained with beef-tea and rectal mucus, and she had placed it under the tube several times in twenty-four hours, as she "did not want to stain the bed-clothes." So far she was right, but it was fortunate that I ascertained that an improper kind of receptacle was being used.

The ovariectomy nurse must exercise great judgment in feeding the patient, according to directions, and must carefully observe the effects of diet and of drugs. She must take the temperature with perfect regularity; about once in four hours is sufficient. It is advisable to train her to take the pulse, only the surgeon had best never rely upon a nurse for this office, which is seldom properly done, except by those who have had a professional medical education. Still, there are circumstances under which it will aid the surgeon, if the nurse takes the pulse every two or three hours.

It is essential that she should make notes of everything that has been done, and of everything concerning the patient's condition. For this purpose, it will be of great advantage to the surgeon if he leave her his special note-book of the case, in which she can enter her clinical record. This will save him much unnecessary trouble, in sitting long in the patient's room copying pencil notes into his book. Some exemplary and enthusiastic nurses like to keep note-books of their own. Then, their good tendencies should be encouraged, and they may be suffered to enter the records in their own books. A nurse of this class will seldom object to entering notes in the surgeon's book as well, and, indeed, often does so as a matter of course without being ordered.

The nurse must also know how to manage the ice-cap, and the apparatus associated with it, and she must be able to empty the drainage-tube, though this must always be done by the surgeon, if possible. She must support the abdominal parietes when the wound is being examined, and not leave go of them till directed. When the bowels are to be opened, she must implicitly obey the surgeon, who, of course, has the right of ordering an enema, a pill, or a powder, as he thinks proper. A strange nurse may disobey such orders, and do as directed by some other surgeon in a

previous case. She should always give direct replies, especially in questions relating to the bowels, so that the surgeon may be sure that not only have they been opened, but that they have been opened by the means which he desired.

There are many other qualities and duties requisite for an ovariectomy nurse, not of a character which can be described in general terms. The surgeon cannot always expect perfection, and certainly will not always get it. He must never be surprised if the nurse gives him more anxiety than the patient.

Treatment before Operation.—The patient should be kept quiet for three or four days before ovariectomy. For two days at least she should be kept to her room, and subjected, as old-fashioned physicians used to say, to a bland, unstimulating regimen, including but little butcher's meat. Some patients try to live well in order to keep up their strength, and this they do according to current notions of popular physiology: that is to say, they prepare for the trials of an operation by eating chops and steaks, and drinking good wine of that well-known but indefinite brand which, according to their husbands, "cannot do anybody any harm." This system tends to cause gastric disturbance, an excessive excretion of urates, and restlessness, so that confinement to the bed-chamber is not well borne. Hospital patients are often found to have been "fed up" in this manner, but women of the humbler classes of life frequently eat very little before subjecting themselves to an operation of this kind, and they do right. I believe that loss of appetite, due to anticipation of an operation, has, as a rule, a salutary effect upon the patient. The physical condition of patients before ovariectomy is as variable as before many other major operations. In one instance in my experience, a stoical woman, who seemed quite indifferent whether the operation was performed or not, took little or no food, because she had "other things to think of." In another case the patient exhibited abject cowardice (a rare vice, somehow, in human beings about to face real danger) and extreme fear of death, yet she ate freely till the morning of operation, and soon regained her appetite afterwards.

Sir Spencer Wells has rightly turned attention to the im-

portance of examination of urine in every patient preparing for operation. Urine loaded with urates demands the administration of alkalies, for, independently of the renal mischief which this condition implies, it increases the chance of irritability of the bladder after operation. The citrate of potash is, altogether, the best remedy, and may be given in fifteen grain doses, dissolved in a tumblerful of pure water or soda-water three times daily. Ferruginous tonics are useful for the anæmic, and are indicated when there is a faint trace of albumen in the urine. Tartarated iron, with alkalies, is the most valuable form of tonic under these circumstances.

The bowels must always be attended to, and it is reasonable to consult the patient as to her usual purgative. Compound liquorice powder is very efficacious in some cases, but others are either over-purged or not in the least affected by it. Saline purgatives sometimes cause flatulence. As a rule, the colocynth and hyoscyamus pill is the best purgative to administer before operation. Ten grains should be given two nights before operation. The purgative should not be given later, as diarrhoea may follow its administration, and last for many hours.

It is of great importance that the lower part of the alimentary canal should be cleared of scybala shortly before operation. About six hours previous to ovariectomy a simple enema must be administered. The last meal should be taken about four hours before the operation, and should consist of a cup of good beef-tea. This may be seasoned with sweet herbs to make it palatable, for agreeable diet is a great remedy against depression.

Clothing for Operation.—The patient should wear her night-dress, a short flannel jacket, and a pair of warm stockings during the operation, as recommended by Sir Spencer Wells. As she mounts the operating table she should be directed to turn with her back to the operator, who then raises her night-gown and jacket high above the loins and abdomen. Then she must lie down with the clothing well folded back under the loins, and not rucked up; whilst a blanket is wrapped round the lower extremities. The sleeves of the flannel jacket should be drawn down well over the wrists, so that the handcuffs may

be fastened round them, and not over the bare skin of the forearms.

Before any operation where it is certain that much fluid will be evacuated, it is a good plan to cover the arms with towels, so that the sleeves may not be drenched. It is also best not to trust too much to the waterproof sheet, which may become detached above, and to lay a towel over the epigastrium to protect the dress in front.

Should the dress become blood-stained, or partly soaked in fluid, the soiled portions must be cut away at the end of the operation, and it is sometimes necessary to change everything. In this case, the change must be effected with as little disturbance of the patient's position as possible, and the clean night-gown and jacket must be well warmed before they are put on.

II.—THE OPERATION OF OVARIOTOMY.

Steps of the Operation.—I shall now enter into full details concerning the different steps of the operation of ovariectomy. I will not merely describe an ordinary case. That would be setting a bad example, for no surgeon can feel certain, before he has opened the abdominal cavity, whether the operation will be easy or difficult. I shall, therefore, note the principal difficulties which may be encountered in connection with those stages of the operation where they are most likely to be first recognized, or where they must be finally overcome. A description of the course of an operation, based on such principles, must of necessity be rather long, and I cannot avoid this disadvantage, for, as I have just hinted, I object to speak about "simple ovariectomy." To simplify the account, however, I may tabulate the steps of the operation thus:

1. Placing the patient in a correct position on the table; application of waterproof sheet.
2. Abdominal incision.
3. Inspection of surface of cyst; tapping of cyst.
4. Extraction of cyst collapsed after tapping; management of adhesions.
5. Ligature and division of the pedicle.

6. Exploration of opposite ovary.
7. Introduction of sutures into abdominal wound.
8. Cleaning of the peritoneum.
9. Counting sponges and forceps.
10. Closing of abdominal wound.
11. Application of dressings.

This classification is, of course, purely arbitrary. Difficulties may arise at any step, even at the first should the patient be much deformed through spinal disease.

Instruments required for Ovariectomy.—The following instruments and appliances, most of which have been described in Chapter III., will be required. Lister's apparatus is excluded.

1. Wristlets, and thigh-belt.
2. Waterproof sheet for abdomen.
3. Two trays for instruments, and two bowls for sponges.
4. Two stout scalpels.
5. Twenty pressure-forceps.
6. Stanley's director for dividing peritoneum.
7. Scissors bent on the flat.
8. Adams' peritoneum hook (not indispensable).
9. Ovariectomy-trocar and cannula, with tubing.
10. Nélaton's volsella, and a plain volsella.
11. Cyst or large pressure-forceps, straight and elbowed.
12. Artery-forceps (torsion or ligature).
13. Pedicle-needle (mounted on handle).
14. Long free pedicle-needle, with large eye.
15. Nos. $\frac{1}{2}$, 1, 2, 3 and 4 silk (Chinese twist).
16. Sponge-holder. (The ordinary kind, made on the crayon-holder principle, will answer; some operators prefer a long forceps with fenestrated blades, like ovum-forceps.)
17. Eight pairs of needles, bearing silkworm-gut or No. 2 Chinese twist silk threaded to a needle at each end. The pairs to be pinned on to a roll of muslin, folded and placed in the tray.
18. Needle-holder.
19. Twenty sponges (two large flat, two small flat; the remainder ordinary conical form).
20. Strapping, gauze (carbolic or absorbent), woollen pad. These will be fully described.
21. Many-tailed abdominal binder.

22. Three or four glass drainage-tubes of different lengths, and india-rubber cloth for same.

Also apparatus for administration of anæsthetic, brandy, and anything else desired by the chloroformist.

Amongst the extra instruments advisable to have at hand are: a tapping trocar and tubing, a Paquelin's thermo-cautery, Koeberlé's serre-nœud with wire, and pliers for fixing the wire, and pedicle-pins (for transfixing a solid uterine growth, if necessary: see page 124). A hand-mirror should not be forgotten (see page 87).

Two mackintosh aprons should be at hand, as the operator and the senior assistant will require them. Each apron should have a bib, but no arms. It must be long enough to protect the surgeon's clothes from the collar to the boots, and must be carefully washed after every operation.

Arrangement of the Instruments.—Before the patient is brought into the room, the instruments and sponges must be carefully counted by the operator, and he must see them put in the trays and basins, and covered with antiseptic solution, or pure water, as the case may be. They must then be covered over with towels, as it is barbarous to leave an array of glittering metallic instruments exposed in full sight of the patient, as she enters the room. The thigh-belt and wristlets should also be concealed. The operator must not permit many persons to be present when the patient is brought in. Should the chloroformist be a stranger, or likely to require such a reminder, the surgeon must request him to cover the patient's face with the lint or mask before the straps are applied.

The patient should now be brought into the room. If very timid, it is good to give her chloroform in the ward whence she is taken—indeed, I believe this practice should be more generally adopted. When, however, the patient walks to the table, it is certainly easier to place her in a comfortable position. Her dress must be raised high above the loins and abdomen before she lies down, and a blanket should then be wrapped round her lower extremities, and tucked under her feet. I have spoken at page 194 of special precautions with regard to dress. The operator and chloroformist must make sure that the patient lies comfortably on the table, in the supine position. Then the

latter functionary commences his special duties. There is no necessity for him to keep his hand on the radial pulse, as this cannot be done unless one of the patient's arms be left free, an objectionable arrangement. Even when a Junker's inhaler is employed, the little finger of the hand which holds the inhaler can be kept against the carotid artery. Directly the patient's face is covered by the chloroformist, the wristlets should be applied, and the thighs strapped down just above the knees. In hospital practice, it is fair to admit the spectators at this stage, for it is but just that they should learn as much as possible without any kind of detriment to the patient.

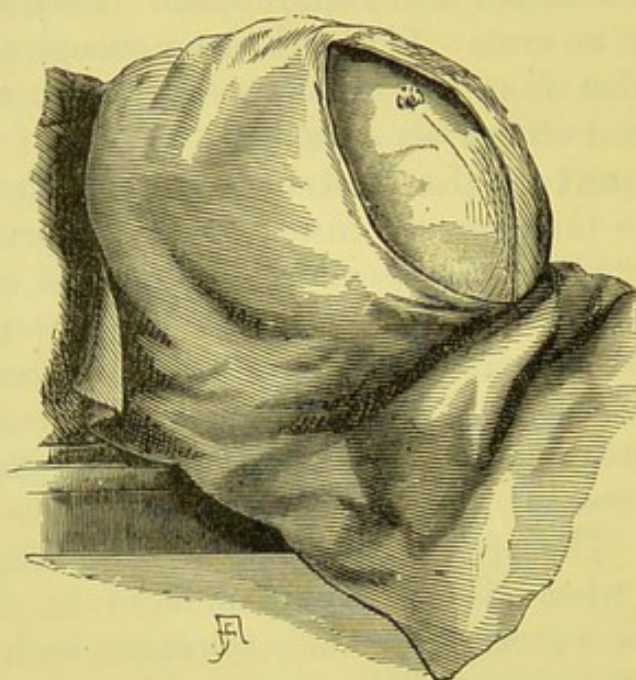


FIG. 93.—OVARIOTOMY: THE WATERPROOF SHEET APPLIED TO THE ABDOMEN.
The line of incision is indicated by a dotted line. (*Spencer Wells.*)

The abdomen should then be washed with a sponge and antiseptic solution, and the pubic hair may be partly shaved off if it grow high above the pubes, as in some cases. The waterproof-sheet is then applied to the abdomen. I have already given directions for its application at page 87. Care must be taken that the hole in the mackintosh is neither too large nor too small. Its adhesive edges must be neatly adapted to the integuments (Fig. 93). Particular caution is needed in sticking it firmly and evenly to the skin over the pubes. The hair, if thick or long, prevents firm adhesion, and a gap is thus left,

through which blood and fluid may freely escape, soiling the clothes, or settling on the hair around the vulva, where it may decompose.

The operator and his assistants now take off their coats and wash their hands in soap and water, taking care to clean their nails. Then they must put on mackintosh aprons. They next must dip their hands and forearms into a solution of carbolic acid, 1 part in 20, if Listerian precautions are to be followed. The spray, also, should be turned on. Some operators, however, do not use the spray until the peritoneum is laid open. The operator, assistants, and nurses now take their places.

Number of Assistants.—Though I have already entered into details of most of the subjects introduced in this chapter, and desire that it should be chiefly descriptive, I think it right to observe that the question of a second assistant is important. It may raise a difficulty at the last moment. If the surgeon be little experienced in ovariectomy, or be called upon to operate where the chief assistant and nurses have no such experience, a second assistant is important. At the Samaritan Hospital we seldom employ more than one, but he is always experienced, and generally has performed ovariectomy himself. A second assistant is useful to report if there be a free flow of fluid through the tube the moment that the trocar is plunged into the cyst. He can hold the tumour steady whilst the other surgeons are attending to the pedicle. Otherwise a heavy tumour, with a thin broad pedicle, may slip over the side of the abdomen and tear itself partly away from its attachments. During the closing of the abdominal wound, his services are useful in holding its edges well together whilst the operator ties the sutures, and the senior assistant sponges the margins of the wound immediately in front of each suture as it is made fast. However, the second assistant's services are by no means indispensable at this stage. A third or fourth assistant is worse than useless. The surgeon never requires any intermediate person to transfer the instruments from his hands to the trays and from the trays to his hands. Instruments, during ovariectomy, should pass through as few hands as possible.

Position of the Operator, Assistants, and Nurses.—The operator, seeing that the light is good, must stand on the

right side of the patient, with the table for the instruments well within reach of his right hand. The first assistant stands on the left, facing the operator. The junior assistant, if present, stands on the right of the patient, close to the operator's left elbow, the chloroformist standing at the head of the table. The chief nurse must stand close to the junior assistant, holding a basin for dirty sponges or pieces of structures cut away in the course of the operation. She should hold also a small pan, containing clean sponges to be handed to the operator, and across to the senior assistant. A junior nurse must be ready to take the dirty sponges from her senior colleague and to wash and return them as quickly as possible, with the assistance of a ward-maid. The following sketch will explain the position of all who take part in the operation.

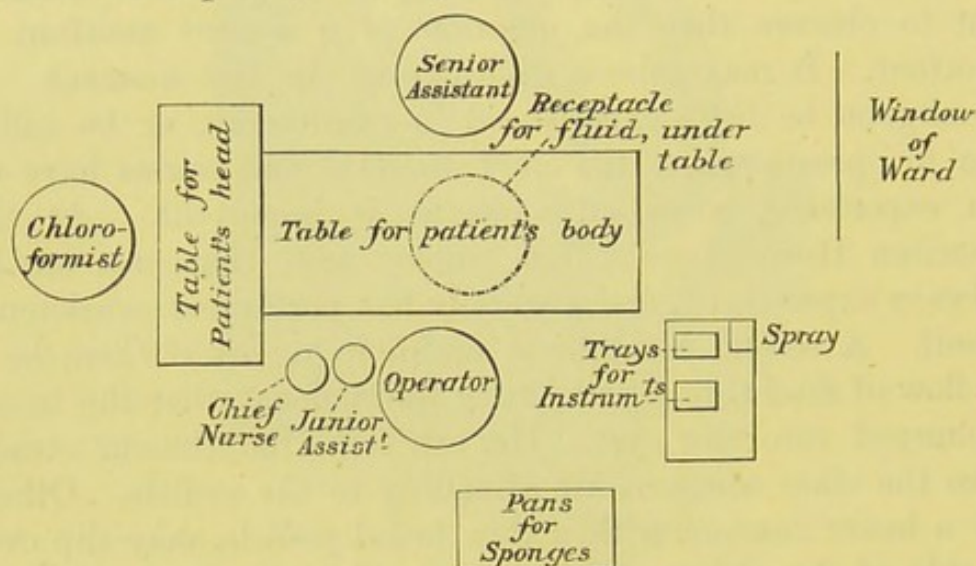


FIG. 94.—POSITION OF TABLES, OPERATOR, ASSISTANTS, ETC., DURING OVARIOTOMY.*

The Abdominal Incision.—The operator now takes up a scalpel, and the senior assistant holds a sponge in his right hand. It being ascertained that the patient is completely under the influence of the anæsthetic, the operator makes an incision through the integuments in the middle line of the abdomen, beginning about three inches below the umbilicus, and continuing

* It is advisable to place the spray-apparatus in front of the window; the spray and the light will then fall in the same line on the area of operation. When the light is obstructed the operator will know that there is also something in the way of the spray.

for a little under three inches downwards. If the patient winces, the senior assistant must cover the wound with a sponge till she is made thoroughly insensible by the chloroformist. A violent action of the abdominal muscles, very probable if this precaution be not taken, may cause the operator's scalpel to cut what ought not to be cut, so that the cyst may be opened or a solid tumour wounded before the different layers of the abdominal wound have been evenly laid open.

When the wound in the integuments is made, the senior assistant should press and not rub his sponge against bleeding vessels. The operator then takes pressure-forceps out of the trays and secures the vessels. It is obvious, now, that the trays should be close at hand so that he may never have to walk to them, nor even to stretch out his right hand further than is absolutely necessary. As I have already hinted, this arrangement is better than the system of having the instruments handed by an assistant. It economizes labour and promotes silence. No one should be permitted to stand between the operator and the trays. The assistant must be strictly forbidden to slip a sponge into the peritoneal cavity at any stage of the operation. He must, however, hold a sponge, frequently changed, in his hand, in order to check all oozing and to keep the wound clean. For controlling the bleeding at this stage, some operators prefer that the assistant should place his finger on a vessel the moment that it is divided. A large sponge is, however, far better, for it will cover half a dozen spouting vessels if necessary. The operator need not do more than secure the vessels with the pressure-forceps at this stage, but if a great number require attention, the instruments may be economized by twisting a few of the vessels. The pressure-forceps should, however, be left on the larger vessels as long as possible. I strongly recommend the beginner to study the observations on the pressure-forceps (pages 93-100). A vessel is not likely to bleed if grasped by the forceps for over five minutes; should hæmorrhage occur under these circumstances the bleeding vessel must be twisted. I would much rather, judging from long experience, leave a ligature in the abdominal cavity than in the abdominal wound. In actual practice the pressure-forceps is sufficient for every divided

vessel in the abdominal wound. At the Samaritan Hospital it is rare to see the ligature employed. The pressure of the sutures will be sufficient to check recurrent hæmorrhage. When the pressure-forceps is used, the vessel and the surrounding tissues should be seized obliquely, then the handles of the instrument will lie conveniently on the abdominal wall. Should the vessel be seized vertically, the forceps will stick up awkwardly and get knocked about or torn off.

The operator now divides the structures composing the linea alba, keeping his eye on the umbilicus and cutting straight. In many women there is a dark line of pigment running from the umbilicus to the pubes, and a faint trace of this line is generally to be found. In some cases a very deep layer of fat has to be divided. The operator and his assistant must take care, later on, lest particles of the fat be brushed off by their hands and pushed into the peritoneal cavity. The sheath of one of the recti is almost certain to be opened. As much care as possible must be taken not to cut outwards, lest more of the rectus than its edge be exposed. The posterior part of the aponeurosis is then divided. In the course of these manipulations, the senior assistant must ply his sponges steadily but not officiously. When a large vessel is seen in the sub-peritoneal fat, it may be seized by two forceps and divided between them, so as to anticipate hæmorrhage. The urachus is sometimes seen as a stout white cord.

The confidence inspired by skill in the use of the scalpel and a fair knowledge of anatomy must not be overweening, as the operator's knife will now pass close to very delicate normal and morbid structures. In an ordinary case, the fascia transversalis and sub-peritoneal fat are reorganized and divided. Then comes the peritoneum, and the bladder must not be forgotten. I have seldom seen that organ during this stage of the operation, but have never neglected to take it into account.* Should it be detected or suspected the nurse must be ordered to draw off the urine at once, the knee-strap being loosened for the purpose; but this should never be necessary if the nurse be competent. On no account should the operator

* I have never seen the bladder wounded by the knife at this or any other stage, but I have twice seen it lacerated during the separation of adhesions.

introduce the catheter himself, nor attempt any other manipulation in the region of the vulva or anus. The first difficulty which the surgeon is likely to meet is due to thickening of the peritoneum, or its close adhesion to the cyst-wall. He must then proceed with great caution, being careful to cut at an even depth along the whole line. In spite of all care, the cyst may be cut into before expected. The surgeon must then let the contents escape and see how far the adhesions extend; in fact, continue the operation in a later stage yet to be described. Cutting too soon into the cyst is much less serious than the opposite error of taking the peritoneum for the cyst-wall and detaching it from the parietes. To avoid this mistake the operator must keep his eye on the parietes whenever he detaches an adhesion.

There may be a source of confusion of another kind. If much ascitic fluid or a very tense thin-walled cyst lie behind the peritoneum, the appearances are sometimes very puzzling. The peritoneum may bulge forward, so as to resemble a cyst containing blood or dark fluid. A vertical scratch should be made in the middle line; then, when a little fluid has leaked or shot out in a jet, the true nature of the case may generally be recognized. If the edges of a wounded thin-walled cyst be seen they had best be seized at once, and the cyst can readily be drawn out. Here I may observe that the peritoneum never looks like the surface of a healthy cyst, but an inflamed or degenerating cyst may resemble diseased peritoneum.

Ascitic fluid may always be allowed to flow out, the senior assistant pressing both flanks gently. When this happens, especially if the case be not very clear, the operator must look out for evidence of free malignant or papillomatous growths. More will be said on this matter shortly.

The ovariologist should never be unprepared nor startled; that is why I have dwelt upon difficulties first. As a rule, he will recognize the peritoneum readily. He should raise a piece of that serous membrane on the point of the scalpel, and make a small hole in it. Adams' peritoneal hook (page 101) seems to me an unnecessary instrument. Not rarely the peritoneum is found to be evidently free from adhesion to deeper structures.

Then it may be gently scratched through with the point of the scalpel, care being taken not to damage the cyst-wall. The hole being made, a Stanley's director,* or any other stout director, may be passed upwards along the middle line; the peritoneum is then laid open with a scalpel or scissors, and the same manœuvre is repeated downwards, so that the serous membrane is divided along the whole line of the abdominal wound. The operator will now feel a sensation akin to satisfaction on seeing the shiny white surface of the ovarian cyst.

Morbid Conditions discovered after the Peritoneum is laid Open.—Yet before turning to the management of the cyst, I must take into account some more difficulties which may present themselves at this stage, when the peritoneum is freely laid open. The tumour may prove to be uterine, or to be a solid ovarian growth. What then should be done will be described later on. It may be a ruptured ovarian cyst. If the effused fluid be sweet, it may be removed by sponging and pressure on the abdominal walls. If it be colloid or otherwise semi-solid, it may be removed by the hands. When it is clearly foetid, the hands must be scrupulously kept out of it. I do not like sponging under these circumstances. The sponges will be tainted and difficult to purify, and yet they may be wanted for an untainted part of the peritoneum, since foetid fluid may lie in a circumscribed area. Far better, when decomposing fluid has to be removed, is Mr. Lawson Tait's plan of pouring pitchers full of water, at blood heat, into the peritoneal cavity.† This may be done till the water flows out clear and sweet. Of course, weak carbolized solutions may be used by those who adopt Listerian precautions. As the water escapes, the senior assistant should see that the mackintosh has not become detached from its adhesion to the skin of the pubes, else the patient's thighs and the linen beneath her will be drenched.

* See reference to this instrument and to Adams' hook in Chapter III.

† Mr. Tait's name has been rightly associated with this practice, as far as its use in abdominal section is concerned. The hæmostatic properties of hot water, one of the most important factors in producing the excellent results which follow the flushing out of the peritoneum, was first pointed out by Mr. Keetley in 1879 ("Hot Water as an Hæmostatic in Surgery," *Practitioner*, vol. xxii., p. 113). Dr. Gill Wylie believes that the hot water counteracts shock.

Then, when the peritoneum is laid open, the tumour may turn out to be a diffuse malignant or papillomatous mass covering the parietes or the omentum and intestines or standing high out of the pelvis. There is sure to be free fluid under these circumstances. The operator must handle the growths quite gently, just enough to recognize them by touch, and the assistant must not press the flanks to accelerate the escape of the free fluid. If these precautions be neglected, free hæmorrhage will take place, and will prove very troublesome, if not impossible, to check. When as much fluid as will run out spontaneously has escaped, the operation must be at once concluded by sewing up the abdominal wound.

The management of a multilocular ovarian cyst, properly exposed, must now be described. When the cyst-wall is free from inflammatory changes it is white and shiny. Its appearance is highly characteristic. The boldest as well as the most timid and inexperienced operator must never feel overconfident when he has arrived in full sight of a tumour bearing the aspect of a multilocular ovarian cyst, for if it be a growth of that class there may yet be great difficulties in the further stage of the operation. If, however, the surface of the tumour present a different appearance, caution will be particularly necessary, both as regards diagnosis and the further steps of the operation. First comes the chance of error in diagnosis; next, the high probability of some complication should the tumour be really ovarian.

The appearance of a pregnant uterus is characteristic, but not so as to be readily described or figured. The operator must never leave pregnancy entirely out of his calculations; even at this stage singular errors have arisen from neglecting this precaution.* Uterine fibroids are of a pale brick-red colour,

* When assisting Dr. Bantock at an operation for the removal of a multilocular cyst from a woman known to be over seven months pregnant, I observed that the uterus was of the "pale brick-red colour" described above as a characteristic of a uterine fibroid, and it felt not unlike a somewhat soft tumour of that class. The softness of the expanded cervix, the detection of the foetal head, with distinct ballottement close to the brim of the pelvis in front of the cervix, and a very reliable history, were sufficient safeguards against error in this case. Had, however, the patient fancied that she was not pregnant; had the cyst, and not the uterus, lain nearest to the pelvic brim, so that the cervix might have been too

owing to the presence of plain muscular fibres and considerable vascularity. Sometimes the surface of a fibroid is very pale indeed, so as closely to resemble that of an ovarian cyst; and if the fibroid be cystic, there will be some difficulty in diagnosis at this stage. A fibroid bleeds violently even if only slightly cut with the scalpel. In many ovarian or broad ligament tumours which have become invested anteriorly by a layer of the broad ligament, the surface also appears reddish in tint. The presence of the tube, stretched and elongated over the wall of the tumour, also indicates a tumour of this class, and may presage an easy operation, or else imply that some deeper complication exists, for tumours which burrow into the folds of the broad ligament often have very troublesome pelvic connections. The tube and broad ligament may happen to lie on the front of an ordinary multilocular cyst; in this case the exposed surface appears like a veil of thin red membrane, covering deeper structures and very vascular; the tube, generally below, can be recognized. On pushing this membrane aside, the characteristic surface of the cyst-wall will be exposed. When uncertainty exists about the tumour being of ovarian or uterine origin, further exploration will be necessary even for bare diagnosis. The abdominal wound will have to be enlarged, and the pelvis carefully explored, until the relations of the uterus can be made out.

When secondary cysts bulge freely from the surface, the chances are that the tumour is an ordinary multilocular cyst. When the cyst-wall is smooth and shiny, but greenish-grey and semi-transparent, the tumour probably contains a great quantity of adenomatous growth. Malignant ovarian tumours are usually dull brown or yellow coloured; sometimes they may be recognized at once as solid masses of sarcoma, but when they contain large cysts their diagnosis before tapping is often uncertain, the cyst which presents at the wound possibly bearing no malignant characters. A cyst with a whitish surface, rather dull, and not very smooth, is probably an ovarian cyst with a twisted pedicle. A dull-white cystic

high for digital exploration; and, lastly, had the patient been under the care of a relatively inexperienced operator, I believe that the gravid uterus might very probably have been mistaken, during the operation, for a fibroid tumour.

tumour with orange or ochreous patches is very possibly dermoid.

So far will the operator see his way at this stage. In most, if not all the above cases, excepting pregnancy, and in some kinds of uterine fibroid and advanced malignant disease, he will have to continue the operation. The chief object of the above remarks is to remind the surgeon that he must be the more cautious in using the trocar the less characteristic the surface of the tumour appears. Plunging that instrument into a soft uterine fibroid would cause severe hæmorrhage, impossible to check without removing the tumour entire. When the surface of a uterine fibroid has been exposed and wounded by the scalpel, and the surgeon finds that the tumour is not suitable for removal, a needle threaded with No. 1 silk must be passed under the bleeding point, so that two ends of the silk lie on each side of that point. Should the bleeding not cease when the ends of the silk are drawn tight, one end must be threaded on to the needle, passed over the bleeding point, and then through the tissues under that point. On tying the ends, the tissues will then pucker and the bleeding vessel will be firmly held.

Tapping the Cyst.—When, however, the surface of the tumour bears the characters seen in multilocular, dermoid, or broad-ligament cysts, it is best to proceed at once to tapping. Adhesions of every kind are more manageable when the cyst has collapsed than when it is full. If the operator should attempt to break down adhesions at the upper limits or sides of the cyst before tapping, there may be severe hæmorrhage behind the tumour, difficult to reach until the whole process of emptying the tumour and drawing it more or less out of the abdominal wound has been concluded. Besides, the operator may lacerate a portion of intestine tightly stretched over a tense cyst and firmly adherent to its walls, without even recognizing the nature of the adherent structure till it is too late. Such an accident is far less probable when the cyst is collapsed. Still, slight parietal adhesions close around the abdominal wound may be gently separated by passing the hand into the abdominal cavity between the cyst-wall and the peritoneum. A piece of omentum evidently adherent to the front of the cyst should be separated and held in the grasp of

pressure-forceps, to be tied later on. These two last manœuvres will prevent difficulties in fixing the spring hooks of the cannula, which may arise if there be close adhesions up to the very limits of the abdominal wound.

The trocar (page 102) is now thrust into the cyst (Fig. 95),

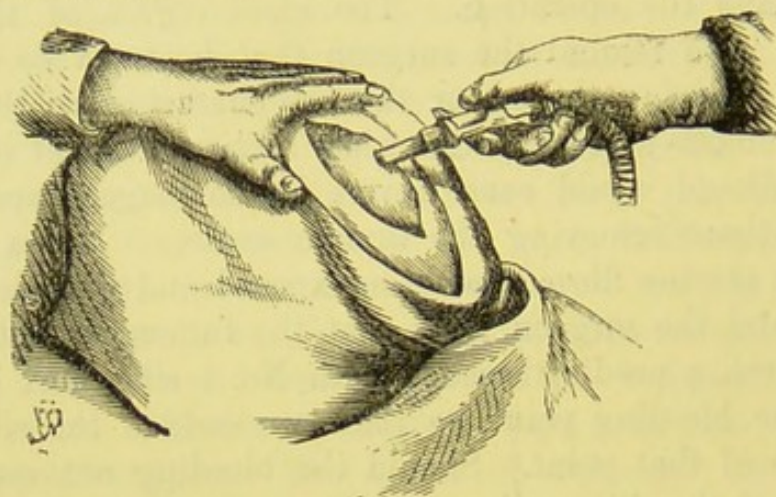


FIG. 95.—OVARIOTOMY: THE TROCAR PLUNGED INTO THE CYST.
(*Spencer Wells.*)

and the operator will know if the fluid be escaping by the collapse of the cyst-walls and the rush of the fluid into the receptacle below. As the cyst collapses the point of the trocar is drawn up into the cannula, and the cyst-walls around the aperture are pulled up and caught in the spring hooks (Fig. 96).

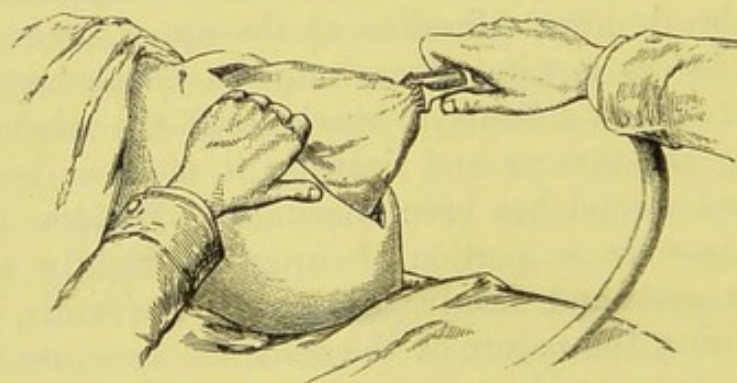


FIG. 96.—OVARIOTOMY: EXTRACTION OF THE CYST THROUGH THE
ABDOMINAL WOUND. (*Spencer Wells.*)

In order to bring the walls well up to the hooks, the long-handled volsella (page 106) should be used. If the cyst be pulled up by the assistant's hand there will be more risk of the

escape of fluid into the peritoneal cavity. The operator must never think of thrusting the trocar deeply into the cyst cavity, with the teeth opened so as to catch a piece of cyst-wall at haphazard, without the aid of another hand or instrument. In the simplest cases, the tumour may now come out with a run. A second assistant may support it, if it slides out rapidly, and the senior should see that no prolapse of intestines occurs. This he can prevent by pressing a sponge gently on the upper angle of the wound whilst the cyst is coming out. Some operators, dreading the chance of a sponge being slipped into the abdominal cavity by any one but themselves, forbid this practice. They, however, direct the senior assistant to prevent prolapse by catching hold of the integuments on each side of the upper part of the wound, between the fingers and thumb. I object to this, as the assistant's hands being generally moistened with blood, with the water from the sponges, or even with glairy fluid escaped from the cyst, he is very apt to let the integuments slip at the most critical moment, when they fly apart, and the accident which it was intended to prevent will probably occur. This misadventure I have witnessed more than once. In short, the assistant had better be trusted with his sponge.

Sometimes a large secondary cyst is detected ; then it may be tapped by means of the trocar. More than one such cyst may require this treatment. Should the fluid contents be foetid or purulent, it is very advisable, if possible, to complete the emptying of the cyst entirely by means of the trocar. In this way, not a drop need escape except into the receptacle below the table. The collapsed cyst must then be hung well to the operator's side of the patient, so that the fluid which remains may not leak over the patient's body.

Reduction of the Bulk of the Tumour by Breaking down Secondary Cysts.—If, however, the contents be clear, glairy, and evidently aseptic, the operator may without scruple break down secondary cysts with his hand, after unfixing the spring hooks of the trocar and letting it drop into the bath. Too great reliance on the trocar may involve wounding of the posterior part of the cyst-wall. In any case when the secondary cysts are small and numerous, or when abundant glandular growths exist, the interior of the tumour must be broken down

by means of the operator's hand, until the tumour is reduced to a bulk sufficiently small to allow of its removal through the abdominal wound.

This manipulation must be done with caution, yet not too slowly, and the beginner will find it harder than he expected. The cannula having been withdrawn, the hole in the cyst must be widened by tearing, or cutting with scissors. The edges of

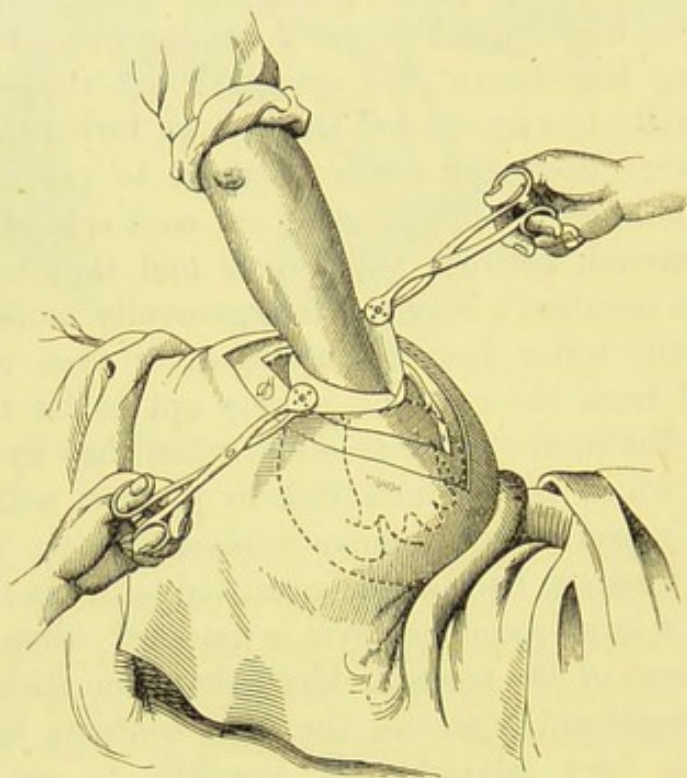


FIG. 97.—OVARIOTOMY, BREAKING DOWN SOLID MATTER.

The operator's hand is introduced into the cavity of the cyst, in order to break down secondary cysts and solid matter. The cut edges of the cyst are kept apart by Nélaton's volsellæ, held by an assistant; his left hand is represented considerably to the left of its true position, so as not to cover the outline of the operator's hand. (*After Savage.*)

each side of the rent are seized by means of a Nélaton's volsella. The senior assistant should then hold the two forceps, one in each hand, well apart so as to make the rent as wide as possible (Fig. 97). Then the operator thrusts his right hand into the cyst. The assistant must see that he holds the edges of the rent well above the level of the wound, and must take care that the cyst-wall does not get torn away from one of the forceps. If this occur at a critical moment, he should catch the cyst-

wall, below the yielding point, between the nails of his fingers and thumb and hold it well up. No doubt, the less the operator and assistants touch the interior of the cyst the better, but I am speaking of a comparatively exceptional condition of things. The cyst-wall is generally tough enough to bear gentle traction with the forceps. As long as the assistant keeps the cyst held up properly, there is little fear of prolapse of the viscera.

The operator, with his right hand, deliberately breaks down small cysts and solid matter, taking great care not to burrow too deep and endanger the back of the cyst. If that be wounded, the contents will run into the pelvis, and prolapse of some of the viscera into the cyst-cavity may take place. After a little breaking down the tumour can generally be drawn out with facility, provided there be no adhesions. If adhesions exist they must be separated, for the great danger of too free breaking down of the interior of the tumour is copious hæmorrhage, which cannot always be thoroughly arrested till the pedicle is reached. Before the adhesions have been attended to, it may not be possible to reach the pedicle. If free hæmorrhage suddenly occur during the process, the surgeon should draw up one side of the cyst, from without, as far as he can, so as to reach the pedicle, and then secure it by means of a large pressure-forceps with bent blades (page 109). If the pedicle cannot be reached, the lowest portion of the tumour must be seized by the large pressure-forceps. That instrument must be used in a similar manner should the cyst be extensively rent or burst during the process which is now being described.

Absence of Pedicle: Abnormalities in the Pedicle, and how to treat them.—In the more abnormal cases, as in a perfectly sessile tumour, the lowest part, secured by large pressure-forceps, will have to be made into a pedicle. On the other hand, the tumour may prove to be ovarian, yet severed from its pedicle (Fig. 100). In this case it is generally adherent to the great omentum, which may be tied in one, two, or more pieces, with No. 1 silk, and then cut away; the tumour may then be gently drawn out. The pelvic viscera should be explored with the finger to make sure that the tumour has not really been torn off in the course of the operation. If the ovary be missing

on one side, the nature of the case will be self-evident. Sometimes a detached tumour is universally adherent, and the absence of the pedicle will not be discovered till after the adhesions have been separated. There are cases in which the pedicle can be easily reached after the collapse of the empty cyst, though the latter be strongly adherent to the peritoneum and intestines. In such cases the surgeon may be thoroughly justified in applying the ligature to the pedicle and separating it from the tumour. The adhesions, especially if high in the abdomen, may then be broken down with comparative ease. In this case the distal or tumour side of the pedicle must be secured with large pressure-forceps before the pedicle is cut through, else the tumour may bleed whilst vascular adhesions remain undivided.

Treatment of Adhesions.—After the tapping, adhesions may have to be divided. Firstly, there may be none at all, and as this sometimes is the case when their presence has been suspected, the surgeon must never pull hard on the cyst-wall in extracting the tumour. Should he do so when the cyst happens to be heavy and unfettered by adhesions, it may slip out of the abdominal wound too quickly, and be followed perhaps by several coils of intestine.

Adhesions to omentum are very common. The omentum must be carefully tied with No. $\frac{1}{2}$ or No. 1 silk, a pressure-forceps should then be placed on the distal side of the ligature, and the omentum must, lastly, be cut through between the silk and the forceps. The omentum may require two or more ligatures, to be applied in this manner. Holes often form in adherent omentum. The omentum must be tied separately on each side of a hole and then divided. This precaution is obvious, when we remember that hernia of intestine and subsequent strangulation might be caused by leaving a hole in the omentum. In cancerous tumours of the ovary, the omental vessels may be so large as to need No. 2 silk for ligature.

Soft, vascular, parietal adhesions must be broken down, slowly and steadily, by gentle pressure with a sponge. Before separating them the surgeon must wash his hands, if they be stained with cyst fluid. When a large raw surface is left on the parietal peritoneum after separation of an adhesion, a sponge should be kept against it, and this will generally check hæmor-

rhage. When a small artery is divided, it should be seized with pressure-forceps, or secured with No. 1 silk.

It is not always easy to catch hold of the artery with forceps owing to the oblique position of the vessel in relation to the plane of the peritoneum where it lies. Its retractility under the surface of the peritoneum, and the mechanical obstacles to placing that surface in a comfortable position for the surgeon who uses the forceps, add to the difficulty of securing the vessel. Hence, when a bleeding vessel is hard to secure for any of the reasons just stated, the best way of settling the difficulty is to pass the ligature, by means of a needle, behind the vessel just above its bleeding orifice. In this way the peritoneum is transfixed on both sides of the vessel. The ligature being tied, the vessel will be firmly secured. In some cases many freely bleeding points may be detected on examining the peritoneum. The hæmorrhage must then be checked by the application of Paquelin's cautery.

Adhesions to intestine require very careful treatment. The sponge must be gently pressed against the line of adhesion, the pressure being directed towards the cyst, and not in the direction of the bowel. In this way the adhesion will separate, and possibly a thin lamina from the cyst will remain on the intestine. If the pressure be directed too much towards the intestine, the surgeon may soon expose its muscular coat, or, worse still, its interior. The senior assistant should keep a sponge gently pressed on the intestine. This is particularly necessary if it be distended, yet even if flaccid its outline along the line of adhesion is more readily seen by the operator when it is pressed down in this manner. When the cyst is strongly adherent, it is best to cut a piece away and leave it on the intestine, peeling off as many laminæ as can safely be managed. A very thick piece of cyst-wall may slough, as I have proved by post-mortem evidence; and as a cyst-wall is nearly always laminated, this peeling can generally be managed. As a rule, however, intestinal adhesions are not over tough. There is often free hæmorrhage requiring ligature of small arteries.

If a piece of intestine be torn the wound must be sewn up by a continuous silk suture. The needle must transfix the serous coat on each side of the rent at every stitch, so that when the

suture is tied, the peritoneal surfaces may be brought well into contact. Wells, in one case, removed about three inches of diseased and adherent intestine, and obtained complete union of the open ends by two rows of suture through the serous coat. In applying the sutures care must always be taken not to transfix the mucous coat.

When adhesions exist high up, the abdominal incision must be extended. This is best done with the ovariectomy-scissors (page 92). I have never seen delayed union in a wound made by scissors. The senior assistant should guard the viscera, as the wound is being extended, by pushing his left forefinger upwards below the point of the lower blade of the scissors. As the point is perfectly blunt, there will be no fear of the finger being wounded. A flat sponge is, of course, the best guard when it can be applied, as in cases where the tumour is simply large or solid, but under the circumstances now described this cannot always be done owing to the high adhesions. The operator must keep to the middle line—a simple task, for by passing the blades into the upper angle of the wound, the recti will fly apart as he cuts through the walls, so that if he does not cut too fast he can easily see where he is going. If he be too precipitate, he may wound one of the recti, but he can readily find the right track again, along the linea alba. Perhaps he may prefer to guard the cyst and other structures himself by keeping his left fore and middle fingers under the lower blade of the scissors, raising the walls as he cuts; this is best if his assistant be inexperienced. I have never seen any injury to the deeper structures, but in one case, in England, the intestine was wounded and an artificial anus resulted.

CHAPTER VIII.

THE OPERATION OF OVARIOTOMY.

(Continued.)

Ligature of the Pedicle.—A pedicle being found, it will now be necessary to secure it by ligature. The typical pedicle is easily recognized, the enlarged Fallopian tube presenting a characteristic appearance (Fig. 98). When the pedicle is broad

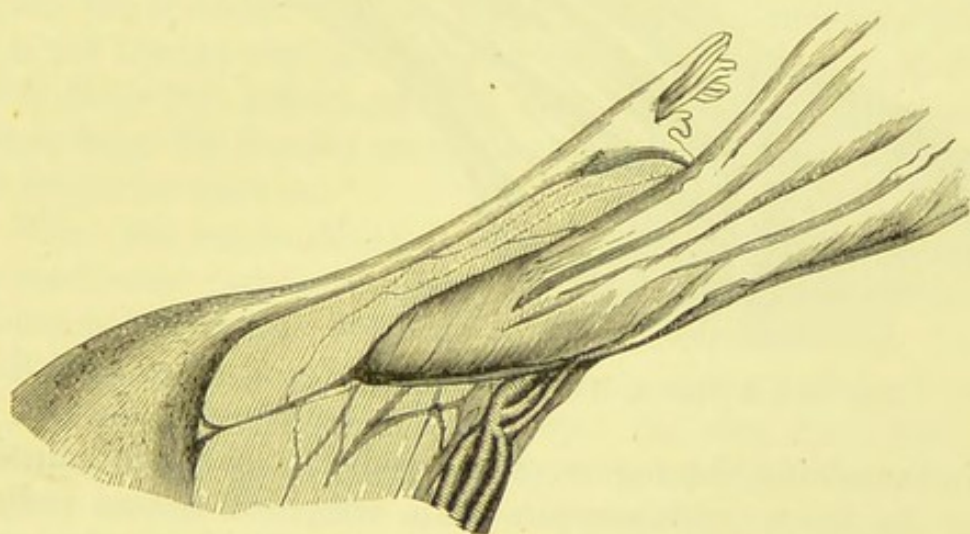


FIG. 98.—A LONG PEDICLE.

The cyst has been tapped and is collapsed. The vessels in the outer border of the pedicle are indicated. (*Semi-diagrammatic.*)

and thin, the operator may pass his finger down it till he can detect the uterus, should that organ be out of sight. When the pedicle is very broad, it is important to ascertain the precise relations of the uterus to the cyst. In the shortest and broadest kind of pedicle, the base of the cyst will be found close to the side of the uterus, separated from that structure by a short

segment of the broad ligament (Fig. 99), or, in some cases, actually touching uterine tissue. The fundus uteri will, in such a case, be considerably displaced to the opposite side. This displacement is easy to understand, for the base of the distended cyst, lying in almost immediate contact with the side of the uterus, and unable to rise high out of the pelvis, must press heavily on the organ. When the pedicle is long, this displacement does not necessarily occur, the cyst rises out of the pelvis, and its base simply lies over the fundus of the uterus.

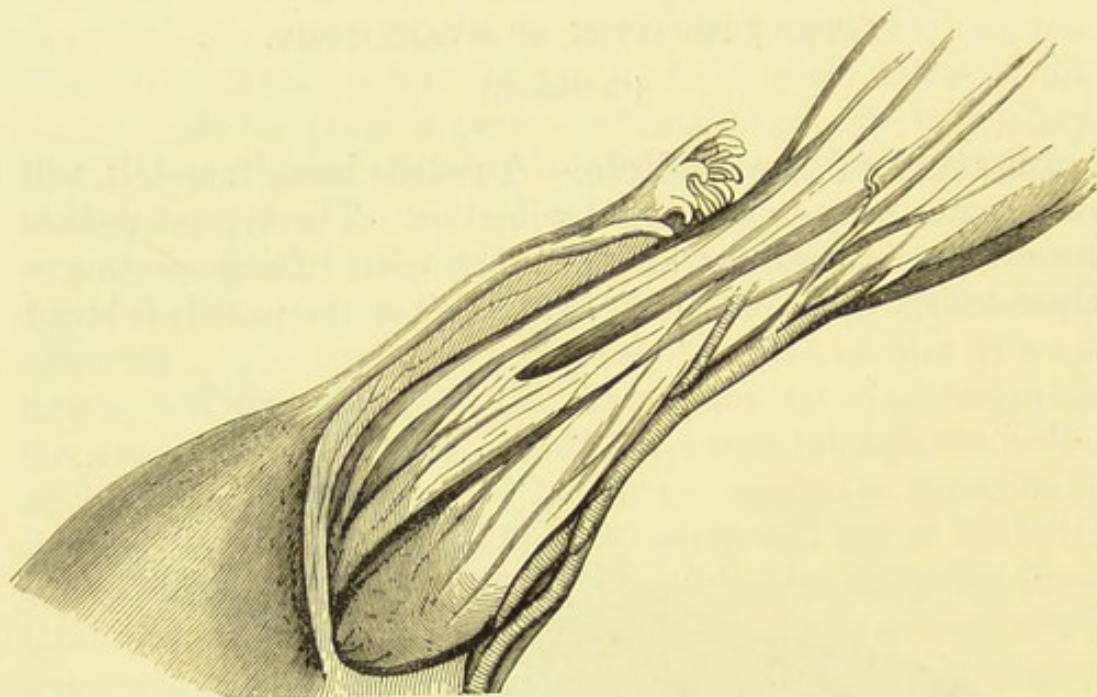


FIG. 99.—A SHORT, BROAD PEDICLE. (*Semi-diagrammatic.*)

In examining the region of the pedicle any pelvic adhesion must be taken into account. An atrophied second pedicle, the tumour consisting of two cystic ovaries fused together, may be taken for an adhesion. I have seen this condition at several operations, and it was just at this stage, and never earlier, that the true pathology of the case was detected. By feeling and inspecting the adhesion, its attachments will be discovered. Should it be found that the apparent adhesion runs to the side of the uterus opposite to the pedicle already in sight, the condition just described will probably exist, and its existence can be proved by examination of the relations of the Fallopian tube and broad ligament. Being proved to be a pedicle, it

must be treated as such. The pedicle first discovered should be first secured.

When the suspected pelvic adhesion proves to be a true adhesion to neighbouring viscera or peritoneum, then, if very thin, it will be sufficient to tie it with a piece of No. 1 silk, and to sever it with a pair of scissors, on the distal or tumour side of the ligature. If broad, yet long enough to allow of such a manipulation, it should be transfixed by means of a small pedicle-needle, armed with No. 1 or No. 2 silk, and secured just as the pedicle is secured, after the manner presently to be explained. Then a pair of pressure-forceps must be made to grasp the adhesion on the distal side of the ligature. Lastly, the adhesion is cut across between the ligature and the forceps. The object of the forceps is to prevent hæmorrhage from the distal side of the adhesion. This would not necessarily be dangerous, but the blood would run into Douglas's pouch, and although not difficult to remove, its presence there might puzzle the operator. When blood is found in Douglas's pouch, it is not always easy to remember whence it came. So the less of it there the better, and the more precautions the operator takes, from the first, to avoid hæmorrhage, the less trouble will he encounter later on.

When the pelvic adhesions are very broad, short, and intimate, a practicable pedicle existing, then, as in the case of strong abdominal adhesions, it is best to secure the pedicle first.

Before coming to the direct treatment of the pedicle, I must once more remind the surgeon that he may find that the tumour is not sessile, and that there is no pedicle at all. In such a case he must have discovered parietal or intestinal, or at least omental, adhesions, for the tumour could not exist without its blood-supply. (Fig. 100). This condition is apt to startle inexperienced operators; they may even fear that they have torn through a pedicle. This accident, however, would entail serious hæmorrhage, which would only too soon make itself apparent. When the pedicle is missing, the nature of the case may be proved by passing the hand along the sides of the uterus. Then, if an entire appendage be wanting, the truth will be revealed. Sometimes, in these cases, the proximal end of the pedicle is reduced to a mass of fatty or fibrous tissue,

ending in an irregular, cord-like structure, the sole relie of tube and broad ligament. (Fig. 101).

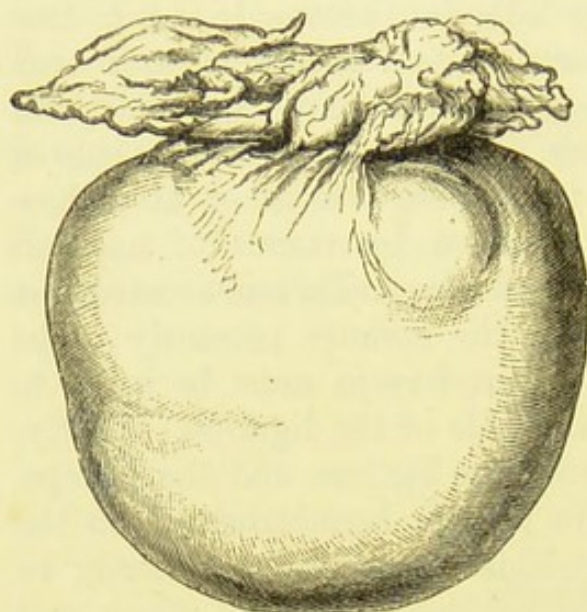


FIG. 100.—A DERMOID CYST SEPARATED FROM ITS PEDICLE AND NOURISHED BY OMENTAL ADHESIONS. (*Author.*)

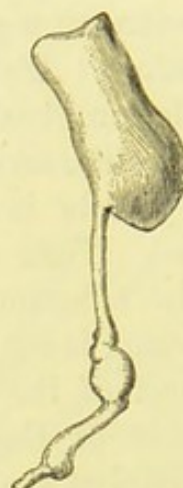

FIG. 101.—STUMP OF THE PEDICLE FROM THE SAME CASE.

Now the pedicle itself must be considered. When twisted, or reduced to a mere cord, almost devoid of vessels, a single ligature of No. 2 or No. 3 silk may safely be tied around it. Even in such a case, however, the surgeon must be very judicious about trusting to single ligatures.

It is with a good, long, and tolerably broad pedicle that the operator has, as a rule, to deal. Mathematical rules about cutting it long or short cannot possibly be framed for the benefit of the inexperienced. The operator must be guided by the dictates of common-sense. It is evident that the ligature needle must not be thrust through the pedicle deep down and close to the uterus, nor, on the other hand, so near the cyst as to leave a stump several inches in length.

The ordinary pedicle will consist of a plane surface, two or three inches wide, and about the same length, representing the tube, always conspicuous, the broad ligament, the ovarian ligament, which may or may not be readily detected, and lastly, an elevated ridge, running from the back and outer part of the plane, upwards, outwards, and backwards towards the lumbar region. This ridge, which forms the outer border of the

pedicle, is filled with the large veins forming the pampiniform plexus and the ovarian artery. It represents the normal infundibulo-pelvic ligament (see pages 27, 35, 37, 38).

Dr. Bantock and some other operators invariably compress the pedicle, before applying the ligature, by means of a large pressure-forceps with bent blades applied to the distal side of the point to be transfixed by the pedicle-needle. This compresses the tissues, so that the ligature can be drawn more firmly and safely, provided that the assistant takes off the forceps at the moment that the operator begins to tie the threads. In oöphorectomy, this practice is always advisable; but in ovariectomy it may cause difficulties to inexperienced operators and assistants.

The surgeon now takes in his right hand a small pedicle-needle armed with No. 2 silk. He then raises the outer edge of the pedicle with his left thumb and forefinger. The vessels are now pushed outwards, and the needle is made to transfix the tissues of the outer edge on the inner side of the vessels, at the same level as the operator thinks right for the future ligature of the main part of the pedicle. He must take care not to transfix any vessels. This may be avoided by gently stretching the tissues of the pedicle, entering the point of the needle on the outer side, and watching its egress on the inner side. The point may then be seen, possibly threatening a vessel. It must be safely guided through, away from that vessel. In some cases, a stout curved suture-needle answers better than a pedicle-needle for the present purpose. The operator will know, at the time, which will prove the more handy.

The ligature-silk must now be drawn through, not in a loop, and the ends tied tightly on the outer side of the pedicle. In pulling them, when the operator feels that the tissues are yielding, he may be sure that he has pulled tightly enough. He must avoid snapping the silk, a troublesome accident which may usually be prevented. Mr. Thornton leaves this ligature untied in anæmic patients till the main part of the pedicle has been secured. He believes that, as this permits the return of much blood through the veins into the general circulation, it may avoid loss of blood. For blood taken away in the tumour is, physiologically, blood which is shed.

The main part of the pedicle must next be transfixed. The pedicle is carefully raised by the operator's left fingers and thumb. A stout pedicle-needle (page 113), armed with No. 3 silk, is thrust through the pedicle with care and deliberation. The operator must take the same precautions as when engaged in securing the outer edge of the pedicle. The moment that the loop of the ligature appears as the point of the needle passes through (Fig. 102), it must be seized by the senior

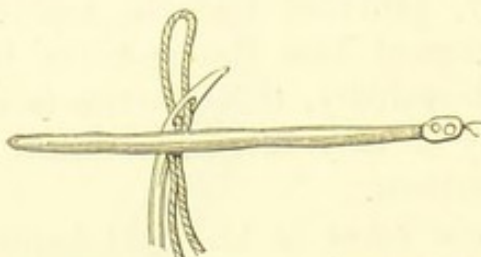


FIG. 102.—LIGATURE OF THE PEDICLE.
Transfixion with the needle.*

assistant, who may hook his right forefinger into it. The operator then withdraws the needle. By the above manœuvre the needle is not thrust through the pedicle to an unnecessary extent.

The operator may now tie the ligatures after the method of Sir Spencer Wells, or of Mr. Tait. Perhaps the simplest and easiest method is that explained by Fig. 103. One end of the

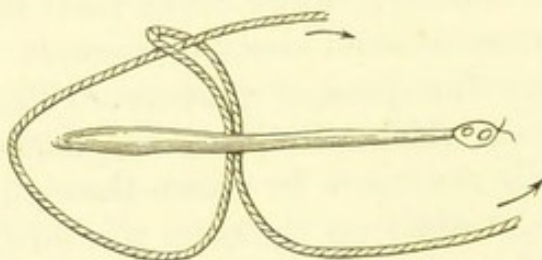


FIG. 103.—LIGATURE OF THE PEDICLE.
One end of the thread passed through the loop.

silk is brought half round the pedicle, passed through the loop which is not to be cut through, and then tied to the other end of the silk round the opposite half of the pedicle. Thus the

* All these sketches representing the process of ligature of the pedicle are diagrammatic. The thickness of the pedicle is indicated, and the ligatured outer border is also represented in three of the drawings.

pedicle will be firmly held by two loops. This is an excellent and exceedingly simple method, always employed by Dr. Bantock. In tightening the ligature, the ends must be pulled steadily and firmly, and in one direction throughout, else the silk may get frayed and snapped as it passes through the loop, or the loop itself may be cut. An accident of this kind is not unfrequent when the surgeon is inexperienced. The intending operator should practise this method with a loop of twine passed through a towel; he will then understand how to avoid fraying the ligature against its own loop as it is being tightened. This loop is highly suitable for oöphorectomy.

In this, and in any other method, the senior assistant must hold up the flaccid tumour firmly and to one side during the application of the ligatures. Whilst the operator is drawing the knots tight* the assistant must never neglect to relax the pedicle by ceasing to drag on the tumour.

There is yet another method very easy to carry into practice; it answers all purposes admirably. The loop (Fig. 102) must

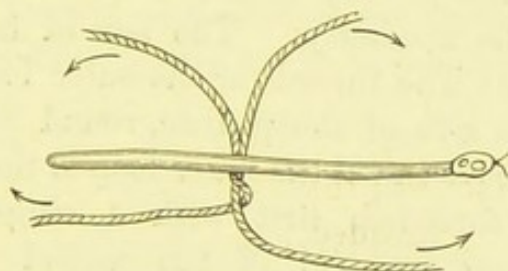


FIG. 104.—LIGATURE OF THE PEDICLE.

The loop cut and the threads crossed on one side.

be cut through. Then two threads will lie in the pedicle. The operator and assistant make sure of the right ends of the threads, and then the operator twists the end of the thread intended for the outer loop round the corresponding end of the remaining thread (Fig. 104). The importance of this precaution has been explained at page 187, where Fig. 92 demonstrates the danger which its omission may entail. It

* Sir Spencer Wells and all the surgeons at the Samaritan Hospital, including myself, invariably tie in a "double reef" or "surgeon's knot." "This is made by passing one end of the thread twice over the other before turning each end back again to form the second noose" (Fergusson, *System of Practical Surgery*, 4th ed., p. 33 and Fig. 38). It is easily applied and very safe for this purpose.

must only be done on one side of the pedicle. The two ends of one thread are then tied firmly on the outer side of the pedicle, care being taken that the loop slips into the groove occupied by the ligature already applied to the outer border. The ends of the remaining thread are then tied around the inner side of the pedicle. If the pedicle be short, the surgeon must be cautious, as he may be compelled to tie uterine tissue, which requires very firm ligature (page 17).

These loops must be drawn firmly, so that the tissues on the distal and proximal side bulge over and touch each other. The advantage of this condition has already been explained; but the surgeon must be cautious about drawing the ligatures too firmly. A triumphant jerk at the end may easily snap the ligature, nor is the silk always trustworthy, however slowly and carefully the operator may pull it tight. The breaking of the ligature, under these circumstances, is most untoward, and involves yet more trouble and danger than when it occurs during the ligature of the outer edge of the pedicle.*

When the pedicle is very broad, a second or even a third transfixion will be necessary. The second transfixion must thus be performed: The thread for the outer loop (*a*, Fig. 105) is twisted, on one side of the pedicle, round the other thread (*b*) as described above; then the outer loop is tied. The pedicle-needle is then threaded, first with a single ligature (*c*), and then with one end (*b*) of the untied thread already passed through the pedicle. The transfixion is then performed (Fig. 105).

This second threading and transfixion is best managed with the assistance of the long, free (or unhandled) pedicle-needle, for, as has been explained in describing that instrument at page 114, its large eye is suited for the present purpose. Re-threading a curved, handled needle, in the middle of the operation, is often a troublesome process.

* I will not dwell here on Sir Spencer Wells' controversy on the question of the necessary tightness of the ligature. (See *Diagnosis and Surgical Treatment of Abdominal Tumours*, 1885, p. 92, and author's *Tumours of the Ovary*, p. 151.) Sir Spencer says:—"I always tie as tightly as I can." If he did so he would certainly snap the ligature, and so would anybody whose hands were not very weak. He means that he always ties the ligatures as tightly as his manipulative instinct, the result of long experience, knows to be sufficient for its purpose.

The third thread, *c*, must be once twisted round the second, *b*; this is best done, perhaps, on the side where *b* forms a loop (see Fig. 105). Then, on the opposite side, the two free ends of the second thread, *b*, are firmly tied. The ends of the third thread, *c*, are then tied on the inner side of the pedicle. The threads will then lie as in Fig. 106. Thus the three threads, firmly interlocked, will hold the pedicle tightly.

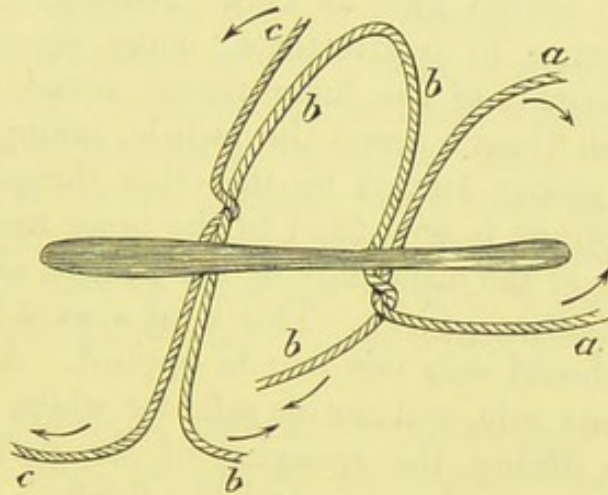


FIG. 105.—LIGATURE OF THE PEDICLE.

Double transfixion, showing how the threads are to be crossed.

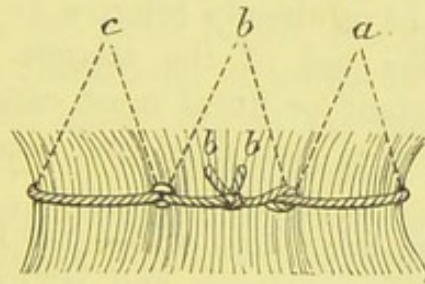


FIG. 106.—LIGATURE OF THE PEDICLE.

Double transfixion: the threads tied, as seen on a side view of the pedicle.

Should a third transfixion be required, the third thread, instead of being tied, must be threaded on the needle in company with a fourth, and the process just described will be repeated. Care must be taken not to neglect interlocking the threads once more, as before.

When any loop is tied, in the course of the above manipulations, the ends of the threads must be cut short; if all the threads be left uncut until the ligature is complete, much needless confusion may be entailed.

In order to make assurance doubly sure, it is advisable to bring the two ends of the inner ligature round the entire pedicle, and to tie them once more, taking great care that the ligature sinks into the groove already formed by the threads. In tying this final knot, each end of the thread must be pulled back from the first knot, which will thus be made tighter. If the ends be crossed over the knot it may be loosened as the second knot is tied. Through fear of such an accident, owing to inadvertence, many operators object to bringing the ends of the inner thread round the pedicle. They tie a fresh thread round the pedicle, taking care to let it sink in the groove formed by the other threads.

A pressure-forceps is now fixed to the inner and another to the outer border of the distal side of the pedicle, about half an inch from the ligature-groove. This must always be done, and on no account should only one pair be applied. A single pair, made fast to one side, will not be safe, for whilst the assistant holds it firmly during the sponging of the peritoneum, the pedicle may be dragged upon, and the ligature consequently strained in one direction. The pedicle is now cut across with scissors about, or rather less than, one inch beyond the ligature-groove. I have already referred to this step at page 92, in describing the use of the scissors. Whilst this is being done, the assistant or nurse must carefully support the tumour, so that it does not drag and tear itself off when half divided.

The senior assistant takes hold of the two forceps attached to the pedicle directly it is cut across, and, letting the stump sink, grasps them by the bows in one hand until the operator wishes them removed, or desires for any reason that the assistant should let go of them. The operator, under the latter circumstances, may place the handles of the forceps within the abdominal cavity with little risk, since anything which has been attached to the pedicle is not likely to be forgotten. Forceps should not be so placed under any other condition, if it can possibly be avoided. If left attached to omentum, they are very apt to be overlooked at the end of the operation.

The moment that the tumour has been cut away, a large flat sponge must be slipped into the abdomen under the upper part,

and above the upper limit of the abdominal wound. The operator raises the upper angle of that wound by hooking it up with his left forefinger, as he pushes in the sponge with his right hand. The peritoneum in the front of the pelvic cavity, Douglas's pouch, and the lumbar region must be cleaned with sponges. The senior assistant then washes away the blood, etc., from the abdominal integuments, and the waterproof sheet, taking care to clean the latter last, and not to use the sponge which has been scoured over it, to wipe any structure near the seat of operation. Both operator and assistant should now wash their hands and forearms in carbolized water. It may happen that the tumour has two pedicles, being made up of two cystic ovaries fused together (*see* page 216). In such cases, the second pedicle must be secured after the manner of the first, unless it be so atrophied that it may be safely tied by a single No. 3 silk ligature.

When the pedicle is distinct, but exceedingly short, so that manipulations must be carried on close to the uterus, the large pressure-forceps should be applied to it, or even, when the shortness is extreme, to the base of the cyst beyond the pedicle, so that room is left, between the forceps and the uterus, for securing the outer vessels, transfixion, and ligature. As the first of the transfixing ligatures is being tied by the operator, the assistant must take off the forceps. This process is constantly resorted to in oöphorectomy.

Difficulties respecting the Pedicle or other relations of the Tumour.—Before proceeding further, I must note certain conditions which are sometimes discovered at the pedicle stage, as it may conveniently be termed, of the operation. There may be no true pedicle, or the tumour may prove irremovable.

Treatment of Sessile Tumours.—The surgeon must be careful to distinguish between deep pelvic adhesions and absence of a pedicle. A new surgical problem has then to be faced.

Encapsuled Ovarian Cysts.—On exposing or on tapping an ovarian cyst, it may be found that the cyst-wall is invested in front by a capsule, generally of a very pale red colour, and contrasting strongly with the white cyst-wall behind it. The capsule is formed by the distended layers of the broad ligament into

which the tumour has forced itself, and by peritoneum detached from adjacent parts of the pelvis. When we remember the intimate relations of the most important pelvic viscera to the pelvic peritoneum, it stands to reason that those relations are greatly disturbed when a cyst burrows under the serous membrane beyond the limits of the broad ligament. In extreme cases the inferior part of the cyst may lie below its serous capsule, touching the pelvic fascia, and in close proximity to large vessels, the ureters, and the adjacent viscera.

When a capsule is detected, the operator should draw it upwards with the cyst-wall after the cyst has been tapped. He may then find that capsule and all can be removed entire, there being enough space between the uterus and the tumour to form a true pedicle. This, however, is rare; the cyst has generally burrowed deeply in the manner noted above; besides, the capsule may be intimately connected externally with important structures. When, therefore, on drawing up the capsule, it is found to be deeply connected with other parts, the surgeon must not venture to take it out entire. He must enlarge the abdominal wound, and carefully shell the cyst-wall out of the capsule. This can be done by gentle traction on the cyst, the assistant brushing a sponge against the capsule as it comes away. Large vessels will be torn through, and must be secured with pressure-forceps. Great care must be taken that the capsule be not perforated or lacerated, as this will seriously affect results. This process of enucleation often causes much shock.

The surgeon can generally find the fundus uteri outside the capsule as he reaches the deep part of the tumour. When he succeeds in finding the fundus, he will have the advantage of a valuable landmark. I once assisted at an operation where the cyst had detached the whole of the peritoneum from the back of the uterus; thus the uterus formed part of the anterior, and its posterior serous investment formed part of the posterior, wall of the capsule.

As a rule, the base of the cyst can be found and detached from the deepest part of the capsule which, inferiorly, may be no longer peritoneal, but formed out of the pelvic fascia, as above described. The base of the cyst must be very carefully separated from its attachments, and several large vessels

will require immediate ligature ; they can generally be detached and secured before division.

The management of the empty capsule is most important. In some cases its deeper part can be transfixed and ligatured, as though it were a normal pedicle ; the ligature may include uterine tissue (pages 17, 222). After ligature the capsule is cut short, and its free edges beyond the ligature should be sewn together by a continuous No. 1 silk suture. In one case where I operated, I secured the capsule in this way, sewing it up from the side of the pelvis to the side of the uterus as far as the stump of the uterine end of the Fallopian tube. The patient recovered with no local trouble whatever. In many cases the base of the capsule lies very deep in the pelvis, and cannot be treated in this manner. As much of the capsule as possible must then be raised out of the abdominal wound, so that the greater part can be cut away, the remainder being left behind and drained. When the upper part of the capsule, or as much as can be safely pulled forwards, is cut away, all bleeding vessels in the cut edge must be secured with pressure-forceps as they are divided. The free edge is then attached by suture to the borders of the lower part of the abdominal wall. Bleeding points on the inner surface of the capsule are secured by ligature, and then search is made to make sure that the capsule is not lacerated and that no omentum or intestine protrudes into its cavity ; in fact, the surgeon must see that the remnant of the capsule is entirely cut off from the peritoneal cavity. Protruding viscera must be reduced, and holes in the capsule sewn up. This should be done from the outer or peritoneal side of the capsule.

Lastly, a glass drainage-tube is passed into the capsule. The sutures holding the edges of the capsule to the abdominal incision are tied, then the peritoneal cavity above the capsule is cleaned, and the upper part of the abdominal wound closed. Drainage must be conducted on the usual principles (page 127).

Irremovable Base of Cyst.—Sometimes the base of the cyst itself cannot be shelled out of its capsule. It must then be left behind and sutured, together with the remains of the capsule, to the edges of the abdominal wound, and drained. This may have to be done in cases of non-encapsuled cysts,

where the base is strongly adherent. The operator must endeavour to take away all solid growths from the piece of cyst left behind, else both sepsis and recurrence will be very probable.

In all enucleations and divisions through capsules and cyst-walls in the course of an operation, the assistant must make free use of the sponges, so that the operator may see his way. A great number of pressure-forceps will be needed, and, when all used up, those which secure the largest vessels should be removed after the vessels have been tied.

Incomplete Ovariectomy.—This subject must be considered now, in the midst of the details of the complete operation. For I am endeavouring to describe the stages of ovariectomy in their natural order, making, at the same time, allowance for serious contingencies and complications, and indicating at what stage they may occur, and how they should be met. It is evident that nobody undertakes to perform an incomplete operation. Such an operation represents accidental conditions which he may meet in the course of almost any ovariectomy where the tumour is partly solid. These conditions may be recognized very early. The surgeon may detect intimate adhesions between the front of the tumour and important viscera; besides, the tumour itself may bear an ugly malignant aspect. Then he can leave the adhesions alone, and sew up the abdominal wound. Perhaps he may be tempted to tap the tumour, and to break down adhesions, or he may find intimate adhesions at the back and base of the tumour, and all this after he has broken down the solid contents of the tumour. Lastly, the lower part of the tumour may be of a nature which will not permit of enucleation. All these unfavourable conditions the ovariectomist must be prepared to meet. It is not sufficient for him to feel sure that he can separate separable adhesions, and secure a pedicle in the orthodox fashion. He must be ready, never to surrender, but to beat a retreat in as good order as he would have advanced to a surgical triumph. It is a moral duty for a surgeon to play the difficult part of a Xenophon, whenever circumstances render that step necessary. When, about the stage of the operation now under consideration, the operator feels that he would not be justified in

removing the tumour, he must first check all hæmorrhage, securing vessels on the tumour as well as elsewhere. He must also see that he has not lacerated intestine. The transverse colon, when strongly adherent to the upper part of the cyst, and tightly stretched upon it, is liable to be inadvertently torn. All other portions of adherent intestine which have been separated must be carefully inspected. Then the back of the tumour and the structures behind it must be carefully cleaned with sponges.

The abdominal wound will probably be long, in a case of this kind. If so, the upper part should be closed by sutures. The lacerated margins of the rent made in the tumour by the

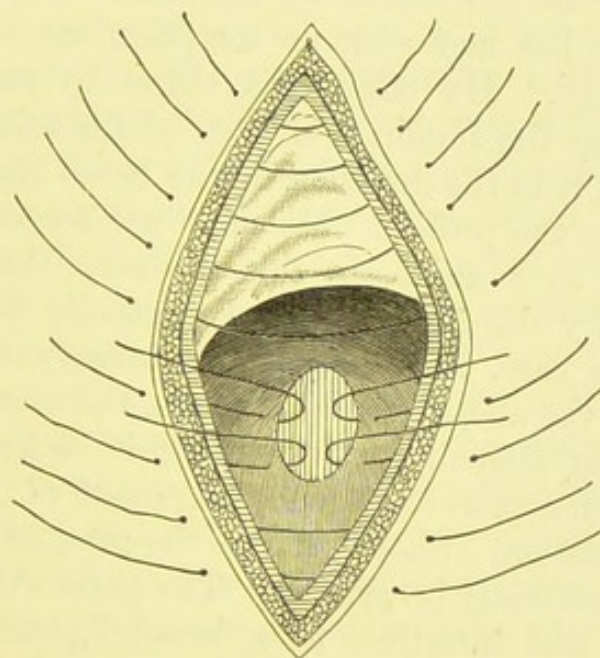


FIG. 107.—AN OPENED CYST OR CAVITY, SECURED BY SUTURES TO THE ABDOMINAL WOUND.

trocar, and by the hand of the operator endeavouring to empty the contents, must then be fixed by sutures to the corresponding sides of the wound, which must be left open. In fixing the tumour in this manner, the suture-needles must be passed through the peritoneum, about a quarter of an inch from its cut edge, so as to bring that membrane in contact with the cyst-wall. The wound will then be entirely cut off from the cavity of the abdomen (Fig. 107). This practice is adopted in some cases of pelvic abscess and extra-uterine foetation.

Sometimes a tumour requiring the above treatment is multilocular. In such a case it is advisable to cut and clear away everything contained in those loculi which the surgeon has broken open, and then to wash the walls of the chasm left behind with carbolized solution, or with strong iodine. Lastly, a drainage-tube must be inserted, long enough to touch the bottom of the opened space in the cyst, whilst its upper orifice lies in the lower angle of the wound. The cavity must be washed out every four hours, or oftener, if much foetid fluid escape from it.

Exploration of the Ovary opposite the Tumour.—

The operator must now search for the other ovary, provided, of course, that he has met with no complications rendering that step unnecessary. He effects his object by passing his left forefinger along the fundus and back of the uterus, and then searching with it in the direction of the broad ligament on the side opposite to the pedicle. He must not forget to make use of the uterus as a guide, in this manner. Any attempt to reach the ovary direct, unless it be actually in sight, as is sometimes the case, may involve unnecessary disturbance of intestine. If the above advice be taken, the ovary is generally reached without difficulty, provided that it be healthy, and not involved in some morbid process, the result of old or recent pelvic inflammation. Should this be the case, an inexperienced operator will certainly be puzzled. The parts will be very hard to recognize, and intestine, tube, broad ligament, and other structures may be firmly adherent to the ovary, and may, perhaps, completely conceal it. Sometimes the finger comes to a dead stop, the pelvic structures being embedded in some organized inflammatory deposit. In cases of this kind, the ovary had best be left alone. Attempts to break down its morbid connections may cause troublesome hæmorrhage, and the intestine may be torn or the tube burst.

If the broad ligament, tube, and ovary can be reached, but are found to be matted together by old inflammatory adhesions, they ought to be removed. This should certainly be done when the patient has been troubled with great pain in the iliac fossæ and loins, and other symptoms more likely to arise from pelvic inflammation than from the

presence of a large ovarian cyst. The operator, in fact, will have to perform an oöphorectomy. It will be a comparatively easy operation under these circumstances, as the abdominal walls are already very lax since the removal of the ovarian cyst, and the pedicle of the small diseased ovary can be much more safely secured than in cases of uterine fibroid. It is the facility and safety with which oöphorectomy can be performed under these circumstances, which make some operators conclude, too hastily, that oöphorectomy is an easy operation. In the chapter on the subject, I note the reasons why that operation often proves to be so difficult.

Supposing the operator feels a big, succulent ovary, then he must draw it up to the level of the abdominal wound and examine it carefully. He must remember that the ovary in a healthy young girl or a robust woman who still menstruates is a very different thing to that organ as seen in the post-mortem room of a large general hospital, where it has, as a rule, been removed from the body of a sickly hospital patient (see page 27). Even in the latter case, the ovary is usually larger than in a dissecting-room subject, the body of an elderly, underfed pauper. Yet, owing to the manner in which the surgeon learns the anatomy and pathology of the ovary, he is apt to under-rate its normal size. A follicle about to burst may be as big as a filbert, and will stand out very prominently from the surface of the ovary, as a red ill-conditioned looking mass which the surgeon must not mistake for incipient malignant disease.

True cystic disease is not highly difficult to recognize in its incipient form. A cyst of considerable size may be completely concealed in the pelvic cavity until detected by the operator's forefinger at this stage of the operation. It must be drawn out and removed, like the larger tumour. Of course, if there be the least difficulty in getting it out of the abdominal wound it should be punctured with a small tapping-trocar (page 105). Indeed, tapping is always advisable, in order to facilitate ligation of the pedicle. When the pedicle is rather deep, the large pressure-forceps, elbowed or straight as seems most convenient according to circumstances, may be applied to the base of the cyst or to the pedicle close to its attachment to the cyst, and the ligature passed through the pedicle on the proximal

side of the forceps. The process of ligature must be performed with as great care as when a large tumour is severed from its pedicle.

As a rule, however, the operator will find the ovary healthy, small or perhaps atrophied. Having drawn it upwards to ascertain that fact, he then pushes it down again. A sponge, mounted on a holder, should be introduced into Douglas's pouch with the left hand as the right is being withdrawn, as the disturbance of the pelvic viscera may have caused fluid to run into the peritoneal space.

The operator must be cautious about meddling with any fibroid outgrowth from the uterus which he may discover. He should bear in mind Sir Spencer Wells' words, "In one case, after completing ovariectomy, I also removed a fibroid outgrowth from the fundus uteri. This patient died, and I think she would have recovered if I had left the uterus alone, as I have done in several cases since, where the size of the growth was insignificant." If the patient be young and the uterus be studded with small fibroid outgrowths, then oöphorectomy may be performed by simple removal of the remaining ovary. In one of my own ovariectomies, I thought it best to do this, and the result justified my resolution. No circumstances could be more favourable for thorough oöphorectomy, and under no conditions is that operation more likely to effect its object in arresting morbid uterine development. But the surgeon must not enucleate a small outgrowth, with a light heart. It may cause hæmorrhage so severe as to necessitate clamping the uterus and removal of its body.

Sometimes, in the course of these explorations of the pelvic cavity, previous to the final steps of the operation, the body of the uterus is found to be soft and enlarged. This may lead to a suspicion of early pregnancy, especially when there has been amenorrhœa, nor is the question always easy to decide at the time. In any case the uterus must be handled very gently, and never squeezed; then, should pregnancy really exist, there will not be much danger of abortion.

The Introduction of Sutures into the Abdominal Wound.—The condition of the opposite ovary having been ascertained, and any necessary complication in this direction

properly encountered, the sutures are now introduced into the abdominal wound. This is not to be considered as the last manœuvre in the course of the entire operation; that is to say, the wound is not to be closed directly the sutures are introduced. The large flat sponge guarding the viscera at the upper angle of the wound must be inspected. If any portion of it be covered with coagula or deeply stained, the operator must search for bleeding points in the direction where that portion lay. Unless this sponge be almost dry and free from serous effusion, it must be taken out and at once replaced by the other large flat sponge. Sometimes, when the intestines tend to protrude, it is safe to place a small flat sponge over them before introducing the sutures. A sudden straining effort, which is likely to occur at this stage when the chloroformist may have neglected to keep the patient thoroughly under the influence of the anæsthetic, will endanger the viscera as the needle is being applied to the inner side of the wound. As a rule, however, the lower part of the large flat sponge will sufficiently guard the exposed viscera. It is only when the wound is very long that the second sponge becomes necessary. A large conical sponge should be placed in Douglas's pouch; the beginner had better fix a sponge-holder on to it. If adhesions have been broken down between the cyst and the parietal peritoneum laterally, a flat or round sponge should be placed under the abdominal walls on one or each side of the wound. The two pressure-forceps may now be taken off the pedicle, and it is best to cut away with them the small pieces of pedicle tissue which they have compressed. Before the two forceps are removed the pedicle must be carefully examined; any pressure-forceps remaining on vessels in the edge of the abdominal wound may safely be removed; it is very improbable that ligature or torsion will be required. The above precautions having been taken, the surgeon now proceeds to the introduction of the sutures. If the edge of one of the recti be ragged, through a bruise from the handles of a pressure-forceps, the torn fibres may be trimmed with scissors.

The surgeon now takes one of the needles, attached to one end of a suture, between the blades of the needle-holder (see page 115), applied close below the eye of the needle, with the nozzle directed towards its point. The peritoneum at the left

side of the upper angle of the wound is slightly everted by the operator's left thumb, and then the point of the needle is pushed through it less than a quarter of an inch from its cut border (Fig. 108). Then the aponeurotic structures are transfixed, and lastly the integuments, so that the needle comes out through the skin about a quarter of an inch from the margin of the abdominal wound. The needle should be pushed straight and steadily, then it will go easily and safely through the thickest structures. If pushed when it is beginning to bend, it will probably snap.

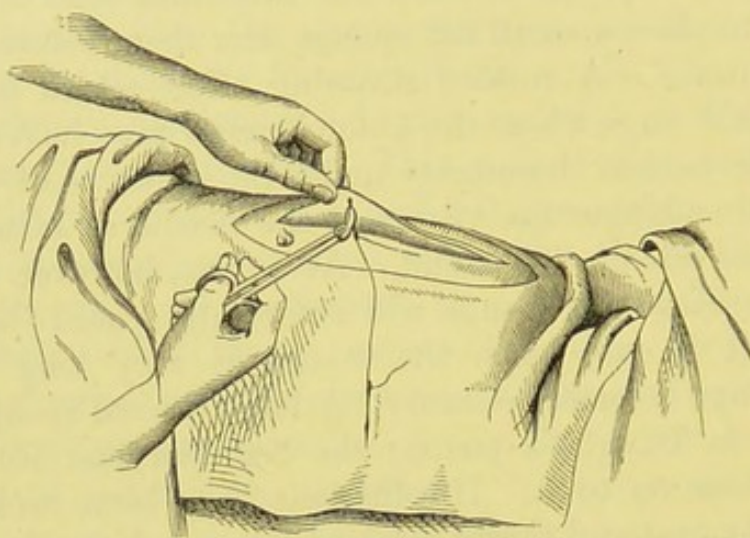


FIG. 108.—OVARIOTOMY: INTRODUCTION OF SUTURES INTO THE ABDOMINAL WOUND.

The needle is being passed through the peritoneum on the left edge of the wound.
(After Savage.)

The needle attached to the other end of the same suture is now taken up in the holder. The peritoneum at the right side of the upper angle of the wound is everted by the left forefinger and transfixed, together with the more superficial structures, as above described. The needle is then detached, and the assistant takes hold of the two ends of the suture in his right hand and pulls them a little upwards and forwards, previously pressing the sponge between the lips of the wound with his left hand. This sponging process should be repeated after the application of every suture.

A suture is then passed into the lower angle of the wound in the same manner. The ends, if in the way, may be held down by pressure-forceps. Then the remaining sutures are

introduced from below upwards, at intervals of about half an inch. They must be made to lie evenly on the two sides. The nurse must be ready to thread some more sutures should the supply appear to be running short.

Some operators introduce the sutures through the skin on one side, and inwards till the peritoneum is transfixed, and then pass the needle through the peritoneum on the opposite side, and through the other structures outwards. There is no

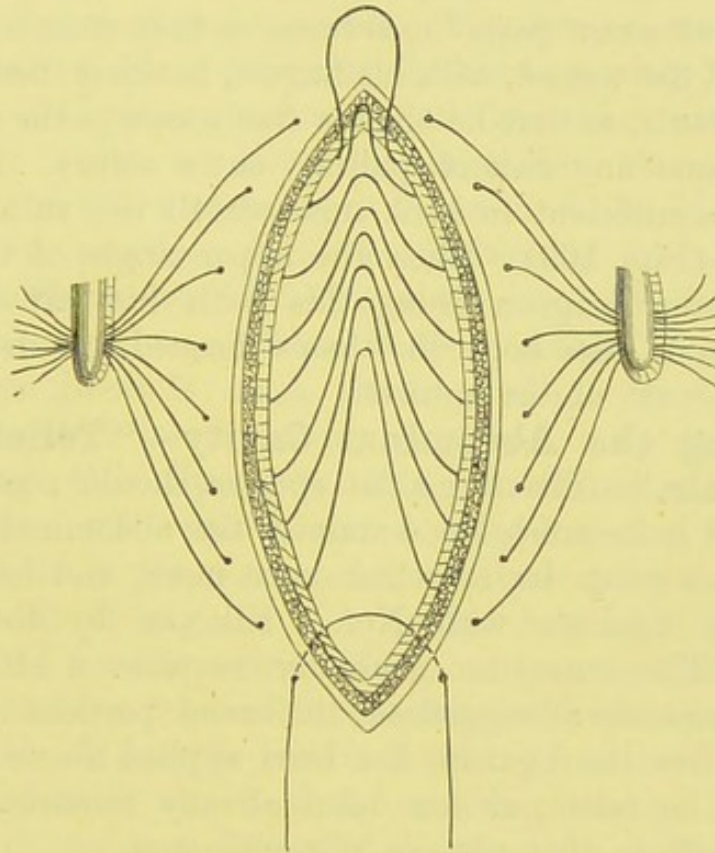


FIG. 109.—THE SUTURES IN THE ABDOMINAL WOUND.

Showing the arrangement described in the text (page 236) for cleaning the abdominal cavity, without the risk of pulling out any of the threads.

serious objection to this method, excepting that, perhaps, when the point of the needle is much blunted by thick integument, it may push the peritoneum from its connections, instead of transfixing it. The point of the needle is also apt to run into the flat sponge, and, in dark weather, it may be inadvertently passed through a bow of a pressure-forceps left, for some reason, in the abdominal cavity. These accidents, especially the latter, involve waste of time. The less

experienced should always pass the sutures from within outwards on both sides of the wound.

Arrangement of the Sutures for the further Steps of the Operation.—When all the sutures have been introduced, the ends are gathered together on each side. Each collected set should then be firmly grasped close to the extremities of the threads by a pressure-forceps (Fig. 109). This arrangement, introduced, I believe, by Dr. Bantock, saves a great deal of manipulation.

The operator now parts the sutures, as they cross between the two sides of the wound, with his fingers, hooking them upwards and downwards, so that he obtains free access to the abdominal cavity without any risk of pulling out a suture. In a short wound it is sufficient to hook upwards all the sutures except the lowest (Fig. 109). Then the upper angle of the wound is raised, the surgeon doing this with his left forefinger, which should also hold the loops formed by drawing up the middle part of the sutures.

Cleaning the Abdominal Cavity—"Toilet of the Peritoneum."—The large flat sponge should now be withdrawn. If it be much blood-stained, the abdominal structures and parietes must be searched once more, and hæmorrhage checked by ligature with No. 1 silk, or by the thermo-cautery. The omentum generally requires a little further judicious scrutiny; ragged or thickened portions should be cut away after the ligature has been applied above them, and care must be taken, as has been already remarked, that no holes are left in that process of peritoneum.

All other sponges must now be removed, with the same precautions—that is, bleeding vessels must be looked for when a sponge appears much blood-stained. The sponge removed from Douglas's pouch must be carefully inspected; then a sponge is gently passed over the parietal peritoneum, and Douglas's pouch is cleaned by another sponge, which should be mounted on a holder. If the sponging be done roughly, the peritoneum will be irritated, and copious oozing of blood-stained serum will rapidly take place.

Flushing the Peritoneum.—Mr. Tait and others prefer to wash out the peritoneum with water warmed to blood heat.

For this purpose, the lips of the wound are held wide apart, and the water is poured in* from a pitcher. The fundus of the uterus may be pushed forwards to ensure the flushing out of Douglas's pouch. If a bleeding vessel remain, its position will be indicated by a small stream of blood running in the water in the abdominal cavity. The water should be poured in till it escapes clear. It is extremely serviceable for checking capillary hæmorrhage,† and when the wound is closed the temperature will remain at blood heat, maintained by the natural heat-producing agents of the organism. The surgeon must always test the heat of every pitcherful before emptying it into the abdomen. Cold water produces great depression, and is a bad hæmostatic; water too hot may cause fatal damage to the serous coat of the intestines, as occurred, I am informed, in one case very recently. After the flushing of the peritoneum, a sponge should be applied to Douglas's pouch, to soak up any water remaining there. This flushing process is always advisable when there is much serous oozing. It is a highly efficacious method for detaching clots from deep parts.

Counting the Sponges and Instruments.—Before tying the sutures, the operator must make sure that no sponges are left behind in the peritoneum. I have spoken about this danger already at page 91. A sponge may have fallen into the receptacle for the ovarian fluid, or may be lying in the pan which contains the tumour, possibly inside the cavity of the tumour itself. It may be lost on the floor, or a nurse may have mislaid it when it was used for washing the hands of the operator and assistant immediately after the division of the pedicle. A sponge may also have been torn in half, and if the halves be counted as two sponges, another sponge, perhaps left behind in the abdomen, may be overlooked. I have heard that nurses have been seen to thrust a sponge into an apron-pocket.

On the other hand, when much sponging is needed, the operator may very naturally forget how many sponges he has

* It must not be allowed to trickle in slowly, else much heat will be lost; nor must it be poured in violently. A full stream must be steadily emptied into the abdomen.

† See Keetley, *op. cit.* p. 204, footnote.

left in the body of the patient. The assistant may have slipped a sponge unawares into the abdomen. Lastly, the nurse may be careless, and may reckon one more sponge than can actually be accounted for. To avoid all accidents in respect to sponges, they must be counted in the operator's presence, at this stage.

The nurse must collect the sponges in a large bowl or basin, and place an empty bowl by its side. Then she must take the sponges, one by one and not in pairs, out of the first bowl, counting audibly. The full number ought to be at hand, accounting, of course, for those known to be still in the patient's body. If one should remain unaccounted for, the set must be counted again. Then, if it be not found, it must be searched for in any place that it may occupy outside the patient, unless the operator has good reason to believe that it is in the peritoneal cavity. This must at length be searched if the sponge be still missing.

The inexperienced operator must not trust too much to his sense of touch. The bare surface of a sponge is not always easy to detect by the fingers alone, especially when soaked in serum. The matter becomes very troublesome when it lies under the omentum, a not unfrequent hiding-place. Hence that fold of peritoneum must always be well searched. The hand must be passed under the parietes towards the loins, the epigastrium, and Douglas's pouch. In the course of the above precautions, there is but little fear that the sponge will not be found.

The same precaution is necessary with regard to pressure-forceps. I have already said a great deal on the subject of these instruments. Strange as it may seem, they have been left behind in the peritoneum by the most experienced operators. I once witnessed an accident of this kind, but as I was administering the anæsthetic, I did not take part in the counting of the forceps during the operation. Afterwards, they were counted, and one was missing. My services were at once called for; the patient had not quite recovered from the anæsthetic, the wound was opened, and the forceps discovered, high in the abdomen, attached to the omentum. There were no untoward results, but the incident caused us great mental worry.

The forceps should be counted separately, as in the case of the sponges, and, if missing, must be searched for in the same manner. They are very apt, owing to their weight, to fall into the receptacle for the ovarian fluid; and if a forceps should drop on some soft solid matter from the ovary, lying in the receptacle, no noise is heard, and its fall is overlooked. They may also be carried away with the tumour, to which they have been fixed for the arrest of hæmorrhage during the separation of adhesions.

Closure of the Wound.—The surgeon having made sure that all the sponges and forceps have been removed from the abdominal cavity, the pressure-forceps holding, on each side, the collected ends of the sutures (Fig. 109) are now detached. The assistant holds the sutures by both ends in his left hand. The surgeon then takes the uppermost suture by both ends, the assistant sponges the edges of the wound immediately beneath it, and then the surgeon ties it in a reef knot. The suture should not be tied in a double reef, or “surgeon’s knot,”* as if it be drawn too tightly, which is very probable, it will then be hard to loosen. The operator must take great care to draw the suture just firmly enough to bring the edges of the skin into apposition without the least tension, much less puckering. Proper adjustment of the edges of the skin ensures perfect union; excessive tightness of the suture prevents the formation of the firmest possible cicatrix. The remaining sutures are tied in the same way, the assistant taking care to sponge the wound before each thread is drawn firmly. The ends of each suture should be cut after it is tied, and must not be left more than a quarter of an inch long. In the case of silkworm-gut (page 120), as the cut ends are stiff and apt to twist about, care must be taken that some of them do not sink between the edges of the wound. When the last suture is tied, if the skin gape at one or two points, superficial sutures may be applied; they are most readily introduced by the aid of a stout curved needle.

In order to prevent the omentum or intestines from catching in the sutures, some operators direct a second assistant to grasp the edges of the wound between the sides of his left

* See p. 221, footnote.

thumb and forefinger—the most convenient manner of holding the parts if he stand at the left hand of the operator. This manœuvre also ensures the apposition of the edges of the peritoneum. Other surgeons prefer to leave the top suture untied till after the others have been secured, so that the assistant may hold it upwards, raising the abdominal wound. Lastly, some leave a small flat sponge in the wound almost till the very end, pulling it out before the last three or four sutures are secured. This method is sure and simple, but the greatest care must be taken lest it be left behind.

Before tying the last suture, the surgeon must press his hand gently on the abdominal walls over the wound, so as to expel any air lying in the peritoneal cavity. It is always important to bear in mind how many sutures have been introduced, especially when the wound is long.

Dressing the Wound at the Close of the Operation.—When Listerian precautions are taken, the dressings should be thus applied, after the manner recommended by Mr. Thornton:—The wound is covered with a pad made of six or eight layers of carbolic gauze, cut large enough to overlap the edges of the incision to the extent of an inch in all directions, and damped by immersion in the 1 in 40 carbolic solution. Over this, three or four larger pads are placed, one over the upper, another over the lower, a third over the right, and a fourth over the left half of the first pad, so as to cover its edges and surface thoroughly. A big pad, about four inches broad, is placed over the others, so as to overlap the upper and lower angles of the wound by about two inches; a piece of pink mackintosh is placed, in accordance with Listerian principles, under the uppermost layer of this pad, so that blood soaking through the centre of the gauze may be kept from contact with the air. This pad must not be too broad, else it will not lie accurately, without puckering, over the abdomen around the wound. The spray may now be turned off. Straps of adhesive plaster about two inches broad are then applied over the dressings, being fixed at each end to the integuments of the loins, which they must support thoroughly. The skin must not be puckered, by too great pressure inwards, at the

parts where the ends of the strapping are applied. This may occur if the surgeon attempts to drag the skin inwards by traction on the strapping after one end has been made fast. If the abdominal walls be very relaxed and concave, as after the removal of an unusually large cyst, layers of cotton-wool should be placed over the dressings so as to fill up the hollow, and the strapping must cover the wool. A towel, folded once on itself, is placed over the plaster so as to overlap the lower edge of the dressing; the flannel bandage is applied over this, and made fast by means of safety-pins.

A dressing of this kind may be left untouched for a week. In the meantime the possibility of discharge soaking through its lower border must not be overlooked. The lower edge should be inspected daily, but not lifted up. After the sutures have been removed, a thinner gauze dressing is laid over the incision for a week. The wound will then probably be healed; it should be supported by strapping for at least two months.

I think it advisable, in any case, to keep a pad of gauze over the wound so as to protect it from the strapping. Portions of adhesive plaster may block the orifices of the suture-tracks, and cause small abscesses to form.

Surgeons who do not adopt Listerian precautions make use of a somewhat simpler dressing, and with excellent results. I must first observe that the wound begins to unite very rapidly, so as to cut off danger of septic infection from the peritoneal cavity. It is rather towards the end of the treatment that care is particularly necessary in the dressing of the wound, for any lack of precautions in keeping the parts clean may cause suppuration in the tracks of the sutures, or even along the edges of the incision. With care and experience, however, the wound will heal in the most satisfactory manner, with the simplest dressings, provided only that the broad rules already indicated be duly followed.

A few layers of absorbent gauze are placed over the wound, in the manner above described. A large woollen pad, enveloped in gauze, and sufficiently wide to cover the front of the abdomen without puckering, is laid over the other dressings, and a many-tailed binder is made fast, from below upwards,

over the pad. The surgeon must follow the directions given at page 130 for the proper application of this binder, according to certain circumstances which are there noted. This bandage must be inspected daily, to make sure that it does not slip upwards. The lower part of the dressing must also be watched, lest any discharge should soak through it. If any be seen, fresh gauze should be applied over the wound.

Drainage.—When this measure is necessary, the glass or india-rubber tube must be introduced, and the wound dressed in the manner described in the chapter on Instruments (page 126).

CHAPTER IX.

OVIARIOTOMY: AFTER-TREATMENT AND MANAGEMENT OF COMPLICATIONS.

Putting the Patient to Bed.—I have spoken at page 189 of certain arrangements with regard to the bed. After the operation, the patient should be carefully lifted from the table and laid, on her back, on the bed, in which a foot-warmer has already been placed. A pillow must be put under the knees, and three or four are neatly arranged to receive the head and shoulders, which must not lie too low. The bed must be protected beneath the patient's waist by a mackintosh covered with a draw-sheet arranged in several folds. The room must then be cleared, the nurse staying by the patient's bedside, whilst the operator and assistant, with the under-nurses, take away the instruments and appliances, the tables, and the receptacle for the fluid.

The Instruments after Ovariectomy.—In the paragraphs on the trays for holding the instruments, in the chapter on Instruments and Appliances, I have noted that the forceps, needles, and other implements, not excluding the trays themselves, must be carefully washed clean and dried directly after operation (page 85). This should be done by the senior assistant rather than by a nurse; and when the operator has seen that the patient is lying comfortably in bed, he should himself superintend the process.

Diet after Operation.—For the first twenty-four hours, at least, no food should be given by the mouth. To relieve sickness caused by the anæsthetic, the mouth may be rinsed out with lukewarm water, and the patient may suck small pieces of ice. In healthy young subjects, or robust women of mature

age, nothing more will be needed; and on the second day, barley-water, and soda-water with milk in equal proportions, may be sipped, not more than a teaspoonful being taken at a time. Some patients cannot tolerate cold drinks; for them warm milk will be beneficial, and a few drachms of beef-tea may be administered from time to time on the second evening after operation. When, however, the subject is feeble, or has gone through a severe operation, nutrient enemata will usually be needed. On the morning of the third day the patient can generally take tea and toast, and may dine off a cup of beef-tea. By the fourth or fifth, boiled sole or whiting may be given, for, although nothing should be hurried on, it cannot be denied that slops may disagree, and cause flatulence or nausea, when solids agree perfectly. Many patients complain of pain along the jaws, due to the unaccustomed want of something to masticate, if kept too long without solid food. After taking fish for dinner, and bread-and-butter with tea for breakfast and supper for two days, a wing of a chicken may be tried, and, later on, a mutton-chop well minced. The appetite may fail through the means taken to make the bowels act for the first time, and then meat must not be given for a day or two. When the patient loses her appetite at the end of the first week, before any aperient or enema has been given, without evidences of peritonitis or local troubles near the pedicle, nor of exhaustion, it will be necessary to administer a laxative, with or without the enema, as will presently be directed. The nurse must be allowed to exercise judgment with regard to diet during the first few days. Some cases can swallow milk with impunity six or twelve hours after operation, but, as a rule, the nurse must be slow to give anything by the mouth till the second day. Exclusive milk-diet promotes the formation of troublesome scybala. The surgeon should always prescribe the dinner for a week or two after the second day, as the patient otherwise may be allowed butcher's meat too freely, and restlessness, abnormal excretion of urates, and other troublesome symptoms may follow. The above general rules must be observed, but it is clearly impossible to lay down an unvarying law for the dietary of an ovariectomy patient.

The Administration of Opium.—Some operators give

opium as a matter of routine ; others never administer the drug excepting to ease the agonies of a dying patient. From experience in the wards of the Samaritan Hospital, I must express myself strongly against the indiscriminate or routine administration of opium. Sir Spencer Wells' observations on concentrated urine in ovarian cases have been already noted. Such cases I have ever found to be the most intolerant of opium after operation. Under its influence the urine is scanty, and more loaded with urates than before ovariectomy, and these abnormal constituents appear to irritate the bladder, even when the catheter has been carefully used by the most experienced nurse. Still more unfavourably does opium act in those yet more serious cases where the urine is scanty, slightly albuminous, and of low specific gravity. On the other hand, when the patient is restless from individual intolerance of the pain generally felt in the iliac region for the first few days, and when all unfavourable symptoms are absent, twenty minims of the tincture of opium, administered in an ounce of warm water as an enema, about every six hours, will have a good effect in calming her. The drug should be discontinued as soon as possible. Some specialists administer the opium in the beef-tea enemata.

Beef-tea Enemata.—It cannot be denied that nutrient injections of beef-tea into the rectum are of great service in the earliest stages of the after-treatment of patients who have undergone ovariectomy or any other form of abdominal section. Whether the vomiting, so frequent and so troublesome after operation, be due to the anæsthetic or to shock, or to the influence of the ligature, it certainly interferes with the administration of nourishment in the ordinary manner. If the patient be kept without any food for twenty-four or forty-eight hours, she is liable to become restless, and may suffer from attacks of faintness, not only distressing and dangerous to herself, but also misleading to the surgeon, who may overlook the true cause of the tendency to syncope, and suspect some mischief in the region of the pedicle.

The surgeon may have to conduct his treatment under circumstances where good beef-tea cannot be procured with any certainty or regularity. Among the best artificial preparations

is Johnston's peptonized fluid beef. A drachm is dissolved in two ounces of boiling water, and an ounce of cold water is afterwards added. Wherever there is a cook or nurse who can make good fresh beef-tea, that preparation is the best. It must be prepared without salt.

Some robust young patients will certainly require but one or two nutrient enemata within the first twenty-four hours, and some of my own cases have fared excellently without this method of nourishment. After moderately prolonged or severe operations, and, I believe, even after simple operations, in middle-aged or elderly women, nutrient enemata should always be administered. They must be given so as to nourish, without causing distension of the abdomen, so as to be retained with certainty, and, lastly, so as to be absorbed without partially remaining to decompose in the rectum. The injections should be given about once every four hours. If the patient be very weak, the interval may be reduced to two hours; if she be strong, and only suffering from slight shock, it may be extended to six hours. The first enema should be given six hours after operation.

Before the enema is given, a short O'Beirne's tube, or the vaginal pipe of an ordinary siphon enema of the Higginson type, must be passed for about two or three inches into the rectum, and left there for a few minutes. A small bowl or soap-dish must be placed under the part of the pipe hanging out of the rectum; then flatus and small particles of fæcal matter can escape freely, and the latter are received in the receptacle. The pipe is then removed, and three ounces of the enema are introduced. The enema must not be too hot, else it will not be retained; if just warm enough to be fluid, that will be sufficient. When the patient is in great pain, twenty drops of laudanum may be added to the enema, and this may be done to a second if the first, not containing any opiate, has been ill-retained. The enema must be repeated every four hours, the pipe being always introduced first. When the patient is very weak, enemata will be required at intervals of three, or only two, hours.

Mr. Thornton recommends that if the refuse from the rectal feeding be offensive, or if too much comes away, a couple

of grains of quinine, in a dessert-spoonful or table-spoonful of port wine, must be added to each injection. Septic mischief may manifestly be set up by the retention of putrid enemata in a rectum the mucous membrane of which has become sore. The operator must never overlook this source of danger from injections. After the first forty-eight hours they may be discontinued, especially if the patient can take nourishment by the mouth.

The question of opium after ovariectomy has been already considered. I believe that the drug is useful, not only when the patient is in great pain, but also when the enemata are not well retained if administered without it.

Bed-sores.—As the patient lies on her back for a week or longer after ovariectomy, it stands to reason that care must be taken to avoid bed-sores. Careless catheterism and soiling of the bed-clothes during voluntary micturition, rucking up of the night-dress, creasing of the sheets, and escape of bread-crumbs, etc., under the patient's body, may be the cause of these untoward complications. As there are seldom any paralytic conditions in patients with ovarian disease, and as no surgeon undertakes ovariectomy without either employing the best nurse he can find, or at least exercising strict personal supervision during the after-treatment, bed-sores after ovariectomy, or any other kind of abdominal section, are rare.

The prophylaxis of bed-sores is well known. The evils above referred to must be avoided. Careful adjustment of the clothes and sheets under the patient is ever necessary, and the application of fuller's-earth to the integuments over the sacrum and trochanters will prove of great benefit whenever there is the least fear of any trouble, especially in heavy, old, or feeble subjects. Boracic lint is an excellent dressing for a bed-sore, after separation of the slough, and iodoform should be blown over its surface, daily, by means of an insufflator (see page 138).

Opening the Bowels.—I have carefully observed the after-treatment of several hundred patients under the charge of my colleagues and myself. I find that it is a very good rule to take steps to open the bowels by the evening of the seventh day. Sometimes, but rarely, they act spontaneously

much earlier, but this is no disadvantage, excepting that it must be seen that the nurse does not disturb the patient too much in adjusting the bed-pan. Towards the eighth day, however, the patient, who has begun to eat well, is apt to feel uncomfortable.

Should the tongue be clean, and the patient free from nausea, loss of appetite, high pulse, or other symptoms of gastro-intestinal irritation, the enema will be the best means of opening the bowels, and the patient's appetite need not be spoilt by drugs. The surgeon, unless he has an experienced nurse to aid him, should explore the rectum for scybala. If such be found, four ounces of warm olive oil should be injected; if there be no scybala, about two ounces will be sufficient. Four hours later, a pint and a half of soap-and-water should be injected. Should several hours elapse, and the enema be retained, it is a good plan to introduce a tube to the extent of about four inches, supporting the outer end by a soap-dish containing a little water. If the tube be left in the rectum for about ten minutes, a quantity of flatus will often pass, and then the patient will experience a desire to defæcate, and will pass a free motion. If this means fail, a pint more of the enema may be injected, and the treatment continued till the bowels act. Should the patient, however, complain of nausea and lose her appetite in the meanwhile, a purgative will be advisable. As a rule, the enema soon acts. It may be repeated every forty-eight hours till the bowels are opened without its assistance, and should be administered in the morning.

In very bad cases, on the other hand, the enema keeps the lower bowel clear, whilst purgatives upset the patient. I refer to cases where large malignant tumours have been removed, or multiple adhesions broken down, and where, at the same time, the bad symptoms do not point in the direction of simple gastro-intestinal irritation.

Purgatives without enemata are very popular with patients and nurses, and sometimes prove highly efficient. When scybala lie in the rectum, the enema is, so far, preferable, for pills and powders sometimes cause a loose motion to pass from the upper part of the intestinal tract, whilst the

scybala are not expelled. They tend to become particularly irritating under these circumstances. From what I have observed, however, I think that the patient is always the better for a purgative if her tongue be thickly furred, her skin sallow, and her appetite bad, after having been good towards the end of the first week. To this condition may be added nausea, borborygmi, and griping pains, with little or no rise of pulse or temperature, and possibly there may be slight bilious vomiting. It is now my practice, when such a combination of symptoms occur, however mildly, to administer a drachm of compound liquorice powder at the same time that the preliminary olive oil enema is injected. Should the patient be subject to constipation, I prefer two and a half grains of colocynth and hyoscyamus pill. After the soap-and-water enema has been injected, a free motion will generally pass, and the lower bowel will be well cleared by the mechanical agency of the injection, whilst the drug will exercise a beneficial action higher up. As intestinal trouble of the kind above described is very frequent in middle-aged women, I generally, in their case, combine the enema and the purgative in this way. The same powder or pill may be given as required, should there be similar trouble later on. The enema will not then be needed, unless the surgeon should detect symptoms of rectal irritation and find scybala.

If there be any doubt about the efficiency of the nurse the enema should not be ordered, even under circumstances described above as particularly demanding it. Ill-trained nurses are apt either to allow much of the enema to be spilt out of the anus, or to inject with too great force, so as to injure the intestine and tear down vascular adhesions that are not causing obstruction. One operator tells me that he has seen severe symptoms follow clumsy use of the enema.

With regard to the above observations on purgation after ovariectomy, I may say that the operators with whom I am personally acquainted differ widely in their practice, and more than one are still undecided, notwithstanding years of experience, as to the relative value of enemata and drugs.

I have spoken above chiefly of cases where the patient is quite well, or subject to intestinal irritation with no evi-

dence of peritonitis. When the latter complication exists in a mild form, it is better, as I have already stated, to clear the lower bowel with enemata than to begin with drugs. The question of purgatives in severe peritonitis is very much disputed. During that affection the patient takes little nourishment, and therefore cannot need frequent purgation, which must mechanically disturb the seat of disease. Mr. Tait strongly advocates saline purgatives, and claims excellent results. As a rule, however, surgeons prefer to rely on opiates, and leave the bowels alone for a few days in these grave circumstances. To begin on the second or third day with purgatives, when no bad symptoms are present, seems to me a great mistake. I know of a case where hysterectomy was performed, and sulphate of magnesia was administered twenty-four hours later. The patient was immediately seized with vomiting, and died in a few hours.

The Bladder and the Catheter.—For a short time after the operation the bladder will require to be emptied by the catheter, but it is advisable that the use of that instrument be discontinued as soon as possible. Hence, the surgeon must study each case intelligently, in respect of the condition of the bladder, and should not adhere to routine. At the same time, the skill of the nurse is a factor always to be taken into consideration (see page 191).

A few patients seem predisposed to a loss of the power of voluntary micturition for many days after the operation, independently of its severity, and of their age, health, or strength. Strange to say, this idiosyncrasy appears also to be independent of vesical irritation, which may be absent, or present in a mild or severe form, whilst, on the other hand, other subjects pass urine voluntarily in a day or two, though troubled with severe cystitis. Nor does this difficulty in micturition necessarily depend on some neurosis. A large proportion of patients can pass their urine voluntarily after the first forty-eight hours. I have known this to occur after the most severe operations, where adhesions were all but universal, or where malignant growths were left behind. Neither paralysis of the bladder, nor enuresis, is usual after ovariectomy.

The catheter should be used every six hours for about two days and two nights. The surgeon must ascertain, towards the end of forty-eight hours after operation, whether the patient can or cannot micturate without difficulty or pain. When she can do so, the catheter may be discontinued, the surgeon warning the nurse to disturb the patient as little as possible when placing or removing the urinal. How often the urine is passed voluntarily must be ascertained, lest retention should come on and be overlooked for a time.

It is always advisable that a silver catheter be employed, as that is far easier to keep clean than a gum-elastic instrument. It must be kept in a 1 in 20 solution of carbolic acid, and mucus should be washed off the end and the perforations on the sides immediately after use. Whenever a new nurse is employed, the surgeon must carefully exercise his judgment, and make sure that catheterism is done properly. Some enthusiastic young nurses tend to use the instrument longer than it is needed, so as to get as much practice as possible. Very many nurses are only too ready to dispense with it as soon as they think convenient. To counteract such evils, the surgeon must question both nurse and patient discreetly, so as to make sure whether the latter really requires the catheter, or can pass her urine without its aid. Both too long and too short a term of catheterism may be the direct or indirect causes of cystitis—probably the most frequent, and not the least troublesome, complication after ovariectomy. Of that affection more will be said presently (see page 256).

Removal of the Sutures.—The wound having been examined on the eighth day, the sutures are now removed. The surgeon must remember several facts in regard to this question. In the first place, as far as mere union is concerned, the apposed peritoneal surfaces become united in a very few hours, and the integuments in two or three days. Then, as long as the patient lies on her back, there is no agency, excepting great accumulation of flatus, which is likely to pull the sides of the wound asunder. I have repeatedly watched an abdominal wound when a patient happened to cough or strain. The recti become shorter for a few seconds; the integumental part of the wound seems to sink between those muscles, but,

whatever theory may be advanced with regard to the mechanism of the abdominal muscles as a whole, the wound is certainly not dragged upon during these efforts. As soon as the patient lies on one side, or sits upright, the contents of the abdomen cause pressure in the direction of the wound, and the pressure will more or less steadily persist during the maintenance of either of those positions. From the above observations it follows that the surgeon need not fear to remove the sutures, if necessary, before the bowels are opened, but he must be particular about the position of the patient after they are removed, and must ascertain personally that the abdomen is well supported by bandages. If, in a case that has progressed up till the eighth day, he leaves everything to nurses after the removal of the sutures, it is very possible that the patient may be allowed to lie on one side when the abdominal bandage is loose or has slipped upwards so as not to exercise even pressure. This oversight will cause traction on the wound, and possibly a hernial protrusion afterwards.

Although the sutures are of little or no use after the eighth day, the surgeon may prefer not to remove them all at once, and will leave half for a day or two later. If, however, there be redness around the point of exit of any one suture, that suture must be removed at once. It should be cut on the healthy side, if both sides be not involved, so that the part of the suture which has been lying in irritated or inflamed tissues will not be pulled through the healthy part of the track.

The wound must be gently washed first, and then the nurse or assistant supports the abdominal walls on each side near the wound. The surgeon then seizes the knot, rather than one of the ends, of the uppermost or lowermost suture, and pulls it forwards, so that the part of the suture behind the knot is to a certain extent exposed. One side of that part of the suture is now cut across, and then the entire suture is pulled out. Care must be taken not to cut through both sides of the suture, else a portion will be left in the track, and may be very difficult to remove. This warning applies to the removal of a suture anywhere, but, owing to the position of the surgeon in relation to the abdomen, and to the chance that the patient may cough

or hiccough during the process, the accident is more likely to occur in an abdominal wound than in wounds made in parts which the surgeon can face more comfortably and fix with greater certainty.

The remaining sutures are removed in the same manner. The wound should again be washed, care being especially taken to remove minute incrustations of dried blood sometimes seen round the suture-holes. As a rule, it is best to remove the sutures under spray, especially when the abdominal walls are thick through fat. After the removal of the sutures, the wound must be carefully dressed with carbolic gauze. If the wound be carelessly dressed after the sutures have been taken out, there will be danger of irritating particles of dust, dirt, and epidermic scales getting into some of the suture holes and causing a small abscess.

Great care must be taken to ensure the removal of every suture. Sutures are not at all unfrequently overlooked. In the first place, a portion may be left in through the misadventure above described. Secondly, the ends of a suture may have been cut too short, so that the surgeon takes the knot for a small dried clot hard to wash away, and leaves it for another dressing, and then forgets all about it. When a long wound has been made, and a bulky tumour removed, the wound shortens and puckers, so as to conceal some of the ends of its sutures. Hence, the longer the wound, the more careful must be the scrutiny when it is dressed. The importance of noting the number of sutures in the case-book is self-evident.

The Cicatrix.—The Abdominal Belt.—The wound having been dressed with the greatest care, and the sutures duly removed, the surgeon must never forget that a long cicatrix remains, and that it may stretch and form a hernial sac, into which a large mass of intestine and omentum may obtrude itself, to the great annoyance of the patient. A distinguished operator once observed, in speaking to some spectators at an operation which he had just concluded, that, owing to his former ignorance of the proper manner of closing the abdominal wound, some patients on whom he had operated many years since were suffering from hernia of the cicatrix, and they had informed him that they felt more inconvenience

from that complication than they ever experienced from the tumour before it was removed. This fact suggests more than careful application of the sutures: it shows the importance of protecting the cicatrix long after convalescence.

The woodcut (Fig. 110) represents part of the integuments of

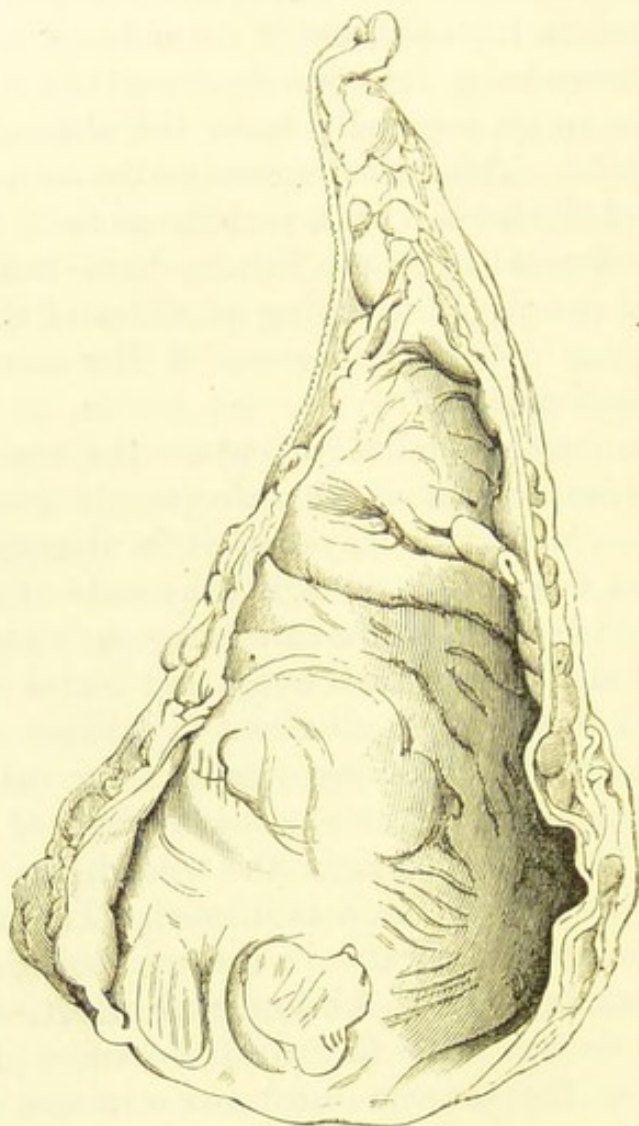


FIG. 110.—A HERNIAL POUCH DEVELOPED IN THE CICATRIX OF THE ABDOMINAL WOUND AFTER OVARIOTOMY, AND EXCISED DURING LIFE.

It is seen from its inner aspect, so as to show the shallow secondary pouches in the peritoneum. (*Museum R.C.S.*, No. 4,562.)

the abdomen around the cicatrix of an ovariectomy incision, as seen from the inner side. They have become distended into a pouch by the gradual yielding of the cicatricial tissue. The peritoneal lining of the pouch is well displayed. This pouch

was excised by Mr. Thornton, in the course of a second ovariectomy. The first operation had been performed by another surgeon fifteen years earlier. I have seen more than one pouch of this kind removed, and with unfailing benefit to the patient. I have also seen this complication in cases where there was no second ovarian tumour, and it always appeared as an ugly ventral hernia, not very dangerous, since, in a rupture of this kind, the neck of the sac is extremely wide, but in every case very troublesome, so as almost to justify excision of the redundant integuments and cicatricial tissue as an operation by itself. After the use of the clamp, where failure of union by first intention was common, this complication was more frequent than it is in these days when the clamp is practically discarded.

Distension of the cicatrix occurs not so much from frequent coughing, or straining, as from passive pressure from within (see page 251); this occurs when the patient sits upright too soon, or may be caused simply by a large collection of flatus in the intestines. When the surgeon is dressing the wound during the convalescence of the patient, he will probably have an opportunity of seeing this pressure in active progress. If the abdominal walls be left unsupported for a minute, a few more or less distended coils of intestine will be seen behind the area of the cicatrix. This pneumatic force is, be it observed, in action when the patient lies in bed. Hence, she must be reminded not to leave off the binder for a year, or longer. She may take off the abdominal belt worn in the day-time, but she must not leave the abdominal walls entirely unsupported at night. In the day-time, of course, the powerful support of the belt is needed, to overcome the passive force of the viscera bearing forwards and downwards on the abdominal walls, and to support the sides so as to prevent undue lateral action by means of the obliques and transversales muscles.

Gastro-intestinal Disturbance.—Some patients are very sick after recovering from the anæsthetic. They should then be allowed to suck ice and to take an occasional teaspoonful of barley-water. Drugs will seldom be needed. When the retching is severe, the stomach may be washed out with a tumbler-full of warm water. This will cause the patient to bring

up much frothy mucus, or even green fluid with great relief. The straining will necessarily be much less than before the administration of the water, which, indeed, generally causes that symptom to disappear altogether. Diarrhœa is very unusual, and when it occurs it is oftentimes the result of giving an aperient within a day of the operation (see page 194). The nurse should place her right hand firmly but gently over the patient's abdomen during an attack of vomiting. An action of the bowels soon after ovariectomy is not a grave accident, provided that the patient be disturbed as little as possible during the adjustment of the bed-pan. In all early troubles of this kind the principle is to keep the patient without food, except in the form of beef-tea enemata. Twenty minims of the tincture of opium may be mixed with the enema and given every six hours when there is a tendency to diarrhœa. For simple sickness I do not consider that any opiate should be given.

Flatulence is sometimes very troublesome during the first few days. The rectal tube should always be employed for its relief; but when there is marked nausea or other indication that gas has collected in the small intestines or stomach, half-drachm doses of aromatic spirits of ammonia will prove highly beneficial.

Towards the seventh and eighth day, most patients suffer more or less from the effects of enforced constipation. The appetite, which had improved, becomes bad again, fur collects on the tongue, and flatulence with griping pain is very frequent. Sometimes there is sickness, but very often nausea. In severe cases of this kind, perfectly uncomplicated, I have seen the temperature fall to 97.5° . Severe pain, yet absence of abdominal tenderness on touch, is very characteristic of this condition, which always disappears after successful purgation.

Cystitis.—Inflammation of the bladder is a common complication after ovariectomy. The patient complains of hypogastric pains, and feels a cutting sensation during micturition. Sometimes, however, the disease is so mild that frequent desire to pass water is the sole subjective symptom. In one case of a woman aged sixty-three, even this symptom was absent, though the urine was charged with mucus. The urine deposits ropy mucus, often mixed with a considerable amount of phosphates.

The surgeon must remember that pain during micturition may be due to a vascular urethral growth.

I certainly believe that the presence in the bladder of concentrated urine, loaded with urates, and the difficulty which many patients experience in emptying the bladder thoroughly into a slipper or bed-pan, are predisposing causes of cystitis; but the immediate cause is almost invariably bad catheterism. New or inefficient nurses often thrust the end of the catheter into the vagina, or push it about the vestibule freely, before they succeed in passing it into the urethra. In this manner, dust and dirt from the pubic hairs, sebaceous matter from the labia, and mucus from the vagina and vestibular glands, are more or less freely introduced into the bladder. In a long series of operations, cystitis will be found to be frequent in inverse proportion to the skill of the nurses employed to conduct the after-treatment.

Fortunately, the inflammation is generally mild, disappearing when its cause is removed. Barley-water should be administered, and, if the symptoms be severe, buchu will be advisable, but it is always best to avoid drugs during the first week after ovariectomy. Sometimes the disease will require active treatment. When urates are deposited in abundance, and cystitis exists, ten grains of citrate of potash should be given three times a day. Free deposit of phosphates demands the administration of dilute nitro-hydrochloric acid.

I referred above to the difficulty which many patients experience in emptying the bladder sufficiently into a bed-pan; that is, in the recumbent instead of the usual posture. I have known slight cystitis to occur in invalids suffering from various maladies, upon whom the catheter had never been passed, and in these cases the patients complained of the above-mentioned difficulty, and the symptoms of vesical irritation disappeared when they became strong enough to get out of bed and pass urine in the usual position. In a few ovariectomy cases under my observation, I have reason to believe that cystitis was caused in this way. In such cases, again, the nurse may be to blame. Feeling herself incompetent to pass the catheter, she encourages the patient to micturate voluntarily too soon after the operation.

Rise of Temperature after Ovariectomy, Hyperpyrexia.—Whatever may be said to the contrary, this symptom always will, and always should, give cause for anxiety, especially when the temperature exceeds 102° ; nevertheless, it must not be forgotten that it may be due to a definite cause other than septic changes, readily to be detected by the surgeon. Should he, then, find that a patient is suffering from coryza, bronchitis, ague, or some other self-evident complication, he should not assume that, because the temperature rises to 102° or 103° septicæmia necessarily lurks behind the disease which evidently exists.

Recently, there has been a tendency to place great stress on the pulse, making temperature a secondary consideration. This, however, is simply the outcome of a long-recognized clinical fact. In exhausting fevers, and most septic conditions, a fall of temperature, say from 104° to 102° , with a rise of pulse, frequently precedes death.

I have seen the temperature rise to 105.8° on the fourth day in a patient subject to ague; she recovered. Bronchitis, and even coryza, may send the temperature up to over 102° , when the special symptoms of those complications are otherwise trivial. The approach of the period, and metrostaxis caused by the inclusion of uterine tissue in the ligature of the pedicle, are both accompanied by rise of temperature. This symptom may, of course, arise from comparatively trifling causes in the weak or aged.

Treatment of High Temperatures.—This must always mainly depend upon the source of the rise of temperature. Whilst the skin is still dry for the first twelve hours after operation, a considerable rise of temperature is seldom of serious import. When, however, the temperature rises to over 102° , with concomitant rise of pulse, it will be necessary to take measures having for their direct aim the reduction of temperature. Thornton's ice-cap, already described (page 133), is excellent for this purpose; and Leiter's temperature regulator (page 135) also answers very well—it is employed in Dr. Bantock's wards with excellent results. The cap must not be put on till the skin has acted, and must not be taken on and off, but kept on till the temperature has steadily gone down, remaining below 100° .

Wet-packing is seldom needed, but in some cases, when the temperature keeps very high notwithstanding the ice-cap, it may be necessary. The arms should first be packed in wet towels, kept moist by ice-cold water squeezed upon them from a sponge. The lower extremities and even the chest may require packing, if the application of cold to the arms fail to reduce the temperature. The pulse and temperature must be frequently taken, as great depression may suddenly occur during wet-packing.

Septicæmia, Pyæmia, and Peritonitis.—These deadly septic complications, which may follow any operation, are fully described in works on surgery and pathology, so that it is not necessary for me to write at length on septicæmia and the subtle questions associated with that condition. One of these questions is, the relation of septicæmia to peritonitis. All that need here be said is that, as regards the results of ovariectomy, this relation appears to be very close. Every surgeon knows how acute peritonitis with marked symptoms often passes into a condition indicating septic infection, and how, on the other hand, evidences of inflammation of the peritoneum are found after death from septicæmia, where the most prominent symptoms of peritonitis were absent. The nature of septic pneumonia must not be overlooked, in relation to septicæmia after ovariectomy, and the symptoms of gastro-intestinal irritation depend upon conditions well known to the pathologist. The proximate cause of septicæmia after ovariectomy is, in the great majority of cases, absorption of septic fluid by the peritoneum. That it may sometimes arise from damage to vessels in the pedicle, inflicted by the ligature or clamp, there can be, I believe, no doubt. Improved methods of securing the pedicle have, however, made septicæmia from this cause very rare.

Septicæmia generally sets in between the second and the seventh day. It must be diagnosed through the combination of symptoms by which it is manifested clinically—a combination only too well known. Vomiting, after the subsidence of the more or less distinct nausea caused, in some subjects, by the anæsthetic, is a serious symptom. Steady rise of temperature with simultaneous rise of the pulse constitutes a particularly grave and characteristic symptom. A fall of high temperature

to the extent of one degree or more, with increase of frequency of the already high pulse, or with a distinct decrease in the force of the pulse-beats without increase in their frequency, is yet more grave. The respirations are always increased.

Persistence of vomiting, especially when the ejecta become no longer white and frothy, but green or dark, is highly unfavourable, as is tympanites. The surgeon will have to consider in special cases whether flatulent distension of the intestines be due to the effect of septic infection on the innervation of the muscular coat of the bowel, or to some mechanical obstruction. It is a bad sign when flatus does not pass through the tube. The abdominal walls are generally tender to touch, though seldom to a marked degree.

The facial aspect of the patient seldom fails to attract the surgeon's attention. The complexion becomes muddy, the expression nearly always dull. A dark red flush on the cheek is a very bad sign. The mental condition is depressed and pessimistic at first, but soon becomes apathetic.

The condition of the tongue and skin varies considerably, and is therefore, in itself, a less reliable symptom than even the change of facial aspect. As a rule, the tongue grows rough, red, and dry, and the skin remains dry till near death; but the tongue may remain moist and the skin act profusely throughout.

True pyæmia is rare after ovariectomy. The suppurative inflammation of the parotid gland, to which I will presently allude, appears to represent this condition; it certainly arises about the period that pyæmia might be expected.

As for prognosis, the more the above group of symptoms prevail and continue, the graver will it be. The treatment of septicæmia is, speaking generally, essentially prophylactic. Cleansing the peritoneum, securing the pedicle properly, checking all sources of hæmorrhage, and making use of the drainage-tube when necessary, are the most potent causes of the decline of septicæmia after operation.

Judging from what I have seen, septicæmia when it has once set in is very unamenable to any active kind of treatment. The re-opening of the abdominal wound and the introduction of a drainage-tube into Douglas's pouch are sometimes almost

airily recommended as duties, easy to perform. The fact is, that there is a great difference between introducing a tube during and after operation. In the latter case the patient is in a highly unfavourable condition to bear interference, and it is very difficult to get the end of the tube well to the bottom of Douglas's pouch; the intestines are generally distended with flatus, and glued more or less together by lymph; their coats may even be dangerously softened by inflammatory changes; above all, it is impossible to make sure that drainage can be effected at all. In several cases which I have observed, this introduction of a tube seemed only to aggravate the patient's condition. When some objective local symptom is marked, such as hardness or fluctuation in the pelvis, or in the abdominal walls around the wound, the case is different; abscess is probably forming and will require suitable treatment. Such cases are relatively less serious than those where only general symptoms of septicæmia prevail.

The vomiting must be relieved. If the vomit be bilious or dark, the stomach should be washed out with warm water by means of the stomach-pump or through a long red-rubber rectum-tube every six or twelve hours till the vomiting and accumulation of fluid cease. Shortly after each washing, some liquid nourishment may be given, with stimulants if necessary. The temperature, if over 102° , should always be reduced by means of the ice-cap or Leiter's temperature regulator, applied in the manner already described. After the washing out of the stomach and reduction of the temperature, a considerable number of cases of septicæmia get better. The poison eliminated by the gastric mucous membrane, which the patient is too weak to throw up by herself, is removed so that it cannot be re-absorbed, and tissue-waste is checked. After this treatment, the prognosis will be good if the temperature and pulse both fall distinctly and steadily. The patient's aspect improves, and flatus passes freely through the rectum-tube.

Drugs are, I believe, of little use in these cases; aromatic spirits of ammonia will, however, greatly relieve the flatulent distension of the stomach. Beef-tea enemata must be administered independently of what is introduced into the stomach after it is washed out.

Internal Hæmorrhage after Operation : Slipping and Splitting of the Pedicle.—The mechanics of the ligature and the pedicle are differently understood by different authorities. Some write as though, when hæmorrhage occurs from the stump of the pedicle, the ligature becomes loosened by pressure of the tissues on its knot, and slips from the pedicle. Others appear to believe that it is the pedicle that slips from beneath the loop. Of course a badly-tied knot may yield to pressure from within the loop. On the other hand, the stump of the pedicle may, in certain cases, be exposed to great traction, especially at the outer border.

The most experienced operators occasionally lose cases from this accident. I have already spoken of the correct way of securing the pedicle, and the precautions necessary to observe during the process. It is particularly important that the assistant should not drag on the pedicle, but should, on the contrary, relax it as the operator tightens the knot of the ligature (page 221). When the pedicle slips, symptoms of internal hæmorrhage, presently to be described, will be almost certain to appear, and the operator will be compelled to reopen the abdominal wound and discover the source of hæmorrhage. The bleeding pedicle must be immediately seized with the fingers and compressed. Then it is best to secure the pedicle temporarily with a large pressure-forceps, transfixing beneath its blades, and tying the ligature as before. If this instrument be not at hand, the pedicle may be temporarily tied with stout silk encircling it with a single loop ; then the transfixion may be effected without further risk.

Accidents of the kind just described are rare in the present day. The systems of tying the loops are now well understood. The practice of tying the ovarian vessels in the outer border of the pedicle separately, whenever that border appears to be tense (see page 219), has probably saved a large number of lives. This practice protects the pedicle from a heavy drag on its outer border. The ovarian artery alone is not likely to slip even from under a ligature applied to the entire pedicle without the extra thread on the outer border ; but if that border itself should slip, the artery will be set free and will bleed freely.

Hæmorrhage may also follow splitting of the pedicle. This

accident is generally caused by neglecting to cross the threads, so that the two halves of the pedicle are pulled asunder as each loop is being tied (Fig. 92, page 187). A similar mechanism may produce the same disastrous result when the surgeon attempts to tie the ligatures after some principle which he does not thoroughly comprehend. The pedicle must be transfixed and tied below the split in its substance, whether the accident be discovered before or after the close of the operation.

The transfixion of a vessel involves, I believe, other dangers rather than hæmorrhage.

When the pedicle has been split, symptoms of internal hæmorrhage usually appear within twelve hours after operation, and probably come on with less rapidity than in cases of slipping of the pedicle. The patient becomes faint and anæmic with the characteristic pulse. In one case, at least, within my knowledge, there was dulness in the hypogastrium, caused, as the opening of the abdomen proved, by the effused blood. The duty of the surgeon is evident. The abdominal aorta should be compressed whilst the preparations for opening the abdomen are being made. Directly the peritoneal cavity is laid open, the operator should, as I have already observed, make at once for the pedicle, and secure it, at least temporarily, before turning out clots. If the pedicle be buried in coagula, he should pass his fingers over the fundus of the uterus, and, so guided, should grasp with them the remains of the broad ligament on the affected side. This will check the hæmorrhage whilst the clots are being cleared off the pedicle.

After the first few days, these accidents rarely, if ever, occur, the pedicle shrinking rapidly, and its vessels becoming occluded. The pedicle certainly manages to free itself from its ligatures not very long after operation, without any consequent hæmorrhage in some cases. That which results in dangerous hæmorrhage, when it occurs within forty-eight hours of operation, probably causes, when it takes place at a later date, morbid changes of another kind.

Hæmorrhage from adhesions may cause similar symptoms, and the treatment will be the same. The surgeon must carefully search the peritoneum and viscera till he can find the bleeding point and secure it by ligature.

Intestinal Obstruction.—This may occur early or late after operation, from the adhesion of a raw surface on the serous coat of the intestine (itself representing an adhesion broken down during the operation) to some neighbouring structure, so as to bend or drag the gut sufficiently to obstruct its channel. The neighbouring structure may be the stump of the pedicle. The obstruction may cause fatal collapse, or, as in one case which I examined after death, perforation of the intestine. The latter termination is generally observed when the complication comes on late. There are several other ways in which obstruction may occur, besides that just named, which is probably the most frequent. The omentum may adhere to the ileum so as to form a tight band, pressing possibly on some other coil of intestine than that to which it is connected, so that the former becomes obstructed. A piece of intestine may be included in one of the sutures applied to the abdominal wound, through the operator neglecting to guard the contents of the abdomen with a flat sponge. I have known this accident to occur at a large general hospital. Shively has described a case (*New York Medical Journal*, vol. xl., 1884, page 292) where fatal occlusion occurred six years after ovariectomy, through adhesion of a portion of the ileum to the lower part of the abdominal cicatrix. A loop of small intestine was found twisted twice around the ileum, between the adhesion and the cæcum.

The symptoms will be the same as when intestinal obstruction occurs from other causes. Abdominal pain, constant vomiting, and tympanitic distension, without a marked rise of temperature, will be almost pathognomonic. Unfortunately, when the complication follows within the first week or two after operation, the symptoms are often masked by other conditions, especially septicæmia and peritonitis.

The prophylactic treatment of obstruction will chiefly depend upon minute attention to certain precautions already noted. Ragged pieces of omentum should be cut off, and the distal part of the stump of the pedicle must not be cut too long; when the tumour is cut away, it must also be cut even, so as to leave no tags. When properly cut, the free edges generally curl in towards each other so as to leave no raw surface which might adhere to intestine. The state of the gastro-intestinal

tract previous to a contemplated ovariectomy should be carefully ascertained.

When symptoms of obstruction slowly come on shortly after operation, relief is sometimes afforded by a mixture of ten minims of liquor morphinæ hydrochloratis and two minims of liquor atropiæ in a teaspoonful of water, administered every three or four hours till the distension is relieved, as Mr. Thornton recommends. This, or any similar mixture, however, is probably of real benefit in those cases, but in those cases only, where the gut is paralysed as a result of septic peritonitis.

In cases where the symptoms of mechanical obstruction have been marked, especially when they have occurred later than the first or second week, and independently of general peritonitis, the abdominal wound has been reopened and the obstruction removed.

Fæcal Fistula.—Sir Spencer Wells describes some interesting cases of this complication, now all but unknown after ovariectomy. In Dr. Lyon's case, performed in 1866, and quoted by Wells,* there were pin-hole perforations in the intestine, exposed through opening of the lower part of the abdominal wound after an attack of vomiting. Dr. Keith informs me that the perforations were believed to have been made by wounds from the needles used in applying sutures to the abdominal incision—an accident which may also cause, as I have stated, obstruction. When some of the sutures were removed, fæces poured out from holes on the surface of the intestine. In January, 1880, the patient was alive and well, but a fæcal fistula remained at the lower angle of the abdominal cicatrix.

The surgeon may profitably remember the above facts concerning obstruction and fistula when called in to a case of abdominal trouble of any kind in a patient who has an ovariectomy cicatrix. After recovery from ovariectomy, the patient should be warned that it will be best for her to consult a practitioner whenever constipation or other abdominal symptoms appear, not forgetting to inform him that she has undergone the operation.

Foreign Bodies left in the Abdominal Cavity.—I have already referred to the dangers of leaving sponges, forceps,

* *Diseases of the Ovaries*, 1872, p. 397.

etc., behind in the peritoneal cavity, and noted the precautions to be observed by the operator. Intense pain and acute peritonitis, commencing within the first two days after operation, are always suspicious symptoms. Nearly all the cases where foreign bodies have been left in the abdomen die if those bodies be not removed.* In a case recorded by Dr. Wilson, of Baltimore, a sponge was removed several months after the operation, from an abscess in the abdominal walls. Olshausen relates a case where a pressure-forceps was passed by the rectum nine months after ovariectomy. In a case of Dr. Nussbaum, of Munich, a drainage-tube remained for two months in the patient's body, when a part of the wound opened after a dance, and the tube was at once pulled out by the patient herself, who suffered no further inconvenience.

When a sponge or forceps is missing, the wound must be carefully reopened. It is useless to search for the foreign body by external manipulations. I have known a life saved in one case after the forceps had lain in the abdomen nearly twenty-four hours. The patient must never be allowed to run the risk of almost certain and speedy death on the chance that the foreign body may be discharged, probably after great impairment of health, through the abdominal walls, vagina or rectum.

Morbid Changes in the Pedicle.—These are very rare in this country and in America at the present day. In a case under Dr. Hegar, the distal end of the stump was passed at stool on the sixteenth day. When the pedicle suppurates, the ligature may find its way into the bladder and form the nucleus of a calculus, or it may be discharged, through an abscess, out of the abdominal wound or into the intestine.

Abscess.—This complication is also very rare in the practice of British and American operators. The abscess may be due to morbid changes in the pedicle, just described, or to irritation of the track of a suture in the abdominal wound. It must be treated on general surgical principles. Suture-track abscesses may cause much suffering, but they rapidly heal when opened.

Thrombosis, Phlegmasia, Parotitis.—A slight swelling of the lower extremity, on the side corresponding to the ovarian

* The accident must have been occasionally overlooked in fatal cases, where no necropsy was allowed.

tumour which has been removed, is occasionally observed during convalescence, especially in simple cases where a very large tumour has been taken away, and the patient, feeling remarkably well by the end of the first fortnight, attempts to walk or stand too soon. In many of such cases a previous history of swelling of the limb can be traced. In the mildest and most frequent form of this complication, the patient complains that one leg seems bigger than the other. On examination, the integuments over the tibia are found to be œdematous, but no tender, cord-like veins can be detected. Sometimes the swelling is marked and extends to the thigh, whilst a plugged vein can be discovered, and all the symptoms of phlegmasia may be present, with much constitutional disturbance.

When any sign of thrombosis occurs, the patient must be kept in the recumbent position, and the œdematous limb must be covered with a layer of wool and lightly bandaged. Iron should be administered, and attention must be paid to the bowels. After the subsidence of the œdema, she must not be permitted to place her foot on the ground; the limb must be supported as she is shifted from the bed to the couch or sofa. In fact, this complication demands careful treatment, and is in any case a cause for anxiety. A more serious set of symptoms, where inflammatory changes suddenly appear in the parotid region, occasionally occurs after ovariectomy. This parotitis is sometimes of a septic type, when suppuration or even periostitis of the inferior maxilla, and yet wider spread mischief, may follow. In other cases it is very mild; its precise significance is then somewhat obscure.*

Pulmonary Embolism.—This deadly complication is not unknown after ovariectomy. In one case, in the practice of a colleague, the patient was twenty-three years old; both ovaries, subject to cystic disease, were removed, and the patient appeared to be getting well very rapidly, when she died suddenly on the eleventh day while talking to her nurse. There

* See Goodell, "Inflammation of the Parotid Glands following Operations on the Female Genital Organs" (*Transactions of the American Gynecological Society*, vol. x., 1885). An exhaustive paper on "Parotitis after Injury or Disease of the Abdomen or Pelvis" was read before the Medical Society of London in February, 1887, by Mr. Stephen Paget (see *British Medical Journal*, vol. i. 1887, p. 613).

was no necropsy in this case ; still the evidence was in favour of pulmonary embolism.

The possibility of this accident should be borne in mind, especially, as the case just noted may suggest, in reference to strict caution with regard to young and active patients who recover rapidly from the operation. Notwithstanding the greatest powers of enforcing discipline, and the highest gifts of inspiring confidence, nurses generally find patients of this class difficult to manage. Yet, should a fatal accident occur, the surgeon will always feel that he is to a certain extent responsible.

Syncope from Anæmia of the Brain.—Palpitations.

—Olshausen lays some stress on this complication and its physiological explanation. Syncope certainly occurs, not unfrequently, after the removal of a very large tumour, and it has been attributed to anæmia of the brain. Severe attacks of palpitation are not rare ; they come on generally at night, and seem partly due to the removal of the large circulating area included in the vessels of the tumour, but partly, if not entirely in some cases, to prolonged rest in the supine position which is enforced on the patient. In fact, each attack is simply nightmare from sleeping on the back. It may give great alarm to an inexperienced nurse. In one of my own patients where this symptom occurred, I found out that she had been subject to palpitations after every labour, the first occurring twenty-seven years before the operation. Half a drachm of aromatic spirits of ammonia, in half a wine-glassful of water, will give great relief, and the patient must be assured that her condition is not serious. Display of fear on the part of the nurse always aggravates this condition.

Tetanus.—This formidable complication sometimes follows ovariectomy, as it may follow any other operation. It may complicate a perfectly simple case, as in one instance which occurred at the Samaritan Hospital. This disease, rare as it is under the circumstances, is generally in itself sufficient to prevent a very long series of ovariectomies from showing one hundred per cent. of recoveries.

The surgeon must remember that it has been demonstrated by experience that faulty methods of securing the pedicle, and

injudicious meddling with its stump during after-treatment, are amongst the most frequent causes of tetanus after ovariectomy. Olshausen shows that one Continental operator lost seven out of twenty-nine ovariectomies through tetanus! There was strong evidence that this terrible mortality was due to irritation of the pedicle by retained hair-lip pins, and to its frequent disturbance, partly, perhaps, through the over-anxiety of the operator, but in some cases, on account of secondary hæmorrhage, which indicated, according to Olshausen, an insufficient tightness of the clamp or ligature, so that the nerves of the pedicle were not so thoroughly crushed as to be rendered powerless in exerting morbid reflex action.

In a case described by Dr. G. Thomas, the tetanic symptoms developed between the tenth and fifteenth day, and were chiefly confined to trismus and pain in the muscles of the neck. The disease ran a chronic course; the patient was kept quiet, hydrate of chloral was administered as an enema, and hypodermic injections of morphine were given. "A mild galvanic current was also used, and the patient expressed herself as feeling the better for it." She recovered.

Krassowsky, of St. Petersburg, observed tetanic symptoms during ovariectomy in two of his patients. Both of these died within four days, one from internal hæmorrhage, the other from peritonitis.

From what has been just stated, it may be gleaned that no special treatment of this grave complication is of any avail. Indeed, the only form of special treatment which has been tried, namely, examination of the pedicle, appears to have simply aggravated the tetanic spasms. As the clamp is now discarded, the pedicle is not accessible, and it is not likely that any surgeon would open the abdominal wound and add a tighter ligature. Tetanus must be treated, in these cases, as it is treated when it complicates other diseases. No doubt certain practices and precautions, already described or suggested, will tend to act in a prophylactic manner. The pedicle must be tied as tightly as possible. The free border of its stump, after division, must not be pulled about. The small portions of tissue at each end of that border, held by pressure-forceps during the cleansing of the peritoneum, as I have already

directed, should be cut away with the forceps, rather than left behind. Lastly, great care must be taken to protect the patient from draughts, even in those climatic conditions where tetanus occurs but rarely. In two cases within my knowledge there was a distinct history of exposure to draughts. In a convalescent ward there is generally one draughty corner at least, and tetanus—or, more surely, other scarcely less dangerous complications—is liable to attack mysteriously the patient whose bed lies in that corner.

Menstruation after Ovariectomy: Hæmatocele of the Pedicle.—When menstruation occurs a few days after operation, a rise of temperature invariably occurs, though sometimes to a very limited extent. Some writers believe that the show of blood, so frequently seen under these circumstances before the period is due, is not truly menstrual; but this theory is part of a physiological question which cannot be discussed in these pages. The surgeon should always inquire about “show” when the patient’s temperature rises during convalescence after ovariectomy. When this “show” appears, there is often more or less depression of spirits, and the pulse may rise considerably. These symptoms, most marked in cases of short pedicle, or sessile tumours where uterine tissue is included in the ligature, subside before the “show” disappears.

The patient must always be warned to keep quiet during the first two or three periods after ovariectomy, lest hæmatocele of the pedicle should occur. The symptoms may be alarming, though serious results are rare.

Notes of the Operation.—It is very advisable that the surgeon should write a note of the operation as soon after it has been performed as possible. The note-book (page 167) must be kept in the patient’s room until her discharge. The condition of the pedicle of the pelvic and abdominal viscera must be noted, and, above all, the number of sutures placed in the abdominal wound must be recorded (page 253). The tumour should be weighed and the fluid measured. All purely pathological researches must be carried on outside the patient’s chamber.

The surgeon must insist upon the nurse writing down notes, not only of temperature, but also of diet, of the time which the

patient spends in sleep, etc. (page 192). He should not neglect to copy these notes, as far as he may deem them trustworthy, and add them day by day to his own note-book. In this way he will accumulate material of simply incalculable value. No sophistry about the abuse of note-taking must deter him from making short accurate records of his patients' condition, as far as can be done consistently with their welfare. At the same time, purely experimental clinical work—such as digital exploration of the vagina and bimanual examination when there are no symptoms of pelvic mischief—is utterly unjustifiable.

The surgeon should carefully endeavour to obtain an account of each patient's condition a year after the operation, entering it in that portion of the case-book which is headed "Subsequent History."

CHAPTER X.

OOPHORECTOMY AND ALLIED OPERATIONS.

Oöphorectomy.—By the term oöphorectomy, I signify the removal of one or both of the uterine appendages for any reason excepting the extirpation of what is generally known as an ovarian tumour. The term is open to great objections, I admit, but it is compact and convenient. Some operators, it must be remembered, leave the ovary behind when removing the tube, and there are varieties of this operation to which distinct names can hardly be given. All other terms applied to proceedings of this class are equally open to criticism. The surgeon should in all cases specify what he has removed in any particular operation, then no term which he may choose to employ can lead to error.

Oöphorectomy is performed in order to check hæmorrhage from fibroid tumours of the uterus and to arrest their growth, and also in order to remove hopelessly diseased ovaries and tubes. In the case of a bleeding fibroid, the operation has a physiological aim, the induction of a premature menopause. The removal of diseased appendages resembles, to a certain extent, the amputation of a limb crippled and rendered dangerous to the organism by the results of chronic inflammatory changes in the bone or soft parts. In some cases of dysmenorrhœa with malformed genitals, and in certain diseases of the nervous system, oöphorectomy has been recommended and performed with an uncertain degree of success. Many authorities deny that this operation can be justifiable under these circumstances.

It may well be understood that it would be out of place for

me to attempt to unravel in this manual the tangled skein of the history of oöphorectomy. The fact that this history is in itself so complicated has no mean scientific value. I must refer the reader to some of the original sources of information on the early history of the subject,* and to the records and opinions of authorities who have within the last few years written and spoken more or less on their own experience.†

Pathology of the Diseases where Oöphorectomy is Performed.—Even were I to exclude all neuroses and the entire subject of dysmenorrhœa with or without objective symptoms, it would yet remain impossible for me to describe at any length the morbid conditions where oöphorectomy may offer a fair chance of cure with the minimum of risk. I cannot enter into the pathology of fibro-myoma of the uterus, the relation of that disease to uterine hæmorrhages, and the physiology of the ovaries as far as relates to those hæmorrhages. Nor can I demonstrate in full those morbid changes in the appendages which are produced by inflammatory conditions, such as pelvic peritonitis, inflammation of the ovary, inflammation of the Fallopian tube, pyosalpinx and hydrosalpinx.

Inflammation of the Appendages.—Inflammatory affections of the appendages probably arise, as a rule, from extension of inflammation from the vaginal and uterine mucous membrane, which may advance through the ostium of the tube into the peritoneal cavity (see page 17). Abortion and the sequelæ of parturition at term are by far the most frequent causes of these inflammations, especially when complicated by gonorrhœa. The latter disease undoubtedly renders patients liable to inflammation of the appendages, independently of gestation. As far as I can ascertain, however, the patients subject to this form of inflammation have generally aborted

* A valuable series of references will be found in Dr. Alexander R. Simpson's "History of a Case of Double Oöphorectomy" (*Brit. Med. Journal*, vol. i., 1879, p. 763).

† Spencer Wells, Hegar, and Battey's "Symposium on Castration in Mental and Nervous Diseases" (*International Jour. Med. Sciences*, October, 1886). Tait "On the General Principles involved in the Operation of Removal of the Uterine Appendages" (*Brit. Med. Journal*, vol. ii., 1886, p. 852), abstract of a paper read before the Medical Society of London.

or borne a child. Another cause of inflammation is a chill during menstruation. The inflamed tube becomes obstructed, the fimbriæ adhering to each other (Fig. 111). The tube gradually swells through retention of its secretion, till it, in very rare cases, may form a tumour rising above the pubes, so as to simulate cystic ovarian disease, as in Fig. 112, which represents the larger of a pair of dropsical tubes removed by Sir Spencer Wells from a young woman. The tube may be obstructed and filled with a serous fluid; this condition is termed "hydrosalpinx." When the fluid is purulent, the term "pyosalpinx" is used; it implies a dangerous form of

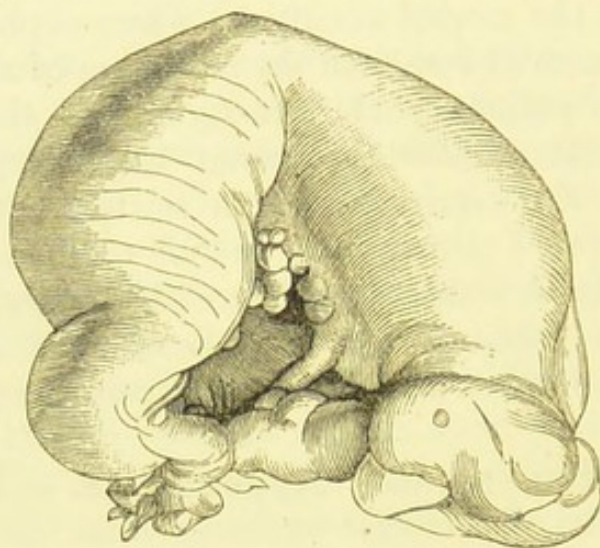


FIG. 111.—AN OBSTRUCTED FALLOPIAN TUBE.

The fimbriæ can still be distinguished on the right hand of the woodcut. The uterine end, much lacerated, must not be mistaken for the fimbriæ. (*Museum R.C.S.*, No. 4,567.)

disease, liable to set up general peritonitis through rupture of the tube. Distension of the tube with blood is termed hæmato-salpinx; this is seen in inflammation, but may be due to other causes. When pelvic peritonitis occurs through, or independent of, escape of inflammatory material from an unobstructed tube, that tube may become obstructed by bands of adhesions.*

The ovary may inflame, or become surrounded by inflammatory products interfering with its functions. After an uncertain interval this organ becomes adherent to the tube and broad ligament, and very often to the omentum. The changes

* Dr. Horrocks has recently stated that, according to post-mortem evidence, tubal obstruction is often secondary to ovarian inflammation.

in the substance of the ovary are not thoroughly understood; suppuration may occur. Its parenchyma sometimes becomes abnormally tough, and at others undergoes cystic degeneration.

For a more complete description of the morbid anatomy of inflamed appendages, I must refer the reader to Dr. Kingston Fowler's "Contribution to the Pathology of Hydro- and Pyosalpinx" (*Proc. Med. Soc.*, vol. vii., 1884), and to Mr. Tait's

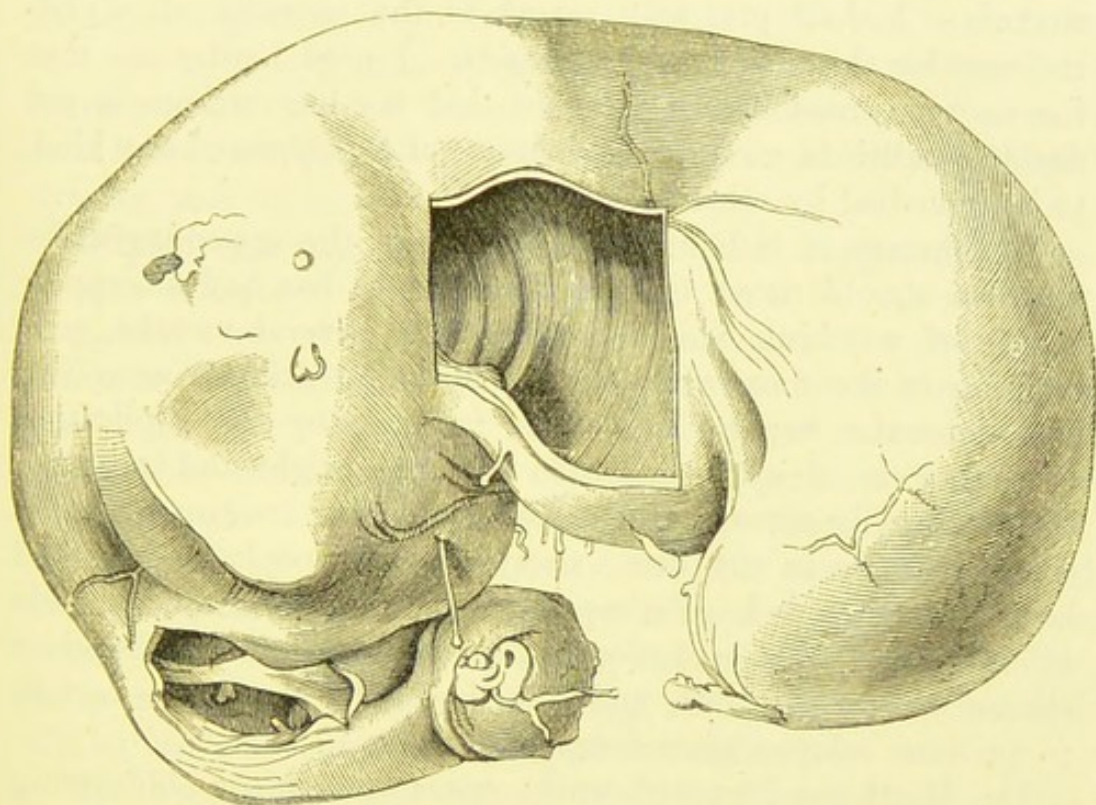


FIG. 112.—A FALLOPIAN TUBE DISTENDED SO AS TO FORM A LARGE CYSTIC TUMOUR.

A square piece of the wall has been cut away to expose the interior. (*Museum R.C.S.*, No. 4,571.)

"Fourteen Specimens of Hydro- and Pyosalpinx" (*Trans. Path. Soc.*, vol. xxxiii., 1882).

Symptoms of Inflammation of the Appendages.—

The patient, generally after an attack of acute pelvic inflammation, suffers more or less constantly from fixed pain in one or both iliac fossæ, pain during coitus, and some disorder of menstruation, usually menorrhagia. Bimanual examination must be conducted on sound principles (see page 53). A solid body

is then detected on one or both sides of the uterus. It may move with the uterus or be fixed, and is almost invariably tender to touch. An enlarged and tender ovary, the seat of chronic inflammation, is more readily detected than a distended tube.

When should Oöphorectomy be Performed?—In the case of a small uterine fibroid tumour, it is justifiable to remove the ovaries when intractable menorrhagia has caused great anæmia. I shall presently revert to the question of oöphorectomy for the cure of large fibroids. I need hardly say that the surgeon must first make sure that the hæmorrhage is not due to conditions, such as the presence of a polypus of any kind, to be remedied by other means.

In the case of inflammatory diseases of the appendages, the surgeon should never operate till after he has had an opportunity of watching the case himself for several months, prescribing in the meanwhile rest in bed, abstention from coitus, and hot-water vaginal injections, followed by the application to the cervix of wool soaked in glycerine night and morning. Most assuredly some cases get well under this treatment, as has occurred twice in my own experience after oöphorectomy had been recommended. Perhaps some allowance may be made in favour of the operation in workwomen of the humbler classes who cannot rest, and who live under conditions certain to produce relapse after temporary cure.

Dr. Matthews Duncan* warns operators against obliterating the distinction between the feasibility and the advisability of any operation of this or any other kind, and bids us beware of maintaining the doctrine that in aiming at the relief of continued suffering, a considerable proportion of the lives of the sufferers may justly be sacrificed. Dr. Coe† has issued the important warning that oöphorectomy fails to cure in many cases where it has been performed for inflammation of the appendages, because the inflammatory process has already spread over the peritoneum beyond the amputated structures.

* "On Recent Gynæcology" (*International Journal of Medical Sciences*, vol. xci., p. 89).

† "Is Disease of the Uterine Appendages as frequent as has been represented?" *American Journal of Obstetrics*, vol. xix., 1886.

Conservative Surgery in Inflammation of the Appendages.—Efforts have been made to examine inflamed appendages through an abdominal incision, and to attempt to break down adhesions, and set the tube and ovary straight without removing them. Unfortunately, this process is often impossible, the parts being so closely matted together. In other cases it is very dangerous, owing to the hæmorrhage which follows the breaking down of adhesions, or to the risk of rupturing some suppurating structure. At the best, there can never be any guarantee that the parts set straight will resume their normal functions. Yet I believe that science will some day indicate a right way to save and cure inflamed ovaries and tubes by operation.

Oöphorectomy for Disease of the Appendages.—I shall describe this, the more essential form of oöphorectomy, first, and then proceed to speak of removal of the ovaries for the cure of bleeding fibroids. The surgeon must banish from his mind the vulgar error that oöphorectomy is necessarily easier than ovariectomy. In the former operation, now to be described, the abdominal walls have not been stretched by the presence of a large tumour, hence the operator will find that manipulations are much more difficult than during ovariectomy after the cyst has been emptied. On account of adhesions and inflammatory roughening, it becomes very hard to distinguish the parts by touch or by sight.

The Operation.—The patient must be placed on the table, as in ovariectomy. A waterproof sheet need never be used, as probably little or no fluid will escape, but towels should be placed under the loins and between the thighs, to catch any blood which may run down the flanks or over the pubes. Another towel is folded over the epigastrium, and another over the upper part of the thighs.* The patient must be kept thoroughly under the influence of the anæsthetic. If narcosis be incomplete, the contractions of the recti will greatly hinder manipulations within the abdominal cavity. A sudden spasm of these muscles is particularly dangerous when the surgeon is drawing the appendages up to the level of the

* The same instruments will be required as for ovariectomy (p. 196), excepting the ovariectomy-trocar and Nélaton's volsella.

abdominal wound. It may cause him to tear the broad ligament. If the surgeon be compelled to keep his hand for many minutes within the abdomen, for the exploration of the extent of disease and the true anatomical relations of the affected parts, muscular contractions will cause great fatigue, and impair his sense of touch.

The Incision.—The incision should be commenced about three inches below the umbilicus, and need not be extended downwards for more than two inches and a half. The walls are generally more vascular than in ordinary ovarian cases. On opening the abdominal cavity, the small intestines may be found in a healthy condition, and if so, the surgeon may at once pass his right or left forefinger downwards in the direction of the fundus uteri, in order to ascertain the extent and nature of the disease.

Adhesions.—Very frequently, however, the operator will meet with a difficulty at this stage, owing to omental adhesions. The omentum, fortunately, presents, as a rule, its natural appearance, but may be strongly adherent to intestine, bladder, or uterus. Irregular adhesions to the parietal peritoneum are common and puzzling. I have seen part of the lower border of the omentum dragged upwards, and adherent to the parietes not very far below the umbilicus, so that a double fold or pouch lay below the point of adhesion. The two layers of this omental pouch were irregularly adherent to each other and to adjacent viscera. It is difficult to conceive any condition more puzzling at this stage of the operation. The omentum is sometimes adherent to the diseased appendages, and held down by them in the pelvis; this involves great stretching of the upper part of the serous fold, and sometimes the transverse colon and stomach are much displaced. On the other hand, the tube and ovary may be drawn high up out of the pelvis by omental adhesions (Fig. 113).

When the omentum is adherent to structures low down in the abdominal cavity, it must be divided with scissors before the appendages can be reached. The free part must be cut through as low down as possible after pressure-forceps have been placed on the proximal side of the line of division. The omentum may be ligatured later in the course of the

operation. It is best to apply a ligature to the distal side of the omentum to be divided; if not the pressure-forceps must be used, and the ligature applied after the omentum has been cut through. The distal portion being usually very vascular, should not be detached from its adhesions, for it will not slough, and if torn off will cause hæmorrhage.

When the omentum adheres to the diseased appendages themselves, the adherent portion should always be seized

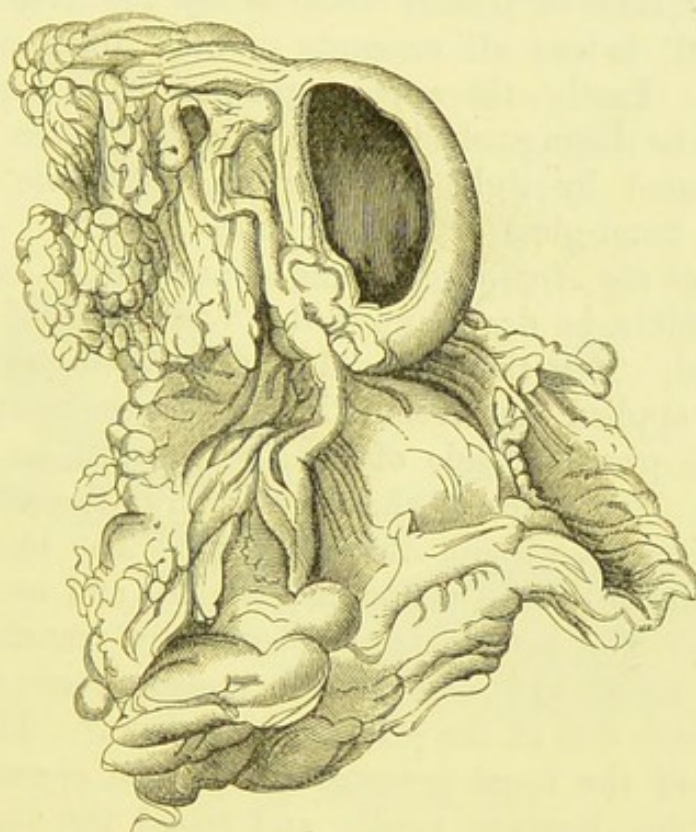


FIG. 113.—AN OVARY STRONGLY ADHERENT TO THE GREAT OMENTUM.

The ovary has become cystic, and a part of the cyst-wall has been cut away. The Fallopian tube appears as a stout, tortuous cord running upwards and along one side of the ovary. The opposite ovary formed a large papillomatous cyst. (*Museum R.C.S.*, No. 4,550B.)

before division with a pair of pressure-forceps, which are then entrusted to the assistant. The operator next passes a ligature round the proximal side of the piece of omentum, which is then cut through. He will find the appendages at hand, and may proceed with the next stage of the operation.

Exploration of the Appendages.—Whether these omental adhesions exist or not, the surgeon will have to search for

the appendages by passing the fingers of his right hand into the pelvic cavity. The forefinger should first be pressed against the fundus of the uterus, and then slipped down in the direction of the right appendages. Now several conditions may be discovered. The ovary and tube may be diseased, but easily drawn up. This is not the rule. They may be readily pulled out of the pelvis, yet not without the occurrence of profuse hæmorrhage, caused by the breaking down of adhesions. Again, they may be plainly detected by the finger, yet not easily moved, indeed all attempts to draw them up may be of no avail. Lastly, the appendages may be so diseased that they cannot be distinguished by the fingers, or even by inspection, facilitated by light thrown into the pelvic cavity by means of a hand-glass or electric lamp.

Removal of the Appendage.—The appendage to be removed must, if possible, be drawn upwards to the level of the abdominal wound. It is then secured by a large elbowed pressure-forceps,* so applied that room is left to pass the ligature needle through the proximal side of the pedicle without wounding the uterus. The shape of the blades allows the pedicle to be held conveniently, without any dragging. The blades should be held parallel to the abdominal wound, and as close to it as possible. The pedicle is then carefully transfixed below the blades (Fig. 114), and small pressure-forceps must be applied to each side of the pedicle above them.† The assistant takes hold of the large pressure-forceps, the operator having withdrawn the ligature needle and seized the ligature silk. As he begins to tie the pedicle, after the manner adopted in ovariectomy (p. 220), the assistant takes off the large pressure-forceps, and catches hold of the small pressure-forceps already attached to the appendages. He may have to assist the operator, whose hands are now occupied with the ligature silk, by pressing down the abdominal walls to the level of the ligature with his left hand.

The ligature being made fast, the operator takes hold of

* I have already referred to this practice as applied to ovariectomy proper at p. 219.

† I do not advise the inexperienced to omit this precaution, as do some specialists (see p. 224).

the free end of the appendages which he cuts away. The assistant should keep hold of the pressure-forceps, and they ought not to be removed until the opposite appendages have been attended to. The raw surface of the stump should be examined very carefully, so that the condition of the tube may be ascertained. Should the tube be diseased, it will not be safe to leave a piece of its mucous membrane projecting freely into the peritoneal cavity, and possibly discharging puriform mucus. Sometimes, too, a cast of a portion of the

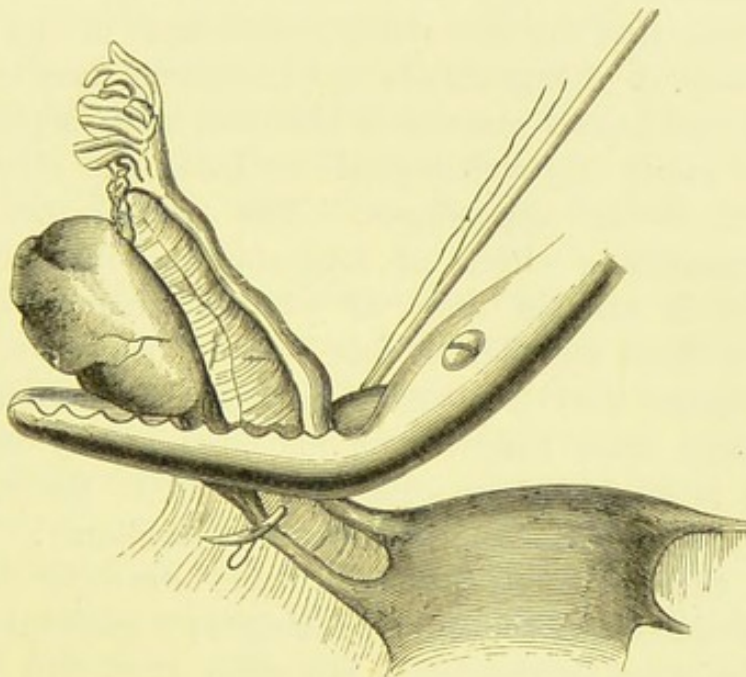


FIG. 114.—OÖPHORECTOMY.

Showing the appendages grasped by large elbowed pressure-forceps. The pedicle-needle, bearing a loop of silk, perforates the broad ligament below the forceps and near the uterus.

tube, consisting of dried pus or tubercular matter, projects from the cut surface of the tubal canal. Whenever, then, the exposed portion of tubal tissue is evidently diseased, it is advisable to touch the everted mucous membrane with the point of a Paquelin's cautery, or with a drop of strong solution of iodine, or of carbolic acid just melted from the crystalline state.

The opposite appendages must then be searched, and treated in the same manner, if necessary. In most cases where this

operation is performed there is much capillary oozing from the surface of the pelvic peritoneum, where adhesions have been broken down. These are best treated by flushing out the peritoneum with water heated to about 100° (see p. 236). Should the oozing continue after free flushing, a drainage-tube must be inserted into Douglas's pouch. The abdominal wound is then sewn up. The after-treatment, and the management of the drainage-tube, will be the same as after ovariectomy. Sometimes patients who have been ill for a long time before operation are very troublesome during convalescence. I do not think that the excitability, intolerance of the slightest pain, and display of ingratitude and insubordination to medical attendants and nurses sometimes observed after oöphorectomy necessarily imply a psychological condition the direct result of removal of the appendages. The mental state is due to the demoralizing effects of long-standing invalidism of a kind which is rare in cases of ovarian tumour, but quite common in those disorders which demand oöphorectomy.

The surgeon who proposes to perform this operation for the first time must banish from his mind a very misleading expression to be found in some text-books, to the effect that the steps are precisely the same as in ovariectomy. Properly speaking, the order in oöphorectomy, drawing a parallel between it and ovariectomy, and taking as a guide my tabulation of the steps in the latter operation at p. 195 would be 1, 2, 6, 4, 5, 6, 4, 5, 6, 7, 8, 9, 10, 11. In other words, after making the abdominal incision, the surgeon must perform a manœuvre precisely similar to the searching deep in the pelvis for the ovary opposite to that which is the site of the tumour, and having found it, to extract it through the abdominal wound, attending to adhesions, to apply the ligature, and then to divide the pedicle; the whole process is then repeated on the opposite side. There is nothing homologous to step 3 in oöphorectomy, and in this operation step 4 will not involve tapping.

Oöphorectomy for Neurotic Conditions, etc.—When the surgeon deems it justifiable to remove the appendages for the relief of some nervous affection—a step never to be taken without grave deliberation and long personal experience of

the nervous diseases of women,—the operation will be performed in the manner described above. Should the appendages be healthy, the operation will not be very difficult; but they often prove to be diseased.

Oöphorectomy in Fibroid Disease of the Uterus.—

The uterine appendages are sometimes removed to check hæmorrhage in cases of fibroid disease of the uterus, where that symptom has become serious. Some surgeons perform this operation for the same disease, not with the view of checking hæmorrhage, which may or may not exist, but to arrest the growth of the tumour. When the uterine tumour is small, the operation is relatively easy, and would then appear to be quite justifiable when much hæmorrhage has taken place. When the tumour is large, the operation is always difficult and dangerous, indeed it may become impossible.

In removal of the appendages for cure of a small bleeding fibroid, the patient is prepared in the manner already described in relation to oöphorectomy for disease of the appendages. The abdominal incision should be about three inches long, as there will be a tumour in the way of the operator's hand throughout the subsequent proceedings. The surgeon must bear in mind the possibility that the bladder may be somewhat displaced. When the peritoneal cavity is opened, the uterine tumour must be closely inspected, and care is particularly needed if there be one or more subperitoneal outgrowths springing from short, thin pedicles on the surface of the uterus. If such an outgrowth be torn off, as may very probably happen should the operator catch hold of it for the purpose of altering the position of the uterus, serious hæmorrhage may ensue, and probably supra-vaginal amputation of the uterus will be needed.

The operator must slip the fore and middle fingers of one hand over one side of the uterus till the appendages are reached; often the junction of the tube with the fundus is within sight, and in any case the tube is the best guide, to the touch as well as to the eye. In some cases it is best to explore with all four fingers. The tube and ovary are now drawn up out of the abdominal wound. They will generally be found free from adhesions, but exceedingly vascular. The broad ligament

is transfixed and secured by ligature as in ovariectomy; the needle should be passed through it about half an inch from the uterus. Pressure-forceps should be fixed to the two extremities of the pedicle on the distal side of the ligature before the pedicle is divided, and left on the stump of the pedicle. The reasons for this step are given at page 224. It is especially important that the stump should be inspected before closing the abdominal wound, and the precaution just noted facilitates the inspection and renders it safe.

The opposite appendages are treated in the same way; then the stumps of the pedicles are thoroughly examined. It is best, after securing the transfixing ligatures on each side, to pass a single loop of No. 3 silk round the pedicle and tie it tight, making sure that it slips accurately into the groove already made by the former ligatures.

When the fibroid tumour of the uterus is large, this operation will never be safe and will often be difficult. The distortions of the uterus caused by large fibroid growths will be noted (see Fig. 115, page 291). These distortions displace the appendages. The fundus may be rotated so that one extremity looks almost directly backwards, or backwards and downwards, or simply downwards. One ovary will then lie almost in front, or high in the pelvis laterally, the other will then be behind the great tumour or deep in the pelvis. Occasionally, one appendage will be hidden, or practically inaccessible, in a deep groove between two outgrowths from the surface of the tumour. The most serious condition, however, is that where, on raising the appendages on one side, the broad ligament is seen to form a pyramid with its base on the side of the tumour—that is to say, when its two folds have been widely parted along their line of reflection on to the uterus. Large vessels run behind each fold, lying far apart from each other towards the base of the pyramid. Now the apex of the pyramid is formed by the ovary and the outer part of the tube held up in the surgeon's hand, and the ligatures must be passed through the middle of the pyramid. This condition I have witnessed more than once with my own eyes. It is self-evident that the chances that the large and turgid vessels will slip must be great, for the broad ligament becomes very tense when its layers are pulled tight by the

ligature. Hence, as I have seen, some of the vessels may slip, fortunately, in a few minutes, before the close of the operation. Hæmorrhage is then very difficult to check, as the vessels retract far in the overgrown connective tissue of the broad ligament. In one case where I assisted, the uterus had to be amputated as in ordinary hysterectomy before the hæmorrhage could be checked. This has occurred in the experience of several operators.

Hence when the appendages are inaccessible, the operation will have to be abandoned, or hysterectomy must be performed. When the layers of the broad ligament are widely parted close to the tumour, so that when the ovary is raised the ligament forms a pyramid in the manner described above, it will also be safer to amputate the uterus. Should the operator be determined to remove the appendages only, he had better secure the large vessels separately along the same level, and then transfix and tie the ligatures along that level.

After-Treatment.—In all cases of oöphorectomy the principles which guide the surgeon in his after-treatment of an ovariectomy must be strictly observed. Above all, he must take every step within his power to obtain the after-history of every case, never losing sight of it as long as the patient's address remains known to him.

Results.—No satisfactory idea of the results of oöphorectomy can be given by statistics. The operation requires much skill and experience to ensure anything like safety to life, and the low percentages of mortality which have been published depend therefore on the operator rather than on the operation. Bantock, Thornton, Tait, and Keith, however, have all shown that the mortality after oöphorectomy is distinctly higher than that after ovariectomy, in their own experience. The danger of fatal hæmorrhage after removal of the appendages for fibroid disease of the uterus is, to my knowledge, considerable, and recovery from the same operation when performed for disease of the appendages does not invariably mean relief of the symptoms. It is neither probable nor advisable that the operation will ever be performed largely by general surgeons, as is the case with ovariectomy at the present day.

CHAPTER XI.

SUPRA-VAGINAL HYSTERECTOMY—OPERATIONS ON FIBROID
TUMOURS AND POLYPI.

Operations for the Removal of Uterine Fibroids.—I shall throughout this chapter employ the term “fibroid,” as it is convenient and universally understood, although I admit that the exigencies of pathology demand a more accurate nomenclature. For the pathology of all forms of myoma or fibro-myoma of the uterus, I must refer the reader to systematic text-books. The ethical aspect of the question of operation has been the subject of grave controversy. Distinguished British and foreign specialists are much divided in opinion on the matter. I recommend the reader to consult gynæcological literature for the last ten years, and to judge for himself of the opinions of Spencer Wells, Keith, Tait, Bantock, Thornton, and others, who can claim authority through long experience.

I shall content myself with remarking that uterine fibroids do not advance steadily to the destruction of life after the manner of cystic ovarian tumours, but some forms, independent of fibroid polypi and allied conditions which can be operated upon through the vagina, damage the patient's health, and even put her life in danger through frequent hæmorrhage. A very large fibroid may cause certain and permanent misery, and no small risk to life even when there are no hæmorrhages. On the other hand, the removal of a large fibroid is undoubtedly dangerous. I believe, however, that oöphorectomy for a large fibroid is yet more dangerous (see page 284). Hence, after due deliberation, I consider that it is justifiable to remove a large fibroid tumour of the uterus in a patient far from the menopause, if it be the cause of permanent ill-health and discomfort

through its size or through metrorrhagia. Small bleeding fibroids are best left alone, or else oöphorectomy may be undertaken. Small fibroids that do not bleed should not be touched.

I shall first describe the operation of amputation of the body of the uterus, or supra-vaginal hysterectomy, as performed at the Samaritan Hospital by Dr. Bantock. I have had the opportunity of assisting that surgeon at a large number of these operations at that institution, and the following description is based on notes taken after the conclusion of each case. This operation, though almost invariably performed for the removal of general fibroid enlargements of the uterus, may be deemed necessary for sarcoma of the body of that organ, or even for cancer in the same anatomical locality. It may also be said to form a part of Porro's operation. In some cases of ovariectomy, and oöphorectomy, hysterectomy becomes a necessity as the only means of checking dangerous hæmorrhage.

Supra-Vaginal Hysterectomy.—The surgeon, assistant, and nurses, should take up the same positions as at an ovariectomy (page 200). The same instruments will be required (page 196), except the trocar and cannula which is replaced by Koeberlé's serre-nœud (page 122) in three sizes, with several wires and a pair of nippers. Care should be taken that they are clean, dry, and in working order. Above all, the operator must see that the key is not forgotten, else the screw cannot be turned. The pedicle-needles (page 112) should be at hand, as the appendages may require ligature. A Tait's screw, an instrument which resembles a large corkscrew, will prove useful.

A single assistant is quite sufficient, though towards the end of the operation somebody should be at hand to hold the string that keeps the pins and the pedicle well down whilst the abdominal wound is being closed, in the manner which will presently be explained. The manœuvres in hysterectomy are complicated, but at the same time they are of such a nature as to be best conducted by two persons. The waterproof sheet is not necessary, as no mass of fluid will escape from the tumour; the abdomen is protected by the arrangements noted in the chapter on oöphorectomy. The surgeon and assistant must have their sleeves tucked up as high as possible. Bare arms are more readily cleaned than mackintosh sleeves, but the shirt-sleeves

must be kept out of danger, as the fear of soiling them may worry the operator and so interfere with his movements. The operator's and assistant's aprons should be long enough to protect the lower part of their dress and boots from blood.

The Abdominal Wound.—An incision about three inches in length is now made in the middle line, as in ovariectomy. The bladder must be borne in mind, as there is sometimes considerable difficulty in emptying it artificially, even when the nurse thoroughly understands the use of the catheter. There is far more risk of injuring the bladder in hysterectomy than in ovariectomy. The abdominal walls are also very vascular in fibroid disease. Indeed, the free hæmorrhage which follows the incision is almost diagnostic in doubtful cases. The assistant must use his sponges freely, and the surgeon will require the aid of the pressure-forceps. When the peritoneum is divided, if diagnosis be accurate, the characteristic pale brick-red surface of the tumour will be observed. If there be much fibrous tissue, the surface will be very pale and almost silvery, as in some ovarian tumours. In cases where repeated hæmorrhages have occurred and the patient has become exceedingly anæmic, the tumour is often of a pale yellow colour, like a sarcoma or a mass of fat.

Exploration of the Tumour.—The first thing to be determined will be the pelvic relations of the tumour and the possibility of its removal without too great risk. If it be found that the broad ligaments are not opened up by extensive lateral growth of the tumour, then it may be desirable to ascertain whether there be adhesions to the parietes and other structures. This can be done by the forefinger, passed down to the level of the pelvic brim on each side.

As a rule, the incision will require considerable extension upwards in proportion to the size of the tumour. A fibroid cannot be pulled out of the abdomen unless the incision extend almost as high as its upper border, especially if it be broad. In pulling the tumour through a small opening, outgrowths may be torn off, and this may cause troublesome hæmorrhage. Besides, it is most important to be able to find out adhesions above. There is no objection to using the scissors; indeed, it is safer than the knife if the assistant guard the structures

behind with a sponge. The umbilicus may be cut through, and its tissues should be dissected away before the wound is closed.* Those who hold that foetal relic is sacred may cut to its left side.

Inspection and Management of Adhesions.—The adhesions in front must be divided before the tumour is raised out of the abdomen. Parietal adhesions, so frequent in ovarian tumours, are rare in these cases. On the other hand, intimate connections between the omentum and the fibroid are very common. The omentum undergoes a remarkable hypertrophy when this condition has lasted long. The vessels become enormously enlarged. The great veins, the arteries sometimes of the calibre of the radial, pulsating visibly, and the lymphatic vessels, in some cases widely dilated,† may startle even a bold operator. Another difficulty may be experienced, for the connective tissue of the omentum occasionally undergoes pathological changes, so that it is hard to get well behind a distinct piece of omēntum. Owing to atrophy of the omental tissues around them, some of the vessels may run for an inch or more almost separate from any other structure and well to the front, whilst others run closely adherent to the surface of the tumour behind the main part of the omentum.

Where this condition exists, the omentum must be traced upwards and secured above the level of the tumour, even if that point lie close to the transverse colon. A No. 3 silk ligature must be passed through the omentum and one side secured, then the opposite side is tied with the same material. If, however, the vessels be very large, the omentum will have to be tied in several pieces, and the surgeon may ligature some of the larger vessels separately. Before dividing the ligatured parts, the distal portions must be carefully secured. If this be neglected, dangerous hæmorrhage may follow, for the circulation in the uterus and the tumour is, at this stage, still

* This will cause the wound to be firmer, at the level of the umbilicus, than when the umbilical tissues are left behind.

† They do not enlarge so frequently as the blood-vessels, but in one case I observed a complete plexus of lymphatic vessels of about the calibre of the dorsalis pedis artery. The constrictions marking the valves were characteristic, and gave a remarkable appearance, as though white beads had been embroidered into the omentum along the course of the blood-vessels.

continuing actively. Each distal portion should be secured by pressure-forceps, small or large, according to circumstances. In many cases it is perhaps best to economize forceps by tying the distal portion carefully, but this takes up time in an operation which is in itself lengthy. The omentum being thus secured, it is divided. The proximal portion is returned into the abdomen, guarded by a large flat sponge. I may here observe that the dilated omental vessels are seldom a source of danger when properly secured. They rapidly dwindle in size after the mass which they formerly supplied has been removed.

Intestinal adhesions require very great care in management. When in process of separation, some of the uterine tissue may be torn, and then a kind of active capillary hæmorrhage follows which cannot possibly be stopped by ligatures. It is best checked by the pressure of a sponge, which the assistant must hold against the bleeding spot. This complication must sometimes be deliberately incurred, since it is far less serious than laceration of the intestine.

Extraction of the Tumour.—Adhesions having been freed, the tumour is now pulled out of the wound. If it be evidently firm, Tait's corkscrew may be thrust into its most prominent part. The operator then pulls forwards until the tumour comes out. Soft fibroids, however, cannot be treated in this manner; the corkscrew drags out when firmly pulled upon, and troublesome hæmorrhage occurs. Such a tumour must be deliberately lifted out, the operator slipping his hands over the fundus and pulling forwards. Some operators employ, at this stage, a large instrument something like lion-forceps, with the blades mounted scissors-fashion, and with a wide gape and a firm grip. Where the corkscrew fails, however, the forceps will be as likely to tear away part of the tumour as to haul it out entire. As the tumour comes out, a large flat sponge should be placed over the viscera and pushed under the parietes, partly above the upper angle of the abdominal wound.*

Examination of the Relations of the Uterus.—The

* When this wound is very long it is advisable to close two or three inches of its upper part, or, at least, to introduce one suture at this stage, to prevent the escape of intestines through a sudden action of the abdominal muscles.

tumour having been extracted, the surgeon will have to examine its lower part, in order to make sure of its relations to the portion of the uterus not involved, to the appendages, to the cervix, and to the bladder. The broad ligaments are the best guides whenever the fundus is out of sight, or merged into the general mass of the tumour. They often are subject, in these cases, to a remarkable pathological change, very puzzling to the operator if he has never seen them previously. In this case their course is indicated by large thin-walled cystoid bodies containing a yellowish fluid, running downwards and outwards from each side of the tumour. These bodies form

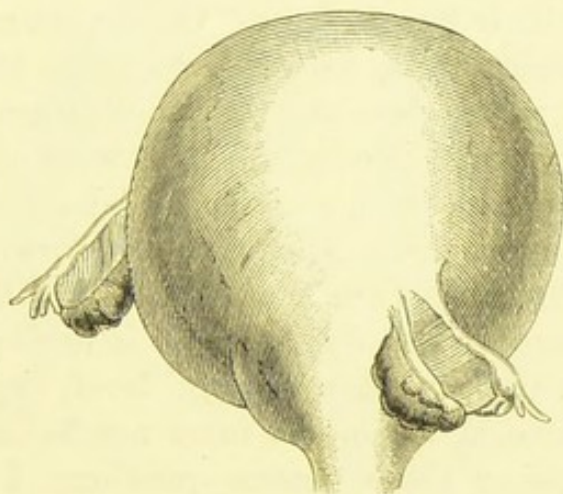


FIG. 115.—A FIBROID UTERUS SEEN FROM THE FRONT.

The pedicle is narrow. The natural position of the appendages is altered, so that the left tube and ovary lie almost on the front of the tumour. (From a sketch made by the author directly after the removal of the specimen.)

two collections of bullæ, completely concealing the Fallopian tubes. On careful inspection, the tubes, the ovaries, and the engorged vessels in the broad ligament may readily be detected. The bodies are the *kystes lacuneux* or *hygromes sous-séreux* of Verneuil, and are quite different from thin-walled broad ligament cysts. They appear to be due to a simple long-standing oedema of the broad ligaments, and disappear entirely when the adjacent structures are divided in the later stages of the operation. When one of these cystoid structures bursts in the course of an operation, the escaping fluid may be taken for urine, to the great alarm of the operator.

The ligaments, as a rule, proceed from the sides of the tumour, somewhat anteriorly, and never quite symmetrically. But one, or even both, may come from the back of the tumour.

In some cases (Fig. 115), the natural axes of the pelvic organs are entirely altered by unsymmetrical growth of a large fibroid or of several fibroid outgrowths. Hence, the search for the appendages may be attended with great difficulties. When found, their treatment depends very much on their position. This question is closely related to the next stage of the operation. The ovaries vary greatly in appearance. They are generally swollen, with large follicles, often full of blood, projecting from their free surfaces. On the other hand, I have seen them stretched and flattened, so as to look like white ribbons, hardly wider than the ovarian ligaments.

The Level of the Pedicle.—The wire of a Koeberlé's clamp must now be passed round the pedicle. This involves three practical questions. Firstly, the nature of the pedicle must be remembered. Then the treatment of the appendages must be considered. Lastly, when it is decided to pass the wire round the tumour at a certain level, the protection of important anatomical structures must not be overlooked.

Before discussing these serious questions, I must observe that the practice of applying large pressure-forceps, elastic ligatures, or temporary clamps of any kind, to the pedicle, cutting away the tumour, and then applying the *serre-nœud*, involves great dangers and difficulties. Hard as it may sometimes be to distinguish the relations of the pedicle before the removal of the tumour, the task becomes far harder afterwards, and the risk of damaging the bladder or a ureter will be greater. The application of the *serre-nœud* and pins will also be very troublesome. There may be cases where this practice of applying the *serre-nœud* to the pedicle after the removal of the tumour is justifiable, but such cases are exceedingly rare. The inexperienced are liable to get into great trouble over a divided stump of a uterine pedicle not properly secured.

The pedicle is simply the lower part of the uterus or the upper part of the cervix. When the enlargement lies chiefly towards the fundus, and when, at the same time, the appendages

proceed from the sides of the tumour symmetrically, so that it is evident that the wire can readily be passed round the lower part of the uterus, below them, there will be little difficulty in this stage of the operation. Often, however, the tumour invades the lower part of the uterus (Fig. 116), or, what is still more frequent, small dense fibro-miomata are developed in its walls at the level of the proposed pedicle. In these cases it may be necessary to shell the tumour out of its capsule. A scalpel is passed horizontally round the growth so as to divide the cap-

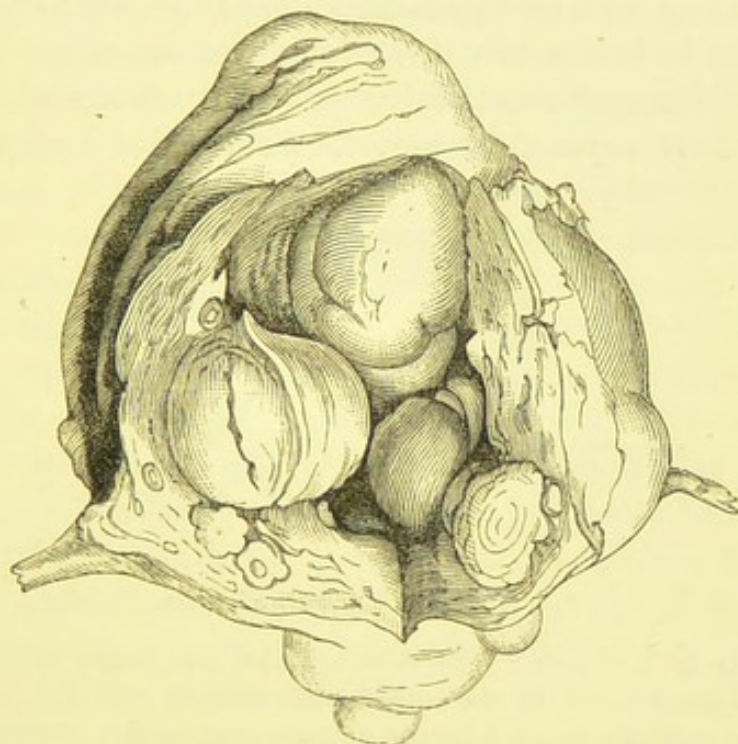


FIG. 116.—A FIBROID UTERUS REMOVED DURING LIFE.

The uterine cavity is laid open, showing interstitial growths bulging into it. Similar growths lay in the part of the uterine walls through which the knife passed.

sule, which is peeled off below the incision, bleeding vessels being secured by pressure-forceps. When the tumour is sufficiently enucleated the wire loop and pins are applied to the portion of the capsule which is left behind.

The relations of the appendages to the proposed pedicle must also be ascertained. When they lie even, and high up on the sides of the tumour, the wire may be passed entirely under them; that is to say, as the wire is slipped round the pedicle, the tubes, ovaries, and greater part of the broad ligaments are

held or pulled, by the assistant, well above the level of the loop of wire, which will grasp them, as experience has proved, with sufficient firmness. Sometimes, however, one or both appendages lie too low for this kind of treatment (Fig. 117), for the wire cannot be safely passed round the middle of the appendages, which are often tense, so that the proximal part will not be secure against hæmorrhage after the tumour has been cut away.

Management of the Uterine Appendages.—The best way of dealing with an appendage placed too low to be included in the loop is to remove it, as in oöphorectomy. When the appendages lie unsymmetrically, as already described, the lower often requires separate removal, whilst the higher can be

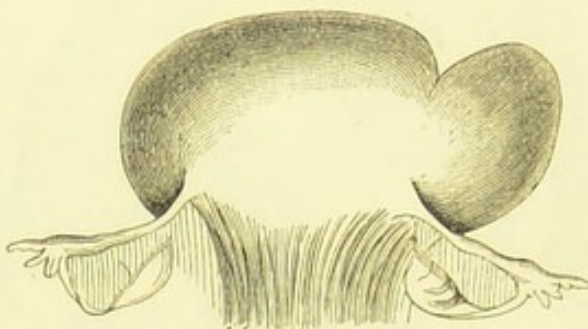


FIG. 117.—A FIBROID UTERUS.

The pedicle is very broad. In this case the appendages required separate ligation. (From a sketch by the author made directly after the removal of the tumour; the appendages are represented entire, as though undivided.)

included in the wire loop of the *serre-nœud*. The details of the process of removal are described at page 280, and illustrated by a drawing (Fig. 114).

Lastly, before the wire is passed round the tumour, the position of the bladder must be noted. It is sometimes drawn up on the surface of the tumour. In such cases, it may be desirable to pass a catheter in order to ascertain the position of the fundus. It will be a valuable guide to the operator, who will see its point pushing the fundus of the bladder upwards. I have twice seen the fundus accidentally and inadvertently included in the wire, and cut across during the division of the pedicle. In both cases the patient died. In

one, at least, the wire appears to have slipped downwards over the bladder during the process of tightening.

The operator must also see how the loop lies posteriorly, and must keep the intestine out of its way, and above any suspicious peritoneal folds in the pelvis.

Application of the Wire Loop.—All the above precautions being considered, the surgeon, having settled the level, which should always be, if possible, a little above the os internum, passes the wire loop round the pedicle. The assistant must hold the tumour well up.

Whilst the intestines are protected by a flat sponge, the free end of the wire is carried round the pedicle, passed under the bridge at the end of the *serre-nœud*, and twisted round the button (see Fig. 52). The wire is then tightened by means of the key, and care must be taken not to use so much force as to cut the tissues or snap the wire.

Application of the Pins.—When the wire loop has been properly tightened, the pins (page 124) must be passed through the pedicle close to the wire, and on its distal side. I have heard of the pins being passed on the proximal or cervical side of the wire loop. This practice is not in accordance with the principle on which the pins should be applied, for they are meant to support the stump so as to keep the loop level with the parietes; it is open to yet graver objections. As a rule, a single pin is not sufficient. The process of transfixion is not always easy, and requires care on the part of the assistant as well as the operator. The guard is taken off the point of the pin, and the operator enters the point into the right side of the pedicle a little superiorly. With a firm thrust, the pin is run through the pedicle till its point emerges on the left side, towards the assistant, who must guard the edge of the abdominal wound and other more important structures with a sponge. As the point comes out of the tissues, he slips his left forefinger under it and guides it as the needle is pushed farther by the operator over the abdominal integuments. At the same time, the assistant presses the edge of the abdominal wound against the pedicle. When the pin has been pushed so far as to project equally from both sides, the assistant places the guard over the point. The operator repeats the process with

the second pin. The pins should be entered nearer the anterior and posterior boundaries of the pedicle, respectively, than the centre. The serre-nœud (*a* Fig. 118) and the anterior (*c c*), and posterior (*b b*) pins will lie, after the division of the pedicle, as indicated in the accompanying woodcut.

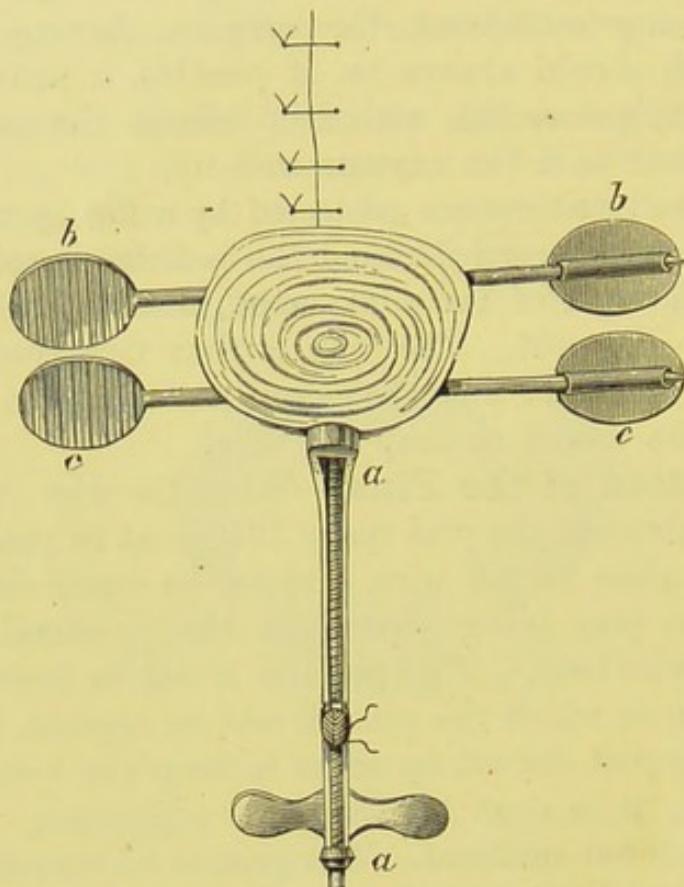


FIG. 118.—THE STUMP OF THE PEDICLE OF A UTERINE FIBROID SECURED BY KOEBERLE'S SERRE-NŒUD AND TWO SPECIAL PINS.

Part of the abdominal wound, with the sutures, is represented above the stump, which lies in the lower angle of that wound. The wire-loop, which passes behind the pins, is not represented.

The passage of a pin is sometimes much impeded by a small, tough interstitial growth. The surgeon must take care not to push the pin to the least extent downwards, else the point may strike against the wire on the left side, or even emerge on the cervical side of the pedicle, and possibly wound an important structure. The assistant's duties, as indicated above, are not always easy, especially when he has to support a very heavy tumour. He is liable to get his fingers wounded by the pin, if he fails to

keep the abdominal integuments well down below the level of the constricting wire on the pedicle, and this accident not only involves pain to himself, but may cause him to let go of the parts suddenly, so that the surgeon may thrust the pin into the peritoneum behind the wound, or even into the intestine. Therefore the assistant must carefully observe where the point of the pin issues from the pedicle. He should direct the tumour a little towards the operator at this stage of the proceeding. When the tissue of the pedicle is very tough, the operator should hold the head of the pin between the jaws of the pliers employed to make fast the wire of the *serre-nœud*.

Division of the Pedicle.—The pins being in place (Fig. 118), the wire must be tightened a little by aid of the key. The tumour is now cut away. There will be great bloodshed, but it will be from the tumour. The uterine arteries are held secure by the *serre-nœud* (see A A, Fig. 12). The surgeon takes a stout scalpel in his hand. The assistant holds a large sponge in his right hand and supports the tumour with his left. Then the tumour is cut through from an inch and a half to two inches above the pins, by a semi-circular sweep along the operator's side, and another carried round the opposite side. As the incisions are being made, the assistant presses the sponge against the cut surface of the tumour, so as to keep the parts from being concealed by blood, but the sponge must be held out of the way of the operator's scalpel. Three or more large sponges will be soaked through at this stage. Directly the tumour is cut away the wire of the *serre-nœud* must be tightened. The tumour is dropped into a pan held by a nurse the moment that the pedicle is completely divided. Then a thorough cleaning of all the parts around the pedicle by means of sponges, and a good washing of the hands and arms of the operator and assistant, will generally be necessary. It is especially advisable that all coagula be cleared out of the abdomen, and above all that the space between the lower or anterior part of the pedicle and the bladder and pubes, including the lower angle of the abdominal wound be attended to, for clots are very liable to collect and putrefy there.

Management of the Stump of the Pedicle.—The stump is trimmed down until just sufficient tissue is left to prevent the pins from tearing out. This may be done either by means of scissors, or by a scalpel with the aid of toothed forceps. Then the edges are stitched across from one side to the other. Hagedorn's needle (page 116) with No. 4 silk is very convenient for this purpose. The object is to make the stump as small as possible and to prevent the edges from becoming everted over the wound. In the case of a very thick and fleshy stump it may be desirable to dust the surface lightly with iodoform, by aid of a Kabiersky's insufflator (page 138). A loop of stout silk should now be passed round the upper or posterior pin on each side, and the ends of the two silks are given to a nurse or second assistant, who pulls upon them so as to keep the pedicle well against the lower angle of the wound. This is done by standing to the left of the assistant, close to the patient's left leg, and exercising traction, on the silks, downwards towards the patient's knees. This traction should be kept up till the abdominal wound is closed above the pedicle.

The wound is closed as in ovariectomy, but the three lowest sutures must be inserted close to each other, not more than a quarter of an inch apart, so as to give mutual support at the part of the wound where the traction is greatest. The sutures being introduced, the peritoneal cavity, not forgetting Douglas's pouch, is cleaned with sponges, and the sutures are tied.

A pad of absorbent gauze is now placed under the pins on each side of the pedicle, and a similar dressing under the nozzle of the *serre-nœud*. Once more, the wire should be gently tightened. Several larger folds are then placed over the stump and the upper part of the wound, as in ovariectomy. A large pad of wool is then placed over the whole abdomen. A many-tailed bandage is very useful to cover in the dressings, as the stump must be frequently inspected, and a bandage of this kind is particularly suitable for that purpose; it involves as little disturbance of the dressings as possible. The directions for its proper application are given at page 131.

After - Treatment.—There is always more pain after hysterectomy than after an ovariectomy of corresponding severity. It is particularly important that the catheter be used frequently—that is, at least every four hours, for severe attacks of pain often come on, and are invariably relieved more or less completely by emptying the bladder. Hence the paramount necessity of an experienced and dexterous nurse for a case of hysterectomy, for as has been already observed, in speaking of the after-treatment in ovariectomy, clumsy catheterism is certain to set up cystitis. An inflamed bladder after hysterectomy causes the patient extreme torment. As soon, however, as she can do so, the patient should be allowed to pass water without the aid of catheterism.

The stump must be carefully watched. The thicker it is the greater the danger of hæmorrhage, especially during the first twenty-four hours, and bleeding must be checked, by tightening the *serre-nœud* from time to time, not only for the inherent dangers of hæmorrhage, but also to prevent the stump from keeping moist, and thereby being the more exposed to sepsis. A careful turn of the screw will control the bleeding. The raw surface should, at the same time, be wiped dry, if necessary, with wool and dusted with iodoform. The stump should be inspected daily, and the wire made tight whenever desirable. Within two or three weeks the distal part of the stump will separate.

During the separation of the stump, its tissues must be kept very dry, and should be gradually cut away. When the wire is removed, the pins must remain on for a few days, and the surgeon must not trim the tissues too freely around their track, for the great danger to be avoided is the slipping back of the proximal end of the stump into the abdominal cavity before it has begun to heal by granulation, and has become quite free from shreds or discharge. When the stump does slip back too soon, the risk of septic peritonitis is, it is true, very slight, as the parts behind the stump have generally become cut off from the peritoneal cavity. On the other hand, troublesome local results are certain to ensue. The wound forms a deep pit with the stump at the bottom,

and the process of healing will be retarded for weeks—indeed, a fistulous track may remain for months.

Convalescence after the removal of a uterine fibroid is never quite so rapid as after an average ovariectomy. Great care is needed to keep the abdominal walls well supported by a good belt, for the cicatrix of the abdominal wound is very apt to yield.

The general treatment after hysterectomy will be much the same as after ovariectomy. The upper sutures may be removed about the same period, and the bowels should be made to act, for the first time, on the day after their removal. The lower sutures, especially the two or three next the pedicle, should be left as long as possible. Many of the complications are similar to those which may follow the removal of an ovarian cyst. The greatest special danger will be snapping of the wire and hæmorrhage from the stump. This must be guarded against by the employment of a stout, soft wire, free from any sharp edges due to bad finish, and not worn by frequent previous use; and by repeated inspections of the stump. When the wire has broken it can readily be taken off and replaced; the new wire must be slipped into the groove formed by its predecessor, and the free end made fast to the shank of the button (see page 295) by means of the pliers. This involves less disturbance of part than when the fingers alone are used for the purpose.

Another precaution is the protection of the structures around the lower angle of the wound from bruising through pressure of the end of the *serre-nœud* and the pins. This is avoided by keeping a stout fold of lint constantly underneath the instrument in this situation and also under the pins. When there is much dragging on the pedicle, sloughing of some of the integument under the pins is sometimes unavoidable.

Removal of Uterine Fibroid Outgrowths.—By the term “removal of a fibroid outgrowth,” I mean the amputation of what is pathologically known as a pedunculated subperitoneal fibro-myoma of the uterus. This operation should, even under the most favourable circumstances, be considered as a serious proceeding, and must not be looked upon as safer and easier

than hysterectomy. The danger of wounding the bladder, or a ureter, or some pelvic structure, may be absent, and the uterine cavity is not opened up, but adhesions very difficult to separate are frequent, and the pedicle may be so thick and short as to baffle any attempt to secure it, in the literal sense of the word "secure," so that either the entire uterus must be removed or else the parts must be left untouched.

A group of small spherical fibroids, feeling like a pile of round cannon-balls under the abdominal integuments, is not suited for an operation of this kind. The outgrowths, in the first place, do not, in themselves, give rise to much pain or to hæmorrhage. When such outgrowths are discovered, in a case where these symptoms exist, they should not be removed separately; either the entire uterus or the appendages will require removal. Trifling with a small fibroid is a great mistake; if it be thought good to remove it, its pedicle must at least be trans-fixed with No. 3 or 4 silk, and if tough it had better be secured with the *serre-nœud*. If simply tied within a single surrounding loop, the pedicle will, almost to a certainty, slip and place the patient in imminent peril from hæmorrhage.

A large fibroid outgrowth may weigh ten, twenty, or over twenty pounds, cause grave pressure symptoms, and be impossible to diagnose from fibroid disease of the substance of the uterus, until the abdominal cavity is opened. The pedicle may be several inches long and shaped like a leather strap, being made of tough uterine tissue, or it may be very short and perfectly cylindrical, or, as in many small spherical fibroids, it may be chiefly made up of connective tissue with large vessels and but little uterine tissue.

Operation.—The surgeon should have ready all the instruments used for hysterectomy, including the pins as well as the clamp. The fibroid is drawn out of the abdominal wound; sometimes its true nature can only be detected when this has been done. Having, therefore, made sure that it is an outgrowth, and not a mass forming part of the uterus itself, its pedicle must be carefully examined.

In the first place, however, adhesions may have to be separated. I have seen, in some of Dr. Bantock's cases of uterine fibroid outgrowths, the worst forms of omental

adhesions. In one instance, where the fibroid weighed twenty-five pounds, not only were the omental vessels as large as they often are in cases of fibroid uterus, but the lymphatics were dilated to the calibre of a crowquill. The surgeon must remember that a ureter may get lodged in a groove between the fibroid and the body of the uterus, where it may become adherent to the uterine or tumour-tissues and lie in danger of injury during operation.

I have generally found the pedicle to be under two inches long, subcylindrical, and springing from the uterus close behind the fundus. I have, however, seen a very long, flat, strap-like pedicle. The surgeon had better make it a rule, provided that he thinks it proper to remove the fibroid *alone*, to secure the pedicle by the wire of a Koeberlé's clamp, and then to pass one pin, or two pins if the pedicle be broad and cylindrical, through it on the distal side of the wire, finally cutting it through beyond the pin. In fact, the pedicle is treated exactly as if it were the stump of the uterus after hysterectomy.

Transfixion and ligature is very unsafe, even for a strap-like pedicle as in Fig. 119. The contractile power of a pedicle of this kind, made up as it is of plain muscular fibres, is extraordinary; if the ligature slips, the stump appears as a wide surface, bleeding actively, and but little, if at all, raised above the level of the surrounding uterine tissue. This property of the pedicle is best seen during hysterectomy when a small fibroid gets torn off before the wire of the *serre-nœud* is made firm. In January, 1886, I assisted Dr. Bantock at an operation for the removal of a fibroid from a woman aged thirty-four. The tumour formed a large movable mass in the abdomen and caused great trouble from pressure. On opening the abdomen it was found to be a large spherical fibroid, connected with the left side of the fundus of the uterus by a strap-like pedicle about an inch long when unstretched. It was transfixed with No. 4 silk ligatured, and divided. In a few minutes the central part of the cut surface began to cup, the ligature simultaneously loosening. Another was applied, by transfixion as before, but it was found untrustworthy, so a Koeberlé's *serre-nœud* was used, and a single pin passed through the pedicle. The patient made a very good recovery. In four more cases

where I assisted the same surgeon, in 1886, the *serre-nœud* proved to be indispensable. In the case already noted where the fibroid outgrowth weighed twenty-five pounds, the pedicle was perfectly cylindrical and nearly three inches in diameter. It sprang from behind the right angle of the fundus and was very difficult to secure, requiring two pins as well as the *serre-nœud*. The patient recovered. It frequently happens that disease of the appendages exists in association with large fibroids, so that

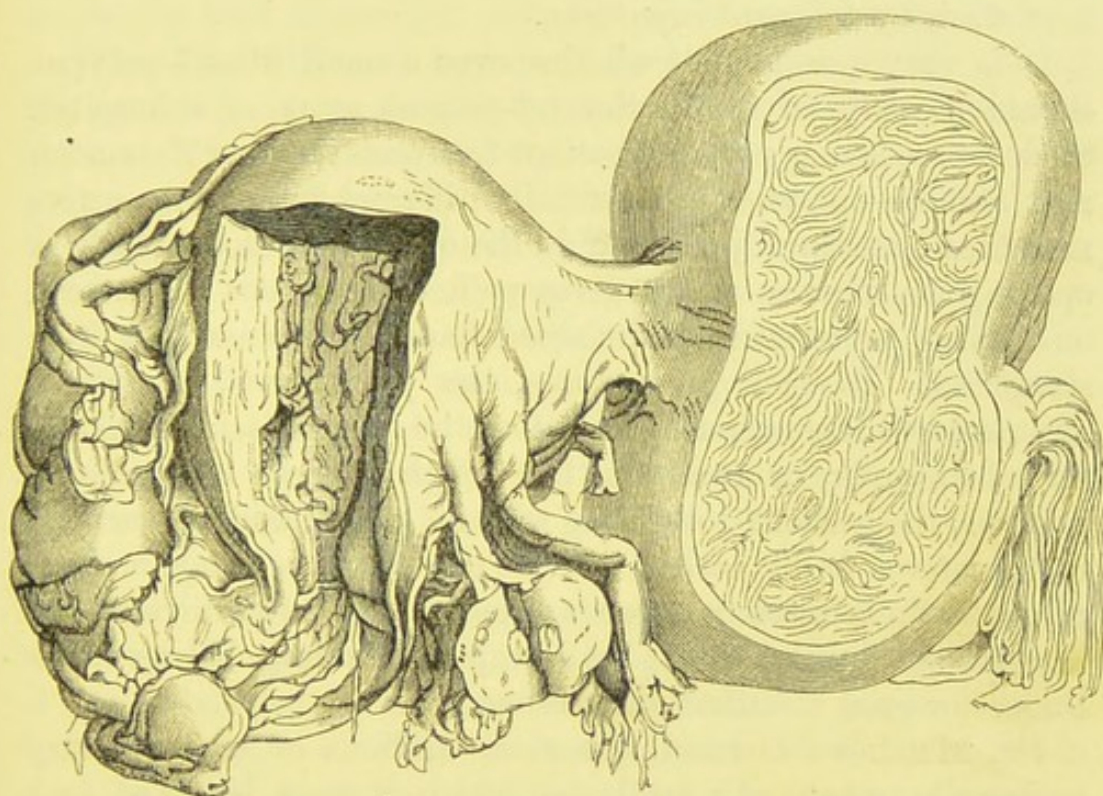


FIG. 119.—UTERUS WITH LARGE FIBROID OUTGROWTH.

The pedicle measured over four inches in length before the parts were taken out of the body. The patient died after abortion at the fourth month. (*Museum R.C.S.*, No. 4,639.)

oöphorectomy is needed, and this cannot be safely done, in many cases, without hysterectomy as well. Such cases are amongst the most difficult and dangerous in abdominal surgery, and should never be performed excepting when intractable chronic hæmorrhage and distressing symptoms exist.

Excision of Fibroid Polypi.—It is quite comprehensible that the surgeon should feel ready to cut away a solid yet well-

pedunculated mass, which he has detected protruding freely into the vagina. He is right to advise operation, and in cases where there is marked menorrhagia, or, more correctly speaking, metrostaxis, it is his duty to urge operative interference as soon as possible. At the same time, he must never treat the case as a "minor" operation. It must be done in the operating theatre, or in the patient's room, like an amputation or a lithotomy, and the patient must be kept in bed for a day or two, her pulse and temperature taken regularly, and her vagina kept clean by frequent injections.

It is very questionable whether even a small fibroid polypus should be snipped off in the out-patient room of a hospital. Such a proceeding puts the patient to a certain, even if remote, risk, and the operation is essentially different from other active measures sometimes justifiable in the out-patient room, such as opening an abscess which gives pain or threatens to burrow, or making incisions in an inflamed hand to save tendons from sloughing. In such proceedings, the pathological conditions are rendered less serious than before the surgeon's interference. After snipping or crushing the tough pedicle of a fibroid polypus, the patient goes home with an open bleeding surface* in the uterus freely bathed with its discharges. For the tissue of the pedicle retracts to an extreme extent after division, so that its site is marked not by a projecting stump, but by a raw surface or even a distinct depression.

Dr. Matthews Duncan, the most cautious of contemporary authorities, speaks of a fatal case, which, it must be noted, took place in a hospital ward. "The case was a simple one, a common fibrous polypus of the size of an apple, and a stalk as thick as your little finger. It was removed easily by volsella and scissors. In a few days the patient was dead. A post-mortem examination was made and nothing peculiar was found. The little wound near the os uteri seemed quite healthy. In no other case have I had even alarm."

The patient will not require an anæsthetic when the polypus

* There is generally little hæmorrhage, it is true, after division of the pedicle, owing to retraction of the proximal end. But vessels which cease to bleed do not at once cease to absorb through their open ends, and the thrombi which close them may be the source of a worse peril than the hæmorrhage which they check.

is small and its pedicle readily accessible on digital examination through the vagina. In such a case the vagina is simply washed out, and the patient laid on her left side. The surgeon seizes the polypus with a volsella or speculum-forceps, held in his left hand, and then draws it well down, so as to get the pedicle in sight. The pedicle is then divided with scissors curved on the flat. The vagina should be syringed out once more, with a weak iodine or carbolic solution, and the patient is put to bed for twenty-four hours. The vagina must, of course, be kept thoroughly clean by injections for a few days.

When the fibroid is large and likely to give trouble during manipulation, an anæsthetic must be administered. This will facilitate thorough exploration, so that the existence of other polypi or of partial inversion of the uterus may be ascertained. The patient should be placed in lithotomy position, and when she is well under the influence of the anæsthetic, the finger must be passed round the pedicle. Its insertion, as well as the position of the fundus uteri, is then determined. Sometimes the finger cannot reach the pedicle, then its thickness may be estimated by a sound, or by the ease with which the tumour can be rotated when grasped by forceps, as Berry Hart suggests.

It may happen that the polypus is so large as to require reduction in size before it can be pulled out of the vagina. A wedge-shaped piece may be cut out, or Hegar's spiral incision practised. The accessible part of the tumour is grasped with a strong volsella, which the surgeon holds in his left hand. He takes in his right hand a strong pair of scissors curved on the flat, and then cuts deeply and obliquely into the tumour. The incision is continued upwards, as the tumour is rotated and pulled down with the volsella. In this way a long flap is gradually dragged out by the forceps, and at length the pedicle can be reached. This ingenious method is preferable to the use of midwifery-forceps, or to cutting open the perineum, yet resort to the latter extreme measure is sometimes necessary. It not unfrequently happens, especially in the case of large polypi of long standing, with their nutrition impaired by pressure of the walls of the uterus on the pedicle, that the substance of the tumour is very brittle and

tears away when traction with the volsella is attempted. This makes the operation long and tedious, and much blood may be lost until the pedicle is divided.

The pedicle being reached, if very thin, it can be twisted off, by simple rotation of the volsella. If tolerably thick, the surgeon should entrust the forceps to his assistant, who keeps the tumour well drawn down. Then the operator takes a pair of scissors curved on the flat in his right hand, and guarding the uterus by passing two fingers of the left hand in front of the scissors, he cuts through the pedicle. If the pedicle be very thick a wire *écraseur* may be used, but even a thick pedicle may be divided by the scissors with little risk of hæmorrhage. The stump of the pedicle retracts, and is, in fact, lost. The vagina must be well washed out before the patient is put to bed.

The patient, after the operation, should remain in bed for a few days, and the vagina should be kept clean with injections. Owing to the contractility of the pedicle, hæmorrhage is even more rare during recovery than on the operating table.

Ligature of Fibroid Polypi.—The strangulation of the pedicle of a fibroid polypus by ligature should never be attempted. Experience has shown that the sloughing of the tumour often causes septic changes. This proceeding, once very popular, is only mentioned to be condemned.

Removal of Fibroid Polypi by the *Écraseur*.—Some authorities still prefer the *écraseur* to the scissors, Dr. Matthews Duncan declares that hæmorrhage is in reality very rare when the scissors are used. Should the *écraseur* be preferred it must be stout in the stem, and a single strong wire, or a rope made by twisting several strong wires, will be needed, according to circumstances. The application of the noose may be difficult if the pedicle be short. The vagina must be syringed out before the operation, and an anæsthetic is not advisable, for, as Dr. Galabin has pointed out, the division of the pedicle gives little or no pain, while pain is severe if the uterine wall be included in the loop, and thus an error may be revealed in time, when the patient is not under chloroform. Of course the volsella or a tenaculum will be useful in drawing down the polypus, so that the loop of wire may be passed round the pedicle.

Enucleation of Fibroid Growths.*—This operation is an imitation and anticipation of a natural process. The sloughing of the capsule of a submucous fibroid and its delivery through the vagina is a phenomenon long known in the history of medicine, but nature unassisted may fail to cure, the patient succumbing to pain or to septic changes in the sloughy tumour.

When the fibroid tumour has distended the os, its artificial enucleation is perfectly justifiable, according to modern ideas. On the other hand, to seek a fibroid in the uterine cavity after dilatation of the os by means of tents, to cut through the capsule and then to shell out the tumour, is a difficult and hazardous proceeding. Experience has proved the dangers which theory could foresee. The operation was frequent before oöphorectomy and supra-vaginal hysterectomy were performed, but it is probably far more perilous than those proceedings. When a fibroid growth bulges evenly, as far as bimanual palpation can prove, towards the uterine cavity and towards the peritoneum, its capsule may be very thin on the peritoneal side so as to be in great danger of laceration when the tumour is shelled out. Therefore, instead of attempting enucleation, it must either be left alone, or one of the abdominal operations just named should be performed.

The case is otherwise when the fibroid presents at the os uteri, or lies more or less in the vagina, especially should the capsule be sloughy or deeply congested, whilst bimanual examination of the uterus gives fair reason to suppose that there are no other large fibroid growths besides that which is being slowly delivered. To enucleate is then only to assist nature, and it is hard to see why the dangers of abdominal section should be incurred under the circumstances.

The Operation of Enucleation.—I put aside all cases where the fibroid tumour is not presenting at the os, and where dilators would be needed, and will confine myself to cases where the tumour has commenced to protrude through the os. The patient's bowels must be thoroughly cleared in the way recom-

* "An intra-uterine growth, not intra-cervical, is either sessile or has only a neck; it has no distinct stalk to make it a polypus." (Matthews Duncan, *Clinical Lectures on the Diseases of Women*, Third edition, Lecture xxxiv.) He admits that little mucous intra-uterine polypi may be pedunculated.

mended in the chapters on Ovariectomy, for an action of the bowels during the operation is an intolerable hindrance to the surgeon. The patient should be placed on her back in lithotomy position, and a Clover's crutch (page 132) placed between her knees to keep them apart. This arrangement is better than entrusting an assistant to hold the lower extremities in the correct position, as it economizes labour in an operation where many helping hands may be needed. Some surgeons prefer to place the patient on the left side.

The patient is anæsthetized, and, when the tumour is not so far delivered as to present at and block the vulva,* a Sims' speculum is now passed along the posterior wall of the vagina, until it exposes the projecting part of the tumour. The surgeon should carefully explore the pelvic viscera, especially if he has not examined the patient before under chloroform. Having made sure of his diagnosis, particularly as regards the relation of the margin of the os to the tumour, he directs his assistant to push the fundus of the uterus well downwards by firm pressure through the integuments of the hypogastrium. Sometimes it can be pressed down so low that the speculum is no longer necessary.

The surgeon then makes a deep incision in the exposed part of the capsule. This incision should be transverse if he can safely cut for about an inch and see his incision all the way, crucial if he cannot cut far enough in one direction without getting the point of his scalpel out off sight. He next begins to peel the capsule off the fibroid. The cut edges of the capsule should be seized with stout pressure-forceps and held apart by assistants. The operator must endeavour to peel off the capsule with his forefinger, and the more he can dispense with instruments the better. He first grasps the exposed part of the tumour with a strong volsella. The light puny instrument used for pulling the ovarian cyst-wall under the teeth of the trocar in ovariectomy is quite useless for this purpose, and will probably be spoilt if so employed. Kidd's strong volsella†

* When this is the case it does not follow that the operation will be short and easy, for the widest part of the tumour is not necessarily in sight. The most bulky and wider part may still be in the uterine cavity, perhaps above the pelvic brim.

† Sir James Simpson's volsella for intra-uterine fibroids is also very useful. The operator should prefer the longest handled instrument of this kind which he finds available. A short forceps is highly inconvenient.

(Fig. 120) will be found very serviceable. The handles are pulled open by the left hand of the operator, so that he can draw the tumour towards him with a slight rotatory movement, and extract it steadily as his right forefinger detaches it from its capsule.

So great is the difficulty sometimes experienced at this stage, that many instruments have been devised to assist

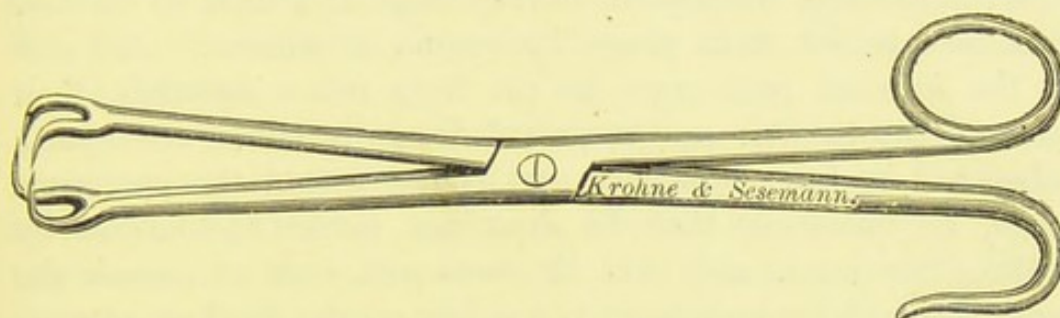


FIG. 120.—KIDD'S VOLSELLA.

in the process of detaching the capsule. Of these instruments it may be affirmed that none can, to say the least, be safely used unless the operator has frequently seen them employed by experts. The late Dr. Thorburn recommended a strong steel male sound and a blunt-edged lithotomy scoop as the safest aids to the surgeon's forefinger. They can be swept over the tumour along lines of adhesion to the capsule. There is a formidable instrument—familiar to



FIG. 121.—SIMS' GUARDED TUMOUR-HOOK.

many only as an ornament in instrument-makers' windows, called Sims' guarded tumour-hook (Fig. 121), which is useful in pulling down a large mass of detached fibroid. The piece of black wood is pulled up towards the handle, then the left forefinger is slipped over the convex surface of the fibroid till it reaches the part still undetached from the capsule; into the substance of the tumour just below that part the prongs of the instrument are thrust, then the piece of wood is pushed against the lower point of the fibroid. The

surgeon can then pull hard on the tumour-hook till the unenucleated part of the fibroid is brought within reach of his forefinger. The mechanism of the instrument protects surrounding structures from injury from the prongs, which become guarded by the piece of wood directly they tear away from their attachments. Still, this tumour-hook requires careful adjustment, and is never indispensable.

When, indeed, the tumour is very large and hard to deliver, it is best to cut it in pieces by means of scissors. One side of the exposed part must be cut from below upwards, then more of the tumour can be pulled down by aid of the strong volsella. As the uppermost part comes within the operator's reach, he must see that he does not invert the uterus by pulling too hard, and that the assistant does not cause the same accident by pushing too forcibly on the fundus. Inversion has repeatedly occurred during enucleation, even in the experience of cautious and skilful operators, and sometimes with fatal results.




FIG. 122.—SIMS' TAMPON-SCREW OR FIXATEUR.

The operator must beware of and examine every mass that comes down either slowly or suddenly in the course of the operation, and must bear in mind that an inverted uterus is not always to be distinguished at a glance. When the uterus is unfortunately inverted, it should be carefully washed with solution of iodine, and returned after the attachment of the tumour has been cut away. A few wool-plugs, each attached to a piece of string, and soaked in tincture of iodine, may be inserted into the uterine cavity, and carefully removed two or three days afterwards piece by piece. When thus extracted, it is not advisable to pull at all the strings at once, nor is it easy to find out which string belongs to the plug nearest to the os—to that, in fact, which should be pulled out first. Extraction is best effected by means of an instrument known as Sims' screw (Fig. 122).

It consists of a slender steel bar five or six inches long,

and mounted on a wooden handle. At the point is a fine screw. The bar being introduced like a sound, the point is guided to the os and pressed against the wool. By gently rotating the instrument on its long axis the screw soon gets entangled in the wool, then the first plug can be drawn out. The other plugs are successively removed in the same manner, though the last can, as a rule, be safely drawn out by its string. The instrument saves the operator from the risk of inverting the uterus once more, during traction on the strings.

There is yet another danger besetting this operation, even more serious than inversion of the fundus or of the entire uterus. In drawing down a fibroid which has a broad attachment to the inner wall of the uterus, especially when it projects from near the cervix posteriorly, the portion of the wall whence it springs may become inverted. As the line of junction between the tumour and the uterine wall is difficult to define, the operator may, in such a case, cut through the latter, laying open the peritoneal cavity.

After the fibroid has been completely enucleated, the uppermost part of the capsule, kept well in sight, should be freely washed—first with water, then with tincture of iodine,—and then the entire capsule, which will be greatly shrunk, must be plugged with pledgets of wool soaked in iodine. The vagina is next plugged in the same manner; the external parts are then cleaned, and the patient is put to bed.

The plugs may be left in place for about forty-eight hours, but in the meantime the patient must be carefully watched, and the pulse and temperature taken at regular intervals of four or six hours, lest hæmorrhage or septic infection should arise. When signs of the former appear, which is, fortunately, very unusual, the plugs must be removed, together with any clots or collection of fluid blood that may be discovered, and after a thorough cleaning with a weak iodine solution (about a drachm of the tincture to a pint of tepid water) the plugging must be repeated. When the temperature and pulse rise high, and remain so for several hours, the vagina should be explored in the same manner, but a stronger solution of iodine should be used.

When all goes well, allowing for a rise of temperature to about 100° , and for various relatively mild forms of constitutional disturbance due to shock and the anæsthetics, the plugs should be carefully removed on the second day, and the state of the parts explored with the aid of a Sims' speculum. Ragged shreds of tissue should be cut away, and if any part of the interior of the capsule be still exposed, it may be touched with tincture of iodine, applied on wool mounted on a sponge-holder. If all signs of hæmorrhage have ceased, as is almost invariably the case, the plugging need not be repeated, and the vagina should be well washed out with weak iodine solution night and morning until all discharge has ceased. The speculum must be used occasionally for inspection of the cervix and the os. I admit that, owing to the nature of the capsule, hæmorrhage is rare after enucleation, and septicæmia is not very common, but both have occurred, and the surgeon can never be too careful about after-treatment in operations performed in the region of the uterine cavity and the vagina.

Incision of the Capsule.—When a fibroid is presenting at the os externum, and is evidently in process of expulsion, when that process is progressing slowly but steadily, and is influenced by the administration of ergot, it is sometimes sufficient to incise the capsule so as to hasten the expulsion of the tumour without incurring the difficulties and dangers of artificial enucleation. Experienced specialists sometimes incise the capsule before the tumour has passed out of the uterine cavity; they first dilate the cervix by means of tents or hydrostatic bags. I have, however, already noted the dangers of an operation of this kind.

It is best to employ the cautery for incising the capsule. When Paquelin's thermo-cautery is used, a point of suitable size is heated, and an incision about one inch long is burnt through the capsule. The point should be made to penetrate the capsule to the extent of a quarter of an inch, or even deeper. It matters little if the tumour be burnt.*

When the galvano-cautery is needed for incising the capsule,

* Burning the tissues of the tumour itself has been practised systematically and successfully by Dr. Greenhalgh and others.

a firm platinum knife (Fig. 69) is used. It is applied hot to the surface of the capsule, with a kind of sliding or cutting movement, till a burn of about an inch in length is thus made through the capsule. It does not matter if the tumour itself be also burnt. After the tumour has been exposed by burning through its coverings, its further attachment to the capsule should be broken down, by means of the fingers, as far round as is possible until the part is reached where the growth is attached to the wall of the uterus. If this attachment be sufficiently pedunculated, the operation may be completed at once by passing the platinum wire of a galvanic *écraseur* (Figs. 70, 71) over the tumour, tightening it round the neck, and then allowing the wire to burn through after the circuit is closed, in the same way as when a cancerous cervix uteri is amputated, an operation which will be described in the next chapter.

If the base of the tumour be very broad, ergot should be given to increase the expulsive action of the uterus, which is already present, or has been set up by the dilatation of the os and rupture of the capsule of the tumour. By this means, the tumour becomes gradually elongated, and may be extruded through the os externum. It sometimes almost blocks up the vagina. About the end of a fortnight, an attempt may again be made to remove the tumour by the galvanic *écraseur*, or, at least, part of it may be removed in this way, especially any portion that may have become sloughy; and again, at a subsequent operation, the remaining part of the tumour may possibly be removed. The risk of septic poisoning in all operations about the vagina and uterus should constantly be borne in mind, and antiseptic irrigation frequently practised both during the extrusion of the fibroid and after its ultimate removal. For this purpose, a solution of corrosive sublimate (1 in 2,000) may occasionally be used, but more frequent irrigations should be practised with carbolic acid solution (1 in 80), or tincture of iodine diluted with one or two parts of water.

Removal of a Mucous Polypus.—The vagina must first be well washed with some weak antiseptic solution, such as carbolic acid 1 in 40, sulphurous acid 1 in 10, or twenty

minims of tincture of iodine to the pint of water. The cervical canal should then be cleaned by pledgets of wool introduced by means of a speculum-forceps. The wool, after the mucus has been wiped away, must be dipped in the antiseptic solution. These preliminary precautions must never be omitted. A Fergusson's speculum will answer very well for the cleaning of the cervical canal and for the operation, the patient lying on her left side. If, however, there be difficulty in bringing the cervix and the polypus into view, a Sims' or Neugebauer's speculum is preferable, and the patient should be placed in lithotomy position.

A uterine polypus-forceps (Fig. 123) will be necessary for the removal of the growth. It is of considerable length, and has a catch, so that the handles can be fixed whilst the polypus is

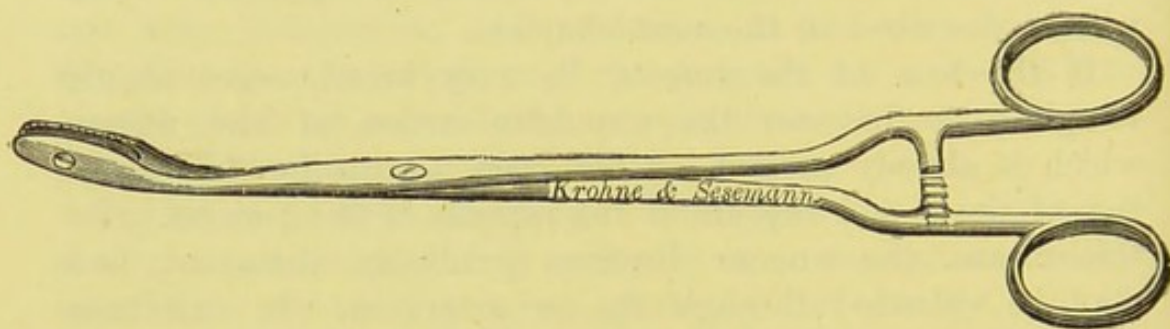


FIG. 123.—UTERINE POLYPUS-FORCEPS.

being twisted; without a catch, the process becomes clumsy, and the teeth of the forceps may slip off the polypus before complete avulsion. It does not matter whether the catch be placed on the shanks a little above the bows, or between the bows, or mounted on a hinge at the free end of one of the bows. The first two varieties of catch will be found most convenient to those surgeons who are accustomed to use pressure-forceps in abdominal operations.

If there be any difficulty in drawing down the polypus, a tenaculum-forceps may be fixed to the fundus of the growth, and the polypus-forceps can then be applied close to or on the pedicle, but as a rule this can be done by the latter instrument alone. It is always advisable to catch the pedicle if possible, for when the polypus is grasped by its fundus, it may be

simply crushed, so that the forceps comes away bringing a small piece of tissue between its teeth, and a lacerated mass is left behind. When the forceps has been made to grasp the pedicle satisfactorily, the bows of that instrument are slowly rotated in one direction, till the polypus is twisted away. The stump of the pedicle does not retract to such an extreme extent as that of a fibrous polypus.

This operation is generally very easy of performance, the only difficulty arises from crushing the tissue of the fundus, as just described. It should never be performed whilst the patient is under treatment for any acute or sub-acute form of pelvic inflammation. It is not a safe operation when a large fibroid tumour of the uterus exists, or when the uterus is infested with small fibroids. I was called upon, in 1877, to make a necropsy of a woman aged fifty who had suffered from a large fibroid tumour. A mucous polypus, about two inches in length, had been twisted off ten days before death. Septic symptoms followed, ultimately there were marked rigors, yet the patient had been apparently in good health before the operation. I found an abscess in the right ovary, another in the right broad ligament, and a third below it, where its peritoneal folds diverged. There was diffuse suppuration in the cellular tissue of the right ovarian vessels, extending from an inch below the kidney to the brim of the pelvis. The fibroid was a large myoma, eleven inches in vertical diameter; it weighed 7 lbs. 11 ozs., and had developed in the posterior wall of the uterus, whence it could be completely enucleated, and its only vascular supply were three large vessels running from the walls of the cervix close to the os externum. There was no pus around these vessels. The pedicle of the polypus sprang from the anterior wall of the uterus close above the os internum. It looked like a long decolourized clot, and was sloughy at its extremity. The kidneys showed signs of recent congestion; the heart was large and flabby. There was much turbid serum in the pericardium and peritoneum.

This case illustrates the dangers of interfering with a mucous polypus when the uterus is otherwise in a morbid condition. The cervix was two and a half inches in length, and the external os was narrow, so that there was not sufficient means

for the free escape of discharges. The vagina had been kept clean by injections. When the patient is in good health and the polypus is troublesome, projecting into the vagina and giving rise to discharge or hæmorrhage, it is right that the surgeon should advise and perform the operation. The patient should rest for at least twenty-four hours, and a weak solution of Condyl's fluid should be injected night and morning into the vagina.

CHAPTER XII.

VAGINAL EXTIRPATION OF THE UTERUS—AMPUTATION OF THE CERVIX—TRACHELORRHAPHY.

Operations for Uterine Cancer: General Observations.—There can be no doubt that, compared with the breast or either of the extremities, the uterus is in a highly unfavourable position for radical operations, when it is subject to cancer. This disease almost invariably commences at the cervix. Amputation of the cervix by the *écraseur*, or better still by the galvanocautery, is still the most popular and widely practised operation; it is far less difficult than more extreme measures, and is not unsurgical, for, as Koeberlé and John Williams have shown, the disease generally begins near the os externum and spreads over the surface of the cervix, attacking the vagina and adjoining organs before it mounts upwards beyond the level of the os. Dr. Williams has noted the important fact that when recurrence takes place after supra-vaginal amputation of the cervix, its seat is in the adjacent connective tissue and not in the uterine stump.

Many experienced operators, however, often prefer more complete operations than amputation of the vaginal portion of the cervix. They practise supra-vaginal amputation of the cervix—a most difficult operation, which will presently be described—or else remove the uterus completely. Provided that the latter be done through the vagina and not by abdominal section, the risk is not very high. Brennecke states (see *Year Book of Treatment for 1886*) that “while the mortality, as given by Hoffmeier for supra-vaginal amputation, compared with total extirpation, is lower (12 per cent. against 26); return of disease occurred in 28 per cent. of the total extirpation for 41·5 per cent. of the partial.” Statistics of special operators in this

country, and particularly in Germany, have displayed almost brilliant results, but the mortality in nearly three hundred cases collected by Dr. William Duncan exceeded 28 per cent. As in the case of oöphorectomy, the general surgeon must not rely on the results of an experience which he may not possess.

Cases suitable for Total Extirpation.—Koeberlé goes so far as to say that this operation is only justifiable when rendered relatively simple and safe by the existence of complete prolapse of the uterus. Cancer beginning in the body of the uterus—a very rare condition—and sarcoma of the fundus may be treated by supra-vaginal hysterectomy, as in fibroid disease, should there be fair evidence that the morbid growth does not extend to the cervix. The objections to this operation for the ordinary form of cancer will be stated after the description of supra-vaginal amputation of the cervix. When cancerous disease has evidently advanced high up the cervical canal, as in the rarer form of cancer of the cervix which extends upwards and not downwards, and when, at the same time, the mobility of the uterus remains unimpaired, and no deposit* can be felt near the cervix, total extirpation may be considered as fairly justifiable. The state of the broad ligaments and adjacent connective tissue should be ascertained by rectal and recto-abdominal exploration (see pages 69, 71).

Total Extirpation of the Uterus through the Vagina.†—The instruments required for this operation will be—

Clover's crutch.	Two large pressure-forceps,
Higginson's syringe.	straight-bladed (Fig. 40).
Sims' speculum.	Broad metal retractor.
Strong and slender volsellæ.	Nos. 1, 3 and 4 silk twist for
(Figs. 23, 120).	ligature.
Scalpel.	Pedicle-needle (Fig. 44),
Six sponge-holders with	armed with No. 3 silk ligature.
small sponges.	Two glass drainage-tubes
Two pairs of long-handled	(page 126).
scissors bent on the flat.	Needle-holder.

* Induration caused by cellulitis ("parametritis"), complicating cancer, cannot well be distinguished from true cancerous infiltration of the connective tissue around the cervix.

† Total extirpation of the uterus by abdominal section ("Freund's Operation")

The patient is laid on her back, and then the anæsthetic is administered. When under its influence, she is placed in lithotomy position, and it will greatly economize assistance if the lower extremities be kept apart by means of a Clover's crutch (page 132). The nates are brought close to the edge of the operating table, and a pan is placed on the floor vertically below the seat of operation. The operator sits on a stool or low chair facing the perineum; the chief assistant stands on his right, and the chief nurse on his left hand.

The vagina is thoroughly washed out with carbolized water, by means of a Higginson's syringe. A Sims' speculum is then passed along the posterior vaginal wall. The cancerous ulcer should have been previously plugged with iodoform wool, or otherwise rendered as clean as possible. The anterior lip is then seized by means of a volsella (Fig. 23), and the uterus is drawn down till the os externum is brought as near as possible to the vulvar aperture. The volsella is then given in charge of the assistant.

Separation of the Cervix from the Vagina and other Structures.—The assistant grasps the volsella with his left hand* and depresses its handles so as to pull the cervix backwards and downwards. The operator then cuts through the vaginal mucous membrane along its anterior reflection on to the cervix by means of the scissors, so that a semi-circular wound is made in the anterior fornix, with its convexity forwards. From this stage onwards the assistant must keep the hæmorrhage constantly in check, by means of the mounted sponges.

A catheter is passed into the bladder. The anterior part of the uterus is then cut away, with scissors, from its cellular connections with the bladder. The blades of the instrument must be kept close to the uterus. The peritoneum should not be opened at this stage, for in attempting to cut through it the operator, as I have witnessed, may push it upwards out of reach, and even partially detach it from the uterus. If the

is very perilous, and appears to be almost discarded. I shall presently describe a case of a kindred form of operation where the cancerous uterus was pregnant.

* The operator will require his left forefinger to explore the structures through which he cuts. It is, therefore, not advisable for him to hold the volsella in his left hand.

mucous membrane be really cut through, the viscera may be wounded.

The speculum is now removed and the cervix completely separated from the vaginal mucous membrane. To do this, the assistant should seize the posterior lip of the os with the volsella, and draw the cervix downwards and well forwards, so as to bring its posterior aspect into view. Then the operator divides the vaginal mucous membrane along its posterior reflection on to the cervix with the scissors; in this manner another semi-circular wound is made, its ends uniting with those of the first, which lie to the front of the cervix. As before, the scissors must be kept close to the cervical tissue.

The cervix being thus detached, Douglas's pouch is now opened up. Care must be taken not to cut too far laterally, lest the broad ligaments be wounded.

At this stage of the operation the uterus will remain connected to surrounding parts by the broad ligaments and the utero-vesical fold of peritoneum. Some operators secure and divide the ligaments first. It is best, except in cases where some peculiarity due to the extent and direction of the morbid growth or any unforeseen contingency renders it advisable, in the opinion of the surgeon, to proceed in an opposite manner, to divide the remaining peritoneal connection first. Otherwise the broad ligament will be less accessible and too tense for the safe application of the ligature.

The utero-vesical fold of peritoneum should, therefore, be divided. In order to do so, the operator slips his left forefinger (and middle finger as well, if there be room) through the hole in Douglas's pouch, over the fundus and front of the body of the uterus, till the point of the finger presses on the reflection of peritoneum from the bladder on to the uterus. The peritoneum is then divided by a scalpel or scissors, the operator holding the instrument in his right hand, and cutting close against the uterus: the finger behind the peritoneum serves as a guide. The catheter should remain in the bladder at this stage of the operation. The above manœuvres are much simplified should the uterus happen to be retroflexed.

The uterus is now entirely free, excepting at its lateral connections with the broad ligaments, which have been rendered

as accessible as possible by the previous dissection. The operator should calmly and deliberately explore them, so as to recognize thoroughly what he is about. He must avoid pushing malignant tissue into the peritoneal cavity.

Securing the Broad Ligaments.—In order to get at the broad ligaments for the purpose of securing them as safely as possible, the fundus is pulled through the posterior part of the wound, with the aid of a strong volsella (Fig. 120)—that which has held the cervix should not be used—or a large pressure-forceps (Fig. 40). This forcible retroflexion of the uterus is especially necessary when that organ is bulky. It is, however, never very easy to effect. The right hand should be pressed on the hypogastrium, whilst the left forefinger is passed through the posterior part of the wound, and hooked over the fundus. When the body of the uterus is pulled down into the wound, the operator must take hold of it with the volsella or forceps held in his right hand.

The broad ligaments must now be secured. When that is effected, all sources of hæmorrhage will be controlled, since the uterine and ovarian arteries will then be included in the forceps or ligature applied to the ligaments (B B, Fig. 12, page 42). This part of the operation is the most dangerous. The removal of the ovaries and tubes entire is desirable, and it is especially important that the tubes—integral parts of the cancer-infected uterus—should come away. When the ovary is left behind, the patient is liable to suffer from distressing pain during the menstrual period. Unfortunately, whilst the transfixion and ligature of the broad ligament on the uterine side of the ovary are comparatively easy and safe, the application of the ligature external to the ovary and tube is very difficult and hazardous. In tying the ligature in ovariectomy, the pedicle, already kept moderately tense and well in sight during transfixion, can be relaxed as the loop is drawn tight. Thus, the operator can see where he has applied the ligature, and, by being able to relax the pedicle, can make sure that it is drawn tight enough. In vaginal extirpation of the uterus, the structures to be transfixed can never be brought so well into view, and it is very difficult to be able to relax the ligament sufficiently as the loop is being tied. In order to understand this, the surgeon

need only remember that the ligament is drawn down close to the vulva, and that, if the appendages are to be amputated entire, the ovarian vessels in the infundibulo-pelvic ligament, naturally high in the pelvis, have to be tied. They must, it is clear, be made very tense, in order to allow of the necessary manipulation.

In one case where I was present, the pedicle was transfixed on each side external to the tube and ovary with comparative ease. The vagina and pelvis were capacious, and the tubes and ovaries could be brought fairly into sight. Just as the operation was being concluded violent hæmorrhage occurred, and the abdominal aorta needed compression. The ligature on the stump of the left pedicle had given way. Sir Spencer Wells' advice was followed, and cyst-forceps were applied to both pedicles. The patient died, but not from hæmorrhage.

I have known the uterus, not in itself very bulky, to block up the vagina to such an extent, that only the left broad ligament could be reached. It was therefore secured, and the uterus was then cut vertically into halves, from the fundus to the cervix, by means of the scissors. The right half hardly bled at all, as its vessels in the unsecured right broad ligament were stretched and twisted. The left half of the uterus was cut away, then the right broad ligament was readily transfixed and ligatured.

I believe that the above manœuvre, originally practised by Dr. A. R. Simpson, is frequently advisable. In any case, when the broad ligament is secured, a straight-bladed large pressure-forceps (Fig. 40) must be made to hold it close to the uterus. A strongly-curved pedicle-needle (Fig. 44), armed with No. 3 or 4 silk, is made to transfix the broad ligament from behind, external to the forceps. The ligature is then secured, as in ovariectomy (Figs. 103, 104). As the ends of the thread are being pulled tight, the assistant must remove the large pressure-forceps. The ends of the other thread are then tied round the opposite side of the broad ligament.

The broad ligament is now cut through between the ligature and the uterus; the ends of the ligature should be left uncut till the vaginal wound has been attended to, later on. The uterus is then drawn to the ligatured side, and the opposite

broad ligament is secured in the same manner. Many operators tie a single ligature round each broad ligament, sinking it into the groove already formed by the transfixing ligatures. Dr. W. Duncan employs a broad flat retractor to facilitate this stage of the operation.

I have been speaking of the ligature and division of the broad ligament on the uterine side of the ovary. When the ovary and the fimbriated extremity of the Fallopian tube are removed, the process will be far more difficult. In some cases the proximal side of the ligament will be so tense that no ligatures can be trusted; then it must be seized with a large pressure-forceps, which is left on for a day or two. The forceps is, however, no sheet-anchor in this operation. It compresses much tissue besides the vessels which it is designed to secure, and may set up sloughing; it may also tear away by its own weight if improperly supported. It takes up much room in the vagina, and I have known it to cause very severe pain. It does not always succeed in stopping hæmorrhage. In one operation, where I was assistant, I noticed that it crushed the structures of the broad ligament and made them bleed; but, fortunately, in this case the forceps had been applied on the distal side of the ligature.

Removal of the Uterus.—Both broad ligaments having been divided, the uterus now comes away. The cut surfaces of the pedicles should be inspected, and any bleeding points must be secured by ligature, or, if more convenient, by pressure-forceps, which must be left on for six or eight hours.

The Treatment of the Vaginal Wound: The Question of Drainage.—The vaginal wound, after the removal of the uterus, appears smaller than the inexperienced operator might perhaps expect. Through it omentum, or the remains of the appendages, are apt to prolapse. Some operators simply leave the flaps of the vaginal wound free after pushing up any prolapsed structure, using no sutures, and trusting to the packing of the vagina to prevent further prolapse. When the operator prefers to close the wound, a curved needle, armed with No. 3 silk, is passed, by the aid of a needle-holder, through the anterior fornix, close to the edge of the wound, and near its outer extremity. It is then made to transfix one pedicle, and to

emerge close to the opposite edge of the wound through the tissues of the posterior fornix.* The suture is then tied, and the other pedicle is treated in the same manner. The inclusion of the pedicles is never easy, and may be impossible.

The propriety of drainage is much disputed. Some surgeons sew up the wound* after pushing the stumps of the appendages, with the ligatures cut short, into the abdominal cavity; drainage is probably advisable in most cases. The simplest form is a long Keith's drainage-tube (Fig. 55); this is passed about half an inch beyond the vaginal wound. The vagina is then packed with iodoform-wool, put in piece by piece, with the aid of a speculum-forceps (Fig. 15). It is advisable to blow iodoform powder over each pledget, by the aid of an insufflator (Fig. 63). Dr. W. A. Duncan has devised a T-shaped drainage-tube, so arranged as to allow of washing-out the parts very effectually (see "On Extirpation of the Entire Uterus," *Transactions of the Obstetrical Society*, vol. xxvii., 1885, page 11).

The question is not settled. Five years ago, when making a necropsy on a patient who died on the second day after this operation, where no tube had been inserted, I found a pool of brick-dust coloured fluid in the hollow in front of the sacrum. It is difficult to understand how that part, perfectly dependent as the patient lay on her back, could have been readily drained. The peritoneal relations are greatly altered, and it is not easy for the operator to know where to place the end of the tube to ensure escape of serum. When he employs the tube, the point should simply lie a little within the vaginal wound.

Dressing of the Case and Management after Operation.—A thick pad of iodoform-wool is laid over the vulva after the vagina has been dressed; and a sponge is placed over the mouth of the drainage-tube, if that appliance has been employed. The iodoform-wool plugs must be frequently inspected and changed. When the drainage-tube is used the pelvic cavity must be washed out, should the temperature rise high or the discharge from the tube become foetid. The sutures in the vaginal wound must be removed at the end of a fortnight, a Sims' speculum being passed along the posterior wall of the vagina after the

* Dr. Staude, of Hamburgh, uses a continuous catgut suture.

patient has been placed on her back, so as to bring the wound well into view.

Amputation of the Cervix.—This operation is performed either for malignant disease, or for the cure of the troublesome results which may follow hypertrophic elongation of the cervix. The question of operation in malignant disease has been discussed in relation to the total extirpation of the uterus. Amputation as performed for malignant disease will first be described. In cases of hypertrophic elongation, the same kind of amputation is often adopted, but some authorities add certain plastic proceedings.

Amputation of the cervix may be performed after several distinct methods. I shall describe amputation by the galvano-cautery and by the *écraseur*; supra-vaginal amputation, or complete removal of the cervix by the knife; amputation by the knife with application of caustics; and amputation of the vaginal portion of the cervix by the knife and scissors. The first three are more frequently performed in this country than the remainder.

Amputation of the Cervix Uteri by the Galvano-Cautery.*—The patient having been brought under the influence of an anæsthetic is placed in the lithotomy position. The knees are held apart by assistants or a Clover's crutch (page 132). A Sims' speculum is introduced into the vagina, and the cancerous cervix is secured by the volsella. This may be drawn down very gently, as the cancerous tissues are readily torn. The volsella should be made to seize, as far as possible, healthy tissue above the diseased portion of the cervix, care being taken to avoid Douglas's pouch behind and the bladder in front.

The loop of platinum wire (Fig. 70, page 152) is passed over the handles of the volsella, and adjusted above its prongs while the wire is cold. The wire is then drawn tight enough to touch evenly all round the part of the cervix to be removed. Care is again taken to avoid, if possible, Douglas's pouch, and a firm stout catheter is passed into the bladder and pushed up so as to raise it out of danger. If the shape of the cervix be

* This description of the operation is written by Dr. Steavenson. See Introduction to Chapter V.

such that the wire easily slips down on to the volsella, it can be kept in its place by an ivory pin passed through the tissues, just below the part through which it is desired that the wire should burn its way.

When the operator is perfectly satisfied that the wire is in the right position the circuit is closed, and he orders his assistant to increase gradually the strength of the current until a slight hissing sound proclaims that the wire is hot, and has commenced burning its way through the mucous membrane. This must be done slowly, and the wire should, if possible, be kept at a dull red heat. It is seldom that the operator or his assistant can see the colour of the wire; they will therefore have to be guided to a great extent by the slight amount of smoke and hissing noise produced. The operator can also feel, by keeping slight traction on the wire, whether it is passing too easily and quickly through the tissues. The traction maintained should be just sufficient to keep the wire tight against the unsevered part of the cervix, and not enough to make the wire itself cut through. The wire ought to progress simply by its cauterizing action. If the traction be so great as to make the wire cut its way through as with an ordinary *écraseur*, or if the wire be raised to a white heat—in which case it cuts as freely and quickly as a knife—hæmorrhage will follow, and one of the great advantages of the galvanic *écraseur* will be lost. If the wire be used, as it ought to be, at a dull red heat, the ends of the severed vessels are closed by its cauterizing action as it proceeds through the tissues, and the ends of the nerve are also destroyed as in a burn of the third degree, so that the after-pain is less than when the knife or ordinary *écraseur* is employed. Should the wire slip during the progress of the operation the circuit must be broken, and in a few seconds the wire will have cooled down sufficiently for the operator to readjust it with his fingers. If the wire proceed in the desired direction, no interruptions are necessary for the purpose of injecting ice-cold water to cool the parts, as directed by some writers. The wire is speedily cooled, if necessary, by breaking the circuit, and the vagina and vulva can be well protected by ivory retractors. Care should be taken that the conducting metal rods of the *écraseur* do not come in contact with the metal speculum or

blades of the volsella, as the current might thereby be short circuited. It is often an advantage from time to time to arrest the current, so that the operator may ascertain with his finger whether the wire is burning its way through in the direction he wishes.

When the part to be removed is quite severed the loop will have disappeared, and the short remaining portion of the wire is found quite tightly approximated to the small piece of porcelain which keeps apart the ends of the conducting rods.

The serious consequences which may follow the opening of Douglas's pouch are not so great when the galvanic *écraseur* is used as with other modes of performing the operation. In the account of the operation given by Dr. Karl Pawlik in the *Wiener Klinik, Jahrgang viii., Heft xii., 1882*, many operations are mentioned in which Douglas's pouch was opened without any serious consequences. It was found that, in most cases, the hot wire glued together the severed surfaces of the peritoneum, and no ill result followed. This advantage of the galvanic over all other methods of removal of the cervix uteri must be borne in mind when deciding what means to adopt. It is not difficult to determine, by examination of the eschar on the stump, whether any cancerous material is left, as such material will appear as a raised whitish-coloured tissue on what ought to be an even browner-coloured burnt surface marked by crescentic lines, showing the progress of the wire. Should any diseased tissue be left it may be removed by readjusting the galvanic *écraseur* and again proceeding as already described; or a Volkmann's spoon may be used to scrape out all the cancerous substance, and the cavity thereby made cauterized by a galvano-cautery porcelain point (page 151). Atresia of the os is said to follow the removal of the cervix uteri by galvano-cautery, but this drawback to the operation does not occur nearly so frequently as is supposed, and when it does take place it is easily remedied, either by dilating the os by graduated bougies or by the use of electrolysis in the same way as it is employed for strictures in other parts; the passage will then be speedily restored to its normal calibre.

The eschar left after removal of the cervix uteri by galvano-cautery separates in from eight to fourteen days. Antiseptic

solutions may be injected daily into the vagina before and after the separation of the eschar, except when the peritoneum has been opened, when it is advisable not to use any injection until the eschar has come away, by which time the wound in the peritoneum will have become healed. Should any hæmorrhage take place, either at the time of the operation or subsequently, it can be best arrested by the application of the galvano-cautery porcelain point, or by the Paquelin's cautery. The objections to the latter method are that its action cannot be so easily limited as with the galvano-cautery point, and more tissue is destroyed than is necessary. It is liable to injure the vulva or vagina at its introduction or removal, and the suffering is greater if used without an anæsthetic.

Whatever may be the relative results of this operation, of total extirpation of the uterus, and of supra-vaginal amputation of the cervix in the practice of experts, amputation by the galvano-cautery is probably the favourite and certainly the more advisable proceeding for general surgeons, and for those who have not operated extensively on the female organs. It is very probable that it may entirely replace the other two operations, which, though described in this manual because largely practised, are considered by many authorities as somewhat desperate undertakings (see page 317).

Amputation by the Écraseur.—There are often certain difficulties in the way of the galvano-cautery; the battery is not very portable, and it may happen that when the surgeon is ready to operate, the cautery cannot be made to act, owing to some mismanagement on the part of assistants. Hence, the écraseur is preferred by some operators. It is by no means so safe as the cautery. The wire is apt to drag down the posterior fornix, and to tear through Douglas's pouch, and then the results are certainly more serious than when the same parts are accidentally damaged by the cautery wire.

The écraseur is, on the other hand, very portable, and when the surgeon happens to be accustomed to operate on the cervix and on parts in its neighbourhood, or has used that instrument frequently on other parts, he may feel justified in preferring it to the galvano-cautery. The straight écraseur, as used in amputating the tongue, is dangerous, as the cervix must be drawn

very low down before the chain can be applied. This entails the risk of tearing diseased parts of the cervix, and of disturbing any products of inflammation which may happen to lie near the cervix above the vagina. Hence, it is best to employ a curved écraseur (Fig. 124).

The patient should be placed in the lithotomy position, with the knees secured by a crutch (page 132). Experienced operators with experienced assistants often prefer the semi-prone posture. The parts are cleaned by free application of tepid water, thrown up by means of a Higginson's syringe, and subsequent sponging, small sponges mounted on holders being necessary. The point of the instrument is then passed into the posterior fornix, and the chain is slipped round the cervix above the level of the cancerous growth and made fast in the usual manner. The reflection of the vaginal mucous membrane on to the cervix must be avoided. The chain is then made firmer at intervals of half a minute, until the parts are cut through. The handle must only be worked once at each

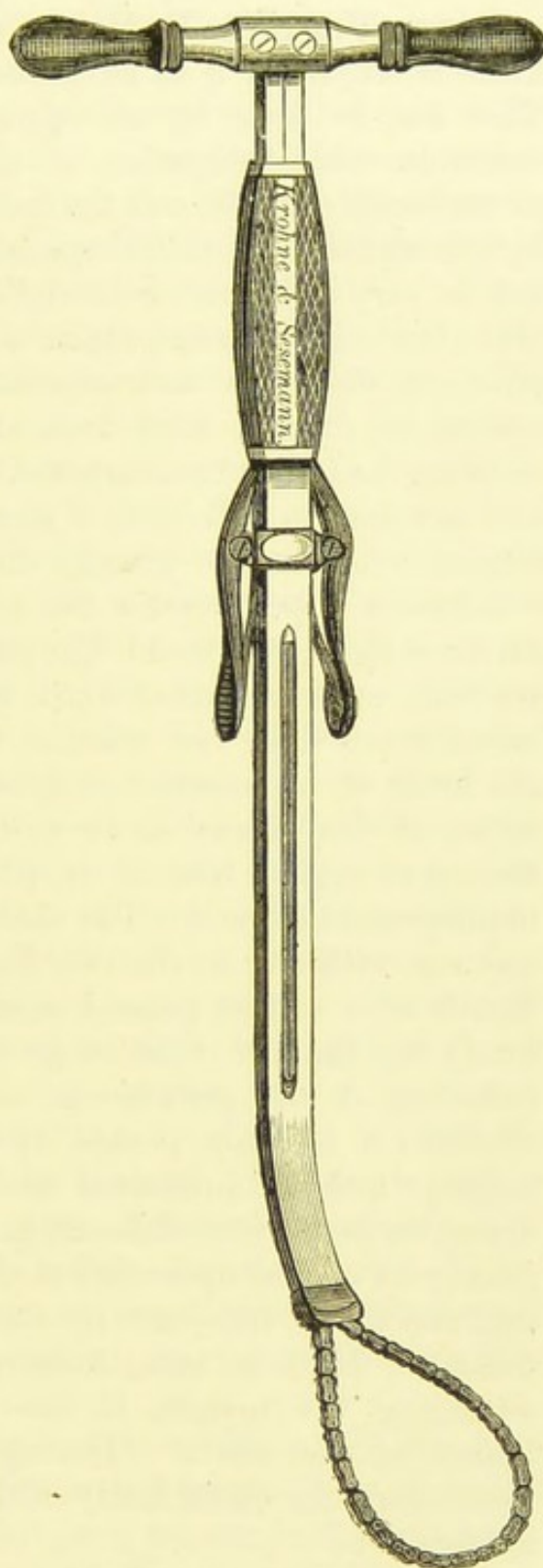


FIG. 124.—CURVED ÉCRASEUR.

interval. The after-treatment will be the same as when the galvano-cautery is employed.

Supra-Vaginal Excision of the Cervix.—When the knife is employed it is advisable to remove the entire cervix. This can be done by an operation which in many respects resembles total extirpation of the uterus. The operation is of necessity difficult, and the inexperienced must not be misled by the statistics of skilled specialists, which, in these cases, are not so very brilliant. Schröder's mortality was but 12·37 per cent., but others cannot claim so low a percentage. Demonstrations, diagrams, and experiments on dead subjects make operations of this kind look almost easy, but the rules for avoiding ureters, uterine arteries, and other important structures are less easy to follow on a live patient, especially when anatomical relations are greatly disturbed by morbid conditions.

Schröder's operation for the supra-vaginal amputation of the cervix is thus performed: The patient being placed in lithotomy position, and the knees fixed by the crutch (page 132), the cervix is seized by two volsellæ, the fundus being depressed by the hand of an assistant, applied to the hypogastrium. The cervix is then drawn down to the vulva, and the anterior reflection of vaginal mucous membrane is divided by a scalpel or blunt-pointed scissors. The bladder is separated from its connections with the cervix (see Fig. 10) by the finger, or by the handle of a scalpel pressed against the cervix, which is held firmly by the two volsellæ in the operator's left hand. The reflection of the peritoneum on to the bladder must not be divided; it is easily pushed upwards. Should the tissues be healthy, and not infiltrated with inflammatory products, this dissection is not very difficult, and the bladder and ureters will readily be pushed upwards out of harm's way. Unfortunately, infiltration is not rare in the neighbourhood of cancerous disease. In any case, however, there is little danger of damaging the ureters, if the surgeon dissect close to the tissues of the cervix. During this dissection the assistant must clean the parts freely with small sponges mounted on holders.

The cervix is next pulled towards the pubes by means of the volsellæ. The surgeon cuts through the posterior reflection of

vaginal mucous membrane, bringing the knife or scissors round to both extremities of the anterior incision, so as to free the cervix from the vagina entirely. Douglas's pouch is sometimes laid open.

The surgeon must now separate the supra-vaginal part of the cervix from its lateral connections. This part of the operation is difficult and dangerous, and since the body of the uterus is not to be removed, the broad ligaments cannot be secured as in the operation for total extirpation (see page 321). Small pressure-forceps should be at hand, and may be applied to the dense connective tissue which surrounds the cervix. The scissors are then applied to the uterine side of the forceps till the connective tissue is entirely cut away from the cervix. Then silk ligatures must be passed round the tissue grasped by each of the forceps. Experienced operators secure and tie the vessels as they are divided, but the tissues retract, so that this process is very difficult. The uterine artery itself does not touch the uterus till it rises above the level of the uppermost part of the cervix (see Fig. 12, page 42), but the secondary branches of the artery of the cervix (see page 41) are abundant, and enter the surface of the supra-vaginal part of the cervix almost at right angles, so that they must be divided. The ureters have already been pushed upwards with the bladder.

The process of amputation must now be commenced. This must be performed after Schröder's ingenious and simple plan for avoiding inconvenient retraction of the divided parts.* A scalpel is made to cut through the anterior part of the cervix only, the incision being carried obliquely upwards towards the cervical canal, and at a sufficiently high level in the supra-vaginal portion, well above the malignant growth. The cervical canal must be exposed; then the cut surface of the cervix is united by silk sutures to the anterior vaginal wall. This is done by means of a strongly curved needle, grasped by a holder.

When the stump of the anterior part of the cervix has been thus secured, the posterior portion is amputated in a similar manner, the knife being carried from the cervical canal some-

* It has been adopted by Dr. John Williams and other British authorities who have had considerable experience in this operation.

what downwards to the surface of the cervix. In this way, a wedge-shaped incision will have been made, with the apex on the stump pointing upwards. The stump of the posterior part of the cervix is sewn to the posterior vaginal wall.

The lateral parts of the vaginal walls must, lastly, be united by silk sutures passed deeply through the superjacent structures. This practice controls hæmorrhage, as experience has shown.

The vagina must be carefully syringed out night and morning for a week or ten days after operation; at the end of that term the sutures are removed. For this purpose, the patient should be placed in the semi-prone position.

Amputation and Caustics.—In any operation where the cervix is amputated, the surface of the stump should be examined, especially where the cervical canal is exposed, and any suspicious tissue should be destroyed by the cautery or solid chloride of zinc.

Sims and Schröder have advocated the systematic combination of excision with caustics. The cancerous mass is first broken down till its base is reached. The surgeon should never do this with his forefinger. I know of a case where an operator, a most accomplished obstetrician, was laid up for several weeks with severe inflammation of the hand in consequence of using his finger in this manner. A pair of scissors, curved on the flat, will remove the mass. The instrument must, of course, be used cautiously. The uterine tissues above the base of the tumour are then cut out by incisions, with the scissors directed upwards and towards the cervical canal or uterine cavity. The depth of these incisions will depend upon the extent of suspicious tissue discovered in the individual case. When a clean funnel-shaped cavity has thus been cut out of the cervix and lower part of the uterus, it is dried with sponges and plugged with cotton-wool carefully soaked and squeezed after immersion in a 1 in 40 solution of carbolic acid containing 1 in 12 parts of powdered alum. The vagina is plugged, above in the same manner, below with wool soaked in the carbolic solution without alum.

At the end of five days the plug is removed, and the cavity is packed with wool soaked in chloride of zinc solution (five drachms to the ounce of distilled water). The vagina is

plugged above with wadding soaked in a solution of bicarbonate of soda. The caustic plug is removed from the cavity five days later. The cavity will be lined by a slough, which often comes away entire on traction. The subjacent tissues will gradually heal by granulations.

This operation is objectionable in several respects. The inexperienced will find it difficult to cut upwards in the dark through the uterine tissue. A strong mineral caustic, when applied in this manner to uterine tissue above the cervix, produces frightful agony, which the free administration of opiates can but imperfectly palliate; it may also bring away too much of the uterine tissue and damage adjacent parts. This occurred, at least once, in the practice of Dr. Marion Sims himself.* In this case the greater part of the interior of the uterus, including about half the thickness of its muscular portion, came away. The patient lived for a few months.

Amputation of the Vaginal Portion of the Cervix by the Knife and Scissors.—This operation is advocated by Schröder and Marckwald. It is only advisable, in cases of cancer, when but a small extent of the lower part of the vaginal portion of the cervix is involved in malignant disease. The operation will be described in connection with the subject of amputation of the cervix for hypertrophy.

Electrolysis in Cancer of the Cervix.—When an operation for cancer of the cervix is not deemed advisable, or will not be submitted to, great benefit and relief of pain, with prolongation of life, can be obtained by destruction of the cancerous growth by electrolysis. For this purpose an electrode



FIG. 125.—ZINC ELECTRODE FOR THE DECOMPOSITION OF CANCEROUS TISSUE.

(Fig. 125), composed of a broad piece of zinc, is connected with the positive pole of a constant current battery; the negative electrode, in the form of a metal and amadou pad, being placed

* See specimen 4,600, *Museum R. C. S., Pathological Series*. The case was a patient of that distinguished specialist, who presented the specimen to the donor, Sir Spencer Wells.

on some indifferent part of the body. When the circuit is closed, decomposition of the diseased tissue takes place by a formation of chloride of zinc around the positive electrode. This has an advantage over destruction of tissue by ordinary chloride of zinc or the actual cautery, inasmuch as the action can be localized and arrested at pleasure, and the amount of the destruction to be wished for is entirely under the control of the operator, the pain ceasing immediately the current is cut off.

The partial destruction of a cancerous surface on the cervix, by electricity or caustics, will not fail to give great relief to the patient, provided that the sloughy and ulcerating part of the disease is thoroughly destroyed.

Primary Hypertrophy, or Elongation of the Cervix.

—This remarkable condition consists of an extreme elongation of the cervix, which becomes so long as to reach the vulva or even to protrude beyond the labia. In other respects the cervix remains healthy, and the uterus is not displaced. Thus the fornices of the vagina are found, on digital exploration, to exist uneffaced and to lie at their usual high level. The fundus uteri also occupies its natural position, and on passing the sound no displacement can be detected, though it will pass four, five, or more inches up the cervical and uterine cavity before it reaches the fundus. This gain in length will be entirely due to increase in the length of the canal of the elongated vaginal part of the cervix; on rectal examination (see page 69), the supra-vaginal portion and the body of uterus will be found to occupy their normal position.

This condition must be distinguished from certain other affections. It differs entirely from hypertrophy, or apparent hypertrophy of the cervix, due to inflammation or œdema. It is quite a different condition from laceration of the cervix with hypertrophy and true or supposed ectropion. Lastly, it must never be confounded with the secondary elongation, or hypertrophy of the cervix, which occurs in prolapsus uteri. In this last affection, the relations of the vaginal fornices and the body of the uterus will be markedly abnormal.

Hypertrophy of the cervix is probably congenital. I have seen this condition in women who have consulted me for

other maladies, and it appeared to cause no pain or discomfort. On the other hand, it may give rise to troublesome symptoms. The protruding cervix sometimes becomes excoriated or even ulcerated, there may be much bearing-down pain, and locomotion may even be impeded. In married life hypertrophy of the cervix is an obvious source of inconvenience.

Treatment.—The surgeon should not attempt to interfere with this condition until he has not only duly considered the circumstances of the case, but also studied the experience of authorities, which may be found recorded in systematic text-books. Most of these authorities admit that amputation is allowable and advisable in cases of primary hypertrophy when it is a cause of sterility or of great inconvenience. Amputation may then be performed either by the *écraseur*, the galvano-cautery, or by special plastic proceedings where the knife, scissors, and needle are employed.

Amputation by Écraseur.—This operation has been already described (page 328). It is of questionable merit in cases of hypertrophy, as non-cancerous tissues are removed, and it is important that the structures left behind should be not only healthy from the first but should, in healing, assume a condition closely resembling that of a naturally formed cervix. After a crushing operation, this is impossible.

Amputation by Galvano-Cautery (see page 325).—Thomas, Byrne of Brooklyn, and others, speak highly of this method, and Thorburn considers that it should be adopted by the general practitioner. It is preferable, in every respect, to the *écraseur*, but can hardly restore the parts to a natural condition fit to discharge active functions.

Amputation combined with Plastic Operations.—Schröder* considers that there is scarcely any organ more fitted for plastic operations than the cervix. He has entirely rejected the *écraseur* and galvano-cautery in favour of the practice of cutting out a portion of the cervix with a lance-shaped knife and using sutures. In hypertrophy of the cervix an operation of this kind is probably the best which can be

* *Zur Technik der plastischen Operationen am Cervix Uteri. Charité Annalen V. Jahrgang.*

adopted. Such a proceeding, however, demands dexterity and experience. The manipulations are, for the most part, difficult, and the risk of hæmorrhage considerable. With the advantage of some experience in plastic and uterine surgery, however, a surgeon may be justified in operating in this manner in a suitable case of elongation of the cervix.

Varieties of Amputation of the Cervix by the Knife.—I shall not describe the simple circular amputation of the cervix, with cauterization of the raw surface of the stump. This proceeding entails risks of hæmorrhage during the operation, and the certainty of a subsequent formation of dense cicatricial tissue, with constant tendency to atresia of the cervical canal. The knife should be used as a preliminary to plastic measures, else the galvano-cautery is preferable. The plastic measures in question may be divided into three varieties.

1.—*Sims' Amputation.*—The patient is placed in the semi-prone position, and the blade of a Sims' speculum is passed along the posterior vaginal wall. After the vagina has been well washed out with an antiseptic solution, the cervix is drawn a little downwards by a volsella; a stout india-rubber ring is slipped over the cervix till it rests close to the vaginal fornices. The cervix is then split by a scalpel on each side, beginning at one extremity of the os and carrying the incision upwards to about an inch from the vault of the vagina. The incision must not be carried too high, as the relations of the parts are often altered in these cases of elongation of the cervix, and it would be dangerous to cut into the vascular surroundings of the supra-vaginal part of the cervix. An anterior and posterior flap are thus formed; these are cut through horizontally at their upper limits. An oval raw surface will be left, with the cervical canal in the centre, and the cut edge of the mucous membrane at the circumference. "This operation is often a bloody one," says Dr. Galliard Thomas. Though the cautery or styptics may check the hæmorrhage, they will interfere with the union of the wound. It is, therefore, better to seize any bleeding points with light pressure-forceps such as Péan's (see page 95), and to leave the instruments on for a few minutes, or the vessels may be twisted.

The second part of the operation consists of plastic proceedings. About four silver-wire sutures are passed through the vaginal mucous membrane, so as to stitch it over the raw surface. This is the principle of Sims' amputation.

The edge of the mucous membrane is seized with tenaculum-forceps, anteriorly, near one extremity of the cervix, and a silver wire is passed through it, about one-eighth of an inch from the free border, by means of a short, stout, curved needle mounted on a holder. The wire is drawn across the raw surface of the cervix, not penetrating the tissues, and through the mucous membrane posteriorly. One or two more sutures are passed through the edges of the mucous membrane, anteriorly and posteriorly, crossing the stump, on the same side of the canal of the cervix. The suturing process is repeated on the other side, the last suture being inserted near the opposite extremity to that near to which the first was passed.

The anterior and posterior ends of each of the sutures are twisted so that the mucous membrane is brought over the raw surface of the stump, excepting near the cervix. Here the surface will heal by granulation. The india-rubber ring is, lastly, cut slowly through. Great care must be taken to pass a sound frequently for many months after the operation, lest atresia should occur. The patient must remain in bed for a week at least; at the end of ten days the sutures should be removed. The vagina, in the meantime, is kept clean by means of antiseptic injections, morning and evening.

Hegar's Amputation.—In this operation a circular amputation is performed, as in the preceding. The mucous membrane of the outer side of the cervix is then united to that lining the cervical canal, both being brought over the raw surface of the stump. About eight sutures will be required; they must radiate from the canal of the cervix, and pass not over, but through the cervical tissues.

Marckwald's and Simpson's Amputations.—Simon, Marckwald, and Schröder have practised and advocated a very ingenious method of removing part of the cervix by a flap amputation, with wedge-shaped excision of the lips separately, and union of the mucous membranes, as in Hegar's amputation, over each

lip which remains. Dr. A. R. Simpson has modified the method. This amputation should not, however, be attempted by any who have not enjoyed the advantage of long experience, personal and indirect, in operations on the cervix. A good description of Dr. Simpson's modification will be found in Drs. Hart and Barbour's *Manual of Gynecology*, third edition, page 271.

Finally, the inexperienced should not think of amputating a cervix that has undergone hypertrophy in association with prolapsus uteri. Few, if any, specialists now recommend amputation of a cervix subject to the chronic changes which may follow laceration.

Atresia of the Cervix.—This affection, when sufficient to cause retention of menses in the uterine cavity, is always serious. Even when the cervix is forced open by the sound in the course of an examination for an undiagnosed uterine swelling, and treacly blood begins to flow away, the surgeon should at once take great precautions. He must on no account press upon the fundus to hasten the escape of the retained fluid, nor must he throw up injections of any kind. The patient must be put to bed as soon as possible, and treated precisely as though a congenitally closed hymen or vaginal septum had been laid open. The treatment of such cases, and the dangers which surround them during and after operation, will be presently described.

Breisky's Operation.—The successful treatment of more severe forms of atresia of the cervix requires long experience in uterine diseases. There is always much difficulty and danger in dissecting a new cervical canal, and the parts above it may be malformed. Breisky has operated in seven cases of retention of menses from atresia of the cervix with deficiency of the vagina. He dissects between the bladder and rectum, in the manner which will be described in the account of the operation for deficiency of the vagina, and opens the cervix by means of a special sharp-edged trocar and cannula. He then keeps the trocar-wound dilated, as the retained fluid escapes through the cannula by the aid of special long-handled forceps, with long smooth blades which are slipped along each side of the cannula. The latter is withdrawn when the fluid has ceased to flow, and the nozzle of a tube is then inserted into the cervix between the

blades of the forceps. A tube is fitted to the nozzle, and the uterine cavity is syringed out; the tube is constructed with two channels, so as to conduct away the return-current.

This operation, as may be judged from the above brief description, is exceedingly difficult from beginning to end. Breisky lays great stress on the importance of washing out the retained menses. This proceeding, as will be explained in the chapter on Atresia of the Vulva and Vagina, is contrary to newer principles which have at least met with success in the treatment of so-called imperforate hymen. He admits that the tendency of the parts to contract is, as might be expected, very great. A full account of his operation will be found in his *Krankheiten der Vagina*, edition of 1886, in Billroth and Luecke's *Deutsche Chirurgie* series.

Operations for Laceration of the Cervix Uteri.—The treatment of lacerations of the cervix by a plastic operation has been strongly advocated by Emmet, Pallen, Thomas, Breisky, and several other American and Continental authorities, and recommended to a less extent by Dr. Playfair. The most important argument in favour of operation is the theory that a laceration may become the seat of epithelioma. That this may happen there can be no doubt, but the careful scrutiny of some painstaking pathologist is yet needed, to trace the relation of cause, effect, and coincidence in any conditions of the cervix found in association with malignant disease. Chronic discharges, subinvolution, displacements, and, lastly, all kinds of general symptoms, have been attributed to the effects of laceration of the cervix.

In common fairness, Dr. Emmet's arguments in his *Principles and Practice of Gynecology* should be studied, and when the surgeon is induced to operate, he must remember all that distinguished American's directions as to denuding the angles of the flaps thoroughly, clearing away cicatricial tissue, and avoiding injury to the pelvic connective tissue near the cervix. The intending operator should also read Dr. Playfair's "Notes on Trachélo-raphé, or Emmet's Operation," in the *Transactions of the Obstetrical Society of London*, vol. xxiv., where the operation is temperately advocated. Particular attention must be paid to Dr. Matthews Duncan's remarks in the discussion which

followed the reading of this memoir (*ibid.*, page 71): He "had seen the most exaggerated laceration of the cervix interfere in no degree with health, comfort, and fertility." Dr. Duncan also noted that the so-called ectropion may in many cases be purely artificial, and simply due to the pressure of some part of a speculum.

Nevertheless, the surgeon may meet with cases where, after careful watching, he may feel justified in attributing severe local symptoms to a laceration of the cervix. In no case must he operate should any of the physical signs of cellulitis (parametritis) be present. The laceration should always be explored with the assistance of the volsella (page 76), as well as by means of the finger and speculum.

The Operation of Trachelorrhaphy*: *Preparatory Treatment.*—Before this operation is performed, the surgeon must first make sure that any local complication, such as pelvic cellulitis, is cured. For about a week, hot-water injections should be thrown up night and morning. It is especially important to remedy any uterine displacement. The uterus must be replaced and kept in position by means of a properly adjusted Hodge's pessary. After each injection a cotton-wool plug, with a piece of string attached to it, dipped in glycerine, or in glycerine of tannic acid, should be pressed against the cervix, and removed before the application of the next injection.

When there is marked ectropion of the surface of the laceration, with cystic degeneration of the mucous follicles, the affected surface should be scarified frequently, and painted with glycerine and iodine till the size of the flaps is much reduced. After each scarification, a pledget of wool dipped in glycerine may be packed against the cervix, so as to press the lacerated flaps together. After a week or two of the above treatment the patient will be ready for operation, provided that no tenderness or hardness can be felt through the vaginal walls on either side of the cervix.

Position during Operation.—Emmet prefers to place the patient in the semi-prone position (see page 57), but he admits that the operation can sometimes be performed with

* In this description I have chiefly followed the directions given in Dr. Emmet's *Principles and Practice of Gynecology*, third edition, 1885.

the patient on her back, when the vaginal outlet is large, since the uterus is then so low that it can be readily drawn outside, and returned after the operation. Most English operators prefer the lithotomy position. Formerly, Dr. Emmet used to constrict the cervix above the laceration by means of a uterine tourniquet, which resembled a chain *écraseur*, excepting that the chain was replaced by a loop of watch-spring. This he now employs solely in extreme cases where the tissues of the cervix are very soft and liable to bleed. In ordinary cases, an injection of water heated to about 110° , thrown up just before the operation, will be sufficient to prevent severe hæmorrhage. Hart and Barbour recommend a stout india-rubber umbrella-ring to be slipped on to the upper part of the cervix over a volsella. At the end of the operation it is notched with scissors, so as to be gradually slackened before it is cut through.

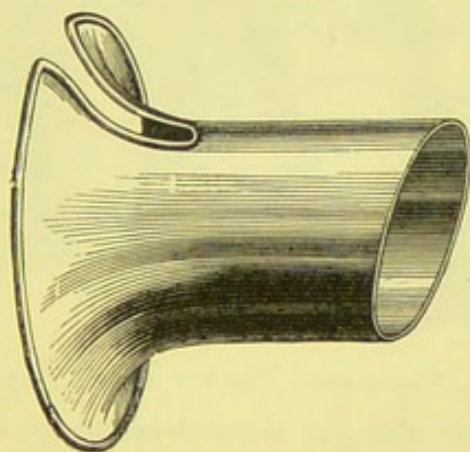


FIG. 126.—SHORT SPECULUM FOR TRACHELORRHAPHY. (*Percy Boulton.*)

The Speculum in Trachelorrhaphy.—When the cervix can readily be drawn down, this operation is not very difficult; when it can not, neither the dissecting up of raw surface nor the introduction of sutures can be easily effected. Dr. Boulton has devised a special short speculum (Fig. 126), made of metal, which he has found to be very convenient for the first stage of the operation, when the raw surfaces are formed. It dispenses with a multiplicity of assistants, it steadies the uterus and prevents excessive dragging on the uterine ligaments, and can be kept in place by the pressure of one assistant's thumb against its edge. When the sutures are being inserted, this instrument

should be removed, and a blade of Sims' speculum is slipped along the posterior vaginal wall. Dr. Emmet recommends great caution in handling the cervix during operation, especially when any manipulation involves dragging-down of the uterus. As a certain amount of cellulitis exists in many cases, traction may disturb inflamed tissue and cause a possibly fatal, and certainly mischievous, extension of the morbid process.

Trachelorrhaphy for Bilateral Laceration: Denudation of the Flaps.—A tenaculum with a short curve, and as stout as possible, is fixed on to one flap, and another on to its fellow. The pair are then approximated. The operator can

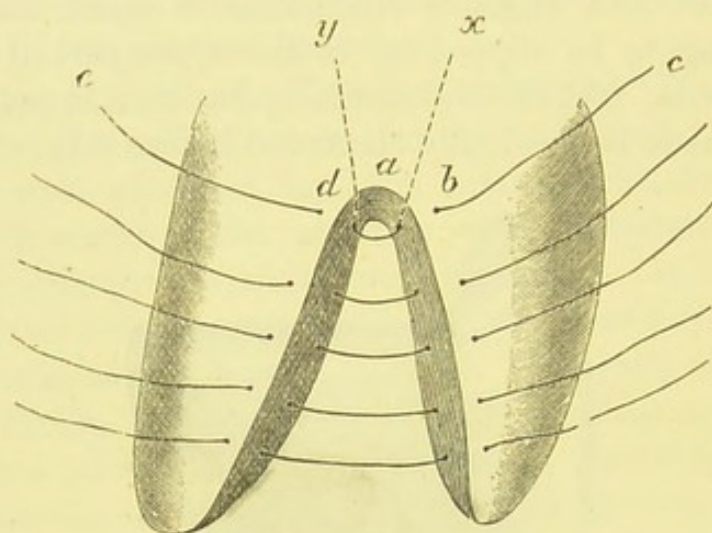


FIG. 127.—LACERATED CERVIX AFTER DENUDATION,

As seen from one side after the introduction of the sutures for the closure of the denuded surface which lies on that side. The flaps are somewhat approximated.

then judge if the flaps will lie in correct apposition after simple denuding of their surfaces. If this be the case, then, it being supposed that the laceration is bilateral, the flaps are opened out and the lacerated surfaces well exposed. The surgeon, fixing one flap with the tenaculum which he holds in his left hand, then cuts away a strip of mucous membrane, with a little of the subjacent tissue. The simplest and safest method, perhaps, of dissecting up the flaps (as practised by Dr. Percy Boulton) is to thrust the point of a small long-handled scalpel carefully into the outer aspect of the apex of the angle between the flaps (Fig. 127, *a*), so as to raise the mucous membrane.

By turning the blade towards the flap to be first denuded, a strip of the desired breadth is raised; the remainder may be cut away with scissors, and the corresponding side of the opposite flap is then denuded. In whatever manner this process is carried out, two precautions are to be taken whenever any cutting instrument is used near the angle between the flaps. Firstly, the tissues must be thoroughly vivified, else union of the deepest part of the surfaces to be drawn into apposition will not take place. Secondly, care must be taken not to cut deeply at the outer extremity of the angle, which lies close to

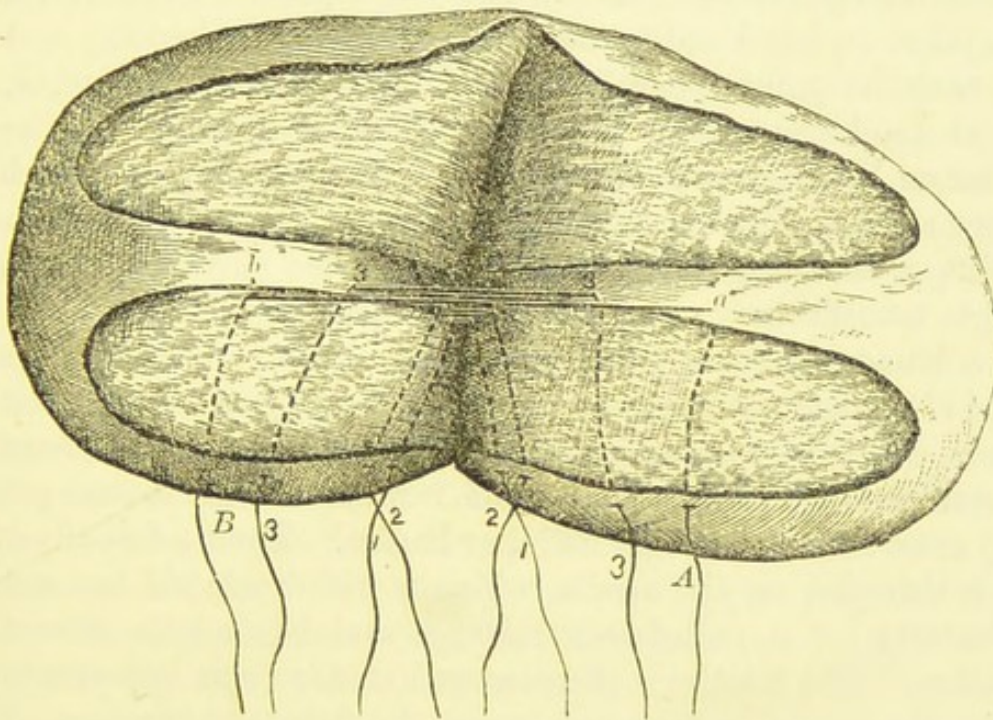


FIG. 128.—LACERATED CERVIX AFTER DENUDATION,

As seen from below after the introduction of the sutures for the closure of one of the denuded surfaces. The figures indicate the end of the higher sutures. 1 1 corresponds to *e d*, *b c*, in the preceding figure. The lowest thread is marked *A a*, *B b*. (*Emmet.*) The flaps are widely parted.

the reflection of the vaginal mucous membrane, else the circular artery (see Fig. 12, and page 41) may be wounded.

The process of denudation is now repeated on the other side of the flaps. A broad tract is left undenuded between these vivified strips (Fig. 128). This tract will form the cervical canal and the external os when the operation is completed. It must be left widest towards the outer extremities of the flaps,

but after healing, the new canal, at first trumpet-shaped, will become uniform in diameter. The surfaces are now cleaned by mounted sponges pressed against them till hæmorrhage has ceased.

Application of the Sutures.—The flaps are next approximated by the tenacula, so that the operator can make sure that they will then lie easily in apposition. If this be the case, so that no further trimming is required, the sutures are now applied. This is a difficult process, owing to the position of the flaps and the extreme toughness of the uterine tissue. A Sims' speculum is passed along the posterior wall of the vagina. The surgeon then takes in his hand a needle mounted on a handle, and eyed near the point, where it is very slightly curved, or, rather, bent at an obtuse angle. This needle will be described in the chapter on Vesico-vaginal Fistula. For trachelorrhaphy it must be very stout, as the uterine tissue is tough. Any clumsiness in handling a needle as it is forced through the parts which it is made to transfix may cause it to snap. The flap being steadied with a tenaculum, the point of the needle is entered (at *b* in Fig. 127) about one-eighth of an inch external to the raw surface, close to the outer aspect of the angle between the flaps (*a*), and pushed inwards under the raw surface till it emerges (at *x*) close to (not beyond) its inner border. Then a fine silver wire is threaded on the needle, which is withdrawn till one end of the wire (*c*) is pulled well through and beyond the site of operation. The needle is then entered at *d*, a point opposite to *b*, near the angle, and passed under the flap (emerging at *y*) in the same manner. The other end of the same wire is threaded on to it; then the needle is withdrawn till that end of the wire (*e*) is pulled through. Three or four more wires are then introduced in the same way lower down the flaps. They will lie as shown in Fig. 127; in Fig. 128 (from Dr. Emmet's work) their position, as seen from the inner aspect of the flaps, is demonstrated.

A stout curved Hagedorn's needle (page 116) may be used for the introduction of sutures. A beginner, however, will not find this needle and its holder easy to work in trachelorrhaphy.

The sutures are, lastly, drawn together after the flaps have been well cleaned by means of sponges. They must be care-

fully twisted and cut off, so as to leave the ends about half an inch long. These cut ends are then bent downwards, against the side of the cervix, where they will produce no irritation.

After-treatment.—Emmet lays great stress upon after-treatment, and to the rigorous injunctions which he enforces, rather than to the operation which he advocates, the opponents of his theory and practice attribute his success. The patient is confined to bed for a fortnight or more after the operation, lest the flaps should separate. Rest in the horizontal position facilitates, in Dr. Emmet's opinion, the necessary decrease in the size of the enlarged uterus. The patient's diet need not be restricted, and the bowels should not be allowed to remain constipated. A warm-water injection must be thrown up the vagina after catheterism or micturition, to avoid irritation of the wound through urine which may escape into the vagina. After the second day, especially if there be much discharge, a vaginal injection of tepid water should be given night and morning.

Removal of Sutures.—The sutures may be removed on the seventh day. "When the patient is placed on the left side, and the cervix has been brought into view by the use of Sims' speculum, the lower portion of the loop should be cut close to the end of the twist, and then withdrawn. Each portion of the loop will then bind the parts together until it has been removed, while, if we should cut the upper part and make traction, the surfaces would be drawn asunder. It is best to remove first the suture nearest to the vaginal junction, for, if there should be any tendency to gape in the line, the others can be left for several days longer, so that the ununited portion may heal by granulation" (Emmet). Dr. Boulton prefers to leave the sutures alone till the fourteenth day, as they appear to cause little, if any, irritation.

Emmet insists that the patient should not sit up in bed for ten or twelve days after the operation. If this rule be neglected, a portion of the line of union is very apt to separate. "Moreover, to get up would expose her to the effects of cold, and cellulitis, if it has existed, is likely to recur on a slight provocation." Where retroversion of the uterus exists, a pessary should be applied when the patient is convalescent.

Parotitis has occurred during convalescence from this opera-

tion in at least two cases—one in Dr. Emmet's experience ; the second, where there had been much hæmorrhage, in the practice of Dr. Goodell. The latter records this fact in a contribution on "Inflammation of the Parotid Gland following Operations on the Female Genital Organs," in the *Transactions of the American Gynecological Society*, vol. x., 1885.

Trachelorrhaphy under other Conditions.—The operation has been above described as performed when some time has elapsed since the labour when the cervix was lacerated, and when the laceration is bilateral and free from much hypertrophy of the torn surfaces, or formation of abundant cicatricial tissue. It is, however, also performed under different conditions.

Immediate Trachelorrhaphy.—Dr. Montrose Pallen, of New York, is an advocate of trachelorrhaphy immediately after labour. He asserts* that, when the laceration is positively diagnosed, the best treatment is to close the wound in the cervix with silver-wire sutures. This, he believes, checks hæmorrhage, and removes a serious cause of subsequent septicæmia. The torn edges being well fitted together, and the wires twisted sufficiently tight, no suppurative foci remain, and no raw surfaces are left exposed to absorb septic material from the lochia. Of course, no denudation will be necessary ; the surfaces are simply washed before operation. As in the process of healing much contraction will ensue, the wires must be passed at one-third to half an inch from the margin of the torn surfaces. As many sutures should be passed as are absolutely necessary to prevent any gaping of the wound, so that the lochia may bathe no raw surfaces. The vagina is washed out with antiseptic solutions every six or eight hours, and the sutures are removed in the manner above described.

Dr. Pallen and other operators, chiefly American, claim excellent results from this practice. It has not, however, met with much practical approval in this country.

Operation in Cases of Ectropion.—At the onset of the operation, it may be found that the flaps cannot be approximated, on account of great bulging of hypertrophied tissue from their surfaces. The hypertrophied tissues must then be

* "On the Etiology and Treatment of Lacerations of the Cervix Uteri" (*British Medical Journal*, vol. i. 1881, p. 764).

cut away (Fig. 129), in such a manner that two raw surfaces can be approximated, leaving space for the cervical canal, as before (Figs. 129, 130).

Management of Cicatricial Tissue in the Flaps.—Next to the precaution against traction involving tissues possibly affected with cellulitis (see page 342), nothing in respect to trachelorrhaphy is more important for the surgeon to remember than the bad results which may follow any neglect to remove cicatricial

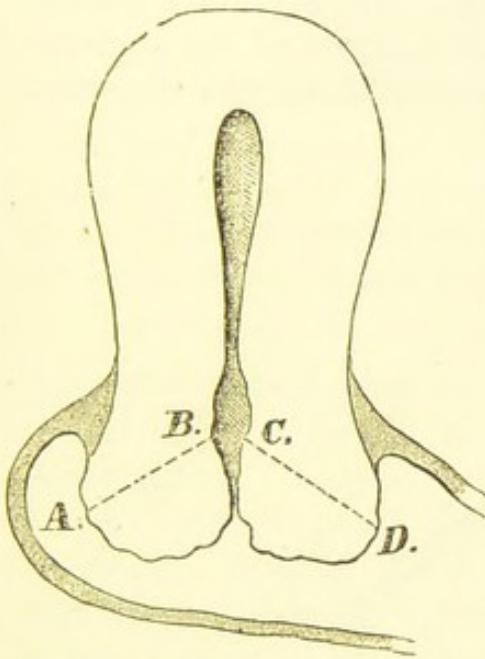


FIG. 129.—CICATRICIAL HYPERTROPHY AFTER LACERATION.

The lines A B, C D indicate the portion to be removed. (*Emmet.*)

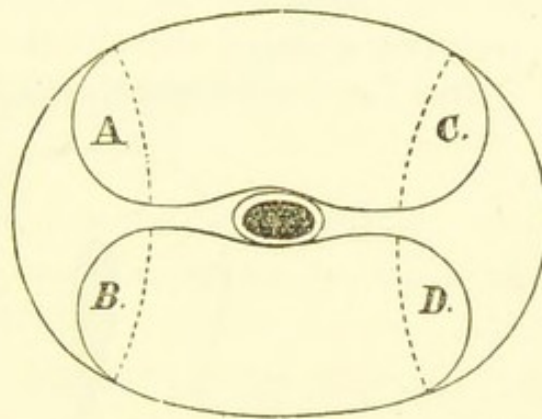


FIG. 130.—HORIZONTAL PLANE OF CERVIX.

From same case as Fig. 129.

The hypertrophied tissue is indicated by A, B, C, D, and is to be removed to the bottom of the laceration, along the dotted lines, so that the surfaces A and B, C and D can be united by sutures after A C, B D have been denuded. (*Emmet.*)

tissue. This accident is the result of not thoroughly denuding the necessary surfaces along the angle between the flaps. In this angle granulations are often observed, representing a growth of cicatricial tissue beginning to fill up the flap. Should these granulations be left untouched, or only pared superficially along the line T in Fig. 131, the flaps cannot be properly closed, just as the sides of two contiguous fingers cannot be thoroughly approximated when a reel is kept in the angle between them. Hence, a V-shaped wedge of this tissue must be cut out, and the sutures must also be carefully applied to the

part of the flap whence it was excised. This must be done on both sides—that is to say, a wedge is cut out from the angle in each of the vivified surfaces. In so doing, the surgeon must be careful not to cut deeply through the tissues external to the angle, lest the circular artery be endangered (see page 343).

Unilateral Lacerations.—In this variety there will simply be but one strip of mucous membrane to sew up. Operation, under these circumstances, is by no means easier than when the laceration is bilateral. It is difficult to cut along the angle and the inner side of the flaps. Dr. Boulton's practice of thrusting a scalpel through the outer aspect of the angle, so as to free the tissues there, and then finishing the dissection

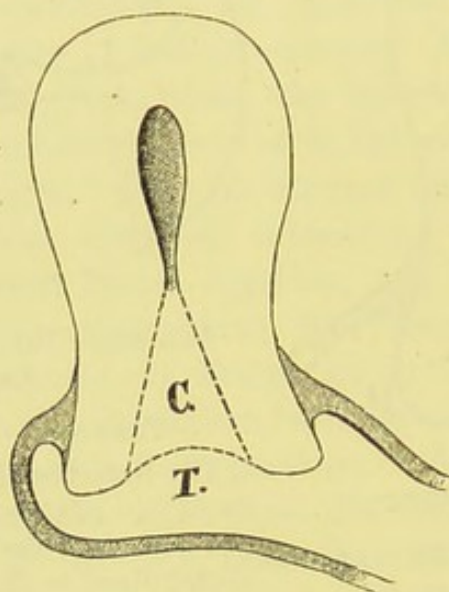


FIG. 131.—CICATRICAL PLUG IN A LACERATED CERVIX. (*Emmet.*)

C represents the plug, T the surface of the laceration.

with scissors (page 342), may be very advantageously applied in these cases.

Multiple Lacerations.—It is useless to pare all the edges of multiple lacerations and to unite them with sutures, as this proceeding would involve traction in opposite directions, tending to part the apposed surfaces and to tear out the stitches. As a rule, two of the lacerations are tolerably close together. In such a case the tissue between them may be cut out in the form of a wedge, and the surfaces left facing each other are denuded (Fig. 132).

Amputation of Lacerated Cervix.—When abundant cicatricial tissue or extensive cystic degeneration has taken place in the region of a laceration, the advocates of trache-

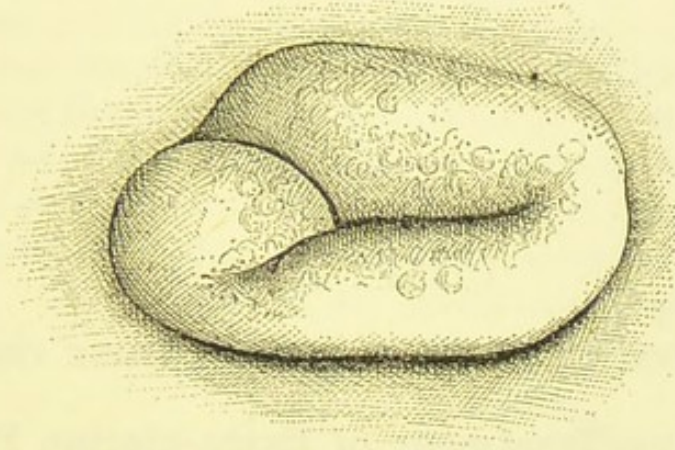


FIG. 132.—BIFID LACERATION OF THE CERVIX. (*Emmet.*)

The portion between the two fissures would, according to Dr. Emmet, require excision.

lorrhaphy contend that amputation of one lip or of the entire cervix may be needed to prevent the chance of malignant degeneration. Emmet has amputated the anterior lip with scissors, removing all the morbid tissue. The stump was covered by drawing the vaginal tissue over it from each side, and securing it by six interrupted silver sutures. Most British gynæcologists are averse to these extreme measures.

CHAPTER XIII.

OPERATIVE TREATMENT OF EXTRA-UTERINE PREGNANCY.

Operative Treatment of Extra-uterine Pregnancy.

—The principles of palliative and expectant treatment of extra-uterine pregnancy are laid down in systematic text-books on obstetrics. Works of that class contain descriptions of incomplete operative measures—that is to say, operative proceedings where the foetus is not removed; in contradistinction to operations, which I shall describe in full, where the products of conception are completely or partially taken away, with or without the sac which contains them.

Leading obstetricians are not agreed as to the treatment of this affection, but, as a whole, they remain averse to active operative measures until septic symptoms have developed. They still advocate injections of morphine or other agents into the sac, puncture of the sac and removal of liquor amnii, and destruction of the ovum by electricity. The surgical operations which I shall describe, after a brief sketch of the diagnosis and varieties of extra-uterine gestation, are—incision of the sac through the vagina, and delivery of the foetus; extirpation of the sac by abdominal section at the time of rupture; removal of the foetus through incision of the sac unruptured or at the time of rupture; extirpation of the unruptured sac before term, and extirpation of the sac after term. The less radical measures, just named, will, however, be briefly noticed.

Diagnosis and Varieties of Extra-uterine Pregnancy.—I am compelled to dismiss these two important subjects in a few short paragraphs. The excellent summary

published by Freund a few years since* will form the basis of my remarks.

In the earlier stages of pregnancy the position of the tumour, distinct from the uterus, is easily detected. Later on it becomes more and more difficult to distinguish. On the other hand, the general symptoms of pregnancy are at first absent, and later they are more likely to be present. This is an excellent rule, but every individual case will present more or less puzzling features. Careful examination of the pelvic viscera and the tumour should be made under chloroform, without the use of the sound. The nature of all recent discharges must be

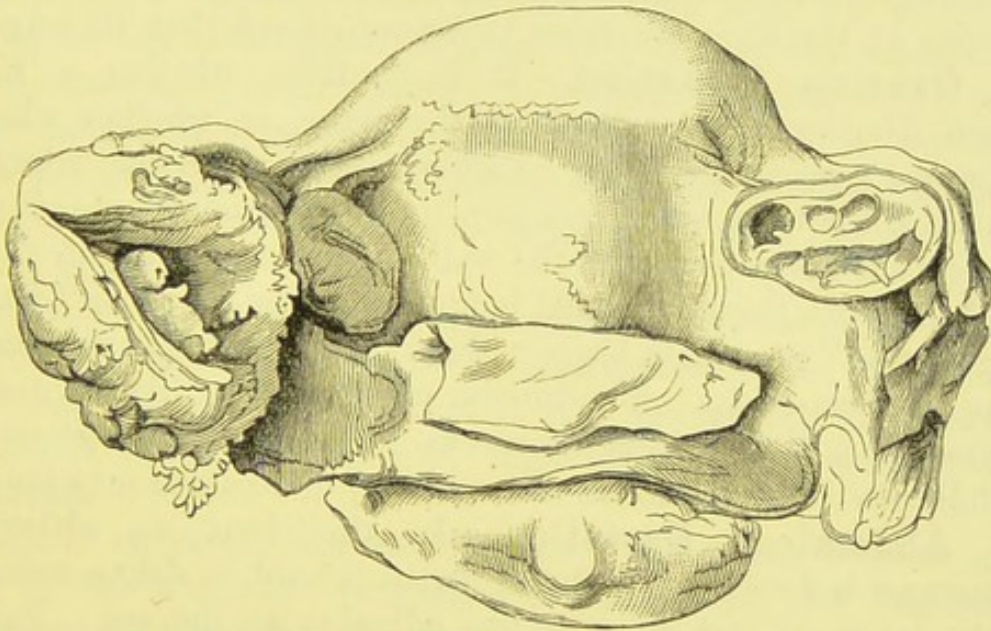


FIG. 133.—GESTATION IN OUTER PORTION OF LEFT FALLOPIAN TUBE.
Death after three attacks of hæmorrhage. (*Museum R.C.S.*, No. 4,696.)

inquired into, with the view of ascertaining if any decidua has been expelled from the uterus. Diarrhœa and colicky pains may indicate the attachment of placenta to the serous coat of the intestine.

Tubal Gestation.—This condition is recognized by intermittent pains resembling dysmenorrhœa and coming on early in pregnancy, and by sudden attacks of peritonitis with symptoms of internal hæmorrhage. It is certain that these

* See translation of Freund's "Extra-uterine Gestation," by Dr. David Smart, in the *Edinburgh Medical Journal*, September, November, and December, 1883.

attacks end fatally in a large number of cases, as in that whence the specimen represented in Fig. 133 was taken; and perhaps Freund is too confident that in a considerable proportion of cases the peritonitic symptoms subside entirely within the first three months.* The tubal cyst remains flattened, and always tends to rupture early. According to Tait and others, tubal pregnancy is the primary condition in all other forms of extra-uterine gestation, which result from rupture of the tubal sac and partial or complete transplantation of the contents. I am of opinion that this theory is, in the main, correct. As far as regards operation, it is of little importance, since when a sac is incised or extirpated its connections at the time are more to be considered than its origin.

Ovarian Gestation.—It is doubtful whether a foetus can develop in the tissues of the ovary, or whether what is termed ovarian gestation signifies pregnancy in the outermost part of the tube, with absorption of the ovarian tissues or with their amalgamation with the wall of the sac. I am in favour of the latter theory. What is understood by the term "ovarian gestation" appears to begin without pain, or with but moderately painful sensations. The tumour grows rapidly, like an ovarian cyst; it is distinct from the uterus. Pregnancy may go on till full time; then the foetus dies, and may desiccate or may putrefy.

Abdominal Gestation.—In this form an abdominal tumour is developed, and the uterus is hard to define owing to displacement and more or less adhesion to the sac. Pain is often absent, and gestation generally continues to term; then, after indications of labour, and death of the foetus, characteristic changes follow, with final spontaneous elimination of the foetus through different channels. In cases of abdominal pregnancy with insertion of the placenta on the serous coat of a coil of intestine, intestinal catarrh sets in during the first few months, and, when the foetus dies, the sac decomposes and the whole system is affected.

Of some less frequent varieties, such as tubo-uterine or tubo-ovarian gestation, I shall speak in the course of the description of operative proceedings. I must further remind the reader that

* He admits that care must be taken to avoid mistaking a hæmatocele for an abortive gestation.

pregnancy in a monstrous or malformed uterus may simulate or may practically be identical with extra-uterine pregnancy.

Palliative Treatment.—Rest is always imperative in cases of extra-uterine pregnancy, and further directions for the management of patients subject to this affection will be found in works on obstetrics.

Active Treatment.—Obstetricians are generally agreed in recommending for the earlier stages of extra-uterine pregnancy electricity, puncture of the sac, or injection of chemical solutions, to kill the foetus, or else removal of the foetus through a vaginal incision. The proper treatment of advanced pregnancy of this kind is much disputed, some recommending that the patient should be left alone until the foetus is dead, and that when its death occurs no operation should be performed unless septic or other dangerous symptoms appear. Others are in favour of "the primary operation," which signifies the removal of the living foetus by abdominal section, generally with the view of saving mother and child.

In cases of extra-uterine pregnancy where the foetus has died and the nine months have passed, most authorities are in favour of leaving the sac alone so that it may shrivel up, unless bad symptoms, already noted, set in; then laparotomy is considered justifiable.

Certain surgeons, however, advocate abdominal section as soon as the abnormal pregnancy is diagnosed, and further recommend immediate operation when symptoms of rupture of the sac appear. The more complete operations have already been named and will be described.

Puncture of the sac is generally effected by means of a Cock's trocar or some similar instrument, which is thrust into the sac through the rectal or vaginal wall. It has often proved fatal, as in a case which will presently be mentioned, and may fail to destroy the foetus.

Injections of Chemical Solutions.—One-fifth of a grain of morphine has been injected into the sac by means of a hypodermic syringe with a long nozzle in at least four cases, with the result of arresting the pregnancy. A single injection has proved sufficient to destroy a five months' foetus; in another case the injection was repeated every other day till the sac

began to diminish in size. The nozzle of the syringe may be passed either through the vaginal or abdominal wall.

Electricity.—The ovum has been destroyed by the Faradaic and galvanic currents in many cases which have occurred in the practice of distinguished specialists. The Faradaic current appears to be preferable.

In records of successful results following the above procedures the possibility of errors in diagnosis must ever be taken into account.

I shall now proceed to describe the more radical operations already noted.

Removal of Fœtus by Vaginal Section.—As some part of the fœtus generally presses down into Douglas's pouch, it is natural that incision into the vagina and extraction of the fœtus through the wound should not only have been suggested, but also practised with good results. When the fœtus is large this method is hardly permissible, for then the operator may meet with some of the ordinary, and with other and extraordinary, obstacles to delivery through the vagina. The foetal sac often presents more in the direction of the abdominal walls than towards the vagina. In most cases a vaginal operation appears unsurgical in comparison with an abdominal section; the former is done in the dark, and drainage is not so easily nor so safely maintained as when it is adopted after abdominal section.

There are, however, cases where the removal of the fœtus through a wound in the vagina appears justifiable. When the evidences of extra-uterine pregnancy are strong, when the fœtus is still small, when the sac does not rise above the hypogastrium so as to press against the abdominal walls, and when, on the other hand, the foetal head appears to lie well down in Douglas's pouch, then, if the surgeon should judge that an immediate operation is necessary, the method now under consideration may be the best. The operator may be far more used to deliver a fœtus than to open the abdominal cavity. This fact must not be forgotten.

The woodcut (Fig. 134), represents a case of tubal pregnancy where this method might have been practicable. A fœtus of about the third month occupied the outer part of the right tube.

The ovary, as I found on careful dissection, had become atrophied, and was completely concealed between the foetal sac and the uterus. The patient was a woman aged twenty-two, there were signs of pregnancy ; a tumour could be detected deep in the hypogastrium, and it projected into Douglas's pouch. Large

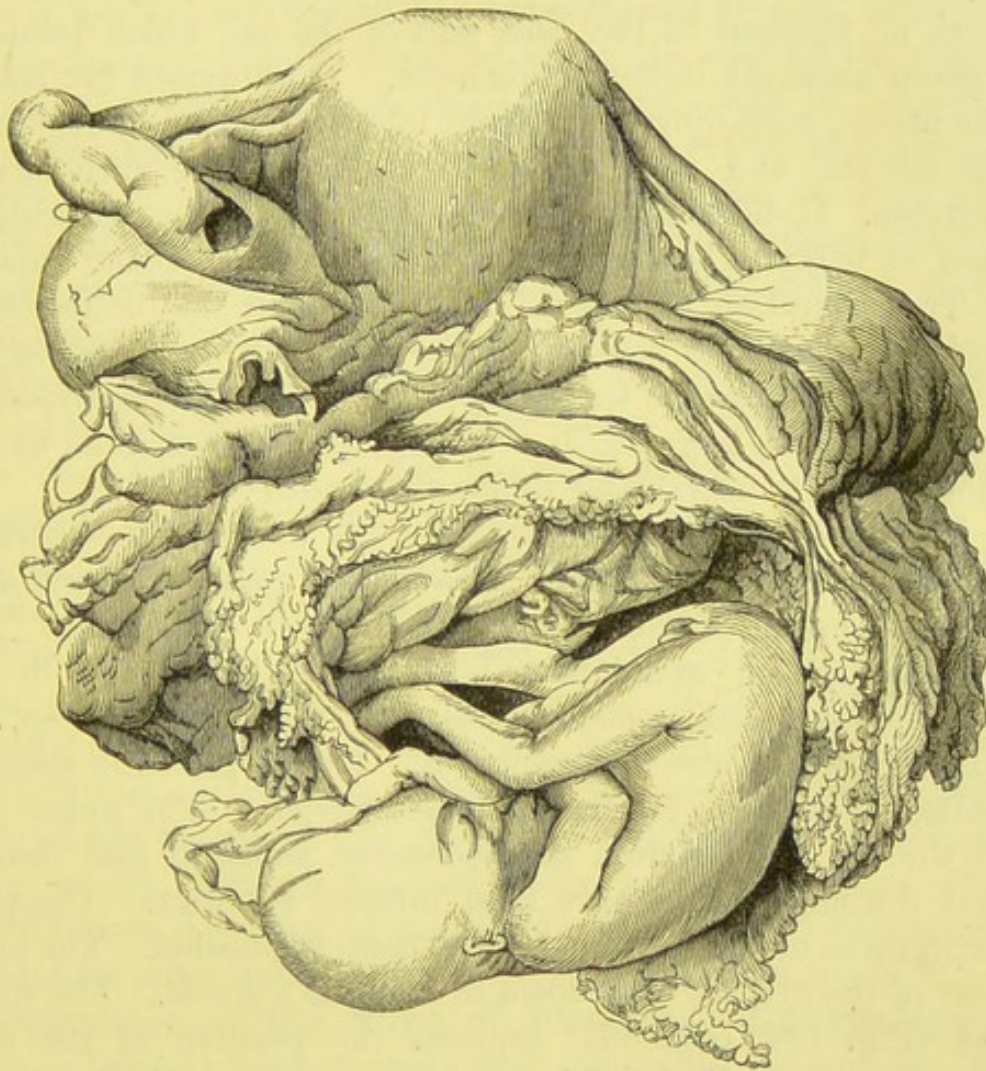


FIG. 134. —UTERUS AND APPENDAGES.

Showing a sac in the outer part of the right Fallopian tube containing a foetus. The lower part of the sac lies in the direction of Douglas's pouch. The left tube is obstructed and dilated. (*Museum R.C.S.*, No. 4,694.)

pulsating vessels could be felt on the surface of the tumour. The sac was in this case tapped with an aspirator through the rectum, as it was very tense and threatened to burst. A pint of bloody fluid was removed, and a little iodine solution was injected by the aspirator and removed again. Subsequently, as

the bleeding persisted, a solution of equal parts of liquor ferri perchloridi and water was injected, and this checked the hæmorrhage. The patient passed a decidua from the uterus on the third day, but died rather suddenly with symptoms of internal hæmorrhage on the fourth. I performed a necropsy and discovered that the peritoneum was full of blood. This had issued from an aperture in the back part of the sac, which formed a tumour about six inches in diameter. This tumour lay behind the uterus, extending to the right into the iliac fossa, displacing the cæcum, and also backwards as far as the fifth lumbar vertebra. It did not approach the abdominal walls. It could be seen as it lay to be a dilatation of the right Fallopian tube.

The aspiration of the sac was done after due deliberation, and the operator's account of the case will be found in the twenty-first volume of the *Transactions of the Obstetrical Society of London* (1879), page 93, in a monograph supplemented by Dr. Routh with some valuable tables of reference.

The object of the above history of the case may now perhaps be apparent to the reader. In a similar case, in future, some other operation might appear preferable to aspiration. Abdominal section would have been extremely difficult in this instance, even as a secondary measure. As a primary step, few surgeons would care to perform it. I shall presently speak of radical operations on tubal cysts before term. The upper part of the sac lay far from the abdominal walls, so that incision and drainage would have been difficult to effect. Complete extirpation of the sac would have been impossible. The lower part of the cyst lay well down in Douglas's pouch. The wood-cut (Fig. 134, page 355) explains the position of the cyst. Hence it was well placed for an incision through the vagina.

The Operation.—Paquelin's thermo-cautery is very efficacious for the purpose of cutting through the posterior fornix of the vagina. The surgeon, if unskilled in its use, should practise cutting with the cautery-knife through organic tissues of different density. The galvano-cautery, with the strong platinum knife (Fig. 69), is in some respects preferable to the thermo-cautery (see page 155).

The rectum must be cleared and the bladder emptied. The patient is laid on her left side, after the anæsthetic has been

administered, or on her back, should circumstances make that position desirable. The vagina must be washed out with carbolized or iodized water, and then thoroughly explored. A Sims' speculum should be passed along the posterior wall close up to the vaginal roof, and when the thermo-cautery is used, the rest of the vagina must be well guarded by means of a pad of wet lint pressed against the anterior wall by a flat retractor. Then the cautery-knife is passed up to the roof of the vagina behind the cervix, and an incision, curved, with its concavity forwards and about an inch in length, is cut through the vaginal wall into the cyst. The knife must be kept just sufficiently hot to burn well and to check hæmorrhage; this is, of course, effected by the assistant plying the bellows of the cautery gently and slowly.

The placenta may be cut through, but the risk of uncontrollable hæmorrhage when this occurs is not so serious as was once supposed. When the incision has been made, the operator passes his forefinger through it into the cavity of the sac, and after ascertaining the position of the foetus, delivers it, leaving the placenta.

The cyst-cavity must be washed out with an antiseptic solution and carefully drained afterwards. Some authorities recommend that it should be packed with salicylic or iodoform wool, frequently changed. Otherwise, a curved glass drainage-tube should be passed into the cyst, which must be washed out, very gently, through the tube twice a day, or more often should there be signs of septic infection. The placenta will gradually come away, and the wound will close up.

Operation at the Time of Rupture.—Extirpation of Sac.—Taking for granted that diagnosis, symptoms, the actual condition of the patient, and the experience of the surgeon justify immediate radical operative measures, the following paragraphs will show the steps of the operation, as described by its chief advocate, Mr. Lawson Tait.

I must first repeat a declaration of a general principle which particularly applies to this operation, that the surgeon must not leave himself out of account as one of the factors of the whole proceeding. He is most assuredly justified in refraining from operation, should he feel that his experience in abdominal

surgery has not been sufficient to inspire him with the confidence necessary in an encounter with the gravest complication of one of the deadliest of disorders. He must remember that clearing clots and fluid blood out of the peritoneal cavity, and seeking the source of hæmorrhage, require much nerve, and that in the pelvis things are not as they seem, or rather, as they feel. An "educated finger" is indispensable. If, on the other hand, the surgeon who contemplates an operation of this kind has had considerable experience in abdominal sections, he is justified in at least making an exploratory incision. Then, the abdominal cavity being opened, he can but search for the appendages; he is well qualified to do such work, nor will blood or clot affright him. However deep in the pelvis the seat of disease may lie, he is accustomed to search the pelvic structures by the sense of touch as well as by sight, and therefore he is competent to attempt, not only the arrest of hæmorrhage, but the deliberate extirpation of the foetal cyst. Mr. Tait, an extreme advocate of the proceeding under consideration, writes: * "For this treatment, of course the difficulty was the diagnosis, but as I have now completely adopted the principle of always opening the abdomen when I find a patient in danger with abdominal symptoms, this barrier no longer exists. The diagnosis is, however, not so very difficult after all, for in many cases the existence of pregnancy has been suspected before the rupture occurred. It may be in the majority, however, that this misleading feature is present; the patient has never been pregnant, or has not been so for many years, and then the arrest of menstruation attracts no particular attention. If, however, it be found that the patient has been eight weeks or more without a period, that there is a pelvic mass fixing the uterus and on one side of it, and that sudden and severe symptoms of pelvic trouble and hæmorrhage came on, the rupture of a tubal pregnancy may be at once suspected, and if an operation is to be done—and it clearly ought to be done—it must be done without delay. Early interference is clearly a chief element of success in modern abdominal surgery."

Whilst the preparations are being made for the operation,

* "Five Cases of Extra-uterine Pregnancy operated upon at the Time of Rupture" (*British Medical Journal*, vol. i., 1884, p. 1,250.)

the patient's abdominal aorta should be compressed, if possible. It is probably best to select chloroform as the anæsthetic, for the patient can be brought very speedily under its influence. This is specially advisable, since there is no time to be lost, and struggling may increase the danger. Sudden contractions of the recti during imperfect insensibility will assuredly increase the surgeon's difficulties and the patient's peril.

The patient's body had better be protected with towels, as directed in the account of the operation of oöphorectomy. The incision is made in the usual manner in abdominal sections, and should not exceed three inches in length. It must be brought down sufficiently low, else there will be great difficulty in reaching the pelvic organs. The surgeon then clears out as much clot as will enable him to get at the appendages, for, especially if the symptoms be urgent, it is evident that the arrest of hæmorrhage is all-important, whilst the peritoneal cavity can be cleaned at leisure later on.

The surgeon's left hand * is then passed down till the fundus uteri can be detected; the operator will then know his bearings, and can feel the relations of the uterus to the tumour. The exact limits of the tumour may be very hard to define. As in oöphorectomy, adhesions may be manifold, nor is it always easy to distinguish adherent empty intestine by touch. The next thing to ascertain is whether the cyst be small and of such a nature as to be readily removed with the tube, or large so as to require stitching to the abdominal wound. The broad ligament between the uterus and the sac must, if possible, be grasped between the left finger and thumb, so that the hæmorrhage may be controlled.

If the sac be small, as in Fig. 135, it must be removed with the tube. Gentle pressure with a sponge will check the bleeding; this should be done by the assistant. The affected appendage is then drawn up, sac and ovary included, by the surgeon's right hand, and removed precisely after the manner described in the account of oöphorectomy at page 280. The large pressure-forceps is made to secure the appendage, and the pedicle-needle armed with No. 4 silk is passed on its proximal

* That is, if the sac lie in the right appendages. For operations on the other side, the position of the hands, as here described, should be reversed.

side as in Fig. 114, page 281. It is evident that when the tubal cyst is small, as in Figs. 133, 135, there may be relatively little difficulty in removing it, together with the ovary, as though the two formed a diseased appendage. On the other hand, should the pregnancy prove to be tubo-uterine or "interstitial," as in Fig. 136, supra-vaginal hysterectomy (Chapter XI.) would be necessary.

The management of adherent intestine and omentum (page 278), the cleaning of the peritoneum, and the after-treatment

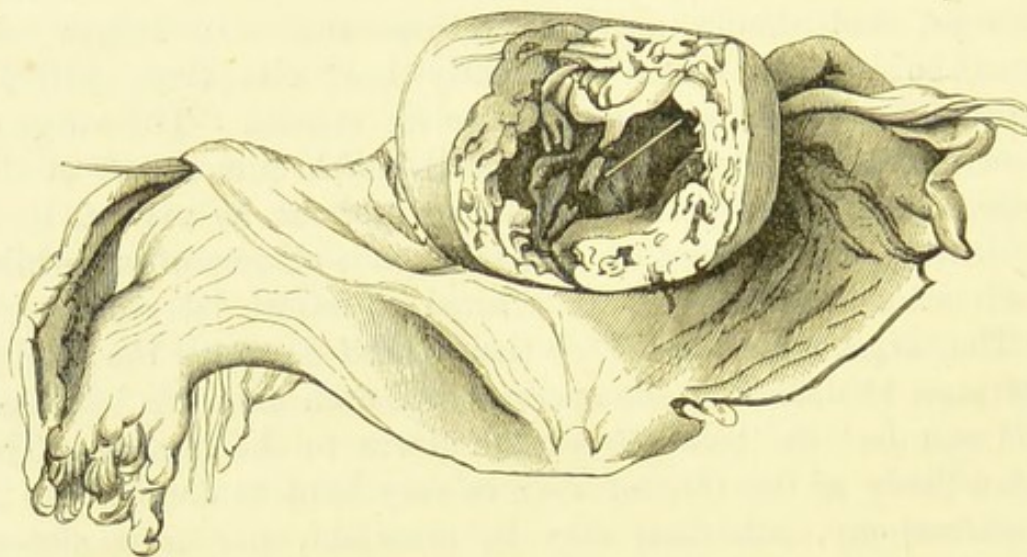


FIG. 135.—TUBAL PREGNANCY.

A bristle is seen passing from the interior of the cavity to the uterine end of the tube. The fimbriated extremity has been split open for some distance, and a bristle passed into the tubal canal; this bristle could not be passed into the cavity. The embryo has been lost. From a woman aged thirty-three, who died suddenly, with signs of internal hæmorrhage. Dr. Walter Lowe, of Burton-on-Trent, discovered the cause of hæmorrhage when making a necropsy of the case. (*Museum R.C.S.*, No. 4,695.)

will be the same as in ovariectomy. It is advisable to exercise some caution in pulling out clots with the hand, as they are not firm, so that if a large clot be pulled out of some deep part of the pelvis or abdomen, a portion may be left behind, escaping the notice of the operator. No method of clearing the peritoneal cavity, in the course of this operation, is superior to thorough washing out with several pints of water at blood heat. I have spoken of this practice in the chapters on Ovariectomy, where I have noted the necessary precautions (page 204). In respect

to extirpation of the extra-uterine sac, as in all other abdominal sections, I have left the antiseptic question open. Here as elsewhere I should prefer to employ the spray. I mention this matter in relation to the subject of washing out the peritoneum because, consistently with antiseptic principles, the water should be carbolyzed, in the usual proportion of 1 in 40, or about 2 per cent. of phenol.

Lastly, the pelvic viscera must be carefully examined before the wound is closed. There may be very considerable capillary

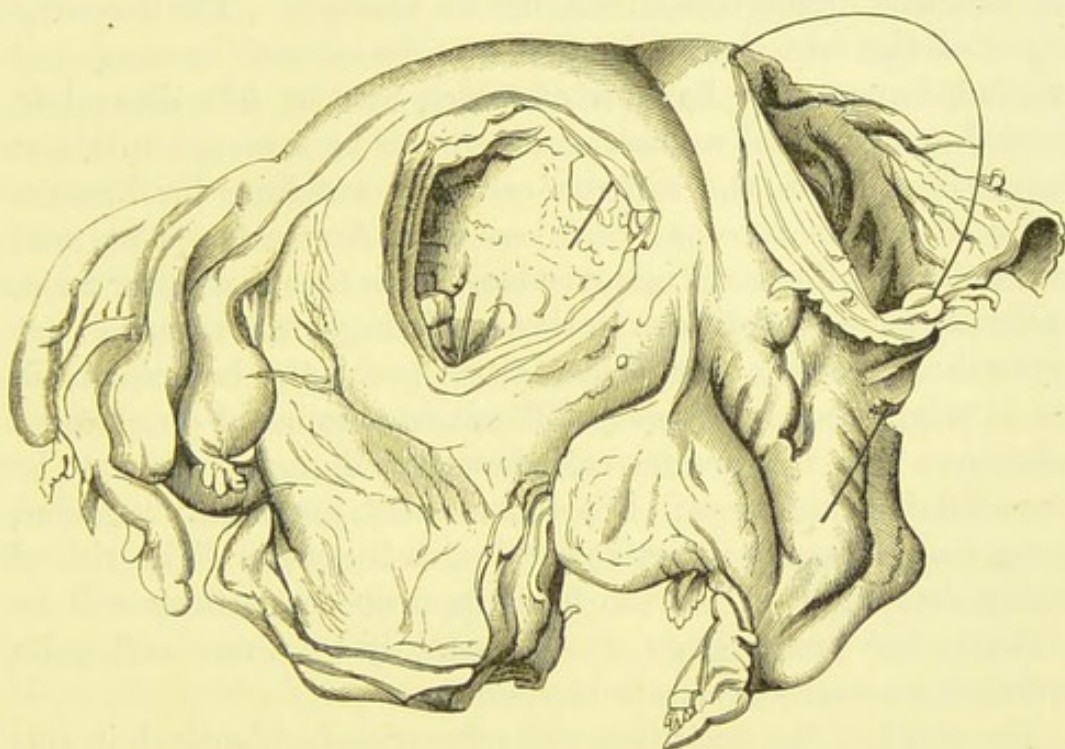


FIG. 136.—TUBO-UTERINE OR "INTERSTITIAL" PREGNANCY.

The posterior wall of the uterus has been partly removed. A black bristle passes from the uterus, across the cavity which contained the fœtus, into the tube beyond it, emerging from an incision artificially made through the tube. (Dr. Carr Roberts' case, *Museum R.C.S.*, No. 4,691.)

oozing from the side of old adhesions to the sac. In such a case, it will be best to insert a glass drainage-tube into Douglas's pouch, and drain in the manner already narrated. The abdominal wound is, lastly, closed and the patient is returned to bed, and treated as an ovariectomy case.

Operation at Time of Rupture—Simple Incision of Sac.—I have just described the operation of extirpation of the sac at the time when symptoms of rupture have appeared and

the sac is found to be small. It may happen, however, that the pregnancy is advanced to the third or fourth month, if not later, then the sac will be of considerable size and its extirpation would be difficult and dangerous. The proper radical course will then be incision of the sac, and removal of the foetus, the edges of the sac being afterwards sewn to the abdominal wound. The rent may be wide enough to allow of the extraction of the foetus, and if not, the incision must be made to include it. Should the rent unfortunately lie deep, in the posterior part of the sac, this arrangement will not be possible. The bleeding edges of the rent should, in this case, be secured by means of pressure-forceps, the handles of which can be left dependent from the abdominal wound, and they can be removed in about twenty-four hours, the surgeon carefully watching for hæmorrhage after the forceps are taken off. Any attempt at total extirpation of the sac is unadvisable. It is true that, after term, under different conditions to those existing after rupture, that proceeding may be justifiable, as will shortly be explained, yet it might then prove very difficult on account of complicated adhesions. In the present case, however, though there may be few adhesions, the sac will be soft, succulent, and highly vascular, being full of vessels in active service, so to speak. The risk of rashly detaching such a sac from its deep connections will be evident; the hæmorrhage would certainly be severe and quite sufficient to startle even a bold operator.

The steps of the operation will otherwise be identical, in this case, with those of the same operation performed when there has been no rupture, or after term, as will now be described.

Removal of an Extra-uterine Foetus by Incision through the Unruptured Sac.—This operation may become necessary when there is strong evidence that a foetus which has died before or after term is decomposing and setting up complications of a serious character. Should abnormal pregnancy and retention of a foetus be diagnosed, should the sac present well towards the abdominal walls, and should the patient lose flesh, suffer from chronic or sub-acute peritonitis or exhibit symptoms of septic infection, this operation will be thoroughly justifiable. There may be evidence, too, that some communication between the sac and the rectum, vagina, or other organ

is in process of formation, threatening fistulous tracks, and discharge of the foetus and placenta piecemeal, to the certain discomfort, at least, of the unfortunate patient. Some surgeons believe that all the above complications should be anticipated, and that in any case of extra-uterine pregnancy prolonged beyond term, the foetus should be removed in case such evil results should follow and render the patient less fit for a serious operation.

The patient should be prepared as for ovariectomy, and the abdominal incision made about four inches long. Great care must be exercised when the surface of the sac is exposed. It is here taken for granted that the diagnosis is correct. Feeling assured on this point, the operator must ascertain the relations of the front of the sac. If it be adherent to the parietes he must not disturb its connections, but must at once lay it open. If not adherent superficially, the right hand should be passed over the surface of the sac to ascertain its attachments. During this manoeuvre any deep adhesions which may exist will be detected. Such adhesions must be on no account disturbed, and the operator must not be over-anxious to trace the precise anatomical relations of the sac to the uterus and other organs at the cost of tearing down adhesions, setting up hæmorrhage, or bursting the sac itself posteriorly. A sac of this kind should be stitched to the margin of the abdominal wound, an elliptical portion being first cut out of its wall, so as to leave a hole, wide enough for the extraction of the foetus. The sutures must be applied separately to each side of the abdominal incision, and the corresponding border of the incision in the sac, and not passed through both sides of the same, crossing the cavity of the sac. If the sac be not made fast in the manner just described (as in Fig. 107), some of its contents will escape into the peritoneal cavity as the foetus is being extracted, an accident to be avoided throughout and after the operation. For the stitching process, a stout curved suture-needle, armed with No. 4 silk or with thick silkworm-gut, will be found convenient, and it should be entered, if possible, through the healthy tissues of the abdominal wound, and cleaned in carbolic solution after it has traversed the diseased wall of the sac.

When the sac is adherent, a simple incision may be sufficient; still it is usually advisable to secure its edges to the abdominal wound, lest the adhesions be broken down during the later stages of the operation. Should the placenta be cut through, there will be little fear of hæmorrhage, as that structure is generally degenerate and does not bleed much.

The extraction of the foetus must be managed with great deliberation, as the sac may otherwise be ruptured, or the placenta detached. The foetus should be seized by its feet and drawn out slowly, the umbilical cord being divided. If it be putrid it should be extracted by a large volsella or by lithotomy-forceps. Then the cavity of the sac is washed out with any antiseptic fluid in which the operator specially puts his trust. A drainage-tube is passed into the deepest part of the sac and the cavity is packed with iodoform wool. Some operators dust the walls of the cavity with a dry antiseptic powder. An india-rubber cloth, already described (page 128) should be fitted over the mouth of the tube. Over the whole a large woollen pad and a many-tailed bandage are adjusted.

The sac must be well washed out through the drainage-tube, twice daily, or more frequently if necessary, until the antiseptic fluid used for washing returns clean, and the cavity of the sac is free from foetor. When bad odours and much discharge continue for several weeks, the walls of the cavity should be well explored, for in some cases, especially when a putrid foetus has been removed in pieces, a foetal bone may be left embedded in the wall of the sac, and until it is cautiously extracted, these dangerous symptoms will persist.* The placenta will gradually come away. After each washing, the cavity must be packed with iodoform wool. When the discharge becomes trifling and the sac has begun to dry and shrink, the tube may be removed and the packing discontinued. Care must be taken lest the abdominal wound close too soon.

As it often happens, where this operation is necessary, that the patient is in a very feeble state of health, her strength must be well supported. Should there be a tendency to vomit, or even simple nausea, nutrient beef-tea enemata must be given, for by persisting in the administration of food by the mouth,

* See Spanton, *British Medical Journal*, vol. i., 1884, p. 14.

serious gastric disturbance will be set up, and even a very slight complication may turn the scale against the patient's recovery. Scrupulous attention is needed to avoid the formation of bed-sores. Opium should be used as sparingly as possible.

Extirpation of the Unruptured Sac before Term.—

In the course of an exploratory operation, an extra-uterine pregnancy may be discovered. If the sac be of a nature suitable for extraction—that is, if it bear a good pedicle, as in Fig. 135, and be free from strong adhesions—it may be removed, the pedicle being ligatured as in ovariectomy. As a rule, however, the operation just described is the best to perform under the circumstances.

Extirpation of the Extra-uterine Sac after Term.—

This is an operation of extreme difficulty and danger. Even an experienced ovariectomist or obstetrician may shun it on account of the numerous risks which it involves. It may happen that in the course of an exploratory operation, where extra-uterine pregnancy is hardly expected, that condition may be discovered when the surgeon has already separated a great part of the sac from close adhesions which supply it with blood. He may then fear to leave the sac behind. Still more will he object to incomplete measures should the diagnosis be revealed by sudden rupture of the sac during manipulation, and escape of the foetus. The rupture may be so wide, or placed in such a position, as to prevent the operator from contenting himself with simple extraction of the foetus. The sac and placenta may also be extensively diseased, rotten, or sloughy.

Under these circumstances, and especially where the tissues of the sac are as great sources of danger to the patient as the dead foetus itself, simple extraction of the foetus may be insufficient. Extirpation of the sac would then be justifiable.

The abdominal incision being made, it will first be necessary to explore the surface of the sac. Sometimes it is quite thin, and the foetus can be felt through its walls. Often, however, it is very thick, being partly made up, anteriorly, of overgrown placenta. The surface is generally dull brown, but may vary to an indefinite degree. Omental and intestinal adhesions usually exist, and may be extremely difficult to separate. In one case in my own and one in a distinguished

colleague's practice, the sac looked so like an ovarian cyst, that the trocar was thrust into its substance; no fluid escaped, but the wound in the wall of the sac presented no pathognomonic appearances, indeed the wounded tissues resembled the substance of a somewhat firm sarcoma, nor could any foetus be felt by the finger thrust into the wound. As in simple extraction of the foetus, the operator must prove the nature of the tumour by a small, carefully-made incision into its anterior wall, and must be prepared for the contingency of error in diagnosis, shown by profuse hæmorrhage and escape of soft sarcomatous material. On the other hand, he may have erred in the opposite direction, and may not find out his mistake until he sees a foetus escape through a rent in what he took for a uterine or ovarian tumour.

It is advisable to remove the foetus from the cavity of the sac and to divide the umbilical cord at this stage. The sac must then be raised, and all adhesions at its upper and back part very carefully and deliberately separated. In the meantime, the abdominal incision may have required extension upwards, even above the umbilicus. The intestines must be well guarded with flat sponges. When the base of the cyst appears to be within range of the operator's hand, he must thoroughly explore the pelvic viscera with one hand, holding up the cyst with the other. Most probably he will find the fundus of the uterus, but he must not be surprised if he fail to find either or both ovaries or tubes, nor must he be too ready to diagnose the precise character of the pregnancy on the strength of manual examination alone. In more than one case of this operation even the uterus could not be found.

When the uterus is detected, its relation to the sac being verified, the surgeon should endeavour to form a pedicle, and transfix it with No. 3 or No. 4 silk as in ovariectomy. This manœuvre has proved comparatively easy. Sometimes the base of the tumour has to be enucleated from the broad ligament, and the ragged remains of the ligament will afterwards require trimming and transfixing. Unfortunately, the connections of the base of the cyst with the deeper pelvic structures may prove very intimate and impossible to separate with safety. In such a case, the greater part of the sac must be cut away,

and the edges of the remaining portion sewn to the edges of the lower part of the abdominal wound with silkworm-gut sutures. A glass drainage-tube is then passed into the cavity of the remains of the sac. Before this is done, it is best to peel off any placenta. If adhesions have been extensively broken down in the pelvis towards Douglas's pouch, another drainage-tube should be passed into the pouch, issuing from the abdominal wound above the point where the sac is sewn to its edges.

In the course of these proceedings the pressure-forceps will probably be required freely. The hæmorrhage will arise chiefly from broken-down adhesions and from their proximal side, for there will be little bleeding from the surface of the sac. Nor must the surgeon expect profuse hæmorrhage from its interior. It is not the placenta, nor the sac wall, which will give him most anxiety in this respect. The chief difficulty in regard to the placenta may be its identification. In one operation, where I was present, it was so much altered that "the notion that it was placenta was contested, even after it had been removed from the body and cut completely across, by some of the most eminent members of the (Obstetrical) Society."* This change of the placenta into a thick solid mass, resembling the substance of some forms of uterine fibroid, is not by any means invariable after term. I have found a large, very characteristic battle-dore placenta in an extra-uterine sac.

The intestinal adhesions are sometimes extremely firm, so that, notwithstanding ordinary precautions, the walls of the adherent gut are lacerated and require very careful suture. It need hardly be said that important structures are liable to be injured during the separation of deep pelvic adhesions, especially the ureters and large vessels.

In some cases the base of the sac is most readily secured by the wire of a Koeberlé's *serre-nœud*; this is best when its tissues are very thick and liable to bleed, on account of vessels entering its walls through pelvic adhesions. Should the operator have the misfortune to wound the uterus, he may be compelled to amputate it above the cervix, using a *serre-nœud* to secure the stump. It is impossible, however, to make allowance for every contin-

* Thornton, *Trans. Obstet. Soc.*, vol. xxiv., 1882, p. 84.

gency which may arise in the course of an operation of this kind. The operator must quietly proceed, meeting and overcoming each difficulty as it is encountered, and must not cease till he has managed to secure the base of the sac after one of the methods just described.

The after-treatment must be conducted on the same principles as when a large ovarian or uterine tumour has been removed. There is usually much constitutional debility in these cases, hence the strength must be kept up and great caution exercised for the prevention of bedsores. When a pedicle has existed and has been ligatured and returned into the peritoneal cavity, the case will resemble an ovariectomy. When the base of the sac is left behind and drained, the cavity must be washed out regularly about every four hours till the fluid comes away clear and scentless. Then the glass tube may be removed, and replaced for a time by a piece of gutta-percha tubing, if necessary, as when the cavity is very deep. The cavity should be kept dry, dusted with iodoform, and packed, when it gets shallow, with iodoform wool; but surgeons are likely to insist on their own ideas of antiseptic dressing, and many will prefer other materials. As the tissues of the sac do not generally bear the least physical or chemical violence, the surgeon must handle the parts very carefully and avoid strong applications like pure liquor iodi or solid persulphate of iron.

Great care must be taken that the most superficial part of the abdominal wound does not close till all the parts behind it appear healthy, else abscesses, sinuses, or worse complications may result.

When Koeberlé's *serre-nœud* is used, its adjustment and removal must be effected after the manner described in the chapter on Supra-vaginal Hysterectomy.

CHAPTER XIV.

CÆSAREAN SECTION AND PORRO'S OPERATION.

Preliminary Observations.—These operations lie entirely within the province of obstetrics. A surgeon more skilled in abdominal sections than experienced in midwifery is, however, occasionally called upon to perform them. For this reason I introduce descriptions of these procedures into this manual. For the obstetrical and ethical questions in connection with the subject, especially the relative merits of these two operations and craniotomy, and the conditions under which either should be performed, standard works on obstetrics must be consulted.

Cæsarean Section.—Professor Säger has devised a method of performing this operation, which has proved so satisfactory during the past five years, that I consider it justifiable to describe this method alone at length. Earlier operators of great experience never met with the good results which Säger and Leopold can claim, especially in respect to the high proportion of cases where both mother and child were saved. The life of the mother is always the first thing to be considered, but if the mortality amongst the children alone continued high, in the statistics of Cæsarean section, that operation would, for obvious reasons, still remain unsatisfactory.

I shall not, therefore, describe any older method, but, on the other hand, I shall quote Dr. Säger's rules for the simplification of his operation. Had he invented, so to speak, a surgical proceeding only practicable in a large hospital or, at the best only to be undertaken elsewhere by a surgeon experienced in abdominal section, his method would be of comparatively little value. For, often when it is necessary, not only are the patho-

logical conditions unsatisfactory, but the patient's surroundings are yet worse.

On that account I shall first describe Säger's operation, as it should be performed when the appliances required for abdominal section are at hand, as in cases where the patient can be removed to the wards of a hospital, or attended by experienced specialists and nurses. I shall then add a sketch of his simplified method, which may be employed in an emergency. For more complete particulars, Säger's "Neue Beiträge zur Kaiserschnittsfrage" (*Archiv für Gynäkologie*, vol. xxvi., 1885), and a more recent paper by the same, "Ueber Vereinfachung der Technik des Kaiserschnittes" (*Centralblatt für Gynäkologie*, No. 28, 1886), must be consulted.

It is not necessary for me to add the details of a controversy as to the precise share which Professor Säger can legitimately claim in the establishment of this modification of the older method of performing Cæsarean section. This question is discussed by Dr. Garrigues in a paper named "The Improved Cæsarean Section" (*American Journal of Obstetrics*, vol. xix., page 1,009).

Säger's Cæsarean Section: The Operation.—The patient should be prepared as for ovariectomy. The waterproof sheet will not be needed. I have already spoken about the question as to when this appliance should be employed or discarded (page 87). Towels must be placed so as to guard the surrounding parts, as in oöphorectomy. Säger recommends the spray, and several pints of phenol solution, as well as a 1 per cent. solution of corrosive sublimate, must be at hand.

The pubes must be well shaved. Two large flat sponges, at least, will be required; it is better to have four at hand. A set of smaller sponges must be prepared; ten will be sufficient (indeed, Säger only uses four). The other instruments and appliances that will be needed are—a scalpel; a probe-pointed knife; a catheter; two volsella; six pressure-forceps; a pair of straight-bladed scissors, and a pair curved on the flat; a needle-holder; suture-needles, straight and curved; silver wire for sutures; ligature silk, Nos. 1, 2, 3, and 4 (and silkworm-gut if desired); a yard of gutta-percha tubing, with a lumen of about one-fifth of an inch, for elastic ligature; a bottle of iodoform; and,

lastly, several soft napkins. The dressings will be the same as in ovariectomy, and the surgeon will, in any case, employ them according to his fancies and preferences in the conduct of that operation.

The patient is placed under the influence of the anæsthetic, and the bladder is emptied. The abdomen, vulva, vagina, and cervix are thoroughly washed with the antiseptic solution.

The abdominal incision should be made about four and a half inches long; it must of course be longer than when a collapsible cyst has to be removed, and should begin higher up than, and not be brought down so low as, in ovariectomy. Indeed, Säger recommends that one-third of the entire length of the incision should lie above the navel. Three sutures, of raw silk or silk-worm gut, are now passed through the upper third of the wound and left untied. In this way that part of the incision may readily be closed after the uterus is drawn out of the abdomen, later on.

The operator must, before opening the uterus, ascertain that it lies centrally, and not rotated to the right or left. It will generally be found twisted to the right, so that its left side presents; it must be put straight in any case, and the foetus is manipulated into a favourable position should it lie transversely, as is often the case.

Should it be evident that the foetus is dead and decomposing, the uterus must now be turned out of the abdominal incision before it is opened. Otherwise, that organ must be laid open as it lies in the abdomen.

If the patient has been several hours in labour and the cervix is extremely expanded, the incision may require to be made horizontally, and low down on the anterior surface of the uterus. As a rule, however, the incision should be made vertically, and must exactly agree with the abdominal wound in length and position. Great care must be taken not to bring it down too low, else the circular venous sinus, which lies in the uterine walls at the level of the os internum, will be opened. This misadventure is said to be the most frequent cause of fatal hæmorrhage during or after Cæsarean section.

The foetus must now be extracted—by the head, if possible. If the arms be brought over the head, they will save

the neck from constriction during its passage through the uterine incision. The conditions of delivery are different from those which exist when the child is born through the natural channel.

The uterus is now gently drawn forwards out of the abdominal wound. A flat sponge is passed into the abdominal cavity behind the uterus, and high up beyond the upper angle of the wound, as in ovariectomy when the cyst is drawn out. The edges of the upper part of the wound are approximated by dragging on the sutures, which are then held together by pressure-forceps in such a manner that the wound is practically closed, yet can be opened directly, when necessary, by taking off the forceps.

The body of the uterus is then protected by a napkin soaked in the phenol solution. The lower segment and the cervix may now require manual compression.

The elastic ligature is then passed round the neck of the uterus, its ends are crossed in front, and held together by means of a pressure-forceps. The operator next awaits the spontaneous detachment of the placenta, or, if necessary, carefully detaches it, and removes the membranes. With regard to wounds of the placenta made during the passage of the knife through the abdominal wall, they do not give rise to serious hæmorrhage, as was once supposed. The chief source of loss of blood has already been noted. The operator now ascertains that the internal os, or its site, is viable. If not, he must make it so by clearing away placenta and mucus; then there will be a free outlet for discharges in the uterine cavity to escape into the vagina.

The uterine cavity and cervix are now freely dusted with iodoform. It is best to clean the cavity first with carbolic or, better still, sublimate solution, and to syringe the solution into the vagina from the cavity.

The next stage of the operation consists in the application of the sutures to the uterine wound. This is done after several methods, all based upon two principles. The muscular coat should be deeply transfixed, but the decidua avoided. The surfaces of the serous coat on each side of the incision should be made to lie in apposition. In this manner the

deep part of the wound is well held together, and the serous surfaces will rapidly unite, as they do in an ovariectomy wound, and close the superficial part. Many sutures should be used, as the tendency of the uterine contractions and relaxations to act deleteriously on the wound is thereby most readily counteracted.

Of the different ways of attaining these objects I shall describe the simplest, which I find has been related, after Säger and Leopold's original directions, by Dr. Lusk.* Säger, in the paper to which I have already referred, mentions several far more complicated methods, but they are not of a kind which would be readily practicable to an operator, however experienced, who is suddenly called upon

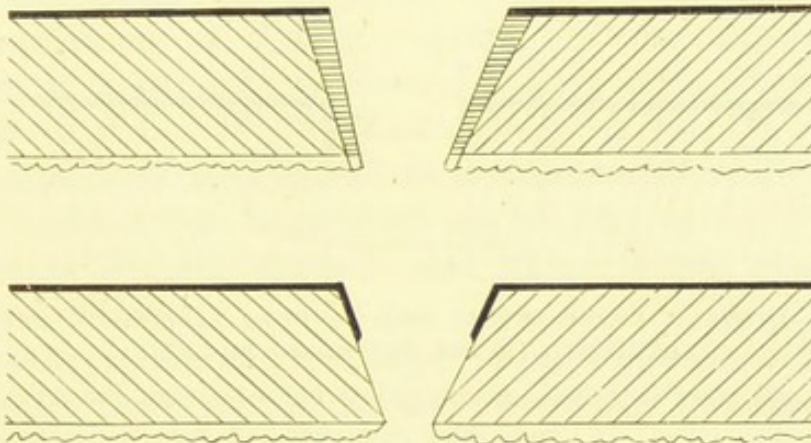


FIG. 137.—DIAGRAM REPRESENTING THE EDGES OF THE UTERINE WOUND AS PREPARED FOR THE SUTURES IN SÄNGER'S MODIFIED CÆSAREAN SECTION.

The black line represents the serous coat, the wavy line the decidua. (*See text.*)

to perform Cæsarean section; moreover, it will be seen presently that Säger himself has laid out a scheme for the greatest possible simplification of the operation under such circumstances.

The cut surface of the serous coat on each side of the uterine wound is raised with forceps, and about a quarter of an inch is dissected up, together with a thin layer of the muscular wall. Towards the extremities of the wound only half as much of the serous coat should be raised, as midway between them. When this dissection is completed on each side, a wedge-shaped piece of the muscular wall (closely shaded in the

* *The Science and Art of Midwifery.* New York. 1885.

diagram, Fig. 137) is cut away on each side of the wound, the base corresponding to the level of reflection of the serous coat superficially, whilst the apex of the wedge touches the decidua. Thus two muscular surfaces, readily made to lie in apposition, are formed, and they are overlapped by a layer of the serous coat. The lower sketch in Fig. 137 represents this layer turned down on the muscular tissue.

Eight to ten silver sutures are now passed into the muscular wall, at about half an inch from the margin of the wound, and made to run deeply through the wall, just avoiding the decidua, and passing across to the wall on the opposite side (Fig. 138). Then a large number of fine silk

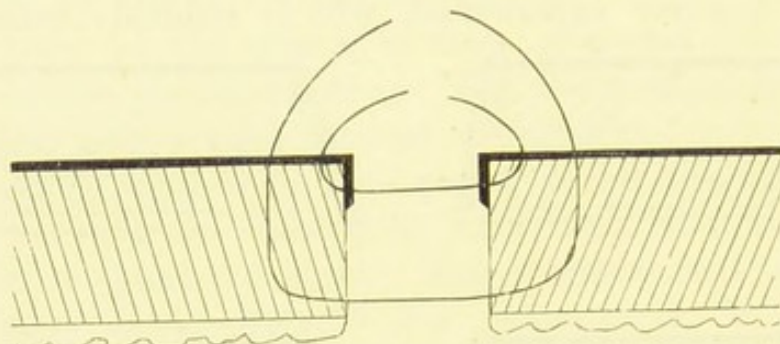


FIG. 138.—DIAGRAM REPRESENTING THE SUTURES APPLIED TO THE WOUND SKETCHED IN THE PRECEDING FIGURE.

The inner and more superficial suture passes twice through the serous coat on each side. (*See text.*)

sutures (No. 1, as recommended for ovariectomy) are passed through the serous coat (Fig. 138), the dissected part of which must be turned down against the muscular coat, so that the needle may transfix it on both sides. In this manner, when the wires are made fast, the muscular walls will be brought firmly together, and the surfaces of the inverted portions of the serous coat will lie in perfect apposition, and unite rapidly.

The elastic ligature is now removed, the uterus thoroughly washed out with the sublimate solution, the sutures made fast, and the line of suture dusted with iodoform. Any bleeding point on the uterus must be secured by a fine silk suture, passed under it by the aid of a needle, and the two ends are tied over it. If the bleeding be very severe, then, as was recommended when speaking of a wound in the surface

of a uterine fibroid that is not found suitable for removal (page 207), one end of the silk may be passed once more under the vessel, as nearly as possible along the same track, and brought out at its original point of exit; then the ends are tied across, and the vessel will be tightly gripped.

The uterus is now replaced, with its fundus forwards, and not upwards or backwards, so that the intestine should not get between that organ and the abdominal wound. The wound is then closed, and the line of suture dusted with iodoform; the abdomen is dressed with iodoform gauze and wool, held on by means of broad strips of plaster.

With regard to the dressings and antiseptics, the English surgeon would in many cases prefer other materials to those above mentioned, but I have throughout adhered to the recommendations of Säger. From my own experience of iodoform in abdominal sections, I believe it to be very serviceable.

The after-treatment should be as simple as possible. The vagina ought not to be washed out as long as the pulse and temperature remain normal, and there is no evidence of retention of lochia.

Last year (1886), at a meeting of a medical society (*Deutsche Gesellschaft für Gynäkologie*, see *Centralblatt für Gynäkologie*, No. 28, 1886) in Munich, Dr. Säger gave statistics of his modification of Cæsarean section. The total number of operations amounted to thirty. In these, the mother recovered in twenty-one cases, and twenty-seven children were thereby saved. Leopold was the most successful operator. In his eleven cases, ten mothers and eleven children were saved.

Equally interesting are Dr. Säger's simplifications of his operation for the benefit of practitioners in emergencies. As they may prove very useful, I quote them below almost literally.

Preparation.—No special instrument, such as an ordinary surgeon is not likely to have at hand, is needed. Abdomen, vulva, vagina, and cervix to be washed with sublimate solution, the instruments with carbolic solution. Sponges, if not to be had, may be replaced by wool carefully washed in one of the above solutions. Two persons sufficient to assist. "In an emergency, the anæsthetic may be confided to a layman."

Abdominal Incision.—Pressure-forceps and the early introduction of sutures in the upper part of the wound not indispensable. Except when the foetus is dead, it is not advisable to lift the unopened uterus out of the wound, as the latter might then need to be enlarged, and there would be fear of escape of intestine.

The Uterine Wound should be made vertically in the median line, avoiding the lower segment of the uterus. A horizontal incision is difficult and unsuited for the conditions under which these simplifications are especially needed. When the placenta lies in the line of incision, cut quickly through it, or detach it laterally. Säger finds that these manœuvres may be done without difficulties from hæmorrhage or during the application of the sutures. The foetus is most readily pulled out by the feet. In some positions of the head the uterine wound may require prolongation upwards.

Temporary Extraction of the Body of the Uterus from the Abdominal Wound.—A napkin, antisepticized, to be spread over the intestines; another to be folded over the uterus. In place of the elastic ligature, compression of the lower part of the uterus with the hand, or rotation of the uterus on its long axis. Manual detachment of the placenta. The patency of the os to be proved. Disinfection of the uterine cavity (iodoform). A sponge or strips of antiseptic gauze to be laid in the cavity till the deep sutures are applied.

Sutures.—For the sake of simplicity, the dissecting up and bending inwards of the serous coat, and resection of the muscular wall may be omitted when there is no marked retraction of the former nor great bulging of the latter, nor much gaping of the entire wound. The edges of the wound may be pared and adjusted, just as in any other operation. The principle to observe is to pass eight to ten deep silver sutures through the serous coat and muscular walls, avoiding the decidua, and to apply sixteen to thirty-five silk sutures to the serous coat alone, with double transfixion of that coat on each side of the incision, so as to ensure the coaptation of two serous surfaces when these sutures are tied. Other material, fine silk, antiseptic or silkworm-gut, may be used in default of silver wire. Carbolyzed catgut should never be used for the uterine

sutures. In one case, as I was informed by an obstetrician who was present at the necropsy, fifteen carbolized sutures were used. All came loose excepting one at the lower angle of the wound, which gaped freely. Säger insists on wire for the deep sutures. English operators will probably differ from him in this respect.

Irrigation of the Uterus from within with a one-half per cent. sublimate solution; application of iodoform to the line of suture, closure of the sutures; replacement of the uterus in the abdominal cavity, but not until all bleeding from the line of suture or from the tracks of the sutures has been checked by passing a fine silk thread under any bleeding point. No drainage; washing or sponging out the peritoneal cavity not always necessary. Abdominal wound to be closed with silk sutures. Then the integuments should be dusted with iodoform. The abdominal walls are gently supported with thin strips of plaster.

Bladders containing ice to be placed on the abdomen, and frequent subcutaneous injections of ergotin to be given. The after-treatment must be as passive as possible.

There can be little doubt that, with sundry modifications in accordance with the practice of surgeons outside the frontiers of the German and Austrian empires, Säger's method of performing Cæsarean section will be widely and successfully practised in the immediate future.

Cæsarean Section for Rupture of the Uterus.—I shall presently speak of a modification of Porro's operation, performed when rupture of the uterus has occurred, and will show that the usual situation of the rupture is unfavourable for the application of the *serre-nœud*. Unfortunately, the usual situation of the rupture is almost equally inconvenient for the performance of an operation which may be considered as a variety of Cæsarean section.

When rupture of the uterus has been diagnosed, it may be said, in the words of Dr. Routh,* that it is an unnecessary piece of cruelty and malpraxis to attempt to extract the child through the vagina, and to irritate the bowels with the hand.

* Discussion on Drs. Swayne and Cox's "Cases of Ruptured Uterus" (*Transactions of the Obstetrical Society of London*, vol. xxviii., 1886, p. 227).

That practice involves the risk of enlarging the rent in the uterus, and increases hæmorrhage and shock. The rule should be to proceed at once to abdominal section. The circumstances implied in this aphorism are sufficient to show that it is generally the obstetrician who is called upon to operate for ruptured uterus. Still, as in the case of Cæsarean section under more usual circumstances, he may prefer to leave that duty to some surgeon who may be at hand.

In any case, as regards the decision of the operator in favour of Cæsarean section or a modified Porro's operation, it will be necessary to make the abdominal incision first. Then, supposing that the rent lies near the fundus, it may be of a character suitable for treatment by dissecting up the serous coat, paring the muscular walls, and introducing the sutures, after Säger's method (page 373), the placenta being first extracted. The freedom of the os from any obstruction preventing free escape of the lochia must be ensured. Directly the fœtus is removed, previous to further manipulation of the uterus, the fundus of that organ should be raised out of the abdominal wound, and a large flat sponge passed behind it. An elastic ligature or the hand of an assistant will also be needed directly the abdominal cavity is opened. In general respects, the steps of this operation will be the same as in the usual kind of Cæsarean section.

When the rent is unfortunately in its most frequent position, namely, along the lower segment of the uterus, extending upward towards the body, or, worse, downward towards the vagina, the difficulties and dangers of Cæsarean section will be greatly increased. The rent is chiefly horizontal in these cases, turning upwards or downwards, almost at a right angle, at one extremity.

This fact may be remembered in connection with the suggestion of Kehrer, that in an ordinary Cæsarean section the incision should be made transversely and at the level of the os internum. The great objection to this position of the incision is the presence of the circular venous sinus at this very point (page 371).

In the case of rupture, however, the operator has no choice, or rather, he has not to select the site of an incision and then make it, but to repair a ready-made wound. This simple principle must not be overlooked. The steps of the operation, when the rupture is transverse, will be much the same as in

ordinary Cæsarean section, excepting that the foetus will probably be more or less entirely outside the uterine cavity. Other necessary modifications have just been suggested in relation to operation for rupture of the fundus. The transverse rupture will require very careful application of the sutures after Säger's method.

I will conclude with Dr. Lusk's comments on gastrotomy for rupture of the uterus*:—"The results of gastrotomies performed for the removal of the child after its escape into the abdomen are extremely encouraging, Trask's statistics† showing 76 per cent. of recoveries, those of Jolly 69 per cent., and the United States' statistics, collected with indefatigable zeal by Harris, 53½ per cent. In the autopsies I have witnessed upon women who have died from rupture after delivery by the natural passages it has always seemed to me that a timely gastrotomy, performed before peritonitis had set in, would have afforded a good chance of saving a patient's life."

It must be remembered that in most of the cases included in these statistics the wound was not sewn up in the systematic manner adopted by recent German authorities. Had it been always so treated, not to speak of other precautions only lately suggested, the mortality would undoubtedly have been much lower.

Porro's Operation.—By this term I signify, according to Dr. Godson's definition,‡ Cæsarean section followed by removal of the uterus, together with its appendages (including the ovaries), leaving only the cervical portion of the uterus. Hence, the surgeon may liken it to supra-cervical hysterectomy for fibroid tumour of the uterus; but for the conditions involved

* *Loc. cit.*, p. 610.

† The surgeon interested in the subject of rupture of the uterus should consult Dr. Trask's valuable "Statistical Inquiry into the Causes of Rupture of the Uterus" (*American Journal of the Medical Sciences*, vol. xv., new series, 1848). He noted that in only 11 out of 265 cases of rupture during parturition was the laceration found to occur at the fundus. On the other hand, it was discovered at the fundus in 7 out of 38 cases of rupture during gestation. Subsequent researches have confirmed the accuracy of these statistics.

‡ "Porro's Operation": Introduction to a Discussion in the Section of Obstetric Medicine, Fifty-first Annual Meeting of the British Medical Association (*British Medical Journal*, vol. i., 1884, p. 142).

in that disease he must substitute the conditions involved in pregnancy when the foetus is viable.

The patient should be prepared as for ovariectomy, but the waterproof sheet is not required. The incision through the abdominal walls must be of a fair length, at least four inches, beginning close below the umbilicus, for in relation to the incision the conditions are, in this case, not the same as in ovariectomy. The walls will probably be found to be very vascular, as in cases of fibroid, but the temporary application of pressure generally proves sufficient to arrest hæmorrhage. When the surface of the uterus comes into sight, it should be examined to see if the placental attachment lies in front. This happened in Dr. Godson's case. "The uterus being exposed, its anterior surface was noticed to be very livid in appearance, suggesting that the placenta was attached to the anterior wall, and therefore I made as low down as possible—that is, about the junction of the lower with the middle third—a small incision just large enough to admit the finger; a gush of venous blood occurred, and the membranes were seen. I immediately inserted the tip of each forefinger, and tore the womb open transversely. There was no resistance. The membranes were not ruptured by this manipulation; therefore, knowing the exact position of the foetus, I thrust my hand through them into the right iliac region, and seizing the neck without difficulty, extracted the child." When the anterior surface of the uterus does not appear to be livid, then a freer incision may be carefully made through its walls, for the extraction of the foetus.

Whilst the child is being removed, and the umbilical cord divided, an assistant grasps the neck of the uterus with his left hand introduced into the pelvis, so as to control hæmorrhage. With his right hand he slips the wire of a Koeberlé's *serre-nœud* (described at pages 122, 295) around the uterus at the level of the os internum, taking care that both ovaries and tubes are included—that is, that they both lie on the distal side of the wire. The wire is now made tight. Two pins are then made to transfix the uterine tissues about half an inch above the wire. This must be done precisely as in hysterectomy for fibroids, and it is best that the surgeon

should do it at this stage, and not after the uterus is cut away. The pins will serve as additional landmarks and safeguards, and there cannot be too many such aids to the operator.

The surgeon himself having ascertained that the wire is sufficiently tight, and given the child, if alive, into proper hands, now amputates the uterus above the pins. The intestines above the stump should be at once guarded by a large flat sponge, as in ovariectomy. The lower part of the abdominal incision must be firmly secured by sutures introduced as in other abdominal sections, and brought close to the stump of the uterus, below the wire. It is not, as a rule, necessary to apply a suture to the walls below the stump, which should be pushed down to the lower angle of the wound. Then the sutures are applied to the upper part of the wound, the flat sponge removed, and the peritoneum carefully freed from clots. Very little blood need be lost during this operation.

The free surface of the stump should be lessened in area in the manner which I have described in the chapter on Hysterectomy, and any portion of it which must be left exposed should be dusted with iodoform or solid perchloride of iron.

The operation is best performed with full antiseptic precautions. A catheter should be kept in the bladder during the operation. The dressings are applied as after hysterectomy. As in all clamp or *serre-nœud* cases, much care must be taken to draw off the urine regularly every six hours, else the patient will be sure to suffer great pain. The stump must be inspected daily, and the wire tightened whenever necessary. The stump or pedicle will become slowly detached, and will separate entirely in about three weeks. The raw surface left after separation should be carefully dressed with iodoform powder or carbolic lotion.

Operations allied to Porro's.—There are several operations related to that which, according to Dr. Godson's definition, bears the name of Porro. These are all performed on a pregnant uterus, but otherwise differ considerably in many respects from Porro's operation.

Of these, the first is total amputation of a pregnant uterus, including the cervix.

The second is supra-cervical amputation of the uterus, and removal of the ovaries, performed during pregnancy, but before the foetus is viable.

The third is removal of a foetus from the abdominal cavity after rupture of the uterus, and amputation of the ruptured uterus, with removal of the ovaries.

Total Amputation of a Pregnant Uterus, or "Porro-Freund's Operation," has been successfully performed by Sir Spencer Wells in one case where I was present and had the advantage of closely inspecting every step of the operation. It has been described more than once,* but deserves notice here, since similar cases may occur in the future and may require similar treatment.

The patient was a woman aged thirty-seven, suffering from epithelioma of the cervix, and six months pregnant. She had borne five children already. The cervix was long and enlarged, the os admitting one finger easily for an inch, and the canal and os were covered with an exuberant epitheliomatous mass. After several less severe measures had been proposed, and rejected for various reasons, it was decided to remove the uterus entire.

Full Listerian precautions were taken. The patient was placed in ovariectomy position. It was considered advisable to keep a catheter in the bladder, and an opening was made for it in the waterproof sheet which was applied to the abdominal walls as in the operation for removal of an ovarian tumour. The vagina, which must always be thoroughly washed out with an antiseptic solution before any proceeding of this kind, was plugged with thymol cotton moistened in a tepid 1 per cent. solution of thymol. The abdominal incision was commenced two inches above the umbilicus, and prolonged for six inches below it. The pregnant uterus being thus freely exposed was lifted out of the upper part of the wound. A flat sponge was placed over the intestines, to protect them from injury, to avoid sudden prolapse, and to prevent chilling of the peritoneal cavity by the action of the spray. This arrangement,

* "Case of Excision of a Gravid Uterus with Epithelioma of the Cervix" (*Med.-Chir. Trans.*, vol. lxx., 1882). *Diagnosis and Surgical Treatment of Abdominal Tumours*, p. 171.

described by the operator, was, as may be seen from what I have said elsewhere in this work, in accordance with the general principles of abdominal surgery. The edges of the upper part of the wound were then united by four silk sutures.

In order to secure the ovarian vessels, the broad ligament was transfixed below the ovary, and tied with strong silk, on both sides. The ovaries were found at a higher level and nearer the fundus than was expected, so that this proceeding was not very difficult. Here I may note that, in pregnancy, the uterine appendages are drawn up high out of the pelvis, and lie symmetrically* on each side of the gravid uterus.

The bladder was then dissected from the anterior surface of the uterus. The thin, tense walls of that organ suddenly gave way. The membranes were ruptured, and the foetus extracted, the cord being tied and cut. The connections between the uterus and the vagina were separated, the operator cutting close round the cervix, and securing by pressure-forceps all bleeding vessels as they were divided. In this manner the entire uterus, with the cancerous mass in the cervix, was removed. The forceps were taken off successively, and every bleeding vessel tied with carbolized silk. The vaginal plugs were taken out, and the opening in the vagina and the edges of the divided broad ligaments were united with silk sutures. The pelvis was cleaned with sponges. Silk sutures were applied to the lower part of the abdominal wound, and then the entire wound was closed. The abdomen was lastly covered with dressings, as in a case of ovariectomy.

This operation† was completed within an hour. The foetus was of about the sixth month. The abdominal wound opened on the eighth day, through frequent vomiting, but was readily closed again. The patient returned to her home on November 21st, 1881, a calendar month after the operation. She enjoyed good health for eight or nine months, though in February, 1882, a suspicious thickening was discovered in the

* See p. 292.

† Systematic writers speak of it as "Porro-Freund's operation," as it is a combination of Porro's operation with total extirpation of the cancerous uterus as practised by Freund (see p. 318, *note*).

vaginal cicatrix. Thirteen months after the removal of the uterus she died, a large mass having formed in the left iliac fossa.

In this case I examined the uterus after its removal, and it appeared to me that the whole of the area of visible cancerous disease had been taken away. Some of the broad ligament left behind probably contained cancerous elements (see page 317). The result of this case certainly tended to justify the operation. Delivery through the cancerous os after three months of further progress of the malignant disease would have entailed great risks.* As it was, those three months, or at least the last two, were spent in comfort, to which may be added another month *not* spent in childbed, and a few more months of relative ease while the patient still remained in good general health.

Supra-vaginal Hysterectomy during Pregnancy.—

The second variety of operation allied to that known as Porro's is supra-vaginal and supra-cervical amputation of the uterus and removal of the ovaries, performed during pregnancy, but before the foetus is viable.

This operation practically implies removal of a pregnant uterus affected with fibroid disease. It is, however, conceivable that it might be done for other complications.

Pregnancy during fibroid disease may be overlooked, even by the experienced. There may be frequent discharges of blood from the vagina, mistaken for menstruation; the abdominal enlargement may be attributed, very naturally, to the fibroid tumour alone; besides, the patient, probably feeling sensations different from those experienced in previous pregnancies, may fail to direct the surgeon's attention to matters which would suggest pregnancy. These matters, on the other hand—enlargement of the breasts, for example,—may be duly noted by the surgeon, yet attributed to other causes. Oozing from the nipple is observed in some cases of fibroid disease where there is no pregnancy. Lastly, as in many other diseases, it has been taken for granted that undersized, repulsive, and otherwise ill-conditioned single females are never exposed to those unfavour-

* Hence this operation differs in principle from total extirpation of the non-pregnant uterus.

able ethical conditions which involve pregnancy. This has led to error, in one case at least, as I am aware.

Removal of a pregnant fibroid uterus is a very difficult and dangerous operation. When it is performed late in an undiagnosed pregnancy the alterations in the cervix interfere with a firm application of the serre-nœud wire, and intra-peritoneal treatment of the pedicle will be yet more hazardous. Moreover, the discovery of an unexpected foetus will disconcert even a strong-nerved operator. I have known disastrous consequences to follow in two cases. In a third, at which I assisted, the patient was a miserable, sickly single woman aged thirty-two, who had been more or less confined to her bed for a year. A solid oblong tumour extended nearly to the ensiform cartilage, and the abdominal incision had to be extended two inches above the umbilicus. On extracting the tumour from the wound, a tense globular swelling, looking like a cricket ball, was observed on its lower aspect; its walls were much paler than the surface of the growth. This swelling proved to be the uterus. Dr. Bantock passed the wire of a Koeberlé's serre-nœud round the cervix, the pins were applied, as in an uncomplicated hysterectomy, and the tumour and uterus were cut away. As the knife passed through the uterine tissue, a dead foetus, three inches long, with placenta, escaped. Recovery was rapid.

Mr. Knowsley Thornton successfully operated, in 1882, on a case where pregnancy at four and a half months was evident, and a large fibroid gave great distress. Sir Spencer Wells performed a true Porro's operation last May (1887), removing a pregnant fibroid uterus close upon term. Both mother and child were saved.

In short, when this operation is decided upon, before or during abdominal section, it must be performed precisely as an ordinary hysterectomy for fibroid disease, but with more than usual deliberation. When, on opening the abdominal cavity, unsuspected pregnancy is discovered, and the fibroid growth proves to be small and not in a position to interfere with delivery at term, it will be advisable to close the wound and wait.

No general rules can be laid down for these grave cases, and much will depend upon circumstances and on the surgeon. They demand considerable experience in abdominal surgery.

Supra-vaginal Hysterectomy for Rupture of the Uterus: Removal of the Fœtus from the Abdominal Cavity.—The results of this bold proceeding have proved highly unsatisfactory. I have noted some of the features of rupture of the uterus in the observations on Cæsarean section (page 377). The rent being usually near the cervix, it is placed in the situation most unfavourable for the safe application of the wire of the serre-nœud. Should it be near the fundus, and should the surgeon determine upon this operation, he must secure the uterus by means of an elastic ligature directly the abdominal cavity is opened, remove the fœtus, and then proceed as in Porro's operation properly so called.

Laparo-elytrotomy,* or Thomas's Operation.—This operation consists in cutting down on the upper part of the vagina through an incision above Poupart's ligament, the peritoneum being pushed aside. The fœtus is then delivered through the wound. Thus the peritoneal cavity is not opened, and the fœtus has not to pass through the pelvis, which, it is to be assumed, is contracted in cases where this operation is undertaken. Recently Dr. Gaillard Thomas has practised and advocated it, and has been followed by several American and British operators. Up to 1885 the statistical results were the saving of six mothers in twelve operations; but as Dr. Lusk points out, the cases were mostly in the hands of exceptionally good and experienced operators. Dr. Playfair believes that "the operation has a great future before it."† British operators are not likely to adopt it, at present, in preference to Porro's operation or Cæsarean section. Its chief merit lies apparently in the fact that the uterus is not wounded; as for the peritoneum, few operators now fear to open its cavity.

* "Λᾱπάρα, Ion. λαπάρα, the soft part of the body between the ribs and hips, the flank, loins. Latin, *ilia*."—*A Lexicon abridged from Liddell and Scott's*. "Laparo" is, therefore, fairly correct in this case, when we remember the situation of the abdominal incision.

† *A Treatise on the Science and Practice of Midwifery*. Sixth edition. 1886.

CHAPTER XV.

OPERATIONS FOR THE REPAIR OF RUPTURED PERINEUM, AND
FOR THE RELIEF OF PROLAPSUS UTERI.

Rupture of the Perineum.—This injury is so frequent, that the operation for its repair is the commonest and best known plastic procedure in the neighbourhood of the female organs.

In the large majority of cases, rupture of the perineum takes place during labour. The perineum is exposed to considerable violence during the expulsion of the child from the vagina, especially in certain unfavourable presentations. The hands and instruments of the obstetrician may cause the injury. The anterior part of the perineum may alone be torn, whilst in other cases the rupture is complete so as to involve the sphincter ani. In very rare instances, the vaginal wall has been torn above the vulva, and the child forced through the rent and out of the middle of the perineum, making for itself a rupture through the perineal integuments which does not reach either forwards to the vulva or backwards to the anus. This condition is termed "central rupture of the perineum." It is now generally agreed that when a rupture of the perineum is discovered after labour it should be sewn up at once. This it appears can often be readily and successfully performed, even when the sphincter ani is much involved. When that complication does not exist, there can be no doubt that the perineum should be repaired directly. In cases where it does exist a successful immediate operation saves the patient from certain misery, and economizes the time which she must spend in the sick-bed. Yet when the laceration extends far into the rectum

the operation directly after labour may be very difficult, and the wounds may heal badly. Hence, after it has been performed, the parts must be examined from time to time during recovery, and the surgeon must make sure that the sphincter regains its functions, nor must he be discouraged should a fresh operation be necessary.

Dr. Gaillard Thomas has observed that for laceration of the perineum there is but one cause—parturition. It may occur, however, during the instrumental delivery, not of a child, but of a fibroid polypus, or a sessile fibroid tumour shelled out of its capsule. The rent may then be caused by one blade of a large volsella, but I have seen it produced in a middle-aged single woman, by the simple dilatation of the posterior part of the vulva during careful extraction of the tumour piece by piece. The laceration in this case was slight, and extensive damage can always be prevented by avoiding hurry in the extraction of the tumour, and by removing small fragments only at a time.

Anatomy of the Perineum.—The term perineum is not understood precisely in its dissecting-room sense, when a ruptured perineum is signified. The integuments between the vulva and the anus, the perineal body and the vaginal, and often the anal mucous membranes are torn when the perineum is ruptured. The sphincter ani may or may not escape damage; the sphincter vaginae, it would appear at first sight, cannot escape laceration. This muscle, however, is of less importance than was formerly supposed.

A pyramidal collection of connective-tissue fibres chiefly elastic, with its apex upwards, lies beneath the integument of the true perineum, and extends between the walls of the rectum and vagina. This is the perineal body described by Savage. It acts as a point of attachment for several muscles, and keeps the canal of the anus well back, also preventing the anterior wall of the rectum from bulging into the vagina. The perineal body protects the soft parts inferiorly and posteriorly during labour. Berry Hart compares it, in this respect, to the brass-bound edge of a doorstep. On the other hand, this body is not the main support of the vagina, uterus, and abdominal viscera above them. Even if it were made of dense bone, it could not

prevent them, under unfavourable circumstances, from sliding down in front of its boundaries.*

Pathology of Ruptured Perineum, and Principles of Treatment.—The inconvenience of ruptured perineum hardly needs explanation. The relations of the recto-vaginal septum are disturbed, the attachments of several important muscles displaced, and the sphincter ani is often torn. No doubt the perineal body takes a share in the support of the parts above it, though not nearly to such an extent as was formerly supposed. The frequent coincidence of prolapse of the uterus, however, is not to be entirely explained by the rupture of the perineum.

It does not require much argument to prove that the way to relieve the symptoms of ruptured perineum is to repair the rupture, and experience proves that when properly repaired, the relief is perfect. Hence surgical considerations are the most important in respect to this subject. Distinguished authorities in all parts of the civilized world have studied the anatomy and surgery of the perineum; but there is no room in these pages for a fair summary of their conclusions. Many practical surgeons have successfully operated on large series of cases of ruptured perineum, guided by one principle, the recognition of the necessity of sewing up the parts so that they should hold together and heal, and ensuring that the repaired parts do not break down afterwards. The innumerable variations in the details of this operation, which is often termed perineorrhaphy, are nearly all founded on this principle. One operator prefers one kind of suture, another adopts a partially or totally novel line of practice. Again, surgeons differ greatly in their opinions as to the best kind of after-treatment—that is to say, as to the best manner of allowing a strong cicatrix to develop, with as little risk as possible from the passage of fæces in its immediate neighbourhood.

The surgeon should remember that when the solid pyramid of more or less elastic tissues forming the perineum is torn through, the parts originally lowest and most central—that is,

* For fuller details concerning the anatomy of the perineum and other scientific considerations relating to that region, the reader should consult Dr. Savage's *Atlas* and Dr. Matthews Duncan's *Papers on the Female Perineum*.

along the raphe—fly more widely asunder than the remainder of the lacerated tissues, and constitute the lateral boundaries of the raw surface formed by the injury. The upper limit of the laceration will descend so as to occupy a central position along the raw surface, on a plane almost as low as that of the lateral boundaries. The raw surface itself will represent the deep tissues torn through between the lower and the upper limit of the laceration, and gaping apart in two halves. When sutures have been passed behind the two halves of the raw surface, emerging beyond its lateral boundaries, the two halves will be brought together when the threads are pulled tight; the lateral boundaries will be drawn downwards and inwards till they meet along the middle line, and what was the middle line of the raw surface will lie anatomically uppermost. Thus the parts will be restored to their normal position.* Anteriorly and posteriorly lie the vaginal and anal mucous membranes. If torn, here, again, the uppermost limit of the laceration will lie in the middle of the torn edge. Certain special precautions, however, are needed in sewing these parts together, lest mucous membrane should be forced between the edges of the line of suture.

Preparation for Operation on Ruptured Perineum.

—The surgeon has not only to make and to promote the healing of a wound, but he must ensure the formation of a strong cicatrix. Hence he should attend to the patient's general health, and make sure that the bowels are in a satisfactory condition. Dr. Gaillard Thomas gives good advice on this subject in his *Practical Treatise on the Diseases of Women*. He observes that the intestinal canal is about twenty-five feet long, and keeps fæcal masses stored up in it for months. Therefore, he recommends that two entire weeks should be devoted to complete evacuation of all scybalous masses. This may be effected by the frequent administration of purgatives, such as rhubarb or colocynth, not so as to produce continual purging, but so as to open the bowels twice every twenty-four hours. The dose must be given according to the patient's susceptibility to purgatives. An enema should always be administered shortly before

* These changes of plane and position are explained in the diagrams illustrating the operation for the restoration of a complete rupture of the perineum.

operation. Once more, I repeat, the purgative must not be given so frequently or in such large doses as to set up diarrhoea, as that condition may cause serious inconvenience during operation.

Great care must be taken to relieve any symptoms of hæmorrhoids or discharges from the uterus and vagina. Internal piles are a frequent complication of ruptured perineum, and the trouble which they cause is mixed up with the inconvenience produced by the rupture. Owing to the destruction of the entirety of the sphincter, some of the most distressing subjective symptoms of piles will be absent; but the presence of hæmorrhoidal swellings will cause inconvenience to the operator, and they always imply a more or less unhealthy state of the surrounding mucous membrane. When they exist, then, it is advisable to pay particular attention to the rectum, guarding it from prolapse as much as possible, and keeping it supported (before, not after the operation, be it strictly understood) by a T-bandage.

Discharges from the genital tract may prove very prejudicial to the healing process. When they occur in acute local disorders, the latter must, of course, be cured before any operation is attempted. When they are unaccompanied by evidence of uterine, ovarian, or tubal disorder, they are generally associated with some visceral disease, such as emphysema and bronchitis or hepatic congestion. In these cases the discharge is none the less mischievous because it does not represent a local disease. In plethoric women of intemperate habits, it may be very hard to check. Hot-water injections and the application of cotton-wool plugs, soaked in glycerine, to the cervix will generally do much good. In these cases, not only is the discharge irritant, but the wounds do not tend to heal quickly. It is, therefore, just among such cases that failures are most frequent.

The Operation for Rupture including the Sphincter Ani.—I have no intention of attempting to describe all the varieties of operations for the cure of ruptured perineum. I shall confine myself to the description of two or three methods which at present commend themselves to different operators, without critically discussing their relative merits.

I believe that the simplest method for the beginner is that

which is practised, on modifications, to a certain extent, of details introduced by previous operators, by Dr. Bantock, and described in his work *On the Treatment of Rupture of the Female Perineum*. This method is widely adopted by other experienced specialists. I find that it is followed by excellent results. For these reasons I think it best to give the method the first place on the list of those which I now propose to describe. Dr. Bantock has kindly revised the following account of the operation, as he has altered certain details, especially those which concern after-treatment, since the publication of his work on the subject.

I must first remark that division of the sphincter ani, or incisions through the integument on each side of the line of union to relieve tension, are considered unadvisable by most living authorities.

The patient must be placed in the lithotomy position directly she is fairly under the influence of the anæsthetic. As in ovariectomy, the preparations for fixing her in the proper posture should not be commenced until she is no longer in a condition to observe and to be frightened by them. A Clover's crutch (page 132) should always be employed, if possible, as it greatly economizes assistance. The parts are washed, and the hairs of the posterior part of the vulva and the perineum are shaved away or cut close. A large pan or footbath should lie vertically below the parts, so as to catch blood, forceps, or water used for cleansing purposes. The labia are held apart. This is best done by a different person on each side. The fingers of one hand can hold back the greater labium by dragging on the integuments external to it, whilst the palm of the same hand presses back the buttock. The two assistants will each have a hand free for holding sponges and instruments. They must stand so as to keep well out of the operator's light.

Sometimes the area for denudation is well marked out by a wide surface of pale cicatricial tissue, but this is not the rule. The operator makes an incision with a small scalpel on each side (Fig. 139, *a b* and *c d*), from before backwards, beginning at the point where the lesser labium is lost on the inner aspect of the greater, and ending at the level of the anal orifice, which in severe cases lies wide open.

The posterior extremities of these two incisions are now united by a third, which passes across the line of junction between the vaginal and rectal mucous membranes (Fig. 139, *b*, *e*, *d*). The best way to make this incision is to hold the scalpel with the edge of the blade uppermost, and to enter the point at the left extremity of the line between the mucous membranes. The point is then pushed under the tissues along the line to its right extremity, so that the edge of the blade cuts through them. The rectal mucous membrane often bulges, and may

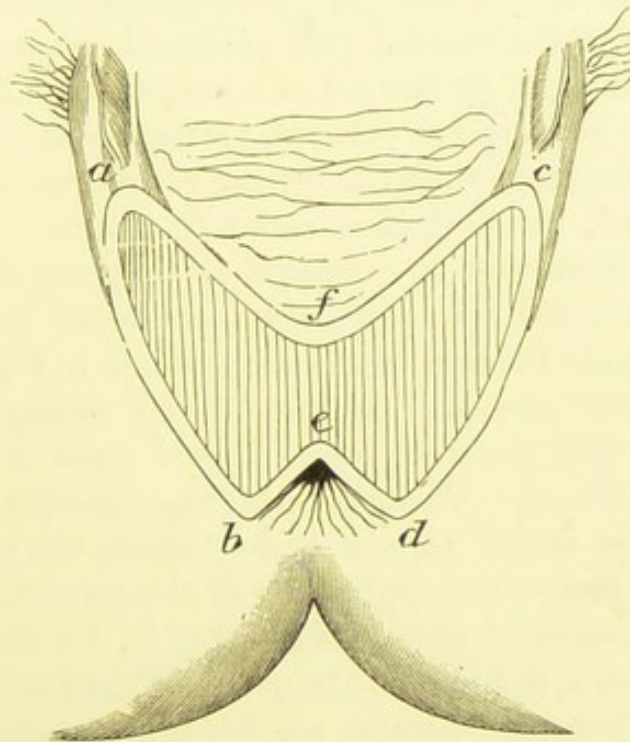


FIG. 139.—OPERATION FOR RUPTURED PERINEUM.
The raw surface. (*Bantock.*)

present hæmorrhoidal dilatations. When such is the case, the edge of the protruding mucous membrane must be seized by a long-bladed spring-forceps, which is then allowed to hang down, thereby dragging the mucous membrane out of the operator's way, or it may be held by an assistant. During all these manœuvres, the bleeding, sometimes very free, must be checked by sponges wrung out in hot water and mounted on holders. Any spouting artery should be secured by pressure-forceps, or by torsion if the hæmorrhage be considerable and the vessel large. In many cases no vessel will require ligature,

provided that the operation is not done in a hurry, and that the pressure-forceps are not removed until the perineum is closed. It is always best to avoid ligatures, if possible.

The mucous membrane must now be dissected up, the limits of the area thus denuded being the longitudinal incisions *a b, c d* laterally, the transverse incision *b e d* posteriorly, and the line *a f c* anteriorly. The vaginal mucous membrane is dissected up, from behind near *b e d*, forwards as far as *a f c*. None of it must be cut away, for as it is raised by dissection it will retract. If this part of the vaginal mucous membrane be redundant, or the vaginal wall prolapsed, an assistant should hold up its cut edge, by the aid of a long-toothed forceps. For this dissection scissors are perhaps preferable to the scalpel, as there is less bleeding when the former instrument is used. On the other hand, the scalpel is easier to handle.

When the dissection is complete, so that the mucous membrane has retracted up to the limit indicated by *a f c*, the parts will assume the appearance represented in Fig. 139. Two triangles of raw tissue will be formed. By closing on itself the line *b e d*, so that the raw edges *b e, d e* come in contact, the anus will be closed. Then, by bringing together the surfaces of the triangles which gape so widely apart, the perineum will be restored. Before the application of the sutures, the parts lie gaping, the tissues in the middle—that is, between *f* and *e*—being almost as low down as the plane of the limiting incisions *a b, c d*. When the sutures are brought together, the lines *a b, c d* will be drawn inwards and meet each other, forming the middle line of the perineum; *f e* will be high up in the recto-vaginal septum, and the raw surfaces, instead of looking almost directly downwards, and only meeting along the middle line, will look inwards, touching each other along the vertical mesial plane of the perineal body.

Such is the problem to be solved. This must clearly be understood by the operator. The patulous condition of the parts and the bulging mucous membrane often confuse the inexperienced.

The mucous membrane of the anus is first united—that is, the lines *e b, e d* are brought together. Silkworm-gut is very useful for this purpose. Each suture must be threaded on two

small curved needles, one at each end. Then one needle is seized between the blades of a holder, and passed through the raw surface close to the free edge of the mucous membrane just below *e*, towards *b*, transfixing the membrane close to its edge,* so that one end of the thread is brought out. The other needle is made to bring the opposite end of the thread out through the rectal mucous membrane below *e*, towards *d*. Three, four, or more sutures are thus inserted, from above downwards (Fig. 140).

The needle-holder must always be used for the application of sutures; if the fingers alone be employed, the needles will be difficult to pass, and the parts may get bruised by the knuckles.

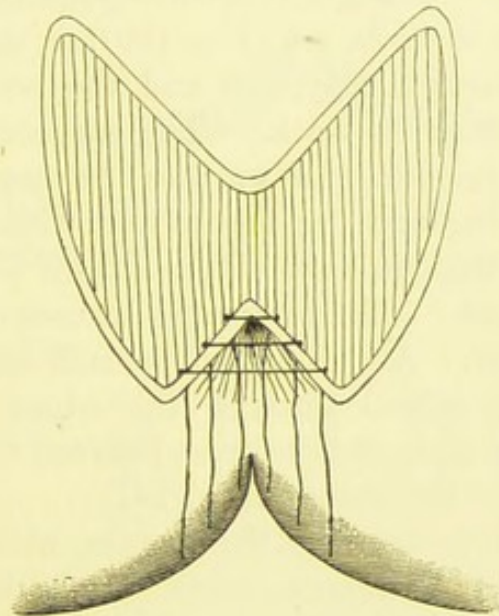


FIG. 140.—OPERATION FOR RUPTURED PERINEUM.
The anal sutures. (*Bantock.*)

The needle should always be passed in the manner just described, as inversion of mucous membrane into the wound and faulty apposition are thereby most readily avoided. The sutures, when all inserted, are drawn together, and after a good washing of the parts by a jet of cold water from a Higginson's syringe, the ends are tied and cut short. When this is done, the edges *b e* and *d e* (Fig. 139) will be brought together, as in Figs 141, 142.

* It is a great mistake to introduce the needle too far from the edge. Such a practice results in the inclusion of portions of mucous membrane between the sutures, and consequent failure of union of more or less of the wound.

The perineum itself has now to be restored. For this object a surgeon not used to plastic operations will find a mounted needle with a strong curve most satisfactory. The use of a free needle and a needle-holder for this purpose requires practice. A well-curved handled needle, eyed near the point, is the most satisfactory kind of free needle. As in the case of the rectal sutures, silkworm-gut is the best material.

The needle, whether mounted or not, must be entered about a quarter of an inch from the margin of the longitudinal incision, *c d* (Fig. 139), on the left side, and about the same distance in front of the anal orifice. It is then pushed under the raw surface till it emerges at a corresponding point external to the longitudinal incision, *a b* (Fig. 139), on the opposite side; then the suture thread is applied and the needle withdrawn, leaving the thread in its track. The surgeon keeps his left forefinger in the rectum, and watches the raw surfaces as he passes the needle through the tissues and withdraws it, so that he can make sure that no part of the suture lies in the rectum or crosses the wound. The remaining sutures are then applied in the same manner. About five will be sufficient. The higher sutures should be passed through the edges of the vaginal mucous membrane, and made to cross between them in the open—that is, not under the tissues (Fig. 141).

Sometimes much prolapse of the rectum, with redundancy of the vaginal mucous membrane, exists. It is then advisable to dissect away a wedge of the mucous membrane, beginning at the point, *f* (Fig. 139), and to unite the edges after the manner adopted for the rectum (Fig. 142). The amount of tissue dissected away will differ according to the degree of redundancy of the mucous membrane.

The sutures having been inserted, the opposite ends must be held up by the assistant; he will find it advantageous to secure the ends by the aid of pressure-forceps, as I have recommended in the chapters on Ovariectomy (page 236). Then he can hold the sutures loosely, but well upwards out of harm's way. The operator sponges the wound and washes it out by syringing as before. When the bleeding has ceased, the crutch must be taken off and the patient's knees brought together.

The operator now holds the ends of all the deep sutures in

his right hand and draws them towards himself. He, at the same time, presses gently on the recto-vaginal septum by

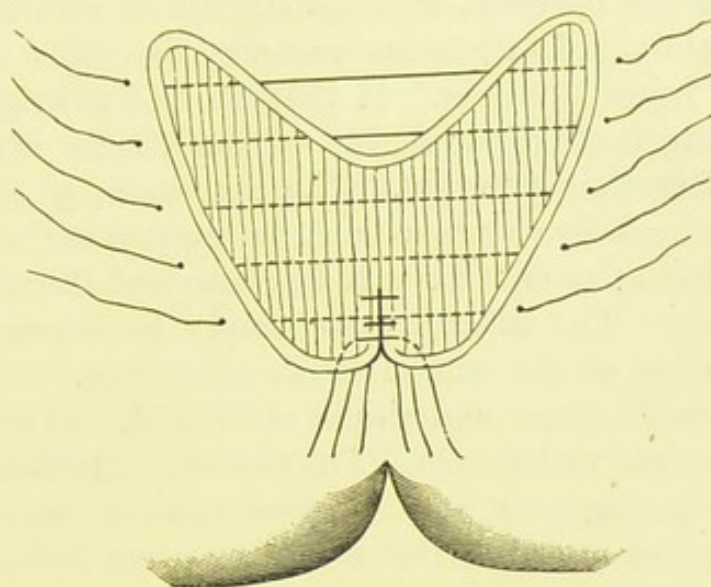


FIG. 141.—OPERATION FOR RUPTURED PERINEUM.

The perineal sutures. Anal sutures tied. (*Bantock.*)

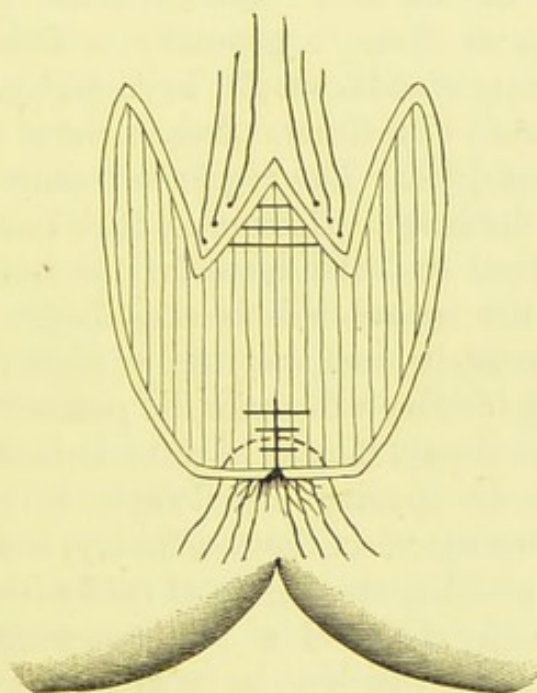


FIG. 142.—OPERATION FOR RUPTURED PERINEUM.

Sutures applied to vaginal mucous membrane. (*Bantock.*)

introducing the left forefinger into the vagina, so as to ensure proper adaptation of the raw surfaces. Then the assistant

takes charge of the ends of the sutures, excepting the lowest, holding them firmly, but a little upwards, so as not to be in the way of the operator, who ties the lowest suture firmly but not too tightly. In the same manner, the other sutures are tied, from below upwards. If they be tied too tightly, there will be danger of strangulation of the tissues when œdema sets in, after the operation. The sutures may cut through the tissues and leave tracks apt to suppurate; and, should the parts heal, the cicatrix will be weak and ill-supplied with blood-vessels. The sutures must simply be drawn firmly, so that the edges of the wound lie in apposition.

The patient's knees and thighs are flexed, and she is put to bed, on her right or left side. The parts must be left uncovered by any T-bandage, so that all discharge can escape. Small doses of opium are given by many surgeons during the first few days. Bantock and Tait believe this drug to be prejudicial.

The patient must continue to lie on her side, her position being made comfortable by pillows, until a day or two after the removal of the sutures. The external parts, as a rule, require washing, as there is generally a little discharge. If there be none, they should simply be kept dry. The washing is effected by means of a stream of tepid water from a syringe; the parts are then dried. The vagina will only require washing should there be discharge. This must then be done gently, and care must be taken to leave space for the return-current, else the parts near the wound will be stretched.

The catheter must be used every six or eight hours for several days, as a loaded bladder will make the patient restless. There is probably little, if any, danger of urine irritating the wound.

The question of opening the bowels is most important. Dr. Bantock administers, on the fourth day, a drachm of compound liquorice powder, or a grain of colocynth and a grain of hyoscyamus, in the form of a pill, every four hours until the bowels act. If the bowels be kept closed for a week, scybala will form and will put the united parts to great danger, especially in the region of the anus, where repair is most important. It is not advisable, as a rule, to administer opium. This drug certainly appears to increase the tendency to the formation of scybala, particularly when the patient is

kept on a milk diet. As to this question of diet, the patient is best without any form of alcohol. Milk and farinaceous diet should be given for two days: oatmeal gruel is particularly good. Fish may be allowed on the fourth and meat on the fifth or sixth.

Removal of Sutures.—The deep perineal sutures should be removed between the eighth and tenth days after operation. The knot of each suture is gently drawn down, by means of a pair of forceps, and the thread is cut on one side of the knot with scissors, then it can be pulled out. The rectal sutures often do not require removal. If they cause pain, they may be taken away in the same manner as the others.

Purse-string Operation.—There is an important modification of the ordinary operation for the repair of a complete rupture of the perineum, especially adapted for cases where the sphincter ani and an inch or less of the recto-vaginal wall are torn through. The purse-string operation has been advocated by several distinguished specialists, and I describe it as performed by Dr. Percy Boulton. I am of opinion that it requires more experience and dexterity than the operation which has just been detailed. The patient is first placed in the lithotomy position. The parts having been well shaved and washed with antiseptic lotion, the left forefinger is introduced into the rectum. The operator then takes a scalpel in his right hand and, cutting from left to right, makes a wound between the everted rectal mucous membrane and the vaginal mucous membrane at their line of union. The incision must begin and end at the points marked $\times \times$ in Fig. 143, as they have to be brought together anteriorly in order to close the anus. A tongue of vaginal mucous membrane above the rent must be dissected up to the extent of about three-quarters of an inch, and its edges must be held up by pressure-forceps, out of the operator's way, by an assistant. Sometimes, though rarely, an artery requires to be secured by forcipressure. The finger is now taken out of the rectum. The wound is prolonged backwards along the side of the anus, and then forwards, to about the extent of an inch and a half along the junction of skin and mucous membrane. The latter is

dissected inwards and may be cut off with scissors, or simply turned inwards so as to be continuous with the tongue of mucous membrane already dissected up. More tissue must be removed posteriorly near the anus, than anteriorly. These dissections form the raw surface represented in Fig. 143. The assistant must freely use the sponges at this stage.

The surgeon now begins the first part of the reparative process by the introduction of sutures. He takes a slightly curved needle about two inches long, and threads it with a stout piece of silkworm-gut. It is entered, on the right side, at the point \times , Fig. 143, in the anal integument, so as to pierce the angle of the torn sphincter muscle, passed under the tissues of the wound, brought out, for the sake of convenience, on the free surface of the centre of the wound at $+$, Fig. 143, re-entered into the wound and passed under it till its point issues at \times on the left side; the needle then completely encircles the tear through the recto-vesical wall. The needle is then withdrawn from the thread. The two ends of the thread will hang out of the integument close to \times on each side. The operator may keep the needle entirely under the surface of the wound if he please, but this elegant though difficult manipulation is of no advantage to the patient, and requires a clumsy, and very strongly curved needle, else the point of the instrument is liable to break before it is brought out on the left side. The suture (*a a*, Fig. 143) may now be tied, if the operator likes to see tangible proofs of progress, though all tying may be left till the last perhaps with advantage. When the two ends of the silkworm-gut are tied, the points $\times \times$ are brought together in front at $+$; that is to say, the ring of the anus having been torn through in front at $+$, and having flown asunder so as to form a straight line with its torn surfaces at each extremity, $\times \times$, is now restored, these surfaces being brought once more together.

The next step consists in restoring the sphincter ani to its original position. The surgeons who operate after the method now described do not attempt to unite the edges of the muscle they merely bring it, with its surrounding tissues, to the front, just as the ring of the anus has already been restored. The silkworm-gut is introduced a little behind the point of entry of

the former suture, piercing the skin and torn end of the sphincter ani muscle, and carried upwards under the surface of the wound till it is brought out a little above +; that is to say, higher in the vagina than the former suture, and re-entered and once more brought out to the left opposite the point of entry (*b b*, Fig. 143). The vaginal mucous membrane must be pulled well up at +, by the assistant, and a small piece of its hinder surface should be included in the suture.

The third stage consists in passing sutures for closing the

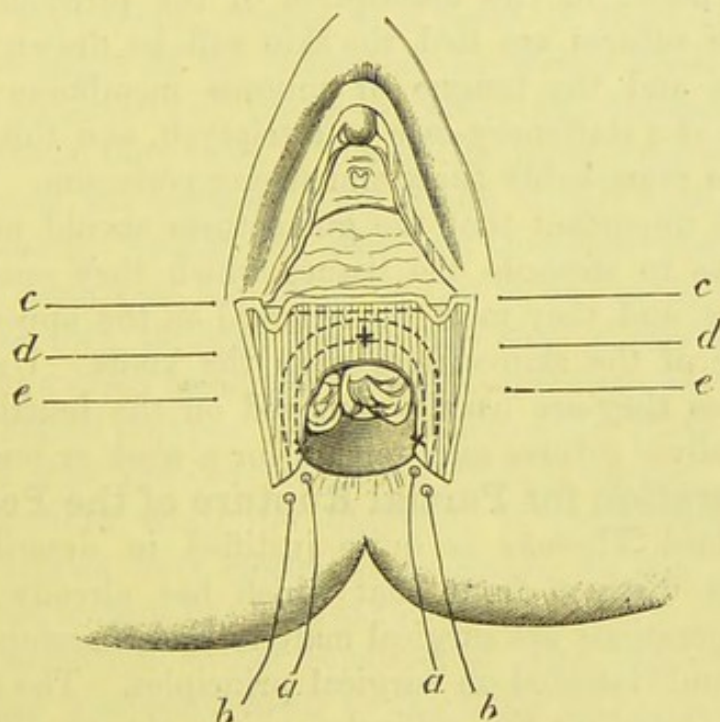


FIG. 143.—PURSE-STRING OPERATION.

x x mark the extremities of the lacerated anal ring. + indicates the point to which these extremities are brought by the sutures, so as to restore the ring. (*Boulton.*) Two hæmorrhoids protrude from the torn margin of the rectum.

perineum. A stout handled and largely-curved needle is passed under the surface of the wound and the vaginal mucous membrane, and brought out at the opposite side. The point of entry should be about a quarter of an inch from the margin of the wound on the right side. When the point of the needle issues from the corresponding point on the left side, a stout silver wire suture is slipped into the eye; the needle is then withdrawn (*c c*, Fig. 143). Two or three more sutures (*d d*, *e e*, Fig. 143) are then passed, below the first, as indicated in the diagram.

The highest of these sutures (*c c*) must include the tongue of vaginal mucous membrane which was dissected upwards and raised at the beginning of the operation, and which now will cover the inner side of the line of incision when the wire sutures are brought together.

The ring of the anus has been restored by securing the threads, *a a, b b*; or if they have not been tied yet, they may be tied at this stage. The perineal sutures, *c c, d d, e e*, are then drawn forwards and tied after careful washing of the raw surface as noted in the description of the previous method. When these sutures are tied, the skin will be drawn over the raw surface and the tongue of mucous membrane like the folding lids of a stationery-case or a triptych, and this duplication makes a remarkably thick and strong perineum.

It is most important that the gut sutures should not be tied so tightly as to strangle the tissues which they encircle like purse-strings, and they must be removed on the appearance of any cutting of the skin-surface near the knots. Under any circumstances they are usually removed on the fourth or fifth day. The silver sutures may remain for a week or ten days.

The Operation for Partial Rupture of the Perineum.

—Dr. Gaillard Thomas is quite justified in describing this operation as distinct from that which has already been recorded. Operations are surgical matters, and therefore must be considered and classified on surgical principles. The operation for rupture including the sphincter ani is always difficult and uncertain. The restoration of a rupture of the perineum which does not involve the sphincter is seldom attended with much difficulty.

A laceration of the perineum produced in the course of some operation where that part is exposed to injury, should be repaired at once. The pressure of the shanks of a heavy volsella against the posterior commissure, or the sudden escape from the vagina of a large tough fibroid polypus dragged upon by that instrument, may cause a laceration of this kind.

Partial lacerations caused by injuries received during labour are occasionally so trifling as to produce no symptoms, nor must the surgeon conclude that any symptom of which a patient may complain must be due to a partial laceration which

he discovers on examination. Nevertheless, troublesome results not rarely follow this condition, and when the perineum is torn through apparently almost as far as the sphincter ani, and the posterior vaginal wall shows a distinct tendency to prolapse, the surgeon is perfectly justified in proposing an operation even though there be no loss of power over the sphincter.

In partial rupture the tissues of the perineum simply gape.* The structures along the middle line are torn through at the extremity of the vulva, the laceration extending backwards along the raphe, and ceasing at a point in front of the anus. Hence, the edges of the laceration lie widely apart anteriorly, and meet posteriorly at the point where the laceration ceased; in other words, they form a V with its point backwards. The solid tissue of the perineal body is also deeply torn through in front. Passing backwards, the rent becomes shallower and shallower, ceasing at the point of the V, and each half of the deep tissues torn through lies on one side of the middle line. I have seen a fresh laceration, after an operation for the extraction of a fibroid polypus, and it presented all these characters. In fact, it was precisely the kind of raw surface which the surgeon denudes when the operation is performed after the exposed surfaces have cicatrized, as shown at Fig. 141, where, however, the rectum has been involved.

If the laceration be not repaired at once, the raw surfaces tend to come gradually down to the same plane as that of the margins of the laceration, as in complete rupture, in the manner already described at page 390. It is evident, however, that this can only occur to any appreciable extent in front. Still, whatever part the perineum may or may not play in supporting the pelvic structures, the pelvic floor must be materially affected by this descent of the lacerated tissues.

Cicatrization tends to alter relations yet further, the laceration being at length reduced to a V-shaped line of scar-tissue, forming the anterior boundary of the remains of the perineum. The vaginal mucous membrane often bulges downwards conspicuously along this line.

* I must refer to the works of Matthews Duncan, Emmet, and Thomas, *passim*, for scientific opinions as to how much of the laceration involves vaginal and perineal tissues respectively.

Principles of the Operation.—When the laceration is recent, all that is necessary is to pass sutures above the raw surface, emerging through the integuments external to its borders. On drawing the sutures together, the V-shaped gaping margins will be closed and the two halves of the lacerated surface will be in apposition. When the parts have cicatrized, a V-shaped surface must first be dissected up.

Steps of the Operation.—When the laceration is produced during an operation, as above noted, it should be sewn up at once, unless the surgeon has reason to believe that particular circumstances, such as the proximity of inflammatory changes, discharges, etc., might interfere with union. The manner of applying the sutures will be described.

Before a deferred operation, the patient should be prepared as for the more severe procedure when the sphincter ani is involved. She is placed in the lithotomy position. A V-shaped incision is made through the integuments, by means of a scalpel. Each half of this incision should begin at the extremity of the labium majus, and end posteriorly by joining its fellow in the middle line, in front of the untorn remains of the perineum. Then an incision, curved backwards, is made across the vaginal mucous membrane, between the anterior extremities of the V-shaped line. The mucous membrane and cicatricial tissue lying within the limits of the incision are now dissected up so that a wide raw surface is formed (as in Fig. 141). The surgeon must not make his incisions too short or the area of raw surface too narrow, as his aim is to form a deep and strong perineum.

The sutures are now applied (Fig. 141), omitting the anal sutures which will not be needed, as in the operation for complete laceration, and are closed with the same precautions.

The after-treatment will be the same as after that operation. There will be little fear of damage when the bowels are opened, but the parts should be kept at rest for three or four days; then an aperient should be given, and the sutures may be removed at the end of a week.

Plastic and other Operations for the Relief of Prolapse of the Uterus or Vaginal Walls.—In this Handbook the pathology of uterine displacements cannot be

discussed. The extreme forms of prolapse of the vaginal walls, with or without descent of the uterus, are familiar to every practitioner. Several operative measures have been devised for their relief, in cases where pessaries can no longer be worn, or fail to give support. All these operations demand considerable experience in the treatment of diseases of women, and even when they are performed by experts, the results are not on the whole satisfactory. I shall briefly describe these operations, which may be grouped as follows:—1. Plastic operations on the perineum and adjacent structures. 2. Plastic operations on the vagina. 3. Operations performed on the round ligaments. Hysterorrhaphy, where the fundus uteri is sewn to the parietal peritoneum, is an operation which is not likely to commend itself to the general surgeon. It has, however, found advocates among experienced specialists.

Plastic Operations on the Perineum in Prolapsus—Perineorrhaphy.—When partial rupture of the perineum exists in a case of prolapse of the pelvic viscera, the latter condition is decidedly aggravated,* nor is it always possible for the patient to wear a pessary. The distension of the perineum in an old case of procidentia, or complete prolapse of the uterus, causes it to become atrophied, thinned, and stretched out, so that the descending viscera push it backwards and readily slip down through the enlarged vulvar orifice. In cases of this kind no pessary can possibly be retained. Hence the repair of a partial rupture is often undertaken for the relief of prolapse. When the perineum is stretched, without previous traumatic injury, its anterior part is sometimes vivified, so that a raw surface is made, in form more or less like that which is dissected up in the operation for ruptured perineum. This surface is then united by sutures. The raw surface is sometimes prolonged at each extremity so as to involve the posterior part of the labia majora (episiorrhaphy). When the surface is closed, in this operation, the vulvar orifice will be much diminished in circumference. The patient must rest as long after any of the above operations as when a traumatic rupture of the perineum has been repaired. The heavy uterus will become smaller and lighter after this prolonged repose.

* See Matthews Duncan, *Papers on the Female Perineum*, 1879, p. 137.

None of these proceedings afford a permanent cure. The patient feels great comfort from rest after the operation, and can wear a ring or a Zwank's pessary. The bulky uterus, however, ultimately forces its way once more beyond the vulva.

Plastic Operations on the Vagina in Prolapse.—The narrowing of the calibre of the vagina by operation is a far more effectual proceeding for the relief of prolapse. When part of the perineum and posterior part of the labia majora are made raw, the dissection may be continued half an inch or an inch up the posterior vaginal wall, or even close up to the cervix. The edges of the dissected surface are afterwards brought together by sutures, which are passed behind them, as in the operation for repair of partial rupture of the perineum (page 396, and Fig. 141). The edges of the greater part of the vaginal wound will require union by superficial sutures (Fig. 142). This operation is known as *elytoperineorrhaphy*. Specialists differ very much in certain details, especially as regards the form of the area of the vaginal mucous membrane which is vivified. Some dissect away a wedge-shaped piece, with its point upwards and its base continuous with the raw surface in the perineal region. This is, perhaps, the simplest kind of dissection. Others make two triangles of raw surface on the vaginal wall, the apices pointing upwards, the bases meeting the raw perineal surface and joining each other in the middle line. The edges of each triangle are sewn up. When both have been treated in this manner, the calibre of the vagina will be greatly diminished.

Elytrorrhaphy or Colporrhaphy.—These formidable terms are given to some ingenious operations for the direct diminution of the calibre of the vagina, as a remedy in cases of prolapse of the pelvic viscera.

Any condition which makes the vagina narrower will act, to a certain extent and for a certain period, beneficially on uterine and vaginal prolapses. Even cicatrization after the use of caustics has proved sufficient for a time. It is clearly more surgical to employ the knife, and to diminish the redundant walls of the vagina by dissecting off pieces of the mucous membrane and sewing together the edges. Different operators have devised many methods of dissecting up the

mucous membrane. Perhaps it is more correct to say that they have designed a large series of patterns of the area to be vivified. A study of these details is apt to confuse the beginner, but Dr. Gaillard Thomas's assertion, that "any figure which results in constriction of the vaginal wall will remove traction from the uterus and keep the vagina from prolapsing," includes a truth that will, for a time, greatly simplify the problem. Thus Dieffenbach's oval denudation is the easiest for the inexperienced. Sims' and Emmet's methods are well known, so that these different plans of denuding the vaginal mucous membrane will be described.

Sims' Elytrorrhaphy or Colporrhaphy.—This is one of the most recognized of the ingenious operations devised by Dr. Marion Sims. It is, however, more familiar to us in the pages of text-books than in the operating theatre; indeed, it is not often performed.

Sims, Gaillard Thomas, Schröder, and others insist that this and all other forms of elytrorrhaphy are primarily intended to remedy the vaginal prolapse, and so to prevent the descending vaginal walls from dragging the uterus after them. Hence, according to these views, the operation necessary for prolapse of the uterus will be the same as that which is needed for prolapse of the vaginal wall. Elytrorrhaphy cannot support the uterus by narrowing the calibre of the vagina, for no vagina, narrow or wide, is a uterine support.

The transitory character of the benefits derived from elytrorrhaphy is, on the other hand, due to the deep-seated nature of the cause of prolapse of the vagina. This condition is very often a form of hernia, represented amongst the patient's relatives by inguinal, femoral, and umbilical herniæ.* Thus, after operation, the pressure of the abdominal viscera continues to bear, as it did before, to an abnormal extent in the direction of the pelvic outlet. Hence, the cicatrices ultimately stretch, and the descent of the vaginal wall occurs once more. In so far that a prolapse of the anterior vaginal wall is cured for a time, elytrorrhaphy performed upon that wall is at least logical.

* I recorded three strong family histories of this kind in a paper entitled "The Relation of Prolapse of the Vagina to Hernia" (*Transactions of the Obstetrical Society of London*, vol. xxvi. 1884, p. 88).

The pressure of the bladder, however, tends to stretch the cicatrix from the first, as practice can abundantly prove.

In Sims' operation, the patient is placed on her left side, and the posterior wall of the vagina is retracted by the larger blade of a Sims' speculum. A special curved sound with forked points is then passed straight along the middle line of the anterior vaginal wall till the points are fixed in the anterior aspect of the cervix. Then an assistant takes hold of the handle of the sound and keeps the shank of that instrument evenly and firmly pressed against the middle line of the anterior wall. As that wall is very lax under the conditions where elytrorrhaphy is performed, a deep depression is formed, hiding the sound.

The operator, by pressing together the folds of vaginal mucous membrane on each side of the depression, can estimate how far the vagina must be narrowed. Then he catches up the mucous membrane half an inch above and on one side of the meatus urinarius, with tenaculum or spring-forceps, and cuts away a thin strip of mucous membrane extending upwards and outwards to one side of the cervix. Another strip is then cut on the opposite side, beginning at the same point above the meatus. Thus a V-shaped area of denudation, about a quarter of an inch wide, is formed on the anterior vaginal wall, with the point just above the meatus, and the end of the arm below and external to the cervix. The special sound is then removed. The cervix is pulled down by a volsella, and a strip of mucous membrane is cut away transversely from the inner side of each upper extremity of the V. These transverse denudations run beneath the front of the cervix and nearly meet each other. The assistant must make free use of stick-sponges to restrain the hæmorrhage.

A silver wire or silkworm-gut suture is then passed under the point of the V, entering and emerging about an eighth of an inch from the margin of the raw surface. Sutures are then passed in the same manner under the surfaces all the way up, running free across the surface of mucous membrane left between the arms of the V. The highest sutures must pass under the transverse denudations on the inner sides of the upper extremities of the arms of the V. The sutures are lastly tied. Then the two arms of the V and the transverse pieces are brought into appo-

sition. Thus the vagina is, as it were, buttoned up tightly in front from the vulva to close below the cervix.

The patient must lie in bed for over a fortnight, and the bladder must never be allowed to become distended, else the cicatrix will be stretched or broken down. The lower sutures may be removed on the tenth, the upper on the fifteenth day. The patient must avoid prolonged or violent exercise for many months.

This operation may certainly give relief for several years. In one case, however, where Dr. Marion Sims operated, the patient, after living in comfort for four years, was suddenly seized with severe pain following a muscular effort. Constant tenesmus and great suffering persisted for three months. Dr. Emmet then saw the patient, and found that the cervix had slipped into the pouch behind the septum formed by the operation; the fundus lay in the hollow of the sacrum. The incarcerated cervix was disengaged, and the uterus returned to its normal position, to the great relief of the patient. Owing to the possibility of this accident, and the tendency of the anterior vaginal wall to descend again, Dr. Emmet devised an operation which he believes to be superior to that which has just been described.

Emmet's Elytrorrhaphy or Colporrhaphy for Pro-lapse and Procidentia.—The steps of this operation, like those of the former, have frequently been described in text-books. Most authors have condensed Dr. Emmet's original account; I think it preferable to reproduce that account in full. (*The Principles and Practice of Gynæcology*, Third Edition, 1885.)

"I first antevert the uterus with my finger, as the patient lies on the back. The neck of the uterus is then kept crowded up into the posterior cul-de-sac by a sponge-probang in the hands of an assistant, while the patient is being placed on the left side for the introduction of the speculum. I then endeavour to find two points, one about half-an-inch from the cervix on each side, and a little behind the line of its anterior lip, which can be drawn together in front of the uterus by means of a tenaculum in each hand. When two such points can be thus brought together without undue tension, forming triangular-shaped folds, the surfaces are to be freshened. One of the tenacula must be

securely hooked in the tissues, to indicate the point. Then, one hand being disengaged, a surface about half an inch square around the point of the other tenaculum is to be denuded with

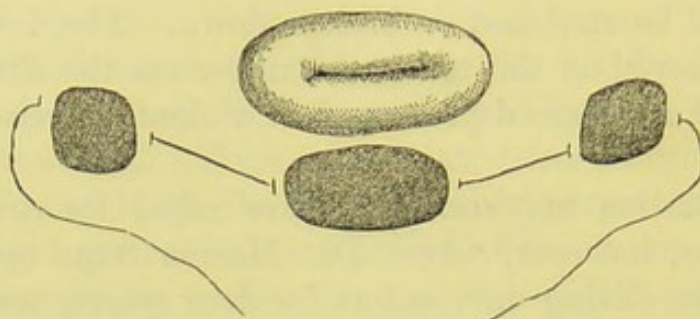


FIG. 144.—EMMET'S ELYTRORRHAPHY.

Diagram representing the wire passed under the three freshened surfaces on the mucous membrane of the anterior vaginal wall, below the os uteri.

a pair of scissors. Next a similar surface is to be freshened around the point of the first tenaculum, and a strip afterwards removed from the vaginal surface, in front of the uterus, about

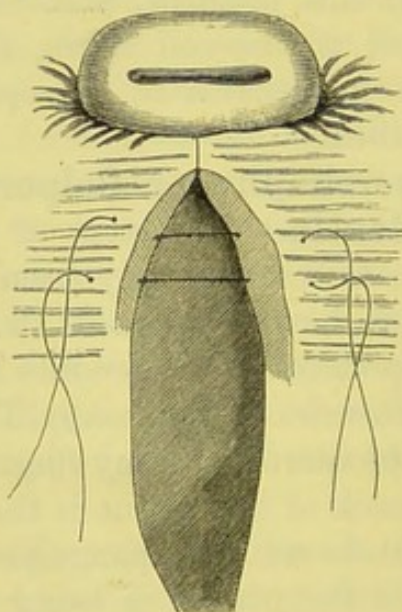


FIG. 145.—EMMET'S ELYTRORRHAPHY.

The raw surfaces are united close to the cervix. The two folds in the anterior vaginal wall are vivified, and two sutures already introduced. See text.

an inch long by half an inch wide. Having passed a needle, armed with a silk loop, beneath each of these freshened surfaces, as shown in Fig. 144, a silver wire is to be attached to the loop

and secured by twisting, thus bringing together in front of the cervix, as will be seen in Fig. 145, these three points.

"The completion of the operation, after the cervix is thus fixed in position, is very simple. Fig. 145 shows the two folds on the anterior wall, in the shape of an ellipse, extending from the surfaces secured in front of the uterus nearly to the vaginal outlet. These are to be turned in by finding, with tenacula, from time to time, opposite points near the crest of each fold, which can be brought together without tension. With the object of preventing any unnecessary loss of blood, only half an inch on each side need be denuded at a time, one or more sutures being introduced and secured. Thus advancing step by step, the operation is completed by turning in these folds until at length they become lost on the vaginal surface near the neck of the bladder. Four or five sutures should be inserted to the inch, passing first a silk loop to which the silver suture is to be attached for the purpose of drawing it through. The needle should be introduced so as to include a liberal amount of tissue, and the sutures twisted only just sufficiently to bring the raw surfaces in contact, that strangulation from the swelling of the parts may be avoided. The sutures are usually removed on the eighth to the tenth day. No special after-treatment is needed, beyond keeping a self-retaining sigmoid catheter in the bladder until the parts have become well united. When from any cause the catheter cannot be retained, the bladder should be emptied every few hours, so that the weight of a quantity of urine may not be borne by the recently united surfaces. If it be necessary to empty the bladder on a bed-pan, a little tepid water should be thrown into the vagina immediately afterwards, for fear that some urine may have passed in; by this method its effects on the uniting surfaces would be neutralized. It is absolutely necessary to confine the patient to the recumbent position for two or three weeks."

Dr. Emmet sometimes performs a modification of this operation when the upper portion of the vagina has become dilated by an enlarged uterus resting on the floor of the pelvis. The folding in of the anterior vaginal wall, and the vivifying and suturing of the apposed surfaces need only be extended for a short distance downwards, so that but two or three sutures will

be needed. He prefers this operation to temporary relief by a pessary.

Other Modifications of Elytrorrhaphy.—Neither Sims' nor Emmet's method just described, is often performed in this country. The soundness of the principle of operating on the anterior wall is much questioned. Lefort devised an operation for uniting the anterior and posterior vaginal walls. The prolapsed uterus is kept down, and two raw surfaces, each about two and a half inches long and three-quarters of an inch broad, are formed by dissecting the mucous membrane off the anterior wall of the vagina by means of forceps and scissors. The uterus is then drawn forwards and two similar strips are dissected off the posterior vaginal wall. The uterus is then partially reduced, till the uppermost parts of the four raw surfaces are in apposition; these surfaces are united by carbolized catgut sutures passed through their apposed edges. This must be done on both sides of each surface. If silk or silkworm-gut be used, the removal of the sutures will be necessary, and this will be difficult. Then the uterus is pushed up a little higher and the raw surfaces are sutured again, as before. The process is repeated until the lower extremities of the surfaces have been sutured. Neugebauer dissects up a raw surface, about an inch and a half long and half an inch wide, on the anterior and posterior vaginal walls, and unites them by suture.

Thomas, Simon, and others advocate, more or less strongly, posterior elytrorrhaphy. A simple oval tract of mucous membrane, reaching from the cervix to the posterior extremity of the vulvar orifice, and wide or narrow according to the greater or less redundancy of the tissues, may be dissected up from the posterior wall of the vagina, the patient having been placed in the lithotomy position. Then silkworm-gut sutures are passed through the mucous membrane close to the edge of the raw surface, then transversely under the surface, emerging through the mucous membrane on the opposite side. The sutures are lastly tied; the posterior wall will then be greatly diminished in dimensions. The after-treatment will be the same as in cases where a rupture of the perineum has been repaired.

Operations for the Relief of Prolapse, &c., performed from the Abdominal Side of the Uterus.—

Caneva proposed to unite the fundus uteri to the peritoneum, on the anterior part of the abdominal walls, by sutures, without opening the abdominal cavity. Several specialists have stitched the uterus to the abdominal walls after removal of the appendages, and advocate this step whenever the uterus has been long prolapsed or retroflexed, and is unable to stand alone when elevated. This operation, which has been termed "hysterorrhaphy," is based on disputed theories, and is not likely to become universally established.*

There is another operation which has been frequently performed, and has met with many advocates. It consists in exposing the round ligaments in the inguinal canal, and shortening them so as to draw up the uterus and vagina. This operation is generally known by the name of Dr. Alexander, of Liverpool; but Freund, Aran, Rivington, and Adams, of Glasgow, have all had a share in its introduction. It has been performed for retroflexion, retroversion, prolapse, and allied displacements. The operation is difficult and by no means unattended by danger. I have known of cases where it has proved fatal. As the maladies for the relief of which it is undertaken are not dangerous to life, the justifiability of this proceeding is questionable. Many specialists, however, practise it, and I therefore shall not pass it over. I agree with Drs. Hart and Barbour that "sufficient is not yet known about the results of this operation." It must be admitted that Dr. Alexander has detailed his experience in an explicit and conscientious manner. He insists that any surgeon who proposes to operate, however experienced in surgery and learned in practical anatomy, should first perform the steps of the operation a few times on the dead subject. He also admits that the operation was originally devised to get rid of the swarm of patients with uterine displacements that infested the gynæcological wards at Liverpool Workhouse.

Shortening of the Round Ligaments, or Alexander's Operation.—I shall now describe the operation according to the directions given by Dr. Alexander himself † :—

* See Dr. Howard Kelly, *American Journal of Obstetrics*, January, 1887.

† *The Treatment of Backward Displacements of the Uterus, and of Prolapsus Uteri, by the New Method of Shortening the Round Ligaments*, 1884, "The

After the patient has been narcotized, the pubes is shaved on each side from the spine outwards. An incision about two inches in length is made along the course of the inguinal canal, beginning from the spine of the pubes. This incision must be free; if under two inches, the subsequent and more important manipulations of deeper structures cannot be safely accomplished. The subcutaneous fat is sometimes thick, and the layer of superficial fascia may, in such cases, be mistaken for the aponeurosis of the external oblique; it lies in the fat midway between that aponeurosis and the skin. Bleeding vessels must be secured by means of pressure-forceps. When the pearly glistening tendon of the external oblique muscle has been exposed, the external abdominal ring must be found. The inter-columnar bands, oblique fibres in the aponeurosis immediately above the ring, will aid the operator in his search. When the subject is fat, retractors will be necessary. The orifice of the ring is occupied by a little mass of connective and adipose tissue. The pubic spine and the ring will be discovered by the introduction of the forefinger into the wound.

The inter-columnar bands are then cut across, in the direction of the inguinal canal. A fleshy rounded structure of a dull red colour now bulges out; it is mixed with, and often concealed by fat. Dr. Alexander states that he has never met with any difficulty in recognizing it; but some good operators have informed me that this is not in accordance with their own experience of the operation. This fleshy structure is the end of the histologically ligamentous part of the round ligament, immediately above its termination in the tissues of the mons veneris. Close along its anterior surface runs the genital branch of the genito-crural nerve. If there be any difficulty in recognizing the ligament, the inguinal canal may be opened up for half an inch. Fasciculi of the internal oblique may be taken for the round ligament. An aneurysm needle is then passed under the whole of this tissue, so as to raise it out of its bed in the inguinal canal, when it may be grasped by the fingers. The operator must make sure that the whole of the tissue of the ligament is raised by the aneurysm needle, and

Operation of Correcting some Uterine Displacements by Shortening the Round Ligaments" (*British Gynaecological Journal*, vol. i., p. 246).

forceps, if employed at all, should be blunt-pointed, and must be used with caution, for it is essential that the ligament be grasped entire and protected from splitting or tearing.

The end of the round ligament is now gently pulled out by the fingers or by broad blunt-pointed forceps, and separated by scissors from the bands of connective tissue which bind it to adjacent structures. Its nerve will require division during this process, and there is some risk of the ligament itself being torn asunder. When the adhesions are separated, the ligament comes well into sight; it appears as a strong white cord which can be drawn out with ease. The operator must not forget that the ligament, which runs outwards and slightly upwards in the inguinal canal, changes its course abruptly at the internal ring, turning downwards, backwards, and inwards towards the uterus. Hence when it is held up, at the external ring, and pulled, it is subjected to a considerable strain at the point where it bends sharply as it enters the canal. Indeed, at this point it has become torn in more than one case. On the other hand, Dr. Alexander declares that, when properly set free, the round ligament comes out so easily that an inexperienced operator may think that it has been ruptured.

The structures already exposed are now covered with a sponge, and the above-described stages of the operation are repeated on the opposite side. The operator should change sides with his assistant, always standing opposite to the side on which he operates. Both the round ligaments being liberated, a second assistant passes a sound into the uterus and holds the organ in its natural position by the aid of that instrument, keeping his finger against the cervix. The ligaments are then drawn evenly and gently by the operator until the sound is slightly moved.*

* "How far are the ligaments to be pulled out? My reply is, to put the uterus in position and pull out the slack. After the ligaments have been freed they come out readily for a certain distance, and then decided resistance is felt, accompanied by movement of the replaced uterus. Any further traction pulls up the broad ligaments and the uterus, and finally is met by the resistance of the opposite ligament till the uterus is elevated to the abdominal wall. Now this lifting of the uterus is an unnatural procedure. That organ never hangs suspended under any normal conditions, and to suspend it by the ligaments must lead to failure. All we can do is to replace the uterus in its normal position, and this occurs generally when the decided check upon the pulling out of the ligaments takes place."—Dr. Alexander, *loc. cit.*

The first assistant now holds the ligaments in place, whilst the operator fixes them. This is done by stitching each ligament to both pillars of the ring by two moderately fine catgut sutures on each side, introduced by means of a curved needle. This secures the closure of the external ring, and fixes the ligament, without strangulating it. The assistant lets go of the ends of the ligaments after they have been fixed, and these ends are cut short. The stumps of the ligaments are stitched into the wound by means of the sutures which close the incision. Dr. Alexander always inserts a drainage-tube and washes out the wound with carbolic lotion before tying the sutures. The wound may be dressed after any accepted method, according to the opinions of the operator. Then, in cases of retroversion and prolapse, a Hodge's pessary is placed in the vagina, and the sound is removed. Other precautions of this kind are taken by different operators, in accordance with their belief as to the action and utility of special stems and pessaries.

The patient is put to bed with her knees bent over a pillow. Dr. Alexander says, "The after-treatment of the operation consists in rest. The wound I generally dress on the second day, when I remove the tubes, the small aperture left where they are removed being sufficient to maintain the necessary drain in most cases. The ligaments should be allowed time to unite to the wound, to the pillars of the ring, to the canal; and for this purpose three weeks is quite short enough time. Several of my private patients have taken a longer rest, and with benefit, as thus all the pelvic organs have become accustomed to their new position. The rest need not be in bed—a sofa and the sitting posture may vary the monotony of lying in bed; whilst sewing, reading, and other feminine arts may be indulged in after the first few days."

In cases of retroflexion, Dr. Alexander inserts a galvanic stem "to keep the uterus straight during the healing of the wound." He further declares that this stem is only applied for mechanical purposes.

Dr. Alexander thus sums up his results: "As regards my own practice, I can honestly say that I have never yet met with a relapse of any backward displacement after this had been placed in position by the operation." In 26 out of 27 cases of

retroflexion and retroversion, no relapse occurred. "In prolapse the mechanical results have also been nearly, although not quite so favourable. I have operated on sixteen cases, and, strange to say, my penultimate case has failed completely, whilst all the others have been successes. . . . Some of my hospital prolapse cases I have never seen after they left hospital, but the majority I have examined again and again."

Dr. Alexander admits that he has lost one case, where the nurse had been attending a patient with pyæmia. Two more deaths had occurred, to his knowledge,—one in America, the other in the practice of a Liverpool surgeon.

On the other hand, Mr. Lawson Tait considers that although the shortening of the round ligaments is easily effected, and is an efficient remedy for retroversion, the operation is dangerous. A case in his own practice nearly died. Dr. Mundé admits that he has in two instances failed to find the ligaments.

CHAPTER XVI.

OPERATIONS FOR THE RELIEF OF URINARY FISTULÆ, RECTO-VAGINAL FISTULÆ, AND ECTOPIA VESICÆ.

Vesico-Vaginal Fistula and Allied Affections.—Under this heading I include all fistulous communications between the vagina and the urinary tract. An abnormal channel of this kind generally opens into the bladder, and this condition is termed a vesico-vaginal fistula. The vagina may, however, be brought by disease or accident into communication with the urethra (urethro-vaginal fistula) or with one ureter (uretero-vaginal fistula).

Causes.—These fistulæ may be the result of cancer of the uterus. In such cases they occur in subjects who are hurt past all surgery. By far the most frequent cause is damage to the anterior wall of the vagina during labour. Since enlightened principles have universally prevailed in this country amongst obstetricians, vesico-vaginal fistula has become a rare affection. Its worst forms are to be seen amongst semi-civilized or barbarous nations, where labour is habitually mismanaged, amongst sections of society where women are ill-cared for or personally careless, and lastly, in cases where, for sad and self-evident reasons, the patient hides herself during labour and conceals her condition. The worst case that I ever saw was that of a girl of seventeen who had lived for several years amongst gypsies and other vagrants, and after being in labour for three or four days, was admitted into a country workhouse. She was totally ignorant of the real nature of her condition. On the fifth day she was delivered of a stillborn child. The upper part of the anterior wall of the vagina sloughed away, and almost complete atresia with

vesico-vaginal fistula resulted. Cases nearly as bad are occasionally seen in remote country districts where the patients are delivered without medical assistance, and careless midwives may, both in town and country, be responsible for this accident.

The fistula is produced by damage to the vesico-vaginal septum through continuous compression between the child's head and the pelvic walls. If the pressure be violent, the tissues may be irreparably damaged within half-an-hour; but, as a rule, the condition is brought on by very prolonged compression. A full bladder increases all risks of this kind. Once many obstetricians laid the blame of the accident upon forceps, now it is generally admitted that the injuries which produce fistula are due to neglect of its use, or to its being employed too late. If the forceps caused serious injuries to the soft parts, we should expect to find such injuries laterally, and not in the direction of the bladder; on the other hand, the damage caused by pressure of the foetus and the site of the damage explain themselves, as repeatedly testified by clinical experience. Whenever the forceps is used, however, the bladder may certainly be injured if the urine be not drawn off beforehand.

Injuries from foetal bones during craniotomy and the incision of a cystocele, mistaken for the bag of waters, have been known to cause vesico-vaginal fistula. Deroubaix has traced the affection to ulceration, arising, as a rule, from some small wound of the vagina inflicted during childbirth, but possibly in some cases in a more spontaneous manner. This ulcerative process increases, until a fistula is formed. It is, according to Deroubaix, most frequently observed during epidemics of puerperal fever. In most cases of vesico-vaginal fistula, it must be remembered, the urine does not escape through the new passage directly after the injury, as the damaged tissues do not break down at once.

Vesico-vaginal fistula may also be caused by the constant pressure of a pessary for many months, or through damage more rapidly produced by an instrument badly made or too large. Hence the necessity of warning patients against wearing a pessary over two months. A patient soon gets used to the instrument, and finds or believes that it is doing her good. Then, she may even forget all about it, and when it

begins to damage the vesico-vaginal septum, she is apt to think that the consequent pain and irritation is "the womb," or "ulceration."

Vesico-vaginal fistula is also caused by wounds made with surgical or other instruments, from sharp-pointed foreign bodies in the bladder, and from abscesses in the septum.

Pathology.—The surgeon will perceive, from the above recapitulation of the causes of vesico-vaginal fistula that it may be, at first, a clean-cut wound, but that, as a rule, especially in the great majority of cases, namely those where the fistula arises through injuries received during labour, there is loss of tissue. Again, the fistula, even if caused by the cleanest wound, is constantly irritated by the passage of urine.

The fistula may be very minute, or may involve a more or less extensive area of the vesico-vaginal septum. Its margin is swollen and irregular at first, but ultimately becomes smaller, thin and tough through the formation of cicatricial tissue. The vesical mucous membrane bulges into large fistulæ, so as to form a red mass which can be seen from the vagina. The bladder, if the urine escapes freely through the fistula, becomes permanently contracted and thickened, the urethra also contracts and may even become impervious. Another serious complication is contraction of the vagina through cicatrices caused by other injuries during childbirth.

A very troublesome condition is that where the ureters are involved in the fistula. This may occur in a large fistula, or in a small fistulous opening situated somewhat laterally in the anterior vaginal wall. Sometimes a fistula in the anterior vaginal fornix is very small, and allows for the protrusion of the orifice of one of the ureters only. This is called *uretero-vaginal fistula*. The urine may sometimes be seen trickling from the orifice of a ureter exposed in a large fistula.

The vulva becomes excoriated and swollen, and the integuments of the thighs erythematous, through the constant escape of urine.

Symptoms.—The inability to retain urine, which in cases occurring through injury during labour does not come on, as a rule, till the slough separates, is the cardinal symptom of vesico-vaginal fistula. Irritation of the integuments produced by the

dribbling of urine over the vulva, and an odour characteristic of incontinence of urine, are seldom absent, though in some forms of fistula the dribbling is not so constant as in others. The constitution soon becomes impaired. In certain cases menstruation is suppressed, returning after cure by operation, as though the fistula caused amenorrhœa in some manner more direct than the production of pure debility. Dyspareunia is frequent, partly through vaginismus, a direct result of the local irritation, and sterility is said to be very common in such cases, through damage to the spermatozoa from its admixture with urine in the vagina. The discomfort and uncleanness involved in this affection make even timid patients anxious for surgical relief.

Diagnosis.—Incontinence of urine may follow labour, from over-distension of the bladder, and from other causes besides the affection now being considered; still, this symptom when it follows childbirth, is always in the highest degree suggestive of vesico-vaginal fistula. On making a digital exploration of the vagina, the fistula may sometimes be detected; a sound should be passed into the bladder and held in the left hand, at the same time. The sound may be made to pass through the fistula, so that its point touches the right forefinger in the vagina. If no fistula be detected, a distinct puckering in the anterior fornix is suspicious. In most cases, however, unless the fistula be very large, it cannot be readily, if at all, discovered by digital exploration of the vagina. Nevertheless, this method must never be neglected, however confident the surgeon may feel about diagnosis, not even, indeed, when he has previously been informed by a colleague on whom he relies, that a vesico-vaginal fistula exists. The condition of the pelvic viscera must be systematically explored, as other diseases may be present.

Exploration of Vagina in Cases of Suspected Fistula.—This, however, must always remain the essential part of the diagnosis. The vagina may be explored when the patient lies in the semi-prone position (see page 57), and then, with the aid of the volsella, which draws down the uterus (page 76), a fistula high up in the anterior fornix may conveniently be inspected. Lithotomy position is, however, the best for this

purpose, as it is the easiest for inspecting the parts in a good light, and is that in which the operation must be performed, so that the surgeon will be best able to judge of the accessibility of the fistula when the patient is placed in this position.

The patient should therefore be placed in lithotomy position, in a part of the room where a good light can be obtained. A Sims' speculum (page 62) is then passed along the posterior vaginal wall, and a sound is introduced into the bladder. The anterior wall must be carefully searched. Sometimes a large piece of deep-red vesical mucous membrane protrudes through the fistula; generally the fistula can be seen, but there remain cases where its discovery is a matter of great difficulty, even though the concavity of the speculum keeps filling with urine during the examination. Sometimes the fistula is hidden behind a fold or a puckering of the mucous membrane. *Fistulæ* high in the vagina are very hard to detect. The following method is the best to adopt in these cases, or indeed, in all, for these *fistulæ* may be multiple. Clean the vaginal mucous membrane with pledgets of wool applied by means of speculum-forceps; then clean the cervix by the aid of a Playfair's probe with wool wrapped round its point. The os externum is plugged with cotton-wool applied dry. Warm milk is then injected into the bladder, and the vagina is watched. If a vesico-vaginal fistula be present, the white fluid dribbling from it will soon betray its position. If no milk dribbles away from the vaginal walls, but the plug in the cervix is found to be soaked in that fluid, and especially if the milk is seen to escape from the os externum, the fistula is vesico-uterine. When this experiment fails to detect any fistula, yet the involuntary escape of urine is still evident and not accounted for by incontinence of a less mechanical kind, there may be a uretero-vaginal or uretero-uterine fistula, with the vesical mucous membrane acting as a valve so as to prevent the escape of the milk. For these comparatively rare lesions Bérard's test should be employed. This test is based on the principle that the urine escaping from the ureter involved in the fistula runs away through the vagina, whilst that which issues from the opposite ureter distends the bladder. The patient's urine is first drawn off, and then she is placed for two hours over

a nightstool made as comfortable as possible, being at the same time strictly ordered not to empty her bladder voluntarily. At the end of that time, the urine which has escaped involuntarily is measured, and then that which remains in the bladder is drawn off, or the patient may be allowed to pass it. If the amount of urine passed by the former way is about equal to that passed by the latter, then, especially if each amount be considerable,—that is, over four or five ounces,—there will be strong evidence of a ureteric fistula. A fresh examination of the vagina will be necessary, and careful search must be made near the cervix laterally. The urine may possibly be then seen escaping in intermittent jets; and sometimes a fine probe may be passed into the ureter. In any case, however, these fistulæ are hard to detect. When a uretero-vaginal fistula cannot be found, the surgeon must dry the cervix with wool, and watch it through a Fergusson's speculum for some time, endeavouring to see if urine escapes from it. If so, a uretero-uterine fistula exists.

Sometimes, the fistula is urethro-vaginal; in these cases there is often but little incontinence of urine, as the muscular fibres of the urethra aid in the retention of that fluid. In this form of fistula, however, the lower part of the bladder is generally involved.

Whenever a distinct vesico-vaginal fistula extends laterally, the surgeon must remember, both in diagnosing and during operation, that a ureter is very near to, or actually involved in the fistula (Fig. 11, page 32).

The permeability of the urethra and the general condition of the vagina will be discovered in the course of the above examinations. Urinary salts become deposited around the edges of these fistulæ.

Prognosis.—A small fistula will often heal spontaneously during convalescence after childbirth, especially if the vagina be kept clean. If, however, the fistula be of any size, so that a permanent aperture which is too large to be plugged by protruding mucous membrane exists, it is most unlikely to cure spontaneously, and the patient will be exposed to all the miseries which this disease of necessity produces.

Treatment.—When a very small fistula is detected, the vagina should be kept thoroughly clean by frequent syringing

with warm water. A catheter must be retained in the bladder: a special form of self-retaining catheter will be described after the account of the operation for repair of a fistula (page 434). Emmet has noted that in two cases where the fistula was detected immediately after delivery, and was in each case large enough to allow the introduction of the finger, a cure was effected within a month, no treatment being adopted beyond frequent injections of warm water. These injections must always be kept up, even when an operation is intended, as they promote the arrest of morbid processes around the fistulæ. Attempts to heal small fistulæ by the application of the thermo-cautery to their edges have not, as far as I have seen, met with good results. It is more successful, I believe, when used to close an angle of the wound formed in the operation for the repair of a large fistula.

As a rule, however, a vesico-vaginal fistula requires to be repaired by a plastic operation. Any attempt to teach the steps of an operation of this kind by verbal directions must be to a great extent unsatisfactory, and this fact applies with particular force to the operation for repair of vesico-vaginal fistulæ. The principles of the operation must be kept in mind. The edges of the fistula are to be made raw, and then united with sutures. These sutures must not pass through the vesical mucous membrane, else the needle-wound may set up troublesome hæmorrhage, and calculous concretions will be deposited along the sutures as they lie exposed in the cavity of the bladder.* The sutures must be tied, and when the fistula has healed they must be removed. Principles of this kind are amongst the easiest to lay down and the most difficult to carry into effect. The operation always demands a considerable amount of manual dexterity.

The vagina must not only be kept clean, but it must be explored for any complication. Cicatricial bands in the vagina must be divided with scissors, the vagina being kept open afterwards by means of a dilator, such as the elastic gum dilator (Fig. 146) used for vaginismus. Calcareous incrusta-

* A specimen of a calculus, with a wire suture as its nucleus, is in the collection of calculi in the Museum of the Royal College of Surgeons. This kind of calculus can also be formed if the operator neglect to remove all the sutures, so that one or more ulcerates into the bladder.

tions, which often form on the vaginal mucous membrane and around the edges of the fistula, must be carefully washed away by sponging with warm water, very slightly acidulated with hydrochloric acid; about five minims to the pint will be sufficient. The patency of the urethra must be ascertained, especially in old cases, where it is always more or less contracted through disuse. Its canal must be dilated to the normal calibre, if necessary. When the urine is alkaline, it should be rendered acid by doses of boracic or hydrochloric acid.

The surgeon is not likely to forget that both the common form of vesico-vaginal fistula, following child-birth, and that which results from the pressure of a pessary, involve either loss of substance or at least a very morbid condition of the surrounding tissues. In this lies one of the main difficulties of




FIG. 146.—ELASTIC GUM VAGINAL DILATOR.

the operation. A simple clean wound in the vesico-vaginal septum is not very difficult to heal by suturing.

Dr. Marion Sims advisedly recommended delay of the operation till a few months after delivery, in cases where the fistula was caused by injuries received during labour. Some German authorities believe that the operation is best performed from six weeks to two months after labour. The surgeon, however, does not always see the patient till many months after the formation of the fistula.

In any case where it may happen to be advisable to attempt the repair of a part only of a fistula at one sitting, reserving the completion of the repair for another occasion, the patient should not be kept in hospital or treated as an invalid between the two operations, but, on the contrary, allowed fresh air and exercise as soon as she has recovered from the first.

The Operation.—The general principles have been already given; but there are two distinct methods in vogue at the present day. The first is the American or Sims' operation. In this procedure the edges of the fistula are pared obliquely, and particular care is taken not to involve the vesical mucous membrane; the fistula is closed with silver wire, and a catheter is retained in the bladder. The second is the German or Simon's operation. Here, the edges of the fistula are pared vertically, the mucous membrane of the bladder not being specially respected; silk sutures are used, and the patient is allowed to pass her urine voluntarily, the catheter being only employed to prevent great distension of the bladder. The differences are, with one exception, confined to matters of detail. A modified variety of the American operation, as practised by Sims and Bozeman, will be described.

Position.—The general surgeon will probably prefer to operate with the patient placed in the lithotomy position, and this is always the most convenient for the handling of the Sims' speculum by the assistant, for the chloroformist, and for the operator also, provided that the fistula lies in a position easily reached by the knife and suture-needle, when the patient is placed on her back. Sometimes, however, the lateral or semi-prone (page 57) position will be necessary. Dr. Bozeman prefers the genupectoral, and fixes the patient in that position by means of a special apparatus. Few surgeons, however, who are not specialists, are likely to attempt to operate with the patient so placed. I must here refer to the observations on the genupectoral position at page 57.

In the following description the patient is supposed, throughout, to be on her back. The bowels must be thoroughly cleared out by a laxative administered about forty-eight hours before operation, followed by an enema shortly before the patient is laid on the table.

The patient is brought under the influence of the anæsthetic. Then, her knees are kept apart by means of a Clover's crutch (page 132). The vagina is syringed out, and the blade of a Sims' speculum (page 62) is passed along its posterior wall. An assistant holds the speculum in place with his right hand during the remainder of the operation.

Paring the Fistula.—An assistant stands on the left hand side of the operator, bearing a sponge-holder (Fig. 147). The sponge itself should be very small. The best form of knife is a small straight scalpel, mounted on a long polygonal




FIG. 147.—SPONGE-HOLDER.

handle, something like the uppermost in Fig. 148. The lower knives, bent on their handles, are difficult to manipulate without much practice. Two light pairs of long-handled scissors, one with curved, the other with straight blades, will be required; they are very convenient for detaching the last piece of tissue from the part whence it is dissected. The old idea that scissor-wounds cannot heal by first intention is quite false, as long as sharp instruments are used.

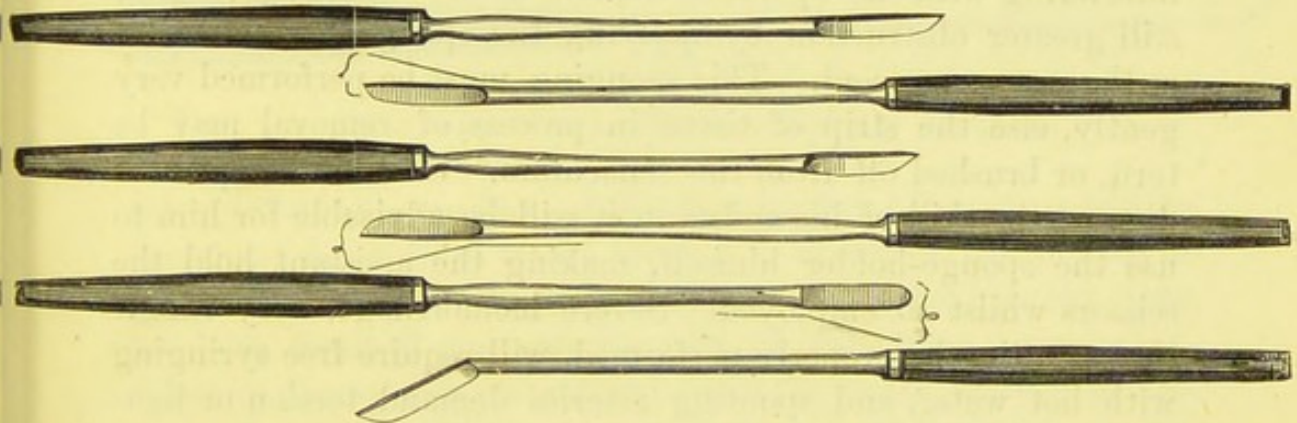


FIG. 148.—VESICO-VAGINAL FISTULA KNIVES.

The lines at the side of the blades indicate the angles at which they are bent.

The vaginal mucous membrane is caught up close to the edge of the fistula by means of a simple tenaculum, with a wide curve. This instrument is more handy than special contrivances employed by individual authorities. Long-shanked tenaculum-forceps tire the left thumb and forefinger if held, and tear away the tissues if left dependent. The mucous membrane is then cut away obliquely and evenly to the extent of about one-eighth of an inch. The lower border should be cut

first, so that blood may not obscure the parts as they are being thinned. Care must be taken to so handle the tenaculum that the lateral parts of the fistula may be pared, and to avoid wounding the vesical mucous membrane, as this accident causes hæmorrhage into the bladder. The strip of tissue should be cut away in one piece, if possible, else a minute portion of vaginal mucous membrane may be left behind, and so prevent union. The more the fistula lies centrally with its long diameter transverse, the easier will be the paring and the subsequent processes, if the patient lie in the lithotomy position, as the handles of the instruments will not be impeded by the position of the patient's thighs. When the fistula lies high up, or considerably to one side of the middle line, the relations of the ureter (page 31) must be borne in mind.

During this process the assistant who has charge of the sponge-holder must keep cleaning the part subjected to operation, in such a manner as to prevent the hæmorrhage from interfering with the operator, without at the same time causing still greater obstruction by applying the sponge to the wound at the wrong moment. This sponging must be performed very gently, else the strip of tissue in process of removal may be torn, or brushed off from the tenaculum. Should the operator distrust the skill of his assistant, it will be advisable for him to use the sponge-holder himself, making the assistant hold the scissors whilst so employed. Severe hæmorrhage, very rare if the operation be properly performed, will require free syringing with hot water, and spouting arteries demand torsion or ligature. It is unadvisable to apply ligatures if this can possibly be avoided, particularly if a vessel bleed in the direction of the vesical mucous membrane so that there is a risk, not only of interference with the union of the edges of the fistula, but also of calculous concretions round the knot of the ligature. Hence it is a good plan to secure the vessel with pressure-forceps (page 94), and to wait a few minutes should the instrument interfere with further proceedings. As a rule, this will be sufficient, and the tying of the sutures will check further bleeding.

Protrusion of Vesical Mucous Membrane.—In large fistulæ this protrusion is often very troublesome, the mucous

membrane getting into the surgeon's way, interfering with the paring process, and subjecting itself to great risk of injury from the scissors or suture-needles. It may be kept back with a sponge introduced into the bladder, so that the sutures are applied over it, very much as in ovariectomy before the abdominal wound is closed; the sponge must be pulled out at the last moment before the sutures are tied.

Application of the Sutures.—This process is yet more delicate than the paring of the edges. Sometimes a hollow tubular needle is used; but this instrument is not very trustworthy, as in spite of all precautions the silver wire or silkworm-gut will not always run freely through it, just when required. The simplest contrivance is a handled needle, with an eye near the point which is curved but slightly, or rather bent at a very obtuse angle; this is employed by Dr. Percy Boulton (Fig. 149). It is most suitable for the application of silver wire



FIG. 149.—VESICO-VAGINAL FISTULA NEEDLE. (*Boulton.*)

sutures; but this question of the best material for suture will be explained more fully when I come to speak of the process of tying threads. The handle of the needle is held in the right hand, in front of the anterior part of the vulva; the point, directed downwards, is entered near the outer margin of the upper (anatomically the lower) border of the wound, as far external to it as the width of the denuded surface.* It is then pushed through the tissues, emerging close to the vesical mucous membrane, which must not be included in the suture (Fig. 150). The point of the needle then enters the opposite side of the wound at a spot corresponding with the point of exit, and traverses a corresponding tract of tissues. A blunt hook (Fig. 151) is very useful in making counterpressure against the point of the needle when the tissues are dense. It

* When the sutures are inserted too far from the edge of the wound, the mucous membrane will be turned in when they are tied. This condition will greatly hinder union.

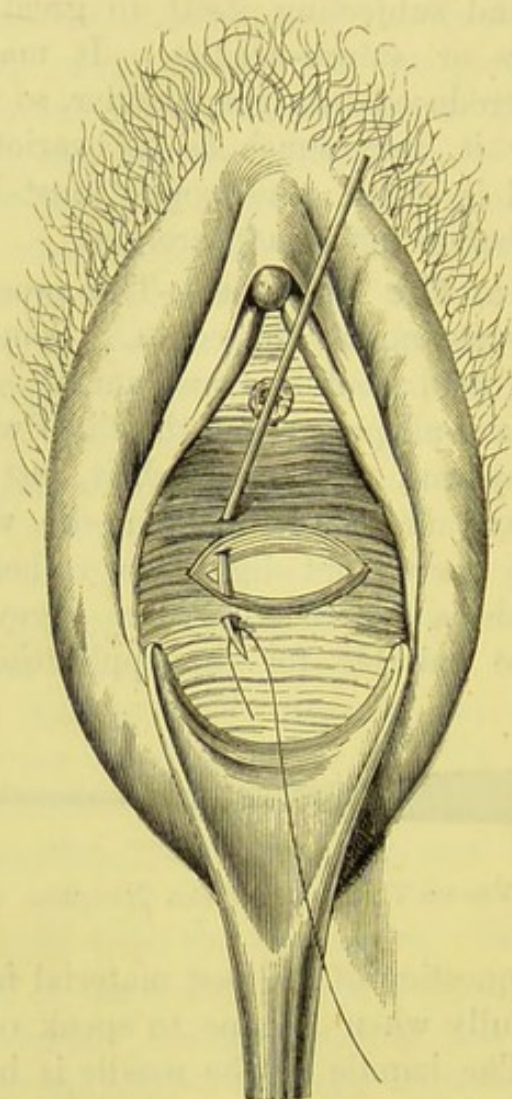


FIG. 150.—OPERATION FOR THE REPAIR OF VESICO-VAGINAL FISTULA.
Passage of the needle through the edges of the fistula, for introduction of suture.*



FIG. 151.—BLUNT-HOOK FOR VESICO-VAGINAL FISTULA OPERATION. (*Bouillon.*)

* In this drawing, which I sketched during an operation, the posterior vaginal wall is seen to be depressed by the blade of a Sims' speculum. The labia are supposed to be kept apart by the fingers of assistants. In some illustrations which follow, and which are taken from foreign publications, the labia are drawn with retractors applied to them, so as to keep the vulvar aperture open.

avoids the danger of tearing the wound, and facilitates the issue of the point of the needle at the desired spot. When the eye of the needle is pushed far enough, the wire is passed through it and the needle then withdrawn, so that the wire occupies its former track. I need not refer to the innumerable modifications of this stage of the operation suggested or practised by ingenious

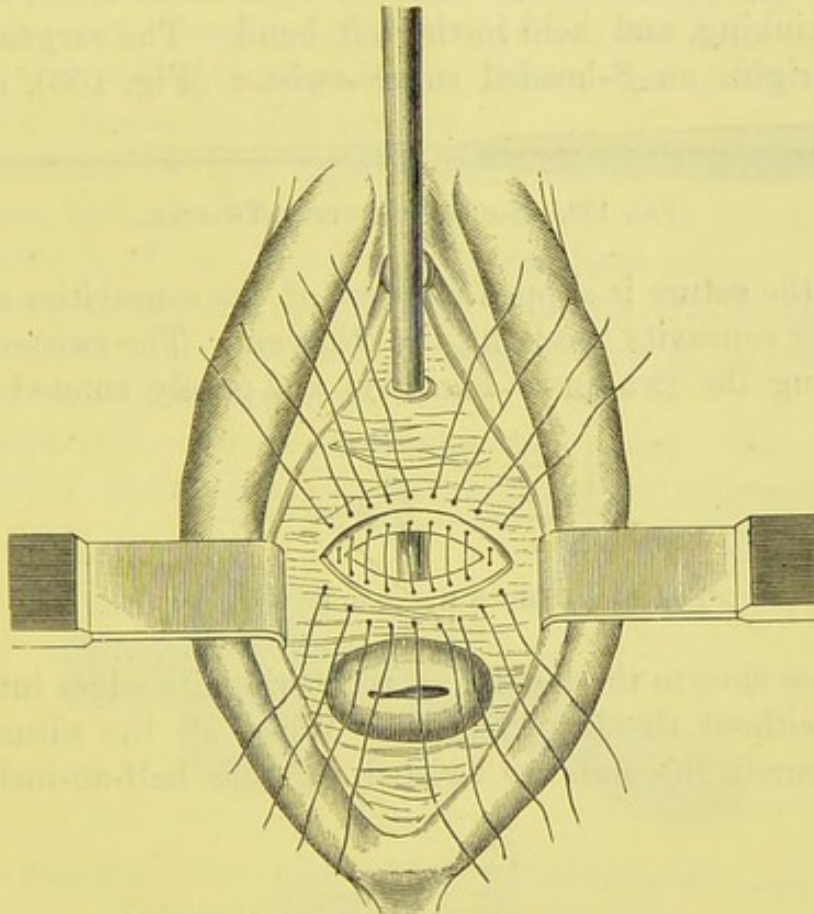


FIG. 152.—THE SUTURES AFTER INTRODUCTION. (*Simon.*)

specialists. The remaining sutures are passed in the same manner till the wound appears as in Fig. 152.

Tying the Sutures.—In the above directions for the different stages of the operation the question of the material used for the purposes of suture has been left open, excepting that the choice has been limited to silver wire and silkworm-gut. This question is perhaps most important in regard to the stage now to be described. Silkworm-gut, well soaked in water, is an excellent material. It may be secured without the aid of any instrument, the ends of each suture being tied together in a

double reef-knot, firmly but not tightly, so as to bring the edges of the fistula well together. This manœuvre is, however, not easy when the fistula is high and the vagina narrow. For the relatively inexperienced operator No. 4 or No. 6 silver wire is the better material for the purpose, and many experienced specialists employ it. In order to tie a wire suture, the two ends are first drawn downwards to make them tense, so as to avoid kinking, and held in the left hand. The surgeon takes, in his right, an S-headed suture-twister (Fig. 153), and one



FIG. 153.—S-HEADED SUTURE-TWISTER.

end of the suture is slipped into one of the concavities of the S, the other concavity receiving the other end. The twister is then slid along the two ends (Fig. 154) and gently rotated four or




FIG. 154.—THE S-HEADED TWISTER IN USE.

five times close to the fistula, so as to bring its edges into apposition, without the least tension. When all the sutures have been secured, the ends are twisted together half-an-inch below

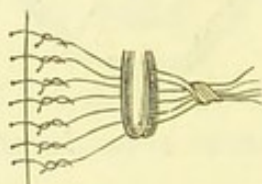


FIG. 155.—THE WIRES TWISTED AND SECURED.

the fistula and cut short. They then lie very conveniently for subsequent proceedings, and cause no irritation of the vagina. Before twisting them, they should be grasped in the blades of a pressure-forceps, so as to avoid any dragging on the tissues around the fistula (Fig. 155).

It will now be seen that, as has been already noted, it is easier to apply and tie the sutures when the fistula runs transversely to the operator, the patient lying in the lithotomy

position. If the fistula be vertical, the needle and twister have to be passed laterally, then the patient's thighs will greatly impede manipulation. In such a case, the semi-prone position (page 57) may be convenient.

When the fistula is wide and irregular, it sometimes requires to be closed in a T-shaped form. The horizontal or vertical bar should be pared and closed first, the other portion being repaired at a subsequent operation, after the patient has been sent for a holiday and well fed (page 425). Simon has often operated with great success in this manner.

Conclusion of the Operation.—When all the sutures have been tied, the bladder is washed out with warm water. This clears it of any blood which may have escaped into its cavity, and allows the operator to ascertain if the fistula be securely closed. If any water escape through it, an additional suture or two will be required.

Catheterism.—Professor Simon and many other experienced living authorities reject the principle of retaining a

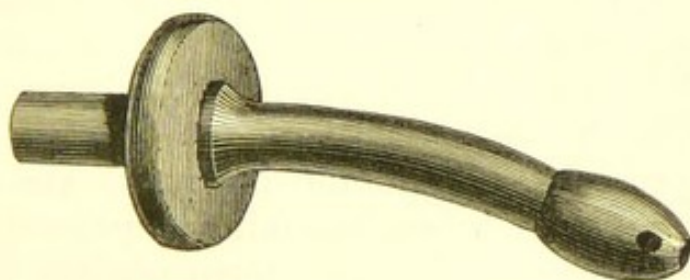


FIG. 156.—SELF-RETAINING CATHETER FOR URETHRO-VAGINAL AND VESICO-URETHRO-VAGINAL FISTULE. (*Boulton.*)

catheter after this operation. They order the nurse to draw off the urine about every six hours for the first two days, and afterwards allow the patient to micturate voluntarily. The management of Sims' stationary catheter requires great experience on the part of the nurse, and even then it does not always act in a satisfactory manner. If its point should touch the fundus, it will soon become displaced, and though termed stationary, it must be changed daily and thoroughly cleaned, so that two of these special catheters must be kept on hand for one patient.

When, however, the fistula is close to the urethra or is

urethro-vaginal (more will be said, presently, on this variety) a catheter must be retained, else the nurse, however skilful, must disturb the seat of operation whenever she attempts to pass that instrument. To meet requirements in cases of this kind, Dr. Boulton uses the catheter represented in Fig. 156. It is made of vulcanite. It measures only two and a half inches in length, and is therefore too short to press against the fundus. The bulbous extremity* prevents it from slipping out of the bladder, but is not so wide in diameter as to endanger the cicatrix of the fistula when the instrument is removed. It is perhaps best for a catheter of this kind to be introduced and retained after any operation for the vesico-vaginal fistula; certainly, at least, when the most skilled nursing cannot be procured. This catheter may be worn for a month, if it be occasionally removed and washed in a strong solution of acetic acid in water.

After-treatment.—The patient is placed in bed on her left side. When a catheter has been introduced, under circumstances just noted, a bed-pan with a hollow handle should be placed in the bed behind the bent knees, which must be tied together by means of a bandage. A piece of flexible rubber tubing is fitted on to the catheter, at one end, the other being passed into the bed-pan. The practice of placing the patient on her back after the operation is open to the great objection that any receptacle for the urine is then liable to be pushed out of place. Tubing passed from the catheter to a receptacle kept on one side of the bed will entail a great deal of trouble, and even then may fail in its object of facilitating a free escape of urine.

The bowels must not be allowed to become too much confined, so as to cause irritation through the collection of hard scybala. An enema should be thrown up, as after ovariectomy (page 248), about the sixth day, before the removal of the sutures.

Unfavourable Symptoms after Operation.—The chief unfavourable symptom is *hæmorrhage* into the bladder. It may often be checked, at the beginning, by injections of warm

* In most other forms of self-retaining catheter the bulb is made too large. This renders the instrument unfit for cases of urethral fistula, whilst the variety above figured is peculiarly fitted for that affection.

water, but if vesical irritation increase and it is found that the bladder is distended, yet nothing can be drawn off by the catheter, the distension must be due to clots, and the fistula must be opened again and the clots removed.

The gravest accident is the *inclusion of the ureter* in a stitch. This danger is likely to occur when the fistula extends considerably to one side. The ureteric orifice may even be stitched up, by mistake, as a fistula. The symptoms are severe pain radiating from the kidney downwards along the course of the ureter, followed by all the phenomena of uræmia. In such a case, the sutures must be removed. This has been done with the effect of causing the disappearance of all the above symptoms.

Cystitis is manifested by the characteristic changes in the urine, pain in the hypogastrium and great desire to empty the bladder. The tenesmus which accompanies this complication is very prejudicial to the healing of the fistula. Cystitis must be treated by the usual therapeutic measures, opiates and diluents being administered. The bladder should be frequently washed out with warm water containing about ten grains of chlorate of potash to the pint, and the catheter must not be retained.

Removal of the Sutures.—The sutures are removed about the eighth or tenth day. The patient is laid on the left side, and a Sims' speculum is passed along the posterior vaginal wall and held in position by an assistant. Each twisted end is grasped by a dressing-forceps, and the suture is then cut above the knot by a pair of long-handled scissors. For this process the patient should, if possible, be placed on a table about three feet high and in a good light. If she should persist in remaining in bed the manipulations will be very troublesome.

Imperfect Union of the Wound.—This, if extensive, must be treated by paring and suture of the ununited part. When only a pin-hole opening exists, it may be closed by cauterization. For this purpose, the edges are touched by a small platinum point heated by the battery. This platinum point will be figured together with the instruments which are employed for cauterizing urethral caruncles (page 471).

Operations allied to the Closure of a Simple Vesico-Vaginal Fistula.—The above observations refer to cases where a vesico-vaginal fistula is not very large nor very high, and where its edges are not in a markedly morbid condition, thin and atrophied, or thick from cicatricial tissue. The inexperienced are recommended to have as little to do as possible with more complicated cases. They may baffle the most skilful operators. These remarks are not intended to glorify the practice of specialists. No doubt Sims, Simon, and others have been enabled to make advances in this branch of plastic surgery entirely through their wide experience as specialists. On the other hand, general hospital surgeons, Bryant, Thomas Smith, Langton, and many other operators in London and the provinces, have succeeded in curing the most complicated cases. Some of these gentlemen have thought good to publish their results; others have not done so. Whilst profoundly respecting the motives of the latter class, I still believe that the history of the cure of complicated cases, at least, should be recorded.

The more complicated forms of fistula, to which the above remarks refer, are: Fistula near the cervix; urethral fistula; vesico-vaginal fistula with atresia of the urethra; vesico-uterine fistula; uretero-vaginal and uretero-uterine fistula; and extensive vesico-vaginal fistula, requiring closure of the vagina by a plastic operation ("colpocleisis"). Recto-vaginal fistula will be described separately.

Vesico-Vaginal Fistula near the Cervix Uteri.—

When a vesico-vaginal fistula lies so high in the anterior fornix of the vagina that its uppermost border is uterine tissue, Simon's plan may be adopted. The tissues are dissected up all round the fistula, as in the simpler operation, so that, in this case, a portion of the cervix uteri is vivified. Then, the sutures are passed through the anterior lip of the os uteri, and through the tissues behind the vivified lower edge of the fistula. When the sutures are tied, the anterior lip will cover up the fistula, bringing the raw surfaces on the cervix and on the lower edge of the fistula into contact. Provided that the edges of the fistula are fairly healthy, this operation will probably be successful. Passing sutures through uterine tissue is, it must be remembered, a practice entailing a considerable amount of risk.

Sometimes, however, a fistula of this kind is very large, or its vaginal borders unhealthy, and its uterine aspect in a yet worse condition; in fact, there may be great loss of uterine tissue. In this case, some authorities recommend that the posterior lip of the os be sewn to the lower edge of the fistula after complete and wide vivifying of the edges; the sutures are passed just in the same manner as when the anterior lip is included, a process which, in its turn, is only a modification of the simple operation. The sutures being tied, the cervix henceforward opens into the bladder, discharging menstrual blood into its cavity. The vagina becomes an absolutely blind canal, cut off from its natural communication with the uterus and its abnormal connection with the cavity of the bladder. This operation must be distinguished from colpocleisis or closure of the vagina, presently to be described.

Urethral or Urethro-Vaginal Fistula.—In this form the patient can often exercise more or less control over the urine, which, however, will generally escape involuntarily at times, especially during sleep. A urethral fistula is closed by the usual paring and suturing process. It must be repaired first when a vesico-vaginal fistula also exists. The catheter (Fig. 156) must be introduced before the paring of the edges of the fistula is commenced. Then the operation is performed, as it were, upon the catheter, which must be retained for about seven days (see notes on after-treatment in cases of the operation for vesico-vaginal fistula, page 433). In one case where the wall of the urethra had been torn through, Dr. Boulton pared the edges and stitched them over the catheter, which was worn for a month. The urethra healed perfectly. The employment of this catheter obviated frequent catheterization, or the other objectionable alternative of draining the bladder through an artificial vesico-vaginal fistula.

Atresia of Urethra complicating Vesico-Vaginal Fistula.—This complication must be remedied before the fistula is subjected to operation. It is a result of extensive damage to the parts involved, and general surgeons must bear in mind that by "atresia" specialists signify a far more complete obliteration of the urethral canal than is observed in any form of stricture of the male urethra.

Simon* describes a case of atresia of the urethra between a urethro-vaginal and a vesico-vaginal fistula, which he cured by two operations, the second being the repair of the latter fistula, whilst the urethro-vaginal fistula and the urethra were first repaired by a very ingenious procedure, which will now be described.

A woman had been subject for sixteen years to incontinence

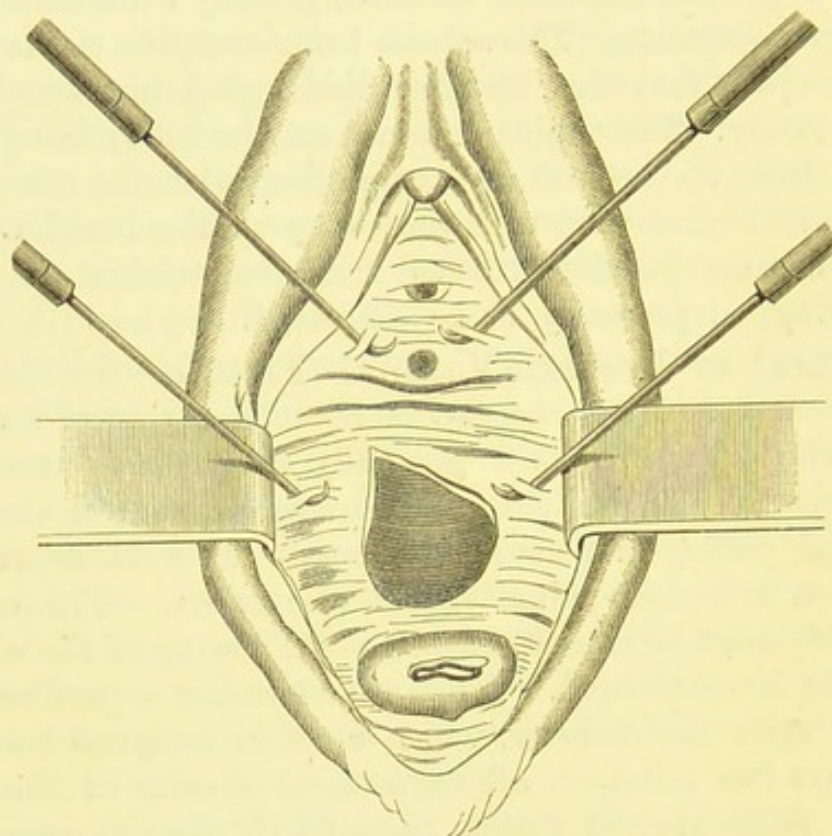


FIG. 157.—SIMON'S CASE OF ATRESIA OF THE URETHRA BETWEEN A URETHRO-VAGINAL AND A LARGE VESICO-VAGINAL FISTULA. (See text.)

of urine, originating from injuries during labour. Professor Simon discovered a small urethral fistula, and a very wide communication between the vagina and bladder. In Fig. 157, the vestibule, the anterior vaginal wall, and the os uteri are displayed. The meatus is seen, and just above it (anatomically) the tenacula hold up portions of mucous membrane; between these portions is the urethral fistula. Higher up, a tenaculum

* *Mittheilungen aus der Chirurgischen Klinik des Rostocker Krankenhauses während der Jahre, 1861-65, II. Abtheilung, p. 207, and Plates III. and IV.* Simon's description of this operation has been repeatedly quoted by other writers, often second-hand.

is seen to be fixed to the mucous membrane on each side of the vesico-vaginal fistula, which is very large. Immediately above the urethral fistula, the urethra and a small portion of the bladder close to the vesical end of that canal were completely impervious, and were represented by a cicatricial mass firmly adherent to the pubic arch, and causing a deep transverse

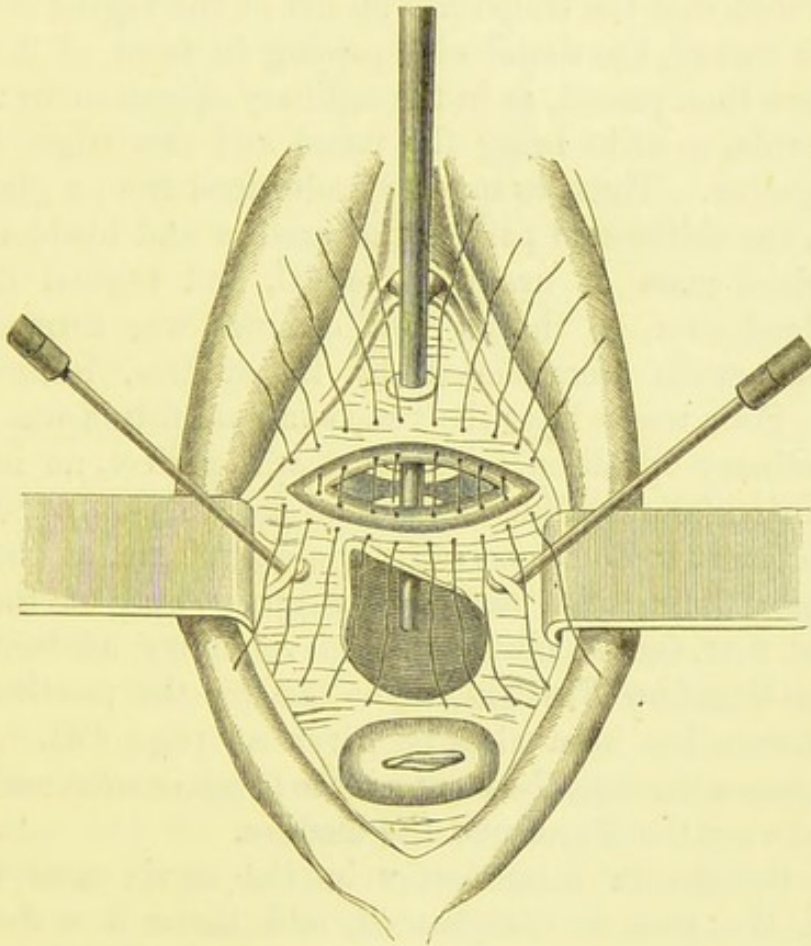


FIG. 158.—SIMON'S CASE OF ATRESIA OF THE URETHRA BETWEEN TWO FISTULÆ.

First operation. (*See text.*)

pucker in the vaginal mucous membrane, represented in Fig. 157.

The first operation, for the closure of the urethral fistula and the formation of a pervious canal for the urine, is explained by Fig. 158. The anterior, or (anatomically) lower part of the fistula was pared, together with a considerable portion of the vaginal wall on each side of it. Then the part of the wall of the bladder and the adjacent vaginal wall just above the

puckered portion adherent to the pubes were set free and pared, each extremity of the pared portion being united to the corresponding end of the part of the vagina already vivified. An elliptical wound was thus formed; it is represented in Fig. 158, where a sound is seen, passing through the meatus, and behind the wound, till its end appears behind the vesico-vaginal fistula. It will be seen that the transverse pucker of the vagina now lies behind the wound, the sound also passing in front of it. Ten sutures were then passed, as in the ordinary operation for vesico-vaginal fistula, so as to bring the pared and raw edges of the wound together. Thus, as may be understood from a glance at Fig. 158, the obliterated part of the urethra and bladder, with the cicatricial mass of urethral, vesical, and vaginal tissues, were bridged over, so that a new channel was formed and the vaginal walls were closed, by the sutures, behind that channel. Four weeks later the vesico-vaginal fistula was closed by the ordinary operation. The cure was perfect, no incontinence of urine followed, but the patient had to pass a catheter, which she learnt to do for herself, for a short time, as the cicatricial tissue lining the anterior or upper wall of the new channel at first caused obstruction to voluntary micturition.

Vesico-Uterine Fistula.—The test for the position of a urinary fistula has been already given at page 422. When the milk passes through the os uteri, the fistulous communication will be between the uterus and the bladder.

When the fistula is evidently in the cervix near the os externum the case is complicated, and there is a choice of several operations, none easy of performance. The best plan, if possible, is to pass a director up to the uterine orifice of the fistula and to slit up the anterior lip of the os uteri, making sure that the fistula is reached. The edges of the fistula are vivified and sutures are passed through the cervix direct, so as to bring together the walls of the cervix and the edges of the fistula (Fig. 159).

When the fistulous passage is too high to be accessible for paring and suturing, the edges of the os uteri are pared and united by suture. The uterus henceforwards discharges menstrual fluid through the fistula into the bladder. After these operations, where the bladder is made the receptacle for discharges from

the uterus, as in the two already described (pages 437, 440) and in closure of the vagina, it has been observed that menstruation, often scanty, irregular, or suppressed before, as is frequently the case in urinary fistulæ, becomes free and regular afterwards, and does not set up vesical irritation.

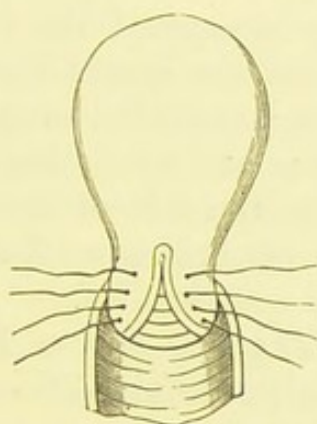


FIG. 159.—VESICO-UTERINE FISTULA.

Anterior lip of os uteri slit up to fistula, which has been pared; sutures passed through cervix on each side of the line of incision. (Thomas.)

Uretero-Vaginal and Uretero-Uterine Fistula.—Dr. Parvin, of Philadelphia, writes in the sixth volume of Ashhurst's *International Encyclopædia of Surgery*:—"In 1867 I operated successfully upon a *uretero-vaginal* fistula of fourteen years' duration, by making, first, a vesico-vaginal fistula, cutting from the ureter into the vagina, then after a few days denuding a comparatively large surface of the latter, and finally inverting that surface so as to throw the ureteral orifice into the bladder. At that time I had never seen any report of a similar lesion, and the diagnosis was not readily made. The treatment was still more difficult, and it was not until after more than one failure that I finally succeeded."

Uretero-Uterine Fistula.—The test for this condition has been described at page 422. It is, fortunately, very rare. Ingenious operations have been practised, with more or less success, by different operators, but no two cases are likely to resemble each other to a sufficient extent to justify a strict adherence to rules which may have been observed in some solitary successful case, nor must it be forgotten that we do not always hear of failure. Some of these operations are described in Dr. Gaillard

Thomas's *Practical Treatise on the Diseases of Women*. Simon and other German authorities recommend that an artificial vesico-vaginal fistula be made, and that the vagina be closed, by the plastic operation presently to be described, below that fistula. This appears to be good practical advice, for a uretero-uterine fistula entails great discomfort from incontinence of urine, and this is relieved by closure of the vagina; on the other hand, cicatrization around the seat of the ureteric fistula may make a direct operation impossible, even to the most expert.

Other German surgeons and specialists have thought it right to remove the kidney on the side of the fistula. One case, at least, under the care of Professor Zweifel, recovered, but surgery of this kind is questionable.

Closure of the Vagina by a Plastic Operation, Kolpokleisis or Colpocleisis.—Some of the forms of urinary fistula above described cannot be closed by paring of the edges and uniting of the raw surfaces by means of sutures. The surrounding tissues may be too unhealthy for any such operation to succeed, the fistula may be inaccessible for any operative manipulation, and may be too large to close. In these cases, the relations of neighbouring parts and the consistence of their tissues are so altered that important organs might be injured by the knife.

In any such case, it is often best to pare the vaginal walls, along their entire circumference, below the fistula, and well in sight of the operator, and to pass sutures through the pared surfaces, so that when they are tied those surfaces are brought together. If this operation should succeed, the vagina will be completely closed,* and the part above the line of adhesion of the pared edges will form, as it were, a portion of the bladder. The menstrual blood and other uterine discharges will escape with the urine, passing out of the cervix, into the closed part of the vagina, and thence through the fistula into the bladder and out of the urethra.

The surgeon, remembering how much irritation is set up, as

* Complete closure of the labia or episiorrhaphy, leaving the meatus free, has been attempted for cases of this class, but the anterior part of the pared track often remains open, so that urine trickles out of it involuntarily, and the object of the operation is totally defeated.

a rule, by urine when it escapes out of its natural channel to a part of the organism not naturally intended to receive or transmit it, how it tends to putrefy when retained in an unnatural pouch or cavity, and how readily solid concretions form on any rough or irregular surface in the bladder, can hardly look on this operation as theoretically sound. Practice, however, has shown that the expected evils just noted do not necessarily arise after plastic closure of the vagina. Calculous concretions do not appear to form, and the urine neither stagnates nor causes irritation. It is certain that a successful operation of this class is far more satisfactory than a partially successful plastic operation performed directly on the vesico-vaginal fistula.

There are two grave objections to plastic operations for closure of the vagina. In the first place, it puts an end to the reproductive function, some of the physiological machinery of which may still remain active; indeed, with the return of comfort and good health, menstruation, previously suppressed, may reappear and become regular. This must be remembered, yet in most cases where the operation is needed, the morbid condition has completely upset the functions of the parts involved. Secondly, this operation may be almost as difficult, though not so likely to prove a failure, as direct closure of the fistula. I have, indeed, seen the vagina successfully sewn up in cases where the operator avowedly closed it on the plea that under his hands the more direct operation would less probably succeed. In a case of this kind, however, the vagina must be fairly capacious and its tissues healthy along the line of operation. Too often the vagina is contracted from cicatrization, and the line for paring will pass through dense cicatricial patches and areas of over-vascular tissue unhealthy in other respects. The vivifying process will then be difficult and the chance of complete union uncertain. Incomplete union means failure, for the great cause of discomfort and ill-health, the incontinence of urine, will not be cured.

The Operation.—When the vagina is closed for the relief of urinary fistula, the entire circumference a little below the lower border of the fistula must be pared, just as the entire circumference of the fistula itself is pared in the direct operation;

and the sutures are introduced in the same manner. In Fig. 160 the process is explained. A sound has been passed into the bladder and out into the vagina through the fistula. In the woodcut it is seen entering the meatus, and its extremity lies in the upper part of the vagina. The entire circumference of

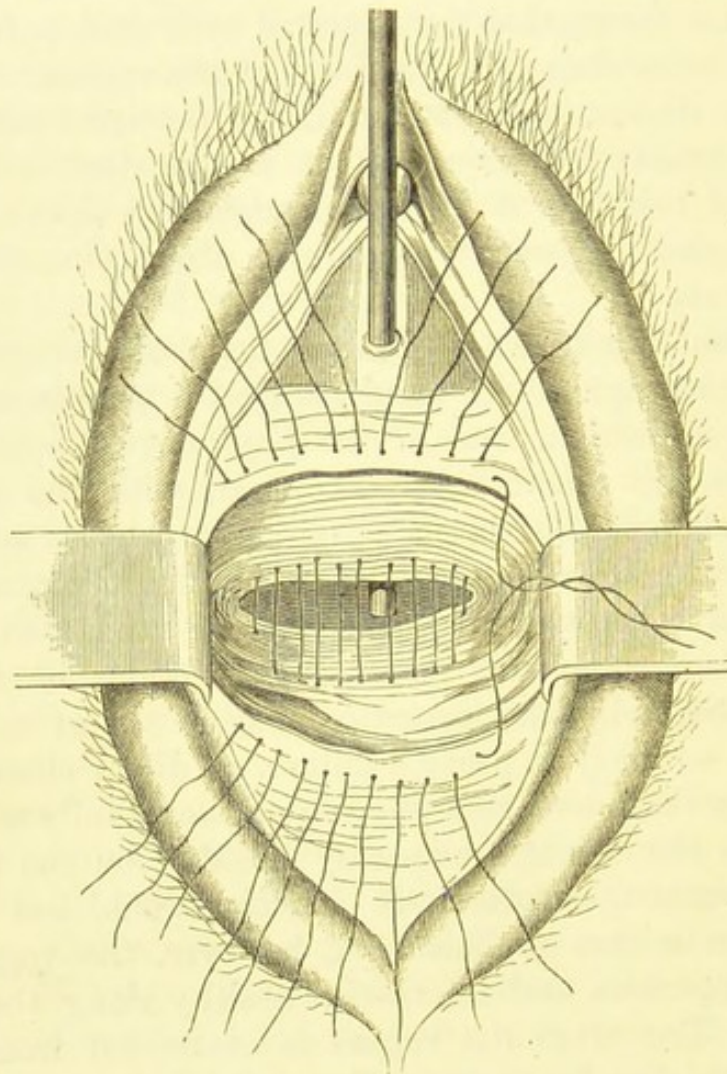


FIG. 160.—COLPOCLEISIS,

Showing the entire circumference of the vaginal mucous membrane pared, and the sutures introduced. (*Simon.*)

the vagina has been pared, below the fistula which is not seen in the drawing. Sutures have been passed through the opposite sides of the pared area, emerging through the mucous membrane at the anterior and posterior borders of the lower limit of that area. The vulva is held apart by flat retractors.

Precise rules cannot be given, as the operation varies in every case. Lithotomy position is probably the best, and retractors may answer better in some cases than Sims' speculum introduced as in the operation for vesico-vaginal fistula. The vaginal mucous membrane should be seized with spring-forceps and a vesico-vaginal fistula knife passed completely round; thus will be formed the lower border of the area about to be pared. The mucous membrane is then dissected up to the extent of a little over a quarter of an inch; care must be taken to make the upper border even. Free cleansing with small mounted sponges will be needed throughout this process. The sutures, of silkworm-gut or silver wire, may be passed by means of a handled-needle eyed near the point and well curved. A catheter should be retained in the bladder after the sutures are tied, and the bladder is then injected with warm water, so that the surgeon may ascertain if the closure of the vagina be complete. The urine should be regularly drawn off, and the sutures may be removed about the tenth day.

This operation was performed successfully by Dr. Bantock in the case described in the introductory observations on vesico-vaginal fistula (page 418). The vagina was found to end in a blind extremity about two and a half inches from the vulva. The fistula had contracted, during the twelve months, to an opening about a quarter of an inch in diameter, through which a small portion of the wall of the bladder protruded. The uterus could not be reached; it could, however, be felt by recto-bimanual palpation, and appeared to be very small in size. The precise relations of the cervix, the bladder, and the vagina above the seat of atresia could not be made out. It did not seem advisable to attempt to open up the cicatricial tissue, as the relations of important parts were so much disturbed, and therefore the only operation likely to afford relief was closure of the vagina. The patient had not menstruated since her pregnancy.

The mucous membrane of the vagina below the fistula and the corresponding part of the posterior vaginal wall were dissected up partly by scissors and partly by dissection, to the extent of about half an inch. This proceeding was difficult owing to the diseased state of the tissues, but when six silkworm-gut sutures had been introduced (see Fig. 160), by means of a tubular needle

(No. 3 size), the raw surfaces were readily approximated, for owing to the narrowness of the vagina they were not far apart. Thus, in this particular case a segment of vagina, cut off from the uterus by the cicatricial atresia and from the vulva by the sutured operation-wound, was left in communication with the bladder. A catheter was passed into the bladder and made fast to the pudendal hairs, and a long piece of elastic tubing conveyed the urine into a bottle by the side of the bed, containing a 1 in 10 solution of sulphurous acid. This operation was performed on June 11th, 1880. The catheter was changed on June 13th and 15th; on the 16th it was removed altogether and passed occasionally. On June 20th the sutures were removed, and the parts were found well united. The patient was sent to a nursing home, whence she was discharged in a few weeks with perfect control over the bladder.

Fæcal Fistula—Recto-Vaginal Fistula.—This condition is generally the result of cancer of adjacent organs. It occasionally occurs in syphilitic patients, especially in connection with stricture low down in the rectum. Recto-vaginal fistula may follow wounds of the recto-vaginal septum; such wounds may be received accidentally, as when the patient falls on the end of a sharp or blunt object which can penetrate the body sufficiently far to damage the pudenda. An accident of this kind is not rare late in childhood. Thus, a schoolgirl may fall, during play, astride upon a spiked rail-post, or on a stick or umbrella; or, as in a case which I once saw in a general hospital, a slate-pencil may cause the wound. The injury may also be caused by felonious attempts at abortion, and by foreign bodies introduced for various other objectionable reasons. Specimen 4,673 in the pathological collection of the Royal College of Surgeons shows a large laceration of the posterior vaginal fornix, opening not into the rectum but into the peritoneum. The patient, a woman aged thirty, had herself caused the injury by introducing a candle into the vagina, and death ensued in a few days. This shows that not very great force is required to rupture the posterior vaginal wall. It has even been torn in coitus, in old subjects. Lastly, after the surgical repair of ruptured perineum, the upper part of the opposed surfaces may fail to unite. The surgeon who is acquainted with the pathology of the healing of

wounds, and the results of neglecting such injuries, can understand how often wounds in the recto-vaginal septum may result in fistula. Ulceration, through the pressure of a badly-fitting or a broken pessary, may cause a wound which is practically a fistula from the first.

Abscesses in the recto-vaginal septum, from any cause whatever, may produce a fistula. In labour, injuries to the septum of a kind likely to be followed by recto-vaginal fistula are rare; but the condition may be caused by complications during the puerperium, as pelvic cellulitis with suppuration, or diphtheritic vaginitis (Schröder).

Symptoms.—A recto-vaginal fistula, when small, may cause very little inconvenience, but when large enough to allow of the involuntary escape of flatus and fæces it is certain to keep the patient in a miserable condition until it is repaired. The patient applies for relief from the distressing symptoms just noted, and then the fistula may generally be detected by touch, or by careful exploration of the posterior vaginal wall, as the patient lies on her back in a good light. A Sims' speculum is introduced and passed along the anterior vaginal wall, then the posterior wall is carefully examined. The surgeon must remember that the vaginal mucous membrane does not bear handling with the volsella, being far more sensitive than the cervix uteri. The forefinger will answer the purpose of pressing down and pushing aside any part of the posterior wall. When there is some difficulty in finding the fistula, milk and water, or water stained with decoction of logwood or cochineal, may be injected into the rectum, as in a similar kind of test for vesico-vaginal fistula.

Operation.—A plastic operation for the repair of a recto-vaginal fistula will always be needed, excepting in cases of cancer, or of syphilitic disease of the rectum.* The operation must be conducted on the same principles as when a vesico-vaginal fistula is cured. The bowels must first be thoroughly cleared out by an aperient, administered about forty-eight hours before operation, followed by an enema to be thrown up an hour or two before the patient is placed on the operating table.

When the fistula is very low down, it is best to divide the

* When complicated by stricture of the rectum the latter, the primary condition, must be cured first.

perineum in the middle line, as far as the fistula, the edges of which are pared; the parts are then reunited by the ordinary operation for the repair of a completely ruptured perineum.

Should the fistula be higher, the patient must be placed in lithotomy position, the labia held well apart by assistants, and a Sims' speculum passed along the anterior vaginal wall. The late Dr. Thorburn considered that using Sims' speculum thus "is certainly not in accordance with the principles upon which the use of that instrument is based," nevertheless it throws a good light on the posterior vaginal wall.

That part of the vagina being exposed, the operator must ascertain how he may keep the fistula well in sight and within reach during the paring of its edges. The sphincter ani should first be well stretched by the forefingers. Then the fistula is best supported by a large rectal bougie passed through the anus. The vaginal mucous membrane should be pared freely. The operator should bear in mind, as Dr. Thorburn has noted, that the bevelling of the edges is often already very great before any paring is done, as the fistula is widest on the vaginal side. The edges of the fistula being thoroughly pared, and hæmorrhage checked, the sutures are applied as in the operation for vesico-vaginal fistula. A rectal tube should be retained after the operation. The rules for after-treatment will be the same as in repair of the perineum, the chief trouble arising not from the bladder and the catheter, as after the operation for vesico-vaginal fistula, but rather from uncertainty in relation to the choice of a proper time for opening the bowels and for removing the sutures. Some operators close the fistula from the rectal surface.

Entero-Vaginal Fistula.—A communication between the intestine above the rectum and the vagina is rare, and is generally associated with conditions which render an operation unadvisable. The fistula is, in fact, an artificial anus.

Epispadias.—This malformation is rare in the female. Dr. Dohrn* has recently described a distinct case of this deformity, unaccompanied by ectopia vesicæ, in an adult female. In epispadias the external organs are generally more or less

* *Zeitschrift für Geburtshülfe und Gynäkologie*, Band xii., Heft 1, 1886.

imperfectly developed. The clitoris may be simply notched, or deeply cleft, or completely divided into two halves, lying wide apart. In addition, the anterior wall of the urethra may be defective, so that that canal may appear as a wide funnel-shaped depression, with an orifice, at the bottom of the funnel, surrounded by a weak sphincter. The finger can readily be introduced into the orifice, and then will be found to enter the bladder immediately. Sometimes the mucous membrane of the open urethra bulges and presents an appearance puzzling to the observer. The condition of the clitoris will explain the anomaly. More or less incontinence of urine is certain to exist when the urethra is thus deficient.

Operative interference is hardly necessary in cases of bifid or completely split clitoris, yet when such a deformity exists, the urethra must be examined. When epispadias involves the urethra, causing incontinence of urine, a plastic operation will be required. The inner sides of the divided clitoris and its prepuce must be denuded of their integument, and those structures can then be sewn together. They will then lie in front of the urethra, which will be restored to its natural position.

Ectopia Vesicæ.—In this malformation the anterior wall of the bladder and urethra is deficient. Mr. John Wood insists upon the necessary existence of epispadias in cases of ectopia of the bladder, though, as is well known, epispadias does not necessarily involve ectopia. In female still-born children, or female infants who survive their birth but a few days or hours, ectopia vesicæ is not very rare. It is certain that in females it is often associated with other malformations of a yet more serious character, whilst in males ectopia vesicæ frequently exists as a distinct disease, thoroughly deserving that term in its etymological sense *dis ease*, yet unaccompanied by any other deformity. Mr. Wood gives the proportion of female cases to males as one in ten.

The scientific aspects of ectopia cannot be considered in these pages. The surgeon who contemplates operation on a very young subject should study Dr. Champneys' valuable essay on "Extroversion of the Bladder," in the thirteenth volume of the *St. Bartholomew's Hospital Reports*, where a complete sum-

mary of cases will be found. Although most female children with ectopia vesicæ die from other malformations incompatible with life, yet some live to adult age and have even married and borne children. Some cases have passed through life as reputed hermaphrodites. This error is, however, most likely to occur when the patient is a male.

The appearances of the affected parts in a case of ectopia vesicæ are characteristic. The open bladder forms a red projecting mass in the hypogastrium. The orifices of the ureters can generally be seen without difficulty. The symphysis pubis is usually imperfect—indeed, the pubic bones lie often three or four inches apart at the middle line, and are otherwise abnormally developed. This malformation of the pelvis affects the patient's gait. It is needless to describe the loathsome inconveniences which arise from the deformity of the bladder.

The first thing to be done when a case of ectopia vesicæ is examined is to ascertain for certain the sex of the patient. This is a self-evident proposition, but not always easy of solution. Hermaphroditic malformations may exist in a case of this infirmity. The surgeon must remember that the testicles may be arrested in their descent, and that an involution of the integument resembling a vagina has been observed in males. The rectum must be cleared of scybala before examination, since fæcal masses may lead to grave errors during vaginal exploration. The anus is often placed abnormally forward and the perineum is short.

Various operations have been devised for the relief of ectopia vesicæ. They are based upon one of two principles. The first principle is the diversion of the stream of urine into the rectum. The second is the closing in of the bladder by making for it an anterior wall out of the abdominal integuments. This is done in the course of operations performed on the first principle, but only as a more or less secondary measure. The second principle can and has been followed without the manufacture of a fistulous communication with the rectum.

Operations performed upon the first principle are open to numerous objections. They are based upon two false theories. Firstly, they professedly imitate the cloaca or common excretory canal of the monotrematous mammals, and the lower vertebrata.

Secondly, they are supposed to take away one cause of irritation without substituting another.

The morphological theory is thoroughly unsound. The cloaca of an *Ornithorhynchus*, or bird, is meant and made to transmit urine and fæces without irritation. The rectum in man is not so constructed. Hence it is not advisable to make a man or woman monotrematous. The attempt may entirely fail, and the urine may escape into the peritoneum or pelvic connective tissue. When, on the other hand, the operation succeeds, the anatomical cloaca thus formed may be a triumph of surgical skill, but it will never act to physiological perfection. A natural cloaca, of course, allows of evacuation of excreta in complete comfort. This artificial cloaca involves great irritation and perhaps ultimately fatal results.

In these operations, either the ureters are separated from the bladder and fastened to a wound in the rectum, or a communication with that part of the alimentary canal is made by means of an incision through the base of the bladder. The front of the bladder is then closed in.

Far better results have followed the class of operation based on the second principle, namely, the simply covering-in of the bladder. Pancoast, Timothy Holmes, and John Wood have caused these operations to be admitted into the ranks of established and legitimate surgical procedures.

In the operation for closing in the walls of the bladder, as performed by Wood and Mayo Robson, a flap of integument is cut from the abdominal wall above the bladder, the cutaneous surface of the flap is turned against the bladder, and two lateral flaps are made and fastened with their raw surfaces touching the raw surface of the first flap. Thus the anterior wall of the bladder after operation is cutaneous. Experience has shown that the hairs on the cutaneous surface give trouble at first, but the bulbs are ultimately destroyed by the action of the urine. It has also been discovered that this cutaneous surface becomes converted into mucous membrane, just as the reverse change occurs in prolapse of the vagina.

The Operation.—The parts should be prepared on the excellent principles advocated by Mr. John Wood.* The

* Heath's *Dictionary of Practical Surgery*, article "Ectopia Vesicæ."

hypogastrium and genitals, and the abdominal integuments above the bladder, are first well shaved. A depilatory should be used for the integument over the site of the future anterior flap. A drop of strong nitric acid should be applied to the several groups of hairs on the integument at intervals. During the application of the acid, the bladder and the adjacent parts must be

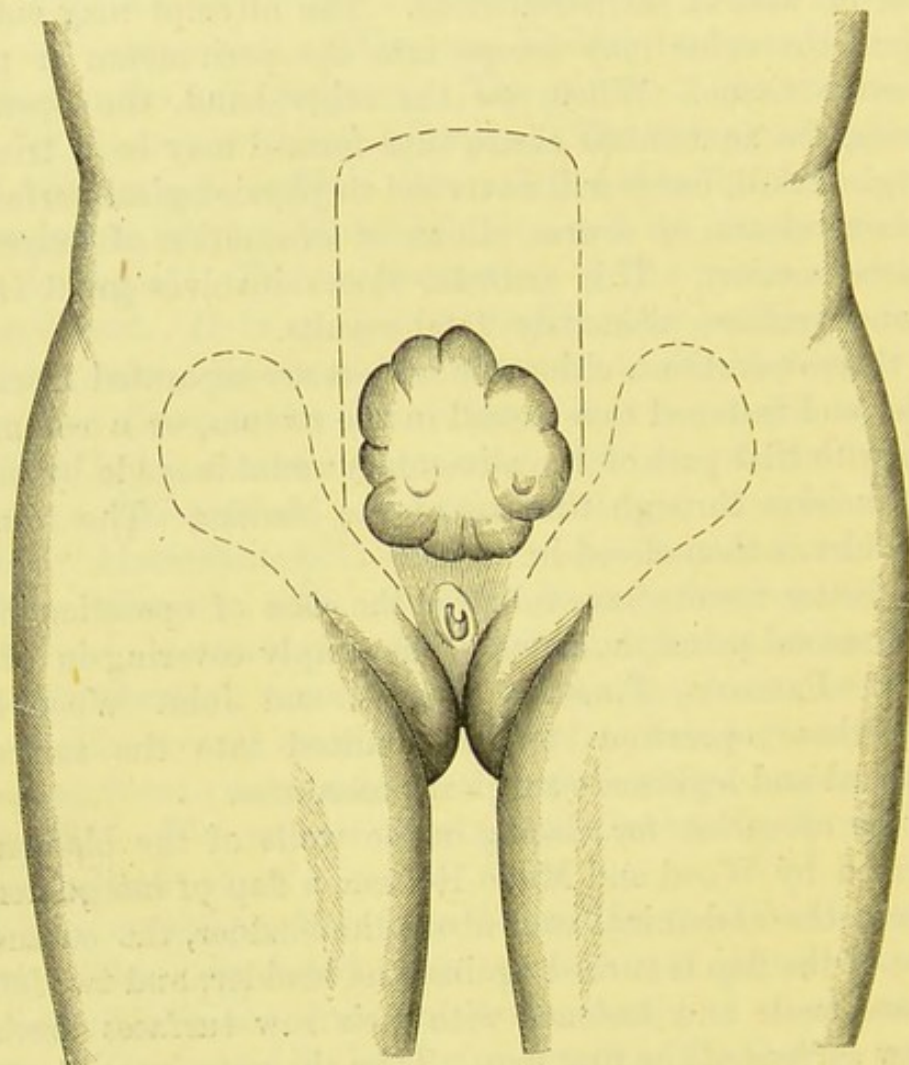


FIG. 161.—WOOD'S OPERATION FOR THE CURE OF ECTOPIA VESICÆ.

1. The flaps marked out. (*Mayo Robson.*)

protected by a thick layer of olive oil and chalk. When the skin has healed it must be washed before operation, with a carbolized solution. The strength which Mr. Wood uses is $2\frac{1}{2}$ per cent.

When the patient is under chloroform and laid on her back, the outline of the flaps should be marked with pen and ink. The vertical, upper or umbilical flap (Fig 161) is marked out by a pair of parallel lines running along the sides of the

bladder upwards. They must extend beyond the upper limit of the bladder a little farther than the distance between that point and the umbilicus. This rule is far more important when the operation is being performed on a female subject, than when the patient is a male. Above, the lines are united by a curve with its convexity upwards. The lateral or groin flaps are to be marked out each as a pyriform surface of integument with the outer extremities broad and well rounded (Fig. 161). The upper border must be prolonged inward on the labium as far as the site of the normal urethra. When complete, the vertical line representing one border of the vertical flap should bisect it. The lower border need not extend quite so far inwards. These flaps must be long enough to meet in the middle line when folded inwards.

The knife is now carried along the lines marked for the vertical flap, which is then carefully dissected downwards. The flap should be gently held by the operator's left thumb and finger. Surgeons accustomed to abdominal section, where pressure-forceps are used lavishly and without injurious results, must remember that long skin-flaps will not tolerate these instruments, so it is best to twist bleeding vessels at once. As the vertical flap is being dissected downwards, Mr. Wood's caution must be borne in mind—that is to say, care must be taken not to cut the flap too thin. This accident is most likely to occur close above the upper limits of the bladder, where the subcutaneous tissue is scanty or absent, and the aponeuroses around the tense linea alba thin and easily wounded. Hence the operator must dissect slowly, and look where he is cutting, lest he should cut the flap too thin and run the risk of a slough, or too thick so as to cut into the peritoneum or subserous cellular tissue. This latter accident may entail fatal extravasation of urine.

The lateral flaps are then dissected up. The external pudic vessels are divided in the course of the dissection, and sometimes require ligature. All the flaps are then folded back, bleeding allowed to cease, and the exposed raw surfaces cleaned so as to be free from clots. Mr. Wood employs a spray of a saturated solution of boracic acid. The raw surfaces should be allowed time enough to become glazed.

The vertical flap is now turned downwards, and Mr. Wood unites each of its corners to the cut edge of integument on each side of the site of the urethra, by wire or silkworm-gut sutures. The lateral flaps are then folded over the vertical flap. The latter now lies with its raw surface forward, so by bending the lateral flaps inwards their raw surfaces will touch that of the vertical flap. The inner edges of the lateral flaps are

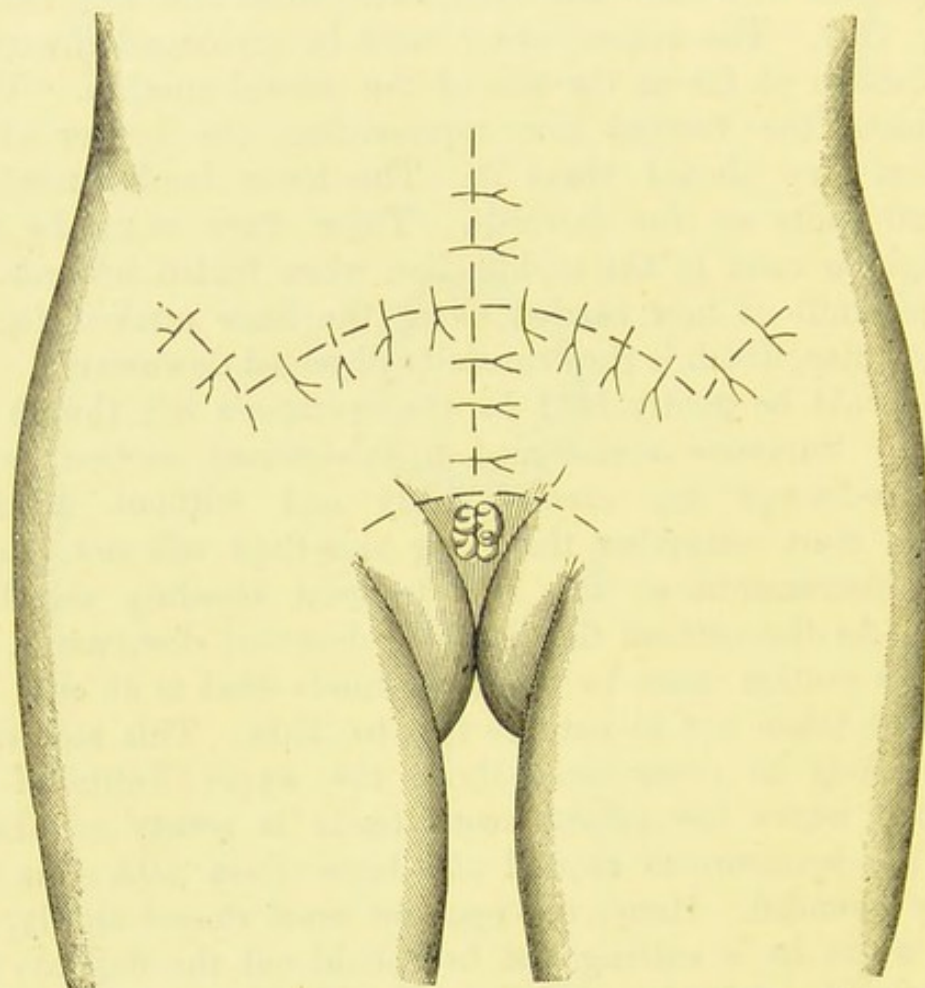


FIG. 162.—WOOD'S OPERATION FOR THE CURE OF ECTOPIA VESICÆ.

2. The lateral flaps stitched over the vertical flap. The gaps left behind the three flaps covered in by suture of the integument. (*Mayo Robson.*)

united across the middle line by a few closely-applied wire or silkworm-gut sutures (Fig. 162). The raw surface, on the abdomen above the bladder, whence the vertical flap was dissected, is covered by drawing the cut edges of integument together and holding them in place by means of sutures. This manœuvre not only closes in the exposed surface, but

also takes the strain off the reflected flaps. The edges of the gap formed by the displacement of the lateral flaps must be united in the same way (Fig. 162).

Mr. Wood rightly warns operators against a danger which is not encountered in plastic operations on the face or perineum. Sudden movements of the abdominal walls, from coughing or

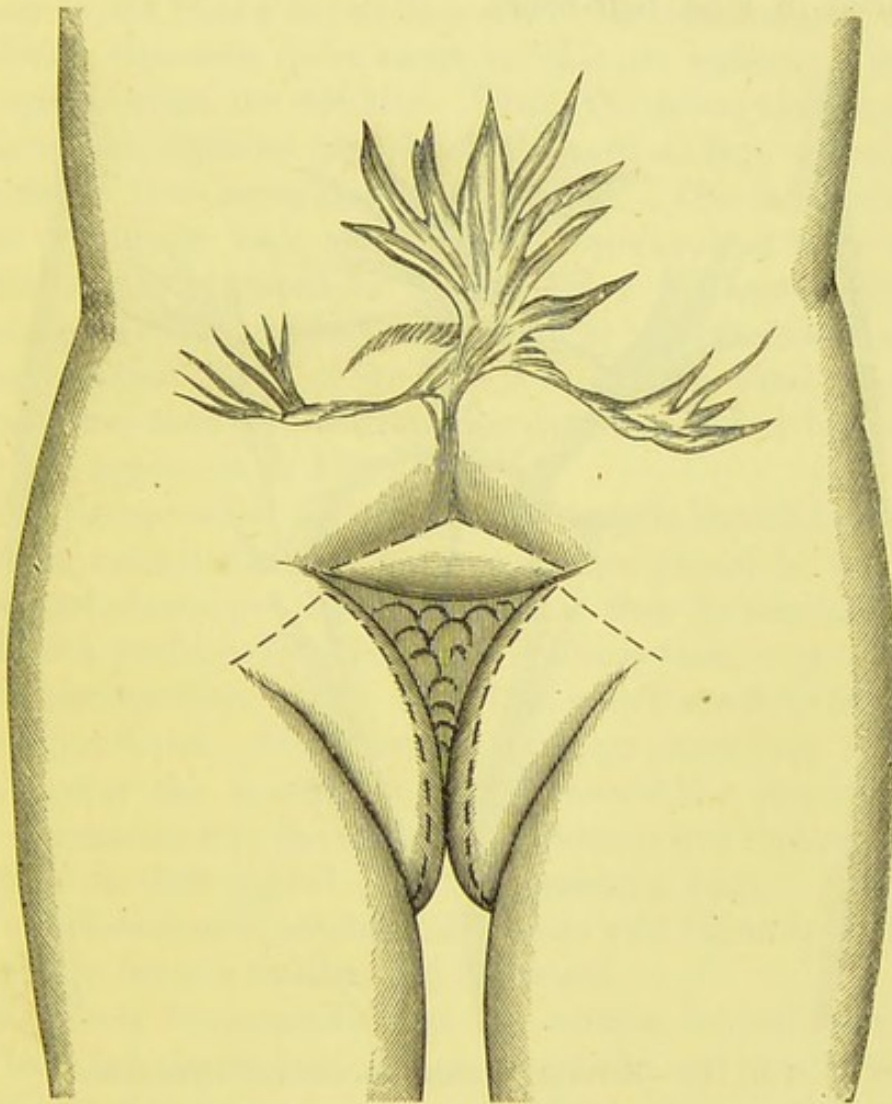


FIG. 163.—ECTOPIA VESICÆ AFTER OPERATION.

Retraction of lateral flaps, lower part of vertical flap exposed and drawn upwards, bladder uncovered below. Cicatricial tissue along line of flaps above. New flaps indicated by dotted lines. (*Mayo Robson.*)

straining, may cause a penetrating wound from the knife, which instrument may also cut the suddenly protruded bladder. Moreover, such movements are very troublesome when the flaps are being dissected.

I have already observed that the vertical flap must be cut long and broad. Care must also be taken that the lateral flaps be not too narrow. I have been describing the operation as performed on the female only, so that by "long and broad" and "too narrow," I signify longer and broader than, and as narrow as, when the operation is performed on the male, as described in most text-books.

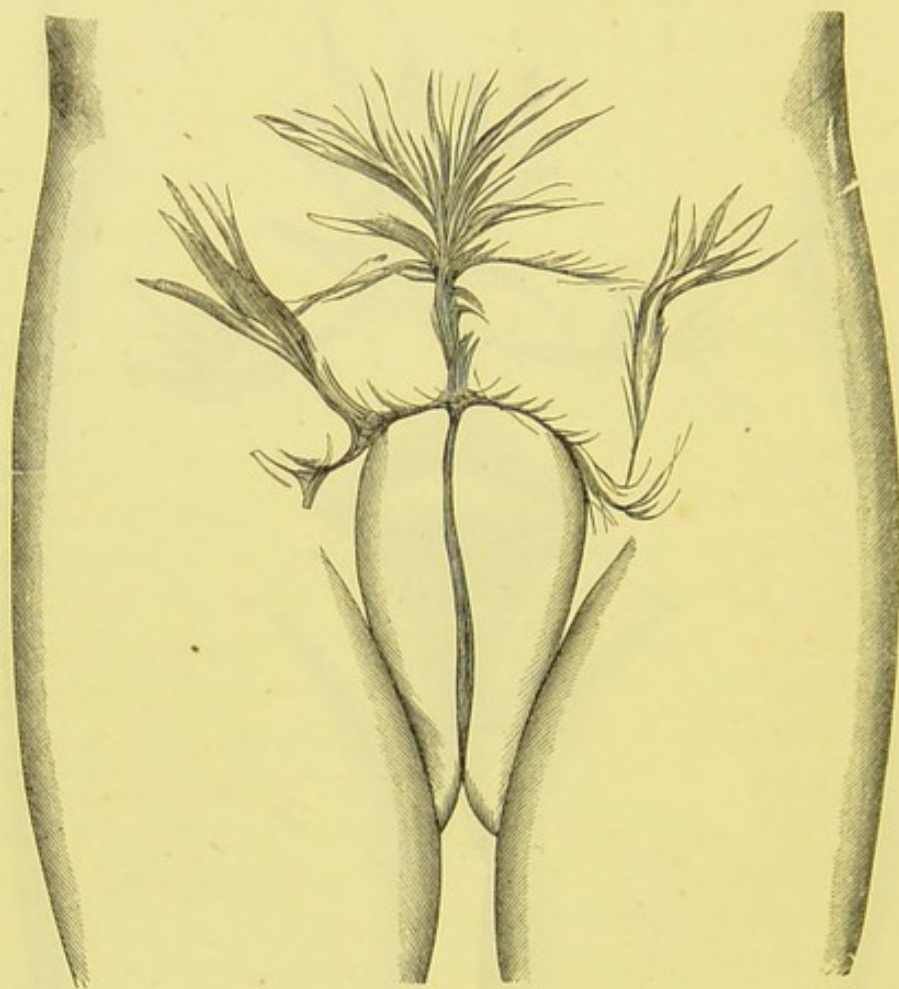


FIG. 164.—ECTOPIA VESICÆ, SECONDARY OPERATION.

New flaps (see preceding figure) united and healed. (*Mayo Robson.*)

Still, notwithstanding the greatest care in making the flaps as wide as possible, experienced operators have met with unsatisfactory results. In the process of healing, the side flaps have been known to retract to such an extent as to draw upwards the lower margin of the vertical flap, exposing a portion of its cutaneous surface and laying bare the lower part of the bladder (Fig. 163). In such a case Mr. Mayo Robson's

operation will be necessary.* The prominent folds of integument forming the labia majora are incised for about three inches vertically. From the upper end of each incision, another is carried outwards (Fig. 163). In this manner two triangular flaps of skin are formed and dissected up. The everted lower portion of the old vertical flap (which in Fig. 163 appears as the triangular surface above the exposed part of the bladder) is dissected downwards, so that its cutaneous surface once more covers the bladder. Then, the triangular flaps are slid over the replaced portion of the vertical flap. Their raw surfaces are thus brought into apposition. The inner margins of the triangular flaps are united by sutures, and their upper margins similarly united to the cut lower surfaces of the old lateral flaps, thus refreshed in the process of detachment of the everted vertical flap. Fig. 163 will explain these manipulations better than any written description. When healed the parts will appear as in Fig. 164.

After the operation for ectopia, the wounds should be painted over with collodion. The patient is then placed in bed, on a waterproof sheeting. Her knees must then be carefully fixed in a flexed position by a bandage holding them together and approximating them to the shoulders, which must be well supported by pillows. High temperatures are sometimes observed shortly after the operation. An india-rubber drainage-tube must be inserted into the vagina, and cleaned and replaced daily. A cradle is then placed over the patient's body. Irrigation with a half-saturated solution of boracic acid lotion is advisable if the flaps become swollen and inflamed.

Mr. Wood recommends that the sutures be left alone till they have become useless. Then, about the end of a fortnight, the patient may be put under chloroform, and all the sutures that have not dropped off may be removed.

* "Extroversion of Bladder" (*British Medical Journal*, vol. i. 1885, p. 222).

CHAPTER XVII.

OPERATIONS ON THE VAGINA, VULVAR STRUCTURES, AND
URETHRA.**Congenital Atresia of the Hymen and Vagina.**—

By this term I include the affection rightly or wrongly described as “imperforate hymen” in most text-books, together with cases of closure of the lower part of the vagina without any further deficiency of the genital canal. The symptoms will be retention of menses or hæmatocolpos, causing serious changes in the more important organs higher up. In the first chapter of this manual I dwelt at length on the varieties of the hymen, some of which are occasionally mistaken for morbid conditions, especially in infancy. A correct knowledge of the anatomy of the vulva and of the more frequent malformations of the vagina is absolutely necessary for the surgeon who proposes to operate for the relief of atresia.

Atresia in Infancy and Childhood.—The surgeon must not mistake natural or other appearances for imperforate hymen, when examining an infant. The labia often adhere. The inner surfaces of the natural labieform hymen of infants (page 5, Fig. 3, I.), frequently stick together. A linguliform hymen (page 5, Fig. 3, II.) may also have adherent edges. Its unusual appearance gives the observer the idea that disease or malformation must exist, and the morbid condition with which the hymen is generally associated is want of patency. Hence this kind of adhesion, produced by tenacious mucus between the apposed surfaces, is often mistaken for “imperforate hymen,” and so described in text-books. Forcible traction on the two halves of the hymen separates them at once; sometimes a little bleeding follows, just as occurs at the angles of the

mouth when the lips are sore. The surgeon instinctively believes that he has torn through an imperforate hymen, when he has simply parted the two halves of a natural infantile hymen. The cause of this false imperforate hymen is want of cleanliness, or mild vaginal catarrh. In the more acute catarrh, so common in strumous children, the edges of the hymen often become thickened. It is probably through this disease that some of the peculiar forms of hymen already described (page 6) are developed.

Before puberty atresia generally produces no symptoms. Mucus rarely accumulates, as menstrual blood does later on. Matthews Duncan believes that the mucus is reabsorbed; Dohrn considers that the vagina secretes little or none of that substance under the circumstances. We do not hear of atresia with vaginitis and retention of discharge in children. Yet cases of accumulation of mucus are said to have occurred. As Mr. Owen rightly recommends,* when an obstruction is torn open in the way above described, a small piece of cotton-wool, covered with vaseline, may be placed between the edges of the linear wound for a few days. This may be done even when it is evident, as is almost invariably the case, that the edges of a normal labieform hymen have simply been pulled apart.

Atresia at and after Puberty.—Whilst before puberty true atresia gives rise to no symptoms and is rarely discovered even by accident, when the menstrual functions are established important symptoms appear, which oblige the patient to seek for medical relief. There is amenorrhœa, and the gradual formation of a tumour. The menstrual fluid distends the vagina above the obstruction, the molimen is felt, but there is no "show." Gradually the entire vagina becomes dilated, then the cervix. The cavity of the body of the uterus is slow to fill. The Fallopian tubes also tend to become distended with blood, not, it appears, by the same mechanism which distends the vagina and uterus, but through hæmorrhage from the tubal mucous membrane. Thus the tubes may be completely cut off, by closure of their uterine extremities, from the uterus, and yet be full of blood. The tubes may rupture, with fatal

* *The Surgical Diseases of Children*, 1885.

results. On the other hand, spontaneous rupture of the obstructing septum is most unusual. The accumulation of retained menstrual fluid not only mounts the genital canal in the way described, but also causes bulging in the region of the vulva and perineum, and forms a large tumour, very tense and elastic.

The retained menstrual blood varies greatly in amount. From eight or ten to fifty or even over a hundred ounces have been removed. It is prevented from coagulating by the vaginal mucus, and some of its fluid is probably reabsorbed, since Puech has noted that the collection in a given case is less than might be expected on calculating the accumulation of the blood shed at each period before observation. It is dark brown in colour, treacly or tar-like in consistence, and almost or quite odourless. When air is admitted into the vagina, this fluid rapidly begins to decompose.

Symptoms.—Strange to say, the serious pathological conditions just described are slow to produce subjective symptoms. This, I believe, is partly owing to the fact that young girls have not learnt to pay great attention to occasional dull pains in the pelvic and lumbar regions, so that when present, the patient troubles less about them than she would were she older and imbued with the physiological ideas and superstitions of adult women. Duncan lays stress on the absence of symptoms. In a lecture on *Retention of Menses*, he says: "In two recent cases of great accumulation, we may well say that there were no symptoms and no constitutional disturbance. Certainly, even at last, there was no constitutional disturbance in either of them. In one, S. P., aged twenty-one, a florid girl, beaming in health and vigour, it was only eight months before coming into hospital that she knew she had a lump in the lower belly; it was discovered accidentally by her doctor, who happened to examine her in bed for a passing illness; and she had no symptoms till the doctor told her she had this lump. Then she began to find out that she had irregular achings, for about the half of each month, probably suggested, or what are called imaginary symptoms." The last sentence is highly instructive.

Pain, however, is rarely altogether absent, and may be strictly periodical. Retention of urine is frequent. Some of

the symptoms of early pregnancy, sickness, tenderness of the breasts, and slight development of the areolæ may be observed, and lead to grave suspicions, greatly increased by the other

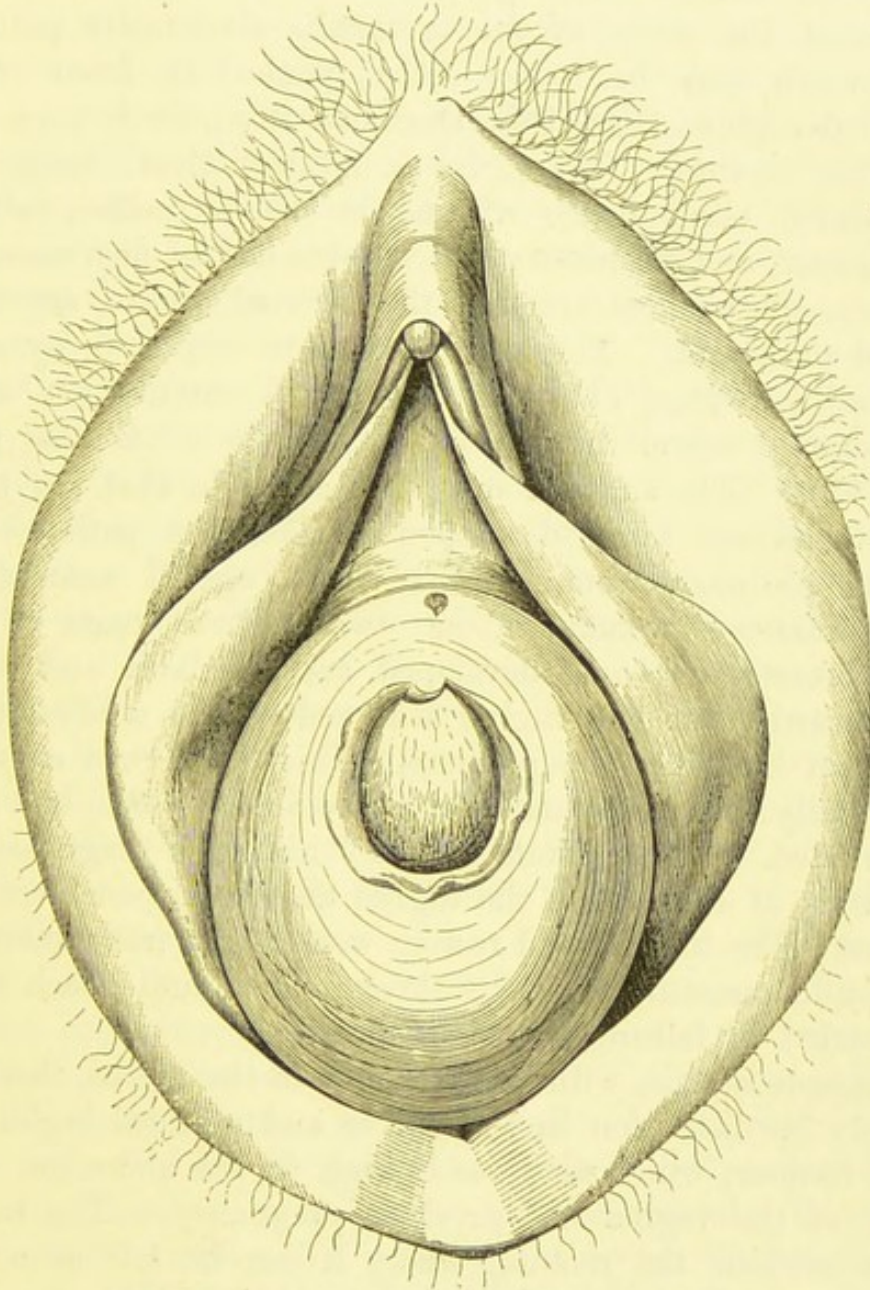


FIG. 165.—ATRESIA VAGINÆ, WITH THE HYMEN WELL DEVELOPED AND PATULOUS. (*Matthews Duncan.*)

principal symptoms of atresia, which are amenorrhœa and the presence of a swelling. This leads to the subject of diagnosis.

Diagnosis.—In a case of atresia, the objective symptoms just given will be present. When, in a young patient who

has never seen any menstrual "show," the vagina is found to be closed, the vulva and probably the obstructing septum distended, and a tumour discovered, the diagnosis of atresia will be all but certain. The bulging of the vulva varies in character. Sometimes, the orifice of the urethra is abnormally patulous. The hymen may be found entire, pushed in front of the distended septum (Fig. 165, Duncan's case), or it may itself form the septum. When, in an adult patient, there is an undistended blind pouch within the vulvar orifice, without any tumour, and no history can be obtained of any menstrual molimen, the chances are that the internal organs are undeveloped or absent. The pelvis must be explored by rectal bimanual (see page 71) and recto-vesical examination, where a catheter or sound in the bladder will be a valuable guide (page 72). The surgeon must not conclude that the uterus and ovaries are fairly developed because the patient looks like an ordinary woman. Six years ago, I examined a young married woman, about twenty-three years of age, whose breasts were well developed, and the labia and clitoris well formed,* but the vagina was reduced to a blind pouch hardly an inch deep on pressure. This pouch was employed functionally, but all sexual desire was absent. She had never menstruated. "Imperforate hymen" had been diagnosed, but not a trace of uterus or of the vagina above the pouch could be detected. The bladder and rectum were almost in contact; any attempt to puncture or dissect through the blind pouch would have ended in failure, if not in disaster.

In simple atresia, without deficiency of the uterus, there will not only be distension in the vulvar and perineal region, but also a tumour, which may reach high in the abdomen. The closure of the vagina will preclude pregnancy. The tumour bulges towards the rectum, where it can be felt as a tense elastic bag. The distension of one or both Fallopian tubes may be detected. In a case recently under the care of Mr. Mayo Robson, where the vagina was considerably deficient, the right tube formed "a prolongation like a sausage."

* See plate III. in Duncan's "Case of so-called Imperforate Hymen" already quoted (page 9). It represents the well-formed external parts, including the hymen, of a woman in whom the vagina and uterus were absent.

The amount of perineal bulging in relation to the size of the elastic tumour which can be felt through the rectal walls and above the pubes, is a point of considerable diagnostic value. When the tumour is present, and the bulging of the perineum and vulva distinct, the obstruction probably lies in the hymen, or low down in the vagina. When the tumour is present, but no bulging can be detected in the perineal and vulvar regions, the vagina will probably be deficient to a considerable extent.

Operation.—All authorities agree that operations for the relief of atresia are of a very serious character. It must be remembered that the operation has to be done, else the retention of menses will continue, and, owing to its toughness, the obstructing septum is not likely to yield, whilst some internal part of the swelling may burst. However simple the malformation may look, more of the vagina may be involved than might be expected, so that, instead of a simple puncture or incision, a difficult dissection will be needed. Lastly, the opening up of a cavity full of decomposable material, and walled in by the tissues of important structures, must inevitably expose the patient to risk. Hence the surgeon must make up his mind for an operation, and must be very careful how he performs it, and how he carries out the after-treatment.

An excellent method of operating for atresia is adopted by Dr. Matthews Duncan in the wards for diseases of women at St. Bartholomew's Hospital. I know that the results are satisfactory. It is best, I believe, to follow the advice of Hart and Barbour and others, and to operate between two menstrual molimina, as far as can be calculated. The patient is placed in the lithotomy position, and an incision an inch long is made in the region of the hymen, running from before backwards. It is not necessary to make the incision crucial. Paquelin's cautery-knife answers this purpose far better than a scalpel. Layer after layer is divided, until the thick treacly retained fluid flows freely, accelerated at each inspiration. The surgeon must judge in each particular case how long the incision should be; it must be more than a mere hole just allowing the fluid to flow, and must not, of course, be prolonged so as to damage the bladder, urethra, or rectum. The septum often proves to be thick and tough.

The fluid must be allowed to flow, without any assistance by pressing on the abdominal walls, or on the rectal side of the recto-vaginal septum ; nor is it necessary or advisable to use the syringe during operation. When the fluid has ceased to flow freely, lint soaked in carbolic oil is laid over the vulva, and the patient is placed in bed, with napkins carefully adjusted to receive further discharge.

The characteristic discharge, as a rule, flows for a few days, and the next coloured discharge is generally brighter, representing the unobstructed menstrual "show." The forefinger should be introduced between the edges of the wound two or three times a week. In eight or ten days the wound is usually healed. Duncan strongly advises that the patient should remain in bed for three or four weeks, in order that the restoration of the vagina and uterus to a natural state may meet with no interruption. When the patient is quite young, and the amount of retained fluid does not exceed from ten to twenty ounces, the vagina presents but little abnormality. As a rule, however, its walls are at first exceedingly thick and hard, through true hypertrophy, and Breisky noted, during digital exploration of one case a week after operation, that they then underwent powerful and painful contractions. He seems to imply that these spasms were caused by the hypertrophied muscular walls of the vagina, and not by the sphincter vaginæ and levator ani, which so often contract when the genitals receive any painful impression (page 48). The mucous membrane forms thick transverse folds. The cervix uteri is difficult, at first, to reach ; indeed, its vaginal portion appears very frequently to be ill-developed. The vagina slowly gains its normal character.

Dr. Matthews Duncan claims the best results for his cases "treated by Paquelin's cautery incision and otherwise left alone."* Indeed, syringing sometimes appears to set up septic or other dangerous symptoms.

No doubt, symptoms of blood-poisoning may follow the most

* In December, 1886, Dr. Duncan kindly wrote to me in reply to a letter on this important feature in after-treatment—"I regularly use no syringing after hæmatocolpos operation. If there is much of yellow discharge, a warm wash out by syringe may be ulteriorly used. Generally that is not required."

carefully performed operation of this kind. This is probably due to the decomposition of some of the fluid which lies in a part of the affected tract, whence it cannot be readily dislodged by muscular contractions. The flow of the treacly fluid backwards through the tubes into the peritoneal cavity has been known to occur; it has been explained differently by various authorities. Some speak of reversed peristaltic action of the tubes, excited by the escape of fluid. The action being directed backwards, some fluid is forced into the peritoneal cavity. Others think that the tubes rupture by sudden contractions too violent to expel their contents steadily. Others believe that the tubes are often fixed by old adhesions to the pelvic walls. When the fluid escapes, the distended uterus collapses and sinks downwards, dragging on the tubes until one of them is ruptured and allows the escape of its contents into the peritoneal cavity. This last remarkable condition has been proved by dissection. These evil results all warn the surgeon to be very careful about after-treatment, and to allow the fluid to empty itself slowly, so that the contractions of the distended parts may be slow, uniform, and steady, ensuring the expulsion of all the fluid, and avoiding sudden traction on any delicate structure.

Deficiency of the Vagina.—By this term I imply absence of more or less of the vagina, with or without retention of menses.

Deficiency of the lower part of the vagina, a tract of tissue rather than a mere septum lying between it and the vulva, with retention of menses, is an affection bearing most of the characters of atresia as already defined and described, nor can the two conditions be readily distinguished. The sac of retained menses may bulge towards the vulva, as in simple atresia. Unfortunately, in some cases of retention, not even a tract of tissue lies between the vulva and the upper part of the vagina, but the walls of the bladder and rectum lie close together.

This last condition is yet more frequent when no menses are retained, and when no molimen has been experienced by the patient. As I have already stated (page 462), the internal organs may be ill-developed when all the external physical attributes of a perfect woman are present.

Treatment.—When a sac of retained menses can be plainly detected, the patient may be subjected to the operation for atresia, great care being taken to ascertain, by means of the catheter in the bladder and the finger in the rectum, how near those viscera may lie to one another. When it is evident that the bladder and rectum are in very close contact, either a vaginal passage must be dissected out between them, as will be described, or else the collection of menses must be emptied by puncture through the rectum.

Where no collection of retained menses can be found, the presence and relations of the uterus must be carefully ascertained by recto-abdominal and vesico-rectal exploration (page 71). That organ may prove to be altogether absent or quite impalpable, owing to extreme atrophy or rather arrested development. On the other hand, a little tough, anteflexed virgin uterus may be distinctly defined; the cervix may even be detected by simple rectal exploration.

Opinions are much divided as to the advisability of an operation in these cases. In the first place, when no uterus is discovered after careful exploration, I believe that, for many reasons, no operation should be performed.

The case is otherwise when a uterus can be distinctly felt. The ethical aspects of an operation for the formation of a functional vagina must be considered. The uterus, though formed, is probably a sterile uterus, so that the vagina will only serve one function and never give transit to a foetus or even to catamenial blood. Yet the unexpected establishment of menstruation after an operation of this kind is not unknown.

Dr. Matthews Duncan entirely discountenances the artificial dissection of a vagina. He declares that judging from past experience "the attempts to make a new vagina result in a troublesome and most imperfect imitation of nature, as bad, indeed, as the new noses that surgeons amuse themselves by making." The wound becomes a cicatricial, indurated passage, constantly needing dilatation. There can be no doubt that the good results claimed by certain operators are too often temporary.

Nevertheless, when the fundus and cervix can be distinctly felt, circumstances may render an operation advisable.

Operation for Deficiency of the Vagina.—The patient must be placed in the lithotomy position, an assistant holds a sound in the bladder as in lithotomy, and at the same time presses with his disengaged hand on the abdominal walls immediately above the pubes, so as to push the uterus well downwards. A bougie or the forefinger of an assistant is kept in the rectum; the operator will not find it convenient to keep his own left hand engaged for that purpose.

There is rarely room between the urethra and anus to allow of a fairly long antero-posterior incision; it is, therefore, generally necessary to make it transverse. With the usual appliances for checking hæmorrhage, the connective tissue above the incision must be carefully broken down with the forefinger. The operator will, in that way, generally manage to push between the bladder and rectum until he opens up the upper or patent part of the vagina or reaches the cervix. He must bear in mind possibility of congenital malformations such as double vagina or uterus. The open tract is packed for about twenty-four hours with lint soaked in carbolized oil. Then a special vaginal plug must be kept in. Several forms are sold by instrument makers; the best is made of glass, and constructed so that it may be fixed with tapes to a bandage passed round the abdomen. It should be perforated, and removed, cleaned, and replaced daily. After a few weeks the patient must learn to introduce and remove the plug daily. This must be done for at least a year, and is often advisable throughout the whole of the patient's life until the end of the child-bearing term, as far as that can be estimated in a subject neither likely to menstruate nor to bear children. A Hodge's pessary is useful as a dilator.

Acquired Atresia and Contraction of the Vagina.—The vagina is sometimes greatly obstructed by cicatricial changes following injuries received during labour, wounds, and syphilitic ulceration. Adhesion of surfaces of its mucous membrane in apposition, as a result of inflammation, has been observed even after parturition.

The worst and most frequent cases of acquired atresia are the result of damage during labour; contrary to the rule in the congenital forms, it is the upper part of the vagina which is generally involved. Small cicatrices are often observed in the

course of digital exploration in the out-patient room. They form elevated spiral or crescentic ridges running from the cervix downwards along the walls of the vagina. Their edges are generally sharp, and they feel tough like cicatrices elsewhere. The cervix is often displaced, and the cicatrices may be so much developed that the finger can only with difficulty, if at all, be brought in contact with the os. Matthews Duncan writes (*Clinical Lectures*): "But though cases of stricture more or less tight, and, having a small lumen from these causes, are not uncommon, I have not seen one of complete closure (atresia) with retention and accumulation."

Operative Treatment.—Small crescentic cicatrices should not be interfered with. When the cicatrization is extensive, threatening difficulties in future labours, and causing marked displacement or dyspareunia, some of the more prominent bands should be notched by means of a probe-pointed bistoury. A vaginal dilator (page 424) must afterwards be inserted; the patient will require frequent attention for many years after this proceeding. When there is real atresia, with retention of menses, the most bulging part of the vaginal swelling should be cautiously opened by means of the thermo-cautery, and the case is afterwards treated as when a congenital septum is opened; but when the accumulated menstrual fluid has come away, a vaginal dilator must be worn. The surgeon must not only remember the dangers attending operative measures in these cases of acquired contraction and atresia, but must be prepared for discouraging results.

Atresia of the Cervix Uteri.—The treatment of this affection by operative measures has been already described at page 338.

Removal of Tumours of the Labia.—When a labium is affected with hypertrophy, or with a tumour innocent or malignant, it is best to remove it by means of the galvano-cautery. The galvanic *écraseur* is not so easy to guide as a wire attached to the two clip-handles already described and figured (page 153). The patient is placed in the lithotomy position, the affected labium is seized by means of a strong volsella, held by an assistant. The operator takes a handle in each hand and guides the wire, heated to a red heat, through

the integuments and deeper structures, along the desired line of amputation, till the labium is severed.

When the knife or any other cutting instrument is used, hæmorrhage will be severe, and a Paquelin's cautery should be at hand. The platinum-knife, worked by the thermo-cautery, is not suited for dividing the integument, it does not cut cleanly like the wire of the galvano-cautery, and the tissues consequently heal badly.

Removal of Diseased Clitoris.—True hypertrophy of the clitoris must be distinguished from the apparent hypertrophy observed when the other external organs are small and ill developed. In the true form, alone, is an operation justifiable. Epithelioma may commence in the clitoris, which should then be amputated. Removal of the clitoris must never be attempted on the ground that it may cure a neurosis.

The galvano-cautery, employed as in the case of diseased labia, is the best instrument for amputation of the clitoris. I have been present when the knife and Paquelin's cautery were used for the removal of an epitheliomatous clitoris. The hæmorrhage was difficult to check, and a painful cicatrix remained. In epithelioma, the adjacent parts of the labia are often involved, and will require removal. Simple dressing with lint steeped in carbolized oil, and the administration of opiates for the first twenty-four hours, will be necessary. As a rule the parts heal quickly.

Treatment of Urethral Caruncle.—A small urethral caruncle may produce no symptoms, and may be discovered quite accidentally, in searching for some other condition. In such a case it is not justifiable to interfere with it. On the other hand, a patient may complain of severe local pain, difficult micturition and other symptoms, attributed to a prolapse of the uterus or vaginal walls which really exists. Should the surgeon, on examining the parts, discover a urethral caruncle as well, the latter affection is probably the chief cause of the painful symptoms.

The surgeon must refrain from two lines of treatment frequently adopted. He must not content himself with pulling down as much of the caruncle as the forceps or tenaculum will hold without crushing, and snipping it off. In that case the

operation will most certainly be incomplete, some of the growth will be left behind, and the patient, after suffering from the smarting of the wound, will soon be subject once more to the pain of the original disease. Nor must he, on the other hand, smear the growth or the entire urethra with caustics: a stick of nitrate of silver applied to the urethra will cause intense pain at the time of its introduction, followed by temporary relief, which may last for a month or longer, but it cannot cure, and is more disagreeable to the patient than the proper mode of treatment. Operations on caruncles are looked upon as "minor" surgery, and consequently enter too often into the category of bad surgery. Cucaine may cover malpraxis. A painless excision does not, as a rule, mean a complete excision.

Removal of Urethral Caruncle.—The right treatment for urethral caruncle is excision and application not of caustics, but of the cautery to the wound. This requires that the patient should be placed under the influence of an anæsthetic. For that reason some surgeons prefer cucaine to chloroform or ether, local to general anæsthesia. But cucaine does not always act well, and the parts cannot be so thoroughly explored when the patient is conscious, as there is always hyperæsthesia.

The patient, after her urine has been drawn off, is placed on her back, and the anæsthetic is administered. Then her legs may be kept apart by a Clover's crutch or else by an assistant, a Sims' speculum is passed into the vagina and depressed; the labia are also held apart anteriorly. In this manner the vestibule and meatus are brought well into view. In the meantime, an assistant prepares the cautery. The finest point of a Paquelin's thermo-cautery should always be preferred, if that instrument be at hand. Should no special form of cautery be at the surgeon's disposal, any fine-pointed piece of iron, properly mounted, will serve. It must be made as hot as possible in the fire or in the flame of a gas-jet or candle. A fine-pointed bradawl has been frequently used in this way, and appears to answer very well.

The surgeon first dries the urethra by means of wool wrapped round the point of a Playfair's probe. He then seizes the caruncle with a fine volsella, or, better still, transfixes it with the point of a tenaculum. Taking the forceps or tenaculum in

the left hand, he raises the caruncle very gently, and cuts through its base with scissors curved on the flat. The wound is certain to bleed, and it is best to check the bleeding by pressure of a piece of wool, mounted as above described, for half a minute or so. Then, when the bleeding no longer interferes with a view of the cut surface, the cautery is applied to that surface, just long enough to burn its tissues perceptibly.

The after-treatment is very simple—the patient should keep at rest for a couple of days, and the urine should be drawn off, if possible, twice or oftener during the first twelve hours after operation. I have found it advisable to give carbonate of potash with tincture of hyoscyamus, as in gonorrhœa, during this period. Micturition then becomes far less painful, and when the patient is free from apprehension of pain, there is

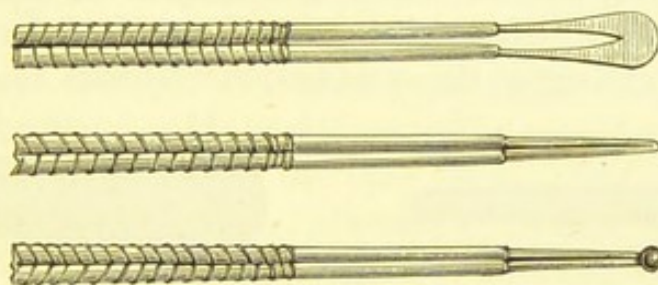


FIG. 166.—CAUTERS FOR TREATMENT OF URETHRAL CARUNCLE.*

less chance of trouble in this respect every time that the bladder is emptied. Indeed, the catheter is often unnecessary from the first.

Removal of Caruncle by the Galvano-cautery.—

For the removal of urethral caruncles by the galvano-cautery, an anæsthetic having been administered, the patient is placed in the lithotomy position, and the urine drawn off by a catheter. The knees are held apart by assistants or a Clover's crutch. The labia are protected by several folds of wet lint and held apart by the fingers of assistants. The caruncle is then seized by a small volsella or by a pair of ordinary artery-forceps, and a short loop of platinum wire, attached to handles

* The second cauter in this drawing is useful for cauterizing a pin-hole vesico-vaginal fistula, left after operation (see p. 435).

as in Fig. 72, or to an *écraseur* (Fig. 70) is passed down to the base of the caruncle. When the loop is adjusted the circuit is closed and the growth is very quickly removed, the wire being raised to a red heat. No bleeding ought to take place, but it is best to cauterize the base of the growth by the hot wire or by a platinum point (Fig. 166). Some surgeons prefer to use the platinum knife (Fig. 69); but the loop of platinum wire is better for this operation. After the removal of the caruncle a piece of lint dipped in carbolic oil is placed between the parts, and held in position by a T-bandage. The after-treatment will be as above described.

Urethro-Vaginal Fistula.—The operation for this affection is described in Chapter XVI., page 437.

For the principles on which **Dilatation of the Urethra** should be conducted for purposes of diagnosis or for facilitation of operative measures, the systematic text-books on diseases of



FIG. 167.—SIMON'S DILATOR, WITH THE PLUG INSERTED.

women must be consulted. The general surgeon must be very slow to undertake dilatation of the urethra, as it may be followed by intractable incontinence of urine, even when performed by an experienced hand.

For the extraction of small calculi, dilatation by Simon's instrument (Fig. 167), may prove very satisfactory. I have removed a stone measuring an inch in its long diameter, and weighing two drachms and a half, from the bladder of a child aged nine,* after dilatation with that instrument, and the patient regained power over the bladder in a few hours; I last saw her four years after the operation, and then she was in perfect health. I have learnt from others, however, that incontinence of urine has followed a very trifling amount of dilatation.

* *Medical Press and Circular*, 1878, p. 66.

Operations on the Female Bladder do not lie precisely within the scope of this handbook. It is probable that the **Supra-pubic Operation** will supersede all other forms of lithotomy and all operations for calculus, when the stone is large. Some surgeons advocate lithotripsy for large calculi in women. For small calculi the operation above described is still preferred. Vaginal lithotomy is not likely to be widely practised. The supra-pubic operation may be undertaken for the removal of tumours of the bladder. Sir Henry Thompson, Mr. Pye, Mr. R. W. Parker, and others have successfully removed morbid growths by this operation. The last-named surgeon employed the aid of the electric lamp (Fig. 73), and a galvanic écraseur of a slender make was passed into the bladder through the urethra. The loop of platinum wire was then slipped round the growth, which was removed without loss of blood. Nevertheless, this operation is still in the hands of hardy pioneers or surgeons of very wide experience; it is not yet so far established as to be a suitable subject for this manual. The reader will find a valuable series of papers on the supra-pubic operation in the second volume of the *British Medical Journal* for the year 1886. The report of the "discussion on Supra-pubic Lithotomy," opened by Sir Henry Thompson in the section of Surgery at the fifty-fourth annual meeting of the British Medical Association, is particularly instructive.

ADDENDUM ON DRAINAGE.

Management of the Drainage-Tube.—The manner of introducing the drainage-tube is described at page 126. After ovariectomy, oöphorectomy, or any other form of abdominal section where a glass drainage-tube is introduced, the tube should be emptied every two hours. The lower strips of the binder are undone (page 131), the india-rubber cloth (page 128) is unfolded, and the conical sponge, which is placed over the orifice of the tube, is removed and dropped into a 1-in-10 solution of sulphurous acid. The india-rubber tubing attached to the syringe (page 127) must be dipped into the same solution before it is passed into the drainage-tube, which being done as described at page 128, the fluid is placed in a glass vessel for examination, and more is then removed if necessary. It is advisable to dip the tubing into a 1-in-20 solution of sulphurous acid every time before its re-introduction into the drainage-tube. When all the fluid is removed, a fresh conical sponge, well washed out in a 1-in-5 solution of the acid, is placed over the orifice of the drainage tube and enveloped in the india-rubber cloth. The sponge not in use should be kept in a 1-in-10 solution of the acid.

When the fluid which rises in the tube has become quite pale and only amounts to a drachm, or less, at each dressing the tube may be removed. The orifice in the wound through which it passed should be dressed with a pad of absorbent gauze. The tube must never be taken out as long as the fluid remains of a reddish colour or smells sour.

INDEX.

A

Abdominal binder, many-tailed, etc., 129. Application of, 130, 242.
 Abdominal gestation, 352.
 Abdominal section. See *Ovariectomy*, *Oöphorectomy*, etc.
 Abdominal tumours, diagnosis of, 165, 172. Examination of, 168. Table of, for diagnosis, 174.
 Abdominal wound in ovariectomy, 185, 200. Abscess in suture-track in, 241. Cicatrix of, 253. Closure of, 239. Dressing of, 240. Hernial distension of, 254. Length of, 185. Mechanism of distension of, after operation, 251, 255. Rapidity of its healing, 241. Sutures for, 119, 185. Union of edges delayed, 185.
 Abdomino-recto-vaginal examination, 72.
 Abscess after ovariectomy, 241, 266.
 Absorbent wool and gauze, how to test, 131.
 Accessory fimbriæ on Fallopian tube, 25.
 Adams' peritoneum-hook, 101, 203.
 Adhesions: In ovariectomy, abdominal, 212. Pelvic, 216. In hysterectomy, 289.
 Administrator of anæsthetics. See *Chloroformist*.
 Ague and high temperature after ovariectomy, 258.
 Alexander, Dr., his operation for shortening the round ligaments, 413.
 Ampère, 144.
 Anæsthesia, etc. See *Chloroformist*.
 Apartment for ovariectomy patient, 187.
 Aperients. See *Purgatives*.

Appendages, uterine, inflammation of, 275. See *Oöphorectomy*.
 Apron, mackintosh, for operator, 197.
 Arteries of the pelvis, 37.
 Artery: Azygos, of vagina, 38. Of cervix uteri, 41. Coronary of cervix, 41. Iliac, common and external, 37. Internal, 38. Iliac in relation to ureters, 31. Ovarian, 37, 38. Ovarian, how divided in ovariectomy, 39. Uterine, 39. In hysterectomy, 297. In supravaginal excision of cervix, 331. In vaginal extirpation of uterus, 321.
 Aspiration of ovarian cysts, 177, 179.
 Assistants during ovariectomy, number of, 199.
 Atresia: Of the cervix, Breisky's operation for, 338. Of the vagina, 9, 458. Operation for, 463. Cicatricial, 424, 445, 467.

B

Bandage, abdominal. See *Abdominal Binder*.
 Bantock, Dr. G. Granville, case of colpocleisis, 445. Koeberlé's serre-nœud, his modification of, 123. Ligature of ovarian pedicle, his method of, 220. Pregnant fibroid uterus, his case of removal of, 385. On opium after perineorrhaphy, 298. Application of large pressure-forceps to pedicle, 219, 280. Ruptured perineum, his operation for, 392. Sutures in abdominal wound, his arrangement of, during the cleaning of peritoneum, 236.
 Barnes' speculum, 65.

Basins, objectionable as receptacles for instruments during abdominal section, 84.

Bath to receive ovarian fluid, etc., 85.

Battery, bichromate of potash, 144, Bunsen's 147, Grove's 148.

Bed for ovariectomy patient, 189.

Bed-room for ovariectomy patients, 187.

Bed-pan, difficulty of micturition into, a cause of cystitis, 257.

Bed-sores after ovariectomy, 247. After operations in extra-uterine pregnancy, 365, 368.

Belt, abdominal, 255. See also *Abdominal Binder*.

Belt, thigh, for ovariectomy, 86.

Bichromate of potash battery, 144.

Bimanual examination, 53. Recto-abdominal bimanual, 71. Abdomino-recto-vaginal bimanual, 72.

Binder. See *Abdominal Binder*, many-tailed.

Bivalve speculum, 66.

Bladder, 27. Extroversion of, 449. Inflammation of, after ovariectomy, 256. After operation for vesico-vaginal fistula, 435. See *Vesico-vaginal fistula*, etc. Supra-pubic operation, observations on, 473. For application of ice, 137.

Boulton, Dr. Percy, his self-retaining catheter, 433. His needle for vesico-vaginal fistula, 429. Purse-string operation for ruptured perineum, as performed by, 399. His speculum for trachelorrhaphy, 341. Case of urethro-vaginal fistula, 437.

Bowels, opening the, after ovariectomy, 247.

Bozeman. Speculum, 62. His operation for vesico-vaginal fistula, 426.

Breisky, his operation for atresia of the cervix, 338. On Müller's ducts, 8. On vaginal walls in atresia, 464.

Broad ligament, 35. Relation to Fallopian tube, 23.

Broad ligament cysts, simple or "par-ovarian" cysts, 163. Tapping, 180.

Bronchitis, cause of rise of temperature after ovariectomy, 258.

Bryant, Mr. Ovariectomy-trocar, 103 *note*.

Bulb of ovary, 26, 43. Of vagina, 44.

Bunsen's battery, 147.

Burrowing of ovarian cysts beneath peritoneum, 226.

Byrne, Dr., on the galvano-cautery in elongated cervix, 335.

C

Cæsarean section, 369. Säger's modified, 370. His rules for simplification of, 375.

Calculus formed around ligature of ovariectomy pedicle escaped into bladder, 266.

Cancerous uterus, removal of. See *Vaginal extirpation of uterus*.

Caneva, his hysterorrhaphy, 413.

Cannula, 103 and *note*. Fitch's dome-shaped, 105.

Capsuled or encapsuled ovarian cysts, 225. Management of, 227.

Carunculæ myrtiformes, 9.

Caruncle, urethral, 469.

Case-book for ovarian cases, 167, 192.

Catheter, Boulton's, for vesico-vaginal and urethro-vaginal fistula, 433. After ovariectomy, 191, 250.

Cauters for galvano-cautery, 149. For urethral caruncles, 470.

Cautery in ovariectomy, 185.

Cervix uteri, 20. In digital exploration, 50. Not tender to touch, 50, 52. Artery of, 41. Coronary artery of, 41.

— Amputation of, for cancer, with use of caustics, 332. By *écraseur*, 328. By galvano-cautery, 325. By knife and scissors, 333.

— Atresia of, Breisky's operation for, 338.

— Electrolysis in cancer of, 338.

— Elongation or primary hypertrophy of, 334. Operations for relief of, 335.

— Laceration of, 339. Operation for. See *Trachelorrhaphy*.

— Supra-vaginal excision of, 330.

Champneys, Dr. On extroversion of the bladder, 449.

Chloroformist in ovariectomy, 197, 198.

Cicatricial atresia of vagina, 424, 445, 467.

Cicatrix of abdominal wound after ovariectomy. See *Abdominal wound in ovariectomy*.

Cintrat's *serre-nœud*, 124.

Clamp, in ovariectomy, 185.

Clamp, Koeberlé's. See *Serre-nœud*.

Clip-handles, for galvanic *écraseur*, 153.

Clitoris, 4. Amputation of, 469. Bifid in epispadias, 449.

Clover's crutch, 132.

Cocaine in treatment of urethral caruncle, 470.
 Coe, Dr. On unsatisfactory results after oöphorectomy, 276.
 Colpocleisis, 442.
 Colporrhaphy. See *Elytrorrhaphy*.
 Conservative surgery of the uterine appendages, 277.
 Corkscrew, Tait's, 287, 290.
 Coryza and high temperature after ovariectomy, 258.
 Coulomb, 144.
 Cowper's ducts, 12. Gland, 12.
 Crescent speculum, Barnes', 65.
 Crutch, Clover's, 132.
 Cucaïne in treatment of urethral caruncle, 470.
 Cul-de-sac, posterior vaginal. See *Fornix, posterior vaginal*.
 Cusco's speculum, 67.
 Cystic diseases of uterine appendages, surgical pathology of, 158.
 Cyst-forceps. See *Large pressure-forceps*, Nélaton's, 107.
 Cystitis: After ovariectomy, 256. After repair of vesico-vaginal fistula, 435.

D

Dermoid ovarian tumour, 161.
 Deroubaix on vesico-vaginal fistula, 419.
 Dieffenbach's elytrorrhaphy, 407.
 Diet after ovariectomy, 243. Milk-, and formation of scybala, 244, 398.
 Digital exploration of vagina, 46.
 Dilator, Simon's urethral, 472. Vaginal, 425.
 Director: Key's, 102. Stanley's, 102, 204.
 Discoloration of vulva in pregnancy, 3, 46.
 Dohrn: On absence of vaginal secretion in atresia, 459. On the hymen, 4.
 Dome-trocar, Fitch's, 103 *note*, 105.
 Douglas's pouch, 19, 34.
 Drainage, 126, 474. Primary, 126. Secondary, 128. Of capsule of sessile cyst, 227. Cure of ovarian cyst by, its futility, 181. Of cyst in incomplete ovariectomy, 230. After ovariectomy, 242, 474. After vaginal extirpation of uterus, 324.
 Drainage-tube, 125, 474. India-rubber, 129. India-rubber cloth for, 129. Keith's, 126. Koeberlé's, 125. Nussbaum's case of escape of, from abdominal cavity, 266.

Duckbill speculum. See *Sims' speculum*.
 Duncan, Dr. J. Matthews: On atresia, 9, 459, 460, 462, 463, 468. On laceration of cervix, 339. On patency of the Fallopian tube, 24. On the labia majora, 1. On ethical aspect of an operation, 276. On the perineum, 389 *note*, 405. On danger of cutting off a fibroid polypus, 304. On absence of pedicle in purely intra-uterine polypi, 307. On hæmorrhage from pedicle of fibroid polypi, 306. On uterine contractions and expansions, 17 *note*. On dissection of an artificial vagina, 466. On vesical systole, 30 *note*. On laceration of vestibule during labour, 11.
 Duncan, Dr. William, on total extirpation of the uterus, 318, 323, 324.
 Dyspareunia: In chronic inflammation of appendages, 275. In vesico-vaginal fistula, 421.

E

Écraseur chain, 329. In cancer of cervix, 328. In elongation of cervix, 335.
 Écraseur, galvanic, 152. See *Galvano-cautery*.
 Ectopia vesicæ, 449. Wood's operation for, 451.
 Ectropion in laceration of cervix: Treatment of before trachelorrhaphy, 340. Modification of trachelorrhaphy in extreme, 346.
 Electrical apparatus in gynæcological surgery, 141.
 Electrolysis apparatus, 141. In cancer of the cervix, 333.
 Elytrorrhaphy or colporrhaphy, 406. Dieffenbach's, 407. Emmet's, 409. Lefort's, 412. Neugebauer's, 412. Simon's, 412. Sims', 407. Gailard Thomas's, 412.
 Embolism after ovariectomy, 267.
 Emmet, Dr. T. A.: His elytrorrhaphy, 409. On trachelorrhaphy, 339. His operation, 340. On spontaneous cure of vesico-vaginal fistula, 424.
 Emmet's operation. See *Trachelorrhaphy*.
 Emplastrum resinæ for waterproof sheet, 87.
 Encapsuled ovarian cysts, 225.

- Endometrium, 19.
 Enemata after ovariectomy, 248. Beef tea, after ovariectomy, 245.
 Entero-vaginal fistula, 448.
 Enucleation: Of ovarian tumour, 226. Of uterine fibroid during hysterectomy, 293. Of intra-uterine fibroid, 307.
 Episiorrhaphy, 405.
 Epispadias, 448.
 Examination, methods of pelvic, 45. Of abdominal tumours, 168.
 Exploratory puncture of ovarian cysts, 177.
 Extirpation of uterus, abdominal, 318 *note*. Vaginal, 318.
 Extra-uterine pregnancy, 350. Varieties of, 351. Abdominal, 352. Ovarian, 352. Tubal, 351.
 — Treatment of: Active, 353. By electricity, 354. Extirpation of sac at time of rupture, 357. When unruptured before and after term, 365. Incision of ruptured sac, 361. Of unruptured sac, 362. By injection of chemicals, 353. Palliative, 353. Puncture of sac, 353. Vaginal section, 354.
 Extroversion of bladder. See *Ectopia vesicæ*.

F

- Fæcal fistula, 446. After ovariectomy, 265.
 Fallopian tubes, 22. Accessory fimbriæ of, 25. Canal of, 17, 24, 25, 75. Fimbriæ of, 24. Inflammation of, 273. Papilloma of, 163.
 Fascia, pelvic, 36.
 Fergusson's speculum, 58.
 Fibroid polypus, uterine: Excision of, 303. Fatal case, 304. Ligature of, 306. Removal of, by *écraseur*, 306.
 Fibroid, uterine submucous: Enucleation of, 307. Matthews Duncan on, 307 *note*. Incision of capsule of, 312.
 Fibroid, uterine subperitoneal, 300. Danger of removing small, during ovariectomy, 232.
 Fibroid, uterine tumour, 286. Operations for relief of: see *Hysterectomy*, *Oöphorectomy*, and *Porro's operation*.
 Fibro-myoma of uterus, 286.

- Fil-de-Florence*, 120
 Fimbriæ, accessory, of Fallopian tubes, 25.
 Fistula, fæcal, after ovariectomy, 265.
 Fitch, his dome-trocar, 105.
 Fixateur or tampon-screw, Sims', 311.
 Flushing the peritoneum, 204, 236.
 Fætation, extra-uterine. See *Extra-uterine pregnancy*.
 Forcippressure, 93.
 Forceps: Artery, 93.
 — Clamp, 112.
 — Large pressure, or cyst-forceps, 109.
 — Large pressure: In securing ovarian pedicle, 219. In oöphorectomy, 280.
 — Pressure, Koeberlé's, 94; Péan's, 95; Tait's, 99; Wells' old form, 96; Wells' new, 97.
 — Speculum, 60; T-bladed, 100.
 Fornix, anterior vaginal, 13.
 Fornix, posterior vaginal or posterior cul-de-sac, 14. In digital exploration, 52.
 Fossa navicularis, 3.
 Fourchette, posterior, 2.
 Frænulum, 2.
 Freund, his operation, 318 *note*. On extra-uterine pregnancy, 351, 352.
 Fristo's case of abnormal vaginal septa, 7.
 Fused ovarian cysts with double pedicles, 216, 225.

G

- Galvanic *écraseur*, 152.
 Galvano-cautery, 141. Advantages and disadvantages of, 155. Battery, 144. Amputation of cervix by, 325, 335. For incision of extra-uterine gestation sac, 356.
 Gangrene of ovarian cyst, operation for, 176.
 Garrigues, Dr.: On the course of the ureters, 31. On Cæsarean section, 370.
 Gauze, absorbent, how to test, 131.
 Genupectoral position, 57.
 Gestation, extra uterine. See *Extra-uterine pregnancy*, *Tubal pregnancy*, etc.
 Godson, Dr. Clement: Case of Porro's operation, 379.
 Goodell, Dr., on parotitis after trachelorrhaphy, 346.
 Grove's battery, 148.

H

- Hæmatosalpinx, 274.
 Handcuffs for ovariectomy, 86.
 Hart, Dr. Berry, his suggestion for testing thickness of pedicle of uterine polypus, 305.
 Hart and Barbour: On Alexander's operation, 413. On operation for atresia, 463. On the genupectoral position, 57. On the vaginal walls, 15.
 Hegar, Professor: His amputation of the elongated cervix, 237. Case of passage of ovarian pedicle into the rectum, 266. His spiral incision of fibroid polypus, 305.
 Hermaphroditic malformations in ectopia vesicæ, 450.
 Hernia of abdominal cicatrix after ovariectomy, 253.
 Hilum of ovary, 26.
 Holmes, Mr. Timothy: Operation for ectopia vesicæ, 451.
 Hot water as a hæmostatic, 204 *note*.
 Hot water: Washing out peritoneal cavity with, 204, 236. Precautions in applying waterproof sheet before, 88.
 Hydatid of Morgagni, 163.
 Hydrosalpinx, 274.
 Hymen, 4. In atresia, 9, 458, 462. Absence of, 8. Laceration of, 8. Present in some forms of atresia, 462. Varieties and abnormalities of, 6, 458.
 Hyperpyrexia after ovariectomy, 258.
 Hysterectomy, supra-vaginal, 287. Management of pedicle in, 292, 297. For rapture of pregnant uterus, 386. See also *Porro-Freund's operation*, *Porro's operation*, and *Vaginal extirpation of uterus*.
 Hysterorrhaphy, 405, 413.

I

- Ice-bladders, 137.
 Ice-cap, Thornton's, 133.
 Imperforate hymen. See *Atresia*.
 Incision and drainage: Futility of attempting cure of ovarian cysts by, 181. Of sac in extra-uterine pregnancy, 361.
 Incomplete ovariectomy, 228.
 India-rubber cloth for drainage-tube, 128.

- India-rubber drainage-tube, 129.
 Infundibulo-pelvic ligament, 27, 35, 37, 38. In ovariectomy, 219.
 Inspection, pelvic, 45.
 Insufflator, Clay's uterine, 138. Kabiersky's, 138, 298.
 "Interstitial," or tubo-uterine pregnancy, 361.
 Irremovable base of ovarian cyst, 227.

K

- Kabiersky's insufflator, 138, 298.
 Keetley, Mr., on hot water as a hæmostatic, 204, 237.
 Kehrer, his incision in Cæsarean section, 378.
 Keith, Dr. T.: His drainage-tube, 126. His note on a case of fæcal fistula after ovariectomy, 265. On tapping broad ligament cysts, 180.
 Kelly, Dr. Howard, on hysterorrhaphy, 413 *note*.
 Key's director, 102.
 Kidd's volsella, 309.
 Kolpokleisis, 442.
 Knot: For ligature of ovarian pedicle, 221 *note*. For abdominal sutures, 239.
 Koeberlé's drainage-tube, 125. Pressure-forceps, 94. Serre - noeud, 122, 295, 299, 302, 367.
 Krassowsky, cases of tetanus during ovariectomy, 269.
Kystes lacuneux of Verneuil: Their appearance in hysterectomy, 291.

L

- Labia: Majora, 1; Minora, 3. Removal of tumours of, 468.
 Laminaria tents, 79.
 Lamp, electric, 156.
 Laparo-elytrotomy, 386. Relations of ureters most important in, 33.
 Large pressure-forceps or cyst-forceps, 109. In oöphorectomy, 280.
 Lefort's elytrorrhaphy, 412.
 Leiter's tube, cap, and temperature regulator, 135.
 Leopold, statistics of Cæsarean section, 375. And Säger, their method of closing the uterine wound after Cæsarean section, 373.
 Levator ani, 48.
 Ligament. See *Broad ligament*, *Ovarian ligament*, etc.

Ligature of ovarian pedicle, pathology of, 185. See *Pedicle, Ovarian*.
 Lowe, Dr. Walter : Case of extra-uterine pregnancy, 360.
 Lusk, Dr. : On Cæsarean section, 373. On gastrotomy for rupture of the uterus, 379. On laparo-elytrotomy, or Thomas's operation, 386.
 Lymphatics, pelvic, 44.
 Lyon, Dr., case of fæcal fistula, 265.

M

Mackintosh apron, 197. Sheet for ovariectomy, 87, 198.
 Marekwald's amputation of the elongated cervix, 337.
 Matthieu's catch, 96, 107.
 Meatus urinarius, 11.
 Menstruation after ovariectomy, 270.
 Meso-salpinx, 35.
 Mirror for abdominal sections, 87.
 Milk diet and scybala, 244, 398.
 Morphine or morphia (see *Opium*), injections of, in extra-uterine gestation sac, 353.
 Mundé, Dr., on Alexander's operation, 417.
 Muscles, pelvic, 36. As detected on digital exploration of the vagina, 48.
 Myoma, 286. See *Hysterectomy, Fibroid Polypus*, etc.

N

Needles, pedicle, 112. Hagedorn's, 117. Used for sutures in ovariectomy, 116.
 Needle-holder, 115, 233. Hagedorn's, 118.
 Nélaton's volsella, 107.
 Nerves, pelvic, 37. Pressed upon in pelvic exploration, 37, 49.
 Neugebauer's speculum, 64. His elytrorrhaphy, 412.
 Nightmare after ovariectomy, 268.
 Nomenclature of instruments, 82.
 Note-book, ovariectomy, 167, 192, 270.
 Nurse for ovariectomy, 190.
 Nussbaum : Singular case of escape of drainage-tube from abdominal cavity, 266.
 Nymphæ, 3.

O

Obturator internus, 49.
 Ohm, 143.
 Olshausen : On cause of tetanus after ovariectomy, 269.
 Oöphorectomy, 272. When justifiable, 276. For disease of the appendages, 277. For fibroid of uterus, 283. For relief of neuroses, 272, 282.
 Operating table for ovariectomy, 189.
 Opium : After ovariectomy, 244. After plastic operations on the perineum, 398.
 Ovarian artery, 37, 38. Fluid, receptacle for, during operation, 85. Ligament, 18, 26. Pregnancy, 352.
 Ovariectomy : Abdominal wound. See *Abdominal wound in ovariectomy*. Abscess after, 266. Adhesions, abdominal, management of, 212 ; pelvic, management of, 216. Age of patient, 182. Ague after, 258. Apartment for patient after, 187. Assistants, 199. Bed for patient, 189. Bed-sores after, 247. Bladder, catheterism of, after, 250 ; inflammation of, after, 256. Bowels, opening after, 247. Cautery in, 185. Catheterism after, 250. Cicatrix. See *Abdominal wound in ovariectomy*. Clamp in, 185. Cleaning the peritoneal cavity, 236. Closure of abdominal wound, 239. Clothing of patient during, 194. Counting sponges and instruments, 237. Cystitis after, 256. Diarrhœa after, 256. Diet after, 243. Drainage, 126, 242, 474. Dressing abdominal wound, 240. Embolism, pulmonary, after, 267. Enemata after, 248 ; nutrient, after, 245. Enucleation of a cyst, 226. Exploration of ovary opposite the tumour, 230. Extraction of cyst, 208. Flatulence after, relief of, 256. Foreign bodies left in abdominal cavity after, 265. Gastric disturbance after, 255. Hæmatocele of the pedicle after, 270. Hæmorrhage, internal, after, 262. Hernia of cicatrix after, 254. Incomplete, 228. In infancy, 182. Instruments required for : Arrangement of, 197 ; list of, 196 ; cleaning, after, 85, 243. See also *Scissors, Trocar*, etc. Intestinal irritation after, 256. Intestinal

- obstruction after, 264. Ligature of pedicle, 185, 218. Menstruation after, 270. Nightmare after, 268. Note-book and notes for cases of, 167, 192, 270. Nurse, 190. Nutrient enemata after, 245. Operating table for, 189. Opium after, 244. Palpitations after, 268. Parotitis after, 267. Pedicle : See *Pedicle, Ovarian*. Phlegmasia after, 266. Position of operator and others during, 199. In pregnancy, 184. Purgatives : Before operation, 194 ; danger of administering them within a few hours of the operation, 194, 256 ; after ovariectomy, 248. Pyæmia after, 259. Septicæmia after, 259. Solid matter and secondary cysts, breaking down, 209. Sponges and instruments left in peritoneal cavity after, 238. Steps of the operation, 195. Sutures : Introduction of, into abdominal wound, 234. Removal of, 251. Syncope from anæmia of the brain after, 268. Temperature, rise of, after, 258. Tetanus after, 268. Thrombosis after, 266. Treatment before, 193. Trocar : See *Trocar, Ovariectomy*. Vomiting after, 243, 255, 256, 260.
- Ovary, 26. Surgical pathology of cystic disease of, 158. Inflammation of, 274.
- Owen, Mr. Edmund, on atresia in infants, 459.
- P**
- Paget, Mr. Stephen, on parotitis, after ovariectomy, 267.
- Pallen, Dr. Montrose, on trachelorrhaphy in childbed, 346.
- Palpation : Abdominal, Bimanual, 53.
- Pampiniform plexus, 37, 43.
- Pancoast : Operation for ectopia vesicæ, 451.
- Papilloma : Of broad ligament, 162. Of Fallopian tube, 163. Of ovary, 161.
- Paquelin's cautery. See *Thermo-cautery*.
- Parker, Mr. R. W. : The supra-pubic operation for removal of vesical tumours, 473.
- Parotitis : After ovariectomy, 267. After trachelorrhaphy, 345.
- Parovarian cysts. See *Broad ligament cysts, simple*.
- Parovarium, 27.
- Parvin, Dr., case of uretero-vaginal fistula, 441.
- Pawlik, Dr., on amputation of the cervix uteri, 327.
- Péan's forceps, 95.
- Pedicle needles, 112.
- pins (for hysterectomy), 124.
- Pedicle, in hysterectomy, 292.
- Pedicle, ovarian, 215. Changes, morbid, in, 266. Detachment, spontaneous, of, discovered during operation, 177, 211, 217. Double, in fused ovarian cysts, 216, 225. Hæmatocele of, 270. Ligature of, 185, 215, 218. Slipping of, from ligature, 262. Splitting of, 186, 262. Stump of, passed at stool, 266. Transfixion of, 220. Twisting of, 177. See also *Sessile tumours and Uterine tissue*.
- Pedicle of pedunculated uterine fibroids, 302. Of fibroid uterine polypi, 305. Of mucous uterine polypi, 314.
- Pelvic arteries, etc. See *Arteries of the pelvis and Artery*.
- Perineorrhaphy : For relief of prolapsus, 405. See *Perineum, rupture of*.
- Perineum : Anatomy of, 388. Rupture of, 387. Operation for repair of (perineorrhaphy), 391. Bantock's method, 392. Purse-string operation, 399. Pathology of, 389. Partial rupture of, 402.
- Peritoneum-hook, Adams', 101, 203.
- Peritoneum : Pelvic, 33. Uterine, 20, 34. "Toilet," 236. Cleaning or washing out, or flushing with water, 204, 236.
- Peritonitis after ovariectomy, 259.
- Phlegmasia after ovariectomy, 266.
- Pigmentary line along linea alba, 202.
- Pins : For uterine pedicle, 124. In hysterectomy, 295.
- Placenta, wounds of, in operations on pregnant uteri and extra-uterine foetal sacs, 364, 372.
- Platinum knife, for galvano-cautery, 151.
- Playfair, Dr., on trachelorrhaphy, 339. On laparo-elytrotomy, or Thomas's operation, 386.
- Plexuses : Pampiniform, 43. Venous, 41.
- Plugging the vagina, 61.

Polarization, 146.
 Polypus-forceps, uterine, 314.
 Polypus, uterine fibroid. See *Fibroid polypus, uterine*.
 Polypus, uterine mucous: Removal of, 313. Fatal case, 315.
 Porro's operation: Dr. Godson's definition of, 379. Details of the operation, 380. Allied operations: Porro-Freund's, 382. Supra-vaginal hysterectomy during pregnancy, 384. After rupture of the uterus, 378, 386.
 Porro-Freund's operation, 382.
 Pouch of Douglas. See *Douglas's pouch*.
 Pregnancy: Discoloration of vulva in, 3, 46. Extra-uterine: See *Extra-uterine pregnancy*. Hysterectomy during, 384. Ovariectomy during, 184. See *Cæsarean section and Porro's operation*.
 Pregnant fibroid uterus: Operations on, 384. Removal of, at term, 385.
 Pressure-forceps, 93. See *Forceps*.
 Prolapse of vaginal walls and uterus, operations for, 404. Its relation to hernia, 407.
 Puech on retained menstrual blood, 460.
 Purgatives and aperients after ovariectomy, 248.
 Pyæmia after ovariectomy, 260.
 Pye, Mr. Walter: The supra-pubic operation for removal of vesical growths, 473.
 Pyosalpinx, 274.
 Pyriformis, 49.

R

Receptacle for ovarian fluid during operation, 85.
 Rectal examination, 69. By introduction of entire hand, 70.
 Recto-abdominal examination, 71, 462, 466.
 Recto-vaginal examination, 72.
 Recto-vaginal fistula, 446. Operation for, 447.
 Recto-vesical examination, 72, 462, 466.
 Reef-knot, double, 221 *note*.
 Resin plaster for waterproof sheet: How to prepare, 87.
 Rheophore, 149.
 Rheostat, 145.
 Roberts, Dr. Carr: Case of tubo-uterine pregnancy 361.

Robson, Mr. Mayo: Case of atresia with distension of Fallopian tubes, 462. Operation for ectopia vesicæ, 451.
 Round ligaments, 18. Alexander's operation on, 413.
 Routh, Dr. C. H. F.: Case of extra-uterine pregnancy, 356. On the treatment of rupture of uterus, 377.

S

Sänger, Professor: His modification of Cæsarean section, 370. Rules for simplification of same, 375.
 Sarcoma of ovary, 164. See *Solid ovarian tumours*.
 Savage, Dr. Henry: On the Fallopian tube, 25. On the perineal body, 388. On the vestibular glands, 11.
 Scalpel, for abdominal sections, 91.
 Schröder: His method of supra-vaginal excision of the cervix, 330. Of excision of cervix and use of caustics, 332. Of amputation of the elongated cervix, 335, 337.
 Scissors, for ovariectomy, 92.
 Scybala and milk diet, 244.
 Screw, Tait's, 287, 290.
 Semi-prone position, 57, 63.
 Septa, abnormal, in vagina, 7.
 Septicæmia after ovariectomy, 259.
 Sessile ovarian tumours, 211, 225.
 Serre-nœud, 122. Cintrat's, 124. See *Koeberle's Serre-nœud*.
 Sheet, waterproof, for ovariectomy, 87.
 Shively Dr.: His case of intestinal obstruction six years after ovariectomy, 264.
 Silk, for ligature, 119.
 Silkworm-gut, 120, 239.
 Simon, Professor: His amputation of the elongated cervix, 337. His dilator, 472. His elytrorrhaphy, 412. His case of atresia of urethra between two fistulæ, 438. His principle in operations for vesico-vaginal fistula, 426.
 Simpson's volsella, 308 *note*.
 Simpson, Dr. A. R.: His method of vaginal extirpation of the uterus, 322. Of amputation of the elongated cervix, 338.
 Sims, Dr. Marion: Treatment of cancerous cervix, 332. Of elongated

- cervix, 336. Elytrorrhaphy, 407. Guarded tumour-hook, 309. Speculum, 62. Tampon-screw or fixateur, 310. Principles of operation for vesico-vaginal fistula, 426.
- Skene's tubes, 12.
- Smart, Dr. David, and Freund, on extra-uterine gestation, 351.
- Solid ovarian tumours, 164. Abdominal incision in removal of, 185.
- Sound, uterine, 73. How to introduce, 74.
- Spanton, Mr., on foetal bone left in gestation sac, 364.
- Specula, relative merits of different kinds, 68.
- Speculum-forceps, 60.
- Speculum, 58. Barnes', 65. Boulton's, for trachelorrhaphy, 341. Boze-man's, 62. Cusco's, 67. Fergusson's, 59. Neugebauer's, 64. Sims', 62. Valvular, 64.
- Sphincter vaginae, 48.
- Sponge-holder, 427.
- Sponge-tents, 79.
- Sponges, 89. Cleaning and counting after abdominal section, 90, 237. In ovariectomy, 196, 237. Preparation of new, 89.
- Stanley's director, 102, 204.
- Staude, Dr.: His method of vaginal extirpation of uterus, 324.
- Straps for ovariectomy, 86.
- Subperitoneal uterine fibroid, removal of, 300.
- Surgeon's knot, 221 *note*.
- Sutures for ovariectomy, 119. Arrangement of, after introduction, 236. Introduction of, 232. Needle for, 116. Removal of, 251. Accidentally passed through intestine, 264, 265. Silkworm-gut, 120.
- Suture-twister, S-headed, 432.
- T
- Table, operating, for ovariectomy, 189.
- Tait, Mr. Lawson: On Alexander's operation, 417. On extra-uterine pregnancy, 352. On extirpation of ruptured foetal sac, 357. On opium after perineorrhaphy, 398. Ovariectomy trocar, 104. On washing out peritoneum, 204, 236. Pressure-forceps, 99. Screw for extracting uterine fibroid, 287, 290.
- Tampon-screw, Sims', 310.
- Tangle-tents, 79.
- Tapping ovarian cysts, 177. During ovariectomy, 207, 231.
- T-bladed pressure-forceps, 100, 111.
- Teale's, Mr. Pridgin, *Dangers to Health*, 189.
- Temperature, rise of, after ovariectomy, 258.
- Tents, 79. Disinfection of, 81. Introduction of, 80. Removal of, 81.
- Tetanus after ovariectomy, 268.
- Thermo-cautery: Paquelin's compared with galvano-cautery, 155. In atresia, 463. In incision of capsule of submucous uterine fibroid, 312. In vaginal section of extra-uterine gestation sac, 356.
- Thomas, Dr. Gaillard: On elytrorrhaphy, 407, 412. On the galvano-cautery in elongation of the cervix, 335. Laparo-elytrotomy, 386. On partial rupture of the perineum, 402. On Sims' amputation of the elongated cervix, 336. Chronic tetanus after ovariectomy, 269. On uretero-uterine fistula, 442.
- Thompson, Sir Henry: Supra-pubic operation for removal of vesical growths, 473.
- Thorburn, Dr.: On the galvano-cautery in elongation of the cervix, 335. On the speculum in recto-vaginal fistula, 448.
- Thornton, Mr. J. Knowsley: Ice-cap, 133. Excision of a hernial pouch formed in abdominal cicatrix, 255. Ligature of pedicle in anæmic patients, 219. Intestinal obstruction: His therapeutic treatment of, 265. Listerian dressing of wound, 240. Ovariectomies in cases where incision and drainage had failed, 181. Degenerate placenta in extra-uterine pregnancy, 367. On quinine in beef-tea enemata, 247. Removal of pregnant fibroid uterus, 385.
- Thrombosis after ovariectomy, 266.
- Tilt's, Dr., *Toucher*, or recto-vaginal examination, 72.
- "Toilet of the peritoneum," 236.
- Toucher*, or recto-vaginal examination, 72.
- Trachelorrhaphy, or Emmet's operation, 340. Pallen's "immediate," 346. Parotitis after, 345.
- Trask, Dr., on seat of rupture of pregnant and parturient uterus, 379.
- Trays for instruments, 83.

Trocar, dome, 103 *note*.
 Trocar: Ovariectomy, 102. Tait's, 104.
 Wells', 102.
 Trocar, tapping, 105, 179, 231.
 Tubal pregnancy or gestation, 351.
 Tubes. See *Fallopian tubes*, *Skene's tubes*, etc.
 Tupelo-tents, 79.
 Twisting of pedicle, 177.

U

Umbilicus: Removal of its tissues to facilitate union of abdominal wound, 185, 289.
 Urachus, 202.
 Uretero-vaginal and uretero-uterine fistula, 422, 441.
 Ureters, 31. Relation of artery of cervix to, 43.
 Urethra: Atresia of, complicating vesico-vaginal fistula, 437. Dilatation of, 472. Meatus of, 11. As felt through vaginal wall, 50. Caruncle or vascular tumour of, its removal, 469.
 Uterine artery, 39. In hysterectomy, 297. In supra-vaginal excision of cervix, 331. In vaginal extirpation of uterus, 321.
 Uterine insufflator, Clay's and Kabiersky's, 138.
 Uterine tissue: Unsafe for ligature, 17, 222. Sometimes included in ovarian pedicle, 39, 222, 227.
 Utero-sacral ligaments, 19.
 Utero-vesical ligaments, 19.
 Uterus. Anatomy of, 16. Circular venous sinus of, 371, 378. See *Cervix uteri*.
 Uterus: diseases of and operations upon. See *Fibroid, uterine*; *Fibroid polypus, uterine*; *Polypus, uterine mucous*; *Hysterectomy*; *Vaginal extirpation of uterus*, etc.
 Urethral or urethro-vaginal fistula, 437.
 Urinary fistula, 418.
 U-teeth, in blades of pressure-forceps, 98.

V

Vagina, 12. Deficiency of, 465. Exploration of, 46, 53, 57. Plugging of, 61. Operations for prolapse of, 404-406.

Vaginal dilator, elastic gum, 425.
 Vaginal extirpation of uterus, 318.
 Vaginal septa, abnormal, 7.
 Valvular speculum, 64.
 Vascular tumour of urethra, or urethral caruncle, 469.
 Veins, pelvic, 41.
 Vesico-rectal examination, 72, 462, 466.
 Vesico-uterine fistula, 440.
 Vesico-uterine pouch, 33.
 Vesico-vaginal fistula, 418. Operation for relief of, 426. Operation in cases of, near cervix uteri, 436. Colpocleisis for extreme cases of, 444.
 Vessels, pelvic, 37.
 Vestibule, 11.
 Volsella: For diagnosis, 58, 69, 71, 76, 78. For ovariectomy, 106. For removal of fibroid polypi—Nélaton's, 107. Kidd's, 309. Simpson's, 308 *note*.
 Volt, 142.
 Vomiting after ovariectomy: From the anæsthetic, 243, 255. From septic conditions, 260. From gastrointestinal disturbance, 256.
 V-teeth, in blades of pressure-forceps, 99.
 Vulsellum. See *Volsella*, and page 76 *note*.

W


Washing out peritoneal cavity, 204, 236.
 Watson, Professor, on the ureters, 33.
 Waterproof apron, for operator and assistants, 197.
 Waterproof-sheet: For drainage-tube, 128. For ovariectomy, etc., 87, 198. Not needed in oöphorectomy, 277.
 Wells, Sir T. Spencer: Clamp-forceps, 112. Forcepressure, 93. Ovariectomy-trocar, 102. Pedicle-ligature in ovariectomy, the knot for, 221 *note*; the tightness of, 222 *note*. Pedicle-needle, 114. Porro-Freund's operation, 382. Porro's operation in case of fibroid uterus, 385. Pressure-forceps: Old form, 96. New form, 97.
 Wet-packing after ovariectomy, 259.

Wire-loop. See *Koeberlé's serre-nœud*.
Williams, Dr. John : On the vascular supply of the uterus, 40. On recurrence of uterine cancer, 317. His adoption of Säger's method of supra-vaginal excision of the cervix, 331 *note*.
Wood, Mr. John : Operation for ectopia vesicæ, 451.
Womb. See *Uterus*.
Wool, absorbent, how to test, 131.

Wristlets or handcuffs for ovariectomy, 86.
Wylie, Dr. Gill : On hot water as a preventive of shock, 204 *note*.

Z

Zweifel, Professor : Removal of kidney in ureteric fistula, 442.



Catalogue B]

London, 11, New Burlington Street
March, 1887

SELECTION

FROM

J. & A. CHURCHILL'S GENERAL CATALOGUE

COMPRISING

ALL RECENT WORKS PUBLISHED BY THEM

ON THE

ART AND SCIENCE OF MEDICINE



N.B.—As far as possible, this List is arranged in the order in
which medical study is usually pursued.

J. & A. CHURCHILL publish for the following Institutions
and Public Bodies:—

ROYAL COLLEGE OF SURGEONS.

CATALOGUES OF THE MUSEUM.

Twenty-three separate Catalogues (List and Prices can be obtained of J. & A. CHURCHILL).

GUY'S HOSPITAL.

REPORTS BY THE MEDICAL AND SURGICAL STAFF.

Vol. XXVIII., Third Series. 7s. 6d.

FORMULÆ USED IN THE HOSPITAL IN ADDITION TO THOSE
IN THE B.P. 1s. 6d.

LONDON HOSPITAL.

PHARMACOPŒIA OF THE HOSPITAL. 3s.

CLINICAL LECTURES AND REPORTS BY THE MEDICAL AND
SURGICAL STAFF. Vols. I. to IV. 7s. 6d. each.

ST. BARTHOLOMEW'S HOSPITAL.

CATALOGUE OF THE ANATOMICAL AND PATHOLOGICAL
MUSEUM. Vol. I.—Pathology. 15s. Vol. II.—Teratology, Anatomy
and Physiology, Botany. 7s. 6d.

ST. GEORGE'S HOSPITAL.

REPORTS BY THE MEDICAL AND SURGICAL STAFF.

The last Volume (X.) was issued in 1880. Price 7s. 6d.

CATALOGUE OF THE PATHOLOGICAL MUSEUM. 15s.

SUPPLEMENTARY CATALOGUE (1882). 5s.

ST. THOMAS'S HOSPITAL.

REPORTS BY THE MEDICAL AND SURGICAL STAFF.

Annually. Vol. XV., New Series. 7s. 6d.

MIDDLESEX HOSPITAL.

CATALOGUE OF THE PATHOLOGICAL MUSEUM. 12s.

WESTMINSTER HOSPITAL.

REPORTS BY THE MEDICAL AND SURGICAL STAFF.

Annually. Vol. II. 6s.

ROYAL LONDON OPHTHALMIC HOSPITAL.

REPORTS BY THE MEDICAL AND SURGICAL STAFF.

Occasionally. Vol. XI., Part III. 5s.

OPHTHALMOLOGICAL SOCIETY OF THE UNITED KINGDOM.

TRANSACTIONS.

Vol. VI. 12s. 6d.

MEDICO-PSYCHOLOGICAL ASSOCIATION.

JOURNAL OF MENTAL SCIENCE.

Quarterly. 3s. 6d. each, or 14s. per annum.

PHARMACEUTICAL SOCIETY OF GREAT BRITAIN.

PHARMACEUTICAL JOURNAL AND TRANSACTIONS.

Every Saturday. 4d. each, or 20s. per annum, post free.

BRITISH PHARMACEUTICAL CONFERENCE.

YEAR BOOK OF PHARMACY.

In December. 10s.

BRITISH DENTAL ASSOCIATION.

JOURNAL OF THE ASSOCIATION AND MONTHLY REVIEW
OF DENTAL SURGERY.

On the 15th of each Month. 6d. each, or 7s. per annum, post free.

A SELECTION

FROM

J. & A. CHURCHILL'S GENERAL CATALOGUE,

COMPRISING

ALL RECENT WORKS PUBLISHED BY THEM ON THE
ART AND SCIENCE OF MEDICINE.

N.B.—*J. & A. Churchill's Descriptive List of Works on Chemistry, Materia Medica, Pharmacy, Botany, Photography, Zoology, the Microscope, and other Branches of Science, can be had on application.*

Practical Anatomy :

A Manual of Dissections. By CHRISTOPHER HEATH, Surgeon to University College Hospital. Sixth Edition. Revised by RICKMAN J. GODLEE, M.S. Lond., F.R.C.S., Demonstrator of Anatomy in University College, and Assistant Surgeon to the Hospital. Crown 8vo, with 24 Coloured Plates and 274 Engravings, 15s.

Wilson's Anatomist's Vade-

Mecum. Tenth Edition. By GEORGE BUCHANAN, Professor of Clinical Surgery in the University of Glasgow; and HENRY E. CLARK, M.R.C.S., Lecturer on Anatomy at the Glasgow Royal Infirmary School of Medicine. Crown 8vo, with 450 Engravings (including 26 Coloured Plates), 18s.

Braune's Atlas of Topographi-

cal Anatomy, after Plane Sections of Frozen Bodies. Translated by EDWARD BELLAMY, Surgeon to, and Lecturer on Anatomy, &c., at, Charing Cross Hospital. Large Imp. 8vo, with 34 Photolithographic Plates and 46 Woodcuts, 40s.

An Atlas of Human Anatomy.

By RICKMAN J. GODLEE, M.S., F.R.C.S., Assistant Surgeon and Senior Demonstrator of Anatomy, University College Hospital. With 48 Imp. 4to Plates (112 figures), and a volume of Explanatory Text. 8vo, £4 14s. 6d.

Harvey's (Wm.) Manuscript

Lectures. *Prelectiones Anatomiae Universalis*. Edited, with an Autotype reproduction of the Original, by a Committee of the Royal College of Physicians of London. Crown 4to, half bound in Persian, 52s. 6d.

Anatomy of the Joints of Man.

By HENRY MORRIS, Surgeon to, and Lecturer on Anatomy and Practical Surgery at, the Middlesex Hospital. 8vo, with 44 Lithographic Plates (several being coloured) and 13 Wood Engravings, 16s.

Manual of the Dissection of the

Human Body. By LUTHER HOLDEN, Consulting Surgeon to St. Bartholomew's Hospital. Edited by JOHN LANGTON, F.R.C.S., Surgeon to, and Lecturer on Anatomy at, St. Bartholomew's Hospital. Fifth Edition. 8vo, with 208 Engravings. 20s.

By the same Author.

Human Osteology.

Sixth Edition, edited by the Author and JAMES SHUTER, F.R.C.S., M.A., M.B., Assistant Surgeon to St. Bartholomew's Hospital. 8vo, with 61 Lithographic Plates and 89 Engravings. 16s.

Also.

Landmarks, Medical and Surgical. Fourth Edition. 8vo. [*In the Press.*]

The Student's Guide to Surgical

Anatomy. By EDWARD BELLAMY, F.R.C.S. and Member of the Board of Examiners. Third Edition. Fcap. 8vo, with 81 Engravings. 7s. 6d.

The Student's Guide to Human

Osteology. By WILLIAM WARWICK WAGSTAFFE, late Assistant Surgeon to St. Thomas's Hospital. Fcap. 8vo, with 23 Plates and 66 Engravings. 10s. 6d.

The Anatomical Remembran-

cer; or, Complete Pocket Anatomist. Eighth Edition. 32mo, 3s. 6d.

Diagrams of the Nerves of the Human Body, exhibiting their Origin, Divisions, and Connections, with their Distribution to the Various Regions of the Cutaneous Surface, and to all the Muscles. By W. H. FLOWER, F.R.S., F.R.C.S. Third Edition, with 6 Plates. Roya. 4to, 12s.

General Pathology.

An Introduction to. By JOHN BLAND SUTTON, F.R.C.S., Sir E. Wilson Lecturer on Pathology, R.C.S.; Assistant Surgeon to, and Lecturer on Anatomy at, Middlesex Hospital. 8vo, with 149 Engravings, 14s.

Atlas of Pathological Anatomy.

By Dr. LANCEREAUX. Translated by W. S. GREENFIELD, M.D., Professor of Pathology in the University of Edinburgh. Imp. 8vo, with 70 Coloured Plates, £5 5s.

A Manual of Pathological Anatomy.

By C. HANDFIELD JONES, M.B., F.R.S., and E. H. SIEVEKING, M.D., F.R.C.P. Edited by J. F. PAYNE, M.D., F.R.C.P., Lecturer on General Pathology at St. Thomas's Hospital. Second Edition. Crown 8vo, with 195 Engravings, 16s.

Post-mortem Examinations:

A Description and Explanation of the Method of Performing them, with especial reference to Medico-Legal Practice. By Prof. VIRCHOW. Translated by Dr. T. P. SMITH. Second Edition. Fcap. 8vo, with 4 Plates, 3s. 6d.

The Human Brain:

Histological and Coarse Methods of Research. A Manual for Students and Asylum Medical Officers. By W. BEVAN LEWIS, L.R.C.P. Lond., Medical Superintendent, West Riding Lunatic Asylum. 8vo, with Wood Engravings and Photographs, 8s.

Manual of Physiology:

For the use of Junior Students of Medicine. By GERALD F. YEO, M.D., F.R.C.S., Professor of Physiology in King's College, London. Crown 8vo, with 300 Engravings, 14s.

Principles of Human Physiology.

By W. B. CARPENTER, C.B., M.D., F.R.S. Ninth Edition. By HENRY POWER, M.B., F.R.C.S. 8vo, with 3 Steel Plates and 377 Wood Engravings, 31s. 6d.

Syllabus of a Course of Lectures on Physiology.

By PHILIP H. PYE-SMITH, B.A., M.D., F.R.C.P., Physician to Guy's Hospital. Crown 8vo, with Diagrams, Notes, and Tables, 5s.

A Treatise on Human Physiology.

By JOHN C. DALTON, M.D. Seventh Edition. 8vo, with 252 Engravings, 20s.

Elementary Practical Biology:

Vegetable. By THOMAS W. SHORE, M.D., B.Sc. Lond., Lecturer on Comparative Anatomy at St. Bartholomew's Hospital. 8vo, 6s.

Histology and Histo-Chemistry

of Man. By HEINRICH FREY, Professor of Medicine in Zurich. Translated by ARTHUR E. J. BARKER, Assistant Surgeon to University College Hospital. 8vo, with 608 Engravings, 21s.

A Text-Book of Medical Physics,

for Students and Practitioners. By J. C. DRAPER, M.D., LL.D., Professor of Physics in the University of New York. With 377 Engravings. 8vo, 18s.

The Law of Sex.

By G. B. STARKWEATHER, F.R.G.S. With 40 Illustrative Portraits. 8vo, 16s.

Influence of Sex in Disease.

By W. ROGER WILLIAMS, F.R.C.S., Surgical Registrar to the Middlesex Hospital. 8vo, 3s. 6d.

Medical Jurisprudence:

Its Principles and Practice. By ALFRED S. TAYLOR, M.D., F.R.C.P., F.R.S. Third Edition, by THOMAS STEVENSON, M.D., F.R.C.P., Lecturer on Medical Jurisprudence at Guy's Hospital. 2 vols. 8vo, with 188 Engravings, 31s. 6d.

By the same Authors.

A Manual of Medical Jurisprudence. Eleventh Edition. Crown 8vo, with 56 Engravings, 14s.

Also.

Poisons,

In Relation to Medical Jurisprudence and Medicine. Third Edition. Crown 8vo, with 104 Engravings, 16s.

Lectures on Medical Jurisprudence.

By FRANCIS OGSTON, M.D., late Professor in the University of Aberdeen. Edited by FRANCIS OGSTON, Jun., M.D. 8vo, with 12 Copper Plates, 18s.

The Student's Guide to Medical

Jurisprudence. By JOHN ABERCROMBIE, M.D., F.R.C.P., Lecturer on Forensic Medicine to Charing Cross Hospital. Fcap. 8vo, 7s. 6d.

Microscopical Examination of

Drinking Water and of Air. By J. D. MACDONALD, M.D., F.R.S., Ex-Professor of Naval Hygiene in the Army Medical School. Second Edition. 8vo, with 25 Plates, 7s. 6d.

Pay Hospitals and Paying

Wards throughout the World. By HENRY C. BURDETT. 8vo, 7s.

By the same Author.

Cottage Hospitals — General,

Fever, and Convalescent: Their Progress, Management, and Work. Second Edition, with many Plans and Illustrations. Crown 8vo, 14s.

A Manual of Practical Hygiene.

By F. A. PARKES, M.D., F.R.S. Sixth Edition, by F. DE CHAUMONT, M.D., F.R.S., Professor of Military Hygiene in the Army Medical School. 8vo, with numerous Plates and Engravings. 18s.

A Handbook of Hygiene and Sanitary Science.

By GEO. WILSON, M.A., M.D., F.R.S.E., Medical Officer of Health for Mid-Warwickshire. Sixth Edition. Crown 8vo, with Engravings. 10s. 6d.

By the same Author.

Healthy Life and Healthy Dwellings:

A Guide to Personal and Domestic Hygiene. Fcap. 8vo, 5s.

Sanitary Examinations

Of Water, Air, and Food. A Vade-Mecum for the Medical Officer of Health. By CORNELIUS B. FOX, M.D., F.R.C.P. Second Edition. Crown 8vo, with 110 Engravings, 12s. 6d.

Dangers to Health:

A Pictorial Guide to Domestic Sanitary Defects. By T. PRIDGIN TEALE, M.A., Surgeon to the Leeds General Infirmary. Fourth Edition. 8vo, with 70 Lithograph Plates (mostly coloured), 10s.

Hospitals, Infirmarys, and Dispensaries:

Their Construction, Interior Arrangement, and Management; with Descriptions of existing Institutions, and 74 Illustrations. By F. OPPERT, M.D., M.R.C.P.L. Second Edition. Royal 8vo, 12s.

Hospital Construction and Management.

By F. J. MOUAT, M.D., Local Government Board Inspector, and H. SAXON SNELL, Fell. Roy. Inst. Brit. Architects. In 2 Parts, 4to, 15s. each; or, the whole work bound in half calf, with large Map, 54 Lithographic Plates, and 27 Woodcuts, 35s.

Manual of Anthropometry:

A Guide to the Measurement of the Human Body, containing an Anthropometrical Chart and Register, a Systematic Table of Measurements, &c. By CHARLES ROBERTS, F.R.C.S. 8vo, with numerous Illustrations and Tables, 8s. 6d.

By the same Author.

Detection of Colour-Blindness

and Imperfect Eyesight. 8vo, with a Table of Coloured Wools, and Sheet of Test-types, 5s.

Illustrations of the Influence of

the Mind upon the Body in Health and Disease: Designed to elucidate the Action of the Imagination. By DANIEL HACK TUKE, M.D., F.R.C.P., LL.D. Second Edition. 2 vols. crown 8vo, 15s.

By the same Author.

Sleep-Walking and Hypnotism.

8vo, 5s.

A Manual of Psychological

Medicine. With an Appendix of Cases. By JOHN C. BUCKNILL, M.D., F.R.S., and D. HACK TUKE, M.D., F.R.C.P. Fourth Edition. 8vo, with 12 Plates (30 Figures) and Engravings, 25s.

Mental Diseases.

Clinical Lectures. By T. S. CLOUSTON, M.D., F.R.C.P. Edin., Lecturer on Mental Diseases in the University of Edinburgh. With 8 Plates (6 Coloured). Crown 8vo, 12s. 6d.

Private Treatment of the Insane

as Single Patients. By EDWARD EAST, M.R.C.S., L.S.A. Crown 8vo, 2s. 6d.

Manual of Midwifery.

By ALFRED L. GALABIN, M.A., M.D., F.R.C.P., Obstetric Physician to, and Lecturer on Midwifery, &c. at, Guy's Hospital. Crown 8vo, with 227 Engravings, 15s.

The Student's Guide to the

Practice of Midwifery. By D. LLOYD ROBERTS, M.D., F.R.C.P., Lecturer on Clinical Midwifery and Diseases of Women at the Owens College; Obstetric Physician to the Manchester Royal Infirmary. Third Edition. Fcap. 8vo, with 2 Coloured Plates and 127 Wood Engravings, 7s. 6d.

Lectures on Obstetric Opera-

tions: Including the Treatment of Hæmorrhage, and forming a Guide to the Management of Difficult Labour. By ROBERT BARNES, M.D., F.R.C.P., Consulting Obstetric Physician to St. George's Hospital. Fourth Edition. 8vo, with 121 Engravings, 12s. 6d.

By the same Author.

A Clinical History of Medical

and Surgical Diseases of Women. Second Edition. 8vo, with 181 Engravings, 28s.

Clinical Lectures on Diseases

of Women: Delivered in St. Bartholomew's Hospital, by J. MATTHEWS DUNCAN, M.D., LL.D., F.R.S. Third Edition. 8vo, 16s.

By the same Author.

Sterility in Woman.

Being the Gulstonian Lectures, delivered in the Royal College of Physicians, in Feb., 1883. 8vo, 6s.

Notes on Diseases of Women:

Specially designed to assist the Student in preparing for Examination. By J. J. REYNOLDS, L.R.C.P., M.R.C.S. Third Edition. Fcap. 8vo, 2s. 6d.

By the same Author.

Notes on Midwifery:

Specially designed for Students preparing for Examination. Second Edition. Fcap. 8vo, with 15 Engravings, 4s.

The Student's Guide to the Diseases of Women. By ALFRED L. GALABIN, M.D., F.R.C.P., Obstetric Physician to Guy's Hospital. Third Edition. Fcap. 8vo, with 78 Engravings, 7s. 6d.

West on the Diseases of Women. Fourth Edition, revised by the Author, with numerous Additions by J. MATTHEWS DUNCAN, M.D., F.R.C.P., F.R.S.E., Obstetric Physician to St. Bartholomew's Hospital. 8vo, 16s.

Dysmenorrhœa, its Pathology and Treatment. By HEYWOOD SMITH, M.D. Crown 8vo, with Engravings, 4s. 6d.

Obstetric Aphorisms :

For the Use of Students commencing Midwifery Practice. By JOSEPH G. SWAYNE, M.D. Eighth Edition. Fcap. 8vo, with Engravings, 3s. 6d.

A Manual of Obstetrics.

By A. F. A. KING, A.M., M.D., Professor of Obstetrics, &c., in the Columbian University, Washington, and the University of Vermont. Third Edition. Crown 8vo, with 102 Engravings, 8s.

Handbook of Midwifery for Midwives : By J. E. BURTON, L.R.C.P. Lond., Surgeon to the Hospital for Women, Liverpool. Second Edition. With Engravings. Fcap. 8vo, 6s.

A Handbook of Uterine Therapeutics, and of Diseases of Women. By E. J. TILT, M.D., M.R.C.P. Fourth Edition. Post 8vo, 10s.

By the same Author.

The Change of Life

In Health and Disease: A Clinical Treatise on the Diseases of the Nervous System incidental to Women at the Decline of Life. Fourth Edition. 8vo, 10s. 6d.

The Principles and Practice of Gynæcology. By THOMAS ADDIS EMMET, M.D., Surgeon to the Woman's Hospital, New York. Third Edition. Royal 8vo, with 150 Engravings, 24s.

Diseases of the Uterus, Ovaries, and Fallopian Tubes : A Practical Treatise by A. COURTY, Professor of Clinical Surgery, Montpellier. Translated from Third Edition by his Pupil, AGNES McLAREN, M.D., M.K.Q.C.P.I., with Preface by J. MATTHEWS DUNCAN, M.D., F.R.C.P. 8vo, with 424 Engravings, 24s.

The Female Pelvic Organs :

Their Surgery, Surgical Pathology, and Surgical Anatomy. In a Series of Coloured Plates taken from Nature; with Commentaries, Notes, and Cases. By HENRY SAVAGE, M.D., F.R.C.S., Consulting Officer of the Samaritan Free Hospital. Fifth Edition. Roy. 4to, with 17 Lithographic Plates (15 coloured) and 52 Woodcuts, £1 15s.

Ovarian and Uterine Tumours :

Their Pathology and Surgical Treatment. By Sir T. SPENCER WELLS, Bart., F.R.C.S., Consulting Surgeon to the Samaritan Hospital. 8vo, with Engravings, 21s.

By the same Author.

Abdominal Tumours :

Their Diagnosis and Surgical Treatment. 8vo, with Engravings, 3s. 6d.

A Practical Treatise on the Diseases of Women. By T. GAILLARD THOMAS, M.D., Professor of Diseases of Women in the College of Physicians and Surgeons, New York. Fifth Edition. Roy. 8vo, with 266 Engravings, 25s.

Backward Displacements of the Uterus and Prolapsus Uteri : Treatment by the New Method of Shortening the Round Ligaments. By WILLIAM ALEXANDER, M.D., M.Ch.Q.U.I., F.R.C.S., Surgeon to the Liverpool Infirmary. Crown 8vo, with Engravings, 3s. 6d.

The Student's Guide to Diseases of Children. By JAS. F. GOODHART, M.D., F.R.C.P., Physician to Guy's Hospital, and to the Evelina Hospital for Sick Children. Second Edition. Fcap. 8vo, 10s. 6d.

Diseases of Children.

For Practitioners and Students. By W. H. DAY, M.D., Physician to the Samaritan Hospital. Second Edition. Crown 8vo, 12s. 6d.

A Practical Treatise on Disease in Children. By EUSTACE SMITH, M.D., Physician to the King of the Belgians, Physician to the East London Hospital for Children. 8vo, 22s.

By the same Author.

Clinical Studies of Disease in Children. Second Edition. Post 8vo, 7s. 6d.

Also.

The Wasting Diseases of Infants and Children. Fourth Edition. Post 8vo, 8s. 6d.

A Practical Manual of the Diseases of Children. With a Formulary. By EDWARD ELLIS, M.D. Fifth Edition. Crown 8vo, 10s.

A Manual for Hospital Nurses and others engaged in Attending on the Sick. By EDWARD J. DOMVILLE, Surgeon to the Exeter Lying-in Charity. Fifth Edition. Crown 8vo, 2s. 6d.

A Manual of Nursing, Medical and Surgical. By CHARLES J. CULLINGWORTH, M.D., Physician to St. Mary's Hospital, Manchester. Second Edition. Fcap. 8vo, with Engravings, 3s. 6d.

By the same Author.

A Short Manual for Monthly Nurses. Fcap. 8vo, 1s. 6d.

Notes on Fever Nursing.

By J. W. ALLAN, M.B., Physician, Superintendent Glasgow Fever Hospital. Crown 8vo, with Engravings, 2s. 6d.

By the same Author.

Outlines of Infectious Diseases :

For the use of Clinical Students. Fcap. 8vo.

Hospital Sisters and their Duties.

By EVA C. E. LÜCKES, Matron to the London Hospital. Crown 8vo, 2s. 6d.

Diseases and their Commence-

ment. Lectures to Trained Nurses.

By DONALD W. C. HOOD, M.D., M.R.C.P., Physician to the West London Hospital. Crown 8vo, 2s. 6d.

Infant Feeding and its Influence on Life ;

By C. H. F. ROUTH, M.D., Physician to the Samaritan Hospital. Fourth Edition. Fcap. 8vo. [*Preparing.*]

Manual of Botany :

Including the Structure, Classification, Properties, Uses, and Functions of Plants. By ROBERT BENTLEY, Professor of Botany in King's College and to the Pharmaceutical Society. Fifth Edition. Crown 8vo, with 1,178 Engravings, 15s.

By the same Author.

The Student's Guide to Structural, Morphological, and Physiological Botany.

With 660 Engravings. Fcap. 8vo, 7s. 6d.

Also.

The Student's Guide to Systematic Botany,

including the Classification of Plants and Descriptive Botany. Fcap. 8vo, with 350 Engravings, 3s. 6d.

Medicinal Plants :

Being descriptions, with original figures, of the Principal Plants employed in Medicine, and an account of their Properties and Uses. By Prof. BENTLEY and Dr. H. TRIMEN. In 4 vols., large 8vo, with 306 Coloured Plates, bound in Half Morocco, Gilt Edges, £11 11s.

The National Dispensatory :

Containing the Natural History, Chemistry, Pharmacy, Actions and Uses of Medicines. By ALFRED STILLÉ, M.D., LL.D., and JOHN M. MAISCH, Ph.D. Fourth Edition. 8vo, with 311 Engravings, 36s.

Royle's Manual of Materia

Medica and Therapeutics. Sixth Edition, including additions and alterations in the B.P. 1885. By JOHN HARLEY, M.D., Physician to St. Thomas's Hospital. Crown 8vo, with 139 Engravings, 15s.

Materia Medica.

A Manual for the use of Students. By ISAMBARD OWEN, M.D., F.R.C.P., Lecturer on Materia Medica, &c., to St. George's Hospital. Second Edition. Crown 8vo, 6s. 6d.

Materia Medica and Therapeutics :

Vegetable Kingdom — Organic Compounds — Animal Kingdom. By CHARLES D. F. PHILLIPS, M.D., F.R.S. Edin., late Lecturer on Materia Medica and Therapeutics at the Westminster Hospital Medical School. 8vo, 25s.

The Student's Guide to Materia

Medica and Therapeutics. By JOHN C. THOROWGOOD, M.D., F.R.C.P. Second Edition. Fcap. 8vo, 7s.

The Pharmacopœia of the Lon-

don Hospital. Compiled under the direction of a Committee appointed by the Hospital Medical Council. Fcap. 8vo, 3s.

A Companion to the British

Pharmacopœia. By PETER SQUIRE, Revised by his Sons, P. W. and A. H. SQUIRE. 14th Edition. 8vo, 10s. 6d.

By the same Authors.

The Pharmacopœias of the Lon-

don Hospitals, arranged in Groups for Easy Reference and Comparison. Fifth Edition. 18mo, 6s.

The Prescriber's Pharmacopœia:

The Medicines arranged in Classes according to their Action, with their Composition and Doses. By NESTOR J. C. TIRARD, M.D., F.R.C.P., Professor of Materia Medica and Therapeutics in King's College, London. Sixth Edition. 32mo, bound in leather, 3s.

Clinical Medicine :

A Systematic Treatise on the Diagnosis and Treatment of Disease. By AUSTIN FLINT, M.D., Professor of Medicine in the Bellevue Hospital Medical College. 8vo, 20s.

By the same Author.

A Treatise on the Principles

and Practice of Medicine. Sixth Edition. By the AUTHOR, and W. H. WELCH, M.D., and AUSTIN FLINT, jun., M.D. 8vo, with Engravings, 26s.

Climate and Fevers of India,

with a series of Cases (Croonian Lectures, 1882). By Sir JOSEPH FAYRER, K.C.S.I., M.D. 8vo, with 17 Temperature Charts, 12s.

Family Medicine for India.

A Manual. By WILLIAM J. MOORE, M.D., C.I.E., Honorary Surgeon to the Viceroy of India. Published under the Authority of the Government of India. Fifth Edition. Post 8vo, with Engravings. [*In the Press.*]

By the same Author.

A Manual of the Diseases of

India : With a Compendium of Diseases generally. Second Edition. Post 8vo, 10s.

Also.

Health-Resorts for Tropical

Invalids, in India, at Home, and Abroad. Post 8vo, 5s.

Practical Therapeutics :

A Manual. By EDWARD J. WARING, C.I.E., M.D., F.R.C.P., and DUDLEY W. BUXTON, M.D., B.S. Lond. Fourth Edition. Crown 8vo, 14s.

By the same Author.

Bazaar Medicines of India,

And Common Medical Plants : With Full Index of Diseases, indicating their Treatment by these and other Agents procurable throughout India, &c. Fourth Edition. Fcap. 8vo, 5s.

A Commentary on the Diseases

of India. By NORMAN CHEVERS, C.I.E., M.D., F.R.C.S., Deputy Surgeon-General H.M. Indian Army. 8vo, 24s.

The Principles and Practice of

Medicine. By C. HILTON FAGGE, M.D. Edited by P. H. PYE-SMITH, M.D., F.R.C.P., Physician to, and Lecturer on Medicine at, Guy's Hospital. 2 vols. 8vo, 1860 pp. Cloth, 36s. ; Half Persian, 42s.

The Student's Guide to the Practice of Medicine.

By MATTHEW CHARTERIS, M.D., Professor of Materia Medica in the University of Glasgow. Fourth Edition. Fcap. 8vo, with Engravings on Copper and Wood. 9s.

Hooper's Physicians' Vade-

Mecum. A Manual of the Principles and Practice of Physic. Tenth Edition. By W. A. GUY, F.R.C.P., F.R.S., and J. HARLEY, M.D., F.R.C.P. With 118 Engravings. Fcap. 8vo, 12s. 6d.

The Student's Guide to Clinical

Medicine and Case-Taking. By FRANCIS WARNER, M.D., F.R.C.P., Physician to the London Hospital. Second Edition. Fcap. 8vo, 5s.

How to Examine the Chest :

Being a Practical Guide for the use of Students. By SAMUEL WEST, M.D., F.R.C.P., Physician to the City of London Hospital for Diseases of the Chest ; Medical Tutor and Registrar at St. Bartholomew's Hospital. With 42 Engravings. Fcap. 8vo, 5s.

The Contagiousness of Pulmo-

nary Consumption, and its Antiseptic Treatment. By J. BURNEY YEO, M.D., Physician to King's College Hospital. Crown 8vo, 3s. 6d.

The Operative Treatment of In-

tra-thoracic Effusion. Fothergillian Prize Essay. By NORMAN PORRITT, L.R.C.P. Lond., M.R.C.S. With Engravings. Crown 8vo, 6s.

Diseases of the Chest :

Contributions to their Clinical History, Pathology, and Treatment. By A. T. HOUGHTON WATERS, M.D., Physician to the Liverpool Royal Infirmary. Second Edition. 8vo, with Plates, 15s.

The Student's Guide to Medical

Diagnosis. By SAMUEL FENWICK, M.D., F.R.C.P., Physician to the London Hospital, and BEDFORD FENWICK, M.D., M.R.C.P. Sixth Edition. Fcap. 8vo, with 114 Engravings, 7s.

By the same Author.

The Student's Outlines of Medi-

cal Treatment. Second Edition. Fcap. 8vo, 7s.

Also.

On Chronic Atrophy of the

Stomach, and on the Nervous Affections of the Digestive Organs. 8vo, 8s.

The Microscope in Medicine.

By LIONEL S. BEALE, M.B., F.R.S., Physician to King's College Hospital. Fourth Edition. 8vo, with 86 Plates, 21s.

Also.

On Slight Ailments :

Their Nature and Treatment. Second Edition. 8vo, 5s.

The Spectroscope in Medicine.

By CHARLES A. MACMUNN, B.A., M.D. 8vo, with 3 Chromo-lithographic Plates of Physiological and Pathological Spectra, and 13 Engravings, 9s.

Notes on Asthma :

Its Forms and Treatment. By JOHN C. THOROWGOOD, M.D., Physician to the Hospital for Diseases of the Chest. Third Edition. Crown 8vo, 4s. 6d.

What is Consumption ?

By G. W. HAMBLETON, L.K.Q.C.P.I. Crown 8vo, 2s. 6d.

Winter Cough

(Catarrh, Bronchitis, Emphysema, Asthma). By HORACE DOBELL, M.D., Consulting Physician to the Royal Hospital for Diseases of the Chest. Third Edition. 8vo, with Coloured Plates, 10s. 6d.

By the same Author.

Loss of Weight, Blood-Spitting,

and Lung Disease. Second Edition. 8vo, with Chromo-lithograph, 10s. 6d.

Also.

The Mont Dore Cure, and the

Proper Way to Use it. 8vo, 7s. 6d.

Pulmonary Consumption :

A Practical Treatise on its Cure with Medicinal, Dietetic, and Hygienic Remedies. By JAMES WEAVER, M.D., L.R.C.P. Crown 8vo, 2s.

Croonian Lectures on Some

Points in the Pathology and Treatment of Typhoid Fever. By WILLIAM CAYLEY, M.D., F.R.C.P., Physician to the Middlesex and the London Fever Hospitals. Crown 8vo, 4s. 6d.

Treatment of Some of the Forms

of Valvular Disease of the Heart. By A. E. SANSOM, M.D., F.R.C.P., Physician to the London Hospital. Second Edition. Fcap. 8vo, with 26 Engravings, 4s. 6d.

Diseases of the Heart and Aorta :

Clinical Lectures. By G. W. BALFOUR, M.D., F.R.C.P., F.R.S. Edin., late Senior Physician and Lecturer on Clinical Medicine, Royal Infirmary, Edinburgh. Second Edition. 8vo, with Chromo-lithograph and Wood Engravings, 12s. 6d.

Medical Ophthalmoscopy :

A Manual and Atlas. By WILLIAM R. GOWERS, M.D., F.R.C.P., Assistant Professor of Clinical Medicine in University College, and Senior Assistant Physician to the Hospital. Second Edition, with Coloured Autotype and Lithographic Plates and Woodcuts. 8vo, 18s.

By the same Author.

Pseudo-Hypertrophic Muscular

Paralysis : A Clinical Lecture. 8vo, with Engravings and Plate, 3s. 6d.

Also.

Diagnosis of Diseases of the Spinal Cord. Third Edition. 8vo, with Engravings, 4s. 6d.

Also.

Diagnosis of Diseases of the Brain. 8vo, with Engravings, 7s. 6d.

Also.

A Manual of Diseases of the Nervous System. Vol. I. Diseases of the Spinal Cord and Nerves. Roy. 8vo, with 171 Engravings (many figures), 12s. 6d.

Diseases of the Nervous System.

Lectures delivered at Guy's Hospital. By SAMUEL WILKS, M.D., F.R.S. Second Edition. 8vo, 18s.

Diseases of the Nervous System:

Especially in Women. By S. WEIR MITCHELL, M.D., Physician to the Philadelphia Infirmary for Diseases of the Nervous System. Second Edition. 8vo, with 5 Plates, 8s.

Nerve Vibration and Excitation, as Agents in the Treatment of Functional Disorder and Organic Disease. By J. MORTIMER GRANVILLE, M.D. 8vo, 5s.

By the same Author.

Gout in its Clinical Aspects.

Crown 8vo, 6s.

Regimen to be adopted in Cases

of Gout. By WILHELM EBSTEIN, M.D., Professor of Clinical Medicine in Göttingen. Translated by JOHN SCOTT, M.A., M.B. 8vo, 2s. 6d.

Diseases of the Nervous System.

Clinical Lectures. By THOMAS BUZZARD, M.D., F.R.C.P., Physician to the National Hospital for the Paralysed and Epileptic. With Engravings, 8vo. 15s.

By the same Author.

Some Forms of Paralysis from Peripheral Neuritis: of Gouty, Alcoholic, Diphtheritic, and other origin. Crown 8vo, 5s.

Diseases of the Liver :

With and without Jaundice. By GEORGE HARLEY, M.D., F.R.C.P., F.R.S. 8vo, with 2 Plates and 36 Engravings, 21s.

By the same Author.

Inflammations of the Liver, and their Sequelæ. Crown 8vo, with Engravings, 5s.

Gout, Rheumatism,

And the Allied Affections; with Chapters on Longevity and Sleep. By PETER HOOD, M.D. Third Edition. Crown 8vo, 7s. 6d.

Diseases of the Stomach :

The Varieties of Dyspepsia, their Diagnosis and Treatment. By S. O. HABERSHON, M.D., F.R.C.P. Third Edition. Crown 8vo, 5s.

By the same Author.

Pathology of the Pneumogastric Nerve: Lumleian Lectures for 1876. Second Edition. Post 8vo, 4s.

Also.

Diseases of the Abdomen,

Comprising those of the Stomach and other parts of the Alimentary Canal, Oesophagus, Cæcum, Intestines, and Peritoneum. Third Edition. 8vo, with 5 Plates, 21s.

Also.

Diseases of the Liver,

Their Pathology and Treatment. Lettisonian Lectures. Second Edition. Post 8vo, 4s.

Acute Intestinal Strangulation,

And Chronic Intestinal Obstruction (Mode of Death from). By THOMAS BRYANT, F.R.C.S., Senior Surgeon to Guy's Hospital. 8vo, 3s.

A Treatise on the Diseases of

the Nervous System. By JAMES ROSS, M.D., F.R.C.P., Assistant Physician to the Manchester Royal Infirmary. Second Edition. 2 vols. 8vo, with Lithographs, Photographs, and 332 Woodcuts, 52s. 6d.

By the same Author.

Handbook of the Diseases of the Nervous System. Roy. 8vo, with 184 Engravings, 18s.

Also.

Aphasia :

Being a Contribution to the Subject of the Dissolution of Speech from Cerebral Disease. 8vo, with Engravings, 4s. 6d.

Spasm in Chronic Nerve Disease.

(Gulstonian Lectures.) By SEYMOUR J. SHARKEY, M.A., M.B., F.R.C.P., Assistant Physician to, and Joint Lecturer on Pathology at, St. Thomas's Hospital. 8vo, with Engravings, 5s.

On Megrim, Sick Headache, and

some Allied Disorders: A Contribution to the Pathology of Nerve Storms. By E. LIVEING, M.D., F.R.C.P. 8vo, 15s.

Food and Dietetics,

Physiologically and Therapeutically Considered. By F. W. PAVY, M.D., F.R.S., Physician to Guy's Hospital. Second Edition. 8vo, 15s.

By the same Author.

Croonian Lectures on Certain Points connected with Diabetes. 8vo, 4s. 6d.

Headaches :

Their Nature, Causes, and Treatment. By W. H. DAY, M.D., Physician to the Samaritan Hospital. Fourth Edition. Crown 8vo, with Engravings. [*In the Press.*]

Health Resorts at Home and Abroad. By MATTHEW CHARTERIS, M.D., Physician to the Glasgow Royal Infirmary. Crown 8vo, with Map, 4s. 6d.

The Principal Southern and Swiss Health-Resorts : their Climate and Medical Aspect. By WILLIAM MARCET, M.D., F.R.C.P., F.R.S. With Illustrations. Crown 8vo, 7s. 6d.

Winter and Spring

On the Shores of the Mediterranean. By HENRY BENNET, M.D. Fifth Edition. Post 8vo, with numerous Plates, Maps, and Engravings, 12s. 6d.

By the same Author.

Treatment of Pulmonary Consumption by Hygiene, Climate, and Medicine. Third Edition. 8vo, 7s. 6d.

The Riviera :

Sketches of the Health-Resorts of the Coast of France and Italy, from Hyères to Spezia : its Medical Aspect and Value, &c. By EDWARD I. SPARKS, M.B., F.R.C.P. Crown 8vo, 8s. 6d.

Medical Guide to the Mineral Waters of France and its Wintering Stations. With a Special Map. By A. VINTRAS, M.D., Physician to the French Embassy, and to the French Hospital, London. Crown 8vo, 8s.

The Ocean as a Health-Resort : A Practical Handbook of the Sea, for the use of Tourists and Health-Seekers. By WILLIAM S. WILSON, L.R.C.P. Second Edition, with Chart of Ocean Routes, &c. Crown 8vo, 7s. 6d.

Ambulance Handbook for Volunteers and Others. By J. ARDAVON RAYE, L.K. & Q.C.P.I., L.R.C.S.I., late Surgeon to H.B.M. Transport No. 14, Zulu Campaign, and Surgeon E.I.R. Rifles. 8vo, with 16 Plates (50 figures), 3s. 6d.

Ambulance Lectures :

To which is added a NURSING LECTURE. By JOHN M. H. MARTIN, Honorary Surgeon to the Blackburn Infirmary. Crown 8vo, with 53 Engravings, 2s.

Handbook of Medical and Surgical Electricity. By HERBERT TIBBITS, M.D., F.R.C.P.E., Senior Physician to the West London Hospital for Paralysis and Epilepsy. Second Edition. 8vo, with 95 Engravings, 9s.

By the same Author.

How to Use a Galvanic Battery in Medicine and Surgery. Third Edition. 8vo, with Engravings, 4s.

Also.

A Map of Ziemssen's Motor Points of the Human Body : A Guide to Localised Electrification. Mounted on Rollers, 35 x 21. With 20 Illustrations, 5s.

Also.

Electrical and Anatomical Demonstrations Delivered at the School of Massage and Electricity. Crown 8vo, with Illustrations, 5s.

Surgical Emergencies :

Together with the Emergencies attendant on Parturition and the Treatment of Poisoning. By PAUL SWAIN, F.R.C.S., Surgeon to the South Devon and East Cornwall Hospital. Third Edition. Crown 8vo, with 117 Engravings, 5s.

Operative Surgery in the Calcutta Medical College Hospital. Statistics, Cases, and Comments. By KENNETH MCLEOD, A.M., M.D., F.R.C.S.E., Surgeon-Major, Indian Medical Service, Professor of Surgery in Calcutta Medical College. 8vo, with Illustrations, 12s. 6d.

A Course of Operative Surgery.

By CHRISTOPHER HEATH, Surgeon to University College Hospital. Second Edition. With 20 coloured Plates (180 figures) from Nature, by M. LÉVEILLÉ, and several Woodcuts. Large 8vo, 30s.

By the same Author.

The Student's Guide to Surgical Diagnosis. Second Edition. Fcap. 8vo, 6s. 6d.

Also.

Manual of Minor Surgery and Bandaging. For the use of House-Surgeons, Dressers, and Junior Practitioners. Eighth Edition. Fcap. 8vo, with 142 Engravings, 6s.

Also.

Injuries and Diseases of the Jaws. Third Edition. 8vo, with Plate and 206 Wood Engravings, 14s.

Injuries and Diseases of the Neck and Head, the Genito-Urinary Organs, and the Rectum. Hunterian Lectures, 1885. By EDWARD LUND, F.R.C.S., Professor of Surgery in the Owens College, Manchester. 8vo, with Plates and Engravings, 4s. 6d.

The Practice of Surgery :

A Manual. By THOMAS BRYANT, Surgeon to Guy's Hospital. Fourth Edition. 2 vols. crown 8vo, with 750 Engravings (many being coloured), and including 6 chromo plates, 32s.

The Surgeon's Vade-Mecum :

A Manual of Modern Surgery. By R. DRUITT, F.R.C.S. Twelfth Edition. By STANLEY BOYD, M.B., F.R.C.S. Assistant Surgeon and Pathologist to Charing Cross Hospital. Crown 8vo, with 373 Engravings 16s.

Regional Surgery :

Including Surgical Diagnosis. A Manual for the use of Students. By F. A. SOUTHAM, M.A., M.B., F.R.C.S., Assistant Surgeon to the Manchester Royal Infirmary. Part I. The Head and Neck. Crown 8vo, 6s. 6d. — Part II. The Upper Extremity and Thorax. Crown 8vo, 7s. 6d. Part III. The Abdomen and Lower Extremity. Crown 8vo, 7s.

Surgical Enquiries :

Including the Hastings Essay on Shock, the Treatment of Inflammations, and numerous Clinical Lectures. By FURNEAUX JORDAN, F.R.C.S., Professor of Surgery, Queen's College, Birmingham. Second Edition, with numerous Plates. Royal 8vo, 12s. 6d.

Illustrations of Clinical Surgery.

By JONATHAN HUTCHINSON, F.R.S., Senior Surgeon to the London Hospital. In occasional fasciculi. I. to XVIII., 6s. 6d. each. Fasciculi I. to X. bound, with Appendix and Index, £3 10s.

By the same Author.

Pedigree of Disease :

Being Six Lectures on Temperament, Idiosyncrasy, and Diathesis. 8vo, 5s.

Treatment of Wounds and Frac-

tures. Clinical Lectures. By SAMPSON GAMGEE, F.R.S.E., Surgeon to the Queen's Hospital, Birmingham. Second Edition. 8vo, with 40 Engravings, 10s.

Electricity and its Manner of

Working in the Treatment of Disease. By WM. E. STEAVENSON, M.D., Physician and Electrician to St. Bartholomew's Hospital. 8vo, 4s. 6d.

Lectures on Orthopædic Sur-

gery. By BERNARD E. BRODHURST, F.R.C.S., Surgeon to the Royal Orthopædic Hospital. Second Edition. 8vo, with Engravings, 12s. 6d.

By the same Author.

On Anchylosis, and the Treat-

ment for the Removal of De-
formity and the Restoration of
Mobility in Various Joints. Fourth Edition. 8vo, with Engravings, 5s.

Also.

Curvatures and Diseases of the
Spine. Third Edition. 8vo, with Engravings, 6s.

Diseases of Bones and Joints.

By CHARLES MACNAMARA, F.R.C.S., Surgeon to, and Lecturer on Surgery at, the Westminster Hospital. 8vo, with Plates and Engravings, 12s.

Injuries of the Spine and Spinal

Cord, and NERVOUS SHOCK,
in their Surgical and Medico-Legal Aspects. By HERBERT W. PAGE, M.C. Cantab., F.R.C.S., Surgeon to St. Mary's Hospital. Second Edition, post 8vo, 10s.

Face and Foot Deformities.

By FREDERICK CHURCHILL, C.M., Surgeon to the Victoria Hospital for Children. 8vo, with Plates and Illustrations, 10s. 6d.

Clubfoot :

Its Causes, Pathology, and Treatment. By WM. ADAMS, F.R.C.S., Surgeon to the Great Northern Hospital. Second Edition. 8vo, with 106 Engravings and 6 Lithographic Plates, 15s.

By the same Author.

On Contraction of the Fingers,

and its Treatment by Subcutaneous Operation; and on Obliteration of Depressed Cicatrices, by the same Method. 8vo, with 30 Engravings, 4s. 6d.

Also.

Lateral and other Forms of

Curvature of the Spine: Their
Pathology and Treatment. Second Edition. 8vo, with 5 Lithographic Plates and 72 Wood Engravings, 10s. 6d.

Spinal Curvatures :

Treatment by Extension and Jacket; with Remarks on some Affections of the Hip, Knee, and Ankle-joints. By H. MACNAUGHTON JONES, M.D., F.R.C.S. I. and Edin. Post 8vo, with 63 Engravings, 4s. 6d.

On Diseases and Injuries of the

Eye: A Course of Systematic and
Clinical Lectures to Students and Medical Practitioners. By J. R. WOLFE, M.D., F.R.C.S.E., Lecturer on Ophthalmic Medicine and Surgery in Anderson's College, Glasgow. With 10 Coloured Plates and 157 Wood Engravings. 8vo, £1 1s.

Hinton Ophthalmic Out-Patient

Practice. By CHARLES HIGGENS, Ophthalmic Surgeon to Guy's Hospital. Third Edition. Fcap. 8vo, 3s.

Short Sight, Long Sight, and

Astigmatism. By GEORGE F. HELM, M.A., M.D., F.R.C.S., formerly Demonstrator of Anatomy in the Cambridge Medical School. Crown 8vo, with 35 Engravings, 3s. 6d.

Manual of the Diseases of the

Eye. By CHARLES MACNAMARA, F.R.C.S., Surgeon to Westminster Hospital. Fourth Edition. Crown 8vo, with 4 Coloured Plates and 66 Engravings, 10s. 6d.

The Student's Guide to Diseases

of the Eye. By EDWARD NETTLESHIP, F.R.C.S., Ophthalmic Surgeon to St. Thomas's Hospital. Fourth Edition. Fcap. 8vo, with Engravings and a Set of Coloured Papers illustrating Colour-Blindness, [Nearly Ready.]

Normal and Pathological His-

tology of the Human Eye and Eyelids. By C. FRED. POLLOCK, M.D., F.R.C.S. and F.R.S.E., Surgeon for Diseases of the Eye to Anderson's College Dispensary, Glasgow. Crown 8vo, with 100 Plates (230 drawings), 15s.

Atlas of Ophthalmoscopy.

Composed of 12 Chromo-lithographic Plates (59 Figures drawn from nature) and Explanatory Text. By RICHARD LIEBREICH, M.R.C.S. Translated by H. ROSBOROUGH SWANZY, M.B. Third edition, 4to, 40s.

Glaucoma :

Its Causes, Symptoms, Pathology, and Treatment. By PRIESTLEY SMITH, M.R.C.S., Ophthalmic Surgeon to the Queen's Hospital, Birmingham. 8vo, with Lithographic Plates, 10s. 6d.

Refraction of the Eye :

A Manual for Students. By GUSTAVUS HARTRIDGE, F.R.C.S., Assistant Physician to the Royal Westminster Ophthalmic Hospital. Second Edition. Crown 8vo, with Lithographic Plate and 94 Woodcuts, 5s. 6d.

The Electro-Magnet,

And its Employment in Ophthalmic Surgery. By SIMEON SNELL, Ophthalmic Surgeon to the Sheffield General Infirmary, &c. Crown 8vo, 3s. 6d.

Hare-Lip and Cleft Palate.

By FRANCIS MASON, F.R.C.S., Surgeon to St. Thomas's Hospital. 8vo, with 66 Engravings, 6s.

By the same Author.

The Surgery of the Face.

8vo, with 100 Engravings, 7s. 6d.

A Practical Treatise on Aural

Surgery. By H. MACNAUGHTON JONES, M.D., Professor of the Queen's University in Ireland, late Surgeon to the Cork Ophthalmic and Aural Hospital. Second Edition. Crown 8vo, with 63 Engravings, 8s. 6d.

By the same Author.

Atlas of Diseases of the Mem-

brana Tympani. In Coloured Plates, containing 62 Figures, with Text. Crown 4to, 21s.

Endemic Goitre or Thyreocoele :

Its Etiology, Clinical Characters, Pathology, Distribution, Relations to Cretinism, Myxœdema, &c., and Treatment. By WILLIAM ROBINSON, M.D. 8vo, 5s.

Diseases and Injuries of the

Ear. By Sir WILLIAM B. DALBY, Aural Surgeon to St. George's Hospital. Third Edition. Crown 8vo, with Engravings, 7s. 6d.

By the Same Author.

Short Contributions to Aural

Surgery, between 1875 and 1886. 8vo, with Engravings, 3s. 6d.

Diseases of the Throat and

Nose : A Manual. By MORELL MACKENZIE, M.D. Lond., Senior Physician to the Hospital for Diseases of the Throat.

Vol. II. Diseases of the Nose and Nasopharynx ; with a Section on Diseases of the Œsophagus. Post 8vo, with 93 Engravings, 12s. 6d.

By the same Author.

Diphtheria :

Its Nature and Treatment, Varieties, and Local Expressions. 8vo, 5s.

Lectures on Syphilis of the

Larynx (Lesions of the Secondary and Intermediate Stages). By W. M. WHISTLER, M.D., Physician to the Hospital for Diseases of the Throat. Post 8vo, 4s.

Sore Throat :

Its Nature, Varieties, and Treatment. By PROSSER JAMES, M.D., Physician to the Hospital for Diseases of the Throat. Fifth Edition. Post 8vo, with Coloured Plates and Engravings, 6s. 6d.

A Treatise on Vocal Physio-

logy and Hygiene. By GORDON HOLMES, M.D., Physician to the Municipal Throat and Ear Infirmary. Second Edition, with Engravings. Crown 8vo, 6s. 6d.

By the same Author.

A Guide to the Use of the

Laryngoscope in General Practice. Crown 8vo, with Engravings, 2s. 6d.

A System of Dental Surgery.

By Sir JOHN TOMES, F.R.S., and C. S. TOMES, M.A., F.R.S. Third Edition. Fcap. 8vo, with many Engravings.

[Nearly Ready.]

Dental Anatomy, Human and

Comparative: A Manual. By CHARLES S. TOMES, M.A., F.R.S. Second Edition. Crown 8vo, with 191 Engravings, 12s. 6d.

The Student's Guide to Dental

Anatomy and Surgery. By HENRY SEWILL, M.R.C.S., L.D.S. Second Edition. Fcap. 8vo, with 78 Engravings, 5s. 6d.

Notes on Dental Practice. By

HENRY C. QUINBY, L.D.S.R.C.S.I. 8vo, with 87 Engravings, 9s.

Mechanical Dentistry in Gold

and Vulcanite. By F. H. BALKWILL, L.D.S.R.C.S. 8vo, with 2 Lithographic Plates and 57 Engravings, 10s.

A Practical Treatise on Mechanical Dentistry. By JOSEPH RICHARDSON, M.D., D.D.S., late Emeritus Professor of Prosthetic Dentistry in the Indiana Medical College. Fourth Edition. Roy. 8vo, with 458 Engravings, 21s.

Principles and Practice of Dentistry : including Anatomy, Physiology, Pathology, Therapeutics, Dental Surgery, and Mechanism. By C. A. HARRIS, M.D., D.D.S. Edited by F. J. S. GORGAS, A.M., M.D., D.D.S., Professor in the Dental Department of Maryland University. Eleventh Edition. 8vo, with 750 Illustrations, 31s. 6d.

A Manual of Dental Mechanics. By OAKLEY COLES, L.D.S.R.C.S. Second Edition. Crown 8vo, with 140 Engravings, 7s. 6d.

Elements of Dental Materia Medica and Therapeutics, with Pharmacopœia. By JAMES STOCKEN, L.D.S.R.C.S., Pereira Prizeman for Materia Medica, and THOMAS GADDES, L.D.S. Eng. and Edin. Third Edition. Fcap. 8vo, 7s. 6d.

Dental Medicine :

A Manual of Dental Materia Medica and Therapeutics. By F. J. S. GORGAS, A.M., M.D., D.D.S., Editor of "Harris's Principles and Practice of Dentistry," Professor in the Dental Department of Maryland University. 8vo, 14s.

Atlas of Skin Diseases.

By TILBURY FOX, M.D., F.R.C.P. With 72 Coloured Plates. Royal 4to, half morocco, £6 6s.

Diseases of the Skin :

With an Analysis of 8,000 Consecutive Cases and a Formulary. By L. D. BULKLEY, M.D., Physician for Skin Diseases at the New York Hospital. Crown 8vo, 6s. 6d.

By the same Author.

Acne : its Etiology, Pathology, and Treatment : Based upon a Study of 1,500 Cases. 8vo, with Engravings, 10s.

On Certain Rare Diseases of the Skin. By JONATHAN HUTCHINSON, F.R.S., Senior Surgeon to the London Hospital, and to the Hospital for Diseases of the Skin. 8vo, 10s. 6d.

Diseases of the Skin :

A Practical Treatise for the Use of Students and Practitioners. By J. N. HYDE, A.M., M.D., Professor of Skin and Venereal Diseases, Rush Medical College, Chicago. 8vo, with 66 Engravings, 17s.

Parasites :

A Treatise on the Entozoa of Man and Animals, including some Account of the Ectozoa. By T. SPENCER COBBOLD, M.D., F.R.S. 8vo, with 85 Engravings, 15s.

Manual of Animal Vaccination, preceded by Considerations on Vaccination in general. By E. WARLOMONT, M.D., Founder of the State Vaccine Institute of Belgium. Translated and edited by ARTHUR J. HARRIES, M.D. Crown 8vo, 4s. 6d.

Leprosy in British Guiana.

By JOHN D. HILLIS, F.R.C.S., M.R.I.A., Medical Superintendent of the Leper Asylum, British Guiana. Imp. 8vo, with 22 Lithographic Coloured Plates and Wood Engravings, £1 11s. 6d.

Cancer of the Breast.

By THOMAS W. NUNN, F.R.C.S., Consulting Surgeon to the Middlesex Hospital. 4to, with 21 Coloured Plates, £2 2s.

On Cancer :

Its Allies, and other Tumours; their Medical and Surgical Treatment. By F. A. PURCELL, M.D., M.C., Surgeon to the Cancer Hospital, Brompton. 8vo, with 21 Engravings, 10s. 6d.

Sarcoma and Carcinoma :

Their Pathology, Diagnosis, and Treatment. By HENRY T. BUTLIN, F.R.C.S., Assistant Surgeon to St. Bartholomew's Hospital. 8vo, with 4 Plates, 8s.

By the same Author.

Malignant Disease of the Larynx (Sarcoma and Carcinoma). 8vo, with 5 Engravings, 5s.

Cancerous Affections of the Skin.

(Epithelioma and Rodent Ulcer.) By GEORGE THIN, M.D. Post 8vo, with 8 Engravings, 5s.

Cancer of the Mouth, Tongue, and Alimentary Tract : their Pathology, Symptoms, Diagnosis, and Treatment. By FREDERIC B. JESSETT, F.R.C.S., Surgeon to the Cancer Hospital, Brompton. 8vo, 10s.

Clinical Notes on Cancer,

Its Etiology and Treatment ; with special reference to the Heredity-Fallacy, and to the Neurotic Origin of most Cases of Alveolar Carcinoma. By HERBERT L. SNOW, M.D. Lond., Surgeon to the Cancer Hospital, Brompton. Crown 8vo, 3s. 6d.

Lectures on the Surgical Disorders of the Urinary Organs. By REGINALD HARRISON, F.R.C.S., Surgeon to the Liverpool Royal Infirmary. Second Edition, with 48 Engravings. 8vo, 12s. 6d.

Hydrocele :

Its several Varieties and their Treatment. By SAMUEL OSBORN, late Surgical Registrar to St. Thomas's Hospital. Fcap. 8vo, with Engravings, 3s.

By the same Author.

Diseases of the Testis.

Fcap. 8vo, with Engravings, 3s. 6d.

Diseases of the Urinary Organs.

Clinical Lectures. By Sir HENRY THOMPSON, F.R.C.S., Emeritus Professor of Clinical Surgery in University College. Seventh (Students') Edition. 8vo, with 84 Engravings, 2s. 6d.

By the same Author.

Diseases of the Prostate :

Their Pathology and Treatment. Sixth Edition. 8vo, with 39 Engravings, 6s.

Also.

Surgery of the Urinary Organs.

Some Important Points connected therewith. Lectures delivered in the R.C.S. 8vo, with 44 Engravings. Students' Edition, 2s. 6d.

Also.

Practical Lithotomy and Lithotripsy; or, An Inquiry into the Best Modes of Removing Stone from the Bladder. Third Edition. 8vo, with 87 Engravings, 10s.

Also.

The Preventive Treatment of Calculous Disease, and the Use of Solvent Remedies. Second Edition. Fcap. 8vo, 2s. 6d.

Also.

Tumours of the Bladder :

Their Nature, Symptoms, and Surgical Treatment. 8vo, with numerous Illustrations, 5s.

Also.

Stricture of the Urethra, and Urinary Fistulæ: their Pathology and Treatment. Fourth Edition. With 74 Engravings. 8vo, 6s.

Also.

The Suprapubic Operation of Opening the Bladder for the Stone and for Tumours. 8vo, with 14 Engravings, 3s. 6d.

The Surgery of the Rectum.

By HENRY SMITH, Professor of Surgery in King's College, Surgeon to the Hospital. Fifth Edition. 8vo, 6s.

Modern Treatment of Stone in the Bladder by Litholopaxy. By P. J. FREYER, M.A., M.D., M.Ch., Bengal Medical Service. 8vo, with Engravings, 5s.

Diseases of the Testis, Spermatic Cord, and Scrotum. By THOMAS B. CURLING, F.R.S., Consulting Surgeon to the London Hospital. Fourth Edition. 8vo, with Engravings, 16s.

Diseases of the Rectum and Anus. By W. HARRISON CRIPPS, F.R.C.S., Assistant Surgeon to St. Bartholomew's Hospital, &c. 8vo, with 13 Lithographic Plates and numerous Wood Engravings, 12s. 6d.

Urinary and Renal Derangements and Calculous Disorders. By LIONEL S. BEALE, F.R.C.P., F.R.S., Physician to King's College Hospital. 8vo, 5s.

Fistula, Hæmorrhoids, Painful Ulcer, Stricture, Prolapsus, and other Diseases of the Rectum : Their Diagnosis and Treatment. By WILLIAM ALLINGHAM, Surgeon to St. Mark's Hospital for Fistula. Fourth Edition. 8vo, with Engravings, 10s. 6d.

Pathology of the Urine.

Including a Complete Guide to its Analysis. By J. L. W. THUDICHUM, M.D., F.R.C.P. Second Edition, rewritten and enlarged. 8vo, with Engravings, 15s.

Student's Primer on the Urine.

By J. TRAVIS WHITTAKER, M.D., Clinical Demonstrator at the Royal Infirmary, Glasgow. With 16 Plates etched on Copper. Post 8vo, 4s. 6d.

Syphilis and Pseudo-Syphilis.

By ALFRED COOPER, F.R.C.S., Surgeon to the Lock Hospital, to St. Mark's and the West London Hospitals. 8vo, 10s. 6d.

Genito-Urinary Organs, including Syphilis : A Practical Treatise on their Surgical Diseases, for Students and Practitioners. By W. H. VAN BUREN, M.D., and E. L. KEYES, M.D. Royal 8vo, with 140 Engravings, 21s.

Lectures on Syphilis.

By HENRY LEE, Consulting Surgeon to St. George's Hospital. 8vo, 10s.

Diagnosis and Treatment of Syphilis. By TOM ROBINSON, M.D., Physician to St. John's Hospital for Diseases of the Skin. Crown 8vo, 3s. 6d.

Coulson on Diseases of the Bladder and Prostate Gland. Sixth Edition. By WALTER J. COULSON, Surgeon to the Lock Hospital and to St. Peter's Hospital for Stone. 8vo, 16s.

The Medical Adviser in Life Assurance. By Sir E. H. SIEVEKING, M.D., F.R.C.P. Second Edition. Crown 8vo, 6s.

A Medical Vocabulary :

An Explanation of all Terms and Phrases used in the various Departments of Medical Science and Practice, their Derivation, Meaning, Application, and Pronunciation. By R. G. MAYNE, M.D., LL.D. Fifth Edition. Fcap. 8vo, 10s. 6d.

A Dictionary of Medical Science:

Containing a concise Explanation of the various Subjects and Terms of Medicine, &c. By ROBLEY DUNGLISON, M.D., LL.D. Royal 8vo, 28s.

Medical Education

And Practice in all parts of the World. By H. J. HARDWICKE, M.D., M.R.C.P. 8vo, 10s.

INDEX.

- Abercrombie's Medical Jurisprudence, 4
 Adams (W.) on Clubfoot, 11
 on Contraction of the Fingers, 11
 on Curvature of the Spine, 11
 Alexander's Displacements of the Uterus, 6
 Allan on Fever Nursing, 7
 Outlines of Infectious Diseases, 7
 Allingham on Diseases of the Rectum, 14
 Anatomical Remembrancer, 3
 Balfour's Diseases of the Heart and Aorta, 9
 Balkwill's Mechanical Dentistry, 12
 Barnes (R.) on Obstetric Operations, 5
 on Diseases of Women, 5
 Beale's Microscope in Medicine, 8
 Slight Ailments, 8
 Urinary and Renal Derangements, 14
 Bellamy's Surgical Anatomy, 3
 Bennet (J. H.) on the Mediterranean, 10
 on Pulmonary Consumption, 10
 Bentley and Trimen's Medicinal Plants, 7
 Bentley's Manual of Botany, 7
 Structural Botany, 7
 Systematic Botany, 7
 Braune's Topographical Anatomy, 3
 Brodhurst's Anchylosis, 11
 Curvatures, &c., of the Spine, 11
 Orthopaedic Surgery, 11
 Bryant's Acute Intestinal Strangulation, 9
 Practice of Surgery, 11
 Bucknill and Tuke's Psychological Medicine, 5
 Bulkley's Acne, 13
 Diseases of the Skin, 13
 Burdett's Cottage Hospitals, 4
 Pay Hospitals, 4
 Burton's Midwifery for Midwives, 6
 Butlin's Malignant Disease of the Larynx, 13
 Sarcoma and Carcinoma, 13
 Buzzard's Diseases of the Nervous System, 9
 Peripheral Neuritis, 9
 Carpenter's Human Physiology, 4
 Cayley's Typhoid Fever, 8
 Charteris on Health Resorts, 10
 Practice of Medicine, 8
 Chavers' Diseases of India, 8
 Churchill's Face and Foot Deformities, 11
 Clouston's Lectures on Mental Diseases, 5
 Cobbold on Parasites, 13
 Coles' Dental Mechanics, 13
 Cooper's Syphilis and Pseudo-Syphilis, 14
 Coulson on Diseases of the Bladder, 14
 Courty's Diseases of the Uterus, Ovaries, &c., 6
 Cripps' Diseases of the Rectum and Anus, 14
 Cullingworth's Manual of Nursing, 6
 Short Manual for Monthly Nurses, 6
 Curling's Diseases of the Testis, 14
 Dalby's Diseases and Injuries of the Ear, 12
 Dalton's Human Physiology, 4
 Day on Diseases of Children, 6
 on Headaches, 10
 Dobell's Lectures on Winter Cough, 8
 Loss of Weight, &c., 8
 Mont Doré Cure, 8
 Domville's Manual for Nurses, 6
 Draper's Text Book of Medical Physics, 4
 Druitt's Surgeon's Vade-Mecum, 11
 Duncan on Diseases of Women, 5
 on Sterility in Woman, 5
 Dunglison's Medical Dictionary, 14
 East's Private Treatment of the Insane, 5
 Ebstein on Regimen in Gout, 9
 Ellis's Diseases of Children, 6
 Emmet's Gynaecology, 6
 Fagge's Principles and Practice of Medicine, 8
 Fayrer's Climate and Fevers of India, 7
 Fenwick's Chronic Atrophy of the Stomach, 8
 Medical Diagnosis, 8
 Outlines of Medical Treatment, 8
 Flint on Clinical Medicine, 7
 on Principles and Practice of Medicine, 7
 Flower's Diagrams of the Nerves, 4
 Fox's (C. B.) Examinations of Water, Air, and Food, 5
 Fox's (T.) Atlas of Skin Diseases, 13
 Freyer's Litholopaxy, 14
 Frey's Histology and Histo-Chemistry, 4
 Galabin's Diseases of Women, 6
 Manual of Midwifery, 5
 Gamgee's Treatment of Wounds and Fractures, 11
 Godlee's Atlas of Human Anatomy, 3
 Goodhart's Diseases of Children, 6
 Gorgas' Dental Medicine, 13
 Gowers' Diseases of the Brain, 9
 Diseases of the Spinal Cord, 9
 Manual of Diseases of Nervous System, 9
 Medical Ophthalmoscopy, 9
 Pseudo-Hypertrophic Muscular Paralysis, 9
 Granville on Gout, 9
 on Nerve Vibration and Excitation, 9
 Guy's Hospital Formulæ, 2
 Reports, 2
 Habershon's Diseases of the Abdomen, 9
 Liver, 9
 Stomach, 9
 Pneumogastric Nerve, 9
 Hambleton's What is Consumption? 8
 Hardwicke's Medical Education, 14
 Harley on Diseases of the Liver, 9
 Inflammations of the Liver, 9
 Harris's Dentistry, 13
 Harrison's Surgical Disorders of the Urinary Organs, 13
 Hartridge's Refraction of the Eye, 12
 Harvey's Manuscript Lectures, 3
 Heath's Injuries and Diseases of the Jaws, 10
 Minor Surgery and Bandaging, 10
 Operative Surgery, 10
 Practical Anatomy, 3
 Surgical Diagnosis, 10
 Helm on Short and Long Sight, &c., 11
 Higgins' Ophthalmic Out-patient Practice, 11
 Hillis' Leprosy in British Guiana, 13
 Holden's Dissections, 3
 Human Osteology, 3
 Landmarks, 3
 Holmes' (G.) Guide to Use of Laryngoscope, 12
 Vocal Physiology and Hygiene, 12
 Hood's (D. C.) Diseases and their Commencement, 7
 Hood (P.) on Gout, Rheumatism, &c., 9
 Hooper's Physician's Vade-Mecum, 8
 Hutchinson's Clinical Surgery, 11
 Pedigree of Disease, 11
 Rare Diseases of the Skin, 13
 Hyde's Diseases of the Skin, 13
 James (P.) on Sore Throat, 12
 Jessett's Cancer of the Mouth, &c., 13
 Jones (C. H.) and Sieveking's Pathological Anatomy, 4
 Jones' (H. McN.) Aural Surgery, 12
 Atlas of Diseases of Membrana Tympani, 12
 Spinal Curvatures, 11
 Jordan's Surgical Enquiries, 11
 Journal of British Dental Association, 2
 Mental Science, 2
 King's Manual of Obstetrics, 6
 Lancereaux's Atlas of Pathological Anatomy, 4
 Lee (H.) on Syphilis, 14
 Lewis (Bevan) on the Human Brain, 4
 Liebreich's Atlas of Ophthalmoscopy, 12
 Liveing's Megrim, Sick Headache, &c., 9
 London Hospital Reports, 2
 Lückes' Hospital Sisters and their Duties, 7
 Lund's Hunterian Lectures, 10
 Macdonald's (J. D.) Examination of Water and Air, 4
 Mackenzie on Diphtheria, 12
 on Diseases of the Throat and Nose, 12
 McLeod's Operative Surgery, 10
 MacMunn's Spectroscope in Medicine, 8
 Macnamara's Diseases of the Eye, 11
 Bones and Joints, 11
 Marcet's Southern and Swiss Health-Resorts, 10
 Martin's Ambulance Lectures, 10
 Mason on Hare-Lip and Cleft Palate, 12
 on Surgery of the Face, 12
 Mayne's Medical Vocabulary, 14
 Middlesex Hospital Reports, 2
 Mitchell's Diseases of the Nervous System, 9
 Moore's Family Medicine for India, 7
 Health-Resorts for Tropical Invalids, 7
 Manual of the Diseases of India, 7
 Morris' (H.) Anatomy of the Joints, 3
 Mouat and Snell on Hospitals, 5
 Nettleship's Diseases of the Eye, 12
 Nunn's Cancer of the Breast, 13
 Ogston's Medical Jurisprudence, 4
 Ophthalmic (Royal London) Hospital Reports, 2
 Ophthalmological Society's Transactions, 2
 Oppert's Hospitals, Infirmarys, Dispensaries, &c., 5
 Osborn on Diseases of the Testis, 13
 on Hydrocele, 13
 Owen's Materia Medica, 7
 Page's Injuries of the Spine, 11
 Parkes' Practical Hygiene, 5
 Pavy on Diabetes, 10

[Continued on the next page.]

Pavy on Food and Dietetics, 10
 Pharmaceutical Journal, 2
 Pharmacopœia of the London Hospital, 7
 Phillips' Materia Medica and Therapeutics, 7
 Pollock's Histology of the Eye and Eyelids, 12
 Porritt's Intra-Thoracic Effusion, 8
 Purcell on Cancer, 13
 Pye-Smith's Syllabus of Physiology, 4
 Quinby's Notes on Dental Practice, 12
 Raye's Ambulance Handbook, 10
 Reynolds' (J. J.) Diseases of Women, 5
 ——— Notes on Midwifery, 5
 Richardson's Mechanical Dentistry, 13
 Roberts' (C.) Manual of Anthropometry, 5
 ——— Detection of Colour-Blindness, 5
 Roberts' (D. Lloyd) Practice of Midwifery, 5
 Robinson (Tom) on Syphilis, 14
 Robinson (W.) on Endemic Goitre or Thyrocele, 12
 Ross's Aphasia, 9
 ——— Diseases of the Nervous System, 9
 ——— Handbook of ditto, 9
 Routh's Infant Feeding, 7
 Royal College of Surgeons Museum Catalogues, 2
 Royle and Harley's Materia Medica, 7
 St. Bartholomew's Hospital Catalogue, 2
 St. George's Hospital Reports, 2
 St. Thomas's Hospital Reports, 2
 Sansom's Valvular Disease of the Heart, 8
 Savage on the Female Pelvic Organs, 6
 Sewill's Dental Anatomy, 12
 Sharkey's Spasm in Chronic Nerve Disease, 9
 Shore's Elementary Practical Biology, 4
 Sieveking's Life Assurance, 14
 Smith's (E.) Clinical Studies, 6
 ——— Diseases in Children, 6
 ——— Wasting Diseases of Infants and Children, 6
 Smith's (Henry) Surgery of the Rectum, 14
 Smith's (Heywood) Dysmenorrhœa, 6
 Smith (Priestley) on Glaucoma, 12
 Snell's Electro-Magnet in Ophthalmic Surgery, 12
 Snow's Clinical Notes on Cancer, 13
 Southam's Regional Surgery, 11
 Sparks on the Riviera, 10
 Squire's Companion to the Pharmacopœia, 7
 ——— Pharmacopœias of London Hospitals
 Starkweather on the Law of Sex, 4
 Steavenson's Electricity, 11
 Stillé and Maisch's National Dispensatory, 7
 Stocken's Dental Materia Medica and Therapeutics, 13
 Sutton's General Pathology, 4
 Swain's Surgical Emergencies, 10
 Swayne's Obstetric Aphorisms, 6
 Taylor's Medical Jurisprudence, 4

Taylor's Poisons in relation to Medical Jurisprudence, 4
 Teale's Dangers to Health, 5
 Thin's Cancerous Affections of the Skin, 13
 Thomas's Diseases of Women, 6
 Thompson's (Sir H.) Calculous Disease, 14
 ——— Diseases of the Prostate, 14
 ——— Diseases of the Urinary Organs, 14
 ——— Lithotomy and Lithotripsy, 14
 ——— Stricture of the Urethra, 14
 ——— Suprapubic Operation, 14
 ——— Surgery of the Urinary Organs, 14
 ——— Tumours of the Bladder, 14
 Thorowgood on Asthma, 8
 ——— on Materia Medica and Therapeutics, 7
 Thudichum's Pathology of the Urine, 14
 Tibbits' Medical and Surgical Electricity, 10
 ——— Map of Motor Points, 10
 ——— How to use a Galvanic Battery, 10
 ——— Electrical and Anatomical Demonstrations, 10
 Tilt's Change of Life, 6
 ——— Uterine Therapeutics, 6
 Tirard's Prescriber's Pharmacopœia, 7
 Tomes' (C. S.) Dental Anatomy, 12
 Tomes' (J. and C. S.) Dental Surgery, 12
 Tuke's Influence of the Mind upon the Body, 5
 ——— Sleep-Walking and Hypnotism, 5
 Van Buren on the Genito-Urinary Organs, 14
 Vintras on the Mineral Waters, &c., of France, 10
 Virchow's Post-mortem Examinations, 4
 Wagstaffe's Human Osteology, 3
 Waring's Indian Bazaar Medicines, 8
 ——— Practical Therapeutics, 8
 Warlomont's Animal Vaccination, 13
 Warner's Guide to Medical Case-Taking, 8
 Waters' (A. T. H.) Diseases of the Chest, 8
 Weaver's Pulmonary Consumption, 8
 Wells' (Spencer) Abdominal Tumours, 6
 ——— Ovarian and Uterine Tumours, 6
 West and Duncan's Diseases of Women, 6
 West's (S.) How to Examine the Chest, 8
 Whistler's Syphilis of the Larynx, 12
 Whittaker's Primer on the Urine, 14
 Wilks' Diseases of the Nervous System, 8
 Williams' (Roger) Influence of Sex, 4
 Wilson's (Sir E.) Anatomists' Vade-Mecum, 3
 Wilson's (G.) Handbook of Hygiene, 5
 ——— Healthy Life and Dwellings, 5
 Wilson's (W. S.) Ocean as a Health-Resort, 10
 Wolfe's Diseases and Injuries of the Eye, 11
 Year Book of Pharmacy, 2
 Yeo's (G. F.) Manual of Physiology, 4
 Yeo's (J. B.) Contagiousness of Pulmonary Consumption, 8

The following CATALOGUES issued by J. & A. CHURCHILL will be forwarded post free on application:—

A. J. & A. Churchill's General List of about 650 works on Anatomy, Physiology, Hygiene, Midwifery, Materia Medica, Medicine, Surgery, Chemistry, Botany, &c., &c., with a complete Index to their Subjects, for easy reference. N.B.—This List includes B, C, & D.

B. Selection from J. & A. Churchill's General List, comprising all recent Works published by them on the Art and Science of Medicine.

C. J. & A. Churchill's Catalogue of Text Books specially arranged for Students.

D. A selected and descriptive List of J. & A. Churchill's Works on Chemistry, Materia Medica, Pharmacy, Botany, Photography, Zoology, the Microscope, and other branches of Science.

E. The Half-yearly List of New Works and New Editions published by J. & A. Churchill during the previous six months, together with particulars of the Periodicals issued from their House.

[Sent in January and July of each year to every Medical Practitioner in the United Kingdom whose name and address can be ascertained. A large number are also sent to the United States of America, Continental Europe, India, and the Colonies.]

AMERICA.—J. & A. Churchill being in constant communication with various publishing houses in Boston, New York, and Philadelphia, are able, notwithstanding the absence of international copyright, to conduct negotiations favourable to English Authors.

LONDON: 11, NEW BURLINGTON STREET.

