

**The Gulstonian lectures on secondary degenerations of the spinal cord : delivered at the Royal College of Physicians, March, 1889 / by Howard H. Tooth.**

**Contributors**

Tooth, Howard H.  
Royal College of Physicians of Edinburgh

**Publication/Creation**

London : J. & A. Churchill, 1889.

**Persistent URL**

<https://wellcomecollection.org/works/czna899d>

**Provider**

Royal College of Physicians Edinburgh

**License and attribution**

This material has been provided by This material has been provided by the Royal College of Physicians of Edinburgh. The original may be consulted at the Royal College of Physicians of Edinburgh. where the originals may be consulted.

This work has been identified as being free of known restrictions under copyright law, including all related and neighbouring rights and is being made available under the Creative Commons, Public Domain Mark.

You can copy, modify, distribute and perform the work, even for commercial purposes, without asking permission.


SECONDARY DEGENERATION


OF THE

SPINAL CORD



TOOTH





Feb. 5. 1771

R39890


THE  
GULSTONIAN LECTURES ON SECONDARY  
DEGENERATIONS OF THE SPINAL CORD

*DELIVERED AT THE ROYAL COLLEGE OF PHYSICIANS,  
MARCH, 1889,*

BY

HOWARD H. TOOTH, M.D., F.R.C.P.,

*Assistant Physician to the National Hospital for the Paralysed and the  
Epileptic, and Assistant Medical Tutor to St. Bartholomew's Hospital.*



LONDON  
J. & A. CHURCHILL  
11, NEW BURLINGTON STREET

1889.

## PREFACE.

---

**I**T is my pleasant duty to acknowledge here the kind help that I have received from many friends and colleagues in the preparation of these lectures. I have specially to thank Dr. Gowers for his valuable hints. Without the help of Mr. Horsley I should have been quite unable to supply any experimental illustrations of spinal degeneration.

The present volume is a reprint, with very slight additions, of the lectures as they appeared in *The Illustrated Medical News*, to which periodical I am much indebted for the facilities which they have afforded me in reprinting my lectures, and for the excellent and faithful manner in which the illustrations have been produced direct from my pencil drawings.

H. H. TOOTH.

34, HARLEY STREET, W.

*June, 1889.*

# THE GULSTONIAN LECTURES ON SECONDARY DEGENERATIONS OF THE SPINAL CORD.

---

## LECTURE I.

MR. PRESIDENT and Gentlemen,—It was with feelings almost apologetic that I announced the subject of these lectures. I felt that it might be expected that a subject of wider clinical interest should be chosen. But on referring to the terms of the bequest of the founder of this lectureship, I discovered that he had anticipated my difficulty. He was evidently aware that the younger Fellows would be more able to do useful work in the realm of pathology than in clinical medicine. He provides that the lecturer shall give what is more of a demonstration than a lecture on the dead body (if such be procurable!).

Two hundred and fifty years and more have elapsed since his death, and yet the wisdom of the method implied in the wording of his bequest becomes, not less, but more apparent. If our art is to be raised from the level of mere empiricism, it must be grounded on the sure basis of pathology. In ordinary pathological inquiries it is usual to study the normal, and to reason from it concerning the abnormal. This method is followed in my first lecture, on the Histology of Secondary Degeneration. But when we wish to study the course of the fibres in the cord we reverse the usual process, and make use of pathology to teach us anatomy. It is not too much to say that without this method our knowledge of the anatomy of the cord would be of the vaguest and most rudimentary description.

When we have learnt all the lessons that pathology can teach



us concerning the paths in the cord which conduct the multitudinous motor, sensory, and visceral impressions, then, and not till then, shall we fully understand all the symptoms that present in many diseases better known by name than by nature. Let it not, then, be supposed that the subject I have chosen is one of academic interest only. It is true that at present our knowledge of the anatomy of the cord and medulla is ahead of our diagnosis, and also that our diagnosis is far in advance of our treatment; but who dares to say how long this shall remain so? It is but a very few years since the workers at cerebral localisation, too well known to need even mention by me, were looked upon as scientific dreamers, and now their dreams have become the most striking *facts* in the medicine and surgery of the day.

Spinal localisation follows close, and already begins to bear fruit. These facts, then, must be my justification, if, indeed, such be needed, for dwelling minutely on points that appear to be of little practical importance at the present moment.

**Histology of Degeneration.** It is a common thing for observers to speak of degeneration of nerve tubes in the spinal cord as being comparable to, and moreover of the same nature as, the corresponding lesions in nerves.

As I wish to institute a close comparison between the two, it would be well to sum up the features of the so-called Wallerian degeneration first.

**Wallerian Degeneration.** When a nerve is cut its peripheral end degenerates, because it is cut off from the centre, which is believed to exert some nutritive or trophic influence over it. Certain changes make their appearance in the ultimate nerve tubes.

The first change that occurs is a loss of transparency of the nerve fibres to the naked eye. This is coincident with, and probably caused by, a cleavage of the myeline, or white medullary substance of Schwann. It may be seen to occur in forty-eight hours, or later, up to four days. This change is more rapid in summer than in winter, and is associated with diminution of irritability of the nerve to all stimuli. Under the microscope at this period the white substance is seen to split across into masses or cylinders,

these masses being separated from one another by distinct intervals.

Later on, about the seventh day, the medullary sheath undergoes further changes, likened by some authors to "fatty degeneration." At any rate, the altered myeline becomes more or less liquefied, and tends to run into droplets of all sizes, which lie about within the sheath of Schwann; at the same time the nuclei, or "nerve corpuscles" of the nerve, increase in size.

So far all accounts seem to agree. But there appears to be some difference of opinion concerning the state of the axis cylinder; some writers, Schiff, Vulpian, Weir Mitchell, contend that the axis cylinder remains, while the medullary sheath goes. Schiff even maintains that it may persist for six months. But it is more probable that the earliest view of Waller, and later of Ranvier and others,\* is the correct one, that the axis cylinder undergoes changes *pari passu* with those of the medullary sheath. *A priori* it would appear probable, inasmuch as the axis cylinder is the means of conduction of stimuli, and not the medullary substance, that it would be rather the first constituent of the nerve tube to show signs of degeneration than the last.

Another important feature in nerve degeneration is the part played by the nerve nuclei. These early swell and undergo proliferation; this process must be distinguished from the appearance of nuclei in the neighbourhood of the injury, which are inflammatory.

Later on the myeline becomes more and more broken up, and according to the latest accounts becomes mixed with the degenerated remains of the axis cylinder, and finally tends to leave the primitive sheaths to become absorbed. The primitive sheaths then remain, and in them the nuclei.

The result of separation of a nerve fibre from its centre is, as Ranvier suggests, not exactly death of the fibre, but an active change, as evidenced by the proliferation of the nerve nuclei. This idea is further borne out by the tendency to regeneration which all peripheral nerves exhibit.

\* For the latest article on this subject see Bowlby's Hunterian Lectures, *Lancet*, 1887, I., p. 863.

**Regeneration of Nerves.** After the degenerated myeline material has disappeared, or even before that, in the second month, or later, primitive fibrils make their appearance. These are said to appear in the primitive sheaths of the old nerves. They are at first without myeline; however, they soon acquire a medullary sheath, but are for a long time smaller than the natural nerve fibres.

This slight sketch may serve for the purpose of comparison with the analogous condition of the spinal cord. I propose to show that though, as might be expected, the two processes resemble each other in the main, yet they differ in several rather important points of detail.

**Distinction between Fibres of Cord and Peripheral Nerves.** It must be remembered that there are certain striking histological points of difference between the nerve fibre of the peripheral nerves and that of the cord. The nerve tube of the cord consists of an axis cylinder and a medullary sheath, which are indistinguishable from those of a nerve. A *cord* fibre has no definite primitive sheath. It is surrounded by the close network of the neuroglia, which takes the place of the tough structureless sheath coating the *nerve* fibre from end to end. We shall see that this may account for some of the histological phenomena of degeneration. The *cord* fibre is apparently devoid of the nerve nuclei or corpuscles which take such an important share in the nutrition of the *nerve* fibre.

The causes of secondary degeneration come under three categories:—

- Causes of Secondary Degeneration.**
1. Destruction of trophic centres in brain or medulla.
  2. Interruption in the continuity of fibres, or bundles of fibres, in their course; that is, either by complete section, crushing, slow pressure by new growths, or displacement of vertebræ, or lastly by invasion and consequent strangulation of fibres by new growths or transverse myelitis.
  3. Section of, or other injury to, posterior roots, by which centripetal fibres are cut off from their trophic centres in the posterior root ganglion. Under the first we have principally to

consider descending lesions from cortical injury. For our present purpose the first two may be considered together. The third requires special consideration.

**“Traumatic Degeneration.”** In the close neighbourhood of the initial lesion we have to consider the “traumatic degeneration.” This was first described by Schiefferdecker\* (1876), but more fully later by Homén.† It is found both above and below the lesion for about the distance of 1 cm. It is essentially inflammatory in character, and must be distinguished from secondary degeneration proper. It affects the whole diameter of the cord, but even here shows a tendency to affect certain tracts above and others below. There are many leucocytes crowding the tissues. The large cells of the grey matter are swollen and granular. There are many lacunæ, some filled with “vitreous masses” (Homén) which do not take any stain easily. In some cases, even after many months, the inflamed tissue contains masses of material which stains faintly by Weigert’s hæmatoxylin, and is presumably broken down myeline. Homén describes oval masses lying in the long axis of the cord, believed by him to be altered axis cylinders. They stain deeply with anilines. There is a tendency often to the formation of small local collections of purulent matter, even as far as two roots from the lesion. Both Schiefferdecker’s and Homén’s accounts refer to cases of experimental lesions in which one would expect to find signs of inflammation, as well as degeneration, in the vicinity of the wound. In cases of crushing after fracture-dislocation, in which of course there could be no septic contamination, there is in my experience very little sign of *active* inflammation at all, and yet in the immediate neighbourhood of the injury, both above and below, we find a more advanced stage of degeneration usually than in points remote from the injury; and in cases which have survived many months there is a considerable thickening of the neuroglia mesh-work. The

\* Schiefferdecker, “Ueber Regeneration und Architectur des Rückenmarkes,” *Virch. Arch.*, 1876, p. 542.

† Homén, “Contribution Experimentale à la Pathologie, et à l’Anatomie Pathologique de la Moelle Epinière,” 1885.

endothelium of the perivascular lymphatics is also proliferated even as late as six months, presenting an appearance analogous to catarrhal inflammation elsewhere, but inflammatory nuclei in numbers comparable to what obtains in experimental lesions are not present in my experience at any date after injury. In the neighbourhood of the lesion, however, the axis cylinders are remarkably enlarged in the first eleven days, as will be seen in Case I. (*vide infra*), which enlargement may perhaps be of an inflammatory nature.

**Secondary Degeneration Proper.** We now come to consider the secondary degeneration proper. The methods of examination followed are—

*Naked eye*, in the fresh state, or after hardening in bichromate of potash or ammonia.

*Microscopical.*—I have used the following methods in preparing material for these lectures : Weigert's hæmatoxylin and the modification by Pal for medullated nerve fibres.

In many cases Weigert's hæmatoxylin has been used for staining *in toto* ; this is good for gross results, but at some loss of sharpness.

*Acid fuchsin*, Weigert's method,\* for medullated nerve fibres, and also for the early change in the axis cylinders, after Homén.

*Ficro-carmin*, *in toto*, for neuroglia and axis cylinders.

*Alum carmin*, Upson's method,† for neuroglia and nuclei.

*Cochineal*, for nuclei only.

*Aniline*, blue-black.

The sections were cut after imbedding in celloidin as a rule, but after staining *in toto* the paraffin method was used.

**Earliest Changes.** Although no doubt the fibres begin to degenerate the moment they are separated from their trophic centres, yet the changes are not appreciable till about the third day (Homén). Schiefferdecker puts it much later ; he says no change of any kind is visible till seven days have elapsed.

In the fresh state to the naked eye nothing can be seen very shortly after death, but according to Mr. Horsley,‡ if the degene-

\* Weigert, *Centralbl. für die Med. Wissensch.*, 1882, p. 753.

† Upson, *Neurol. Centralbl.*, 1888, p. 319.

‡ Horsley, *Brain*, vol. ix., p. 52.

rated area be examined five days after section in the living animal under ether, "the dead white of the area, as compared with the semi-translucency of the natural parts, is very striking." In the course of twenty or thirty minutes after death this translucency of the natural tissue disappears, and then the difference between the diseased and the healthy parts becomes invisible. This will explain the invisibility of even advanced lesions in the human subject after death. But after hardening by the bichromates the area of degeneration is very early visible, how early I am unable to say, but it is well marked in six days, and is probably visible before any microscopical changes have shown themselves, if not earlier. The area of degeneration appears as a yellow or lighter brown patch, on a brown ground. It indicates, no doubt, some preliminary chemical change. At this time (third day) the changes, according to Homén, are only visible in the tracts *above* the lesion. Under the microscope the axis cylinders of the affected area appear larger than natural. They also stain very deeply by the acid fuchsin method. In sections stained by other anilines and picro-carminé the fibre appears to be without an axis cylinder, because the enlarged axis cylinder takes these stains so feebly. Owing to this swelling, the whole diameter of the fibre is larger than natural. In five days the same changes have made their appearance below the lesion.

In a semisection of the cord in the monkey (monkey 9) between the eighth cervical and the first dorsal, done for me by Mr. Horsley, the animal was killed on the sixth day. After hardening in ammonium bichromate the degenerated areas above and below, in the cord, can be seen perfectly by the naked eye. Microscopically in the neighbourhood of the section there was infiltration of leucocytes, showing traumatic inflammation. Close to the wound above, the axis cylinders in the cerebellar tract and posterior column were many of them enlarged. They stained deeply with carminé, and also by acid fuchsin.

This enlargement of the axis cylinder was more apparent near the wound (probably traumatic, see Case I. below); in the upper cervical region it was made out with difficulty, though the appearances to the naked eye were the same as lower down.

Below the wound the appearances were much less marked, though several of the axis cylinders showed signs of enlargement. In the monkey, then, we may say that the changes in the nerve tubes have begun at the sixth day, that they are more advanced near the wound than remote from it, but that the naked-eye appearances after hardening exist equally well away from as near the wound.

In seven days the axis cylinder is more swollen, the whole tube is broader. Only a small layer of myeline is left round the swollen axis cylinder, but this myeline does not appear to be altered in character. This peripheral layer of the myeline in a normal cord fibre stains more deeply than the internal layer of the same. It is called by Weigert the "Erythrophile Substanz," from the strong affinity it shows for the acid fuchsin stain, and also for the Weigert hæmatoxylin. It is therefore this *erythrophile* ring which remains. Homén suggests that this ring is a condensed form of neuroglia; this to my mind is more than doubtful.

It is a question what becomes of the central part of the myeline sheath at this stage; if it be fused with the enlarged axis cylinder it has for the time lost its affinity for Weigert's hæmatoxylin and osmic acid.

**Degeneration in Human Cord at Eleventh Day.** CASE I.—Fracture-dislocation of fifth cervical vertebra. Compression of cord between sixth and seventh cervical roots. Patient, *æt.* 58, fell out of a cart on to the back of his head, on July 17th, 1887; admitted to St. Bartholomew's Hospital four days after, under Mr. Langton, who has very kindly allowed me to examine the cord; was then found to be paralysed in both arms, most in the left. Sensation fairly good. In the trunk, breathing abdominal only, sensation was much impaired, but not absolutely. Reflexes absent; complete paralysis of bladder and rectum. There was the same loss of sensation in legs, with loss of knee-jerks. Temperature abnormally low all the time, varying only from 95° to 96°. Patient died on July 28th, eleven days after the injury.

The cord is specially interesting on account of the date after injury. At the level of the crush there is no alteration of the shape externally; reduction must have followed rapidly. There was





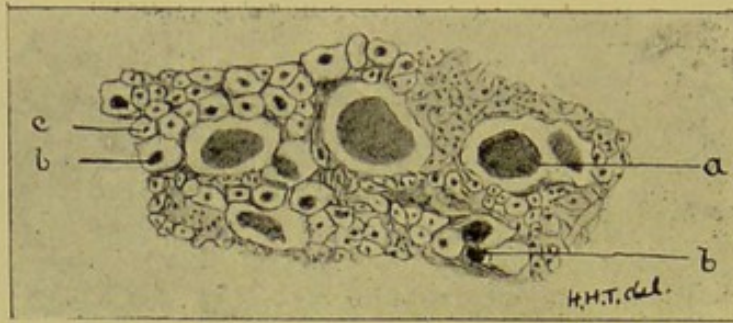


Fig. 1.

Fracture Dislocation of the Fifth Cervical Vertebra (Case I).  
 Transverse section, close to compressed spot. Eleventh day.  
*a*, greatly swollen axis cylinders. *b*, axis cylinders less swollen  
 than *a*. *c*, normal axis cylinders. Picrocarmine *in toto*. Zeiss  
 obj. D, oc. 2.

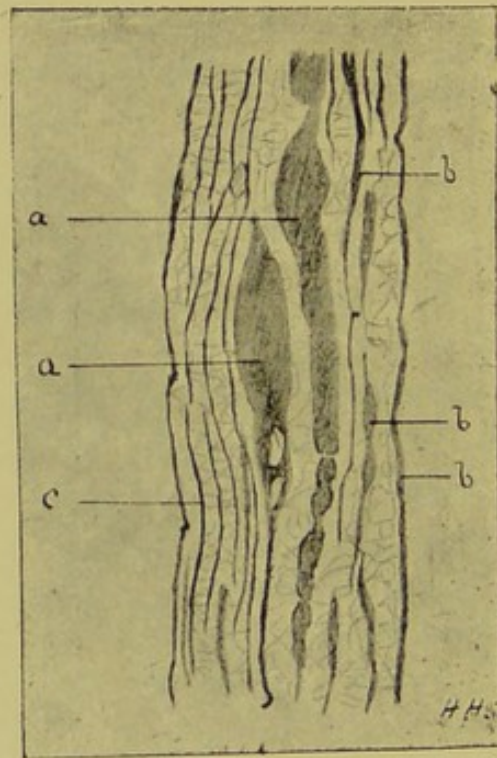


Fig. 2.

From the same case as fig. 1. Longitudinal section. *a*, greatly swollen  
 axis cylinders. *b*, axis cylinders less swollen than *a*. *c*, normal  
 axis cylinders. Picrocarmine *in toto*. Zeiss obj. D, oc. 2.

complete absence of inflammation of the meninges. This was at the level of the seventh cervical root. Here, on cutting across, the cord appears to be disorganised, soft, and the distinction between grey and white matter not to be made out. Under the microscope the posterior region seems to have fairly escaped damage, the lateral and anterior region being much more affected, but in all parts there seem to be many normal fibres. There are affected nerve fibres of two kinds. Large, rounded homogeneous masses (fig. 1), staining deeply with carmine and acid fuchsin. They do not stain with Weigert's hæmatoxylin, but round the periphery of the masses in sections stained with hæmatoxylin we see a fine dark line, which is the remnant of the myeline. These masses, seen in longitudinal sections, are obviously axis cylinders enormously enlarged (fig. 2).

These enlarged axis cylinders cannot be found except in the vicinity of the wound; they cease at the level of the fourth cervical above and the third dorsal below. They were found in monkey 9, just mentioned, and I have seen them in many other cases.

Homen describes a similar condition near the wound in his experiments. It seems to me that this great enlargement of the axis cylinders must be distinguished from the enlargement of the same in true secondary degeneration at an early date. They differ in their affinity for stains from the true secondary enlargement. The former stain readily with carmine and anilines generally, but less readily with acid fuchsin, while the latter stain only with acid fuchsin. Again, the enlargement in true secondary degeneration is never so great as this near the wound. Lastly, I am not aware that the true secondary enlargement ever takes on a varicose appearance at all resembling fig. 2. When the enlargement seems to have attained its greatest extent vacuoles make their appearance. This, again, is peculiar. I think there can be little doubt that this change in the axis cylinders near the wound is traumatic in its nature.

Hayem\* describes and figures swollen axis cylinders in a case of acute myelitis, *i.e.*, in undoubted inflammation of a very similar appearance to those in fig. 2. At points above the fourth cervical


\* Hayem, *Arch. de Physiol.*, 1874, p. 603.

and below the third dorsal the section is that of a perfectly normal cord, neither can anything be seen by the naked eye after hardening. It is not too much to say that had the patient lived a week or two longer, there would have been well-marked degeneration of ascending and descending bundles of fibres.

The results of Homen's and Schiefferdecker's experiments on animals and those in monkey 9 are misleading when applied to man. It is probable that in man degeneration is a slower process than in animals. When a fibre is cut off from its centre every point in its length is believed to degenerate equally and at the same time.\* This was Bouchard's opinion. Westphal considers that the degeneration, as it were, creeps along the nerve as an inflammatory process. Singer found, after division of posterior lumbar roots in puppies, that naked eye changes had appeared on the sixth day, but that microscopically no degeneration could be found above the twelfth dorsal. This accords with the results in monkey 9. It is probable, therefore, that Bouchard's view is correct as far as the early chemical changes are concerned, but that the actual histological changes travel along the nerve fibre at varying rate.

**Degeneration in Two Weeks.** During the second week there takes place a complete fusion of the remains of the axis cylinder with the myeline. Now we have a complete breaking up of the continuity of the degenerated tubule. In cross-section we fail to make out any differentiation between axis cylinder and medullary sheath. The fused mass has become of a finely granular nature, which takes the ordinary stains, such as carmine, very faintly. In its extent it is larger than natural, and appears as a droplet of granular material in the meshes of the neuroglia. These granular masses stain deeply with Weigert's hæmatoxylin, and the degenerated area now appears by this method studded with black masses which have taken the place of the proper nerve fibres. At this stage they occupy the exact position of the original fibres, as they do even at later dates (see fig. 4 and fig. 5), both in transverse and longitudinal sections.

\* See also Langley, "Critical Digest: Brain," 1886, p. 92.



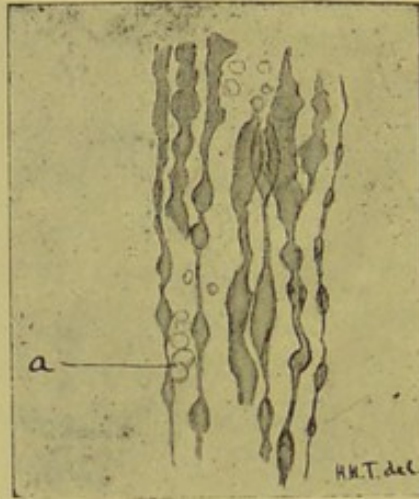


Fig. 3.

Longitudinal section in the dorsal region, showing an early stage of decomposition. *a*, Globules of escaped Myeline. Weigert hæmatoxylin staining *in toto*. Zeiss obj. D, oc. 2.

**Degeneration in Four Weeks.** As time goes on, during the fourth week no swollen axis cylinders are any longer to be seen anywhere in the section; the whole area is degenerated, and we cannot say that one fibre is in a more or less advanced stage than another; the black granular masses by Weigert's hæmatoxylin are still very distinct.

**Decomposition Compared with Degeneration.** The appearances here described may be simulated by decomposition. In decomposition the myeline and the axis cylinder appear to fuse and form a more or less liquid material. This process takes place at varying periods after death, according to the manner of death and the temperature of the air at the time. The result of this liquefying of the contents of the tubules is the varicosity of the fibres (see fig. 3), which is very characteristic and quite distinct from the changes after degeneration. These varicose fibres take the Weigert stain well, as one might expect. Later the myeline escapes, and no normal fibre appearances are visible anywhere. This may be mistaken for degeneration, but the granularity of the degenerated fibre is absent. Then, again, the whole cord is affected equally.

**Degeneration in Two Months.** In two months the myeline element of the degenerated fibre has begun to be absorbed. The masses above mentioned now stain very lightly or not at all by Weigert's hæmatoxylin. The result is that the whole degenerated area now, for the first time, becomes visible to the naked eye by this method.

I have sections, however, from a case reported by Dr. Harris,\* in the *British Medical Journal*, which I take to show typical degeneration at two months.†

CASE II.—A young man, aged eighteen, was admitted into Victoria Park Hospital with aortic disease and a pain in the side, supposed to be pleuritic. After lying in the hospital about two months, one morning on trying to get out of bed he discovered

\* Harris, *British Med. Jour.*, 1887, p. 1380.

† I have already published a note of the cord of this case (*St. Bartholomew's Hospital Reports*, vol. xxiii., p. 141); but the appearances are so typical that I shall refer to it several times in these lectures.

that his legs were quite paralysed and devoid of sensation. His urine was retained, and the reflexes were increased. In a few days girdle pains developed at the level of the ninth intercostal space; at the same time loss of all reflexes. Bed sores rapidly formed; the patient lingered for two months, and then died.

Post-mortem a growth of a sarcomatous nature was found growing from the laminæ of the sixth, seventh, and eighth dorsal vertebræ. It blended with the dura mater, and pressed the cord to the side. The cord pressed upon was softened and disintegrated beyond recognition, and the softening extended to the whole cord below the lesion. But above the lesion we have very typical instances of ascending degeneration. In the posterior-median column, for instance, we find that the tract all the way up is extremely plain to the naked eye by Weigert's hæmatoxylin method. But on staining with carmine we fail to make any gross difference between the degenerated area and the natural. The microscope, however, shows that in the degenerated area lower down there is scarcely a single natural fibre in this tract. The meshes of the neuroglia are filled with a granular mass of the nature already described, and staining more or less with Weigert's hæmatoxylin. It is important to notice that even in two months we find but little increase of neuroglia tissue. There is also practically no increase of nuclei. I have said that the typical naked-eye appearances by Weigert's hæmatoxylin staining are apparent at two months in the human cord. This, of course, means that there has been sufficient absorption of the altered myeline material to give the degenerated area a lighter colour than the surrounding natural tissue. I am inclined to put this absorption at two months at the earliest. I have a series of sections from a case of fracture dislocation of the sixth cervical vertebræ, with degeneration of five weeks', and another with degeneration of six weeks' standing. In both the naked-eye changes are distinct after hardening, but after staining by any method there is absolutely no distinction visible between degenerated and natural parts, because the degenerated parts are yet so full of altered myeline, which takes the stain well. Of course the microscope

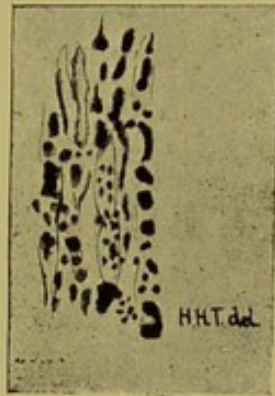


Fig. 4.

Degenerated Fibres of Post-median Column after crushing of cord at level of seventh cervical pair. Longitudinal section. Fifth week. Weigert hæmatoxylin staining. Zeiss obj. D, oc. 2.

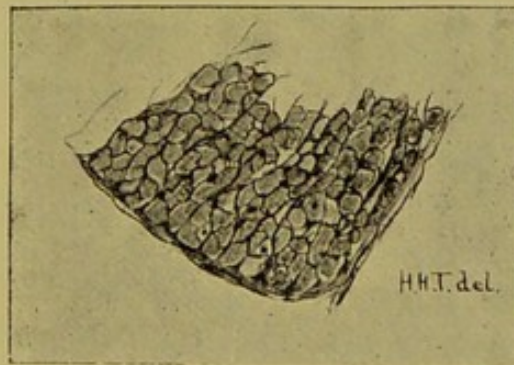


Fig. 5.

Degeneration of direct Cerebellar Tract, after semisection between seventh and eighth cervical (monkey 9). Ninth week. Granular remains of nerve fibres staining faintly by all stains. Weigert hæmatoxylin and alum carmine, Zeiss obj. D, oc. 2,





at once shows the degeneration. Fig. 4 was taken from the first of these two cases.

**Degeneration in Monkey in Nine Weeks.** As this date is an interesting one, I may here refer to the appearances in the degenerated areas in the monkey. Mr. Spencer kindly did for me a semisection of the cord at a level between the seventh and eighth cervical roots. The semi-section was not complete; that is, the anterior column and the posterior median column were not cut, but the whole of the lateral and most of the postero-external columns on the left side were divided. The monkey completely recovered from the operation, and was killed by ether nine weeks and four days after it. Very characteristic tract degenerations were found after hardening, to be described in my next lecture. The direct cerebellar tract offers special facilities for examination, because it contains in the cervical region almost only large nerve fibres.

Here we find by ordinary carmine staining the neuroglia mesh-work, exactly as on the opposite side, with no appreciable increase of nuclei. The greater part of the meshes contain no nerve fibres at all, but by staining appear to be either empty or to contain a homogeneous material which only stains faintly. "On using the Weigert hæmatoxylin stain, however, the meshes are seen to be not empty, but each filled by a material which stains distinctly, but not so deeply as the normal fibres." This is the myeline material which is in process of absorption, and no doubt a few days more would have completed the process (fig. 5).

**Degeneration in Four Months.** In four months the appearances differ surprisingly little from those of the second month. I reported a case in the St. Bartholomew's Hospital Reports\* of fracture-dislocation of the fifth and sixth dorsal vertebræ. The patient died four months after the accident, during which time he had complete paraplegia, with loss of sensation. The cord was found to be quite cut across, with well-marked lesions above and below. At this date there appears to be a decided thickening of the neuroglia, in other words a tendency to sclerosis. This is well marked in the posterior median column high up in the cervical

\* St. Bartholomew's Hosp. Repts., vol. xxi., p. 137.

region, and therefore well away from traumatic influence. There is a general look of inflammatory process about it, which has in earlier cases been absent. The effect of Weigert staining is more marked than in the preceding cases, that is, the mapping out of the degeneration is more distinct; and under the microscope the reason of this is obvious; there is much less of the myeline material in the granular masses, lying in the neuroglia meshes. They are still there, and they are still granular, and under carmine stain appear exactly similar to the same in the cords above described, but they no longer take the Weigert hæmatoxylin stain. There is still, generally speaking, a marked absence of inflammatory nuclei. Here would be, perhaps, the best place to draw attention to the relative extent and intensity of the degeneration of the various tracts at any given time. Homén says that the ascending tracts are the first to degenerate, the descending not showing any signs of degeneration for two days after the former. This precedence of the ascending over the descending tracts may be said roughly to prevail all through. For instance, the posterior median column in any case of transverse section of the cord may be said to show the greatest intensity of degeneration. The crossed pyramidal tract comes next in degree, but after these the direct cerebellar, and then the direct pyramidal. The direct cerebellar is distinctly behind the posterior median, and also behind the crossed pyramidal tract in intensity of degeneration at a given time. Perhaps it would be more correct to say, instead of intensity of degeneration, amount of sclerosis or connective tissue increase. The direct cerebellar may be devoid of normal nerve fibres equally with the posterior median column, but may present no sign of connective tissue increase, while the latter is thickly sclerosed.

**Degeneration in** In five months these appearances have altered  
**Five Months.** somewhat. We have now a distinct thickening of the neuroglia. The material filling the neuroglia spaces, that used to contain nerve fibres, is no longer granular, but homogeneous. Again, these spaces are distinctly smaller than they were in the last month, probably due to contraction of the tissue. There are nuclei scattered about over the area. We have now the beginning of a true sclerosis, but as yet there is no contraction

of the same sufficient to cause any deformity in the shape of the section. In illustration of this stage I shall quote the following case.

CASE III.—A woman, aged sixty-six, a patient of Dr. Hughlings Jackson, at Queen Square Hospital, who has very kindly permitted me to use the case.\*

Her history was briefly this: Four months before admission into the hospital she was suddenly seized with vomiting, which lasted half an hour, then lost her senses for about an hour; and when she recovered consciousness she was found to be paralysed on the left side, face and speech not affected. When admitted there was very slight affection of the mouth, none of the tongue, paralysis and rigidity of both arms and legs, with increase of reflexes. An extremely interesting point was that there was hemianæsthesia and hemianalgesia of trunk and limbs.

Post-mortem there was found a softening involving the middle and posterior third of the right internal capsule. I shall speak of the anatomical distribution of the lesions in my next lecture; suffice it to say now that the anterior median column or direct pyramidal tract and the crossed pyramidal tract were profoundly degenerated, the latter rather more advanced than the former. In double-stained sections by carmine and Weigert's hæmatoxylin we find even so late as this a large number of black masses. The neuroglia connective tissue occupies considerable patches. It is of a granular structure. Here and there can be seen small holes in it, filled with homogeneous material, which takes the carmine stain fairly well. These are the remains of the original nerve fibres, and it may be presumed that they are on the way to be closed up by contraction of the connective tissue. It can easily be seen that if only a few nerve fibres were degenerated, say from a small cortical lesion, they would at this stage be probably quite unrecognisable.

There is a distinct increase of nuclei, at any rate in the crossed pyramidal tract. These nuclei are scattered broadcast over the area of degeneration, but they are found in the greatest number about the vessels.

\* This case was one of the subjects of a paper by Dr. Ferrier before the Medical Society. See Transactions, November 21st, 1887.

There are, of course, many natural fibres scattered over the degenerated area.

**Degeneration  
after Six  
Months.**

I have no instances of degeneration much later than the sixth month. The following case lived six months and twenty days; it was a case of Dr. Buzzard's, at Queen Square Hospital, and I am indebted to him for his kindness in allowing me to use it:—

CASE IV.—H. C., aged sixteen, one month before admission stumbled in getting out of bed; legs weak all that day, most on the right side. Next day was obliged to take to his bed. Was found to have a rounded spinal curvature, involving the fourth to tenth dorsal spines. Legs quite paralysed, with loss of tactile sensation, and also of sensation of pain in many parts. Knee-jerk much exaggerated both sides, with ankle clonus. Bed-sores developed, and the patient gradually sank.

Post-mortem, advanced disease of the seventh and eighth dorsal vertebræ, extending in a less degree to two or three vertebræ above and below; the cord at the angle formed by the destruction of the seventh and eighth vertebræ was much narrowed, but not destroyed. I have had no opportunity of examining the compressed spot, but very decided ascending lesions were visible in the parts that I was able to examine. The cord is remarkably free from signs of decomposition, though it is not well hardened. The posterior median column is in a more advanced state of sclerosis than the direct cerebellar tract, though the latter is much more sclerosed than in the last case. The posterior median column consists principally of a dense connective tissue; few, if any, of the holes described in the last case as containing homogeneous lighter staining material are to be seen; that is to say, the last trace of the old nerve tubes has disappeared, and we now have little else but connective tissue (fig. 6). However, in longitudinal section there is to be seen an occasional mass of myeline material, faintly stained with Weigert's hæmatoxylin, showing how long this material seems to be able to resist the process of absorption.

At this date, again, one cannot say that there is any sign of contraction of the sclerotic tissue; at any rate, the cord retains

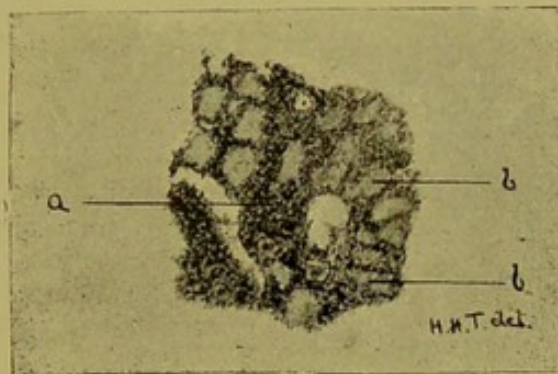


Fig. 6.

Compression from Caries at about eighth dorsal. Transverse section, at level of third cervical. Degeneration at six months and twenty days. *a*, coarsely granular neuroglia tissue without nuclei. *b*, Loculi filled with homogeneous material not staining by Weigert hæmatoxylin. Weigert hæmatoxylin and alum carmine staining. Zeiss. obj. D, oc. 2.

THE UNIVERSITY OF CHICAGO  
LIBRARY  
540 EAST 57TH STREET  
CHICAGO, ILL. 60637  
TEL: 773-936-3000

its natural shape on section, while any considerable contraction would be certain to cause distortion of the shape of the cross section.

**Date at which Degeneration is complete.** The exact date at which all the fibres of a bundle have disappeared is at present not determined. Loewenthal\* finds that the number of altered fibres increases with the date, that is, that there are fewer altered fibres at the third week than at the sixth, and that at three months all the fibres of a tract, say the pyramidal, are degenerated after transverse section of the cord.

It is quite possible that different fibres of a tract degenerate at different dates, and therefore of course disappear at corresponding dates. I have very little material to reason from. In a semisection between the fourth and fifth cervical, done for me by Mr. Horsley (monkey 5), the animal died on the thirteenth day, and at that date practically all the fibres of the crossed pyramidal tract below the lesion were degenerated.

In the later stages of degeneration we find that the definition of the diseased area becomes less and less distinct after hardening by the bichromates. Under the microscope the degeneration now appears as simple area of connective tissue, devoid of nerve fibres or their remains. This area contracts, and may eventually occupy a much smaller space in the section than it originally did. In other words, we have a *scar*, and little more, to mark the site of the lesion.

**Degeneration after Section of Posterior Roots.** I designedly describe this form under a separate head, because, in the first place, it differs somewhat in its histological appearances, and again because in cutting a posterior root we are cutting a nerve before it enters the cord, and therefore it is possible that its fibres in the cord may differ from those which run from point to point in the cord.

I propose to describe the gross results of the experiments in my next lecture, but I may say here that the experiments were performed on three monkeys by Mr. Horsley, whom I cannot

\* Loewenthal, "Dégénération Secondaires, Dissertation," 1885.



sufficiently thank for his generous and eminently skilful help. The monkeys are known as 2, 3, 4.\*

In each the surgical *modus operandi* was the same—strict antiseptic precautions; the use of pressure to stop bleeding; the removal of one or more laminae of the vertebræ; slitting up of the dura mater; section of the posterior roots close to the cord; turning back of their peripheral ends into the wounds, so as to preclude any possibility of junction; after this, irrigation of the parts with carbolic acid solution, stitching up of the skin wound with horsehair sutures, careful drying of the surface, and the application of a pad of antiseptic gauze, soaked in collodion. The wounds always healed by first intention.

In monkey 2 all the posterior roots of the right side of the cauda equina were divided. In monkey 3 the posterior roots of the sixth, seventh, and eighth cervical and first dorsal on the left side were divided, and in monkey 4 the posterior roots of the last dorsal and upper three lumbar.

In each case there followed complete anæsthesia and analgesia of the parts supplied by these roots, and also probably loss of muscular sense; a point difficult to determine in animals.

Monkey 2 lived thirty-eight days, monkey 3 lived twenty-eight days, monkey 4 lived fifty-two days, after operation.

The histological appearances in these cords were the same practically in each case.

In monkey 2 unfortunately twelve hours elapsed between the time of death and the post-mortem, but in the other two cases the animals were killed by ether, and the cord and brain removed immediately after death.

In all these experiments we have to consider degenerated nerve fibres—

First, in the divided root.

Second, in the white matter of the cord.

Third, in the grey matter of the cord.

In the first situation of the degenerated fibres there is little to

\* As control experiments Mr. Horsley has since done two more similar operations, which, however, I have not had time to examine microscopically. I shall refer to them in my last lecture.

say. Both in transverse and longitudinal section of the root there is the picture of "Wallerian" degeneration; near the point of section, however, there is an enormous increase of nuclei. The ganglionic end of the divided root degenerates for a short distance, but this is probably traumatic.

In the cord at the level of the division we find the fibres radiating through the postero-external columns, showing marked signs of degeneration, *i.e.*, many interruptions in their continuity and varicosities in their calibre. On comparing the two sides at this level we find a great diminution in their numbers on the side of the lesion, showing that many of the degenerated fibres have become absorbed.

In the grey matter, which is the destination of a large number of these fibres, we notice the same degeneration, and can trace the affected fibres towards the posterior vesicular column of Clarke, or still farther towards the anterior horn.

To return to the white matter, we find that at first the bulk of the degeneration is in the postero-lateral column, but very soon this column becomes free from altered fibres, which now are collected in the posterior median column. As to the degeneration itself, it shows one marked peculiarity from its earliest beginning to its highest distribution, and that is the large number of nuclei it presents. The monkey's cord has scattered over the section normally a considerable number of small round nuclei. These occur especially in the lines of the connective tissue trabeculæ dipping in from the thin sheath which surrounds the cord. They are distinct from the branched neuroglia cells, but are probably of connective tissue origin. This increase of nuclei appears to be peculiar to lesions following division of posterior roots. It does not occur to anything like the same extent in the transverse lesions of the cord in monkeys; and in man, as I have before remarked, it is conspicuous by its absence.

**"Tertiary Degeneration."** I cannot omit to mention here the observations by Messrs. Langley and Sherrington,\* concerning what they call "tertiary degeneration." In Professor Goltz's dog, whose cord they carefully examined,

\* Langley and Sherrington, *Journal of Physiology*, vol. v., p. 42.

several operations had been at different times performed on the cortex of the brain, the last being two and a half months before death. The secondary changes in the cord were all of comparatively advanced date then, but in the anterior and antero-lateral column they found a quite recent degeneration with swollen axis cylinders. They suggest that this may be consequent on degeneration of lower centres, secondary to those in the cortex. I am not aware that any similar observation has been published.

**Secondary Spinal  
and "Wallerian"  
Degeneration  
Contrasted.**

Enough has been said now, I think, to show that it is scarcely correct to speak of degeneration in the cord as the same thing as Wallerian degeneration of nerves. Without doing more than mention the fact that the changes commence in the axis cylinders always, a condition of things which may, and probably does, obtain in the degeneration of nerves, the essential points of difference seem to come out in the later stages of the change.

In the cord we apparently have no nerve nuclei comparable to those in peripheral nerve fibres. When a cord fibre is cut off from its trophic centre it dies, or undergoes a change analogous to necrosis. And yet it is not a true necrosis. If it were, the appearances of decomposing and degenerating nerve fibres would surely be identical. This is not the case, as I have been at some pains to show. Neither has it the least semblance to an inflammation. Inflammatory nuclei are conspicuous by their absence. Moreover, the appearances in the immediate vicinity of the initial lesion, where, if anywhere, inflammation may be supposed to exist, are, as I have shown, very different from the appearances in true secondary degeneration. The nerve fibres are rendered useless, and from that moment a change occurs which does not cease till their last vestige has been removed by absorption. When that has happened their place is taken by the thickened neuroglia. This thickening of the neuroglia is, however, of a languid nature, not inflammatory. Now, in the "Wallerian" degeneration of nerves, on the other hand, the changes are of a much more active nature. The breaking up of the axis cylinder and myeline are necrotic, no doubt, but at the same time the nerve

nuclei within the primitive sheath wake up, as it were, and show by their active enlargement and proliferation that the nerve is not dead. It is true that the old nerve fibre dies and is absorbed, but after a time new fibres make their appearance; in other words, regeneration follows close on death.

**Regeneration of Cord Fibres.** This brings me to a point of cardinal importance. Is there in the cord any tendency to regeneration at all comparable to that in nerves? There has been considerable controversy round this subject, and I propose to give a short summary of the most important observations.

In 1849 Brown-Séquard\* made experiments on guinea-pigs, rabbits, and pigeons, of transverse sections of the spinal cord. In some cases slight movement returned in the paralysed limbs, but they read more like reflex than voluntary movements.

In 1850 † he made a complete section of the cord in the pigeon; three months after, the ends were quite reunited; very slight return of voluntary movement, and none of sensation resulted. In some of his cases he says he found nerve fibres in the scar tissue.

In 1852 ‡ he was apparently more successful. After complete section high up in the pigeon there followed, of course, complete paralysis and anæsthesia. At the end of three months attempts at voluntary movements were seen, as well as reflex. In six months the bird could stand, but not walk. In seventeen months it could walk, with the help of its wings, and in eighteen months could walk fairly well. His results with guinea-pigs were very inconclusive.

In 1864 Müller, § in studying the regeneration of the vertebral column in lizards and triton, says also that the cord was regenerated at the same time. There was also slight return of

\* Brown-Séquard, "Expériences sur les Plaies de la Moelle Epinière," *Gaz. Med.*, 1849, p. 232.

† Brown-Séquard, "Régénération des Tissus de la Moelle Epinière," *Gaz. Med.*, 1850, p. 250.

‡ *Ibid.*, "Sur plusieurs cas de Cicatrisation des Plaies faites à la Moelle Epinière avec retour des fonctions perdues." *Ibid.*, 1851, p. 477.

§ Müller, W., "Ueber Regen. d. Wiebelsäule und d. Rückenm. bei Tritonen und Eidechsen," *Canstatt's Jahrb.*, 1864, i., p. 53.

dislocation of the spinal column. The actual lesion of the movement. These are the only experiments recorded on reptiles, so far as I know.

In 1869 Masius and Van Lair\* excised pieces 1-2 mm. long from the cord of the frog. There was complete loss of sensation and motion. Both returned after a time; they do not say how long; movement first, sensation later. In the scar tissue between the two ends they claim to have found ganglion cells and nerve fibres.

It is not necessary to do more than refer to Dentan's dissertation, and to say that what he mistook for return of voluntary movement was obviously reflex (*c.f.* Scheifferdecker's trenchant criticism).†

Eichorst,‡ in 1874, records some careful experiments on dogs and rabbits, very young, three or four days old. The advantages of using young animals are the rapid tendency to regeneration of all tissues, cartilaginous vertebræ, less tendency to bladder and rectal trouble than in adults, and nourishment by the mother. The lesion was either section or crushing. Fifty-five operations were performed, thirteen of which were casualties. The usual traumatic degenerations followed. In two weeks regeneration had commenced, and in four weeks new nerve elements had appeared. These new nerves had, however, nuclei in them or on them which are not seen in normal cord fibres. It is suggested that these nuclei are the means by which regeneration takes place. Eichorst found no regeneration of ganglion cells. He found in no case degeneration of the cord away from the lesion. Regeneration took place *only* in the scar tissue.

Our conclusions from these researches, then, as to regeneration in the cord, are, that the tendency to regeneration appears to be stronger as we descend the animal scale. It is claimed to

**Conclusions as to Regeneration.**

\* Masius und Van Lair, "Anatomische und Functionelle Wiederherstellung des Rückenm. beim Frosch," *Centralbl. f. die Med. Wissensch.*, 1869, p. 609.

† Schiefferdecker, *op. cit.*

‡ Eichorst, "Ueber Nerven Degeneration und Nerven Regeneration," *Virch. Arch.*, 1874, p. 1.

have been established in birds and amphibia ; it is very doubtful in reptilia, and equally so in adult mammals. But it must be remembered that the cord itself possesses more of automatism in lower animals than in higher. As a centre for reflex actions, also, its activity becomes more and more marked as we descend, till in the frog we find it at its highest development, perhaps. Everybody knows how difficult it is to distinguish purposive from reflex acts in that animal. It is also an extremely difficult thing to determine in any animal whether or not sensation is altered or absent. I am inclined to doubt every one of the results that I have yet read of as pointing to a real regeneration of degenerated nerve fibres. The clinical evidence is questionable, and the histological still more so.

My own observations lead me to the same conclusion. I have never seen anything, after the most careful search, which can be construed into even an attempt at regeneration of cord fibres. It is true that I have not had for examination cords with lesions of later than seven months' standing, but the absorption of degenerated fibres is complete at that date or nearly so, and their place is taken by dense neuroglia tissue.

It is, however, extremely encouraging to read the excellent results obtained in the case reported by Dr. Gowers and Mr. Horsley in the *Medico-Chirurgical Transactions*.\* Here a tumour had, by pressure on the cord, caused not only paralysis of the lower limbs and bladder, but also greatly increased reflexes. The tumour, moreover, indented deeply one side of the cord, and it is almost impossible to suppose that there was not actual destruction of nerve-fibres at that spot ; and yet the removal of the tumour was followed by complete recovery. The results here encourage further operation in cases of *compression*, from whatever cause.

The subject of regeneration is one of immense importance. It involves the question of surgical interference in injuries and tumours of the cord ; it enters into the question of prognosis in a large number of nervous affections. One of the saddest of all the accidents to which the body is liable is fracture-

\* Gowers and Horsley, "Tumour of Spinal Cord : Removal ; Recovery," *Med. Chir. Trans.*, vol. lxxi., p. 377.

column is of the smallest account ; it is nearly always reduced, that is, the pressure is taken off the cord, but the damage done is practically irreparable. If we could hold out any hope of regeneration modern surgery would no doubt be able to step in. As I have elsewhere described the spinal lesion, the cord is cut across without injury to the membranes, in the same manner as the middle coat of an artery is cut by the ligature. The parts are in perfect apposition. Is it the crushed or scar tissue intervening that prevents possibility of regeneration? It is not so in the peripheral nerves ; regeneration begins, even though the severed ends be never brought into apposition. The surgeon does no more than place the new nerves into continuity with each other, and even then it is inconceivable that no scar-tissue intervene. The new nerves have apparently the power to pierce a thin layer of scar-tissue.

Could we hold out hope of regeneration of cord-fibres, with what renewed energy should we strive to find out the *fons et origo* of such lesions as obtain in the terrible diseases known as tabes dorsalis, lateral and disseminated sclerosis, to say nothing of the numbers of old hemiplegias that haunt the out-patient rooms of our hospitals.

I propose in my next lecture to trace the course of the degeneration in the cord both above and below the lesion.

## LECTURE II.

My first lecture has been devoted to the study of the histological appearances of degenerations. My present task is one of much wider scope.

If we examine a transverse section of a normal cord we see grey matter and white matter only, the division into regions being of the most superficial character. We can have no idea, from the appearances, which part transmits motor, and which sensory impressions, which carries fibres passing from above downwards, and *vice versa*.

But pathology does the work of the anatomist with the greatest precision, and we find that fibres which pass from the brain run invariably in certain areas of the transverse section, and those which pass to the brain travel up in equally definite paths. Moreover, fibres passing from one point of the cord to another, upwards and downwards, have also their own place.

It has become the custom to speak of degenerations of tracts containing efferent fibres as descending, of those containing afferent fibres as ascending degenerations. But it must be clearly understood that the terms descending and ascending apply to the course of the fibres in the tracts themselves, and not to the degeneration. Therefore the full expression of the term descending lesion should be a "lesion of a descending tract." There is every reason to believe that the degeneration of a fibre cut off from its trophic centre takes place, if not equally and simultaneously all along its course, at any rate very rapidly.

**Early Observations.** The earliest observer to study this method was Cruveilhier,\* in 1835. But it was Türck,† in 1851, who really gave us the first complete account of the descending tracts, and later, in 1853, he studied and

\* Cruveilhier, *Anat. Pathologique*, vol. xxxii., p. 15.

† Türck, *Sitzungsb. der Akad. der Wissensch. in Wien*. 1851 and 1853.



figured with great exactness the principal ascending tracts. There does not appear to have been anything of particular importance in this direction written after Türck's time till 1866, when Bouchard wrote some admirable papers in the *Archives Générales de Médecine*.\* After Bouchard we have numbers of writers treating of this subject, with more or less minuteness, too numerous to mention in this place, but to whom I shall refer as occasion shall arise.

The anatomical facts established by pathological methods are strikingly borne out by the study of the embryology of the cord, a branch of investigation followed most completely, first by Flechsig, later by Bechterew, Von Monakow, and others.

**Preliminary Anatomical Considerations.** In addition to the gross anatomical division of the white matter, we have one or two histological points to draw attention to. There are two forms of larger white medullated nerve fibres. First, the large fibres which are familiar to all. Secondly, there are medium-sized fibres, smaller than the last. Schwalbe has tried to show some relation between the size of a fibre and its length, but Gaskell, with more probability, suggests that the size varies with the function of the nerve; for instance, the hypoglossal nerve supplying the tongue is composed of very much smaller calibre fibres than we find in an ordinary anterior root. Whether this theory can be applied to the cord fibres I am unable to say. It is certain that the fibres supplying the smaller and larger muscles only communicate with the cord through ganglion cells in the grey matter. It is possible that the medium and large-sized fibres are in connection with medium and large-sized ganglion cells, and these, in their turn, with corresponding fibres in the cord. Lastly, there are the small medullated fibres. These are very minute, a tenth part of the size of the large fibres. They are morphologically exactly similar to the large fibres. They tend to run in certain tracts of the cord, and I shall deal with them in detail hereafter. They are connected with correspondingly small ganglion cells.

We shall also have to notice the white fibres which run into

\* Bouchard, *Arch. Gén. de Méd.*, 1866, t. vii., viii.

the grey matter. Among these are very few large fibres, but there are many of the small fibres just mentioned. The larger number of the white fibres in the grey matter are extremely minute; seen in cross section by Weigert staining they appear as little black dots displaying no structure to the highest powers. In longitudinal section they are by the same method fine black lines with an occasional varicosity. These are axis cylinders diminished in size and coated with a trace of myeline, sufficient to take the stain. It is highly probable that the hardening and staining operations may have some contracting effect on them.

**Fibres which  
Degenerate  
Downwards.**

When any considerable portion of the motor area of the cortex is destroyed the fibres in connection with that part are degenerated. The degenerated fibres can be traced through the middle third of the internal capsule, through the crista of the crus cerebri, through the pons, the anterior pyramid of the same side, across in the decussation to the crossed pyramidal tract, down the cord in that tract to certain cells in the grey matter, and no farther. Though the motor impulses originating in the cortex of the brain must take this course, and pass out to their destination through the anterior roots, degenerating fibres are never found in these roots, they must therefore stop at the ganglion cells in the grey matter. This fact was fully recognised by Bouchard.

As I have not had the opportunity of examining lesions passing down through the capsule and crus, nor had the time to undertake experiments in that direction, I confine my remarks to lesions in the cord and medulla only.

**Descending  
Fibres in Pons  
and Medulla.**

In the pons the motor fibres lie in bundles separated from one another by the transverse fibres of the pons. Case III., mentioned in my first lecture, a lesion of the middle and posterior part of the right internal capsule, would naturally afford the most extensive and complete degeneration of the motor tract below the lesion. All the longitudinal fibres of the right side of the upper and middle pons are deeply degenerated, but no degenerated fibres can be found in the fillet. The next section, at the commencement of the pyramids, shows that the

total sectional area of degeneration has undergone a very great diminution in size. It must be supposed, in explanation of this, that the motor tract here is constantly giving off fibres to the various nuclei of grey matter, as, in fact, it must do to a less degree in its course down the cord. At the decussation the degenerated fibres can be seen crossing to the opposite lateral tract, interlacing with healthy fibres. When this crossing has been completed we have the crossed pyramidal tract.

**Crossed  
Pyramidal  
Tract.**


This area forms roughly an isosceles triangle, with one of its sides close to, and parallel with, the posterior horn, its apex at the point of junction of the posterior horn with the rest of the grey matter, and its base lying parallel with the periphery of the lateral column, but not touching it in the upper parts of the cord. The description of the shape I have just given applies to the human cord. In dogs and monkeys it appears to be more circular in its outline. It will naturally also vary in its shape according to the extent of the lesion. Most of my cases are of total transverse section, which of course will give the greatest possible degeneration of this tract. It would appear that certain parts of the tract convey fibres from corresponding regions of the brain. This has not been made out with exactitude, but Langley and Sherrington\* found in Professor Goltz's dog, in which parts of the motor area had been removed at different times, distinct patches of degeneration at different stages in the crossed pyramidal tract. For further information I must refer to their paper.

I shall here relate very briefly the clinical details of a case which I shall have occasion to refer to several times, especially in connection with the ascending degenerations.

CASE V.†—A. P., *æt.* 18, fell forty feet, fracturing left thigh, and sustaining a fracture-dislocation of the seventh cervical vertebra. On admission the breathing was diaphragmatic and remained so; manipulation of the fractured thigh gave no sign of pain. Sensation was retained in the hands and arms, but there was some

\* Langley and Sherrington, *Journal of Physiology*, vol. v., p. 49.

† The clinical features of this case have been detailed in the *Lancet*, 1887, ii., p. 261, by Mr. Baker, who allows me to make use of the spinal cord.



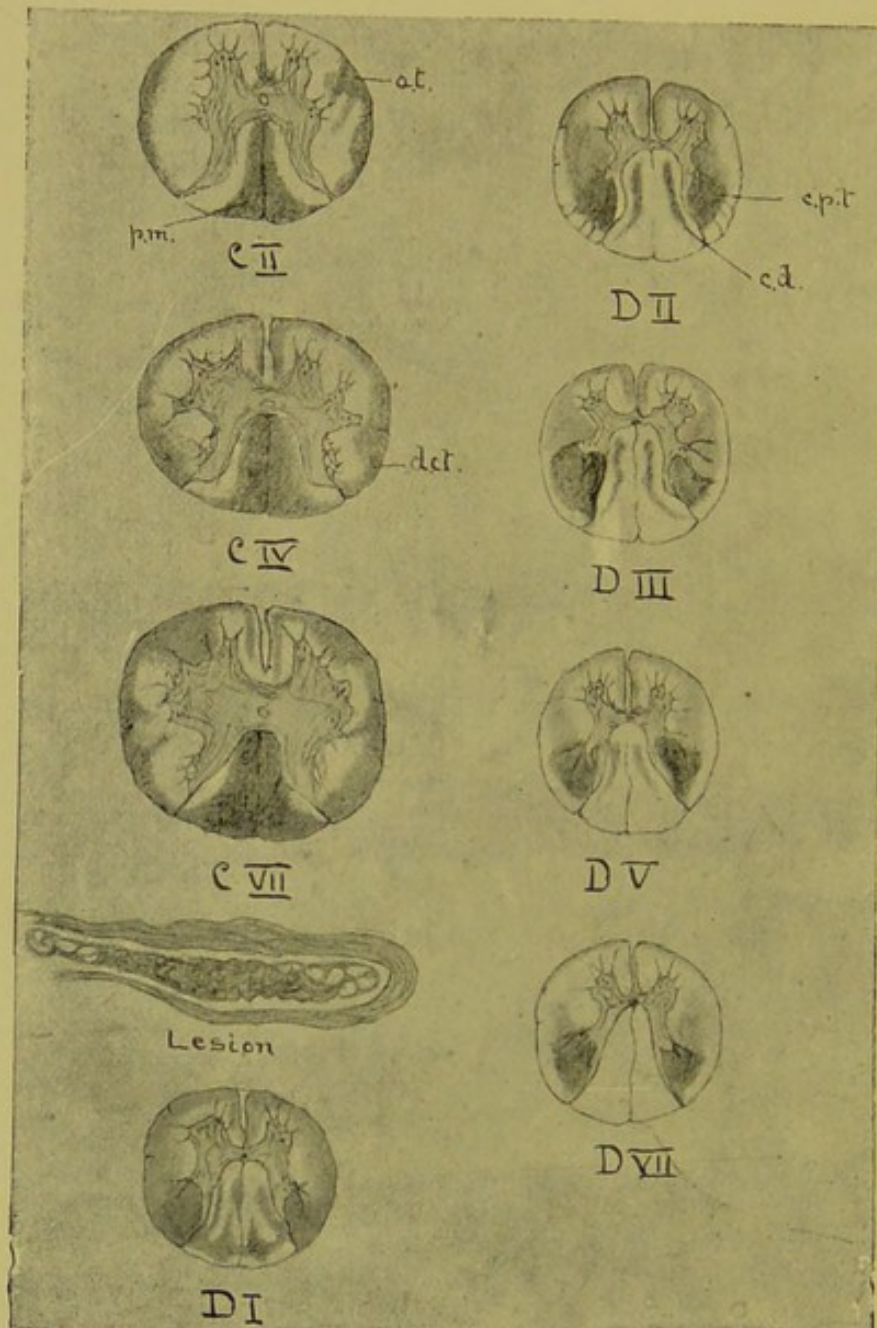


Fig. 7.

Fracture-dislocation of Seventh Cervical Vertebra, with Crushing of Cord between the Eighth Cervical and First Dorsal Roots (Case V.). *a.t.*, Antero-lateral ascending Tract. *d.c.t.*, Direct Cerebellar, *p.m.*, Posterior Median. *c.p.t.*, Crossed Pyramidal. *c.d.*, "Comma-shaped" Tract.  $\times 2$  diam.

paresis. There was retention of urine and involuntary defæcation and priapism. There was complete anæsthesia and paralysis below a line drawn round the body two and a half inches above the nipples. There was also complete absence of reflexes. He complained of pain in the upper part of the back, which became more localised in the lower part of the neck as time went on.

I mention this case here because it affords the best illustration I have of descending lesions following complete transverse crushing high up in the cord. It will be noticed how extensive the degeneration is for the distance of a root below, that is at least one inch (fig. 7, D I.) There can only be said to be natural fibres close round the grey matter; all the rest is degenerated; of course this degeneration is principally traumatic. At the level of the second dorsal (fig. 7, D II.) the crossed pyramidal tract may be said to have its greatest possible development. At the next root it is considerably smaller, and then diminishes gradually and regularly from above downwards. Vulpian, Singer, Lœwenthal, and others say that the crossed pyramidal tract ends at the level of the second lumbar. From my own observations I come to the conclusion that degenerated fibres can be found as low as the fourth lumbar, and even lower (fig. 8, S); neither is this contrary to what might be expected, for the fourth lumbar root enters obviously into the formation of the lumbar plexus. And though the nerves given off below this point are many of them visceral, yet, as I shall endeavour to show later, they must have their connection with the higher centres, and the path for this connection is probably the lateral column. In the upper parts of the cord the crossed pyramidal tract, as we have already noticed, does not reach to the edge of the section, because the direct cerebellar tract intervenes. In the middle of the dorsal region the crossed pyramidal tract comes to the surface. I find that this takes place at levels varying from the sixth to the eighth dorsal roots (fig. 8, D VII.). The significance of this will be apparent on consideration of the direct cerebellar tract. The crossed pyramidal tract having gained the surface, retains its shape and its position close to the posterior horn at first, but farther down the triangle becomes smaller and smaller, and gradually leaves the

posterior horn till at last it is a small patch on the periphery of the lateral column (fig. 8, L III. and S).

Bouchard speaks of the crossed pyramidal tract as composed of short and long commissural fibres; the short are on the inner side of the tract, and the long on the outside. He also makes the statement that the long fibres are degenerated after injury to the medulla, and not after injury to the brain.

What becomes of the fibres forming this bundle? The most careful examination fails to discover any degenerated fibres in the anterior roots. It is highly probable, therefore, that they in some way form connections with the ganglion cells of the grey matter. On physiological grounds it is certain that they do not cross, at least as a whole. As Schiefferdecker has remarked, it is impossible to understand how such small bundles of fibres as the two descending tracts can convey the multitude of voluntary impulses, unless we regard them as bearing only fibres which control subordinate centres in the cord.

I am not aware, however, that any observer has been able definitely to trace the degenerated fibres to their ganglion cells, and it is curious to note that the bundle takes up and maintains a position in the section as far away from the anterior roots as it is possible to assume.

**Development of Crossed Pyramidal Tract.** The position and shape of the tract in the cord at birth resembles very much the degenerated tract; but considering the size of the cord, the former is rather larger than the latter. In both the tract diminishes from above downwards, but that of course means that the process of development as a whole takes place from below upwards. The tract comes to the surface at about the fifth or sixth dorsal root level. It can be traced to the upper sacral region with certainty, but shows a tendency to leave the position close to the posterior horn, and to take up one a little farther along the periphery of the section.

**The Direct Pyramidal Tract.** This consists of fibres, which after leaving the pyramids, do not cross, but run down in the anterior median column on the same side. It may be said to commence in the cord at the same time as the

crossed pyramidal tract. It occupies a position close to the anterior median fissure, any lessening of size being on the side next to the anterior root zone. In cases in which the degeneration is extensive its anterior part may be extended towards the anterior roots along the outer edge of the section. In its fullest development it is a strip of degeneration extending the whole length of the anterior fissure (fig. 7, D III.). It is, so far as I know, always associated in degeneration with the crossed pyramidal tract. I have never seen or heard of a case in which this tract only was degenerated secondarily.

Pitres\* has shown that the tract is sometimes, though not always, affected in cortical lesions of the brain, and also that both tracts may be degenerated secondarily to an unilateral lesion.

Bouchard says the fibres composing it do not reach below the middle dorsal; but this is plainly not the case, for in Case III. it is distinct as low as the eleventh dorsal, and in another case, to which I shall refer later, it can be seen by the naked eye as low even as the level of the second lumbar.

The destination of these fibres is a disputed point. They must be for conduction of motor impulses, because in semi-sections, as Homén points out, the paralysis is much more complete if the anterior column be cut as well as the lateral than if the lateral be cut only. Dr. Gowers† considers that the direct pyramidal tract conducts motor impressions for the upper extremities. This may be the case, but it can scarcely be the whole answer, because the degeneration, as I have said above, can be traced as low as the second lumbar. It is possible that it may contain many commissural fibres.

It is almost certain that the fibres composing this bundle cross somewhere in the cord, for in cases in which it is deeply degenerated we get no paralysis of the same side. If they cross it is only reasonable to suppose that they should go by way of the anterior commissure. This commissure is practically a decussation

\* Pitres, "Recherches Anatomico-cliniques sur les Scléroses bilatérales de la Moelle Épineuse," etc., *Arch. de Phys.*, 1884, p. 142.

† Gowers, "Diseases of Nervous System," vol. i., p. 114.



to spring from the anterior column of one side, to pass into the corresponding column or anterior horn of the opposite side. And yet the most careful examination fails to discover a single degenerated fibre in the commissure. The destination of this tract is therefore at present conjectural.

**Development of Direct Pyramidal Tract.** Developmentally the direct pyramidal tract resembles the crossed; that is, the fibres are medullated late, and therefore these two tracts remain as unstained patches by osmic acid or Weigert's hæmatoxylin, when all the rest of the white matter is stained black. It is also developed from below upwards, but generally speaking it is farther advanced in development at birth than is the crossed pyramidal tract.

**Recrossed Fibres.** In cortical lesions of the motor area another descending tract in the lateral tract of the same side as the lesion has been often noticed. Pitres,\* in the important paper just referred to, brings forward ten out of forty cases of hemiplegia from unilateral brain lesions, many with contractures and increased tendon jerks. In all he found a degeneration of the pyramidal tract on the same, as well as on the opposite side. In several of these the degenerations on the two sides were of equal intensity; in others it was less intense on the same side. In six cases the direct pyramidal tract was also affected, and in three both direct pyramidal tracts. The pyramid of the opposite side was quite unaffected. He remarks also that there is clinical ground for the suspicion of this double degeneration; that in many hemiplegias we find loss of power, slight, it is true, of the same side. He moreover draws attention to the very common occurrence of increased reflexes and the less common occurrence of contractures on the same side. It must be said, however, that in many of his reported cases these symptoms are not noted, though the degeneration was obvious after death.

He considers that these fibres come from the pyramid of the same side; that is, that the fibres of that pyramid may pass into of medullated fibres from one side to the other. The fibres seem

\* Pitres, *op. cit.*

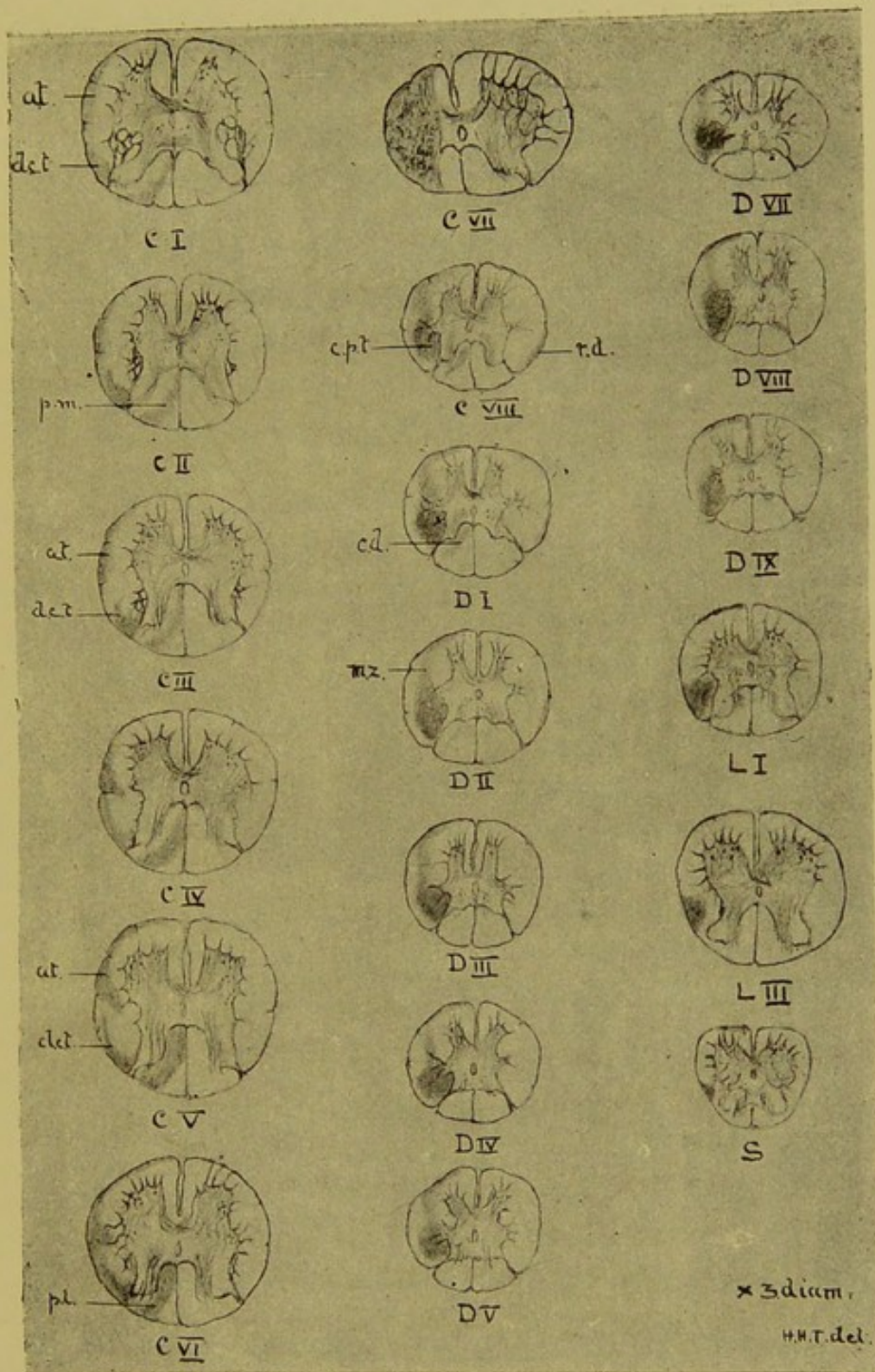


Fig. 8.

Semi-section between Seventh and Eighth Cervical Roots on the left side (Monkey 7). *a.t.*, Antero-lateral ascending Tract. *d.c.t.*, Direct Cerebellar. *c.p.t.*, Crossed Pyramidal. *r.d.*, ? Recrossed Fibres. *c.d.*, "Comma-shaped" Tract. *m.z.*, Descending Fibres in the "Mixed Zone,"  $\times 3$  diam.

Faint, illegible text at the bottom of the page, possibly bleed-through from the reverse side.

the crossed pyramidal tract, the direct pyramidal tract, and the pyramidal tracts of the same side.

Charcot,\* who recognised this degeneration, suggests that the fibres re-cross from the crossed pyramidal tract of the opposite side by way of the anterior commissure. The absence of any anatomical evidence for this statement must be the answer to it for the present. Drs. Hadden and Sherrington† add another case in the human subject, in which they discover a few degenerated fibres in the opposite pyramid.

According to Dr. Sherrington,‡ this "re-crossed tract," as he calls it, does not make its appearance till about the third cervical root. It is much smaller, and the degenerated fibres in it are fewer than in the tract of the opposite side. It cannot be traced so far down the cord. Dr. Sherrington found it after extensive experimental lesions on the dog.

Professor Schaeffer§ figures the same tract in the monkey. In some monkeys' cords that I have examined for Messrs. Horsley and Spencer, in which the lesion of the cortex was sufficient to cause a very obvious degeneration of the crossed pyramidal tract, there was at this time a very scanty degeneration of fibres in the corresponding tract on the same side as the lesion. Another important piece of evidence of the existence of these re-crossed fibres is that of Homén,|| who, after semi-section in the cervical region in dogs, found distinct degenerating fibre in the opposite lateral tract, beginning about one ctm. below the level of the lesion. He traced the degeneration as far down as that on the opposite side. This experiment would show that this so called re-crossing of the fibres is going on all through the cord. He found at the same time degeneration of the anterior pyramidal tract, which appears to me to answer the question of

\* Charcot, "Legons sur les Localisations dans les Maladies du Cerveau," etc., Paris, 1876, p. 252.

† Hadden and Sherrington, *Brain*, vol. viii., p. 502, "Bilateral Degeneration in Spinal Cord."

‡ Sherrington, "Degeneration in Spinal Cord," *Journ. of Physiol.*, 1885, p. 177.

§ Schaeffer, *Journ. of Phys.*, vol. iv., 1883, p. 316.

|| Homén, *op. cit.*

Messrs. Langley and Sherrington as to whether that tract exists in the dog in the affirmative. The most difficult points in connection with this degeneration are that it causes such slight symptoms, and that it is not really very common, and therefore perhaps, ought to be regarded as a deviation from the normal. To look at the figures and sections in Pitres' paper one would certainly expect a double hemiplegia. Again, one must suppose a similar re-crossing of healthy fibres from the crossed pyramidal tract of the same side into that of the opposite side, and therefore, if they be motor fibres, so much less a degree of paralysis on that side, but the clinical evidence lends no colour to this view. In my Case III., of extensive lesion of the middle and posterior parts of the capsule, I can find no degeneration on the same side in the lateral tract.

The descending lesions after a half-section of the cord are very well shown in monkey 7 (fig. 8), already mentioned in Lecture I. The semi-section was not complete; that is, the anterior column and posterior median column escaped. The lesion was between the seventh and eighth cervical. The crossed pyramidal tract was very completely degenerated, and could be traced as low as the sacral region, and came to the surface as low as the seventh dorsal.

In the antero-lateral region and extending round the anterior periphery, that is, in the anterior root zone, are seen many degenerated fibres, but in these situations are many normal ones also. This diffuse descending degeneration of the antero-lateral region, or "mixed zone" (Flechsig), extends to about the eighth dorsal, but in the anterior root zone a thin strip can be seen as low as the sacral region.

This degeneration is also seen in fig. 7 for a considerable distance below the crush. It is figured by Drs. Hadden and Sherrington in the paper referred to above.

For a short way below the lesion, at about the level of the second dorsal, degenerated descending fibres are found in the periphery of the opposite lateral column, in a position respected by the ascending fibres of the direct cerebellar tract in the

section above the lesion. (See fig. 8, *r.d.*) These are the only fibres corresponding to re-crossed degeneration that I could find in this experiment.

**Postero-lateral Descending Degeneration, or "Comma-shaped" Tract.** In complete transverse sections can be seen by the naked eye, and after staining, a distinct tract of degeneration in the postero-lateral column below the lesion. It is situated so as to divide the column, as seen in transverse section, into two almost equal halves (fig. 7, *c.d.*, and fig. 8). It has the shape of a comma, that is, with a rounded thickened head and thin curved tail, reaching nearly to the periphery of the section. It was noticed first by Schultze,\* but it was figured, not described, by Drs. Bastian † and Westphal ‡ previously to Schultze's observation, and later by Kahler and Pick.§

I have seen several instances of this degeneration, and I believe that it is rarely absent in cases of transverse lesion. Schultze figures it in a case of complete compression by tumour of the middle of the cervical swelling, 2 ctm. below the lesion.

In Case V. (fig. 7), in which the cord was crushed completely between the eighth cervical and first dorsal roots, the degeneration is very distinct as low as the fifth dorsal root, and can be traced without much trouble with the microscope as far down as the seventh and eighth dorsal.

In another case, in which the cord was crushed between the sixth and seventh cervical roots, the degeneration to the naked eye, after hardening, was very distinct in the cervical and upper dorsal region, and could be seen as far as the sixth dorsal. In a case of fracture-dislocation of fifth dorsal vertebra, that I reported elsewhere, I have since by careful examination found it, but it is very faint, and extends little more than one inch below the lesion. It may be said that the "comma-shaped" tract is generally more distinct after lesion of the higher parts of the cord, above the

\* Schultze, "Beitrag zur Lehre von der secund. Degen." etc., *Arch. f. Psych.*, 1883, p. 375.

† Bastian, "Case of Concussion Lesion with second. Degen." etc., *Med.-Chi. Trans.*, 1887, p. 499.


‡ Westphal, *Arch. f. Psych.*, Bd. x., 1880, p. 788.

§ Kahler and Pick, *ibid.*, p. 179.

fifth dorsal root, probably. Homén finds that this tract degenerates downwards on the same side after semi-sections ; an observation borne out by my monkey 7 (fig. 8, *c.d*). It is rather unexpected to find descending fibres in the middle of a column which is essentially a conductor of centripetal fibres. As to the function of its fibres we are at present quite ignorant. Schultze considers that it must either consist of fibres which degenerate both upwards and downwards when cut in their course, a condition which is quite irreconcilable with recognised facts, or else that it contains fibres from the posterior roots, which are bent back, as it were, after entering the cord, to pass into the grey matter at a point below. This supposed bending back of the posterior root fibres has been suggested by Stilling and Brown Séquard. It is, however, extremely improbable that such bending back of posterior root fibres can possibly extend so far as this degeneration does ; then, again, if the fibres of the "comma-shaped" tract were derived from the posterior roots they should degenerate after section of those roots, but I can find no evidence of such in my experiments. It seems more likely that the fibres forming it are commissural.

|  |   |
|--|---|
| <p><b>Fibres which<br/>Degenerate<br/>Upwards.</b></p> | <p>Degeneration of ascending tracts may be secondary to complete or partial transverse sections of the cord, crushing, pressure, invasion of new growths, focal inflammation, involving the whole or part of the transverse section, and lastly to section or disease of the posterior roots.</p> |
|--|---|

Close above the lesion, supposing it to be a crush, for instance, we find the traumatic degeneration affecting most of the section but even here tending to affect the ascending tracts most. As a rule, the whole of the posterior region is deeply degenerated ; the same may be said of the whole periphery of the section, even including to a greater or less extent the anterior column and the anterior radicular zone (fig. 7, C VII.). The fibres, however, lying next the grey matter in the lateral region, called the "lateral limiting layer," usually escape, unless, of course, there be much inflammation, in which case the whole section may be affected, grey matter as well as white. The traumatic degeneration is said





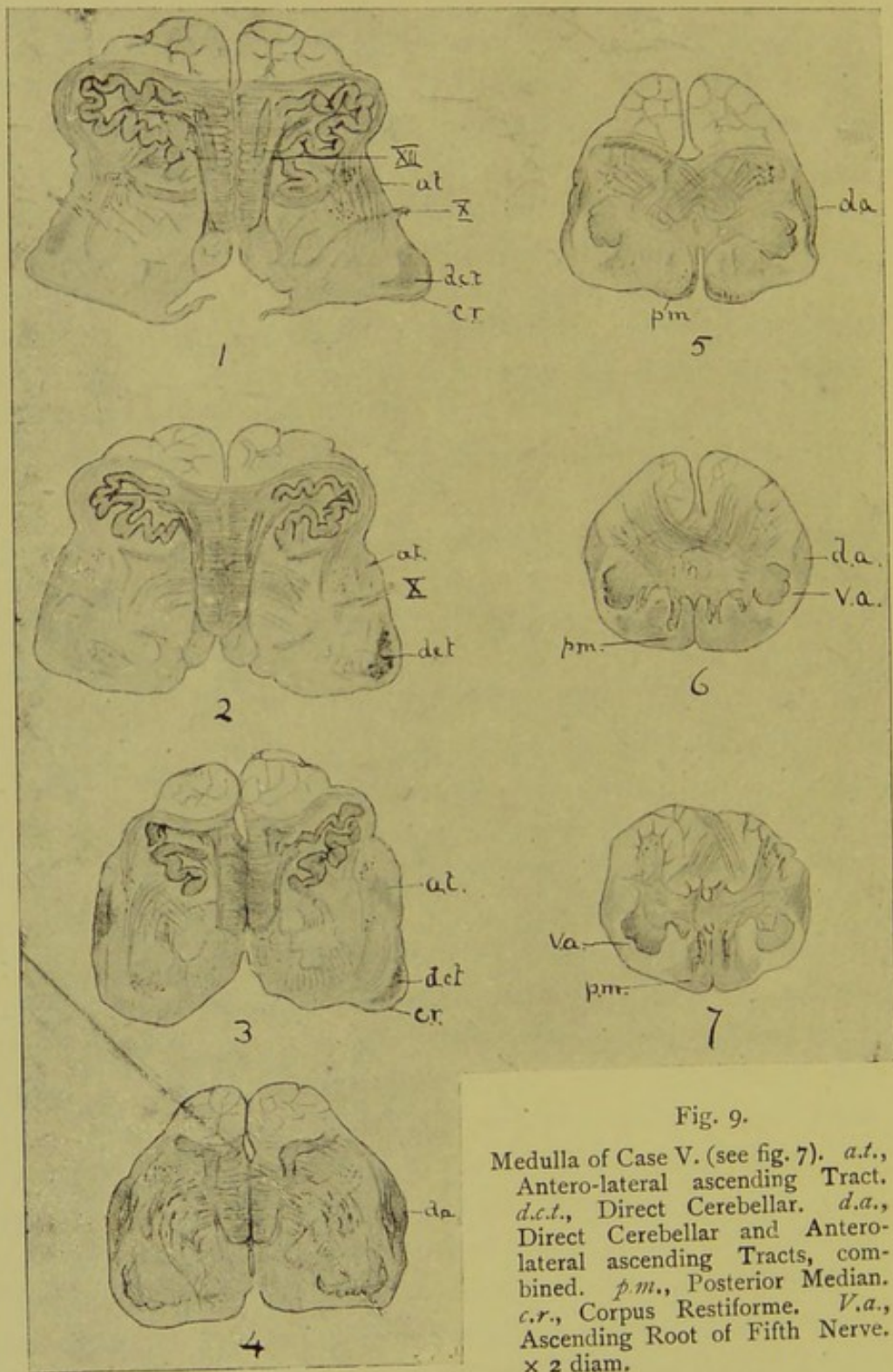


Fig. 9.

Medulla of Case V. (see fig. 7). *a.t.*, Antero-lateral ascending Tract. *d.c.t.*, Direct Cerebellar. *d.a.*, Direct Cerebellar and Antero-lateral ascending Tracts, combined. *p.m.*, Posterior Median. *c.r.*, Corpus Restiforme. *V.a.*, Ascending Root of Fifth Nerve.  $\times 2$  diam.

by Homén and Schiefferdecker to extend for about 1 to 2 ctm. above the lesion. Above this we may speak of the degeneration as being true secondary degeneration.

**Postero-lateral Degeneration.** The posterior region consists of the postero-lateral column and the posterior median column.

The postero-lateral column is never degenerated far from the point of lesion. At the second root, from the lesion in Case V., this column begins to show a few normal fibres, and these fibres are obviously principally acquired from the posterior root. The normal fibres can be seen if the section be made through the point of entrance of the root, flowing in in considerable numbers into the posterior part of the column, where they form a little group.

At the next root above there is quite a considerable area of non-degenerated fibres, extending forwards parallel to the posterior horn of the grey matter. With each root, as we ascend from the lesion, then, the postero-lateral area seems to receive a fresh contingent of normal fibres; and at the fifth root from the lesion we find the postero-lateral area beginning to assume its normal dimensions. This influx of new fibres from the posterior roots is, however, scarcely enough to account for the whole of the postero-lateral column, as we shall see when we come to study degeneration from sections of the root. It is, therefore, probable that a large number of these are commissural. The above statements are based principally on the examination of Case V., but they apply equally well to lesions lower down in the cord.

We may look upon the postero-lateral column as one of the principal conductors of the posterior root fibres. This of course explains many of the phenomena of tabes dorsalis, which is essentially a disease of this column.

**Posterior Median Column.** With the appearance of the postero-lateral column the position and shape of the posterior median column becomes defined. The two together make up an area having a **V** shape, the angle of the **V** being truncated and applied to the posterior commissure. The sides of the **V** bend outwards and backwards towards the posterior roots at first. Root by root, however, this tract becomes

smaller, compressed, as it were, by the increasing number of fibres from the postero-lateral region, till at last it becomes a thin strip of degeneration each side of the posterior septum, but still reaching forwards to the posterior commissure.

If the lesion be below the fourth or fifth dorsal the tract in the cervical region not only becomes thinner, but at about the third cervical root retreats backwards, forming a wedge with the thin end forwards. The farther down the cord the lesion is, the sooner this shape of the degeneration is assumed, till at last the lesion is only a small triangular patch at the posterior extremity of the posterior septum. The ascending degeneration of the posterior median column is one of the most constant lesions we have to do with. Any considerable damage of the cord high up or low down is certain to be followed by more or less degeneration of this tract. From remarks above made concerning the postero-lateral fibres it is practically certain that large numbers of the fibres of that tract pass directly into the posterior median column. Hence it is that in tabes, in which the postero-lateral column is sclerosed in the lower parts of the cord, in the higher parts we find the posterior median column affected only.

A large number of the fibres composing the posterior median column run from one end of the cord to the other, that is, into the medulla. This is shown by the records of many cases of pressure and disease of the cauda equina; moreover, I shall quote experiments on monkeys in further proof of this point.

It is probable that very few, if any, of the fibres cross, in unilateral lesions, to the opposite column, that is, they run up on the same side. This is certain from semi-sections by Homén and others, and by my own cases.

**Destination of Posterior Median Fibres in Cord.** But though a large number of the fibres run straight up to the medulla, yet the tract progressively diminishes in size from below upwards, and therefore its fibres must be diminishing in numbers *pari passu*. But this diminution appears, according to Schiefferdecker,\* to be not regular, but subject, at certain points, to sudden alterations in size. These points were (1st) between the fourth

\* Schiefferdecker, *op cit.*

and fifth dorsal, (2nd) between first and second dorsal, (3rd) between seventh and eight cervical, and lastly between second and third cervical.

His method of determining this was ingenious, but seems open to many errors of observation; it consisted of drawing very accurately, by the camera lucida, the outline of the degeneration on paper, and then cutting out the drawn figure and weighing it with the most delicate balance. Of course this takes no account of normal fibres in the area of degeneration, of which the tract receives many as it passes upwards. Between the points of sudden diminution in size the tract alters very slightly in area from root to root. Schiefferdecker concludes, therefore, that these fibres end in certain centres or collections of ganglion cells in the cord.

But though large numbers of the fibres disappear  
**In Medulla.** in the grey matter of the cord, yet there is no doubt that a certain number, more or less, traverse the whole length of the cord to the medulla. As we trace the postero-lateral column and the posterior median column upwards to about the level of the first cervical root we find that the angle formed by the two posterior horns becomes wider, owing to their divergence. At the same time the tips of the posterior horns become swollen, as it were, by a local increase of the so-called *substantia gelatinosa Rolandi*, this local swelling being named the tubercle of Rolando; still at this level the general appearance of the spinal cord section remains. But above this the appearance changes. The whole section is larger, owing to the appearance of new material. Anteriorly we have the lowest part of the decussation of the pyramids, pushing the remains of the anterior horns of the grey matter aside, so that the lateral region is relatively smaller than it is in the lower part of the cervical regions. The *substantia gelatinosa* retains its position, but assumes a crescent shape; between this crescentic *substantia gelatinosa* and the periphery lie a number of medullated fibres, part of which, at any rate, make up the ascending root of the fifth cranial nerve (fig. 9 *v.a.*). At this level, moreover, a change takes place in the constitution of the posterior region. In both the

posterior median column and the postero-lateral column we find what appears as a prolongation backwards of the grey matter around the central canal ; this is no longer the thin commissure that it was lower in the cord, but a large mass, containing many ganglion cells, which higher up are grouped to become the nuclei of certain cranial nerves, such as the hypo-glossal, glosso-pharyngeal, etc. This central grey mass then sends back prolongations of its substance into the posterior median and the postero-lateral columns. So that at this level the posterior median and postero-lateral columns consist each of a peninsula of grey matter, with white matter nearly surrounding it. They here have received other names : the posterior median is called the funiculus gracilis, the grey matter in it the nucleus gracilis, or nucleus clavatus ; the postero-lateral is called the funiculus cuneatus, with its nucleus cuneatus.

It is with the nucleus gracilis that we are now more particularly concerned. The ganglion cells in it are peculiar ; they are not so large as those in the anterior horns of the grey matter anywhere in the cord, and they are also of the oval, bipolar, or unipolar kind, such as are found in the posterior vesicular column of Clarke. Among these ramify, horizontally, medullated fibres. As we pass still higher in the medulla the two funiculi graciles become separated by a fissure, the first beginning of the calamus scriptorius. At the same time the central canal, with its grey matter and nerve nuclei, passes backwards to open into the fourth ventricle, and finally the grey matter forms the floor of that ventricle.

To return to the degeneration of the posterior median column. Where the degeneration is extensive, as in Case V. (fig. 9, sections 6 and 7, *p.m.*), the peninsula of grey matter, or nucleus gracilis, has a mass of degenerated fibres lying along its inner side and also along its posterior aspect. If, however, the degeneration be that of posterior root fibres, as in monkeys 2 and 4 (*vide infra*), it will be found lying against the internal aspect only.

Higher up the encroachment of the nucleus gracilis, as it were, forces backwards the degenerated fibres, till at last there remains little more than a small patch posterior to the nucleus, and finally

this disappears also (fig. 9, section 5, p.m.). There can be no doubt that these degenerated fibres are absorbed one by one into this nucleus gracilis. It is probable that the fibres are in direct communication with the bipolar ganglion cells of the nucleus. Seeing the great similarity between the cells of this nucleus and those of the posterior vesicular column, it is not unreasonable to suppose that the fibres which are disappearing from time to time in the upward progress of the tract end in a similar manner in the posterior vesicular column of the cord.

Now, I shall speak more particularly concerning the posterior vesicular column and its relations in my next lecture, but it will not be out of place to remark here that the posterior median column carries vast numbers of small nerve fibres which have been proved, by Gaskell, Onodi, and others, to be visceral in function and to be probably in direct communication with the posterior vesicular columns; also that lesion of posterior median column alone gives rise to no known symptoms at all comparable, at least, to such as follow corresponding lesion of the postero-lateral column; also that the fibres of this column do not cross, at least in the white matter, whatever they may do when they reach the grey, but tend to run a very long course on the same side.

I may mention here that the posterior median column, as is the case with the other columns of the white matter, develops from below upwards, and therefore the tract of the unmedullated fibres appears to diminish from above downwards, the opposite of the degenerated tract.

We have seen, then, that the posterior median column degenerates secondarily after lesions involving the columns themselves and after lesions involving the postero-lateral column; we have next to consider the course of degenerations following on lesions of the posterior roots.

**Results of  
Division of  
Posterior Roots.** At the suggestion of Dr. Gowers, and with the kind help of Mr. Horsley, I have been enabled to try the experiments on monkeys of such sections. I have made careful examination of the cords of three monkeys, which I know as monkeys 2, 3, and 4. I have already referred to them in my first lecture,

and have mentioned in what respects the resulting degeneration differs from ordinary secondary degeneration.

In monkey 2 Mr. Horsley divided all the posterior roots of the right side of the cauda equina, at a level about 1 cm. above the tip of the sacral end of the cord. The operation was quite successful, and the animal rapidly recovered, without a bad symptom. There was complete loss of common and pain sensation, and probably of muscular sense, in the lower limb of that side. There was also loss of knee-jerk on the same side. The animal lived thirty-six days, and then died from diarrhoea, which was causing a high mortality at that time among the monkeys at the Brown Institution. Unfortunately, the autopsy was made twelve hours after death, and therefore there is some post-mortem change, but not very much. Fig. 10, L V, is made from a section of the cord with the nerves of the cauda round it, at the level of Lumbar V., about. The degenerated nerves are shaded, as is the degeneration in the other figures. At this level no affection of the posterior region can be made out, except just close to the tip of the posterior horn, where the posterior root fibres begin to enter; here the entering fibres are deeply degenerated, and can be traced into the grey matter as short broken bundles of varicose deeply staining fibres. A root above, the area of the postero-lateral column next the horn is highly degenerated, but as can be seen in fig. 10, L IV., only a small area is affected. At Lumbar III. the greater part of the posterior region—in fact, nearly all the postero-lateral column—is affected.

At Lumbar I. the degenerated area has attained its largest extent, the whole of the posterior region, except a very small triangle at the posterior part of the posterior septum, and a small patch close to the tip of the posterior horn. This small area close to the posterior septum is found to consist under the microscope almost exclusively of fine nerve fibres (p.v.), and is continued right up the cord. That next the posterior horn indicates the entrance of new nerve fibres from the unaffected posterior roots, a glance at the remaining figures is sufficient to show the course of the degeneration. Though it affects the posterior

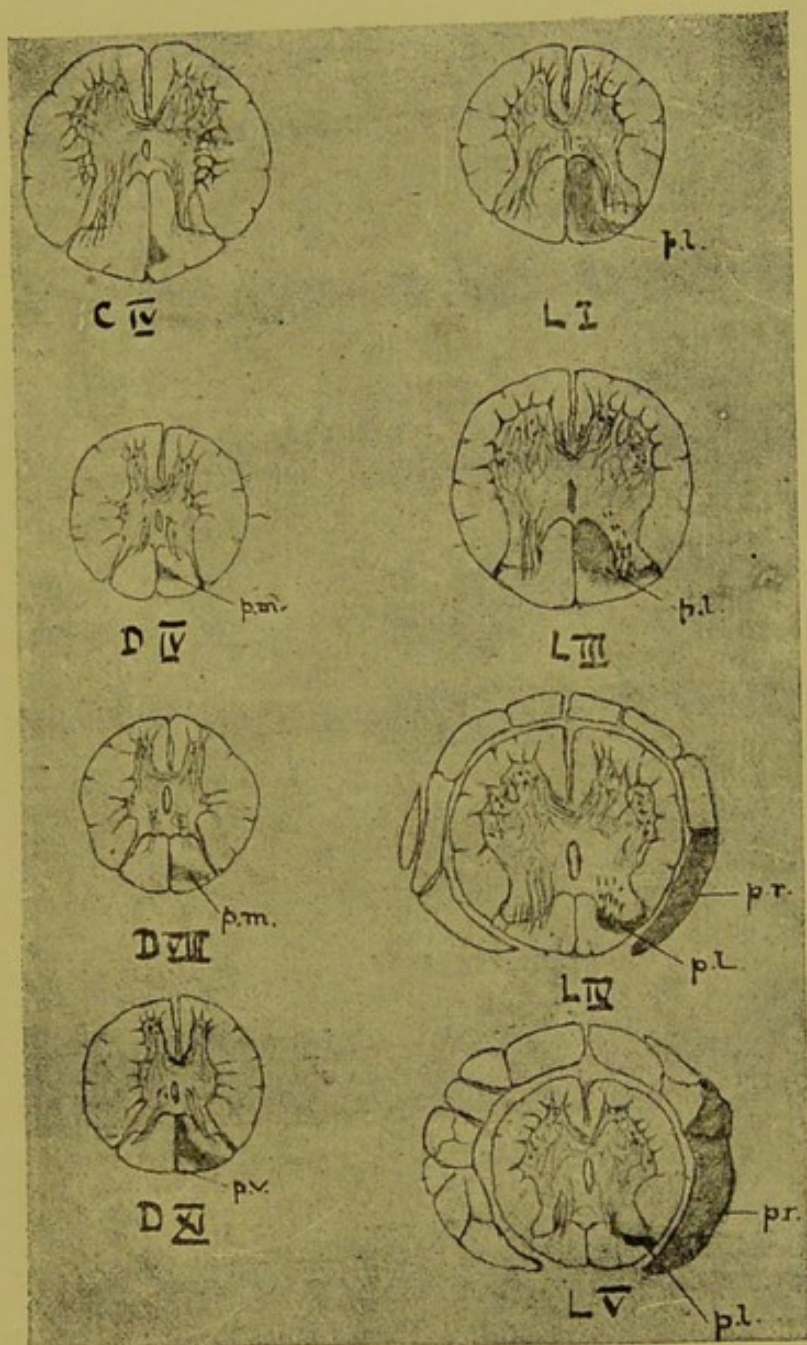


Fig. 10.

Section of Posterior Roots of Cauda Equina on the right side (Monkey 2). *p.l.*, Postero-lateral Degeneration. *p.r.*, Degenerated Posterior Roots, proximal end. *p.v.*, Visceral Fibres of Posterior Column. *p.m.*, Posterior Median Degeneration.  $\times 4$  diam.



13

Section of the ...  
...

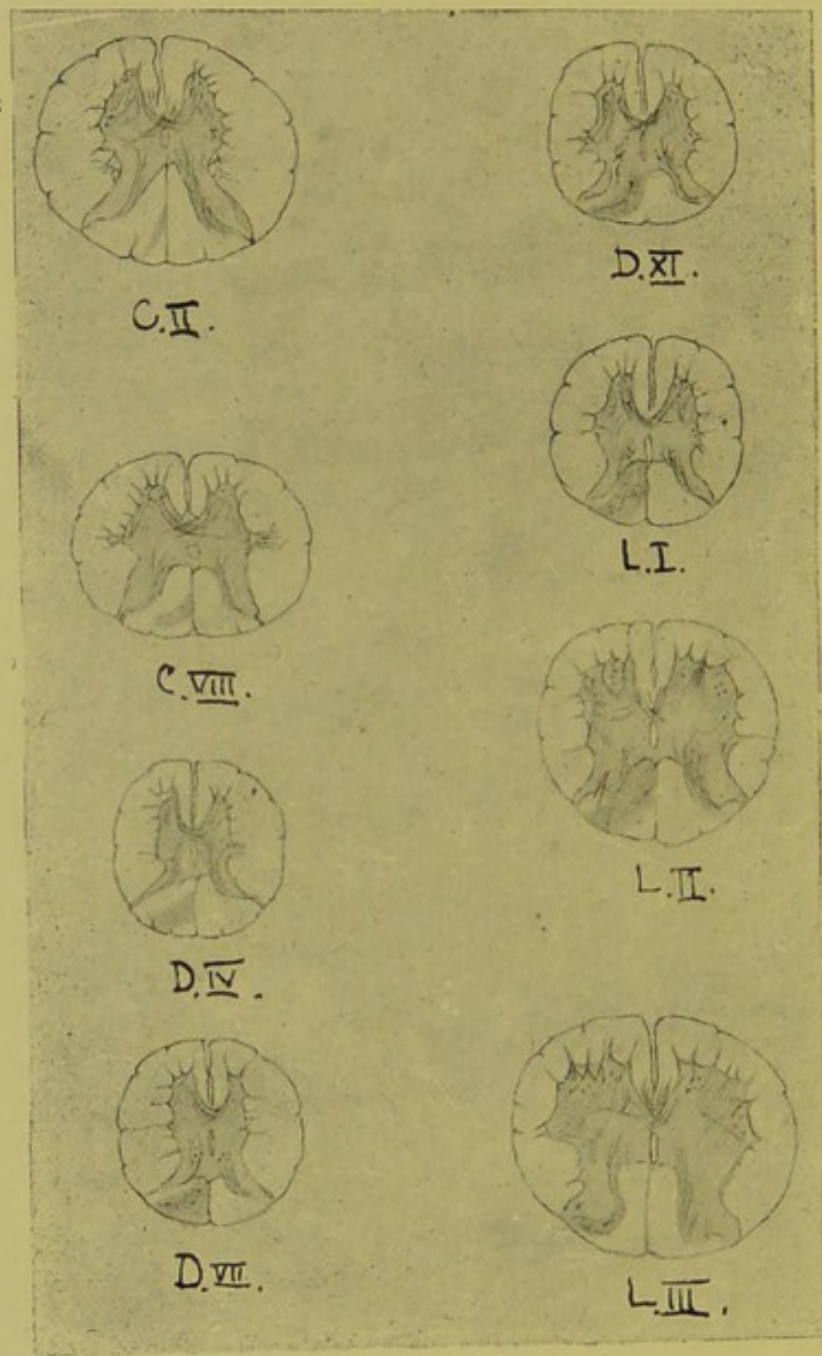


Fig. 11.

Section of Posterior Roots of Twelfth Dorsal and First Three Lumbar on the left side (Monkey 4).

median column, it affects it most extensively at Dorsal XI, and even there respects the small area above mentioned (p.v.)

Higher up it dies away till it remains as a small patch against the posterior septum, rather below its middle.

On closer microscopical examination it is found that degenerated fibres can be traced passing into the posterior horn at levels from Lumbar V. to Lumbar III. inclusive. The posterior vesicular column, as a collection of ganglion cells, does not commence till about Lumbar II. Therefore, if these degenerated fibres enter that column they must do so by passing up in the grey matter for some distance. The evidence seems to point to the correctness of this supposition. If the section at Lumbar IV. be examined, large bundles of degenerated fibres can be seen entering the horn, but then they seem to stop suddenly; only a few can be traced forwards. It is therefore probable that they do pass upwards. I have been unable to trace with certainty any fibres crossing to the opposite side of the grey matter; but a considerable number of these fibres can be seen passing towards the anterior horns, probably to form communication with the ganglion cells for reflex purposes.

The experiment on monkey 4 was of a similar description. Mr. Horsley divided the posterior roots of the last dorsal and upper three lumbar nerves on the left side. The result was anæsthesia of the side of the trunk corresponding to the distribution of the nerves. The animal was killed on the fifty-second day. It will be seen from fig. 11 that the resulting degenerations exactly correspond to those of the last case.

At the level of Lumbar III. the fibres entering the horn are practically all degenerated; the result is, that comparing the horn on that side with the opposite healthy horn, we find that whereas in the latter there is a wealth of fibres, in the former there is a great dearth of them. Apparently, the animal had lived long enough for complete disappearance of the degenerated fibres. Again, comparing the grey matter of the central and lateral regions, we find a similar difference between the two sides, though less marked. Even in the anterior horns there appear to be fewer medullated fibres on the side

of the lesion. At Lumbar II. the posterior vesicular column has commenced, and there is in it on the side of the lesion scarcely a normal fibre visible, contrasting in that respect very strongly with the opposite side.

This is also very striking at Lumbar I. There is, however, no sign of alteration of the ganglion cells of the posterior vesicular column themselves. Between the tenth and eleventh dorsal the degenerated fibres have ceased to flow into the posterior horn, but even here the posterior vesicular column shows few normal fibres.

It should be noticed that the postero-lateral and posterior median columns are the only two columns affected in these two experiments; and that the direct cerebellar and antero-lateral ascending tracts escaped entirely.

There is a number of vacuoles on the other side of the posterior septum, at the levels of the twelfth dorsal and first and second lumbar, but whether they mark degenerated fibres or not, I am not prepared to say.

So far as I know, the first to study degeneration after section of posterior roots was Singer,\* in 1881, though a short notice exists of experiments in the same direction by Bufalini and Rossi†. Singer's experiments were on dogs and, in the main the resulting degenerations coincided with those in monkeys 2 and 4.

Rossolymo,‡ in 1886, made similar experiments on guinea-pigs. He found degeneration of the postero-lateral column, and also some degeneration of the lateral column near the tip of the posterior horn, but says that none was found in the posterior median column at any level. No doubt results will vary in detail in different animals. I cannot help thinking that the results in the monkey must resemble closely those in man, the anatomical features of the spinal cord being remarkably alike in both.

\* Singer, "Ueber secund. Degen. im Rückenmark des Hundes Sitzungsber. Wien. Akad.," 1881, p. 403.

† Bufalini et Rossi, "Atroph. de la Moelle Épinière par la section des Racines Nerveuses," *Arch. de Phys.*, 1876.

‡ Rossolymo, "Zur Frage über den Weiteren Verlauf der Hinterwurzelfasern," *Neurol. Centralbl.*, 1886, p. 391.

Singer's experiments, and monkeys 2 and 4, seem to show that though some of the fibres of the posterior roots undoubtedly pass straight into the posterior horn, and so in the direction of the posterior vesicular column, and probably also end in the posterior vesicular column, yet a very large number pass up in the postero lateral and posterior median columns even to the medulla.

**Lesions of  
Posterior Roots  
in Man.**

Such pathological data as we possess in man point in the same direction as the experiments above quoted. Several observers have suggested that in many cases of tabes dorsalis the initial lesion may be in the peripheral nerves. It is difficult to understand, however, how the degeneration can pass up the nerves, past the ganglion on the posterior roots. After section of peripheral nerves, the central end certainly does degenerate to a certain extent, but the degeneration has not been traced beyond the ganglion. After amputation, the side of the cord corresponding to the amputated limb becomes smaller, but no true degeneration has been observed. But if the initial lesion be in the posterior roots, that is, between the ganglion and the cord, then we may have the same degeneration resulting as follows experimental section. Many cases have been recorded of lesions of the roots, more particularly of the cauda equina. In all, secondary degeneration has followed of the postero-lateral column first, higher up of the posterior median.

In this connection also should be mentioned an exceedingly interesting case of locomotor ataxy of the upper extremities only, reported by Déjèrine.\* The lesion was situated in the cervical and upper dorsal cord only. There was the most intense degeneration of the posterior roots of the region affected. There was also posterior sclerosis, complete in the upper cervical region, with the exception of the small triangle at the posterior part of the posterior median column. Lower down the postero-lateral column was much affected, the posterior median column less so; in fact, the case presented the same lesions as result from section of the posterior roots.

\* Déjèrine, "Contrib. à l'Étude de l'Ataxie Locomotrice des Membres Supérieurs," *Arch. de Phys.*, 1888, p. 331.

Lange\* records a case which appeared to give all the signs of locomotor ataxia. Post-mortem was found a tumour involving and pressing on the posterior roots of the cauda equina, most on the right side, with ascending lesions to as high as the middle dorsal region.

**Summary of  
Course of  
Posterior  
Root Fibres.**

In conclusion, then, we may say that the fibres of the posterior roots in the lower parts of the cord, most of them, pass into the postero-lateral column, though some undoubtedly pass straight into the tip of the posterior horn. In the postero-lateral column the fibres remain only for a short distance of their course. They then pass in one of two directions. They may either pass into the grey matter of the posterior horn at various levels, or else they may pass into the posterior median column.

In the grey matter they form connections undoubtedly with the posterior vesicular column, and also with ganglion cells in the anterior horns. In the posterior median column they run a long course right up to the medulla, where they end in the nucleus gracilis.

Physiological experiments point undoubtedly to the probability of a crossing of these fibres in the grey matter to the opposite side. Do they cross in the posterior white columns? In the first of the above experiments there was an appearance of degenerated fibres in the opposite posterior column, but this may be accounted for by an accidental injury of one or more of the posterior roots of that side. In the second experiment the appearances are more difficult to explain, except on the supposition that some of the posterior median fibres cross through the septum. Singer's experiments show nothing of the kind, and in a third experiment (monkey 3), to be described in my next lecture, in which there was section of lower cervical posterior roots, there was no such affection of the opposite posterior median column. The appearance may be due to the reagents used; at any rate, I draw no definite conclusions from them. It has yet to be determined by experiment what kind of impressions the fibres of the posterior

\* Lange, "Ueber die Leitungs-verhältnisse in den hinteren Rückenmarkssträngen," etc., *Schmidt's Jahrb.*, Bd. 155, 1872, p. 281.

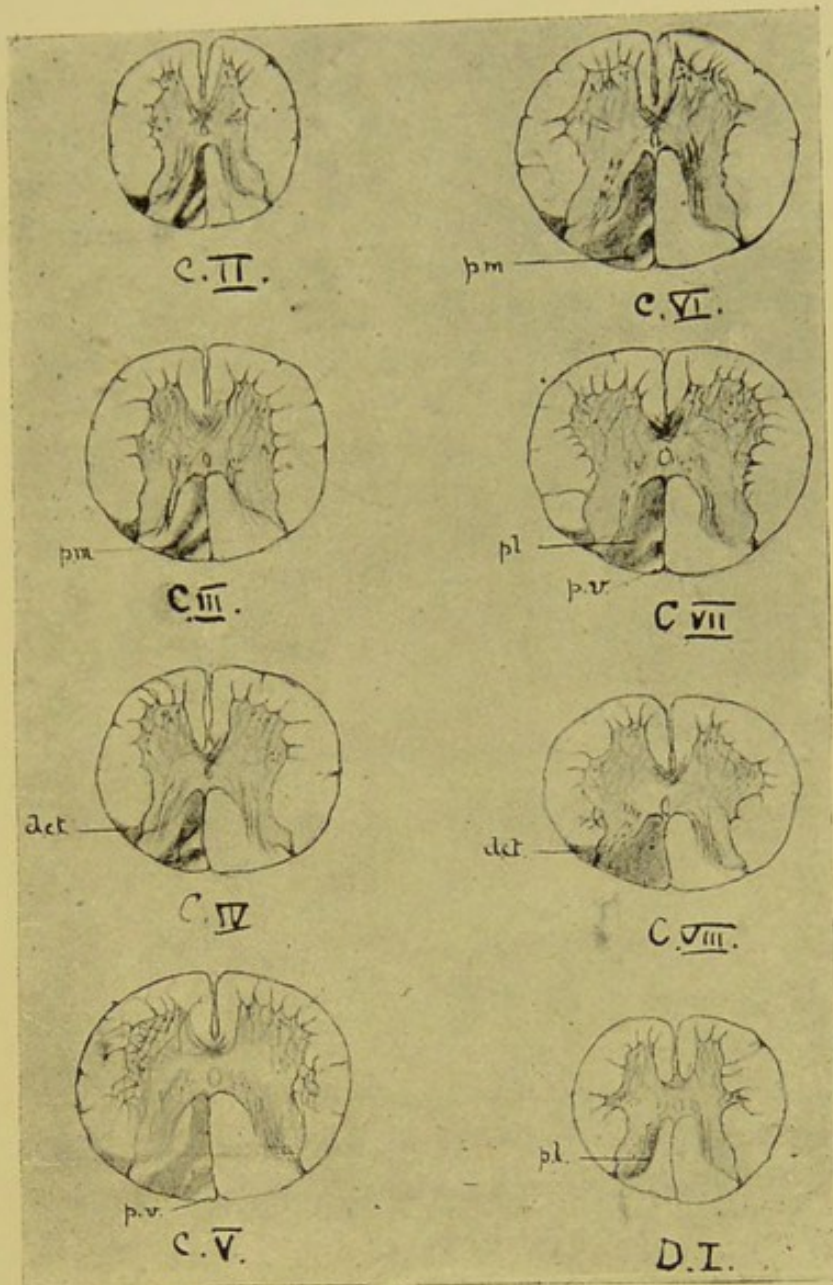


Fig. 12.

Section of Posterior Roots of Sixth, Seventh, Eighth Cervical and First Dorsal on the left side (Monkey 3). *d.c.t.*, Direct Cerebellar Tract. *p.m.*, Posterior Median. *p.v.*, Posterior Tract of Visceral Fine Fibres unaffected.  $\times 4$  diam.



Faint, illegible text or markings at the bottom of the page, possibly bleed-through from the reverse side.

median column convey. The effect of lesion of the postero-lateral column is better known, but such lesion includes affection of both the sets of fibres above mentioned. It is highly probable, as I shall insist in my next lecture, that most of the fibres of the posterior median column are visceral in function.

In my next lecture I shall study the course of the ascending fibres in the lateral column, and their destination in the medulla, and also the course of the visceral fibres in the cord.

### LECTURE III.

**Direct Cerebellar Tract.** After the posterior median column the direct cerebellar tract is most constantly degenerated. This tract was figured by Türck, who traced it to the restiform body, but Flechsig was the first, I believe, to suggest its destination in the cerebellum. It is situated in the periphery of the lateral column, and in its fullest development is a thin strip bordering the lateral column, having its largest end against the posterior horns, and thinning off to about the middle of the arc of the lateral column. But its position in this arc appears to vary considerably with the position of the initial lesion and the point at which the section is made from it. It appears that degeneration does not show itself in the site of this tract after lesions of the lumbar region.

**Lowest Point of Origin of Direct Cerebellar Tract.** Schultze\* gives a case of fracture of the ninth dorsal vertebra, causing complete compression of the cord, therefore, at the level of the tenth pair. Here there was an annular degeneration, spreading round the periphery of the section from the posterior horn to the anterior roots. This was continued up to the cervical region.

In the interesting case of Dr. Gowers, described by him first in his "Diagnosis of Diseases of the Spinal Cord," † the crush was situated at about the eleventh dorsal, and though the antero-lateral ascending tract was affected, the direct cerebellar was not degenerated at all. From these two observations, then, we may place the lowest point of origin of the fibres in the direct cerebellar tract at somewhere between the ninth and the eleventh dorsal. It is probably usually higher up than this (monkey 8).

Kahler and Pick ‡ give a list of twenty-seven cases, collected

\* Schultze, "Beitrag zur Lehre von der secund. Degen," etc., *Arch. für Psych.*, 1883, p. 364.

† Afterwards in the *Lancet*, June, 1886, p. 1,153.

‡ Kahler u. Pick, "Weitere Beiträge zur Pathol. und Path. Anat. der Centralnervensystem," *Arch. für Psych.*, Bd. x., 1880, p. 196.

from various authors, of transverse lesions, with the relative frequency of affection of the posterior median and direct cerebellar tracts. In all the posterior median column was affected, and in those above the ninth dorsal the direct cerebellar tract as well. In those in which the lesion was below that point the direct cerebellar tract was not affected.

The lowest case of compression that I have is Case II. ; here the compressing tumour sprang from the laminae of the sixth, seventh, and eighth dorsal vertebrae. Owing to injury in removing the cord, unfortunately, the sections begin at the first dorsal. Here the direct cerebellar tract is plainly degenerated as a thin strip joining anteriorly with the antero-lateral ascending tract presently to be described. There are many normal large fibres, and a few small ; nearly all the degenerated fibres are evidently of the large variety, and therefore if any of the small fibres are degenerated they have become absorbed. That large numbers of degenerated fibres have been absorbed is evident from the considerable amount of tissue intervening between what fibres remain, whether degenerated or not. From these facts the obvious inference is that new fibres are coming into the tract from somewhere, and that these are principally large fibres. Anteriorly the tract appears to expand into the antero-lateral ascending, which contains large numbers of degenerated fibres, both large and small, and very few normal ones at all. The tract retains these characters, but getting smaller and smaller, till we arrive at a section at the level of the fifth cervical, where it is quite distinct from the antero-lateral, and it is gathered up as a small patch against the tip of the posterior horn. Here it is only to be distinguished from the rest of the lateral column by its lighter colour by Weigert staining, but it contains a large number of normal fibres. At the level of the second cervical the direct cerebellar tract degeneration has disappeared, except for the presence of one or two isolated fibres. Meanwhile the antero-lateral remains highly degenerated. It may be said, then, that the direct cerebellar tract, if degenerated secondarily to lesions of the *lower* dorsal region, is small and tends to disappear soon, that is before reaching the medulla. If, however, the lesion be high up

in the cord, say in the cervical, we have a different condition of things.

I must here again refer to the appearances in Case V., fig. 7, in which the lesion was a fracture-dislocation, involving the cord between the eighth cervical and the first dorsal. One root above the lesion we find degeneration of practically the outer half of the lateral region, an extension of the degeneration round the anterior root region into the anterior column (fig. 7, C VII., Lecture II.). In fact, there can only be said to be normal fibres in the immediate vicinity of the grey matter. Moreover, the degeneration is absolute, except close to the posterior horns, where, of course, normal new fibres are entering, and here perhaps there are some fibres, but unfortunately there is so much alteration of the normal parts by decomposition that exact histological observations are untrustworthy. The condition resembles the annular sclerosis of Charcot. A root higher, viz., the sixth cervical, the same appearances obtain, but the area of degeneration is smaller. At the fourth cervical (fig. 7, C IV.) we have a long strip of degeneration stretching from the posterior horn round the edge of the section and thinning off to the anterior root. There now appear many normal fibres in the degenerated area. Till we reach the level of the third cervical we may speak of the degeneration as one strip occupying the periphery of the section, but at this level we discover a tendency, more particularly on the right side, to division of the strip, at about its middle, by the invasion, as it were, of a mass of normal fibres. The posterior part is the direct cerebellar tract, the anterior the antero-lateral ascending tract. At the second cervical (fig. 7, C II.) this division is still more evident on the right side. On the left there can scarcely be said to be any such division at all.

I propose to leave the discussion of the further course of the tract in the medulla oblongata till I have spoken of the antero-lateral ascending tract, because the two bundles of fibres are closely intermingled in the lower part of the medulla

**Origin and Constitution of Direct Cerebellar Tract.**

To return to the question of the origin and constitution of the direct cerebellar tract. The fact that degeneration of this bundle does not

follow lesions of the lumbar region has been already stated. It is obvious, therefore, that the fibres composing it do not come by way of the posterior roots from the *lower* extremities. If further proof were necessary, the results of the experimental section of posterior roots, above related, would supply it, to say nothing of recorded cases of pathological lesions of the same. It has long been suggested that the posterior vesicular column supplies fibres to this tract. Drs. Lockhart Clarke and Gowers have maintained this view on anatomical grounds. In longitudinal section of the natural cord fibres can be seen passing straight across the lateral column which *appear* to pass in the direction of this tract. Another anatomical point in favour of this view is the position and shape of the posterior vesicular column. This column is circular in section, and in man extends from about the eighth dorsal to the second lumbar. But there are a few scattered cells in this situation up as high as the first or second dorsal. They quite disappear in the cervical swelling, to reappear in the upper cervical region, and in the medulla, as already suggested, there are patches of ganglion cells much resembling these in the clavate and cuneate fasciculi. Dr. Ross\* has pointed out that there are nuclei in the vicinity of the central canal in the lower part of the medulla which may actually be the upward continuation of this column.

Now, this column contains many ganglion cells, the prevailing type of which is the small, elongated bipolar variety, but there are also unipolar and larger multipolar cells. It is admitted by most to be in direct communication with fibres entering by the posterior roots; these can be seen degenerated in monkeys 2 and 4 already described.

Dr. Mott† has described fibres passing from the posterior vesicular column across the lateral column towards the direct cerebellar tract. These, he says, are principally of the large variety. Dr. Mott, in the same paper, records a case of injury to the roots of the cauda equina, with degeneration of the postero-lateral and

\* Ross, "Dis. of Nervous Syst.," 1883, vi., p. 791.


† Mott, "Microscopical examination of Clarke's column in Man, Monkey, and Dog," *Journ. of Anat. and Phys.*, vol. xxii., p. 479.

posterior median columns, but none of the direct cerebellar tract. A careful examination of the posterior vesicular column showed no alteration of the ganglion cells, but an atrophy of the plexus of fibrillæ, with an increase of nuclei, a condition which I can detect in my monkeys. It must be conceded, then, that there is considerable anatomical evidence in favour of some connection between the posterior vesicular column and the lateral column.

Now, Dr. Gaskell has given the most convincing reasons for supposing that the posterior vesicular column has intimate connection with the innervation of the visceral system, whether blood-vessels or abdominal viscera it does not matter much for our present purpose. The visceral and vaso-motor nerves differ from the ordinary cord fibres in being of the very finest calibre. It is almost certain that the fibres passing to and from the posterior vesicular column are of this description. Therefore, if they go to the direct cerebellar tract we should expect that tract to have many of these fibres in it. This brings me to examine the tract in the normal cord, or rather to examine the situation in which the tract appears when degenerated.

**Anatomical  
Examination of  
the Direct Cerebellar Tract.**

If we examine carefully the constitution of that part of the lateral region lying close to the tip of the posterior horn in the cervical cord at the level of the first cervical, we find a very great preponderance of large fibres, but there is a very small number of fine medullated fibres scattered about. At the level of the third cervical we may say that this area is practically free from small fibres; so that in the monkey, after staining by carmine, the direct cerebellar tract region looks to the naked eye lighter than the rest of the lateral column, because the latter contains vast numbers of fine fibres much in excess of the large, and therefore stains deeply. This condition obtains as low down as the seventh cervical, where again a *small* admixture of fine fibres appears. Root by root in the upper dorsal region more and more fine fibres make their appearance in this tract, till at about the sixth dorsal there are nearly as many fine as large fibres. Below this, however, the fine fibres are much in the majority, till in the lower dorsal and lumbar region there can be said to be





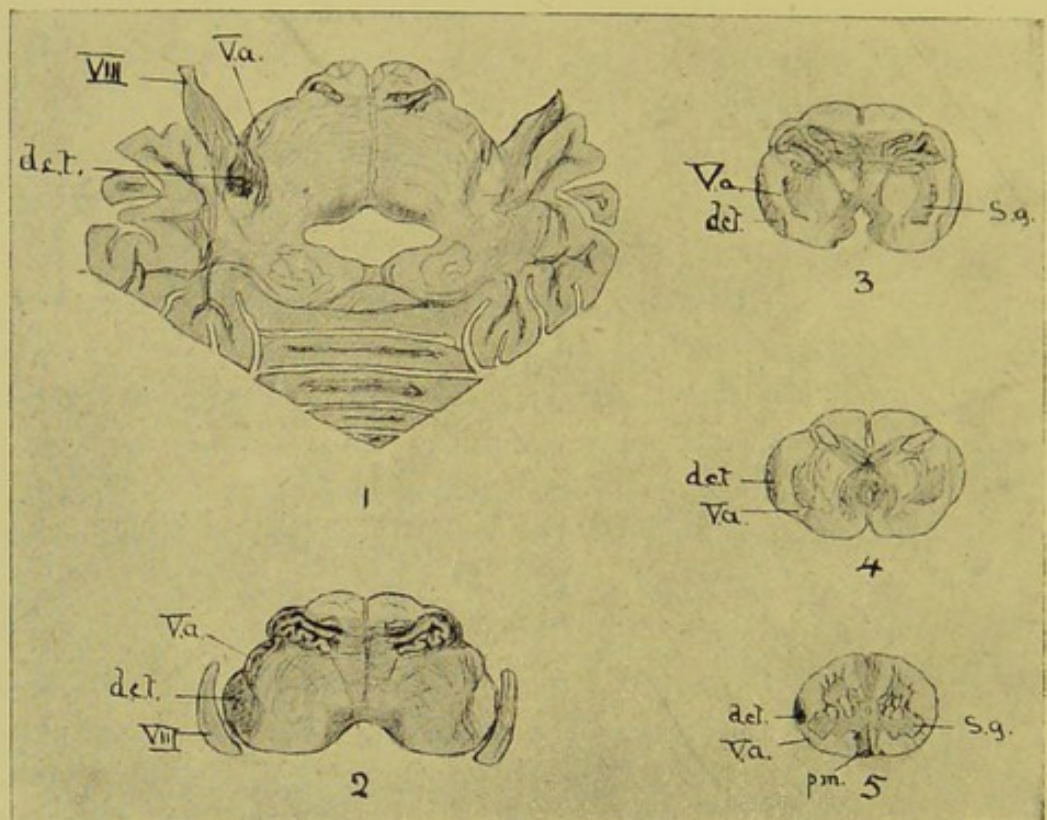


Fig. 13.

Section of Posterior Roots of Sixth, Seventh, Eighth Cervical and First Dorsal on the left side (Monkey 3). *d.c.t.*, Direct Cerebellar Tract. *p.m.*, Posterior Median. *s.g.*, Substantia Gelatinosa. *V.a.*, ascending Root of Fifth Nerve.  $\times 2$  diam.

little else. These observations have been made on monkeys' cords, because we can get the cord immediately after death, and therefore can rely on the histological appearances with certainty. I have little doubt that what I have said applies equally to the human cord. The region of the direct cerebellar tract, then, differs in its anatomical structure in the lower dorsal from that in the cervical and upper dorsal regions, in that, in the former there is a preponderance of small fibres, while in the latter there is a preponderance of large.

But these anatomical differences are confirmed by experiment. In a monkey which I call monkey 3 Mr. Horsley divided the posterior roots of the sixth, seventh, and eighth cervical and the first dorsal. The animal recovered perfectly from the operation. The cord was not injured in any way. The result was anæsthesia of the left upper extremity. The animal was killed on the twenty-eighth day. The appearances in the cord in section at different levels are shown in fig. 12.

At the level of the first dorsal (fig. 12, D I.) there is only a small slip of degeneration in the postero-external column, close by the posterior horn. At the next root above (fig. 12, C VIII.) there is extensive degeneration of the posterior region, with the exception of a small wedge at the posterior part of the posterior septum, exactly similar to that already described in monkeys 2 and 4 (fig. 12, *p.v.*). But what is very noteworthy is the fact that there is complete and absolute degeneration of the direct cerebellar tract, not the whole of it, but that part lying next the posterior horn; in other words, that part of it which consists in this region of large fibres only. This is continued up the whole of the cervical region to the medulla in the restiform body, and I shall refer again to it in that connection. From this experiment we may say, then, that the fibres of the posterior roots of the cervical region, and probably of the upper dorsal region, enter largely into the formation of the direct cerebellar tract. In speaking of monkeys 2 and 4, posterior root sections of the lower cord, I emphasised the fact that the direct cerebellar tract was *not affected*. So that we have again evidence of the difference between the direct cere-

bellar tract in the upper cord as compared with the same in the lower cord.

As these observations are important, and rather subversive of hitherto accepted ideas, and as it might be said that some accidental lesion of the tract was caused in cutting the posterior roots, Mr. Horsley was so good as to do two more operations for me as control experiments. I have not had time to cut sections of the cords, but the lesions are quite obvious to the naked eye after hardening. The first of these two was monkey 10, in which there was section of the left posterior roots of the second, third, and fourth dorsal. The second was monkey 11, in which there was division of the left posterior roots of the fifth, sixth, seventh, and eighth cervical, and first and second dorsal. In both these the direct cerebellar tract is obviously degenerated, as well as the postero-external and median columns. In fig. 12 there will be seen a small strip of undegenerated fibres in the middle of the posterior degeneration. This does not exist in degeneration of the posterior region after transverse lesions of the cord; it is probably therefore of ascending commissural fibres. Now, how can these results be reconciled with the other facts concerning the tract? As far as the posterior roots are concerned, we can say with confidence that they do not enter in the direct cerebellar tract in the lower dorsal regions, and that they do so largely in the cervical. We can also say with certainty that the direct cerebellar tract is not degenerated after transverse lesions below the tenth or eleventh dorsal.

But in the lower dorsal there are vast numbers of fine fibres in the position of this tract. These fibres *cannot be ascending ones*, or they would, of course, degenerate upwards. It must be remembered that at about the seventh or eighth dorsal the fibres of the crossed pyramidal tract come to the surface, and take the position of the direct cerebellar tract. Now, the crossed pyramidal tract contains vast numbers of small fibres, probably all descending. Therefore it is highly probable that the great number of fine fibres in the peripheral part of the lateral column in the lower dorsal region are really descending fibres. It is also extremely likely that these descending fine fibres enter into

communication with ganglion cells in the grey matter, probably with the cells of the posterior vesicular column, and that these fibres are those which so many observers have seen crossing the lateral column. In the monkey the posterior vesicular column has its greatest development at about the level of the last two dorsal roots (Mott), and therefore if it supplied the ascending fibres of the direct cerebellar tract we should expect extensive degeneration of that tract from transverse lesions at those levels, but I cannot find record of such cases.

But there can be little doubt that many of the small fibres in connection with the posterior vesicular column do ascend the cord, and there are at least two paths by which they may do so. One of these paths is the posterior-median column, which in the monkey, and probably in man, has what appears to be a special area set apart for that purpose. I shall refer to that shortly. The second path by which these fibres may ascend is the antero-lateral ascending tract, to which I propose now to devote some attention.

The first to describe this tract was Dr. **Antero-lateral Ascending Tract.** Gowers,\* in 1880, but after he had described it, it could be seen to have been figured by many observers,† but apparently by all to have been considered as merely the anterior termination of the direct cerebellar tract, a conception which is still held by some. This tract lies in the anterior part of the lateral column, in continuity in many cases with the direct cerebellar tract, behind and close to the anterior root zone in front. It is not a thin strip like the direct cerebellar tract, but a wedge-shaped area, with its base at the periphery of

\* Gowers, *op. cit.* In spite of Dr. Gowers's protest against cognominal nomenclature, Continental writers (Obersteiner, for instance) have named this tract after him. I have all through these lectures endeavoured to use strictly anatomical names for regions and tracts. For this tract I use the name originally suggested by Dr. Gowers, though one of less cumbersome proportions is much to be desired. In the copy of these lectures which appeared in the *British Medical Journal* I used the term "antero-lateral tract." This, as Dr. Gowers has pointed out, is open to the objection of confusion with the old anatomical name "antero-lateral column."

† Bastian, *Med. Chi. Trans.*, 1867, p. 499. Westphal, *Arch. f. Psych.*, 1879, p. 413, 1886, p. 788.

the section and its apex towards the grey matter, and sometimes bent posteriorly, so as to insinuate itself between the crossed pyramidal and the direct cerebellar tracts. It is situated in an area of the cord called by Flechsig the "mixed zone." Now, in every transverse lesion of the cord degenerated fibres can be found in the position of this tract.

Case II., in which the lesion was lower down, shows it particularly well. It will be remembered that in this case the cerebellar tract, though at first degenerated, became very insignificant by about the third cervical, and might be said to have disappeared at the second cervical, but the ascending antero-lateral is at this level extremely well marked and extensive. (The figures illustrating this case will be found in the St. Bartholomew's Hospital Reports, vol. xxiii., p. 141.)

If the lesion be high up in the cord, as in Case V., the distinction between the two tracts is never so well marked as in the lower lesions. This will account for the confusion between the two. But if the lesion be very low down in the cord, below the tenth dorsal, we still find the tract degenerates. This is below the point at which the direct cerebellar tract degeneration begins.

This was the condition, as before mentioned, in Dr. Gowers's case. The crush was at about the eleventh dorsal; the posterior median column and the antero-lateral only were degenerated, not the direct cerebellar tract.

Schultze\* gives a case of crushing of the lumbar region following fracture of the first lumbar vertebra; there was extensive degeneration of the posterior column and the antero-lateral, but no affection of the direct cerebellar tract.

**Origin of  
Antero-lateral  
Ascending  
Tract Fibres.**

These cases seem to show that the antero-lateral has its origin in the cord low down. It obviously derives none of its fibres from the posterior roots, for in none of my posterior root sections can any degeneration be found; and the same may be said of Singer's. If any further proof of its existence as a tract distinct from the direct cerebellar tract be required, it may be said that Bechterew† has described it developing at a period

\* Schultze, *op. cit.*, p. 363. † Bechterew, *Neurol. Centralbl.*, 1885, p. 155.

distinct from other parts. He was apparently unaware of Dr. Gowers's observation.

If we examine the antero-lateral region in any part of the cord we find that it contains many fine fibres resembling in this respect the crossed pyramidal tract and posterior-median column. In the cervical region it contains still many, but not so many as in the lower parts of the cord. This may be because the cervical cord has no true posterior vesicular column. But the antero-lateral ascending tract in any part of the cervical region contrasts strongly in this particular with the direct cerebellar tract in the same region. I therefore suggest that the antero-lateral fibres arise solely from the grey matter, that its fine fibres, which are very numerous in the lower cord, are centripetal from the posterior vesicular column, and that the large fibres are in connection with one or more of the groups in the anterior horns. Both these suggestions are hypothetical, however, and are arrived at by a process of exclusion rather than by any positive evidence.

Drs. Hadden and Sherrington\* contribute an exceedingly interesting observation in this connection. The case was one of locomotor ataxy in which was found sclerosis of the antero-lateral and posterior regions. The area of fine fibres in and about the posterior horn (Lissauer's tract, so called) was profoundly degenerated; so were the fine fibres of the posterior vesicular column; but though there is no obvious degeneration of the ganglion cells of the posterior vesicular column, the larger variety of them seem to be fewer than normal. The degenerated fibres in the lateral column are diffused at first, that is, about the sixth dorsal, but in the cervical region they are concentrated into the antero-lateral, and can be traced up into the medulla. This case seems to me to confirm the idea that the antero-lateral ascending tract fibres are largely derived from the posterior vesicular column. It is possible that the primary lesion may be situated in the fine fibres, constituting the so-called Lissauer's tract, and that there may be a degeneration of the posterior vesicular column, leading to corresponding degeneration

\* Hadden and Sherrington, "Path. Anatomy of a Case of Locomotor Ataxy," *Brain*, 1888, p. 325.

of the antero-lateral tract, which I have shown probably receives many of its fibres from the posterior vesicular column. One must, however, I think, be careful not to reason too closely from observation on system lesions. It does not seem to me to meet the case to call this tract a part of the direct cerebellar tract. It contains quite a different set of fibres. The true direct cerebellar tract consists of large fibres, the antero-lateral principally of small. The direct cerebellar tract derives its fibres from the posterior roots, the antero-lateral from the grey matter of the cord, or at any rate *not* from the posterior roots. A transverse lesion of the cord high up, say lower cervical, will show degeneration of both antero-lateral and direct cerebellar tracts, but there will be a joining of the two areas, with the result of a strip of degeneration occupying the whole arc of the periphery of the lateral region, and perhaps also, as Dr. Gowers has shown, a continuation of the strip round the anterior root zone to the anterior column. The farther down the cord the lesion is, the less the cerebellar tract element will be, and the more distinct will be the severance between antero-lateral and direct cerebellar tracts, till at last a point is reached below the ninth or tenth dorsal, at which the direct cerebellar tract is not degenerated at all, but the fibres in its position are all descending fibres from the crossed pyramidal tract, and the ascending antero-lateral is affected only.

The above statement seems to me to offer the only explanation which will meet all the facts. Why the upper part of the cord should show such an important difference in its anatomical arrangement from the lower I can at present see no reason, developmental or other.

**Destination of Direct Cerebellar Tract.** A point of extreme interest is the termination of the fibres of these two tracts.

First, as to the direct cerebellar tract alone; this may be seen very well in the medulla of monkey 3 (fig. 13). It maintains its position close to and in front of the posterior horn, while the horn becomes enlarged and rounded into the so-called tubercle of Rolando at the level of the first cervical pair. Very soon, however, the tubercle leaves the edge of the section and assumes the crescent shape of the substantia gelatinosa. Between it and the

edge of the section now appears a bundle of fibres, which is the ascending root of the fifth. The direct cerebellar tract still keeps its position, and is then in front of the ascending root of the fifth (fig. 13, section 5).

A little higher, at the level of the upper decussation, the ascending root of the fifth can be seen to be sending fibres past the substantia gelatinosa, between it and the direct cerebellar tract (fig. 13, section 4). Higher still the direct cerebellar tract is found to be passing externally to the ascending root of the fifth, so that at one point the direct cerebellar tract and the ascending root of the fifth are both external to the substantia gelatinosa (fig. 13, section 4). Finally, the direct cerebellar tract and the ascending root of the fifth change places; that is, the direct cerebellar tract is found posterior to the ascending root of the fifth, and even posterior to the substantia gelatinosa. At this point the direct cerebellar tract, however much it may be degenerated, receives a large accession of normal fibres, in fact, is now in the restiform body (fig. 13, section 2).

I have been unable in my sections to trace the degeneration beyond the level of the origin of the eighth nerve, where it lies between the roots of that nerve. Here the fibres begin to take an oblique or horizontal direction to pass to their destination in the cerebellum, and are therefore very difficult to follow. Türk followed the tract as far as this, so also have Singer and Westphal. Flechsig believes that the fibres eventually reach the cortex of the cerebellum in the region of the inferior vermiform process.

Von Monakow\* did a semisection of the cord below the decussation in a new-born rabbit. After six months he found total degeneration of the direct cerebellar tract and part of the corpus restiforme, atrophy of the auditory nucleus, and also of the cortex of the superior vermiform process of the cerebellum on the same side.

I am much indebted to the important paper on ascending secondary degeneration by Lœwenthal,† and for further biblio-

\* Von Monakow, "Zur Kenntniss der äusseren Acusticuskerns und der Corp. restiforme," *Neurol. Centralbl.*, 1882, p. 481.

† Lœwenthal, "Dégénération secondaires Ascendantes," etc., *Rev. de Med. de la Suisse Romande*, 1885, p. 511.



graphical information I must refer to his paper. Lœwenthal's experiments were on two dogs, in one of which the cord was cut between the first and second cervical roots, and in the other between the fifth and sixth cervical. The direct cerebellar tract he traces to the dentate nucleus in the cerebellum, and supposes that its further course is to the superior vermiform process. I shall refer to the rest of his paper later on.

The true direct cerebellar tract then passes entirely into the restiform body to the cerebellum. I believe that it is only after lesion of the posterior roots of the upper cord that a simple uncomplicated degeneration of the direct cerebellar tract can be produced. In all lesions of the cord itself in which this tract is degenerated there is a large admixture of the antero-lateral element, which has no direct connection with the posterior root fibres.

**Destination of the  
Antero-lateral  
Ascending Tract.**

I will now trace the antero-lateral ascending tract to the medulla. I have no case of simple degeneration of this tract only, except Case II., and the medulla unfortunately is wanting, except one section that I have, in which the appearances are quite unreliable. I am reduced, then, to those cases in which both tracts are affected, such as monkey 7, fig. 14, and Case V., fig. 9. At the level of the first cervical (fig. 8, C I., Lecture II.) the two tracts, antero-lateral and direct cerebellar, are distinct and separated from each other. As they pass upwards, however, they approach each other, and at the level of the commencement of the olive they appear as one long tract (fig. 14, section 7), lying along the lateral periphery of the section. A little higher (fig. 14, section 6) this combined degeneration is nearly divided into two by the appearance of normal fibres, and also by many horizontal arciform fibres. This is the point at which, as before described, the direct cerebellar tract passes behind the ascending root of the fifth. At the next section (fig. 14, section 5) the severance between the two tracts is quite unmistakable. The direct cerebellar tract is now in the restiform body. The ascending root of the fifth has passed in front, and has gained the edge of the section, and thus the antero-lateral tract has taken up its position in front of this, in the angle formed

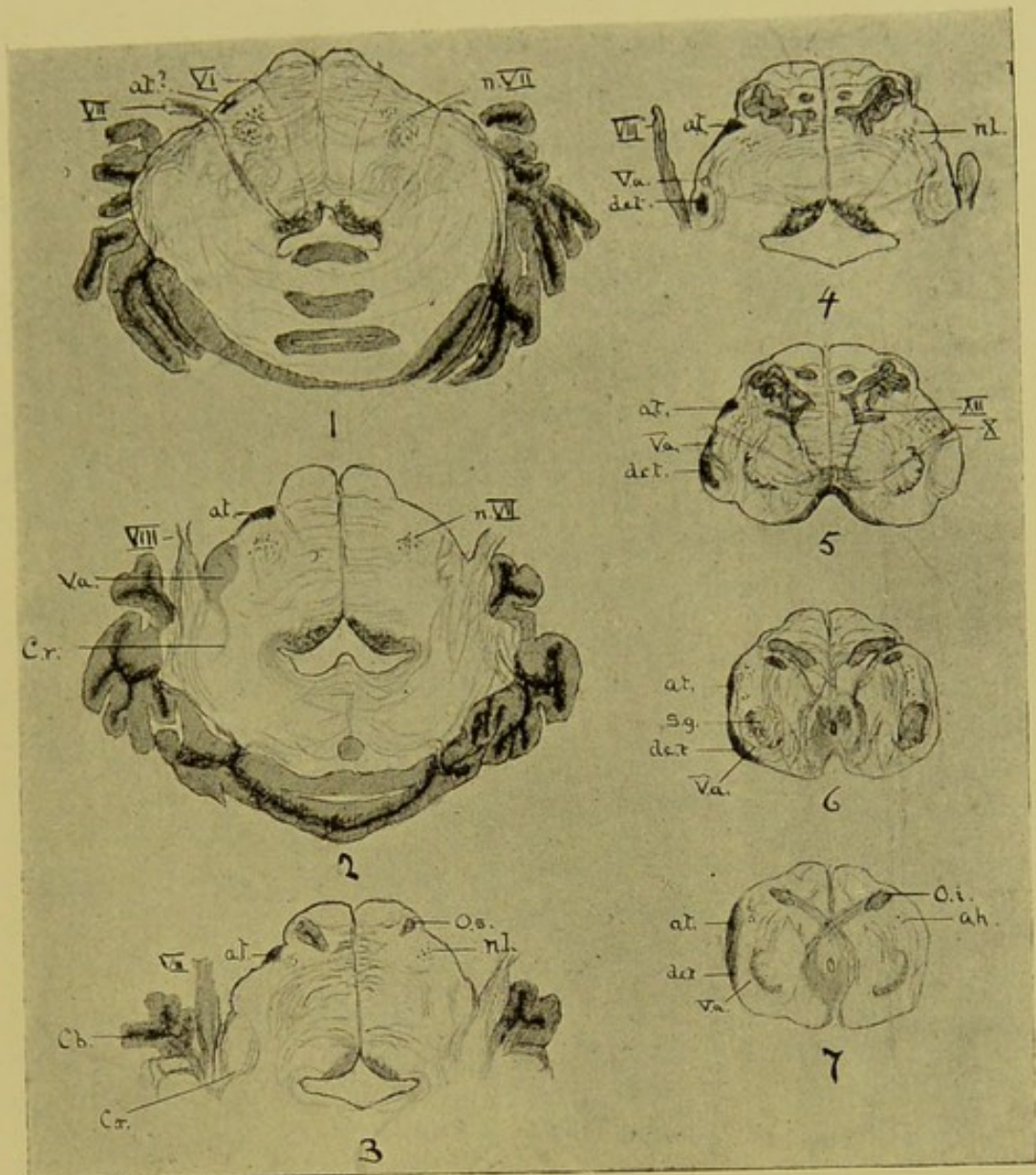



Fig. 14.

Semisection of Cord between Seventh and Eighth Cervical (Monkey 7) Medulla (see fig. 8). *d.c.t.*, Direct Cerebellar Tract. *a.t.*, Antero-lateral Ascending. *c.r.*, Corpus Restiforme. *s.g.*, Substantia Gelatinosa. *O.s.* and *O.i.*, Upper and Lower Olive. *V.a.*, Ascending Root of Fifth  $\times 2$  diam. Nerve.



Faint, illegible text or markings at the bottom of the page, possibly bleed-through from the reverse side.

by the projecting olive with the lateral edge of the section, close in front of the point of exit of the vagus nerve. It maintains this position as far as I can trace it, that is, in this series of sections, at the level of the points of exit of the seventh and sixth nerves (fig. 14, section 1); here there are very few degenerated fibres.

This observation on monkey 7 is the most complete that I have to offer, and I admit that it leaves much to be desired in further elucidation of this interesting question. I feel perfectly secure in reasoning from the monkey's medulla to that of man, because of the extremely close similarity in anatomical respects between the two.

I have sections and diagrams from my Case V. (fig. 9), which I referred to in tracing up the posterior degeneration. It will be remembered that the division between the antero-lateral and the direct cerebellar tract was never very complete in the cervical region. In the lower medulla, as in the monkey last described, there is one degeneration only (fig. 9, sections 4 to 7, *d.a.*), a large, comma-shaped area, with its head in front of the substantia gelatinosa, and its tail passing back outside the ascending root of the fifth (fig. 9, *v.a.*). This appearance obtains till we reach a point a little above the commencement of the olive (fig. 9 section 3). Here, on the right side, the direct cerebellar tract has taken its place in the corpus restiforme (*c.r.*), and anteriorly not far below the olive lies a patch of degenerated fibres, not compact like the direct cerebellar tract, but more diffuse. This is faintly represented in the two succeeding sections (fig. 9, sections 1 and 2), the highest of which is through about the middle of the olive. Unfortunately, I had no more of the medulla for examination. The ultimate destination of the tract is conjectural. It certainly appears to have some relations with the nucleus lateralis. In the lower part of the medulla, at the commencement of the olive, there is a collection of ganglion cells (fig. 14, section 7, *a.h.*) which is the remnant of the anterior horn of the cord. The cells are of the usual large multipolar type of the anterior horn. A little posterior to it can be seen a small group of cells of the small bipolar type. This is the nucleus lateralis, and is the

upward continuation of the lateral horn of the cervical cord,\* also called the "visceral horn." Higher up the large cells of the old anterior horn become very few, while those forming the nucleus lateralis become more numerous. Eventually, just above the olive, the small bipolar cells in their turn can no longer be seen, but in their place a compact nucleus of large cells makes its appearance, the nucleus of the seventh nerve. It seems, then, to me scarcely correct to say that the seventh nerve arises from the upward continuation of the lateral horn. It arises from a mass of large multipolar cells, as one might expect an essentially motor nerve to do, these large cells having replaced the small cells of the nucleus lateralis. It is at this point that in monkey 7 (fig. 14, section 1) the last trace of degeneration can be seen.

I must here again refer to Bechterew's work on the development of this tract. He distinctly states that the developing bundle ends in the nucleus lateralis.

This countenances the supposition that the tract has some relations with the nucleus lateralis. I have said above, in discussing the minute anatomy of the tract, that it consists, unlike the direct cerebellar tract, of fine visceral fibres as well as large. I suggest, therefore, that the fine fibres really end in the nucleus lateralis.† I can form no conclusions from my own observations as to the further course of the fibres, but the work of Lœwenthal,‡ already referred to, may throw some light on the question.

Lœwenthal performed a transverse section of the cord in the cervical region. The result was degeneration of what he called the direct cerebellar tract, but a glance at his figures shows that he had produced a combined degeneration similar to that in fig. 7, C II. (right side); in other words, he had degeneration of the direct cerebellar tract, and also degeneration of the antero-lateral

\* Hill, "Plan of Central Nervous System," Graduation Thesis, Cambridge, 1885.

† Von Monakow, *Arch. f. Psych.*, 1883, p. 1, describes and figures the results of a half-section of the cord just below the decussation in a new-born rabbit. He found almost complete atrophy of the cells of the nucleus lateralis. This result seems to confirm the view above suggested, that certain ascending fibres enter into direct connection with the nucleus lateralis.

‡ Lœwenthal, *op. cit.*

ascending tract, which was not at that time generally recognised as a distinct tract. In the medulla he describes the true direct cerebellar tract passing into the restiform body, and as he says, a part of it taking up a position in the medulla anterior to this; in fact, exactly the position I have described above in monkey 7. He calls these fibres the "ventral cerebellar fibres." The interest of his observation lies in the fact that he traces these "ventral fibres," which I believe to be the antero-lateral tract, through the pons into the superior peduncle of the cerebellum. It is possible, then, that the fine fibres of the tract end in the nucleus lateralis, with its small ganglion cells, and that the large fibres take a further course, and eventually gain the cerebellum by way of the superior peduncle.

As to the function of these two tracts I have little to say. The direct cerebellar must, I think, conduct some form of sensory impression from the upper part of the body, the antero-lateral fibres from the lower.

The direct cerebellar fibres admittedly pass into the cerebellum. The antero-lateral large fibres possibly also pass to the same, by way of the superior peduncle.

Disease of the cerebellum causes marked loss of co-ordination of muscular movements of both upper and lower limbs, besides other obscure symptoms. May, then, the large fibres of the antero-lateral and the direct cerebellar tract be for the conduction of kinæsthetic impressions?

Dr. Gowers\* places the path of conduction of impressions of pain in the antero-lateral region. This he bases on a case of gunshot injury of the cervical region, which, however, produced such extensive lesion of the grey matter as well as the white in one-half of the cord that the case might almost be regarded as a semi-section. Bechterew also supposes that the antero-lateral region conducts pain-sense, because he says that analgesia follows transverse section of the anterior half of the cord, but not after the same lesion in the posterior half.

In neither of these observations can we eliminate the grey

\* Gowers, "Case of Unilateral Gunshot Injury to the Spinal Cord," Clin. Soc. Trans., vol. xi., 1877.

matter; any crossing that takes place must take place there. The direct cerebellar tract does not appear to cross at all in the cord. The antero-lateral does not cross after leaving the cells of the grey matter, but of course the impressions it conducts may have crossed in the grey matter.

More precise experiments on animals are needed before any definite conclusions can be arrived at.

**Visceral Nerve  
Fibres.**

I have many times incidentally drawn attention to the fibres in the cord, which are medullated, but of the finest calibre. I propose now to deal with these a little more systematically, both from the standpoint of anatomy and secondary degeneration. These fibres have been recognised for many years, but no real significance seems to have been attached to them till the researches of Onodi, Gaskell, and Lissauer. Of these observers we undoubtedly owe most to Dr. Gaskell.\* His work on the subject is of the profoundest anatomical and physiological interest, and marks to my mind a most important departure in neurology. According to his researches, the following conclusions may be arrived at:—

Every typical spinal nerve consists of three branches—dorsal, ventral, and visceral. The visceral branch is the white ramus communicans, and consists almost entirely of fine medullated fibres; the grey ramus contains nothing but non-medullated fibres, and is distributed as a peripheral branch to the blood-vessels of the cord and membranes.

The anterior and posterior roots of such a typical spinal nerve also contain large numbers of fine medullated nerve fibres. Those in the anterior root are efferent, and pass out to make up the white ramus aforesaid; those in the posterior root are, presumably, afferent. The visceral branch, or white ramus communicans, passes to its destination in the vessels, glands, or viscera, but is sooner or later brought into communication with a ganglion belonging to what is known as the sympathetic system. Its fibres either pass on through the ganglion to other ganglia of the same

\* Gaskell, "Visceral Nerves," *Journ. of Phys.*, vol. vii., 1886. Also Marshall Hall, Oration, *Med.-Chi. Trans.*, 1888, p. 363.

kind, or else enter into direct communication with the cells of the ganglion. In the latter case the fibres lose their medulla, and continue to their final distribution in the vessels or viscera as non-medullated fibres. So that the conception of the nerves and roots of a typical spinal segment would be—

1. A posterior root, with a ganglion having a fixed position, the root being made up of large fibres (somatic) and small fibres (splanchnic) afferent in direction.

2. An anterior root, consisting of large and small fibres not in connection with any ganglion, and a number of small fibres which are in connection with ganglia, but the ganglia are remote and of no fixed position.

This typical arrangement of large and small fibres only exists obviously in the cord from the second dorsal to the second lumbar (in the dog). At first sight it would seem that the cervical and lower were without such visceral nerves. In the cervical region, however, the upper roots of the spinal accessory and lower roots of the vagus contain all the fine visceral fibres arising from that part of the cord. They pass to the ganglion of the vagus trunk, where many of them lose their medulla.

Again, in the lower sacral region there is another "outflow" of visceral nerves, forming the so-called "nervi erigentes." So that we have three principal "outflows" of fine visceral nerve fibres:—

1. A cervico-cranial outflow in connection with the vagus and spinal accessory nerves (cervical splanchnics).

2. A thoracic outflow (abdominal splanchnics).

3. A sacral outflow (pelvic splanchnics).

So far we have considered the relation of these fine visceral nerve fibres with the spinal roots and nerves. We have now to examine their course and connection in the cord itself. My remarks on this subject are based on examination of the monkey's cord, because as these fibres are very fine, high powers are required, and it is quite essential that decomposition should not have even begun.

The fine fibres of the cord may be said to be disposed in two

**Visceral Nerve  
Fibres in the  
Cord.**



ways—in the ordinary large fibre tracts, or in bundles by themselves, practically unmixed with large fibres.

It is highly probable, speaking generally, that the fine fibres included under the first head course in the same direction as that of the tract in which they are situated. It is certain that in cases of complete degeneration of a tract, after section of the cord, the fine fibres have disappeared with the large. This disappearance can only be accounted for by the degeneration of the fibres themselves, unless we suppose with Schiefferdecker that the degeneration can spread laterally beyond the affected fibres. Fine fibres degenerate in exactly the same manner as large, and exhibit the same decomposition changes.

If we examine the anterior pyramids of the medulla we are at once struck by the vast numbers of fine fibres they contain; this may be said also of the pyramidal tracts above in the pons. The crossed pyramidal tract all the way down the cord is closely packed with these fibres, so closely that this tract in normal monkeys' cords takes ordinary stains so deeply as to be quite apparent to the naked eye. When the crossed pyramidal tract is cut across, as in monkey 7, fig. 8, we find the degeneration of the tract below the lesion is very complete; very few, if any, normal fine fibres can be seen in it. This condition obtains in the tract to its termination in the sacral region. We may say, then, I think, that the crossed pyramidal tract, besides containing descending large and medium-sized fibres, contains also descending or efferent fine fibres. The anterior columns also contain large numbers of fine fibres, but the bulk of them lie close to the anterior horns in the anterior radicular zone. I cannot find that these degenerate downwards, and therefore probably they are commissural or on their way out into the anterior roots.

As is the case with the large fibres of the crossed pyramidal tract, so the small fibres of this tract run from the higher centres in the medulla or brain to lower centres in the cord, and no farther. As Dr. Gaskell has pointed out, one of the most important of these lower centres is the posterior vesicular column (of Clarke). The principal, if not the only efferent path of com-

munication between the brain and the vessels and viscera is the crossed pyramidal tract. The fibres of the crossed pyramidal tract have been long known by physiologists to influence the vaso-motor system.

The paths by which these fibres ascend to the higher centres are also well defined. One important ascending tract at any rate we may exclude, as I have shown, from having any share in the transmission of the visceral fibres, namely, the direct cerebellar tract. Any small fibres that this tract may contain are derived from the crossed pyramidal tract, and therefore not ascending at all. The antero-lateral ascending tract is not so exclusively composed of large fibres, and contains a large number of small fibres. In my monkey 7 this tract is largely degenerated above the lesion; the degeneration affects large and small fibres. Moreover, the degeneration is also, according to my other observations, of a diffuse character, and even when most affected the tract always seems to present many normal fibres mixed up with the degenerated ones. Then, again, for some way below the lesion we find degenerated descending fibres in the antero-lateral tract. Therefore the name "mixed zone," originally given by Flechsig to this region, is still applicable. However, it is probable that this tract is one of the paths by which the visceral fibres reach the higher centres.

The whole of the posterior region is thickly supplied with fine fibres; no doubt large numbers of these are on their way to the centres in the grey matter. They are found in the posterior roots of the lumbar and dorsal regions, but very few in the lower and middle cervical. In fact, their presence in the posterior roots is governed by the presence of the posterior vesicular column. But there is a part of the posterior region which is specially devoted to conducting the visceral fibres.

In 1886 Lissauer\* drew special attention to the anatomy of the posterior horn. Strictly speaking, the posterior horn never reaches the edge of the section, but ends at varying distances

\* Lissauer, "Beitrag zum Faserlauf des Hinterhorns," etc., *Arch. f. Psych.*, 1886, p. 377.

from it, according to the level of the section, in what appears to be a rounded tubercle. This is the substantia gelatinosa Rolandi, and is probably not nervous at all. What appears as the tip of the horn is in reality the posterior root fibres passing to pierce the substantia gelatinosa. The zone which lies between the substantia gelatinosa and the edge of the section is called by Lissauer the "Randzone," or border zone. This zone in the lumbar and sacral region is broad because the substantia gelatinosa is broad, and short because the substantia gelatinosa comes close to the surface. In the lower dorsal region the substantia gelatinosa is a long way from the surface, and therefore the border zone is long and narrow, lying on each side of the fibres passing to enter the horn. Now, this zone after staining by Weigert's hæmatoxylin has a fine stippled appearance, which is due to the great number of fine fibres seen in transverse section. This zone in the upper dorsal region recedes from the surface more and more, till it becomes, as it were, applied in the substantia gelatinosa. It is small in the cervical region, but in the vicinity of the entering fibres of the posterior roots there are always grouped a number of small fibres, and therefore this "border zone" cannot be said to be absent anywhere in the cord. Its significance is that it marks the entry of the fine fibres from the posterior roots. It is very consistently sclerosed, as Lissauer has pointed out, in tabes, a circumstance which will, as our knowledge grows, no doubt account for many of the obscure visceral symptoms of that disease.

It is, of course, degenerated secondarily to section or disease of posterior roots of that side, but the degeneration rarely extends far up, and therefore it is most likely that its fibres pass sooner or later into the posterior vesicular column or into the posterior median. The border zone then bears the same relation to the fine fibres as the postero-lateral does to the large. Bechterew,\* in 1885, had anticipated Lissauer somewhat by showing that this zone develops in the embryo at a time distinct from the rest of the posterior region.†

\* Bechterew., *Neurol. Centralbl.*, 1885, p. 369.

† See also Sherrington, *Brain*, vol. ix., p. 342.

But it is probable that many visceral fibres entering by the posterior roots ascend the cord without communicating with the grey matter at all. The path taken by them is the posterior median column. In man this column is crowded with fine fibres. In the monkey, though the whole of the posterior median column is packed closely with them, there is a small part of the column set aside apparently for the special path of the fine fibres. This appears as a small wedge at the posterior part of the posterior septum (see figs. 10, 11, and 12, p. v.); in it there are very few, if any, large fibres. This little tract runs right up to the medulla, and perhaps ends in the grey matter of the floor of the fourth ventricle.

We have now a complete visceral system in the cord, on the same plan as the motor and sensory system of large fibres. The study of the visceral system of nerves is yet in its infancy, and its bearing upon clinical medicine is practically a new field. Is it not possible that we may by it throw some light on the pathogeny of such obscure diseases as diabetes, Addison's and Graves's disease, and perhaps even myxœdema?

My task, as far as these lectures are concerned, is ended, and yet it can scarcely be said to have begun. I have adhered strictly to my text, perhaps too strictly. I am quite aware that I have left untouched the important field of the physiology or functions of the various bundles of fibres in the cord. To deal with this subject at all satisfactorily on clinical grounds requires an experience to which I can lay no claim. To study it from the standpoint of physiological experiment would be practically impossible in the time allowed for the preparation of these lectures. It has taken fifty-three years to arrive at our present state of knowledge concerning the anatomy only of the spinal cord, from the point of view of degenerations; and I have spoken to little purpose if I have not made it evident that there is yet much to learn. If this be true of the anatomy, it is still more so of the physiology of the cord. If our art be so long that one life is too short to compass it, how much longer, then, must it be before we can pretend to understand the secrets locked up in a structure the highest and most subtle result of evolution that Nature can show?



Catalogue B]

London, 11, New Burlington Street,  
June, 1889.

*SELECTION*

FROM

J. & A. CHURCHILL'S GENERAL CATALOGUE

COMPRISING

*ALL RECENT WORKS PUBLISHED BY THEM*

ON THE

ART AND SCIENCE OF MEDICINE



N.B.—As far as possible, this List is arranged in the order in  
which medical study is usually pursued.

**J. & A. CHURCHILL** publish for the following Institutions  
and Public Bodies:—

**ROYAL COLLEGE OF SURGEONS.**

CATALOGUES OF THE MUSEUM.

Twenty-three separate Catalogues (List and Prices can be obtained of J. & A. CHURCHILL).

**GUY'S HOSPITAL.**

REPORTS BY THE MEDICAL AND SURGICAL STAFF.

Vol. XXX., Third Series. 7s. 6d.

FORMULÆ USED IN THE HOSPITAL IN ADDITION TO THOSE  
IN THE B.P. 1s. 6d.

**LONDON HOSPITAL.**

PHARMACOPŒIA OF THE HOSPITAL. 3s.

**ST. BARTHOLOMEW'S HOSPITAL.**

CATALOGUE OF THE ANATOMICAL AND PATHOLOGICAL  
MUSEUM. Vol. I.—Pathology. 15s. Vol. II.—Teratology, Anatomy  
and Physiology, Botany. 7s. 6d.

**ST. GEORGE'S HOSPITAL.**

REPORTS BY THE MEDICAL AND SURGICAL STAFF.

The last Volume (X.) was issued in 1880. Price 7s. 6d.

CATALOGUE OF THE PATHOLOGICAL MUSEUM. 15s.

SUPPLEMENTARY CATALOGUE (1882). 5s.

**ST. THOMAS'S HOSPITAL.**

REPORTS BY THE MEDICAL AND SURGICAL STAFF

Annually. Vol. XVII., New Series. 7s. 6d.

**MIDDLESEX HOSPITAL.**

CATALOGUE OF THE PATHOLOGICAL MUSEUM. 12s.

**WESTMINSTER HOSPITAL.**

REPORTS BY THE MEDICAL AND SURGICAL STAFF.

Annually. Vol. IV. 6s.

**ROYAL LONDON OPHTHALMIC HOSPITAL.**

REPORTS BY THE MEDICAL AND SURGICAL STAFF.

Occasionally. Vol. XII., Part III. 5s.

**OPHTHALMOLOGICAL SOCIETY OF THE UNITED KINGDOM.**

TRANSACTIONS. Vol. VIII. 12s. 6d.

**MEDICO-PSYCHOLOGICAL ASSOCIATION.**

JOURNAL OF MENTAL SCIENCE. Quarterly. 3s. 6d.

**PHARMACEUTICAL SOCIETY OF GREAT BRITAIN.**

PHARMACEUTICAL JOURNAL AND TRANSACTIONS.

Every Saturday. 4d. each, or 20s. per annum, post free.

**BRITISH PHARMACEUTICAL CONFERENCE.**

YEAR BOOK OF PHARMACY. 10s.

**BRITISH DENTAL ASSOCIATION.**

JOURNAL OF THE ASSOCIATION AND MONTHLY REVIEW  
OF DENTAL SURGERY.

On the 15th of each Month. 6d. each, or 7s. per annum, post free.

# A SELECTION

FROM

## J. & A. CHURCHILL'S GENERAL CATALOGUE,

COMPRISING

ALL RECENT WORKS PUBLISHED BY THEM ON THE  
ART AND SCIENCE OF MEDICINE.

N.B.—*J. & A. Churchill's Descriptive List of Works on Chemistry, Materia Medica, Pharmacy, Botany, Photography, Zoology, the Microscope, and other Branches of Science, can be had on application.*

### Practical Anatomy :

A Manual of Dissections. By CHRISTOPHER HEATH, Surgeon to University College Hospital. Seventh Edition. Revised by RICKMAN J. GODLEE, M.S. Lond., F.R.C.S., Teacher of Operative Surgery, late Demonstrator of Anatomy in University College, and Surgeon to the Hospital. Crown 8vo, with 24 Coloured Plates and 278 Engravings, 15s.

**Wilson's Anatomist's Vade-Mecum.** Tenth Edition. By GEORGE BUCHANAN, Professor of Clinical Surgery in the University of Glasgow; and HENRY E. CLARK, M.R.C.S., Lecturer on Anatomy at the Glasgow Royal Infirmary School of Medicine. Crown 8vo, with 450 Engravings (including 26 Coloured Plates), 18s.

**Braune's Atlas of Topographical Anatomy,** after Plane Sections of Frozen Bodies. Translated by EDWARD BELLAMY, Surgeon to, and Lecturer on Anatomy, &c., at, Charing Cross Hospital. Large Imp. 8vo, with 34 Photolithographic Plates and 46 Woodcuts, 40s.

**An Atlas of Human Anatomy.** By RICKMAN J. GODLEE, M.S., F.R.C.S., Assistant Surgeon and Senior Demonstrator of Anatomy, University College Hospital. With 48 Imp. 4to Plates (112 figures), and a volume of Explanatory Text, 8vo, £4 14s. 6d.

**Harvey's (Wm.) Manuscript Lectures.** *Prelectiones Anatomiae Universalis.* Edited, with an Autotype reproduction of the Original, by a Committee of the Royal College of Physicians of London. Crown 4to, half bound in Persian, 52s. 6d.

### Anatomy of the Joints of Man.

By HENRY MORRIS, Surgeon to, and Lecturer on Anatomy and Practical Surgery at, the Middlesex Hospital. 8vo, with 44 Lithographic Plates (several being coloured) and 13 Wood Engravings, 16s.

### Manual of the Dissection of the

**Human Body.** By LUTHER HOLDEN, Consulting Surgeon to St. Bartholomew's Hospital. Edited by JOHN LANGTON, F.R.C.S., Surgeon to, and Lecturer on Anatomy at, St. Bartholomew's Hospital. Fifth Edition. 8vo, with 208 Engravings. 20s.

*By the same Author.*

### Human Osteology.

Seventh Edition, edited by CHARLES STEWART, Conservator of the Museum R.C.S., and R. W. REID, M.D., F.R.C.S., Lecturer on Anatomy at St. Thomas's Hospital. 8vo, with 59 Lithographic Plates and 75 Engravings. 16s.

*Also.*

**Landmarks, Medical and Surgical.** Fourth Edition. 8vo, 3s. 6d.

**The Student's Guide to Surgical Anatomy.** By EDWARD BELLAMY, F.R.C.S. and Member of the Board of Examiners. Third Edition. Fcap. 8vo, with 81 Engravings. 7s. 6d.

**Diagrams of the Nerves of the Human Body,** exhibiting their Origin, Divisions, and Connections, with their Distribution to the Various Regions of the Cutaneous Surface, and to all the Muscles. By W. H. FLOWER, C.B., F.R.S., F.R.C.S. Third Edition, with 6 Plates. Royal 4to, 12s.



**General Pathology :**

An Introduction to. By JOHN BLAND SUTTON, F.R.C.S., Sir E. Wilson Lecturer on Pathology, R.C.S. ; Assistant Surgeon to, and Lecturer on Anatomy at, Middlesex Hospital. 8vo, with 149 Engravings, 14s.

**Atlas of Pathological Anatomy.**

By Dr. LANCEREAUX. Translated by W. S. GREENFIELD, M.D., Professor of Pathology in the University of Edinburgh. Imp. 8vo, with 70 Coloured Plates, £5 5s.

**A Manual of Pathological Anatomy.**

By C. HANDFIELD JONES, M.B., F.R.S., and E. H. SIEVEKING, M.D., F.R.C.P. Edited by J. F. PAYNE, M.D., F.R.C.P., Lecturer on General Pathology at St. Thomas's Hospital. Second Edition. Crown 8vo, with 195 Engravings, 16s.

**Post-mortem Examinations :**

A Description and Explanation of the Method of Performing them, with especial reference to Medico-Legal Practice. By Prof. VIRCHOW. Translated by Dr. T. P. SMITH. Second Edition. Fcap. 8vo, with 4 Plates, 3s. 6d.

**The Human Brain :**

Histological and Coarse Methods of Research. A Manual for Students and Asylum Medical Officers. By W. BEVAN LEWIS, L.R.C.P. Lond., Medical Superintendent, West Riding Lunatic Asylum. 8vo, with Wood Engravings and Photographs, 8s.

**Manual of Physiology :**

For the use of Junior Students of Medicine. By GERALD F. YEO, M.D., F.R.C.S., F.R.S., Professor of Physiology in King's College, London. Second Edition. Crown 8vo, with 318 Engravings, 14s.

**Principles of Human Physiology.**

By W. B. CARPENTER, C.B., M.D., F.R.S. Ninth Edition. By HENRY POWER, M.B., F.R.C.S. 8vo, with 3 Steel Plates and 377 Wood Engravings, 31s. 6d.

**Elementary Practical Biology :**

Vegetable. By THOMAS W. SHORE, M.D., B.Sc. Lond., Lecturer on Comparative Anatomy at St. Bartholomew's Hospital. 8vo, 6s.

**A Text-Book of Medical Physics,**

for Students and Practitioners. By J. C. DRAPER, M.D., LL.D., Professor of Physics in the University of New York. With 377 Engravings. 8vo, 18s.

**Medical Jurisprudence :**

Its Principles and Practice. By ALFRED S. TAYLOR, M.D., F.R.C.P., F.R.S. Third Edition, by THOMAS STEVENSON, M.D., F.R.C.P., Lecturer on Medical Jurisprudence at Guy's Hospital. 2 vols. 8vo, with 188 Engravings, 31s. 6d.

*By the same Authors.*

**A Manual of Medical Jurisprudence.** Eleventh Edition. Crown 8vo, with 56 Engravings, 14s.

*Also.*

**Poisons,**

In Relation to Medical Jurisprudence and Medicine. Third Edition. Crown 8vo, with 104 Engravings, 16s.

**Lectures on Medical Jurisprudence.**

By FRANCIS OGSTON, M.D., late Professor in the University of Aberdeen. Edited by FRANCIS OGSTON, Jun., M.D. 8vo, with 12 Copper Plates, 18s.

**The Student's Guide to Medical**

**Jurisprudence.** By JOHN ABERCROMBIE, M.D., F.R.C.P., Lecturer on Forensic Medicine to Charing Cross Hospital. Fcap. 8vo, 7s. 6d.

**Microscopical Examination of**

**Drinking Water and of Air.** By J. D. MACDONALD, M.D., F.R.S., Ex Professor of Naval Hygiene in the Army Medical School. Second Edition. 8vo, with 25 Plates, 7s. 6d.

**Pay Hospitals and Paying**

**Wards throughout the World.** By HENRY C. BURDETT. 8vo, 7s.

**Hospitals, Infirmaries, and Dis-**

**pensaries: Their Construction, Interior Arrangement, and Management; with Descriptions of existing Institutions, and 74 Illustrations.** By F. OPPERT, M.D., M.R.C.P.L. Second Edition. Royal 8vo, 12s.

**Hospital Construction and**

**Management.** By F. J. MOUAT, M.D., Local Government Board Inspector, and H. SAXON SNELL, Fell. Roy. Inst. Brit. Architects. Half calf, with large Map, 54 Lithographic Plates, and 27 Woodcuts, 35s.

**Public Health Reports.**

By Sir JOHN SIMON, C.B., F.R.S. Edited by EDWARD SEATON, M.D., F.R.C.P. 2 vols. 8vo, with Portrait, 36s.

**Sanitary Examinations**

Of Water, Air, and Food. A Vade-Mecum for the Medical Officer of Health. By CORNELIUS B. FOX, M.D., F.R.C.P. Second Edition. Crown 8vo, with 110 Engravings, 12s. 6d.

**A Manual of Practical Hygiene.**

By E. A. PARKES, M.D., F.R.S. Seventh Edition, by F. DE CHAUMONT, M.D., F.R.S., Professor of Military Hygiene in the Army Medical School. 8vo, with 9 Plates and 101 Engravings, 18s.

**A Handbook of Hygiene and Sanitary Science.**

By GEO. WILSON, M.A., M.D., F.R.S.E., Medical Officer of Health for Mid-Warwickshire. Sixth Edition. Crown 8vo, with Engravings. 10s. 6d.

*By the same Author.*

**Healthy Life and Healthy Dwellings:**

A Guide to Personal and Domestic Hygiene. Fcap. 8vo, 5s.

**Epidemic Influences:**

Epidemiological Aspects of Yellow Fever and of Cholera. The Milroy Lectures. By ROBERT LAWSON, LL.D., Inspector-General of Hospitals. 8vo, with Maps, Diagrams, &c., 6s.

**Detection of Colour-Blindness and Imperfect Eyesight.**

By CHARLES ROBERTS, F.R.C.S. Second Edition. 8vo, with a Table of Coloured Wools, and Sheet of Test-types, 5s.

**Illustrations of the Influence of the Mind upon the Body in Health and Disease:**

Designed to elucidate the Action of the Imagination. By D. H. TUKE, M.D., F.R.C.P., LL.D. Second Edition. 2 vols. crown 8vo, 15s.

*By the same Author.*

**Sleep-Walking and Hypnotism.**

8vo, 5s.

**A Manual of Psychological Medicine.**

With an Appendix of Cases. By JOHN C. BUCKNILL, M.D., F.R.S., and D. HACK TUKE, M.D., F.R.C.P. Fourth Edition. 8vo, with 12 Plates (30 Figures) and Engravings, 25s.

**Mental Affections of Childhood and Youth**

(Lettsomian Lectures for 1887, &c.). By J. LANGDON DOWN, M.D., F.R.C.P., Senior Physician to the London Hospital. 8vo, 6s.

**Mental Diseases:**

Clinical Lectures. By T. S. CLOUSTON, M.D., F.R.C.P. Edin., Lecturer on Mental Diseases in the University of Edinburgh. Second Edition. Crown 8vo, with 8 Plates (6 Coloured), 12s. 6d.

**Intra-Uterine Death:**

(Pathology of). Being the Lumleian Lectures, 1887. By WILLIAM O. PRIESTLEY, M.D., F.R.C.P., LL.D., Consulting Physician to King's College Hospital. 8vo, with 3 Coloured Plates and 17 Engravings, 7s. 6d.

**Manual of Midwifery.**

By ALFRED L. GALABIN, M.A., M.D., F.R.C.P., Obstetric Physician to, and Lecturer on Midwifery, &c. at, Guy's Hospital. Crown 8vo, with 227 Engravings, 15s.

**The Student's Guide to the Practice of Midwifery.**

By D. LLOYD ROBERTS, M.D., F.R.C.P., Lecturer on Clinical Midwifery and Diseases of Women at the Owens College; Obstetric Physician to the Manchester Royal Infirmary. Third Edition. Fcap. 8vo, with 2 Coloured Plates and 127 Wood Engravings, 7s. 6d.

**Lectures on Obstetric Operations:**

Including the Treatment of Hæmorrhage, and forming a Guide to the Management of Difficult Labour. By ROBERT BARNES, M.D., F.R.C.P., Consulting Obstetric Physician to St. George's Hospital. Fourth Edition. 8vo, with 121 Engravings, 12s. 6d.

*By the same Author.*

**A Clinical History of Medical and Surgical Diseases of Women.**

Second Edition. 8vo, with 181 Engravings, 28s.

**Clinical Lectures on Diseases of Women:**

Delivered in St. Bartholomew's Hospital, by J. MATTHEWS DUNCAN, M.D., LL.D., F.R.S. Third Edition. 8vo, 16s.

**The Female Pelvic Organs:**

Their Surgery, Surgical Pathology, and Surgical Anatomy. In a Series of Coloured Plates taken from Nature; with Commentaries, Notes, and Cases. By HENRY SAVAGE, M.D., F.R.C.S., Consulting Officer of the Samaritan Free Hospital. Fifth Edition. Roy. 4to, with 17 Lithographic Plates (15 coloured) and 52 Woodcuts, £1 15s.

**Notes on Diseases of Women:**

Specially designed to assist the Student in preparing for Examination. By J. J. REYNOLDS, L.R.C.P., M.R.C.S. Third Edition. Fcap. 8vo, 2s. 6d.

*By the same Author.*

**Notes on Midwifery:**

Specially designed for Students preparing for Examination. Second Edition. Fcap. 8vo, with 15 Engravings, 4s.

**A Manual of Obstetrics.**

By A. F. A. KING, A.M., M.D., Professor of Obstetrics, &c., in the Columbian University, Washington, and the University of Vermont. Third Edition. Crown 8vo, with 102 Engravings, 8s.

**The Student's Guide to the Diseases of Women.** By ALFRED L. GALABIN, M.D., F.R.C.P., Obstetric Physician to Guy's Hospital. Fourth Edition. Fcap. 8vo, with 94 Engravings, 7s. 6d.

**West on the Diseases of Women.** Fourth Edition, revised by the Author, with numerous Additions by J. MATTHEWS DUNCAN, M.D., F.R.C.P., F.R.S.E., Obstetric Physician to St. Bartholomew's Hospital. 8vo, 16s.

**Obstetric Aphorisms :**

For the Use of Students commencing Midwifery Practice. By JOSEPH G. SWAYNE, M.D. Ninth Edition. Fcap. 8vo, with 17 Engravings, 3s. 6d.

**Handbook of Midwifery for Midwives :** By J. E. BURTON, L.R.C.P. Lond., Surgeon to the Hospital for Women, Liverpool. Second Edition. With Engravings. Fcap. 8vo, 6s.

**A Handbook of Uterine Therapeutics,** and of Diseases of Women. By E. J. TILT, M.D., M.R.C.P. Fourth Edition. Post 8vo, 10s.

*By the same Author.*

**The Change of Life**

In Health and Disease: A Clinical Treatise on the Diseases of the Nervous System incidental to Women at the Decline of Life. Fourth Edition. 8vo, 10s. 6d.

**Diseases of the Uterus, Ovaries, and Fallopian Tubes :** A Practical Treatise by A. COURTY, Professor of Clinical Surgery, Montpellier. Translated from Third Edition by his Pupil, AGNES McLAREN, M.D., M.K.Q.C.P.I., with Preface by J. MATTHEWS DUNCAN, M.D., F.R.C.P. 8vo, with 424 Engravings, 24s.

**Gynæcological Operations :**

(Handbook of). By ALBAN H. G. DORAN, F.R.C.S., Surgeon to the Samaritan Hospital. 8vo, with 167 Engravings, 15s.

**Diseases and Accidents**

Incident to Women, and the Practice of Medicine and Surgery applied to them. By W. H. BYFORD, A.M., M.D., Professor of Gynæcology in Rush Medical College, and HENRY T. BYFORD, M.D., Surgeon to the Woman's Hospital, Chicago. Fourth Edition. 8vo, with 306 Engravings, 25s.

**A Practical Treatise on the Diseases of Women.** By T. GAILLARD THOMAS, M.D., Professor of Diseases of Women in the College of Physicians and Surgeons, New York. Fifth Edition. Roy. 8vo, with 266 Engravings, 25s.

**Abdominal Surgery.**

By J. GREIG SMITH, M.A., F.R.S.E., Surgeon to the Bristol Royal Infirmary and Lecturer on Surgery in the Bristol Medical School. Second Edition. 8vo, with 79 Engravings, 21s.

**The Student's Guide to Diseases of Children.** By JAS. F. GOODHART, M.D., F.R.C.P., Physician to Guy's Hospital, and to the Evelina Hospital for Sick Children. Third Edition. Fcap. 8vo, 10s. 6d.

**Diseases of Children.**

For Practitioners and Students. By W. H. DAY, M.D., Physician to the Samaritan Hospital. Second Edition. Crown 8vo, 12s. 6d.

**A Practical Treatise on Disease in Children.** By EUSTACE SMITH, M.D., Physician to the King of the Belgians, Physician to the East London Hospital for Children. 8vo, 22s.

*By the same Author.*

**Clinical Studies of Disease in Children.** Second Edition. Post 8vo, 7s. 6d. *Also.*

**The Wasting Diseases of Infants and Children.** Fifth Edition. Post 8vo, 8s. 6d.

**A Practical Manual of the Diseases of Children.** With a Formulary. By EDWARD ELLIS, M.D. Fifth Edition. Crown 8vo, 10s.

**A Manual for Hospital Nurses** and others engaged in Attending on the Sick, and a Glossary. By EDWARD J. DOMVILLE, Surgeon to the Exeter Lying-in Charity. Sixth Edition. Cr. 8vo, 2s. 6d.

**A Manual of Nursing, Medical and Surgical.** By CHARLES J. CULLINGWORTH, M.D., Obstetric Physician to St. Thomas's Hospital. Second Edition. Fcap. 8vo, with Engravings, 3s. 6d.

*By the same Author.*

**A Short Manual for Monthly Nurses.** Second Edition. Fcap. 8vo, 1s. 6d.

**Hospital Sisters and their Duties.** By EVA C. E. LÜCKES, Matron to the London Hospital. Second Edition. Crown 8vo, 2s. 6d.

**Diseases and their Commencement.** Lectures to Trained Nurses. By DONALD W. C. HOOD, M.D., M.R.C.P., Physician to the West London Hospital. Crown 8vo, 2s. 6d.

**Infant Feeding and its Influence on Life.** By C. H. F. ROUTH, M.D., Physician to the Samaritan Hospital. Fourth Edition. Fcap. 8vo. [*Preparing.*]

**Manual of Botany :**

Including the Structure, Classification, Properties, Uses, and Functions of Plants. By ROBERT BENTLEY, Professor of Botany in King's College and to the Pharmaceutical Society. Fifth Edition. Crown 8vo, with 1,178 Engravings, 15s.

*By the same Author.*

**The Student's Guide to Structural, Morphological, and Physiological Botany.** With 660 Engravings. Fcap. 8vo, 7s. 6d.

*Also.*

**The Student's Guide to Systematic Botany,** including the Classification of Plants and Descriptive Botany. Fcap. 8vo, with 350 Engravings, 3s. 6d.

**Medicinal Plants :**

Being descriptions, with original figures, of the Principal Plants employed in Medicine, and an account of their Properties and Uses. By Prof. BENTLEY and Dr. H. TRIMEN, F.R.S. In 4 vols., large 8vo, with 306 Coloured Plates, bound in Half Morocco, Gilt Edges, £11 11s.

**Outlines of Infectious Diseases :**

For the use of Clinical Students. By J. W. ALLAN, M.B., Physician Superintendent Glasgow Fever Hospital. Fcap. 8vo., 3s.

**Materia Medica.**

A Manual for the use of Students. By ISAMBARD OWEN, M.D., F.R.C.P., Lecturer on Materia Medica, &c., to St. George's Hospital. Second Edition. Crown 8vo, 6s. 6d.

**The Prescriber's Pharmacopœia:**

The Medicines arranged in Classes according to their Action, with their Composition and Doses. By NESTOR J. C. TIRARD, M.D., F.R.C.P., Professor of Materia Medica and Therapeutics in King's College, London. Sixth Edition. 32mo, bound in leather, 3s.

**Royle's Manual of Materia**

**Medica and Therapeutics.** Sixth Edition, including additions and alterations in the B.P. 1885. By JOHN HARLEY, M.D., Physician to St. Thomas's Hospital. Crown 8vo, with 139 Engravings, 15s.

**Materia Medica and Therapeutics :**

Vegetable Kingdom — Organic Compounds — Animal Kingdom. By CHARLES D. F. PHILLIPS, M.D., F.R.S. Edin., late Lecturer on Materia Medica and Therapeutics at the Westminster Hospital Medical School. 8vo, 25s.

**The Student's Guide to Materia**

**Medica and Therapeutics.** By JOHN C. THOROWGOOD, M.D., F.R.C.P. Second Edition. Fcap. 8vo, 7s.

**A Companion to the British Pharmacopœia.** By PETER SQUIRE, Revised by his Sons, P. W. and A. H. SQUIRE. 14th Edition. 8vo, 10s. 6d.

*By the same Authors.*

**The Pharmacopœias of the London Hospitals,** arranged in Groups for Easy Reference and Comparison. Fifth Edition 18mo, 6s.

**A Treatise on the Principles and Practice of Medicine.** Sixth Edition. By AUSTIN FLINT, M.D., W. H. WELCH, M.D., and AUSTIN FLINT, jun., M.D. 8vo, with Engravings, 26s.

**Climate and Fevers of India,** with a series of Cases (Croonian Lectures, 1882). By Sir JOSEPH FAYRER, K.C.S.I., M.D. 8vo, with 17 Temperature Charts, 12s.

*By the same Author.*

**The Natural History and Epidemiology of Cholera :** Being the Annual Oration of the Medical Society of London, 1888. 8vo, 3s. 6d.

**Family Medicine and Hygiene for India.** A Manual. By Sir WILLIAM J. MOORE, M.D., K.C.I.E., late Surgeon-General with the Government of Bombay. Published under the Authority of the Government of India. Fifth Edition. Post 8vo, with 71 Engravings, 12s.

*By the same Author.*

**A Manual of the Diseases of India :** With a Compendium of Diseases generally. Second Edition. Post 8vo, 10s.

**The Prevention of Disease in Tropical and Sub-Tropical Campaigns.** (Parkes Memorial Prize for 1886.) By ANDREW DUNCAN, M.D., B.S. Lond., F.R.C.S., Surgeon, Bengal Army. 8vo, 12s. 6d.

**Practical Therapeutics :**

A Manual. By EDWARD J. WARING, C.I.E., M.D., F.R.C.P., and DUDLEY W. BUXTON, M.D., B.S. Lond. Fourth Edition. Crown 8vo, 14s.

*By the same Author.*

**Bazaar Medicines of India,**

And Common Medical Plants : With Full Index of Diseases, indicating their Treatment by these and other Agents procurable throughout India, &c. Fourth Edition Fcap. 8vo, 5s.

**A Commentary on the Diseases of India.** By NORMAN CHEVERS, C.I.E., M.D., F.R.C.S., Deputy Surgeon-General H.M. Indian Army. 8vo, 24s.

- The Principles and Practice of Medicine.** By C. HILTON FAGGE, M.D. Second Edition. Edited by P. H. PYE-SMITH, M.D., F.R.S., F.R.C.P., Physician to, and Lecturer on Medicine in, Guy's Hospital. 2 vols. 8vo. Cloth, 38s.; Half Leather, 44s.
- The Student's Guide to the Practice of Medicine.** By M. CHARTERIS, M.D., Professor of Therapeutics and Materia Medica in the University of Glasgow. Fifth Edition. Fcap. 8vo, with Engravings on Copper and Wood, 9s.
- Hooper's Physicians' Vademecum.** A Manual of the Principles and Practice of Physic. Tenth Edition. By W. A. GUY, F.R.C.P., F.R.S., and J. HARLEY, M.D., F.R.C.P. With 118 Engravings. Fcap. 8vo, 12s. 6d.
- Preventive Medicine.** Collected Essays. By WILLIAM SQUIRE, M.D., F.R.C.P., Physician to St. George, Hanover-square, Dispensary. 8vo, 6s. 6d.
- The Student's Guide to Clinical Medicine and Case-Taking.** By FRANCIS WARNER, M.D., F.R.C.P., Physician to the London Hospital. Second Edition. Fcap. 8vo, 5s.
- An Atlas of the Pathological Anatomy of the Lungs.** By the late WILSON FOX, F.R.C.P., Physician to H.M. the Queen. With 45 Plates (mostly Coloured) and Engravings. 4to, half-bound in Calf, 70s.
- The Bronchi and Pulmonary Blood-vessels: their Anatomy and Nomenclature.** By WILLIAM EWART, M.D., F.R.C.P., Physician to St. George's Hospital. 4to, with 20 Illustrations, 21s.
- The Student's Guide to Diseases of the Chest.** By VINCENT D. HARRIS, M.D. Lond., F.R.C.P., Physician to the City of London Hospital for Diseases of the Chest, Victoria Park. Fcap. 8vo, with 55 Illustrations (some Coloured), 7s. 6d.
- How to Examine the Chest:** A Practical Guide for the use of Students. By SAMUEL WEST, M.D., F.R.C.P., Physician to the City of London Hospital for Diseases of the Chest; Assistant Physician to St. Bartholomew's Hospital. With 42 Engravings. Fcap. 8vo, 5s.
- Contributions to Clinical and Practical Medicine.** By A. T. HOUGHTON WATERS, M.D., Physician to the Liverpool Royal Infirmary. 8vo, with Engravings, 7s.
- Fever: A Clinical Study.** By T. J. MACLAGAN, M.D. 8vo, 7s. 6d.
- The Student's Guide to Medical Diagnosis.** By SAMUEL FENWICK, M.D., F.R.C.P., Physician to the London Hospital, and BEDFORD FENWICK, M.D., M.R.C.P. Sixth Edition. Fcap. 8vo, with 114 Engravings, 7s.
- By the same Author.*
- The Student's Outlines of Medical Treatment.** Second Edition. Fcap. 8vo, 7s.
- Also.*
- On Chronic Atrophy of the Stomach, and on the Nervous Affections of the Digestive Organs.** 8vo, 8s.
- Also.*
- The Saliva as a Test for Functional Diseases of the Liver.** Crown 8vo, 2s.
- The Microscope in Medicine.** By LIONEL S. BEALE, M.B., F.R.S., Physician to King's College Hospital. Fourth Edition. 8vo, with 86 Plates, 21s.
- Also.*
- On Slight Ailments:** Their Nature and Treatment. Second Edition. 8vo, 5s.
- Medical Lectures and Essays.** By G. JOHNSON, M.D., F.R.C.P., F.R.S., Consulting Physician to King's College Hospital. 8vo, with 46 Engravings, 25s.
- By the same Author.*
- An Essay on Asphyxia (Apnoea).** 8vo, 3s.
- Winter Cough** (Catarrh, Bronchitis, Emphysema, Asthma). By HORACE DOBELL, M.D., Consulting Physician to the Royal Hospital for Diseases of the Chest. Third Edition. 8vo, with Coloured Plates, 10s. 6d.
- By the same Author.*
- Loss of Weight, Blood-Spitting, and Lung Disease.** Second Edition. 8vo, with Chromo-lithograph, 10s. 6d.
- Also.*
- The Mont Dore Cure, and the Proper Way to Use it.** 8vo, 7s. 6d.
- Vaccinia and Variola:** A Study of their Life History. By JOHN B. BUIST, M.D., F.R.S.E., Teacher of Vaccination for the Local Government Board. Crown 8vo, with 24 Coloured Plates, 7s. 6d.
- Treatment of Some of the Forms of Valvular Disease of the Heart.** By A. E. SANSOM, M.D., F.R.C.P., Physician to the London Hospital. Second Edition. Fcap. 8vo, with 26 Engravings, 4s. 6d.

**Diseases of the Heart and Aorta :**

Clinical Lectures. By G. W. BALFOUR, M.D., F.R.C.P., F.R.S. Edin., late Senior Physician and Lecturer on Clinical Medicine, Royal Infirmary, Edinburgh. Second Edition. 8vo, with Chromo-lithograph and Wood Engravings, 12s. 6d.

**Notes on Asthma :**

Its Forms and Treatment. By JOHN C. THOROWGOOD, M.D., Physician to the Hospital for Diseases of the Chest. Third Edition. Crown 8vo, 4s. 6d.

**Medical Ophthalmoscopy :**

A Manual and Atlas. By W. R. GOWERS, M.D., F.R.C.P., F.R.S., Physician to the National Hospital for the Paralyzed and Epileptic. Second Edition, with Coloured Plates and Woodcuts. 8vo, 18s.

*By the same Author.*

**Diagnosis of Diseases of the Brain.** Second Edition. 8vo, with Engravings, 7s. 6d.

*Also.*

**Diagnosis of Diseases of the Spinal Cord.** Third Edition. 8vo, with Engravings, 4s. 6d.

*Also.*

**A Manual of Diseases of the Nervous System.**

Vol. I. Diseases of the Spinal Cord and Nerves. Roy. 8vo, with 171 Engravings (many figures), 12s. 6d.

Vol. II. Diseases of the Brain and Cranial Nerves: General and Functional Diseases of the Nervous System. 8vo, with 170 Engravings, 17s. 6d.

**Diseases of the Nervous System.**

Lectures delivered at Guy's Hospital. By SAMUEL WILKS, M.D., F.R.S. Second Edition. 8vo, 18s.

**Gout in its Clinical Aspects.**

By J. MORTIMER GRANVILLE, M.D. Crown 8vo, 6s.

**Regimen to be adopted in Cases**

of Gout. By WILHELM EBSTEIN, M.D., Professor of Clinical Medicine in Göttingen. Translated by JOHN SCOTT, M.A., M.B. 8vo, 2s. 6d.

**Diseases of the Nervous System.**

Clinical Lectures. By THOMAS BUZZARD, M.D., F.R.C.P., Physician to the National Hospital for the Paralyzed and Epileptic. With Engravings, 8vo. 15s.

*By the same Author.*

**Some Forms of Paralysis from**

Peripheral Neuritis: of Gouty, Alcoholic, Diphtheritic, and other origin. Crown 8vo, 5s.

**Diseases of the Liver :**

With and without Jaundice. By GEORGE HARLEY, M.D., F.R.C.P., F.R.S. 8vo, with 2 Plates and 36 Engravings, 21s.

*By the same Author.*

**Inflammations of the Liver, and**

their Sequelæ. Crown 8vo, with Engravings, 5s.

**Gout, Rheumatism,**

And the Allied Affections; with Chapters on Longevity and Sleep. By PETER HOOD, M.D. Third Edition. Crown 8vo, 7s. 6d.

**Diseases of the Stomach :**

The Varieties of Dyspepsia, their Diagnosis and Treatment. By S. O. HABERSHON, M.D., F.R.C.P. Third Edition. Crown 8vo, 5s.

*By the same Author.*

**Pathology of the Pneumo-**

gastric Nerve: Lumleian Lectures for 1876. Second Edition. Post 8vo, 4s.

*Also.*

**Diseases of the Abdomen,**

Comprising those of the Stomach and other parts of the Alimentary Canal, Œsophagus, Cæcum, Intestines, and Peritoneum. Fourth Edition. 8vo, with 5 Plates, 21s.

*Also.*

**Diseases of the Liver,**

Their Pathology and Treatment. Lettsomian Lectures. Second Edition. Post 8vo, 4s.

**On the Relief of Excessive and**

Dangerous Tympanites by

Puncture of the Abdomen. By JOHN W. OGLE, M.A., M.D., F.R.C.P., Consulting Physician to St. George's Hospital. 8vo, 5s. 6d.

**Acute Intestinal Strangulation,**

And Chronic Intestinal Obstruction (Mode of Death from). By THOMAS BRYANT, F.R.C.S., Senior Surgeon to Guy's Hospital. 8vo, 3s.

**Handbook of the Diseases of**

the Nervous System. By JAMES ROSS, M.D., F.R.C.P., Assistant Physician to the Manchester Royal Infirmary. Roy. 8vo, with 184 Engravings, 18s.

*Also.*

**Aphasia :**

Being a Contribution to the Subject of the Dissolution of Speech from Cerebral Disease. 8vo, with Engravings, 4s. 6d.

**Food and Dietetics,**

Physiologically and Therapeutically Considered. By F. W. PAVY, M.D., F.R.S., Physician to Guy's Hospital. Second Edition. 8vo, 15s.

*By the same Author.*

**Croonian Lectures on Certain**

Points connected with Diabetes. 8vo, 4s. 6d.

**Headaches :**

Their Nature, Causes, and Treatment. By W. H. DAY, M.D., Physician to the Samaritan Hospital. Fourth Edition. Crown 8vo, with Engravings, 7s. 6d.

**Health Resorts at Home and**

Abroad. By M. CHARTERIS, M.D., Professor of Therapeutics and Materia Medica in the University of Glasgow. Second Edition. Crown 8vo, with Map, 5s. 6d.

**Winter and Spring**

On the Shores of the Mediterranean. By HENRY BENNET, M.D. Fifth Edition. Post 8vo, with numerous Plates, Maps, and Engravings, 12s. 6d.

**Medical Guide to the Mineral**

Waters of France and its Wintering Stations. With a Special Map. By A. VINTRAS, M.D., Physician to the French Embassy, and to the French Hospital, London. Crown 8vo, 8s.

**The Ocean as a Health-Resort :**

A Practical Handbook of the Sea, for the use of Tourists and Health-Seekers. By WILLIAM S. WILSON, L.R.C.P. Second Edition, with Chart of Ocean Routes, &c. Crown 8vo, 7s. 6d.

**Ambulance Handbook for Volun-**

teers and Others. By J. ARDAVON RAYE, L.K. & Q.C.P.I., L.R.C.S.I., late Surgeon to H.B.M. Transport No. 14, Zulu Campaign, and Surgeon E.I.R. Rifles. 8vo, with 16 Plates (50 figures), 3s. 6d.

**Ambulance Lectures :**

To which is added a NURSING LECTURE. By JOHN M. H. MARTIN, Honorary Surgeon to the Blackburn Infirmary. Second Edition. Crown 8vo, with 59 Engravings, 2s.

**Commoner Diseases and Acci-**

dents to Life and Limb: their Prevention and Immediate Treatment. By M. M. BASIL, M.A., M.B., C.M. Crown 8vo, 2s. 6d.

**How to Use a Galvanic Battery**

in Medicine and Surgery. By HERBERT TIBBITS, M.D., F.R.C.P.E., Senior Physician to the West London Hospital for Paralysis and Epilepsy. Third Edition. 8vo, with Engravings, 4s.

*By the same Author.*

**A Map of Ziemssen's Motor**

Points of the Human Body: A Guide to Localised Electrification. Mounted on Rollers, 35 x 21. With 20 Illustrations, 5s.

*Also.*

**Electrical and Anatomical De-**

monstrations. A Handbook for Trained Nurses and Masseuses. Crown 8vo, with 44 Illustrations, 5s.

**Surgical Emergencies :**

Together with the Emergencies attendant on Parturition and the Treatment of Poisoning. By W. PAUL SWAIN, F.R.C.S., Surgeon to the South Devon and East Cornwall Hospital. Fourth Edition. Crown 8vo, with 120 Engravings, 5s.

**Operative Surgery in the Cal-**

cutta Medical College Hospital. Statistics, Cases, and Comments. By KENNETH MCLEOD, A.M., M.D., F.R.C.S.E., Surgeon-Major, Indian Medical Service, Professor of Surgery in Calcutta Medical College. 8vo, with Illustrations, 12s. 6d.

**A Course of Operative Surgery.**

By CHRISTOPHER HEATH, Surgeon to University College Hospital. Second Edition. With 20 coloured Plates (180 figures) from Nature, by M. LÉVEILLÉ, and several Woodcuts. Large 8vo, 30s.

*By the same Author.*

**The Student's Guide to Surgical**

Diagnosis. Second Edition. Fcap. 8vo, 6s. 6d.

*Also.*

**Manual of Minor Surgery and**

Bandaging. For the use of House-Surgeons, Dressers, and Junior Practitioners. Eighth Edition. Fcap. 8vo, with 142 Engravings, 6s.

*Also.*

**Injuries and Diseases of the**

Jaws. Third Edition. 8vo, with Plate and 206 Wood Engravings, 14s.

*Also,*

**Lectures on Certain Diseases**

of the Jaws. Delivered at the R.C.S., Eng., 1887. 8vo, with 64 Engravings, 2s. 6d.

**The Practice of Surgery :**

A Manual. By THOMAS BRYANT, Consulting Surgeon to Guy's Hospital. Fourth Edition. 2 vols. crown 8vo, with 750 Engravings (many being coloured), and including 6 chromo plates, 32s.

*By the same Author.*

**On Tension : Inflammation of Bone, and Head Injuries.** Hunterian Lectures, 1888. 8vo, 6s.

**Surgery : its Theory and Practice** (Student's Guide). By WILLIAM J. WALSHAM, F.R.C.S., Assistant Surgeon to St. Bartholomew's Hospital. Second Edition. Fcap. 8vo, with 294 Engravings, 10s. 6d.

**The Surgeon's Vade-Mecum :**

A Manual of Modern Surgery. By R. DRUITT, F.R.C.S. Twelfth Edition. By STANLEY BOYD, M.B., F.R.C.S. Assistant Surgeon and Pathologist to Charing Cross Hospital. Crown 8vo, with 373 Engravings 16s.

**The Operations of Surgery :**

Intended for Use on the Dead and Living Subject alike. By W. H. A. JACOBSON, M.A., M.B., M.Ch. Oxon., F.R.C.S., Assistant Surgeon to Guy's Hospital, and Teacher of Surgery in the Medical School. 8vo, with 200 Illustrations, 30s.

**Regional Surgery :**

Including Surgical Diagnosis. A Manual for the use of Students. By F. A. SOUTHAM, M.A., M.B., F.R.C.S., Assistant Surgeon to the Manchester Royal Infirmary. Part I. The Head and Neck. Crown 8vo, 6s. 6d. — Part II. The Upper Extremity and Thorax. Crown 8vo, 7s. 6d. Part III. The Abdomen and Lower Extremity. Crown 8vo, 7s.

**A Treatise on Dislocations.**

By LEWIS A. STIMSON, M.D., Professor of Clinical Surgery in the University of the City of New York. Roy. 8vo, with 163 Engravings, 15s.

*By the same Author.*

**A Treatise on Fractures.**

Roy. 8vo, with 360 Engravings, 21s.

**Lectures on Orthopædic Surgery.**

By BERNARD E. BRODHURST, F.R.C.S., Surgeon to the Royal Orthopædic Hospital. Second Edition. 8vo, with Engravings, 12s. 6d.

*By the same Author.*

**On Anchylosis, and the Treatment for the Removal of Deformity and the Restoration of Mobility in Various Joints.**

Fourth Edition. 8vo, with Engravings, 5s.

*Also.*

**Curvatures and Disease of the Spine.**

Fourth Edition. 8vo, with Engravings, 7s. 6d.

**Surgical Pathology and Morbid**

**Anatomy** (Student's Guide). By ANTHONY A. BOWLBY, F.R.C.S., Surgical Registrar and Demonstrator of Surgical Pathology to St. Bartholomew's Hospital. Fcap. 8vo, with 135 Engravings, 9s.

**Illustrations of Clinical Surgery**

By JONATHAN HUTCHINSON, F.R.S. Senior Surgeon to the London Hospital. In fasciculi. 6s. 6d each. Fasc. I. to X. bound, with Appendix and Index, £3 10s. Fasc. XI. to XXIII. bound, with Index, £4 10s.

**Diseases of Bones and Joints.**

By CHARLES MACNAMARA, F.R.C.S., Surgeon to, and Lecturer on Surgery at, the Westminster Hospital. 8vo, with Plates and Engravings, 12s.

**Injuries of the Spine and Spinal**

**Cord, and NERVOUS SHOCK,** in their Surgical and Medico-Legal Aspects. By HERBERT W. PAGE, M.C. Cantab., F.R.C.S., Surgeon to St. Mary's Hospital. Second Edition, post 8vo, 10s.

**Spina Bifida :**

Its Treatment by a New Method. By JAS. MORTON, M.D., L.R.C.S.E., Professor of Materia Medica in Anderson's College, Glasgow. 8vo, with Plates, 7s. 6d.

**Face and Foot Deformities.**

By FREDERICK CHURCHILL, C.M., Surgeon to the Victoria Hospital for Children. 8vo, with Plates and Illustrations, 10s. 6d.

**Clubfoot :**

Its Causes, Pathology, and Treatment. By WM. ADAMS, F.R.C.S., Surgeon to the Great Northern Hospital. Second Edition. 8vo, with 106 Engravings and 6 Lithographic Plates, 15s.

*By the same Author.*

**Lateral and other Forms of**

**Curvature of the Spine : Their Pathology and Treatment.** Second Edition. 8vo, with 5 Lithographic Plates and 72 Wood Engravings, 10s. 6d.

**Electricity and its Manner of**

**Working in the Treatment of Disease.** By WM. E. STEAVENSON, M.D., Physician and Electrician to St. Bartholomew's Hospital. 8vo, 4s. 6d.

**On Diseases and Injuries of the**

**Eye : A Course of Systematic and Clinical Lectures to Students and Medical Practitioners.** By J. R. WOLFE, M.D., F.R.C.S.E., Lecturer on Ophthalmic Medicine and Surgery in Anderson's College, Glasgow. With 10 Coloured Plates and 157 Wood Engravings. 8vo, £1 1s.

**Hinton Ophthalmic Out-Patient**

**Practice.** By CHARLES HIGGENS, Ophthalmic Surgeon to Guy's Hospital. Third Edition. Fcap. 8vo, 3s.



**The Student's Guide to Diseases of the Eye.** By EDWARD NETTLESHIP, F.R.C.S., Ophthalmic Surgeon to St. Thomas's Hospital. Fourth Edition. Fcap. 8vo, with 164 Engravings and a Set of Coloured Papers illustrating Colour-Blindness, 7s. 6d.

**Manual of the Diseases of the Eye.** By CHARLES MACNAMARA, F.R.C.S., Surgeon to Westminster Hospital. Fourth Edition. Crown 8vo, with 4 Coloured Plates and 66 Engravings, 10s. 6d.

**Normal and Pathological Histology of the Human Eye and Eyelids.** By C. FRED. POLLOCK, M.D., F.R.C.S. and F.R.S.E., Surgeon for Diseases of the Eye to Anderson's College Dispensary, Glasgow. Crown 8vo, with 100 Plates (230 drawings), 15s.

**Atlas of Ophthalmoscopy.** Composed of 12 Chromo-lithographic Plates (59 Figures drawn from nature) and Explanatory Text. By RICHARD LIEBREICH, M.R.C.S. Translated by H. ROSBOROUGH SWANZY, M.B. Third edition, 4to, 40s.

**Refraction of the Eye :**  
A Manual for Students. By GUSTAVUS HARTRIDGE, F.R.C.S., Surgeon to the Royal Westminster Ophthalmic Hospital. Third Edition. Crown 8vo, with 96 Illustrations, Test-types, &c., 5s. 6d.

**Squint :**  
(Clinical Investigations on). By C. SCHWEIGGER, M.D., Professor of Ophthalmology in the University of Berlin. Edited by GUSTAVUS HARTRIDGE, F.R.C.S. 8vo, 5s.

**Practitioner's Handbook of Diseases of the Ear and Nasopharynx.** By H. MACNAUGHTON JONES, M.D., late Professor of the Queen's University in Ireland, Surgeon to the Cork Ophthalmic and Aural Hospital. Third Edition of "Aural Surgery." Roy. 8vo, with 128 Engravings, 6s.

*By the same Author.*

**Atlas of Diseases of the Membrana Tympani.** In Coloured Plates, containing 62 Figures, with Text. Crown 4to, 21s.

**Endemic Goitre or Thyreocele :**  
Its Etiology, Clinical Characters, Pathology, Distribution, Relations to Cretinism, Myxœdema, &c., and Treatment. By WILLIAM ROBINSON, M.D. 8vo, 5s.

**Diseases and Injuries of the Ear.** By Sir WILLIAM B. DALBY, Aural Surgeon to St. George's Hospital. Third Edition. Crown 8vo, with Engravings, 7s. 6d.

*By the Same Author.*

**Short Contributions to Aural Surgery, between 1875 and 1886.** 8vo, with Engravings, 3s. 6d.

**Diphtheria :**  
Its Nature and Treatment, Varieties, and Local Expressions. By Sir MORELL MACKENZIE, M.D., Senior Physician to the Hospital for Diseases of the Throat. 8vo, 5s.

**Sore Throat :**  
Its Nature, Varieties, and Treatment. By PROSSER JAMES, M.D., Physician to the Hospital for Diseases of the Throat. Fifth Edition. Post 8vo, with Coloured Plates and Engravings, 6s. 6d.

**Studies in Pathological Anatomy,** Especially in Relation to Laryngeal Neoplasms. By R. NORRIS WOLFENDEN, M.D., Senior Physician to the Throat Hospital, and SIDNEY MARTIN, M.D., Pathologist to the City of London Hospital, Victoria Park. I. Papilloma. Roy. 8vo, with Coloured Plates, 2s. 6d.

**A System of Dental Surgery.** By Sir JOHN TOMES, F.R.S., and C. S. TOMES, M.A., F.R.S. Third Edition. Crown 8vo, with 292 Engravings, 15s.

**Dental Anatomy, Human and Comparative: A Manual.** By CHARLES S. TOMES, M.A., F.R.S. Second Edition. Crown 8vo, with 191 Engravings, 12s. 6d.

**The Student's Guide to Dental Anatomy and Surgery.** By HENRY SEWILL, M.R.C.S., L.D.S. Second Edition. Fcap. 8vo, with 78 Engravings, 5s. 6d.

**A Manual of Nitrous Oxide Anæsthesia, for the use of Students and General Practitioners.** By J. FREDERICK W. SILK, M.D. Lond., M.R.C.S., Anæsthetist to the Great Northern Central Hospital, and to the National Dental Hospital. 8vo, with 26 Engravings, 5s.

**Mechanical Dentistry in Gold and Vulcanite.** By F. H. BALKWILL, L.D.S.R.C.S. 8vo, with 2 Lithographic Plates and 57 Engravings, 10s.

**Principles and Practice of Dentistry :**

including Anatomy, Physiology, Pathology, Therapeutics, Dental Surgery, and Mechanism. By C. A. HARRIS, M.D., D.D.S. Edited by F. J. S. GORGAS, A.M., M.D., D.D.S., Professor in the Dental Department of Maryland University. Twelfth Edition. 8vo, with over 1,000 Illustrations, 33s.

**A Practical Treatise on Mechanical Dentistry.**

By JOSEPH RICHARDSON, M.D., D.D.S., late Emeritus Professor of Prosthetic Dentistry in the Indiana Medical College. Fourth Edition. Roy. 8vo, with 458 Engravings, 21s.

**Elements of Dental Materia**

Medica and Therapeutics, with Pharmacopœia. By JAMES STOCKEN, L.D.S.R.C.S., Pereira Prizeman for Materia Medica, and THOMAS GADDES, L.D.S. Eng. and Edin. Third Edition. Fcap. 8vo, 7s. 6d.

**Papers on Dermatology.**

By E. D. MAPOTHER, M.D., Ex-Pres. R.C.S.I. 8vo, 3s. 6d.

**Atlas of Skin Diseases.**

By TILBURY FOX, M.D., F.R.C.P. With 72 Coloured Plates. Royal 4to, half morocco, £6 6s.

**Diseases of the Skin :**

With an Analysis of 8,000 Consecutive Cases and a Formulary. By L. D. BULKLEY, M.D., Physician for Skin Diseases at the New York Hospital. Crown 8vo, 6s. 6d.

*By the same Author.*

**Acne : its Etiology, Pathology, and Treatment :** Based upon a Study of 1,500 Cases. 8vo, with Engravings, 10s.

**On Certain Rare Diseases of the**

Skin. By JONATHAN HUTCHINSON, F.R.S., Senior Surgeon to the London Hospital, and to the Hospital for Diseases of the Skin. 8vo, 10s. 6d.

**Diseases of the Skin :**

A Practical Treatise for the Use of Students and Practitioners. By J. N. HYDE, A.M., M.D., Professor of Skin and Venereal Diseases, Rush Medical College, Chicago. Second Edition. 8vo, with 2 Coloured Plates and 96 Engravings, 20s.

**Leprosy in British Guiana.**

By JOHN D. HILLIS, F.R.C.S., M.R.I.A., Medical Superintendent of the Leper Asylum, British Guiana. Imp. 8vo, with 22 Lithographic Coloured Plates and Wood Engravings, £1 11s. 6d.

**On Cancer :**

Its Allies, and other Tumours; their Medical and Surgical Treatment. By F. A. PURCELL, M.D., M.C., Surgeon to the Cancer Hospital, Brompton. 8vo, with 21 Engravings, 10s. 6d.

**Sarcoma and Carcinoma :**

Their Pathology, Diagnosis, and Treatment. By HENRY T. BUTLIN, F.R.C.S., Assistant Surgeon to St. Bartholomew's Hospital. 8vo, with 4 Plates, 8s.

*By the same Author.*

**Malignant Disease of the Larynx (Sarcoma and Carcinoma).**

8vo, with 5 Engravings, 5s.

*Also.*

**Operative Surgery of Malignant Disease.**

8vo, 14s.

**Cancerous Affections of the Skin.**

(Epithelioma and Rodent Ulcer.) By GEORGE THIN, M.D. Post 8vo, with 8 Engravings, 5s.

*By the same Author.*

**Pathology and Treatment of Ringworm.**

8vo, with 21 Engravings, 5s.

**Cancer of the Mouth, Tongue, and Alimentary Tract :**

their Pathology, Symptoms, Diagnosis, and Treatment. By FREDERIC B. JESSETT, F.R.C.S., Surgeon to the Cancer Hospital, Brompton. 8vo, 10s.

**Clinical Chemistry of Urine**

(Outlines of the). By C. A. MACMUNN, M.A., M.D. 8vo, with 70 Engravings. [Nearly Ready.]

**Lectures on the Surgical Dis-**

orders of the Urinary Organs. By REGINALD HARRISON, F.R.C.S., Surgeon to the Liverpool Royal Infirmary. Third Edition, with 117 Engravings. 8vo, 12s. 6d.

**Hydrocele :**

Its several Varieties and their Treatment. By SAMUEL OSBORN, late Surgical Registrar to St. Thomas's Hospital. Fcap. 8vo, with Engravings, 3s.

*By the same Author.*

**Diseases of the Testis.**

Fcap. 8vo, with Engravings, 3s. 6d.

**Diseases of the Urinary Organs.**

Clinical Lectures. By Sir HENRY THOMPSON, F.R.C.S., Emeritus Professor of Clinical Surgery and Consulting Surgeon to University College Hospital. Eighth Edition. 8vo, with 121 Engravings, 10s. 6d.

*By the same Author.*

**Diseases of the Prostate :**

Their Pathology and Treatment. Sixth Edition. 8vo, with 39 Engravings, 6s.

*Also.*

**Surgery of the Urinary Organs.**

Some Important Points connected therewith. Lectures delivered in the R.C.S. 8vo, with 44 Engravings. Students' Edition, 2s. 6d.

*Also.*

**Practical Lithotomy and Litho-**

trity; or, An Inquiry into the Best Modes of Removing Stone from the Bladder. Third Edition. 8vo, with 87 Engravings, 10s.

*Also.*

**The Preventive Treatment of**

Calculous Disease, and the Use of Solvent Remedies. Third Edition. Crown 8vo, 2s. 6d.

*Also.*

**Tumours of the Bladder :**

Their Nature, Symptoms, and Surgical Treatment. 8vo, with numerous Illustrations, 5s.

*Also.*

**Stricture of the Urethra, and Uri-**

nary Fistulæ: their Pathology and Treatment. Fourth Edition. With 74 Engravings. 8vo, 6s.

*Also.*

**The Suprapubic Operation of**

Opening the Bladder for the Stone and for Tumours. 8vo, with 14 Engravings, 3s. 6d.

**Electric Illumination of the Male**

Bladder and Urethra, as a Means of Diagnosis of Obscure Vesico-Urethral Diseases. By E. HURRY FENWICK, F.R.C.S., Assistant Surgeon to the London Hospital and Surgeon to St. Peter's Hospital for Stone. 8vo, with 30 Engravings, 4s. 6d.

**Modern Treatment of Stone in**

the Bladder by Litholopaxy. By P. J. FREYER, M.A., M.D., M.Ch., Bengal Medical Service. 8vo, with Engravings 5s.

**The Surgical Diseases of the**

Genito-Urinary Organs, including Syphilis. By E. L. KEYES, M.D., Professor of Genito-Urinary Surgery, Syphilology, and Dermatology in Bellevue Hospital Medical College, New York (a revision of VAN BUREN and KEYES' Text-book). Roy. 8vo, with 114 Engravings, 21s.

**The Surgery of the Rectum.**

By HENRY SMITH, Emeritus Professor of Surgery in King's College, Consulting Surgeon to the Hospital. Fifth Edition. 8vo, 6s.

**Diseases of the Rectum and**

Anus. By W. HARRISON CRIPPS, F.R.C.S., Assistant Surgeon to St. Bartholomew's Hospital, &c. 8vo, with 13 Lithographic Plates and numerous Wood Engravings, 12s. 6d.

**Urinary and Renal Derange-**

ments and Calculous Disorders. By LIONEL S. BEALE, F.R.C.P., F.R.S., Physician to King's College Hospital. 8vo, 5s.

**The Diagnosis and Treatment**

of Diseases of the Rectum. By WILLIAM ALLINGHAM, F.R.C.S., Surgeon to St. Mark's Hospital for Fistula. Fifth Edition. By HERBERT WM. ALLINGHAM, F.R.C.S., Surgeon to the Great Northern Central Hospital, Demonstrator of Anatomy at St. George's Hospital. 8vo, with 53 Engravings. 10s. 6d.

**Syphilis and Pseudo-Syphilis.**

By ALFRED COOPER, F.R.C.S., Surgeon to the Lock Hospital, to St. Mark's and the West London Hospitals. 8vo, 10s. 6d.

**Diagnosis and Treatment of**

Syphilis. By TOM ROBINSON, M.D., Physician to St. John's Hospital for Diseases of the Skin. Crown 8vo, 3s. 6d.

*By the same Author.*

**Eczema: its Etiology, Patho-**

logy, and Treatment. Crown 8vo, 3s. 6d.

**Coulson on Diseases of the**

Bladder and Prostate Gland. Sixth Edition. By WALTER J. COULSON, Surgeon to the Lock Hospital and to St. Peter's Hospital for Stone. 8vo, 16s.

**The Medical Adviser in Life As-**

surance. By Sir E. H. SIEVEKING, M.D., F.R.C.P. Second Edition. Crown 8vo, 6s.

**A Medical Vocabulary :**

An Explanation of all Terms and Phrases used in the various Departments of Medical Science and Practice, their Derivation, Meaning, Application, and Pronunciation. By R. G. MAYNE, M.D., LL.D. Sixth Edition, by W. W. WAGSTAFFE, B.A., F.R.C.S. Crown 8vo, 10s. 6d.

**A Dictionary of Medical Science:**

Containing a concise Explanation of the various Subjects and Terms of Medicine, &c. By ROBLEY DUNGLISON, M.D., LL.D. Royal 8vo, 28s.

# INDEX.

- Abercrombie's Medical Jurisprudence, 4  
 Adams (W.) on Clubfoot, 11  
     on Curvature of the Spine, 11  
 Allan's Outlines of Infectious Diseases, 7  
 Allingham on Diseases of the Rectum, 14  
 Balfour's Diseases of the Heart and Aorta, 9  
 Balkwill's Mechanical Dentistry, 12  
 Barnes (R.) on Obstetric Operations, 5  
     on Diseases of Women, 5  
 Basil's Commoner Diseases and Accidents, 10  
 Beale's Microscope in Medicine, 8  
     Slight Ailments, 8  
     Urinary and Renal Derangements, 14  
 Bellamy's Surgical Anatomy, 3  
 Bennet (J. H.) on the Mediterranean, 10  
 Bentley and Trimen's Medicinal Plants, 7  
 Bentley's Manual of Botany, 7  
     Structural Botany, 7  
     Systematic Botany, 7  
 Bowlby's Surgical Pathology and Morbid Anatomy, 11  
 Braune's Topographical Anatomy, 3  
 Brodhurst's Anchylosis, 11  
     Curvatures, &c., of the Spine, 11  
     Orthopædic Surgery, 11  
 Bryant's Acute Intestinal Strangulation, 9  
     Practice of Surgery, 11  
     Tension. Inflammation of Bone, Injuries, &c. 11  
 Bucknill and Tuke's Psychological Medicine, 5  
 Buist's Vaccinia and Variola, 8  
 Bulkley's Acne, 13  
     Diseases of the Skin, 13  
 Burdett's Pay Hospitals, 4  
 Burton's Midwifery for Midwives, 6  
 Butlin's Malignant Disease of the Larynx, 13  
     Operative Surgery of Malignant Disease, 13  
     Sarcoma and Carcinoma, 13  
 Buzzard's Diseases of the Nervous System, 9  
     Peripheral Neuritis, 9  
 Byford's Diseases of, and Accidents to, Women, 6  
 Carpenter's Human Physiology, 4  
 Charteris on Health Resorts, 10  
     Practice of Medicine, 8  
 Chevers' Diseases of India, 7  
 Churchill's Face and Foot Deformities, 11  
 Clouston's Lectures on Mental Diseases, 5  
 Cooper's Syphilis and Pseudo-Syphilis, 14  
 Coulson on Diseases of the Bladder, 14  
 Courty's Diseases of the Uterus, Ovaries, &c., 6  
 Cripps' Diseases of the Rectum and Anus, 14  
 Cullingworth's Manual of Nursing, 6  
     Short Manual for Monthly Nurses, 6  
 Dalby's Diseases and Injuries of the Ear, 12  
     Short Contributions, 12  
 Day on Diseases of Children, 6  
     on Headaches, 10  
 Dobell's Lectures on Winter Cough, 8  
     Loss of Weight, &c., 8  
     Mont Doré Cure, 8  
 Domville's Manual for Nurses, 6  
 Doran's Gynæcological Operations, 6  
 Down's Mental Affections of Childhood, 5  
 Draper's Text Book of Medical Physics, 4  
 Drutt's Surgeon's Vade-Mecum, 11  
 Duncan (A.) on Prevention of Disease in Tropics, 7  
 Duncan (J. M.) on Diseases of Women, 5  
 Dunglison's Medical Dictionary, 14  
 Ebstein on Regimen in Gout, 9  
 Ellis's Diseases of Children, 6  
 Ewart's Bronchi and Pulmonary Blood Vessels, 8  
 Fagge's Principles and Practice of Medicine, 8  
 Fayrer's Climate and Fevers of India, 7  
     Natural History, etc., of Cholera, 7  
 Fenwick (E. H.), Electric Illumination of Bladder, 14  
 Fenwick's (S.) Chronic Atrophy of the Stomach, 8  
     Medical Diagnosis, 8  
     Outlines of Medical Treatment, 8  
     The Saliva as a Test, 8  
 Flint's Principles and Practice of Medicine, 7  
 Flower's Diagrams of the Nerves, 3  
 Fox's (C. B.) Examinations of Water, Air, and Food, 4  
 Fox's (T.) Atlas of Skin Diseases, 13  
 Fox (Wilson), Atlas of Pathological Anatomy of Lungs, 8  
 Freyer's Litholopaxy, 14  
 Galabin's Diseases of Women, 6  
 Galabin's Manual of Midwifery, 5  
 Godlee's Atlas of Human Anatomy, 3  
 Goodhart's Diseases of Children, 6  
 Gowers' Diseases of the Brain, 9  
     Diseases of the Spinal Cord, 9  
     Manual of Diseases of Nervous System, 9  
     Medical Ophthalmoscopy, 9  
 Granville on Gout, 9  
 Guy's Hospital Formulæ, 2  
     Reports, 2  
 Habershon's Diseases of the Abdomen, 9  
     Liver, 9  
     Stomach, 9  
     Pneumogastric Nerve, 9  
 Harley on Diseases of the Liver, 9  
     Inflammations of the Liver, 9  
 Harris's (C. A.) Dentistry, 13  
 Harris's (V. D.) Diseases of Chest, 8  
 Harrison's Surgical Disorders of the Urinary Organs, 13  
 Hartridge's Refraction of the Eye, 12  
 Harvey's Manuscript Lectures, 3  
 Heath's Certain Diseases of the Jaws, 10  
     Injuries and Diseases of the Jaws, 10  
     Minor Surgery and Bandaging, 10  
     Operative Surgery, 10  
     Practical Anatomy, 3  
     Surgical Diagnosis, 10  
 Higgens' Ophthalmic Out-patient Practice, 11  
 Hillis' Leprosy in British Guiana, 13  
 Holden's Dissections, 3  
     Human Osteology, 3  
     Landmarks, 3  
 Hood's (D. C.) Diseases and their Commencement, 6  
 Hood (P.) on Gout, Rheumatism, &c., 9  
 Hooper's Physician's Vade-Mecum, 8  
 Hutchinson's Clinical Surgery, 11  
     Rare Diseases of the Skin, 13  
 Hyde's Diseases of the Skin, 13  
 Jacobson's Operations of Surgery, 11  
 James (P.) on Sore Throat, 12  
 Jessett's Cancer of the Mouth, &c., 13  
 Johnson's Asphyxia, 8  
     Medical Lectures and Essays, 8  
 Jones (C. H.) and Sieveking's Pathological Anatomy, 4  
 Jones' (H. McN.) Diseases of the Ear and Pharynx, 12  
     Atlas of Diseases of Membrana Tympani, 12  
 Journal of British Dental Association, 2  
     Mental Science, 2  
 Keyes' Genito-Urinary Organs and Syphilis, 14  
 King's Manual of Obstetrics, 5  
 Lancereaux's Atlas of Pathological Anatomy, 4  
 Lawson's Milroy Lectures on Epidemiology, 5  
 Lewis (Bevan) on the Human Brain, 4  
 Liebreich's Atlas of Ophthalmoscopy, 12  
 London Hospital Pharmacopœia, 2  
 Lückes' Hospital Sisters and their Duties, 6  
 Macdonald's (J. D.) Examination of Water and Air, 4  
 Mackenzie on Diphtheria, 12  
 MacLagan on Fever, 8  
 McLeod's Operative Surgery, 10  
 MacMunn's Clinical Chemistry of Urine, 13  
 Macnamara's Diseases of the Eye, 12  
     Bones and Joints, 11  
 Mapother's Papers on Dermatology, 13  
 Martin's Ambulance Lectures, 10  
 Mayne's Medical Vocabulary, 14  
 Middlesex Hospital Reports, 2  
 Moore's Family Medicine for India, 7  
     Manual of the Diseases of India, 7  
 Morris' (H.) Anatomy of the Joints, 3  
 Morton's Spina Bifida, 11  
 Mouat and Snell on Hospitals, 4  
 Nettleship's Diseases of the Eye, 12  
 Ogle on Puncturing the Abdomen, 9  
 Ogston's Medical Jurisprudence, 4  
 Ophthalmic (Royal London) Hospital Reports, 2  
 Ophthalmological Society's Transactions, 2  
 Oppert's Hospitals, Infirmaries, Dispensaries, &c., 4  
 Osborn on Diseases of the Testis, 13  
     on Hydrocele, 13  
 Owen's Materia Medica, 7  
 Page's Injuries of the Spine, 11  
 Parkes' Practical Hygiene, 5  
 Pavy on Diabetes, 10  
     on Food and Dietetics, 10  
 Pharmaceutical Journal, 2  
 Phillips' Materia Medica and Therapeutics, 7  
 Pollock's Histology of the Eye and Eyelids, 12  
 Priestley's Intra-Uterine Death, 5

[Continued on the next page.]

- Purcell on Cancer, 13  
 Raye's Ambulance Handbook, 10  
 Reynolds' (J. J.) Diseases of Women, 5  
     Notes on Midwifery, 5  
 Richardson's Mechanical Dentistry, 13  
 Roberts' (C.) Detection of Colour-Blindness, 5  
 Roberts' (D. Lloyd) Practice of Midwifery, 5  
 Robinson (Tom) on Eczema, 14  
     on Syphilis, 14  
 Robinson (W.) on Endemic Goitre or Thyroecole, 12  
 Ross's Aphasia, 9  
     Diseases of the Nervous System, 9  
 Routh's Infant Feeding, 6  
 Royal College of Surgeons Museum Catalogues, 2  
 Royle and Harley's Materia Medica, 7  
 St. Bartholomew's Hospital Catalogue, 2  
 St. George's Hospital Reports, 2  
 St. Thomas's Hospital Reports, 2  
 Sansom's Valvular Disease of the Heart, 8  
 Savage on the Female Pelvic Organs, 5  
 Schweigger on Squint, 12  
 Sewill's Dental Anatomy, 12  
 Shore's Elementary Practical Biology, 4  
 Sieveking's Life Assurance, 14  
 Silk's Manual of Nitrous Oxide, 12  
 Simon's Public Health Reports, 4  
 Smith's (E.) Clinical Studies, 6  
     Diseases in Children, 6  
     Wasting Diseases of Infants and Children, 6  
 Smith's (J. Greig) Abdominal Surgery, 6  
 Smith's (Henry) Surgery of the Rectum, 14  
 Southam's Regional Surgery, 11  
 Squire's (P.) Companion to the Pharmacopœia, 7  
     Pharmacopœias of London Hospitals, 7  
 Squire's (W.) Essays on Preventive Medicine, 8  
 Steavenson's Electricity, 11  
 Stimson's Dislocations, 11  
     Fractures, 11  
 Stocken's Dental Materia Medica and Therapeutics, 13  
 Sutton's General Pathology, 4  
 Swain's Surgical Emergencies, 10  
 Swayne's Obstetric Aphorisms, 6  
 Taylor's Medical Jurisprudence, 4  
 Taylor's Poisons in relation to Medical Jurisprudence, 4  
 Thin's Cancerous Affections of the Skin, 13  
     Pathology and Treatment of Ringworm, 13  
 Thomas's Diseases of Women, 6  
 Thompson's (Sir H.) Calculous Disease, 14  
     Diseases of the Prostate, 14  
     Diseases of the Urinary Organs, 14  
     Lithotomy and Lithotrity, 14  
     Stricture of the Urethra, 14  
     Suprapubic Operation, 14  
     Surgery of the Urinary Organs, 14  
     Tumours of the Bladder, 14  
 Thorowgood on Asthma, 9  
     on Materia Medica and Therapeutics, 7  
 Tibbits' Map of Motor Points, 10  
     How to use a Galvanic Battery, 10  
     Electrical and Anatomical Demonstrations, 10  
 Tilt's Change of Life, 6  
     Uerine Therapeutics, 6  
 Tirard's Prescriber's Pharmacopœia, 7  
 Tomes' (C. S.) Dental Anatomy, 12  
 Tomes' (J. and C. S.) Dental Surgery, 12  
 Tuke's Influence of the Mind upon the Body, 5  
     Sleep-Walking and Hypnotism, 5  
 Vintras on the Mineral Waters, &c., of France,  
 Virchow's Post-mortem Examinations, 4  
 Walsham's Surgery: its Theory and Practice, 11  
 Waring's Indian Bazaar Medicines, 7  
     Practical Therapeutics, 7  
 Warner's Guide to Medical Case-Taking, 8  
 Waters' (A. T. H.) Contributions to Medicine, 8  
 West and Duncan's Diseases of Women, 6  
 West's (S.) How to Examine the Chest, 8  
 Wilks' Diseases of the Nervous System, 8  
 Wilson's (Sir E.) Anatomists' Vade-Mecum, 3  
 Wilson's (G.) Handbook of Hygiene, 5  
     Healthy Life and Dwellings, 5  
 Wilson's (W. S.) Ocean as a Health-Resort, 10  
 Wolfe's Diseases and Injuries of the Eye, 11  
 Wolfenden and Martin's Pathological Anatomy, 12  
 Year Book of Pharmacy, 2  
 Yeo's (G. F.) Manual of Physiology, 4

The following CATALOGUES issued by J. & A. CHURCHILL will be forwarded post free on application:—

**A.** *J. & A. Churchill's General List of about 650 works on Anatomy, Physiology, Hygiene, Midwifery, Materia Medica, Medicine, Surgery, Chemistry, Botany, &c., &c., with a complete Index to their Subjects, for easy reference.*  
 N.B.—This List includes B, C, & D.

**B.** *Selection from J. & A. Churchill's General List, comprising all recent Works published by them on the Art and Science of Medicine.*

**C.** *J. & A. Churchill's Catalogue of Text Books specially arranged for Students.*

**D.** *A selected and descriptive List of J. & A. Churchill's Works on Chemistry, Materia Medica, Pharmacy, Botany, Photography, Zoology, the Microscope, and other branches of Science.*

**E.** *The Medical Intelligencer being a List of New Works and New Editions published by J. & A. Churchill.*

[Sent yearly to every Medical Practitioner in the United Kingdom whose name and address can be ascertained. A large number are also sent to the United States of America, Continental Europe, India, and the Colonies.]

AMERICA.—*J. & A. Churchill being in constant communication with various publishing houses in Boston, New York, and Philadelphia, are able, notwithstanding the absence of international copyright, to conduct negotiations favourable to English Authors.*

LONDON: 11, NEW BURLINGTON STREET.

0/12

