

**A guide to the examination of the nose : with remarks on the diagnosis of diseases of the nasal cavities / by E. Cresswell Baber.**

**Contributors**

Baber, E. Cresswell.  
Royal College of Physicians of Edinburgh

**Publication/Creation**

London : H.K. Lewis, 1886.

**Persistent URL**

<https://wellcomecollection.org/works/fffcjsjz>

**Provider**

Royal College of Physicians Edinburgh

**License and attribution**

This material has been provided by This material has been provided by the Royal College of Physicians of Edinburgh. The original may be consulted at the Royal College of Physicians of Edinburgh. where the originals may be consulted.

This work has been identified as being free of known restrictions under copyright law, including all related and neighbouring rights and is being made available under the Creative Commons, Public Domain Mark.

You can copy, modify, distribute and perform the work, even for commercial purposes, without asking permission.



Wellcome Collection  
183 Euston Road  
London NW1 2BE UK  
T +44 (0)20 7611 8722  
E [library@wellcomecollection.org](mailto:library@wellcomecollection.org)  
<https://wellcomecollection.org>

A GUIDE TO THE EXAMINATION  
OF THE NOSE

---

E. CRESSWELL BABER









70  
Fc 4. 63

R52175

A GUIDE TO THE EXAMINATION OF THE NOSE






A GUIDE  
TO THE  
EXAMINATION OF THE NOSE

WITH REMARKS ON THE DIAGNOSIS OF DISEASES OF  
THE NASAL CAVITIES.

BY

E. CRESSWELL BABER, M.B. LOND.

SURGEON TO THE BRIGHTON AND SUSSEX THROAT AND EAR DISPENSARY



WITH ILLUSTRATIONS

LONDON

H. K. LEWIS, 136 GOWER STREET, W.C.

1886

[All rights reserved]



LONDON  
PRINTED BY H. K. LEWIS,  
136 GOWER STREET.

TO

JOHN BABER, M.D.

THIS BOOK IS AFFECTIONATELY DEDICATED

BY HIS SON.





Digitized by the Internet Archive  
in 2015

<https://archive.org/details/b21905733>

## PREFACE.

---

EXAMINATION of the interior of the nose has lately assumed an increasing importance, not only on account of the local diseases to which this organ is liable, but also owing to the discovery that many reflex-phenomena are associated with it, and point to its influence on neighbouring and even remote parts of the body. There can be no doubt that a systematic and intelligent exploration of the nasal cavities will throw much light, both on this subject, and upon the wider one of the nature of the intimate relation which subsists between certain nasal affections and those of other organs. Towards a cultivation of this interesting field of study, it is hoped that the present work will, in some measure, contribute.

Some of the illustrations are original; others have been obtained from the various sources indicated in the text. I am here anxious to acknowledge my indebtedness to those who have furnished me with wood-engravings.

My best thanks are due to my valued friend,

Dr. Wilhelm Meyer, of Copenhagen, for his able criticism of the manuscript, and for the interest which he has taken in the work. I am also glad of the opportunity of thanking my friend, Dr. W. Ainslie Hollis, Physician to the Sussex County Hospital, for the kind literary help he has given me in seeing the book through the press.

E. CRESSWELL BABER.

97 Western Road, Brighton.  
1885.



# CONTENTS.

---

## CHAPTER I.

### REMARKS ON THE ANATOMY AND PHYSIOLOGY OF THE NOSE.

	PAGE
Anatomy:—1. External nose—2. Nasal cavities—3. Naso-pharynx.	
Physiology:—Respiration and smell—Taste—Effect of the nasal cavities on the voice . . . . .	1

## CHAPTER II.

### SYMPTOMS OF NASAL DISEASE.

Nasal obstruction and its consequences—Discharge—Hæmorrhage—Sneezing—Loss of smell and the taste of flavours—Sensation of dryness—Feeling of pain or weight in the nose—Sensation of something moving to and fro in the nose—Affections of the voice—Deafness and noises in the ears—Reflex phenomena . . . . .	35
---	----

## CHAPTER III.

### PHYSICAL EXAMINATION OF THE NOSE.

Preliminary examination:—1. Exterior of the nose and aspect of the face—2. Character of the voice—3. Test for patency of nasal passages—4. Character of patient's breath—5. Examination of the senses of smell and taste . . . . .	43
--	----

## CHAPTER IV.

### ANTERIOR RHINOSCOPY.

Nasal specula—Methods of illumination—Anterior nasal probe—Cleansing the nasal cavities—Method of performing anterior rhinoscopy—Anterior rhinoscopic view, when the erectile body on the anterior extremity of the inferior turbinated bone is collapsed—Ditto, when the erectile body on the anterior extremity of the inferior turbinated bone is swollen—Conditions under which this swelling occurs—Cucaine in anterior rhinoscopy—Other methods of examination through the anterior nares . . . . .	48
---	----



## CHAPTER V.

## POSTERIOR RHINOSCOPY.

	PAGE
Illumination—Rhinoscopic mirrors—Tongue-depressors—Method of performing posterior rhinoscopy—Posterior rhinoscopic view—Examination with the probe—Difficulties in performing posterior rhinoscopy—Anæsthetics—Modifications of posterior rhinoscopy—Auto-rhinoscopy . . . . .	98

## CHAPTER VI.

## PALPATION.

Anterior—Posterior—Method of performing the same—Difficulties .	128
---	-----

## CHAPTER VII.

## DIAGNOSIS OF THE COMMONER DISEASES OF THE NASAL CAVITIES.

Acute nasal catarrh—Chronic nasal catarrh—Hypertrophic nasal catarrh—Erection of the anterior extremity of the inferior turbinated body—Hay asthma—Atrophic catarrh and ozæna—Epistaxis—Necrosis—Deviations and perforations of the septum—Tumours of the nasal cavities—Foreign bodies—Rhinoliths—Adhesions—Atresia—Anosmia—Chronic naso-pharyngitis—Adenoid vegetations of the naso-pharynx—Fibrous tumours of the naso-pharynx—Reflex neuroses connected with the nose .	132
---	-----

## CHAPTER VIII.

## OUTLINE FOR EXAMINING A CASE.

Instruments necessary for an examination of the nose . . .	145
--	-----

## APPENDIX.

Cases illustrating sudden erection of the anterior extremity of the inferior turbinated body . . . . .	151
--	-----

INDEX . . . . .	157
-----------------	-----

## LIST OF ILLUSTRATIONS.

---

FIG.	PAGE
1. Vertical antero-posterior section of skull and soft parts, immediately to the right of the septum nasi, exposing the outer wall of left nasal fossa. (Natural size) . . . . .	4
2. Vertical transverse section through the nasal fossæ, rather behind their centre. (After Zuckerkandl) . . . . .	15
3. Vertical transverse section through the anterior region of the nasal fossæ, showing the tubercle of the septum. (After Zuckerkandl) . . . . .	16
4. Portrait of a patient suffering from nasal obstruction due to adenoid vegetations of the naso-pharynx. (From a photograph) . . . . .	44
5. One hook of Jurasz's nasal speculum . . . . .	48
6. B. Fränkel's speculum . . . . .	50
7. Sigmund's tubular speculum . . . . .	51
8. Thudichum's speculum . . . . .	51
9. Duplay's speculum (from Dr. Morell Mackenzie's <i>Diseases of the Throat and Nose</i> ) . . . . .	52
10. Elsberg's trivalve speculum (from Dr. Morell Mackenzie, <i>op. cit.</i> )	53
11. The author's self-retaining speculum . . . . .	54
12. Mode of application of the author's self-retaining speculum .	54
13. Zaufal's speculum (from Dr. Morell Mackenzie, <i>op. cit.</i> ) . .	55
14. Markusovsky's speculum . . . . .	57
15. Plane reflector with head band attached to a spectacle frame .	58
16. Rack-movement lamp (from Dr. Morell Mackenzie, <i>op. cit.</i> ) .	60
17. Concave reflector with head band . . . . .	61
18. The author's folding plane and concave reflectors . . . .	62
19. Trouvé's electric photophore (longitudinal section) . . .	62
20. Trouvé's electric photophore as worn on the head . . . .	63
21. Trouvé's electric photophore used as a standard lamp . . .	64
22. Steel nasal probe . . . . .	67
23. Cotton holder . . . . .	69
24. Nasal douche (from Dr. Morell Mackenzie, <i>op. cit.</i> ) . . .	71
25. Lynch's nasal syringe . . . . .	72
26. W. Meyer's nasal irrigator . . . . .	73



FIG.	PAGE
27. Diagram of vertical section of head showing the position necessary for examining the lower part of the middle, and the anterior end of the inferior turbinated body. ( <i>Designed by the Author</i> ) . . . . .	75
28. Diagram of vertical section of head showing the position necessary for examining the "neck" of the middle turbinated body, and roof of nasal cavity. ( <i>Designed by the Author</i> ) .	76
29. Diagram of vertical section of head showing the position necessary for examining the inferior meatus, palatal movements, and the lower border of the inferior turbinated body. ( <i>Designed by the Author</i> ) . . . . .	77
30. Anterior rhinoscopic view (left) . . . . .	78
31. Three diagrams illustrating different appearances presented by the tubercle of the septum . . . . .	81
32. Slightly abnormal anterior rhinoscopic view (left) . . . .	84
33. View of naso-pharyngeal cavity from the front, in a state of rest. ( <i>After Zaufal</i> ) . . . . .	86
34. View of naso-pharyngeal cavity from the front, during phonation. ( <i>After Zaufal</i> ) . . . . .	86
35. Right anterior rhinoscopic view with the inferior turbinated body collapsed . . . . .	89
36. Same view after the lapse of twenty minutes, during which the inferior turbinated body had become erected . . . . .	89
37. Apparatus for anterior rhinoscopy, with transmitted light .	96
38. Ordinary rhinoscopic mirrors. . . . .	99
39. B. Fränkel's rhinoscopic mirror (from Dr. Morell Mackenzie, <i>op. cit.</i> ) . . . . .	100
40. The author's angular tongue-depressor with bent blade . .	101
41. Türck's tongue-depressor . . . . .	102
42. The author's thimble tongue-depressor for children . . .	103
43. Sketch of the ordinary position for holding the rhinoscopic mirror and tongue-depressor . . . . .	106
44. Posterior rhinoscopic view . . . . .	109
45. View of the left Eustachian orifice, with salpingo-pharyngeal fold, and posterior surface of soft palate. ( <i>After Zaufal</i> ) .	114
46. Czermak's palate hook . . . . .	118
47. Voltolini's palate hook, with wings . . . . .	119
48. Voltolini's uvula spatula . . . . .	122
49. Uvula noose . . . . .	122
50. Uvula twitch (from Dr. Morell Mackenzie, <i>op. cit.</i> ) . . .	123

# A GUIDE TO THE EXAMINATION OF THE NOSE.

---

## CHAPTER I.

### REMARKS ON THE ANATOMY AND PHYSIOLOGY OF THE NOSE.

#### ANATOMY.

THE nose, speaking broadly, may be divided into three parts.\* 1. The external nose. 2. The nasal fossæ. 3. The naso-pharynx.

1. The **External Nose** is composed, at the upper part, of a bony framework consisting of the nasal bones, and the nasal processes of the superior maxillary bones. Below these it is made up of certain cartilages which are loosely united by fibrous tissue, and are held forward in their prominent position by the anterior extremity of the triangular cartilage of the septum.

The *cartilages of the nose* are as follows:—The *upper*

\* In these remarks on the anatomy and physiology of the nose, many details which are found in the usual text-books have been omitted, or but slightly referred to, while more attention has been devoted to other important points, which are perhaps less widely known. For many of the anatomical facts I am indebted to Zuckerkandl's elaborate researches, (*Normale und Pathologische Anatomie der Nasenhöhle und ihrer pneumatischen Anhänge*, Wien, 1882,) and to those of Luschka (*Der Schlundkopf des Menschen*, Tübingen, 1868).



*lateral cartilages*, two in number, are flattened and triangular in shape, being attached by their upper margins to the lower border of the nasal bones, and to the nasal processes of the superior maxillary bones; by their anterior margins to the septum nasi; and by their lower margins, through the intervention of fibrous tissue, to the lower lateral cartilages. The *lower lateral cartilages* are two thin plates, situated just below the preceding. They are so curved that each cartilage forms a part of the inner, as well as of the outer wall of each nostril, whilst the convexity of the bend of the two cartilages constitutes the tip of the nose. The portion of each cartilage which enters into the formation of the inner wall is loosely connected with its fellow and forms a small part of the columna. That which forms the outer wall of the nose is oval in shape and flattened. Behind, it is attached to the nasal process of the superior maxilla by means of a tough fibrous membrane, in which three or four *sesamoid cartilages* are found. Immediately below these structures, is the *ala of the nose*, which is somewhat everted, and is formed by dense masses of cellular tissue.

The *cartilage of the septum* is single, situated in the median line, and is somewhat triangular in form. In front it is joined to the nasal bones, to the two upper lateral cartilages, and to the inner part of the lower lateral cartilages, firmly with the former, but loosely with the latter (*Quain*), and it separates the two vestibules. Its posterior part forms a portion of the septum, dividing the two nasal fossæ, and is attached to the perpendicular plate of the ethmoid, and to the vomer.

The mobility and elasticity of the lower part of the



nose resulting from these structural peculiarities, has an important bearing on the examination of the nasal fossæ from the front, as it enables the tip to be raised, and the nostrils to be expanded by artificial means.

The *base or inferior surface* of the nose presents two more or less elliptical openings, the *nostrils*, whose direction is almost horizontal. In the adult they are often much compressed from side to side, but in children they are much more nearly circular. They are separated by the lower margin of the septum, which is here somewhat thickened, forming the *columna nasi*.

Six small *muscles* are attached to the external nose and exert movements on its cartilages. Of these, the most important are the dilatator naris (consisting of two parts, an anterior and a posterior), and the levator labii superioris alæque nasi, both of which dilate the nostrils and raise the alæ of the nose.

The *outer surface* of the nose is formed by ordinary integument, which in the region of the alæ and of the tip is considerably thickened. Over the alæ and in the groove immediately above them, it contains numerous sebaceous follicles. The *interior* of the nose contains two somewhat pyramidal cavities, having their apices directed upwards, and separated by the cartilaginous septum.

Each cavity, the *vestibulum nasi*, (fig. 1, *a*) is directly continuous behind with the nasal fossa through the anterior naris, while below it opens on to the surface of the body through the corresponding nostril. The vestibule is narrowed from side to side by a projection on its outer wall, formed by the lower lateral cartilage, and with the exception of part of the inner wall, which is covered by mucous membrane, continuous with that



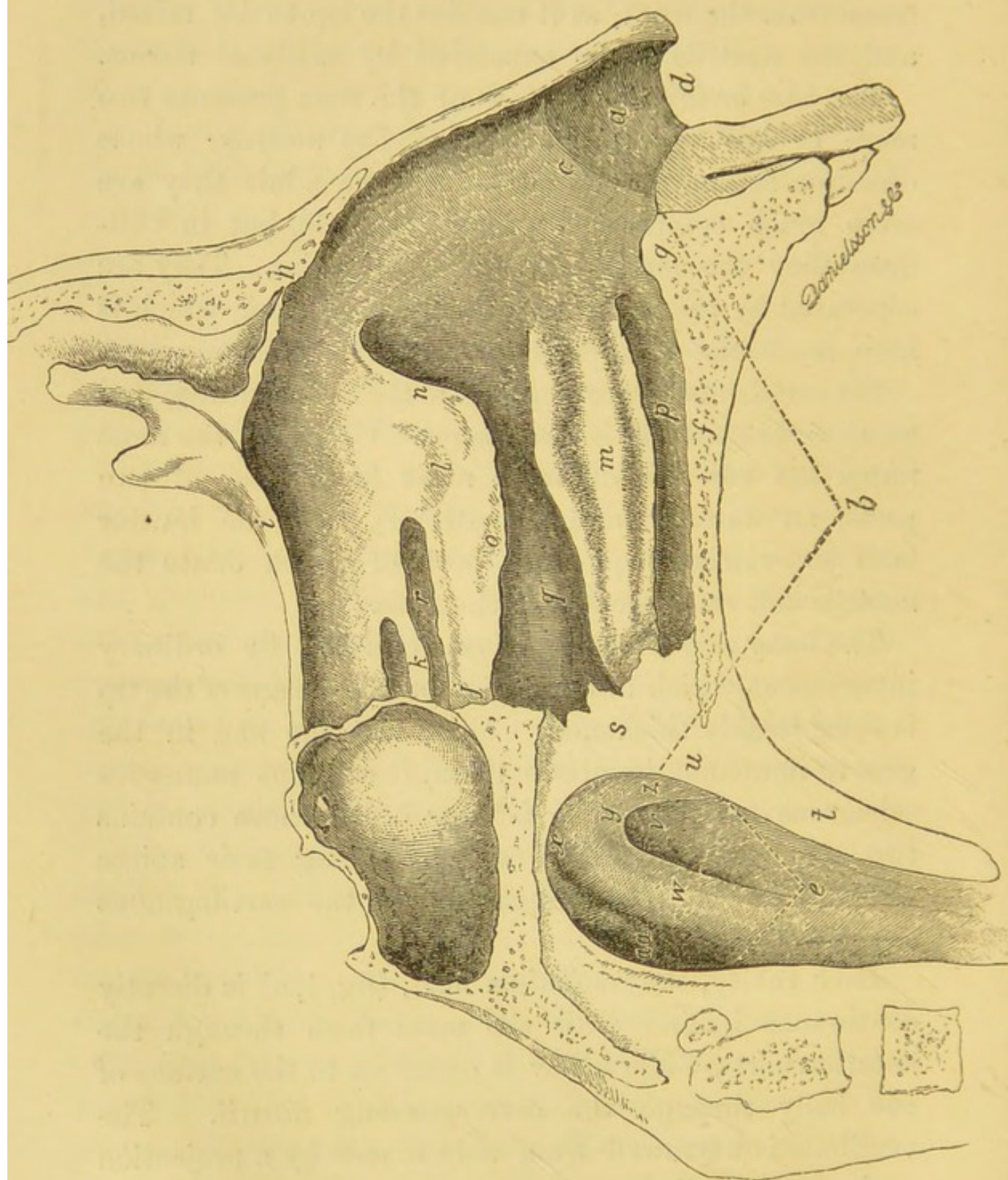




FIG 1.—Vertical antero-posterior section of skull and soft parts immediately to the right of the septum nasi, the greater part of the latter having been broken away, exposing the outer wall of the left nasal fossa. The drawing has been taken from a preparation of an adult cranium, and the outlines of the nasal fossa and naso-pharyngeal cavity with their contents have been accurately drawn to size. The pharyngeal tonsil is not shown. (*Drawn by the Author*).

- |  |  |
|--|--|
| a. Vestibule.  | o. Inferior border of middle turbinated body.                  |
| b. Nasal fossa.  | p. Inferior meatus.  |
| c. Anterior naris.   | q. Middle meatus.  |
| d. Nostril.  | r. Superior meatus.  |
| e. Naso-pharyngeal cavity.                                       | s. Posterior portion of septum which has been left.            |
| f. Floor of the nasal fossa raised in front into the eminence g. | t. Soft palate and uvula.                                      |
| h. Roof of nasal fossa, anterior ascending portion.              | u. Fold of mucous membrane on posterior margin of bony septum. |
| i. Roof of nasal fossa, middle horizontal portion.               | v. Eustachian orifice.   |
| j. Roof of nasal fossa, posterior descending portion.            | w. Salpingo-pharyngeal fold.                                   |
| k. Superior turbinated body.                                     | x. Roof of naso-pharynx.                                       |
| l. Middle " "  | y. Eustachian cushion.   |
| m. Inferior " "  | z. Salpingo-palatine fold.                                     |
| n. Anterior border of middle turbinated body.                    | aa. Fossa of Rosenmüller.                                      |



of the nasal fossæ, it is lined with skin, which is plentifully supplied with short stout hairs, *vibrissæ*.

Like ordinary skin it is furnished with a layer of stratified pavement epithelium, and a *stratum Malpighii*. It also contains numerous glands with branched alveoli, (*Klein*).

Practically the occurrence of mucous membrane on the inner wall of the vestibule is important, as it renders it necessary to avoid any undue pressure on this sensitive surface during the introduction of the speculum.

2. The **Nasal Fossæ** or **Cavities** are two irregularly shaped spaces, separated by an osseo-cartilaginous septum, the *septum nasi*, which occupies the median line.

Regarded from the side, each nasal cavity (fig. 1, *b*), is, speaking very roughly, quadrilateral in shape. It is much flattened from side to side and has projecting into it, from the external wall, several bony prominences. In front it opens into the vestibule (*a*) through the anterior naris (*c*) whilst behind it communicates by means of the posterior naris (choana) with the naso-pharyngeal cavity (*e*).

It will be convenient to consider first, the characters of the different walls of each nasal fossa, with regard to their bony and cartilaginous framework, and afterwards to describe the mucous membrane lining the cavity.

The *floor* of the nasal fossa (*f*) is formed by the palatine processes of the superior maxillary and palate bones. It measures 12 to 15 millimetres (about  $\frac{1}{2}$  to  $\frac{3}{8}$  inch) in width and is concave from side to side. It is also concave from before backwards, being raised at the fore part into a rounded eminence (*g*).



The *roof* may be divided into three portions. An anterior portion (*h*) which is formed by the nasal bones and the nasal processes of the superior maxillary bones and which from before backwards has an upward direction. A middle portion (*i*) which is more nearly horizontal, inclines only slightly in the same direction and is formed by the cribriform plate of the ethmoid bone. This is the narrowest part of the roof measuring only 2 to 3 mm. (about  $\frac{1}{12}$  to  $\frac{1}{8}$  of an inch) across. On account of its extreme delicacy it also constitutes the weakest part of the base of the skull necessitating great care in any operative procedure in its immediate vicinity. Behind is the posterior or sphenoidal portion (*j*) which descends abruptly to the upper margin of the posterior naris and is formed by the body of the sphenoid. Its direction varies in different specimens, in fig. 1 it appears unusually vertical. It is broader from side to side than the preceding, and attains its greatest width close to the choana.

The *outer wall* of the nasal fossa is the most complicated in structure and has a very irregular surface. It presents three distinct prominences, the superior (*k*) the middle (*l*) and the inferior (*m*) turbinated bones. Its bony construction is as follows:—The portion of the outer wall which is above the inferior turbinated bone is formed in front by the nasal process of the superior maxilla, behind this, the bony skeleton presents a large gap, which is partially closed by the palate bone, the pterygoid process of the sphenoid, the ethmoid process of the inferior turbinated bone and the unciform process of the ethmoid. The remainder of this portion is formed by the thin plates covering the ethmoidal cells and by the lachrymal bone. Below the attachment of



the inferior turbinated bone, the outer wall of the fossa is formed in front by the superior maxillary bone; behind by the palate bone, by the pterygoid process of the sphenoid, and occasionally by the maxillary process of the inferior turbinated bone.

The *turbinated bones* are so called on account of their curving inwards into the nasal cavity after the fashion of scrolls. They are also termed *conchæ* from a supposed resemblance to shells, and *spongy bones*, on account of their highly porous structure. The term "*turbinated body*" is best reserved for a turbinated bone *plus* its covering of soft tissues. The turbinated bones usually number three on either side. The superior is both shorter and smaller than the middle, and the middle than the inferior. It results from this, that as they all three reach almost equally far backwards, their anterior extremities form a succession of steps extending upwards and backwards. The superior and middle spongy bones are portions of the ethmoid whilst the inferior is an independent bone.

The *inferior turbinated bone* (*m*) is a thin curved plate the lower margin of which projects free into the nasal cavity, whilst its upper edge articulates by means of its curved maxillary process with the superior maxillary bone. The anterior extremity passes, by means of a gradual slope, into the outer wall of the fossa; the posterior extremity on the other hand terminates more abruptly. The length of the inferior turbinated bone including its covering of mucous membrane, is from 25 to 49 mm. (about 1 inch to  $1\frac{9}{10}$  inch), its width from 5 to 16 mm. (about  $\frac{1}{5}$  to  $\frac{3}{5}$  inch). Notches measuring sometimes as much as 7 to 13 mm. (about  $\frac{1}{4}$  to  $\frac{1}{2}$  inch) in depth, occasionally occur in the lower border of the bone (*Zuckerkandl*).



The *middle turbinated bone* (*l*) terminates in front in an anterior margin (*n*) measuring 10 to 12 mm. ( $\frac{2}{3}$  to nearly  $\frac{1}{2}$  inch) in length which projects free into the nasal cavity. Its lower margin (*o*) is broad and presents an inner and an outer edge. As is the case with the inferior turbinated bone, it is more curved from above downwards in the centre than at its anterior part. This curvature being convex on its median aspect, presents on its outer side a depression into which the ethmoidal cells often project.

*Variations* in the character of the middle turbinated bone are of frequent occurrence. It may be so strongly curved as to touch the septum, or its anterior extremity may be transformed into a bony cavity, communicating with the middle meatus. In the latter case it sometimes attains such a size as to be in contact with both inner and outer walls of the nasal cavity, while pressing the latter into the antrum of Highmore (*Zuckerhandl*). Sometimes a limited portion of the middle turbinated bone is thus inflated causing a protuberance which may readily be mistaken for a growth. The spot where the ethmoid bone articulates with the ethmoidal crest of the nasal process of the superior maxilla, also sometimes projects as a spherical prominence. A linear thickening running downwards and forwards from this point is termed by H. Meyer the *agger nasi*. Considerable importance has been attached to this by some authors, but according to Zuckerhandl's researches it is often absent and therefore cannot have much physiological significance. Occasionally the middle turbinated bone is curved in the opposite direction, so as to be concave on its inner (or median) and convex on its outer aspect, thus leaving a



wide space between it and the septum. This anomaly is always bilateral (*Zuckerkandl*). Longitudinal grooves on its inner surface as well as notches in the lower border are of occasional occurrence.\*

The *superior turbinated bone* is shorter and altogether smaller than the preceding. In front it coalesces with the middle turbinated bone, but behind it forms a separate projection. It may present a bladder-like excrescence, more or less confined to a limited area of the bone. When this bone is divided longitudinally it forms a *fourth turbinated bone*. This appears to be of common occurrence, as *Zuckerkandl* reports having found a fourth turbinated bone present in 55 instances out of 150; he also states that four turbinated bones are present in the cranium of the new born child. *Voltolini*† finds that this is the normal condition in the negro.

Below the concave surface of each turbinated bone is the corresponding meatus. Each meatus is therefore bounded externally by the outer wall of the nasal fossa, whilst internally it communicates directly with the general cavity of the nose.

The *inferior meatus* (*p*) usually presents a slightly concave surface on its outer wall, which is then convex towards the maxillary antrum (see fig. 2, D, p. 15). Occasionally, however, this wall is much hollowed out towards the nasal cavity and projects markedly into the antrum. At other times the posterior part of the wall forms a distinct projection into the inferior meatus

\* The middle turbinated bone, as seen from the front, often appears *sigmoid* in form, its inner surface being convex above and slightly concave below.

† *Die Rhinoskopie und Pharyngoskopie*, 2nd edition, Breslau, 1879, p. 70.



(Zuckerkan dl). It is evident that the latter variation may have an important bearing on nasal obstruction.

The *middle meatus* (*g*) presents at its upper part a deep semilunar groove, the *hiatus semilunaris*,\* the convexity of which is directed downwards and forwards. Its lower margin is formed by the unciform process of the ethmoid, whilst its upper margin is composed of one of the ethmoidal cells—the *bullæ ethmoidalis*. The hiatus semilunaris leads into a deeper groove, the *infundibulum*, which at its lower and back part communicates with the ethmoidal cells and (by means of the *ostium maxillare*) with the antrum of Highmore, whilst above and at its front part it opens into the frontal cells. The *bullæ ethmoidalis* varies much in size. Sometimes it fills the whole concavity on the outer surface of the middle turbinated bone and even presses this bone against the septum. The hiatus semilunaris varies in width from a thread-like groove to one measuring 4 mm. (about  $\frac{1}{6}$  of an inch) across. This circumstance is of practical importance, as in the former case a swelling of the mucous membrane at the margins of the hiatus may lead to occlusion of the antrum, although the actual ostium is perfectly free. This swelling of the lips of the hiatus does not necessarily close the opening into the frontal sinus, as the latter is more favourably situated. In every ninth or tenth case, there is a second opening into the antrum behind the ostium maxillare—the *ostium maxillare accessorium* (Zuckerkan dl). Between the lower border of the unciform process of the ethmoid and the inferior turbinated bone, two or three openings are left in the skeleton.

\* In fig. 1 these structures are hidden from sight by the middle spongy bone.



These are completely closed by mucous membrane in the living state. The outer wall of the middle meatus occasionally bulges outwards, forming a large concavity and encroaching on the antrum to a considerable extent. If the middle turbinated bone be not too large, this peculiarity can be recognised in the living subject (*Zuckerkindl*). Protuberances of the outer wall of the middle meatus *towards* the nasal cavity are also met with, either at its anterior or posterior part.

The *superior meatus* (fig. 1, *r*) is much shorter and narrower than the two lower ones.

The *inner wall* of the nasal cavity is formed by the *septum nasi*. The anterior and smaller portion of this is cartilaginous and formed by the triangular cartilage, the posterior and larger part is osseous and composed chiefly of the vomer and the perpendicular plate of the ethmoid. The nasal spine of the frontal, the crest of the nasal bones, the rostrum of the sphenoid, and the crests of the superior maxillary and palate bones also enter slightly into its formation. According to *Zuckerkindl* the septum is straight up to the age of seven years, but in later life it often presents irregularities.

*Deviations of the Septum*, as these irregularities are termed, have such an important bearing both on the functions of the nose and on the facility with which operative procedures can be carried out in the nasal cavities, that for years past they have formed the subject of numerous investigations. They have been recently studied by *Zuckerkindl*, *Löwenberg*, *Morell Mackenzie* and others. The frequency with which asymmetry of the septum occurs, is seen from the following results: *Theile* found that in 117 skulls, the septum was un-



symmetrical in 88, *i.e.* 75·2 *per cent.* Zuckerkandl in 370 crania found it unsymmetrical in 37·8 *per cent.*\* Morell Mackenzie's recent observations, which have been on an extensive scale,† show that in 2152 skulls (the cartilaginous portions not being taken into consideration) the septum was unsymmetrical in no less than 1657, *i.e.* 76·9 *per cent.* Whilst of 538 symmetrical septa only 22·6 *per cent.* were in European skulls and nearly one half of these again occurred in Italian crania. As these figures apply to the bony septum only, it is evident that asymmetry of the septum, as a whole, occurs even more frequently than is shown by them. This preponderance of symmetrical septa in non-European skulls, was also noticed by Zuckerkandl who found the septum unsymmetrical only 24 times out of 103 non-European crania, *i.e.* 23·3 *per cent.* Lœwenberg's researches‡ give a still lower percentage of straight septa. He found an absolutely straight septum only in one case out of every seven. Deviations are according to Morell Mackenzie, limited almost always to the anterior three-fourths of the septum. Zuckerkandl, moreover, has never seen them affecting the posterior third of this structure, but has always found the posterior margin of the septum in the median line and the two choanæ of equal width.§

\* This percentage is open to some doubt as it rests on the following statement of Zuckerkandl (*op. cit.*, p. 45). "My own observations showed amongst 370 crania, 123 with symmetrical and 140 with unsymmetrical septa. Amongst the latter the septum was bent to the right in 57 cases, to the left in 51 cases, and in 32 presented a sigmoid curvature."

† *Diseases of the Throat and Nose*, vol. ii., 1884, p. 432, *et seq.*

‡ "Anatomical Researches on the Deviation of the Nasal Septum." *Archives of Otology*, vol. xii., no. 1.

§ It is worth notice here that Harrison Allen (*Archives of Laryn-*



The deviations have been variously classified according to their form and position. For practical purposes they may be conveniently divided into :—(1) Processes (or protuberances), in which the septum is thickened at certain parts producing a projection into the corresponding nasal cavity. (2) Deflections (or bendings), wherein the septum simply deviates from the median line without being distinctly thickened.

(1.) *Processes.* Zuckerkandl describes wedge- or hook-shaped processes projecting at right angles from the bony septum, opposite either the middle or the superior turbinated bones. Their size varies from 4 to 12 mm. (about  $\frac{1}{8}$  to  $\frac{1}{2}$  inch). They occur in front or behind or may extend the whole length of the bony septum. They often come in contact with the outer wall of the nasal cavity obstructing it in parts. The processes are said to be formed from cartilaginous remains in the bony septum, and from the latter itself. Limited thickenings of the cartilage are also commonly found.

A deviation occurs very frequently at the junction of the triangular cartilage with the vomer and palate process of the superior maxillary bone, *i.e.* near the floor of the cavity and just behind the anterior naris. It results according to Lœwenberg from the fact that the bone and the cartilage at this point are not in the same vertical plane, but join at an angle projecting towards one side. This deviation may be limited to the anterior part of the osseo-cartilaginous suture, when it

*gology*, vol. iv., part 4) reports having observed asymmetry of the nasal cavities *without* deviation of the septum, and an unequal width of the choanæ. He considers this condition connected with peculiarities of development of the cerebral hemispheres.



forms the small conical protuberance so often seen just within the nasal cavity opposite the anterior end of the inferior turbinated bone (see fig. 3, *c*, p. 16, and fig. 35). When extending further backwards it is seen to rise,

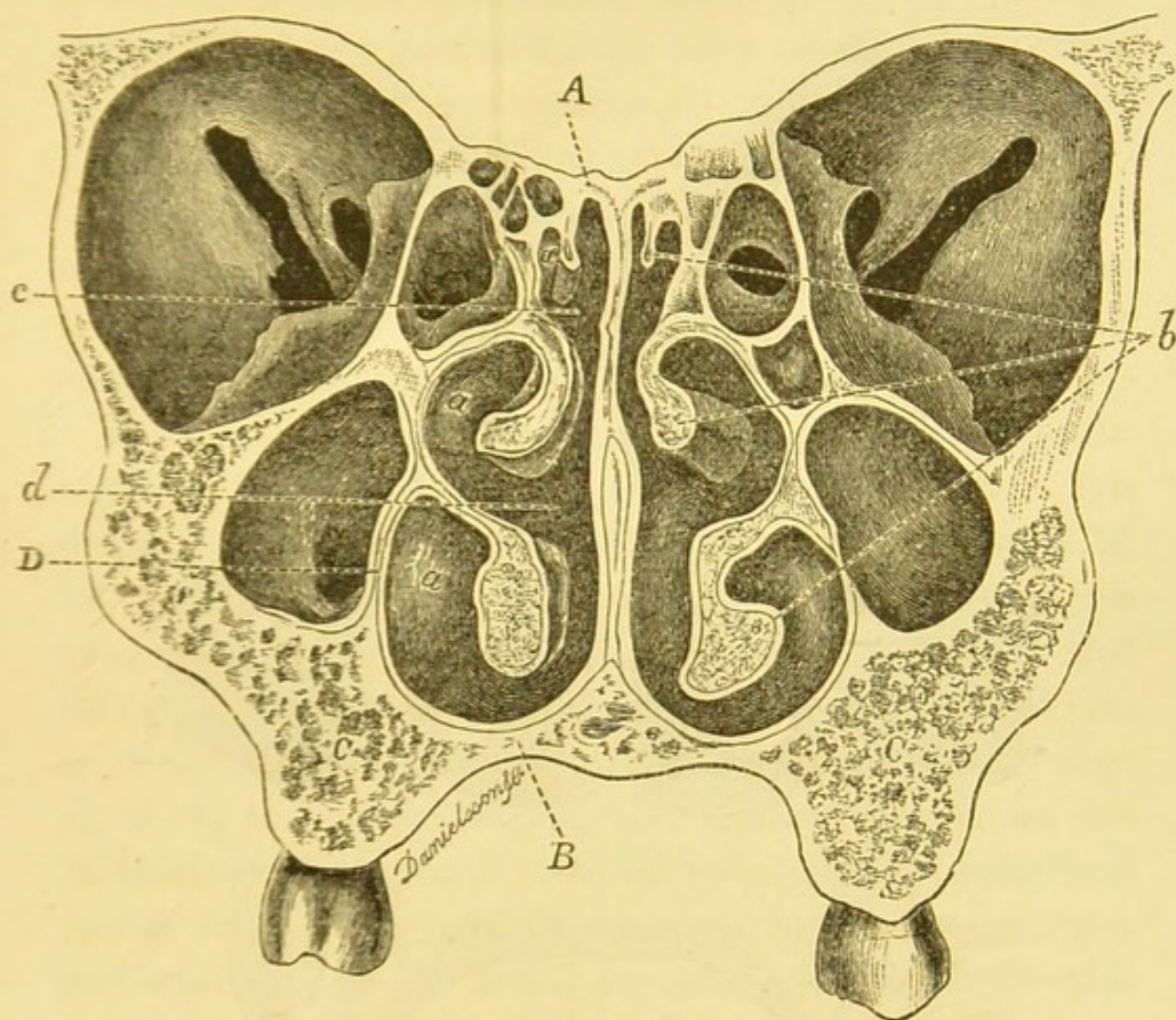


FIG. 2.—Vertical transverse section through the nasal fossæ, rather behind their centre (after Zuckerkandl).

A. Roof of nasal cavity. B. Floor of nasal cavity. CC. Alveolar processes. D. External wall of nasal cavity. *a.a.a.* Three meatuses. *b.b.b.* Three turbinated bodies. *c*. Olfactory slit. *d*. Respiratory region.

following the course of the anterior margin of the vomer; it may then constitute a deflection or bending of the septum. Morell Mackenzie\* found these ridges in 31·2 per cent. of the total number examined. In 375

\* *Op. cit.*, vol. ii., p. 390.



instances they were on the left, in 231 on the right side, and in 67 cases on both sides.

(2.) *Deflections* or true bendings may affect either a limited area or a large portion of the septum. They

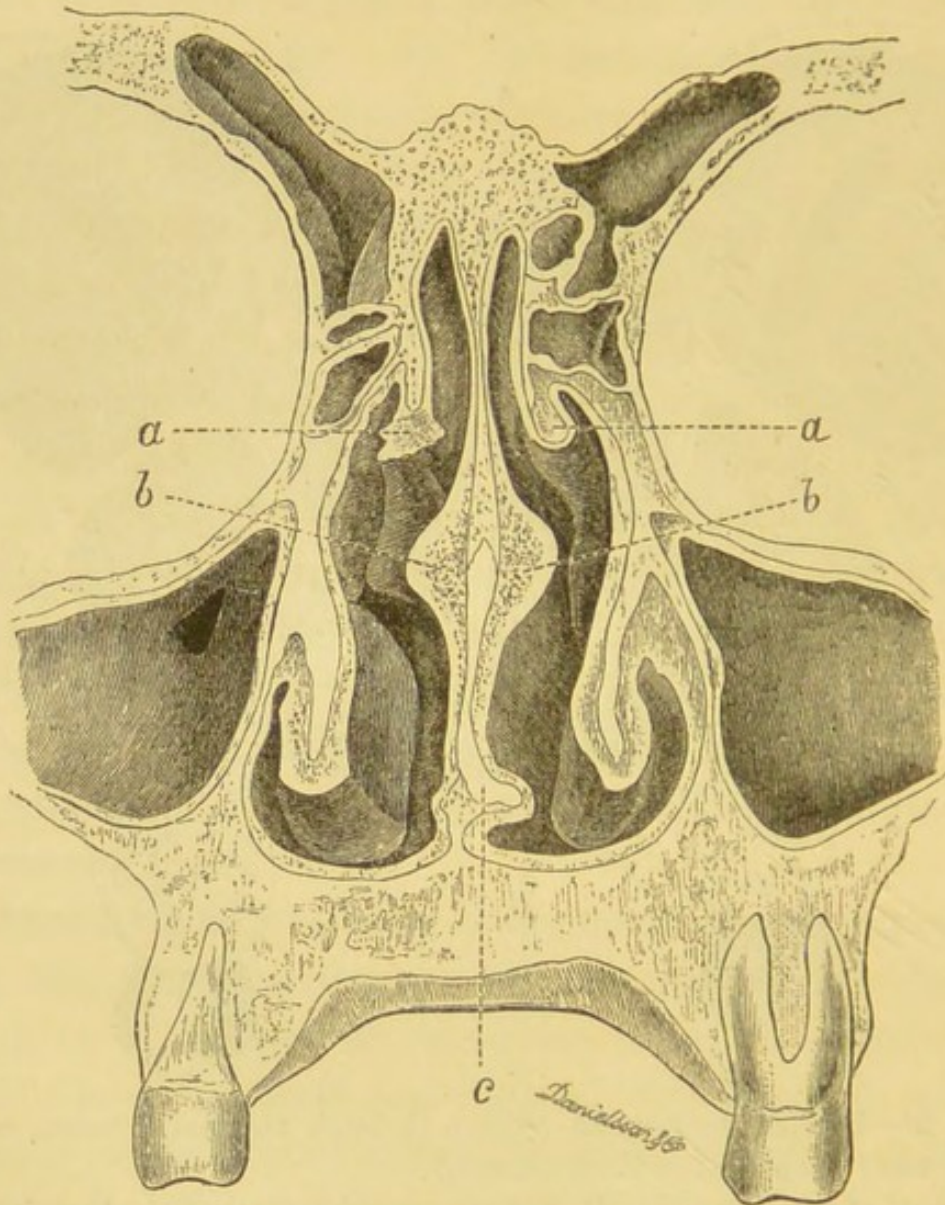


FIG. 3.—Vertical transverse section through the anterior region of the nasal fossæ, showing the tubercle of the septum (after Zuckerkandl).

*a. a.* Middle turbinated bodies. *b. b.* Tubercula septi. *c.* Lower end of the cartilaginous septum, which projects into the left nasal fossa immediately above the floor.

may be single, the septum being simply bent towards one side, or they may be double, the septum at one part being bent towards the right, while at another



part it is curved towards the left (the so-called sigmoid flexion). When the deflection is great the septum often presses on the turbinated bones, obstructing one side, whilst the other is abnormally dilated. It is noticeable that in the dilated nasal cavity the inferior turbinated body (including its bony elements) is often considerably larger than normal. The convexity of the deflection is usually towards the left.

The *relation of the several parts* composing the nasal cavities is made still clearer by the examination of fig. 2, which represents a vertical transverse section of the nasal fossæ rather behind their centre.

It is seen that at this point the cavities increase steadily in diameter, from above downwards. By drawing a horizontal line across the lower margins of the middle turbinated bones, the olfactory can be roughly separated from the respiratory region. The former is sometimes spoken of as the *olfactory slit* (*c*). A section in front of the superior turbinated bone (fig. 3), shows the thickening on the septum, known as the *tuberculum septi*, which will be subsequently described (see p. 20). A vertical transverse section through the posterior end of the nasal cavities exhibits above, the anterior surface of the body of the sphenoid, and below, on either side the posterior naris, the upper margin of which opening often presents on its *anterior* aspect, two curved ridges, the one a slight distance above the other. Each choana is half as high again as it is broad.

*Nasal Mucous Membrane.*—The bony and cartilaginous framework forming the nasal cavities above described, is lined with mucous membrane, which varies in character in its different parts. Like the mucous



membrane of the tympanum, it is inseparably united with the periosteum and perichondrium over which it lies (*Quain*).

The mucous membrane of the nasal cavities is divisible into two parts, viz.:—(1) That of the *olfactory region*, which occupies the superior and middle turbinated bones, and the upper part of the septum, and (2) that of the *non-olfactory* or *respiratory region*, which lines the remainder of the cavity, and is commonly known as the Schneiderian or pituitary membrane.

(1) In the *olfactory region* ("olfactory places," *Klein*) the mucous membrane contains the ramifications of the olfactory nerve, and is the seat of the organ of smell. In a practical work of this description it is not necessary to describe the minute anatomy of this mucous membrane.

It will suffice to state that it is provided with pigment which gives it a brownish or yellowish hue, and is covered by non-ciliated cylindrical epithelium.

According to *Klein*, not the whole of the olfactory region as usually described is covered with olfactory mucous membrane, but in many places we find smaller olfactory portions alternating with those of a non-olfactory character.

(2) In the *non-olfactory* or *respiratory region*, the nasal mucous membrane varies much in thickness in different parts. On the septum, and especially over the margins and extremities of the conchæ it is very thick, whilst in the intervals between the turbinated bones, and on the floor, it has a much thinner character. For practical reasons it is necessary to describe its structure more in detail. It is covered with columnar ciliated epithelium, similar to that of the larynx and trachea, containing



numerous secreting goblet cells (*Klein*). Below the epithelium and separated from it by a hyaline basement membrane, is a mucosa of fibrous tissue containing numerous lymph corpuscles. The infiltration with lymph corpuscles amounts in many places to diffuse adenoid tissue, or to actual lymph follicles. In addition to a network of capillaries in its superficial layer, the mucosa contains a remarkably rich plexus of venous vessels. The deeper parts of the mucous membrane contain numerous mucous and serous glands.

In parts where the mucous membrane is very thick, the glands are larger, and between them are found bundles of unstriped muscular tissue. This thickening of the respiratory mucous membrane is most marked on the inferior turbinated bone, and in this situation it forms the *erectile tissue*, (German "*Schwellgewebe*"), originally described by Kohlrausch in 1853, afterwards by Kölliker and Henle, and which has been recently carefully examined by Voltolini. According to this author, the erectile tissue is not confined to the posterior extremity of the inferior concha as supposed by Kohlrausch, but extends over the whole of that bone. It is probably most noticeable after death in the posterior part, on account of the blood gravitating into that portion of the turbinated body. The framework of this erectile body consists\* of connective tissue fibres, with many connective tissue corpuscles, and fibres of elastic tissue. The blood vessels are provided with endothelium, but are devoid of any other coats. The spaces formed by the vessels—*lacunæ*—are few, but of large size in the *anterior* part, whereas at the *posterior* part of the concha they are

\* Voltolini, *op. cit.*, p. 68.



smaller, but more numerous. A vertical section of the front part of the inferior concha, shows that the bony support contributes only about *one-twentieth part* of the whole turbinated body, the remainder consists of erectile tissue, which measures as much as 4 mm. (about  $\frac{1}{8}$  inch) in thickness (*Voltolini*).

*Tuberculum septi*.—The mucous membrane covering the septum is thicker in the olfactory than in the respiratory region. This thickening is especially marked at the front entrance to the olfactory slit, opposite the anterior end of the middle turbinated bone, where the accumulation of glandular elements leads to the formation of a distinct prominence, the *tuberculum septi*, (see fig. 3, *b. b.*, p. 16). This tubercle, which was first described by Morgagni, and has been recently figured by Zuckerkandl, as we shall see hereafter, has an important bearing on the examination of the nasal cavities from the front.

Each fossa communicates with five sinuses; the *frontal*, which with the *maxillary* and *anterior ethmoidal* opens into the middle meatus through the infundibulum; the *sphenoidal*, communicating behind with the middle meatus; and the *posterior ethmoidal*, opening by means of a small channel into the superior meatus. The nasal mucous membrane is continued through the openings into the different sinuses where it becomes very pale and thin in character. During life these apertures are much diminished in size by the surrounding mucous membrane.

The nasal mucous membrane is also continuous with the conjunctiva through the nasal duct, which opens at the front part of the inferior meatus, its mouth being defended by one or two folds of mucous membrane (*Quain*).



The *arteries* of the nasal fossæ require no special description. They are derived from the ophthalmic, which supplies the roof and the ethmoidal and frontal sinuses, whilst the lower part of the nasal cavities is provided with branches from the internal maxillary. The *veins* terminate chiefly in the internal jugular, but a few of them communicate with the veins in the interior of the skull through the cribriform plate of the ethmoid. The *lymphatics* join the retro-pharyngeal glands, (two small glands placed in front of the spine upon the recti capitis antici majores muscles) and others beneath the upper part of the sterno-mastoid.\* Some also enter glands situated on the surface and in the substance of the parotid gland (*Curnow*).†

The *sensory nerves* may be divided into those of special and those of general sensation. The *olfactory*, the special nerve of the sense of smell, is distributed to the olfactory portion of the nasal mucous membrane, as already mentioned. The nerves of general sensation are as follows: the *nasal branch of the ophthalmic* which supplies the upper and anterior part of the septum and the outer wall of the nasal fossa; the *anterior dental branch of the superior maxillary* which is distributed to the inferior meatus and inferior concha; the *Vidian nerve* and the *upper anterior branches of Meckel's ganglion* supplying the upper and back part of the septum and the superior turbinated bone; the *naso-palatine nerve* which ramifies on the middle of the septum; and lastly, the *anterior palatine nerve* which supplies the middle and lower spongy bones. All these branches are derived

\* B. Fraenkel, *Ziemssen's Cyclopædia*, London, 1876, vol. iv., p. 126.

† "Gulstonian Lectures on the Lymphatic System and its Diseases." *The Lancet*, 1879, vol. i., p. 833.



from the fifth nerve, and all excepting the first named are connected with its second division.

Branches from the *sympathetic* are also present in the nasal mucous membrane.

3. The **Naso-pharynx** (naso-pharyngeal cavity or post-nasal space) is that portion of the pharynx which is situated above the level of the floor of the nose (fig. 1, *e*, p. 4). Its position is behind the nasal fossæ, below the body of the sphenoid and in front of the vertebral column.

It is roughly speaking cubical in shape, though measuring somewhat more from side to side than from before backwards.

According to Luschka\* its height is 1·8 centimetres (nearly  $\frac{3}{4}$  inch) its antero-posterior measurement 2 centimetres (rather over  $\frac{3}{4}$  inch) and its greatest width  $3\frac{1}{2}$  centimetres (about  $1\frac{3}{8}$  inch). Its average capacity is barely 14 cubic centimetres.

It presents four walls, a roof and a floor.

The *anterior wall* is incomplete presenting two large openings, the *posterior nares* or *choanæ narium* leading into the nasal fossæ. The choanæ are separated by the posterior margin of the septum nasi which is thin and sharp in the centre, but expands towards the upper and lower parts. The margin of the septum is concave from above downwards, (see fig. 1, *u*) and is either vertical in position or, as commonly met with, extends considerably further backwards above than below. The turbinated bones do not normally extend into the naso-pharynx.

Each *lateral wall* of the naso-pharynx (fig. 1, p. 4)

\* Luschka, *op. cit.*, p. 17. He remarks that the dimensions of the naso-pharyngeal cavity are subject to considerable variations, independently of the size of the individual.



presents in front the pharyngeal orifice of the Eustachian tube (fig. 1, *v*). This is sometimes funnel-shaped, at other times triangular or semilunar, and is directed upwards backwards and outwards.\* It corresponds with the posterior end of the inferior turbinated body from which it is 7 millimetres (rather over  $\frac{1}{4}$  inch) distant. It is situated 7 centimetres (about  $2\frac{3}{4}$  inch) from the anterior nasal aperture (*Luschka*).

Above and behind, the Eustachian opening is bounded by a well marked ridge, the *cushion of the Eustachian orifice* (fig. 1, *y*), which is formed by a projection of the cartilage composing the walls of the tube.† Passing downwards from this and blending gradually with the mucous membrane on the posterior wall of the lower pharynx is the *salpingo-pharyngeal fold* (*plica salpingo-pharyngea*) which has been the subject of careful study by Professor Zaufal.‡

The lower part of this fold can be seen below the palate during life. It is just behind the posterior pillar of the fauces, and is often observed studded with granular elevations. The direct continuity of this fold with the Eustachian cushion above renders an examination of its lower part of importance to the otologist. In front, the Eustachian orifice is bounded by another though less marked ridge, the *salpingo-palatine fold* (*plica salpingo-palatina*) (fig. 1, *z*) which extends from the anterior part of the tubal orifice, to

\* Roosa, *Diseases of the Ear*, 4th edit., 1881, p. 209, describes it as "a trumpet-shaped orifice 9 mm. high and 5 mm. broad."

† In children the Eustachian orifice is comparatively large and is situated rather lower down. On the other hand, the Eustachian cushion scarcely projects at all, and the opening itself appears as a mere slit. (*Politzer*).

‡ "Die Plica salpingo-pharyngea (Wulstfalte)." *Archiv f. Ohren- heilkunde*, vol. xv., p. 95.



the lower margin of the choanæ. Below, it is limited by the prominence of the levator palati known as the levator cushion.

Behind the Eustachian opening, and separated from it by the Eustachian cushion and the salpingo-pharyngeal fold, is a depression, *Rosenmüller's fossa* ("Recessus Pharyngis lateralis" *Tourtual*, fig. 1, *aa*), which is sometimes crossed by irregular bands of mucous membrane. This fossa is much broader above than below, and varies in depth in different subjects. Its chief practical interest resides in the circumstance that in attempting catheterization of the Eustachian tube, the point of the instrument often becomes lodged here, instead of in the tubal orifice. Normally, except during contraction of certain muscles, the walls of the Eustachian tube lie more or less firmly in contact.\*

The *posterior wall* of the naso-pharynx commences below at the upper margin of the anterior arch of the atlas. Its lower part is vertical in direction, but above it curves forward forming the *fornix pharyngis* and passing insensibly into the roof of the cavity. The point of boundary is usually assumed to be the pharyngeal spine of the occipital bone. The posterior wall lies between the recti antici muscles, and in front of the anterior occipito-atloid ligament.

The *roof* of the naso-pharynx is horizontal and extends from the posterior margin of the septum nasi, to the spine of the occipital bone. It measures on an average two centimetres (rather over three-quarters of an inch) from before backwards, and corresponds externally to a line drawn immediately above the antitragus of the auricle (*Luschka*).

\* Politzer, *Lehrbuch der Ohrenheilkunde*, vol. i., p. 61.



A *floor* of the naso-pharynx exists only as such during contraction of the palatal muscles, when the naso-pharynx is occluded from the lower pharynx (oro-pharynx).

In the uncontracted state of these parts (as seen in fig. 1), the naso-pharynx is directly continuous with the lower pharynx, by means of a large space, which for convenience may be termed the *post-palatal orifice*. Just behind the posterior naris on each side, the soft palate usually presents a rounded eminence, the *levator cushion*, which may be seen even after death (*Zaufal*).

In *structure* the naso-pharynx consists of a fibrous aponeurosis attached above to the basilar process of the occipital and to the petrous portions of the temporal bones. On its outer surface, it has, in parts, muscular fasciculi; whilst its internal surface is lined by mucous membrane. A part of the lateral wall, together with the whole of the posterior wall and the roof are devoid of a muscular coat. Certain muscles enter into the formation of the soft palate and therefore form a part of the walls of the naso-pharynx. A brief allusion to them here, is all that is necessary.

The *levator palati* (petro-salpingo-staphylinus), from its origin on the petrous portion of the temporal bone and Eustachian tube,\* and its insertion into the upper surface of the soft palate in the median line, by its contraction raises the velum and renders the Eustachian orifice smaller, but at the same time less resistant to the passage of air (*Politzer*).

The *tensor palati* (spheno-salpingo-staphylinus) arising from the sphenoid bone and from the Eustachian

\* This attachment is denied by Politzer, *op. cit.*



tube and hooking round the hamular process tightens the palate, and at the same time opens the Eustachian tube, hence called by Von Tröltsch the *dilatator tubæ*.

The *azygos uvulæ* shortens the uvula and completes the partition between the upper and the lower pharynx during deglutition.

The *palato-pharyngeus* forms the posterior pillar of the fauces and passes from the soft palate downwards to be inserted into the thyroid cartilage after joining with the stylo-pharyngeus. It may be divided into two parts a palato-thyroid and a palato-pharyngeal portion (*Luschka, Zaufal*).

The *palato-glossus* forms the anterior pillar of the fauces. Together with the palato-pharyngeus it serves to contract the fauces and acting with the levator muscle it helps to keep the palate horizontal (*Morell Mackenzie*).

The method by which occlusion of the naso-pharynx from the lower pharyngeal cavity is effected, is, according to Zaufal (*op. cit.*), as follows:—In front is the levator cushion on the anterior part of the velum, behind this are the two contracted salpingo-pharyngeal folds which swell up greatly and meet in the middle line during retching and forced swallowing, but are not quite in contact during phonation and ordinary deglutition. The interval between them is filled up by the contracted azygos muscles, whilst behind the opening is closed by a projection forwards of the posterior pharyngeal wall. The portion of the velum behind the levator cushion (including the uvula) takes only a secondary part in the closure of the post-palatal orifice, and serves as additional security to the primary occlusion.



The *mucous membrane* lining the naso-pharynx, unlike that of the lower portions of the pharynx, is covered with cylindrical ciliated epithelium. It contains glands of two kinds, conglomerate and follicular. The former are the more abundant particularly at the posterior margin of the Eustachian tubes and on the posterior surface of the velum palati (*Morell Mackenzie*).

At the upper part of the cavity the follicular glands are collected together to form a body of some size termed by Luschka the "*pharyngeal tonsil*."

The *pharyngeal tonsil* is a soft mass measuring normally not more than 7 millimetres (rather over a  $\frac{1}{4}$  inch), in thickness. It occupies the roof and the upper part of the posterior wall of the naso-pharynx, reaching from the posterior margin of the roof of the nasal cavities to the edge of the foramen magnum of the occipital bone. Laterally it extends into Rosenmüller's fossæ, and on to the Eustachian cushions. It is always present, although its size varies in different subjects. It usually takes the form of a cushion, with irregular indentations, measuring as much as 7 millimetres (rather over a  $\frac{1}{4}$  inch), in depth, at other times it occurs as folds which are either longitudinal or form a regular network, most rarely it forms a cushion with small round elevations on its surface. Its lower part presents a larger opening leading into an oblong pouch-like dilatation, the *bursa pharyngea*, which may measure as much as  $1\frac{1}{2}$  centimetres (about  $\frac{3}{8}$  inch) in length, and 6 millimetres (nearly  $\frac{1}{4}$  inch) in width. The pharyngeal tonsil is covered by the ciliated epithelium of the cavity, and consists of an ill-defined glandular mass similar in structure to the palatine tonsils, being composed of acinous glands and



of numerous follicles of adenoid (or lymphoid) tissue. The pharyngeal tonsil is closely connected with the cartilaginous tissue which unites the pharynx to the base of the skull.

The *arteries* of the naso-pharynx are the ascending pharyngeal from the external carotid, some terminal branches from the internal maxillary, and the ascending palatine branch of the facial.

The *veins* terminate in the internal jugular.

The *lymphatics* of the naso-pharynx empty themselves into glands on the surface and in the substance of the parotid glands, and into the retro-pharyngeal glands. Those from the soft palate partly enter glands around the internal, and near the bifurcation of the common carotid, and partly join glands on a level with the hyoid bone (*Curnow*).

The *sensory nerves* of the naso-pharynx are branches of the second and third divisions of the fifth nerve, the latter supplying chiefly the soft palate.

## PHYSIOLOGY.

The nose, in addition to being the seat of the special sense of smell, forms the uppermost part of the respiratory tract, and is intimately concerned in the production of the voice and in the sense of taste. The external nose also modifies the expression of the face. Indirectly, moreover, the nasal cavities assist in the functions of the eye and ear.

**Respiration and Smell.**—Normally (unless the breathing be hurried, *e.g.* by violent exercise), respira-



tion takes place entirely through the nasal cavities, the mouth at the same time being closed.

Here it is interesting to notice Ziem's remark that all animals breathe with their mouths shut.\* During quiet nasal respiration the main current of air passes through the lower or respiratory channel, (see p. 18), some of the air becoming diffused into the olfactory region, as shown by our spontaneous recognition of strong smells. When it is desired to smell any substance, the air containing the odoriferous particles is drawn more directly into the olfactory region by repeated short sharp inspirations, which we term "sniffing." The effect of this proceeding is, in the first place, to create a vacuum in the naso-pharynx, which would naturally be replaced by a current of air passing through the lower or respiratory channel. Owing to the horizontal position of the external nostrils, however, the current of air enters in a *vertical* direction. The result of these two circumstances being, as Zuckerkandl points out, that the air in the nasal fossæ assumes a diagonal direction, and thus enters both portions of the nasal cavity. During the process of "sniffing," the vestibule becomes flattened from side to side from the pressure of the outer air on the lateral cartilages, rather than from any muscular action. In all probability this arrangement also favours the vertical direction of the current on entering the nostrils. We see, therefore, that the horizontal position of these openings has an important bearing on the mechanism of smell. The results occurring from a want of this

\* *Monatsschrift f. Ohrenheilkunde*, xiii., i. An exception occurs (*e.g.*, in dogs) when the mouth is kept open to allow the tongue to serve as an organ of perspiration to equalise the temperature of the body.



position are seen in cases in which the nostrils form two almost vertical openings, owing to the absence of the cartilaginous nose. Under these circumstances the sense of smell is almost or entirely lost, but can often be restored by an artificial nose. Spencer Watson\* attributes the loss of smell in these cases to excessive dryness of the mucous membrane. It is more probably due, as Zuckerkandl suggests, to the vertical position of the nostrils, allowing air to enter the naso-pharynx, through the lower part of the nasal cavities, without entering the olfactory region in sufficient quantity to produce a well marked sensation of smell.

Bidder's idea that the inferior turbinated body was essential to olfaction, does not appear to have been in any way proved; although when we consider how narrow is the slit (fig. 30), through which the air has to pass *before it reaches the olfactory region*, there can be no doubt, I think, that it becomes to a certain extent warmed and more highly charged with moisture, both of which qualities probably facilitate the perception of the odoriferous particles which it contains. Morell Mackenzie's observations have shown that the air passing through the nasal cavities becomes warmed *before it reaches the pharynx*.† He thinks, however, that the real use of nasal inspiration consists rather in the protection it affords against the entrance of minute foreign bodies suspended in the air, than in its thermic effect. The narrowness of the anterior part of the nasal

\* *Diseases of the Nose and its Accessory Cavities*, London, 1875, p. 312.

† *Op. cit.*, vol. ii., p. 373. By fixing the bulb of a thermometer in the pharynx without allowing the instrument to touch the lips, it was found that gentle nasal inspiration lowered the temperature half a degree below 90°, whilst gentle oral inspiration lowered the temperature a degree and a half.



passage and consequently its efficiency in warming the air, which enters both olfactory and respiratory regions, is of course much increased by erection of the anterior extremity of the inferior turbinated body (see fig. 36). I leave out of consideration the theories regarding the perception of impressions by the terminal branches of the olfactory nerve (such as Dr. W. Ogle's view\* which associates olfaction with the presence of pigment in the cells) as they have no immediate practical bearing on our subject. It must be mentioned, however, that a normal condition of the mucous membrane appears to be essential to the due performance of the function of olfaction. Thus, long-continued paralysis of the fifth nerve destroys smell by interfering with the proper nutrition of the mucous membrane (*Morell Mackenzie*). Both excessive dryness and excessive moisture undoubtedly interfere with the sense of smell. Thudichum† gives the effect produced by different liquids on the olfactory mucous membrane, thus:—After *water* has been allowed to run through the nose, it takes two and a half minutes before the sense of smell returns in its integrity; after *saline* solutions one and a half minutes; but after *alkaline* solutions one minute allows the perception of odours to be clearer than before the application. The different impediments to the access of odoriferous particles to the olfactory region will be subsequently considered.

**Taste**, as popularly understood, consists in reality in large part of smell. Only four qualities, those of acidity, bitterness, saltiness, and sweetness, are appreciated by

\* See paper on Anosmia, *Medico-Chirurgical Transactions*, vol. xxxv. p. 263.

† *On Polypus in the Nose, etc.*, 3rd edition, 1877, p. 31.



the nerves of taste, the glosso-pharyngeal and lingual. Other "tastes" are in reality "smells" of substances contained in the mouth, appreciated by means of the odoriferous particles passing through the posterior nares to the olfactory nerves. This is very simply proved by closing the anterior nares and taking a highly flavoured substance (such as a piece of cheese) into the mouth, when the flavour is hardly, if at all appreciated, until the anterior nares are unstopped. For a like reason the appreciation of a flavour is most intense, the moment *after* swallowing, when, as is always the case, a slight expiratory puff through the nares occurs.

**The effect of the nasal cavities on the voice** has been carefully studied by C. Seiler\* who arrives at the following conclusions:—The nasal cavity exerts a great influence on the sound of the voice, especially during articulation. Being separated from the mouth by a thin partition only, the air contained in it participates in the vibratory motion. It therefore acts as a resonating cavity which adds both volume and character to the sound. In order to exert its full influence the nasal cavity should have free communication with the outer air through the anterior nares, and should be closed behind except during the pronunciation of M and N, in which case it does not act as a resonant cavity but simply as an outlet for the breath. When paralysis or perforation of the soft palate exists, the voice has a nasal sound from there being too strong a resonance in the nasal cavity. The formation of consonants is also interfered with in such a case, because most of the air escapes through the nose and not enough through the mouth to produce them sufficiently loud and distinct.

\* *Archives of Laryngology*, vol. iii., part i.



On the other hand if there be stenosis of the posterior opening of the nasal cavity, from adhesion of the soft palate or other causes, little alteration in speech is noticed, except that the patient cannot pronounce M or N. When there is stenosis of the anterior nares, the vibrations of the air within the cavity cannot come out, they are therefore inaudible to another person, though very loudly heard by the speaker himself. The listener hears the voice without its being qualified and intensified by the nasal resonance. There is no difficulty in pronouncing the consonants, except M and N, which, as in posterior stenosis, become B and D.

With most of these views other observers are in accord, but exception may I think be fairly taken to the statement of the effect on the voice produced by closure of the anterior nares. Closure of the anterior nares according to Michael Foster,\* renders the voice nasal in character, the nasal cavities then forming a cavity of resonance. Morell Mackenzie† also says, that when the anterior nares are completely obstructed, the voice has a nasal twang in all its tones, whilst when the stoppage is confined to the posterior nares, the general character of the voice is normal, but the articulation of M and N is defective, M becoming B and N being sounded as D. Lennox Browne and Behnke‡ consider on the other hand, that there can be no nasal twang whatever, whilst the singer or speaker has the power to raise the soft palate sufficiently to prevent the tone from entering the nostrils. But they admit further on, that however tight the closure of the soft palate may be, it is never

\* *Text Book of Physiology*, London, 1877, p. 468.

† *Op. cit.*, pp. 288 and 289.

‡ *Voice, Song, and Speech*, 3rd Edit., 1884, p. 213.



sufficient to prevent the air in the nasal cavities from being thrown into co-vibrations with that in the mouth. If these are prevented by stoppage of the posterior openings of the nasal passages, the voice will sound dull and muffled from an absence of nasal resonance.

The discrepancy in these opinions is probably dependant, in a large measure, on different meanings attached to the words "nasal resonance," "nasal voice," and "nasal twang."

As far as I have been able to form an opinion, the truth lies between these conflicting statements. Complete closure of the anterior nares affects the voice, as heard by another person, in the following manner:—The *non-nasal vowels* (i.e. vowels pronounced properly, so that no air enters the nose) are not appreciably affected. The *non-nasal consonants* (such as B, D, C, S, etc.), are not altered. The *nasal vowels* (i.e. vowels pronounced with an escape of air into the nose) become more distant, their resonance is altered in character. The *nasal consonants* (M and N) are heard more distantly and with an altered nasal resonance, in contradistinction to obstruction of the naso-pharynx, which deprives them of all nasal resonance.

W. Meyer\* draws attention to the fact that when growths obstruct the posterior nares, but do not project into the naso-pharynx, a certain resonance of the voice still remains, as the naso-pharynx is possessed of a resonance of its own.

\* *Ueber Adenoide Vegetationen der Nasenrachenhöhle*, Leipzig, 1873, p. 36, (reprint from *Archiv für Ohrenheilkunde*).



## CHAPTER II.

## SYMPTOMS OF NASAL DISEASE.

BEFORE proceeding to the physical examination of the nose, it will be useful to consider briefly the chief symptoms of persons suffering from affections of this organ.

**Nasal obstruction and its consequences.—**

The nose being the natural air-way during repose, any interference with its patency is usually noticed by the patient. If marked, it necessitates the mouth being kept constantly open. The obstruction may affect one or both sides, and may be inspiratory or expiratory, but is usually both. It may also be temporary or constant, and is often increased by the patient's assuming the horizontal posture. A common result of nasal obstruction is *inability to sleep*. The patient wakes up, as he will tell you, "fighting for his breath." A further consequence of nasal stenosis is *noisy respiration*. The patient's friends notice that he makes much snoring noise when sleeping, and even at other times the breathing of such a person is sometimes plainly heard at a distance. This is particularly noticeable during meals from the interference with mouth-breathing caused by the act of eating. In infants, nasal obstruction has still more serious consequences; it not only prevents sleep, but also renders them unable to suck, thus seriously impairing their health.\* Dryness

\* Compare the observations of Kussmaul and Honsell, made on new-born children, (Ziem, *Monatsschrift f. Ohrenheilkunde*, xiii. 1).



of the mucous membrane of the mouth and pharynx are also frequent consequences of nasal obstruction.

**Discharge.**—Discharge from the nose may be of any consistence, varying from a clear serous liquid to a thick purulent secretion. It may also present the form of hard crusts of inspissated pus. In the latter case it often has a very offensive smell. The quantity of discharge varies greatly. When serous it may be so great as to produce a constant stream running from the nostrils. When the secretion is purulent or muco-purulent in character, it is often very copious and may necessitate the use of many handkerchiefs during a single night. The discharge may escape through the anterior or posterior nares, in the latter case passing into the pharynx.

**Hæmorrhage** from the nose—epistaxis—is often the result of injury to that organ. It may also arise from local disease in the nasal cavities, but is more commonly met with as a concomitant of disorders of the blood generally, or of a strain on the vascular system. The hæmorrhage no doubt often proceeds from the rupture of a vessel on a swollen inferior turbinated body.

**Sneezing** is a reflex phenomenon which is usually caused by some irritation of the branches of the fifth nerve distributed to the nasal mucous membrane. It may, however, be produced by the irritation of nerves in other parts, as for example sneezing caused by exposure to strong light. As a symptom, it is of importance, indicating as it does, intra-nasal irritation. Apart from the application of a direct irritant, such as powdered pepper, the galvanic cautery, etc., it occurs perhaps especially in acute catarrh, in hay-fever and in morbid swelling of the inferior turbinated body.



**Loss of smell and the taste of flavours** are of frequent occurrence in diseases of the nose. They may occur together or separately, in the latter case it is usually the sense of taste, rather than that of smell, which persists.

**A sensation of dryness** in the nose is sometimes complained of, and is chiefly noticed in the atrophic form of catarrh leading to ozaena. This symptom is more commonly referred to the naso-pharynx than to the nasal cavities proper. We all know it in the first stage of acute nasal catarrh, and it is frequently met with in chronic naso-pharyngitis.

**Feeling of pain or weight in the nose.**—Pain is not a very usual symptom of nasal disease; but a sensation of weight in the bridge of the nose is often complained of by patients, particularly by those suffering from thickening of the mucous membrane of the middle turbinated body. Pain and weight are felt in the forehead when the frontal sinuses participate in inflammatory affections of the nose, similar symptoms occur in the cheek when the maxillary antrum is involved.

**A sensation of something moving to and fro in the nose on respiration** is occasionally met with. It may be produced by a mucous polypus (or other pedunculated growth), or by loose hypertrophied mucous membrane at the posterior extremities of the inferior turbinated bones. A case of the former kind recently under my care, will be mentioned on a subsequent page. (*See Appendix, Case III.*)

**Affections of the voice.**—Thickness of articulation, undue nasal resonance, inability to pronounce certain consonants and impairment of the high notes of the singing voice, are often mentioned by patients and



should lead to a careful examination of the nasal cavities.

**Deafness and noises in the ears**, in other words, diseases of the ear, are very common indirect consequences of intra-nasal disease. Speaking generally, diseases of the nose may affect the ears in two ways:—1, by extension of the inflammatory condition of the nose to the Eustachian tubes and tympanic cavities; 2, by the interference with the proper ventilation of the middle ear, in consequence of the nasal obstruction. A clear passage for air through the nose is undoubtedly necessary for normal hearing, for when the nostrils are completely obstructed, at each act of deglutition the tympanic cavities, instead of being filled with air, are exhausted and the membranes drawn in, in fact Toynbee's experiment is performed. A very slight passage of air, however, is sufficient to ventilate the tympanic cavities, as cases are often met with, in which the hearing is not appreciably affected although there is almost complete nasal obstruction. Actual pressure on the mouth of the Eustachian tube by a growth such as an adenoid vegetation or a nasal polypus, though of rarer occurrence, may affect the ear by closure of the tube.

**Reflex phenomena.**—*Serous or mucous discharge* from the nose is frequently a phenomenon of a reflex character and due to nervous influence on the glands of the nasal mucous membrane. In estimating the amount of this secretion, we must not forget that the flow of tears may be reflexly increased by an irritation applied to the lining membrane of the nose.

*Sneezing* is, as has been already mentioned, a reflex phenomenon. There are moreover other symptoms



produced in a reflex manner by certain states of the nasal mucous membrane. The attention of observers has only recently been drawn to these phenomena, our knowledge of them is therefore still very imperfect.

*Cough* is frequently due to nasal disease (John Mackenzie,\* Seiler,† Hack‡). I have several times observed that on touching the anterior extremity of one inferior turbinated body gently with a probe, a slight hacking cough was produced in patients who were not suffering from spontaneous cough, and I have recently had under my care a young woman with a violent spasmodic cough, an attack of which could be immediately induced by touching the anterior part of either inferior turbinated body with the blunt end of a probe. The case was much improved, for a time at least, by a single application of the galvanic cautery to each inferior turbinated body. The conclusion, therefore, is that in cases of cough not accounted for by symptoms in the chest or throat, the nasal cavities should be subjected to a careful examination.

*Asthma*, as a result of nasal stenosis produced by polypi, was first described by Voltolini in 1871. Since then attention has been gradually drawn to the subject, and there are now many cases on record in which bronchial asthma has been ascribed to intranasal irritation (amongst numerous other cases, those of

\* *American Journal of Medical Science*, July, 1883, and *New York Medical Record*, May 3rd, 1884.

† *Archives of Laryngology*, vol. iii., part 3, 1882.

‡ *Ueber eine operative Radical-Behandlung bestimmter Formen von Migräne, Asthma, Heufieber, etc.* (On the Radical Treatment by operation of certain forms of Migraine, Asthma, Hay Fever, etc.), Wiesbaden, 1884.



Hack,\* Morell Mackenzie,† Sommerbrodt,‡ Meyerson,§ B. Fränkel,|| A. Klein,¶ Schäffer,\*\* and Götze.†† Polypi have sometimes been the cause, but there are other cases in which there was only present a swollen condition of the inferior turbinated body. The removal of the polypi or the cauterisation of the swollen erectile body has sufficed to cure the asthma either temporarily or permanently. A remarkable feature noticed by some observers (*e.g.*, Hack, Sommerbrodt) is that occasionally the asthma affects only one side of the chest.‡‡

*Redness and swelling of the outside of the nose* may be due to reflex vessel-dilatation, produced by irritation of the turbinated bodies. It was noticed among the first by Bresgen,§§ Elsberg,||| and more recently by Hack, Schäffer,¶¶ and Götze.\*\*\* Hack has described numerous cases of well-marked redness and swelling of the

\* *Ibidem*, 1884.

† *Op. cit.*, vol. ii., pp. 361 and 362, 1884.

‡ *Berliner Klin. Wochenschrift*, 1884, No. 10, abstract in *Centralblatt für Laryngologie*, I, 2.

§ *Centralblatt für Laryngologie*, I, 2, 1884.

|| *Berliner Klin. Wochenschrift*, 1881, Nos. 16 and 17.

¶ *Wiener Mediz. Presse*, 1884, No. 24; (*Centralblatt für Laryngologie*, I, 8).

\*\* *Deutsche Medizin. Wochenschrift*, Nos. 23 and 24, 1884, (*Centralblatt für Laryngologie*, I, 8).

†† *Monatsschrift für Ohrenheilkunde*, xviii., 9 and 10, 1884.

‡‡ Ringer has evidently for some time past recognised the connection between nasal symptoms and asthma for he has related several cases, (*Handbook of Therapeutics*, 10th Edition, p. 290, *et seq.*), in which sneezing and itching of the nose were associated with asthmatic symptoms, but it does not seem to have occurred to him that light might be thrown on these cases by an examination of the nasal cavities.

§§ *Der chronische Nasen- u. Rachenkatarrh*, 1883, quoted by Morell Mackenzie.

||| "Reflex and other phenomena due to nasal disease," *Archives of Laryngology*, vol. iv., 1883.

¶¶ *Loc. cit.*

\*\*\* *Loc. cit.*



skin of the nose and adjacent parts which were relieved by treatment (galvanic cautery) applied to the interior of the nose. As far as I have seen it, this redness is most marked on the *ala of the nose* from whence it runs forward towards the tip. In acute catarrh it is a matter of every day occurrence. In this disease I have seen it distinctly confined to one half of the nose and limited by the median line.

So common is reflex vascularity of the ala of the nose that unless there be any other obvious cause for the redness, such as acne, I consider its presence should at least lead us to suspect irritation within the nasal cavities.

*Itching* of the ala of the nose and of the interior of the vestibule is a common symptom of intra-nasal irritation. When occurring on the ala it is occasionally associated with redness, and is probably due to reflex dilatation of the vessels.

*Nightmare, migraine, constant headache, supraorbital neuralgia, pain in the eyelids, giddiness, epilepsy, chorea,* and other reflex phenomena have been ascribed to intra-nasal affections and apparently with justice, for according to Hack and others these symptoms have been benefited or relieved by treatment applied to the nasal cavities.\*

The combined experience of many independent observers therefore appears to show that certain symptoms not hitherto suspected of having any relation to the nose, are in a reflex manner dependent upon disease of that organ.†

\* It is possible, however, that in some cases the galvanic cautery and other energetic modes of treatment may alleviate the symptoms by their counter-irritant effect.

† See Proceedings of the Laryngological section of the eighth Inter-



The exact mode, however, in which they originate and whether from any special parts of the mucous membrane is still undecided.\*

national Medical Congress at Copenhagen, 1884, *Centralblatt für Laryngologie, Rhinologie, etc.*, I, 4, edited by F. Semon; also Proceedings of the Laryngological section of the 57th meeting of German Naturalists and Physicians, Magdeburg, 1884, *Ibidem*, I, 5.

\* Whether the anterior or posterior parts of the turbinated bodies more commonly give rise to these reflex neuroses is still an open question. John Mackenzie is in favour of the latter region, whilst Hack, and with him many other observers, regard the anterior parts as the usual seat of the irritation. There is no doubt, however, that the irritation may originate in other parts of the nasal mucous membrane, such as the middle turbinated body. Woakes (*Post-Nasal Catarrh*, 1884, p. 107) considers that many wide-reaching reflexes originate in the naso-pharyngeal cavity. Hack (*op. cit.*), was at first of opinion that these reflex neuroses only occurred after erection of the anterior part of the inferior turbinated body, but he now (*Deutsche Medizinische Wochenschrift*, July 10th, 1884) admits that this is not necessary for their production. It is to be noted that when the nasal passages are completely blocked by polypi, reflex neuroses are often absent, but that they may make their appearance after the fossæ have been made pervious by operative means (compare Hack, *op. cit.*, p. 10, and author's Case III., in Appendix). They are therefore not produced by nasal obstruction.



## CHAPTER III.

## PHYSICAL EXAMINATION OF THE NOSE.

HAVING had our attention drawn to the nose by one or more of the symptoms described in the previous chapter, we proceed to an examination of the organ.

Before doing so, however, there are two or three points to which attention should be directed, as they may afford important clues for subsequent guidance.

1. **Exterior of the nose, and aspect of the face.**

It is not the purpose of this work to treat of diseases of the external nose, but we must not neglect its inspection, for examination of the exterior will often assist in the diagnosis of internal disease.

Bendings of the dorsum nasi from the median line should be noticed, as they will be a guide to deflections seen in the interior. The dorsum of the nose may, however, be externally quite straight, though marked deflections are present within. The bones and cartilages are sometimes bulged outwards by polypi or other intra-nasal growths, which in some cases may even appear through the nostrils.

When the nasal cavities are completely impervious, or in a less degree, when they have been much obstructed for a length of time, the nose presents a pinched aspect. Its alæ are pressed against the septum and wasted. The mouth being constantly more or less open, the folds between the nose and upper lip are obliterated, whilst owing to the connection which sub-



sists between the orbicularis oris and other muscles of the face,\* the inner canthi of the eyes are drawn down, the eyebrows pushed upwards, and the skin of the forehead corrugated. The face altogether acquires a dull listless expression. (Fig. 4). This picture is most common in children suffering from adenoid vegetations of the naso-pharynx, but may result from any form of nasal obstruction.

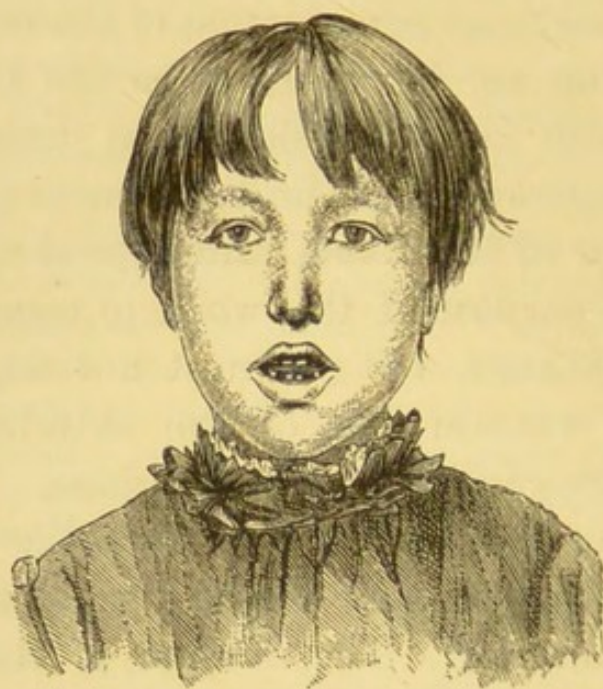

FIG. 4.—Portrait of a patient aged 9 years, suffering from nasal obstruction due to adenoid vegetations of the naso-pharynx. The pinched nose and general characteristics of nasal stenosis are well seen. (From a photograph).

The broad flattened bridge in cases of ozæna, the great depression of the nasal bones occurring from loss of bone in tertiary syphilis, need only a passing mention.

Redness of the alæ and tip of the nose, as already noticed, unless due to some other obvious cause, should

\* W. Meyer, *op. cit.*, p. 25.



lead us to suspect irritation in the nasal mucous membrane.

Excoriations at the edges of the nostrils are common when there is much secretion from the nasal cavities.\*

**2. Character of the voice.**—Important information may be gathered by observing the character of the voice. The effect on the voice produced by obstruction of the nasal passages in front and behind has already been described. (See p. 32 *et seq.*).

**3. Test for patency of nasal passages.**—The patency of the nasal passages may be simply ascertained as follows:—Close one nostril with the finger, directing the patient to shut his mouth and expire forcibly. The sound produced by the escape of air, will, with a little practice, enable the observer to estimate roughly the patency of the unclosed side. The broad soft sound of a wide canal contrasts markedly with the shrill note of a much obstructed passage.

A comparison of the sound heard on the two sides, renders it still easier to form a correct estimate. The amount of exertion required by the patient to empty his lungs through one nostril, and the time occupied in so doing, also assist us, almost unconsciously, in forming a judgment.

Inspiration may be used in a similar manner, but the expiratory sound is generally sufficient.

For practical purposes it is also extremely important to ascertain whether the patient can breathe for several minutes comfortably with his mouth closed, (*i.e.*

\* Dr. W. Meyer (verbal communication) has frequently observed that in cases of chronic nasal catarrh, the *cutis* extends further into the floor of the nose than is normally the case. On either side a longitudinal groove lined with epidermis, passes from the upper lip into the vestibule and even into the nasal fossa.



whether the air-way through the two nostrils combined is sufficient for quiet respiration).

4. **Character of the patient's breath.**—During the proceedings just described there is no difficulty whatever in ascertaining whether the air emanating from the patient's nostrils, has the foetid smell characteristic of ozæna. It is important to notice this and it may be necessary to ascertain if the smell is confined to one side or occurs in both. Unilateral ozæna is said to be connected with abscess in the antrum.

5. **Examination of the senses of smell and taste.** This is by no means always needful, and the patient's word may generally be taken as to his capacity in these respects; still when there is any doubt, especially if the patient be an unintelligent person, these senses should be tested by the surgeon.

In examining the power of smell, the manner is simply to close one nostril and apply some strong smelling article, such as peppermint, oil of cloves, etc., to the other. The scent used should be one with which the patient is acquainted and care must be taken not to employ any substance, such as ammonia, which acts on the branches of the fifth and not on the olfactory nerve. In trying the sense of flavour-taste, no mistake can be made, if the distinction between *true taste* (by means of the glossopharyngeal and lingual nerves) and the *taste of flavours* (by means of the olfactory nerve) be borne in mind. (See p. 31).

These preliminary observations over, we may proceed to a direct examination of the nose. This may be accomplished by two methods, viz:—Inspection and Palpation. Inspection (technically called Rhinoscopy) may be either anterior or posterior, according to whether it



takes place from the front through the anterior nares or from the back behind the velum palati.

Each of these methods, from its importance will require a detailed description.



## CHAPTER IV.

## ANTERIOR RHINOSCOPY.

By placing the patient opposite a strong light and raising the tip of his nose forcibly with the thumb, the orifice can be examined, and a glimpse of the interior of the vestibule and nasal cavities obtained, but in order to examine the deeper parts, it is necessary to have a speculum for dilating the nostril and for raising the tip of the nose; also some means of throwing a powerful light into the interior. A probe is, moreover, required for controlling the appearances presented to the eye, and for ascertaining the reflex irritability of the different intra-nasal structures.

**Nasal Specula.**—Much ingenuity has been shown by different observers in devising these instruments.

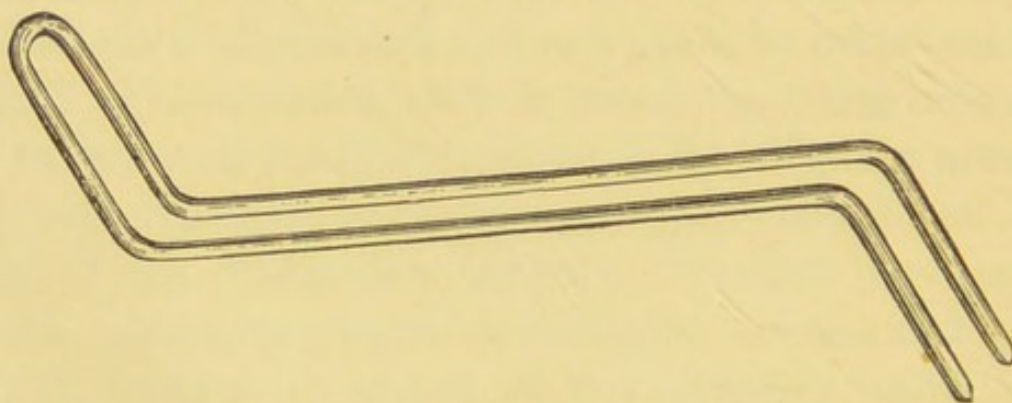


FIG. 5.—ONE HOOK OF JURASZ'S NASAL SPECULUM. Reduced in length. (C. Wright & Co., London).

The simplest of all, and one which can be extemporised at a moment's notice consists of a *bent hair-pin*. The prongs of an ordinary hair-pin are separated about half an inch, and at rather over three quarters of an



inch from the closed end they are bent over at right angles. *Jurasz's Speculum*\* (fig. 5), is composed of two hooks of stout wire made on this principle, with the addition that the free ends of the wire are also bent at right angles to the shaft, but in the opposite direction. The shaft measures about  $2\frac{3}{4}$  inches in length. In using the hair-pin speculum, the observer raises the tip of the patient's nose by means of his thumb, whilst with the hook he draws the ala outwards. Jurasz employs his hooks either by inserting one into each nostril and drawing the alæ apart or by fixing the septum by means of one hook, whilst with the other the ala nasi is pulled aside. When he wishes to avoid all contact with the inferior turbinated body, he uses the pointed end of the hook, passing one point into the inferior and one into the middle meatus.

In my hands, these specula have not been very useful. I should feel inclined to employ them only in the absence of others. They possess the great disadvantage of requiring the observer to use both hands.

*Fränkel's Speculum* (fig. 6) has two oblong-shaped blades of stout wire, attached to a light frame-work provided with a screw, by means of which they can be accurately separated to any given distance. A common fault in those found at surgical instrument makers is that the blades themselves are too much curved on the flat, they should be only slightly bent. This is the speculum which I almost invariably employ for simple examination in adults. The distance between the blades can be so accurately regulated that its use is by no means painful to the patient.

With a little practice, it can be inserted and dilated

\* *Monatsschrift f. Ohrenheilkunde*, 1881, No. 6.



with the left hand only, leaving the right hand free to direct the light or to guide the patient's head. I generally insert both blades into one nostril, but the inventor of the instrument rather favours the plan of placing one blade in each nostril,\* thereby avoiding any

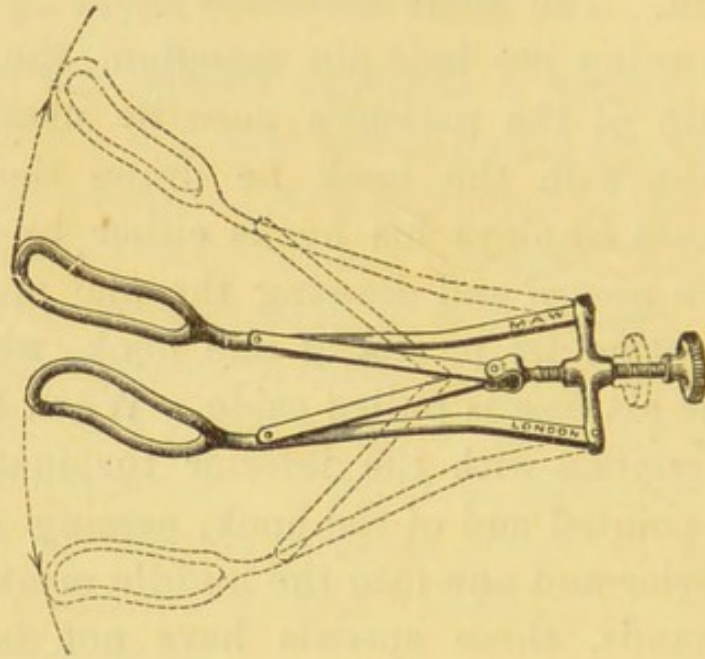


FIG. 6.—B. FRÄNKEL'S SPECULUM.

pressure on the septum, a point which is of great practical importance in the use of any nasal speculum.

*Modifications of Fränkel's Speculum.*—Von Tröltsch has modified this instrument by giving it solid blades about one inch in length placed almost at right angles to the branches.† Sometime ago I had one made with blades of thick silver wire so that they could be bent as occasion required, and joined to the shaft by hinges allowing them to be moved backwards and forwards; but I have not found it of any special advantage.

*Tubular Specula.*—A simple speculum which comes

\* Article on "The general diagnosis of diseases of the Nose, Pharynx, and Larynx." Ziemssen's *Cyclopædia*, London, 1878, vol. iv., p. 57.

† *Ibidem*.



from Germany is Sigmund's, a somewhat flattened conical vulcanite tube. Its length is  $1\frac{7}{8}$  inch, the diameters of the smaller end measuring  $\frac{1}{4}$  and  $\frac{5}{16}$  inch, those of the larger end  $\frac{9}{16}$  and  $\frac{3}{4}$  inch (fig. 7).

For a small round nasal orifice, a large sized Gruber's ear speculum is serviceable.

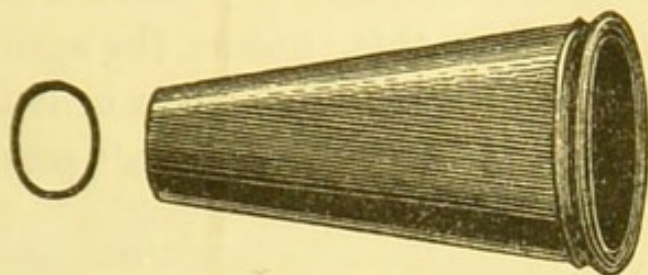


FIG. 7.—SIGMUND'S TUBULAR SPECULUM OF VULCANITE. (C. Wright & Co., London).

These specula, especially the last named, are very useful for children.

*Thudichum's Speculum.*—One of the earliest specula used for the systematic examination of the nose was Thudichum's (fig. 8)\*.

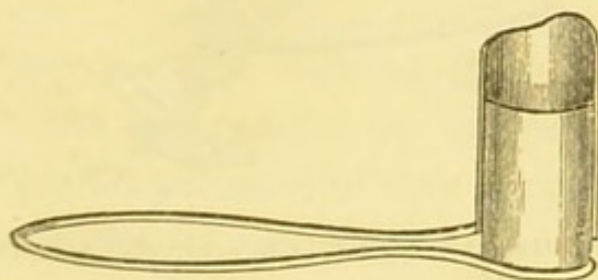


FIG. 8.—THUDICHUM'S SPECULUM.

This instrument has two short polished metallic blades which are united by a U-shaped spring. It is commonly sold with the blades of equal length, but

\* *On Polypus in the Nose, etc.*, 3rd edit., 1877. It was described by the inventor as long ago as 1868, and at that time was undoubtedly a decided advance on the means possessed for examining the nose from the front. Duplay's speculum was also described in 1868. B. Fränkel's did not see the light till 1872 (*Morell Mackenzie*).



according to Thudichum\* that which expands the ala should be from  $\frac{1}{4}$  to  $\frac{3}{5}$  inch longer than the inner one. The latter should never be long enough to reach the sensitive mucous membrane on the septum. When closed the blades should form a canal of oval bore about  $\frac{3}{4}$  inch in length. It is therefore necessary to have a speculum for each side which is a decided drawback in practice. Apart from this, unless the spring be very weak, the instrument when it expands is liable to produce uncomfortable pressure on the soft parts.

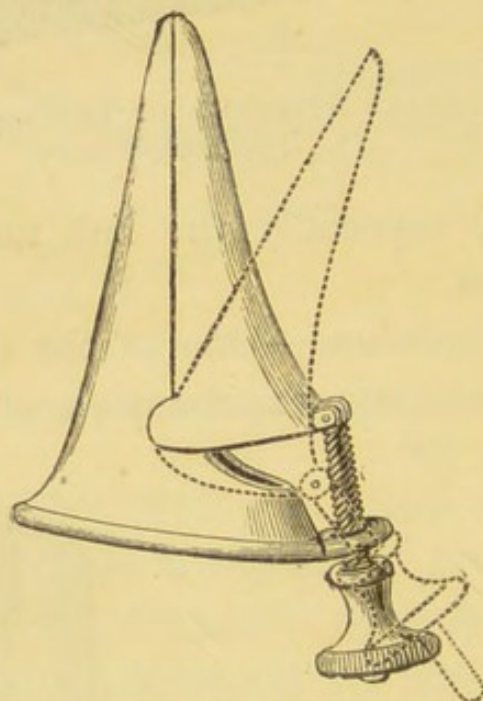


FIG. 9.—DUPLAY'S SPECULUM.—(Morell Mackenzie).

*Duplay's Speculum* (fig. 9).—This consists of two concave polished blades which, when in apposition, form a flattened cone, closed at the apex. The blade to be placed against the septum is rather flatter than its fellow. The blades are separated by means of a running screw.

*Voltolini's speculum* is merely a larger modification of

\* *Op. cit.*, p. 7.



this last instrument, in which the running screw is replaced by a rack movement. Several other specula are recommended by Voltolini, but this is the instrument usually known by his name.

*Elsberg's trivalve speculum* is composed of three metallic blades, separable by a handle. It is recommended

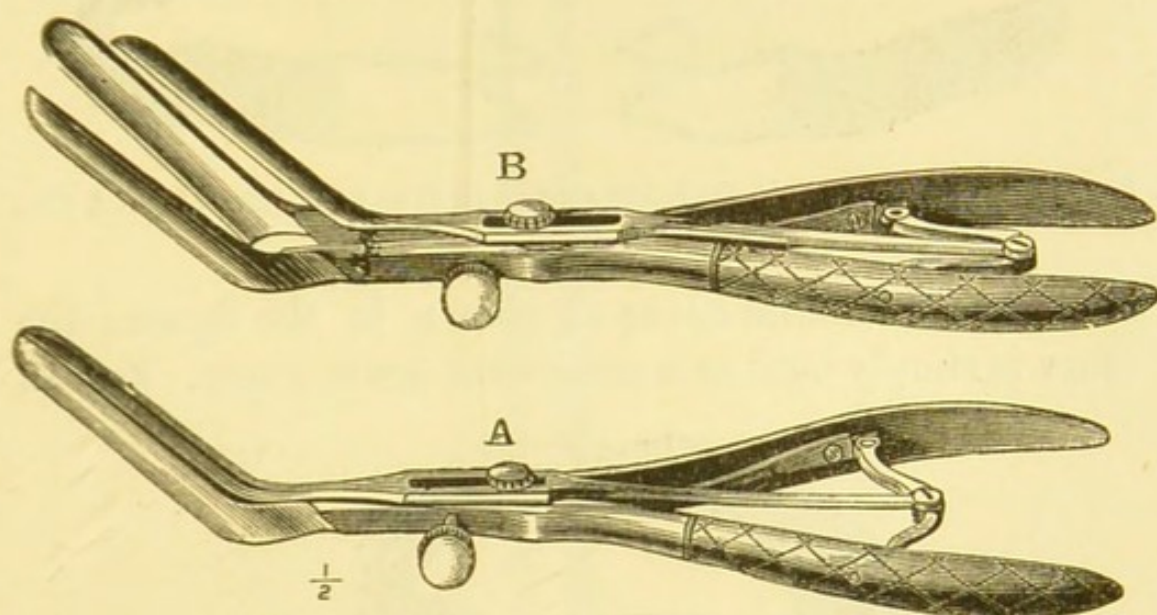


FIG. 10.—ELSBERG'S SPECULUM.—(Morell Mackenzie).

A. Closed. B. Open.

by several observers. A rack to keep it open at any desired width has been added by Lennox Browne.\* I have no practical experience of this speculum.

*The Author's self-retaining speculum* (fig. 11).—All the specula previously described require to be held in position with one hand, whilst the nose is being examined, otherwise even if they remain in the nasal aperture, they fall downwards to such an extent that no good view of the interior can be obtained. This objection is obviated by the speculum I devised in 1880,† for use when, in the absence of an assistant, it is de-

\* *The Throat and its Diseases*, 1878, p. 20.

† See *British Medical Journal*, Jan. 8th, 1881.



sirable to have both hands free. It is formed of two wire hooks united by an elastic band with a buckle. One

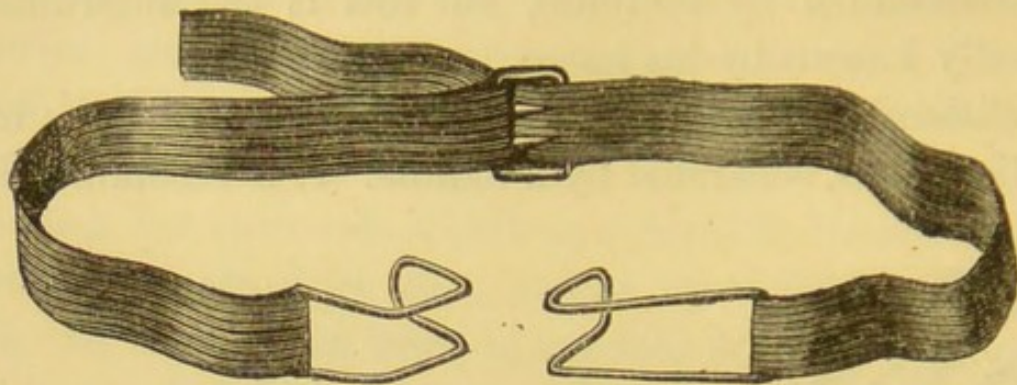


FIG. 11.—THE AUTHOR'S SELF-RETAINING SPECULUM. (*C. Wright & Co., London*).

hook has a double curve as shown in the figure; the other is simply bent at a somewhat acute angle. Fig. 12

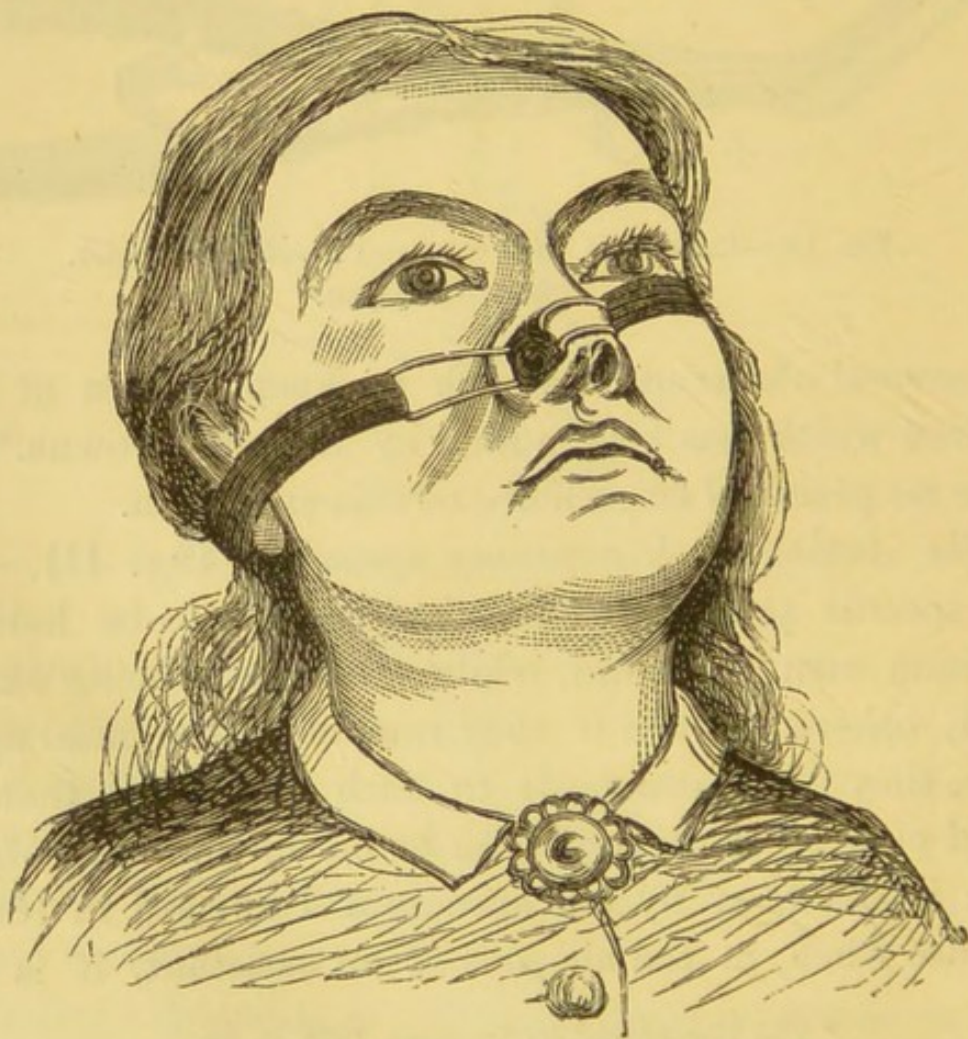


FIG. 12.—Mode of application of the Author's self-retaining Speculum.



shows the mode of application. The double curved hook passes over the tip of the nose, which it draws

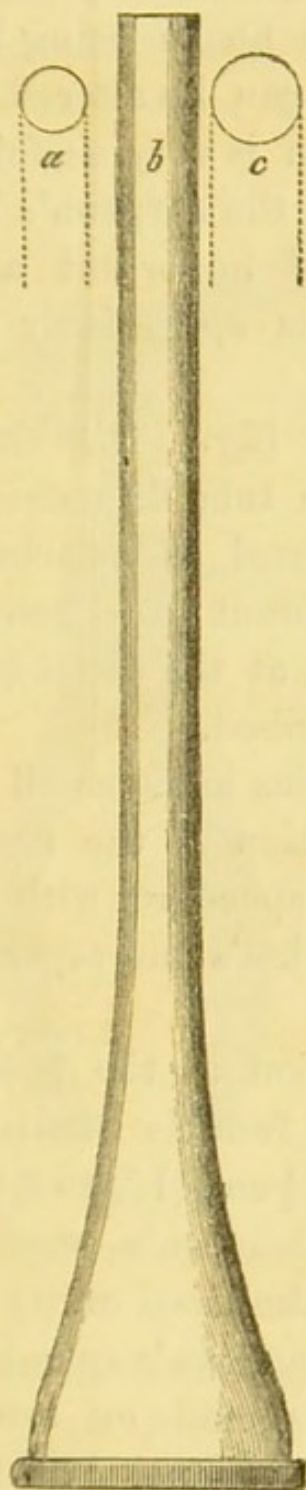


FIG. 13.—ZAUFAL'S SPECULUM.—(*Morell Mackenzie*).

*a. b. c.* Three different sizes.

upwards; whilst the other hook is inserted into the



outer angle of the nostril. The elastic band passes obliquely round the patient's head and by tightening or loosening it the amount of dilatation can be accurately regulated. The hooks being to a certain extent flexible, their curve can be altered to suit individual cases. This speculum is very useful in operative procedures in which both the surgeon's hands are required. It also possesses the important advantage, that no portion of it projects appreciably beyond the nasal aperture.

*Zaufal's Speculum* (fig. 13).—This instrument is a metallic or vulcanite tube  $3\frac{1}{4}$  inches in length, to one end of which a funnel is attached. Zaufal's specula are made in different sizes, measuring 3 mm. and upwards in diameter, at the distal end. Their use will be subsequently described.

This list by no means includes all the specula recommended for examination of the nose. Goodwillie for instance, employs a speculum with three blades of the shape found in Fränkel's and separable by means of a spring.

Voltolini in addition to the speculum already described recommends funnels similar to Zaufal's, but measuring from 4 to  $7\frac{1}{2}$  cm. ( $1\frac{7}{12}$  to 3 in.) in length, which are attached to a Brunton's otoscope. In cases of great narrowness of the nasal cavity he also employs a modification of *Markusovsky's speculum* (fig. 14).

This instrument is made on the principle of Kramer's dilating ear speculum, but with blades nearly six centimetres long ( $2\frac{3}{8}$  inches). When closed the blades form a tapering tube, having an oval-shaped section. Voltolini has added to it a rack movement by which dilatation can be arrested at any point. He also



employs it for pressing aside the swollen erectile body on the anterior end of the inferior turbinated bone.

W. Meyer has devised a nasal speculum which is a modification of Bonnafont's aural speculum. The blades are more slender and flatter and measure about  $3\frac{1}{2}$  inches in length.

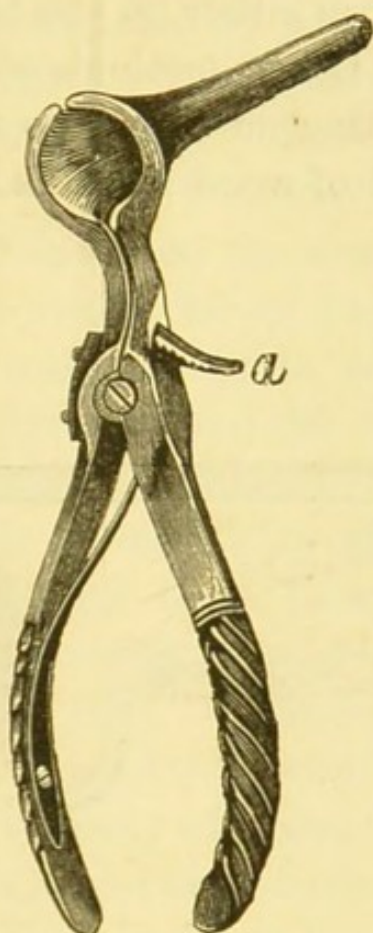


FIG. 14.—MARKUSEVSKY'S SPECULUM.

The blades can be kept apart at any required distance by means of the catch, *a*.

**Methods of Illumination.**—A powerful source of light is the second requirement for anterior rhinoscopy.

As ordinary daylight, even when condensed by a concave reflector, is quite insufficient for this purpose we must have recourse either to sunlight or to artificial light.

*Sunlight.*—The method of employing it is as fol-



lows:—Both patient and observer are placed in the sunlight in such a manner that the rays of the sun passing either above or to one side of the patient's head fall on a *plane* mirror, with central perforation, placed in front of the observer's eye. The mirror should be attached to a headband in the manner shown in fig. 17, p. 61, so that it can be worn either on the head or held in the hand as desired. Other methods of using the mirror are by having it attached either to a spectacle frame (fig. 15) or to a rod of wood which is held between the

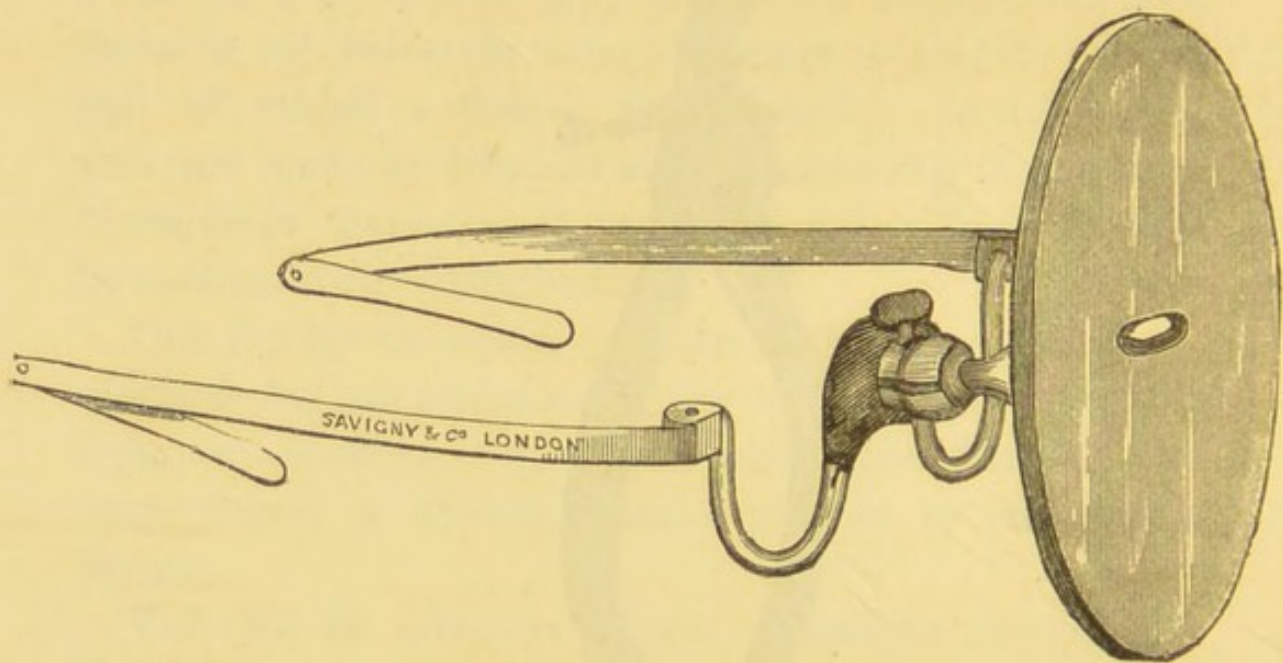


FIG. 15.—PLANE REFLECTOR ATTACHED TO A SPECTACLE FRAME.

(A lighter kind of frame is also made).

surgeon's teeth (Czermak). It is important for the observer to wear the reflector over one eye and to look *through* its perforation. In this way the line of vision coincides as nearly as possible with the axis of the light thrown into the nasal cavity. The necessity for this will become evident when we consider through what an extremely narrow tube we have to project the light, in examining the hinder parts of the nasal fossa. Instead



of receiving the sunlight directly on the forehead mirror, it may be reflected on to the same by means of a plane mirror about six inches square, attached by a ball and socket joint to a convenient stand. This arrangement is advantageous when the sun stands very high. The immense superiority of sunlight over artificial light will be recognised by any one who has employed the two. It shows up the deeper parts of these narrow irregular cavities with surprising distinctness. This is due not only to the brilliancy of the illumination, but also to the fact that the sun's rays projected by means of a plane mirror being parallel, throw shadows and therefore make the parts stand out in relief. When converging rays are used the shadows are more or less done away with.\* Over artificial light it has the great advantages of simplicity and cheapness, involving as it does nothing but a plane reflector which might, if needful, be extemporised out of any ordinary mirror. It is only too true, that sunlight is not always at our disposal in this country especially in large towns. On the other hand, in many of these nasal cases there is no immediate hurry, and their thorough examination can often without inconvenience be postponed for a few days until the sun shines. For these reasons I feel that this method of illumination is especially suited for the practitioner residing in the country, who is only called upon occasionally to examine such cases.

As a general rule, it may be said, that *where the case is at all a puzzling one, reflected sunlight should always, if possible, be used in examining the anterior nares.*

\* According to Voltolini sunlight also apparently magnifies the objects seen by it. My own experience is in accord with this. If too dazzling for the observer's eye, blue glasses can be worn without materially interfering with the view.



*Artificial Light.*—The uncertainty of sunshine, however, often renders it necessary to employ artificial illumination.

*Gas.*—The best form of gas arrangement is similar to that employed in laryngoscopy, *i.e.*, either an argand burner (Sugg or Silber) in an ordinary glass chimney, or fitted in a metallic chimney with a bull's eye condenser attached. There should be some arrangement for lowering and raising the burner to any height which may be conveniently done by means of Morell Mackenzie's rack-movement lamp (fig. 16); or an ordinary reading lamp which moves up and down on a pedestal can be employed.

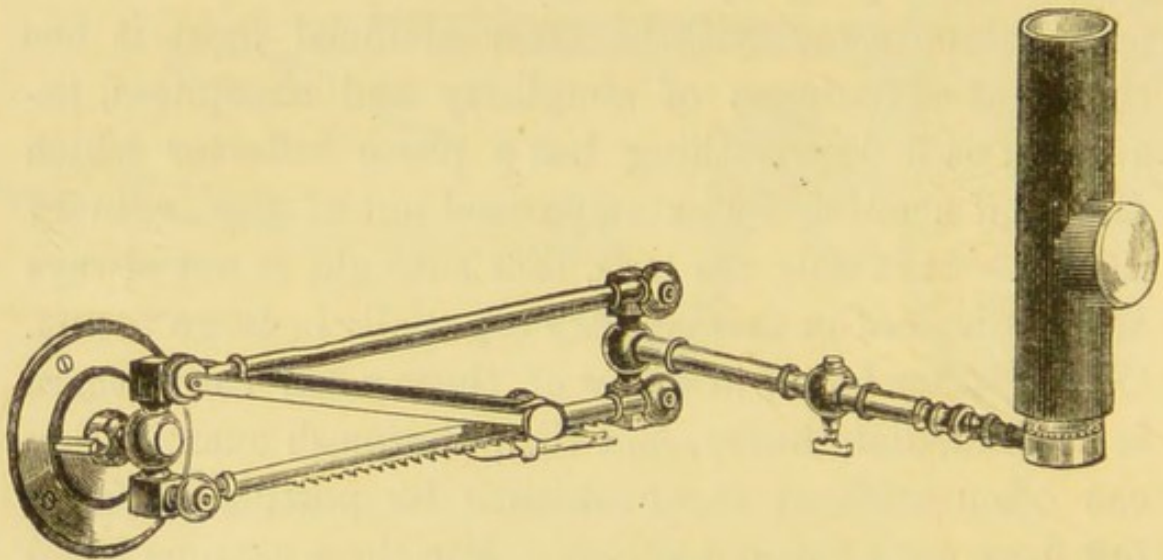


FIG. 16.—RACK-MOVEMENT LAMP.—(Morell Mackenzie).

The lamp being placed to one side of the patient's head on a level with his nose, the rays of light are concentrated by means of a concave mirror of about six inches focal distance attached to a forehead band\* (fig. 17).

Fig. 18 shows a concave and a plane reflector com-

\* The focal distance must vary according to the observer's eyesight.



bined which I had made.\* They are constructed to fold up for carrying in the waistcoat pocket, and are useful both for ear and nose work.

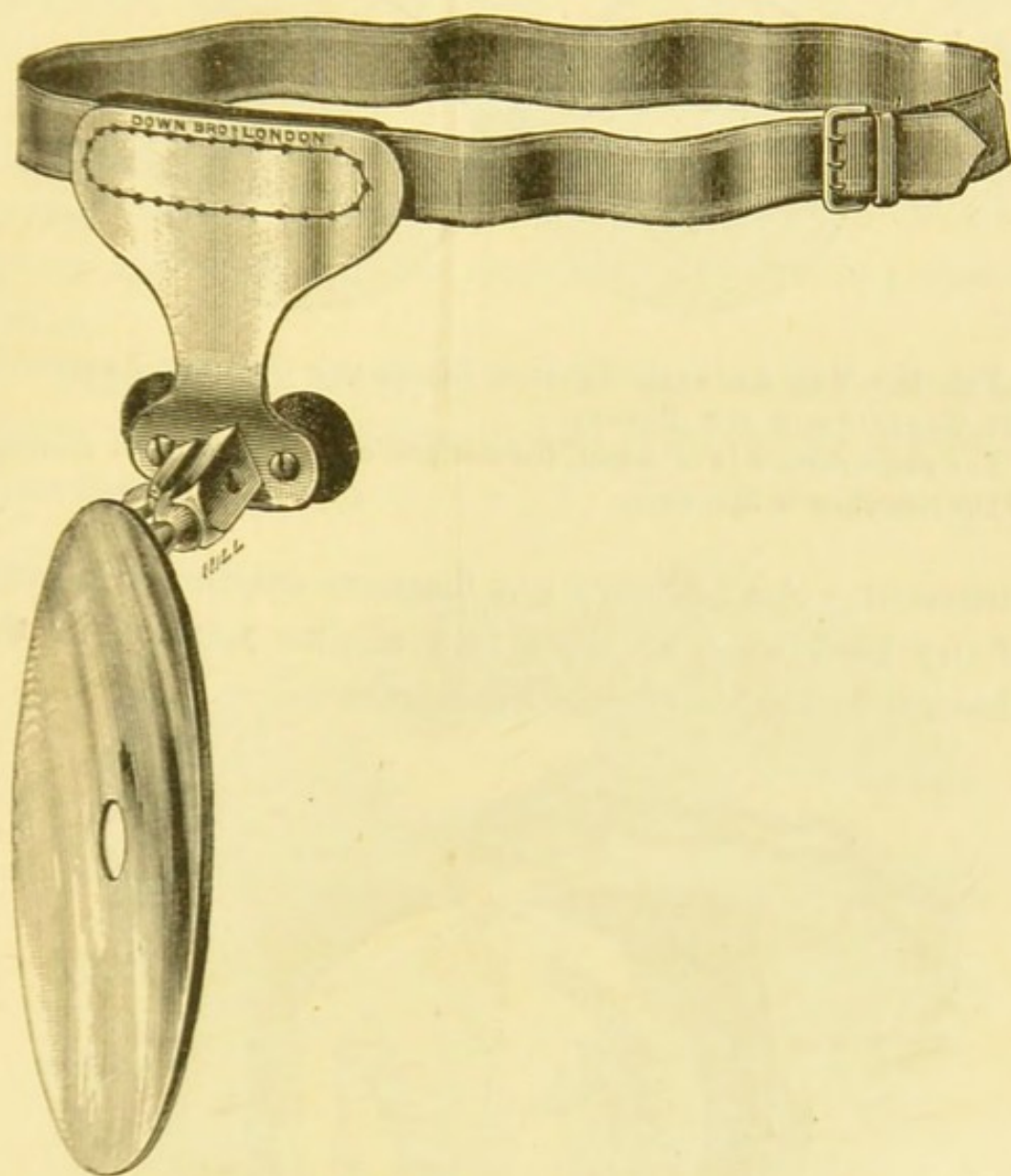


FIG. 17.—CONCAVE REFLECTOR ATTACHED TO HEAD-BAND, having two small pads which rest upon the bridge of the nose.

For anterior rhinoscopy I prefer placing the lamp by the side of the patient's *right ear* for although by this method the angle of reflection is greater than when it is placed on the other side, still we avoid the incon-

\* See the *Lancet*, September 2nd, 1882.



venience of the observer's right hand obstructing the rays of light during the use of the probe or other in-

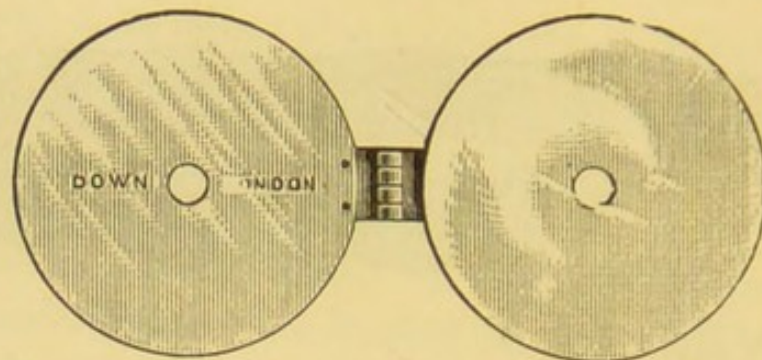


FIG. 18.—THE AUTHOR'S FOLDING PLANE AND CONCAVE REFLECTORS FOR CARRYING IN THE POCKET.

The plane surface is of metal, the concave one of glass. The diameter of the reflectors is  $2\frac{3}{8}$  inches.

strument. An ordinary gas flame or candle, or a lamp of any kind may be used in a similar manner in the absence of a more perfect illumination.

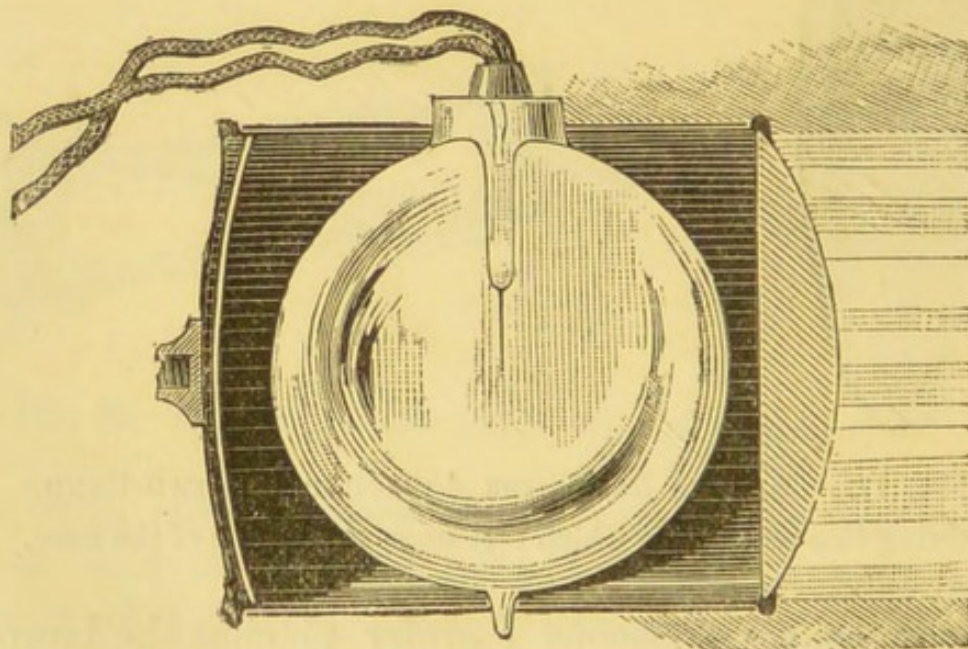


FIG. 19.—TROUVE'S ELECTRIC PHOTOPHORE (Longitudinal Section).

*Electric Light.*—A more powerful source of illumination is to be found in the electric light, used in the form



of a small incandescent lamp attached, in a suitable case, to the observer's forehead. *Trouvé's Electric Photophore\** (*Photophore Électrique Frontale*) is constructed on this principle. It (fig. 19) is an incandescent lamp of from eight to ten candle power, fitted in a light metallic cylinder, one end of which is closed by a concave reflector, the other end is provided with a bull's eye lens, the distance of which from the lamp can be regulated by drawing out the tube.

The lamp is fixed by a ball and socket-joint, to a plate which is attached to the forehead by means of a headband (fig. 20).

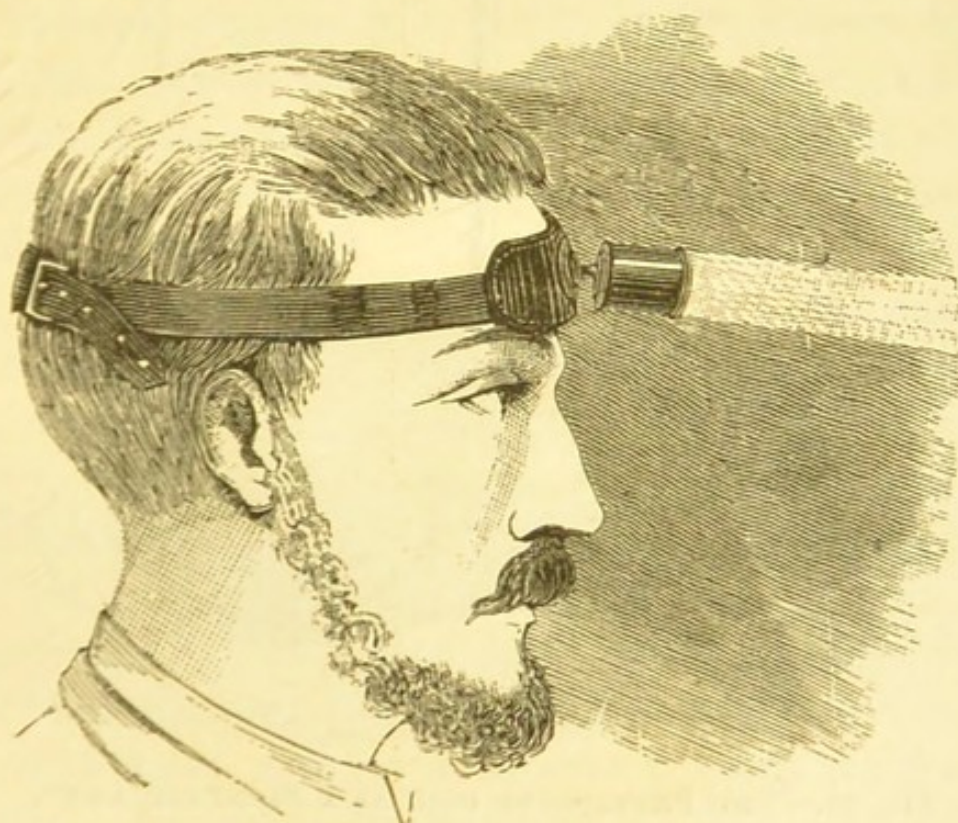

FIG. 20.—THE PHOTOPHORE AS WORN ON THE HEAD.

The Photophore can also be used as a standard lamp by screwing it to a rod fixed on the top of the leather case, into which it packs (fig. 21).

\* See note by the Author, *British Medical Journal*, Nov. 10th, 1883.



The battery used for lighting this lamp consists of a wooden case, in which are fitted from four to six ebonite cells, each containing one zinc and two carbon elements. The elements are connected by means of moveable clamps, and are attached to a windlass, by which




FIG. 21.—THE PHOTOPHORE USED AS A STANDARD LAMP.

they are raised from, or lowered into, the exciting solution as may be required to regulate the current. The battery I use has six cells and was made for me in this town, on the same principle as Trouvé's. Each cell holds 50 oz. of liquid, and contains one zinc and



two carbon plates, measuring each  $7 \times 2 \times \frac{1}{2}$  inches. As the case is  $31\frac{1}{2}$  inches high, 17 inches long, and  $6\frac{1}{2}$  inches broad, it takes up very little space in the consulting room. The composition of the exciting solution for six cells is as follows:—Water, 8 kilos. (about  $17\frac{1}{2}$  lb.); powdered bi-chromate of potash, 1 kilo. (about 2 lb. 3 oz.); sulphuric acid, 3 kilos. 600 grammes (about 6 lb. 10 oz.). It is prepared as follows:—Place the eight kilos. of water in a jar, which would hold a larger quantity, then add the powdered bi-chromate of potash and stir well to facilitate its solution, afterwards drop in slowly little by little, whilst constantly stirring, the sulphuric acid. This process requires from eight to ten minutes to accomplish. Under the influence of the sulphuric acid the mixture heats gradually, and a perfect solution of the bi-chromate which has no tendency to recrystallize on cooling, is the result. The solution should be quite cold before it is placed in the battery.\* The expense of the photophore and battery is decidedly less than that of the oxy-hydrogen lime-light, and it is less cumbersome and troublesome to manage.

The advantages of the photophore are first, that the light is whiter, more intense and steadier than that of gas; and secondly, that the light being attached to the observer's head, follows all his movements without any adjustment, such as is necessary when using a reflector.† Its chief disadvantage is, that with it, the

\* The above directions, as well as numerous further particulars of the photophore, are contained in a pamphlet on the subject by Dr. Paul Hélot, an English translation of which is published by Armand Levy, 20 Chiswell Street, London, E.C., agent for the United Kingdom.

† This advantage is especially noticeable in operations for the removal



observer's eye is not exactly in the axis of light, as in the case of the perforated head mirror. This is not noticeable in posterior rhinoscopy or in laryngoscopy, when the photophore can be worn on the forehead as shown in fig. 20. In anterior rhinoscopy and in the examination of the ear it is, however, necessary to avoid this drawback as far as possible by placing the photophore down over one eyebrow. I accomplish this by supporting the frontal plate in this position by means of a small leather pad placed between it and the bridge of the nose. The pad may easily be attached to the frontal plate. My own experience of the photophore dates from September, 1883, since which time I have had it in regular use, and I have found that with care it works very well. The fluid in the battery requires renewal every six weeks or less often according to the amount of use.

On trying a new lamp, great care should be exercised not to apply too much power, otherwise the carbon may be burnt through. The plan is to remove the bull's eye lens, and watching the carbon carefully to lower the elements until a bright light is obtained. By fixing a graduated strap round the windlass and rod supporting the elements, they can be prevented from being more deeply immersed, until the weakening of the solution requires it.\*

One more precaution may be mentioned; when not in use the elements must be raised quite out of the liquid,

of polypi with a snare. With the mirror the slightest movement on the part of the patient interferes with the adjustment of the light on the required spot, and we are unable to follow the application of the snare with the eye.

\* For a Trouvé's lamp marked "4," I find it safest to begin by using only five cells of my battery.



it is *not* sufficient to raise them until the lamp is just extinguished.\*

After being in use for a few minutes the photophore becomes warm, though not sufficiently so to inconvenience the operator.

Felix Semon† recommends a minute incandescent lamp to which a rhinoscopic mirror can be attached. It is lighted by means of a portable accumulator or battery.




FIG. 22.—STEEL NASAL PROBE WITH FLAT METALLIC HANDLE AFTER W. MEYER'S MODEL.—(C. Wright & Co., London).

(The probe is drawn half an inch too short).

*Oxy-hydrogen lime-light* and *Magnesium light*.—The former of these two lights has been perfected and cheapened by Lennox Browne,‡ but it still remains decidedly more expensive and cumbersome than the electric light. Similar objections are attached to the light produced by burning magnesium wire.

A very powerful source of illumination, the arrangements for which are said to be very simple, is obtained by leading oxygen from a gasometer into an argand petroleum flame.

\* I have learnt this by experience as by leaving the ends of the plates in the liquid, I so damaged them as to require both new plates and new liquid.

† *The Lancet*, March 14th and 21st, 1885.

‡ *The Specialist*, September 1st, 1880.



**Anterior Nasal Probe.**—An ordinary surgical probe bent at an angle of  $135^{\circ}$ , at about  $3\frac{1}{4}$  inches from its tip, will serve for use in anterior rhinoscopy. But a probe similarly bent and fitted into a light bone handle, (measuring  $3\frac{1}{2}$  inches in length), or one provided with a flat metallic handle, such as is used by W. Meyer for the ear\* (fig. 22), is more convenient. I prefer the latter and employ one made of steel, on account of its greater firmness. It is well rounded, but *not* enlarged at the tip.

Woakes† recommends a flexible silver probe terminating in a small loop, for pressing aside the mucous membrane in the deeper parts of the nasal cavities.

**Cleansing the Nasal Cavities.**—When the nasal cavities contain discharge it is necessary to cleanse them, before a satisfactory examination can be made. This may often be accomplished by directing the patient to blow his nose or if this fails by wiping the discharge out by means of a pellet of absorbent wool on a cotton holder such as is employed for the ear (fig. 23).

If these means are insufficient, the discharge must be washed out by the application of a saline or other liquid, by one of the methods about to be described. They are not generally required, however, except in cases in which the secretion is thick, or when it forms crusts, and they are especially to be avoided when there is much tendency to erection of the inferior turbinated body. Under these circumstances the introduction of liquid into the nasal cavities may be sufficient to cause complete erection of the anterior part of inferior turbinated body, which, as we shall see sub-

\* *Archiv f. Ohrenheilkunde*, vol. xxi., parts 2 and 3, p. 151.

† *Op. cit.*, p. 95.



sequently, interferes very much with an anterior rhinoscopic examination. Fortunately in cases of ozæna in which liquids are mostly required, such an accident is very unlikely to occur. The methods by which the nasal cavities may be cleansed with liquids are four:—

1. *Aspiration*, or *sniffing the liquid up the nose*.—To do this, place some of the liquid in the palm of the hand or in a saucer, and immerse the nostrils in the liquid. A forcible inspiration with the mouth closed, will draw the liquid through the nasal cavities. It can then be ejected by the mouth. Woakes' nasal irrigator may also be used for the same purpose.\* This consists of a curved glass tube, the centre of which is blown into a bulb filled with fluid. One end has a tip of india-rubber which fits into one nostril, the other is funnel-shaped to aid the charging of the in-



FIG. 23.—COTTON HOLDER.

Consisting of a steel rod with fine screw at the end, fitted into a hexagonal bone-handle.—(C. Wright & Co., London).

\* *Op. cit.*, p. 140.



strument. During its use the opposite nostril is closed with the finger. Aspiration is very convenient for the patient's use at home, but not so suitable for cleansing the nose before an examination.

2. *Sprays*, both anterior and posterior, are also recommended with the same object. I have no experience of them for immediate cleansing, though I frequently employ them as a means of treatment.

Woakes\* recommends a preliminary spraying, but acknowledges that it may excite a flow of mucus, which is certainly a considerable drawback to its use. An ordinary spray apparatus with one or two bulbs, and fitted with a nozzle sufficiently small to pass a little distance into the nostril is all that is required to spray from the front. For spraying from behind, an instrument with a long curved nozzle is necessary.

3. *The Nasal Douche* is a time-honoured means of removing discharge from the nose. It consists in utilizing the discovery of E. H. Weber of Leipzig, who found that when the mouth is open, a stream of liquid introduced through one nostril causes reflex contraction of the velum palati, and passing over this structure escapes through the opposite nostril. Theodore Weber was the first to introduce this method of cleansing the nose.† Thudichum‡ has invented and largely used an improved form of nasal douche.

In its simplest form the instrument consists of a piece of india-rubber tubing about 4 feet in length

\* *Op. cit.*, p. 75.

† Compare Adam Politzer, *Lehrbuch der Ohrenheilkunde*, 1878, p. 360. and D. B. St. John Roosa, *A Practical Treatise on Diseases of the Ear*, 6th edition, London, 1885, p. 382.

‡ *On Polypus in the Nose, etc.*, by J. L. W. Thudichum, 3rd edit., London, 1877, p. 17.



which is used as a syphon. One end has a weight attached to it, while the other end is provided with a vulcanite nozzle fitting into one nostril (fig. 24). The weighted end being dropped into a vessel con-

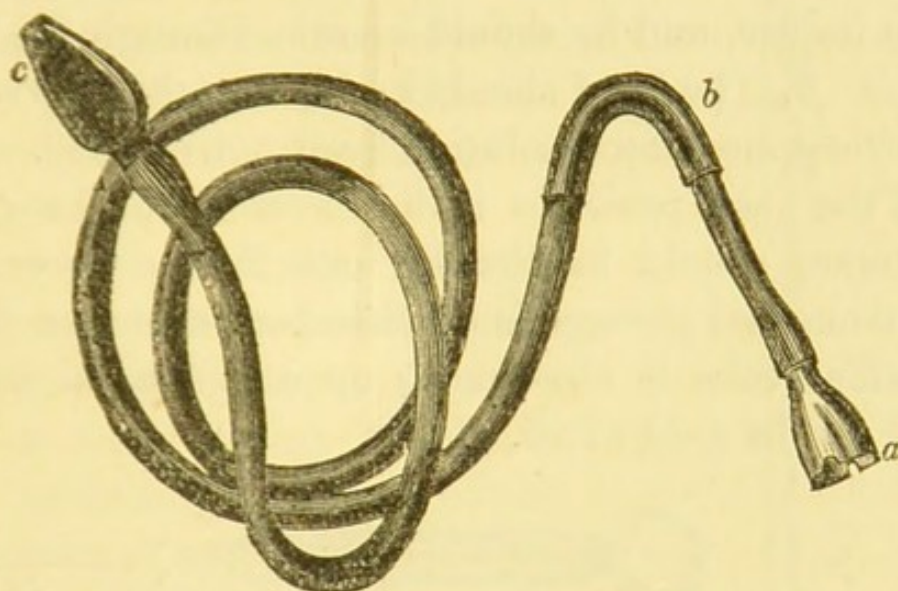


FIG. 24.—NASAL DOUCHE.—(*Morell Mackenzie*).

*a.* Weighted end for insertion into the liquid. *b.* Firm shoulder for resting on the edge of the vessel. *c.* Nozzle for insertion into the nostril.

taining the liquid placed on a higher level than the patient's head, the tube is filled either by suction or by pouring it full of the liquid. The nozzle is then fitted into one nostril and the liquid allowed to flow through the nasal cavities, which it does, carrying with it the discharge. In a more convenient form of apparatus, the vessel containing the liquid has an opening at its lower part, to which an india-rubber tube, fitted with a nozzle, is attached. By simply raising the vessel above the patient's head, a flow of liquid is obtained. As the employment of the nasal douche sometimes gives rise to acute inflammation of the middle ear, owing to the entrance of fluid into the



tympanum,\* the following precautions are usually recommended† when it is employed:—

1. The vessel containing the fluid should not be situated too high, and the stream should be occasionally interrupted.
2. The patient must not swallow during its use, and he should breathe through the open mouth.
3. The head should be bent slightly forwards.
4. A *strong* medicated solution must not be used.
5. If one of the nasal passages is narrower than the other, the stream should be directed into the *narrower* one.
6. If one nasal passage is quite impermeable, or if the Eustachian tube is abnormally open, the nasal douche should not be used at all.




FIG. 25.—LYNCH'S NASAL SYRINGE.

(Reduced in size).

I seldom use the nasal douche myself; I am consequently almost unable to say from experience whether these precautions are effective in preventing this accident. As a matter of fact, the use of the nasal douche has, on this account, now been to a great extent abandoned. When there is a thick discharge obstructing the nasal passages, I almost always cleanse them in the following way:—

4. *Syringing*.—The patient may use for this purpose an ordinary glass or pewter syringe (holding about 2 oz.). A larger one (such as an aural syringe), may be used by the surgeon. Lynch's nasal syringe, which

\* D. B. St. John Roosa, *loc. cit.*

† *Manual of Diseases of the Ear*, by Thomas Barr, M.D., Glasgow, 1884, p. 82.



has an olive-shaped nozzle, is also convenient (fig. 25). After having introduced the nozzle into the vestibule, the operator must remember to point it *horizontally* in the direction of the inferior meatus. As a precautionary measure, the patient should be directed not to swallow while the liquid is in the nose, and to allow it all to run out before blowing the nose with a handkerchief. A post-nasal syringe, *i.e.*, one with a long curved nozzle to pass up behind the soft palate, is sometimes useful.

The liquids I employ for cleansing the nose by any of these methods, are, either a watery solution of common salt (one teaspoonful to a pint),\* or one containing Sod. Bicarb. and Pot. Chlor.,  $\text{āā } 3j$ , to the pint. Except when used for stopping hæmorrhage the solution should always be employed *warm*. Numerous other liquids are recommended, many of which I have tried. My experience has, however, led me to select the above formulæ as the simplest, and as those which are at the same time most agreeable to patients.



FIG. 26. — W. MEYER'S  
NASAL IRRIGATOR.

Reduced in size. — (C.  
Wright & Co., London).

\* The proportion of salt required varies in different persons, and may be changed according to the patient's sensations.



Disinfectant and other medicated fluids do not require consideration here.

In order to avoid the danger attending the use of the nasal douche, W. Meyer\* employs a slender metallic tube six inches in length (fig. 26), which is passed along the floor of the nose. It is made with a cruciform opening at the distal end, if required for the naso-pharynx only; if used for the nasal cavities it is provided with minute lateral openings. The two forms may be combined if necessary. The liquid is forced through it by means of an ordinary or a Higginson's syringe.

**Method of performing Anterior Rhinoscopy.—**

The patient being seated facing the observer, and a strong beam of light directed on to one nostril,† one of the above described expanding specula is inserted into the vestibule, and opened out until the latter is dilated as widely as is possible without hurting the patient. The speculum should not be introduced far enough to press upon the inferior spongy bone, nor to injure the septum.‡ When the head is tilted slightly backwards—the best position to commence with—the inferior and part of the middle turbinated bodies come into view (fig. 27). By tilting the head further back as shown in fig. 28, the uppermost part of the middle turbinated

\* *Transactions of the International Medical Congress*, London, 1881, vol. iii., p. 281.

† The importance when any form of artificial light is used, of darkening the room and accustoming the eye to the comparative darkness before commencing the examination, need hardly be insisted on, but it is of real advantage.

‡ Sometimes in nervous patients a contraction of the nasal muscles, compressing the upper part of the vestibule will interfere with a view of the nasal cavity. This can be readily overcome by drawing the patient's attention to it. If necessary, vibrissæ must be removed with scissors, but the occasion for this is very rare.



body, and the roof of the nasal fossæ can be seen. Again, by bending the patient's head sharply forwards,

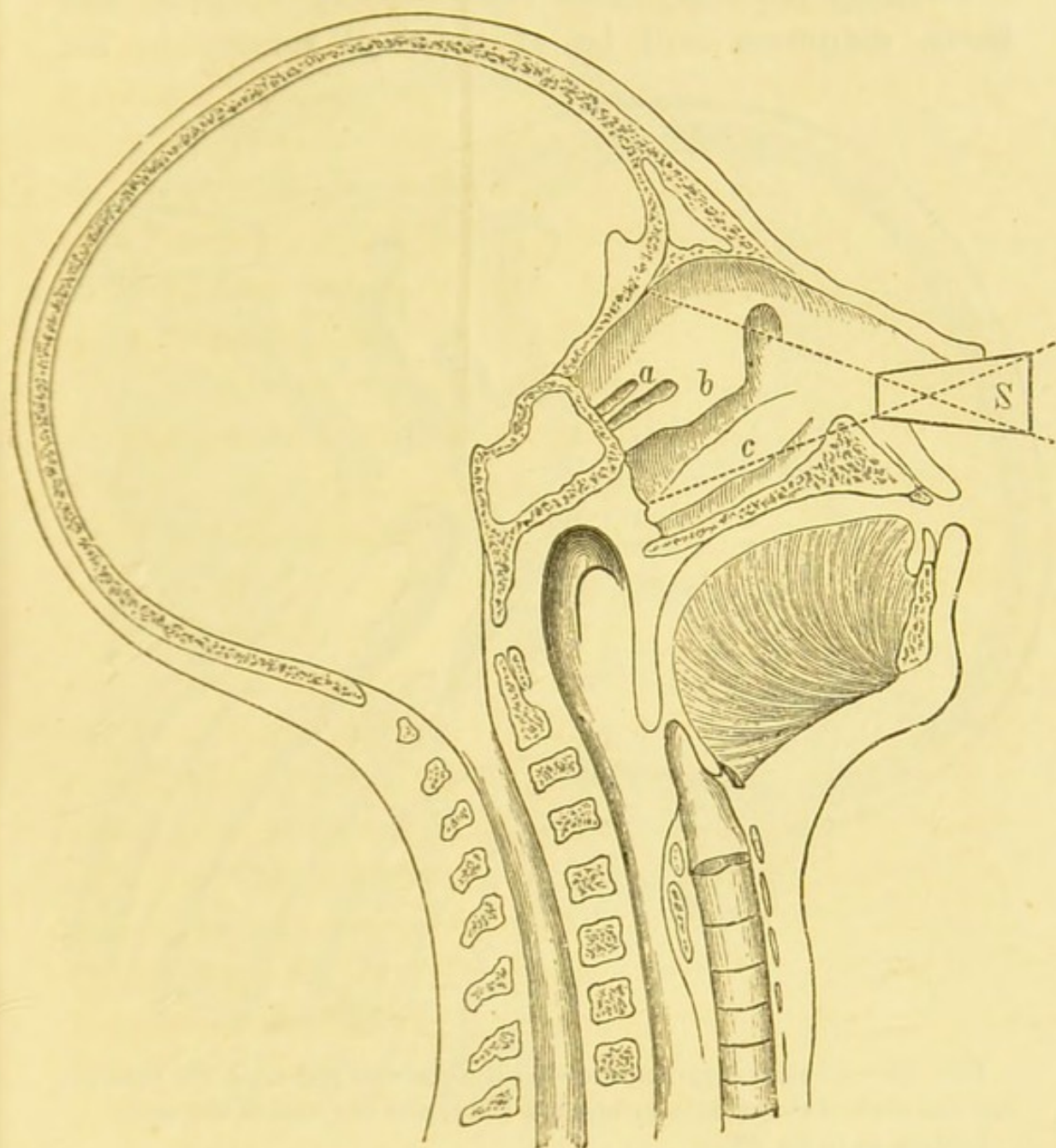


FIG. 27.—DIAGRAM OF A VERTICAL SECTION OF THE HEAD.

Showing the position necessary for examining the lower part of the middle and the anterior end of the inferior turbinated body from the front.

S. Section of tubular speculum.

a, b, and c. Superior, middle and inferior spongy bodies. The dotted lines show the limits of the field of vision, with the speculum in this position.



the inferior meatus and the floor of the nose become visible (fig. 29).

Judging from my own recollections, I think that these diagrams will be of practical service to the

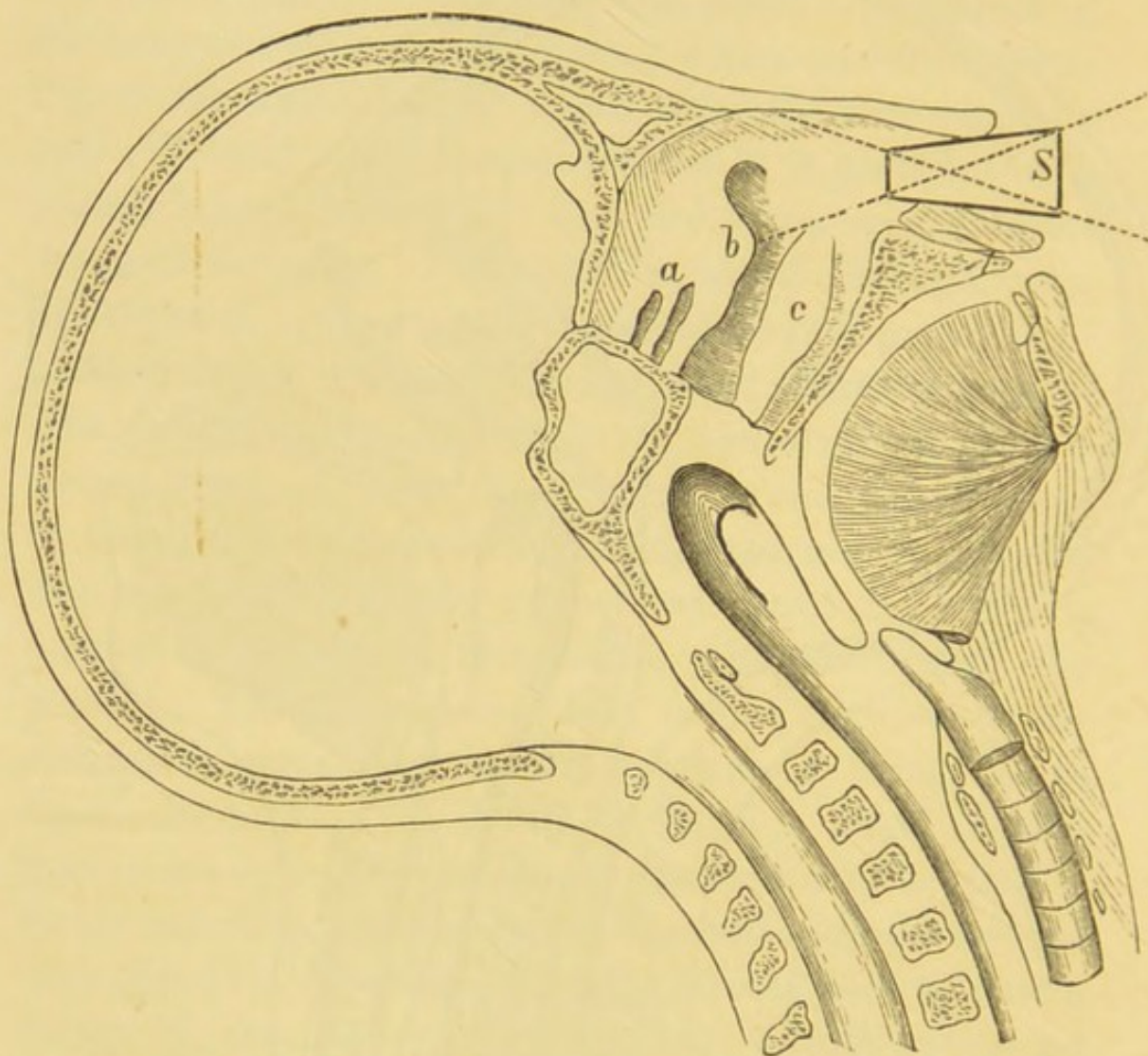


FIG. 28.—Similar diagram, showing the position required for examining the neck of the middle turbinated body, and the roof of the nose.

Letters as in fig. 27.

student. The limited portion only of the anterior rhinoscopic view which can be seen with the speculum *in any one position*, renders the recognition of the different structures by the tyro a matter of uncertainty, however easy it may appear after a little practice.

If all these positions be repeated with the patient's



face slightly turned towards the opposite side to that under examination, the corresponding portions of the septum can be inspected. When the patient is at all

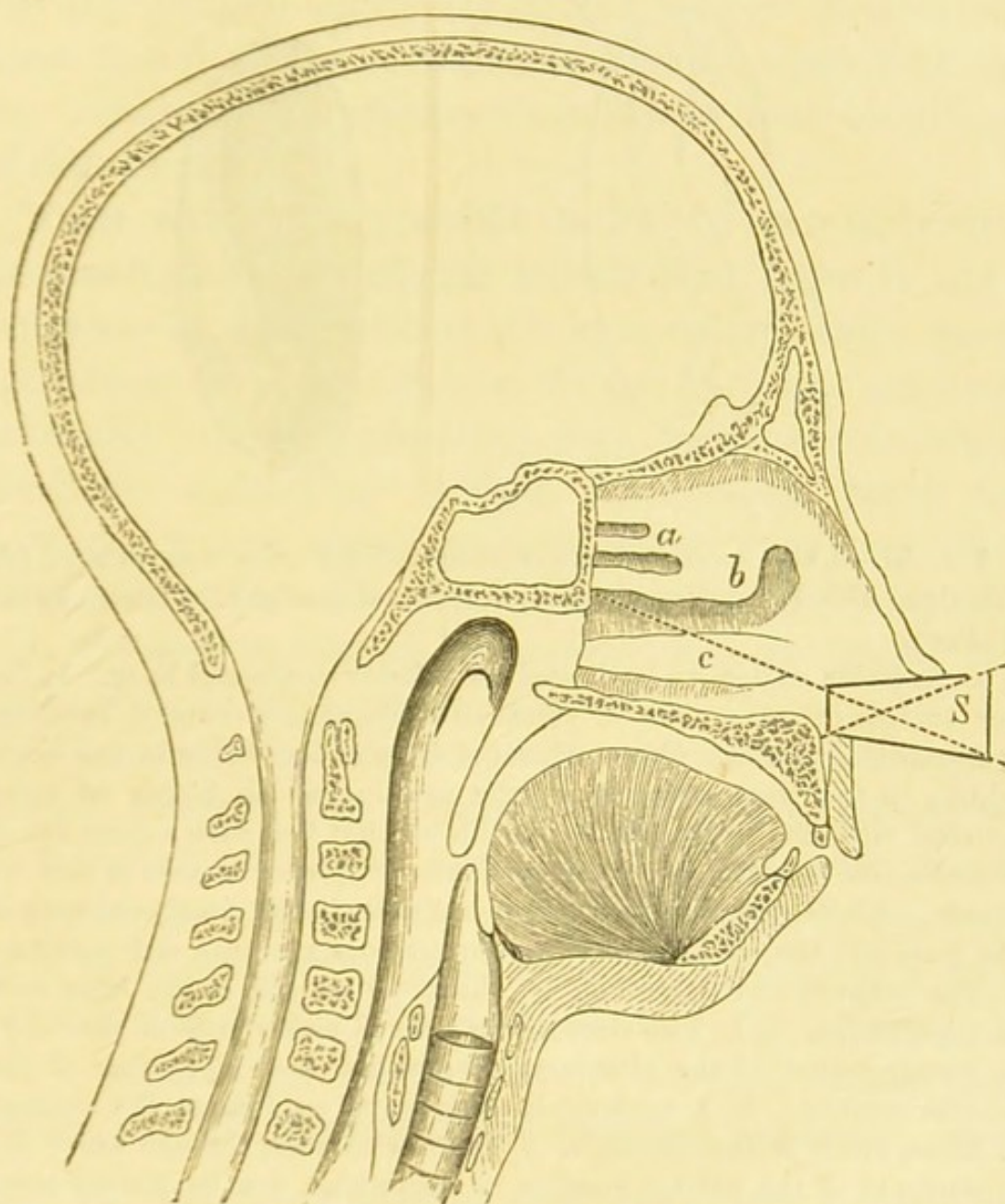


FIG. 29.—Similar diagram indicating the position necessary for examining the inferior meatus, the palatal movements, and the lower border of the inferior turbinate body. Letters as in fig. 27.

nervous and cannot control himself sufficiently to hold his head in the different positions thus indicated, the best plan is for the operator to wear the reflector (or electric lamp) on the forehead, to hold the speculum



with the left hand, and to adjust the patient's head with the right hand. In this manner a systematic exa-

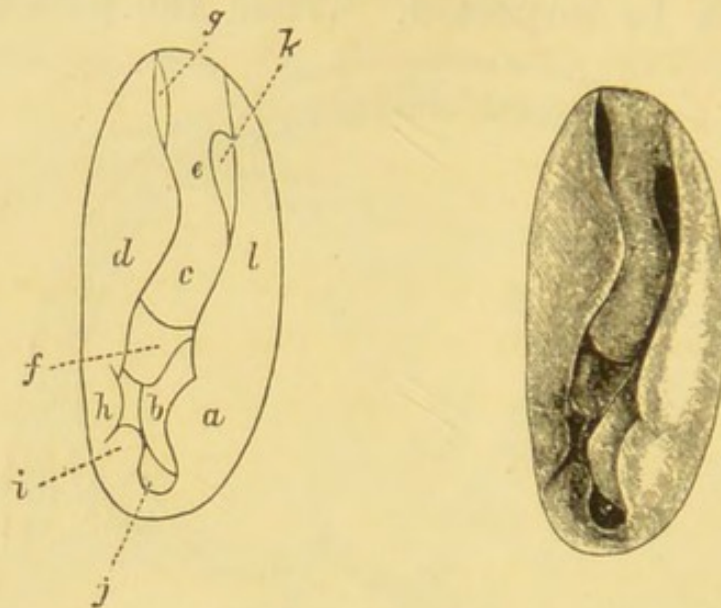


FIG. 30.—LEFT ANTERIOR RHINOSCOPIC VIEW of a woman aged 26, examined with Fränkel's speculum, in reflected sunlight. (*Drawn by the Author*).

*a.* Anterior extremity (collapsed) of inferior turbinated body. *b.* Inner surface of ditto, seen in perspective, showing a rounded swelling. *c.* Anterior border of middle turbinated body ending below in the angle which, in this case, presents a puffy swelling which bleeds on being touched with the probe; it is on this account that such a clear line of demarcation between the angle and inferior border is seen in this instance. Above, the anterior border terminates in the clearly cut neck of the bone (*e*); the whole of this border presents a minute red mottling. *d.* The tubercle of the septum. *f.* The lower margin of the bone seen in perspective. *g, k.* Two depressions, one on either side of the neck; *g*, forming part of the olfactory slit; whilst *k* is a portion of the middle meatus. *h.* A moderately deep-seated swelling on the septum. *i.* Ditto, much farther inwards. *j.* Inferior meatus, through which the movements of the palatal muscles in deglutition can be plainly seen. *l.* "Neck" of the inferior turbinated body.\*

mination of the whole of the intra-nasal structures, as far as they are visible from the front can be made. I shall now proceed to describe these parts in detail.

\* The form which these sketches should take was only arrived at after many unsuccessful drawings had been made. Strange to say, in all the rhinological literature to which I have had access, I have not



**Anterior rhinoscopic view.**—The appearances seen in anterior rhinoscopy depend so much upon the amount of swelling present in the erectile body, covering the anterior extremity of the inferior turbinated bone, that it will be advisable to describe them first in the collapsed, and afterwards in the swollen condition of this organ.

**View when the erectile body on the anterior extremity of the inferior turbinated bone is collapsed.**—In this condition the *inferior turbinated body* appears as shown in figures 30 and 35. Its anterior extremity (*a*), the presenting part, forms a somewhat irregular undulating surface, terminating below in a more or less sharp margin which overhangs the inferior meatus. The inner surface of the body (*b*) (*i.e.*, the surface next to the septum) can be traced far back, often to its posterior extremity.

The greatly fore-shortened view of this surface frequently presents the appearance of a shallow concavity from before backwards (see fig. 35). At other times it appears as a somewhat rounded eminence (*b*, fig. 30). It is, of course, best seen by turning the patient's face towards the side under examination. On account of the comparatively small size of the bone itself (see above, p. 20) this position is sometimes necessary, even

found any attempt at representing these parts as they appear in the living subject. The necessarily perspective view of most of the structures, and the fact that the sketch itself is a composite one made up, as in posterior rhinoscopy, of numerous views pieced together, render their representation a matter of some difficulty. It is thought, however, that these figures will be of service to the rhinoscopist. Drawing of these parts is certainly to be encouraged, as it leads to accuracy of observation, and by merely pencilling an outline of the appearance in any given case, it can be much more satisfactorily compared with that seen in other cases or in the same patient at a future time.



to see the inferior turbinated body. Above, it tapers gradually into the outer wall of the nasal cavity, forming, as viewed from the front, a kind of "neck" (fig. 30, *l*).

The mucous membrane covering the inferior turbinated body has a soft velvety appearance; when touched with a probe, the bone can be felt underneath, and the instrument does not sink in to any depth.

*Middle turbinated body.*—Above, and at a considerably greater distance from the nasal orifice, is seen the middle turbinated body (*c*, figs. 30, 31, 32).

A glance at fig. 1 (p. 4) will show, that provided there be nothing to intercept the view, the parts of the middle spongy bone visible, will be the *anterior* and *inferior borders*, both of which, especially the latter, are seen somewhat in perspective, the *angle* of junction of the two being the part which is nearest to the observer's eye. Each of these borders presents, it will be remembered, an inner and an outer lip. Moreover, as the surgeon's eye is usually nearer to the septum than to the outer wall of the nasal fossa, a part of the inner surface of this bone will be visible.

Theoretically, these are the parts which should be seen, but practically a considerable portion of the middle turbinated body is hidden by the *tubercle of the septum* (*d*, figs. 30, 32, see also fig. 3, p. 16). The view obtained, therefore, depends to a great extent upon the shape and size of this structure. If the tubercle be small, as in fig. 30, the inner lip of the anterior margin of the middle turbinated bone is to a great extent hidden from view, but above the tubercle is seen the *neck* of the bone, (*e*), *i.e.*, the narrow portion where it joins the body of the ethmoid bone. On its inner



side, a portion of the olfactory slit (*g*) is visible; on its outer side is a depression (*h*) which forms part of the middle meatus.

The three diagrams in fig. 31 have been drawn to explain the other appearances which, according to the configuration of the tubercle, the middle turbinated body presents, when viewed from the front.

Diagram A, fig. 31, shows the parts as very commonly seen. The tubercle which is large and extends to the top of the field of vision conceals the neck and whole of the inner lip of the anterior border of the

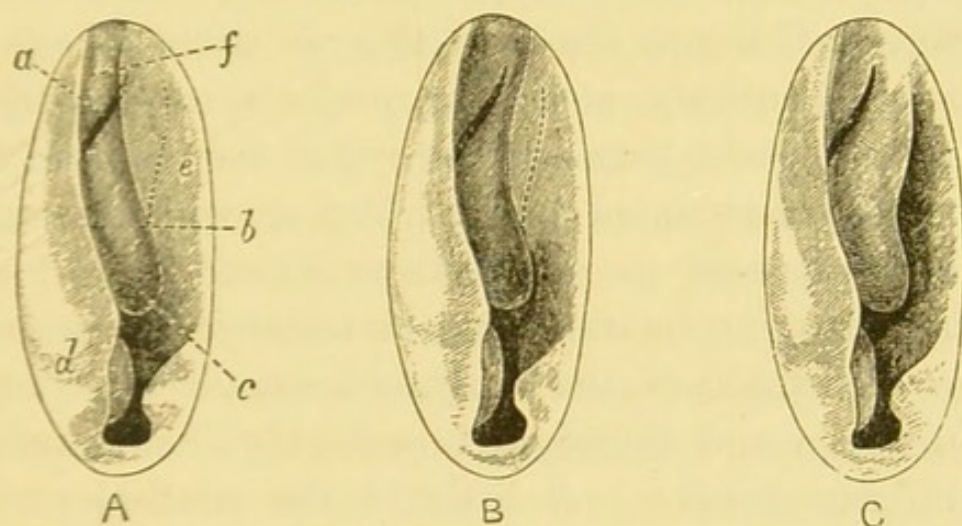


FIG. 31.—Diagrams illustrating different appearances presented by the tubercle of the septum. (*Drawn by the Author*).

*a.* Outer lip of anterior border of middle turbinated body. *b.* Angle of middle turbinated body. *c.* Lower border of middle turbinated body. *d.* Inferior turbinated body. *e.* Tubercle of septum. *f.* Outer wall of nasal cavity.

In diagrams A and B, the margins of the middle turbinated body, hidden by the tubercle, are indicated by dotted lines.

body leaving only a small portion of the outer lip of the anterior border (*a*), the angle (*b*) and the lower border of the body (*c*) exposed to view. The visible portion of the outer lip of the anterior border appears frequently to be bounded by a well-marked groove. According to



the greater or less curvature of the bone, the groove occupies either an almost horizontal or an oblique direction (see figs. 31 and 35). This lip is sometimes hidden by a projection on the outer wall of the nasal cavity (*f*). In the collapsed state of the inferior turbinated body the inner and outer walls of the nasal cavity run nearly parallel for some distance, leaving between them only a slit measuring less than a quarter of an inch across.

In diagram B (fig. 31), the *whole* of the inner lip of the middle turbinated body is hidden by the tubercle, but a part of the neck can be seen.

Diagram C shows the condition of parts where the tubercle is entirely absent or projects so slightly as not to intervene between the eye of the observer and the middle turbinated body. The anterior margin of the body appears to run downwards and usually *outwards*, increasing in transverse diameter as it descends. Below the angle of the body and rapidly receding in the distance and therefore less highly illuminated, is the inferior border. A little of the internal surface can also sometimes be seen. Between it and the septum is the *olfactory slit*.

All these different appearances are met with in practice, but in my experience it is much more rare to find the tubercle flat or absent, than to see it hiding a considerable portion of the middle concha. It is therefore remarkable that in the whole course of my reading I have not found any reference to this structure as seen in the living subject. When I first recognised this eminence on the septum, I was for some time at a loss to account for its presence, but on studying Zuckerkandl's description of the tubercle in the dead subject, I recog-



nised that it was in reality the tubercle which I had before me.

It must be borne in mind that the tubercle of the septum is not a deflection of that organ, which, in the living subject, it resembles in appearance, but is (see above p. 20) a thickening of the mucous membrane containing glandular elements. It is commonly seen *on both sides* in the same individual. By inserting one branch of a Fränkel's speculum into each nostril, the tubercles on the two sides may be compared, but it is necessary to remember that a deflection of the septum in this situation may modify the aspect presented by the tubercles, by making one appear more, the other less, prominent than usual. I have not yet been able to ascertain positively whether the tubercle can become *temporarily* swollen, like the inferior turbinated body, but I think that it probably can. It is soft to the touch of the probe, by means of which it can to a certain extent be pushed aside. It may be fairly suggested, I think, that the tubercle guards and protects the anterior extremity of the olfactory slit, in the same manner that the anterior end of the inferior turbinated body, especially when erected, guards the respiratory region.

I have thus endeavoured to sketch the usual appearances of the middle turbinated body, in the normal state. These, provided there be no distinct deflection of the septum, depend, as we have seen, chiefly on the shape of the turbinated bone itself and on the conformation of the tubercle. Other variations, however, occur; indeed, these parts are subject to as many physiological variations as are found in other parts of the body in which a more or less unrestrained growth



can take place, *e.g.* the epiglottis\* or the external nose.

The mucous membrane covering the middle turbinated body is normally smooth and shining in appearance and has a bright reflection of light. It often presents a *very minute red and yellow mottling* which is best seen with reflected sunlight.

On touching it gently with the probe the bone can be felt, but the mucous membrane is generally slightly moveable over it.

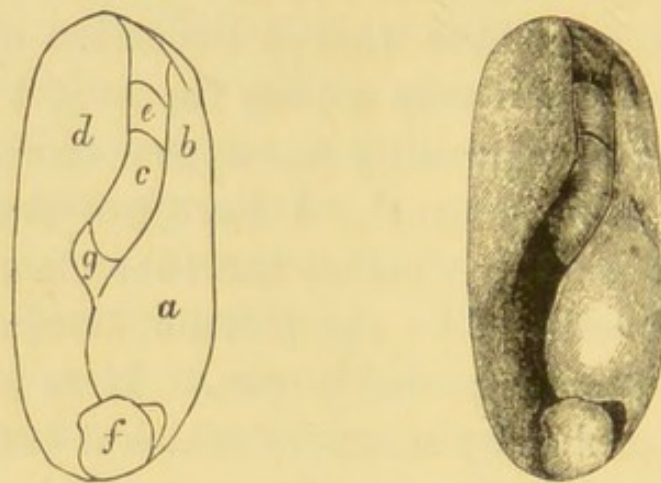


FIG. 32.—Left anterior rhinoscopic view of a woman aged 26, examined with Fränkel's speculum and reflected sunlight. (*Drawn by the Author.*)

*a.* Inferior turbinated body. *b.* "Neck" of ditto. *c.* Middle turbinated body to a great extent hidden by the tubercle (*d*). *e.* A rounded swelling above the middle turbinated body but distinct from it. *f.* A globular swelling completely occluding the inferior meatus. The probe showed that this was a soft fringe-like growth hanging from the lower margin of the inferior turbinated body. *g.* Middle meatus through which the patient evidently breathes chiefly on this side.

The adjoining figure (fig. 32) gives a slightly abnormal anterior rhinoscopic view. There was no complaint of the nose in this case and it was only examined for the purpose of drawing. Nevertheless, as is often the case, pathological changes were found. On enquiry it ap-

\* See J. Solis Cohen, *Diseases of the Throat and Nasal Passages*, p. 55, where six figures are given of normal variations of the epiglottis.



peared that nearly three years before there had been an accident to the nose. The side sketched was freely pervious to air.

Above the middle turbinated body is seen the roof of the nasal cavity formed in front by the under surface of the nasal bone.

In regard to the *superior turbinated body*, from its far-back position (see fig. 1, p. 4) it is unlikely that it would be visible from the front. I have never recognised it. Morell Mackenzie\* has occasionally seen it from the front, but Voltolini† considers it impossible that it can be seen, or at least recognised by anterior rhinoscopy.

*Septum.*—The septum next demands our attention. At its lower part it is seen very much in perspective as a slightly undulating surface passing directly backwards to the posterior naris. Its upper part projects into the nasal cavity as the *tubercle* in the manner already described. Moreover, slight irregularities and prominences on the septum are so common that they can scarcely be considered abnormal. The one most usually met with, in my experience, is a small conical elevation opposite the anterior inferior end of the lower spongy bone; it is shown in fig. 35. A ridge can sometimes be seen running upwards and backwards from this projection; other prominences occur higher up and further back on the septum (see *h*, fig. 30). General or partial bendings of the septum to one side are common, rendering one nasal passage wider and the other narrower than usual.

Below the lower margin of the inferior turbinated

\* *Op. cit.*, vol. ii., p. 244.

† *Op. cit.*, p. 69.



body is seen the *inferior meatus*. This forms a more or less circular canal, which is bounded below by the floor of the nasal cavity. The latter presents a much foreshortened hollow aspect. By projecting through the inferior meatus a strong light, such as that of the sun the movements of the palate during deglutition can often be seen. I have found this to be *very commonly* the case. It is only a question of projecting a strong light in the right direction. Sometimes the palatal movements are observed through the space between the inferior turbinated body and the septum, rather than through the inferior meatus itself.

The character of these movements as they appear

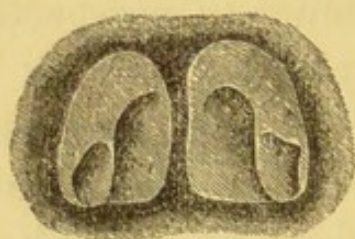


FIG. 33.—Naso-pharyngeal cavity from the front in a state of rest (after Zaufal).

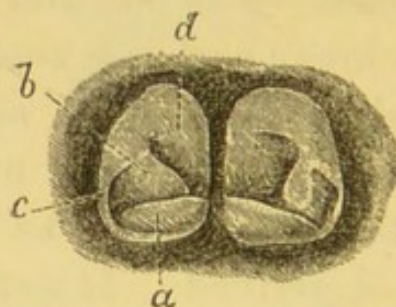


FIG. 34.—The same during phonation (after Zaufal). *a*. Levator cushion. *b*. Eustachian cushion extending towards the median line as the salpingo-pharyngeal fold. *c*. Salpingo-palatine fold. *d*. Posterior wall of naso-pharynx.

from the front is shown in the two accompanying figures from Zaufal's monograph on the subject.

They were taken from a lad suffering from ozaena and and were drawn as seen with a Duplay's speculum. Fig. 33 shows the muscles during rest; fig. 34 the same during phonation, in which procedure a similar though a less marked action of the muscles takes place, to that occurring in deglutition. The velum palati



rises upwards as a rounded eminence (*a*) the levator cushion, and behind it is seen the Eustachian cushion (*b*) extending towards the median line as the salpingo-pharyngeal fold. In front of the Eustachian orifice is the less marked salpingo-palatine fold (*c*). This is the appearance seen in an abnormally spacious nasal cavity or with the use of Zaufal's speculum. Ordinarily, however, we see only the levator cushion and the salpingo-pharyngeal fold. The characteristic feature to look for is the levator cushion rising upwards, whilst behind it, the salpingo-pharyngeal fold slides obliquely inwards towards the median line. Oftentimes the uprising of the levator cushion is all that can be seen, but if this be clearly recognised it is sufficient for practical purposes. During deglutition the action of the muscles of course takes place with momentary rapidity.

Two conditions produce movements in deglutition which may be mistaken for the action of the palatal muscles, viz. :—1. A bubble of mucus far back in the inferior meatus, this can readily be distinguished by its movement to and fro in respiration and can be expelled by a forced expiration; and 2. A moveable growth of mucous membrane on the posterior end of the inferior turbinated body. Such a growth may be lifted up by the palate during deglutition and thus give rise to the mistake. It will, however, probably move to and fro on forcible respiration. If not, it must be distinguished by means of the probe under guidance of the eye. I met with a case of this description not long since. It occurred in a girl aged 14, and the diagnosis was made by seeing the growth move during respiration as well as during deglutition.

*Perception of the palatal movements through the nos-*



*trils* is therefore a ready and convenient test for ascertaining the patency of the inferior meatus, including under this term the space between the inferior turbinated body and the septum. The fact that the palatal movements are indistinguishable, does not necessarily indicate obstruction of these parts, for the whole canal may be so curved as to prevent a view of the nasopharynx. If this condition cannot be recognised by inspection, the judicious use of the nasal probe will show whether the obstruction be bony or otherwise.

Above the levator cushion and to the inner side of the Eustachian cushion is seen the posterior wall of the naso-pharynx (*d*). It generally has a hillocky aspect with several small light-spots, but is decidedly more difficult of recognition, than the movement of muscles just described\*. In exceptionally wide nasal passages, the upper margin of the choana with its *two arches*, one immediately above the other, can sometimes be distinctly recognised.

Above the inferior turbinated body the *middle meatus*, a part of which is seen in fig. 32, *g*, forms a large irregular canal, through which (as is shown in the case from which that figure is taken) respiration can to a great extent take place, when the inferior meatus is blocked.

The *colour* of these parts depends of course upon the source of illumination employed. Gas light gives them a reddish tint. They are paler with electric light, and whitest of all in reflected sunlight.

The inferior turbinated body is the darkest, being of a deeper colour than the mucous membrane lining the mouth. The septum is the next darkest portion. The

\* According to Zaufal (*op. cit.*) it rises upwards at each act of deglutition.



mucous membrane covering the middle turbinated body is decidedly lighter in colour than either of these.

**View when the erectile body on the anterior extremity of the inferior turbinated bone is swollen** (fig. 36). In this case the inferior turbinated body (*a*) appears as *a round shining eminence having*

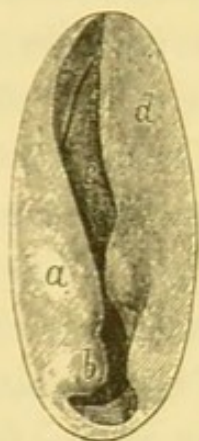


FIG. 35.

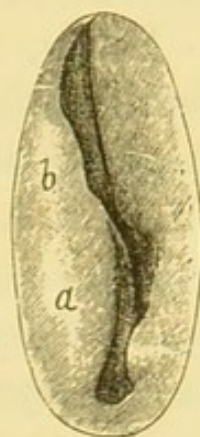


FIG. 36.

Figs. 35 and 36 are both taken from Case II. (see Appendix) and represent respectively the right anterior rhinoscopic view of a man aged 24, before and after erection of the anterior end of the inferior turbinated body (about twenty minutes elapsed between the times of drawing the two sketches). (*Drawn by the Author*).

In fig. 35 (*a*) is the collapsed anterior end of the inferior turbinated body; (*b*) is the inner surface of ditto, which leaves a space between it and the septum, through which the palatal movements can be plainly seen. Above, the middle turbinated body (*c*) is visible, its neck being hidden by the tubercle (*d*).

In fig. 36 (*a*) is the erected inferior turbinated body terminating above in the swollen "neck" (*b*), which almost entirely conceals the middle turbinated body.

The upper parts of the drawings are slightly diagrammatic.

*a smooth surface*, which is in contact with, or in close proximity to, the septum nasi. Above, it is prolonged into a broad neck (*b*), the inner or free margin of which, if the erection be extreme, is in contact with the septum, and completely conceals the middle turbinated body.



When the swelling is less marked, it allows a view to a greater or less extent of these parts. I draw particular attention to this neck, as it is formed by erection of the mucous membrane above the inferior turbinated bone, rather than of that on the bone itself, and is of great practical importance on account of the way in which it hides the upper part of the nasal cavity from view. Below, the swollen erectile body practically occludes the inferior meatus. The sensation produced by touching the inferior turbinated body with a probe, is that of a soft cushion which can be *deeply indented by pressure, but rapidly regains its original globular shape*. This characteristic serves to distinguish it from true hypertrophy of the turbinated body.\*

Its colour does not necessarily differ from that of the non-erected body, but it may be paler or more florid in appearance.

According to my experience, the view of the deeper parts is much more commonly interfered with by swelling of the anterior erectile body, than by malformation of the septum or inferior turbinated bone. If necessary, however, the swollen tissues can be pressed aside with a probe or blunt hook, and a limited view of the deeper parts obtained. Better still, the erection may be reduced by cucaine (*vide infra*). Except when it is extreme, erection of the anterior part of the inferior

\* This general rule holds good, but if there be any doubt between a soft form of hypertrophy and simple erection, the smooth regular outline and the greater compressibility of the latter, will assist in forming a diagnosis, which is of course rendered certain, either by finding the body collapsed on a future occasion, or by seeing it disappear under one's eyes from the action of cucaine. A little practice is required to recognise that these swellings which *appear* like large hypertrophies are really simple erections.



turbinated body alone, does not produce marked nasal obstruction.

*Conditions under which swelling of the anterior erectile body takes place.*—Little is known about these at present, for this erectile swelling has only been recognised within the last few years. It has always hitherto been confounded with hypertrophy of the inferior turbinated body, and spoken of as such.

In his able work on Rhinoscopy, Voltolini\* refers to erection of these parts simulating polypi, and describes the case of a child, aged 14, in whom marked swellings of the anterior ends of the inferior turbinated bodies, which he proposed to operate upon, had disappeared in two hours' time, probably from the effects of fright. More recently the subject has been studied by John Mackenzie and by Hack.†

Temporary erection of the inferior turbinated body is very common, and probably occurs in health as a means of preventing the entrance of any irritating particles into the nostrils. It is difficult to draw the line between its occurrence as a physiological and as a pathological phenomenon. Direct irritants in the inspired air will produce it, and the same result can also be brought about by gently stroking with a probe the mucous membrane of either of the turbinated bodies, or

\* *Rhinoskopie u. Pharyngoskopie*, 1879, p. 290.

† In 1880, Goodwillie of New York, drew attention (*Medical Gazette*, July 31, 1880) to Bigelow's description of the erectile bodies on the turbinated bones. Goodwillie, whose remarks seem to refer chiefly to the erectile tissue on the posterior end of the inferior turbinated bones, considers that this erection and collapse is a physiological fact in the normal condition, and is intended to purify the tidal air passing in respiration from all impurities, and so protect the pulmonary organs against disease. Hairs in the vestibule and this erectile tissue are faithful sentinels to arrest impurities in the respired air.



of the septum (*Hack*). According to the same observer, it is also produced by very cold or over-heated air, or by a strong wind. The swelling can also be caused, in a reflex manner, through the optic nerve, by the action of strong light; through the olfactory nerve by certain smells (*Hack*); and through the pharyngeal nerves by the imbibition of alcohol, even much diluted, (*vide* Case III. in the Appendix, and a case reported by *Hack*, *op. cit.*, p. 41, in which this appears to have occurred). According to the same observer it may be produced by the application of cold to the skin. The nasal douche will often cause it (*Hack*), and in my own case just mentioned, syringing even with cold salt water did not arrest, and probably promoted, the swelling. John Mackenzie has frequently seen it swollen during the menstrual periods.\* It is also erected during acute nasal catarrh (*Cohen*),† and especially in the chronic forms of the disease (*Politzer*).‡

The exact significance of this erection in regard to the production of reflex phenomena is still uncertain, but it is evident that swelling of these organs is not essential to their occurrence, (compare foot note p. 42).

Both Voltolini and Hack have seen the erectile bodies collapse under the influence of fright. Repeated examinations are therefore sometimes necessary, if we have reason to suppose that these organs are liable to undue swelling.

**Cucaine in Anterior Rhinoscopy.**—The recent discovery of the contracting power possessed by hydro-

\* *American Journal of Medical Sciences*, April, 1884.

† *Op. cit.*, p. 333.

‡ *Lehrbuch der Ohrenheilkunde*, vol. i., p. 350.



chlorate of cucaïne on the inferior turbinated bodies, has furnished us with a very important aid in anterior rhinoscopy. The discovery of this fact by Jellinek\* has been confirmed by Bosworth,† myself,‡ and others, and has now become common property.

By simply painting the swollen inferior turbinated body, by means of a camel's hair brush, with a four per cent. solution of the salt, the erection becomes reduced in the course of a minute or two, so that the inferior turbinated body can be seen in perspective and the deeper parts of the nasal cavity become clearly visible. It sometimes also blanches the mucous membrane. When therefore, we wish to examine a nasal cavity which is occluded by erection of the anterior end of the inferior turbinated body, cucaïne (in four per cent., or if necessary, stronger solution) should be freely applied, either with a camel's hair brush, the application being with advantage repeated after five minutes interval, or by means of a pellet of wool moistened with the solution and left for a short time in the nasal cavity. This drug is also to be employed if any doubt exist between hypertrophy and simple erection.

**Use of the Anterior Nasal Probe.**—The use of the nasal probe for ascertaining the consistence and form of the inferior and middle turbinated bodies has already been mentioned. Speaking generally, it is of service for controlling the appearances seen in any part of the nasal cavity. Its assistance is necessary, for in examining the nasal cavities from the front, we can

\* B. Fränkel, *Monatsschrift für Ohrenheilkunde*, xix., no. 1, p. 18.

† *New York Medical Record*, November 15th, 1884.

‡ *British Medical Journal*, March 7th, 1885.



only make use of monocular vision, and we are more likely therefore to be deceived. The probe should also be used for ascertaining the reflex irritability of the different intra-nasal structures. By stroking gently in turn the inferior and middle turbinated bodies and septum, and by observing whether any reflex phenomena (such as sneezing, watery secretion, erection of inferior turbinated body or cough) be produced, important information may be gained. Touching the anterior extremity of the *inferior turbinated body* produces usually, in my experience which is based on a large number of cases, no reflex phenomena. It merely gives rise to a peculiar sensation to the patient. Exceptionally it produces cough (see above, p. 39). Concerning the effect of touching the *middle turbinated body*, I cannot speak so definitely. It occasionally produces sneezing, but whether only in pathological states I am at present unable to say. Sometimes if the mucous membrane be moist, the introduction of a cold probe will obscure the view by filling the nasal passage with vapour. This need only be mentioned to be avoided by previously warming the instrument.

**Other Methods of Examination through the Anterior Nares.**—*Employment of Zaufal's Speculum.* After being sufficiently warmed the speculum is gently introduced along the inferior meatus until the distal end of the speculum is at the choana.

It affords a good view of the palatal movements and of the Eustachian folds, but of the practically more important nasal cavities it gives no more information than can be gained at less inconvenience to the patient by means of an ordinary speculum and a probe. The use of a Zaufal's speculum pre-supposes a nasal cavity which is



straight as regards its bony parts. It can easily be made to pass a soft obstruction such as a swollen erectile body on the inferior turbinated bone. Zaufal employs his specula not only for examining the palate and Eustachian cushion, but also for investigating the state of the naso-pharyngeal cavity. I have often tried them, but in my hands they have not been of much practical value.

*Wertheim's Conchoscope* consists of a metallic tube having a window on one side near the extremity. In the tube opposite the window is a small mirror placed at an angle of  $45^{\circ}$ . The previously warmed mirror and tube having been introduced through the nostril, a strong light is projected along it, and a limited part of the nasal cavity may thus be illuminated and inspected. A slide covering the window which can be withdrawn by means of a wire after the insertion of the instrument, has been suggested by Voltolini, to prevent the mirror from becoming soiled with mucus. I have no experience of the instrument. It has not met with any general adoption.

*Rumbold's mirror* is an oval-shaped glass mirror measuring about  $\frac{1}{2}$  by  $\frac{1}{4}$  inch in size and attached to a flexible wire. It is used in a similar manner, but I imagine can only be of service in an unusually large nasal cavity.

Voltolini's funnels attached to a Brunton's otoscope (mentioned on page 56) appear to be more practical than either of these instruments as far as can be judged without actual experience.

*Anterior rhinoscopy with transmitted light.* A method has been recently recommended by Voltolini\* in which

\* *Monatsschrift für Ohrenheilkunde*, January, 1884.



the observer inspects the nasal cavity from the front, whilst an assistant illuminates the naso-pharynx by holding a rhinoscopic mirror in the ordinary position and concentrating a strong light upon it.

I have simplified this\* by attaching the rhinoscopic mirror to Trouvé's electric photophore in the manner shown in fig. 37. By this means the method can be put into practice without the help of an assistant.



FIG. 37.—APPARATUS FOR ANTERIOR RHINOSCOPY WITH TRANSMITTED LIGHT.

*a.* Trouvé's electric photophore, head-band not represented. *b.* Spring collar with metallic tube for holding rhinoscopic mirror (*c*).

An ordinary mirror (*c*) of say  $\frac{1\frac{1}{8}}{1\frac{1}{8}}$  inch diameter, is fitted into a metallic tube which is attached to the lamp (*a*) by means of a spring collar (*b*). The metallic tube is bent (rather more than is shown in the figure) until the mirror occupies the centre of the beam of light projected from the lamp.

The distance of the mirror from the lamp can be regulated at will, a suitable distance from *b* to *c* being, I find, five or six inches. It is most convenient to rotate the lamp so that its platinum loops (which are not drawn in the woodcut) point to one side. The head-piece which is likewise not represented in the figure, is left attached to the lamp, and serves as a handle for holding it. The examination may be conducted as follows:—A conical vulcanite nasal speculum (fig. 7, p. 51) having been inserted into one nostril,

\* *British Medical Journal*, May 3rd, 1884.



the patient is directed to open his mouth widely and hold down his tongue with an angular depressor. Taking the lighted lamp in his right hand, the observer then inserts the previously warmed mirror in the usual position for posterior rhinoscopy. The speculum in the anterior naris is next grasped by the thumb and fore-finger of the left hand; and by either tilting the patient's head downwards a little, or by raising himself slightly, the observer is able to inspect the nasal cavity by transmitted light, and can, if necessary, transfer the speculum to the opposite nostril with his left hand. This method is much more simple in execution than would appear from this detailed description. Light transmitted forwards from the naso-pharyngeal cavity, can thus be recognised, when, with an ordinary speculum, no view whatever of the naso-pharynx can be obtained through the nostril, not even with reflected sunlight. With a wide nasal cavity, and an unobstructed naso-pharynx, the light can of course be perceived with much greater clearness. The value of this method in practice has yet to be determined.



## CHAPTER V.

## POSTERIOR RHINOSCOPY.

POSTERIOR rhinoscopy, or inspection of the nasal cavities from behind, is accomplished by placing a small mirror at a suitable angle in the pharynx, and concentrating a strong light upon it, in the direction of the observer's optical axis. Light is thus thrown into the naso-pharynx and the image of the illuminated parts is seen by the surgeon. The appliances required for this method of examination are:—1. A powerful light. 2. A small mirror for insertion in the pharynx; and 3. A tongue depressor. A post-nasal probe is also sometimes necessary.

1. **Illumination.**—The sources of light already recommended for anterior rhinoscopy (see above, p. 57, *et seq.*) are equally well adapted for the examination of the nose from behind. Sunlight, reflected by means of a plane mirror is the best; but the small electric lamp answers admirably for this purpose. When neither of these can be had, the examination may be conducted with the light of an Argand gas-burner, with or without a bull's-eye condenser, the light being concentrated by means of a concave reflector worn on the forehead in the manner already described.

2. **Rhinoscopic mirrors.**—These resemble laryngeal mirrors (fig. 38), but are smaller and joined to the shaft at a somewhat more acute angle. As far as I am aware they are now-a-days only used of a circular form.



Those I usually employ vary from half an inch to three-quarters of an inch in diameter, though I some-

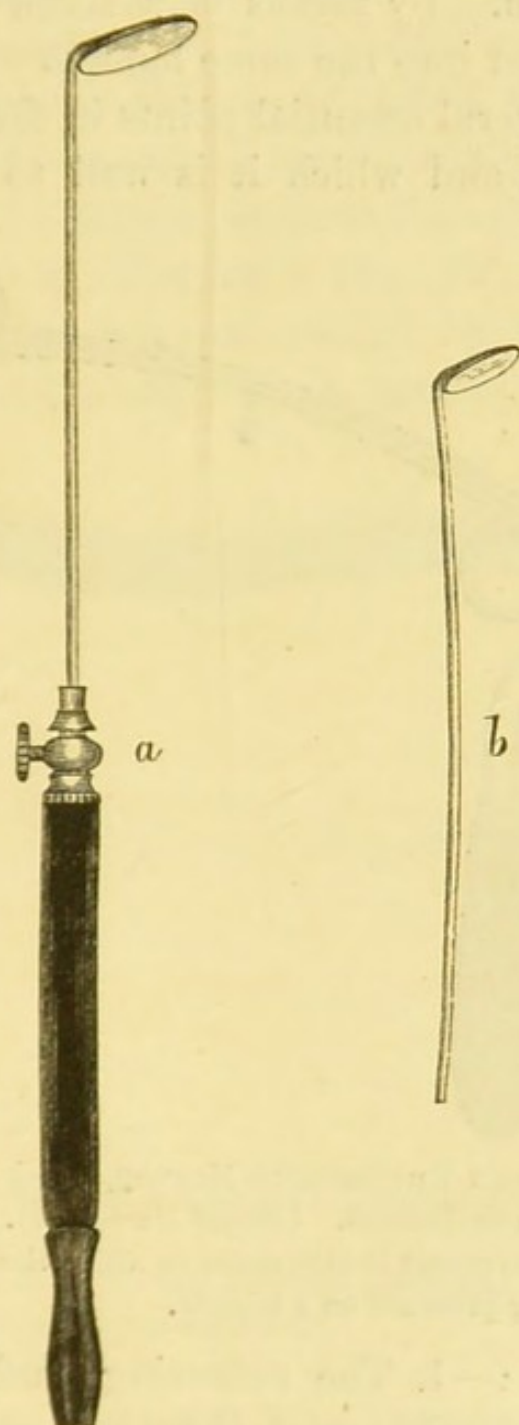


FIG. 33.—*a*. Ordinary rhinoscopic mirror, large size, with straight stem and handle. *b*. Small ditto, with slightly bent stem, which can be introduced into the same handle. A medium-sized mirror is also recommended. (Drawn half size).

times use them larger. They are attached to the shaft at an angle of  $110^{\circ}$ , but a larger angle is convenient



for viewing the roof of the naso-pharynx. The shaft measures about  $3\frac{1}{2}$  inches, and the handle about  $4\frac{1}{2}$  inches in length. By means of a screw different mirrors can be fitted into the same handle.

There are several essential points in the construction of the mirrors, and which it is well to remember in

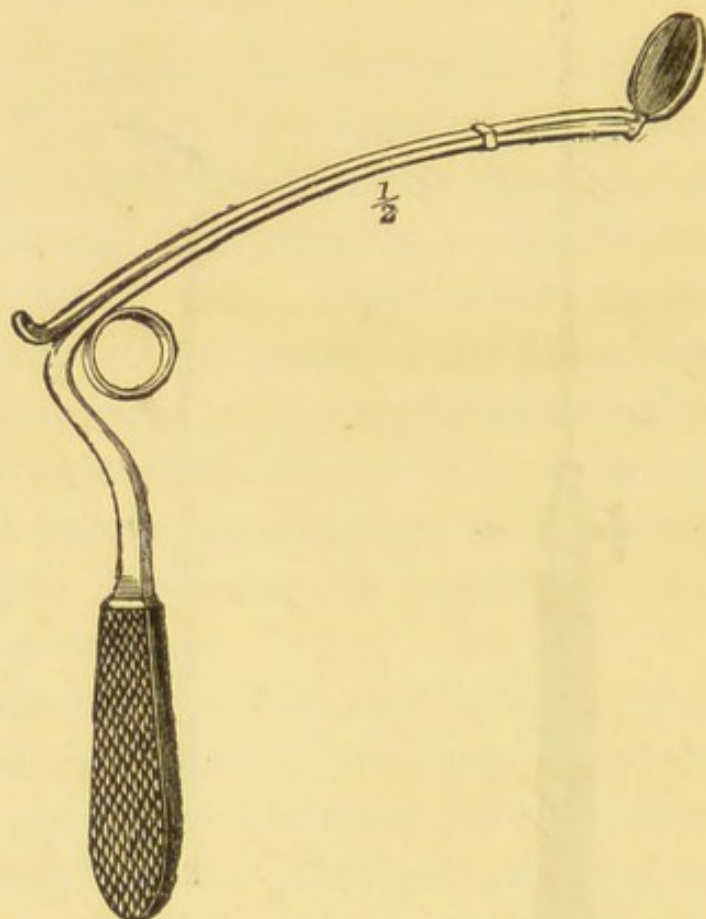


FIG. 39.—FRÄNKEL'S RHINOSCOPIC MIRROR, which can be adjusted to any angle after its introduction. (*Morell Mackenzie*).

A form of this instrument is also made in which the angle of the mirror can be altered by pressure on a trigger.

selecting them:—1. The reflecting surface should be as perfect as possible, and the whole mirror *thin*, not measuring more than  $\frac{1}{16}$  of an inch in thickness. 2. The shaft should come off directly from the margin of the mirror (as shown in fig. 38), and not form an angle after leaving it (thereby losing valuable space in the examination); and 3. The shaft of the instrument



should be capable of being bent slightly with the fingers, as sometimes one forming a very obtuse angle near its centre, is preferable to a shaft which is perfectly straight. I have been so satisfied with the simple mirror thus constructed, that I have had no occasion to use those more complicated—the angle of which can be altered while the mirror is in position. Of this kind is Fränkel's (fig. 39), which has recently been highly recommended by Woakes. Morell Mackenzie, on the other hand, prefers the simple form.

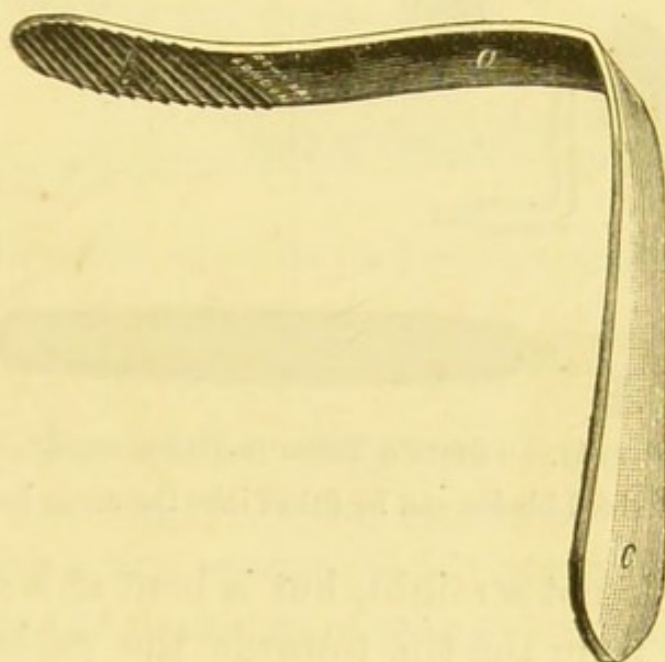


FIG. 40.—THE AUTHOR'S ANGULAR TONGUE-DEPRESSOR WITH BENT BLADE.

*a. b.* Blade, showing the two different portions. *c.* The handle, which also forms a broader tongue-depressor.

**3. Tongue depressors.**—Tongue depressors are usually, though not always, required for posterior rhinoscopy. One or more must therefore be ready to hand. The essential points for a depressor for this purpose, are, that the handle be fixed to the blade at about a right angle, and that the latter be not unduly



thick, nor broader than is necessary to keep down the tongue. Probably every rhinologist has a particular liking for a certain tongue-depressor. I confess to a prejudice in favour of one which I had made some five or six years ago, and which I have constantly used since then. It is made of metal, and the blade (fig. 40, *a*, *b*) is nearly half an inch wide, 3 inches long, and about  $\frac{1}{16}$  of an inch in thickness.

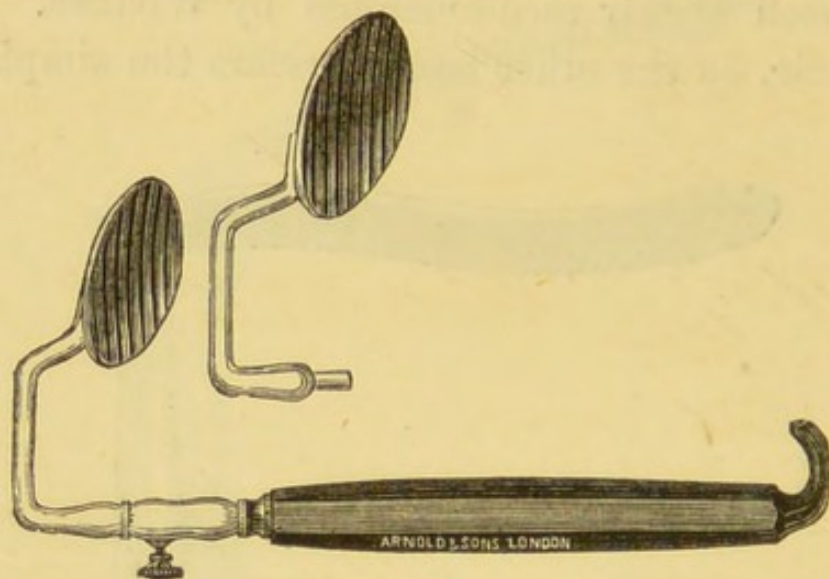


FIG. 41.—TÜRCK'S TONGUE-DEPRESSOR.

Different sized blades can be fitted into the same handle.

The blade is not straight, but is bent at a distance of half an inch from the tip, towards the patient's right (supposing the instrument to be in position) at an angle of  $160^{\circ}$  (see *b*, fig. 40). By this arrangement, while the tongue is sufficiently depressed by the bent tip of the blade, the angle of the depressor rests near the right corner of the patient's mouth, out of the way of the surgeon. The portion of the blade (*a*) forms rather less than a right angle with the handle; the portion (*b*) is again bent slightly upwards. The under surface of the latter is transversely grooved to prevent it slipping.



A broader tongue-depressor is sometimes required, such as Türk's (fig. 41), or that forming the handle in fig. 40.

Fig. 42, shows a thimble tongue-depressor for fitting on the surgeon's forefinger. It was not intended for posterior rhinoscopy, though on occasion it can be used for this purpose. Its chief use is for children who have naturally a great objection to tongue-depressors. By carrying this little instrument in the pocket, it can be slipped on and used before the little patient is aware of it. It must be made to fit the surgeon's

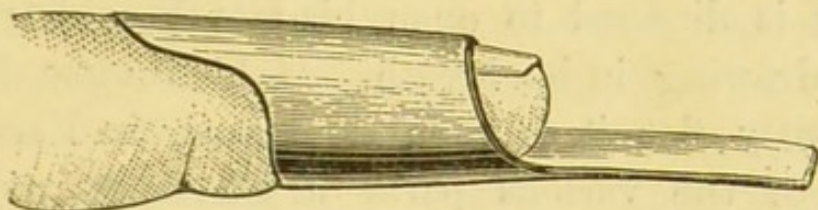


FIG. 42.—THE AUTHOR'S THIMBLE TONGUE-DEPRESSOR. (*C. Wright & Co., London*).

The thimble is cut across on one side to allow of its better adaptation to the finger.

finger tightly. Some observers depress the tongue with the fore-finger during posterior rhinoscopy, but I do not think this practice is advisable.

Voltolini and Jarvis have each devised an instrument in which tongue-depressor and rhinoscopic mirror are combined.

**Post-nasal probe.**—A probe for use in posterior rhinoscopy should be a long one, fitted into a light handle, and bent at right angles at a distance of about  $1\frac{1}{2}$  inch from its distal end. It may be conveniently made of silver, so that its curve can be altered as required.

**Method of performing Posterior Rhinoscopy.**—It is almost needless to say that posterior rhinoscopy



should always be preceded by a careful examination of the fauces by direct inspection, as important information can thus be gained for the subsequent examination.

*Inspection of fauces.*—For this purpose the means of illumination which we have ready for posterior rhinoscopy may be employed, or the fauces may be more simply, but less thoroughly examined by direct daylight. In the latter case the patient is seated facing a window and the surgeon stands to his right side, holding the tongue-depressor in his right hand. The patient is directed to open his mouth widely, but to avoid drawing in his breath. If his tongue do not lie sufficiently flat it is then depressed, and account is taken of the various parts of the fauces and lower pharynx. As pointed out by Cohen, taking up a position on the patient's right, enables the surgeon to bring his head closer to the patient's mouth, and to obtain a clearer view than he otherwise could.

Having noticed the condition of the faucial pillars and tonsils, whether the latter be enlarged or not, we turn to what is of first importance from a rhinoscopic point of view, viz., the state of the soft palate and its relative position as regards the posterior pharyngeal wall.

Special notice should therefore be taken of the depth to which the soft palate hangs down, and the distance, which during quiet respiration is left between it and the pharynx. The condition of the latter is also to be noted, whether it is normal, or studded with granulations, or dry and glazed.

The last named condition is usually more favourable for practising posterior rhinoscopy than a granular



state of the mucous membrane. The view of the pharyngeal wall especially of the salpingo-pharyngeal folds, which stretch upwards on either side from behind the pillars of the fauces to the posterior lips of the Eustachian orifices, may be further extended by making the patient say "ah," or by drawing up the soft palate with a hook. (This latter manipulation is not to be attempted before performing posterior rhinoscopy as it would irritate the parts and so add difficulty to the examination).

*Method of procedure.*—The patient being seated, with his head vertical or bent slightly forwards, the observer takes up his position directly facing him on a rather lower stool. Directions are given to the patient to keep down his tongue if possible, and to breathe quietly through the nose. The observer then holds down the patient's tongue gently but firmly with a depressor, and projects the light on to the posterior wall of the pharynx immediately below the soft palate. With his right hand he next introduces the previously warmed\* rhinoscopic mirror in the following manner:—With the reflecting surface turned upwards and its handle somewhat raised, the mirror is rapidly passed through the cavity of the mouth, until it nearly, but not quite, reaches the posterior pharyngeal wall, just below the velum.

Sometimes it is necessary to insert the mirror first on

\* The method of warming the mirror is to hold it a few inches above the gas flame. The moment to remove it being when the moisture with which it becomes covered disappears. If sun or electric light be used, a spirit lamp is necessary to heat the mirror. In all cases its temperature should be carefully tested before use, by placing its back on the dorsum of the surgeon's hand. Moistening the mirror with glycerine or mucilage instead of warming it, is recommended by some observers.



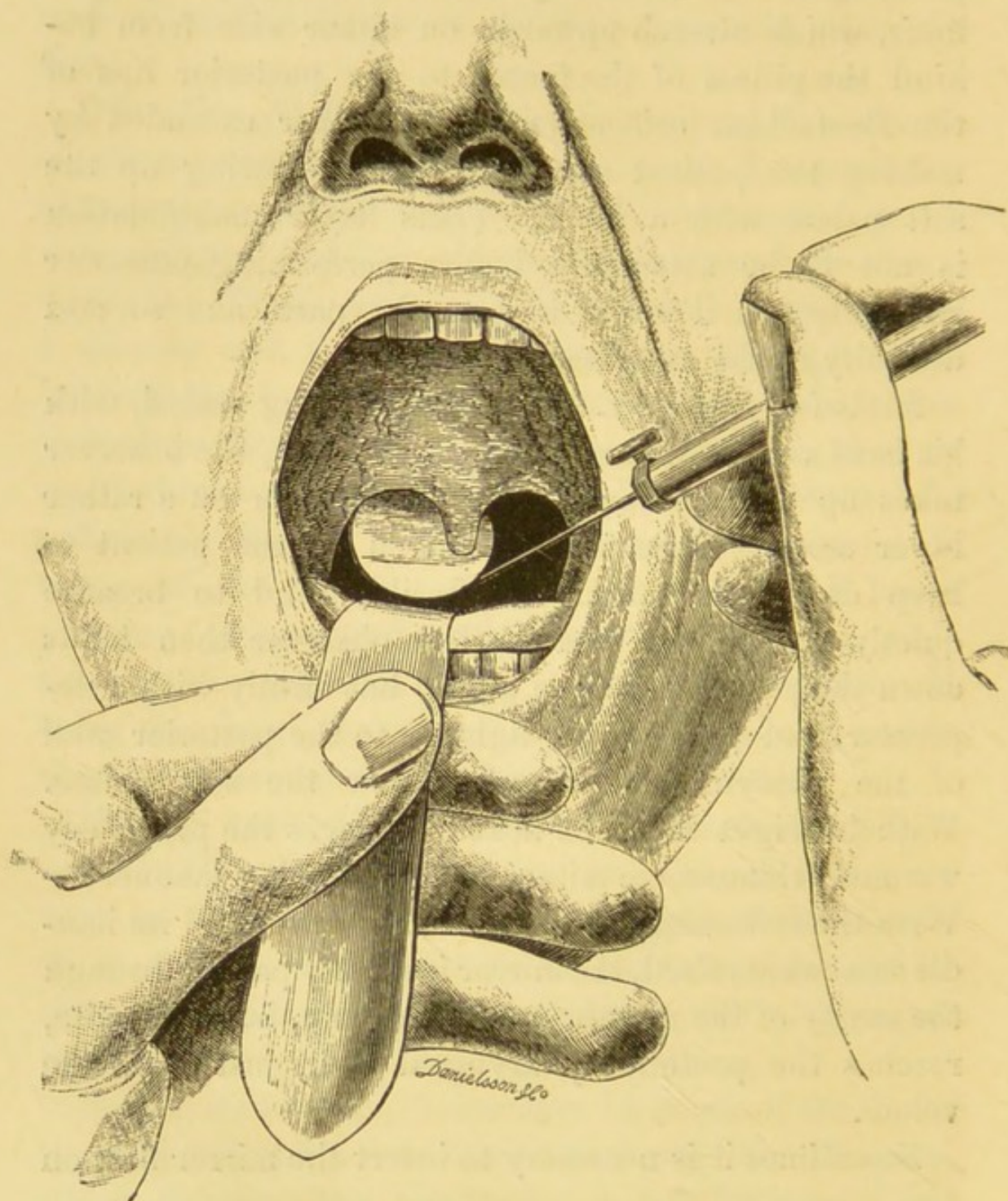


FIG. 43.—Sketch, slightly altered from a photograph, showing the ordinary position for holding the rhinoscopic mirror and angular tongue-depressor. (In practice the mouth would directly face the observer. In the figure it is shown turned a little to one side).



one, and then on the other side of the uvula. But, if possible it is better, I think, to insert it near the central line and move it gently from side to side. A favourite position for the mirror is shown in fig. 43 (which was taken from a photograph), *i.e.*, just to the right side and slightly below the uvula.

By gently depressing the handle (which now comes to occupy the lower corner of the patient's mouth) the mirror is rendered more vertical, and if there be sufficient space between the velum and pharyngeal wall, the posterior rhinoscopic image comes into view.

The points first seen are probably the hinder surface of the velum and uvula. By raising the mirror and making it more nearly horizontal a whitish vertical band is seen, the posterior septum of the nose. This is a point which should always be looked for, as it serves as the most convenient landmark in this somewhat obscure territory. By raising the handle so as to render the mirror still more horizontal, the upper broadening part of the septum becomes visible.

Again, by turning the mirror sideways the posterior nares come into view, in each of which, always the two lower, and often the superior, turbinated bodies are seen. Turning the mirror still more obliquely to one side, we see the depression leading to the orifice of the Eustachian tube, the latter surrounded by its cartilaginous lip. Behind it, appears Rosenmüller's fossa, a depression of some importance, as being the spot where the point of the Eustachian catheter often becomes engaged instead of in the Eustachian orifice. The exact situation necessary for examining the latter opening, and the effect on its appearance produced by different positions of the mirror will be



described when considering the posterior rhinoscopic view in detail. By directing the surface of the mirror back to the median line, the roof of the nasopharynx can be seen occupied by the irregular elevations of the pharyngeal tonsil; and by making it almost horizontal the posterior wall of the nasopharynx comes into view very much fore-shortened.

In commencing an examination it is well to use a small mirror; but it must be borne in mind that the larger the mirror, not only the greater the extent of surface visible without changing its position, but also, the better the illumination of the naso-pharynx, for the mirror of course serves the double purpose of transmitting the light into the naso-pharynx, and of reflecting the image.

**Posterior rhinoscopic view** (fig. 44). — Before entering into the details of the posterior rhinoscopic view, there are certain points connected with the optical conditions under which the different parts are seen, which it is necessary to dwell upon shortly.

In the first place, the rhinoscopic mirror being usually placed about *three quarters of an inch below the floor of the nasal cavities*, both anterior and lateral walls of the naso-pharynx will be considerably *fore-shortened in a vertical direction*. This vertical fore-shortening is to be overcome as far as possible by seating the patient high, by raising the palate, (by the means to be subsequently described), and by holding the mirror as high as the case will allow. Again, that part of the lateral wall of the naso-pharynx which is in front of the mirror, (and which therefore requires the mirror to make with it an angle larger than  $45^{\circ}$ ), is subjected to a *horizontal fore-shortening*. This can



be overcome to a certain extent by placing the mirror

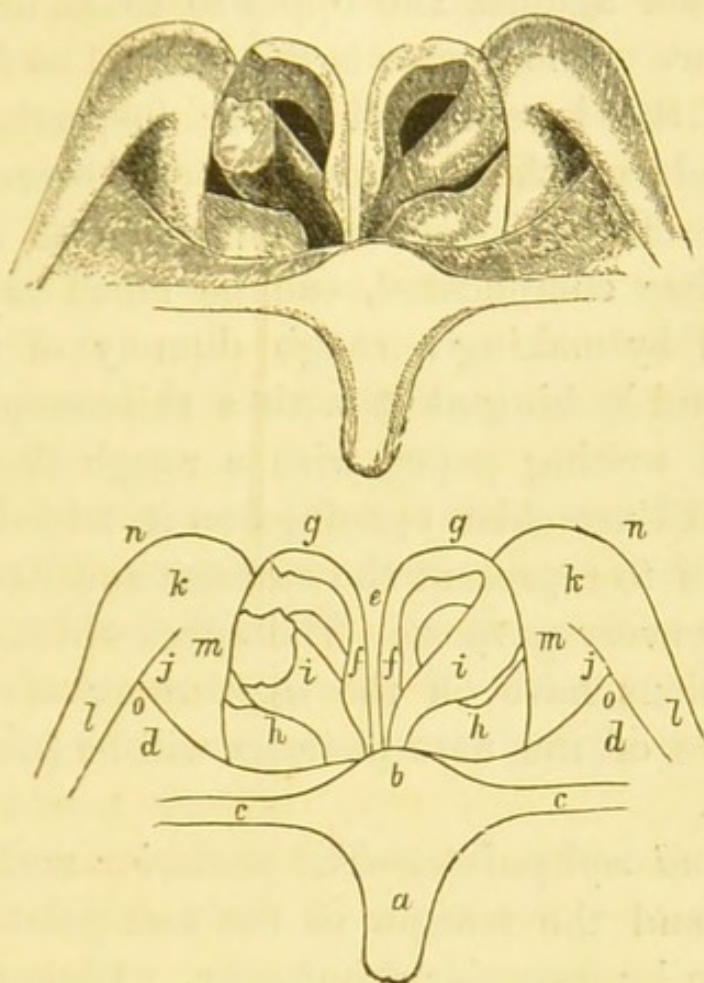


FIG. 44.—POSTERIOR RHINOSCOPIC VIEW, as seen with the mirror in the ordinary position and without the use of any instrument to draw forward the palate. (The posterior nares and Eustachian openings were carefully sketched under illumination with electric light, from a male adult in whom there was paresis of the soft palate. The Eustachian cushions and folds have been semi-diagrammatically drawn as they were not very clearly marked, but the upper margins of these cushions appeared distinctly above the level of the summits of the choanæ. *Drawn by the Author*).

*a.* Posterior surface of uvula. *b.* Uvula cushion. *c.c.* Posterior margin of palate (arcus palato-pharyngei). *d.d.* Levator cushions. *e.* Septum nasi. *f.f.* Swellings on the sides of septum. *g.g.* Choanæ or posterior nares. *h.h.* Inferior turbinated bodies. *i.i.* Middle turbinated bodies. *j.j.* Eustachian openings, more strictly the depressions leading to them. *k.k.* Eustachian cushions. *l.l.* Salpingo-pharyngeal folds. *m.m.* Salpingo-palatine folds. *n.n.* Position of upper part of Rosenmüller's fossæ. *o.o.* Posterior tubal sulci.

in the position recommended by Zaufal for seeing the



salpingo-pharyngeal fold, viz., low down in the pharynx with its back against the opposite tonsil or posterior faucial pillar. The mirror is thus placed as far as possible from the lateral wall under inspection, which position reduces the horizontal fore-shortening to a minimum. These considerations which at first sight appear rather complicated, can be much more easily understood by making a rough dummy of the naso-pharynx, and looking at it with a rhinoscopic mirror. A piece of writing paper, with a rough sketch of the choanæ and Eustachian openings on it, folded twice at right angles to represent the anterior and lateral walls, will answer every purpose. The effect which these optical conditions have on the *appearance* of the individual parts of the naso-pharynx will be subsequently considered.

*Uvula and soft palate.*—The posterior surface of the uvula (*a*) and the margin of the soft palate (*cc*) are plainly seen by posterior rhinoscopy. Owing to their proximity to the mirror they appear relatively larger than usually depicted in drawings of this region. Above the uvula is a rounded fleshy eminence (*b*), the uvula cushion, and on either side receding into the distance is the levator cushion (*d*). The colour of these parts is a florid red.

The *septum* (*e*) is seen as a pale median ridge, which is narrow in the centre, but broadens above where it merges into the roof of the naso-pharynx. It also expands at the floor of the nose, but this enlargement is often hidden by the palate. On either side of the septum it is common to see bulgings of the mucous membrane (*ff*). These are so frequently present in a slight degree that I am disinclined to regard them as



pathological appearances. When large, they are, however, no doubt morbid in character.

The *choanæ* or *posterior nares* (*g g*) are visible as two oval-shaped openings, one on either side of the septum. The lowermost part of the oval, as in fig. 44, is usually concealed by the soft palate. The choanæ appear shorter than they really are owing to the vertical foreshortening. In each choana are commonly seen the three turbinated bodies, also the middle and superior meatuses.

The *inferior turbinated body* (*h*) appears as a rounded swelling at the lowermost part of each choana, a large portion of it being hidden by the *velum palati*. Its mucous membrane is generally of a grey colour, and presents an uneven surface, often being so corrugated as to resemble a sponge.

The *middle turbinated body* (*i*) which is seen just above the inferior, has a light red colour and smoother surface than the preceding. Its inner (septal) surface can often be traced in perspective running forwards into the nasal cavity, making it seem in close proximity to the septum.

The *superior turbinated body* may appear as a distinct narrow ledge projecting from the outer wall of the choana and running parallel to the middle turbinated body. In some cases, however, it is not clearly visible, whether it is then represented by the indistinct ridge, above the middle turbinated body shown in fig. 44, or whether it is really hidden by the latter is doubtful.

As seen in this figure the turbinated bodies are often unsymmetrical on the two sides.

Like its anterior extremity, the posterior end of the inferior turbinated body may become temporarily swol-



len by the distension of its erectile tissue. Voltolini\* has drawn attention to this phenomenon, and has been able to demonstrate on a patient with cleft palate, that irritation of the posterior extremities of the inferior turbinated bodies with a sponge, caused them immediately to swell and assume a blue colour. When fully erected they form tumours which project into the nasopharynx, and often meet across the septum in the median line. The posterior end of the middle turbinated body appears likewise to undergo temporary erection.

Of the *three meatuses*, the inferior cannot (owing to the position of the mirror) be seen, even with the use of the palate hook. The middle and superior are visible to a varying extent below and above the middle spongy bone.

*Eustachian orifice.*—Immediately to the outer side of each choana and *apparently* on a level with the middle meatus is seen the orifice of the Eustachian tube (*j*) or rather the depression leading to it. With the mirror in the ordinary position (*i.e.*, below the velum and near the uvula), it appears as a light triangular depression with a dark outline, the base of the triangle being directed inwards towards the margin of the choana. Above this depression is seen the Eustachian cushion (*k*) which appears as a thick red lip. Behind, it curves downwards as the salpingo-pharyngeal fold (*l*), and in front it passes into the less marked salpingo-palatine fold (*m*). Though in reality on a lower level, the upper margin of the Eustachian cushion *appears higher than that of the choana*. This is merely an effect of the fore-shortening which makes the Eustachian tube look

\* *Op. cit.*, pp. 290 and 291.



comparatively larger in a vertical direction than it is. In consequence of this fore-shortening, it is to be noticed that the higher and more vertically the mirror is placed, the lower will the upper margins of the Eustachian cushions appear relatively to the top of the posterior nares, and *vice versa*. Again, if the mirror be moved horizontally across the pharynx, the nearer it is to the side under examination, the higher will the Eustachian cushion appear in relation to the anterior wall. Immediately above the upper margin of the Eustachian cushion is seen the *roof* of the naso-pharynx, which, when prominent, may appear to overlap the upper part of the cushion hiding it partly from view. To the outer side of the cushion (using the term "outer" in regard to the view) the fossa of Rosenmüller appears, often traversed by numerous bands at the point (*n*). The lips of the Eustachian tube, in some cases, appear to project across the outer margin of the choana, towards the median line.

Behind, as already remarked, the Eustachian cushion bends downwards, and merges into the salpingo-pharyngeal fold (*l*).

It is convenient to show this in the figure in order that the student may know where to look for it; but as a matter of fact, with the mirror in the ordinary position, the inner margin of the fold cannot always be clearly distinguished from the levator cushion (*d*), which forms the lower margin of the Eustachian depression. To see the fold more clearly, it is necessary to hold the mirror lower down against the opposite lateral wall of the pharynx in the position already mentioned as Zaufal's. The appearance then presented is shown in the accompanying figure (fig. 45). The fold (*b*) is seen



in its whole length, and appears to run almost horizontally; indeed, in examining the salpingo-pharyngeal fold, it will be found that the lower the mirror is in the pharynx, the more nearly horizontal in direction will it appear. It is always more oblique in direction in the rhinoscopic mirror than it is in reality.

It is not always possible to see the salpingo-pharyngeal fold plainly, even in Zaufal's position; but whether it is only in pathological cases in which it is not clearly distinguishable, I am not prepared to say.

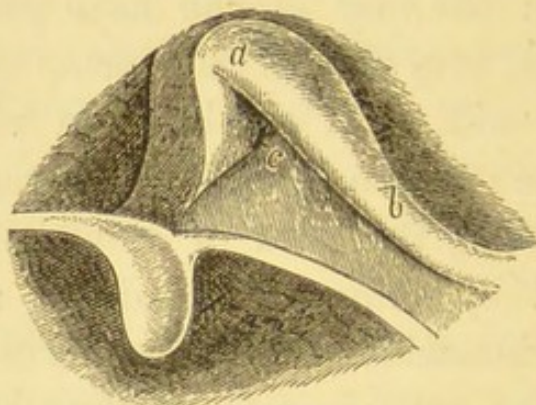


FIG. 45.—View of the left Eustachian orifice, with salpingo-pharyngeal fold and posterior surface of soft palate (after Zaufal).

*a.* Eustachian cushion. *b.* Salpingo-pharyngeal fold. *c.* Posterior tubal sulcus.

The depression between the salpingo-pharyngeal fold and the levator cushion, is known as the posterior tubal sulcus (*c*), and is best seen with the mirror in Zaufal's position; that in front of the levator cushion is called the anterior tubal sulcus.

The immense variety in the rhinoscopic views, of different observers, is doubtless owing partly to the perspective fore-shortening just explained, and partly to the fact that the least alteration in the position of the mirror, changes the relative position of the component parts of the image. On this account also, a representation of the structures seen in posterior rhino-



scopy, must to a certain extent be diagrammatic in character. By far the best figure which I have seen is Zaufal's, as given by C. H. Burnett (*Treatise on the Ear*, 2nd edit., p. 106). But whilst recognising the fact that the lateral walls of the naso-pharynx appear relatively large compared to the anterior wall, he makes the Eustachian cushions extend barely above the upper margins of the choanæ. Other recent figures, such as those of Morell Mackenzie and Woakes, represent the Eustachian cushions as reaching to a much lower level than the summits of these openings. Voltolini, on the other hand, recognises the true appearance of the Eustachian cushions, and makes them extend distinctly above the upper margins of the posterior nares, but he does not show the salpingo-pharyngeal folds.

**Examination with the probe.**—The consistence, form, and mobility of these parts may, under favourable circumstances, be ascertained by the use of a post-nasal probe, under guidance of the rhinoscopic mirror. This method is chiefly of service in distinguishing the character of any growths which may be present. Its employment demands more practice, and it is less frequently required than the anterior nasal probe. The necessary information can often be gained more easily by the use of the finger, or by the introduction of a straight or slightly curved probe through one nasal cavity, the naso-pharynx being viewed in the rhinoscopic mirror.

**Difficulties in performing posterior rhinoscopy.** There are two chief difficulties in carrying out posterior rhinoscopy. The first rests with the tongue; the second with the soft palate.



A very large uvula and enlarged tonsils occasionally interfere with an examination, and extreme irritability of the fauces is sometimes a bar to its successful performance.

*The tongue.*—Generally speaking, when a patient can hold his tongue down fairly well, there is yet considerable advantage in flattening its base still further with a depressor, as additional space is thus gained for the insertion of the mirror. But when the tongue is arched in the cavity of the mouth, the use of a depressor is a *sine quâ non*; and if at the same time this organ be so sensitive as to give rise to retching when attempts are made to depress it, rhinoscopy is rendered decidedly more difficult. Violent handling of the tongue is to be deprecated, as it only induces gagging; but in a case of this description much may be accomplished by the careful and patient use of a depressor, and by directing the patient's attention to the position which it is necessary for his tongue to assume. He may also, with advantage, be advised according to Schalle's plan, to practice at home, depressing his tongue with the handle of a spoon, before a looking-glass, for, as in other regions, repeated contact with instruments will blunt the sensitiveness of the tissues.

*The soft palate.*—The chief difficulty encountered in posterior rhinoscopy depends upon the soft palate. A glance at fig. 1 (p. 4) will show that unless there be a fair space between the velum palati and the posterior pharyngeal wall, posterior rhinoscopy is impracticable. It frequently happens, that directly the patient opens his mouth, the soft palate, especially if it is irritable, rises upwards and cuts off all access to the nasopharynx from below. By explaining to the patient



beforehand, that on opening his mouth, he is to breathe quietly as usual and *not* to draw in, or hold his breath, this difficulty is often avoided. If this fails, one of the following devices may be tried, viz.:—

1. Direct the patient to sniff up through the nose, as if smelling at something.

2. Make him pronounce a nasal sound, such as the French word “on,” or the English “hang.”

3. Cause him to make a snoring noise.

4. Instruct him to take a succession of short sharp gasping inspirations (*Spencer Watson*).

Any of these means may be successful, and may be of value in cases in which there was sufficient space, before the palate contracted. The drawback to the first three methods is, that at the same time that they lower the palate, they give rise to elevation of the base of the tongue, which we require especially low when the palate hangs flaccid. There are, however, instances in which, even when the velum is relaxed, there is scarcely any interval between it and the posterior pharyngeal wall.

If in a case of this description sufficient view cannot be obtained with the *smallest* sized mirror, some other means must be used for drawing forward the soft palate.

Since Czermak originally invented his hook for pulling forward the velum, numerous instruments have been devised for this purpose. They may be divided into:—(1) Palate hooks; and (2) Bands for passing through the nose.

1. *Palate hooks*.—Czermak\* describes his instrument

\* *On the Laryngoscope and its employment in Physiology and Medicine*, Translated by Dr. Gibb (New Sydenham Society), London, 1861, p. 30.



as a "flat hook with a long stem, assuming the form of a spatula of which the front part contained an opening,"

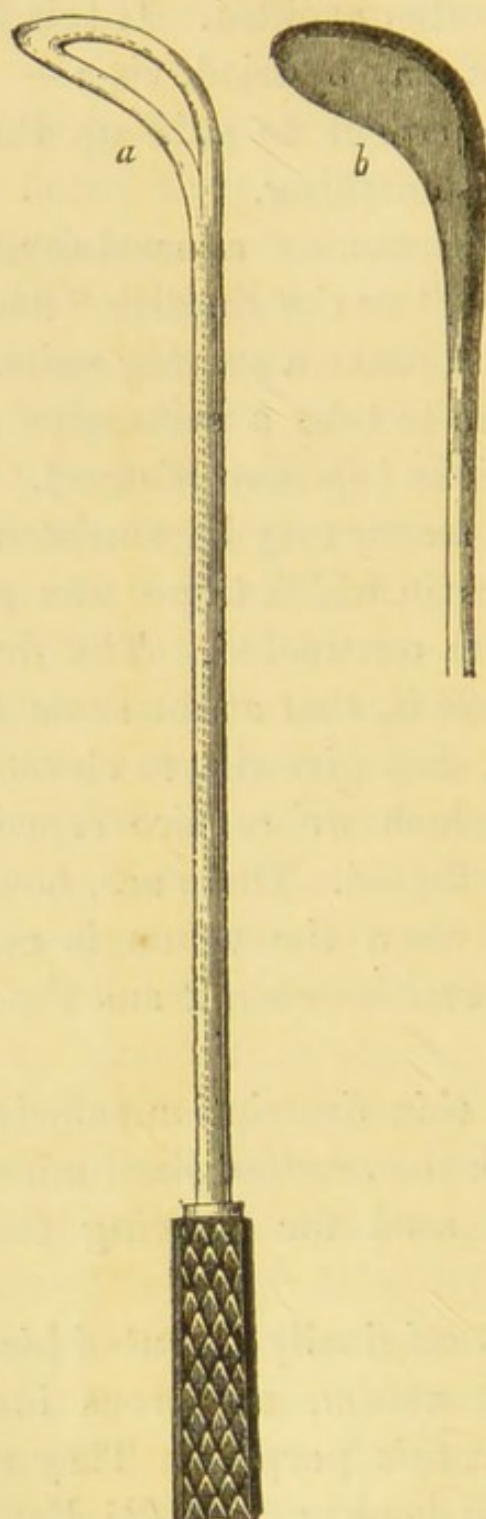


FIG. 46.—CZERMAK'S PALATE HOOK (after Czermak).

*a.* With an opening. *b.* Without one.

it is shown in fig. 46 (*a*). Czermak also figures a similar instrument without the opening in the blade (*b*). I have



no experience of this hook, the only one I have used

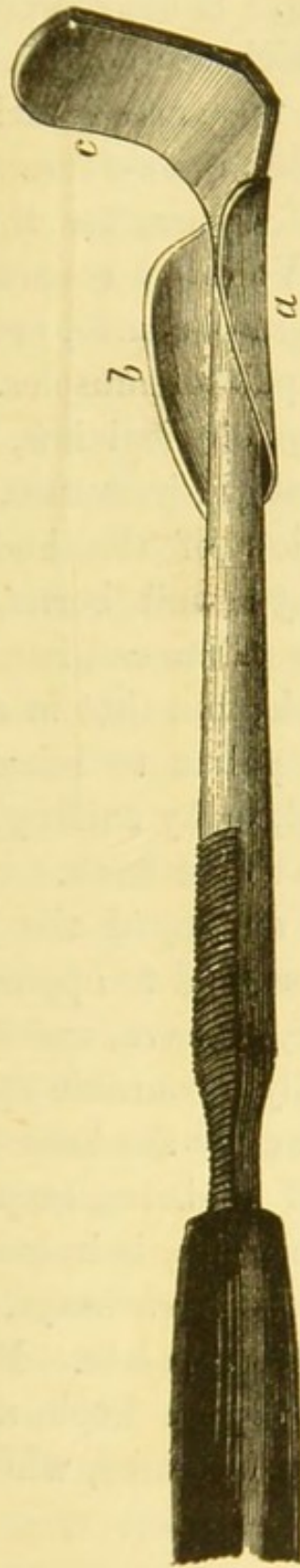


FIG. 47.—VOLTOLINI'S PALATE HOOK (with wings).

*a, b.* Wings for supporting the uvula. *c.* Bent portion for seizing the palate.



being that employed by Voltolini,\* and very strongly recommended by him. It consists (fig. 47) of a strong steel retractor of which the portion (c) bent at right angles to the shaft measures  $\frac{1}{2}$  inch across and  $\frac{7}{8}$  inch in length. It is made in two forms, one without, and one with two lateral wings, for the purpose of supporting the uvula. Voltolini considers the large size of his hook of great importance, enabling it to obtain a firm grip on the palatal muscles. He explains its usefulness by the physiological law, that firm pressure is better borne than slight irritation,† and asserts that the rapid introduction of the hook to the floor of the choanæ is always well borne, and that in the majority of cases the palate can immediately be drawn forward with the hook; but that in other cases it is necessary to cause the palate to relax by the pronunciation of a nasal sound, or by sniffing, or by practice to accustom the patient to the hook.

Although I have employed the hook in numerous cases, and I do not pretend to oppose my experience to that of the inventor, I have, unfortunately, not been able to form an equally favourable opinion of it. I have found in fact, that usually the hook provokes too much irritation to allow of its being employed, but where it has really proved of service, is in cases in which, as the Germans say, there is *Rachenenge*, i.e., a very small interval behind the soft palate. By accustoming the patients to the use of the hook, a good view of the naso-pharynx can be obtained, which otherwise would be quite impossible.

\* A similar hook was invented by Prof. Bruns of Tübingen, but having the blade cleft for the reception of the septum.

† *Op. cit.*, p. 18.



In applying the hook, both hands are required, one for the hook and the other for the mirror. Voltolini, therefore, recommends the use of an automatic tongue depressor. I have not had much success with this instrument, it is apt to slip off, and it does not depress the base of the tongue sufficiently.

In practice, it will be found more convenient to let the patient hold down his own tongue with an angular depressor.

2. *Bands* passed through the nose, and drawn out at the mouth, have been frequently recommended as a means of drawing forward the soft palate.

They appear to have been first employed for this purpose by Stoerk, who used a silk ribbon. Other materials put to this use have been elastic cords (*Jarvis, Wales*), india rubber tubing (*Walsham*), catgut (*Bosworth*), and string (*Wales, Woakes*). The latter is certainly a convenient method in some cases. When employing it, the passage of the string through the nares may be facilitated if it is previously hardened by soaking in gum for a distance of five or six inches from one end. If it do not pass easily by this means, it can be introduced without difficulty through a Eustachian catheter, or similar tube. The two ends of the string are then tied over the patient's lip.

The general conclusion at which I have arrived is, that by the careful use of a small mirror, and a little training on the part of the patient, these instruments may be dispensed with in the great majority of cases.

In the remaining cases, if sufficient information cannot be obtained by other means (anterior rhinoscopy and palpation), these instruments must be tried and will often give valuable assistance. Sometimes the



hook is necessary to give a clear view of the *lower* part of the posterior nares; without it, the upper part alone being visible.

*Enlarged uvula.*—It is very rare in my experience that an enlarged uvula is any serious hindrance to posterior rhinoscopy. By depressing the tongue well, and by placing the mirror to one side of the uvula, a satisfactory examination can generally be made. If needed it could be raised by Voltolini's uvula spatula (fig. 48), or by Türeck's uvula noose, modified by



FIG. 48.—VOLTOLINI'S UVULA SPATULA.

Voltolini (fig. 49), which consists of a wooden or vulcanite tube about one inch in length, through which is passed a loop of cord, one end of which passes out through an opening in the side of the tube, and terminates in a knot.

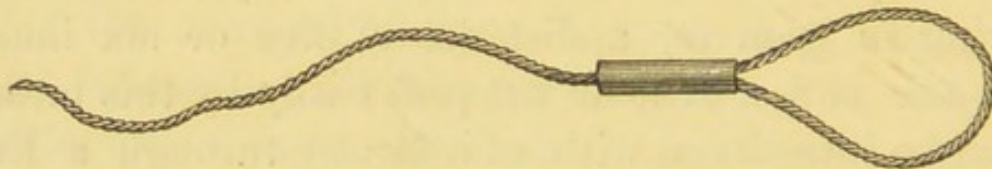


FIG. 49.—UVULA NOOSE.

A more practical instrument appears to be Morell Mackenzie's uvula twitch (fig. 50), which consists\* of a small piece of string threaded through the end of a rod four or five inches long. The uvula is caught in the loop, and by a few twists of the shank can be held in the required position. Several kinds of small forceps have also been recommended for seizing and drawing forwards the uvula.

\* *Op. cit.*, p. 250.



*Hypertrophied tonsils*, when almost in contact with each other, interfere with the introduction of the rhinal mirror. If a small or oval shaped mirror cannot be introduced, abscission of the tonsils, which for other reasons also would probably be required, is the only remedy.

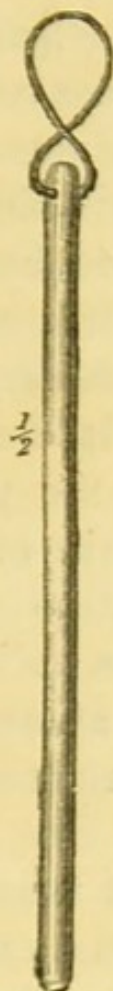

FIG. 50.—UVULA TWITCH. — (Morell Mackenzie).

Apart from these difficulties the presence of *adenoid vegetations of the naso-pharynx* may embarrass the beginner in rhinoscopy.

When these growths are well-marked the naso-pharynx being practically filled with them, no view of the posterior nares can be obtained. All that can be seen in the mirror is a confused red mass. Examination with the finger will easily clear up the case, and show why the choanæ are not visible.

*Thickening of the soft palate*, which is often associated with adenoid vegetations, also adds considerably to the difficulty in performing posterior rhinoscopy, and may, as pointed out by W. Meyer,\* give rise to symptoms similar to those produced by the vegetations.

**Anæsthetics in posterior rhinoscopy.**— Ever since the invention of the rhinoscope, various expedients have been tried for allaying the irritability of the

\* *Ueber Adenoide Vegetationen der Nasenrachenhöhle*, Leipzig, 1873, p. 32 (reprint from *Archiv f. Ohrenheilkunde*).



pharynx during its use.\* The internal and local use of bromide of potassium, sucking small pieces of ice, the local application of tannin and aconite, have been some of the chief means adopted for the purpose. Recent experience, however, of the action of cocaine leads to the belief, that in this drug we have a more convenient anæsthetic. Whenever, therefore, there is any difficulty in performing rhinoscopy owing to irritability of the parts, or if instrumental means have to be employed to draw forward the soft palate, the free application of a four per cent., or where necessary, of a stronger solution, is to be advocated. It deadens the sensation and the reflex irritability of the parts, and sometimes produces temporary anæmia of the mucous surfaces. It is necessary simply to paint the fauces with it once (or several times at intervals of three to four minutes),† and shortly afterwards the sensitiveness is reduced so that the rhinoscopic mirror is more freely tolerated.

On account of its recent introduction it is necessary to speak with some reserve, but this has been its action in several cases in which I have tried it. Its effectiveness appears, however, to vary in different individuals.

**Modifications of posterior rhinoscopy.**—*Posterior rhinoscopy with concave mirrors* which give a magnified image of the parts examined, is recommended by Voltolini.‡ He advises mirrors with a focal distance of four inches. I have no experience of

\* Cohen's remark (*op. cit.*, p. 30), that irritability of the fauces is partly due to indigestion, and may be avoided by not examining until three or four hours after a meal, deserves attention.

† A few drops may also be introduced into the nasal cavities, and allowed to run backward into the throat.

‡ *Die Rhinoskopie, etc.*, 2nd edit., p. 55.



this method myself, but it appears a very feasible proceeding, and certainly more practical than the same observer's plan of examining the lower parts of the posterior nares *by means of two mirrors*.\* The one is held high up in the naso-pharynx and reflects the floor of the nasal cavities; the other placed in the ordinary rhinoscopic position receives the image from the first and reflects it into the observer's eye. Voltolini also employs two mirrors to examine the Eustachian orifices, and the posterior wall of the naso-pharynx.

**Auto-rhinoscopy.**—Auto-rhinoscopy, *i.e.*, examination of one's own posterior nares, may be accomplished in various ways. When sunlight is used it may be done according to Voltolini's method. The surgeon seated in the sunlight allows the rays to fall into his fauces. A mirror held in the left hand just above the beam of sunlight shades the observer's eyes, and gives him an image of the rhinal mirror introduced with the right hand, and of the parts reflected therein.

George Johnson's plan is also a very simple one. He recommends the surgeon to sit opposite a toilet mirror, with an ordinary concave reflector on his head. A lamp is then placed by the side of the toilet glass, and the observer condenses the light in the usual way *on to the image* of his fauces reflected in the same, and inserts the rhinoscopic mirror. The advantage claimed for this method is that it teaches the student to manage the light in the same manner as he would on a patient. Its disadvantage is that the light undergoing an additional reflection before it reaches the naso-pharynx loses in intensity, and therefore produces a less clear image.

By substituting for the reflector, Trouvé's electric

\* *Op. cit.*, p. 169.



photophore the disadvantage of insufficient illumination is avoided and the method becomes, as I have found, very simple and convenient.

Czermak\* has devised a special apparatus for auto-laryngoscopy, which is equally well adapted for auto-rhinology. It consists essentially of a concave reflector and a plane mirror placed opposite the surgeon's mouth. The reflector which is placed on a level just above the plane mirror, and about one foot distant behind it, projects the light on the observer's fauces from a lamp which is situated to the side of the plane mirror. The image of the parts illuminated by the rhinal mirror is then seen by the observer in the latter, and is visible to a second person looking through a central perforation in the concave reflector.

Some surgeons recommend auto-rhinology very strongly as a means of educating the student. After the beginner has first mastered the effect of the perspective on the chief parts, and their relation to each other on a dummy, he is more likely to learn on a tolerant patient, who may if necessary be cucainised. By practising auto-rhinology, he undoubtedly learns to appreciate the necessity for great gentleness in introducing the rhinoscopic mirror, but as all the movements to be executed by the fingers in auto-rhinology are the *reverse* of those required in altero-rhinology, they do not afford much help. Moreover, on account of the image in auto-rhinology being again reflected before it reaches the eye it loses in distinctness, and its parts are in my experience less easy to recognise than in another person.

In order to *demonstrate a patient's naso-pharynx*

\* *Op. cit.*, p. 18.



to him, Voltolini\* lets him hold a plane mirror close to the observer's eye, on the same level as that organ, avoiding as far as possible covering up the forehead reflector. The patient's hand holding the mirror is to be guided by the surgeon. This is the rule when the surgeon is short-sighted and only uses one eye in observing the image. When on the other hand, he is long-sighted and makes use of binocular vision, the mirror may be placed in front of the surgeon's eye, which is not covered by the reflector. A third person standing immediately behind the patient and regarding the mirror can likewise see the rhinoscopic image.

In an ordinary examination, if reflected sunlight is used, the parts which are visible to the surgeon can be seen by a third person in the plane forehead mirror.

\* *Op. cit.*, p. 184.



## CHAPTER VI.

## PALPATION.

PALPATION or examination with the finger may take place either from the front or from the back.

**Palpation of the anterior nares** is a proceeding but little resorted to in practice. The plan is to introduce the previously oiled or greased little finger into one vestibule, when its point can be insinuated to a greater or less depth through the anterior naris, and part of the septum, and sometimes the anterior extremity of the inferior turbinated body felt. The usual object is to ascertain the nature and shape of swellings and deflections on the cartilaginous septum.

**Palpation of the posterior nares** is accomplished by passing the finger behind the palate into the nasopharynx. It is a much more important procedure, and therefore requires description at greater length.

**Method of performing the same.**—The patient being seated, the surgeon stands on one side and steadies the head with a hand on the vertex. He then passes the fore-finger of the opposite hand (preferably the *left* on account of its smaller size), rapidly to the posterior wall of the pharynx and up behind the soft palate until the posterior edge of the nasal septum is felt as a thin hard ridge. On either side of the septum, the posterior ends of the inferior turbinated bodies (sometimes those of the middle turbinated bodies also), especially if they are at all swollen, give



the impression of soft cushions. In this case they may be easily mistaken for polypi; which error may, however, be avoided by a comparison of the sensation experienced on the two sides. The situation of the Eustachian cushion and orifice, and the salpingo-pharyngeal fold can also be felt on either side and behind these, of course, Rosenmüller's fossæ. The roof and posterior wall of the naso-pharynx should be carefully examined, as it is in these situations that adenoid vegetations usually have their seat. Normally, owing to the presence of the pharyngeal tonsil, these parts have an uneven irregular surface, but when adenoid vegetations are present they are studded with more or less pedunculated growths of all sizes and shapes, which in well-marked cases completely fill the naso-pharynx giving to the finger the sensation of a bunch of worms. They are sometimes pressed together forming a soft cushion-like mass. The posterior margin of the septum instead of being nearly vertical, as shown in fig. 1, p. 4, often assumes an oblique direction, the upper part extending further backwards than the lower (see above, p. 22). This condition is soon recognised after a little practice. If the naso-pharynx be occupied by any other tumour, its shape and point of origin must be ascertained by coasting round it with the point of the finger.

When palpation is practised merely as a means of diagnosis the observer's finger-nail should be short. But if used at the same time for treating adenoid vegetations by scraping, it is convenient to have it about an eighth of an inch in length. In either case it should be well-rounded. Some authors recommend the insertion first of one fore-finger, and then of the other



to examine all the walls of the cavity. In my experience this is rarely necessary. I find that with the left fore-finger all the walls can be carefully investigated.

Palpation of the naso-pharynx should be rapidly executed, as it is a disagreeable proceeding to the patient, and if prolonged produces retching.

In all cases it is well to guard the first phalanx and metacarpo-phalangeal joint of the fore-finger with a covering of india-rubber or similar substance. This is required not so much on account of any risk of being bitten, as to guard against the firm pressure which the lower incisors often exert on the finger.

Nasty abrasions are often produced by a child throwing its head back suddenly, and are especially likely to occur during the lateral movements necessary for scraping out adenoid vegetations with the finger nail. I formerly employed an india-rubber or metallic ring slipped round the finger, but this is really insufficient, as often the part coming in contact with the teeth is the knuckle, rather than the first phalanx. I now use a thick kid (or dog-skin) glove, the thumb and three of the fingers of which are cut short off, whilst the fore-finger is removed at the first phalangeal joint.\* The jointed metallic sheaths for enclosing the fore-finger which one sometimes sees, are quite unnecessary, and can only have the effect of rendering the proceeding more unpleasant to the patient.

The difficulty which occasionally occurs in getting a

\* The same purpose is accomplished by W. Meyer by means of a gag which is held between the patient's left molar teeth by an assistant. It consists of a triangular piece of ebony, armed on either side with a larger metal plate, and attached to a curved stem which bears a wooden handle. (*Transactions of the International Medical Congress*, London, 1881, vol. iii., p. 281).



child to open its mouth can usually be overcome by moral suasion. If not, pressure of the cheek between the jaws with the surgeon's fingers will accomplish it. I have never resorted to the strong measures recommended by Schalle.

The beginner in this method of examination is liable to meet with a difficulty in passing his finger behind the soft palate, for of course, the moment the palate is touched it generally contracts, coming in close contact with the posterior pharyngeal wall. By keeping the finger against the back wall of the pharynx, and by inserting it at one side rather than at the centre of the palate, it can always be insinuated behind the velum. No force should be used, but there is no necessity to wait for the palate to relax. It is a common error for beginners not to reach the roof of the naso-pharynx. The finger which on passing the soft palate is firmly grasped by that structure, remains there, and the naso-pharynx is not examined at all. This mistake can be avoided by pushing the finger rapidly and boldly to the roof of the naso-pharynx as soon as it is behind the velum.

Those who have no experience of this method of examination, are advised to form a clear idea of the shape, size, and relations of the naso-pharyngeal cavity (see above, p. 22) before practising palpation.



## CHAPTER VII.

## DIAGNOSIS OF THE COMMONER DISEASES OF THE NASAL CAVITIES.

**Acute nasal catarrh** is theoretically an inflammation of the nasal mucous membrane running successively through the stages of dryness, swelling of the erectile tissue, and the secretion of a clear and finally thick discharge. Its symptoms are so familiar that any description is quite unnecessary. The only error likely to occur is, in mistaking a neurotic attack of swelling of the turbinated bodies with sneezing and serous secretion from the nostrils, for one of acute catarrh. The distinguishing mark of the former is its suddenness of onset, and its equally rapid disappearance. It is also of frequent occurrence, is unaccompanied by fever, and often follows immediately on some obviously irritating cause.

Patients so often say they have a fresh cold, when in reality but a neurosis of this character is present. A little experience will suffice in the majority of cases to distinguish the one condition from the other.

**Chronic nasal catarrh** is characterised by a long-continued more or less constant mucous or mucopurulent discharge from the nostrils. Anterior and posterior rhinoscopy show simply excessive redness and perhaps swelling of the intra-nasal structures. They are seen covered with an opaque mucous secretion.



The chief point in examining these cases is to ascertain the absence of any more marked tissue changes, such as hypertrophy of the mucous membrane, growths, ulcers, diseased bone, etc.

**Hypertrophic nasal catarrh** is so named on account of the hypertrophy of the mucous membrane which is present. The hypertrophy which is usually the result of long-standing catarrh, may affect any part of the lining membrane, but is most commonly found over the inferior and middle spongy bones. *Hypertrophy of the anterior extremity of the inferior turbinated body* is generally easily distinguished from simple swelling of the erectile body. When hypertrophied it presents a more or less irregular outline and lobulated surface, and can hardly be indented with the probe. When simply erected it is soft and resilient to the probe, and has a smooth shining appearance. In the latter case the swelling varies from day to day, in the former it remains permanent.

Cucaine owing to its power of contracting the cavernous tissues in the nose, as described above (p. 92), should be thoroughly and carefully employed in any case in which hypertrophy cannot be clearly distinguished from simple erection of the turbinated bodies.

*Hypertrophy affecting the posterior end of the inferior turbinated body.*—This form of hypertrophy is more difficult to distinguish from simple swelling of the erectile tissue on the one hand, and from mucous polypus on the other. Hypertrophy of the mucous membrane in this situation assumes the form of lobulated growths, projecting through the choanæ, red or pale in colour (*Morell Mackenzie*). Their pre-



sence is ascertained by posterior rhinoscopy and palpation.

They are distinguished from simple erection of the cavernous tissue by the permanent character of the nasal obstruction, and by their constant appearance in the mirror. They can easily be distinguished from mucous polypi projecting into the naso-pharynx, if the latter are hard, smooth and freely moveable, but at times the diagnosis is not easy.

*Hypertrophy of the mucous membrane at the centre of the inferior turbinated bone* is more easily recognised from the front, the diagnosis being assisted by the use of a probe.

*Hypertrophy of the mucous membrane on the middle turbinated bone* as seen from the front, is to be distinguished from polypi originating on or near that bone by the probe. In thickening of the mucous membrane the subjacent bone can be felt, whilst growths attached to it are diagnosed by their softness and mobility.

**Erection of the anterior extremity of the inferior turbinated body**, though only a symptom, needs separate mention. If it is present in a marked degree, its cause should, if possible, be ascertained; whether it is due to nasal catarrh, to a local irritation deeper in the nasal cavity, or to one of the many causes mentioned on page 91.

When accompanied by much serous discharge it probably constitutes the condition termed by Morell Mackenzie *rhinorrhœa*, a neurotic secretion by the glands of the Schneiderian membrane. It is often attended by excessive sneezing, and if there be much swelling, by nasal obstruction. The erection of the anterior



part of the inferior turbinated bodies may be and doubtless is often accompanied by a similar condition of the middle and posterior parts; the nasal obstruction in the latter case being more marked.

**Hay asthma** (or **hay fever**) appears to be simply a neurosis of the nasal mucous membrane, accompanied by certain reflex symptoms which at particular seasons of the year is produced by the pollen of plants in persons specially predisposed to it. There are no physical symptoms as far as I am aware, to distinguish it from a similar neurosis due to other causes. The diagnosis must be made by the fact that the attacks only occur under certain conditions, and by the general history of the case. Puffiness of the eyelids and absence of pyrexia are, according to Morell Mackenzie, important diagnostic points.

**Atrophic catarrh and ozæna.**—In atrophic catarrh the nasal mucous membrane appears wasted and thin, with a thick discharge on it. In the advanced stages it is attended by the formation of hard crusts of discharge, and is often, though not always, accompanied by a very foetid smell, which I can only liken, in some degree, to the odour of *Gruyère* cheese. It is then known as *ozæna*, though this term is often loosely applied to cases in which there is a stinking discharge from the nose due to other causes, such as diseased bone, foreign bodies, etc.

In any case in which there is a foetid smell from the nose, we must ascertain by careful rhinoscopic examination with use of the probe, whether there is any diseased bone present. The odour characteristic of *ozæna* is by no means confined to the condition of atrophy of the mucous membrane, but may occur at any stage of an acute or chronic catarrh (*Ziem*).



**Epistaxis.**—It is unnecessary to make any remarks on bleeding from the nose, which is after all only a symptom, beyond pointing out the advisability of finding out if possible by a rhinoscopic examination, the exact source of the hæmorrhage. It may then, perhaps, be easily stopped by the application of a styptic directly to the part affected.

**Necrosis** of the bones entering into formation of the nose is usually the result of tertiary syphilis. Destruction of the septum gives rise to the characteristic flattening of the nasal bones seen in this disease. Apart from the history, the diagnosis is made by the use of the probe under good illumination. In secondary syphilis the nasal phenomena are generally easily recognised from the fact that they are mostly accompanied by syphilitic symptoms in the throat and other parts. Necrosis in the nose may also be due to scrofula, cancer, and the exanthemata.

**Deviations of the septum** will be recognised without any difficulty after the remarks made on anterior rhinoscopy. They are distinguished from swellings or growths, by observing that the one side of the septum has a concavity corresponding to the convexity on the other. When the deviation is great, the external nose is usually, but not always, deflected to one side. In marked deflection the inferior turbinated body on the dilated side is often much increased in size, from an increase of its bony as well as of its soft constituents.

**Perforations of the septum** are generally evident on anterior rhinoscopy, unless large they do not produce much inconvenience. They are usually, but not always, of syphilitic origin.

**Tumours of the nasal cavities.**—*Mucous polypi*



(myxomata) are by far the most common. They are recognised partly by their smooth, round shape and pearly colour; but mainly by the use of the probe which shows them to be soft bodies which are freely moveable (except when very small). As they usually grow from the upper part of the nasal cavity (middle meatus and two upper turbinated bones) they can be distinguished from an enlarged inferior turbinated body by the circumstance that the probe passes beyond them both on their inner and outer side. This is not an unnecessary precaution, as a pale, much erected inferior turbinated body in a child is at a superficial glance not unlike a polypus. (Sir Astley Cooper cautions us against this mistake. *Ziem, op. cit.*) At the same time it must be remembered, that polypi are extremely rare in childhood. When a polypus projects into the nasopharynx, the diagnosis is made by posterior rhinoscopy and palpation. When the polypi are very crowded, the nasal cavities may be dilated. These growths are often accompanied by a great tendency to erection of the inferior turbinated body which adds difficulty to the treatment.

Other benign tumours of the nasal cavities are *fibrous polypi, cartilaginous and bony growths, and papillomata*. They are of much rarer occurrence than mucous polypi.

*Fibrous tumours* are distinguished from mucous polypi by their firmness, slight mobility, and by their denser and more opaque aspect. From carcinomatous disease they are diagnosed by their firmness and comparatively slow growth and by the absence of enlarged glands (*Spencer Watson*).

*Cartilaginous and bony growths* are sometimes met with on the septum, and osseous hypertrophy of the



turbinated bones may occur. They are recognised by the usual methods. Woakes describes a form of exostosis of the septum, originating from the posterior part of the vomer, near the floor, associated with a bulge of the septum towards that side and giving rise to serious nasal obstruction. Under the head of *osteomata* is described a form of bony growth (either ivory or cancellous in structure) which is unconnected with the osseous frame-work of the nose, and which as it grows erodes and frequently perforates the walls of the nasal cavities. Its mobility at first helps to distinguish it from an exostosis. The diagnosis from a foreign body or nasal calculus (rhinolith) is not always easy, but the harder surface of the osteoma may serve as a guide.

*Papillomata* are, according to Hopmann, not of uncommon occurrence on the inferior turbinated body. They vary from the size of a pea to that of a hazel nut, and are sometimes multiple. They should be looked for in examining the inferior turbinated body. I may here mention a thickening of the mucous membrane on the side of the *septum* close to its posterior end. This enlargement (see above, p. 110) is in my experience so common that except when excessive it cannot be considered pathological.\* It is recognised by posterior rhinoscopy. In this situation I have seen, a small erectile tumour, which became swollen in the recumbent position. Its removal by the cold wire snare introduced through the nostril gave relief to the symptoms of obstruction.†

\* This appearance has been described by Von Schrötter, Michel, Cohen and others. Cohen speaks of it as a sub-mucous infiltration, and with Voltolini has seen these tumours produce considerable nasal obstruction.

† "Cases of nasal polypus projecting into the naso-pharynx," *Lancet*, Jan. 27th, 1883.



*Hæmorrhage under the mucous membrane of the septum* occurring from injury, or in the course of typhus or measles, produces blood tumours, which may resemble enchondroses\*. *Abscesses of the septum* which are occasionally seen, may according to Fränkel (*Ziemssen*) produce such a bulging downwards of the mucous membrane as to resemble polypi.

*Malignant tumours* of the nasal cavities are either carcinomatous or sarcomatous in character, the former being by far the most common. They rarely originate in these cavities, but most usually arise from the surrounding parts, and affect the nose by pressure or extension of the growth. This circumstance will assist in forming a diagnosis. The rapid increase, moreover, in the nasal obstruction, the presence of very foetid ichorous discharge and occasional hæmorrhage from the nose, will lead to a suspicion of malignant disease. Enlarged glands are often met with in these cases.

Objective examination may show a tumour with a broad base, and an ulcerated easily-bleeding surface. A small portion removed and examined microscopically will confirm or disprove the diagnosis. Cases occur in which malignant disease arising in the meninges presents in the orbito-nasal region, and from the absence of cranial symptoms may resemble cancerous growths of intra-nasal origin. Instances have also been recorded in which intra-cranial tumours subsequently simulated polypi. In all cases of doubt, therefore, enquiry should be made regarding any symptoms of disease within the skull. *Hydrocephalocele* is a hernia of the brain through the cribriform plate of the ethmoid, which may resemble a

\* *Ziem, op. cit.*



fibrous nasal polypus. Its congenital character, and its pulsation, will generally render the diagnosis easy (*Spencer Watson*).

In any case in which there is evidence of encroachment on the orbital cavity, the tumour if not exactly of intra-cranial origin must be in close proximity to the cribriform plate of the ethmoid.

**Foreign bodies** of all kinds are pushed into the nostrils by children, and by persons of unsound mind. If left in for some time they give rise to a purulent discharge, and granulations spring up around them.

On this account, in every case of purulent discharge, the nasal cavities, after cleansing, should be subjected to a thorough examination, to ascertain whether the discharge be caused by the presence of any foreign body. They can generally be recognised without difficulty.

**Rhinoliths** (nasal calculi), are hard irregularly-shaped structures, which are usually formed by foreign bodies having remained for a length of time in the nasal cavities, and become coated with a calcareous deposit—a precipitate from the fluid discharge. Their diagnosis from osteomata has been already mentioned.

The slower growth and absence of pain are said to distinguish them from malignant disease.\* I should rather rely on the discovery of a hard, dark, irregular body in the nasal cavity.

**Adhesions** between different intra-nasal structures are not uncommon. I have frequently observed bands of greater or less thickness, extending from the inferior turbinated body to the septum. They are easily diagnosed by means of the probe.

\* Morell Mackenzie, *op. cit.*, vol. ii., p. 445.



**Atresia**, or complete occlusion of a nasal passage, may be congenital or acquired. The congenital form is usually membranous when it occurs in front; cartilaginous or bony when it is situated behind (*Ziem*). The ordinary methods of diagnosis, together with the history of the case, will generally remove all doubt as to the nature of the obstruction. Additional information might be gained by examining the anterior nares with transmitted light. Acquired atresia occasionally results from syphilis (*Virchow*).

**Anosmia** (loss of smell), may be a congenital defect, but in its acquired form is a symptom which may be due to many causes (compare remarks on the Physiology of Smell, p. 28, *et seq.*). It may be produced by affections of the mucous membrane, or by growths in the nasal cavities (most commonly mucous polypi), which prevent the access of odoriferous particles to the olfactory region. It may also be caused by blows on the head giving rise to injury of the olfactory nerves,\* and by disease of the olfactory bulbs and centres. According to Morell Mackenzie it occurs in paralysis of the seventh nerves. The means of ascertaining the cause are, therefore:—(1) A thorough examination of the nasal cavities; and (2) a consideration of the history of the case (especially in regard to accidents to the head and general nervous symptoms).

In **chronic naso-pharyngitis** (as in chronic nasal catarrh), it is of chief importance to ascertain the *absence* of growths or ulcers, giving rise to the inflammatory condition, and this is best done by palpation and posterior rhinoscopy.

**Adenoid vegetations of the naso-pharynx.**—

\* W. Ogle, *op. cit.*



The diagnosis of this complaint is made as follows:—The patient, usually a child, comes before us with symptoms of nasal obstruction, shown by the pinched wasted nose, the open mouth, and the dead speech, (*i.e.*, inability to pronounce the nasal consonants *m* and *n*, and want of resonance of voice in the naso-pharynx). Examination of the fauces exhibits nothing abnormal, or, may be, enlarged tonsils or granular pharyngitis. On testing, we find the patient unable to sit with his mouth shut, and that his nostrils are almost impervious to air. Examination of the anterior nares shows the nasal cavities either occluded with erected inferior turbinated bodies or patent, allowing a view of the palatal movements on deglutition. Palpation, which should then be performed, shows the roof and posterior wall, perhaps also the sides of the naso-pharynx studded with more or less soft growths of all sizes and shapes, which bleed readily on being touched. If posterior rhinoscopy be practicable (which it rarely is in children), they can also be seen. But palpation is by far the most important means of diagnosis.

**Fibrous tumours of the naso-pharynx** may originate from the base of the skull, from the cervical vertebræ, or from the posterior nares. They almost always occur in males between the ages of fifteen and twenty-five years, and in the early stages are distinguished by rhinoscopy and palpation with the finger or probe. In the later stages, they cause great disfigurement and injury, by extending either forwards into the nasal fossæ, laterally into the antra and orbits, downwards behind the soft palate, or upwards into the cranial cavity. The great importance as regards treatment of an *early* recognition of these



growths by the improved methods now at hand, has been well insisted on by Morell Mackenzie, and his remark can be justly extended to all the more important diseases of the nasal cavities.

**Reflex neuroses connected with the nose.**—

These have been already detailed (see above, p. 38, *et seq.*). In endeavouring to ascertain in a given case, whether the symptoms in question are due to the nose, the nasal cavities should be carefully searched for any source of irritation such as growths, especially on the middle turbinated bodies. Hack\* considers that transitory swelling of the erectile bodies on the anterior extremities of the inferior turbinated bones, together with frequent sneezing and serous secretion, are indications of the symptoms being of nasal origin; but other observers† have not found these alone pathognomonic. These nasal symptoms, moreover, are very commonly seen without any other reflex neuroses. When the extra-nasal symptoms from which the patient is suffering can be reflexly excited by touching the nasal mucous membrane with a probe (*e.g.*, in the case of reflex nasal cough, p. 39), there can be little doubt about their nasal origin, and the same may probably be said if they can be temporarily relieved by painting the nasal cavity with cucaine. Whilst, therefore, the extra-nasal symptoms already referred to, are often due to irritation within the nose, it is still in the majority of cases impossible to ascertain whether or not they are owing to this cause, except by the result of treatment applied to the nasal cavities‡

\* *Laryngological Section of the 57th Meeting of German Naturalists and Physicians, Magdeburg, Sept., 1884.*

† Semon, in "*Yearbook of Treatment*" for 1884, p. 284.

‡ For possible exception to this test, see first foot note, p. 41.



The application of the galvanic cautery to the nasal mucous membrane, according to Hack, often produces an attack of the extra-nasal symptom, from which the patient has been previously suffering, and which it subsequently cures.



## CHAPTER VIII.

## OUTLINE FOR EXAMINING A CASE.

THE following outline may serve as an epitome of the points to be noted in examining a nasal case:—

**History.**—Ascertain the supposed cause, duration, and course of present and any previous attacks, and their connection with general diseases. Make especial enquiry as to any “colds” which the patient remembers to have had, and in regard to the introduction of a foreign body into the nose. Also whether any other members of the family have suffered from similar affections.

**Symptoms.**—Find out whether the patient has been, or is, suffering from any of the following symptoms, and if so, whether on one or on both sides:—

<i>Discharge</i>	{	Amount.	{	Serous, muco-purulent, purulent, or crusts. Fœtid or inodorous. Through anterior nares. Through posterior nares.
		Character		
		Mode of escape		

<i>Hæmorrhage</i>	{	From the anterior nares.
		From the posterior nares.

<i>Nasal obstruction</i>	{	Partial or complete.
		Constant or intermittent—supposed immediate cause, e.g., imbibition of alcohol, recumbent posture, exposure to cold winds, etc.
		Inspiratory or expiratory.

*Sneezing.*—Its frequency and apparent cause.

*Itching.*—Whether inside the vestibule, or on the ala nasi.

*Pain.*—Its character and situation.

<i>Sleep</i>	{	Impossible.
		Disturbed.
		Noisy (ascertained from friends).



*Sensations of dryness, of weight, or of a body moving to and fro in the nose.*

*Alteration of voice and pronunciation, whether they are occasionally or permanently affected, if so, in what manner.*

*Loss of smell and taste of flavours (particulars noticed by patient).*

*Deafness and noises in the ears.*

Reflex symptoms	{	Cough
		Asthma { Enquire as to association of any local nasal symptoms with the onset of the attack.
		Attacks of redness and swelling of outside of nose (when occurring).
		Nightmare.
		Migraine.
		Constant headache.
		Supra-orbital neuralgia.
Giddiness and other neuroses.		

## Physical examination.

### EXTERNAL.

Note the general aspect of the patient, and whether his face presents the characteristics of nasal stenosis (see above, p. 43).

Examine the external nose for	{	1. Redness of alæ or tip.
		2. Flattening of bridge.
		3. Deflection or distortion.
		4. Flattening of alæ and pinched state of the nose above them.
		5. Presence of morbid growths, etc.

Notice the character of the voice and pronunciation, whether	{	Dead.
		Muffled.
		Nasal.
		Normal.

Ascertain whether the patient can sit with his mouth shut.

Test the perviousness of each nasal passage.

### INTERNAL.

*Anterior.*—Examine by *anterior rhinoscopy* on each side, the appearance presented by :—

1. *The vestibule.*
2. *The anterior naris (its patency).*



3. *The inferior turbinated body.* { Appearance of mucous membrane whether erected at anterior part.  
Presence of growths, etc.
4. *The inferior meatus and space between inferior turbinated body and septum.* { How far the lower margin and inner surface of the inferior turbinated body can be traced backwards.  
How far the floor of the nose can be traced.  
Whether the movements of the palate in deglutition can be plainly seen, also the upper margin of the choana with its double arched contour, and the posterior wall of the naso-pharynx.
5. *The middle turbinated body . . . . .* { To what extent visible. { Anterior border.  
Angle.  
Inferior border.  
Neck.  
Appearance of mucous membrane.  
Presence of growths, etc.
6. *The middle meatus*, including the interval which is visible between the outer lip of the middle turbinated body and the outer wall of the nasal fossa, especially in regard to the presence of growths.
7. *The septum* . { Position and character of any deviations and deflections.  
Shape and size of tubercle.  
Comparison of the tubercles on the two sides.

Examine the various parts *with a probe* under guidance of the eye, with regard to :—

1. Their consistence.
2. Their mobility.
3. Their reflex irritability when gently stroked.

In recording the appearances presented by anterior rhinoscopy, a rough sketch of the anterior rhinoscopic view, accompanied by a few marginal notes, is far simpler and more effective than many lines of description. To aid the student and practitioner in accomplishing this, Messrs. Danielsson and Co., of 23 Southampton Buildings, Chancery Lane, London, have, at my suggestion, added to their admirable clinical figures, a nasal sheet containing a right and left anterior rhinoscopic view, a posterior view, also vertical antero-posterior sections of the nasal cavities and naso-



pharynx, and an anterior and lateral view of the external nose. By means of these the situation and shape of any pathological change in this organ can be accurately and rapidly recorded.

*Posterior.*—Examine the fauces and oro-pharynx during quiet respiration, if necessary with an angular tongue-depressor, noticing:—

1. *The position of the tongue*, whether it remains flat on the floor of the mouth, or whether it is arched upwards; also in the latter case, whether it can be thoroughly depressed without producing retching.

2. *The soft palate.*—Its appearance and the distance separating it from the posterior pharyngeal wall.

3. *The uvula.*—Its size, general characters, and direction.

4. *The tonsils.*—Their size and shape, and the distance intervening between them, or between the two posterior pillars of the fauces.

5. *The condition of the posterior wall of the pharynx and of the salpingo-pharyngeal folds* (especially in regard to granulations on the posterior wall, to swelling of the folds, or to growths projecting below the soft palate). The view may be extended by raising the palate with a hook, but this is not to be done if we intend to employ posterior rhinoscopy.

If the patient be a young child, it is needless to attempt posterior rhinoscopy, but the state of the nasopharynx should be examined by palpation. If the patient be an adult, examine by posterior rhinoscopy, having if necessary previously painted his pharynx with cocaine. If in spite of this a sufficient view cannot be obtained, which coupled with anterior rhinoscopy will help to form a satisfactory diagnosis, use means to draw forward the palate forcibly (by hook or band) or practice palpation.

In *posterior rhinoscopy* ascertain (if necessary using a probe under guidance of the eye) the state of:—

1. *Posterior surface of the uvula, posterior margin of the soft palate, and the levator cushion.*

2. *Septum* (whether the swellings of mucous membrane on either side, if present, are of large size).



3. *Turbinated bodies* (whether the superior is at all visible and whether either the middle or inferior is unduly swollen).

4. *Lateral walls of the naso-pharynx.*

a. Eustachian orifice.

b. Eustachian cushion.

c. Salpingo-palatine fold.

d. Salpingo-pharyngeal fold.

e. Rosenmüller's fossa.

5. *Superior and posterior walls of the naso-pharynx* (state of the pharyngeal tonsil and presence of growths).

In *palpation* the condition of the same parts is ascertained by the finger, attention being specially directed to the posterior and superior walls for the discovery of vegetations and to the choanæ for the detection of hypertrophied turbinated bodies and nasal polypi.

*Accessory means of examination* are:—the use of Zaufal's specula, anterior rhinoscopy by transmitted light, the introduction of Rumbold's mirror or of Wertheim's conchoscope.



INSTRUMENTS NECESSARY FOR EXAMINING THE NOSE.

1. A Fränkel's speculum.
  2. A largest size aural speculum, with oval diameter, for children.
  3. A concave reflector with head band.
  4. A plane reflector with head band.
  5. An anterior nasal probe.
  6. A cotton holder.
  7. Three rhinoscopic mirrors.
  8. An angular tongue-depressor.
  9. Voltolini's palate hook, and some pieces of string stiffened at one end with gum.
  10. A powerful lamp (if sunlight be not available).
  11. An ordinary, or a Lynch's nasal syringe.
- 

A four per cent., or stronger solution of cocaine is a valuable addition to the above.



## APPENDIX.

## CASES ILLUSTRATING SUDDEN ERECTION OF THE ANTERIOR EXTREMITY OF THE INFERIOR TURBINATED BODY.

CASE I.—*Catarrhal inflammation of both tympanic cavities.—Sudden erection of the right inferior turbinated body, after Politzerising and examination with reflected sunlight.*

H. W., aged 23, was admitted a patient at the Throat and Ear Dispensary, February 20, 1884, suffering from true catarrhal inflammation of both tympanic cavities.

February 23rd.—The following observations were made on his nose, of which, by the way, he had previously made no complaint:—Nasal passages quite pervious; alæ rather compressed. Rhinoscopic examination with Fränkel's speculum, and reflected sunlight:—*Right side.*—Middle turbinated body visible, also the palatal muscles very plainly seen. *Left side.*—Middle turbinated body hardly visible. He was then Politzerised twice, though not very forcibly. The nozzle used was a tubular metallic one (resembling a large-sized Eustachian catheter), and was passed about half an inch into the right nostril. Immediately afterwards the nasal fossæ appeared, if anything, more patent, and the left middle turbinated body was partly visible. I then decided to sketch the right nasal cavity, but on examining it a few minutes later, I found to my astonishment the inferior turbinated body so swollen, that the palatal muscles could scarcely be seen. On the left side, the nasal cavity had become completely filled with the swollen inferior turbinated body.

*Remarks.*—The rapid erection of the inferior turbinated bodies which took place in this case, was apparently due, either to the irritation produced by the Politzerising, or by the introduction of Fränkel's speculum; or else to the heat (or bright light) of the sun. Most probably, I think, to the first-named cause acting in a catarrhal subject.

CASE II.—*Acute catarrhal inflammation of both tympana. Erection in the course of a few minutes of the right inferior turbinated body, after Politzerising and examination with reflected sunlight. Ditto, after examination with reflected sunlight only. Injection of manubrial plexus on the right membrana tympani, associated with erection of the right inferior turbinated body. Recovery of hearing.*



A. H., aged 24, waiter, was admitted at the Throat and Ear Dispensary, on February 27th, 1884. He was a pale unhealthy-looking man, suffering from acute catarrhal inflammation of both middle ears without perforation. He had had a cold in the head, but at this time there was no discharge from his nostrils.

*February 29th.*—The following observations were made on his nose:—Nasal passages pervious to air. Anterior rhinoscopic examination with Fränkel's speculum, and reflected sunlight:—*Right side.*—Naso-pharynx plainly seen, also middle turbinated body and septum, which latter presents two projections. After repeated Politzerising with the nozzle above described, and examination for a short time, the right inferior turbinated body became swollen, and hid to a great extent the naso-pharynx and the middle turbinated body, but not so completely as in the previous case.

*March 5th.*—Examination with sunlight gave the following results:—*Right side.*—Naso-pharynx plainly visible, and movements of palatal muscles on deglutition distinctly seen, likewise the middle turbinated body. This view was carefully sketched (see above, p. 89, fig. 35), but whilst the sketch was being made, the inferior turbinated body began to swell, and in about twenty minutes it had assumed such a size as to completely prevent all view of the naso-pharynx and to hide almost entirely the middle turbinated body. It was then drawn again (see p. 89, fig. 36). The nose had not been subjected to any manipulation, beyond the simple examination above described. When first examined the right side was freely pervious to air, but afterwards it became partly obstructed.

*March 11th.*—The right inferior turbinated body was much swollen.

*March 15th.*—Examination showed the right nostril in much the same condition. Left nostril quite free, and palatal muscles plainly visible. Minute red mottling on middle turbinated body mentioned on page 84, as of normal occurrence, was also noted. An outline of the left anterior rhinoscopic view was then drawn; but although this was carefully done (with reflected sunlight), and occupied at least twenty minutes, no swelling of the inferior turbinated body took place. This was the side of the less affected ear, as the right membrana tympani was still much injected, the left scarcely at all. Two of Zaufal's specula (diameters 5 and 6 mm.), passed easily through the right nostril (with the inferior turbinated body erected), and showed plainly the movements of the palatal muscles on deglutition. The hearing had so far recovered that a whisper was heard by the patient across the room with either ear.

At several, though not at all, subsequent examinations, the right manubrial plexus was found injected, and the inferior turbinated body on the same side swollen. Such was the case when he was last seen on May 7th.

*Remarks.*—The erection on February 29th, occurred as in Case I.,



after Politzerising and examination in sunlight. On March 5th, it took place after simple examination in sunlight, and must, therefore, have been due to the heat of the sun, to the action of the strong light on the patient's eye, or to irritation produced by Fränkel's speculum. The latter supposition is, I think, improbable.

It is interesting to notice that similar treatment applied to the left nostril, produced no erection of the turbinated body, and that on the erected side, the tendency to injection of the manubrial vessels, very possibly accompanied by some Eustachian obstruction, continued much longer than in the opposite ear. Both the right ear and right half of the nose were evidently more severely implicated in the catarrh than the left. I have on several occasions observed this association of vascularity of the tympanic membrane with erection of the inferior turbinated body on the same side, and hope to enter into the subject more fully on a future occasion.

CASE III.—*Mucous polypi in both nasal cavities and projecting into the naso-pharynx, with considerable deflection of septum to the left. Partial removal of polypi. Rapid temporary erection of the right inferior turbinated body. Patient's and author's observations on the causes giving rise to the erection. Attacks of sneezing and tightness of breathing occurring after the right nasal cavity had been rendered pervious.*

A. B., aged 33, was admitted a patient at the Throat and Ear Dispensary on June 11th, 1883, with the following *history*:—For about a year he has noticed loss of smell, and obstruction of the nose which began on the left side. He has had no asthma or difficulty in breathing, but sometimes has a pain at the heart. At times, owing to the mouth-breathing, his throat feels dry and sore. His nose also sometimes burns at the back part, as if he had been sniffing cayenne pepper. He often wakes up in a fright owing to his mouth becoming closed, in consequence of which he has not had an entire night's rest for three or four months. He can feel something moving to and fro in the back part of the nose. He has had very slight deafness only since his ears have been affected, also a stuffed up feeling in the ears which he has relieved by pulling out the auricles.\* He has one sister who is troubled with hay asthma, and another who suffers from nasal polypi. For eight years he has been employed in the wholesale department of a chemist's business, and has found the trituration of various powders very irritating to his nose.

\* Compare an article by Dr. John M. Crombie in *Nature*, December 7th, 1882, in which he states that the upper part of the membrane (*membrana flaccida*) has attached to it a piece of moveable skin which runs along the whole length of the upper wall of the bony meatus, and is immediately continuous with the upper membranous wall of the cartilaginous meatus.



I ascertained afterwards that he could not recollect ever being able to breathe through the left nostril, or to smell on that side. He remembered when quite young suffering from hay asthma, with much sneezing and discharge.

On examination there was complete stoppage on the left side, and but a very slight passage for air on the right. The septum was found much deflected to the left and both cavities were filled with polypi. Similar growths were seen in the mirror, projecting into the naso-pharynx. Uvula elongated and reddened. Fauces congested.

Numerous pieces of polypus were then removed on different occasions through the anterior nares with the cold wire snare, and an attempt was made to snare off the polypi in the naso-pharynx in the manner which I had previously employed in several other cases,\* by passing the wire loop through one nostril, and inserting a finger behind the soft palate, but without success, as mere pressure of the finger caused the polypi to disappear into the nasal cavities. (The chief growth originated from within the left choana, on which side there was great difficulty in passing the wire loop on account of the deflection). The result of the treatment was, however, that on August 30th, 1883, he could sleep well, though the posterior nares still appeared occluded with polypi.

The patient was then seen very irregularly until January 16th, 1884, when he reported that his nose was getting rather more obstructed, and that on forcible breathing he could feel something moving to and fro in the right side. Examination of the right nasal fossa with electric light showed numerous small polypi at the upper anterior part. The inferior meatus could not be deeply inspected, but appeared to be blocked with polypi. Three applications of the cold wire snare brought away as many pieces of polypus. After syringing with *cold* salt and water, and repeated forcible blowing of the nose, I examined again with a view of applying the snare a fourth time, when it was found that the inferior turbinated body, especially at its upper part (compare fig. 36, *b*), had become so swollen, that only a glimpse of the polypi remaining could be obtained.

*March 2nd.*—A similar experience was made to that on January 16th. The right side was fairly open, but the removal of two pieces of polypus from the region of the middle turbinated body with the cold wire snare and subsequent syringing with cold salt and water, caused the inferior turbinated body to swell up to such an extent, as almost to occlude the nostril, and to be quite in contact with the septum. Before operating on this occasion, the polypi were sprayed through the anterior naris with ether spray, but this had to be stopped as it caused much giddiness.

\* See "Cases of nasal polypus projecting into the naso-pharynx; with remarks," *Lancet*, January 27th, 1883.



About this time the patient, who is an intelligent man, gave me on different occasions his experience in regard to the occurrence of swelling of the right inferior turbinated body as follows:—He has noticed that when he is coming to see me, the obstruction in the nose always seems less (probably the effect of timidity on the erectile body). It varies much during the day; as a rule, when he is heated by work or exercise his nose becomes quite clear, when he is at all chilly it is more obstructed. He finds that injections, both cold and warm, into the nose bring on the swelling and immediately cause obstruction. Alcohol in any form (such as a glass of beer) always causes the interior of his nose to swell up, and then discharge freely. On that account, he has not dared to take any alcohol for some months past. On one occasion the application of a galvanic cauterizing point to the right inferior turbinated body caused a copious flow of liquid in the right nostril. This secretion was evidently not due to the simultaneous flow of tears, as the former could be clearly seen on the *upper part* of the inferior turbinated body.

The patient then remained away till August 15th, 1884. On that occasion the *left* side was blocked with a polypus which was removed with the galvanic cauterizing snare. The *right* inferior turbinated body was not erected, but on removing several small polypi from the middle turbinated body in the same manner, it immediately swelled up, so as to completely occlude the passage. Immediately after the application of the cauterizing the alæ and tip of the nose became red and slightly swollen, and both conjunctivæ were vividly injected. He was ordered to spray with the following solution:—

R Sodii Sulpho-carbolatis, ʒij  
Acidi Boracici, ʒss  
Aquam ad fl ʒviij.

*August 17th.*—He reported that the spray appeared to irritate the nose, causing erection of the inferior turbinated body and redness of the alæ.

After this date, some considerable-sized pieces of polypus were removed from the naso-pharynx, with the cold wire snare, introduced *behind the palate* under guidance of the mirror, likewise several from the front part of the middle turbinated body.

*September 17th.*—He stated that his nose was much freer, but that morning he woke up with violent sneezing, and much watery running from the *left* (the occluded) nostril. There was a bright pseudo-erysipelatous redness of the skin covering the left ala, and of that immediately above it. It extended forwards about half-way to the tip of the nose.

\* In these observations, it was of course impossible absolutely to exclude swelling of the polypi or mucous membrane at the back part of the nasal fossa, but there could be little doubt that the obstruction which the patient referred to, was mainly, if not entirely, due to erection of the anterior part of the inferior turbinated body.



*September 20th.*—There were numerous small vesicles on the margin of the left nostril and just within the vestibule.

*September 21st.*—He reported that since September 10th there had been scarcely any tendency to erection of the right inferior turbinated body. As a matter of fact snaring off two small polypi on that day from the middle turbinated body did *not* make the lower one swell up to any extent.

*October 16th.*—The whole of the septum was visible from the back, but both choanæ appeared blocked with polypi. By passing the wire loop through the right nostril, and guiding it with the mirror in the pharynx two good sized pieces of polypus were removed from the right choana. This caused the right inferior turbinated body which was already swollen to become completely erected, so that no space between it and the septum could be discerned. On this occasion the patient volunteered the statement, that for about three weeks past he had been subject to attacks of sneezing, which were followed by tightness of breathing, wheezing in the chest, and a sensation of irritation, making him wish to scratch the front of his chest, the attack lasting about a quarter of an hour.

*October 19th.*—He could blow freely through the right side, and there was no polypus to be seen in the right choana, except a minute one at the upper part.

*October 31st.*—The application of the galvanic cautery to the roots on the right middle turbinated body, did not cause the upper part of the lower one to become swollen.

*November 2nd, 1884.*—The attacks of tightness of breathing, etc., were stated to be less intense.

*Remarks.*—This case is introduced not on account of the polypi and the operations which they necessitated, but because it forms an interesting study of sudden temporary erection of the inferior turbinated body, and incidentally illustrates one or two of the reflex phenomena associated with the nasal cavities. With regard to the attacks of sneezing and tightness of breathing, although I never had an opportunity of seeing him during one of them, it seems probable from his description, that they were asthmatic in character, the result of irritation within the right nasal cavity, occurring as the latter became pervious to air. The removal of the polypi was protracted over a long period partly on account of the patient's irregular attendance, and partly from his refusal to take an anæsthetic.

There is no doubt that in all the three cases above described, there existed an abnormal predisposition to swelling of the inferior turbinated body, the result, probably, as already mentioned in Cases I. and II. of a pre-existing catarrh, and in Case III. perhaps produced by the long-continued irritation of the polypi.

I may say that the whole of Cases I. and II., and the portion of Case III. up to August, 1884, were observed before I became acquainted with Hack's interesting observations on the subject.



# INDEX.

---

- Adenoid vegetations of naso-pharynx, hindrance in posterior rhinoscopy, 123; examination of, by palpation, 129; diagnosis of, 141
- Adhesions in nasal cavities, 140
- Ala nasi, redness of, from intra-nasal irritation, 41; itching of, 41
- ALLEN, HARRISON, asymmetry of the nasal cavities, 13
- Anæsthetics in posterior rhinoscopy, 123
- Anatomy of external nose, 1; of nasal fossæ, 6; of naso-pharynx, 22
- Anosmia, 141
- Anterior nares, 3, 4; palpation of, 128
- Anterior rhinoscopic view, when the anterior erectile body is collapsed, 79; showing different appearances presented by the tubercle of the septum, 81; slightly abnormal, 84; colour of different parts of, 88; when the anterior erectile body is swollen, 89
- Anterior rhinoscopy, 48, 146; specula for, 48; method of illumination in, 57; method of performing, 74; cocaine in, 92; modifications of, 94; with transmitted light, 95
- Anterior tubal sulcus, 114
- Appendix of cases, 151
- Aspiration, cleansing of nasal cavities by, 69
- Asthma, produced by intra-nasal irritation, 39; hay-, 135
- Atresia of nasal passages, 141
- Atrophic nasal catarrh, 135
- Auto-rhinoscopy, 125
- BARR, THOMAS, precautions necessary in using the nasal douche, 72
- BEHNKE, effect of the nasal cavities on the voice, 33
- BIDDER, supposed action of the inferior turbinated body on olfaction, 30.
- BIGELOW, erectile bodies on the turbinated bones, 91
- Blood-vessels of nasal cavities, 21; of naso-pharynx, 28
- BONNAFONT, aural speculum, 57
- BOSWORTH, action of cocaine on the inferior turbinated bodies, 93; catgut for drawing forward the soft palate, 121
- Breath, character of, 46
- BRESGEN, reflex redness and swelling of the outside of the nose, 40
- BROWNE, LENNOX, effect of the nasal cavities on the voice, 33; modification of Elsberg's nasal speculum, 53; oxy-hydrogen lime-light, 67
- BRUNS, palate hook, 120
- BRUNTON, otoscope, 56, 95
- Bulla ethmoidalis, 11
- BURNETT, C. H., 115
- Calculi, nasal, 140
- Cartilages of the nose, anatomy of, 1
- Cases illustrating sudden erection of the anterior extremity of the inferior turbinated body, I., 151; II., 151; III., 153
- Catarrh (*see* nasal catarrh)
- Choanæ, as seen by anterior rhinoscopy, 88; by posterior rhinoscopy, 111; palpation of, 128
- Cleansing of nasal cavities, 68; by absorbent wool, 68; by aspiration, 69; by sprays, 70; by nasal douche, 70; by
- Bands for drawing forward the soft palate, 121



- syringing, 72; by Meyer's nasal irrigator, 74; liquids for, 73
- COHEN, J. SOLIS, normal variations of the epiglottis, 84; erection of the inferior turbinated body during acute nasal catarrh, 92; favourable position for inspecting the fauces, 104; irritability of the fauces due to indigestion, 124; sub-mucous infiltration on the back part of the septum, 138
- Colour of parts seen by anterior rhinoscopy, 88
- Conchoscope, Wertheim's, 95
- COOPER, SIR ASTLEY, resemblance of erected inferior turbinated body to nasal polypus, 137
- Cough, reflex, from nasal disease, 39
- CROMBIE, JOHN M., a connection of the membrana flaccida with the cartilaginous meatus, 153
- Cuaine, hydrochlorate of, in anterior rhinoscopy, 90, 92; in posterior rhinoscopy, 124; in the diagnosis of hypertrophy, 133
- CURNOW, lymphatics of the nasal cavities, 21; of the naso-pharynx, 28
- CZERMAK, method of holding the reflector, 58; palate hook, 117, 118; method of auto-rhinoscopy, 126
- Deafness and noises in the ears in nasal disease, 38
- Demonstro-rhinoscopy, 126
- Depressors (*see* tongue-depressors)
- Deviations of septum, 12; diagnosis of, 136
- Difficulties in posterior rhinoscopy, 115; in palpation, 130
- Discharge from the nose, 36; reflex ditto, 38
- Diseases of the nose, symptoms of, 35; diagnosis of commoner, 132
- Dryness, sensation of, in the nose, 37
- DUPLAY, nasal speculum, 51, 52, 86
- Electric lamp, Trouvé's, 62; Semons', 67
- ELSBERG, reflex redness and swelling of the outside of the nose, 40; trivalve nasal speculum, 53
- Epistaxis (*see* hæmorrhage from nose)
- Erectile bodies (tissue) on the inferior turbinated bones, anatomy of, 19; appearance of, by anterior rhinoscopy, 79, 89; by posterior rhinoscopy, 111; causes producing swelling of, 91; diagnosis of swelling of, 133
- Eustachian cushion, anatomy of, 23; seen by posterior rhinoscopy, 113
- Eustachian orifice, anatomy of, 23; view of, by posterior rhinoscopy, 112
- External nose, anatomy of, 1; reflex redness and swelling of, 40; itching of, 41; appearance of, in nasal obstruction, 43
- Fauces, inspection of, 104, 148
- Finger-guard for use in palpation, 130
- Foreign bodies in nasal cavities, 140
- FOSTER, MICHAEL, effect of closure of the anterior nares on the voice, 33
- FRAENKEL, B., lymphatics of the nasal cavities, 21; asthma produced by intra-nasal irritation, 40; nasal speculum, 49, 50, 51, 150; Jellinek's discovery of the action of cuaine, 93; rhinoscopic mirror, 100, 101; abscesses of the septum, 139
- Gaslight, method of employing, 60
- GIBB, 117
- GOODWILLIE, nasal speculum, 56; erection of the turbinated bodies, 91
- GÖTZE, asthma produced by intra-nasal irritation, 40; reflex redness and swelling of the nose, 40
- Grooves of cutis in nasal catarrh, 45
- GRUBER, JOSEF, aural speculum, use of in rhinoscopy, 51
- HACK, W., reflex phenomena produced by nasal disease, 39, 40, 41, 42; conditions under which swelling of the erectile body on the anterior part of the inferior turbinated bone takes place, 91, 92; diagnosis of reflex neuroses connected with the nose, 143, 144
- Hæmorrhage from the nose, 36, 136
- Hair-pin speculum, 48
- Hay fever, 135



Head, positions of, necessary for examining by anterior rhinoscopy, 74  
 HELOT, PAUL, the electric photophore, 65  
 HENLE, erectile tissue of the nasal mucous membrane, 19  
 Hiatus semilunaris, 11  
 History of a case, 145  
 HOPMANN, papillomata on the inferior turbinated body, 138  
 HONSELL, nasal obstruction in newborn children, 35  
 Hydrencephalocele, 139  
 Hypertrophic nasal catarrh, 133

Illumination in anterior rhinoscopy, 57;  
 in posterior rhinoscopy, 98  
 Inferior meatus, anatomy of, 10; growth in, 84; view of, by anterior rhinoscopy, 86; view of palatal movements through, 86; view of, by posterior rhinoscopy, 112  
 Inferior turbinated body, view of, by anterior rhinoscopy, when collapsed, 79; when erected, 89; examination of, with probe, 80, 90, 94; "neck" of, 80; conditions under which erection of the anterior extremity takes place, 91; view of, by posterior rhinoscopy, 111; swelling of posterior end of, 111; hypertrophy of anterior extremity of, 133; hypertrophy of posterior end of, 133; hypertrophy of centre of, 134  
 Infundibulum, 11  
 Instruments *necessary* for examining the nose, list of, 150  
 Irrigator (*see* nasal irrigator)  
 Itching of the nose, 41

JARVIS, combined tongue-depressor and rhinoscopic mirror, 103; elastic cords for drawing forward the soft palate, 121  
 JELLINEK, the action of cocaine on the inferior turbinated bodies, 93  
 JOHNSON, GEORGE, method of auto-rhinoscopy, 125  
 JURASZ, nasal speculum, 48, 49

KLEIN, A., asthma produced by intranasal irritation, 40  
 KLEIN, E., lining membrane of the vestibule, 6; "olfactory places," 18; respiratory nasal mucous membrane, 19  
 KOHLRAUSCH, the erectile tissue of the nasal mucous membrane, 19  
 KÖLLIKER, the erectile tissue of the nasal mucous membrane, 19  
 KUSSMAUL, nasal obstruction in newborn children, 35

Liquids for cleansing the nasal cavities, 73  
 LÖWENBERG, deviations of the nasal septum, 12, 13; formation of projection on the same, 14  
 LUSCHKA, researches on the naso-pharynx, 1, 22, 23, 24, 26; pharyngeal tonsil, 27

MACKENZIE, JOHN, cough due to nasal disease, 39; origin of reflex nasal neurones, 42; conditions under which swelling of the anterior erectile body takes place, 91, 92

MACKENZIE, MORELL, deviations of the nasal septum, 12, 13, 15; action of the palato-glossus, 26; mucous membrane of the naso-pharynx, 27; warming effect of the nasal cavities on the air passing through them, 30; loss of smell from paralysis of fifth nerve, 31; effect of closure of the anterior nares, 33; asthma due to nasal disease, 40; dates of invention of different nasal specula, 51; rack-movement lamp, 60; superior turbinated body by anterior rhinoscopy, 85; rhinoscopic mirrors, 101; appearance of the Eustachian cushions, 115; uvula twitch, 122; hypertrophy of inferior turbinated bodies, 133; diagnosis of rhinoliths, 140; anosmia in paralysis of seventh nerves, 141; importance of an early recognition of fibrous tumours of the naso-pharynx, 143

Magnesium light, 67  
 MARKUSOVSKY, nasal speculum, 56, 57  
 MEYER, H., the agger nasi, 9



- MEYER, W., the resonance of the naso-pharynx, 34; facial expression in nasal obstruction, 44; grooves of cutis in nasal catarrh, 45; nasal speculum, 57; probe, 68; nasal irrigator, 73, 74; thickening of the soft palate, 123; gag for palpation, 130
- MEYERSON, asthma produced by intra-nasal irritation, 40
- MICHEL, thickening of mucous membrane on the septum, 138
- Middle meatus, anatomy of, 11; view of, by anterior rhinoscopy, 88; by posterior rhinoscopy, 112
- Middle turbinated body, view of by anterior rhinoscopy, 80; examination of with probe, 84, 94; view of, by posterior rhinoscopy, 111; neck of, 80
- Migraine from nasal disease, 41
- Mirrors (*see* rhinoscopic mirrors)
- MORGAGNI, the tubercle of the septum, 20
- Mottling on middle turbinated body, 84
- Movements of palate (*see* soft palate)
- Mucous membrane, anatomy of nasal, 18; of naso-pharyngeal, 22
- Mucous polypi, diagnosis of, 136
- Nasal catarrh, acute, 132; chronic, 132; hypertrophic, 133; atrophic, 135
- Nasal cavities, anatomy of, 6; cleansing of, 68; tumours of, 136; foreign bodies in, 140; adhesions in, 140; atresia of, 141
- Nasal douche, 70; precautions in use of, 72
- Nasal irrigator, Woakes', 69; W. Meyer's, 74
- Nasal mucous membrane (*see* mucous membrane)
- Nasal obstruction, consequences of, 35; aspect of face in, 43
- Nasal passages, test for patency of, 45
- Nasal probe, anterior, 68, 147; use of, 93; posterior, 103; use of, 115
- Nasal respiration, tests for, 45
- Nasal specula, 48; hair-pin, 48; Jurasz's, 48; Fränkel's, 49; Von Tröltsch's, 50; tubular, 50; Thudichum's, 51; Duplay's, 52; Voltolini's, 53, 56; Elsberg's, 53; Author's self-retaining, 53; Zaufal's, 56; employment of, 94; Goodwillie's, 56; Markusovsky's, 56; W. Meyer's, 57
- Nasal syringe, Lynch's, 72; posterior, 73
- Naso-pharyngitis, chronic, 141
- Naso-pharynx, anatomy of, 22; muscles of, 25; structure of, 25; manner of occlusion of lower pharynx from, 26; mucous membrane of, 27; diagnosis of adenoid vegetations of, 141; fibrous tumours of, 142
- Necrosis of bones of nose, 136
- Nerves of nasal cavities, 21; of naso-pharynx, 28
- Nightmare from nasal disease, 41
- Nose, discharge from, 36; hæmorrhage from, 36; physical examination of, 43
- Obstruction, nasal (*see* nasal obstruction)
- OGLE, W., perception of impressions by the olfactory nerve, 31; anosmia due to blows on the head, 141
- Olfaction (*see* smell)
- Olfactory mucous membrane, 18
- Olfactory slit, 17, 82
- Optical conditions under which the posterior rhinoscopic view is seen, 108
- Osteomata, diagnosis of, 138
- Outline for examining a case, 145
- Outlines for recording nasal diseases, 147
- Oxy-hydrogen lime-light, 67
- Ozæna, 46, 135
- Pain in the nose, 37
- Palate (*see* soft palate)
- Palate hooks, 117; Czermak's, 117; Voltolini's, 119; Bruns', 120
- Palpation of anterior nares, 128; of posterior nares, 128, 149; method of performing, 128; finger-guard for use in, 130; difficulties in, 130
- Patency of nasal passages, test for, 45
- Perforations of septum, 136
- Pharyngeal tonsil, 27, 129
- Photophore, Trouvé's electric, 62; battery for, 64; precautions in using, 66
- Physical examination of the nose, 43, 146
- Physiology, of the nose, 28; of respiration and smell, 28; of taste, 31; of the effect of nasal cavities on the voice, 32



- POLITZER, ADAM, anatomy of the Eustachian orifice in children, 23; closure of the Eustachian tube, 24; action of the levator palati, 25; the nasal douche, 70; erection of the turbinated bodies in chronic nasal catarrh, 92
- Polypi, mucous, 136, fibrous, 137
- Position for inspection of the fauces, 104
- Posterior nares (*see* choanæ)
- Posterior rhinoscopic view, 108
- Posterior rhinoscopy, 98, 148; anæsthetics in, 123; illumination in, 98; mirrors for, 98; tongue depressors for, 101; method of performing, 103; difficulties in, 115; modifications of, 124; with concave mirrors, 124; by means of two mirrors, 125
- Posterior tubal sulcus, 114
- Probe, anterior nasal, 68, 93; posterior nasal, 103, 115
- QUAIN, the cartilage of the septum, 2; the nasal mucous membrane, 18; the opening of the nasal duct, 20
- Rack-movement lamp, 60
- Redness and swelling of the outside of the nose, reflex, 40, 44
- Reflector, plane, 58; concave, 61; author's pocket plane and concave, 62
- Reflex irritability of intra-nasal structures, method of testing, 94
- Reflex phenomena connected with the nose, 38; most common seat of origin of, 42; diagnosis of, 143; production of, by the galvanic cautery, 144
- Respiration, nasal, 28
- Respiratory nasal mucous membrane, 18
- Rhinoliths, diagnosis of, 140
- Rhinorrhœa, 134
- Rhinoscopic mirrors, 98; essential points of, 100; Fränkel's, 100; method of introduction of, 105
- Rhinoscopy (*see* anterior and posterior)
- RINGER, S., the connection between nasal symptoms and asthma, 40
- ROOSA, D. B. ST. JOHN, anatomy of the Eustachian orifice, 23; the nasal douche, 70; the danger in its use, 72
- Rosenmüller's fossa, anatomy of, 5, 24, 27; examination of, 107, 109, 113, 129
- RUMBOLD, mirror, 95, 149
- Salpingo-palatine fold, anatomy of, 23
- Salpingo-pharyngeal fold, anatomy of, 23; direct inspection of, 105; view of, by posterior rhinoscopy, 113
- SCHAEFFER, asthma and redness of the outside of the nose produced by intra-nasal irritation, 40
- SCHALLE, means of blunting the sensitiveness of the fauces for posterior rhinoscopy, 116; difficulty in palpation, 131
- SCHRÖTTER, VON, thickenings of mucous membrane on the septum, 138
- SEILER, C., effect of the nasal cavities on the voice, 32; cough due to nasal disease, 39
- Self-retaining nasal speculum, author's, 53
- SEMON, FELIX, 42, 143; electric lamp, 67
- Sensation of movement of a body in the nose, 37
- Septum nasi, anatomy of, 12; deviations of, 12; processes of, 14; deflections of, 16; anatomy of tubercle of, 20; appearances presented by tubercle of, 81; view of, by anterior rhinoscopy, 85; by posterior rhinoscopy, 110; diagnosis of deviations of, 136; perforations of, 136; hæmorrhage under mucous membrane of, 139; abscesses of, 139
- SIGMUND's speculum, 51
- Sleeplessness from nasal obstruction, 35
- Smell, sense of, 29; examination of, 46; loss of, 141
- Sneezing, a symptom of nasal disease, 36
- Soft palate, movements of, seen through the nasal cavity, 86; view of, by posterior rhinoscopy, 110; difficulty in posterior rhinoscopy from contraction of, 116; from thickening of, 123
- SOMMERBRODT, asthma produced by intra-nasal irritation, 40
- Specula (*see* nasal specula)
- Sprays for cleansing nasal cavities, 70
- STOERK, means of drawing forward the soft palate, 121



Sunlight, method of employing, 57; advantages of, 59; magnifying effect of, 59  
 Superior meatus, anatomy of, 12; view of by posterior rhinoscopy, 112  
 Superior turbinated body, visibility of, by anterior rhinoscopy, 85; by posterior rhinoscopy, 111  
 Symptoms of nasal disease, 35, 145  
 Syringe (*see* nasal syringe)

Taste, sense of, 31; examination of, 46  
 THEILE, asymmetry of the septum, 12  
 THUDICHUM, J. L. W., effect of different liquids on the olfactory mucous membrane, 31; nasal speculum, 51; the nasal douche, 70  
 Tongue, a source of difficulty in posterior rhinoscopy, 116  
 Tongue depressors, essential points of, 101; the author's angular, 101; Türck's, 102; the author's thimble, 103  
 Tonsils, hypertrophied, a source of difficulty in posterior rhinoscopy, 123  
 TOURTUAL, recessus pharyngis lateralis, 24  
 Toynbee's experiment, 38  
 TRÖLTSCH, VON, the dilatator tubæ, 26; nasal speculum, 50  
 Tubercle of the septum, anatomy of, 20; view of, by anterior rhinoscopy, 80; supposed function of, 83  
 Tubular specula, 50  
 Tumours of nasal cavities, mucous, 136; fibrous, 137; cartilaginous and bony, 137; papillomatous, 138; malignant, 139  
 Turbinated bodies (*see* inferior, middle, and superior)  
 Turbinated bones, anatomy of, 8  
 TÜRCK, tongue-depressor, 102, 103; uvula noose, 122

Uvula, enlarged, a source of difficulty in posterior rhinoscopy, 122

Uvula spatula, 122; noose, 122; twitch, 122

Vestibule of the nose, anatomy of, 3

VIRCHOW, acquired atresia, 141  
 Voice, effect of nasal cavities on, 32; affections of, in nasal disease, 37  
 VOLTOLINI, R., the presence of a fourth turbinated bone, 10; the erectile tissue of the nasal mucous membrane, 19; asthma produced by nasal disease, 39; nasal specula, 52, 56; magnifying effect of sunlight, 59; superior turbinated body by anterior rhinoscopy, 85; erection of the inferior turbinated body simulating polypus, 91; collapse of the erectile bodies from fright, 92; Wertheim's conchoscope, 95; anterior rhinoscopy with transmitted light, 95; combined tongue-depressor and rhinoscopic mirror, 103; erection of the posterior ends of the inferior turbinated bodies, 111; the Eustachian cushions in posterior rhinoscopy, 115; palate hook, 119, 120, 150; automatic tongue-depressor, 121; uvula spatula, 122; uvula noose, 122; posterior rhinoscopy with concave mirrors, 124; posterior rhinoscopy with two mirrors, 125; auto-rhinoscopy, 125; demonstro-rhinoscopy, 127; thickenings of mucous membrane on the septum, 138

WALE, bands for drawing forward the soft palate, 121

WALSHAM, india-rubber tubing for drawing forward the soft palate, 121

WATSON, SPENCER, loss of smell due to absence of the external nose, 30; mode of causing the palate to descend during rhinoscopy, 117; diagnosis of fibrous tumours, 137; of hydrencephalocele, 140

WEBER, E. H., discovery of the nasal douche, 70

WEBER, THEODORE, introduction of the nasal douche, 70

WERTHEIM, conchoscope, 95, 149

WOAKES, E., reflexes originating in the naso-pharyngeal cavity, 42; nasal probe, 68; nasal irrigator, 69; spraying as a means of cleansing the nose, 70; value of Fränkel's rhinoscopic mirror, 101; the Eustachian cushions in posterior



rhinoscopy, 115; string for drawing forward the soft palate, 121; exostosis of the septum, 138

ZAUFAL, the salpingo-pharyngeal fold, 23; the levator cushion, 25; the palatopharyngeus, 26; method of occlusion of naso-pharynx from lower pharynx, 26; speculum, 55, 56, 149, 152; employment of, 94; the palatal movements seen through the nasal cavities, 86; movement of the posterior wall of the nasopharynx, 88; position of mirror for ex-

amining salpingo-pharyngeal fold, 109 113, 114; the Eustachian cushions in posterior rhinoscopy, 115

ZIEM, 35, 137; nasal respiration in animals, 29; the occurrence of ozæna, 135; hæmorrhage under the mucous membrane of the septum, 139; congenital atresia, 141

ZIEMSEN, 21, 50, 139

ZUCKERKANDL, anatomy of the nasal cavities, 1, 8, 9, 10, 11, 12, 13, 14, 20; physiological effect of the horizontal position of the nostrils, 29; loss of smell from absence of the same, 30







January, 1886.

SELECTED LIST OF  
NEW AND RECENT WORKS

PUBLISHED BY

H. K. LEWIS,

136 GOWER STREET, LONDON, W.C.

---

\*.\* For full list of works in Medicine and Surgery published by  
H. K. Lewis see Complete Catalogue sent post free on application.

---

FREDERICK T. ROBERTS, M.D., B.SC., F.R.C.P.

Examiner in Medicine at the Royal College of Surgeons; Professor of Therapeutics in University College; Physician to University College Hospital; Physician to the Brompton Consumption Hospital, &c.

A HANDBOOK OF THE THEORY AND PRACTICE  
OF MEDICINE. Sixth Edition, with Illustrations, in  
one volume of over 1000 pages, large 8vo, 21s. [*Just published.*]

NOTICES OF THE PRESS.

"The amount of information in this book, is, for its size, enormous. . . . The book seems to be thoroughly trustworthy, and those who read it may be sure that the views put before them are not the fanciful notions of the few, but the well-considered and generally adopted ideas of our leading scientific practitioners." "Abounds in information supplied in a thoroughly systematic manner."—*Lancet.*

"The various subjects have been treated in a complete and masterly manner. . . . We heartily commend this handbook, not only to gentlemen preparing for the medical profession, but to those who have finished their professional education; as this work contains, in a brief and concise shape, all that the busy practitioner needs to know to enable him to carry on his practice with comfort to himself and with advantage to his patients."—*British Medical Journal.*

"We have already on more than one occasion expressed a high opinion as to the merits of this work. . . . From our experience of the 'Handbook,' we believe that it will always be popular amongst medical students, and that it is sufficiently classical to deserve a place on the bookshelves of every physician. . . . We heartily commend it as a reliable guide not less to the practical than to the theoretical study of medicine."—*Dublin Journal of Medical Science.*



BY THE SAME AUTHOR.

**NOTES ON MATERIA MEDICA AND PHARMACY.**  
Fcap. 8vo, 7s. 6d. [Now ready.]

NOTICES OF THE PRESS.

"Will soon be a favourite handbook for students."—*Medical Chronicle*.

"Well adapted to the requirements of students preparing for examination."—*Lancet*.

"An admirably constructed recapitulation of facts necessary to be recollected."—*Pharmaceutical Journal*.

"As a handbook to Materia Medica and Pharmacy it is eminently the one most suited for examination purposes."—*Student's Journal*.

---

JOHN R. WARDELL, M.D., F.R.C.P.

Late Consulting Physician to Tunbridge Wells General Hospital.

**CONTRIBUTIONS TO PATHOLOGY AND THE  
PRACTICE OF MEDICINE.** Medium 8vo, 21s.

GENERAL CONTENTS.

Hypertrophy of the Heart—Diseases of the Spleen—Diseases of the Pancreas—Enteralgia—Peritonitis—Enteritis—Ulceration of the Bowels—Carcinoma of the Bowels—Fatal Obstruction of the Bowels caused by a Band of Lymph—Acute Peritonitis and Displacement of the Cæcum—Pelvic Cellulitis—Apoplexy—Pleuritic, Serous, and Purulent Effusions—Chronic Ulcer of the Stomach—Carcinoma of the Liver—Typhoid or Enteric Fever—Relapsing Fever—Subclavian Aneurism—Aneurism of the Left Ventricle—Diffuse Aneurism of the Abdominal Aorta—Obesity—Hydronephrosis—Hæmatocele connected with the Left Kidney—Uræmia—Chronic Ulceration of the Urinary Bladder, with Hæmorrhage—Exfoliation of the Bladder—Small Fatty Growths obstructing the Cystic and Common Ducts—Chorea—Tubercular Meningitis—Myeloid Sarcoma Tumour of the Brain—Syphilitic Tumour at the Base of the Brain—Syphilitic Hemiplegia—Scorbutus—Erythema Circinatum—Lupus Erythematosus treated by Lemon-Juice—Puerperal Convulsions—Enlargement of the Spleen in Leucocythæmia—Spasmus Glottidis—Croup—Chronic Glossitis—Tæniæ—Infanticide—Suspected Poisoning—Poisoning by Laudanum—Lead Palsy—Poisoning by Sulphuric Acid—Poisoning by Burnett's Disinfecting Fluid—A Thorn in the Flesh—Advanced and Present Medicine.



C. H. RALFE, M.A., M.D. CANTAB., F.R.C.P. LOND.

Assistant Physician to the London Hospital; late Senior Physician to the Seamen's Hospital, Greenwich.

**A PRACTICAL TREATISE OF DISEASES OF THE KIDNEYS AND URINARY DERANGEMENTS.** With Illustrations, crown 8vo, 10s. 6d. [Now ready. *Lewis's Practical Series.*]

#### GENERAL CONTENTS.

General Symptomatology of Kidney Disease—Clinical Examination of Urine—Diffuse Inflammation of the Kidney—Suppurative Inflammation of the Kidney, etc.—Degenerations and Infiltrations of the Kidney—New Growths in the Kidney—Parasites in the Kidney—Abnormalities of the Kidney—Variations in the Amount of Urine—Stone and Gravel—Functional Albuminuria, Peptonuria and Hæmoglobinuria—Quantitative estimation of Urea, etc.—Diet Table.

---

HENRY R. SWANZY, A.M., M.B., F.R.C.S.I.

Examiner in Ophthalmic Surgery at the Royal College of Surgeons, Ireland; Surgeon to the National Eye and Ear Infirmary, Dublin; Ophthalmic Surgeon to the Adelaide Hospital, Dublin; Formerly Assistant to the late Professor A. von Graefe, Berlin.

**A HANDBOOK OF DISEASES OF THE EYE AND THEIR TREATMENT.** Illustrated with Wood Engravings, Colour Tests, etc., large post 8vo, 10s. 6d.

#### NOTICES OF THE PRESS.

"We have great pleasure in recommending this work to all students and practitioners who desire to acquire such a knowledge of the defects and diseases of the eye as will render them competent to recognise and undertake the treatment of any ordinary case which may present itself in practice."—*Lancet*.

"We must admit that this (textbook) justifies its presence by its admirable type illustrations and dress, by its clear wording, and above all by the vast amount of varied matter which it embraces within the relatively small compass of some 400 pages."—*British Medical Journal*.

"This is an excellent textbook, written by a surgeon of large experience and a thorough knowledge of the literature of his subject."—*The Edinburgh Medical Journal*.

"This handbook is in our opinion an admirable one. . . . There is throughout a clearness of detail, especially in regard to treatment, therapeutic as well as operative, which denotes the surgeon of wide experience, and which will certainly make the book a favourite. . . . The book is capitally illustrated and well printed."—*Ophthalmic Review*.



EDGAR M. CROOKSHANK, M.B. LOND.

Demonstrator of Physiology, King's College, London.

**AN INTRODUCTION TO PRACTICAL BACTERIOLOGY**, based upon the methods of Koch. With thirty Coloured Plates from Original Drawings and numerous Wood-engravings. Demy 8vo, 14s. *[Just published.]*

GENERAL CONTENTS.

PART I. Apparatus, Material, and Reagents employed in a Bacteriological Laboratory—Microscopical Examination of Bacteria, in Liquids, Cultivations on Solid Media, and Tissues—Preparation and Staining of Tissue Sections—Preparation of Nutrient Media and Methods of Cultivation—Experiments upon the Living Animal—Examination of Animals Experimented upon, and Methods of Isolating Micro-Organisms.

PART II. History of our knowledge of Bacteria. Classification and Description of Bacteria.

APPENDIX.—Yeast and Moulds. Examination of Air, Soil, Water. Literature.

---

BERKELEY HILL, M.B. LOND., F.R.C.S.

Professor of Clinical Surgery in University College; Surgeon to University College Hospital, and to the Lock Hospital.

**THE ESSENTIALS OF BANDAGING**. For Managing Fractures and Dislocations; for administering Ether and Chloroform; and for using other Surgical Apparatus. Fifth Edition, revised and much enlarged, with Illustrations, fcap. 8vo, 5s.

---

BERKELEY HILL, M.B. LOND., F.R.C.S.

Professor of Clinical Surgery in University College; Surgeon to University College Hospital, and to the Lock Hospital.

AND

ARTHUR COOPER, L.R.C.P., M.R.C.S.

Surgeon to the Westminster General Dispensary, &c.

**SYPHILIS AND LOCAL CONTAGIOUS DISORDERS**. Second Edition, entirely re-written, royal 8vo, 18s.

II.

**THE STUDENT'S MANUAL OF VENEREAL DISEASES**. Being a Concise Description of those Affections and of their Treatment. Third Edition, post 8vo, 2s. 6d.



SYDNEY RINGER, M.D., F.R.S.

Professor of the Principles and Practice of Medicine in University College;  
Physician to, and Professor of Clinical Medicine in, University  
College Hospital.

**A HANDBOOK OF THERAPEUTICS.** Eleventh Edition,  
revised, 8vo, 15s. *[Just published.]*

---

W. H. O. SANKEY, M.D. LOND., F.R.C.P.

Late Lecturer on Mental Diseases, University College, and School of Medicine, London; Formerly Medical Superintendent (Female Department) of Hanwell Asylum; President of Medico-Psychological Society, &c.

**L ECTURES ON MENTAL DISEASE.** Second Edition, with coloured plates, 8vo, 12s. 6d.

---

EDWARD WOAKES, M.D.

Senior Aural Surgeon and Lecturer on Aural Surgery at the London Hospital;  
Senior Surgeon to the Hospital for Diseases of the Throat.

**ON DEAFNESS, GIDDINESS, AND NOISES IN THE HEAD.**

**PART I.—POST-NASAL CATARRH, AND DISEASES OF THE NOSE CAUSING DEAFNESS.** With Illustrations, crown 8vo, 6s. 6d.

**PART II.—ON DEAFNESS, GIDDINESS, AND NOISES IN THE HEAD.** Third Edition, with Illustrations, crown 8vo. *[In preparation.]*

---

E. CRESSWELL BABER, M.B. LOND.

Surgeon to the Brighton and Sussex Throat and Ear Dispensary.

**A GUIDE TO THE EXAMINATION OF THE NOSE WITH REMARKS ON THE DIAGNOSIS OF THE NASAL CAVITIES.** With Illustrations, small 8vo. *[Just ready.]*



G. GRANVILLE BANTOCK, M.D., F.R.C.S. EDIN.

Surgeon to the Samaritan Free Hospital for Women and Children.

ON THE USE AND ABUSE OF PESSARIES.  
With Illustrations, Second Edition, 8vo, 5s.

---

FANCOURT BARNES, M.D., M.R.C.P.

Physician to the Chelsea Hospital; Obstetric Physician to the Great Northern Hospital, &c.

A GERMAN-ENGLISH DICTIONARY OF WORDS  
AND TERMS USED IN MEDICINE AND ITS  
COGNATE SCIENCES. Square 12mo, Roxburgh binding, 9s

---

ROBERTS BARTHOLOW, M.A., M.D., LL.D.

Professor of Materia Medica and Therapeutics in the Jefferson Medical College of Philadelphia, etc.

I.

A TREATISE ON THE PRACTICE OF MEDICINE  
FOR THE USE OF STUDENTS AND PRACTITIONERS. With Illustrations, 5th Edition, large 8vo, 21s.  
[Just published.]

II.

A PRACTICAL TREATISE ON MATERIA MEDICA  
AND THERAPEUTICS. Fifth Edition, Revised and  
Enlarged, 8vo, 18s. [Now ready.]

---

GEO. M. BEARD, A.M., M.D.

Fellow of the New York Academy of Medicine.

AND

A. D. ROCKWELL, A.M., M.D.

Fellow of the New York Academy of Medicine.

A PRACTICAL TREATISE ON THE MEDICAL  
AND SURGICAL USES OF ELECTRICITY; including  
Localized and General Faradization; Localized and Central  
Galvanization; Electrolysis and Galvano-Cautery. Fourth Edit.  
With nearly 200 Illustrations, roy. 8vo, 28s.



A. HUGHES BENNETT, M.D.

Member of the Royal College of Physicians of London; Physician to the Hospital for Epilepsy and Paralysis, Regent's Park; and Assistant Physician to the Westminster Hospital.

I.

**A PRACTICAL TREATISE ON ELECTRO-DIAGNOSIS IN DISEASES OF THE NERVOUS SYSTEM.** With Illustrations, 8vo, 8s. 6d.

II.

**ILLUSTRATIONS OF THE SUPERFICIAL NERVES AND MUSCLES, WITH THEIR MOTOR POINTS,** A knowledge of which is essential in the art of Electro-Diagnosis. (Extracted from the above). 8vo, paper cover 1s. 6d., cloth 2s.

---

ALFRED H. CARTER, M.D. LOND.

Member of the Royal College of Physicians; Physician to the Queen's Hospital, Birmingham; Examiner in Medicine for the University of Aberdeen, &c.

**ELEMENTS OF PRACTICAL MEDICINE.** Fourth Edition, crown 8vo, 9s. *Just published.*

---

P. CAZEAUX.

Adjunct Professor in the Faculty of Medicine of Paris, &c.

AND

S. TARNIER.

Professor of Obstetrics and Diseases of Women and Children in the Faculty of Medicine of Paris.

**OBSTETRICS: THE THEORY AND PRACTICE;** including the Diseases of Pregnancy and Parturition, Obstetrical Operations, &c. Seventh Edition, edited and revised by ROBERT J. HESS, M.D., with twelve full-page plates, five being coloured, and 165 wood-engravings, 1081 pages, royal 8vo, 35s.

---

W. H. CORFIELD, M.A., M.D. OXON.

Professor of Hygiene and Public Health in University College, London.

**DWELLING HOUSES:** their Sanitary Construction and Arrangements. Second Edition, with Illustrations, crown 8vo, 3s. 6d.



EDWARD COTTERELL, M.R.C.S. ENG., L.R.C.P. LOND.

Late House Surgeon, University College Hospital; Atkinson Morley Surgical Scholar, University College, London, etc. etc.

**ON SOME COMMON INJURIES TO LIMBS:** their Treatment and After-Treatment including Bone-Setting (so-called). Imp. 16mo, with Illustrations, 3s. 6d.

---

J. MILNER FOTHERGILL, M.D.

Member of the Royal College of Physicians of London; Physician to the City of London Hospital for Diseases of the Chest, Victoria Park, &c.

I.

**THE HEART AND ITS DISEASES, WITH THEIR TREATMENT; INCLUDING THE GOUTY HEART.** Second Edition, entirely re-written, copiously illustrated with woodcuts and lithographic plates. 8vo, 16s.

II.

**INDIGESTION, BILIOUSNESS, AND GOUT IN ITS PROTEAN ASPECTS.**

PART I.—INDIGESTION AND BILIOUSNESS.

Post 8vo, 7s 6d.

PART II.—GOUT IN ITS PROTEAN ASPECTS.

Post 8vo, 7s. 6d.

---

HENEAGE GIBBES, M.D.

Lecturer on Normal and Morbid Histology in the Medical School of Westminster Hospital; late Curator of the Anatomical Museum at King's College.

**PRACTICAL HISTOLOGY AND PATHOLOGY.**

Third Edition, revised and enlarged, crown 8vo, 6s.

*[Just ready.]*

---

J. B. GRESSWELL, M.R.C.V.S.

Provincial Veterinary Surgeon to the Royal Agricultural Society.

**VETERINARY PHARMACOLOGY AND THERAPEUTICS.** Fcap. 8vo, 5s.



WILLIAM A. HAMMOND, M.D.

Professor of Mental and Nervous Diseases in the Medical Department of the University of the City of New York.

I.

A TREATISE ON THE DISEASES OF THE NERVOUS SYSTEM. Seventh Edition, with 112 Illustrations, large 8vo, 25s.

II.

A TREATISE ON INSANITY. Large 8vo, 25s.

---

GEORGE LINDSAY JOHNSON, M.A., M.B., B.C. CANTAB.

Clinical Assistant, late House Surgeon and Chloroformist, Royal Westminster Ophthalmic Hospital.

A NEW METHOD OF TREATING CHRONIC GLAUCOMA: Based on Recent Researches into its Pathology. With Illustrations and Coloured Frontispiece, demy 8vo, 3s. 6d.

---

RUSTOMJEE NASERWANJEE KHORY, M.D. BRUX., M.R.C.P.

THE PRINCIPLES AND PRACTICE OF MEDICINE. Second Edition, revised and much enlarged, 2 vols., large 8vo, 28s.

---

J. WICKHAM LEGG, F.R.C.P.

Assistant Physician to Saint Bartholomew's Hospital, and Lecturer on Pathological Anatomy in the Medical School.

I.

ON THE BILE, JAUNDICE, AND BILIOUS DISEASES. With Illustrations in chromo-lithography, 719 pages, roy. 8vo, 25s.

II.

A GUIDE TO THE EXAMINATION OF THE URINE; intended chiefly for Clinical Clerks and Students. Sixth Edition, revised and enlarged, with additional Illustrations, fcap. 8vo, 2s 6d.



LEWIS'S PRACTICAL SERIES.

Under this title Mr. Lewis is publishing a complete series of Monographs embracing the various branches of Medicine and Surgery.

The volumes, written by well-known Hospital Physicians and Surgeons recognised as authorities in the subjects of which they treat, are in active preparation. The works are intended to be of a thoroughly Practical nature, calculated to meet the requirements of the general Practitioner, and to present the most recent information in a compact and readable form; the volumes will be handsomely got up, issued at low prices, varying with the size of the works.

THE FOLLOWING ARE NOW READY.

**BODILY DEFORMITIES AND THEIR TREATMENT:** A Handbook of Practical Orthopædics. By H. A. REEVES, F.R.C.S. Ed., Senior Assistant Surgeon and Teacher of Practical Surgery at the London Hospital, Surgeon to the Royal Orthopædic Hospital, etc. With numerous Illustrations, crown 8vo, 8s. 6d.

**DENTAL SURGERY FOR GENERAL PRACTITIONERS AND STUDENTS OF MEDICINE.** By ASHLEY W. BARRETT, M.B. Lond., M.R.C.S., L.D.S., Dental Surgeon to, and Lecturer on Dental Surgery and Pathology in the Medical School of, the London Hospital. With Illustrations, crown 8vo, 3s.

**A PRACTICAL TREATISE ON DISEASES OF THE KIDNEYS AND URINARY DERANGEMENTS.** By C. H. RALFE, M.D. Cantab., F.R.C.P. Lond., Assistant Physician to the London Hospital, late Senior Physician to the Seamen's Hospital, Greenwich. With Illustrations, crown 8vo, 10s. 6d. [Now ready.]

\*.\* Prospectus of the Series, with Specimen page, etc., post free on application.

---

**LEWIS'S POCKET MEDICAL VOCABULARY.** [In the press.]

---

**WILLIAM THOMPSON LUSK, A.M., M.D.**

Professor of Obstetrics and Diseases of Women in the Bellevue Hospital Medical College, &c.

**THE SCIENCE AND ART OF MIDWIFERY.** Third Edition, revised and enlarged, with numerous Illustrations, 8vo, 18s.

---

**JOHN MACPHERSON, M.D.**

Inspector-General of Hospitals H.M. Bengal Army (Retired).  
Author of "Cholera in its Home," &c.

**ANNALS OF CHOLERA FROM THE EARLIEST PERIODS TO THE YEAR 1817.** With a map. Demy 8vo, 7s. 6d.



A. COWLEY MALLEY, B.A., M.B., B.CH. T.C.D.

**PHOTO-MICROGRAPHY**; including a description of the Wet Collodion and Gelatino-Bromide Processes, together with the best methods of mounting and preparing Microscopic Objects for Photo-Micrography. Second Edition, with Illustrations and Photographs, crown 8vo, 7s. 6d.

---

PATRICK MANSON, M.D., C.M.

Amoy, China.

**THE FILARIA SANGUINIS HOMINIS AND CERTAIN NEW FORMS OF PARASITIC DISEASE IN INDIA, CHINA, AND WARM COUNTRIES.** Illustrated with Plates, Woodcuts, and Charts. Deny 8vo, 10s. 6d.

---

S. E. MAUNSELL, L.R.C.S.I.

Surgeon-Major, Medical Staff.

**NOTES OF MEDICAL EXPERIENCES IN INDIA** PRINCIPALLY WITH REFERENCE TO DISEASES OF THE EYE. With Map, post 8vo, 3s. 6d.

---

J. F. MEIGS, M.D.

Consulting Physician to the Children's Hospital, Philadelphia.

AND

W. PEPPER, M.D.

Lecturer on Clinical Medicine in the University of Pennsylvania.

**A PRACTICAL TREATISE ON THE DISEASES OF CHILDREN.** Seventh Edition, revised and enlarged roy. 8vo, 28s.

---

WILLIAM MARTINDALE, F.C.S.

Late Examiner of the Pharmaceutical Society, and late Teacher of Pharmacy and Demonstrator of Materia Medica at University College.

AND

W. WYNN WESTCOTT, M.B. LOND.

Deputy Coroner for Central Middlesex.

**THE EXTRA PHARMACOPŒIA** with the additions introduced into the British Pharmacopœia 1885; and Medical References, and a Therapeutic Index of Diseases and Symptoms. Fourth Edition, revised, limp roan, med. 24mo, 7s.

[Now ready.]



WM. JULIUS MICKLE, M.D., M.R.C.P.

Member of the Medico-Psychological Association of Great Britain and Ireland; Member of the Clinical Society, London; Medical Superintendent, Grove Hall Asylum, London.

**GENERAL PARALYSIS OF THE INSANE.** 8vo, 10s.

---

A. STANFORD MORTON, M.B., F.R.C.S. ED.

Senior Assistant Surgeon, Royal South London Ophthalmic Hospital.

**REFRACTION OF THE EYE:** Its Diagnosis, and the Correction of its Errors, with Chapter on Keratotomy. Second Edition. Small 8vo, 2s. 6d.

---

WILLIAM MURRELL, M.D., F.R.C.P.

Lecturer on Materia Medica and Therapeutics at Westminster Hospital; Examiner in Materia Medica and Therapeutics in the University of Edinburgh, and to the Royal College of Physicians, London.

**WHAT TO DO IN CASES OF POISONING.** Fourth Edition, revised and enlarged, royal 32mo, 3s. 6d.

---

DR. FELIX VON NIEMEYER.

Late Professor of Pathology and Therapeutics; Director of the Medical Clinic of the University of Tübingen.

**A TEXT-BOOK OF PRACTICAL MEDICINE, WITH PARTICULAR REFERENCE TO PHYSIOLOGY AND PATHOLOGICAL ANATOMY.** Translated from the Eighth German Edition, by special permission of the Author, by GEORGE H. HUMPHREY, M.D., and CHARLES E. HACKLEY, M.D. Revised Edition, 2 vols., large 8vo, 36s.

---

G. OLIVER, M.D., M.R.C.P.

I.

**ON BEDSIDE URINE TESTING:** a Clinical Guide to the Observation of Urine in the course of Work. Third Edition, considerably enlarged, fcap. 8vo, 3s. 6d. [*Just published.*]

II.

**THE HARROGATE WATERS:** Data Chemical and Therapeutical, with notes on the Climate of Harrogate. Addressed to the Medical Profession. Crown 8vo, with Map of the Wells, 3s. 6d.



R. W. PARKER.

Surgeon to the East London Hospital for Women and Children and to the Grosvenor Hospital for Women and Children.

**TRACHEOTOMY IN LARYNGEAL DIPHTHERIA;  
AFTER TREATMENT AND COMPLICATIONS.**

Second Edition, with Illustrations, 8vo, 5s.

---

G. V. POORE, M.D., F.R.C.P.

Professor of Medical Jurisprudence, University College; Assistant Physician and Physician in charge of the Throat Department of University College Hospital.

**L**ECTURES ON THE PHYSICAL EXAMINATION  
OF THE MOUTH AND THROAT. With an appendix  
of Cases. 8vo, 3s. 6d.

---

R. DOUGLAS POWELL, M.D., F.R.C.P., M.R.C.S.

Physician to the Hospital for Consumption and Diseases of the Chest at Brompton, Physician to the Middlesex Hospital.

**D**ISEASES OF THE LUNGS AND PLEURÆ.

Third Edition, re-written and enlarged, with Illustrations,  
8vo. *[In the press.]*

---

A. DE WATTEVILLE, M.A., M.D., B.SC., M.R.C.S.

Physician in Charge of the Electro-therapeutical Department of St. Mary's Hospital.

**A** PRACTICAL INTRODUCTION TO MEDICAL  
ELECTRICITY. Second Edition, re-written and en-  
larged, copiously Illustrated, 8vo, 9s.

---

A. R. ROBINSON, M.B., L.R.C.P. & L.R.C.S. EDIN.

Professor of Dermatology at the New York Polyclinic.

**A** MANUAL OF DERMATOLOGY. With 88 Illustrations, large 8vo, 21s.

---

D. B. ST. JOHN ROOSA, M.A., M.D.

Professor of Diseases of the Eye and Ear in the University of the City of New York; Surgeon to the Manhattan Eye and Ear Hospital; Consulting Surgeon to the Brooklyn Eye and Ear Hospital, &c., &c.

**A** PRACTICAL TREATISE ON THE DISEASES OF  
THE EAR, including the Anatomy of the Organ. Sixth  
Edition, Illustrated by wood engravings and chromo-lithographs,  
large 8vo, 25s.



ROBSON ROOSE, M.D., F.R.C.P. EDIN.

**GOUT, AND ITS RELATIONS TO DISEASES OF  
THE LIVER AND KIDNEYS.** Second Edition, Crown  
8vo, 3s. 6d.

---

ALDER SMITH, M.B. LOND., F.R.C.S.

Resident Medical Officer, Christ's Hospital, London.

**RINGWORM: ITS DIAGNOSIS AND TREATMENT.**  
Third Edition, rewritten and enlarged, with Illustrations,  
fcap. 8vo, 5s. 6d.

---

J. LEWIS SMITH, M.D.

Physician to the New York Infants' Hospital; Clinical Lecturer on Diseases  
of Children in Bellevue Hospital Medical College.

**A TREATISE ON THE DISEASES OF INFANCY  
AND CHILDHOOD.** Fifth Edition, with Illustrations,  
large 8vo, 21s.

---

FRANCIS W. SMITH, M.B., B.S.

**THE SALINE WATERS OF LEAMINGTON:** Chemi-  
cally, Therapeutically, and Clinically Considered; with  
Observations on the Climate of Leamington. Second Edition,  
with Illustrations, crown 8vo, 1s. *nett*.

---

EDWARD T. TIBBITS, M.D. LOND.

Physician to the Bradford Infirmary and to the Bradford Fever Hospital.

**MEDICAL FASHIONS IN THE NINETEENTH  
CENTURY:** including a sketch of Bacterio-Mania and  
the Battle of the Bacilli. Crown 8vo, 2s. 6d.

---

FREDERICK TREVES, F.R.C.S.

Hunterian Professor at the Royal College of Surgeons of England; Surgeon  
to, and Lecturer on Anatomy at, the London Hospital.

**THE ANATOMY OF THE INTESTINAL CANAL  
AND PERITONEUM IN MAN.** Hunterian Lectures,  
1885. 4to, 2s. 6d.



D. HACK TUKE, LL.D., F.R.C.P.

THE INSANE IN THE UNITED STATES AND  
CANADA. 8vo, 7s. 6d.

---

A. DUNBAR WALKER, M.D., C.M.

THE PARENTS' MEDICAL NOTE BOOK.  
Oblong post 8vo, cloth, 1s. 6d.

---

W. SPENCER WATSON, F.R.C.S., M.B.

Surgeon to the Great Northern Hospital; Surgeon to the Royal South London  
Ophthalmic Hospital.

DISEASES OF THE NOSE AND ITS ACCESSORY  
CAVITIES. Profusely Illustrated, demy 8vo, 18s.

---

FRANCIS WELCH, F.R.C.S.

Surgeon-Major, A.M.D.

ENTERIC FEVER: its Prevalence and Modifications;  
Etiology; Pathology and Treatment; as illustrated by  
Army Data at Home and Abroad. Demy 8vo, 5s. 6d.

---

W. WYNN WESTCOTT, M.B. LOND.

Deputy Coroner for Central Middlesex.

SUICIDE: its History, Literature, Jurisprudence, Causation  
and Prevention. Crown 8vo, 6s.

---

E. T. WILSON, B.M. OXON., F.R.C.P. LOND.

Physician to the Cheltenham General Hospital and Dispensary.

DISINFECTANTS AND HOW TO USE THEM.  
In Packets of one doz. price 1s.

---

CLINICAL CHARTS FOR TEMPERATURE OBSERVATIONS, ETC.

Arranged by W. RIGDEN, M.R.C.S. Price 7s. per 100, or  
1s. per doz.

Each Chart is arranged for four weeks, and is ruled at the back for making  
notes of cases; they are convenient in size, and are suitable both for hospital  
and private practice.



---

PERIODICAL WORKS PUBLISHED BY H. K. LEWIS.

*THE NEW SYDENHAM SOCIETY'S PUBLICATIONS.* Annual Subscription, One Guinea.

(Report of the Society, with Complete List of Works and other information, gratis on application).

*THE NEW YORK MEDICAL JOURNAL.* A Weekly Review of Medicine. Annual Subscription, One Guinea, post free.

*ARCHIVES OF PEDIATRICS.* A Monthly Journal, devoted to the Diseases of Infants and Children. Annual Subscription, 12s. 6d., post free.

*MEDICAL BULLETIN.* A Monthly Journal of Medicine and Surgery. Edited by Dr. J. V. Shoemaker. Annual Subscription, 5s.

*THE THERAPEUTIC GAZETTE.* A Monthly Journal, devoted to the Science of Pharmacology, and to the introduction of New Therapeutic Agents. Edited by Drs. H. C. Wood and R. M. Smith. Annual Subscription, 10s., post free.

*THE GLASGOW MEDICAL JOURNAL.* Published Monthly. Annual Subscription, 20s., post free. Single numbers, 2s. each.

*LIVERPOOL MEDICO-CHIRURGICAL JOURNAL,* including the Proceedings of the Liverpool Medical Institution. Published twice yearly, 3s. 6d. each number.

*THE PROVINCIAL MEDICAL JOURNAL.* Edited by Thomas M. Dolan, M.D. Annual Subscription, 7s. 6d., post free.

*TRANSACTIONS OF THE COLLEGE OF PHYSICIANS OF PHILADELPHIA.* Volumes I. to VI., now ready, 8vo, 10s. 6d. each.

*THE INDIAN MEDICAL JOURNAL.* A Journal of Medical and Sanitary Science specially devoted to the Interests of the Medical Services. Annual Subscription, 24s., post free.

---

\* \* MR. LEWIS has transactions with the leading publishing firms in America for the sale of his publications in that country. Arrangements are made in the interests of Authors either for sending a number of copies of their works to the United States, or having them reprinted there, as may be most advantageous.

MR. LEWIS'S publications can be procured of any bookseller in any part of the world.

*Complete Catalogue of Publications post free on application.*

---

*Printed by H. K. Lewis, Gower Street, London, W.C.*















