

Graphic illustrations of abortion and the diseases of menstruation. Consisting of twelve plates from drawings engraved on stone, and coloured by Mr. J. Perry, and two copperplates from the Philosophical transactions, coloured by the same artist. The whole representing forty-five specimens of aborted ova and adventitious productions of the uterus, with preliminary observations, explanations of the figures, and remarks, anatomical physiological / by A.B. Granville.

Contributors

Granville, A. B. 1783-1872.
Royal College of Physicians of Edinburgh

Publication/Creation

London : printed for J. Churchill, 1834.

Persistent URL

<https://wellcomecollection.org/works/zk75rymb>

Provider

Royal College of Physicians Edinburgh

License and attribution

This material has been provided by This material has been provided by the Royal College of Physicians of Edinburgh. The original may be consulted at the Royal College of Physicians of Edinburgh. where the originals may be consulted.

This work has been identified as being free of known restrictions under copyright law, including all related and neighbouring rights and is being made available under the Creative Commons, Public Domain Mark.

You can copy, modify, distribute and perform the work, even for commercial purposes, without asking permission.



Wellcome Collection
183 Euston Road
London NW1 2BE UK
T +44 (0)20 7611 8722
E library@wellcomecollection.org
<https://wellcomecollection.org>

DR GRANVILLE'S
GRAPHIC ILLUSTRATIONS
OF
ABORTION
AND
THE DISEASES
OF MENSTRUATION

A. B. / 54.

Cb 8.8

R32274

GRAPHIC ILLUSTRATIONS
OF
ABORTION
AND
THE DISEASES OF MENSTRUATION.

GRAPHIC ILLUSTRATIONS
OF
ABORTION
AND
THE DISEASES OF MENSTRUATION

GRAPHIC ILLUSTRATIONS
OF
A B O R T I O N
AND
THE DISEASES OF MENSTRUATION.

CONSISTING OF

TWELVE PLATES FROM DRAWINGS ENGRAVED ON STONE,
AND COLOURED BY MR. J. PERRY,

AND

TWO COPPER-PLATES
FROM THE PHILOSOPHICAL TRANSACTIONS,
COLOURED BY THE SAME ARTIST.

THE WHOLE

REPRESENTING FORTY-FIVE SPECIMENS OF ABORTED OVA AND ADVENTITIOUS PRODUCTIONS
OF THE UTERUS,

WITH

PRELIMINARY OBSERVATIONS, EXPLANATIONS OF THE FIGURES,

AND

REMARKS,
ANATOMICAL AND PHYSIOLOGICAL.

BY

A. B. GRANVILLE, M.D., F.R.S., F.L.S., F.G.S., F.R.A.S.,
ETC. ETC. ETC.

FOR FIFTEEN YEARS PHYSICIAN-ACCOUCHEUR TO THE WESTMINSTER GENERAL DISPENSARY, AND DURING
TEN YEARS PHYSICIAN TO THE BENEVOLENT LYING-IN INSTITUTION.

LONDON :

PRINTED FOR JOHN CHURCHILL,
Medical Bookseller and Publisher,
16, PRINCES STREET, SOHO.

MDCCCXXXIV.

LIBRARY
COLL. REG.
MED. EDIN.

GRAPHIC ILLUSTRATIONS

ABORTION

THE DISEASES OF MENSTRUATION

AND ILLUSTRATED BY MR. J. T. T. T.

TWO COPIES PLATE

FROM THE PHYSIOLOGICAL TRANSACTIONS

EDITED BY THE SAME AUTHOR

G. WOODFALL, ANGEL COURT, SKINNER STREET, LONDON.

ANATOMICAL AND PHYSIOLOGICAL

A. B. GRAYVILLE, M.D., F.R.S., F.R.S., F.R.S.

LONDON

PRINTED FOR JOHN JOHNSON

STATIONER, LONDON

IN PRINCE STREET, LONDON

HENRICO HALFORD,

BARONETO,

EX GUELPHORUM EQUITUM PRIM^A COHORTE;

BRITANNIARUM REGIS ARCHIATRO;

COLLEGII REGALIS MEDICINÆ LONDINENSIS

PRÆSIDI;

MEDICO DOCTO, PERITO, FELICI,

IN OMNI DOCTRINÆ GENERE ILLUSTR,

OBSERVANTIÆ ET AMICITIÆ ERGO

GRAPHICA HÆC LINEAMENTA

D.D.D.

A U C T O R.



Digitized by the Internet Archive
in 2015

<https://archive.org/details/b21904716>

CONTENTS.

DEDICATION.

Advertisement, xi.

PROLEGOMENA, p. i.—xxi.

Perfect (Normal) Animal Reproduction, prop. 1—3.

Imperfect (Anormal) Animal Reproduction (Abortion) prop. 4—7.

Study of Abortion, prop. 8—12.

CONCEPTION, prop. 13.

Ovulum (Description of before Fecundation), prop. 14—17.

FECUNDATION, prop. 18.

Ovulum (Description of after Fecundation), prop. 19—22.

CORTICAL MEMBRANE of the Ovulum, prop. 23—26.

Deciduous Membrane of the Uterus, prop. 27—31.

Corpora Lutea, prop. 34—37.

Transit, Volume, and First Development of the Ovulum, prop. 38—42.

THE CHORION, prop. 43—44.

Structure, Function and Vascularity of the Chorion, prop. 45—51.

Fluid of the Chorion, prop. 55.

THE AMNION, prop. 54.

Structure, Function and Vascularity of the Amnion, prop. 52—54.

Fluid of the Amnion, prop. 53.

Progressive Increase of the Ovulum, prop. 56.

Independent Life of the Ovulum, prop. 57—59.

Earliest or Mechanical Connection of the Ovulum with the Uterus, prop. 60.

Metamorphoses of the newly engendered Being, prop. 61.

Growth and Progress of the Embryo and Fœtus, prop. 62—66.

Priority of the Vascular over the Nervous System in the Fœtus, prop. 67.

Formation of the Blood in the Fœtus, prop. 68.

Formation of the Nerves in the Fœtus, prop. 69.

Apparatus for Digestion, prop. 70.

VESICULA UMBILICALIS, prop. 71.

THE ALLANTOID, prop. 72.

THE UMBILICAL CORD, prop. 73—75.

- Omphalo-mesenteric Vessels, prop. 76.
 More advanced, or Vascular Connection of the Ovum with the Uterus, prop. 77.
 FIRST FORMATION OF THE PLACENTA, prop. 77.
 Cotyledons of the Placenta, prop. 78—80.
 Deciduous Vessels of the Placenta, prop. 81—83.
 Membrana Propria of the Placenta, prop. 84.
 Proofs of the Existence of Deciduous Vessels in the Placenta, prop. 85.
 Deciduous Vessels, form the connecting Vascular Link between the Uterus and Placenta, prop. 86.
 Proofs of it from Anormal Anatomy, prop. 87.
 CIRCULATION, Utero-fœtal, prop. 88 and 90.
 Recent Fallacies respecting the Structure of the Placenta, prop. 89.
 FUNCTIONS OF THE PLACENTA, prop. 91.
 Physiological Proofs of the Deciduous and Fœtal Structure of the Placenta, prop. 92.
 NUTRITION of the Fœtus through the Placenta, prop. 93.
 Lymphatics and Lymphatic Absorption in the Placenta, prop. 94.
 Pretended Nutrition by the Amnionic Fluid, prop. 95—96.
 RESPIRATION of the Fœtus in Utero, prop. 97.
 Nature of the Changes in the Fœtal Blood, prop. 98.
 Bile secreted by the Placenta, prop. 99.
 Distinction between Life and Nutrition in the Fœtus, prop. 100—102.

EXPLANATIONS OF PLATES, AND REMARKS.

PLATE I. page 1—6.

SPECIMENS OF VERY EARLY MISCARRIAGES.

Remarks on Fig. 1 and 2. page 2.

Remarks on Fig. 5, 6, 7, 8, 9. p. 5.

PLATE II. p. 7—8.

MISCARRIAGE BETWEEN TWO AND THREE MONTHS.

Remarks on Fig. 10, 11, 12. p. 8.

PLATE III. p. 9—12.

MISCARRIAGE BETWEEN TWO AND THREE MONTHS.

Remarks on Fig. 13, 14, 15. p. 11.

PLATE IV. p. 13—16.

MISCARRIAGE DURING THE THIRD AND BEFORE THE COMPLETION OF THE FOURTH MONTH.

Remarks on Fig. 16. p. 14.

Remarks on Fig. 17. p. 15.

PLATE V. p. 17, 18.

MISCARRIAGE BETWEEN THE THIRD AND FOURTH MONTH.

Remarks on Fig. 18. p. 17.

Remarks on Fig. 19. p. 18.

PLATE VI. p. 19—24.

MISCARRIAGE BETWEEN FOUR AND FIVE MONTHS.

Remarks on Fig. 20. p. 20.

Remarks on Fig. 21. p. 22.

Remarks on Fig. 22. p. 23.

PLATE VII. p. 25—26.

MISCARRIAGE AT FIVE MONTHS.

Remarks on Fig 1. p. 26.

PLATE VIII. p. 27.

FIRST SPECIMEN OF ABERRANT GESTATION.

Remarks on Fig. 1. p. 28.

PLATE IX. p. 29.

SECOND SPECIMEN OF ABERRANT GESTATION.

Remarks on Fig. 1. p. 30.

PLATE X. p. 33—36.

THIRD SPECIMEN OF ABERRANT GESTATION.

Remarks on Fig. 1. p. 33.

Remarks on Fig. 2. p. 35.

Classification of Erratic (Extra-uterine) Gestation. p. 35.

PLATE X. (A.) p. 37—38.

FOURTH SPECIMEN OF ABERRANT GESTATION.

References to Do. p. 37.

PLATE X. (B.) p. 39—40.

CONTINUATION OF ABERRANT GESTATION.

Remarks on Do. p. 39.

PLATE XI. p. 41—44.

DYSMENORRHOIC ORGANIZATIONS.

PLATE XII. p. 45—51.

POLYMERORRHOIC STRATIFICATIONS.

Remarks on Figs. 1, 2, 3, 4, 5. p. 48.

Classification of the Adventitious Productions of the Uterus. p. 48.

Classification of the Diseases incidental to Menstruation. p. 48—49.

Synopsis of a Work on Abortion. p. 51—52.

LIST OF THE FORTY-FIVE COLOURED FIGURES OF HUMAN OVA, AND ADVENTITIOUS PRODUCTIONS OF THE UTERUS REPRESENTED IN THE PLATES.

1. Ovulum bigeminum lanuginosum.
2. Ovulum semilanuginosum.
3. Ovulum lanuginosum.
4. Ovulum semilanuginosum.
- 5 and 6. Ovula of the same species.
7. Ovum denudatum, or diaphanous Ovum.
- 8 and 9. Ova of the same species.
10. Ovum piriforme externè opacum.
11. The same laid open.
12. Ovum opacum plethoricum.
- 13 and 14. Ova semi-coriacea.
15. Ovum omnino opacum rotundum.
16. Ovum pseudo-membranosum.
17. Ovum uviforme.
18. Ovum coriaceum cum hydrope funis et placentâ hydaticâ.
19. Ovum cum placentâ, nec vasculare nec plene cotyledonica, sed filiforme. Amnion morbosum.
20. Ovum tuberculosum.
21. Ovum pene solidum. Placenta sarcomatosa cum tuberculis. Involucra fœtus solidificata.
22. Ovum cum involucris internis ab amnio-chorionitide condensatis.
23. Ovum fœtiferum optimè conditum, subito, ab amnio-chorionitide interfectum.
24. Ovum fœcundum in receptaculo Ovarico.
- 25 and 26. Ovum fœcundum in receptaculo Tubico.
- 27 and 28. Ovum fœcundum in receptaculo Interstitiale.
29. Ovum fœcundum in receptaculo Ovarico.
30. The sac of the preceding Ovum laid open.
31. Membrana pseudo-textilis intro-uterina bi-tubulata.
32. Membrana pseudo-textilis intro-uterina sine tubulis.
33. Coagulum intro-uterinum hæmatosum pseudo-membranaceum incavum.
34. Coagulum intro-uterinum hæmatosum laminare cavum.
35. Coagulum intro-uterinum spongiosum cavum, interne velatum.
- 36 and 37. Coagulum intro-uterinum, interne solidum, externe membranaceum.
38. Mola avellana tunicata.
39. The same laid open.
40. Mola avellana nuda.
41. The same laid open.
42. Mola conchula.
43. The same laid open.
44. Mola Mytilus.
45. The same laid open.

N. B. In the last Plate, the figures 2 and 3 should be reversed, in order to correspond with the text or printed explanations.

ADVERTISEMENT.

I SUBMIT to my professional friends and acquaintances, as well as to all those medical brethren who take an interest in the progressive advancement of the sciences they cultivate, a series of beautifully executed Drawings of anatomical preparations, intended to explain and illustrate the important subjects of "Abortion", and "The Diseases incidental to Menstruation"; subjects in which all classes of the medical profession, whether specifically devoted or not to obstetrical practice, are equally interested. The drawings speak for themselves. The Artist, under my immediate and constant superintendence, and with the anatomical preparations in every case before him, explained and demonstrated to him, has, in the course of six years, been able to produce twelve plates, containing upwards of forty anatomical figures, lithographed and coloured by himself, which reflect no small honour on the arts of this country, and are highly creditable to his abilities. These plates, I will venture to say, leave nothing to be desired in such a mode of representing anatomical subjects, (a mode which appears from the present endeavours to be the best calculated of any for that purpose,) whilst they remove every cause of regret, hitherto entertained, that the most successful efforts of anatomical lithographic representation, of which foreign countries can boast, had never yet been equalled in England. It may now be asserted that those efforts have been triumphantly rivalled by Mr. Joseph Perry on the present occasion; and, in some of the plates, unquestionably surpassed.

Having said thus much in favour of the Artist, I hope I shall be excused if I add, for myself, that I have selected such specimens only as I considered likely to illustrate some of the most interesting points of the physiology of human generation, and which might assist in unravelling the various practical difficulties which beset that mysterious question;—that I have chosen those which, I believe, (with the

exception of one or two preparations,) have never been published before either in this or any other country, and many of which are to be found only in some private anatomical collection;—that I have explained them in such a way as to render their meaning and usefulness evident to all my brethren;—and that, under such circumstances, I venture to believe that the plates so explained will prove of no inconsiderable service to every medical practitioner as a work of reference, where either a private or a public museum is not at hand to solve cases of doubt.

I am aware that I might have extended this series of representations to more than double the present number of analogous preparations; but I purposely limited it to what it is, from a consciousness that any unnecessary increase in the number of plates, which the peculiarity of the subject did not absolutely require, would only tend to increase the bulk, and with it the expense of the “Graphic Illustrations”, without any adequate or corresponding advantage.

It may, after all, be asked: were these delineations wanted? Were there not already in existence works of a similar, or at least analogous character, executed in an equally masterly style, to which the medical reader and the physiologist could refer for information and in cases of doubt? I reply, yes, to the first—and negatively, to the second question.

And first, of the second question. Not to speak of the many authors on matters of this description, who preceded Dr. Hunter and Professor Soemmering, in giving representations of the human embryo in many of its metamorphoses, such as Ruysch, Noortwyk, Albinus, Krapft, Wrisberg, Camper, Blumenbach, Denman, and others, I am ready to admit that both Hunter and Soemmering had given to the world delineations, such as are here referred to, which ought to satisfy the medical profession. The one in his splendid work on the “Gravid Uterus”, gigantic folio edition—the other in his no less valuable folio plates of the human embryo. But, unfortunately, neither of those works can be considered as accessible to the generality of professional readers, on account of their high price and rarity; and even if either were accessible, the subjects therein treated are viewed differently from those collected in the present work. Those works, moreover, present no coloured specimen of delineations of parts, most of which, if not all, from that simple circumstance, lose their principal value;—and as productions of art they are not equal to what Mr. Perry has enabled me to offer to the public. Soemmering himself, in his “*Icones Embryonum Humanorum*”, admits, that although those who had gone before him in the same channel of inquiry, had produced valuable works and splendid plates, particularly Dr. Hunter and Dr. Denman; there was yet room for a more complete, and, above all, for a more minute representation of the

metamorphoses of the human embryo. "*Elegans profecto et utilis admodum speculatio!*" exclaims the veteran physiologist; and forthwith he proceeds to compare what he had been able to give to the public on the subject of embryology with that which his predecessors had done. This leads him to the conclusion that, from having paid greater attention to minuteness, from being more strictly accurate, from the advantage of having a better collection of specimens than fall to the lot of most anatomists, and from the circumstance of both his delineator and engraver being much superior to those of former times—he had been able to complete a work of art on the progressive development of the human foetus which left those of his predecessors far behind.

With one or two exceptions, the representations in Soemmering's work are simply those of the foetus in its progressive advancement from the third week after fecundation, to the fifth or sixth month of gestation. Those representations have no reference to the whole ovum at those several periods of fecundation: and they are not coloured. Still they are, as he has stated, superior as a work of art to any that had appeared before. Soemmering tells us that he selected for his plates the best specimens of the human embryo, the best draughtsman, and the most skilful engraver; and that when he compared those plates with those of Trioenius, Albinus, Wrisberg, Hunter, and Denman, in order that he might better understand, explain, and perhaps correct his own: "*magnopere delectabatur*", to find, on such a comparison, that the superiority of his plates was not inconsiderable. Well, then, let the reader who has the means of doing so, turn to the two folio plates of Soemmering, and then direct his attention to the fourteen plates contained in the present volume, and I will abide by their decision whether or no, in all such delineations as relate to either parallel or identical subjects in the two publications, the palm of superiority (in every circumstance of design, precision, and execution,) which Soemmering claimed for *his* publication, ought not to be yielded by him to *another* sent forth under the advantage of recent improvements in drawing, and a newly invented art admirably adapted for such imitations of nature. Independently of which advantages there is to be added the charm of colour—a circumstance which so greatly embellishes, without disfiguring, truth.

With such impressions, I can feel no hesitation in giving publicity to my collection; and if in selecting, denominating, and appropriating to particular views of my own the several specimens I now publish, there should be found neither taste nor judgment, novelty nor utility, the blame must rest on me—but the merit of superiority will still remain to it as a work of art, which, in the department of morbid embryology, has at present no equal either in England or on the Continent.

Now to the first question—whether these delineations were wanted? I support the affirmative by appealing to all those of the profession who have had occasion to be consulted in cases of abortion and the expulsion of those singular productions of the uterine cavity, which seem connected with menstruation or faulty conception. Let them say whether a work, in which the principal of the infinitely varied aborted human ova, and of the uterine productions alluded to, are faithfully represented, be not likely to be useful; whether, in fact, it be not wanted—or whether it exist already anywhere. If the want of such a work be made manifest, its importance must be self-evident. But that importance is not a little enhanced when we find Denman—a plain unsophisticated practitioner—with quite enough of science to constitute him an authority in physiological questions concerning human generation,—recommending the inquiry, in his own work on an analogous subject, entitled “Engravings representing the Generation of some Animals”, in which he has given three drawings of aborted ova. “It must be allowed”, observes the Doctor, “that the generality of these things (the aborted ova) are preserved for their beauty, or as matter of curiosity, rather than of use. I suspect, nevertheless, that there are some appearances besides the *vesicula umbilicalis* not yet perfectly understood, and therefore recommend the whole subject as worthy of being reviewed”: and, in a subsequent part, he says, that “in every collection there must be some example, which may enable us to distinguish the different parts of which an ovum is composed, the proportion which they bear to each other at different periods of pregnancy, and sometimes the process of utero gestation which failed”. What greater encouragement, therefore, needed I than this opinion and advice of one of the best obstetricians England can boast of, to select, prepare, and point out the importance of this species of anatomical and physiological delineations?

I shall conclude, by remarking, that the plates are intended to illustrate a work “On Abortion and the Diseases incidental to Menstruation”, which I have been preparing for several years, and a prospectus of the contents of which will be found at the end of the present volume. That work will appear, *Deo favente*, in the course of the present year; but for the convenience of such persons as may not feel inclined to purchase it, the collection of plates has been purposely so arranged, as to be published, with a corresponding text, in a separate form, and independently of the forthcoming volume.

Grafton-street, Berkeley-square, 30th March, 1833,

PROLEGOMENA
OF
THE DEVELOPMENT AND METAMORPHOSES
OF
THE HUMAN OVUM.

PROLEGOMENA.

1. THE ultimate purpose of nature, in associating the two sexes in the human species, is to bring to maturity and produce, in a fit state to live and procreate, a constant succession of individuals, that shall perpetuate the species to the end of time.

2. This object is invariably accomplished by one uniform series of laws and phenomena, which have been studiously inquired into, accounted for, and, in most instances, explained in a satisfactory manner, amounting almost to demonstration.

3. The study of the function of reproduction, in all the other classes of animals, affords no other nor any dissimilar evidence. On the contrary, both by comparison and analogy, the study in question serves to confirm us in the notion, that Man differs in nought, in this respect, from the animated beings placed below him in the scale of creation. One same primary intention is manifest in their sexual distinctions; the means to ensure the ultimate purpose—their perpetuation—are the same; the same laws and the same phenomena mark the appearance, the development, and the final production of successive generations of individuals.

4. Any deviation from those laws—any violent change in those phenomena—and, still more so, any impediment to the accomplishment of the *ultimate purpose* of Nature, is a defeat of her intention.

5. Such a deviation, change, or impediment may occur at any time previously to the period established for the appearance of a new and perfect being. If it occur at such a time as shall be incompatible with the maturation, and consequently with the life of the new creature, or even with its maturation alone, (although tokens of life be observed at the time in question,) a *MISCARRIAGE* is said, in common parlance, to have taken place; for Nature has *miscarried* in her undertaking: she has been foiled in her expectations.

6. In the reproduction of the human species, such an event might justly be considered to have occurred, if, at any time before the completion of the natural period of gestation, the foetus be expelled, whether dead or alive. But as in many instances, notwithstanding its premature expulsion, the foetus has grown and has continued to live its extrauterine life, in spite of the want of maturity, (a case known to have occurred even so early as between the sixth and the seventh month,) the expression, before mentioned, (5) is not applied to any untimely expulsion of the foetus that may take place later than that period—at which, and after which, and till the completion of the ninth month of gestation, such an expulsion would be called a *premature labour*. The distinction, however, is more specious than useful: it is an offering to social etiquette, rather than to science.

7. The premature expulsion of the produce of conception before the seventh month, has also received the name of *ABORTION*. This denomination has been generally adopted, and is used by the

writers of every civilized nation, ancient or modern, according to their respective languages. It is that which has been employed in the following explanations of figures taken from nature, which are intended to exhibit several examples of abortion in the human species.

8. The study of abortion, in this point of view, (7) is an infinite source of interest, whether considered in reference to science and the important question of generation, or simply in reference to medical practice. On the continent of Europe, and even in the States of America, but more particularly in Germany, the subject, under its two-fold aspect, has engaged the serious attention of some of the most learned philosophers and most skilful practitioners. I know of no other professed writer on the same subject, besides Burns, in this country. His work on abortion is brief, and more valuable for the practical suggestions it contains, than for any luminous or accurate view of the various scientific points connected with that subject. But like every thing which proceeds from the hands of that able practitioner, the performance is respectable.

9. It is impossible, thoroughly and accurately, to comprehend the mode in which abortion takes place, without being previously acquainted with the origin, formation, progress, and metamorphoses of the fœtus, and its connection with the mother. On all these points, we have, until lately, been in the habit of professing the same articles of belief as our predecessors: we have repeated what we heard them say, or what we read in their writings; and many, both here and elsewhere, repeat still the antiquated theories respecting conception and the structure of the human ovum, which they have learned on the obstetrical benches.

10. The great advancement—the great and forward strides which physiology has made in France, as well as in Germany, have contributed to explode those antiquated theories. Acute and indefatigable anatomists have been busy watching Nature in all her movements, from the first moment of her calling the rudiments of a human embryo into existence, until her magnificent work has been completed by the production of a new, life-gifted, individual of the species. They have called to their aid the much improved art of microscopical observation, and have thereby succeeded in almost tracing the very earliest instant of embryonic existence. The register of their observations constitutes the biography of the human fœtus.

11. It is with the view of contributing to the common stock of new and interesting information on this all-important question, that I bring forth the result of my inquiries into the morbid state of the human Ovum, and its structure under circumstances of premature expulsion. If such inquiries have led me to adopt the improved notions of the more modern physiologists and anatomists in these matters (which I have professedly studied, and have had the most ample opportunities of studying for many years); they have, likewise, enabled me to detect some of the oversights of those observers, and to add a little to what has already been brought forward; while, at the same time, they have induced me to join that class of writers who dismiss, as inconsistent with facts, the theories and assumptions of olden times, whose strongest authority has been their mere repetition.

12. The ideas which are now entertained respecting fecundation, after the successful congress of the two sexes, in the human species—respecting its seat—respecting the first origin, station, and rudimental creation of the embryo—respecting the journey of the latter into the womb, its sojourn in that cavity, and the various metamorphoses it undergoes therein, up to the period fixed for its projection into the world, may be comprised within a small number of propositions. I shall support those propositions by references to facts, or the quotations of competent authorities, and the allegation of anatomical discoveries. But as the object of the present work is to illustrate abortion, and not the complete life-circle of the fœtus, I shall stop the number of my propositions at the *fifth*

month of its intruterine existence. After that period, the various phenomena of foetal gestation are so uniform, that they afford less matter of interest to the philosopher.

13. CONCEPTION, or that result which follows sexual congress, in virtue of which one, or more individuals, of the same species is called into being, takes place in the ovarium of women. This is doubted by Meckel and others, who look upon all cases of ovaric gestation (see Plates IX. and X, A. and B.) as mere accidents, and as only proving that if conception has not before taken place in the womb, it *may* take place in some other part connected with it; but the point has been set at rest by the more recent experiments and microscopical observations of Professor BOER, of Königsberg. I adopt his conclusions. Their correctness is corroborated by the interesting experiments of Prevost and Dumas, although these experimenters admit not that fecundation takes place in the ovarium.

14. The intended receptacle of the embryo is the OVULUM. An ovulum exists in all the vesicles of Graaf, which the ovarium of a woman, who has reached maturity, contains.

15. Viewed by means of a powerful microscope, the ovulum is found to consist of a small yellow spherical body, placed within the vesicula Graafiana, with the upper portion of which it is, internally, in contact; so that it does not float freely in the liquid of that vesicle. This contact becomes more and more intimate as the ovulum enlarges, when that part of the capsule of the vesicle which lies over it becomes, in a correspondent degree, thinner.

16. At first, the little yellow body, being rather opaque, is distinctly seen even without a magnifying glass; but as it advances, it becomes more transparent and, consequently, less distinguishable.

17. This little yellow body is a minute spherical mass, with a roughish or slightly granular surface, and is hollow. Its parietes are thick; around them is an envelope of a much thinner texture, which is distinctly seen, owing to a small space lying between it and the surface of the little yellow body, which space is filled with a fluid substance of a peculiar nature.

18. When FECUNDATION takes place, that part of the vesicle of Graaf to which adheres, internally, the ovulum, bursts, and the ovulum escapes with its external envelope, together with a small portion of the liquid peculiar to the Graafian vesicle, and thus it passes into the fallopian tube.

19. Independently of the external envelope, and within it, the microscope has detected, after fecundation, the existence of another covering, completely investing the little spherical yellow body.

20. The ovulum has been traced, after fecundation, into the cavity of the womb, where the external covering (16) becomes what Boer has called "the cortical membrane", (*cortex ovi* of the present work,) improperly considered as a uterine production by preceding writers, and denominated the *reflected* caducous or deciduous membrane.

21. The more intimate covering of the yellow body of the ovulum, that which closely invests its surface, and appears only after fecundation, (19) is afterwards changed into what has been denominated the shaggy chorion: my observations and my plates shew this. Boer, however, professes not to know what becomes of it during the progressive intruterine development of the ovulum.

22. The hollow and spherical yellow body of the ovulum corresponds with the yolk or *vitellus* of the ovum of oviparous animals, and from it all the other several parts of the foetiferous ovum are derived or formed, as gestation advances, and a progressive development of the parts takes place, from within, without*.

* Professor Boer, who fills the Chair of Zoology at Königsberg, is a man of undoubted veracity, a keen and accurate observer, and has been engaged for many years in the investigation of that most interesting function—reproduction—in mammiferous animals. He made a great number of minute and extremely delicate experiments and microscopical observations on animals and the ovaria of women, which led him to the conclusions I have embodied in my propositions, and which he forwarded in a Latin epistle, intitled "De Ovi mammalium et hominis genesi", to the Imperial Academy of St. Petersburg, with a plate, carefully engraved, representing all the details above alluded to. These he afterwards, and within the last four years, enlarged upon very considerably in a subsequent publication.

23. The existence of the cortical membrane is proved in many parts of the present work, but particularly by Fig. 15, Plate III., and Fig. 17, Plate IV. in both of which specimens of abortion, the said *cortex* had persisted to a longer period than usual during gestation, and had become, consequently, thickened, opaque, fleshy indeed, and the cause of abortion. Figure 15, too, shews strongly the probability of my notion that the thin membrane investing the surface of the yellow body of the ovulum is, in good truth, what has been usually denominated the shaggy chorion.

24. Another proof, amounting to demonstration, of the existence of a cortical covering to the human ovulum, and that of the filiform envelope called the shaggy chorion within it, I find in a striking and beautiful preparation belonging to Sir Charles Clarke, marked 87. We there see a complete cast of the lining (caducous membrane) of the uterine cavity after fecundation, thrown off at a very early period, and with it the ovulum, (of the size of a Portugal grape,) exhibiting the *cortex ovi*, shelly and membranaceous, of a dense texture, yet flexible, which has burst like the pericardium of some seeds, and allows the shaggy chorion beneath it to be seen. It is a curious fact, that even Ruysch has, in his fanciful manner, represented a human ovulum of about three weeks with the cortex burst, yet still *in situ*, and the shaggy chorion beneath it, in every way resembling the specimen of Sir Charles Clarke's in the Museum of St. George's Hospital.

25. Even the errors of some of the very able anatomists of the present day come in beautifully to corroborate Professor Boer's observations of the cortical membrane. Breschet and Velpeau, for instance, state, that within what they (with their predecessors) have looked upon as the decidua in the human ovum, there is a cavity containing a peculiar liquid which, in their opinion, is essential to the nutrition of the fœtus. Now what is this but the very description of the ovulum by Boer (17), proving that there is a cortical membrane in the human ovum?

26. The cortical membrane is destined to be absorbed during the first months of utero-gestation, thus exposing the next membrane to the contact of the uterine lining (decidua), with which a connection takes place in that part where the placenta is to be formed. In that part, however, the *cortex ovi* is never altogether obliterated, but only made thinner; and, in process of time, it is converted into a mere pellicular envelope, which not only serves to divide the filiform vessels of the chorion into groups or cotyledons in order to form the placenta, but also covers all over those cotyledons or groups of vessels. (Plate I. Expl. of Fig. 1.) I have called this the *membrana propria**.

27. While the process or metamorphosis of the ovulum noticed by Boer takes place in the ovarium, in consequence of fecundation, the cavity of the womb does not remain idle, but forthwith sets about weaving for itself a general lining—a sort of pseudo-textile membrane—which extends all over the cavity, descends partly into the cervix, and is *often*, (not necessarily always,) projected even into a great portion of the fallopian tubes.

28. This adventitious lining of the cavity of the womb is formed quite independently of the presence of the ovum, for it has been found in most cases of devious gestation, where the fœtus was *extra muros uteri* (Plate VIII. IX. X. Fig. 1 and 2, and page 35), and has been found advanced in its progress of formation, while the ovulum was, as yet, on its way through the fallopian tube after fecundation. (Haller, Lobstein, Velpeau, Meckel, Pockels.)

* If the reader can procure a placenta which has been thrown off immediately after the birth of the child, without any effort, and cleaning it of all coagula from off the surface which lay next to the uterus, by careful maceration and washing, he will afterwards introduce a small quill or pointed tube into one of the arteries of the navel-string, and blow strongly into it, he will find that the air raises upon that surface, to various degrees of puffiness, a very delicate pellicular covering, through which none of the air can escape, unless through an accidental laceration. I have often made the experiment, which I used to relate to my class in my lectures on midwifery many years ago. Lauth, of Strasburgh, has stated the same thing; so had Ruysch long since, and others, proving at once that there is not a direct communication with the mother from the fœtus.

29. To this adventitious lining described by many ancient authors, but by none better than by Harvey, the name of decidua already mentioned (24, 26) has been given by Hunter, because, viewed as a production of the uterus it is caducous and not permanent like its own natural lining; as, however, it is no more caducous than any other of the involucre of the ovum, the denomination is not strictly correct. It is, nevertheless, more generally adopted than that of epi-chorion, given to the same pseudo-membrane by Chaussier.

30. Its mode of formation and its structure have been differently explained by different authors. The explanation offered by Burns runs counter to facts and realities. That author speaks of all the minute steps of generation, with the same confidence as if all had been demonstrated. His imaginings respecting primary and secondary vessels shooting out from the inner surface of the womb to form the decidua must be gratuitous, as no other anatomist or physiologist, either before or after him, has been able to ascertain the reality of such a process.

31. It is probable that the decidua consists of two laminae, inasmuch as we always find it with one surface perfectly smooth and the other rough. If so, they are most intimately connected. It is at least one-twentieth of an inch in thickness during the first five or six weeks of uterofoetation, when its tissue is found to be more knotty, coarse, and full of short threads, (not unlike a very ordinary mat,) than a purely membranaceous or cloth-like lining would be. It is not until a more advanced period of gestation that the decidua becomes distinctly membranaceous, in which state it lines the entire cavity of the uterus. (Plate IX. and prep. 73, 75, 76, of Sir Charles Clarke's Collection: also Dr. Agar's beautiful specimen of impregnated uterus, Mus. Coll. Reg. Lond. Med., and several specimens in the College of Surgeons, particularly Sir W. Blizard's case.)*

* It has hitherto been supposed, and Dr. Hunter first gave rise to the opinion, that on reaching the uterine orifice of the tube, the ovulum found an obstacle in the presence of the inner lamina of the decidua, which latter is said to be projected across that orifice. This obstacle the ovulum overcomes, Dr. Hunter supposes, by pushing the said lamina forward, and following it close, so at last to make good an entrance into the womb, surrounded by this inner lamina of the decidua, which the ovulum compels to enlarge with its own gradual enlargement, until both fill the entire cavity of the uterus, and the inner lamina of the decidua comes in contact with itself. It is impossible to conceive a more improbable operation, or one more contrary to facts. Yet such is the notion formed by Hunter of an imaginary membrane, to which he has given the name of reflected decidua; and so enamoured was he of this notion, that he has not hesitated to portray in his large work on the gravid uterus a section of the womb at several weeks after conception, (again purely imaginary,) representing things as he supposes them to be in regard to that membrane! Hunter's notion was gradually converted into an opinion, which most of his successors have repeated over and over again, out of respect for him, and without ever inquiring experimentally into the correctness of it. No one has advanced a single fact to prove it. There is no such a thing as a *decidua reflexa*. The improbability of such a process as has been imagined to account for its supposed existence, has been demonstrated very adroitly by Dr. Dewees, as skilful and clear-sighted an obstetrical writer, of the United States of America, as any that have appeared in Europe. (Comp. of Midwifery, 1824, page 66.) He there shews, that if we adopt Burn's description of the *decidua reflexa*, given by that author in a tone of positiveness, as if Hunter's notion was a mathematical proposition, either that membrane must have three, instead of two, laminae, as admitted by them, or it must have even a fourth lamina, namely, one more than has ever been imagined by any body. But the truth of the non-existence of a membrane formed in the manner in which the *reflexa* is said to be formed, is proved by actual facts. A few will suffice. A specimen of an impregnated uterus marked 3468 C. Gallery, Coll. Surg. of London, exhibits distinctly a round ovum naturally suspended within the decidua, as a globe may be supposed to hang from some point of the inside of an oblong sack. Here the ovum has pushed no part of the uterine decidua forward. The ovum has only its natural involucre, and there is a large space between them and the deciduous lining of the womb. In Dr. Agar's case, alluded to before, in the Museum of the R. C. of Physicians, (impregnated uterus 2½ months,) no decidua reflexa is seen. Specimen 73, in Sir Charles Clarke's collection, exhibits an ovulum which has already penetrated about an inch into the cavity of the uterine decidua, without pushing any part of it forward. Specimen 75 in the same collection is another illustration of the same fact. In good truth, the existence of the decidua reflexa is disproved by facts, and is moreover rendered inconceivable and inexplicable by the very account and explanation given by those who contend for that existence. It is now scarcely admitted by one out of ten Continental anatomists.

There

32. Into this chamber, then, so lined and so prepared the fecundated ovulum, in the condition described by Professor Boer, is received after its journey from the ovarium through the fallopian tube.

33. The pre-existence of an ovulum in the Vesiculæ Graafianæ, or Ovarian Vesicles—and its metamorphosis, after fecundation (14, 15, 16, 17, 18,) have been amply confirmed by Plagge of Bentheim, who published an account of his experiments and observations, illustrated by figures, in Meckel's Journal of Physiology. (See also Prevost and Dumas, 3rd memoir.)

34. As soon as the Ovulum has departed from its vesicular nest in the Ovarium, the cavity which remains begins to fill up with a yellow substance, different in texture from the surrounding tissue of the Ovarium, and having, generally, a radiated centre of a whiter colour. This is the *corpus luteum*. (Plate IX., page 30 and 31; also, Spec. 3468 B and C, Gallery College of Surgeons, and Dr. Agar's case Royal College of Physicians *.)

35. The presence of *corpora lutea* in the Ovarium of women, is always an indication that as many ovula have escaped from that organ; but it is not necessarily an evidence that the individual has been impregnated, as ovula have escaped without the congress of the two sexes.

36. It is inaccurate, therefore, to state that a woman has been pregnant because a *corpus luteum* has been found in one of the Ovaria after death, or to calculate the number of children she has borne from the number of *corpora lutea* so detected. *Corpora lutea* have been found in the Ovaria of very young girls, of unmarried women of the strictest virtue, in newly-born female infants, and lastly, in sterile animals, such as mules. (Brugnone, Joer. Roose.)

37. Sir Everard Home's notion that the *corpus luteum* was formed first, and that, too, independently of sexual congress, and that the Ovulum was formed afterwards, is disproved by more accurate and recent observers. (Boer, Plagge.) There is reason to believe that Sir E. Home had been too precipitate in his inquiry †.

There is another physiological fact which we have overlooked—it is this: That the uterine decidua is always pervious at the uterine orifices of the fallopian tubes, as well as over the internal orifice of the cervix uteri. The error thus signalized has arisen from not knowing that the ovulum comes from the ovarium with a *cortical membrane* over the shaggy chorion. It is curious to see how, even among some of the most skilful of the modern physiologists, their ignorance of the existence of a *cortex ovi* has misled them in their respective descriptions of the decidua or uterine lining. Carus, for example, has asserted, that the decidua uteri had an opening over the internal orifice of its cervix. Velpeau and Breschet have denied this to be the fact, and consider the decidua to be a complete sac, to which they have ascribed the functions of a serous membrane. Professor Heusinger confirms the opinion of the two French authors, but denies that the decidua is a serous membrane. The truth lies between: Carus described the real decidua, which has three apertures; while Breschet, Velpeau, and Heusinger evidently refer to the *cortex ovi* which has no aperture whatever, when the ovulum enters the cavity of the womb. Well might Meckel exclaim, "il n'est pas très facile d'expliquer le mode de formation de la caduque réfléchie." (See specimen 73, 75, 76, 87, Museum of Sir Charles Clarke.)

* It is impossible to desire a stronger or a more beautiful illustration of the modern theory of fecundation, than we find in the preparation here alluded to. It is the impregnated uterus (between two and three months) of a female who died of hydrophobia. Both the ovaria are laid open. In the left there are no appearances, beyond the Vesiculæ Graafianæ hardened by the alcohol: but in the right, namely, the ovarium of that side on which it is supposed that the fecundated Ovulum entered the womb, (from the circumstance of the placenta being implanted in that quarter,) we find not only a scar still red on the surface of the ovarium, but corresponding with it, and beneath it, in the thickness of the ovarium, a large shallow depression or hollow from which the Ovulum had escaped, and which is beginning to fill with the substance that is to constitute the *corpus luteum* destined to stop up the gap in the ovarium.

† Meckel, with many others, entertain still the opinion that the *corpus luteum* precedes fecundation—but instead of supposing with Sir E. Home that it generates an Ovulum, the physiologist of Halle imagines that, like a *testis*, it serves to secrete a generating liquor—the semen feminæ. This theory is demolished by Boer's, Plagge's, and Messrs. Prevost and Dumas's positive observations.

38. The Ovulum, on entering the womb, is about the size of a small pea. The cavity, on the contrary, into which it enters, from the very first, is of considerable dimensions. One cannot help being struck at this great disparity in the relative dimensions of the Ovulum and the cavity of the womb. When they first come in apposition, that of the latter is from ten to twenty times greater than that of the former. (See Sir W. Blizard's case, Royal College of Surgeons, and Spec. 73, 75, 76, in Sir C. Clarke's Collection*.)

39. The time at which the Ovulum enters the womb after fecundation is not precisely known. (Meckel.) The fimbriated end of the fallopian tube has been found actually applied to a Graafian vesicle after copulation. (Magendie.) An ovulum, containing the rudiments of an embryo has been observed in the human subject half engaged within the tube, and half still resting on the Ovarium. (Bussieres.) The Ovulum has been detected on its way through the fallopian tube.—(Burns, Haygton, Cruikshank, Prevost, Dumas.) It is said to have been detected in the uterine cavity on the eighth day. (Home.) Although it has lately been the fashion to doubt the accuracy of such a fact, there is reason to believe it to be correct, from the circumstance of M. Bauer's microscopical examination of that Ovulum and description of its structure corresponding with more recent discoveries. (Boer.) The embryo contained in an Ovulum of a week's growth has been seen and measured. (Autenrieth *Supplementa ad Historiam Embryoni Humani*.) The Ovulum, until the eighth day, has been observed in the uterus under a gelatinous form by another anatomist. (Walker.) Ovula in the fallopian tubes have also been seen on the eighth day by Prevost and Dumas.

40. I have had occasion, within the last two months, to see a perfect Ovulum ejected from the womb fourteen days after a single sexual congress, which had taken place the day after the cessation of the menses. Dr. Pockels (Isis, December 1825,) examined more than fifty human Ova, among whom four had been expelled from the womb between the eighth and sixteenth day after conception. On the fourteenth day the Ovulum is about the size of a Spanish nut. The chorion is surrounded by a thick membrane†.)

41. An Ovulum at three weeks is mentioned by Hunter (Gravid Uterus). At twenty-two days a perfect Ovulum, with the embryo clearly defined, was shewn by Dr. Combe to Dr. Baillie. Blumenbach asserts seeing an Ovulum of the size of a small cherry, which could not have had more than twenty-three days' existence. M. Ogle's case, published in the "Transactions of the Society for the Improvement of Medical and Surgical Knowledge", was one of an Ovulum in Utero at five weeks. These facts contradict Burns' assertion, that at "three weeks or a month after impregnation no fœtus is in the uterus."

42. After being safely lodged within the cavity of the womb, the Ovulum continues to grow on its own life-principle, for a while, until its connection with the mother is effected, through the medium of the deciduous membrane, which becomes, at a more advanced period, as it were, a new and additional covering to the Ovulum. The growth of the Ovulum causes the *cortex* to burst,

* This disparity has not been noticed before by writers. Like many other circumstances, it militates, not a little, against the theory of the decidua reflexa.

† Dr. Pockels calls this the Decidua—but in good truth it is the *Cortex Ovi*—for this good reason, that at so early a period, and even as late as the end of the first six weeks, the Decidua is many times larger in capacity than the ovulum, and is never globular like the latter. Besides, when Ovula of such early periods are thrown out, the decidua remains behind, and is ejected in its triangular shape, a little while, and sometimes even a day, after. In other respects, Dr. Pockels confirms Boer's more precise description of the "*Structure of the Ovum*."

as happens with the receptacle or cortex of certain seeds, and with the outer shell of the ova of some oviparous animals. (See Plate I., fig. 1, 2, 3, 4.)

43. On the cortex bursting, the lanuginous or fibrillous membrane within it (21) is exposed, when the fibrils will forthwith entwine themselves with the flocculi of the decidua, and thus the Ovulum fastens itself to the uterus by one or more contiguous points. (Carus.)

44. The membrane having these fibrils on its surface, has been called the Chorion—and from the circumstance that these fibrils, both before the cortex which lies over them has burst, as well as afterwards, serve to promote the nourishment of the fœtus, I have styled it, the nutritive membrane or involucrum of the fœtus. It has been so considered by Ruysch, who calls the villous side of the Chorion, “*succosa nutritioni fœtus inserviens*.”

45. The fibrils of the Chorion have generally been considered as filiform vessels. When examined with the microscope, they appear diaphanous and ramiform; some of them terminate into little bulbs like the ampullæ of the villousities of the intestines. These bulbs adhere so firmly to the cortex ovi, that when an attempt is made to detach them, many are lacerated. (Carus.) It is only when the cortex bursts of its own accord that they are set at liberty. (43.)

46. These fibrils, however, are not all vessels. Some (5) are only suckers, others are real vessels. (Carus.) The existence of any vessels among the fibrils of the Chorion has been denied very recently upon the same ground, namely, microscopical observations. (Breschet and Raspail.) But there must be an evident mistake in such observations; for the actual progress of those filiform vessels, and their gradual swelling into large veins and arteries, at an advanced period of fœtation, have been noticed in examining various human ova of different ages. (Lobstein, Velpeau, Dutrochet, and myself.)

47. The nutritive envelope or involucrum, or membrane (Chorion) of the Ovum is bifoliated. I have a beautiful preparation of the transparent membranes of the Ovum, even after regular parturition, which proves this fact. It is probably even trifoliated. (Dutrochet.) A fluid has been found between the two laminæ of the Chorion. (Meckel.)

48. The internal surface of the Chorion is likewise supplied with fibrils, which connect it with the next and innermost involucrum of the fœtus, called the Amnion. Between the fibrils or filiform vessels of the two surfaces, a communication is kept up by small vascular trunks which meander between the two laminæ of the Chorion. (Meckel and myself.)

49. The vascularity of the Chorion is further proved by its diseases, chiefly of an inflammatory character, ending in the thickening of its texture. (Plate III., page 12—Plate IV., page 13—Plate V., page 17—and many other examples in this Work.) There is a preparation in Sir Charles Clarke's collection which shews the vessels of the Chorion as evidently as if they were injected.

50. But the vascularity of the transparent membranes is proved further by fine injections thrown into the vessels of the ovaria of women; on which occasion a beautiful net-work of minute vessels is rendered manifest, forming a species of vascular ring around the *Vesiculæ Graafianæ*. The same observation has been made by comparative anatomists. (Cuvier, Home, Lobstein.)

51. These facts, demonstrative and corroborative of the vascularity of the Chorion, (45, 46, 48, 49,) explain and account for the reality of that self-existing life-principle inherent in the fecundated Ovum (42), which detaches it from its nest (vesicula Graafiana), enables it to travel through the tube, to grow or expand while thus travelling, and to maintain that same power of growth and development for a short time after its reception into the womb, until its final and effectual implantation on the maternal stock (uterus).

52. The same holds good with regard to the amnion, or inner transparent membrane of the Ovum, which, although normal anatomy has failed, morbid anatomy has succeeded in proving to be vascular. (Plate VI. fig. 20, and Description, p. 19, and Remarks, pp. 20—24.) (Haller, Monro, Chaussier, Meckel.)

53. If it be true that the amnion is a vascular membrane, there is no difficulty in viewing it also as a secreting membrane. Hence the source of that particular fluid, to which the name of *Liquor Amnii* has been given, and in which the embryo is suspended to the end of gestation. (Plate I. fig. 4, but particularly fig. 7, 8, and 9, and Remarks.)

54. The amnion is a sac formed by the reflected epidermis of the embryo. (Velpeau, Boer, Pockels.) It does not exist before the twelfth day. (Velpeau.) At the eighteenth day it is found as a bladder placed on the back of the embryo, and continuous to it along its edges or sides and at its extremities. (Velpeau.) It has been distinctly seen on the twelfth day. (Pockels.) It is then not a concentric membrane within the chorion, but a vesicle, on the outside of which the embryo rests as on a bed. Until the day in question the embryo is connected to the vesicular amnion at the back, by a cellular transparent membrane. From that time till the sixteenth day the embryo progressively gets into the cavity of the amnion, which before was connected with the chorion by one of its piriform extremities, while the other conical extremity penetrates slowly into the albuminous fluid of the chorion. (Pockels.)

55. While the embryo is within the chorion (nutritive involucre) and rests on the vesicular amnion, the former membrane, or sac, contains a reddish transparent fluid having the consistency of the albumen of an egg, (54.) with a colourless and very slender membrane crossing it in various directions. (Pockels.)

56. The progressive increase of the Ovulum, from the time of its quitting the Ovarium until it has stationed itself firmly within the womb, has been demonstrated (Magendie, Prevost). In examining, between eight and twelve days after fecundation, the female organs of such of the mammalia as are multiparous at a single gestation, one Ovulum has been found near the fimbriated end of the fallopian tube of one size; a little farther into the tube another of a larger size; and lastly, near to the uterine orifice of the tube, a third of a still larger size; shewing the relative progressive increase that had taken place in such Ovula subsequently to a single act of fecundation, and proportionate to the time employed by such Ovula in travelling to the spot in which they were found. (Prevost, and Dumas's 3rd Memoir on Generation.)

57. While thus circumstanced, the Ovulum is never connected with the part through which it passes. On plunging that part into water, the Ovulum is found not only to rise to the surface, but to float. (Home, Prevost, Dumas.)

58. What stronger proofs need be required of the existence of an inherent life-principle in the Ovulum, which is, at one time at least, (indeed I suspect throughout the period of gestation,) independent of any connection with the parent mother? (Plate I., and several of the explanations of figures throughout the work.) Yet none of the earlier writers who adopted the Ovarian theory of generation have ever asked themselves this question: What supports the vitality of a fecundated Ovulum after it has left the Ovarium, and previously to its becoming connected with the womb? In fact, the subject had never been mooted, before the more modern physiologists took it up and satisfactorily explained it*.

* The whole of the English physiologists, writers on midwifery, and lecturers, whether ancient or modern, are entirely silent on this important stage of embryonic life. They have talked rather loosely on the subject without a single reference to facts or anatomical remarks of their own. Burns, in his work on abortion, never once alludes to

59. That the embryo probably lives in utero in virtue of its own life-principle, even through the entire period of gestation, (51, 56, and 58,) is rendered probable by many facts related by unimpeached authorities, which go to prove that when the whole intact Ovum has been expelled at an advanced period of gestation, or at the natural termination of that period, the fœtus has continued to live, and the circulation of the blood has not ceased for an instant during a space of time of from nine minutes to a quarter of an hour. (Roederer, Wrisberg, Osiander, and Meckel, who repeated the experiments of the latter.) It has been asserted by a venerated authority that in an intact Ovum, expelled at seven months, the fœtus lived upwards of an hour. (Harvey.) The truth of this assertion is confirmed by very recent observers (Green, Velpeau, Gardien, Dr. Campbell)*. I once destroyed a female cat by prussic acid near the time of parturition; and having removed from the horns of the uterus the entire Ova, with their beautiful annular placentæ, while the fœtus in each of them was still perfectly lively, and could distinctly be seen, through the membranes, to move, I found that at the end of thirty-five, forty, and even forty-two minutes, some of them were still alive, the Ova remaining entire all the time, and upon the table †.

60. When the Ovulum has made good its fastening to the adventitious lining of the womb (decidua), the circulation of the blood in it is as yet imperfect. The Ovulum does not—cannot—receive the blood of the mother. How could such a gossamer-like being, organized as the Ovulum has been proved to be, during the first days after fecundation, be made a part of so impetuous a torrent as the circulation of the blood of the mother, without instant destruction to the produce of conception? No. The blood of the embryo is first formed within itself. (Prevost, Home, Magendie, Adelon, Serres, Rolando.)

61. The newly-engendered being passes through two striking metamorphoses previously to the enjoyment of its extra-uterine life. These are the Embryonic and the Fœtal states. The latter succeeds immediately to the former; beginning at the moment when the new being is grafted on the maternal womb, and continuing until its expulsion from thence at the full period of gestation. It follows, therefore, that the Embryonic or former state is that in which the new being is as yet, without any direct or indirect communication with the mother, and still less so with external objects. This state persists for about two weeks after fecundation, during which the Embryo continues to derive its nourishment from the cortical membrane of the Ovum. (Boer, Soemmering, Plagge, myself.)

62. The growth and progress of the Embryo or Fœtus follow a very irregular march. Up to the second month the increase is somewhat slow—it is accelerated during the third—it slackens again at the fourth and fifth months—between which and the last month the increase is more rapid, until it has acquired its proper maturity. (Autenrieth, Soemmering.) ‡

63. The Embryo may be perceived, with the naked eye, at the fourteenth day after conception. It measures then 1-12th of an inch in length. (Dr. Pockels.) On the third week, it is 1-10th of an inch long. It is as large as a house-fly at four weeks, and as a horse-fly at six

the species of life which he must suppose the embryo to enjoy. He tells us, that even at the end of three weeks the Ovum is not found in the uterus, but how it exists during that period, wherever it may be, he has not even alluded to.

* See a very interesting paper on the Structure of the Human Placenta, by T. Radford, Surgeon, &c. Manchester, 1832.

† I shall submit to the Profession these curious and interesting experiments very shortly.

‡ Autenrieth, in his "*Supplementa ad Historiam Embryonis Humani*", has given the dimensions of the embryo and fœtus from a week to the 126th day of growth, with a description of the several parts as they appear at each period. From these he has drawn several conclusions respecting the growth of the human fœtus which have been generally adopted. Soemmering, in his "*Icones Embryonum Humanorum*," has also given the dimensions of the human fœtus, from the earliest period he has seen it to its full maturity, with plates.

weeks. At two months it weighs twenty grains, and is one inch long. It weighs an ounce and a half at three months, and measures three inches; between which time and the sixth month it increases in dimensions from three to nine inches, and in weight from one ounce and a half to one pound. The relative weights of augmentation of length for the seventh, eighth, and ninth months stand thus:—from two to four pounds, and twelve inches; from four to five pounds, and seventeen inches: from five to eight pounds and twenty-two inches. (Averages of minute and accurate observations made by Autenrieth, Soemmering, Bichat, Pockels, Carus, &c.—confirmed by my own observations made on several early ova, and many fœtuses examined in the course of seventeen years' obstetrical practice.)

64. Towards the end of the first month it is easy to distinguish the head of the fœtus, which has the appearance of a vesicle composed of thin membranes, and is as large as the rest of the body. The latter is straight—and there is in one part of the head a black dot, marking the spot for the eyes. (Plate I. fig. 5.)* But it is during the second month that the various parts of the face, as well as the superior and inferior extremities, become visibly delineated in the fœtus. The eyes are indicated by two black spots of considerable size, compared to the volume of the fœtus. The eyelids are not spread over them until the tenth week, at which time the external concha of the ear, as well as the profile form of the nose, become properly defined. At this same period we find the mouth, which was at first a simple opening of no mean size, becoming more distinctly delineated, owing to the formation of the lips. These soon approach each other, leaving a simple transversal slit or depression between them. (Plate II. fig. 11 and 12.)

65. The extremities appear in the form of globular tubercles at first; the superior preceding the inferior by a short period of time. Until between the third and fourth month, the lower are smaller than the superior extremities. Even at the latter month they are shorter than the projection of the os coccygis. The parts of reproduction may then be distinctly seen. In the male as well as in the female, these parts are exceedingly prominent. (Plate V. fig. 18 and 19.) But the difference of the sexes may be deduced from other circumstances besides the sexual organs. Such as the particular structure of the thorax and abdomen, the form of the head, the extremities, and the dorsal spine. (Autenrieth, Soemmering, Meckel, Velpeau.)

66. The external organs of the fœtus are all well defined at the end of the fourth month. The abdomen is fully covered in; the intestines are no longer visible. By the sixth month the fœtus is perfect in its shape and formation. In the seventh, eighth, and ninth months, its successive development is limited to mere size, volume, or amplitude, and a proportionate increase in weight. It is well to keep in mind, that although the growth of the various parts of the fœtus bears a proportion to the general development of its body, that part of the body which is above the navel, measures in length more than the part below it, until the full and complete period of gestation, when the navel marks the precise middle of the length of the fœtus. This circumstance assists us materially in forming our opinion respecting the age of any fœtus, either as a matter of curiosity, or as a guide in questions of forensic medicine. (Foderé, Chaussier.)

67. It was supposed, until within the last fifteen years, that the nervous system was the first to be formed in the human embryo; but recent discoveries have proved that the vascular system has precedence of the former. The nerves invariably appear after the arteries which they are intended to accompany. The spinal marrow appears before the brain, and the latter before the

* "*Caput nutans per omne tempus quo in Ovo continetur.*" And again,—"*Quò junior embryo, eo major est volumen capitis.*" (Soemmering.)

cerebellum, and accordingly it is found that the arteries of the spinal marrow shew themselves before those of the brain, and the arteries of the brain become manifest before those of the cerebellum. In this respect the organogenesis of the human fœtus is analogous to that of birds. (Serres, Desmoulins, Adelon.)*

68. The blood is formed independently of the heart, and appears at two distinct points from it, and acquires a motion independently of it. (Prevost, Dumas, Baer.) The veins are formed first—next, the heart—lastly, the arteries, &c. (French Physiologists.) The arteries are, by an Italian physiologist, said to be the first to appear. (Rolando.)†

69. The nervous system is not developed, beginning at the centre and proceeding towards the circumference of the embryo, but the reverse. Thus the lateral nerves of the head, trunk, and pelvis, are already formed, when the cerebro-spinal system is yet in a liquid state. It follows hence that those nerves cannot be considered (as it has all along been supposed) in the light of emanations from, but as distinct bodies proceeding to, that particular portion of the nervous system. (Serres.)

70. Of the apparatus for digestion, the intestinal canal is the first to appear. It consists, during the first days of its formation, of an open gutter, extending the whole length of the embryo, placed before the vertebral column, and gently curved like a canoe. It is in communication with the *vesicula umbilicalis*, or intestinal vesicle. (Wolf, Meckel, Oken, Baer.) The gutter, without losing altogether its communication with that vesicle or chamber during the first ten or twelve weeks, becomes closed at last, and extends, lengthens, and expands in a variety of ways. One of its extremities, the mouth, appears between the fourth and fifth week. It is open on the sixth. The other extremity, the anus, opens on the seventh week. About the ninth week, the outlines of a stomach are visible. (Meckel, Adelon, Velpeau.)‡

71. The *VESICULA UMBILICALIS* (intestinal vesicle) corresponds to the vitelline sac of birds. The discovery is due to Bojanus. In the human embryo it measures about half an inch in diameter. It is situated immediately against the anterior surface of the embryo (Lobstein); but it gets further from it at the end of the first month, when it is found on the outside of the sheath of the cord. (Meckel.) It is composed of a granular membrane of considerable tenacity. It contains a whitish liquid, which gradually diminishes—becomes thicker, and ultimately, hardened; while the vesicle itself withers, and becomes opaque. It receives the blood vessels called omphalo-

* This doctrine has been controverted by two more recent experimentalists, Prevost and Dumas, as far as the chick is concerned. They assert that the rudiments of the spinal marrow appear before any other important organ.

† In describing the figures in Plate I. under the head of "remarks" it is to be understood that by the expression of "the mossy vessels discharge their blood" is meant that they present themselves, immediately after the expulsion of the Ovulum, with very feeble tokens of the presence of blood at that early period of gestation.

‡ The consideration of the development of the human embryo in its minutest parts, progressively watched and carefully examined and described, as those parts appear in succession, appertains to transcendent physiology, and would be out of place in these Prolegomena to a work which is intended to supply my brethren with practical information, obstetrical as well as medico-forensic. It is sufficient for my purpose to mention (as I have endeavoured to do) the forms which the fœtus presents, its different sizes, and the weights which correspond with those forms. To those of my readers who take an interest in embryogenesy, I recommend the careful perusal of the various continental modern authors repeatedly named in these Prolegomena. Unfortunately, since Hunter and Home, there has not been a single British practical and experimental physiologist who has investigated this subject either originally or otherwise. This fact, not at all flattering to us, is no where placed in so strong a light as in Breschet's very erudite and classical memoirs, entitled "*Etudes anatomiques, physiologiques et pathologiques de l'Oeuf dans l'Espèce humaine*;" in which that indefatigable inquirer has enumerated and analyzed every statement and experiment made on that subject by upwards of thirty physiologists, down to the present day; among whom there is not, since Hunter and Home, a single English name besides that of Dr. Burns, recorded.

mesenteric. (Pockels.) It disappears generally about the third month. (Meckel.) It has been observed, though extremely rarely, at the full period of gestation—placed at a short distance from the insertion of the cord into the placenta, but not larger than when seen at between two and three months. (Hunter, Meckel.) It is connected, as stated before, by a short neck, and by vessels, with the smaller intestines at the termination of the ileum (Meckel)—or at the cæcum, which is, in reality, the representative of the vesicula vitellaria drawn into the abdomen as in birds. (Oken.)

72. At the lower end of the anal intestines, there projects another vesicle or sac, to which the name of Allantoid has been given. It exists in birds—in all the mammalia—and in the human embryo. In the latter it appears about the fourth week, and by the sixth week it has almost disappeared. Its existence is therefore but short, while the size it attains is always trifling. Not so with the mammalia, in which it acquires great amplitude. The communication of this sac with the bladder, by a canal called the urachus, and which canal is found impervious after the first three or four months of gestation, is admitted by all observers. (Meckel, Baer, Dutrochet.)

73. The umbilical cord or navel string, in man, has been found to spring from a vesicle to which the discoverer has given the name of Erythroid. (Dr. Pockels.) This vesicle had been before observed in the mammalia. (Oken.) The cord appears at the end of the third week. (Pockels.) It then consists of a vein and two arteries, the urachus, a species of gelatine of a rosy nature, called the *gelatine of Wharton*, a portion of the intestinal canal, (larger in proportion as the embryo is younger,) the vesicula umbilicalis, in part, and the omphalo-mesenteric vessels, the whole enveloped by a sheath proceeding from the involucra of the ovum already described. The last three constituent elements of the cord, however, become obliterated or disappear after the third or fourth month of gestation—the others remain permanent throughout that period.

74. The umbilical vein and the arteries are spirally twisted together and in the majority of cases they are so from left to right. (Hunter.) The former contrivance is evidently intended for the purpose of giving the greatest possible extension of tubular passage for the blood compatible with the smallest increase in the length of the cord. The cord which is very short at five or six weeks, becomes at the conclusion of gestation from one foot six to two feet long. (Chaussier.)

75. The umbilical arteries, two in number, are a continuation of the primitive iliac arteries; they pass over the lateral regions of the bladder, ascend along the internal surface of the anterior abdominal covering of the fœtus, approaching each other as they get nearer to the navel, through which they emerge in order to enter the sheath of the cord, winding round the vein in their way to the placenta. (77) The vein on the contrary which proceeds from the placenta is of a larger calibre than that of the two arteries taken together. It is soft and extensible—and after having slightly meandered within the umbilical sheath penetrates through the navel into the abdomen of the fœtus, directs its course towards the inferior surface of the liver, enters the antero-posterior fissure of that viscus, unites with the left branch of the hepatic and vena portarum, and reaches under the name of the venous duct, the inferior cava. It has no valves, except one at its intro-abdominal bifurcation. This vessel, throughout its course, becomes obliterated after birth.

76. The omphalo-mesenteric vessels consist of a vein and an artery, the ramifications of which, externally to the fœtus, are seen distinctly on the umbilical vesicle (vesicula intestinalis). They accompany the cord as far as the navel through which they pass into the abdomen. They then separate, the former proceeding on the right to join the trunk or one of the branches of the mesenteric vein, and the latter on the left to join the superior mesenteric artery. These vessels are obliterated, as the vesicula umbilicalis to which they belong disappear, and lastly disappear in their

turn. They have, however, been observed sometimes in the cord of the full grown foetus, like whitish solid filaments. (Chaussier, Beclard.) In the recent case of an individual twenty years of age, who died of consumption, these vessels were found as pervious as when existing in the embryonic state, and contained blood. (Spakenberg.)*

77. When the Ovum is advanced to the second or third month of its fecundated existence (for the period varies in different examples I have had under my observation); its attachment to the Uterus, is firm and complete. Many of the vessels of the external surface of the chorion, which by this time have increased in size, while their free ends have luxuriantly branched out in innumerable minute vessels, have clustered together and formed what are in reality cotyledons—by means of which the said attachment is principally effected. (Personal observations and experiments.) The congeries of these clusters of vessels constitute the principal part of what has been called the Placenta, which grows in size and expands as the gravid uterus expands progressively during gestation.

78. The Cotyledons sometimes consist of only one short and very thick principal trunk—dividing itself, at a short distance from the surface whence it springs, into two, three, sometimes more, lesser trunks, and then again subdividing into thousands of smaller tubes;—at other times the cotyledons consist of two or three distinct straight trunks of different calibre springing from the chorion close to each other (as insulated clusters of lofty and straight trees are often seen here and there on a plain); in which case, the corresponding subdivisions being more numerous, the cotyledon is necessarily larger. (Personal observations, 1825, 1826.)

79. The main trunks of these cotyledons are ramifications of the umbilical vein and arteries, seen to spring from the subdivision of those vessels which are observed to run horizontally on the foetal surface of the placenta, and which are the termination of the umbilical cord. Between these cotyledons there are spaces of various sizes in which the surface of the Chorion is clear of all filaments, vessels, or any other attachment or projection whatever,—such surfaces are smooth and shining. (Personal experiments, 1825, 1826.)†

80. The trunks of the cotyledons and their subdivisions whether springing from the vein or from the arteries of the cord have their coats made of the Chorion and amnion which accompany each cluster so as to form the thinnest pellicular receptacle for their ramifications. It follows hence, that when a coloured liquid, or even air is injected through the arteries of the cord, no escape of the injection takes place, nor can take place, from the terminal vessels of the clusters or cotyledons—and as it is found also that the same injection, if projected long enough (without lacerating any part of the gossamer-like structure we act upon) is brought back by the vein of the cord (which has no valves to prevent such a return) another conclusion is inevitable, namely that the terminal arterial vessels become, by a continuous arrangement, incipient radicles of the venous tubes. (Personal experiments, 1825, 1826.)

81. Now in as much as in the human placenta, expelled at the full period of gestation, before any experiment be undertaken to disturb its integrity, the lobes which it presents have each the appearance of a continuous mass, without any intervening spaces (79); and as these appear only

* See *Journal Complementary*, Vol. 6. p. 375.

† I possess a placenta exhibiting these appearances (78, 79) in so distinct and beautiful a manner, that it would be a violation of truth and sincerity, or a sure sign of ignorance, to state that they do not properly resemble those which are observed in the Chorion of some of the mammalia. Those are cotyledons. So are these. I shewed the preparation to Dr. Hugh Ley. He was delighted with it, and instantly admitted the similarity in question.

clear, smooth, and shining, after maceration and much patient dissection that leaves nothing rough, or lacerated or divided by violence, behind; it follows that something must have been removed, during the process of maceration and dissection, which before the employment of those processes occupied the spaces in question. (79.)

82. That something consists in a congeries of blood-vessels, arterial as well as venous, proceeding from the longitudinal vessels of the decidua covering the placenta (Dr. Hunter, Chaussier, Meckel, Lesauvages, myself). These vessels ramify in a manner analogous to that in which those of the fœtus have been described to ramify, (78, 79.) They penetrate between the interstices left by the minutest branches of the umbilical cotyledons. Their direction is lateral, perpendicular, oblique, and variously tortuous, in reference to the plane of the decidua whence they originate. Wherever they form a thick cluster, they are found to occupy one of the spaces already described (79). To facilitate this arrangement, and to render the distribution of the decidual vessels throughout the masses of the umbilical cotyledons more effectual—the membrane itself (decidua) is found to dip among the latter, dividing the general mass into lobes of various sizes, by which contrivance the decidua acquires an additional extension. (Personal Observations and Experiments.)

83. The decidual vessels are formed by continuous arterio-venous tubes. They reach, but do not connect themselves with the chorion. In the same manner as the terminal vessels of the umbilical cotyledons reach, but do not connect themselves with the superimposed decidua. When an attempt is made to remove (peel off) the latter from the surface of the placental mass, we notice certain attachments between them which are torn in the removal. These are the decidual vessels (82) and not as stated incorrectly by some, the terminal vessels of the umbilical system. (Recent German, and French, and Personal Experiments.) In the same manner as the umbilical vessels are accompanied by the chorion, the decidual vessels are accompanied by a membrane peculiar to the placenta, which I have called the *membrana propria*.

84. If we take a placenta which has been expelled from the womb, in all its integrity, between the fifth and seventh month, when the vascularity of the decidua is considerable, and after carefully washing its surface in tepid water, we plunge it in a weak solution of alcohol, so as to harden the decidua in some degree, we shall be able to slice off the latter from the surface of the placenta, at the depth of about the tenth of an inch, without injuring the delicate texture of the membrane. This should then be carefully macerated by turning the under surface upwards, under water, when, after a time, much of the tomentous attachment seen floating, will gradually be detached, and leave part of a smooth surface behind. If the membrane be then viewed with a strong magnifying glass, on its upper surface several orifices, with regular edges, but of various aperture, will be observed, through which, if we introduce a slender pipe and blow air into them, not only the longitudinal vessels in the decidua will be seen to fill with that fluid; but the short fragments of their ramifications pendent from the under surface of the membrane, will be distended, and the air will pass through them bubbling up through the water, thus denouncing their own vascular nature and arrangement. This is an *experimentum crucis*. (Original, 1826—27).

85. The orifices in the decidua have been denied by one or two recent writers, particularly by Professor Lauth; but they are admitted by all the rest of the modern physiologists and anatomists, from Dr. Hunter down to the latest experimentalist on the subject. It is through these that the injection, thrown into the uterine vessels, while the placenta is still adhering to the uterus, passes into that part of the placental mass which is formed by the decidual ramifications. In a very

beautiful and most accurately conducted experiment made at the Middlesex hospital, by Dr. H. Ley, (March, 1833,) the particulars of which, I hope, to see published by that able physician; a red injection was pushed, without any difficulty,—laceration,—or extravasation, towards the adherent placenta, from the uterine vessels of a pregnant woman, who died of a disease of the heart, undelivered; when it was found to have penetrated, in the most regular and uniform manner, to the very remotest terminal ramifications of the decidual vessels. The placenta was then carefully detached, the decidual surface was carefully examined with magnifying glasses, no laceration could be detected, except what had been made by accident or violence in a small part of its circumference while the placenta was being detached from the womb. Orifices, as distinct and as properly organized as orifices can be in membranous textures, were seen in many parts of it by more than one competent and unbiassed person; and air was blown through some of them, or a small silver pipe introduced, without effort or laceration. Not the slightest vestige of extravasation, or lump of injection, was observed in any part of the intact placenta when cut into. This same result has been obtained, it is understood, in a recent injection by Sir A. Cooper, but the nature of the experiment is not yet known. The same result was obtained by Dr. Hunter, whose positive affirmation has been so recently questioned. The same result has been obtained by Lobstein. The same result has been obtained by Chaussier. Such a result is believed to be correct by Magendie. Professor Mende, in a report to the Obstetrical Society of Gottingen, states having made the experiment of injecting the uterine vessels with air—and with milk, in the case of a woman who died (1830) after the Cæsarean operation, the placenta remaining firmly adherent to the uterus, and he obtained the like result—as Hunter and others. Can we, therefore, refuse credence to such a host of eminent men and experimenters?

86. The decidual vessels derive their fluid from the uterine vessels. The arteries which convey uterine blood to the decidual vessels, are tortuous and very small; they are the adventitious produce of the *membrana propria* of the womb acting under the influence of a peculiar stimulation which produces the decidual membrane, as inflamed surfaces produce organized exudations. Though the latter be formed in the uterus, even when the embryo is lodged, by aberration, in some other part of the abdomen, its presence must not be deemed, on that account, unessential to the embryo; for a vascular membrane, as nearly alike to it in texture as can be, has invariably been found to connect, by blood-vessels, the embryo to some vital part nearest to where that embryo has been casually deposited, that part having, at the same time, its circulation and vascularity greatly increased, and becoming, in fact, the parent of the connecting vascular membrane in question.

87. Nothing proves more distinctly, (it might be said, almost to demonstration,) the accuracy of the views (82, 83, 84, 85) which tend to establish the fact of a vascular communication between the arterio-venous system of the mother and the placenta (by intermediate decidual circulation) and to shew the fallacy of those who deny such a communication, than the very phenomenon just noticed (86). Here, morbid anatomy again comes to the assistance of normal anatomy and physiology, and affords evidence which is not liable to the errors that have been unjustly affixed to experimenters with injected fluids. Of the many examples that might be quoted in support of this proposition, the one which is stamped with the authority of Lallemand may be selected as the most striking*. In a case of ventral aberrant foetation, which had proceeded to the end of the sixth month, before it destroyed the patient, a vascular and tomentous membrane had been formed on the

* Observations relatives à la Génération. Par F. Lallemand. Paris, 1813.

surface of the peritoneum, to which adhered the regular placenta and chorion of the fœtiforous ovum. This membrane resembled in every respect the decidua, at six months—it was thicker, and more red and vascular where the placenta was adherent than any where else. “Vessels as visible as those of the inflamed conjunctiva,” observes the author, “passed from the highly injected peritoneum, opposite the placenta, into the membrane which lay between them; while other vessels from the placenta reached as far as the same membrane, and were lost in it where they probably anastomosed by their very minute terminal ramifications.” (Lallemand). The conclusion which this really eminent physiologist and good man has come to, upon this subject, is striking, and truly to my purpose. “The decidua,” says he, “has no other function to perform than that of serving as a capillary system, intended to be the medium of communication between the blood-vessels of the mother and those of the fœtus” (page 21).

88. It is possible that the venous blood of the decidual vessels may be returned through the great uterine sinuses, the large open orifices of which, covered with an almost valvular flap, have been described by the best anatomists, as being applied to the surface of the decidual placenta. Magendie* thus states his opinion on this subject. “In women large openings, which communicate with the uterine veins, are observed on that part of the uterus to which the placenta adheres; but it is not clear whether these venous orifices are destined to absorb the blood of the fœtus, or to suffer that of the mother to escape on the surface of the placenta. I am inclined to admit the latter idea—but no proof whatever exists of its correctness.” (page 554).

89. Such is the real structure of the human placenta (77 to 88, inclusive). Its description is founded on positive and direct experiments, first-rate authorities, and anatomical inquiries, which may be repeated, referred to, or ascertained any day, and to which many can bear witness: any other description differing from it and not so grounded, must be erroneous. This view of the real structure of the placenta differs from that of Dr. Hunter only in the non-adoption of that great man’s notion that continuous vessels go from the uterus, *through* the decidua, direct into appropriate cells or laminae, where he supposed that the arteries deposited their blood, which the veins pumped back into the uterine system of the mother, after it had served the purpose of bathing the terminal or cotyledonic vessels of the fœtus. The existence of cells, however, has been frequently denied, and by none more stoutly than by Professor Lauth, of Strasburgh, and others; but as these individuals deny, at the same time, that which a hundred anatomists of great skill and veracity have seen, namely, the transmission of fluids, by means of decidual vessels, from the uterine system into the placenta, their opinion is liable to suspicion. However, it is unquestionably true, that on looking at the appearance exhibited by the fluid injected from the uterine vessels, in those portions of the placenta which it reaches, (Experiment at the Middlesex Hospital, 85,) we feel more inclined to consider it as dendritic and ramose, than extravasated or diffused. I entertain the former opinion. I submitted a thin section of the injected placenta (March, 1833) (85) to a powerful magnifying lens before a very strong flame of an argand burner, and could not perceive any sensible difference between the appearance of the red and that of the yellow injection. Now, that the latter, which was thrown in through the umbilical vessels, had been deposited within minute vessels, and not within cells, no one doubts. It is, therefore, likely that the other fluid is also so deposited. If Hunter and his followers were wrong in their conclusions, (though accurate in their experiments,) Professor Lauth, and the author of a paper on the placenta, inserted in the Philosophical Transactions for 1832, (who, by a most singular coincidence repeats all that Lauth had said long before him respect-

* *Precis Elementaire de Physiologie*, 2d edit. Paris, 1825.

ing the non-existence of cells and of continuous vessels from the uterus in the placenta) are not less chargeable with even greater errors; inasmuch as they have denied anatomical facts which have been observed and ascertained by many. They have overlooked the function of the decidual vessels, and they have said not a word of that beautiful arrangement of the foetal vessels of the placenta which Dr. Hunter compared to the "vascular portion of the chorion forming part of the placentulæ in a calf,"* and which I have succeeded in demonstrating in a human placenta prepared for that purpose, and still in my possession (79, note). It is evident that under such negative circumstances their view of the structure of the human placenta, and its connection with the uterus, will be repudiated.

90. The circulation of the blood in the Ovum is independent of that of the mother (personal experiment (59), and all the more recent physiologists). The embryo creates its own blood, and through it, sustains its own existence. But its blood, like that of all other animals, whether during its intro or extra-uterine life, requires to undergo certain changes at every minute period of that life—and those changes it experiences through the influence of the blood of the mother. (Magendie, Mende, Pockels, Baer, Chaussier).

91. The function of the Placenta, therefore, seems to be to facilitate, and in good truth to effect, the necessary changes in question (90). The decidual vessels receive the arterial blood of the mother. This is spread over a very considerable surface of tubular structure, which being, in its distribution, made to come in apposition with the infinite ramifications of the umbilical placental vessels, at innumerable points, (like the inspired air distributed through the bronchial passages is made to come in apposition with the myriads of vascular rami of the lungs); the required changes in the blood of the foetus are produced, just as the changes called for in the pulmonic blood, are produced by the peculiar arrangement of that part of the animal economy. When the arterial blood of the mother has produced the desired effect on that of the foetus—it is returned by the decidual veins to the uterine sinuses applied, like absorbing mouths, to the surface of the decidua, when it enters into the general venous system of the mother (Magendie; Personal Observations).

92. Of the two vascular systems, forming the machinery of the utero-decidual and foeto-placental circulation, (82 and 77,) that of the former is the smallest and least extensive (See injections in all the Museums). In point of origin, also, the latter has precedence. The Umbilical vessels unite the foetus to the chorion before any regular placenta is formed outside of the membrane. Up to the tenth week the decidual vessels are as yet slender, straight, and insulated; while the umbilical vessels begin already to arrange themselves into minute cotyledons†. The reason of these arrangements is obvious. The embryo needs growth. This it gets through the maternal blood. But as its gossamer frame, for the space of two and three months, requires but little assistance from such a source for the promotion of growth; and as a large supply of maternal blood, at that early period, would overwhelm, instead of enlarging, the embryonic fabric, such an arrangement of means only obtains, in the reciprocal circulation, as is calculated to ensure the desired effect (Personal Observations).

93. This effect is nutrition. "Considering the power which the Ovulum displays when it

* Dr. Hunter on the Placenta. In *Gravid Uterus*, page 43, 9th edit. 1794.

† A complete ovum, with the investing cortical membrane, and the entire decidua expelled nine weeks and three days after the last regular menstruation, in the case of a lady recently married, whom I attended (March, 1833), has afforded me ample opportunity of verifying the above and most of the previous propositions, through a careful dissection of the parts under water, and the use of the microscope.

first reaches the uterine cavity, of imbibing matter for its growth, together with the facility with which, according to Dutrochet, fluids may be drawn through animal membranes, it is not difficult to believe that nourishment is directly imbibed from the vessels of the mother by the circulating fluid of the embryo, through the fine intervening membranes." (Mayo's Outlines of Physiology, p. 437. 3d. Edit.)

94. It is possible, also, that other means may be at play in the promotion of such an effect (93) in the foetus, besides the one before mentioned (91). We may instance as a probable one, lymphatic absorption. The probable existence of lymphatics in the placenta was admitted by Dr. Hunter. "It is most probable that it (the foetus) is nourished by thousands of small lymphatic vessels which absorb nourishment from the blood of the mother and carry it along the navel-strings. It is true we cannot see any lymphatics running upon the navel-string, *yet it is reasonable to conclude they do.*"* Hunter's conjecture has since been realized (Chaussier, Fohman, Uttini, Lauth). The second of these anatomists has delineated them in rich profusion, extending from the placenta along the funis, leaving the funis at the navel, and directing their course to the groin (Mayo).

95. Some have ascribed the nutrition of the foetus to a regular deglutition and digestion of the amnionic fluid. Many facts render this opinion probable (Meckel). But there are also facts which would make nutrition by such a means impossible (Dr. Hunter). 1st. An embryo, at an early period, cannot be nourished by the mouth. 2dly. The amnionic fluid is mere water with a vestige only of albumen, the only nutritive quality in it. 3dly. A foetus was seen whose intestine, a little below the duodenum, was impervious and divided through, and the lower end began at some distance from the higher portion. (Dr. Hunter's MS. Lect.) 4thly. A full grown child was brought into the world without head, heart, lungs or intestines (Dr. Cooper, in Dr. Hunter's MS. Lect.) 5thly. A kitten was sent to the Royal Society, full grown, born without either nose or mouth. (Dr. Hunter, *ibid.*) 6thly. I have the drawing of a pig (the preparation of which I exhibited at the Med. Ch. Soc. in 1814,) which was born, at the proper period, and full grown, without any vestige of the under jaw, and consequently without either mouth or any passage into the stomach.

96. Some have thought that the amnionic fluid was absorbed through the pores of the skin (Osiander), others through the mammæ of the foetus (Oken). That the vesicula intestinalis (umbilicalis) contributes to the growth of the embryo is a great deal more probable (Blumenbach, Sœmmering, Lobstein, Joerg.) It is also not improbable that the gelatine of Wharton, contributes to that object (Lobstein). But these are all conjectures, for the probability or improbability of which as many arguments and real facts have been alleged on equally unquestionable authority. "Ce sujet," observes Magendie, "a souvent exercé l'imagination des physiologistes, sans aucun profit réel pour la science."

97. I am more inclined to believe in the existence of respiration in the foetus as an additional means of facilitating growth and entertaining inherent life (Geoffroy St. Hilaire, Müller). The presence of air, analogous to atmospheric air, in the amnionic fluid, has been detected (Lassaigne). I once had in my possession an intact ovum at five months (30th June, 1826,) which served me for the purpose of studying more particularly the real structure of the placenta, and which contained, besides the amnionic fluid, a bubble of air about the size of a small plumb. Only a portion of this was, through the awkwardness of my assistant, received in a glass tube containing distilled water, while I punctured, under water, the membranes in the centre of the bubble. This portion was after-

* MS. Lectures of Dr. Hunter, taken by John Sheldon, 2 Vol., formerly in the possession of Joshua Brooks, Esq. and now before me (Vol. II. page 485).

wards made to pass through a saturated solution of lime in water, and produced a visible cloudiness denoting the presence of carbonic acid. The respiration of the foetus is supposed to be effected by the cutaneous pores, as in aquatic insects (Geoffroy St. Hilaire). In addition to which the placenta is looked upon as performing the office of lungs (Müller). Dr. Edwards's experiments on the asphyxia of the *Batraciens*, may serve to throw light upon this question (Breschet).

98. The nature of the changes which the blood in the foetus may be supposed to undergo from arterial to venous, and the converse, has not been satisfactorily ascertained. The colour of the blood in the umbilical vein is something lighter than that in the umbilical arteries (Mayo). This alleged change is not admitted by others (Meckel). I have never been able to detect the least difference between the arterio-umbilical and venous-umbilical blood, in the many cases I have examined. But the absence of any change of colour does not necessarily imply the absence of any inherent change in the blood of the two systems. The globules of the foetal blood do not resemble those of the blood of the mother (Experiments alluded to by Dr. Breschet).

99. Connected with the subject of the nutrition of the foetus and the changes which take place in the blood of it, may be mentioned certain recent discoveries*, which would lead to the belief, that the function of the placenta is probably analogous to that of the liver during the intro-uterine life of the foetus, and that the presence of bile in the blood of the placenta, discovered by modern chemists, is necessary to the maintenance of foetal life (Breschet).

100. It is of the utmost importance to bear in mind the great distinction which exists between the independence of the foetus, *quoad* life, and its dependence, *quoad* nutrition, in respect to the mother. The former state is secured by a total separation of the two circulations (maternal and foetal). The latter by the close reciprocal contact of the organs of those circulations. Thence is it that we find the foetus to live on, notwithstanding that its connection with the mother has been partially and sometimes even wholly, severed;—while on the other hand we cannot help admitting that, albeit this independence, the influence of the mother over the fabric of her offspring is unquestionable.

101. Here are two important positions. I have mentioned my experiments on the intact ova of the genus cat, (59,) to illustrate the first of them, and Dr. Prevost has since come to my assistance with as strong a case in further support of it†. This gentleman having observed an ovum still alive in the uterus of a ewe, which was a short time advanced in gestation, removed it and placed it upon a warm glass plate exposed to the rays of the sun, and attentively examined it with the microscope. The beatings of the heart became more lively. He noticed the blood arise to the surface of the chorion from the foetus, there ramify plentifully, and by anastomosing vessels, return to two of the larger trunks which were the veins of the embryo. He concluded, therefore, that the ovum was an isolated substance.

102. In proof of the accuracy of the second position, we have equally strong evidence founded on experiments. Magendie introduced camphor into the veins of a pregnant bitch, and he found that the blood of the foetus had, at the expiration of a quarter of an hour, acquired distinctly the smell of that drug (Physiology, 2d Edit. 1825). Quadrupeds carrying young were made to take with their food four ounces of madder-root. The colouring matter of that substance was found to have passed from the mother to the foetus; as all the serum of the blood of the latter, the urine, the liquor amnii, the teeth and the bones were tinged with it (Dr. Mussy, 1829)‡. In 1827, I under-

* Communicated to the Philomatic Society of Paris, 1830.

† Memoires de la Societé de Physique de Genève, T. IV. part 1.

‡ American Journal of the Medical Sciences, Nov. 1829.

took, at the request of Sir E. Home, a set of experiments on the human subject, with a view to ascertain the truth of my second position. Six gravid patients of one of the lying-in institutions under my direction, who required the constant use of aperient medicines, were instructed, towards the close of their time of gestation, to take at night, for a period which averaged about a week, from ten to fifteen grains of rhubarb in powder. After two or three days the effect was visible in the colour and smell of the urine of the patients previous to their confinement, and in one of them, in the colour and smell of the transpiration also. During the labour care was taken to preserve part of the amnionic fluid in a cup, the umbilical vessels were suffered to bleed on the side of the child after their recision, and the blood set apart so as to separate the serum, which was obtained in small quantity only.—Lastly, the first urine of the child was collected in sufficient portions. Each of these secretions appeared distinctly tinged by the yellow root, and bore the smell of it. When carbonate of magnesia was mixed with the fluids their colour became lateritious, and a reddish sediment was thrown down, evincing the presence of the drug which the mother had ingested. (MS. notes.)

ERRATA.

PROLEGOMENA.—Page iii, Prop. 20, *for reference (16), read (17).*

Page vii, Prop. 39, *for Haygton, read Haighton.*

——— *idem, for Embryoni, read Embryonis.*

Page viii, Prop. 46, 1st line, *dele (5).*

PLATE III.—Page 9, Exp. of Fig. 13, *for membrana proper, read membrana propria, and the same mistake occurs at pages 11, 14, and 26.*

THE following letter from the artist to whose skill and patience I am indebted for the principal part of the engravings, and the entire colouring of the present collection, is inserted in this place, with the hope of increasing that confidence in the reader, with which it is desirable that graphic representations of extraordinary or anomalous objects should be received.

9, Warren Street, Fitzroy Square,
January 27, 1832.

DEAR SIR,

IN sending you the last of the series of engravings on stone which I have executed under your directions for your work on *Abortion, &c.*, I cannot omit stating, that I have endeavoured, to the best of my abilities, to copy in every instance and every minute particular the anatomical preparations which you placed before me and explained to me as I proceeded in my designs. The figures, in every case, have been drawn of the natural size, and are perfect facsimiles of the originals.

It gives me great pleasure to learn that they have given you satisfaction, and I am not a little flattered at having been assured by several medical gentlemen of eminence, who have seen my drawings, that the manner in which they are executed, and the work altogether, meet with their unqualified approbation.

I have the honour to be,

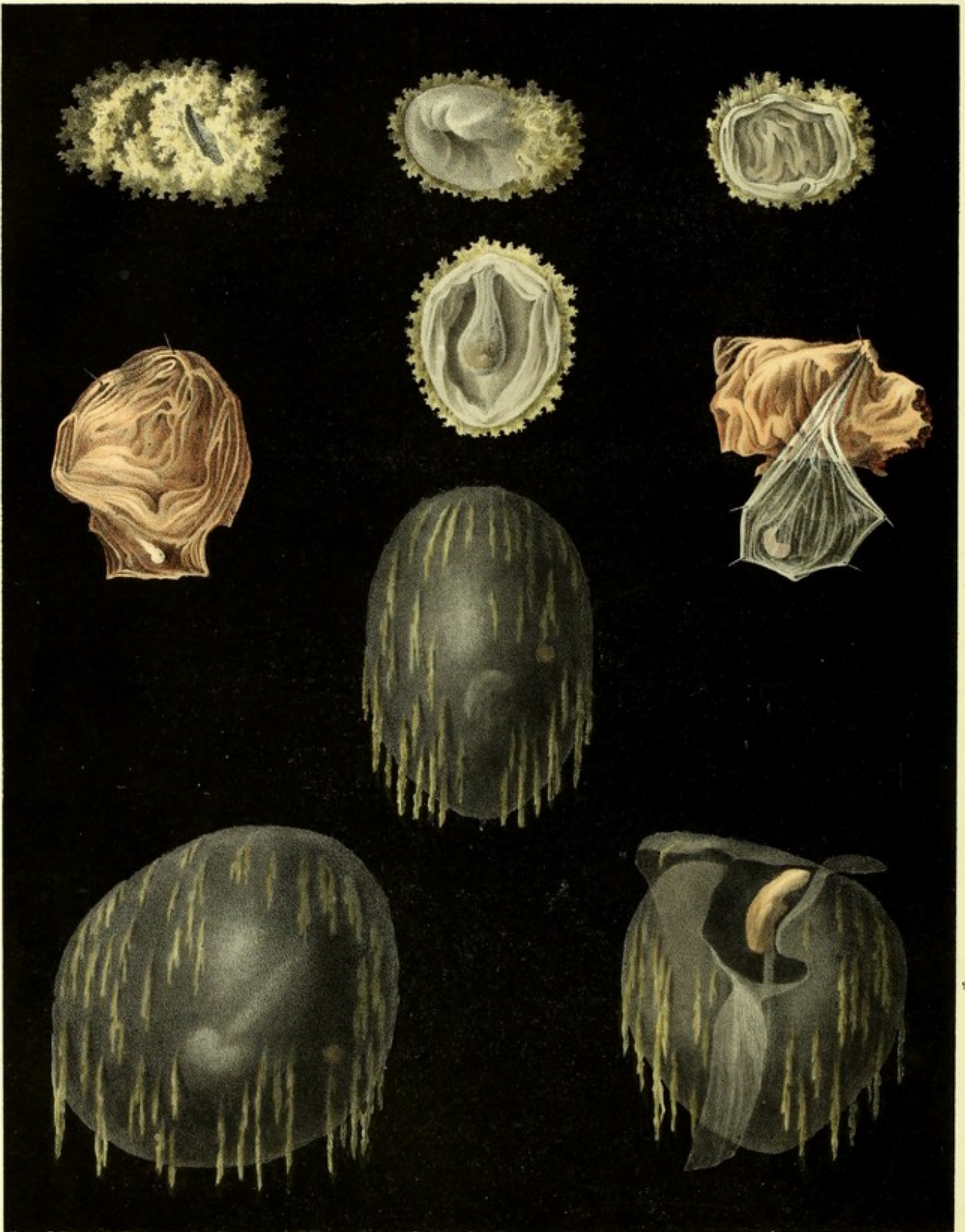
Dear Sir,

Your obedient servant,

JOSEPH PERRY.

TO DR. GRANVILLE,
&c., &c., &c.

GRAPHIC ILLUSTRATIONS
OF
ABORTION
AND
THE DISEASES OF MENSTRUATION.



Joseph Perry del et lithos

Printed by G. Halliwell

EXPLANATIONS,

ETC.

PLATE I.

SPECIMENS OF VERY EARLY MISCARRIAGES.

Fig. 1. Ovulum bigeminum lanuginosum.

(Four weeks after menstruation.)

This twin Ovulum has lost its outer shell or *cortex*, within which it originally made its way from the Ovarium into the womb.

The mossy or filiform vessels which, like an efflorescence, surround the present surface of the Ovulum, are, as yet, deprived of that extremely delicate membrane, which at a more advanced period of utero-gestation will cover them, and dipping amongst them, (after the fashion of the inner membranous envelope of the brain,) will separate them into vascular groups or cotyledons, having a single principal trunk in each, and many short and tortuous branches besides, constituting the placenta.

The slit visible in one part of the Ovulum leads to a small cavity from which the embryo escaped. In the second cavity to the left, which is still intact, the embryo is visible when the Ovulum is placed before a strong light.

Fig. 2. Ovulum semi-lanuginosum.

(Three weeks and a half after menstruation.)

In this specimen of an early miscarriage, the Ovulum exhibits the filiform vessels as in No. 1; but one half of its circumference is denuded of them,

and the diaphanous involucra are distinctly visible in that part. They are represented flaccid owing to the escape of a part of the liquor amnii. In size the embryo (which required to be viewed in a very strong light) resembled that of No. 6.

Fig. 3. Ovulum lanuginosum.

(Three weeks after menstruation.)

A mossy Ovulum, shewing the inner or secreting membrane, within which I could not discover any embryo at the time of the miscarriage occurring. On searching among the coagula consequent on a very extensive hemorrhage, the Ovulum was found flat, and appeared like a confused mass. The liquor amnii had escaped, and probably the embryo along with it. The artist has most skilfully delineated the peculiar turns of the involucra where they have been divided so as to display those marked inflexions which are still more distinctly seen in No. 4.

Fig. 4. Ovulum semi-lanuginosum.

(Four weeks after menstruation.)

I look upon this as one of the most perfect specimens of mono-embryoforous Ovula at four weeks, I have seen; exhibiting as it does, not only the mossy or *nutritive*, but also the inner, amnionic, or *secreting* involucrum, with its peculiar inflected turn, forming a *sacculum* within which is lodged the embryo. The nutritive involucrum is separated from the middle membrane by the *allantoïd* cavity, and the middle membrane itself stands aloof from the amnion, owing to the *vesicula umbilicalis*. The existence of these various elementary parts of the human Ovum in the present specimen, shews its early development, and serves to fix its age, which I consider to be of about three weeks and a half.

As gestation advances, some of those elements are obliterated, and others confounded together.

REMARKS.

I imagine that these Ovula pass away from the womb almost immediately after they have entered it, owing to a tardy or deficient formation of that peculiar lining which the

uterine cavity begins to weave for itself from the first moment of a successful copulation, and to some part of which the Ovula are destined to adhere.

The preceding objects are represented of their natural size, and as they lost their colour during the first maceration in water, owing to the great readiness with which the mossy vessels discharge their blood, the colour adopted in the Plate is that which they attain afterwards, and such as it appeared when the artist sketched them. They have in every instance been examined and dissected under water. Such early Ovula are not rare. In the Museum of the Royal College of Surgeons of London there are four such specimens, marked 3432—3—4—5 in red ink on the black varnished cover of the bottles*. In Sir Charles Clarke's collection there are also several. I have likewise examined many of them in Meckel's magnificent museum; but it is in that of the late Professor Sœmmering that I have been gratified by the sight of not a few beautifully prepared and arranged specimens of this early stage of the human Ovum. Among them were the identical preparations which he selected and arranged in a graduated series of human embryos, and afterwards caused to be delineated and engraved, for his valuable work entitled "*Icones Embryonum humanorum.*"

Fig. 5.

The rudiments of the embryo in this specimen are more than usually diminutive, compared to the mass which constituted the entire Ovum before it was flattened and pinned to a piece of blue pasteboard placed in spirits within a glass jar. This preparation, now in the museum of St. George's Hospital, exhibits the transparent involucra and the placental envelope with the intermediate membranes, imperfectly developed, of an Ovum which I should judge to have been fecundated about three weeks. At this period of conception the embryo is generally straight, consisting of that part which is to be the trunk, terminated, as in this case, by a round swelling, which is the head. Here the embryo is in reality straight, and has the appearance of a worm. It is attached to the inside of the secreting membrane by its abdominal surface without any visible cord. As illustrative, and that in a very distinct manner, of this early stage of pregnancy, Fig. 5 is a valuable specimen.

* I am thus particular, because there is a second and even a third series of numbers in this collection, which are differently marked on the preparations and in the MS. lists, although belonging to the same specimens. This confusion which has crept in, in spite of Mr. Clift's vigilance and endeavours to prevent it, will disappear as soon as that skilful naturalist shall have been able to complete the laborious task of making a catalogue *raisonné*, of the museum.

Fig. 6.

The same remarks apply to this as to No. 5. The embryo is somewhat more clearly delineated. Its trunk is gently curved forward, and the tubercular-like rudiments of the extremities appear visibly marked. This circumstance denotes its age to be of five weeks.

The volume of the transparent involucra is disproportionate to the embryo itself: yet the placental covering, with its filiform vessels, bears a still larger proportion to them; so that the want of equilibrium between the external and internal apparatus of the Ovum has destroyed, first the growth, and next the life of the embryo. The preparation is in the museum of St. George's Hospital, and like the preceding preparation (5), has been flattened and pinned to a pasteboard—a mode which, for the *steady* display of the peculiarities of the Ovum in both cases, was, perhaps, the most judicious.

Fig. 7. Ovum denudatum, or diaphanous Ovum.

(About eight weeks after menstruation.)

Its structure is imperfect. It wants the nutritive membranes or involucra. It is defective also in the arrangement of the inner or secreting membranes. Hence the great accumulation of fluid within, and the scanty appearance of the filiform vessels without. The embryo has consequently been retarded in its development, which is scarcely greater than that of Ovulum No. 4, although the period at which the former had been ejected, was nearly twice as long as that of the latter.

Fig. 8, and 9,

Are also examples of denuded or diaphanous Ova, to which the same remarks apply as to the preceding specimen. The enlargement of Ovum 8 is even greater than that of Ovum 9: yet the embryo of the latter is more advanced and more clearly delineated by nature than is the case with Embryo 8. We know that these two Ova and No. 7, are more than two months old from the length of the umbilical cord as compared to that

of the foetus: for from the second to the sixth month of pregnancy, the length of the cord is proportionately greater than that of the foetus.— (See Meckel and others.)

In examining these denuded or diaphanous Ova, I have been struck with that small circular spot on their surface, generally of an opaque colour, which has been called the *cicatricula*, and is not unlike that which is found in some of the Ova of birds. This spot is well marked by the artist in the last three specimens, and in two of the figures of *Plate 3*. I take the *cicatricula* to be that part of the *Ovulum* which adhered to its ovarian nest (called the *vesicula graafiana*), before it burst from the Ovarium to pass into the womb consequently on fecondation. It is to be seen on all the ovula so situated in the Ovaria of women, and is considered to contain the rudiments of the embryo, which certainly begin from a little straight line that may be distinctly seen in the *cicatricula*.— (See Meckel, Adelon, Geoffroy St. Hilaire, Prevost, &c.)

REMARKS.

This class of human Ova throw no inconsiderable light on the progress of foetal intra-uterine life. They prove that the embryo, called into existence by the mysterious act of fecondation (the only point that is mysterious about the process of generation according to Cuvier) may, and will, and does live independently of the mother,—with a life wholly its own, and that it derives from its parent growth only, or accretion of substance, as I stated in my preliminary observations. The museum of the Royal College of Surgeons supplies a most striking illustration, and I may add, corroboration of this opinion.

No. 3448 is a single spherical denuded diaphanous Ovum about six inches in diameter, without the slightest appearance of any placenta, filiform or cotyledonous vessels, or other of the nutritive involucra or membranes. The secreting or amnionic membrane, is capable of containing more than six ounces of fluid; yet the embryo is not larger than an embryo at one month. When this specimen was sent by Mr. Lugar, of Richmond, to the College, Mr. Clift found it attached to a PLACENTAL OVUM, containing a perfect foetus of the proper size at four months and a half, with an umbilical cord nine inches long. The attachment of the two or *twin* Ova, was by a spot not larger than a shilling, which is still visible on the smaller or diaphanous Ovum, and was of a bright red colour at the time

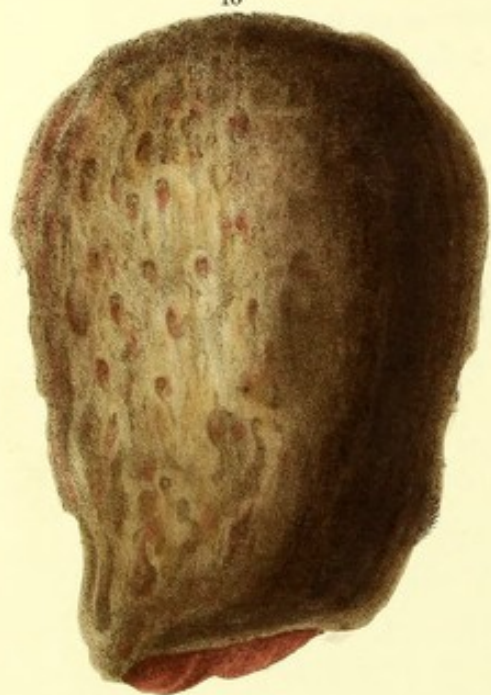of separating the two Ova for the purpose of making a distinct preparation of the more complete Ovum, marked in the museum 3448 A.

It appears that the twin Ova were ejected together five months after menstruation.

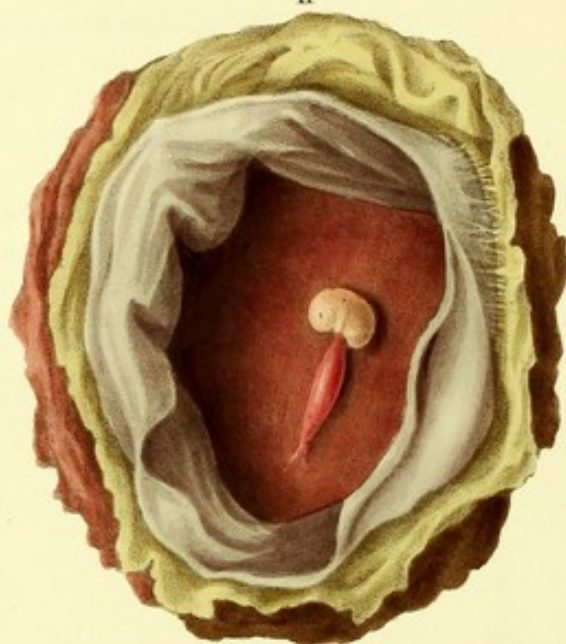That the embryo in the smaller Ovum *lived* is proved by its size as well as by the secreting involucre having enlarged with fluid to the capacity afore stated. But it did not grow, because *unconnected* with the mother; while the twin foetus properly encircled by the placental envelopes, which placed it in immediate communication with its parent, lived as well as acquired growth.

Plate 2.

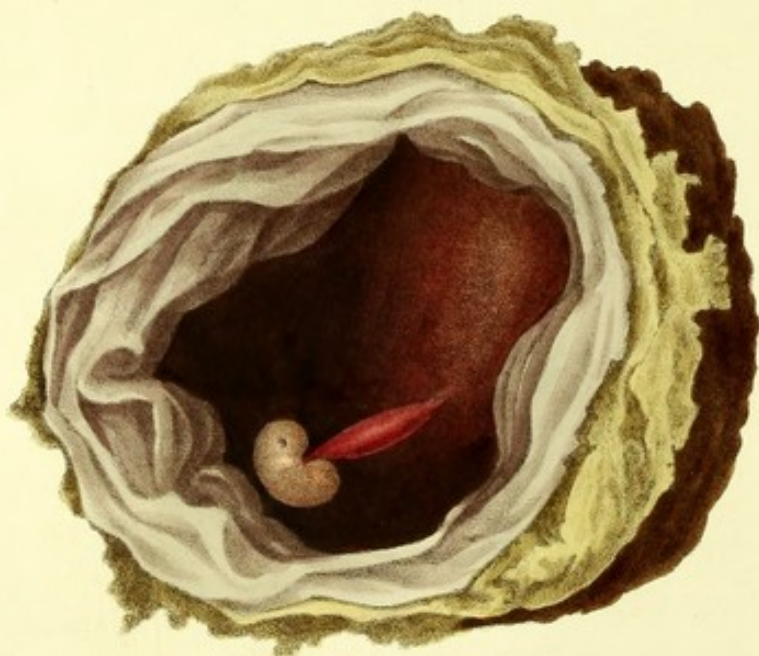10



11



12



D^r Granville on Abortion.
and the Diseases of Menstruation.

PLATE II.

SPECIMENS OF MISCARRIAGES BETWEEN TWO AND THREE MONTHS.

Fig. 10. Ovum pyriforme externe opacum.

(Eleven weeks after menstruation.)

None of the transparent involucra were visible in this Ovum, when, after excruciating and prolonged sufferings, it was expelled in the intact state here represented. The external or placental envelope invests the entire Ovum, and explains the cause of the abortion. The artist has seized with much felicity the uneven and almost cribriform surface of the fleshy envelope, exhibiting numerous orifices, through which its adherence to the uterine vascular lining, resulting from the act of fecondation, was effected.

Fig. 11.

We here see the immediate and direct effects of the peculiarity of an *entire placental covering*, as represented in the preceding Ovum (10.). The secreting or inner involucrum (amnion) of that Ovum, when laid open, was found tinged with blood and the cord distended by the same fluid which pervaded also the *liquor amnii*, as well as the fœtus itself. The morbid adhesions, contracted by the middle membrane with the chorion in consequence of plethora, are well marked in one part of the drawing by the artist to whom I carefully dissected the preparation. The chorion itself is in a morbid state.

Fig. 12. Ovum opacum plethoricum.

(Eleven weeks after menstruation.)

Placental or cortical covering, lying over three-fourths of the Ovum. A pellucid membrane entirely surrounds the placental covering to which it adheres. The chorion is thickened, and has contracted morbid adhesions with the middle membrane. The transparent or inner involucra are easily separated into four laminæ, three of which belong to the middle membrane.—(Dutrochet.) The liquor amnii was of a brilliant red colour—the cord large, flattened, and the vein ruptured.

Here we see the same direct consequences from the same defects in the structure of the Ovum which we noticed in Fig. 11. This abortion was brought to me by a midwife immediately after its expulsion. I carefully examined and dissected it, and before the least change could take place in its parts or colour, it was drawn by Mr. Perry (1827). No hemorrhage followed the expulsion of this Ovum. The woman had had several children, and miscarried three times between every two successful pregnancies; whereupon her general health was greatly impaired.

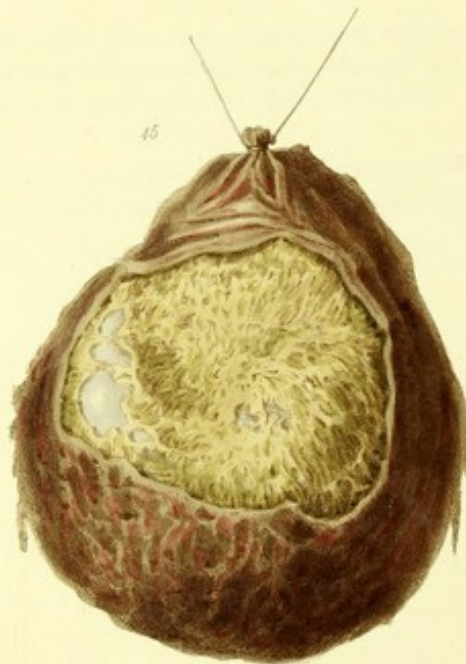
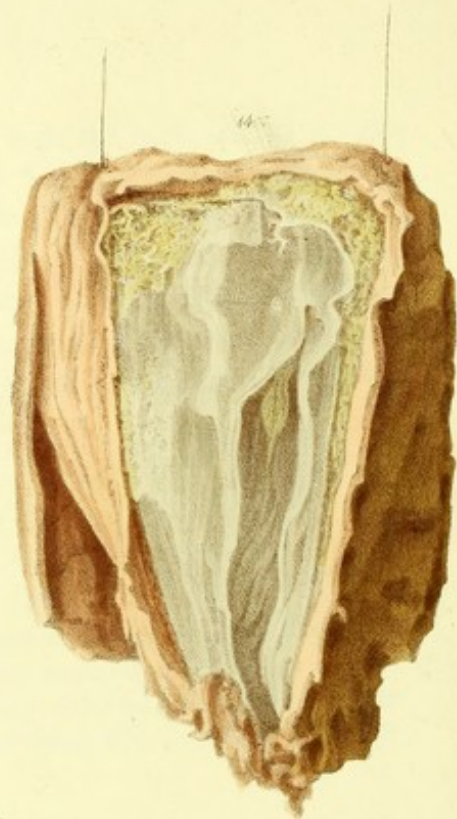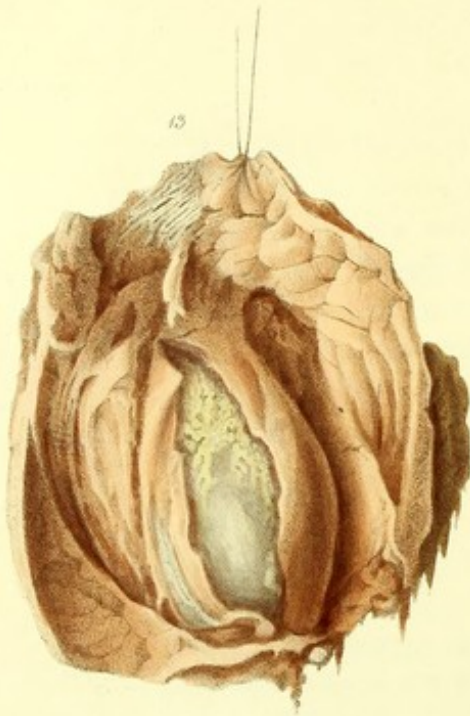REMARKS.

These two morbid Ova are represented of their natural size, and were carefully drawn and coloured as soon after their expulsion as could be accomplished. I believe they are unique of their kind. At least I have not seen any such in the various collections I have visited: neither do I think that they have been mentioned, still less delineated, by any writer.

It is manifest, that under the various unpropitious circumstances in which these Ova were placed, growth must have been materially retarded and ultimately impeded; while life must have ceased sometime before the Ova were expelled.

Judging from their size and the length of time during which they lodged in the uterine cavity, these Ova must have acted the part of parasitic animals upon that organ.

Plate 3



D^r Granville on Abortion.
and the Diseases of Menstruation.

PLATE III.

SPECIMENS OF MISCARRIAGE BETWEEN THE SECOND AND THIRD MONTH.

Fig. 13. Ovum semi-coriaceum.

(Nine weeks after menstruation ?)

The external covering has been laid open. It is thick and fleshy. A second or inner covering is observed equally dense in texture and opaque ; and a third involucrum, lying over the secreting membranes, (which are seen through a wide slit, bearing at their upper portion the filiform vessels,) is not only thick, like the second involucrum, but is actually seen passing from the transparent into the dense and opaque texture. The artist has portrayed this circumstance most accurately in his engraving. The placental cotyledons are at the posterior part of the figure, mossy, in groups, and some of them covered with their *membrana proper*. The embryo of this, and of Ovum 15, are not visible.

There can be little doubt but that intro-uterine inflammation, extended to the involucra of the Ovum, has produced, first, its morbid change of structure, and lastly, its early expulsion from the womb.

Fig. 14. Ovum semi-coriaceum.

(Ten weeks after menstruation ?)

This is somewhat larger than the preceding Ovum, although of the same tissue and structure. The withered foetus is visible through the opening

made in the secreting membranes, and the *cicatricula* may also be perceived on one part of the inner layer of the middle membrane, or involucrum, which lies immediately over the amnion.

I attribute both the structural condition, and the untimely expulsion of the Ovum, to the same causes.

Fig. 15. Ovum omnino opacum, rotundum.

(After the lapse of three menstrual periods ?)

The external covering, or *cortex*, is one twelfth of an inch thick, with an uneven surface, having vascular orifices upon it to the extent of about three fourths of that surface. The rest is smooth, shewing that in that part, the Ovum had not contracted any adhesion, by vascular connexion, to the inner cavity of the womb. That connexion was accomplished by means of the placenta, which is seen at the posterior part of the preparation, and appears quite compact, and one twentieth of an inch thick, judging by the portion which has been purposely laid open. It is through this aperture that the *cortex Ovi* is seen, as described above. On removing a good portion of this thick cortex, a large cotyledon, or group of vessels belonging to the middle membrane, is exposed to view. The middle membrane itself is seen perfectly transparent, and upon it the *cicatricula*.

I have been the more particular in designating this Ovum as globular, because the fact of its having such a configuration assists (with other circumstances) in proving that these solid and thick general envelopes, found over human Ova expelled from the sixth to the twelfth, and even fourteenth week, *cannot* (as pretended by some) be the so called caducous membrane of the womb. We have here a thick and solid shell, perfectly round, closely embracing in every part the lanuginous surface of the Ovum; whereas the cavity of the womb is never otherwise than triangular in its shape, or like unto a congeries of triangular vertical planes, however much the organ itself may be developed. Nor could any membrane (lining such a cavity) in detaching itself from its walls, or falling off during abortion, surround in a globular form, and in so compact a manner, the Ovum, as we see in the

present instance. Here again, slow, insidious, persisting inflammatory action, must have done the mischief.

REMARKS.

The three preparations here represented of morbid human Ova, or abortions, are in the museum of St. George's Hospital, and belong to Sir Charles Clarke's collection. They admirably illustrate the *morbid* development of the external involucre. Although the specimens retain scarcely any colour, (as is the case with most of the morbid preparations not injected,) the artist was directed in the choice of the colours applied to his drawings, by recent specimens of analogous abortions, which offered themselves to my attention in the exercise of my profession, during the six years that he was engaged in the present work. I regret that I can procure no data respecting the three abortions delineated in this Plate, nor have I any positive knowledge of their age—but judging of the latter by their appearance and from analogy, I affixed that age to them which seemed to me the most probable.

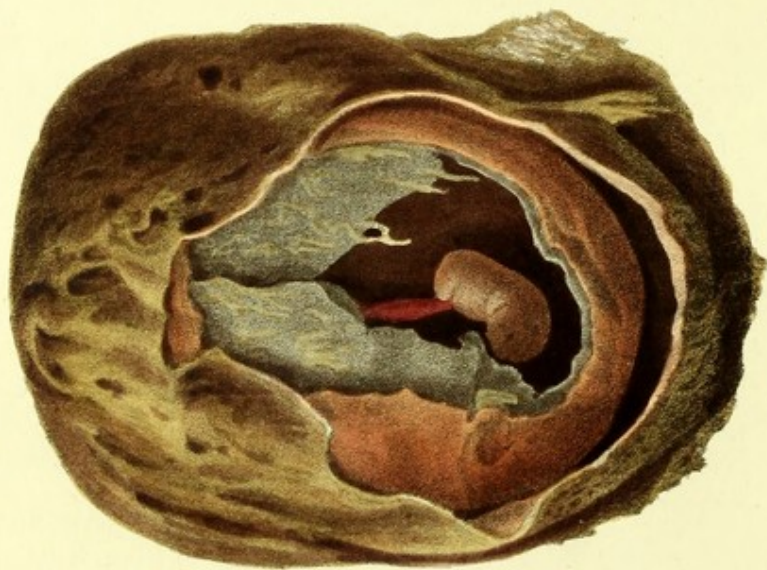
There are many similar specimens in the museum of the Royal College of Surgeons, and I have seen some in that of Professor Meckel at Halle, and of the late venerable Professor Sæmmering, both of whom honoured me with their friendship. In the first of these three establishments there is a preparation which in many respects resembles Ovum 14. It is marked 3447 and was presented by Mr. Lawrence. Viewed externally, the Ovum in the latter case looks almost sarcomatous. It has a triangular outline with two short prolongations at each of the two upper angles corresponding with the situation of the uterine orifices of the fallopian tubes. The inner or transparent involucre of the Ovum (which is *bigeminum*) are covered by the cotyledonous prolongations weaved into a general placenta with its *membrana proper*, and a coriaceous envelope over all. The internal cavity is laid open so as to exhibit an embryo in each half of the Ovum, the one being double the size of the other. The smaller embryo is about as large as a good-sized house-fly. The cord of the largest embryo is nearly an inch and a half long, sacculent, and expanding towards the abdomen so as to form the only covering of that cavity. The cord of the smaller embryo is half an inch in length and filiform.

I have before me two other specimens of the semi-coriaceous Ovum obtained in cases of abortion which occurred in the course of my practice last year: the one in June, the other in December. In the first case the lady had had several live children, and had also miscarried often before. In the second case the lady was primiparous. Both suffered dreadfully—and it is to be remarked, that the pains experienced by the patient during the process of this species of miscarriage is always excessive, and the escape of the Ovum generally followed by violent hemorrhage. Many years ago I succeeded in saving the life of a patient of high rank, then in the country, who was sinking under an almost total loss of blood, consequent on a miscarriage of this kind, in which a large portion of the

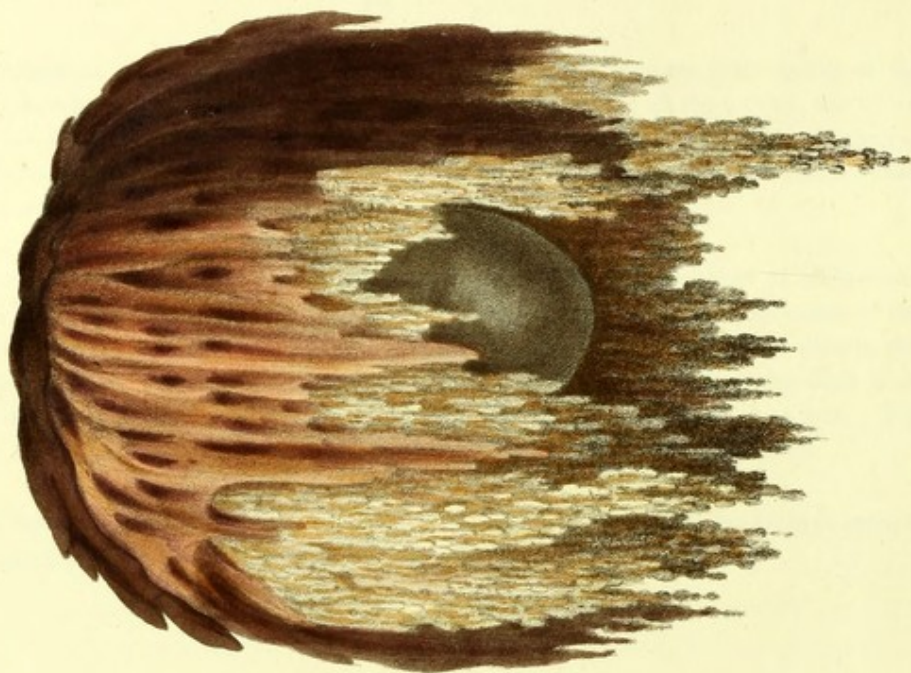
semi-coriaceous envelopes had remained behind adhering partly to the inner orifice of the womb, thereby producing and keeping up the hemorrhage. In all these cases, the Ovum could not have been in existence more than three months, reckoning from the cessation of the menses. They were all nearly of the same volume, but the size of the fœtus varied in proportion to the greater or less thickness of the envelopes.

On examining that part of the anatomical collection of the Royal College of Physicians, in London, which relates to these subjects, I found a very interesting specimen of the globular and wholly opaque Ovum, marked 7. G. No. 19. All the involucra, without any distinction, adhere together most compactly, so as to form a species of egg-shell of an equal thickness throughout; that thickness being no less than one third of an inch. The Ovum resembles in size a large duck's egg, though more spherical than the latter.

The inscription on the label is, "A Miscarriage at Six Weeks", but the embryo appears of no more than four weeks' growth.



See Perry's Hist. of the Ovary



Printed by C. H. Blandford

PLATE IV.

SPECIMENS OF MISCARRIAGE DURING THE THIRD AND BEFORE THE COMPLETION OF THE
FOURTH MONTH.

Fig. 16. Ovum pseudo-membranosum.

(Three months and a half after the cessation of the menses.)

There are not fewer than seven membranes, or involucra of some sort or another, in this example of aborted Ovum. Its age is unknown to me, as well as its medical history. I can only judge from appearances, as the preparation speaks for itself. In one point of view, more especially, is the present diseased Ovum particularly interesting to me; for it exhibits the most distinct proof that what I call the *cortex* of the Ovum, and which others have, without direct evidence, considered as a membrane of the uterus, is, in good truth, a natural covering of the Ovum. It is this very natural covering of the Ovum which is liable, from disease, to become fleshy, opaque, vascular, and lastly coriaceous, thereby cutting short the supply, or accretion of substance to the fœtus, and thus destroying its life and producing abortion. Were it not so, we should not observe, as in the design before us, another membrane external to the one I allude to, as seen at the bottom and on the right of the figure, which is the true caducous or uterine membrane of authors. Its structure is far different from the former; it is of a loose texture,—I was about to say, almost gelatinous, or like a reticulated gauze.

The chorion, in this instance, is thickened nearly as much as the *cortex Ovi*. A considerable space intervenes between those two involucra; and

within this thickened chorion a false membrane is distinctly seen to surround the Ovum. The embryo is advanced to about the third month, but retarded in its growth.

A specimen, analogous to the present, was deposited in 1817, by Mr. Lawrence, in the Museum of the Royal College of Surgeons of London, where it is to be seen marked 3437 C. The involucra are coriaceous, but we have besides, over the nutritive membrane (chorion), not fewer than three false membranes, the result of *uteritis post conceptionem*. The foetus has evidently been stunted in its growth, and in size resembles a small insect.

REMARKS.

Instances of additional or pseudo membranes in aborted Ova are by no means of unfrequent occurrence. On one of the shelves in the Museum in Lincoln's Inn Fields, I observed one marked 3443, in which a pseudo membrane has formed externally to the placenta, pressing on the cotyledons of the latter. The embryo is stunted. Upon another shelf I find No. 3442, with the nutritive as well as the secreting (amnion) involucre thickened and pergamenous—the coat which they form being one twentieth part of an inch in thickness. The amnion, internally, is lined with a delicate pseudo-membrane. Here, also, although the entire Ovum is of such capacity as to admit about half a pint of fluid, the embryo has not acquired more than the size of an ordinary house-fly. The placenta is compressed and covered by an adventitious membrane, besides its *membrana proper*.

In Ruysch's Thes. Anat. VI. Tab. II. Fig. 5, there is represented a specimen of human Ovum, with a pseudo inter-membrane, not unlike my present preparation; like it, too, it exhibits the cord hydropical.

Fig. 17. Ovum uviforme.

(In the third month after the suspension of the menses.)

A *uviform* abortion is so rare an occurrence that when Mr. Clift first saw the figure of it in the present work, he remarked that it appeared more pictorial than true. The preparation, however, of the size of the design, and as it was sketched by Mr. Perry in 1827, is still in my possession, and I hold it to be most valuable on many accounts.

Under a *shower* of minute grape-like or granular bunches, is seen suspended that portion of a transparent Ovum, (exhibiting through its diaphanous involucra an embryo bearing no proportion to the magnitude of the Ovum,) which has been denuded of its nutritive involucra. The latter are superimposed to the granular bunches, and are curiously fringed at their margins. They are two in number, and externally to them may be seen the loosely weaved caducous membrane. During three months of uterogestation, from the moment of conception, has this mass lived—but the embryo has not advanced from what it was at four or five weeks, nor could it. The time was spent by Nature in playfully modelling, forming, and cutting out what would almost appear an artificial plaything; so fantastical it looks.

REMARKS.

There can be no difficulty in understanding how this curious formation came about. The Ovum with its *cortex* adhered to the ceiling (*fundus*) of the womb, and contracted an intimate connexion with that organ through its caducous lining. During the first weeks, that external covering, *cortex*, or membrane, became fleshy and vascular. Plethora took place in consequence, as we have seen in some of the preceding cases of abortion; but, instead of an increased secretion of amniotic fluid, as was the case in the *Ova denudata*, or diaphanous, of Plate I., the effect has been a dropsical bead-like enlargement of the mossy or filiform vessels of the Ovum. In proportion as these advanced and enlarged, they detached and forced outwardly the coriaceous envelopes, which began to absorb at their inferior edges in that irregular progression which left them as they are now seen, irregularly *echancrés*. This process of absorption in the outer envelopes of the Ovum, from the first to the fifth month, is what takes place generally, even when they are not morbidly affected in their texture in the way in which they are in the present instance, and is the process by which the placenta is formed. But in order to effect this properly, the mossy or filiform vessels, of nearly three fourths of the circumference of the young Ovum should also become progressively obliterated; while those which remain, mingling with the superimposed envelopes, swell into large blood vessels to assist in the formation of the placenta. Here, however, such a process was impossible, inasmuch as the mossy or filiform vessels, having taken up a morbid action and become distended with the serosity, which kept constantly pouring into them, could not become absorbed to the extent required to form the placental cake, but on the contrary continued to increase in size and number. This operation took place at the expense of the growth and life of the embryo, which is consequently seen to be stunted and undeveloped. Abortion, therefore, was inevitable sooner or later.

The specimen is also valuable, as it affords positive evidence of the mode in which the placenta is formed, for here we actually see the process of absorption of part of the involucra, on which that process depends.

Some who have seen this specimen, confound it with a case of hydatous placenta; and a few similar preparations exist under that name in more than one collection. It is evidently by mistake that they are so styled, as we shall see in a succeeding Plate.

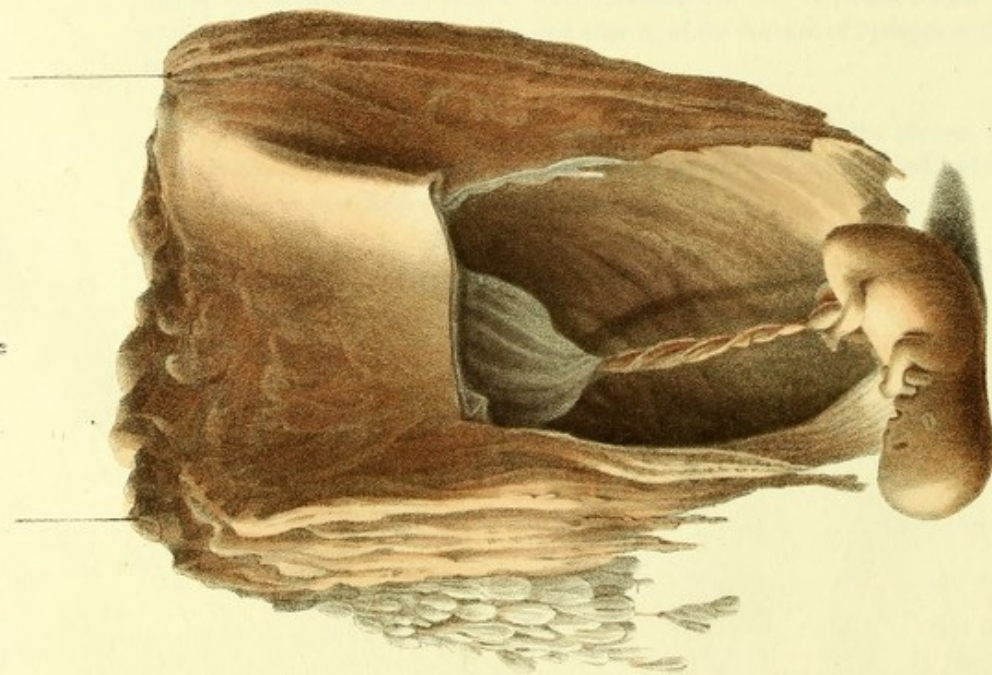
Professor CARUS of Dresden, (a name revered by anatomists and physiologists,) here comes to my assistance. That accurate and indefatigable observer, on submitting an entire Ovum, expelled towards the sixth week of gestation, to a powerful microscope, remarked that the greater number of the filiform vessels were diaphanous as well as their ramifications, and that their free extremities terminated into little roundish knobs, not unlike the terminal bulbs of the villousities of the intestines. These bulbous expansions of the filiform vessels of the Ovum adhered so firmly to a superincumbent dense membrane (which Carus calls decidua, but must be the *cortex*) that they could not be separated from it without tearing some of them*. These very expansions, or roundish knobs then, of the filiform vessels of the Ovum, are precisely those which, from plethora of the involucra lying over them, acquired what, in my specimen, I have called "a dropsical bead-like enlargement," as represented in figure 17 of an "Uviform Ovum." SOEMMERING has also noticed these terminal bulbs of the filiform vessels, which he calls *noduli vel vesiculæ*, somewhat like hydatids.

In questions of natural history, it is impossible to desire and meet with a more satisfactory corroboration of the explanation of any given fact, than the above observation of Carus affords to my view of the conformation of the "Uviform Ovum." Nor can a more convincing refutation be required after it, of the doctrine of hydatids in the placenta being the cause of that singular conformation.

There was but a trifling hemorrhage after the coming away of the present Ovum, and scarcely any suffering. During the three preceding weeks the patient had had some slight, colourless, and thin discharge from the vagina.

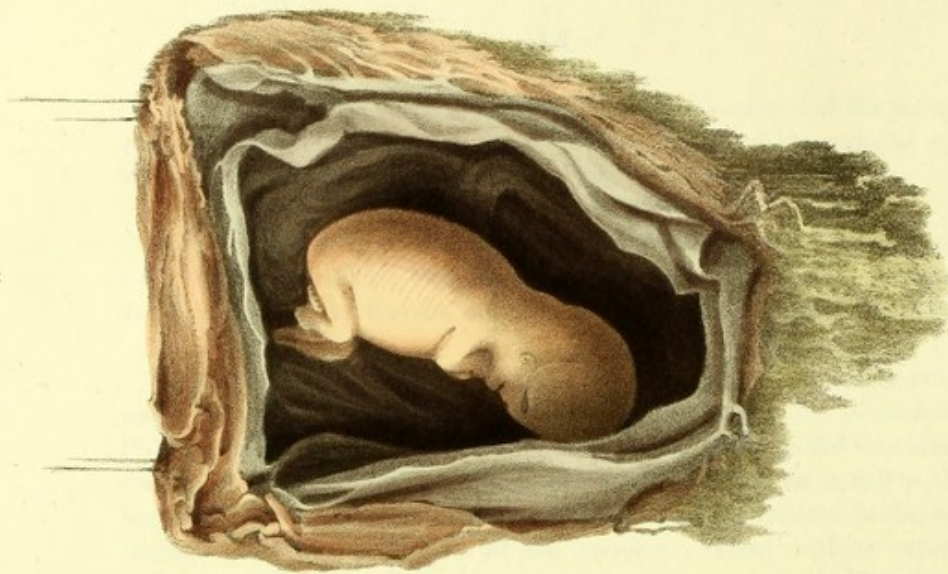* See SIEBOLD Journ. für Geburt Shülfe 1827. T. VIII. p. 1—11.

48



See 6. See 10. at bottom

49



Printed by C. Hollenbeck

Dr Granville on Abortion,
and the Diseases of Menstruation.

PLATE V.

SPECIMENS OF MISCARRIAGE BETWEEN THE THIRD AND FOURTH MONTH.

Fig. 18. Ovum coriaceum, cum hydropè funis et placentâ hydatica.

(Aborted at twelve or thirteen weeks?)

It is impossible to describe in words, better than Mr. Perry's pencil has done, the two lovely specimens consigned to this Plate. The drawings speak for themselves. They convey, with a precision which is one of the great merits of that artist, every minute feature of two preparations calculated to afford a fund of knowledge, on the subject of the formative process of the human Ovum, for which we should look elsewhere in vain.

The nutritive involucre are fleshy or coriaceous. Bunches of real hydatids hang pendulous from a part of their external surface—while internally they are lined with the secreting membrane in a morbid state, and that portion of the cord which is farthest from the fœtus appears to be dropsical. The hydatids are connected with the placenta. The fœtus is well formed, and in its growth no impediment seems to have intervened.

REMARKS.

The contrast between this and the preceding Ovum, fig. 17, cannot fail to strike my readers. In the present specimen we have the regular involucre of the Ovum thickened around its whole circumference; but the mossy or filiform vessels have disappeared inside and out, being converted, in the latter situation, into the placenta, and having become obliterated in the former. The placenta (the intervening means of affording accretion of substance to the fœtus by the mother) being once formed, the fœtus grew; but the placenta at last was stricken with disease, (the hydatids,) and this produced the dropsical swelling of the cord, which began to interrupt the growth, and lastly destroyed the life of the fœtus. In Ovum 17, circumstances are reversed. We have no regular placenta; the coriaceous envelopes cover the dropsical bulbs of the filiform vessels, and the growth of the fœtus is consequently checked at the first onset.

Fig. 19. Ovum cum placentâ, nec vasculare, nec plenè cotyledonicâ, sed filiforme. Amnion morbosum.

(Aborted at twelve or thirteen weeks after menstruation?)

Another of the manifold species of deviation from the natural process of growth and development in the human Ovum. By its size I should judge

the fœtus to be about fourteen weeks old. About that period the amnion became probably affected, and the life of the child fell a sacrifice to that circumstance. That membrane is translucent and of a brownish colour, thicker than usual, and in parts nearly opaque. Next, (reckoning outwardly,) and separated from the amnion, is another membrane, resembling closely that which lines the outer-shell of a hen's egg. No filiform vessels appear on either of its surfaces. Between these two membranes a third is distinguishable on the left of the opening made into the Ovum, and the three are very well separated from each other. The filiform vessels which connect the outer or third membrane with the thick envelopes lying over it, are well marked in the drawing. The placenta is amorphous—not local and defined, but general and mossy. The umbilical cord is covered over by its membranes, lies by the side of the fœtus, and is about twice its length, but withered down to a bare filament. Yet the proper fœtus itself is of fair growth and plump.

REMARKS.

One cannot help comparing together the two Ova, thus placed side by side in this Plate. In the figure which represents a larger fœtus, we have a smaller ovum altogether, and a smaller inner cavity; than in the other figure representing a larger Ovum with a larger inner cavity, from which has escaped a smaller fœtus. Yet I hold their respective ages to be the same. This apparent paradox is to be explained by a consideration of the difference of circumstances in which the two Ova were placed. In Ovum 18, the disease was of slow progress; the increase of the fœtus was retarded from the beginning; and its life became extinct after the disorganization of the Ovum had lasted some time: the appearances of the various parts of the Ovum, as pointed out in my explanation of the figure, shew these facts. In Ovum 19 there was nothing in the least analogous. Though the placenta is imperfectly formed; even in its filiform or mossy or primitive texture, it might serve and has served the purpose, of forwarding the nutrition and growth of the fœtus. The disease which destroyed the latter, being of an inflammatory nature, must have been more rapid in its effect. It put an end to *life* before there could have been time for *growth* to be much affected.

These facts and inductions may perchance be looked upon by some as merely curious, or at most singular, without being useful. But I think it will be found hereafter, unless I am much mistaken, that by studying such facts and such inductions, as the consideration of the human ovum in its many varieties of diseased development can afford, we may expect no inconsiderable facility in the unravelling of that mystery which yet hangs over the process of uterogestation.

Plate 6.

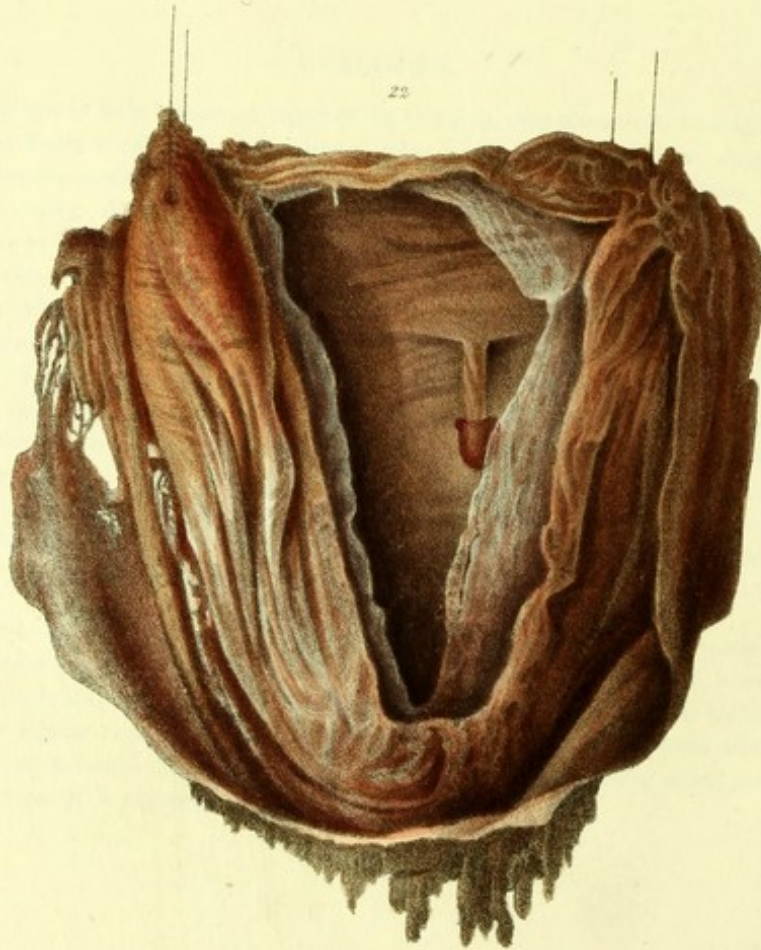
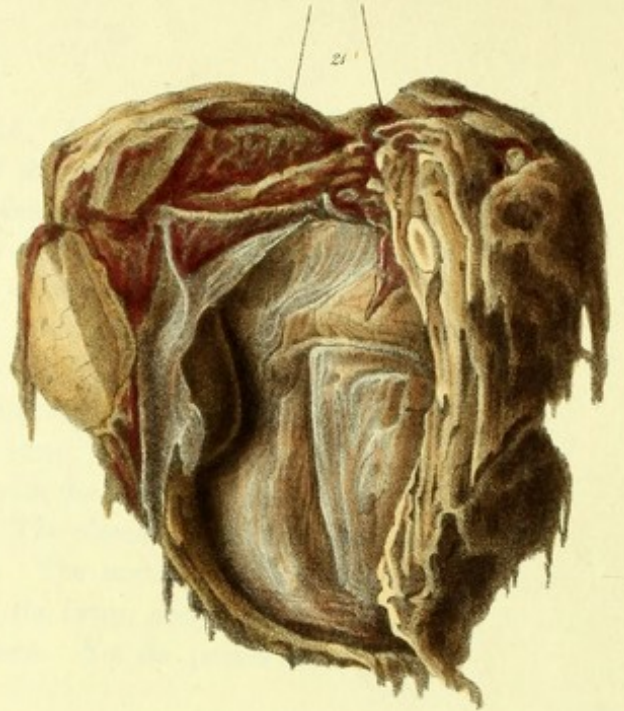
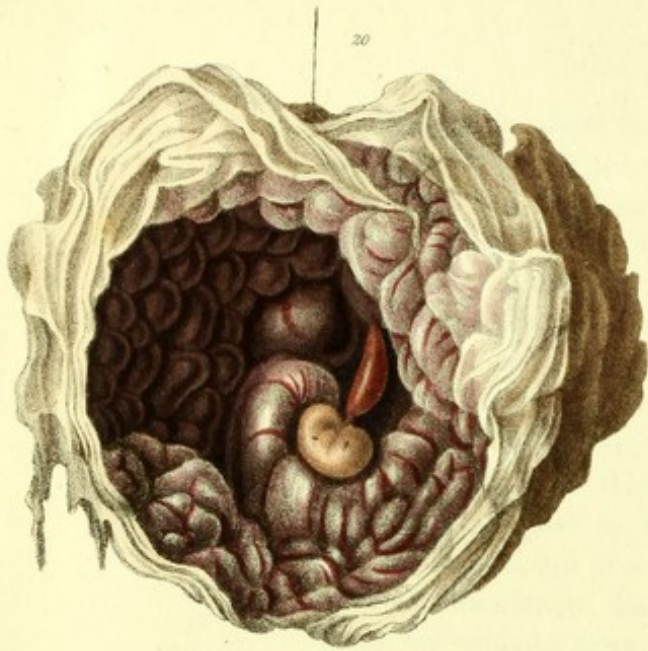


PLATE VI.

SPECIMENS OF MISCARRIAGE BETWEEN FOUR AND FIVE MONTHS.

Fig. 20. Ovum tuberculosum.

(Aborted at four months and a half after menstruation.)

I do not apply to the term *tuberculosum* the more usual meaning, but by it I wish to imply that there are in the structure of this Ovum a great many small swellings like tubercles, some of which are larger than the rest, and not a few of them granular, while others present a great variety in their configuration. All of them have very prominent blood vessels running across their surface, which, while the preparation was still very recent, exhibited a very florid tint. In this state, the specimen was submitted to Mr. Pearsall, late of the Royal Institution, who is very well skilled in the art of sketching and colouring, and still more so in science, and who undertook very kindly to draw it for me. The drawing corrected by Mr. Perry, was afterwards transferred by that gentleman on stone for the present work.

The tubercles are *sub-amnionic*, and the presence of these morbid accretions will settle the question of the vascularity of the inner, or as I call it, the secreting membrane (amnion) in the human Ovum. That the transparent membranes of the human Ovum are vascular, has been supposed from mere analogy to what we observe in other viviparous animals, particularly of the larger class of quadrupeds; but no proof has ever been adduced of the reality of such a fact, for no anatomist ever succeeded in injecting the supposed vessels of those involucri. What art has failed in demonstrating however, nature has shewn quite manifest in its career of disease. And thus it is that morbid anatomy, besides its more direct effect of teaching us the nature of diseases, produces the no less beneficial consequence to those who carefully investigate it, of unravelling structures which from their minuteness in the normal condition would have escaped detection.

Look at the figure of the fœtus in this Ovum, see how its growth has been checked!—In size it represents an embryo scarcely five weeks old—

yet the Ovum came away at four months and a half from a patient whom I was engaged to attend in her confinement. Examine the cord; it is like the amnionic vessels, distended with florid blood.

REMARKS.

In the knowledge of the doctrine of abortion and the treatment of it, a preparation like the present is of infinite value. But this is not the place to enter into practical views and details which are reserved for my professed work on that subject.

I saw, on the 29th of May, 1828, in Sir Charles Clarke's collection, which was then in Mr. Stone's possession, a specimen of tuberculated placenta, larger than, yet in other respects similar to, my own. The fœtus, however, was not of greater dimensions than the one in the present figure. In the same collection there were two smaller specimens of this identical disease of the human Ovum, very neatly put up, one of which, like my own case, exhibits most distinctly the injected state of the amnionic vessels. It was stated on the label of the largest specimen, that the growth of the child had been impeded by the pressure of the tubercles on the cord. This is not apparent on examination of the preparation. The cause of that impediment is manifestly the defective structure of the placenta.

The College of Surgeons possesses two specimens of tuberculated placenta. One is small, marked 3443, (old series,) and placed in the Gallery; the other, a very large specimen, is among the morbid preparations in the body of the Museum, No. 983. (old series). The latter was presented by Sir E. Home, who has entitled it a case of *Cysts of the Amnion*. On close examination it will be found that these pretended cysts (or, as he has called them afterwards in a printed paper, *hydatids*) are nothing more than elevations of the amnion, beautifully exhibiting the vessels of that membrane, elevations which are produced by no other process than the one described below.

No. 3447 in the same Museum, demonstrates by another fact and process the vascularity of the amnion. The case is one of twins, aborted at about two months and a half. The fœtus in the one cavity is as fully and properly developed as that in the other, and they are separated by a translucid septum, formed by two layers of the amnion. Into this septum, and not into the placental cake, terminates the cord of one of the fœtusses, expanding itself on its surface; while the cord of the other proceeds regularly to the placenta. It is manifest, therefore, that the vessels of the amnion must have carried blood to the umbilical vessels in the one fœtus, as he was not in direct communication with the placenta.

The preparation before alluded to, as being in the collection of the Royal College of Physicians, marked 7 G. 19, is another excellent specimen of tubercular amnion. Denman has given us a very striking example of this same diseased structure of the Ovum, which I strongly suspect, must be a delineation of the largest specimen in Sir Charles Clarke's collection mentioned before. The fœtus, like the one in the present plate, is small, and the cord inflated, but the entire Ovum remained in the womb until the completion of the ninth month.

All the tubercles of placentas which I have seen, were on the fœtal and not on the uterine side of the membranes. They seem to be formed by the enlargement of those filiform vessels which exist on the inside of the same involucrum, (Chorion,) the outer surface of which bears the mossy or filiform vessels, destined to group themselves into cotyledons for the purpose of forming the placenta. When the Ovum, after having lived and grown on its own life-principle, through its journey from the Ovarian nest into the cavity of the womb, has accomplished that connexion with the mother which before did not exist, the filiform vessels on the inner surface of the membrane in question, ought forthwith to begin to wither and be absorbed. When this is not the case, and they on the contrary enlarge, tubercles are formed, which are nothing else than cotyledons, or groups or tufts of vessels, like those on the external surface, and which push the innermost membranes, the amnion in particular, forward, and give rise to congestion and diffusion of blood.

Ruysch, who has published some engravings of this structural deviation in the human Ovum, has accompanied them with an explanation of its causes.

Fig. 21. Ovum pene-solidum; placenta sarcomatosa cum tuberculis hæmatis; involucra fœtûs solidificata.

(Gestation four months and a half?)

What havoc has disease effected in this Ovum! Scarcely can we recognize a single element of its structure. The placental covering is composed of many substances, has lost its spongy vascularity—it has acquired several solid tumours, and is altogether unfit for its intended function. The cortex of the Ovum is fleshy; but within it a supernumerary fine membrane is seen, which might, but must not, be mistaken for the chorion. The latter involucrum, and the rest of the membranes within it, have become compact, they adhere together, and form a solid whole, which has scarcely the appearance of what it is—a human Ovum.

It is said to have been aborted in the fifth month of pregnancy; yet the embryo that can lodge within so narrow a chamber can scarcely have more than a few weeks' growth. It is in Sir Charles Clarke's collection, and I am indebted to Mr. Stone for permission to have it drawn by Mr. Perry, with three or four more specimens contained in the present publication.

On the right of the drawing, the real extent of the thickening of the external covering is not sufficiently denoted. There are in the substance of

that thickening, not fewer than three tumours as large as Spanish nuts ; which from their section, I consider to be composed of extravasated blood, arranged in concentric layers.

REMARKS.

Calculous, steatomatous, and solid placentas are not of unfrequent occurrence in practice. I have seen several such cases. Sir Wm. Blizard presented to the Royal College of Surgeons a very instructive specimen of a human Ovum having a sarcomatous and calculous placenta, which had been expelled at three months and a half, by a patient who had miscarried three times within the three previous months.

There is also in the same college a magnificent specimen of a solid Ovum, of the size of a hen's egg and shape. A small portion of the *shell* of this Ovum having been cut off, the embryo is seen, of the size of a common fly, within the cavity, which may be just large enough to admit the top of a man's thumb. The ordinary involucra are so compact, and so firmly adhesive to one another, that they cannot be separately distinguished. The parietes thus formed are at least one fourth of an inch in thickness. On the right of the inside of the cavity there is seen a large swelling, which projects within the said cavity, and is probably the receptacle of another embryo, or a deposition of blood between what ought to be the translucent membranes or involucra.

Sometimes the fœtus alone has been found to have become an in-formed, hardened, or steatomatous mass. This is the case with a preparation, a striking one, in the Museum of St. George's Hospital, midwifery division, marked F. 94. The fœtus, two inches long and perhaps one inch in diameter, is converted into a solid mass, retaining barely the outline of some parts of its form, with the exception of the vertex of the head, which is clearly defined. The mass appears to be steatomatous, and is suspended at a point considerably below the centre, by a regular umbilical cord pending from a large placenta, having the transparent and other involucra, which are laid open for inspection. A minute dissection of these various parts could not fail to throw considerable light on many important points connected with the diseases of the human Ovum, the fœtus, and its structure. At present the preparation is only imperfectly instructive.

Fig. 22. Ovum cum involucris internis, ab amnionitide et chorionitide, condensatis.

(Gestation, near upon five months?)

Here we have a specimen which will embarrass not a little those writers in obstetrics who, either through respect for olden authorities, or from

habit, keep repeating what has been said before them, respecting the structure of the human ovum. I will describe the ovum as it stands before me this day, the 21st of January, 1833, on which occasion I again compared it with the drawing made some years before, and found the latter most strikingly correct in all its parts.

Beginning externally, we find a thin pellicle, many fragments of which are seen floating, covering the whole of the placenta, which seems consolidated and to have been compressed. These parts are not visible in the figure here represented, as they are placed at the posterior portion of the specimen. From each side of, and at the edge of the placental cake, comes a loosely-webbed, semi-transparent, coarse membrane, in some parts porous, in other parts opaque, which proceeds from *under the placenta*, and must have embraced the entire ovum before it was laid open. This membrane resembles that called *the caducous*,—and is in fact the membrane marked as such in all the preparations of human Ova in most obstetrical collections. Within this membrane we find another, considerably thickened, which, judging from the several portions that remain yet transparent, is actually passing from the latter into the opaque state: it is bifoliated. Immediately within the last-described envelope, and at the inferior part of the Ovum, we observe a thick cake, which was probably extravasated blood: it extends upwards on the right of the observer, getting less thick as it proceeds. The cake itself, on the side next to the fœtus, is lined, but loosely, by another bifoliated transparent involucrum, held fast to the involucrum just described by filiform vessels, which in some parts are distinctly visible even to the length of half an inch, with a space of the same dimension between the membrane and the cake before mentioned. The inside lining of the whole is the amnion, from the upper and lateral portion of which hangs an umbilical cord of three quarters of an inch in length, with an imperfect fœtus the size of half a wasp, in which however the rudiments of the abdominal extremities are quite distinct. The whole Ovum measures four inches vertically, and three inches transversally.

REMARKS.

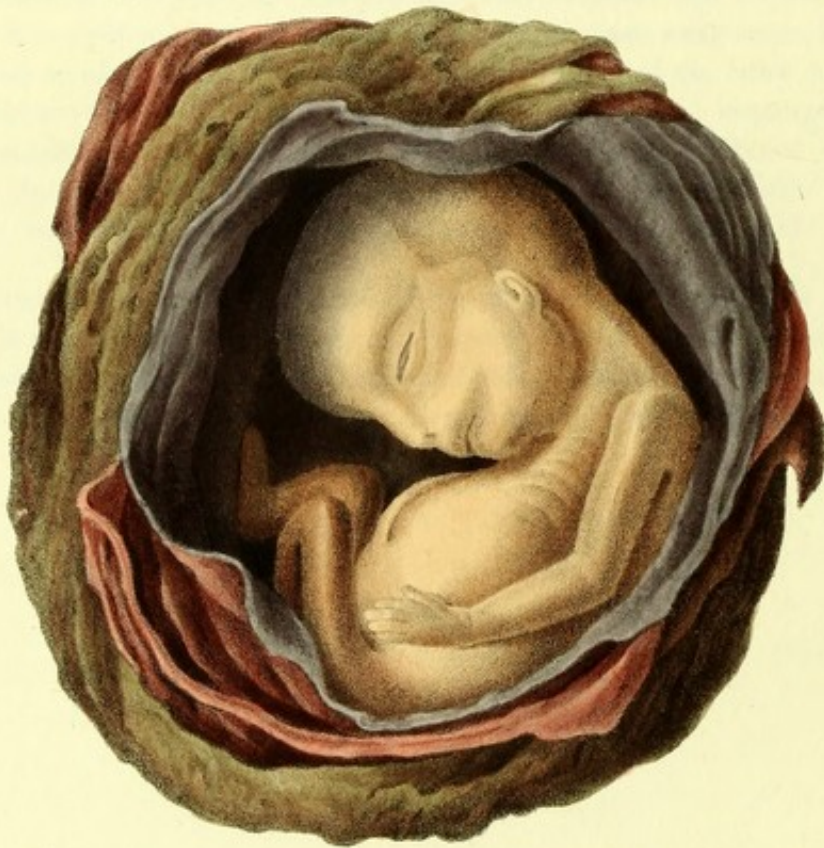That some of the involucri here enumerated are the produce of inflammation and of diffused blood in consequence of it, I entertain no doubt. The cake of blood between two of the involucri, the variously shaped points of solid matter deposited in that invo-

lucrum, which is actually passing from a transparent into a thickened or opaque state, demonstrate in my mind the above position, and prove, moreover, the vascularity of the secreting or inner involucrum of the human Ovum. Again, look at the great expansion of the Ovum and amnionic cavity compared to the size of the foetus. Could the great quantity of fluid contained in such a cavity be otherwise than the result of inflammation of secreting vascular membranes?

Another beautiful illustration of the amnio-chorionitis producing thickening of those membranes, in an Ovum which contained a well-formed foetus at four months' growth, and in which the placenta is also condensed as if it had been artificially compressed, was in my possession some years ago, and was accurately sketched and coloured by Mr. Perry before it was pilfered from my collection. The Ovum came away entire, having simply the two inner membranes and the placenta,—from the edges of the latter hung fragments of a thicker envelope—and from the external of the two pellucid membranes hung some of those peculiar filiform vessels which are seen on the chorion on Ova of very recent formation. In this specimen the amnion was in some parts quite fleshy. I attended the patient, who considered herself five months and a half gone with child.

I have likewise seen another striking case of amnio-chorionitis, in a specimen marked F 84, in the museum of St. George's Hospital, midwifery division, which has produced thickening of the transparent membranes and diffusion of blood throughout the Ovum, to the degree that even after long maceration the red tint prevails throughout the entire structure.

Plate 7.



D^r Granville on Abortion
and the Diseases of Menstruation.

Joseph Perry del et lithog.

Printed by C. Hullmandel.

PLATE VII.

SPECIMEN OF A MISCARRIAGE AT FIVE MONTHS.

Figura unica. Ovum foetiferum optimè conditum, subitò ab amnio-chorionitide interfectum.

I had an opportunity of satisfying myself most completely as to the state and condition of this Ovum, it having been aborted at more than four months and three weeks, according to the lady's reckoning, while I was in attendance upon her in consequence of considerable flooding, which had been going on for some days, and had preceded its expulsion. The Ovum came away entire; and through that part of its envelopes which were transparent, the foetus and the liquor amnii appeared of a deep bluish red. The hemorrhage ceased almost immediately after the ejection of the Ovum. The case occurred in the spring of 1828. The lady had been ill from inflammation in the chest, with cough and other symptoms of pleurisy.

I carefully dissected and examined the Ovum, taking down the various appearances as they presented themselves to view; and having requested the immediate attendance of Mr. Perry, it was sketched and coloured without loss of time, in order to avoid any misrepresentation of parts or colouring.


The Ovum is perfect in all its parts, and has evidently progressed through its successive changes and developments during the first four months of gestation in the most satisfactory manner. The foetus is of the proper size for its age, and, judging from the state of the cutaneous covering, appeared to have lived up to the very latest hours antecedent to its expulsion.

The remarkable facts in this Ovum, in a physiological point of view, are the number and arrangement of its envelopes; the morbid state of some of them; and the effusion of bloody serum within the cavity of the amnion.

Externally we find the placenta covering three-fourths of the Ovum, pulpy, vascular, almost cotyledonous, and covered with the *membrana proper*. It was gorged with blood. That portion of the outer envelope of the Ovum which is not covered by the placenta, seems to originate from the thinning edges of the latter, and to be denser than usual. On being carefully divided and laid open, it appeared bifoliated,—the laminæ are connected by cross filaments. Within this, another membrane is seen, separated however by a slight space which was occupied by effusion of bloody serum, and is itself tinged with red. Next came two less dense and transparent membranes, within which the fœtus lay coiled up, immersed in a bloody fluid.

REMARKS.

In all probability we have had here first, an extension of the complaint under which the mother laboured, (membranous inflammation,) to the Ovum; next, an inundation of blood into its internal cavities, through an engorgement of the placental cotyledons. How to explain the actual facts presented to us by this interesting preparation, in any other manner than what is here suggested, I know not.



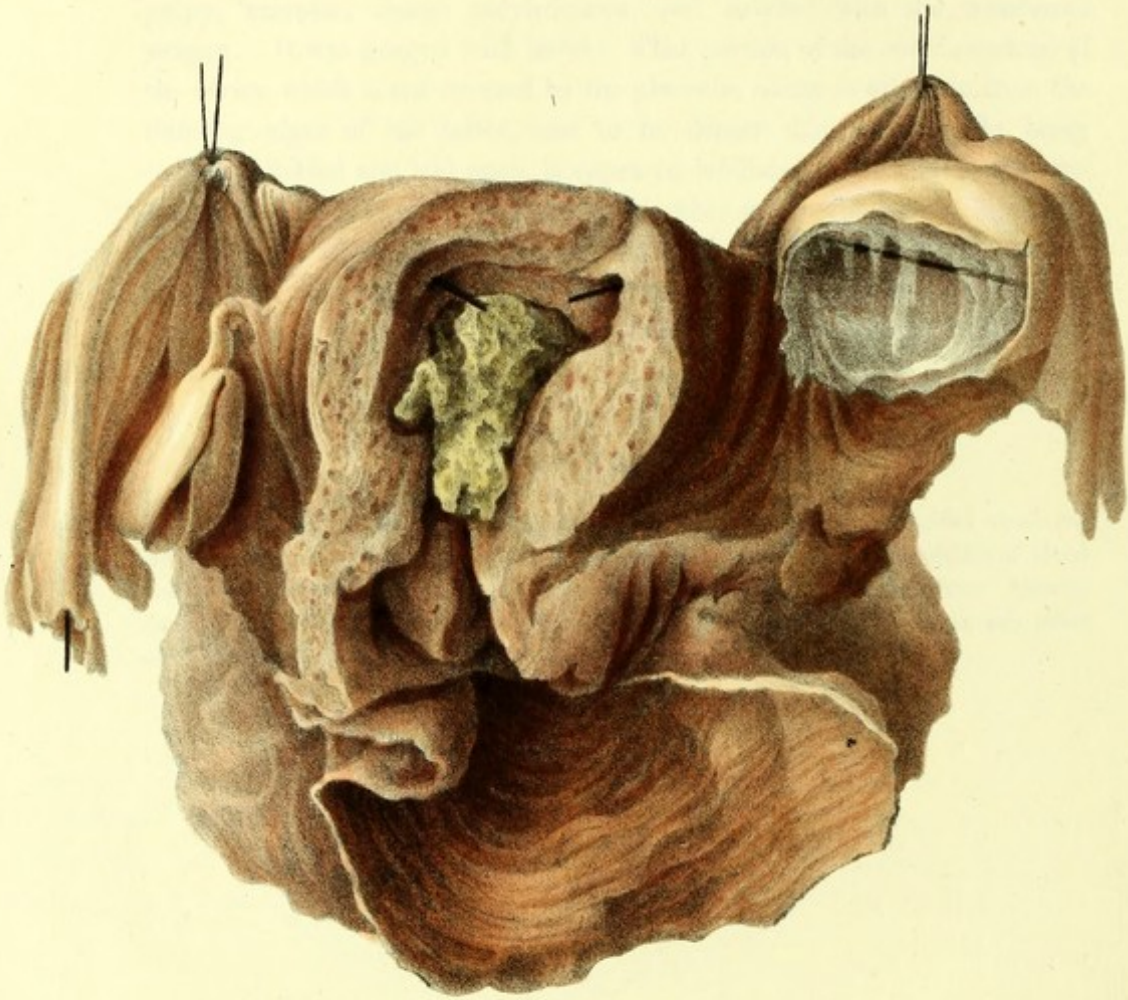
*

6. The first of these is the fact that the
 of the world is not a uniform one, but a
 of the world is not a uniform one, but a
 of the world is not a uniform one, but a

The second of these is the fact that the
 of the world is not a uniform one, but a
 of the world is not a uniform one, but a
 of the world is not a uniform one, but a

The third of these is the fact that the
 of the world is not a uniform one, but a
 of the world is not a uniform one, but a
 of the world is not a uniform one, but a

Plate 8



Joseph Perry del et lithog.

D^r Granville on Abortion
and the Diseases of Menstruation.

Printed by C. F. H. and Co.

PLATE VIII.

FIRST SPECIMEN OF ABERRANT FŒTAL GESTATION.

(EARLY PERIOD).

Figura unica. Ovum fœcundum in receptaculo ovarico.

Through a transversal aperture in the left Ovarium we see the remains of some membranes, three in number at the least, lining a cavity which measures transversely one inch and a quarter, and about an inch vertically.

The membrane in contact with the parietes of the cavity is pulpy—the other membranes are better weaved and clothly. The cavity itself seems to occupy nearly the entire volume of the ovarium, which is enlarged to nearly four times the size of the right ovarium. The fallopian tube corresponding to the enlarged ovarium, is not in the least involved in that enlargement, although it is adhering to the periphery of its ovarium by a portion of the fimbriated end,—the fimbriæ, however, being left free. We have neither disease nor enlargement in the ovarium and fallopian tube of the right side.

The uterus is larger than in the unimpregnated state. Nevertheless, its triangular cavity does not appear to have enlarged, in proportion to the general increase of volume, which is rather due to a thickening of its walls. Amorphous and flocculent depositions, in very moderate quantity, occupy a portion of that cavity. They are not membraniform.

No filiform vessels are to be seen or detected on any of the three linings of the Ovaric cavity.

REMARKS.

Sir Charles Clarke, who was kind enough to accompany me to the museum of St. George's Hospital very lately, and who greatly admires the present drawing of his preparation*, assured me, that a small embryo hung pendulous from the yet visible rudiment of an umbilical cord. That embryo, however, is not now to be seen. Sir Charles also stated that the case which furnished this specimen was that of an unmarried female, who acknowledged herself to be pregnant, and who died from a natural disorder. On examining the uterine system after death, with a view to ascertain the state of the parts under the presumed condition of impregnation, the appearances portrayed in this plate presented themselves to view,—certainly of sufficient interest to be preserved.

Sir Charles does not recollect any account being published of the Case; nor any other particulars.

* The Cases to which this plate refers occurred in the practice of Sir Charles Mansfield Clarke, Bart., many years ago.

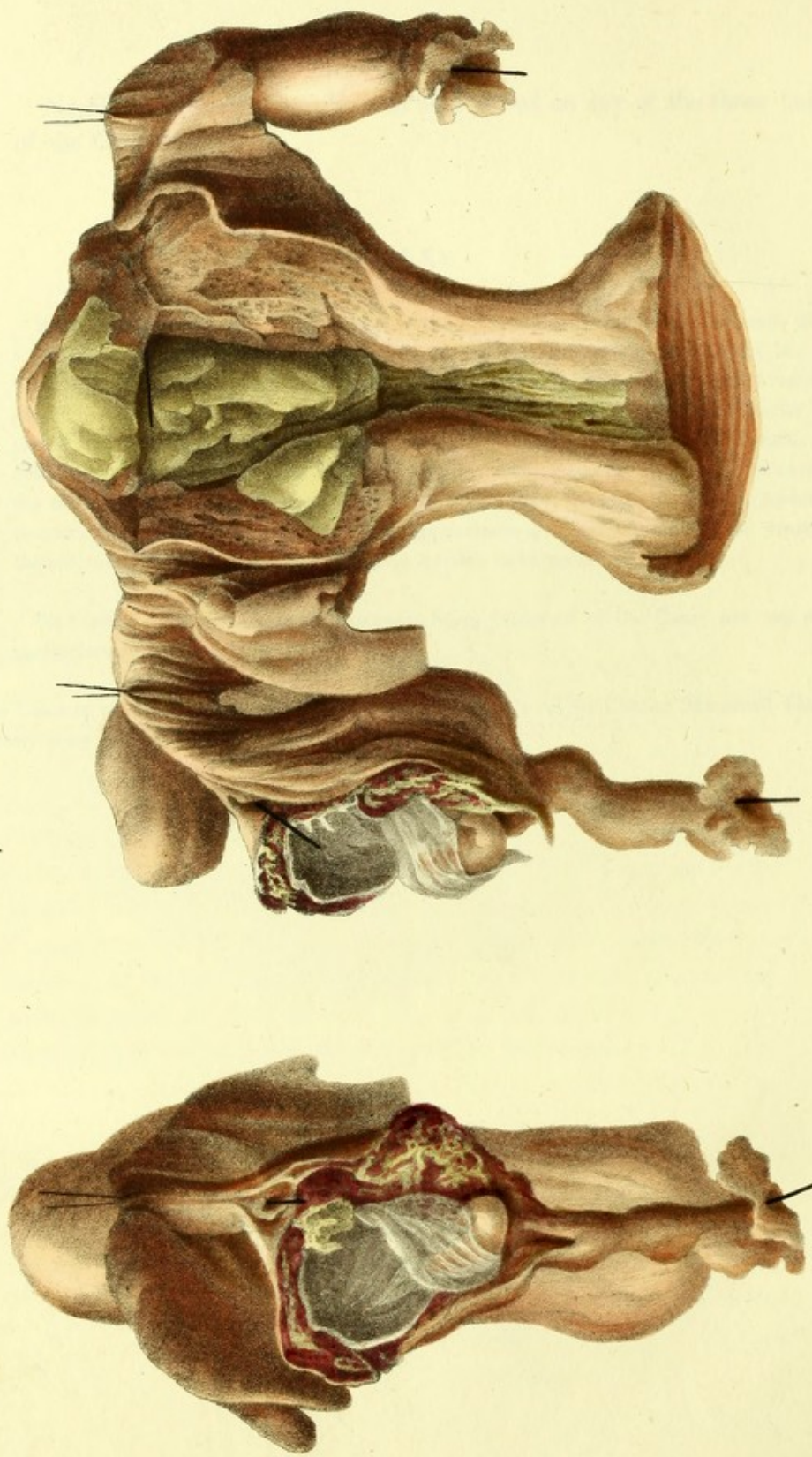


PLATE IX.

SECOND SPECIMEN OF ABERRANT FETAL GESTATION.

(MORE ADVANCED PERIOD).

Figura Præcipua. Ovum foecundum in receptaculo tubico.

The uterus is about double the size of its unimpregnated form ; but neither the enlargement of its cavity, nor the shortening of its cervix, corresponds to this general increase of outline, which is due rather to the thickening of its walls. Nay, the cervix is unusually long even for an unimpregnated uterus. In it, as well as within the upper cavity, we observe some adventitious production, differing so far from each other in appearance, that the one, (that of the cervix,) is flocculent and of small texture ; while the other is composed of broken flakes, or thickish laminæ, of a smooth, compact, suetty substance. This corresponds in its visible character with the adventitious coating cast off by the uterus two or three weeks after successful copulation, whenever the Ovum has been blighted in its development during that period. In my collection, in that of St. George's Hospital, and of the two Royal Colleges, there are specimens of this species of production, which by most writers is looked upon as the decidua.

Proceeding with our description of the parts as they appear in the preparation, we find that the middle third of the whole length of the right fallopian tube is lacerated, being also in that part, pouchy and larger than usual ; that a fecundated Ovum is lodged within the portion of the tube in question, which has acquired sufficient development to shew all its component parts ; and that a foetus with its navel string is contained within the transparent membranes or involucra of that ovum. The membranes are two in number, and as the drawing beautifully represents them, accurately separated in the preparation. Now, according to the common doctrine, the outer of these invo-

lucra, being the chorion, ought to have the shaggy or filiform vessels which are said to characterize that membrane. Nothing of the kind, however, is here seen, nor any vestige of them. But externally to this outer transparent membrane we have the cortex Ovi, which has contracted adhesion by means of branches of vessels, indistinctly made out in the preparation, owing to the dried clots of blood with which they are interspersed. These clots of blood are the remains of the accumulation of that fluid around the Ovum, which led to the laceration of the tube, and with it to the fatal hemorrhage that inundated the abdomen and produced death. I have not hesitated a moment in colouring these clots as blood in the drawing, although in the preparation, as is generally the case, they look brown instead of being of a bright red.

Both ends of the fœtiferous tube are made to appear pervious, by the insertion of bristles.

The rudiments of the inferior extremities in the fœtus are well marked; the cord is of the length of the fœtus, which is itself about half an inch long, and coiled up anteriorly.

Turning now the preparation to examine the ovarium of the same side, as it lies open before us, we find the vesicula Graafiana (the nest) from which the ovulum escaped into the tube, quite evident. The centre of that nest, itself yellow in colour, presents a white radiated *scar* or cicatrix, which must have formed subsequently to the escape of the ovulum, and during the period between that escape and the death of the patient. This yellow substance with its scar is the *corpus luteum* of the authors.

The left appendages of the uterus were sound.

The side figure represents a front view of the tubic seat of the fœtus.

REMARKS.

I have ventured to rescue this interesting case, which my readers will find most ably detailed by the late Dr. Clarke (a truly philosophical obstetrician) in the first volume of the transactions of the Society for improving Medical and Surgical Knowledge, from the very imperfect and indistinct representation given of all its most important details by the artist

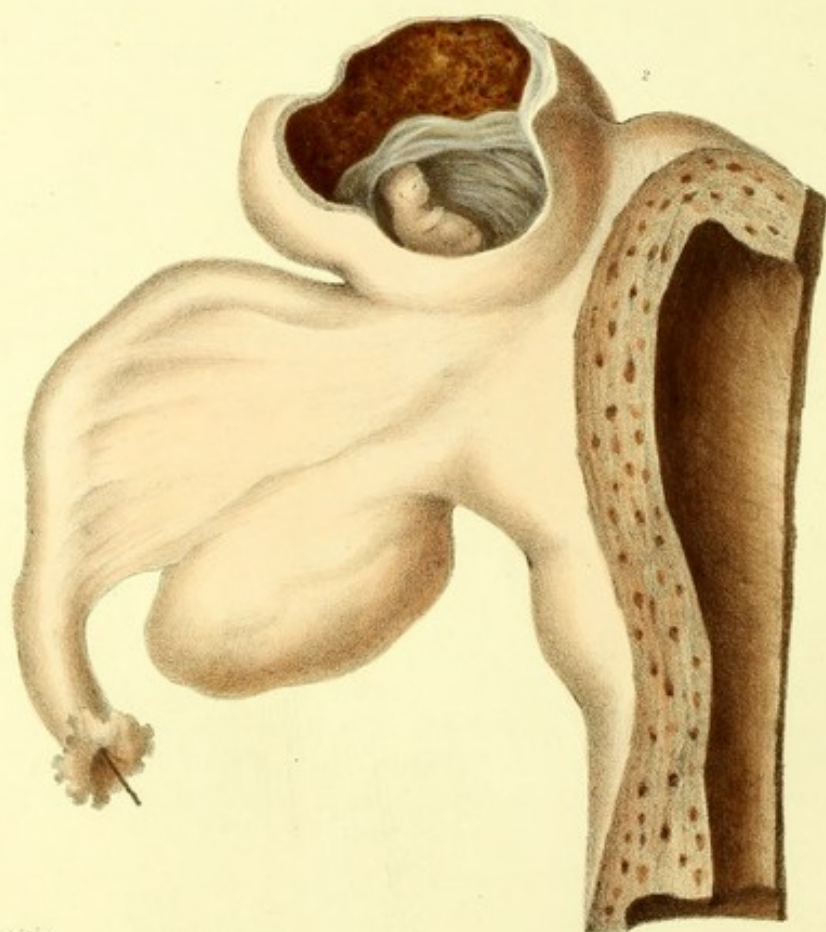
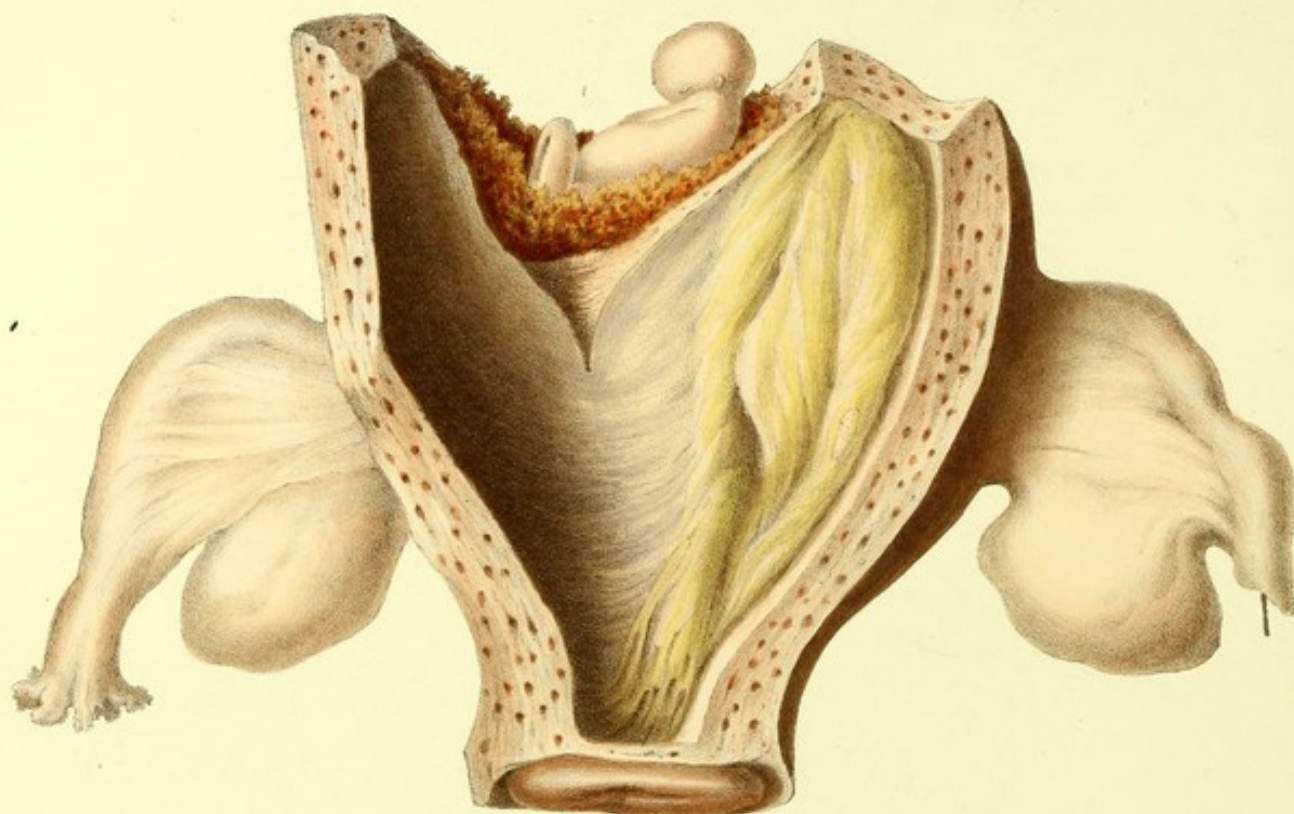
employed on the occasion. Three plates accompany the original paper, professing to be delineations of the preparation, as seen anteriorly, posteriorly, and laterally; and I have no hesitation to assert, that the fine arts must have been at a very low ebb indeed (as far as anatomical subjects are concerned) in those days, if such were the productions of the pencil and the graver at that time. When I say that it is next to impossible to distinguish in the plates any of the parts referred to in the narrative, and that the important details exhibited by the preparation itself, are not only indistinct, but faulty and deficient in design, I may be deemed to have advanced sufficient grounds for offering to the public a far more accurate and perfect picture of this highly instructive and almost proverbial case. Such is my first reason for introducing it in this place. My second reason is, that it is marvellously adapted to advance my object in publishing the present graphic illustrations of abortion—for it affords me not only some curious facts respecting the formation of the impregnated Ovum, but also a contrast to the preceding and two following species of fecundation *extra muros uteri*. Thus the present work will contain a striking and well authenticated specimen of each of the four kinds of impregnation that occasionally takes place in some part or other of the uterine system of woman beside its cavity.

Dr. Clarke's preparation being still in existence, and in the collection of his worthy successor and brother, I requested permission to have a front and lateral view of it made by Mr. Perry; and I fearlessly challenge a comparison, first between the old and the present engraving, and next between these and the preparations themselves, which may be viewed in the Museum of St. George's Hospital. I have described the parts as I found them in the preparation in question, which I have again, for the fortieth time, examined this day, January 23d, 1833.

Dr. Clarke, in his account of this case, says, that the substance in the cervix was gelatinous in the recent state, and that within the uterine cavity it is the decidua which we observe. The Doctor afterwards remarks that such decidua is *always* formed in the cavity in question, whether the fœtus gets into it or not; but his own description of another and even more important case of *tubic* gestation, which occurred at St. Bartholomew's Hospital and was carefully examined by Mr. Abernethy, gainsays the assertion; for it is there stated, "that in the cavity of the uterus nothing remarkable was found"; and in my own case of Ovarian gestation, "no production whatever" was found within the cavity of the enlarged uterus.

From the state of the right Ovary and the appearances and situation of the corpus luteum, we gather two probable facts. First, that the actual seat of the Ovulum is the place occupied afterwards by the corpus luteum, which fills the vesicula Graafiana considerably enlarged subsequently to fecundation. The fecundated Ovulum escapes from the Ovary by bursting through the coats of the said vesicula Graafiana, which is generally found close to the periphery of the Ovary. Secondly, that the process by which the breach made in the structure of the vesicle (or egg-nest) by the escape of the Ovulum is restored, is cicatrization, and that much time is not required for such a restoration.

Does not the first of these probable facts explain the acute pain which many women feel in the course of the first week subsequent to successful coition,—which some experience even for some time after,—and which is by all assigned to that part, of one or the other of the iliac regions, which corresponds to the situation of the Ovarium? Indeed, I have known Ovaritis of a very serious nature to follow shortly after impregnation.



Joseph Perry del. & sculp.

Printed by C. Hullmandel.

PLATE X.

THIRD SPECIMEN OF ABERRANT FETAL GESTATION.
(EARLY PERIOD).

Fig. 1. Ovum embryoferum in receptaculo interstitiale.

The uterus is enlarged in its general volume and appendages to the size which it more commonly acquires at the second month of pregnancy. The section of its coats shews their increased thickness, and the many hundred orifices of its enlarged blood-vessels. Within the cavity of the womb there was no vestige of any ovum, but in its stead a spongy and woolly membrane was found.

On the upper and outer surface or basis of the uterus, a swelling of a red colour was observed, nearer to the left than to the right side. It was richly streaked with blood-vessels, which gave it the appearance of inflammation. Two lacerations had taken place in the thinnest part of the coats of this eminence or tumour. These lacerations led to a cavity or sac, or cyst, which contained an embryo of from eleven to twelve weeks' growth: it was regularly enveloped within the two transparent membranes, on the external of which the rudiments of a placenta were found. This embryoferous cyst was separated from the real cavity of the womb; there being no communication whatever between them.

The left Fallopian tube was impervious throughout its whole length.

On opening the body of the patient, who had before borne three children, and had also miscarried twice, and died when she supposed herself two months gone with child, the cavity of the abdomen was found filled with blood.

This case is related by Hendrick in the "archives", by Horn, Sept. and Oct. 1817; transmitted and vouched to Dr. Breschet of Paris by Professor Carus of Dresden, who sent the drawing, from a lithographic copy of which the present plate is taken.

Fig. 2. Ovum embryoferum in receptaculo interstitiale.

Uterus enlarged; more so on the right than on the left side. A three-lobulated tumour or swelling of the substance of the womb immediately above the insertion of the right Fallopian tube, and on the external surface. Ulceration of the coats of this swelling, which had taken place during life, exhibits to view an excavation or cyst in the interstitial substance of the uterus, containing an embryo which appeared to have acquired a growth of six weeks.

The cavity of the womb had no communication whatever with the foetiferous cyst. It was found lined with a woolly pseudo-like membrane.

The internal or uterine orifice of the right Fallopian tube was absolutely impervious: that of the left open; but the fimbriated end of the latter was closed, and some serum was found within the tube.

The patient had had several children before: the last time she was pregnant she miscarried at four months. On the present occasion she was not conscious of being with child, as she continued to be regular every month; whereas during every preceding pregnancy her menstruation had ceased. She felt better than usual on the day of her death, soon after

which, on opening the abdomen, the above appearances offered themselves to view. There was a large quantity of blood in the cavity of that region.

This case is quoted by Dr. Breschet from a memoir in the Transactions of the Medico-Chirurgical Society of Vienna for 1801, drawn up by Professor Schmidt, and farther vouched by Professor Carus.

REMARKS.

Cases of aberration in the first development and ultimate station of the human embryo like these, were not known to science (according to Dr. Breschet's statement) before the two preceding instances were laid before the profession. I selected them, therefore, on account of their priority, from among the six cases collected by that indefatigable and highly gifted anatomist, whom I am proud to call a very old friend, in his memoirs on "A New Species of Extra-uterine Pregnancy," published in the first volume of a very valuable work, edited by himself, Dupuytren, and others, in 1826, entitled, "Repertoire General d'Anatomie et de Physiologie." The facts are singular, yet authentic in all their particulars. It is, therefore, impossible to deny the existence of another distinct species of pregnancy, *extra muros uteri*, in which the foetus is lodged among the interstitial elements of that viscus, and has no communication whatever either with the cavity of it on the one side, or the cavity of the abdomen on the other; unless ulceration or laceration take place.

We may, therefore, reckon four species of erratic gestation, namely:—

1. Gestatio Ovarica.
2. Gestatio Tubica.
3. Gestatio Interstitialis.
4. Gestatio Abdominalis.

The design of the parts, the statement of facts, and all the particulars connected with such cases of gestatio interstitialis, I give on the authority of the respective authors whose names I have mentioned. It has never fallen to my lot to witness a single instance of such anomaly in the mode of propagation of our species. Of the six cases reported by Breschet, the last only fell immediately under his care, at the Hôtel Dieu, in July 1825.

It is to be remarked, that in all these cases the uterus was found enlarged, its cavity filled with some adventitious production of variable texture and not always membranaceous, and the Fallopian tube on the side next to the seat of the embryoferous tumour invariably impervious. The mother dies from internal hemorrhage, in consequence of the

laceration of the coats of the cyst containing the embryo. During life menstruation has ceased in some and not in other cases of this description.

The reader will not fail farther to notice the very great difference which appears manifest in the drawing of the present plate, and that of the rest of the plates, from the hand of our artist. Mr. Perry had, in this instance, a very inferior lithographic delineation of the facts only to copy,—instead of having to imitate nature, as he has done in every other instance. The consequence has been, that we see but a feeble, and not always an intelligible, representation of the several interesting points connected with these two cases, the nature of which has been attempted to be explained by Breschet himself, and Geoffroy St. Hilaire, in his report to the Institute of France—but with indifferent success.

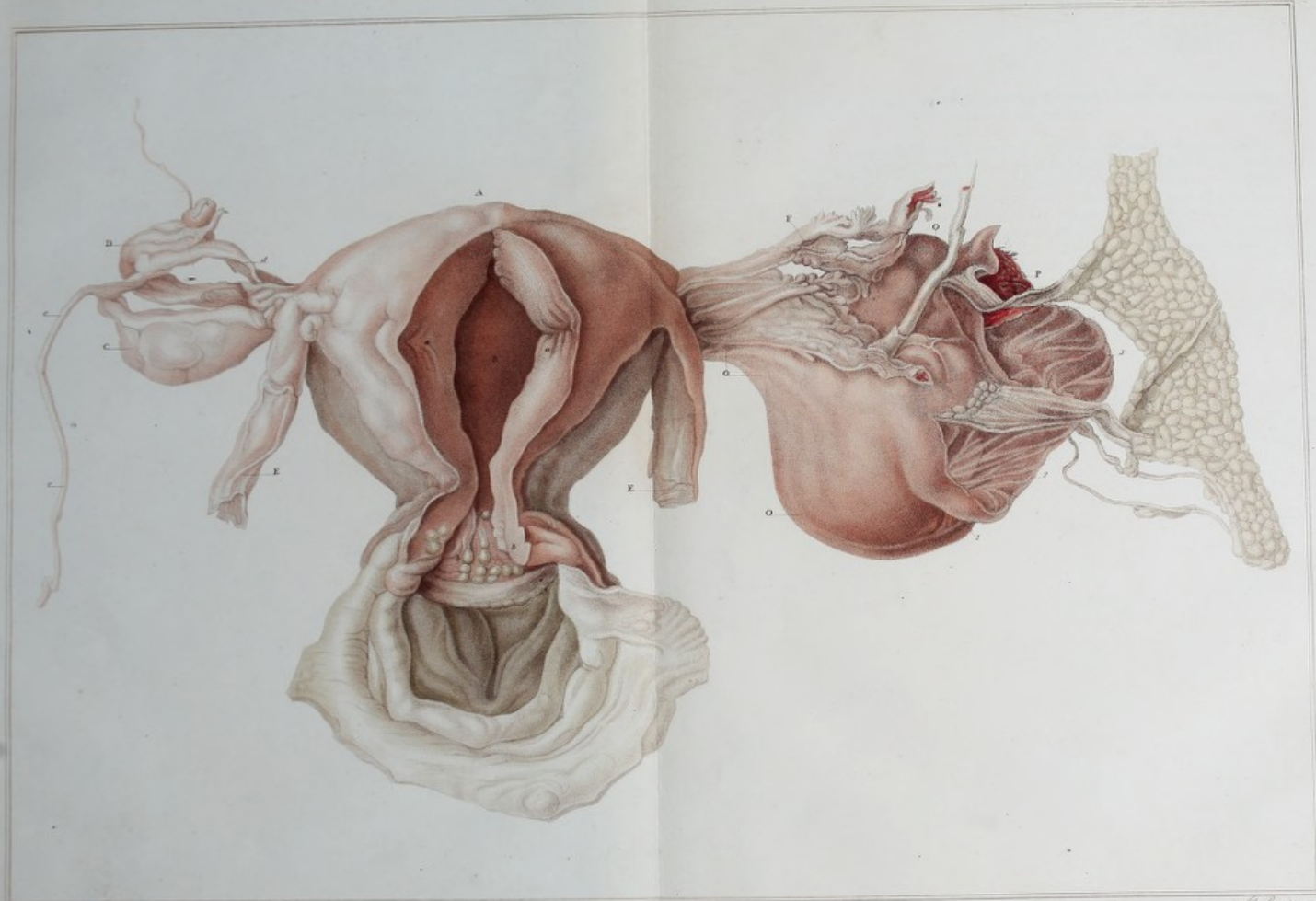

PLATE X. (A).

(BEING PLATE VI. OF THE PHIL. TRANS. FOR 1820.)

FOURTH SPECIMEN OF ABERRANT FŒTAL GESTATION.
(ADVANCED PERIOD).

Fig. Duplex. Ovum fœtiferum in receptaculo ovarico.

Uterus considerably enlarged, so as nearly to have reached the size which it is known to attain when bearing the produce of conception between three and four months. Its parietes thickened in proportion. The cavity free from either fluid or membrane, or indeed from any adventitious production.

The left ovarium presented a large swelling, which contained within its own outward covering an Ovum bearing a fœtus with all its appendages, of about four months' growth. The ovarian covering burst in three places, and allowed the partial protrusion of the ovum, whereby the adhesion of the placenta to the inner surface of the ovarian envelope was torn asunder, and a sudden and fatal hemorrhage took place, which destroyed the life of both mother and child, and filled the cavity of the abdomen with blood.

The corresponding Fallopian tube was perfectly sound, and loose, particularly at its fimbriated extremity, which had no connection whatever with the embryoferous tumour in its neighbourhood. Like its fellow tube, it was pervious only from its loose extremity inwards to about half its length and no farther; nor were their uterine orifices discovered.

REFERENCES TO THIS PLATE.

A. The uterus enlarged. B, its cavity, with a section of its coats, a a, to exhibit their thickness; and b b, marking a cluster of enlarged vesicles in and about the inner cervix of the womb.

C, is the right ovarium, having a singular long thread-like appendix, c c, of a tendinous nature, which connected it with the neighbouring viscera.

D. The Fallopian tube of the same side turned and fastened to the womb by an adventitious band, the result no doubt of some previous inflammation. Had conception taken place in the right ovarium, the transmission of the ovulum through that tube could not have taken place.

E E. The ligamenta rotunda dissected and truncated. The broad ligaments were carefully removed, to free all the other parts from every species of obstruction that might impede a proper investigation of the nature of the case.

F. The Fallopian tube of the left side.

O O O. The left ovarium containing the fœtus.

P. Portion of the placenta visible.

1 2 3. The lacerations in the ovarian envelope, through which the Ovum protruded. The omentum had contracted adhesions with the tumour.

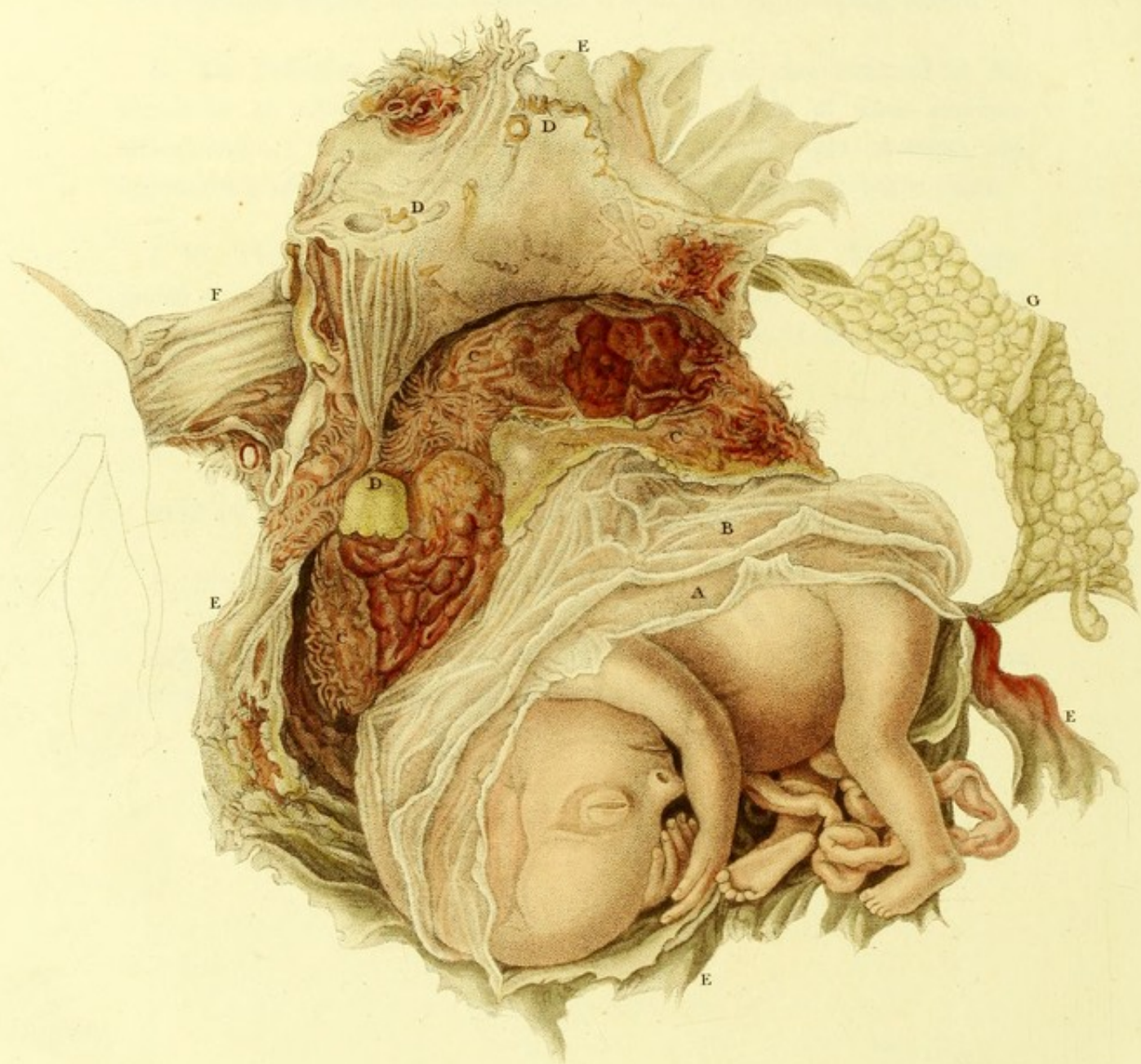


PLATE X. (B).

(BEING PLATE VII. OF THE PHIL. TRANS. FOR 1820.)

Fig. Unica. Ovum ovaricum foetiferum patefactum.

The cavity formed in the substance of the ovarium by the progressive advancement of the fecundated ovum, is here laid open, in order to exhibit how distinctly and perfectly the foetus had, up to the time of the death of the mother, found station, nourishment and growth without the assistance of the cavity of the uterus, or of those membranes which physiologists are wont to look upon as essential to the development of the child in utero.

A placental mass with distinct cotyledonous vessels, connects the child with the inner covering of the ovarian cyst. The secreting or transparent involucre are quite distinct. The *cortex ovi* is almost wholly absorbed, as it ought to be at such an advanced period. The foetus is perfect.

REFERENCES TO THE PLATE.

A, the amnion. B, the chorion. C C C, the placental cotyledons. D D D, fragments of the corpus luteum, which surrounded the ovum, and was broken to pieces by the enlargement of the foetus. Some of these fragments adhere to the inside of the ovarian coat, others are among the placental cotyledons. E E E E the covering or coat of the ovarium; F the Fallopian tube, which passes behind the flap of the ovarian coat thrown back. G the omentum, &c.

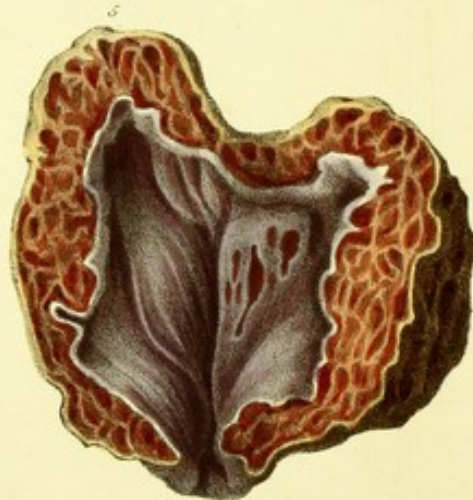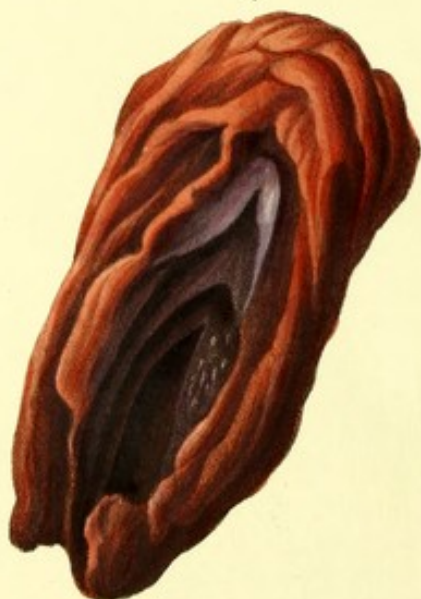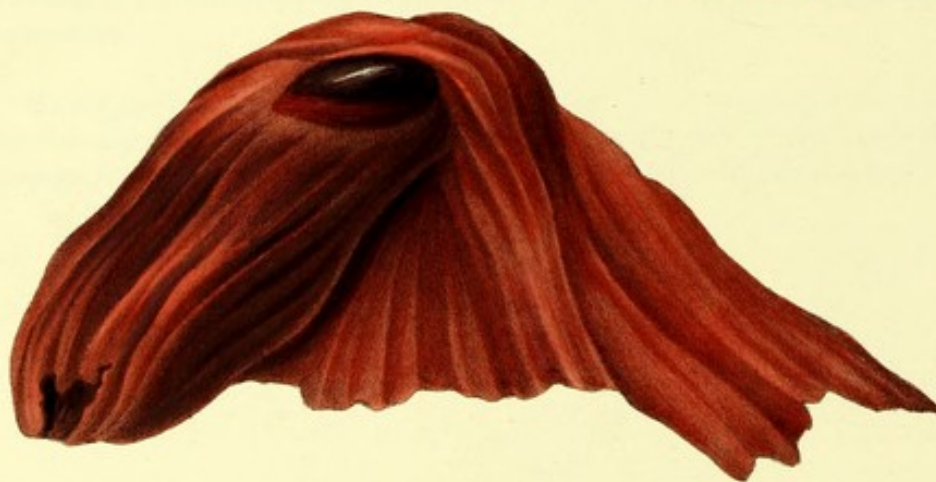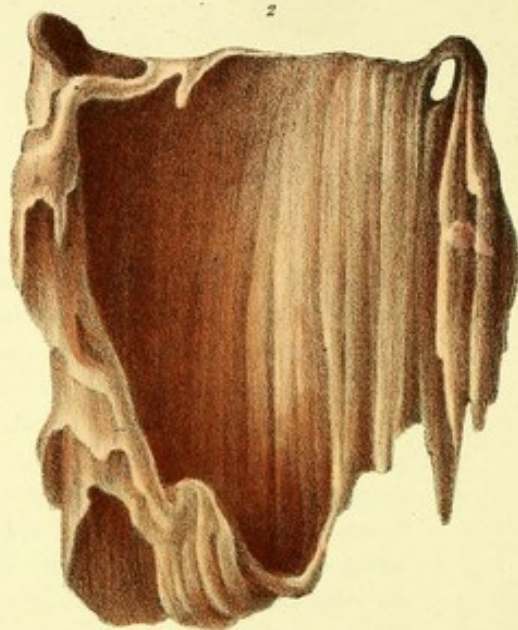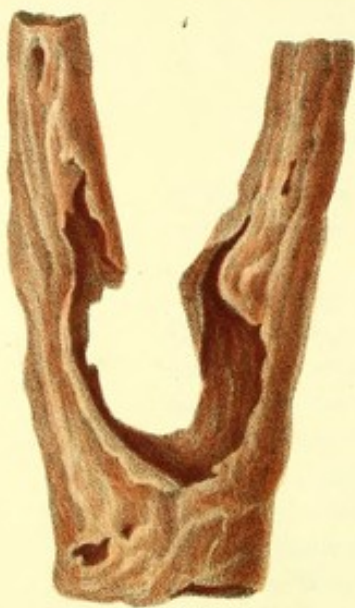REMARKS.

The paper, accompanied by the drawings from which the Plates, (so kindly lent me for my present purpose by the Council of the Royal Society) were engraved, was transmitted by

me to that scientific body in June 1819; and was honoured with a place among the Philosophical Transactions for 1820.

The drawings were made for the Royal Society, soon after the death of the patient, by Mr. Bauer, under my inspection, and coloured by him from the preparation, which has remained ever since in my possession, and may be considered as perfectly unique. It is sufficient to mention that gentleman's name to vouch for the accuracy of every part of this interesting representation. A case so perfect, so indubitable, and so far advanced, of a fecundated Ovarian Ovum had never been recorded before, and completely gainsays the hasty, and I must admit, unwarrantable *dictum* of a venerable naturalist and philosopher whom I highly esteem, Geoffroy St. Hilaire, who, in a report made to the Institute of France on the subject of Breschet's memoir, respecting the interstitial extra-uterine gestation already mentioned, ventured to make the following assertions, *six years after the publication* of my undisputed case of purely ovarian fœtiferous Ovum in the Philosophical Transactions.

“Il n'y a *jamais* de grossesse Ovarique, dans ce sens que le fœtus *puisse se développer dans l'intérieur de l'Ovaire*; on connaît des cas de fœtus arrivé *sur* l'Ovaire; mais très certainement l'ovule en était sorti pour n'y rentrer, ni comme œuf, ni comme embryon.”



J. Perry del et lithog.

D^r Granville on Abortion,
and the Diseases of Menstruation.

Printed by C. Hullmandel.

PLATE XI.

A. DYSMENORRHOIC ORGANIZATIONS.

Fig. 1. Membrana pseudo-textilis introuterina bi-tubulata.

A pulpy tissue of a very loose texture, scarcely deserving of the name of membrane,—of a bright red colour when thrown off by the womb, but, soon after maceration in water, assuming a yellowish tint, and appearing like a gelatinous, thickish, and translucent web, the component molecules of which possess but slightly the power of cohesion, being easily lacerated. Examined with a powerful lens, it looks like a congeries of globules of gelatine, arranged together into a flat, but not even surface. It possesses flexibility, but scarcely any elasticity.

This tissue lines the womb; and the two superior tubes drawn up vertically in the preparation are the prolongations of that lining into the fallopian tubes.

It was thrown off in the case of a patient suffering habitually from dysmenorrhoea, after acute pain; and on the third day of a very scanty menstruation. The patient was not a married lady, and under twenty-five years of age. The same production had been observed on more than one occasion before by the attendant, but not especially noticed until after I began to visit the patient.

Fig. 2. Membrana pseudo-textilis introuterina sine tubulis.

A pulpy tissue like the preceding,—rather firmer in its texture, but presenting in every other particular the same characters.

This also must have lined the uterus; for it was pulled away from the orifice of it, through which it was found to hang partially during an examination made in consequence of sharp *forcing* pains being experienced the day after the complete cessation of the menses. The patient, a married

lady from Scotland, suffered considerably at every return of the monthly period, and had done so on the present occasion. She had had no children; and was thirty years of age.

Here, there were no tubular prolongations of the lining, but two apertures near to the upper margin of this *cloth*, with smooth, rounded edges, as if they had corresponded with the uterine orifices of the fallopian tubes. A similar aperture, considerably larger, existed at the inferior margin; or rather, I should say, that the inferior margin of the cloth, perfectly smooth, was drawn round, so as to leave an opening in the centre, which must have been placed over the internal orifice of the womb.

Both this, and the preceding tissue had one of their surfaces more *lisse* than the other.

B. POLYMENORRHOIC STRATIFICATIONS.

Fig. 3. Coagulum introuterinum hæmatosum pseudo-membranaceum incavum.

This sanguineous mass consists of a series of layers of the same species of pseudotextile membrane described at No. 1 and 2: rather striated, neatly wrapt over one another, and easily separable without laceration, until we come near to the nucleus, where the layers are thinner and adhere more firmly together.

Some of these quasi-membranaceous wrappings are generally entire at one of the extremities of the mass, and open at the other, while two of the innermost are open at both ends, as if their organization had been checked by the supervening of another and external coating. This is properly marked by the artist on the second membrane, reckoning from the outside covering.

The colour of the latter is most brilliant, and has been well and correctly represented by Mr. Perry, from nature. The former, or inner layer, is darker in places, not so gelatinous in appearance, more distinctly striated, and puckered up superficially into slender longitudinal ridges, giving it the

semblance (in form though not in colour) to a dry Egyptian date, or a very ripe banana.

Fig. 4. *Coagulum introuterinum hæmatosum laminare cavum.*

There is no nucleus in this species of coagulum. In its centre, we remark an oblong cavity, which extends nearly the whole length of the mass, and remains partially open longitudinally. The walls of this cavern are not thick.

Over the latter another coat is thrown, likewise open, the margins of whose aperture do not reach those of the inner coat. Over these again arrange themselves one, two, three, and sometimes more stratifications of grumous blood, bearing a nearer resemblance to fleshy laminæ than to membranes. Their colour is of a bright vermilion, whereas that of the two innermost coats is of a dark violet, while the central cavity itself has a perfectly dark tint.

Like the *coagulum in-cavum*, the present measures three inches in length, is oblong, and rounded at both ends, one of which has an open orifice not unlike that of the unimpregnated womb in its configuration.

Fig. 5. *Coagulum introuterinum spongiosum cavum interne velatum.*

A spongy substance, irregularly globular, flattened into a sort of depression at one part, and terminated by a round teat-like extremity at the opposite parts of its circumference.

Externally this coagulum might be taken for a cast of the interior of the uterus about three weeks after conception. This resemblance is even greater when the coagulum is cut into and laid open. A cavity is then found of shape almost triangular, with an open, smooth, and rounded orifice, the whole inside being lined by a pellucid silvery-looking membrane, not unlike a serous membrane. This membrane prolongs itself through the orifice, which it lines also, and passing outwardly, goes to join and merges into the coarser external covering of the coagulum.

A section of the walls of this introuterine mass, exhibits a thickness of two fifths of an inch, studded with a vast number of small apertures, not unlike a honey-comb. The colour of the divided coagulum is of a bright vermilion, but the inside of the several apertures is of a much deeper tint. The lining of the cavity consists of a very fine pellucid whitish membrane, (as I before stated,) which resting on a dark red, assumes in aspect a lilac hue : while externally the mass presented a dirty brown colour at the time of its coming into my possession, *immediately* after its expulsion.



D^r Granville on abortion
and the Diseases of Menstruation.

PLATE XII.

(POLYMENORRHOIC STRATIFICATIONS CONTINUED.)

Fig. 1. Coagulum hæmatosum introuterinum internè solidum, externè membranaceum.

An oblong mass, rounded at each extremity, one of which is more tapering than the other, and is perforated by an external orifice. Its whole length is $2\frac{1}{2}$ inches, the difference in the circumference at the two opposite ends is as 1:2. The orifice is puckered at its edge: the colour of the mass of a marbled red.

This mass may be carefully unravelled in a weak mixture of alcohol and water, when it is found to consist of several membranaceous oblong pouches, placed one within the other, until we arrive at the centre, which is found occupied by a solid black coagulum of blood, perfectly homogeneous, friable when dried, shining in its fracture, and leaving streaks of a brown red colour on paper, when rubbed over its surface.

The appearance of the mass is here represented as it came away, of its natural size and colour, and by its side is placed the same mass after undergoing the process of careful separation of some of its different investitures or coatings. It should be observed that the orifice which exists at the pointed end of the external membrane corresponds with a similar orifice in each of the different subincumbent coverings. These, in their texture and appearances, differ scarcely from the Dysmenorrhœic pseudo-textile membranes described in a former plate.

C. PSEUDO-OVA: MOLE. (VULGO, FALSE CONCEPTIONS.)

Fig. 2. *Mola Avellana tunicata*.

A small, round, and oblong body, shaped not unlike a good-sized Spanish nut, which it resembles in colour even, and smoothness of surface. This led me to adopt the distinguishing appellative of *Avellana*. It measures about one inch in length, and is wide at one end and nearly pointed at the other.

When expelled it was covered by a tunic, which is easily detached, and is tolerably flexible. The external surface of this tunic is tomentose or lanuginous—the internal surface smooth, almost shining, and in its centre pellicular.

The nut itself, or mole, being cut open longitudinally, exhibits a cavity lined with a thin stratum of coagulated blood, interspersed by pellicles in all directions. On examining the cut edges of the mole, they appear to consist of at least three superimposed layers.

There is no communication whatever between the internal cavity of the mole and its surrounding tunic, and consequently none with external objects.

Fig. 3. *Mola Avellana nuda*.

This is a smaller uterine production than the last, and it differs also in one essential character, that of the surrounding tunic being wanted.

In other respects the resemblance is perfect externally as well as internally, and also with regard to the total absence of any outlet from its interior. The coats are similarly constructed, but the deposition of a bloody stratum on the inner surface is thinner and smoother.

Fig. 4. *Mola conchula*.

It is the external tunic of this mole that resembles a little shell, and which circumstance induced me to distinguish this species of *Mola* by the surname *Conchula*.

The mole itself is more like a small date, the well-known Egyptian fruit. When just discharged it felt pulpy, yet firm, and I should imagine, from the feeling it imparted to the fingers, that it contained some fluid. That it has a central cavity there can be no doubt, for when compressed, it immediately returned to its former state as soon as the pressure was withdrawn. Having laid open so many of these curious productions, I was unwilling to do so in the present instance.

The tunic in this case was not cut open, but separated by a needle in the direction of what appeared to be a *raphe* or joint running the whole length of the mass in a waved line. When the edges were sufficiently parted, the *naked* mole was withdrawn without much effort.

Internally the tunic had a loose lining, dense, opaque, and membranaceous, between which lining and the external coat of the tunic a thin deposition of blood was observed.

Fig. 5. *Mola Mytilus*.

This is a highly interesting case of *Mola*, to which I have given the designating appellation of *Mytilus* from its suggesting, when laid open longitudinally, the idea of that shell (muscle).

It is an oblong mass, broader at one end than at the other, as all these productions of the uterine cavity are found to be. In its external appearance it is fleshy, pulpy, of variegated tints even at the very moment of its expulsion, irregularly smooth, and free from any pellicle or membranaceous covering.

Internally it exhibits an oblong cavity, corresponding in figure, relative breadths, and length to the containing mass, which looks like a thick coagulum at the sectional edges. This cavity, however, is not a mere hollow in the general mass, but looks like an oblong membranous pouch imbedded in that mass. Its interior is lined by an exquisitely delicate and almost fumiform pellicle—lactescent or opalescent. The pointed extremity of this cavity loses itself in the brilliantly red mass of the tapering end of the mole, at neither of whose extremities is there the least semblance of any aperture.

When I laid open this curious mole, its cavity contained a small quantity of clear fluid.

REMARKS.

I have for a great many years past been in the habit of arranging into three distinct groups all those adventitious productions, or excretions of the uterine cavity, connected either with irregular menstruation or faulty conception, which authors have described under so many different names. I consider that all such productions are either the result of an organizing effort on the part of the uterus during painful menstruation, or a successive arrangement of coagula of blood pending a profuse or critical menstruation; or lastly a blighted ovum, passed as an originally-imperfect seed into the womb from the ovarium, or which has become imperfect subsequently to its reception within that organ.

To the first of these groups I have given the name of Dysmenorrhœic organizations.

To the second the name of Polymenorrhœic stratifications.

To the third the name of Pseudo-Ova, or Molæ, including what are vulgarly called *False Conceptions*.

In order to understand the first two appellations, it is necessary that I should state in this place that they are denominations adopted by me, (in my work on Abortion and Menstruation,) to signify certain modifications of the latter function, which have been considered and treated as diseases, and as such variously denominated by nosologists and others. In the work alluded to, wishing to simplify as well as to rectify the uncertain and incorrect nomenclature generally employed in such cases, I formed, and have ever after used the following scheme of classification.

- Menorrhœa, (the radical) Menstruation, from $\mu\eta\acute{\nu}$ mensis, $\acute{\rho}\acute{\iota}\omega$, to flow.
A-Menorrhœa, Suspended Menstruation, from α , privative.
Dys-Menorrhœa, Painful or Difficult Menstruation, from $\delta\upsilon\varsigma$, difficult.
Poly-Menorrhœa, Profuse Menstruation, from $\pi\omicron\lambda\upsilon$, a great deal.
Lego-Menorrhœa, Ceasing, Decreasing Menstruation, from $\lambda\acute{\epsilon}\gamma\omega$, to cease.
Allo-Menorrhœa, Vicarious (erratic) Menstruation, from $\acute{\alpha}\lambda\lambda\omicron$, one for another.

Of these five modifications of the menses, the first four may produce either organized substances, or stratifications in the cavity of the womb; but those modifications, which more commonly give rise to such productions are Dysmenorrhœa and Polymenorrhœa, and from them, therefore, I have borrowed my denominations of the groups.

Having said thus much as to generalizations, I come to speak more particularly of the specimens which I have selected, with a view to illustrate my groups. These, although not numerous, are the most complete of their kind. They have in themselves *all* the generic as well as the specific characters which distinguish them from every other preparation. Few of those characters, perhaps one or two, are to be met with in other specimens, but in that case the latter are mere varieties of the species I have represented. Membranous organizations,—coagula,—stratifications,—moles,—false conceptions, may vary from one another in some slight point, so as to appear different to different observers; but in the end, and in reality, they can only be referred to the groups I have adopted, and to these therefore I must take leave to adhere.

With respect to the pseudo-ova, or molæ, it would have been an endless task had I attempted to transcribe the smallest part of the long list which ancient as well as modern authors have drawn up of such substances; or had I registered their singular names: most of which imply some anatomical or physiological error. My scheme of classification contains only four species, and I have limited myself to that number because they are the most distinct forms of pseudo-ova or moles I have seen in the course of twenty years' practice. I have preferred giving them an unmeaning name,—one of supposed resemblance to some well-known object,—rather than to run the risk of misleading people by the use of denominations which must give rise to false notions.

One word more by way of general remarks on these important points before I conclude.

Almost every author who has written on the subject of moles, has differed from his predecessor in the use of that term, applying it to very different productions of the uterus. Some have indiscriminately called by this name the polypi of the uterus; hardened, soft or spungy coagula of blood; carneous masses expelled by the uterus; diseased or deformed ova; and in fact almost any thing in the shape of a mass that has come away from the genital passages of a female after supposed conception, or subsequently to parturition. To embrace so many different substances under one general denomination, is surely wrong, (as Denman said,) and accordingly we find such a practice condemned by many. But as

the difficulty of distinguishing a real mole from an organized coagulum was supposed to be very considerable, no successful attempt was ever made to prevent the confusion which ensues from that practice. Denman himself, for instance, has not been very felicitous in pointing out a distinction between a morbid ovum and a coagulum of blood. That writer assumes that every mole, consisting of a decayed ovum, will be found to present, "notwithstanding the external appearance of a shapelessness of flesh, various parts of a child, &c.," and also that, "although a coagulum of blood long retained in the womb, may, at the first view of its external surface, appear like organized flesh, the internal part, if cut into, will be found to consist merely of coagulated blood." Now neither of these positions is exclusively true, for, as may be seen by a reference to plates 11 and 12 of this series, we have *organized* coagula without any nucleus of hardened blood, but on the contrary with a centre or cavity lined by a membrane, on the one hand; and we have on the other hand pseudo-ova, or real moles, entirely free from the slightest trace of embryonic rudiment.

What then is the distinction between a real mole and a coagulum, no matter of what species or variety the latter be? It is this: that the former has invariably a central cavity wholly inclosed *without any opening or aperture*; whereas the latter—let it be formed in any way you please, stratified, laminated, concentric, membranaceous, solid, hollow, or with a regular cavity lined by a membrane, no matter,—will be found invariably to have at one of its extremities *an aperture*, either leading straight into the inner cavity, where such an one exists, or simply passing from one membrane or stratum of coagulated blood to the next, until it reaches the innermost, which is also perforated like the rest. This is a striking and important distinction, and I am not aware that it has been noticed or made public by any author before me.

Having been accustomed, for many years, to examine and compare together every uterine production that came away during abortion, or morbid menstruation, whenever an opportunity offered itself to me to do so, either in public or private practice; I was led to make those observations which enabled me to establish the above distinction, and which have afforded me the advantage of selecting clear and well-defined specimens of the two kinds of productions alluded to, and of afterwards submitting them to the strictly correct copying powers of Mr. Perry, the artist. The result of his accurate copies from nature is registered in the present collection of plates.

I may add that such representations are not to be found in the medical literature of either this or of any other country; and that I hope they will be the means, (even if they should fail to do any other good,) of preventing the recurrence of erroneous opinions, which lead to injurious aspersions, and often fatal conclusions.

I need scarcely repeat, at the conclusion of these Explanations, that as the plates are illustrations of the views I entertain respecting abortion, and the diseases incidental to menstruation, formed in the course of, and corroborated by, twenty years' experience,—the result of which experience I have embodied into a large volume preparing for the press; all the cases which relate to the individual delineations given in this collection of plates, will be found detailed in that work, particularly those connected with the specimens of dysmenorrhoeic organizations, polymenorrhoeic stratifications, and pseudo-ova.

END.

✂ The Work, in connection with the present Graphic Illustrations, which the Author has been preparing for the press since the year 1826, and to which allusion has been made in the course of the Explanations to the Plates, will be published without delay, entitled as follows :

ON
A B O R T I O N
 AND
 THE DISEASES INCIDENTAL TO
M E N S T R U A T I O N ;
 PRACTICAL COMMENTARIES
 BY A. B. GRANVILLE, M.D. F.R.S.
 ETC. ETC. ETC.

An Octavo Volume of about Five Hundred Pages.

Contents, overleaf.

CONTENTS.

PRELIMINARY REMARKS.

FIRST COMMENTARY, ON ABORTION.

EIGHT SECTIONS.

- | | |
|--|--|
| Sect. 1. Literary and Medical History of Abortion. | Sect. 5. Abortions in Biparous Gestation. |
| — 2. Definition of Abortion, and mode in which it takes place. | — 6. Diagnosis and Prognosis in Cases of Abortion. |
| — 3. Classification of Abortions. | — 7. Treatment of Abortion. |
| — 4. Frequency of Abortion. | — 8. Moles and False Conception. |

APPENDIX.—VARIOUS JURIDICAL QUESTIONS RESPECTING ABORTION.

SECOND COMMENTARY, ON MENSTRUATION (MENORRHŒA) AND ITS DISEASES.

FIVE SECTIONS.

- | | |
|--|---|
| Sect. 1. Literary and Medical History of Menstruation. | Sect. 4. Enumeration of the principal Diseases attendant or consequent on Menstruation. |
| — 2. Physiology of Menstruation. | — 5. Precautions to be adopted in regard to Menstruation. |
| — 3. Experiments on the Menstrual Fluid. | |

THIRD COMMENTARY, FEVERS OF MENSTRUATION.

FOURTH COMMENTARY, A - MENORRHŒA,

(TARDY, CHECKED, OR TOTALLY INTERRUPTED MENSTRUATION.)

- | | | |
|--------------------------|---------------------|-----------------|
| Sect. 1. Its definition. | Sect. 2. Treatment. | Sect. 3. Cases. |
|--------------------------|---------------------|-----------------|

FIFTH COMMENTARY, DYS-MENORRHŒA,

(DIFFICULT, OR PAINFUL MENSTRUATION.)

- | | | |
|--------------------------|---------------------|-----------------|
| Sect. 1. Its definition. | Sect. 2. Treatment. | Sect. 3. Cases. |
|--------------------------|---------------------|-----------------|

SIXTH COMMENTARY, POLY-MENORRHŒA,

(INORDINATE—PROFUSE—HEMORRHAGIC MENSTRUATION.)

- | | | |
|--------------------------|---------------------|-----------------|
| Sect. 1. Its definition. | Sect. 2. Treatment. | Sect. 3. Cases. |
|--------------------------|---------------------|-----------------|

SEVENTH COMMENTARY, LEGO-MENORRHŒA,

(CEASING OR RETREATING MENSTRUATION; AT THE CRITICAL AGE.)

- | | |
|--------------------------|---------------------|
| Sect. 1. Its definition. | Sect. 2. Treatment. |
|--------------------------|---------------------|

EIGHTH COMMENTARY, ALLO-MENORRHŒA,

(TRANSFERRED, ERRATIC, OR VICARIOUS MENSTRUATION.)

- | | |
|--------------------------|---------------------|
| Sect. 1. Its definition. | Sect. 2. Treatment. |
|--------------------------|---------------------|

CONCLUSION.

