

The examination of the pulse : including a description of the sphygmograph / by Byrom Bramwell.

Contributors

Bramwell Byrom, Sir, 1847-1931.
Royal College of Physicians of Edinburgh

Publication/Creation

Edinburgh : MacLachlan and Stewart, 1881.

Persistent URL

<https://wellcomecollection.org/works/m9tts4ck>

Provider

Royal College of Physicians Edinburgh

License and attribution

This material has been provided by This material has been provided by the Royal College of Physicians of Edinburgh. The original may be consulted at the Royal College of Physicians of Edinburgh. where the originals may be consulted.

This work has been identified as being free of known restrictions under copyright law, including all related and neighbouring rights and is being made available under the Creative Commons, Public Domain Mark.

You can copy, modify, distribute and perform the work, even for commercial purposes, without asking permission.



Wellcome Collection
183 Euston Road
London NW1 2BE UK
T +44 (0)20 7611 8722
E library@wellcomecollection.org
<https://wellcomecollection.org>

The College of Physicians

*Lt D. B. Bramwell
Amliant*

THE
EXAMINATION OF THE PULSE;

INCLUDING A

DESCRIPTION OF THE SPHYGMOGRAPH.

BY

BYROM BRAMWELL, M.D., F.R.C.P. EDIN.,

LECTURER ON THE PRINCIPLES AND PRACTICE OF MEDICINE AND ON PRACTICAL
MEDICINE AND MEDICAL DIAGNOSIS IN THE EXTRA-ACADEMICAL SCHOOL
OF MEDICINE, EDINBURGH, LATE PHYSICIAN AND PATHOLOGIST
TO THE NEWCASTLE-ON-TYNE INFIRMARY, ETC.

(Reprinted from the Edinburgh Medical Journal for December 1880.)

EDINBURGH; MACLACHLAN AND STEWART.

MDCCCLXXXI.

R37871

THE
EXAMINATION OF THE PULSE;

INCLUDING A

DESCRIPTION OF THE SPHYGMOGRAPH.

BY

BYROM BRAMWELL, M.D., F.R.C.P. EDIN.,

LECTURER ON THE PRINCIPLES AND PRACTICE OF MEDICINE AND ON PRACTICAL
MEDICINE AND MEDICAL DIAGNOSIS IN THE EXTRA-ACADEMICAL SCHOOL
OF MEDICINE, EDINBURGH, LATE PHYSICIAN AND PATHOLOGIST
TO THE NEWCASTLE-ON-TYNE INFIRMARY, ETC.

(Reprinted from the Edinburgh Medical Journal for December 1880.)



EDINBURGH; MACLACHLAN AND STEWART.

MDCCCLXXXI.

In the Press, by the same Author.

Clinical Lectures on Cerebral Tumours;

WITH APPENDIX CONTAINING NOTES OF ORIGINAL CASES.

THE EXAMINATION OF THE PULSE.¹

By observing the characters of the pulse we obtain valuable information as to—(a) the condition of the heart and arterial system; (b) the condition of the general tone (the system as a whole); the frequency and strength of the pulse being chiefly valuable in this respect. The radial is the artery which is usually examined, and in speaking of *the pulse* the radial pulse is meant; but, in cases of cardiac and arterial disease, the condition of other vessels, the carotid, temporal, brachial, etc., should be noted.

Mode of Observing the Pulse.—We observe the characters of the radial pulse by—(a) the fingers (palpation); (b) the eye (inspection); (c) the sphygmograph.

Palpation, or the Examination of the Radial Artery by the Finger.—The correct observation of the exact characters of the pulse of the finger is a matter of extreme difficulty, and is only acquired by long practice. Since, however, it is *the* method which is universally available, the student should spare no pains to make himself master of it. Two or three fingers should be applied over the artery where it becomes superficial at the lower end of the radius, and the condition of the pulse noted as regards—(a) its frequency; (b) its rhythm; (c) its volume; (d) its compressibility or tension; (e) the special characters of each pulse-wave (celerity, dirotism, etc.); (f) the condition of the arterial coats; (g) in cases of suspected aneurism or intra-thoracic tumour a comparison of the two radial pulses should be made.

Inspection of the Pulse.—In well-nourished individuals the radial pulse is hardly, if at all, visible when the circulation is tranquil. During cardiac excitement, and in emaciated subjects, the pulsation can often be distinctly seen. Pulsation is very visible in certain cases of disease, notably in atheroma, where the artery stands out as a rigid, tortuous cord, and in aortic regurgitation, where it is

¹ Being a lecture delivered in the Extra-Academical School of Medicine, Edinburgh.

visible, jerking, collapsing, and tortuous (the locomotive pulse). In cases, too, of vaso-motor relaxation and excited action of the heart it may present some of these characters.

THE SPHYGMOGRAPH.

The exact characters of the pulse are graphically demonstrated by means of the sphygmograph. This instrument is chiefly valuable as an indicator of the general condition of the vascular system and the mode in which the circulation is being carried on, and as a means of studying the individual characters of each pulse-wave. It is comparatively useless and superfluous as a means of diagnosing individual cardiac lesions. Mahomed's modification of Marey's instrument is the best form.¹

Description of the Instrument.—The sphygmograph consists of—

1. A steel spring, A (see figs. 1, 2, and 3), which rests on the artery, and which moves up and down with each movement of the vessel.

One end of the spring, A' (see figs. 2 and 3), is so attached by a hinge to the framework of the instrument that vertical (up and down) movement is alone permitted. To the under surface of the free end of the spring an ivory pad, A'', is fixed. The ivory pad rests on the artery.

2. An arrangement of levers, by means of which the movements of the spring (*i.e.*, of the artery) are magnified and recorded on a piece of smoked paper.

There are two levers. The lower one, B, is so hinged by its proximal end, B', to the middle of the steel spring, that up and down movement is alone permitted. The free end of this lever, B'', is turned up at a right angle, and ends in a rounded or knife-shaped edge. Through the free extremity of this lever a screw, D, is passed. The point of the screw (by the force of gravity) is always in contact with the steel spring (*i.e.*, the artery). The lever, and therefore its knife-edge, is raised or lowered by turning the screw. The screw D and the lever B are practically the same; any movement of one (the steel spring being fixed) necessitates a corresponding movement of the other.

The second lever, C, is so fixed at its distal end, C'', to the framework of the instrument, that vertical movement is alone possible. The free end of this lever, C', carries a pen which records its movements on a strip of smoked paper propelled past it at a fixed rate by means of clockwork. In order that the movements of the steel spring (*i.e.*, the artery) may be communicated to the writing lever, the knife-edge of lever B must be in contact with lever C, as shown in figure 2. This is effected, as has been already stated, by alteration of the screw D.

3. An arrangement by which the amount of pressure excited by the steel spring on the artery can be regulated and measured. This is a most important part of the instrument, and is the modification made by Mahomed. It consists of a concentric, E, by depression of which, as in fig. 3, any definite degree of pressure can be made upon the steel spring. The amount of pressure exerted is shown on a dial (M, in fig. 1) in ounces troy. The concentric is depressed by turning the screw L (see fig. 1).

¹ The instrument is made by Krohne & Sesemann, 8 Duke Street, Manchester Square, London.

PLATE I.

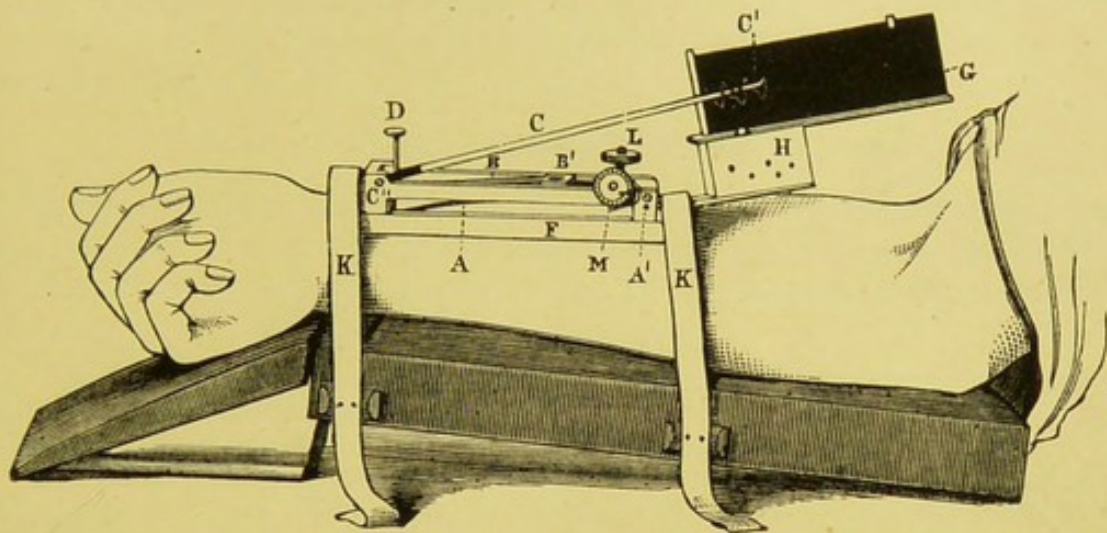


FIG. 1.

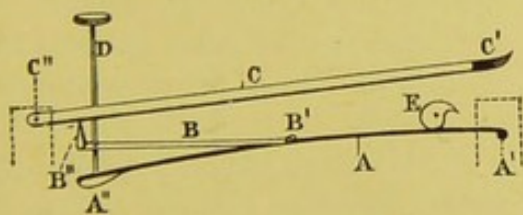


FIG. 2.

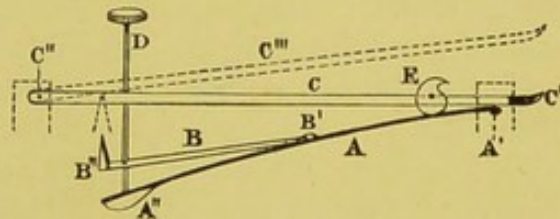


FIG. 3.


DESCRIPTION OF FIGURES.

FIG. 1.—The Sphygmograph *in situ*.—A, points to the steel spring; A', to its point of attachment to the framework; B, the first lever; B', its point of attachment to the steel spring A; C, the writing lever; C', its free end, which carries a pen; C'', its point of attachment to the framework; D, the screw for bringing the turned up free end of lever B in contact with lever C; G, the slide carrying the strip of smoked paper; H, the clockwork, which is wound up by a screw on the opposite side to that shown in the fig.; L, the screw for increasing the pressure; M, the dial on which the amount of pressure is indicated; K K, the straps by which the instrument is attached to the double inclined plane.

FIG. 2.—Scheme showing the essential parts of the instrument *when in working order*—i.e., the turned up knife-edge B'' of the short lever in contact with the writing lever C. Every movement of the steel spring, at A'', i.e., the artery, will in this position be communicated to the writing lever. The letters have the same significance as in Fig. 1.

N.B.—(The framework of the instrument has been removed.)

FIG. 3.—Scheme showing the essential parts of the instrument *after increase of the pressure*. The knife-edge B'' is no longer in contact with the writing lever, and the movements of the steel spring A'', i.e., the artery, are no longer communicated to it. In order to put the instrument into working order the knife-edge B'' must be raised to the position indicated by the dotted lines. This is effected by means of the screw D.



4. A clockwork, H, which propels at a fixed rate a slide, G, to which a strip of smoked paper is attached.

5. A framework, F, to which the various parts of the instrument are fixed, and by means of which the instrument is fastened to the arm by straps, K, K.

Mode of taking a Sphygmographic Tracing.

1. *The Position of the Patient.*—The patient should be seated by the side of a low table, his arm resting on the pad (a double inclined plane) as represented in fig. 1, the fingers semiflexed into the palm.

If the fingers are quite extended, jerking movements of the tendons are apt to occur and interfere with the tracing. If the fingers are quite flexed, the rigidity of the tendons prevents the perfect application of the instrument.

The position should be as easy as possible, for it is essential that the arm be kept at perfect rest. The shirt sleeve should be turned up, and must be quite loose. If tight, it is apt to interfere with the circulation through the arm.

The position of the artery is then to be marked with ink. The ink line should be prolonged to the ball of the thumb, *i.e.*, below the instrument when it is applied. By this means we can, without removing the sphygmograph, ascertain if the ivory pad is still *in situ*, *i.e.*, exactly over the artery.

Before applying the sphygmograph the harmless nature of the procedure must be explained to the patient, for it is of the greatest importance to avoid anything which will excite or disturb the action of the heart. Some persons become considerably agitated, thinking that an operation is about to be performed. (One of my patients left the hospital rather than have the instrument applied.) In such cases a preliminary application to a fellow-patient or nurse is advisable.

The Application of the Instrument.—1. Screw up the clockwork, and see that the instrument is in working order. 2. Apply the ivory pad *accurately* over the *very centre* of that part of the artery which lies to the inner side of the styloid process of the radius. (At this point the artery is superficial, and rests upon bone. By compressing the vessel at this spot we can be quite certain that the entire pressure of the spring will be exerted upon it.) The instrument is then firmly strapped to the arm. The straps should be unyielding—not elastic. The slide carrying the strip of smoked paper is next to be fitted into the frame. Care must be taken that the paper is firmly and evenly stretched. This is best effected by first accurately fitting it and doubling its edges over the frame, then removing and smoking it over a piece of burning camphor, and finally fitting it to the frame again. The paper should not be over-smoked, and the point of the pen must not press too heavily against it, or friction will prevent free movement, and the tracing will be imperfect.

The Adjustment of the Pen.—The point of the pen is then (by

alteration of the position of the screw D, see fig. 3) to be brought level with the centre of the strip of smoked paper, as in figs. 1 and 2.

The Adjustment of the Pressure.—The pressure of the spring must be altered until the maximum amount of movement of the lever is obtained. Every alteration of the pressure necessitates a corresponding alteration of the screw D; otherwise the point of the pen is removed from its proper position. The clockwork, which has been previously wound up, is then to be set into motion, and a tracing taken. If the tracing is satisfactory, the name of the patient, the date, and the amount of spring pressure, should be inscribed upon it (by a needle or other fine-pointed instrument). The tracing is then rendered permanent by dipping it in a rapidly drying¹ varnish.

Where a comparison of tracings from different arteries (*i.e.*, the two radials) is required, (1) the greatest care must be taken that all the conditions (the position of the patient, amount of spring pressure, etc.) are the same; (2) the best obtainable tracing from each side must also be compared. In this case it may be necessary to have the pressure on the two sides different, but all the other conditions must be rigidly the same. A comparison of the *best attainable tracing* is of great importance where there are slight differences in the pulse-waves. In this connexion it is important to remember that where the heart's action becomes excited or accelerated as the result of mental or other causes the character of the tracing is materially modified (see figs. 4, 5, 6, and 7). *Tracings should always, so far as is possible, be made during tranquil action of the heart.*

Character of a good Tracing.—The best tracing is that which has the highest up stroke and the most pointed apex. In some pathological conditions—as, for example, in some aneurisms (see figs. 36 and 37), and in aortic stenosis (see fig. 13)—the apex is rounded; but this is so extremely rare that a tracing in which the apices are not pointed should always be regarded as imperfect until verified by repeated and careful readjustments of the instrument.

The chief points to be attended to in order to obtain a good tracing are—(1) the accurate adjustment of the ivory pad to the centre of the artery; (2) the proper regulation of the pressure. Figures 8 and 9 show tracings from the same pulse with different degrees of pressure.

Having described the mode of applying the instrument, the character of the normal and pathological pulse-tracings will now be considered.

Analysis of a Sphygmographic Tracing.—A tracing consists of a number of curves, each of which represents one beat of the pulse.

¹ The varnish recommended by Mahomed is made by macerating an ounce of gum benzoin in five ounces of rectified spirit, with frequent agitations for two days, and then pouring off the clear liquor from the insoluble constituents of the gum.





PLATE II.



FIG. 4.—Pressure, 2½ oz.

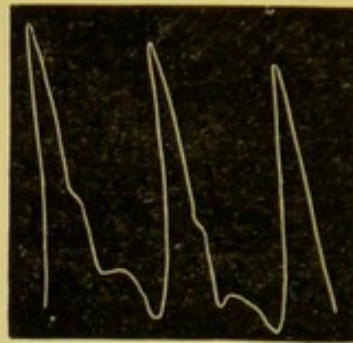


FIG. 5.—Pressure, 2½ oz.

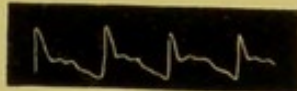


FIG. 6.—Pressure, 3 oz.

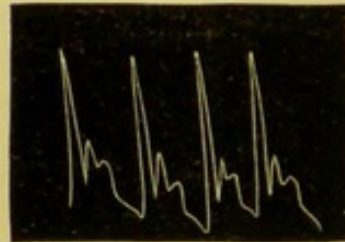

FIG. 7.—Pressure, 3 oz.




FIG. 8.—Pressure, 1½ oz.



FIG. 9.—Pressure, 2¾ oz.

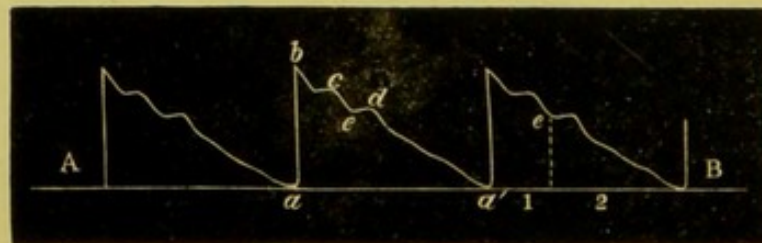


FIG. 10.—Pressure, 3 oz.

DESCRIPTION OF FIGURES.

- FIGS. 4 and 5.—Alterations in the Pulse-tracings as the result of Cardiac Excitement.—A. M., æt. 48, admitted to the Newcastle Infirmary under Dr Byrom Bramwell, suffering from obscure spinal symptoms. The heart became excited, and the tracing shown in Fig. 5 was taken, immediately after that shown in Fig. 4, the instrument in the meantime remaining *in situ*. The spring pressure was the same in each case.
- FIGS. 6 and 7.—Alterations in the Pulse-tracing which result from Cardiac Excitement.—Figs. 6 and 7 show two tracings from a case of chlorosis. Case: E. F., æt. 19, admitted to Newcastle-on-Tyne Infirmary under Dr Byrom Bramwell, 3d March 1878. The tracing shown in Fig. 6 was taken on 8th March; the tracing shown in Fig. 7 was made three minutes later, the instrument having remained *in situ*; the heart had become excited. Pressure in both cases=3 oz.
- FIG. 8.—Aortic Stenosis and Dilated Aorta.—J. C., puddler, æt. 25, admitted to Newcastle Infirmary under Dr Byrom Bramwell, 20th February 1879. The patient had been under observation for four years previously. Marked thrill and loud systolic murmur over base of heart and over aortic region. Heart moderately hypertrophied. Pressure=1½ oz.
- FIG. 9.—Tracing taken from the same patient with a slightly increased pressure; the apex is now pointed.
- FIG. 10.—Sphygmographic Tracing of Normal Pulse.—Male, æt. 25, admitted to the Newcastle Infirmary under the care of Dr Byrom Bramwell, suffering from psoriasis.
- (1.) Line of ascent, up-stroke or percussion stroke = a to b.
 - (2.) Apex = b
 - (3.) Line of descent = b to a'; d = aortic or dirotic wave; e = aortic notch; c = tidal wave.
- A B = base or respiratory line.
 1 = Systolic portion of the tracing, *i.e.*, with reference to the systole and diastole of the ventricle, not of the artery.
 2 = Diastolic portion of the tracing.

Each pulse-curve may be divided into (1) the line of ascent; (2) the apex; (3) the line of descent.

The Line of Ascent.—Up-stroke, or percussion stroke of Mahomed (*a* to *b*, see fig. 10), is in the normal pulse-tracing nearly vertical. It corresponds to the shock which is communicated to the whole arterial system by the sudden bursting open of the aortic valves. Its height varies with the amount of shock communicated to the arterial system, and depends upon—(1) the force with which the aortic valves are burst open, *i.e.*, the force of the ventricular contraction less the resistance offered by the valve-cusps; (2) (to a less extent) the condition of the arterial walls (the degree of their elasticity) and the fulness of the arterial system.

The *direction of the line of ascent* (whether vertical or oblique) depends chiefly upon—(1) the condition of the aortic segments; (2) the suddenness of the ventricular contraction.

Where there is no obstruction to the free opening of the valve-cusps, and where the contraction of the ventricle is sudden, the line of ascent is *vertical*, as, for example, in most cases of aortic regurgitation (see figs. 11 and 12), and in cases of nervous palpitation (see figs. 5 and 7), etc., etc. *Vice versâ*, where there is stenosis of the aortic orifice, and where the ventricular contraction is slow and gradual, the line of ascent is oblique (see fig. 13). When, too, the primary impulse of the ventricle is lost in the sac of an aneurism (a fusiform dilatation into elastic walls for choice), the up-stroke is oblique (see figs. 36 and 37).

The Apex, Percussion Wave.—In the normal pulse-tracing the apex, *b* in fig. 10, is pointed. In some cases of aneurism, and in aortic stenosis, it may be rounded. As previously observed, a rounded apex is so exceptional that it should always be regarded with suspicion, and should never be accepted as a fact without repeated and most careful readjustment of the instrument, alteration of the pressure, etc.

The Line of Descent.—In the normal pulse-tracing the line of descent, *b* to *a'* (see fig. 10), is gradual, and is interrupted by one or more secondary waves.

The dicrotic wave, d, occurs about the middle of the line of descent, and is always present in a normal tracing. The dicrotic wave occurs immediately after the closure of the aortic valves. The point of the tracing corresponding to the closure of the valves is termed the aortic notch, *e*. If a line be carried down the base line from the aortic notch, as in the third pulse-wave (fig. 10), it will divide the tracing into two portions corresponding to the systole and the diastole of the ventricle. The dicrotic wave is partly due to a recoil current from the closed aortic valves, partly to oscillations of the arterial walls (Foster).¹

¹ According to Dr Burdon Sanderson, "dicrotism is characteristic of that condition of the circulation in which the arterial pressure is diminished while the venous is increased. It denotes that the capillary current, instead of being constant in its rate of movement, is markedly accelerated during diastole and retarded during the diastolic interval."—*The Pulse*, p. 26.

The dicrotic wave is absent in free aortic regurgitation (see figs. 11 and 12). It is feebly marked in many pulses of high tension (fig. 20) and where the arteries are rigid, atheroma. In some cases it is greatly exaggerated, and the pulse is then said to be dicrotic (see figs. 17, 18, and 19). In such cases each pulsation may seem (to the finger) to consist of two beats (the double pulse).

The conditions which favour the occurrence of dicrotism are:—1. A sudden, sharp ventricular systole. 2. Low arterial tension. 3. Extensibility with elastic recoil of the arterial walls. 4. According to Roy, dicrotism is due to an active contraction of the arterial walls.

Clinically dicrotism is chiefly seen in cases of pyrexia. In persons in vigorous health it is developed when considerable elevation of temperature—102°-104° F.—has continued for some time (as in typhus, enteric fever, etc.) In feeble persons and in those emaciated by disease a slight elevation of temperature is sufficient to produce it (see figs. 17, 18, and 19). Dicrotism is a sign of weakness, and indicates the use of stimulants.

A hyperdicrotic pulse is a dicrotic pulse in which the full development of the dicrotic wave is prevented by the occurrence of the ventricular systole. A dicrotic pulse becomes, therefore, hyperdicrotic when the rapidity of the pulse-rate is increased. The hyperdicrotic pulse is usually only seen in cases of high fever with great exhaustion. I have, however, seen it occur in a greatly debilitated patient with only a moderate rise in temperature (see fig. 18). If the pulse becomes still more rapid, the dicrotic wave is altogether lost and the pulse becomes monocrotic.

The *predicrotic* or true tidal wave, *c*, is situated between the apex and the aortic notch. It corresponds to the prolongation of the ventricular systole, and is the true blood or tidal wave. It is not always present as a distinct wave (see figs. 14, 15). According to Dr Galabin, the separation of the percussion and tidal waves is due to the inertia of the sphygmograph, and does not occur within the artery. In cases of low arterial tension, and where the arterial walls are elastic, it is often absent. *Vice versâ*, it is best marked where there is great difficulty of arterial collapse, as in cases of contracted kidney (see fig. 20), where the arterial collapse is delayed by the high tension, and in cases of atheroma (see fig. 23), where the arteries are inelastic, and hence do not readily contract. In atheroma the pulse is usually of *low tension*, *i.e.*, readily effaced by a small amount of pressure. The predicrotic wave may be present in some and absent in other pulse-curves of the same tracing. In one of my cases (see fig. 24) it occurred with every alternate beat. (The explanation of this circumstance was obscure.)

Other secondary waves sometimes occur in the lower part of the line of descent. Their causation is obscure, but, so far as is known, they are of little practical importance. In a normal tracing the different pulse-waves are identically the same, and the base line is horizontal (see fig. 10).

PLATE III.

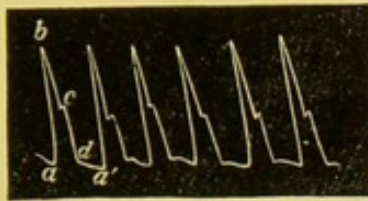


FIG. 11.—Pressure, 2½ oz.

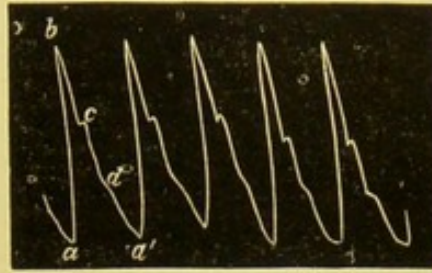


FIG. 12.—Pressure, 3 oz.



FIG. 13.—Pressure, 1½ oz.




FIG. 14.—Pressure, 3 oz.

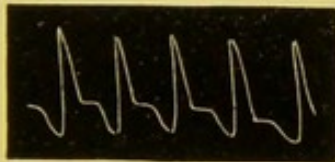


FIG. 15.—Pressure, 2 oz.




FIG. 16.—Pressure, 2½ oz.

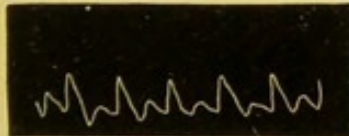


FIG. 17.—Pressure, 3 oz.

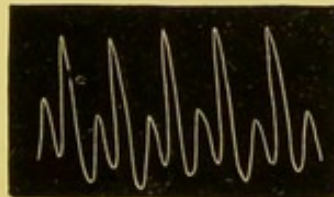


FIG. 18.—Pressure, 3 oz.








FIG. 19.—Pressure, 4 oz.

DESCRIPTION OF FIGURES.

- FIG. 11.—*Aortic Regurgitation*.—Case: G. A., æt. 56, admitted to Newcastle Infirmary under Dr Byrom Bramwell, 21st February 1878, suffering from shortness of breath and swelling of feet. Had been ill for three months. The face was pale and anxious, lips slightly dusky. Double aortic murmur; heart considerably hypertrophied; apex between 6th and 7th ribs, 3 inches below and 2 inches outside left nipple. Considerable hypertrophy and engorgement of right heart. Died 5th March 1878. Aorta very atheromatous; aortic valves very incompetent; segments shrunken, turned in towards the ventricle; coronary arteries much obstructed; cardiac walls fatty; left ventricle dilated; pericardium adherent. The arteries were practically empty during cardiac diastole. *a - b* = percussion stroke; *b* = apex; *c* = tidal wave; *d* indicates the position of the aortic wave, which is absent in this tracing.
- FIG. 12.—*Aortic Regurgitation*.—Taken from same patient as No. 11 after administration of digitalis. The letters have the same significance as in Fig. 11.
- FIG. 13.—*Aortic Stenosis*.—J. B., æt. 51, admitted to Newcastle Infirmary under Dr Byrom Bramwell, 29th November 1878, suffering from anemia and dropsy. There was a well-marked aortic systolic murmur; the left ventricle was not hypertrophied. The pulse-tracing seems to show that the murmur was organic, and not hæmic.
- FIG. 14.—*Mitral Regurgitation*.—M. A. C., æt. 16, admitted to Newcastle Infirmary under Dr Byrom Bramwell, 24th January 1878, suffering from cough and shortness of breath, dating from an attack of rheumatic fever two months previously. Heart's action very rapid (120-130). The first sound appeared to be reduplicated; a systolic murmur at the apex, audible when the heart became slower.
- FIG. 15.—*Weak Pulse*.—R. R., æt. 17, admitted to Newcastle Infirmary under Dr Byrom Bramwell, 21st February 1878, suffering from idiopathic anemia. Died 12th April. There was a systolic (anæmic) mitral murmur. The pulse-tracing resembles that of mitral regurgitation (see Fig. 14). Tracing made 23d February.
- FIG. 16.—*Progressive Pernicious Anæmia*.—Same patient (see Fig. 15). Tracing taken 19th March. The artery is almost empty during diastole.
- FIG. 17.—*Dicrotism*.—A. H., æt. 32, admitted to Newcastle Infirmary under Dr Byrom Bramwell, 21st March 1878, with an enormous scrofulous kidney. There were occasional rigors. This tracing was made during a rigor, the temperature being 100° F. A draught of hot milk was administered, and the tracing, shown in Fig. 18, was taken. Tracing Fig. 19 a few minutes later.
- FIG. 18.—*Hyperdicrotism*.
FIG. 19.—*Hyperdicrotism*.





Faint, illegible text or bleed-through from the reverse side of the page, located in the lower half of the document.

PLATE IV.




FIG. 20.—Pressure, $3\frac{1}{2}$ oz.

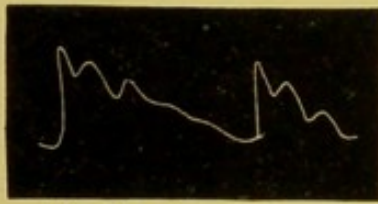

FIG. 21.—Pressure, 5 oz.

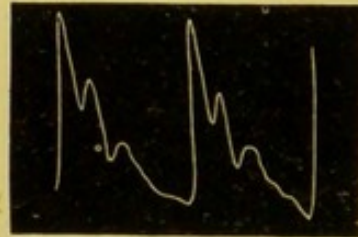


FIG. 22.—Pressure, 4 oz.

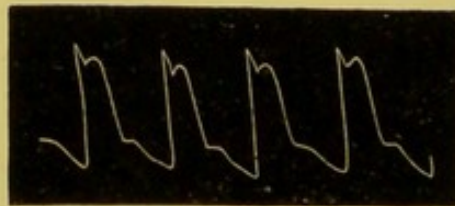


FIG. 23.—Pressure, $2\frac{1}{2}$ oz.




FIG. 24.—Pressure $4\frac{1}{2}$ oz.

DESCRIPTION OF FIGURES.

- FIG. 20.—*Hypertrophy of Left Ventricle*.—A. T., æt. 54 , admitted to Newcastle Infirmary under Dr Byrom Bramwell, suffering from cirrhotic kidney.
- FIG. 21.—*Chronic Bright's Disease*.—D. G., æt. 40 , admitted to Newcastle Infirmary under Dr Byrom Bramwell, 5th September 1878, suffering from renal dropsy (large white kidney). The pulse is one of high tension; the tidal wave is strongly marked.
- FIG. 22.—*Acute Bright's Disease*.—Tidal wave strongly marked, from a patient admitted to the Newcastle Infirmary under the care of Dr Drummond.
- FIG. 23.—*Atheroma and Aneurism of Aortic Arch*.—J. D., æt. 52 , admitted to Newcastle Infirmary under Dr Byrom Bramwell, 21st February 1878, suffering from aneurism of the ascending portion of the aortic arch and atheroma. The tidal wave is very strongly marked. There was no perceptible difference between the two pulses.
- FIG. 24.—*General Atheroma*.—J. D., æt. 60 , admitted to Newcastle Infirmary under Dr Byrom Bramwell, 21st October 1878. The radials were very tortuous and rigid; there was no valvular lesion. The tidal wave only occurs every alternate beat.

The Characters of the Pulse in Health and Disease.

1. *The Frequency of the Pulse.*—The frequency of the pulse is determined by counting the number of pulsations per minute.

The pulse should be counted for a whole, not for part of a minute.

When the pulse at the wrist is very feeble the number of cardiac contractions can be determined by auscultation over the left ventricle. In some cases, where the pulse is too feeble to be felt, its frequency can be determined by the careful application of the sphygmograph.

In the case of children and nervous persons it is often difficult to get a proper estimate of the pulse-rate owing to the increased action of the heart which results from mental agitation, the presence of the doctor, etc. Due allowance must be made for this and other disturbing causes. It is often possible at the end of the visit, when the patient's agitation has subsided, to correct the preliminary observation.

Frequency in Health.—The normal frequency varies in different individuals, and in the same individual under different circumstances. The average normal rate in the adult male in a state of rest is 72. In some individuals the normal pulse-rate is as high as 100, in others as low as 50. The possibility of such idiosyncrasies must therefore be kept in view. The pulse is quicker in children than in adults, in women than in men. Its frequency is lessened in old age. It is increased by mental excitement, by food, etc., etc. It varies, too, with the position of the patient, being quicker in the standing than in the sitting, and in the sitting than in the recumbent position. The frequency also varies with the time of day, being lower during the early morning hours. It is also decreased during sleep.

The pulse-rate is either increased or diminished by disease.

Increased Frequency.—The chief pathological conditions in which the frequency of the pulse-rate is increased are:—

1. Pyrexia (increased temperature), see fig. 18. As a rule, the amount of increase varies with the height of the temperature. According to Dr Aitken, an increase of temperature of one degree Fahr. above 98° Fahr. corresponds with an increase of ten beats of the pulse per minute, as shown in his table.

Temp. Fahr.	Pulse-rate.	Temp. Fahr.	Pulse-rate.
98°	60	103°	110
99°	70	104°	120
100°	80	105°	130
101°	90	106°	140
102°	100		

In some cases of typhoid, especially in its earlier stages, and in meningitis, the pulse may be slower than natural. At the commencement, too, of some cases of pericarditis the frequency of the pulse is diminished (Stokes).

2. In many affections associated with extreme debility (see fig.

15). This is chiefly the case where there has been some previous elevation of temperature, or where the nerve irritability of the heart is increased.

3. In deranged innervation of the heart (paralysis of the vagus or irritation of the sympathetic, the latter being the most common cause). In some of these cases the pulse is extremely rapid, as in exophthalmic goitre.

4. In some cases of organic cardiac disease, especially mitral lesions (see fig. 14), and to a less extent in aortic regurgitation (see fig. 11).

The Clinical Significance of Increased Frequency of the Pulse.

Increased frequency of the pulse, when not merely temporary, is very suggestive of the presence of pyrexia. It is, however, *per se*, an unreliable sign of fever, for, on the one hand, fever may be present without increased frequency of the pulse, as in typhoid and meningitis; or, on the other, increased frequency of the pulse may occur without fever, or even with a low temperature, as in pro-agonistic collapse. In order to ascertain the cause of the increased frequency of the pulse, the first step is to ascertain the presence or absence of pyrexia (by means of the thermometer). If there is no pyrexia, the causes mentioned under heads 2, 3, 4 must be looked for.

Diminished Frequency of Pulse (slow pulse).

The chief pathological conditions associated with a slow pulse are:—

1. Functional derangement of the heart, as in some cases of gout, jaundice.

2. Organic lesions of the heart, as fatty degeneration, aortic stenosis (see fig. 13).

3. Organic lesions of the nervous system, causing irritation of the vagi or their roots, as meningitis, compression, etc.

4. In the rapid defervescence of fever the frequency of the pulse is often very strikingly diminished.

The Clinical Significance of a Slow Pulse.

Where it occurs *per se*—i.e., without any obvious cause, as in senectus—it is of little importance. The possibility of its being due to irritation about the roots of the vagi must be remembered, and the symptoms of disease at the base of the brain, medulla, looked for.

In other cases its clinical significance depends upon the cause of the associated condition, jaundice, etc., etc.

The Rhythm of the Pulse.

In health the pulse is perfectly regular both in time¹ and volume (see fig. 10).

¹ Exceptions to this rule sometimes occur, and depend on idiosyncrasy.

1914







PLATE V.

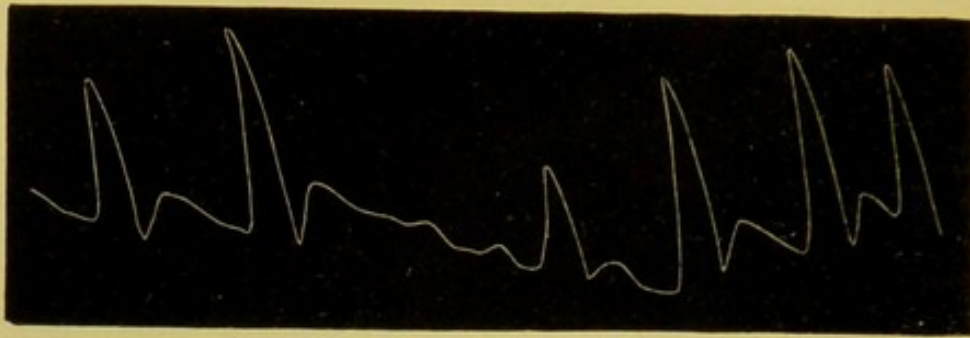


FIG. 26.—Pressure, 2 oz.




FIG. 27.—Pressure, 4 oz.




FIG. 28.—Pressure, 3½ oz.




FIG. 29.

DESCRIPTION OF FIGURES.

- FIG. 26.—*Extreme Irregularity and Failure of the Heart.*—J. R., *æt.* 68, admitted to the Newcastle Infirmary under Dr Byrom Bramwell, 28th December 1878. Died 31st December. Croupous pneumonia, limited to the upper lobe of the right lung. No cardiac affection.
- FIG. 27.—*Intermittent Pulse.*—J. B., *æt.* 38, admitted to the Newcastle Infirmary under Dr Byrom Bramwell, 11th July 1878, suffering from mitral regurgitation. The heart was much hypertrophied. Tracing made 6th January, when patient was much improved and attending as an out-patient.
- FIG. 28.—*Irregularity of the Pulse.*—W. M., *æt.* 50, admitted to Newcastle Infirmary under Dr Byrom Bramwell, 30th November 1878, suffering from the usual symptoms of mitral disease. The heart's action was extremely irregular. The left ventricle much hypertrophied. There was no rheumatic history. The symptoms were of two months' duration.
- FIGS. 28 and 29 were two consecutive tracings taken on 10th December, after the patient had improved under digitalis. The intermittent action of the heart is well shown in Fig. 29.

Alterations in rhythm are frequent in disease.

Time Irregularities.—All degrees of irregularity are met with. In some cases the alteration is only occasional, every ten, twenty, or thirty beats; in others the normal rhythm of the pulse is very much altered or entirely lost (see fig. 26).

Intermittent Pulse.—In some cases the irregularity consists in the omission of a beat (see fig. 27). This is due either to arrest of the ventricular systole, a common and often unimportant condition, or to feeble contraction of the ventricle, the blood-wave being too weak to reach the wrist—a very serious indication of failure of the heart's action. In some cases the irregularities occur at fixed intervals, *i.e.*, every two, three, or four beats. One of the most interesting of these varieties is the *pulsus bigeminus* of Traabe, in which the pulse-beats run in pairs, each pair being separated by a considerable interval.

The chief pathological conditions associated with irregularities in time are:—

1. *Functional derangements of the nervous mechanism of the heart* (venereal excess, gouty affections, tobacco, etc.).

2. *Mitral lesions*—both stenosis and regurgitation—especially after failure of compensation (see figs. 28, 29, 30, 31).

3. *Disease of the central nervous system*, such as meningitis.

In these cases a sudden change in the position of the patient—*i.e.*, rising from the recumbent position—often causes a striking alteration in the rhythm and frequency of the pulse.

4. *Extreme fatty degeneration.*

Clinical Significance of Time Irregularities.

The importance of irregularity depends upon its cause: *per se*—*i.e.*, without any organic disease of the heart or nervous system—it is of very little consequence.

Irregularities in Volume.—Irregularity in different pulse-beats depends upon unequal quantities of blood being discharged into the arterial system by the left ventricle.

Inequality in volume often depends upon and is associated with irregularity in time, for when the time between the ventricular contractions varies, the amount of blood which the ventricle has to discharge into the arteries will vary. Inequality in volume is chiefly seen in mitral lesions (see figs. 28, 29, 30, 31) and structural lesions of the cardiac walls.

Inequality due to the Influence of Respiration.—Irregularities both in time and volume sometimes depend upon the changes produced in the intra-thoracic tension by inspiration and expiration.

In the normal condition of respiration the line uniting the bases of a series of pulse-curves as obtained by the sphygmograph is even and horizontal (see fig. 10); hence it has been called the respiratory line. In the forced expiration of health, and still more markedly in some cases of disease (see fig. 32), this base line becomes

uneven, the frequency of the pulse and the arterial tension being increased by expiration, lowered by inspiration.¹

In extreme cases the pulse-wave may be entirely absent during inspiration. This is the *pulsus paradoxicus* of Kussmaul. The most striking examples of this condition are seen where fibrous adhesions pass between the thoracic parietes and the roots of the aorta and great vessels. During a full inspiration these fibrous bands are stretched, the vessels are constricted, and the pulse-wave is unable to reach the wrist.

The *pulsus paradoxicus* has also been noted in cases of pericarditis without constricting adhesions; also in cases of stenosis of the air-passages.

The *volume* of the pulse depends upon—(1) the size of the artery; (2) the amount of blood propelled into it at each ventricular systole.

The volume of the pulse is judged of by the finger, or accurately measured by means of the sphygmograph. In the pulse-curve the height of the tidal wave is the true measure of the volume of the pulse.

In *health* the volume of the pulse varies, of course, in different individuals, and in the same individual under different circumstances.

The Volume of the Pulse in Disease.—A large pulse is seen—1. In all conditions in which the arteries are dilated or relaxed, as in atheroma, febrile conditions with relaxed vessels, hot stage of intermittent fever, rheumatic fever, the early stage of the fastigium of the specific fevers. 2. In all cases in which the left ventricle is discharging a large quantity of blood into the aorta, as in hypertrophy, simple nervous excitement, etc. (see figs. 5, 20).

A *small* pulse is met with in all cases where—

1. A small quantity of blood enters the arterial system at each ventricular systole. (1.) Where the blood in the body is diminished in quantity, inanition, etc. (see fig. 17). (2.) Cases of obstruction or regurgitation at the mitral valve (fig. 14), or obstruction at the aortic orifice (fig. 14). (3.) Cases in which the left ventricle is acting very feebly (fig. 33). A small thready pulse from this cause is a very serious indication. It occurs towards the termination of many diseases, degeneration of the cardiac muscle (figs. 17, 33), etc.

2. In cases where the vessels are in a state of contraction. The

¹ At the beginning of inspiration the arterial pressure falls; it soon, however, begins to rise, but does not reach the maximum until some time after expiration has begun. The fall continues during the remainder of expiration, and passes on into the succeeding inspiration (Foster, page 344). In speaking of the cause of the respiratory undulations, Foster says, "We may conclude, then, that the respiratory undulations of blood-pressure are of complex origin, being partly the mechanical results of the thoracic movements, possibly also produced by the alternate expansion and collapse of the pulmonary alveoli, but probably, in addition, brought about by a rhythmical variation of the vascular peripheral resistance, the result of a rhythmical activity of the vasomotor centre."

PLATE VI.




FIG. 30.—Pressure, 4 oz.

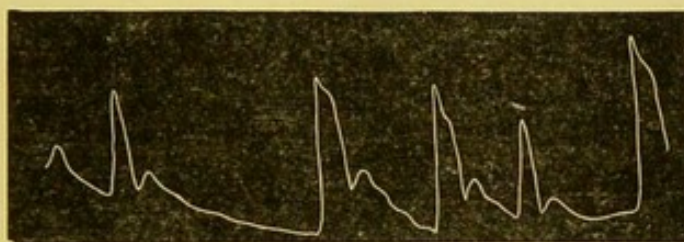


FIG. 31.—Pressure, 3 oz.




FIG. 32.—Pressure, 3½ oz.



FIG. 33.—Pressure, 2 oz.

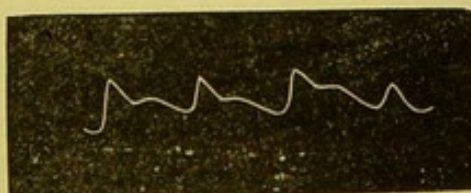


FIG. 34.—Pressure, 1½ oz.

DESCRIPTION OF FIGURES.

- FIG. 30.—*Mitral Regurgitation*.—S. B., æt. 58, admitted to the Newcastle Infirmary under Dr Byrom Bramwell, 25th February 1878, suffering from cardiac dropsy. There was a well-marked mitral systolic murmur, which disappeared under treatment. The heart was considerably enlarged (hypertrophied and dilated).
- FIG. 31.—*Irregular and Intermittent Pulse*.—O. M., æt. 40, admitted to the Newcastle Infirmary under Dr Byrom Bramwell, suffering from cardiac dropsy. The heart was very much enlarged; apex beat 4½ inches below and 3 inches outside left nipple; systolic mitral murmur.
- FIG. 32.—*Uneven Respiratory Line*.—J. R., æt. 31, admitted to Newcastle Infirmary 26th December 1878, under Dr Byrom Bramwell, suffering from acute bronchitis.
- FIG. 33.—*Small Weak Pulse*.—J. M., æt. 18, a soldier, admitted to the Newcastle Infirmary under Dr Byrom Bramwell, 23d January 1879, suffering from abscess of the liver and pericarditis. The heart was displaced upwards and to the left.
- FIG. 34.—*Small Pulse of Mitral Regurgitation*.—M. H., æt. 7, admitted to the Newcastle Infirmary under Dr Byrom Bramwell, 16th October 1878, suffering from mitral regurgitation and severe bronchitis. There was considerable hypertrophy of the left ventricle. The tracing was made when the patient was convalescent from the bronchitis.

[Faint, illegible text block]

[Faint, illegible text block]

[Faint, illegible text block]

[Faint, illegible text block]

[Faint, illegible text block]

[Faint, illegible text block]

cold stage of fevers, some cases of collapse (cholera), in inflammatory affections of the abdomen (small wiry pulse of peritonitis).

The *compressibility* or tension of the pulse depends upon the tone of the arterial walls. It is measured by the finger or the sphygmograph. The amount of pressure required to obliterate the pulse is the true measure of its tension. In vigorous health the tension of the pulse is considerable. In delicate persons and in those who lead effeminate lives the tension is low.

A pulse of *high tension* is sometimes large, sometimes small. An example of the former is seen in cases of contracted kidney, in which the high tension is associated with hypertrophy of the left ventricle. The pulse of peritonitis is an example of the latter. In some cases of kidney disease (especially the cirrhotic form) the tension of the pulse is of great importance as a means of diagnosis and as a guide to treatment.

A pulse of *low tension* is very common in disease, and is of great importance for diagnosis and treatment. Low tension is associated with relaxation of the vessels, and often with feeble action of the heart. A low-tension pulse may be small or large. The former is seen in mitral lesions; the latter in certain inflammatory conditions, as, for example, rheumatic fever, hot stage of ague, also in atheroma, where the pulse is large in volume but easily compressible. A pulse of low tension is often dicrotic.

THE INDIVIDUAL CHARACTERS OF THE PULSE-WAVE.

The Duration of the Systole to the Diastole (the celerity of the pulse).—In some cases the artery quickly reaches its point of maximum distention, and quickly subsides. Such a pulse is jerking in character. It is seen in its most marked form in aortic regurgitation (see figs. 11 and 12); also in nervous palpitation with relaxed vessels (see fig. 7). In other cases the pulse remains full for a considerable time. The rise in many of these cases is gradual; in others, as in atheroma (see fig. 23), it may be sudden. The celerity of the pulse is well brought out by the sphygmograph.

Dicrotism.—The presence or absence of dicrotism is of great importance, as has been already stated (see page 8).

Thrill.—In some cases a thrill can be felt over the radial pulse, and a murmur heard through the stethoscope. Thrill occurs in some cases of aortic regurgitation, and in some cases of vaso-motor dilatation with excited action of the heart.

The Condition of the Arterial Coats.—It is important to note the condition of the superficial vessels with regard to the presence or absence of atheroma. The chief indications of that condition are, rigidity of the arterial coats, tortuosity of the vessel, which is generally visible (stands out like a cord), and a well-marked tidal wave. The tension of the pulse is usually low.

When the superficial vessels are atheromatous the aorta is always in the same condition. The vessels of the brain are frequently

affected too. The presence or absence of atheroma in the superficial vessels may therefore be of diagnostic importance, as, for example, in the case of a doubtful intra-thoracic tumour. Other points being equal, its presence would be in favour of an aneurism as against a solid growth.

The comparison of the two radial pulses is sometimes useful in the diagnosis of aneurisms and intra-thoracic tumours. In comparing the two pulses, attention must be paid to (a) their synchronism as to time; (b) the character of the pulse-wave in each vessel.

Differences in time are most readily appreciated by the finger. In health the two radial pulses are synchronous. Where the blood-current passes through the sac of an aneurism the flow is sometimes delayed and the pulse retarded. Thus, for example, a globular elastic aneurism of the innominate artery will cause retardation in the right radial and carotid pulses.

Differences in the character of the two pulse-waves are ascertained by the finger, or more accurately by the sphygmograph. These differences consist in alterations in the size and tension of the pulse, and in the form of the pulse-curve.

The precautions which it is necessary to observe in taking comparative tracings of the two pulses have already been described (see page 6). In some individuals there is a slight difference in the size of the two pulses, even when the distribution of the vessels is normal. All the other characters of the two pulses, when normal, are the same.

In some cases the distribution of the artery is irregular (high division of the radial). In cases of inequality of size this fact must always be remembered, and the condition of the vessels higher up (brachial and axillary arteries) must be examined.

Differences in the two pulses may be due to—(1), the pressure of a tumour, solid or aneurism, on the vessels of one side (see figs. 43 and 44); (2), the alteration of the blood-wave on one side in its passage through an aneurismal sac; (3), obstruction or obliquity of the vessels arising from a diseased aorta (atheromatous or aneurismal); (4), local disease in one radial artery. The alteration produced by the passage of the blood-wave through an elastic aneurism consists chiefly in rounding of the apex of the tracing and obliteration or defacement of the normal curves. This is sometimes of considerable diagnostic importance. Figs. 35 and 36 represent the right and left pulse-tracings for a patient who was admitted to the Newcastle-on-Tyne Infirmary, under my care, suffering from dyspepsia. There was no complaint of any thoracic trouble. On taking a tracing of the left radial (I was at that time working at the sphygmograph, and taking tracings of every case admitted to hospital) I was, of course, at once struck with its aneurismal character, and on careful physical examination found decided dulness, faint pulsation, and marked accentuation of the cardiac sounds over the chest at a point corresponding to the origin of the left subclavian artery.

PLATE VII.




FIG. 35.—(Right radial). Pressure, $3\frac{1}{2}$ oz.



FIG. 36.—(Left radial). Pressure, $2\frac{1}{4}$ oz.



FIG. 37.—Pressure, 3 oz.

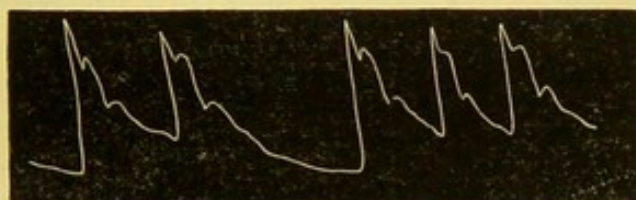


FIG. 38.—Pressure, 3 oz.




FIG. 39.—(Right radial). Pressure, $\frac{1}{2}$ oz.



FIG. 40. (Left radial). Pressure, $\frac{2}{3}$ oz.

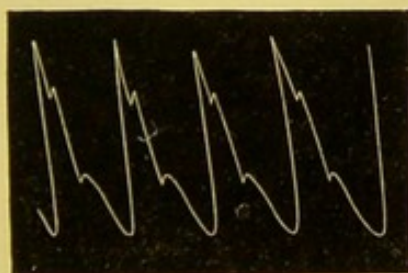


FIG. 41.—(Right radial.) Pressure, 3 oz.

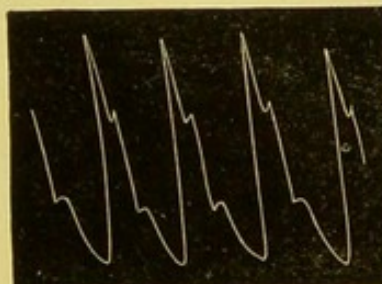


FIG. 42.—(Left radial). Pressure, 3 oz.

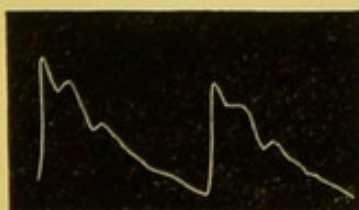


FIG. 43.—(Right radial). Pressure, $2\frac{1}{2}$ oz.





FIG. 44.—(Left radial). Pressure, $2\frac{1}{2}$ oz.

DESCRIPTION OF FIGURES.

- FIGS. 35 and 36.—*Aneurism of Left Subclavian*.—J. M., *set*. 50, admitted to Newcastle Infirmary under Dr Byrom Bramwell, 5th September 1878; all the waves in the left tracing are obliterated.
- FIG. 37.—*Aneurism of Left Axillary Artery (left radial tracing)*.—L. G., *set*. 63, admitted to the Newcastle Infirmary under Dr Byrom Bramwell, 7th March 1878, with a large aneurism of the left axillary artery. The apex is rounded; all the curves are obliterated.
- FIG. 38.—*Aneurism of Left Axillary Artery (right radial)*.—Right radial tracing for the same patient. The pulse is intermittent, but all the curves are well marked.
- FIGS. 39 and 40.—*Aneurism of Ascending Portion of Aortic Arch*.—J. D., *set*. 50, admitted to Newcastle Infirmary under Dr Byrom Bramwell, suffering from a large aneurism of the ascending thoracic aorta and atheroma. There is no important difference between the two pulses.
- FIGS. 41 and 42.—*Case of Multiple-Aneurisms*.—M. F., 64, admitted to the Newcastle Infirmary under Dr Byrom Bramwell, 18th February 1878, suffering from symptoms of intra-thoracic pressure. Died 10th March. *Post-mortem* showed dilatation and small aneurism of aortic arch. Fusiform aneurisms of the innominate, left common carotid arteries, and left subclavian, just above their origins. The aneurisms were filled with firm clots, through which a straight narrow channel for the blood remained.
- FIGS. 43 and 44.—Difference in the radial pulses, the result of pressure by an intra-thoracic tumour on the innominate artery. J. F., *set*. 50, admitted to the Newcastle Infirmary under Dr Byrom Bramwell, 24th January 1878.



Figs. 37 and 38 represent tracings for a large aneurism of the axillary artery.

In all aneurisms this difference in the pulse-tracings will not be observed. If, for example, the aneurism involves the aortic arch before the origin of the great vessels, the pulse-wave at the two wrists will present the same characters (each pulse-wave will be affected, *quoad* its waves, in a like degree). Figs. 39 and 40 illustrate this point. Again, it may so happen that an aneurism is situated on the vessel of each side, or that an aneurism is so filled up with clot that the pulse-wave is very little if at all affected in its passage through it. Such was the fact in a remarkable case of multiple-aneurism which I have recorded in this Journal (see *Edinburgh Medical Journal*, June 1878, p. 1076). The pulse-tracings in that case were almost identically the same (see figs. 41 and 42). In figs. 43 and 44 the difference in the two tracings was probably due to the pressure of a solid tumour on the innominate artery.

Asynchronism of the radial pulse and cardiac contractions occurs sometimes in—1. Fatty degeneration; 2. Extreme mitral regurgitation; 3. Utter irregularity of the heart (Walshe). As a rule, in such cases the frequency of the pulse is considerably increased.

