

Engravings of the arteries; illustrating the second volume of the Anatomy of the human body, and serving as an introduction to the Surgery of the arteries / by Charles Bell.

Contributors

Bell Charles, Sir, 1774-1842.
Royal College of Physicians of Edinburgh

Publication/Creation

London : And T. Cadell, and W. Davies, 1806.

Persistent URL

<https://wellcomecollection.org/works/up3rv8n7>

Provider

Royal College of Physicians Edinburgh

License and attribution


This material has been provided by This material has been provided by the Royal College of Physicians of Edinburgh. The original may be consulted at the Royal College of Physicians of Edinburgh. where the originals may be consulted.

This work has been identified as being free of known restrictions under copyright law, including all related and neighbouring rights and is being made available under the Creative Commons, Public Domain Mark.


You can copy, modify, distribute and perform the work, even for commercial purposes, without asking permission.





Wellcome Collection
183 Euston Road
London NW1 2BE UK
T +44 (0)20 7611 8722
E library@wellcomecollection.org
<https://wellcomecollection.org>



C. 8. 5
E. 8. 5







Digitized by the Internet Archive
in 2016

<https://archive.org/details/b21726152>

28/5
L.g. 20

ENGRAVINGS

OF THE

ARTERIES.

2.7.20

Printed by James Ballantyne and Co. Edinburgh.

ENGRAVINGS

OF THE

ARTERIES ;

ILLUSTRATING

THE SECOND VOLUME

OF THE

ANATOMY OF THE HUMAN BODY,

AND SERVING AS

AN INTRODUCTION

TO THE

SURGERY OF THE ARTERIES.

BY

CHARLES BELL, SURGEON.

SECOND EDITION.

LONDON :

PRINTED FOR LONGMAN, HURST, REES, AND ORME,
PATERNOSTER-ROW ; AND T. CADELL, AND W. DAVIES,
IN THE STRAND.

1806.

BLDG. H.
COLL. REC.
M.D. 1806

ENGRAVINGS

ARTERIES

THE SECOND VOLUME

ANATOMY OF THE HUMAN BODY

AN INTRODUCTION

SECRET OF THE NERVE

CHARLES WELLS, STATIONER

LONDON

IN THE YEAR

1800

PREFACE

TO THE

FIRST EDITION.

To facilitate the acquisition of the leading principles ought to be the first object of an elementary book, and most of all ought we to study simplicity in a work treating of Anatomy. When the way is smoothed, the student feels a rapid progress, and is pleased with his own exertions ; and it requires only a little self-examination to be assured that much of our partiality for any parti-

cular line or object of study, often results from a real or fancied superiority of knowledge ; perhaps in Anatomy, more than in any other pursuit, it is necessary to make the student sensible of his progress, before he can feel any thing like enthusiasm, or even partiality for it.

It is upon the simplicity of these Plates, therefore, more than upon their elegance, or their accuracy, (though I am confident that in this last respect they are not deficient,) that I would place their merit. When the importance of the study of the Arteries is considered—a point so fully enforced and illustrated in the

volume of the text to which I mean these plates to be attached—this book must, I think, be an acquisition to the student, since I am conscious that I should myself have found it to be so in the commencement of my studies ; it is with this feeling that I offer it with confidence to the public. I am assured, also, that the study of the Blood-vessels and Nerves from Plates, prepares us better for undertaking any surgical operation than that of bare description, however accurate, however simple, or however constantly the true practical inferences may be kept in view. It is upon the eye that the impression must be made, which is to enable us, in looking upon a

limb, to mark the course of the Arteries : Drawings are a kind of notes, too, more easily consulted; and bring to the mind, in a more lively manner, all that was associated in our first studies.

IN following the course of the Arteries, we must have continual occasion to observe, that if one branch deviate from the more general course, or be of an unusual size, the neighbouring branches have also an unusual form. In the arteries of the arm, for example, were we to observe the great Thoracic Artery of an uncommon size, and sending large branches under the *Latissimus Dorsi*, and un-

der the Scapula; were we to take our drawings of this Artery as an example of a beautiful distribution of the external Mammary Artery, without attending to the effect of such distribution on the Subscapular Artery; or again, were we to draw the Subscapular Artery of the great comparative size which it not unfrequently takes; we should not give a just representation of the natural and most usual distribution of those Arteries: for, as we find that the distribution of the Thoracic Arteries materially affects the distribution of the Articular Arteries and of the Profunda, although it be absolutely necessary in the text to describe the size and im-

portance of this Artery, because in our operations at this part we must keep in view the more dangerous and unfavourable circumstances, it does not follow that we are to make our drawings by the same rule; we should by doing so make them monstrous and unnatural.

WE thus see the necessity of combining drawing with description. In the latter we mark all the variety of distribution, and the peculiarities of each branch considered individually; but this again naturally produces intricacy, unless, by comparison with the drawings, and their short explanations, we can take a rapid and ge-

neral view of the course of the vessels. The drawings ought, therefore, to give the representation of the more general distribution, while the varieties and peculiar forms are left to description. And here comes a question of some consequence—How is a selection from the great variety of distribution of the vessels and nerves of the body to be made ?

I AM very averse from the ideas most prevalent regarding Anatomical Tables, that it is impossible to make a true representation of the parts from any individual body ; for, as we see, in looking over the variety of Anatomical Tables, that those which have

the characters of the parts distinctly marked, and have been evidently drawn from the parts dissected and laid out before the artist, are in greatest esteem for the accuracy of the anatomy, and best bear the only true test of excellence, the immediate comparison with the subject in the dissecting room ; so, on the other hand, those made by first drawing the outlines of the parts, and then the vessels, are plans merely, in which the character of the parts, and the peculiar course and turnings of the vessels, are lost.

BUT I hope I shall not be understood to say, that if a drawing be

made accurately from the subject, it will therefore answer all the purposes required. Of twenty bodies, not one, perhaps, will be found fit for drawing; but still I conceive that we are not to work out a drawing by piecing and adding from notes and preparations; we are to select carefully from a variety of bodies, that which gives largeness of parts, where the characters of parts are well marked, and where there is the most natural and usual distribution of vessels. In making our drawings of such dissections, let us allow ourselves no licence, but copy accurately. By noting in the description any little deviation, every necessary end is answered.

By long attention to the subject, I hope that I have been able to make these Plates simple, intelligible, and accurate. While the design of this book of Plates is to present to the student, at one glance, the general distribution of the vessels, and to fix them in his memory in a way which no description can accomplish, it will be found to give the most usual distribution of the branches ; for I have been careful in the selection of my subjects.

In studying the Arteries, or any part of Anatomy, we should, in the first place, run the eye over the corresponding plate, then read the ge-

neral description in the text ; and lastly, proceed to study more closely, step by step.

I KNOW the difficulties which the student must encounter in acquiring a comprehensive knowledge of the nerves ; the books on that subject being more confused and intricate to study, than the most irregular dissection. The next part, therefore, of this work, comprehends the NERVOUS SYSTEM, though the present book I conceive to be complete in itself.

PREFACE
TO THE
SECOND EDITION.

IN this edition, I trust I have shown my regard for the approbation of the public, already bestowed upon this little work, by endeavouring to improve it.

I HAVE added a Plate of the Aortic System, by my young friend and pupil, Mr Charles Cheyne, whose steady pursuit of that science to which I am devoted, has gained my esteem

and confidence. I have added some other Plates, in illustration, as of the foot, hand, and jaw, where I thought the smallness of the original scale precluded the possibility of fully disclosing the anatomy.

I HAVE also added some schemes of arrangement, of the more intricate branches, in foot-notes.

THE most essential addition, however, which I have made, is the introduction of some rules for cutting down upon the Arteries, in cases of dangerous bleedings. They were taken by a pupil, from my public lectures on the Arteries, when I had the

subject before me, and was describing and measuring the depth of parts, previous to my entering upon the rules deduced from the projecting points of bone, and the course of the tendons and muscles in the living body.

LONDON, }
Leicester Street, Leicester Square. }

ENGRAVINGS

OF THE

ARTERIES.

B

ENGRAVINGS

AND


EXPLANATION

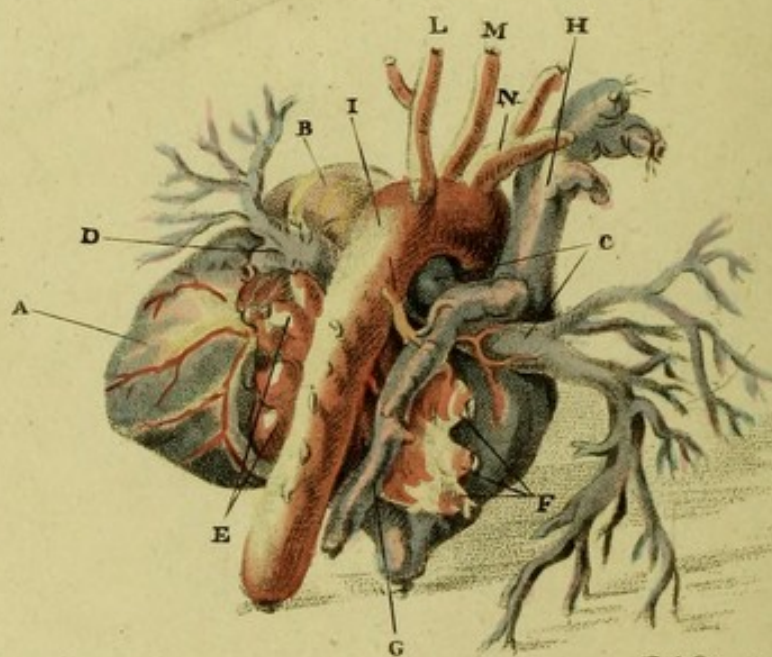
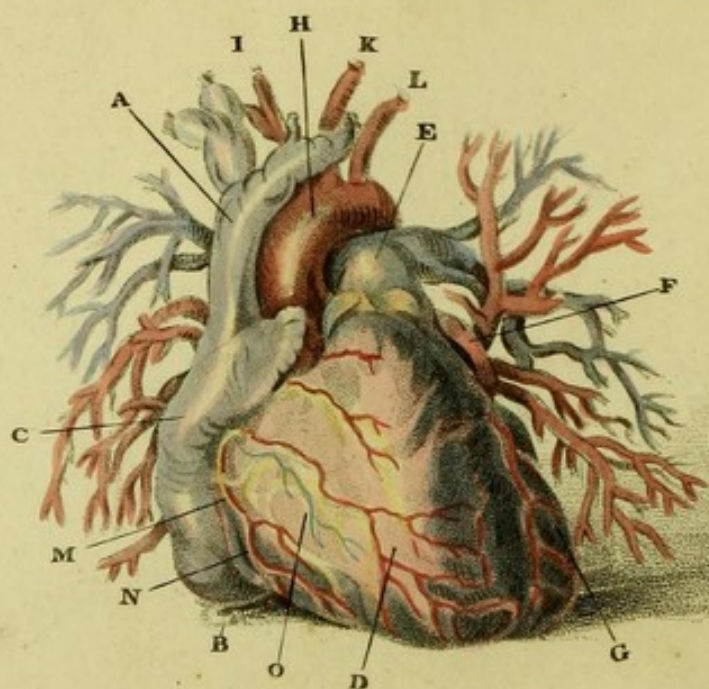
OF

PLATE I.

EXPLANATION

PLATE I





Charles Bell del.

T. Medland sculp.

EXPLANATION

OF

PLATE I.

FORE AND BACK VIEWS OF THE HEART.

FIG. I.

A View of the Heart, nearly in the Situation in which it is seen when the Breast is opened.

- A. The SUPERIOR VENA CAVA, returning the blood from the head and arms.
- B. The INFERIOR CAVA, tied where it pierces the diaphragm to convey the blood from the lower parts of the body into the right auricle.
- C. The RIGHT SINUS, or AURICLE.
- D. The RIGHT VENTRICLE.

- E. The PULMONARY ARTERY ; it is seen to divide ; one branch to pass, under the arch of the aorta, to the lungs of the right side ; the other to take an acute turn to those of the left side.
- F. The Top of the Left Sinus of the Heart, or that which is properly the auricle.
- G. THE LEFT VENTRICLE ; it is seen Fig. II. A.
- H. The Arch of the AORTA.
- I. The SUBCLAVIAN and CAROTID of the right side, rising together from the Aorta.
- K. The CAROTID ARTERY of the left side.
- L. The SUBCLAVIAN ARTERY of the left side.
- M. A Branch of the right CORONARY ARTERY.
- N. The LEFT CORONARY VEIN.
- O. A Branch of the CORONARY VEIN.

FIG. II.

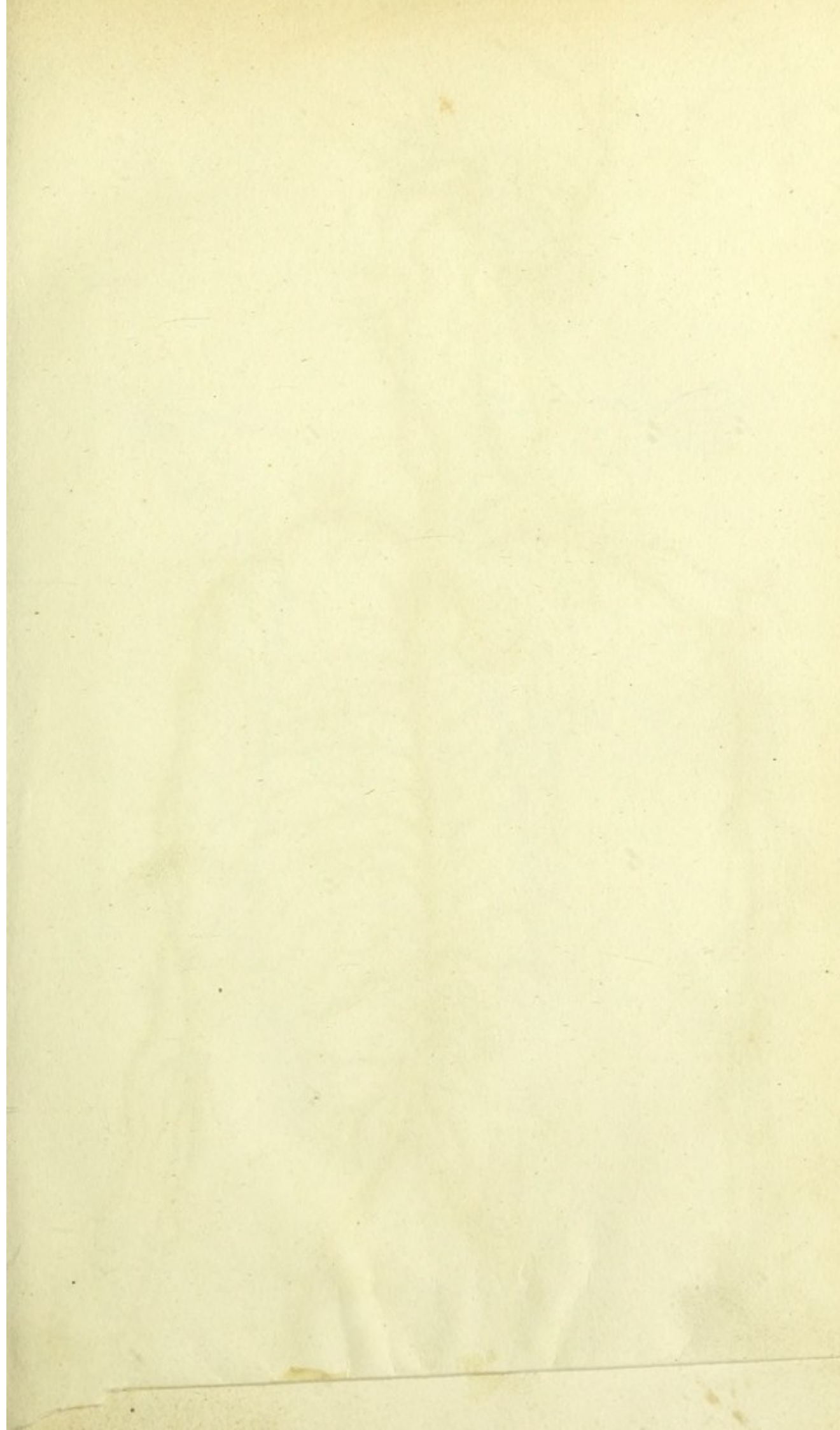
The Arteries and Veins, which are attached to the Spine, are seen in this View.

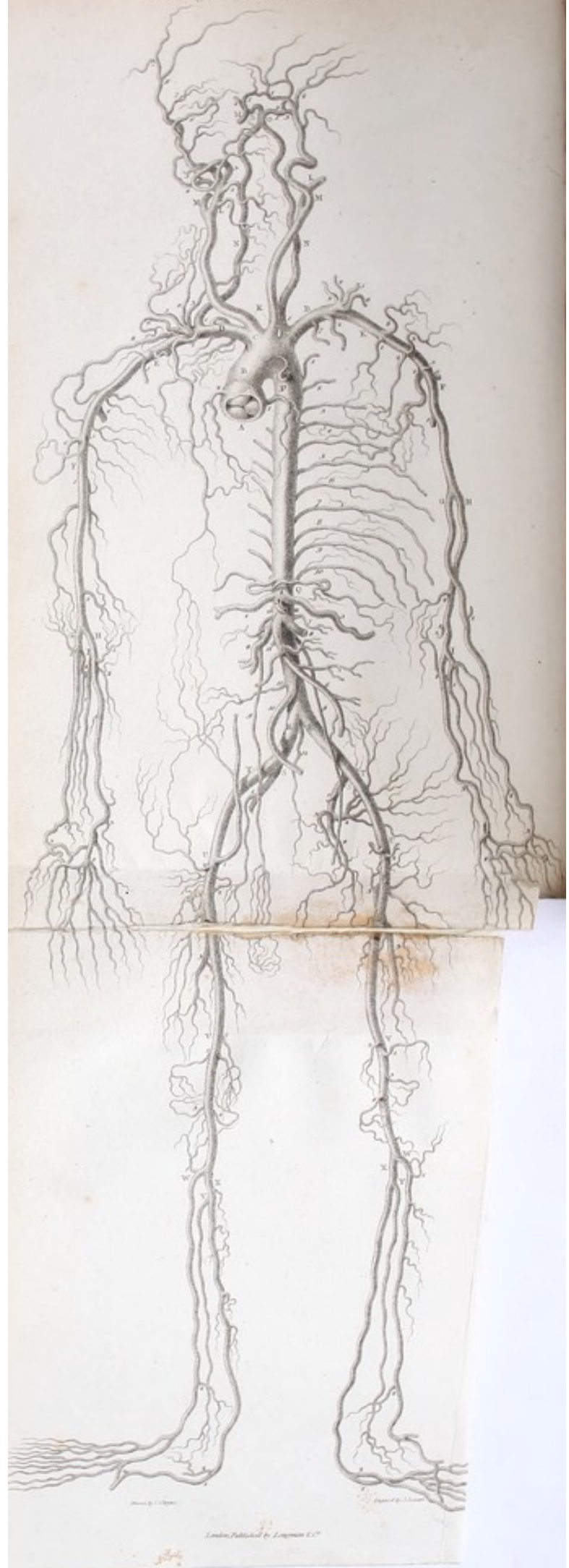
- A. The LEFT VENTRICLE of the Heart.
- B. The Trunk of the PULMONARY ARTERY.

- c. The Right Branch of the Pulmonary Artery.
- d. The Left Branch of the Pulmonary Artery.
- e. The Buds of the Pulmonary Veins of the left side, entering the left sinus of the heart.
- f. The Pulmonary Veins of the right side.
- g. The VENA SINÆ PARI, or AZYGOS ; this vein lies upon the spine, collects the blood from the back part of the thorax, and conveys it to the superior vena cava.
- h. The SUPERIOR VENA CAVA.
- i. The Aorta, where it first touches the Spine.
- k. One of the Bronchial Arteries, going to supply the lungs.
- l. The LEFT AXILLARY ARTERY.
- m. The LEFT SUBCLAVIAN ARTERY.
- n. The ARTERIA INNOMINATA, or common origin of the subclavian and carotid of the right side.

The first thing I noticed when I stepped out
of the train was the cold. It was a sharp
contrast to the heat of the train. I had
heard that the weather was bad, but I
hadn't realized it would be so cold. I
shivered as I walked down the platform.
The people around me were all bundled
up in coats and hats. I looked at my
hands. They were red from the cold.
I needed something to warm them.
I looked around. There was a small
shop. I went in. The shopkeeper
looked at me. "What can I do for
you?" he asked. "I need something to
warm my hands," I said. He pointed
to a pair of gloves. "Those are perfect
for you," he said. I took them. They
were warm. I put them on. I felt
better. I walked out of the shop. I
looked at my hands. They were warm.
I smiled. I was home.

I had heard that the weather was bad, but I
hadn't realized it would be so cold. I
shivered as I walked down the platform.
The people around me were all bundled
up in coats and hats. I looked at my
hands. They were red from the cold.
I needed something to warm them.
I looked around. There was a small
shop. I went in. The shopkeeper
looked at me. "What can I do for
you?" he asked. "I need something to
warm my hands," I said. He pointed
to a pair of gloves. "Those are perfect
for you," he said. I took them. They
were warm. I put them on. I felt
better. I walked out of the shop. I
looked at my hands. They were warm.
I smiled. I was home.





EXPLANATION

OF THE

PLATE OF THE AORTIC SYSTEM.

*Principal Divisions of the
Arteries.*

Branches of the Arteries.

B. The ASCENDING AORTA. { 1. The Left Coronary Artery.
2. The Right Coronary Artery.

C. The ARTERIA INNOMINATA. *

DD. The SUBCLAVIAN { 1. The Vertebral Artery.
2. The Internal Mammary.
3. The lower Thyroid Artery.
4. The ascendant Branch of the
Thyroid.
5. The Transversalis Colli.
6. The Transversalis Humeri.
7. The first and second Intercos-
tals.
8. The Suprascapularis.

* The Arteria Innominata commonly divides into the Right Carotid and Subclavian, but here the Left Carotid also is given from it.

*Principal Divisions of the
Arteries.*

Branches of the Arteries.

EE. AXILLARY ARTERY	<ol style="list-style-type: none"> 1. Superior Thoracic Artery. 2. Thoracica Longior. 3. Thoracica Humeraria. 4. Subscapularis. 5. Circumflexa Posterior. 6. Circumflexa Anterior.
FF. The BRACHIAL ARTERY	<ol style="list-style-type: none"> 1. Profunda Humeri Superior.* 2. Anastomoticus Major.
G. The RADIAL ARTERY	<ol style="list-style-type: none"> 1. Recurrens Radialis Anterior. 2. Arteria Superficialis Volæ. 3. Arteria Palmaris Profunda.
H. The ULNAR ARTERY	<ol style="list-style-type: none"> 1. Recurrens Ulnaris Anterior. 2. Recurrens Ulnaris Posterior. 3. Arteria Dorsalis Ulnaris. 4. Arteria Palmaris Profunda.
I. INTEROSSEOUS ARTERY	<ol style="list-style-type: none"> 1. Interossea Superior Perforans. 2. Recurrens Interossea.
K. CAROTID ARTERY.	
L. EXTERNAL CAROTID	<ol style="list-style-type: none"> 1. Arteria Thyroidea Superior. 2. Arteria Lingualis. 3. Arteria Labialis vel Facialis. 4. Arteria Occipitalis. 5. Posterior Auris. 6. Arteria Maxillaris Interna. 7. Arteria Transversalis Faciei. 8. Arteria Temporalis.

* The Lesser Profunda is seen at 16, Plate VI.

*Principal Divisions of the
Arteries.*

Branches of the Arteries.

M. INTERNAL CAROTID	{	1. Arteria Anterior Cerebri.
		2. Arteria Media Cerebri.
		3. Arteria Communicans.
N. VERTEBRAL ARTERY		* Arteria Cerebelli Posterior and Anterior.
O. BASILAR ARTERY	{	1. Arteria Communicans.
		2. Arteria Cerebri Posterior.
P. THORACIC AORTA		Arteriæ Intercostales.†
Q. ABDOMINAL AORTA	{	1. Arteria Phrenica.
		2. Arteria Cæliaca.
		3. Coronaria Ventriculi.
		4. Arteria Hepatica.
		5. Arteria Splenica.
		6. Mesenterica Superior.
		7. Arteriæ Capsulares.
		8. Arteriæ Emulgentes.
		9. Arteriæ Spermaticæ.
		10. Mesenterica Inferior.
		11. Arteriæ Lumbares.
		12. Arteriæ Media Sacra.
R. COMMON ILIACS.		
S. INTERNAL ILIAC	{	1. Arteria Obturatoria.
		2. Arteria Glutea.
		3. Arteria Ischiadica.
		4. Arteria Pudica.

* For the arteries of the Cerebellum, see Plate V. 10, 11, 12.

† The Aorta, when it is behind the root of the lungs, gives three or four arteries to nourish their substance, called Bronchial Arteries. Lying beside the Œsophagus, also, it gives to it a few arteries, the Œsophagial Arteries.

*Principal Divisions of the
Arteries.*

Branches of the Arteries.

T. EXTERNAL ILIACS.


- U. FEMORAL ARTERY { 1. Arteria Epigastrica.
2. Circumflexa Ilii.
3. Profunda Femoris. { 1. Circumflexa Externa.
2. Circumflexa Interna.
3. Perforantes.

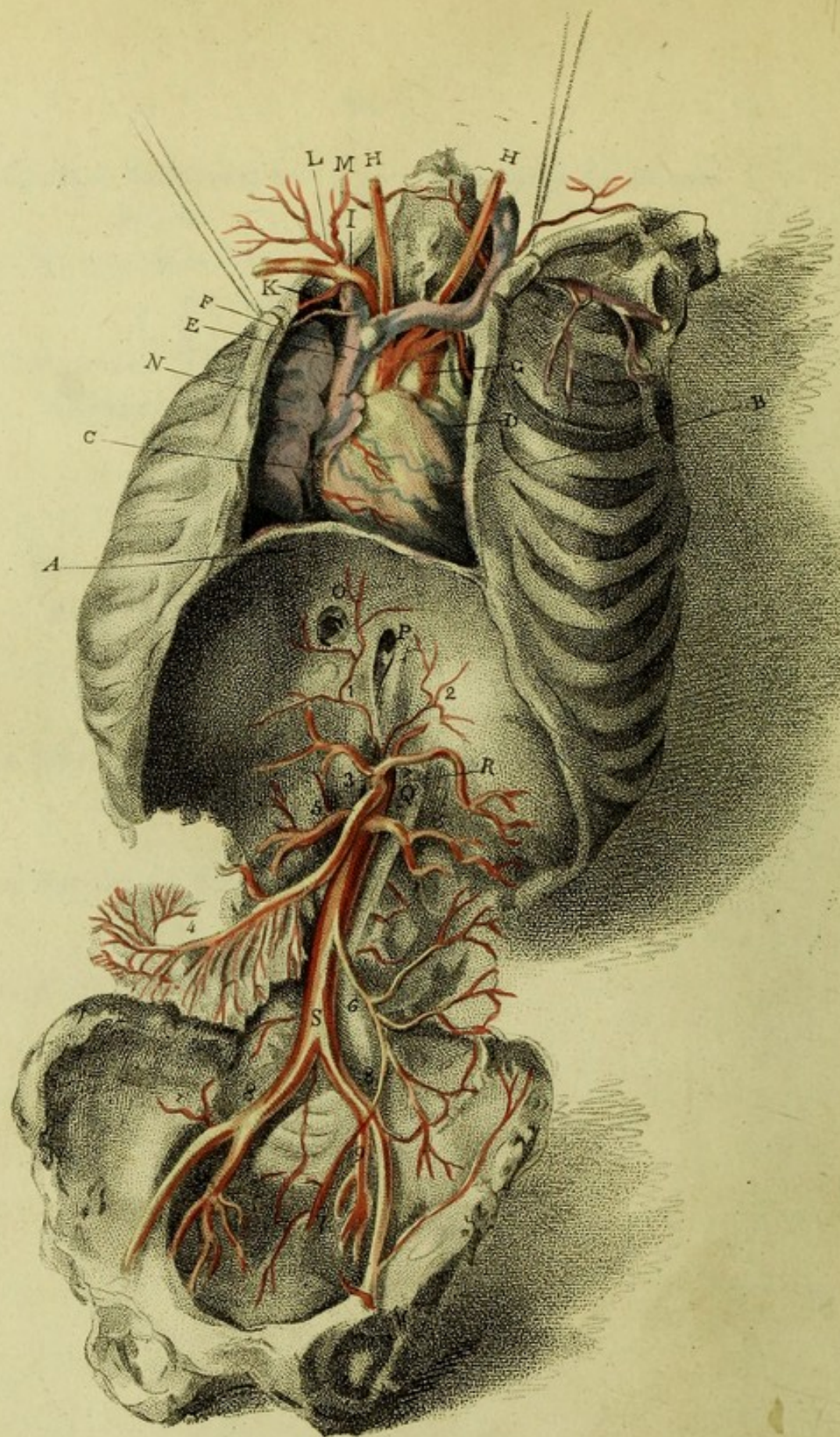
- V. POPLITEAL ARTERY { 1. Arteria Articularis Superior Externa.
2. ————— Interna.
3. ————— Media.
4. ————— Inferior Externa.
5. ————— Interna.

- X. ANTERIOR TIBIAL ARTERY { 1. Recurrens Tibialis Anticæ.
2. Malleolaris Interna.
3. ————— Externa.
4. Arteria Tarsea.

- Y. POSTERIOR TIBIAL ARTERY { 1. Plantaris Externa.
2. ————— Interna.

- Z. FIBULAR ARTERY { 1. Anterior.
2. Posterior.





Charles Bell del.

J. Medland sculp.

EXPLANATION

OF

PLATE II.

Explaining the Diaphragm, the Situation of the Heart, the Blood-vessels of the Breast, and the Abdominal Aorta.

Read the Text from p. 245—252, and p. 408.

- A. The DIAPHRAGM, dividing the thorax from the abdomen. *
- B. The HEART, lying upon the diaphragm, and with the apex obliquely to the left side. †

* A thrust made with a small sword on the left side of the chest, immediately above the seventh rib, perpendicularly to the convexity of the chest, will pass through the diaphragm into the stomach, the heart escaping.

† A thrust immediately above the left pap, and above the fifth rib, perpendicularly to the surface of the chest,

C. The RIGHT AURICLE.

D. The LEFT AURICLE; that which receives the blood from the lungs.

E. The SUPERIOR VENA CAVA, returning the blood from the arms and head to the right auricle.

F. The ARCH of the AORTA. *

transfixes the body of the left ventricle of the heart, perforating the anterior and extreme margin of the right.

A thrust made perpendicularly to the convexity of the chest, immediately under the anterior head of the fifth rib, will pass through the anterior edge of the right lung, and pierce the apex of the heart.

Perpendicularly to the convexity of the right side of the chest, and immediately below the anterior head of the third rib, the thrust made will pierce the lungs and mediastinum, and pass through the right auricle.

A thrust perpendicularly down by the left side of the sternum, betwixt the fourth and fifth ribs, will pass through the upper part of the heart, near the root of the pulmonary artery.

A thrust perpendicularly to the convexity of the chest, immediately under the right pap, and of course the fifth rib, will pass through the root of the lungs among the great vessels.

A thrust with the small-sword, horizontally from the greatest lateral convexity and upper edge of the seventh rib, will pass through the middle of the lower portion of the posterior lobe of the right lung, behind the heart, into the posterior mediastinum, when the aorta and œsophagus are about to pass through the diaphragm.

* The arch of the aorta lies three-fourths of an inch below the level of the upper part of the sternum.

- G. The PULMONIC ARTERY.
- H H. The RIGHT and LEFT CAROTID ARTERY.
- I. The SUBCLAVIAN ARTERY.
- K. The INTERNAL MAMMARY ARTERY.
- L. The THYROID ARTERY, to the shoulder, the neck, and the thyroid gland.
- M. The VERTEBRAL ARTERY.
- N. The LUNGS of the right side.
- O. The Perforation of the Diaphragm, for the transmission of the inferior cava.
- P. The Hole by which the Œsophagus passes into the Abdomen.
- Q. The Lesser Muscle of the Diaphragm. See the Text, p. 325, Vol. II.
- R. S. The whole length of the Abdominal Aorta. It is seen embraced by the diaphragm at R., and immediately giving off the phrenic and cæliac arteries.

If the assassin strikes within the clavicle, obliquely down, with the stiletto, the point will, at the depth of , pass into the arch of the aorta, and occasion a more sudden death than if struck into the heart; if the aorta should escape, some of the great branches will be wounded; even if the great branches should escape, and the trachea be wounded, the patient is in danger of instantaneous death, from the blood passing into the trachea suffocating him.

1. The RIGHT PHRENIC ARTERY.
2. The LEFT PHRENIC ARTERY.
3. The Root of the CÆLIAC ARTERY, (See Plate VII.)
4. 4. The UPPER MESENTERIC ARTERY, (See Plate VIII.)
5. 5. The EMULGENT ARTERIES.
6. The LOWER MESENTERIC ARTERY.
7. The HÆMORRHOIDAL ARTERY, a branch of the last.
8. 8. The COMMON ILIAC ARTERIES.
9. The INTERNAL ILIAC. It is seen to give off the gluteal, the ischiatic, and obturator artery.

EXPLANATION

OF

PLATE III.

EXPLANATION

PLATE III

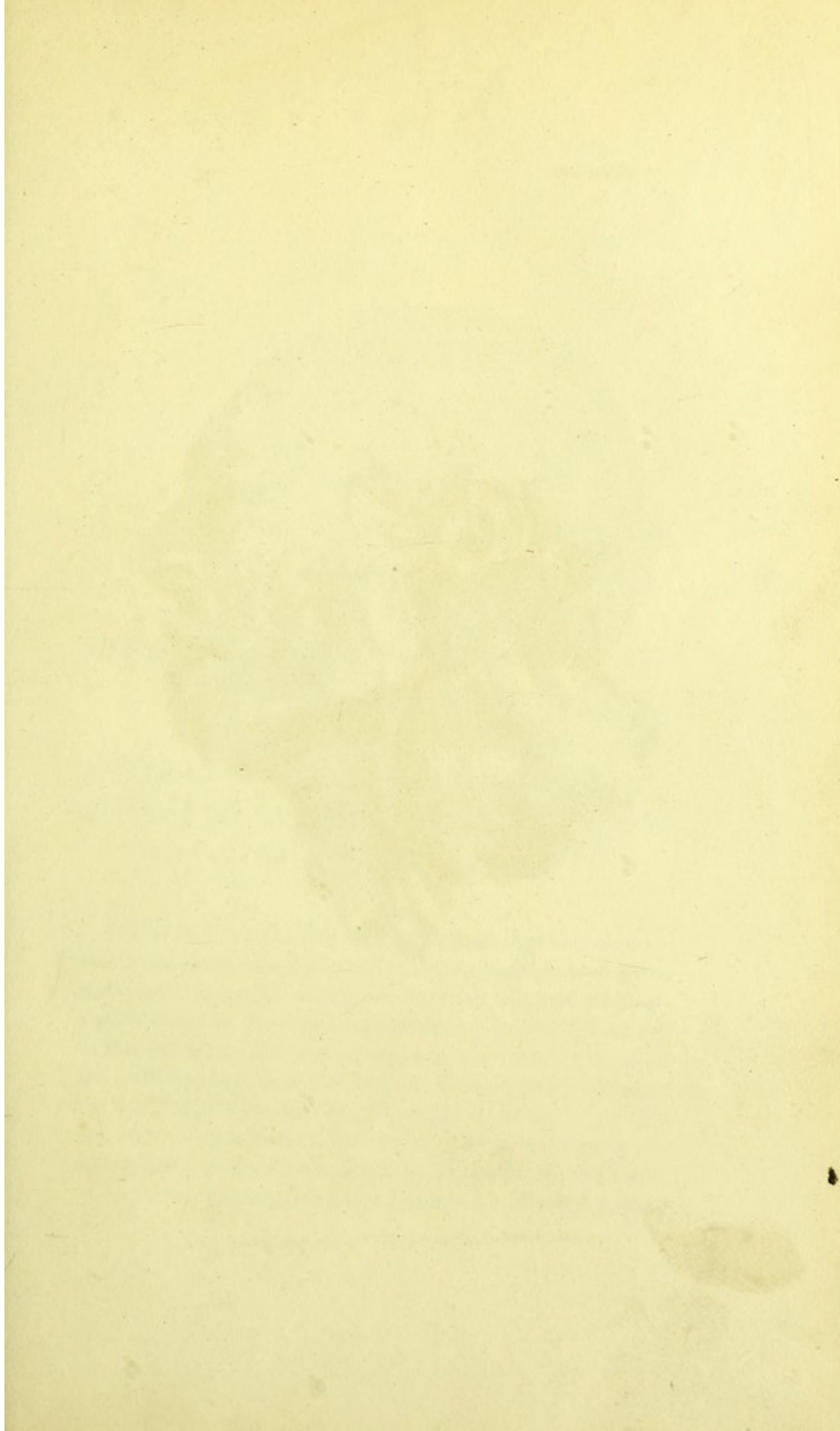
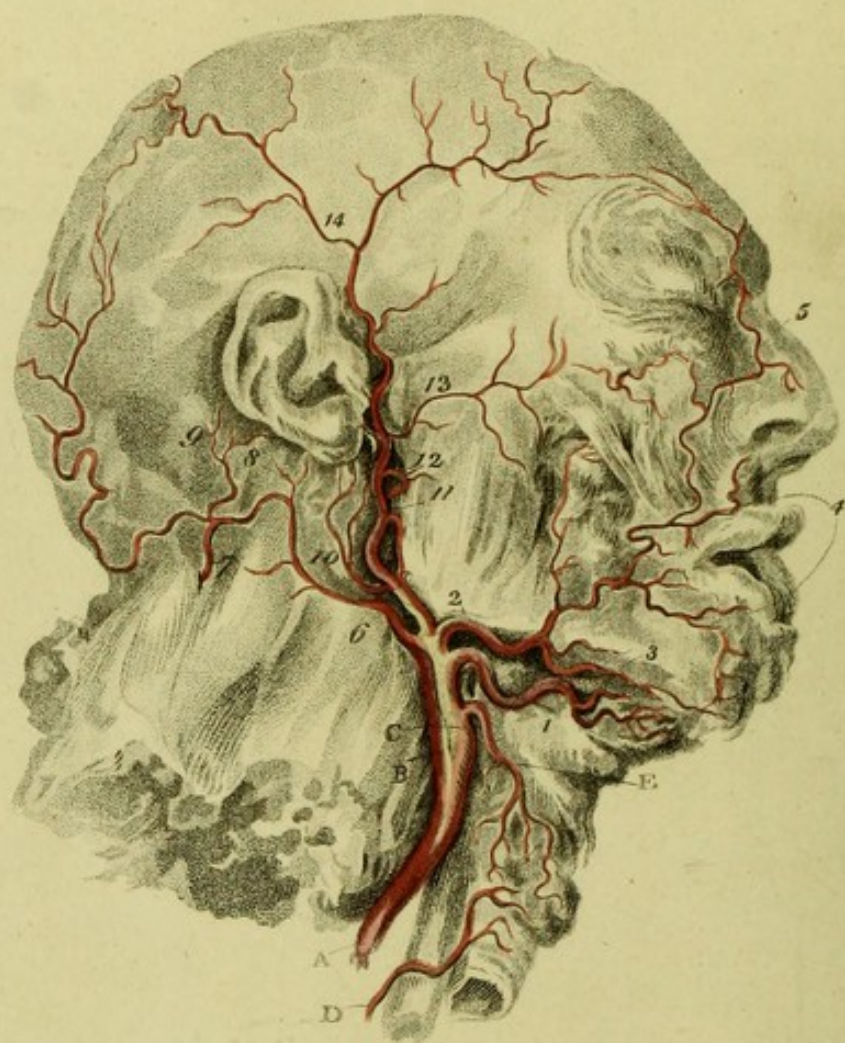


Plate III



Charles Vall del^t


The Medland sculp^t

London Published Jan^y 1801 by M^{rs} Longman & Rose Paternoster Row

EXPLANATION

OF

PLATE III.



*This and the following Plate illustrate the Text
from Page 242 to 294.*

- A. The COMMON CAROTID ARTERY. *
- B. The INTERNAL CAROTID ARTERY, or Ar-
tery of the Cerebrum.

* To cut down for this artery, I would turn the chin to-
wards the same side, and then make an incision two inches
and a half in length along the anterior edge of the ster-
noid portion of the cleido mastoideus. In doing this, the
firm cellular membrane, and some of the anterior fibres of
the platysma myoides must be cut. Having fairly laid bare
the edge of the mastoideus, we ought to do no more with
the edge of the knife; we ought then to hold aside the
mastoideus, and, with the fingers and handle of the knife,
we dig down to the artery, and insulate it: We find a small

- c. The External Carotid Artery.
- d. The LOWER THYROID ARTERY, being a branch of the Subclavian Artery. *
- e. The UPPER THYROID ARTERY, being the first branch of the Carotid. †

muscle, the omo-hyoideus passing obliquely over the artery, about an inch and a half from the head of the clavicle. The great internal jugular vein is close on the outside of the artery, the par vagum betwixt them, the sympathetic nerve below, and close upon the vertebræ. If a small nerve be observed running above the artery, it is the descendens noni.

If vessels bleed in making this incision, they are muscular branches of the thyroid artery.

* The Inferior Thyroid lies in a situation not to be tied. It lies near the side of the vertebræ, where it is, on the outer side of the carotid artery, fully five fingers breadth from the clavicle. It should be sought for directly under the omo-hyoideus, and betwixt the carotid and the anterior edge of the scaleni. It cannot be taken up there. In cutting for it, I cut the sympathetic, and probably the phrenic nerve. It would be better to endeavour to reach the artery, by turning over the side of the gland which lies before the carotid trunk. By thus stretching the gland, we find the artery as if descending from above, in two branches, to the lower part of the gland.

† It may be proposed, previous to the attempt of extirpating the thyroid gland, to tie the four arteries which supply it. We cannot reach the inferior thyroid artery before it has passed under the carotid: The only possible way is, to lift up the inferior lobe of the tumour separating

BRANCHES OF THE EXTERNAL CAROTID ARTERY.

1. The LINGUAL ARTERY. *
2. The FASCIAL ARTERY, or LABIAL ARTERY.
3. The SUBMENTAL ARTERY.
4. The UPPER and LOWER CORONARY ARTERIES.
5. The INOSCULATIONS of the extreme Branches of the Fascial Artery, with the OPHTHALMIC ARTERY.
6. The OCCIPITAL ARTERY. †

the carotid from it ; when we find the inferior thyroid artery rising in two branches, to be distributed to the gland. It would appear that these branches were descending from the carotid, by the acute turn they take downwards from their highest point on the neck.

* The Lingual Artery makes its great curve (being tortuous) immediately above the great horn of the os hyoides ; it then passes under the mylo-hyoideus. Were it ever necessary to cut upon it here, let the extreme point of the os hyoides be the mark ; for it turns just above it to pass under the mylo-hyoideus.

† The Occipital is found immediately under the mastoid process, from under the insertion of the mastoid muscle ; it runs backwards, on a level with the tip of the ear, under the insertion of the trapezius, and, of course, under

7. The place where it frequently sends down inosculation to the vertebral artery.
8. The Lesser Posterior Artery of the Ear.
9. A branch sometimes called Posterior Temporal Artery.
10. Posterior Artery of the Ear.
11. The continued Branch of the External Carotid, or sometimes the Temporal Artery; it divides into the submaxillary and proper temporal artery.
12. The INTERNAL MAXILLARY ARTERY.
See the distribution of this artery in the next Plate, fig. I. 14, and fig. II.
13. The TRANSVERSE ARTERY of the Face.
14. The TEMPORAL ARTERY, dividing into anterior and posterior temporal arteries. There are other branches less superficial.

the superior transverse ridge of the occipital bone, on the side of the neck. The internal jugular vein is above it; it is also under the origin of the digastricus, and under the ninth pair of nerves.




Fig. 1.

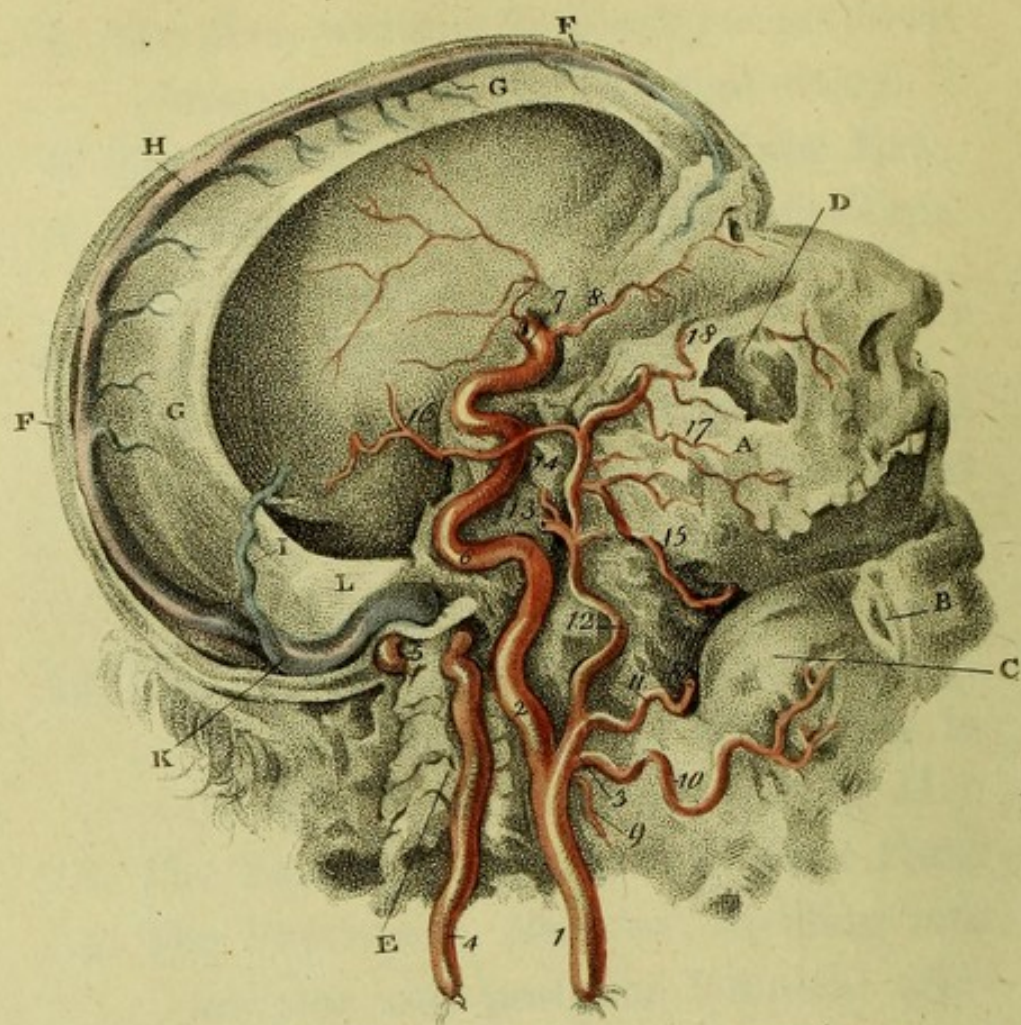
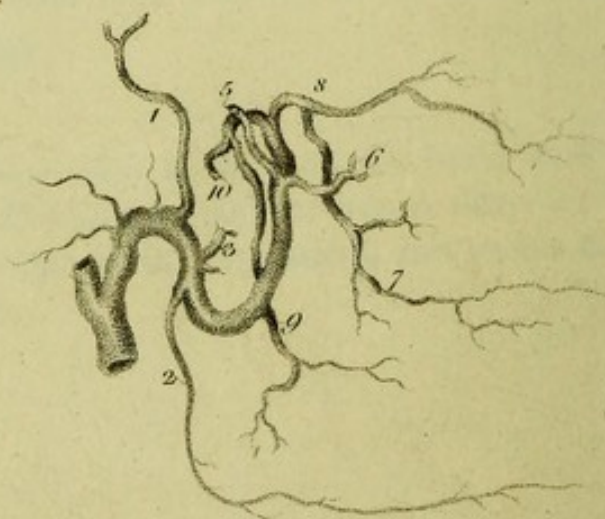


Fig. 2.



Charles Bell del.

J. Mollart sculp.

EXPLANATION

OF

PLATE IV.

*Being the Distribution of the Internal Carotid,
the Vertebral and Internal Maxillary Arteries,
as seen upon making a vertical Section
of the Head.*

FIG. I.

- A. The Upper Jaw Bone; part of it is torn away.
- B. The Lower Jaw Bone; all the angle of the right side is taken away, to shew the internal maxillary artery.
- C. The Tongue.
- D. The Antrum Highmorianum, torn open.

- E. The Vertebrae of the Neck, cut to shew the passage of the artery, encased in the bones.
- F. F. The Scull-cap, sawn through exactly in the length of the longitudinal sinus.
- G. The Falx, which divides the hemispheres of the Brain.
- H. The Longitudinal Sinus.
- I. The Fourth Sinus, returning the blood from the lower sinus of the falx, and from the vena galeni.
- K. Right Lateral Sinus.
- L. The Tentorium, which covers the cerebellum, and supports the posterior lobes of the cerebrum.

ARTERIES.

- 1. The COMMON CAROTID ARTERY.
- 2. The INTERNAL CAROTID ARTERY.
- 3. The EXTERNAL CAROTID ARTERY.
- 4. The VERTEBRAL ARTERY ; the processes of the vertebrae being cut away.
- 5. The last and violent turn of the Vertebral Artery, before entering the foramen magnum of the occipital bone.

6. The violent contortions of the Internal Carotid Artery, before entering the skull.
7. The point of the internal Carotid Artery, where, after making its turns in its passage through the bone, it appears by the side of the sella turcica. See Plate V. 1.
8. The OPTHALMIC ARTERY, derived from the carotid. It is this artery which is seen to inosculate with the Fascial Artery, in the preceding Plate, at 5.
9. The THYROID ARTERY.
10. The LINGUAL ARTERY.
11. The FASCIAL ARTERY cut short; it is seen in the third Plate, fig. 2, passing over the jaw.
12. The Continued Trunk of the External Carotid Artery; it is about to divide into the temporal and internal maxillary arteries. See the preceding Plate (11.)
13. The TEMPORAL ARTERY, cut short.
14. The INTERNAL MAXILLARY ARTERY.
15. That Branch of the Internal Maxillary Artery, which passes into the lower jaw.

16. The GREAT OR MIDDLE ARTERY of the DURA MATER; a branch of the internal maxillary. *
17. The Artery of the Upper Jaw.
18. The infra Orbital Artery; it is seen to pass out upon the face.

EXPLANATION OF FIG. II.

Read the Text from p. 278 to p. 286.

This is a Plan of the INTERNAL MAXILLARY ARTERY.

1. The MENINGEAL ARTERY, or great middle artery of the dura mater.
2. The LOWER MAXILLARY ARTERY.
3. Irregular Arteries: the PTERYGOID ARTERIES.

* It is this artery which rises through the spinous hole in the sphenoid bone, and then runs on the lower angle or spinous process of the parietal bone: here it generally lies in a deep channel, and gives occasion to a kind of rule in surgery, to avoid applying the trephine at this part.

5. The Deep INTERNAL TEMPORAL ARTERY.
6. The ARTERY of the CHEEK.
7. The Artery of the Upper Jaw.
8. The INFRA ORBITAL ARTERY.
9. The UPPER PALATINE ARTERY.
10. The Origin of the Upper Pharyngeal Artery.

1. The origin of the human race.
2. The origin of the human mind.
3. The origin of the human body.
4. The origin of the human soul.
5. The origin of the human spirit.
6. The origin of the human intellect.
7. The origin of the human will.
8. The origin of the human emotions.
9. The origin of the human passions.
10. The origin of the human actions.

THE HUMAN RACE

The human race is a collection of individuals who are united by a common origin and a common destiny. The origin of the human race is a subject of great interest and importance. It is a subject which has attracted the attention of philosophers, scientists, and theologians for many centuries. The origin of the human race is a subject which is still a matter of debate and controversy.

The origin of the human race is a subject which is still a matter of debate and controversy. It is a subject which has attracted the attention of philosophers, scientists, and theologians for many centuries. The origin of the human race is a subject which is still a matter of debate and controversy. It is a subject which has attracted the attention of philosophers, scientists, and theologians for many centuries. The origin of the human race is a subject which is still a matter of debate and controversy.


EXPLANATION

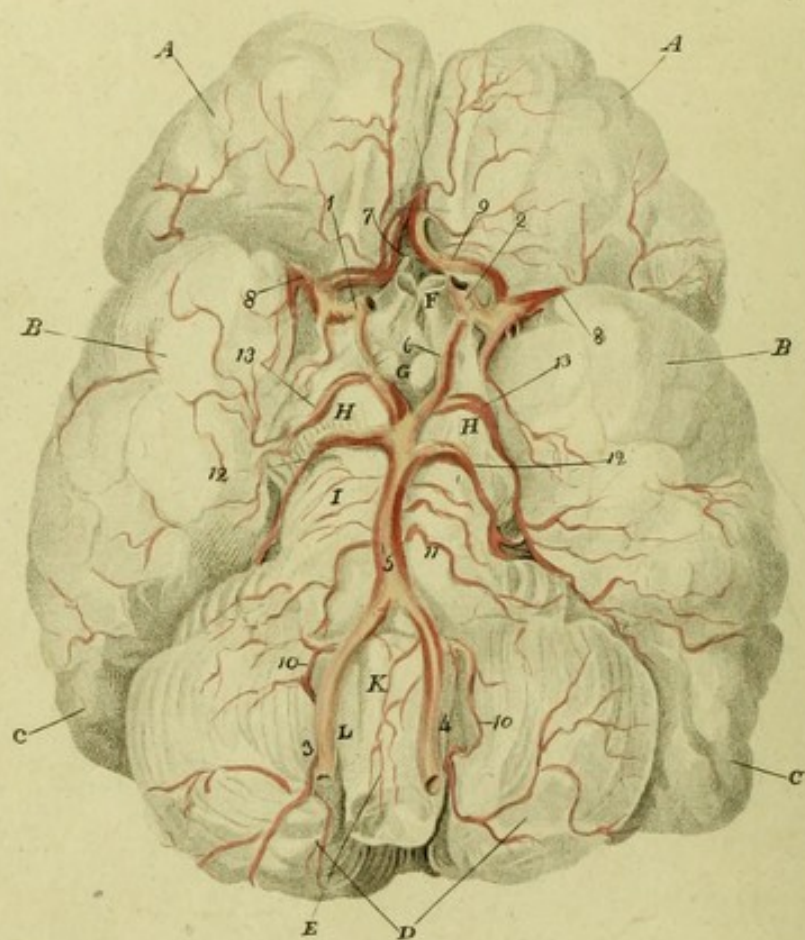
OF

PLATE V.

EXPLANATION

PLATE I





Charles Bell del.

J. Medland sculp.

EXPLANATION

OF

PLATE V.

ARTERIES OF THE BRAIN.

See the Text from page 295—317.

DIVISIONS AND EMINENCES OF THE BRAIN.

- A. A. The Anterior Lobes of the Cerebrum.
- B. B. The Middle Lobes of the Cerebrum.
- C. C. The Posterior Lobes of the Cerebrum,
which rest upon the tentorium.
- D. The Right and Left Lobes of the Cerebellum.
- E. The MEDULLA OBLONGATA.
- F. The OPTIC NERVES, cut at their union.

- G. The CORPORA ALBICANTIA ; the INFUNDIBULUM is seen betwixt these and the optic nerves.
- H. H. The CRURA CEREBRI.
- I. The PONS VAROLII, or Tuberculum Annulare.
- K. The Eminences of the Medulla Oblongata, called CORPORA PYRAMIDALIA.
- L. The CORPORA OLIVARIA.

ARTERIES.

- 1. The Right and Left Carotid Arteries, raised with the brain, and cut off as they rise at the point marked in the preceding Plate (7.), that is, as they rise by the side of the sella turcica.
- 3, 4. The Right and Left VERTEBRAL ARTERIES.
- 5. The union of the Vertebral Arteries to form the BASILAR ARTERY.
- 6. The Communicating Artery, or Anastomosis, betwixt the Basilar Artery and Carotid.
- 7. The Union of Communication betwixt the carotids of each side by the anterior ar-

tery of the cerebrum ; these anastomoses
6 and 7 form the CIRCLE OF WILLIS.

DIVISIONS OF THE INTERNAL CAROTID ARTERY.

8. The MIDDLE ARTERY OF THE BRAIN
passing into the FISSURA SILVII.
9. The ANTERIOR ARTERY of the CERE-
BRUM.

BRANCHES OF THE VERTEBRAL AND BASILAR ARTERIES.

10. The POSTERIOR ARTERY of the CERE-
BELLUM from the Vertebral Arteries.
11. A very considerable branch of the Basi-
lar Artery to the pons varolii and cere-
bellum, which however has no name.
12. The ANTERIOR ARTERY of the CERE-
BELLUM.
13. The Posterior Artery of the Cerebrum.
The lesser branches of vessels seen in this
Plate are mentioned in the text, but
are not distinguished by any particular
name.

of the ...
and ...

DIVISIONS OF THE INTERNAL CANTON

1. The ...
2. The ...
3. The ...

BRANCHES OF THE ...

4. The ...
5. The ...
6. The ...
7. The ...
8. The ...
9. The ...
10. The ...
11. The ...
12. The ...
13. The ...
14. The ...
15. The ...
16. The ...
17. The ...
18. The ...
19. The ...
20. The ...
21. The ...
22. The ...
23. The ...
24. The ...
25. The ...
26. The ...
27. The ...
28. The ...
29. The ...
30. The ...
31. The ...
32. The ...
33. The ...
34. The ...
35. The ...
36. The ...
37. The ...
38. The ...
39. The ...
40. The ...
41. The ...
42. The ...
43. The ...
44. The ...
45. The ...
46. The ...
47. The ...
48. The ...
49. The ...
50. The ...
51. The ...
52. The ...
53. The ...
54. The ...
55. The ...
56. The ...
57. The ...
58. The ...
59. The ...
60. The ...
61. The ...
62. The ...
63. The ...
64. The ...
65. The ...
66. The ...
67. The ...
68. The ...
69. The ...
70. The ...
71. The ...
72. The ...
73. The ...
74. The ...
75. The ...
76. The ...
77. The ...
78. The ...
79. The ...
80. The ...
81. The ...
82. The ...
83. The ...
84. The ...
85. The ...
86. The ...
87. The ...
88. The ...
89. The ...
90. The ...
91. The ...
92. The ...
93. The ...
94. The ...
95. The ...
96. The ...
97. The ...
98. The ...
99. The ...
100. The ...


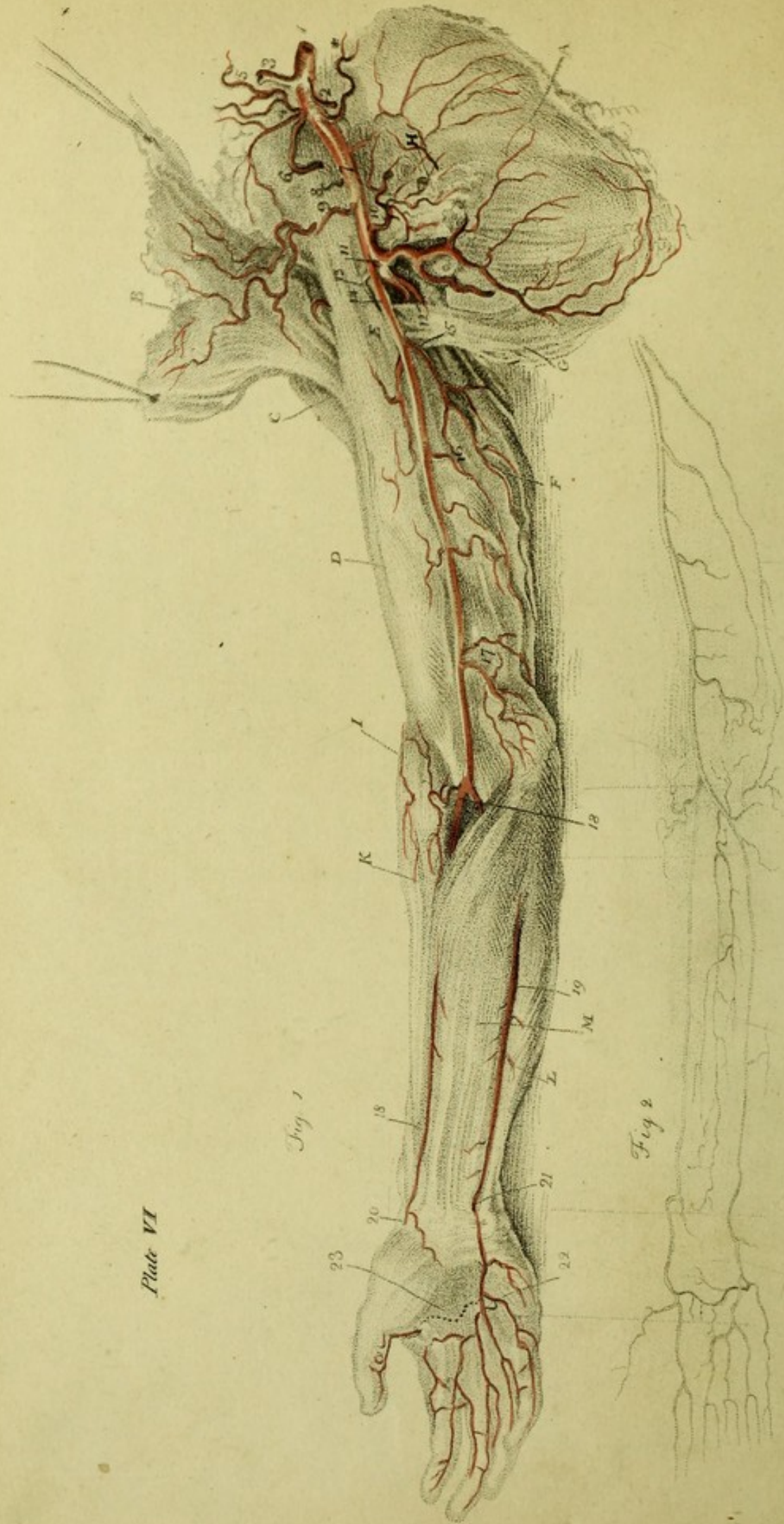



Plate VI



EXPLANATION

OF

PLATE VI.

Read the Text from p. 340 to p. 402.

OF THE ARTERIES OF THE ARM.

FIG. I.

- A. The SCAPULA.
- B. The PECTORAL MUSCLE held up.
- C. The DELTOID MUSCLE.
- D. The BICEPS MUSCLE.
- E. The CORACO-BRACHIALIS MUSCLE.
- F. The TRICEPS EXTENSOR MUSCLE.
- G. The TERES MAJOR.
- H. The TENDON of the LESSER PECTORAL MUSCLE.
- I. The SUPINATOR LONGUS.

K. The EXTENSOR CARPI RADIALIS.

L. The FLEXOR CARPI ULNARIS.

M. The PALMARIS LONGUS and FLEXOR MUSCLES of the Fingers.

From the Aorta till the Artery passes over the first rib, it is called,

1. The SUBCLAVIAN ARTERY. When this artery is injected, and tolerably full, it makes two pretty acute turns, in the form of an Italic S, before it escapes under the clavicle. Its larger curve is just where it comes through the anterior and middle portions of the Scalenus muscle. It then descends directly across the first rib. It then comes out under the clavicle, three fingers breadth from the inner extremity of the clavicle. Just at this point, viz. where it passes over the bulging of the rib, it may be compressed in the living body. Its branches are,

2. The *Internal Mammary Artery*. *

* Branches of the *Internal Mammary Artery*. 1. To the *Thymus*. 2. Accompanying the Phrenic Nerve. 3. To the Pericardium. 4. To the Mediastinum. 5. Several

3. The *Vertebral Artery*.

4. The *Thyroid Artery*.

5. The *Ascending Thyroid Artery*, a branch of the last. The *Transversalis Colli* is also generally a branch of the *Thyroid*, very irregular in its origin. Sometimes it comes from the *Thyroid*, and then receives the name of *Transversalis Humeri*; sometimes it comes from the place of the *Cervicalis Superficialis*, or even from the *Subscapularis*; sometimes from the *Subclavian* itself.

THE DEEP AND SUPERFICIAL CERVICAL ARTERIES.

6. The *Supra Scapular Artery*.

branches to the *Pectoral Muscle* and *Mamma*. 6. To the *Diaphragm*. 7. To the *Abdominal Muscles*, inosculating with the *Epigastric Artery*. If a thrust be made with a small sword in any part (below the second rib) in a line parallel with the *Sternum*, and three-fourths of an inch from its edge, it will wound the *internal Mammary Artery*.

THE AXILLA.

7. The Trunk now assumes the name of *AXILLARY ARTERY*. Its branches are, three or four to the chest; three to the scapula and shoulder.
8. The *Lesser Superior Intercostal Artery*, or *Superior Thoracic Artery*.
9. The *Greater or Longer Thoracic Artery*, or *External Mammary Artery*.
10. The *Thoracica Acromialis*, or *Humeraria*.
The *Thoracica Alaris* is not in this subject.
11. The *Subscapular Artery*; it is seen to divide upon the edge of the Scapula, into a deeper and a more superficial branch.
12. The *Posterior Circumflex Artery* of the arm.
13. The *Anterior Circumflex Artery* of the arm.

IN THE ARM.

14. The trunk now assumes the name of
HUMERAL ARTERY ; * it gives off
these branches :

15. The Superior, or GREATER PROFUN-
DA.

16. The *Lesser Profunda*.

17. The *Anastamoticus Major*; the lesser anastamosing branch comes off higher up, and follows the same direction round the inner condyle.

* The Humeral Artery does not run a perfectly straight course down the arm. When the subject is laid on its back, the arm by the side, and the palm of the hand flat upon the table, if we push a point horizontally under the arm-bone, one hand's breadth from its head *from without*, the artery escapes. When in the same horizontal direction, two hands' breadth from the head of the bone, the artery is transfixed. LOWER DOWN the arm, it again rises towards the fore part of the humerus.

To find the Humeral Artery before passing over the elbow joint, we make the patient bend his arm against a force, to show the expansion of the biceps. Having marked its place, we put the arm into a relaxed position, and make an incision along the inner edge of the biceps, or rather, we might say, just where it begins to throw off its tendinous expansion, two fingers breadth from the inner condyle of the os humeri, carrying it upwards. We find here not immediately the artery, but the radial nerve covering the artery; laying this aside, we find the artery lying betwixt its two venæ comites.

ARTERIES OF THE FORE ARM.

Extremity of the HUMERAL ARTERY. The artery divides three-fourths of an inch below the part of the *Medean Basilic Vein*, where we generally bleed.

18, 18. The RADIAL ARTERY.

19, 19. The ULNAR ARTERY.

The INTEROSSEOUS ARTERY, which divides into the *Inner* and *Outer Interosseous*.

The Recurrent Arteries from these last are, the

Recurrans Radialis Anterior.

Recurrans Ulnaris Anterior.

Recurrans Ulnaris Posterior.

Recurrans Interossea.

20. At this point the Radial Artery turns round under the supinator tendon and extensor tendons of the thumb.*

* *Radial Artery.* 1. To take up this artery on the wrist, we cut a quarter of an inch from the radial edge of the *Flexor Carpi Radialis*. N. B. The insertion of the *Supinator Radii Longus* is on the outside, but flat, giving no mark outwardly. The *Extensor Primi Internodii Po-*

Superficial Artery of the Palm.

21. The ULNAR ARTERY passing over the wrist. *

Dorsalis Ulnaris.

Arteria Palmaris Profunda Ulnaris.

22. The Great Palmar Arch, from which the arteries of the fingers are seen to proceed.

licis comes obliquely over the head of the Radius, and the insertion of the Supinator.

A fascia covers the artery here. A small nerve (from the *external cutaneous*) runs above the fascia.

2. To cut for the Radial Artery, when it has passed from the fore part of the wrist, we carry the knife on the outside of the insertion of the *Extensor Radialis Longior*, and the inside of the *Extensor Tertii Internodii Policis*. Betwixt these tendons the artery lies very deep, and over it the extreme branch of the *Muscular Spiral Nerve*.

* *Ulnar Artery*. 1. In the middle of the fore arm the artery lies under the fascia, and under the margin of the *Flexor Ulnaris* and *Flexor Digitorum Sublimis*, rather more under the margin of the last. To tie the artery, we would have to cut down betwixt these muscles. The *Ulnar Nerve* lies on the ulnar edge of the artery.

2. To cut for the Ulnar Artery near the wrist. We carry the knife upon the inside of the *Flexor Ulnaris Carpi*; we raise the fascia, which binds down the tendon; but still we have another layer of the fascia, under which the artery and its *Venæ Comites* lie. The *nerve* is lying still more under the tendon of the ulnaris than the artery, but close upon it.

23. This dotted line marks the seat of the Lesser Arch under the tendons.

FIG. II.

From this Sketch of the Arteries we can follow in idea their continued course among the muscles.

EXPLANATION
OF
ADDITIONAL PLATE VI.

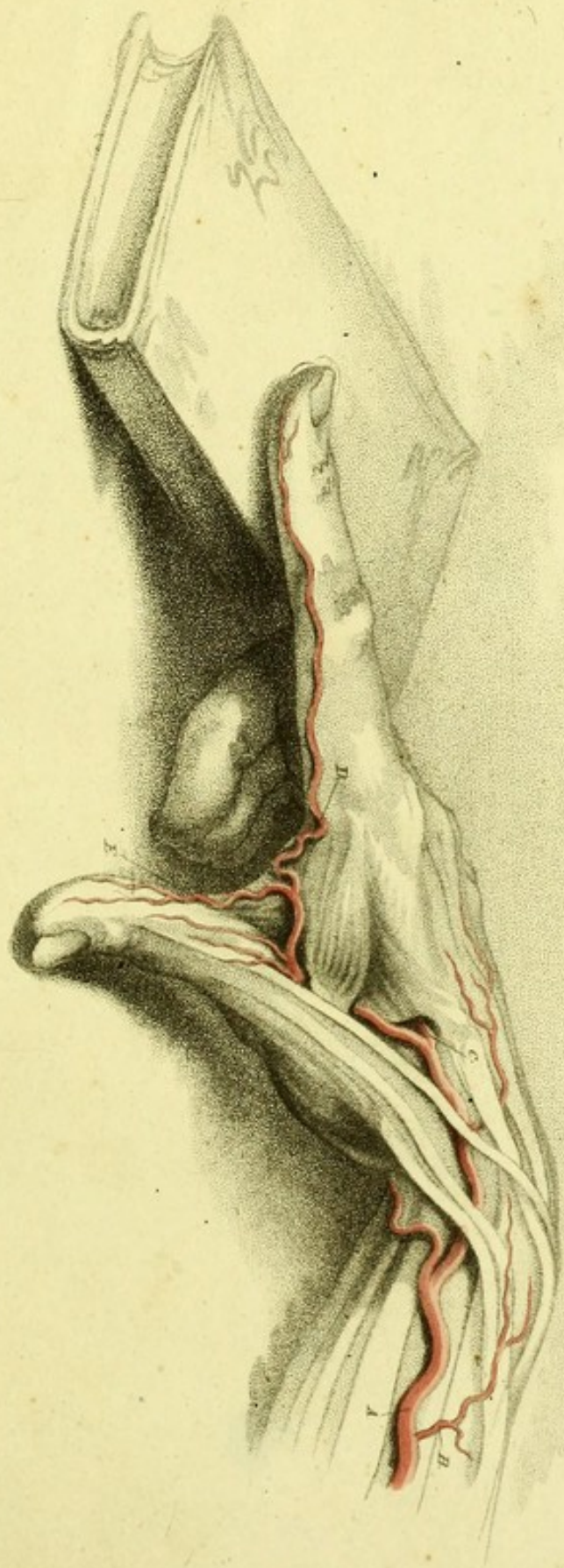
- A. ARTERIA RADIALIS.
- B. RAMUS DORSALIS.
- C. PALMARIS PROFUNDA.
- D. RAMUS AD INDICEM.
- E. RAMUS AD POLLICEM.

EXPLANATION

ADDITIONAL PLATE VI


- A. *Asperula Radialis*
- B. *Asperula Dorealis*
- C. *Asperula Prostrata*
- D. *Asperula Laidiana*
- E. *Asperula Fendleri*


ADDITIONAL PLATE VI.

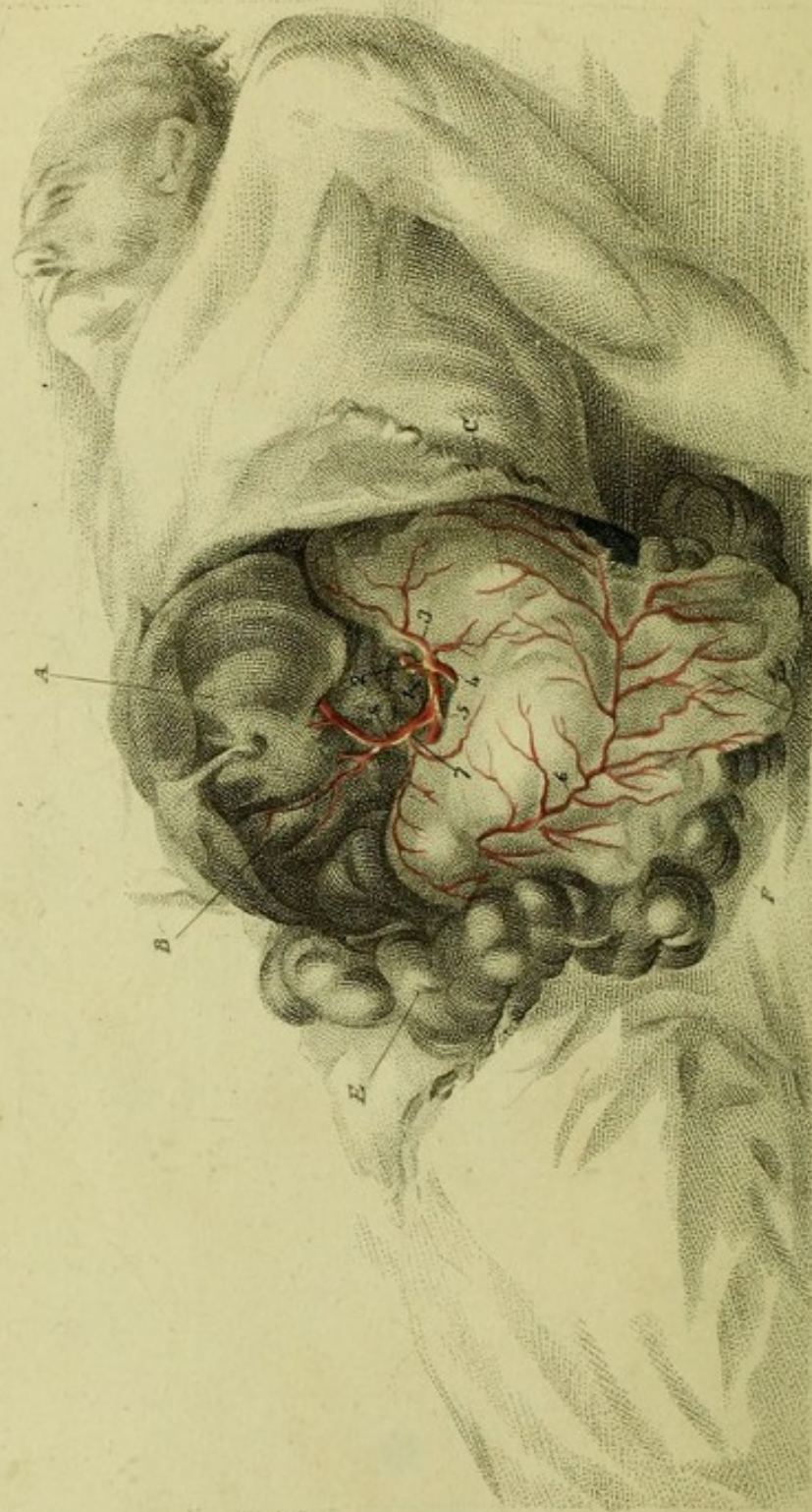


W. Hunter sculp.

W. Hunter sculp.







The Medland sculp^d

Charles Wall del^d

EXPLANATION

OF

PLATE VII.

*THE DISTRIBUTION OF THE CÆLIAC
ARTERY.*

See the Text, page 412 to 422.

- A. The LIVER raised so as to show its concave surface.
- B. The GALL BLADDER.
- C. The STOMACH laid down to the left side.
- D. The OMENTUM.
- E. The COLON.
- F. The SMALL INTESTINES.
 - 1. The AORTA.
 - 2. The Root of the CÆLIAC ARTERY.

3. The Superior Coronary Artery of the Stomach.
4. The SPLENIC ARTERY.
5. The GASTRO-EPIPLOIC ARTERY.
6. The same Artery running upon the great Arch of the Stomach.
7. The PANCREATICA DUODENALIS, a branch of the last.
8. The HEPATIC ARTERY ; it is seen to divide into the right and left hepatic arteries ; the right hepatic artery is seen to give off the CYSTIC ARTERY ; a small branch is seen passing from the trunk of the hepatic artery to the PYLORUS, *viz.* the LOWER PYLORIC ARTERY.


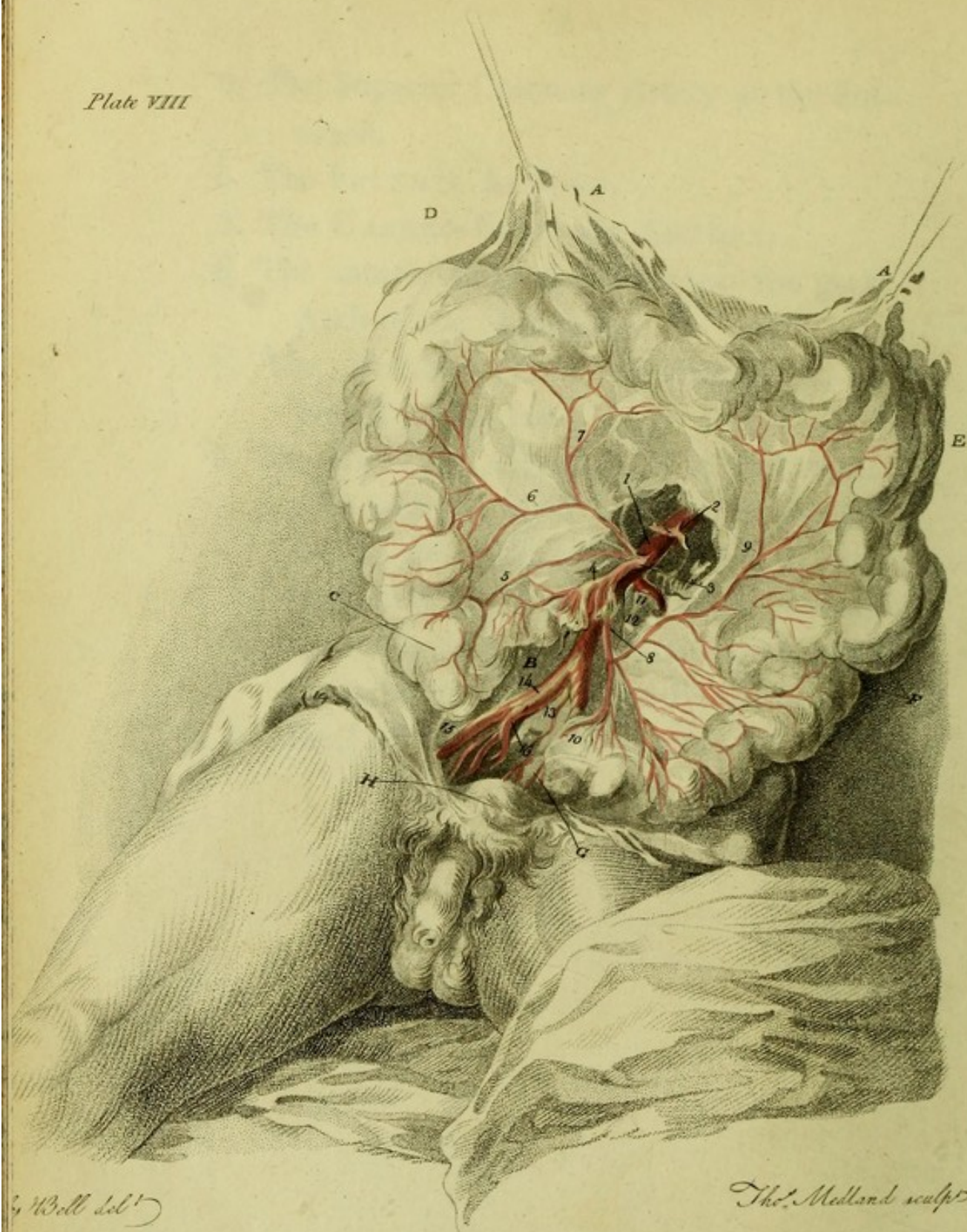



Plate VIII



EXPLANATION


OF

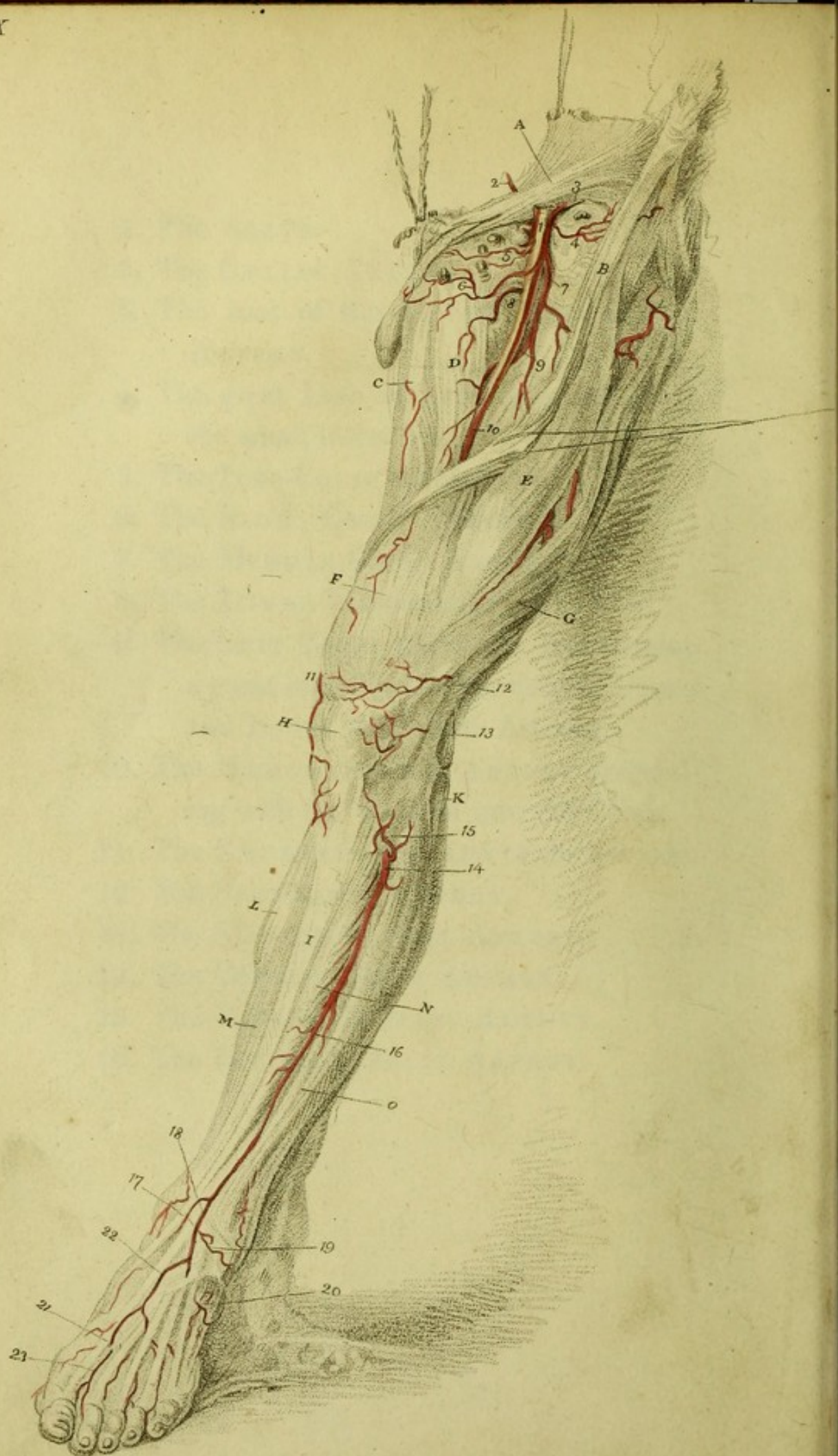
PLATE VIII.*THE MESENTERIC ARTERIES.*

See page 422 of the Text.

- A. A. The OMENTUM held up, and bearing the great Arch of the Colon.
- B. The termination of the INTESTINUM ILEON in the Caput Coli.
- C. CAPUT COLI.
- D. E. The ARCH of the COLON, which stretches across the belly.
- F. The SIGMOID FLEXURE of the COLON.
- G. The RECTUM.
- H. The BLADDER of URINE.

1. The AORTA.
2. The CÆLIAC ARTERY.
3. The root of the UPPER MESENTERIC ARTERY.
4. The great Lash of Arteries which go to the small intestines.
5. The ILEO-COLIC ARTERY.
6. The RIGHT COLIC ARTERY.
7. The MIDDLE COLIC ARTERY.
8. The LOWER MESENTERIC ARTERY.
9. The LEFT COLIC ARTERY ; this forming a great inosculation betwixt the Upper and Lower Mesenteric Arteries.
10. The HÆMORRHOIDAL ARTERY descending with the Rectum into the Pelvis.
11. The EMULGENT ARTERY of the left side.
12. The SPERMATIC ARTERY.
13. The MIDDLE SACRAL ARTERY.
14. The COMMON ILIAC ARTERY.
15. The EXTERNAL ILIAC ARTERY.
16. The INTERNAL ILIAC ARTERY.





EXPLANATION

OF

PLATE IX.*OF THE ARTERIES OF THE LOWER
EXTREMITY.*

See p. 452 of the Text.

- A. The Tendon of the External Oblique Muscle.
- B. The SARTORIUS MUSCLE.
- C. The GRACILIS.
- D. The TRICEPS MUSCLE.
- E. The RECTUS FEMORIS.
- F. The VASTUS INTERNUS.
- G. The VASTUS EXTERNUS.
- H. The PATELLA.
- I. The TIBIA.
- K. The Head of the FIBULA.
- L. The GASTROCNEMIUS MUSCLE.

- M. The SOLEUS MUSCLE.
- N. The TIBIALIS ANTICUS.
- O. The EXTENSOR TENDONS of the Toes.

ARTERIES.

- 1. The FEMORAL ARTERY.
- 2. The EPIGASTRIC ARTERY.
- 3. The REFLEXA ILII.
- 4. A Cutaneous Branch to the head of the Sartorius, and glands, and fat.
- 5. To the Inguinal Glands and Fat ; it sends out a pudic branch also.
- 6. The EXTERNAL PUDIC ARTERY.
- 7. The PROFUNDA.
- 8. The INTERNAL CIRCUMFLEX ARTERY.
- 9. The PROFUNDA, proceeding deep into the flesh of the thigh before it gives off the perforating branches.

The branches of the Profunda are seen in the interstices of the rectus and vastus externus. *

* They are these :

Arteria Circumflexa Externa	{	To the Dorsum Ilii. To the outside of the hip. The greater and lesser descending branches.
<hr style="width: 20%; margin: 0 auto;"/> Interna.		


10. The FEMORAL ARTERY, where it lies betwixt the triceps and vastus internus muscle, before it perforates the triceps.
- 11,* 12, 13. ARTICULAR ARTERIES, branches of the Popliteal Artery.
14. The ANTERIOR TIBIAL ARTERY. †
15. The Reflected Branch of the Anterior Tibial Artery.
16. The ANTERIOR TIBIAL ARTERY, continuing its course, and distributing small branches to the surrounding muscles.
17. At this part it passes under the Annular Ligament.
18. The INTERNAL MALEOLAR ARTERY.

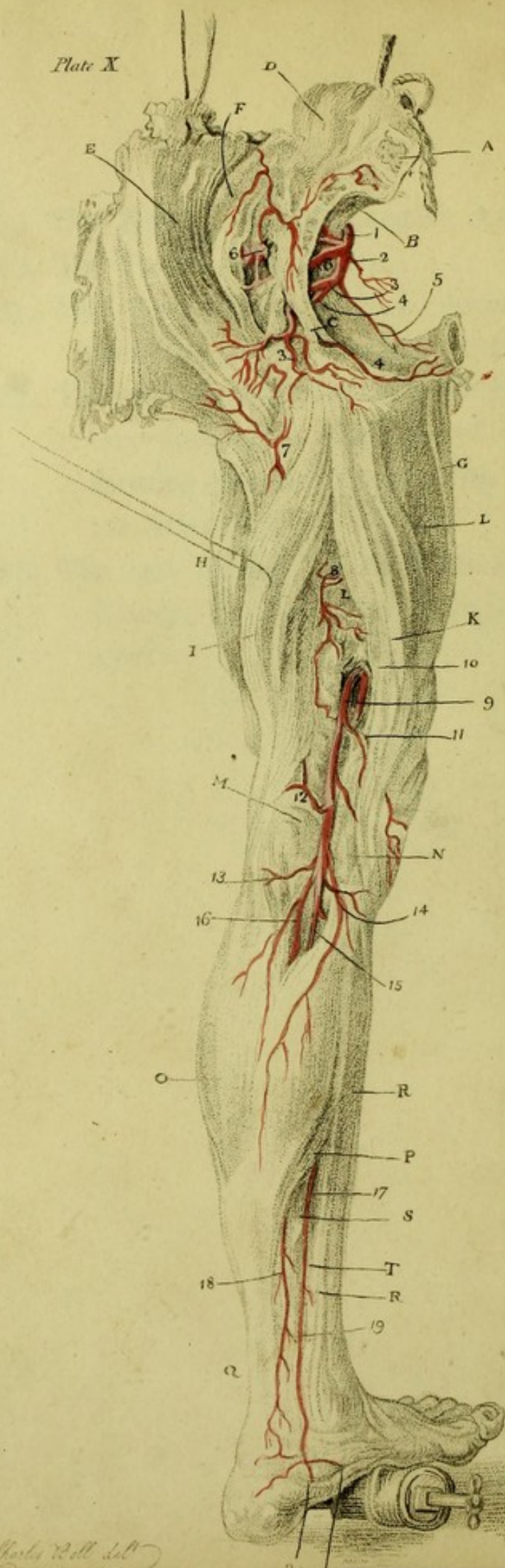
* This branch (the first perforating branch of the Popliteal Artery) is remarkably enlarged in Popliteal Aneurism.

† To cut upon the Anterior Tibial Artery about the middle of the leg, I should take the spine of the tibia for my mark. I should cut through the strong fascia at such a distance from the ridge of the tibia, as to be able to carry my knife between the Tibialis Anticus and Extensor Pollicis Longus.

To cut upon the artery as it passes over the lower end of the tibia to go forward upon the foot, we make our incision between the projecting tendons of the Extensor Longus Pollicis and Communis Digitorum.

19. The EXTERNAL MALEOLAR ARTERY.
20. The TARSAL ARTERY.
21. The ANTERIOR TIBIAL ARTERY descending on the fore part of the foot.
22. The part at which the Anterior Tibial Artery sinks into the sole of the foot, forming communications with the Plan-
tar Arteries.
23. The last branch of the Anterior Tibial Artery, the ARTERIA DORSALIS PO-
LICIS.





EXPLANATION

OF

PLATE X.

EXPLANATION

PLATE X.

EXPLANATION

OF

PLATE X.

See the Text, page 442 to the End.

- A. The body of the last Lumbar Vertebra
sawn through.
- B. The SACRUM.
- C. ISCHIATIC LIGAMENTS.
- D. The LUMBAR MUSCLES.
- E. The GREAT GLUTEUS MUSCLE.
- F. The LESSER GLUTEUS MUSCLE.
- G. The GRACILIS MUSCLE.
- H. The VASTUS EXTERNUS MUSCLE.
- I. The Outer Hamstring Muscles, *i. e.* the
Biceps.

K. The Inner Hamstring Muscles, *i. e.* the
SEMI-TENDINOSUS and SEMI-MEMBRA-
NOSUS.

L. L. The TRICEPS.

M. The OUTER CONDYLE of the Thigh-bone.

N. The INNER CONDYLE.

O. The Belly of the GASTROCNEMIUS Muscle.

P. The SOLEUS MUSCLE.

Q. The Achilles Tendon.

R. The Tibia.

S. The Great Flexor Pollicis.

T. The Flexor Digitorum Communis.

1. The INTERNAL ILIAC ARTERY, giving
off,

2. HYPOGASTRIC ARTERY.

3. 3. ISCHIATIC ARTERY. *

* To hit upon the Ischiatic Artery as it COMES OUT from the Pelvis, begin the incision by the side of the Sacrum, three fingers breadth from the posterior spinous process of the Ilium, and carry it down, in the length of the fibres of the Gluteus Maximus, to the outside of the tuberosity of the Ischium. Even in a thin man, the artery lies two inches deep. Now, pushing in the finger as if under the Sacrum, we there feel the acute edge of the sacro-sciatic ligament; on the lower margin of the sacro-sciatic hole, (which is distinctly felt with the finger amongst the looser parts,) the ARTERY is felt CROSSING the LIGAMENT OBLIQUELY; near it, upon its OUTER side, are some LESSER nerves; the great Sciatic Nerve is removed an inch from it.

4. 4. The PUDIC ARTERY.
5. The OBTURATOR ARTERY.
6. 6. The GLUTEAL ARTERY. *
7. A branch from the INTERNAL CIRCUMFLEX ARTERY.
8. Branches of the Perforating Arteries of the PROFUNDA.
9. The Popliteal Artery after it has pierced the Triceps Muscle.
10. Those branches sent off from the main artery as it is passing the Tendon; they are called the perforating branches of the Popliteal Artery.
11. The UPPER and INTERNAL ARTICULAR ARTERY.
12. The UPPER EXTERNAL ARTICULAR ARTERY.

* To strike upon the GLUTEAL Artery, we cut in the direction of the fibres of the Gluteus Maximus, beginning about two fingers breadth beneath the posterior spine of the Ilium; we cut through the Gluteus MAXIMUS and MEDIUS just upon the lower edge of the Ilium; we find the trunk of this artery rising to mount upon the back of the Ilium; we must observe, too, that CONSIDERABLE branches are carried OUTWARDS through the muscle, into which we must cut to arrive at the seat of the trunk,

13. The LOWER EXTERNAL ARTICULAR ARTERY.

14. The LOWER INTERNAL ARTICULAR ARTERY.

15. The POSTERIOR TIBIAL ARTERY; the Anterior Tibial Artery (Plate ix. 16.) is a branch sent off from this. *

16. The PERONEAL ARTERY, or Fibular Artery. †

* *Posterior Tibial Artery* gives off the outer Tibial; piercing betwixt the heads of the bones exactly four fingers breadth below the upper end of the Tibia; lying upon the Popliteus Muscle, it is about two fingers breadth removed from the inner edge of the Tibia.

† *Fibular Artery*. It comes through the bones one inch below the projection of the knob of the Fibula. To hit upon it, 1. We cut through the strong fascia. 2. Betwixt the heads of the *Extensor Digitorum Longus*, and of the *Peroneus Longus*, we find it lying on the interosseus ligament. N. B. We must cut through some of the fibres of the *Extensor Digitorum Longus*.

To cut for the *Fibular Artery* lower in the leg than a hand's breadth from the head of the Fibula. 1. The fascia. 2. By the outside of the *Tibialis Anticus*; betwixt it and the *Extensor Proprius Pollicis*.

It seems a shocking alternative to be obliged to saw out the Fibula, in order to tie this artery. To find this artery two hands' breadth from the heel, cut down on the out-

17. The POSTERIOR TIBIAL ARTERY appears here again from under the SOLEUS MUSCLE. *
18. The FIBULAR ARTERY; it is seen to form large inosculations with the Tibial Artery.

side of the Gastrocnemius, where it is becoming tendinous; turn up the edge of the tendons; you then find the *Flexor Pollicis Magnus* covered with its sheath. If you seek for the Fibular Artery, by going deep into the leg without piercing this fascia, you find the *Tibial Nerve*, and may come on the *Tibial Artery*. To find the Fibular, then, we cut down by the side of the bone (fibula), and raise the fibrous origins of the *Flexor Pollicis*. We then find the artery by the acute edge of the bone, lying on the ligament, accompanied only by its *Venæ Comites*.

* *The Posterior Tibial Artery*. For complicated wounds in the sole of the foot, this artery may require to be taken up behind the ankle joint, and before it pierces under the *Flexor brevis pollicis pedis*. We shall be directed to the exact place, by observing the lowest projecting part of the tibia. The tendons, which run close upon this tuberosity of the bone, are the *Tibialis Posticus*, and *Flexor Communis*; the first lies so closely braced to the bone in its particular sheath, that it will not be observed; the artery runs a little nearer the heel than the tendon of the *Flexor Communis*; a fascia braces down the artery, the nerve is under the artery.

19. A remarkable inosculation betwixt the
TIBIAL and FIBULAR ARTERIES.
20. The EXTERNAL PLANTAR ARTERY.
21. The INTERNAL PLANTAR ARTERY.

EDINBURGH:

Printed by James Ballantyne and Co.

