

Elements of the comparative anatomy of vertebrates / adapted from the German of Robert Wiedersheim by W. Newton Parker ; with additions by the author and translator.

Contributors

Parker W. Newton
Wiedersheim Robert, 1848-1923.
Royal College of Physicians of Edinburgh

Publication/Creation

London : Macmillan, 1886.

Persistent URL

<https://wellcomecollection.org/works/fqvamjz4>

Provider

Royal College of Physicians Edinburgh

License and attribution


This material has been provided by This material has been provided by the Royal College of Physicians of Edinburgh. The original may be consulted at the Royal College of Physicians of Edinburgh. where the originals may be consulted.


This work has been identified as being free of known restrictions under copyright law, including all related and neighbouring rights and is being made available under the Creative Commons, Public Domain Mark.

You can copy, modify, distribute and perform the work, even for commercial purposes, without asking permission.



Wellcome Collection
183 Euston Road
London NW1 2BE UK
T +44 (0)20 7611 8722
E library@wellcomecollection.org
<https://wellcomecollection.org>





*By order of the College, this Book is not to be taken out
of the Library (except after 10 P.M. until 10 A.M.) for one
month from this date.*

PHYSICIANS' HALL,

8th Oct 1886

* F. b. 6. 3.
—

R37997

ELEMENTS
OF THE
COMPARATIVE ANATOMY
OF
VERTEBRATES.



ELEMENTS
OF THE
COMPARATIVE ANATOMY
OF
VERTEBRATES.



ADAPTED FROM THE GERMAN OF
ROBERT WIEDERSHEIM,

PROFESSOR OF ANATOMY, AND DIRECTOR OF THE INSTITUTE OF HUMAN AND COMPARATIVE ANATOMY
IN THE UNIVERSITY OF FREIBURG-IN-BADEN,

BY

W. NEWTON PARKER,

PROFESSOR OF BIOLOGY IN THE UNIVERSITY COLLEGE OF SOUTH WALES AND MONMOUTHSHIRE.

WITH ADDITIONS BY THE AUTHOR AND TRANSLATOR.

TWO HUNDRED AND SEVENTY WOODCUTS.

London:
MACMILLAN AND CO.
AND NEW YORK.
1886.

REVISED

AND

COMPLETELY REWRITTEN

BY THE AUTHOR

RICHARD CLAY & SONS,
BREAD STREET HILL, LONDON,
Bungay, Suffolk.

PREFACE.

PROFESSOR WIEDERSHEIM'S *Grundriss der vergleichenden Anatomie der Wirbelthiere*, published at Jena in 1884, was written to supply a need which had been felt for some time past for a short text-book on Vertebrate Anatomy embodying some of the more recent views on the subject. The present book is a modified translation of the *Grundriss*, and it is hoped that it will serve to render Professor Wiedersheim's work more widely known amongst English students.

The plan of the original has been retained throughout, though numerous additions and modifications have been made to the work; for many of these I have to thank Professor Wiedersheim, —for others I am myself responsible. I must also express my indebtedness to Professor Wiedersheim for revising the whole translation with me last summer, and for much help while the work was in progress.

Within the limits of a short text-book like the present, much of the matter is of necessity greatly condensed: more detailed accounts of the various parts and organs will be found in the new edition of Professor Wiedersheim's *Lehrbuch der vergl. Anatomie der Wirbelthiere*, which is to appear shortly, and on the first edition of which the *Grundriss* was founded.

The brevity of the descriptions is, however, to some extent made up for by the number of woodcuts. Most of these are taken from the German edition, but several new figures have been added.

The arrangement of the book according to organs, and not according to groups of animals, is likely to render it more difficult for a beginner, and a general knowledge of zoology will be of great assistance. The pages on which the different groups are described are, however, collected together in the index, so that the sections relating to any one group can be easily referred to. The present arrangement seems to be the only possible one if the book is to be founded on a scientific basis, for it is most important that the student should grasp the fact that there has been an evolution of organs, as well as of animals.

The more theoretical and detailed matter is printed in small type, and in the form of notes: the student should in most cases pass this over when reading the book for the first time. A black and a spaced type have been used to render prominent important words or sentences.

A bibliography is appended at the end of each chapter. This in no case presumes to be anything like a complete list of the literature of the subject: our object has been more particularly to mention the recent and the more important works, though many of these have doubtless been omitted. References to other researches can be found by consulting the works mentioned.

At Professor Wiedersheim's suggestion, I have not inserted a translation of the preface to the original, as it seemed unnecessary so to do. I may, however, mention that the book was written for students of Medicine, as well as for those of Comparative Anatomy: the intimate connection of the two subjects renders it

most important that medical students should have a general scientific basis for their special anatomical knowledge.

My sincerest thanks are due to my friends Professors F. Jeffrey Bell and G. B. Howes, who have kindly read through the proof-sheets. To them I am indebted for numerous valuable suggestions, as well as for correcting many faults of style and expression which had escaped my notice. I must also express my thanks to my father, Professor W. K. Parker, and to Dr. Gadow, for many special details in connection with the skeleton, as well as to Mr. E. Radford for help in making the index.

W. N. PARKER.

UNIVERSITY COLLEGE, CARDIFF,
May 1886.

ERRATA AND ADDENDA.

- Page 46, 9th line, for "centra" read "centre."
,, 83, 5th line, for "when" read "where."
,, 136, in Fig. 109, *SR* should indicate the space below *DM*, and the line from *A* should point to the layer indicated by *SR*.
,, 249, Fig. 203, for "Siluris" read "Silurus."

Insert under Bibliography :—

On p. 160 :—

- GRAAF, HENRI W. DE.—*Zur Anatomie und Entwicklung der Epiphyse bei Amphibien und Reptilien. Zool. Anzeiger*, IX. Jahrgang, No. 219, 1886.
SPENCER, W. BALDWIN.—*The Parietal Eye of Hatteria. Nature*, May 13th, 1886. (De Graaf shows that the epiphysis really corresponds to an unpaired sense-organ, and Mr. Spencer has found a well-developed median eye in *Hatteria* and other Lizards. Compare p. 133 of this book.)
JOHNSON, ALICE, and SHELDON, LILIAN.—*On the Development of the Cranial Nerves in the Newt. Proc. Roy. Soc.* 1886.

On p. 294 :—

- PARKER, T. JEFFERY.—*On the Blood-Vessels of Mustelus antarcticus. A Contribution to the Morphology of the Vascular System in the Vertebrata. Abstract in Proc. Roy. Soc.* 1886. (Not yet published in full.)

CONTENTS.

	PAGE
Preface	v
Errata and Addenda	viii
List of Woodcuts	xv
List of General Works on Comparative Anatomy and Embryology	xxv
INTRODUCTION	1
I. On the Nature and Meaning of Comparative Anatomy	1
II. Development and Structural Plan of the Vertebrate Body	2
III. Classified List of the Principal Vertebrate Groups	13
IV. Table showing the Gradual Distribution of the Vertebrata in Time	15
SPECIAL PART.	
A. INTEGUMENT	16
of Fishes	17
of Amphibians	18
of Reptiles	20
of Birds	20
of Mammals	23
Mammary Glands	27
Bibliography	28
B. SKELETON	30
I. DERMAL SKELETON	30
II. ENDOSKELETON	33
I. VERTEBRAL COLUMN	33
of Fishes	34
of Amphibians	39
of Reptiles	42
of Birds	44
of Mammals	46
Bibliography	47
II. RIBS	48
of Fishes and Dipnoans	48
of Amphibians	48
of Reptiles, Birds, and Mammals	49

CONTENTS.

	PAGE
III. STERNUM	51
Bibliography	54
IV. THE SKULL	54
Theory of the Segmentation of the Skull	54
<i>a.</i> Brain-case (cranium)	57
<i>b.</i> The Visceral Skeleton (general description and develop- ment)	59
<i>c.</i> The Bones of the Skull (general description and develop- ment)	61
Anatomy of the Skull (special part)	63
A. The Skull of Fishes	63
B. ,, of Amphibians	70
C. ,, of Reptiles	74
D. ,, of Birds	78
E. ,, of Mammals	80
Bibliography	84
V. LIMBS	84
<i>a.</i> Unpaired Limbs	85
<i>b.</i> Paired Limbs	86
Pectoral Arch	87
of Fishes	87
of Amphibians and Reptiles	87
of Birds	90
of Mammals	91
Pelvic Arch	92
of Fishes	92
of Amphibians	92
of Reptiles and Birds	94
Mammals	98
Free Limbs	99
of Fishes and Dipnoans	99
General Considerations on the Limbs of the higher Vertebrata	101
Free Limbs of Amphibians	104
of Reptiles	105
of Birds	106
of Mammals	108
Bibliography	111
C. MUSCULAR SYSTEM	112
DERMAL MUSCULATURE	113
MUSCULATURE OF THE SKELETON	113
MUSCLES OF THE TRUNK	113
of Fishes and Amphibians	113
of Reptiles	116
of Birds	117
of Mammals	117

PAGE

MUSCLES OF THE VISCERAL SKELETON AND HEAD	118
of Fishes	118
of Amphibia	119
of Amniota	120
MUSCLES OF THE APPENDAGES	121
DIAPHRAGM	122
Bibliography	122
D. ELECTRIC ORGANS	124
Bibliography	128
E. NERVOUS SYSTEM	129
I. THE CENTRAL NERVOUS SYSTEM	129
1. THE SPINAL CORD	129
2. THE BRAIN (general description and development)	131
MEMBRANES OF THE BRAIN AND SPINAL CORD	135
The Brain of Cyclostomi	136
of Elasmobranchii	137
of Teleostei	139
of Ganoidei, Dipnoi, and Amphibia	142
of Reptiles	144
of Birds	147
of Mammals	148
II. PERIPHERAL NERVOUS SYSTEM	151
SPINAL NERVES	152
CRANIAL NERVES	153
SYMPATHETIC	160
SUPRARENAL BODIES	161
Bibliography	162
III. SENSORY ORGANS (general description)	162
SENSE-ORGANS OF THE INTEGUMENT	163
Rod-shaped Organs of Fishes, Dipnoi, and Amphibia,—Segmental Sense-Organs	163
End-Bulbs	166
Terminal Ganglion-Cells	167
Bibliography	169
OLFACTORY ORGAN (general description and development)	170
of Fishes	171
of Dipnoi and Amphibia	172
of Reptiles	174
of Birds	175
of Mammals	176
JACOBSON'S ORGAN	177
THE SPOUTING APPARATUS OF GYMNOPIHONA	179
Bibliography	180

	PAGE
EYE (general description and development)	181
of Fishes	184
of Amphibians	186
of Reptiles and Birds	186
of Mammals	188
Retina	189
Accessory Organs in Connection with the Eye	191
<i>a.</i> Eye-Muscles	191
<i>b.</i> Eyelids	191
<i>c.</i> Glands	192
Bibliography	194
AUDITORY ORGAN (general description and development)	194
of Fishes	198
of Amphibians	198
of Reptiles and Birds	199
of Mammals	201
Histology of the Mammalian Cochlea	206
Relation of the Auditory Organ to the Air-Bladder in Fishes	207
Bibliography	207
 F. ORGANS OF NUTRITION	 208
ALIMENTARY CANAL AND ITS APPENDAGES (general description)	208
I. MOUTH	212
Teeth (general description)	212
of Fishes and Amphibians	214
of Reptiles	215
of Mammals	216
Glands of the Mouth	220
of Amphibians	221
of Reptiles	221
of Birds	222
of Mammals	222
Tongue	222
Thyroid Gland	225
Thymus Gland	226
II. OESOPHAGUS, STOMACH, AND INTESTINE	228
of Fishes and Amphibians	228
of Reptiles	231
of Birds	233
of Mammals	234
Histology of the Mucous Membrane of the Alimentary Canal	237
APPENDAGES OF THE ALIMENTARY CANAL	240
Liver	240
Pancreas	243
Bibliography	243

	PAGE
G. ORGANS OF RESPIRATION	245
I. GILLS	245
of Amphioxus	246
of Cyclostomi	246
of Fishes	248
of Dipnoi	250
of Amphibia	250
II. AIR-BLADDER AND LUNGS	251
1. THE AIR-BLADDER	251
2. THE LUNGS	252
Air-Passages	253
of Amphibians	253
of Reptiles	254
of Birds	255
of Mammals	255
The Lungs in a more Restricted Sense	257
The Lungs of Dipnoi	257
of Amphibia	257
of Reptiles	258
The Lungs and Air-Sacs of Birds	259
The Lungs of Mammals	263
ABDOMINAL PORES	265
Bibliography	267
H. ORGANS OF CIRCULATION	268
(VASCULAR SYSTEM)	268
Development of the Heart and Blood-Vessels	268
The Foetal Circulation	270
The Heart and its Vessels	277
of Fishes	277
of Dipnoi	280
of Amphibia	281
of Reptiles	284
of Birds and Mammals	286
Arterial System	288
Venous System	291
Retia Mirabilia	292
Lymphatic System	292
Bibliography	294
I. URINOGENITAL ORGANS	296
Development	296
URINARY ORGANS	302
of Fishes and Dipnoans	302
of Amphibians	304
of Reptiles and Birds	307
of Mammals	308

	PAGE
GENERATIVE ORGANS	310
of Amphioxus	310
of Fishes	310
of Amphibians	314
of Reptiles and Birds	317
of Mammals	320
COPULATORY ORGANS	327
Bibliography	330
INDEX	335

LIST OF WOODCUTS.

FIG.	PAGE
1. Diagram of the Unimpregnated Ovum	3
2. Diagrams of the Segmentation of the Ovum	4
3. Diagram of a Segmented Meroblastic Ovum	5
4. Blastosphere	5
5. Gastrula	6
6. Early Stage in the Differentiation of the Embryo	7
7, A and B. Diagrammatic Transverse Sections through a Developing Vertebrate Embryo	8
8. Diagrammatic Transverse Section through the Body of an Adult Vertebrate	9
9, A, B, and C. Diagrams illustrating the Formation of the Amnion, Allantois, and Yolk-Sac. A and B, in Longitudinal Section; C, in Transverse Section	11
10. Diagrammatic Transverse Section illustrating the Structure of the Skin in Fishes	17
11A. Skin of Larva of Salamander (<i>Salamandra maculosa</i>)	19
11B. Section through the Skin of Adult Salamander (<i>S. maculosa</i>)	19
12. Six Stages in the Development of the Feather. (Mainly after Th. Studer.)	21
13. Six Stages in the Development of Hair	23
14. Longitudinal Section through a Hair. (Diagrammatic.)	25
15. Section through the Human Skin	26
16. A, True (Secondary) Teat; and B, Pseudo- (Primary) Teat	27
17. <i>a</i> , Dermal Armature of <i>Hypostoma commune</i> (a Siluroid); <i>b</i> , Denticles from the Skin of the Abdomen of <i>Callichthys</i> ; <i>c</i> , Plates from the Tail-fin of <i>Hypostoma</i> . (After O. Hertwig.)	30
18. Dermal Denticles of <i>Protopterus</i>	31
19. Dermal Armature of <i>Callichthys</i>	31
20. Transverse Section of the Vertebral Column of <i>Ammocoetes</i>	34
21. Portion of the Vertebral Column of <i>Spatularia</i> . (Side view.)	35
22. Transverse Section of the Vertebral Column of <i>Acipenser ruthenus</i> (in the anterior part of the body)	35
23. Portion of the Vertebral Column of <i>Protopterus</i> . (Side view.)	35
24. Portion of the Vertebral Column of <i>Polypterus</i>	36

FIG.	PAGE
25. Diagram showing the Intervertebral Remains of the Notochord	36
26. Portion of the Vertebral Column of <i>Lepidosteus</i> . (After Balfour and Parker.)	37
27. Portion of the Vertebral Column of a Young Dogfish (<i>Scyllium canicula</i>). (After Cartier.)	38
28. Portion of the Vertebral Column of <i>Scymnus</i>	38
29. Tail of <i>Protopterus</i>	39
30. Tail of <i>Lepidosteus</i>	39
31. Longitudinal Section through the Vertebral Column of Various Urodeles. A, <i>Ranodon sibericus</i> ; B, <i>Amblystoma tigrinum</i> ; C, <i>Gyrinophilus porphyriticus</i> ; D, <i>Salamandrina perspicillata</i>	40
32. Vertebral Column of <i>Discoglossus pictus</i>	41
33. Tail of <i>Archæopteryx</i>	44
34. Pelvis of Owl (<i>Strix bubo</i>). (Ventral view.)	45
35. Third Cervical Vertebra of Woodpecker (<i>Picus viridis</i>). (Viewed anteriorly.)	46
36. Skeleton of the Trunk of a Falcon	49
37. Costal Arch of Man	50
38. Ventral Portion of the Pectoral Arch of <i>Rana esculenta</i>	52
39. Pectoral Arch and Sternum of a Gecko (<i>Hemidactylus verrucosus</i>)	52
40. A, Sternum of Fox; B, of Walrus; and C, of Man	53
41. Diagram showing the Primitive Metameric Condition of the Head	55
42. First Cartilaginous Rudiments of the Skull	57
43. Diagrammatic Transverse Sections, of the Head in Embryo—(A) Sturgeons, Elasmobranchs, Anura, and Mammals; (B) Urodeles and Snakes; and (C) Certain Teleosteans, Lizards, Crocodiles, Chelonians, and Birds	58
44. Second Stage in the Development of the Primordial Skull	58
45. Diagrammatic Transverse Section of the Third Stage in the Development of the Primordial Skull	59
46. Diagram showing the Relations of the Embryonic Visceral Skeleton	60
47. Semidiagrammatic Figure of an Elasmobranch Skull, showing the Relations of the Segmental Cranial Nerves	60
48. Semidiagrammatic Figures of the Suspensorial Apparatus in Various Vertebrates. (Mainly after Gegenbaur.) A, Notidanus; B, Other Elasmobranchs; C, Torpedo; D, Teleosteans; E Amphibians, Reptiles, and Birds; F, Mammals	61
49. Skull and Branchial Basket of <i>Petromyzon planeri</i>	64
50. Skull of <i>Heptanchus</i>	64
51. Cranial Skeleton of <i>Raja oxyrhyncha</i>	65
52. Cranial Skeleton of Sturgeon (<i>Acipenser</i>) after Removal of the Exoskeletal Parts	66
53. Skull of <i>Polypterus bichir</i> from the Dorsal Side	67
54. Cranial Skeleton, Pectoral Arch, and Anterior Extremity of <i>Protopterus</i>	68
55. Cranial Skeleton of Trout	69
56. Skull of Young Axolotl. (Ventral view.)	71
57. Skull of <i>Salamandra atra</i> (Adult). (Dorsal view.)	71

FIG.	PAGE
58. Skull of <i>Salamandra atra</i> (Adult). (Ventral view.)	71
59. Skull of <i>Rana esculenta</i> . (Ventral view.) (After Ecker.)	72
60. Hyobranchial Apparatus of Urodeles. A, Axolotl (<i>Siredon pisciformis</i>); B, <i>Salamandra maculata</i> ; C, <i>Triton cristatus</i> ; D, <i>Spelerpes fuscus</i>	73
61. Skull of Lizard (<i>Lacerta agilis</i>). (Dorsal view.)	76
62, A and B. Skull of Snake (<i>Tropidonotus natrix</i>)	76
63. Skull of Young Water-Tortoise (<i>Emys europæa</i>). (Side view.)	77
64. Skull of a Young Crocodile. (Ventral view.)	77
65. Skull of a Wild Duck (<i>Anas boschas</i>). (A, from above; B, from below; C, from the side.)	79
66A. Longitudinal Vertical Sections through the Skulls of—A, <i>Salamandra maculosa</i> , B, <i>Testudo græca</i> , and C, <i>Corvus corone</i> , to show the Relations between the Cranial and Visceral Portions	81
66B. Longitudinal Vertical Sections through the Skulls of—A, Deer, B, Baboon, and C, Man, to show the Relations between the Cranial and Visceral Portions	82
67. Skull of Embryo of Armadillo (<i>Tatusia hybrida</i>). (Modified from a drawing by W. K. Parker.)	83
68. Diagram showing (A) the Undifferentiated Condition of the Paired and Unpaired Fins in the Embryo, and (B) the Manner in which the Permanent Fins are formed from the Continuous Folds	85
69. Pectoral Arch and Fin of <i>Heptanchus</i>	88
70. Left Pectoral Arch and Fin of the Trout. (From the outer side.)	88
71. Diagram of the Ground-Type of Pectoral Arch met with in all Vertebrata, from the Amphibia up to Mammalia	89
72. Semidiagrammatic Figure of the Pectoral Arch and Sternum of <i>Urodela</i>	89
73. Pectoral Arch of a Chelonian. (Ventral view.)	89
74. Pectoral Arch and Sternum of <i>Bombinator igneus</i>	90
75. Pectoral Arch of <i>Ornithorhynchus paradoxus</i>	91
76. Pelvis of <i>Protopterus</i> . (From the ventral side.)	92
77. Pelvis of Salamander (<i>Salamandra maculosa</i>). (Ventral view.)	93
78. Pelvic Arch of Frog (<i>Rana esculenta</i>). (A, from below; B, from the side.)	94
79. Pelvis of <i>Lacerta muralis</i> . (Ventral view.)	94
80. Pelvis of a Young <i>Alligator lucius</i> . (A, ventral, and B, side view.)	95
81. Pelvis of <i>Iguanodon bernissartensis</i> . (After Dollo.)	96
82. Pelvis of <i>Apteryx australis</i> . (Lateral view.) (After Marsh.)	96
83A. Pelvis of a Six-Days' Chick. (After A. Johnson.)	97
83B. Diagram showing the Relations of the Pelvic Bones to the Acetabulum	97
84. Pelvis of <i>Echidna</i> . (From the left side.) (After Gegenbaur.)	97
85. Pectoral Fin of <i>Ceratodus fosteri</i>	100
86. Diagram of the Predominant Uniserial Type of the Anterior Extremity of Elasmobranchs	100
87. Diagrammatic Figures to show the Relations of the Free Extremity to the Trunk in Fishes (A), and the Higher Vertebrates (B)	102
88. Posterior Extremity of <i>Ranodon sibericus</i>	103

FIG.	PAGE
89. Right Fore-Arm, Carpus, and Hand of <i>Salamandra maculosa</i> . (From above.)	103
90. Right Tarsus of <i>Discoglossus pictus</i> . (From above.)	104
91. Right Carpus of a Young <i>Alligator lucius</i> . (From above.)	105
92. Anterior Extremity of <i>Archæopteryx</i> . (After C. Vogt.)	106
93. Anterior Extremity of Blackbird (<i>Turdus merula</i>)	107
94. Posterior Extremity of Blackbird (<i>Turdus merula</i>)	108
95. Fore-Foot of Ancestral Forms of the Horse. 1. Orohippus (Eocene). 2. Mesohippus (Upper Eocene). 3. Miohippus (Miocene). 4. Protohippus (Upper Pliocene). 5. Pliohippus (Uppermost Pliocene). 6. Equus	110
96. Skeleton of the Left Fore-Limb of <i>A</i> , Pig; <i>B</i> , Hyomoschus; <i>C</i> , Tragulus; <i>D</i> , Roebuck; <i>E</i> , Sheep; <i>F</i> , Camel. (From Bell, after Garrod.)	110
97. Lateral Muscles of <i>Amphioxus</i>	114
98. The Entire Musculature of <i>Siredon pisciformis</i>	114
99. The Musculature of <i>Siredon pisciformis</i> . (From the ventral side.)	115
100. <i>Torpedo marmorata</i> , with the Electric Organ (<i>E</i>) exposed	124
101, A and B. The Electric Organ of <i>Gymnotus electricus</i> . (B, from a prepara- tion by A. Ecker.)	125
102. Electric Prisms of <i>Torpedo marmorata</i> . (Semidiagrammatic.)	126
103. Section through the Electric Chambers. (Greatly enlarged and semidia- grammatic.)	127
104. The Entire Nervous System of the Frog. (After A. Ecker.) (From the ventral side.)	130
105. Diagram of the Embryonic Condition of the Central Nervous System	132
106. Longitudinal Section through the Skull and Brain of an (ideal) Vertebrate Embryo. (In part after Huxley.)	133
107. Diagram of the Ventricles of the Vertebrate Brain	134
108. Cerebral Flexure of a Mammal	135
109. Brain-Membranes of Man. (After Schwalbe.)	136
110. Brain of <i>Ammocetes</i> . (Dorsal view.)	137
111. Brain of <i>Galeus canis</i> , <i>in situ</i> . (Dorsal view.) (After Rohon.)	138
112. Brain of <i>Myliobatis aquila</i> , <i>in situ</i> . (From the ventral side.) (After Rohon.)	139
113A. Longitudinal Vertical Section through the Anterior Part of the Teleostean Brain. (Founded on a figure of the Trout's brain by Rabl-Rückhard.)	140
113B. Transverse Section through the Fore-Part of the Teleostean Brain	141
114. Brain of Perch (<i>Perca schraetser</i>). (Side view.)	141
115. Brain of <i>Perca schraetser</i> . (Dorsal view.)	141
116. Brain of <i>Polypterus bichir</i> . (Side view.)	142
117. Brain of <i>Salamandra maculosa</i> . (A, dorsal, B, ventral view)	143
118. Brain of <i>Rana esculenta</i> . (From the dorsal side.)	143
119. Brain of Blindworm (<i>Anguis fragilis</i>). (A, from the dorsal, B, from the ventral side.)	144
120. Brain of <i>Emys europæa</i> . (A, side, B, ventral view.)	145
121. Brain of Alligator. (From the dorsal side.) (After Rabl-Rückhard.)	146
122. Brain of Pigeon. (A, from above; B, from the side.)	147


FIG.		PAGE
123.	Human Brain. (Median longitudinal vertical section.) (Mainly after Reichert.)	148
124.	Convolutions of the Human Brain. (After A. Ecker.)	149
125.	Diagrammatic Figure of the Principal Bands of Nerve-Fibres of the Mammalian Brain. (From a drawing by A. Ecker.)	149
126.	Casts of the Brain-Cases of Eocene Mammals. (After Marsh.)	150
127.	Cranial Nerves and Brachial Plexus of <i>Salamandra atra</i>	153
128.	Chiasma of the Optic Nerves. (Semidiagrammatic.) A, chiasma as seen in the greater number of Teleostei; B, in Herring; C, in <i>Lacerta agilis</i> ; D, in an Agama; E, in a higher Mammal.	156
129.	Cranial Nerves of <i>Anguis fragilis</i>	157
130.	Cranial Nerves and Brachial Plexus of <i>Scyllium canicula</i>	159
131.	A, peripheral nerve-ending, as seen in all the higher sensory nerves; B, rod-shaped end-cell of a sensory organ of the integument of a Fish or Amphibian, or a taste-cell; C, free, and D, ganglionated nerve-ending of the integumentary sensory organs of terrestrial Vertebrates	163
132.	Transverse Section of a Freely-Projecting Segmental Sense-Organ	164
133.	Distribution of the Lateral Sense-Organs in a Salamander Larva	164
134.	Diagram showing the Distribution of the Sensory Organs of the Lateral Line in Fishes	165
135.	Organ of the Lateral Line of a Urodele. (Semidiagrammatic.)	165
136.	A Tactile Spot from the Skin of the Frog. (Modified from Merkel.)	167
137.	Tactile Corpuscle from the Tongue of a Bird	167
138.	A Tactile Corpuscle (End-Bulb) from the Conjunctiva of a Mammal	168
139.	A Pacinian Corpuscle from the Beak of the Duck. (After J. Carrière.)	168
140.	Epithelium of the Olfactory Mucous Membrane. A, of <i>Petromyzon planeri</i> ; B, of <i>Salamandra atra</i>	170
141.	Anterior Portion of Head of <i>Acipenser sturio</i>	171
142.	Anterior Portion of the Head of <i>Polypterus</i>	172
143.	Olfactory Organ of <i>Menobranthus lateralis</i> . (From the dorsal side.)	173
144.	Transverse Section through the Olfactory Cavities of <i>Plethodon glutinosus</i> (<i>Myctodera</i>)	173
145.	Diagram of the Olfactory Organ of a Lizard. (Longitudinal vertical section.)	174
146.	Transverse Section through the Right Nasal Cavity of a Shrike (<i>Lanius minor</i>)	175
147.	Transverse Vertical Section through the Nasal Cavity of Man	177
148.	Dissection of the Head of <i>Epicrium glutinosum</i> . (Dorsal view.)	178
149.	The Left So-called "Tentacle" of <i>Cæcilia oxyura</i> . (Opened from the dorsal side.)	179
150.	Diagrams showing the Mode of Formation of the Eye in Invertebrates (A) and Vertebrates (B)	181
151A.	Diagram showing the Mode of Formation of the Primary Optic Vesicles (ABI)	182
151B.	Semidiagrammatic Figure of the Secondary Optic Vesicle, and of the Lens becoming separated off from the Epiblast	182

FIG.		PAGE
152.	Diagram of a Horizontal Section through the Right Human Eye. (Seen from above.)	183
153.	Eye of a Teleostean	185
154.	Eye of <i>Lacerta muralis</i> , showing the Ring of Bony Sclerotic Plates	187
155.	Eye of an Owl	187
156.	Retina. (After Merkel.)	189
157.	Harderian Gland (<i>H</i> , <i>H</i> ¹) and Lacrymal Gland (<i>Th</i>) of <i>Anguis fragilis</i>	193
158.	Diagrammatic Transverse Vertical Section through the Eye of a Mammal	193
159.	Diagram of the Lacrymal Apparatus of Man	194
160.	Head and Anterior Portion of Body of a Chick. (In part after Moldenhauer.)	195
161.	Semidiagrammatic Figure of the Auditory Organ of a Teleostean. (Modified from a figure of that of <i>Muraena anguilla</i> by Hasse.)	196
162.	Longitudinal Section of an Ampulla of Gobius. (After Hensen.)	197
163.	Membranous Labyrinth of <i>Lacerta</i> . (From the outer side.) (After C. Hasse.)	200
164.	Membranous Labyrinth of the Crocodile. (From the outer side.) (After C. Hasse.)	200
165.	Membranous Labyrinth of the Pigeon. (After C. Hasse.)	201
166.	Membranous Labyrinth of the Ox. (After C. Hasse.)	201
167.	Diagram of the Entire Auditory Organ of Man	203
168.	Bony Cochlea of Man. (After A. Ecker.)	204
169.	Diagrammatic Transverse Section of the Cochlea of a Mammal	204
170.	The Organ of Corti. (After Lavdowsky.)	206
171.	Diagrams of the Oral Cavities of a Fish (A), Amphibian (B), Reptile or Bird (C), and Man (D)	210
172.	Diagram of the Entire Alimentary Tract of Man	211
173.	Semidiagrammatic Figure of a Longitudinal Section through a Tooth	213
174.	Skull of <i>Batrachoseps attenuatus</i> . (From the ventral side, showing the teeth on the parasphenoid.)	214
175.	A, Diagrams of Transverse Sections through the Jaws of Reptiles, showing Pleurodont (<i>a</i>), Acrodont (<i>b</i>), and Thecodont (<i>c</i>) Dentitions. B, <i>a</i> , Lower Jaw of <i>Zootoca vivipara</i> ; <i>b</i> , of <i>Anguis fragilis</i> . (After Leydig.)	215
176.	Figures of the Poison-Fangs of a Viperine Snake	216
177.	Dentition of the Hedgehog (<i>Erinaceus europæus</i>). (The teeth of both jaws from the side, and those of the upper jaw from below.)	217
178.	Dentition of the Dog (<i>Canis familiaris</i>)	218
179.	Dentition of the Porcupine (<i>Hystrix hirsutirostris</i>)	218
180.	Dentition of Sheep (<i>Ovis aries</i>)	219
181.	Dentition of a Catarrhine Monkey (<i>Nasalis larvatus</i>)	219
182.	The Poison-Apparatus of the Rattlesnake	221
183.	Head of <i>Spelerpes fuscus</i> , with the Tongue extended	223
184.	A, Tongue, Hyoid Apparatus, and Bronchi of a Gecko (<i>Phyllodactylus europæus</i>); B, Tongue of <i>Lacerta</i> ; C, of <i>Monitor indicus</i> ; D, of <i>Emys europæa</i>	224
185.	Thymus and Thyroid of a Young Stork	227
186.	Intestinal Tract of a Shark	229

FIG.	PAGE
187. Alimentary Viscera and Air-Bladder of <i>Lepidosteus</i> , <i>in situ</i> . (After Balfour and Parker.)	230
188. Intestinal Tract of Perch	231
189. Intestinal Tract of <i>Siren lacertina</i>	232
190. Intestinal Tract of <i>Rana esculenta</i>	232
191. Diagram of the Oesophagus and Stomach of a Bird	233
192. Different Forms of Mammalian Stomachs	235
193. Diagram of the Structure of a Coelenterate	237
194. Semidiagrammatic Transverse Section of a Portion of the Wall of the Intestine. (Combined from the condition seen in both Lower and Higher Vertebrates.)	238
195. Semidiagrammatic Figures of the Mucous Membrane of the Intestine of Fishes, showing Intermediate Forms between Longitudinal Folds and Round Crypts	240
196. Liver of <i>Rana esculenta</i> . (From the ventral side.)	241
197. Pancreas and Liver of Frog, to show the Arrangement of their Ducts	241
198. Viscera of <i>Lacerta agilis</i> , <i>in situ</i>	242
199. <i>Amphioxus lanceolatus</i> , $\times 2\frac{1}{2}$. (From Gegenbaur, after Quatrefages.)	247
200. Diagram of a Longitudinal Section through the Head of <i>Ammocetes</i> (A) and <i>Petromyzon</i> (B)	248
201. Longitudinal Section through the Head of <i>Ammocetes</i>	248
202. Horizontal Section through the Ventral Side of the Head of a Selachian. (Semidiagrammatic.) The floor of the mouth is exposed	249
203. Horizontal Section through the Ventral Side of the Head of <i>Silurus glanis</i> . (Semidiagrammatic.)	249
204. A, B, C, Diagrams showing the Mode of Development of the Lungs	252
205. Diagram Illustrating the Phylogenetic Development of the Lungs	253
206. Cartilaginous Skeleton of the Laryngo-Tracheal Chamber of <i>Rana esculenta</i> . (A, from above; B, from the side.)	254
207. Larynx of <i>Phyllodactylus europæus</i> . (A, skeleton, and B, musculature of larynx.)	254
208. Larynges of Various Mammals	256
209. Abdominal Viscera and Air-Sacs of a Duck after the Removal of the Ventral Body-Wall. (From an original drawing by H. Strasser.)	260
210. Left Lung of the Duck, <i>in situ</i> . (From an original drawing by H. Strasser.)	261
211. Diagram of the Arrangement of the Bronchi in Mammals. (From the ventral side.)	264
212. Diagram of the Pleural and Pericardial Cavities of Mammals, founded on the relations of these parts in Man. (A, horizontal section; B, transverse section.)	265
213. Abdominal Pores of Various Vertebrates. (A, Cyclostome; B, Elasmobranch; C, Protopterus; D, Spatularia.)	266
214. Diagram showing the Primitive Relations of the Different Chambers of the Heart	269
215. Diagram of the Embryonic Vascular System	271

FIG.	PAGE
216. Diagram of the Circulation of the Yolk-Sac at the end of the Third Day of Incubation in the Chick. (After Balfour.)	272
217. Diagram of the Venous Circulation in the Chick at the Commencement of the Fifth Day. (After Balfour.)	273
218. Diagram of the Venous Circulation in the Chick during the Later Days of Incubation. (After Balfour.)	274
219, A, B, C. Diagrams of the Development of the Paired Venous System of Mammals (Man). (From Gegenbaur.)	275
219, D. Diagram of the Chief Venous Trunks of Man. (From Gegenbaur.)	275
220. Diagrammatic Section through the Human Gravid Uterus	276
221. Diagram showing the Transformations of the Aortic Arches—A, in a Lizard; B, in a Snake; C, in a Bird; and D, in a Mammal. (After Rathke.) (Seen from below.)	277
222. Hearts of Various Fishes—A, of the Hammer-headed Shark (<i>Zygena malleus</i>); B, of <i>Silurus glanis</i> ; C, of a Selachian, cut open	278
223. Diagram of the Arterial System of Fishes	279
224. Diagram of the Heart and Branchial Vessels of <i>Ceratodus</i> . (Mainly after J. E. V. Boas.)	280
225. Diagram of the Branchial Circulation of <i>Protopterus</i>	281
226. Diagram showing the Course of the Blood through the Heart in <i>Urodela</i> (A) and <i>Anura</i> (B)	282
227. The Arterial Arches of the Larva of a Salamander. (Slightly diagrammatic.) (After J. E. V. Boas.)	283
228. Arterial Arches of an Adult <i>Salamandra maculosa</i> , shown spread out. (After J. E. V. Boas.)	284
229. A, Heart of <i>Lacerta muralis</i> , and B, of a large <i>Varanus</i> , shown cut open; C, Diagram of the Reptilian Heart.	285
230A. Heart of the Swan, with the Right Ventricle cut open	286
230B. Transverse Section through the Right (<i>Vd</i>) and Left (<i>Vg</i>) Ventricle of <i>Grus cinerea</i>	286
231. Five Different Modes of Origin of the Great Vessels from the Arch of the Aorta in Mammals	287
232. The Arterial System of <i>Salamandra maculosa</i>	289
233. The Arterial System of <i>Emys europæa</i>	290
234A. Diagram of the (Secondary) Connection of the Mesonephric Tubules with the Segmental Duct (<i>Sg</i>)	297
234B. Horizontal Section through an Embryo of <i>Lacerta agilis</i> . (After M. Braun.)	297
234C. The Entire Excretory System of the Embryo of <i>Hylodes martinicensis</i> (3 millimetres long). (After E. Selenka.)	298
235. Diagrammatic Transverse Sections of the Body of a Lower Vertebrate, to show the Relations of the Segmental Organs. (After Hensen.) The right side of the figure represents a later stage than the left	299
236. Diagram Exhibiting the Relations of the Female (A) and of the Male (C) Reproductive Organs to the General Plan (B) of these Organs in the Higher Vertebrata	301

FIG.	PAGE
237. Diagram of the Primitive Condition of the Kidney in an Elasmobranch Embryo. (After Balfour.)	303
238A. Diagram of the Arrangement of the Urinogenital Organs in an Adult Female Elasmobranch. (After Balfour.)	303
238B. Diagram of the Arrangement of the Urinogenital Organs in an Adult Male Elasmobranch. (After Balfour.)	303
239. The Entire Viscera of <i>Siphonops annulatus</i> (♀), <i>in situ</i>	305
240. Diagram of the Urinogenital System of a Male (A) and Female (B) Urodele; founded on a preparation of <i>Triton teniatus</i> . (After J. W. Spengel.)	306
241. Excretory Apparatus of <i>Monitor indicus</i>	308
242. Male Urinogenital Apparatus of Heron (<i>Ardea cinerea</i>)	309
243. Diagrammatic Longitudinal Section through the Kidney of a Mammal . .	310
244. Male Urinogenital Apparatus of the Sturgeon	312
245. Female Urinogenital Apparatus of <i>Protopterus annectens</i> . (From the ventral side, natural size.) (After H. Ayers.)	313
246. Diagram of a Portion of the Male Generative Apparatus of the Gymnophiona	315
247. Testis and Anterior End of Kidney of <i>Rana esculenta</i> . (Semidiagrammatic.)	315
248. Urinogenital Organs of a Female <i>Rana esculenta</i>	317
249. Female Urinogenital Apparatus of <i>Lacerta muralis</i>	318
250. Male Urinogenital Organs of <i>Anguis fragilis</i> . (After F. Leydig.) . . .	319
251. A, Male Urinogenital Organs of <i>Ornithorhynchus paradoxus</i> ; B, Female Urinogenital Organs of <i>Echidna hystrix</i>	321
252. Female Generative Apparatus of Certain Marsupials. A, <i>Didelphys dorsigera</i> (juv.); B, <i>Phalangista vulpina</i> ; C, <i>Phascalomys wombat</i> . (After A. Brass.)	323
253. Various Forms of Uteri. A, B, C, D, diagrams showing the different stages in the fusion of the Müllerian ducts: A, uterus bicornis; B, uterus simplex; C, uterus duplex; D, uterus bipartitus. E, female urinogenital apparatus of <i>Mustelina</i> , with embryos in the uterus; F, ditto of Hedgehog (<i>Erinaceus</i>)	324
254. Section through a Portion of the Ovary of a Mammal, showing the Mode of Development of the Graafian Follicles	325
255. Diagrammatic Section of the Testis of a Mammal	325
256. Male Urinogenital Apparatus of the Hedgehog (<i>Erinaceus</i>)	326
257. Semidiagrammatic Figure of the Human Penis. (A, transverse section; B, side view; C, from below.)	329



LIST OF GENERAL WORKS ON COMPARATIVE ANATOMY AND EMBRYOLOGY:

- BALFOUR, F. M.—A Treatise on *Comparative Embryology*. 2 vols. London, 1881–1882. A Monograph on the *Development of Elasmobranch Fishes*. London, 1878.
- BELL, F. JEFFREY.—*Comparative Anatomy and Physiology*. London, 1885.
- BRONN, H. G.—*Die Classen und Ordnungen des Thierreiches*. Leipzig and Heidelberg, 1873 and onwards. (The volumes on Amphibia, Reptilia, and Aves have appeared up to the present time.)
- CHAUVEAU, A.—*L'Anatomie comparée des Animaux domestiques*. Paris, 1883. Earlier Edition translated by Fleming. London, 1873.
- CUVIER, G.—*Leçons d'Anatomie comparée*. 5 vols. Paris, 1799–1805. 2nd Ed. 1835–1845.
- ECKER, A.—*Icones Physiologicae*. Leipzig, 1852–1859.
- Encyclopædia Britannica*. Edinburgh, 1875 and onwards. (20 vols. have appeared up to the present time.) (See articles on *Amphibia, Anatomy, Ape, Biology, Birds, Embryology, Evolution, Histology, Ichthyology, Mammalia, Physiology, Reproduction, Reptiles, &c.*)
- FOL, H.—*Lehrbuch der vergleichenden microscopischen Anatomie mit Einschluss der vergleichenden Histologie und Histogenie*. Leipzig, 1884. Now appearing in parts.
- FOSTER, M., and BALFOUR, F. M.—*The Elements of Embryology*. 2nd Ed. edited by Sedgwick and Heape. London, 1883.
- GEGENBAUR, C.—*Elements of Comparative Anatomy* (translated by F. Jeffrey Bell). London, 1878.
- GÖTTE, A.—*Entwicklungsgeschichte der Unke*. Leipzig, 1875.
- HAECKEL, E.—*Generelle Morphologie der Organismen*. 2 Bde. Berlin, 1866.
- HERTWIG, O.—*Die Coelomtheorie*. Jena, 1881.
- HOWES, G. B.—*Atlas of Practical Elementary Biology*. London, 1885. (Contains numerous figures of the anatomy, histology, and development of the Frog.)
- HUXLEY, T. H.—*Anatomy of Vertebrated Animals*. London, 1871. Reprinted 1882.
- KÖLLIKER, A.—*Grundriss der Entwicklungsgeschichte des Menschen und der höheren Thiere*. Leipzig, 1880.
- LEYDIG, F.—*Lehrbuch der Histologie des Menschen und der Thiere*. Frankfurt, 1857.
- MACALISTER, A.—*Introduction to Animal Morphology*. 2nd Vol. (Vertebrates.) London, 1878.
- MARTIN, H. N., and MOALE, W. A.—*Handbook of Vertebrate Dissection*. (Three parts have appeared up to the present time: these contain descriptions of the Turtle, Pigeon, and Rat.) Macmillan & Co., 1884.

- MECKEL, J. F.—*System der vergl. Anatomie*. 6 Bde. Halle, 1821–1833.
- MILNE-EDWARDS, H.—*Leçons sur la Physiologie et l'Anatomie comparées de l'Homme et des Animaux*. 20 Tom. Paris, 1857–1880.
- MONRO, A.—*The Structure and Physiology of Fishes*. Edinburgh, 1785.
- MÜLLER, E.—*Vergl. Anatomie der Myxinoïden*. Berlin, 1834–1845.
- OWEN, R.—*Anatomy of Vertebrates*. London, 1866–1868.
- PARKER, T. J.—*A Course of Instruction in Zootomy (Vertebrates)*. London, 1884.
- ROLLESTON, G.—*Forms of Animal Life*. Oxford, 1870.
- SCHMIDT, O.—*Handbuch der vergl. Anatomie*, 8 Aufl. Jena, 1882.
- STANNIUS, H.—*Handbuch der Anatomie (Zootomie) der Wirbelthiere*. Berlin, 1854.
(Contains detailed descriptions of Fishes, Amphibians, and Reptiles.)
- VOGT, C., and JUNG, E.—*Lehrbuch der pract. vergl. Anatomie*. Braunschweig, 1885. *Traité d'Anatomie comparée pratique*. Paris, 1884 and onwards.
(Only parts relating to Invertebrates have yet appeared.)
- WEBER, MAX.—*Studien über Säugethiere. Ein Beitrag zur Frage nach dem Ursprung der Cetaceen*. Jena, 1886.
- WIEDERSHEIM, R.—*Lehrbuch der vergl. Anatomie, auf Grundlage der Entwicklungsgeschichte*. 2nd Ed. Jena, 1886.
- WILDER, BURT G., and GAGE, S. H.—*Anatomical Technology*. New York and Chicago, 1882.

ELEMENTS
OF THE
COMPARATIVE ANATOMY
OF
VERTEBRATES.



COMPARATIVE ANATOMY.

INTRODUCTION.

I. ON THE NATURE AND MEANING OF COMPARATIVE ANATOMY.

A THOROUGH knowledge of the animal body cannot be gained by **Comparative Anatomy** alone, and it is therefore necessary to call in the aid of other branches of science also, viz. :—

1. **Ontogeny**; 2. **Palæontology**; 3. **Histology**; and 4. **Physiology**.

The first of these treats of the developmental history of the individual, while the second has to do with the development of the races of animals in time (**Phylogeny**). As the different phases of development of the race are usually repeated to a greater or less extent in those of the individual, these two subjects help to complete one another. Thus the object of both alike is to enable us to ascertain the past by observing the present.

The third-mentioned branch, Histology, teaches us about the **structural elements**—the building-stones of the organism. It shows how these elements are combined to form **tissues**, and how **organs** are constructed out of the latter. The organs again combine to form **systems of organs**.

The structural elements consist primarily of **cells** and secondarily of cells and **fibres**, and the different tissues may be divided into four principal groups :—

1. **Epithelium**, and its derivative, **glandular tissue**.
2. **Supporting-tissue** (connective-tissue, cartilage, bone).
3. **Muscular tissue**.
4. **Nervous tissue**.

In accordance with their physiological character, epithelium and supporting-tissue may be described as passive, and muscular and nervous tissue as active.

By an organ we understand an apparatus constructed to perform a definite physiological function, as, for instance,—the liver, which secretes bile, the gills and lungs, in which an exchange of gases is effected with the surrounding medium, and the heart, which pumps blood through the body.

The organ-systems, which will be treated of in order in this book, are as follows:—1. The outer covering of the body, or integument; 2. The skeleton; 3. The muscles, together with electric organs; 4. The nervous system and sense-organs; 5. The organs of nutrition, respiration, circulation, excretion, and reproduction.

The closely-allied branches of science defined above are united together as **Morphology**, as opposed to Physiology, which concerns the functions of organs, apart from their morphological relations.

Morphology alone leads us to a satisfactory explanation of the structural phenomena of the animal body, for it not only reveals to us the law of heredity and the consequent relationship of animals to one another, but it also helps to explain certain degraded and rudimentary forms, which, considered as isolated adult animals, would always remain absolutely incomprehensible. Further, it shows us on the one hand how the animal organism is acted upon by the influence of its surroundings, and how it is apt to change gradually and more or less continuously; and on the other hand how the capacity of adaptation resulting from these changes varies inversely with the persistence of inherited qualities. These two important opposing factors, adaptation and heredity, constitute the formative principle of the animal body.

II. DEVELOPMENT AND STRUCTURAL PLAN OF THE VERTEBRATE BODY.

The structural elements described in the preceding section as the building-stones of the organism, *i.e.* the cells, all arise from a single primitive cell, the **egg-cell** or **ovum**. This forms the starting-point for the entire animal-body, and a somewhat full account of its structure and relations must therefore be given here. The stages in its development will only be described in a very general manner.

The unimpregnated ovum consists of a rounded vesicle (Fig. 1), in the interior of which the following parts can be distinguished:—The vitellus (*D*), the germinal vesicle (*KB*), and one or more germinal spots (*KF*). Of these, the germinal vesicle is the most important physiologically (comp. p. 3). The outer-covering of the ovum is spoken of as the vitelline membrane.

Since the ovum in its primitive form as above described represents a single **cell**, we may speak of the vitellus¹ as the protoplasm of the egg-cell, the germinal vesicle as its nucleus, and the germinal spot as its nucleolus. An outer limiting membrane, corresponding to the vitelline membrane, is not an

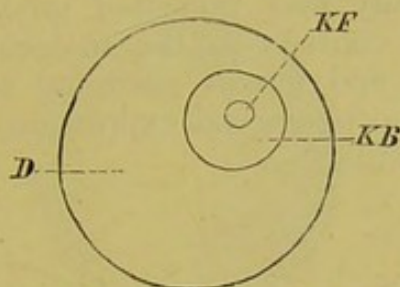


FIG. 1.—DIAGRAM OF THE UNIMPREGNATED OVUM.
D, vitellus ; *KB*, germinal vesicle ; *KF*, germinal spot.

integral part of the cell, but may be developed as a hardening of the peripheral protoplasm, consequent on a process of differentiation.

In all Vertebrates, the contact of the generative products of the male, the **sperm-cells** (spermatozoa) is an absolute necessity for the development of the ova. A spermatozoon makes its way into the interior of the ovum, and a portion of it finally unites in a definite manner with the modified germinal vesicle to form a single body—the **first segmentation nucleus**.

This modification of the germinal vesicle takes place as follows. Before fertilisation occurs, two polar cells² are constricted off from the ovum, part of the germinal vesicle passing into each, and the remainder being spoken of as the female pronucleus. The polar bodies are given off at different times in different animals: they may be formed while the ovum is still within the ovary, or, on the other hand, they may arise at the time of fertilisation.

¹ The vitellus consists of two different substances—protoplasm and deutero-plasm (yolk)—in varying proportions in different animals.

² The two most important views as to the meaning of the polar cells are those of (1) Balfour and van Beneden, and (2) Weismann. The first-named authors suppose that the egg, being a product of both sexes, is primitively hermaphrodite. By the extrusion of the polar bodies, the male portion of the egg is thrown out, and the remainder thus becomes unisexual (female), and ready for the entrance of the spermatozoon. This process would thus be a contrivance for the prevention of parthenogenesis.

Weismann distinguishes in every animal body two kinds of cells, somatic and generative cells. As all the cells arise as products of the segmentation of the ovum, they are originally quite similar morphologically, and each would thus consist of a "somatic" and of a "generative" portion. In order that certain of them should give rise to definite generative cells, it is necessary that the somatic portion should be got rid of, and this is effected by the extrusion of the polar bodies.

The first hypothesis presupposes that in parthenogenesis no polar bodies are formed. Weismann has lately, however, proved their existence in the parthenogenetic summer eggs of *Daphnidæ*, and this view is consequently rendered improbable. In the development of the male generative cells, a certain portion of each primitive seminal cell also remains passive, not giving rise to spermatozoa.

The head of the spermatozoon, on entering the ovum, is transformed into the male pronucleus,¹ which fuses with the female pronucleus to form the first segmentation nucleus.

Impregnation then consists in a material fusion of the generative products of both sexes, and hence in the new individual we naturally find inherited qualities. The essential cause of inheritance consists in the molecular structure of the nuclei of both male and female germinal cells. This structure (idioplasm) is the morphological expression of the characters of the species and individual.

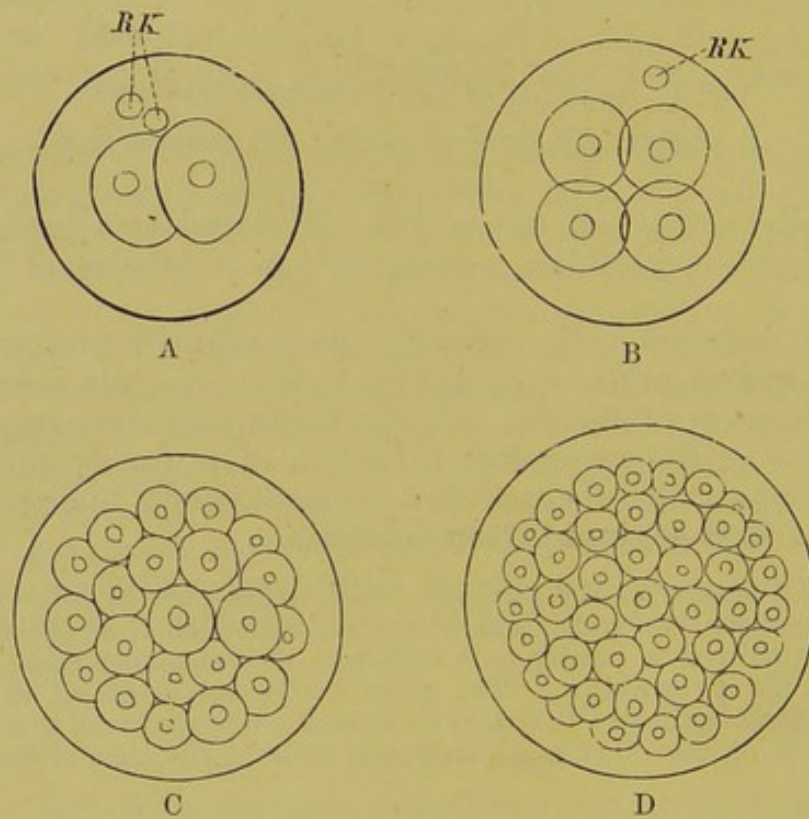


FIG. 2.—DIAGRAMS OF THE SEGMENTATION OF THE OVUM.

A, first stage (two segments): *RK*, polar bodies. B, second stage (four segments). C, further stage. D, morula stage.

The next stages (Fig. 2) are as follows. The first segmentation nucleus divides into two equal parts, each of which forms a new centre for the division of the ovum into two halves. This division, the beginning of the process of **segmentation**, takes place by the formation of a furrow round the egg, which becomes deeper and deeper, until the division is complete.

The first stage in the process of segmentation is thus completed; the second takes place in exactly the same way, and results in a

¹ If the egg is to be normally developed, not more than one spermatozoon must enter. The latter may either pass through a definite opening (micropyle), or else bore its way through the vitelline membrane.

division of the ovum into four parts, and by a similar process are formed eight, then sixteen, then thirty-two spheres, and so on, the spheres becoming smaller and smaller, and each being provided with a nucleus. In short, out of the original ovum, corresponding

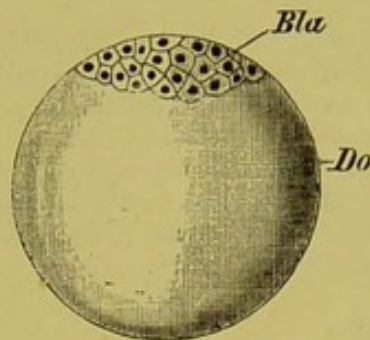


FIG. 3.—DIAGRAM OF A SEGMENTED MEROBLASTIC OVUM.

Bla, blastoderm; *Do*, yolk.

to a single cell, a mass of cells is formed, which represents the building-material of the animal body, and which, from its likeness in appearance to a mulberry, is spoken of as a **morula**.¹

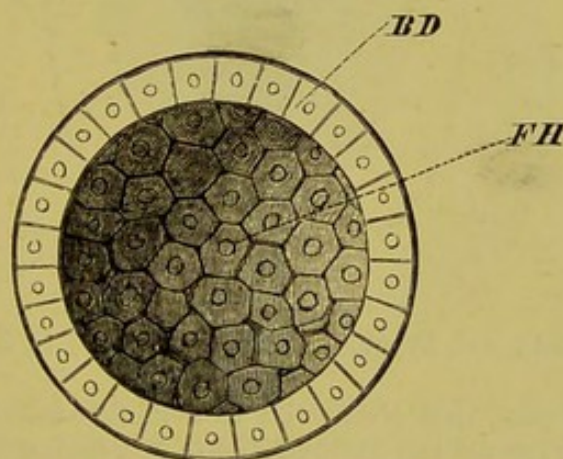


FIG. 4.—BLASTOSPHERE.

BD, blastoderm; *FH*, segmentation cavity.

In the interior of this morula a cavity (segmentation cavity) filled with fluid is formed, and the morula is now spoken of as the **blastosphere** or **blastula**. The peripheral cells enclosing this cavity form the **germinal membrane** or **blastoderm** (Fig. 4,

¹ A segmentation of the entire ovum occurs in Amphioxus, Cyclostomes, Sturgeon, Lepidosteus, Amphibians, and Mammals (with the exception of Monotremes). In Elasmobranchs, Teleosteans, Reptiles, Birds, and Monotremes, in which a very large amount of food-yolk (deuteroplasm) is present in the protoplasm, the egg undergoes only a partial segmentation, the main mass of the yolk remaining undivided and serving merely as nutritive material for the developing embryo. The former are spoken of as holoblastic (Figs. 1 and 2), the latter as meroblastic (Fig. 3). The eggs of the Sturgeon, Lepidosteus, and in a less degree those of Cyclostomes and Amphibians, though holoblastic, approach the meroblastic type.

BD).¹ Consisting at first of a single layer of cells, the blastoderm later on becomes two- and then three-layered. From the relative positions of these, they are spoken of respectively as the **outer**, **middle**, and **inner germinal layers**, or as **epiblast**, **mesoblast**, and **hypoblast**.²

The question as to the origin of the germinal layers, on account of its important signification, is one of the most burning problems in Morphology, and as yet we cannot arrive at any full and satisfactory conclusion on the subject. It may, however, be affirmed with certainty that in all Vertebrates the blastosphere passes—or did so in earlier times—into a stage called the **Gastrula**.³ One must imagine this form as being derived primitively from the blastula by supposing that the wall of the latter (Fig. 4, *BD*) became pushed in, or

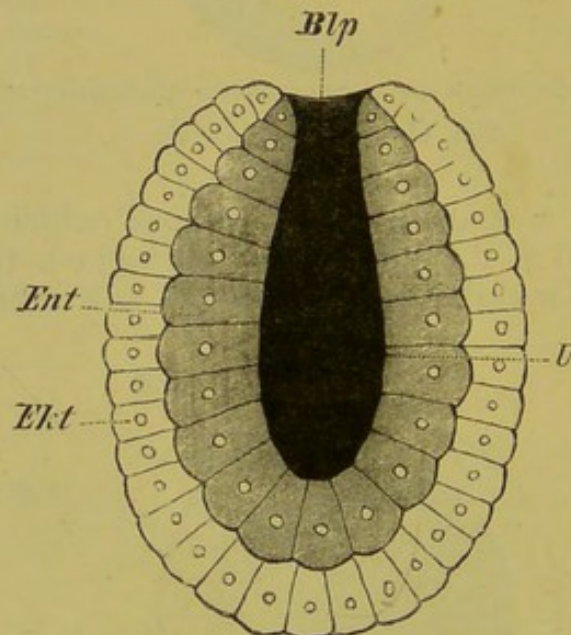


FIG. 5.—GASTRULA.

Ekt, epiblast; *Ent*, hypoblast; *Blp*, blastopore; *U*, archenteron.

invaginated, at one part, thus giving rise to a double-walled sac (Fig. 5). The outer wall then represents the epiblast (*Ekt*), which functions as an organ of protection and sensation, while the inner, or hypoblast (*Ent*), encloses a central space, the primitive intestinal cavity (archenteron), and represents the assimilating and digestive primary alimentary canal. The opening of the latter to the exterior, where the two germinal layers are continuous, represents the primitive mouth, and is called the **blastopore** (Fig. 5, *Blp*).

Out of the epiblast arise later the epidermis and its derivatives, as well as the entire nervous system. The latter is formed as an

¹ In meroblastic Vertebrate ova the blastoderm only extends part of the way round the periphery of the ovum (Fig. 3).

² The terms **ectoderm**, **mesoderm**, and **endoderm** are applied to the corresponding layers in an adult animal.

³ The process of the formation of the gastrula may be actually observed at the present day in the holoblastic ova of certain Fishes (see note, p. 5) and of Amphibia, and the same process essentially occurs in the meroblastic ova of other Fishes, though it is here more difficult to recognise. In the case of the Amniota the difficulty is still greater, but although we have no direct proof of the existence of a gastrula stage, the intimate connection of the developmental processes throughout the animal kingdom renders it *a priori* certain that the gastrula is represented in them.

involution of the thickened dorsal region of the embryo (medullary plate), which soon becomes constricted off from the epiblast in the form of a hollow tube—the medullary cord or tube (comp. Figs. 6 and 7), from which the brain and spinal cord are formed. The hypoblast gives rise eventually to the epithelium of the alimentary canal (Fig. 7, A and B, *Ent*) with its glands, as well as to the epithelial parts of the lungs, thyroid and thymus glands, liver, and pancreas.

Though we can look upon the epiblast and hypoblast,—that is, both the primary germinal layers,¹—as arising in the manner above described, the problem as to the origin of the mesoblast is as yet by no means settled. All that can be said at present is briefly as follows:—The mesoblast is a secondary

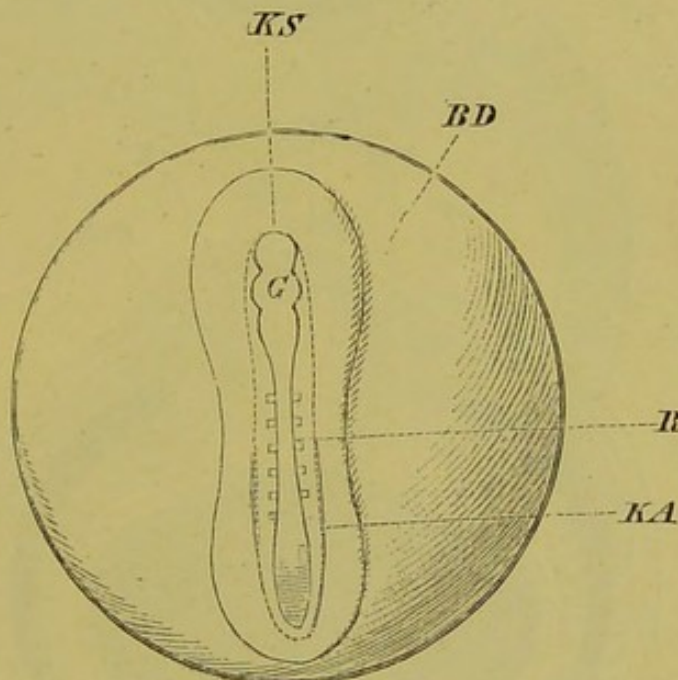


FIG. 6.—EARLY STAGE IN THE DIFFERENTIATION OF THE EMBRYO.

BD, blastoderm; *KS*, germinal disk; *KA*, body-walls; *R*, medullary cord, right and left of which are seen the mesoblastic somites; *G*, brain.

formation, and phylogenetically younger than the other two germinal layers. Reminding one in many points of the "mesenchyma" of Invertebrates, it always arises at first from the point where epiblast and hypoblast pass into one another, that is, from the region of the blastopore, or, what comes to the same thing in the higher Vertebrates, from the primitive streak. Originating between the other two layers, its first and most important function is the formation of blood-corpuscles—first of white cells (leucocytes, lymph-corpuscles); later it gives rise to the heart, blood-vessels, supporting and connective substances (connective-tissue, adipose tissue, cartilage, and bone), serous membranes (peritoneum, pleura, pericardium, arachnoid), excretory and reproductive apparatus, and muscles.

¹ It must be observed that this important difference in the histological differentiation of the individual germinal layers cannot be so definitely stated as regards the whole animal kingdom: in certain types of Invertebrates it is not so strongly marked.

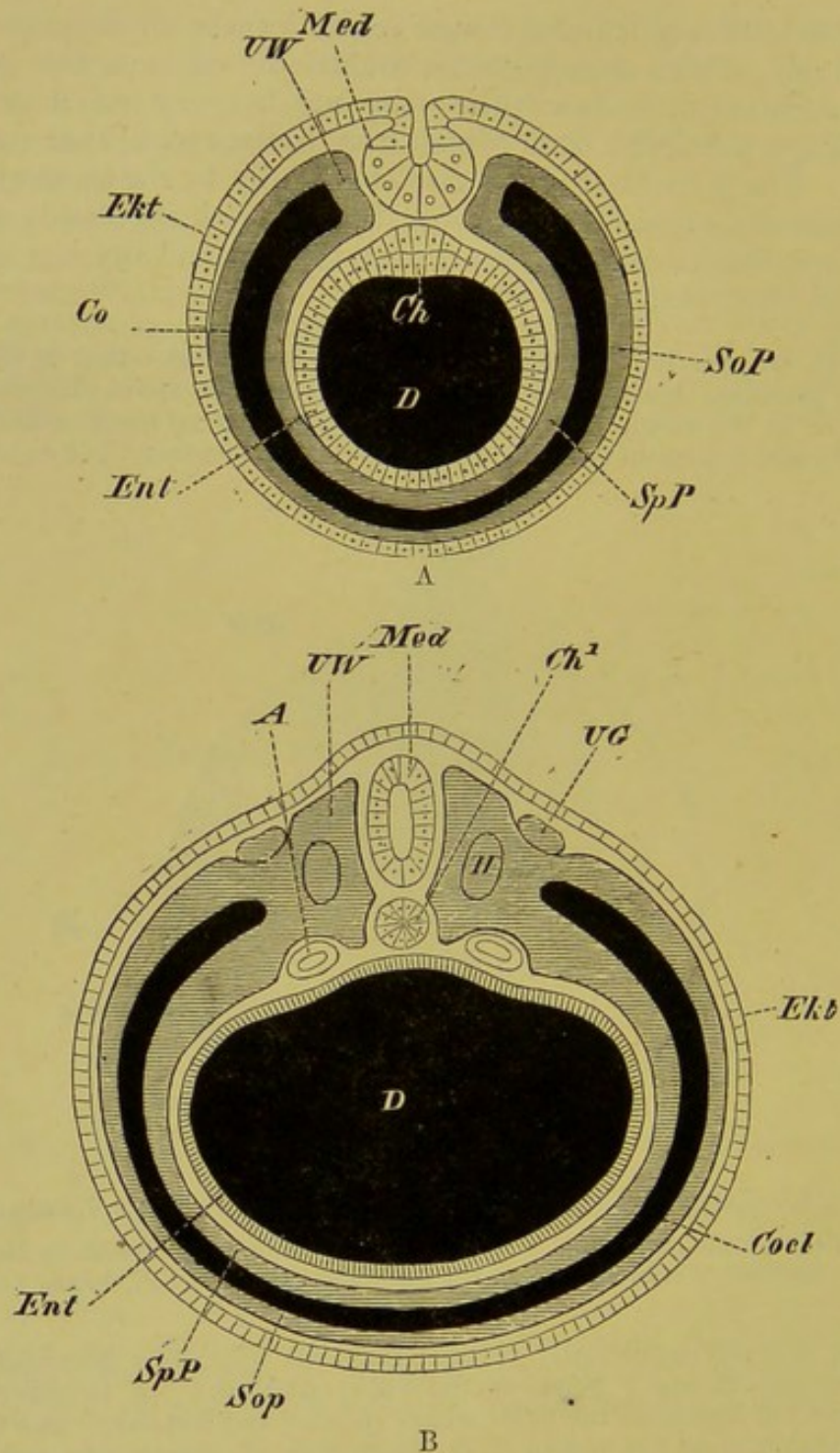


FIG. 7, A AND B.—DIAGRAMMATIC TRANSVERSE SECTIONS THROUGH A DEVELOPING VERTEBRATE EMBRYO.

D, alimentary canal; *Ent*, hypoblast, showing in Fig. A the thickening which will form the notochord; *Ch¹* (Fig. B), the notochord now constricted off from the hypoblast; *UW*, mesoblastic somite; *UG*, primary urinary duct (segmental duct); *A*, aorta; *SpP*, splanchnic and *SoP*, somatic mesoblast; *Co*, *Coel*, coelome; *H*, remains of the upper part of the coelome in the interior of the mesoblastic somites; *Ekt*, epiblast; *Med*, medullary cord:—in Fig. A it is shown still connected with the epiblast, from which it has become constricted off in Fig. B.

A large cleft appearing in the mesoblastic tissue divides it into a parietal layer (Fig. 7, A and B, *SoP*), lying along the inner

side of the epiblast, and into a visceral layer (*SpP*), which becomes attached to the hypoblast. The former, together with the epiblast to which it is united, constitutes the somatopleure, and the latter, together with the hypoblast, the splanchnopleure. The cavity separating these is the body-cavity, or **cœlome**.¹ The upper part of the mesoblast, or that which lies on either side of the medullary cord and notochord (see p. 10), becomes separated from the lower, and segmented to form a series of mesoblastic

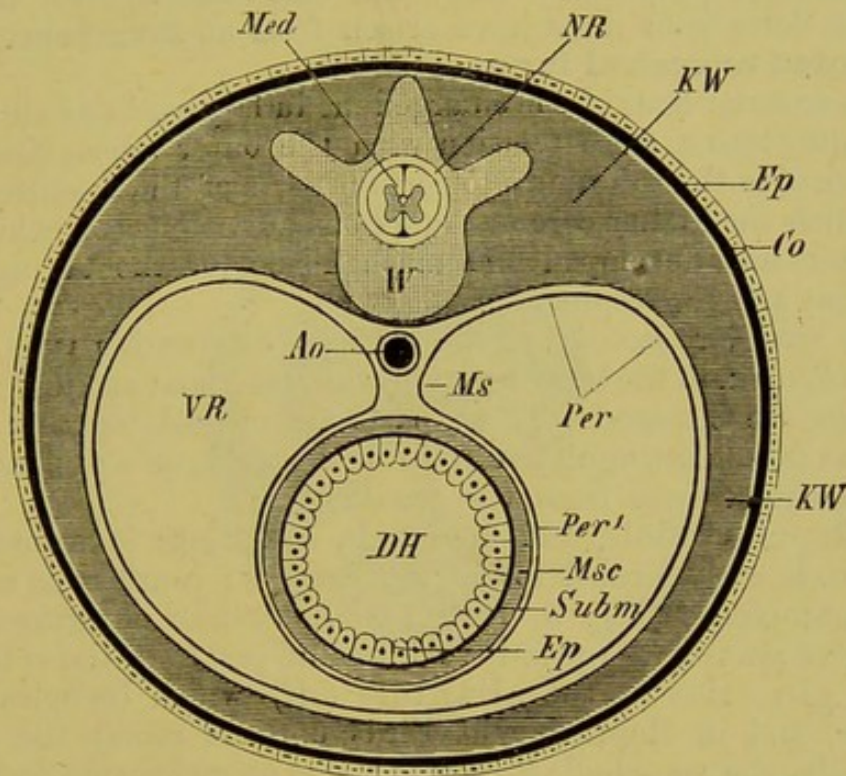


FIG. 8.—DIAGRAMMATIC TRANSVERSE SECTION THROUGH THE BODY OF AN ADULT VERTEBRATE.

Med, spinal cord; *NR*, neural tube; *KW*, body-wall; *Co*, derma; *Ep*, epidermis; *VR*, visceral tube; *Ao*, aorta; *Ms*, mesentery; *Per*, parietal layer of the peritoneum; *Per*¹, visceral layer of the peritoneum; *Msc*, musculature of intestine; *Subm*, connective-tissue coat of the intestine; *Ep*, epithelium of intestine; *DH*, lumen of intestine; *W*, vertebral column.

somites, or protovertebræ (Fig. 7, B, *UW*, *H*), which lose their cavities, and eventually give rise to the vertebral column and longitudinal lateral muscles.

The Vertebrate body is formed on a bilaterally symmetrical plan, and it may be described as consisting in the adult of two tubes, a dorsal and a ventral (Fig. 8, *NR*, *VR*). The former, or cerebro-spinal cavity, encloses the central nervous system (brain and spinal cord), and may therefore be spoken of as the neural

¹ The cœlome may arise as a segmentally arranged series of outgrowths from the archenteron, as, *e.g.*, in *Amphioxus* (enterocœles), or it may be formed secondarily by a splitting (delamination) of the mesoblastic tissue (schizocœle). The first of these must be considered as the most primitive.

tube; the latter surpasses the former considerably in size, and, as it encloses the viscera, it may be called the visceral tube.

A cellular, cartilage-like rod—the **notochord** (chorda dorsalis), arising primitively as an axial thickening of the hypoblast (Fig. 7, A and B, *Ch*, *Ch*¹), forms the basis of the vertebral column, that is, the segmented axial skeleton which characterises the Vertebrate body.¹ This segmentation of the axis, as well as of other organs and systems of organs (musculature, ribs, roots of spinal nerves, sympathetic cord, pro- and mesonephros), indicates that the Vertebrata must have arisen from an **invertebrate and segmented ancestral form**.

The anterior ends of the enlarged medullary cord and alimentary tract enter into a close relation with the outer world, the former giving rise to the brain and to certain parts of those sense-organs with which the higher cerebral functions are connected, while from the latter are developed the mechanisms for the taking in of nutriment and for respiration.

The anterior section of the embryo, or head, passes behind into the trunk, in the hinder part of which the anal and urinogenital apertures are situated. These parts are classed together as the body-axis, as distinguished from the limbs, or appendicular organs, which arise from the trunk.

In Reptiles, Birds, and Mammals, a delicate investment, the amnion, is early formed round the embryo; it arises as a fold of the somatopleure (Fig. 9, *AF*, *A*). A sac-like out-growth from the hinder part of the primitive intestine (*i.e.* from the splanchnopleure) gives rise to the allantois (*Al*) which becomes highly vascular, and in Reptiles and Birds extends round the embryo close under the egg-shell; it here serves as an embryonic respiratory organ. In all Mammals, except Monotremes and Marsupials, the allantois becomes attached to a definite region of the uterine wall, and from it vascular processes or villi grow out into crypts of the latter, which is also plentifully supplied with blood-vessels. Thus a **placenta** is formed, in which interchanges can take place both as regards nutritive materials and aëration between the blood of the mother and that of the fœtus.

Considerable differences are observable in the form of the placenta in different Mammals. The most primitive arrangement is most probably one in which the allantois becomes attached along a discoidal region of the wall of the uterus, and the various modifications seen in the different groups may be looked upon as having arisen in order to increase the absorptive surface. This may be effected either by the area of that part of the allantois which is covered by placental villi becoming extended, or by the increase in complexity of the villi and crypts. In the latter case, the interlocking between foetal and maternal parts is so close that the mucous membrane of the uterus is torn away with the foetal part of the placenta at birth, and the latter is then said to be deciduate. In the former case, the discoidal placenta may extend so as to

¹ In the lowest Vertebrates, the segmentation of the body is indicated mainly by somites.

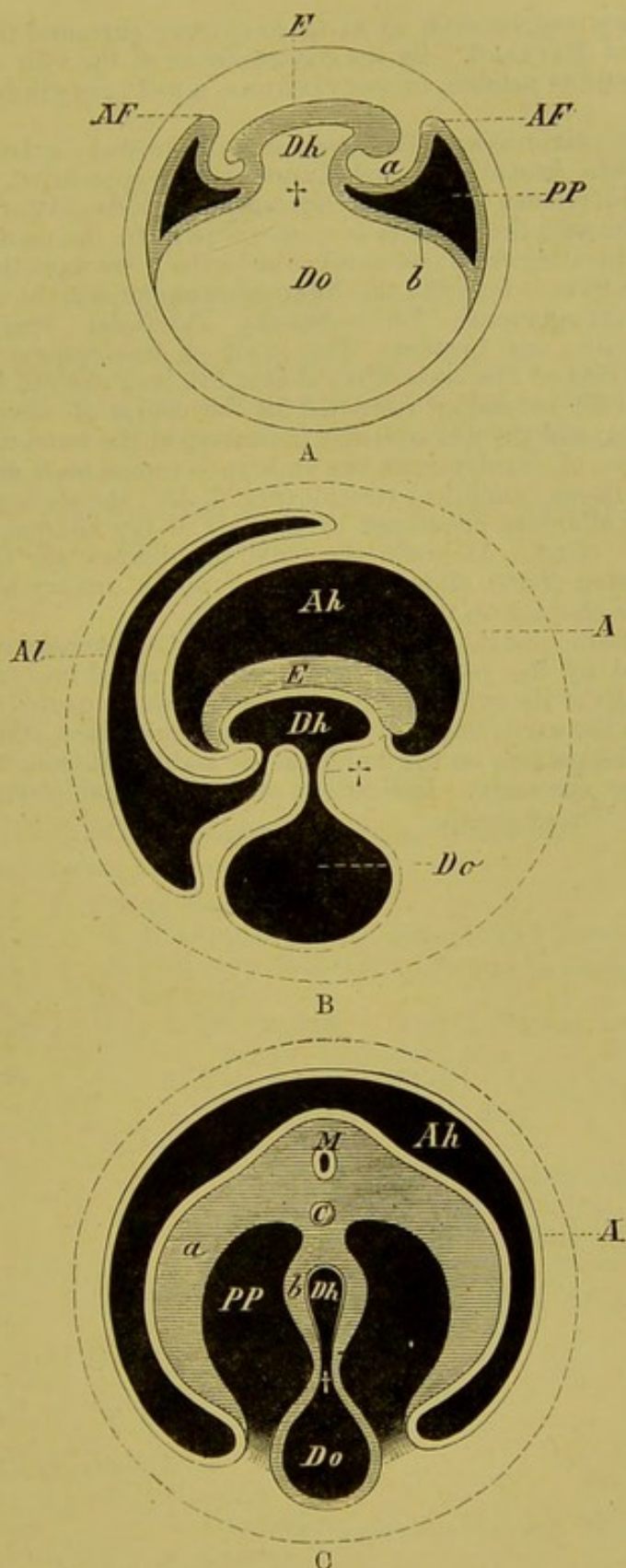


FIG. 9, A, B, AND C.—DIAGRAMS ILLUSTRATING THE FORMATION OF THE AMNION, ALLANTOIS, AND YOLK-SAC. A AND B, IN LONGITUDINAL SECTION; C, IN TRANSVERSE SECTION.

E, embryo; *Dh*, alimentary tract; *Do*, yolk-sac; †, vitello-intestinal duct; *PP*, body-cavity; *Ah*, amniotic cavity; *AF*, amniotic fold; *A*, amnion; *Al*, allantois; *a*, somatopleure; *b*, splanchnopleure; *M*, medullary cord; *C*, notochord.

occupy a zonary area, or even so as to completely surround the fœtus, when it is spoken of as diffused. By the concentration of the villi of the diffused placenta into definite patches, or cotyledons, a polycotyledonary form is produced.

Rodents, Insectivores, and Bats possess a discoidal deciduate placenta, and that of Sloths, Armadilloes, and Myrmecophaga approaches the same type. In Carnivores, Elephants, Hyrax, and Orycteropus, it is deciduate and zonary. In all other Mammals the placenta is non-deciduate, the maternal and fœtal parts simply separating from one another at birth. Amongst these the polycotyledonary form is found in the Ruminants proper, and the diffused form in Suidæ, Hippopotamus, Perissodactyla, Tylopoda, Tragulidæ, Manis, Lemuridæ, Sirenia, and Cetacea. The mode of development of the meta-discoidal placenta of Primates shows that it has been derived from a diffused placenta, the villi becoming restricted in the course of development to a disk-shaped area, and their complexity increasing at the same time (Balfour).

In the course of development the embryo becomes more and more folded off from the yolk-sac (umbilical vesicle) (Fig. 9, *Do*), the stalk of which latter, and that of the allantois, enveloped by the base of the amnion, together form the umbilical cord. At birth, the fœtal membranes are shed, the intra-abdominal portion of the allantois persisting as the urinary bladder and the urachus (cp. the chapter on the vascular system).

Amongst Elasmobranchs, *Mustelus lævis* and *Carcharias* possess a kind of placenta formed by the yolk-sac, which becomes raised into folds fitting into the vascular walls of the oviduct. Indications of such an umbilical placenta are also seen in the early stages of Insectivora, Cheiroptera, and Rodentia.

Further investigations on the umbilical sac and allantois in Marsupials and Monotremes are necessary. Indications of an umbilical placenta have been observed in the former group.

SYSTEMATIC ZOOLOGY.

On the ground of their relationship to one another, animals have been classified into certain divisions and subdivisions, which are designated as Classes, Orders, Suborders, Families, Genera, and Species.

A general classification of the principal existing Vertebrate groups is given in the following table.

A. **Acrania.**

Amphioxus.

B. **Craniata.**I. **CYCLOSTOMATA** (Suctorial Fishes).

1. Petromyzontidæ.
2. Myxinoïdæ.

II. **GNATHOSTOMATA** (Animals provided with jaws).(a.) **ANAMNIA** (without amnion).1. **PISCES** (True Fishes).

- α.* Elasmobranchii (Sharks and Rays).
- β.* Holocephali (Chimæra and Callorhynchus).
- γ.* Ganoidei.
 1. Selachoidei (Cartilaginous Ganoids—Acipenser, Polyodon, &c.).
 2. Teleostoidei (Bony Ganoids—Polypterus, Lepidosteus, Amia, &c.).
- δ.* Teleostei.
 1. Physostomi (with open pneumatic duct between the air-bladder and pharynx, *e.g.* Cyprinus, Salmo, Silurus, Mormyrus).
 2. Physoclisti (air-bladder, when present, with closed pneumatic duct, *e.g.* Perca, Gadus, Lophius).

Ichthyopsida.

2. **DIPNOL**

1. Monopneumones (Ceratodus).
2. Dipneumones (Protopterus).

3. **AMPHIBIA.***a.* **Urodela.**

1. Perennibranchiata (Proteus, Siren, Monobranchus).
2. Caducibranchiata.

Derotremata (Amphiuma, Menopoma).

Myctodera (Salamandra, Triton, Amblystoma).

β. **Anura** (Frogs and Toads).*γ.* **Gymnophiona** (Footless Cæcilians).

(b.) AMNIOTA (Vertebrates which develop an amnion during foetal life).

Sauropsida.

1. REPTILIA.

a. Crocodilia (Crocodiles and Alligators).

β. Lacertilia (Lizards).

γ. Chelonia (Turtles and Tortoises).

δ. Ophidia (Snakes).

2. AVES.

a. Ratitæ (Cursorial Birds—Ostrich, Rhea, Emeu, &c.).

β. Carinatae (Birds of flight).

3. MAMMALIA.

a. Prototheria or Ornithodelphia (Monotremata
--Ornithorhynchus and Echidna).

β. Metatheria or Didelphia (Marsupialia—Kangaroos, Phalangers, Opossums, &c.).

γ. Eutheria or Monodelphia (Placentalia).

Edentata.

Sirenia.

Cetacea.

Ungulata.

Hyracoidea.

Proboscidea.

Rodentia.

Cheiroptera.



















Insectivora.

Carnivora.

Lemuroidea.

Primates.

TABLE SHOWING THE GRADUAL DEVELOPMENT OF THE VERTEBRATA IN TIME. MODIFIED FROM H. CREDNER.

Formation.	Period	Fishes.	Amphibians and Reptiles.	Birds.	Mammals.	Man.
Recent.	Of the prevalence of warm-blooded animals, particularly Man.					
Kainozoic Quaternary. Tertiary.	Of the prevalence of mammals; the first Man.					
Mesozoic Cretaceous. Jurassic. Triassic.	Of the maximum development of Reptiles; the first Birds and Mammals.					
Palæozoic Permian. Carboniferous.	Of the first Amphibians and Reptiles.					
Devonian.	Of tolerably numerous Fishes (armoured Ganoids).					
Upper Silurian.	Of the first Fishes.					
Lower Silurian. Cambrian.						
Archæan.						

SPECIAL PART.

A. INTEGUMENT.

THE **skin** consists of a superficial ectodermal and a deeper mesodermal layer. The former is called the **epidermis** (scarf-skin) and the latter the **derma** (corium, cutis). The subcutaneous connective tissue is usually not sharply marked off from the derma, but either passes gradually into the other. The epidermis always consists of cells only, while the derma is made up principally of connective-tissue fibres, as well as those of an elastic and contractile nature. Nerves, glands, pigment-cells (chromatophores), bony-structures, and vessels occur principally in the derma, the last two being found in this part of the integument only.

The derma is also permeated throughout by leucocytes (white blood-corpuscles), and this is especially the case in Fishes. These leucocytes penetrate to the superficial layer of the epidermis, and carry pigment granules.¹ Here they take on amoeboid movements, and break up into numerous small pigment-containing particles, which are taken up by the epithelial cells.

From what has been said above, it is clear that the skin presents much variety both in form and function, and this cannot be wondered at when one considers how accessible its outer surface is to external modifying influences.

In the epidermis two layers may always be distinguished:—an outer, composed of horny cells (stratum corneum, horny layer), and a deeper, made up of soft protoplasmic cells (stratum Malpighii, mucous layer). The latter serves as a matrix for the regeneration of the horny layer, the superficial part of which is continually scaling off. From the epidermis all the glands of the skin, and all other parts spoken of as epidermic structures take their origin. Such are hairs, bristles, feathers, nails, claws, hoofs, &c. The peripheral sensory end-organs of the skin are to be considered as arising by a differentiation of epidermic cells: the definite relation which many of these organs have with the derma must be looked upon as a secondary acquirement.

¹ Pigment is never formed in the epithelial cells themselves, but always originates in the derma.

Animals living in the water mostly possess a thinner horny layer which is more capable of imbibition than that of land animals, which latter are usually exposed to more mechanical dangers than the former. It may also be mentioned that the connective-tissue bundles in the derma of Fishes, Amphibians, and Reptiles show a typical arrangement in alternating horizontal and vertical strands. Their disposition in Birds and Mammals is irregular, that is, the fibres are more thoroughly felted.

Fishes.—In *Amphioxus*, the surface of the epidermis is covered with cilia in the larval (gastrula) condition, and this

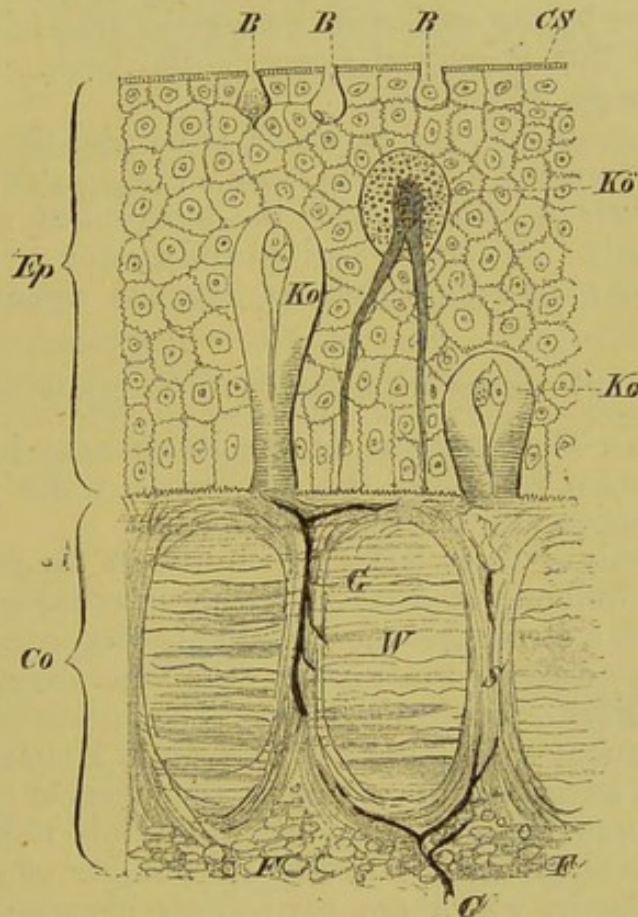


FIG. 10.—DIAGRAMMATIC TRANSVERSE SECTION ILLUSTRATING THE STRUCTURE OF THE SKIN IN FISHES.

Ep, epidermis; *Co*, derma; *F*, subcutaneous fat; *CS*, cuticular margin; *B, B*, slime-cells (goblet-cells which open on the surface); *Ko*, goblet-cells; *Kö*, granular cells present in *Petromyzon*; *G*, vessels which pass upwards in the vertical connective-tissue bundles of the derma; *W*, horizontal connective-tissue bundles.

must undoubtedly be considered as inherited from Invertebrate ancestors. The striated cuticular border of the outer epidermic layer in many fishes (*e.g.* *Cyclostomes*, *Teleostei*, and *Dipnoi*), and, as will be mentioned presently, in Amphibian larvæ, is perhaps to be explained in the same way, the striation possibly corresponding to coalesced cilia (Figs. 10 and 11A, *CS*).

In *Amphioxus* and the *Cyclostomes* long cylindrical cells provided with stiff bristle-like processes appear amongst the ordinary epithelial cells. These,

as well as similar elements connected with complicated pieces of apparatus will be treated of later in connection with the sense-organs.

The meaning of the "granular cells" present in the integument of Petromyzon, as well as of the so-called "club-" and "goblet-cells" in the many-layered epidermis of osseous Fishes, is as yet by no means clear; it is, however, not improbable that the latter of these have to do with the preparation of a secretion which protects the outer skin from the action of the water.

The scales of Fishes lie in connective-tissue pouches of the derma, and are formed as ossifications of the latter. In Teleostei they are covered by the epidermis throughout life; in Ganoids and Elasmobranchs this is only the case in the larva. (For further details compare pp. 31 and 32.)

Pigment-cells (cp. p. 16), which are under the influence of the nervous system and are able to cause a change of colour, are present sometimes in both layers of the integument, sometimes in the epidermis only. Muscles and glands, such as are found in the skin of other Vertebrates, are not usually present in Fishes.¹

Phosphorescent organs are present in the integument of some Fishes.

Amphibia.—The structure of the integument in larval Amphibians somewhat resembles that of Fishes, while in adults it more nearly approaches that seen in Reptiles.

The epidermis of those larvæ which live in the water consists of two sharply differentiated layers. The outer layer is made up of flat cells with a striated border (Fig. 11A, *CS*) on their free edge, like that already described in Fishes: the inner layer is composed of more cylindrical or cubical cells (*b*). The former corresponds to the stratum corneum, the latter to the stratum Malpighii.

Later, with advancing development, the layers of the epidermis become more numerous, and involutions towards the derma take place in all parts, giving rise to a great number of globular and tube-shaped glands, which are particularly abundant in certain regions—more especially in the head and flanks.

Their secretion serves to keep the skin moist, but, as experiments have shown, it also forms an important weapon of defence, on account of its poisonous properties.²

¹ There are, however, several exceptions to this rule. In male Elasmobranchs there is a large glandula pterygopodii (gland of the clasper) at the base of each pelvic fin. It arises as a tube-like invagination of the skin, and is in relation with the copulatory organs (cp. the chapter on these organs). In the Weever (*Trachinus*) there is a series of poison-glands lying on either side of the bases of the spines of the dorsal fin; they are situated at the bottom of integumentary sacs, and their ducts open close to the bases of the spines. In *Thalassophryne* the operculum is provided with a hollow spine, at the base of which a poison-sac is situated, and in *Synanceia* there are also a series of "poison-bags" at the bases of the grooved dorsal spines (Günther). Poison organs appear to be present in certain other Fishes (many Siluroids, *Aëtobatis*) but the existence of actual glands is not certainly known.

² The poison has no effect on other individuals of the same species; but it acts very powerfully on closely allied forms, as well as on the higher animals.

This richness in glands is a characteristic of the skin of Amphibia, and to it they owe their moist and slippery nature. Frequently, as for instance in Toads, the skin is not smooth, but has a rough, warty appearance, caused by local proliferations of the epidermis.

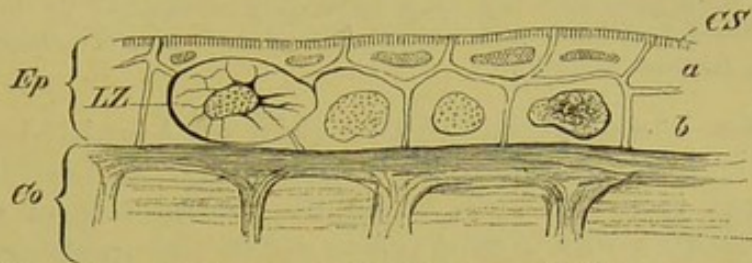


FIG. 11A.—SKIN OF LARVA OF SALAMANDER (*Salamandra maculosa*).

Ep, epidermis; *Co*, derma; *a*, stratum corneum; *b*, stratum Malpighii; *LZ*, Leydig's cells; *CS*, striated border.

The pigment, accumulated principally in the derma—partly diffused, partly enclosed within the cells—is under the control of the nervous system, and thus renders a change of colour possible; and as the colour becomes modified according to the surroundings of the animal, it may serve as a protection.

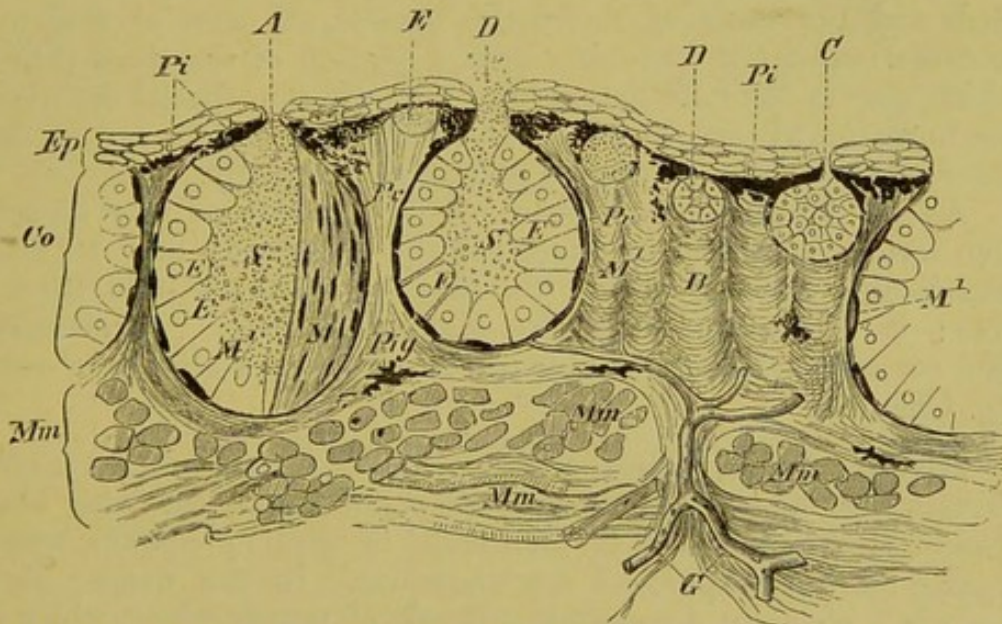


FIG. 11B.—SECTION THROUGH THE SKIN OF ADULT SALAMANDER (*S. maculosa*).

Ep, epidermis; *Co*, derma, in the richly pigmented (*Pi*) connective-tissue stroma of which the various sized integumentary glands (*A*, *C*, *D*, *D*, *E*) lie embedded; *M*¹, the muscular layer of the glands, lying within the membrana propria (*Pr*); *M*, the same, seen from the surface; *E*, epithelium of glands; *S*, secretion of glands; *Mm*, subcutaneous layer of muscles, through which vessels (*G*) extend towards the derma.

Calcifications may also occur in the derma, or, as in *Ceratophrys dorsata*, definite bones may be formed. Such bony plates

were much more abundant in Amphibians of former times; those of the Carboniferous and Trias (Stegocephala, Labyrinthodonta) were richly provided with them.

For a further reference to the ring-like scutes and scales found in Cæcilians, the reader is referred to the chapter on the dermal skeleton, and it is only necessary to state here that the rings accurately correspond in number with the vertebrae,—a very rare occurrence. The same is true of certain Amphibænians (*e.g.* *Blanus cinereus*).

Reptilia.—In contrast to the skin of Amphibians, that of Reptiles is very deficient in glands. In Lizards, a series of “femoral glands” occur along the ventral side of the thigh, the secretion from which, as it passes out of the apertures, hardens so as to form a series of papillæ or warts, which appear to serve as clasping organs during copulation. In Amphibænians integumentary glands are also present: they lie anteriorly to the cloaca, and open into the “pre-anal pores.”

The characteristic peculiarity of the skin of Reptiles is its capacity of producing **scales, warts, prickles, shields** (*e.g.* the “tortoiseshell” of Chelonians), **claws, rattles** (of Rattlesnake), and suchlike structures.

All these integumentary organs, as already mentioned (p. 16), are to be included in the same category as the feathers of Birds and the hairs of Mammals: that is, all arise at first by a proliferation of the epidermic cells, a portion of the dermal tissue taking part in their formation later on. Certain special differences are, however, always to be observed in the development of these different structures, as will be mentioned presently.

As in Amphibia, calcifications or ossifications may occur in the derma. The horny layer of the epidermis may be either periodically cast off entire (Snakes), or in shreds from time to time: it is renewed from the Malpighian layer. Pigment-cells also occur, rendering possible in many cases a change of colour (*e.g.* Chameleon).

Birds.—Birds possess a thinner derma than do any other Vertebrates, and it is not very plentifully supplied with blood-vessels, although, as will be mentioned in another chapter, sensory organs (tactile corpuscles) are abundant. In the deeper layers there is a strongly developed network of muscle-fibres, which are inserted into the feather-sacs, and serve to erect the feathers.

The feathers, arranged in so-called “feather-tracts” (pterylæ) separated by naked regions (apteria), form the most marked peculiarity of the body of Birds, and their development is very instructive. In the region where a feather is to be formed, the dermal tissue becomes raised up towards the ectoderm (Fig. 12, A, *Cu, Sc, SM¹*), and thus gives rise to a papilla (*Pap*). As this papilla grows out to form an elongated cone with a pointed apex, the feather-germ (Fig. 12, B, *FK*), its base sinks gradually deeper and

deeper into the derma, and thus becomes surrounded by a sort of pocket—the feather-follicle (*F*, *F*¹).

The horny, as well as the Malpighian layer of the epidermis (*Sc*, *SM*) extends into the base of the follicle, and thence into the feather-germ (*Sc*¹, *SM*¹), the interior of which is throughout filled by cells of the derma, which give rise to the pulp (*P*). As the feather-germ keeps on growing, the cells of the Malpighian layer

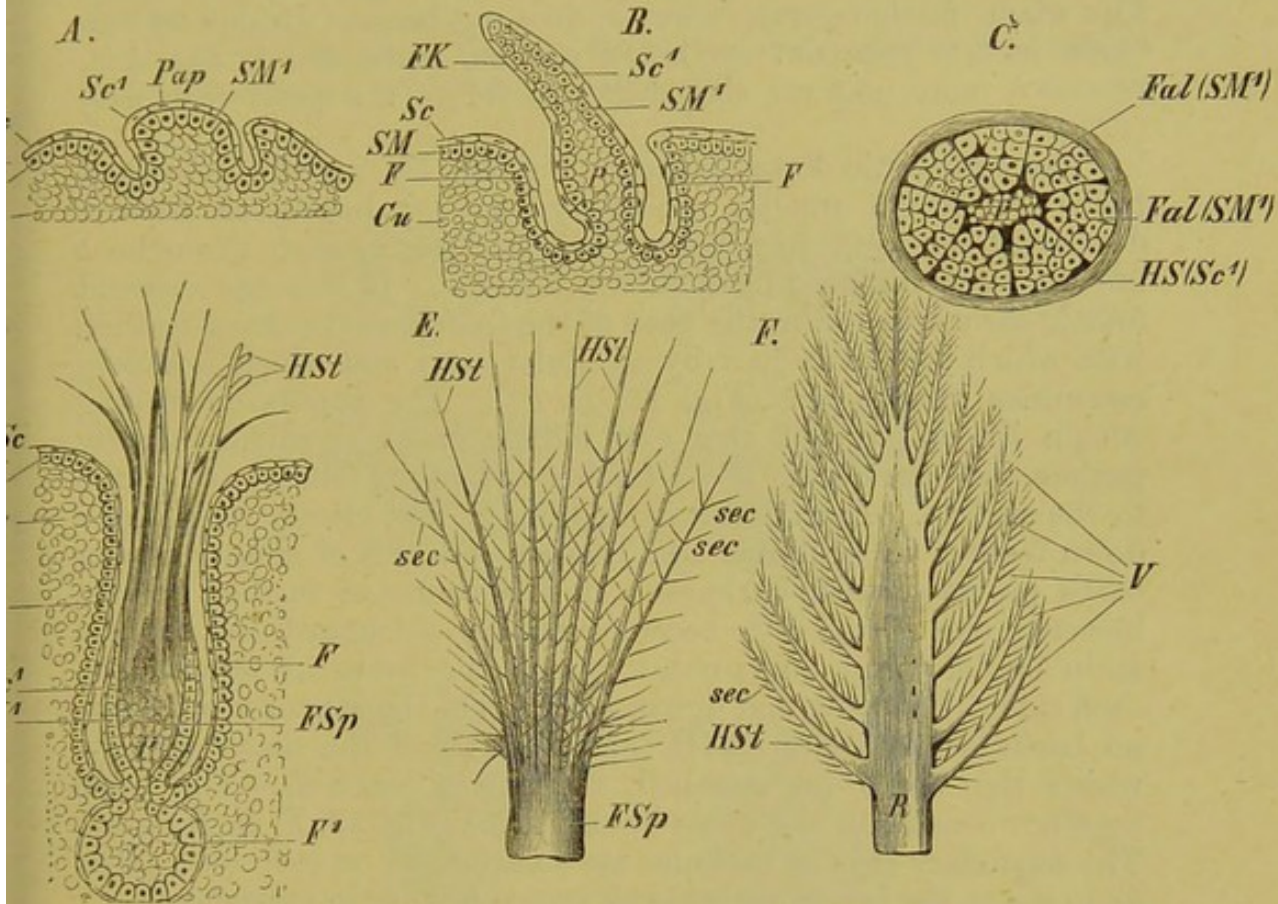


FIG. 12.—SIX STAGES IN THE DEVELOPMENT OF THE FEATHER.
(Mainly after Th. Studer.)

Cu, derma; *SM*, stratum Malpighii; *Sc*, stratum corneum; *SM*¹, *Sc*¹, extensions of these tissues into the feather-papilla, *Pap*; *FK*, feather-germ; *F*, *F*¹, feather-follicle; *P*, pulp; *Fal* (*SM*¹), folds of the Malpighian layer extending into the feather-germ, and enclosed externally by the horny layer, *HS* (*Sc*¹): both layers are seen in the transverse section (*C*); *FSp*, quill of feather, which breaks up above into a tuft of rays or barbs (*HSt*); *sec*, *sec*, secondary rays (barbules) arising from the latter; *R*, rachis; *V*, vexillum.

For further details as to the different stages A–F, compare text.

If one supposes that in Fig. A the papilla grows and becomes flattened and bent downwards posteriorly, and that ossification occurs in the dermal portion, the essential mode of development of a scale would be arrived at.

begin to proliferate rapidly, giving rise to a series of radial folds arranged along a central axis, which extend inwards towards the pulp, and are immediately bounded by the horny layer (Fig. 12, C, *Fal* (*SM*¹) and *HS* (*Sc*¹)). These folds then become cornified and separated from the surrounding cells, and, by a gradual drying of the

central pulp-substance, give rise to a tuft of horny rays, which are, however, at first bound together by the enclosing stratum corneum. Most Birds are hatched when the feathers are in this stage of development, and they thus appear as if covered with pencil-like hairs.

By the shedding of the surrounding horny layer the rays or barbs become free (Fig. 12, D, *HSt*), and if they are all similar to one another, an embryonic down-feather (*pluma*) is formed. The whole feather-germ, however, does not become divided up into barbs in this manner: its lower portion, embedded in the skin, retains a more uniform character and forms the quill (*calamus*) (*FSp*).

The embryonic down-feathers (Fig. 12, E), on the individual barbs of which smaller secondary rays or barbules become developed (*sec, sec*), may retain their character as such throughout life or may be replaced by definitive feathers. In this case a second follicle early arises from the base of the follicle of the down-feather, with which it is connected by a cellular cord, and which it closely resembles in structure (Fig. 12, D, *F¹*). The papilla developing within the interior of this new follicle grows rapidly, gradually pushes the base of the down-feather out of its follicle, and comes to the surface. Each definitive feather at first closely resembles a down-feather in structure, and consists of a tuft of similar rays or barbs provided with barbules. In the course of further growth, however, one of the rays becomes rapidly thickened, and forms a main axis or stem (*scapus*), to which the barbs are attached on each side. The proximal or basal portion of the scapus which bears no barbs is called the quill (*calamus*), and the distal part, to which the barbs are attached, the shaft (*rachis*). The barbs together constitute the vane (*vexillum*) (Fig. 12, F, *R, HSt, sec*). The secondary rays or barbules are so arranged on each barb (*HSt*) as to make the latter resemble an entire feather in appearance.

In many Birds, each quill of the ordinary feathers of the body bears two vexilla, the second being spoken of as the aftershaft (*hyporachis*).

In this manner the contour feathers (*pennæ*) are formed, such, for instance, as those on the wings and tail. The individual portions of the vexillum usually become very closely united together, so that an extremely strong and resistant though pliant structure is formed.

A periodic casting of feathers, or "moulting," takes place in all Birds, and corresponds to the similar process of the casting of the outer skin in Reptiles; in Mammals there is a continual scaling off of the epidermic cells of a similar nature.

The feather-covering of Birds must have been acquired in very early geological periods, for *Archæopteryx*, found in the Jurassic strata of Bavaria, possessed well-formed feathers with a very delicate shaft and vane.

Palaeontological researches have not yet brought to light any definite intermediate stages between scales and feathers, but that they must once have existed is shown by the development of these structures (comp. Fig. 12 and description).

There is no trace of proper dermal bones (dermostoses)¹ or calcifications in the skin of Birds, and the glands are reduced to a single mass—the uropygial gland: this is situated at the base of the tail (uropygium), and its secretion serves to oil the feathers.

Epidermic structures, such as claws, spurs, foot-scales, and beak-sheaths, are strongly developed.

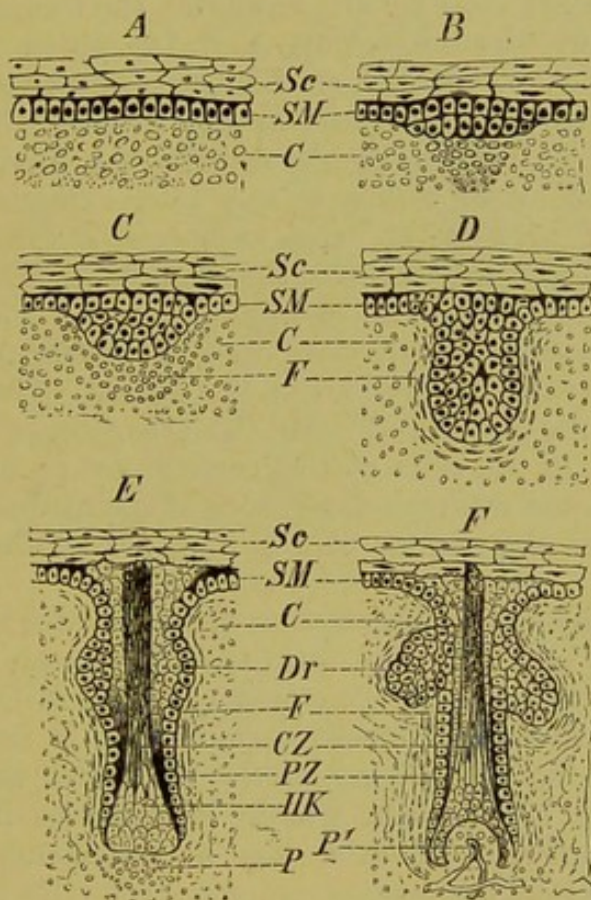


FIG. 13.—SIX STAGES IN THE DEVELOPMENT OF HAIR.

Sc, stratum corneum; *SM*, stratum Malpighii; *C*, derma; *F*, follicle; *Dr*, sebaceous gland; *CZ*, central, and *PZ*, peripheral zone of the hair-germ; *HK*, hair-knob; *P*, beginning of the formation of the hair-papilla; *P'*, the same in a later stage of development, when it has become vascular.

Mammals.—The hair-like structures possessed by certain Reptiles and Birds are histologically quite distinct from the true hairs of Mammals. The possession of hairs characterises Mammals quite as much as feathers distinguish Birds from all other animals.

¹ See note on p. 62.

Each hair arises first as a proliferation of the epidermic cells in the region of the Malpighian layer, which projects inwards towards the derma (Fig. 13, A and B, *Sc, SM, C*). In this manner the hair-germ is formed. The thickening of the epidermis then grows out into the form of a papilla, and becomes surrounded by the cells of the derma, so that, as in the case of the feather, it comes to lie within a kind of pocket, the hair-follicle (Fig. 13, C, D, *F*). The originally uniform mass of cells of the hair-germ later becomes differentiated into a peripheral and a central portion (Fig. 13, E, F, *PZ, CZ*). The latter consists of more elongated cells, and gives rise later to the hair-shaft with its medulla or pith, and to the cortex, as well as to the cuticle of the shaft, and to the so-called inner root-sheath; the former gives rise to the outer root-sheath (comp. Fig. 14, which represents the fully-formed hair). The base of the hair-shaft which fills up the bottom of the follicle is broadened out to form the hair-knob (Fig. 13, E, F, *HK*), and the richly vascular hair-papilla (Fig. 13, E, F, *P, P¹*), which arises comparatively late, extends into it from below. At *Dr*, in Fig. 13, the sebaceous glands are seen arising by a proliferation of the Malpighian cells. The hair usually breaks through the skin in an oblique direction. The character of the medulla varies so much that upon it principally depend the differences observable in the hair of Mammals.¹ The colour of the hair is due to three causes:—Firstly, to the greater or less accumulation of pigment in the cells of the cortical layer; secondly, to the air contained in the intercellular spaces of the medulla; and lastly, to the nature of the surface of the hair, *i.e.* whether it is rough or smooth.

The hair-sheaths consist of an outer, or dermic coat (Fig. 14, *F, F¹*), and of an inner or epidermic coat, the so-called root-sheath (*WS, WS¹*). The first of these is formed entirely from the connective-tissue of the derma—that is, from the above-mentioned hair-sac or follicle,—while the latter is a product of the Malpighian layer, with which it remains in connection. Between the two hair-sheaths lies a homogeneous and thin hyaline-layer (*GH*).

The follicular tissue, which is richly provided with blood-vessels, extends into the knob-like base or root of the hair-shaft (bulbus), and gives rise to the hair-papilla (Fig. 14, *HP*). The latter is the real matrix of the hair, and from this region a new hair-shaft may develop when the hair is shed, periodically or non-periodically as the case may be, by the formation of a new papilla. Whether new hairs arise in the same manner as in the embryo (“primary hair-formation”) cannot be stated with certainty.

Smooth muscles (*arrectores pili*) and nerves, as well as seba-

¹ In Bats, the hairs are usually distinguished by scale-like projections of their surface.

aceous glands (Fig. 14, *HBD*), are in connection with each hair-sac, the latter serving to oil the hair.¹

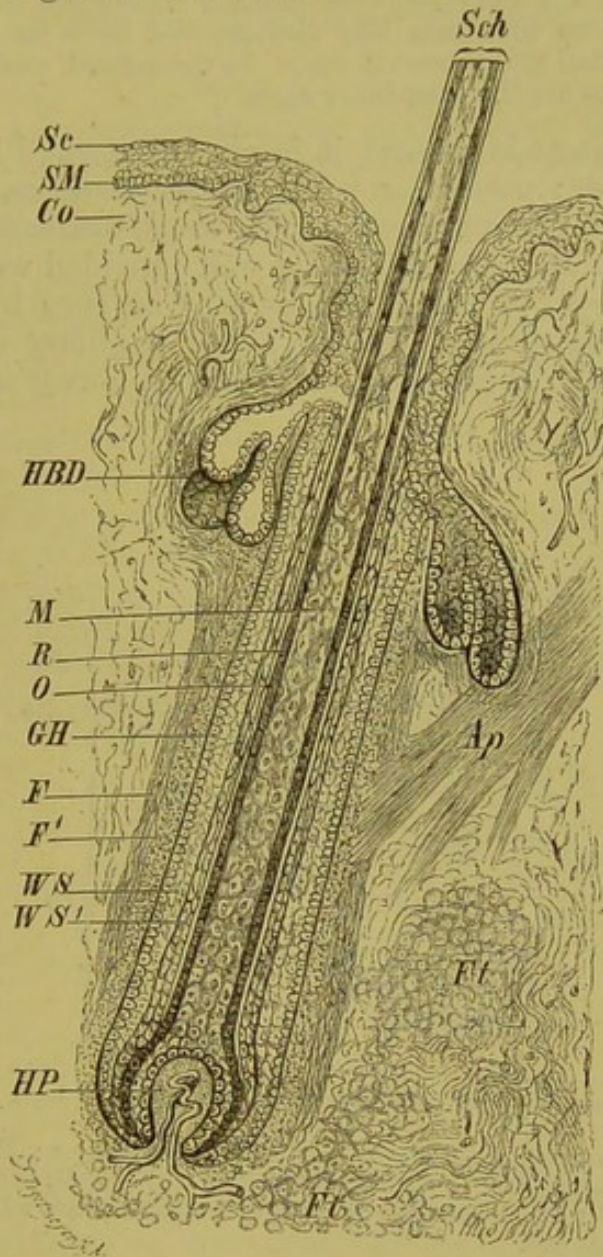


FIG. 14.—LONGITUDINAL SECTION THROUGH A HAIR. (Diagrammatic.)

Sc, stratum corneum; *SM*, stratum Malpighii; *Co*, derma; *Ap*, arrectores pili; *Ft*, adipose tissue; *F*, outer longitudinal layer, and *F'*, inner transverse layer of dermic coat (both composed of connective-tissue); *Sch*, hair-shaft; *M*, medulla; *R*, cortex; *O*, cuticle of shaft; *WS*, *WS'*, external and internal root-sheath,—the latter reaches above only as far as the point of entrance of the ducts of the sebaceous glands (*HBD*); *HP*, hair-papilla, containing vessels; *GH*, hyaline layer, which lies between the inner and outer hair-sheaths, *i. e.*, between the root-sheath and the follicle (dermic coat).

As feathers are arranged in definite tracts, so also hairs are disposed more abundantly on some parts of the body than on others.

¹ The arrectores pili have also the function of compressing the glands, though the latter are provided with muscles of their own, the development of which is in inverse proportion to that of the proper hair-muscles.

A richer hairy covering (lanugo) is often met with in the embryonic condition—as, for instance, in the human fœtus—than occurs later; and this fact, together with the occasional appearance of abnormally hairy individuals, indicates that at one time man was distinguished by a far more abundant clothing of hair than at the present day. In the normal condition the Ainos and the Australians are the most hairy races.

When pigment is present, it is always situated in cells of the Malpighian layer; particular parts, as, for instance, the external genitals (labia majora and scrotum), the arms, the teats, and the skin of the axillæ in Man, are especially well provided with it.

The outer layer of the derma, as may be seen by a glance at Fig. 15, may be divided into an outer papillary and an inner reticular portion. The former contains both nerves and blood- and

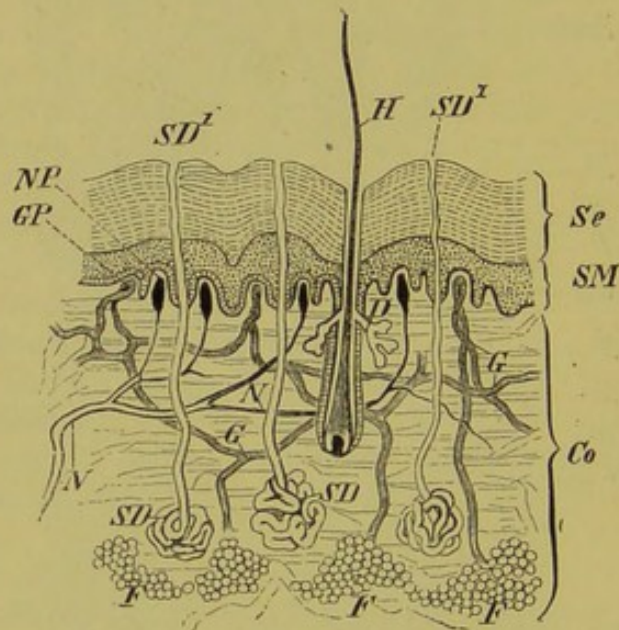


FIG. 15.—SECTION THROUGH THE HUMAN SKIN.

Se, stratum corneum; *SM*, stratum Malpighii; *Co*, derma; *F, F*, subcutaneous fat; *NP*, nerve-papillæ; *GP*, vascular papillæ; *N* and *G*, nerves and vessels of the derma; *SD, SD*, sweat-glands, with their ducts (*SD*¹, *SD*¹); *H*, hair with sebaceous glands (*D*).

lymph-capillaries; the latter, on the other hand, becomes lost without any sharp boundary line in the sub-dermal connective-tissue, and in the more or less strongly-developed fatty layer (panniculus adiposus). Smooth muscle elements are distributed throughout the derma; they are particularly abundant in the scrotum (dartos) and in the teats.

The integumentary glands are tube-shaped or else berry-shaped or globular. The former kind, which we must consider as the most simple and primitive, include the sweat-glands and their modifications (*e.g.* ceruminous glands); while the latter, which are more highly developed histologically, are spoken of as sebaceous glands. To the latter group belong the already-mentioned glands

of the hair-sacs, the glands of the prepuce, the perineal glands present in many Mammals, the glandular dorsal grooves of the neck of the Chamois, the Meibomian glands of the eyelids, and many others.

Epidermic structures play a very important part in Mammals: such are—claws, nails, hairs, bristles, and spines (Hedgehog, Porcupine); the so-called whale-bone (baleen) of the Mystaceti, the nasal horns of the Rhinoceros, the scales of Manis, and the palatal plates of Sirenia, belong to the same category.

MAMMARY GLANDS.—The mammary glands, which stand in such a close relation to reproduction, are entirely confined to the Mammalia, which owe their name to the possession of these organs. Their phylogenetic relations are by no means clear; they must, however, be considered as modified integumentary glands (sebaceous glands).

The so-called mammary pouch of *Echidna*¹ may be taken as a point of origin of the different forms of teats. It consists of a pocket-like in-sinking of the skin of the abdomen, which is possibly only formed periodically; in it the eggs or unripe young appear to be protected. How the latter, in the absence of true teats, take in the milk is not at present known.

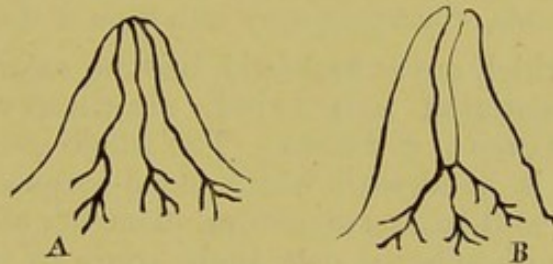


FIG. 16.—A, TRUE (SECONDARY) TEAT; AND B, PSEUDO- (PRIMARY) TEAT.

This pouched condition repeats itself ontogenetically in every Mammal by the epidermis extending inwards towards the derma, and cylindrical more or less branched processes arising from the base of the pouch thus formed. These processes only are the proper glands, the mammary pouch being simply a part of the outer surface of the skin which has sunk inwards, and thus it may give rise to hairs and other integumentary structures.

The teats may become developed in one of two ways. In the first of these, the skin surrounding the pouch becomes raised up, and so forms a teat perforated by a canal, into the base of which the proper ducts of the gland open (Fig. 16, B). In the second case, the gland surface itself becomes elevated into a papilla, while the surrounding skin remains almost on a level with the rest of the integument (Fig. 16, A). In the latter

¹ Whether the absence of a pouch in *Ornithorhynchus* is the more primitive or secondary condition is not certain: possibly one is formed periodically during "heat."

case the teat may be described as true or secondary (Marsupials, Rodents (? all), Lemurs, Monkeys, and Man), and in the former as a pseudo- or primary teat (Carnivora, Pigs, Horses, and Ruminants). The latter condition is already sketched out in certain Marsupials (*Phalangista vulpina*).

As a rule the number of teats corresponds to the number of young born at a time. They are often situated in two nearly parallel rows along the ventral side of the thorax and abdomen, which gradually converge towards the inguinal region: in other cases they may be restricted either to the inguinal (Ungulates and Cetaceans) or to the thoracic region (Elephants, Sirenia, many Lemurs, Cheiroptera, and Primates).

In the human male, the mammary apparatus becomes aborted, though usually at birth and puberty true milk, the so-called "witches' milk" (Hexenmilch), is produced. Male goats and castrated sheep have also been known to give milk. The occasional existence in men of supernumerary teats, and in women of supernumerary mammae and teats (polymastism and polythelism) is very remarkable. They are usually situated in the thoracic region, and must be considered as an atavism to a characteristic primitive form which possessed numerous teats, and which produced a number of young at a time. Such a transition from polymastism to bimastism may be seen plainly at the present day in the Lemurs: in them the inguinal and abdominal teats are undergoing a retrogressive metamorphosis, while a single pair of thoracic teats remain well developed.¹ This accords with the fact that most Lemurs bear only a pair of young ones at a time, which they carry with them at the breast.

The glands, which are at first solid, become secondarily hollowed out and differentiated into acini, mammary ducts, milk sinuses, and excretory ducts. The whole intermediate tissue during lactation is filled with white blood-corpuscles (leucocytes), and possibly the well-known structural elements of milk, known as colostrums and milk-spheres, owe their origin to these corpuscles, which have passed through the walls of the acini.

BIBLIOGRAPHY.

- CARRIÈRE, J.—*Die postembryonale Entwicklung der Epidermis des Siredon pisciformis.* *Archiv f. mikros. Anat.* Bd. XXIV. 1884.
- DOMBROWSKI, R. VON.—*Geweibe u. Gehörne.* *Naturwiss. Studie.* Wien, 1885. (With 40 plates.)
- ECKER, A., und WIEDERSHEIM, R.—*Die Anatomie des Frosches.* Braunschweig, 1864—82.
- GEGENBAUR, C.—*Zur Morphol. des Nagels.* *Morph. Jahrbuch*, Bd. X. 1885. *Zur genaueren Kenntniss der Zitzen der Säugethiere.* *Morphol. Jahrb.* Bd. I. 1876.
- HUXLEY, T. H.—*Tegumentary Organs.* *Todd's Cyclopaedia of Anat. and Physiol.*
- KERBERT, C.—*Ueber die Haut der Reptilien und anderer Wirbelthiere.* *Arch. f. mikr. Anatomie*, Bd. XIII.
- KLAATSCH, H.—*Zur Morphologie der Säugethierzitzen.* *Morphol. Jahrb.* Bd. IX. 1883.
- LEICHTENSTERN, *Ueber überzählige Brüste.* *Arch. f. pathol. Anat.* 1878.
- LEYDIG, F.—*Ueber die allgem. Bedeckungen der Amphibien.* *Arch. f. mikr. Anatomie*, Bd. XII. 1876.
- LIST, J.—*Ueber Wanderzellen in Epithel.* *Archiv f. mikros. Anat.* Bd. XV. 1885, und *Zool. Anzeiger*, No. 198, VII. Jahrgang, 1885.

¹ In *Hapallemur griseus* the single pair of teats is situated on the arm (Beddard).

- PAULICKI.—*Ueber die Haut des Axolotls. Archiv f. mikros. Anat.* Bd. XXIV. 1884.
- PFITZNER, W.—*Die Epidermis der Amphibien. Morphol. Jahrb.* Bd. VI. 1880.
- RAUBER, A.—*Ueber den Ursprung der Milch und die Ernährung der Frucht im Allgemeinen.* Leipzig, 1879.
- REIN, G.—*Untersuch. über die embr. Entw.-Geschichte der Milchdrüse. Arch. f. mikr. Anat.* Bd. XX. und XXI. 1882.
- SCHULZE, F. E.—*Epithel. und Drüsenzellen. Arch. f. mikr. Anat.* Bd. III.
- STUDER, TH.—*Die Entwicklung der Federn. Inaug.-Diss. Bern, 1873. Beiträge zur Entwicklungsgeschichte der Feder. Zeitschr. f. wiss. Zool.* Bd. XXX.
- UNNA, P.—*Beitr. zur Histologie und Entw.-Geschichte der menschl. Oberhaut und ihrer Anhangsgebilde. Arch. f. mikr. Anat.* Bd. XII. 1876.
- WALDEYER, W.—*Atlas der menschl. und thier. Haare, &c.* Lahr, 1884.
- WIEDERSHEIM, R.—*Die Kopfdrüsen der geschwänzten Amphibien, &c. Zeitschr. f. wissensch. Zoologie,* Bd. XXVII.
- ZANDER, R.—*Die frühesten Stadien der Nagelentwicklung und ihre Beziehungen zu den Digitalnerven. Arch. f. Anat. u. Entw.-Gesch.* 1884.

B. SKELETON.

I. DERMAL SKELETON.

THE dermal skeleton, as phylogenetically the older, is best considered before the endoskeleton. Its relative age is shown

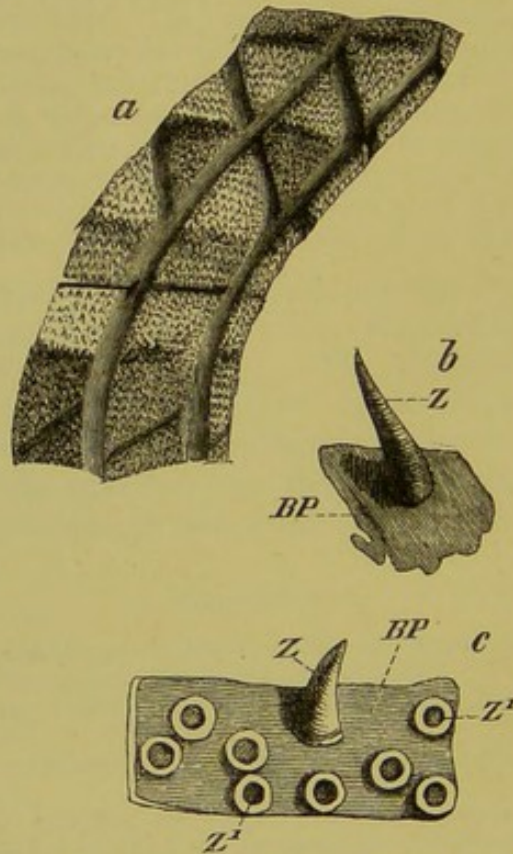


FIG. 17 (after O. Hertwig).—*a*, DERMAL ARMATURE OF *Hypostoma commune* (a Siluroid); *b*, DENTICLES FROM THE SKIN OF THE ABDOMEN OF *Callichthys*; *c*, PLATES FROM THE TAIL-FIN OF *Hypostoma*.

Z, dermal denticles, shown broken off from their bases at *Z'*; *BP*, basal plate.

not only by Palæontology,¹ but also by Ontogeny, inasmuch as calcifications and ossifications in the derma or perichondrium

¹ As examples of ancient forms which were protected by well-developed dermal skeletons, may be mentioned the armoured Fishes of the Devonian and Silurian strata, and the armoured Amphibians of the Carboniferous, Trias, and Jurassic.

appear much earlier in the developing animal than do definite ossifications within particular parts of the cartilaginous skeleton. The condition which obtains in Fishes and Amphibia well illustrates

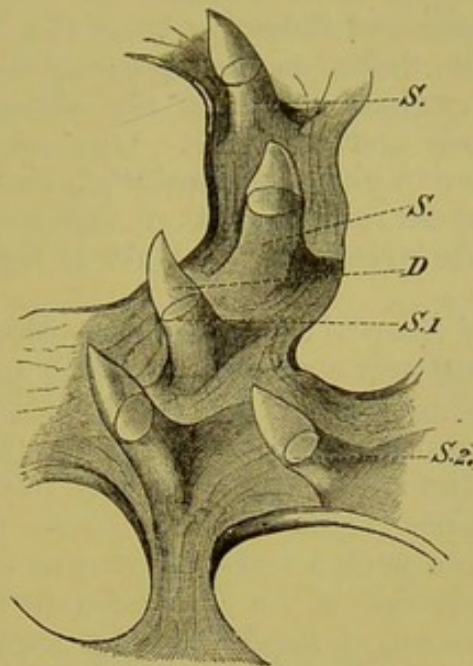


FIG. 18.—DERMAL DENTICLES OF *Protopterus*.

D, the apical portion of the denticle; *S, S*, the base of the denticle, the cavity of which is seen in optical section through the transparent apical portion at *S.1* and *S.2*.

this. To take a single example: the young File-fish (*Balistes*) is provided with a complete dermal armour at the time when the ossification of the primordial cranium has hardly begun.

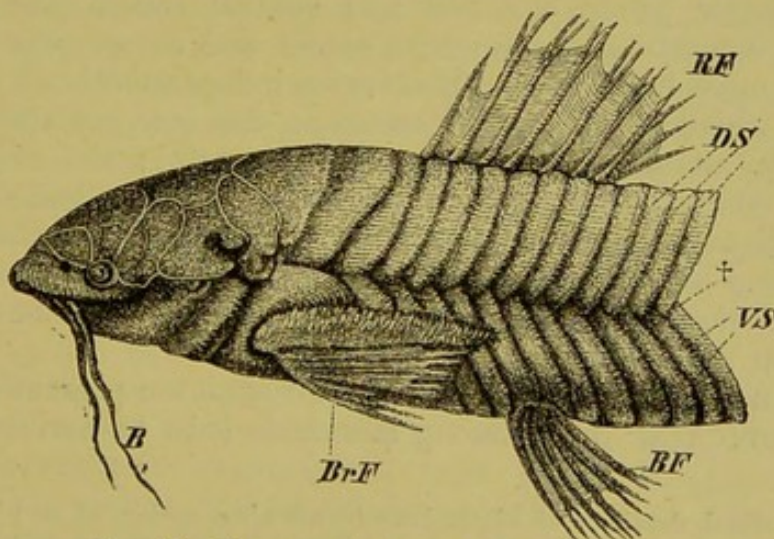


FIG. 19.—DERMAL ARMATURE OF *Callichthys*.

B, barbules; *BrF*, pectoral fin; *BF*, pelvic fin; *RF*, dorsal fin; *DS* and *VS*, dorsal and ventral bony shields; †, lateral line.

The exoskeleton originates by the formation of small denticles (Figs. 17 and 18) attached to basal plates, which lie scattered over

the whole skin, and which exhibit exactly the same structure as the teeth proper, which will be described later.

Such dermal denticles are found in the skin of Elasmobranchs, Ganoids, Siluroids, and Dipnoans; the large shields, which, in the armoured Ganoids and Siluroids (Fig. 19), Lophobranchii and Plectognathi, become united to form a strong bony cuirass, may be derived from the gradual fusion of the above-mentioned basal-plates to form bands and networks. One may even extend this still further, and derive phylogenetically all the scales of Fishes, as well as the investing bones of the pectoral arch (*e.g.* Teleostei) and of the primordial skull in the same manner (cp. Fig. 53).¹

Fossil genera of Amphibia have bequeathed but slight traces of this strong dermal armour to the existing forms of the group: as examples may be mentioned the bony plates in the skin of the back of certain Anura (*Ceratophrys dorsata* and *Ephippifer aurantiacus*), as well as the scales lying between the ring-like scutes of the footless Amphibia (*Gymnophiona*) (comp. p. 20). The latter may be derived from such a scaly covering as that of the ancient Salamander (*Discosaurus*) of the Carboniferous formation.

The dermal skeleton of fossil Reptilian genera, as, for instance, of many Ornithoscelida (*Stegosaurus*), was still more highly developed. In these, enormous bony plates and spines, sometimes as much as 63 centimetres long, were present in the dorsal region. *Teleosaurus* also, as well as the Triassic *Aëtosaurus ferratus*, possessed a strong exoskeleton. Amongst existing Reptiles, the Crocodiles, many Lizards (*Anguis*, *Cyclodus*, *Scincus*), and more especially the Chelonia, exhibit a well-developed dermal skeleton. In the latter group a dorsal and ventral shield (carapace and plastron) consisting of numerous pieces and completely enclosing the body must be noticed. Both arise independently of the endoskeleton, which is preformed in cartilage, that is to say, they are true exoskeletal membrane bones (cp. note on p. 62); the exoskeleton, however, comes into the closest relation with the endoskeleton, and may supplant it here and there: thus, in *Testudo*, for instance, the thoracic and lumbar vertebræ and ribs become quite rudimentary.

Birds have no dermal skeleton, as already mentioned in the chapter on the integument.

It is uncertain whether the dermal skeleton present in *Armadillos* (*Loricata*)² only among Mammals is to be derived directly

¹ The dermal denticles of Elasmobranchs are often spoken of as placoid, and the firmly-jointed scales of *Lepidosteus* and *Polypterus* as ganoid scales: both are covered by a layer of enamel (probably) developed from the ectoderm, and thus both epidermis and derma take part in their formation. Some Fishes (*e.g.* Electric Ray, *Spatularia*, some Eels) are scaleless.

² In *Armadillos* the dermal skeleton consists of a series of transverse bony scutes, which are movable on one another, while in *Glyptodon*, a fossil member of this group, the dermal plates were firmly united together to form a large shield, which covered the whole body.

from that of Reptiles, or whether it is to be considered as formed independently, that is, as a new acquisition or "neomorph" (Gadow).

Thus it will be seen that the exoskeleton tends gradually to disappear as we ascend in the scale of the Animal Kingdom, while, on the other hand, the endoskeleton becomes of greater and greater importance.

BIBLIOGRAPHY.

- CREDNER, H.—*Die Stegocephalen (Labyrinthodonten) aus dem Rothliegenden des Plauen'schen Grundes bei Dresden. Zeitschr. der deutsch. geolog. Gesellschaft, 1881, 1882, 1883.*
- FRITSCH, A.—*Fauna der Gaskohle und der Kalksteine der Permformation Böhmens. Prag. (not yet completed).*
- HERTWIG, O.—*Ueber Bau und Entwicklung der Placoidschuppen und der Zähne der Selachier. Jenaische Zeitschr. Bd. VIII. N.F. I. Ueber das Hautskelet der Fische (3 Essays). Morphol. Jahrb. Bd. II. 1876; Bd. V. 1879; Bd. VII. 1881.*
- MARSH, O. C.—Numerous papers in the *American Journal of Science and Arts.*
- WIEDERSHEIM, R.—*Die Anatomie der Gymnophionen. Jena, 1879. Zur Histologie der Dipnoërschuppen. Arch. f. mikr. Anatomie, Bd. XVIII. 1880.*

II. ENDOSKELETON.

I. VERTEBRAL COLUMN.

An elastic rod, the **notochord (chorda dorsalis)**, lying in the long axis of the embryo, between the neural and visceral tubes (see Fig. 7, B), is to be considered as the foundation of the axial skeleton. Consisting of a meshwork of cells, which are early vacuolated, the outer protoplasmic part of the notochord becomes differentiated into a structureless cuticular sheath (the sheath of the notochord, or *elastica limitans interna*), which, however, disappears almost entirely after the notochord has ceased to grow (Fig. 20, *Cs*).

Outside this inner sheath, a skeletogenous layer is formed round the notochord from that part of the mesoblast which is distinguished as the mesoblastic somites or protovertebræ. Round the outer periphery of this layer another sheath is formed, the outer sheath of the notochord, or *elastica limitans externa* (Fig. 20, *Ee*).

The skeletogenous layer, consisting of fibrous tissue, now extends dorsally over the spinal cord on each side, and thus gives rise to a continuous membranous tube, which is only broken through at the points of exit of the spinal nerves. No proper segmentation,—like that seen in the muscular system,—is to be noticed in this **membranous** stage. The first indication of segmentation is the formation of cartilaginous areas in the membrano-fibrous mass of the skeletogenous tissue, in the immediate neighbourhood of the notochord: these show a segmental arrangement (formation of metameres), and represent the first

traces of the vertebral bodies and arches. This is the second or **cartilaginous stage** of the vertebral column, and now ossification may occur (**bony stage**). Those parts of the fibrous tissue which do not become consolidated in this manner give rise to certain ligaments of the vertebral column.

During these differentiations of the skeletogenous tissue, the notochord suffers a very different fate in the various Vertebrate

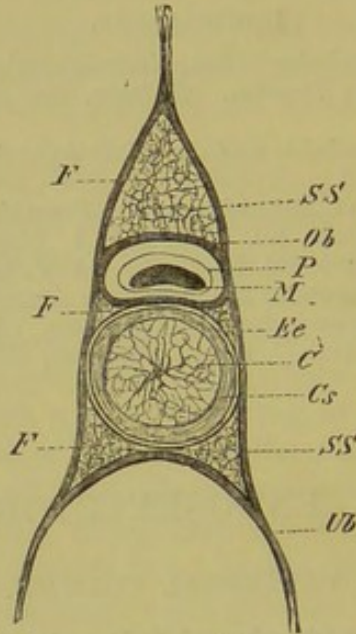


FIG. 20.—TRANSVERSE SECTION OF THE VERTEBRAL COLUMN OF *Ammocetes*.

C, notochord; *Cs*, inner sheath, and *Ec*, outer sheath, of the notochord; *SS*, skeletogenous layer; *Ob*, upper arch; *Ub*, lower arch; *F*, fatty tissue; *M*, spinal cord; *P*, pia mater.

groups; it may increase in size and persist as a regular cylindrical rod, or it may become constricted at definite intervals by the formation of vertebral bodies, or even entirely disappear.

During the cartilaginous and bony stages the various processes (spinous, transverse, articular processes, &c.) are formed: and the individual vertebræ may sometimes become fused together, as for instance, in the regions of the neck, sacrum, and coccyx.

All these ontogenetic stages find their exact parallel in the phylogenetic development of Vertebrates, as the following pages will show.

Fishes.—The vertebral column of all Fishes is distinguished by a very uniform character of its elements, so that one can only distinguish between trunk and caudal vertebræ.

The most embryonic type of notochord is seen in *Amphioxus*, *Ammocetes*, and *Myxinoids*, in which it is entirely unsegmented. In the metamorphosed *Petromyzon*, cartilaginous elements already make their appearance in the form of rudimentary arches and spines, which do not meet above the spinal cord (comp. Fig. 49).

To the condition found in *Petromyzon*, that seen in the Cartilaginous Ganoids, *Chimæra*, and *Dipnoi*, is directly connected, inasmuch as the metameric character is mainly indicated by upper or dorsal arches.

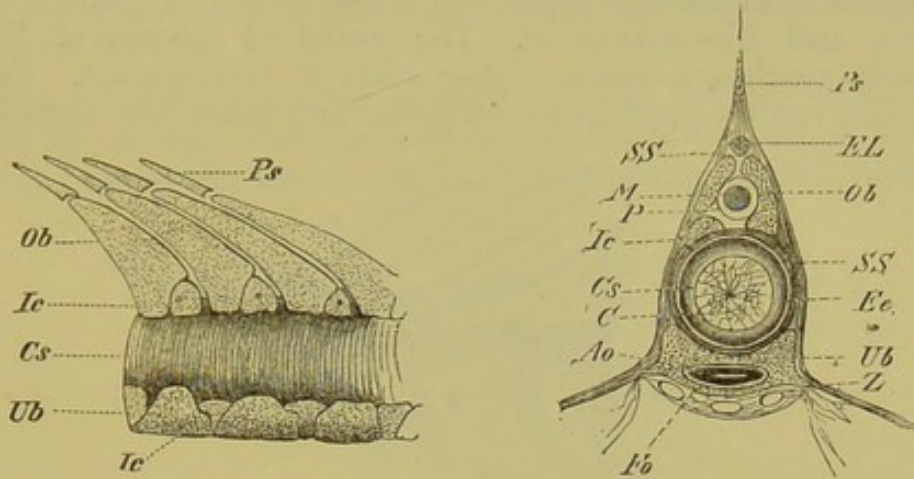


FIG. 21.—PORTION OF THE VERTEBRAL COLUMN OF *Spatularia*. (Side view.)

FIG. 22.—TRANSVERSE SECTION OF THE VERTEBRAL COLUMN OF *Acipenser ruthenus* (in the anterior part of the body).

Ps, spinous process; *EL*, longitudinal elastic band; *SS*, skeletogenous layer; *Ob*, upper arch; *M*, spinal cord; *P*, pia mater; *Ic*, intercalary pieces; *Cs*, notochordal sheath; *C*, notochord; *Ee*, elastica externa; *Ub*, lower arch; *Ao*, aorta; *Fo*, median parts of the lower arches, which enclose the aorta ventrally; *Z*, basal processes of the lower arches.

The strong, concentrically-layered notochordal sheath (Fig. 22, *Cs*) here plays the part of vertebræ, and is surrounded by a fibrous skeletogenous layer (Fig. 22, *SS*), in which paired dorsal and ventral cartilages become developed. The former give rise to the above-mentioned upper or neural arches, the latter to the lower or hæmal arches (Figs. 21, 22, *Ob*, *Ub*). In the caudal region

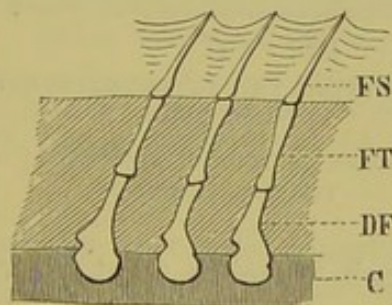


FIG. 23.—PORTION OF THE VERTEBRAL COLUMN OF *Protopterus*. (Side view.)

C, notochord; *DF*, spinous process; *FT*, interspinous bone; *FS*, fin-ray.

the latter enclose the aorta and caudal vein; further forwards the cartilages do not meet in the middle line below, and consequently the lower arches end on either side in a laterally-directed cartilaginous projection, or "basal process," which may develop an

articulation at its base, and thus give rise to a rib (cp. p. 48). The relations of these parts in Elasmobranchs and Teleosteans is similar to that above described. For the further strengthening of the vertebral column so-called "intercalary pieces" (Figs. 21, 22, *Ic*) appear between the upper and lower arches in Cartilaginous Ganoids and Elasmobranchs. The vertebral column of Bony Ganoids reaches a much higher stage of development. Paired dorsal and ventral cartilages arise above and below the notochord,

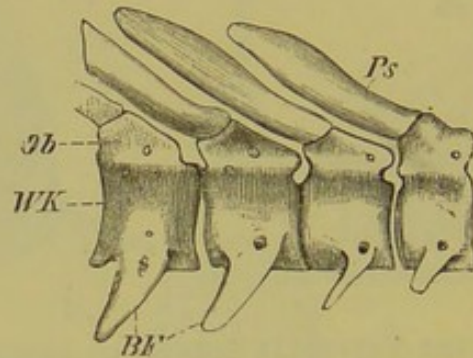


FIG. 24.—PORTION OF THE VERTEBRAL COLUMN OF *Polypterus*.
WK, centra; *BF*, basal processes; *Ob*, upper arches; *Ps*, spinous processes.

but in the course of development so extend at the base as to completely surround it. From the dorsal cartilages the upper arches take their origin, and from the ventral the lower, while the cartilage surrounding the notochord gives rise to the vertebral bodies or centra. The whole vertebral column also becomes strongly ossified (Fig. 24). The notochord is now no longer equal in diameter throughout, but becomes constricted or actually divided

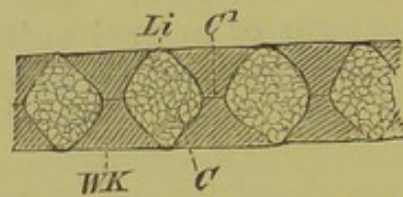


FIG. 25.—DIAGRAM SHOWING THE INTERVERTEBRAL REMAINS OF THE NOTOCHORD.
C, *C*¹, expanded and constricted portions of notochord; *WK*, centra; *Li*, intervertebral ligaments.

in the centrum of each vertebra (that is, vertebrally), while intervertebrally it remains expanded, and so serves as a sort of connecting- or packing-substance between two contiguous vertebræ (Figs. 25 and 27, *C*, *C*¹). The same thing takes place in other Fishes—Elasmobranchii and Teleostei—and thus deeply biconcave (amphicœlous) centra are formed.

One of the Bony Ganoids, *Lepidosteus*, forms a marked exception to other Fishes as regards its vertebral column, inasmuch as definite articulations are formed between the vertebræ. A concavity is formed at the hinder end of

each centrum (Fig. 26, *A*, *cn*¹), which articulates with a convexity (*cn*) on the next vertebra behind (opisthocœlous vertebra). The notochord (except in the caudal region) entirely disappears in the adult; in the larva it is seen to be expanded vertebrally, and constricted intervertebrally, a condition of things which appears again in the higher types, as, for instance, in Reptiles. In a still earlier larval stage, however, the constrictions are vertebral, as in other Fishes (see Fig. 27).

The primitive character of the vertebral column of Fishes is shown by the fact that the arches only meet dorsally in rare instances. As a rule, the closing in of the arch is effected by special

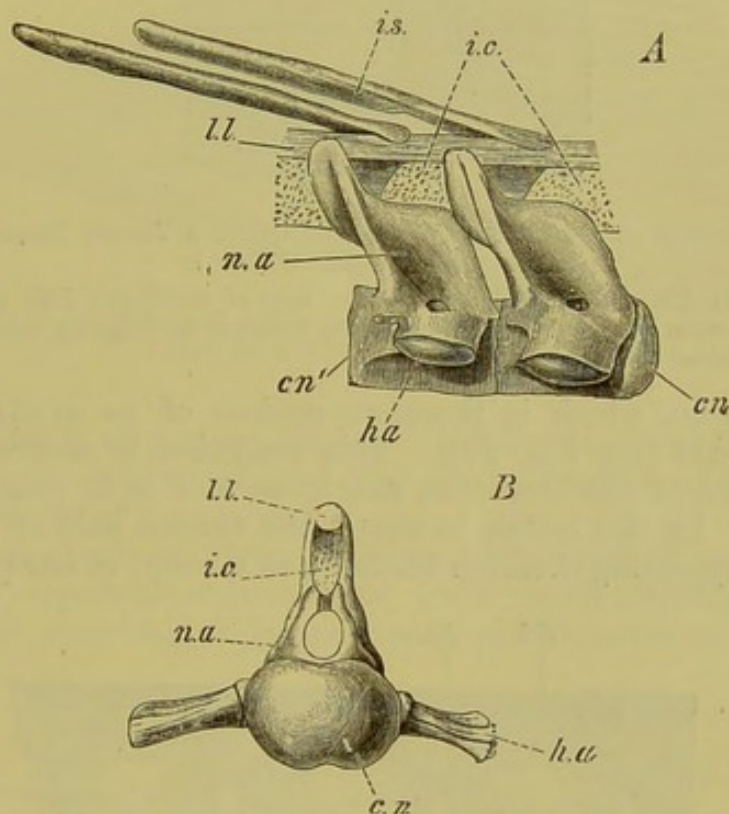


FIG. 26.—PORTION OF THE VERTEBRAL COLUMN OF *Lepidosteus*.
(After Balfour and Parker.)

A, a vertebra from anterior surface; *B*, two vertebrae from the side; *cn*, anterior convex face, and *cn*¹, [posterior concave face of centrum; *h.a.*, basal process; *n.a.*, upper arch; *i.c.*, intercalary cartilages; *ll.*, longitudinal ligament; *i.s.*, interspinous bone.

pieces of cartilage and by an elastic longitudinal band (Figs. 22, 26, *i.c.*, *ll.*) which is always present. This description of the upper arches applies also to the lower ones present in the caudal region. Elasmobranchs and Ganoids possess a greater number of vertebrae¹ than Teleosteans, in which we seldom meet with more than 70: the Eel, however, possesses more than 200. In Rays and Chimærae only amongst Fishes are definite articulations formed between the skull and vertebral column.

¹ In *Alopias vulpes* there are 365; in *Carcharias glaucus*, 240; in *Lamna*, 150; in *Pristiurus*, 140; in *Scyllium*, about 124; in *Squatina*, 117.

The caudal region of the vertebral column deserves particular attention in Fishes, and the primitive condition of this region in Amphioxus, Cyclostomi, and Dipnoi, may be taken as a starting-point. In these, the notochord extends straight backwards to the hinder end of the body, and is surrounded quite symmetrically

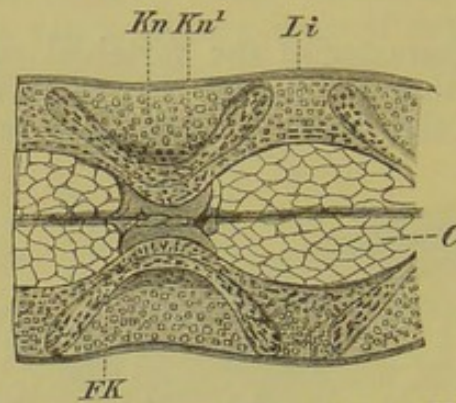


FIG. 27.—PORTION OF THE VERTEBRAL COLUMN OF A YOUNG DOGFISH (*Scyllium canicula*). (After Cartier.)

C, notochord; *Kn*, outer, and *Kn¹*, inner, zone of cartilage; *FK*, the fibro-cartilaginous mass lying between these zones, which is undergoing calcification; *Li*, intervertebral ligament.

by the tail-fin, which is therefore spoken of as protocercal or diphyccercal (see Fig. 29). This condition is met with also in many Fishes of the Devonian strata, as well as in young stages of Teleostei. In the latter, however, the ventral half of the tail-fin with its supporting skeleton becomes, as a result of unequal growth,

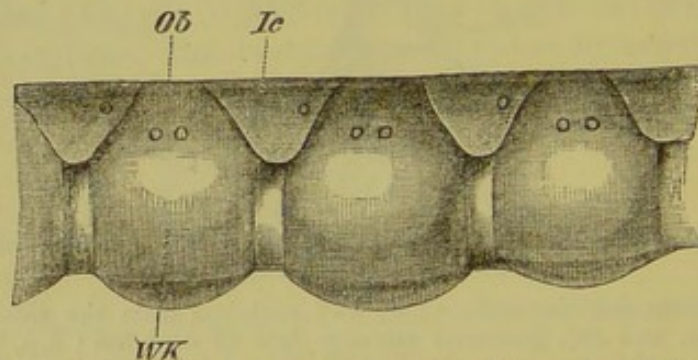


FIG. 28.—PORTION OF THE VERTEBRAL COLUMN OF *Scymnus*.
WK, centra; *Ob*, upper arches; *Ic*, intercalary pieces. The apertures for the spinal nerves are seen in the arches and intercalary pieces.

more strongly developed than the dorsal, and thus the vertebral column is bent up dorsally, giving rise to a heterocercal tail. This form of tail may be recognised externally, as in many Elasmobranchs, Ganoids, and numerous fossil Fishes, or may be masked by a more or less symmetrical tail-fin, when it is only visible internally (Lepidosteus (Fig. 30) and *Amia* to some extent, but more particularly in most Teleosteans,¹ e.g. *Salmo*, *Esox*).

¹ The term homocercal is sometimes used to describe the masked heterocercal condition of the tail in Teleostei.

Amphibia.—The vertebral column of Urodeles may be divided into cervical, thoraco-lumbar, sacral, and caudal regions, and these regions can be recognised, except in certain modified forms such as Snakes, from Urodeles up to the Mammalia. On account of the absence of extremities in Cæcilians, the vertebral column can only be divided into three regions, cervical,

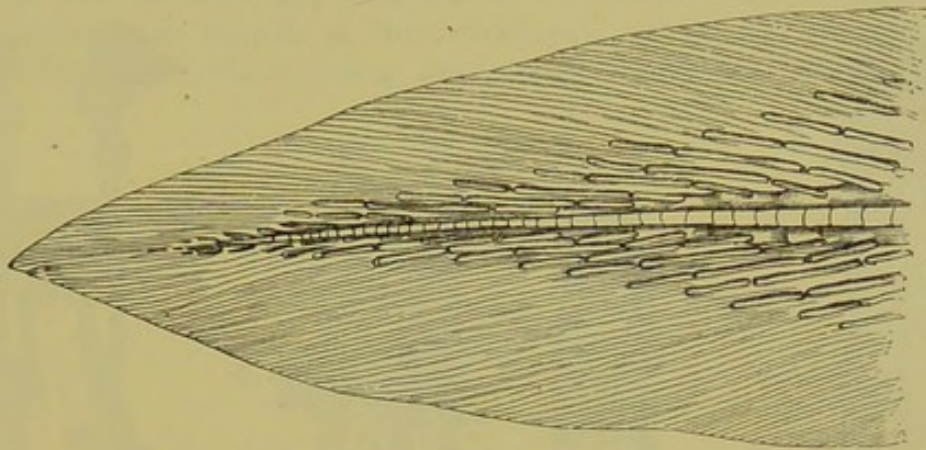


FIG. 29.—TAIL OF *Protopterus*.

thoracic, and a very short caudal. In Anura, no special lumbar region can be recognised, and the caudal portion is modified to form a "urostyle" (see p. 42).

The notochord of Urodele larvæ, like that of most Fishes, undergoes vertebral constrictions, while intervertebrally it grows thicker, and accordingly appears expanded. Thus the vertebræ here

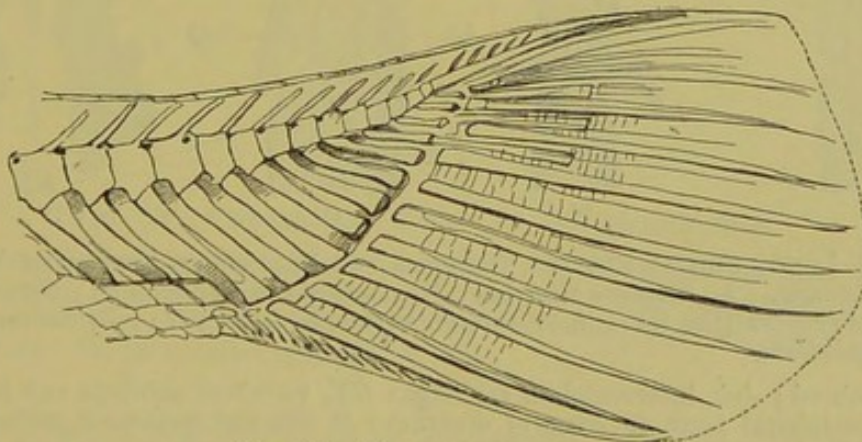


FIG. 30.—TAIL OF *Lepidosteus*.

also are amphiçelous. Later, intervertebral masses of cartilage become developed, which, together with the bone which is formed at the same time in the surrounding connective-tissue, extend inwards towards the centre, gradually constricting the notochord so that eventually it may become entirely obliterated. Finally a differentiation, as well as a resorption, extending inwards from the

periphery occurs in these cartilaginous parts: in the interior of each an articular cavity is formed, so that in the vertebræ of the higher Urodeles (*Salamandrina perspicillata* and certain Tritons) an anterior convexity and a posterior concavity may be distinguished, both covered with cartilage; they are, therefore, opisthocœlous. A glance at Fig. 31, A to D, will make this clear.

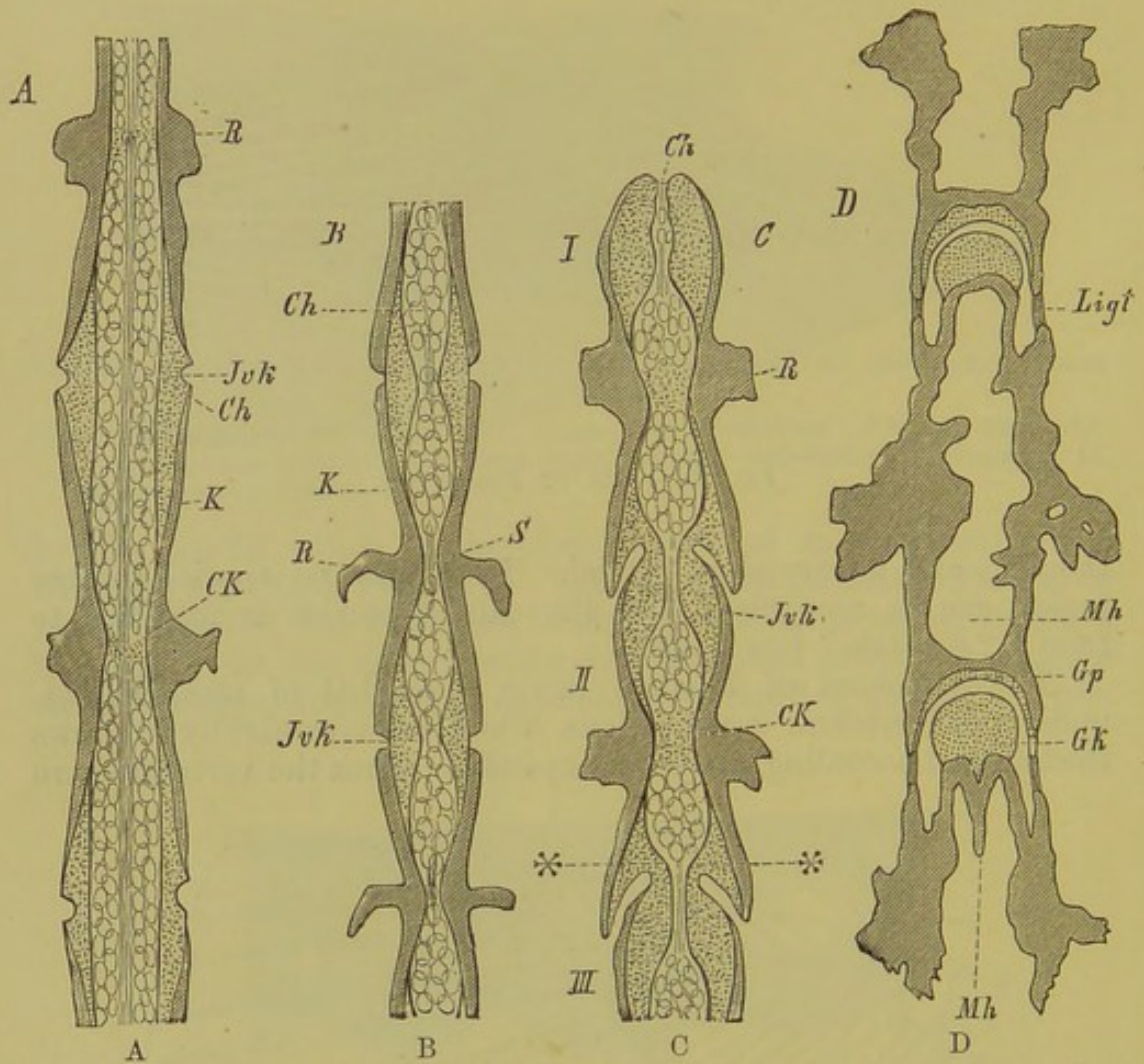


FIG. 31.—LONGITUDINAL SECTION THROUGH THE VERTEBRAL COLUMN OF VARIOUS URODELES. A, *Ranodon sibericus*; B, *Amblystoma tigrinum*; C, *Gyrodactylus porphyriticus* (the three most anterior vertebræ, I, II, III); D, *Salamandrina perspicillata*.

Ch, notochord; *Jvk*, intervertebral cartilage; *CK*, vertebral cartilage and fat-cells; *K*, peripheral bony covering of centrum; *R*, ribs and transverse processes; *S*, vertebral constriction of notochord in *Amblystoma tigrinum*, without cartilage and fat-cells; ***, intervertebral cartilaginous tracts; *Mh*, *Mh*, marrow cavities; *Gp*, *Gk*, articular socket and head; *Ligt*, intervertebral ligaments.

In the development of the vertebral column then of Urodeles we can distinguish three stages:—(1) A connection of the individual vertebræ by means of the intervertebrally expanded notochord; (2) a connection by means of intervertebral masses of cartilage; and finally (3) an articular connection. These three

different stages of development find a complete parallel in the phylogeny of tailed Amphibians, inasmuch as all fossil forms, *e.g.* the Stegocephala of the Carboniferous Period and the Labyrinthodonts, as well as the Perennibranchiata, Derotremata, and many Salamanders, possess simple biconcave vertebræ, without differentiation into definite articulations.

The bony parts of the vertebræ of Urodeles are not formed from the cartilaginous sheath of the notochord, but in the surrounding connective-tissue, there being only an intervertebral cartilaginous

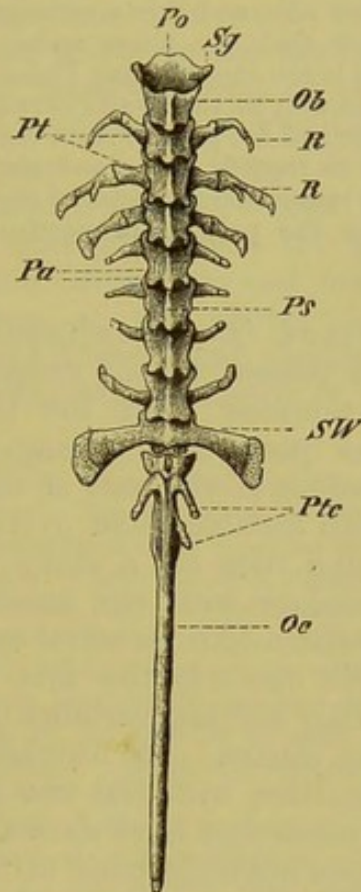


FIG. 32.—VERTEBRAL COLUMN OF *Discoglossus pictus*.

Pa, articular processes; *Ps*, spinous processes; *Pt*, transverse processes of trunk vertebræ; *Ptc*, transverse processes of caudal vertebræ (urostyle, *Oc*); *SW*, sacral vertebra; *Ob*, upper arch of first vertebra; *Sg*, its lateral articular surfaces; *Po*, its anterior process; *R*, ribs.

zone, extending into the ends of the centra. In the Anura, on the other hand, as well as in Elasmobranchs, bony Ganoids, and the higher Vertebrata, the vertebræ are preformed in cartilage. In the Anura true articulations are always formed between the vertebræ, and, as a rule, the convexity is posterior, and the concavity anterior (procœlous). A further difference is seen in the relations of the notochord, which persists vertebrally longer than intervertebrally, a condition which leads towards the Reptiles. The configuration of the caudal region of the vertebral column must

also be remarked upon, as it differs in tailed and tailless Amphibians. The long caudal portion of the tadpole's vertebral column, which is very similar to that of Urodeles, undergoes during metamorphosis a gradual retrogressive change, and the vertebræ of its proximal end become fused together and ossified to form a long unsegmented dagger-like bone, the urostyle (Fig. 32, *Oc*).

The upper as well as the lower arches of the vertebræ are in direct connection with the centra. Lower arches are present only in the caudal region of Urodeles, and evidently correspond to the already-mentioned basal processes of the vertebræ of Ganoids. The most anterior in some cases function as supports for the ribs, and this circumstance is sufficient to render untenable the earlier view that the lower arches are modified transverse processes¹ or fused ribs, as is the case in some Fishes.

The neural spines, as well as the transverse processes, which are as a rule bifurcated at the base and are present from the second vertebra onwards, show the greatest variety as regards shape and size, differing in the several regions of the body. The transverse processes of the single sacral vertebra, which give attachment to the pelvis, are particularly strongly developed, especially in the Anura.

Articular processes (zygapophysys) which are usually present in Fishes that possess a bony vertebral column, are well developed in all Vertebrates from the Urodela onwards, and consist of two pairs of projections arising respectively from the anterior and posterior edges of the base of the neural arch. Their surfaces are covered with cartilage, and overlap one another from vertebra to vertebra like tiles on a roof: not unfrequently the neural spines also articulate with one another, and thus a well-articulated and mobile chain-like vertebral column results.

From the Amphibia onwards the first vertebra, or so-called atlas (and this is the only cervical vertebra of Amphibia), becomes differentiated from the others. In Amphibians it consists of a simple ring which articulates with the two condyles and the basis cranii. As numerous researches have shown, however, the first vertebra of Amphibians does not correspond to that (*i.e.* the atlas) of the higher Vertebrates, but is much more nearly homologous with the second cervical vertebra of the latter—the axis (*epistropheus*). This is demonstrated by a study of its development, which shows that the real atlas loses its individuality as a separate mass, and becomes united with the occipital region of the skull.

Reptilia.—In contrast to the numerous fossil forms, only a few existing Reptiles, viz., Hatteria and the Geckos (*Ascalabota*) retain throughout life the primitive biconcave character of their vertebræ, with the notochord expanded intervertebrally.

In all the others, the notochord remains expanded longer in the vertebral regions than intervertebrally, but in the adult it becomes entirely aborted and replaced by bony tissue. This stronger and more solid ossification of the whole skeleton forms a characteristic

¹ Traces of the transverse processes are present nearly to the end of the tail.

difference between the skeleton of Ichthyopsida on the one hand and Amniota on the other. As a rule the vertebræ of Reptiles become definitely articulated with one another, and are of the procœlous type: the above-named genera, with intervertebral remains of the notochord, form an exception to this rule, as do also Crocodiles and Birds, in which intervertebral disks or menisci exist; in the latter, however, they are not present in the cervical region.¹

What has been said as to the classification of the vertebræ into different regions in Amphibia, as well as to the presence of processes, applies here also, though there are always several cervical vertebræ instead of a single one: there are also always at least two sacral vertebræ. An atlas, usually consisting of three pieces, and an axis, with an odontoid bone, are always well developed.²

The spinous processes of the upper arches vary in size, and transverse processes arise from the centra themselves or close to them. Lower arches (chevron bones) are present in the tail in Lizards, Chelonians, and Crocodiles; and besides these, median or paired inferior processes of the centra themselves are seen in many of the vertebræ of Lizards and Snakes, as well as in Birds, and to some extent in the lumbar region of certain Mammals.

In consequence of the absence of a pectoral arch, the vertebral column of Snakes and Amphisbænians, like that of Cæcilians, can only be divided into trunk and caudal vertebræ. The vertebral column of Chelonians deserves particular notice as a large portion of it becomes anchylosed with the dermal bones of the carapace, and it is thus rendered immovable in a certain region.

In Snakes and some Lizards (Iguana) extra articular processes (zygosphenes and zygantra) are developed on the vertebræ. In Lizards small separate ossifications or subvertebral wedge-bones are often present on the ventral side of the vertebral column between the centra; and in the caudal region, an unossified septum remains in the middle of each centrum, so that the tail easily breaks off at these points. When this happens the tail grows again, but proper vertebræ are not formed.

In fossil Reptiles, which, both as regards size and number of species, usually surpassed the existing representatives of the group, the sacrum, which gives attachment to the pelvis, often consists of more than two vertebræ, the number being four or five (Ornithoscelida).

The following facts will give some idea of the monstrous proportions of these old genera of Reptiles:—*Atlantosaurus immanis*, a North American Dinosaur, reached a length of about 80 feet, and its femur was 8 feet long and 25 inches thick at its proximal end. The transverse diameter of the individual vertebræ amounted to 16 inches, and *Apatosaurus laticollis*, found in the same strata, possessed cervical vertebræ which reached a diameter of 3½ feet.

A knowledge of fossil genera of Reptiles is of the greatest interest, as we can see, in many groups, important points of con-

¹ In Crocodiles the vertebræ are mostly procœlous, an exception being seen in the two sacrals and first caudal; and in Chelonians there is great variation in the form of the individual centra of the cervical vertebræ, while the thoracic and lumbar have flattened faces, and are firmly united together by cartilage.

² The os odontoides corresponds morphologically to a part of a centrum of the atlas.

nection with Birds. At the present day it cannot appear doubtful to any morphologist that the latter are descended from Reptilian ancestors.

Birds.—In *Archæopteryx*, found in the Solenhofen slates of the Bavarian Jurassic, and already mentioned on p. 22, many of the special peculiarities of Reptiles and Birds are united. The hinder extremities are distinctly Reptilian, as is also the tail, which, like that of a Lizard, is composed of numerous elongated free vertebræ. A covering of true feathers, on the other hand, characterises it as a Bird: the biserial arrangement of the tail-feathers is seen in Fig. 33.

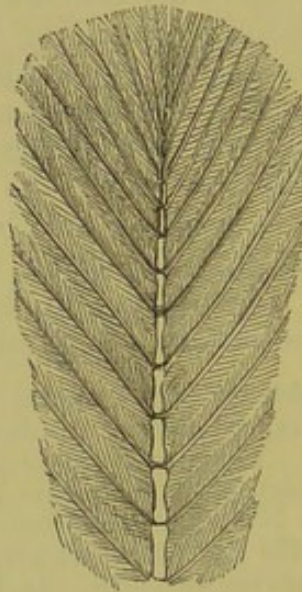

FIG. 33.—TAIL OF *Archæopteryx*.

The vertebral column of Birds corresponds with that of Reptiles not only in its phylogenetic relations, but also ontogenetically. In both groups the notochord eventually disappears entirely, and the whole skeleton becomes strongly ossified.¹ The pelvis of Bird-embryos, like that of existing adult Reptiles, is attached to the vertebral column by two vertebræ only; during further development, however, a number of other vertebræ (thoracic, lumbar, and caudal) become fused with the sacrum (Fig. 34).

A further difference between the vertebral column of Reptiles and Birds is seen in the character of the caudal region in the latter group, which always remains apparently rudimentary. In this peculiarity existing Birds stand in sharp contrast to their Jurassic ancestors (see above).

It must, however, be well understood that the pygostyle of Birds may be made up of six or more fused caudal vertebræ, and in

¹ *Ichthyornis* (from the American Cretaceous), as well as *Archæopteryx*, possessed biconcave vertebræ. The same type of vertebra is to be met with in many fossil (*e.g.* in the *Enaliosauria*), and in some existing Reptiles (*Ascalabota* and *Hatteria*), as well as in most of the free caudal vertebræ in existing Birds.

the sacrum even a greater number may be included (cp. the chapter on the pelvis, p. 96): thus in the common Duck (*Anas boschas*), seven become united with the pelvis, eight remain free, and the pygostyle is composed of ten separately ossified and fused segments, making in all twenty-five vertebræ originally present in the caudal region of this Bird. In *Archæopteryx* the pelvis was much shorter than in existing Birds, and much fewer vertebræ were united with it. Moreover, in embryos of an Australian parrot (*Psittacus undulatus*) more vertebræ are formed in the embryo than are seen in the adult. The original type is well preserved to the present day in

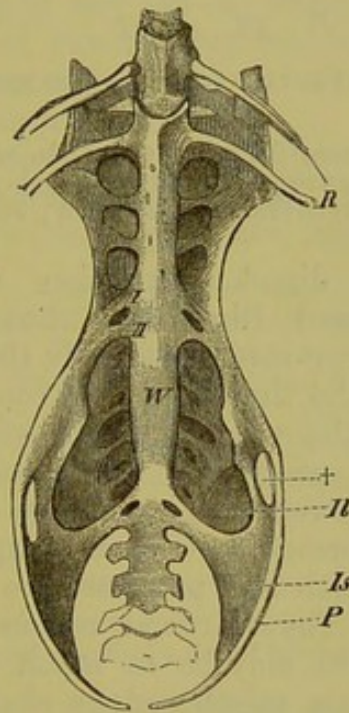


FIG. 34.—PELVIS OF OWL (*Strix bubo*). (Ventral view.)

W, position of the primary sacral vertebræ: between *R* and *II*, and behind *W*, are seen the secondary sacral vertebræ, fused with the primary; *II*, ilium; *Is*, ischium; *P*, pubis; †, foramen between ilium and pubis; *R*, last pair of ribs.

the Ratitæ, in which the posterior caudal vertebræ remain free, instead of uniting to form a pygostyle, and the secondary sacral vertebræ remain longer distinct. Thus the chasm between *Archæopteryx* and existing Birds is in this respect essentially lessened.

The arches always become united into a single mass with the corresponding centra, and are no longer separated from them for life by sutures, as seen *e.g.* in Crocodiles, and exceptionally in Chelonians. The same may be said of the atlas and axis, in which also no sutures persist between the different parts. In the cervical region, where by means of saddle-shaped articulations the vertebræ are able to move easily on one another, the bifurcated transverse

processes may unite with the corresponding ribs (Fig. 35). In the thoracic region, more or fewer of the vertebræ usually become immovably united together.

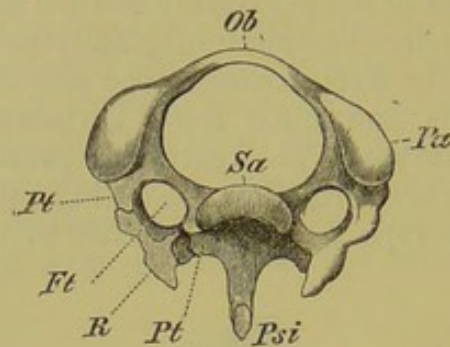


FIG. 35.—THIRD CERVICAL VERTEBRA OF WOODPECKER (*Picus viridis*). (Viewed anteriorly.)

Sa, articular surface of centrum; *Ob*, upper arch; *Pa*, articular process; *Pt*, *Pt*, the two bars of the transverse process, shown on one side ankylosed with the cervical rib (*R*); *Ft*, transverse (vertebrarterial) foramen; *Psi*, hæmal spine.

Mammalia.—No direct connection exists between the vertebræ of Reptiles and Birds and those of Mammals. The notochord persists longer intervertebrally than vertebrally, but it disappears entirely by the time the adult condition is reached. A jelly-like pulpy mass, the nucleus pulposus, persists, however, throughout life in the centra of the fibro-cartilaginous menisci which are developed between the vertebræ. Articulations between the centra are never formed, but as in Amphibians, Reptiles, and Birds, well-developed articular processes are present, arising from the neural arches.¹ The cervical region is usually the most moveable, and the centra may be so much hollowed out in this region as to give them an opisthocœlous character (*e.g.* Ungulata). In some cases, on the other hand, the cervical vertebræ may become firmly fused together (Cetacea). The centra are provided with epiphyses, except in all but those of the caudal region of Monotremes and in Sirenia (?).

The atlas and axis essentially resemble those of Birds, though the differentiation of the vertebral column into regions, characterised by difference of form, is much more sharply marked than in any other Vertebrates.

In long-necked Ungulates (Horse, Camel, Ox) the neural spines of the anterior thoracic vertebræ are greatly developed, and corresponding with this, a strong cervical ligament (ligamentum nuchæ) is particularly well developed to support the weight of the head. This is also true of antler-bearing animals and of the Gorilla. There are as a rule 7 cervical vertebræ; Bradypus, however, possesses 8—9, and Tamandua bivittata 8, while in Manatus and Cholæpus there are only 6.

The transverse processes of the cervical vertebræ usually unite with the rudimentary ribs, as in Birds.

¹ In certain Edentata (*e.g.* Myrmecophaga) extra articular processes are present besides the ordinary zygapophyses on the posterior thoracic and lumbar vertebræ.

In Mammals, as in Reptiles and Birds, two primary sacral vertebræ are present, but as a rule a few caudal become later included in the sacrum, and are usually more or less closely united with it. In Anthropoids, as in Man, the first sacral vertebra is plainly marked off from the last lumbar by the appearance of the so-called promontory.

The caudal vertebræ vary extremely in their development, and excepting in most long-tailed Mammals—more particularly the Sirenia and Cetacea—no longer develop lower arches. When present these “chevron bones” are intervertebral in position.

In the higher Primates the tail forms a stump-like appendage, the coccyx consisting of few (3—6) vertebræ. In the embryo, however, the notochord extends beyond the point corresponding to the apex of the coccyx, and thus a longer caudal region must formerly have been present.

The greatest number of caudal vertebræ is found in *Microgale longicauda* (48), *Manis macrura* (46—49), *Paradoxurus* (about 36), and in certain Monkeys (*Semnopithecus*, *Ateles*, 32—33).

In human embryos of 9—10 millimetres long (5th week) 38 vertebræ are present, and these all consist of a cartilage-like tissue with the exception of the two posterior caudals. In embryos 12mm. long (6th week) the three posterior caudal vertebræ (36th, 37th, and 38th) fuse together, and the 35th also loses its sharp contour. In embryos of 19mm. there are only 34 vertebræ, the number present in the adult. In the stage with 38 vertebræ, the spinal cord and notochord extend to the extreme apex of the tail, almost reaching to the skin, but a reduction of these parts takes place later.

BIBLIOGRAPHY.

- AGASSIZ, L.—*Rech. sur les poissons fossiles*. Neuchâtel, 1833 to 1843.
- CARTIER, O.—*Beitr. zur Entw.-Geschichte der Wirbelsäule*. *Zeitschr. f. wiss. Zool.* Bd. XXV. Suppl. 1875.
- DAMES, W., and KAISER, E.—*Palæontol. Abhandlungen*, Bd. II. Heft 3. Berlin, 1884. (*Monograph on Archaeopteryx*.)
- FLOWER, W. H.—*Osteology of the Mammalia*. London, 1885.
- FOL, H.—*Sur la queue de l'embryon humain*. *Comptes rendus*, 1885.
- GEGENBAUR, C.—*Unters. z. vergl. Anatomie der Wirbelsäule der Amphibien und Reptilien*. Leipzig, 1862. *Beitr. zur Kenntniss des Beckens der Vögel, &c.* *Jenaische Zeitschr.* Bd. VI.
- GERLACH, L.—*Ein Fall von Schwanzbildung bei einem menschl. Embryo*. *Morphol. Jahrb.* Bd. VI.
- GÖTTE, A.—*Beitr. zur vergl. Morphologie des Skelettsystems der Wirbelthiere*. *Arch. f. mikr. Anatomie*, Bd. XV. 1878.
- GÜNTHER, A.—*Description of Ceratodus Forsteri*. *Phil. Trans. of the Royal Society*. London, 1871.
- HASSE, C.—*Das natürl. System der Elasmobranchier, &c.* Jena, 1879-82.
- HOFFMANN, C. K.—*Beitr. z. vergl. Anatomie der Wirbelthiere*. *Niederl. Arch. f. Zool.* Bd. IV.
- MARSH, O. C.—*Odontornithes, a Monograph on the Extinct Toothed Birds of North America*. Washington, 1880.
- MAYER, P.—*Die unpaaren Flossen der Selachier*. *Mittheilungen der Zoolog. Station zu Neapel*. Bd. VI. 1885.
- MIVART, ST. G.—*On Various Axial Skeletons*. *Proc. and Trans. Zool. Soc.* 1865, 1869, 1873.
- ROSENBERG, C.—*Ueber die Occipital-region des Selachier-schädels*. Dorpat, 1884. *Ueber die Entwicklung der Wirbelsäule und das Centrale carpi des Menschen*. *Morphol. Jahrb.* Bd. I. 1876.

SAGEMEHL, M.—*Beiträge zur Anat. der Fische. Morphol. Jahrb. IX., 1884.*

WIEDERSHEIM, R.—*Salamandrina perspicillata. Versuch. einer vergl. Anatomie der Salamandrinen. Genua, 1875. (Annali del Museo civico. Vol. VII.) Die Anatomie der Gymnophionen. Jena, 1879. Das Skelet und Nervensystem von Lepidosiren annectens. Morphol. Studien, Heft I. Jena, 1880.*

II. RIBS.

The ribs, standing in the closest connection with the myocommata (myotomes) of the great lateral muscles of the body, are arranged segmentally, and onto- as well as phylogenetically, pass through a membranous, a cartilaginous, and a bony stage. Their development, which as a rule takes place first in the anterior part of the body and then extends gradually backwards, is usually entirely independent of the vertebral column, their connection with it being a secondary one.¹

Fishes and Dipnoi.—The cartilaginous or bony ribs are attached to the basal processes already described, and extend ventro-laterally from the corresponding vertebræ. The ribs of Fishes show a very primitive condition, usually extending along the whole length of the vertebral column (Lophobranchii, Spatularia). In rare cases they are absent, though many Fishes only possess rudimentary ribs (many bony Fishes, Elasmobranchs).

In others, as in numerous Teleosteans and Ganoids, they are very well developed, and encircle the body-cavity like the hoops of a cask; but they never unite together in the mid-ventral line.

The relations of the anterior portion of the vertebral column to the auditory organ in certain Teleosteans will be described later (see p. 207).

Amphibia.—In the ribs of Amphibia there are evident signs of degeneration; as a rule they are confined to the region of the trunk, or at most they extend in certain Urodeles in a very rudimentary form as far as the first two caudal vertebræ; in other cases, as in the tailless Batrachia, they are so remarkably short that they can no longer be said to encircle the body-cavity. In many Anura the ribs are not distinctly articulated, as they become fused with the broad transverse processes (Fig. 32, R).

The ribs of Urodeles are forked at their proximal ends, and articulate with the bifurcated transverse processes of the vertebræ. The ventral limb only of the transverse process corresponds to the basal process of Ganoids; the dorsal one is to be looked upon as a neomorph. The bifurcated ends of the ribs in Reptiles and Birds as well as the double articular facets of the ribs of Mammals are to be explained in the same manner.

¹ The ribs of Ganoids, and possibly also those of Dipnoi, seem to follow an entirely different plan of development, in that they become segmented off from the lower arches, as mentioned in the chapter on the vertebral column.

Excepting the first, all the trunk vertebræ are usually provided with ribs in Urodeles: ribless (lumbar) vertebræ are met with very rarely (Spelerpes).

Reptiles, Birds, and Mammals.—In these, well-developed ribs are always present, and more or fewer of them almost always unite ventrally with a breast-bone or sternum. Those which unite with the sternum are sometimes spoken of as “true,” the others as “false” ribs.

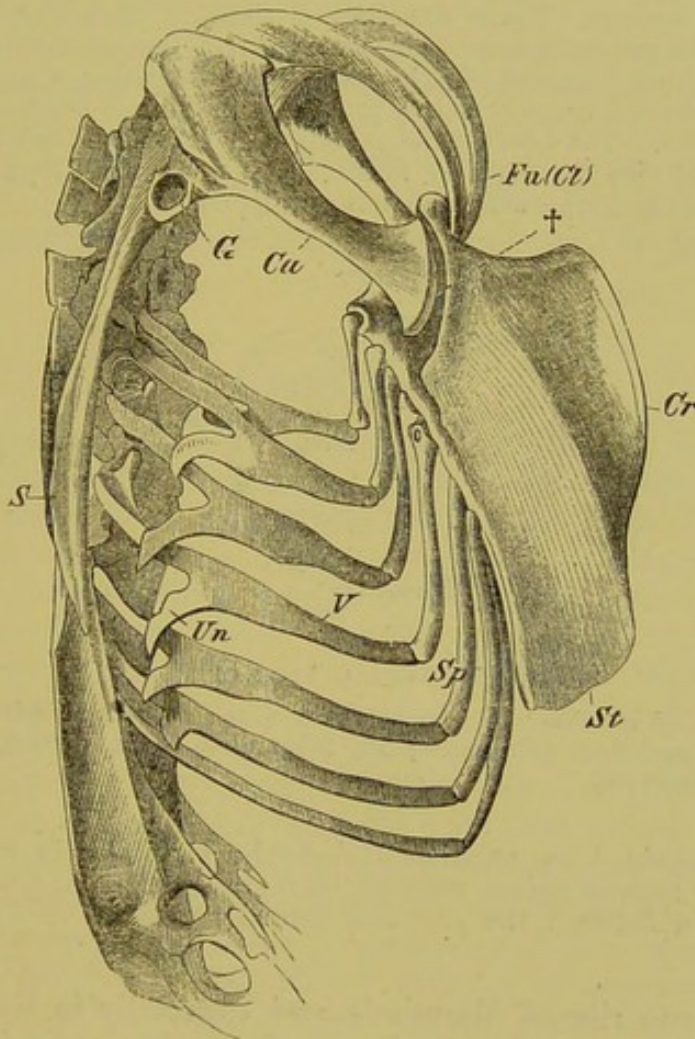


FIG. 36.—SKELETON OF THE TRUNK OF A FALCON.

S, scapula; *G*, glenoid cavity for humerus; *Ca*, coracoid, which articulates with the sternum (*St*) at †; *Fu(Cl)*, furcula (clavicles); *Cr*, keel of sternum; *V*, vertebral, and *Sp*, sternal, portion of rib; *Un*, uncinatè process.

The ribs of Snakes show the least amount of differentiation for, without giving rise to a sternum, they extend along the whole trunk from the third cervical vertebra to the anus, and retain throughout a similar form and size. In Lizards, where a dorsal bony and a ventral cartilaginous portion can be distinguished, three

or four ribs reach to the sternum,¹ and are not always completely segmented off from it.

The ribs of Birds exhibit a much more marked segmentation into vertebral and sternal portions, and this evidently stands in relation to respiration; they moreover develop so-called uncinatè processes (Fig. 36, *Un*). In this latter, as in many other points, they show a relation to certain Reptiles (viz. Hatteria and Crocodiles).

The ribs of Archæopteryx are of special interest, as they are more similar to those of Reptiles than to those of Birds, though they do not closely resemble the former. Their structure is delicate, their ends are pointed, and no uncinatè processes have been observed: in transverse section they are ellipsoidal, and not flattened like those of Birds. Whether a connection with a breast-bone existed is not certainly proved, as nothing is known of a sternum or of sternal ribs. The breast-bone must at any rate have been very small, as the "abdominal ribs" extend far forwards; it was probably provided with a keel, for the quills of the wing are well developed.

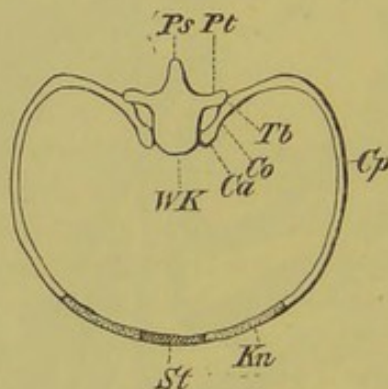


FIG. 37.—COSTAL ARCH OF MAN.

WK, centrum of vertebra; *Pt*, transverse process; *Ps*, neural spine; *Cp*, body of rib; *Ca*, capitulum; *Co*, neck; *Tb*, tuberculum; *Kn*, cartilaginous (sternal) rib; *St*, sternum.

It has already been mentioned that the cervical ribs and transverse processes may become united together in representatives of all the Amniota, and the fusion between the ribs and dermal plates in Chelonians may be here noted.

In the true ribs of Mammals, and especially in those of Man, a capitulum, a neck, a tuberculum, and a body may be distinguished (Fig. 37). The capitulum articulates with the centrum, and the tuberculum with the transverse process of the vertebra. The number of ribs which reach the sternum varies considerably.

¹ In Crocodiles, eight to nine ribs reach the breast-bone; in Birds, three to eight. An ossification of the inscriptions tendineæ of the rectus abdominis takes place in Crocodiles and Hatteria, and similar structures (so-called "abdominal ribs") occur in numerous fossil Reptiles (Nothosaurus of the Trias, Enaliosaurus of the Jurassic, Pterodactylus, &c.). Archæopteryx also possessed twelve to thirteen well-developed "abdominal ribs." These must not be confounded with the remains of true abdominal ribs, which persist without the corresponding vertebral portion in the Chameleon and certain Birds (W. K. Parker).

Development teaches us that in the cervical, lumbar, and sacral regions, where no ribs are apparent in the adult, they are present in the embryo, even in Man, and this points back to primitive conditions. The rudimentary character and variety in size of the eleventh and twelfth ribs of Man shows that they are gradually disappearing (cp. p. 53): a gradual shortening of the thoracic portion of the vertebral column and a corresponding lengthening of the cervical and lumbar regions is also taking place in Mammals generally, and thus the following general rule may be stated:—The reduction in the number of ribs is correlated with a higher stage in development of the Vertebrate body.

It has already been mentioned that sacral ribs are developed, and it is only necessary to add that this statement holds good for all Vertebrates. In other words: the pelvis is always supported by sacral ribs, whether these remain differentiated throughout life (Urodeles), or whether they fuse with the corresponding transverse processes of the sacral vertebræ (Amniota).

III. STERNUM.

Never present in Fishes, the sternum appears for the first time in Amphibians in the form of a small variously-shaped plate of cartilage situated in the middle line of the chest (Figs. 38 and 74, *St*). It originates from two cartilaginous rods lying in the inscriptiones tendineæ of the thoracic region, with which the coracoids, or rather the epicoracoid plates of the pectoral arch come into more or less close connection (Fig. 38, *St*, *Co*¹). In many tailless Batrachians (*e.g.* Rana), the ventral portion of the pectoral arch is continued forwards in the middle line as a slender bone tipped with cartilage—the “omo-sternum” (Parker) (Fig. 38, *Ep*). The phylogenesis of the Amphibian sternum is still entirely unknown, and it is doubtful whether it ought to be placed in the same category with the similarly named structure in the Amniota. In the latter, the sternum has a costal origin, and is due to a number of ribs on either side of the middle line running together to form a continuous cartilaginous tract. An unpaired cartilaginous sternal plate is formed by the tract of either side becoming more or less completely fused with its fellow, and from this plate the ribs become secondarily segmented off by the formation of true articulations. Later it may become calcified (Reptiles), or converted into true bone (Birds, Mammals). In Reptiles, Birds, and Monotremes the coracoids (Fig. 75, *Co*, *Co*¹) always come into direct connection with the upper or the lateral edges of the sternum (comp. Fig. 36, *St*, and *Ca*, and Figs. 38 and 39, *St*, *Co*).

The sternum is greatly developed in Birds, and consists of a broad plate, usually (“Carinate Birds”) provided with a projecting keel (*crista sterni*), which forms a point of origin for the wing-

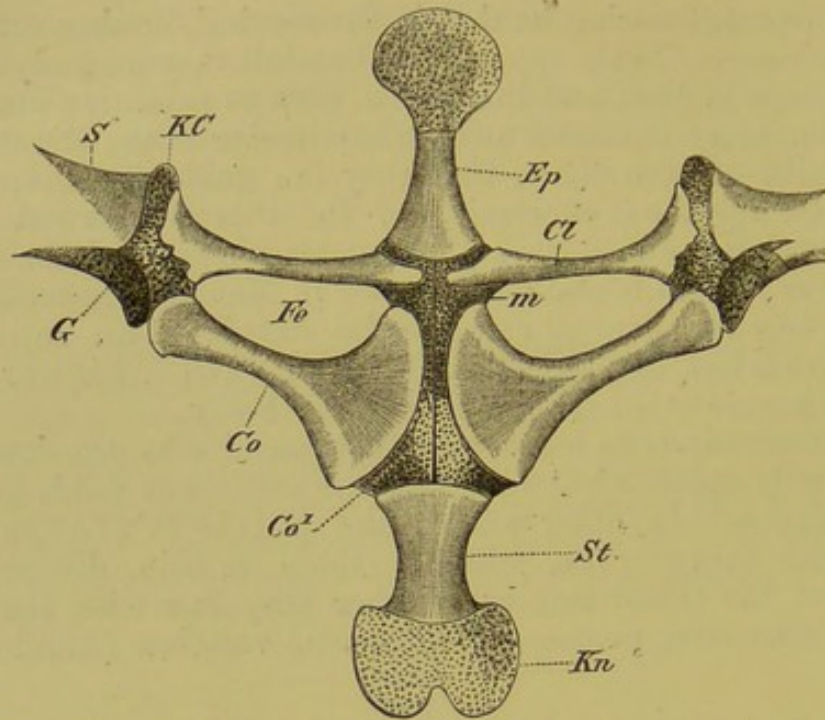


FIG. 38.—VENTRAL PORTION OF THE PECTORAL ARCH OF *Rana esculenta*.

St, bony, and *Kn*, cartilaginous sternum (xiphisternum); *S*, scapula; *KC*, cartilaginous portion between the latter and the clavicle (*Cl*); *Co*, coracoid; *Co*¹, epicoracoid; *m*, line of junction between the two epicoracoids; *G*, glenoid cavity for the humerus; *Fe*, fenestra between the coracoid and clavicle; *Ep*, omosternum.

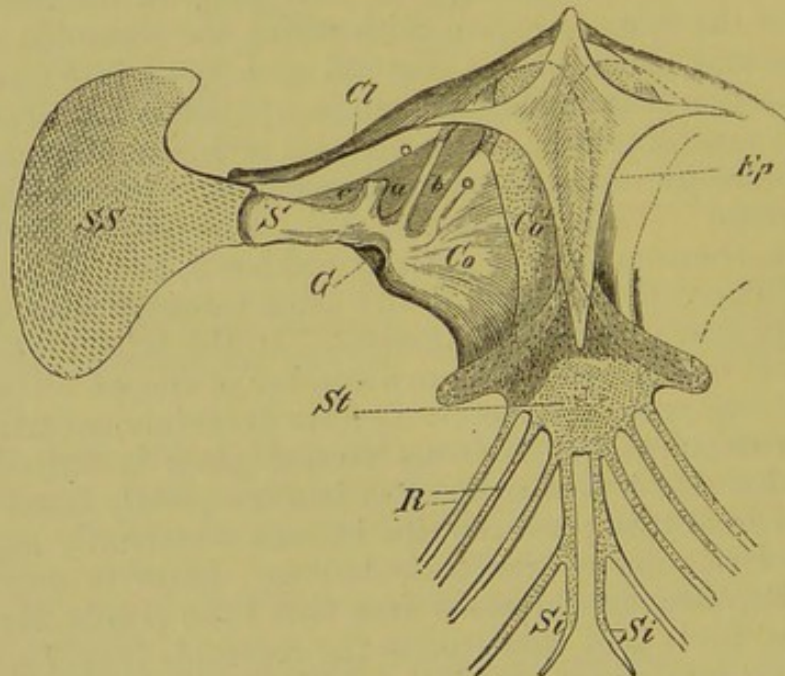


FIG. 39.—PECTORAL ARCH AND STERNUM OF A GECKO (*Hemidactylus verrucosus*).

St, sternum; *R*, ribs; *Si*, cartilaginous cornua to which the last pair of ribs is attached; *SS*, suprascapula; *S*, scapula; *Co*, coracoid; *Co*¹, cartilaginous epicoracoid; *Ep*, interclavicle; *a*, *b*, *c*, membranous fenestræ in the coracoid; *Cl*, clavicle; *G*, glenoid cavity for the humerus.

muscles. In contrast to these, the Ratitæ ("Cursorial Birds") are characterised by a broad, slightly-arched, shield-like sternum without a keel.

In both cases the sternum arises in two bands connected with ribs, a greater number often taking part in its formation than are present in the adult. According to Lindsay, the two parts of this costal sternum, corresponding to the breast-bone of Reptiles and Mammals, become connected by a portion, the metasternum, which gives rise to the median and posterior portion of the sternum of the adult. In the Ratitæ, the metasternum, which probably arises from the fused edges of the costal portion, remains partly cartilaginous in the adult. In the Carinatae, it gives rise to a median ventral outgrowth, the keel. This generally arises at the time of the fusion of the two halves, but in some cases there appears to be a tendency for it to become differentiated from the rest of the sternum. It is either ossified by the fusion of a pair of lateral bony centres, or else by means of a separate endosteal (see p. 63) centre.

Thus the keel of the Bird's sternum is probably of late phylogenetic development, arising in correlation with the large development of the pectoral muscles, and having no relationship to the interclavicle of Reptiles, as is often asserted.

A far greater number of ribs are as a rule concerned in the formation of the breast-bone of Mammals than is the case in

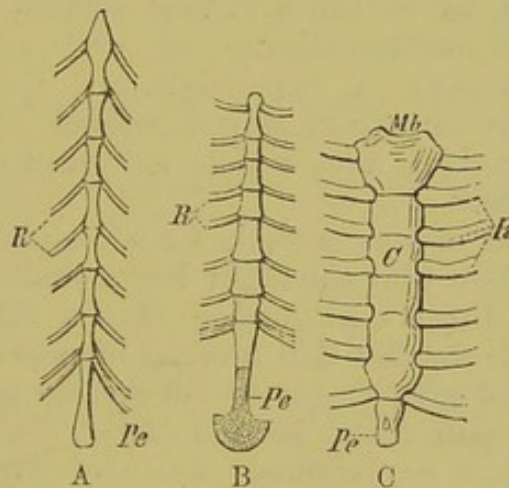


FIG. 40.—A, STERNUM OF FOX ; B, OF WALRUS ; AND C, OF MAN.

Mb, manubrium ; *C*, body ; *Pe*, xiphoid process ; *R*, ribs.

Reptiles and Birds. Consisting at first of a simple cartilaginous plate, it later becomes segmented into definite bony regions, the number of which originally corresponds to the affixed ribs (Fig. 40, A, B). But in other cases, as, for instance, in Primates, the individual bony segments usually run together to form a long plate (*corpus sterni*), of which the proximal end becomes differentiated into the so-called manubrium, and the distal end into the xiphoid process (*processus ensiformis*). The latter (Fig. 40, C, *Pe*) owes its origin in the embryo to the ventral fusion of a true pair of ribs, arising independently or as a direct continuation of the primary sternal tracts, from which it later becomes segmented

off, and, like the manubrium, ossified from a special centre. Thus, in Man, an embryonic stage exists in which the eighth pair of ribs are connected with the xiphoid process.

BIBLIOGRAPHY.

- GÖTTE, A.—*Beiträge zur vergl. Morphologie des Skelettsystems der Wirbelthiere. Arch. f. mikr. Anat.* Bd. XIV.
- HASSE, C., and BORN, G.—*Bemerkungen üb. d. Morphologie d. Rippen. Zool. Anz.* 1879.
- HOFFMANN, C. K.—*Beiträge zur vergl. Anatomie der Wirbelthiere. Nederl. Arch. f. Zoologie*, Bd. IV., V.
- LINDSAY, BEATRICE.—*On the Avian Sternum. Proc. Zool. Soc.* 1885, p. 684.
- PARKER, W. K.—*A Monograph on the Structure and Development of the Shoulder-Girdle and the Sternum. Ray Soc.* 1867.
- RUGE, G.—*Untersuch. üb. Entwick. am Brustbeine d. Menschen. Morphol. Jahrbuch*, Vol. VI. 1880.

IV. THE SKULL.

Theory of the Segmentation of the Skull.

In the skull, as in the vertebral column, three stages may be distinguished ontogenetically as well as phylogenetically, viz., a membranous, a cartilaginous, and a bony stage. There is thus an important correspondence between these two parts of the vertebral axis, which is considerably increased by the following facts.

The notochord always extends for a certain distance into the base of the skull, so that the latter has a similar origin to, and is developed as a direct continuation of, the vertebral axis. Still more important is the fact that a series of mesoblastic somites (protovertebræ) give origin to the greater part of the head as well as to the main dorsal section of the trunk in the embryo, so that both show a metameric mode of origin. Out of these somites, each of which encloses a cavity originating from the coelome, are formed the muscles of this region as well as the foundation of the proper cranial capsule. As development advances, the original segmented arrangement gradually disappears, and thus the cranium, especially in the lowest Vertebrates, as, for instance, in Cartilaginous Fishes, forms a continuous structure.

A cartilaginous system of arches, which often later become ossified, arises in serial order on the ventral side of the brain-case; these encircle the anterior part of the alimentary tract like hoops, and are distinguished from the cranial region as the visceral skeleton. The latter stands in important relation to gill-breathing, inasmuch as each consecutive pair of arches enclose a passage (gill-slit) communicating between the pharynx and the exterior; this is lined by endoderm, and through it the water passes. The foremost visceral arch bounds the aperture of the mouth, and

forming thus a firm support for it, gives rise to the skeleton of the jaws, as well as, in higher types, to the main part of the facial skeleton. The arches lying posterior to this function primarily as gill-supports.

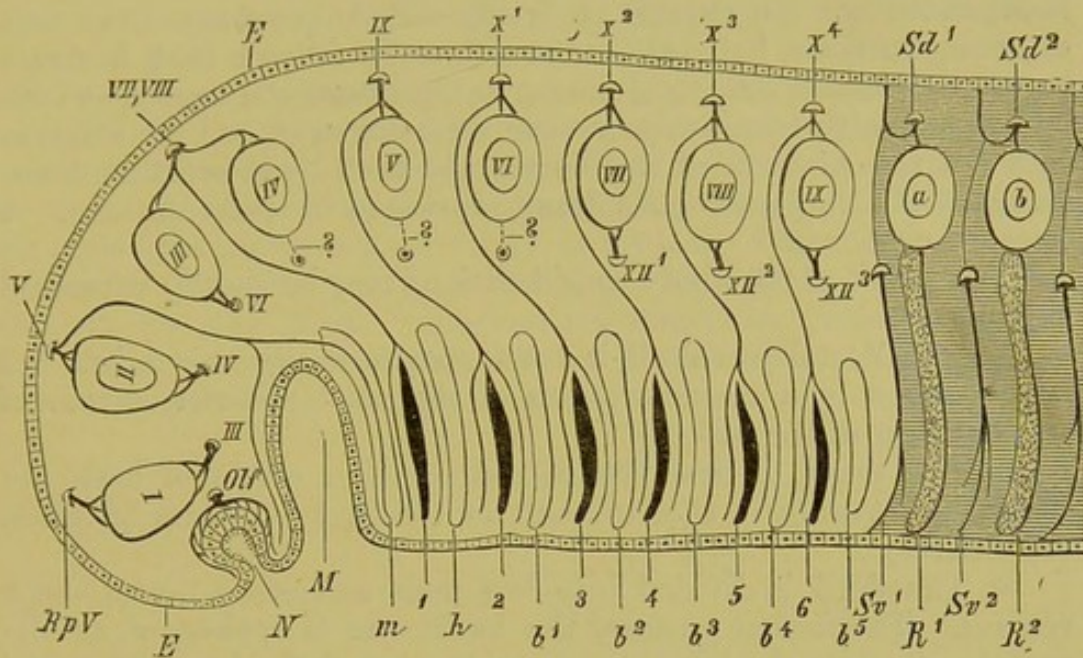


FIG. 41.—DIAGRAM SHOWING THE PRIMITIVE METAMERIC CONDITION OF THE HEAD.

E, *E*, epiblast, which at *N* is invaginated to form the primitive olfactory pit, the epithelium of which is supplied by the olfactory nerve (*Olf*); *M*, oral involution; *I*, first somite, from which arise the superior, internal, and inferior rectus, and inferior oblique muscles; *II*, second somite, from which the superior oblique muscle originates; *III*, third somite, which gives rise to the external rectus; *IV*, *V*, *VI*, fourth, fifth, and sixth somites: only the sixth gives rise to muscle-rudiments; *VII*, *VIII*, *IX*, seventh, eighth, and ninth somites, from which the muscles extending from the skull to the pectoral arch arise: the anterior part of the sterno-hyoid is also formed in this region; *a* and *b* indicate the first somites of the trunk; *III*, oculomotor, *IV*, trochlear, *VI*, abducent, and *XII*¹ to *XII*³, hypoglossal nerves. All the above-named nerves correspond to ventral roots of the nerves belonging to the head-somites, *I*, *II*, *III*, *VII*, *VIII*, and *IX*. The ventral nerves belonging to somites *IV*, *V*, and *VI* are not known: they probably lie in the territory of the trigeminal. *RpV*, ramus ophthalmicus profundus of the trigeminal, the dorsal nerve of the first somite; *V*, the rest of the trigeminal, the dorsal nerve of the second somite, supplying the maxillary and mandibular regions; *VII*, *VIII*, the acustico-facialis, the dorsal nerve of the third and fourth somites, supplying the first primitive gill-cleft (spiracle) (1); *IX*, glossopharyngeal, the dorsal nerve of the fifth somite, supplying the second gill-cleft (2); *X*¹ to *X*⁴, vagus, the dorsal nerves of the sixth to the ninth somites, supplying the third to the sixth gill-clefts (3 to 6); *Sv*¹, *Sv*², ventral, and *Sa*¹, *Sa*², dorsal, roots of the two first spinal nerves; *m*, first (mandibular) visceral arch; *h*, second (hyoid) arch; *b*¹ to *b*⁵, the five branchial arches; *R*¹, *R*², first and second ribs.

On viewing the serial arrangement of the visceral arches, one might be tempted to explain them as being homodynamous with ribs, and to consider this, as well as the corresponding distribution of the branchial nerves as a further support for supposing

for the head a metameric origin of the same nature as that of the body. This, however, is not admissible, inasmuch as the above-described segmentation of the visceral section of the skull by the formation of gill-slits does not correspond to a segmentation of the same nature as that seen in the body, but arises quite independently. To express it briefly—Metamerism does not correspond to branchiomerism. It follows that a direct parallelism of the branchial nerves to the intercostal nerves—which correspond with trunk-metameres—does not exist, and the attempt to solve the problem of the Vertebrate skull by indirect methods, *i.e.* those of Comparative Anatomy, must lead to crude theories and false conclusions.

The result of the above considerations may be shortly expressed as follows:—

1. The Vertebrate skull is not a structure *sui generis*, but has been derived by a metamorphosis of the most anterior section of the skeleton of the body.

2. The proof of this lies in the common origin of both the cranial and vertebral skeleton out of the protovertebræ (somites, metameres).

3. The skull is divided into two main sections, a dorsal and a ventral. The former encloses the brain, and is spoken of as the cranium, while the latter lies in the region of the fore-part of the alimentary tube, has primitively to do with branchial respiration, and is called the visceral skeleton.

4. The cranial section alone is to be looked upon as made up of a series of mesoblastic somites: the segmentation of the visceral skeleton must be regarded as a secondary acquisition, for the gill-arches are developed as secondary supports for the hypoblastic gill-clefts.

5. The attempt to explain the adult skull as a series of vertebræ¹ fails completely; it is a question of protovertebræ (somites) only, and thus is one that can only be solved along the lines of Embryology, and not those of Comparative Anatomy.

6. The number of mesoblastic somites concerned in the formation of the skull may be fixed at nine,² according to researches up to the present time on Cyclostomes, Elasmobranchs, and Amphibians. In no case are there fewer,—in many instances possibly more.

¹ Rosenberg has, however, shown that in *Carcharias glaucus*, but apparently not in other Selachians, the portion of the cranium lying between the exit of the vagus and the vertebral column is clearly composed of three vertebræ, which gradually fuse with, and constitute a part of, the occipital region of the skull (Gadow finds four vertebræ in embryos of *Carcharias* which thus become modified). It follows that the cartilaginous cranium is not completely homologous throughout the Vertebrata; the skull of *Carcharias* corresponds with that of *Scyllium*, for instance, *plus* certain of the anterior vertebræ.

Sagemehl has found a somewhat similar modification in Ganoids.

² Beard, in a recent paper, increases the number of segments in the head in Sharks to eleven.

a. **Brain-Case (Cranium).**

The first cartilaginous rudiments appear in the primitively membranous skull tube in the form of a pair of rods, the trabeculæ cranii. These lie along the base of the brain, their posterior part embracing the notochord, and they thus are divisible into prochordal (anterior) and parachordal (posterior) regions (Fig. 42, *Tr*). The parachordal tract may extend further along the notochord as a direct backward growth of the trabeculæ, or as one or two separate cartilaginous tracts (Fig. 42, *PE*). The parachordals soon unite to form a basilar plate, which grows round the notochord dorsally and ventrally, and thus early forms a solid support for the brain. The slender trabeculæ project forwards and enclose a space, which may be spoken of as the primitive pituitary space (Fig. 42, *PR*).

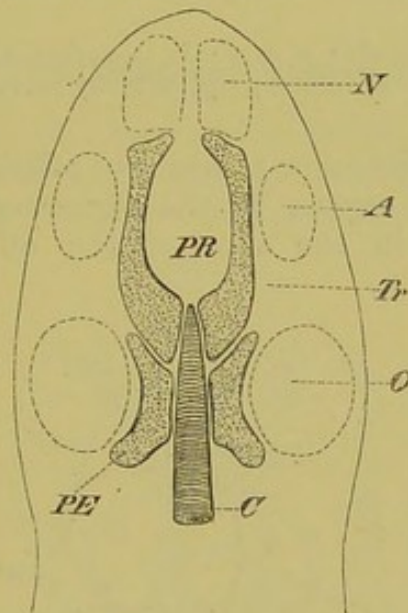


FIG. 42.—FIRST CARTILAGINOUS RUDIMENTS OF THE SKULL.

C, notochord; *PE*, separate parachordal elements; *Tr*, trabeculæ cranii; *PR*, pituitary space; *N*, *A*, *O*, the three sense-capsules (olfactory, optic, and auditory).

These structures may become further developed in many different ways in the various Vertebrate groups: either the trabeculæ become completely united with one another in the median line (Fig. 43, *A*, *Tr*), or the connective-tissue of the oral mucous membrane becomes ossified to form a parasphenoid (Fig. 43, *B*, *Ps*). In other cases, the trabeculæ may become compressed and partly aborted owing to the great development of the eyes; this obtains in certain Teleosteans and Reptiles and in all Birds, where a fibro-cartilaginous interorbital septum appears in their place (Fig. 43, *C*, *Tr*, *IS*).

In most cases a median cartilaginous bar (intertrabecula) is formed between the trabeculæ in front, fusing with them, and forming the ethmo-nasal septum. It occasionally projects forwards to form a rostrum.

We must now follow further the processes of growth, taking as a foundation the primary condition of things described above, in which the trabeculæ have united together in the middle line. The

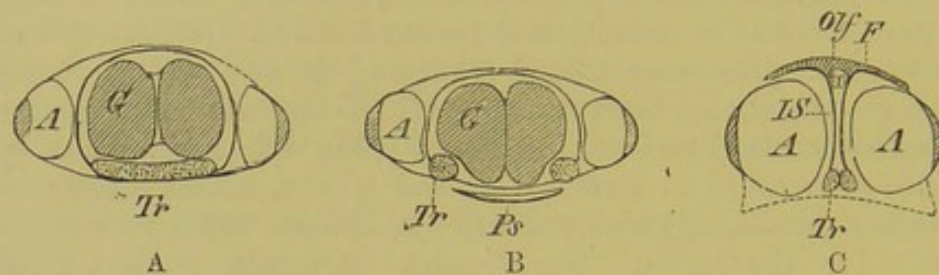


FIG. 43.—DIAGRAMMATIC TRANSVERSE SECTIONS, OF THE HEAD IN EMBRYO—(A) STURGEONS, ELASMOBRANCHS, ANURA, AND MAMMALS; (B) URODELES AND SNAKES; AND (C) CERTAIN TELEOSTEANS, LIZARDS, CROCODILES, CHELONIANS, AND BIRDS.

Tr, trabeculæ cranii; *G*, brain; *A*, eyes; *Ps*, parasphenoid; *IS*, interorbital septum; *F*, frontal; *Olf*, olfactory nerve.

cartilaginous basal plate now comes into relations with the olfactory, optic, and auditory organs by the formation of processes which serve—particularly in the case of the olfactory and auditory

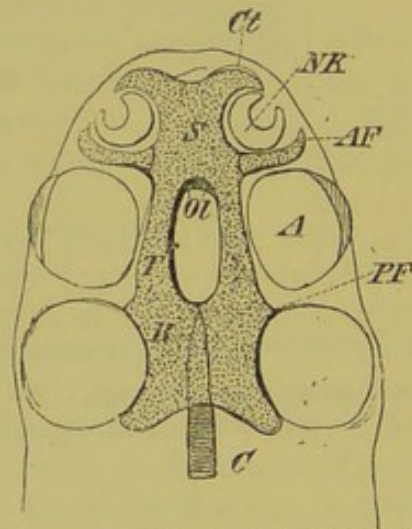


FIG. 44.—SECOND STAGE IN THE DEVELOPMENT OF THE PRIMORDIAL SKULL.

C, notochord; *B*, basilar plate; *Tr*, trabecula, which has united with its fellow in front of the pituitary space to form the ethmonasal septum (*S*); *Ct*, cornu trabeculæ, and *AF*, antorbital process, which supports the olfactory organ (*NK*) in front and behind; *Ol*, foramina for exit of the olfactory nerves from the cranium; *PF*, postorbital process of trabecula; *NK*, nasal capsule; *A*, eye; *O*, auditory capsule.

apparatus—to connect the skull with the cartilaginous sense-capsules, and thus to act as supports for them. Thus an olfactory, an orbital, and an auditory region are early differentiated.

While the first and the last of these are gradually surrounded by cartilage, and, especially in higher types, more and more drawn in to the skull proper, the lateral walls of the basal plate become raised up, and begin to grow round the brain on both sides, eventually extending even to the dorsal region. Thus a continuous cartilaginous capsule is formed, such as persists throughout life in Elasmobranchs for example. But in by far the greater number of Vertebrates, the cartilage does not play so great a part, and is, as a rule, confined to the base and lower parts of the sides of the skull and to the sense-capsules, except in the occipital region, where it always extends over the brain. The rest of the skull, more particularly the roof, becomes directly converted from membrane into bone. Thus it may be stated generally, that the higher the systematic position of the animal, the less extensive are the cartilaginous constituents and the more important the bony.

b. The Visceral Skeleton.

The skeletal parts of the visceral arches, always formed in hyaline cartilage, encircle the anterior section of the alimentary canal, lying embedded in the inner part of the walls of the throat

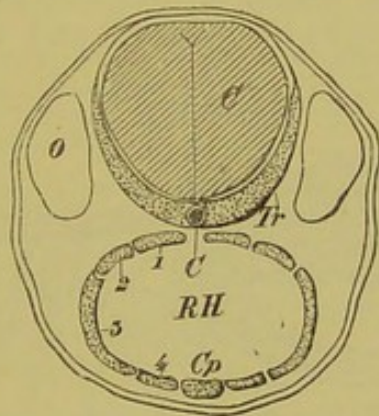


FIG. 45.—DIAGRAMMATIC TRANSVERSE SECTION OF THE THIRD STAGE IN THE DEVELOPMENT OF THE PRIMORDIAL SKULL.

C, notochord; *Tr*, trabeculae, which enclose the brain (*C*) ventrally and laterally; *O*, auditory capsule; *RH*, the cavity of the pharynx, enclosed by the visceral skeleton; 1 to 4, the individual elements composing each visceral arch, which latter is united with its fellow by a basal piece (*Cp*).

(Figs. 45 and 46, *B, B*). Always present in a greater number (up to as many as nine) in gill-breathing animals than in higher types, they gradually become reduced, so that in the Amniota the remains of the three or four anterior at most are seen: they further undergo a change of function, for all but the first of these take on definite relations to the auditory organ and larynx.

The most anterior arch, serving as a support for the walls of the mouth and receiving its nerve supply from the trigeminal,

arises first, and is distinguished from the other or post-oral arches as the mandibular arch. The post-oral arches only, function as gill-bearers in the adult fish: even the first of these, the hyoid, which

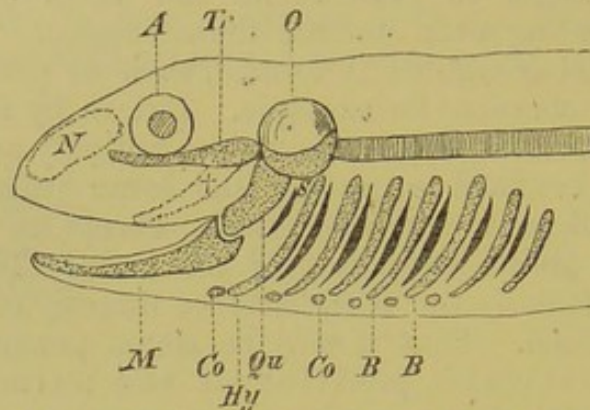


FIG. 46.—DIAGRAM SHOWING THE RELATIONS OF THE EMBRYONIC VISCERAL SKELETON.

N, nasal capsule; *A*, eye; *O*, auditory capsule; *Tr*, trabeculae, which, from being bent down anteriorly (+), again extend forwards in a line with the vertebral axis; *M*, Meckel's cartilage; *Qu*, quadrate; *Hy*, hyoid arch; *B, B*, branchial arches, between which are seen the gill-clefts; *S*, spiracle; *Co, Co*, basi-hyoid and basi-branchials.

is supplied by the facial nerve, becomes modified from those lying behind it: the latter, or branchial arches proper, are supplied by the glossopharyngeal and vagus. Nevertheless,

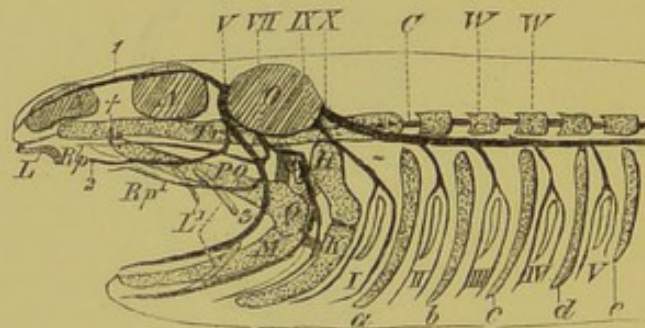


FIG. 47.—SEMI-DIAGRAMMATIC FIGURE OF AN ELASMOBRANCH SKULL, SHOWING THE RELATIONS OF THE SEGMENTAL CRANIAL NERVES.

N, nasal capsule; *A*, eye; *O*, auditory capsule; *Tr*, trabecula; *Q* and *PQ*, quadrate and palatopterygoid, which are bound to the trabecula by ligament at +; *M*, Meckel's cartilage; *L, L¹*, labial cartilages; *H*, hyomandibular; *K*, hyoid arch; *a* to *e*, branchial arches, between which the gill-clefts (*I* to *V*) are seen; *S*, spiracle; *C*, notochord; *W, W*, vertebrae; *V*, trigeminal nerve, and 1, 2, 3, its three main divisions; *Rp¹*, its palatine branch; *VII*, facial nerve; *Rp*, its palatine branch; *IX*, glossopharyngeal; *X*, vagus.

everything goes to prove that formerly a time existed in which all the visceral arches must have borne gills, and in the embryos of Elasmobranchs they even still do so.

Originally unsegmented in most cases, the individual arches may become broken up into different (as many as four) pieces, of

which the uppermost becomes inserted under the base of the skull, while the lowermost comes to lie ventrally, and is connected with its fellow by a median piece, or basi-branchial (Fig. 45, 1 to 4, *Cp*).

The two anterior visceral arches also undergo a segmentation. Thus the first becomes divided into a short proximal piece, the quadrate, and into a long distal Meckel's cartilage (Fig. 46, *Qu*, *M*). The quadrate grows out anteriorly into a process, the palatoquadrate or palatopterygoid (Figs. 47 and 48, A to C, *PQ*), which becomes fixed to the base of the skull, and thus forms a sort of primary upper jaw.

The quadrate, which serves as a support (suspensorium) for the lower jaw, either remains separated from the skull by an articulation, that is, is only united to it by connective-tissue, or it forms one mass with it.

The hyoid arch,—which always stands in close relations to the mandibular, and may also take part in its suspensorial apparatus,¹

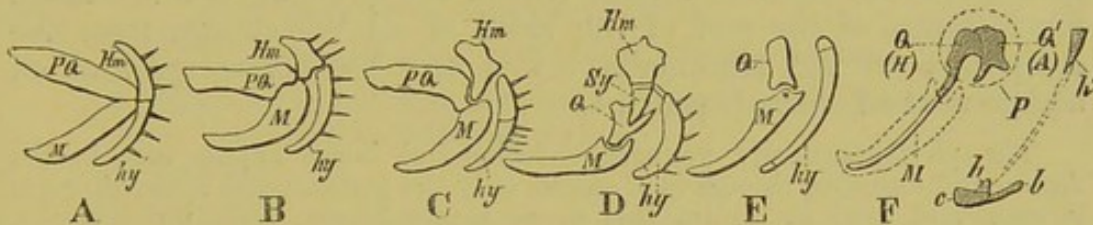


FIG. 48.—SEMI-DIAGRAMMATIC FIGURES OF THE SUSPENSORIAL APPARATUS IN VARIOUS VERTEBRATES. (Mainly after Gegenbaur.) A, NOTIDANUS; B, OTHER ELASMOBRANCHS; C, TORPEDO; D, TELEOSTEANS; E, AMPHIBIANS, REPTILES, AND BIRDS; F, MAMMALS.

M, Meckel's cartilage; *PQ*, palato-quadrate; *Hm*, hyomandibular; *hy*, hyoid arch; *Sy*, symplectic; *Q* (in D and E), quadrate; *Q* (in F), articular (malleus), and *Q'*, quadrate (incus), both of which lie in the tympanic cavity (*P*); *h'*, styloid process, connected with the anterior (lesser) corner of the hyoid (*h*) by the stylohyoid ligament, indicated by the dotted lines; *b*, the posterior (greater) cornu, and *c*, the body of the hyoid in Mammals.

—becomes divided, as do the true branchial arches, into a great number of pieces (Fishes), which are distinguished from above downwards as hyomandibular, symplectic, and hyoid in a narrower sense (Fig. 48, A to D, *Hm*, *Sy*, *hy*). In the mid-ventral line there is a basi-hyal connecting the arch of each side, and this becomes ossified, and is embedded in the tongue as the entoglossal or glossohyal.

c. The Bones of the Skull.

Two kinds of bone, genetically distinct, may be distinguished, one arising within cartilage, the other in connective-tissue, in those

¹ According to Dohrn, Meckel's cartilage and the palatopterygoid are separate in origin, as are also the hyomandibular and hyoid proper, and thus the so-called mandibular and hyoid arches each represents two.

regions of the skull which are only membranous.¹ Again in other cases, true bones are not formed at all, there being only a calcareous incrustation of the cartilage (calcified cartilage).

The bones arising in the membranous regions of the skull come under the category of the dermal skeleton and, as already mentioned with regard to the latter, are to be looked upon as originating genetically (Amphibia, Fishes) or phylogenetically (Amniota) in connection with **tooth-structures**. In this manner, the bones of the mouth-cavity of Fishes and Amphibians, for instance, still arise, and this will not surprise us when we remember that the epithelium of the oral cavity is formed by invagination of the outer skin.

This mode of origin of the first skull-bones appears to be the oldest or most primitive, and it is most apparent in the lower Vertebrates (Fishes). This holds good also for those cases in which bones are formed merely by deposition of calcareous matter directly in the connective-tissue layer, without giving rise to tooth-structures (*e.g.* in all investing bones,—those, for instance, of the roof of the skull of all Vertebrates from the Amphibia to the Mammalia): this may be looked upon as an abbreviated development.

The phylogenetically younger endochondral bones appear first in the Anura and onwards, though in Urodeles only the perichondral mode of origin is seen, and even in Anura this mode occurs largely. Not unfrequently, endochondral bones and investing bones come into apposition, and fuse together. Thus it may happen that in the course of generations an investing bone may take the place of a cartilage bone, and the formation of cartilage be entirely suppressed, and not repeated again ontogenetically.

The following lists give a summary of the most important bones according to their different relations to the skull.

I. Bones of the Mouth Cavity (partly lying within it, partly bounding it on the outer side).

INVESTING BONES.	}	1. Parasphenoid.
		2. Vomer.
		3. Premaxilla.
		4. Maxilla.
		5. Jugal.
		6. Quadratojugal (in part).
		7. Dentary.
		8. Splenial.
		9. Angular.
		10. Supra-angular.
		11. Coronoid.
		12. Palatine.
		13. Pterygoid.

¹ The different varieties of ossification may be conveniently classified as follows :—
I. Membrane Bones. (*a*) Dermostoses—ossifications of the derma; (*b*) Parostoses—ossifications of the looser subcutaneous tissue; (*c*) Ectostoses—ossifications of the inner layer of the fibrous investment (perichondrium) of a tract of cartilage: these may extend into the latter, replacing it, and thus give rise to

II. Cartilage Bones, which may, however, also be formed independently, a bony deposit taking place within the cartilage itself (endostosis).

II. **Bones of the Outer Surface** (enumerated from before backwards).

INVESTING BONES.	{	1. Premaxilla.
		2. Maxilla.
		3. Nasal.
		4. Lacrymal.
		5. Frontal.
		6. Prefrontal (of Reptiles).
		7. Postfrontal or postorbital.
		8. Supraorbital.
		9. Parietal.
		10. Temporal or squamosal.
		11. Supraoccipital (in part).

III. **Cartilage Bones.**

- | | |
|--|--|
| 1. Basioccipital | } Present only in Amniota (forming the base of the skull). |
| 2. Basisphenoid | |
| 3. Presphenoid | |
| 4. Exoccipital (supraoccipital, in part). | |
| 5. Pro-, epi-, and opisthotic, also sphenotic and pterotic (in Teleostei),
(forming the bony auditory capsule). | |
| 6. Orbito- | } sphenoid, developed in the trabecular region. |
| 7. Ali- | |
| 8. Ethmoid, together with the rest of the cartilaginous skeleton of the nose (septum, turbinals, &c.). | |
| 9. Quadrate. | |
| 10. Articular. | |
| 11. Visceral skeleton (in part). | |

ANATOMY OF THE SKULL.

SPECIAL PART.

A. **Fishes.**

The skulls of Fishes vary so greatly in their details that only a general outline can be given here.

In the suctorial Fishes, or Cyclostomes, the skull is developed essentially in the manner described already for all Vertebrates. Later, however, the form of the skull shows so many peculiarities, probably in consequence of the suctorial (Petromyzon) or parasitic (Myxine) mode of life of these animals, that it becomes quite abnormal. The most important peculiarity is the absence of proper jaws such as those of other Vertebrates; for this reason these Fishes are called **Cyclostomata** to distinguish them from the other Vertebrates or **Gnathostomata**. Their visceral skeleton, consisting of a delicate cartilaginous basketwork, also shows many peculiarities (Fig. 49), such as, for instance, its very superficial position; we may accordingly speak of these cartilages as "extra-branchials."

The skull of Elasmobranchs presents the simplest conditions and most easily comprehensible relations, so that it may be taken as the starting-point for the study of the skull of all other Vertebrates. It consists of a simple cartilaginous and fibrous

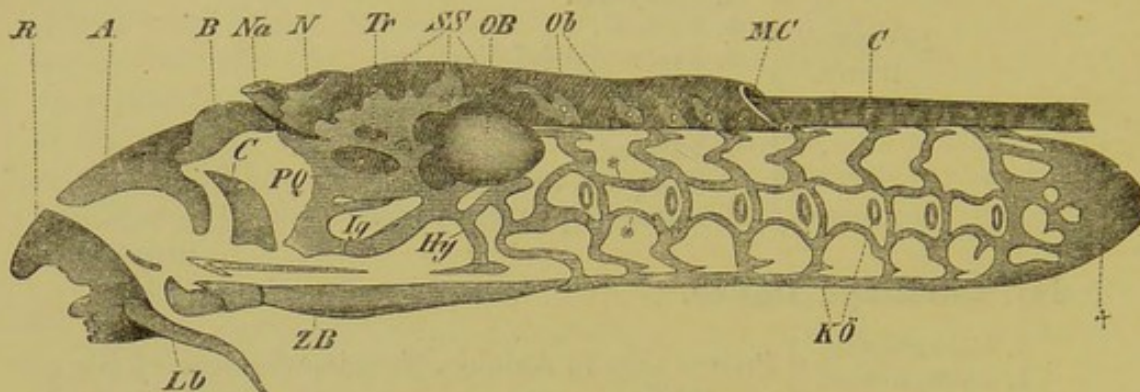


FIG. 49.—SKULL AND BRANCHIAL BASKET OF *Petromyzon planeri*.

Lb, labial cartilage; *R*, cartilaginous ring-shaped support of the suctorial mouth; *A*, *B*, *C*, three other supporting plates of the suctorial mouth; *ZB*, lingual cartilage; *Na*, external nostril; *N*, nasal sac; *Tr*, trabeculae; *PQ*, palatoquadrate; *SS*, fibrous cranial tube, which is cut through behind at *MC* (medullary canal); *OB*, auditory capsule; *Hy*, hyoid; *Kō*, gill-openings; †, posterior (pericardial) cartilage of the branchial basket; *, *, transverse bars of the branchial basket; *C*, notochord.

capsule either immovably united with the vertebral column (*Squalidæ*) or connected with it by articulations (*Rays* and *Chimærae*).

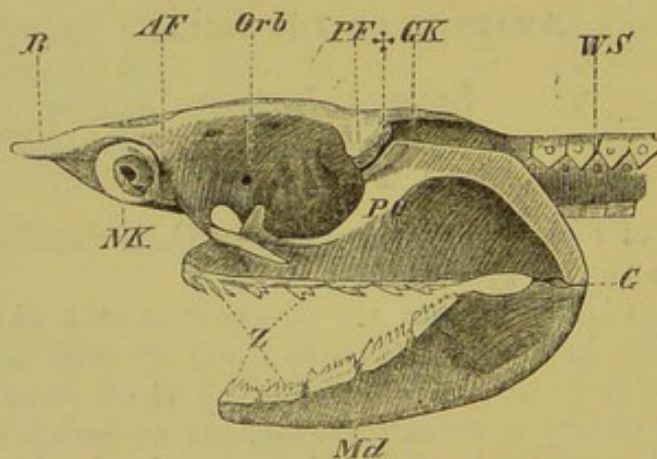


FIG. 50.—SKULL OF *Heptanchus*.

WS, vertebral column; *GK*, auditory capsule; *PF*, *AF*, postorbital and ant-orbital processes; *Orb*, orbit; *R*, rostrum; *NK*, nasal capsule; †, region of articulation of the palatoquadrate (*PQ*) with the skull; *G*, articulation of lower jaw; *Md*, mandible; *Z*, teeth.

True bones are never developed, the cartilage being merely calcified; the palatoquadrate and the lower jaw are nevertheless richly provided with teeth (Fig. 50, *Z*).

The olfactory sacs lie in the ventro-lateral parts of the nasal region, which is often elongated to form a long cut-water or rostrum (intertrabecula). Behind this are seen the deep orbital hollows (Figs. 50 and 51), which are bounded posteriorly by the strongly projecting auditory regions (*GK*).

The palatoquadrate is usually only united to the basis cranii by ligaments, but in the *Chimæra* it becomes immovably fused with it, whence their name of *Holocephali*. In some forms, the palatoquadrate is not directly united to the skull, but is suspended from it by the upper segment of the hyoid arch or hyomandibular (Fig. 51, *Hm*). In this case the skull may be described as *hyostylic*, to distinguish it from *autostylic* skulls, in which the hyoid takes no part in the suspensorium. A cleft, the spiracle, lies on the anterior border of the hyomandibular, and leads into the cavity of the mouth, and on its walls may be found remnants of the embryonic spiracular (mandibular) gill.

The branchial skeleton is always richly developed, owing to secondary segmentation and fusion of its parts, and exhibits characteristic modifications. On the outer circumference of each branchial arch radially-arranged cartilaginous rays are developed,

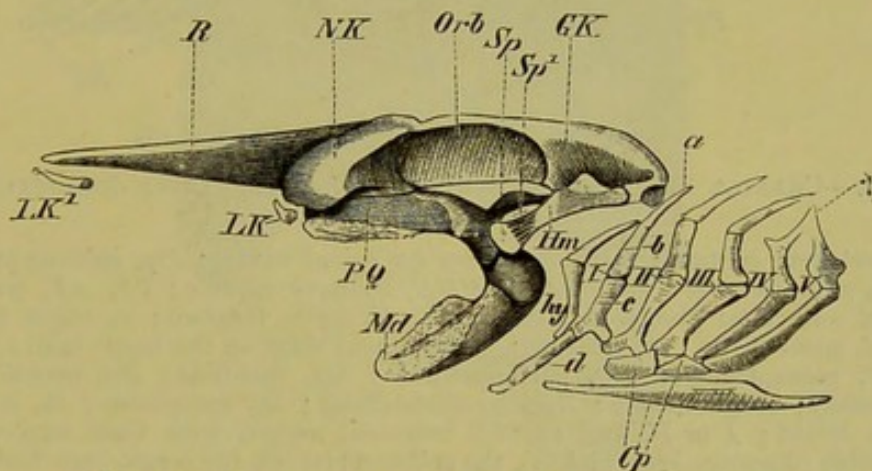


FIG. 51.—CRANIAL SKELETON OF *Raja oxyrinchus*.

GK, auditory capsule; *Orb*, orbit; *NK*, nasal capsule; *R*, rostrum; *LK*, *LK*¹, labial cartilages; *Sp*, spiracular cartilage; *SP*¹, spiracle; *PQ*, palatoquadrate; *Md*, mandible; *Hm*, hyomandibular; *hy*, hyoid; *I* to *V*, first to fifth branchial arches; *a*, *b*, *c*, *d*, the individual segments of the branchial arches, viz. the pharyngo-, epi-, cerato-, and hypobranchials; †, point of union of the fourth and fifth branchial arches; *Cp*, basibranchials.

which serve as supports for the gill-sacs. They are present also on the hyomandibular and hyoid, and rudiments of mandibular rays are present in Sharks.

While in *Elasmobranchs* the gill-slits open freely on to the surface of the body, in *Chimæra* a fold of skin arising from the hinder border of the hyomandibular, lies over them. This is the first indication of a gill-cover or operculum, such as we shall meet with again in *Teleosteans* and *Ganoids*.

Amongst the Ganoids, the lowest condition is met with in those forms in which the hyaline primordial skull, immovably fixed to the vertebral column, is still retained. These forms are spoken of as Cartilaginous Ganoids. The appearance of definite bones, however, divides them sharply off from the Elasmobranchs, and proves their skull to be at a much higher stage of development. These bones have the form of richly sculptured plates and shields, and are developed partly from the mucous membrane of the mouth (as for instance the parasphenoid, which lies along the base of the skull), and partly from the outer skin (compare the chapter on the dermal skeleton, p. 32).

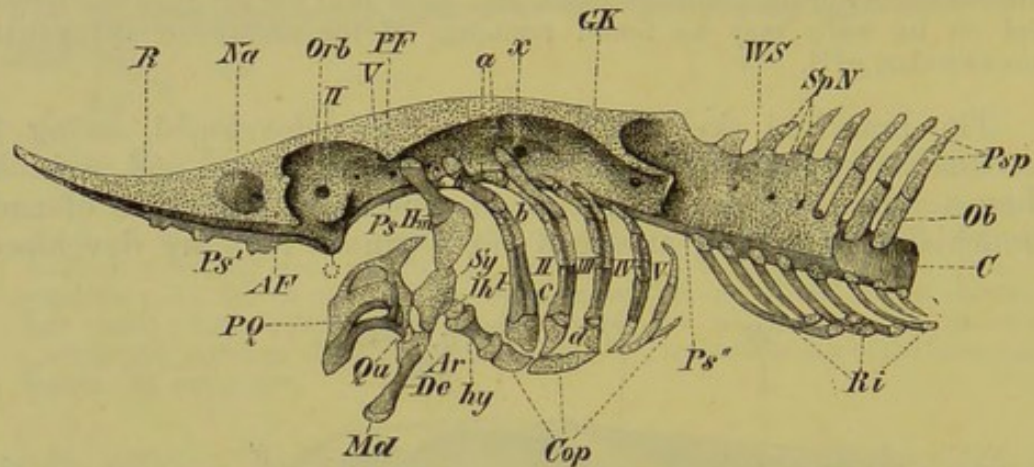


FIG. 52.—CRANIAL SKELETON OF STURGEON (*Acipenser*) AFTER REMOVAL OF THE EXOSKELETAL PARTS.

WS, vertebral column; *SpN*, apertures for spinal nerves; *Psp*, spinous processes; *Ob*, neural arches; *C*, notochord; *GK*, auditory capsule; *PP*, *AE'*, postorbital and antorbital processes; *Orb*, orbit; *II*, optic foramen; *x*, vagus foramen; *Na*, nasal cavity; *R*, rostrum; *, prominent ridge on the basis cranii; *Ps*, *Ps'*, *Ps''*, parasphenoid; *PQ*, palatoquadrate; *Qu*, quadrate; *Md*, mandible; *De*, dentary; *Ar*, articular; *Hm*, hyomandibular; *Sy*, symplectic; *Ih*, interhyal; *hy*, hyoid; *I* to *V*, first to fifth branchial arches, with their segments—the double pharyngo-branchial (*a*), the epibranchial (*b*), the cerato-branchial (*c*), and the hypobranchial (*d*); *Cop*, basal elements of the visceral skeleton; *Ri*, ribs.

This dermal skeleton attains to a much more considerable development in a second group of these Fishes—the bony Ganoids—and gives rise to a strong armour composed of numerous pieces lying on the roof of the skull (Fig. 53). The ossifications are not restricted to the outer surface, but extend into all parts of the skull, as, for instance, the trabecular regions and the lower jaw; the cartilage thus becomes greatly reduced.

The branchial skeleton in Ganoids consists of four or five more or less strongly ossified gill-arches, decreasing in size antero-posteriorly. In bony Ganoids the surface which looks towards the throat is beset with teeth. A gill-cover, often supported by several bony pieces, is always present.

In the form of their skull, the Dipnoi show many points of connection with Elasmobranchs, Ganoids, Teleosteans, and Urodeles.

In other points, however, they differ considerably from all these; and it is clear that the last-named group cannot have been directly derived from them. The suspensorium, as well as the very massive palatoquadrate bar, fuses with the skull, and, as in *Amia calva* (a

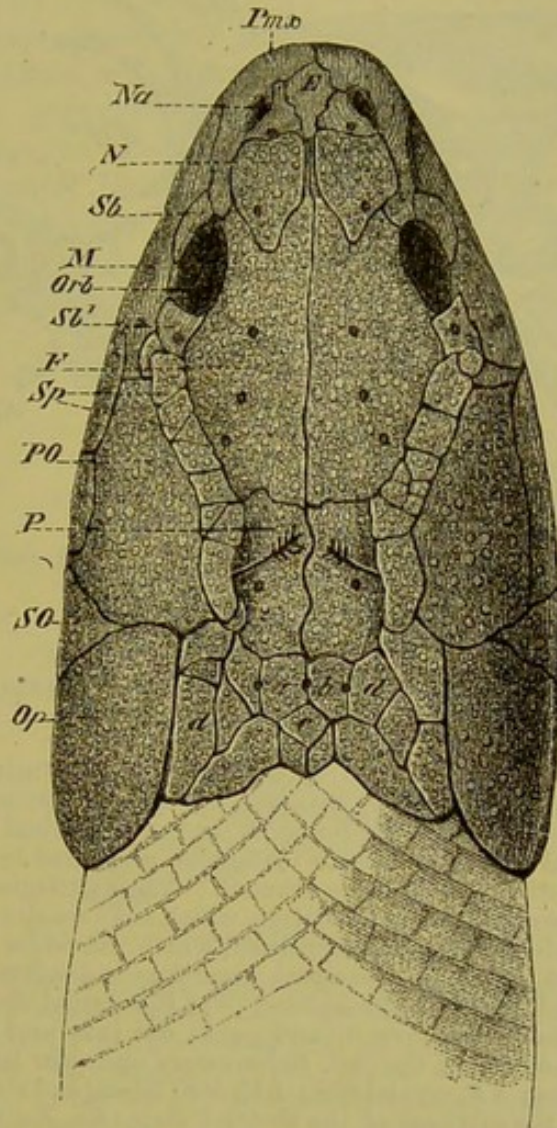


FIG. 53.—SKULL OF *Polypterus bichir* FROM THE DORSAL SIDE.

Pmx, premaxilla; *Nz*, external nostril; *N*, nasal; *Sb*, *Sb*¹, anterior and posterior suborbital; *Orb*, orbit; *M*, maxilla; *Sp*, spiracular bones; *PO*, preoperculum (?); *SO*, suboperculum; *Op*, operculum; *F*, frontal; *P*, parietal; *a*, *b*, *c*, *d*, supra-occipital shields. The two arrows pointing downwards under the spiracular shields show the position of the openings of the spiracles on to the outer surface of the skull.

bony Ganoid), even some of the anterior vertebræ with distinct neural arches and transverse processes are united with the occipital region of the cranium (Fig. 54, *W*, *W*¹). (Cp. note on p. 56.)

Posterior in addition to anterior nasal apertures appear in the Dipnoi for the first time: this is an indication of air-breathing.

Cranial bones are not nearly so numerous as in Ganoids, and

the underlying hyaline primordial skull persists entirely (*Ceratodus*), or to a large extent. Gill-covers and branchiostegal rays

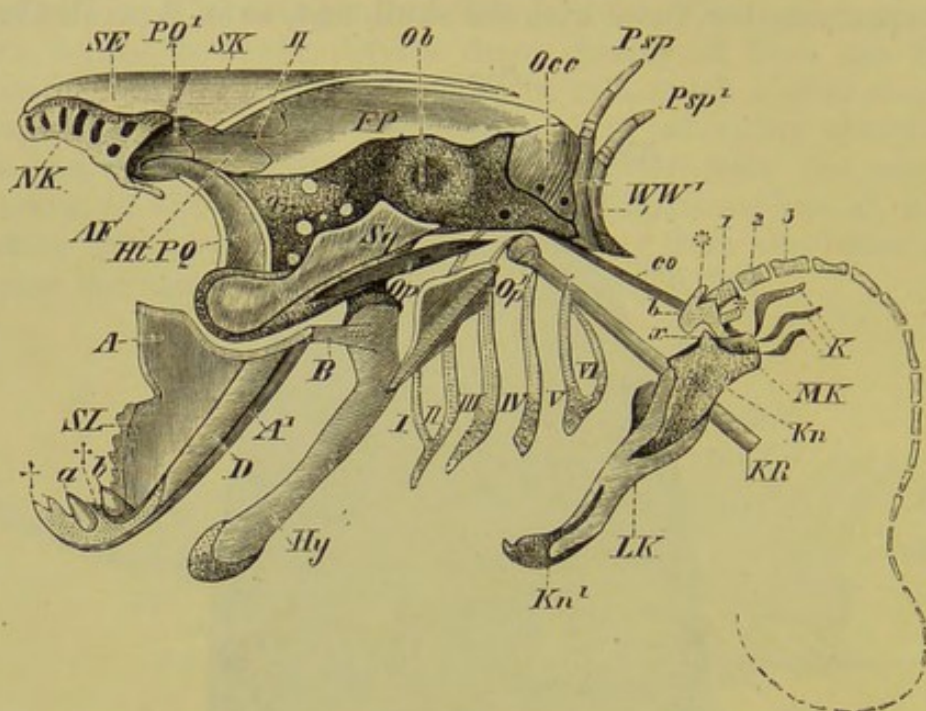


FIG. 54.—CRANIAL SKELETON, PECTORAL ARCH, AND ANTERIOR EXTREMITY OF *Protopterus*.

*W, W*¹, the vertebrae which are fused with the skull, with their spinous processes (*Psp, Psp*¹); *Occ*, supraoccipital, with the hypoglossal foramina; *Ob*, auditory capsule; *Tr*, trabecula, with the foramina for the trigeminal and facial nerves; *FP*, fronto-parietal; *Ht*, membranous fontanelle, perforated by the optic foramen (*II*); *SK*, supra-orbital; *SE*, supra-ethmoid; *NK*, cartilaginous nasal capsule; *AF*, antorbital process (the labial cartilage, which has a similar position and direction, is not indicated); *PQ*, palatoquadrate, which converges towards its fellow of the other side at *PQ*¹; *Sq*, squamosal, covering the quadrate; *A, A*¹, articular joined to the hyoid (*Hy*) by a fibrous band (*B*); *D*, external dentary; ††, Meckel's cartilage, which is freely exposed, and grows out into prominences; *SL*, enamelled ridge; *a, b*, teeth; *Op, Op*¹, rudimentary opercular bones; *I to VI*, the six branchial arches; *KR*, cranial ribs; *LK, MK*, lateral and median bony lamellae, which ensheathe the cartilage of the pectoral arch (*Kn, Kn*¹); *co*, fibrous band, which binds the upper end of the pectoral arch with the skull; *x*, articular head of the pectoral arch, with which the basal segment (*b*) of the free extremity articulates; *,*, rudimentary lateral rays of the extremity (biserial type); 1, 2, 3, the three next segments of the free extremity.

are present, though greatly reduced, and even the five or six cartilaginous gill-arches are in a very rudimentary condition. The sharp, blade-like teeth, covered with enamel, deserve notice.

Teleostei.—In this group, the skull presents a large amount of variation; its ground-plan, however, may always be derived from that of the bony Ganoids, and more particularly from *Amia calva*. On the other hand, no relations with the Amphibia are observable, and we must consider the whole group of the bony Fishes as a side branch of the piscine phylum.

Much of the cartilaginous primordial skull persists in most Teleostei; the cranial cavity, in all skulls described up to the present time, may either reach between the eyes as far as the ethmoidal region, or it may become narrowed and arrested in the orbital region (Fig. 43, C).

The palatoquadrate bar becomes differentiated into a perfect row of bony plates, which are described as quadrate, meso- and metapterygoid, pterygoid, and palatine. In the occipital and auditory regions, as well as on the dorsal surface of the skull, numerous groups of bone are developed, which cannot be further described here. A canal, lying in the axis of the base of the skull of many Teleosteans, must be mentioned: it encloses the eye-muscles, and opens on each side into the orbits.

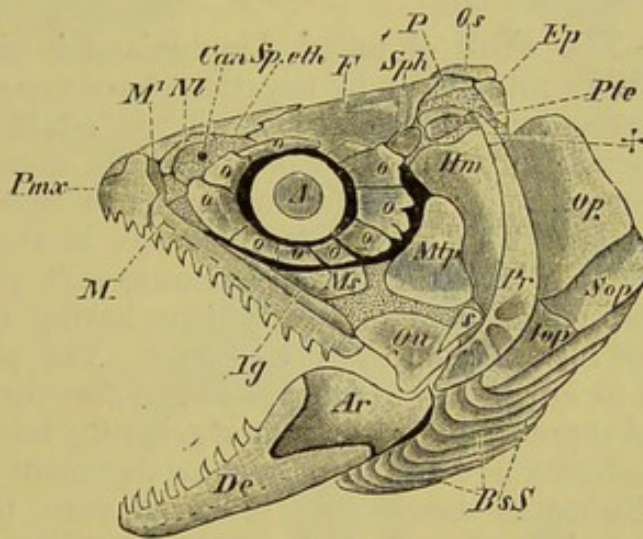


FIG. 55.—CRANIAL SKELETON OF TROUT.

Ep, epiotic; *Pte*, pterotic; *Sph*, sphenotic; *Os*, supraoccipital; *P*, parietal; *F*, frontal; *Sp. eth*, supra-ethmoid; *Can*, aperture of the canal for the olfactory nerve; *Nl*, nasal; *Pmx*, premaxilla; *M*, *M*¹, maxilla; *Ig*, jugal; *Ms*, meso-ptyerygoid; *Mtp*, metapterygoid; *ooo*, orbital ring; *Hm*, hyomandibular; *s*, symplectic; *Qu*, quadrate; *Pr*, preoperculum; *Iop*, interoperculum; *Sop*, suboperculum; *Op*, operculum; *BsS*, branchiostegal rays; *Ar*, articular; *De*, dentary; *A*, eye.

All the bones bounding the oral cavity, viz., the vomer, the parasphenoid, the premaxilla, and the maxilla, may bear teeth. The maxilla, however, is usually edentulous, and both it and the premaxilla vary much as to their development: the latter may even be absent.

Besides the above-mentioned palatoquadrate bar, the proper cranial capsule of Teleosteans is surrounded by other outworks consisting of plates and bars. These arise as dermal bones in the region of the eyes (orbital ring) (Fig. 55, *ooo*), and in the gill-covers (opercular bones) (Fig. 55, *Pr*, *Op*, *Sop*, *Iop*). A large number of branchiostegal rays are developed in the ventral parts of the opercular fold, or branchiostegal membrane (Fig. 55, *BsS*).

Anteriorly, the opercular apparatus lies against a bony chain consisting of three pieces—the hyomandibular, symplectic, and quadrate—which serves as a suspensorial apparatus for the lower jaw (Fig. 55, *Hm*, *S*, *Qu*, and Fig. 48, *D*). The latter consists of Meckel's cartilage and of several bony elements, the largest of which is called the dentary (Fig. 55, *De*). The others are the articular (Fig. 55, *Ar*), angular, and coronoid. The last, however, is as a rule absent, and the angular may also be wanting.

A curious asymmetry is seen in the head of adult Pleuronectidæ. When hatched, these Fishes are quite symmetrical, but later on the eye of one side becomes rotated, so that eventually both eyes come to lie on the same side; in consequence of this, the skull also becomes asymmetrical.

B. Amphibia.

Urodela.—The skull of tailed Amphibians is distinguished from that of Fishes principally by negative characters,—on the one hand by the presence of less cartilage in the adult, and on the other by a reduction in the number of bones. In short, it presents altogether a much simpler plan, reminding us of that of Ganoids and Elasmobranchs. This is seen, for instance, in the larval condition (Fig. 56), in which the chondrocranium still plays a great part, its auditory, nasal, and orbital regions having the relations described in the introduction to this chapter. The auditory capsules (Figs. 56 to 58, *OB*),—which are bound together by cartilaginous basi- and supraoccipital tracts,¹ and generally become strongly ossified later,—show a new and important arrangement as compared with those of Fishes in the presence of an aperture, the fenestra ovalis, which looks outwards and downwards (Figs. 56 and 58, *Fov*). This fenestra is closed by a cartilaginous or bony plug, the stapes, and will be spoken of again in connection with the anatomy of the auditory organ.

In all Amphibians two condyles for articulation with the first vertebra are developed on the ventral periphery of the foramen magnum (Figs. 56 to 58, *Coc*).

The large nasal capsules, consisting throughout life of considerable cartilaginous tracts (Fig. 57, *Na*), are connected with the auditory capsules by means of the trabeculæ,² which form the side walls of the skull, and enclose a large cavity. This cranial cavity becomes closed dorsally by the frontals and parietals (Fig. 57, *F*, *P*), and ventrally by the parasphenoid (Figs. 56 and 58, *Ps*), which is sometimes provided with teeth similar to those of many Teleostei. In front of it lie the vomers (Figs. 56 and 58, *Vo*), which bound the posterior nostrils, and in adults each

¹ There are never more than rudiments of a supra- and basioccipital in Anura, and not even rudiments of these bones in Urodeles.

² The trabeculæ become more or less entirely ossified as the sphenethmoid and prootics.

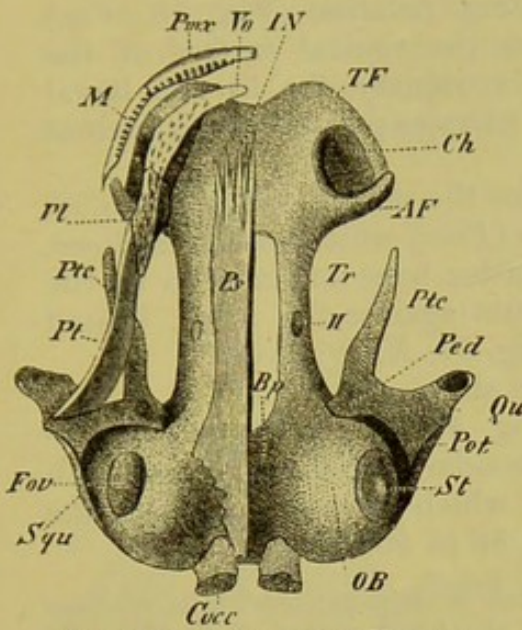


FIG. 56.—SKULL OF A YOUNG AXOLOTL. (Ventral view.)

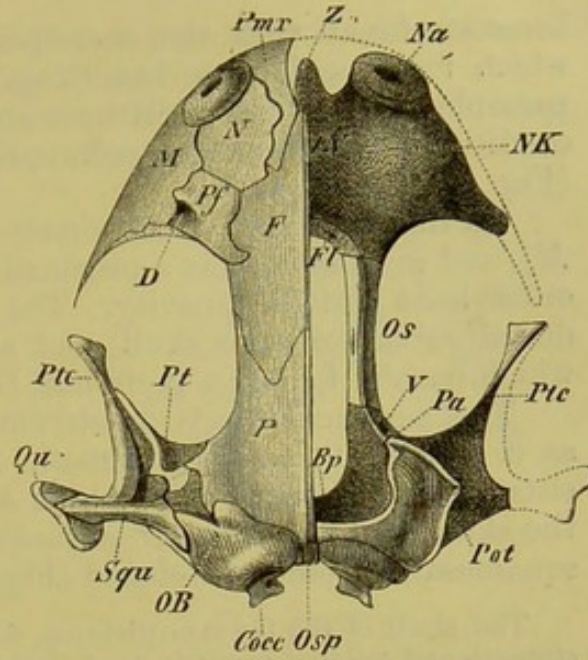


FIG. 57.—SKULL OF *Salamandra atra* (ADULT.) (Dorsal view.)

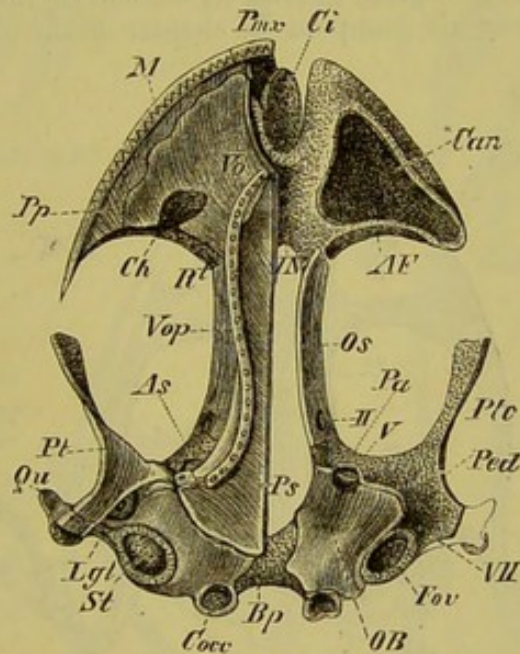


FIG. 58.—SKULL OF *Salamandra atra* (ADULT). (Ventral view.)

Tr, trabecula; *OB*, auditory capsule; *Fov*, fenestra ovalis, closed on one side by the stapes (*St*); *Lgt*, ligament between the stapes and suspensorium; *Cocc*, occipital condyles; *Bp*, cartilaginous basilar plate between the auditory capsules; *Osp*, dorsal tract of the occipital cartilage; *IN*, internasal plate, which extends laterally to form processes (*TF* and *AF*) bounding the posterior nostrils (*Ch*); *NK*, nasal capsule; *Can*, nasal cavity; *Na*, external nostrils; *Fl*, foramen for the olfactory nerve; *Z*, tongue-like outgrowth (intertrabecula) of the internasal plate, which forms a roof for the internasal cavity (Fig. 57); *Qu*, quadrate; *Ptc*, cartilaginous pterygoid; *Pot*, otic process, *ped*, pedicle, and *Pa*, ascending process, of the quadrate; *Ps*, parasphenoid; *Pt*, bony pterygoid; *Vo*, vomer; *Pl*, palatine; *Pp*, palatine process of maxilla; *Vop*, vomero-palatine; *Pmx*, premaxilla; *M*, maxilla; *Os*, sphenethmoid; *As*, prootic; *N*, nasal; *Pf*, pre-frontal, perforated at *D* for the lacrymal duct; *F*, frontal; *P*, parietal; *Squ*, squamosal; *II*, optic, *V*, trigeminal, and *VII*, facial foramen; *R'*, point of entrance of the nasal branch of the fifth nerve into the nasal capsule.

becomes fused with the corresponding palatine (Fig. 58, *Vop*) which forms a delicate bar lying on the ventral surface of the parasphenoid. These relations are secondary, for in the larval condition a typical palatoquadrate or pterygo-palatine bar is present (Fig. 56, *Pt*, *Ptc*, *Pl*).

On the outer side of the vomer lies the maxilla (Figs. 56 to 58, *M*), and in front of this a premaxilla (*Pmx*) which usually encloses, or at least bounds a cavity. The latter bone extends on to the dorsal surface of the skull, and abuts against the nasal, behind which usually follows a prefrontal (Fig. 57, *N*, *Pf*).

The suspensorium is much more simple than that of Fishes, as a glance at the diagrammatic Fig. 48, *E*, will show. It consists of the quadrate only, which secondarily becomes fused with the skull, and on the outer surface of which an investing bone, the squamosal, becomes developed (Figs. 56 to 58, *Squ*).

The skull of the Gymnophiona, which is characterised by its extreme strength and solidity, reminds us of that of the fossil genera of Amphibia of the Carboniferous period. It shows in many points a certain relationship to the skull of Anura, and is of great interest on account of the very complicated structure of the nasal capsule (compare the chapter on the olfactory organ).

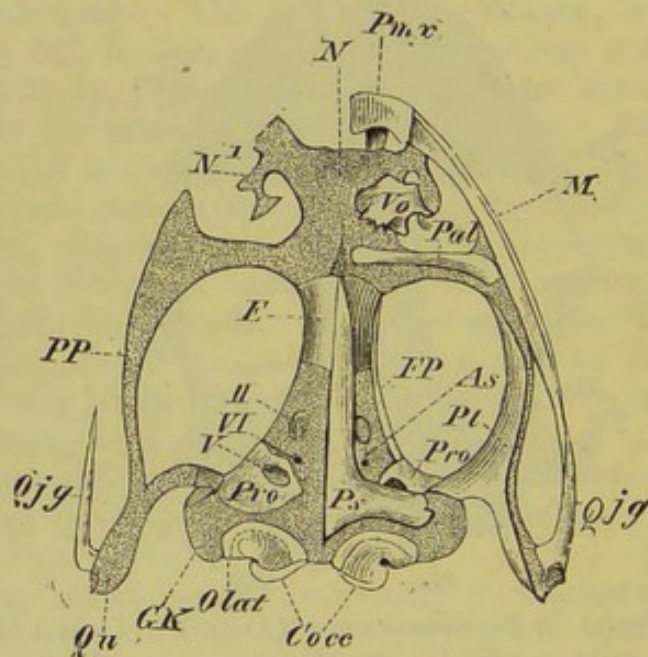


FIG. 59.—SKULL OF *Rana esculenta*. (Ventral view.) (After Ecker.)

The investing bones are removed on the right side.

Cocc, occipital condyles; *Olat*, exoccipital; *GK*, auditory capsule; *Qu*, quadrate; *Qjg*, quadratojugal; *Pro*, prootic; *Ps*, parasphenoid; *As*, alisphenoid region; *Pt*, bony pterygoid; *PP*, palatopterygoid; *FP*, frontoparietal; *E*, sphenethmoid (girdle-bone); *Pal*, palatine; *Vo*, vomer; *M*, maxilla; *Pmx*, premaxilla; *N*, *N'*, cartilaginous supports of the nose; *II*, *V*, *VI*, foramina for optic, trigeminal, and abducent nerves.

Anura.—The skull of the tailless Batrachia is at first sight very similar to that of Urodeles. It undergoes, however, an essentially different and much more complicated development, reminding

one in certain points of that of *Petromyzon*, and it cannot therefore be derived in any way directly from that of *Urodeles*.

A suctorial mouth, provided with labial cartilages and horny teeth, is present in the larva. Far more important, however, is the

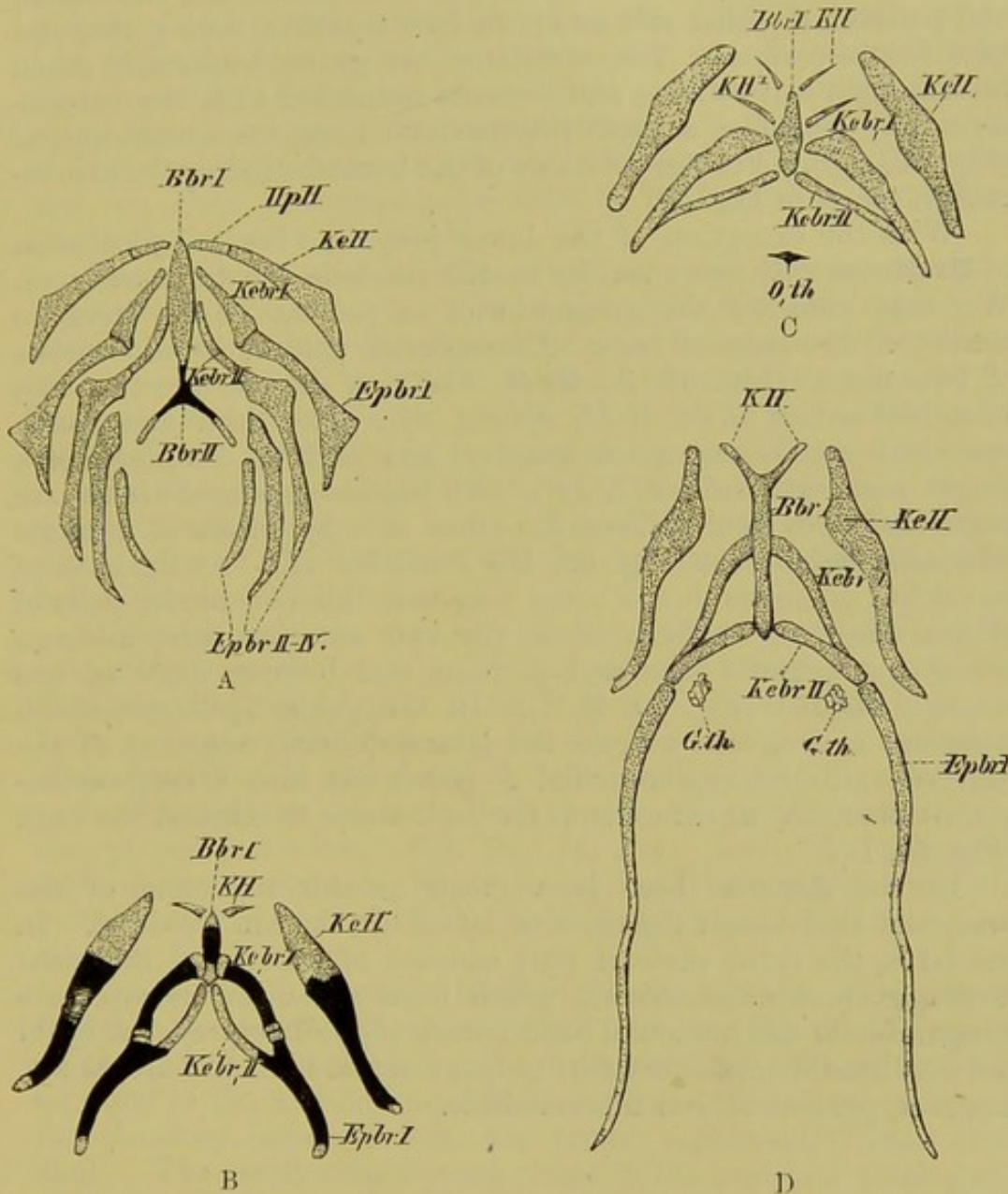


FIG. 60.—HYOBRANCHIAL APPARATUS OF URODELES. A, Axolotl (*Siredon pisciformis*); B, *Salamandra maculata*; C, *Triton cristatus*; D, *Spelerpes fuscus*.

Bbr I, II, first and second basibranchial; *KeH*, ceratohyal; *HpH*, hypohyal; *Kebr I, II*, first and second ceratobranchial; *Epbr I to IV*, first to fourth epibranchial; *KH, KH¹*, small anterior and posterior pairs of cornua; *O.th*, thyroid bone; *G.th*, thyroid gland.

formation of membranous and cartilaginous walls to the tympanic cavity, which is closed externally by a tympanic membrane, while internally it opens into the mouth by a Eustachian aperture. The palatoquadrate bar unites anteriorly with the lateral part of

the cartilaginous nasal capsule (compare the chapter on the auditory organ, p. 199).

With the exception of certain small regions on the dorsal side, the skull of *Anura* consists of a complete cartilaginous box: in the adult the bones are not so numerous as in *Urodeles*, and the frontal and parietal of either side as a rule fuse together, thus giving rise to a fronto-parietal. The maxillary bar grows backwards much further than in *Urodeles*, and becomes connected with the suspensorium by means of a small intermediate bone, the quadratojugal (Fig. 59, *Qjg*). For the relations of the bones bounding the mouth-cavity, compare Fig. 59.

With the exception of the lower jaw, the visceral skeleton of **Urodeles** undergoes various modifications in the different types. We may consider the ground-form, as present in the larva, to consist of five pairs of bars. The anterior pair, or hyoid, consists of two pieces (Fig. 60, A, *HpH*, *KeH*), as do also the two first branchial arches (*Kebr I, II*, *Epbr I, II*). The third and fourth branchial arches are much smaller, and each is composed of a single segment (*Epbr III, IV*). All the above-named arches are connected with their fellows the other side by means of a single or double basal piece (Fig. 60, *Bbr I* and *Bbr II*). At the close of larval life, when the lungs come into use, the two hinder pairs of arches disappear entirely, while the two anterior pairs undergo changes as regards form and position, and become more or less strongly ossified (Fig. 60, B, C). In the genus *Spelerpes*, which possesses a sling-like tongue, the lateral (dorsal) segment of the first true gill-arch (epibranchial *I*) grows out into a long cartilaginous filament, which extends far back under the skin of the back (Fig. 60, D).

In the **Anura** there is a much greater reduction of the branchial skeleton at the close of larval life than in *Urodeles*. In the larva, the main skeletal part consists of superficial branchial cartilages (extra-branchials), which form a continuous structure comparable to the branchial basket-work of the Lamprey. A hyoid and small rudiments of the four proper internal branchial arches are, however, present behind the mandible.

C. Reptilia.

The relationship between the skulls of Reptiles and Birds is very close, while both are widely separated from those of Amphibians and Mammals.

Excepting in the ethmoidal region, the whole chondrocranium becomes almost obliterated by an extensive process of ossification.

In Snakes, Amphisbænians, and Crocodiles, the cranial cavity extends forwards between the orbits as far as the ethmoidal region, while in Lacertilia and Chelonia—in which a fibro-cartilaginous

interorbital septum perforated by the olfactory nerve is present,—it is arrested in the orbital region (compare p. 57).

The parasphenoid, which plays so important a part as an investing bone of the roof of the mouth in Fishes and Amphibians, begins to disappear; amongst Reptiles it only attains to any important development in Snakes, where the anterior part remains, and forms the base of the interorbital region. Its place is taken by two cartilage bones, the basioccipital and basisphenoid, situated along the basis cranii. In contradistinction to the Amphibia, only a single condyle connects the skull with the vertebral column; this, on close examination, is seen to be formed of three parts (basioccipital and exoccipitals).

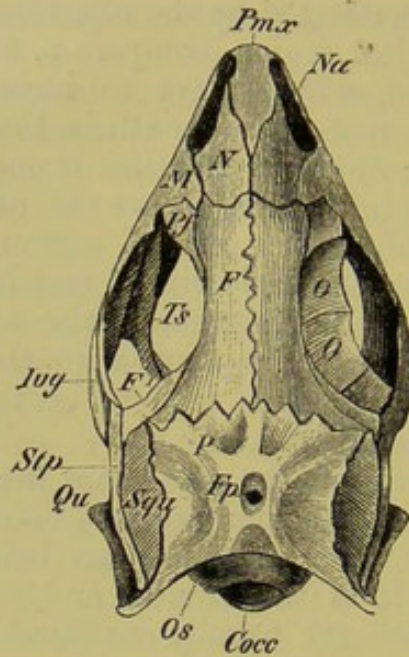
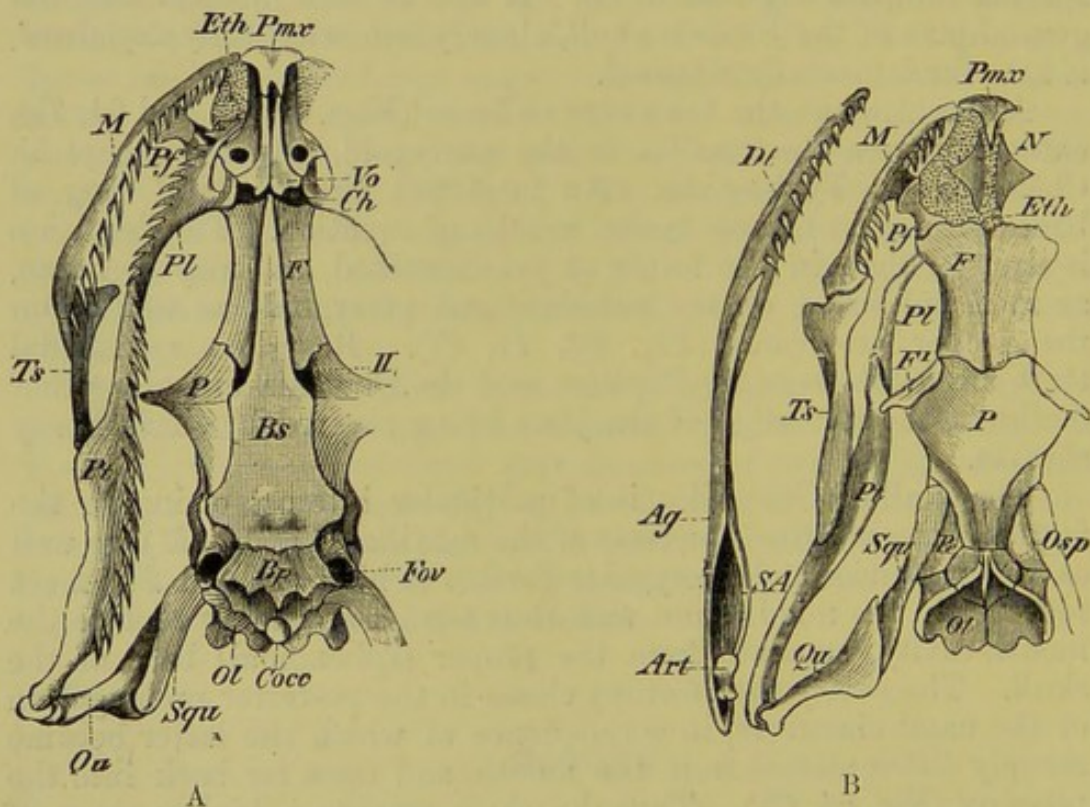
The roofing bones of the skull are well developed, as in Teleostei, while the trabecular region (ali- and orbitosphenoids) becomes of secondary importance, its place being taken by processes growing downwards from the frontal and parietal, especially in Snakes. The parietals are usually confluent in the adult, and in Lacertilia are perforated by an aperture (parietal foramen).

For the topographical relations of the several bones to one another compare Figs. 61 to 64. It will be seen in them that the ground-plan of the Urodele skull, already somewhat fully explained, is here fundamentally retained.

A new element, the transverse bone (Figs. 61, 62, and 64, *Ts*), extending from the maxilla to the pterygoid, appears, except in Chelonia and Typhlopidae. An imperfect circumorbital ring of bones present in Lizards is also worthy of mention. The dentition is stronger than in the forms as yet described, and may be borne, as in Amphibians, on the palatines and pterygoids as well as on the proper jaw-bones (Fig. 62, *Pl*, *Pt*). Rasp-like sphenoidal teeth are not present in Reptiles, and the Chelonia are altogether toothless, the free edge of the jaws being covered by sharp horny sheaths.

The skull of Crocodiles is of particular interest, owing to the fact that the palatine processes of the maxillæ (Fig. 64, *M*), as well as the palatines and pterygoids further behind (*Pl* and *Pt*), meet together in the middle line, and thus form a secondary roof to the mouth-cavity, separate from the proper (sphenoidal) base of the skull. The cavity thus formed closes in the posterior prolongation of the nasal chambers, in consequence of which the latter become sharply differentiated from the mouth, and open far back into the pharynx (Fig. 64, *Ch*). Thus the skull reaches a higher stage of development, which, only indicated in Chelonia, is characteristic of Mammals. In all Reptiles the suspensorium consists mainly of the quadrate, which may be loosely attached to the skull (Snakes,¹ Lacertilia), or firmly fixed to it (Hatteria, Chelonia,

¹ In Snakes (Fig. 62, *Qu*) (except Tortrix), the quadrate is only indirectly connected with the skull by means of the squamosal (*Squ*), which extends backwards, and thus throws the articulation of the lower jaw far backwards, giving rise to a very

FIG. 61.—SKULL OF LIZARD (*Lacerta agilis*). (Dorsal view.)FIG. 62, A and B.—SKULL OF SNAKE (*Tropidonotus natrix*).

Cocc, occipital condyle; *Os*, and *Osp*, supraoccipital; *Ol*, exoccipital; *Fov*, fenestra ovalis; *Pe*, periotic; *P*, parietal; *Fp*, parietal foramen; *F*, frontal; *F¹*, post-frontal; *Pf*, prefrontal; *Eth*, ethmoid; *N*, nasal; *Na*, external nostril; *Pmx*, premaxilla; *M*, maxilla; *O*, orbital ring; *Bp*, basioccipital; *Bs*, basiphosphoid; *Ch*, posterior nostrils; *Vo*, vomer; *Pl*, palatine; *Pt*, pterygoid; *Ts*, transverse bone; *Qu*, quadrate; *Squ*, squamosal; *Stp*, supratemporal; *Jug*, jugal; *Art*, articular; *Ag*, angular; *SA*, supra-angular; *Dt*, dentary; *II*, optic foramen.

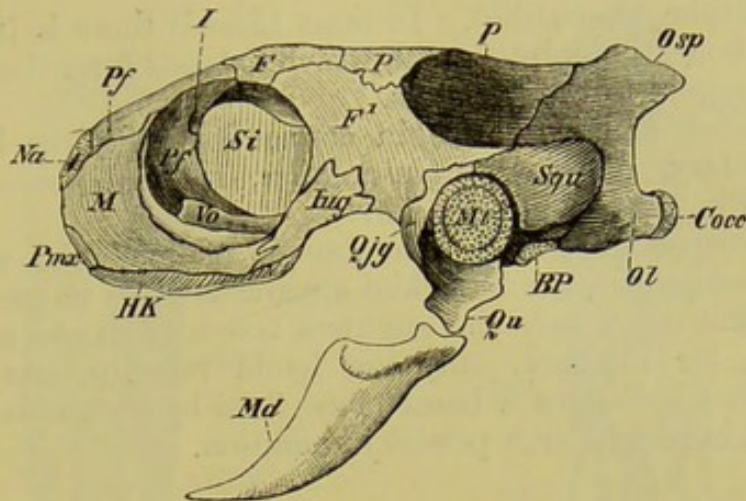


FIG. 63.—SKULL OF YOUNG WATER-TORTOISE (*Emys europæa*). (Side view.)

Osp, supraoccipital, which gives rise to a crest; *Pf*, prefrontal, which forms a great part of the anterior boundary of the orbit; *I*, point of entrance of the olfactory nerve into the nasal capsule; *Si*, interorbital septum; *HK*, horny sheaths of jaws; *Qjg*, quadratojugal; *Mt*, tympanic membrane; *BP*, cartilaginous interval between basioccipital and basisphenoid; *Md*, mandible. Other letters as before.

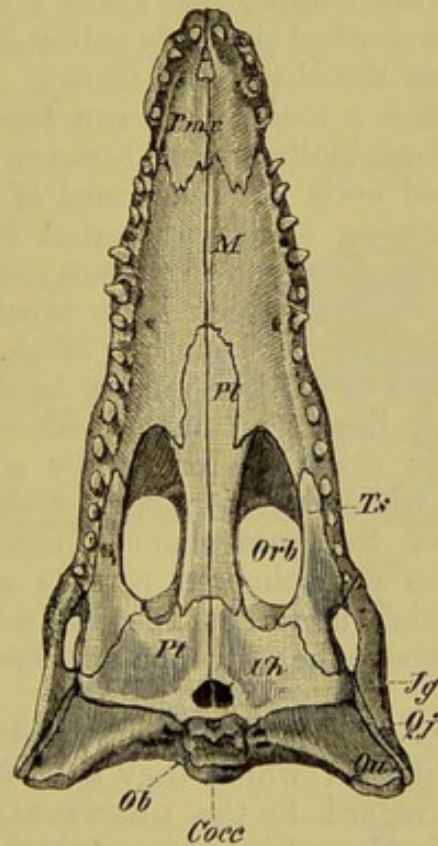


FIG. 64.—SKULL OF A YOUNG CROCODILE. (Ventral view.)

Cocc, occipital condyles; *Ob*, basioccipital; *Ch*, internal nostrils; *Pl*, pterygoid; *Orb*, orbit; *Pl*, palatine; *M*, palatine process of maxilla; *Pmx*, premaxilla; *Ts*, transverse bone; *Jg*, jugal; *Qj*, quadratojugal; *Qu*, quadrate.

Chameleontidæ, Crocodilia). In most Lizards there is in addition a rod-like bone, the epipterygoid, which extends from the hind part of the pterygoid to the parietals.

A number of bones arise in connection with the lower jaw, viz. a dentary, angular, supra-angular, splenial, coronoid, and articular (Fig. 62, *Dt*, *Ag*, *SA*, *Art*).

In correspondence with the absence of branchial respiration during development, the branchial apparatus plays no great part in Reptiles, and often only the slightest traces of it are seen: thus in Snakes, for instance, only the hyoid remains, and this not always. In Chelonians a basal piece (basi-hyo-branchial) as well as the first branchial arch persist in addition.

D. Birds.

The skull of Birds is formed on the same plan as that of Reptiles, and more particularly of Lizards, although it exhibits a greater proportional development of the brain-case (Fig. 65). The skull of Archæopteryx was essentially similar to that of existing Birds, and the bones were firmly united together. Teeth were, however, present in both upper and lower jaws, and the fact that the premaxillæ were toothed probably indicates that no horny beak was present (compare the chapter on teeth).

All the bones have a tendency to run together by the obliteration of the sutures originally present between them, and they thus give rise to a united mass largely formed of endochondral bones. It is only in the region of the nose that the cartilage persists throughout life to any extent, and even here not always. In contrast to all the Vertebrata as yet considered, the unpaired occipital condyle no longer lies at the posterior boundary of the skull, but becomes moved downwards and forwards along the base of the skull, so that the axis of the latter lies at an angle with that of the vertebral column. The basis cranii is formed by a basioccipital and a basisphenoid, from which latter a bony rostrum, the remains of the anterior part of the parasphenoid, extends forwards. The posterior part of the parasphenoid persists as a large plate, the basitemporal, which underlies the basisphenoid and part of the basioccipital. Above the rostrum a small presphenoid is present in the embryo.

All the bones are delicate and spongy, and thus contrast greatly with those of Reptiles, in which they are often of an ivory-like structure. (With regard to the pneumaticity of the bones, already referred to in Crocodiles and certain fossil Reptiles, consult

wide gape. In most Snakes, and particularly in the Viperine forms (cp. Fig. 176, A), the facial bones are capable of movement upon one another, but in Typhlops they are immovably connected with the skull. The two rami of the mandible are connected by a more or less elastic ligament.

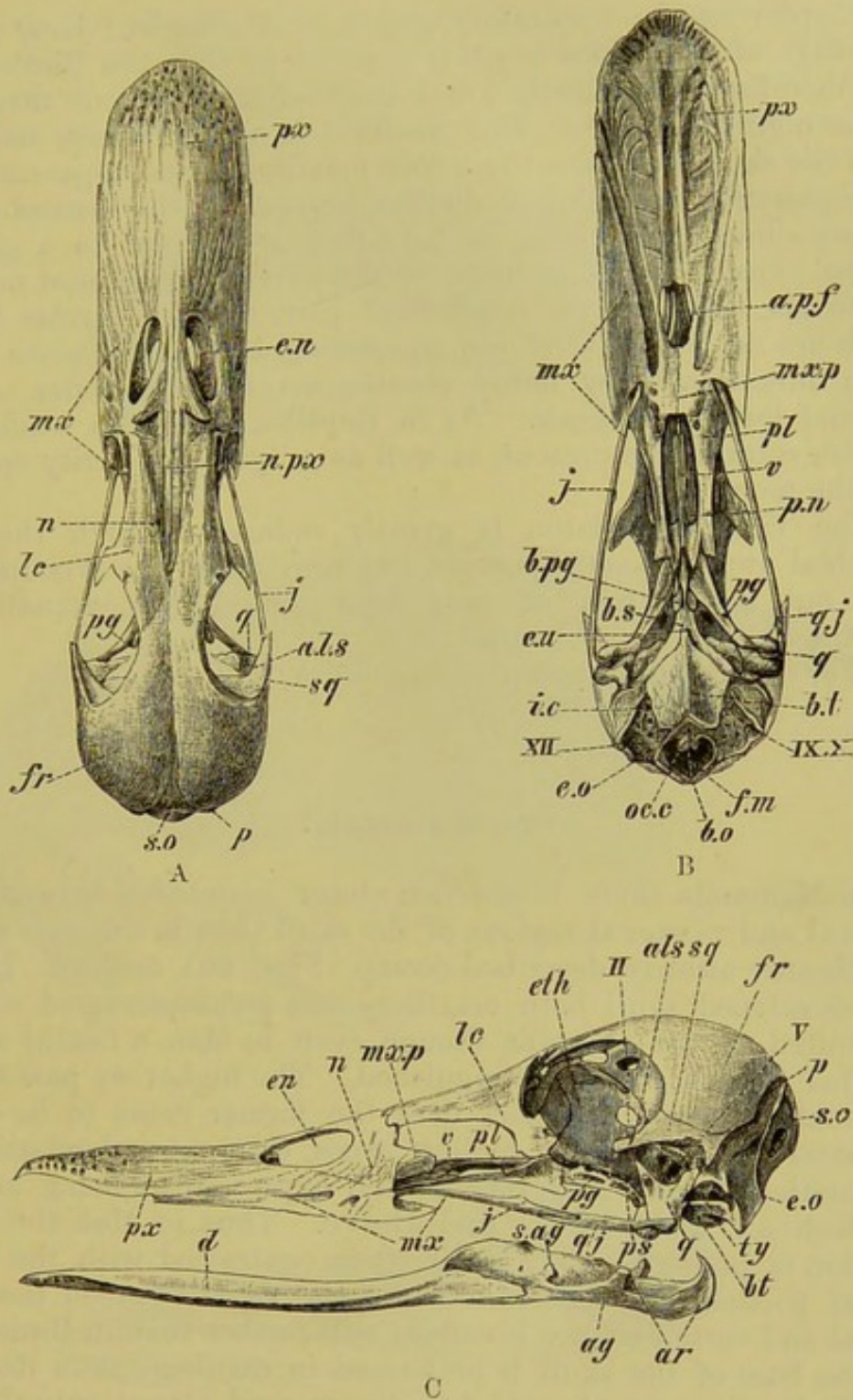


FIG. 65.—SKULL OF A WILD DUCK (*Anas boschas*). A, from above; B, from below; C, from the side.

a.l.s, alisphenoid; *ag*, angular; *ar*, articular; *a.p.f*, anterior palatine foramen; *b.t*, basitemporal; *b.o*, basioccipital; *b.pg*, basiptyergoid; *b.s*, basisphenoid; *d*, dentary; *e.n*, external nostrils; *eth*, ethmoid; *e.o*, exoccipital; *e.u*, Eustachian aperture; *fr*, frontal; *f.m*, foramen magnum; *i.c*, foramen for internal carotid artery; *j*, jugal; *lc*, lacrymal; *mx.p*, maxillopalatine process; *mx*, maxilla; *n*, nasal; *n.px*, nasal process of the premaxilla; *px*, premaxilla; *p*, parietal; *ps*, presphenoid; *pg*, pterygoid; *pl*, palatine; *p.n*, internal nostrils; *q*, quadrate; *q.j*, quadratejugal; *sq*, squamosal; *s.o*, supraoccipital; *ty*, tympanic cavity; *v*, vomer; *II*, foramen for optic nerve; *V*, for trigeminal; *IX*, *X*, for glossopharyngeal and vagus; *XII*, for hypoglossal.

the chapter on the respiratory system.)¹ A complete bony palate like that of Crocodiles is never present; so that the Bird's skull here manifests a decidedly lower stage of development than that of the higher Reptiles. The quadrate is nearly always movable upon the skull, as is also the whole maxillopalatine apparatus, the palatopterygoid bar sliding on the rostrum of the basisphenoid, and so allowing the beak to be raised or lowered to a greater or less extent. This mobility of the upper jaw is most marked in Parrots, in which the frontonasal joint forms a regular hinge. Teeth are no longer developed in existing Birds, their place being taken functionally by horny sheaths covering the bones of the jaw, and forming a beak. As in Reptiles, a fenestra ovalis and fenestra rotunda are present, as well as a tympanic cavity opening into the mouth.

The visceral skeleton is greatly reduced, though the first branchial arch not only persists, but may, as in the Woodpecker, grow out into a pair of very long jointed rods extending far over the skull.

(For other details, compare Fig. 65, A, B, C.)

E. Mammals.

In Mammals there is a much closer connection between the cranial and visceral regions of the skull than is the case in the Vertebrates already described (comp. Figs. 66A and B). In the fully-developed skull both maxillary and palatopterygoid regions are united to the cranium, though even in Man a facial and a cranial region can be distinguished. The higher we pass in the Mammalian series, the more does the former come to lie below the latter; so that, in the highest types, their mutual relations to one another can no longer be so well expressed as being before and behind, as by under and above. Thus in Man the facial skeleton is proportionately small when contrasted with the great cranial portion, and the reduction of the angle between the basi-cranial and vertebral axes is carried still further than in Birds.

The base of the skull is preformed in cartilage, as in Reptiles and Birds: the parasphenoid has disappeared almost entirely, the anterior part of the basis cranii being formed by the ossification of the basal cartilage, which may be distinct, as a presphenoid (Marsupials, Rodents, and some Insectivores), or result from a union of the basal parts of the two orbito-sphenoids: a basi-sphenoid and basioccipital are always present. Most of the bones of the roof of the skull are developed directly in the subcutaneous fibrous membrane.

The cranial cavity is closed in anteriorly by the cribriform plate of the ethmoid, which is perforated by the olfactory nerves.

Turbinals are present in the nasal cavity, but are never more than rudimentary in Cetacea. For further details as to the olfactory and auditory capsules and their mode of ossification, as well as the formation of the auditory ossicles, consult the chapters on the

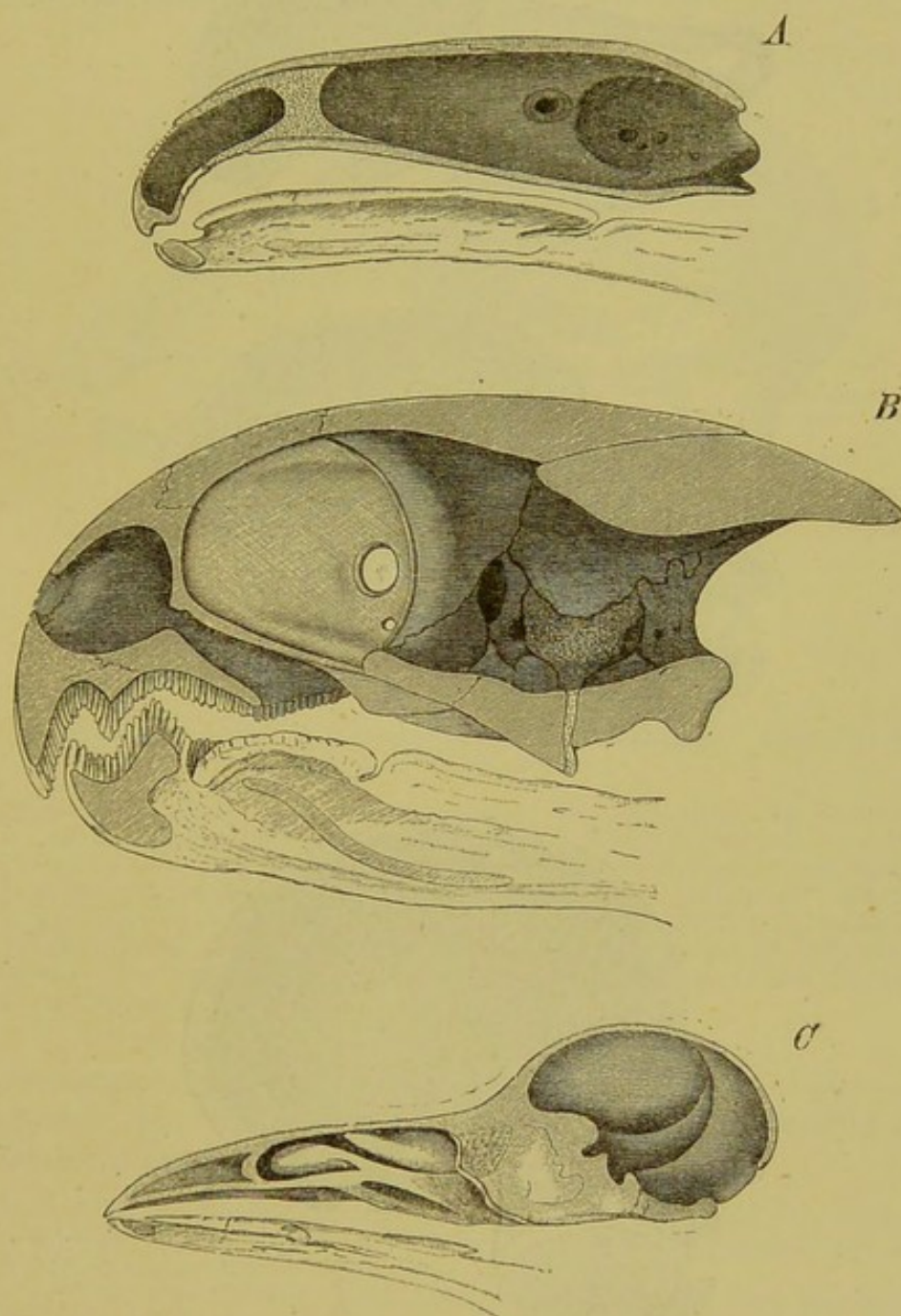


FIG. 66A.—LONGITUDINAL VERTICAL SECTIONS THROUGH THE SKULLS OF—
A, *Salamandra maculosa*, B, *Testudo graeca*, AND C, *Corvus corone*, TO SHOW
THE RELATIONS BETWEEN THE CRANIAL AND VISCERAL PORTIONS.

olfactory and auditory organs. Remains of the primitive cartilage are seen in the nasal region in adult Mammalian skulls.

It has already been stated that, as regards the hard palate, Mammals essentially agree with Crocodiles, but the pterygoids

(except in Anteaters and some Cetacea) do not take part in its formation.

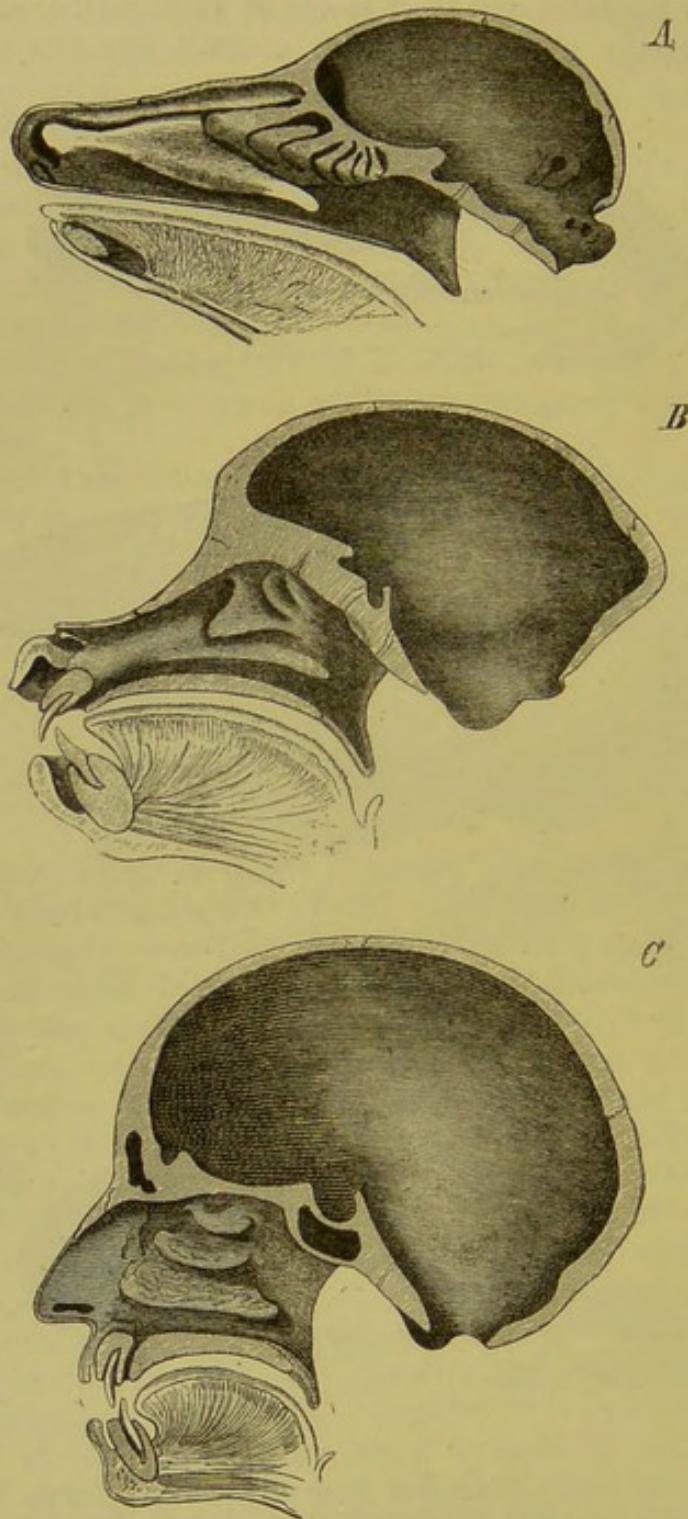


FIG. 66B. — LONGITUDINAL VERTICAL SECTIONS THROUGH THE SKULLS OF—
A, DEER, B, BABOON, AND C, MAN, TO SHOW THE RELATIONS BETWEEN
THE CRANIAL AND VISCERAL PORTIONS.

According to recent researches the premaxilla appears to originate primitively by a double ossification on each side. In the middle line it bounds a canal which forms a communication between

the nasal and oral cavities (incisive or naso-palatine canal). In the lateral parts of the face of most Mammals, the jugal or malar connects the maxilla with a process of the squamosal instead of with the quadrate, as in Amphibia and Sauropsida: in Ungulata

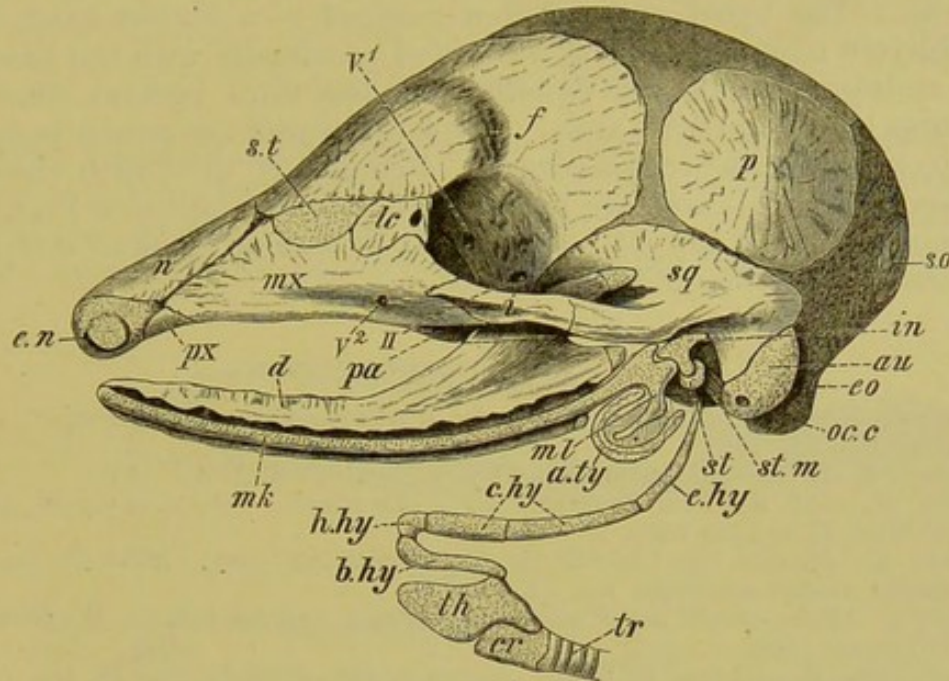


FIG. 67.—SKULL OF EMBRYO OF ARMADILLO (*Tatusia hybrida*). (Modified from a drawing by W. K. Parker.)

a.ty., tympanic annulus; *au.*, auditory capsule; *b.hy.*, basihyal; *c.hy.*, ceratohyal; *cr.*, cricoid; *d.*, dentary; *e.hy.*, epihyal; *e.n.*, external nostril; *eo.*, exoccipital; *f.*, frontal; *h.hy.*, hypohyal; *i.*, jugal; *in.*, incus; *lc.*, lacrymal; *mk.*, Meckel's cartilage; *ml.*, malleus; *mx.*, maxilla; *n.*, nasal; *oc.c.*, occipital condyle; *p.*, parietal; *pa.*, palatine; *px.*, premaxilla; *so.*, supraoccipital; *st.*, stapes; *s.t.*, superior turbinal; *st.m.*, stapedius muscle; *sq.*, squamosal; *th.*, thyroid; *tr.*, trachea; *V*¹, foramen for first, and *V*² for second, division of the trigeminal; *II*, optic foramen.

and Primates, when the jugal is also connected with a process of the frontal,¹ the orbit becomes almost completely separated from the temporal fossa.

¹ Most of the true Ruminants are provided with horns projecting from the frontal bones: these are of three kinds:—1, hollow horns (in the Cavicornia); 2, solid horns (antlers of Cervidæ); and 3, horns of the Giraffe.

In the Cavicornia (Bovinæ, Antelopinæ, Caprinæ, Ovinæ) bony processes are developed from the frontals, which become enveloped by horn formed from the epidermis. In the Cervidæ, a membrane bone becomes developed in the derma round each process of the frontal, with which it fuses. This grows out to form the antler, and after attaining its full development, the skin covering it dries up owing to the development of the "burr" at its base; this constricts the vessels, and the antler, being deprived of nutriment, falls off. This occurs periodically at the close of the breeding season. In the young animal, the antlers are simple, but year by year they become more complicated and branched. Giraffes possess persistent antlers covered by hair without any process from the frontal, which do not become ankylosed to the latter bone.

The differentiation into "horn-" and "antler-bearers" first began in the Miocene epoch.

The lower jaw, each ramus of which is composed of a single piece, corresponds to the anterior portion only (dentary, splenial, and coronoid) of the mandible of Sauropsida, and it articulates secondarily with the squamosal. Concerning the primary relations of these parts, compare the chapter on the auditory organ and Fig. 67. The hyoid arch is often reduced to a fibrous band, the stylo-hyoid ligament, and is connected proximally with the base of the auditory capsule and distally with the third visceral (that is, the first true branchial) arch. The latter forms the proper body of the hyoid with its greater cornua. Remains of the fourth visceral (second branchial) arch are present in some cases, as in the Porpoise (*Phocæna*), for example. For the air-sinuses of the skull compare the chapter on the air-sacs of Birds.

BIBLIOGRAPHY.

- AHLBORN, F.—*Ueber die Segmentation des Wirbelthierkörpers.* *Zeitschr. f. wiss. Zool.* Bd. XL. 1884.
- CALLENDER, G. W.—*Formation, &c., Human Face.* *Phil. Trans.* 1869.
- DAMES, W.—*Ueb. den Bau des Kopfes von Archæopteryx.* *Sitz. d. k. preuss. Akad. d. Wiss.* 37 and 38, 1882.
- DOHRN, A.—*Studien zur Urgeschichte des Wirbelthierkörpers.* *Mittheilungen der Zoolog. Station zu Neapel.* Bd. VI. 1885.
- DURSY, E.—*Entw.-Gesch. des Kopfes des Menschen und der höheren Wirbelthiere.* Tübingen, 1869.
- GEGENBAUR, C.—*Unters. z. vergl. Anatomie der Wirbelthiere*, H. III. *Das Kopfskelet der Selachier.* Leipzig, 1872.
- HERTWIG, O.—*Ueber das Zahnsystem der Amphibien und seine Bedeutung für die Genese des Skelets der Mundhöhle.* *Arch. f. mikr. Anat.* Vol. XI. Suppl. H. 1874.
- HOWES, G. B.—*On some Points in the Anatomy of the Porpoise.* *Journ. of Anat. and Physiol.* Vol. XIX. 1879.
- MARSH, O. C.—*The Dinocerata, a Monograph of an Extinct Order of Gigantic Mammals.* Washington, 1884.
- MOLDENHAUER,—*Die Entwick. d. mittleren u. des äusseren Ohr.* *Morphol. Jahrb.* Bd. III. 1878.
- MÜLLER, J.—*Vergl. Anatomie der Myxinoïden.* Berlin, 1834-1845.
- PARKER, W. K.—Numerous Papers on the Development of the Vertebrate Skull in the *Transactions of the Royal, Zoological, and Linnean Societies for the last twenty years.*
- PARKER, W. K., and BETTANY, G. T.—*The Morphology of the Skull.* London, 1877.
- STOHR, P.—*Zur Entwick. des Kopfskeletes der Teleostei.* *Festschrift z. Feier des 300 Jährigen Bestehens der Jul. Max. Univ. zu Würzburg.* Leipzig, 1882. *Zur Entwick. des Urodelen- und Anurenenschädels.* *Zeitschr. für Wiss. Zool.* Bd. 33 und 36.
- WIEDERSHEIM, R.—*Salamandrina perspicillata, &c. Versuch einer vergl. Anatomie der Salamandrinen.* Genua, 1875. *Das Kopfskelet der Urodelen.* *Morphol. Jahrb.* Bd. III. 1877. *Die Anatomie der Gymnophionen.* Jena, 1879.
- WYHE, J. W. VAN.—*Ueber die Mesodermsegmente und die Entwicklung der Nerven des Selachierkopfes.* Amsterdam, 1882.

V. LIMBS.

The limbs or extremities, which are, as appendicular organs, distinguished from the axial organs (head, neck, and body), serve mainly for locomotion, and may be divided into two groups,

the paired and the unpaired limbs. Both arise in Fishes as linear proliferations of the epiblast, which form four folds or ridges—a dorsal and a ventral, extending from the head backwards to the tail, and two lateral (Fig. 68, A, *D*, *S*, *S*¹).¹ Mesoblastic elements extend into them later.

a. UNPAIRED LIMBS.

The unpaired limbs, which are characteristic of Fishes, are developed from the dorsal and ventral ridges. They either remain continuous in their further development, as in some Fishes and tailed Amphibians, or else certain parts undergo degeneration, so that

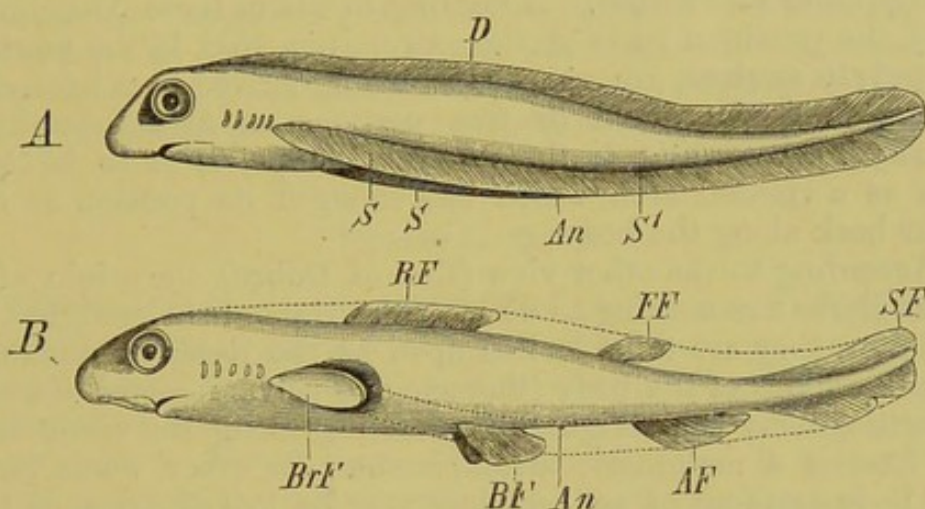


FIG. 68.—DIAGRAM SHOWING (A) THE UNDIFFERENTIATED CONDITION OF THE PAIRED AND UNPAIRED FINS IN THE EMBRYO, AND (B) THE MANNER IN WHICH THE PERMANENT FINS ARE FORMED FROM THE CONTINUOUS FOLDS.

D, dorsal fin-fold; *S*, *S*, lateral folds, which unite together at *S*¹ to form the ventral fold; *RF*, *FF*, dorsal fins; *SF*, tail-fin; *AF*, anal fin; *BrF*, pectoral fin; *BF*, pelvic fin; *An*, anus.

they only persist in certain regions, which are spoken of as dorsal, caudal, and anal fins (Fig. 68, A, B): in these regions muscles and skeletal parts (fin-rays) become formed.

After the formation of the epiblastic fin-folds, the next parts of the unpaired fins which appear are the muscles, and then follow the supporting cartilages; these latter arise, like the skeletal parts of the paired fins, entirely independently of the axial skeleton. The connection between the latter and the unpaired fins is only secondary. This holds good also for the caudal fin, in which the relation between the axial skeleton and that of the fin is a very close one.

The caudal fin is the principal organ of locomotion in most Fishes, and it acts in a horizontal direction: the paired fins play only a secondary part, and are principally concerned in rising and sinking in the water.²

¹ See also p. 86.

² The curious suctorial disk on the dorsal side of the head of the Remora (*Echeneis*), by means of which it attaches itself to foreign objects, arises in the embryo from the anterior portion of the dorsal unpaired fin, and this is indicated throughout life by the arrangement of the blood-vessels, nerves, and skeletal parts.

In many tailed Amphibians and Amphibian larvæ (including those of Cæcilians), the unpaired fins are represented by a fold of the skin extending along the dorsal and ventral sides of the tail. In some cases this fold extends along the back right up to the head, but it never gives rise to bony or cartilaginous supporting elements. In the male Triton it becomes much enlarged during the breeding season.

b. PAIRED LIMBS.

No other morphological problem has given rise during the last twenty years to such extensive researches and to such varied solutions as the question of the origin of the **paired limbs**. Two very opposite views exist. According to one of these (Gegenbaur's view), the proximal parts of the extremities, that is, the **pectoral** and **pelvic arches**, are regarded as being derived from branchial arches, and the distal or free portions as metamorphosed fin-rays. According to this theory, the pelvis is to be looked upon as a visceral arch which has changed its position so as to lie far back along the body.

According to the other view (that of Dohrn), the origin of the paired limbs has nothing to do with the visceral skeleton, but, like the latter, they are to be looked upon as the localised remains in definite regions of the body (thoracic and pelvic regions) of a series of cartilaginous bars originally extending along the whole trunk, and having a metameric arrangement. In other words, just as each body-segment of an Annulate may be looked upon as being provided with a pair of limbs, so also was each primitive segment of the Vertebrate body: recent researches seem to support this.

These researches were made on Elasmobranch embryos, and in these each somite gives rise to a fin-element, each of which consists of two dorsal and two ventral bundles of muscle, two rods of cartilage, and a corresponding spinal nerve. Both pectoral and pelvic fins are made up of a considerable number of these fin-elements. It is interesting to note that these outgrowths from the somites are present along the entire length of the lateral epiblastic folds, that is, they exist at first between the pectoral and pelvic fins, as well as behind the latter, but in these regions they soon become aborted. The lateral epiblastic folds do not run parallel to one another, as was supposed by Thatcher, Mivart, and Balfour, but converge towards the anus (Fig. 68, A): the presence of outgrowths behind the anus, however, points to the possibility of the ventral unpaired fin having been originally paired. This probably was the case when the postanal gut of the embryo, as well as the cœlome, extended through the whole caudal region. After the formation of the definitive anus and the disappearance of the postanal gut, the two lateral halves of each primordial fin-fold fused together to form a median fin. Possibly the dorsal fin was also originally paired, for it arises by paired outgrowths from the dorsal part of the myotomes, so that in this case it was not situated in the middle line, but along each side of it.¹ On the closure of the laminae dorsales in the formation

¹ Dohrn has lately attempted to prove that the unpaired fins of *Petromyzon* arise in a paired manner, and that this Fish must formerly have possessed paired pectoral and pelvic fins, which have gradually become lost.

of the cerebro-spinal axis, these two folds fused together in the median dorsal line. Thus all the four longitudinal epiblastic folds (of Thatcher, Mivart, and Balfour) are possibly to be considered as arising originally from separate metameric outgrowths of the body-segments, that is, from parapodia, which have thus become gradually transformed into the fins existing at the present time.

Paul Meyer supports this hypothesis by finding parapodia-like outgrowths arranged in four rows along the caudal region in embryos of *Pristiurus* and *Scyllium*.

Later investigators in this subject no longer even accept the homodynamy (*i.e.* the serial homology) of the pectoral and pelvic arches and limbs, but suppose that even ontogenetically the two arches can in no way be compared with one another, for, arising in an entirely different manner, they can only be regarded as "apparently similar" structures. Which of these attempts at an explanation of the problem comes nearer to the truth cannot yet be definitely stated, and the relative merits of the views just put forward cannot be discussed here.

Pectoral Arch.

Fishes.—Owing to the absence of paired fins in **Amphioxus** and **Cyclostomi**, pectoral and pelvic arches are also wanting. In Elasmobranchs the pectoral arch consists of an extremely simple cartilaginous bar, the two halves of which are united ventrally by cartilage or fibrous tissue (Fig. 69, *SB*); and it has at first a similar structure in embryos of Ganoids and Teleostei.

Later, however, in both the last-named groups, a row of bony structures arising in the perichondrium becomes developed in this region; so that one can distinguish between a secondary or bony pectoral arch, and a primary or cartilaginous one.

The free extremity, or fin, is connected with the hinder and outer circumference of the (primary) arch, and its point of attachment may be taken as separating an upper dorsal and a lower ventral section. The former, which is often connected with the vertebral column, corresponds to a scapula, and the latter to a coracoid *plus* precoracoid (clavicle) of the higher Vertebrata.¹

In Teleosteans and bony Ganoids, the bony (secondary) arch forms the principal support of the fin in the adult, the main element being a large clavicle (Fig. 70, *D*). The primitive relations are thus much altered. The arch becomes secondarily connected with the skull (*Cm*). For further details, compare Fig. 70.

Amphibia and Reptilia.—In these types, the secondary bony apparatus is of less importance, for the primary arch is more

¹ The pectoral arch of Dipnoi is intermediate in character between that of Elasmobranchs and Ganoids. It shows so many special peculiarities as regards form and position, that it cannot be fully described here.

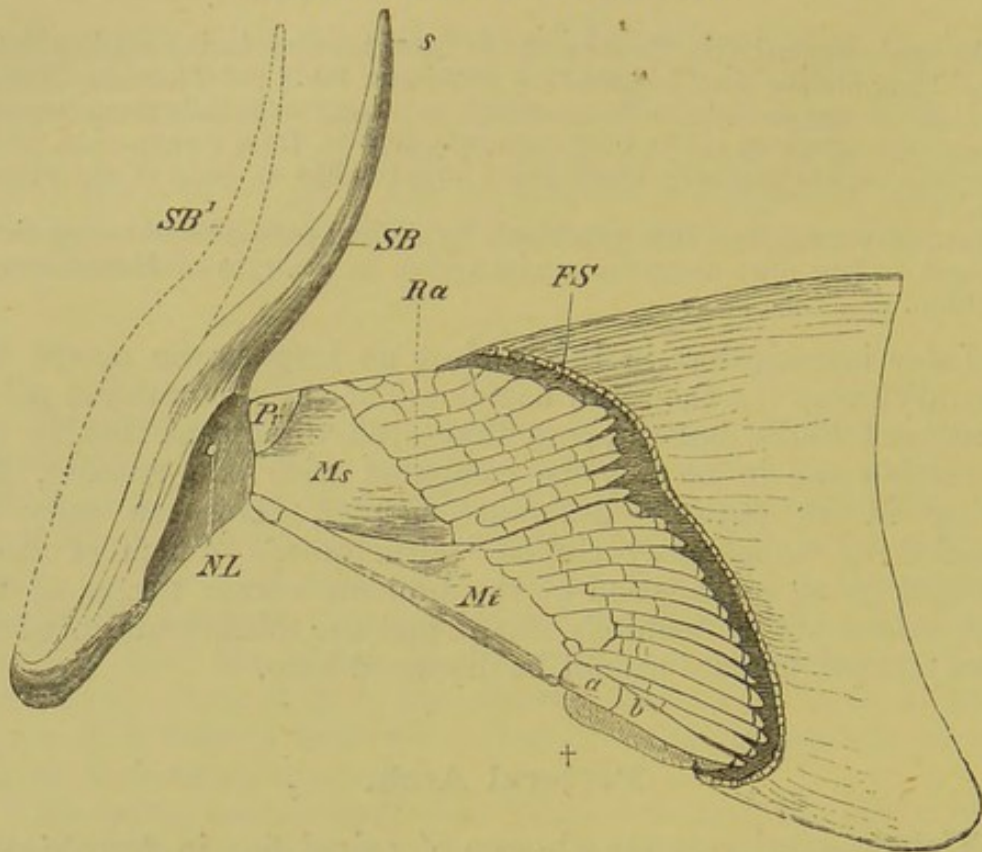


FIG. 69.—PECTORAL ARCH AND FIN OF *Heptanchus*.

SB, *SB*¹, pectoral arch, with a nerve-aperture at *NL*; *Pr*, *Ms*, *Mt*, the three basal elements of the fin—pro-, meso-, and metapterygium; *Ra*, cartilaginous fin-rays; *a*, *b*, the main fin-ray, lying in the axis of the metapterygium; †, single ray on the other side of the axis (indication of a biserial type); *FS*, horny rays, cut through.

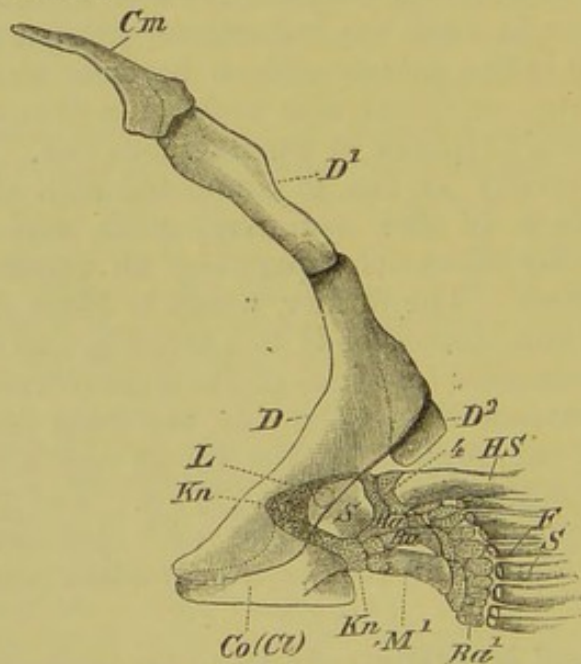


FIG. 70.—LEFT PECTORAL ARCH AND FIN OF THE TROUT. (From the outer side.)

D, *D*¹, *D*², chain of secondary bones of the pectoral arch (clavicle and supraclavicle), which is connected with the skull by means of the post-temporal (*Cm*); *S* and *Co(Ct)*, bony scapula and coracoid, which have become developed in the cartilage (*Kn*); *L*, foramen in scapula; *M*¹, metapterygium; *Ra*, *Ra*¹, the second and third, and 4, the fourth basal element of the fin; *Ra*¹, the second cartilaginous row of radii; *HS*, bony ray on the border of the fin, which is connected with the fourth basal element; *F*, *S*, bony fin-rays, shown cut away from their attachments.

extensively developed. In all the higher Vertebrates it is formed on the same plan as in Amphibia, and becomes more or less completely ossified.

It always consists on each side of a cartilaginous or bony dorsal plate (scapula), which curves round the side of the body, and becomes continuous ventrally with two processes—an anterior

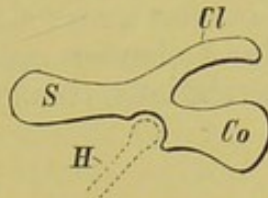


FIG. 71.—DIAGRAM OF THE GROUND-TYPE OF PECTORAL ARCH MET WITH IN ALL VERTEBRATA, FROM THE AMPHIBIA UP TO MAMMALIA.

S, scapula ; *Co*, coracoid ; *Cl*, precoracoid (clavicle) ; *H*, humerus.

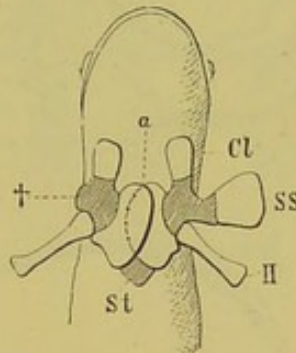


FIG. 72.—SEMIDIAGRAMMATIC FIGURE OF THE PECTORAL ARCH AND STERNUM OF *Urodela*.

St, sternum ; *a*, point where the two coracoids overlap ; *Cl*, precoracoid (clavicle) ; *SS*, suprascapula, shown extended transversely outwards on the left side ; †, bony scapula ; *H*, humerus.

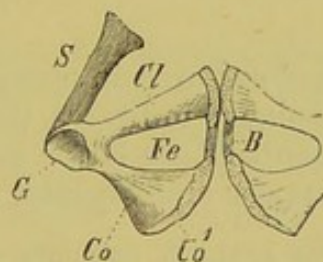


FIG. 73.—PECTORAL ARCH OF A CHELONIAN. (Ventral view.)

S, scapula ; *Co*, coracoid ; *Co'*, epicoracoid ; *Cl*, precoracoid (clavicle) ; *B*, fibrous band between these two elements ; *Fe*, fenestra between them ; *G*, glenoid cavity.

(precoracoid, or clavicle), and a posterior (coracoid) (Fig. 71, *S*, *Cl*, *Co*). It always becomes connected ventrally with the sternal apparatus (compare Figs. 38, 39, 74).

The two coracoid plates either overlap one another in the mid-ventral line, or else their free edges come into apposition and fuse together (Figs. 74 and 38, *Co*, *Co'*).

As in the rest of the skeleton, cartilage plays the most important part in the pectoral arch of Amphibia (see Fig. 74), while in all the higher Vertebrates the cartilage is almost entirely replaced by bone (scapula, coracoid, and clavicle). Unossified spaces are often left in the coracoid, giving rise to fenestræ closed over by fibrous membrane (Lizards) (Fig. 39, *a, b, c*).

In Lizards, a cross or T-shaped parosteal bony plate, the interclavicle, lies in a groove on the under side of the sternum in the middle line. In Crocodiles a slender rod-like interclavicle is also present, and has the same relations, though clavicles are wanting.¹

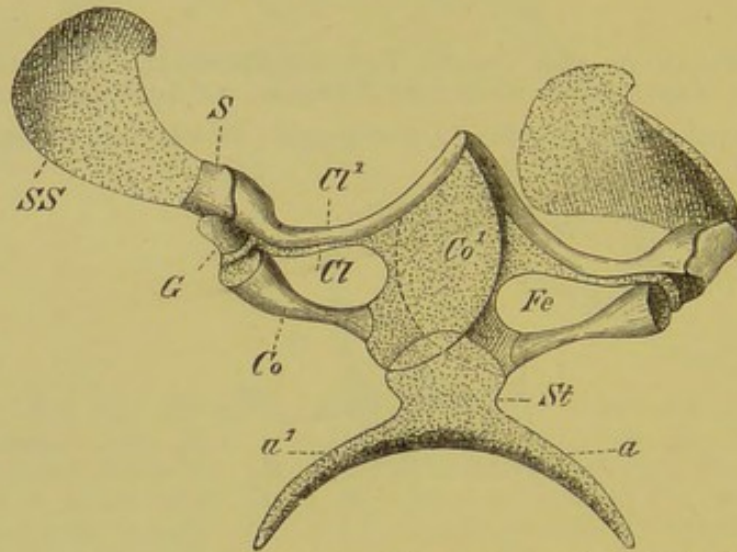


FIG. 74.—PECTORAL ARCH AND STERNUM OF *Bombinator igneus*.

St, sternum, with its two processes, *a, a¹*: *S*, scapula; *SS*, suprascapula, *in situ* on the left side, spread out horizontally on the right; *Co*, coracoid; *Co¹*, epicoracoid, which on both sides overlaps the anterior part of the sternum; *Cl*, precoracoid; *Cl¹*, bony clavicle; *Fe*, fenestra between clavicle and coracoid; *G*, glenoid cavity.

The presence of a pectoral arch in numerous footless Reptiles (some Skinks, Amphisbæniæns) indicates that they formerly possessed extremities; rudiments of the latter may even be seen in the embryo, though they disappear entirely later on (*Anguis fragilis*).

Birds.—In Birds, the scapula consists of a thin and narrow plate of bone, often extending far backwards, the strong coracoid being bent at a sharp angle with it in all Carinate Birds (Fig. 36, *S* and *Ca*). The lower end of the latter is firmly articulated in a groove on the anterior edge of the sternum.

In almost all Flying Birds the clavicle is well developed, and becomes united with its fellow to form a furcula² (comp. Fig. 36,

¹ It is doubtful whether the three anterior elements of the plastron of Chelonians correspond to clavicles and interclavicle, as supposed by Parker and Huxley.

² The median plate often present at the point of junction of the clavicle is sometimes described as an interclavicle, but its late appearance in the embryo seems to negative this view.

Fu(Cl), for its relations to the rest of the pectoral arch and to the sternum).

Amongst the Cursorial Birds, the Emeu (*Dromæus*) and Cassowary (*Casuarius*) possess rudimentary clavicles: in the others they are wanting.

In *Archæopteryx*, the scapular region only of the pectoral arch has been satisfactorily made out, and this resembles that of existing Birds.

Mammals.—In Monotremes only amongst Mammals does the coracoid extend ventrally to reach the sternum; in all the others it becomes reduced, and simply forms a prominent process on the scapula (coracoid process), which becomes ossified from a

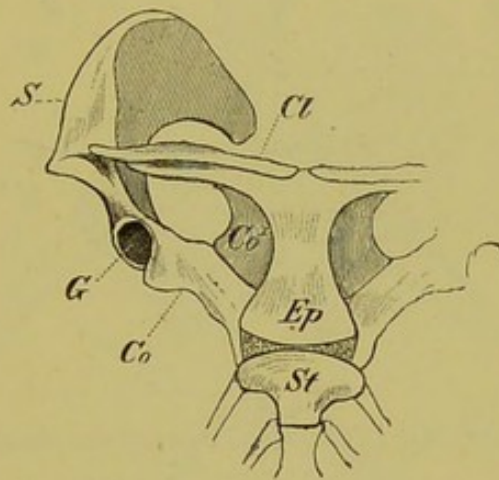


FIG. 75.—PECTORAL ARCH OF *Ornithorhynchus paradoxus*.

St, sternum; *Ep*, interclavicle; *Co*, coracoid; *Co*¹, epicoracoid; *S*, scapula; *Cl*, clavicle; *G*, glenoid cavity.

separate centre. Thus the scapula alone serves to support the extremity; it becomes at the same time greatly broadened out, and gives rise on its outer side—in connection with the highly differentiated muscles of the limb—to a strong ridge (*spina scapulæ*), which extends downwards to form the so-called acromion.

The distal end of the clavicle usually becomes connected with the acromion, its proximal end articulating with the anterior edge of the sternum.

In those Mammals in which the fore-limbs are capable of very varied and free movements, the clavicles are very strongly developed. In others, such as the Carnivora and Ungulata, they may be entirely wanting or only rudimentary, and in the latter case their relations to the scapula become altered.

Pelvic Arch.

Fishes.—The Dipnoi have probably retained the most primitive form of pelvis amongst existing animals. It consists of a cartilaginous plate lying in the mid-ventral line, from which two pairs of processes, an anterior and posterior, arise. The hinder extremities articulate with the posterior (Fig. 76, *b*), while the anterior pair are to be interpreted as iliac processes (Fig. 76, *a*). The latter vary much both in form and size, and, as in young specimens of *Protopterus*, may extend widely outwards, embedded in the intermuscular septa (M^1). A delicate rod-like process

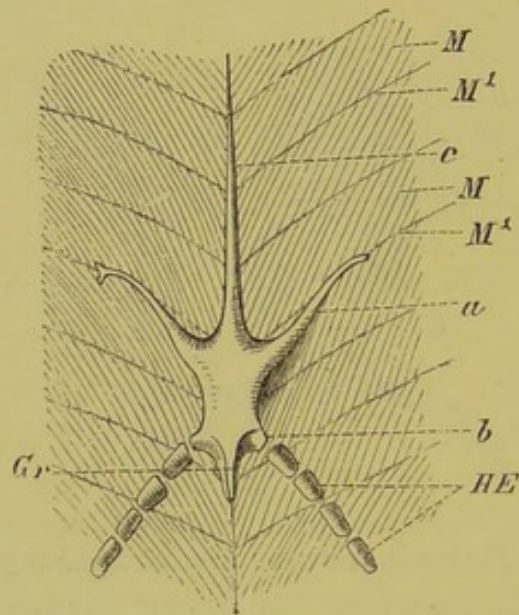


FIG. 76.—PELVIS OF *Protopterus*. (From the ventral side.)

a, iliac process, which may become forked at its distal end; *b*, process to which the hinder extremity (*HE*) is attached; *Gr*, sharp ridge, for attachment of muscles; *c*, median process; *M*, *M*, myotomes; M^1 , M^1 , intermuscular septa.

arises between them from the anterior border of the plate and extends far forwards in the middle line (Fig. 76, *c*).

The pelvis of Elasmobranchs may be derived from that of Dipnoi, although it must be looked upon as a degenerate form. It consists of an unpaired or paired plate of cartilage, on which processes corresponding to those described in Dipnoi may be seen, though these are often very rudimentary. In *Chimæra* an iliac tract is much more plainly marked.

Amongst all other Fishes, the existence of a pelvic rudiment has been proved with certainty only in the case of *Polypterus*.

Amphibia.—In Amphibia, as in all the remaining higher Vertebrata, a dorsal and two ventral pelvic elements may be distinguished. The former, or ilium, is connected with the sacral

vertebræ, and corresponds to the iliac process mentioned above as being present in some Fishes; of the latter, the anterior ventral element is spoken of as the pubis, the posterior as the ischium. The articular cavity for the thigh-bone (acetabulum) is situated at the point of junction of the pelvic elements. Thus we meet here with a ground-form essentially similar to that of the pectoral arch (Fig. 71).

In the pelvis of Urodela and Anura a single ventral plate is seen on each side, which comes into contact with its fellow to form

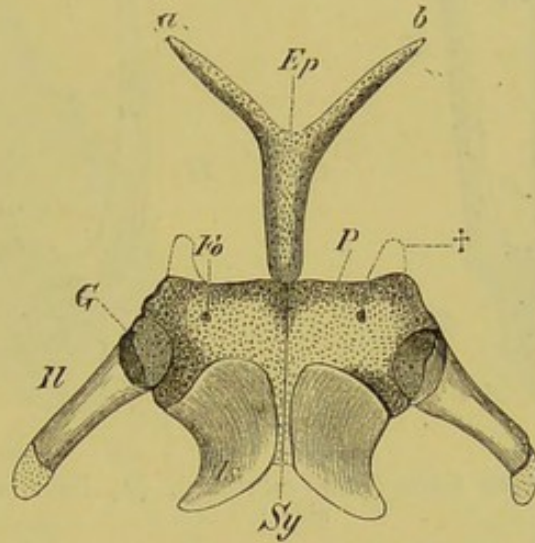


FIG. 77.—PELVIS OF SALAMANDER (*Salamandra maculosa*). (Ventral view.)

Il, ilium; *Is*, ischium; *P*, pubis (?) (pars acetabularis?); *Fo*, obturator foramen; *Sy*, ischio-pubic symphysis; †, two protuberances, present in many Urodeles; *Ep*, epipubic cartilage, with its forked ends (*a*, *b*); *G*, acetabulum.

a symphysis (Fig. 77, *Sy*), and the anterior part of which usually remains cartilaginous throughout life. It cannot, at present, be stated with certainty whether this part corresponds to the pubis, or to a fourth element, the pars acetabularis (Fig. 77, *P*, and 78, *Kn*), which is present in many Amniota, inserted between the pubis and the acetabulum (comp. Fig. 83A). The posterior part, which always becomes ossified, is without doubt an ischium (*Is*). In some Urodeles a delicate rod of cartilage arises from the middle line of the anterior border of the pelvis, and becomes bifurcated distally (Fig. 77, *Ep*, *a*, *b*). Amongst the Anura, this epipubis ("ypsiloid cartilage") is only present in *Dactylethra capensis*, where its form is somewhat different, reminding one of the delicate median process of the pelvis of Dipnoi (Fig. 76, *c*). The so-called "marsupial bones" of Monotremes and Marsupials have probably been developed from the representative of the epipubis.

In correspondence with the mode of progression in Anura, the ilium of each side becomes extended so as to form a long rod (Fig. 78, *Il*), and the two ventral plates, which in Urodeles lie

in the plane of the abdominal walls, 'become closely pressed together in the middle line, and so give rise to a well-marked keel (Fig. 78).

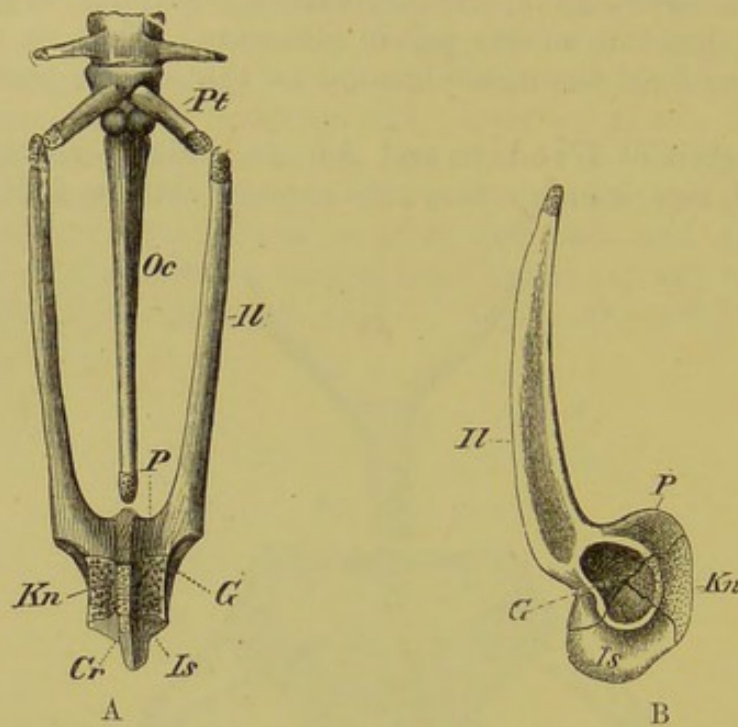


FIG. 78.—PELVIC ARCH OF FROG (*Rana esculenta*). (A, from below; B, from the side.)

Il, *P*, ilium; *Is*, ischium; *Kn*, pubis (?) (pars acetabularis?); *Cr*, the median ventral ischio-pubic crest; *G*, acetabulum; *Oc*, urostyle; *Pt*, transverse process of sacral vertebra.

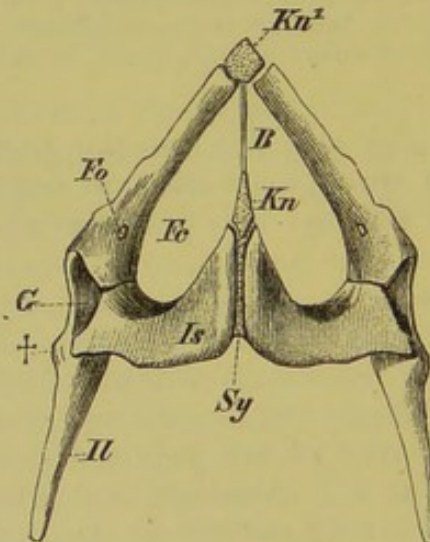


FIG. 79.—PELVIS OF *Lacerta muralis*. (Ventral view.)

Il, ilium; *Is*, ischium; *Fo*, foramen in the pubis for the obturator nerve; *Kn*, *Kn*¹, cartilaginous elements lying at the symphysis of the ischium (*Sy*) and pubis respectively; *B*, fibrous band connecting these cartilages; *Fe*, foramen cordiforme; †, tubercle of ilium; *G*, acetabulum.

Reptiles and Birds.—In these, the well-ossified elements of the pelvis are sharply differentiated, and, as the pubis in

Reptiles usually extends forwards for some distance in the middle line, a large space (foramen cordiforme) is present between it and the ischium: in Lizards, Crocodiles, and Turtles, this space is divided into two halves by a median fibro-cartilaginous band (Fig. 79, *Kn*, *Kn*¹, *B*). In land and fresh-water Tortoises, in place of this band, the median ends of the pubis and ischium extend towards one another and meet in the mid-ventral line, and thus the space (obturator foramen) between them becomes entirely surrounded by bone.

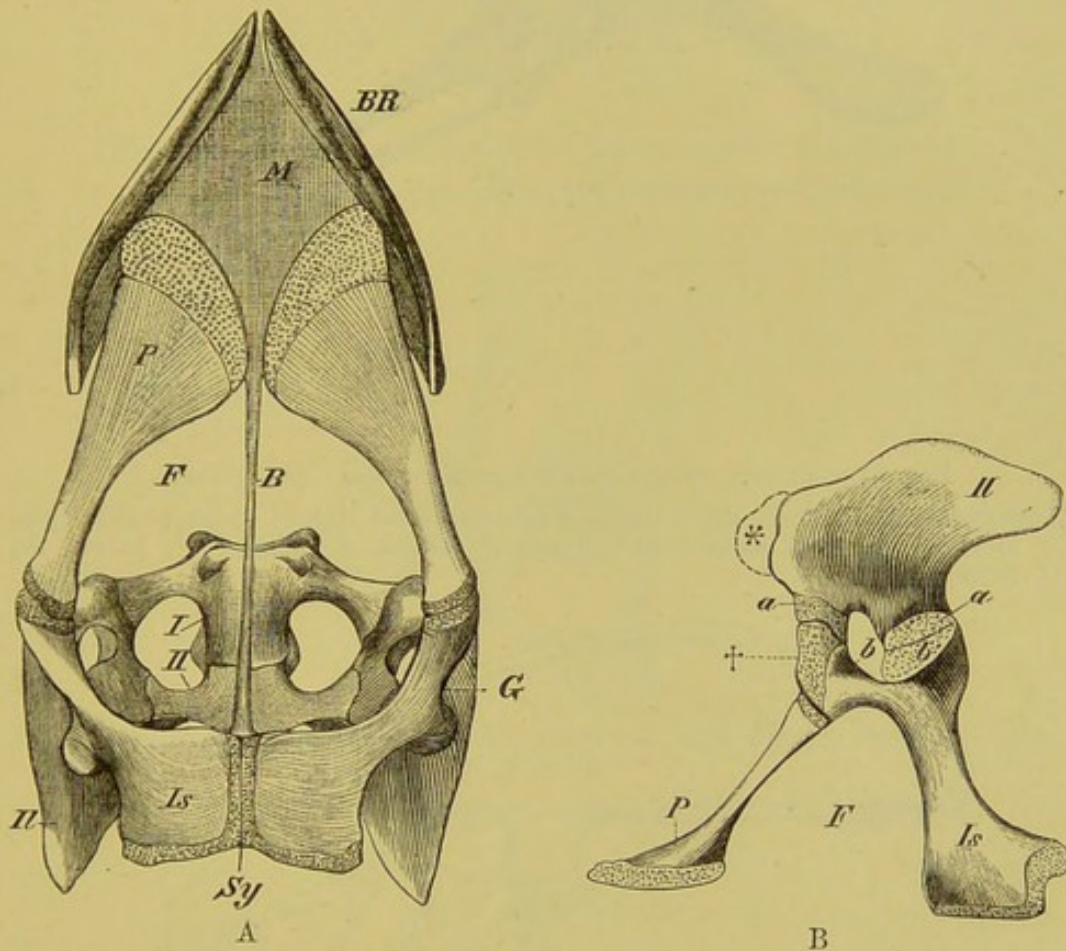


FIG. 80.—PELVIS OF A YOUNG *Alligator lucius*. (A, ventral, and B, side view.)

Il, ilium; *Is*, ischium; *P*, pubis; *Sy*, symphysis of ischium; *F*, foramen cordiforme + obturatum; *B*, fibrous band between the symphyses pubis and ischii; †, cartilaginous apophysis of the ventral acetabular process of the ischium, which is interposed between the process *a* of the ilium and the pubis; *b*, foramen in the acetabulum, bounded posteriorly by the two processes, *a* and *b*, of the ilium and ischium respectively, which here meet one another; *, indication of a forward growth of the ilium, such as is met with in Dinosaurians and Birds; *G*, acetabulum; *I*, *II*, first and second sacral vertebræ; *M*, fibrous membrane extending between the anterior margin of the pubis and the last pair of "abdominal ribs" (*BR*).

In Crocodiles we meet for the first time with a considerable extension of the ilium (Fig. 80, B, *Il*), so that now a longer posterior, and a shorter anterior process may be distinguished. In

Dinosaurians the latter (Fig. 81,*) is more strongly developed, and plainly leads towards the form of pelvis seen in Birds.

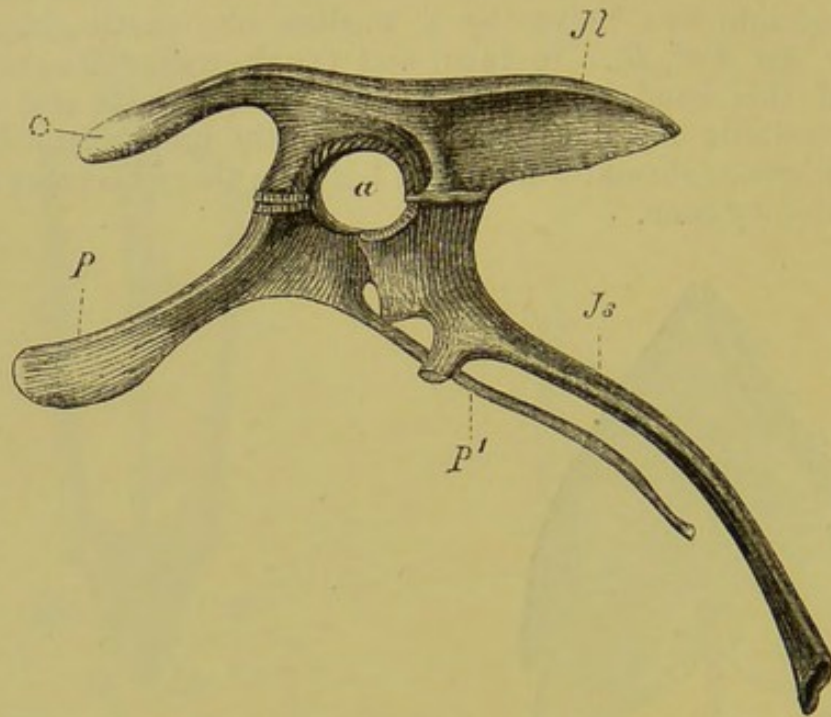


FIG. 81.—PELVIS OF *Iguanodon bernissartensis*. (After Dollo.)

*, preacetabular, and *Il*, postacetabular process of the ilium; *a*, acetabulum (perforated); *P*, pars acetabularis (pectineal process of pubis); *P'*, pubis; *Is*, ischium.

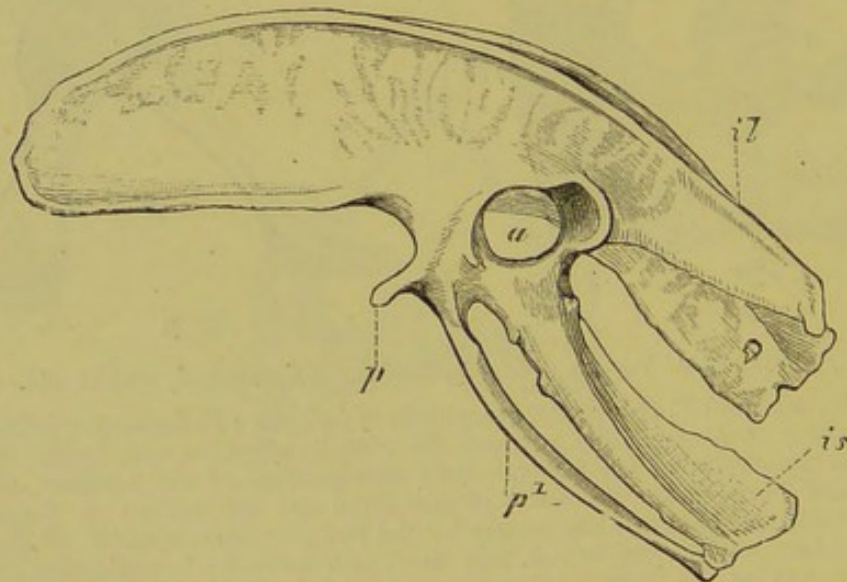


FIG. 82.—PELVIS OF *Apteryx australis*. (Lateral view.) (After Marsh.)
il, ilium; *is*, ischium; *p*, pectineal process of pubis; *p'*, pubis; *a*, acetabulum.

In Birds (Fig. 82), both pre- and postacetabular portions of the ilium are largely developed, but vary in their relative proportions (comp. p. 44). In Crocodiles the pubis is to a great extent

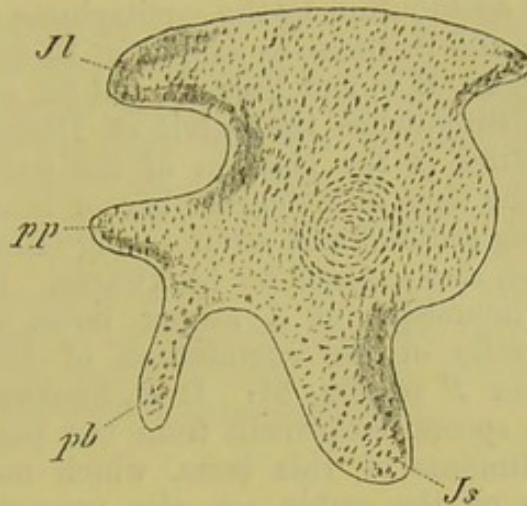


FIG. 83A.—PELVIS OF A SIX-DAYS' CHICK. (After A. Johnson.)
Il, ilium ; *Js*, ischium ; *pb*, pubis ; *pp*, pectineal process of pubis.

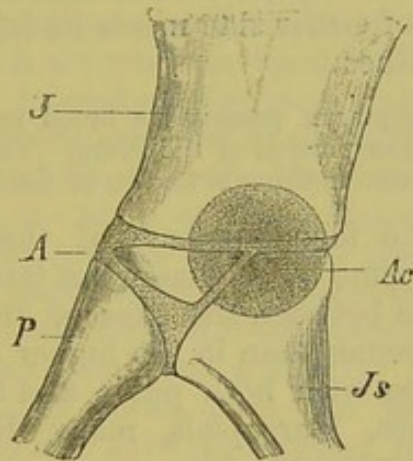


FIG. 83B.—DIAGRAM SHOWING THE RELATIONS OF THE PELVIC BONES TO THE ACETABULUM.

J, ilium ; *Js*, ischium ; *P*, pubis ; *A*, acetabular bone ; *Ac*, acetabulum.

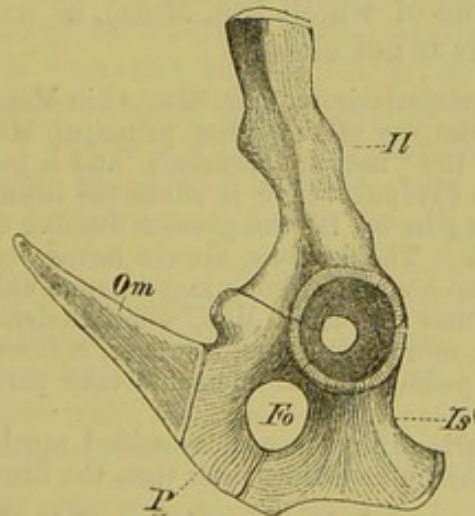


FIG. 84.—PELVIS OF *Echidna*. (From the left side.) (After Gegenbaur.)
Il, ilium ; *Is*, ischium ; *P*, pubis ; *Om*, marsupial bones ; *Fo*, obturator foramen.

shut out from the acetabulum by the cartilaginous pars acetabularis (Fig. 80, B, †, *P*), and in them, as well as, in Birds, the acetabulum is perforated (Fig. 80, B, *b*, and Figs. 81 and 82, *a*).

What most distinguishes the pelvis of Dinosauria and Birds from that of Reptiles is the position of the pubis (Figs. 81 and 82, *P*¹). It has the form of a delicate bar of bone directed backwards, and running parallel and even fusing (Birds of flight) with the ischium, which also extends far backwards. It is very difficult to explain the homology of a strong bone, arising from the antero-ventral border of the acetabulum of Dinosaurians, indicated by the letter *P* in Fig. 81. It is, however, probably to be looked upon as a special outgrowth from the pars acetabularis of each side. Rudiments of this bone, which may be called the pectineal process of the pubis, are also present in Birds (Figs. 82, *p*, 83, *pp*).

In Birds the elements of the pelvis usually become ankylosed to one another, while in Reptiles and Dinosaurians they remain distinct. The pubis of either side meets its fellow only in Struthio, and the ischium in Rhea.

The pelvis of Archæopteryx possessed a broad pre-acetabular and a long and slender post-acetabular portion of the ilium. The ischia appear to have been united by symphysis: nothing is known of the pubis.

Mammals.—The four elements of the pelvis here remain separated for a long time by cartilage, but later they become fused together. The angle between the axes of the ilium and sacrum is smaller in Monotremes than in the higher Mammals.

The original type with both pubic and ischiatic symphyses is seen in Monotremes, Marsupials, many Rodents, Insectivores, Ungulates, and Carnivores. In many other Insectivora and Carnivora, and more particularly in the highest forms, the Primates, the ischia no longer meet below. The greatest amount of variety in the form of the pelvis in any one order is seen in Insectivores, in some of which (*e.g.* Mole), as well as in most Bats, the symphysis pubis is not closed.

There is no pars acetabularis (see Fig. 83b, *A*) in Monotremes and Bats, nor in numerous representatives of the other principal Mammalian groups. It always lies anterior to the "incisura acetabuli," and is most strongly developed relatively in the Mole (*Talpa*), where it shuts the ilium as well as the pubis out of the acetabulum; in by far the greater number of Mammals the pubis only is thus excluded. The ischium always forms part of the acetabulum. In older individuals the acetabular bone may become united with either of the other three pelvic bones: thus in Man, some Rodents, and Marsupials, it fuses with the pubis; more commonly, however, it fuses with the ischium or ilium. In the Pinnipedia all four elements take part in the formation of the acetabulum.

The pars acetabularis always becomes ossified much later than the other pelvic elements, and the pubis ossifies later than the ilium and ischium.

In Monotremes and Marsupials of both sexes, two strong bones ("marsupial bones") (Fig. 84, *Om*) arise from the anterior

border of the pubes, right and left of the middle line, and extend forwards in a straight or oblique direction. At present no satisfactory morphological explanation has been given of them, and we can only compare them with the epipubic cartilage of Dipnoi and Amphibia, which has the same relations to the pyramidalis muscle (comp. p. 117). Fibrous rudiments of them are to be seen among Dogs.

Before leaving the pelvic arch it may be pointed out that, like the pectoral, it is not restricted to any particular body-segment, but that both present much variety as to position, phylogenetically as well as ontogenetically.

FREE LIMBS.

Fishes and Dipnoi.—In the Dipnoi, taking *Ceratodus* more particularly into consideration, both pectoral and pelvic fins are supported by a cartilaginous axis, made up of a great number of small segments which are movable upon one another.

Numerous small jointed cartilaginous rods or radii are disposed serially along the dorsal and ventral sides of this axis, and these gradually decrease in size towards its distal end. Towards the periphery of the fin the place of these cartilages is taken by fine horny rays, which are covered by fibrous tissue as well as by the skin; thus a broad paddle-like fin is formed. Both pectoral and pelvic fins have a similar form and structure, and in their natural position a lateral (external) and a medial (internal) surface can be distinguished. The dorsal radii are much more numerous than the ventral, which have undergone reduction. Thus the biserial type of fin is already modified in *Ceratodus*, and this modification is carried still further in Elasmobranchs (comp. Fig. 86), until eventually only a single series of radii (Fig. 69, *Ka*) remains. This series corresponds to the dorsal row of *Ceratodus*, but in consequence of its position in the adult fin, where it divides a dorsal from a ventral surface, it is spoken of as lateral.¹ The radii are much jointed, the segments being arranged in a mosaic, and closely bound together by fibrous tissue. They are covered over by the shagreen-like skin, and are continued outwards towards the periphery of the fin by a large number of horny rays (Fig. 69, *FS*), so that the size of the fin is thus considerably increased. Three larger cartilaginous basal elements lie proximally to the small radii, and are spoken of as pro-, meso-, and metapterygium respectively (Fig. 69, *Pr*, *Ms*, *Mt*). They are connected with the pectoral arch (*SB*), and the metapterygium (*Mt*) together with the distal elements lying along the same axis (*a*, *b*) represents

¹ Fig. 54 shows how much reduction the skeleton of the fins has undergone in Protopterus, the lateral rays having almost entirely disappeared. The whole extremity consists simply of a long segmented cartilaginous filament, which no longer serves as an organ of locomotion.

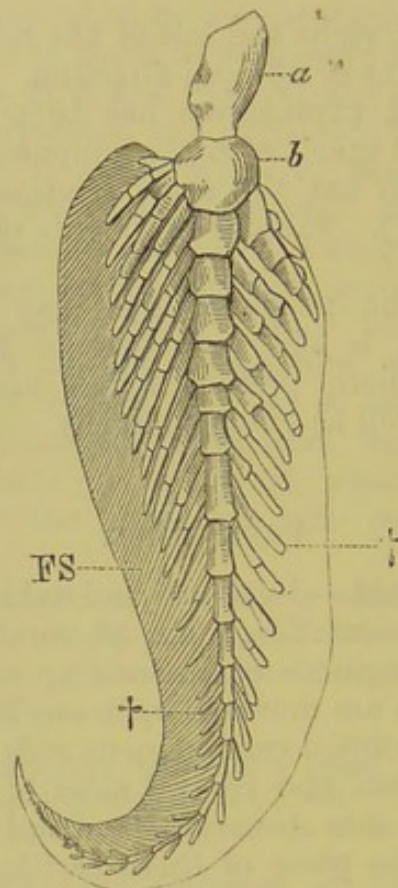


FIG. 85.—PECTORAL FIN OF *Ceratodus fosteri*.

a, b, the two first segments of the main axial ray; +, +, lateral rays, or radii; *FS*, horny rays, shown only on one side.

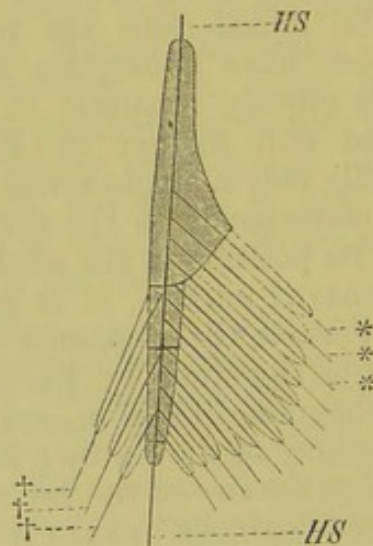


FIG. 86.—DIAGRAM OF THE PREDOMINANT UNISERIAL TYPE OF THE ANTERIOR EXTREMITY OF ELASMOBRANCHS.

HS, the axis passing through the main ray; ***, numerous lateral rays of one side; ++++, few lateral rays of the other side.

the main ray of the fin (basipterygium). This serves as the chief support for all the other rays, and is to be considered as the homologue of the axial ray of *Ceratodus*. The above

description holds good for the pectoral fin only of Elasmobranchs; the pelvic fin, however, is formed on a similar plan, but remains in a lower stage of development, which is mainly expressed by a limitation in the number of its basal segments. Thus a mesopterygium is not developed, and the propterygium is more or less rudimentary, the metapterygium being in this case also the most important element. In male Elasmobranchs, a cartilaginous apparatus—the skeleton of the “claspers”—is connected with the metapterygium (comp. p. 327).

In Ganoids, and still more in Teleosteans, the essential plan of the cartilaginous portions of the fins may be derived from that of Elasmobranchs; the primary skeleton of the fins, however, undergoes a considerable reduction, and, in consequence of the appearance of membrane-bones in connection with it, a primary and a secondary skeleton may be distinguished.

The skeleton of the fins of Siluroids, Cyprinoids, and Gymnotidæ, amongst the Teleostei, comes nearest to that of Ganoidei, that of the Gymnotidæ being the most primitive of the three.

GENERAL CONSIDERATIONS ON THE LIMBS OF THE HIGHER VERTEBRATA.

Though it is easy to derive the skeleton of the fin of all the orders of Fishes from a single ground-type, it is far more difficult to trace the connection of the latter with the extremities of Amphibia. Between these two types of limb there appears to be a wide gap, in consequence of the different conditions of life existing between Fishes and Amphibians; and the question thus arises—In what manner has the limb of an air-breathing Vertebrate, adapted for progression upon land, become derived from the fin, only fitted for use in the water?

Palæontology furnishes no answer to this question; we know of no fossil intermediate forms of limb, and it is at present, therefore, only possible to suggest a hypothesis on the subject. We may suppose that when the primitive Amphibian first began to take on a terrestrial mode of life, its fin, which we may look upon as a single-jointed lever, and which amply sufficed for the movement of the body in a fluid medium, became gradually transformed into a many-jointed system of levers.

In other words, as the function of the limb was no longer simply to propel the body forwards, but also at the same time to lift it up from the ground, the firmly connected elements of the skeleton of the fin gradually became loosened from, and placed at an angle to, one another (knee, elbow), definite articulations being formed between them in a proximo-distal direction. Moreover, the extremity must have changed its position with regard to the body, so that, instead of projecting horizontally outwards, it

became bent downwards, and thus the angle between it and the median plane of the trunk was gradually reduced, until in Mammals eventually, the longitudinal axis of the limb, when at rest, came to lie parallel with the median plane of the body. In the higher types this is more particularly the case as regards the posterior extremities, the anterior undergoing the most varied adaptations and modifications, and giving rise to tactile, prehensile, or flying organs, or, as in aquatic Mammals, becoming once more converted into rowing organs.

Thus we may also reduce the limbs of all the higher Vertebrata to a single ground-type, and we may further connect the latter with the fin of Fishes by taking the ground-plan of the fin of *Ceratodus* and Elasmobranchs, consisting of a main axis and lateral rays, as a starting-point. Figs. 87 and 88 will render this statement clear. In Fig. 88, a thick line (*HS*) is seen beginning at *H*, and passing through *F*, *i*, *c*, *c*, 2, to *II*. This is the main

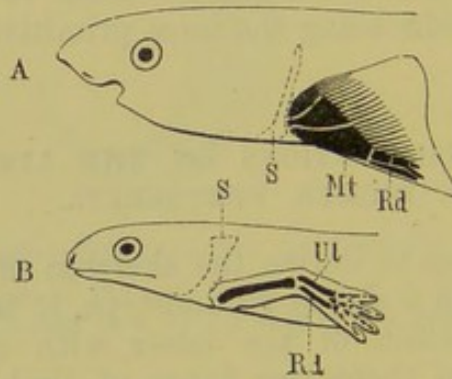
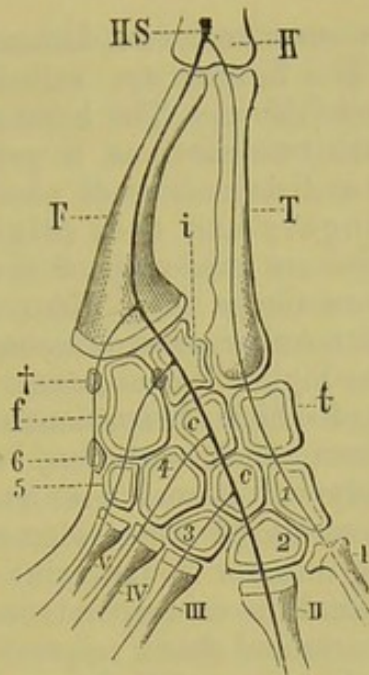


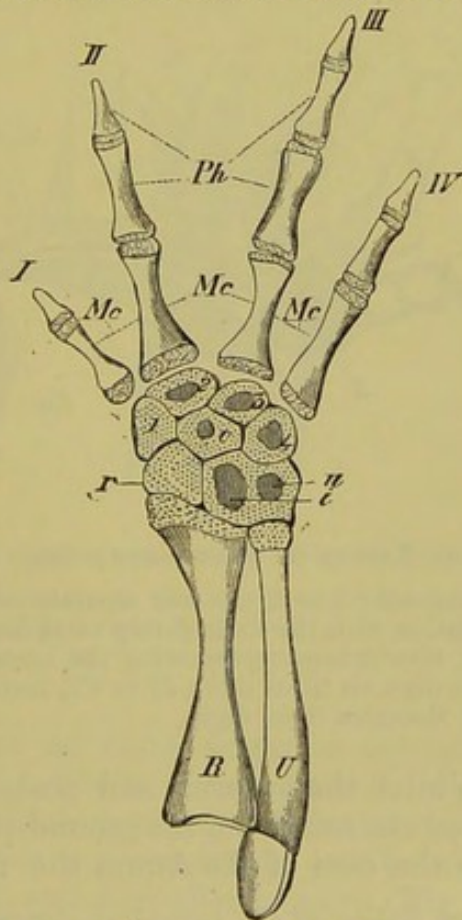
FIG. 87.—DIAGRAMMATIC FIGURES TO SHOW THE RELATIONS OF THE FREE EXTREMITY TO THE TRUNK IN FISHES (A), AND THE HIGHER VETEBRATES (B).
S, pectoral arch; *Mt*, metapterygium, which corresponds to the main ulnar ray (*Ul*); *Rd*, secondary radial ray.

axis, and from its proximal end (at *H*) a lateral ray passes off through *T*, *t*, to *I*. A second series of lateral rays arises from the other side of the axis. Thus we have here also the primitive biserial form, with a marked preponderance of one row of radii. At the same time it must be borne in mind that this arrangement of radii on an axis is less plainly seen in the embryonic condition than in the adult limb, and we must therefore speak of the relations of these parts as similar rather than as strictly homologous.

The fore- and hind-limbs show a great similarity as regards the form and position of their various parts. A division into four principal sections can always be recognised: in the case of the fore-limb these are spoken of as upper arm (brachium), fore-arm (anti-brachium), wrist (carpus), and hand (manus); and in the hind-limb as thigh (femur), shank (crus), ankle (tarsus), and foot (pes). While the bone of the upper arm (humerus) and of the thigh (femur), corresponding probably to the meta-

FIG. 88.—POSTERIOR EXTREMITY OF *Ranodon sibericus*.

H, humerus; *HS*, axial ray; *F*, fibula; *T*, tibia; *i*, intermedium; *t*, tibiale; *f*, fibulare; *c, c*, the two centralia; 1 to 6, distal tarsalia; †, traces of a sixth ray within the proximal row of the tarsus; *I* to *V*, the five metatarsals.

FIG. 89.—RIGHT FORE-ARM, CARPUS, AND HAND OF *Salamandra maculosa*.
(From above.)

R, radius; *U*, ulna; *r*, radiale; *i, u*, intermedio-ulnare; *c*, centrale; 1 to 4, first to fourth carpalia; *Mc, Mc*, metacarpals; *Ph*, phalanges; *I* to *IV*, first to fourth fingers.

pterygium, is always unpaired, two bones are present in the fore-arm and shank. The former are called radius and ulna, and the latter tibia and fibula. The hand and foot may also be respectively divided into two sections, a proximal metacarpus and metatarsus, and a distal series of phalanges, which form the skeleton of the fingers and toes (digits).

Both manus and pes are made up of several series of cylindrical bones. There are never more than five complete series, which, except as regards number, present essentially similar primary relations throughout the higher Vertebrates. The skeleton of the carpus and tarsus, each of which always consists of a series of small cartilages or bones, shows much variation, but the following may be taken as a ground-type. Round a centrale, which may be double, is arranged a series of other elements, in which three proximal, and a varying number (four to six) of distal, may be distinguished. The proximal, in correspondence with their relations to the bones of the fore-arm and shank respectively, are spoken of as radiale or tibiale, ulnare or fibulare, and intermedium; while the distal are called carpalia or tarsalia *I* to *VI* (in the narrower sense). They are counted beginning from the radial or tibial (pre-axial, Huxley) side (Figs. 88 and 89).

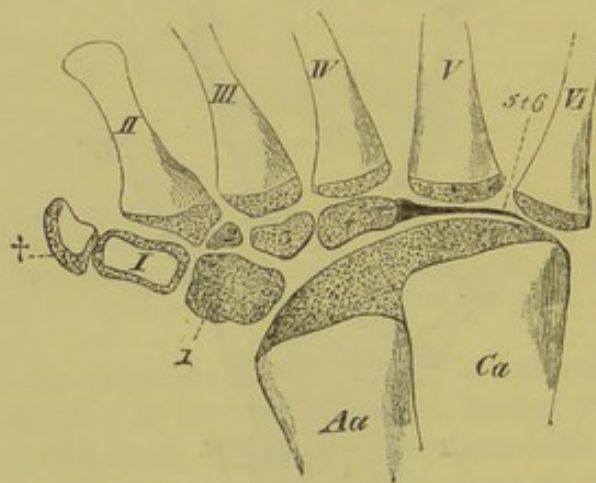


FIG. 90.—RIGHT TARSUS OF *Discoglossus pictus*. (From above.)

Aa, astragalus; *Ca*, calcaneum; 1 to 4, the four separate (cartilaginous) tarsalia on the tibial side, in relation with the rudimentary extra finger (*I*) and digits 1 to 3 (*II* to *IV*); 5 + 6, fibrous band representing the tarsals of digits *V* and *VI*; *I*, rudimentary extra digit on tibial side; *II* to *VI*, metatarsals of digits 1 to 5; †, single phalanx of the extra tibial digit.

Amphibia.—Whilst the anterior and posterior extremities of Urodeles are formed essentially on the ground-plan described above (Figs. 87 to 89),¹ in the case of the Anura the radius and ulna be-

¹ Numerous secondary fusions of the individual elements of both carpus and tarsus may, however, occur; this applies also to the Anura. As a rule the anterior extremity is only provided with four fingers, though there are reasons for supposing that it at one time, like the posterior, possessed five complete fingers. The number of phalanges varies in different Amphibians.

come fused together, and the intermedium is wanting. The proximal row of the tarsus, moreover, consists of only two cylindrical bones, which are usually united together by an envelope of cartilage. One of these corresponds to a tibiale *plus* intermedium, and is called the astragalus; the other or calcaneum answers to a fibulare (Fig. 90, *Aa*, *Ca*).

In the distal row there are as a rule four separate elements. Rudiments of a fifth carpal, as well as of an extra digit on the radial side, are usually present, and traces of an extra toe are also seen on the tibial side of the tarsus.

In Anura, the metatarsals and phalanges, between which the web of the foot is stretched, are very long and slender. The femur, as well as the bones of the shank, which are fused together, are also exceedingly long, in correspondence with the mode of progression of these animals.

The skeleton of the extremities is more strongly ossified in Anura than in Urodeles, in which many of the elements remain cartilaginous.

Reptiles.—Chelonians and Lizards closely resemble Urodeles in the structure of the carpus, and here also traces of the

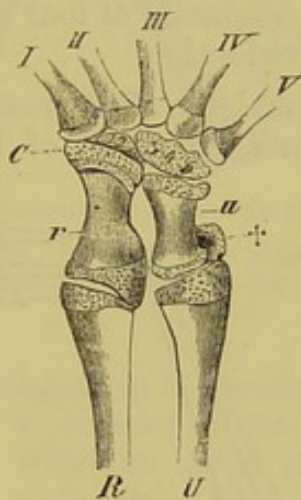


FIG. 91.—RIGHT CARPUS OF A YOUNG *Alligator lucius*. (From above.)

R, radius; *U*, ulna; *r*, radiale; *u*, ulnare; *C*, centrale; 1 to 5, the five carpalia, as yet unossified, of which 1 and 2, as well as 3, 4, and 5, have become fused together; †, pisiform; *I* to *V*, the five metacarpals.

former possession of an extra finger on the radial side are to be seen. The tibia and fibula always remain separate.¹

In Crocodiles, which possess no trace of an intermedium, the proximal row of the carpus consists of two hour-glass-shaped bones—a larger radiale, and a smaller ulnare (Fig. 91). A rudiment of a sixth ray is present on the outer side of the latter, and this

¹ In Hatteria alone, amongst existing Reptiles, a double centrale is present in the young animal.

corresponds to the so-called pisiform bone of Mammals. The distal row of carpals is much less developed than the proximal.

In the fossil Flying Reptiles (*Pterodactylus*, *Rhamphorhynchus*) the fourth finger was produced into a long jointed rod, which supported a wing-like expansion of the integument.

In all Reptiles, the tarsus undergoes considerable fusion, especially in its proximal portion, and leads gradually on to the type seen in Birds. Thus in Chelonians and Lizards the proximal tarsals all run together into a single mass, which corresponds to tibiale, intermedium, fibulare, and centrale. Traces of an extra radial ray are also present here.

In the distal row five separate tarsals are developed, but these may unite partly with one another (Chelonians), and partly with the corresponding metatarsals (Lizards), and thus there is an increasing tendency for the movement of the foot to take place by means of an intertarsal articulation, as in Birds.

In Crocodiles, there are two bones in the proximal row of the tarsus, one of which corresponds to a tibiale, intermedium, and centrale, the other to a fibulare. The former is spoken of as the astragalus, the latter as the calcaneum, and on it a definite heel (calcaneal process) is seen for the first time in the animal series. The distal row consists originally of four small cartilages, but these later undergo a partial reduction.

Birds.—While the skeleton of the manus of *Archæopteryx* (Fig. 92) agrees in many points with that of Reptiles, that of existing

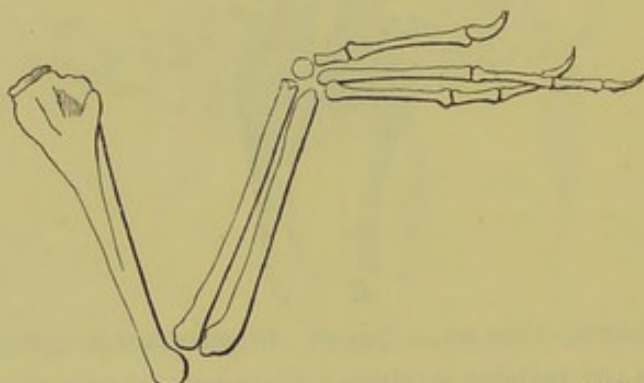


FIG. 92.—ANTERIOR EXTREMITY OF *Archæopteryx*. (After C. Vogt.)

Birds has become considerably modified by adaptation for flight, and correspondingly reduced. Of the five carpals of the embryo, the three distal become fused with the corresponding metacarpals (Fig. 93, *Mc*, *Mc*), while the two proximal remain separate as a radiale and an ulnare. The metacarpals themselves become in part united together, and only bear a very limited number of phalanges at their free ends.

The small size of the head of the humerus, as well as the absence of a ridge for the insertion of the pectoralis major, and the probable small size of the sternum, prove that *Archæopteryx* could not have been a good flier. In

other points the humerus, radius, and ulna correspond closely with those of existing Birds. There was only one carpal (radiale), and the manus consisted of three free metacarpals and digits, of which the first possessed two, the second three, and the third four phalanges: all the digits were provided with claws (Fig. 92).

Ten families of existing Carinate Birds possess the same number (two) of phalanges on the first finger as Archæopteryx, the distal one bearing a claw. Four families of Carinatae also possess three phalanges on the second finger, like Archæopteryx, but in only two of these families is there a claw on this digit. The third finger in all existing Carinates has only one phalanx,¹ as compared with four in Archæopteryx, and this never bears a claw. Amongst the Ratitæ, Apteryx and Casuarius possess only a single digit (the second), and it, like the first finger of Struthio and Rhea, is provided with a claw.

The strongly-developed and pneumatic² bones of the arm and fore-arm stand out in sharp contrast with the greatly reduced skeleton of the manus; and the anterior extremities in most Birds of flight, as the principal organs of locomotion, greatly exceed the posterior in size (Fig. 93, *H, R, U*).

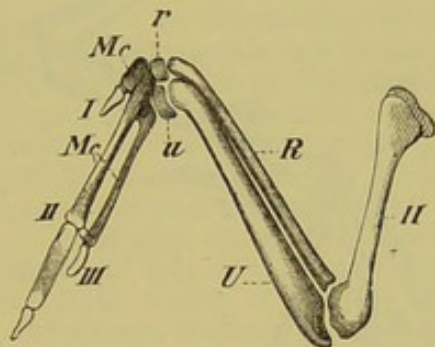


FIG. 93.—ANTERIOR EXTREMITY OF BLACKBIRD (*Turdus merula*).

H, humerus; *R*, radius; *U*, ulna; *r*, radiale; *u*, ulnare; *Mc, Mc*, the three metacarpals, with which the distal row of carpals has united; *I* to *III*, the three digits.

The **tarsus** of Birds consists in the embryo of three elements, two small proximal and a broader distal. The former (tibiale and fibulare) unite later with the distal end of the tibia, thus forming a tibio-tarsus, while the latter, which corresponds to tarsalia *I* to *V*, becomes included in the base of the metatarsus. Thus the foot of adult Birds no longer possesses any distinct tarsal elements, though, as in Chelonians and Lizards, the foot really moves by an intertarsal articulation. Of the original five metatarsals, the fifth soon disappears, while the second, third, and fourth become united with one another and with the distal element of the tarsus to form a single bone, the tarso-metatarsus (Fig. 94, *Mt*). The first metatarsal remains to a greater or less extent independent.

¹ In embryos of the Duck a cartilaginous rudiment of a second phalanx is present in the third finger of the manus. The Ostrich alone amongst existing Birds possesses a second phalanx on the third finger.

² See p. 262, concerning the pneumatic character of the bones.

The number of toes varies between two and four; that of the phalanges is normally 2, 3, 4, 5, reckoning from the first to the fourth digit. The tibia, even from the first, greatly exceeds the fibula in size.

Palæontological discoveries prove clearly that the form of the Bird's tarsus has been gradually evolved from that of Dinosaurian-like forms.

The foot of Archæopteryx was very similar to that of existing Birds, though the primitive separation of the tarsal elements is

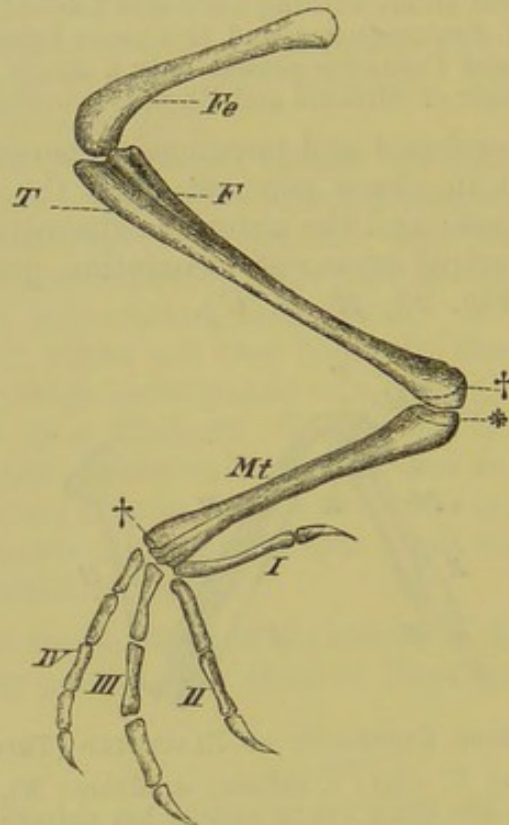


FIG. 94.—POSTERIOR EXTREMITY OF BLACKBIRD (*Turdus merula*).

Fe, femur; *T*, tibia, united with the fibula (*F*); †, *, apophyses of the tibia and metatarsus, corresponding respectively with the proximal and distal tarsal-plate: the original division of the metatarsus (*Mt*) into separate bones is indicated at its distal end at †; *I* to *IV*, first to fourth digits.

much clearer, and marked by deeper furrows. The first metatarsal was turned slightly outwards, and the toe itself backwards, like that of most existing Birds.

Mammals.—In Mammals the anterior extremity either remains in the condition of a simple organ of locomotion, or it gives rise to a prehensile organ.¹ In the latter case the radius and ulna, instead of being firmly connected together, remain separate, and articulate with one another. The movements of rotation which are thus rendered possible are spoken of as pronation and supination.

¹ In Bats, by the elongation of the fingers, between which a wing-membrane is stretched, it serves for flight.

The carpus and tarsus correspond essentially with those of Urodeles and Chelonians, and, as in them, certain of the elements may become fused together. Thus the intermedium and tibiale as a rule unite to form an astragalus,¹ while the fourth and fifth carpals become fused to form the so-called unciform bone, and the corresponding tarsals give rise to the cuboid. A centrale is always present at an early stage in all five-fingered Mammals, but as a rule it becomes fused later with the radiale, as in the case of the Gorilla, the Chimpanzee, and Man, though it may persist (in 4 cases per cent.) in the human subject throughout life. In the tarsus the centrale (navicular) remains distinct, and usually lies on the inner border of the foot. (Compare p. 106 and small type below for mention of the pisiform bone.)

A considerable modification of the homologies of the carpal and tarsal elements described above must be expected shortly. The results of recent researches (Bardeleben, Baur, Albrecht) on this subject are briefly as follows:—

The astragalus corresponds to an intermedium as well as to another element which remains independent in Marsupials, but in other forms (*e.g.* Man) exists only in the embryo, and unites later with the intermedium. This second element is either to be looked upon as a first centrale, or perhaps as a second intermedium, and is represented in the carpus by the cuneiform (ulnare). The navicular corresponds to the scaphoid of the Mammalian carpus, that is, to a navicular proper *plus* a second centrale. The pisiform corresponds to the whole calcaneum. In human embryos of the second month a distinct cartilage is present on the tibial side of the tarsus, and this probably answers to a small bone on the tibial border of the foot of Monotremes, American Marsupials, Edentates, Carnivores, Rodents, Insectivores, and Monkeys. This most likely corresponds to an extra (first) toe ("prehallux," Bardeleben). In the animals mentioned above, with the exception of Monotremes and the addition of Cheiroptera, a "prepollex" is also present in the manus, consisting of a carpal and a rudimentary metacarpal. The distal rows of the carpus and tarsus correspond as regards their individual elements. That the unciform and cuboid originally each represent two elements² (Bardeleben) is shown by the fact that two digits are attached distally to each, and that in Marsupials, Rodents, and Hyperoodon, an indication of a division into two parts persists throughout life. *Centetes madagascariensis* alone has a double centrale in the carpus.³

It is interesting to note the reduction which has taken place in the feet of Ungulates in the course of time. In Fig. 95 sketches of the stages in the phylogenetic development of the fore-foot of the Horse are given, showing how it has been gradually derived from a tetra- or pentadactyle ancestor. While in this case the third digit becomes greatly enlarged relatively (perissodactyle form), and eventually is the only one remaining, in cloven-footed Ungulates the third and fourth digits are both functional, and equally strongly developed (artiodactyle form), and may be united together to form a

¹ In Marsupials only does the intermedium remain as an independent bone. In the human embryo it exists as an independent cartilage, but later almost always becomes fused with the tibiale.

² According to Baur, the cuboid and unciform arise each as a single mass, their double condition being secondary.

³ Baur states that a double centrale is never present in any Mammalian embryo.

“cannon-bone,” while the others are gradually reduced. A similar reduction takes place in the hind-foot, and is here as a rule more rapid.

As far back as the Eocene period Ungulates were separated into Perisso- and Artiodactyles; a long series of ancestors is hereby indicated.

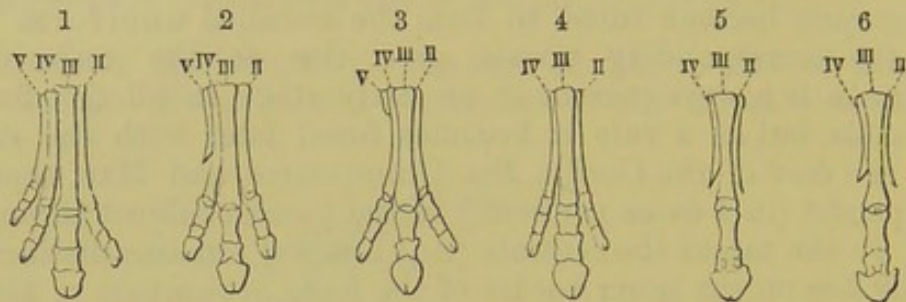


FIG. 95.—FORE-FOOT OF ANCESTRAL FORMS OF THE HORSE. 1. OROHIPPIUS (Eocene). 2. MESOHIPPIUS (Upper Eocene). 3. MIOHIPPIUS (Miocene). 4. PROTOHIPPIUS (Upper Pliocene). 5. PLIOHIPPIUS (Uppermost Pliocene). 6. EQUUS.

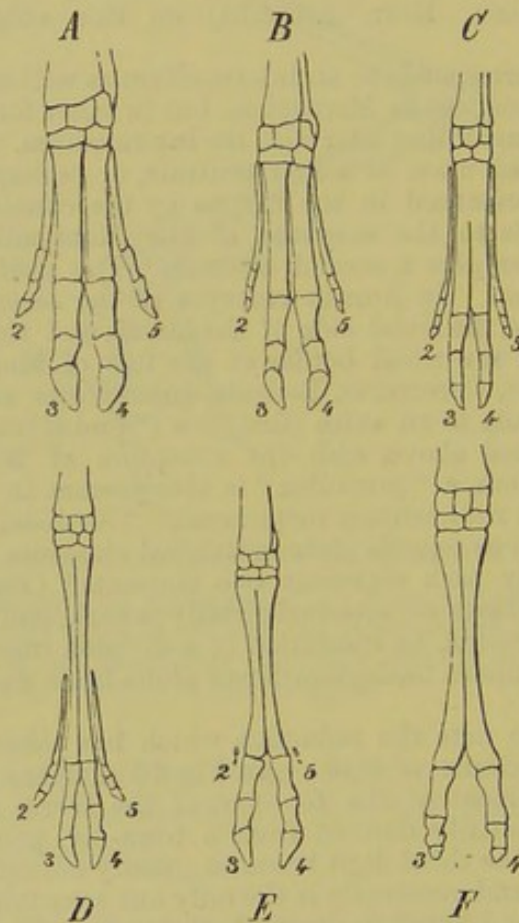


FIG. 96.—SKELETON OF THE LEFT FORE-LIMB OF *A*, PIG; *B*, HYOMOSCHUS; *C*, TRAGULUS; *D*, ROEBUCK; *E*, SHEEP; *F*, CAMEL. (From Bell, after Garrod.)

The tibia is the most important bone of the shank, just as the radius is of the fore-arm, and the thigh is usually shorter than the shank. A sesamoid bone developed in the distal tendons of the great extensor muscles of the shank is known as the knee-cap or patella. This is already present in Lizards and Birds.

The number of phalanges is similar in both hand and foot: in the first digit there are only two, while in the others there are three. An exception to this rule is seen in Cetacea, in which the phalanges are numerous.

BIBLIOGRAPHY.

- BARDELEBEN, K.—*Das Os intermedium tarsi der Säugethiere.* Zool. Anz. VI. Jahrgang, 1883. *Beiträge z. Morphol. des Hand- u. Fuss skeletes.* Sitz. Ber. d. Jen. Gesellsch. f. Medic. u. Naturwiss. 1885.
- BAUR, G.—*Zur Morphologie des Carpus und Tarsus der Wirbelthiere.* Zool. Anz. VIII Jahrgang, 1885. *Zur Morph. d. Carpus und Tarsus der Reptilien.* Zool. Anz. VIII Jahrgang, 1885. *Ueb. das Archipterygium und die Entwickl. des Cheiropterygium aus dem Ichthyopterygium.* Zool. Anz. VIII Jahrgang, 1885. *On the Centrale Carpi of Mammals.* American Naturalist, Vol. XIX. p. 195, and *Morphol. Jahrb.* Bd. X. Heft 3. *On the Morphology of the Tarsus in Mammals.* American Naturalist, Vol. XIX. p. 86, and *Morphol. Jahrb.* Bd. X. Heft 3. *The Trapezium of the Camelidae.* American Naturalist, Vol. XIX. p. 196, and *Morphol. Jahrb.* Bd. XI. Heft 1. *Bemerk. üb. d. "Astragalus" u. d. "Intermedium tarsi" der Säugethiere.* Morphol. Jahrb. Bd. XI. Heft 3.
- BORN, A.—*Die sechste Zehe der Anuren.* Morphol. Jahrb. Bd. I. 1875.
- DAVIDOFF, M. V.—*Beiträge z. vergl. Anat. d. hinteren Gleichmassen d. Fische,* I. *Morphol. Jahrb.* Vol. V. 1879.
- DOHRN, A.—*Studien zur Urgeschichte des Wirbelthierkörpers.* VI. *Die paarigen und unpaarigen Flossen der Selachier.* Mittheil. aus der zool. Station zu Neapel, Bd. V. Heft. 1, 1884.
- GEGENBAUR, G.—*Unters. zur vergl. Anatomie der Wirbelthiere: Schultergürtel der Wirbelthiere. Carpus und Tarsus und Brustflosse der Fische.* Leipzig, 1864, 1865. *Ueber das Archipterygium.* Jen. Zeitschr. Bd. VII.
- GÖTTE, A.—*Beitr. zur vergl. Morphologie des Skelettsystems der Wirbelthiere: Brustbein und Schultergürtel.* Arch. f. mikr. Anat. Bd. XIV. 1877.
- HOFFMANN, C. K.—*Beitr. z. Kenntniss des Beckens der Amphibien und Reptilien.* Niederl. Archiv für Zool. Bd. III.
- HUXLEY, T. H.—*The Characters of the Pelvis in the Mammalia, &c.* Proc. Roy. Soc. Vol. XXVIII. 1879. *On Ceratodus fosteri, with some Observations on the Classification of Fishes.* Proc. Zool. Soc. 1876.
- JOHNSON, ALICE.—*On the Development of the Pelvic Girdle and Hind Limbs in the Chick.* Quart. Journ. of Micros. Science, 1883, and *Studies from the Morphol. Lab. of the University of Cambridge,* Vol. II. Part I. 1884.
- LEBOUCQ, H.—*Résumé d'un mémoire sur la morphologie du carpe chez les mammifères.* Bull. de l'acad. r. de médecine de Belgique. 3 Sér. T. XVIII. Nro. 2; and *Archiv de Biologie,* T. V. 1884.
- LECHE, W.—*Zur Anatomie der Beckenregion bei Insectivoren, &c.* K. Schwedische Academie d. Wissenschaften, Bd. XX. 1882. *Das Vorkommen und die Morphologie Bedeutung des Pfannenknöchens (Os acetabuli).* Internationale Monatschrift für Anatomie und Embryologie, Bd. I.
- MARSH, O. C.—*The Limbs of Sauranodon.* Amer. Journ. of Science and Arts, Vol. XIX. 1880.
- MAYER, P.—*Die unpaaren Flossen der Selachier.* Mittheil. aus d. zool. Station zu Neapel, Bd. VI. 1885.
- MIVART, ST. GEORGE.—*On the Fins of Elasmobranchii.* Trans. Zool. Soc. Vol. X.
- PARKER, W. K.—*Structure and Development of the Shoulder-Girdle and the Sternum.* Ray Society, 1868.
- ROSENBERG, E.—*Ueber die Entwicklung der Wirbelsäule und das Centrale Carpi des Menschen.* Morphol. Jahrb. Bd. I. 1876.
- THACHER, J. TH.—*Median and Paired Fins, &c.* Transact. of the Connecticut Academy, III. 1877.
- WIEDERSHEIM, R.—*Salamandrina perspic. &c.* Versuch einer vergl. Anat. der Salamandrinen. Genua, 1875.

C. MUSCULAR SYSTEM.

THE muscles, commonly spoken of as flesh, may be divided into two groups, according to their histological character, namely, into those with smooth, and those with transversely-striated fibres. The former are phylogenetically the older, and are to be looked upon as the precursors of the latter.

The smooth involuntary muscle-fibres preponderate in the viscera, derma, and vessels, and are not under the control of the will; the striated or voluntary muscles occur principally in the body-walls and organs of locomotion, and are almost without exception under the control of the will. The following general statements refer exclusively to the latter kind of muscles.

In its simplest form, an origin, a belly, and an insertion, may be distinguished in each muscle. The muscles of the trunk are as a rule flat, while those of the extremities have usually an elongated, cylindrical, or prismatic form. In some cases, however, they assume the most various shapes; for instance, there may be more than one origin (bicipital, tricipital, or quadricipital forms), the belly may be double (biventral or digastric form), or the muscle may be saw-shaped, or have its fibres arranged in a single or double series like a feather.

All the muscles are surrounded by fibrous sheaths, or fasciæ, by means of which they are more or less firmly connected with one another (intermuscular septa) and with the integument and skeleton.

A muscle may undergo very considerable modification both in form and position by a change of origin and insertion, by division (intermediate tendons dividing it into two or more parts), or by splitting into layers, and it may thus give rise to one or more new independent muscles. If the action of a muscle becomes unnecessary, it either disappears partly or entirely, or what remains of it contributes to the strengthening of a neighbouring muscle.

In the embryo, the individual groups of muscles (*e.g.* the flexor sublimis and profundus, and the masticatory muscles) are not at first separate from one another, but consist of a uniform (mesoblastic) blastema, the splitting of which takes place later by the ingrowth of fibrous septa. In this manner the individual muscles are differentiated, and they gradually become more distinct by

use, that is, in post-embryonic time. Certain muscles may disappear in the course of development, and changes of position may also take place.

Wherever a marked friction occurs, ossifications (sesamoids) may become developed in the course of a muscle or tendon. The muscle thus gains an extra point of attachment, and a single-jointed lever is converted into a double-jointed one.

The higher one passes in the animal scale, the more numerous do the differentiations of the muscular system become, and the more varied its relations to the skeleton. One portion, the **dermal musculature**, which is sometimes not largely developed, always shows an independence as regards the rest of the muscular system, though this independence is as a rule acquired secondarily. Developed to a very slight extent in Fishes and Amphibia, the dermal musculature is of great importance in Reptiles and Birds on account of its relations to the scutes, scales, and feathers. It reaches its greatest development amongst Mammals, where it may extend over the back, head, neck, and flanks (Echidna, Dasypus, Pinnipedia, Erinaceus, &c.). In Man, only a slight rudiment is found of it in the shape of the *platysma myoides*, which extends over the neck and part of the breast and face.

MUSCULATURE OF THE SKELETON.

MUSCLES OF THE TRUNK.

Under this head are included all the muscles of the body which remain after the removal of those connected with the limbs. They arise from the muscle-plates of the embryo,—that is, from the outer parts of the mesoblastic somites,¹ and, particularly in higher types, may be separated into various groups, viz., a cranial and visceral, a dorsal and ventral.

Fishes and Amphibia.—In Fishes and the lower Amphibia the dorsal and ventral groups of muscles form a uniform mass, which is spoken of as the lateral body-muscle (*M. lateralis*). On each side of the body this consists of two portions, a dorsal and a ventral, which meet together laterally, as well as in the mid-dorsal and ventral lines (Fig. 97, *D, V*), and which are made up of a great number of metamericly arranged portions (myotomes or myocommata), separated from one another by connective-tissue septa (Fig. 97, *M, M*). Along the latter, ribs may be developed, and thus a much greater degree of firmness is attained.

This metameric arrangement of the musculature of the trunk, which has such an important relation to the spinal nerves as well

¹ The development of the sub-vertebral, cutaneous, and diaphragmatic muscles, requires further investigation.

as to the segmentation of the axial skeleton, forms a characteristic feature in Vertebrates, and distinct indications of it may be traced in all representatives of the group up to Man.

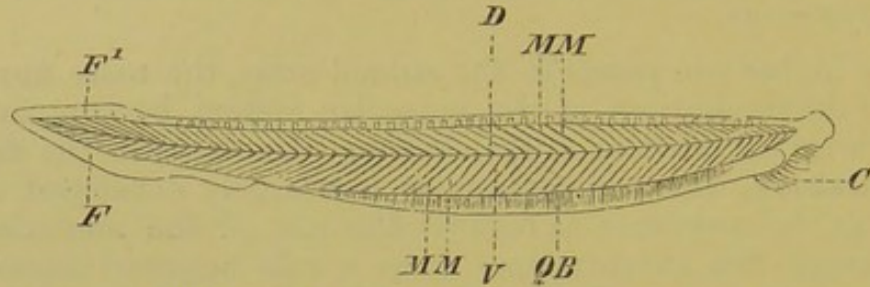


FIG. 97.—LATERAL MUSCLES OF *Amphioxus*.

D, dorsal, and *V*, ventral portions; *M, M*, the individual myotomes; *QB*, transverse muscles of abdominal region; *C*, cirrhi; *F, F¹*, tail-fin.

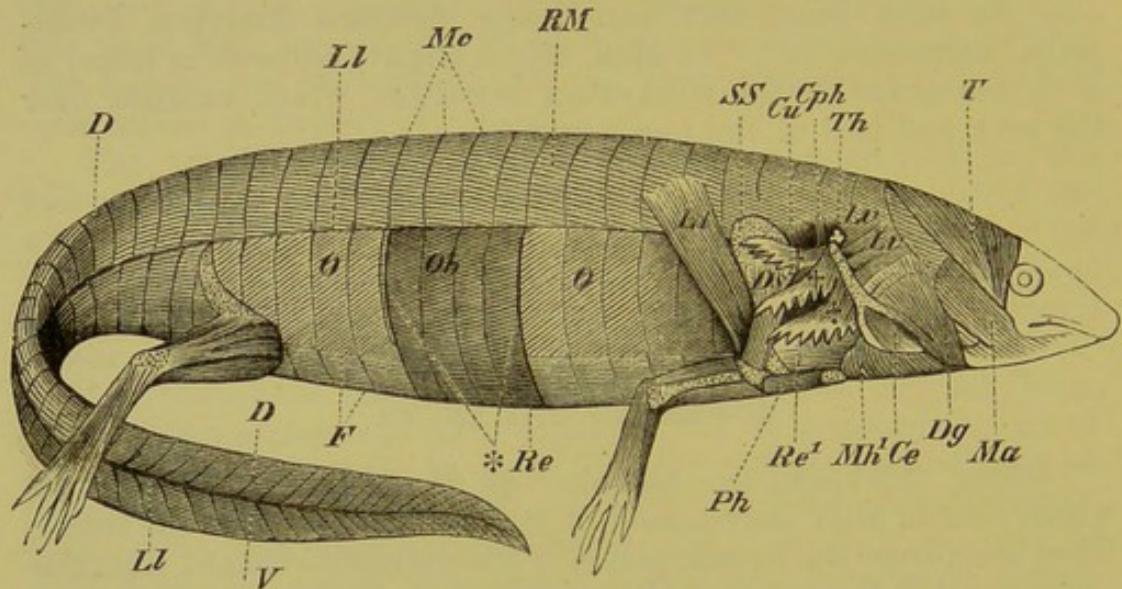


FIG. 98.—THE ENTIRE MUSCULATURE OF *Siredon pisciformis*.

Ll, lateral line; *D*, dorsal, and *V*, ventral portion of caudal muscles; *RM*, dorsal portion of lateral muscles of the trunk; *O, O*, outermost layer of the external oblique muscle, arising from the lateral line, and extending to the fascia, *F*; at * a piece of this layer is removed, exposing the second layer of the muscle (*Ob*); at *Re* the oblique fibres of the latter pass into longitudinal fibres, indicating the beginning of the differentiation of a rectus abdominis; at *Re¹* the rectus-system is seen passing to the visceral skeleton; *Mc*, fibrous partitions between the myotomes of the dorsal portion of the lateral muscles; *T*, temporal; *Ma*, masseter; *Dg*, digastric; *Mh¹*, mylohyoid (posterior portion); *Ce*, external ceratohyoid muscle; *Lv*, levator arcuum branchialium; +++ levator branchiarum; *Cph*, cervical origin of the constrictor of the pharynx; *Th*, thymus gland; *Lt*, latissimus dorsi; *Ds*, dorsalis scapulae; *Cu*, cucullaris; *SS*, suprascapula; *Ph*, procoraco-humeralis.

The cranio-visceral musculature is to be looked upon as having been derived out of the lateral muscles in consequence of the development of the visceral skeleton.

It may be asserted as a general rule that the dorsal portion of the lateral muscles of the trunk,—except in the caudal region,

where the uniform character persists both dorsally and ventrally, —retains throughout more primitive relations than does the ventral,

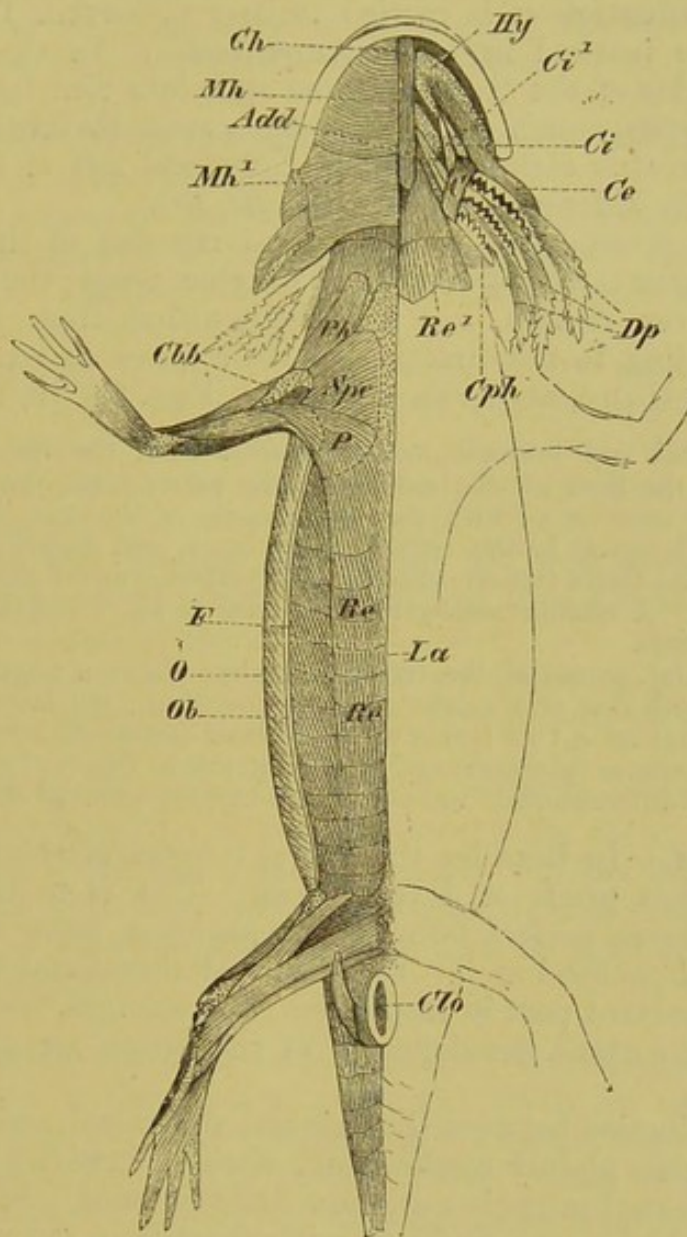


FIG. 99.—THE MUSCULATURE OF *Siredon pisciformis*. (From the ventral side.)

O, outermost layer of the external oblique, passing into the fascia, which is shown cut through at *F*; *Ob*, second layer of the same muscle; *Re*, rectus abdominis, passing into the visceral musculature (sternohyoid) at *Re*¹, and into the pectoralis major at *P*; *Mh*, *Mh*¹, anterior and posterior portions of the mylohyoid, which is cut through in the middle line, and removed on the left side, so as to show the proper visceral musculature; *Ce*, *Ci*, *Ci*¹, external and internal ceratohyoid: the former is inserted on to the hyoid (*Hy*); *Add*, adductor arcuum branchialium; *C*, constrictor arcuum branchialium; *Cph*, portion of the constrictor of the pharynx arising from the posterior branchial arch; *Dp*, depressores branchiarum; *Gh*, genio-hyoid; *Ph*, procoraco-humeralis; *Spc*, supracoracoideus; *Cbb*, coracobrachialis brevis; *Clo*, cloaca; *La*, linea alba.

the latter becoming greatly modified in order to form the walls of the body-cavity.

Thus, even in many Fishes, differentiations occur on the ventral side which bring about the formation of straight and oblique abdominal muscles (*rectus et obliqui abdominis*).

This differentiation is carried further in certain Dipnoi, and is still more marked in tailed Amphibians. In the latter the ventral muscles of the trunk become split into four layers, and in the higher types,—such as the sexually-mature Salamander and Triton,—a *rectus abdominis* lying right and left of the median line is plainly differentiated (Fig. 99, *Re, Re*).

The outermost layer of the lateral muscles of the abdomen does not appear to be retained in the higher types; the other three layers however remain, and are distinguished from without inwards, according to the direction of their fibres, as external and internal oblique, and transversalis (Figs. 98, 99, *O, Ob*).

The external and internal obliques extend from the visceral skeleton, that is, from the floor of the mouth, to the pelvic arch, the former even being directly continuous with the musculature of the tail (Fig. 98); the transversalis ceases in the region of the heart, and stands in the closest relation with the fascia transversalis and the peritoneum, on the outer side of which it lies. A similar arrangement is seen in all Vertebrates from the Urodeles onwards.

The muscular system of the trunk of Anura shows a negative condition as compared with that of Urodeles as above described: the lateral muscles of the abdomen consist of two layers only, and their metameric arrangement seen in the larva becomes later more and more obliterated. The *rectus abdominis* is always well differentiated, and possesses a varying number of myocommata.

Reptiles.—In Reptiles, the lateral muscles of the trunk attain a much higher grade of development. This is to be accounted for by the more perfect form of the skeleton, more especially of the ribs and pectoral arch. The ribs and intercostal muscles now play an important part in respiration, and changes, necessitated by the more important development of the lungs, are thus brought about.

The distinction between thoracic and abdominal regions becomes gradually more plainly marked, and distinct external and internal intercostal muscles are now differentiated. In the lumbar region the ribs become gradually withdrawn from the muscles lying between them; the muscles thus lose their intercostal character, and form connected sheets, extending between the last pair of ribs and the pelvic arch (*e.g.* the *quadratus lumborum*, which lies close against the vertebral column, and the *obliqui*).

The *rectus abdominis*, which is always well developed, becomes divided into three portions,—a ventral, an internal (a subdivision of the latter), and a lateral.

While no important differentiation is noticeable in the dorsal portion of the lateral body-muscles in Urodeles, a great subdivision of these muscles is seen in Reptiles. In them may be distinguished a *longissimus*, an *ileocostalis*, *interspinales*, *semispinales*, *multifidi*, *splenii*, and *levatores costarum*,

together with the scaleni, which belong to the last-mentioned group.

The muscles of the main part of the tail retain primitive relations similar to those seen in Fishes: at the root of the tail, however, new muscles become differentiated.

Birds.—In Birds the primitive character of the trunk-muscles has disappeared far more than in Reptiles.

This is mainly to be accounted for by the excessive development of the muscles of the anterior extremity,—the pectoralis major more particularly,—and the corresponding backward extension of the breast-bone.

External and internal oblique muscles are present, but only slightly developed: this is more particularly true of the internal, which appears to be undergoing degeneration. No trace of a transversalis can be distinguished, but on the other hand, a paired, unsegmented rectus is present.

External and internal intercostals are well developed, and a triangularis sterni appears for the first time on the inner surface of the sternal ends of the ribs.

The dorsal portion of the trunk musculature is only slightly developed in the region of the body, though very strongly marked in the neck.

All these modifications in Birds seem to be accounted for by the great specialisation of the mechanisms for flight and respiration, to assist which the greatest possible number of muscles are brought into play, and which thus greatly influence the whole organism: an essential difference is thus brought about between Birds and Reptiles.

Mammals.—Three lateral abdominal muscles are present in Mammals, an external and internal oblique and a transversalis. Except in a single instance (Tupaia), they are entirely unsegmented, and consist of broad uniform plates of muscle. Towards the middle line, they pass into strong aponeuroses, which ensheath the rectus abdominis. The latter consists of a single band on each side, and possesses a varying number of myocommata; it is no longer connected with the axial muscles of the neck belonging to the same system (sternohyoid, sternothyroid, &c.), as is the case in Urodeles, for the sternum is always interposed between them, as it is in Sauropsida.

In Monotremes and Marsupials, a strong pyramidalis muscle lies on the ventral side of the rectus abdominis. It arises from the inner border of the "marsupial bones" (epipubes), stands in important relation to the pouch (marsupium), and may extend forwards as far as the sternum. In the higher Mammals, where the epipubes are absent, the pyramidalis becomes greatly reduced or entirely lost. Traces of it are, however, commonly to be met

with as far as the Primates, always arising from the anterior border of the pubis, right and left of the middle line.

The external and internal oblique muscles are to be met with in the thoracic region in Mammals, as in Sauropsida, in the form of external and internal intercostals.

What has been said above as to the differentiation of the dorsal portion of the trunk-muscles in Reptiles, applies also in its essentials for Mammals.

MUSCLES OF THE VISCERAL SKELETON AND HEAD.

The common origin of the muscles of the visceral skeleton and the ventral trunk musculature may be much more easily proved than that of the cranial muscles with the latter system. The muscles of the head may be divided into two sections, viz. facial muscles and muscles of the jaws.

Fishes.—Leaving out of consideration the Cyclostomes, which show a remarkable transformation of the cranio-visceral musculature in correspondence with their peculiar cranial skeleton (suctorial apparatus) and branchial basket, these muscles in Elasmobranchs may all be regarded from the same standpoint. They may be divided into the following four groups or systems:—

1. Superficial circular muscles.
2. Upper adductors of the arches.
3. Middle flexors of the arches.
4. Ventral longitudinal muscles.

The latter group occupies a more independent position than the other three, which are more closely connected together.

The superficial circular muscle, receiving its nerve-supply from the vagus, glossopharyngeal, facial, and trigeminal (third division) acts essentially as a constrictor; it narrows the entire oral and pharyngeal cavities, closes the gill-clefts, and elevates the whole visceral skeleton, together with the floor of the mouth and pharynx.

The main mass of the upper and middle flexors is supplied by the vagus and glossopharyngeal, and their muscles act essentially as adductors of the branchial arches, bringing them nearer to one another.

The ventral longitudinal muscles, supplied by the first and second spinal nerves, are to be looked upon as a direct continuation of the ventral portion of the trunk-muscles, that is, of the rectus-system, which is to a certain extent undifferentiated in Fishes. Like the rectus, these muscles possess tendinous inter-sections, and they extend from the anterior border of the pectoral arch forwards to the lower jaw, or only to the hyoid arch (coraco-mandibular and coraco-hyoid muscles).

The structure of the cranio-visceral musculature of Teleostei differs considerably from that roughly sketched out above, so that the different groups of muscles must be arranged in an entirely different manner. Thus the following divisions may be distinguished:—(1) Muscles of the jaws; (2) muscles of the dorsal, and (3) muscles of the ventral ends of the visceral arches.

Each of these groups may again be subdivided, but further details about their arrangement, which is often very complicated, cannot be given here.

Amphibia.—It is to be expected, *a priori*, that the musculature of the visceral skeleton should be more highly developed in gill-breathing than in lung-breathing Amphibians; we thus find that in the former, more primitive relations are met with, connecting them with lower forms, while in the latter a greater modification, or rather reduction, of these muscles takes place.

Between the two rami of the lower jaw there lies a muscle with transverse fibres (the mylohyoid), supplied by the third division of the trigeminal and the facial; this represents the last remnants of the constrictor muscle of Fishes. As the elevator of the floor of the mouth, it stands in important relation to respiration and deglutition, and is retained throughout the rest of the Vertebrata up to Man (Fig. 98, 99, *Mh*, *Mh*¹).

A continuation of the trunk-musculature (the omo-, sterno-, and genio-hyoid) provided with tendinous intersections, lies above the mylohyoid (Fig. 99, *Re*¹, *Gh*). These muscles, which serve to pull the visceral skeleton forwards and backwards, are supplied by the first and second spinal nerves.

In contrast to Fishes, there is in Amphibia a definite differentiation into muscles of the tongue, that is, into a hyoglossus and a genioglossus, but these also must be considered as having been derived from the anterior end of the ventral muscles of the trunk; they are present in all Vertebrates, from the Amphibia onwards, and are supplied by the hypoglossal (the first spinal nerve of Amphibians).

In the Perennibranchiata and in Salamander larvæ the muscles of the hyoid and of the visceral arches may, by analogy with Fishes, be divided into a ventral and a dorsal group: the latter disappears in adult Salamanders and Anura, only the ventral persisting. Their function is to raise and depress the branchial arches, as well as to draw them forwards and backwards. To these may be added constrictors of the pharynx as well as (in gill-breathing animals) levators, depressors, and adductors of the external gill filaments (Figs. 98 and 99). They are innervated by the vagus and glossopharyngeal.

The jaw-muscles may be divided into a depressor (digastric, or biventer mandibulæ, Fig. 98, *Dg*), supplied by the facial, and into elevators of the lower jaw (masseter, temporal, and pterygoid

muscles, Fig. 98, *Ma, T*), supplied by the third division of the trigeminal. All these muscles, which may be derived from the adductor of the mandible of Elasmobranchs and Ganoids, arise from the auditory region of the skull.

Amniota.—With the simplification of the visceral skeleton in Amniota, there is a considerable reduction of the musculature belonging to it. All muscles connected with branchial respiration are of course wanting, and the ventral trunk-muscles, as mentioned above, are always interrupted in their forward extension by the sternum and pectoral arch. At the same time, the muscles along the neck and on the floor of the mouth met with in Amphibia are present here also; they are the mylo-, sterno-, omo-, and genio-hyoid, as well as the hyoglossus and genio-glossus. To these may be also added a sterno-thyroid, and a thyro-hyoid, continued forwards as a prolongation of the former.

The stylo-hyoid, stylo-glossus, and stylo-pharyngeus of Mammals, arising from the styloid process and stylo-hyoid ligament, and undergoing numerous variations, are neomorphs. They are supplied partly by the facial, partly by the glossopharyngeal, and act as retractors of the tongue and levators of the pharynx and hyoid.

The muscles of the jaws resemble those of Amphibia, although, especially in the case of the pterygoids, they are much more sharply differentiated, and are throughout more strongly developed. (A secondary subdivision of the muscles may occur in Birds and Reptiles, as for instance in the case of the temporal muscle.)

The facial muscles, forming a marked feature for the first time in Mammals, arise originally in the neighbourhood of the eyes, mouth, nose, and ears, around which they are principally grouped throughout life; they are thus connected with the most important organs of sense. They are supplied by the facial nerve, and attain their greatest development in Primates.

Following in the lines laid down by Gegenbaur in his *Lehrbuch der Anatomie des Menschen* on the origin of the facial muscles, G. Ruge has made detailed researches on the facial musculature of Lemurs, from which he arrives at the following results.

The fact that all the muscles supplied by the facial nerve belong to the same series indicates that those related to the visceral skeleton, and having originally nothing to do with the face, which are supplied by the same nerve, must have shifted upwards from the region of the lower jaw and neck, so as to come into close relation with the soft parts surrounding the apertures of the ear and mouth, that is, to the secondarily-formed lips and external ear. From these points they extended further, taking on new relations to the eye, nasal aperture, and frontal and temporal regions. The musculature further extended to the parietal region, the parts of it in front of the aperture of the ear arising from the frontal and temporal regions, those behind it from the occipital region. The upward change of position of the musculature thus took place along two lines,—in front of, and behind the ear, as is proved by its innervation, to be described directly.

Into all these regions the facial nerve extended, forming divergent branches and plexuses: a posterior (occipital) and four anterior (temporal, maxillary, mandibular, and a branch to the posterior belly of the biventer muscle) main branches may be distinguished.

The complexity of the branching of the facial nerve is thus proportionate to that of the facial muscles, and is most marked in Primates, in which the musculature gradually takes on new origins corresponding to the more and more highly differentiated cranial skeleton.

The platysma myoides thus forms the matrix for the facial muscles, and it represents the remnant of a musculature continued forwards to the head, which has retained (*e.g.* in Man) an undifferentiated form in the neck (Gegenbaur).

Besides the formation of new independent muscles, modifications of certain of the facial muscles also took place, which resulted in their more or less complete degeneration. Thus they have become replaced by tendinous aponeurotic regions (*viz.* the fascia temporalis, parotideo-masseterica, and the galea aponeurotica of Man), or even entirely obliterated.

Besides the platysma myoides there is a second deeper dermal system of muscles of the neck, the sphincter colli. This, like the platysma, also takes on secondary relations to the head, and gives origin to the levator labii superioris proprius, levator anguli oris, sphincter oris, depressor tarsi, buccinatorius, and the proper muscles of the nose. The facial muscles not mentioned here arise from the system of the platysma.

MUSCLES OF THE APPENDAGES.

The following important factors must be taken into consideration with regard to the muscles of the appendages: (1) the homologies of the parts of the skeleton; (2) the relative positions of the neighbouring soft parts; and (3) the nerve-supply.

The most primitive condition of the muscles of the extremities is met with in Dipnoi, more particularly in *Ceratodus*. In this case, the musculature of each surface of the fin forms a uniform mass, there being hardly any indication of a separation into definite layers and groups. Everything goes to prove that all the muscles of the appendages are to be looked upon as derivatives of the lateral muscles of the trunk.

Two principal groups of appendicular muscles may always be distinguished; one lying in the region of the pectoral and pelvic arches, the other in the free extremity.

In the fins of Fishes, very simple conditions of the muscles are met with; in Amphibia, on the other hand, in correspondence with the more highly-differentiated organs of locomotion, considerable complication is seen, and there is a much more marked separation into individual muscles, corresponding with the different sections of the extremity. In Fishes, only simple elevators, depressors, and adductors, for moving the extremity as a whole, are present, while from Amphibia onwards there are added rotators, flexors, extensors, and adductors of the upper arm and thigh, of the fore-arm and shank, and of the hand and foot. The digits are also moved by a highly-differentiated musculature.

In cases where, as in Primates, the anterior extremity is converted into a prehensile organ, new groups of muscles appear, known as pronators and supinators. The former are derived from flexors, the latter from extensors.

On account of the relatively small amount of movement of the pelvic arch as compared with the pectoral arch, one would naturally not expect similar groups of muscles connected with these two regions: entirely different relations are here frequently to be met with.

DIAPHRAGM.

The first traces of a muscular partition-wall between the thoracic and abdominal cavities are to be met with in Urodeles. In them we find circular and semicircular fibres of the transversalis muscle passing inwards between the pericardium and the liver. In Chelonians, and more particularly in Crocodiles and Birds, where the muscular fibres concerned in the formation of the partition arise from the ribs,¹ the indications of a diaphragm are much plainer, but there is not a complete separation into thoracic and abdominal cavities. A complete dome-shaped diaphragm, arising from the vertebral column, ribs, and sternum, appears first in Mammals, and is of great importance in respiration, as it allows of a lengthening of the thoracic cavity in a longitudinal direction. It is supplied by the phrenic nerve, which arises from one (4th to 6th) of the cervical nerves, and usually consists of two parts, a pericardial and a pleural, arising independently of one another. The former is fibrous, and forms the central tendon, while the latter is muscular. In some cases (*e.g.* Echidna, Phocæna) the diaphragm is entirely muscular. The Mammalian diaphragm is probably not the homologue of the so-called diaphragm of other Vertebrates.

BIBLIOGRAPHY.

- BARDELEBEN, C.—*Muskeln und Fascie*. *Jenaische Zeitschr.* Bd. XV. N.F. VIII.
 CUNNINGHAM, D. J.—*The Relation of Nerve-Supply to Muscle-Homology*. *Journ. of Anat. and Physiol.* Vol. XVI. 1882. *Report on some Points in the Anatomy of the Thylacine, &c., with an Account of the Comparative Anatomy of the Intrinsic Muscles of the Mammalian Pes*. "Challenger" Reports, Vol. V. *The Structure and Development of the Suspensory Ligament of the Fetlock in the Horse*. *American Naturalist*, Vol. XIX. p. 127.
 DOBSON, G. E.—*On the Digastric Muscle*. *Trans. Linn. Soc.* Vol. II. Part 5. *Monograph on the Insectivora*, 1882. *Homologies of the Long Flexor Muscles*. *Journ. of Anat. and Physiol.* Vol. XVII. 1883. *On the Rectus Abdominis and Sternalis*. *Ibid.* *The Comparative Variability of Bones and Muscles*. *Ibid.* 1885.
 DUGÈS, A.—*Rech. sur l'ostéologie et la myologie des batraciens à leurs différents âges*. Paris, 1834.

¹ In Birds, two entirely different structures have been described as a diaphragm. Comp. the chapter on the air-sacs of Birds.)

- ECKER, A., and WIEDERSHEIM, R.—*Die Anatomie des Frosches*. Braunschweig, 1864-1882.
- FÜRBRINGER, M.—*Die Knochen und Muskeln der Extremitäten bei den schlangenähnlichen Sauriern*. Leipzig, 1870. *Zur vergl. Anat. d. Schultermuskeln*. 1st and 2nd parts in *Jenaische Zeitschr.* Bd. VII. und VIII., 3rd part in *Morphol. Jahrb.* Bd. I. 1876.
- GADOW, H.—*Observations on Comparative Myology*. *Journ. of Anat. and Physiol.* Vol. XVI. See also Papers on the *Muscles of Reptiles*. *Morphol. Jahrb.* Bd. VII.
- GÖTTE.—*Entwicklung der Unke*. Leipzig, 1875.
- HENLE, J.—*Handbuch der systemat. Anatomie des Menschen*. Braunschweig, 1868.
- HUMPHRY, G. M.—Numerous Papers in the *Journal of Anatomy and Physiology*, Vols. III. and VI.
- HUXLEY, T. H.—*On the Respiratory Organs of Apteryx*. *Proc. Zool. Soc.* 1882.
- LECHE, W.—*Zur Anat. der Beckenregion bei Insectivora, &c.* *K. Schwed. Acad. der Wissensch.* Bd. XX. No. 4, 1882.
- MARSHALL, A. M.—*On the Head Cavities and Associated Nerves in Elasmobranchs*. *Quart. Journ. Micros. Science*, Vol. XXI. 1881.
- MÜLLER, J.—*Vergl. Anat. d. Myxinoiden*. Berlin, 1834-1845.
- RUGE, G.—*Ueber die Gesichtsmuskulatur der Halbaffen*. *Morphol. Jahrb.* Bd. XI. Heft 2.
- SCHNEIDER, A.—*Beitr. z. vergl. Anat. u. Entw.-Gesch. der Wirbelthiere*. Berlin, 1879.
- SMALIAN, C.—*Beiträge zur Anatomie der Amphisbaenen*. *Zeitschr. für wiss. Zool.* Band XLII.
- TESTUT, L.—*Les anomalies musculaires chez l'homme expliquées par l'anatomie comparée: leur importance en Anthropologie*. Paris, 1884.
- VETTER, B.—*Unters. z. vergl. Anat. der Kiemen- u. Kiefermuskulatur der Fische*. *Jenaische Zeitschr.* Bd. VIII. und XII. N. F. I. Bd.

D. ELECTRIC ORGANS.

ELECTRIC organs are present in certain Fishes, and are most strongly developed in a Ray (*Torpedo marmorata*), found in the southern seas, in a South American Eel (*Gymnotus electricus*) and in an African Siluroid (*Malapterurus electricus*). *Gymnotus*, the electric Eel, possesses by far the strongest electric

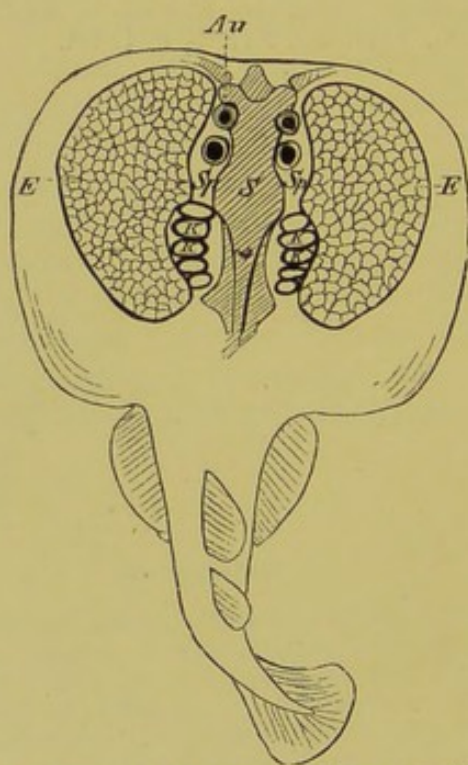


FIG 100.—*Torpedo marmorata*, WITH THE ELECTRIC ORGAN (*E*) EXPOSED.
S, skull ; *Sp*, spiracle ; *KK*, gills ; *Au*, eye.

power, next to it comes *Malapterurus*, and then *Torpedo*. The electric batteries of these three Fishes are situated in different parts of the body ; in *Torpedo* they have the form of a broad mass, extending throughout the substance of that part of the body lying between the gill-sacs and the propterygium on each

side of the head (Fig. 100, *E*); in *Gymnotus* they lie in the ventral portions of the enormously long tail (Fig. 101, *E*) that is, in the position usually occupied by the ventral portions of the great lateral muscles; and finally, in *Malapterurus*, the electric organ extends between the skin and muscles round almost the entire circumference of the body, thus enclosing the Fish like a mantle: it is especially strongly developed along the sides.

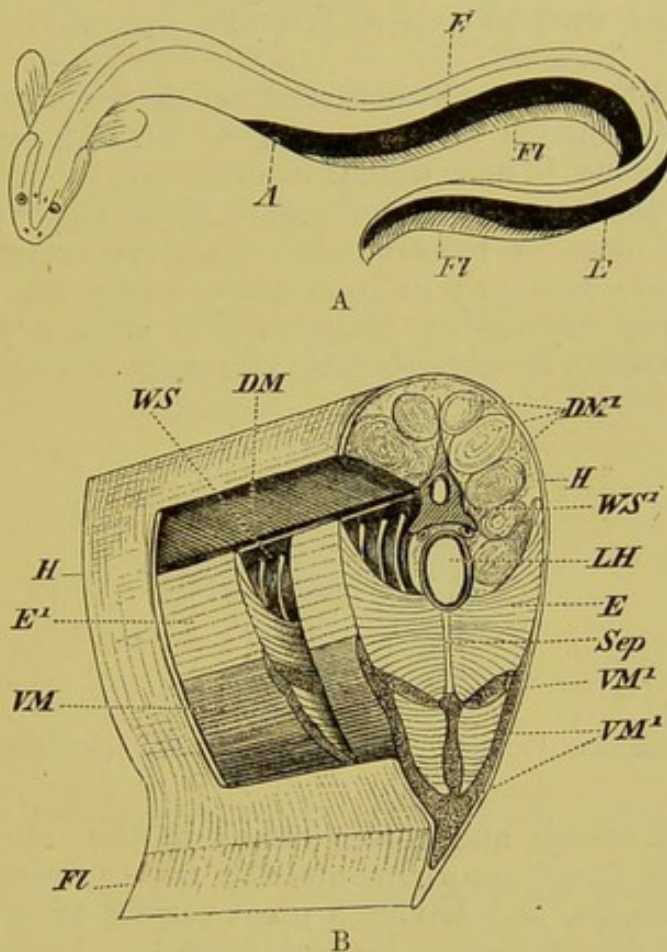


FIG. 101, A and B.—THE ELECTRIC ORGAN OF *Gymnotus electricus*. (B, from a preparation by A. Ecker.)

H, skin; *FI*, fin; *DM*, *DM'*, dorsal portions of the great lateral muscles, seen partly in transverse section, partly in longitudinal; *VM*, *VM'*, ventral portions of ditto; *E*, the electric organ, seen in transverse section at *E* (B), and from the side at *E'*; *WS*, vertebral column, from the side, showing the spinal nerves, and *WS'*, in transverse section; *LH*, posterior end of body-cavity; *Sep*, median longitudinal fibrous septum, which divides the electric organ and the lateral trunk-muscles into two equal halves; *A*, anus.

The electric power of those Fishes which were formerly known as "pseudo-electric" has now been fully demonstrated, though it is much feebler than in the forms described above. To this category belong all the Rays, with the exception of *Torpedo*, the various species of *Mormyrus*, and *Gymnarchus* (both belonging to the Teleostei). In all these, the electric organs lie on either side

of the end of the tail, and have a metameric arrangement like that of the caudal muscles; in the Mormyridæ, for example, there is on each side an upper and an under row of electric organs.

The electric apparatus in all the above-named Fishes is to be regarded from the same point of view both as concerns its mode of development and anatomical relations: all electric organs are to be looked upon as metamorphosed muscular tracts, and the nerve-endings belonging to them as homologues of the motor end-plates which are ordinarily found on muscles.

As regards the minute structure of the electric organs, the same essential arrangements are met with in all. The framework is formed of fibrous tissue, which, running partly longitudinally, partly transversely through the organ, gives rise to numerous polygonal or more or less rounded chambers or compartments. These latter are arranged in rows, either along the longitudinal axis of the body (*Gymnotus*, *Malapterurus*) or in a dorso-ventral direction (*Torpedo*), forming definite prismatic columns (Fig. 102).

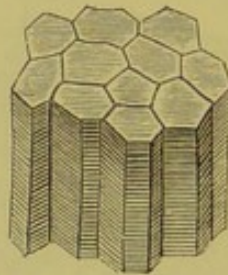


FIG. 102.—ELECTRIC PRISMS OF *Torpedo marmorata*. (Semidiagrammatic.)

Numerous vessels and nerves ramify in the connective-tissue lying between these compartments, the nerves being enclosed in very thick sheaths, and having a great variety of origin according to the species of Fish under consideration. In *Torpedo*, they arise from the "electric lobe" of the medulla oblongata, a single branch coming also from the trigeminal; in all pseudo-electric Fishes, as well as in *Gymnotus*, in which over two hundred nerves pass to the electric organ, they arise from the spinal cord, and most probably are in the closest relation with the ventral cornua of the latter, which are particularly well developed in the last-named Fish. It is very remarkable that the electric nerves of *Malapterurus* arise on each side from a single enormous nerve-cell, which, lying in the neighbourhood of the second spinal nerve, is continued into a very large primitive-fibre, which passes towards the end of the tail, dividing as it goes. The latter is invested by a thick sheath.

On continuing our examination into the more minute histological structure of the peripheral nerve-endings, it becomes necessary to give a definition of those structures which are usually

called "electric-" or "end-plates." These can be summarily described, as they are essentially the same in all electric Fishes.

After the nerve, running in the septum between the compartments, has by degrees lost its thick sheath and thus has almost ceased to show a double contour, it suddenly gives rise to a club-shaped swelling, and then divides up into a number of primitive fibres, which branch out in a tree-like manner, without, however, giving rise to definite meshes, so that we cannot speak of a proper nervous network. In *Torpedo* the nerve spreads out on the ventral side of the structure known as an electric plate (Fig. 103, *EP*), while in *Gymnotus* it passes to the posterior surface, that is to the one turned towards the tail. Finally in *Malapterurus*, the nerve, as in *Gymnotus*, passes on to the posterior surface of the electric plate; it does not stop here, however, but perforates the plate, so

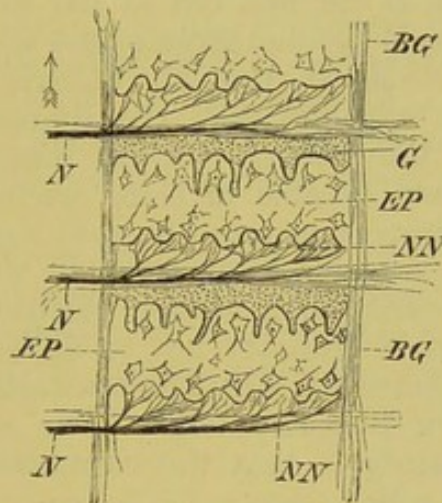


FIG. 103.—SECTION THROUGH THE ELECTRIC CHAMBERS. (Greatly enlarged, and semidiagrammatic.)

BG, framework of connective-tissue, forming walls of compartments; *EP*, electric plates; *N*, nerves entering into the septa between the compartments; *NN*, terminal fibres of the nerve, passing to the posterior (*Gymnotus*) or under (*Torpedo*) surface of each compartment; *G*, gelatinous tissue; the arrow points towards the head (*Gymnotus*), or towards the dorsal side of the animal (*Torpedo*).

as to spread out on the anterior surface, turned towards the head.¹ This difference must be borne in mind on account of the direction taken by the electric current, to be described later on.

Each electric plate consists of a homogeneous disk, transparent in the fresh condition, and surrounded by a special membrane, within which star-like cells with long processes are present. Both surfaces of the plate exhibit irregular protuberances, separated from one another by shallower or deeper notches, and giving the whole an irregular appearance.

¹ Babuchin, who had the opportunity of examining *Malapterurus* in the fresh condition, disputes strongly the perforation of the plate by the nerve; whether rightly or not, new researches must show.

As this disk, which, as already mentioned, is to be looked upon as metamorphosed muscle-substance, becomes inseparably fused with the nerve-plate lying close to it, it follows that the electric plate is not a uniform structure, as was formerly believed, but is to be regarded as having arisen out of two tissue-elements. The compartments are not entirely filled by the electric plates; a space filled by gelatinous tissue (Fig. 103, *G*), or sometimes only by a fluid, always remains in the upper (*Torpedo*) or anterior (*Gymnotus*, *Malapterurus*) side of each compartment along the wall separating it from the next. The side of the electric plate on which the nerve branches out is negative at the moment of discharge, while the opposite side is positive, and thus the different arrangements of the parts in *Gymnotus* and *Malapterurus* render it clear that the electric shock must pass in different directions in these Fishes: thus in *Malapterurus* it passes from the head to the tail, but in the contrary direction in *Gymnotus*. In *Torpedo* the discharge passes from below upwards.

Experiments have shown that all electric Fishes are proof against the electric current, with the limitation that muscles and nerves—even the electric nerves themselves—separated out from the body, are capable of being excited by the current. “The last and most important question with regard to the electric Fishes is naturally concerning the mechanism whereby the electric plates become temporarily charged with electricity. The reply to this question, although probably not so difficult a one as that relating to the mechanism of muscular contraction, is still far from being answered” (Du Bois-Reymond). The only thing that can be stated with certainty is, that the electromotive force is under the influence of the will.

BIBLIOGRAPHY.

- BABUCHIN.—*Uebers. der neueren Untersuchungen über Entwicklung, etc., der elektrischen und pseudoelektrischen Organe.* *Arch. f. Anat. und Physiol.* 1876.
- ECKER, A.—*Entwickl. der Nerven des elektr. Organs von Torpedo Galv.* *Zeitschr. für wiss. Zool.* Bd. I. 1848. *Unters. zur Ichthyologie.* Freiburg, 1857.
- REYMOND, E DU BOIS.—*Gesammelte Abhandlungen zur allg. Muskel- und Nervenphysik.* Bd. II.

E. NERVOUS SYSTEM.

THE following elements, which are all derived from the epiblast, may be distinguished in **nervous tissues**:—(1) Ganglion cells, provided with processes, and supported by a connective-tissue framework, the neuroglia; and (2) Fibres, entering into or arising from the former, and serving as conductors of sensory or motor impulses. Each fibre may be invested by a delicate covering or sheath, the neurilemma (primitive sheath, or sheath of Schwann).

The nervous system may be divided into three main parts, the central (brain and spinal cord), peripheral, and sympathetic systems. The central part is the first to arise, and is formed as a direct product of the epiblast; the other two become established later.

I. THE CENTRAL NERVOUS SYSTEM.

1. THE SPINAL CORD.

The first indication of the central nervous system is a furrow (medullary groove) which appears on the dorsal side of the embryo, and which gradually becomes converted into a tube by the meeting of its edges: this tube then becomes separated from the epiblast and gives rise to the hollow medullary cord (cp. p. 7), the walls of which are at first comparatively thin; it consists of a more expanded anterior, and a longer and more slender posterior section. From the former arises the brain, from the latter the spinal cord.

In an early stage of development the lumen of the medullary cord is as a rule continuous posteriorly with that of the primitive intestine (neurenteric canal). This connection, however, soon disappears, and the spinal cord then consists of a cylindrical or more or less flattened hollow cord, by no means filling the neural canal: its walls become gradually more and more thickened, until finally only a very narrow lumen, the central canal, remains; this is lined by ciliated epithelium.

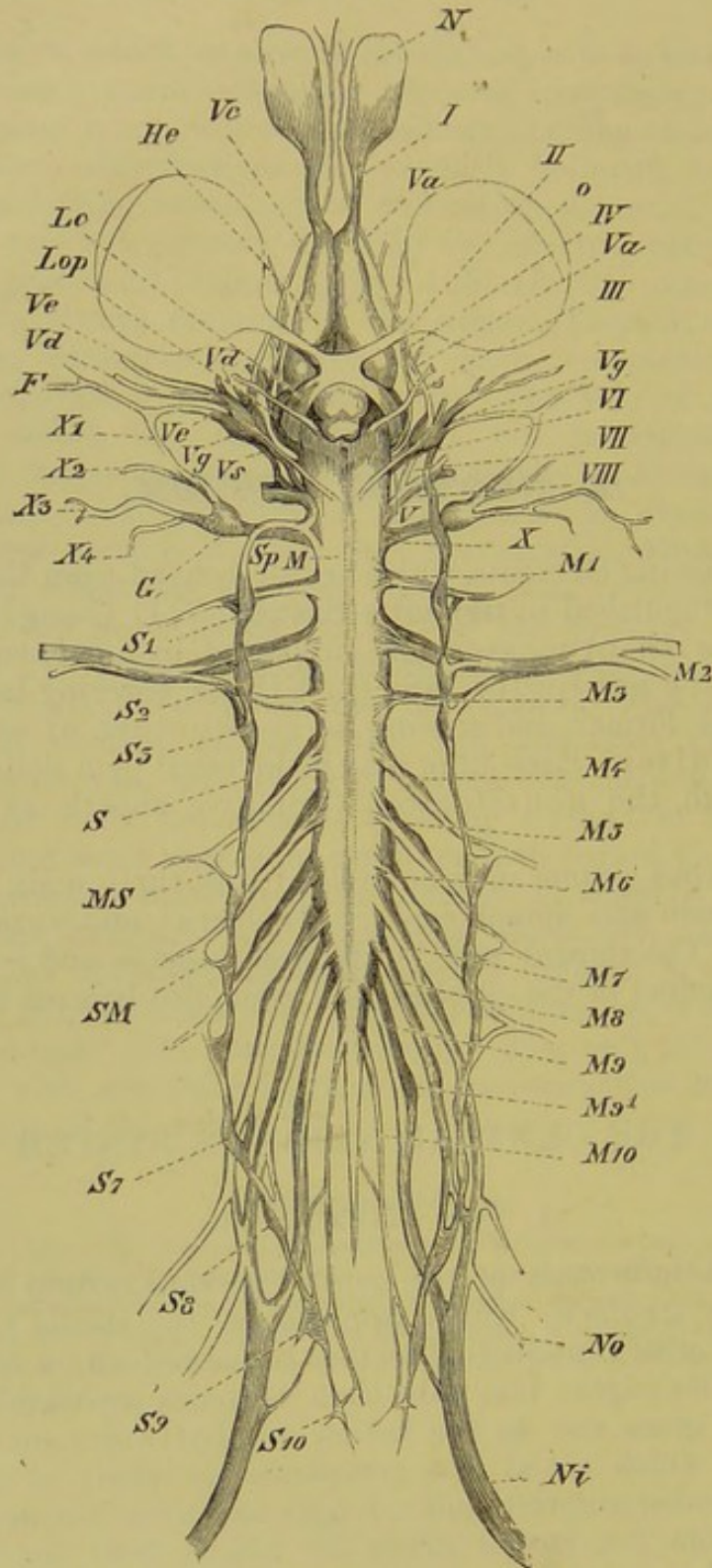


FIG. 104.—THE ENTIRE NERVOUS SYSTEM OF THE FROG. (After A. Ecker.)
(From the ventral side.)

He, cerebral hemispheres (prosencephalon); *Lop*, optic lobes (mesencephalon); *M*, spinal cord; *M1* to *M10*, spinal nerves, which are connected at *SM* by branches (rami communicantes) with the ganglia (*S1* to *S10*) of the sympathetic (*S*); *No*, femoral nerve; *Ni*, sciatic nerve; *I* to *X*, first to tenth cranial nerves (for their names, see text); *G*, ganglia of the vagus; *Vg*, Gasserian ganglion; *o*, eye; *N*, nasal sac; *Va* to *Vc*, the different branches of the trigeminal; *F*, facial nerve; *Vs*, connection of the sympathetic with the Gasserian ganglion; *X1* to *X4*, the different branches of the vagus. Some of the fibres of the sympathetic should be shown accompanying the vagus peripherally.

The cord is at first of a uniform diameter throughout, but later, in cases where the extremities are well developed and a richer nerve-supply becomes needed, it exhibits in these regions definite swellings—the brachial and lumbo-sacral enlargements. The spinal cord originally extends along the whole length of the neural canal, but its growth is usually less rapid than that of the vertebral axis, so that it comes eventually to be considerably shorter than the latter. In such cases (Primates, Cheiroptera, Insectivora, Aves, Anura, &c.) it passes at its posterior end into a brush-like mass of nerves, the so-called cauda equina; these lie mostly within the neural canal, and the nerves of the sacral plexus are given off from them. An axial prolongation of the spinal cord nevertheless extends far back, but is reduced to a thin thread-like appendage, the *filum terminale*.

The bilaterally-symmetrical form of the spinal cord is pronounced by the presence of longitudinal fissures running along it dorsally and ventrally; and if one imagines the points of exit of the dorsal (sensory) and ventral (motor) nerve-roots to be respectively connected together by a longitudinal line, each half of the spinal cord would thus be divided into three columns,—a ventral, lateral, and dorsal (anterior, lateral, and posterior columns of human anatomy).

The external form of the spinal cord in certain Fishes (*Orthogoriscus*, *Trigla*), and in embryos of *Salamandra atra*, as well as its histological structure in the higher Vertebrata, seems to indicate that the unsegmented spinal cord of Vertebrates was primitively segmented and paired, and that it has passed in its phylogenesis through a stage which was closely related to the abdominal chain of ganglia of many Invertebrates (*e.g.* Annelids). A definite segmentation of the mid-brain, cerebellum, and medulla oblongata is also seen in the embryos of all the chief Vertebrate types (Kupffer).

As regards its minute structure, two parts can always be distinguished in the spinal cord,—a white substance, consisting of medullated nerve-fibres, and a gray substance, composed principally of multipolar nerve-cells and non-medullated fibres. Their relative positions to one another vary greatly in the different animal groups, as well as in the different regions of the cord; the white substance, however, has usually a more peripheral, the gray a more central position.

The membranes of the spinal cord will be treated of later.

2. THE BRAIN.

At a very early stage three swellings may be seen on the anterior enlarged part of the medullary tube, which are spoken of as the primary anterior, middle, and posterior cerebral-vesicles (fore-, mid-, and hind-brain). (Fig. 105, *I*, *II*, *III*.)

The cavities of the vesicles, corresponding with the ventricles of the fully-formed brain, are in direct connection with the central

canal of the spinal cord. The primary fore-brain and hind-brain each become differentiated into two parts, and thus five divisions of the brain may be distinguished. Counted from before backwards these are **Prosencephalon** (secondary fore-brain), **Thalamencephalon** (primary fore-brain), **Mesencephalon** (mid-brain), **Metencephalon** (secondary hind-brain), and **Myelencephalon** (primary hind-brain). The prosencephalon is also spoken of later




FIG. 105.—DIAGRAM OF THE EMBRYONIC CONDITION OF THE CENTRAL NERVOUS SYSTEM.

G, brain, with its three primary vesicles, *I*, *II*, *III*; *R*, spinal cord.

as the cerebrum, the mid-brain as the optic lobes, or corpora bigemina,¹ the metencephalon as the cerebellum, and the myelencephalon as the medulla oblongata.

The olfactory lobes arise from the secondary fore-brain, which becomes divided into two cerebral hemispheres by a longitudinal fold, the basal portion of the vesicle becoming thickened to form a great mass of nerve-centres; this may be distinguished from the remaining peripheral part of the vesicle, or pallium, as the central portion (Fig 106, *Cs*).

Throughout the animal kingdom the prosencephalon plays a most important part, for the intellectual condition of the animal depends upon the extent of its development. It consequently attains the greatest perfection in Mammals, and above all, in Man. While in the lower Vertebrates the central portion of the fore-brain is provided with only three small commissures, connecting its two halves, in Mammals the two hemispheres become fused together along one portion of their inner surfaces, and thus give rise to the great commissures spoken of as the corpus callosum and the fornix.² While the outer surface of the hemispheres in all Vertebrates below the Mammalia is more or less smooth, in the latter fissures (sulci) and convolutions (gyri) may be present. These consist of folds of the gray cortical substance, which cause a greater or less increase of the superficial area.

The following structures arise from the thalamencephalon:—the optic thalami, formed as thickenings of its lateral walls; the primary optic vesicles, arising as paired basal and lateral outgrowths, from which the optic nerves and retina are derived later (Fig. 106, *Tho*, *Opt*); the pineal gland or epiphysis (*Z*), developed as a tube-like outgrowth of the roof; and finally, the

¹ In Mammals, each optic lobe becomes divided into two parts, and indications of a similar division are seen in some Lizards (see Fig. 119, *A*).

² Traces of a fornix are seen in certain Reptiles (*e.g.* Psammosaurus).

infundibulum (*I*), formed as a funnel-like extension of the floor, together with a part (the posterior lobe) of the pituitary body (hypophysis) (*H*).¹ The other part (anterior lobe) of the pituitary body arises by a gradual pinching off of the epithelium of the primary oral involution, and gives rise later to a gland-like structure.

The cerebellum, in the higher types, becomes differentiated into two lateral portions (lateral lobes), which may again be subdivided, and a median unpaired portion (superior vermis), which

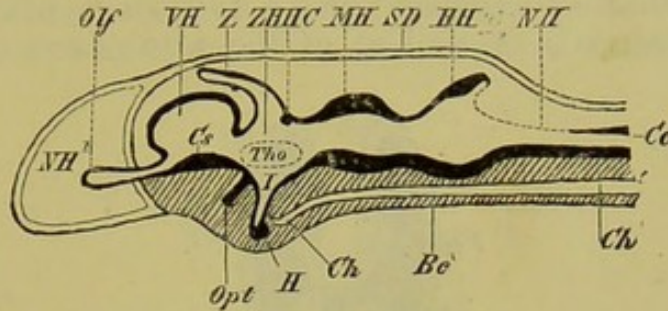


FIG. 106.—LONGITUDINAL SECTION THROUGH THE SKULL AND BRAIN OF AN (IDEAL) VERTEBRATE EMBRYO. (In part after Huxley.)

Bc, basis cranii; *Ch*, notochord; *SD*, roof of skull; *NH'*, nasal cavity; *VH*, secondary fore-brain (prosencephalon), showing the corpus striatum (*Cs*) at the base, and the olfactory lobe (*Olf*) anteriorly; *ZH*, thalamencephalon (primary fore-brain), which has given rise dorsally to the pineal gland (epiphysis) (*Z*), and ventrally to the infundibulum (*I*), to which the pituitary body (hypophysis) (*H*) is attached: anterior to this is seen the optic nerve (*Opt*), arising from the optic thalamus (*Tho*); *HC*, posterior commissure; *MH*, mid-brain (mesencephalon); *HH*, cerebellum (metencephalon, secondary hind-brain); *NH*, primary hind-brain (myelencephalon); *Co*, central canal of spinal cord.

connects these two. The other two portions of the brain (mid-brain and medulla oblongata) do not become so greatly modified as the fore-brain. It is therefore only necessary to mention that the medulla oblongata, the roof of which undergoes a retrogressive metamorphosis, gives origin to the greater number of the cranial nerves, so that its physiological importance is very great.

The following important changes take place in the further development of the brain.

The walls of the cerebral vesicles become more and more thickened, so that their cavities, transformed into the ventricles of the brain, undergo a gradual constriction.

¹ Opinions are much divided as to the meaning of the epiphysis and hypophysis. Some observers consider the epiphysis to be the homologue of the anterior neuropore of embryos of *Amphioxus* and *Tunicata*, that is, as the remains of a last connection of the brain with the epiblast: this opinion, however, is not tenable according to numerous later researches, all of which agree that it arises secondarily from the roof of the thalamencephalon. Others imagine it to be the last rudiment of a sense-organ, and from the fact that it arises in a similar manner to the optic vesicles it has been explained as an unpaired eye.

The hypophysis, as it seems to arise as a paired structure, is thought by Dohrn to correspond to a pre-oral gill-cleft: this is the latest of the many hypotheses which have been put forward on the subject.

A series of unpaired ventricles, lying in the longitudinal axis of the brain, as well as paired ventricles can always be distinguished. The principal paired cavities lie within the cerebral hemispheres, and are known as the lateral ventricles (Ventriculus 1 and 2) (Fig. 107, *SV*); each of these communicates with the unpaired system by means of an opening, the foramen of Monro (Fig. 107, *FM*). In Teleostei, certain Amphibia, and Sauropsida, each optic lobe also contains an optic ventricle, communicating with the unpaired system of ventricles. The latter consists of a third (within the thalamencephalon) and a fourth ventricle (in the medulla oblongata), as well as of the aqueduct of Sylvius,

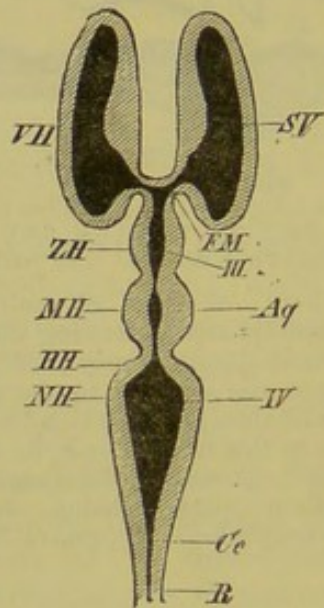


FIG. 107.—DIAGRAM OF THE VENTRICLES OF THE VERTEBRATE BRAIN.

VH, cerebral hemispheres, containing the lateral ventricles (*SV*); *ZH*, thalamencephalon, with the third ventricle (*III*); in Mammals the paired septum lucidum, lying anteriorly to the thalamencephalon, encloses the "fifth ventricle"; each lateral ventricle communicates with the third ventricle by a small aperture, the foramen of Monro (*FM*); *MH*, mid-brain, which encloses the aqueduct of Sylvius (*Aq*), communicating between the third and fourth ventricles; *HH*, cerebellum; *NH*, medulla oblongata, enclosing the fourth ventricle (*IV*); *Ce*, central canal of the spinal cord (*R*).

which passes through the mid-brain and connects these two. For further details, such as the relations of the different ventricles to particular parts of the brain, compare Figs. 106 and 107. A so-called fifth ventricle, lying between corpus callosum and fornix, is found in Mammals, but morphologically it is quite different from the others.

All five cerebral vesicles lie at first in the same horizontal plane, but in the course of development the axis of the vesicles becomes bent downwards, so that at a certain stage the mesencephalon forms the apparent apex of the brain (Fig. 108, *SB*). In Mammals, the parts of the brain become still further folded on one another, so

that a parietal (Fig. 108, *SB*), a Varolian (*BB*), and a cervical (*NB*) bend may be distinguished.

While in Fishes and Amphibia the cerebral flexure later becomes practically obliterated, it persists more or less markedly in the higher types, more particularly in Mammals. In the latter, moreover, the original relation of the parts becomes still further complicated by the large development of the cerebral hemispheres, which grow backwards, and thus gradually come to overlie all the other parts of the brain. This condition of things attains its greatest perfection in Man. Thus from the primitive relations of the various sections of the brain one behind another, they come

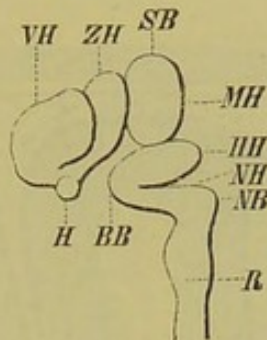


FIG. 108.—CEREBRAL FLEXURE OF A MAMMAL.

VH, prosencephalon; *ZH*, thalamencephalon, with the pituitary body (*H*) at its base; *MH*, mesencephalon, which at *SB* forms the most projecting portion of the brain, representing the so-called "parietal bend"; *HH*, metencephalon; *NH*, myelencephalon, forming the "cervical bend" (*NB*): the "Varolian bend" (*BB*) arises on the ventral circumference, at the junction between *HH* and *NH*; *R*, spinal cord.

to lie eventually more upon one another, the thalamencephalon, mid-brain, cerebellum, and medulla oblongata, becoming covered over by the hemispheres.

MEMBRANES OF THE BRAIN AND SPINAL CORD.

The enveloping membranes of the brain and spinal cord arise by a differentiation of a connective-tissue layer lying between the central organs of the nervous system and the surrounding skeletal parts. In Fishes, only two membranes are distinguishable, one, the **dura mater**, lining the inner surface of the cerebro-spinal canal, and the other, **pia mater**, investing the brain and spinal cord. The latter represents also the **arachnoid** of higher Vertebrates, which is not here differentiated as a separate membrane. The dura mater conveys vessels to the walls of the cerebro-spinal canal, that is, to the perichondrium or periosteum, while the pia mater, which is much richer in blood-vessels, has to do with the nutrition of the cerebro-spinal axis. The dura mater consists of two lamellæ, which, however, only remain distinct along the whole

central nervous system in the lower Vertebrata. In higher Vertebrates, its double nature persists only in the region of the vertebral column, the two layers becoming fused in the cranial portion. As the brain of Fishes by no means fills up the cranial cavity, a large lymph-space lies between the dura and pia mater; this corresponds to the so-called sub-dural space of the higher Vertebrata.

A differentiation of the primary vascular membrane of the brain and spinal cord into pia mater and arachnoid takes place in the higher Vertebrates, and these two layers become separated in those places where there are deep depressions between the individual parts of the brain; the deeper of these (pia)

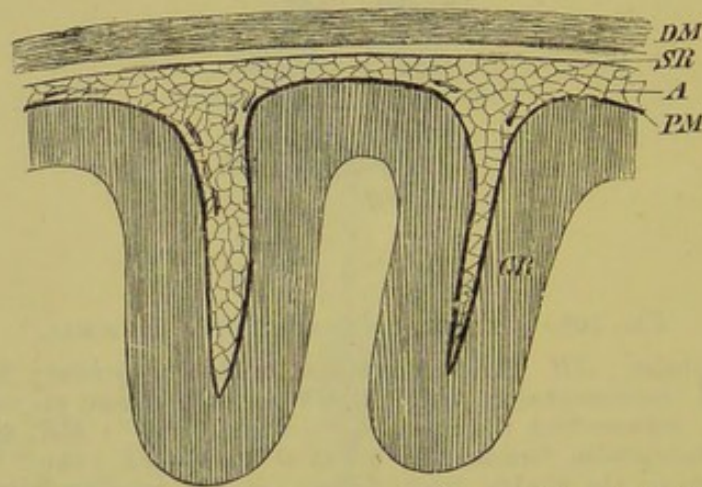


FIG. 109.—BRAIN-MEMBRANES OF MAN. (After Schwalbe.)

DM, dura mater; *SR*, sub-dural cavity; *A*, arachnoid; *PM*, pia mater; *GR*, gray cortical substance of the brain.

adheres closely to the brain, and also penetrates into the ventricles in the form of telæ choroideæ and plexus choroidei, while the superficial one (arachnoid) simply bridges over the depressions.

No certain explanation can as yet be given of the morphological meaning of the hollow anterior end of the spinal cord in *Amphioxus*, nor of the diverticulum connected with it which opens freely to the exterior on the dorsal surface.

Fishes.

The **Cyclostomi** show a very low condition of the brain, which in many points remains in an embryonic condition. This is particularly the case in the larval condition (*Ammocœtes*, Fig. 110), in which the brain possesses a narrow and elongated form. The individual vesicles lie in an almost horizontal direction one behind the other, and it is of great importance to note that

the part described on page 132 as the peripheral region (pallium) of the prosencephalon consists of a single layer of epithelial cells. This is covered on its dorsal surface by the pia mater, and thus here, as is also the case with the secondary fore-brain of Teleostei (see Fig. 113), there is a persistence of that low stage of development in which the prosencephalon is represented by a thin-walled and dorsally unpaired vesicle; that is, there is no separation into two hemispheres by a cleft in the peripheral region. In Fig. 110 the peripheral region is not indicated, and thus the central portion of the prosencephalon is seen, the floor of the latter, or corpora striata, being exposed. The olfactory lobes (*Lol*) are connected with the corpora striata anteriorly.

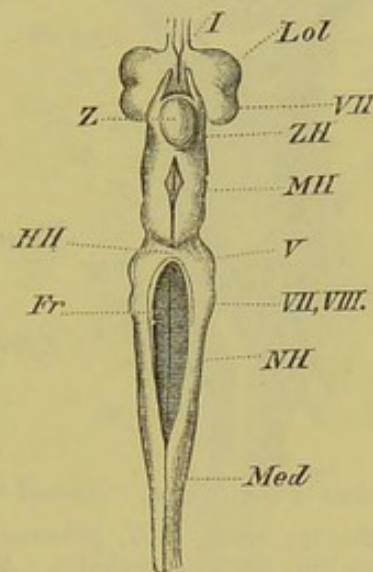


FIG. 110.—BRAIN OF *Ammocetes*. (Dorsal view.)

Lol, olfactory lobes and nerves (*I*); *VH*, basal portion of the prosencephalon; *ZH*, thalamencephalon, with the pineal gland (*Z*); *MH*, mesencephalon; *HH*, metencephalon, on each side of which is seen the origin of the trigeminal (*V*); *NH*, myelencephalon; *Fr*, fourth ventricle; *VII*, *VIII*, the points of origin of the facial and auditory nerves; *Med*, spinal cord.

The meten- and myelencephalon of *Ammocetes* are remarkably long, while in *Petromyzon* and *Myxine*, the individual portions of the brain are broader and more closely approximated. The epiphysis never breaks through the roof of the skull in Cyclostomes, as it does in many Fishes.

Elasmobranchii.—The brain of these Fishes, like that of Cyclostomes, is of a specialised form, characteristic of, and confined to, the group, though the particular regions are much more highly developed than in the Cyclostomi. According to their external form two main types of Elasmobranch brains can be distinguished. One of these, seen in *Spinax*, *Scymnus*, and *Notidanus*, is characterised by its very narrow and elongated form, while in the rest of the Elasmobranchii the individual parts are more closely compressed

and approximated together. In almost all Sharks the prosencephalon is relatively much longer than any of the other regions. The olfactory tracts, the length of which varies much, are connected with the anterior end of the prosencephalon, and pass forwards into the large olfactory lobes, from which the olfactory nerves arise (Fig. 111, *Tro*, *Lol*).

The thalamencephalon, appearing like a small commissure wedged in between the prosencephalon and mid-brain, grows out on its dorsal surface to form a chimney- or tube-like epiphysis;

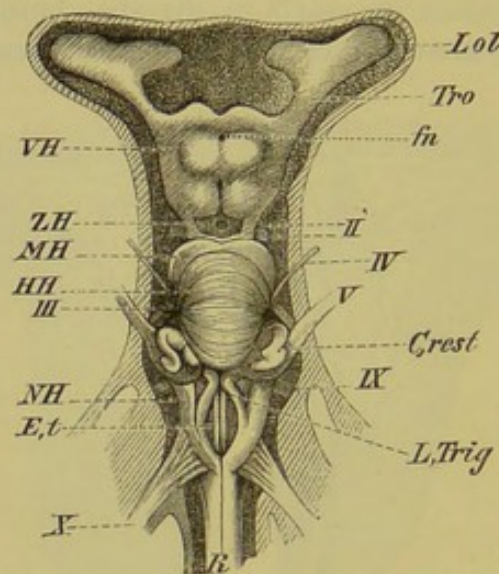


FIG. 111.—BRAIN OF *Galeus canis*, *in situ*. (Dorsal view.) (After Rohon.)

Lol, olfactory lobe; *Tro*, olfactory tract; *VH*, prosencephalon, showing at *fn* a foramen for blood-vessels; *ZH*, thalamencephalon; *MH*, mesencephalon; *HH*, metencephalon; *NH*, myelencephalon; *R*, spinal cord; *II*, optic nerve; *III*, oculomotor; *IV*, trochlear nerve; *V*, trigeminal; *L,Trig*, trigeminal lobe; *C,rest*, restiform body; *IX*, glossopharyngeal; *X*, vagus; *E,t*, eminentie teretes, between which is the calamus scriptorius.

this may reach to such a length as to extend beyond the anterior end of the brain for a considerable distance, and pass distally into the roof of the skull.

Two pairs of small folds, spoken of as lobi inferiores and sacci vasculosi or processus infundibuli (Fig. 112, *UL*), are present on the floor of the thalamencephalon. They probably arise in connection with the infundibulum, or perhaps with the hypophysis also.

The cerebellum is always very large, overlapping the medulla oblongata to a greater or less extent: it is divided up into several folds lying one behind the other (Fig. 111, *HII*). In Sharks the medulla oblongata is an elongated cylindrical body (Fig. 111, *NH*), while in Rays it is more compressed and triangular. In electric Rays a pair of lobi electrici arise from the gray matter of the floor of the fourth ventricle, and these enclose a mass of giant nerve-cells. For further details concerning, *c.g.*, the restiform bodies and trigeminal lobes, compare Figs. 111 and 112.

In the Angler (*Lophius piscatorius*, a Teleostean) there is also a superficial layer of enormous nerve-cells (about 200 in number) behind the calamus scriptorius of the sinus rhomboidalis, filling up the dorsal fissure of the spinal cord for a certain distance: their discoverer, G. Fritsch, calls them "lobi nervi lateralis." The axis fibres arising from these cells accompany the trigeminal and vagus, but do not go to electric organs, which are entirely wanting in *Lophius*, but to the integumentary sense-organs, which are enormously developed in this Fish, and also to the "lure." The similarity in position of these nerve centres to the electric lobes of *Torpedo*, however, deserves notice.

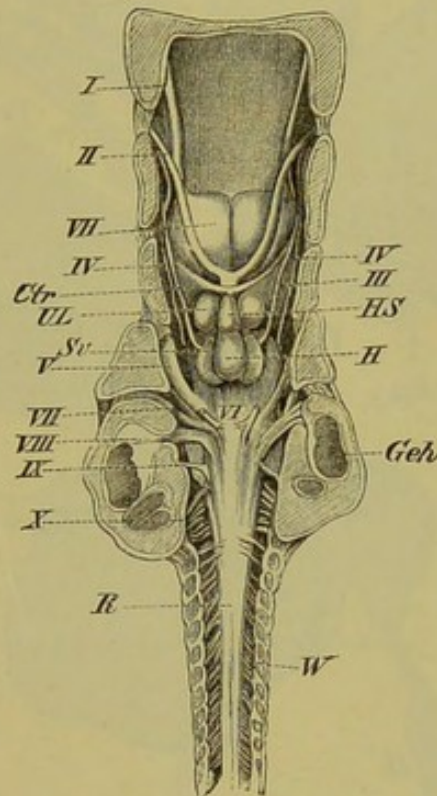


FIG. 112.—BRAIN OF *Myliobatis aquila*, *in situ*. (From the ventral side.)
(After Rohon.)

I, olfactory, *II*, optic, *III*, oculomotor, *IV*, trochlear, *V*, trigeminal, *VI*, abducent, *VII*, facial, *VIII*, auditory, *IX*, glossopharyngeal, and *X*, vagus nerves; *VH*, prosencephalon; *H*, *HS*, hypophysis and infundibulum; *UL*, lobi inferiores; *Sv*, saccus vasculosus; *Ctr*, transverse commissure; *Geh*, auditory capsule; *W*, vertebral column; *R*, spinal cord.

Teleostei.—The type of brain found in Teleosteans is also specialised, and restricted to the members of this order.

As is the case in nearly all Fishes, the brain by no means fills the cranial cavity, as already mentioned in the description of the brain-membranes, and as a rule it is separated from the roof of the skull by a greater or less amount of a lymph-like fluid.

The form of the brain in Teleostei varies greatly, more by far than in any other Vertebrate group. It is therefore difficult to give a general description of it, and only the following essential points can be mentioned here.

It never attains to so large a relative size as does that of Elasmobranchs. The peripheral region, as already mentioned (p. 137),

remains in an embryonic condition, and can hardly be said to have a physiological function; the brain of those Fishes in which this condition is retained probably acts mainly as a reflex machine, and there is little doubt that the mental processes

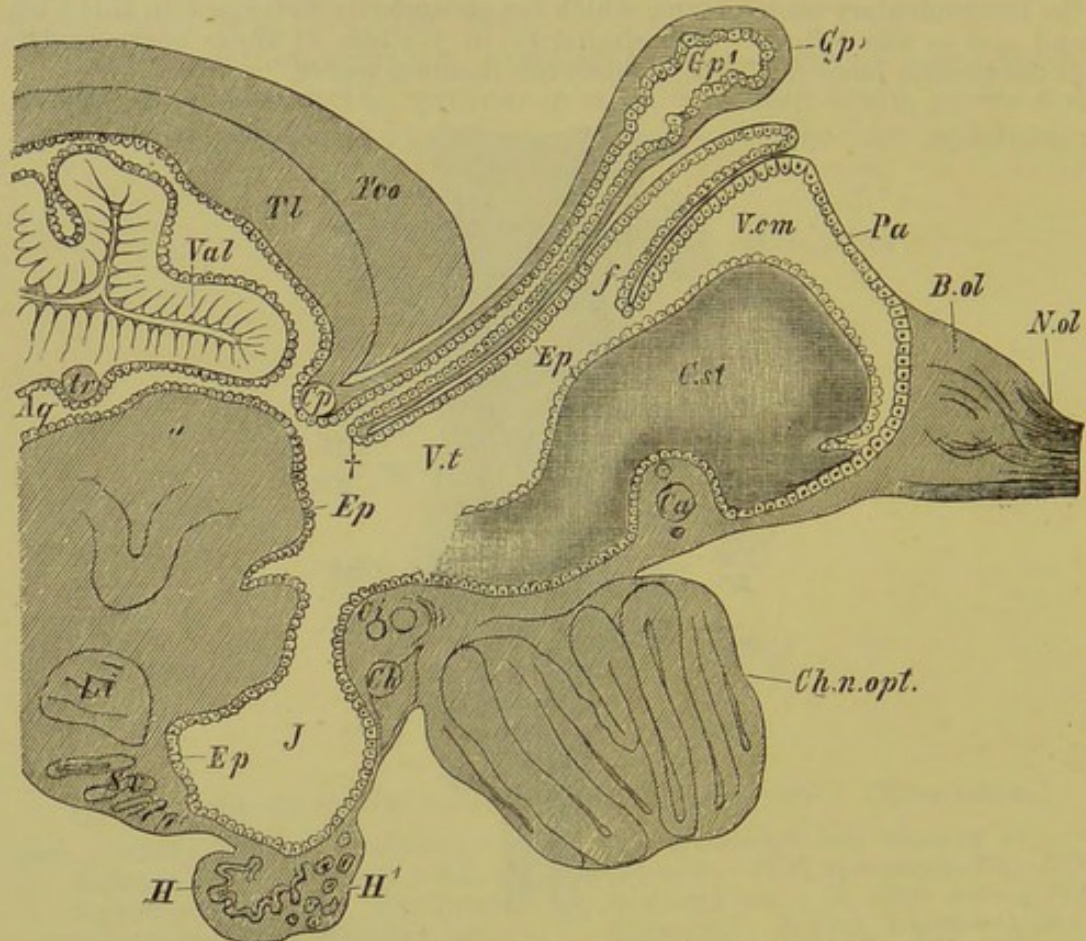


FIG 113A.—LONGITUDINAL VERTICAL SECTION THROUGH THE ANTERIOR PART OF THE TELEOSTEAN BRAIN. (Founded on a figure of the Trout's brain by Rabl-Rückhard.)

Tco, roof of the optic lobes; *Tl*, torus longitudinalis; *Cp*, posterior commissure; *Gp*, pineal gland, with a cavity (*Gp'*) in its interior; *Ep*, *Ep*, the ependyma, which lines the walls of the ventricles; †, point at which the epithelial roof of the secondary fore-brain (pallium, *Pa*) becomes continuous with the lining of the anterior wall of the pineal tube: the former is folded inwards at *f*; *V.cm*, common ventricle of the secondary fore-brain; *V.t*, third ventricle; *B.ol*, *N.ol*, olfactory bulb and nerve; *C.st*, corpus striatum, which was formerly taken to represent the whole of the prosencephalon, and which lies on either side of the middle line; *Ch.n.opt.*, optic chiasma; *Ci*, inferior commissure (Gadden); *Ch*, horizontal commissure (Fritsch); *J*, infundibulum; *H*, *H'*, hypophysis; *Sv*, saccus vasculosus; *Li*, lobi inferiores; *Aq*, aqueduct of Sylvius; *tr*, trochlear nerve; *Val*, valvula cerebelli.

which take place in the cortical gray substance of the brains of higher Vertebrates do not obtain in them.

The mid-brain and cerebellum are by far the largest portions of the brain (Figs. 114 and 115, *MH*, *HH*), while the thalamencephalon is depressed between the prosencephalon and

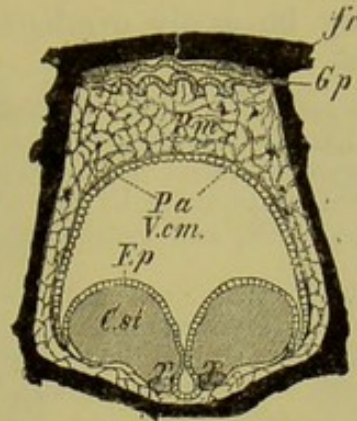


FIG. 113B.—TRANSVERSE SECTION THROUGH THE FORE-PART OF THE TELEOSTEAN BRAIN.

fr, frontal bone, underneath which the pineal tube, *Gp*, is visible in transverse section, and below this the pia mater, *Pm*; *Pa*, the pallium, or roof of the secondary fore-brain, formed of a simple epithelial layer; *V.cm.*, common ventricle; *Ep*, ependyma; *T, T*, olfactory tracts at the base of the corpora striata (*C.st.*).

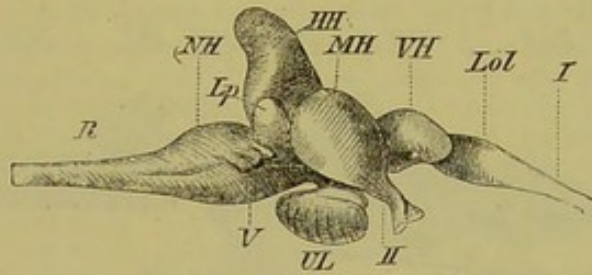


FIG. 114.—BRAIN OF PERCH (*Perca schraetser*). (Side view.)

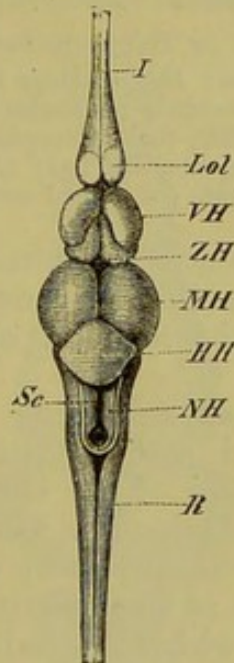


FIG. 115.—BRAIN OF *Perca schraetser*. (Dorsal view.)

Lol, olfactory lobe; *VH*, basal part of prosencephalon; *ZH*, thalamencephalon; *MH*, mesencephalon; *HH*, metencephalon; *NH*, myelencephalon; *R*, spinal cord; *I*, olfactory nerve; *II*, optic chiasma; *V*, trigeminal; *UL*, lobi inferiores; *Sc*, central sulcus at the bottom of the sinus rhomboidalis; *Lp*, lateral elevations of the cerebellum (lobi posteriores).

mid-brain, and thus may be easily overlooked (Figs. 114 and 115, *ZH*).

The prolongation of the cerebellum into the ventricle of the mid-brain, seen only exceptionally in Elasmobranchs, is present as a rule in Teleosteans, but the extent of its development varies much. The pineal gland does not differ essentially from that of Elasmobranchs and Ganoids, though it never extends into the roof of the skull, and usually remains within the brain-membranes.

As in Elasmobranchs, *lobi inferiores* and a *saccus vasculosus* are present in connection with the infundibulum. The *saccus vasculosus* is both glandular and vascular in structure, and its duct passes into the infundibulum; hence it is sometimes called the "infundibular gland."

Ganoidei, Dipnoi, and Amphibia.—Even apart from the brains of *Lepidosteus* and *Amia*, which are formed on the Teleostean type, a common ground-plan cannot be laid down for the brains of other Ganoids, Dipnoans, and Urodeles; in a certain measure they may be said to form one group, but in many points they resemble the brain of *Petromyzon*. They are all distinguished by

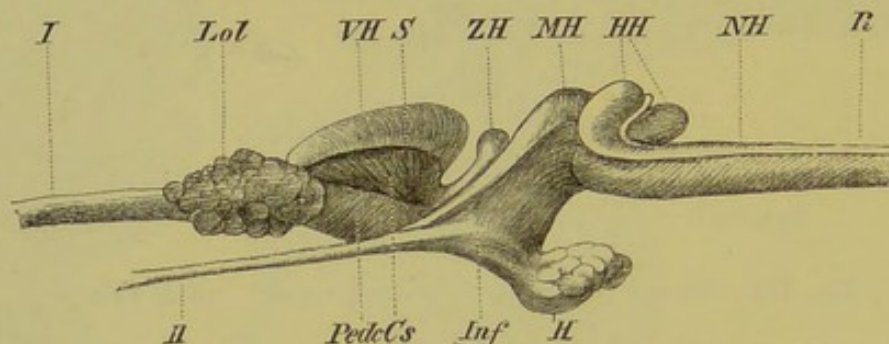


FIG. 116.—BRAIN OF *Polypterus bichir*. (Side view.)

I, olfactory nerve; *II*, optic nerve; *Lol*, olfactory lobe; *VH*, prosencephalon, with a lateral cleft at *S*, and the cerebral peduncles (*Pedc*) at its base, which radiate into the hemispheres at *Cs*; *ZH*, thalamencephalon, at the base of which is the infundibulum (*Inf*) with the pituitary body (*H*); *MH*, mid-brain; *HH*, cerebellum; *NH*, medulla oblongata; *R*, spinal cord.

a marked development of the cerebrum, while the cerebellum is only represented by a small transverse fold of nervous matter on the anterior end of the medulla oblongata (Figs. 116 and 117, *HH*).

The mid-brain is always paired; it encloses the narrow aqueduct of Sylvius, and extends laterally outwards into the optic tract. The extremity of the epiphysis sometimes extends into the roof of the skull (*Acipenser*, *Ceratodus*), and the thalamencephalon is not visible to any great extent on the dorsal side, though much more of it is exposed in *Urodela* than in *Gymnophiona* and *Anura*, in which the individual regions, especially the largely developed hemispheres and the broadened mid-brain (Fig. 118, *VH*, *MH*), are much more closely approximated than in *Urodeles* and *Ganoids*.¹

¹ As in Elasmobranchs, the epiphysis of *Anura* is produced into a long tube, the distal end of which not only passes into the roof of the skull, but (in the embryo) extends even to the skin. It becomes reduced later on.

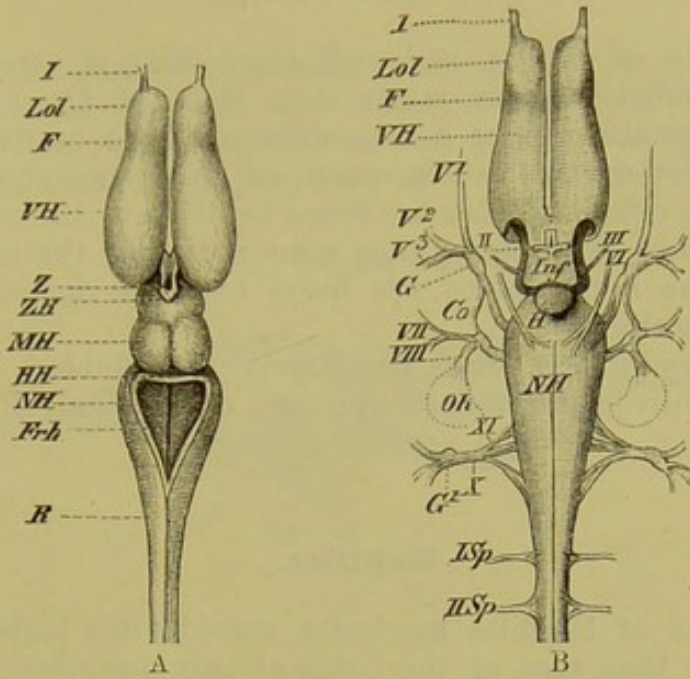


FIG. 117.—BRAIN OF *Salamandra maculosa*. (A, dorsal, B, ventral view.)

VH, cerebral hemispheres, marked off by a furrow (F) from the olfactory lobes (Lol); ZH, thalamencephalon, with the pineal gland (Z) and the ingrowth of the choroid plexus on the dorsal side, the infundibulum (Inf), and the pituitary body (H); MH, optic lobes; HH, cerebellum; NH, medulla oblongata; Frh, fourth ventricle; R, spinal cord; I, olfactory nerve; II, optic nerve, with its chiasma; III, oculomotor; V¹, V², V³, first, second, and third divisions of the trigeminal, which arise from the Gasserian ganglion (G); Co, commissure between the roots of the trigeminal and facial nerves; VI, abducent nerve; VII and VIII, facial and auditory nerves, arising from a common root; Oh, auditory capsule; XI, X, glossopharyngeal and vagus group; G¹, ganglion of vagus; I Sp, II Sp, first (hypoglossal) and second spinal nerves.

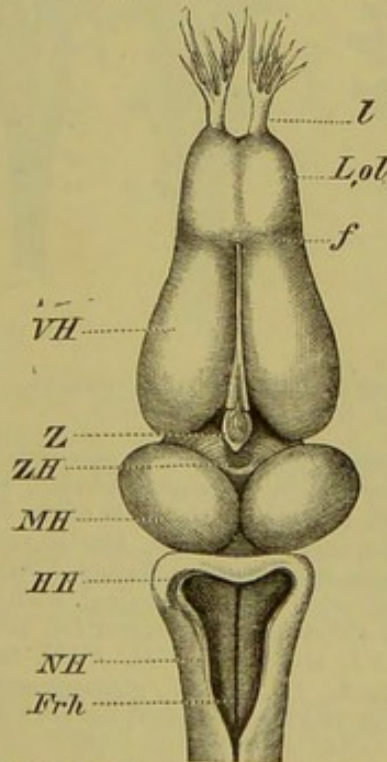


FIG. 118.—BRAIN OF *Rana esculenta*. (From the dorsal side.)

VH, cerebral hemispheres marked off from the olfactory lobes (L, ol) by a furrow (f); l, olfactory nerve; ZH, thalamencephalon, with the pineal gland (Z); MH, mid-brain; HH, cerebellum; NH, medulla oblongata; Frh, fourth ventricle.

The brain of Anura, and still more that of Gymnophiona, reaches a much higher stage than that of Urodeles, which retains to a greater extent a resemblance to the brain of Fishes. In Rana, moreover, the fore-parts of the hemispheres in the region of the olfactory lobes are fused together in the middle line; in Urodeles and Protopterus they remain distinct throughout. In Ceratodus the hemispheres are fused together dorsally, and in Ganoids ventrally.

Olfactory lobes may be largely (Amphibia, Polypterus, Ceratodus), only moderately (Sturgeons), or not at all (Protopterus) developed.

Reptiles.

The brain of Reptiles reaches a considerably higher stage of development than that of the forms already described, and this is

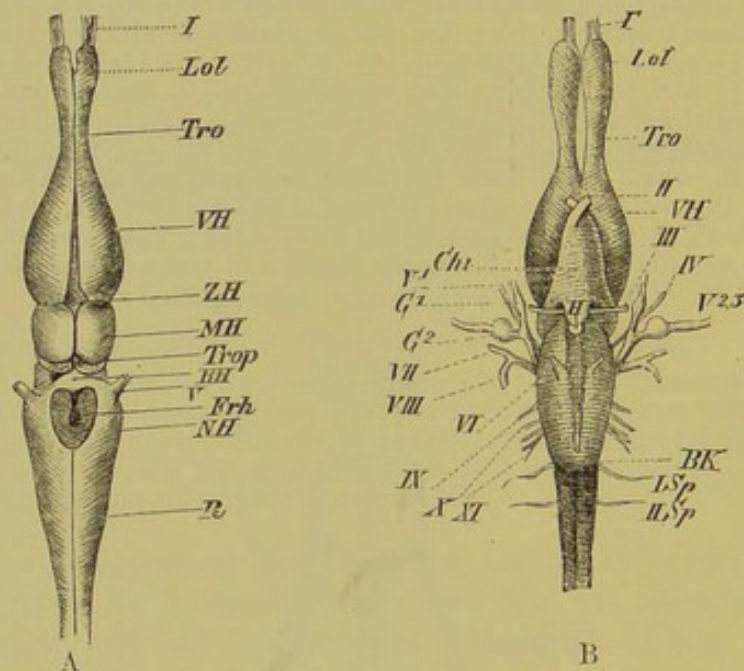


FIG. 119.—BRAIN OF BLINDWORM (*Anguis fragilis*). (A, from the dorsal, B, from the ventral side.)

VH, cerebral hemispheres, narrowing anteriorly to pass into the olfactory tracts (*Tro*) and the olfactory lobes (*Lol*); *ZH*, thalamencephalon, with the hypophysis (*H*); *MH*, optic lobes, encircled behind by the roots of the optic tracts (*Trop*); *HH*, cerebellum; *NH*, medulla oblongata; *Frh*, fourth ventricle; *R*, spinal cord; *I*, olfactory nerve; *II*, optic nerve, with chiasma (*Chi*); *III*, oculomotor; *IV*, trochlear nerve; *V¹*, first division of the trigeminal, with its special ganglion (*G¹*); *V²*, *V³*, second and third divisions of the trigeminal, arising from a common root (*G²*); *VI*, abducent; *VII*, *VIII*, facial and auditory nerves, arising from a common root; *IX*, *X*, *XI*, glossopharyngeal, vagus, and spinal accessory; *I Sp*, *II Sp*, first and second spinal nerves; *BK*, Varolian bend.

most pronounced by the individual parts coming to overlie one another to a greater extent, and by the larger development of both the peripheral and basal portions of the hemispheres.

The former character is seen most plainly in the Agamæ and Ascalabotæ (Geckos), the latter in Snakes, Chelonians, and Crocodiles. A knowledge of the anatomy of the skull will help us as regards the external form of the brain of Reptiles, and

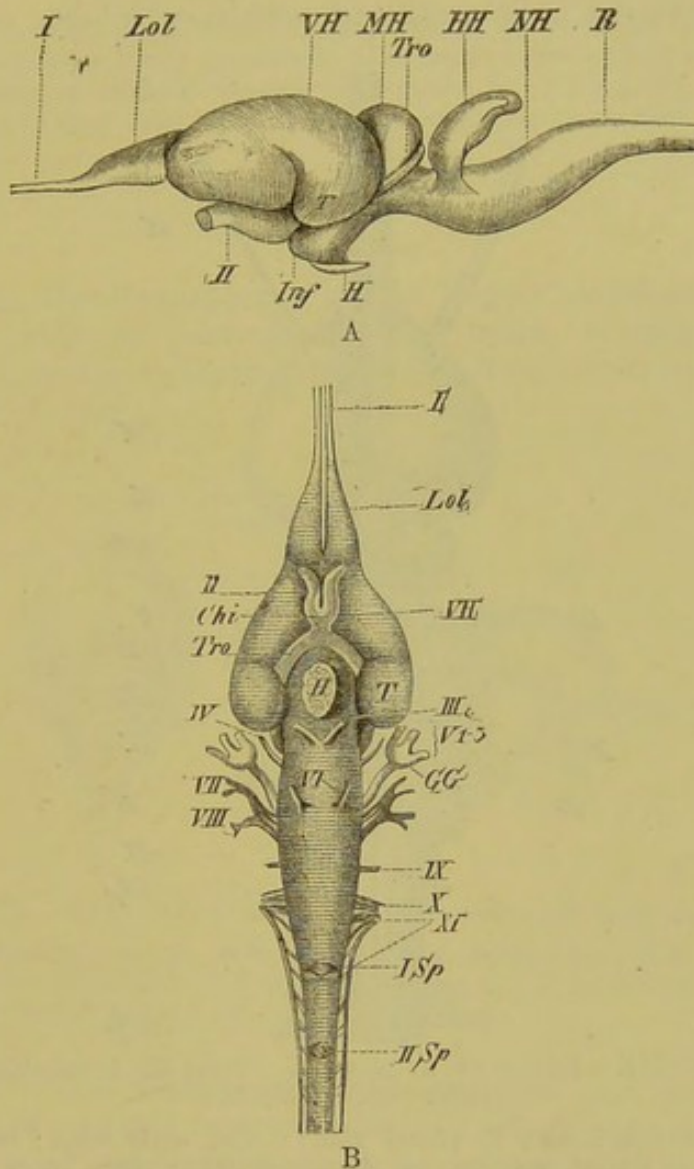


FIG. 120.—BRAIN OF *Emys europæa*. (A, side, B, ventral view.)

VH, cerebral hemispheres; *Lol*, olfactory lobe; *T*, temporal lobe; *Inf*, infundibulum; *H*, hypophysis; *MH*, optic lobes; *HH*, cerebellum; *NH*, medulla oblongata; *R*, spinal cord; *I*, olfactory, and *II*, optic nerves; *Tro*, optic tract; *Chi*, optic chiasmæ; *III*, oculomotor; *IV*, trochlear; *V¹*—*V³*, first, second, and third divisions of the trigeminal, all of which arise from the Gasserian ganglion, *GG*; *VI*, abducent, *VII*, facial, *VIII*, auditory, *IX*, glossopharyngeal, *X*, vagus, and *XI*, spinal accessory nerves; *I Sp*, *II Sp*, first and second spinal nerves.

the reader is referred to that section of the introduction to the chapter on the skull in which the interorbital narrowing of the cranial cavity is described (p. 57).

The brain of Lizards and Blindworms (*Anguis*) exhibits a far

lower organisation than that of other Reptiles. The hemispheres are small and pyriform, and all the different parts are narrower and more extended longitudinally; the brain thus bears a closer resemblance to that of Urodeles (compare Figs. 119, 120, A and B, and 121). Olfactory lobes seem to be wanting in Crocodiles only. An olfactory ventricle is usually present in each lobe.

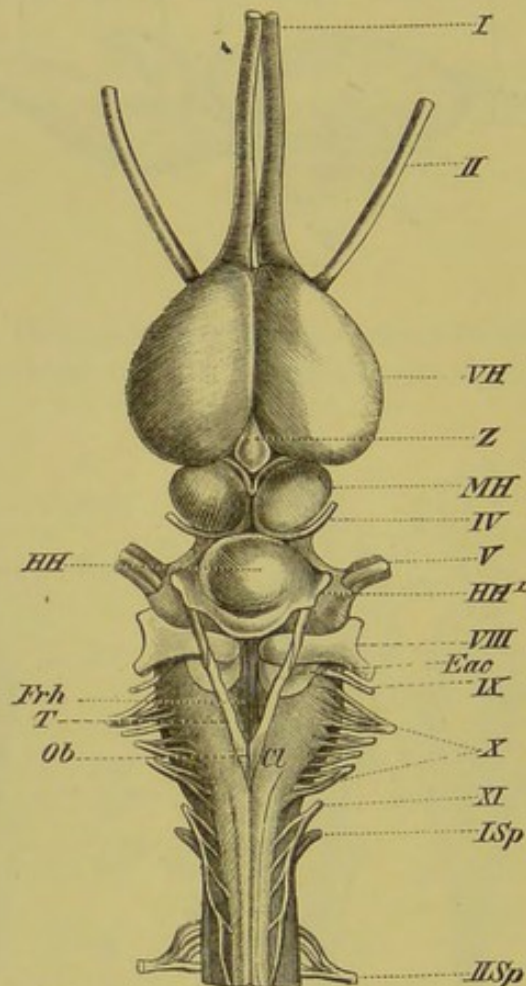


FIG. 121.—BRAIN OF ALLIGATOR. (From the dorsal side.)
(After Rabl-Rückhard.)

VH, cerebral hemispheres; *Z*, pineal gland; *MH*, optic lobes; *HH* and *HH'*, median and lateral portions of the cerebellum; *Frh*, sinus rhomboidalis, bounded by the eminentiæ acusticæ (*Eac*), the tæniæ medullares (*T*), the obex (*Ob*), and the clava (*Cl*); *I*, olfactory nerve; *II*, optic nerve; *IV*, trochlear nerve; *V*, trigeminal, *VIII*, auditory, *IX*, glossopharyngeal, *X*, vagus, *XI*, spinal accessory, and *I Sp*, *II Sp*, first and second spinal nerves.

The thalamencephalon is always depressed, and is hardly, or not at all, visible from the dorsal side. It gives rise to a distinct infundibulum as well as to an epiphysis, which in the embryos of Lizards, as in those of Anura, extends into the roof of the skull, but which becomes narrowed and reduced later.

The mid-brain always consists of a well-marked paired portion, and from it the optic tracts pass downwards and forwards to the chiasma, the fibres of the optic nerve taking on a secondary

connection with the mid-brain. The cerebellum usually consists of a thicker median, and two fold- or wing-like lateral portions. It generally overlies the sinus rhomboidalis for some distance, and attains its greatest development in the Crocodilia (Fig. 121, *HH*).

Judging from the casts of the cranial cavity, the brain of Dinosaurians must have been very lowly organised, and much more nearly related to that of Lizards than to that of Birds. The genus *Stegosaurus* possessed the smallest brain of any terrestrial Vertebrate relatively to its size.

Birds.

In Birds, the hemispheres are so largely developed that they overlie the anterior part of the mid-brain, bending back the pineal gland, and only leaving the cerebellum uncovered (Fig. 122, A and B, *VH*, *HH*).

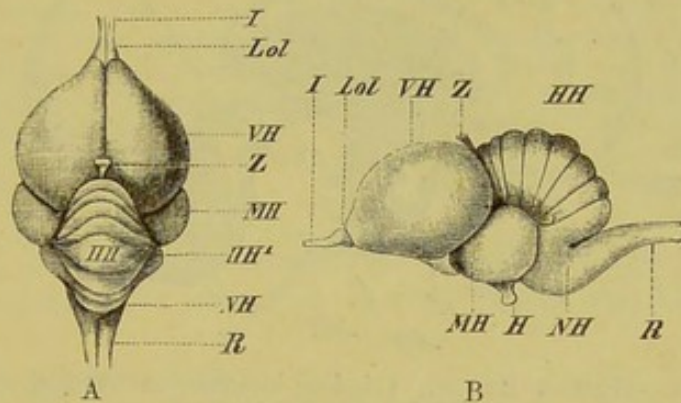


FIG. 122.—BRAIN OF PIGEON. (A, from above; B, from the side.)

VH, cerebral hemispheres; *Z*, pineal gland; *MH*, optic lobes; *HH*, *HH'*, cerebellum (vermis and flocculi); *NH*, medulla oblongata; *R*, spinal cord; *H*, pituitary body; *I*, olfactory nerve; *Lol*, olfactory lobe.

The cerebellum consists of a well-developed and folded median lobe, and of two lateral portions (flocculi), which vary much both in form and size. Posteriorly it completely covers the fourth ventricle. The two optic lobes are separated from one another and pressed downwards, so as to lie on the sides of the brain in the angle between the hemispheres, cerebellum, and medulla oblongata (Fig. 122, *MH*), and they are connected by a broad commissure. Olfactory lobes are always present, but only slightly developed. The corpora striata (basal portion of the cerebrum) lying within the hemispheres are so largely developed that they form by far the greater part of this region of the brain.

The toothed Birds of the Cretaceous period, with *Hesperornis* at their head, possessed a very lowly organised Reptilian-like brain, with small hemispheres and large olfactory lobes. The brain of *Archæopteryx* was highly developed, nearly resembling that of existing Birds.

Mammals.

While in many cases (*e.g.* Marsupials, Rodents, and Insectivores) the mid-brain lies more or less freely exposed, in the series of the Primates the hemispheres gradually come to cover all the other parts of the brain. The presence of large commissures between the hemispheres—the corpus callosum¹ and fornix—is very characteristic of Mammals: the hemispheres are also differentiated into lobes, which are usually more or less convoluted, giving rise to gyri separated by sulci, which serve to increase

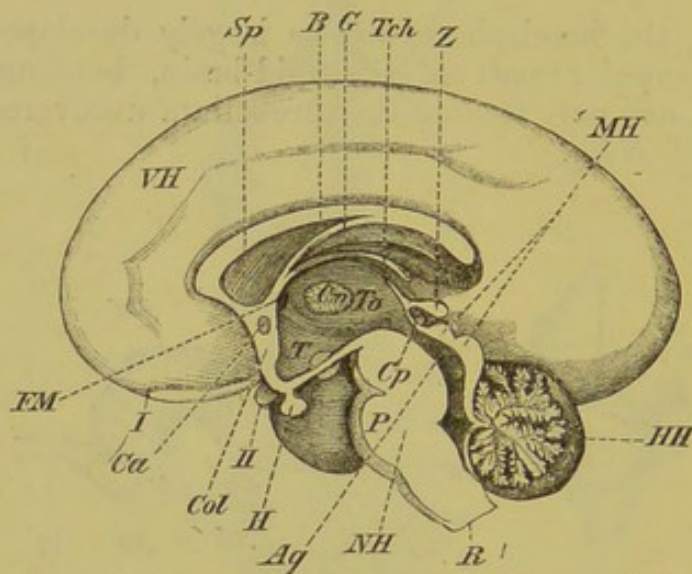


FIG. 123.—HUMAN BRAIN. (Median longitudinal vertical section.)
(Mainly after Reichert.)*

VH, cerebrum; *To*, optic thalamus (thalamencephalon), with the middle commissure (*Cm*); *Z*, pineal gland; *T*, infundibulum; *H*, pituitary body; *MH*, corpora bigemina, with the aqueduct of Sylvius (*Aq*), anterior to which is seen the posterior commissure (*Cp*); *HH*, cerebellum; *NH*, medulla oblongata, with the pons Varolii (*P*); *R*, spinal cord; *B*, corpus callosum; *G*, fornix, which extends antero-ventrally to the lamina terminalis (*Col*), in the upper part of which is seen the anterior commissure (*Ca*), and between the latter and the optic thalami (*To*) the foramen of Monro (*FM*); *Tch*, tela choroidea; *I*, olfactory nerve; *II*, optic nerve.

the superficial area. The amount of convolution varies much in the different orders: thus in the brain of Primates frontal, parietal, occipital, temporal, and central lobes may be distinguished.² The central lobes correspond to the region described above as the basal portion of the prosencephalon.

¹ The corpus callosum is very small in Monotremes and Marsupials, only the part corresponding to the anterior genu of higher types being developed, and this is the part which is the first to appear in the embryo of the latter. The relative size of the anterior commissure is in inverse proportion to that of the corpus callosum.

² Corresponding with this division into definite lobes there is also a marked differentiation of the lateral ventricles, so that an anterior, a posterior, and an inferior cornu can be distinguished in each.

The division of the cerebellum into a median and two lateral portions, already indicated in Reptiles, but much more plainly marked in Birds, is carried to a still further extent in Mammals.

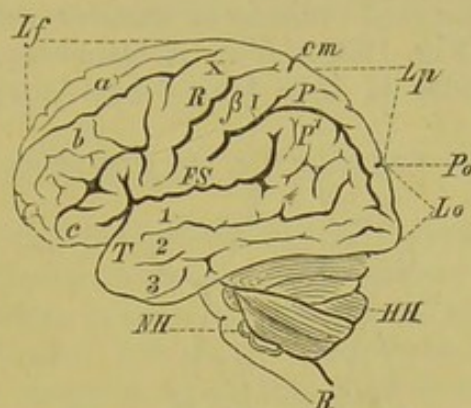


FIG. 124.—CONVOLUTIONS OF THE HUMAN BRAIN. (After A. Ecker.)

Lf, frontal lobe; *Lp*, parietal lobe; *Lo*, occipital lobe; *T*, temporal lobe; *a*, *b*, *c*, superior, middle, and inferior frontal gyri; *X*, β , anterior and posterior central convolutions, separated from one another by the fissure of Rolando (*R*); *em*, the calloso-marginal sulcus, on the dorsal surface; *P*, *P'*, superior and inferior parietal gyri, separated from one another by the interparietal fissure (*I*); *Po*, parieto-occipital fissure; *FS*, Sylvian fissure; 1 to 3, superior, middle, and inferior temporal convolutions; *HH*, cerebellum; *NH*, medulla oblongata; *R*, spinal cord.

The median portion gives rise to the so-called superior vermis, while the lateral parts form the lateral lobes and flocculi.

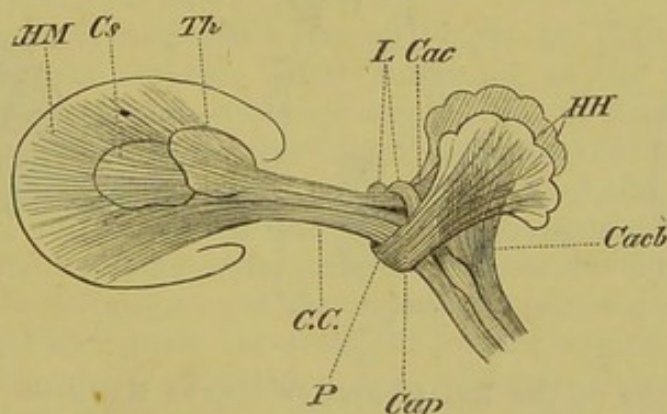


FIG. 125.—DIAGRAMMATIC FIGURE OF THE PRINCIPAL BANDS OF NERVE-FIBRES OF THE MAMMALIAN BRAIN. (From a drawing by A. Ecker.)

Cacb, crura medullæ ad cerebellum; *Cap*, crura cerebelli ad pontem; *Cac*, crura cerebelli ad corpora bigemina; *C.C.*, crura cerebri; *HM*, hemispheres; *Cs*, corpus striatum; *Th*, optic thalamus; *L*, lemniscus; *P*, pons Varolii; *HH*, cerebellum.

The two lateral lobes are connected by a large commissure, the pons Varolii (Fig. 123, *P*): this extends round the medulla oblongata ventrally, and is more largely developed the higher we pass in the Mammalian series.

Other bands of nerve-fibres connecting parts of the brain are spoken of as peduncles of the cerebellum (*crura medullæ ad cerebellum*, *crura cerebelli ad pontem*, and *crura cerebelli ad corpora bigemina*) and cerebrum (*crura cerebri*) (Fig. 125).

In Mammals the mid-brain is of smaller relative size than in other Vertebrates (Fig. 123, *MH*). A transverse furrow across its dorsal surface divides it into four lobes (*corpora bigemina*).

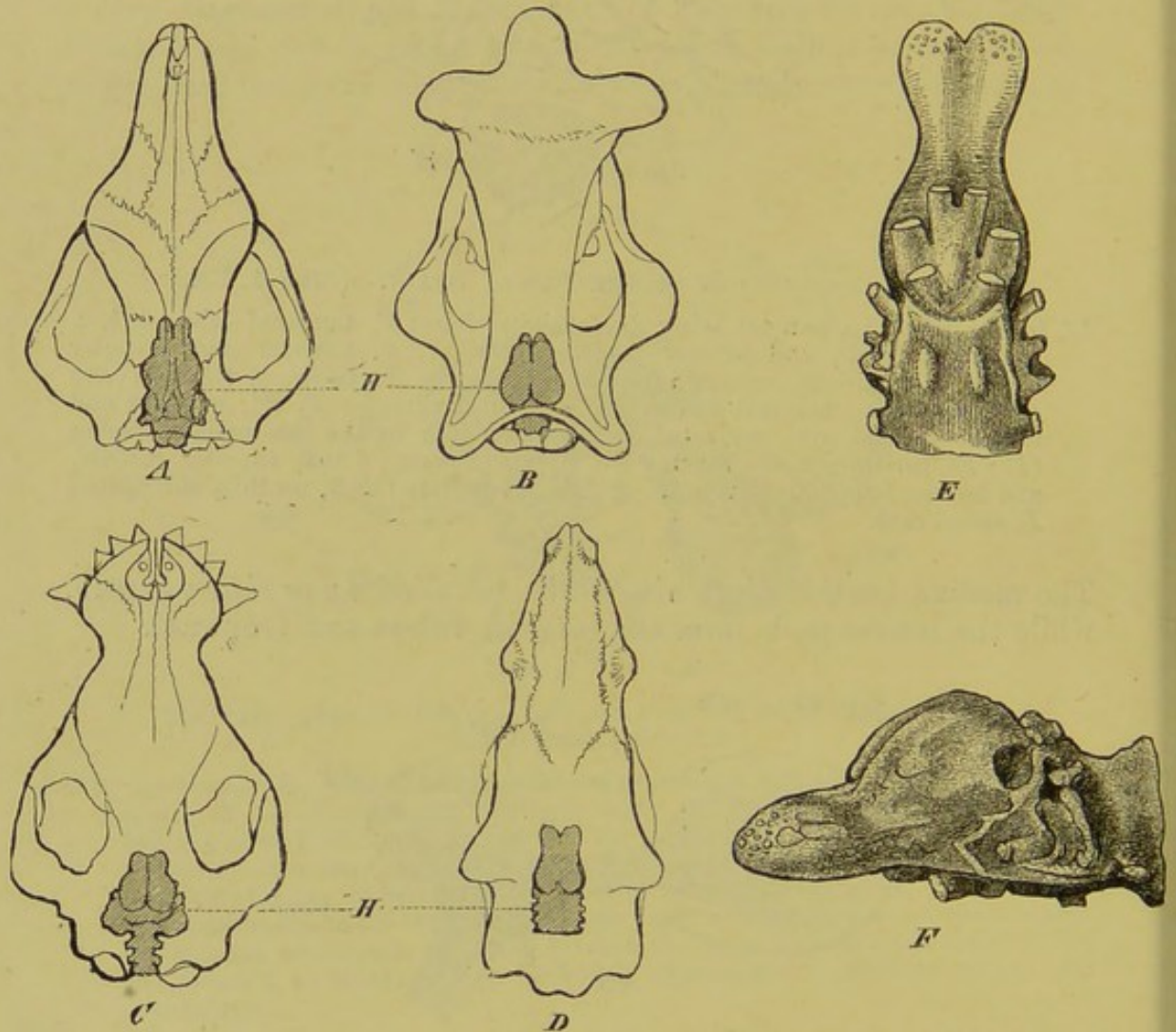


FIG. 126.—CASTS OF THE BRAIN-CASES OF EOCENE MAMMALS. (After Marsh.)

Skull, with brain indicated, of *A*, *Tillotherium fodiens*; *B*, *Brontotherium ingens*; *C*, *Coryphodon hamatus*; *D*, *Dinoceras mirabile*. *E* and *F*, ventral and lateral views of casts of the brain of *Dinoceras mirabile*.

The pineal gland (Fig. 123, *Z*) is displaced by the enlarged hemispheres, and rests upon the anterior lobes.

The reader is referred to Fig. 123 for details as to the relations of the corpus callosum, the fornix, the thalamencephalon, the three commissures of the central portion of the brain, &c. These parts will be better understood by a comparison with the description of their development given in the introduction to this chapter.

The brains of Tertiary Mammals were in a very low stage of development (comp. Fig. 126, *A* to *F*). Quite apart from the relatively diminutive size of the brain, and more particularly of the hemispheres, its structure reminds us in many points of the Reptilian brain, though these animals were probably related to the Ungulata and Proboscidea.

II. PERIPHERAL NERVOUS SYSTEM.

By means of the peripheral nervous system a physiological connection is established between the periphery of the body and the central nervous system in both centripetal and centrifugal directions. All parts of it, whether formed of nerve-cells or fibres, appear to arise as bands or outgrowths of the central nervous system, and are consequently derivatives of the epiblast. Thus the whole nervous system represents a single organ morphologically as well as physiologically, and the connection of the nerves with their peripheral end-organs is to be looked upon, at least as far as we know at present, as a secondary one.

Two principal groups of peripheral nerves may be distinguished, viz. **spinal** and **cranial**, that is, those which arise from the spinal cord and brain respectively. The first are the more primitive and simple structures, and they all show a similar arrangement along both dorsal and ventral sides of the spinal cord, so that each segment of the trunk possesses a dorsal and a ventral pair. The former consists of sensory, the latter of motor fibres.

This regular arrangement can no longer be plainly recognised in all the cerebral nerves. Their condition in the early embryo, however, shows that they have a similar origin to the spinal nerves: both groups arise from two continuous longitudinal ridges of cells lying along the dorso-lateral regions of the medullary cord, which become later differentiated into segmentally-arranged ganglia, the intersegmental portions undergoing no further development.

Nerve-fibres (processes of the multipolar nerve-cells, consisting of axis-fibres) now grow out from the dorsal region of the spinal cord into this chain of ganglia, pass through them, and appear again on the other side. The dorsal nerve-roots thus arise secondarily, that is, after the conversion of the neural ridge into a chain of ganglia, while the ventral roots are developed independently from the medullary cord, and appear to be formed later than the dorsal.

We must thus bear in mind that each dorsal or sensory nerve, whether it belongs to the brain or to the spinal cord, has originally a ganglion in connection with it, while in the ventral nerves a ganglion is wanting.

On the distal side of each ganglion, both nerve-roots become bound up in a common sheath, though many facts seem to indicate

that in the ancestors of existing Vertebrates the dorsal and ventral roots remained distinct.

The common trunk formed by the junction of the two roots divides up again into a dorsal, a ventral, and an intestinal branch. The first of these goes to the muscles and skin of the back, the second supplies the lateral and ventral portions of the body-wall, while the intestinal branch comes into connection with the sympathetic (see p. 160).

1. SPINAL NERVES.

As a general rule, each corresponding pair of dorsal and ventral roots lies in the same transverse plane: an exception to this is seen however, in *Amphioxus*, Cyclostomes, and Elasmobranchs. In *Amphioxus* the mesoblastic somites of the right and left side are arranged alternately, and thus the points of exit of the nerves also alternate, while in the two last-named groups of Fishes each ventral pair alternates with a dorsal pair. In Ganoids also lateral displacements of the nerve-roots are to be met with.

While in Fishes the greatest variations are seen as regards the mode of exit of the nerves (which pass through the intercalary pieces of the vertebral column, through the arches, or between them), from the Amphibia onwards the nerves always make their exit on each side between the arches, through the intervertebral foramina. In their primitive undifferentiated condition the spinal nerves have a strictly metameric arrangement, and are equally developed in all regions of the body. As already pointed out in the chapter on the spinal cord, this condition becomes modified by the development of the appendages, so that a number of spinal nerves unite together to form plexuses,¹ which according to their position are spoken of as **cervical, brachial, lumbar, sacral, &c.** The number and size of the nerves composing them is usually directly proportional to the development of the appendages: a special description of them, however, cannot be given here, and only the following points will be touched upon.

In contrast to Fishes, the great variation in the plexuses of which renders it impossible to reduce them to a common plan, we find from the Amphibia onwards a typical grouping of the branches of the brachial plexus. The following branches may be distinguished:—(1) Anterior thoracic nerves (the dorsalis scapulæ and thoracicus posterior s. lateralis of human anatomy); (2) anterior brachial nerves, the homologues of the subscapulares, cutaneus brachii internus minor (with limitations), axillaris, and radialis; (3) posterior brachial and thoracic nerves (thoracici s. pectorales anteriores, cutaneus internus major s. medius musculo-cutaneus, median, and ulnar nerves (with limitations).

¹ For a description of their composition, see Wiedersheim's *Lehrbuch der vergl. Anatomie*.

The lumbo-sacral plexus shows in general, and more particularly in Mammals, much greater variations than does the

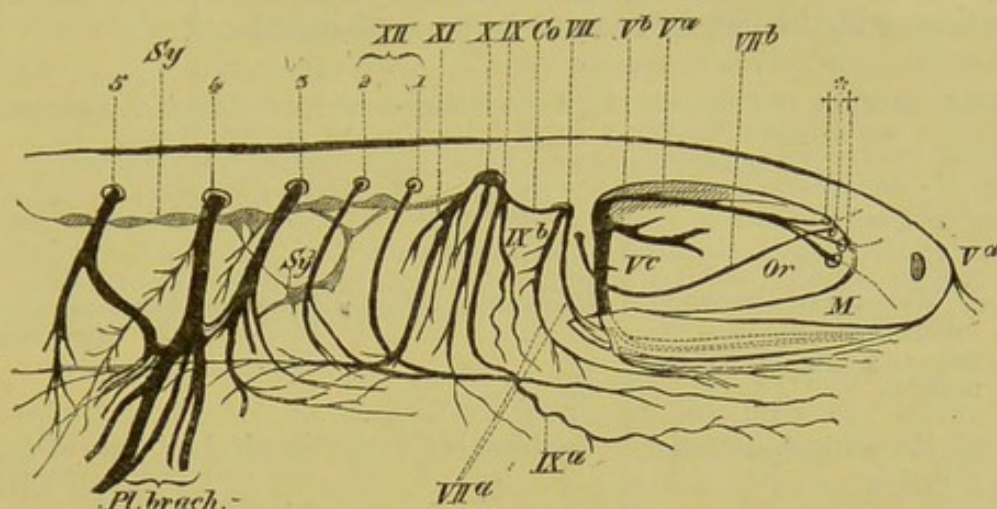


FIG. 127.—CEREBRAL NERVES AND BRACHIAL PLEXUS OF *Salamandra atra*.

V^a , ophthalmic branch of the trigeminal; V^b , its maxillary branch; V^c , its mandibular branch; ††, entrance of the ophthalmic branch into the nasal capsule and V^a , its extension forwards to the snout; VII, facial nerve; VII^a, its hyomandibular branch; VII^b, its palatine branch, which enters the nasal capsule at *; Co, commissure between the facial and glossopharyngeal (IX); IX^a, branch of the glossopharyngeal to tongue; IX^b, its pharyngeal branch; X, vagus; XI, spinal accessory; XII 1, hypoglossal (first spinal nerve, which becomes connected peripherally with the second spinal nerve, XII 2); 1 to 5, the first five spinal nerves; Pl. brach., brachial plexus; Sy, sympathetic cord, showing a connection with the spinal nerves at Sy¹; Or, orbit; M, maxilla.

brachial plexus. The nerves arising from it are spoken of as obturator, crural, and sciatic. The latter divides up in the hind-limb into a tibial and a fibular nerve.

2. CRANIAL NERVES.

As already mentioned, the cranial nerves become so much modified in the course of development that their primary relations, as a rule, can be no longer recognised. Nevertheless, it is important to understand these primary relations thoroughly before pursuing our inquiries further. It must therefore be borne in mind that the head is primitively composed of a series of metameres, and that the brain and skull are correlated genetically.¹

We must now ascertain, as far as is possible in the present state of our knowledge, to which individual metameres the different cranial nerves belong (see Fig. 41). The latest researches on this subject have reference mainly to Elasmobranch embryos, though the results obtained have been confirmed in other Fishes (Cyclostomi, Teleostei), and to a certain extent in Mammals also.

¹ For the appearance of dorsal ganglia of the cranial nerves in the embryo, compare the chapter on the sensory organs of the integument, p. 166.

The following general summary gives a scheme of the primitive relations of the head segments. It is to be noticed that the first and second cranial nerves—the olfactory and the optic—are not mentioned in the list, for reasons to be explained later.

TABLE SHOWING THE SEGMENTAL ARRANGEMENT OF THE CRANIAL NERVES, WITH THEIR RELATION TO THE METAMERES OF THE HEAD.

	Ventral branch.	Dorsal branch.
1st Metamere (superior, inferior, and internal rectus, and inferior oblique muscle).	Oculomotor (<i>III</i>).	Ramus ophthalmicus profundus of the trigeminal (<i>V</i>).
2nd Metamere (superior oblique).	Trochlear (<i>IV</i>).	Trigeminal (with the exception of its ramus ophthalmicus profundus).
3rd Metamere (external rectus).	Abducent (<i>VI</i>).	} Facial (<i>VII</i>), and auditory (<i>VIII</i>).
4th Metamere (muscles which are early aborted).	Wanting.	
5th Metamere (muscles which are early aborted).	Wanting.	Glossopharyngeal (<i>IX</i>).
6th Metamere (very rudimentary muscles).	Appears to be wanting.	} Vagus (<i>X</i>).
7th to 9th Metameres (muscles extending from the skull to the pectoral arch, including the anterior portion of the sterno-hyoid).	Hypoglossal (<i>XII</i>).	

The cranial nerves may be divided into four main groups,¹ quite apart from their metameric signification. The first consists of the olfactory, or first, and the optic, or second cranial nerve; the second of the nerves of the eye-muscles, *i.e.* the oculomotor, trochlear, and abducent nerves, the third of the trigeminal with the auditory and facial, and the fourth of the glossopharyngeal and vagus. The eleventh cranial nerve, or spinal accessory, as well as the twelfth, or hypoglossal, although they occasionally (in Mammals for instance) are included within the cranial cavity, come under the category of spinal nerves.

Olfactory Nerve.—The olfactory, when compared with the other cranial nerves, possesses many peculiarities, which seem to give it an isolated position. It grows out secondarily from the

¹ No satisfactory morphological explanation has yet been given of the two pairs of nerves branching out to supply the anterior end of the body in Amphioxus.

olfactory lobe or from a part of the brain developed from it, and does not at first consist, like the ordinary cranial and spinal nerves, of a series of non-nucleated axis fibres, but has the form of nucleated bundles, which arise from a network of star-shaped cells of the olfactory lobe. These nuclei are therefore identical with the nuclei of nerve-cells.¹

These observations were made on the human subject, and it is very desirable that similar researches should be extended to the lower Vertebrates. It might then be possible to explain the fact that the roots of the olfactory nerve are usually double. The roots either eventually unite on either side to form a common trunk, or else (less commonly) remain entirely separate, so that two olfactory nerves perforate the ethmoid on each side (*Gymnophiona*).

A definite cribriform plate is not always present; far more commonly the whole undivided trunk of the olfactory nerve extends into the nasal cavity, and only then begins to break up. This holds good for by far the greater number of Vertebrates below Mammals, as well as for Monotremes.

It appears very probable that the olfactory nerve, in spite of its peculiarities in the human subject, arises primitively, that is, phylogenetically, in a similar manner to the ordinary cranial nerves. The important circumstance that in Fishes it arises from the primitive ridge of the medullary tube, from which all the other nerves take their origin, is in favour of this supposition.

Optic Nerve.—As already mentioned, the optic nerve arises from the stalk of that outgrowth of the primary fore-brain which is spoken of as the primary optic vesicle. Inasmuch, therefore, as it represents a part of the brain, it cannot be compared with any of the other nerves. It remains for further researches to show whether it is possible, on phylogenetic grounds, to consider it as originally a segmental nerve.

Three more or less sharply differentiated portions may in most cases be distinguished in the optic nerve; these are spoken of from the proximal to the distal end respectively as the optic tract) chiasma, and nerve.

The chiasma, that is, the crossing of the two optic nerves, is always present, though not always freely exposed, for it may retain a primitive position deeply embedded in the base of the brain, as in *Cyclostomes*.

While in most *Teleosteans* the optic nerves simply overlie one another (Fig. 128, A), in some of these Fishes (*Harengus*, *Engraulis*,

¹ The olfactory lobes, which are closely united with the hemispheres, are originally directly applied to the olfactory mucous membrane, which is perforated by numerous fine fibres from them. This condition persists throughout life in *Cyclostomes*: in other Fishes, in correspondence with the separation of the olfactory organs and brain by the secondary growth of the head, each olfactory lobe becomes drawn out into an olfactory tract, the main mass of the lobe remaining in connection with the olfactory organ, and thus being widely separated from the brain. In *Elasmobranchs* the olfactory lobes are usually short and thick, while in *Teleosteans* they are long and slender.

Fig. 128, B), one nerve passes through a slit in the other, and this condition of things is gradually carried still further in Reptiles, until finally the fibres of the two nerves intercross in a very complicated manner (Fig. 128, C, D), giving rise to a sort of basket-work; this is finest and most delicate in Mammals, where its structure can only be analysed by comparing a series of sections.

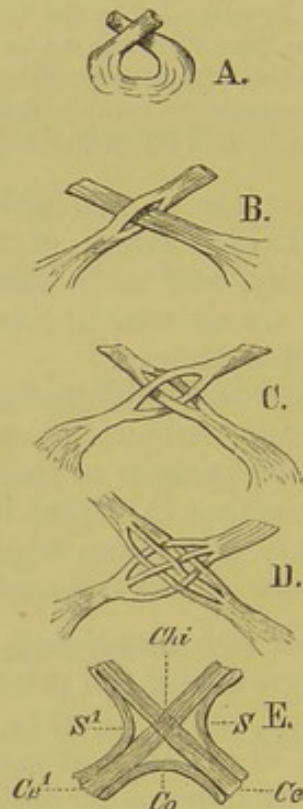


FIG. 128.—CHIASMA OF THE OPTIC NERVES. (Semidiagrammatic.) A, chiasma as seen in the greater number of Teleostei; B, in Herring; C, in *Lacerta agilis*; D, in an Agama; E, in a higher Mammal.

Chi, chiasma of the bundle of nerves lying centrally; *Ce*, *Ce¹*, *S*, *S¹*, lateral fibres; *Co*, commissure.

Nerves of the Eye-muscles.—The nerves of the eye-muscles, that is, the oculomotor, trochlear, and abducent, supply the muscles which move the bulb of the eye, as already mentioned in the table showing the metameric distribution of the cranial nerves (see p. 154).

The so-called ciliary ganglion belongs to the ramus ciliaris, or, what comes to the same thing, to the ramus profundus of the trigeminal, and it thus represents the most anterior ganglion of the head. Its relations to the oculomotor are secondary.

Trigeminal.—This is one of the largest of the cerebral nerves. As its name implies, it divides up on each side into three main branches,—an ophthalmic (1st division) consisting of a super-

ficial and a deep¹ branch, a maxillary (2nd division), and a mandibular (3rd division).

The first of these arises separately, like a dorsal root of a spinal nerve, while the other two represent primitively a single branch, corresponding to the mandibular, from which the maxillary grows out secondarily.

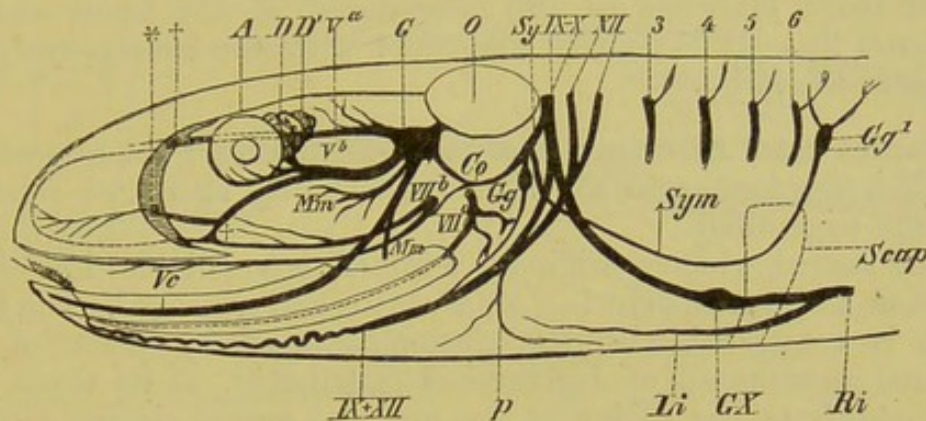


FIG. 129.—CRANIAL NERVES OF *Anguis fragilis*.

G, Gasserian ganglion, from which proceed the three branches of the trigeminal, *V*^{*a*}, *V*^{*b*}, and *V*^{*c*}: behind it is seen a sling-like commissure of the sympathetic (*Sy* and *Co*), which connects the trigeminal with the vagus-group (*IX*, *X*): from this commissure arises a sympathetic ganglion (*Gg*), as well as a long cord (*Sym*) passing to the second sympathetic ganglion, *Gg*¹; *VII*^{*a*}, *VII*^{*b*}, the facial nerve appearing through two separate apertures; †, connection between the palatine branch of the facial and the maxillary division of the trigeminal; *†, points of entrance of the maxillary and ophthalmic divisions respectively of the trigeminal into the nasal capsule; *Mm*, *Mm*, branches of the mandibular branch to the masticatory muscles; *GX*, ganglion of the vagus; *Li*, inferior laryngeal nerve; *p*, superior laryngeal; *Ri*, intestinal branch of the vagus; *XII*, hypoglossal (the two first spinal nerves); 3 to 6, third to sixth spinal nerves; *O*, auditory capsule; *Scap*, scapula; *A*, eye; *D*, *D*¹, lacrymal and posterior part of Harderian gland.

The fact that in many Vertebrates the trigeminal arises by two separate roots indicates its double nature, as does also the fact that, contrary to the general rule, all three divisions do not unite in a single ganglion (the Gasserian), but each main branch may be provided with an independent ganglion.

In all Vertebrates, the first division of the trigeminal, with its deep (naso-ciliary) and superficial branch, supplies the integument of the forehead and snout, as well as the integumentary coverings of the orbit and certain parts of the eyeball. It is entirely sensory.

The second division of the trigeminal, which is also a sensory nerve, is connected with the facial, and extends first along the floor of the orbit, then passes to the upper jaw, supplying the teeth, and finally, as the infraorbital branch, perforates the

¹ In Fishes and Amphibia the deep branch forms an independent twig; in higher forms it is bound up with the superficial branch as the naso-ciliary nerve.

skull to reach the integument in the region of the upper jaw, snout, and upper lip.

The third division of the trigeminal is of a mixed nature ; it supplies on the one hand the masticatory muscles, and also gives rise to the great sensory nerve of the tongue (lingual or gustatory nerve), while another branch, passing through the inferior dental canal, supplies the teeth of the lower jaw, and then gives off one or more branches to the integument of the latter and of the lower lip. It is usually connected with the chorda tympani branch of the facial.

Facial and Auditory Nerves.—Both arise from a common ganglion, the former, as we have seen, coming into close relation with the trigeminal.

The facial, which is originally a mixed nerve, divides into three branches, a hyomandibular, a palatine, and a buccal. The first, which is connected with the glossopharyngeal by means of the so-called anastomosis of Jacobson, is distributed, as its name implies, mainly to the region of the first and second visceral arches ; thus in Fishes it goes to the parts around the spiracle and to the muscles of the operculum and branchiostegal membrane. A small remnant of this branch in the higher Vertebrates supplies the stylohyoid muscle and the posterior belly of the digastric.

In Mammals the facial is a purely motor nerve, supplying mainly the facial muscles, as well as the platysma myoides, which has the closest relations to them (comp. p. 121).

The auditory is always a very large nerve, and soon after its origin from the brain it divides into a cochlear and a vestibular branch. The former passes to the cochlea, while the latter supplies the rest of the auditory labyrinth.

Glossopharyngeal and Vagus.—These, which are of a mixed nature, have not, like the other cranial nerves, their distribution limited to the head.

In Fishes and gill-breathing Amphibians the vagus branches out to the region of the visceral and branchial apparatus, as well as to the muscles of the shoulder and anterior extremity (Protopterus). It then extends backwards along the sides of the body under the skin to the tail as one or more lateral nerves, supplying sensory organs.¹

Further, in all Vertebrates it is distributed to the anterior part of the alimentary canal, giving rise to a pharyngeal, an œsophageal, and a gastric plexus, besides giving off branches to the heart and to the whole respiratory system, from the larynx to the lungs (air-bladder).

Thus cephalic, cervical, thoracic, and abdominal portions of the vagus can be distinguished in the higher Vertebrates.

¹ Compare the chapter on sensory organs, p. 165.

Both vagus and glossopharyngeal are always closely connected with the sympathetic system by anastomoses: in Fishes the glossopharyngeal supplies the region of the first (hyobranchial) cleft, while in the higher Vertebrates it passes to the tongue as the nerve of taste, and, like the vagus, gives rise to a pharyngeal plexus.

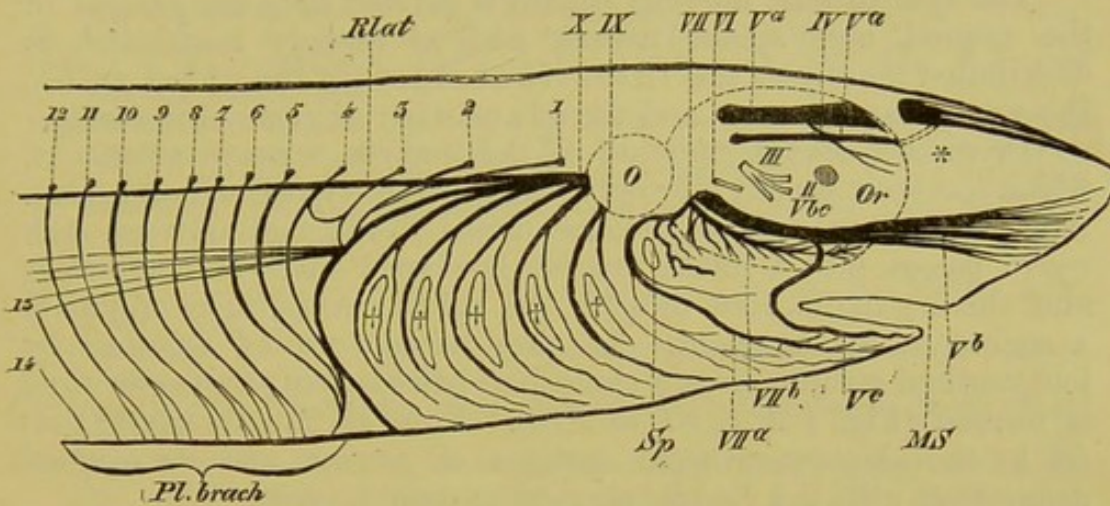


FIG. 130.—CRANIAL NERVES AND BRACHIAL PLEXUS OF *Scyllium canicula*.

II, optic nerve; III, oculomotor; IV, trochlear; V^a (upper), superficial branch, and V^a (lower), deep branch of the first division of the trigeminal (the two branches anastomose at * within the nasal capsule); V^{bc}, maxillo-mandibular branch; V^b, maxillary branch; V^c, mandibular branch; VI, abducent; VII, facial; VII^a, its hyomandibular branch; VII^b, its palatine branch; IX, glossopharyngeal; X, vagus; Rlat, its lateral branch; +++, gill-clefts; 1 to 14, the first fourteen spinal nerves, forming the brachial plexus (Pl. brach); O, auditory capsule; Sp, spiracle; Or, orbit; MS, cleft of mouth.

Spinal Accessory.—This nerve arises some distance back along the cervical portion of the spinal cord, in the region from which the fourth to fifth cervical nerves come off; from this point it passes forwards, taking up fibres from the cervical nerves as it goes. It extends along the side of the medulla oblongata into the cranial cavity, there becomes associated with the root of the vagus, and leaves the skull through the same foramen as the latter. It appears plainly for the first time in Chelonia, and supplies certain of the muscles related to the pectoral arch, e.g. the sternocleidomastoid and the trapezius.

Hypoglossal.—This purely motor nerve closely resembles a spinal nerve, and is distributed (having here and there anastomoses with the cervical plexus) to certain muscles lying on the floor of the mouth, and to others extending between the pectoral arch (sternum) and hyoid (which morphologically are trunk-muscles and not visceral muscles), as well as to the muscles of the tongue proper, which are differentiated from the latter. (Compare p. 119). In the Ichthyopsida it is not included within the skull, and is there

represented by the first and sometimes also the second spinal nerve. Both, to a greater or less degree, take part in forming the brachial plexus.¹

SYMPATHETIC.

The sympathetic nervous system is derived from the ganglia of the cranial and spinal nerves, and, as already mentioned, is distributed mainly to the intestinal tract (in the widest sense), the vascular system, and the glandular organs of the body.

From each spinal ganglion of the embryo, a nerve grows out, which has been already referred to as an "intestinal" nerve (p. 152). After extending a short distance, dorsal to the cardinal vein, each nerve passes into a small, irregularly-shaped mass of nerve-cells, and these ganglia, like those of the spinal nerves, show originally a segmental arrangement. As they become united together by longitudinal commissures, a chain-like paired sympathetic cord is formed (Fig. 104, *S, S1* to *S10*). From its ganglia nerves pass off to the above-mentioned systems of organs, and its original connection with the central nervous system persists.

The sympathetic extends not only along the vertebral column, but passes anteriorly into the skull, where it comes into relations with a series of the cranial nerves similar to those which it forms further back with the spinal nerves. In the Frog, where it becomes connected with the ganglion of the vagus, a considerable number of its fibres pass together with the latter nerve to the heart, and thus the nerve which is generally known as the vagus stem is in reality vagus *plus* sympathetic.

The original segmental character usually disappears later on, and this is especially the case in those regions where marked modifications of the earlier metameric arrangement of the body have taken place, *e.g.* in the neck.

In Crocodiles and Birds a part of the sympathetic cord runs within the vertebral canal alongside the vertebral artery, while in all other Vertebrates the whole cord lies along the ventral side of the vertebral column: it is generally situated close to the latter, and overlies the vertebral ends of the ribs.

BIBLIOGRAPHY.

- AHLBORN, F.—*Unters. über d. Gehirn der Petromyzonten.* *Zeitsch. f. wiss. Zool.* Bd. XXXIX. 1883.
 DOHRN, A.—*Stud. z. Urgesch. d. Wirbelthierkörpers.* *Mitthl. d. zool. Stat. z. Neapel.* Bd. III. 1881 und Bd. IV. 1882.
 ECKER, A.—*Zur Entw. Gesch. der Furchen und Windungen der Grosshirnhemisphären im Fötus des Menschen.* *Arch. f. Anthropologie*, Bd. III. *Die Hirnwindungen des Menschen.* Braunschweig, 1869 (1883).
 EHLERS, E.—*Die Epiphyse am Gehirn der Plagiostomen.* *Zeitsch. f. wiss. Zool.* Bd. XXX.

¹ Traces of dorsal roots of the hypoglossal have been found in Mammalian embryos.

- GASKELL, W. H., and GADOW, H.—*On the Anatomy of the Cardiac Nerves in certain Cold-blooded Vertebrates.* *Journ. of Physiol.* Vol. V. No. 4.
- KUPFER, C.—*Ueber primäre Metamerie des Neuralrohres der Vertebraten.* *Sitzungsber. d. K. Baiierische Academie der Wissenschaften*, Dec. 1885.
- LENHOSSÉK, M. v.—*Untersuch. üb. die Spinalganglien des Frosches.* *Archiv f. mikr. Anat.* Bd. XXVI. 1886.
- MARSHALL, A. MILNES.—Various Papers on the *Development of the Nerves* in the *Journ. of Anat. and Physiol.* Vol. XI. and XVI., and in the *Quart. Journ. of Micros. Science*, Vols. XVIII., XIX., and XXI.
- MIHALKOVICS, V. v.—*Entw.-Gesch. des Gehirns.* Leipzig, 1877.
- OSBORN, H. F.—*Preliminary Notes on the Brain of Menopoma and Rana.* *Proc. Acad. Nat. Sci. Philad.* 1884.
- RABL-RÜCKHARD, H.—*Die gegenseit. Verhältnisse der Chorda, Hypophysis, &c., bei Haiischembryonen.* *Morph. Jahrb.* Bd. VI. 1880. (See also the further works of this author in the *Zeitsch. f. wiss. Zool.* Bd. XXX., and *Archiv f. Anat. und Physiol.* 1882 and 1883, as well as in the *Biolog. Centralb.* 1883, No. 1.)
- REICHERT, C. B.—*Der Bau des menschl. Gehirns.* Leipzig, 1859 und 1861.
- SCHWALBE, G.—*Lehrb. d. Neurologie.* Erlangen, 1880.
- STIEDA, L.—Cp. the works of this author in the *Zeitsch. f. Zool.* Bd. XVIII., XIX., XXIII., und XXV.
- WIEDERSHEIM, R.—*Skelet und Nervensystem von Lepidosiren annectens.* *Morph. Studien*, Heft 1. Jena, 1880.
- WILDER, BURT G.—*Encephalic Nomenclature.* *N. Y. Med. Journ.*, March 21 and 28, 1885.
- WYHE, J. W. VAN.—*Ueber das Visceralskelet und die Nerven des Kopfes der Ganoiden und von Ceratodus.* *Niederl. Arch. f. Zool.* Bd. V. 3. *Ueber die Mesoderm-segmente und die Entwicklung der Nerven des Selachierkopfes.* *Verhdl. der R. Acad. der W. zu Amsterdam*, 1882.

SUPRARENAL BODIES.

These bodies, which owe their name to the position which they occupy in Mammals in front of the kidneys, originate from the mesoblastic tissue lying between the mesonephros and the aorta as well as from the sympathetic.

In Elasmobranchs they are represented by a double row of bodies lying right and left of the vertebral column (that is, arranged segmentally); in these, a mesoblastic portion, consisting of richly nucleated lobules, and a part arising from the sympathetic may be recognised. In Teleostei the suprarenals are often wanting, but when present they sometimes represent the metamorphosed anterior (lymphoid) part of the kidney. In other cases, they are closely united with the kidneys. It is probable that in all Vertebrates they arise in connection with the pro- or meso-nephros. In Amphibia, they either lie on the ventral side (Anura) or on the inner border (Urodela) of the kidneys, receiving their blood-supply both in Amphibians and Reptiles from the renal-portal vein. In the latter group, as well as in Birds, they are of a bright yellow colour, of an elongated or lobulated form, and lie in close contact with the genital glands.

In Amniota, and especially in Mammals, the suprarenal of each side forms a definite and uniform mass, lying close to the corresponding kidney, and in it an ectodermal (*i.e.* sympathetic) medullary, and a mesodermal cortical substance can always be recognised, the two elements here being closely united together.

Their extraordinary richness in blood-vessels, which is seen throughout life, points to the important function of these organs; but it is impossible to say at present what this function is.

BIBLIOGRAPHY.

- BALFOUR, F. M.—*Elasmobranch Fishes*. London, 1878.
 BRAUN, M.—*Ueber Bau und Entwickl. d. Nebennieren bei Reptilien*. *Arb. d. zool. Inst. zu Würzburg*, Bd. V.
 GOTTSCHAU, M.—*Ueber Nebennieren der Säugethiere spec. über die des Menschen*. *Würzb. phys. med. Gesellsch.* 1882. *Structur und embr. Entwicklung der Nebennieren bei Säugethiere*. *Arch. f. Anat. und Physiol.* 1883.
 JANOSIK.—*Bemerkungen üb. die Entwickl. der Nebennieren*. *Archiv f. mikr. Anat.* 1883.
 MITSUKURI.—*On the Development of the Suprarenal Bodies in Mammalia*. *Quart. Journ. of Micros. Science*, 1882.
 ONODI, A. D.—*Ueber die Entwickl. des sympathischen Nervensystems*. *Archiv f. mikr. Anat.* Bd. XXVI. Heft 1.
 WELDON, W. F. R.—*On the Head-Kidney of Bdellostoma, with a Suggestion as to the Origin of the Suprarenal Bodies*. *Quart. Journ. of Micros. Science*, 1884. *On the Suprarenal Bodies of Vertebrata*. *Quart. Journ. of Micros. Science*, 1885.

III. SENSORY ORGANS.

The specific sensory end-organs originate, like the nervous system in general, from the epiblast. The peripheral terminations of the sensory nerves are thus always to be found in cells of epithelial origin, while mesoblastic elements (as investments, for instance) are secondarily added to them.

The individual sense-organs, *e.g.* those of sight, smell, taste, and hearing, are to be regarded as secondary differentiations of a diffused sense, as will be mentioned later on. This is not only indicated in many Invertebrates, but numerous facts in the development of Fishes and Amphibia and in the structure of *Amphioxus* point to the same conclusion.

From the Cyclostomi onwards this differentiation has already taken place, and we find in them and in all Vertebrates above them, that the olfactory, optic, and auditory organs are always closely connected with the head. They are enclosed within certain cavities and hollows of the skull (sense-capsules), and thus differ somewhat from the second main group of sensory organs, which are the means whereby the sensations of taste and temperature, as well as other sensory impressions, are appreciated. These, for the greater part, extend over the whole surface of the body, and thus have a diffused distribution; moreover, they remain throughout life near the ectoderm, from which they originate.

In the higher organs of sense two kinds of cells are to be distinguished, although they are genetically identical with one another. The first of these are the proper rod-shaped **sensory**

cells, connected by nerves with the central nervous system, and the second are the **supporting cells**, which lie between the former and serve as a connecting and isolating material.

In all the higher sensory organs the medium surrounding the end-organ is always moist, and as this is also the case with the sensory organs of the integument of Fishes, we find to a certain extent similar nerve-endings in both. Thus in both cases, we meet with rod-shaped sensory cells, but in the latter, the nerves coming from them do not pass through ganglion cells, as they always do in the higher sensory organs. This indicates a lower stage of development.

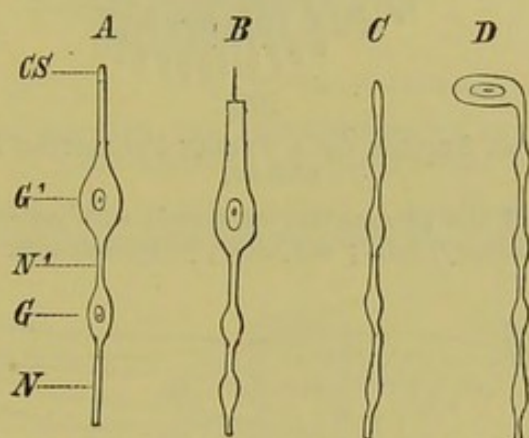


FIG. 131.—*A*, peripheral nerve-ending, as seen in all the higher sensory nerves; *B*, rod-shaped end-cell of a sensory organ of the integument of a Fish or Amphibian, or a taste-cell; *C*, free, and *D*, ganglionated nerve-ending of the integumentary sensory organs of terrestrial Vertebrates.

*N*¹, first, and *N*, second portion of the nerve-fibre in connection with the epithelial end-cell, *G*¹; *G*, ganglion cell interposed between these portions; *CS*, cuticular process of end-cell.

All the figures are diagrammatic, and are based upon a figure by Merkel.

In those animals which in the course of development give up an aquatic life and come on land, the end-organs of the nerves pass further inwards from the surface, undergoing at the same time changes of form.

The rod-shaped end-cell now once for all disappears, and two kinds of nerve-endings are seen in the skin—terminal ganglion-cells and free nerve-endings.

SENSE-ORGANS OF THE INTEGUMENT.

I. ROD-SHAPED ORGANS OF FISHES, DIPNOI, AND AMPHIBIA.

a. Segmental Sense-Organs.

These organs show considerable similarity to certain structures in Chætopods and marine Rhipidoglossa (*e.g.* Fissurella).

They always consist of a central mass of cells, arranged in the form of a rounded and depressed pyramid, and of a peripheral

mass grouped around the former. The central cells are in connection with nerve-fibres; each of them bears at its free end a stiff cuticular hair, and they are to be looked upon as the proper sensory cells (Fig. 132, *CZ*). The others (*MZ*, *MZ*¹) function only as a supporting mass (Fig. 135, *a*, *b*, *c*)

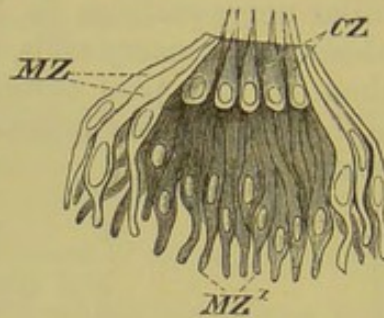


FIG. 132.—TRANSVERSE SECTION OF A FREELY PROJECTING SEGMENTAL SENSE-ORGAN.

The cuticular tube and the surrounding epidermic cells are removed. *CZ*, central (sensory) cells; *MZ*, *MZ*¹, peripheral cells.

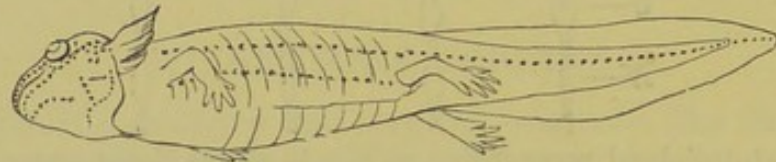


FIG. 133.—DISTRIBUTION OF THE LATERAL SENSE-ORGANS IN A SALAMANDER LARVA.

In cases where these organs project freely from the epidermis—and this is always the case in the embryo—a delicate protective hyaline tube arises from the summit; into it the terminal hairs of the sensory cells project, and the tube opens distally into the surrounding water (Fig. 135, *R*).

While in aquatic Amphibia these organs retain throughout life their peripheral free position, on a level with the epidermis,¹ in Fishes they may in post-embryonic time become enclosed in depressions or complete canals, which are formed either by the epidermis only, or, as is more usually the case, by the scales, and bones of the head, and which open externally. The organs are thus protected, and the hyaline tube is no longer seen.

These sensory organs are distributed over the whole body, but as a general rule they are most abundant along certain tracts, the position of which is very constant. Thus in the head, their course is usually similar to that shown in Fig. 134. From this point

¹ At the time when an Amphibian undergoes metamorphosis, and gives up its aquatic life, these sensory organs sink downwards into the deeper layer of the skin, and, as the epidermis grows together over them, they apparently become shut off from the exterior and reduced, and may finally disappear. According to other authors, however, they persist, and remain open, being connected with the outer surface of the skin by a tube.

backwards the organs are arranged in metameric order, and, always connected by longitudinal nerves, extend along the sides of the body to the caudal fin in one or more "lateral lines" (Fig. 133); they are thus often spoken of as organs of the

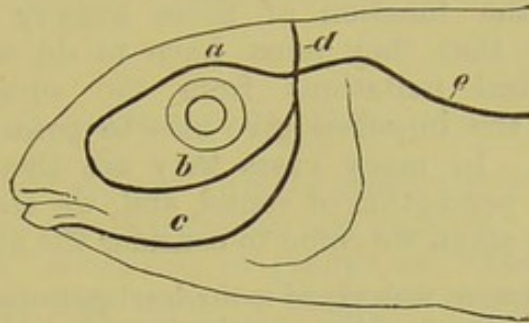


FIG. 134.—DIAGRAM SHOWING THE DISTRIBUTION OF THE SENSORY ORGANS OF THE LATERAL LINE IN FISHES.

a, supra-orbital, and *b*, infra-orbital, portion; *c*, mandibular, *d*, occipital, and *e* lateral portions, the latter extending backwards along the sides of the trunk and tail.

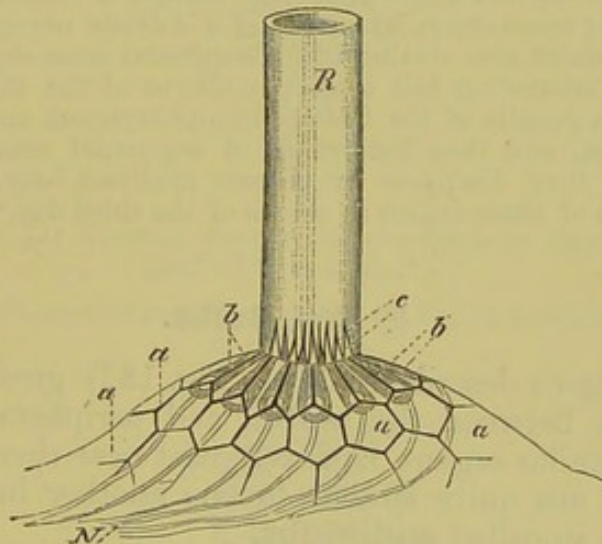


FIG. 135.—ORGAN OF THE LATERAL LINE OF A URODELE. (Semidiagrammatic.

a, a, cells of the epidermis, through which the neuro-epithelium, *b, b*, can be seen; *c*, the terminal hairs of the latter (the peripheral cells are not represented); *R*, the hyaline tube; *N*, the nerve-fibres passing to the sensory cells.

lateral line. The portions lying in the region of the head are innervated by the trigeminal, while the lateral line is supplied by the vagus.¹ (Compare p. 158.)

¹ The development of the lateral branch of the vagus has not yet been satisfactorily made out: it either grows backwards from the vagus ganglion, or, as most authors maintain, it arises by a proliferation or differentiation of the deeper layer of the epidermis *in situ*.

In *Anguilla*, *Gymnotus*, and *Ceratodus*, the lateral nerve is represented by a branch of the facial.

The sensory sacs of Ganoids,¹ which are confined to the head, and the sensory tubes of Elasmobranchs represent peculiar modifications of the sensory organs in question. The former are sac-like invaginations of the epidermis, while the latter have the form of delicate tubes, which give rise at their base to one or more swellings or "ampullæ." Both are lined by a sensory epithelium of the same structure as that described on p. 164.

As regards the function of these sensory organs, it can only be affirmed that they must have to do with the perception of mechanical irritations from the surrounding water: in what manner the impulses give rise to perception cannot be definitely stated. In many cases they are thought to be concerned with the perception of sound, and we shall see that this is not improbable when we come to consider the auditory organ.

The following is known with regard to the development of the lateral segmental organs. The dorsal roots of the cranial nerves (*V*, *VII*, *VIII*, *IX*, and *X*) are during a certain embryonic period connected with the cells of the epiblast, with which they become completely fused. Each of these masses then grows and proliferates very rapidly, and the epiblastic thickenings thus resulting represent the rudiments of the ganglia of the dorsal roots of the cranial nerves as well as the first indications of the segmental sense-organs. Later, each ganglion becomes separated from the skin, though it remains connected with the corresponding sense-organ by means of a delicate nerve-fibre. A similar mode of development also obtains in the segmental sense-organs of the trunk.

It is a very interesting fact that in embryos of the sheep and cow, 8 to 10 mm. long, the ganglia of the facial, glossopharyngeal, and vagus are fused with the epiblast, and thus indications of segmental sense-organs are still present, though they disappear or become modified later. Beard has also found rudiments of these organs in chicks of the third day.²

b. End-Bulbs.

In the organs described above (Fig. 132) great differences in size and form between the central and peripheral cells may be recognised: similar organs, however, exist near them in which both kinds of cells are quite similar to one another in these respects. These are the so-called **end-bulbs**.

In all Fishes they are scattered irregularly over the whole body, but especially over the head; from the Amphibia onwards, they are present in the mouth-cavity only, and are no longer seen outside it.³ In Amphibians they occur on the palate and on the fungiform papillæ of the tongue, and in Lizards and Blind-worms they are also present on the inner sides of the upper and lower jaws. In Mammals they are found on the soft palate, on the walls of the pharynx, and on the epiglottis, and even extend into the larynx; but here also they are most constant and numerous on the tongue, where they occur on the circumvallate and fungiform papillæ, as well as on the papilla foliata.

¹ Similar organs are present in *Amiurus catus*.

² Beard proposes the name of branchial sense-organs for these structures, as he considers them to be primitively the special sensory organs of the gill-clefts.

³ They have also been found in the mouth and pharynx of Dipnoi.

These structures function from the Amphibia onwards as **organs of taste**, while in Fishes they probably serve as tactile organs. This latter function is naturally impossible in those cases where they become somewhat withdrawn inwards from the free surface of the epithelium, as is the case with those situated on the tongue, where they can only be reached by fluid passing in to them.

II. TERMINAL GANGLION CELLS.

These structures are not directly connected with the surface of the epidermis, and supporting cells are wanting.

"Tactile spots," consisting of groups of "**tactile cells**," are met with for the first time in tailless Amphibians, where, situated mainly on small elevations, they are distributed over the skin of the whole body (Fig. 136, *a, a*). In Reptiles they are

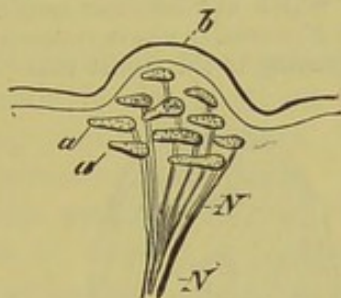


FIG. 136.—A TACTILE SPOT FROM THE SKIN OF THE FROG.
(Modified from Merkel.)

N, nerve, which loses its medullary sheath at *N*¹; *a, a*, neuro-epithelium;
b, epidermis.

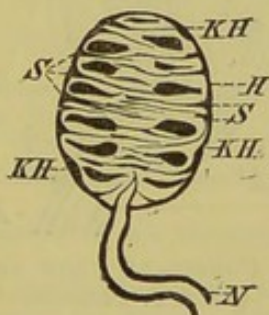


FIG. 137.—TACTILE CORPUSCLE FROM THE TONGUE OF A BIRD.

N, nerve; *H*, outer investment, with nuclei (*KH*); *S, S*, septa.

found chiefly in the region of the head, on the lips and sides of the face, and on the snout, but in some cases (as in Blindworms and Geckos), they extend over the whole body.¹ In Snakes and Birds the tactile cells are confined to the mouth-cavity (tongue)

¹ Similar structures are also present in Crocodiles, and in the skin of the back of *Trionyx* cellular bodies exist, which most probably are to be regarded as tactile organs.

and to the beak (cere), and lie much more closely together, forming definite masses, or "**tactile corpuscles.**" Each of these is surrounded by a nucleated connective-tissue investment, from which septa extend into the interior, partially separating the individual tactile cells from one another.

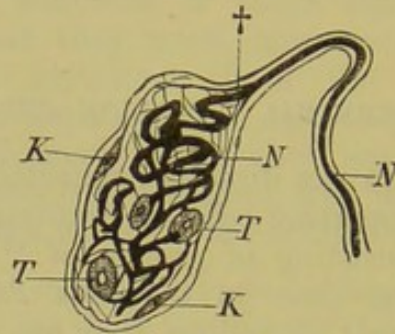


FIG. 138.—A TACTILE CORPUSCLE (END-BULB) FROM THE CONJUNCTIVA OF A MAMMAL.

N, nerve (the neurilemma of which at † becomes continuous with the investment of the tactile corpuscle; *K, K*, nuclei in the investment; *N*, the coiled termination of the nerve (axis-fibre) passing to the tactile cells (*T, T*).

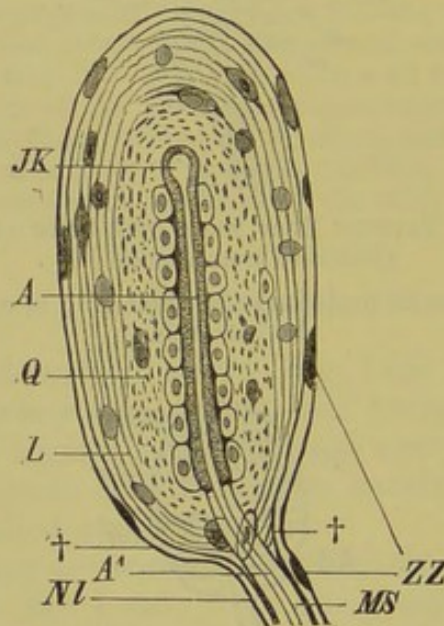


FIG. 139.—A PACINIAN CORPUSCLE FROM THE BEAK OF THE DUCK.
(After J. Carrière.)

ZZ, cells of the nerve-sheath; *L*, longitudinal, and *Q*, circular layers of the investing lamellæ; *JK*, central knob, with the two pillars of cells; *A*, axis-fibre, with protoplasmic investment, entering the corpuscle at *A'*; *MS*, medullary sheath; *Nl*, neurilemma, which becomes continuous with the investment of the corpuscle at †, †.

In Mammals the tactile cells are either isolated, as, for instance, on the hairless portions of the body, or they give rise to oval corpuscles, each consisting of a many-layered and nucleated investment, into which a nerve passes, becomes twisted up, and ends in one or more terminal ganglion cells (Fig. 138).

From the Reptilia onwards, so-called Pacinian corpuscles are present in addition to the above-described tactile organs. They undergo very numerous modifications, but each consists essentially of numerous concentric lamellæ (Fig. 139, *Q, L*), enclosing the termination of the axis-fibre with its protoplasmic sheath, which dilates at the distal end into a sort of knob surrounded by a double row of cells (Fig. 139, *JK*). Thus the axis-fibre receives the external impressions indirectly, that is, by means of the cells investing the knob-like end-organ. Organs of this kind are universally present in the skin of Mammals, and differ from the tactile spots and tactile corpuscles in position: they are found in the deeper layer of the derma, as well as in the panniculus adiposus, the interstitial connective-tissue, and in the various organs of the abdominal cavity (*e.g.* the mesentery, mesocolon, pancreas, and portal fissure of the liver of the Cat), the fasciæ, tendons, vas deferens, periosteum, pericardium, pleura, corpora cavernosum and spongiosum, the wing-membrane of Bats, &c.

These organs are not entirely wanting in any part of the skin of Birds, but are particularly abundant on the beak, and at the bases of the contour-wing- and tail-feathers. So-called corpuscles of Grandry are also present in the beak.

In all the tactile cells and tactile and Pacinian corpuscles we have to do with organs of touch, or, expressed generally, with means for the appreciation of sensations in the skin.

It is impossible to say definitely which nerve-endings have to do with the perception of temperature; it is not improbable that the tactile cells, as well as the nerve-fibres with knob-like swellings ending freely in the epidermis, are concerned in this (Fig. 131, *C*).

BIBLIOGRAPHY.

- BEARD, J.—*On the Segmental Sense-organs, and on the Morphology of the Vertebrate Auditory Organ.* Zool. Anz. Nos. 161 and 162, 1884. *On the Cranial Ganglia and Segmental Sense-organs.* Zool. Anz. No. 192, 1885. *The System of Branchial Sense-organs, and their Associated Ganglia in Ichthyopsida.* Quart. Journ. Micros. Science, 1885.
- GOLDSCHIEDER, A.—*Neue Thatsachen üb. die Hautsinnesnerven.* Arch. f. Anat. u. Physiol. 1885.
- KÖLLIKER, A.—*Stiftchenzellen in der Epidermis von Froschlarven.* Zool. Anz. 1885.
- LEYDIG, F.—*Ueber die Schleimcanäle der Knochenfische.* Arch. f. Anat. u. Physiol. 1850. *Ueber Organe eines sechsten Sinnes.* Nova acta acad. Caes. Leopold. Carol. Germ. nat. curios. Bd. XXXIV. 1868. *Stiftchenzellen in der Oberhaut von Batrachierlarven.* Zool. Anz. No. 212, 1885.
- MALBRANC, M.—*Sinnesorgane der Seitenlinie bei Amphibien.* Zeitsch. f. wiss. Zool. Bd. XXVI. 1875.
- MERKEL, FR.—*Ueber die Endigungen der sensiblen Nerven in der Haut der Wirbelthiere.* Rostock, 1880.
- SCHULTZE, F. E.—*Ueber die becherförm. Organe der Fische.* Zeitsch. f. wiss. Zool. Bd. XII. 1863. *Ueber die Sinnesorgane der Seitenlinie bei Fischen und Amphibien.* Arch. f. mikr. Anat. Bd. VI. 1870.
- SCHWALBE, G.—*Lehrb. der Anatomie der Sinnesorgane.* Erlangen, 1883.
- SOLGER, B.—*Seitenorgane der Fische.* Arch. f. mikr. Anat. Bd. XVII. und XVIII.

OLFACTORY ORGAN.

The olfactory organ, in its simplest form, consists of a paired, pit-like depression of the integument above the cleft of the mouth. A nerve passes to the base of this pit, and becoming enlarged in the form of a ganglion sends off nerves to the sensory cells (**olfactory cells**). The latter must be regarded as phylogenetic derivatives of the end-bulbs of that part of the integument which becomes pushed in to form the primitive olfactory pit ("olfactory bulbs"), and therefore come under the same morphological category as the taste-bulbs. At first (that is in Fishes and Urodeles), they are only separated from one another by interstitial epithelial tissue, but from the Anura onwards this tissue gradually disappears in order to allow of an increased surface for the olfactory epithelium. The ciliated cells lying amongst the sensory cells serve to continually renew the outer medium—whether that be water or air—by which the odoriferous particles are conveyed (Fig. 140, *R*, *E*).

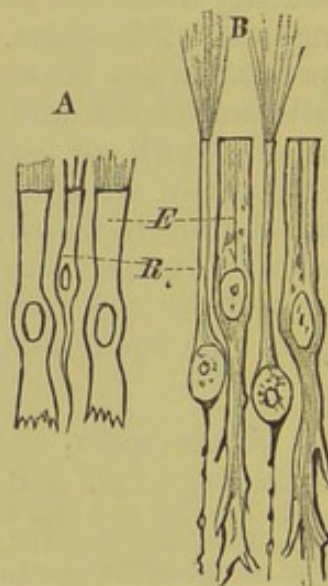


FIG. 140.—EPITHELIUM OF THE OLFACTORY MUCOUS MEMBRANE. A, of *Petromyzon planeri*; B, of *Salamandra atra*.

R, olfactory cells; *E*, interstitial epithelial cells.

While the olfactory organs of all the true Fishes exhibit the above-described simple sac-like form, from the Dipnoi onwards they come to communicate with the cavity of the mouth as well as with the exterior. In consequence of this, anterior or external, and posterior or internal nostrils (choanæ) can be distinguished, and as a free passage is thus formed through which the external medium can pass, the olfactory organ takes on an important relation to the respiratory apparatus.

These facts in the structure and development of the olfactory organ and nerve have caused an attempt to be made to draw a parallel between the olfactory pit and a primitive preoral gill-cleft,¹ and this is further supported by the general structure and histological relations of the olfactory mucous membrane, which corresponds with that of the gills of Fishes in the possession of end-bulbs. In a recent paper, however, Beard has put forward the view that "the nose is really a branchial (segmental) sense-organ, *i.e.* the sense-organ of a non-existent gill-cleft, and not a gill-cleft itself."

Fishes.—In *Petromyzon* (Fig. 49, *N, Na*) and Myxinooids the olfactory organ consists of a sac, unpaired externally, lying close in front of the cranial cavity, and opening on the dorsal surface of the anterior part of the head by a longer or shorter chimney-like tube. Its mode of development and internal structure, however, as well as the double olfactory nerve, seem to prove that the olfactory organ of Cyclostomes must also have been primitively a paired structure.²

The position of the olfactory organ in Elasmobranchs differs from that of Cyclostomes in lying on the under instead of the

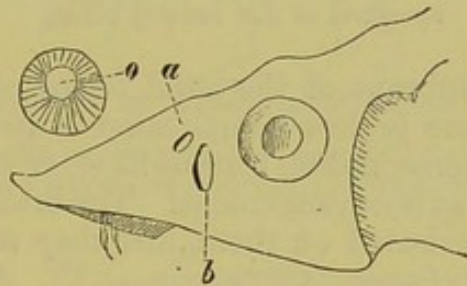


FIG. 141.—ANTERIOR PORTION OF HEAD OF *Acipenser sturio*.

a, anterior, *b*, posterior opening of external nostrils; *o*, isolated rosette of olfactory folds.

upper surface of the snout. From these Fishes onwards throughout all Vertebrates the organ is always paired, and is more or less completely enclosed by a cartilaginous or bony investment, which forms an outwork of the skull.

From the Ganoids onwards it always has a similar position with regard to the skull, being situated between the eye and the end of the snout, either laterally or more or less dorsally. In the course of development each external nostril of Ganoids and Teleostei becomes divided into two portions, an anterior and a posterior (Fig. 141, *a, b*, and Fig. 142, *AN, AN¹*), by a fold of skin. The anterior often lies at the summit of a longer or shorter tube, lined with ciliated cells, and the distance between it and the posterior aperture varies

¹ According to this view, the condition which is seen in Myxinooids and Dipnoans is to be looked upon as the more primitive, and that of all other Fishes as secondary.

² It is improbable that the naso-palatine duct, which opens into the oral cavity in Myxinooids, but ends blindly in *Petromyzon*, is directly comparable to the posterior nares of higher Vertebrates.

greatly, according to the width of the fold of skin which separates them.

The olfactory organ of *Polypterus* is more highly developed than that of any other Fish. It is not a simple sac-like involution, but consists of six radially arranged compartments¹ separated from one another by complicated septa, and lying round a central spindle. A transverse section has somewhat the appearance of a cut orange. A short and distinct oval sac lies against the olfactory organ towards the middle line, and is entirely shut off from the rest of the apparatus; it receives a special branch of the olfactory nerve.

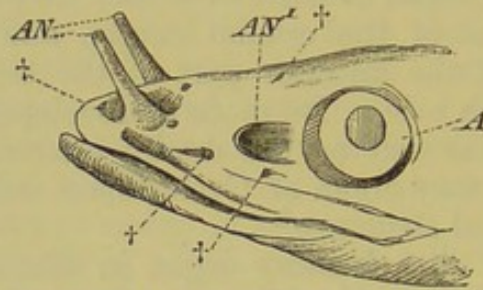


FIG. 142.—ANTERIOR PORTION OF THE HEAD OF *Polypterus*.

A, eye; *AN*, *AN'*, anterior and posterior openings of the external nostril: †, †, †, apertures of the sensory tubes.

The mucous membrane of the nasal organ of Fishes is always raised up into a more or less complicated system of folds, which may have a transverse, radial, rosette-like, or longitudinal (in respect to the cranial axis) arrangement. The branches of the olfactory nerve are distributed on them, and they serve to increase the olfactory surface.

Dipnoi and Amphibia.—The olfactory organ of Dipnoi and Perennibranchiata is always enclosed within a complete or perforated cartilaginous capsule lying without the cranium proper (Figs. 54, *NK*, 143, and *N*), and its mucous membrane is raised into folds like those of Fishes. In all the other Amphibia it becomes included within the cranial skeleton, and lies directly in the longitudinal axis of the skull in front of the cranial cavity.

In Amphibia, turbinals appear for the first time (Fig. 144, *C*, *S*, *E*): they are processes of the cranial skeleton projecting into the nasal cavity, and thus giving rise to an extension of the olfactory surface. These structures, slight traces only of which are present in tailed Amphibians, attain to a very considerable development in Anura and Gymnophiona, especially in the latter, where the nasal chamber is converted into a complicated system of spaces and cavities. A main and an accessory cavity can in all cases be distinguished, but more especially in the Derotremata and Myctodera; the accessory cavity, as it lies in the maxillary bone, may be described as the maxillary cavity. In certain Gymnophiona this becomes entirely shut off from the main cavity, and

¹ Each compartment resembles in structure the entire olfactory sac of other Fishes.

receives a special branch of the olfactory nerve, so that in these cases two separate nasal cavities may be distinguished. This will be referred to again later on (p. 178).

A further neomorph are the internal nostrils (choanæ) already mentioned, as well as the glands lying under the olfactory mucous membrane; these are either diffused, or united to form

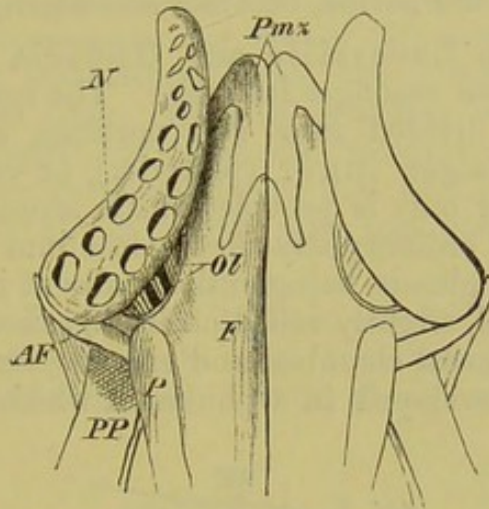


FIG. 143.—OLFACTORY ORGAN OF *Menobranthus lateralis*. (From the dorsal side.)

N, olfactory sac; *Ol*, olfactory nerve; *Pmx*, premaxilla; *F*, frontal; *P*, process of the parietal; *PP*, palato-ptyergoid; *AF*, antorbital process.

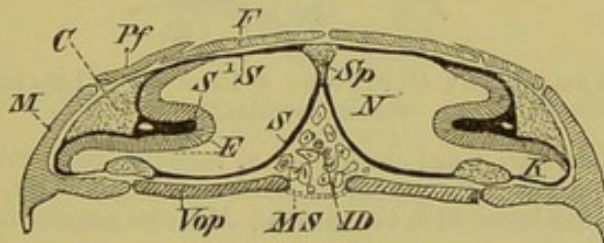


FIG. 144.—TRANSVERSE SECTION THROUGH THE OLFACTORY CAVITIES OF *Plethodon glutinosus* (*Myctodera*).

S, *S*, olfactory mucous membrane; *N*, main nasal cavity; *K*, maxillary cavity; *C*, cartilaginous, and *S¹*, fibrous portion of the turbinal, which causes the olfactory epithelium (*E*) to project far into the nasal cavity; *ID*, intermaxillary gland, shut off from the cavity of the mouth by the oral mucous membrane (*MS*); *F*, frontal; *Pf*, prefrontal; *M*, maxilla; *Vop*, vomero-palatine; *Sp*, nasal septum.

definite organs. They either open directly into the nasal cavity, their secretion serving for the necessary moistening of the mucous membrane (which is effected in Fishes and Dipnoi by the external medium), or they pour their secretion into the pharynx or posterior nostrils.

The latter always lie tolerably far forwards on the palate, and are for the most part enclosed by the vomer, and sometimes by the palatine also.

Finally, the naso-lacrymal duct of Amphibia must be mentioned: it passes out from the anterior angle of the orbit, goes through the lateral wall of the nose, and opens into the nasal cavity on the side of the upper jaw. It conducts the lacrymal secretion from the conjunctival sac of the eye into the nasal cavity, and arises in all Vertebrates, from the Myctodera onwards, as an epithelial cord which is separated off from the epidermis, and, growing down into the derma, becomes secondarily hollowed.

Reptilia.—The Lacertilia and Ophidia possess the simplest olfactory organs amongst Reptiles. The nasal cavity of the former group is divided into two portions, a smaller outer (anterior), and a larger inner (posterior), or olfactory chamber proper. The latter only is provided with sensory cells, the former being lined by ordinary stratified epithelium continuous with the epidermis, and glands being entirely absent in it.

A large turbinal, slightly rolled on itself, arises from the outer wall of the inner nasal chamber, and extends far into its lumen; this is also well developed in Ophidia, in which a distinct outer

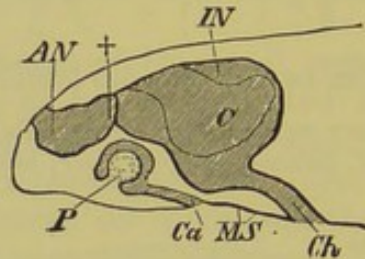


FIG. 145.—DIAGRAM OF THE OLFACTORY ORGAN OF A LIZARD. (Longitudinal vertical section.)

AN, *IN*, outer and inner nasal chambers; †, tube-like connection between them; *Ch*, internal nostrils; *P*, papilla of Jacobson's organ; *Ca*, aperture of communication of the latter with the mouth; *MS*, oral mucous membrane.

nasal chamber is wanting; it may be derived from that of the Amphibia.

A large gland which opens in the boundary between the inner and outer nasal cavities lies within the turbinal. Below the latter is the aperture of the lacrymal duct, though this in some cases opens on the roof of the pharynx (*Ascalabota*), and in others into the internal nostrils (*Ophidia*).

The structure of the nose in Chelonians is very complicated and varied. In marine Chelonians it is divided into two passages, one of which lies above the other, but they are connected by means of a perforation of the septum. The comparative paucity of glands in the olfactory organ of Lizards and Snakes forms a marked contrast to the condition seen in Chelonians, the nasal organ of which is characterised by a great abundance of them.

From the Crocodilia onwards the olfactory organ, which up to this point lies entirely in front of the brain, gradually

extends further and further backwards, in correspondence with the growth forwards of the facial region and the formation of the palate; its posterior part thus comes to lie below the brain and base of the skull.

In Crocodiles, as in other Reptiles, there is only a single true turbinal, but externally to it lies a second prominence, which is spoken of as a pseudo-turbinal.¹ Each nasal chamber of the Crocodile is divided posteriorly into two superimposed cavities, the upper of which represents the proper olfactory chamber, and is lined by sensory epithelium, while the lower functions as a respiratory portion only. Certain accessory chambers are connected with the nasal cavity, which, however, serve only as air-chambers. A large gland, similar to that of Lizards and Snakes, lies in the cavity of the upper jaw, and opens into the nasal cavity.

Birds.—In all Birds, as in Lizards, there is an outer chamber, lined by stratified epithelium, and a proper olfactory chamber, which lies above the former. Birds also possess only a single

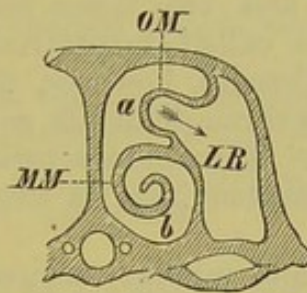


FIG. 146.—TRANSVERSE SECTION THROUGH THE RIGHT NASAL CAVITY OF A SHRIKE (*Lanius minor*).

OM, *MM*, superior (pseudo) and middle (true) turbinal; *a*, upper, and *b*, lower nasal passage; *LR*, air-chamber, which extends into a hollow of the superior turbinal.

true turbinal, if by this term is understood a free independent projection into the nasal cavity supported by skeletal parts. Two other prominences (pseudo-turbinals) are, however, present, one of which² lies like the true turbinal in the proper olfactory chamber, while the other, like the pseudo-turbinal of the Crocodile, is situated in the outer portion: these are simply incurved portions of the whole nasal wall (Fig. 146, *MM*, *OM*).

The form of the true turbinal, which is usually supported by cartilage, more rarely by bone, varies greatly. It is either represented by a moderate-sized prominence, or else it becomes more or less rolled on itself (forming as many as three turns). The lacrymal duct opens below and anteriorly to it. There

¹ The meaning of the pseudo-turbinal will be discussed in the description of the olfactory organ of Birds.

² Its cavity communicates with an air-sinus lying in the anterior orbital space.

is no doubt that this turbinal is comparable to that of Urodeles and Reptiles.

The so-called external nasal gland of Birds does not lie in the region of the upper jaw, but on the frontal or nasal bones.

Mammals.—Corresponding to the much more marked development of the facial portion of the skull, the nasal cavity of Mammals is proportionately much larger than in the forms yet described, and consequently there is much more room for the extension of the turbinals: these give rise to a spongy labyrinth, the cell-like compartments of which are lined by mucous membrane, and thus variously shaped projections, supported partly by cartilage and partly by bone, are seen extending into the nasal cavity. The normal number of these "olfactory scrolls" is five. In Marsupials they have a very typical arrangement; they are situated obliquely, slanting from the postero-dorsal to the antero-ventral side: the inferior is no longer covered by olfactory epithelium, and it becomes connected with the maxilla.

The four other typical (ethmoidal) scrolls may persist as such, or the two upper and two lower become united together, in which case they are called respectively the superior and middle turbinals. Usually, however, the two upper primary turbinals remain separate throughout life, so that in this case there are two upper turbinals. The middle turbinal may also remain partially or entirely separated into its two primitive component parts.

While the superior and middle turbinals of Man, that is the four primitive upper olfactory scrolls of Mammals, are to be regarded as neomorphs, the inferior turbinal, below which the lacrymal duct always opens, must be looked upon as derived genetically from that of the lower Vertebrates. It corresponds to the single true turbinal of Urodeles, Reptiles, and Birds, and in Mammals is represented by an independent bone lying at the entrance of the antrum maxillare s. Highmori (Fig. 147, *I*).¹

In Man each nasal cavity is divided by the three turbinals into three superimposed passages; of these the two upper alone (Fig. 147, *b*, *c*) conduct the air containing the odoriferous particles to the ethmoidal labyrinth, that is to the proper olfactory region of the nose, while the lower passage serves only as a respiratory tract (Fig. 147, *a*).

The nasal chamber of Mammals not only communicates with the maxillary sinus as in the lower Vertebrates, but also with the neighbouring cavities, such as, in Man for instance, the frontal, ethmoidal, and sphenoidal sinuses. These cavities arise in part after birth, and often do not attain their maximum development till the body is fully grown.²

¹ In Cetacea the turbinals are never more than rudimentary.

² Compare the chapter on air-sacs of Birds, p. 259.

Their lining of mucous membrane is in direct connection with that of the nasal cavity; this is also the case with the glandular organs of the nose, which are divided into two sets,—numerous small diffuse Bowman's glands, and a large gland of Stenson. The early appearance of the latter in the embryo indicates that it is an ancient structure (comp. nasal glands of Amphibia, Reptiles and Birds, pp. 173-175). It lies in the lateral walls of the nasal cavity (Carnivora

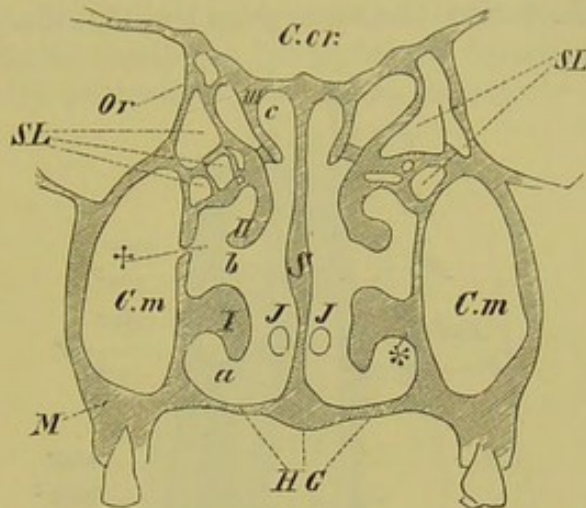


FIG. 147.—TRANSVERSE VERTICAL SECTION THROUGH THE NASAL CAVITY OF MAN.

I, II, III, inferior, middle, and superior turbinal; *a, b, c*, inferior, middle, and superior nasal passage; *S*, septum nasi; *J, J*, remains of septal gland (cp. p. 179); *, point at which the naso-lacrymal duct opens; †, entrance into the maxillary sinus (*C.m*); *SL*, ethmoidal labyrinth; *HG*, hard palate; *C.cr*, cranial cavity; *M*, maxilla; *Or*, wall of orbit.

Rodentia, &c), and in cases where a maxillary sinus is well developed (*e.g.* Man), it extends into the latter, and lies in its inner wall, close to the aperture into the nasal cavity. The duct opens at the anterior end of the middle turbinal.

The appearance of an **external nose** is very characteristic of the olfactory organ of Mammals; we must regard it as a derivative of the outer chamber of the nose of Reptiles and Birds. It is formed by an extension outwards of the nasal bones, and by a special cartilaginous support which arises from the ethmoid. The outer nose undergoes the most varied functional adaptations; it may give rise to a trunk-like organ, or even grow out to form a definite trunk, and, by means of its abundant nerve-supply, serve as a delicate organ of touch, and even as a prehensile apparatus. It is always provided with muscles, which are sometimes very largely developed.

JACOBSON'S ORGAN.

By Jacobson's organ is understood a paired accessory nasal cavity, which in an early embryonic stage becomes entirely separated off from the nasal chamber, and which is supplied by the olfactory and trigeminal nerves; it communicates with the mouth by a special aperture.

This definition applies accurately to the accessory nasal chamber of Cæcilians already mentioned, which is enclosed within the maxillary cavity, and there can be no doubt that the latter is homologous with the maxillary sinus of all Vertebrates. In no other Vertebrates, however, does it retain the character of a kind of separate nasal chamber, but on the contrary, the higher we pass in the Vertebrate series, the more does the maxillary cavity become

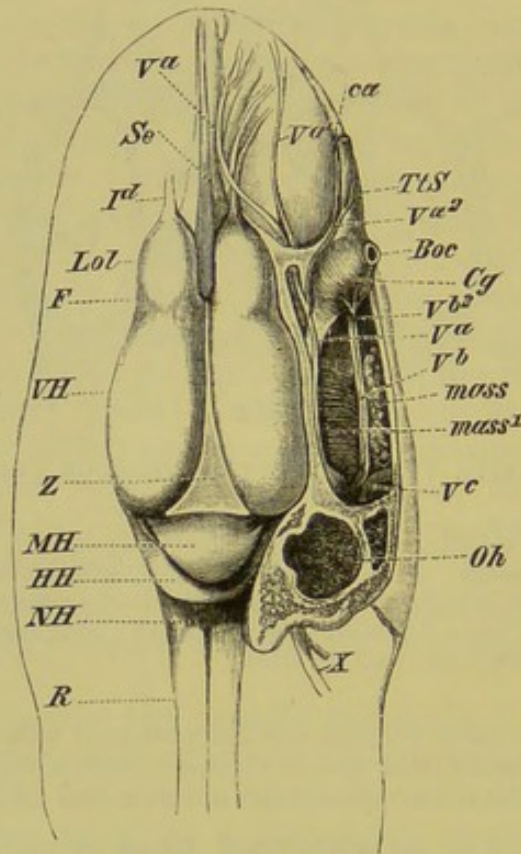


FIG. 148.—DISSECTION OF THE HEAD OF *Epicrion glutinosum*. (Dorsal view.)

VH, cerebral hemispheres, separated by a furrow (F) from the olfactory lobes (Lol); Z, pineal gland; MH, mid-brain; HH, cerebellum; NH, medulla oblongata; R, spinal cord; Se, septum nasi; I^d, dorsal pair of olfactory nerves; V^a, V^b, V^c, first, second, and third division of the trigeminal; V^{a1} and V^{a2}, lateral branches of the first division, one of which goes to the olfactory mucous membrane, and the other to the sheath of the "tentacle" (TtS): the constrictor muscle of the tentacular gland (Cg) is supplied from a lateral branch of the second division of the trigeminal; X, vagus; ca, duct of the tentacular gland, which is surrounded by the sheath of the tentacle; Boc, globe of the eye; mass, mass¹, the two portions of the masseter muscles; Oh, auditory capsule.

separated physiologically from the olfactory organ; it loses its olfactory epithelium, and finally degenerates into a simple air-sinus.

In Lizards and Snakes an apparatus exists which is quite unconnected with the Jacobson's organ of Gymnophiona, but which nevertheless comes under the above definition. This (see Fig. 145, P) lies between the floor of the nasal cavity and the roof of the mouth, and may be described as a small paired cavity lined by

olfactory epithelium, from the floor of which a papilla arises : it communicates with the mouth by a special aperture in front of the internal nostrils.

Jacobson's organs are not known in Crocodiles, Chelonians, or Birds, but are very general in Mammals, being especially well marked in Rodents, Ruminants, and Perissodactyles. They here consist of two tubes lying at the base of the septum nasi, enclosed by definite cartilages (ploughshare cartilages of Huschke) ; they end blindly posteriorly, but open anteriorly into the mouth

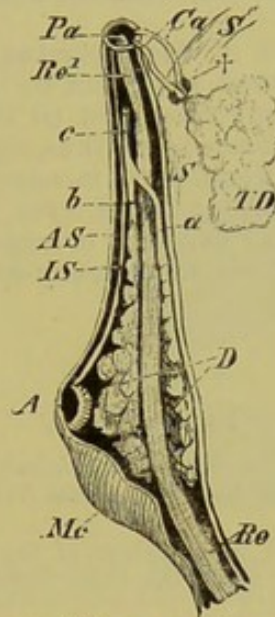


FIG. 149.—THE LEFT SO-CALLED "TENTACLE" OF *Cæcilia oxyura*. (Opened from the dorsal side.)

Mc, constrictor muscle ; *Re*, retractor muscle, which becomes tendinous at *Re*¹, and is inserted into the ridge or papilla, *Pa* ; *D*, the large gland, surrounded by the constrictor, with its two ducts (*a*, *b*), which further forwards unite to form a common duct (*c*) ; *IS*, *AS*, inner and outer fibrous tubes ; *A*, eye ; *S*, *S*, skull, with the tentacular gland (*TD*) lying in the nasal cavity, showing through. At † the ducts of the tentacular gland (*Ca*) pass out from the skull, and after extending a short distance, pass into the tentacular sheath.

by means of the incisive or naso-palatine canals (ducts of Stenson), which extend through the palate behind the premaxillæ.

The structures present in Man which have usually been described as rudiments of Jacobson's organ probably correspond with the remnants of a gland in connection with the nasal septum (Gegenbaur).

The physiological function of Jacobson's organ may consist in bringing the food taken into the mouth under the direct control of the olfactory nerve.

THE SPOUTING APPARATUS (SO-CALLED "TENTACLE") OF GYMNOPHIONA.

A very remarkable organ exists in Cæcilians, which is closely related as regards position both to the nasal cavity and to the orbit.

It consists of a fibrous capsule lying in the orbit, and surrounded by strong muscle (Figs. 148, *Cg*, 149, *Mc*), which extends forwards in the form of a

tube along a canal in the upper jaw, opening on the lateral surface of the head near the snout. This prolongation consists of two fibrous tubes, one lying within the other (Fig. 149, *IS*, *AS*).¹

A longitudinal muscle, acting as a retractor (Fig. 149, *Re*, *Re*¹), extends inside the organ along its whole length, and is inserted into a papilla (*Pa*) lying in the aperture on the side of the head.

A large gland (orbital gland)² (*D*) is grouped around this muscle within the broad vesicular portion of the organ, and empties its secretion into the lumen of the tube-like portion (Fig. 149, *a*, *b*, *c*). The duct of a second large gland (tentacular gland) which is embedded within the maxillary cavity (Fig. 149, *TD*), perforates the lateral wall of the maxilla, and opens into the tube-shaped section of the organ, near its distal end, close to the above-mentioned papilla.

The physiological function of this apparatus, which occurs quite isolated in the Animal Kingdom, cannot at present be explained with certainty. It probably acts as a spouting apparatus, and (if the secretion of the glands be poisonous) as a weapon of offence; and thus, together with the remarkably developed olfactory organ, it would serve in some measure to make up for the non-functional, or partly non-functional eyes and auditory organ. It is improbable that it serves as a "tentacle," or organ of touch, as was formerly supposed, as the necessary nerves and sensory epithelium are not known to be present.

BIBLIOGRAPHY.

- BLAUE, J.—*Untersuch. üb. d. Bau der Nasenschleimhaut bei Fischen und Amphibien, namentl. üb. Endknospen als Endapparate des Nerv. olfactorius.* Arch. f. Anat. u. Physiol. 1884.
- BORN, G.—Numerous Papers on the structure of the nasal cavity of Amphibia, and on the naso-lacrymal duct of all the chief Vertebrate groups, in the *Morphol. Jahrb.* Bd. II., V., VIII.
- GEGENBAUR, C.—*Ueber die Nasenmuscheln der Vögel.* Jen. Zeitschr. Bd. VII. 1873. *Ueber das Rudiment einer septalen Nasendrüse beim Menschen.* Morphol. Jahrb. Bd. XI. Heft 3, 1885.
- KANGRO, C.—*Ueber Entwick. u. Bau der Steno'schen Nasendrüse der Säugethiere.* Inaug. Dissert. Dorpat, 1884.
- KLEIN, E.—*Contributions to the Minute Anatomy of the Nasal Mucous Membrane, and of Jacobson's Organ in the Guinea-pig.* Quart. Journ. Micros. Science, Vol. XXI. 1881.
- KÖLLIKER, A.—*Ueber die Jakobson'schen Organe des Menschen.* Grat.-Schrift der Würzburger med. Facultät für Rinecker, 1877. *Zur Entwickl. d. Auges und Geruchsorganes menschl. Embryonen.* Grat.-Schrift für die Züricher Universität, 1883.
- LEYDIG, F.—*Die in Deutschland lebenden Arten der Saurier.* Tübingen, 1872.
- SCHWALBE, G.—*Ueber die Nasenmuscheln der Säugethiere und des Menschen.* Sitz.-Ber. der physic.-æcon. Gesellsch. zu Königsberg, XXIII. 1882. *Lehrb. der Anatomie der Sinnesorgane.* Erlangen, 1883.
- WIEDERSHEIM, R.—*Das Kopfskelet der Urodelen.* Morphol. Jahrb. Bd. III. 1877. *Die Anatomie der Gymnophionen.* Jena, 1879.

¹ In the embryo the "tentacle" appears to be wanting, but the eye is more distinct than later.

² This probably corresponds to a metamorphosed Harderian gland.

EYE.

In contrast to the eyes of Invertebrates, which arise by a differentiation of the cells of the epiblast (hypodermis),¹ the sensitive elements of the Vertebrate eye are formed from a paired outgrowth of the primary vesicle of the fore-brain (Figs. 150, 151A, *ABl*), as already mentioned on p. 132.

This outgrowth is spoken of as the **primary optic vesicle**, and as it grows outwards towards the outer skin of the embryo,

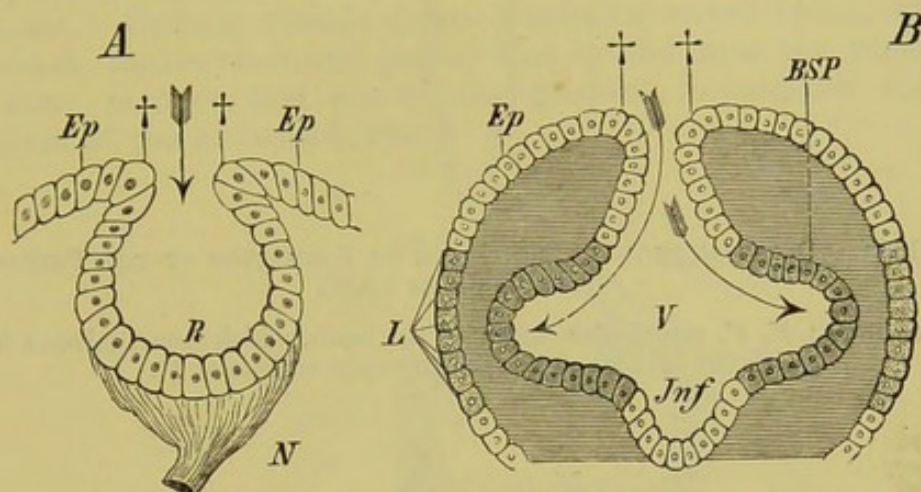


FIG. 150.—DIAGRAMS SHOWING THE MODE OF FORMATION OF THE EYE IN INVERTEBRATES (A) AND VERTEBRATES (B).

Ep, Ep, epiblast, which is invaginated in A to form the retina (*R*), and in B to form the medullary groove, its cavity (*V*) representing the third ventricle of the brain; in both figures ++ indicate the point where the external epiblast becomes continuous with the invaginated portion; the arrow in Fig. A shows the direction in which the rays of light pass, and one can imagine the rays entering in the same manner in Fig. B, and passing in the direction of the curved arrows: they would thus fall upon the shaded cells *BSP* on the walls of the ventricle, that is of the primary optic vesicle, which give rise later to the retina; *L*, the cells of epiblast, out of which the lens is formed later; *Jnf*, infundibulum; *N*, optic nerve.

the portion which connects it with the brain becomes constricted, and by degrees loses its cavity, giving rise to a solid cord, from which the optic nerve is formed.

At the point where the vesicle touches the epiblast, the latter becomes thickened, and gives rise to a mass of cells which is at first hollow, but which becomes compact later. This thickened portion of the epiblast then becomes driven inwards, carrying before

¹ On closer consideration, this distinction does not appear to be an essential one, for the outgrowths of the primary wall of the brain arise in the embryo at a time when the medullary groove is still open to the exterior, and when the cells comprising it consist simply of a thickened portion of the epiblast. When the primary optic vesicle comes into apposition with the epiblast, and the lens and secondary optic vesicle are formed, the relations of the parts are different, the sensitive (neuro-epithelial) elements of the retina being turned away from the light. (Comp. Figs. 150 and 151A and B, and p. 190.)

it the outer wall of the vesicle so as to form a double-walled cup, the **secondary optic vesicle** (Fig. 151B).

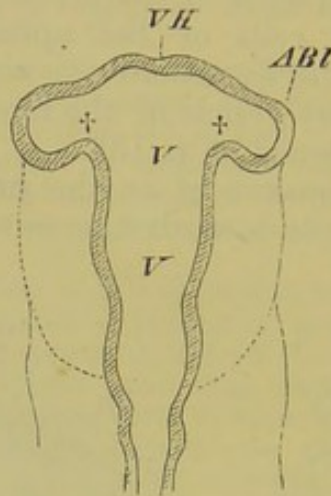


FIG. 151A.—DIAGRAM SHOWING THE MODE OF FORMATION OF THE PRIMARY OPTIC VESICLES (*ABI*).

VH, fore-brain; *V, V*, ventricular cavity of the brain, which communicates freely with the cavities of the primary optic vesicles at †.

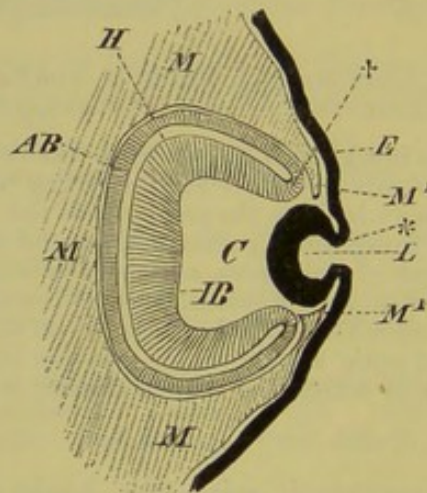


FIG. 151B.—SEMIDIAGRAMMATIC FIGURE OF THE SECONDARY OPTIC VESICLE, AND OF THE LENS BECOMING SEPARATED OFF FROM THE EPIBLAST.

IB, inner layer of the secondary optic vesicle, from which the retina arises; †, point at which the latter is continuous with the outer layer (*AB*), from which the pigment epithelium arises; *H*, remains of the cavity of the primary optic vesicle; *L*, lens which arises as a cup-shaped involution of the epiblast (*E*); *, point of involution of epiblast to form the lens; *MM*, mesoblastic tissue, which at *M¹, M¹* grows in between the epidermis and the lens as the latter becomes separated off, and which gives rise to the cornea as well as to the iris; *C*, vitreous chamber of the eye, between the lens and retina, which becomes later filled by the vitreous humour.

The inner and outer walls of the cup then become fused together, and from the former the sensory epithelium of the

retina is formed, while from the latter the **pigment epithelium** arises.

In the course of further development, the epiblastic thickening mentioned above becomes separated from the epiblast, sinks more and more into the interior of the optic vesicle, and is differentiated to form the crystalline lens (Fig. 151B, *L*). The remaining space within the optic vesicle becomes filled by mesoblastic tissue, which grows in from the ventral side of the secondary optic vesicle through the so-called **choroidal fissure**, and which gives rise to the **vitreous humour** (Fig. 151B, *C*), the bulk of which, as compared with the lens, gradually increases. Certain vessels (vasa centralia nervi optici, arteria hyaloidea, tunica vasculosa lentis) also extend into the vesicle in the same manner, and are of the greatest importance for the nutrition of the embryonic eye.

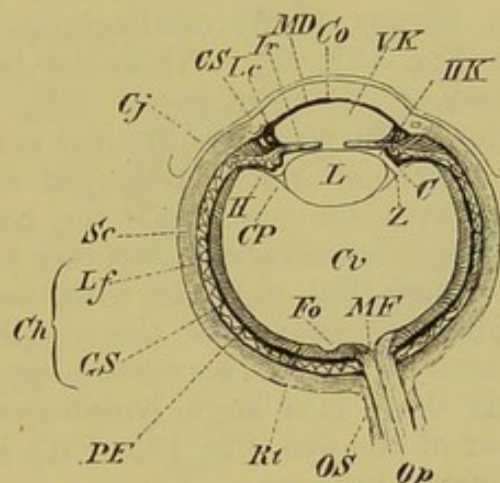


FIG. 152.—DIAGRAM OF A HORIZONTAL SECTION THROUGH THE RIGHT HUMAN EYE. (Seen from above.)

Op, optic nerve; *OS*, sheath of optic nerve; *MF*, blind spot; *Fo*, yellow spot (fovea centralis); *Rt*, retina; *PE*, pigment epithelium of the latter; *Ch*, choroid, with its lamina fusca (*Lf*) and vascular layer (*GS*); *Sc*, sclerotic; *Co*, cornea; *Cj*, conjunctiva; *MD*, membrane of Descemet; *CS*, canal of Schlemm (the dotted line should extend further through the sclerotic to the small oval aperture); *Ir*, iris; *Lc*, ciliary ligament; *C*, ciliary process; *VK*, *HK*, anterior and posterior chamber of the eye; *L*, lens; *H*, hyaloid membrane; *Z*, zone of Zinn; *CP*, canal of Petit; *Cv*, vitreous humour.

The secondary optic vesicle is now plentifully supplied with blood-vessels in its interior, and others arise in its periphery, where a definite vascular membrane, the **choroid**,¹ is formed from the surrounding mesoblast (Fig. 152, *Ch*).

Internally to the lens, the choroid gives rise to the ciliary folds, while more towards the exterior it passes in front of the lens to form the **iris** (Fig. 152, *Ir*), which retains in the centre a circular or slit-like aperture, the **pupil**, through which the rays

¹ *I.e.* the chorio capillaris and lamina fusca; the pigment epithelium, as already stated, is formed from the outer wall of the secondary optic vesicle.

of light pass. The amount of light admitted is regulated by the dilator and constrictor (sphincter) muscles of the iris, which are able to increase or lessen the size of the pupil; the iris thus serves as a screen to regulate the amount of light which enters the eye.

Not only is the size of the pupil inconstant, but the lens is also capable of undergoing considerable change in form, becoming more flattened, or more convex, as the case may be. The former condition occurs when distant, the latter when near objects are looked at. This delicate **accommodating apparatus** is regulated by a muscle (the ciliary, or tensor choroideæ), which arises in a circle all round the eye from the point of junction of the iris and sclerotic, and is inserted along the peripheral border of the iris (Fig. 152, *Lc*).

External to the vascular layer of the choroid lies a lymph-sinus (perichoroideal sinus) the walls of which are known under the name of lamina fusca (Fig. 152, *Lf*), and finally, externally to this is a firm, fibrous, partly cartilaginous or even ossified layer, the sclerotic (Fig. 152, *Sc*). While the latter passes internally into the sheath of the optic nerve (*OS*), and from thence into the dura mater, it becomes continuous externally with the **cornea**, the outer surface of which is covered over by an epithelial layer continuous with the epidermis, the **conjunctiva** (Fig. 152, *Co*, *Cj*). The sclerotic and cornea together form a firm outer support for the eye, and thus, together with the gelatinous mass of the vitreous humour, guarantee the rigidity necessary for the physiological activity of the nerve end-apparatus. Between the cornea and iris there is a large lymph-space, the so-called anterior chamber of the eye (Fig. 152, *VK*), its contained fluid being called the aqueous humour.

The deep orbit, formed by the skull, serves as a further protection for the eye, as do also certain **accessory structures**, which may be divided into three categories, viz. :—

1. **Eyelids (Palpebræ).**
2. **Glandular organs.**
3. **Muscles** (apparatus for moving the eye-ball).

The eyeball then is formed of a series of concentric layers which are called from within outwards retina, choroid (with the iris) (vascular layer), and sclerotic (with cornea) (skeletal layer). The first corresponds with the nervous substance of the brain, the second with the pia mater, and the third with the dura mater. The interior of the eye contains refractive media, the lens and vitreous humour. To these, certain accessory structures are added.

Fishes.¹—The eye of Cyclostomes remains at a very low stage of development: this is seen not only in the structure of the retina, but also (that is, in Myxinoids) in the absence of the

¹ In *Amphioxus* the presence of a visual organ has not been certainly proved.

lens, iris, and of a differentiated sclerotic and cornea. Moreover, the eye of Myxinoids and of Ammocœtes lies beneath the skin and sub-dermal connective-tissue. In Petromyzon the skin covering the eye becomes thinned out, and thus the animal, which was blind in the larval state, can see on reaching the adult condition: at the same time the eyeball increases in size, and becomes more highly organised.

The eyes of all the true Fishes are, with few exceptions (*e.g.* Siluroids and Eels), of considerable size. They have but little power of movement, and as the cornea is very flat, and the lens lies almost directly against it, the eyeball always possesses a hemispherical or ellipsoidal form, and the anterior chamber is very small. In other points, the eye is formed on the same plan as that described in the introductory portion of this chapter, but a few other details concerning it must now be considered.

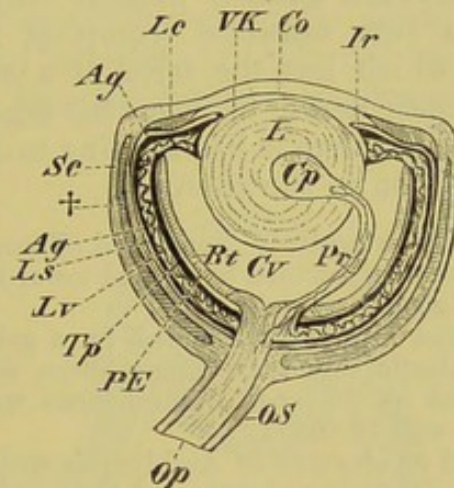


FIG. 153.—EYE OF A TELEOSTEAN.

Op, optic nerve; *OS*, sheath of optic nerve; *Rt*, retina; *PE*, pigment epithelium; *Tp*, tapetum; *Lv*, lamina vasculosa; *Ag*, argentea; *Ls*, lamina suprachoroidea; *Sc*, sclerotic, enclosing cartilage or bone (+); *Co*, cornea; *Ir*, iris; *Lc*, ciliary ligament; *VK*, anterior chamber; *L*, lens; *Cv*, vitreous humour; *Pr*, processus falciformis, and *Cp*, campanula Halleri, here shown as if continuous with one another.

The lens of Fishes, as in all aquatic animals, is globular, and possesses therefore a high refractive index. It fills up the greater part of the eyeball, so that not much space is left for the vitreous humour. It forms an exception to that of other Vertebrates in the fact that, in the condition of rest, it is accommodated for seeing near objects. In place of a ciliary muscle, there is only a fibrous ciliary ligament.

In the eye of Teleostei, a fold, the processus falciformis, arises from the choroid and extends into the vitreous humour towards the lens. The so-called campanula Halleri, which is inserted round the periphery of the lens, and which is usually described as a trumpet-shaped expansion of the processus falciformis, is, according to Virchow, entirely independent of the latter

(Fig. 153, *Pr*, *Cp*). The processus falciformis is never large in Elasmobranchs and Ganoids.

In the interior of this structure lie nerves, vessels, and smooth muscle-fibres, and the latter possibly exert an influence on the lens, and thus serve as an apparatus for accommodation.

External to the choroid proper, that is, between it and the lamina fusca s. suprachoroidea, lies a silvery or greenish-gold iridescent membrane, the so-called **argentea**. It extends either over the whole interior of the eye (Teleostei), or is limited to the iris (Elasmobranchs).

A second layer with a metallic lustre, the **tapetum celluloseum** s. **lucidum**, lies internally to the iridescent portion, and within this again there is the chorio-capillaris of the choroid. No tapetum appears to be present in Teleostei or Petromyzon.

The so-called **choroid gland**, present only in Teleostei and Amia, consists of a rete mirabile (comp. p. 292), composed of arteries and veins, which has the form of a cushion, lying near the entrance of the optic nerve, between the argentea and pigment epithelium of the retina; thus it has nothing to do with a "gland": it corresponds in position to the choroid.

The sclerotic is usually extensively chondrified (Elasmobranchs, Sturgeons), and not unfrequently becomes calcified or ossified towards its junction with the cornea: this also holds good for Teleostei.

The eyeball is almost always surrounded by a gelatinous tissue, penetrated by simple and elastic connective-tissue fibres, and in Elasmobranchs it is curiously articulated on its inner circumference with a rod of cartilage arising from the lateral wall of the skull.

The eyes are reduced or abortive in *Amblyopsis spelæus*, a Fish living in the caves of Kentucky: a similar abortion of the eyes takes place in many Invertebrates which live in caverns or in the deep sea (Vermes, Mollusca, Crustacea, Insecta).

Amphibia.—The eyes of Amphibians are proportionately smaller, and their form rounder than those of Fishes, but there are many points of close correspondence between them. This is true, for instance, of the more or less strongly chondrified sclerotic, the slight convexity of the cornea, and the globular lens. In other important points, however, the Amphibian eye is simpler than that of Fishes; thus it is wanting in an argentea, a tapetum, a choroid gland, and a processus falciformis and campanula Halleri. A proper ciliary muscle is present in the whole series of animals from this point onwards.

The eyes of *Proteus* and of the *Gymnophiona* always lie more or less deeply beneath the skin; they are very small, and are much degenerated (Figs. 148, *Boc*, and 149, *A*). In *Proteus* the crystalline lens and vitreous humour are both wanting.

Reptiles and Birds.—In these also, the sclerotic is in great part cartilaginous, and in Lizards it is provided with a ring of delicate bony plates around the external portion. Very many

fossil Reptiles and Amphibians possessed similar plates, as do also existing Birds (Figs. 154, 155, †); in Birds horse-shoe- or ring-shaped bony structures are also usually present close to the entrance of the optic nerve.

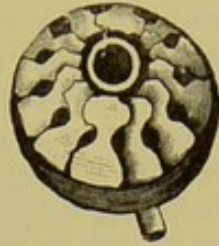


FIG. 154.—EYE OF *Lacerta muralis*, SHOWING THE RING OF BONY SCLEROTIC PLATES.

While the eyeball of Reptiles has a globular form (Fig. 154), that of Birds, and especially nocturnal Birds of prey (Owls), is more elongated and tubular, an external larger segment being sharply marked off from an internal smaller one (Fig. 155). The

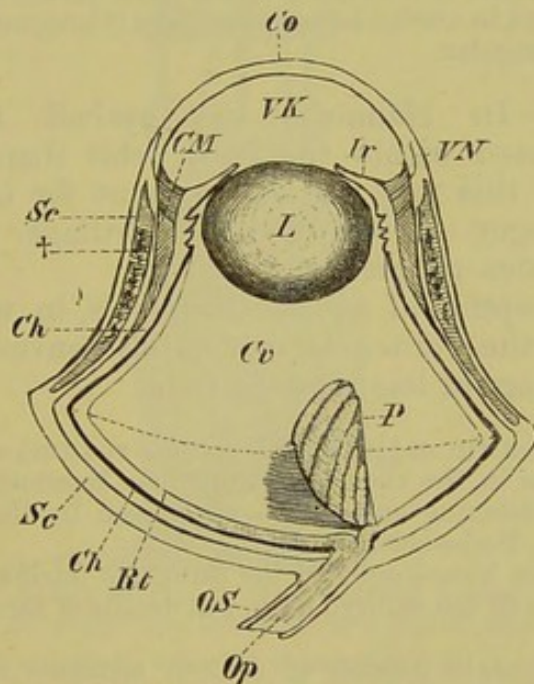


FIG. 155.—EYE OF AN OWL.

Rt, retina; *Ch*, choroid; *Sc*, sclerotic, with its bony ring at †; *CM*, ciliary muscle; *Co*, cornea; *VN*, point of junction between sclerotic and cornea; *Ir*, iris; *VK*, anterior chamber; *L*, lens; *Cv*, vitreous humour; *P*, pecten; *Op*, *OS*, optic nerve and sheath. The dotted line passing across the broadest portion of the circumference of the eye divides the latter into an inner and an outer segment.

former is bounded externally by the very convex cornea (*Co*), and encloses a large anterior chamber (*VK*), as well as a complicated ciliary muscle (Crampton's muscle) composed of striped fibres. This muscle is also transversely striated in Reptiles, and in them

is always well developed, though not to such an extreme degree as in Birds.

In Reptiles (Lizards, for instance) a tapetum may be developed, but an argentea and choroid gland are never present; all these structures are wanting in Birds. A structure which is homologous with the processus falciformis of the eye of Fishes is, however, present in Reptiles and Birds. Absent in Hatteria and Chelonia, this so-called pecten is largely developed in other Reptiles and in Birds (Fig. 155, *P*). In the latter it may extend from the point of entrance of the optic nerve to the capsule of the lens, but as a rule it does not reach so far. In Birds it is always more or less folded, and consists mainly of a closely-felted network of capillaries, and appears in both Reptiles and Birds to have an important relation to the nutrition of the contents of the eyeball and of the retina. It has nothing to do with accommodation.

The iris, which is regulated by striated muscle, by means of which it is able to respond very quickly to visual impressions, is often brightly coloured, and this colour is due to the presence not only of pigment, but also of coloured fat globules.

The pupil is as a rule rounded, but it may have the form of a vertical slit, as in many Reptiles and in Owls. In certain Fishes (*Coregonus*) and Amphibians (*Bombinator*) it is angular.

Mammals.—In Mammals the eyeball is always more completely enclosed within the bony orbit than in most other Vertebrates, and this may partially account for the fact that the sclerotic no longer shows traces of cartilage or bone, but is entirely of a fibrous character.

With the exception of aquatic Mammals, in which it is somewhat flattened, the cornea is moderately convex, and the whole eyeball is of a more or less rounded form.

A tapetum (*tapetum cellulosum vel fibrosum*), consisting either of cells or fibres, exists in the choroid of numerous Mammals, and gives rise by interference to a glistening appearance when seen in the dark (*Carnivora*, *Sirenia*, *Ruminants*, *Perissodactyla*, &c.).

Certain structures homologous to the processus falciformis and pecten are present in Mammals in the embryo only, but details of these structures cannot be described here.

The ciliary muscle consists of smooth elements only, and serves to accommodate the eye for seeing near objects (compare the eye of Fishes). The lens of Mammals in its position of rest is accommodated for distance.

The external surface of the lens is less convex than the internal, which latter lies in the so-called fossa patellaris of the vitreous humour.

The pupil is not always round, but may be transversely oval (*Ungulates*, *Kangaroos*, *Cetacea*), or have the form of a vertical slit (*e.g.* *Cat*).

Retina.

The fibres of the optic nerve, which pass into the eyeball at a right or acute angle, cross one another at the point of entrance,¹ and are then distributed to the sensitive elements of the retina.

The latter is thus thickest at the point of entrance of the nerve, which is known as the "blind-" or "Marriott's spot," and

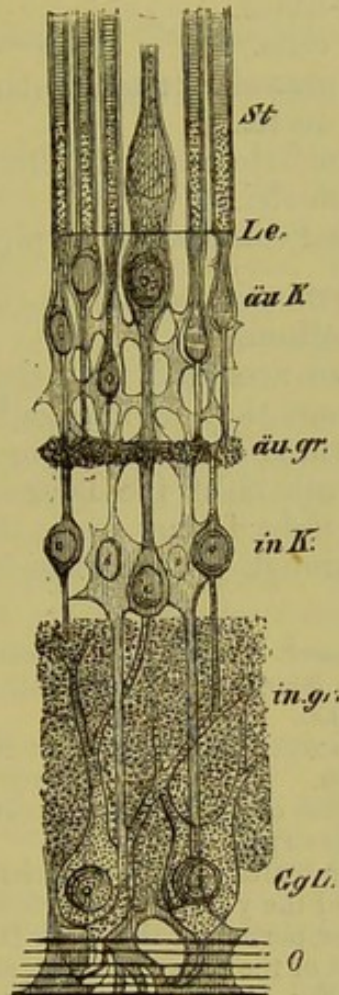


FIG. 156.—RETINA. (After Merkel.) (The nervous portion is shown black, and the supporting substance of a lighter tint.)

O, layer of nerve-fibres; *GgL*, layer of nerve-cells; *in.gr*, inner granular layer; *in.K*, inner nuclear layer; *äu.gr*, outer granular layer; *äuK*, outer nuclear layer; *Le*, limitans externa; *St*, layer of rods and cones.

gradually decreases in thickness towards the ciliary processes, until, at the point of origin of the iris, it consists of a simple layer of cells.

The retina, which is bounded both on its inner and outer periphery² by a structureless hyaline membrane (limitans

¹ This has not been satisfactorily made out in Mammals.

² The limitans externa encloses the entire retina externally in the embryo, but later the rods and cones come to project through it (see Fig. 156).

interna and externa), is quite transparent in the fresh condition, and consists of two structures which are histologically and physiologically quite different: they are, a supporting part and a nervous part. The former, or so-called fulcrum, which is stretched as on a frame between the limitans interna and externa, is shown in Fig. 156 as a light filigree-like tissue, the nervous portion being indicated by a darker and more granular shade. The latter consists of seven concentric layers, viz. :—

1. Layer of nerve-fibres.
2. " " " cells.
3. " " inner granular or molecular layer.
4. " " inner nuclei.
5. " " intermediate nuclei or outer molecular layer.
6. " " outer nuclei.
7. " " rods and cones with the pigment epithelium.

Only the two last-mentioned layers (6 and 7) correspond to the proper neuro-epithelium.

These layers are so arranged that the nerve-fibres lie next to the vitreous humour, that is, internally, while the rods and cones are situated towards the choroid, or are the most external. Thus the terminal members of the neuro-epithelium are turned away from the rays of light falling upon the retina, and the rays must therefore pass through all the other layers before they reach the rods and cones.

Fishes possess the longest, Amphibians the thickest rods, so that in the latter there are only about 30,000 to a square millimetre, while in Man there are from 250,000 to 1,000,000.

In Fishes the rods far exceed the cones in number, while in Reptiles and Birds the reverse is the case. The cones of many Reptiles and all Birds are distinguished by the presence of brightly coloured oil-globules, which are also present in those of Marsupials.

In the retina of all Vertebrates there is a specially modified region of most acute vision. This is called the yellow-spot (fovea centralis or macula lutea), and lies in the inner portion of the eye. It is due to the thinning-out of all the layers except that of the rods and cones, and even the rods disappear, only the cones persisting (Fig. 152, *Fo*). The cones of the macula lutea are distinguished in Fishes and Reptiles by a very elongated and narrow form, while in Amphibia and Mammals they are quite similar to those of the rest of the retina. The physiological function of the pigment-epithelium is to give rise to a colouring material, the so-called visual purple or visual red. This becomes dissipated by the light falling upon the retina, and we may thus compare the latter to a photographic plate, or rather to a whole photographic apparatus, in which the photographer, represented by the pigment-epithelium, by continually laying on new sensitive material ("visual substance") (purple), renews the plate, removing the old picture. Thus the act of seeing may possibly be looked upon as a photo-chemical process. The rods only possess the visual purple, the cones being without it; thus in animals the retina of which possesses no rods (*e.g.* many Reptiles), as well as in the yellow-spot of others, it is wanting. The fact that the visual purple is not present in these Reptiles as well as in certain nocturnal animals (*e.g.* *Caprimulgus*, *Vespertilio serotinus*), and in Fowls and Pigeons, proves, however, that the physiology of vision is not yet thoroughly understood.

In a recent paper, Engelmann has shown that the cones lengthen under the influence of light and shorten in darkness. This contraction of the cones and pigment-epithelium is directly connected with the nervous system, as is proved by the fact that it may occur in eyes which are entirely shut off from the light, as well as in those of decapitated animals when the brain is intact. The optic nerve must thus be looked upon as being made up of both centripetal sensory and centrifugal motor fibres. A reflex excitation of the cones may also be produced in Frogs by allowing light to fall on any one part of the body only, and the same occurs in strychnine-tetanus, quite independently of light.

Accessory Organs in Connection with the Eye.

(a) EYE-MUSCLES.

The movement of the eyeball is always (except in Myxinoids) effected by six muscles, which may be divided, according to the direction they take, into four straight (rectus superior, inferior, externus, and internus) and two oblique muscles (obliquus superior and inferior). The former, which arise from the inner portion of the orbit, usually from the dural sheath of the optic nerve, together circumscribe a pyramidal cavity, the apex of which lies against the inner portion of the orbit, while the base surrounds the equator of the eyeball, that is, the region in which the muscles are inserted into the sclerotic.

Both the oblique muscles usually take their origin, in close proximity to one another, from a point on the anterior or nasal side of the orbit, and as they respectively pass from this point dorsally and ventrally in an equatorial direction round the eyeball, they constitute a sort of incomplete muscular ring.

A deviation from this arrangement is seen in Mammals, in which the superior oblique arises far down in the inner part of the orbit, and then passes forwards in the long axis of the latter towards its anterior (internal) angle, where it becomes tendinous, and passes through a fibro-cartilaginous pulley (trochlea) attached to the upper border of the orbit, on the frontal bone. Hence it is sometimes called the trochlear muscle. From this point it changes its direction, and becomes reflected obliquely outwards and backwards to the globe of the eye.

Besides these six muscles, others are usually present which are known as the retractor bulbi (which is most developed in Ungulates), the quadratus (bursalis), and the pyramidalis. The last two are in connection with the nictitating membrane, and are present in Reptiles and Birds. All three are supplied by the abducent nerve. For an account of the innervation of the straight and oblique muscles, the reader is referred to the chapter on the cranial nerves (p. 154).

(b) EYELIDS (PALPEBRÆ).

In Fishes the upper and lower eyelids are very rudimentary, having simply the form of stiff folds of the skin; and in all other Vertebrates below the Mammalia they never reach a very high stage

of development. They are lined on the surface looking towards the eyeball by the conjunctiva, and in the Ichthyopsida and Sauropsida are usually not sharply marked off from the rest of the skin, being capable of no, or of only very slight movement.¹

The case is quite different in Mammals, in which the eyelids, more particularly the upper one, are extremely moveable, and are provided with hairs (eyelashes) on their free margin. They are closed by a circular muscle which surrounds the whole slit between the lids; a levator is also present in the upper eyelid. In Sauropsida and many Mammalia (*e.g.* Ungulates) there is also a depressor of the lower lid.

The want of or slight development of upper and lower eyelids in all Vertebrates below the Mammalia is compensated for, at any rate to a certain extent, by the presence of a nictitating membrane. This "third eyelid" differs from the others in having nothing to do with the true outer skin, consisting simply of a reduplication of the conjunctiva, and being regulated by special muscles (p. 191).

The nictitating membrane, which is present in rudiment in many Elasmobranchs, and which encloses a cartilage, is situated beneath the lower eyelid, or it may lie more towards the anterior angle of the eye. The former condition is seen in Anura and Reptilia, for instance, in which a third eyelid is so largely developed as to be capable of covering the whole freely exposed portion of the eyeball. In Birds and Mammals it always lies in the anterior angle of the eye; in Primates it becomes reduced to a small half-moon-shaped fold (*plica semilunaris*), and so comes into the category of rudimentary organs.²

(c) GLANDS.

The glands in connection with the eye may be divided into three sections: (1) the **lacrymal**, (2) the **Harderian**, or gland of the nictitating membrane, and (3) the **Meibomian glands**.

The secretions of all these three serve to keep the free surface of the eyeball moist, and to wash away foreign bodies.

In Fishes, the outer medium appears to suffice for this purpose, but the first attempt of a Vertebrate to exchange an aquatic for an aerial existence necessitates the development of a secretory apparatus in connection with the eye.

Thus in Urodeles a glandular organ is developed from the conjunctival epithelium along the whole length of the lower eyelid;

¹ In many Reptiles and Birds the upper eyelid is supported by a membrane-bone or fibro-cartilage, and large lymphatic and cavernous spaces are developed within the tissue of the lid. In Geckos and Snakes the two eyelids grow together to form a transparent membrane overlying the eye, and this comes away with the rest of the outer skin when the latter is shed.

² In the Caucasian race the *plica semilunaris* is only $1\frac{1}{2}$ to 2 millimetres broad, while in the Malayan Orang-Sakai race it reaches a breadth of 5 to $5\frac{1}{2}$ millimetres.

in Reptiles this becomes more developed in the region of the anterior and posterior angles of the eye, and the original connecting bridge gradually disappears: thus two glands are developed from the primitively single one, each of which becomes further differentiated both histologically and physiologically. From one is formed the Harderian gland, which always lies at the anterior angle of the eye, surrounding to a greater or less extent the antero-ventral portion of the eyeball, while the other gives rise to the lacrymal gland (Fig. 157, *H*, *H*¹, *Th*). The latter retains throughout life

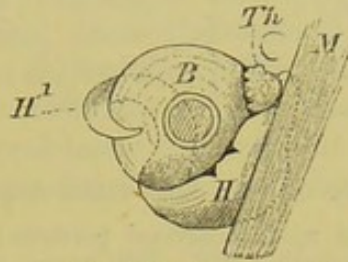


FIG. 157.—HARDERIAN GLAND (*H*, *H*¹) AND LACRYMAL GLAND (*Th*) OF *Anguis fragilis*.

M, muscle of jaw; *B*, eyeball.

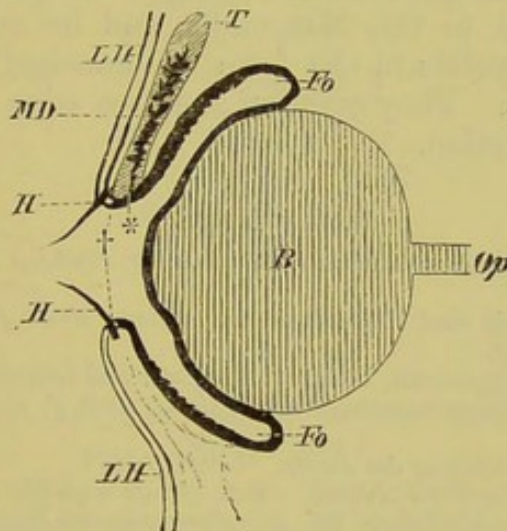


FIG. 158.—DIAGRAMMATIC TRANSVERSE VERTICAL SECTION THROUGH THE EYE OF A MAMMAL.

Op, optic nerve; *B*, eyeball; *Fo*, *Fo*, fornix conjunctivæ; *LH*, *LH*, outer skin of the eyelids, which at the free edges of the latter at † becomes continuous with the conjunctiva; *T*, the so-called tarsal fibro-cartilages, in which the Meibomian glands (*MD*) lie embedded, the latter opening at *; *H*, *H*, eyelashes.

its primitive position at the posterior angle of the eye, and in Reptiles and Birds even lies in the region of the lower eyelid, being supplied by the second division of the trigeminal. In Mammals it becomes gradually further subdivided, and extends into the region of the upper eyelid, so that its ducts open above the eye into the upper conjunctival sac (Fig. 159, **). Nevertheless, even in the Primates, more or fewer ducts are present which open into the lower conjunctival sac, and thus the primitive position of the lacrymal gland is indicated.

A well-differentiated Harderian gland is present in the whole series of animals from the tailless Amphibia to the Mammalia. Amongst the latter it is wanting in the Cetacea and Primates only.

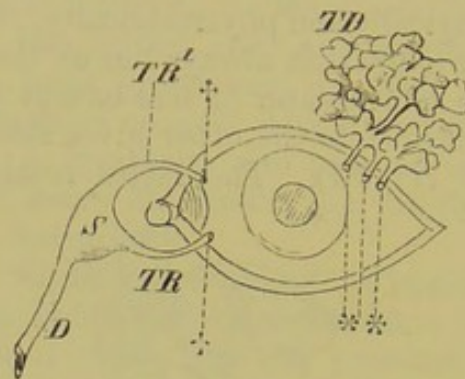


FIG. 159.—DIAGRAM OF THE LACRYMAL APPARATUS OF MAN.

TD, lacrimal gland, divided up into several portions; **, ducts of the lacrimal gland; ++, puncta lacrymalia; *TR*, *TR'*, upper and lower lacrimal canals; *S*, lacrimal sac; *D*, naso-lacrimal duct.

The Meibomian glands, belonging to the group of sebaceous glands, are confined to the Mammalia, and lie embedded in the substance of the eyelids in the form of branched tree-like tubes or clustered masses. They open on the free edge of the lid, and produce a fatty secretion.

BIBLIOGRAPHY.

- BERGER, E.—*Beiträge zur Anatomie des Sehorganes der Fische*. *Morphol. Jahrb.* Bd. VIII. 1882.
- BOLL, F.—*Zur Anatomie und Physiologie der Retina*. *Arch. f. Anat. u. Physiol.* 1877, *Physiol. Abthl.*
- CARRIÈRE, J.—*Die Sehorgane der Thiere*. München und Leipzig, 1885.
- HEINEMANN, C.—*Beiträge zur Anatomie der Retina*. *Arch. f. mikr. Anat.* Bd. XIV. 1877.
- KESSLER, L.—*Zur Entwicklung des Auges*. Leipzig, 1877.
- LEUCKART, R.—*Organologie des Auges*. In *A. Graefe und Th. Saemisch, Handbuch der gesammten Augenheilkunde*. Bd. I. *Anatomie und Physiologie*.
- MANZ, W.—*Entw.-Gesch. des menschl. Auges*. *Ibid.*
- MÜLLER, H.—*Gesammelte und hinterlassene Schriften zur Anatomie und Physiologie des Auges*. Herausgegeben von O. Becker. Leipzig, 1872.
- MÜLLER, W.—*Ueb. die Stammesentwick. des Sehorganes der Wirbelthiere*. *Festgabe von C. Ludwig*. Leipzig, 1874.
- SARDEMANN, E.—*Die Thraenendrüse*. *Preisschr.* Friburg i/B. 1884. Abstract in the *Zool. Anz.* 1884.
- SCHULZE, M.—*Die Retina*. *Stricker's Handbuch der Lehre von den Geweben*. Leipzig, 1871. See also *Archiv für mikr. Anatomie*, Bd. II., III., IV., V., VI., & VII.
- SCHWALBE, G.—*Lehrb. d. Anatomie der Sinnesorgane*. Erlangen, 1883.

AUDITORY ORGAN.

It is very probable that the auditory organ, like those of smell and taste, has been derived primitively from a modified integumentary sense-organ (organ of the lateral line). The

original form of both auditory and lateral line organs is a vesicle derived from the epiblast, from which it later becomes separated off; it is lined by elongated cells of **sensory epithelium** provided with hair-like processes (auditory hairs), and by **supporting cells**. Moreover, both structures are supplied by cranial nerves (*VIII*, *X*) which correspond to dorsal roots.

Like the other higher sense-organs, the paired auditory organ of Vertebrates is situated in the region of the head, and it always lies between the origins of the trigeminal and vagus nerves. The first traces of it in the embryo are seen to the right and left of the hind brain (Fig. 160, *LB*), and after the vesicle of each side has become separated off from the epiblast and connected with the auditory nerve which grows out towards it from the brain, it sinks deeper and deeper into the mesoblastic tissue of the skull: it then loses its original pyriform or rounded shape, and becomes divided into two

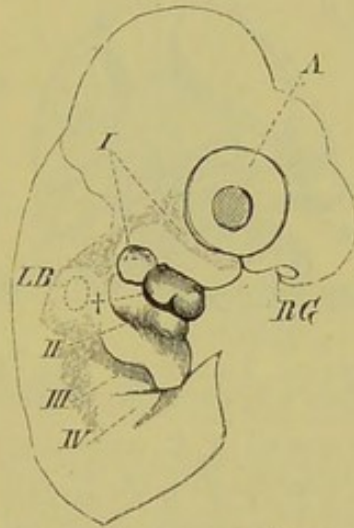


FIG. 160.—HEAD AND ANTERIOR PORTION OF BODY OF A CHICK. (In part after Moldenhauer.)

RG, olfactory pit; *A*, eye; *I* to *IV*, first to fourth visceral arches; †, point at which the external auditory passage begins to be formed; *LB*, primitive auditory vesicle seen through the wall of the head.

parts, called respectively the **utricle** and **sacculus** (Fig. 161, *Ut*, *S*). From the former the **semicircular canals** become differentiated, while from the latter the tube-like **recessus vestibuli** (aquæductus vestibuli *s.* ductus endolymphaticus) and the **cochlea** are formed (Fig. 161, *S.B.*, *F.B.*, *H.B.*, *D.e.*, *C*).

This whole, very complicated, apparatus constitutes the membranous auditory organ or **membranous labyrinth**. It becomes surrounded secondarily by mesoblastic tissue, which is at first in close contact with it; later, however, a process of absorption takes place in the innermost layers of the mesoblast, thus giving rise to a space, which closely repeats the form of the membranous labyrinth, as does also the mesoblast which encloses this space, and which later becomes chondrified, and often also ossified. We thus

get a **membranous** and a **bony labyrinth**, and between them a cavity (**cavum perilymphaticum**) filled with a lymph-like fluid (perilymph). The cavity within the membranous labyrinth, which also contains a fluid (endolymph), is spoken of as the **cavum endolymphaticum**.

With the exception of the Cyclostomi, three semicircular canals are always present, and these lie in planes at right angles to one another. They are distinguished as the anterior vertical, the posterior vertical, and the horizontal (external) canals. The first and last-named (Fig. 161, *S.B.*, *H.B.*) arise from the portion of the utriculus known as recessus utriculi (*Re.ut.*), and each has a vesicle-like swelling or ampulla (*S.A.*, *H.A.*) at its

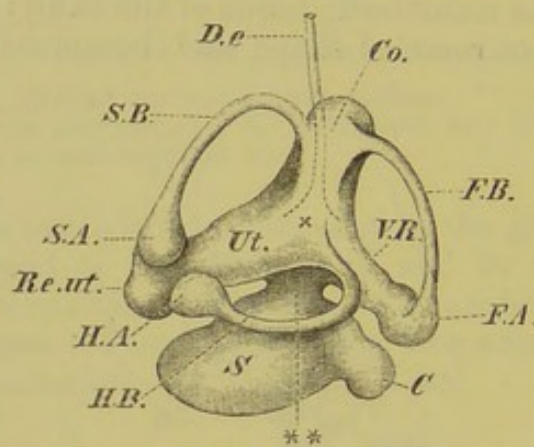


FIG. 161. — SEMIDIAGRAMMATIC FIGURE OF THE AUDITORY ORGAN OF A TELEOSTEAN. (Modified from a figure of that of *Muraena anguilla* by Hasse.)

Ut., utriculus; *Re.ut.*, recessus utriculi; *V.R.*, connecting-tube of the posterior ampulla (*F.A.*); **, wide connecting-duct between the pars superior and pars inferior; *S*, sacculus; *C*, cochlea; *S.B.*, *F.B.*, *H.B.*, anterior and posterior vertical, and horizontal canals; *Co.*, canal commissure, with its apex; *S.A.*, *H.A.*, *F.A.*, ampullæ of the anterior, horizontal, and posterior canals; *D.e.*, ductus endolymphaticus, which arises from the point where the two tubes of the pars superior of the labyrinth and the opening of the horizontal canal (x) join one another.

origin. The posterior canal (*F.B.*) also arises with an ampulla (*F.A.*) from a prolongation of the utriculus, described in Fig. 161 as the "connecting-tube" (*V.R.*).

The other end of the horizontal canal opens by a funnel-shaped enlargement (Fig. 161, x) into the utriculus, while those of the posterior and anterior canals fuse together to form a common tube, the so-called canal commissure (sinus superior) (*Co.*), which also opens into the utriculus.

The distribution of the branches of the auditory nerve and the position of the sensory epithelium in the following parts of the membranous labyrinth must now be considered:¹ (1) the

¹ Concretions composed mainly of carbonate of lime are present in the regions of the various nerve end-plates of the auditory organ in all Vertebrates, as well as in many Invertebrates. These "otoliths" present the greatest variety both in

three ampullæ of the canals, in each of which the auditory cells are situated on a ridge (*crista acustica*) projecting into the lumen; (2) the utriculus, in which a large "macula acustica" is present; this is continued into the recessus utriculi as well as into the sacculus and the rudiment of the cochlea (the recessus cochleæ), which arises from the sacculus. The several portions of the sensory plate or macula acustica, which are originally continuous, become later disconnected from one another, and from the Teleostei onwards are seen as separate maculæ acusticæ.¹

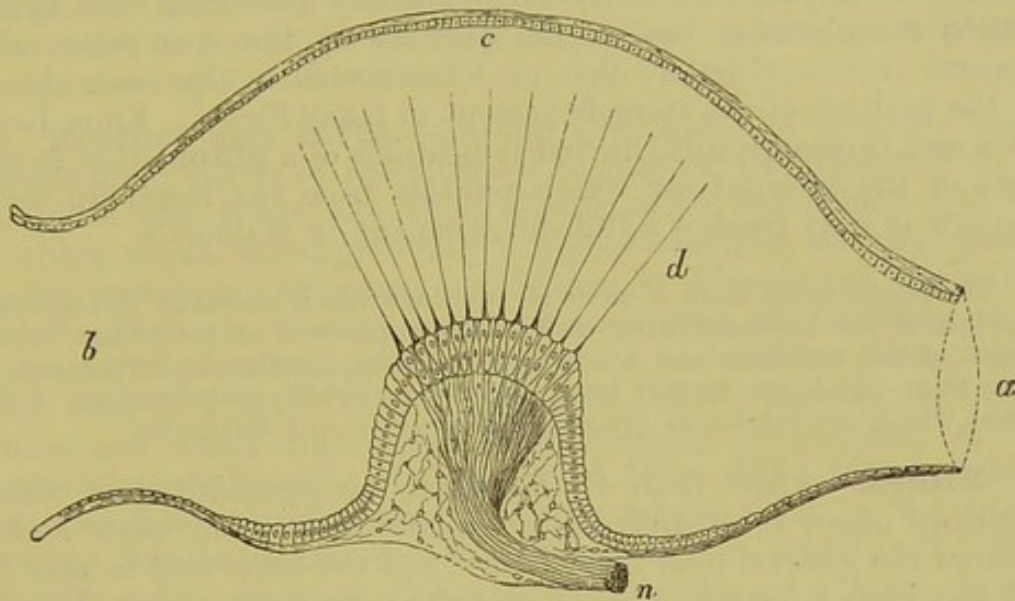


FIG. 162.—LONGITUDINAL SECTION OF AN AMPULLA OF GOBIUS. (The exact form of the epithelium of the crista is not indicated.) (After Hensen.)

n, the nerve passing into the connective-tissue of the crista; *a*, base of semicircular canal; *b*, point of opening of the ampulla into the alveus communis; *c*, the somewhat cylindrical epithelium on the free wall of the ampulla; *d*, the auditory hairs.

The higher we pass in the Vertebrate series, the greater share does the mesoblast take in the formation of the auditory organ. At first, that is, in Fishes, the ear lies close under the roof of the skull, and is thus easily accessible to the waves of sound, which are conducted partly through the operculum (when present), and partly through the gill-slits or spiracle:² as we pass to the higher animals,

form and size. The largest and most massive ones are seen in Teleosteans. They either consist of a single mass, or are arranged in groups in different regions of the labyrinth. Nothing certain is known as to their physiological function.

¹ Besides the above-mentioned areas of distribution of the auditory nerve, there is still another independent one: it lies in Fishes on the floor of the utriculus, close to the ductus sacculo-utricularis, to be described presently, and is called the macula neglecta. It is present from Fishes up to Birds, lying in Amphibia on the inner side of the sacculus, and in Reptiles and Birds in the utriculus, as in Fishes: in Mammals it undergoes a gradual reduction, and finally becomes obliterated. In all Vertebrates except Mammals, all the auditory nerve-endings are characterised by only two forms of cells (auditory and supporting cells): in the Mammalian cochlea the cells of the sensory epithelium possess a peculiar form.

² Howes has shown that in the Skate the structure known as the "fenestra vestibuli cartilaginei" corresponds physiologically to a kind of tympanum.

however, the auditory organ gradually sinks further and further inwards from the surface. Thus a new method for conducting the sound-waves is necessitated, and the following structures become developed:—a canal passing inwards from the surface, the **external auditory passage** or **meatus**; this opens into a spacious chamber, the **tympanic cavity**, in which are situated the **auditory ossicles**, and which is connected by the **Eustachian tube** with the pharynx. The whole of this canal, which is divided into an outer and an inner portion at the junction of the external auditory passage and tympanic cavity by a vibratory membrane, the **tympanic membrane**, lies in the position of the first embryonic visceral (hyomandibular) cleft, or, what comes to the same thing, in the position of the spiracle present in many Fishes. From Reptiles and Birds onwards the first indications of a **pinna** (that is, the part of the external ear which projects from the head) are seen, though it only reaches a full development in Mammals.

The pinna arises from a series of swellings which surround the external aperture of the hyomandibular cleft. These appear at an early stage in the region of the mandible and hyoid, and soon fuse together to form a sort of ring, from which are formed later those characteristic protuberances of the pinna which are known as tragus, antitragus, antihelix, &c.

Fishes.—Apart from Cyclostomes, the peculiarities of whose auditory organ it is difficult to explain, that of all other Fishes follows the general plan given above, and the same may be said for all the higher Vertebrates. Everywhere we meet with a division into a pars superior,—represented by the utriculus and semicircular canals,—which remains essentially much in the condition already described, and a pars inferior,—constituted by the sacculus and cochlea,—which gradually becomes more differentiated, and attains to a higher and higher degree of development and functional perfection (Fig. 161). In Fishes the cochlea consists simply of a small knob-like appendage (“lagena”) of the sacculus, which opens freely into the main cavity of the latter by means of the sacculo-cochlear canal (Fig. 161, *C*). The utriculus and sacculus also communicate with one another by the sacculo-utricular canal.

Amphibia.—Here all the parts remain much as described above, with the exception of the cochlea, which, especially in the Anura, points to a higher stage of development, in that it shows an indication of a pars basilaris with another patch of nerve-endings, the papilla acustica basilaris: it becomes further constricted off from the lumen of the sacculus, with which it is connected only by a very minute canal.

A further advance in structure as compared with Fishes is the appearance of a cartilaginous plate which fits into the fenestra ovalis of the auditory capsule, and corresponds to the base of the stirrup-bone (stapes) of the higher Vertebrata (Figs. 56 and 58,

St. Fov.) In several Urodeles (*e.g.* *Cryptobranchus*, *Menopoma*, *Spelerpes*) the stapedial plate becomes elongated by the addition of a distal element, and thus forms a "columella." A tympanic cavity, with a tympanic membrane lying on a level with the skin, and a Eustachian tube opening into the pharynx, are met with first in the Anura, in which also the columella is more perfect, consisting of a bony and cartilaginous chain, expanded distally to fit against the tympanic membrane. The whole columella probably corresponds to the upper element of the hyoid arch (pharyngo-hyal): the fact that it is sometimes continuous with the wall of the auditory capsule at an early stage may probably be explained as a secondary modification.

Reptiles and Birds.—In the Chelonia, the auditory organ shows many points of resemblance to that of Urodeles, and in all Reptiles and Birds, the chief modifications are confined to the cochlea, which shows gradually a higher condition of development as we pass from Chelonians and Snakes to Lizards and Crocodiles. In the Chelonia, where, as already mentioned, the auditory organ remains in a lower stage of development, the cochlea grows out in the form of a short canal (ductus cochlearis, lagena); in Crocodiles and Birds this canal is considerably longer, and at the same time it becomes slightly coiled (Figs. 163—165). A more marked differentiation also gradually takes place in the membrana basilaris and the papilla acustica basilaris. Both become more and more elongated, and, at the same time, distinct indications of a scala tympani and vestibuli are seen. (Compare the description of these parts on p. 204.)

In the Lacertilia the most varied types of auditory organ are met with; in many (*Phrynosoma*, *Pseudopus*, *Anguis*), the membrana basilaris is hardly more highly developed than in Ophidia. In Iguana, an advance towards Lacerta and the other higher Lizards is to be noticed; the membrana basilaris is longer, though the lagena with its papilla is not so much marked. In *Acantias* and *Platydactylus* this state of things is carried still further, and finally the more highly developed auditory organ of *Plestiodon* and *Egerina* leads up to that of Crocodilia. Thus there is a continuous and unbroken series from the lower forms to the higher.

The structure of the auditory organ of Hatteria shows many striking peculiarities: it thus, like that of *Chamæleo*, occupies an isolated position.

Whilst the cochlea gradually becomes more independent of the sacculus, the latter shows the greatest variety both as to form and size in the different types (Figs. 163, 164, *S*). Thus, for instance, it is usually very small in Birds, while in Lizards (*Lacerta*) it is of considerable size.

The aperture of communication between the utriculus and sacculus persists, though it gradually becomes narrowed, as does also that between the sacculus and cochlea. The connection between the latter may be drawn out to form a canal (*canalis reuniens*), and this is particularly the case in Birds (Fig. 165);

in Crocodiles an intermediate condition between Birds and Lizards is seen. The membranous labyrinth of Birds, however, is always specially characterised by the peculiar arrangement of the

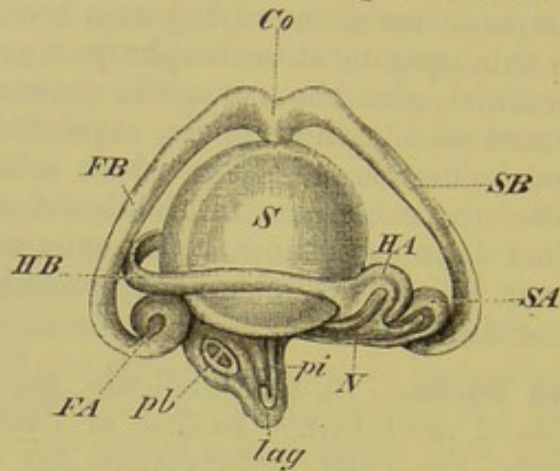


FIG. 163.—MEMBRANOUS LABYRINTH OF *Lacerta*.

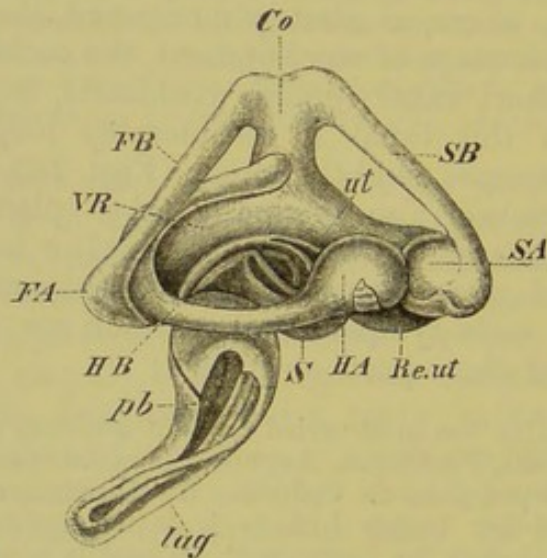


FIG. 164.—MEMBRANOUS LABYRINTH OF THE CROCODILE. (Both from the outer side.) (After C. Hasse.)

S, sacculus; *ut*, utriculus; *Re.ut*, recessus utriculi; *VR*, connecting-duct of the posterior ampulla; *SB*, *FB*, *HB*, anterior and posterior vertical, and horizontal canals, with their ampullæ (*SA*, *FA*, and *HA*); *Co*, commissure of the vertical canals; *pb*, pars basilaris cochleæ; *pi*, macula acustica neglecta; *lag*, lagena; *N*, auditory nerve.

anterior and posterior canals, which are greatly arched, and the position of the openings of which into the sinus superior (canal commissure) is reversed.

In lower types (Swimming Birds) this peculiarity is less marked than in the higher forms, and it would be very interesting to ascertain the condition of these parts in the Struthionidæ, as one would expect to find in them important points of connection with Reptiles.

In spite of this higher stage of development of the auditory organ in Crocodiles and Birds, we cannot speak of the presence

in them of an organ of Corti in the cochlea. A tympanic membrane is present in most Reptiles (with the exception of Ophidia, Hatteria, and Chamæleo) and in all Birds. The osseo-cartilaginous columella is well developed, and varies much in the different forms.

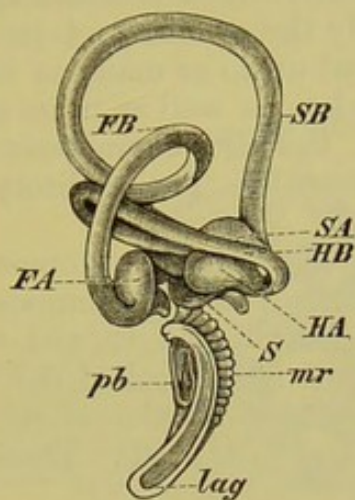


FIG. 165.—MEMBRANOUS LABYRINTH OF THE PIGEON. (After C. Hasse.)

S, sacculus; *pb*, pars basilaris; *mr*, membrane of Reissner; *lag*, lagena; *SB*, *FB*, *HB*, anterior and posterior vertical, and horizontal canals; *SA*, *FA*, *HA*, ampullæ of the anterior and posterior vertical, and horizontal canals.

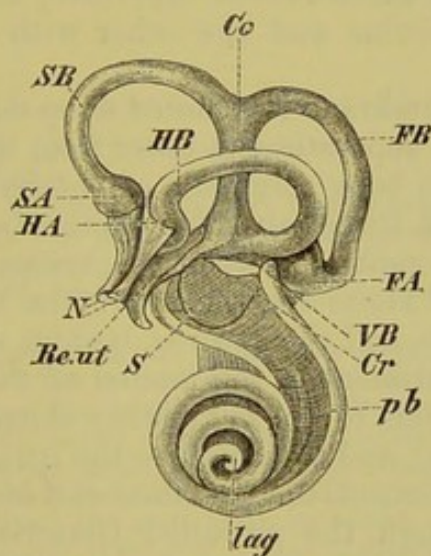


FIG. 166.—MEMBRANOUS LABYRINTH OF OX. (After C. Hasse.)

S, sacculus; *Re.ut*, recessus utriculi; *VB*, blind sac at the origin of the cochlea; *Cr*, canalis reuniens; *pb*, pars basilaris; *lag*, lagena; *SB*, *FB*, *HB*, anterior and posterior vertical, and horizontal canals; *SA*, *FA*, *HA*, the ampullæ of these canals; *Co*, canal commissure; *N*, auditory nerve.

Mammals.—The Monotremes appear to form a connecting link between the Reptilia, or, more correctly perhaps, the post-

Reptilia and other Mammals; and their auditory organ is similar in many points to that of Crocodiles. At the same time nothing is yet certainly known of the phylogeny of the Mammalian auditory organ, concerning which further and more extended researches are necessary. The cochlea here reaches its highest development, for it grows into a long tube which becomes spirally coiled on itself: in Man it forms nearly three coils, and in other Mammals from one and a half (Cetacea) up to as many as four or more.¹ In this spiral form of the cochlea, as well as in its more highly specialised histological structure, lies the characteristic peculiarity of the auditory organ of Mammals. The auditory nerve forms the axis of the spiral (Fig. 166).

In consequence of the large development of the cochlea, the papilla acustica, or, as it is called in Mammals, the **organ of Corti**, is drawn out to a considerable length, and the part of the wall of the cochlea on which this lies is called the basilar membrane, while the opposite wall is spoken of as the membrane of Reissner (Figs. 169 and 170, *B, R*). These parts will be referred to again later on.

The aperture of communication between the pars superior and pars inferior of the membranous labyrinth, that is, between the sacculus and utriculus, is entirely obliterated in Mammals, the two parts being only indirectly connected with one another by means of the ductus endolymphaticus; this bifurcates at its point of insertion into the membranous labyrinth, one limb being connected with the utriculus and the other with the sacculus (Fig. 167, at 2).

The tympanic membrane is situated deep down in the external auditory meatus, and separates the latter from the tympanic cavity. In place of the single bony columella of the Sauropsida there is in Mammals a chain of three auditory ossicles, articulated with one another, and extending between the tympanic membrane and the fenestra ovalis. These are, the malleus, the incus, with its orbicular apophysis, and the stapes, besides which there is often a bony (interhyal) rudiment in the tendon of the stapedius muscle. The malleus corresponds to the articular element of the mandible of lower Vertebrates,² and the incus to the quadrate, the former arising by a constriction of the proximal end of Meckel's cartilage, which extends through the so-called Glaserian fissure into the tympanic cavity. As in the Sauropsida, the stapes corresponds to the upper element of the hyoid arch (pharyngo-hyal or hyo-mandibular of Fishes). The fact that in some cases the stapes

¹ In the Rabbit there are two and a half, in the Ox three and a half, in the Pig almost four, and in the Cat three coils in the cochlea. In other types the cochlea, as well as the sacculus and all parts of the pars superior of the membranous labyrinth, vary considerably both in form and arrangement.

² Cp. the chapter on the skull, and Fig. 67, in which the mode of development of these parts is shown.

appears to be cut out of the substance of the periotic capsule, is taken by some observers (Kölliker, Moldenhauer) to prove that it has not a visceral origin, but this fusion is probably a secondary condition (cp. columella of Amphibia, p. 198). In Monotremes, several Marsupials, and some Edentates, the stapes is imperforate and columelliform; in all other Mammals it is stirrup-shaped, and encloses the stapedia artery.

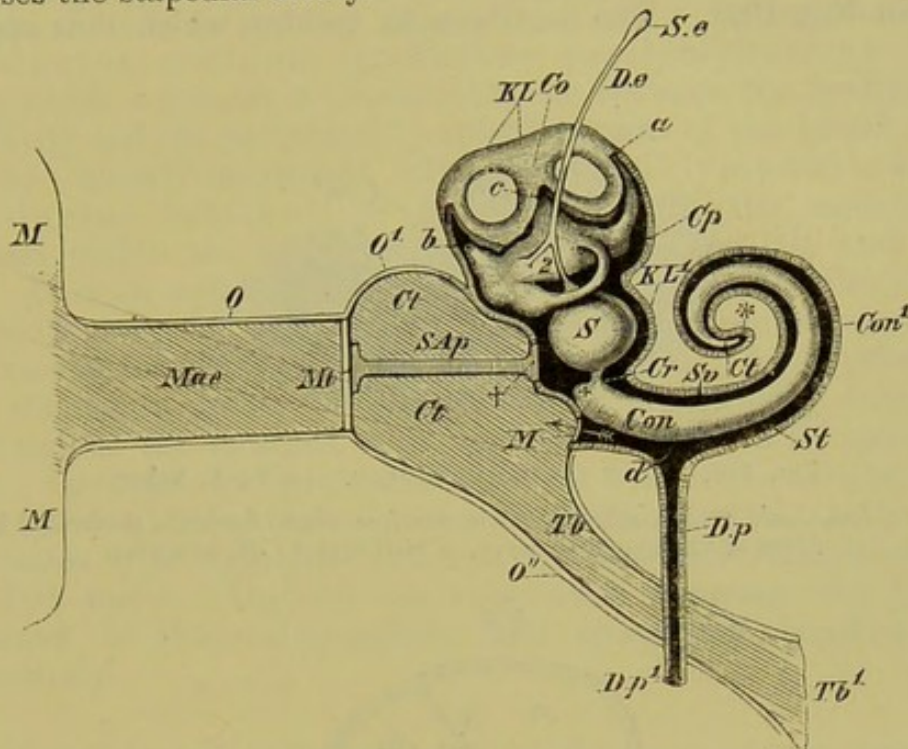


FIG. 167.—DIAGRAM OF THE ENTIRE AUDITORY ORGAN OF MAN.

External Ear.—*M, M*, pinna; *Mae*, external auditory meatus; *O*, wall of latter; *Mt*, tympanic membrane.

Middle Ear.—*Ct, Ct*, tympanic cavity; *O¹*, wall of same; *SAp*, sound-conducting apparatus, drawn in the form of a rod, representing the auditory ossicles; the point † corresponds to the stapes which closes up the fenestra ovalis; *M*, fenestra rotunda; *Tb*, Eustachian tube; *Tb¹*, its opening into the pharynx; *O¹*, its wall.

Internal Ear, with the greater part of the bony labyrinth (*KL, KL¹*) removed.—*S*, saccus; *a, b*, the two vertical canals, one of which (*b*) is shown cut through; *c, Co*, commissure of the canals of the membranous and bony labyrinths respectively; *S.e, D.e*, saccus and ductus endolymphaticus; the latter bifurcates at 2; *Cp*, cavum perilymphaticum; *Cr*, canalis reuniens; *Con*, membranous cochlea, which gives rise to a blind sac at †; *Con¹*, bony cochlea; *Sv* and *St*, scala vestibuli and scala tympani, which at * pass into one another at the cupula terminalis (*Ct*); *D.p*, ductus perilymphaticus, which arises from the scala tympani at *d*, and opens at *D.p¹*. The horizontal canal is seen between 2 and *S*.

To understand the auditory organ, and more particularly the membranous cochlea, of Mammals, it is necessary to examine the bony cochlea. The axis of the latter lessens in size from base to apex (Fig. 168, *A*) and round it a bony lamella (lamina spiralis ossea) winds in a spiral manner; this extends into the cavity of the coils of the cochlea without quite reaching as far as the

opposite wall (Figs. 168, *Lso*, *Lso*¹, and 169, *Lo*, *Lo*¹). This is continued outwards by two laterally-diverging lamellæ (Fig. 169, *B*, *R*), mentioned above as the *membrana basilaris* and *membrana Reissneri*; these lie at an angle to one another and correspond to the inner walls of the membranous cochlea. The outer wall of the latter is completed by a portion of the peripheral part of the bony cochlea (the region between *Ls* and the peripheral end of *R* in Fig. 169). The membranous cochlea, which thus appears

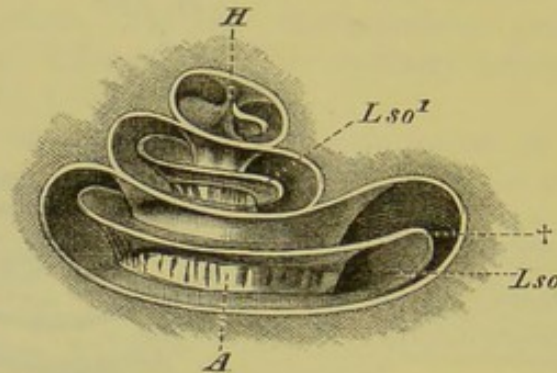


FIG. 168.—BONY COCHLEA OF MAN. (After A. Ecker.)

A, axis; *Lso*, *Lso*¹, lamina spiralis ossea, the free edge of which, perforated by the fibres of the auditory nerve, is visible at †; *H*, hamulus.

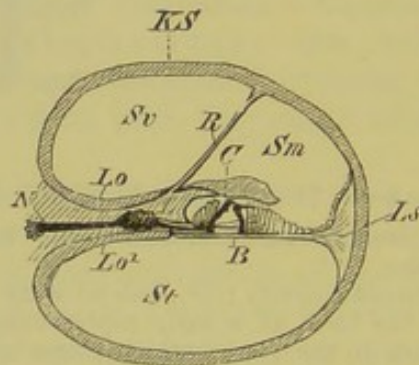


FIG. 169.—DIAGRAMMATIC TRANSVERSE SECTION OF THE COCHLEA OF A MAMMAL.

KS, bony cochlea; *Lo*, *Lo*¹, the two layers of the lamina spiralis ossea, between which at *N* the auditory nerve (together with the ganglion, left of *L*) is seen; *L*, limbus laminae spiralis; *B*, membrana basilaris, on which the neuro-epithelium lies; *R*, Reissner's membrane; *Sv*, scala vestibula; *St*, scala tympani; *Sm*, scala media (membranous cochlea); *C*, membrane of Corti; *Ls*, ligamentum spirale.

approximately triangular in transverse section, is called the ductus cochlearis or scala media. It is apparent that the scala media does not by any means fill up the lumen of the bony cochlea, but that a cavity is left on either side of it, corresponding to those we have already met with in the auditory organ of Birds, and known as the **scala vestibuli** and **scala tympani** (Fig. 169, *Sv*, *St*).

Both of these are continuous with the cavum perilymphaticum, and, following the direction of the scala media, open into one another

at the blind end of the latter, that is, at the so-called cupula terminalis (Fig. 167, *). The scala vestibuli is shut off from the tympanic cavity (*Ct*, *Ct*) by the membrane of the fenestra ovalis, to which the stapes is applied externally (Fig. 167, *SAp*, †); the scala tympani is closed by the membrane of the fenestra rotunda (Fig. 167, *M*).

On the floor of the bony cochlea, not far from the fenestra rotunda, there is an opening (Fig. 167, *d*) into a narrow canal, the aqueductus cochleæ, or ductus perilymphaticus (*D.p*, *D.p*¹), which serves as a communication between the perilymphatic cavity and the peripheral lymphatic trunks of the head.¹

The already-mentioned ductus endolymphaticus s. aqueductus vestibuli is in relation with the endolymph enclosed within the membranous labyrinth (Figs. 161 and 167, *D.e*). It is an archaic structure, and is present from the lowest Fishes (Myxinoids) up to Mammals, undergoing numerous variations and modifications in the Vertebrate series. In its primitive form, the endolymphatic duct consists of a tube arising from the inner wall of the sacculus, with the lumen of which it communicates. Its upper end perforates the inner wall of the cartilaginous or bony auditory capsule, passes into the cranial cavity, and terminates by an expanded extremity (saccus endolymphaticus) in the dura mater. Osmosis can thus occur between the lymph contained in the endolymphatic and epicerebral lymph-spaces respectively.

In Elasmobranchs the ductus endolymphaticus opens on the posterior part of the roof of the skull, and is thus in free communication with the sea-water. In many Reptiles its free end comes to lie close under the roof of the skull beneath the parieto-occipital suture, and in the *Ascalabota* the duct even leaves the cranial capsule, passes back between the muscles of the neck, and in the region of the pectoral arch becomes swollen to form a large folded sac, from which finger-shaped processes extend right to the ventral surface of the vertebral column and to the sub-mucous tissue of the pharynx. These processes may also branch out in a labyrinthic manner into the orbit, and they are always filled with a white semi-solid mass of otolithic substance, consisting of very minute crystals of carbonate of lime: otolithic matter is also present in the ductus endolymphaticus of all Vertebrates, at any rate in the embryo.

In Amphibians, and also in certain Teleosteans, the duct of either side, by means of large sac-like enlargements, may come to lie close to its fellow, either on the dorsal surface only, or on both dorsal and ventral sides of the brain. The latter is the case in *Anura*, for instance.

In Birds and Mammals the ductus endolymphaticus never passes out of the cranial cavity, and in its general relations corresponds with the tube-like ground-form described above.

¹ A ductus perilymphaticus can be plainly made out from Reptiles onwards. It arises in the cavum perilymphaticum on the outer side of the sacculus, then passes along a deep furrow to the median wall of the cochlea, extends over the membrana basilaris (scala tympani), passes through the foramen rotundum, and comes into connection with the epicerebral lymph-sinus.

HISTOLOGY OF THE MAMMALIAN COCHLEA.

The fibres of the auditory nerve running along the axis of the bony cochlea extend in their course laterally outwards, and come to lie between the two plates of the lamina spiralis ossea (Fig. 168, *Lso*, *Lso*¹, Figs. 169, 170, *N*, between *Lo* and *Lo*¹). On the free border of the latter, these pass out, and break up into terminal fibrillæ on the inner surface of the basilar membrane (Fig. 170, *N*, *N*¹, *N*²).

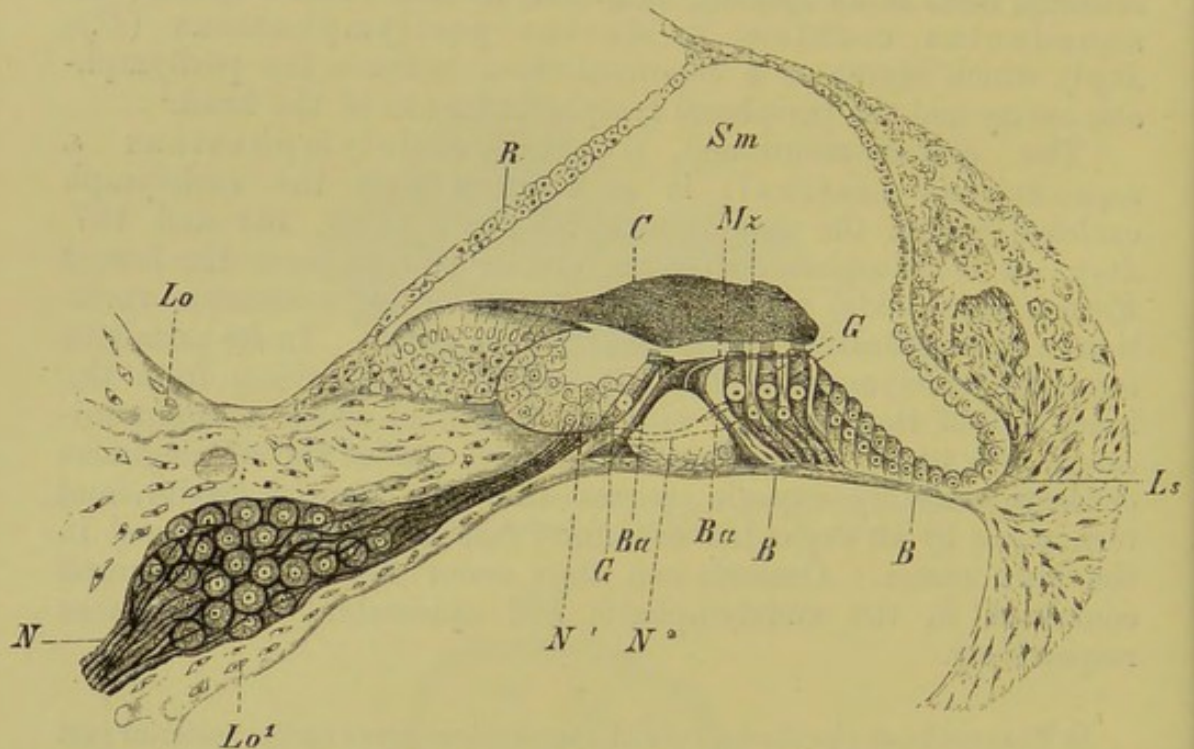


FIG. 170.—THE ORGAN OF CORTI. (After Lavdowsky.)

Lo, *Lo*¹, the two plates of the lamina spiralis ossea; *N*, auditory nerve with ganglion; *N*¹, *N*², the nerve branching up into fibrillæ and passing to the auditory cells (*G*, *G*); *Ba*, *Ba*, bacilli, or supporting cells; *Mz*, membrana reticularis; *C*, membrana of Corti; *Ls*, ligamentum spirale, passing into the basilar membrane; *Sm*, scala media; *R*, membrane of Reissner; *B*, *B*, basilar membrane.

The fibrillæ extend to the sensory or auditory cells (*G*, *G*), and these are stretched as in a frame between the firm supporting and isolating cells or bacilli (*Ba*, *Ba*). From the surface of the bacilli a resistant net-like membrane (membrana reticularis) extends laterally, and through the meshes of the latter the hairs of the auditory cells project (Fig. 170, *Mz*). The number of the outer hair-cells may be estimated at about 12,000. The auditory cells are covered by a thick and firm membrane—the membrana tectoria s. Corti (Fig. 170, *C*)—which probably acts as a damper, and which arises from the labium vestibulare of the lamina spiralis ossea. The whole extent of the basilar membrane consists of clear thread-like and very elastic fibres, of which about 16,000 to 20,000 can be made out in Man. These are capable of vibrating freely, and, as their length varies definitely in different regions of the cochlea, they might be looked upon (were it not that they are absent from Birds) as forming a sort of keyboard or harp, that is, as a definite apparatus of strings capable of analysing the different waves of sound, the vibrations of which are communicated to the auditory cells, and thence by means of the nerves to the brain.

RELATION OF THE AUDITORY ORGAN TO THE AIR-BLADDER IN FISHES.

A relation between the auditory organ and air-bladder is observable in four families of Teleosteans (Siluroidei, Cyprinoidei, Characini, and Gymnoti). The apparatus is formed on the same plan in all these Fishes.¹

A chain of bones extends between the anterior end of the air-bladder and the auditory organ, by means of which the relative fulness of the air-bladder can be appreciated by the Fish. This chain arises by the metamorphosis of certain parts of the four anterior vertebræ (upper arches and spines and transverse processes), and four segments may be distinguished. In many cases processes of the air-bladder are produced outwards to the side-walls of the body, where the skin becomes very thin, forming a sort of tympanic membrane.

(For further details, such as the relation of the whole apparatus to the saccus endolymphaticus, the reader is referred to Wiedersheim's *Lehrbuch der vergl. Anatomie*.)

BIBLIOGRAPHY.

- HADDON, A. C.—*On the Stridulating Apparatus of Callomystax gagala*. *Journ. of Anat. and Physiol.* Vol. XV.
- HASSE, C.—The numerous Papers of this Author, which refer to all the chief Vertebrate groups, are published partly in the *Zeitsch. f. wiss. Zool.* (Bd. XVII. und XVIII.), and partly in "*Anatomischen Studien*." Leipzig, 1870–1873.
- HENSEN, V.—*Physiologie des Gehörs*. In the *Handbuch der Physiologie* by L. Hermann. *Abthl. Sinnesorgane* 2. Leipzig, 1880.
- HIS, W.—*Anatomie mensch. Embryonen*. Leipzig, 1880–1885.
- HOWES, G. B.—*On the Presence of a Tympanum in the Genus Raia*. *Journ. of Anat. and Physiol.* Vol. XVII., 1883.
- KUHN.—See the works of this Author on the auditory organ of Fishes, Amphibia, and Reptiles in the *Arch. f. mikr. Anat.* Bd. XIV., XVII., XX.
- MOLDENHAUER, W.—*Die Entwicklung des mittleren und äusseren Ohres*. *Morph. Jahrb.* Bd. III., 1878.
- PARKER, T. J.—*On the Connection of the Air-Bladder and the Auditory Organ in the Red Cod (Lotella bacchus)*. *Trans. N. Z. Institute*, 1883.
- RETZIUS, G.—*Das Gehörorgan der Wirbelthiere*. I. *Das Gehörorgan der Fische und Amphibien*. Stockholm, 1881. II. *Das Gehörorgan der Reptilien, der Vögel, und der Säugethiere*. Stockholm, 1884.
- WEBER, E. H.—*De aure et auditu hominis et animalium*. Lipsiæ, 1820.
- WIEDERSHEIM, R.—*Zur Anatomie und Physiologie des Phyllodactylus europæus, &c.* *Morph. Jahrb.* Bd. I., 1876.

¹ T. J. Parker has also described a connection between the auditory organ, air-bladder, and skin in the Red Cod (*Lotella bacchus*).

F. ORGANS OF NUTRITION.

ALIMENTARY CANAL AND ITS APPENDAGES.

THE alimentary canal (*tractus intestinalis*) consists of a tube which begins at the aperture of the mouth, passes through the body cavity (*cœlome*), and ends at the anus. Its walls consist essentially of three layers; an inner epithelial, a middle connective-tissue, and an outer muscular layer. The first, which corresponds to the hypoblast of the embryo, forms the lining of the canal (Fig. 8, *Ep*), and gives rise to numerous glandular structures which have a secretory as well as a resorptive nature; the second (*Subm*), consisting of connective and adenoid tissue, serves chiefly to conduct the blood and lymph vessels; while the third (*Msc*) which, together with the second, corresponds to the splanchnic layer of mesoblast of the embryo, is, as a rule, divided into two layers, and consists of smooth muscular elements, the inner being constituted by circular fibres, and the outer by longitudinal ones. These serve for the contraction of the wall of the gut, and thus fulfil the double function of bringing its nutritive contents into the closest possible relation with the whole epithelial surface, and at the same time of removing from the body the substances which have not been absorbed. A fourth accessory serous coat, enclosing the gut externally in the region of the *cœlome*, must be added to these three layers. It is covered on its free surface by pavement epithelium, and is reflected round the entire body-cavity, converting the latter into a large lymph-sinus. Its abdominal portion is spoken of as the peritoneum, and its thoracic portion as the pleura, the heart being invested by a special serous membrane, the pericardium. In the cranial and cervical portions of the alimentary tract the serosa is not developed.

A parietal layer, lining the body-cavity, and a visceral layer reflected over the viscera, can then be distinguished in the peritoneum (Fig. 8, *Per*, *Per*¹). The region where one passes into the other, which is thus primitively double, is called the mesentery (*Ms*), and this serves not only to support the alimentary canal from the dorsal body-wall, but also to conduct

the vessels and nerves passing from the region of the vertebral column to the viscera. By far the greater number of the nerves arise from the sympathetic system; cerebral and spinal elements are present only in the most anterior and posterior sections of the alimentary canal, both of which regions contain striped muscular fibres and are under the influence of the will. The mesentery gives rise to a large system of folds arising from the inner dorsal surface of the body-wall, in which the viscera are enveloped.

The most anterior section of the primitive alimentary tract functions as a **respiratory cavity** as well as a **food-passage**, and possesses for this purpose a row of apertures, lying one behind the other: round these, certain vessels are developed, by means of which a continual interchange of gases can take place between the blood and the water passing through the apertures. In short, **gills** are developed (Fig. 171, A). Although these latter are only functional in Fishes, Dipnoans, and aquatic (or larval) Amphibians, even in the higher Vertebrates, the larger portion of the cavities of the mouth and pharynx lying behind the internal nostrils serves as a common air- and food-passage until a proper palate is formed (Fig. 171, C, D).

With the formation of a definite palate,¹ the primitive mouth-cavity becomes divided into an upper respiratory, and a lower nutritive portion, or into a nasal, and a secondary or definitive mouth-cavity. The separation, however, is not a complete one, the passage being common to both cavities for a certain region (Fig. 171, at †). This region is called the pharynx, and in Mammals it is partially separated from the mouth by a fibrous and muscular fold, the *velum palati*, or free edge of the soft palate.

The alimentary canal of all Vertebrates is divided into the following principal sections:—Mouth (*cavum oris*), pharynx, gullet (*œsophagus*), stomach (*ventriculus*) (not differentiated in rare cases only), small intestine (*duodenum*, *jejunum*, and *ileum*), and large intestine (*colon* and *rectum*). A *cæcum* is often present at the junction of the large and small intestine. Between the stomach and duodenum as well as between the ileum and large intestine there is, as a rule, a marked elevation of the muscular coat serving as a sphincter (*pyloric* and *ileo-colic* valves). There is also a sphincter muscle at the anus.

The small intestine is always the longest section of the alimentary tract: the ducts of the liver and pancreas open into its anterior portion (*duodenum*).

The course of the alimentary canal may be straight or more or less coiled; in the latter case it presents a greater absorptive surface. As a general rule, it is longer in herbivorous than in carnivorous animals.

A considerable increase of surface also commonly results from

¹ Comp. pp. 75 and 81.

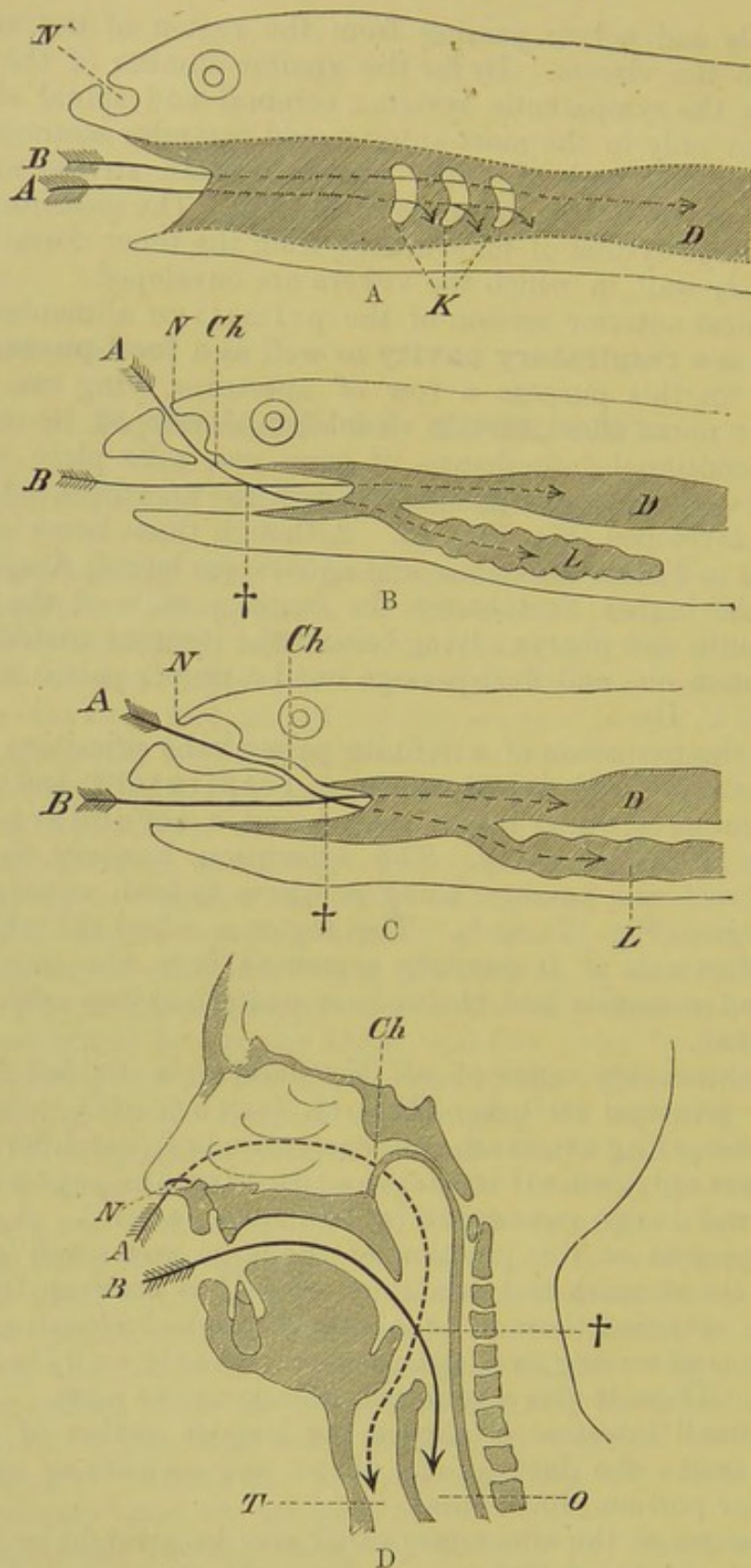


FIG. 171.—DIAGRAMS OF THE ORAL CAVITIES OF A FISH (A), AMPHIBIAN (B), REPTILE OR BIRD (C), AND MAN (D).

N, external nostrils; *Ch*, internal nostrils; *D*, alimentary canal; *K*, gill-slits; *L*, lung; *T*, trachea; *O*, cesophagus: the arrow marked *A* indicates the respiratory passage, that marked *B* the nutritive passage; †, the point where the two passages cross one another.

the elevation of the mucous membrane to form folds, villi, and papillæ.

A diagram of the human intestinal tract and its appendages is given in Fig. 172. All the appendages of the canal arise in the

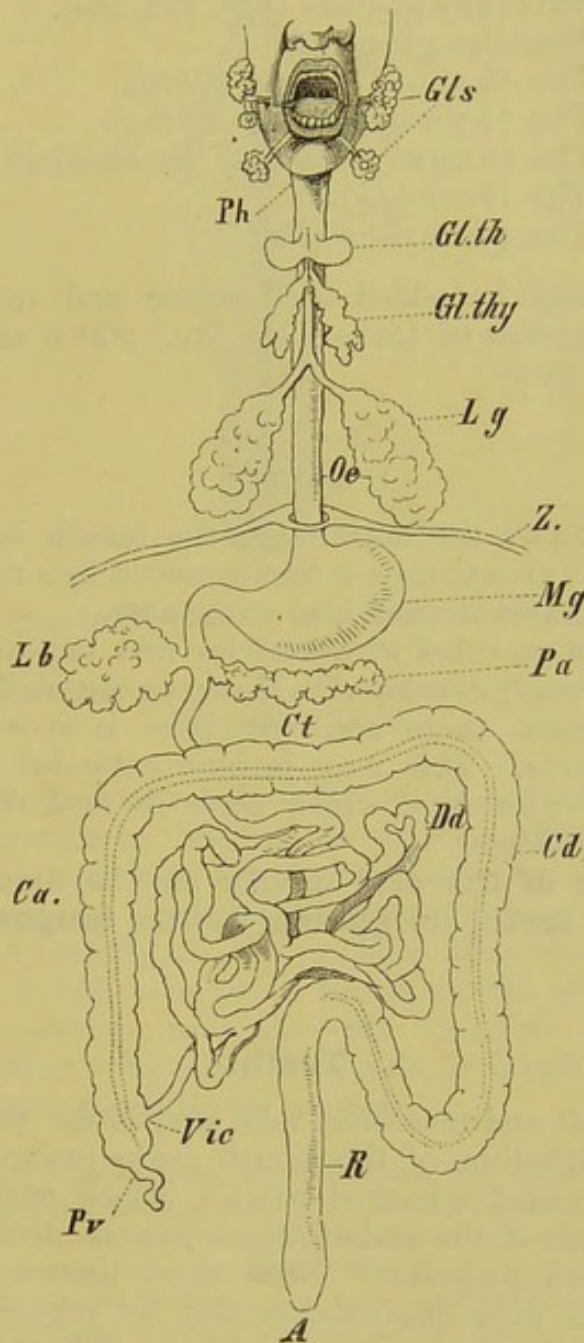


FIG. 172.—DIAGRAM OF THE ENTIRE ALIMENTARY TRACT OF MAN.

Gls, salivary glands; *Ph*, pharynx; *Gl.th*, thyroid gland; *Gl.thy*, thymus gland; *Lg*, lung; *Oe*, œsophagus; *Z*, diaphragm; *Mg*, stomach; *Lb*, liver; *Pa*, pancreas; *Dd*, small intestine; *Vic*, ileo-colic valve; *Pv*, vermiform process of cæcum; *Ca.*, ascending colon; *Ct*, transverse colon; *Cd.*, descending colon; *R*, rectum; *A*, anus.

embryo as outgrowths from the hypoblast, and are thus of epithelial origin: they either remain throughout life as glandular organs, or at

any rate they are formed on the same type as glands (lungs, thyroid, thymus). Mesoblastic elements are added to them secondarily.

Beginning from the mouth the following appendicular organs of the alimentary canal may be distinguished:—

- (1) Salivary glands (Fig. 172, *Gls*).
- (2) Mucous glands.
- (3) The thyroid gland (*Gl.th*).
- (4) The thymus gland (*Gl.thy*).
- (5) The lungs (pulmones) (air-bladder) (*Lg*).
- (6) The liver (*Lb*).
- (7) The pancreas (*Pa*).

To these may be added the gastric and intestinal glands (peptic glands, glands of Lieberkühn, &c.), which are embedded in the wall of the gut.

I. MOUTH.¹

In *Amphioxus* the entrance to the mouth is provided with cirrhi, and in *Cyclostomes* it is surrounded by a ring of cartilage: all other Vertebrates are provided with **jaws**.

Definite **lips** provided with muscles first appear in Mammals,² and are most strongly developed in Monkeys, especially Anthropoids: the space between them and the jaws is spoken of as the vestibulum oris. This may become extended on either side to form cheek-pouches, which serve as food reservoirs (many Monkeys and Rodents).

The **organs of the oral cavity** may be divided into three groups, viz. the **teeth**, the **glands**, and the **tongue**.

Teeth.

Both epiblast and mesoblast take part in the formation of the teeth. The epithelium of the mouth grows inwards so as to give rise to the so-called enamel-organ, which meets with dome-shaped elevations of the underlying connective-tissue, the tooth-germs or tooth-papillæ. Both these tissues come into the closest relations with one another, and, by very complicated processes of differentiation, give rise to the different substances of which the teeth are composed. These substances are, the enamel, dentine (ivory), which is permeated by a fine system of canals, and cement (Fig. 173, *ZS*, *ZB*, *ZC*).

¹ The mouth of the Lamprey serves as a suctorial organ for attaching the animal to foreign objects. The larvæ of *Lepidosteus* and *Anura* are temporarily provided with suctorial organs.

² An exception is seen, however, in Dipnoi, the lips of which are provided with well-developed muscles.

The root of the tooth embedded in the gums is provided at its lower end with a small opening, and this leads into the pulp-cavity (Fig. 173, *PH*¹, *PH*). Into its interior, vessels and nerves extend.

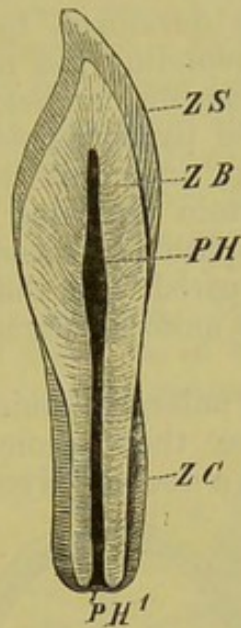


FIG. 173.—SEMIDIAGRAMMATIC FIGURE OF A LONGITUDINAL SECTION THROUGH A TOOTH.

ZS, enamel; *ZB*, dentine (ivory); *ZC*, cement; *PH*¹, aperture of the pulp-cavity (*PH*).

While in Vertebrates below Mammals a succession of teeth takes place throughout life, in the latter group this as a rule occurs only once, that is, the first or so-called milk dentition is only replaced once by a second stronger and more fully-developed permanent dentition. In certain Mammals, such as the Cetacea and Edentata (with the exception of *Dasypus peba*), there is no succession, and they are therefore distinguished as Monophyodonts from other Mammals, or Diphyodonts. The teeth of Edentates are without enamel.

In *Rhinolophus* (Cheiroptera), some Rodents, and Sirenia, the milk-teeth never cut the gum, and become entirely absorbed before birth. In Rodents various conditions of the milk dentition are seen: in the Rabbit they correspond in number with their successors,¹ though the incisors disappear before birth, the outer upper and the lower one being quite rudimentary. In others, and in some Insectivores, no milk teeth at all are known: the Hedgehog has a complete milk dentition, while no milk-teeth are known in the Shrew. In Marsupials and Guinea-pigs only one milk molar is present. All these facts indicate that a gradual reduction of the milk dentition is taking place.

In those cases where the teeth are similar in form throughout, as, for instance, in existing toothed Whales, we have a homodont as opposed to a heterodont dentition. In the latter case the teeth

¹ That is, with the incisors and premolars of the adult.

become differentiated into incisors, canines, and grinders (premolars and molars).

Fishes and Amphibia.—The dermal denticles already described in the chapter on the skeleton are structures homologous with teeth, for both are developed in a similar manner. In Teleostei all the bones bounding the mouth may bear teeth, as may also the hyoid and branchial arches (pharyngeal bones). On the latter, and also on the parasphenoid, they are arranged in a single series, or in masses; numerous teeth are also met with on the parasphenoid in certain Urodeles (Fig. 174). In general, however, there is in Amphibia a considerable diminution in the number of teeth as compared with those of Fishes; and at the same time a much more uniform character is noticeable in their form throughout.¹

In Amphibia they are enlarged conically below, and rest on a definite base, while above they become narrower, and slightly curved, and end either in a double (Myctodera, Anura), or a single

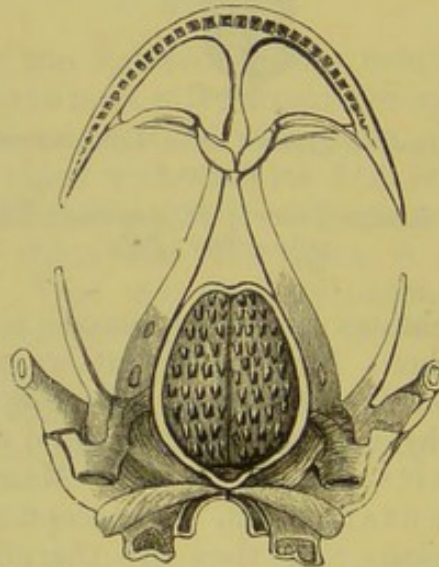


FIG. 174.—SKULL OF *Batrachoseps attenuatus*. (From the ventral side, showing the teeth on the parasphenoid.)

apex (Perennibranchiata, Derotremata, Gymnophiona); the latter is the more primitive condition. The teeth lie deeply embedded in the mucous membrane, and are present, as a rule, on the premaxilla, maxilla, and mandible, as well as on the vomer and palatine, but rarely on the parasphenoid; in the larvæ of Salamanders and in *Proteus* the splenial of the lower jaw is also toothed. Horny jaws and horny teeth are present in larval Anura.²

¹ In Fishes the teeth may be cylindrical, conical, or hooked; or in some cases (*Scarus*, and the *Sarginæ*) they may be chisel-shaped, resembling the incisors of Mammals, and working together like scissors; in others they give rise to a definite pavement, are rounded in form, and serve to crush the food. Again, they may be delicate and bristle-shaped (*Chætodon*), or sabre-shaped (*Chauliodus*).

² The horny structures on the upper jaw in young stages of *Polypterus*, in the mouth of *Cyclostomi*, on the jaws of *Siren lacertina*, and on the lips of *Dipnoi*, belong to the same category as these.

Reptilia.—Corresponding with the great firmness and solidity of the skull in Reptiles, the dentition is usually strongly developed, and occasionally at the same time it is more highly differentiated than in Amphibians. The teeth are either situated upon a ledge on the inner side of the lower jaw, with which they become fused basally (pleurodont dentition,—Skinks, Amphisbæniæ, and others), or they lie on the free upper border of the jaw (acrodont dentition), or finally, as in Crocodiles and numerous fossil Reptiles, they are lodged in alveoli (thecodont dentition) (comp. Fig. 175, A, *a*, *b*, *c*). Both upper and lower jaws, and occasionally the palate also, are toothed; the teeth have a single apex, except in Lizards, in which the apex is double.¹ In many Reptiles, however (*e.g.* Hatteria, *Uromastix spinipes*, *Agamæ*, and numerous fossil forms, especially those of the Trias of South Africa), a heterodont dentition, consisting of incisor- canine- and molar-like teeth, is already seen.

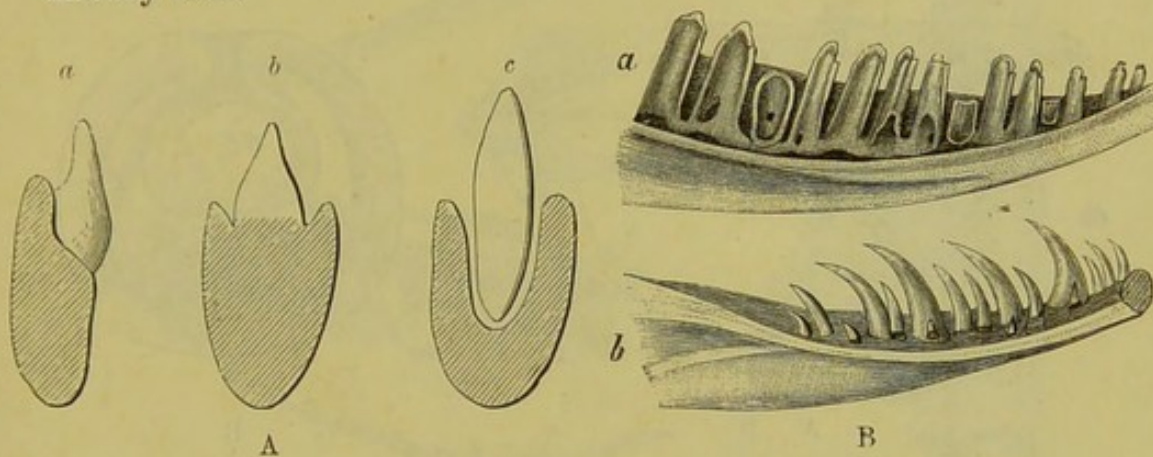


FIG. 175.—A, DIAGRAMS OF TRANSVERSE SECTIONS THROUGH THE JAWS OF REPTILES, SHOWING PLEURODONT (*a*), ACRODONT (*b*), AND THECODONT (*c*) DENTITIONS. B, *a*, LOWER JAW OF *Zootoca vivipara*; *b*, OF *Anguis fragilis*. (After Leydig.)

The dentition of poisonous snakes deserves special attention, for in them a varying number of maxillary teeth are differentiated to form poison-fangs. Thus in the common Viper (*Belias berus* and *P. prester*) there are on each side nine poison-fangs arranged in transverse rows; the stronger ones project freely, while the lesser, reserve teeth, lie within the gum (Fig. 176, A); only one of these teeth, however, is firmly fixed to the maxilla at a time. Each fang is perforated by a poison-canal, which is incompletely surrounded by the pulp-cavity, the latter having the form of a half-ring in transverse section (Fig. 176, B, C, *GC*, *PH*): the duct of the poison-gland passes into an aperture at the base of the tooth which leads into the poison-canal, and the latter opens

¹ A peculiar tooth is present in the embryos of Lizards, Blindworms, and some Snakes. It projects considerably beyond its neighbours, and lies in the median line of the lower jaw extending vertically towards the snout, and serving the young as a means of breaking through the egg-shell.

at a short distance from the apex of the tooth (see the course of the arrow in Fig. 176, A).

Between the ordinary teeth of Snakes and the poison-fangs with closed canals, there are numerous intermediate forms in which certain of the teeth are simply grooved along their anterior side. A similar condition is also seen in the teeth of the lower jaw of a poisonous Mexican Lizard (*Heloderma*). (Comp. p. 222.)

Chelonians, like Birds, are provided with horny sheaths to the jaws instead of teeth. The presence of teeth in embryos of *Trionyx*, however, proves that this is only a secondary condition.

The teeth of the fossil Birds of America (*Odontornithes*) were either situated in definite alveoli (*Ichthyornis*), or simply in grooves (*Hesperornis*). The premaxillæ were toothless, and seem to have possessed a horny beak. The single-pointed smooth teeth of *Archæopteryx* were 1 mm. long, and all of similar size and form. Most probably they were situated in alveoli. All existing Birds, as well as those of the Tertiary and Post-Tertiary strata, are toothless.

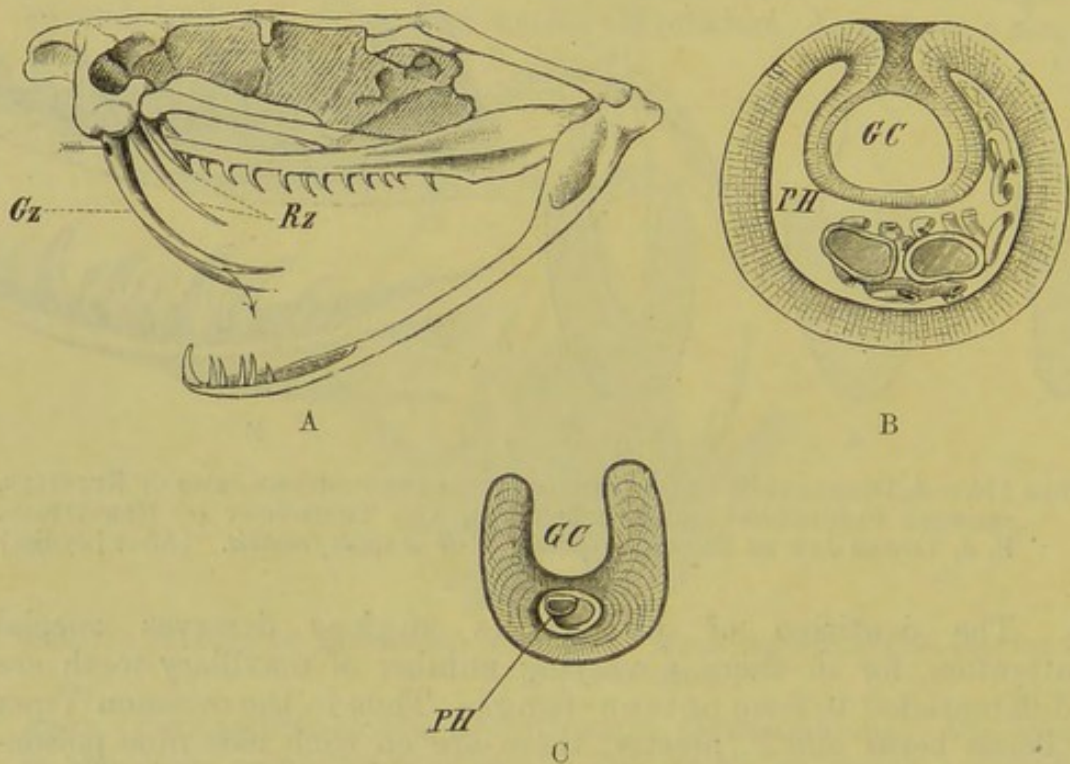


FIG. 176.—FIGURES OF THE POISON-FANGS OF A VIPERINE SNAKE.

A, skull of Rattlesnake; B, transverse section through about the middle of the poison-fang of *Vipera ammodytes*; C, transverse section through the poison-fang of *Vipera ammodytes* near its distal end. (B and C after Leydig.)

Gz, poison-fang; *Rz*, reserve fangs; *GC*, poison-canal; *PH*, pulp-cavity.

Mammals.—The differentiation of the dentition here reaches its extreme limit, corresponding with the manner in which the food is taken in and masticated. As already mentioned, incisor, canine, and grinding teeth (premolars and molars) can as a general rule be distinguished. These are all embedded in

well-developed alveoli of the jaw-bones, and there are no longer any teeth on the roof of the palate. The canine, which is most largely developed in Carnivora, usually lies in a continuous series with the incisors, which are situated in the anterior part of the jaws (premaxilla in upper jaw). The premolars follow behind the canine, the space usually present between them being called the diastema, and then come the molars, which lie mainly in the posterior part of the jaw.¹

The incisors are usually chisel-shaped, while the canines, in those cases where they are most largely developed (Carnivora),

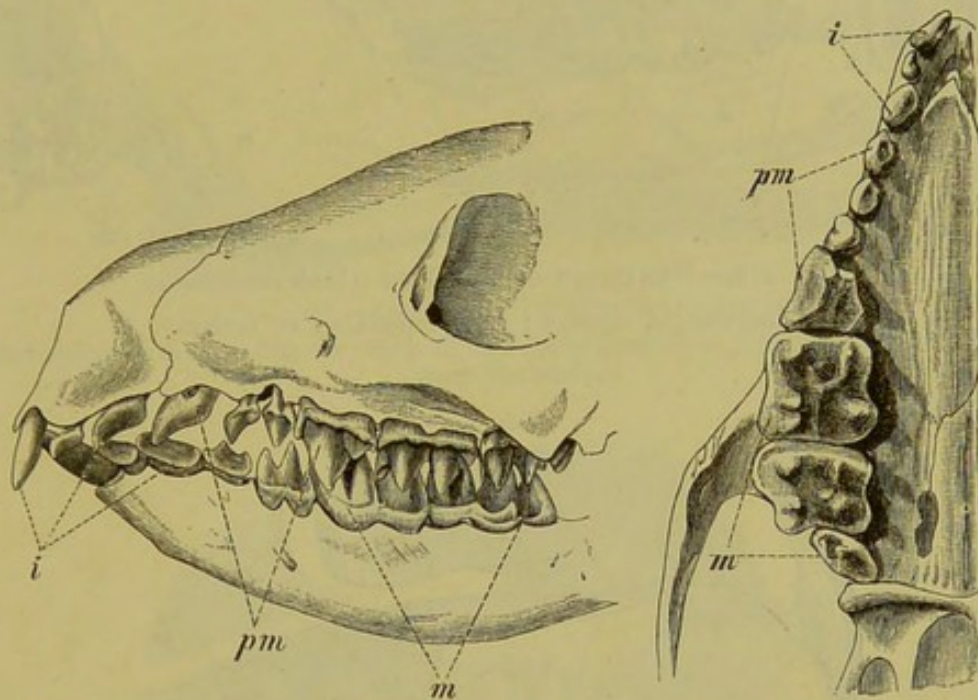


FIG. 177.—DENTITION OF THE HEDGEHOG (*Erinaceus europaeus*). (The teeth of both jaws from the side, and those of the upper jaw from below.)

i, incisors; *pm*, premolars; *m*, molars.

possess a pointed, conical form, and are more or less curved. The form of the premolar and molar teeth may be derived from that of the incisors and canines; originally two lateral and a median cutting-edge can be distinguished in all, these edges having become gradually metamorphosed phylogenetically for mastication in the case of the grinding teeth. In the course of further development the whole grinding surface becomes reduced to the same level, and appears more or less flattened or tubercular.

In describing the teeth of a Mammal it is convenient to make use of a dental formula in which their number and arrangement can be seen at a

¹ The premolars are those teeth which correspond in position with the deciduous milk molars, the molars proper having no predecessors.

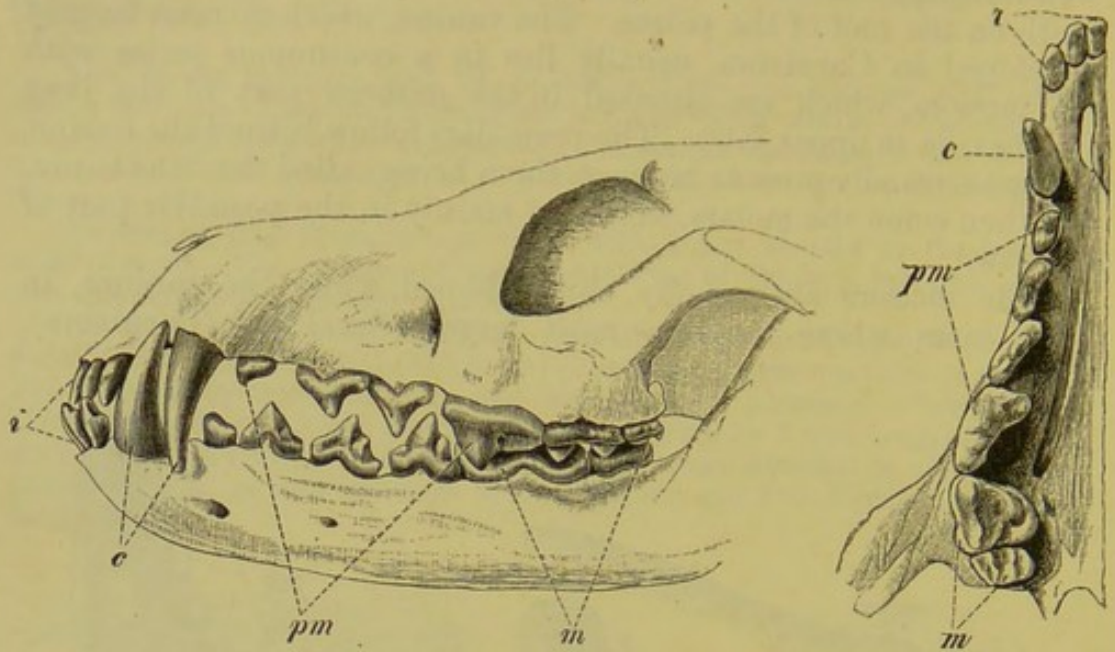


FIG. 178.—DENTITION OF THE DOG (*Canis familiaris*).
i, incisors ; *c*, canines ; *pm*, premolars ; *m*, molars.

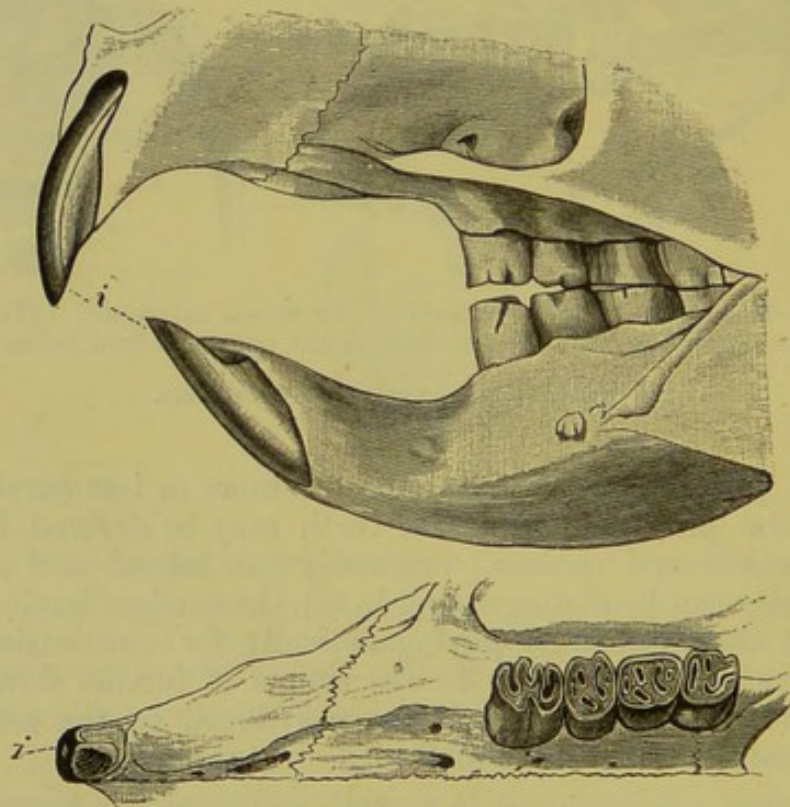


FIG. 179.—DENTITION OF THE PORCUPINE (*Hystrix hirsutirostris*).
 References as before.

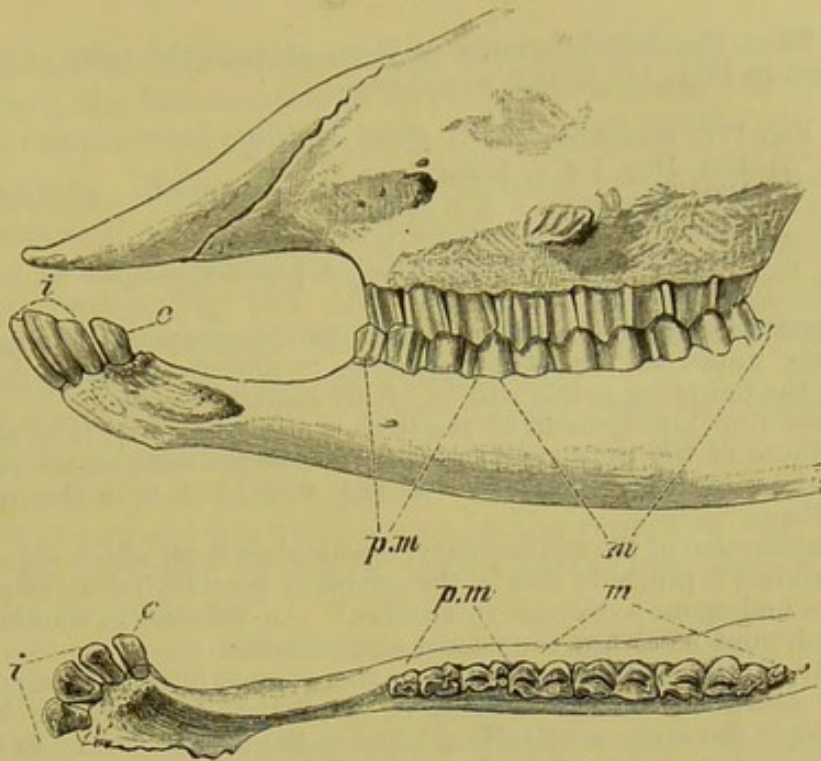


FIG. 180.—DENTITION OF SHEEP (*Ovis aries*).

References as before, but the teeth of the lower instead of the upper jaw are figured from the surface.

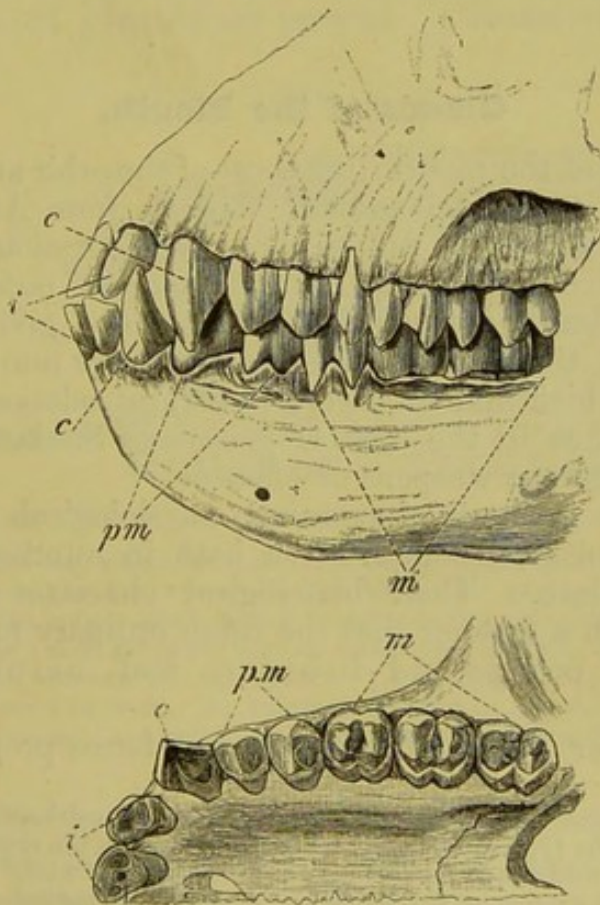


FIG. 181.—DENTITION OF A CATARRHINE MONKEY (*Nasalis larvatus*).

References as before.

glance. Thus the dental formula of those animals the teeth of which are represented in Figs. 177 to 181, would be—

- Fig. 177. Hedgehog, $i. \frac{3}{3}, c. \frac{0}{0}, pm. \frac{4}{2}, m. \frac{3}{3}$.
 „ 178. Dog, $i. \frac{3}{3}, c. \frac{1}{1}, pm. \frac{4}{4}, m. \frac{2}{3}$.
 „ 179. Porcupine, $i. \frac{1}{1}, c. \frac{0}{0}, m. \frac{4}{4}$.
 „ 180. Sheep, $i. \frac{0}{3}, c. \frac{0}{1}, pm. \frac{3}{3}, m. \frac{3}{3}$.
 „ 181. Catarrhine Monkey, $i. \frac{2}{2}, c. \frac{1}{1}, pm. \frac{2}{2}, m. \frac{3}{3}$.

The variations in the dentition of the different groups of Mammals are so exceedingly numerous that it is impossible to describe them in detail here, and only the following points will be briefly remarked upon.¹

The essential arrangement of the teeth is such that there is an alternation between those of the upper and lower jaw; thus the teeth of one jaw do not correspond in position with those of the other, but with the interspaces between them.

A consideration of the rudimentary, functionless teeth which are commonly present renders it probable that in the course of genealogical development the teeth have undergone a decrease in number.² An increase in number, on the other hand, must be always considered as an atavism.

Finally, attention must be called to the commonly-existing sexual differences in dentition, as, for instance, in the Wild Boar, in the Narwhal (Monodon), in the Dugong (Halicore), and in the Musk-deer. In the males of these animals a modification of certain of the teeth (usually the canines) to form tusks occurs, and these serve as fighting weapons. In the Elephant and Walrus tusks are present in both sexes: in the former they correspond to incisors, and in the latter to canines.

Glands of the Mouth.

The glands of the mouth, like those of the orbit and integument, appear first in terrestrial animals, that is, from Amphibians onwards. They have the function of keeping moist the mucous membrane which comes into contact with the outer air. From being at first almost entirely unspecialised, and giving rise simply to a slimy fluid, they become differentiated later into structures the secretions of which take on a very important relation to digestion; they may also, as in the case of poisonous Snakes and Lizards, constitute dangerous weapons of offence.

With their gradually increasing physiological importance a greater morphological complication both in number and arrangement takes place. Their histological character also becomes changed in such a manner that the three ordinary forms of glands, *i.e.* tubular, compound-tubular, and acinous, may be recognised.

In the lower Vertebrata the two first forms preponderate, and

¹ These variations not only consist in the various positions and forms of the teeth, but also in the typical arrangement of the enamel on the crowns. Thus in the non-Ruminant Bunodontia the molars are tubercular, while in the Ruminant Selenodontia the surface of the grinders is made up of crescent-shaped elevations.

² The last molar of Man, or so-called "wisdom-tooth," seems to be gradually disappearing. It appears last and is lost first, and often does not reach the grinding surface.

the glands are mostly arranged in groups; in the higher types, on the contrary, the last-mentioned form, which is considerably higher from a developmental point of view, is the more usual.

Amphibia.—With the exception of the Perennibranchiata, Derotremata, and Gymnophiona, a tubular gland becomes developed in all Amphibia from the anterior portion of the roof of the mouth (comp. Fig. 144, *ID*), the main mass of which lies, in Urodeles, in the cavity of the nasal septum or premaxilla (intermaxillary or internasal gland).

In Anura its position is more anterior than in Urodeles, and it is more largely developed; but in both cases the ducts open on to the anterior part of the palate. In Anura there is a second gland (pharyngeal gland) present in the region of the internal nostrils, the secretion of which passes partly into the latter and partly into the pharynx.

Numerous gland-tubes are also present in the tongue of Amphibia.

Reptiles.—The mouth-glands in Reptilia show an advance on those of Amphibia, inasmuch as they are separated into groups. Thus not only is there a palatine gland, homologous with the intermaxillary gland, but lingual and sublingual, as well as upper and lower labial glands are present. Chameleons and Snakes

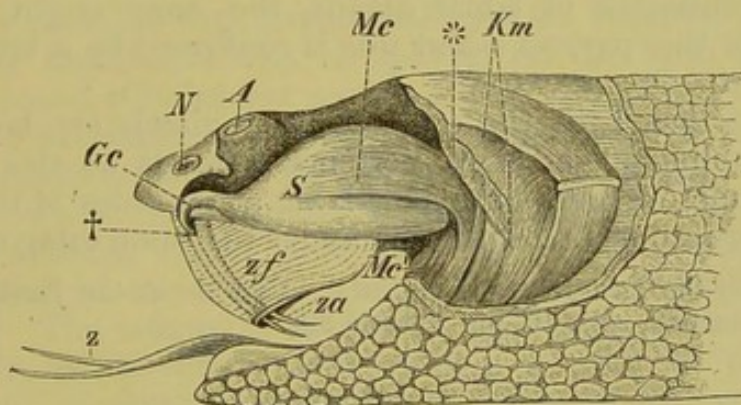


FIG. 182.—THE POISON-APPARATUS OF THE RATTLESNAKE.

S, the fibrous poison-sac, which is surrounded by the constrictor-muscle, *Mc*; at *Mc*¹ an extension of the latter towards the lower jaw can be seen; *Gc*, the duct arising from the poison-gland, which passes into the poison-fang at †; the latter is embedded in a large sac of the mucous membrane, *zf*; *Km*, masticatory muscles, some of which are seen cut through at *; posterior to this the cut edge of the scaly integument is seen; *N*, external nostril; *A*, eye displaced towards the antero-dorsal aspect; *z*, tongue; *za*, aperture of the poison-fang.

are distinguished by a remarkable richness in glands, which become most specialised into definite groups in the latter. In poisonous Snakes the poison-gland (*glandula venenata*) becomes differentiated from a portion of the labial gland in the upper lip. It is enclosed in a strong fibrous sheath, and is acted upon

by powerful muscles, so that its secretion can be poured with great force into the duct (Fig. 182, *Gc*), and thence into the poison-fang (+).

The sublingual gland of a Mexican Lizard, *Heloderma*, has a somewhat similar poisonous nature. Its secretion passes out through four ducts, which perforate the bones of the lower jaw in front of the grooved teeth.

In marine Chelonians and Crocodiles there are no large glands united into groups connected with the mouth.

Birds.—In Birds, and more especially in climbing Birds (Scansores), well-developed lingual glands are present, opening on the floor of the mouth. There is no doubt that they are homologous with those of Lizards, and they probably correspond with the posterior upper labial gland which opens into the angle of the mouth, that is, to the poison-gland of Snakes. The palatine glands of Birds have also their homologues in Reptiles.

Mammals.—Three glands may be distinguished in connection with the mouth in Mammals, which are called, according to their position: (1) parotid, (2) submaxillary, and (3) sublingual (Fig. 172, *Gls*). Each opens by means of a well-defined duct (ducts of Steno, Wharton, and Bartholini respectively) into the mouth. The former corresponds to the gland opening into the angle of the mouth in Birds, and consequently also to the poison-gland of Snakes. As the last-mentioned is to be looked upon as a differentiation of labial glands, the same origin must be supposed for the parotid,—and this is confirmed by a study of its development.

The fact that both the other salivary glands are homologous with the sublinguals of lower Vertebrates needs no special proof, and the numerous mucous glands lying at the sides of the tongue and opening into the mouth come under the same category.

Concerning the tonsils of Mammals, which lie at the junction of the mouth and pharynx, compare pp. 239 and 293.

Tongue.

In Fishes and Dipnoi the tongue is, as a rule, rudimentary, usually consisting simply of a covering of mucous membrane extending over the basal part of the hyoid, which in all the higher Vertebrates serves as the main point of origin for the tongue-muscles. The tongue is not capable of movement apart from the visceral skeleton in Fishes, and, except in Cyclostomes (where it has to do with the suctorial apparatus), is wanting in a proper musculature; it is covered with papillæ, and serves only as a tactile organ, or, when covered with teeth, as a prehensile organ also.

In the Perennibranchiata it remains in a similar condition to that seen in Fishes, but in all other Amphibia except the *Aglossa* (*Pipa* and *Dactylethra*) it reaches a higher stage

and becomes larger in size by the development of definite muscles in connection with it. Its mobility varies greatly in the different groups of Amphibia in accordance with the manner in which it is fixed to the floor of the mouth. It is usually attached only by the anterior end or by a portion of its ventral surface; in other cases it is free all round, and in *Spelerpes* (Fig. 183) is capable of being extended far out of the mouth by means of a complicated mechanism.



FIG. 183.—HEAD OF *Spelerpes fuscus*, WITH THE TONGUE EXTENDED.

In most Reptiles and Birds the tongue is freely moveable, but its form and relative size varies greatly in the different families (see Fig. 184, A to D). It is least mobile in Chelonians and Crocodiles:¹ in Chameleons, on the other hand, it is very long and protrusible.

The tongue of Birds which is usually poorly provided with muscles, may be looked upon as having been derived from a similar form to that of Lizards, and its shape as a rule corresponds more or less to the form of the beak. It possesses a horny covering, usually provided with papillæ and pointed recurved processes; as in many Reptiles, it may be split up at its distal end, being either bifurcated (*Colibris*) or having a brush-like form. In Woodpeckers (the extraordinarily developed epibranchials of which have already been mentioned in the chapter on the skull), the tongue may be thrown far out from the mouth by means of a complicated system of muscles, and it thus serves as a prehensile organ; in this Bird and in the Duck it is richly provided with Pacinian corpuscles. The tongue is largest in predatory Birds (*Rapaces*) and Parrots, but its size is here not due so much to the special development of muscles as to the presence of fat, vessels, and glands.

The tongue reaches its most complete development in Mammals, and, as elsewhere, undergoes the most various modifications as regards size, mobility, and function, according to the method of taking in food. It is as a rule flat, and rounded anteriorly, having a band-like form, and being extensile. A fold, the so-called sublingua (*plica fimbriata* and *mediana*), is present on its lower surface. This represents a primitive organ which must be regarded as the predecessor of the structure which we now speak of as the tongue.

In spite of the various functional modifications of the tongue

¹ The relative importance and degree of development of the tongue does not run parallel with the systematic position of the animal.

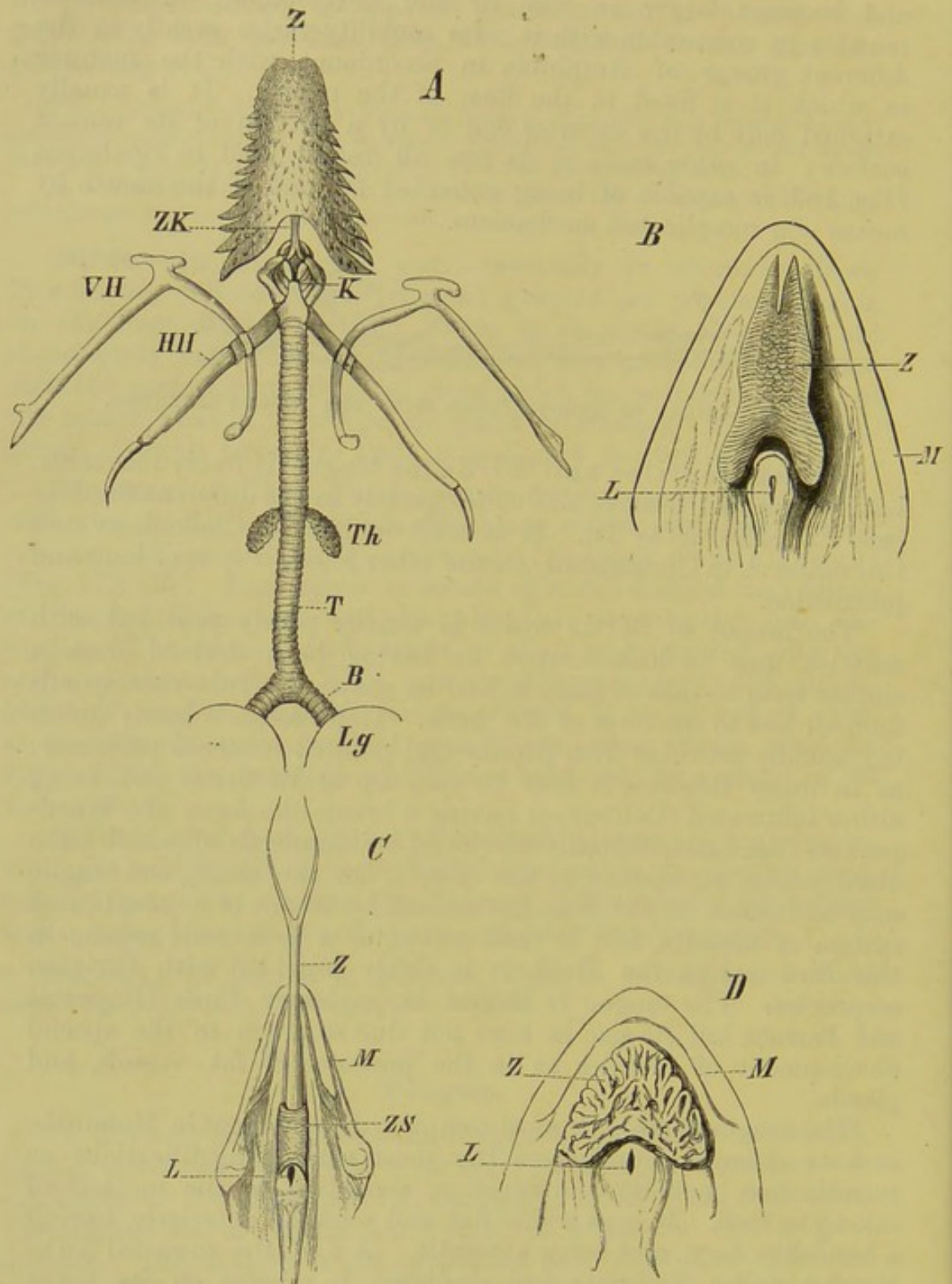


FIG. 184.—A, TONGUE, HYOID APPARATUS, AND BRONCHI OF A GECKO (*Phyllodactylus europæus*); B, TONGUE OF *Lacerta*; C, OF *Monitor indicus*; D, OF *Emys europæa*.

Z, tongue; ZK, body of hyoid; VH and HH, anterior and posterior cornua of hyoid; K, larynx; Th, thyroid gland; T, trachea; B, bronchi; Lg, lung; M, mandible; L, glottis; ZS, sheath of tongue.

in Mammals, it is very uniform both as regards the extrinsic muscles and their attachment to the hyoid and lower jaw, and the arrangement of the intrinsic muscles. Only in such forms as *Myrmecophaga* and *Dasypus* do the intrinsic muscles show a peculiar character: in them a tendinous investment is present lying under the mucosa, and this serves as a point of attachment for all the transverse and vertical muscles.

In many Mammals (*e.g.* Carnivora, Insectivora) a peculiar structure, the *lytta* ("worm"), is present, lying within the longitudinal axis of the tongue. It is partly fibrous and partly muscular, and its thread-like posterior end is connected with the body of the hyoid. Its phylogenetic meaning is not yet clear, and it can only be said that it functions as a point of origin and insertion for the intrinsic muscles of the tongue.

In Man the tongue has a double origin, arising firstly from an unpaired protuberance—the *tuberculum impar* (His)—lying on the floor of the mouth of the embryo, and secondly from the swellings of the second and third visceral arches, which meet together in the middle line. In this manner, a part of the floor of the primary mouth becomes bridged over, forming a narrow depression, covered by the root of the tongue. This depression becomes further isolated by the approximation and union of the body of the tongue—which arises from the above-mentioned *tuberculum impar*—to the tongue-root, which is formed from the visceral swellings. From the cavity thus shut off a double epithelial vesicle is formed,—the median thyroid rudiment. This remains for a time in free communication with the cavity of the mouth by a duct, the *ductus thyreoglossus*, which passes to the surface of the tongue along the region where the body and root of the tongue become later united. The *foramen cæcum*, which can be occasionally traced in the adult human subject into the substance of the tongue for $2\frac{1}{2}$ centimetres or more, is the last remnant of this *ductus thyreoglossus*. From the median thyroid rudiment the middle lobe of the thyroid arises later, and this commonly extends forwards (upwards) as a "*cornu medium*" and sometimes also as a hollow duct. Now and then this duct may become constricted into definite vesicles (from two to four), which are known as *bursa suprahyoidea*, *bursa prehyoidea*, &c. All these are remains of the *ductus thyreoglossus*. The lateral thyroid rudiments of Man arise by the lower part of the primary floor of the pharynx, lying near the glottis, becoming separated off from the main cavity, and thus forming an independent structure lying laterally to the larynx. The lateral and median rudiments of the thyroid later become approximated.

Thyroid Gland.

The thyroid gland arises in all Vertebrates as one or more diverticula of the ventral wall of the pharynx or floor of the mouth. In *Ammocetes* the single diverticulum remains in communication with the pharynx, and a similar condition of things is seen in *Ascidians* and *Amphioxus*; it thus appears probable that we have to do here with a very ancient glandular organ, the secretory function of which in relation to the alimentary canal was of great importance in the ancestors of existing Vertebrates.

In all the higher Vertebrates this organ always becomes

constricted off from the pharynx in the course of development, and the communication between them is once for all abolished. (Comp. also small print on p. 225.) As a rule it shows a paired arrangement, and lies right and left of the median line. Internally it consists of closed glandular vesicles, surrounded by a capillary network, or cylindrical branched tubes may be present (Mammals).

The whole is lobulated in structure, and is characterised, particularly in Mammals, by a great wealth of blood-vessels. It seems very probable that this organ, which is in many respects rudimentary, has undergone a gradual change of function in the course of phylogenetic development, but as yet it is impossible to explain in what its function consists. As regards position, it either remains throughout life in its *locus nascendi* on the floor of the mouth, as in Fishes and Amphibia, or it extends a varying distance backwards. In Birds, for instance, it lies on the origin of the carotid artery (Fig. 185, *Tr*).¹

The development of the thyroid has been studied most completely in the Fowl and in Mammals. In the former, the organ arises as an unpaired hollow vesicle in the median ventral line of the neck. Later, this becomes solid, and then divided into two halves, which gradually separate from one another until eventually they reach the position they occupy in the adult.

Amongst Mammals the development of this organ is best known in the Pig. Here the so-called middle lobe or isthmus arises as an outgrowth of the mucous membrane of the floor of the mouth on the level of the second branchial arch. The lateral lobes arise in the region of the third branchial cleft. The different lobes become united later on (comp. also small print at end of section on the tongue).

Thymus Gland.

The thymus gland arises on either side from the mucous membrane of the pharynx, as a proliferation of the epithelium of the gill-clefts. It is impossible to state with certainty whether it was originally a glandular, that is, a secretory organ, or whether it consists of material that was at one time designed for the formation of gill-filaments. Certain discoveries in Elasmobranch embryos seem to point to the latter view. In them the organ has a segmental arrangement corresponding to the number of gill-clefts, and in *Gymnophiona* indications of a similar arrangement are to be seen.

According to His, the thymus of Man does not arise from the inner or hypoblastic epithelium of the pharynx, that is, of the visceral clefts, but from the epithelial (epiblastic) covering of the fourth, third, and partly also

¹ According to A. Dohrn the hyoid arch corresponds genetically to two arches, the first giving rise to the hyomandibular, and the second to the hyoid arch proper, and the thyroid represents the remnant of a lost gill-cleft between the hyomandibular and hyoid. Dohrn supports this by the relations of the thyroid to the vascular system; the thyroid artery arises like a true branchial vessel from the hyoid artery.

of the second visceral clefts, which extends inwards from the integument, as well as from the covering of the corresponding visceral swellings. All these parts

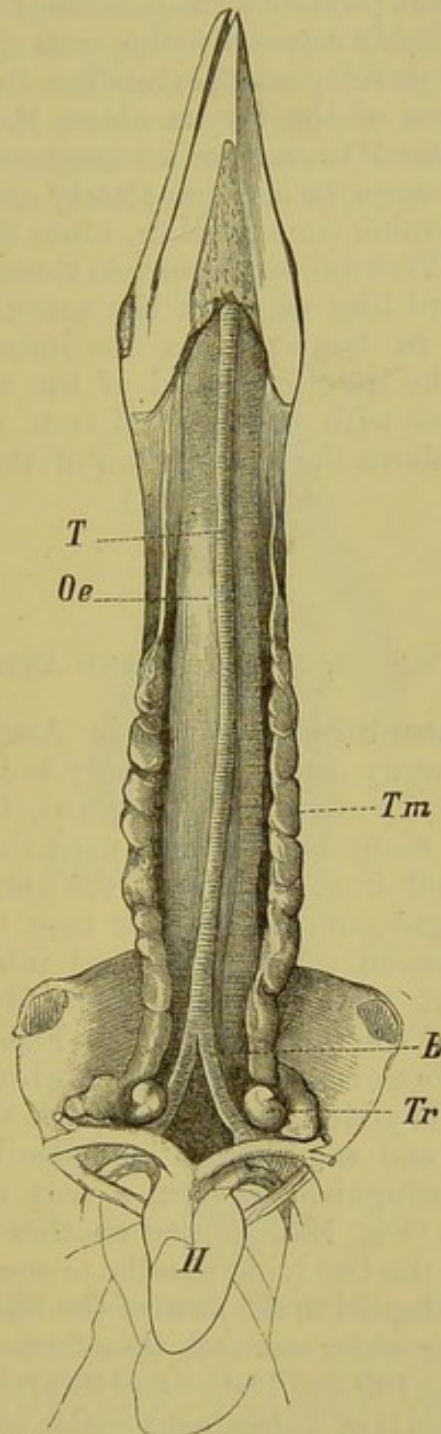


FIG. 185.—THYMUS AND THYROID OF A YOUNG STORK.

T, trachea ; *B*, bronchi ; *Oe*, oesophagus ; *H*, heart ; *Tm*, thymus ; *Tr*, thyroid.

are gradually withdrawn inwards and separated from the surface at the boundary between head and neck.¹

¹ His states that in human embryos the gill-clefts never become perforated, but simply blind slits are formed from both epiblast and hypoblast. The same holds good also for the tympano-Eustachian passage.

In post-embryonic time the organ always shows a lymphoid structure, and, on account of its richness in white blood-corpuscles, certainly has important physiological relations to the organism as a whole. This is probably especially the case in Mammals, as it here attains a large development, extending in the embryo backwards from the region of the larynx above the sternum as far as the diaphragm. Later it undergoes a retrogressive metamorphosis, and finally becomes more or less completely obliterated, though it persists for a considerable time in Man, often for many years after birth. In all other Vertebrates it persists throughout life, and lies as a lobulated or cord-like organ in the anterior or lateral region of the neck; thus in bony Fishes, for instance, it is situated behind the gills in the neighbourhood of the fibrous band which connects the gill-cover with the pectoral arch, and in Amphibians it lies behind and above the articulation of the lower jaw (comp. also Fig. 185, *Tm*).

II. ŒSOPHAGUS, STOMACH, AND INTESTINE.

Fishes and Amphibia.—While in *Amphioxus* a widened section of the alimentary canal is probably to be looked upon as a sort of stomach, in *Cyclostomi*, *Dipnoi*, *Chimæra*, certain *Teleostei*, and many branchiate *Amphibians*, a stomach is not plainly marked off from the rest of the gut, which usually has a more or less straight course. In this case the only externally visible boundary between the stomach and intestine is, as already mentioned, the point where the bile-duct (*ductus choledochus*) perforates the wall of the latter. In other Fishes, as, for instance, in *Squalidæ*, all *Ganoidei*, numerous *Teleostei*, as well as in the *Derotremata*, *Myctodera*, and *Anura*, the stomach appears more or less dilated and sac-like; it may also be curved on itself, so that one can distinguish between a part running backwards (*descending portion*) (Fig. 186, *M*), and another extending forwards (*ascending portion*), the two lying parallel to one another (*PR*). In general, it becomes adapted to the form of the body:—thus Rays and Anurans possess a far wider stomach than do most other Fishes and Amphibians (cp. Figs. 189 and 190)—and this rule holds good also for Reptiles. The stomach of *Teleostei* varies considerably in form.

The Œsophagus is short, and usually not distinctly marked off from the stomach, though exceptions to this often occur, as, for instance, in many *Teleostei*, and in *Siren lacertina* amongst the *Amphibia* (Fig. 189, *Oe*).

A longitudinal fold extending into the lumen of the intestine, the first traces of which are seen in *Ammocætes*, is to be looked upon as a structure designed for increasing the digestive surface: this is also present in *Elasmobranchs*, *Dipnoi*, and *Ganoidei*,

in which it has a spiral form, and is therefore called the spiral valve. In the last-named Fishes, it begins to undergo degeneration (Fig. 187, *sp.v*), and is no longer met with in other Vertebrates.¹

The pyloric cæca (appendices pyloricæ), which are characteristic of the intestine of many Fishes, belong to the same physiological category as the above. They are met with in Ganoids and numerous Teleosteans, and consist of longer or shorter finger-shaped processes of the small intestine, which are situated posteriorly

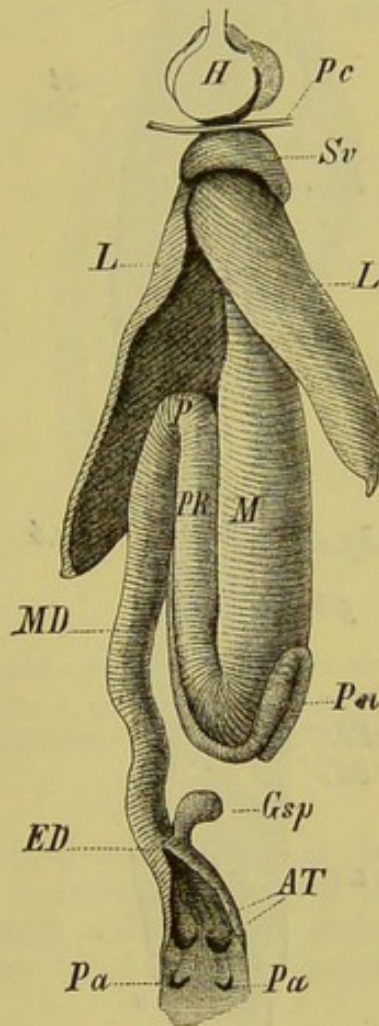


FIG. 186.—INTESTINAL TRACT OF A SHARK.

H, heart ; *Pc*, pericardium cut through ; *Sv*, sinus venosus ; *L, L*, the two lobes of the liver, separated from one another so that the stomach (*M*), with its pyloric tube (*PK*), and the region of the pylorus (*P*) are visible ; *MD*, small intestine, in which the spiral valve lies ; *ED*, large intestine ; *Gsp*, rectal gland ; *AT*, cloacal pockets ; *Pa, Pa*, abdominal pores ; *Pn*, pancreas.

to the pylorus in the region of the bile-duct (Figs. 187, *c*, and 188, *Ap*). Their number varies from 1 (Polypterus and Ammodytes) to 191 (Scomber scombrus). The pyloric cæca and the spiral valve seem to be developed in inverse proportion to one another, for,

¹ Amongst the Teleostei a spiral valve is present in Cheirocentrus, and probably also in Butirinus. An intestinal valve exists also amongst the Salmonidæ.

to a certain extent, the more one is developed, the less important is the other.

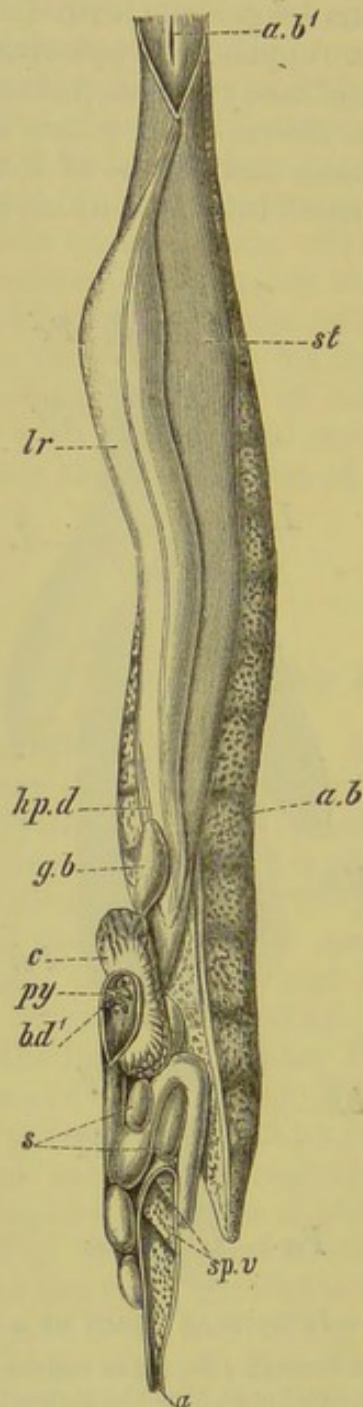


FIG. 187.—ALIMENTARY VISCERA AND AIR-BLADDER OF *Lepidosteus*, *in situ*.
(After Balfour and Parker.)

a, anus; *a.b*, air-bladder; *a.b'*, its aperture into the throat; *b.d'*, aperture of bile-duct into intestine; *c*, pyloric caeca; *g.b*, gall-bladder; *hp.d*, hepatic duct; *lr*, liver; *py*, pyloric valve; *s*, spleen; *sp.v*, spiral valve; *st*, stomach.

In the narrow-bodied Gymnophiona, the intestine is only slightly coiled, while in Anura it becomes considerably folded on itself. Its form in Salamanders is about mid-way between these two extremes.

With the exception of the Cyclostomi, Holocephali, Ganoidei, and Teleostei, in which there is a separate anus, the large intestine of all other Fishes, and of Dipnoi and Amphibia, opens into a cloaca, common to it and to the urinogenital ducts. The large intestine takes a straight course, and in Amphibia, as well as to some extent in certain Ganoids and Teleosteans, is plainly marked off from

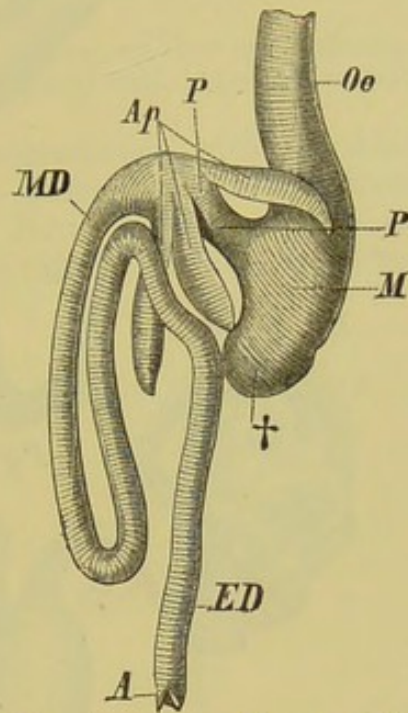


FIG. 188.—INTESTINAL TRACT OF PERCH.

Oe, œsophagus; *M*, stomach; †, cæcal process of latter; *P, P*, short pyloric region; *Ap*, pyloric cæca (appendices pyloricæ); *MD*, small intestine; *ED*, rectum; *A*, anus.

the small intestine: in some cases it is considerably swollen, even exceeding the stomach in capacity (Fig. 190, *R*). An outgrowth of the ventral wall of the cloaca in Amphibia gives rise to the urinary bladder, and represents the rudiment of the allantois.

Reptiles.—Corresponding with the more definitely differentiated neck, we find that Reptiles have a longer œsophagus than the animals as yet considered, and this is always plainly marked off from the much wider stomach, which is usually sac-like, or bent upon itself, when it lies transversely (Chelonians).¹ The stomach of Crocodiles is more specialised than that of other Reptiles, and approaches that of Birds in structure.

Snakes, Snake-like Lizards, and Amphisbænians possess a narrow, spindle-shaped stomach which lies in the long axis of the body; in correspondence with the large size of the masses of

¹ The œsophagus of marine Chelonians, like that of many Birds, is lined by horny papillæ.

food, which are swallowed whole, it is capable of great distension. In these forms the intestine is only slightly coiled; in Lizards the

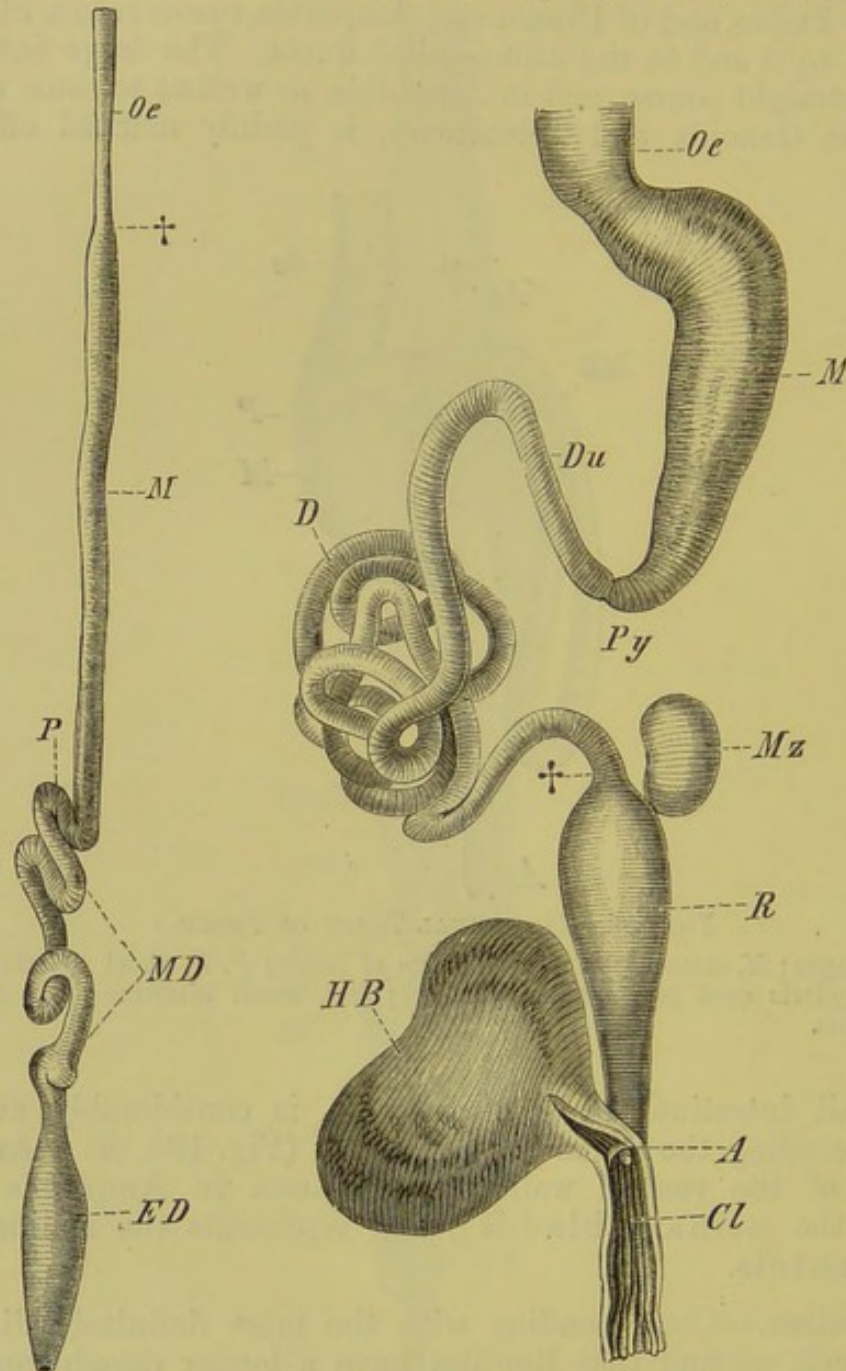


FIG. 189.

FIG. 190.

FIG. 189.—INTESTINAL TRACT OF *Siren lacertina*.

Oe, œsophagus, marked off from the stomach (*M*) by a constriction, †; *P*, pyloric region; *MD*, small intestine; *ED*, large intestine.

FIG. 190.—INTESTINAL TRACT OF *Rana esculenta*.

Oe, œsophagus; *M*, stomach; *Py*, pyloric region; *Du*, duodenum; *D*, ileum; †, boundary between the latter and the large intestine (*R*); *A*, opening of the rectum into the cloaca (*Cl*); *Hb*, urinary bladder; *Mz*, spleen.

coils are more marked, and in the other forms, with broad bodies, the folding is carried still further.

The large intestine has a straight course, is often considerably swollen, and opens into a cloaca. An account of the allantois of the Amniota will be found in a subsequent chapter (p. 273).

From the Reptilia onwards a process (generally asymmetrical) of the anterior portion of the large intestine is usually formed, giving rise to a **cæcum** or blind-gut.

The function of the bursæ anales of Chelonia, which consist of paired cæcal outgrowths of the cloacal wall, is not understood.

Birds.—In correspondence with the kind of nutriment, the mode of life, and the absence of teeth, a division of labour occurs in the stomach of Birds, which, instead of remaining simple, generally becomes divided into two portions, an anterior and a

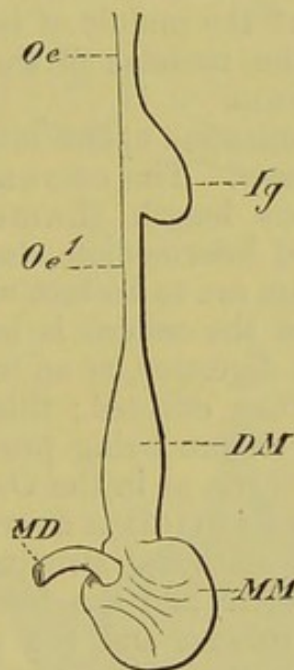


FIG. 191.—DIAGRAM OF THE ŒSOPHAGUS AND STOMACH OF A BIRD.

Oe, *Oe'*, œsophagus; *Ig*, crop; *DM*, glandular stomach; *MM*, muscular stomach; *MD*, duodenum.

posterior. The former (Fig. 191, *DM*), which, on account of its richness in glands, is called the glandular stomach (proventriculus), alone takes part in dissolving the food; while the latter (Fig. 191, *MM*), which is lined by a horny layer consisting of a hardened glandular secretion, has simply a mechanical function, in correlation with which a very thick muscular wall provided with two tendinous disks is developed.

The latter portion is for this reason spoken of as the muscular stomach, or gizzard, and the degree of its development stands

in direct proportion to the consistency of the food. In graminivorous Birds we find the strongest muscular layer and the thickest horny lining, while in the series of insectivorous Birds, up to the Birds of prey, this condition becomes gradually less marked, and the division of labour is less noticeable. Thus in the series of existing Birds we can see the line along which the differentiation of the organ has taken place phylogenetically.

Finally the dilatation of the gullet of Birds, which is known as the crop (ingluvies), must be mentioned (Fig. 191, *Ig*). A false crop serving only as a food reservoir, and entirely wanting in glands, and a true crop, rich in glands, which have a chemical function, can be distinguished. The former is seen, *e.g.*, in many Ducks, in the Cassowary, Haliaetus, and Otis, and the latter in Rasores, Columbidae, and others. The small intestine is usually of a considerable length, and becomes folded on itself to a greater or less degree; it varies, however, both in form, length, and diameter. At about the middle of its extent there is a small cæcum-like structure, the remains of the vitello-intestinal duct, or diverticulum cæcum.

The straight large intestine opens into a cloaca, and varies as to its relative diameter. The cæcum is usually paired, and may reach an enormous length (Lamellirostres, Rasores, Ratitæ). All kinds of intermediate stages between this and an entire absence of a cæcum are to be met with.

In those cases where the cæcum is largely developed, it has an important relation to digestion, as an increase of surface of the mucous membrane is thus effected; this increase may even be carried further by each cæcum being provided with a spiral fold consisting of numerous turns, as in the Ostrich.

The so-called bursa Fabricii is a structure peculiar to Birds. It arises as a small solid epithelial structure, which later becomes excavated to form a vesicle, and lies freely in the pelvic cavity between the vertebral column and the posterior portion of the intestine; it extends to the outer section of the cloaca, into which it opens, posteriorly to the urinogenital ducts. It is probably present in all Birds, but becomes atrophied more or less completely in the adult; its physiological function is quite unknown.

Mammals.—The œsophagus, like that of Birds, is sharply marked off from the stomach, and is differentiated at its proximal end to form a pharynx, which is regulated by strong muscles.

Under the influence of the food the stomach here undergoes much more numerous modifications than are met with in any other Vertebrate class. As a rule it takes a more or less transverse position and has a sac-like form, the portion into which the œsophagus opens being called the cardiac, and the part between this and the duodenum the pyloric portion.

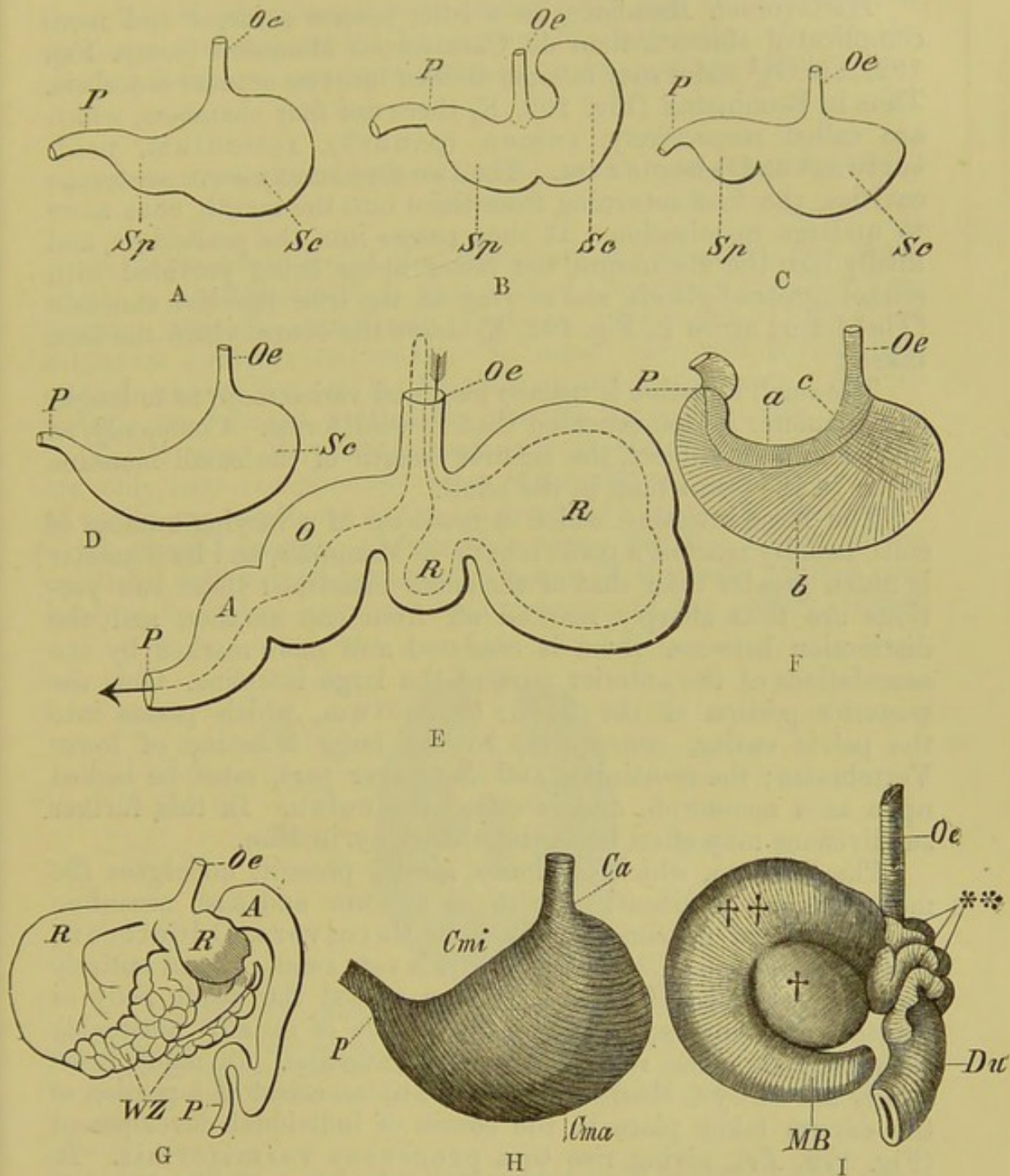


FIG. 192.—DIFFERENT FORMS OF MAMMALIAN STOMACHS.

A, Dog. B, *Mus decumanus*. C, *Mus musculus*. D, Weasel. E, diagram of the Ruminant stomach, the arrow showing the direction which the food takes; R, R, rumen and reticulum; O, psalterium; A, abomasum. F, human stomach inverted and prepared to show the muscles, a, b, c, on the inner side. G, stomach of Camel; R, R, rumen and reticulum; A, abomasum; WZ, water cells. H, stomach of *Echidna hystrix*; Cmi, lesser curvature; Cma, greater curvature. I, stomach of *Bradypus tridactylus*; ††, the portion corresponding to the rumen; †, that corresponding to the reticulum of the Ruminant's stomach; the former is produced to form a cæcal process at MB; **, pouches of the duodenum. Oe, œsophagus; P, pylorus; Sc, cardiac sac; Sp, pyloric sac; Ca, cardia.

(Fig. G after Gegenbaur.)

Herbivorous Mammals, as a rule, possess a larger and more complicated stomach than do Carnivorous Mammals (comp. Fig. 192, A to G),¹ and it may become divided into two or more chambers. Thus in Ruminants (Fig. 192, E) there are four chambers, which are called respectively, rumen (paunch), reticulum, psalterium,² and abomasum. The two first simply serve as storage cavities, the food returning from them into the mouth, once more to undergo mastication. It then passes into the psalterium, and finally into the abomasum, the latter alone being provided with rennet (gastric) glands, and serving as the true digestive stomach. (The dotted arrow in Fig. 192, E, shows the course which the food takes.)

The small intestine is usually long, and varies more as to length and diameter in domesticated than in wild forms. Commonly, as in the human subject, the relative length of the small intestine is less in the fœtus than in the adult.

The large intestine, which is made up of a varying number of coils, usually reaches a great length in Mammals, and its diameter is much greater than that of the small intestine: these two portions are thus sharply marked off from one another, and the distinction between them is rendered still more marked by the sacculations of the anterior part of the large intestine. Only the posterior portion of the latter, or rectum, which passes into the pelvic cavity, corresponds to the large intestine of lower Vertebrates; the remaining and far larger part, must be looked upon as a neomorph, and is called the colon. In this, further subdivisions may often be distinguished, *e.g.* in Man.

The cæcum, which is almost always present, undergoes the most various modifications both as to form and size, according to the kind of nutriment. Thus in Carnivora, Odontoceti, Insectivora, and Cheiroptera, it is very small or even entirely wanting, while in Herbivora, it may exceed the whole body in length. An inverse development in size is usually noticeable between it and the rest of the large intestine. In many cases (many Monkeys, Rodents, and Man) an arrest of a portion of the cæcum takes place in the course of individual development (Fig. 172, *Pv*), giving rise to a processus vermiformis. In *Lepus*, the enormous cæcum is provided with a spiral valve, and in *Hyrax*, besides a large sacculated cæcum at the junction of the small and large intestines, there is a pair of large simple conical cæca further back.

Monotremes only amongst Mammals possess a proper cloaca,

¹ In Cetacea and *Bradypus* (Fig. 192, I) however, the stomach is divided into several chambers, and in some Rodents and the Horse a distinct cardiac and a pyloric division can be recognised: some Marsupials (*e.g.* *Halmaturus*) also possess a complicated stomach. In Ungulates numerous forms between a simple and an exceedingly complex stomach are to be met with.

² The psalterium is the latest to be differentiated, both phylo- and ontogenetically.

though in Marsupials and some Rodents, the anal and urinogenital apertures are surrounded by a common sphincter. In all the others a complete separation between these apertures takes place.

HISTOLOGY OF THE MUCOUS MEMBRANE OF THE ALIMENTARY CANAL.

With the exception of the epithelium of the mouth and anus, which is usually stratified, that of the alimentary canal of Vertebrates consists primitively, that is, phylogenetically, of ciliated cylindrical cells. In some cases this is also true ontogenetically, and in *Amphioxus* and *Petromyzon* (*Ammocetes*),¹ the ciliated epithelium persists throughout life.

In all other Vertebrates, especially in the higher forms, cilia are only seen exceptionally after the embryonic period, so that, as a rule, only ordinary cylindrical epithelium is present.

A striated margin is observable along the free border of the epithelial cells turned towards the lumen of the canal; this is probably to be looked upon as the expression of the earlier ciliated

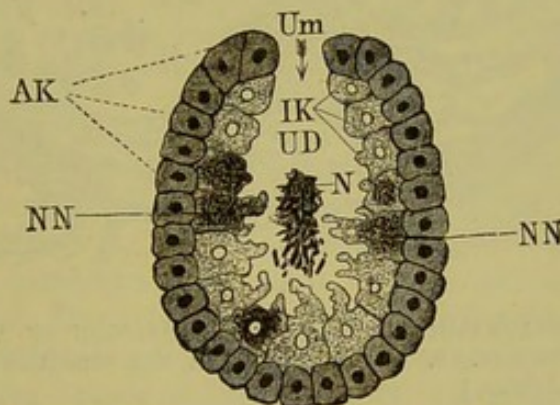


FIG. 193.—DIAGRAM OF THE STRUCTURE OF A CŒLENTERATE.

AK, ectoderm; *IK*, endoderm; *NN*, cells of the endoderm which have thrown out amœboid processes and ingested food-particles; *UD*, primary alimentary cavity (archenteron), containing food-particles (*N*); *Um*, the primary mouth (blastopore).

covering, and in the lower Vertebrates it is capable of an active amœboid movement (Fig. 194, B). In this active participation of the cells in the process of absorption, we recognise an old inheritance from Invertebrates: in this connection the reader is referred to Fig. 193, which represents diagrammatically the structure of a Cœlenterate, in which the endoderm-cells lining the primitive alimentary cavity, or archenteron (*UD*), are directly concerned with the taking in of nutritive particles by means of pseudopodia (*N*) [intracellular digestion]. These endoderm-cells may be com-

¹ It persists throughout the gut in *Ammocetes*, and only in certain parts in *Petromyzon*.

pared with the epithelial cells, E^1E^1 , of the intestine of a lower Vertebrate, in Fig. 194, A, where they are shown putting out

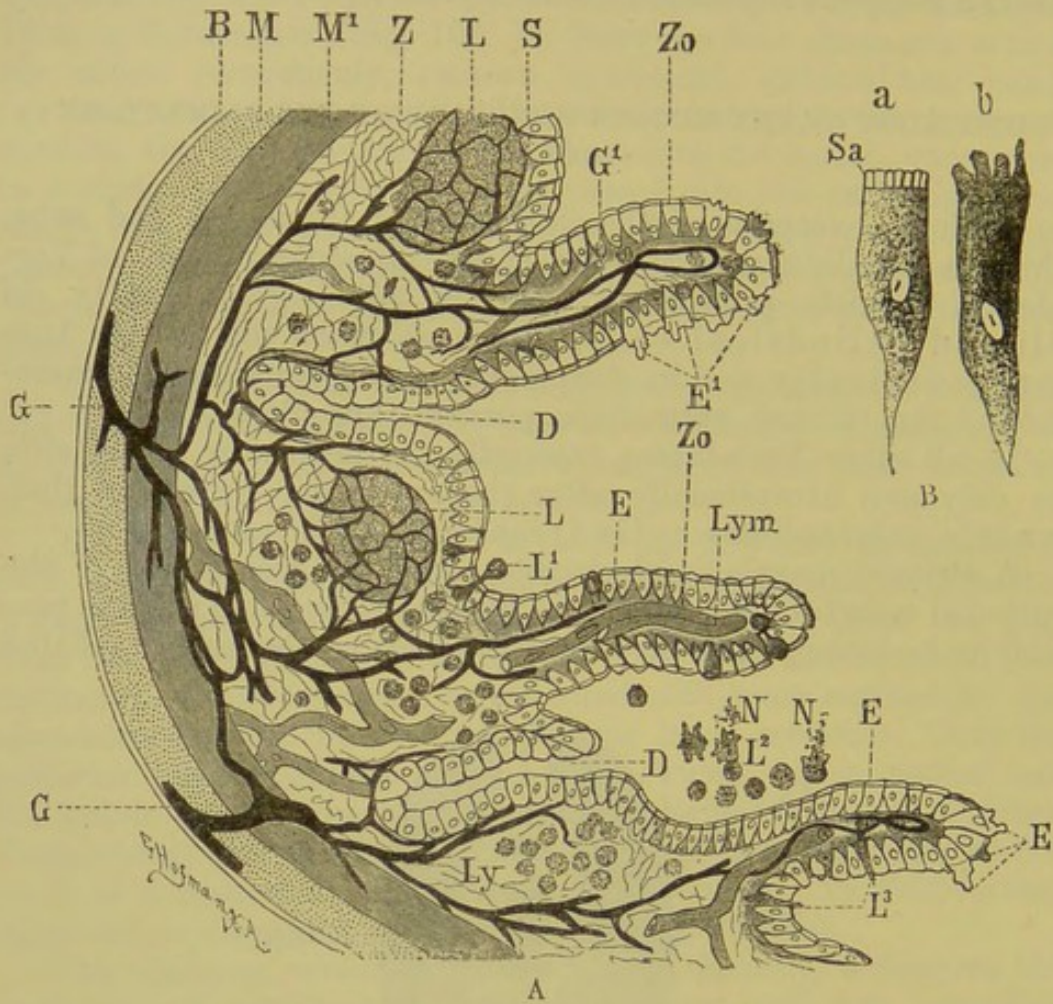


FIG. 194.—A, SEMIDIAGRAMMATIC TRANSVERSE SECTION OF A PORTION OF THE WALL OF THE INTESTINE. (Combined from the condition seen in both lower and higher Vertebrates.)

The connective-tissue layer and epithelium are designedly drawn much too large as compared with the outer coats. To the left of the figure would be the body-cavity; to the right, the alimentary cavity.

P , peritoneal investment of the gut; M , longitudinal muscular layer; M^1 , circular muscular layer; Z , connective-tissue layer; S , mucous membrane, which is raised to form villi at Zo ; G, G , vessels, the larger trunks running between the peritoneum and the muscular layer: the finer vessels branch out into the intermediate layer; these surround the masses of lymph-cells, LL , as well as the glands, and send fine loops into the villi (at G^1); DD , apertures of the glands; E, E , epithelial cells of the mucous membrane, with their striated border, from which at E^1 amœboid processes are extruded: in Fig. B, a, b , these cells are drawn to a much larger scale (Sa , striated border); Ly , scattered lymph-cells in the intermediate layer; L^1, L^3 , lymph-cells in the act of passing through the mucous membrane; at L^2 , several have already passed into the alimentary cavity, and are beginning to ingest the contained nutritive particles by means of their amœboid processes; LL , masses of lymph-cells (solitary follicles); Lym , lymph-vessels in the villi.

amœboid processes, and in Fig. 194, B, where the cells a, b , are shown drawn to a larger scale. Besides these absorptive epithelial

cells, other cells take part in the active ingestion of food, and this again is most marked in the lower Vertebrates, more especially in Fishes and Dipnoans. These are the lymph-cells (leucocytes, which on this account have received the suitable name of phagocytes), which are present in great numbers in the connective-tissue of the mucous membrane (Fig. 194, A, *Ly*), often united into definite masses (*L*). These cells, which are capable of the most complete amœboid movements, become migratory, force their way through the epithelium of the gut (Fig. 194, A, *L*¹, *L*³), and come into contact with the food in the lumen of the intestine (*L*², *NN*). Others of these phagocytes again, seem to take up the nutritious particles only after the latter have penetrated through the epithelium into the connective-tissue layer. Here they become incorporated by the lymph-trunks (*Lym*), and finally, through metabolism, by the whole organism.

The phagocytes possess the further peculiarity of taking up noxious substances or portions of tissues which have undergone retrogressive metamorphosis, wherever they may occur in the body, thus rendering them innocuous. They thus exercise a kind of superintendence over the body, acting as a sort of police force. This function is seen most plainly in the migration of leucocytes from the tonsils into the mouth and pharynx, and from the epithelium of the conjunctiva into the conjunctival sac. It is not improbable that this process of ingestion by the leucocytes takes place at every point where the mucous membrane becomes continuous with the outer skin (*e.g.* nose, urethra, anus).

Thus we arrive at the result that, in the lower Vertebrates,—and, with certain limitations, in the higher types also,—active or mechanical processes take place in digestion. These appear to be of great importance in most of the Anamnia; thus in all Fishes and Dipnoi, for instance, **glands**, provided with specially differentiated epithelial cells, are not present, or at any rate only the first traces of them can be recognised. With the exception of the liver, Amphioxus, Cyclostomi, and Dipnoi possess no trace of glands, and even in Amphibia, a marked differentiation does not seem to occur. It cannot be affirmed that no chemical processes take place in the process of digestion in these animals, for every individual epithelial cell of the gut may be looked upon as a small gland; but, at all events, the chemical processes in the higher types from the Reptilia onwards, become of far greater importance than the merely mechanical absorptive processes, owing to the development of highly differentiated glandular organs (peptic glands and glands of Lieberkühn).

In conclusion, attention must be directed to the formation of folds of the mucous membrane. In Cyclostomes these have only a longitudinal direction (Fig. 195, *A*), while, from Elasmobranchs onwards, they take on a transverse arrangement, and thus crypts arise which possess a sac-like form, often passing deeply into the

wall of the gut (*B* to *E*). By a further development these crypts become more tube-like and elongated, and give rise to the above-mentioned gastric and intestinal glands (peptic glands and glands of Lieberkühn).

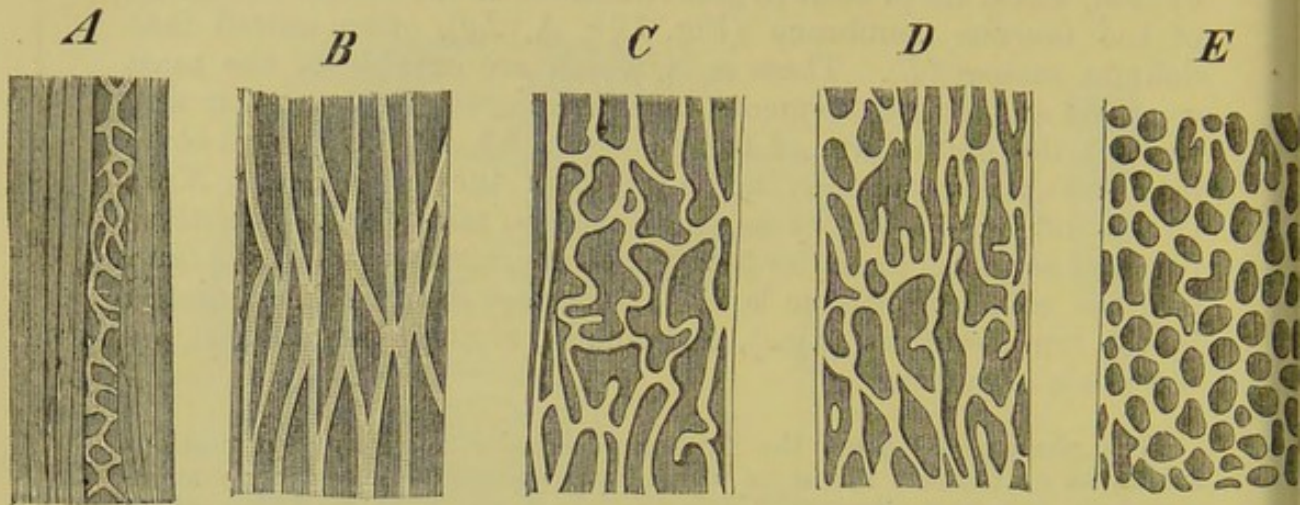


FIG. 195.—SEMIDIAGRAMMATIC FIGURES OF THE MUCOUS MEMBRANE OF THE INTESTINE OF FISHES, SHOWING INTERMEDIATE FORMS BETWEEN LONGITUDINAL FOLDS AND ROUND CRYPTS.

A, Petromyzon, showing the distinct spiral fold; *B*, an Elasmobranch; *C* to *E*, various Teleosteans.

The finger-like outgrowths of the mucosa (villi intestinales) (Fig. 194, *A*, *Zo*, *Zo*) are to be looked at from the same physiological point of view, that is, they have to do with increasing the absorptive surface. They may be derived through numerous intermediate forms from ordinary folds, and appear as distinct papillæ from the Sauropsida onwards, reaching their greatest development in Mammals.

APPENDAGES OF THE ALIMENTARY CANAL.

Liver.

The liver, the form of which is always closely adapted to that of the body, underlies to a greater or less extent the ventral side of the intestinal tract, and is present in every Vertebrate (Amphioxus?). It is united to the body-wall by a fold of the peritoneum, and varies considerably in the number of its lobes. We may nevertheless fix upon a ground-form consisting of two lobes (Myxinoids) as the predecessor of the organ in all Vertebrates. It always arises from the commencement of the small intestine, and develops into a large vascular and glandular organ, (Figs. 196 to 198) which gives rise to bile, and remains in com-

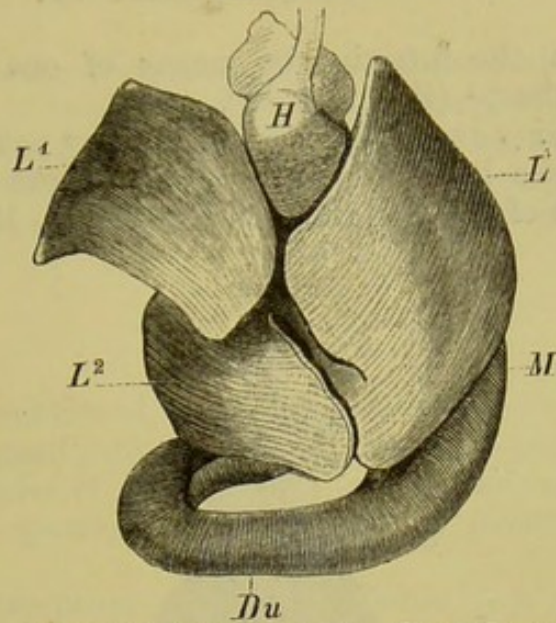


FIG. 196.—LIVER OF *Rana esculenta*. (From the ventral side.)
L, *L*¹, *L*², the different lobes of the liver; *M*, stomach; *Du*, duodenum; *H*, heart.

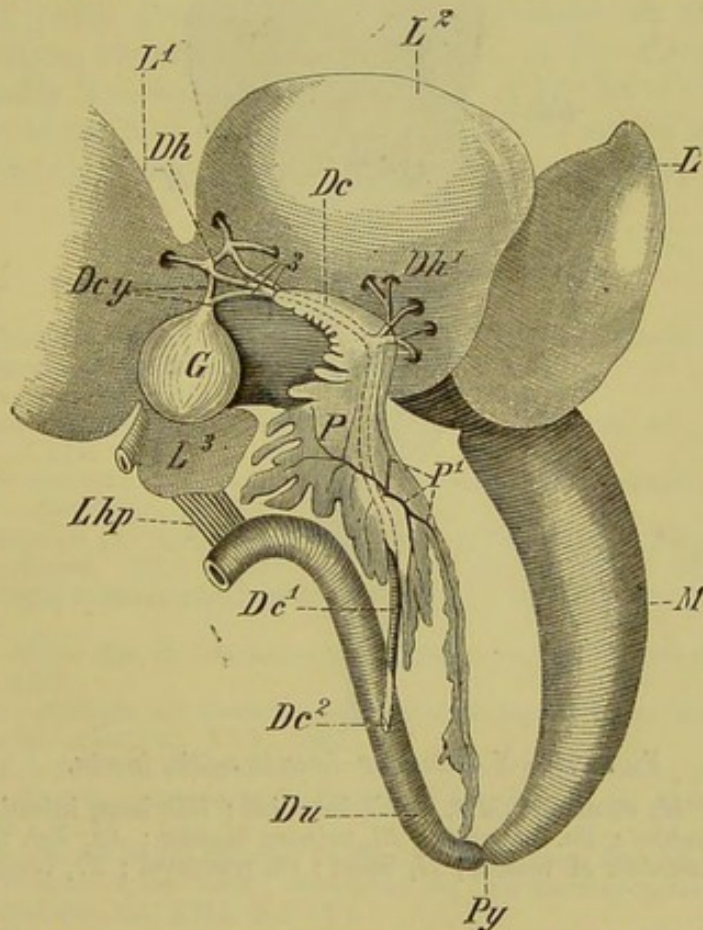


FIG. 197.—PANCREAS AND LIVER OF FROG, TO SHOW THE ARRANGEMENT OF THEIR DUCTS.

L, *L*¹ to *L*³, the lobes of the liver turned forwards; *G*, gall-bladder; *Dcy*, cystic ducts, which, together with the hepatic ducts (*Dh*), form a network from which the collecting ducts arise, and these unite to form the common bile-duct (*Dc*): the latter passes through the substance of the pancreas (*P*), receiving further hepatic ducts (*Dh*¹), and the pancreatic ducts (*P*¹); at *Dc*¹ it becomes free from the pancreas, and passes back to open into the duodenum (*Du*) at *Dc*²; *Lhp*, duodeno-hepatic omentum; *M*, stomach; *Py*, pylorus.

munication with the intestine by means of one or more ducts (ductus choledochus)¹ (Fig. 197, *De*).

A gall-bladder (*vesica fellea*) may or may not be present, and in the former case it is connected with the system of hepatic ducts by means of a cystic duct (comp. Fig. 197, *G*, *Dcy*, *Dh*)

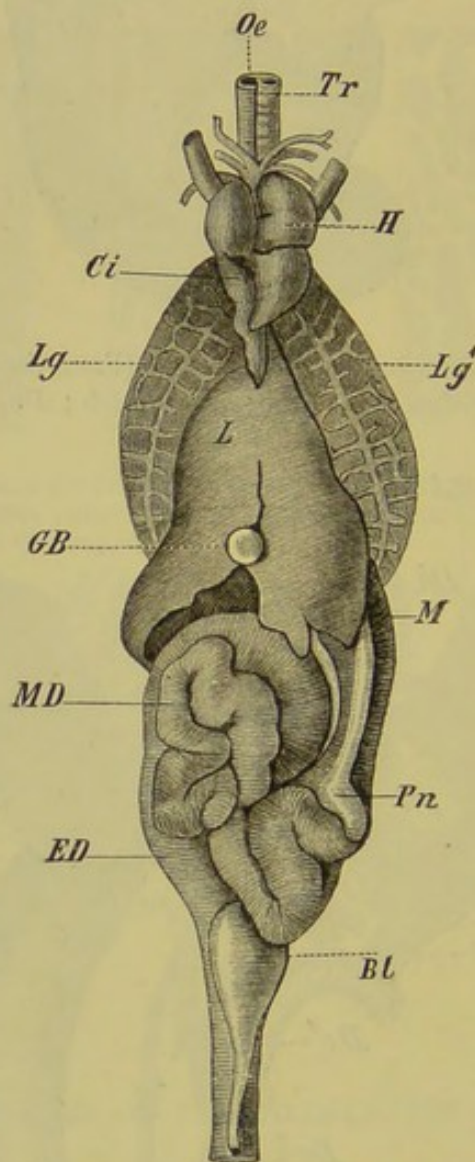


FIG. 198.—VISCERA OF *Lacerta agilis*, *in situ*.

Oe, oesophagus; *M*, stomach; *MD*, small intestine; *ED*, large intestine; *L*, liver; *GB*, gall-bladder; *Pn*, pancreas; *BL*, urinary bladder; *Lg*, *Lg'*, the two lungs, with their network of vessels; *H*, heart; *Ci*, postcaval; *Tr*, trachea.

The liver of the Anamnia (*e.g.* Ganoids and Perennibranchiates) is, as a rule, relatively larger than that of the Amniota. Carnivorous (fat-eating) animals generally possess a larger liver than Herbivores.

¹ The single-lobed liver of the Lamprey undergoes a histological retrogression (fatty metamorphosis) after transformation. The tubuli disappear, and the cells become filled with fat, and the gall-bladder and bile-duct become atrophied.

In Mammals the liver may always be derived from a ground-form consisting of two lobes, but in most cases it becomes further subdivided, so that in some cases there may be as many as six or seven lobes (*e.g.* Dog, Weasel). The right primary lobe is always the longest, and in it the gall-bladder, when present, lies partially embedded.

Pancreas.

As already mentioned, this organ also arises from the proximal portion of the small intestine, and comes into close relation with the liver. Its point of origin from the intestine corresponds to the aperture of the pancreatic duct, which penetrates the entire organ.

With the exception of certain Fishes (*e.g.* Cyclostomi and many Teleostei) and Perennibranchiates (Siren and Proteus), a pancreas is always present in Vertebrates. Varying much in form and size, it early gives rise to a band-shaped or more or less lobulated organ, usually lying in the fold of the duodenum. Its duct frequently becomes united with that of the liver (Fig. 197, *P*¹, *Dc*¹, *Dc*²), or there may be several independent ducts opening into the intestine (*e.g.* Birds, Crocodilia, Emydæ, and some Mammalia).

BIBLIOGRAPHY.

- AYERS, H.—*Beiträge zur Anat. u. Physiol. der Dipnoer. Jenaische Zeitschr. f. Naturwissenschaft.* Bd. XVIII. (N.F. Bd. XI.), 1885.
- BAUME.—*Odontologische Forschungen*, I. Leipzig, 1882.
- BORN, G.—*Ueber die Derivate der embryonalen Schlundbogen, &c. Arch. f. mikr. Anat.* Bd. XXII. 1883.
- CATTANEO, G.—*Istologia e sviluppo dell'apparato gastrico degli uccelli.* Milano, 1884.
- DOBSON, G. E.—*On Peyer's Patches. Journ. Anat.* 1884.
- DOHN, A.—*Studien zur Urgeschichte des Wirbelthierkörpers. Mitthl. aus d. zool. Station zu Neapel.* Bd. V. Heft 1. Bd. VI. Heft 1, 1884. (These include an account of the thyroid gland of Elasmobranchs, Petromyzon, Amphioxus, and Tunicata.)
- EDINGER, L.—*Ueber die Schleimhaut des Fischdarmes, &c. Arch. f. mikr. Anat.* Bd. XIII. 1877.
- FISCHELIS, PH.—*Beiträge zur Kenntniss der Glandula thyroidea u. Glandula thymus. Arch. f. mikr. Anat.* Bd. XXV. 1885.
- FLOWER, W. H.—*Lectures on Odontology. Med. Times and Gazette*, 1871. *Lectures on the Comparative Anatomy of the Organs of Digestion of the Mammalia. Ibid.* Feb. to Dec., 1872.
- FORBES, W. A.—*On the Bursa Fabricii in Birds. Proc. Zool. Soc.* 1875.
- GADOW, H.—*Versuch einer vergl. Anatomie des Verdauungssystemes der Vögel. Jenaische Zeitschr.* Bd. XIII. N.F. VI.
- HENSEL, R.—*Ueber Homologieen und Varianten in den Zahnformen einiger Säugthiere. Morphol. Jahrb.* Bd. V. 1879.
- HERTWIG, O.—*Ueber das Zahnsystem der Amphibien und seine Bedeutung für die Genese des Skelets der Mundhöhle. Arch. f. mikr. Anat.* Bd. XI. 1874.
- HIS, W.—*Anatomie menschlicher Embryonen.* Leipzig, 1880–1885.
- HUXLEY, T. H.—*Tegumentary Organs. Encycl. of Anat. and Physiol.* Vol. V. (See also *Quart. Journ. Micros. Science*, 1853.)
- LEYDIG, T.—*Ueber die Kopfdrüsen einheimischer Ophidier. Arch. f. mikr. Anat.* Bd. IX. 1873.

- LUDWIG, FERDINAND, Königl. Prinz v. Bayern.—*Zur Anatomie der Zunge.* München, 1884. *Ueber Endorgane der sensiblen Nerven in der Zunge der Spechte.* *Sitzungb. d. k. bayr. Acad. d. Wiss.* 1884.
- MAURER, F.—*Schilddrüse und Thymus der Teleostier.* *Morphol. Jahrb.* Bd. XI. 1885.
- MINOT, CH. S.—*Studies on the Tongue.* *Anniversary Memoirs of the Boston Society of Natural History.* Boston, 1880.
- NUNN, EMILY A.—*On the Development of the Enamel of the Teeth of Vertebrates.* *Proc. Roy. Soc.* 1882.
- OWEN, R.—*Odontography.* (With Atlas.) 1840–45.
- PARKER, T. JEFFERY.—*On the Intestinal Spiral Valve in the Genus Raia.* *Trans. Zool. Soc.* Vol. XI. 1880.
- RATHKE, H.—*Zur Anatomie der Fische* (two Papers). *Arch. f. Anat. und Physiol.* 1837.
- REICHEL, P.—*Beitrag zur Morphologie der Mundhöhlendrüsen der Wirbelthiere.* *Morphol. Jahrb.* Bd. VIII. 1882.
- SCHÄFER, E. A.—*On the Part played by Amœboid Cells in Intestinal Absorption.* *Internat. Journ. of Anat. and Hist.* Vol. II. Part I. 1885.
- STIEDA, L.—*Unters. über die Glandula thymus, thyroidea und carotica.* Leipzig, 1881.
- TOMES, CH. S.—*Manual of Dental Anatomy, Human and Comparative.* London, 2nd ed. 1882. *On the Development of Teeth.* *Quart. Journ. Micros. Science,* Vol. XVI. 1876, and *Phil. Trans.* 1875–76.
- WATNEY, H.—*The Minute Anatomy of the Thymus.* *Phil. Trans. Roy. Soc.* p. 111, 1882.
- WIEDERSHEIM, K.—*Die feineren Strukturverhältnisse der Drüsen im Muskelmagen der Vögel.* *Arch. f. mikr. Anat.* Bd. VIII. 1872. *Ueber die mechan. Aufnahme der Nahrungsmittel in der Darmschleimhaut.* *Freiburger Festschrift zur 56 Versammlung deutscher Naturforscher und Aerzte,* 1883.
- WÖLFLER, A.—*Ueber die Entwicklung der Schilddrüse.* Berlin, 1880.

G. ORGANS OF RESPIRATION.

THE respiratory organs are closely connected with the alimentary canal, both in position and development, and are of two kinds, **gills** and **lungs**. The former, as the phylogenetically older organs, are adapted for aquatic respiration, and are connected with the pharynx in the region of the visceral or branchial arches: the latter always arise as sac-like outgrowths of the primitive œsophagus, which grow backwards so as to lie within the body-cavity.

Both gills and lungs may be developed in the same individual, but with few exceptions (Dipnoi, and possibly Siren amongst the Perennibranchiata) they are not functional at the same time.¹ Which of these are to serve as respiratory organs depends upon the condition of the circulation, for respiration can only take place where venous trunks,—the blood in which is laden with carbonic acid,—come into close relation with the surrounding medium; the carbonic acid is then given off, oxygen being taken up in its place. The venous blood is thus converted into arterial blood, which is again distributed over the body.

As long as these conditions for the oxidation of the blood are not fulfilled, we cannot speak of a respiratory organ. Thus the **air-bladder** of Fishes, which arises in a very similar manner to a lung, that is, as an outgrowth of the fore-part of the alimentary tract, has in no period of life the arrangement of the blood-vessels described above: it receives arterial blood only, from the aorta, and venous blood passes from it; it is therefore morphologically, but not physiologically, a lung.

I. GILLS.

The gills arise as a series of laterally-arranged outgrowths of the throat lying one behind the other, and, in the course of their development, they become open to the exterior. A passage is thus formed for the water entering by the mouth, and in order that

¹ Comp. air-bladder of *Lepidosteus*, p. 257.

there may be every means for its contained oxygen to become absorbed, leaf-like or thread-like vascular processes, or gills, become developed in the region of each gill-cleft. These are internal or external according to their position.¹

While Fishes possess gills throughout life, this is only the case in a small section of the Amphibia, viz. in the Perenni-branchiata; all the others simply pass through a gilled stage, and later come to breathe by means of lungs, so that the study of this one group of animals furnishes us with an excellent representation of the course of phylogenetic development through which all the higher Vertebrates must have passed.

The best proof of this, as well as of the important meaning of the branchial apparatus of animals in general, lies in the appearance of gill-clefts and gill-arches throughout the entire series of the Amniota up to Man, that is, in forms in which they no longer possess a respiratory function. They are thus repeated ontogenetically, but have undergone a change of function, coming into relation with the auditory organ and tongue, as already described in connection with the skull and auditory organ (see pp. 78, 80, 84, and 198).

Amphioxus.—The numerous (80, 100, or more) gill-clefts of *Amphioxus*, which are supported by elastic rods, extend backwards nearly to the middle of the body. At first they open freely to the exterior, but in a later period of development they become covered by two lateral folds of the skin.

The water passing through the gill-slits is conducted backwards by means of the peribranchial chamber thus formed, and passes out through an aperture, the atrial pore, which lies somewhat behind the middle of the body (Fig. 199, *c*).

This extension of the branchial apparatus over such a large section of the body, which points back to a very primitive condition, becomes considerably limited even in the Cyclostomi.

Cyclostomi.—In *Ammocetes* the œsophagus is continued directly backwards from the branchial cavity (Fig. 200, *A*), and at the entrance of the latter there is a muscular fold covered by the mucous membrane, the velum (Fig. 201, *V*).

The seven² gill-sacs provided with leaf-like folds of mucous membrane which are present in *Ammocetes*, persist in *Petro-myzon*; but, with the formation of a suctorial mouth, the portion of the œsophagus into which they open (respiratory tube) becomes closed posteriorly, and the œsophagus apparently grows

¹ External gills persist after hatching as functional respiratory organs only in Protopterus and the Amphibia, and even in the latter they are often soon replaced by internal branchiæ (comp. pp. 250 and 251).

² In *Ammocetes* there are primitively eight gill-clefts; but the first pair, which give rise in most Elasmobranchs and many Ganoids to the spiracle, and in Amniota to the tympano-Eustachian passage, does not perforate the skin.

forwards above the latter, and joins the mouth-cavity at the velum. The anterior part of the œsophagus of the adult is thus a neomorph: it is at first solid, but becomes hollowed secondarily.

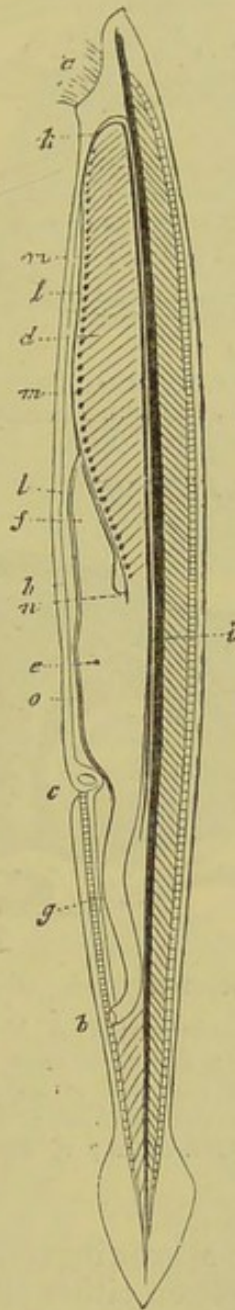


FIG. 199.—*Amphioxus lanceolatus*, $\times 2\frac{1}{2}$. (From Gegenbaur, after Quatrefages.)

a, aperture of mouth, surrounded by cirri ; *b*, anus ; *c*, atrial pore ; *d*, branchial sac ; *e*, stomach-like section of the intestine ; *f*, caecal process (? liver) ; *g*, intestine ; *h*, general body-cavity ; *i*, notochord, and under it the aorta ; *k*, aortic arches ; *l*, aortic heart ; *m*, swellings on the branchial arteries ; *n*, contractile postcaval vein ; *o*, contractile portal vein.

Thus two canals pass backwards from the mouth, a ventral branchial or respiratory tube, and a dorsal œsophagus (Fig. 200, B).

In *Petromyzon* the individual branchial sacs open freely to the exterior; but in *Myxine* this original condition becomes modified

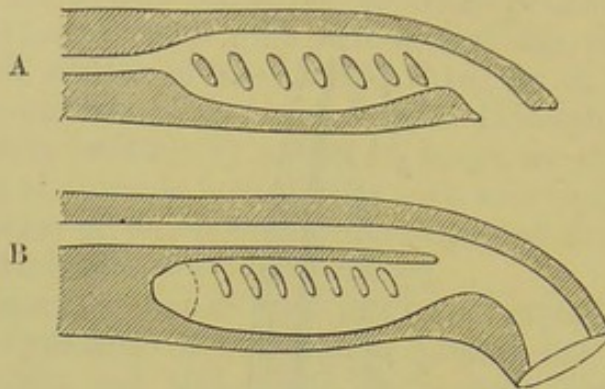


FIG. 200.—DIAGRAM OF A LONGITUDINAL SECTION THROUGH THE HEAD OF *Ammocetes* (A) AND *Petromyzon* (B).

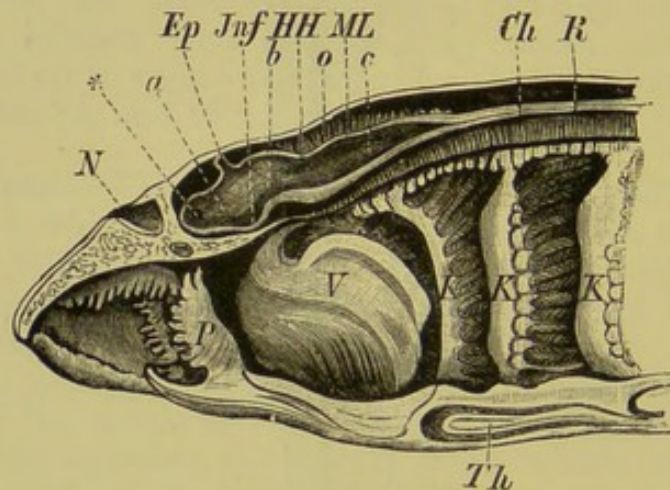


FIG. 201.—LONGITUDINAL SECTION THROUGH THE HEAD OF *Ammocetes*.

V, velum; *P*, papillæ of mucous membrane; *K, K, K*, three anterior gills; *Th*, thyroid gland (hypobranchial furrow); *N*, nasal sac; *, communication between the ventricle of the olfactory lobe and that of the prosencephalon; *Ep*, epiphysis; *Jnf*, infundibulum; *HH*, metencephalon; *ML*, medulla oblongata; *b, c*, ventricles of the mid- and hind-brain; *o*, subdural cavity; *Ch*, notochord; *R*, spinal cord.

by the external gill-passages growing out into long tubes, which unite to form a common duct on either side; this opens far behind the branchial apparatus on the ventral side of the body.

Fishes.—From the Elasmobranchii onwards the gills come into close relation with the skeletal part of the visceral arches, and in these Fishes they consist of closely-approximated transverse laminæ (Fig. 202), which are firmly attached to both sides of the septa which separate the individual gill-sacs from one another, so that each septum bears gill-laminæ on both its anterior and posterior surface. The gill-sacs, of which there are usually five (six or seven in *Notidanus*), usually open separately to the exterior.

In the Holocephali, however, an opercular membrane is present, and traces of a similar structure are seen in *Chlamydoselache*.

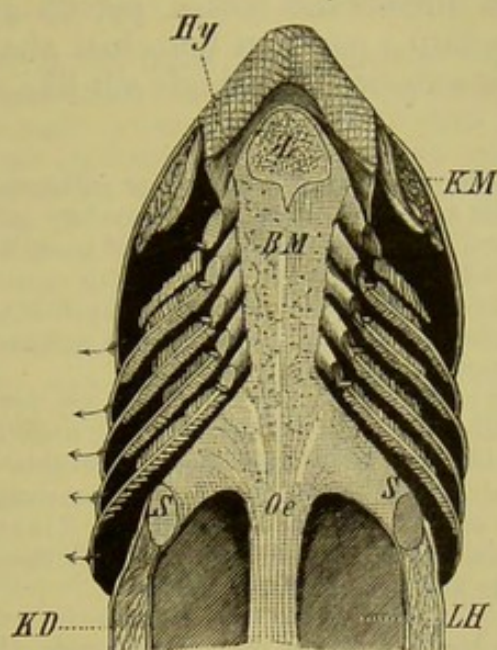


FIG. 202.—HORIZONTAL SECTION THROUGH THE VENTRAL SIDE OF THE HEAD OF A SELACHIAN. (Semidiagrammatic.) The floor of the mouth is exposed.

KM, muscles of jaw; *Z*, tongue; *Hy*, hyoid arch cut through, behind which are seen the five branchial arches, also cut through; *BM*, mucous membrane of the mouth; *Oe*, œsophagus; *S, S*, pectoral arch, cut through; *LH*, body-cavity; *KD*, body-walls; the arrows indicate the external apertures of the five branchial sacs.

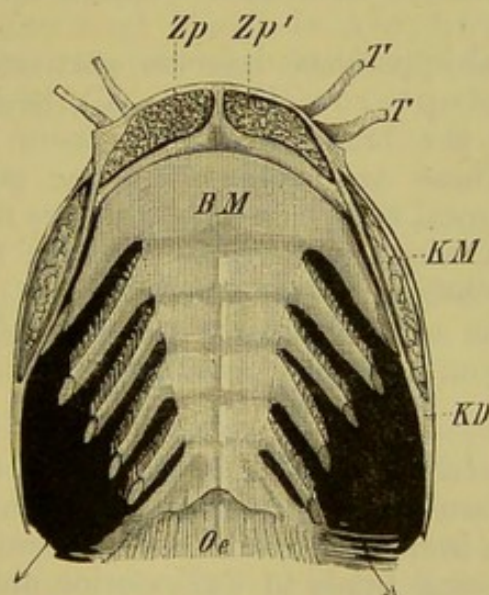


FIG. 203.—HORIZONTAL SECTION THROUGH THE VENTRAL SIDE OF THE HEAD OF *Siluris glanis*. (Semidiagrammatic.)

T, T, tentacles; *Zp, Zp'*, teeth of the lower jaw; *BM*, mucous membrane of the floor of the mouth; *Oe*, œsophagus; *KM*, muscles of jaw; *KD*, gill-cover, behind which (at the arrow) the common branchial cavity opens.

In Ganoids and Teleosteans there are no longer chambered gill-sacs. The septa on which the gill-laminæ are borne become greatly

reduced, so that the apices of the latter extend freely outwards; the whole branchial region is moreover covered over by the operculum and branchiostegal membrane (comp. pp. 66 and 69), and thus the gill-slits open into a common branchial chamber, which communicates with the exterior by a single slit-like aperture on either side (Fig. 203).

As a rule, the Teleostei possess only four gill-bearing visceral arches,¹ and this holds good for all Ganoids. A rudimentary gill or pseudobranch is present on both mandibular and hyoid arches of most Elasmobranchs, on the mandibular arch of all Cartilaginous Ganoids (spiracular gills), and on the hyoid of Teleostei, and a more complete hyoidean gill is seen in *Acipenser* and *Lepidosteus*: this indicates that all these Fishes formerly possessed a more extensive branchial apparatus than at present.

In many Teleostei certain accessory structures are developed in the region of the branchial chamber by a modification of the branchial arches or cavity. These serve to retain the water, and thus the Fish is able to live for some time out of the water (*Anabas*, *Saccobranchus*, *Heterobranchus*, *Clarias*, &c.).

External gills are met with in young stages of *Elasmobranchii*, *Holocephali*, *Polypterus*, and *Cobitis*; these possibly have a nutritive function in connection with the absorption of the yolk.

Fishes breathe by taking in water through the mouth, and, by the contraction of the latter, forcing it out again through the gill-slits.² In this process the gill-arches rise and fall, separating from one another during inspiration, and approximating during expiration.

Dipnoi.—These, as their name implies, breathe both by gills and lungs.

The branchial apparatus deserves particular attention, inasmuch as, in *Protopterus* (Fig. 54, *K*), besides the internal gills situated on the branchial arches, there are also three external gills. These are situated on the posterior and upper border of the pectoral arch, to which they are fixed by connective-tissue and vessels, which latter pass to them from the third and fourth arterial arches.

As in Ganoids and Teleosteans there is only a single external branchial opening on either side, covered by a somewhat rudimentary operculum.

Amphibia.—In all Urodele larvæ as well as in the Perenni-branchiata there are three gill-tufts, lying one over the other, and decreasing in size from the dorsal to the ventral side; these extend backwards, projecting freely to the exterior, and are composed of connective-tissue, unsupported by cartilage. They either have the form of tufts, or they may be delicately branched, showing the most varied arrangements for increasing the respiratory surface.

¹ They may be reduced to three, or to two, and even these may become more or less rudimentary.

² In *Petromyzon*, when holding on by its suctorial mouth, inspiration as well as expiration takes place through the gill-apertures.

These external gills are acted on by a complicated system of muscles, and are covered by ciliated epithelium, which serves to keep up a continual current in the surrounding medium.

In the Axolotl and in the larvæ of Salamanders there are four, and in *Menobranchus* and *Proteus* only two gill-clefts perforating the pharynx. The former thus show a more primitive condition, while in the latter these structures have become reduced. There is always only a single external opening covered over by an opercular-like fold of skin.

In the *Derotremata* the gills disappear entirely, but the gill-aperture between the third and fourth branchial arches persists.

The external gills present at first in *Anura* soon disappear, and their place is taken by internal gills. By the growth of the opercular folds, the external respiratory aperture of either side becomes gradually reduced in size, and the two branchial chambers come eventually to open by a single aperture, which is situated either in the median ventral line, or laterally.

In the larvæ of *Notodelphys* and of *Cæcilia compressicauda* branchial vesicles are developed, covered over by a vascular respiratory network; in the former these are bell-shaped, and in the latter they have an irregular sac-like form. In the embryo of *Epicrium glutinosum*, a feather-like and highly-vascular gill-tuft arises on either side; these are of unequal length, and they move continually backwards and forwards in the egg-albumen. In certain *Batrachia*, the broad and richly vascular swimming-tail lying against the egg-membrane may serve as a larval respiratory organ.

Thus we arrive at the result that the gills of Vertebrates may be divided into four groups, which show no direct connection with one another. The first kind is seen in *Amphioxus*, the second in *Cyclostomes*, the third in the adults of other Fishes, and the fourth in *Amphibians*.

II. AIR-BLADDER AND LUNGS.

1. THE AIR-BLADDER.

As has already been mentioned, the lungs and air-bladder are developed in a similar manner, and differ only from one another in the fact that the lungs always arise from the ventral side of the primary œsophagus, while this is an exceptional case as regards the air-bladder (*Polypterus*, *Erythrina*); that organ is usually formed on the dorsal side. The exact point of origin of the air-bladder from the œsophagus varies, and its duct (*ductus pneumaticus*) may either remain open throughout life, as in all *Ganoids* and some *Teleosteans* (*Physostomi*), or it may later become reduced to a solid fibrous cord, or even entirely obliterated, as in other *Teleostei* (*Physoclisti*). In the latter case there is no communication between the air-bladder and the

external air, and it is probable that the contained gas is given off from the walls of the air-bladder itself.

The air-bladder always lies above the peritoneum on the dorsal side of the body-cavity, between the vertebral column, aorta, and kidneys on the one hand, and the alimentary canal on the other: it is invested by the peritoneum on the ventral side only. It is more or less sac-shaped in form, and is only exceptionally paired (Polypterus); it usually extends along the whole length of the body-cavity, and has walls composed of connective, elastic, and muscular tissue. In some Teleostei it is transversely constricted so as to form several successive divisions; in other cases it may give rise to a more or less numerous series of cæcal processes. Its internal surface may be either smooth or spongy, owing to the formation of a meshwork of trabeculæ, the structure of which reminds one of the lungs of Dipnoi and Amphibia.

Attention has already been directed to the relations which often exist between the air-bladder and the auditory organ (see p. 207).

2. THE LUNGS.

The further development of the primitive lung-sacs is essentially similar to that of a branched gland. They gradually increase in size, and the part which connects them with the œsophagus becomes drawn out into a tube, the windpipe or trachea; this bifurcates to form two bronchi, one of which goes to either lung

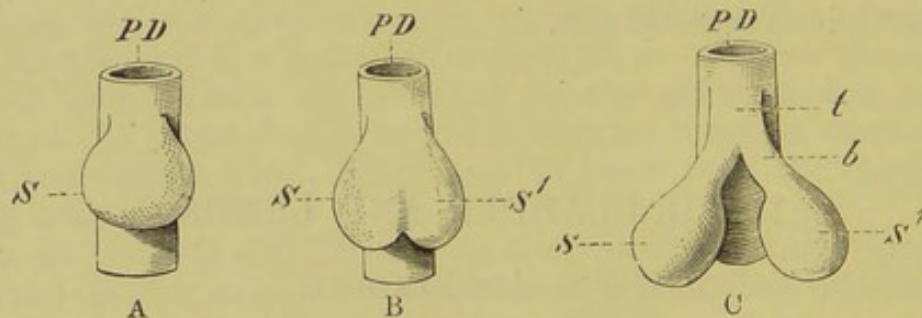


FIG. 204.—A, B, C, DIAGRAMS SHOWING THE MODE OF DEVELOPMENT OF THE LUNGS.

PD, primitive alimentary tube; *S*, *S'*, the lung-sacs, which are at first unpaired; *t*, trachea; *b*, bronchus.

(Fig. 204, *S*, *S'*, *t*, *b*). In their further growth, the bronchi branch out into finer and finer tubes, and finally end in small vesicles or infundibula, which are made up of a number of alveoli, and are surrounded by blood capillaries, through the thin walls of which the interchange of respiratory gases takes place (comp. Fig. 205).

In the course of further development, annular cartilages become developed in this system of tubes: the most anterior of these, that

is, those lying round the glottis or entrance to the trachea (which are phylogenetically the oldest cartilages of the whole apparatus), become differentiated to form a special apparatus, the **larynx**; this is regulated by muscles, and has to do with the production of the voice.

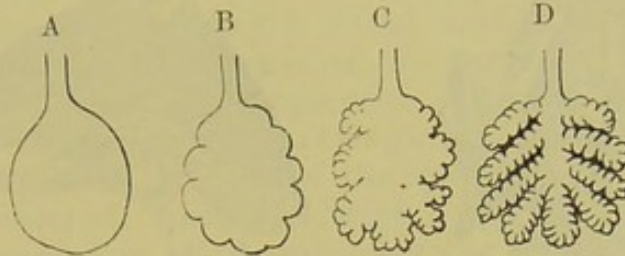


FIG. 205.—DIAGRAM ILLUSTRATING THE PHYLOGENETIC DEVELOPMENT OF THE LUNGS; A GRADUAL INCREASE OF THE RESPIRATORY SURFACE IS SEEN IN PASSING FROM A TO D.

The trachea, bronchi, and larynx thus constitute a kind of hollow skeleton for the whole respiratory apparatus, and, as they are formed secondarily, we should naturally expect them to be most developed in the higher types.

Air-Passages.

Amphibia.—The first traces of cartilaginous supports to the glottis are seen in Urodeles, there being no skeletal elements in this region in Dipnoans (Protopterus). At the same time, dilator and constrictor muscles appear round the glottis.

In Dipnoi, Salamandridæ, and Anura, there is no proper trachea, but only a short laryngo-tracheal chamber leading from the larynx to the lungs; in the two last-mentioned groups this is supported by cartilages. A definite trachea is, however, present in Siren, Amphiuma, and the Gymnophiona; it reaches a length of 4 to 5 or more centimetres, and its wall is strengthened by a series of small irregular cartilages, which usually tend to unite into bands: only in the Gymnophiona, however, do these bands begin to take on the form of half-rings, and to surround the trachea more or less completely.

In Anura a considerable advance is noticeable, as a highly differentiated larynx is present in them. This is regulated by a well-developed series of muscles, and is provided with vocal cords, the sound produced by which is often intensified by the presence of vocal sacs developed from the floor of the mouth. The laryngo-tracheal chamber of *Rana esculenta* lies between the posterior cornua of the hyoid (thyro-hyals), and is supported by a thin cartilage on either side of the glottis (Fig. 206, *Ca*), as well as by a ring-shaped cartilage, from which delicate processes pass backwards to the roots of the lungs (Fig. 206, *Cl*¹—*Cl*⁴). The former correspond

to the arytenoids, and the latter to the cricoid cartilage of higher Vertebrates. These are all firmly united to one another by

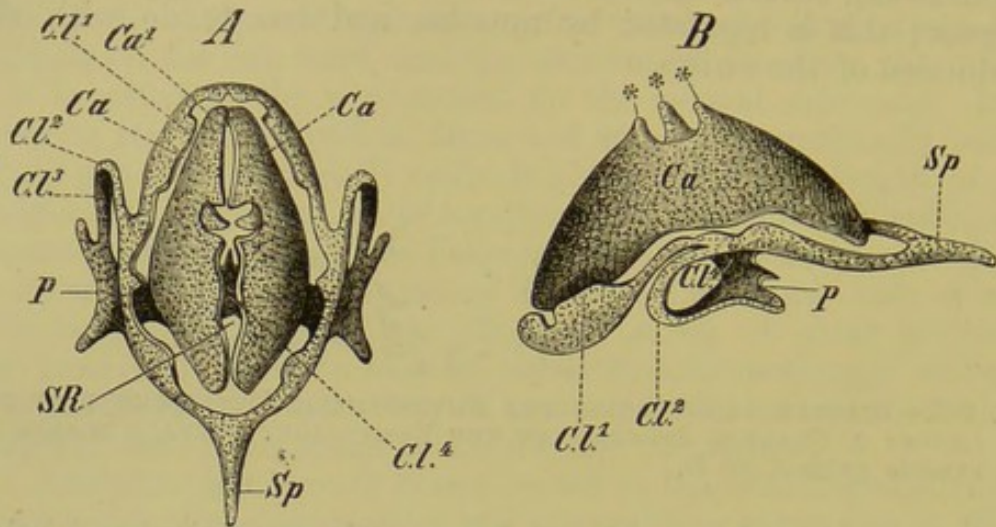


FIG. 206.—CARTILAGINOUS SKELETON OF THE LARYNGO-TRACHEAL CHAMBER OF *Rana esculenta*. (A, from above; B, from the side.)

Ca, Ca, arytenoid cartilage; Cl.1 to Cl.4, cricoid cartilage; Sp, process of the latter; P, plate-like broadening out of the ventral part of the cricoid; SR, glottis; ***, three tooth-like prominences of the arytenoids.

connective-tissue, the vocal cords being situated on the inner surfaces of the arytenoids.

Reptiles.—The larynx of Reptiles is supported by cartilaginous elements comparable to those of Anura, there being two sets of

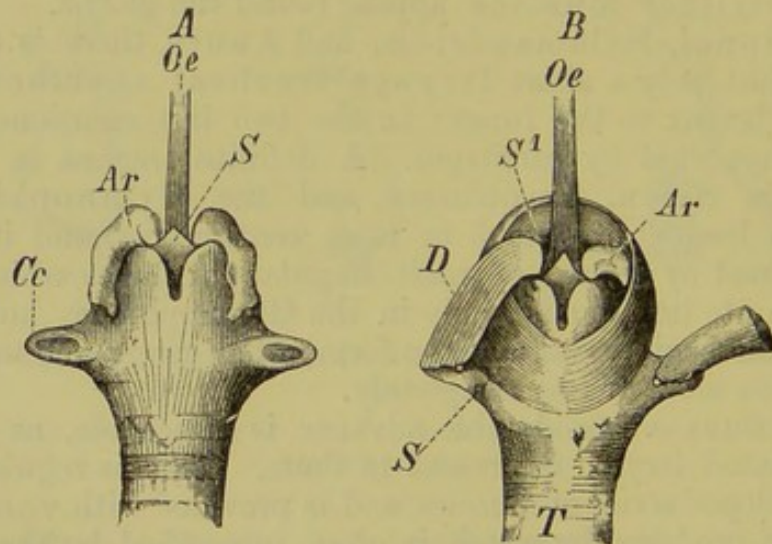


FIG. 207.—LARYNX OF *Phyllodactylus europæus*. (A, skeleton, and B, musculature of larynx.)

Ar, arytenoids; Cc, cricoid; S, anterior median process of cricoid; S1, sphincter; D, dilator; T, trachea; Oe, basi-hyal.

cartilages, a paired arytenoid, and a ring-shaped cricoid (Fig. 207, Ar, Cc).

No considerable advance in structure is, however, seen; there is even a reduction noticeable as regards the musculature, for as a rule, only a single dilator and constrictor are present (Fig. 207, *D, S*¹), instead of several, as in the Frog.

One point, however, must be specially noticed, viz., the close connection which obtains between the larynx and the hyoidean apparatus—more particularly the dorsal surface of the basi-hyal. In Crocodiles and Chelonians, for instance, the larynx is firmly embedded in a shallow depression of the latter, and it seems probable that the thyroid cartilage of Mammals has been derived from a part of the body of the hyoid.

A well-developed trachea, always supported by enclosing cartilages, is present in all Reptiles, but the cartilages are not in all cases fused together to form complete rings. The walls of the bronchi are also usually provided with cartilaginous supports.

Birds.—In Birds there are two larynges, an upper and a lower. The former lies in the usual position behind the tongue on the floor of the pharynx, and is plainly homologous with that of other Vertebrates, though it is incapable of producing sound. This is owing to the fact that both its skeleton and muscles are obviously undergoing a retrogressive metamorphosis.

The lower larynx, or syrinx, is of much greater interest; it is usually situated at the junction of the trachea and bronchi, or more seldom at the lower end of the trachea alone or on the bronchi alone. It functions as the organ of voice, and appears first in, and is restricted to, Birds, no traces of a syrinx, which might be expected, being found in Reptiles. In the most usual form, or broncho-tracheal syrinx, there is a moveable connection between the most anterior bronchial rings, with which a complicated system of muscles is connected; these, by their contraction, cause a stretching or relaxing of certain vibratory membranes (*membrana tympaniformis interna and externa*). The lower specially modified end of the trachea also plays an important part as a "tympanum," which attains a relatively enormous development in some Water-Birds (*e.g.*, the male Duck), where it gives rise to a bony vesicle which serves as a resonance cavity.

The length of the trachea in Birds varies greatly, and its complete cartilaginous rings show a great tendency to become ossified. In some cases (*e.g.* the Swan and Crane) it extends into the hollow keel of the sternum, where it becomes more or less coiled, and then again passes out close to its point of entrance, and enters the body-cavity. In certain representatives of the family of *Sturnidæ* it extends between the skin and the muscles of the thorax, and there gives rise to numerous spiral coils.

Mammals.—The larynx of Mammals is distinguished from that of all other Vertebrates by the following characters: there is always a very marked differentiation of the muscles, the constrictors always exceeding the dilators in number; and an epiglottis and a thyroid cartilage are constantly present.

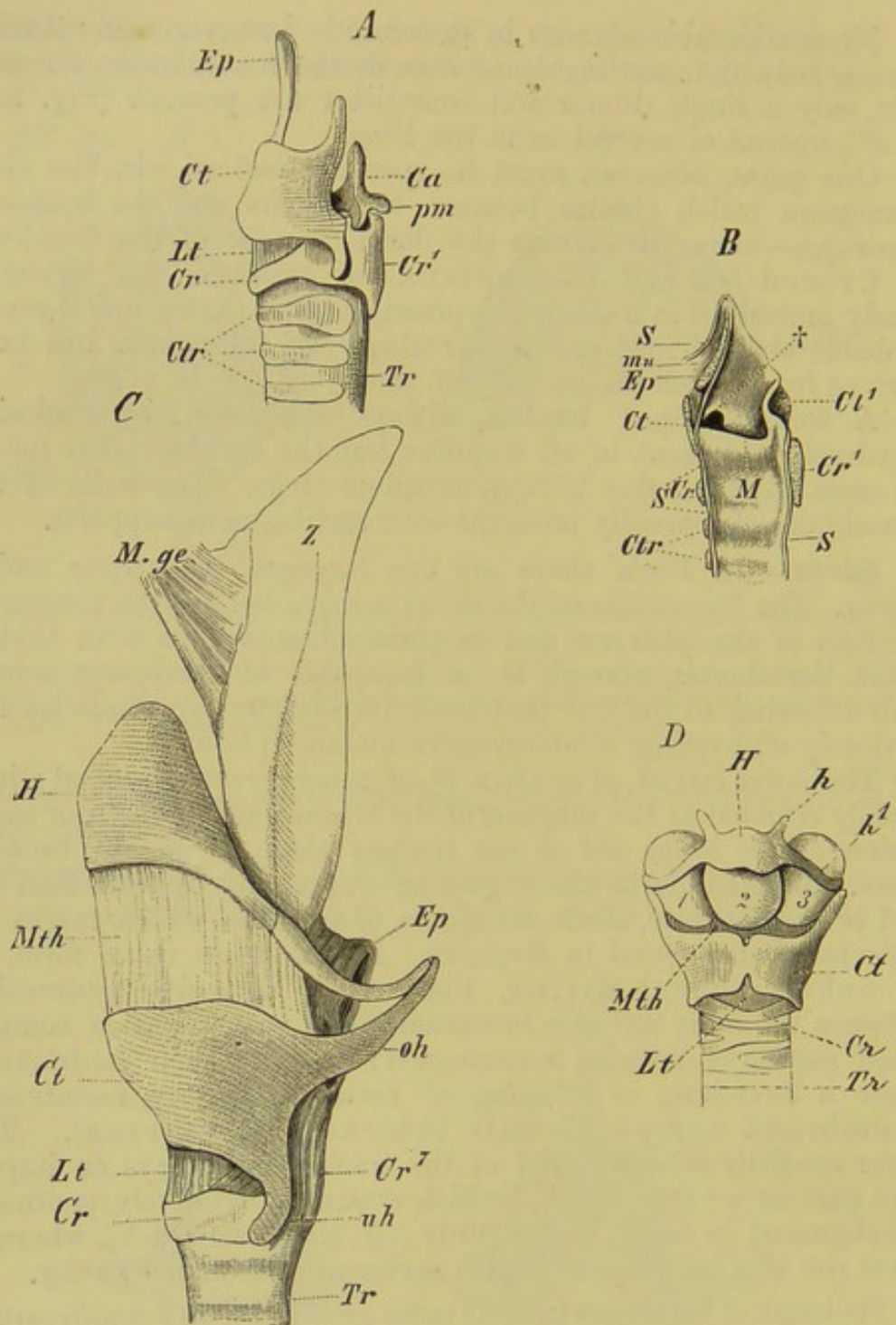


FIG. 208.—LARYNGES OF VARIOUS MAMMALS.

- A, larynx of Deer, seen from the left side; B, longitudinal section through the larynx of the Fox; C, larynx of the Howling Monkey (*Mycetes ursinus*), from the left side; D, larynx of Chimpanzee (*Simia troglodytes*), from the ventral side.
- Tr, trachea; Ctr, cartilaginous rings of the trachea; S, mucous membrane of the trachea and tongue; Cr, ventral, and Cr¹, dorsal plate of the cricoid; Ct, Ct¹, thyro-cornua; oh, uh, anterior and posterior cornua of the latter; Ca, arytenoid cartilage; pm, processus muscularis of the latter; Ep, epiglottis; H, body of hyoid; h, lesser, h¹, greater cornua of the hyoid; Lt, crico-thyroid ligament; Mth, thyro-hyoid ligament; M, laryngeal pouch, which shows an enlargement at †; 1, 2, 3, the three resonance-cavities of *Simia troglodytes*; mu, submucous tissue with muscles; M.ge, genioglossus muscle; Z, tongue.

The epiglottis serves as a protection to the aperture of the glottis, and its form varies much; occasionally it may undergo degeneration. The thyroid cartilage, which, as already mentioned (see p. 255), is probably to be derived from the visceral skeleton, is originally paired (Monotremes). In higher types, it forms a cartilaginous capsule which encloses the cricoid and arytenoids¹ on the ventral side. The thyroid serves as a point of origin and insertion for important muscles which stretch the vocal cords.

The vocal cords extend between the thyroid and the arytenoids, and the mucous membrane above them becomes involuted to form the laryngeal pouches. In Anthropoids, and certain other Monkeys, these may reach such a large size that they serve as resonance cavities, and come to lie partially within the body of the hyoid, which is swollen to form a large bony chamber (Fig. 208, D, 1, 2, 3).²

The folds of mucous membrane bounding the pouches of the larynx anteriorly are spoken of as false vocal cords; these are not present in all Mammals.

An interesting adaptation for the method of lactation is seen in the larynx of Marsupial embryos, in which it becomes elongated so as to extend upwards into the internal nostrils, where it is firmly embraced by the soft palate. Thus respiration can go on freely while the milk passes down the œsophagus on either side of the larynx. In Cetacea (*e.g.* Phocœna) a similar arrangement is observable, and is here adapted for the aquatic life of the animal. In many other Mammals the epiglottis is embraced by the soft palate, so that feeding and respiration can go on without interfering with one another.

The Lungs in a more Restricted Sense.

Dipnoi.—In *Ceratodus*, the lungs form a wide unpaired sac, without any trace of a dividing septum, while in other Dipnoi they are distinctly paired posteriorly, though single anteriorly.

They extend through the whole length of the body-cavity, and are covered by the peritoneum only on the ventral surface: the mucous membrane lining them forms bands and networks similar to those seen in the air-bladders of many Fishes (*e.g.* *Lepidosteus*).³

Amphibia.—The lungs of *Menobranchus* and *Proteus* remain at a lower stage of development than those of the Dipnoi,

¹ The cricoid may be complete or incomplete ventrally, and its dorsal portion usually becomes raised to form a broad plate which articulates with the arytenoids (Fig. 208, *Cr*, *Cr*¹, *Ca*). Each of the latter often gives rise to an outgrowth anteriorly, which, becoming separated from it, forms a cartilage of Santorini. A further independent cartilage (cartilage of Wrisberg) is sometimes present in the aryepiglottidean fold.

² In the Gorilla the resonance vesicle extends above the sterno-cleido-mastoideus, and reaches backwards as far as the shoulder and pectoralis major.

³ It is worthy of remark that *Lepidosteus*, like many other Fishes, comes to the surface and appears to swallow air, but it cannot be stated whether its air-bladder has any important respiratory function until the relations of the blood-vessels are known.

inasmuch as their internal surface is perfectly smooth, and has, therefore, a much smaller superficial extent. They consist of two delicate elongated sacs, of unequal length, and constricted in their middle; in *Proteus* they extend much further backwards than in *Menobranchus*. A difference in length between the two lungs is seen also in other Amphibia, such as *Amphiuma* and *Siren lacertina*, in which the two cylindrical lungs lie near together, close to the aorta. Their internal surface is raised into a network, corresponding with the distribution of the blood-vessels, the meshes of which are much finer in *Amphiuma*, and still more so in *Menopoma*, than in *Siren*.

In Salamanders the lungs as a rule are equal in size, and have the form of cylindrical tubes extending backwards as far as the end of the stomach; their internal surface is more or less smooth. The lungs of *Gymnophiona* are similar to those of Salamanders, but the right alone is fully developed, and this shows in its interior a complicated trabecular network: the left is only a few millimetres long. A similar abortion of one lung is also seen in Snakes, and in both cases has to do with the elongated form of the body (cp. the note below). The wide, elliptical lungs of *Anura* are quite symmetrical. Their internal surface, which is partly lined by ciliated epithelium, is raised up into a rich respiratory network of trabeculæ, and numerous smooth muscular fibres are present in their walls.

Reptiles.—In Reptiles, as in all other air-breathing Vertebrates, the form of the lungs is to a great extent regulated by that of the body. In the higher types, such as the *Chelonia* and *Crocodylia*, their structure is much more complicated than in Amphibia; this complication finds expression in a very considerable enlargement of the respiratory surface. With the exception of the thin-walled lungs of Lizards, which retain a very primitive condition, we no longer meet with a large central cavity, but the organ becomes penetrated by a branched system of bronchi, giving it the character of a tubular and sponge-like mesh-work.¹ Thus the phylogenetic stages of development are here again repeated ontogenetically.

The lungs of the Chameleon present a very curious modification. The anterior portion is much more compact and spongy than the posterior, which grows out into numerous sac-like processes, some of which reach as far back as the pelvic region; their form is very variable, being spindle-shaped, club-shaped, or lobulated, and their walls are very thin; they extend in amongst the viscera wherever there is room. If these processes have any respiratory function, it is at most only a very slight one. An indication of a similar arrangement

¹ The lung of Snakes exhibits an intermediate form, for, in spite of the finely-meshed tissue arising from the periphery, it still retains a narrow central cavity. As already mentioned, only the right lung is as a rule fully developed in Snakes and *Amphisbænians*, owing to the elongated form of the body, while the left remains in a rudimentary condition, or even disappears entirely.

is seen in the lungs of *Testudo*, in which a single thin-walled process extends backwards to the pelvic region. These processes seem to foreshadow a condition which reaches its highest development in Birds.

A uniform ground-plan is to be observed in the arrangement of the intra-pulmonary bronchial system through the whole series of the Amniota, from Crocodiles onwards. A continuation of the bronchus, which is almost straight, always passes through the lung to its posterior end. This may be called the main bronchus; from it a series of lateral bronchi arise. The important and typical relations of the latter to the main trunk of the pulmonary artery and vein in Mammals, will be described later (p. 263): it is not yet known whether a similar arrangement obtains in Chelonians, Crocodiles, and Birds.

Birds.—The respiratory apparatus of Birds presents so many remarkable peculiarities, both in the structure of the lungs and the presence of **air-sacs**, that it must be considered in some detail.¹

LUNGS AND AIR-SACS OF BIRDS.

When the ventral body-walls of a Bird are removed, the heart, stomach, liver, and intestines, are seen pressed towards the mid-line, and on either side of them a tightly-stretched fascia, the oblique septum, is observable, which shuts them off from a paired lateral sub-pulmonary chamber (Fig. 209, *D.th.a*). Other chambers are situated in the anterior thoracic region, ventral to the lungs, which latter lie close against the vertebral column and the heads of the ribs, by which they are impressed: others, again, are seen in the region of the heart and in the posterior part of the abdominal cavity.

These chambers are occupied by the **air-sacs**, the development and physiological function of which will be described later on.

The most posterior chamber on either side encloses an abdominal (posterior) air-sac (Fig. 209, *r.Abd.S.*, *l.Abd.S*). In *Apteryx*, this is completely closed in by the oblique septum, but in other Birds it gives rise to a large diverticulum which extends between the corresponding kidney and the body-walls, and even into the latter, as well as between the pelvic muscles. Its volume is naturally dependent upon the state of distension of the viscera at the time.

In front of this there are two air-sacs lying above and externally to the oblique septum, and constituting the main part of the sub-pulmonary chamber; these may be called the anterior and posterior intermediate sacs (Fig. 209, †, ††). A transverse dividing-wall (*s*¹) lies between these two, at the level of the cœliac artery, and a second septum (*s*) shuts off the anterior intermediate sac from the one lying in front of it, to be described presently. The posterior intermediate air-sac presents the simplest and most constant relations, and never communicates with any of the neighbouring chambers, as is often the case with the anterior intermediate.

A pair of prebronchial air sacs lies on either side of the œsophagus above the bronchus, anterior to the hilum of the lung (Fig. 209, *C*, *C*), and below this a sub-bronchial sac is situated, which is separated behind from the anterior intermediate sac by a septum (Fig. 209, *s*). This is usually

¹ For Figs. 209 and 210, as well as for many of the details in the above description, we are indebted to Professor H. Strasser of Freiburg in Baden, who has kindly allowed us to make use of the manuscript of a paper which is not yet published. The terms used are those of Professor Huxley.

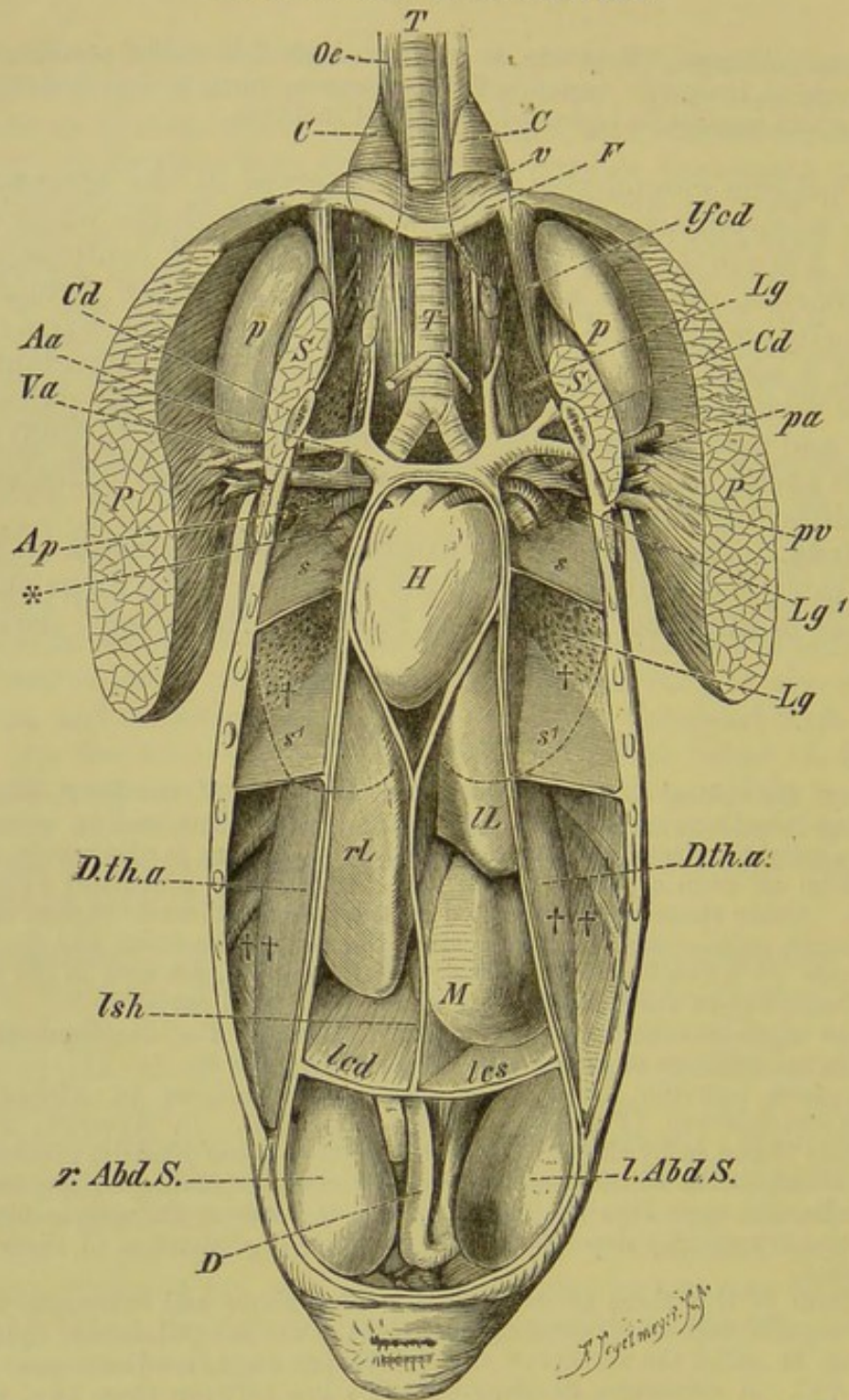


FIG. 209.—ABDOMINAL VISCERA AND AIR-SACS OF A DUCK AFTER THE REMOVAL OF THE VENTRAL BODY-WALL. (From an original drawing by H. Strasser.)

T, trachea; *H*, heart, enclosed within the pericardium; *rL*, *lL*, right and left lobes of liver; *lsh*, suspensory (falciform) ligament, and *led*, *les*, right and left coronary ligament of the liver; *D*, intestine; *P*, pectoralis major; *pa*, *pv*, pectoral artery and vein; *S*, subclavius muscle; *Cd*, coracoid; *F*, furcula; *lfcd*, coraco-furcular ligament; *Lg*, *Lg'*, lung; *r.Abd.S.*, *l.Abd.S.*, right and left abdominal (posterior) air-sac; *D.th.a.*, the fibrous oblique septum; ††, posterior intermediate air-sac; †, anterior intermediate air-sac; *s'*, *s'*, partition-walls between these sacs; *s*, *s*, partition-walls between the anterior intermediate air-sacs and the unpaired sub-bronchial sac, lying in the anterior part of the body-cavity; *v*, portion of anterior wall of latter; *p*, axillary sac lying between the coracoid, scapula, and the anterior ribs, and communicating with the sub-bronchial air-sac; *C*, *C*, prebronchial sacs; *, point of entrance of the bronchi into the lung; *Ap*, pulmonary artery; *Aa* and *Va*, innominate artery and vein with their branches.

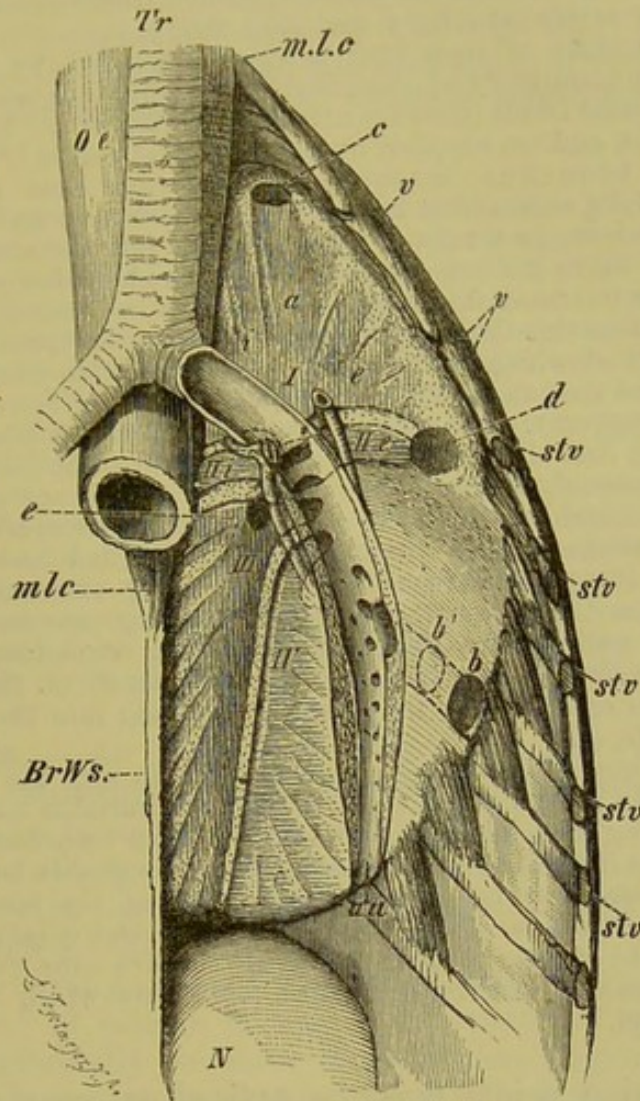


FIG. 210.—LEFT LUNG OF THE DUCK, *in situ*. (From an original drawing by H. Strasser.)

The main bronchus is cut open; internally to it lies the pulmonary vein, and externally the pulmonary artery.

Oe, cesophagus; *m.l.c.*, musc. longus colli; *BrWs*, thoracic vertebræ; *v, v*, ends of free vertebral ribs; *stv, stv*, sections of ribs which are connected with the sternum; *N*, kidney; *Tr*, trachea; *I*, first entobronchium, and *c*, its aperture of communication (ostium) with the prebronchial air-sac; *i, a, e*, its internal, anterior, and external branches; *IIIi, IIIe*, internal and external branch of the second entobronchium: the end of *IIIe* opens into the sub-bronchial sac at *d*; *III*, third entobronchium, with the aperture *e* for the anterior intermediate air-sac; *IV*, fourth entobronchium; *au*, opening of the main bronchus into the abdominal sac; *b*, opening of the outer lateral branch of the mesobronchium into the posterior intermediate sac; *b'*, second ostium of the latter, more towards the middle line (present in Passeres). The boundary of the pulmonary aponeurosis is seen along the outer edge of the lung, and the costo-pulmonary muscles are shown extending to it from the ribs.

unpaired, the sac of either side fusing with its fellow to form an interclavicular chamber, bounded by the furcula; ¹ it communicates with neighbouring

¹ In some Birds (*e.g.* Rhea, Vulture, Adjutant) a median septum is present separating the two sub-bronchial sacs.

air-cavities which lie between the pericardium and sternum, and in the axilla, outside the body-cavity (axillary sac) (Fig. 209, *p, p*).

The lower surface of each lung is closely invested by a thin fibrous membrane, the pulmonary aponeurosis,¹ into which are inserted a variable number of muscular bands (costo-pulmonary muscles). These arise from the vertebral ribs, and are supplied by the intercostal nerves (Fig. 210).

The main bronchus (mesobronchium) runs close to the ventral surface of the lung surrounded by the lung-parenchyma, and extends to its posterior end, where, as a rule, it opens directly into the abdominal air-sac (Fig. 210, *au*). From it a large lateral bronchus branches off, which opens into the posterior intermediate sac by one or two (*e.g.* in Passeres) apertures (Fig. 210, *b, b'*). Besides this there are from four to six other lateral bronchi (Fig. 210, *I to IV*), all of which become broadened out in a fan-like manner on the ventral surface of the lung. These may be called entobronchia (bronchi divergentes, Sappey): they all arise from the anterior portion of the mesobronchium. The first of these radiates out anteriorly to the hilum of the lung, and gives off internal, external, and anterior branches, one of which opens into the prebronchial sac (Fig. 210, *c*). The other entobronchia give rise to two series of branches, one of which extends inwards and backwards between the factors of the pulmonary vein, and the other outwards between the arterial branches. Almost without exception a large aperture or ostium is present on the wall on the third entobronchium, communicating with the anterior intermediate air-sac (Fig. 210, *e*). A branch of the second entobronchium opens externally to the hilum of the lung into the sub-bronchial sac (Fig. 210, *Ile, d*).

The lateral bronchi considered as yet have to do with the ventral surface of the lung only; but besides these there are a variable number of ectobronchia, arising from the dorsal side of the main bronchus posteriorly to the entobronchia (see Fig. 210). These come off in a double longitudinal row, those of the outer row being larger than those of the inner. They pass dorsally to the costal face of the lung. Both ecto- and entobronchia give off numerous bronchi of a third order, or parabronchia: the walls of these are raised into numerous transverse net-like folds, into which the pulmonary capillaries extend.

The following points must be noticed as regards the genesis and function of the air-sacs.

Early in the embryonic period, delicate-walled hollow processes, lined by pavement epithelium, arise from the pulmonary vesicles: these grow rapidly, and soon exceed the lung proper in size, so that they extend amongst the viscera. Their form and extent depend entirely upon their surroundings, and they simply consist of interstitial cavities lined by the membrane of the air-sacs. Moreover, they are not confined to the body-cavity, but in numerous places extend beyond it, passing in between the muscles, beneath the skin, and even into most of the bones. The latter are thus rendered pneumatic,² and consequently the specific gravity of the body is lessened, and the power of flight increased. The pneumaticity of the bones is not, however, an *essential* peculiarity connected with flight, for in many Birds which are extremely

¹ The pulmonary aponeurosis, as well as the oblique septum, is often spoken of as a "diaphragm" (comp. p. 122).

² This cannot of course take place until the marrow of the bones has performed the greater part of its bone-forming function.

good fliers (*e.g.* *Larus*, *Sterna*) the bones are not pneumatic.¹ In these cases, however, a compensation is effected by a more marked development of the muscles, and the abdominal (posterior) air-sac, which in no Birds appears to be entirely wanting, is here well developed.

The air-sacs must be looked upon as integral parts of the respiratory apparatus: a greater amount of air can, by their means, pass in and out during inspiration and expiration, especially through the larger bronchi, and consequently there is less necessity for the expansion of the lung-parenchyma. The function of the prolongations of the air-sacs lying towards the outer surface of the body consists in the giving off of watery vapour and in regulating the heat of the body. Those which extend in between the muscles, and supplant the connective and fatty tissue in these regions, have a further importance in causing less power to be lost in friction.

But by far the greatest importance of the air-sacs lying towards the periphery consists in the enlargement of the anterior thoracic region, principally that surrounded by the pectoral arch. A larger development of the skeleton can thus take place, giving an increase of surface for muscular attachment without any considerable increase in weight. Everything, in fact, combines to establish an organ of flight with a large wing-surface and an increased strength of the muscles.

Mammals.—As already mentioned, main and lateral bronchi can be distinguished in Mammals. The pulmonary artery crosses the main bronchus at its anterior end, and this point may be taken as dividing the lateral bronchi into two systems—an eparterial lying anterior (above) and a hyparterial lying posterior to (below) the artery.

The hyparterial series is always well developed, and consists of a double row² of lateral bronchi; the eparterial system, on the other hand, gradually becomes of much less importance, and in certain cases is represented only by a single lateral bronchus on either side (Fig. 211, *c*, *b*, *a*), and, as a rule, even the left of these disappears, only the right remaining. This eparterial bronchus, whether developed on one or on both sides, may change its position on the main bronchus so as to arise from the trachea.³

In by far the greater number of Mammals then, the left eparterial bronchus has disappeared, while the right is retained; this

¹ The pneumaticity of the bones is not a special peculiarity of Birds: amongst Mammals, frontal, maxillary, and sphenoidal sinuses are present in Anthropoids, Elephants, and Marsupials for instance; the skull of Crocodiles is also strongly pneumatic. All these sinuses communicate with one another, and also with the tympanic cavity. They are in many cases developed in order to give a greater surface for the attachment of muscles, and also to effect a saving of material and a lightening of the skull.

² The pulmonary artery passes backwards between the roots of the hyparterial bronchi, while the corresponding vein runs along the ventral side of the main bronchus (Fig. 211, *A*, *V*).

³ The left eparterial bronchus may also disappear (*Hystrix*), and thus the terminal stage of a process begun in Birds is reached. It is difficult to find an explanation for these facts; they may possibly have something to do with the gradual disappearance of the cervical and lumbar ribs, in connection with the shortening of the thorax (comp. p. 51).

is the case, for instance, in Man. It leads to the following conclusions.

As the anterior lobe of the right lung belongs to the eparterial and that of the left lung to the first hyperarterial bronchus, these lobes

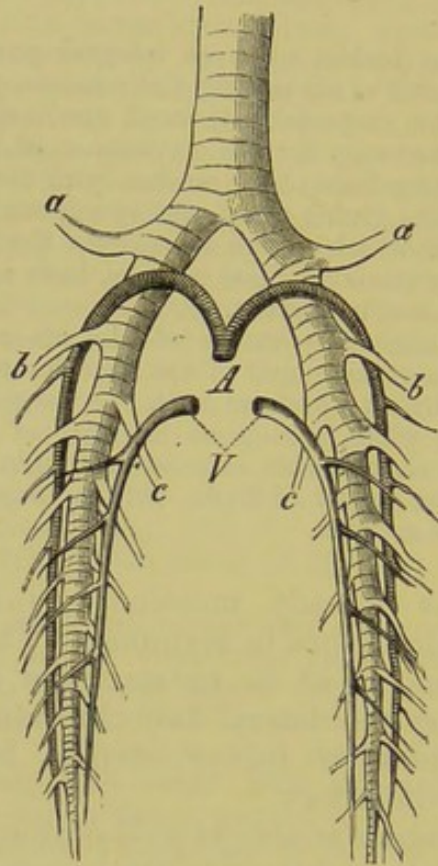


FIG. 211.—DIAGRAM OF THE ARRANGEMENT OF THE BRONCHI IN MAMMALS.
(From the ventral side.)

a, a, eparterial bronchus of either side; *b*, series of ventral, and *c*, of dorsal hyperarterial bronchi; *A* and *V*, pulmonary artery and vein.

are evidently not homologous, the middle right lobe corresponding much more nearly to the anterior lobe of the left side. Thus there is a want of symmetry between the right and left sides, the right lung retaining one element more than the left.

The formation of **lobes**, which always begins at the anterior end of the lung, is of less fundamental importance as regards the structure of the lung than is the arrangement of the bronchial system, as a single lateral bronchus is present to each lobe. Thus it follows that what has hitherto been known in human anatomy as the inferior (posterior) lobe does not correspond to a true lobe, but represents the main axis of the lung, enclosing the main bronchus.

In the description of the peritoneum (p. 208), attention has already been directed to the fact that the thoracic cavity is lined by a serous membrane, the pleura. As in the case of the peritoneum, a parietal and a visceral layer may be distinguished

(Fig. 212, *P*, *P*¹): the latter is spoken of as the pulmonary pleura, the former as the costal pleura. Towards the middle line, the pulmonary pleura of either side is reflected so as to form a septum between the right and left thoracic cavities. This septum

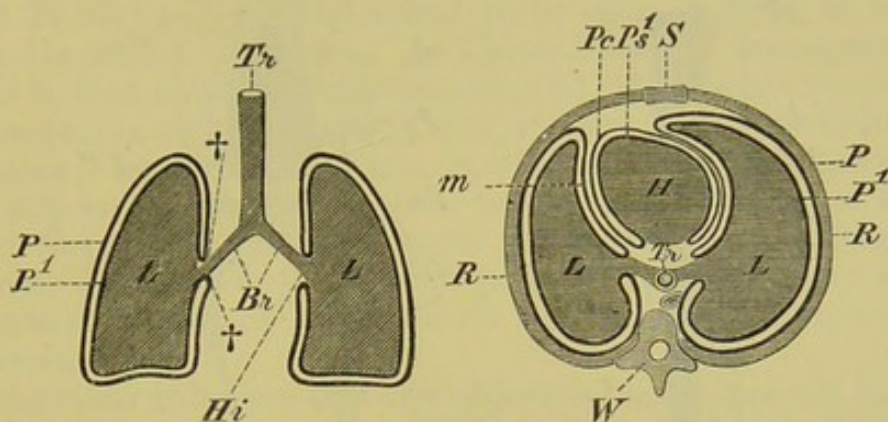


FIG. 212.—DIAGRAM OF THE PLEURAL AND PERICARDIAL CAVITIES OF MAMMALS, FOUNDED ON THE RELATIONS OF THESE PARTS IN MAN. (A, horizontal section; B, transverse section.)

Tr, trachea; *Br*, bronchi; *L*, *L*, lungs; *H*, heart; *W*, vertebral column; *P*, parietal, and *P*¹, visceral layer of the pleura; † †, points at which these pass into one another at the hilum pulmonalis (*Hi*); *m*, mediastinum; *Pc*, *Ps*¹, parietal and visceral layers of the pericardium; *R*, ribs (wall of thorax); *S*, sternum.

is called the mediastinum (Fig. 212, *m*), and the space between its two layers the mediastinal space: through this, the aorta, œsophagus, and postcaval vein run, and in the region of the heart, the mediastinum is reflected over the parietal layer of the pericardium (see p. 268, and Fig. 212, *Pc*).

There is a lymphatic fluid between the two layers of the pleura, which renders the movements of the lungs smooth and easy.

ABDOMINAL PORES.

By the term abdominal pores is understood a perforation—almost always paired—of the posterior end of the peritoneal cavity, which puts the cœlome into direct communication with the exterior.¹ These pores are present in Cyclostomi, Elasmobranchii, certain Teleostei, Dipnoi, Chelonia, and Crocodilia. The perforations always take place through the ectoderm, close to the apertures of the urinogenital organs and intestine; each is either situated on a papilla, or in the walls of the cloaca.

It can only be stated positively as regards the function of the abdominal pores, that in Cyclostomes and a few other Fishes they serve to conduct the generative products to the exterior. As in the rest of the Vertebrata special ducts are present for this purpose,

¹ Other connections of the cœlome with the exterior (nephrostomes of Anamnia and oviducts of all Vertebrata) will be mentioned later on (see pp. 297, 300, and 302).

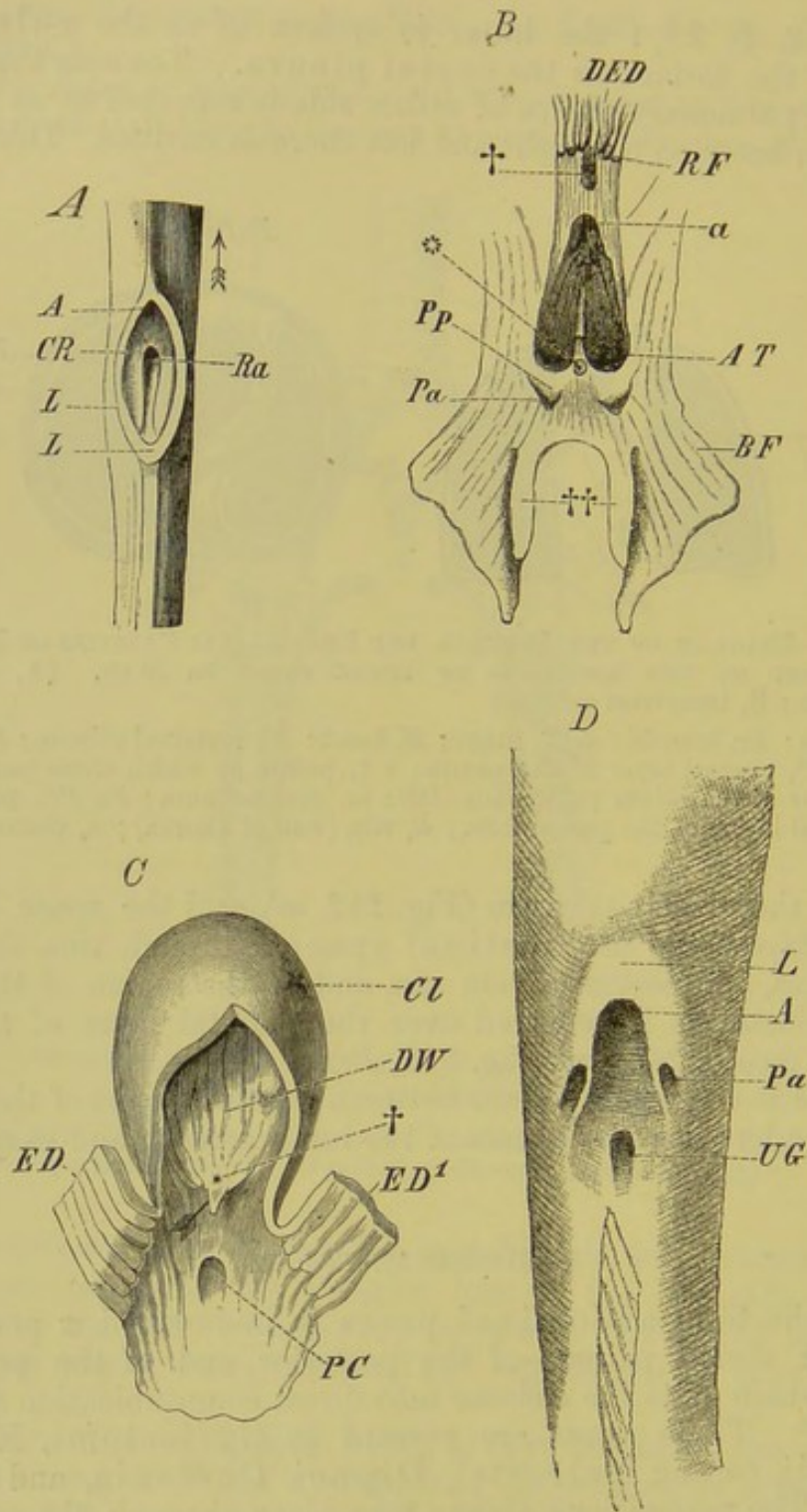


FIG. 213.—ABDOMINAL PORES OF VARIOUS VERTEBRATES. (A, Cyclostome ; B, Elasmobranch ; C, Protopterus ; D, Spatularia.)

A, anus ; *Pa*, *Ra*, *PC*, abdominal pores ; *Pp*, papilla ; *AT*, cloacal pockets ; *UG* and α , urinogenital apertures ; *L*, *L*, lip-like margin of cloacal aperture ; *CR*, cloaca ; *DED*, longitudinal folds of the rectum, which end sharply at *RF* ; †, point at which the rectal gland opens ; *BF*, pelvic fin ; ++, claspers. The arrow in *A* points towards the head, and all the figures are placed similarly to *A*. In Fig. *C*, *Cl* indicates the blind sac of the cloaca, the dorsal wall of which is visible at *DW* ; †, the unpaired aperture of the generative ducts ; *ED*, *ED'*, the rectum, cut open. The arrow indicates the aperture of the ureters.

the persistence of the abdominal pores is difficult to account for; they must have undergone a change of function. It is as difficult to say what this function is as to explain the fact that they have disappeared in the Amphibia, which are certainly a very ancient group, while they are again met with amongst Reptiles.

In Protopterus the abdominal pores open in front of, and in Ceratodus behind the cloaca. In Ceratodus their arrangement is similar to that seen in Elasmobranchs, and they are always paired: in Protopterus, on the contrary, they undergo numerous individual variations; as a rule only one is developed, and this lies on the same side as the vent—sometimes to the right, sometimes to the left of the middle line, and opens either within or without the sphincter of the cloaca. If both pores are present, they always open within the cloaca, on its dorsal wall, behind the aperture of the rectum.

Gegenbaur considers that the abdominal pores are not homologous throughout the series of the Vertebrata, and that they must be considered in relation with other structures—more particularly the generative organs. Rathke and Huxley have pointed out that in the series of the Salmonidæ a gradual disappearance of the oviducts is observable, their function being undertaken by abdominal pores. This would seem to indicate that the abdominal pores present in female Salmonidæ are not homologous with those of other Fishes (*e.g.* Cyclostomi, Elasmobranchii, Dipnoi).

BIBLIOGRAPHY.

- AEBY, CH.—*Der Bronchialbaum der Säugethiere und des Menschen.* Leipzig, 1880.
- AYERS, H.—*Untersuchungen über die Pori abdominales.* *Morphol. Jahrb.* Bd. IX. 1884.
- BRIDGE, T. W.—*Pori Abdominales of Vertebrata.* *Journ. of Anat. and Physiol.* Vol. XIV.
- FISCHER, J. G.—*Anatom. Abhandlungen über die Perennibranchiaten und Derotremen.* Hamburg, 1864.
- FÜRBRINGER, M.—*Beiträge zur Kenntniss der Kehlkopfmuskulatur.* Jena, 1875. (Contains also a copious bibliography of the larynx in general.)
- GEGENBAUR, C.—*Bemerk. üb. die Pori abdominales.* *Morphol. Jahrb.* Bd. X. 1885.
- HENLE, J.—*Vergl. anatom. Beschreibung des Kehlkopfes.* Leipzig, 1839.
- HUXLEY, T. H.—*On the Respiratory Organs of Apteryx.* *Proc. Zool. Soc.* 1882. *On the Oviducts of Osmerus, with remarks on the relations of the Teleostean to the Ganoid Fishes.* *Ibid.* 1883.
- KÖLLIKER, A.—*Zur Kenntniss des Baues der Lungen des Menschen.* *Verhandl. der med. Gesellsch. z. Würzburg.* N. F. Bd. XVI. (Compare also the text-books of Anatomy of Quain, Aeby, Henle, Krause, &c.)
- MÜLLER, J.—*On Certain Variations in the Vocal Organs of Passeres.* *König. Akad. d. Wiss. zu Berlin,* 1846, 1848. Eng. trans. (Bell), Oxford, 1878.
- PARKER, T. J.—*On some Embryos of Callorhynchus antarcticus.* *New Zealand Journ. of Science,* 1883, and *Nature,* Vol. XXIX. p. 46.
- RATHKE, H.—*Zur Anatomie der Fische.* *Arch. f. Anat. und Physiol.* 1838.
- SAGEMEHL, M.—*Beiträge zur vergl. Anat. der Fische.* *Morphol. Jahrb.* Bd. X. 1884. (This includes an account of the anatomy and physiology of the air-bladder.)
- STRASSER, H.—*Die Luftsäcke der Vögel.* *Morphol. Jahrb.* Bd. III. 1877.
- WIEDERSHEIM, R.—*Das Respirations-system der Chamæleoniden.* *Berichte der Naturforsch. Gesellschaft zu Freiburg i/B.* Bd. I. Heft III. 1886.

H. ORGANS OF CIRCULATION.

(VASCULAR SYSTEM.)

THE organs of circulation consist of a central organ, the **heart**, peripheral organs, the **vessels**, and nutritive fluids, composed of plasma and structural elements (cells),¹ the **blood** and **lymph**. The latter, which occurs partly within closed canals, partly in various spaces and cavities of the body, and which penetrates all the tissues, will be spoken of later, and the blood-vascular system in its more restricted sense will be treated of first. This consists of a series of completely closed tubes (vessels), which, according as they contain oxygenated or impure blood, are spoken of as **arteries** or **veins**. This, however, is not an absolute rule, for setting aside the chemical condition of the blood, all vessels which empty their contents into the heart are called veins, while those which arise from the heart are spoken of as arteries.

The heart, which is enclosed within the **pericardium**,² serves as the central organ of the circulation, and acts both as a suction-pump and a force-pump. It arises, like the entire vascular system, from the mesoblast, either as a single or as a paired tubular cavity; it originates in the splanchnic layer along the ventral

¹ The blood- and lymph-corpuscles are the last results of segmentation in the mesoblast. The first to be formed are white corpuscles, which are nucleated and amœboid (these are the only kind present in *Amphioxus*); the red appear secondarily; whether they originate from the white corpuscles or independently is not known, though the former mode of development seems the most probable. Both primitive red and primitive white corpuscles possess a nucleus, which in the case of the latter persists throughout life, though it is often only visible by means of reagents. In the case of the red corpuscles the nucleus persists, and the whole cell is biconvex in all Vertebrates below Mammals, and, even in these, nucleated red cells may be seen in the marrow of the bones, in the blood of the spleen, and often in that of the portal vein. In all other parts of the body of Mammals they lose their nuclei and become biconcave. In all Mammals, except the Camelidæ, the red corpuscles have the form of circular disks; in the last-mentioned group and in all other Vertebrates except Cyclostomes they are oval. *Siren* possesses the largest red corpuscles, then comes *Proteus*, and then *Salamandra*; the smallest are found in the *Tragulidæ*.

² The pericardium consists of a parietal and a visceral layer: the former is invested by the mediastinum (see p. 265), and the latter is closely applied to the heart.

region of the throat, close behind the gill-clefts.¹ Thus it is formed from the same blastema as the muscular coat of the alimentary canal, and its wall becomes differentiated into three layers, an outer serous (pericardial), a middle muscular, and an inner epithelial. In this it essentially corresponds in structure with the larger vessels, in the walls of which three layers can also be distinguished.² By a study of its development we thus see that the heart represents essentially a strongly developed blood-vessel, which at first lies more or less in the longitudinal axis of the body; later, however, it becomes much more complicated by the formation of various folds and swellings. In this manner the folded tubular heart becomes divided into two chambers, an **atrium** and a **ventricle**. Between these, valvular structures arise, which only allow the blood to flow in a definite direction on the contraction of the walls of the heart, viz. from the atrium to the ventricle; any backward flow is thus prevented.

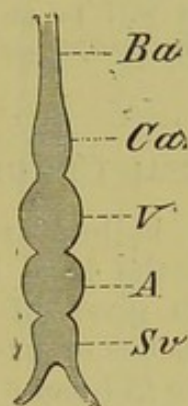


FIG. 214.—DIAGRAM SHOWING THE PRIMITIVE RELATIONS OF THE DIFFERENT CHAMBERS OF THE HEART.

Sv, sinus venosus, into which the veins from the body open; *A*, atrium; *V*, ventricle; *Ca*, conus arteriosus; *Ba*, bulbus arteriosus.

The valves are formed by a process of differentiation of the muscular trabeculæ of the walls of the heart, as will be explained later on. The atrium, into which the blood enters, represents primitively the venous portion of the heart, while the ventricle, from which the blood flows out, corresponds to the arterial portion. The venous end further becomes differentiated to form another chamber, the sinus venosus (Fig. 214, *Sv*), and the arterial end gives rise distally to a conus or truncus arteriosus; this is provided with more or less numerous valves, and is continued forwards into the arterial vessel, the enlarged base of which is spoken of as the bulbus arteriosus (*Ca*, *Ba*).

¹ The primitive aortæ arise independently of the heart: they are formed by peripheral (segmentally arranged?) vascular processes, which pass towards the middle line, and there turn forwards and backwards and become confluent, so as to form longitudinal trunks.

² The walls of the smallest blood-vessels, the capillaries, consist of a single cellular layer, which corresponds to the inner epithelial layer (intima) of the larger vessels.

This condition of things persists throughout life in many Fishes, and is at any rate passed through in the individual development of all Vertebrates.

With the appearance of pulmonary respiration, important changes take place in the primitively simple heart, which finally result in the formation of a septum in both atrium and ventricle, and thus lead to the presence of two atria or auricles, and two ventricles: the conus arteriosus and sinus venosus become eventually incorporated in the ventricles and right auricle respectively. Thus a **right (venous)** and a **left (arterial) half** can be distinguished, and a new vessel, the **pulmonary artery**, arises from the right ventricle; this conveys venous blood to the lungs, while special vessels (**pulmonary veins**) return the oxygenated blood from the lungs to the left side of the heart, from which it passes into the general circulation of the body.

The gradually increasing complications which occur in passing from the lower to the higher Vertebrates will be more easily understood after the condition of the circulation in the embryo has been considered.

THE FETAL CIRCULATION.

In an early stage, the bulbus arteriosus (Fig. 215, *B*) is continued forwards towards the head by a long unpaired vessel (branchial artery), which gives off right and left a series of symmetrical transverse branches or arches (*Ab*), each of which runs between two consecutive gill-clefts (*KL*). After the first pair has given off branches to the head (carotids), they all unite above the clefts to form a longitudinal trunk on either side (*S*, *S*¹). These **branchial veins** give rise further back to the right and left roots of the aorta (*RA*, *RA*).

In all Vertebrates the **aorta** (*A*) is throughout life the most important artery of the body; it extends backwards along the ventral side of the vertebral axis as a large unpaired trunk, which gives off numerous branches, and forms the caudal artery in the tail (*Acd*).

The **vitelline** or **omphalo-mesenteric arteries** (Fig. 215, *Am*, and Fig. 216, *R.Of.A*, *L.Of.A*), which are very important up to a certain stage in development, arise from the aorta, and carry blood to the surface of the yolk, whence it is returned by means of the **vitelline** or **omphalo-mesenteric veins** (Fig. 216, *R.Of*, *L.Of*). In embryos of Fishes these open into a subintestinal vein, lying on the ventral side of the alimentary tract, and opening into the heart: in the higher forms this vein is represented by the caudal vein and the ductus venosus (Figs. 217 and 218, *DV*); the latter passes through the liver on its way to the heart, but disappears on the formation of the portal circulation. Before passing into the sinus venosus the blood becomes mixed

with the venous blood of the ductus Cuvieri or precaval sinus (Figs. 215 to 218, *Si*, *S.V*, *DC*, *D*).

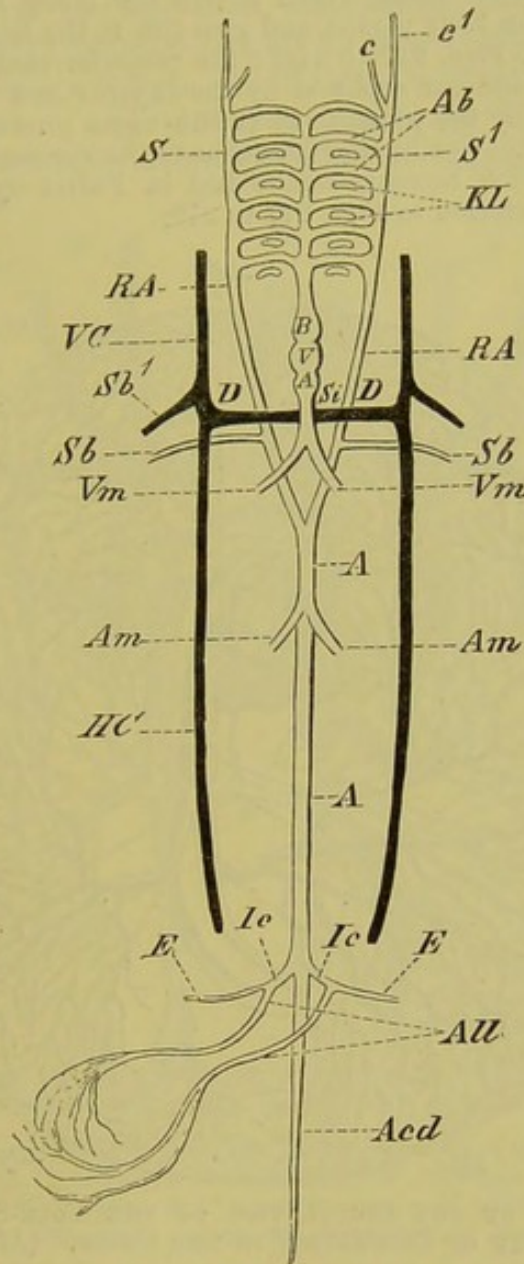


FIG. 215.—DIAGRAM OF THE EMBRYONIC VASCULAR SYSTEM.

A, A, dorsal aorta; *RA, RA*, right and left roots of the aorta, which arise from the branchial vessels, *Ab*, by means of the collecting trunks (branchial veins), *S, S'*; *c, c'*, the carotids; *Sb*, subclavian artery; *KL*, gill-clefts; *Si*, sinus venosus; *A*, atrium; *V*, ventricle; *B*, bulbus arteriosus; *Vm*, vitelline veins; *Am*, vitelline arteries; *Ic, Ic*, common iliac arteries; *E, E*, external iliac arteries; *All*, allantoic (hypogastric) arteries; *Acd*, caudal artery; *VC, HC*, anterior and posterior cardinal veins; *Sb1*, subclavian vein; *D*, Cuvierian duct (precaval veins), into which the anterior and posterior cardinals open.

The ductus Cuvieri, which runs transversely, is formed on either side by the fusion of the anterior and posterior **cardinal veins**—two large vessels which bring back the blood from the

head, mesonephros (see p. 296), and body-walls (Fig. 215, *VC*, *HC* and Fig. 216, *S.Ca.V*, *V.Ca*).

The anterior cardinal veins, which return the blood from the head and anterior portion of the body persist, and give rise to the large jugular veins of the adult (comp. Figs. 217 to 219); the posterior cardinals soon become largely obliterated, and are replaced by the azygos and vertebral veins, and more especially by the postcaval (vena cava posterior *s. inferior*) (see Figs. 217 to 219). For further details as to the venous circulation, *e.g.* the portal system (which becomes established in Fishes by the subintestinal vein), the reader is referred to Figs. 217 to 219.

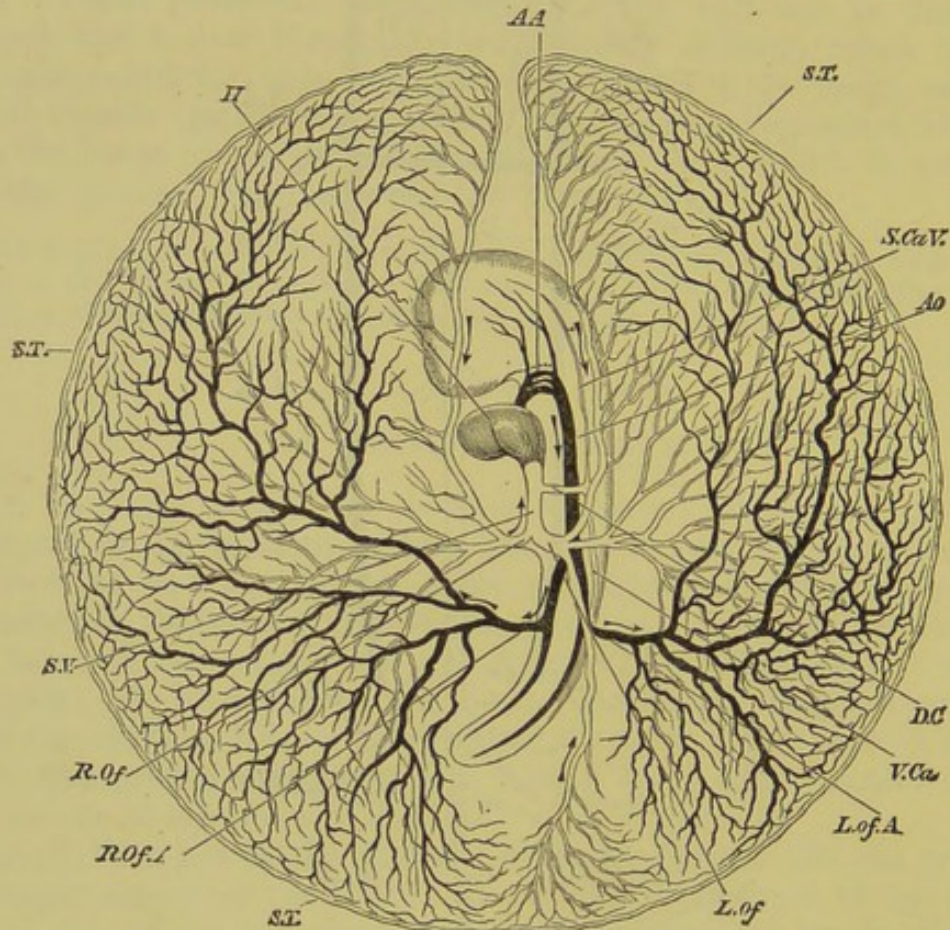


FIG. 216.—DIAGRAM OF THE CIRCULATION OF THE YOLK-SAC AT THE END OF THE THIRD DAY OF INCUBATION IN THE CHICK. (After Balfour.)

H, heart; *AA*, the second, third, and fourth aortic arches: the first has become obliterated in its median portion, but is continued at its proximal end as the external carotid, and at its distal end as the internal carotid; *Ao*, dorsal aorta; *L. Of. A*, left vitelline artery; *R. Of. A*, right vitelline artery; *S. T*, sinus terminalis; *L. Of*, left vitelline vein; *R. Of*, right vitelline vein; *S. V*, sinus venosus; *D. C*, ductus Cuvieri; *S. Ca. V*, anterior cardinal or jugular vein; *V. Ca*, posterior cardinal vein. The veins are marked in outline, and the arteries are made black. The whole blastoderm has been removed from the egg, and is supposed to be viewed from below. Hence the left is seen on the right, and *vice versa*.

To return once more to the arterial system:—We must consider next the two branches of the dorsal aorta known as the **allantoic arteries** (Fig. 215, *All*). As their name implies, these arteries branch out over the allantois, which arises as an outgrowth from

the posterior part of the primitive intestine in all Vertebrates but Fishes (comp. Fig. 9, p. 11). As the allantois grows further and further outwards, it comes, in the Sauropsida, to lie against the internal surface of the egg-shell, and thanks to the porous nature of the latter, which permits the air to pass through it, serves as an important respiratory organ. In Mammals it serves in the embryo both for respiration and nutrition (comp. pp. 10 and 274). The further development of the embryonic vessels may take place in one of three ways.

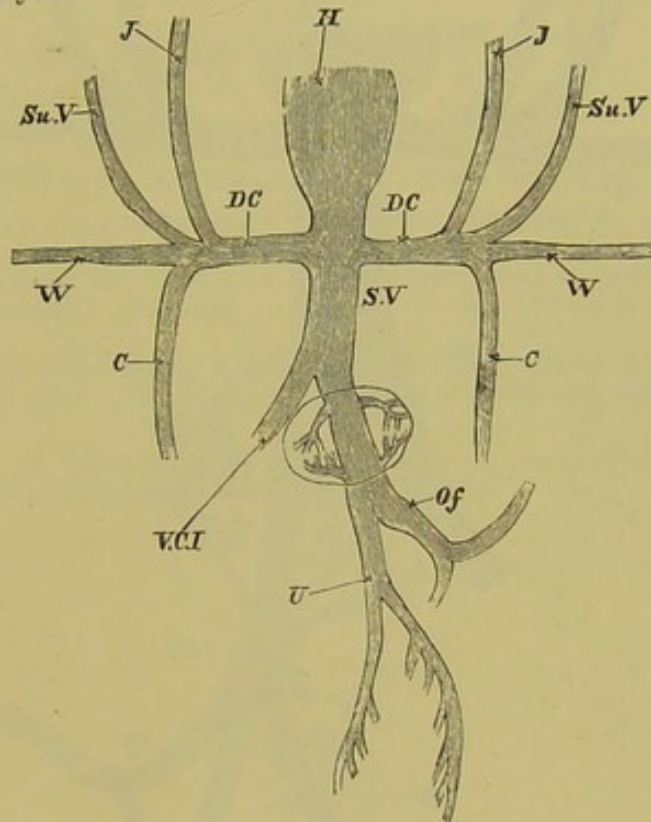


FIG. 217.—DIAGRAM OF THE VENOUS CIRCULATION IN THE CHICK AT THE COMMENCEMENT OF THE FIFTH DAY. (After Balfour.)

H, heart; *DC*, ductus Cuvieri: into the ductus Cuvieri of either side falls *J*, the jugular vein; *Su.V.*, the anterior vertebral; *W*, the vein from the wing, and *C*, the posterior cardinal vein; *S.V.*, sinus venosus; *Of*, vitelline vein; *U*, allantoic vein, which at this stage gives off branches to the body-walls; *V.C.I.*, postcaval.

The embryo may either leave the egg, and take on an aquatic existence (Anamnia), making use of its branchial vessels as a gill-breather; the entire allantois, in the case of the Amphibia, giving rise to the bladder. In the case of terrestrial animals (Amniota), which from the first breathe by means of lungs, a modification and reduction of the branchial vessels and allantois takes place, and the latter may even disappear entirely (certain Reptiles and all Birds) (comp. p. 308).¹ In the third case the

¹ Concerning the amnion, which encloses the embryos of Sauropsida and Mammalia, comp. p. 10 and Figs. 9 and 220.

embryo undergoes a longer intra-uterine existence, the allantois coming into close connection with the walls of the uterus by means of its villi: the allantoic vessels extend into the wall of the uterus and come into more or less close relations with the maternal vessels, thus serving for the respiration and nutrition of the foetus.

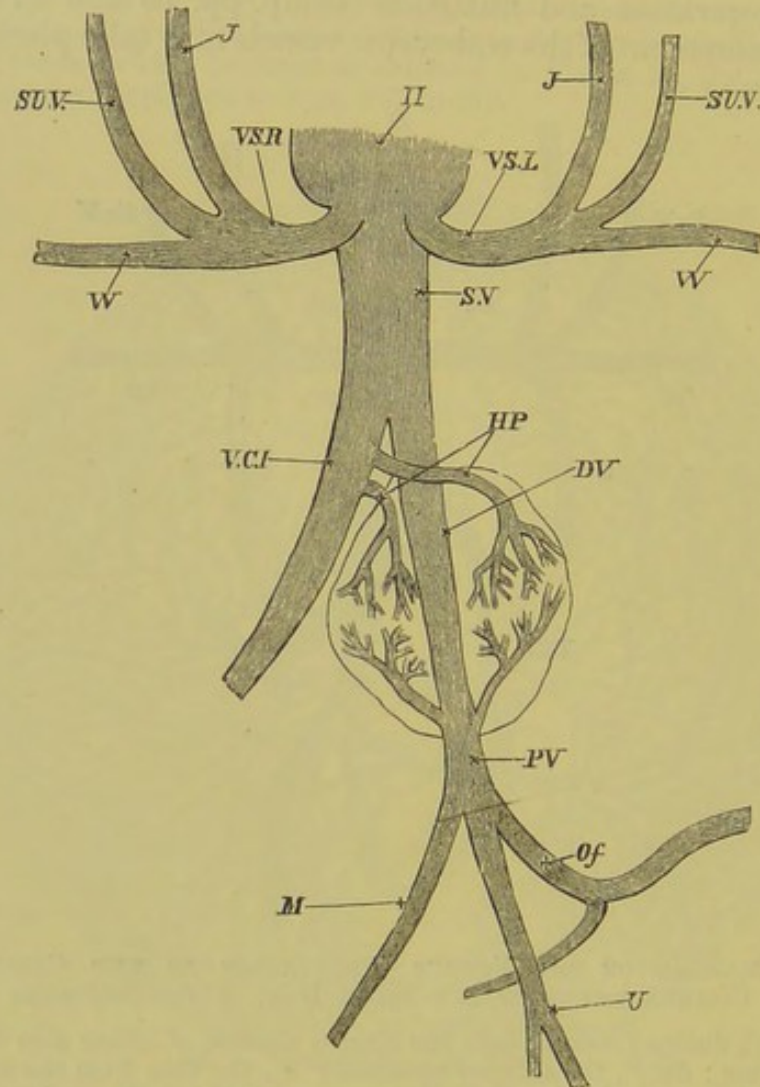


FIG. 218.—DIAGRAM OF THE VENOUS CIRCULATION IN THE CHICK DURING THE LATER DAYS OF INCUBATION. (After Balfour.)

H, heart; *V.S.R.*, right precaval; *V.S.L.*, left precaval; *S.V.*, sinus venosus: the two precavals are the original "ductus Cuvieri": they open into the sinus venosus; *J*, jugular vein; *S.U.V.*, anterior vertebral vein; *W*, subclavian; *V.C.I.*, postcaval; *H.P.*, hepatic veins; *D.V.*, ductus venosus; *P.V.*, portal vein; *M*, mesenteric vein; *O.f.*, vitelline vein; *U*, allantoic vein. The three last-mentioned veins unite together to form the portal vein.

In this way arise a **placenta** and a **placental circulation** (comp. pp. 10-12). The embryos of all Mammals except Monotremes and Marsupials reach this high stage of specialisation.

The allantois then no longer has a simple sac-like form, but becomes solid. The part outside the body of the foetus disappears

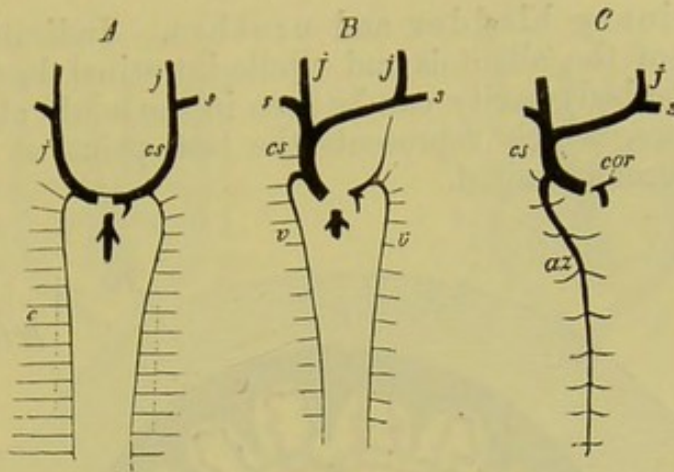


FIG. 219, A, B, C.—DIAGRAM OF THE DEVELOPMENT OF THE PAIRED VENOUS SYSTEM OF MAMMALS (MAN). (From Gegenbaur.)

- A.—Stage in which the cardinal veins have already disappeared. Their position is indicated by dotted lines.
- B.—Later stage, when the blood from the left jugular vein is carried into the right to form the single precaval; a remnant of the left precaval however still remains.
- C.—Stage after the left vertebral vein has disappeared, the right vertebral remaining as the azygos vein. The coronary vein remains as the last remnant of the left precaval.
- j*, jugular vein; *cs*, precaval, *s*, subclavian veins; *c*, posterior cardinal vein; *v*, vertebral vein; *az*, azygos vein; *cor*, coronary vein.

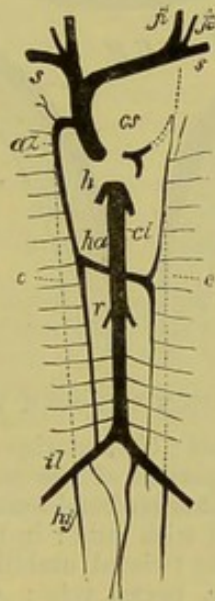


FIG. 219, D.—DIAGRAM OF THE CHIEF VENOUS TRUNKS OF MAN. (From Gegenbaur.)

cs, precaval; *s*, subclavian vein; *ji*, internal jugular; *je*, external jugular; *az*, azygos vein; *ha*, hemiazygos vein; *c*, dotted line showing previous position of cardinal veins; *ci*, postcaval; *r*, renal veins; *il*, iliac; *hy*, hypogastric veins; *h*, hepatic veins. The dotted lines show the position of embryonic vessels aborted in the adult.

entirely at birth, while the intra-abdominal remains of it give rise in part to a solid fibrous cord, the urachus, and in part to the

definitive urinary bladder and urethra. Indications of the point of exit of the allantois and vitello-intestinal duct (umbilical cord) from the body-cavity can be seen in the adult at the navel, or umbilicus, which represents the last point at which the body-walls become united.

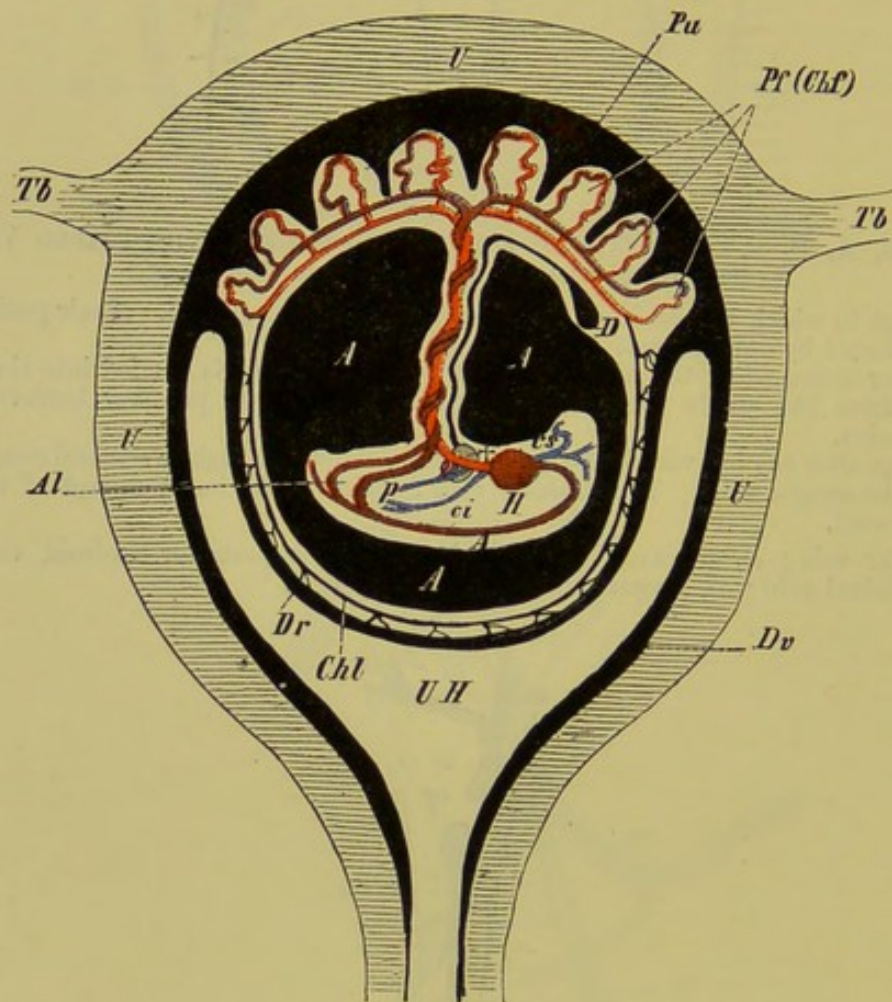


FIG. 220.—DIAGRAMMATIC SECTION THROUGH THE HUMAN GRAVID UTERUS.

U, uterus; *Tb, Tb*, Fallopian tubes; *UH*, uterine cavity; *Dv*, decidua vera, which at *Pu* passes into the uterine portion of the placenta; *Dr*, decidua reflexa; *Pf*, fetal portion of the placenta (chorion frondosum, *Chf*); *Chl*, chorion laeve; *A, A*, the cavity of the amnion filled with fluid: in the interior of the amnion is seen the embryo suspended by the twisted umbilical cord; *H*, heart; *A*, aorta; *cs*, precaval; *ci*, postcaval; *p*, portal vein; *Al*, allantoic (umbilical) arteries; †, the liver, perforated by the umbilical vein; *D*, the remains of the yolk-sac (umbilical vesicle).

The branchial vessels never become functional *as such*, in any period of development either in Mammalia or Sauropsida, but those which persist give rise to important vascular trunks of the neck, head (carotids), upper extremity (subclavian), and lungs (pulmonary artery), and also to the roots of the aorta, one or both of which may remain (comp. Fig. 221, A to D).

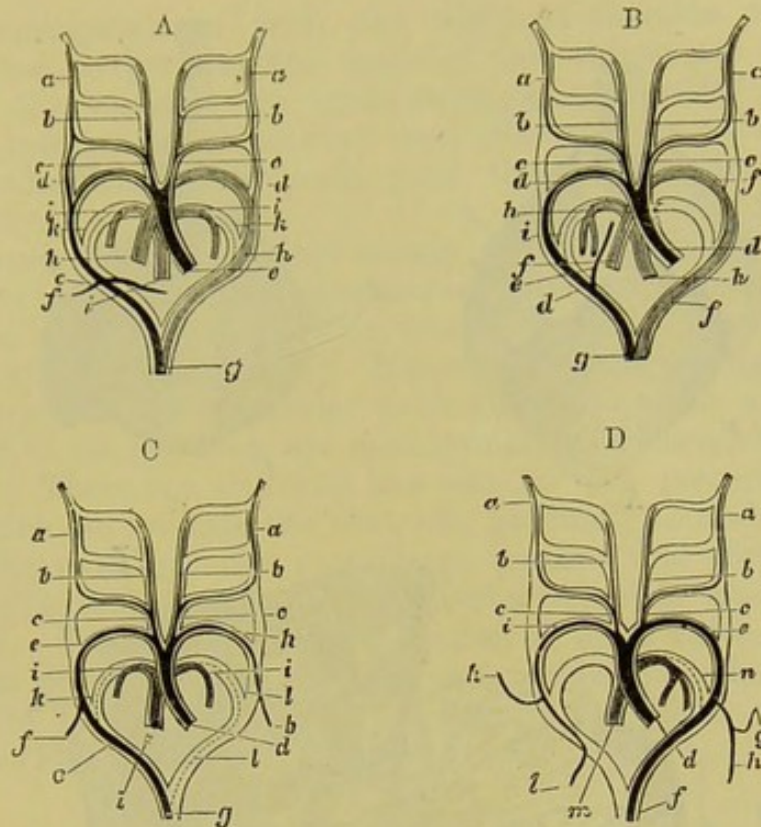


FIG. 221.—DIAGRAM SHOWING THE TRANSFORMATIONS OF THE AORTIC ARCHES—
A, IN A LIZARD ; B, IN A SNAKE ; C, IN A BIRD ; AND D, IN A MAMMAL.
(After Rathke.) (Seen from below.)

- A.—*a*, internal, and *b*, external carotid ; *c*, common carotid ; *d*, ductus Botalli between the third and fourth arches ; *e*, right aortic arch ; *f*, subclavian ; *g*, dorsal aorta ; *h*, left aortic arch ; *i*, pulmonary artery ; *k*, rudiment of the ductus Botalli between the pulmonary artery and the aorta.
- B.—*a*, internal, and *b*, external carotid ; *c*, common carotid ; *d*, right aortic arch ; *e*, vertebral artery ; *f*, left aortic arch ; *h*, pulmonary artery ; *i*, ductus Botalli of the latter.
- C.—*a*, internal, and *b*, external carotid ; *c*, common carotid ; *d*, base of the aorta ; *e*, fourth arch of the right side (root of the aorta) ; *f*, right subclavian ; *g*, dorsal aorta ; *h*, left subclavian (fourth arch of the left side) ; *i*, pulmonary artery ; *k* and *l*, right and left ductus Botalli of the pulmonary arteries.
- D.—*a*, internal, and *b*, external carotid ; *c*, common carotid ; *d*, base of the aorta ; *e*, fourth arch of the left side (aortic root) ; *f*, dorsal aorta ; *g*, left vertebral artery ; *h*, left subclavian ; *i*, right subclavian (fourth arch of the right side) ; *k*, right vertebral artery ; *l*, continuation of the left subclavian ; *m*, pulmonary artery ; *n*, ductus Botalli of the latter.

THE HEART AND ITS VESSELS.

Fishes.—While the heart of *Amphioxus* is not specially differentiated, as it is in the Vertebrata, that of Fishes is well developed, and is situated in the anterior part of the body-cavity, close behind the head. It is always formed on the same type as that described on p. 269.¹ In it may be distinguished a

¹ There is no truncus arteriosus in Cyclostomi.

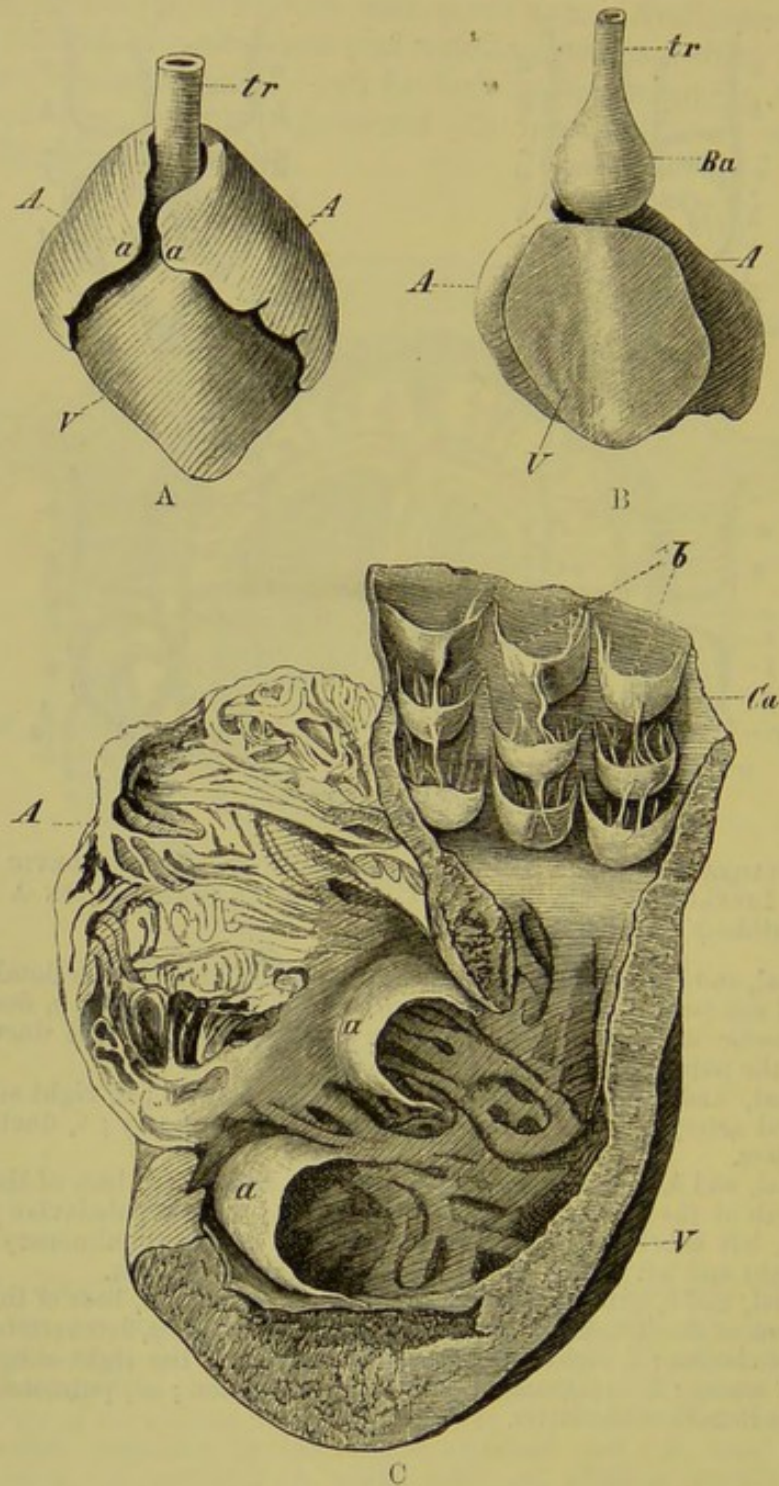


FIG. 222.—HEARTS OF VARIOUS FISHES—A, OF THE HAMMER-HEADED SHARK (*Zygæna malleus*); B, OF *Silurus glanis*; C, OF A SELACHIAN, CUT OPEN.

In A and B, A, A, atria; a, a (in A), auricular appendages; V, ventricle; Ba, bulbus arteriosus; tr, ventral aorta.

In C, a, a, indicate the atrio-ventricular valves, and b, the valves in the conus arteriosus (Ca); A, atrium; V, ventricle.

ventricle (Fig. 222, V) and an atrium (A), the latter receiving its blood from a sinus venosus, and being laterally expanded to form the appendices auriculæ (A, a, a).

In correspondence with the different function which each portion has to perform, the walls of the atrium are thin, while those of the ventricle are much stronger, its muscles giving rise in the interior to a network and also usually to a series of large trabeculæ; this holds good throughout the Vertebrata (Fig. 222, C, *A*).

Between the ventricle and atrium, at the margins of the atrio-ventricular aperture, membranous valves are present; of these there are usually two, but this number may be increased to as many as six (Fig. 222, C, *a, a*). Numerous valves, arranged in rows, are present in the muscular truncus or conus arteriosus (Fig. 222, C, *Ca, b*); these are most numerous in Elasmobranchs and Ganoids. There is a tendency however for the posterior ones, or those which lie towards the ventricle, gradually to undergo reduction. The most anterior row always persists, and corresponds to the single row of valves between the ventricle and bulbus in Teleostei. Together with the reduction of these valves, the conus arteriosus of Teleosteans also becomes reduced, so that the non-contractile bulbus arteriosus usually lies close against the ventricle (Fig. 222, B, *Ba*).

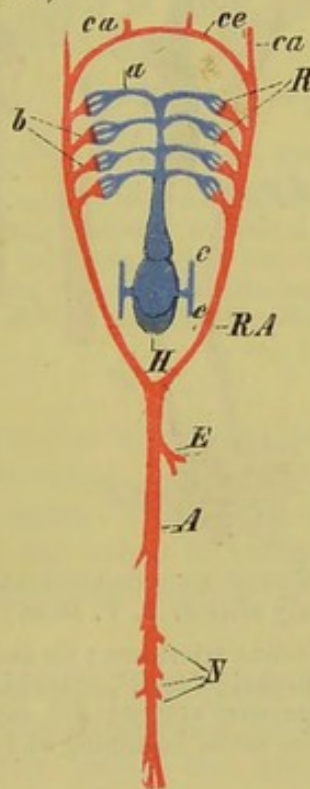


FIG. 223.—DIAGRAM OF THE ARTERIAL SYSTEM OF FISHES.

H, heart; *c, c'*, anterior and posterior cardinal veins; *a*, branchial arteries; *R*, capillaries of the branchial vessels; *b*, branchial veins; *ce*, circulus cephalicus; *ca*, carotids; *RA*, root of the aorta; *A*, dorsal aorta; *E*, artery to viscera (coeliaco-mesenteric); *N*, renal arteries.

The heart of Fishes contains venous blood only, which it forces through the branchial arteries (Fig. 223, *a*) into the capillaries

of the gills (*R*), where it becomes oxygenated, to pass thence into the branchial veins (Fig. 223, *b*). The manner in which the aortic roots become formed from the latter has already been described.

Dipnoi.—In the Dipnoi, as in Fishes proper, the heart lies far forwards, near the head. In correspondence with the double mode of respiration, by lungs as well as by gills, it reaches a stage of development mid-way between that seen in Fishes and in Amphibians. The atrium becomes divided into two chambers by a septum, as does also the ventricle to some extent. The conus arteriosus is

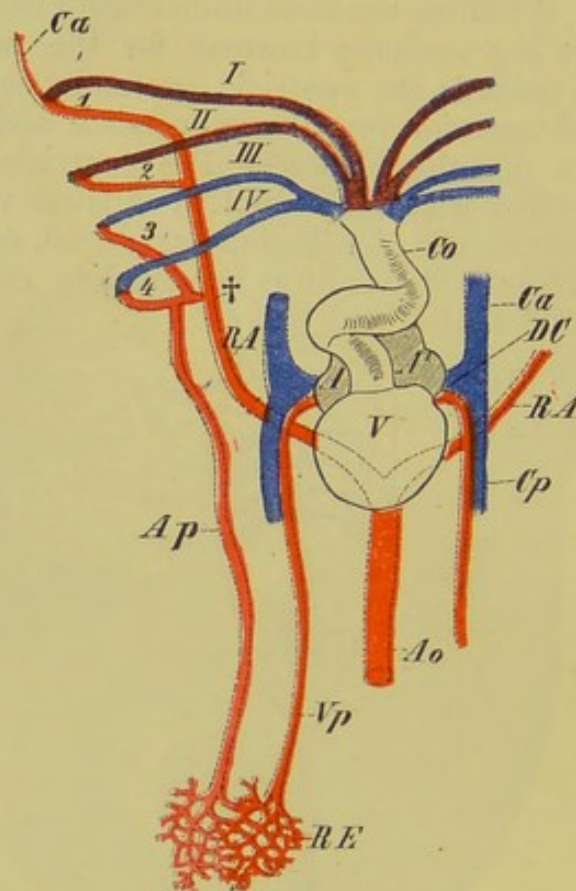


FIG. 224.—DIAGRAM OF THE HEART AND BRANCHIAL VESSELS OF CERATODUS.
(Mainly after J. E. V. Boas.)

V, ventricle; *A*, *A*¹, atria; *Co*, conus arteriosus; *Ca* and *Cp*, anterior and posterior cardinal veins; *DC*, ductus Cuvieri; *I* to *IV*, branchial arteries; *1* to *4*, branchial veins; *Ca*, carotid; *Ap*, pulmonary artery; *RE*, capillaries of lung; *Vp*, pulmonary vein; *RA*, roots of the aorta, beginning at †; *Ao*, dorsal aorta.

twisted spirally on itself (Fig. 224, *Co*): in *Ceratodus* it is provided with eight transverse rows of valves, and begins to be divided into two chambers. In *Protopterus* this division is complete, so that two currents of blood, an arterial and a venous, pass out from the heart side by side (Fig. 225, *a, b*). The former comes from the pulmonary vein, from which it passes into the left atrium, thence into the left ventricle, and so to the two anterior

branchial arteries (Fig. 225, *I, II*). The venous current, on the other hand, passes from the right ventricle into the third and fourth branchial arteries and thence to the corresponding gills, where it becomes purified; it reaches the aortic arches by means of the branchial veins (*III, IV, 3, 4, RA*). The pulmonary artery (*Ap*) arises from the fourth branchial vein, so that the blood is thus

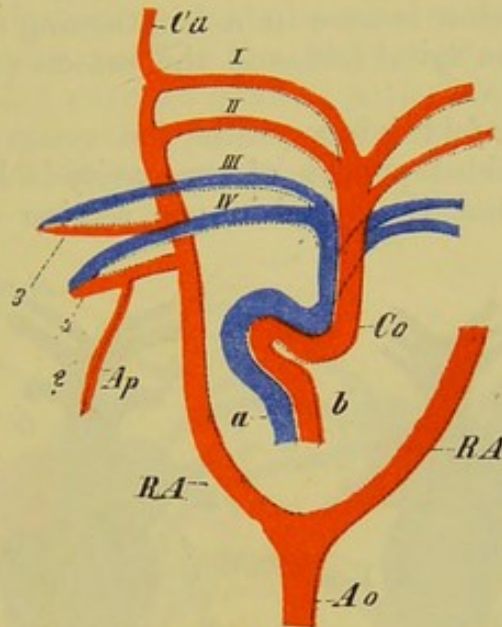


FIG. 225.—DIAGRAM OF THE BRANCHIAL CIRCULATION OF PROTOPTERUS.

Co, conus arteriosus, which consists of two divisions, *a* and *b*: through *b* pure arterial blood passes to the two anterior branchial arteries (*I* and *II*); through *a* venous blood passes to the two posterior branchial arteries (*III* and *IV*); *3* and *4* indicate the branchial veins and capillaries of the gills; *Ap*, the pulmonary artery, present only on the left side (?); *RA*, arch of the aorta; *Ao*, aorta; *Ca*, carotid.

once more purified before it passes by means of the pulmonary vein into the left ventricle. In *Ceratodus* the lung is supplied with blood from the celiac artery, and owing to the fact that the longitudinal valve of the conus is incomplete, the blood passing to the two anterior branchial arteries is of a mixed nature (comp. Fig. 224, *I, II*).

Amphibia.—With the exception of the *Gymnophiona*, in which it is situated some distance back, the heart in all Amphibians lies far forwards, below the anterior vertebræ. As in the *Dipnoi*, there is a more or less complete septum atriorum (that is, the septum is either entire or fenestrated). There are always two fibrous pocket-like atrio-ventricular valves, which are connected with the walls of the ventricle by cords.

The cavity of the ventricle is unpaired, and neither in *Urodela* nor *Anura* shows any trace of a septum, so that the blood passing out from it must have a mixed character (Fig. 226). The ventricle is usually of a short and compressed form, but is more

elongated in *Amphiuma*, *Proteus*, and the *Gymnophiona*. It is continued anteriorly into a *conus arteriosus*, as in *Elasmo-branchs*, *Ganoids*, and *Dipnoans*; this has usually a slight spiral twist, and possesses a transverse row of valves at either end, as well as a spiral fold extending into its lumen.¹ This holds good for the *Axolotl*, *Amblystoma*, *Salamandra*, *Amphiuma*, and *Siren*. In others (*e.g.* *Menobranchus*, *Proteus*, *Gymnophiona*), retrogression is seen in a lengthening of the conus, the disappearance of the spiral fold, and the presence of only a single row of valves.

In *Anura*, the fold lying within the conus extends so far back that no undivided portion of the cavity is left. The consequence of this is that the blood in one section of the branchial

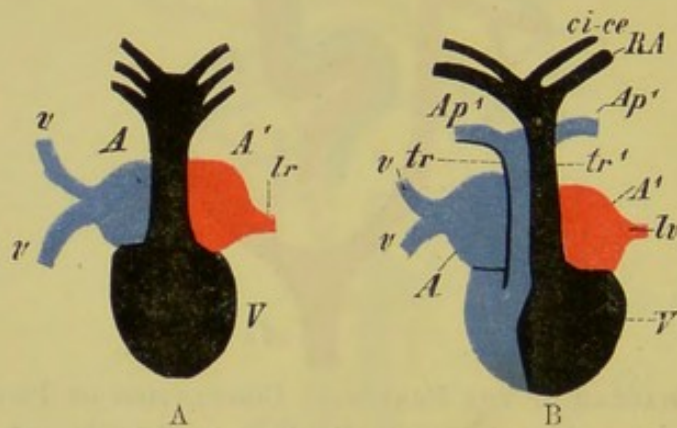


FIG. 226.—DIAGRAM SHOWING THE COURSE OF THE BLOOD THROUGH THE HEART IN *Urodela* (A) AND *Anura* (B).

A, right atrium; *A'*, left atrium; *V*, ventricle; *tr*, conus arteriosus, divided in *Anura* (B) into two portions, *tr*, *tr'*: through *tr* venous blood passes into the pulmonary arteries, *Ap'*, *Ap'*, while through *tr'* mixed blood goes to the carotids, *ci-ce*, and to the roots of the aorta, *RA*; *lr*, *lv*, pulmonary veins; *v*, *v*, pre- and postcavals (only one precaval is indicated) opening into the right atrium.

vessels—that from which the pulmonary artery arises—is mainly venous, while the others contain mixed blood (Fig. 226, B); for, owing to the spongy nature of the ventricle, there is no time for its contained blood to get thoroughly mixed before it is forced into the conus.

As in the *Dipnoi*, four branchial arteries arise on either side from the short conus in the *Amphibia*, which—taking as a good type the larva of *Salamandra*—have the following relations.

The three anterior branchial arteries pass to numerous external gill-tufts, where they break up into capillaries (Fig. 227, 1, 2, 3). From the latter three branchial veins (*I* to *III*) arise, which pass to the dorsal side, and there unite on either side to form the aortic roots. The fourth branchial artery, which is smaller than the others (4), does not pass to a gill, but to the pulmonary artery, which arises

¹ This spiral fold is to be looked upon as derived from a series of fused valves.

from the third branchial vein (Fig. 227, 4, *Ap*). The pulmonary artery therefore contains far more arterial than venous blood, and thus the lungs of the Salamander larva, like the air-bladder of Fishes, can have no important respiratory function.

The internal carotid (*ci*) arises from the first branchial vein, towards the middle line, the external carotid (*ce*) coming off further outwards.

The latter, as it passes forwards, becomes connected with the first branchial arch (1) by net-like anastomoses (†), and these give rise later to the so-called carotid gland¹ of the adult, which functions as an accessory heart. Direct connections exist between the second and third branchial arteries and the corresponding veins (see Fig. 227, *a, a*).

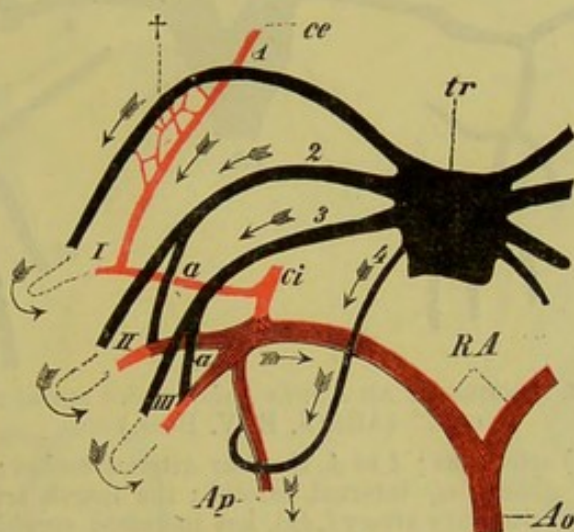


FIG. 227.—THE ARTERIAL ARCHES OF THE LARVA OF A SALAMANDER. (Slightly diagrammatic.) (After J. E. V. Boas.)

tr, conus arteriosus; 1 to 3, the three branchial arteries; I to III, the corresponding branchial veins; 4, the fourth arterial arch, which becomes connected with the pulmonary artery (*Ap*); *a, a*, direct anastomoses between the second and third branchial arteries and branchial veins; *ce*, external carotid; *ci*, internal carotid; †, net-like anastomoses between the external carotid and the first branchial artery, which give rise later to the carotid gland; *RA*, aortic roots; *Ao*, dorsal aorta. The arrows show the course which the blood takes.

Towards the end of the larval period, the second branchial vein increases considerably in relative size, and the fourth arterial arch also becomes larger. By a reduction of the anastomosis with the third branchial vein, the fourth arterial arch furnishes the main amount of blood for the pulmonary artery, and the latter thus contains far more arterial than venous blood. When branchial respiration ceases, the anastomoses between the branchial arteries and veins no longer consist of capillaries, but a direct connection between them becomes established (Fig. 228, 2, 3, 4). Finally, the connection between the first and second branchial arches disappears,

¹ The "carotid gland" loses its character as a rete mirabile (comp. p. 292), and in the adult consists simply of a muscular vesicle with septa in its interior.

the former giving rise to the carotids and the latter forming the large aortic root (Fig. 228, *ce*, *ci*, *RA*); an anastomosis remains throughout life, however, between the fourth arch, which forms the pulmonary artery, and the second and third (Fig. 228). This is the **ductus Botalli**.

The third arch varies greatly in its development; it may be present on one side only, or even may be entirely wanting.

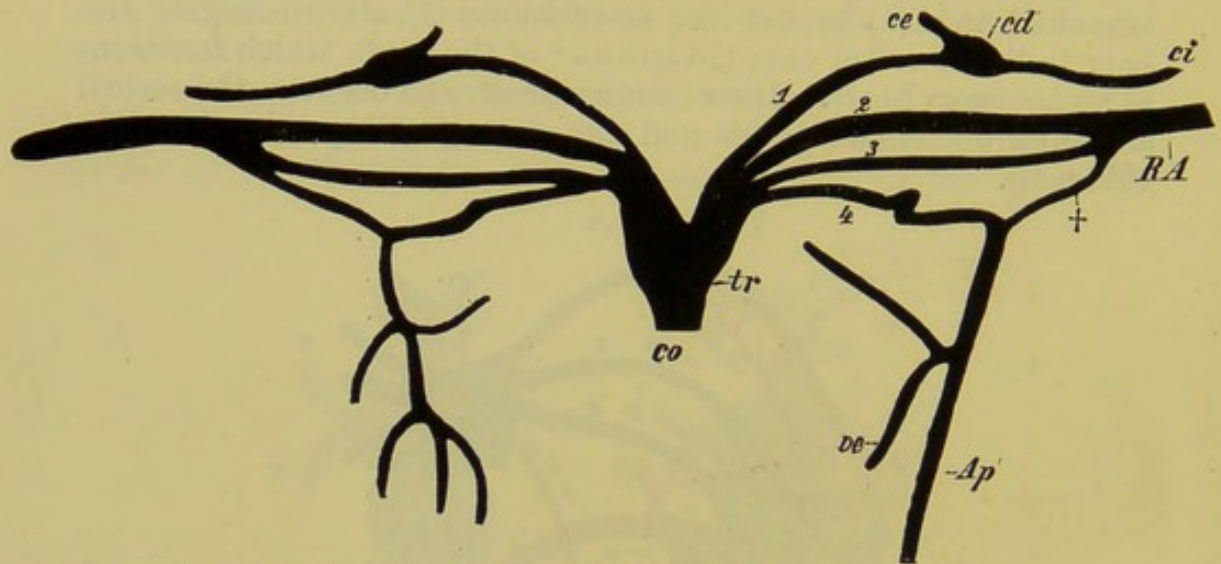


FIG. 228.—ARTERIAL ARCHES OF AN ADULT *Salamandra maculosa*, SHOWN SPREAD OUT. (After J. E. V. Boas.)

co, *tr*, conus (truncus) arteriosus; 1 to 4, the four arterial arches; *ce*, external carotid; *cd*, carotid gland; *ci*, internal carotid; the fourth arterial arch, which gives rise to the pulmonary artery (*Ap*), has increased considerably in size relatively, and is only connected by a delicate ductus Botalli (+) with the second and third arches; *RA*, root of the aorta; *a*, oesophageal vessels.

In the larvæ of Anura there are also four branchial arteries present on either side, but these are connected with the corresponding veins by capillaries only, there being no direct anastomoses (compare Fig. 227, *a*, *a*). The consequence of this is that all the blood becomes oxygenated.

In the adult Frog the third arterial arch becomes entirely obliterated, and the first is completely separated from the second. In other points the arrangement is similar to that seen in the Salamander.

Reptiles.—As in all Amniota, the heart of Reptiles arises far forwards in the neighbourhood of the gill-clefts, but on the formation of a neck it comes to lie much further back than is the case in the Anamnia.¹ The vagus nerve, which supplies the heart, is thus correspondingly elongated, and the carotid arteries and jugular veins also become increased in length.

The principal advance in structure as compared with the

¹ It lies furthest forwards in most Lizards and in Chelonians, while in Amphibians, Snakes, and Crocodiles it is situated much further back.

Amphibian heart is seen in the appearance of a ventricular septum, which may be incomplete, as in Lizards, Snakes, and Chelonians, or complete, as in Crocodiles.¹

A right and left aortic root or arch (Fig. 229, C, † and *) are always present, and unite to form the dorsal aorta. Each

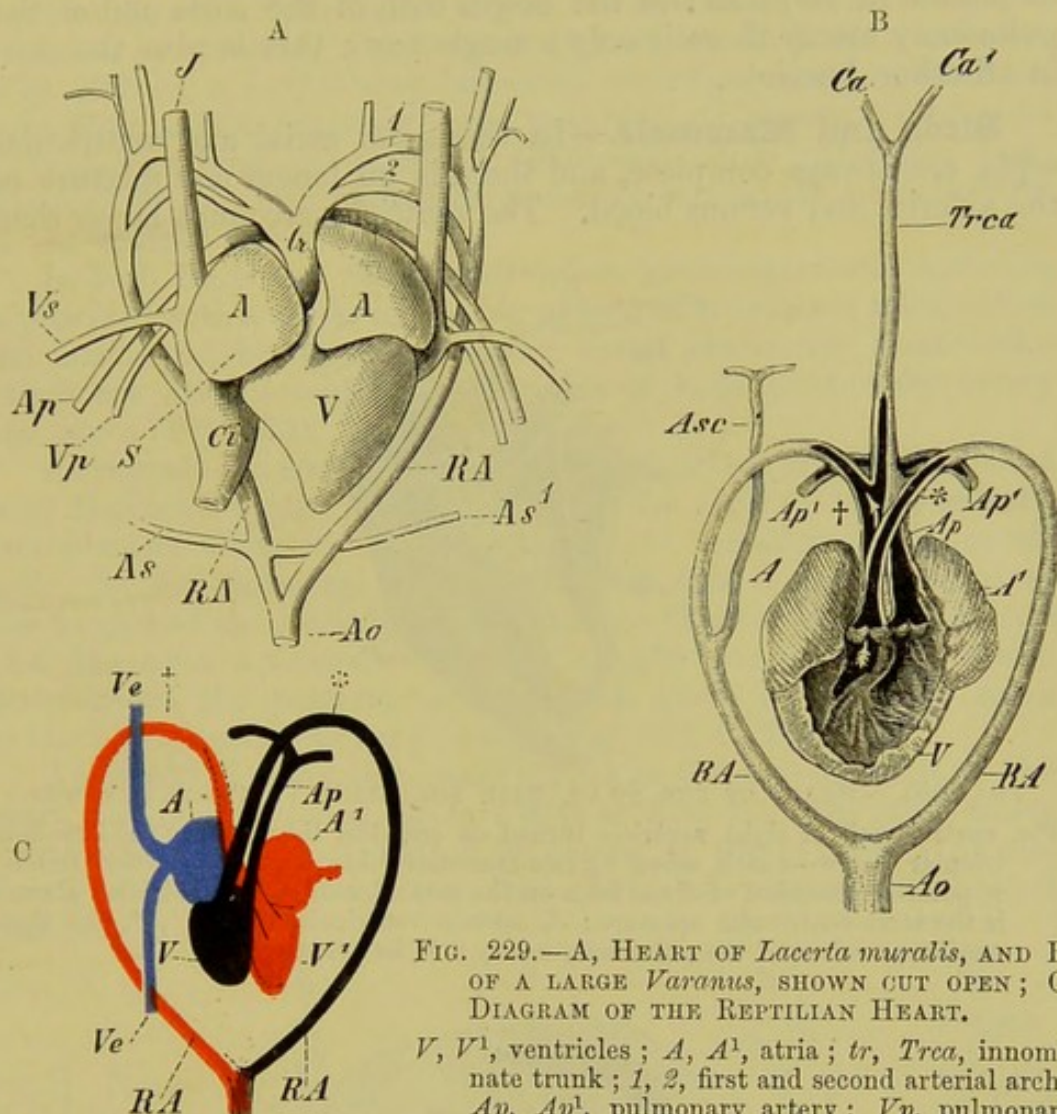


FIG. 229.—A, HEART OF *Lacerta muralis*, AND B, OF A LARGE *Varanus*, SHOWN CUT OPEN; C, DIAGRAM OF THE REPTILIAN HEART.

V, *V*¹, ventricles; *A*, *A*¹, atria; *tr*, *Trca*, innominate trunk; *1*, *2*, first and second arterial arch; *Ap*, *Ap*¹, pulmonary artery; *Vp*, pulmonary vein; † and *, right and left aortic arch; *RA*,

root of aorta; *Ao*, dorsal aorta; *Ca*, *Ca*¹, carotids; *Asc*, *As*, subclavian arteries; *J*, jugular vein; *Vs*, subclavian vein; *Ci*, postcaval. These three veins open into the sinus venosus, which lies on the dorsal side of the heart, above the point indicated by the letter *S*. In the diagram C the pre- and postcavals are indicated by *Ve*, *Ve*, only one precaval being represented.

aortic root may be made up at its origin of two arches, anastomosing with one another (*Lacerta*) (Fig. 229, A, *1*, *2*), or of one only (certain Lizards, Snakes, Chelonians, and Crocodiles) (Fig. 229, B, *RA*, *RA*). The most posterior arterial arch gives rise to the pulmonary artery (*Ap*) (comp. also Fig. 221, A, B).

¹ A small aperture of communication between the ventricles, the foramen Panizzæ, exists in Crocodiles. Near it, between the origin of the left aorta and the pulmonary artery, there is a small cartilage, as in Chelonians.

The blood from the right ventricle passes into the latter as well as into the left aortic arch, and, according as the septum ventriculorum is complete or incomplete, is either entirely venous (Crocodiles) or mixed (other Reptiles, Fig. 229, C).

The valves of the heart have undergone a considerable reduction in Reptiles: at the origin both of the aorta and of the pulmonary artery there is only a single row; this is also the case in all other Amniota.

Birds and Mammals.—In these, the atrial and ventricular septa are always complete, and there is no longer any mixture of the arterial and venous blood. The ventricles are much larger than

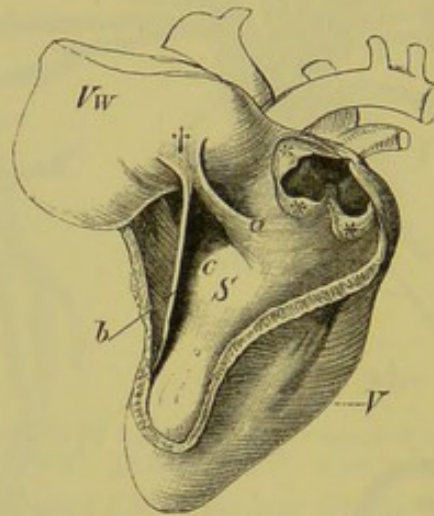


FIG. 230A.—HEART OF THE SWAN, WITH THE RIGHT VENTRICLE CUT OPEN.

Vw, ventral wall of right ventricle turned on one side, thus putting the atrio-ventricular valve—which arises by two muscular folds, *a* and *b*—on the stretch; †, point of insertion of these folds on the ventral wall of the ventricle: above *c* is the atrio-ventricular aperture; *S*, septum ventriculorum; *, *, *, the three semilunar valves of the pulmonary artery; *V*, left ventricle.

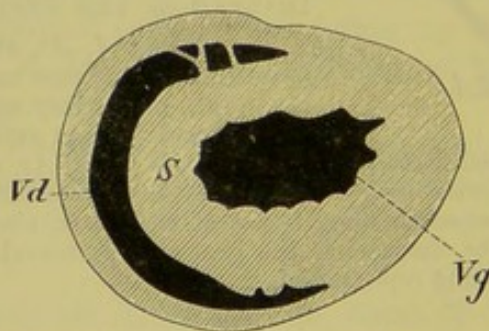


FIG. 230B.—TRANSVERSE SECTION THROUGH THE RIGHT (*Vd*) AND LEFT (*Vg*) VENTRICLE OF *Grus cinerca*.

S, septum ventriculorum.

the atria, and their muscular walls are strongly developed and very compact. This is particularly the case in the left ventricle, on the inner wall of which the papillary muscles are well developed: the left ventricle is partially surrounded by the right, the cavity

of the latter having a semilunar transverse section, and its walls being much thinner than those of the other (Fig. 230B, *Vd*, *Vg*).

In both Mammals and Birds the blood from the head and body passes by means of the precavals and postcaval into the right atrium, as does also that from the walls of the heart through the coronary vein: the right atrium is separated from the right ventricle by means of a well-developed valve. In Birds, the latter (Fig. 230A, *a*, *b*, *c*, †) is very large and entirely muscular, while in most Mammals it consists of three membranous lappets (tricuspid valve), to which are attached tendinous cords (chordæ tendineæ), arising from muscular processes (musculi papillares) of the walls of the heart.

In both Birds and Mammals the left atrio-ventricular aperture is provided with a valve consisting of two membranous folds, called the bicuspid or mitral valve: three semilunar pocket-like valves are also present at the origins of both pulmonary artery and aorta (Fig. 230A, *, *, *).

As regards the origin of the great vessels, Birds are distinguished from Mammals by the fact that in them the right (fourth) arterial arch persists, while in Mammals the left remains as the aortic arch; the corresponding arch of the other side in both cases gives rise to part of the subclavian artery. Thus in both Birds and Mammals there is only a single aortic arch. As in Amphibians, the posterior arterial arch gives rise in both cases to the pulmonary artery (comp. Fig. 221, C, D).

Amongst the more important points in the development of the heart may be mentioned the fact that at first the two atria freely communicate with one another by means of the foramen ovale, through which the blood from the postcaval passes into the left ventricle.

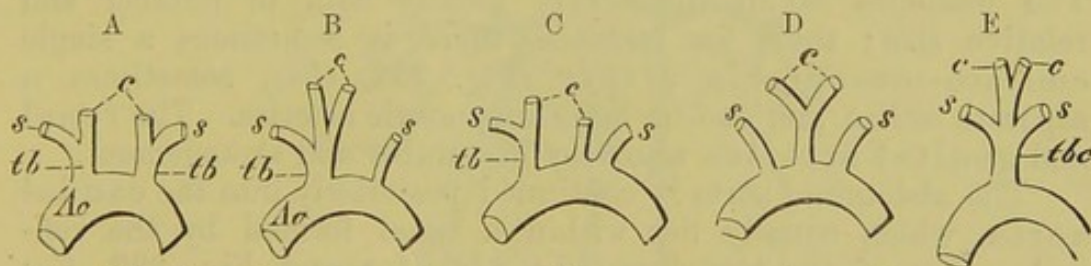


FIG. 231.—FIVE DIFFERENT MODES OF ORIGIN OF THE GREAT VESSELS FROM THE ARCH OF THE AORTA IN MAMMALS.

Ao, aortic arch; *tb*, brachiocephalic trunk; *c*, carotids; *s*, subclavians.

Great variations are seen in the mode of origin of the carotids and subclavians from the arch of the aorta in Mammals. Thus there may be a brachiocephalic trunk on either side (Fig. 231, A), or an unpaired common brachiocephalic, from which the carotid and subclavian of one or both sides arise (B, C, E), or, finally, a common trunk of origin for the carotids, the subclavians arising independently on either side of it (D).

ARTERIAL SYSTEM.

It has already been mentioned that in all Vertebrates there is a large sub-vertebral vessel running in the longitudinal axis of the body, called the aorta (Figs. 215 and 223, *A*), and that this is formed by the union of the branchial vessels. From the latter are also formed the carotids, which go to the head and neck: of these, the internal carotid passes mainly into the cranial cavity, and supplies the brain with blood, while the external carotid goes to the external parts of the head (face, tongue, and muscles of mastication).

The origin of the subclavian artery, which supplies the anterior extremity, is very inconstant, being sometimes symmetrical, sometimes asymmetrical. It arises either in the region of the branchial vessels, or from the roots or main trunk of the aorta (Fig. 215, *Sb*, and Figs. 232 and 233, *Sc*). Extending outwards towards the free extremity, the subclavian passes into the axillary artery, and, on reaching the upper arm, becomes the brachial artery. This finally divides into two branches for the fore-arm—the radial and ulnar arteries; in the hand these give rise respectively to the deep and superficial palmar arches, as well as to the digital arteries.

In the dorsal aorta a thoracic and an abdominal portion can be distinguished, and from them arise intercostal, lumbar, and intestinal arteries, supplying the body-walls as well as the thoracic and abdominal viscera. The intestinal arteries may again be divided into two principal groups, namely, those which supply the intestinal tract with its appendages (liver and pancreas) and the spleen, and those which go to the urinogenital organs. The branches of all these vary greatly both in number and relative size; thus, for instance, there is sometimes a single cœliaco-mesenteric artery (Fig. 232, *Cm*), sometimes a separate cœliac, and one or more mesenteric arteries. The renal and genital arteries also vary in number and arrangement.

The abdominal aorta is continued posteriorly into the caudal aorta, which usually lies within a canal formed by the ventral arches of the vertebræ (Fig. 232, *Aoc*, and Fig. 233, *C*); the degree of its development naturally corresponds to the size of the tail. In cases where the latter is rudimentary, as in Anthropoids and Man for instance, the caudal aorta is spoken of as the median sacral artery, and the aorta here appears to be directly continued, not by it, but by the common iliac arteries, which pass outwards into the pelvic region (Fig. 232, *Ile*).

Each common iliac artery becomes divided into an internal iliac, or hypogastric, supplying the viscera of the pelvis, which is derived from the embryonic allantoic artery, and an external iliac which is continued into the crural, and supplies the

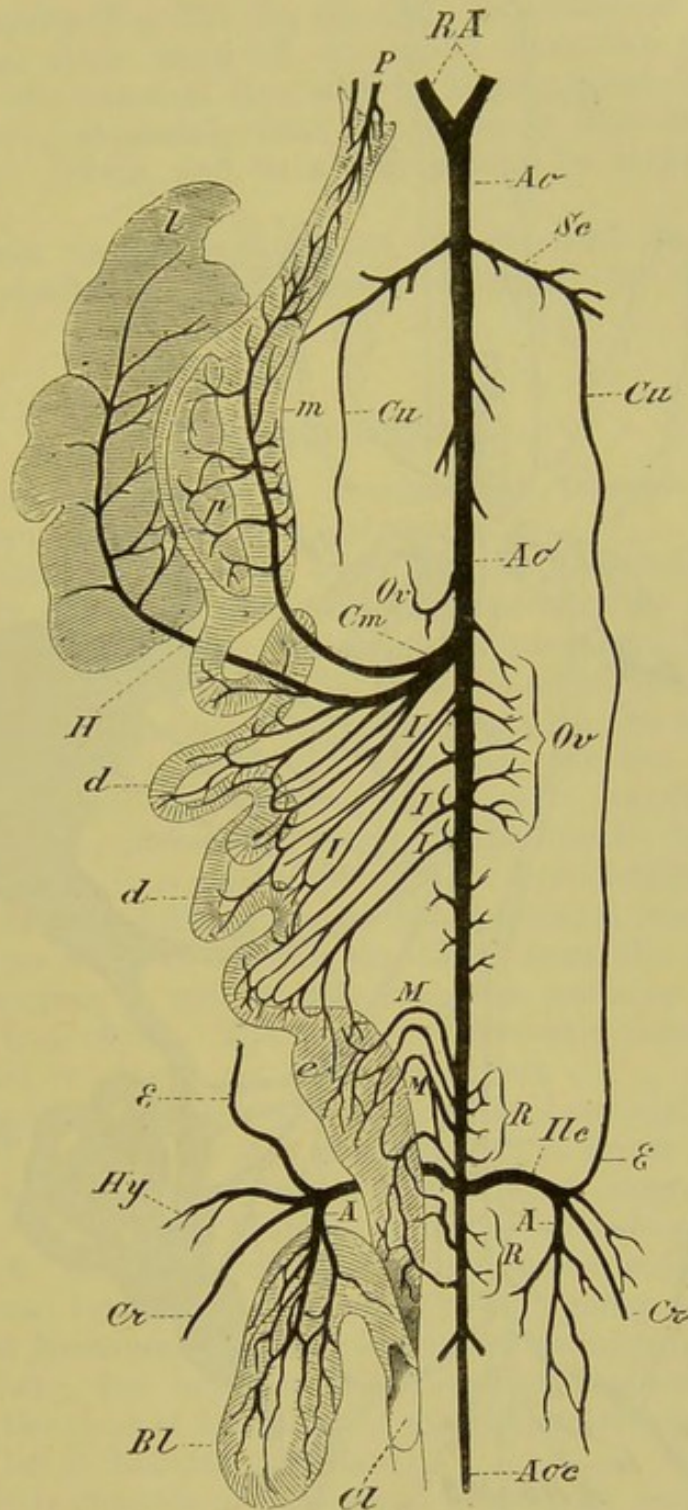


FIG. 232.—THE ARTERIAL SYSTEM OF *Salamandra maculosa*.

RA, roots of the aorta; *Ao, Ao*, dorsal aorta; *Sc*, subclavian artery, from which the cutaneous artery (*Cu*) arises: the latter anastomoses posteriorly with the epigastric artery *E*; *Ov*, ovarian arteries; *Cm*, coeliaco-mesenteric; *H*, hepatic artery; *I, I, I*, intestinal arteries passing to the small intestine; *M, M*, rectal (haemorrhoidal) arteries; *R, R*, renal arteries; *Ilc*, common iliac; *Cr*, crural artery; *Hy*, hypogastric artery; *A, A*, vesical (allantoic) arteries; *Aoc*, caudal aorta; *P*, pharynx and oesophagus; *m*, stomach; *p*, pancreas; *l*, liver; *d, d*, small intestine; *e*, rectum; *Bl*, urinary bladder; *cl*, cloaca.

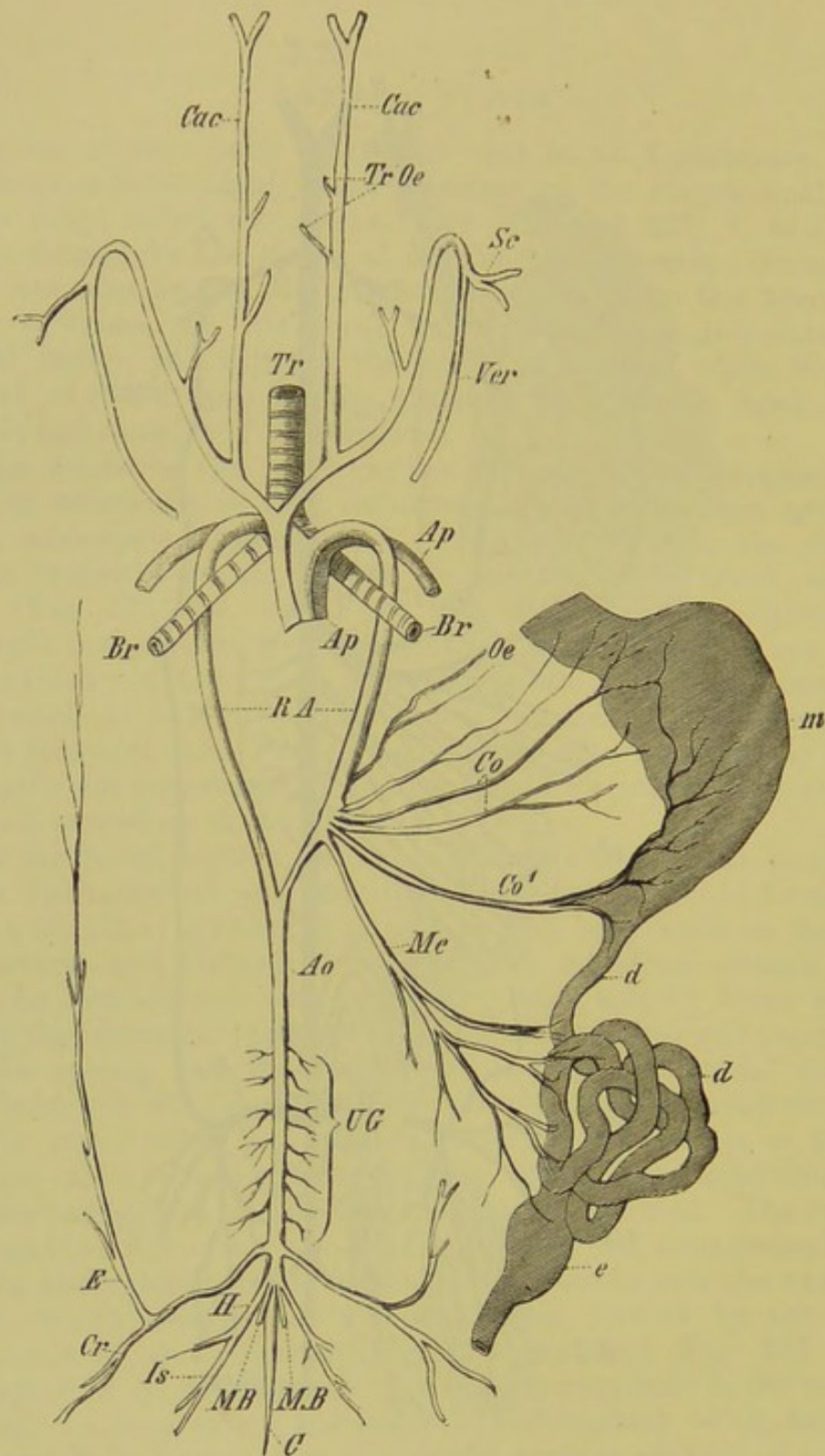


FIG. 233.—THE ARTERIAL SYSTEM OF *Emys europæa*.

Tr, trachea; *Br, Br*, the two bronchi; *m*, stomach; *d, d*, small intestine; *e*, large intestine; *Ap, Ap*, pulmonary artery; *Cac*, common carotids; *Tr, Oe*, tracheal and oesophageal branches; *Sc*, subclavian artery; *Ver*, vertebral artery; *RA*, roots of the aorta; *Ao*, dorsal aorta; *Co, Co'*, and *Me*, coeliac-mesenteric artery, which here arises as a bundle of separate vessels; *UG*, urinogenital arteries; *Cr*, crural artery; *E*, epigastric artery; *H*, hypogastric artery; *Is*, sciatic artery; *MB, MB*, rectal arteries; *C*, caudal aorta.

hinder extremity (Fig. 232, *Ilc*, *Hy*, *Cr*). In some cases the internal and external iliacs come off separately from the aorta. The function of the external iliac may be largely taken by a sciatic artery arising separately from the aorta or iliac artery in the pelvic region (Birds, and to a less extent in Reptiles) (comp. Fig. 233, *Is*).

The main vessels branch out in the limb in a manner essentially similar to that already described for the anterior extremity.

VENOUS SYSTEM

The numerous phases of development through which the venous system passes are very instructive.

The cardinal veins,¹ which open into the ductus Cuvieri, have been already described, and it is only necessary to add that in Fishes there is a renal-portal system interposed between the posterior cardinals and the caudal vein, the latter dividing up into capillaries in the kidney. The vessels returning the venous blood from the alimentary canal, the pancreas, and the spleen, also divide up into capillaries in the liver (hepatic portal system). The blood passes out from the latter by the hepatic veins into the postcaval, whence it is conducted into the right auricle.²

From the Amphibia onwards the postcaval becomes of increasing importance; it receives the blood from the kidneys and generative organs, as well as that from the posterior extremities, pelvis, and body-walls. The posterior cardinals decrease proportionately, and become to a certain extent lost.

The unpaired anterior abdominal (allantoic) vein plays a great part in Reptiles and Amphibians: it arises mainly from the crural vein of either side, and to a lesser degree also from the veins of the urinary bladder; it then passes along the ventral body-walls to the liver, where it anastomoses with the portal system, a small branch sometimes (*e.g.* Frog) going to the heart. In Birds and Mammals the allantoic vein has an important function in the embryo, but becomes obliterated on the atrophy of the allantois at the close of foetal life: it seems, however, to be retained throughout life in Echidna (Beddard).

From Birds onwards a renal-portal system no longer appears; but a hepatic portal system persists in all the higher Vertebrates.

¹ It is interesting to note the almost lacunar condition of the veins in many Elasmobranchs: the two posterior cardinals, for instance, unite in the middle of the body-cavity to form a large sinus, with which others bringing back the blood from the generative organs are connected.

² In the Skate a large lateral vein lies along the outer side of the body-cavity on either side, and receives the blood from the pectoral fins, abdominal walls, and iliac region. A similar vein has been found in embryos of other Elasmobranchs (*e.g.* Scymnus, Acanthias, Mustelus), and it seems highly probable that it corresponds to the vein of the primitive lateral fin-folds (T. J. Parker) (comp. pp. 85 and 86).

The two anterior cardinal veins give rise to the right and left precavals and to the jugular veins. In Monotremes and Marsupials, as well as in many Rodents and Insectivores, both precavals persist throughout life; but in other Mammals the main part of the left disappears, all the blood from the head and anterior extremities passing into the right: this explains how it is that the left azygos gives up its connection with the left precaval and unites by means of transverse anastomoses with the right precaval.

Most of the veins are provided with valves, which are adapted to prevent the reflux of the blood: they have the form of semilunar folds of the internal coat, and each is usually made up of two folds, placed opposite to one another.

RETIA MIRABILIA.

By this term is understood the sudden breaking-up of a venous or arterial vessel into a cluster of fine branches, which, by anastomosing with one another, give rise to a capillary network; the elements of this network may again unite to form a single vessel. The earlier condition may be described as a unipolar, the later as a bipolar rete mirabile. If it is made up of arteries or of veins only, it is called a rete mirabile simplex; if of a combination of both kinds of vessels, it is a rete mirabile duplex.

The retia mirabilia serve to retard the flow of blood, and thus cause a change in the conditions of diffusion. They are extremely numerous throughout the Vertebrate series, and are found in the most varied regions of the body, as, for instance, in the kidneys (glomeruli),—where their above-mentioned function is most clearly seen;—on the ophthalmic branches of the internal carotid; on the pseudobranchia of Fishes; along the intercostal arteries of Cetacea; on the mesentery of Man; on the portal vein; on the vessels of the air-bladder of Fishes; and along the caudal portion of the vertebral column in Lizards and Blindworms. In the last-mentioned case they are relatively very large, and probably have to do with the power these animals have of reproducing the tail when it is lost (comp. p. 43). A well-developed bipolar rete mirabile may also be seen on the dorsal wall of the pharynx in the Frog.

LYMPHATIC SYSTEM.

In the Anamnia and Reptilia the lymphatic vessels occur mainly alongside the great blood-vessels, as well as on the bulbus arteriosus and ventricle, and lie in the connective-tissue surrounding these structures. Numerous independent lymphatic vessels are also found in Fishes, arising from a capillary network

under the skin, and extending into the intermuscular septa and the bases of the fins. The intestinal tract and the viscera generally, of Sharks and Skates, are especially well provided with lymphatic vessels. Elasmobranchs, moreover, possess a large number of small lymph-hearts communicating with delicate venous networks. Lymph-hearts are also to be met with in Amphibians,¹ Reptiles, and Birds, but are fewer in number in the two last-mentioned groups than in the first; they are either confined to the posterior end of the body (pelvic region), or, as in the Frog, are present also between the transverse processes of the third and fourth vertebræ. Their walls are capable of rhythmical contraction, owing to the presence of muscular fibres. Similar structures are not known to be present in Mammals.

Large lacunar lymph-sinuses are present under the skin of tailless Amphibia, and the skin is thus only loosely attached to the underlying muscles. These subcutaneous lymph-sinuses are connected with those of the peritoneal cavity. Amongst the latter the subvertebral lymph-sinus is of great importance in Fishes and Amphibia: it surrounds the aorta and is connected with the (mesenteric) sinus lying amongst the viscera, into which the lymphatic vessels of the intestine open. In Fishes there is also a large longitudinal lymphatic trunk lying within the spinal canal.

The higher we get in the animal series the more commonly are lymphatic trunks with independent walls to be met with; thus from Birds onwards a large longitudinal subvertebral trunk (the thoracic duct) is always present. In Mammals this arises in the lumbar region, where it is usually dilated to form the cisterna or receptaculum chyli; it receives the lymph from the posterior extremities, the pelvis, and the urinogenital organs, as well as the lacteals or lymphatics of the intestines. In Mammals it opens anteriorly into the left, and in Sauropsida into both left and right brachiocephalic veins. The lymphatics of the head, neck, and anterior extremities open into the same veins.

The lymphatic vessels of Birds and Mammals are, like the veins, provided with valves, the arrangement of which allows the lymph-stream to pass in one direction only, and that a forward one.

The lymph, like the blood, consists of two elements, a fluid (plasma) and cells (lymph-corpuscles, leucocytes). The latter have been already mentioned and their important physiological function indicated in the chapter on the alimentary canal. We have seen that they migrate from the solitary follicles and Peyer's patches through the mucosa into the lumen of the gut; and the same thing occurs with the leucocytes of the so-called **tonsils**. These appear to be present only in Mammals, and have the form

¹ In *Salamandra maculosa* and *Siredon pisciformis*, eight to twelve lymph-hearts are present under the skin along the sides of the body and tail, at the junction of the dorsal and ventral body-muscles.

of a paired organ lying on either side of the fauces, that is, in the region where the mouth passes into the pharynx: they consist of a retiform (adenoid) connective-tissue ground-substance enclosing a number of lymph-corpuses, which are arranged in so-called follicles.

Lymphoid tissue plays a very important part in the body-cavity of Fishes and Amphibia. Apart from the alimentary canal, it is present in considerable quantity in the region of the urinary and genital glands, which are often regularly embedded in it (*e.g.* Dipnoi). The mass of lymphoid tissue on the heart of the Sturgeon, and possibly also the so-called "fat-bodies" of Amphibia and Reptilia, and the "hibernating gland" of certain Rodents, may be placed in this category.

The agglomeration of a number of these follicles gives rise to those structures which are spoken of as "**lymphatic glands.**" These are always interposed along the course of a lymphatic trunk so that an afferent and efferent vessel to each can be distinguished. They probably appear first in Birds, and are most numerous in Mammals, where they are present in abundance in various regions of the body; they differ greatly in size.

The **spleen**, which is present in almost all Vertebrates, is closely related to these structures. It usually lies near the stomach, though it is occasionally met with in other regions of the intestinal tract, as, for instance, at the commencement of the rectum (Anura, Chelonia). In some cases (*e.g.* Sharks) it is broken up into a number of smaller constituents.

Both the lymphatic glands and the spleen have to do with the formation of lymph-cells, but their complete physiological function is as yet by no means clear.

BIBLIOGRAPHY.

- AYERS, H.—*Beitr. zur Anatomie und Physiologie der Dipnoer.* Jena'sche Zeitschrift für Naturwissenschaften, Bd. XVIII. N. Folge, Bd. XI. 1885.
- BEDDARD, F. E.—*Note on the Presence of an Anterior Abdominal Vein in Echidna.* Proc. Zool. Soc. 1884. *On the Heart of Apteryx.* Ibid. 1885.
- BOAS, E. V.—See numerous Papers *On the Vascular System of Fishes and Amphibia* in the *Morphol. Jahrb.* Bd. VI. 1880, Bd. VII. 1881, and Bd. VIII. 1882.
- GOMPERTZ, C.—*Ueber Herz und Blutkreislauf bei nackten Amphibien.* Arch. f. Anat. und Physiologie (Physiologische Abtheilung), 1884. (This contains a masterly description of the Anatomy and Physiology of the Heart of Anura.)
- LANKESTER, E. RAY.—*On the Valves in the Heart of Ornithorhynchus paradoxus compared with those of Man and the Rabbit, with some Observations on the Fossa Ovalis.* Proc. Zool. Soc. 1882. *On the Right Cardiac Valve of Echidna and Ornithorhynchus.* Ibid. 1883. *On the Heart described by Professor Owen in 1841 as that of Apteryx.* Ibid. 1885. *On the Right Cardiac Valve of the Specimens of Apteryx dissected by Sir Richard Owen in 1841.* Ibid. 1885.
- MASCAGNI.—*Prodrome d'un ouvrage sur le système des vaisseaux lymphatiques.* Sienne, 1784. *Vasorum lymphaticorum corporis humani historia et iconographia.* Senis, 1787.
- MÜLLER, J.—*Ueber die Lymphherzen der Amphibien.* Arch. f. Anat. u. Physiol. 1854.
- MÜLLER, W.—*Ueber den feineren Bau der Milz.* Leipzig, 1865.

- PARKER, T. J.—*On the Venous System of the Skate. Trans. of the N. Zealand Institute, Vol. XIII. 1880.*
- RATHKE, H.—*Ueber die Entwicklung der Arterien, welche bei den Säugethieren von den Bogen der Aorta ausgehen. Arch. f. Anat. u. Physiol. 1843.*
- RUSCONI.—*Hist. nat., développement et métamorphose de la Salamandre terrestre. 1854.*
- SABATIER, A.—*Observations sur les transformations du système aortique dans la série des Vertébrés. Annal. d. Sc. Nat. 5 Sér. Tom. XIX. Études sur la cœur dans la série des Vertébrés. Montpellier et Paris, 1873.*
- SAPPEY, PH. C.—*Études sur l'appareille mucipare et sur le système lymphatique des poissons. Paris, 1880.*
- STÖHR, PH.—*Conus arteriosus der Selachier und Ganoiden. Morphol. Jahrb. Bd. II. 1876. Ueber den Bau der Conjunctiva palpebrarum. Sitz. Ber. d. phys.-medicin. Gesellsch. zu Würzburg, 1885.*
- WELIKY, W.—*Ueber vielzählige Lymphherzen bei Salamandra maculosa und Siredon pisciformis. Zool. Anzeiger, Jahrgang VII. Nr. 183, 1884.*

(Further references may be found in the Text-Books on Anatomy mentioned at the beginning of this book.)

I. URINOGENITAL ORGANS.

THE urinogenital organs of all Vertebrates arise in the region of the dorsal body-wall, right and left of the middle line.

The first part to be developed is an unsegmented and paired duct, which arises from the somatic mesoblast, and runs parallel to the long axis of the body. This duct opens anteriorly into the body-cavity by means of one or more ciliated funnel-shaped apertures, which communicate with it by means of convoluted tubes. The latter constitute the **pronephros** or head-kidney; they are formed as outgrowths of the tube itself, which opens posteriorly into the cloaca, and which is known as the **segmental** or **pronephric duct**.

The pronephros, as far as is known, is always present in types with a larval development (*i.e.* all Fishes except Elasmobranchs, and Amphibians), but it is usually only transitory. In other types (Elasmobranchii and Amniota) it is practically absent, or at any rate never has any physiological function.¹ The segmental duct, however, persists, and serves to carry off the products of excretion from a second series of glandular segmental tubules, which appear later, and constitute the **mesonephros** or Wolffian body. This also consists of a series of segmentally-arranged ciliated tubules or nephridia, lying transversely to the longitudinal axis of the body, which arise as buds from the peritoneal epithelium,

¹ Mikalovics has lately shown that the primitive excretory organ in the embryos of the Lizard, Duck, and Fowl consists of two parts, an anterior and a posterior. The former consists of a number of vesicles, the cavities of which in a certain stage of development communicate on one hand, by means of funnels, with the coelome, and on the other with the cavities of the mesoblastic somites. The posterior portion of the organ arises as a series of primitively solid structures in the mesoblastic tissue, which do not communicate either with the coelome or with the cavities of the somites. The segmental duct arises on the outer and dorsal side of this apparatus, all the constituent parts of which give rise later to hollow tubules, which come to open into the segmental duct, and in each of which a glomerulus is formed. Mikalovics considers that the anterior part of the organ corresponds to the pronephros of the Anamnia, and the hinder part to the mesonephros. Sedgwick has also found traces of a pronephros in chick embryos. We may hope for confirmation of these views in further researches.

and only secondarily communicate with the segmental duct (Fig. 234A to C, and Fig. 235).

Each pronephric and mesonephric tubule is made up of the following portions (see Fig. 234A):—(1) a funnel-shaped ciliated aperture, communicating with the body-cavity (**peritoneal funnel, nephrostome**, Fig. 234A, *ST*); (2) a rounded mass of capillaries

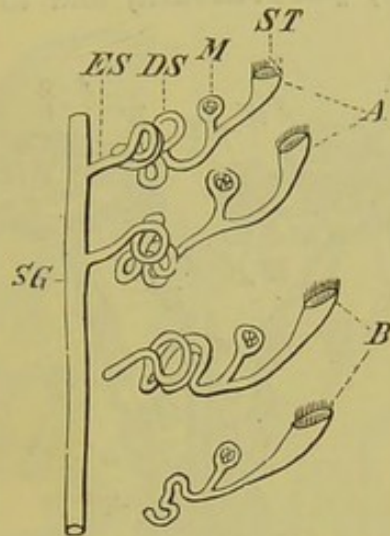


FIG. 234A.—DIAGRAM OF THE (SECONDARY) CONNECTION OF THE MESONEPHRIC TUBULES WITH THE SEGMENTAL DUCT (*SG*).

The two anterior tubules are already connected with the duct, while the two posterior have not yet reached so far.

ST, nephrostome; *M*, glomerulus; *DS*, coiled glandular tubule; *ES*, terminal portion of latter.

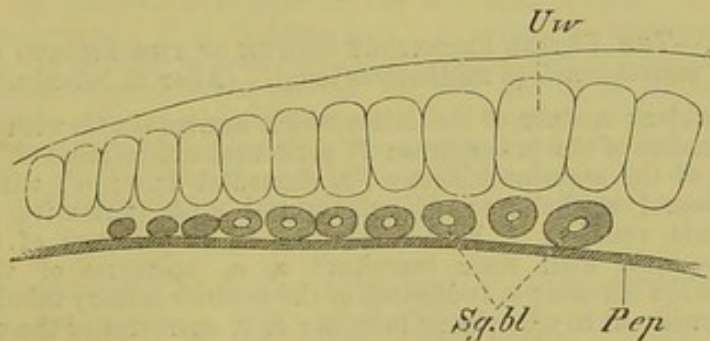


FIG. 234B.—HORIZONTAL SECTION THROUGH AN EMBRYO OF *Lacerta agilis*. (After M. Braun.)

Pep, peritoneal epithelium; *Sg.bl*, segmental vesicles; *Uw*, mesoblastic somites.

(glomerulus) (*M*), arising from the renal artery, which lies within an expanded portion of the tubule—the **Malpighian capsule**, the outer wall of which is pushed in to receive it; (3) a coiled glandular tubule (*DS*); and (4) a **terminal portion** (*ES*), connecting the latter with the segmental duct (*SG*). (Comp. also Fig. 235.)

Thus the primitive urinary system, besides its main function of excreting waste products by means of the epithelial cells, serves also to conduct the peritoneal fluid from the body.

This secondary urinary system, or mesonephros, is of greatest importance in the Anamnia: in most Fishes it serves exclusively as a urinary organ, but in others (most Elasmobranchs) it also takes on certain relations to the generative apparatus, giving rise to the **parorchis**, **parovarium**, and to other more or less

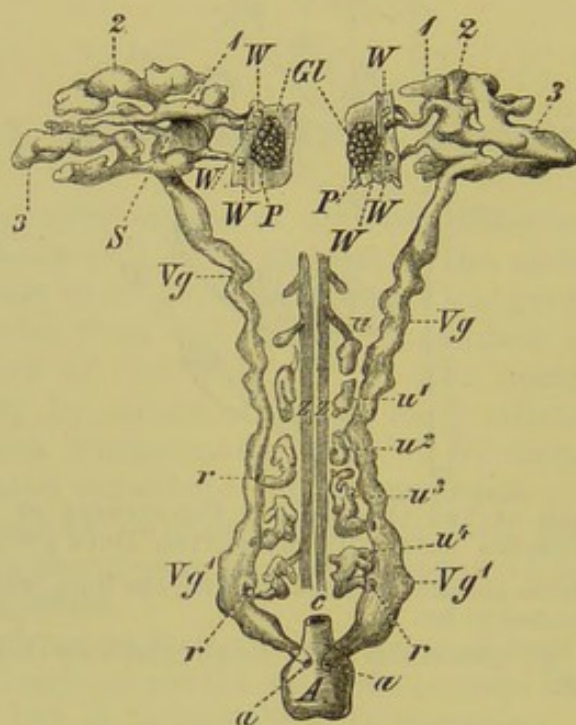


FIG. 234c.—THE ENTIRE EXCRETORY SYSTEM OF THE EMBRYO OF *Hylodes martinicensis* (3 millimetres long). (After E. Selenka.)

A, urinary bladder; *c*, stalk of the latter which communicates with the intestine; *Gl*, glomerulus of the pronephros; *P*, peritoneal epithelium; *S*, S-shaped convolutions of the segmental duct; *Vg*, segmental duct; *W*, ciliated regions of the mesonephric vesicles; *1, 2, 3*, the three caecal processes of the right and left pronephros, with their branches; *a, a*, apertures of the pronephric ducts into the bladder; *u*, rudiments of the anterior urinary tubules, in the form of solid cords; *u¹ to u⁴*, urinary tubules; *r, r*, apertures of the urinary tubules into the segmental duct (*Vg¹, Vg¹*), which thus becomes the duct of the mesonephros.

rudimentary organs of secondary importance. Nevertheless, it may remain as the permanent urinary organ (Elasmobranchs, Amphibians¹), or may entirely disappear as such (Amniota); in the latter case, a third series of tubules are formed, giving rise to the

¹ The glands formed by the posterior urinary tubules in Elasmobranchs and Urodeles which give rise to the functional excretory organs, and which may be provided with special ureters, are considered by Balfour to be the equivalents of the kidneys proper (metanephros) of Amniota (comp. Fig. 238).

kidney proper (metanephros¹), together with its special duct, the **ureter**.²

The **generative cells**, that is, the ova and seminal cells, have a similar origin throughout Vertebrates. They become differentiated from the peritoneal epithelium. This **germinal epithelium** arises on the dorsal side of the body-cavity, on either

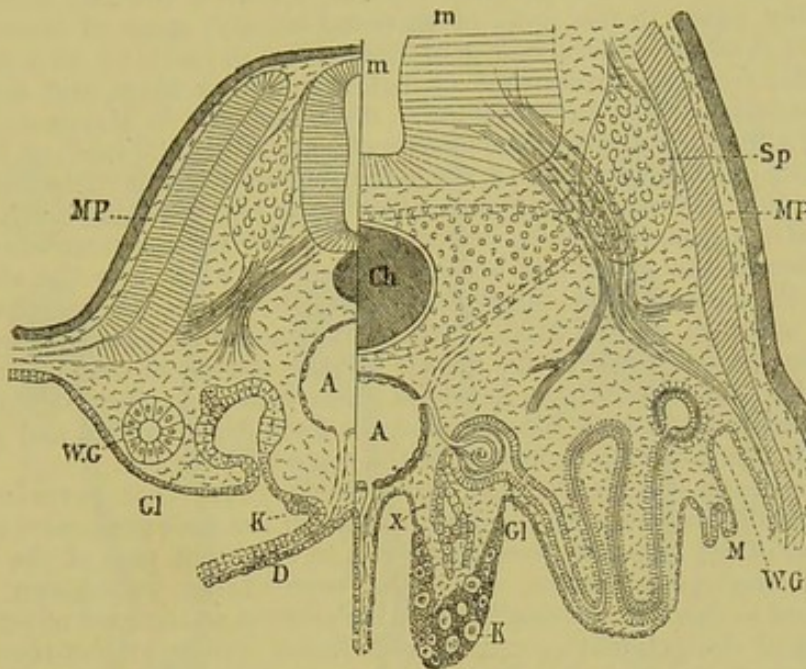


FIG. 235.—DIAGRAMMATIC TRANSVERSE SECTIONS OF THE BODY OF A LOWER VERTEBRATE, TO SHOW THE RELATIONS OF THE SEGMENTAL ORGANS. (After Hensen.) The right side of the figure represents a later stage than the left.

m, spinal cord; *Sp*, ganglion of a spinal nerve; *MP*, muscle-plate; *D*, wall of intestine; *Ch*, notochord; *WG*, Wolffian duct; *A*, aorta; *K*, germinal epithelium; above *K* on the left side is seen the peritoneal aperture of a segmental tubule; *Gl*, Malpighian capsule, shown on the left side arising as an expansion of a urinary tubule, and on the right in a fully-formed condition, containing a glomerulus, and communicating with the segmental duct by means of the convoluted tubule; *M*, Müllerian duct in process of formation; *X*, cellular trabeculae growing out from the Malpighian capsule into the generative gland (*K*).

side of the mesentery, and the adjacent mesoblastic stroma penetrates into it (comp. Fig. 235, *K*). The primitive germinal cells are at first entirely undifferentiated, so that it is impossible to

¹ According to the researches of Mikalovics the mesonephros does not disappear, as such, suddenly, but its greater part remains functional together with the metanephros for some time: in Lizards, for instance, it only becomes reduced after the first winter's sleep, that is, in the second year. Thus, to a certain extent, intermediate stages exist between the condition of things seen in the Anamnia and Amniota respectively. At one time Amniota must have existed in which the mesonephros served as the main excretory organ throughout life, but on the appearance of the metanephros it became no longer needed, and was gradually reduced.

² The metanephric duct arises in the form of a paired canal, which grows out from the Wolffian duct at the point where the latter opens into the cloaca. Its anterior end then comes into relation with a series of segmental tubules, provided with glomeruli, and the posterior end loses its connection with the Wolffian duct, and comes to communicate with the allantois (urinary bladder).

say which will give rise to spermatozoa, and which to ova. In the course of further development, this differentiation takes place, and the germinal epithelium comes into relation with the mesonephros, as already mentioned. The final result is the formation of a male or a female generative gland, *i.e.* a **testis** or an **ovary**.

The mode of development of the ova and spermatozoa is briefly as follows:—

Ova.—The cells of the germinal epithelium grow inwards amongst the stroma of the ovary in the form of clustered masses: some of these increase in size more than the others, and give rise to the primitive ova, while the smaller cells form an investment or follicle round them, and serve as a nutritive material. The investing cells multiply, and in Mammals a cavity containing a fluid is formed in the middle of each follicle (Graafian follicle) (see Fig. 254): the main mass of the follicular cells which enclose the ovum project, as the discus proligerus (Fig. 254, *D*), into the cavity of the follicle. When ripe, the ovum, surrounded by its vitelline membrane, comes to the surface of the ovary and breaks through its walls into the abdominal cavity; it then passes into the Fallopian tube by means of the cilia on the fimbriated aperture of the latter. A certain amount of blood is poured out through the broken ends of the vessels in the stroma of the ovary into the cavity of the Graafian follicle in which the ovum lay: this “wound” then closes up, and its contained blood undergoes fatty degeneration, and gives rise to a body of a yellow colour, known as the corpus luteum.

Spermatozoa.—As in the case of the female, primitive germinal cells can be at first distinguished in the development of the male generative elements. The nucleus of the larger of these gives rise to the main part of the so-called “head” of the spermatozoon, while the surrounding protoplasm becomes differentiated to form the motile “tail,” which serves as an organ of propulsion. Either each of the primitive germinal cells forms one spermatozoon only, or a division of its nucleus into several portions takes place, and the cell divides up into several spermatozoa. But there is no important difference between these two modes of development, for in both cases we have to do with a simple cell-division. Thus each spermatozoon is really the morphological equivalent of an ovum, so that an absolutely similar and equal portion from either parent is concerned in the production of the embryo.¹

In order to understand the general relations of the urinogenital organs as a whole, we must now consider briefly the canals which carry off the generative products.

In Cyclostomi and a very few other Fishes the generative products are simply shed from the ovary or testis into the body-cavity, whence they pass to the exterior by means of the abdominal pores (see p. 265). This is probably to be looked upon as the most primitive condition.

In all other Vertebrates except bony Fishes, a canal, called the **Müllerian duct**, is formed in the female. This either becomes split off from the segmental duct (Elasmobranchs, Amphibia), or arises independently as an involution of the peritoneum near the latter (Amniota).²

¹ It must be remembered that the process of fertilisation has to do essentially with the fusion of the nuclei only of the male and female cells (Weismann and Van Beneden). (Comp. pp. 3 and 4.)

² According to Mikalovics, the Müllerian duct arises in the Lizard, Duck, and Chick as a solid mesodermal rod, and thus has originally no connection with the coelome.

In the first case the other product of the segmental duct, or so-called **secondary mesonephric duct**, serves primarily in the male as the **urinogenital duct** (Leydig's duct), and in the female simply as the **urinary duct** (Figs. 237, 238A and B, *w.d*, *vd*, and 240, A, B, *lg*, *lg* (*Ur*).

In the second case, the entire primary mesonephric duct gives rise in the male to the **seminal duct** (Fig. 236, C, *Vd*)

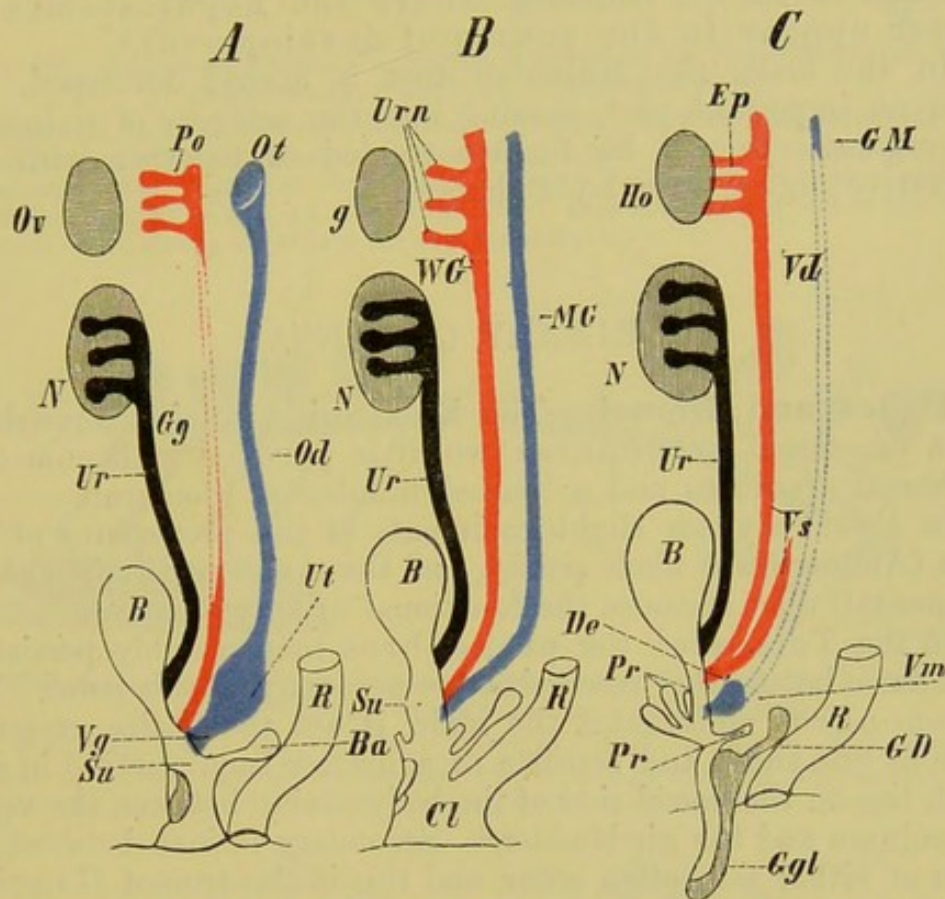


FIG. 236.—DIAGRAM EXHIBITING THE RELATIONS OF THE FEMALE (A) AND OF THE MALE (C) REPRODUCTIVE ORGANS TO THE GENERAL PLAN (B) OF THESE ORGANS IN THE HIGHER VERTEBRATA.

MG, Müllerian duct; *Ut*, uterus; *Ot*, abdominal aperture of the Fallopian tube; *Vg*, vagina; *Vm*, uterus masculinus; *GM*, hydatid of Morgagni; *WG*, Wolffian duct; *Gg*, Gärtner's duct; *Vd*, vas deferens; *De*, ductus ejaculatorius; *Vs*, vesicula seminalis; *Urn*, mesonephros (Wolffian body); *Po*, parovarium; *Ep*, epididymis; *g*, genital gland; *Ov*, ovary; *Ho*, testis; *N*, kidney; *Ur*, ureter; *B*, urinary bladder; *Su*, urinogenital sinus; *Cl*, cloaca; *Ba*, gland of Bartholini; *GD*, Cowper's gland; *Pr*, *Pr*, prostate gland; *R*, rectum; *Ggl*, copulatory organ. (In Fig. A the clitoris is indicated, but not lettered.)

(**Wolffian duct**¹ or **vas deferens**), while in the female it usually becomes rudimentary, and is then spoken of as **Gärtner's duct** (Fig. 236, A, *Gg*). The metanephric duct or **ureter** (Fig. 236, *Ur*) (which is possibly confined to the Amniota),² serves to carry off the products of urinary excretion in both sexes.

¹ The term **Wolffian duct** is used to describe the duct of the mesonephros after the formation of the Müllerian duct, whether the latter is developed independently or not.

² Comp. note on p. 298.

The Müllerian duct (Fig. 236, B, *MG*) of the female gives rise to the **oviduct**, and in Mammals becomes distinctly differentiated into three portions,—a Fallopian tube, a uterus, and a vagina, the latter of which opens to the exterior (Fig. 236, A, *Ot*, *Ut*, *Vg*). The Fallopian end of the oviduct always opens into the abdominal cavity by a ciliated funnel-shaped aperture. This abdominal aperture represents the only connection between the body-cavity and the exterior in the Amniota, where the nephrostomes no longer appear in the course of development.¹

In the male, the Müllerian duct is always developed, but plays no important part, coming into the category of rudimentary organs. It will be further treated of together with the generative organs in a later chapter.

URINARY ORGANS.²

Fishes and Dipnoi.—The Myxinoids retain throughout life a functional pronephros which is provided with numerous peritoneal apertures and a limited number of glomeruli.

In *Petromyzon* slight rudiments of the pronephros of the larva (*Ammocœtes*) alone persist, and the mesonephros with its (segmental) duct becomes the functional urinary organ.

In the Teleostei the pronephros may possibly persist in some cases, but further researches are necessary on this point. The mesonephros constitutes the main, if not the entire, excretory organ of the adult, and consists of a narrow band varying in size, which lies on the dorsal side of the body-cavity, between the vertebral column and the air-bladder.³ Secondary fusions between the organ of either side often occur, and this is also true of Ganoids. The urinary duct in both groups probably represents the primary segmental duct, and may lie more or less freely, or be embedded in the substance of the kidney. Posteriorly the two ducts usually fuse together and become expanded to form a kind of urinary bladder, which has evidently nothing to do with the similarly-named organ (allantoic bladder) of Amphibia and Amniota (comp. p. 273). The "bladder" usually opens behind the anus,—either independently, or together with the genital ducts,—by a simple pore, or on the summit of a urinogenital papilla.

The splitting of the segmental duct into a Wolffian and a Müllerian duct is not known to occur in Teleostei; in Elasmobranchs this differentiation does take place, and at the same time a

¹ For a different view see Mikalovics in the notes on pp. 296 and 300.

² No urinary organ is at present known to exist in *Amphioxus*.

³ The delicate glistening threads from which the nest of the Sea-Stickleback (*Spinachia vulgaris*) is made are formed as a secretion of the urinary tubules, which undergo a change of function at the breeding-season. The secretion is mucin, which becomes hard in water (Möbius).

division of the mesonephros into an anterior and a posterior section may be observed (comp. Figs. 237, *pd*, and 238, *m.d*, *w.d*, *s.t*). In

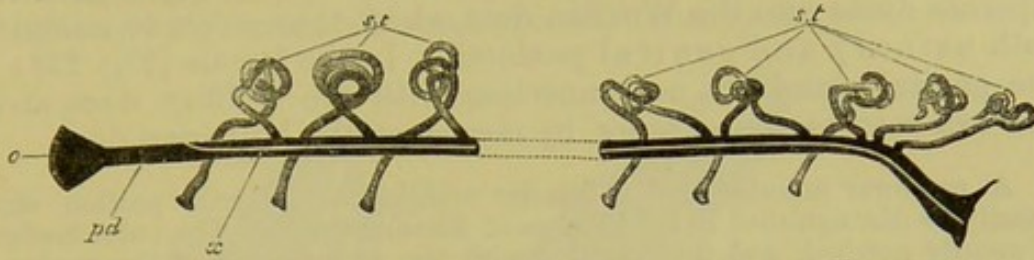


FIG. 237.—DIAGRAM OF THE PRIMITIVE CONDITION OF THE KIDNEY IN AN ELASMOBRANCH EMBRYO. (After Balfour.)

pd, segmental duct: it opens at *o* into the body-cavity, and its other extremity communicates with the cloaca; *x*, line along which the division appears which separates the segmental duct into Leydig's (Wolffian) duct above, and the Müllerian duct below; *s.t*, segmental tubes: they open at one end in the body-cavity, and at the other into the segmental duct.

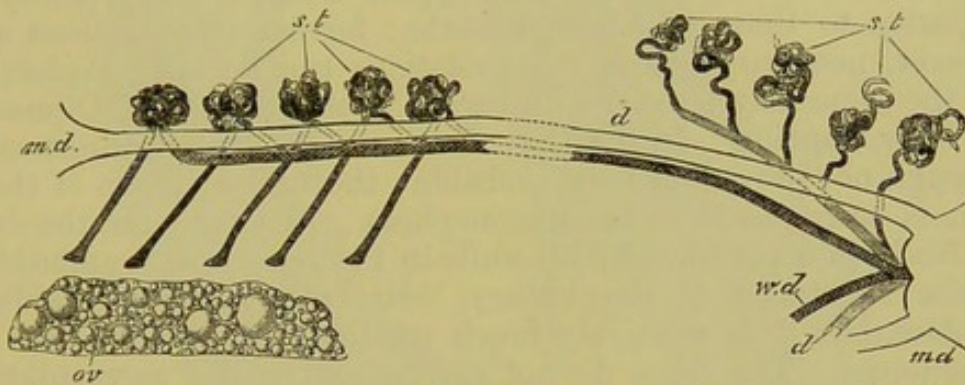


FIG. 238A.—DIAGRAM OF THE ARRANGEMENT OF THE URINOGENITAL ORGANS IN AN ADULT FEMALE ELASMOBRANCH. (After Balfour.)

m.d, Müllerian duct; *w.d*, Leydig's (Wolffian) duct; *d*, ureter; *s.t*, segmental tubes: five of them are represented with openings into the body-cavity: the posterior segmental tubes form the mesonephros; *ov*, ovary.

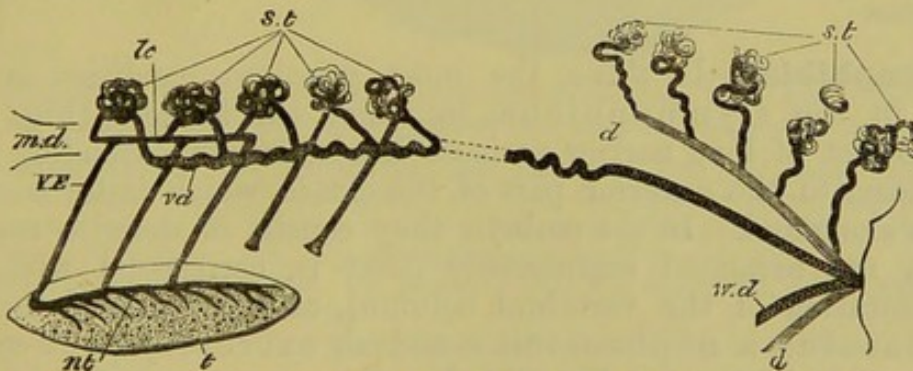


FIG. 238B.—DIAGRAM OF THE ARRANGEMENT OF THE URINOGENITAL ORGANS IN AN ADULT MALE ELASMOBRANCH. (After Balfour.)

m.d, rudiments of Müllerian duct; *w.d*, Leydig's (Wolffian) duct, marked *vd* in front, and serving as vas deferens; *s.t*, segmental tubes: two of them are represented with openings into the body-cavity; *d*, ureter; *t*, testis; *nt*, canal at the base of the testis; *VE*, vasa efferentia; *lc*, longitudinal canal of the Wolffian body.

the male, the former comes into connection with the genital gland (Fig. 238B, *VE*, *nt*, *t*), and its tubules open directly into the

Wolffian duct; while the latter, which persists as the permanent kidney (comp. note on p. 298), empties its secretion by means of separate ducts into the Wolffian duct, which thus serves to conduct both urinary and genital products. In the female (Fig. 238A) the genital gland has no connection with the Wolffian duct, and the ova pass to the exterior by means of the Müllerian duct.

A narrower anterior, and a broader middle and posterior portion can usually be distinguished in the kidneys of Elasmobranchs. The outer border is usually notched, and this, together with the arrangement of the nephrostomes in the embryo, points to the original segmental arrangement of the organ. The segmental character, however, disappears later on; in the adult the nephrostomes are without exception much less numerous than the vertebræ of this region, but their number and size varies much in different genera and even in individuals.

The kidneys of Sturgeons appear to show many points of similarity to those of Elasmobranchs; further investigations are, however, necessary before their relations can be fully explained, and the same may be said with regard to the kidneys of Dipnoans and bony Ganoids. In the Dipnoi, the existence of nephrostomes, although not proved, is very probable; the urinary organ of these animals corresponds to the mesonephros. In *Ceratodus*, the duct lies freely in a peritoneal fold, while in *Protopterus* it is embedded in the substance of the kidney. In both forms the kidney is lobulated; it is relatively much smaller in *Ceratodus* than in *Protopterus*. The lobes do not correspond to the segmentation of the vertebral column.

A close examination of the organ which has usually been spoken of as the kidney in Teleostei and Ganoids shows that a larger or smaller portion of it—more particularly the anterior part—consists of an adenoid or lymphoid substance.

Amphibia.—In these, the most primitive condition is met with in the *Gymnophiona*, in which the kidneys (Fig. 239, *Ni*) consist of long narrow varicose bands, usually extending from the heart to the anterior part of the cloaca, which latter is often much elongated. In the embryo they consist of definite masses, which are arranged segmentally (that is, correspond with the segmentation of the vertebral column), and in each of them a glomerulus, a nephrostome, and an excretory duct can be distinguished (compare Fig. 234A).

This condition sometimes persists in the anterior portion of the kidney, while, owing to secondary processes of growth, as many as twenty nephrostomes are later on met with in a single body-segment. The number of nephrostomes in the entire kidney may amount to a thousand or more.

As regards the urinary duct and the relations of the entire renal apparatus to the generative organs, the *Gymnophiona* in all essential points resemble other Amphibians.

The kidneys of Urodela and Anura lie in the usual position on the dorsal side of the body-cavity; in the former they are band-like and more extended longitudinally than in the latter, in which

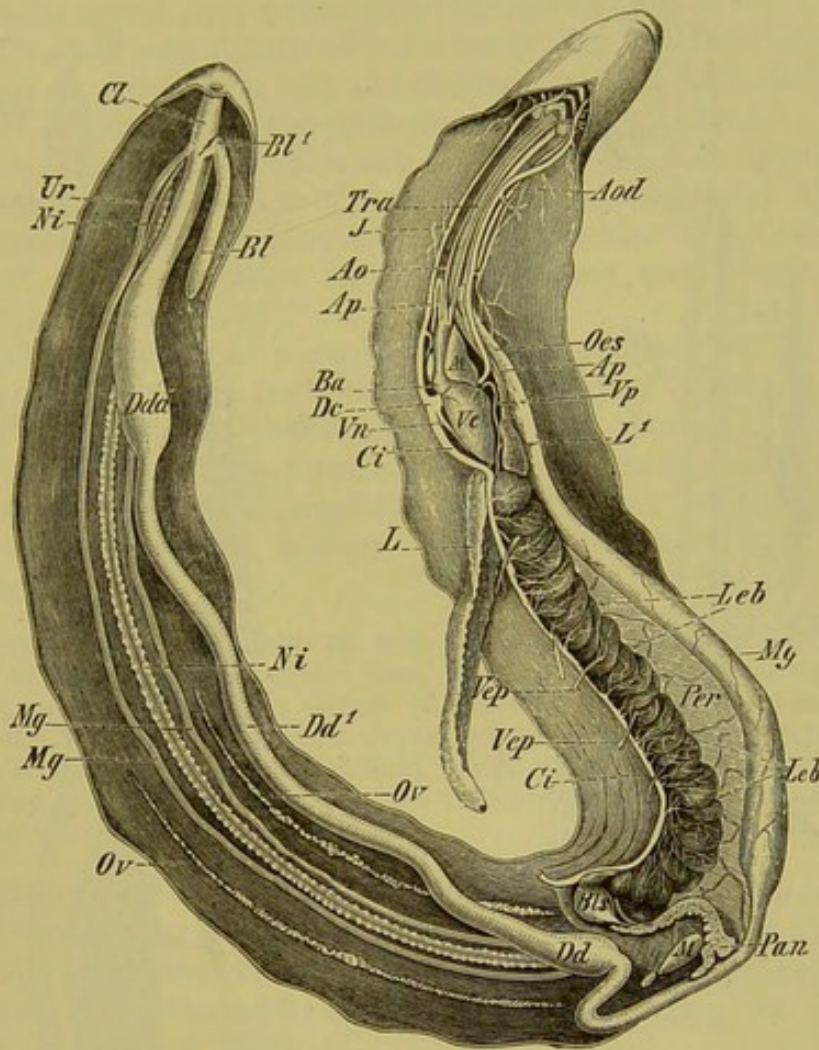


FIG. 239.—THE ENTIRE VISCERA OF *Siphonops annulatus* (♀) *in situ*. (The body-wall is slit up along the median ventral line, and its two halves reflected.)

Intestinal tract.—*Oes*, œsophagus; *Mg*, stomach; *Dd*, *Dd*¹, small intestine; *Dda*, large intestine; *Cl*, cloaca; *Bl*, *Bl*¹, the anterior larger and posterior smaller end of the urinary bladder; *Leb*, liver; *Bls*, gall-bladder; *Pan*, pancreas; *M*, spleen; *Per*, peritoneum (gastro-hepatic omentum).

Urinogenital organs.—*Ov*, *Ov*, ovaries; *Mg*, *Mg*, Müllerian ducts (oviducts); *Ni*, *Ni*, kidneys; *Ur*, ureter.

Respiratory organs.—*L*, well-developed right lung; *L*¹, rudimentary left lung; *Tra*, trachea.

Organs of circulation.—*Vc*, ventricle; *At*, atrium; *Ba*, conus arteriosus; *Ao*, aorta ascendens of left side: that of the right is not specially indicated; *Aod*, aorta descendens of left side; *Ap*, *Ap*, pulmonary artery; *Vp*, pulmonary vein; *Vn*, vein receiving blood from the urinogenital organs, the muscles of the back, and the vertebral canal; *J*, jugular vein; *Ci*, postcaval; *Dc*, ductus Cuvieri; *Vep*, *Vep*, hepatic portal veins.

they are shorter and more compact, and confined to the middle portion of the cœlome.

In Urodèles they always consist of a narrow anterior, and a

broader and more compact posterior portion. The latter gives rise to the functional kidney (Fig. 240, *N*), while the former becomes connected in the male with the generative organs. Delicate ducts,

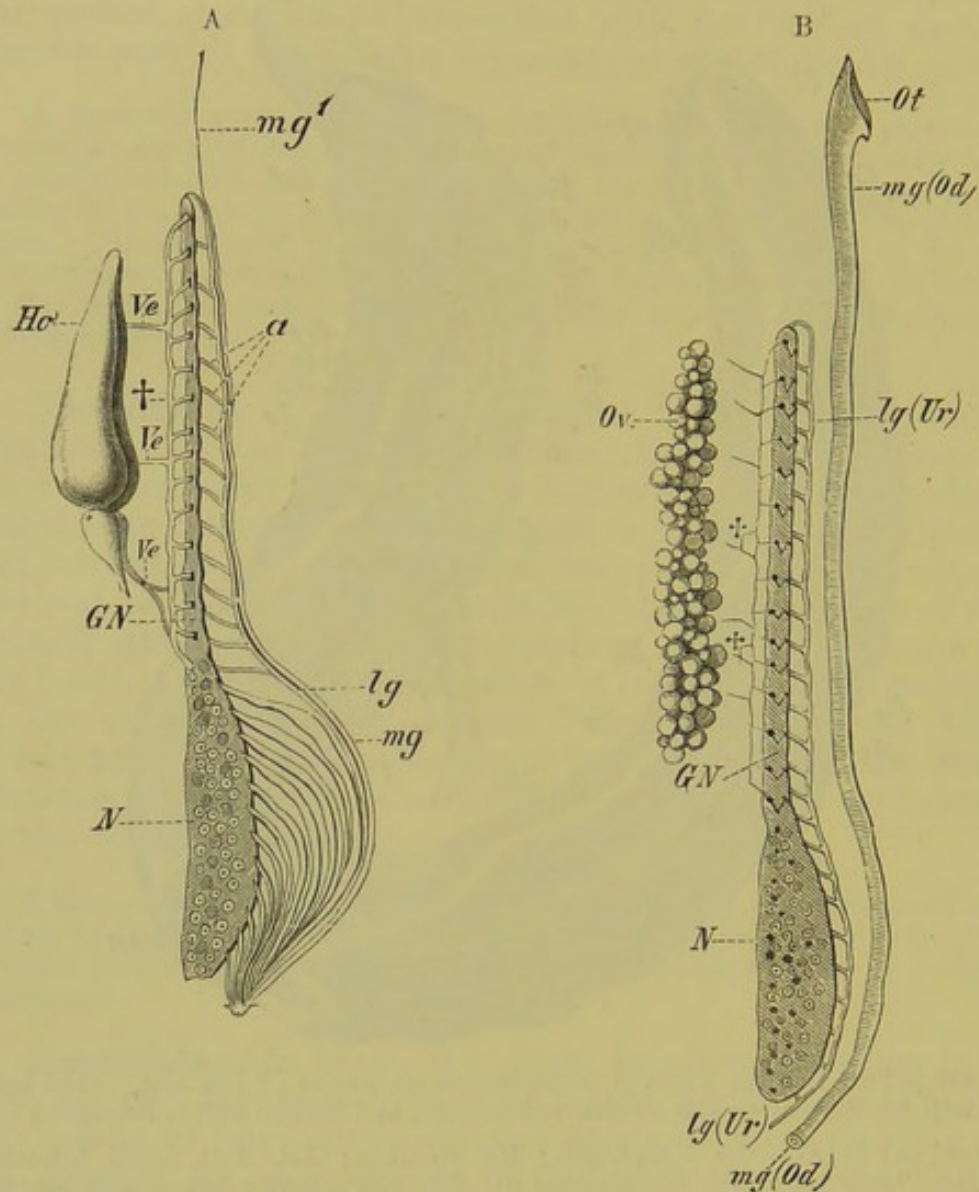


FIG. 240.—DIAGRAM OF THE URINOGENITAL SYSTEM OF A MALE (A) AND FEMALE (B) URODELE; FOUNDED ON A PREPARATION OF *Triton taeniatum*. (After J. W. Spengel.)

Ho, testis; *Ve*, *Ve*, vasa efferentia of testis, which fall into the longitudinal canal of the Wolffian body, †; *a*, collecting tubes of the mesonephros, which fall into the Wolffian (urinogenital or Leydig's) duct (*lg*, *lg*); the latter serves in the female (Fig. B, *lg*) simply as the urinary duct (*Ur*); the system of the vasa efferentia (testicular network) is here rudimentary; *mg*, *mg*¹ (*Od*), Müllerian duct; *Ot*, peritoneal aperture of latter in the female; *Ov*, ovary; *GN*, anterior sexual portion of kidney (parorchis of the male); *N*, posterior non-sexual portion of kidney.

or vasa efferentia, pass out from the testis (Fig. 240, A, *Ho*, *Ve*, *Ve*) into the substance of the anterior portion of the kidney, and there open into the urinary tubules; they may either enter the kidney

direct, or else open first into a longitudinal collecting duct (†), from which fine canals pass to the urinary tubules. Thus the seminal fluid passes through the nephridia as well as through the Wolffian duct, which serves as a urinogenital duct (Fig. 240, A, *lg, a*).

In Urodela and Anura of both sexes the Wolffian duct opens separately on either side into the cloaca, receiving first, in Urodeles, a number of ducts from the posterior part of the kidney.¹

The urinary bladder, which is usually bilobed, opens on the ventral wall of the cloaca opposite to the urinogenital apertures. The morphological signification of the bladder has already been explained in the chapters on the alimentary canal and vascular system (pp. 231 and 273).

Slight indications of a segmental arrangement are found only in the anterior sexual portion of the kidney of Urodeles; in the posterior part, and in the entire kidney of Anura, all traces of segmentation have disappeared. In both cases, however, the nephrostomes remain throughout life in great numbers on the ventral surface of the kidney, which is covered over by the peritoneum.

The nephrostomes are connected with the urinary tubules in larval Anura, but later on they become separated from them, and open into the renal-portal vein. In consequence of this change of function, for such it must be considered, the body-cavity of adult Anura serves as a closed lymph-sinus, as in the Amniota; the peritoneal fluid, which in the larva was carried to the exterior and lost, is in the adult poured into the general circulation, like the rest of the lymph.

Reptiles and Birds.—In these, as in all other Amniota, the mesonephros, so far as it is retained beyond the embryonic period, is entirely separate from the functional excretory apparatus; this consists of a metanephros, entirely wanting in nephrostomes (compare p. 298).

The metanephros never extends so far along the body-cavity as does the mesonephros; as a rule it has the form of a small compact or lobulated organ, usually lying within the posterior half of the body-cavity, or even entirely confined to the pelvic region; it has the latter position, for instance, in most Reptiles (Fig. 241, *N*) and all Birds (Fig. 242, *N*). The posterior end of the kidney, which is generally narrower than the rest, may even extend under the root of the tail, as in *Lacerta*, in which region there is a fusion of the organ of either side.

Thus, according to the position of the kidneys, the ureters either do not extend any distance along the body-cavity, or they may have a longer or shorter free course. The latter is the case, for instance, in Crocodiles, and more especially in Birds (Fig. 242, *Ur*): in the last-named the kidneys lie closely embedded

¹ In Anura the Wolffian ducts pass some distance independently along the body-cavity, in correspondence with the position of the kidneys; in the male each is often provided with an enlargement, the vesicula seminalis.

within the pelvis, and their ventral flattened surface is usually lobulated, and often penetrated by deep furrows and clefts in which the veins lie embedded (Fig. 242, *V*, *V'*); their posterior ends may fuse together in the middle line, as in Lizards.

There is not always a perfect symmetry between the organ of either side, and this is most marked in Snakes, in which the

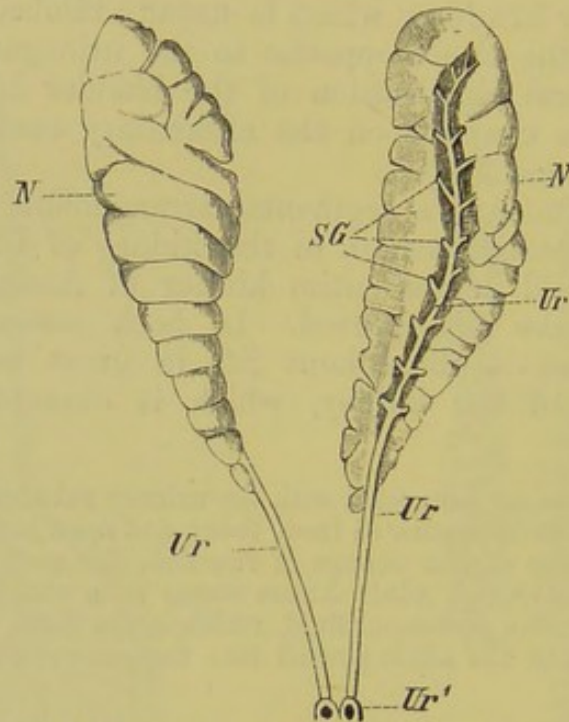


FIG. 241.—EXCRETORY APPARATUS OF *Monitor indicus*.

The right kidney is shown in its natural position, while the left is turned on its longitudinal axis, so that the ureter and the collecting tubes are visible. The urinary bladder is not represented.

N, *N*, kidneys; *SG*, collecting tubes which open into the ureter (*Ur*, *Ur*²); *Ur*¹ aperture of ureter into the cloaca.

greatly lobulated kidneys, like those of limbless Lizards, are elongated, narrow, and band-like, in correspondence with the form of the body.

A urinary bladder, arising from the ventral wall of the cloaca, is present in Lizards and Chelonians; it is usually bilobed, as in Amphibia, and so points to a primitively paired condition. A bladder is wanting in Snakes, Crocodiles, and Birds.

Mammals.—The kidneys of Mammals are proportionately small, and lie on the quadratus lumborum muscle and ribs. They usually possess a convex outer, and a concave inner border; the latter is called the hilum, and at this point the ureters arise and the blood-vessels enter. The expanded proximal portion of the ureter is divided up to form one or more calyces (Fig. 243, *Ca*), into which small papilliform processes of the pyramids (see

p. 310) project; on the summits of these the urinary tubules open in varying number (between *Pr* and *Ca*). The calyces are continuous with a large cavity in the widened portion of the ureter called the pelvis (*Pe*), and from this the ureter (*Ur*) passes backwards to

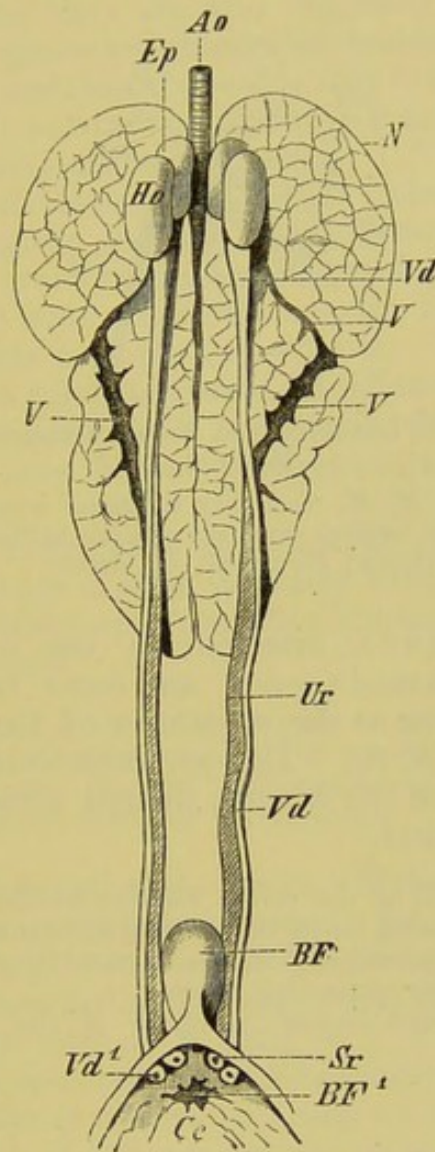


FIG. 242.—MALE URINOGENITAL APPARATUS OF HERON (*Ardea cinerea*).

N, kidneys; *Ur*, ureter, opening into the cloaca (*Ce*) at *Sr*; *Ho*, testis; *Ep*, epididymis; *Vd*, vas deferens, which opens at *Vd*¹ on a papilla in the cloaca; *V*, *V*, furrows on the ventral surface of the kidney in which veins lie embedded; *Ao*, aorta; *BF*, bursa Fabricii, which opens into the cloaca at *BF*¹.

open into the bladder on its dorsal side, sometimes nearer the apex, sometimes towards the fundus.

The urethra, arising from the bladder, is always short in the female, while in the male it is drawn out into a long tube which extends through the penis, and is lined by erectile tissue (corpus spongiosum) (comp. p. 329).

The definitive kidney (metanephros) is greatly lobulated in

the embryo; this condition may remain throughout life (*e.g.*, Cetacea, Pinnipedia, Ursus, Lutra, Bos), or the lobes may become more or less completely united. In the latter case the original division into lobes may still be recognised more or less plainly internally. A section of the kidney shows an inner layer, the

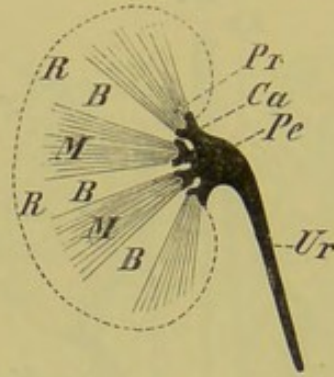


FIG. 243.—DIAGRAMMATIC LONGITUDINAL SECTION THROUGH THE KIDNEY OF A MAMMAL.

R, R, cortical substance; *M, M*, medullary substance arranged in pyramids (*Pr*): between the latter the cortical substance extends in the form of the columns of Bertini (*B, B*); *Ca*, calyces; *Pe*, pelvis; *Ur*, ureter.

medullary substance, arranged in the form of wedges,—the urinary pyramids,—and an outer layer, or cortical substance, extending as the columns of Bertini between the pyramids (Fig. 243, *R, B*). The pyramids correspond roughly to the embryonic lobes of the kidney, though several lobes may fuse together in one pyramid.

The glomeruli as well as the coiled tubules, which are surrounded by a network of blood-capillaries, lie in the cortical substance, while the so-called straight tubules occur principally in the pyramids, where they gradually anastomose to form larger collecting tubes.

Concerning the morphological relations of the urinary bladder of Mammals, comp. p. 274.

GENERATIVE ORGANS.

In **Amphioxus** the generative “glands” or **gonads** remain for a long time in an undifferentiated condition as regards sex. They have a marked segmental arrangement, and each portion opens separately into the peribranchial cavity, whence the generative products pass to the exterior through the atrial pore.

Fishes.—Specially differentiated generative ducts are wanting in Cyclostomes, as well as in Eels, female Salmonidæ, and *Læmargus borealis* (an Elasmobranch). In these cases, both sperm and ova are shed directly into the body-cavity, whence they pass out through the abdominal pores (see p. 265.)

The generative gland of Cyclostomes consists of a long unpaired organ suspended to the dorsal wall of the body-cavity by a fold of peritoneum, the mesoarrium or mesorchium, as the case may be. In other Fishes, the gonads are only exceptionally unpaired, and even then, this is only a secondary condition: in all other Vertebrates they are also originally paired. There is usually a want of symmetry observable between the organ of the right and left sides, and that of one side may even entirely disappear, as in *Ammodytes tobianus*, *Cobitis barbatula*, and others. Secondary fusions may also take place.

The ovaries and testes of Teleostei closely correspond with one another as regards position and the arrangement of their ducts. The ovary usually forms an elongated sac, which is blind anteriorly, and on the inner walls of which the ova arise; this sac is continued backwards to form the oviduct. The latter, which is generally short, as a rule fuses with its fellow to form an unpaired canal; this opens either on a level with the integument or on a papilla, which may become elongated to form a tube or "ovipositor."¹

The testis of Teleosteans is elongated, and often lobulated in form. Its duct, which is often intensely white, opens between the rectum and the urinary aperture, after uniting with its fellow to form an unpaired canal.

In cases where traces of copulatory organs or other accessory structures—which are spoken of as "seminal vesicles," or "prostates,"—are present, they, like the so-called urinary bladder, have nothing whatever to do with the similarly-named structures of higher Vertebrates.

In the above description the terms "Müllerian" and "Wolffian ducts" have been purposely avoided, for it is very doubtful whether the generative ducts of Teleostei are in any way homologous with them, and further investigations are necessary to decide the question (comp. note on p. 313).

In by far the greater number of Elasmobranchs the ovaries are paired, and this is always the case as regards the oviducts, which, unlike those of Teleosteans, are always separate from the ovaries, and correspond to the Müllerian ducts. Their anterior portion has a common opening into the body-cavity, and further back each is provided with a so-called "oviducal gland." The anterior part of the oviduct is always narrower and more delicate than the posterior, which dilates to form a kind of uterus, in which (when the shark is viviparous) the embryo undergoes

¹ In the genus *Girardinus*, which, like many other Fishes (numerous Elasmobranchs for instance), brings forth its young alive, the body-cavity of the female is much longer than that of the male, and the ovary serves also for a uterus. Contrary to the general rule, the ova do not become free from their place of origin before fertilisation, so that the spermatozoa must bore their way through the germinal and follicular epithelium, and thus even pass into the parenchyma of the ovary.

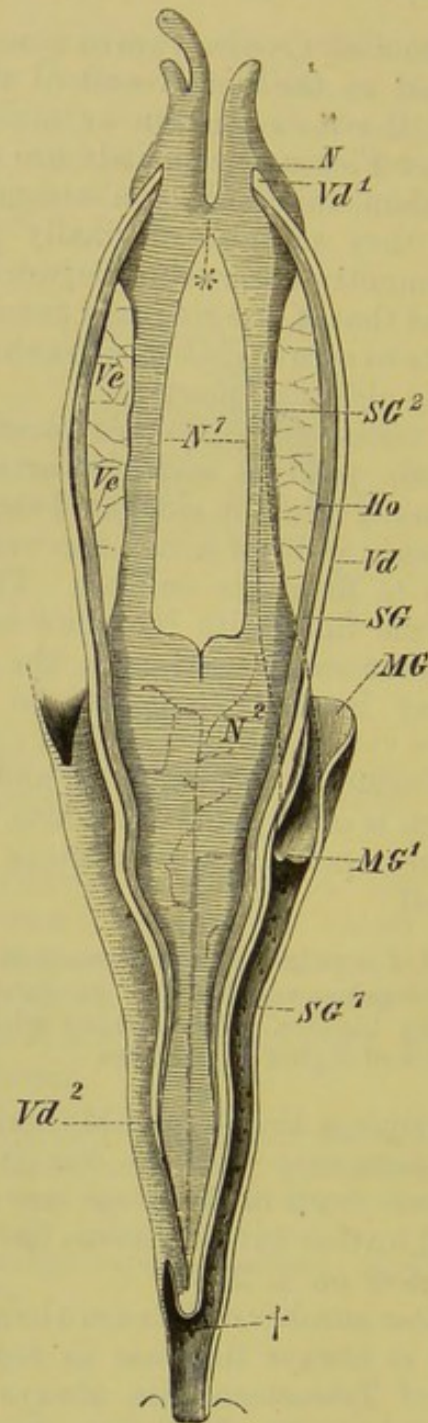


FIG. 244.—MALE URINOGENITAL APPARATUS OF THE STURGEON.

N, *N¹*, *N²*, the different portions of the kidneys; *SG*, *SG¹*, *SG²*, the different parts of the ducts of the kidneys; *Vd*, *Vd¹*, *Vd²*, vas deferens; *Ho*, testis; *Ve*, *Ve*, network of the vasa efferentia; *MG*, Müllerian duct, which unites with the collecting duct of the kidneys at *MG¹*; †, point at which the two collecting ducts of the kidneys unite.

development.¹ Posteriorly, the oviducts open into the cloaca somewhat behind the apertures of the ureters—either separately, or by a common canal.

¹ The greater number of Sharks are viviparous. (Concerning the umbilical placenta found in *Mustelus laevis* and *Carcharias*, comp. p. 12.)

The embryos of *Mustelus antarcticus* are provided with membranes which bear

The testis of Elasmobranchs is always paired and symmetrical, and usually lies, supported by the mesorchium, towards

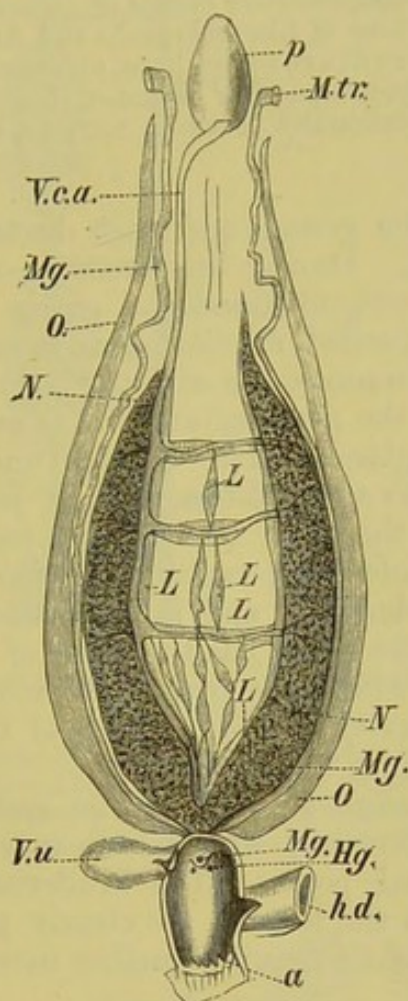


FIG. 245.—FEMALE URINOGENITAL APPARATUS OF *Protopterus annectens*. (From the ventral side, natural size.) (After H. Ayers.)

a, vent; *h.d.*, rectum; *Hg*, apertures of ureters into cloaca; *L, L*, lymphoid tissue; *Mg*, Müllerian duct; *M.tr.*, abdominal aperture of latter; *N*, kidney; *O*, ovary; *p*, lung; *V.c.a.*, postcaval vein; *V.u.*, urinary bladder.

the anterior portion of the body-cavity. The relations of the vasa efferentia to the mesonephros have been already mentioned (comp. pp. 298 and 303, and Fig. 238B), and a somewhat similar arrangement is seen in *Lepidosteus*.

Amongst Ganoids, the female organs of *Lepidosteus*¹ are formed on the same type as those of the Teleostei, while in cartilaginous Ganoids a more or less incomplete splitting of the segmental duct into a Müllerian and a

a superficial resemblance to the amnion and chorion of Mammals, but these are both formed from the maternal tissues (T. J. Parker).

¹ The cavity within the ovary of *Lepidosteus* is formed by a fold of peritoneum on either border of the gland growing towards its fellow, and meeting in the middle line: into this cavity the ova are shed, and are carried to the exterior by an oviduct which is probably formed by continuations of these peritoneal folds behind the ovary. A similar mode of development of the oviduct possibly also obtains in Teleostei.

Wolffian duct takes place (Fig. 244, *MG*). The latter probably serves in the male as a urinogenital duct, and in the female as a urinary duct only. Should more complete histological examination confirm these statements, the mode of development of the generative organs of cartilaginous Ganoids will be seen to resemble closely those of Elasmobranchs and Amphibians.

Hermaphrodite structures have been observed in certain Fishes: in the different species of Serranus, for instance, they are constantly present. Hermaphroditism also occasionally occurs in Sargus, Gadus morrhua, and many others.

In the Dipnoi, the gonads and their ducts lie along the outer border of the kidneys. During the breeding-season they become greatly enlarged, and extend round the entire gut. The oviducts are long and slightly coiled, reminding us in many points of those of Amphibia: each communicates with the body-cavity by a funnel-shaped aperture near the pericardium, and is provided with a well-developed albumen gland. The ovaries undergo the greatest variations according to age and the time of year. In the unripe condition they have the form of long and narrow bands, which extend along the whole body-cavity. In the young *Ceratodus* they are distinctly lobulated, and in both *Ceratodus* and *Protopterus* each ovary of the adult has the form of a thin-walled sac, in the inner walls of which the ova are developed. The eggs are shed into the body-cavity by the bursting of the walls of the sac, and they pass thence into the oviducts.

In the male, the manner in which the sperm is conducted to the exterior is not certainly known: it may possibly pass out through the abdominal pores. The Müllerian ducts, although less developed than in the female, are clearly present in the male. The structure of the testis requires further investigation.

Amphibia.—The gonads of Amphibia are usually situated in about the middle of the body-cavity: they are paired and symmetrical, and lie right and left of the vertebral column; their form is usually modified by the shape of the body. Thus in the *Gymnophiona* (Fig. 239, *Ov*), the ovary has the form of a long and narrow band, while the testis is made up of a long chain of small bodies united together by a collecting duct (Fig. 246, *Ho*, *Sg*). Each individual portion of the testis of Cæcilians is made up of a double row of rounded capsules (Fig. 246, *K*), in which the sperm is formed, and from which it is passed into a collecting duct (*Sg*), which perforates each portion of the organ. A transverse canal (*Q*) is given off from the free portion of the collecting duct lying between every pair of testis lobes; this passes towards the kidneys (*N*, *N*), and opens into a longitudinal canal (*L*). From the latter the sperm passes through a second system of transverse canals (*Q*¹, *Q*¹) to the Malpighian capsules, and thence through the urinary tubules into the urinogenital duct (*HS*).

The male generative apparatus of all Urodela and certain Anura (*Bufo*idæ), corresponds in the main with the arrange-

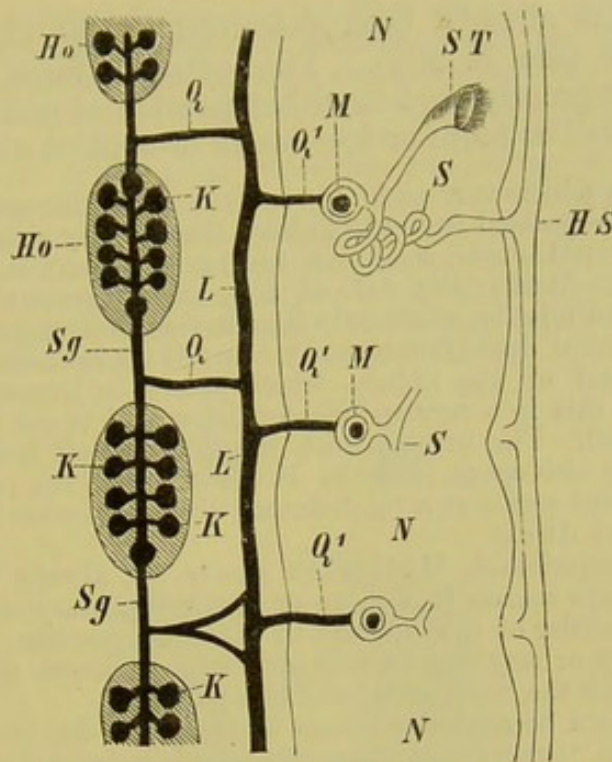


FIG. 246.—DIAGRAM OF A PORTION OF THE MALE GENERATIVE APPARATUS OF THE GYMNOPHIONA.

Ho, Ho, testis; *Sg*, collecting duct of testis; *K, K*, testicular capsules; *Q, Q*, transverse canals connecting the collecting duct with the longitudinal canal (*L, L*); *Q¹, Q¹*, second series of transverse canals; *M, M*, Malpighian capsules; *N, N*, kidney; *ST, ST*, nephrostome; *S*, convoluted portion of urinary tubule; *HS*, urinogenital duct.

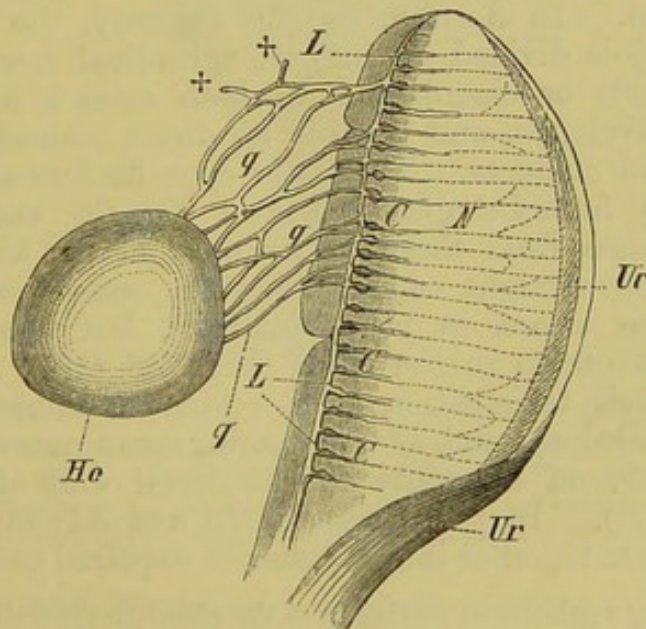


FIG. 247.—TESTIS AND ANTERIOR END OF KIDNEY OF *Rana esculenta*.
(Semidiagrammatic.)

Ho, testis; *q, q*, transverse canals of the testicular network, which give rise to blind processes at ++; *L*, longitudinal canal of the testicular network, from which the inter-renal network (*C, C*) arises; *N*, kidney; *Ur*, urinogenital duct.

ment which has already been described in the chapter on the urinary organs (see p. 306). The external form of the testis, however, varies greatly, and is either pointed at one or both ends (Fig. 240, A, *Hv*), or more or less round or oval (*Anura*).

In *Rana*, *Bombinator*, and *Alytes* the vasa efferentia of the testis become gradually separated from the kidney, that is, they either open directly into the urinogenital duct, without becoming connected with the urinary tubules (*Rana*) (Fig. 247, C, *Ur*), or the greater number of the posterior canals end blindly, while only the anterior ones are directly connected with the urinogenital duct (*Bombinator*). In *Alytes*, those vasa efferentia at the anterior end of the kidney which possess a lumen open into the Müllerian duct: this is a very special condition, and is not known to occur in any other animal. The urinary duct, which comes off from the posterior end of the kidney also opens into the Müllerian duct, the portion of which anterior to this point serves as a vas deferens, while its posterior part functions as a urinogenital duct.

In all other Amphibians, Müllerian ducts are always present, but in the male they always remain in a more or less rudimentary condition, and lie along the outer border of the kidneys in a similar position to those of the female. They may or may not be provided with a lumen and apertures of communication with the body-cavity and cloaca.

Hermaphroditism occasionally occurs amongst the *Anura*. In the males of *Rana temporaria* "ova" are at times developed, embedded within the substance of the testis (Hermaphrodite gland, or ovotestis), and one testis may even be replaced by a rudimentary ovary. In these cases, the Müllerian duct may be as well developed as in the female. A body attached to the anterior end of the testis in various species of Toads ("Bidder's organ") also apparently represents a rudimentary ovary.

The ovaries of *Urodela* are always formed on a common plan. Each consists of an elongated closed tube, with a continuous lumen. In *Anura*, on the contrary, the ovarian sac (Fig. 248, *Ov*) is divided up into a longitudinal row of (3 to 20) separate pockets or chambers. In both cases a mesoarium is always well developed, and there is no direct connection between the ovaries and oviducts. The latter open far forwards into the body-cavity by funnel-shaped apertures (*Od*, *Ot*), and at a considerable distance from the anterior ends of the kidneys: they take a tolerably straight course along the outer borders of the kidneys to the cloaca in young animals, but become greatly coiled and convoluted in the adult (Fig. 248, *Od*). A short distance from their termination each oviduct becomes dilated to form a thin-walled sac, and, after becoming again narrowed, usually opens separately on a papilla on the dorsal wall of the cloaca (Fig. 248, *Ut*, *P*). In the genera *Bufo* and *Alytes* alone, the two oviducts fuse together into a posterior unpaired canal.

After receiving a gelatinous coating from the glands in the wall of the middle part of the oviduct, the eggs pass into the dilated portion of the duct, and become united together into irregular masses (*Frog*) or chains (*Toad*).¹

¹ According to P. B. and C. F. Sarasin, *Epicrion glutinosum* (*Gymnophiona*) is oviparous. The eggs are very similar to those of *Sauropsida*: they are exceptionally large (9 mm. long), of an oval shape, and possess a large yolk, which is light-

Finally, the so-called fat-bodies (*corpora adiposa*) must be mentioned: these are present in all Amphibia in connection with the generative glands, and are formed of adenoid substance, fat, and leucocytes, and contain numerous blood-vessels. They are apparently formed by the degeneration of the anterior part of the genital ridge, and "Bidder's organ" (see p. 316) in the Toad seems to represent a part of the ridge which has not become degenerated so far. The *corpora adiposa* probably have an important physiological (nutritive) relation to the generative glands; this gives an explanation of the fact that Amphibians, after remaining for months, throughout their winter sleep, without food, are able as soon as spring arrives to give rise to thousands of offspring. The curious lymphoid organs of many Fishes and Reptiles have probably a similar function (comp. pp. 304 and 320, and Fig. 245).

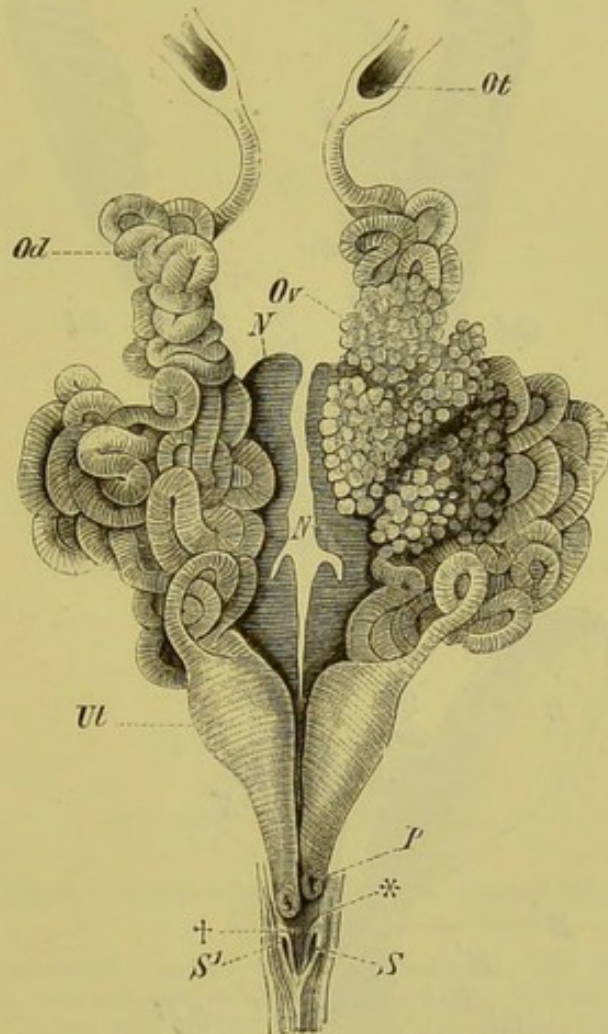


FIG. 248.—URINOGENITAL ORGANS OF A FEMALE *Rana esculenta*.

Ov, left ovary (that of the right side is removed); *Od*, oviduct; *Ot*, abdominal aperture of oviduct; *Ut*, the dilated posterior end of the oviduct; *P*, opening of latter into the cloaca; *N*, kidneys; *S*, *S'*, apertures of ureters into the cloaca, surrounded by longitudinal folds (*), which are separated by a deep depression (+).

Reptiles and Birds.—In these, as in other animals, the form of the gonads becomes modified by that of the body. Thus in

yellow in colour, and consists of both yellow and white granules. They are coated with a tough albumen in the oviduct, and this becomes drawn out at the poles into chalazae, by means of which the eggs are connected together like the beads of a necklace. They are laid in the earth, and the mother coils herself round them.

Chelonians they are broad, while in Snakes and snake-like Lizards they are more elongated. In the latter cases, as well as in other Lizards, they are asymmetrical, so that the organ of one side comes

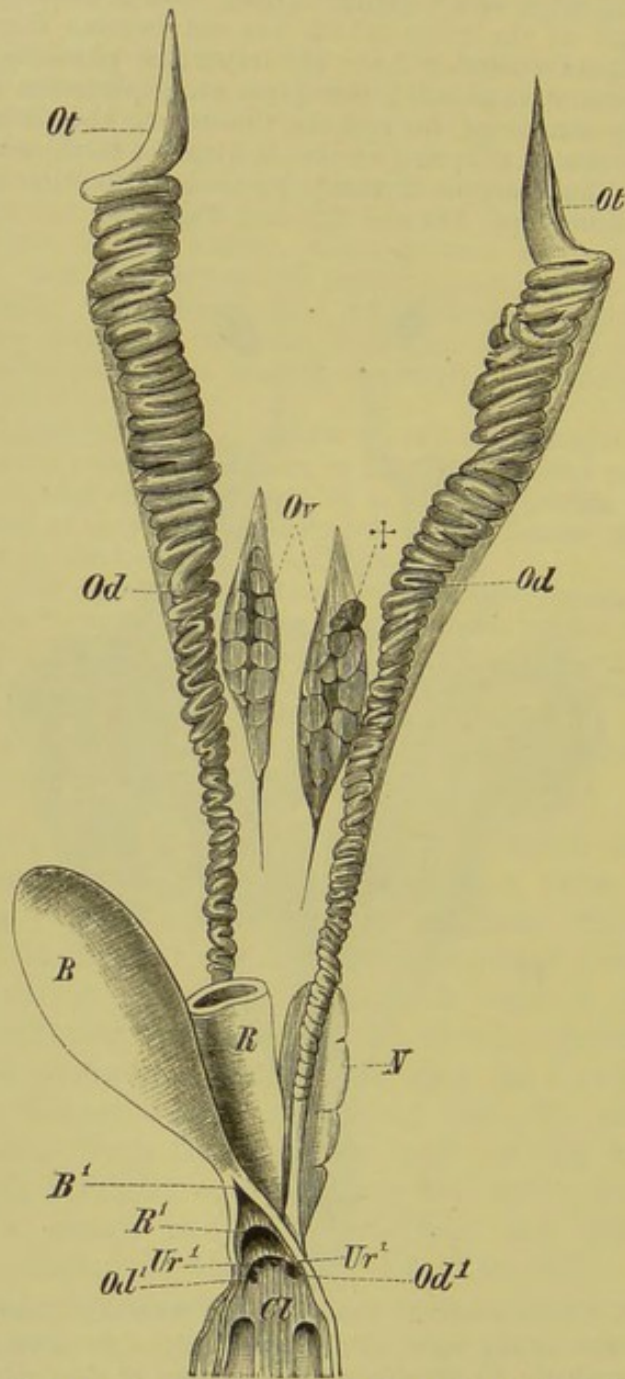


FIG. 249.—FEMALE URINOGENITAL APPARATUS OF *Lacerta muralis*.

N, kidneys; *Ur*¹, apertures of the ureters into the cloaca (*Cl*); *B*, urinary bladder; *B*¹, neck of the latter (cut open); *R*, rectum; *R*¹, opening of rectum into the cloaca; *Ov*, ovaries; †, remains of mesonephros; *Od*, oviducts, which open into the cloaca at *Od*¹; *Ot*, abdominal openings of oviducts.

to lie in front of that of the other. More room is thus obtained for the development of the ovaries, and, in cases where the eggs are very large, the organ of one side tends to disappear; in Birds,

for instance, the left ovary only is completely developed and functional.

In Reptiles the ovaries lie near the vertebral column, and are covered by peritoneum; their lumen is penetrated by a highly vascular network of trabeculæ, enclosing the ova. In the lymph-cavities thus formed the formation of ovarian follicles takes place. The development of follicles occurs throughout life in Reptiles, as

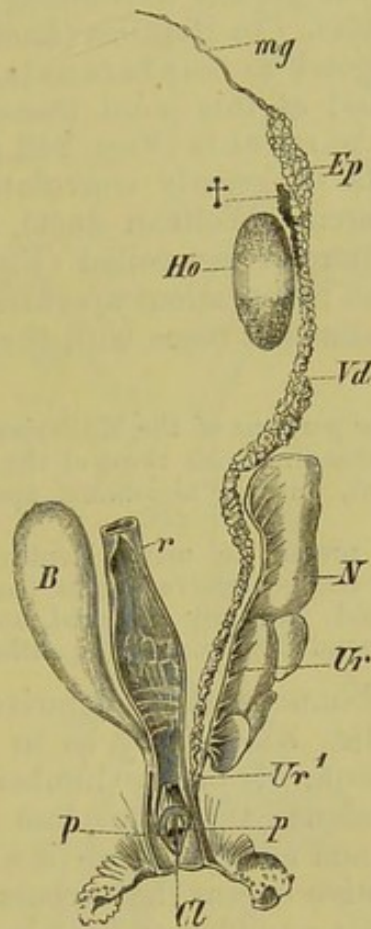


FIG. 250.—MALE URINOGENITAL ORGANS OF *Anguis fragilis*. (After F. Leydig.)

Ho, testis; †, the so-called "yellow body" (suprarenal); *Ep*, parorchis; *Vd*, vas deferens; *p, p*, common aperture of the ureter (*Ur, Ur¹*) and vas deferens on a papilla on the dorsal wall of the cloaca (*Cl*); *B*, urinary bladder; *r*, rectum; *N*, kidney; *mg*, rudiment of the Müllerian duct.

in the Anamnia, while in other Amniota it takes place only in the embryo, or at any rate for only a short time after birth.

The oviducts (Fig. 249, *Od, Ot*) possess wide funnel-shaped abdominal apertures, and are usually much folded transversely; their walls are provided with numerous muscular elements and glands for the formation of the albumen and egg-shell. They increase in size in the breeding-season. In Birds they are considerably coiled.

Only slight remnants of the mesonephros and Wolffian duct remain in the female in Reptiles, and these undergo fatty degeneration. They lie asymmetrically, arranged in a single row on either side, between the oviduct and vertebral column. The remains of the Wolffian duct are more marked in female Snakes, Chelonians, and in Geckos than in other Lizards.

The testes of Sauropsida correspond in position with the ovaries, and, like them, increase in size in the breeding-season. They have an oval, round, or pyriform shape (Figs. 242 and 250, *Ho*), and are made up of greatly convoluted seminal tubules, held together by fibrous tissue. In Reptiles (*Lacerta*, *Anguis*), "yellow bodies," which correspond to suprarenals, lie along the outer border of the testes, and at this point transverse canals pass out from the testis to the parorchis (Figs. 242 and 250, *Ep*).

The latter consists of greatly convoluted canals, and from it arises the vas deferens (Wolffian duct), which either takes a straight course, or is more or less coiled (Figs. 242 and 250, *Vd*). In Birds it opens by an independent aperture (Fig. 242, *Vd¹*) into the cloaca, while in Lizards it fuses with the ureter shortly before entering the latter.

Remains of the anterior portions of the Müllerian ducts are present in the male, their position corresponding with those of the female. Their lumen is not continuous throughout, but the abdominal aperture may remain open (*Emys europæa*).

Lymphoid organs are present in many Reptiles, and probably have a physiological relation to the generative organs (comp. p. 317). In many Lizards they are large and variously coloured, and lie within the pelvic region; in Snakes they extend along almost the entire body-cavity.

Mammals.—In Mammals the generative apparatus no longer extends along the entire body-cavity, as in the lower groups of Vertebrates, but is confined to the lumbar and pelvic regions. Moreover, in correspondence with the close relations which take place between mother and embryo, there is a much greater differentiation of the generative organs than occurs in lower types. The transition is not, however, a sudden one, for in the lowest Mammals, viz. the Monotremes¹ and Marsupials, these organs show many points of resemblance with those of Reptiles and Birds (comp. Figs. 251 and 252).

Thus in Monotremes the left ovary is more strongly developed than the right, and each has the appearance of a bunch of grapes; the cloaca persists, and the Müllerian ducts (oviducts) remain distinct from one another. A more or less complete separation of the oviducts is also seen in Marsupials, and this point deserves special attention on account of its important morphological significance.

In order to explain the gradual differentiation of these parts, their condition in the Didelphidæ (Opossums),—which come

¹ It has been recently proved that both *Ornithorhynchus* and *Echidna* lay eggs (Caldwell and Haacke) (comp. p. 5). Further details on these points are to be expected shortly.

nearest to the Monotremes,—must now be described in greater detail.

A dilated portion of each oviduct (Fig. 252, A, *Od*), giving rise to a uterus (*Ut*), is plainly distinguishable from the rest, and its

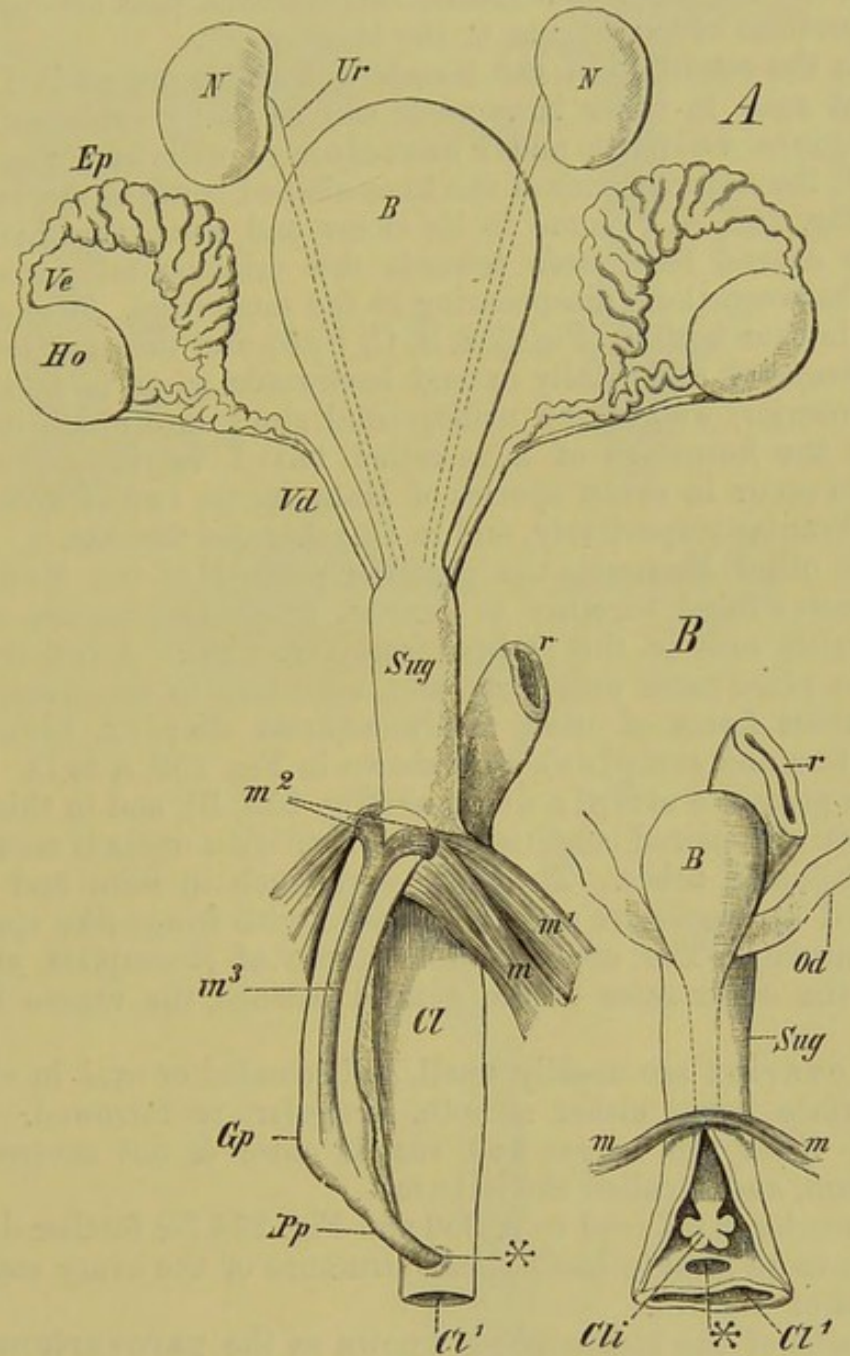


FIG. 251.—A, MALE URINOGENITAL ORGANS OF *Ornithorhynchus paradoxus* ;
 B, FEMALE URINOGENITAL ORGANS OF *Echidna hystrix*.

N, kidneys; *Ur*, ureter; *B*, urinary bladder; *Sug*, urinogenital sinus; *Ho*, testis; *Ve*, vas efferens; *Ep*, epididymis; *Vd*, vas deferens; *Od*, oviduct; *r*, rectum; *Cl*, cloaca, opening to the exterior at *Cl'*; *m* to *m*³, muscles of the cloaca and penis; *Gp*, glans penis, enclosed within its fibrous tube; *Pp*, prepuce; *Cli*, clitoris; *, *, aperture through which the copulatory organ extends into the cloaca.

narrowed posterior end comes into close contact with its fellow in the middle line. At this point (†) each uterus is connected with

the portion of the oviduct lying more posteriorly, or vagina (*Vg*), by a distinct os uteri. The vagina then curves sharply outwards, and, passing backwards, opens close to its fellow into the elongated urinogenital sinus (*Sug*). The ureters, as in all other Marsupials in which the vaginæ have a similar arrangement, pass between the curved portions of the vaginæ to the bladder (*B*).

From the condition of the female generative organs in Didelphys that seen in other Marsupials can be easily explained. In *Phalangista vulpina* and *Phascolomys wombat* (Fig. 252, B and C) the anterior ends of the knee-shaped bends of the vaginæ (comp. Fig. 252, A, †) come to lie closer and closer together, and begin to extend backwards towards the urinogenital sinus, the septum between them disappearing at the same time. A vaginal cæcum is thus formed (Fig. 252, B, C, *VgB*), and this may become more elongated, and finally extend backwards so as to meet the upper (anterior) wall of the urinogenital sinus, into which it may open by the formation of a so-called third vagina. This is known to occur in seven species of *Halmaturus*, two of *Petrogale* and *Osphranter* respectively, and in *Onychogalea frænata*.

In all other Mammals the posterior portions of the Müllerian ducts become fused together to form an unpaired vagina, and a cloaca exists only in the embryo (comp. p. 236). A fusion may also take place more anteriorly, and, according to its extent, the most various forms of uteri result (uterus duplex, bicornis, bipartitus, and simplex), as is shown in Fig. 253, A to D. The Primates possess a simple uterus¹ (Fig. 253, B), and in this case the primitively paired condition of the Müllerian ducts is seen only in the Fallopian tubes. The latter vary much in form, and their abdominal apertures are usually provided with fringe-like appendages (fimbriæ). The ureters, unlike those of Marsupials, always pass to the outer sides of the genital passage, the vagina being single.

The ovaries are usually small, and rounded or oval in shape, their surface being either smooth, irregular, or furrowed. The point at which the nerves and vessels enter is not covered by peritoneum, and is called the hilum.

The reader is referred to p. 300 and Fig. 254 for further details as to the more minute histological structure of the ovary and the formation of the ova.

Remains of the mesonephros, known as the **parovarium**, are present in the neighbourhood of the ovary, oviduct, and uterus. These usually consist of small cæcal tubes, forming a network, which are connected together by a collecting duct. In cases where the Wolffian duct persists in the female, it passes from the parovarium to the urinogenital sinus, and is spoken of as **Gärtner's duct** (Fig. 236, A, *Gg*), as already mentioned on p. 301.

¹ The abnormalities which sometimes occur in the human uterus and vagina can be often explained as atavisms.

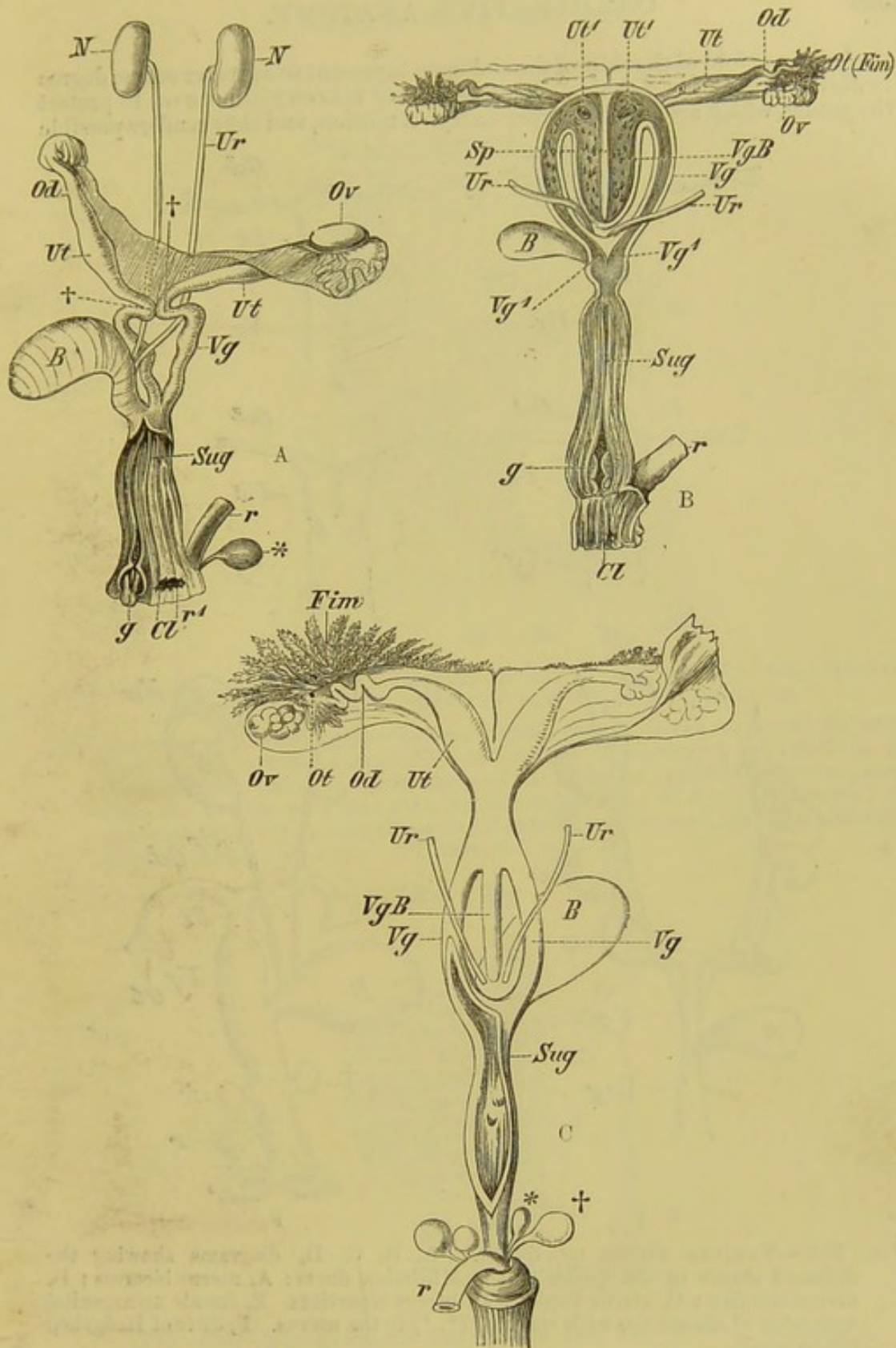


FIG. 252.—FEMALE GENERATIVE APPARATUS OF CERTAIN MARSUPIALS. A, *Didelphys dorsigera* (juv.); B, *Phalangista vulpina*; C, *Phascolomys wombat*. (After A. Brass.)

NN, kidneys; Ur, ureters; Ov, ovary; Ot (Fim), abdominal opening of Fallopian tube; Od, oviduct; Ut, uterus; Ut', openings of uteri into the vaginal caecum, VgB; †, bend between uterus and vagina, Vg; Vg', apertures of vagina into the urinogenital sinus (Sug); B, urinary bladder; r, rectum, which opens into the cloacal region (Cl) at r¹; g, clitoris; *, †, rectal glands.

A curious fold of the skin of the abdomen is present to a greater or less degree in Marsupials and in Echinidna. This pouch, or marsupium serves to protect the young, which are born in a very unripe condition, and thus renders possible

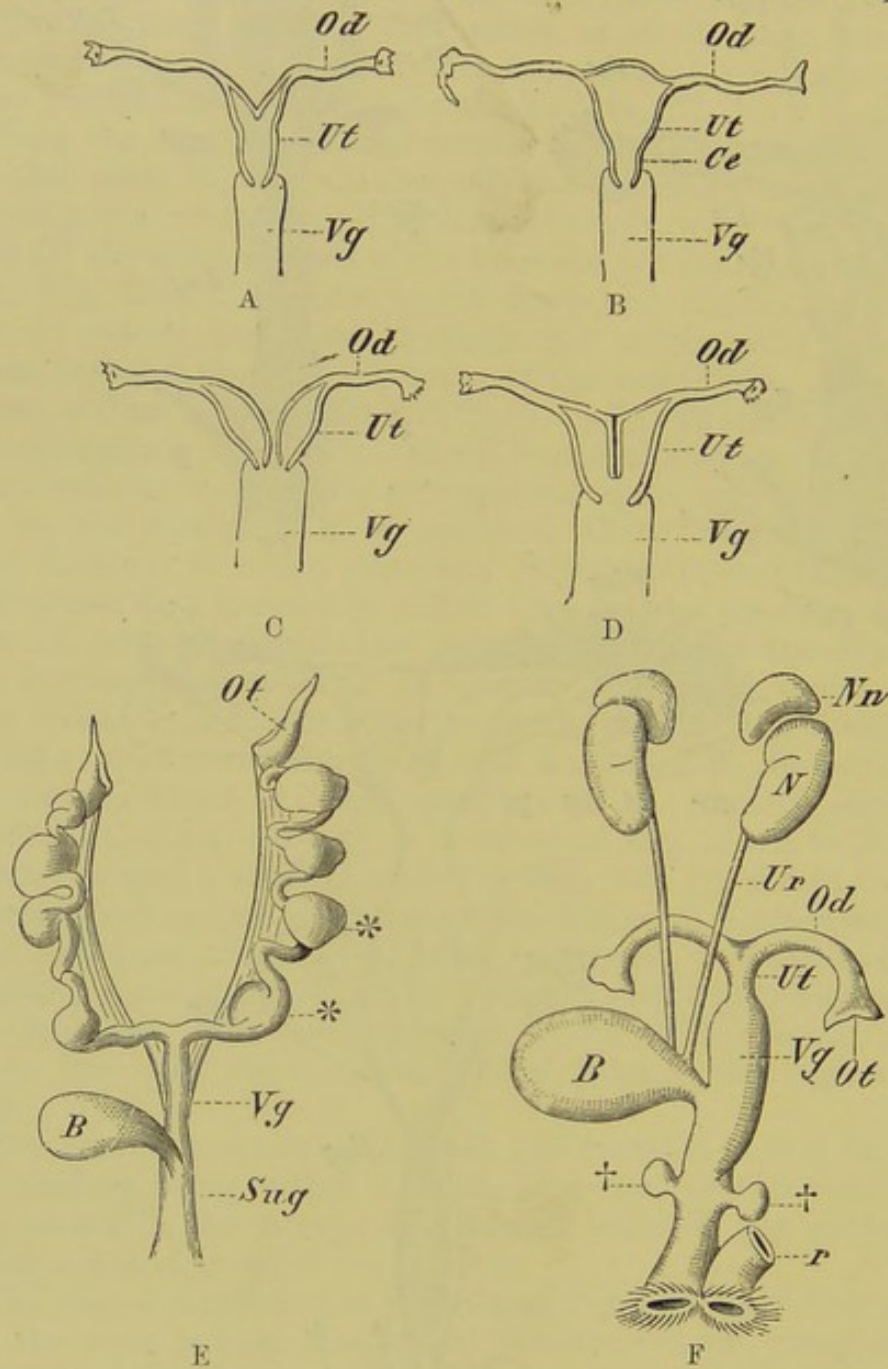


FIG. 253.—VARIOUS FORMS OF UTERI. A, B, C, D, diagrams showing the different stages in the fusion of the Müllerian ducts: A, uterus bicornis; B, uterus simplex; C, uterus duplex; D, uterus bipartitus. E, female urinogenital apparatus of *Mustelina*, with embryos (*, *) in the uterus. F, ditto of Hedgehog (*Erinaceus*).

Od, Fallopian tube; *Ut*, uterus; *Vg*, vagina; *Ce*, cervix uteri; *Ot*, abdominal aperture of Fallopian tube; †, †, accessory sexual glands; *r*, rectum; *Sug*, urinogenital sinus; *N*, kidney; *Nn*, adrenal; *Ur*, ureter; *B*, urinary bladder.

a longer connection between the mother and embryo during lactation. The aperture of the marsupial pouch opens anteriorly or posteriorly, according to the mode of life of the animal, and is provided with a muscle capable of closing it.

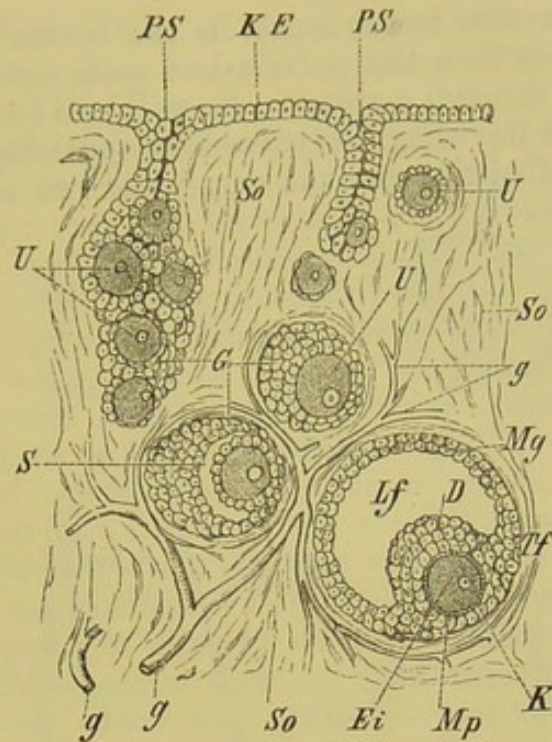


FIG. 254.—SECTION THROUGH A PORTION OF THE OVARY OF A MAMMAL, SHOWING THE MODE OF DEVELOPMENT OF THE GRAAFIAN FOLLICLES.

KE, germinal epithelium, ingrowths from which extend into the stroma of the ovary to form the ovarian tubes (*PS*): the stroma is penetrated by vessels (*g, g*); *U, U*, primitive ova; *S*, cavity between the follicular epithelium (tunica granulosa, *Mg*) and the primitive ova; *Lf*, liquor folliculi; *D*, discus proligerus; *Ei*, ripe ovum, with its germinal vesicle (*K*) and germinal spot; *Mp*, zona pellucida, showing radiated structure; *Tf*, theca folliculi.

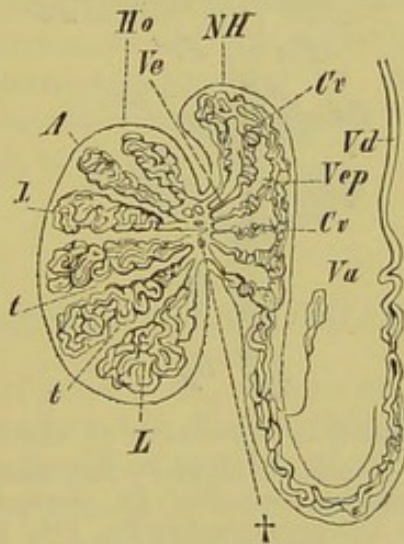


FIG. 255.—DIAGRAMMATIC SECTION OF THE TESTIS OF A MAMMAL.

Ho, testis; *NH*, epididymis; *Vd*, vas deferens; *A*, albuginea of the testis, which gives rise to the trabeculae (*t, t*) and the corpus Highmori (+); *L, L*, coils of the seminal tubules; *Ve*, vasa efferentia (rete Halleri); *Cv*, coni vasculosi, which are connected together by the collecting duct, *Vep*; *Va*, vas aberrans.

As regards the male generative organs of Mammals, the testes arise in the same position as do the ovaries of the female.

The ovaries, however, never move in the course of development further backwards than the pelvis; but each testis may pass out of the abdomen through a space in its wall, the inguinal canal; it thus comes to lie within a purse-like appendage of the hypogastric region called the scrotal sac. The two scrotal sacs may

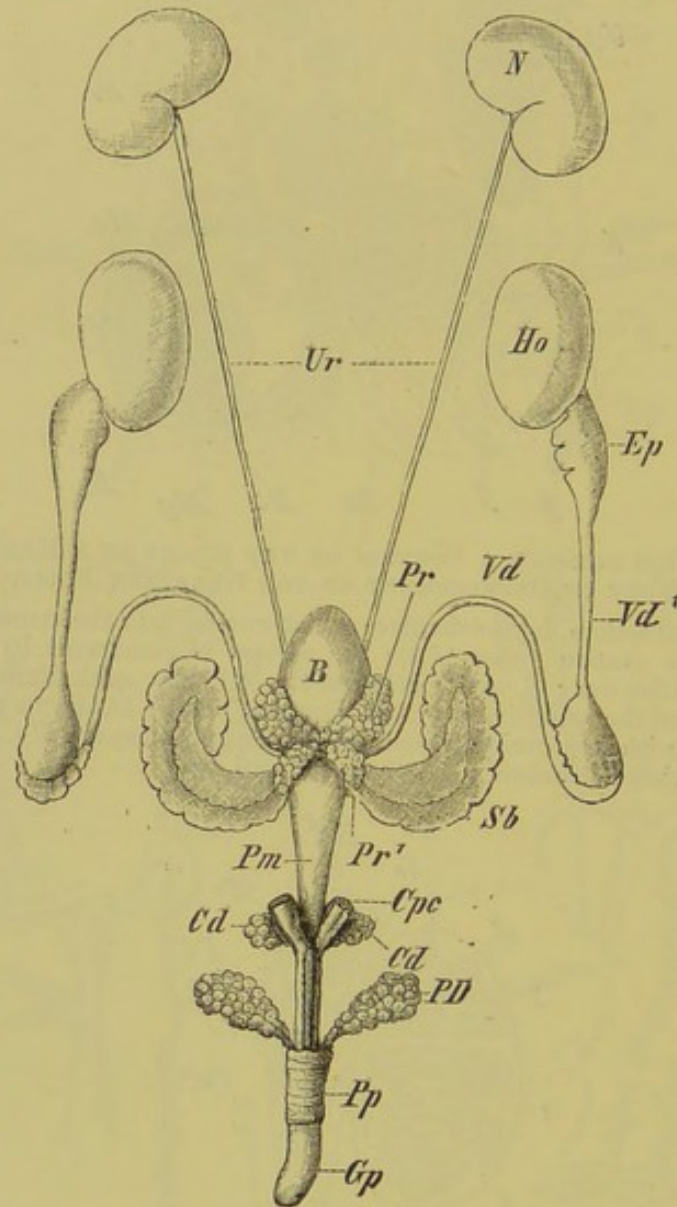


FIG. 256.—MALE URINOGENITAL APPARATUS OF THE HEDGEHOG (*Erinaceus*).

N, kidney; *Ur*, ureters; *B*, urinary bladder; *Pm*, membranous portion of urinogenital tube; *Cpc*, corpus cavernosum; *Pp*, prepuce; *Gp*, glans penis; *PD*, preputial glands; *Cd*, Cowper's glands; *Pr*, *Pr'*, the different lobes of the prostate; *Sb*, vesicula seminalis; *Ho*, testis; *Ep*, epididymis; *Vd*, *Vd'*, vas deferens.

remain separate, or unite to form a scrotum. In passing out, the testes carry with them a portion of the peritoneum—the tunica vaginalis: if the inguinal canals remain open, they may be at times again withdrawn into the abdomen (*e.g.* in Rodentia); this is effected by means of the cremaster muscle,

a continuation of the fibres of the internal oblique and transversalis. When the inguinal canals become obliterated, the testes remain throughout life in the scrotum.

In many Mammals, however, the testes remain permanently within the abdomen. Their size is not always proportionate to that of the body; they are smooth, and somewhat oval in form, and are covered by a fibrous investment (Fig. 255, *A*), from which processes (trabeculæ) usually extend inwards. In this way the seminal tubes are separated into definite bundles (*L, L*), and a sort of lattice-work is also formed (corpus Highmori, †), by means of which the elements of the rete Halleri (that is, the vasa efferentia, *Ve*) pass to the epididymis (*NH*).

In the epididymis the seminal tubules become rounded off to form the so-called coni vasculosi, and these are connected together by a collecting duct, the vas epididymis (Fig. 255, *Cv, Cv, Vep*). The vas deferens (*Vd*) arises from the last conus vasculosus, and gives rise towards its distal end, shortly before it opens into the urinogenital sinus, to glandular outgrowths (vesiculæ seminales), which may attain a relatively enormous size in Rodents and Insectivores (Fig. 256, *Sb*). From this point to its termination the seminal canal is spoken of as the ductus ejaculatorius.

In many Mammals rudiments of the Müllerian ducts are present, and open into the urinogenital sinus. In some (*e.g.* Man), only the most posterior end of the latter remain, in the form of an unpaired vesicle (uterus masculinus), which lies embedded within an accessory genital gland, the **prostate**. This gland, which more or less completely surrounds the urinogenital sinus, consists of glandular tubules, connected together by means of fibrous and muscular tissue: its secretion is poured into the urinogenital sinus (compare Figs. 236, *A* to *C*, and 256).

COPULATORY ORGANS.

External organs of generation, such as are present in the higher Vertebrates, are never found in Fishes, though in male Elasmobranchs a specially modified portion of the pelvic fin serves as a copulatory organ ("clasper" or "pterygopodium"). It consists of a series of cartilages which are moveable upon one another, is covered by skin and muscles, and is provided with a channel along the inner side. It must be looked upon as a derivative of the fin-rays.

These claspers are inserted, in a closed condition, into the cloaca of the female, and thence into the oviducts; they are then opened out by means of special muscles, and the seminal fluid flows along their channels into the distended oviducts. In

connection with this apparatus,—which looks like a series of surgical instruments,—there is a gland, surrounded by muscular fibres, which is formed as an involution of the integument; in its histological character this calls to mind the uropygial gland of Birds.

Amongst the Amphibia, male *Gymnophiona* alone possess a true copulatory organ; this simply consists of the eversible cloaca, which reaches a length of five centimetres, and is regulated by a well-developed musculature. In *Urodeles* there is merely a marked swelling of the lips of the cloaca and urinogenital papilla during the breeding-season.

Two kinds of copulatory organs are found in Reptiles, the one being seen in Lizards and Snakes, and the other in Chelonians and Crocodiles.

In the former case, there are two erectile **penes** lying outside the cloaca, under the skin at the root of the tail. By a complicated muscular mechanism these can be drawn into the cloaca and thence everted, the seminal fluid passing along a spiral furrow in each. Similar organs are present—though much less developed—in the female also.

Chelonians and Crocodiles possess a copulatory organ which is united to the ventral wall of the cloaca: it consists of two fibrous masses which are fused together in the middle line. Each half encloses a large cavity, which contains a large number of blood-vessels. The organ is regulated by well-developed muscles, and possesses a groove along its free surface, which may divide up into a series of channels at its apex. A representative of this organ is also present in the female.

In most *Ratitæ*, as well as in some *Carinatae* (*e.g.* in Water-Birds), a copulatory organ is present, and consists of an eversible tube, strengthened by two fibrous bodies; in a condition of rest it lies coiled up in the left side of the cloaca. The everted organ is retracted by means of an elastic band. The penis of the Ostrich lies within a diverticulum of the cloaca, and somewhat resembles that of Chelonians and Crocodiles.

The copulatory organs of Mammals may be divided into two groups,—viz., those of *Monotremes*, and those of other Mammals: the organs of *Marsupials* may be placed in a subdivision of the latter. In all cases the female apparatus (**clitoris**),—although as a rule less developed and usually not perforated by the urethral canal,—is formed essentially on the same type as that of the male.

In *Monotremes*, the copulatory organ lies enclosed within a sac situated on the boundary between the urinogenital sinus and cloaca, and is fused with the ventral wall of the latter (Fig. 251, *Gp*): in all other Mammals the organ arises in the embryo from the “genital prominence” on the ventral wall of the cloaca. A channel passes along the side facing the cloaca to the opening of the urinogenital sinus: this condition is usually retained through-

out life in the case of the female, while in the male the groove becomes closed to form a canal, and the urethra is considerably lengthened. Three cylindrical bodies, composed of erectile tissue (two lateral corpora cavernosa and a median corpus spongiosum), become developed in connection with the penis: these are connected with one another by a network of fibrous tissue, and are partially invested by muscles (Fig. 257, *Ccp*, *Ccu*). Corpora

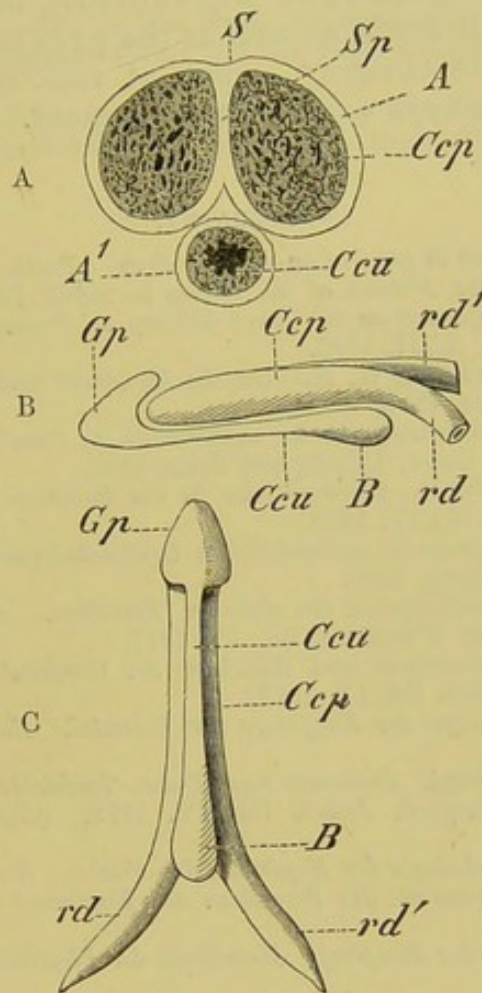


FIG. 257.—SEMIDIAGRAMMATIC FIGURE OF THE HUMAN PENIS. (A, transverse section; B, side view; C, from below.)

A, albuginea penis; *A'*, albuginea urethrae, which gives rise to a septum at *Sp*; *S*, sulcus dorsalis penis; *Ccp*, corpus cavernosum; *Ccu*, corpus spongiosum, which gives rise to the glans penis at *Gp*, and forms an oval enlargement (bulbus) at *B*; *rd*, *rd'*, crura of the corpora cavernosa.

cavernosa are also present in the clitoris, but a corpus spongiosum is wanting. In Marsupials and the higher Mammals the corpora cavernosa diverge at their proximal ends to form two crura (*rd*, *rd'*) which are almost always attached to the corresponding ischia.

In many Mammals a membrane bone (os penis) becomes developed in the septum between the corpora cavernosa (*e.g.* many Monkeys, Rodents, Bats, Carnivores). In the Seal there is an os clitoridis in the female also.

The apex of the organ is spoken of as the glans (glans penis *vel* clitoridis); this varies much in form, and lies enclosed within a fold of the skin, which in the male is called the foreskin or prepuce. The glans is provided with a special kind of tactile corpuscle.

Finally, the accessory organs, which are known in the male as preputial and Cowper's glands, and the representatives of the latter in the female (glands of Bartholini), must be mentioned (Fig. 256, *Cd*). All these, as well as the prostate (*PD*),—which belongs to the same category,—open at various points into the urethra, and have always a paired arrangement.

BIBLIOGRAPHY.

- BALBIANI, G.—*Leçons sur la génération des Vertébrés*. Paris, 1879.
- BALFOUR, F. M.—*On the Nature of the Organ in Adult Teleosteans and Ganoids, which is usually regarded as the Head-Kidney or Pronephros*. *Quart. Journ. Micros. Science*, Vol. XXII. 1882.
- BALFOUR, F. M., and PARKER, W. N.—*On the Structure and Development of Lepidosteus*. *Phil. Trans.* 1882.
- BENEDEN, E. VAN.—*Recherches sur la maturation de l'œuf, la fécondation et la division cellulaire*. Gand, Leipzig and Paris, 1883.
- BOURNE, A. G.—*On Certain Abnormalities in the Common Frog*. *Quart. Journ. Micros. Science*, Vol. XXIV. 1884.
- BRASS, A.—*Beitr. z. Kenntniss des weiblichen Urogenitalsystems der Marsupialier*. *Inaug. Dissert.* Leipzig, 1880.
- BRAUN, M.—*Das Urogenitalsystem der einheim. Reptilien*. *Arb. a. d. zool. zootom. Institut d. Universität Würzburg*, Bd. IV. 1877.
- BROCK, J.—*Beitr. zur Anatomie und Histologie der Geschlechtsorgane der Knochenfische*. *Morphol. Jahrb.* Bd. IV. 1878.
- EMERY, C.—*Zur Morphologie der Kopfniere der Teleostei*. *Zool. Anz.* VIII. Jahrgang, 1885.
- FÜRBRINGER, M.—*Zur vergl. Anatomie und Entw.-Geschichte der Excretionsorgane der Vertebraten*. *Morphol. Jahrb.* Bd. IV. 1878. (Contains also a complete bibliography.)
- GROSLIK, S.—*Zur Morphologie der Kopfniere der Fische*. *Zool. Anz.* VIII. Jahrgang, 1885. *Zur Frage üb. die Persistenz der Kopfniere der Teleosteer*. *Ibid.* IX. Jahrgang, 1886.
- HENSEN, V.—*Physiologie der Zeugung*. *Handbuch der Physiologie von L. HERMANN*. Bd. VI. 2 Thl.
- KNAPPE.—*Das Bidder'sche Organ, &c.* *Morphol. Jahrb.* Bd. XI. Heft 4, 1886.
- LEREBOULET.—*Rech. sur l'anatomie des organes génitaux des animaux vertébrés*. *Nov. act. Acad. Leop.-Carol, &c.* 1851.
- LISTER, J. J., and FLETCHER, J. J.—*On the Condition of the Median Portion of the Vaginal Apparatus in the Macropodidæ*. *Proc. Zool. Soc.* 1881. In reference to same subject, see also J. J. FLETCHER in *Proc. Linn. Soc. N.S.W.* 1881, 1882, and 1883.
- MARSHALL, A. MILNES.—*On Certain Abnormal Conditions of the Reproductive Organs in the Frog*. *Journ. of Anat. and Physiol.* Vol. XVIII. 1884.
- MIHALKOVICS, V. V.—*Entwick. d. Harn- u. Geschlechtsapparat der Amnioten*. I. *Abhandl. Der Excretionsapparat*. *Internat. Monatschrift f. Anat. und Hist.* Bd. II. 1885.
- MÖBIUS, K.—*Ueber die Eigenschaften und den Ursprung der Schleimfäden des Seestichlingnestes*. *Archiv f. Mikr. Anat.* Bd. XXV. 1885.
- PARKER, T. J.—*On the Gravid Uterus of Mustelus antarcticus*. *Trans. N. Zealand Inst.* 1883.
- PFLÜGER, E.—*Die Eierstöcke der Säugethiere und des Menschen*. Leipzig, 1863.
- SACK, ARNOLD.—*Ueber die Verbindung der Crura penis mit dem Becken bei Beuteltieren*. *Zool. Anz.* IX. Jahrgang, 1886.

- SARASIN, P. B. and C. F.—*Ueber die Entwick. von Epicrium glutinosum. Arbeit. zool. zootom. Inst. Würzburg, Bd. VII. 1885.*
- SEDGWICK, A.—*Several Papers On the Development of the Excretory System in the Chick. Quart. Journ. Micros. Science, Vols. XX. and XXI. 1880 and 1881.*
- SEMPER, C.—*Das Urogenitalsystem der Plagiostomen, &c. Arbeiten a. d. zool. zootom. Inst. z. Würzburg, Bd. II. 1875.*
- SPENGLER, J. W.—*Das Urogenitalsystem der Amphibien. Arb. a. d. zool. zootom. Institut d. Universität Würzburg, Bd. III. 1876.*
- WALDEYER, W.—*Eierstock und Ei. Leipzig, 1870.*
- WEISMANN, A.—*Die Entstehung der Sexualzellen bei den Hydromedusen. With Atlas. Jena, 1883.*
- WELDON, W. F. R.—*Note on the Early Development of Lacerta muralis. Quart. Journ. Micros. Science, 1883. On the Head-Kidney of Bdellostoma. Ibid. 1884.*

(For further references compare the text-books on Human Anatomy by QUAIN and HENLE, and also other works mentioned at the beginning of this book.)

The first part of the book is devoted to a general history of the United States from its discovery to the present time. It is divided into three volumes, the first of which contains the history of the discovery and settlement of the continent, the second the history of the colonies, and the third the history of the United States from its independence to the present time.

The second part of the book is devoted to a general history of the world from its creation to the present time. It is divided into three volumes, the first of which contains the history of the world from its creation to the time of the birth of Christ, the second the history of the world from the birth of Christ to the present time, and the third the history of the world from the present time to the end of the world.

The third part of the book is devoted to a general history of the United States from its discovery to the present time. It is divided into three volumes, the first of which contains the history of the discovery and settlement of the continent, the second the history of the colonies, and the third the history of the United States from its independence to the present time.

INDEX.

INDEX

INDEX.

AMPHIOXUS:—segmentation of ovum, 5; development of body-cavity, 9; integument, 17; notochord, 34, 38; spinal cord, 136; mouth, 212; thyroid, 225; alimentary canal, 228, 237, 239; gills, 246; blood-corpuscles, 268; generative organs, 310

CYCLOSTOMES:—segmentation of ovum, 5; integument, 17; vertebral column, 34, 38; skull, 63; branchial basket, 64, 118; brain, 136; cranial nerves, 153; olfactory organ, 171; eye, 184; semicircular canals, 196; mouth, 212; horny teeth, 214; thyroid, 225; alimentary canal, 228; alimentary epithelium, 237, 239; liver, 240; pancreas, 243; gills, 246; abdominal pores, 265; blood-corpuscles, 268; heart, 277; urinogenital organs, 300, 302, 310

FISHES:—integument, 16; dermal skeleton, 30; vertebral column, 34; ribs, 48; skull, 63; unpaired fins, 85; paired fins, 86; pectoral arch, 87; pelvic arch, 92; free limbs, 99; dermal muscles, 113; muscles of the trunk, 113; muscles of the visceral skeleton and head, 118; muscles of the appendages, 121; electric organs, 124; spinal cord, 131; brain, 134, 136; spinal nerves, 152; cranial nerves, 153; suprarenal bodies, 161; sense-organs of the integument, 163; olfactory organ, 171; eye, 184; retina, 189; eye-muscles and eyelids, 191; auditory organ, 198, 205; relations of auditory organ with air-bladder, 207; teeth, 214; tongue, 222; thyroid, 225; thymus, 226; alimentary canal, 228; liver, 242; pancreas, 243; gills, 246, 248; air-bladder, 251; abdominal pores, 265; blood-vessels, 270; heart and its vessels, 277; arterial system, 288; venous system, 291; retina mirabilia, 292; lymphatic system, 292; spleen, 294; urinary organs, 296, 302; generative organs, 300, 310; claspers, 327

DIPNOANS:—integument, 17; dermal skeleton, 30; vertebral column, 35, 38;

ribs, 48; skull, 66; pectoral arch, 87; pelvic arch, 92; free limbs, 99; muscles of the trunk, 116; muscles of the appendages, 121; brain, 142; cranial nerves, 153; sense-organs of the integument, 163; olfactory organ, 172; lips, 212; tongue, 222; alimentary canal, 228; alimentary epithelium, 239; gills, 246, 250; laryngo-tracheal chamber, 253; lungs, 257; abdominal pores, 265; heart and its vessels, 280; urinary organs, 302; generative organs, 314

AMPHIBIANS:—segmentation of the ovum, 5; integument, 17, 18; dermal skeleton, 19, 32; vertebral column, 39; ribs, 48; sternum, 51; skull, 70; pectoral arch, 87; pelvic arch, 92; free limbs, 104; muscles of the trunk, 113; muscles of the visceral skeleton and head, 119; muscles of the appendages, 121; "diaphragm," 122; spinal cord, 131; brain, 134, 142; spinal nerves, 152; cranial nerves, 153; suprarenal bodies, 161; sense-organs of the integument, 163; tactile cells, 167; olfactory organ, 172; spouting apparatus of Gymnophiona, 179; eye, 186; retina, 189; eye-muscles and eyelids, 191; glands of the eye, 192; auditory organ, 198, 205; teeth, 214; glands of the mouth, 221; tongue, 222; thyroid, 225; thymus, 226; alimentary canal, 228; liver, 241; pancreas, 243; gills, 246, 250; air-passages, 253; lungs, 257; blood-corpuscles, 268; allantois, 273; heart and its vessels, 281; arterial system, 288; venous system, 291; lymphatic system, 292; spleen, 294; urinary organs, 296, 304; generative organs, 310; copulatory organs, 328

REPTILES:—integument, 20; dermal skeleton, 32; vertebral column, 42; ribs, 49; sternum, 51; skull, 74; pectoral arch, 87; pelvic arch, 94; free limbs, 105; muscles of trunk, 116; muscles of the visceral skeleton and head, 120; muscles of the appendages, 121; "diaphragm," 122; brain, 132, 134, 144; spinal nerves, 152; cranial

- nerves, 153; suprarenal bodies, 161; end-bulbs, 166; tactile cells, 167; Pacinian corpuscles, 169; olfactory organ, 174; Jacobson's organ, 178; retina, 189; eye-muscles and eyelids, 191; glands of eye, 192; auditory organ, 199; teeth, 215; glands of mouth, 221; tongue, 223; alimentary canal, 231; alimentary epithelium, 239; pancreas, 243; air-passages, 254; lungs, 258; abdominal pores, 265; allantois, 273; heart and its vessels, 284; arterial system, 288; venous system, 291; retia mirabilia, 292; spleen, 294; urinary organs, 296, 307; generative organs, 317; copulatory organs, 328
- BIRDS:**—segmentation of ovum, 5; integument, 20; vertebral column, 43, 44; ribs, 50, 53; sternum, 51; skull, 78; pectoral arch, 90; pelvic arch, 94; limbs, 106; muscles of the trunk, 117; muscles of the visceral skeleton and head, 120; spinal cord, 131; brain, 134, 147; cranial nerves, 153; suprarenal bodies, 161; tactile cells, 167; Pacinian corpuscles, 169; olfactory organ, 175; eye, 186; retina, 189; eye-muscles and eyelids, 191; glands of the eye, 192; auditory organ, 199, 205; glands of the mouth, 222; tongue, 223; thyroid, 225; thymus, 226; alimentary canal, 233; pancreas, 243; air-passages, 255; lungs and air-sacs, 259; circulation in embryo, 272; allantois, 273; heart and its vessels, 286; arterial system, 288; venous system, 291; lymphatic system, 293; lymphatic glands, 294; urinary organs, 296, 307; generative organs, 300, 317; copulatory organs, 328
- MAMMALS:**—segmentation of ovum, 5; integument, 23; mammary glands, 27; dermal skeleton, 32; vertebral column, 43, 46; ribs, 50; sternum, 51; skull, 80; pectoral arch, 91; pelvic arch, 98; limbs, 108; muscles of trunk, 117; muscles of visceral skeleton and head, 120; muscles of appendages, 121; diaphragm, 122; spinal cord, 131; brain, 132, 134, 148; spinal nerves, 152; cranial nerves, 153; suprarenals, 161; end-bulbs, 166; tactile cells, 168; Pacinian corpuscles, 169; olfactory organ, 176; Jacobson's organ, 179; eye, 188; retina, 189; eye-muscles and eyelids, 191; glands of eye, 192; auditory organ, 201; histology of cochlea, 206; lips, 212; teeth, 213, 216; glands of mouth, 222; tongue, 223; thyroid, 225; thymus, 226; alimentary canal, 231, 234; alimentary epithelium, 239; liver, 243; pancreas, 243; air-passages, 255; lungs, 263; blood-corpuscles, 268; allantois and placenta, 274; heart and its vessels, 286; arterial system, 288; venous system, 291; retia mirabilia, 292; lymphatic system, 293; tonsils, 293; lymphatic glands, 294; urinary organs, 296, 308; generative organs, 300, 320; copulatory organs, 328
- A.
- Abdominal pores, 265
 Abomasum, 236
 Acetabulum, 93—98
 Acrodont dentition, 215
 Acromion, 91
 Adrenals, 161
 Aëtosaurus, exoskeleton, 32
 Air-bladder, 245, 251
 Air-passages, 253
 Air-sacs, 259
 Alimentary canal, 208—237
 development of, 7
 appendages of, 240—243
 mucous membrane of, 237
 Allantois, 10, 231, 273, 274
 Alopecias, number of vertebræ, 37
 Alveoli of lung, 252
 Amblyopsis, abortion of eyes, 186
 Amblystoma, development of vertebral column, 40
 Amia, fusion of anterior vertebræ with skull, 67
 Amiurus, sensory sacs, 166
 Ammocetes:—notochord, 34; brain, 137; eye, 185; thyroid, 225; alimentary epithelium, 237; gills, 246
 Ammodytes, pyloric cæcum, 229
 Amnion, 10, 276
 Amphicæalous vertebræ, 36
 Amphiuma, trachea, 253
 Ampullæ of semicircular canals, 196
 Anabas, branchial chamber, 250
 Anastomosis of Jacobson, 158
 Anguilla, lateral nerve, 165
 Anguis:—embryonic limbs, 90; brain, 144; teeth, 215
 Anteater, palate, 82
 Antibrachium, 102
 Antihelix, 198
 Antitragus, 198
 Antlers, 83
 Antrum maxillare, 176
 Apatosaurus, dimensions of vertebræ, 43
 Aponeurosis, pulmonary, 262
 Appendices auriculæ, 278
 Apteryx: pelvis, 96; manus, 107
 Aqueduct of Sylvius, 134, 142
 Aqueductus cochleæ, 205
 Aqueductus vestibuli, 205
 Arachnoid, 135
 Archenteron, 6, 237
 Arches, neural and hæmal, 85

- Archæopteryx:—vertebræ, 44; ribs, 50; skull, 78; scapula, 91; pelvis, 45, 98; wing, 106; foot, 108; brain, 147; teeth, 216
- Argentea of choroid, 186
- Armadillo:—dermal skeleton, 32; skull, 83
- Arteries, development of, 268, 270
- Arteries:—allantoic, 272, 276, 289; aorta (dorsal), 270, 277—290; aorta (ventral), 278; aortic arches or roots, 270, 276—290; arterial arches, 270, 283—285; axillary, 288; brachiocephalic, 287; branchial, 270, 279—283; carotid, 270, 277, 288, 290; caudal, 270, 288—290; cœliac, 288, 290; cœliaco-mesenteric, 279, 288—290; crural, 288—290; cutaneous, 289; digital, 288; epigastric, 289, 290; genital, 288; hepatic, 289; hyaloid, 183; hypogastric, 288—290; iliac, 288, 289, 291; intercostal, 288; intestinal, 288, 289; lumbar, 288; median sacral, 288; mesenteric, 288; œsophageal, 284, 290; omphalo-mesenteric, 270; ovarian, 289; palmar arches, 288; pulmonary, 270, 277—287, 290; radial, 288; rectal, 289, 290; renal, 279, 288, 289; sciatic, 290, 291; stapedial, 203; subclavian, 276—288, 290; urinogenital, 290; ulnar, 288; vertebral, 277, 290; vesical, 289; vitelline, 270
- Artiodactyle foot, 109
- Arytenoid cartilages, 254
- Ascalabota, vertebræ, 42; ductus endolymphaticus, 205
- Ascidians, thyroid, 225
- Ateles, caudal vertebræ, 47
- Atlantosaurus, dimensions, 43
- Atlas:—of Amphibians, 42; of Reptiles, 43; of Birds, 45; of Mammals, 46
- Atrial pore of Amphioxus, 246
- Atrio-ventricular aperture, 279, 287
- Atrium, 269
- Auditory organ, 194—207:—development of, 195; relations with air-bladder, 207
- Auditory ossicles, 198, 202
- Auditory region of skull, 58
- Autostylic skulls, 65
- B. C.
- Bacilli of basement membrane of cochlea, 206
- Baleen, 27
- Balistes, exoskeleton, 31
- Basal processes of vertebræ, 35, 42
- Basilar plate, 57
- Basipterygium, 99
- Bidder's organ, 316, 317
- Bile-duct, 242
- Blastoderm, 5
- Blastopore, 6
- Blastosphere, 5
- Blastula, 5
- Blood-corpuscles, development and form of, 268
- Boar, tusks of, 220
- Body-cavity, 9
- Bones, cartilage-, membrane-, and investing-, 62
- Brachium, 102
- Bradypus, cervical vertebræ, 46
- Brain, 131—151:—development of, 131; membranes of, 135; cerebellum, 132, 133; cerebrum, 132; convolutions, 132; corpora bigemina, 132; corpora restiformia, 138; corpus callosum, 132, 148; crura cerebri et cerebelli, 150; epiphysis, 133; foramen of Monro, 134; fornix, 132; hypophysis, 133; infundibulum, 133; lobi electrici, 138; lobi inferiores, 138, 142; lobi nervi lateralis, 139; lobes, central, of prosencephalon, 148; medulla oblongata, 132; mesencephalon, 132; metencephalon, 132; myelencephalon, 132; optic chiasma, 155; optic lobes, 132; optic thalami, 132; optic vesicles (primary), 132, (secondary), 182; pallium, 132, 137; peripheral portion of prosencephalon, 132—137; pineal gland, 132, 142; pituitary body, 133; processus infundibuli, 138, 142; prosencephalon, 132, 137—150; sacci vasculosi, 138, 142; thalamencephalon, 132; ventricles, 131, 133, 134; vermis, 133
- Brain-case, 57
- Branchial arches, 60, 65—68, 74, 78, 80, 84, 248
- Branchial clefts, 54, 159, 198, 245
- Branchiomerism, 56
- Branchiostegal membrane and rays, 69
- Bronchi, 252:—main and lateral, 259, 262, 263; eparterial and hyparterial, 263
- Bulbus arteriosus, 269, 279
- Bursa Fabricii, 234
- Bursæ anales, 233
- Butirinus, spiral valve, 229

Cæcum, 209, 233, 236

Calamus, of feather, 22

Calcaneum, 105, 106, 109

Calyces, 308

Campanula Halleri, 185

Canalis reuniens, 199

Canine teeth, 214, 216

Canis:—teeth, 218; stomach, 235

Cannon-bone, 110

Capillaries, 269

Carapace, 32

Carcharias:—placenta, 12; number of vertebræ, 37

Cardiac portion of stomach, 234

Carina sterni, 51

- Carpus, 102—109
 Cartilages :—Meckel's, 61, 202 ; plough-share, of Huschke, 179 ; of Wrisberg and Santorini, 257
 Cartilage-bones, 62
 Cauda equina, 131
 Cavicornia, horns of, 83
 Cavum endolymphaticum, 196
 maxillare, 172, 176, 178
 perilymphaticum, 196
 Cells, 1 :—granular, 18 ; goblet, 18 ; ganglion, 129, 163 ; sensory and supporting, 162
 Cement of teeth, 212
 Centra of vertebræ, 36
 Centrale, 104, 105, 109
 Ceratodus :—fins, 99 ; muscles of fins, 121 ; lateral nerve, 165 ; lungs, 257 ; abdominal pores, 267
 Ceratophrys, dermal skeleton, 32
 Cere, tactile cells of, 167
 Cerebral flexure, 135
 Ceruminous glands, 26
 Cetacea :—cervical vertebræ, 46 ; phalanges, 111 ; dentition, 213
 Chætodon, teeth, 214
 Chameleon :—tongue, 223 ; lungs, 258
 Chauliodus, teeth, 214
 Cheirocentrus, spiral valve, 229
 Chevron bones, 43, 47
 Chimpanzee, larynx, 256
 Chlamydoselache, operculum, 249
 Choanæ, 170, 173
 Choloepeus, cervical vertebræ, 46
 Choroid, 183
 Choroid fissure, 183
 Choroid "gland," 186
 Chorion frondosum and læve, 276
 Ciliary folds, 183
 Ciliary ligament, 185
 Cirrhi of mouth of Amphioxus, 212
 Circulation (fœtal), 270
 Cisterna chyli, 293
 Claspers, 101, 327
 Classification of Vertebrates, 13
 Clavicles, 87—91
 Clitoris, 328
 Cloaca, 231—234, 236
 Cobitis, external gills, 250
 Coccyx, 47
 Cochlea, 195 ; bony, 203 ; histology of, 206
 Cœlenterate, diagram of, 237
 Cœlome, 9
 Colibris, tongue, 223
 Colon, 209, 236
 Colostrums, 28
 Columella auris, 199
 Columns of Bertini, 310
 Cones of retina, 190, 191
 Coni vasculosi, 327
 Conjunctiva, 184, 192
 Contour feathers, 22
 Conus arteriosus, 269, 279—282
 Copulatory organs, 327
 Coracoid, 89—91
 Corium, 16
 Cornea, 184
 Corpora adiposa, 317
 Corpora cavernosa and corpus spongiosum, 329
 Corpus Highmori, 327
 Corpuseles :—of blood, 268 ; Pacinian, 169, 223 ; of Grandry, 169
 Cortex of hair, 24
 Cranial nerves, 153
 Cranium, 57
 Cribriform plate, 80
 Crista acustica, 197
 Crop, 234
 Crus, 102
 Crypts of intestine, 239
 Cuboid, 109
 Cuneiform, 109
 Cupula terminalis, 205
 Cuticle of hair, 24
 Cutis, 16

 D.
 Dactylethra, epipubis, 93
 Dasypus, milk dentition, 213
 Decidua, vera and reflexa, 276
 Dental formulæ, 220
 Denticles, dermal, 31
 Dentine, 212
 Dentition, milk, 213
 Deer, larynx, 256
 Derma, 16
 Dermal skeleton, 30—33
 Dermostosis, 62
 Deuteroplasm, 5
 Development :—general, 2—12 ; feathers, 20 ; hairs, 24 ; teats, 27 ; dermal skeleton, 31 ; vertebral column, 33 ; tail of Fishes, 38 ; coccyx, 47 ; ribs, 48 ; sternum, 51, 53 ; skull, 54, 57, 59, 61 ; horns, 83 ; limbs, 85, 86 ; muscles, 112, 120, 121 ; electric organs, 126 ; central nervous system, 129 ; brain, 131 ; nerves, 151 ; sympathetic, 160 ; suprarenals, 161 ; sensory end-organs, 162 ; olfactory organ, 170 ; eye, 181 ; glands of eye, 192 ; auditory organ, 194 ; teeth, 212 ; tongue, 225 ; thyroid, 225 ; thymus, 226 ; intestinal crypts, 239 ; gills, 245 ; air-bladder, 251 ; lungs, 252 ; air-sacs, 262 ; heart, 269 ; placenta, 274 ; urinogenital organs, 296—302
 Diaphragm, 122
 Diastema, 217
 Didelphys, urinogenital organs, 320
 Digestion, intracellular, 237
 Digits, 104—110
 Dinosauria :—dimensions, 43 ; pelvis, 96, 98
 Diphycceral tail, 38

Diphyodonts, 213
 Discosaurus, dermal skeleton, 32
 Diverticulum cæcum, 234
 Down-feathers, 22
 Duck :—caudal vertebræ, 45 ; rudiment of third finger, 107 ; lungs and air-sacs, 260, 261
 Duct :—Leydig's, 301, 303 ; hepatic, 242 ; naso-lacrymal, 174 ; naso-palatine of Myxinoids, 171 ; pancreatic, 243 ; pneumatic, 251 ; of Steno, Wharton, and Bartholini, 222
 Ductus Botalli, 284
 cochlearis, 199, 204
 Cuvieri, 271
 endolymphaticus, 202, 205
 ejaculatorius, 327
 perilymphaticus, 205
 thyreoglossus, 225
 sacculo-utricularis, 177, 199
 venosus, 270
 Dugong, teeth, 220
 Duodenum, 209
 Dura mater, 135

E.

Ear :—internal, 195—206 ; external, 198
 Echeneis, suctorial disk, 85
 Echidna :—mammary pouch, 27 ; pelvis, 97 ; anterior abdominal vein, 291 ; eggs, 320 ; urinogenital organs, 321
 Ectobronchia, 262
 Ectoderm, 6
 Ectostosis, 62
 Edentata, teeth, 213
 Egg-cell, 2
 Elastica limitans externa and interna, 33
 Electric organs, 124—128
 Electric plate, 127
 Emys, tongue, 224
 Enaliosaurus, abdominal ribs, 50
 Enamel, 32, 212
 End-bulbs, 166
 Endoderm, 6
 Endolymph, 196
 Endostosis, 62
 Ensiform process, 53
 Enterocoel, 9
 Entobronchia, 262
 Entoglossal, 61
 Ehippifer, exoskeleton, 32
 Epiblast, 6, 151
 Epicrium :—external gills, 251 ; eggs, 316
 Epidermis, 16
 Epididymis, 327
 Epiglottis, 255
 Epiphyses of vertebræ, 46
 Epiphysis cerebri, 132, 142
 Epipubis, 93, 98, 117
 Epithelium, 1 :—pigment of retina, 183 ; of alimentary canal, 237 ; germinal, 299
 Erinaceus, teeth, 217

Erythrina, air-bladder, 251
 Ethmonasal septum, 58
 Eustachian aperture, 73
 Eustachian tube, 198
 Exoskeleton, 30—33
 Extra-branchials, 63, 74
 Eye, 181—194 :—glands in connection with, 192 ; muscles of, 191
 Eyelids, 191

F.

Fallopian tube, 302, 322
 Fat-bodies, 294, 317
 Feathers, 20
 Femur, 102
 Fenestra :—rotunda, 80, 205 ; ovalis, 70, 80, 198, 205 ; vestibuli cartilaginei, 197
 Fertilisation of ovum, 3
 Fibres, 1 :—connective-tissue, 16 ; nerve, 129
 Fibula, 104
 Fibulare, 104
 Filum terminale, 131
 Fimbriæ of Fallopian tube, 322
 Fin-rays, 85, 99
 Fins, 85
 Food-yolk, 5
 Foramen cordiforme, 95
 Foramen ovale (of heart), 287
 Foramen Panizzae, 285
 Fulcrum of retina, 190
 Furcula, 90

G.

Gall-bladder, 242
 Ganglia of sensory nerves, 151
 Ganglion, ciliary, 156
 Gärtner's duct, 301, 322
 Gastrula, 6
 Generative cells, development of, 299, 300
 Generative organs, 310—327
 Germinal epithelium, 299
 Germinal membranes, 5
 Germinal spot, 2
 Germinal vesicle, 2
 Gill-arches, 59—61, 63—66, 68, 74, 80, 84
 Gill-clefts, 54, 159, 198, 245
 Gill-cover, 65
 Gills, 245, 251
 Gills, external, 246, 251
 Gills, spiracular, 250
 Giraffe, horns of, 83
 Gizzard, 233
 Glands :—Bowman's, 177 ; of Bartholini, 330 ; ceruminous, 26 ; cervical, of Chamois, 27 ; of claspers, 327 ; Cowper's, 330 ; digestive, 239 ; femoral, 20 ; genital, 310—320, 325—327 ; Harderian, 193 ; hibernating, 294 ; integumentary, 18—20, 23—28 ; intermaxillary or internasal, 193 ;

- labial, 221; lacrymal, 198; of Liëberkükn, 239; lingual, 221, 222; lymphatic, 294; mammary, 27; Meibomian, 27, 194; nasal (external) of Birds, 176; of olfactory mucous membrane, 173, 175; orbital, of Gymnophiona, 180; oviducal, 311; palatine, 221; parotid, 222; peptic, 239; perineal, 27; pharyngeal, 221; poison, 221; preputial, 27, 330; prostate, 327, 330; sebaceous, 24, 26; of Stenson, 177; sublingual, 222; sweat, 26; "tentacular," of Gymnophiona, 180; uropygial, 23
- Glans penis and clitoridis, 330
- Glaserian fissure, 202
- Glomerulus, 297, 304
- Gnathostomata, 63
- Gonads, 310—320, 325—327
- Guinea-pig, milk dentition, 213
- Gullet, 209, 228, 234
- Gut, postanal, 86
- Gymnarchus, electric organ, 125
- Gymnophiona:—scutes, 20, 32; olfactory nerves, 155; spouting apparatus, 179; external gills, 251; eggs, 316
- Gymnotus:—electric organs, 124; lateral nerve, 165
- Gyri, 132
- Gyrinophilus, vertebral column, 40
- H.
- Hair, 24
- Halmaturus, third vagina, 322
- Hatteria:—vertebræ, 42; uncinatæ processes, 50; teeth, 215
- Heart, 268—287
- Hedgehog, teeth, 217, 220
- Heloderma, teeth, 216
- Heptanchus, skull, 64
- Heredity, 2
- Hermaphrodite structures, 314, 316
- Hesperornis:—brain, 147; teeth, 216
- Heterocercal tail, 38
- Heterodont dentition, 213
- Hilum, of kidney, 308
of ovary, 322
- Histology, 1
- Holoblastic ova, 5
- Homocercal tail, 38
- Homodont dentition, 213
- Homodynamy of limb-arches, 87
- Horns, 83
- Humour, vitreous, 183
aqueous, 184
- Hyoid, 60, 78, 84, 199, 202, 222
- Hyomandibular, 61, 70, 202, 226
- Hyostylic skulls, 65
- Hypoblast, 6
- Hypophysis cerebri, 132
- Hyrax, cæca of, 236
- Hystrix, teeth, 218
- I.
- Ichthyornis, vertebræ, 44
- Idioplasm, 4
- Iguanodon, pelvis, 96
- Ileum, 209
- Iliac processes of Dipnoi, 92
- Iliac tract of Chimæra, 92
- Ilium, 92—98
- Impregnation, 4
- Incisor teeth, 214, 216
- Incisura acetabuli, 98
- Incus, 202
- Infundibula of lung, 252
- Inguinal canal, 326
- Insectivora, milk dentition, 213
- Integument, 16—28; sensory organs of, 163
- Intercalary pieces of vertebræ, 36
- Interclavicle, 90
- Intermedium, 104, 109
- Interorbital septum, 57, 75
- Interspinous bones, 37
- Intertrabecula, 58, 65
- Intestine, small and large, 209
- Iris, 183
- Ischium, 93—98
- J.
- Jacobson, anastomosis of, 158; organ of, 177
- Jejunum, 209
- K.
- Kidney, 296—310
- L.
- Labium vestibulare, 206
- Labyrinth:—membranous, 195; bony, 196
- Lacerta:—internal ear, 200; tongue, 224
- Lacteals, 293
- Lagena, 198, 199
- Lamina fusca, 184
- Lamina spiralis ossea, 203
- Lamna, number of vertebræ, 37
- Lanugo, 26
- Laryngeal pouches, 257
- Laryngo-tracheal chamber, 253
- Larynx, 253, 257
- Lateral line, sensory organs of, 165, 194
- Lemurs, teats of, 28
- Lens, 183, 185
- Lepidosteus:—vertebræ, 37; tail, 38; development of oviduct, 313
- Leucocytes, 28, 239, 293
- Ligaments, intervertebral, 34
- Ligamentum nuchæ, 46
- Limbs:—unpaired, 85; paired, 86—111
- Limitans externa and interna of retina, 189
- Liver, 209
- Lizards:—subvertebral wedge-bones, 43; caudal vertebræ, 43

Lobes of lung, 264
 Lophius, lure of, 139
 Lophobranchii, ribs, 48
 Lungs, 252—265
 Lymph, 268, 293
 Lymph-hearts, 293
 sinuses, 293
 Lymphatic glands, 294
 system, 292
 trunks, 205, 293
 Lymphoid substance in relation with
 urinogenital organs:—of Teleostei and
 Ganoidei, 304; of Amphibia, 317; of
 Reptilia, 320
 Lytta, 225

M.

Macula lutea, 190
 acustica, 197
 neglecta, 197
 Malapterurus, electric organs, 124
 Manatus, cervical vertebræ, 46
 Mandible, 64—84
 Mandibular arch, 60
 Manis:—scales, 27; number of caudal
 vertebræ, 47
 Manubrium sterni, 53
 Manus, 102
 Marsupial bones, 93, 98, 117
 Marsupium, 324
 Meatus, external auditory, 198
 Meckel's cartilage, 61, 202
 Mediastinum, 265
 Medullary plate, 7
 cord, 7, 129
 groove, 129
 Membrana basilaris, 199, 202, 204
 Reissneri, 202, 204
 reticularis, 206
 tectoria s. Corti, 206
 tympani, 73, 198, 199
 tympaniformis, 255
 Membranous labyrinth, 195
 Menisci of vertebræ, 43
 Meroblastic ova, 5, 6
 Mesentery, 208
 Mesoarrium, 311
 Mesoblast, 6
 Mesoblastic somites, 9
 Mesobronchium, 262
 Mesoderm, 6
 Mesonephros, 296—299, 302—304, 322
 Mesopterygium, 99
 Mesorchium, 311
 Metacarpus, 104
 Metamerism of head and body, 54
 Metanephric duct, 301, 307, 309
 Metanephros, 299, 307—310
 Metapterygium, 99
 Metasternum, 53
 Metatarsus, 104
 Microgale, number of caudal vertebræ, 47
 Micropyle, 4
 Milk dentition, 213
 Molars, 214, 216
 Monitor, tongue, 224
 Monophyodonts, 213
 Morphology, 2
 Morula, 5
 Moulting, 22
 Mouth, 212
 Müllerian duct, 300—304, 316, 320
 Mus, stomach, 235
 Muscles, 112—122:—of appendages, 121;
 arrectores pili, 24; of branchial arches,
 118; buccinatorius, 121; bursalis, 191;
 ciliary, 184; constrictor of iris, 184;
 constrictor of glottis, 253, 255; coraco-
 hyoid, 118; coraco-mandibular, 118;
 costo-pulmonary, 262; Crampton's,
 187; cranio-visceral, 118; cremaster,
 326; depressor of eyelid, 192; de-
 pressor tarsi, 121; dermal, 112, 113;
 diaphragmatic, 122; digastric, 119,
 158; dilator of glottis, 253, 255; dila-
 tor of iris, 184; of eye (recti, obliqui,
 and retractor bulbi), 191; facial, 120;
 genio-hyoid, 119, 120; genioglossus,
 119, 120; hyoglossus, 119, 120; ileo-
 costalis, 116; intercostal, 116, 118;
 interspinales, 116; lateral, 113; levator
 anguli oris, 121; levatores costarum,
 116; levator of eyelid, 192; levator
 labii superioris proprius, 121; longissi-
 mus, 116; masseter, 119; masticatory,
 112; multifidi, 116; mylohyoid, 119,
 120; obliquus abdominis, 116, 117;
 omohyoid, 119, 120; pectoralis major,
 117; platysma myoides, 113, 121; pro-
 nators, 122; pterygoid, 120; pyramid-
 alis abdominis, 99, 117; pyramidalis
 of eye, 191; quadratus of eye, 191; quad-
 ratus lumborum, 116; rectus abdominis,
 116, 117; scaleni, 116; semispinales,
 116; sphincter oris, 121; sphincter
 collis, 121; splenii, 116; stapedius,
 202; sternocleidomastoid, 159; sterno-
 hyoid, 117, 119, 120; sternothyroid, 117,
 120; stylohyoid, 120, 158; styloglossus,
 120; stylopharyngeus, 120; supinators,
 122; temporal, 119, 120; thyro-hyoid,
 120; transversalis abdominis, 116, 117,
 122; trapezius, 159; triangularis sterni,
 117; of trunk, 113; of visceral skele-
 ton and head, 118
 Musk-deer, teeth, 220
 Mustelus:—umbilical placenta, 12; foetal
 membranes, 312
 Mycetes:—larynx, 256
 Myocommata or myotomes, 48, 113

N.

Nares, external and internal, 67, 170,
 173
 Narwhal, teeth, 220

- Nasalis, teeth, 219
 Naso-palatine duct of Cyclostomes, 171
 Naso-lacrymal duct, 174, 194
 Navicular, 109
 Neomorph, 33, 48, 236
 Nephridia, 296
 Nephrostomes, 297, 302, 304, 307
 Nerve, lateral, 158, 165
 phrenic, 122
 Nerve-roots, 151, 152
 Nerves:—cranial, 153—160; olfactory, 154;
 optic, 132, 155; oculomotor, trochlear,
 and abducent, 156; trigeminal, 118—120,
 126, 156, 165, 193; facial, 60, 118—120,
 158; auditory, 158; glossopharyngeal,
 60, 118—120, 158; vagus, 60, 118, 119,
 158, 160, 165, 284; spinal accessory,
 159; hypoglossal, 119, 159
 Nerves:—spinal, 152
 Nervous system:—central, 129—151; peri-
 pheral, 151—160; sympathetic, 129, 152,
 160
 Neural tube, 9
 Neurenteric canal, 129
 Neurilemma, 129
 Neuroglia, 129
 Neuropore, of Tunicata and Amphioxus,
 133
 Nictitating-membrane, 192
 Nose, external, 177
 Nothosaurus, abdominal ribs, 50
 Notochord, 10, 33—47
 Notodelphys, external gills, 251
 Nucleus, 3
- O.
- Obturator foramen, 95
 Odontoid bone, 43
 Odontornithes, teeth, 216
 Oesophagus, 209, 228, 234
 Olfactory organ, 170—177
 Olfactory region of skull, 58
 Olfactory scrolls, 176
 Omosternum, 51
 Ontogeny, 1
 Opercular bones, 69
 Operculum, 65, 158, 249, 250
 Orbicular apophysis, 202
 Orbital region of skull, 58
 Orbital ring, 69
 Organ of Corti, 201, 202, 206
 Organs, 1:—electric, 128; sensory, 162—
 207; of nutrition, 208—243; of respira-
 tion, 245—265; of circulation, 268—
 294; urinogenital, 296—330
 Ornithorhynchus:—eggs, 5, 320; pectoral
 arch, 91; urinogenital organs, 321
 Ornithoscelida, sacral vertebræ, 43
 Orthagoriscus, spinal cord, 131
 Os penis and clitoridis, 329
 Ossification, 62
 Otoliths, 196
- Ovary, 311—320, 322, 325
 Oviducal gland, 311
 Oviduct, 302, 311—32
 Ovipositor, 311
 Ovotestis, 316
 Ovum, 2
- P.
- Palæontology, 1
 Palate, 75, 81, 209
 Palpebræ, 184
 Pancreas, 243
 Panniculus adiposus, 26
 Papilla acustica, 198, 199, 202
 Papillæ, of tongue, 166, 222
 Parabronchia, 262
 Parachordal cartilages, 57
 Paradoxurus, number of caudal vertebræ,
 47
 Parorchis, 298, 306, 320
 Parostosis, 62
 Parovarium, 298, 322
 Parrot:—number of vertebræ, 45; fronto-
 nasal joint, 80
 Pars acetabularis, 93—98
 Pars basilaris, 198
 Pars superior and inferior of membranous
 labyrinth, 198
 Patella, 110
 Pecten, 188
 Pectineal process of pubis, 98
 Pectoral arch, 86—91
 Pelvic arch, 86, 92
 Pelvis of kidney, 309
 Penis, 328
 Pennæ, 22
 Pericardium, 208, 265, 268
 Perilymph, 196
 Perissodactyle feet, 109
 Peritoneal funnels, 297, 302
 Peritoneum, 208
 Pes, 102
 Phalanges, 104
 Phalangista, urinogenital organs, 322
 Phagocytes, 239
 Phascalomys, urinogenital organs, 322
 Pharynx, 209
 Phyllodactylus:—tongue, 224; larynx, 254
 Phylogeny, 1
 Physiology, 2
 Physoclisti, 251
 Physostomi, 251
 Pia mater, 135
 Pigment of retina, 183
 Pigment of skin, 19
 Pineal gland, 132, 142
 Pinna of ear, 198
 Pisiform bone, 106, 109
 Pituitary body, 133
 Pituitary space, 57
 Placenta, 10, 274
 Placenta, umbilical, 12

Plastron, 32
 Pleura, 208, 264
 Pleurodont dentition, 215
 Pleuronectidæ, asymmetry of head, 70
 Plexus choroidei, 136
 Plica semilunaris, 192
 Pluma, 22
 Pneumatic bones, 107, 262
 Poison-fangs, 215
 Polar cells, 3
 Polymastism, 28
 Polypterus :—olfactory organ, 172 ; horny teeth, 214 ; external gills, 250 ; air-bladder, 251, 252
 Polythelism, 28
 Precoracoid, 87, 89
 Prehallux, 109
 Premolars, 214, 216
 Prepollex, 109
 Prepuce, 330
 Pristiurus :—number of vertebræ, 37 ; development of fins, 87
 Processus falciformis, 185
 Processus vermiformis, 236
 Prochordal cartilages, 57
 Pronation, 108
 Pronephric duct, 296, 303
 Pronephros, 296, 298, 302
 Pronucleus, male and female, 3, 4
 Proteus, eyes, 186
 Protocerebral tail, 38
 Protoplasm, 3
 Protopterus :—dermal denticles, 31 ; vertebral column, 35 ; skull and pectoral fin, 68 ; pelvis, 92 ; abdominal pores, 267 ; urinogenital organs, 313, 314
 Protovertebræ, 9, 56
 Proventriculus, 233
 Psalterium, 236
 Pseudobranch, 250
 Pseudo-turbinal, 175
 Pterodactylus :—abdominal ribs, 50 ; manus, 106
 Pterygopodium, 327
 Pubis, 93—99
 Pulp-cavity, 213
 Pupil, 183, 188
 Purple, visual, 190
 Pyloric cæca, 229
 Pyloric portion of stomach, 234
 Pyramids of kidney, 308, 310

Q.

Quill, 22

R.

Radiale, 104
 Radii, of fins, 99
 Radius, 104
 Rana :—alimentary canal, 232 ; liver and pancreas, 241 ; laryngo-tracheal cartilages, 254

Ranodon :—development of vertebral column, 40
 Rattlesnake, poison-apparatus, 221
 Receptaculum chyli, 293
 Recessus cochleæ, 197
 utriculi, 196
 vestibuli, 195
 Rectum, 209, 228—236
 Reproduction of tail in Lizards, 43, 292
 Resonance-cavities, 257
 Respiratory organs, 245—265
 Respiratory tube, 246
 Rete Halleri, 327
 Retia mirabilia, 292
 Retina, 182, 189
 Rhamphorhynchus, manus, 106
 Rhinolophus, milk-teeth, 213
 Ribs, 48—51
 Ribs, abdominal, 50
 Rodentia, milk-teeth, 213
 Rods of retina, 190, 191
 Root-sheaths of hair, 24
 Rostrum of skull, 58, 65
 Ruminant stomach, 235, 236

S.

Sacci vasculosi, 138, 142
 Sacculo-cochlear canal, 198
 Sacculus, 195
 Saccus endolymphaticus, 205
 Salamandrina, development of vertebral column, 40
 Salmonidæ :—intestinal valve, 229 ; abdominal pores, 267
 Sarginæ, teeth, 214
 Scala vestibuli, tympani, and media, 190
 204
 Scales, 18, 32
 Scapula, 87—94
 Scapus, 22
 Scarf skin, 16
 Scarus, teeth, 214
 Schizocoæles, 9
 Sclerotic, 184
 Scrotal sacs, 326
 Scyllium, number of vertebræ, 37
 Segmental duct, 296, 303
 Segmental sense-organs, 163
 Segmentation of ovum, 4
 Semicircular canals, 195
 Seminal duct, 301
 Seminal tubes, 327
 Sennopithecus, number of caudal vertebræ, 47
 Sense-capsules, 58
 Sensory organs, 162—207
 of integument, 163, 194
 Sensory tubes and sacs, 166
 Septum, interorbital, 57, 75
 Septum, oblique, 259
 Sesamoids, 110, 113
 Shark, intestinal tract, 229

- Sheath of Schwann, 129
 Shrew, milk-teeth of, 213
 Sinus:—frontal, ethmoidal, and sphenoidal, 176; maxillary, 172, 176, 178
 Sinus superior of membranous labyrinth, 196
 Sinus venosus, 269
 Siphonops, viscera, 305
 Siren:—horny teeth, 214; intestinal tract, 232; trachea, 253
 Sirenia:—palatal plates, 27; milk-teeth, 213
 Skeletogenous layer of vertebral column, 33
 Skeleton, 30—111
 Skin, 16
 Skinks, pectoral arch of, 90
 Skull, 54—84
 bones of, 61:—alisphenoid, 75, 79; basioccipital, 75, 76; basisphenoid, 75, 76, 79; basitemporal, 78, 79; epipterygoid, 78; ethmoid, 80; exoccipital, 72—77; frontal, 70, 75; frontoparietal, 74; jugal, 83; maxilla, 69—79; mesopterygoid, 69; metapterygoid, 69; orbitosphenoid, 75; palatine, 69—79; palatopterygoid, 61—72; palatoquadrate, 61—72; parasphenoid, 57, 66—72, 80; parietal, 70—79; premaxilla, 69—82; prefrontal, 76, 77; presphenoid, 78, 80; pterygoid, 69—81; quadrate, 61, 70—79, 202; quadratojugal, 72, 74; squamosal, 71—83; supraoccipital, 68, 69, 76, 77, 79; symplectic, 61, 66, 69, 70; transverse, 75—77; turbinals, 81, 172, 175—177; vomer, 69—79
 bones of mandible:—angular, 70, 76, 79; articular, 70, 76, 79, 202; coronoid, 70, 84, 87; dentary, 70, 76, 79, 84; splenial, 78, 84; supraangular, 78, 79
 Somatopleure, 9
 Somites, 9, 54
 Spatularia:—vertebral column, 35; ribs, 48
 Spelerpes, tongue, 74, 223
 Spermatozoa, 3, 300
 Sphincters of intestine, 209
 Spina scapulae, 91
 Spinachia, nest of, 302
 Spinal cord, 129
 Spinal nerves, 152
 Spiracle, 65, 198, 246
 Spiral valve of intestine, 229
 Splanchnopleure, 9
 Spleen, 294
 Spots, blind and yellow, of retina, 189, 190
 Spouting apparatus of *Gymnophiona*, 179
 Squalidae, connection of skull with vertebral column, 64
 Squatina, number of vertebrae, 37
 Stapes, 70, 198, 202
 Stegosaurus:—dermal skeleton, 32; brain, 147
 Stomach, 209, 228—236
 Stork, thymus and thyroid, 227
 Stylo-hyoid ligament, 84
 Stratum corneum and Malpighii, 16
 Structural elements, 1
 Subdural space, 136
 Sublingua, 223
 Sub-pulmonary chamber, 259
 Suctorial organs, 85, 212
 Sulci, 132
 Supination, 108
 Suprarenal bodies, 161, 320
 Suspensorium, 65, 70
 Sympathetic, 160
 Symphysis pubis, 98
 Syrinx, 255
- T.
- Tactile cells, 167
 corpuscles, 168
 Tamandua, cervical vertebrae, 46
 Tapetum, 186
 Tarsus, 102, 105—109
 Taste, organ of, 167
 Teats, 27
 Teeth, 212—220
 Teeth, horny, 214
 Telæ choroideæ, 136
 Temporal fossa, 83
 "Tentacle," of *Gymnophiona*, 179
 Testis, 311—326
 Testudo:—dermal skeleton, 32
 Thecodont dentition, 215
 Thoracic duct, 293
 Thymus gland, 226
 Thyroid cartilage, 255—257
 Thyroid gland, 225
 Tibia, 104
 Tibiale, 104
 Tibio-tarsus, 107
 Tissues, 1
 Tongue, 222
 muscles of, 119
 Tonsils, 239, 293
 Tooth-structures, 62
 Torpedo, electric organ, 124
 Trabeculae cranii, 57, 70
 Trachea, 252
 Tragus, 198
 Trigla:—spinal cord, 131
 Triton, dorsal fin, 85
 Truncus arteriosus, 269, 279, 280, 282
 Tuberculum impar, 225
 Tubules, of kidney, 295
 Tunica vaginalis, 826
 Tupaia, abdominal muscles, 117
 Turbinals:—of Amphibians, 172; of Reptiles, 174; of Birds, 175; of Mammals, 81, 176

Tusks, 220
 Tympanic membrane and cavity, 73, 198
 Tympano-Eustachian passage, 227, 246
 Typhlops, skull, 78

U.

Ulna, 104
 Ulnare, 104
 Umbilical cord, 276
 vesicle, 12
 Umbilicus, 276
 Unciform bone, 109
 Uncinate processes, 50
 Ungulata:—cervical vertebræ, 46; orbit,
 83; brain of Eocene forms, 151
 Urachus, 275
 Ureter, 299, 301, 322
 Urethra, 276, 309
 Urinary bladder, 231, 276, 307, 308; of
 Fishes, 302
 duct, 302, 314
 organs, 302—310
 Urinogenital duct, 301, 307, 314, 316
 organs, 296—330
 sinus, 322
 Urostyle, 42
 Uterus, 276, 302, 311, 321, 322
 masculinus, 195

V.

Vagina, 302, 322
 Valves, atrio-ventricular, 279, 287
 of conus arteriosus, 279
 ileo-colic, 209
 pyloric, 209
 semilunar, 286, 287
 of veins, 292
 of lymphatics, 293
 Vane, 22
 Vas deferens, 301, 327
 epididymis, 327
 Vasa centralia nervi optici, 183
 efferentia, 306, 316, 327
 Vascular system, 268—294
 Veins:—allantoic, 273, 274, 291; anterior
 abdominal, 291; azygos, 272, 275;
 branchial, 270, 279—283; cardinal,
 anterior and posterior, 271, 272, 275,
 280, 291; caudal, 35, 270, 291; coro-
 nary, 275, 287; ductus Cuvieri, 271,
 273, 280; ductus venosus, 270, 273,

274; hepatic, 274, 275, 291; hypo-
 gastric, 275; iliac, 275; jugular, 272—
 275, 285, 292; lateral, 291; omphalo-
 mesenteric, 270, 273, 274; portal
 (hepatic), 272, 274, 291, (renal) 161,
 291; postcaval, 272—275, 291; precaval,
 274, 275, 282, 292; pulmonary, 270;
 renal, 275; subclavian, 274, 275, 285;
 subintestinal, 270, 272; umbilical, 276;
 vertebral, 272—275; vitelline, 270, 273,
 274

Velum, 246
 Velum palati, 209
 Venous system, 291
 Ventricles of heart, 269, 277, 285—287
 Vertebral column, 33—47
 Vertebrarterial canal, 46
 Vesicles, cerebral, 131
 Vesicula seminalis, 307, 327
 Vestibulum oris, 212
 Villi of intestine, 211, 240
 of placenta, 10, 274
 Viper, teeth, 216
 Vitelline membrane, 2
 Vitellus, 2
 Vocal chords, 253, 257
 Vocal sacs of Anura, 253

W.

Weasel, stomach, 235
 Wolffian body, 296
 Wolffian duct, 301, 303, 304, 322
 Woodpecker:—cervical vertebræ 46;
 tongue, 223

X.

Xiphoid process, 53

Y.

Yolk-sac, 12
 Ypsiloid cartilage, 93

Z.

Zootoca, teeth, 215
 Zygantra, 43
 Zygosphenes, 43

RICHARD CLAY & SONS,
BREAD STREET HILL, LONDON,
Bungay, Suffolk.

TEXT-BOOKS FOR STUDENTS.

- Applied Mechanics:** an Elementary General Introduction to the Theory of Structures and Machines. By Professor JAMES H. COTTERILL, F.R.S. 8vo. 18s.
- A Text-Book of the Principles of Physics.** By ALFRED DANIELL, M.A., LL.B., D.Sc., F.R.S.E. Second Edition. Revised and Enlarged. Medium 8vo. 21s.
- The Kinematics of Machinery.** Outlines of a Theory of Machines. By Professor F. REULEAUX. Translated and Edited by Professor A. B. W. KENNEDY, C.E. With 450 Illustrations. Medium 8vo. 21s.
- Spectrum Analysis.** Lectures delivered in 1868 before the Society of Apothecaries of London. By Professor Sir HENRY E. ROSCOE, LL.D., F.R.S. Fourth Edition, Revised and Considerably Enlarged by the Author and by Professor ARTHUR SCHUSTER, F.R.S., Ph.D. With Appendices, numerous Illustrations, and Plates. 8vo. 21s.
- Electrostatics and Magnetism,** Reprints of Papers on. By Professor Sir WILLIAM THOMSON, D.C.L., LL.D., F.R.S., F.R.S.E. Second Edition. 8vo. 18s.
- Popular Astronomy.** By S. NEWCOMB, LL.D., Professor U.S. Naval Observatory. With 112 Illustrations and 5 Maps of the Stars. Second Edition, Revised 8vo. 12s.
- Inorganic and Organic Chemistry.** A Complete Treatise on Inorganic and Organic Chemistry. By Sir HENRY E. ROSCOE, F.R.S., and Professor C. SCHORLEMMER, F.R.S. With numerous Illustrations. Medium 8vo.
Vols. I. and II.—INORGANIC CHEMISTRY.
Vol. I.—The Non-Metallic Elements. 21s. Vol. II. Part I.—Metals. 18s. Vol. II. Part II.—Metals. 18s.
Vol. III.—ORGANIC CHEMISTRY. Two Parts. The Chemistry of the Hydrocarbons and their Derivatives, or Organic Chemistry. 21s. each.
Vol. IV.—Part I. ORGANIC CHEMISTRY, continued. [In the press.]
- Elements of Chemical Physics.** By JOSIAH P. COOKE, Jun., Erving Professor of Chemistry and Mineralogy in Harvard University. Fourth Edition. Royal 8vo. 21s.
- A Manual of the Chemistry of the Carbon Compounds, or Organic Chemistry.** By Professor C. SCHORLEMMER, F.R.S. With Illustrations. 8vo. 14s.
- The Elements of Thermal Chemistry.** By M. M. PATTISON MUIR, M.A., F.R.S.E., assisted by DAVID MUIR WILSON. 8vo. 12s. 6d.
- A Text-Book of Physiology.** By Professor MICHAEL FOSTER, M.D., Sec.R.S. With Illustrations. Fourth Edition, Revised. 8vo. 21s.
- A Text-Book of the Physiological Chemistry of the Animal Body.** Including an Account of the Chemical Changes occurring in Disease. By Professor A. GAMGEE, M.D., F.R.S. 2 Vols. 8vo. With Illustrations. Vol. I. 18s. [Vol. II. in the press.]
- Elements of Comparative Anatomy.** By Professor CARL GEGENBAUR. A Translation by F. JEFFREY BELL, B.A. Revised with Preface by Professor E. RAY LANKESTER, F.R.S. With numerous Illustrations. 8vo. 21s.
- The Fertilisation of Flowers.** By Professor HERMANN MÜLLER. Translated and Edited by D'ARCY W. THOMPSON, B.A., Professor of Biology in University College, Dundee. With a Preface by CHARLES DARWIN, F.R.S. With numerous Illustrations. Medium 8vo. 21s.
- A Text-Book of Pharmacology, Therapeutics, and Materia Medica.** By T. LAUDER BRUNTON, M.D., D.Sc., F.R.C.P., F.R.S. Adapted to the United States Pharmacopœia by FRANCIS H. WILLIAMS, M.D. Second Edition. Adapted to the New British Pharmacopœia, 1885. Medium 8vo. 21s.
- Tables of Materia Medica: a Companion to the Materia Medica Museum.** By the same Author. With Illustrations. New Edition Enlarged. 8vo. 10s. 6d.
- Text-Book of Pathological Anatomy and Pathogenesis.** By Professor ERNST ZIEGLER of Tübingen. Translated and Edited for English Students by DONALD MACALISTER, M.A., M.D., B.Sc., F.R.C.P. With numerous Illustrations. Medium 8vo.
Part I.—GENERAL PATHOLOGICAL ANATOMY. 12s. 6d.
Part II.—SPECIAL PATHOLOGICAL ANATOMY. Sections I.—VIII. 12s. 6d. Sections IX.—XVII. in the press.
- Text-Book of Geology.** By ARCHIBALD GEIKIE, LL.D., F.R.S. With numerous Illustrations. Second Edition. Fifth Thousand. Revised and Enlarged. 8vo. 28s.
- A Treatise on Ore Deposits.** By J. ARTHUR PHILLIPS, F.R.S., V.P.G.S., F.C.S., M.Inst.C.E. With numerous Illustrations. 8vo. 25s.
- The Principles of Political Economy.** By Professor HENRY SIDGWICK, M.A., LL.D. 8vo. 16s.
- Political Economy.** By FRANCIS A. WALKER, M.A., Ph.D. 8vo. 10s. 6d.
- The Methods of Ethics.** By Professor HENRY SIDGWICK, M.A., LL.D. Third Edition. 8vo. 14s. A Supplement to the Second Edition, containing all the important Additions and Alterations in the Third Edition. Demy 8vo. 6s.

* * Other Volumes to follow.

MACMILLAN AND CO., LONDON.

MANUALS FOR STUDENTS.

- Heat. By P. G. TAIT, M.A., Sec. R.S.E. Crown 8vo. 6s.
- Elementary Practical Physics, Lessons in. By Professor BALFOUR STEWART, F.R.S., and W. W. HALDANE GEE, B.Sc. Crown 8vo.
 Part I. GENERAL PHYSICAL PROCESSES. 6s.
 II. OPTICS, HEAT, AND SOUND. *a* [In the press.
 III. ELECTRICITY AND MAGNETISM. [In preparation.
- On Light. Being the Burnett Lectures, delivered in Aberdeen in 1883-1884. By GEORGE GABRIEL STOKES, M.A., P.R.S., etc. First Course.—ON THE NATURE OF LIGHT. Second Course.—ON LIGHT AS A MEANS OF INVESTIGATION. Third Course.—ON THE BENEFICIAL EFFECTS OF LIGHT. Crown 8vo. 2s. 6d. each.
- Organic Chemistry, or an Introduction to the Study of the Compounds of Carbon. By IRA REMSEN, Professor of Chemistry in the Johns Hopkins University. Crown 8vo. 6s. 6d.
- The Study of Chemistry, an Introduction to. By IRA REMSEN, Professor of Chemistry in the Johns Hopkins University. Crown 8vo. 6s. 6d.
- A Handbook of European Butterflies. By F. DE VISMES KANE, M.A., F.E.S.L. With Illustrations. 10s. 6d.
- A Course of Instruction in Zootomy (Vertebrata). By T. JEFFREY PARKER, B.Sc. With Illustrations. Crown 8vo. 8s. 6d.
- The Morphology of the Skull. By Professor PARKER and G. T. BETTANY. Illustrated. Crown 8vo. 10s. 6d.
- Practical Embryology. By Professor MICHAEL FOSTER, M.A., F.R.S., and the late F. M. BALFOUR, F.R.S. Second Edition, revised and enlarged. Edited by ADAM SEDGWICK, M.A., and WALTER HEAPE. With Illustrations. Crown 8vo. 10s. 6d.
- Practical Physiology. A Course of Elementary Practical Physiology. By Professor MICHAEL FOSTER, M.D., F.R.S., and J. N. LANGLEY, M.A., F.R.S. Fifth Edition enlarged. Crown 8vo. 7s. 6d.
- A Course of Practical Instruction in Elementary Biology. By T. H. HUXLEY, F.R.S., assisted by H. N. MARTIN, B.A., M.B., D.Sc. New Edition. Crown 8vo. 6s.
- A Treatise on Comparative Embryology. By F. M. BALFOUR, M.A., F.R.S. With Illustrations. Second Edition, reprinted without alteration from the First Edition. In 2 vols. 8vo. Vol. I. 18s. Vol. II.—21s.
- The Osteology of the Mammalia, an Introduction to. By WILLIAM HENRY FLOWER, LL.D., F.R.S. Third Edition. Revised with the assistance of HANS GADOW, Ph.D. Crown 8vo. 10s. 6d.
- Class-Book of Geology. By ARCHIBALD GEIKIE, F.R.S. With 200 new Illustrations. Crown 8vo. 10s. 6d.
- A Course of Practical Instruction in Botany. By Professor F. O. BOWER, M.A., F.L.S., and SYDNEY H. VINES, M.A., D.Sc., F.R.S. With a Preface by W. T. THISELTON DYER, M.A., C.M.G., F.R.S., F.L.S. Crown 8vo.
 Part I.—PHANEROGAME—PTERIDOPHYTES. 6s.
- The Student's Flora of the British Islands. By Sir J. D. HOOKER, K.C.S.I., C.B., M.D., F.R.S. Third Edition. Globe 8vo. 10s. 6d.
- Structural Botany; or, Organography on the Basis of Morphology. To which are added the Principles of Taxonomy and Phytography, and a Glossary of Botanical Terms. By Professor ASA GRAY. 10s. 6d.
- Physiography. An Introduction to the Study of Nature. By THOMAS HENRY HUXLEY, F.R.S. New Edition. Crown 8vo. 6s.
- Agricultural Chemical Analysis, a Handbook of. By PERCY FARADAY FRANKLAND, Ph.D., B.Sc., F.C.S. Founded upon *Leitfaden für die Agricultur-Chemische Analyse*, von Dr. F. KROCKER. Crown 8vo. 7s. 6d.
- Marine Surveying, an Elementary Treatise on. Prepared for the use of Younger Naval Officers. By the Rev. JOHN L. ROBINSON. With Illustrations. Crown 8vo. 7s. 6d.
- Micro-Organisms and Disease: An Introduction to the Study of Specific Micro-Organisms. By E. KLEIN, M.D., F.R.S. With 121 Engravings. Third Edition, Revised. Crown 8vo. 6s.
- A Brief Text-Book of Political Economy. By FRANCIS A. WALKER, M.A., Ph.D. Crown 8vo. 6s. 6d.
- The History of Ethics, Outlines of. By HENRY SIDGWICK, M.A., LL.D., Knightbridge Professor of Moral Philosophy in the University of Cambridge, &c. Crown 8vo. 3s. 6d.

MACMILLAN AND CO., LONDON.

