

## **Diseases of the anus and rectum / by D.H. Goodsall and W. Ernest Miles.**

### **Contributors**

Goodsall D. H.  
Miles W. Ernest 1869-1947.  
Royal College of Physicians of Edinburgh

### **Publication/Creation**

London : Longmans, Green, 1900-1905.

### **Persistent URL**

<https://wellcomecollection.org/works/wjy7ppvt>

### **Provider**

Royal College of Physicians Edinburgh

### **License and attribution**


This material has been provided by This material has been provided by the Royal College of Physicians of Edinburgh. The original may be consulted at the Royal College of Physicians of Edinburgh. where the originals may be consulted.

Conditions of use: it is possible this item is protected by copyright and/or related rights. You are free to use this item in any way that is permitted by the copyright and related rights legislation that applies to your use. For other uses you need to obtain permission from the rights-holder(s).



Wellcome Collection  
183 Euston Road  
London NW1 2BE UK  
T +44 (0)20 7611 8722  
E [library@wellcomecollection.org](mailto:library@wellcomecollection.org)  
<https://wellcomecollection.org>







Jc\* 6. 56.

R52356







6/net



DISEASES  
OF THE  
ANUS AND RECTUM,

BY

D. H. GOODSALL, F.R.C.S. (ENG.),

*Senior Surgeon to the Metropolitan Hospital; late Senior Surgeon to St. Mark's Hospital for Fistula and other Diseases of the Rectum.*

AND

W. ERNEST MILES, F.R.C.S. (ENG.),

*Surgeon to the Gordon Hospital for Diseases of the Rectum; Surgeon to the Cancer Hospital, Brompton; late Senior Assistant Demonstrator of Anatomy at St. Bartholomew's Hospital Medical School, and House Surgeon to St. Mark's Hospital for Fistula and other Diseases of the Rectum, etc.*

IN TWO PARTS (*Illustrated*).

---

PART II.

---

LONGMANS, GREEN & CO.,

39, PATERNOSTER ROW, LONDON,


NEW YORK AND BOMBAY.

1905.

[ALL RIGHTS RESERVED.]







## P R E F A C E.

### GENERAL PREFACE.

This work on the diseases of the anus and rectum is the outcome of our personal experience of the subject extending over periods of thirty years and six years respectively.

The conclusions drawn are the results of the observation of many cases of which we have kept records. We have endeavoured to convey to the reader the clinical features of the various forms of disease described, and also to set forth those methods of treatment which we have found to be most successful.

This volume contains 91 illustrations, of which 15 are not original. These latter have been made use of for illustrating the chapter on Anatomy. For permission to reproduce the illustrations from the works of other authors, our best thanks are due to Messrs. Young J. Pentland, of Edinburgh, for figures 1 and 6 from Cunningham's Manual of Anatomy; to Charles Griffin & Co. for figure 3 from Macalister's text-book of Human Anatomy; and to Messrs. Longmans, Green & Co. for figures 4, 5, 7, 9, 10, 13 and 18 from Quain's Anatomy.

We have taken figures 8, 11, 14, 15 and 17 from MM. Quénu and Hartmann's most excellent and elaborate work entitled "*Chirurgie du Rectum*," published by G. Steinheil of Paris.

The remaining 76 illustrations are original and, with the exception of the diagrammatic figures 21, 23, 25—28, 30, 32—39, and figures 12 and 16, have been made from photographs of cases under our care.

For some of these photographs we are much indebted to Messrs. P. G. Harvey and L. Galsworthy of St. Bartholomew's Hospital, who took the greatest interest in making them as perfect as possible.

To Dr. Hugh Walsham, for his observations upon the relation of ano-rectal abscess and fistula to phthisis (see page 131), and



also for making the skiagrams reproduced in figures 64 and 66, our very best thanks are given.

Finally we thank Mr. W. R. Hall, Registrar of the Medical Society of London, for his kindness in reading the proof sheets with so much care, and for preparing the index.

D. H. GOODSALL.  
W. ERNEST MILES.

London, December, 1900.

#### PREFACE TO PART II.

In this volume we have adhered to the general arrangement of Part I., and have limited ourselves to setting forth those methods of treatment which, from personal experience, we have found to yield the most satisfactory results.

In the chapter on carcinoma of the rectum we have endeavoured to describe the various symptoms as they occur during the five distinct stages of the clinical course of the neoplasm, and hope, by so doing, that an appreciation of the more or less indefinite symptoms exhibited during the early stages may lead, in many cases, to an earlier diagnosis of the existence of this disease.

Our best thanks are accorded to Professor E. Klein and to Professor Woodhead for the careful investigations they have made into the cause of infective ulceration of the rectum, and it affords us much pleasure to include their reports (pp. 73 and 79) in the chapter on ulceration.

Both Mr. Harrison Cripps and the late Mr. Herbert Allingham very kindly revised the description of their operations for excision of the rectum which we have included in the chapter on malignant growths.

There are 44 illustrations (all original) in this volume, and we thank Dr. T. Johnston English for his kindness in taking the photographs and photo-micrographs from which the illustrations contained in Figs. 7, 9—11, 14, 15, 17—24, 31, 34—36, 41, 42 have been made.

Finally we acknowledge our indebtedness to Mr. Bethell for the care he has bestowed upon making the index as complete as possible.

D. H. GOODSALL.  
W. ERNEST MILES.

London, May, 1905.

# TABLE OF CONTENTS.

## CHAPTER I.

### PROLAPSE OF THE RECTUM.

Prolapsus Mucosæ Recti—Etiology—Predisposing Causes—Exciting Causes—Symptoms: (*a*) protrusion; (*b*) escape of rectal mucus; (*c*) pain; (*d*) loss of power of control in the sphincters; (*e*) frequency in the action of the bowels; (*f*) loss of weight; (*g*) hæmorrhage—Physical Examination—Redundant Skin—Palpation—Condition of the Sphincters—Examination of the Rectum—Differential Diagnosis—Absence of Lobulation—The Absence of Dilated, Thickened and Tortuous Veins—Size of the Protrusion—Character of the Aperture—Existence of Dividing Sulci—Absence of Transverse Furrows—Structure of the Protrusion—Treatment—Palliative Treatment—Reduction of the Protrusion—Prevention of the Protrusion—Improving the Tone of the Sphincter Muscles—Operative Treatment—The Operation by Ligature—Method of Operating: (*a*) when silk is used; (*b*) when silkworm gut is used—After Treatment.

Procidentia Recti—Etiology: (*a*) predisposing causes, sex, occupation, constitutional condition; (*b*) exciting causes; (1) causes in children; (2) causes in adults—Symptoms—Physical Examination—Differential Diagnosis: (*a*) from prolapsus mucosæ recti; (*b*) from invagination of the upper part of the rectum or intussusception of the colon—Treatment: (*a*) palliative treatment; (*b*) operative treatment—Choice of Operation; (*a*) the application of nitric acid; (*b*) operation by cautery; (*c*) operation by ligature—After Treatment

... .. I



## CONTENTS.

### CHAPTER II.

#### INVAGINATION OF THE RECTUM.

Etiology — Symptoms: (*a*) prior to protrusion having occurred; hæmorrhage; pain; discharge of mucus; (*b*) after protrusion has occurred—Physical Examination: (*a*) prior to protrusion having occurred; (*b*) after protrusion has occurred—Differential Diagnosis: (*a*) before protrusion of the invaginated part; (1) from simple annular stricture; (2) from intussusception of the colon; (3) from ulceration of the rectum; (4) from carcinoma of the rectum; (5) from a villous growth; or (*b*) after protrusion of the invaginated part; (1) from prolapsus mucosæ recti; (2) from procidentia recti; (3) from protruded intussusceptum coli—Treatment. 38

### CHAPTER III.

#### ULCERATION.

Anal Ulceration: (*a*) the local contagious ulcer—Treatment: (*b*) the tuberculous ulcer — Treatment — After Treatment: (*c*) the syphilitic ulcer; (*d*) the lupoid ulcer—Treatment: (*e*) the rodent ulcer — Treatment — Rectal Ulceration — Circumscribed Ulceration: (*a*) the traumatic ulcer—Symptoms: (*a*) pain; (*b*) discharge; (*c*) slight loss of blood; (*d*) inability to force the anus down — Physical Examination—Treatment—Palliative Treatment—Operative Treatment — After Treatment: (*b*) tuberculous ulcer — Symptoms—Physical Examination—Treatment.

Diffuse Ulceration—Infective Ulceration—Description of the ulceration: (*a*) appearance of the wound; (*b*) discharge — Etiology—Professor Klein's Report—Professor Woodhead's Report—Physical Examination—Symptoms: (*a*) pain and tenderness in the wound; (*b*) alterations in the character of the discharge; (*c*) Bleeding; (*d*) increased frequency in the actions of the bowels—Treatment. ... .. 47

## CONTENTS.

### CHAPTER IV.

#### STRICTURE OF THE ANUS AND OF THE RECTUM.

Cicatricial or Fibrous Stricture—Varieties of Stricture—The Linear or Annular Stricture—Symptoms—Physical Examination—Treatment: (*a*) when the stenosis is situated at the anal orifice; (*b*) when the stenosis is situated at the level of the upper border of the internal sphincter; (*c*) when the stenosis is situated at a level of three or more inches above the level of the anal orifice—The Tubular Stricture—Etiology: (*a*) local tissue destruction; (*b*) chronic inflammatory processes—Symptoms: (*a*) frequent desire for an action of the bowels; (*b*) alteration in the size and character of the *fæces* passed; (*c*) the passage of blood, mucus and pus from the rectum; (*d*) abdominal distension; (*e*) loss of weight; (*f*) *œdema* of the lower extremities—Physical Examination—Treatment: (*a*) local treatment—Treatment by Dilatation: (1) forcible or rapid dilatation; (2) gradual dilatation; (*b*) general treatment—Results of Stricture: (*a*) intestinal obstruction; (*b*) pelvi-rectal suppuration; (*c*) amyloid degeneration of the kidneys. ... .. 88

### CHAPTER V.

#### MALIGNANT GROWTHS OF THE ANUS AND RECTUM.

Carcinoma of the Anus—Treatment—Carcinoma of the Rectum—Etiology—Occupation—Age—Parentage—Sex—Locality—Pathological Varieties—Part of the Bowel Affected—Clinical Course of the Neoplasm—Symptoms: (*a*) prior to disintegration of the surface of the growth; (1) primary attack of constipation; (2) slight loss of weight; (3) frequent action of the bowels; (*b*) during the process of surface disintegration; (1) increased frequency in the actions of the bowels; (2) the appearance of blood and mucus in the stools; (3) local and reflected pain; (4) difficulty in obtaining complete or satisfactory evacuation of the rectum; (5) progressive loss of weight; (*c*) when the growth has infiltrated the peri-rectal tissues and perforation of the



## CONTENTS.

rectal wall has supervened ; (1) hæmorrhage ; (2) the escape of mucus and pus without the admixture of fæces ; (3) deep seated pain in the pelvis, over the sacrum and extending down the thighs ; (4) general cachexia ; (*d*) when almost complete occlusion of the bowel has supervened ; (1) obstinate constipation alternating with diarrhœa ; (2) local pain and intermittent attacks of abdominal pain ; (3) intermittent hæmorrhage ; (4) increasing abdominal distension ; (5) rapid emaciation ; (6) vomiting ; (7) attacks of absolute obstruction ; (*e*) when secondary deposits have occurred in the abdominal lymphatic glands and in the liver, lungs, pluræ, etc.—When the Pelvic and Lumbar Lymphatic Glands are the seat of Secondary Deposits : (1) the presence of a tumour or tumours in the abdomen ; (2) œdema of the scrotum and penis in the male and of the vulva in the female ; (3) œdema of one or both lower extremities ; (4) ascites—When Secondary Deposits have taken place in the Liver, Lungs, Pluræ, etc. : (1) enlargement of the liver ; (2) the appearance of jaundice ; (3) vomiting ; (4) hæmatemesis ; (5) cough ; (6) dyspnœa ; (7) heart failure — Physical Examination—Differential Diagnosis : (*a*) from the adenomatous polypus ; (*b*) from the papilloma or villous tumour ; (*c*) from benign stricture ; (*d*) from invagination of the rectum ; (*e*) from gummatous deposits ; (*f*) from tuberculous ulceration ; (*g*) from extensive induration round a blind internal fistula—Treatment : (*a*) cases in which extirpation is practicable—Resection of the Rectum—Preparation before Operation — Instruments Required — Description of the Operation : (1) preliminary incision and exposure of the rectum ; (2) isolation of the portion of the rectum to be resected together with the removal of the sacral glands ; (3) removal of the growth ; (4) treatment of the proximal and distal ends ; (5) completion of the operation—Treatment after the Operation—Excision of the Rectum : (1) perineal excision with the formation of an inter-ischial artificial anus—Cripp's Method — Allingham's Method : (2) trans-sacral excision of the rectum with the formation of a sacral



## CONTENTS.

artificial anus—Kraske's Method—Bardenheuer's Method :  
 (3) extirpation of either a part or the whole of the rectum,  
 subsequent to the establishment of an abdominal artificial  
 anus (iliac colostomy)—The Advantages of a Preliminary  
 Abdominal Anus : (a) from the patient's point of view ;  
 (b) from the surgeon's point of view—Method of Operating :  
 (a) preliminary incision and exposure of the rectum ; (b) isola-  
 tion of the rectum at and above the level of the growth ;  
 (c) section of the rectum above the growth ; (d) removal of  
 the rectum ; (e) completion of the operation—The After  
 Treatment—Mortality from the Operation—Complications  
 during and after Excision of the Rectum, and their Treat-  
 ment—Complications during the Operation : (a) shock ;  
 (b) collapse from hæmorrhage—Complications during the  
 After-treatment : (a) recurrent or intermediary hæmorrhage ;  
 (b) secondary hæmorrhage ; (c) abscess ; (d) urethral fistula ;  
 (e) peritonitis ; (f) iodoform delirium ; (g) mercurial  
 poisoning—Recurrence of the Growth after Removal—Signs  
 of Recurrence—Treatment. Cases unsuitable for Removal  
 of the Growth : (a) prior to the occurrence of obstruction—  
 Left Iliac Colostomy—Preparation of the Patient for the  
 Operation—Instruments Required—Method of Operating :  
 (1) the skin incision ; (2) making the opening through the  
 abdominal parietes ; (3) method of dealing with the parietal  
 peritoneum ; (4) locating the sigmoid colon and determining  
 the segment to be fixed in the wound ; (5) method of fixing the  
 segment of colon in the wound ; (6) completion of the opera-  
 tion—After-Treatment—Complications during and after the  
 Operation and their Treatment—Complications after the  
 Operation : (a) abdominal distension ; (b) extrusion of a loop  
 of small intestine or a mass of omentum between the inner  
 margin of the wound and the loop of the colon ; (c) when the  
 symptoms of obstruction are present—Cæcostomy : (1) that  
 there is a continuous escape of fluid fæces from the artificial  
 anus on account of its proximity to the ileo-cæcal valve ; (2)  
 that the patient becomes emaciated on account of the whole of  
 the large intestine having been almost completely short-



## CONTENTS.

circuited; (3) that the patient's life is shortened. Method of Operating—After-Treatment—Complications after the Operation and their Treatment—Closure of the Cæcal Artificial Anus—Method of Operating—Further Treatment of Cases unsuitable for the Removal of the Growth; (a) increased secretion of rectal mucus; (b) hæmorrhage; (c) pain due to pressure upon or involvement of nerves of the sacral plexus; (d) pelvi-rectal and ischio-rectal suppuration; (e) recto-vesical or recto-vaginal fistula; (f) ascites	113
--	-----

## CHAPTER VI.

### BENIGN TUMOURS OF THE ANUS AND RECTUM.

Benign Tumours of the Anus and its vicinity: (a) the papilloma—Symptoms—Treatment; (b) the soft fibroma or fibro-cellular tumour—Symptoms—Treatment; (c) the lipoma—Symptoms—Treatment—Benign Tumours of the Rectum: (a) the adenoma or glandular polypus—Symptoms—Physical Examination—Treatment—After-Treatment; (b) the fibroma or fibrous polypus—Symptoms—Physical Examination—Treatment; (c) the villous tumour—Etiology—Symptoms—Physical Examination—Treatment—Method of Operating—After-Treatment—Recurrence of the Growth after removal—Treatment of the Recurrent Growth; (d) the myxoma or myxomatous polypus—Symptoms—Treatment	216
--	-----

## CHAPTER VII.

### FOREIGN BODIES IN THE RECTUM.

(a) Foreign bodies that have been introduced into the rectum; (b) foreign bodies that have been swallowed—Symptoms: (a) when it is impacted in the anal canal; (b) when the foreign body has perforated the rectal wall—Treatment—The Notes of Cases of Foreign Bodies in the Rectum.	241
---	-----

## CHAPTER VIII.

### PRURITUS ANI.

Etiology—Symptoms—Treatment	259
-----------------------------	-----

CONTENTS.

CHAPTER IX.

SYPHILIS OF THE ANUS AND RECTUM.

Congenital Syphilis — Treatment — Acquired Syphilis — Primary Lesions—Secondary Lesions—Treatment—Tertiary Lesions—Gummatous Tumour of the Rectum—Gummatous Ulceration of the Rectum—Cicatrization of a Gummatous Ulcer of the Rectum—Treatment—Synopsis of the Notes of fifty-five Cases of Syphilis ... ..	264
---	-----





## LIST OF ILLUSTRATIONS.

FIG.	PAGE.
I.—A case of Prolapsus Mucosæ Recti    ...    ...	9
II.—A case of Procidentia Recti    ...    ...	18
III.—A case of Procidentia Recti    ...    ...	19
IV.—A case of Procidentia Recti    ...    ...	23
V.—Showing the slit-like relaxed condition of the Anal Orifice after Reduction of the Proci- dentia had been effected in the same patient as in Fig. II.    ...    ...    ...    ...	25
VI.—A Tuberculous Ulcer of the Ano-Rectal Margin	50
VII.—Section of the Margin of the Tuberculous Ulcer shown in Fig. VI.    ...    ...    ...	51
VIII.—Lupoid Ulcer of the Anal Region    ...    ...	53
IX.—Infective Ulceration Reinfected a Scar    ...	69
X.—Infective Ulceration of the Anus and Rectum...	71
XI.—Naked Eye appearance of Infective Ulceration of the Rectum    ...    ...    ...	83
XII.—Rectal Tubes    ...    ...    ...	108
XIII.—The India-Rubber Coated Shot Bougie    ...	109
XIV.—Squamous Cell Carcinomatous Ulcer (Epithe- lioma) involving the Anal Canal    ...    ...	114
XV.—Microscopical appearance of a Section of the Growth shown in Fig. XIV.    ...    ...	115
XVI.—Typical Adeno-Carcinoma of the Rectum    ...	119
XVII.—An Adeno-Carcinoma of the Rectum in the pre- ulcerative stage    ...    ...    ...	121
XVIII.—An Adeno-Carcinoma of the Rectum, showing Superficial Ulceration in the centre of its surface    ...    ...    ...	123
XIX.—An Adeno-Carcinomatous Ulcer extending nearly completely round the Rectum for about two inches in depth    ...    ...    ...	125


# LIST OF ILLUSTRATIONS.

FIG.	PAGE.
XX.—Microscopical Section of the Specimen in Fig. XIX., showing Infiltration of the Muscular Coat ... ..	127
XXI.—Edema of the Anal Skin, and of the Vulva in a case of Carcinoma of the Rectum ... ..	139
XXII.—Showing the appearance of the Scar fourteen days after the complete removal of the Rectum and a wide area of Peri-Anal Skin ... ..	169
XXIII.—Artificial Anus Resulting from direct union of the Colon to the Muscular Parietes ... ..	185
XXIV.—An Artificial Anus Resulting from Inter-peritoneal Adhesion ... ..	186
XXV.—An Artificial Anus, showing the two distinct openings after removal of the spur. An Extensive Ventral Hernia has also resulted from that procedure. ... ..	192
XXVI.—Showing the Belt with the Cup and Receiver adjusted ... ..	193
XXVII.—Showing the Oval Aperture in the Belt for the Cup-shaped Pad and also the Elastic Bands for assisting in keeping the Pad in position ... ..	194
XXVIII.—Showing the Cup-shaped Pad with the Receiver attached ... ..	195
XXIX.—Internal view of the Cup-shaped Pad, showing the solid Rubber Margin or Rim, and the Aperture leading into the Tube ... ..	196
XXX.—Showing the Belt and the Receiver adjusted on the Patient ... ..	197
XXXI.—Showing Sigmoid Colostomy on the right side ... ..	200
XXXII.—A Permanent Cæcal Anus ... ..	209
XXXIII.—Showing several clusters of Papillomata of the Anus ... ..	217
XXXIV.—Papilloma completely surrounding the Anal Orifice and concealing it from view ... ..	218
XXXV.—Section showing the Microscopical appearance of a Lymphadenoma of the Rectum ... ..	223
XXXVI.—The Microscopical appearance of a Fibroma or Fibrous Polypus of the Rectum ... ..	226



## LIST OF ILLUSTRATIONS.

FIG.	PAGE.
XXXVII.—Showing two Fibrous Polypi of the Anal Canal extruded from the Anal Orifice during anæsthesia ... ..	227
XXXVIII.—A small Fibroma of the Anal Canal spontaneously protruded ... ..	228
XXXIX.—Showing Multiple Fibrous Polypi of the Anal Canal ... ..	230
XL.—A Villous Tumour drawn down through the Anal Orifice ... ..	232
XLI.—Showing the Microscopical appearance of a Villous Tumour ... ..	233
XLII.—Showing the Structure of the Villi ... ..	234
XLIII.—Showing the size and character of the Foreign Bodies removed from the Twenty-three cases	258
XLIV.—Showing a single Mucous Patch on the left side of the Anus and a Chancre on the Right Labium Majus ... ..	267





# DISEASES OF THE ANUS AND RECTUM.

---

## CHAPTER I.

### PROLAPSE OF THE RECTUM.

By this term is meant an eversion and protrusion of a part or the whole of the rectum through the anal orifice, the point of commencement of the eversion being at the muco-cutaneous junction. All observers are agreed that there are two varieties of the condition; the protruded parts, in the one, consisting of the mucous coat only, and, in the other, of all its coats. To the former variety the term *prolapsus ani* has been applied; to the latter that of *procidentia recti*. It is desirable to have definite terms by which these two distinct conditions can be recognised; because not only does each give rise to a distinct train of symptoms, but the treatment of each differs in important respects. The term *prolapsus ani*, however, does not commend itself because it fails to convey to the mind an exact interpretation of the morbid state—the term signifying a descent of the anal orifice rather than a protrusion through it. Cripps,\* in his work, does not adopt the terms *prolapsus ani* and *procidentia recti*, but divides *prolapse of the rectum* into *partial prolapse*,

---

\* "Diseases of the Rectum and Anus," 2nd Ed., p. 116.

in which the mucous membrane alone is extruded, and *complete prolapse*, when all the coats of the rectum, including the peritoneal, are involved. This division, however, is not, we think, quite satisfactory, because the terms used might be interpreted as referring to the circumference of the bowel rather than to its coats; and this is more probable on account of the clinical fact that, where the mucous coat alone is involved, the protrusion is often confined to one side only. Consequently, we think it advisable to call a protrusion of the mucous coat a *prolapsus mucosæ recti*, and a protrusion of all the coats of the rectum a *procidentia recti*.

#### PROLAPSUS MUCOSÆ RECTI.

This variety of *prolapsus*, consisting, as we have seen, of the mucous coat of the rectum alone, never attains large dimensions. The extent of the protrusion, when measured from the muco-cutaneous junction to its free border, does not exceed, so far as we have observed, two inches in length and generally is much less. The protrusion may be *unilateral* or *bilateral*. When *unilateral*, the more common condition, the protrusion may involve a part or the whole of one lateral margin of the anus. We have seen a case in which the protrusion remained limited to the posterior two-thirds of the left margin ten years after its first appearance. When *bilateral*, the appearance is that of two lateral flaps separated anteriorly and posteriorly by a distinct sulcus, which is very characteristic, and, therefore, of value in the differential diagnosis from *procidentia recti*. The sulci referred to are best illustrated in the more recent cases of bilateral protrusion, but even in long-standing instances they are not entirely obliterated.

The protruded mucous membrane is, as a rule, healthy in appearance, unless it has become excoriated or ulcerated from constant friction against the clothing. There is no dilatation



and thickening of the hæmorrhoidal veins, though the mucous membrane itself is sometimes indurated from long-standing passive congestion, and may be somewhat darker in colour than the non-prolapsed mucous membrane.

### *Etiology.*

In a normal condition, protrusion, to a slight extent, of the rectal mucous membrane through the anal orifice, may take place during the act of defæcation, returning spontaneously directly the expulsive effort ceases. Such protrusion of the mucous membrane is seen to occur in the horse, in which animal not only does a considerable protrusion occur, but this is accompanied by eversion as well.

The readiness with which, in some cases, the mucous membrane can be protruded is accounted for by the looseness of the sub-mucous tissue, whereby a considerable degree of movement upon the muscular coat is allowed, and also by the redundant folds into which the mucous coat is normally thrown.

Bearing these facts in mind, it is obvious that frequent and prolonged straining at stool, the wasting of advanced life, and diminished health-tone are three of the most important factors in the causation of this disease.

*Age.*—A simple prolapse of mucous membrane very rarely occurs in children. We have seen but a single case—a female aged two years, in whom a bilateral flap of mucous membrane was constantly protruded. Instances of rectal prolapse met with during the first decade of life will, if closely examined, almost invariably be found to consist of all the coats of the bowel. It is most important that this fact should be recognised lest serious mistakes be made in the treatment. It is in adult life, during the fifth, sixth, or even later decades, that prolapse of rectal mucous membrane usually first makes its appearance.

*Sex.*—Females are far more frequently affected than males.



*Occupation.*—So far as we have been able to ascertain, occupation does not appear to exert any influence in its production.

### *Predisposing Causes.*

A general laxity of tissue, resulting in the rectal mucous membrane becoming abnormally movable upon the muscular coat; loss of tone in the sphincter muscles, whereby efficient closure of the anal orifice is impaired; and the absence of fat in the ischio-rectal fossæ (a marked condition in nearly all cases), undoubtedly predispose to protrusion of rectal mucous membrane. Prolonged residence in the Tropics and debilitating diseases tend to bring about the above results. All the adult patients we have seen have been under the normal weight for their height.

### *Exciting Causes.*

Given the predisposing conditions, it is easy to understand how readily prolonged and frequent straining at stool may result in protrusion. Obstinate constipation may be one of the primary and is one of the most potent causes. When the bowels are not thoroughly evacuated every day, there is always a fæcal accumulation in the rectum which becomes hard by absorption of moisture. Such hardened fæces require stronger and more prolonged straining for their expulsion, and, sooner or later, the mobility of the mucous coat is increased to such an extent that protrusion may readily occur. Chronic diarrrhœa and dysentery also tend to produce the same result.

A pedunculated growth in the rectum, such as a villous tumour or an adenomatous polypus when of sufficient size and length to come within the grip of the sphincters, may so drag upon the mucous membrane during expulsive efforts that it may be wholly protruded together with a partial or complete ring of mucous membrane. We have recently had



under our care a woman in whom a large villous tumour,\* attached by a broad pedicle about two inches above the anal orifice, was protruded at each act of defæcation, causing a complete ring of mucous membrane to prolapse at the anal margin. The effect of the protrusion upon the sphincters was well marked, the relaxation and loss of tone being so great that two fingers could be readily inserted at the same time into the anal canal without meeting with any resistance. After the removal of the tumour the sphincters gradually regained their tone and the protrusion of mucous membrane no longer occurred.

In addition to the over-stretching of the sphincters above described, a loss of contractile power may be the result of partial or complete division of the internal sphincter muscle during an operation for fistula. We have notes of a case, a female patient, in whom protrusion of the rectal mucous membrane occurred twenty years after an operation for fistula. In her case there was evidence of the internal sphincter having been divided, with the inevitable consequence of permanently diminished contractile power.

In men, when advanced in life, prolapse of rectal mucous membrane is sometimes consequent upon enlargement of the prostate gland.

### *Symptoms.*

The symptoms associated with this condition are (a) *protrusion*; (b) *escape of rectal mucus*; (c) *pain*; (d) *loss of power of control*; (e) *increased frequency in the action of the bowels*; (f) *loss of weight*; (g) *hæmorrhage*.

(a) *Protrusion*.—In the early stages the protrusion is small and only occurs during defæcation, being spontaneously retracted as soon as the expulsive effort has ceased. Repeated protrusion causes both an increase in the bulk of the prolapsed mucous membrane and inertia of the

---

\* The specimen No. 7 is preserved in the Museum of the Cancer Hospital.



sphincter muscles, until, as time advances, spontaneous has to be replaced by manual reduction, and finally all power of retention is lost, so that if the protrusion recur during coughing, singing, standing, or walking, it eventually becomes permanent except when the patient remains recumbent. In these respects the history obtainable closely resembles that of internal piles, differing only in the absence of the large and repeated hæmorrhages which characterize the primary and secondary stages of that disease.

When the protrusion has become permanent, the prolapsed mucous membrane is usually found to be somewhat indurated from impeded venous return, darker in colour than the non-prolapsed mucous membrane, and occasionally thickened or ulcerated from constant irritation by the clothing. When considerable protrusion has occurred, as the result of a violent straining effort during the earlier stages before the sphincters have quite lost their tone, strangulation and sloughing of the protruded mass may result.

(b) *Escape of Rectal Mucus*.—One of the most constant symptoms complained of by a patient suffering from prolapse of rectal mucous membrane, is a constant feeling of dampness in the anal region which manifests itself even after the most careful cleansing and drying of the part. The dampness is due to an increased secretion of rectal mucus, which is either expelled periodically during the passage of flatus or after slight expulsive efforts, if protrusion occur only during defæcation, or escapes continuously when the protrusion is permanent. This increased secretion of mucus is no doubt due to irritation of the mucous membrane when it is protruded. The accumulation of the mucus in the rectum, when the patient is recumbent, leads to its frequent evacuation, and forms another prominent symptom of the disease in its early stages.

(c) *Pain*.—There is very little, if any, pain in these cases unless the anal region is inflamed or excoriated from the



constant dampness of the part caused by the escape of rectal mucus. When the protrusion is large and more permanent, a feeling of soreness and a smarting sensation are sometimes the result of irritation caused by friction against the clothing. When, as a result of long-continued irritation and congestion, ulceration has supervened, pain of an aching, throbbing character will be experienced and will be constant as long as the part remains protruded. Reflex pain in the lower part of the sacrum, in the hips, and extending down the thighs is sometimes complained of, especially in the more severe forms of the disease.

(d) *Loss of Power of Control in the Sphincters.*—The inefficiency of the muscles closing the rectal outlet, which is met with in all these cases, is the cause of the distressing symptoms of flatulent and fæcal incontinence. In advanced cases difficulty is often experienced in retaining even solid fæces. Such loss of control over the contents of the rectum is due to atony of both external and internal sphincters, made more complete by their being over-stretched by the permanent protrusion.

(e) *Frequency in the Action of the Bowels* is a well-marked symptom in all stages of the disease. It is partly due to increased secretion of mucus and its accumulation in the cavity of the rectum. The increased secretion is the result of irritation of the mucous membrane when protruded, and the quantity secreted has much to do with the frequency with which the bowels act. Patients usually describe this condition as uncontrollable diarrhœa, and have usually had recourse to anti-diarrhœa medicine without relief.

(f) *Loss of Weight.*—When the protrusion is of moderate size and recent, it causes little inconvenience, and, therefore, may not interfere with the general health. In the later stages, however, the patient gradually loses weight, and eventually may become emaciated.

(g) *Hæmorrhage.*—As a rule there is very little, if any,



bleeding with these cases, but when the mucous membrane is permanently protruded and has become excoriated and ulcerated as a result of sticking to the clothing, slight bleeding may occur, in sufficient quantity to smear the fæces and underlinen. There is never the profuse bleeding so commonly observed in cases of internal piles, and its absence during the earlier stages of the prolapse serves as another important factor in the differential diagnosis between the two diseases.

### *Physical Examination.*

As mentioned above, prolapse of the mucous membrane may be *unilateral* or *bilateral*. When *unilateral*, the prolapse is either of recent date or it is the result of some definite weakness in the sphincter muscles on one side, such as would result from their division on the corresponding side or from hemiplegia. In such cases, the protruded mucous membrane will be found to be confined to a part or to the whole of one side of the anal orifice, or it may extend slightly to the opposite side as well, either anteriorly or posteriorly. In other words, a protrusion affecting the right margin of the anus may extend into the left posterior (L.P.) quadrant, or less frequently into the left anterior (L.A.) quadrant. When such a condition is met with, it will be observed that between the main fold and the smaller one on the opposite side, there is usually a well marked sulcus.

When the protrusion is *bilateral*, a sulcus is present both anteriorly and posteriorly, and one side is usually more extensively prolapsed than the other (see fig. 1). Even in the most advanced cases, the length of the protruded fold of mucous membrane, as measured from its free extremity to the muco-cutaneous junction, rarely exceeds two inches. In those instances in which the protruded mucous membrane has been subjected to friction against the clothing sufficient to cause ulceration, the ulcerated areas will be found at the apices of the folds. Beyond the anterior and posterior sulci



above alluded to, it will be observed that there is no other subdivision of the protruded mass at the muco-cutaneous junction, such as is always met with in cases of prolapsed internal piles. If this latter fact be thoroughly appreciated,

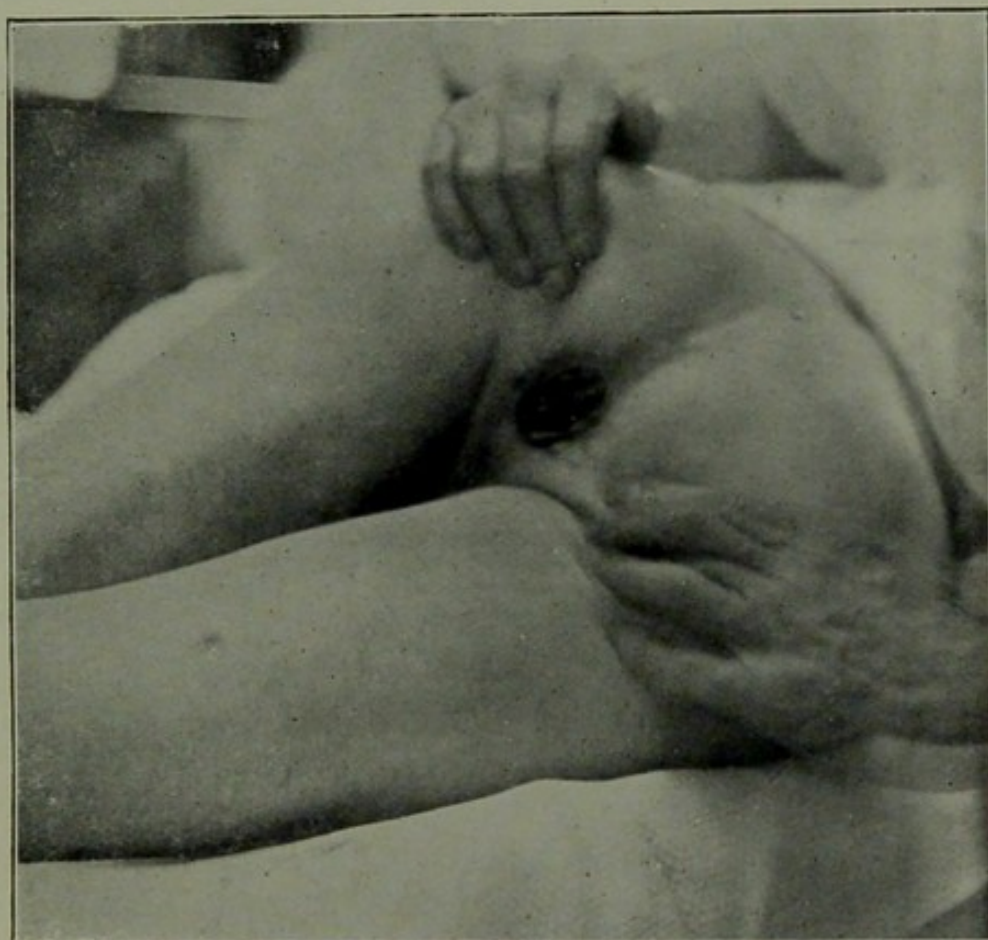


FIG. 1.—CASE OF PROLAPSUS MUCOSÆ RECTI.  
Showing Bilateral Protrusion.

there ought never to be difficulty in the differentiation of the two diseases.

*Redundant Skin.*—Folds of redundant skin are seldom present in cases of prolapsed mucous membrane.

*Palpation.*—If the protrusion be grasped between the finger and thumb and carefully palpated, the absence of dilated, thickened and tortuous veins, between the layers of the protruded fold, will be readily appreciated, and moreover the two layers, entering into the formation of the fold, will be found to move freely over each other, unless the



intervening connective tissue has been infiltrated from chronic inflammation.

*Condition of the Sphincters.*—Both sphincters will be found greatly deficient in contractile power and, in some cases, it will be completely absent. The examining finger passes easily and without impediment into the anal canal, failing to excite the smallest degree of reflex contraction. The muscles are really in a state of atony from habitual over-stretching. The degree of the atony of the muscles may be taken as an index of the duration of the protrusion. The absence of contractile power in the sphincters accounts for the readiness with which the protrusion recurs after reduction.

*Examination of the Rectum.*—Further digital examination of the rectum will indicate an increase in the normal quantity of mucus; flaccidity of the muscular coat of the rectal wall; absence of distension by flatus; and, almost invariably, an absence of fæces in the rectum. In cases of prolapsed mucous membrane, fæces are very seldom retained in the rectum, a condition which is quite the reverse of that met with in cases of internal piles.

### *Differential Diagnosis.*

There are two conditions with which prolapse of the mucous membrane may be confused, namely, *prolapsed internal piles* and *procidentia recti*. The diagnosis from prolapsed internal piles may be arrived at by bearing the following facts in mind.

*The Absence of Lobulation.*—The protruded part in prolapsed internal piles is divided by vertical sulci into distinct segments, of which the right anterior (R.A.), the right posterior (R.P.), and the left (L.) are the primary divisions. In prolapsed mucous membrane the protrusion, even when complete, is interrupted only anteriorly and posteriorly by sulci.

*The Absence of Dilated, Thickened, and Tortuous Veins.*—If an internal pile be grasped between the finger and thumb,



a mass of veins will be distinctly felt between the two layers of mucous membrane, but if the protruded fold in a case of prolapsed mucous membrane be felt in the same way, it will not only be found that the veins are neither dilated nor thickened, but also that the two layers of mucous membrane glide easily over each other, except in those instances in which chronic inflammation has caused so much exudation that cohesion has taken place.

Of much greater importance, however, is the diagnosis from *proci dentia recti*, upon the correctness of which depends the success and safety of the treatment to be adopted.

The following points will aid in arriving at a correct diagnosis.

*Size of the Protrusion.*—In prolapsed mucous membrane it seldom exceeds two inches, and one side is generally longer than the other. In *proci dentia recti*, the protrusion is generally equal all round, and, as a rule in adults, measures three, four, or more inches in length.

*Character of the Aperture.*—In prolapsed mucous membrane the aperture is oval or circular, patulous, and centrally placed. In *proci dentia recti* the aperture is often slit-like and looks backwards on account of the traction exerted by the meso-rectum.

*Existence of Dividing Sulci.*—In a complete case of prolapsed mucous membrane, there are almost invariably well-marked sulci anteriorly and posteriorly, whereas in *proci dentia recti* these sulci are absent.

*Absence of Transverse Furrows.*—The surface of the protrusion is quite smooth in prolapsed mucous membrane, but is marked by several concentric furrows in *proci dentia recti* (see figs. 2 and 4).

*Structure of the Protrusion.*—In prolapsed mucous membrane two layers of mucous membrane with the submucous tissue only are contained in the protrusion. In *proci dentia* of the



rectum two layers of mucous membrane, of submucous tissue and of the muscular coats of the rectum constitute the protruded mass.

### *Treatment.*

Cases of prolapsed mucous membrane can be completely cured by operative measures. The pathology of the disease being merely a sliding down of the mucous coat of the lower part of the rectum with protrusion through the anal orifice of the resulting fold, it is clear that the simplest and surest method of treatment is removal of the redundant tissue. There are conditions, however, such as debility and constitutional disorders, which may render an operation inexpedient. In such cases palliative measures may afford considerable relief.

### *Palliative Treatment.*

This should be directed towards attaining three important objects, namely, *reduction of the protrusion, prevention of its recurrence, and improvement in the tone of the sphincter muscles.*

*The Reduction of the Protrusion.*—The patient should be directed to push back the protruded part as soon as possible after protrusion has occurred. For this purpose he should lie on his right side, and, having smeared the part with vaseline or other lubricant, should carefully manipulate the protrusion back into the rectum. He should pass his finger well into the anal canal as soon as the reduction has been completed, so as to ensure the protrusion being pushed up beyond the level of the internal sphincter. After this has been effected he should remain in the prone position for at least an hour. In the majority of cases there will be no difficulty in effecting reduction, but occasionally it is not possible to keep the folds of the mucous membrane in the rectum.

*Prevention of the Protrusion.*—All straining efforts, such as



lifting heavy weights, should be carefully avoided, as well as standing for any length of time and exercise of a fatiguing nature. In the early stage the avoidance of constipation with its attendant straining at stool is of the utmost importance. The diet should be regulated so that the quantity of fæces to be passed is as small as possible. The bowels should be encouraged to act immediately before bed-time, so that the prolapse may be retained in the rectum all night. Rest in the recumbent position for an hour or so immediately after the bowels have acted during the day-time will diminish the tendency to a recurrence of the protrusion. In order to prevent the fæces becoming hard, an injection of an ounce of olive oil into the rectum at bed-time, to be retained all night, is exceedingly useful. In many cases it is advisable that a similar oil injection should be made shortly before each action of the bowels so as to ensure the fæces being well lubricated and, therefore, evacuated without any straining. Whenever protrusion occurs it should be immediately reduced.

*Improving the Tone of the Sphincter Muscles.*—The inevitable result of constant protrusion is loss of power in the sphincter muscles. Not only is this brought about by the over-stretching, but actual atrophy of the muscular fibres ensues as a consequence of their long-continued inactivity. Hence it is clear that the sooner the protrusion is reduced and the more completely its recurrence is prevented, the more speedily will the loss of power be regained. Instructing the patient to forcibly contract and draw up the anal orifice for about five minutes at a time for many times during the day, so as to exercise the sphincters and the *levatorès ani*, has, in our experience, been most beneficial in several cases. To carry out this plan of treatment, however, more persistency and energy are required than old and enfeebled patients can generally exercise.

In those cases in which the loss of sphincteric control is due to cerebral disease or affections and injuries of the spinal



cord, or when it is the direct result of division of both external and internal sphincters during an operation for fistula, the above mentioned expedient will not be so successful.

### *Operative Treatment.*

An operation should be performed in all cases in which the general constitutional condition of the patient does not contra-indicate surgical treatment. Old age alone should not influence the decision against the operation, because Mr. Goodsall has operated upon a female patient at the advanced age of eighty-four with most satisfactory results, as she lived to the age of eighty-nine without recurrence of the prolapse. After the operation she regained considerable power in her sphincters.

The operation which we always perform, and from which we have had excellent results, is that by ligature of the prolapsed mucous membrane in sections.

### *The Operation by Ligature.*

*Instruments required* are: Ligatures (plaited silk No. 12 or silk-worm gut); straight hagedorn needles three inches in length; and a pair of scissors.

### *Method of Operating.*

The bowels having been freely relieved in the morning before the operation, the patient should be placed in the right lateral and semi-prone position. The prolapsed mucous membrane should be gently drawn down to its full extent and carefully examined. In those cases in which the protrusion is confined to one side only, the condition of the mucous membrane of the opposite side should be carefully ascertained, so that the possibility of leaving untreated a commencing prolapse on the apparently unaffected side may be avoided.

All the mucous membrane which can be gently drawn down



beyond the anal margin should then be treated in the following manner.

As the methods of introducing the ligature differ slightly according to the material used, we shall describe them separately.

(a) *When Silk is Used.*—Assuming that the prolapse is confined to one side of the rectum, a piece of silk, about four feet long, is threaded through three needles, which are placed thus: one in the centre and the others on either side, midway between it and the extremity of the ligature. The fold of mucous membrane to be ligatured is now grasped between the thumb and the index finger of the left hand, and held so that a good view of the muco-cutaneous junction is obtained. The middle needle is now passed through the entire thickness of the fold at its centre, the point of entry being about one-eighth of an inch above the muco-cutaneous junction, while that of exit is about half an inch above the lower margin of the anal canal. The remaining needles are then similarly introduced midway between the centre needle and the anterior and posterior extremities of the fold respectively. The ligature should then be divided close to each needle, and be thus converted into four separate loops. The extremities of each loop are then secured by pressure forceps and held by an assistant. Each loop is then tied as tightly as possible without interlocking with its neighbours, the two inner ones being tied first. In this way the entire fold is completely strangulated, and, as the ligatures are not interlocked, there is no occlusion of the anal canal.

When there is a fold on the opposite side equal in extent it should be similarly dealt with; but if it be smaller, as is more often the case, two loops may be found to be sufficient for the purpose, a single needle being introduced through the centre of the fold.

(b) *When Silk-worm Gut is Used.*—The thickest gut



obtainable (fishing gut is the best) should be provided for the purpose, and should not be less than twelve inches in length. A single needle is sufficient, and should be threaded with two pieces of gut. Thus armed, it is introduced in the same manner as described previously, at a point about one-fourth of the length of the fold from its posterior extremity. The needle is then removed, and the extremities of one of the ligatures are secured by pressure forceps and held aside by an assistant. This ligature, when subsequently tied, will strangulate the posterior fourth of the fold. The outer extremity of the free ligature is now threaded through the needle, which also carries a fresh piece of gut, and the needle is introduced through the centre of the fold. The needle is then disengaged, and the extremities of the second ligature are secured, the second fourth of the fold being thus surrounded. The third and fourth ligatures are similarly introduced and, when all are in position, are tied in the same order, and without interlocking, as when silk ligatures are used. Great care should be taken not to break the ligatures when they are tied, though sufficient force should be used to completely strangulate the included tissue. The ligature is apt to break when the second part of the knot is being completed, if too much force be applied when making that part of the knot. When the operation is performed by this method of introducing the ligatures, it is almost bloodless—a matter of great importance to an enfeebled or aged patient.

We have seen some operators divide the prolapsed fold of mucous membrane into segments, by longitudinal cuts with scissors, and subsequently applying the ligatures as in the operation for internal piles. Our objection to this procedure is that sometimes a considerable quantity of blood is lost when the incisions are made, and, moreover, if a vein happens to be divided longitudinally, the bleeding may be difficult



to control or may recur after the patient has been put back to bed.

As soon as all the ligatures have been tied, the strangulated parts should be returned into the rectum and kept in position by a plug of cotton wool soaked in a twenty per centum solution of cocaine. A firm pad of cotton wool should then be applied to the anus and a T bandage adjusted. The cocaine prevents pain and the reflex straining for three or four hours, if not altogether.

### *After Treatment.*

The bowels should be prevented from acting for about ninety-six hours, after which period two ounces of olive oil should be injected into the rectum every night and morning. Until the bowels have acted the patient should be kept on a milk diet. As soon as the bowels have been fully and regularly relieved, ordinary diet may be resumed, and then a daily evacuation should be ensured by the injection of an ounce of olive oil at night. We never give aperients in these cases. The ligatures will usually separate on the ninth or tenth day, and after the twelfth day the finger should be introduced to its full extent into the rectum. Should any contraction be detected the finger should be introduced daily until the wounds are completely healed. Contraction does not occur when only one side has been operated on.

The details of the after treatment are similar to those described on p. 293, Part I.

### PROCIDENTIA RECTI.

By this term is meant a sliding down of the lower part of the rectum in its entirety, the protrusion consisting of the muscular coats as well as the mucous membrane and sub-mucous tissue. The whole circumference of the bowel participates in the protrusion, which begins at the mucocutaneous junction. There is no sulcus between the walls of



the anal canal and that of the protrusion, such as always exists in cases of intussuscepta descending through the anal orifice. In other words, the mucous membrane of the protruded mass is directly continuous with the skin of the anal margin (see fig. 2). The extent of the protrusion varies from less than one inch to the full extent of the rectum, the

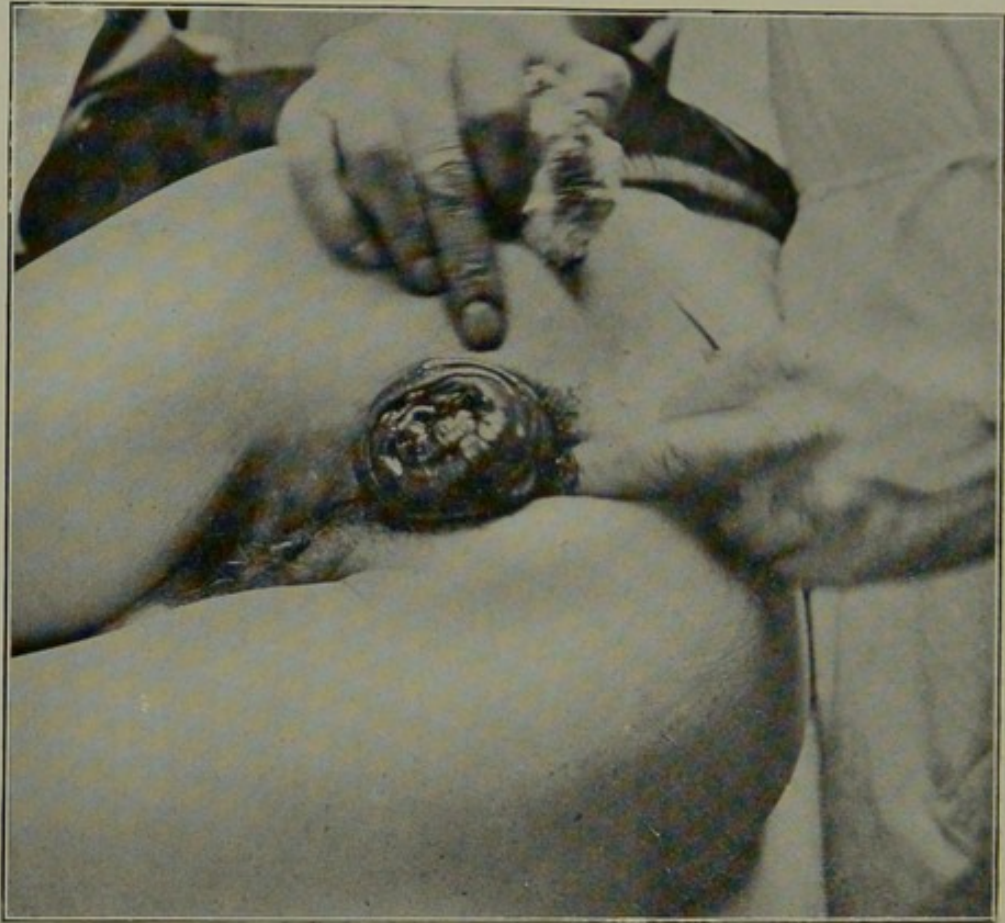


FIG. 2.—CASE OF PROCIDENTIA RECTI.

The index finger shows the continuity between the skin of the anal margin and the base of the tumour.

tumour in some cases being as large as a foetal head (see fig. 3). In such advanced cases, the bulk of the tumour is often partly due to coils of small intestine contained in a pouch of peritoneum, which is drawn down with the anterior wall of the rectum. Even in cases of much smaller dimensions, especially in children, the possibility of the tumour



containing small intestine, or at all events a pouch of peritoneum, anteriorly, should always be borne in mind when operative measures are undertaken.

It is interesting to note, in reading the literature of the subject, that some former writers denied that the muscular coat of the rectum entered into the formation of the tumour.

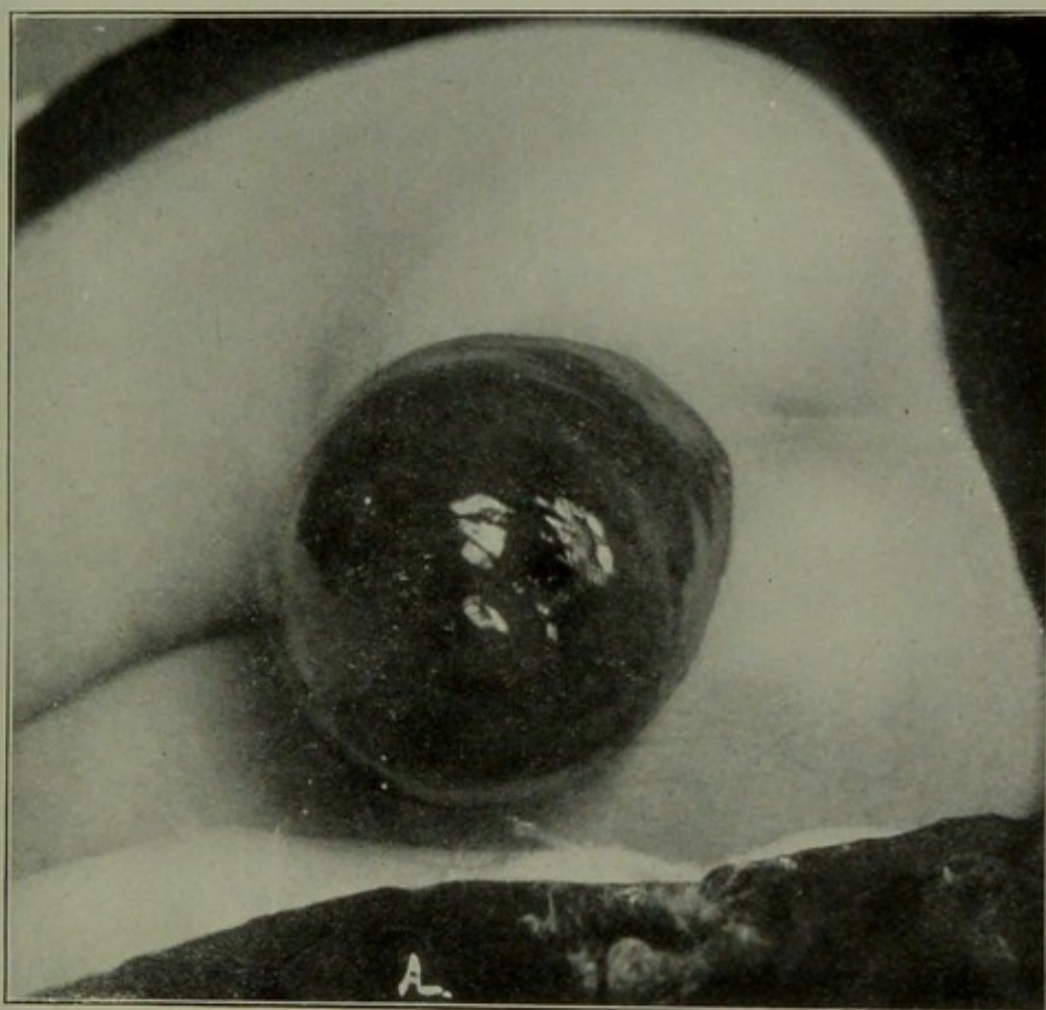


FIG. 3.—A CASE OF PROCIDENTIA RECTI.  
Showing ulceration at the apex of the protrusion.

For instance, Copeland\* makes the following statement: "In almost every case of *prolapsus ani*, it is the internal membrane only of the intestine which descends through the sphincter muscle. The connection of the external surface of

\* "Observations on the Principal Diseases of the Rectum and Anus," 3rd Ed., 1824, p. 73.

the rectum, with the surrounding parts, is so firm that it is almost impossible the whole should be protruded together; a separation or elongation of the union between the coats of the intestine must therefore precede the disease, and form its essential character; whether it be produced by the effusion of blood between them, or by continued tenesmus, or efforts to pass the fæces, or peculiarity of structure, or any other cause."

It appears to us that the cases which Copeland described as due to *prolapsus ani* were really cases of prolapsed mucous membrane, and not cases of true procidentia of the rectum.

### *Etiology.*

The causes of procidentia may be divided into (a) *predisposing*, and (b) *exciting*.

#### *(a) Predisposing Causes.*

These may be considered under the heads of age, sex, occupation, and constitutional condition.

*Age.*—From the cases that have come under our observation it would appear that the disease is most frequently met with during the first decade and after the fourth. It is not an uncommon experience to obtain a history from an adult that, when a child, he was treated for "a falling down of the body," of which he had no recurrence until he had reached middle life. In these cases, the muscular tissues of the pelvic floor have regained their tone during the period of vigorous life. In other cases, the procidentia occurred in adult life, being almost always either associated with an impaired constitution or the result of some well marked exciting cause.

*Sex.*—In adults, males appear to be quite as much predisposed to this disease as females. In children under eight years of age, boys are more often affected than girls. This is no doubt accounted for by the fact that boys are disposed



to suffer from difficulty in micturition caused by phimosis, or vesical calculus, or both.

*Occupation.*—Work of a laborious nature, necessitating repeated straining, such as lifting heavy weights, sometimes produces procidentia. Sedentary vocations, beyond the fact that they conduce to a general enfeeblement of muscular power and to constipation, do not appear to exert much influence.

*Constitutional Condition.*—The disease does not occur in individuals in robust health during adult life, but is occasionally met with in those whose general health is impaired from any cause, combined with much wasting and loss of tone in muscular tissue. In children who are improperly fed, and especially in those who live under bad hygienic surroundings, it is apt to occur.

(b) *Exciting Causes.*

These are most conveniently divided into (1) those that operate during child life, and (2) those that are incidental to adult life.

(1) *Causes in Children.*—In either sex, protracted diarrhœa is one of the frequent causes. The frequent straining thus engendered not only relaxes the sphincters, but so weakens the muscular coats of the rectum and its connections with the pelvic floor that inversion and protrusion of the terminal portion of the rectum occur as a natural sequence. In like manner, the repeated straining to evacuate the bowel in the chronically constipated produces the same result. In this connexion, it may be pointed out that the practice so often followed by nurses in insisting upon a child sitting on the stool for long periods in order to get the bowels to act, cannot be too strongly condemned, and in many cases, is the direct cause of the procidentia in such children.

The chief special factors in boys are, so far as we



have seen, phimosis and vesical calculus. So impressed have we been with this fact that we make a practice of inspecting the penis in every case of procidentia met with in a male child. If phimosis exist, we at once recommend circumcision as soon as possible, and, while the child is under the influence of the anæsthetic, the bladder is also carefully sounded. In this way we have found in several patients an unsuspected vesical calculus. In one case we discovered a stone which weighed 107 grains. There was no recurrence of the procidentia in any of our cases after the removal of the vesical calculus.

(2) *Causes in Adults.*—Among the exciting causes is constipation, especially when occurring in old and feeble subjects who have also lost very much of their normal weight. As a result of constipation the rectum is constantly over distended by fæces; this, in time, conduces to great loss of muscular tone. Both the external and the internal sphincters in these cases are generally overstretched, and the *levator ani* fail to give adequate support to the pelvic floor. Under such conditions, it is not surprising that eversion and protrusion of the rectum should ensue upon straining during defæcation. The existence of rectal polypi or a large growth (such as a villous tumour), is, in some instances, the exciting cause of procidentia on account of the dragging down of the seat of attachment of the growth during expulsive efforts. We have seen at least three cases in which the protrusion of the bowel was apparently produced by such a growth. We had, in 1897, under our care a patient, aged sixty, in whom the procidentia was caused by a small pedunculated subperitoneal fibroid tumour of the uterus. We removed the growth, and the patient has not had any recurrence of the procidentia since. Excessive diarrhœa, by producing undue relaxation of the sphincters and rectal tenesmus is, in some cases, a cause, especially in females.

In men, straining during micturition, such as is met with



in stricture of the urethra and enlargement of the prostate, accounts for some cases. In women, a ruptured perineum extending through both sphincters will tend to produce the protrusion.

In either sex, paralysis of the sphincter muscles, either as a consequence of spinal disease or as the result of division of both muscles during an operation for fistula, may be followed by procidentia. The accompanying illustration (fig. 4) is taken from a patient in whom procidentia has

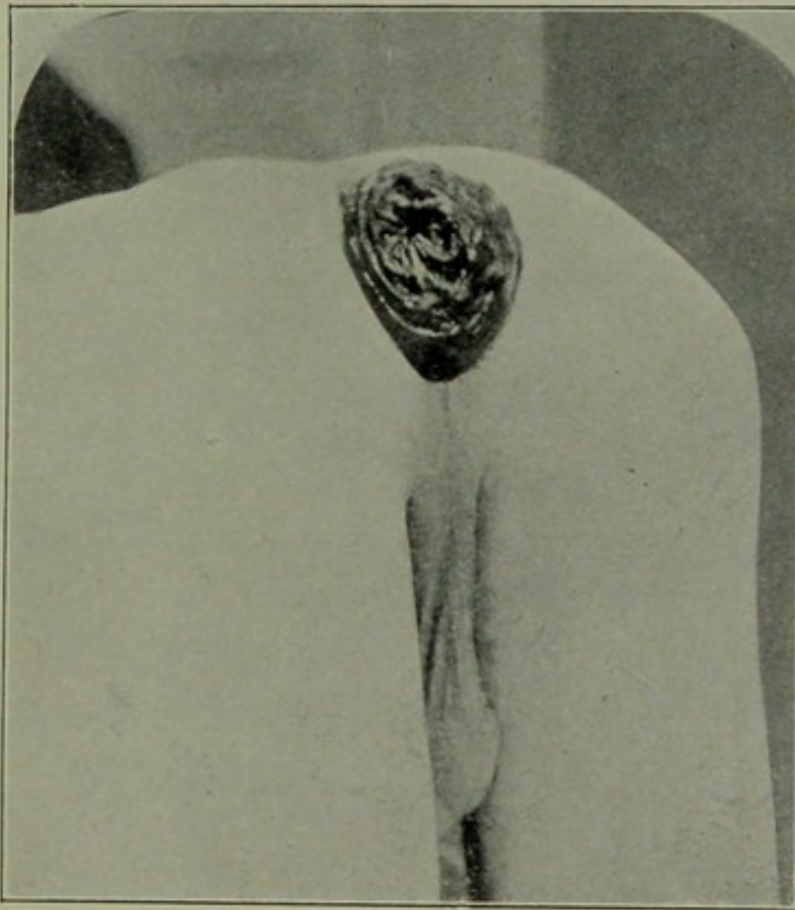


FIG. 4. - A CASE OF PROCIDENTIA RECTI.

Caused by the division of the internal sphincter in a case of posterior horse-shoe fistula.

followed the loss of sphincteric control resulting from an operation upon a fistula. Both the external and internal sphincters had been divided in this case.

*Symptoms.*

The chief symptom of *proidentia recti* is a more or less extensive protrusion through the anal orifice during defæcation, micturition or any straining effort. In an early stage, the protrusion is slight, and is either readily replaced by pressing the part upwards and backwards with the fingers or it becomes spontaneously reduced if the patient rest in the recumbent position. As time goes on, the protrusion gradually increases in size, more and more of the bowel becoming everted, so that, in the later stages, the protruded mass assumes greater proportions both in diameter and length. Spontaneous reduction does not then always occur even when the patient assumes the horizontal position, and the protrusion, unless artificially replaced, remains constantly down, causing much discomfort. It then incapacitates the patient for active exercise, and, in some cases for even walking; moreover, unless some mechanical support be worn, the protrusion returns as soon as the patient assumes the erect position. In still more advanced cases, mechanical contrivances are practically useless, the patient's condition becoming extremely miserable from the persistent dampness of the perianal region, causing a chronic dermatitis with excoriation of the part.

When the bowel is protruded there is generally a dull, aching, throbbing pain, but this ceases almost immediately after reduction has been effected. Constant protrusion, on account of friction against the clothing, causes the mucous membrane to lose its natural appearance and to become indurated and in some parts slightly ulcerated. Such ulceration is most apt to occur at the apex of the protrusion, and when present gives rise to slight bleeding from time to time. Moreover, the clothing readily adheres to the ulcerated surfaces and when detached sometimes gives rise to fresh bleeding. We have never seen profuse hæmorrhage in



these cases, although, by some authorities, it is stated to occur.

Control is greatly diminished, there being often none at all in those in which the bowel is constantly protruded, the anal orifice being extremely patulous and gaping widely when the patient bears down. As a consequence, the bowels act involuntarily, the patient complaining that he suffers

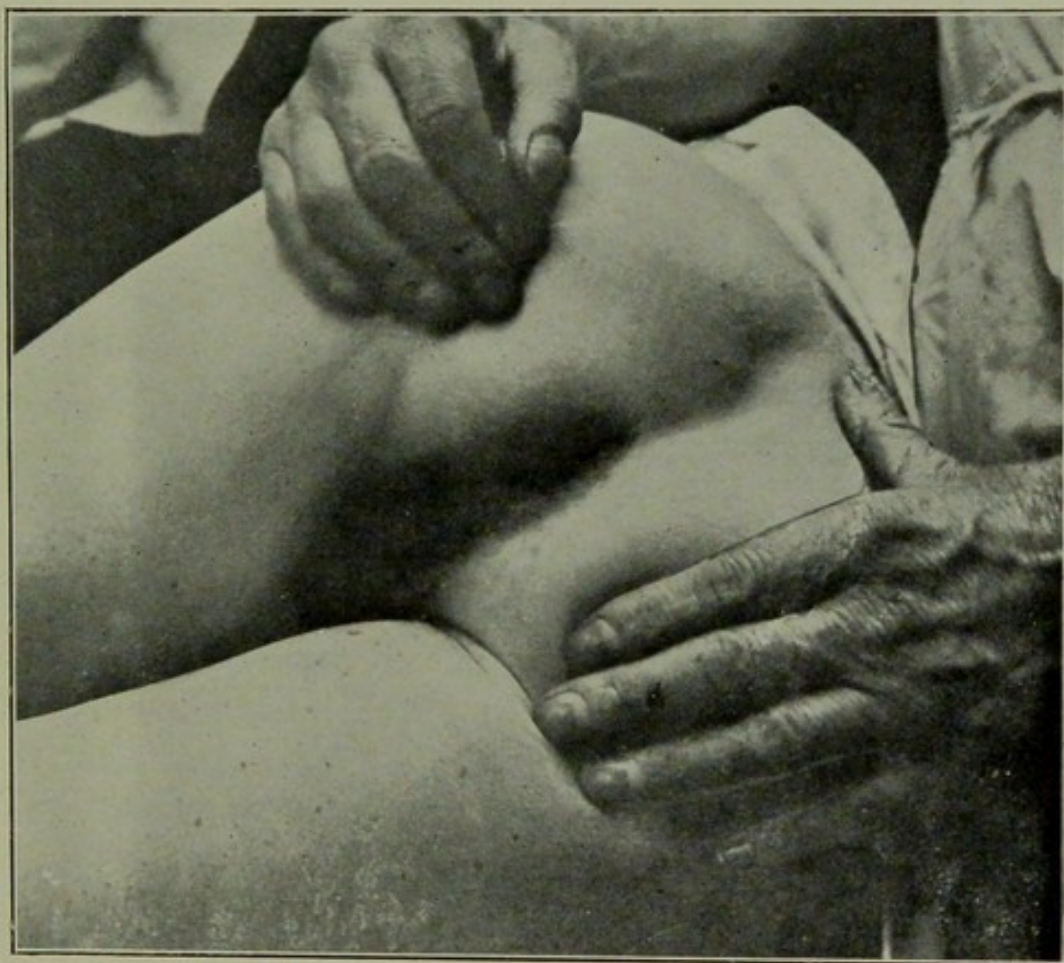


FIG. 5.—SHOWING THE SLIT-LIKE RELAXED CONDITION OF THE ANAL ORIFICE AFTER REDUCTION OF THE PROCIDENTIA HAD BEEN EFFECTED IN THE SAME PATIENT AS IN FIG. 2.

from diarrhœa. In some cases, especially in women, frequency of micturition together with incontinence of fæces is complained of. When the surface is ulcerated, pain of a burning character is experienced whenever the bowels act, and for some time after the action.



*Physical Examination.*

When the part is not protruded, the anus will be found markedly patulous, sodden, dark coloured in appearance, and generally free from folds of redundant skin (see fig. 5). The sphinteric control will be found to be almost absent, and reflex contraction is not excited by the digital examination. When the part is protruded, a cylindrical, oval or globular tumour will be found. Its size will depend upon the duration of the disease, the age of the patient, and the severity of the straining effort which has produced the protrusion. The tumour is red in colour, though, if there be much impediment to venous return, a purplish hue is imparted to it. The base of the tumour is situated at the muco-cutaneous junction, the diameter at this point being often considerably less than that of the widest part of the protrusion. The surface of the tumour is covered by healthy mucous membrane, which is thrown, as a rule, into transverse and more or less parallel folds (see fig. 4), but when a hernial sac containing coils of intestine enters into the formation of the tumour the folds may be obliterated (see fig. 3). If it has been constantly subjected to friction against the clothing, the mucous membrane will often have lost its natural healthy appearance and will have become indurated and perhaps ulcerated in parts, more especially at the apex. The mucous membrane covering the surface of the tumour will be found to be directly continuous with the skin of the anal margin, there being no sulcus between the wall of the anal canal and the tumour into which either a finger or a probe can be introduced,—a feature characteristic of a protruded invagination of the rectum or an intussusception of the colon. The orifice leading into the interior of the bowel is situated at the apex of the tumour or just to one side of it, and is usually filled with mucus. When the protrusion is of moderate dimensions, the orifice is usually in the centre of the tumour and somewhat oval in



shape, but when the tumour is several inches in length, the orifice is elongated and slit-like, and directed backwards on account of the traction exerted by the attachment of the mesorectum. When the finger is introduced into this orifice, and the wall of the protruded bowel is grasped between it and the thumb, the presence of the muscular coat of the rectum in the protruded part will be readily appreciated by the feeling of thickness and solidity of the tissues. Moreover, in those cases in which the length of the protrusion does not exceed one inch and a half, the outer and inner layers of the reduplicated bowel will be found to be in close apposition. When, however, the size of the protrusion is greater than this, there is often a pouch of peritoneum anteriorly, containing one or more loops of small intestine. The existence of intestine in this situation can be determined by a resonant percussion note over the anterior part of the tumour, and by a gurgling sensation imparted to the hand when pressure is made for the purpose of reducing the procidentia. A gurgling sound may in some cases be heard during the reduction.

### *Differential Diagnosis.*

*Procidentia recti* has to be diagnosed from (a) *prolapsus mucosæ recti*, and (b) *protrusion of an invagination of the upper part of the rectum, or of an intussusception of the colon*.

(a) *From Prolapsus Mucosæ Recti*.—This has been fully dealt with on page 10, to which the reader is referred.

(b) *From Invagination of the Upper Part of the Rectum or Intussusception of the Colon*.—In both of these conditions there is, between the anal canal and the protruded mass, a distinct space into which the finger can be easily introduced and passed round the entire circumference of the protrusion, whereas, in *procidentia*, the mucous membrane of the base of the protrusion is directly continuous with the anal skin.



### *Treatment.*

The treatment of *procidentia recti* may be (a) *palliative* or (b) *operative*. It must be borne in mind that, in some cases, the protrusion is due to a definite exciting cause, quite outside the rectum, which, if removed, may altogether prevent a recurrence of the protrusion. Accordingly, the existence of phimosis, or vesical calculus, should always be sought for in children and appropriately treated. In adults, uterine or other pelvic tumours causing the *procidentia* should be removed if possible. When a rectal polypus or growth is present its removal may cure the *procidentia*.

When *procidentia* has existed for some length of time, there is a tendency for the apex of the protrusion to become constricted, especially if ulceration of the surface has occurred as a result of pressure or friction against the clothing. Hence it is important that this possibility be borne in mind, and, if constriction exist, steps should be taken to overcome it at least three months before any operation is undertaken.

#### *(a) Palliative Treatment.*

This consists in reducing the protrusion as soon as possible and preventing its recurrence. In some cases, as when the protrusion has occurred as the result of a sudden and violent expulsive effort, speedy reduction may be followed by permanent cure. When, however, the protrusion is due to general loss of tone in the musculature of the pelvic outlet, recurrence is likely to take place during the slightest straining effort. Under these conditions, especially in children, the protrusion occurs during defæcation or micturition, and precautions should accordingly be taken to prevent it. In children under three years of age, the fæces should either be voided in the recumbent position or while the child is suspended vertically. This can readily be done by the nurse lifting the child off the ground with her hands in



the child's armpits. This latter method renders straining impossible, and often prevents the descent of the bowel. In children above three years of age, and also in adults, defæcation should always take place while dorsally recumbent.

It is important that the protrusion be returned as soon as possible after its occurrence, for two reasons; (1) because the longer the protrusion remains down the more congested it becomes and the more difficult will its reduction be, owing, in early cases, to the constricting effects of the sphincters; and, (2) because prolonged stretching of the sphincters causes loss of muscular control, which predisposes to the recurrence of the protrusion.

The best way of effecting the reduction is to place the patient in the right lateral and semi-prone position, and then to grasp the protruded mass laterally between the fingers and thumb of the left hand. While firm lateral pressure is being kept up in this way, the thumb of the right hand is placed on the most dependent part of the protrusion, and thus pressure is exerted upwards in the direction of the longitudinal axis of the bowel. A piece of cotton-wool placed over the protrusion will, by adhering to the mucous membrane, assist in effecting the reduction. When the cotton-wool is used, the thumb of the right hand should be placed on it over the orifice, and, when the upward pressure is made, the thumb, together with the cotton-wool, should be carried into the lumen of the bowel. The reduction having been completed, the thumb should be withdrawn and then the cotton-wool carefully removed by first twisting it several times on its axis before withdrawing it from the anal canal. If the case be one of primary protrusion, so much spasm of the sphincters may have been evoked that the reduction will be greatly impeded by constriction at the anal orifice. Under these circumstances it is expedient to place the patient under the influence of a general anæsthetic. After reduction, a



pad of cotton-wool should be placed over the anus and a T bandage firmly adjusted.

The most important feature of palliative treatment, however, is the continuous avoidance of either constipation or diarrhoea, both of which give rise to straining at stool. The patient should live upon light, nutritious diet, and the general health should be improved by suitable tonics, etc. We have found cod-liver oil to be extremely useful in these cases, on account of its tendency to make the motions soft. When constipation exists, an injection of an ounce of olive oil for an adult patient and a smaller quantity for a child, at bed-time, is particularly effective in softening the fæces to be voided, and in securing a daily action of the bowels.

Various forms of artificial supports have from time to time been tried, but so far as our experience goes none of them is satisfactory. When the sphincters are deficient in contractile power, the exercise mentioned on page 13 may be carried out with very much benefit. We have found this treatment most successful in many cases when it has been diligently persevered with.

#### *(b) Operative Treatment.*

An operation should be advised in cases of long standing or when palliative treatment has failed or is unlikely to be productive of any good results, and also when the bowel continues to descend in spite of all efforts to keep it up. It is important to bear in mind the fact that, when once a protrusion of the rectum has occurred, the tendency is for it to become worse as time goes on, so that if palliative measures do not prevent the protrusion at stool, etc., the sooner an operation is performed the better. In an early stage of the disease, when the protrusion is small and the sphincters still retain some of their contractile power, an operation is much more likely to be successful than when they are in a state of atony.



Several operative measures have from time to time been suggested, of which the most important are:—

- (a) The application of nitric acid ;
- (b) The application of the actual cautery or the thermo-cautery ;
- (c) The operation by ligature.

Recently, some authorities have advocated fixation of the sigmoid colon to the pelvic and abdominal parietes for the cure of advanced and intractable cases of procidentia. Thus Murphy, of Chicago\* performs an operation which he terms *abdominal colopexy*, whereby he sutures the sigmoid to the ilio-psoas in the false pelvis, and the descending colon to the lumbar and ventral muscles as high as the twelfth rib.

We have not had any personal experience of this operations, nor have we seen it performed, so that at present we are unable to judge of its merits. We have recently seen a patient on whom colopexy had been performed about one year previously. In this case, however, there was no benefit to the patient, the procidentia recurring with each action of the bowels as it did prior to the colopexy.

Hitherto, we have obtained most satisfactory results from the application of nitric acid in children, and from the operation by ligature or cautery in adults, one of which methods we always employ according to the requirements of the case, having first satisfied ourselves that the patient is not suffering from either phimosis, vesical calculus, a villous or other growth in the rectum, or a pelvic tumour.

### *Choice of Operation.*

When the cause is clearly due to straining during micturition from phimosis or vesical calculus, no operation should be contemplated upon the rectum until sufficient time has elapsed, after the removal of the phimosis or vesical calculus, to prove that further operative treatment is required.

---

\* "Clinical Review," 1901.



In children, when the procidentia has been caused either by constipation or by diarrhoea, the application of nitric acid is attended by the most satisfactory results.

In adults the choice of operation is determined by the presence or absence of internal piles. When internal piles co-exist with the procidentia, the probability of being able to cure the latter by ligaturing all the piles is extremely good. This operation, in the majority of such cases, is attended with perfect success. When internal piles do not co-exist the operation by the cautery may be performed. In two such cases, operated on by us within the last year, instead of using the cautery we ligatured four pieces of the lower inch and a-half of the rectal mucous membrane, with corresponding pieces of the skin of the anal region. One piece was taken from each quadrant of the circumference. In this way the circumference of the anal margin was reduced by about three-eighths. The result has been most satisfactory. In one of these patients, a female aged sixty-seven, the procidentia had existed for twenty years, and in the other case, a female aged fifty-three, the procidentia had existed for twenty-two years. Neither of the patients has had recurrence of the procidentia since the operation

(a) *The Application of Nitric Acid.*

For this purpose, the pure nitric acid of the British Pharmacopœia should be used. The bowel should be made to protrude to its fullest extent, and then the mucous membrane, throughout the circumference of the protruded bowel and covering a zone from a quarter to half an inch in depth above the muco-cutaneous junction, should be carefully dried in order that all the mucus may be removed. When this has been done, the acid should be applied by means of a glass brush to the mucous membrane in the form of a band from a quarter to half an inch in depth, its lower margin commencing at the muco-cutaneous junction. Immediately after the application



has been made, the whole of the surface, which has been touched with the acid, should be carefully dried by clean white blotting paper in order to prevent any excess of acid from either penetrating too deeply or extending further up the rectum. This is an important point, because, if the excess of the acid be allowed to remain, the resulting slough may be more extensive than desired, with the risk of severe hæmorrhage following its separation, and thus producing an irregular contraction. The excess of acid may also be removed by neutralization with a solution of bicarbonate of soda. When these precautions have been taken, the protruded part should be returned through the anal orifice and kept in place by a plug of cotton-wool soaked in sterilized olive oil.

The rationale of applying the acid in this manner is that the resulting constriction is situated at the anal orifice, where it is most required. In cases of procidentia in adults, it frequently occurs that the hæmorrhoidal veins at the base of the tumour are varicose. Jessop, of Leeds, showed, many years ago, that when these internal piles were ligatured the resulting constriction of the anal canal frequently cured the procidentia. In consequence of the effective narrowing of the anal canal occurring in cases which had been operated on by Jessop's method, and assuming that the same principle could be applied to procidentia in children in whom dilated veins are absent, we sought to produce some degree of circular constriction of the anal canal by the application of nitric acid in the manner above described. The result in several of our cases has been extremely satisfactory.

Some surgeons apply the acid in a different manner.

Thus, Allingham\* says: "Chloroform should be given, and the protruded gut well dried. The acid must be applied all over it, care being taken not to touch the verge of the

---

\* "Diseases of the Rectum," 6th Ed., p. 217.



anus or the skin. The part is then to be oiled and returned, and the rectum stuffed with wool. . . . "

Cripps\* applies the acid in the same manner as he uses the cautery, that is, by tracing four longitudinal lines, one along the back of the bowel, one along its front, and one along each side.

Van Buren† advises that the acid be applied in vertical stripes. He says: "I would caution you not to paint the acid, nor any other escharotic, indiscriminately over the whole surface of a prolapse without careful consideration."

Christopher Fleming‡ cured an aggravated case of procidentia in an adult by applying the acid at four points in lines a quarter of an inch wide and two inches long.

Whichever of the above methods may be adopted we are quite convinced that under no circumstances should the acid be applied to the apex of the protrusion. If this be done the resulting contraction may, and frequently does, produce circular constriction of the bowel at a level of two or more inches from the anus, thereby making the patient's condition far worse and more deplorable than it was before the application of the acid. We have seen cases in which this plan of procedure has been carried out, and the result has been most unsatisfactory.

Circular constriction being required for the purpose of preventing the recurrence of the procidentia, its seat should be immediately above the anal orifice, and this can be attained by the method we have advocated.

The application of nitric acid is more suitable for cases of procidentia in children than in adults. In children, when there is no other cause for the procidentia than loss of sphincteric control, nitric acid applied, as we have suggested, has been, in our experience, uniformly successful.

---

\* "Diseases of the Rectum and Anus," 2nd Ed., p. 128.

† "Diseases of the Rectum," 1881, p. 84.

‡ "Am. Journal Med. Sciences," 1835.



(b) *The Operation by Caution.*

This method of procedure has been practised by many surgeons, among whom may be mentioned Allingham, Cripps, Gowlland, Henry Smith, and Van Buren.

*Allingham*\* writes: "The patient is put under the influence of ether, and if the part be not quite down, it can be readily drawn fully out of the anus by the vulsellum. We then, having the intestine held firmly out, with the iron cautery at a dull red heat, make four or more longitudinal stripes from the base to the apex of the protruded intestine, taking care not to make cauterization so deep towards the apex as at the base, because near the apex the peritoneum may be close beneath the intestine, while a deep burn near the base is not dangerous. One should avoid the large veins which can be seen on the surface of the bowel. If the pro-  
 cidencia be very large, as many as six stripes may be made; the intestine is then oiled and returned within the anus; having done this, we partially divide the sphincters on both sides of the anus with a sawing motion of the hot iron, and then insert a small portion of oiled wool."

*Cripps*† thus describes the procedure: "The patient being placed in the lithotomy position, with the prolapse reduced, a large-sized Sims' speculum is introduced into the bowel, and then, with Paquelin's cautery, at a dull red heat, a line is traced in the long axis of the bowel, commencing three or four inches from the orifice, and terminating on the mucocutaneous surface of the anus. The bulb of the cautery should be a sixth of an inch in width, and bent abruptly at right angles close to the end. Four lines may thus be traced, one along the back of the bowel, one along its front and one along each side, the speculum being shifted as may be necessary."

\* "Diseases of the Rectum," 6th Ed., p. 229.

† "Diseases of the Rectum and Anus," 2nd Ed., p. 126.



If the stripes meet at the apical orifice, there is considerable danger of cicatricial contraction occurring, which will subsequently lead to a recurrence of the protrusion on account of the stenosis.

(c) *The Operation by Ligature.*

This operation is applicable in cases of procidentia in adults, especially in those where internal piles co-exist. The object of the operation is that the scars resulting from the removal of the internal piles, should cause sufficient narrowing of the anal orifice and canal to prevent subsequent protrusion of the bowel.

The procidentia should be completely reduced as soon as the patient is fully under the influence of the anæsthetic. The internal piles will usually be found to be most prominent in the right anterior and the right posterior quadrants, and on the left side of the anal canal, and should be ligatured in the order named. When there are no folds of redundant skin, the usual condition, the incision for the reception of the ligature should be made by raising a V-shaped piece of skin at the base of the pile—the apex of the V being directed outwards. Each pile should be lifted well off the subjacent muscular coat with the hook or pressure forceps, and the ligature tied as high up as possible. When three or four ligatures have been applied, the lumen of the anal canal will be found to be considerably narrowed, though not sufficiently to necessitate the introduction of the finger for the restoration of the lumen, as is advocated in the operation for internal piles (see page 291, Part I.).

*After Treatment.*

The patient should be kept in bed for at least five weeks. During the first four days the directions given for the after treatment of internal piles (see page 293, Part I.) should be carried out. On the fifth day the bowels should



be induced to act by an injection of an ounce of olive oil injected every night and morning. The injections of oil should be continued night and morning throughout the after treatment, and all the evacuations should be passed in the recumbent position, in order to minimise, so far as possible, the risk of a recurrence of the protrusion. The bowels may not act until the eighth or ninth day, or even later. This method of relieving the bowels should be continued for at least three months. Should protrusion occur, it should be reduced without delay. Aperients should not be given. As soon as the bowels have acted freely for three or four days, ordinary diet may be resumed unless the fæces are solid. The patient should be urged not to strain when the bowels are acting. Systematic exercise, as described above, should be advised (see page 13).

## CHAPTER II.

### INVAGINATION OF THE RECTUM.

An invagination of the upper into the lower part of the rectum occasionally takes place. The invaginated portion may consist of the mucous coat only, or it may involve the whole thickness of the bowel, constituting a true intussusception of the rectum. The point at which the invagination begins may be situated anywhere between the commencement of the rectum and the upper border of the internal sphincter. The invaginated part increases at the expense of the rectum, especially when the whole thickness of the bowel is involved, and consequently the point of reflection tends to approach the anal orifice as the condition advances. When the disease has existed for some time, the invaginated portion may be protruded through the anal orifice, and then it will closely resemble a protruded intussusception of the colon.

#### *Etiology.*

This somewhat rare condition is more often met with in adults than in children, and in females than in males. The exciting cause may be traction exerted by a pedunculated growth attached to the rectal wall, or stenosis of the rectum produced by fibrous stricture or carcinoma. Apart from these causes, however, it is certain that obstinate constipation is a factor in the production of invagination of an otherwise healthy rectum. The constant straining at defæcation



necessitated by a hypertrophied and indurated external sphincter, so far as our experience goes, undoubtedly produces invagination of the mucous coat. A case of this nature has recently been under our care in which complete division of the external sphincter, with subsequent olive oil injections at bed-time, was followed by the disappearance of a well-marked invagination of the mucous coat.

Habitual distension of the rectum by fæces or flatus undoubtedly weakens the muscular coat of the bowel, and favours invagination of the upper into the lower part.

### *Symptoms.*

In the early stages the symptoms are indefinite, and may easily be overlooked. They consist chiefly of undue straining at defæcation, a sense of incomplete evacuation, and slight loss of blood with much mucus discharge. As the invagination becomes more marked they are more pronounced. The symptoms may be considered as they become evident—(a) *prior to protrusion through the anal orifice*, and (b) *after protrusion has occurred*.

#### *(a) Prior to Protrusion having occurred.*

In a well-marked case the symptoms consist of slight hæmorrhage, pain, frequent discharge of mucus, and desire for evacuation of the rectum.

*Hæmorrhage.*—This is, as a rule, slight, and only in sufficient quantity to smear the fæces evacuated, or to tinge the mucus. There is seldom a copious loss of blood, unless either internal piles or malignant disease co-exist. This slight loss of blood is, however, very persistent, and is not readily amenable to palliative treatment.

*Pain* in the rectum or referred to the sacral region is nearly always present unless the patient be recumbent. In many of these cases the patient is quite free from pain when in bed. Active exercise invariably aggravates it. The characteristic



feature of pain accompanying invagination is that it subsides soon after the patient retires to rest at night, and recurs shortly after he has risen in the morning. The effort of straining during an evacuation increases the pain, and conveys the impression to the patient that the bowel has not been completely relieved. Consequently, after the lapse of a few minutes, a fresh effort is made to rid the bowel of its supposed contents, but this only increases the discomfort.

*Discharge of mucus* is a constant symptom of invagination, the quantity discharged varying in different cases. The cause of the increased secretion of mucus is, no doubt, passive congestion of the mucous membrane of the invaginated part. This mucus accumulates in the rectal cavity, and, when a sufficient quantity has been secreted, gives rise to a desire to evacuate the bowel. Hence frequent evacuations, as many as ten, twelve, or more occurring during the twenty-four hours, are persistent symptoms of the disease. Of these evacuations, the first two or three contain fæcal material, but the remainder are composed of mucus sometimes tinged with blood. The presence of blood in the mucus may lead to the affection being mistaken by the surgeon for dysentery or even malignant disease.

*(b) After Protrusion has occurred.*

When the invaginated portion has once protruded through the anal orifice, there is a tendency for it to recur whenever the bowels act, and, later on, as soon as the upright position is assumed. In these respects the symptoms are those of procidentia of the rectum. When the part is protruded, the hæmorrhage is increased and the discharge of mucus is continuous. On account of the constricting effect of the sphincter muscles and the dragging down of the intussusception, the pain is constant, being of a throbbing character in the protruded part, with a dull aching over the sacrum.



*Physical Examination.*

When the above train of symptoms and signs is present, a thorough and systematic exploration of the rectum should be carried out. In slight cases, and especially when the point of commencement of the invagination is high up, *i.e.*, at the junction of the rectum and the sigmoid colon, the exact condition may be very easily overlooked, and the symptoms attributed either to dysentery or to malignant disease. It is well, therefore, that we should be acquainted with the condition of the parts both prior to the occurrence of protrusion and after that event.

(a) *Prior to Protrusion having occurred.*—On introducing the finger into the bowel, the cavity will be usually found free from faeces. If the finger be passed upwards, and, at the same time, kept in close contact with the rectal wall, a point will eventually be reached where it will meet with a distinct deflection of the mucous membrane. The sulcus, produced by the deflection, varies in depth according to the extent of the invagination and extends completely round the bowel. At the free extremity of the invaginated part, the orifice leading into the cavity of the bowel above can be distinctly made out. Its margin is circular, smooth, soft and regular, unless the invagination has been caused by a growth in the wall of the bowel at the apex of the invagination. When the invaginated portion is much congested, there may be some œdema of the margin of the orifice. When the orifice is within easy reach, the finger may be passed through it into the bowel beyond.

(b) *After Protrusion has occurred.*—Under these circumstances the appearance closely resembles procidentia of the rectum. The anus is found to be damp and sodden. There are usually no folds of redundant skin though there may be, in some cases, a fulness of the anal skin all round the orifice. In other cases this fulness is entirely absent, and both the external and the internal sphincters are deficient in tone and



greatly overstretched. The extent of the protrusion varies from half an inch to six or more inches in length. The protruded bowel is elongated and sausage-shaped, the orifice being situated in the centre of its apex, and oval or circular in shape. There is a distinct sulcus between the protruded part and the anal orifice into which the finger can be readily introduced. At a distance, varying from one to four or more inches, the upward progress of the finger is arrested by the deflection of the wall of the bowel on to the part which is protruded. This deflection extends all round the circumference of the bowel. The protruded part can nearly always be reduced, but generally returns during the slightest straining effort and sometimes, even when the patient assumes the erect position.

### *Differential Diagnosis.*

Invagination of the rectum may be confused with other diseased conditions of the rectum both before and after protrusion of the invaginated part. Accordingly it is necessary that we should consider the differential diagnosis under these heads.

#### *(a) Before Protrusion of the Invaginated Part.*

When the invagination is high up and yet in an early stage of development, the diagnosis has to be made from (1) *simple annular stricture*; (2) *intussusception of the colon*; (3) *ulceration of the rectum or colon*; (4) *carcinoma*; and (5) *villous tumour*.

(1) *From Simple Annular Stricture*.—When the lumen of the bowel is sufficiently narrowed so as to impede evacuation of the contents of the colon, an invagination of the rectum, beginning at the seat of the stricture, four or more inches from the anal orifice, may occur as a direct result of the straining at stool. In these cases there is, almost invariably, some distension of the abdomen, and the whole length of the colon will be found to be distended with both flatus and fæces.



Digital examination will reveal the fact that the orifice at the apex of the invagination is narrowed, firm, and rigid, and, if the finger can be introduced through it, the bowel above will be found to be greatly increased in diameter. When there is ulceration above the seat of stricture the surface of the distended bowel will be found to be roughened and devoid of mucous covering. Above this the mucous coat may be healthy. When the finger is withdrawn, after examination, it is often smeared with blood and pus.

(2) *From Intussusception of the Colon.*—When the intussusceptum has entered the rectum and can be felt there, it may be at first difficult to decide whether it is due to intussusception of the colon or to invagination of the rectum. The following considerations will, however, aid the diagnosis. Intussusception of the colon or small intestine occurs most often in children under five years of age. When of an acute form, continued vomiting, abdominal distension, and increasing collapse are prominent symptoms. Moreover, a distinct sausage-shaped swelling may be felt in the left iliac fossa unless the abdominal wall is very thick or the abdominal distension very great. When the intussusception pursues a more chronic course, vomiting will probably be present at intervals; there will be a history of the occasional appearance of a swelling, if one be not constantly present in the left iliac fossa, and of a well marked discharge of blood and mucus from the rectum. In either the acute or the chronic form digital examination of the rectum will reveal the fact that the intussusceptum is somewhat curved from the traction of the mesentery. Moreover, the finger cannot reach the bottom of the sulcus between the intussusceptum and the intussusciens, which conclusively proves that the intussusception did not start in the rectum.

(3) *From Ulceration of the Rectum.*—When the rectum is extensively ulcerated, and especially if the whole circumference



be involved, the lower margin of the healthy mucous membrane above may be considerably swollen by exudation. Such œdema of the margin may simulate very closely an invagination, but can always be distinguished by the shallowness of the sulcus, the irregularity of the margin, and by the existence of extensive destruction of the mucous coat of the lower part of the rectum.

(4) *From Carcinoma of the Rectum.*—When this disease involves either a part or the whole of the circumference at the same time, narrows the lumen of the bowel, and is situated more than three or four inches above the anal orifice, invagination commencing at the seat of the stenosis may result. Part or the whole of the margin of the orifice will be hard, everted, and irregular. Moreover, there will also be noted a distinct hardness of the invaginated part, and perhaps fixation in front or behind. There is a tendency to bleeding at and after the examination, and small pieces of the growth may be brought away on the finger; these, if subjected to microscopical examination, will reveal the true nature of the disease.

(5) *From a Villous Growth.*—When a growth of this nature is high up and fills the lumen of the bowel, it may be perhaps confused with invagination of the rectum. There will not, however, be an orifice at its most dependent part. The tumour may be felt to be minutely lobulated, and a distinct attachment to the rectal wall can nearly always be made out. When the finger is passed up between the growth and the wall of the bowel, faeces will probably be found in the rectum above the growth. There is very little, if any, hæmorrhage but there is a considerable quantity of watery discharge.

(b) *After Protrusion of the Invaginated Part.*

When the invagination of the rectum is protruded through the anal orifice, the diagnosis will have to be made from



(1) *prolapsus mucosæ recti*; (2) *procidentia recti*, and (3) *protruded intussusceptum coli*.

(1) *From Prolapsus Mucosæ Recti*.—In this disease, the extent of the protrusion rarely exceeds one and a-half or two inches in length. The protrusion is nearly always more marked on one side than on the other. There is usually a distinct division anteriorly and posteriorly. The skin of the anal margin is directly continuous with the mucous membrane of the protruded part, there being no sulcus between the anal canal and the protrusion.

(2) *From Procidentia Recti*.—The protrusion in these cases is more globular in shape, and, when of large size, there is nearly always a pouch of peritoneum anteriorly, in which a coil of small intestine is sometimes present. There is no sulcus between the anal canal and the protrusion. The hæmorrhoidal veins are often distinctly enlarged, and in quite fifty per centum of the cases, internal hæmorrhoids co-exist.

(3) *From Protruded Intussusceptum Coli*.—When suffering from this disease the patient is generally under five years of age. There is a history of vomiting, with discharge of mucus and blood from the rectum, and abdominal distension extending over a longer or shorter term in accordance with the acuteness of the disease. When of the ilio-cæcal variety, the ileo-cæcal valve may be plainly discernible at the apex of the protrusion. There is a well-marked sulcus between the protrusion and the anal canal, but the junction of the intussusciens and the intussusceptum is beyond the reach of the finger.

### *Treatment.*

The treatment of uncomplicated invagination of the rectum is, in our experience, extremely unsatisfactory, especially in its advanced stages. When the disease is produced by a polypus, or by a fibrous or carcinomatous stricture, the treatment suitable for those diseases should be adopted.

When the mucous coat alone is invaginated, it will

generally be found that the external sphincter muscle is indurated, hypertrophied, and becomes spasmodically contracted whenever the patient tries to pass either flatus or fæces, thereby necessitating considerable straining during defæcation. Moreover, the anal orifice is physically incapable of the normal degree of expansion, thus constituting a mechanical obstruction. Under these circumstances, complete division of the external sphincter obviates the straining at stool and permits of the rectum being completely evacuated. Hence the cavity of the rectum is not constantly distended by fæces or flatus, and there is consequently less tendency to invagination. This method of treatment has proved successful in some of these cases. When all the coats of the bowel are involved in the invagination, more radical treatment is required. It seems to us that the best plan is to perform left inguinal colostomy, as by so doing the forcing down during defæcation is prevented. Before deciding upon colostomy, the patient should be clearly told what his condition will be after that operation. He must decide between the advantages of an artificial anus and the continuance of the discomfort produced by the rectal condition.



## CHAPTER III.

### ULCERATION.

The ano-rectal region is occasionally the seat of ulcerative processes. Being the terminal portion of the intestinal venous system, the flow of blood through the tissues is liable to be interfered with by various causes. Impediment to venous return is well known to induce a passive congestion from which nutrition suffers, and then slight injuries may lead to more or less extensive destruction of tissue. The varicose ulcer of the leg is a good example of such a cause and effect. Just in the same way, in obstruction to the portal circulation from any cause, the mucous membrane of the rectum may have its vitality impaired, and thus be predisposed to ulceration.

The ulcerative processes may be either circumscribed or diffuse, and may be confined to the skin around the anus, or to the mucous membrane of the rectum or to both, the latter being the more common condition.

#### ANAL ULCERATION.

This is generally circumscribed, and occurs in the following forms:—(a) *local contagious ulcer (chancroidal ulcer)*; (b) *tuberculous ulcer*; (c) *syphilitic ulcer*; (d) *lupoid ulcer*;

(e) *rodent ulcer*; and (f) *infective ulceration*. In some of these forms of ulceration the lower quarter or half-inch, if not more, of the whole or parts of the circumference of the anal canal is also involved in the ulceration.

(a) *The Local Contagious Ulcer.*

This form of ulcer is seldom met with. It almost invariably occurs in females as the result of auto-inoculation.

When the result of auto-infection by the discharge of an ulcer upon the vulva, there is usually more than one ulcer in the anal region.

In shape it is irregular, the edges are often undermined, the surface is covered by greyish sloughy granulations, and there is a small quantity of purulent discharge. The base is not, as a rule, indurated.

In debilitated persons, and especially in those addicted to alcohol, the ulcers may extend rapidly and become *phagedænic*. The discharge is highly infective. The inguinal glands are nearly always enlarged and are prone to suppurate.

*Treatment.*

This should consist in an endeavour to convert the ulcer into a healthy granulating surface. For this purpose the ulcer should be cleansed and cocaine or eucaine should then be applied to it and the ulcerated surface destroyed by the application of sulphate of copper. After this the ulcer should be dressed with antiseptics several times a day, and its surface dusted with iodoform or calomel. Should it assume a *phagedænic* tendency more energetic measures will be necessary. Under these circumstances its surface should be rendered insensitive, thoroughly cleansed and dried, and then destroyed with either nitric acid or formalin. When treated in this way, the *phagedæna* will usually be arrested, the surface of the ulcer soon becoming covered



with healthy granulation tissue and cicatrization quickly ensues. It is important that the ulceration should be arrested as soon as possible lest narrowing of the anal orifice result from the subsequent cicatricial contraction.

Should suppurating adenitis occur in the groin, the abscess should be freely laid open without delay.

(b) *The Tuberculous Ulcer.*

This variety of anal ulcer is seldom met with unless associated with a tuberculous fistula. In such cases the ulcer is really the undermined external opening of a tuberculous fistula into the main track of which a probe can be readily passed. Apart, however, from fistula, an ulcer of a tuberculous nature is sometimes, though rarely, met with. An excellent example of such an ulcer, from which the accompanying illustration was made (see fig. 6), has recently been under our care. The tuberculous nature of the ulcer was proved by microscopical sections of a piece of tissue taken from its margin. Several typical giant cells are plainly demonstrated in the section from which the accompanying micro-photograph was made (see fig. 7). The tuberculous ulcer, so far as we have seen, involves part of the anal margin as well as a corresponding portion of the mucous membrane of the lower part of the anal canal.

In shape the ulcer is oval, its edges are distinctly undermined, and the floor is covered by large greyish granulations. Here and there, small caseating nodules may be seen on the surface. Though generally single, two or more ulcers may be present. The common situation of the ulcer is at the posterior commissure of the anus. We have never seen a case in which the whole of the skin of the anus had been destroyed by the ulcer. A glairy sero-purulent discharge escapes from the ulcerated surface, and the granulations do not readily bleed when touched. This form of ulcer does not give rise to much pain, a feature, among others, which distinguishes it

from fissure. The disease occurs more commonly in men than in women, and generally during the fourth, fifth, and sixth decades of life.

*Treatment.*

This should consist in thorough scraping of the surface with a Volkmann's spoon so as to remove all the tuberculous

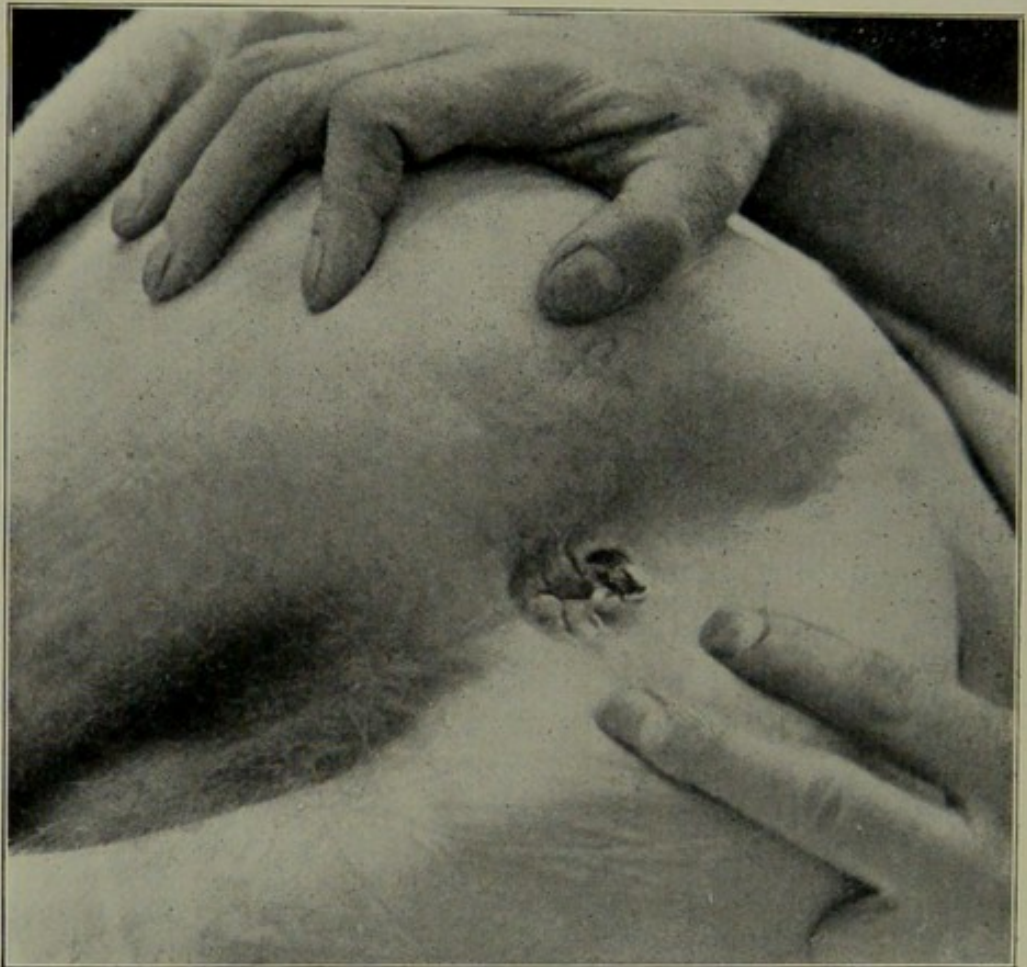


FIG. 6.—A TUBERCULOUS ULCER OF THE ANO RECTAL MARGIN.

tissue. The undermined edges should then be completely removed, and the external sphincter should be divided through the floor of the ulcer. If more than one ulcer exist, a single division of the sphincter is sufficient.



*After Treatment.*

This consists in improving the general nutrition of the patient by tonics, cod-liver oil, and a light nutritious diet. Stimulating repair by touching the surface of the wound, from time to time, with nitrate of silver or sulphate of copper is often necessary. Should any fresh caseating nodules make

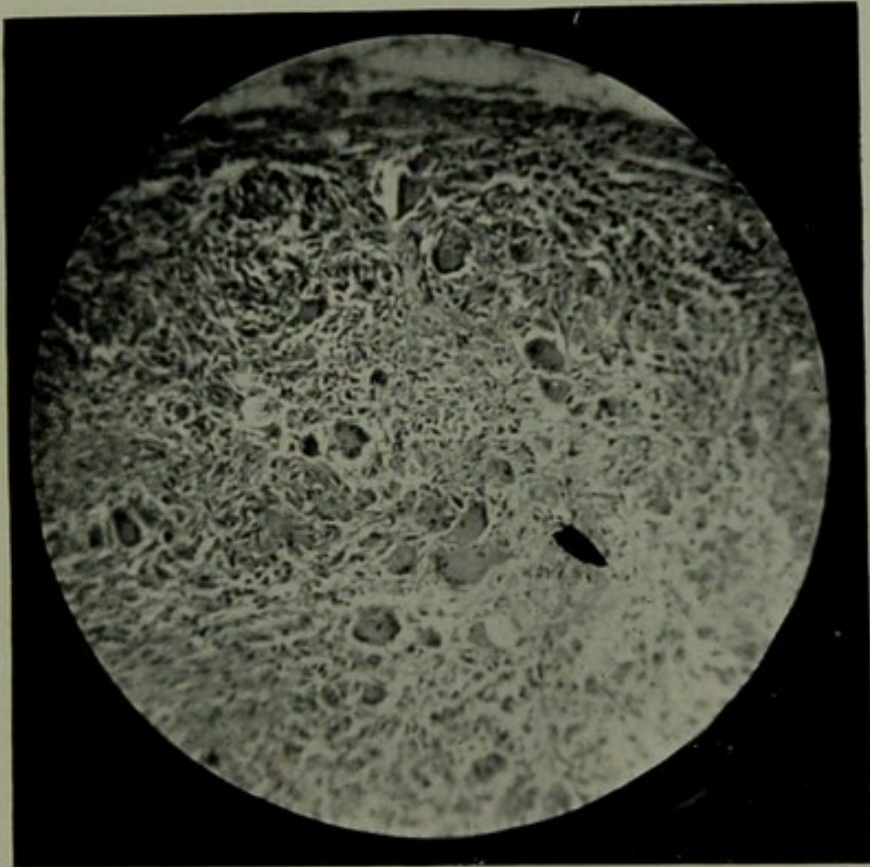


FIG. 7.—SECTION OF THE MARGIN OF THE TUBERCULOUS ULCER SHOWN IN FIG. 6.

(Several typical giant cells are to be seen in the section.)

their appearance during the healing process, they should be removed by scraping as soon as their presence has been detected. These wounds usually heal slowly but, eventually, complete cicatrization occurs if the patient's general nutrition is well maintained. Whenever possible, the patient should reside in a healthy bracing locality during the healing of the ulcer. We have found iodoform in powder one of the best local applications for this form of ulceration.

*(c) The Syphilitic Ulcer.*

This may occur in the congenital or the acquired form and will be described in the chapter on syphilis.

*(d) The Lupoid Ulcer.*

Lupus is rarely met with in the anal region; we have seen only five well marked cases. The accompanying illustration was taken from one of them. All the cases were well advanced, a considerable area of peri-anal skin having been involved when they first came under our notice, so that we have not had the opportunity of observing the initial stages of the disease. These patients do not seek relief as soon as they would if exposed parts of the body were attacked.

The characteristic feature of the lupoid ulcer is that it heals in some parts, while it spreads in others. In consequence the ulcer is usually serpiginous in shape (see fig. 8). The margins of the ulcer are slightly raised and indurated, and its floor is covered with granulations, which may, at times, be exuberant. There is usually a thin purulent discharge, which has a tendency to form scabs. When the skin of the anal orifice is involved there may be considerable pain, especially during defæcation. The ulcer does not penetrate deeply, a feature which serves to distinguish it from the rodent ulcer.

*Treatment.*

This form of ulcer is very intractable and difficult to cure. Even when cicatrization is complete, the scar tissue often breaks down as a consequence of the reappearance of the disease. When the ulcer is situated in close proximity to the anal orifice, it is important that there should be as little destruction of tissue as possible; but when it is situated some distance away, as, for instance, on the buttock, extensive



scarring causes but little inconvenience. We treated two of our cases with thorough scraping and the application of Vienna paste. By this method we had excellent results.

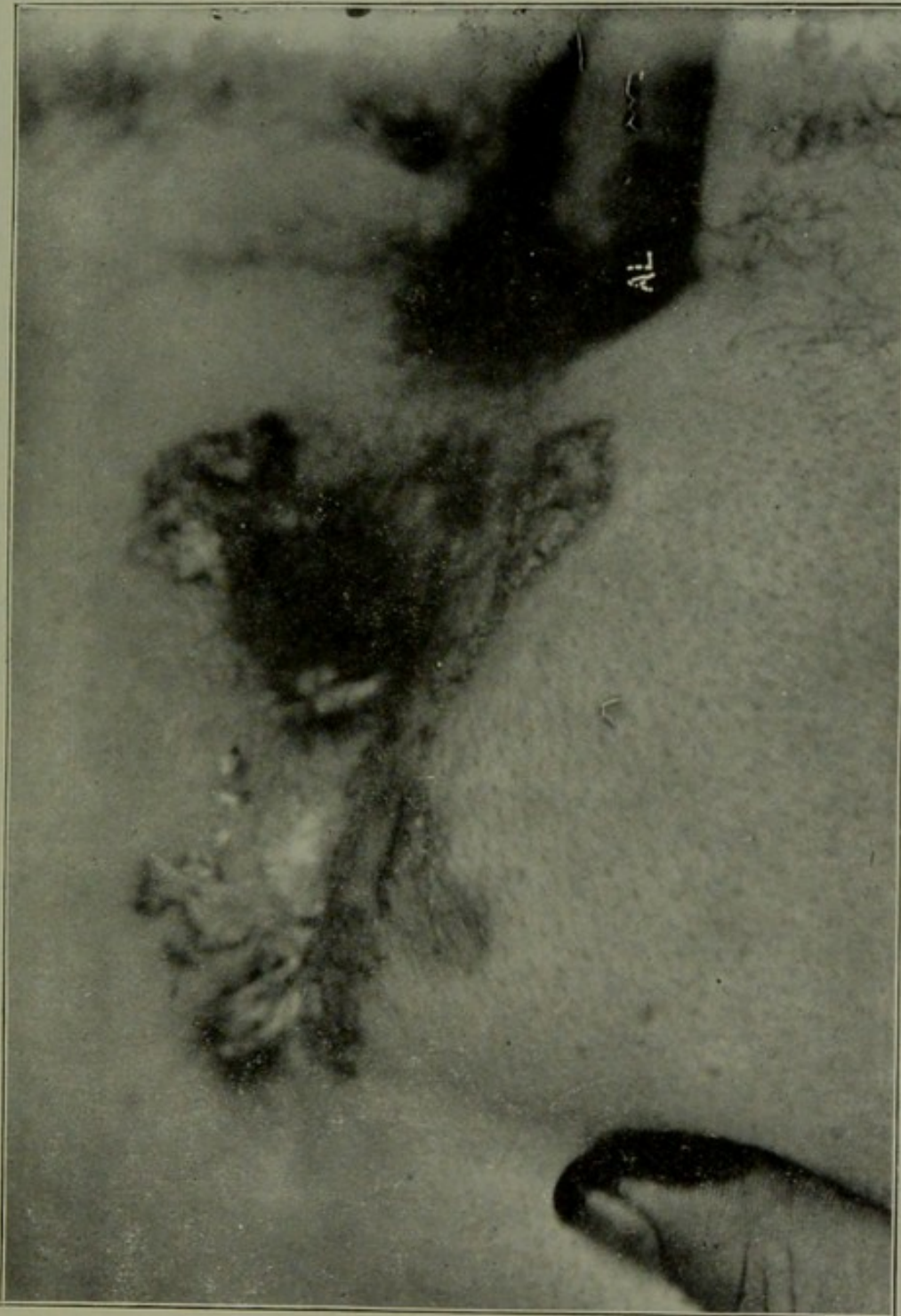


FIG. 8.—LUPOID ULCER OF THE ANAL REGION.

The Finsen light, formalin, or radium may answer equally well, but we have not had an opportunity of trying them on lupus in this part of the body.

(c) *The Rodent Ulcer.*

The rodent ulcer is very rarely met with in the region of the anus. We have seen only two instances of it, both of which were situated close to the anal orifice. Allingham\* refers to ten cases which he had seen. Curling\* saw this form of ulcer in a medical man, who died with the disease at the advanced age of eighty-one.

*Treatment.*

The ulcer should be destroyed as completely as possible. In one of the cases under our care the ulcer had been continuously treated for several months before we saw it. We filled the ulcer with Vienna paste, and, after the lapse of about ten minutes, the whole of the ulcer area was dissected out. As soon as the hæmorrhage had ceased, the wound was filled with Vienna paste, which was allowed to remain for about ten minutes, and then the wound was carefully scraped out and dressed with olive oil on cotton wool. The subsequent treatment was by fomentations. The wound quickly and soundly healed, and the patient remained well. The object we had in view, in applying the Vienna paste before the removal of the area of the ulcer, was the prevention of the possible infection of the wound by the diseased tissue during the operation.

RECTAL ULCERATION.

When the mucous membrane of the rectum is the seat of ulceration, the ulcer may be either *circumscribed* or *diffuse*.

*Circumscribed Ulceration.*

The circumscribed ulcer may be due to (a) traumatism, (b) the tubercle bacillus, and (c) syphilis. Hence we meet with

---

\* "Diseases of the Rectum," 6th Ed., p. 402.

+ "Diseases of the Rectum," p. 121.



(a) *the traumatic ulcer*, the most common form ; (b) *the tuberculous ulcer*; and (c) *the syphilitic ulcer*. The syphilitic ulcer is described in the chapter on syphilis.

(a) *The Traumatic Ulcer.*

This form of ulcer is due to a laceration of the rectal mucous membrane either by a foreign body, or by a mass of hard fæces partially tearing through the base of attachment of a pedunculated growth or pile. The laceration so produced is prevented from healing partly by the action of the sphincter muscles and partly because the return flow of blood from the wounded area is interfered with by the pressure of fæces in the rectum. It does not follow, however, that every wound in the rectal mucous membrane necessarily degenerates into an ulcer, because those remaining after the separation of ligatured internal piles or as the result of operations for fistula usually heal perfectly. When, however, a tear in the mucous membrane is the result of the passage of a foreign body, the pain therefrom causes spasm of the sphincters and levatores ani, which renders defæcation difficult, producing retention of fæces, and consequent irritation of the wound by the subsequent passage of scybalous motions. Just as in cases of fissure, so in these there is always an accumulation of fæces in the rectum which exerts pressure upon the veins and induces passive congestion. It is this passive congestion, combined with the spasmodic action of the sphincters and the levatores ani, which retards the healing of the wound and causes it to degenerate into an ulcer.

The traumatic ulcer is usually single and situated in the anal canal. Its lower extremity frequently involves the anal margin, and can be seen when the patient strains down. The ulcer may extend upwards for an inch or an inch and a-half, and usually ends at the upper border of the internal sphincter. In some cases it may reach a little higher. Occasionally



there are two distinct ulcers placed almost exactly opposite to each other, in which case both have been probably produced simultaneously by the passage of a fish-bone or other foreign body. In other instances again, the ulcer is situated at the side of the base of a pedunculated growth or polypoid pile (see page 104, Part I.) having been produced by the partial tearing through of the pedicle during the expulsion of a hard mass of fæces. Very often an ulcer in this situation is completely hidden from view by the growth or pile, and may be easily overlooked.

The ulcer has well defined margins, which may or may not be indurated. The degree of induration varies according to the duration of the ulcer and the efforts made for repair. Occasionally, when an ulcer has existed for several months, the induration of its edges is so well marked that it may lead to the suspicion of malignant disease.

The floor of the ulcer is covered with granulations, and there is usually some purulent exudation.

The surface is extremely sensitive, and, when touched, marked spasm of the sphincters and levatores ani is produced.

### *Symptoms.*

These consist of (a) *pain*; (b) *discharge*; (c) *slight loss of blood*; and (d) *inability to force the anus down*.

(a) *Pain*.—This is usually severe, and of a burning character. It begins immediately before defæcation, continues during the passage of the fæces and persists afterwards for a short interval, varying from a few minutes to half an hour, or even longer. It differs in character from that attending a fissure, which usually begins within half an hour after the act of defæcation is over, and may persist for four or six hours or much longer (see page 220, Part I.).

(b) *Discharge*.—From every traumatic ulcer there is always a certain quantity of purulent discharge which, provided that



there is no submucous burrowing from its margins, is not profuse. In fact, a drop of pus is generally all that can be seen when the margins of the anus are separated for the purpose of exposing the lower edge of the ulcer. When, however, the ulcer leads to the formation of an abscess, and a blind internal fistula results, the quantity of pus secreted is increased, being greater when the burrowing is downward and submuscular into the ischio-rectal fossa, than when the burrowing is only upwards and submucous. It is important to bear this point in mind when operating upon an ulcer of this nature, because, unless the presence of a blind internal fistula be detected and its track laid open, the ulcer will not completely heal. A copious discharge of pus from an ulcer, when accompanied by more or less continuous pain, is strong evidence of the existence of a blind internal fistula.

(c) *Slight loss of blood.*—Since the traumatic ulcer is due to laceration of the mucous coat of the rectum, it follows that its production is attended by loss of blood. This rarely exceeds a few drops when the ulcer is due to a tear by a fish-bone or similar foreign body, the reason probably being that the rent is superficial, involving the capillaries of the mucous membrane only. When, however, the ulcer is due to the tearing of the pedicle of a polypoid pile or a pedunculated growth, the bleeding is more copious, and probably emanates from a ruptured submucous vein. A slight loss of blood may also attend each action of the bowels, whatever the cause may have been.

(d) *Inability to force the Anus down.*—This is most marked, and, as we have already shown (see page 225, Part I.), is due to the spasmodic action of the levatores ani and of the external and internal sphincters. This condition should always induce the surgeon to make a digital examination of the anal canal and the rectum, more especially of the lower two inches.



*Physical Examination.*

The history of a sudden onset of the above symptoms, beginning either during or immediately after an action of the bowels, should lead us to look for a traumatic ulcer. A thorough examination of the lower part of the rectum should be made with the finger, and also, if necessary, with the speculum. There is usually so much spasm of the sphincters and the levatores ani, that it is extremely difficult and very painful to conduct the examination without either local or general anæsthesia. Should the patient prefer not to take an anæsthetic for the purpose of examination, the complete exploration of the rectum should be left until the time of the operation, and, in the meantime, sufficient examination should be made to make it clear that operative interference is necessary. For this purpose the margins of the anus should be gently drawn aside, and the patient requested to strain down slowly. If the ulcer be due to the laceration of a foreign body, its lowermost extremity will usually extend down to the muco-cutaneous junction, and will come into view as soon as the spasmodic action of the muscles subsides. A single ulcer may, under these conditions, be mistaken for a fissure; but if two are found to exist, one diametrically opposite to the other, the presumption is strong that the passage of a fish-bone or similar foreign body has been the cause of the lesions. If the ulcer be due to a tear at the side of a polypoid pile or a pedunculated growth, it will be situated entirely within the anal canal, and will not be seen in this way. Still, its presence may be suspected should the polypoid pile or growth become protruded during the straining effort. Such an examination is usually sufficient to show whether an operation is necessary or not, and consequently, further exploration may be dispensed with until the patient is under the influence of anæsthesia, when a thorough examination can be conducted.



It is always well to make this before the operation, lest some additional lesion should be overlooked.

The sphincters, if necessary, should be gently stretched, and then the full extent of the ulcer can be made out. If its lower extremity reaches the muco-cutaneous junction, and the ulcer extends upwards for an inch or an inch and a-half, the diagnosis of *traumatic ulcer due to a foreign body* is probably correct. If a polypoid pile or a pedunculated growth be found in the anal canal, a careful search should be made at the side of its pedicle for a laceration, which may be the cause of the symptoms complained of, although concealed from view by the growth. The discovery of the cause of the ulcer is very important from the point of view of treatment.

If, during the examination, pus be found to escape, the margins of the ulcer should be carefully examined for sub-mucous or submuscular burrowing. An ulcer of this kind is very often the cause of a blind internal fistula, which, if overlooked, will prevent healing from taking place. When a blind internal fistula has been caused by a traumatic ulcer the rectum will generally be found to be empty, and consequently the absence of fæces in the rectum should not be taken as an indication of the non-existence of an ulcer.

### *Treatment.*

When a well defined ulcer is present, and especially if it has existed for some length of time, that is to say, if it has become callous owing to natural attempts at repair having been thwarted, operative measures will be necessary to effect a cure. Lacerations will heal under palliative treatment if this be commenced within a few days of their origin. When the ulcer is due to the tearing down of the pedicle of a polypoid pile, the latter must be removed by operation, as no other treatment will permanently cure the patient. The treatment of uncomplicated traumatic ulcer is therefore either palliative or operative.



*Palliative Treatment.*

This consists in procuring daily one or two free actions of the bowels, so that the formation of hard masses of fæces in the rectum may be prevented. For this purpose an ounce of olive oil should be injected into the rectum every night and morning. In most cases this is all that will be necessary, but, in others, a mild laxative should be given as well. An important part of this treatment is the maintenance of strict cleanliness of the anus, which should be carefully washed after each action of the bowels and before each injection of the olive oil, because in many of these cases pruritus of the anus readily supervenes. Throughout the treatment the patient should be kept upon a light nutritious diet, and, if debilitated, suitable tonics should be prescribed. To ensure success, even in the most recent and favourable case, great attention must be paid to the above details. If a hard motion be allowed to pass, fresh laceration will probably occur, and undo the progress made during weeks of constant care. It must be borne in mind, however, that even the most careful palliative treatment may end in failure, and therefore it is always advisable to forewarn the patient that an operation may be eventually necessary.

*Operative Treatment.*

This consists of (a) *the application of caustics*, such as nitrate of silver or sulphate of copper, (b) *the application of the thermo-cautery*, (c) *scraping the ulcer with a sharp spoon*, (d) *stretching the sphincters*, and (e) *complete division of the external sphincter muscle*.

All these measures require either local or general anæsthesia. In our experience we find that division of the external sphincter yields the best results, and therefore we invariably adopt it. The operation is performed in exactly the same manner as for fissure (see page 239, Part I.). When



performing the operation for a traumatic ulcer, the muscle may be divided at the seat of the ulcer, care being taken that the lower border of the ulcer is included in the incision. The division may however be made in the right posterior (R.P.) quadrant irrespective of the position of the ulcer or tear. When two ulcers are present, one opposite the other, division of the muscle on one side usually suffices to effect a cure of both, and should always be tried before a second division of the muscle in the locality of the other ulcer is effected. When a polypoid pile or a pedunculated growth is the cause the growth must be removed, preferably by ligature, before the operation is completed. In some of the cases of ulcer, due to the tearing of the base of the attachment of the growth or pile, the removal of the growth or pile alone will sometimes cure the ulcer; but a more certain result is secured by removal of the growth or pile together with the complete division of the external sphincter in the right posterior quadrant.

If much pus be observed to escape from the rectum, a careful search should be made for the co-existence of a blind internal fistula, the internal opening of which will be found beneath the edge of the ulcer. This should then be dealt with as detailed in the chapter on fistula (see page 151, Part I.).

### *After Treatment.*

This is identical with that advised after the operation for fissure (see page 245, Part I.). The wound usually takes from three to four weeks to heal completely, during the greater part of which period the patient should be kept recumbent.

### *(b) The Tuberculous Ulcer.*

This form of ulcer is seldom met with in the rectum, and then it is usually an extension of tuberculous disease



of the genito-urinary tract. In such instances the implication of the rectum is a complication of existing tuberculosis of adjacent organs, and needs no special mention here.

A tuberculous ulcer, however, occasionally occurs in the rectum, quite apart from any contiguous focus, and, therefore, may be looked upon as a primary manifestation so far as the rectum is concerned, though it is probably secondary to pulmonary tuberculosis. Usually single, there may be more than one ulcer separated from each other by apparently healthy mucous membrane. When situated close together, two or more of these ulcers may coalesce, forming an irregularly-shaped ulcerated surface. The single ulcer is somewhat oval, or irregularly rounded in shape, and its margins are distinctly undermined. The floor is usually yellowish-gray in colour, and level with that of the surrounding mucous membrane. There is no bright shining areola, and the base of the ulcer is not indurated. It may be found in any part of the rectum. Tuberculous ulceration of a more extensive character, though manifesting the above characteristics, is sometimes met with at the upper part of the rectum, as a result of an extension downwards of a similar condition of the sigmoid colon. We have recently had three such cases under our care, all of which were admitted into the hospital on the supposition that the disease was carcinoma of the rectum. In each of the cases well-marked invagination of the sigmoid into the upper part of the rectum had occurred, producing obstruction to the passage of fæces and a firm indurated mass in the rectum, which bled readily when touched. The invagination in these cases was explained by the fact that the sigmoid colon was converted into a rigid, inextensible tube, which had become invaginated into the upper part of the rectum, and then closely bound down to the structures with which it was in contact, causing considerable resistance to the onward passage of fæces, and necessitating con-



stant straining down. In each case, left iliac colostomy, which was undertaken for the relief of impending intestinal obstruction, had to be abandoned in favour of cæcostomy, as it was found impossible to draw the sigmoid up to the surface. In one of the cases the middle portion of the sigmoid was firmly adherent to the posterior surface of the bladder, and had given rise to a vesico-colic fistula. In all these cases, the general peritoneal surface, the mesentery of the small intestines, and the intestines themselves, were studded with minute tubercles, thus proving the tuberculous nature of the disease. This form of tuberculous ulceration of the rectum, therefore, is but a part of a general tuberculosis of the intestinal tract, and its inclusion among purely rectal diseases is justified by the fact that in these cases the symptoms which primarily draw attention to the condition are those of intestinal obstruction accompanied by the discharge of pus and mucus, and occasionally blood, from the rectum.

### *Symptoms.*

A simple tuberculous ulcer of the rectum is productive of very few symptoms. In fact, beyond an increased frequency in the action of the bowels, and an admixture of a small quantity of mucus and sero-pus with the fæces, with occasionally a little blood, no other complaint is made. The persistence, however, of these symptoms when unaccompanied by pain or other discomfort in the rectum, and especially if signs of pulmonary tuberculosis are present, should lead us to suspect the presence of this form of ulcer. When the ulceration is the result of extension from the sigmoid, the symptoms produced very closely resemble those of the obstructive stage of carcinoma of the rectum, and may easily be mistaken for them. The bleeding, however, is seldom so severe and though a certain degree of emaciation is present, there is no sign of the advanced malignant cachexia.



*Physical Examination.*

In tuberculous subjects there is very often a marked absence of ischio-rectal fat, giving a hollow excavated appearance to the peri-anal region, and an abnormal prominence to the sacro-coccygeal articulation. As a rule, too, there is an abnormal quantity of hair round the anus. On introducing the finger into the rectum the presence of the ulcer is not readily detected, because there is no induration. The speculum affords the best means of locating and determining the nature of this lesion. In this way its characteristics can be made out and a small piece of the margin of the ulcer or a scraping from its floor can be removed for microscopical examination. If this examination reveal typical giant cells and the presence of Koch's bacillus, the tuberculous nature of the ulcer is definitely settled. It must be remembered however, that the failure to find either giant cells or Koch's bacillus does not prove the non-tuberculous nature of the lesion. The presence or absence of other signs of tuberculosis in other parts of the body, especially the lungs and larynx should also be determined before making a diagnosis.

When the sigmoid colon is affected and invagination into the rectum has been produced, a firm indurated mass will be felt in the upper part of the rectum somewhat resembling a carcinomatous tumour. It may be difficult to differentiate between the two diseases, as there is no distinctive physical sign that can be alone relied upon, beyond the fact that the tumour in tuberculous invagination is more uniform in contour, and involves the whole circumference of the bowel.

*Treatment.*

The simple tuberculous ulcer is best treated by physiological rest and close attention to general hygiene. The patient should be ordered a light, nutritious diet, and should live in the open air as much as possible. The internal administra-



tion of cod-liver oil is especially useful in these cases, because, in addition to its nutritive properties, it softens the fæces to be passed. The injection of olive oil into the rectum at bed-time also promotes the easy passage of the motions, and prevents injury to, or friction over the surface of the ulcer. The introduction of a small vulcanite tube during the daytime prevents distension of the rectum by flatus, and thus promotes rest to the ulcer.

When the sigmoid colon is involved and invagination of the rectum has taken place, the symptoms of impending intestinal obstruction call for relief. This is best afforded by the operation of cæcostomy. In all our cases left iliac colostomy was first attempted, but could not be carried out on account of the sigmoid colon having been so firmly bound down to the iliac fossa.

#### DIFFUSE ULCERATION.

This form of ulceration is characterised by its tendency to progressively involve the whole of the mucous and sub-mucous coats of the rectum. We believe it to be of microbic origin, and so far as we have been able to ascertain may be due to the *Bacillus coli communis*, or some closely analagous species of bacillus. There is probably but one variety of this form of ulceration, and we have termed it *infective*.

#### *Infective Ulceration.*

A well-marked form of widely-spreading superficial ulceration of the rectal mucous membrane and sub-mucous tissue, often involving the skin of the anus and its subcutaneous tissue, was frequently observed by us at St. Mark's Hospital, prior to the ward-buildings being altered and enlarged, in 1895. Cases of this form of ulceration were met with both in patients who had been operated upon there for rectal disease, and also in those who had undergone similar



operations in some of the general hospitals in London, the provinces, and abroad.

The disease was observed to follow operations upon internal piles and fissure more frequently than upon those for fistula, but it was liable to supervene after any operation in the ano-rectal region. We repeatedly observed that, prior to the operation there was no sign whatever of ulceration as a complication of the original disease, and, after the operation, the wound healed healthily for many days or weeks, the patients up to the time of their discharge as in-patients showing a perfectly healthy wound. In a week or two after their discharge from the wards the wounds, instead of being soundly healed, as they should have been if they had pursued a normal course, had degenerated into ulcers, showing the usual characteristics. On the other hand, some of the patients whose stay in the hospital was prolonged by reason of the extensive nature of their wounds manifested signs of this ulceration while still in-patients. The latter cases showed clearly that either some insanitary condition of the building or direct inoculation from patient to patient produced this after complication, whereas the former class of cases tended to prove that the building and its wards were not the cause. We have never had a case of this form of ulceration in our private practice, presumably because such patients were isolated when under treatment, and were not therefore exposed to direct inoculation. Since the alterations at St. Mark's, and the use of a solution of 1 in 500 of perchloride of mercury\* during the operation and throughout the after treatment, we have not seen a case of this form of ulceration supervening upon an operation performed there. We were particularly careful to rigidly exclude all suspicious cases of ulceration from entering the wards, and

---

\* It was the desire to prevent the possibility of the recurrence of this ulceration which prompted us to use such an unusually strong solution of perchloride of mercury.



did not make a digital examination of such cases at the hospital, so that there should be no risk of inoculating those who were free from the disease. At one time it was thought that the cause of the ulceration was due to there being too many cases in wards with an insufficiency of cubic space, only about 700 cubic feet being allowed to each bed. This surmise was, to a considerable extent, supported by the fact that, after the wards had been thoroughly cleansed, almost every case operated upon during the first month or two did well, but after that period cases of ulceration began to reappear and steadily increased in frequency until it became necessary to again close the wards. Ultimately this cleansing was carried out bi-annually. The old building was erected to accommodate fifty patients, but it was found that the cases did better when only twenty-six patients were under treatment at the same time. Still the reduction in the number of patients did not prevent the ultimate recurrence of the ulceration. On careful investigation, however, it seemed clear that the ulceration was probably conveyed from patient to patient by re-admitting a case of ulceration for further treatment. In carrying out the alterations and additions to the hospital, it was arranged that in the new wards 1,500 cubic feet should be allotted to each bed, while in the old wards, after the alterations had been completed, 1,760 cubic feet were allowed per bed. Moreover, in the old wards the deal flooring was replaced by polished teak, and the space under the flooring thoroughly cleaned out.

The first case of this form of ulceration recorded at St. Mark's occurred in 1859, and the in-patient records subsequent to this date show that many cases of ulceration supervening upon operations were admitted into the wards for further treatment.

Between 1870 and 1894 the question of removing the hospital to some other locality was seriously discussed from



time to time by the Committee. On more than one occasion sites in the suburbs were inspected, because it was thought that the site in the City Road might have had an important influence in the persistent recurrence of the ulceration. In 1894, prior to the alterations at the Hospital, Dr. E. Klein\* kindly made a most thorough bacteriological investigation of the discharge from the ulceration and of portions of the ulcerated surfaces, and also of the pus from a suppurating bubo which was opened for his examination. The buboes in these cases of ulceration always healed soundly though very slowly, and without the application of escharotics.

The late Professor Kanthack, as well as Professor Sims-Woodhead,† also investigated the disease, but neither of these observers was able to throw any additional light upon the cause of the ulceration beyond that contained in Dr. Klein's report.

We have notes of several cases of ulceration similar in every respect to that met with at St. Mark's, which have followed rectal operations performed in general hospitals in London, the provinces, and abroad, showing conclusively that the disease was not due to the locality or to the building, but to some other cause. We have been informed that ulceration following rectal operations is common in India, and it is possible that the disease may have been introduced into this country from thence or from some other tropical climate.

### *Description of the Ulceration.*

The best way, we think, of describing this form of ulceration is to describe in detail the changes that take place in a wound, which, prior to infection, was following the course of a healthily granulating surface. The changes affect both the

---

\* The full Report will be found on page 73.

† The full Report will be found on page 79.



general appearance of the wound and the character of the discharge.

(a) *Appearance of the Wound.*—The surface becomes reddened, its margins undermined and slightly irregular, the surrounding skin slightly inflamed, and extending, in chronic cases, for an inch or more all round the margin of the skin wound. The tendency to extend laterally to either skin or mucous membrane is well marked, but the ulceration does

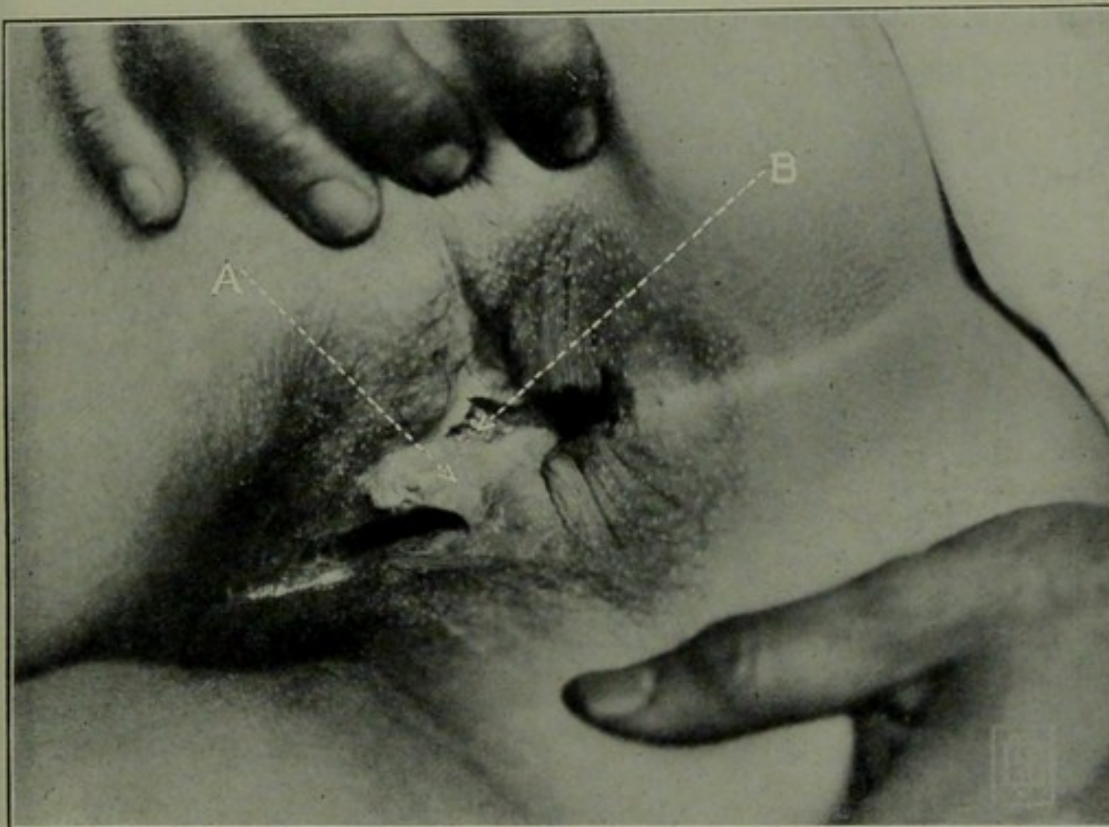


FIG. 9.—INFECTIVE ULCERATION REINFECTING A SCAR.

A. Healthy scar tissue. B. Portion of scar tissue destroyed by reinfection.

A case in which the primary ulceration in the anal canal and external to it had been destroyed with Vienna Paste. The external wound almost completely healed and then the ulceration reappeared, and, as the photograph shows, was actively destroying the scar tissue. The Vienna Paste was applied about three months before the ulceration reappeared in the external scar tissue.

In this case the disease extended too high up to safely permit of the destruction of the whole area of the ulceration with Vienna Paste.

(Photo taken February 20th, 1904.)

not, so far as we have observed, extend deeper than the subcutaneous or sub-mucous tissue. The signs of healthy healing are lost, the granulations losing their bright red appearance and becoming glazed.



(b) *Discharge*.—The exudation of the wound is at first sero-purulent and then assumes a brownish colour, looking very much like beef-tea, with a slight admixture of blood after the ulceration has existed for some days. The discharge from the ulcerated mucous membrane will re-infect the scar of the healed skin ulceration, thereby showing its powerfully infective properties (see fig. 9).

The most marked character of the ulceration is its superficiality. When this ulcerative change has taken place (both internally and externally to the anal orifice) in an ano-rectal or a rectal wound, the disease tends to progressively involve the whole of the granulating surface as well as the cicatrized portion. Ultimately the ulcerative process may involve the whole of the mucous and sub-mucous coats of the rectum, as well as those of the sigmoid and the lower portion of the descending colon. We have never seen a case in which the ulceration extended as far as the cæcum. We have had the opportunity of making a post-mortem examination on only two of these cases, and have preserved the rectums as specimens. These specimens show superficial ulceration extending from the anal margin up to and including the lower part of the sigmoid, but throughout involving the mucous coat and the sub-mucous tissue only. The ulceration is most persistent. We have had one patient under observation for more than twenty years who is still suffering from this ulceration, besides several cases for shorter periods. Fortunately, with few exceptions, all that we have been able to follow up have been cured of the ulceration eventually, but in most cases after a considerable lapse of time from the commencement of the disease. One case—which came under our notice when in an advanced condition, the ulceration having followed an operation for piles performed at Hong Kong four years previously—



died a few weeks after his arrival in England, nine days after coming under our care, and before any active treatment was adopted by us. He was greatly emaciated, and at the post-mortem there was a marked absence of fat throughout the greater part of the body, even in the great omentum. In several of the cases, a permanent stricture, usually commencing about an inch above the anal orifice, has resulted. Oedematous folds of redundant skin of the anal orifice are often present (see fig. 10).

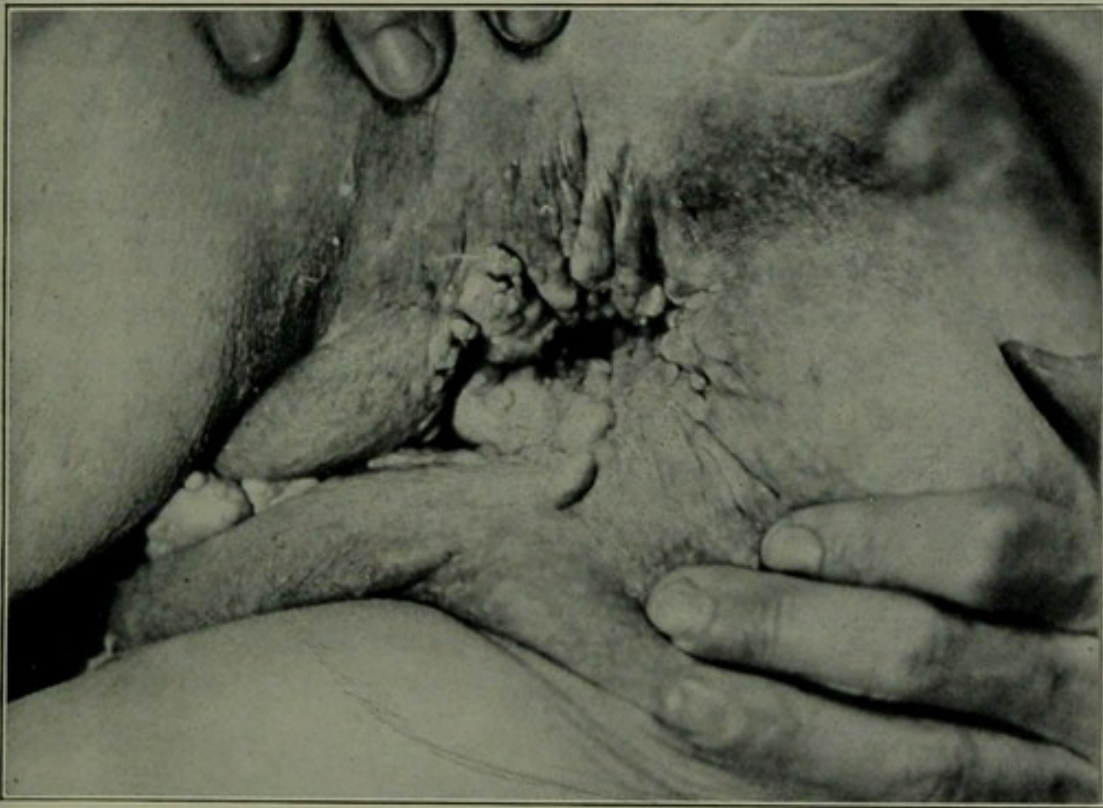


FIG. 10. — INFECTIVE ULCERATION OF THE ANUS AND RECTUM.

Showing oedematous folds of skin in a case of infective ulceration following an operation for fissure, in 1896, at one of the general hospitals of London. Some of the folds on the right side were removed five years ago at another hospital.

(Photo taken Feb. 5th, 1904.)

As one of the results of stricture following the ulceration, an extensive fistula may form, for a good example of which see fig. 45, Part I., page 123. In one of our cases—a female—a communication formed between either the rectum or the sigmoid colon and the bladder, so that flatus and fæces were passed *per urethram*. This



fistula was preceded by an abscess, which discharged freely through the rectum and later on through the bladder. The ulceration had extended upwards into the sigmoid and descending colon in this case, such extension having been verified by a left iliac colostomy which was performed for the relief of the symptoms due to the passage of flatus and fæces *per urethram*. About a year after the colostomy had been established, it became evident that the ulceration had extended into the descending colon, which five years later became so contracted as a result of the extension of the ulceration that it ultimately became necessary to perform cæcostomy. The cæcum was found to be healthy, and up to the present time, six years after the cæcostomy, there is no sign of the ulceration having reached the cæcum. This case clearly shows that this form of ulceration may extend upwards beyond the rectum and pass beyond the sigmoid portion of the colon. It is therefore advisable that in advanced cases of the disease the operation of cæcostomy should be performed in preference to left iliac colostomy.

### *Etiology.*

The cause of the ulceration is undoubtedly microbic infection. Both Dr. Klein and Professor Sims-Woodhead have made a most thorough investigation of the discharge from the ulcerated surfaces and also of portions of the diseased tissues with a view to the determination of the cause of this disease, as their Reports (see pages 73, 79) clearly show. These investigations have not led to the discovery of any specific bacillus other than the *Bacillus coli communis*, so that it is possible this organism may, under certain altered conditions of soil, be capable of producing the disease in question. The exact nature of the exciting cause is still in doubt, but that the predisposing cause is an *unhealed wound* the histories of our cases clearly indicate. These records, with very few exceptions, show that the ulcera-



tion only supervened in the operation wounds of patients who had been allowed either to leave the hospital or to get about before complete cicatrization had occurred, and we have never personally met with an exception to this rule. We would strongly urge, therefore, that patients who have undergone rectal operations should not be discharged from the wards until their wounds have been completely healed. It is true that partially healed wounds, in the majority of rectal cases, proceed to complete cicatrization after the patients have been discharged to the out-patient department, but we think that the risk of infective ulceration supervening is sufficient to justify keeping such patients in bed until the wounds are soundly healed. A week or two longer in hospital is, to our minds, much preferable to the risk of contracting a disease which may take years to cure, and invariably gives rise to sequelæ, that decidedly tend to make the patient's life miserable, at least for a time, and in some cases to shorten it.

### PROFESSOR KLEIN'S REPORT.

*The materials examined were of the following character:—*

Case I.—*Man. February 12, 1894.*

- (a) *Piece of rectal membrane in the process of healing.*
- (b) *Purulent contents and piece of swollen inguinal gland.*

Case II.—*Woman. February 14, 1894.*

- (a) *Purulent matter from rectal membrane.*
- (b) *Pieces of rectal membrane in a state of ulceration.*

Case III.—*Pieces of ulcerated rectal membrane preserved in glycerine.*



Case I.—(a) *The rectal membrane was advanced in the process of healing, and therefore only microscopic sections of the hardened material were examined. The examination showed the usual characters of a healing mucous membrane—viz., slight infiltration of the corium with leucocytes, the epithelium of the surface was already present, but was still considerably thinner than that on the surrounding healthy parts. No microbes could be seen anywhere in the tissue.*

(b) *The viscid grey purulent matter that oozed out of the gland on incision, as also bits of the tissue of the gland were examined in the fresh condition, and in suitably stained specimens; nothing special was noticed; there were no foreign particles present, only the ordinary leucocytes of various sizes and also granules resulting from tissue débris.*

*Cultivations were made both with the purulent matter, as also with particles of the gland tissue, by rubbing these materials in considerable amount over the slanting surface of solidified sterile blood serum, Agar, and gelatine all contained in tubes; of each set four tubes being used. The tubes were then incubated; the gelatine tubes at 20° C., the serum and agar tubes at 37° C. In no single tube was any growth produced, the materials remained free of colonies of microbes. From this it must be concluded that the gland did not contain any bacteria, discoverable either by the usual microscopic examination, or by the usual culture tests, and it can further be stated that the inflammatory changes in the gland were not due to the known pyogenic bacteria, such as are commonly*



found either in acute or chronic purulent inflammatory processes.

My attention was also directed to the possible presence of amœbæ, for it is known that in certain forms of secondary purulent inflammations consecutive on dysenteric processes of the large intestine—e.g., liver abscess following certain forms of dysentery, amœbæ, which caused the primary dysenteric disease, find their way into and cause the aforesaid secondary abscess of the liver.

Nothing resembling amœbæ could be discovered in the purulent matter, or in the tissue of the inguinal gland in our case.

The result then of the microscopic and cultural examination of this case I., was wholly negative as far as the discovery of the cause of the disease is concerned.

Case II.—(a) The purulent matter from the rectal mucous membrane was examined in coverglass specimens, stained and unstained, and by cultivation. The coverglass specimens as might be expected, contained a very large number of bacteria, which, judging by their shape and size, evidently belonged to different species; they were distributed between the pus cells singly and in larger and smaller clumps, and many of them were contained also within the substance of the pus cells. Cultivations on the surface of nutrient gelatine (in tubes and in plates), and on the surface of agar, proved these bacteria to belong to the following species:—

- (1) *Bacillus proteus vulgaris*; this microbe is constantly present in the contents of the normal rectum.



(2) *Bacillus coli*; also this microbe is a constant inhabitant of the rectum and large intestine in general; the colonies of *bacillus coli* that came up in the cultivations were very numerous and, as might be expected, preponderated over all others; but it was ascertained that these colonies did not belong to one single species, but represented rather different varieties of *bacillus coli*; all, however, possessed the fundamental characters of *bacillus coli*: as regards size, shape and motility, and as regards the power to form gas bubbles when growing in the depth of gelatine, as regards the power to form indol in broth cultures, and of coagulating milk.

(3) *Streptococcus*: This was present in a few colonies. Its difference from *streptococcus pyogenes* consisted in the extremely minute size of the individual cocci and in the rather deficient power to form long chains, the chains observed in this present *streptococcus* being very short. But in other respects of cultural characters it possessed the general aspect of *streptococci*.

(b) The microscopic examination of sections of the hardened ulcerated membrane showed the appearances of severe ulceration: the blood vessels of the mucosa filled with blood in a state of stasis, infiltration of the mucosa—particularly at the margin of the ulcer—with nuclei and fibrin, some of the nuclei, particularly those in the superficial layers, as also in the matrix of the ulcerated



part, in a state of disorganisation and necrosis; the epithelium around the ulcerated part raised and loosened, undermined and infiltrated by exudation cells, the cells of the epithelium swollen and their substance disintegrating. The sections were stained by the usual methods to demonstrate the presence of bacteria: some in alcoholic gentian violet, others in rubin and methyl blue, others in methyl blue and eosin, and still others in alkaline methyl blue with subsequent treatment by acetic acid solution; except on the free surface on which bacilli could be found, in the tissue of the ulcerated part and in the surrounding parts only here and there a rod-shaped particle or a coccus-like granule could be seen which might or might not be of the nature of bacilli or cocci respectively.

(c) Cultivations were also made from the ulcerated membrane while fresh: after cleaning the surface by washing it well with sterile salt solution a particle of the ulcerated membrane was rubbed over the slanting surface of solidified serum, agar and gelatine.

Twelve tubes (four of each medium) were used, but only in two agar tubes and one gelatine tube were a few colonies obtained: two colonies of bacillus coli in one agar tube, one colony of bacillus coli and two colonies of streptococcus in the second agar tube, one colony of bacillus coli and one colony of streptococcus in the gelatine tube.

This result was unsatisfactory as it showed an extremely limited number of microbes in the tissue of the ulcerated membrane, and of these more than half were colonies of the common bacillus coli.



But notwithstanding this result I devoted my attention to a further study of the streptococcus and sub-cultures proved that it was of the same character as that obtained from the purulent matter of the rectal membrane above referred to.

As the bacillus coli, as a causative agent, must be left out of consideration, the streptococcus isolated was tested by experiment as to any pathogenic action it might possess. Accordingly of a pure culture relatively considerable quantities were injected into cutaneous and sub-cutaneous incisions:— (1) In the ear of four rabbits; (2) in the inguinal region of two further rabbits; and (3) in the inguinal region of four guinea pigs.

The result of these inoculations was absolutely nil: no swelling, no suppuration, no ulceration followed. This streptococcus then is barren of pathogenic action on these rodents.

But whether it has anything to do with the disease in the human being, I am unable to say, and I do not think, from its extremely limited presence in the ulcerated tissue, any definite relation between it and the cause of the disease could be easily maintained.

Case III.—The ulcerated membrane of this case having been preserved in glycerine was unsuited for cultural experiments, all that could be done with it was to harden it and use it for microscopic examination. The result of this was the same as described sub. (b) of Case II.

9th March, 1894.



## PROFESSOR WOODHEAD'S REPORT.

*During the last few months I have made no fewer than four sets of plate cultures from the material you have, from time to time, sent to me, and on each occasion I have obtained practically the same result. I have been able to isolate a few common organisms usually found in air and water, but the most abundant and important organism has always been one which, in most respects, grows and behaves like the *Bacillus coli communis*. In some cases the material sent contained this organism in almost pure culture.\**

*Grown on Gelatine Plates.—This organism has the peculiar leaf-like appearance usually associated with the *Bacillus coli communis*. In the depth of the gelatine the colonies have the granular balled appearance also characteristic.*

*In Stab Cultures into Gelatine.—There is a grey granular growth along the track of the needle, and at intervals small nodules, but no spikes. In twenty-four hours gas bubbles are developed, and in forty-eight hours there are large bubbles along the whole track of the needle splitting the gelatine freely. Very little surface growth at this period.*

---

\* "27th October, 1903.—A piece of tissue embracing a portion of the ulcerated patch was carefully hardened by various methods, and a number of sections were cut with the view to examine them for tubercle bacilli, and for any histological evidence of tubercle. Under both heads the evidence was absolutely negative, and, as far as I can see (I am now speaking after an interval of six years), there was not the slightest evidence that the ulcer under consideration was of tubercular origin. It may be, however, that had we been able to examine the whole of the ulcer some such evidence might have been found, though this appears to me to be scarcely probable."



On Agar Agar.—The organism has the same crenated leaf-like surface growth that was noted on gelatine, but to the naked eye the colonies are more translucent. Moist thin grey layer with crenated margins would perhaps best describe the growth.

On Milk, rendered slightly alkaline to which sufficient litmus solution to give a blue tinge has been added, there is evidently an abundant growth; the surface (and upper part) of the milk becomes acid, the litmus turning distinctly red. Very slight coagulation.

On Glucose Gelatine, neutralized and coloured with blue litmus, there is an abundant growth. Gas bubbles are developed in large numbers, and of considerable size, along the track of the needle and the upper half of the gelatine in the tube becomes distinctly acid, the lower half remaining blue—i.e., in the part of the gelatine into which the needle has not passed.

In Broth.—A distinct cloudiness makes its appearance in twenty-four hours. Later the supernatant fluid becomes clear, and a light yellowish grey deposit collects as a fairly thick layer in the bottom of the test tube.

Microscopically.—The organism has all the characters of the *bacillus coli communis*. Short rods with rounded ends, stained at the poles with light band between. Size and other appearance also characteristic. Two or three flagella.

Effects on Animals.—When a twenty-four hours



*culture in broth is injected into guinea-pigs we have the following results :—*

*Intraperitoneal.—2 C.C., dead in 15—18 hours.*

*$\frac{1}{2}$  C.C., dead in 15—18 hours.*

*Subcutaneous.—2 C.C., marked swelling at the end of 15—18 hours. On the fourth day there is a large hard swelling. On the 6th day this is evidently suppurating, and burst on the 8th. On the twenty-first day there is still suppuration, and the wound continued to discharge from time to time.*

*$\frac{1}{2}$  C.C., very slight swelling at the end of 15—18 hours. Swelling less, but more indurated on the fourth day. This did not burst until the ninth day. Slight discharge from small ulcer, which by the twenty-first day had become quite clean and was healing rapidly.*

*I think there is no doubt that the organism belongs to the B.C.C. group, and that it is only slightly modified from the ordinary B.C.C. usually found in the colon.*

*April 17th, 1897.*

From observation of our cases, we are convinced that this form of ulceration is not of a syphilitic nature, our reasons for this statement being :—

- (a) Anti-syphilitic treatment is absolutely ineffective.
- (b) It is seldom associated with syphilitic lesions, and when it is, the curing of these does not in any way modify the ulceration.
- (c) It is not followed by syphilitic lesions.



- (d) The ulceration has not the appearance of either secondary or tertiary syphilitic ulcers.
- (e) The fact that when buboes occur in the groin they readily suppurate, thus following the opposite course to syphilitic enlargement of the inguinal glands.
- (f) Auto-infection by direct contact takes place. In three cases which we have seen, a superficial abscess on the flexor aspect of the right wrist joint appeared, its occurrence being most probably due to direct inoculation of the wrist whilst cleansing the anus.

### *Physical Examination.*

The skin surrounding the external part of the ulcerated surface is reddened and œdematous. The margins of the cutaneous portion of the ulcer are slightly undermined, irregular in outline and soft to the touch, there being no induration. The surface is red, glazed, often very tender, and has a tendency to bleed when touched. There is no induration of the base. The edges of the ulcerated mucous membrane are undermined, and the ulcer usually involves the whole circumference of the lower inch or two of the bowel. The upper border is well defined, the line of demarcation between ulcerated and smooth mucous membrane being abrupt. In the majority of the cases for two or three inches above the upper border of the ulcer, the rectal mucous membrane is œdematous and thrown into longitudinal folds but its surface remains smooth.\* The passage of the finger into the bowel always causes pain and is generally followed by slight bleeding. Both pain and bleeding cease soon after the withdrawal of the finger. We have never met with a case where the pain continued for any length of time after digital examination, nor have we ever had trouble in arresting the bleeding. When the ulceration

---

\* See Fig. 11.



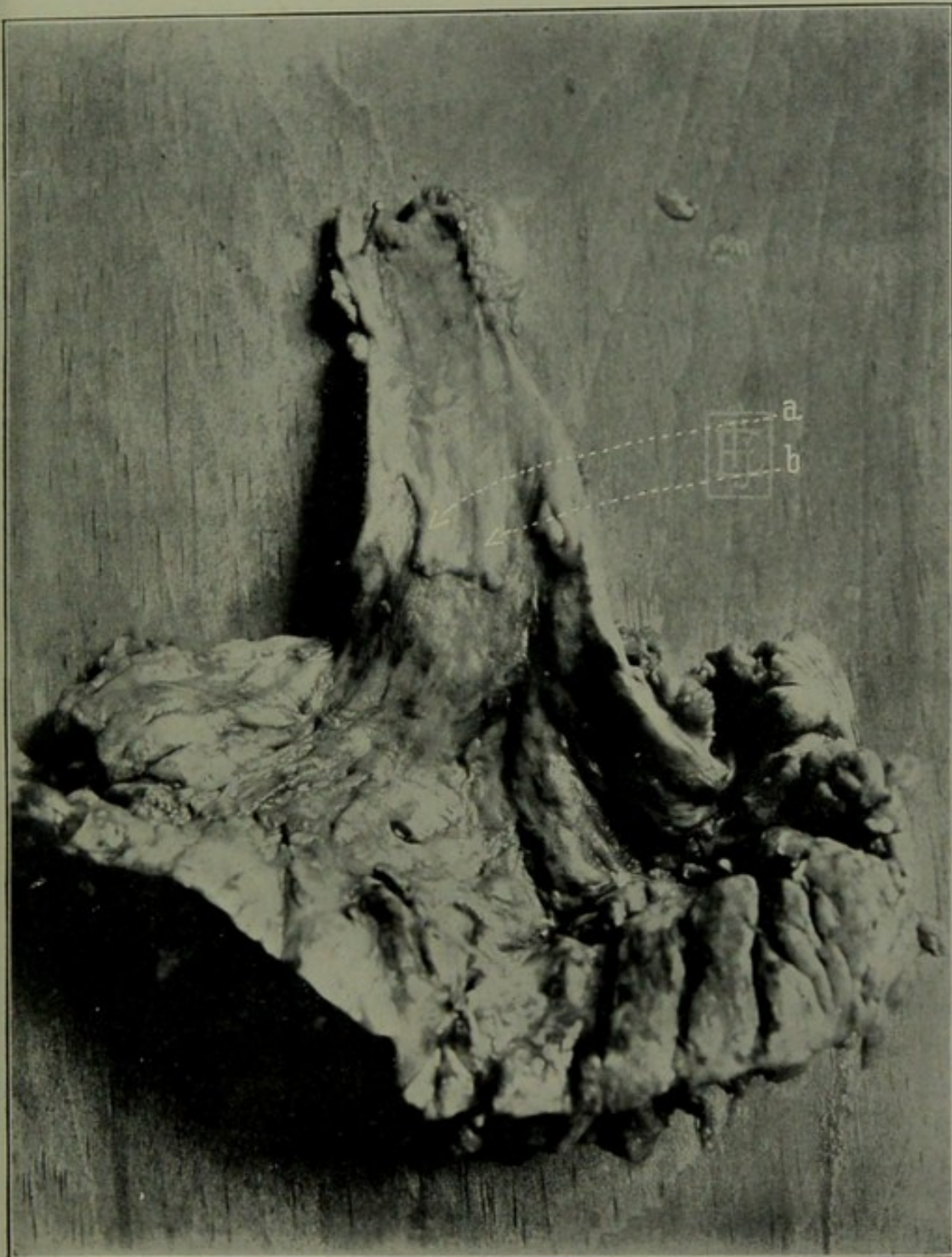


FIG. 11.—NAKED EYE APPEARANCE OF INFECTIVE ULCERATION OF THE RECTUM.

(Removed after death from the same case as shown in Fig. 10.)

The abrupt upper margin of the ulceration is clearly shown as are also two longitudinal folds of mucous membrane marked *a* and *b*.

(Photo taken March 22nd, 1904.)



has existed for several months and has completely involved the lower two or three inches, if not more, of the rectum, signs of stenosis are well marked. This contraction of the passage steadily increases. In cases in which colostomy has been performed the lumen of the ulcerated portion of the rectum, if left alone, will ultimately be found to be almost completely obliterated. There is always some discharge from the rectum, but when the quantity passed greatly varies the ulceration is probably complicated with either a pelvi-rectal or an ischio-rectal abscess or fistula. When this complication exists the patient will usually complain of a more or less constant dull aching pain in one or both buttocks, and often also of pain in the course of one or both great sciatic nerves.

### *Symptoms.*

These are (a) *pain and tenderness in the wound*, (b) *alteration in the character of the discharge*, (c) *bleeding*, and, (d) *increased frequency in the action of the bowels*.

(a) *Pain and Tenderness in the Wound*.—The presence of pain and tenderness in a wound, which was previously healing in a healthy manner and keeping free from those symptoms, should lead one to suspect the possibility of the supervention of infective ulceration. The pain is of a smarting, throbbing character, made worse by the passage of fæces over the wound. Unless the bowels act, the pain is absent during the night. The margins of the wound are extremely tender, especially when the wound is dressed. The passage of the finger into the rectum always causes much pain, but this subsides very quickly after the withdrawal of the finger.

(b) *Alteration in the Character of the Discharge*.—The discharge from the wound which, during healthy repair, consisted of healthy pus in steadily diminishing quantity, will, soon after the onset of the ulceration, become increased in quantity, much thinner in consistency, changed in colour,



often assuming a brownish tint, and be occasionally mixed with a small quantity of blood, especially after a recent digital examination, or the passage of fæces.

(c) *Bleeding*.—This takes place when the wound is touched, when the bowels are acting, and when the dressings have become adherent to the wound. The quantity of blood lost is, as a rule, very small. The hæmorrhage quickly ceases when its cause has been removed.

(d) *Increased Frequency in the Action of the Bowels*.—In the early stage of the ulceration, the bowels do not act more often than usual, but as the disease progresses the desire for the bowels to act oftener becomes more marked. When stricture supervenes, the bowels act many times during the twenty-four hours, but only on one or two of these occasions do they contain any quantity of fæces, the other evacuations consisting chiefly, and often entirely, of the characteristic discharge mixed with a small quantity of blood.

### *Treatment.*

The most striking feature of this disease is that constitutional treatment, anti-syphilitic or otherwise, has no effect either in healing the ulceration or in arresting its progress. Change of air, in our experience, beyond improving the patient's general condition, has no effect in curing the disease. In one of our cases the patient was sent by subscription for a voyage to the Cape, but beyond some improvement in his general condition the ulceration was not improved, and so far as we know still persists. The cases which we succeeded in curing were, up to three years ago, treated by the free application of either nitric acid or Vienna paste. The ulceration by these means is readily destroyed in the part external to and just within the anal orifice. We have not applied Vienna paste to the rectal wall when the ulceration has extended more than from a-half to one



inch above the anal margin. In the cases so treated care was always taken that the agent used had completely destroyed the margins as well as the floor of the ulcer. So far as the mucous surface is concerned it appears that, if even a small part be left undestroyed, a reinfection of the scar surface will ultimately take place. The thickening which extends upwards beneath the mucous coat, shows that the sub-mucous tissue may be infiltrated prior to the destruction of the mucous membrane itself. Perchloride of mercury (1 in 500) is of great use in dressing the wound after destruction of the ulcerated surface by the cauterizing agent. In recent years we have used injections of nitrate of silver up to the strength of forty grains to the ounce. In four out of the five cases in which we have used this remedy the ulceration has been cured but the stricture has remained. In all cases of this ulceration the earlier the existence of the disease is recognised the greater is the prospect of completely curing the patient without the supervention of a stricture. When the ulcerated area is small it may be readily, safely, and completely destroyed with either nitric acid or Vienna paste; but when two or more inches of the lower part of the rectum have been invaded by the ulceration the application of nitric acid may lead to much sloughing and subsequent profuse hæmorrhage. In such extensive cases Vienna paste is preferable to nitric acid for the destruction of the ulcerated area, but it is difficult, if not impossible, to apply it, as it must be applied to make the application successful, when the upper margin of the ulcer is more than two inches above the anal orifice. In all these cases we should now use injections of nitrate of silver, beginning with ten grains to the ounce once a day soon after an action of the bowels; from half an ounce to one ounce of the solution being injected at a time. The pain produced lasts from half an hour to one hour, and the lotion is usually spontaneously evacuated within an hour after it has been injected. When the pain from the repeated



injection ceases to recur the strength of the solution of nitrate of silver should be gradually increased. The increase may be continued until the strength of forty grains to the ounce has been attained, unless the weaker solutions have already proved quite effective. When the stronger solutions are being used it is well to make the injection on every second or third day, because with the forty grains to the ounce solution the pain lasts usually for three or four hours, and there is much more blood passed from the rectum than with the weaker solution. Whichever of these three remedies is used about two ounces of olive oil should be injected into the rectum every night at bed-time, so that the fæces may be well lubricated and broken up before they pass over the ulcerated area. Unless the ulceration be detected and promptly treated in its early stages, a stricture, limited to the mucous membrane and sub-mucous tissue, is certain to result from the progressive extension of the ulceration. The extension by direct continuity of tissue is much more rapid in the mucous coat than in the skin. The ulcerated parts of the skin heal more rapidly under treatment than those of the mucous membrane, probably on account of their greater accessibility to destructive treatment. When the ulceration has apparently soundly healed the patient should still be kept under frequent observation for at least six months, lest any portion of the ulcerated area should have escaped destruction. If only a small portion of the ulceration should have been left undestroyed, it will almost certainly re-infect the greater part of the scar tissue, and, if neglected, will extend further up the bowel. Should a stricture have resulted from the ulceration it should be treated as directed in the following chapter.

## CHAPTER IV.

### STRICTURE OF THE ANUS AND OF THE RECTUM.

By the term *stricture* we understand that a *permanent* abnormal narrowing of the calibre of the bowel has been produced. Strictures, such as are here meant, are produced either by a malignant growth or by cicatricial tissue. Some authors designate a variety of stricture which they attribute to muscular spasm, *spasmodic stricture*; but, as this is not permanent, we do not take it into consideration here. Strictures due to malignant disease have been dealt with in the chapter on malignant growths. We shall, therefore, confine our remarks in this chapter to cicatricial or fibrous stricture.

#### *Cicatricial or Fibrous Stricture.*

This form of stricture may be met with in any part of the rectum, but its lower margin is most usually found at a level of from one and a half to two inches above the anal margin. We have frequently observed during a digital examination that the lowermost margin of the stricture is felt when the finger has been introduced nearly as far as the second joint, *i.e.*, about one and three-quarter inches above



the anal orifice. The next situation in order of frequency is at the anal orifice itself, and the least common at the upper part of the rectum.

### *Varieties of Stricture.*

There are two distinct varieties of cicatricial stricture, namely, *the linear or annular stricture* and *the tubular stricture*.

#### THE LINEAR OR ANNULAR STRICTURE.

This does not exceed a depth of a quarter of an inch, and is usually found either at the anal orifice or at the level of the upper border of the internal sphincter muscle, and is generally due to traumatism.

When a stricture of this nature is met with *at the anal orifice*, it has nearly always been produced by a too free removal of the anal skin. Consequently in such cases expansion of the anus cannot occur to a natural extent during defæcation. The degree of limitation of expansion varies in different cases, in some instances being so marked that the little finger cannot be introduced through the anal orifice. The unyielding scar tissue does not extend deeper than the skin, and therefore the external sphincter is not directly concerned in the stenosis. In fact, the anal orifice is simply prevented from expanding by an unyielding covering.

When the stenosis is situated at the upper border of the internal sphincter, *i.e.*, about one inch and a quarter from the anal margin, it is sometimes due to a puckering of the mucous membrane produced by the cicatrization of the granulating surfaces left after the separation of the sloughs of ligatured internal piles. Such puckering only occurs if cohesion of the lateral instead of the upper and lower margins of a granulating area be allowed to take place and is, therefore, readily preventable by careful treatment during the healing process as mentioned in the treatment



after the operation by ligature of internal piles (see page 302, Part I).

When an annular stricture is located two and a half or more inches above the anal margin, it is sometimes due to the destruction of the mucous coat and sub-mucous tissue by an excessive application of nitric acid or other caustic to the apex of a procidentia of the rectum (see page 32).

### *Symptoms.*

In all cases of annular stricture there is an increased frequency in the action of the bowels, very small quantities of fæces being passed at a time. An obstruction to the passage of the fæces is complained of, and, after an action has taken place, there is a well-marked sensation that the rectum has been incompletely evacuated. As a result, the colon is always full of fæcal material, and the abdomen becomes greatly distended, especially after breakfast and afternoon tea, though the discomfort is increased after partaking of any kind of food. Digestion becomes impaired and the patient gradually loses weight. More or less complete loss of control over the rectal contents is manifest, a discharge consisting of liquid fæces and rectal mucus more or less continuously escaping from the anus. The above symptoms are met with in strictures situated at the anal orifice and at or about the level of the upper border of the internal sphincter. When an annular stricture is situated higher up in the rectum, invagination of the rectum is generally produced, and therefore the symptoms characteristic of the latter condition are super-added (see page 39), the only difference being that when the intussusception protrudes from the anal orifice during straining at defæcation, spontaneous reduction occurs after the straining effort has ceased.

When the stricture is situated at the anal orifice, impaction of fæces in the rectum is usually met with, the fæcal mass distending the rectum and acting like a ball-valve, so that



only liquid fæces are passed, and of this there is an almost constant escape. When this condition exists the patient sometimes describes his condition as that of continuous diarrhœa.

### *Physical Examination.*

When the seat of constriction is *at the anal orifice*, inspection will reveal a scarcity of anal skin. The natural rugæ are absent and there is no redundancy. When the patient is requested to strain down a characteristic tense appearance of the margin of the orifice is observed, showing that the limit of expansion is reached. The integument covering the external sphincter muscle is of a whiter colour than the normal on account of the cicatricial tissue present. When an attempt is made to introduce the finger into the anal canal, the margin of the orifice is found to be firm and unyielding. Straining efforts on the part of the patient force the anal region down, making it prominent, but do not produce relaxation of the anal orifice. The degree of constriction varies in different cases, in some being so marked that it is impossible to introduce the finger through the orifice without causing pain. If the finger can be introduced into the cavity of the rectum, an impaction of fæces is nearly always found to be present.

When the constriction is situated *at the level of the upper border of the internal sphincter*, the anal orifice is generally somewhat patulous. There is often œdema of the anal skin. There is no spasm of the external sphincter, that muscle being relaxed. When the finger is introduced into the anal canal, a diminution of its calibre is met with as soon as the insertion has extended to the first joint. The diameter of the stenosed area is generally large enough to admit the tip of the finger, so that the length of the stricture can be ascertained. This usually measures from one-eighth to one-quarter of an inch and feels like a stout piece of cord encircling the bowel.



The mucous membrane both above and below the stenosed area is smooth, and there is no discharge unless the finger has been forced through the stenosis thereby causing slight bleeding and much pain. The stricture itself is found to consist of a puckering of the mucous coat and sub-mucous tissue only. The constriction yields to dilatation so that it is often possible to introduce the examining finger to its full extent. When this can be done, fæces will be often found above the constriction, the rectum dilated, and the mucous coat smooth and healthy to the touch, showing that the diseased area is very limited.

When the stenosis is met with *at a level of from three to four or more inches above the anal orifice* there is generally some invagination of the rectum, the stricture in such cases being situated at the apex of the intussusceptum. Such an intussusceptum may or may not be protruded from the anal orifice. The physical signs of this condition have been described under that head (see page 41). The existence of a firm unyielding margin to the orifice of the intussusceptum is sufficient evidence to enable us to attribute its cause to the stricture.

### *Treatment.*

Annular strictures can often be permanently cured by the methods we shall now describe, the particular procedure differing according to the seat of the stricture.

(a) *When the Stenosis is Situated at the Anal Orifice.*—The cicatricial tissue in this situation is of a particularly unyielding character, attempts at forcible dilatation being liable to cause one or more lacerations of the circumference, thus producing much pain and also predisposing to the formation of an abscess. Consequently treatment by bougies is not advisable. The object to be kept in view is to increase the diameter of the contracted orifice, without causing any permanent damage to the



part. We have found that the best way of effecting this is to increase the circumference by dividing it in one or two places, and ensuring that healing occurs by granulation and the formation of a wide scar. In this way the circumference may be increased by half an inch even with one incision, thus overcoming the stenosis which is partly due to the œdema caused by the irritation of the constricted orifice. An incision, therefore, should be made in the right posterior quadrant of the contracted anal orifice, and should extend completely through the external sphincter muscle but not beyond it. The tension at the circumference causes the wound to gape widely, the diameter of the passage being thus considerably increased. If additional increase be required an incision should subsequently be made in the left anterior quadrant (*i.e.*, diametrically opposite to the first incision), but this must be confined to the skin and subcutaneous tissues only. It is quite unnecessary, and in women inadvisable, to divide the external sphincter in two places. The wounds should be made to granulate slowly from the bottom by careful packing, in order that the resulting scar shall be as wide as possible. In fact, the scar should be wedge-shaped, and, when healing has taken place, the base of the wedge should measure from three-eighths to half an inch in width. In order to obtain a scar of requisite width, the wound must be firmly packed, which sometimes causes much discomfort, but this can generally be relieved by soaking the material used for packing in a twenty per centum solution of cocaine.

When healing has been completed the scar if left to itself will contract from side to side, so that a scar measuring a quarter of an inch in width may eventually measure only one-eighth of an inch. If, however, the contraction of the scar be made to take place vertically instead of transversely, an increase instead of a diminution in the width of the scar can be obtained. Such vertical contraction can be ensured



by introducing a vulcanite tube three-quarters of an inch in diameter and two and a half inches long into the rectum every night at bed time, and leaving it *in situ* for half an hour or as much longer as the patient is able to bear. The use of the tube should be continued every night for about a month, then twice a week for a similar period, and, finally, once a week until all tendency in the scar to contract has subsided, a result which is usually attained in from three to four months after the operation. In order to ascertain whether the result of this method of treatment has been satisfactory, the left index finger should be introduced into the anal canal as far as the distal inter-phalangeal joint, and then the index finger of the right hand passed along it for a similar distance, the palmar surfaces of the two fingers being in contact. If this can be done without creating a feeling of tension or causing pain to the patient, it may be safely assumed that the diameter of the anal orifice is sufficient for the purpose of natural defæcation and that undue straining to expel even firm fæces is no longer necessary. If, at the expiration of six months, such an introduction of the two fingers be still possible, a permanent cure will have been effected. Should some degree of stenosis have recurred during the interval, the treatment described above should be repeated, though we have never had occasion to do so.

(b) *When the stenosis is situated at the level of the upper border of the internal sphincter.*

A stricture in this situation, unless of long standing, yields readily to gradual dilatation. In recent cases this method is generally all that is necessary, though in some cases supplementary division of the scar tissue in one or more places may be required. The duration of the stenosis is an important factor in the amenability to dilatation. Originating as a result of cohesion of the lateral margins of the granulating surfaces left after the separation of the sloughs of ligatured internal piles, it is obvious that the bond of union becomes tougher



and more resistant as time goes on. If stenosis supervene after the operation upon internal piles by ligature (a preventable sequela as we have already shown on page 291, Part I) symptoms referable to the condition may be manifested within two or three weeks after the operation, and therefore an early diagnosis of the condition can be made. In such recent cases the passage of the index finger through the stricture by slow and gentle insinuation is nearly always possible at the first examination. When the finger has been inserted into the rectum to its full extent it should be withdrawn, no further dilatation being made on that occasion. This procedure should be repeated every other day for a week, then once a week for a month, and, finally, once a fortnight for two months. At the end of this period the stenosis will have usually disappeared and, as a rule, will not then tend to recur. It is unnecessary to dilate such a stricture beyond the diameter of the index finger. Bougies or tubes are not often required in the treatment of these cases. When they are used the greatest gentleness must be employed in their introduction, lest the stricture be torn and an abscess result therefrom.

When the stricture comes under observation at an interval of three or four months from the date of the operation, it does not so readily yield to digital dilatation. Therefore, in such cases, either bougies or still better vulcanite tubes about two and a half or three inches in length and from half to five-eighths of an inch in diameter should be used, or the stricture should be divided on the right and left sides and in the middle line posteriorly, the angles of each incision being sutured together with either chromicized catgut or silkworm gut. For this purpose either a rectal bivalve or a vaginal duckbill speculum will greatly facilitate the application of the sutures. Each incision should not exceed half an inch in length. When silkworm gut is used the ends should be left long



enough to protrude from the anal orifice in order that they may not irritate the rectum.

(c) *When the stenosis is situated at a level of three or more inches above the anal orifice.*

The treatment to be adopted depends upon the presence or absence of invagination.

When invagination is present the stricture should be divided, if possible, on its right and left sides and in the middle line posteriorly. These three incisions should extend completely through the stricture and into healthy mucous membrane for about one-eighth of an inch both above and below the stricture. The angles of each incision should then be sutured together, thus increasing the circumference of the lumen of the rectum at the seat of stricture from one to one and a half inches. When the invagination in these cases frequently protrudes through the anal orifice it is desirable in order to prevent a continuance of the protrusion to perform left iliac colostomy before operating on the stricture itself. After the stricture has been successfully treated the colostomy may be safely closed.

When invagination is absent and the stricture is so high that it cannot be reached for incision its dilatation must be attained either with vulcanite tubes or with soft elastic bougies. We have had under our care since 1880 a patient, now aged sixty-one, who has had an annular stricture situated about five inches above the anal orifice for thirty years. When she first came under our observation the bowels were acting twelve or more times in the twenty-four hours, the fæces being unformed. For the last twenty years the bowels have acted only once or twice in twenty-four hours, and the motions have nearly always been formed. The treatment adopted has been the passing of a shot-bougie once in three or four months, and retaining it *in situ* for half an hour. As an aperient half an ounce of olive oil has been injected into the rectum at bed time.



## THE TUBULAR STRICTURE.

In this variety the length of bowel involved is usually from a half to one inch, but occasionally the constriction may extend to three, four, or more inches. It is met with more often in women than in men, and is practically incurable, though much can be done to relieve it. Tubular strictures under one or two inches in length are chiefly met with in women during the child-bearing period of life. In these cases the constriction usually begins about one and a half inches from the anal orifice, that is, near the level of the deflection of the peritoneum from the anterior wall of the rectum. The more extensive tubular strictures are met with as often in men as in women, and at any age, though we have never seen a case under twenty years. We think they are always caused by infective ulceration of the rectum.

*Etiology.*

Stricture is due to the contraction of fibrous tissue deposited in the rectal wall. This fibrous tissue is either the medium by which some definite loss of tissue has been repaired, or the organised residue of an inflammatory infiltration. Consequently the precursors of this form of stricture are (a) *local tissue destruction*, and (b) *chronic inflammatory processes*.

*(a) Local Tissue Destruction.*

This may be the result of *traumatism* or *ulcerative* processes. Of the former, especial mention must be made of too free removal of tissue during operative procedures. Thus, during the operation for internal piles a too free removal of the folds of peri-anal skin, or the too long continued application of the cautery when removing hæmorrhoids together with some peri-anal skin by that method, may result in definite narrowing of the anal orifice. In the same manner when a complete ring of anal mucous membrane has been removed,



stenosis may occur as a result of the healing process. This is liable to take place after Whitehead's operation for piles should the stitches, which unite the mucous membrane to the skin, cut out and allow the mucous coat to retract. The best example perhaps of stricture of traumatic origin is that which sometimes results from excision of the whole circumference of the lower part of the rectum when colostomy has not been previously performed. Here, a large surface has healed by granulation, with the result that a stenosis of a very unyielding character occurs. Sloughing of the rectum, either as a result of injury or of acute inflammatory processes produces the same result, unless colostomy has been performed while the sloughing is in progress or very soon after the wound has begun to heal.

All ulcers heal by granulation and are, therefore, liable to cicatricial contraction. A small ulcer situated in the rectal wall may not cause an appreciable narrowing of the lumen when cicatrized, but when the ulcer has extended completely round the circumference of the bowel, cicatrization is certain to end in stenosis. The length of the ulcerated area determines the length of the strictured zone, and consequently the longer strictures are generally the result of infective ulceration. The extensive destruction of the mucous and sub-mucous coats of the rectum resulting from this form of ulceration frequently gives rise to strictures extending to two or more inches in length.

(b) *Chronic Inflammatory Processes.*

These include the manifestations of syphilis and inflammations occurring in neighbouring viscera, especially the uterus. *Syphilis* is considered by many authorities to be the cause of extensive stricture of the rectum, but we venture to question the accuracy of this view. In the first place, we have found that anti-syphilitic remedies have no effect whatever in either curing or relieving the stricture



or the ulceration associated with it. We could not, perhaps, expect to find that the fibrous deposit became entirely absorbed under the influence of iodide of potassium, but the active ulceration which is often found to co-exist with stricture ought to be benefited by it. We have tried large doses of iodide of potassium repeatedly, both alone and combined with mercury, and have never found any improvement take place in the ulceration or the stricture. Again, though a certain number of patients with stricture are undoubtedly syphilitic, there are a considerable number in whom neither a history of syphilis nor any other evidence of the disease can be obtained, and in these patients it does not seem to us justifiable to assume the presence of the syphilitic taint. Moreover, stricture occurs much more frequently in women than in men, while in syphilis the converse obtains. We are, therefore, constrained to state our opinion that a great many of the strictures that are set down as syphilitic are not so, but are the result of *infective ulceration*. At the same time we do not go so far as to say that stricture of the rectum does not occur as a result of syphilis, though we have not yet met with a case in which the question was beyond dispute.

*Chronic inflammation of the uterus* is probably an important factor in the causation of stricture of the rectum. In this connection, we have repeatedly observed that cases of stricture occur at least five times as frequently in women as in men, and almost invariably during the child-bearing period, *i.e.*, during the third and fourth decades of life. Moreover, in these patients, a history of either a pregnancy or a miscarriage is usually obtainable. It is probably due to the latter fact that syphilis is thought to play such an important part in the production of stricture of the rectum. Syphilis, however, is not the only cause of abortion, and therefore it by no means follows that because a woman has had miscarriages she is necessarily the subject of



syphilis. Chronic endometritis is often the result of abortion, and consequently it is justifiable to assume that when a woman gives a history of miscarriages, she has also suffered from inflammation of the uterus.

It is a fact that the development of stricture of the rectum is often preceded by either a miscarriage or parturition, and therefore the question naturally arises, *What is the connection between the two events, and does stricture of the rectum result from inflammation of the uterus?* The following case, we think, throws some light upon this point. We were present at an operation of abdominal hysterectomy which was being performed for intractable metritis. The whole uterus was enlarged, and its interior was extensively ulcerated. When looking into the pelvis it was noticed that the surface of the rectum, just above the line of reflection of the peritoneum was thickened, and its coats for an inch or more in length felt indurated. On making a subsequent rectal examination, a distinct narrowing of the lumen of the bowel at a level of two and half inches from the anal margin could be felt. The mucous membrane of the rectum was healthy, and there was no ulceration in the strictured zone. Now, from anatomical considerations, it appeared to us probable that a round-cell infiltration of the tissues had occurred along the course of the lymphatic vessels as they passed round the rectum from the uterus to enter the pre-sacral lymphatics. If this deduction be correct, it is easy to understand how chronic inflammation of the uterus may be one of the causes of stricture of the rectum in women. Moreover, this hypothesis explains why stricture of the rectum supervenes without previous ulceration or other loss of tissue.

### *Symptoms.*

During the early stage of stricture the first symptom complained of is the increasing frequency in the desire for an action of the bowels, followed by the passing of only a small



quantity of fæces, and an after feeling of incomplete relief. After an interval of a few minutes the urgent desire again returns, such a cycle of events often recurring three or four times in the course of the first hour or two after taking warm fluids. As contraction progresses these symptoms become more frequent, and the patient notices that the fæces are passed in short and round or flattened tape-like pieces. When the stricture has been preceded by ulcerative processes, the discharge of pus or pus and blood with mucus is associated with the above symptoms.

The symptoms indicating the presence of a well-developed stricture are (a) *frequent desire for an action of the bowels*; (b) *alteration in the size and character of the fæces passed*; (c) *the passage of blood, mucus, and pus from the rectum*; (d) *abdominal distension*; (e) *loss of weight*; and (f) *œdema of the lower extremities*.

(a) *Frequent Desire for an Action of the Bowels.*

In cases of stricture the desire is most urgent, and is relieved by passing either discharge or fæces or both. The quantity of the evacuation is usually very small and the patient feels that the bowels have not been completely relieved. This is the most constant symptom of stricture of the rectum, and it is always present when the diameter of the lumen of the bowel has been reduced to less than half an inch. Its presence denotes that there is some degree of obstruction to the passage of fæces through the rectum, but throws no light upon the nature of the obstruction, that is to say, whether it is due to fibrous stricture, malignant stenosis or a neoplasm blocking the lumen of the bowel. The association of other symptoms, together with digital exploration, alone can decide this point.

From cases of fibrous stricture which have been under our care, we have obtained the history that an action of the bowels takes place from ten to fifteen times, or even



more frequently, during a period of twenty-four hours. The majority of these actions occur during the day-time, but, as a rule, two or three take place during the night. These nocturnal actions are so common in cases of fibrous stricture that the question of their occurrence should always be raised when the presence of the disease is suspected, and, when they are complained of, the rectum should invariably be examined. In regard to the day-time our records show that the first action occurs as soon as the patient rises in the morning. Another takes place immediately after breakfast. During an hour or so after that meal there may be three, four, or even more actions at short intervals. Fæces are voided, as a rule, at the first and second actions only, the dejecta in the remainder consisting chiefly of mucus, muco-pus or mucus, pus and blood. Usually after each meal an action of the bowels occurs, and if warm fluids have been partaken of, there may be several during the first hour. With the evening actions fæces may be again voided, but of the total number of actions it is unusual for the dejecta to be fæcal on more than three or four occasions during a period of twenty-four hours. The desire for an action of the bowels is always urgent, the contents of the rectum being usually expelled with considerable force.

*(b) Alteration in the Size and Character of the Fæces Passed.*

In nearly all cases of stricture the fæces when firm are voided in short tape-like pieces, measuring from one inch to an inch and a half in length, and about half an inch in diameter. These differ from the characters of the firm fæces passed in cases of spasmodic action of the sphincters and levatores ani met with in hypertrophy of the external sphincter associated with pruritus ani and fissure. In those cases the fæces are passed in thin round or flattened pieces, varying from two to four or more inches in length and from about half an inch in diameter to the full size natural to the patient.



(c) *The Passage of Blood, Mucus and Pus from the Rectum.*

This is an almost constant symptom, the material evacuated at all actions of the bowels, excepting the first one or two in the morning, and the one or two actions late in the afternoon consisting of a combination of mucus, pus and blood. The quantity evacuated is generally about one or two teaspoonfuls. If the quantity of pus suddenly increases, the probability is that a blind internal fistula, either of the sub-mucous variety or of the pelvi-rectal or ischio-rectal type has formed as one of the results of the stricture. As a rule, the quantity of blood lost is slight, a feature which serves to distinguish the fibrous stricture from the malignant type. When a pelvi-rectal abscess has formed, the purulent discharge will continue to be profuse, even after the stricture has been well dilated. In the majority of cases, however, the abscess is either of the sub-mucous or the ischio-rectal variety.

(d) *Abdominal Distension.*

The tendency of every fibrous stricture is towards obliteration of the lumen of its portion of the bowel. Consequently the obstruction to the passage of the contents of the colon becomes more and more marked the longer the stricture remains untreated. The large intestine becomes chronically distended from flatulent and faecal accumulation, and may reach an enormous size. As a result of this, the abdomen is nearly always considerably distended as soon as the lumen of the bowel has been sufficiently narrowed by the stricture to prevent the healthy evacuation of the colon. One of the most marked features of this distension is the accumulation of faeces in the caecum. The flatulent distension is more complained of than the faecal accumulation, and is very distressing to the patient, especially during the first two hours after food has been taken.



*(e) Loss of Weight.*

As soon as the effects of a stricture begin to make themselves felt, the patient commences to lose weight. This is probably due to general digestive disturbances, with consequent mal-assimilation. The frequent actions of the bowels, and especially the disturbance of rest at night have, however, a good deal of influence in producing this loss of weight. In the more advanced stages of the disease, the patient may be greatly emaciated, especially in the arms and legs.

*(f) Œdema of the lower extremities.*

The pressure of the fæces in the distended colon above the seat of stricture sometimes causes a gradually increasing œdema of either one or both lower extremities. The left lower extremity is more commonly affected than the right.

*Physical Examination.*

The anus is generally patulous and several more or less œdematous redundant folds of anal skin are usually present. The peri-anal region in some cases is natural in appearance, but in others there is extensive scarring, particularly when fistulæ resulting from the stricture have been operated upon, or when the stricture is the result of infective ulceration.

On introducing the finger into the rectum, the sphincter muscles will be found to be deficient in contractile power. The lower margin of the stenosis will usually be met with at a level of about from one and a half to two inches above the anal orifice. If the finger can be passed into the stenosed area it may be possible to determine the length of the stricture. Occasionally the diminution in the lumen is so great that it is impossible to insinuate the finger into the stricture without using undue force. Under such conditions the length of the stricture must be determined by other means.



In women, palpation of the recto-vaginal septum from the vagina will often greatly assist in the estimation of the length of a stricture. In men, olive-headed bougies or similar instruments may with advantage be used for this purpose.

If the finger can be introduced into the stenosed area, the bowel will be found to have been converted into a more or less rigid tube, the internal surface of which is firm and irregular. In all long standing cases, and especially in those in which the stricture has been the result of previous ulceration, the mucous membrane of the bowel immediately above and below the stenosed region is ulcerated. From these surfaces there is a continuous secretion of pus, and, therefore, when the finger is withdrawn, it will generally be found to be smeared with pus and blood.

When the stricture is short, and the finger can be introduced through it into the rectum above, the cavity of the latter will generally be found to be distended with fæces. If there be much thickening in the vicinity of the rectum, either pelvi-rectal suppuration has probably occurred or an ischio-rectal abscess has formed as a result of the stricture. The co-existence of a pelvi-rectal or an ischio-rectal abscess is substantiated if pus escape in considerable quantity either during or after an examination.

### *Treatment.*

The treatment of a tubular stricture of the rectum should be both local and general.

(a) *Local treatment.*—This treatment of a tubular stricture, is not radical, because a permanent cure cannot be effected. The fibrous deposit in the rectal wall cannot, by any known means, be entirely removed; and, therefore, unless active treatment be continuously persevered with, a recurrence of the stenosis results. In this respect tubular strictures of the rectum are comparable to strictures of the urethra. When, therefore, a patient presents himself for treatment, and is



found to be suffering from the *tubular* variety of stricture, he should be told that his disease cannot be cured, though considerable relief of his symptoms and, perhaps, immunity from serious sequelæ, can be obtained by persistent treatment throughout the remainder of his life.

In tubular strictures of the rectum the treatment by *dilatation* is the safest and best. Other methods, such as division of the stricture (*posterior linear proctotomy*), resection of the stenosed portion of the rectum, and excision of the rectum itself are practised by some, but have not found favour with the majority of surgeons. In some of the extensive strictures resulting from infective ulceration of the rectum, which cannot be much relieved by continuous dilatation, left iliac colostomy is the only measure, in our opinion, which will prolong and possibly save the patient's life.

#### *Treatment by Dilatation.*

Dilatation of a tubular stricture may be accomplished either forcibly or gradually. Therefore, the two methods are (1) *forcible or rapid dilatation* and (2) *gradual dilatation*.

(1) *Forcible or rapid dilatation*.—This method we cannot recommend; and, in our opinion, it should never be resorted to. When attempted, either by inserting bougies of gradually increasing diameter, one after the other, as when dilating the cervix uteri, or by employing Todd's dilator or one of the powerful expanding metal instruments designed for the purpose, there is considerable risk of splitting the strictured portion of the bowel, and so permitting peri-rectal extravasation. The result of such an accident depends upon the situation of the stricture. If the bowel be ruptured below the level of the peritoneal reflection, extensive peri-rectal suppuration, terminating in a pelvi-rectal abscess, may supervene; but, if the stricture be situated above the peritoneal reflection, fæcal extravasation into the general peritoneal



cavity may ensue and be followed by diffuse peritonitis and death.

(2) *Gradual dilatation*.—This is by far the safest and best method and should always be tried and persevered with before resorting to any other form of treatment. The dilatation is accomplished either by the use of bougies or tubes, and is in several respects comparable to the methods employed for the gradual dilatation of urethral strictures. The selection of the bougie or the tube for the purpose, depends upon the nature of the stricture. In short straight strictures situated near the anal orifice, the tube (see fig 12) possesses the distinct advantage of being retainable *in situ* for a considerable length of time without causing discomfort to the patient, because of the ready escape afforded for flatus, discharge, etc.

When the stricture is long and tortuous, the tube cannot be used. In such cases a bougie of the flexible type is indispensable. The shot-bougie (see fig 13), used by us, is, we think the best for this purpose, as it can be easily made to follow the tortuosities of the stricture.

Whether tubes or bougies are used for dilating a stricture, the question of primary importance is—*To what extent should the dilatation be carried?* Our experience of these cases has convinced us that when a stricture has been dilated sufficiently to admit easily an ordinary index finger (*i.e.*, about five-eighths of an inch in diameter), its lumen is quite large enough for the purposes of effective defæcation. Consequently we seldom introduce either a bougie or a tube of a larger diameter than three-quarters of an inch, and we have repeatedly observed that when the lumen of the stricture is maintained at this size, the actions of the bowels are steadily reduced in number (the nocturnal actions completely ceasing), the abdominal distension is reduced and the colicky pain resulting from the accumulation of fæces and flatus does not recur. Some surgeons recommend that the dilatation be persevered with until a






FIG. 12. --RECTAL TUBES.

These tubes are made of vulcanite. Those shown in the accompanying illustration are of the actual length and diameter, namely, three and four inches long. B is half, A nine-sixteenths and C eleven-sixteenths of an inch in diameter. Both the external and the internal diameters of each tube is the same throughout, thus facilitating cleansing. The wall of the tube is three-sixteenths of an inch thick. Its free extremity is bevelled off with the object of avoiding a sharp edge. The shield or footpiece is detachable by means of a screw and measures two inches long and one and a quarter inch wide, and is three-eighths of an inch thick. Its margin is bevelled. At both extremities there is a slit-like aperture for securing retaining tapes. The tubes have been made for us by Messrs. S. Maw, Son & Sons.






FIG. 13.—THE INDIA-RUBBER COATED SHOT-BOUGIE.

This Bougie was made for us by Messrs. Weiss & Son, and consists of a linen case coated with India-rubber and filled with No. 8 Shot. It is twelve inches in length. The first six inches from the base of the bougie is of the same diameter throughout, but the remaining six inches gradually taper to a slightly bulbous point as shown in Fig. A. The Bougie is made in sizes varying from three-eighths of an inch to one inch in diameter in gradations of one-sixteenth of an inch. The most useful sizes are those from three-eighths of an inch to three quarters of an inch, those of a larger size being seldom required. Figs B and C show the perfect pliability of these bougies after they have been immersed for a minute or two in warm water. Glycerine alone should be used for lubricating purposes as it tends to preserve the India-rubber, but vaseline or oil rapidly destroy it.



diameter of an inch and a half has been attained. This we do not consider either desirable for or beneficial to the patient because it is not possible to estimate the limit of possible expansion of a given stricture, and therefore a continuation of the dilatation may result in splitting the wall of the bowel and so set up peri-rectal suppuration. When the dilatation is carried beyond five-eighths or three-fourths of an inch in diameter, the stenosed area is generally irritated by such further dilatation, and the patient is, therefore, subjected to much pain and more or less constant discomfort without receiving any compensating benefit.

We think, then, that as soon as a diameter of sufficient size to permit a free evacuation of the contents of the colon has been attained, further increase in the dilatation should be dispensed with and our efforts should be directed simply to preventing re-contraction. In order that the method of gradual dilatation may be successfully carried out, it is essential that the surgeon should be provided with sets of bougies and tubes, the diameters of which increase in the same ratio as in urethral instruments, the smallest measuring three-sixteenths of an inch and the largest five-eighths or three-fourths of an inch at its thickest part. In a given case, the diameter of the stenosis should first be ascertained by introducing successively the smaller instruments until the size that can first be passed easily is reached. This should be left *in situ* for twenty minutes or half an hour and then withdrawn. On the third day it should be again introduced, and then the next larger size. If the latter pass easily the next larger size should then be introduced, left *in situ* for half an hour and then withdrawn. This procedure should be repeated every third day, commencing with the size that had been left in on the previous occasion, and then introducing one or two larger sizes. When the size of five-eighths or three-fourths of an inch has been reached, it should be reintroduced every other day for a week, then twice a



week for a month, then once a week for two months, then once a fortnight for three months, and finally once in three months for the remainder of the patient's life.

(b) *General treatment.*—The general treatment consists in the careful selection of articles of diet which will give the maximum of nutriment with the minimum of excreta. A patient suffering from a tubular stricture should be induced to recognise the fact that errors in diet may at any time cause either impaction of fæces above the stricture or diarrhœa, either of which may lead to perforation of the bowel above the strictured zone. Potatoes and rice, especially the latter, and red wines of all kinds should not be taken. We have found cod-liver oil, in doses of one to four drachms, taken two or three times a day, most useful in making the fæces soft. The injection of one or two ounces of olive oil into the rectum at bed-time, the oil being retained all night if possible is a most useful remedy in causing the bowel to act freely and easily once or twice a day without the use of any other aperient.

### *Results of Stricture.*

The following are three of the most important sequelæ which result from the neglect of a stricture of the rectum, namely, (a) *intestinal obstruction*; (b) *pelvi-rectal suppuration*; and (c) *amyloid degeneration of the kidneys*.

(a) *Intestinal obstruction.*—This is usually of the chronic type, and is due to the gradually increasing difficulty in evacuating the contents of the colon. The cæcum, as a rule, is greatly over distended with fæces and may, in protracted cases, slough on its anterior surface and give rise either to a localized abscess or to acute general peritonitis. Hyperdistension of the sigmoid colon in some cases leads to rupture of the bowel just above the stricture zone, causing localized pelvic suppuration.

(b) *Pelvi-rectal suppuration.*—This is always due to a perforation of the rectal wall occurring as a result of



co-existing ulceration. An extensive abscess in the pelvi-rectal space may then be formed which may extend and find an exit on the surface after having first invaded the ischio-rectal fossa, or it may rupture into adjacent hollow viscera, such as the vagina or bladder and so establish a communication between them and the rectum (see page 105, Part I). The discharge of pus in these cases is usually profuse, and, if long continued, gradually debilitates the patient and threatens his life.

(c) *Amyloid degeneration of the Kidneys*.—This is always the result of prolonged suppuration. Its onset is marked by the appearance of albumen in the urine, attacks of diarrhœa, steadily increasing anæmia, loss of weight, and, later on, anasarca. These changes usually begin about three or four years after the commencement of profuse suppuration.



## CHAPTER V.

### MALIGNANT GROWTHS OF THE ANUS AND RECTUM.

Both varieties of malignant growth, viz., the carcinoma and the sarcoma are met with in the ano-rectal region. The former are so frequently seen that, according to statistics compiled by Jessett,\* they form nearly eighty per centum of the carcinomatous growths of the whole of the alimentary canal. The latter are extremely seldom met with.

#### CARCINOMA OF THE ANUS.

This may occur either as a primary growth of the anal skin, in which case it is always a squamous carcinoma (epithelioma), or as a secondary invasion from a growth starting low down in the rectum, and then it presents the histological characters of an adeno-carcinoma. As the latter variety is but the advanced stage of a carcinomatous growth of the rectum it will be dealt with under that head.

The squamous carcinoma of the anus is seldom seen, and is nearly always met with in patients who have attained to the sixth or later decades of life. It is usually seen when the stage of ulceration has already been reached, and then it presents the characters of a typical squamous-cell carcino-

---

\* Cancer of the alimentary tract 1886, page 238.



matous ulcer, as met with in other parts of the body. The accompanying photograph (see Fig. 14) was taken from a typical specimen of the disease, the patient being fifty-seven years of age.\*

The histological characters of the growth are shown in Fig. 15. The symptoms are those of an ulcer which steadily

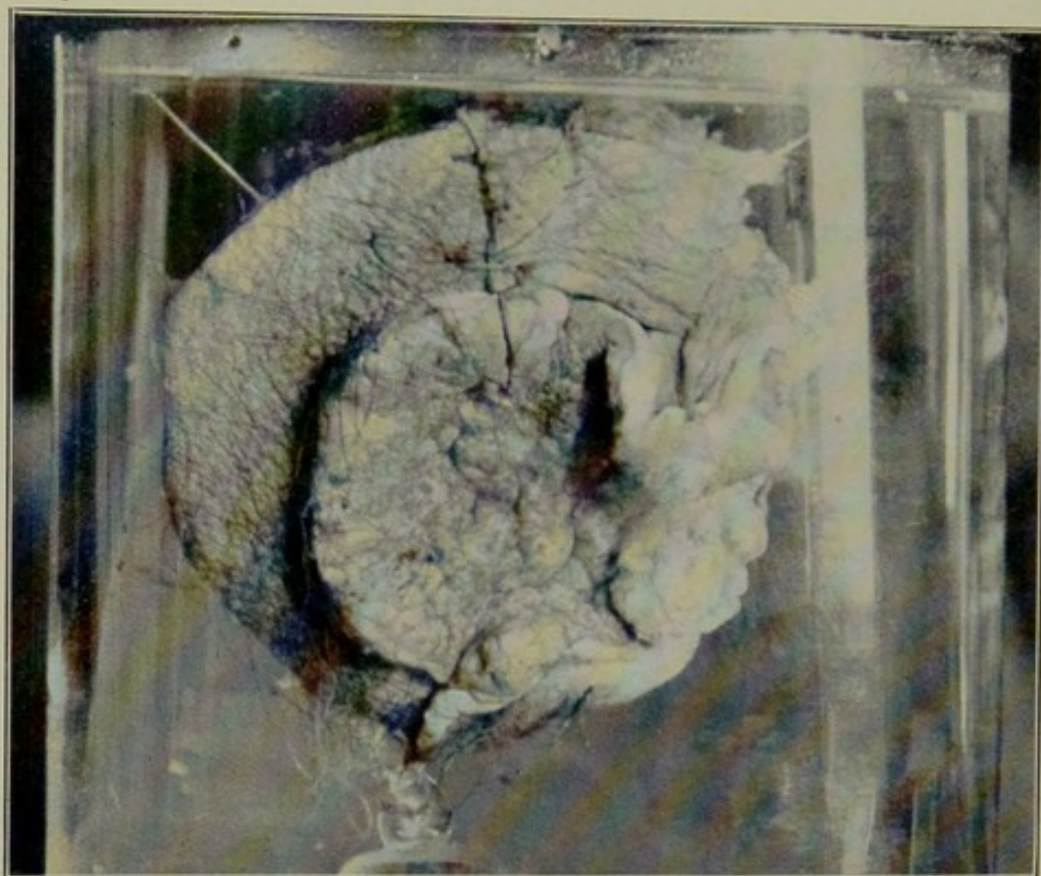

FIG. 14.—SQUAMOUS-CELL CARCINOMATOUS ULCER (EPITHELIOMA) INVOLVING THE ANAL MARGIN.

extends, without healing in any part, and bleeds more or less freely when touched. The inguinal glands on the corresponding side soon become enlarged.

#### *Treatment.*

The ulcer cannot be too soon or too freely removed. The anal margin on the affected side should be completely removed,

---

\* Specimen No. 173 in the museum of the Cancer Hospital.



and no attempt made to preserve the corresponding half of the external and internal sphincters. Complete removal of one-half of the anal margin, as we have advised, does not cause stenosis of the anal orifice. Should the inguinal lymphatic glands be implicated, or subsequently become so, they should be completely removed.

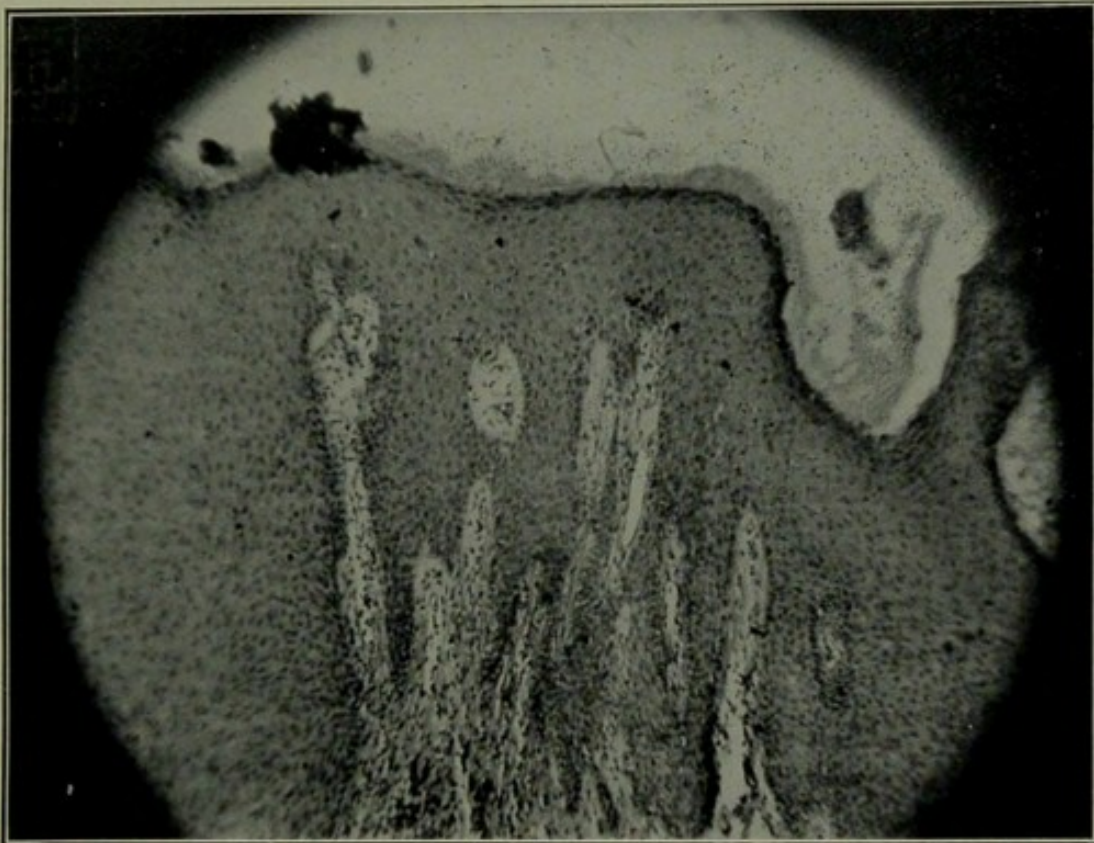


FIG. 15.—MICROSCOPICAL APPEARANCE OF A SECTION OF THE GROWTH SHOWN IN FIG. 14.

#### CARCINOMA OF THE RECTUM.

*Carcinoma* is the most grave of the diseases of the rectum. As in carcinoma of other organs, early recognition of the disease is of paramount importance. The laws which govern the onset of carcinoma are as yet unknown, and, for the present, early and complete removal of the growth holds out the only prospect of cure. Accordingly, it is most important that the earliest symptoms and signs indicating the presence of a carcinoma of the rectum should be known and recognised.



The disease is insidious in its growth and may exist for six months or more before occasioning symptoms which compel the patient to seek a rectal examination. Consequently it is the frequent experience of surgeons that the disease is already well advanced when the cases first come under their observation. Of the large number of instances of carcinoma of the rectum which we have seen, we have only one case among our records which came under our care prior to the stage of ulceration and partial disintegration having been reached. This is explained by the fact that, until the patient loses blood from the rectum or notices a constant discharge, he is not aware that anything of a serious nature is amiss with him. From the first appearance of objective symptoms the patient generally dates the commencement of his trouble. By obtaining full histories from our patients, we have endeavoured to find some symptom which manifested itself sometime during the year or two preceding the appearance of objective phenomena. In almost every case one symptom appears to have been almost always present, and that is *a prolonged and well-marked attack of constipation supervening in those whose bowels had hitherto acted regularly every day without the aid of aperients*. With the exception of this attack of constipation, the majority of the patients say they had enjoyed good health for many years. There is seldom any history of previous serious illness. When this departure from the natural and unaided movement of the bowels has existed for a period varying from three to six weeks, *diarrhœa*, slight at first but showing a steady tendency to become more marked as time goes on, supervenes. At first the *diarrhœa* occurs after meals, especially breakfast and afternoon tea. During this period the general health of the patient remains as good as it usually has been, and he does not appreciably lose weight, certainly not to a sufficient extent to make him anxious about the loss. In short, beyond the fact that he has observed a change in his wonted habit of natural evacuation, he attaches no importance to his condition, and



seeks relief only for the regulation of the bowels. Our records show that at the end of a period varying from six to nine months after the onset of the initial attack of constipation, slight losses of blood begin to occur, and then these patients seek medical advice because they have noticed the presence of blood in their stools. It is surprising how little pain or discomfort a carcinomatous growth of the rectum causes in the earlier stages of its development, unless the disease is situated quite low down and speedily involves the sensitive mucous membrane of the anal canal. In the latter cases early abrasion of surface occurs from friction during the passage of firm fæces and the movements of the bowels are accompanied by pain, which induces the patient to seek advice earlier than he otherwise would.

We cannot help feeling that if patients were subjected to a rectal examination during the period in which diarrhœa or frequent action of the bowels is the only symptom, the existence of the growth would be ascertained much earlier, and before extensive infiltration of the rectum and adjacent structures had occurred, and the prospect of being able to remove the disease, widely and completely, would, in the large majority of instances, be much greater than it is now. We would strongly urge, therefore, *that a digital examination of the rectum be made in every case in which diarrhœa supervenes upon an attack of constipation and persists in an otherwise healthy patient, more especially if he has reached the fifth or later decades of life.* It should be borne in mind also that during the later decades of life there is a natural tendency for a healthy patient to become more constipated than he formerly was, so that when diarrhœa, steadily increasing in frequency, makes itself manifest, the question of the possibility of the existence of carcinoma of the rectum as its cause should never be lost sight of. A complete rectal examination should do no harm and may, by revealing the true cause of the diarrhœa, do a great deal of good, as it will enable the surgeon



to render much more valuable assistance to the patient than he otherwise would have an opportunity of doing. When the rectum is extensively involved by carcinoma, the possibility of complete extirpation of the disease is very doubtful, and, in the majority of such instances, all that can be accomplished is the relief of urgent symptoms and some prolongation of life by means of colostomy.

### *Etiology.*

The exciting cause of carcinoma in the rectum, as in other localities, still remains undiscovered. The possible predisposing causes, however, may be considered under the following heads :

*Occupation.*—So far as we have been able to observe, no form of occupation either predisposes to or gives immunity from carcinoma of the rectum. In males, two-thirds of our cases have occurred in those who have followed a sedentary occupation, and, in females, not one had led a distinctly active life.

*Age.*—The average age of patients suffering from rectal carcinoma is about fifty-four years in both men and women—from twenty to twenty-five per centum of the cases are met in patients in the seventh or later decades of life. We have seen more cases in women than in men during the third decade of life.

*Parentage.*—The occurrence of this disease in two or three generations of the same family is sometimes most marked. But it is usually not easy to get reliable information as to the cause of death of distant members of a family.

*Sex.*—Males are more liable to carcinoma of the ano-rectal region than females, the proportion being about two to three males to one female.

*Locality.*—This question is still undecided, and, so far as we have seen, we have not been able to arrive at any decision on the subject. We have notes of two instances in which



both husband and wife became affected with the disease at an interval of about two years while residing in the same house. In one instance the house was in South London and, in the other, in North London.

*Pathological Varieties.*

The carcinomatous tumour of the rectum belongs to the

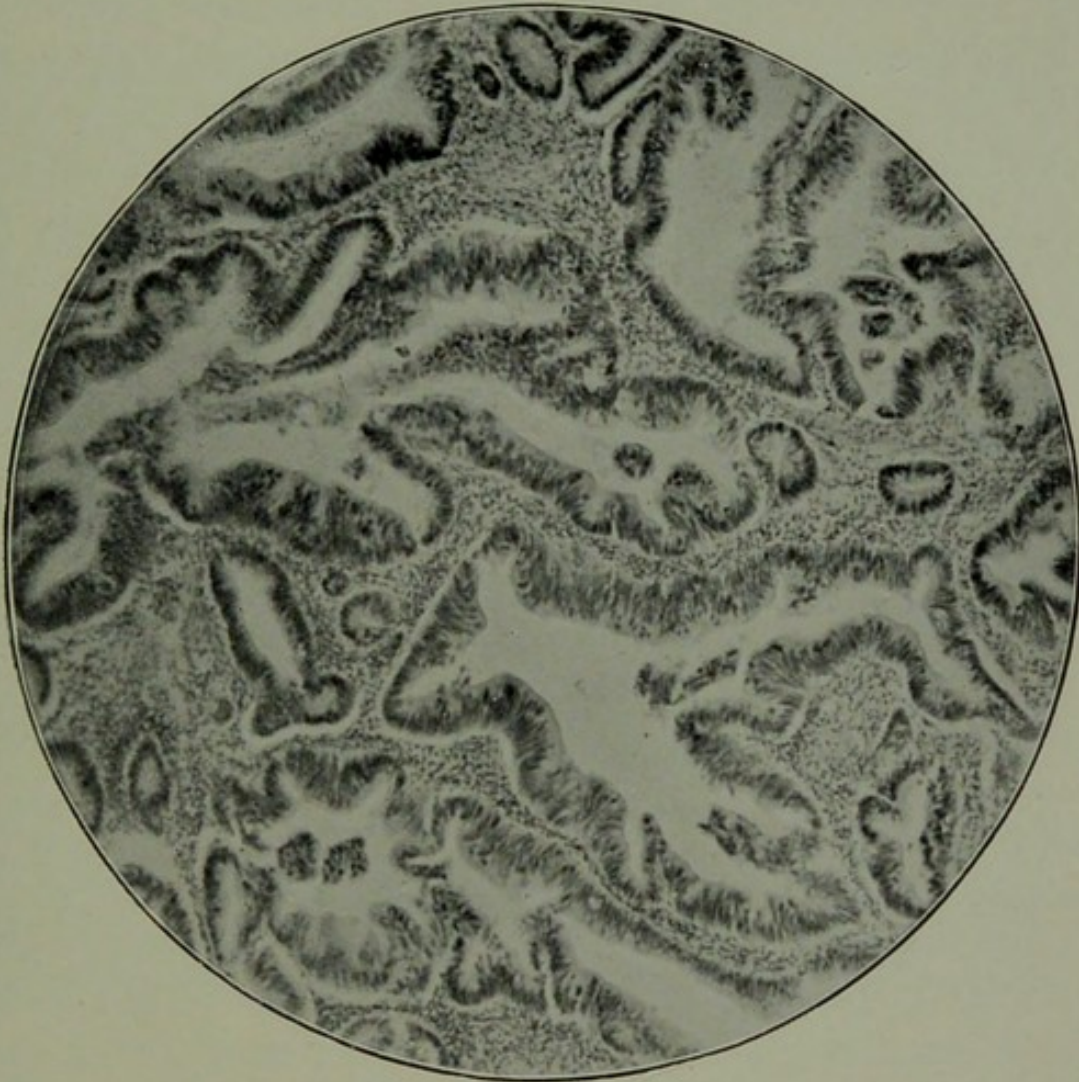

FIG. 16.—TYPICAL ADENO-CARCINOMA OF THE RECTUM.

class of *adeno-carcinomata* and arises from the glandular elements of the mucous membrane, known as Lieberkuhn's follicles. The epithelial elements are columnar in shape, whence the term *columnar-cell epithelioma* of former writers. The adeno-carcinoma differs from the simple adenoma in



microscopical appearance by the a typical growth of the glandular elements and by the fact that the muscular is mucosæ is penetrated (see fig. 16). In some instances, whereas the bulk of the tumour presents the characters of a simple adenoma, the appearances at the base of attachment conform to those of adeno-carcinoma. To this class of tumour the name of *malignant adenoma* has been given by pathologists. The quantity of the inter-cellular stroma present, determines the degree of malignancy of a given tumour. When the stroma is plentiful and dense in texture, the growth is hard and develops slowly, whereas, when the converse obtains, the growth is soft in consistence and increases rapidly in size. To these varieties respectively, the terms *scirrhus* and *medullary* were formerly applied. Moreover, either of the above may undergo degenerative change of a *colloid* nature, whence the term *colloid carcinoma*.

#### *Part of the bowel affected.*

The neoplasm may be located in any part of the rectum, but, in the majority of cases, it is situated in the terminal four inches of the bowel. According to our experience the three usual points at which carcinoma occurs in the rectum are at the junction between the rectum and the sigmoid colon, at the middle of the lower half, and lastly, just above the anal canal. When the growth is situated at the junction between the rectum and the sigmoid, it usually, when first recognised, involves the whole circumference of the bowel and tends to produce invagination. When the middle part of the lower half of the rectum is the seat of the disease, the growth, when first observed, usually involves from one-half to four-fifths of the circumference, and is nearly always found to have infiltrated the posterior wall; whereas when the growth is situated in the terminal two inches of the bowel, it frequently involves the anterior wall and implicates from one-third to one-half of the circumference, the earlier recognition of the



disease being due to the greater discomfort caused by a growth in this position.

*Clinical course of the Neoplasm.*

The adeno-carcinoma of the rectum in an early stage forms a sessile, rounded or oblong, tumour involving the mucous and sub-mucous coats of the bowel. In the majority of instances the surface of the growth is flattened. The

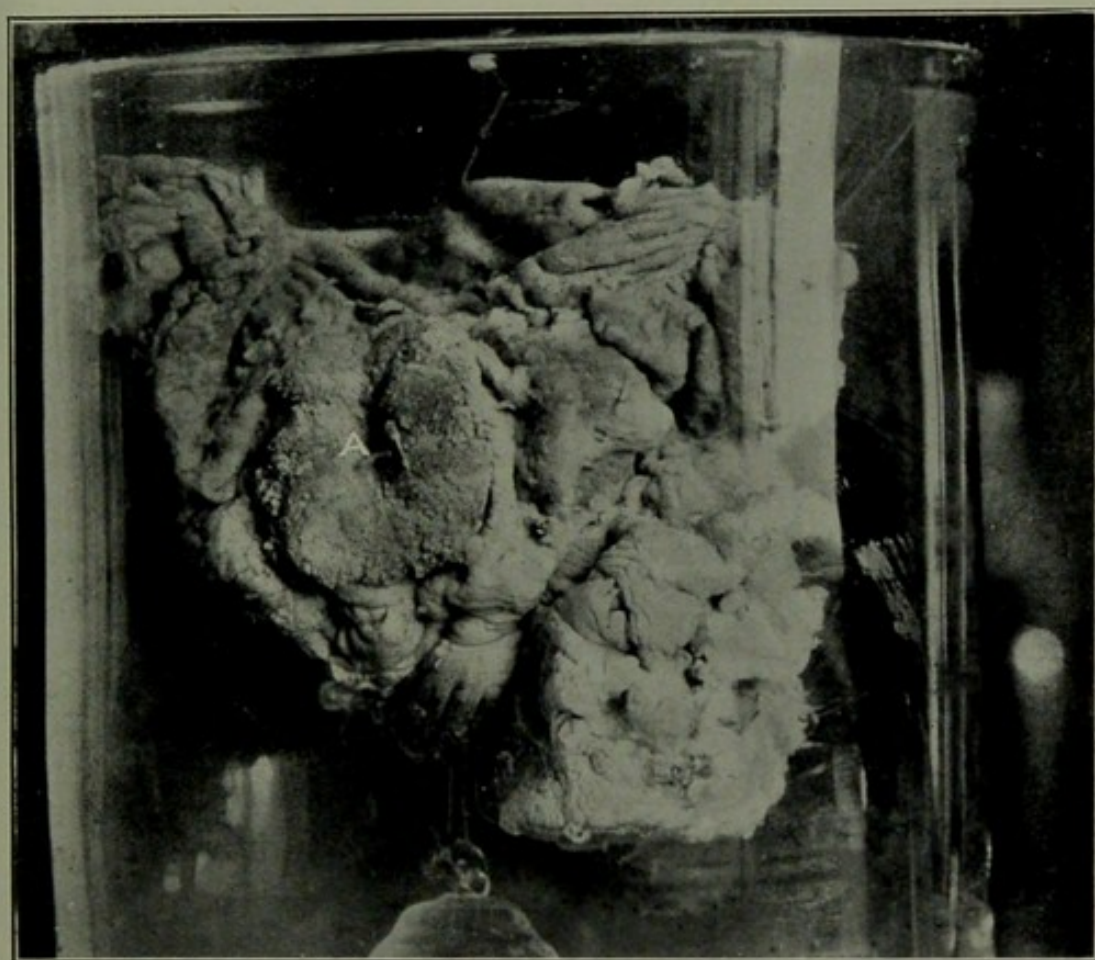


FIG. 17.—AN ADENO-CARCINOMATOUS TUMOUR OF THE RECTUM IN THE PRE-ULCERATIVE STAGE.

A the centre of the surface of the growth.

growth increases in size in all directions and though at first freely movable upon the subjacent muscular coat of the bowel, it soon infiltrates the latter and becomes adherent to it. It is difficult to determine how long after the first appearance of the growth as a definite tumour, infiltration of the muscular coat occurs, because, in any given case it is not possible to



ascertain its exact age; but, from our own observations, we should say that such infiltration occurs within six months. As the growth increases in size, its centre disintegrates on the surface with the formation of a definite ulcer exhibiting the well known malignant features; but we do not know how soon this change occurs after the commencement of the growth. We have only met with one case in which the growth was in the *pre-ulcerative* stage. The patient was a gentleman sent to us by Dr. Marcus Allen, of Brighton, who recognised the serious nature of the disease. The accompanying illustration (see fig. 17) depicts the specimen\* which we presented to the museum of the Cancer Hospital. In another case, also an early one, disintegration of the surface in the centre of the growth had apparently just commenced as the ulcer was quite limited and superficial (see fig. 18). In this instance the pre-sacral lymphatic glands were enlarged and were the seat of carcinomatous deposit proving that such extension of the disease may occur during the pre-ulcerative stage. As soon as disintegration occurs, the growth rapidly becomes transformed into an excavated ulcer with sinuous, everted and indurated edges, the base becoming firmly fixed to the subjacent muscular coat. Fig. 19 depicts such an ulcer which had extended nearly all round the bowel, a small portion of unaffected mucous membrane alone remaining. In this case the ulcer was firmly fixed to the muscular coat, the infiltration of which is clearly shown in the microscopical section from which the following illustration was made (see fig. 20). As soon as the ulcer has extended nearly all round the bowel, stenosis of the lumen results from the rigidity of the rectal wall and then the stage is reached, when symptoms of impending intestinal obstruction begin to make themselves manifest. By this time, as a rule, the infiltrating process has extended beyond the muscular coat of the bowel into the peri-rectal structures and has led to fixation of the rectum.

\* Specimen No. 108, Museum of the Cancer Hospital.



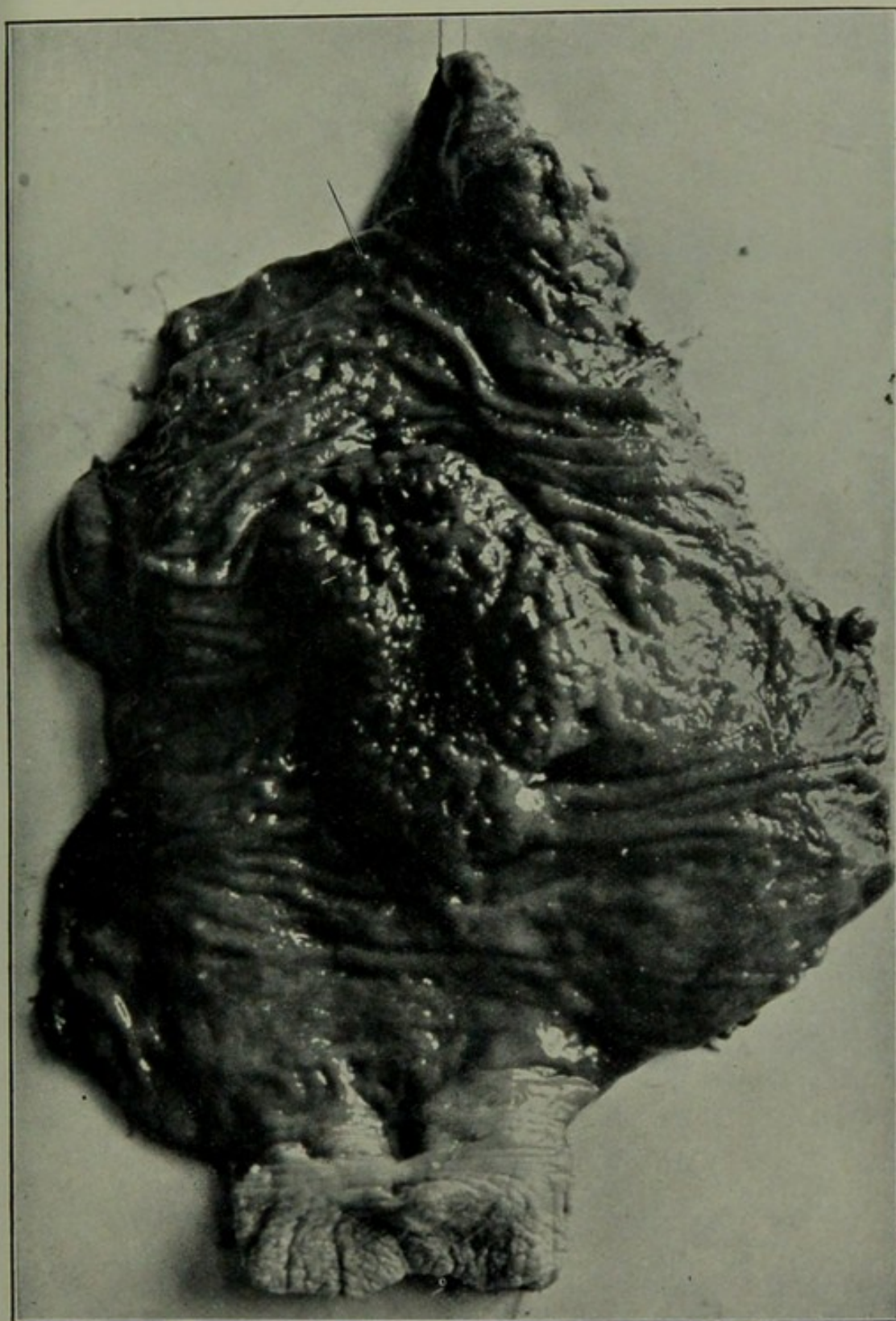


FIG. 18.—AN ADENO-CARCINOMATOUS TUMOUR OF THE RECTUM SHOWING SUPERFICIAL ULCERATION IN THE CENTRE OF ITS SURFACE.



Invasion of neighbouring viscera, such as the bladder prostate and vagina, soon follows and the abdominal lymphatic glands and liver become the seat of metastatic deposits marking the beginning of the final stage of the disease.

### *Symptoms.*

The symptoms which indicate the presence of a carcinomatous growth in the rectum are most conveniently considered as they occur during the five distinct stages of its clinical course, namely (a) *prior to disintegration of the surface of the growth*; (b) *during the process of surface disintegration*; (c) *when the growth has infiltrated the peri-rectal tissues and perforation of the rectal wall has supervened*; (d) *when almost complete occlusion of the lumen of the bowel has supervened*; and (e) *when secondary deposits have occurred in the abdominal lymphatic glands and in the liver, lungs, pleuræ, etc.*

#### *(a) Prior to disintegration of the surface of the growth.*

We have seen only two examples of a carcinomatous growth of the rectum in this stage, and, therefore, our opportunities for directly observing the symptoms manifested by such a growth have been limited. Still, from having kept careful records of many of the histories furnished by the cases of carcinoma of the rectum which have come under our observation, we have been able to tabulate certain symptoms which have been uniformly present during the six or nine months preceding the appearance of those indicating the commencement of the disintegration of the growth. All these symptoms are at first apt to attract little attention. They appear to be: (1) *a primary attack of constipation*, (2) *slight loss of weight*, (3) *frequent action of the bowels*.

(1) *Primary attack of constipation*.—By this, we do not



mean mechanical obstruction of the bowels due to narrowing or occlusion of the lumen of the rectum, but merely a departure from the natural habit of daily evacuation. Such attacks are common enough in many individuals as a result of their occupation, or of disorders of digestion, etc., and at first sight it might be thought that little importance

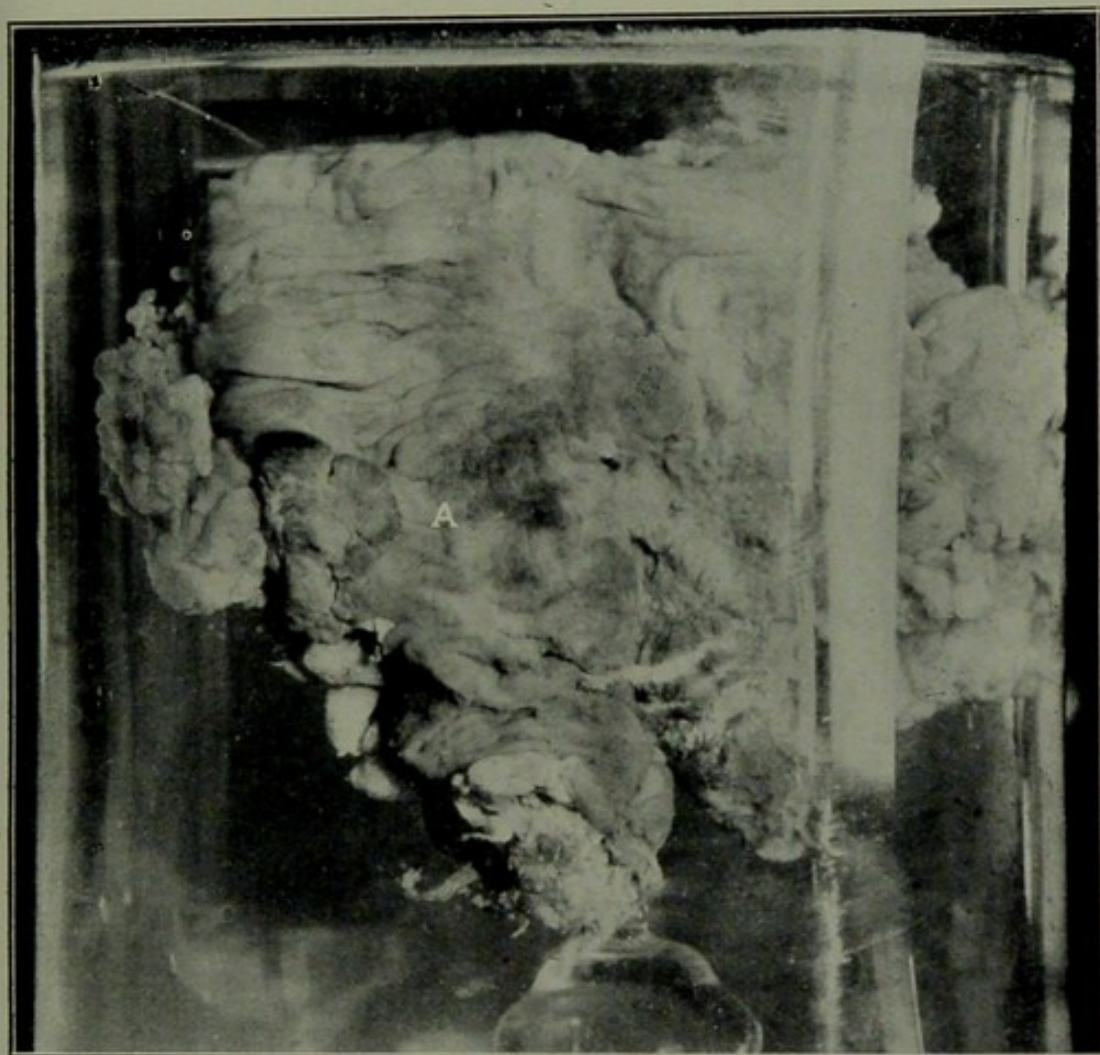


FIG. 19.—AN ADENO-CARCINOMATOUS ULCER EXTENDING NEARLY COMPLETELY ROUND THE RECTUM FOR ABOUT TWO INCHES IN DEPTH.

The area marked A shows a narrow strip of apparently healthy mucous membrane between the two lateral extremities of the ulcer.

could be attached to them. But it has been our experience that carcinoma of the rectum is met with much more frequently in those patients who give a history showing that, up to a definite date, their bowels had acted every



day without the aid of aperients, and that, following a sudden attack of constipation, there has been a definite change of habit. This temporary cessation of the natural daily evacuation does not appear to be associated with abdominal distension, clearly showing that there is no mechanical obstruction at this stage of the disease. The explanation of the onset of the attack of constipation is not quite clear, but it is possible that the presence of the growth, even when small, may intercept peristaltic action, either directly or reflexly. Be this as it may, for practical purposes we think it safe to assume that, when a patient is found to be suffering from carcinoma of the rectum, the history of a well marked attack of constipation having occurred as a departure from the habit of natural daily evacuation of the bowels, may be taken to indicate the onset of the disease. If this deduction be correct, it is clear that such an attack, when followed by steadily increasing diarrhoea, especially when occurring in an individual above forty years of age, should be regarded with suspicion, and a diagnosis should not be made until the rectum has been thoroughly explored.

(2) *Slight loss of weight.*—During the early stage of carcinoma of the rectum, loss of weight undoubtedly occurs, but it is usually so slight that it may escape attention unless the patient is particularly observant. He will perhaps say that he thinks he has been getting a little thinner. We have often observed that the subjects of this disease are or have been well above the normal weight for their height, so that when the patient first seeks advice for his rectal symptoms he often appears to be in robust health. Accordingly, although the slight loss of weight is progressive, the disease is usually well advanced before emaciation to a marked degree manifests itself, and before the patient pays much attention to it.

(3) *Frequent action of the bowels.*—After a period of



several weeks from the commencement of the initial attack of constipation, frequency in the action of the bowels begins to manifest itself. The stools are semi-solid and consist of fæces only. Warm fluids appear to excite an action of the bowels, because the evacuations take place more especially after breakfast and afternoon tea. During this stage,

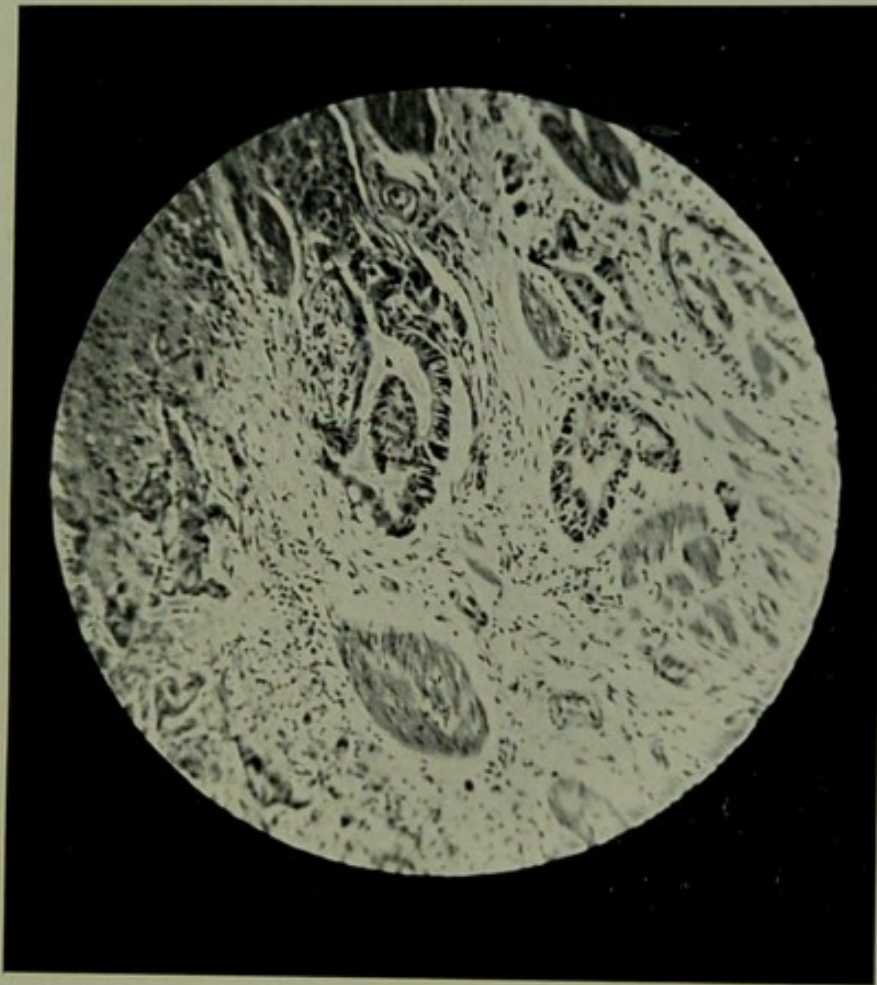


FIG. 20.—MICROSCOPICAL SECTION OF THE SPECIMEN IN FIG. 19, SHOWING INFILTRATION OF THE MUSCULAR COAT.

although the bowels may act four or five times during the daytime, they may not act at night. This fact serves to differentiate early carcinoma from neglected fibrous stricture of the rectum, in which disease one or more nocturnal actions of the bowels is a rule to which there are few exceptions. The above train of symptoms usually attracts so little attention that, unless a careful inquiry be made, the patient does



not mention them at all. In some instances he seeks advice for the increased frequency in the action of the bowels, in the belief that he is suffering from ordinary diarrhœa. There is no attendant pain, and there is nothing in the character of his stools, beyond the fact that they are relaxed, to cause any uneasiness. Hence it is that these patients do not seek an examination of the rectum until symptoms of a more pronounced character develop; in fact usually, until the second stage of the disease has been reached. We would suggest that a thorough rectal examination should be made in all cases in which there is a history like the one we have above described, since by such an examination only can the presence of a carcinoma in the primary stage of its growth be detected.

*(b) During the process of surface disintegration.*

When the surface of the growth has become abraded either from the continued passage of fæces over it, or when the centre of the growth necroses from diminished blood supply, disintegration commences. The growth thus becomes transformed into an ulcer, and local symptoms of a more definite and objective character manifest themselves. These are (1) *increased frequency in the action of the bowels*; (2) *the appearance of blood and mucus in the stools*; (3) *local and reflected pain*; (4) *difficulty in obtaining complete or satisfactory evacuation of the rectum*; and, (5) *progressive loss of weight*.

(1) *Increased frequency in the action of the bowels*.—As a direct result of the presence of an ulcerated surface, the rectum becomes irritable and intolerant of the presence of the fæces. There is a desire to evacuate frequently, and the bowels are relieved between twelve and twenty times, or still more frequently, during twenty-four hours, and especially in the morning and evening. As a rule, fæces are chiefly passed at the first and second evacuations, the remainder consisting



almost entirely of small quantities of mucus, or mucus and blood, or of mucus, blood, and pus. Nearly all the actions occur during the daytime, but occasionally the patient may be disturbed if he does not sleep well or is in the habit of taking food during the night. A nocturnal action of the bowels, however, is exceptional during this stage of the disease.

(2) *The appearance of blood and mucus in the stools.*—As soon as the surface of the growth has been abraded, bleeding occurs, and is repeated with each action of the bowels. The quantity of blood lost varies with the variety of the growth, being more when the growth is exuberant and growing rapidly, and less when the converse obtains. Occasionally profuse hæmorrhage may occur as a result of forcible straining during an evacuation or from laceration of the surface of the growth. It must be borne in mind, however, that copious loss of blood may occur from co-existent internal piles and not to any great extent from the growth.

The appearance of an increased quantity of mucus in the stools is characteristic of the second stage of the disease. The existence of an abraded surface in the rectum reflexly stimulates the glands in the mucous membrane and the mucus accumulating in the rectum, gives rise to the frequent desire for evacuation. Consequently nearly all the evacuations consist of much mucus more or less tinged with blood and sometimes mixed with pus or disintegrating portions of the growth. The mucus so passed has a peculiarly offensive odour, which is characteristic of rectal carcinoma.

(3) *Local and reflected pain.*—When disintegration of the surface of the growth has taken place a considerable area of the rectal wall has usually become involved by the disease. The margins of the ulcerated surface become sensitive, and the constant straining at stool gives rise to pain at the seat of the disease. When the growth involves the anal canal, acute



pain is experienced at each evacuation, and persists for some time afterwards. When the lowermost margin of the growth is situated more than two inches above the anal orifice, the pain is less severe, and is chiefly felt as a bearing-down sensation in the rectum (tenesmus). Dull aching pain is also frequently complained of in the region of the sacrum, and occasionally in the glans penis both before and during an action of the bowels, and also at other times.

(4) *Difficulty in obtaining complete or satisfactory evacuation of the rectum.*—When the growth involves the rectal wall above the level of the sphincteric region, its presence gives rise to the sensation that the bowel has not been completely evacuated, and consequently the patient continues to strain down after the rectal contents have been voided. Such tenesmus is very distressing to the patient and is also characteristic of the disease. As the growth infiltrates the rectal wall more extensively the lumen of the bowel is diminished, and then some of the rectal contents are retained in spite of persistent straining. When the growth invades the anal canal defæcation is so painful that spasm of the sphincters ensues and prevents complete evacuation of the rectum, occasionally terminating in faecal impaction.

(5) *Progressive loss of weight.*—Soon after disintegration of the surface of the growth has commenced, the patient begins to lose flesh in a more marked and recognisable manner. This loss of weight usually begins to show itself in from six to twelve months after the initial attack of constipation. When much blood is being lost or when suppuration is profuse, emaciation sets in sooner and is frequently rapid. As a rule, however, the patient notices that he is steadily losing weight long before symptoms, pointing to the serious nature of the disease, manifest themselves. In those instances in which the growth completely encircles the bowel, intestinal obstruction may occur before there is appreciable loss of weight.



(c) *When the growth has infiltrated the peri-rectal tissues and perforation of the rectal wall has supervened.*

When the disease has reached this stage the symptoms are pronounced, and usually indicate the implication of neighbouring viscera, such as the bladder, vagina, uterus, &c. They consist of (1) *hæmorrhage*, (2) *the escape of mucus and pus without admixture of fæces*, (3) *deep-seated pain in the pelvis, over the sacrum and extending down the thighs*, and (4) *general cachexia*.

(1) *Hæmorrhage*.—This is sometimes copious, and is partly due to the involvement of the hæmorrhoidal vessels by the ulcerative process. Large quantities of blood may be lost suddenly. When the larger vessels are implicated, the bleeding may be so profuse that the patient's life is speedily terminated by it.

(2) *The escape of mucus and pus without admixture of fæces*.—In the earlier stages of the disease, mucus and pus are, as a rule, passed only when the bowels act, and therefore are mixed with the fæces, but in the later stages there is practically a continuous escape of these discharges. This is explained to some extent by the fact that the sphincters, as the disease advances, lose their power of control, the anus being generally relaxed, so that the discharges drain away through the anal canal. The increase in the quantity of pus is due to suppuration occurring in the peri-rectal cellular tissue and the formation of abscesses which empty their contents into the rectum. Not infrequently these abscesses extend, and open on to the skin surface in the neighbourhood of the rectum, forming definite fistulæ. Under these conditions the perineum is continuously bathed in pus.

(3) *Deep-seated pain in the pelvis, over the sacrum and extending down the thighs*.—With the occurrence of peri-rectal suppuration, deep-seated pain, of a continuous and distressing



character, supervenes in the pelvis. During the formation of an abscess the pain becomes acute and throbbing, being relieved only when the pent-up pus is afforded an outlet. When the abscesses extend into the ischio-rectal fossa, the symptoms of an ordinary ischio-rectal abscess are super-added. Apart, however, from the advent of suppuration, the pain in these cases may also be caused by the implication of the sacral plexus of nerves in the growth. When this occurs, pain of a shooting and lancinating character is experienced anywhere within the area of the distribution of these nerves, *e.g.*, over the sacrum, in the lower lumbar region, over the hips and down the back of the thighs along the course of the great sciatic nerves.

(4) *General cachexia*.—At this stage of the disease the patient becomes typically cachectic. His appetite fails and he sleeps little, on account of the pain, unless sedatives are freely administered. More marked wasting appears, and gradually the final stages of the disease are entered upon.

(d) *When almost complete occlusion of the lumen of the bowel has supervened.*

This stage is generally reached in about eighteen months or two years after the onset of the earliest symptoms. Unfortunately the majority of the cases of carcinoma of the rectum do not come under the observation of the surgeon until this time, when complete removal may be quite impossible, and consequently little can be done by way of surgical treatment beyond a palliative colostomy and the subsequent scraping away of the exuberant part of the growth. On the other hand, cases occur from time to time in which the stage of obstruction is reached before the presence of the disease has given rise to any symptoms beyond those of chronic constipation. The disease in these instances consists of a circular infiltration of the sub-mucous and muscular coats of the bowel, pro-



ducing considerable narrowing of its lumen, while the growth is still in an early stage of its development. When this happens the seat of the growth is usually high up, often at or about the junction of the sigmoid colon and the rectum. We have recently had two cases of this nature under our care, both having been admitted into hospital suffering from symptoms of chronic intestinal obstruction supervening upon chronic constipation. In both, one a male the other a female, the bowel at the level of the left sacro-iliac synchondrosis was occluded by an infiltrating columnar-cell carcinoma involving the whole circumference.\* Such instances as these, however, are exceptional, and it is more usual to find that the symptoms of obstruction gradually supervene after those of the preceding stages have been for some time in evidence, provided that the operation of colostomy has not been previously performed. In the latter cases, diminution of the calibre of the bowel at the seat of the disease occurs as a result of exuberance of the growth itself, or in consequence of lateral compression of the bowel by the extension of the disease into the peri-rectal connective tissue and neighbouring viscera, or on account of an invagination of the diseased portion of the bowel.

The symptoms indicating that this stage has been reached are:—(1) *Obstinate constipation, alternating with diarrhœa.* (2) *Local pain,* and *Intermittent attacks of abdominal pain.* (3) *Intermittent hæmorrhage.* (4) *Increasing abdominal distension.* (5) *Rapid emaciation.* (6) *Vomiting,* and finally (7) *Attacks of absolute obstruction.*

(1) *Obstinate constipation alternating with diarrhœa.*—The constipation met with in this stage of the disease is that of obstruction to the onward progress of the fæces through the

---

\* In both cases the diseased segment was removed and an end-to-end anastomosis accomplished. Both specimens are preserved in the museum of the Cancer Hospital, Nos. 112 and 170.



diseased portion of the bowel, and it differs materially from that observed during the early stage. Thus, whenever a day passes without an evacuation, the abdomen becomes distended chiefly with flatus, and paroxysmal efforts on the part of the intestine to overcome the obstruction give rise to more or less severe pain. The obstruction is nearly always due to a hard mass of fæces having become impacted in the narrowed lumen of the bowel, thus preventing, for a time, the passage of either flatus or even liquid fæces. After a period varying from twenty-four or forty-eight hours to four, five or more days, the impacted fæcal mass is softened by an increased secretion of mucus from above, and then a more or less liquid stool is evacuated. There is now generally some admixture of blood and other discharge with the fæces. The liquid motions persist for a day or two or longer and then cease. The abdominal distension is also relieved and the attacks of pain disappear. Later on the bowel becomes again obstructed and the cycle of symptoms is repeated, but often with increased severity. Thus it is that *alternating attacks of constipation and diarrhœa* indicate that the stage of approaching obstruction has been reached.

It is perhaps well to point out in this place that, with each successive attack of obstruction, the bowel becomes more and more distended above the area of the growth and its coats at the upper border of the growth are often more or less deeply ulcerated. This fact can be verified either in the *post-mortem* room or among museum specimens. It is, therefore, particularly dangerous to administer any form of aperient with a view to overcoming any such attack of obstruction, lest rupture of the wall of the bowel immediately above the diseased area should result from the violent peristaltic action thus engendered. We have seen this accident happen in more than one case, when an aperient had been given for the purpose of clearing out the bowels preparatory to the operation of colostomy, a practice which we strongly



*condemn* in any case of carcinoma of the rectum. The result of this procedure was that the patients became suddenly collapsed after an attempt to relieve the bowels, and in from 12 to 16 hours expired. At the autopsy it was found that the bowel had given way just above the growth, and that some of the contents of the colon had been evacuated into the peritoneal cavity.

(2) *Local pain and intermittent attacks of abdominal pain.*—The period of obstruction to the passage of fæces is accompanied by intense bearing down pain in the rectum. The patient is in great distress from the constant bearing down and, since at this stage the growth has nearly always infiltrated the peri-rectal structures, the sacral plexus of nerves is generally involved, the continued forcing down causing radiating pain over the sacrum and down the back of the thighs. In addition to this there is added the griping pain in the abdomen attendant upon the paroxysmal efforts of the colon to force its contents past the obstruction. When the attacks recur the patient gets no rest, either by day or night, without the aid of sedatives, and therefore rapidly becomes exhausted.

(3) *Intermittent hæmorrhage.*—During the attacks of obstruction some hæmorrhage may take place either as a direct result of the straining efforts or from laceration of the surface of the growth, but, as a rule, the loss of blood is not excessive. It is, however, soon after the attacks of obstruction that the more copious hæmorrhages occur. Whatever may be the explanation of this occurrence, it appears that an attack of obstruction predisposes to subsequent hæmorrhage, and this circumstance is an argument in favour of performing iliac colostomy prior to the advent of obstruction. In one of our cases the operation of cæcostomy was performed\* for the relief of an attack of obstruction. On the tenth day

---

\* Left iliac colostomy was found to be impracticable on account of the sigmoid having been bound down with adhesions, due to the advanced stage of the disease.



after the operation profuse hæmorrhage occurred, which caused the patient's death. At the autopsy the colon was found filled with blood clot, the hæmorrhage having taken place from the growth in the rectum.

(4) *Increasing abdominal distension*.—One of the surest signs that the lumen of the rectum is becoming occluded by the growth is distension of the abdomen. Despite the fact that he is losing weight rapidly, the patient complains that he is becoming stouter in the abdomen. On examination the reason for this is soon discovered. The abdomen is tympanitic, especially in the course of the transverse colon. The cæcum is found on percussion to be markedly distended, especially in some instances. The distension, however, is not entirely due to flatus, and it is often surprising how great an accumulation of fæcal matter the large intestine is capable of holding. In one of our cases, that of a cabman, who was admitted into the Metropolitan Hospital suffering from chronic obstruction due to carcinoma of the rectum, this accumulation of fæces was well exemplified. His bowels had not acted for nearly three weeks. At the operation left iliac colostomy was attempted, but could not be performed because the descending colon and the sigmoid were so greatly distended with firm fæces. In fact, this part of the colon presented the appearance of a large German sausage. Cæcostomy was therefore performed, and, during the three or four subsequent weeks, large quantities of fæces were evacuated through the artificial anus.

(5) *Rapid emaciation*.—During the second and third stages of the disease loss of weight is evident and progressive, though perhaps slow, but as soon as the lumen of the bowe begins to be lessened in diameter it becomes more rapid. The emaciation observed during this stage is chiefly due to three causes, viz., disorders of digestion, irregular actions of the bowels (*i.e.* diarrhœa alternating with constipation), and want of sleep. When the obstruction has been relieved by colostomy the patient increases in weight for a time,



clearly showing that the emaciation was due in great measure to the obstruction itself, and not to the vitiating influence of the disease.

(6) *Vomiting*.—The onset of nausea heralds the commencement of the stage of obstruction. Later on nausea is followed by vomiting, especially after taking food, and, finally, when the obstruction is complete the vomiting usually becomes fæcal.

(7) *Attacks of absolute obstruction*.—Absolute intestinal obstruction ultimately sets in unless colostomy has been performed. The patient is now no longer able to void even flatus, the abdominal distension increases, coils of distended intestine can be plainly seen through the abdominal wall and the vomiting at last becomes fæcal. The case is now desperate, and unless relief be speedily given death will soon take place, probably from rupture of the intestine immediately above the growth.

(e) *When secondary deposits have occurred in the abdominal lymphatic glands and in the liver, lungs, pleuræ, &c.*

This stage is usually reached in from two to three years after the onset of the primary symptoms, provided either that the original growth has not been removed, or that after removal recurrence has taken place.

Extension of the disease occurs both directly by continuity of tissue and indirectly through the lymph stream. Direct invasion of the prostate and bladder in the male and the vagina and uterus in the female adds symptoms referable to disease of those organs. Thus hæmaturia, cystitis and the passage of flatus, and later on of flatus and fæces, per urethram, or of urine per rectum, indicate that either the prostate or the base of the bladder has become involved. Similarly hæmorrhage from the vagina or the passage of fæces per vaginam point to the extension of the growth to the vagina.



Indirect extension leads to secondary growths in the pelvic and lumbar lymphatic glands, and also in the liver, lungs, pleuræ, &c.

*When the pelvic and lumbar lymphatic glands are the seat of secondary deposits.*—The symptoms are:—(1) *The presence of a tumour or tumours in the abdomen.* (2) *Œdema of the scrotum and penis in the male and of the vulva in the female.* (3) *Œdema of one or both lower extremities.* (4) *Ascites.*

(1) *The Presence of a Tumour or Tumours in the Abdomen.*—These can generally be made out as abdominal swellings soon after the lumbar lymphatic glands are infected. They are situated to one or other side of the middle line, are rounded or elongated in shape when a single gland is affected or nodular and irregular in outline when a number of glands are affected. These tumours are firm, fixed and increase steadily, sometimes rapidly, in size. They may or may not be tender to the touch.

(2) *Œdema of the Scrotum and Penis in the Male and of the Vulva in the Female*—This is the direct result of the obstruction to the lymph stream from these parts. The œdema of the penis and scrotum is sometimes so great that the penis disappears from view. The skin becomes glazed, and is especially liable to become excoriated. The accompanying illustration shows the œdema of the labia majora, and also of the anal folds of skin which occurred in a patient about two years after the onset of the primary symptoms (see fig. 21).

(3) *Œdema of one or both lower Extremities.*—This is the result of the pressure exerted by the enlarged lymphatic glands upon the main venous trunks. When the common iliac vein on one side only is compressed œdema of the corresponding lower extremity results, but when the inferior vena cava is obstructed œdema of both extremities together with both buttocks occurs.

(4) *Ascites.*—This may come on at any time after the



lumbar glands have become enlarged, and it may precede œdema of the lower extremities.

*When secondary deposits have taken place in the liver, lungs pleuræ, &c., the symptoms indicating such extension are—*

- (1) *Enlargement of the liver.* (2) *The appearance of jaundice.*
- (3) *Vomiting.* (4) *Hæmatemesis.* (5) *Cough.* (6) *Dyspnœa.*
- (7) *Heart failure.*

The onset of these symptoms shows that the disease has

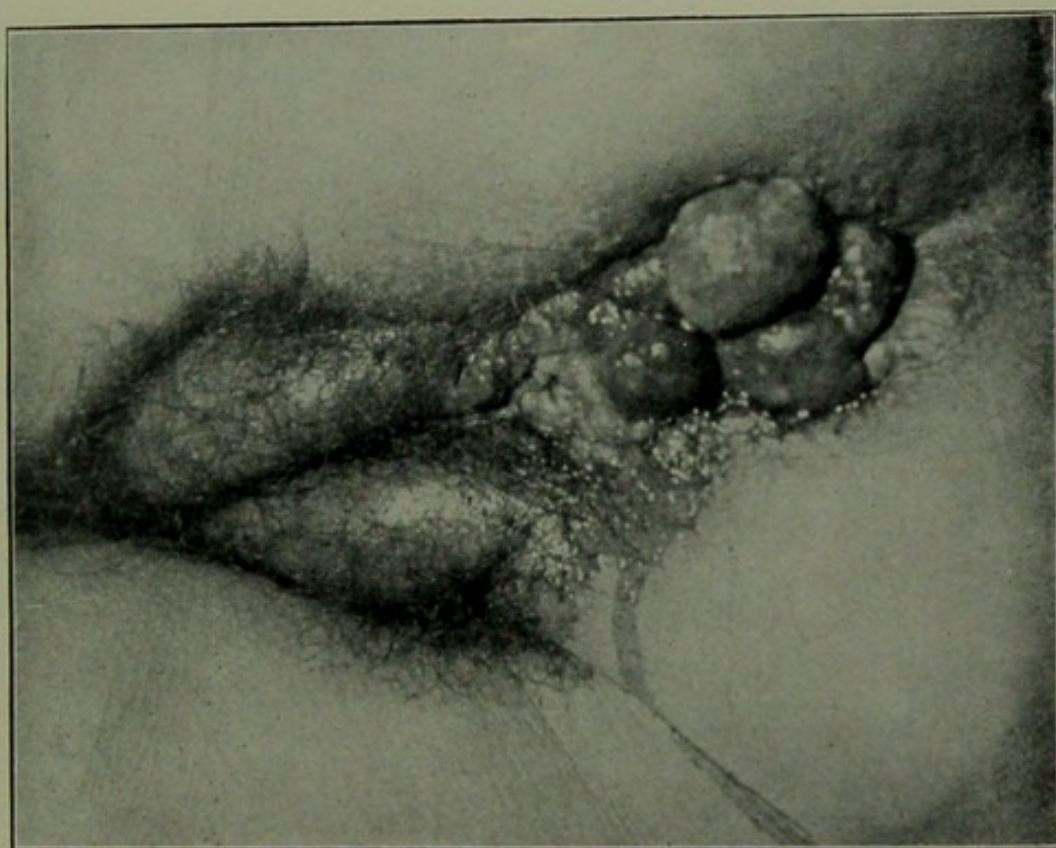


FIG. 21.—ŒDEMA OF THE ANAL SKIN, AND OF THE VULVA IN A CASE OF CARCINOMA OF THE RECTUM.

The lower margin of the growth was just within the anal orifice.

nearly run its course and that the end is not far distant. They are due to the dissemination of the disease in the various organs of the body. How long a patient will linger on in this state it is impossible to say, but, so far as we have observed, the appearance of jaundice seems to indicate a time limit. We have repeatedly observed that from the time when the earliest sign of a yellowish discolouration of the ocular



conjunctiva appears, death takes place in from six weeks to three months. Accordingly in these cases, when the jaundice is thus manifest, a decided prognosis may be made as to the further duration of the patient's life.

### *Physical Examination.*

In nearly all cases of rectal carcinoma, the anal orifice is relaxed, somewhat patulous and of a darker colour than the surrounding skin. This condition is probably produced by frequent actions of the bowels, to some extent by the protrusion of co-existent internal piles and by obstruction to venous return. The peri-anal skin usually presents a sodden appearance. The anal canal, except in advanced cases, is usually found to be free from disease and therefore when the examining finger is introduced into the rectum spasmodic action of the sphincters is not induced and there is no pain. The cavity of the rectum below the growth will usually be found to be free from fæces.

These points having been ascertained a careful examination of every part of the rectal wall is made with a view to determining the position, extent and characters of the neoplasm. In most instances the lower border of the growth is within three inches of the anal margin, but in some the disease is situated at so high a level that it can only just be reached by the finger. With the exception of the carcinomata situated at the junction of the rectum and sigmoid colon, the growth will seldom be found to involve the whole circumference of the bowel, there nearly always being a well marked strip of apparently healthy mucous membrane intervening between its lateral extremities (see Fig. 19). The extent of the circumference involved is an important factor in the estimation of the duration of the disease and therefore of the probability of the growth having extended beyond the limits of the rectal wall at its seat of origin. If the growth be small, involving less than a sixth of the circumference of the bowel,



and especially if it be sessile and attached by a broad base to the mucous coat, if its surface be smooth though somewhat irregular, and if its margins are firm and indurated, it is in the *early* or *pre-ulcerative* stage of its development. Even at this stage some degree of fixation to the muscular coat may be found to exist. If the growth involves a quarter or more of the circumference of the bowel, it will nearly always be found that its surface is excavated in parts, that its margins are nodular, everted and indurated, and that its base is infiltrated and firmly fixed to the muscular coat. These characteristics show that the growth is undergoing disintegration at its surface and has been in existence for some time. When the growth involves from three-quarters to five-sixths of the circumference of the bowel, there is generally considerable narrowing of the lumen, into which the finger can with difficulty be passed. In such a case if the upper border of the growth cannot be reached while its lower border is within three inches of the anal orifice, the disease is usually of long duration and has probably not only extended into the perirectal structures but has given rise to extensive involvement of neighbouring lymphatic glands.

When these points have been ascertained in regard to the growth itself, the condition of the neighbouring viscera should be enquired into with a view to determining the question of the possibility of the removal of the growth.

Lastly, evidences of the invasion of the inguinal, pelvic and lumbar lymphatic glands and the existence of secondary deposits in the liver or other organs should be carefully sought for.

### *Differential Diagnosis.*

From a purely clinical point of view the conditions which are most likely to be mistaken for carcinoma are as follow:—

(a) the *adenomatous polypus*, (b) the *papilloma* or *villous tumour*, (c) *benign stricture*, (d) *invagination of the rectum*,



(e) *gummatous deposits*, (f) *tuberculous ulceration*, and (g) *extensive induration around a blind internal fistula*. Hence it is of the utmost importance that no doubt as to the exact nature of the disease should exist, and that other non-carcinomatous affections should not be mistaken for it. In all cases in which the slightest element of doubt exists a small piece of the growth should be removed for microscopical examination, the question of an operation being deferred until the histological characters of the neoplasm have been ascertained. When the diagnosis of carcinoma has been confirmed, information of its serious nature should be conveyed to the patient, as it involves, even under the most favourable circumstances, the possible submission to an extensive and severe operation, and, therefore, every source of error in the diagnosis should be eliminated, if possible.

(a) *From the adenomatous polypus*.—This form of growth is usually pedunculated, and is generally met with in the lower two inches of the rectum. The pedicle consists of a simple fold of mucous membrane devoid of induration even at the seat of attachment. The surface of the growth is soft, and often minutely lobulated. It seldom attains a large size, and does not grow rapidly. It causes pain during defæcation, and sometimes it is protruded at stool when the seat of attachment is near the anal orifice, or when the pedicle has become elongated. Occasionally there is a small hæmorrhage. This growth most generally occurs in children; it is occasionally met with in women, but is extremely rare in men.

(b) *From the papilloma or villous tumour*.—This growth is also distinctly pedunculated, but is characterised by the breadth and obliquity of the attachment of the pedicle. It may attain a large size and sometimes nearly fills the rectal cavity. The surface is soft and velvety to the touch, somewhat irregular, and often subdivided into distinct lobes. Its most characteristic feature is the large quantity of watery fluid it secretes, which may cause twelve or



more actions of the bowels during the twenty-four hours. It is met with usually after middle life and, in our experience, is more common in women than in men. It grows slowly, and may protrude through the anal orifice when the pedicle has become sufficiently elongated. It rarely gives rise to loss of blood except when it is protruded, and then the bleeding spontaneously ceases soon after the tumour has been returned into the rectum. When the tumour is *in situ*, its surface may be readily mistaken (during digital examination only) for redundant healthy mucous membrane. It is prone to recur and may after several years become carcinomatous.

(c) *From benign stricture.*—An ordinary fibrous stricture cannot well be mistaken for carcinoma except when it produces invagination, in which case the stricture is situated at the apex of the invaginated portion of the bowel; but the margin of the lumen is firm and even in outline, and there is a complete absence of the hard irregularity of the surface which is so characteristic of a malignant growth. Slight bleeding may follow digital examination, but it is never copious. There is also usually a purulent discharge. The rectum is freely movable. This kind of stricture occurs much more often in women than in men, and usually during the third and fourth decades of life. A neglected benign stricture, however, may resemble a carcinoma even when there is no invagination, but the previous long duration of the disease should indicate its true nature. We have not met with a case of fibrous stricture which has ultimately become carcinomatous.

(d) *From invagination of the rectum.*—This affection, when in an advanced stage, may simulate carcinoma. It may be distinguished, however, by its even contour, the regular outline of its lumen, and the absence of induration. The long period during which the disease must have existed is against the diagnosis of carcinoma.

(e) *From gummatous deposits.*—A gumma in the rectum



is rarely met with. We have seen only one case. It differed from a malignant growth in being smooth, rounded, and somewhat elastic. The mucous membrane over it was healthy.

The history that the patient has had syphilis, the presence of other signs of the disease, and the fact that the swelling becomes smaller under the influence of iodide of potassium will assist in arriving at the correct diagnosis.

(f) *From tuberculous ulceration.*—This rare form of disease may be mistaken for carcinoma, because the chronic inflammatory thickening around the diseased area of the rectum gives rise to considerable tumefaction, simulating that met with in advanced cases of carcinoma of the rectum (see page 62). There is a marked difference in the condition of the anal orifice and canal. There is no outgrowth from the orifice or contraction of the canal; the rectum is dilated and the wall is hard and indurated; there is seldom any hæmorrhage on digital examination, and there is an escape of pus. When invagination is present the apex is not hard and irregular. In one case which came under our care, a communication between the bladder and the lower part of the sigmoid resulted from the ulceration. There was a firm mass, which, when examined by the finger, felt like a carcinomatous growth. The patient was much emaciated. Microscopical examination, however, of a piece of the margin of the ulcer proved the absence of malignant disease and showed the existence of tubercle.

(g) *From extensive induration around a blind internal fistula.*—An ordinary sub-mucous fistula cannot well be mistaken for carcinoma, but when the fistula occupies the pelvi-rectal space, the irregular outline of the induration, often met with in such cases, may very closely resemble that disease. The facts that the mucous membrane over the swelling is intact, except where there is an opening, that the tumour is smooth though irregular in contour, and that



there was a discharge of pus as one of the earlier symptoms, point to the inflammatory nature of the disease. When, on examination, there occurs a sudden gush of pus (as often happens in these cases), accompanied by a diminution in the size or firmness of the swelling and an amelioration of the pain, its non-malignant nature is established.

### TREATMENT.

As in the case of carcinoma in other regions, so in the rectum, wide removal of the diseased area holds out, at present, the only known possible prospect of cure. From an extensive experience in the treatment of these cases, we are convinced that complete extirpation of the rectum below a line one and a half to two inches above the uppermost margin of the growth, together with the surrounding areolar tissue and all the lymphatic glands in the neighbourhood, is the measure that should be accomplished, if possible, when an operation for the removal of the growth is undertaken. Partial operations, such as a limited rectectomy, except under special circumstances, should not be performed, because the probability of speedy local recurrence is very great, especially in patients under forty years of age. In fact, when the rectum is attacked by carcinoma, the organ should be regarded as functionally lost, and should, if possible, be widely removed. Every effort should be made, consistent with the future comfort of the patient, to attain *the perfect eradication of the disease*.

Accordingly it is obvious that, from a surgical point of view, cases of carcinoma of the rectum are to be divided into two classes, namely--(a) *those in which extirpation is practicable,* and (b) *those in which it is not.*



(a) CASES IN WHICH EXTIRPATION IS  
PRACTICABLE.

In deciding whether a given case is suitable for removal, the most important points for consideration are the *depth* of the infiltration of the rectal wall and the *position* of the upper border of the diseased area. In early cases the growth is confined to the mucous coat and the sub-mucous tissue, and there is always present a certain degree of mobility upon the muscular coat. Such growths as these, in whatever part of the rectum they may be met with, can be removed. Similarly, cases in a later phase, *i.e.*, when disintegration has commenced and infiltration of the muscular coat of the bowel has occurred, as evidenced by the fixation of the ulcer to the muscular coat, are amenable to removal so long as the disease has not extended to the peri-rectal tissues, causing the rectum to become fixed to neighbouring structures, such as the sacrum behind, the pelvic vessels and nerves laterally and the prostate, bladder or vagina and uterus in front. The difficult cases upon which to express an opinion are those in which the disease is situated high up, and extends upwards beyond the reach of the finger. We think a good guide in estimating whether the disease has extended beyond the upper part of the rectum is for the surgeon to ascertain if he can, with his finger in the rectum, touch the promontory of the sacrum. If so, and the uppermost limit of the disease still remains out of reach, it is clear that the sigmoid colon is involved, and, therefore, an attempt at removal from the perineum will be not only dangerous, but, in all probability, will be speedily followed by a recurrence of the disease. At the same time, it does not follow that all cases in which the uppermost border of the disease can be reached are suitable for removal. It sometimes happens that a growth, by completely encircling the bowel, causes sufficient stenosis to produce invagination of



the diseased portion of the bowel into the part below it. In such a case it may be possible to introduce the finger through the stenosis and to feel healthy bowel above the site of disease. The circumstance of invagination, however, indicates that the disease is a great deal higher up in the bowel than is apparent from digital examination, and, therefore, it may be altogether out of reach so far as removal from the perineum is concerned.

It should be borne in mind that an operation for the removal of a carcinomatous growth of the rectum may cause a serious loss of blood, and, therefore, in addition to deciding whether it is possible to perform the operation successfully, a thorough investigation of the patient's general condition should also be made. The age of the patient is of less importance than his general health, though it must be borne in mind that aged patients do not bear well large losses of blood. The general nutrition should be good, and freedom from all forms of organic disease is most desirable.

When the growth can be removed, two methods of procedure are available according to its position and extent. These are (1) excision of the diseased segment of the bowel with end-to-end suture, and (2) removal of the growth, together with either a part or the whole of the rectum below it, and as much as possible of the healthy bowel above it. The one is known as *resection of the rectum*, the other as *excision of the rectum*.

### RESECTION OF THE RECTUM.

This is the ideal method from a surgical point of view. It possesses the distinct advantage of not depriving the patient of his natural anus, and therefore leaves him with control over flatus and fæces. Unfortunately, however, the cases to which this procedure is applicable are seldom met with. In the first place, the growth must be of very limited extent, certainly not more than one inch in its



longitudinal diameter, and its lowermost margin should not be less than three inches distant from the anal orifice. If the growth be of larger dimensions, or otherwise situated, there will be the danger of removing too little bowel both above and below the growth, if the divided ends are to be approximated. This circumstance probably accounts for the high percentage of recurrences following this operation. We have had occasion to employ this method in a typically suitable case. The patient (a female, aged 58) was operated on sixteen months ago, and is keeping quite well.\* A small indurated ulcer, about the size of a three-penny piece, was situated upon the posterior wall of the rectum, its lower margin being three inches from the anal orifice. The bowel was divided two inches above the ulcer, and one and a-half inches below it, and the proximal and distal ends were united by means of a Murphy's button. The patient made an excellent recovery, and up to the present time there is no sign of recurrence. The patient, however, has had to pass a rectal bougie about once a month in order to prevent cicatricial stenosis.

*Preparation before Operation.*—The most important point is to be certain that the colon has been thoroughly emptied of its contents. Nothing could be more undesirable than the escape of fæces from the proximal end of the bowel during the operation. As this operation is unsuitable for cases in which the growth is causing obstruction, it should never be undertaken unless the lumen of the bowel at the seat of the disease is quite patent. For several days before the operation the colon should be washed out once or twice daily with plain water enemata. The anal and sacral regions should be carefully shaved and cleansed and an antiseptic compress applied for at least twelve hours beforehand, the dressings being changed and the part recleansed every time anything is passed from the rectum.

---

\* The specimen No. 113 is preserved in the museum of the Cancer Hospital.



*Instruments required.*—These are scalpels, scissors (straight and curved on the flat), curved round intestinal needles, straight and curved hagedorn needles, needle holder, pressure forceps, dissecting forceps, lion forceps, cutting pliers, Murphy's button or Mayo Robson's bobbin, silk in various sizes, catgut and silk-worm gut, and sponges.

*Description of the operation.*

The operation will be described in the following five stages, viz.: (1) *preliminary incision and exposure of the rectum*; (2) *isolation of the portion of the rectum to be resected together with the removal of the sacral glands*; (3) *removal of the growth*; (4) *treatment of the proximal and distal ends*; and (5) *completion of the operation*.

(1) *Preliminary incision and exposure of the rectum.*—The patient having been placed in the right lateral and semi-prone position, an incision is made in the middle line extending from the centre of the sacrum to a point about one inch from the posterior-margin of the anal orifice. This incision is carried at once down to the sacrum and to the coccyx and ano-coccygeal ligament. The dorsal ligaments of the sacro-coccygeal articulation are now divided transversely, and the lateral attachments of the coccyx close to the bone. The coccyx is then removed, care being taken in doing this not to injure in any way the subjacent bowel. If more room be required than is afforded by the removal of the coccyx a portion of the left border of the sacrum should be removed after the method of Kraske (see page 161), but this will seldom be found necessary. The layer of connective tissue, containing fat, lymphatics and blood vessels separating the sacrum and coccyx from the rectum is next divided transversely and the ends turned upwards and downwards respectively. The posterior surface of the rectum is now exposed.

(2) *Isolation of the portion of the rectum to be resected, together with the removal of the sacral glands.*—The index



finger is now insinuated between the rectum and the levator ani, first on one side and then on the other, just above the attachment of the latter to the bowel. By a process of blunt dissection the loose connections of the rectum are separated as far as the middle line anteriorly. At this point some little difficulty may be experienced in the process of separating the rectal wall from the prostate in the male, or from the vagina in the female, because of the density of the connective tissue. The dissection should be continued until the finger can be passed round the rectum from one side to the other. The lower portion of the bowel having been thus isolated, attention must be paid to its upper part, and here the utmost gentleness must be used as the diseased segment of the bowel will now have to be dealt with. Commencing posteriorly the blunt dissection is carried upwards between the posterior wall of the rectum and the mass of fat and connective tissue between it and the sacrum. As soon as the separation has been carried to the necessary level above the upper border of the growth, the fatty connective tissue in front of the sacrum, together with its lymphatic glands should be cut away with scissors and all bleeding vessels secured and tied. This having been done, the process of separation is carried on laterally and anteriorly to the level already reached posteriorly. In order to do this the peritoneal pouch between the rectum and bladder demands attention. In many cases it is possible to strip this off the anterior surface of the rectum to the required extent without opening the peritoneal cavity—a result always to be attained if possible—but in some instances, and especially when the growth involves the anterior wall, injury to the peritoneum may be unavoidable. Under these circumstances the peritoneal pouch should be opened and a sponge or mass of sterilized gauze inserted to prevent the small intestine falling into the wound. Opening the peritoneum is of service in some cases, as by dividing the lateral peritoneal connections of the rectum



a good deal more of the bowel can be brought down than otherwise would be possible. For this reason some surgeons make a practice of always opening up the recto-vesical pouch. When the bowel has been isolated to the required extent above the upper border of the growth (this should not be less than one and a-half inches), all bleeding should be carefully arrested and the next stage of the operation proceeded with. If the peritoneal cavity has been opened up, the aperture should now be closed by a continuous catgut suture after withdrawing the sponge or plug of gauze which had previously been introduced.

(3) *Removal of the growth.*—The limits of the growth having been carefully made out, the points of section of the bowel above and below it are then decided upon. It is of the greatest importance that as long a piece as possible of apparently healthy bowel, both above and below the growth, should be removed. Having carefully packed the wound with strips of sterilized gauze to prevent infection by the intestinal contents the upper part of the bowel, about one inch from the intended point of section, is either clamped or held firmly between the fingers of an assistant. The section is now made transversely with scissors, and then all bleeding points are secured by forceps and tied. The same procedure is now carried out at the lower part of the bowel and the growth removed.

(4) *Treatment of the proximal and distal ends.*—The first care is to thoroughly wash the divided ends and sponge out the lumen of the bowel with an antiseptic solution and then to repack the wound with fresh gauze. Having ascertained that the ends can be approximated without undue tension, the method of suture is next decided upon. One of three courses may be adopted, viz.: (1) simple suture; (2) Murphy's button; and (3) suture over a Mayo Robson's or similar bobbin. Whichever of these methods is used a faecal fistula nearly always results, and continues for some time during



the after treatment. We prefer simple suture, as it enables us to leave a small portion of the bowel unsutured posteriorly, into which opening a tube can be introduced, and kept there until the healing of the remainder of the wound is well advanced. By this means the possibility of the formation of the faecal fistula in other parts of the circumference of the bowel is greatly diminished. When Murphy's button or Mayo Robson's bobbin is used no such provision can be made. As soon as the anastomosis has been completed the strips of gauze are removed, the wound thoroughly irrigated with a solution of perchloride of mercury (1 in 500), and afterwards carefully dried.

(5) *Completion of the operation.*—When the united bowel has been replaced it will be seen to lie free in a large deep wound. It is clear from this that primary adhesion to the surrounding tissues will not readily take place. Hence, care must be taken to provide for free drainage. The skin wound, therefore, should not be completely closed, the portion opposite the lower end of the sacrum being left open and a drain inserted. We advise the adoption of this precaution, even when a Murphy's button or a Mayo Robson's bobbin has been used, and it is an absolute necessity when an opening has been left in the posterior wall of the bowel. A thick absorbent dressing should now be applied.

Resection as a method for removing malignant growths of the rectum cannot be often practised, because so very few cases come under observation at the stage when they might be suitable for it. In order to effect end-to-end anastomosis in the rectum, the length of the excisable portion is necessarily limited, and, therefore, if a growth be found during the operation to extend farther up the bowel than was anticipated there is a danger of the operator being induced to remove less than is required if, under such circumstances, this operation be proceeded with. Conservative surgery in this respect increases the liability to recurrence, and it is



better under such conditions to abandon the idea of anastomosis altogether, and to resort to one of the methods of excision.

Even in suitable cases the operation is not without its disadvantages. As before remarked, the isolated rectum lies loosely in a large cavity which rarely heals by primary adhesion. After healing has taken place there is, therefore, always cicatricial contraction around the rectum for a considerable distance both above and below the line of union in the bowel. This may occur even when the repair has taken place without suppuration. Thus, the rectum may be converted into a more or less rigid tube which displays a decided tendency to progressively contract. Hence a species of stricture is induced which necessitates the subsequent use of bougies, and consequent irritation of the part. Again it is but a *partial* operation, and the liability to recurrence is greater than when the whole of the rectum is removed, because recurrence in cases of cancer of the rectum so often commences in the lower part which, of necessity, is left *in situ* by this operation.

#### *Treatment after the operation.*

This is most important, as the ultimate success of the operation depends in a great measure upon its details being thoroughly and systematically carried out. The bowels should be confined for about ten days, unless colostomy has been previously performed, and then they should be gently opened. If the colon has been thoroughly emptied before the operation, and the patient has been subsequently carefully dieted, there will not be much risk of fæcal impaction occurring in the sigmoid and rectum above the line of union. Distension of the rectum by flatus, however, is very likely to occur, a circumstance to which the occurrence of fæcal fistula is probably due. The distension is due to the fact that the external sphincter



muscle affords mechanical resistance to the escape of flatus. When simple suture of the divided ends of the bowel has been employed and a gap has been left posteriorly, adequate provision is made for the escape of flatus, but when either a Murphy's button or a Mayo Robson's bobbin has been used flatus cannot escape in this way. In those cases a short rectal tube should be inserted into the anal canal and kept there during the greater part of the after-treatment, but should be removed occasionally for cleansing purposes. The administration of opium in small doses at short intervals is especially serviceable in these cases on account of its action *in causing the fæces to become liquid* at the end of nine or ten days. When opium is thus used, there is no need to relieve the bowels by either aperients or enemata, and consequently the danger of too great a strain being thrown upon the recently united bowel is done away with. Our plan is to administer twenty minims of the tincture of opium as soon as the patient has recovered from the anæsthetic, and to follow it up by five minim doses every four hours for the next twenty-four, every six hours for the succeeding twenty-four, and every eight hours during the remainder of the period until the bowels act. We have found that at the expiration of from eight to ten days an action of the bowels occurs naturally and without any griping pain or other discomfort. The material evacuated is frequently of the consistence of tar and is dark in colour. The action of the opium may be facilitated by injecting one ounce of olive oil into the rectum every night at bed-time commencing about the sixth day.

#### EXCISION OF THE RECTUM.

This is the best way of treating a carcinomatous growth of the rectum which is suitable for removal. By it the diseased organ is either partially or completely extirpated, and an *artificial anus* is established. No attempt should be



made to preserve the sphincters. The circum-anal skin should be widely removed, because recurrence so frequently first shows itself in the subcutaneous lymphatic plexus surrounding the anus, especially when the growth is situated low down in the rectum.

Several methods of performing this operation are practised, but chiefly one of the following three :—

(1) *Perineal excision with the formation of an artificial anus in the natural position—i.e., inter-ischial.*

(2) *Trans-sacral excision with the establishment of a sacral artificial anus, the sphincters being preserved; and*

(3) *Extirpation of a part or the whole of the rectum subsequent to the formation of an abdominal artificial anus.*

As we seldom employ either of the first two methods of procedure, we think it best to detail their technique in their respective author's own words. The third method is the one we usually adopt, and, therefore, we shall describe in full the manner in which we perform that operation.

#### (1) *Perineal Excision with the formation of an Inter-ischial Artificial Anus.*

This is the method recommended by Cripps and Allingham.

##### *Cripps's method.\**

"The patient, being prepared for the operation by a purgative and warm water enema, is placed fully under the influence of an anæsthetic and arranged in the lithotomy position, the legs being drawn up and fixed upon the abdomen by Clover's crutch. This consists of a metal bar 18 inches in length, at each end of which is a semi-circular padded crutch, with a strap and buckle attached. The legs being flexed on the thighs, the bar is placed between them, so that the crutches fit against the legs just below the knee, and are

---

\* "Diseases of the Rectum and Anus," 2nd Ed., p. 386.



kept in position by means of the straps and buckles. The thighs are then bent on the abdomen and a soft leather strap passes over the head and one shoulder, and the free ends being then buckled to the crutch, the strap is then tightened so as firmly to fix the thighs in a bent position. The instruments required for the operation consist of a strong, curved, sharp-pointed bistoury, a straight bistoury, a pair of blunt-pointed scissors, a pair of strong curved scissors, two pairs of large, strong, vulsellum forceps, a steel-wire *écraseur*, the benzoline cautery, artery forceps, and ligatures. The left forefinger being passed into the rectum, feels for the tip of the coccyx: the curved bistoury, held in the right hand, is passed into the bowel, the point being guarded by the finger-nail; the handle of the knife is then raised, and, with a little jerk, the point is made to protrude through the skin on a level with the tip of the coccyx and exactly in the middle line. The whole of the intervening tissue between this part and the margin of the anus is cut through. If this cut be made with a clean sweep as near as possible in the middle line, little hæmorrhage will result. The left hand of the operator is now placed on the right side of the buttock, so as to draw the anus outward, and stretch the tissues at the line of junction of the mucous membrane with the skin. The portion of the rectum or anus through which the lateral incision is to be made must depend upon the distance from the anus of the lower margin of the disease, and, if possible, should be at least half an inch from the growth. The point being selected, the knife is made to cut deeply by using firm pressure, a crescentic incision extending from the margin of the first cut round the anus to a point in the middle of the anterior margin. This cut should be made boldly, and of sufficient depth to extend well into the fat of the ischio-rectal fossa. The forefinger thrust into this incision will readily separate the bowel from the surrounding tissue, except at the insertion of the levator ani,



which should be divided with scissors. A small piece of sponge, pressed into this cut, and held by an assistant, restrains any bleeding, while the opposite side is treated in a similar manner. The lateral and posterior portion of the bowel being freed from their attachments, the next and most delicate step in the operation is the separation of the bowel from its anterior connections. In the case of a man this is much facilitated by having a full-sized catheter passed into the bladder and held during the operation, like the sound in lithotomy. The catheter can be readily felt during the operation, and prevents any chance of the urethra being wounded. The separation of the anterior wall requires the judicious use of the knife and scissors, it being too intimately adherent to be separated by the finger-nail without greatly tearing the parts. During this dissection the bowel should be drawn downwards and backwards by the left hand, while the finger should from time to time be introduced into the bowel cavity to make sure that the dissection be not carried too close to the bowel. When the dissection has been carried to a sufficient distance beyond the disease, the bowel should be drawn down with a moderate amount of force with vulsellum forceps. The wire loop of the *écraseur* is then passed over the forceps and detached bowel, and pushed up as far as possible before being tightened.

“The wire is preferable to the chain *écraseur*; it is more easily worked, and less liable to get out of order. The wire should consist of eight strands of moderate thickness, only slightly twisted together with great evenness. If too much or irregularly twisted, the wire will stretch, and the strands are liable to break by cutting one against another.

“After the diseased portion of the bowel has been slowly cut through and removed, any vessels that happen to bleed should be secured by ligature. If preferred, instead of using the *écraseur* the bowel may be finally detached by means of strong curved scissors. The hæmorrhage varies a good deal



in different cases. It is nearly always free, but seldom, so far as I have seen, to a dangerous extent. It is best treated by making the posterior and two lateral incisions as boldly and rapidly as possible, and not attempting to tie any vessel until the posterior and lateral connections of the bowel have been separated.

“The bleeding vessels are mostly situated in the coats of the bowel, so that when the partially detached bowel can be grasped in the left hand, nearly all hæmorrhage is restrained. The vessels in the partially detached portion of the bowel will again, in the latter part of the operation, be cut across higher up, so that to ligature them in the first stage of the operation only wastes time. Should any vessel in the sides of the wound bleed, it may be secured.”

*Allingham's method.\**

“The patient being in the lithotomy position, a modification of the posterior dorsal incision of Professor Verneuil should be made. The usual way is, on the finger, to pass a bistoury into the rectum as far as the upper limit of the growth, and then to cut right down to the sacrum and tip of the coccyx, dividing the entire bowel dorsally. In our modification of this, the first finger of the left hand is put into the bowel, and a sharp-pointed bistoury is introduced through the skin a little below the anus, making it travel in the cellular tissue up to the top of the growth, but entirely outside the rectal tube. One should then cut down to the sacrum and coccyx, and put a sponge into the incision to arrest bleeding. Next, with a scalpel one cuts deeply all round the rectum above the external sphincter, or, rather, in the space between the internal and external sphincters, so as to leave the external sphincter attached to the skin. Then the external sphincter is divided posteriorly. Now, with the finger in the rectum and the thumb in the cut between the

\* “Diseases of the Rectum,” 6th Ed., p. 354.



sphincters, one blade of a pair of long, blunt-pointed scissors is pushed into the posterior cut, and the other blade into the cellular tissue of the ischio-rectal fossa. After this, one cuts through all the cellular tissue between the blades, and repeats this proceeding on the other side, keeping the finger of the left hand in the rectum while the left side is being incised, and the first finger of the right hand while the right side is being cut. To manage this properly, the surgeon should be ambidexter. After this, sponges are introduced into the incisions on each side of the bowel, and the outer parts are separated from the bowel by broad flat retractors. Bleeding is then prevented, and one need not stop to clip the vessels.

“ We next turn to the perineal part. With the finger still in the bowel, and the thumb outside it, one can tell by the amount of the wall of the gut between finger and thumb how near to the rectum one is cutting. If the scissors are kept touching the thumb-nail, and the rectum is drawn backwards while the cut is made, there is no danger of wounding the urethra or bladder, or of incising the bowel. When all the rectum is separated from the tissues around, to one inch or more above the growth, the sponges may be taken out. On to the rectum, now freed, above the growth, a large pair of Spencer Wells' rectangular pressure forceps are applied, one on one side, and one on the other side, of the gut. When the rectum is removed on the distal side of the clips, a stout ligature is then passed beyond the rectangular part of the clip, and is tightly tied as the clip is slowly slackened. The same is done with the other clip. This secures any large superior hæmorrhoidal vessels that there may be in the cut end of the gut. There is generally little bleeding, because the inferior hæmorrhoidal vessels, and any others running across the ischio-rectal spaces to the rectum, are small, and soon retract and contract. They may be easily made to do so by sponging the wound with equal parts of very hot water and spirit. The only large vessels that may be divided are



the superior hæmorrhoidal, which are situated in the rectal walls. It is well, before cutting the lower part of the bowel off, to secure the upper part with the clip, as it might otherwise slip out of reach and bleed freely. By these means the rectum may be removed in ten minutes with the greatest ease."

By either of the above methods the growth may be completely removed, and the results, from that point of view, are very satisfactory. The wound, however, is large, and must of necessity heal by granulation; consequently, when the healing process has been nearly completed, the proximal end of the bowel sometimes communicates with the skin surface by means of a somewhat rigid canal and aperture. The length of this canal is shorter than might be expected from the original depth of the wound, because during the process of cicatrisation the mucous coat of the bowel is pulled down considerably towards the skin surface. Still, there is sometimes a canal of at least an inch in length, and this is not only a rigid tube, but displays a tendency to contract still further; in fact, unless the passage be kept patent by the use of bougies, it practically becomes an impassable stricture. To obviate this tendency to contraction, attempts are made to bring the cut end of the bowel down to the skin margin, and suture it there. It is usually found, however, that there is so much tension that the sutures speedily cut out, and in the meantime there is considerable risk of locking up discharges and of producing sepsis.

*The inter-ischial artificial anus*, therefore, has several disadvantages. The orifice is rigid, being capable of neither closure nor dilatation; it sometimes requires the periodical use of bougies to prevent absolute obliteration; it rarely affords complete control over the contents of the rectum. In regard to the latter, the control may be fair so long as the patient is constipated and masses of firm fæces, in the bowel above, block the passage; but even then flatus will escape. Even



in those instances in which a redundant fold of mucous membrane acts like a valve or the levatores ani constrict the passage and prevent the involuntary escape of fæces and flatus, there is always present a dampness of the part, due to the escape of rectal mucus, which makes the patient very uncomfortable.

(2) *Trans-sacral excision with the formation of a sacral artificial anus.*

In order to overcome the unsatisfactory condition of the anus resulting from perineal excision, and more particularly to enable the operator to reach and remove high-lying growths of the rectum, Kraske devised an operation by which the coccyx and a portion of the lower part of the sacrum are removed for the purpose of thoroughly exposing the rectum. By this means, not only can the rectum be removed at a much higher level than is possible by perineal excision, but the divided end of the bowel, usually sigmoid, can be brought down and sutured, without undue tension, to the skin opposite the place where a portion of the left side of the sacrum has been removed—*i.e.*, a *sacral anus* is formed. The best account that we have been able to find of this operation is that contained in Tillmann's Text Book of Surgery.\*

*Kraske's method.*

"The patient lies at first upon the right side. The skin incision in the posterior rhapshe begins near the anus, and ends at about the middle of the sacrum. One then cuts down upon the rectum, exposes the edge of the sacrum on the left side, excises the coccyx, and divides on both sides the attachments of the sacro-sciatic ligaments. The outer edge of the wound is now well retracted, and a portion of the left border of the sacrum is resected with a chisel. The line

\* Vol. III., p. 172, 4th German Ed., translated by Tilton.



of the division of the sacrum is curved. It begins on a level with the third posterior sacral foramen, and then runs inward and downward in a curve, with its concavity to the left, past the lower border of the third sacral foramen, and through the fourth, as far as the left cornu of the sacrum. In this way no nerves are injured, the anterior branch of the third sacral nerve is spared, and the sacral canal is not opened. The rest of the operation is performed with the patient in a dorsal position, with elevated buttocks, as in the methods of Bardenheuer and Kocher. After dividing the posterior wall of the rectum in a longitudinal direction, the access to its upper part is now so free that one can easily amputate it, under constant guidance of the eye, at the point of transition into the sigmoid flexure, or resect it in continuity with preservation of the anal portion. It is better, in the latter case, not to divide the lower, sound part of the rectum. After the extirpation is completed, the upper end of the intestine is drawn down into the wound, or united with the anterior circumference of the lower end by a few tension sutures. If the lower part of the rectum is divided longitudinally behind, this open part of the rectum is closed, not by suture, but by a later plastic operation (by means of double flaps from the skin on both sides). If the anal portion is preserved, and has not been divided posteriorly, the two ends of the intestine may be united by circular enterorrhaphy, or sutured only at their anterior circumference."

Kraske's original operation has been modified by several surgeons, according to their particular requirements. The best of these is that described by Bardenheuer.\*

*Bardenheuer's method.*

"The patient lies in the lithotomy position, with elevated buttocks. The skin incision runs in the posterior rhapshe from the anus to the middle of the sacrum. If the anal

---

\* Ibid.. p. 173.



portion of the rectum is likewise to be removed, a circular incision is made about it, and, if desirable, a longitudinal incision in the anterior rhaphe is added. The coccyx and the edges of the sacrum are now exposed, the sacro-sciatic ligaments are severed on both sides close to the bone, the coccyx is seized with bone forceps, drawn backward, and removed, and the sacrum is excised with a bone-cutting forceps as high as possible, according to the extent of the carcinoma, even in the neighbourhood of the third sacral foramen, so that one may pass the whole hand into the pelvic cavity. The rectum is now exposed from behind by a few longitudinal cuts, and then detached by blunt dissection with the finger and by curved scissors, the index finger being introduced as a guide, and for the purpose of drawing the rectum backward. By thus drawing the rectum away from the bladder and the urethra, injury of the ureter, the urethra, and the vagina, is best avoided. The hæmorrhage attending this blunt method of operating is very slight. In detaching the rectum one must constantly keep close to its wall, as the operation is otherwise rendered unnecessarily difficult, and is also more bloody. If the rectum has been freed on all sides, and if the anal portion is to be preserved, a silk ligature is passed about the rectum, and the latter severed with scissors below the ligature. The blunt detachment of the rectum in an upward direction is then continued, as necessity may require, and the reflection of the peritonæum is carefully pushed upward. Should the peritonæum be torn and the intestine prolapse, the latter should be thoroughly disinfected, and the tear in the peritonæum closed with catgut. If the vagina is opened, it should also be sutured. Finally, the rectum is divided transversely above the carcinoma, after it has been detached, so far in an upward direction that the upper end can be easily sutured to the anal region of the wound, or to the lower anal portion of the rectum which has been preserved. The upper end of the rectum is attached



below, in extirpation of both the rectum and the anus, merely by a few tension stitches."

Kraske's operation and the modification of it give, from the operator's point of view, most convenient facilities for removing the rectum either partially or completely, especially when the growth is in the upper part of the rectum. Its disadvantages are that it is an operation which is usually attended with a considerable loss of blood; that the removal of part of the sacrum weakens the pelvic floor and, therefore, unless colostomy has been performed there is ultimately considerable prolapse or procidentia; that the wound heals slowly, that the sacral region is very tender and painful for quite a year after the operation, and that there is much more after-pain following this operation than there is when only the coccyx has been removed.

(3) *Extirpation of either a part or the whole of the rectum subsequent to the establishment of an abdominal anus (iliac colostomy).*

This is the method which we always advise, as, in our experience, it yields the most satisfactory results. We find that the abdominal anus is much more comfortable for the patient than either the *inter-ischial* or the *sacral artificial anus*, and it affords better control over the contents of the bowel, provided that the colostomy has been well performed. We have seen colostomies which have given rise to a great deal of trouble from procidentia of the colon, because the muscles of the abdominal wall had been too freely divided. It would, therefore, be unfair to judge of the merits of an abdominal anus from such cases. Patients—especially women—have a great abhorrence of being obliged to defæcate in an unnatural manner, and therefore shrink from the operation of colostomy; but we are convinced that, if they fully realised the fact that after excision of the rectum an



*artificial anus* must result, and in consequence there must be some considerable degree of loss of power of control, whether the *inter-ischial*, the *sacral*, or the *abdominal variety* has been adopted, they would choose the abdominal anus for the reasons which we give below.

*The advantages of a preliminary abdominal anus.*

These may be considered from (a) *the patient's point of view*, and (b) *the surgeon's point of view*.

(a) *From the patient's point of view.* The anus is easily seen and reached for cleansing by the patient. He can, after a time, by careful dieting, regulate the actions of the bowels so that an evacuation takes place in the morning and again before he retires to rest, thus almost completely ensuring that the escape of *fæces* will not take place during the intervals. He can be easily fitted with an abdominal belt, having a cup-shaped pad, with or without a receiving bag, fixed into it, which, if carefully fitted, will remain in position and prevent soiling of his garments (see page 195). Moreover, should recurrence of the disease take place, he will be relieved of the pain which is usually caused by the passage of *fæces* through the diseased part of the bowel.

(b) *From the surgeon's point of view.*

(1) If the colostomy has been performed at the commencement of the sigmoid loop, the rectum can be much more completely removed than would be possible if colostomy had not been performed. It has been urged by some surgeons that if colostomy be performed before excision, the rectum cannot be drawn down sufficiently owing to the fixation of the sigmoid to the abdominal wall; but this, we think, can only occur when the colostomy has been made in the lower part of the sigmoid.

(2) *Fæces* do not escape during the operation for removal of the rectum.

(3) During the healing of the excision wound *fæces*



are not voided through it, thus saving the patient much discomfort and pain, as well as delay in the healing of the wound.

(4) The necessity for using dilators to keep the passage patent is, in many cases, done away with. This is an important point, because it is well known that local irritation predisposes to recurrence of the disease.

(5) The excision wound often closes completely, and there is therefore no discharge in the anal region.

(6) If recurrence takes place, the growth is not irritated by the passage of fæces over it.

(7) Pelvi-rectal suppuration following on recurrence of the disease is much less frequently met with.

(8) Diverting the passage of fæces diminishes the risk of hæmorrhage, which is one of the causes of death in cases of carcinoma of the rectum.

(9) When the growth has been removed, the patient's weight and general health improve much more than in cases of excision without a preliminary colostomy.

The above considerations appear to us to amply justify the operation of preliminary colostomy in these cases, and consequently we always advise a patient to submit to it, after fully explaining to him the effects of the procedure.

#### *Method of Operating.*

The plan which we now always adopt is to remove the rectum *from above downwards*. In this way the quantity of blood lost during the operation is comparatively small and, consequently, a clear view of the structures to be removed is obtained. The operation will be described in the following five stages:

(a) *Preliminary incision and exposure of the rectum.*—The incision is commenced in the middle line opposite the third piece of the sacrum, and carried down in the inter-natal cleft as far as the posterior border of the anus. The coccyx is



then removed, and the retro-rectal fat and connective tissue divided, as in the operation of resection of the rectum (see page 149).

(b) *Isolation of the rectum at and above the level of the growth.*—By introducing the left forefinger between the rectum and the levator ani, first on one side and then on the other, the bowel is freed from its loose lateral attachments. This process of blunt dissection is carried on until the fingers meet in front. Proceeding upwards with the isolation of the rectum, the peritoneal covering on its anterior surface and lateral aspects is carefully stripped up until the upper part of the rectum has been reached. This isolation should be continued for at least one inch above the uppermost level of the growth and further if possible. If the peritoneal pouch has been opened, the rent should be carefully closed with sutures as soon as the isolation of the rectum has been completed, and before the next stage of the operation is proceeded with.

(c) *Section of the rectum above the growth.*—A strong clamp is now placed upon the bowel as high up as possible, and not less than one inch from the uppermost level of the growth. A second clamp is placed below the first about half an inch from it. A ligature, No. 12 or 16, platted silk, about thirty-six inches in length, is now passed with a needle through the rectum above the first clamp, and the ligature is divided at its centre, and the rectum tightly ligatured in two halves. The bowel is now divided between the two clamps with scissors, and the upper clamp is removed. The clamp on the distal portion of the bowel checks all hæmorrhage from below.

(d) *Removal of the rectum.*—The distal end of the rectum is now drawn down and its removal completed. Some difficulty is usually found in separating the bowel from the prostate in the male and the vagina in the female, rendering the use of scissors necessary in order to divide the somewhat dense connective tissue of this part. When



the growth involves the anterior wall of the bowel, great care should be exercised in the separation, lest injury be inflicted upon important structures. If the growth be adherent to the capsule of the prostate gland, the capsule itself and part of the gland tissue, may with safety be removed, provided that the prostatic portion of the urethra be not damaged. A metal catheter or sound introduced into the bladder, and held steadily by an assistant, is of the greatest service in protecting the urethra from injury. Part of the muscular wall of the vagina may be removed, but care should be taken to leave the vaginal mucous membrane intact. The attachments of the levator ani, first on one side and then on the other, are now divided and the ischio-rectal fossæ are thus opened up. The inferior hæmorrhoidal vessels are isolated and clamped as far outwards as possible. A circular incision is now made round the anus, at least one inch from the anal margin, commencing and ending in the lower extremity of the preliminary incision. The fatty tissue in the ischio-rectal fossæ and the ano-coccygeal ligament are then divided, and the rectum removed.

(e) *Completion of the Operation.*—The pre-sacral connective tissue and fat containing lymphatic glands and vessels are dissected away, and all bleeding points secured. The skin incision is then closed by silk-worm gut sutures as far as the lower extremity of the sacrum, and the remainder of the wound left open. After thorough irrigation, the wound is lightly packed with strips of cyanide gauze and a large pad of aseptic wool, adjusted and kept in position by means of strips of rubber strapping and a broad T-bandage. If the membranous portion of the urethra has been laid bare or encroached upon, it is well to introduce a soft catheter (self-retaining) into the bladder in order to avoid compression of the urethra by the packing in the wound, as this might lead to retention of urine and to rupture of the urethra by the catheter passed to relieve it.



In suitable cases, *i.e.*, in those in which the tissues have not been much bruised during the process of isolating the rectum, the cavity of the wound may be obliterated almost entirely by inserting buried sutures. This procedure greatly shortens the convalescence. The accompanying illustration (see fig. 22) was taken fourteen days after such a method

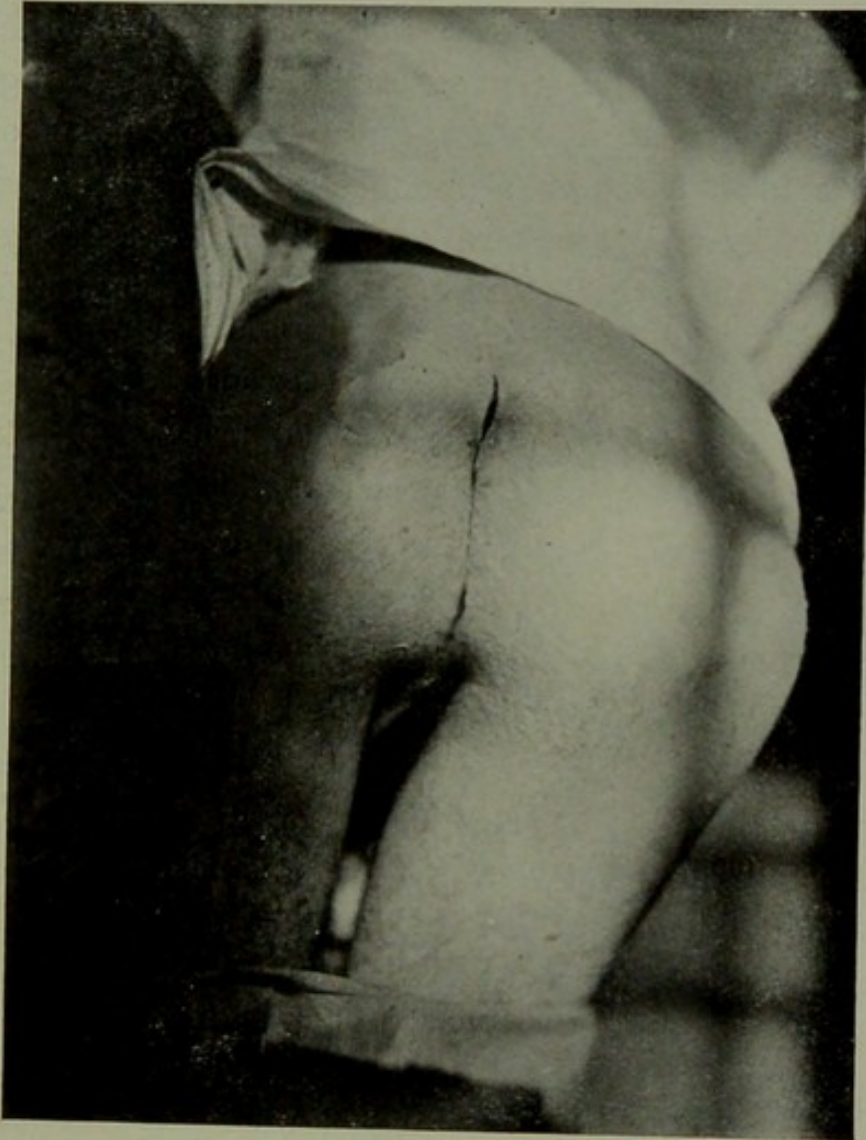


FIG. 22.—SHOWING THE APPEARANCE OF THE SCAR FOURTEEN DAYS AFTER COMPLETE REMOVAL OF THE RECTUM AND A WIDE AREA OF PERI-ANAL SKIN.

of closing the wound had been carried out and shows that the wound had closed entirely with the exception of the part into which a drainage tube had been inserted.



This method of removing the rectum from above downwards possesses the distinct advantage of causing very little hæmorrhage. The reason for this is that the superior hæmorrhoidal arteries are controlled when the upper part of the rectum is clamped in an early stage of the operation. When the rectum is removed from below upwards, copious bleeding occurs from the middle hæmorrhoidal venous plexus, which communicates freely with the superior hæmorrhoidal plexus. The prevention of a severe hæmorrhage during this operation is of great importance, because carcinoma of the rectum occurs much more commonly in men. The patients are usually over fifty years of age, and are generally debilitated by the disease, and bear the loss of blood badly.

#### *The After Treatment.*

Collapse from shock must be carefully guarded against during the first ten or twelve hours after the operation. Morphia should be administered hypodermically, if there be much pain or if the patient be very restless. On the morning after the operation the outer dressings should be removed, and the wound inspected. The gauze packing need not be touched unless there has been much oozing. On the following day this packing should be removed, care being taken not to cause any bleeding in so doing. If the gauze be adherent to the surface of the wound, it should be thoroughly soaked before removal, or hot boracic fomentations may be ordered to promote separation. These wounds are not aseptic, because the blunt dissection employed during the operation leads to considerable tissue necrosis, and constant attention is, therefore, necessary to prevent septic absorption. The sloughs have usually all separated by the tenth or twelfth day, and then the wound assumes a healthy granulating appearance, and ceases to be tender when dressed. The ligatures on the proximal end of the bowel generally separate on the eighth or ninth day. During the first



fortnight the wound should be freely irrigated once or twice a day with a strong solution of perchloride of mercury, 1 in 500, the wound being carefully mopped out afterwards with sponges of absorbent cotton wool. Should the lotion be left *in situ*, symptoms of mercurial poisoning may sometimes supervene. The bowels need not be confined after the operation, but should be opened by a mild purgative, if required, on the fifth day.

The wound gradually contracts and, at the expiration of from four to six weeks, healing is usually completed. During the process of cicatrization the cut end of the bowel is gradually drawn down towards the skin surface and in some cases, especially when only part of the circumference of the rectum has been removed, may become attached to the skin margin. The outlet gradually contracts and sometimes becomes quite obliterated, so that a linear scar is all that can be seen. Such a satisfactory result depends largely upon the efficiency of the spur of the colostomy. If fæces are effectively prevented from passing into the bowel below the colostomy, obliteration takes place; but if, on the other hand, fæces pass into the bowel beyond, a permanent, though stenosed, fæcal outlet remains. It is a matter of great importance, therefore, that the colostomy be carefully watched and note taken of the efficiency of the spur. If this be found to be inefficient measures should be taken to maintain adequate patency of the perineal outlet by the passage of bougies, lest fæcal accumulation and pelvi-rectal abscess result from the stenosis.

#### *Mortality from the Operation.*

Since we have practised our method of removing the rectum from above downwards three or four weeks subsequent to a preliminary colostomy, the mortality after the operation has been very small. Out of thirty-seven operations which we have performed in this way, there has been only one death



within three months of the date of the excision. We think that this reduced death-rate of less than three per centum is chiefly due to the greatly diminished hæmorrhage during the excision, and to the fact that the fæces are not able to pass over the excision wound.

*Complications during and after Excision of the Rectum and their Treatment.*

The complications during the operation are: (a) *shock*, and (b) *collapse from hæmorrhage*.

(a) *Shock*.—While the operation is in progress and usually while the upper portion of the bowel is being isolated, the patient may suddenly become collapsed, even though much blood has not been lost. Such a condition must not be mistaken for the narcosis of anæsthesia, and should be energetically treated. In addition to the usual restoratives, one or more pints of normal saline solution (which should always be ready for use) should be transfused. In those cases in which we have had recourse to this, the effect has been most gratifying.

(b) *Collapse from hæmorrhage*.—This only occurs when there has been sudden and very free hæmorrhage. Serious bleeding is more likely to take place when the operation is performed from below upwards, and, therefore, in such cases great care should be taken to secure all vessels as soon as they have been divided. Should the patient show signs of becoming collapsed the operation must be suspended and the wound firmly plugged with dry gauze, while restorative measures are being adopted. If the patient revive sufficiently the operation should be completed as soon as possible. If, however, it is not thought advisable to continue the operation, care must be taken to prevent further bleeding from the wound, and then the patient may be sent back to bed, and the remainder of the operation performed at a subsequent date.



The complications occurring during the after treatment are : (a) *Recurrent or intermediary hæmorrhage*; (b) *Secondary hæmorrhage*; (c) *Abscess*; (d) *Urethral fistula*; (e) *Peritonitis*; (f) *Iodoform delirium*; and (g) *Mercurial poisoning*.

(a) *Recurrent or intermediary hæmorrhage* usually occurs either from a vessel which has escaped ligature, or from a ligature having slipped, or from general oozing. On this account it is most important that the dressings should be inspected frequently during the first twenty-four hours after the operation. If they are found to be soaked through, and even when they are not, particularly if the patient's condition indicates loss of blood (since hæmorrhage may have taken place upwards into the colon), all the packing in the wound should at once be removed and the source of the bleeding sought for, if necessary, under an anæsthetic. If a definite bleeding point be found, the vessel should be ligatured, but if the escape of blood be due to general oozing, the whole wound should be sprayed with a solution of adrenalin chloride (1 to 2,000), and if this fail to stop the hæmorrhage it should be packed with strips of lint soaked in tincture of perchloride of iron.

(b) *Secondary hæmorrhage*.—This is very seldom met with. It may, however, occur during the separation of a slough, and, therefore, sloughs should never be forcibly removed. It is better, when these are large, to cut away the partially detached portions from day to day. Firm pressure may suffice to check hæmorrhage arising from this cause, but when it continues a ligature should be applied to the bleeding point.

(c) *Abscess*.—Suppuration in the cellular tissue of the pelvi-rectal space is more likely to ensue when excision of the rectum has been performed without a preliminary colostomy. This is probably due to the fact that the intestinal contents must be evacuated through the wound during the healing process.



and before the granulation tissue has established a sufficient barrier against septic absorption. When, therefore, preliminary colostomy has not been performed, it is of great importance that the wound should be carefully cleansed of fæcal material after each action of the bowels. Pelvi-rectal abscess may, however, supervene in cases in which a preliminary colostomy has been performed, and is then due either to septic absorption taking place from sloughing foci in the wound itself, or to extravasation having taken place prior to the colostomy. As pointed out above, the blunt dissection necessary in extirpation of the rectum sometimes results in extensive tissue necrosis, and, therefore, unless the wound is frequently irrigated with antiseptic solutions until all the sloughs have separated, pelvic cellulitis may occur. A collection of pus thus formed may extend and ultimately reach the surface in one of three directions, viz.: (1) in the gluteal region, having made its way beneath the gluteus maximus (*sub-gluteal abscess*) after leaving the pelvis through the greater sacro-sciatic foramen; (2) above Poupart's ligament near the anterior superior spine of the ilium after having extended into the iliac fossa; and (3) in the lumbar region above the crest of the ilium. The treatment consists in free incision into the abscess as soon as its presence is detected and the provision of efficient drainage.

(d) *Urethral Fistula*.—This may result from injury to the membranous or prostatic portion of the urethra during the operation, or from the introduction of a catheter for the relief of retention of urine after the operation. The latter accident may occur if the urethra has been denuded of its supporting tissue, and under such circumstances can be avoided by introducing an indiarubber catheter into the bladder before the patient leaves the operating table, and subsequently taking care to retain it *in situ*. A good method of treating an urethral fistula resulting from excision of the rectum is to carefully introduce a catheter into the bladder and to tie it in



for forty-eight hours. After this period the catheter should be changed and the bladder washed out daily. This plan of treatment answered admirably in a case of this nature which occurred in our practice, the fistulous communication ultimately closing soundly without the supervision of a urethral stricture.

(e) *Peritonitis* may occur when the peritoneal cavity has been opened during the operation, but, as a rule, it may be prevented by carefully shutting off the cavity with gauze tampons while the operation is being completed, and afterwards by accurately closing the wound in the peritoneum.

When peritonitis supervenes it may be either localized or diffuse. When localized an abscess may form and ultimately discharge through the wound. When diffuse it is generally fatal. Nevertheless, as soon as the onset of diffuse peritonitis is detected an effort should be made to save the patient's life. The best chance, we think, is afforded by laparotomy and draining the pelvis through the excision wound by inserting a large drainage tube, the pelvic cavity and its contents being at the same time carefully cleansed and wiped dry. There is some chance of this procedure doing good if the peritonitis has been detected early and is limited to the pelvis.

(f) *Iodoform delirium*.—We have seen four cases of marked delirium following the application of iodoform to the surface of the wound immediately after the operation as a part of the primary dressing. In all the cases the delirium subsided when the iodoform had been discontinued. Since abandoning its use in these cases we have not had a case of delirium.

(g) *Mercurial poisoning*.—When a strong solution of perchloride of mercury is used for dressing the wound great care should be taken to sponge the surface dry. If this is not done the solution left in the wound may be absorbed and produce symptoms of mercurial poisoning.



## RECURRENCE OF THE GROWTH AFTER REMOVAL.

Local recurrence of the growth after an operation for removal is the rule rather than the exception. This is chiefly explained by the fact that in the majority of instances the disease is well advanced when first seen by the surgeon, and partly also by the abundant supply of lymphatics in this region. The age of the patient also seems to directly affect the liability to return of the disease, those in the third decade of life being particularly liable to speedy recurrence. The parts in which reappearance of the disease is most likely to occur are the peri-anal skin, the portion of the bowel immediately above the point of section, the pre-sacral lymphatic glands, the pelvic lymphatic glands, neighbouring viscera and the levator ani muscles. The lines of extension during the existence of the primary growth appear to be downwards as well as upwards and laterally.

If the primary growth involved the lower part of the anal canal or the skin of the anal margin, recurrence should also be looked for in the superior group of the superficial inguinal glands. We have now under observation a case in which these glands became enlarged six months after the rectum had been removed. The glands were removed about one year ago and there has not been any further recurrence in this case either in the rectum or in the inguinal region.

In patients under thirty years of age the growth is usually in the lower half of the rectum and recurrence in such cases is much more likely to begin in the skin margin unless at the time of the excision the skin has been very freely removed (see fig. 22).

*Signs of recurrence.*

In cases where colostomy has also been performed, and the rectum has been subsequently removed, and the wound resulting therefrom has healed, natural healthy mucus is all



that escapes from the perineal opening when such exists. As soon as recurrence begins to take place this mucus is increased in quantity, loses its natural colourless appearance and becomes offensive in odour. Bleeding also begins to reappear though it is seldom as copious as it was before the removal of the primary growth. Pain of an aching character in the lower part of the sacrum and perhaps radiating down the thighs and to the glans penis, reappears as the result of the implication of neighbouring nerves.

When the finger is introduced into the perineal orifice, definite induration is felt at one or other of the points indicated above, and some bleeding nearly always follows the examination. The patient also again begins to lose weight though this will have usually increased considerably since the removal of the primary disease.

In those cases in which colostomy has not been performed, to the above symptoms are added, frequency in the actions of the bowels, later on difficulty in defæcation, local pain when the bowels act and aggravated reflex pain. The bleeding also is much more profuse, in fact, the patient under these circumstances suffers severely, because a preliminary colostomy has not been performed.

### *Treatment.*

When recurrence has been found to have taken place, no time should be lost in attempting to remove, if possible, the recurrent growth. In one case under our care, a female seventy-two years of age, recurrence took place within a year after the primary removal. After the second removal a period of nearly two years elapsed before the growth again recurred. When the recurrent growth, either from its position or from implication of neighbouring viscera, cannot be removed, much can be done to relieve the pain, hæmorrhage and discharge by scraping away as much as possible of the growth under an anæsthetic. The scraping procedure may be carried



out either with the finger nail or with a blunt Volkmann's spoon. No undue force should be used and the base of the growth should not be removed lest perforation of the bowel or neighbouring viscera should occur, but the scraping should be continued as long as soft portions of the growth continue to be brought away. As a rule free bleeding takes place, but this ceases spontaneously after the scraping has been discontinued. So far as we have observed the scraping process is effective in allaying the symptoms, alluded to above, for a period varying from about eight to twelve weeks, after the elapse of which the recurrence of the growth again reproduces the symptoms. A repetition of the scraping is sometimes possible.

#### CASES UNSUITABLE FOR REMOVAL OF THE GROWTH.

Unfortunately this class of case is frequently met with chiefly because the disease is so far advanced when the patient first comes under the notice of the surgeon. The growth has then probably not only extended upwards beyond the reach of the finger, but it has also become firmly fixed from infiltration of the peri-rectal structures. As soon as the case has been adjudicated as *unsuitable for removal*, the question at once arises as to the most appropriate treatment to be adopted. When the disease pursues an unhindered course, obstruction of the lumen of the bowel sooner or later occurs, either from exuberance of the growth, invagination of the diseased segment, or from lateral compression due to involvement of neighbouring structures. The best means of averting obstruction is to provide an artificial anus in the bowel above the disease—that is to say, to perform *colostomy*. This being so, the point to be decided is, *How soon should colostomy be performed?* Opinions differ considerably, many being in favour of postponing the operation until definite signs of impending obstruction have appeared. We do not agree with this view,



and have no hesitation in expressing our conviction that in these cases colostomy should be performed as early as possible. Our reasons for this opinion are—

(1) The mortality after the operation is very much lower in cases in which obstruction is absent at the time of the colostomy than when the converse obtains. In fact, the mortality increases *pari passu* with the degree of obstruction present.

(2) The sigmoid colon, prior to the onset of obstruction, is seldom distended with firm fæces, or bound down by adhesions, and therefore, in the majority of cases, can be drawn well out of the wound in order to ensure an efficient spur.

(3) The constant bearing down pain in the rectum, which steadily increases as the disease advances, is greatly relieved by colostomy.

(4) The rate of growth of the carcinoma is, we believe, diminished by the prevention of the local irritation, due to the passage of fæces over it.

(5) The supervention of peri-rectal abscess and fistula is rendered less probable by the prevention of fæcal extravasation.

(6) Abrasion of the surface of the growth is prevented, and consequently hæmorrhages are not so prone to recur.

(7) Actions of the bowels can take place without attendant pain, and are greatly reduced in frequency. This materially improves the general condition of the patient.

(8) In some instances, growths which, prior to colostomy, appeared to be unsuitable for removal, are found to be amenable to excision after colostomy has been performed, because the irritation of the growth and the congestion of the peri-rectal tissues, due to constant straining, have been removed.

(9) After colostomy has been performed, the patient may be rendered more comfortable by removing a considerable



portion of the lower part of the growth and scraping away the upper part, even when total extirpation is impossible.

Hence the advantages accruing from colostomy in the treatment of cases of carcinoma of the rectum which are unsuitable for excision, seem to us to outweigh all the arguments usually urged against such a procedure.

Inoperable carcinoma of the rectum sooner or later terminates in attacks of obstruction which can be permanently relieved only by colostomy, and, therefore, there is nothing to be gained by postponement. As we have already stated patients, especially women, strongly dislike the idea of passing their motions in an unnatural manner, but we find that they can be induced to overcome this by pointing out that colostomy is really the choice of the less of two evils. On the one hand, there is constant bearing down pain in the rectum, frequent painful actions of the bowels, and daily losses of more or less blood; on the other, there is the inconvenience of an unnatural defæcation, but great amelioration of pain and bearing down, far fewer actions of the bowels, and a considerable decrease in the quantity of blood lost, if not a complete cessation of all hæmorrhage.

It is our experience that those patients who have chosen the latter alternative have not regretted it. It must be said, however, that as the disease advances, the sacral plexus of nerves is ultimately involved, causing pain which colostomy does not relieve, but this does not occur, as a rule, for some considerable time after the growth has reached the stage when removal is impossible. Consequently if the operation of colostomy be postponed until signs of impending obstruction have manifested themselves, the period during which freedom from pain can be obtained will have been considerably shortened. When colostomy is adopted simply as a means of attempting to save the patient from death from intestinal obstruction, much of the relief from pain which could have been given by an earlier artificial anus has been lost. Even



when colostomy has been performed early, the pain eventually returns after a longer or shorter period of ease. But this fact does not, we think, justify either the postponement or the exclusion of colostomy.

As these cases are sometimes seen by the surgeon for the first time when the symptoms of chronic intestinal obstruction have already manifested themselves, it becomes necessary that the treatment of carcinomata of the rectum which are *unsuitable for removal* should be considered under the two following heads, viz.: (a) *prior to the occurrence of obstruction*; and (b) *when the symptoms of obstruction are present*.

(a) *Prior to the Occurrence of Obstruction.*

In these cases the operation of left iliac colostomy should be performed. In order that the operation may effectively serve its purpose, several important points should be attended to. First, the opening through the abdominal parietes should only be made large enough to admit the index finger, the muscular fibres being separated by the handle of the knife and not divided. In this way some degree of sphincteric closure of the artificial anus may be obtained. Secondly, the segment of the sigmoid colon which is to be drawn into the wound, must be that which adjoins the fixed descending colon. In this way the probability of procidentia of the colon taking place from the upper opening is diminished. Thirdly, the parietal peritoneum should not be sutured to the skin, because by doing so the bowel cannot be directly united to the muscular edges of the wound. If the parietal peritoneum be sutured to the skin, union necessarily takes place between two peritoneal surfaces, with the result that in time the bond of union stretches and allows the "spur" of the colostomy to drop back. Should this occur, the artificial anus becomes a lateral opening into the colon and fæces are able to pass into the portion of the bowel below the opening, thus doing away with the most important feature of the operation, *i.e.*, the prevention



of fæces from passing through the diseased rectum. Fourthly, the loop of bowel should be firmly fixed outside the wound so as to form an efficient and durable spur.

### LEFT ILIAC COLOSTOMY.

This operation, when performed *prior to the occurrence of obstruction*, may be regarded as a perfectly safe procedure. The mortality attending it is no greater than that after an ordinary laparotomy performed under aseptic conditions. From an analysis of our own cases, we estimate the mortality at about one per centum.

#### *Preparation of the Patient for the Operation.*

The patient should be kept in bed for at least three days before the operation, during which period a light and nutritious diet should be ordered, of which rice and milk should form a substantial part, in order that the fæces in the colon may be of a firm consistency at the time of the operation. We have also found it advantageous, during this period, to administer small doses of opium in an astringent mixture, so that peristaltic movements of the bowels may be diminished as much as possible. Purgatives should be strictly avoided, because, in addition to the risk of causing rupture of the bowel above the diseased area (see page 134) an empty sigmoid colon is much more difficult to find, through a small opening in the abdominal wall, than one which contains firm fæces. When it is necessary to enlarge the abdominal wound in order to find a collapsed sigmoid, the power of subsequent control over the artificial anus will be materially diminished.

At least twelve hours before the operation the pubes should be shaved and the skin of the abdomen carefully prepared. An aseptic dressing should then be applied. Food of any kind should not be given for at least twelve hours before the operation.



*Instruments Required.*

These are: scalpels, pressure forceps, straight and curved hagedorn needles, needle-holder, silk (No. 12 and 3 plaited) and silk-worm gut sutures, catgut ligatures, director, blunt pointed straight scissors, two pairs of dissecting forceps and retractors.

*Method of Operating.*

The technique of the operation is best described in its various stages, namely: (1) *the skin incision*; (2) *making the opening through the abdominal parietes*; (3) *method of dealing with the parietal peritoneum*; (4) *locating the sigmoid colon and determining the segment to be fixed in the wound*; (5) *method of fixing the segment of colon in the wound*; and (6) *completion of the operation*.

(1) *The Skin Incision.*—This should be from two to two and a half inches long, and should be made at right angles to an imaginary line drawn from the left anterior superior iliac spine to the umbilicus, its centre being at a point one and a half inches from the spine. The length of the incision should be varied according to the depth of the subcutaneous fat. In obese patients an incision of three or more inches may be necessary.

(2) *Making the Opening through the Abdominal Parietes.*—The subcutaneous fatty connective tissue is divided throughout the length of the skin incision until the aponeurosis of the external oblique muscle is exposed. All bleeding vessels are now secured by pressure forceps, and either twisted or tied. An incision about one and a half inches long is then made through the aponeurosis of the external oblique, its centre corresponding to that of the skin incision. The edges of the aponeurosis being held aside by pressure forceps, the fibres of the internal oblique and the transversalis muscles are *separated* in the direction of their respective fibres by means of blunt dissection



either with the handle of the scalpel or some similar instrument, or with the index fingers. *On no account should any of these muscular fibres be divided.* The process of separating the fibres is carried on in the depth of the wound until the *transversalis fascia* is reached. This structure is recognised by its white appearance and should be picked up by pressure forceps. A second pair of forceps having been placed on the fascia close to, and opposite, the first pair, the fascia is drawn towards the surface with the forceps and an incision, an inch long, is then made between them. The extra-peritoneal fat is thus exposed, which, if it exist in any quantity, should then be torn through with dissecting forceps in order to lay bare the peritoneum. All bleeding vessels having been secured the peritoneum should be carefully lifted off the underlying intestine and divided to the extent of an inch. The opening thus made through the abdominal parietes should be just large enough to admit the index finger and no larger. It is true that the subsequent steps of the operation are greatly facilitated by dividing the muscular and peritoneal layers to the full extent of the skin incision, as by so doing two or three fingers, or even the whole hand, can be introduced into the abdominal cavity for purposes of exploration; but against this, there are the distinct disadvantages of subsequent want of control over the artificial anus and the somewhat extensive pro-cidentia of the colon, neither of which will occur in so marked a degree when an opening not exceeding one inch in length has been made.

(3) *Method of dealing with the parietal peritoneum.*—There are at least three methods by which the parietal peritoneum may be dealt with, viz., (1) it may be sutured to the skin by either an interrupted or a continuous suture; (2) it may be sutured to the sides of the loop of extruded colon; or (3) it may be left unsutured. Suturing the edges of the parietal peritoneum to the skin margin is often practised, and is certainly useful on account of affording a peritoneal surface



for the colon to adhere to. We have employed this method in many cases but have now discontinued it, because after a few months the spur recedes so much that at times faeces pass onwards into the bowel below the colostomy. When the wound in the abdominal parietes is large, it may be necessary to suture the peritoneum to the bowel to prevent subsequent extrusion of omentum or coils of small intestine. As we always make a very small opening in the abdominal parietes

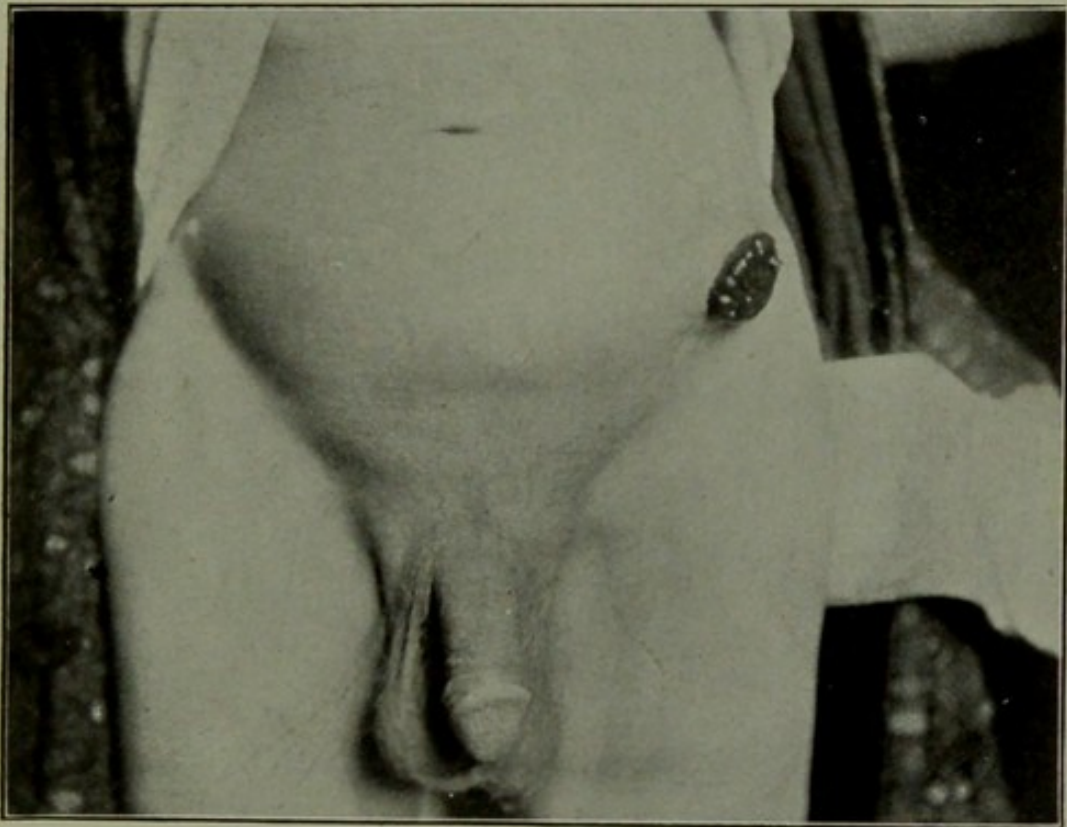


FIG. 23.—ARTIFICIAL ANUS RESULTING FROM DIRECT UNION OF THE COLON TO THE MUSCULAR PARIETES.

we have never adopted this procedure. When the opening in the abdominal wall is small, the edges of the parietal peritoneum need not be sutured to the loop of colon brought out through the wound, because these structures will be in close apposition on account of the loop completely filling the wound. This is the course we now always adopt, and we find that firm and unyielding union takes place when the colon adheres directly to the aponeurotic and muscular structures of the



abdominal wall. Moreover, the tendency to protrusion is less and the spur does not recede. Fig. 23 shows the artificial anus resulting from direct union of the colon to the muscular parietes; whereas, fig. 24 depicts an artificial anus resulting from inter-peritoneal adhesion. It will be seen that whilst in the one there is hardly any protrusion, in the other it is well marked.

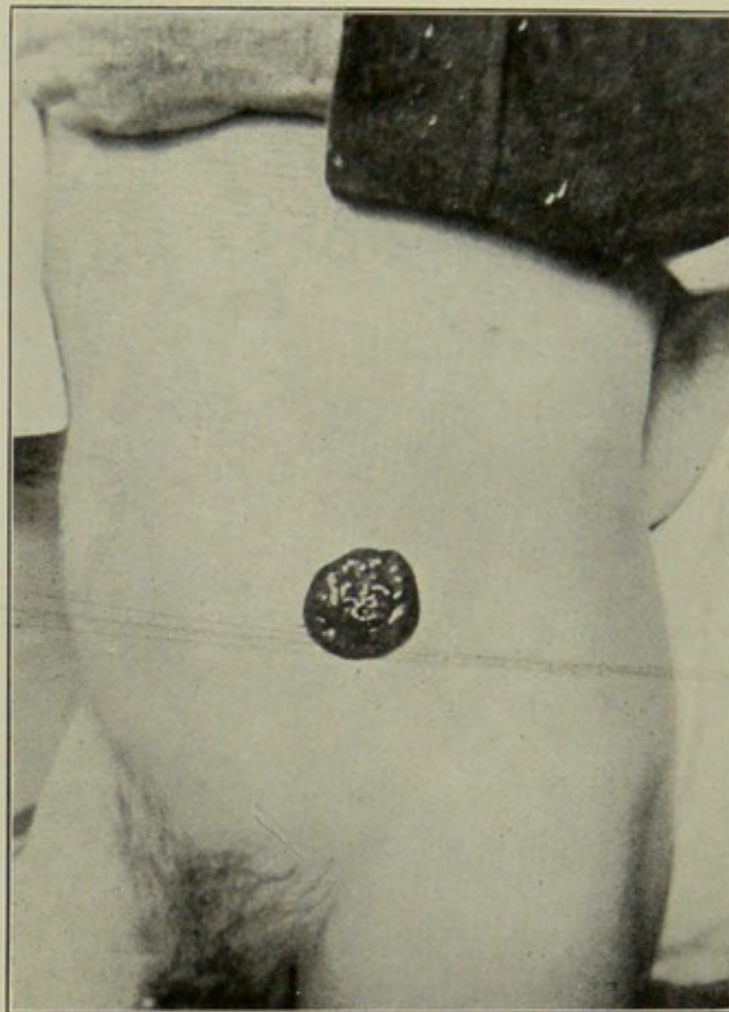


FIG. 24.—AN ARTIFICIAL ANUS RESULTING FROM INTER-PERITONEAL ADHESION.

The spur in the former cannot be readily pressed back, but in the latter it can be easily made to recede. This practice of not suturing the peritoneum should not be made use of, however, in cases in which the colostomy is not intended to be permanent.



(4) *Locating the sigmoid colon, and determining the segment to be fixed in the wound.*—This is easily done when the opening through the abdominal wall is large, and will admit of two or three fingers being introduced into the wound. Under these circumstances the edges of the wound can be held apart by retractors and the sigmoid colon exposed to view. When, however, the opening is only large enough to admit of the introduction of the index finger, some difficulty may be, and often is, experienced in finding the colon unless a definite method be adopted. As a rule, the great omentum or a coil of small intestine lies immediately beneath the opening in the peritoneum and prevents the sigmoid from being felt. The plan which we adopt, and which we have never found to fail, when the sigmoid colon is normally situated, is immediately to pass the tip of the left index finger down to the inner aspect of the anterior superior spine of the left ilium. If from this point the finger is passed along the inner border of the crest of the ilium towards the vertebral column, a portion of intestine, longitudinally placed, will be met with before the psoas muscle is reached. This is the lower part of the descending colon, and usually has no mesentery. By passing the finger over this, and flexing its distal phalanx, and withdrawing it while the tip is maintained in contact with the posterior pelvic parietes, a loop of bowel, which cannot be anything else than the first part of the sigmoid, will be drawn from the abdomen. Having ascertained by the usual characteristic appearances that the portion of bowel withdrawn is the large intestine, traction is made upon the upper part of the loop until all the loose part has been withdrawn. It is thus rendered certain, that the proximal end of the extruded loop is in direct continuity with the fixed descending colon. The distal portion of the loop is then replaced into the abdomen until a segment of requisite size is left protruding through the wound. Having made sure that a piece of omentum or a coil of small intestine is not entangled between the inner margin of the



wound and the segment of colon, the fixation of the latter is next proceeded with. If the operation have, so far, been performed as described above, it will be found that the aperture in the abdominal parietes has been completely filled with the sigmoid loop, and that the edges of the wound are everywhere in apposition with it.

(5) *Method of fixing the segment of colon in the wound.*—We think that the best way of doing this is as follows:—First the mesentery of the extruded loop is anchored to the skin above the inner margin of the wound. This is done by transfixing a piece of skin, one inch wide, at a point one inch above the centre of the inner margin of the wound, with a straight hagedorn needle carrying a long piece of No. 16 plaited silk. The needle is then passed through the mesentery, close to one extremity of the loop of protruded colon, and back again close to the other extremity. When passing the needle through the mesentery, care should be taken to avoid transfixing the blood vessels contained in it. It is important that a piece of the mesentery at least half an inch in width be included between the points of transfixion, lest the suture cut its way out too soon. The ends of the suture are then tied firmly, with the result that the loop of colon is drawn well out of the wound and maintained in that position. This method of anchoring the mesentery to the upper margin of the wound effectively prevents subsequent protrusion of omentum or small intestine, unless the opening through the abdominal parietes has been made larger than we have indicated.

The skin of the lower margin of the wound is transfixed for a quarter of an inch, at a point situated about half an inch from the inner angle, by a needle carrying a suture which is also passed beneath the anterior longitudinal muscular band at the inner extremity of the loop and then firmly tied. A similar procedure is carried out at the outer angle of the wound, the skin of the upper margin being transfixed instead of the lower.



(6) *Completion of the operation.*—The extremities of the skin incision are then closed by silk-worm gut sutures, and all the larger appendices epiploicæ are ligatured and removed. At this stage, the question arises as to the time when an opening into the bowel should be made. We always make a small opening into the protruding loop of colon *as the final step in the operation*. The object of this is to afford a free vent to flatus and so obviate flatulent distension of the abdomen after the operation. So far as our experience goes there is absolutely no risk attending this procedure because, unless an aperient have been administered before the operation, nothing but flatus escapes from the opening for five or six days as a rule. Some surgeons defer making the opening into the bowel in these cases (*i.e.* when intestinal obstruction is absent) for a period varying from twenty-four hours to four or five days, in order to ensure firm union taking place between the edges of the wound and the bowel before the contents of the colon are allowed to escape. We are constrained to think that this is a mistake, because, not only is the intermediate flatulent distension of the abdomen distressing and sometimes dangerous to the life of the patient, but the increasing distension of the loop of colon outside the abdomen interferes with firm union taking place between it and the abdominal wall. Indeed, we cannot help thinking that the somewhat high rate of mortality shown in the statistical returns of some of our large general hospitals is due to the fact that the opening of the bowel is too long deferred. We recommend, therefore, that a small opening, from a quarter to half an inch in length, be made into the centre of the protruded loop of bowel as the final step in the operation. However, before this opening is made, we always carefully pack with small pieces of cotton wool, wrung out in 1 in 500 perchloride of mercury solution, the space between the margin of the skin wound and the loop of colon so as to prevent any leakage into the peritoneal cavity. When this



has been done, the wound should be dressed with a piece of lint, upon which either some zinc ointment, or vaseline has been spread. An aperture should be cut in the lint to correspond to the opening in the bowel. This dressing further protects the margin of the wound should fæces escape before adhesion of the surfaces has taken place. The whole is then covered by sterilized gauze and wool, which are retained in position by strips of indiarubber strapping, and a many-tailed bandage.

### *After Treatment.*

If the patient have been dieted, and small doses of opium have been administered during the three or four days preceding the operation, as before mentioned (see page 182), the fæces in the colon above the seat of the colostomy will be firm, and therefore, flatus alone will escape through the small opening made into the bowel at the time of the operation. It is well, however, to inspect the opening within an hour or two after the patient has been replaced in bed, lest some fæcal matter should have escaped during the removal from the operating table. If this have happened, the part should be carefully cleansed and a fresh dressing applied. As soon as all tendency to post-anæsthetic sickness has passed off, twenty minims of the liquor opii sedativus should be given, with a drachm of water. After this, the liquor opii sedativus or tinctura opii should be given in five minim doses at two-hourly intervals, until sound sleep has been procured. Subsequently five minims should be given every six hours until the bowels have acted freely. The primary effect of the opium is to confine the bowels, but at the expiration of from six to eight days, or perhaps, though rarely, longer, liquefaction of the fæces occurs, and liquid motions are passed without the aid of aperients. When opium in small doses is given continuously for several days it acts as an aperient. We are fully convinced of the value of this



observation, and have found its application most successful in the after treatment of colostomies. One of the objections to the use of opium in abdominal cases is that considerable flatulent distension may result, but this cannot occur when the sigmoid has been opened at the time of the operation because a free vent for flatus has been provided. About twenty-four hours after the operation the small opening in the colon should be enlarged to the extent of an inch to an inch and a-half. Should some flatulent distension occur, the opening in the bowel must have become blocked, and should therefore be inspected. Occasionally, a hard mass of fæces in the descending colon may prevent the escape of flatus. When this occurs the finger should be gently introduced into the descending colon, and the mass broken up by pressing it against the inner aspect of the iliac spine. The utmost care, however, must be exercised in doing this, lest the adhesions of the bowel to the margins of the abdominal wound be torn asunder. As a rule, a sufficiently firm union in this situation will have taken place on the third or fourth day. The "spur" is now found to be prominent and œdematous by reason of the constricting effect of the mesenteric suture. The aperture leading into the descending colon is situated above the spur, while that leading into the sigmoid colon is below it, unless the sigmoid colon has been half turned round during its withdrawal.

At the end of four days the sutures at the angles of the wound may be safely removed, but it is desirable to leave the mesenteric suture *in situ* for seven or eight days, unless a stitch abscess should occur in the vicinity of the skin punctures. The lateral margins of the bowel incision gradually become everted, and at the expiration of about five weeks, the mucous membrane of the bowel appears to be directly continuous with the skin margin. Some surgeons remove the protruding loop of the bowel, but this we think is undesirable, because the continuity of the colon is lost and also the support of the



mesentery. As a consequence of such a procedure, procidentia from these apertures may occur to a considerable extent, and occasion much discomfort. A further and greater

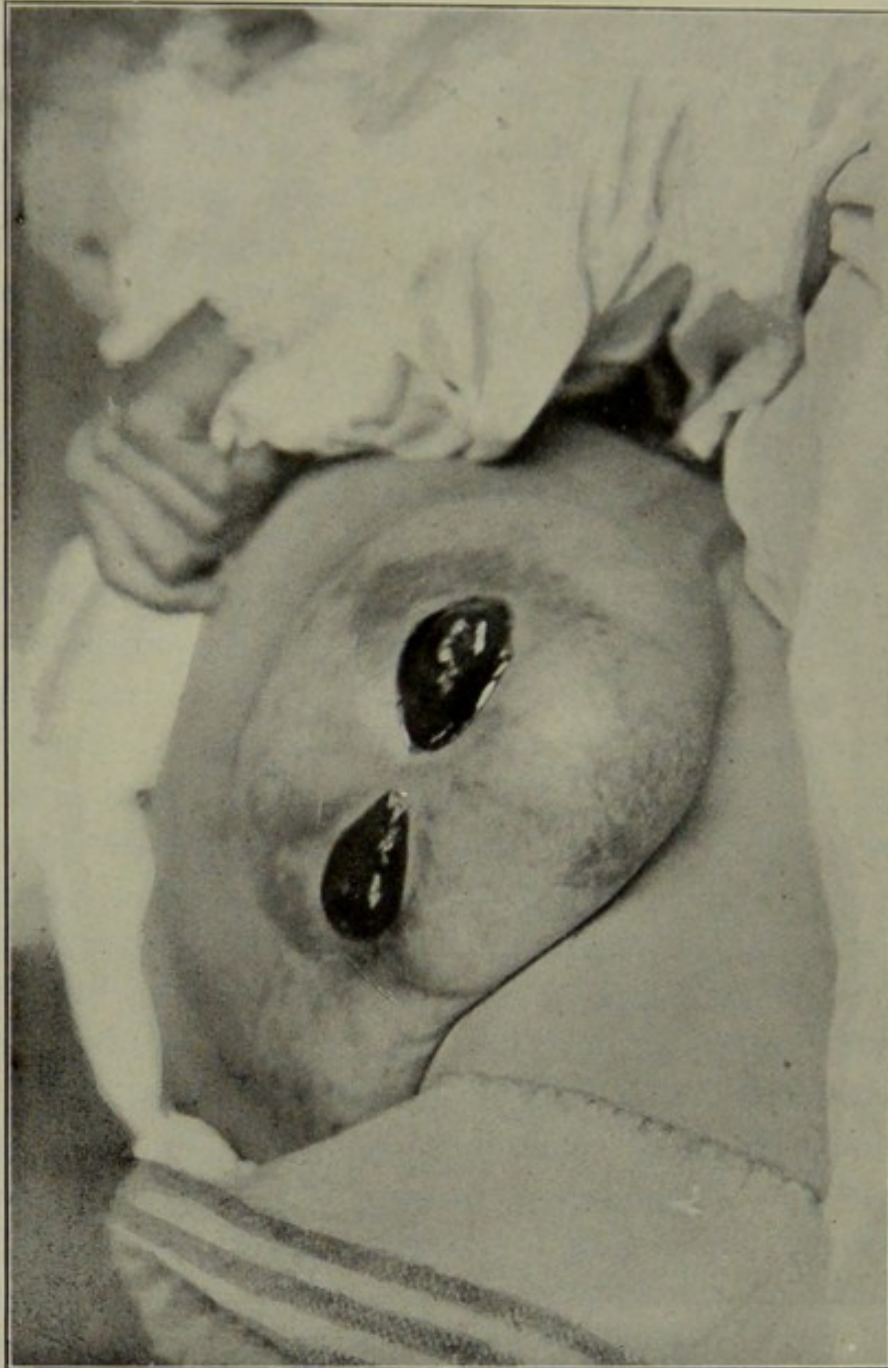


FIG. 25.—AN ARTIFICIAL ANUS SHOWING THE TWO DISTINCT OPENINGS AFTER REMOVAL OF THE SPUR. AN EXTENSIVE VENTRAL HERNIA HAS ALSO RESULTED FROM THAT PROCEDURE.

disadvantage is the possibility of a ventral hernia taking place as a result of the loss of the continuity of the colon and the removal of the support of the portion of the mesentery



attached to the part of the colon removed between the openings. The accompanying illustration (see fig. 25) shows such a condition which resulted after the spur of the

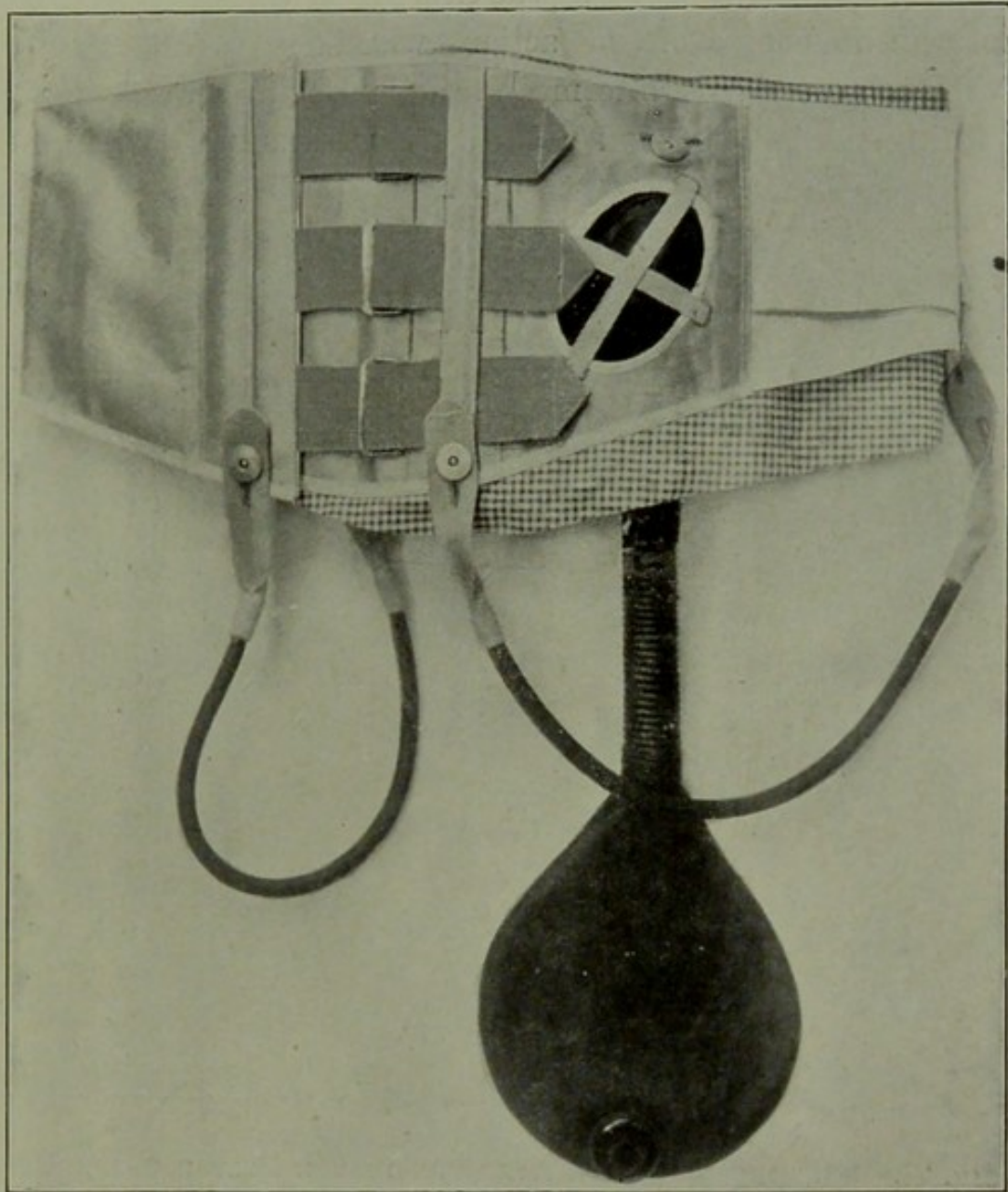


FIG. 26.—SHOWING THE BELT WITH THE CUP AND RECEIVER ADJUSTED.

On the left side the elastic webbing is well shown.

colostomy had been removed. This procedure, however, effectually prevents the passage of fæces into the rectum.

As soon as the bowels have commenced to act of their own accord, an injection of an ounce of olive oil into the descending



colon at night will facilitate the softening in the colon of any remaining hardened masses of fæces. The patient should now be instructed to encourage the bowels to act in the morning and evening by gently massaging the cæcum. If this be persevered with, in the course of time actions will take place at one or both of these periods (intermediate actions being the exception) nothing perhaps beyond a little flatus escaping during the

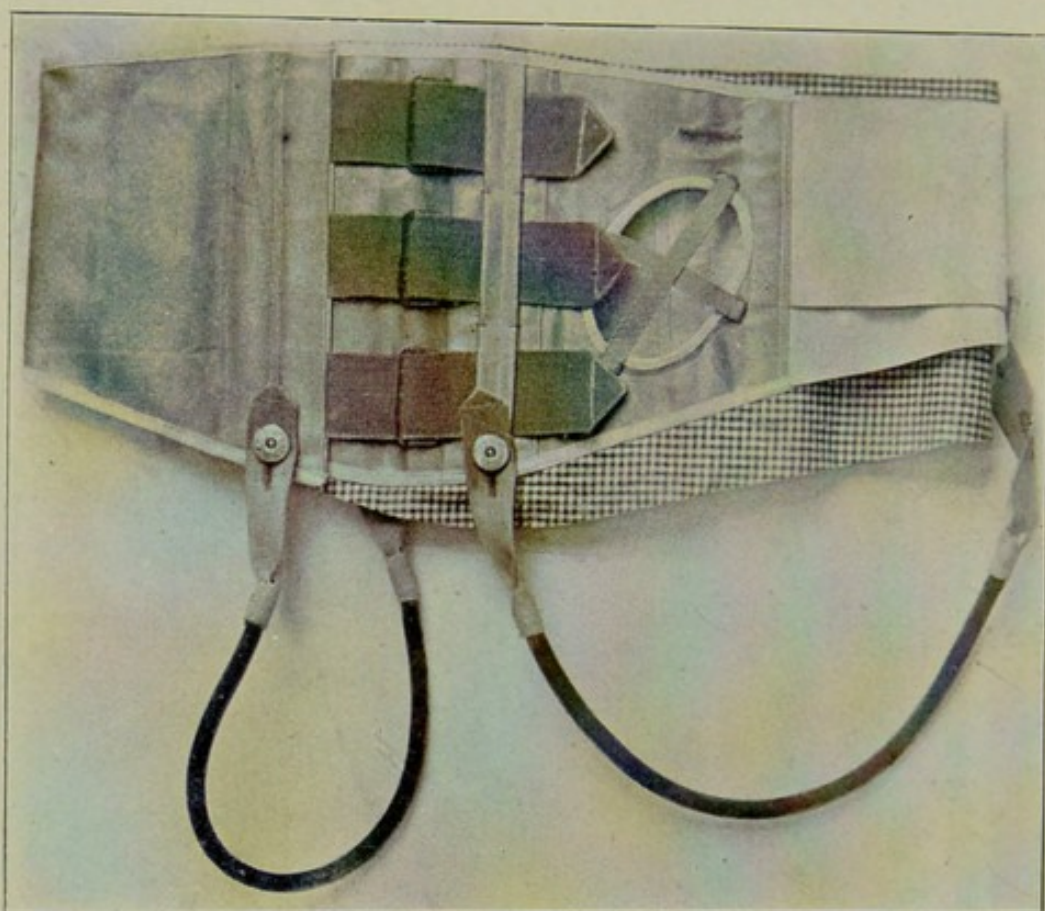


FIG. 27.—SHOWING THE OVAL APERTURE IN THE BELT FOR THE CUP-SHAPED PAD AND ALSO THE ELASTIC BANDS FOR ASSISTING IN KEEPING THE PAD IN POSITION.

intervals. He should, later on, be shown how to introduce the right forefinger to its full extent into the upper opening in order to prevent possible stenosis of that aperture.

At the end of three weeks he may be measured for a belt, and as soon as it has been adjusted, he may be allowed to get



up. The kind of belt which we have found to be most serviceable is that shown in figs. 26 and 27.\*




FIG. 28.—SHOWING THE CUP-SHAPED PAD WITH THE RECEIVER ATTACHED.

The internal diameter of the india rubber tube between the pad and the receiver should be not less than one inch

---

\* Made for us by Coles and Co., 356, Kingsland Road, N.E.



Patients, upon whom the operation of colostomy has been performed, should always wear an abdominal belt for support

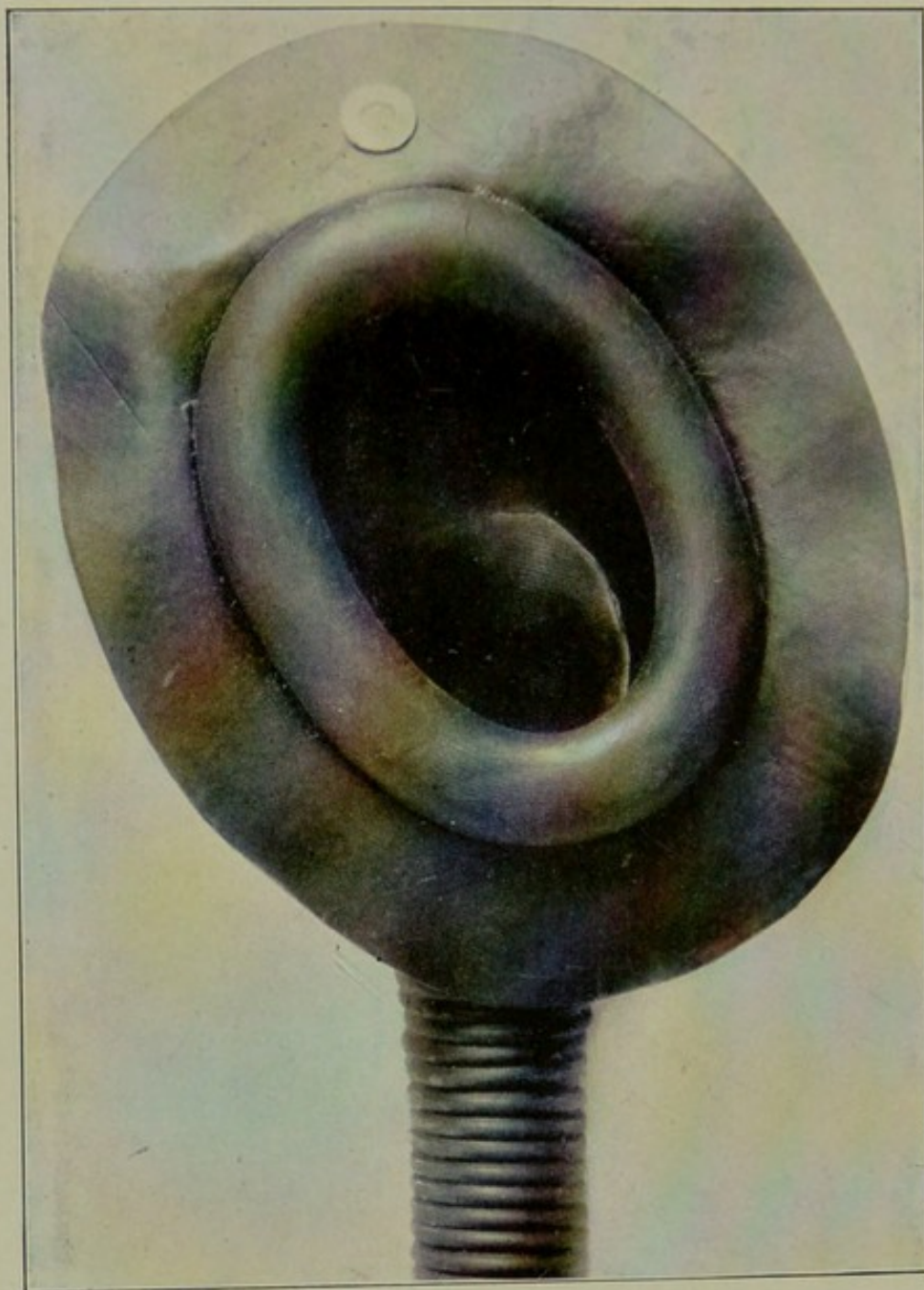


FIG. 29.—INTERNAL VIEW OF THE CUP-SHAPED PAD, SHOWING THE SOLID RUBBER MARGIN OR RIM, AND THE APERTURE LEADING INTO THE TUBE.

when they are out of bed. It should have a cup-shaped pad fixed into it at the site of the artificial anus. We have had a



special kind of belt made for us, which we have found very satisfactory. It consists of an ordinary abdominal belt, into which a double layer of elastic webbing (four inches in width and five inches in depth) has been inserted on both sides




FIG. 30.—SHOWING THE BELT AND RECEIVER ADJUSTED.

where pressure is made over the anterior superior spine of the ilium (see figs. 26 and 27). An oval aperture is situated where the belt crosses the artificial anus. The long diameter of this is directed downwards and inwards (see fig. 27).



Into this aperture an oval cup-shaped pad, with or without a tube and bag for the reception of fæces, is fixed by means of buttons and elastic bands (see fig. 26). The cup, which is from one and a-half to two inches deep, is made of copper covered with india-rubber, having fixed at its brim a solid round band of india-rubber half an inch in diameter (see fig. 29). The brim of the cup measures two and half inches in the long and one and half inches in the short diameter. Two india-rubber perineal straps are fixed to the belt to assist in keeping it in position. When the belt has been adjusted, the receiver rests upon the thigh, its lower margin being just above the knee (see fig. 30).

*Diet after the operation.*—During the first twenty-four hours, only a little water in small quantities should be given. During the second twenty-four hours, half a pint of milk and an equal quantity of water should be allowed. During the third twenty-four hours, one pint of milk and one pint of water is all the nutriment that need be given. After this, and until the bowels have commenced to act, two pints of milk and one of water may be allowed during each period of twenty-four hours. As soon as the bowels have acted freely, solid food should be given in increasing quantities until an ordinary diet is attained. We seldom give alcohol in these cases.

If the patient's powers of mastication are faulty, as they often are in these cases, the light diet with the addition of fish, pounded meat, and bread and butter should be continued.

#### *Complications during and after the Operation and their Treatment.*

*Complications during the operation.*—These arise in connection with the length of the sigmoid mesentery, the mobility of the sigmoid colon and its possible absence from its normal position. When the mesentery is either absent or short, or when the colon itself is bound down to the iliac fossa by an



extension of the disease, it is generally impossible to withdraw from the abdomen a loop of colon of an adequate size to furnish an efficient spur. Under these conditions the choice lies between establishing a sigmoid faecal fistula and abandonment of the operation of left iliac colostomy altogether; or the performing of either cæcostomy or lumbar colostomy. We think that either of the latter is better than a faecal fistula in the sigmoid colon. In rare instances the sigmoid colon does not occupy its normal position, either from defective development or from the transposition of the viscera. As an example of this complication we may mention the following case, in which, after the preliminary stages of the operation of left iliac colostomy had been completed, the sigmoid colon could not be located. The descending colon could not be made out in its natural position in front of the kidney, nor could the sigmoid be felt in front of the left sacro-iliac synchondrosis. Median laparotomy was then performed for the purpose of ascertaining the position of the sigmoid colon. An interesting instance of imperfect development of the large intestine was then revealed. The cæcum was situated high up beneath the right lobe of the liver and the transverse colon extended only to the middle line. The colon then passed downwards and outwards into the right iliac fossa and onwards into the pelvis. This longitudinal portion of the bowel was attached by a long mesentery (about eleven inches wide), which was placed parallel to, and to the right of, the mesentery of the small intestine, and was in fact the abnormally situated sigmoid colon. The median and the left iliac openings into the abdomen were then closed and the sigmoid colon opened on the right side (see fig. 31), an excellent spur resulting.

We have already referred to the complication caused by the distension of the sigmoid and descending portions of the colon with firm faeces (see page 136).

*Complications after the operation.*—After any abdominal operation, there is always the possibility of peritonitis



supervening unless the strictest aseptic precautions have been observed. Fortunately we have not so far met with that complication after this operation, although it has been our practice for many years to make an opening into the bowel as the final step of the operation, thus showing that there is practically no risk of peritonitis being set

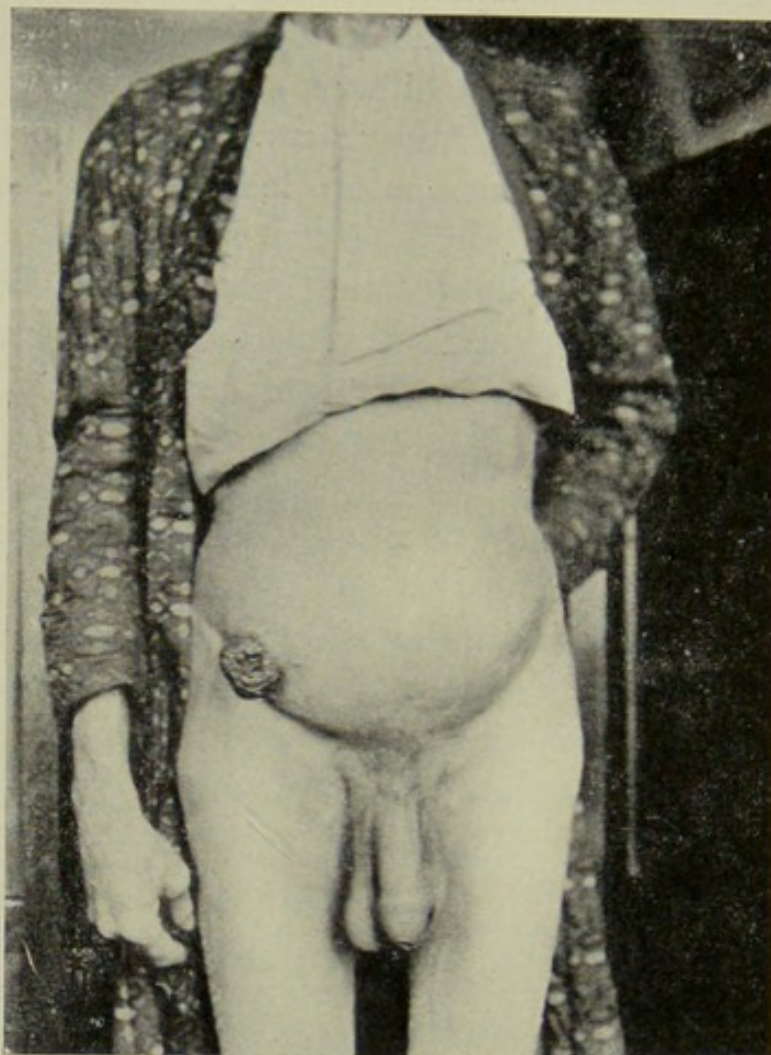


FIG. 31.—SHOWING SIGMOID COLOSTOMY ON THE  
RIGHT SIDE.

up by this procedure. It must be borne in mind, however, that the safeguard against leakage from the colostomy finding its way into the peritoneal cavity consists in the accurate filling of the aperture in the



abdominal parietes by the extruded loop of colon. If it be found that the bowel is not in close contact with the margin of the wound in its entire circumference, sutures must be introduced to obliterate any existing space before the opening is made. Setting aside, therefore, the possibility of peritonitis ensuing after colostomy as being extremely slight, we find that there are two other complications that may occur during the after-treatment, namely, (a) *abdominal distension*; and (b) *extrusion of a loop of small intestine or a mass of omentum between the inner margin of the wound and the loop of the colon*.

(a) *Abdominal Distension*.—It has been already pointed out that flatulent distension of the abdomen cannot occur when an opening has been made into the colon at the time of the operation unless that opening subsequently becomes blocked, either by agglutination of its margins, or by the impaction of a mass of faeces. Inspection of the aperture within two or three hours after the patient has been replaced in bed should prevent the adhesion of the margins. Impaction of faeces may occur at any time after the operation though it is seldom met with. When it does occur the opening in the colon should be enlarged. When, however, the opening of the colon is deferred for one or more days after the operation, a practice which is advocated by many surgeons, flatulent distension of the colon above the extruded loop occurs in the majority of cases, and in some gives rise to untoward symptoms, such as syncope, from interference with the action of the heart. Again distension of the abdomen tends to enlarge the aperture in the abdominal parietes, and so delays firm adhesion from taking place between the margins of the wound and the colon. If then the opening of the colon have been deferred, the onset of flatulent distension should indicate the time when the opening must be made. By thus establishing a free escape for flatus, the abdominal distension at once subsides and is not likely to recur unless the aperture become blocked.



(b) *Extrusion of a Loop of Small Intestine or a Mass of Omentum between the Inner Margin of the Wound and the Loop of the Colon.*—This complication can only occur when the aperture through the abdominal parietes has been made too large and is not completely blocked by the extruded loop of colon; or when the incision of the colon has been deferred so long that considerable distension of the abdomen has ensued, and the abdominal bandage has not been applied with sufficient firmness after the operation. In such cases, vomiting or a fit of coughing may be sufficient to cause this extrusion. We have seen one such occurrence on the third day after the operation. The patient coughed violently and felt something give way in the wound. When the dressings were removed a coil of small intestine was found to have been extruded between the inner margin of the wound and the colon. The small intestine was carefully cleansed and returned into the abdominal cavity. When this had been done a small opening was made into the colon to allow of the escape of flatus, the abdomen being distended. No further extrusion took place, the patient subsequently leaving the hospital none the worse for the accident.

(b) *When the Symptoms of Obstruction are Present*

It not uncommonly happens that a patient suffering from carcinoma of the rectum does not present himself for treatment until he finds that he is unable to obtain a proper action of the bowels, and consequently the abdomen is usually much distended, and paroxysmal attacks of colicky pain are complained of. Vomiting also may have set in, especially if a strong aperient have been taken. Such cases demand prompt relief.

An exploration of the rectum having been made for the purpose of ascertaining whether the cause of the obstruction is really located in the rectum, and this having been found to be the case, attempts should first be made to procure an



action of the bowels by enemata of olive oil (from four to eight ounces at a time). Even when the growth itself has not entirely obliterated the lumen of the bowel, a sudden attack of obstruction may have been induced by a mass of fæces having become impacted at the seat of the stenosis. This fæcal mass may be sufficiently softened by the oil to allow of its passage, the attack of obstruction being thus relieved. It sometimes happens, however, that no benefit whatever is afforded by this means, and surgical interference for the relief of the obstruction becomes imperative. It is obvious that an opening must be made into the colon above the seat of the obstruction, and the question arises—*Should the colostomy be performed on the left or on the right side?* The history of the onset of the attack of the obstruction should be our guide in this matter. If the obstruction have supervened abruptly, the bowels having acted regularly and freely beforehand, the operation of *left iliac colostomy* should be performed, a Paul's tube being used, if necessary, for evacuating the contents of the colon. If, however, the attack of obstruction have gradually supervened after previous threatened attacks, the operation of *right iliac colostomy* (*cæcostomy*) is to be preferred. Our reason for this preference is two-fold. First, because, if left iliac colostomy be attempted, the descending and the sigmoid colon are often found to be so greatly distended by firm fæces that it is impossible to lift the bowel up sufficiently to make even a lateral opening into it with safety. A well-marked instance of this condition of the colon has already been referred to (see page 136). Secondly, because in all cases of chronic obstruction in the lower part of the large intestine, the seat of greatest distension is frequently the cæcum. This portion of the colon often becomes greatly distended with an accumulation of semi-solid fæces and is particularly prone, when in that condition, to ulcerate on account of its poor blood supply. Consequently, even though



left iliac colostomy may have been successfully performed, an existing stercoral ulcer in the cæcum may proceed to perforation. We have seen at least two cases of this nature, and one of these has recently been under our care. This patient, a woman aged fifty-seven, was admitted into the hospital suffering from intestinal obstruction which had existed for three days. She had during that period taken several doses of castor oil but had obtained no relief. The abdomen was considerably distended, severe griping pain was complained of and she had vomited both before and after admission, a slight stercoral odour being present. Rectal examination revealed the presence of a carcinomatous mass and olive oil enemata having been tried without success, operative interference was decided upon. Left iliac colostomy was successfully performed, a loop of the sigmoid colon having been drawn well out of the wound and anchored outside in the manner described on page 188. A Paul's tube was inserted and a large quantity of liquid fæces evacuated. All went well until the morning of the fifth day when the patient suddenly became collapsed and died two hours afterwards. At the autopsy, a perforation of the cæcum\* was found to have taken place at the site of an ulcer in its mucous coat. This ulcer was probably due to the hyper-distension of the cæcum. Another feature of interest was revealed by the post-mortem examination. The lumen of the rectum was not obliterated by the growth, but the obstruction was due to the accumulation of a large mass of fæces in a diverticulum-like distension of the anterior wall of the bowel immediately above the stenosed area. The fæces in this situation so effectively compressed the bowel against the sacrum that the obstruction was practically complete, and accounted for the failure of the enemata of olive oil. Had cæcostomy been performed in this case instead of left iliac colostomy the patient's life would have probably been saved, because the hyper-distension of the cæcum would have been effectively relieved,

\* The specimen No. 180 is preserved in the Museum of the Cancer Hospital.



and perforation of the ulcer thus averted. In such cases as these, cæcostomy need be only a temporary measure, because after the colon has been thoroughly cleared of its faecal accumulation, a process which takes from two to three weeks to be completed, left iliac colostomy may be performed and the cæcostomy closed. In this way some of the objections to making an artificial anus in the large intestine near the ileo-cæcal valve are dispensed with.

### CÆCOSTOMY.

This operation may either be performed as a temporary measure, as suggested in the circumstances mentioned above, or it may be utilized to effect a permanent artificial anus in the *right* iliac region in those instances in which left iliac colostomy is impossible, either from the sigmoid colon being bound down by adhesions, involved by the disease, greatly distended by firm faeces, or from its having too short a mesentery to permit of a loop of it being brought out of the abdominal cavity. Against cæcostomy as a temporary measure there can be no possible objection, but when the artificial anus is intended to be permanent several objections have been urged against it by some surgeons who contend that the operation is inferior to either *lumbar* or *transverse* colostomy.

The chief objections raised against permanent cæcostomy are:—

(1) *That there is a continuous escape of fluid faeces from the artificial anus on account of its proximity to the ileo-cæcal valve.* This, we do not deny, occurs during the first four or five weeks after the anus has been established, but an experience of twenty-seven cases of this operation has shown that after that period, in the majority of those cases, the faeces became firm and were voided in a semi-solid or even solid consistence. We have observed, too, that diet has much to do with the frequency of the



actions of the bowels, and that when due care is exercised in this respect not more than four or five actions take place during a period of twenty-four hours.

(2) *That the patient becomes emaciated on account of the whole of the large intestine having been almost completely short-circuited.* This contention has not been confirmed by our experience. There is, at the present time, a patient (a male) under our care, upon whom the operation was performed nine years ago. During this long interval there has been a most marked increase in weight (twenty-five pounds), and, moreover, the patient has been enabled to lead a far more active life than he was capable of doing before the operation of cæcostomy was performed. In another case, a female, also under observation, the operation was performed six years ago, since which date there has been marked improvement in her general health and her weight has increased by ten pounds. In both these cases the operation was performed for the relief of infective ulceration of the rectum involving the sigmoid colon.

(3) *That the patient's life is shortened.* The two cases cited above clearly show that when cæcostomy is performed for a non-malignant disease it does not tend to shorten life.

Accordingly we contend that for the purpose of establishing an artificial anus in cases in which left iliac colostomy cannot be performed, the operation of cæcostomy is extremely useful and is distinctly preferable to either lumbar or transverse colostomy. In our experience the cæcal artificial anus is free from danger to life, and is certainly more comfortable and convenient for the patient than either lumbar or transverse colostomy.

#### *Method of Operating.*

A vertical incision should be made, the centre of which should be one and a half inches distant from the anterior superior spine of the right ilium along a line drawn from one



anterior superior spine to the other. The length of the incision and the preliminary stages of the operation, as far as opening the peritoneal cavity, being identical with those advocated in the operation for left iliac colostomy, (see page 174) with the exception that they are carried out on the right side, need not be described here. As soon as the parietal peritoneum has been incised the forefinger is introduced to feel for the cæcum. As a rule this lies immediately beneath the wound, and when much distended readily bulges into it, but when there is much abdominal distension a coil of small intestine is generally interposed and presents itself in the wound. In such cases by adopting the plan of first defining the inner aspect of the right iliac spine and passing the finger along the crest of the ilium, there should be little difficulty experienced in finding the cæcum. It can then be hooked up, and as large a portion as possible of its anterior wall drawn through the abdominal wound. Care should be taken that the part thus withdrawn should be as far away as possible from the ileo-cæcal junction in order to avoid subsequent escape of the contents of the small intestine directly through the artificial anus. Having drawn out as much as possible of the bowel wall through the wound without causing undue tension, the bowel is held by an assistant whilst the necessary sutures are being introduced. These should be passed through the skin, the parietal peritoneum, and the peritoneal and muscular coats of the bowel in sufficient number to firmly fix the bowel to the margin of the wound in its entire circumference. This having been done, a Paul's tube may be inserted to allow of the evacuation of the contents of the colon. The following method of opening the bowel and securing the edges of the opening has also proved useful and free from danger, and has been adopted in the majority of our cases. Two pieces of plaited silk (No. 16) having been threaded through straight hagedorn needles, one



is passed through the skin about one inch from the centre of the inner border of the skin incision and for about one inch in length, and then through the whole thickness of the wall of the bowel so as to include about one inch of its length. The second suture is similarly introduced on the opposite side, the two sutures being parallel to each other and about an inch apart in the wall of the cæcum. Two other sutures are now passed, one at each angle of the wound, first, for one-fourth of an inch under the skin about half an inch from the angle of the wound and then under the longitudinal band of the cæcum and firmly tied. When these sutures have been introduced an incision one inch long is made through the wall of the bowel between the two parallel sutures, and then those sutures are firmly tied. The effect of this is that the opening made into the bowel gapes widely, and the line of apposition between the bowel and the margins of the skin incision are protected from being soiled by the escaping fæces. In our hands this method has been quite as successful as when a Paul's tube has been used. In our second case two gallons and one pint of liquid fæces escaped during half an hour after the operation. When the opening into the bowel has been made in this way it is advisable that the patient should not be moved for at least twenty-four hours after the operation. Consequently, we usually prefer to perform the operation on a bed rather than upon an operating table, unless it be possible to utilize the latter as a bed during the above-mentioned period.

A cæcal artificial anus thus made may be either *temporary* or *permanent*. It must of necessity be permanent if the sigmoid colon be affected by the disease, bound down by adhesion, or developed with a short mesentery, thus rendering iliac colostomy impossible (see fig. 32). It need only be temporary when it has been performed in a case of acute obstruction with marked distension of the cæcum, or when the sigmoid colon could not be withdrawn from the



abdomen on account of great distension by solid faeces (see page 136). As soon, therefore, as a temporary caecal anus has effected its purpose, by allowing the colon to thoroughly evacuate its contents, left iliac colostomy should be performed. After this has been done, the caecal anus will gradually

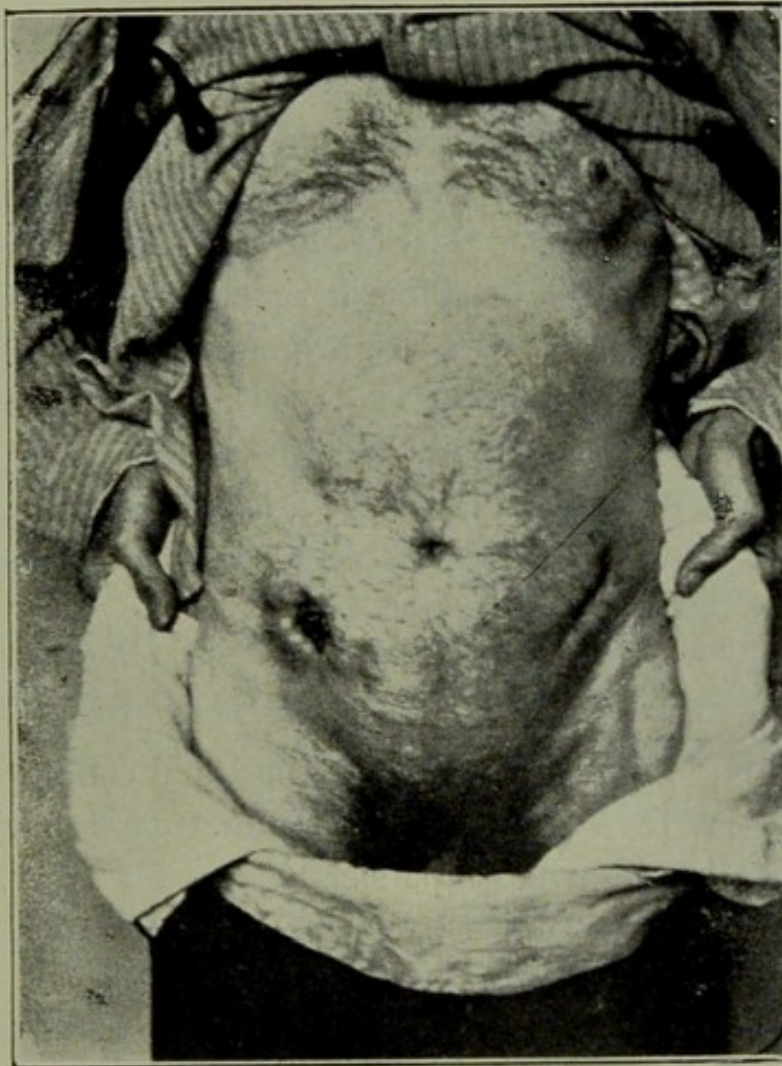

FIG. 32.—A PERMANENT CAECAL ANUS.

In this case left iliac colostomy was attempted, but could not be carried out because of the distension of the sigmoid colon with firm faeces.

contract in diameter and, in some instances, may undergo nearly complete spontaneous obliteration. As a rule, however, it falls short of this, and the greater part of this contraction occurs in about five or six weeks after the sigmoid anus has been established. The closure of the caecal anus can



then be effected with a better prospect of success than if it had been attempted earlier. The method which we adopt for closing the anus is detailed on page 211.

### *After Treatment.*

This, to a large extent, is the same as that detailed for left iliac colostomy (see page 182).

It is, however, necessary to arrange the diet so that it may not promote the passage of fluid fæces. With this object in view, during the first four or five weeks after the operation the diet should mainly consist of milk, meat, boiled rice, and bread and butter. Under this restricted diet the fæces, when passed through the cæcal anus, are often semi-solid or solid.

Before the patient is allowed to get up a colostomy belt as described on page 197 should be adjusted, excepting that the pad should be on the right side, with the long diameter of the cup vertical instead of oblique. The addition of the tube and bag will be found very serviceable.

### *Complications after the Operation and their Treatment.*

The chief of these is caused by the fluid condition of the fæces when passed direct from the cæcum. This characteristic of the material evacuated persists in almost every case for four or five weeks, and, in some, for a longer period. Unfortunately, so far as this operation is concerned, the fluid fæces, escaping on to the skin surface almost immediately after they have passed through the ileo-cæcal valve, retain much of their digestive power. Consequently, the skin immediately around the artificial anus is readily excoriated by them. Care, therefore, should at once be taken to protect the surrounding skin from this action. One of the best applications for this purpose is the Unguentum Gallæ c Opio (B.Ph.). This should be spread upon a piece of lint and kept in contact with the skin for three or four inches surrounding the cæcal anus. Should the skin become excoriated in any



part, notwithstanding the application of the ointment, the following lotion should be applied to the excoriated surface for five or ten minutes each time before reapplying the ointment:—

R Acidi Tannici gr. xxv.  
Spiritus Vini Rectificati ℥ iii.  
Glycerini ℥ i.  
Aquæ ad ℥ i.

Another important complication which may arise, if the patient does not lead a sedentary life, is the extensive protrusion of the cæcum and sometimes also of the ascending colon through the cæcal anus. When such protrusion occurs, an india-rubber tube-plug should be worn as well as the belt and cup-shaped pad.

A further complication sometimes met with in these cases is the persistent contraction of the cæcal anus. To relieve this, a tube-plug, of suitable size, should be worn.

#### *Closure of the Cæcal Artificial Anus.*

Whenever circumstances permit of a cæcal anus being closed we think it advisable to do so. The operation is practically devoid of danger and the patient's subsequent condition is greatly improved. Although, in our experience, a cæcal anus does not appear to shorten a patient's life, there are the disadvantages of frequent actions of the bowels; the fluid condition of the evacuations, unless the most careful regime in the matter of diet is observed; the risk of excoriation of the skin surrounding the anus, and the tendency to procidentia of the cæcum and the ascending colon, unless the patient systematically wears a well fitting belt and cup-shaped pad. Accordingly, we think, that when the subsequent progress of the case shows that a cæcal anus is no longer necessary, a left iliac colostomy may be substituted for it and the cæcal anus closed. The only objections that can be urged against this procedure are, we consider, that two



additional operations are required, and that the convalescence is prolonged by several weeks.

### *Method of Operating.*

An incision involving the skin only is made at the mucocutaneous junction completely encircling the cæcal opening. The incision is then extended upwards for one inch above the upper angle and also for one inch below the lower angle of the cæcal opening. The skin is now reflected on both sides for about three-quarters of an inch. The anus is then closed by suturing together the margins of the mucous coat with a continuous cat-gut suture, thus preventing the escape of fæces during the subsequent steps of the operation.

The wall of the bowel should then be carefully dissected away from the abdominal muscular parietes until the point of union between the parietal and visceral peritoneum is nearly reached. The question now arises as to whether the peritoneal cavity should be opened or not. This may be done, and after closing the aperture in the muscular and peritoneal coats of the bowel in the usual way, the cæcum may be replaced in the abdominal cavity. We do not, however, think that this is necessary and are therefore content to close the aperture in the bowel without interfering with the peritoneal adhesions. The great advantage of so doing is that should the sutures, for any reason, give way, the escape of the contents of the bowel into the general peritoneal cavity is guarded against. Having decided to close the aperture in the muscular coats of the bowel without separating it from the parietal peritoneum, a series of interrupted silk sutures are introduced after the manner of Lembert, so as to ensure sufficient inversion of the edges of the wound when the sutures are tied off. The opening in the abdominal muscles is then closed by buried silk sutures, and finally the edges of the skin wound are brought together by means of silk-worm gut or other suitable material.



We have a patient under observation in whom a temporary cæcal anus was closed eighteen months ago, in the manner described above. The scar remains quite sound and apparently the patient has suffered no inconvenience from the fact that the anterior surface of the cæcum still remains adherent to the abdominal parietes.

The same method has been adopted by us in closing temporary sigmoid artificial ani and we have not observed any ill effect resulting from the permanent adhesion of that portion of the bowel to the abdominal wall. Our first case of this kind was completed thirteen years ago and still remains perfectly sound.

#### FURTHER TREATMENT OF CASES UNSUITABLE FOR REMOVAL OF THE PRIMARY GROWTH.

This consists in treating palliatively the various symptoms as they arise during the later stages of the disease. As above pointed out, the operations of colostomy and cæcostomy are efficacious purely from the point of view that they prevent the occurrence or recurrence of obstruction and also the *distressing symptoms* due to the passage of fæces through the diseased rectum. The growth itself, however, pursues its course, and sooner or later extends by continuity of tissue into adjacent structures and gives rise to metastatic deposits in distant parts, notably the lumbar lymphatic glands and the liver. The symptoms due to such extension are not relieved by an existing colostomy and accordingly call for treatment. These symptoms are (a) *an increased secretion of the rectal mucus*; (b) *hæmorrhage*; (c) *pain due to pressure upon or involvement of nerves of the sacral plexus*; (d) *pelvi-rectal and ischio-rectal suppuration*; (e) *recto-vesical and recto-vaginal fistula*; and (f) *ascites*.

(a) *Increased secretion of rectal mucus*.—This accumulates in the rectum and causes frequent desire for an evacuation, often disturbing the patient's rest at night. We have used



injections of a solution of alum (10 grs. to 5) with benefit, the excessive secretion having been checked considerably for a time. Should it continue, we think the best treatment is to provide free drainage for the mucus by dividing both the external and the internal sphincter muscles (*linear proctotomy*). After so doing, it is true that there is a constant discharge from the anus, necessitating the patient wearing a pad of absorbent dressing, but at the same time he is not disturbed at night.

(b) *Hæmorrhage*.—This usually emanates from blood-vessels of new formation in the growth itself which have been opened by the ulcerative process. At first the application of solutions of adrenalin chloride, hemiscine, or perchloride of iron may check the bleeding, but later on, the best plan is to scrape away with either the finger or a Volkmann's spoon all the soft portions of the growth. We have found this method efficacious in preventing further losses of blood for several weeks. Should a large venous trunk or artery, such as the internal iliac, be involved by the ulcerative process, an extremely rare result, the patient's life is speedily terminated by profuse hæmorrhage.

(c) *Pain due to pressure upon or involvement of nerves of the sacral plexus*.—The onset of pain during the later stages of the disease, is quite distinct from that produced by the passage of fæces through the diseased rectum and is due to the extension of the growth into the peri-rectal structures. Scraping away the growth relieves the pain for a time, when due to pressure upon the nerves in the pelvis, but when the nerves themselves are involved in the growth, little can be done beyond affording respite from suffering by the judicious use of morphia. Commencing with small doses of one-sixth grain every eight hours, the quantity of the drug may be increased until as much as two or three grains every three or four hours is reached. The combination of cocaine with morphia for internal administration is, as Dr. Snow has pointed out,



especially serviceable in the treatment of the later stages of carcinoma. In prescribing preparations of opium in the treatment of these cases, the increase in the strength and the frequency of the dose should be made as slowly as possible, because patients so quickly become tolerant of large doses which soon impair their digestion and general health.

(d) *Pelvi-rectal and ischio-rectal suppuration.*—The indication that this has taken place is generally an escape of pus from the anal orifice. A careful examination, under these circumstances, should be made for the purpose of locating the collection of pus, which, when found, should be freely laid open. If the pus have already reached the surface, the resulting fistulæ should be thoroughly laid open, at least externally. In those cases in which a growth involving the lower portion of the rectum has given rise to fistulæ, the best way of relieving the patient is to excise the lower portion of the rectum together with as much of the growth as possible.

(e) *Recto-vesical or recto-vaginal fistula.*—This is due to the direct extension of the growth into the bladder and vagina respectively. In those instances in which colostomy has not been performed the condition of the patient is most distressing, because both flatus and fæces, and sometimes blood, pass into the bladder on the one hand, causing intense cystitis, and on the other they escape into the vagina, producing incontinence of both flatus and fæces. In such cases the best treatment consists in performing colostomy as soon as possible. When colostomy has already been performed, blood and discharge are all that escape into the bladder and vagina, and are best dealt with by means of frequent irrigation.

(f) *Ascites.*—The onset of ascites generally shows that the liver has become infected by secondary deposits. When the quantity of fluid is large enough to produce pressure symptoms, much temporary relief can be afforded by repeated tappings.



## CHAPTER VI.

### BENIGN TUMOURS OF THE ANUS AND RECTUM.

These tumours are occasionally met with, and present the characteristics of similar growths found in other parts of the body, that is to say, they are of slow growth, they do not infiltrate surrounding structures, and do not, as a rule, tend to recur after removal. Structurally they consist of the more highly developed connective tissue and glandular elements. Thus we have the fibroma, the lipoma, the myoma, the myxoma, the papilloma, and the adenoma. For the sake of convenience, we shall first describe those tumours that are met with at *the anus and in its vicinity*, and subsequently deal with those that originate *within the rectum*.

#### BENIGN TUMOURS OF THE ANUS AND ITS VICINITY.

These arise from the skin and subcutaneous connective tissue, and consist of (a) *the papilloma*, (b) *the soft fibroma or fibro-cellular tumour*, and (c) *the lipoma*,

##### (a) *The papilloma.*

This is due to hypertrophy of the papillary layer of the cutis vera, consisting of elongated wedge-shaped masses of connective tissue, each containing a central artery and vein, and surmounted by ordinary stratified epithelium. The hypertrophied papilla is usually separated at its base from its



neighbours by a narrow strip of healthy skin, though the free extremities are often in close contact. Sometimes they are found in separate clusters upon the peri-anal skin, as shown in fig. 33, or they may be so numerous as to entirely surround the anus and exclude it from view. The best specimen of this kind of growth that we have seen is that shown in fig. 34. In this case the anus was quite hidden from view, though the aperture leading into it was situated in the centre of the mass. The papillæ measured from one-third to three-

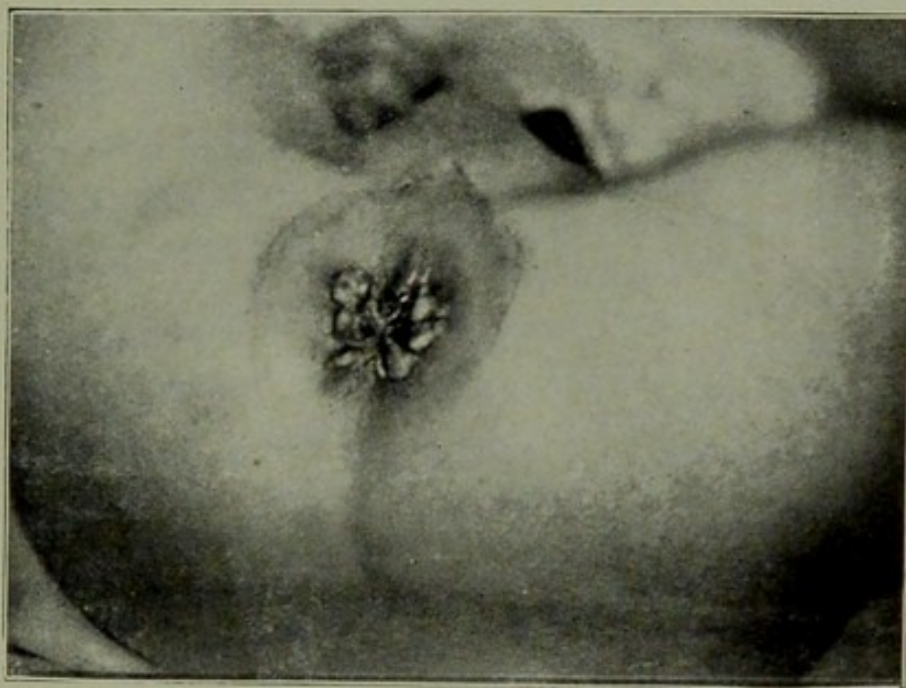


FIG. 33. SHOWING SEVERAL CLUSTERS OF PAPILLOMATA OF THE ANUS.

fourths of an inch in length, and being wedge-shaped (the free extremities corresponding to the base of the wedge), the surface of the tumour appeared to be that of a minutely lobulated single mass. Upon close examination it was found that each papilla was *separate* from its neighbours, and that *narrow strips of healthy skin* intervened between their points of origin. The latter fact was of much value in enabling the diagnosis to be made from epithelioma (*squamous carcinoma*) of the anus.



The papilloma of the anus is apparently identical with that met with on the glans penis and the labia majora, as a result of the irritating effect of gonorrhœal discharge (*gonorrhœal warts*); but there is no reason to believe that those met with

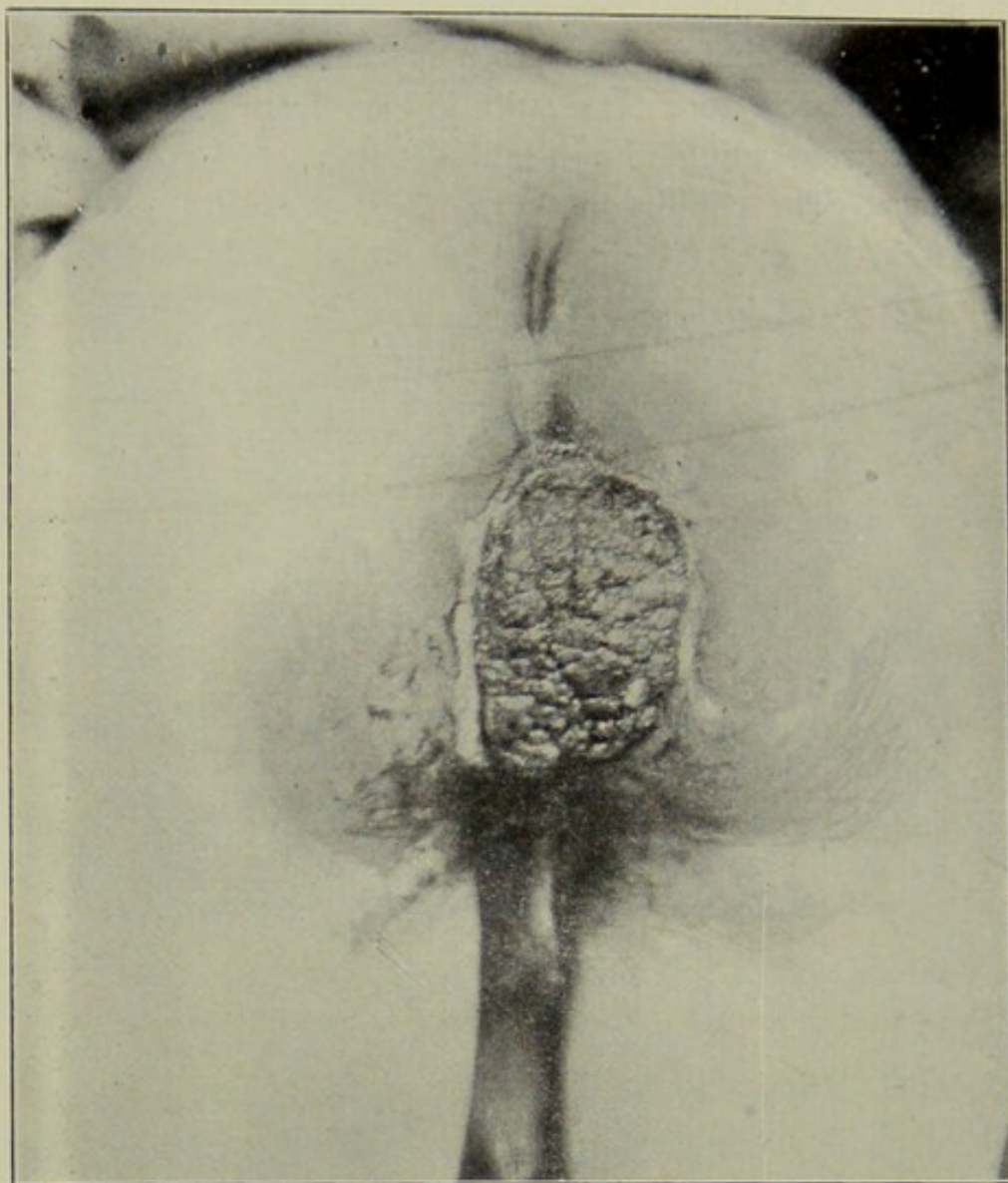


FIG. 34.—PAPILLOMA COMPLETELY SURROUNDING THE ANAL ORIFICE AND CONCEALING IT FROM VIEW.

The patient was a sailor aged 19.

in the region of the anus are due to gonorrhœal infection. Want of cleanliness and a continual damp condition of the peri-anal skin appear to be sufficient to produce the papillary



hypertrophy. It is met with in both sexes, and usually in young adults.

*Symptoms.*

These are chiefly due to the discomfort consequent upon the presence of the tumours, *viz.*, constant irritation and dampness of the part, difficulty in cleansing the anus after defæcation, and occasional slight bleeding. There is rarely any pain, except when the surface of the tumour is abraded.

*Treatment.*

A complete cure can be effected by snipping through each papilla, close to its seat of attachment, with a pair of scissors. There is, as a rule, rather free bleeding from the central artery of each papilla, but this usually ceases under the influence of pressure. Should it continue, a solution of adrenalin may be applied, or the bleeding points may be ligatured. On no account should the skin be removed with the growth lest some stenosis of the anal orifice should result. When the growths have been removed, the peri-anal region ought to be kept quite dry for some time by means of a dusting powder of starch and oxide of zinc. If the patient is subsequently careful in regard to cleanliness, and prevents constant moisture of the anus, recurrence does not take place.

(b) *The soft fibroma or fibro-cellular tumour.*

These tumours, identical in structure with those known as molluscum fibrosum, when occurring on the neck and trunk, are occasionally seen in the peri-anal region. They are distinctly pedunculated, and may attain large size. We have recently seen one, which, after removal, weighed 1 pound and 11 ounces. This tumour was attached by a stout pedicle to the skin in the right posterior quadrant of the anal region, about one and a-half inches distant from the margin of the anus. The patient, a female, stated that it had been



gradually increasing in size for ten years. She would not have presented herself for treatment but for the foul smell and discharge caused by a large gangrenous ulcer situated upon its most dependent surface. Structurally these tumours consist of bundles of white fibrous tissue loosely arranged in a meshwork, the interstices of which contain a serum-like fluid, which readily drains away when the tumour is incised. The pedicle contains blood-vessels of considerable size, which bleed freely when the tumour is removed.

### *Symptoms.*

Beyond the inconvenience caused by the size of the tumour there are no symptoms, unless the surface becomes inflamed and excoriated through friction against the clothing. When the surface of the tumour becomes ulcerated, as in the instance cited above, there may be free bleeding, as well as a most offensive discharge.

### *Treatment.*

This consists in removal of the tumour. When the pedicle is stout, a small flap of skin should be raised on each side, in order that the margins of the wound may be brought together without undue tension. All bleeding vessels should be ligatured before the wound is closed. There is no liability to recurrence.

### *(c) The Lipoma.*

This form of tumour is sometimes met with in the perianal region. We have seen two good examples of it, both having been situated in the right posterior quadrant of this region between the ischial tuberosity and the coccyx. The tumour is due to hypertrophy of one or more of the lobules of fatty tissue contained in the loculi formed by the peculiar arrangement of the deep fascia in this locality. It increases slowly in size. It can be diagnosed from a collection



of pus in the ischio-rectal fossa by the fact that dimpling of the surface is caused by attempting to raise the skin, by the edge of the tumour being felt to slip away from beneath the finger when pressure is made upon it, and by the absence of fluctuation and pain on pressure.

### *Symptoms.*

It may exist for years without giving rise to any symptoms that direct attention to its presence. Even when of considerable size, it causes inconvenience only by its presence in the vicinity of the anus. Should the surface become inflamed through friction against the clothing, the symptoms attendant upon such a condition make themselves manifest.

### *Treatment.*

The tumour should be removed by making a free incision over it extending through the capsule. The fatty tissue is then shelled out, care being taken not to leave behind *any off-shoots* from the main mass. The wound should be allowed to granulate. If it be closed with sutures there is the risk of a fistula resulting.

## BENIGN TUMOURS OF THE RECTUM.

These arise in connection with the glandular and connective tissue elements of the mucous and submucous coats of the rectum. They grow slowly, and may exist for several months or even years before giving rise to symptoms indicating their presence. When in an early phase of development, the neoplasm forms a projection under the superficial layers of mucous membrane, and is therefore *sessile*, but in the course of time the downward traction exerted by the continued passage of fæces over the tumour causes the base of attachment to be attenuated into a distinct pedicle which may vary from one or two lines to an inch or more in length.



The pedicle consists of a fold of mucous membrane enclosing the blood-vessels which supply the growth. The pedunculated character of the benign neoplasms of the rectum has given rise to the term *polypus* being applied to them. Accordingly when we speak of a rectal polypus we do not mean to imply that the growth possesses any distinctive histological character, but simply that the growth itself, whatever its structure may be, is attached to the rectal wall by a pedicle or stalk. Several distinct varieties of benign tumour occur in the rectum, namely (a) *the adenoma or glandular polypus*, (b) *the fibroma or fibrous polypus*, (c) *the villous tumour or villous polypus*, (d) *the myxoma or myxomatous polypus*, (e) *the myoma or myomatous polypus*, and (f) *the lipoma or lipomatous polypus*. As the last two of these are rarely met with, and may be regarded in the light of pathological curiosities, we shall describe only the first four varieties.

(a) *The adenoma or glandular polypus.*

This variety of tumour generally arises in connection with the tubular glands (*crypts of Lieberkuhn*) of the mucous coat, being really a localized hypertrophy thereof. The microscopical appearance is that of a number of tubules, lined by ordinary columnar epithelium arranged upon a distinct basement membrane, and bound together by delicate connective tissue. In some cases the connective tissue elements preponderate, and then the growth is spoken of as a *fibro-adenoma*. A further variety of adenoma (*the lymphadenoma*), though very rarely met with, consists of lymphoid tissue, and arises from hypertrophy of one of the solitary lymph nodules met with in the mucous membrane. The microscopical appearance of this kind of growth is well shown in fig. 35, which was prepared from a growth measuring one-third of an inch in diameter. This growth was removed from the rectum of a boy, aged nine years, having caused profuse and repeated attacks of hæmorrhage.



The adenoma is usually single, but occasionally more than one are met with in the same patient. It varies in size from a quarter of an inch to one inch in diameter, is generally

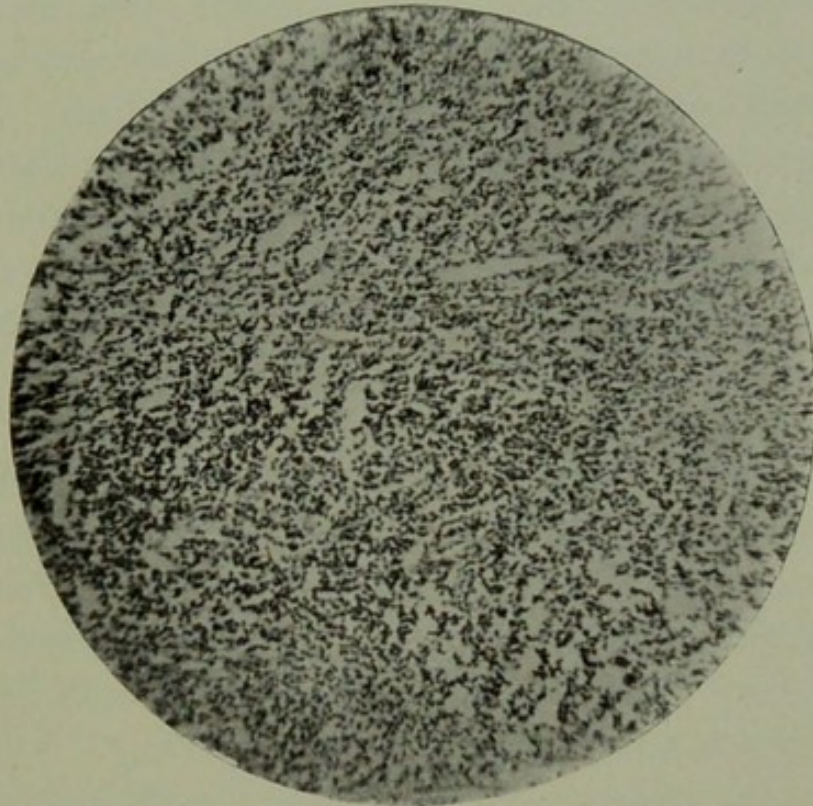


FIG. 35.—SECTION SHOWING THE MICROSCOPICAL APPEARANCE OF A LYMPHADENOMA OF THE RECTUM.

rounded in shape, and attached by a slender pedicle, which sometimes measures an inch or more in length. The growth may arise from any part of the rectum, but is usually situated in the lower two inches. When situated low down, and particularly when furnished with a long pedicle, it is sometimes protruded through the anal orifice during defæcation. As a rule, however, its presence may be undetected for a considerable length of time owing to the absence of symptoms. It is usually found in children under ten years of age, and is seldom met with in adults. The probable reason for this is that when the growth has existed for some time, the pedicle gradually becomes elongated, more and more slender, and is ultimately torn through during an action of the bowels. There can be little doubt that many of these growths are



removed from the rectum in this way, a circumstance which explains the cessation of repeated attacks of hæmorrhage in children as age advances. When these growths are met with in adults, especially in those beyond middle life, they exhibit a tendency to undergo carcinomatous degeneration, especially if they have been subjected to prolonged irritation. A careful microscopical examination of the growth should therefore be made, and if irregularity in the arrangement of the tubules be observed, the patient should be examined from time to time for signs of induration in the neighbourhood of the scar.

### *Symptoms.*

An adenoma of the rectum, when small, may exist for a considerable length of time before giving rise to any symptoms whatever. As the growth increases in size, it becomes more and more dragged upon during the passage of the fæces, especially when the bowels are constipated, when abrasions of its surface may occur from time to time and give rise to attacks of hæmorrhage. When the pedicle attains sufficient length to allow of the growth descending within the grasp of the sphincters, periodical attacks of straining down, accompanied by discharge of blood from the rectum, are complained of. In some instances the growth itself is extruded through the anus at defæcation, occasionally necessitating manual reduction.

### *Physical examination.*

The passage of blood from the rectum in children should always lead the surgeon to suspect the presence of an adenomatous polypus. A careful exploration of the rectum should be made under the influence of anæsthesia, if necessary. A small growth is by no means easy to locate, as its tissue is of the same density as the mucous membrane. Moreover, a growth furnished with a long pedicle may be capable of such free movement that it may readily be



mistaken for a small mass of fæces. The best way of determining the presence of these growths is systematically to sweep the examining finger round the whole circumference of the bowel as far as the highest point that can be reached. In this way a freely movable growth, after having been pushed in front of the finger, is at last arrested by its pedicle. The finger can then be hooked round the pedicle and the growth drawn down, and if possible brought out through the anus. The speculum is of little use for locating growths of small size. We have sometimes had much difficulty in finding a growth by its means even after its presence had been previously determined by the finger.

#### *Treatment.*

These growths should always be removed under the influence of anæsthesia. The sphincters should be stretched and the growth hooked down by the finger. The pedicle can then be clamped by a pair of pressure-forceps as close as possible to its point of attachment to the rectal wall, and a ligature applied on the proximal side of the forceps. The pedicle is then severed on the distal side of the forceps and the latter removed. The ligature, when tightly tied, separates from the fourth to the eighth or ninth day.

#### *After Treatment.*

The bowels should be confined for three or four days and then opened by means of olive-oil injections. In the case of adults at or over middle life, the seat of attachment of the growth should be examined from time to time for signs of induration. In one of our cases a typical carcinomatous ulcer developed in the vicinity of the scar within six months after an adenomatous polypus had been removed. In this case the microscopical appearance of the growth did not indicate carcinomatous degeneration, but the patient, a female, was fifty-seven years of age.



(b) *The fibroma or fibrous polypus.*

This growth is composed almost entirely of fibrous tissue and is usually attached by a short tough pedicle. The

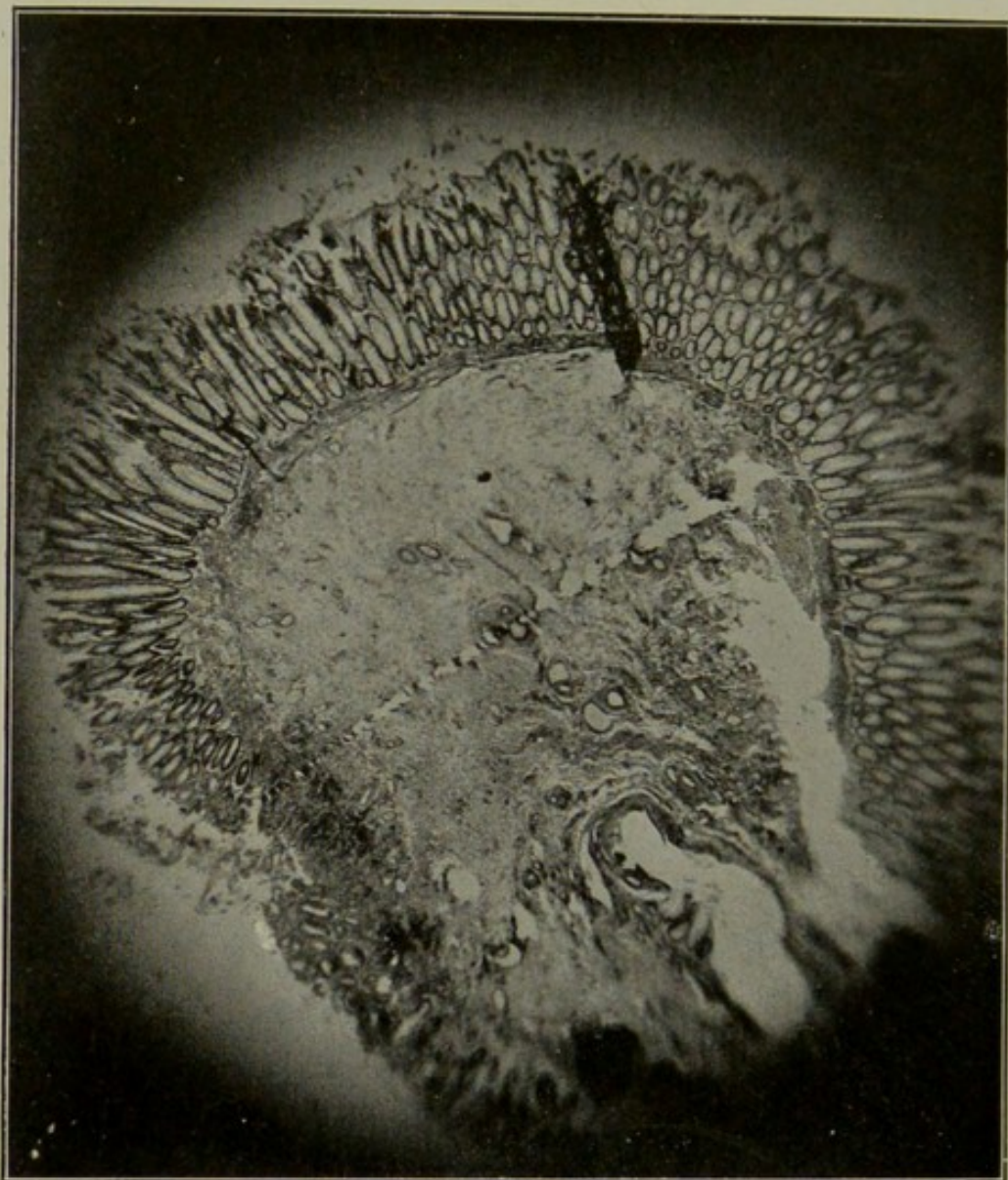

FIG. 36.—THE MICROSCOPICAL APPEARANCE OF A FIBROMA OR FIBROUS POLYPUS OF THE RECTUM.

tumour has a complete investment of mucous membrane when it arises from the rectum or the upper part of the anal canal, but is covered with stratified epithelium when it springs



from the lower part of the anal canal. It is almost invariably situated in the lower two inches of the rectum. Fig. 36 depicts the microscopical appearance of a fibrous polypus, measuring three-quarters of an inch in diameter, which was attached to the rectal wall at a level of one and a half inches above the

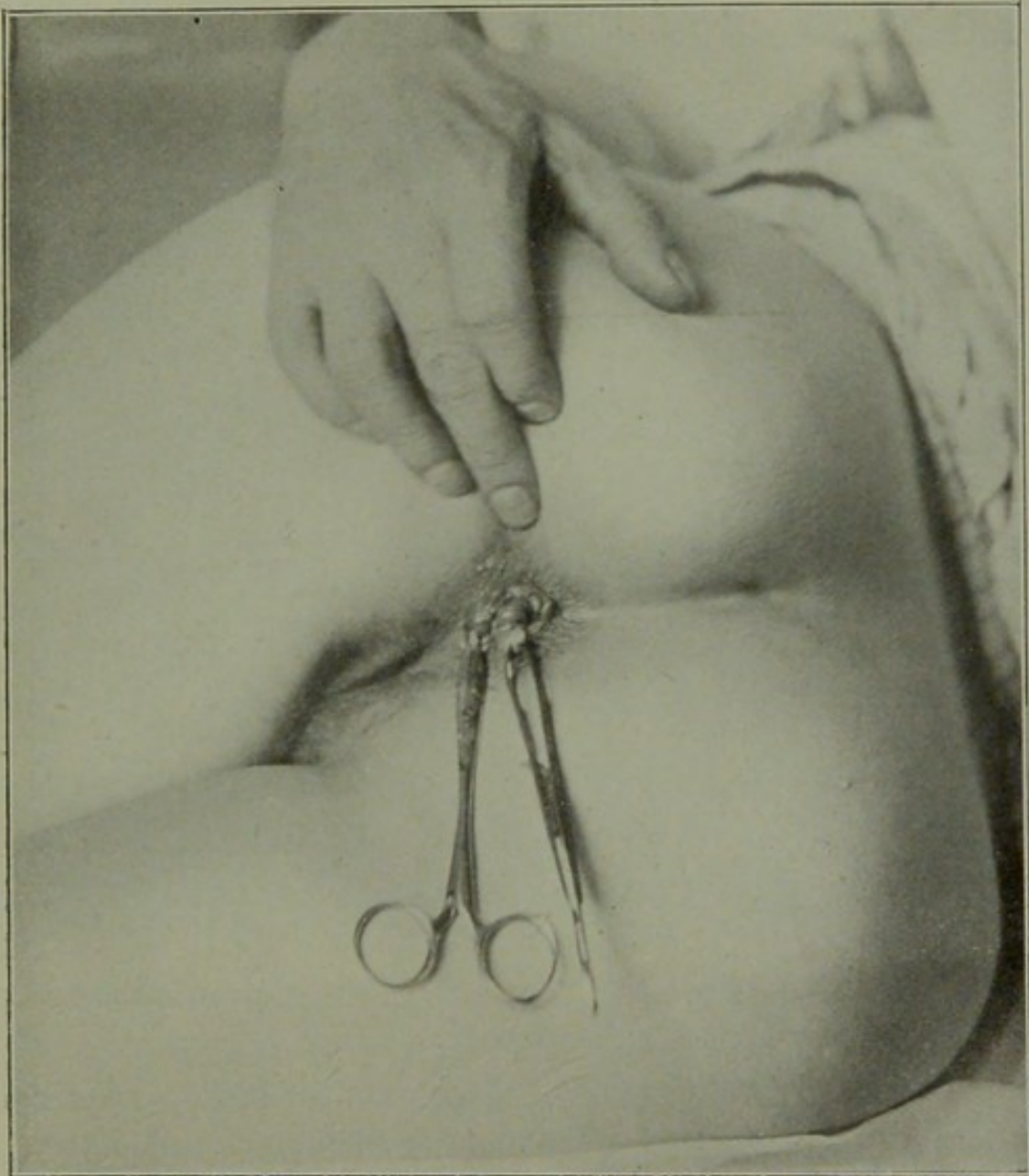


FIG. 37.—SHOWING TWO FIBROUS POLYPI OF THE ANAL CANAL, EXTRUDED FROM THE ANAL ORIFICE DURING ANÆSTHESIA.

The patient was aged 43 years and had suffered from rectal symptoms for twelve years.

anal margin. The size usually varies from that of a split-pea to a walnut, and is seldom larger when consisting of fibrous



tissue alone. Occasionally single, there are usually two, three or more growths of varying sizes in the same case. When multiple growths are present, some of them usually spring from the free edges of the valves of Morgagni and are, therefore, attached to the wall of the anal canal, about a quarter of an inch above *Hilton's white line*. Fig. 37 shows two such fibromata protruded through the anal orifice and

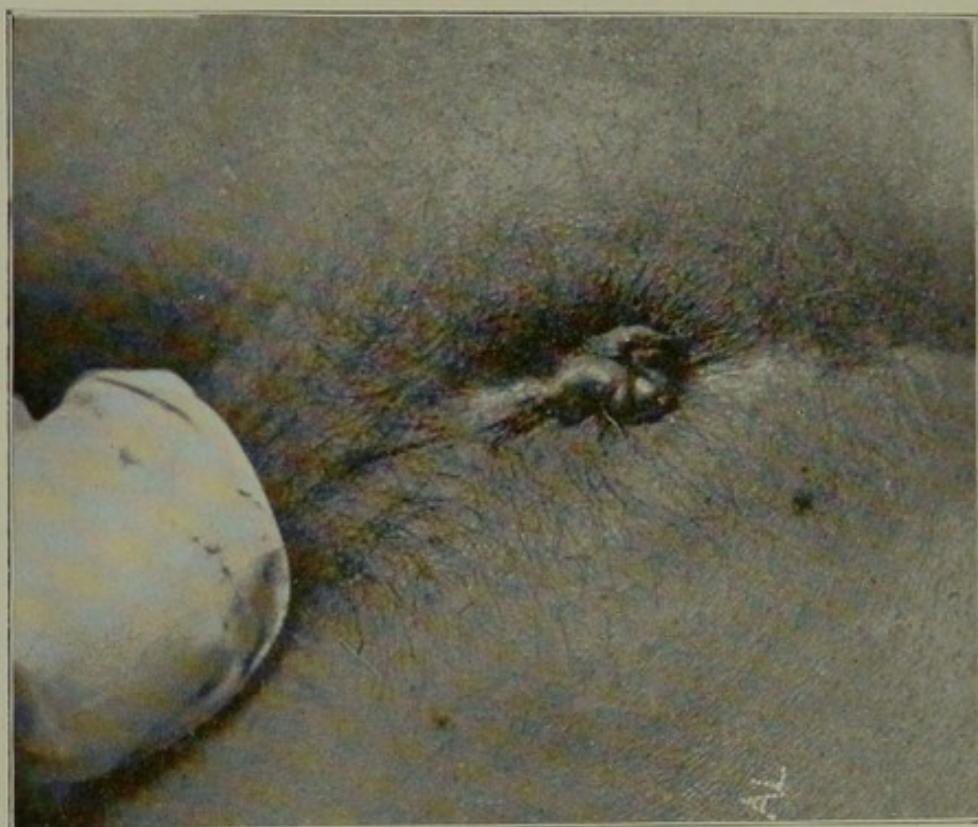


FIG. 38. —A SMALL FIBROMA OF THE ANAL CANAL SPONTANEOUSLY PROTRUDED.

retained outside by means of pressure forceps, whereas, fig. 38 depicts a single growth spontaneously protruded.

The fibromata met with in the rectum have three sources of origin, viz.: (1) localized hypertrophy of the fibrous elements in the sub-mucous tissue; (2) from an internal hæmorrhoid, the dilated veins of which have become thrombosed and have subsequently undergone fibrous transformation (*the fibrosed pile*); and (3) hypertrophy of the



papillæ or nodules normally met with on the free edges or surfaces of the *valves of Morgagni* (see Part I., page 25). The growths, though at first sessile, soon become pedunculated by reason of the traction exerted upon them during defæcation. Consequently they are frequently protruded at stool and are generally associated with internal piles.

### *Symptoms.*

A small fibroma of the rectum may exist for a considerable time without giving rise to symptoms indicative of its presence. This is especially the case with those that arise in connection with the papillæ on the valves of Morgagni. Their presence, however, ultimately induces an unnatural spasmodic action of the external sphincter muscle, which then becomes hypertrophied, inextensible and indurated. The difficulty in defæcation thus engendered causes the patient to seek a rectal examination, when the presence of one or more of these small fibromata may be disclosed. Larger growths are sooner or later protruded at each action of the bowels, and, if associated with internal piles in the third stage of their development, may be constantly protruded. It frequently happens that the pedicle of one of these fibromata is partially torn during the passage of a hard mass of fæces. This causes burning pain and a small loss of blood. The pain sometimes persists for several hours after the action of the bowels, and is suggestive of fissure. In such cases, if on examination there is no sign of a fissure, the finger should be gently passed into the anal canal for the purpose of ascertaining whether a fibrous polypus be present. If so, the possibility of a laceration of its pedicle should be suspected. The detection of such laceration is important because, in addition to the pain which it causes a blind internal fistula may arise therefrom (see Part I., page 104).

### *Physical Examination.*

The presence of a fibroma in the rectum is, as a rule,



readily detected by introducing the finger into the anal canal and sweeping it slowly round its entire circumference. The growths are firm to the touch and can be sometimes readily drawn down and exposed to view (see fig. 39). In those cases

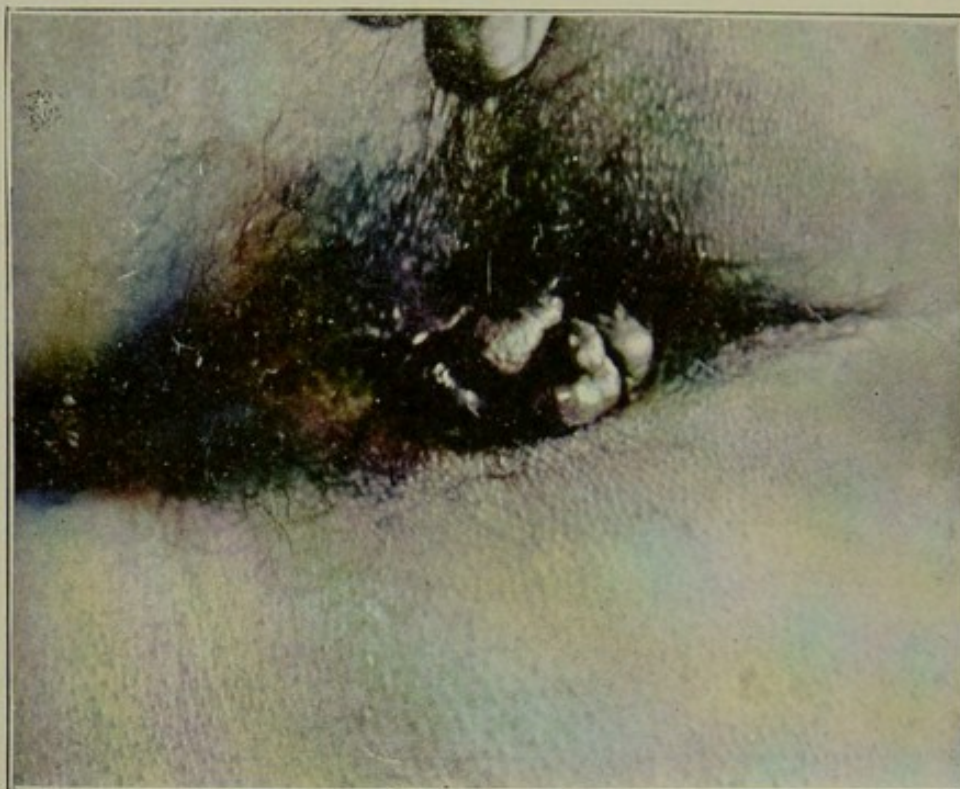

FIG. 39.—SHOWING MULTIPLE FIBROUS POLYPI OF THE ANAL CANAL.

in which a laceration of the pedicle exists, there is usually so much spasm of the sphincter muscles and levatores ani that it is difficult to conduct the examination satisfactorily without an anæsthetic.

#### *Treatment.*

As soon as a fibrous polypus of the rectum is known to exist, the patient should be urged to have it removed without delay, because of the possibility of a laceration of the pedicle occurring and a blind internal fistula resulting therefrom. The growth is easily removed by applying a ligature to its base. When the polypus is semi-sessile it is best dealt with like an internal pile. When a laceration of



the pedicle is present, the external sphincter muscle should be completely divided in the right posterior quadrant and after that has been done the growth should be removed.

(c) *The Villous Tumour.*

The villous tumour is one of the rarest of all the growths met with in the rectum. This statement is warranted by the fact that but a small number of cases have been recorded in the literature of the subject. Thus, Bryant\* describes nine cases, Allingham, with his extensive experience at St. Mark's Hospital, records four examples of the disease; three cases are recorded in the practice of Mr. Gowlland, two in that of Mr. Symes, and one each in those of Cripps, Goselin, Van Buren, and Cook. We have had twelve cases, eight in men and four in women. So far as our experience goes, these growths when seen by the surgeon vary in size from the dimensions of a walnut to that of a Jaffa orange, and are usually semi-oval in shape. The surface is minutely lobulated, resembling very much the appearance of a cauliflower. In the smaller growths this lobulated appearance is not so well marked, the surface being covered by elongated papillæ. An excellent example of this kind of tumour exists in the Museum of St. Bartholomew's Hospital, the growth closely resembling in outward appearance the villous tumour of the bladder.

The villous tumour appears to originate entirely from the mucous membrane of the bowel, the other coats not being involved, unless it is undergoing carcinomatous degeneration. When small the growth is as a rule sessile, but, as it increases in size, it becomes distinctly pedunculated. The pedicle in some cases is not well developed, while in others it is distinctly band-like, consisting merely of a double fold of mucous membrane extending either transversely or obliquely across one or other side of the bowel, usually obliquely. Such a pedicle is clearly produced, we think, by the tumour being

\* On villous growths and common affections of the rectum.—1899, page 43.



dragged away from the muscular wall of the rectum, either by virtue of its own weight or from its being pushed downwards during defæcation. When the pedicle is well-developed the growth has the appearance of being slung to the rectal wall by a mesentery, as it were, of mucous membrane. This pedicle is apt to become extremely lax in its attachment to the muscular coat, and in some cases will allow the

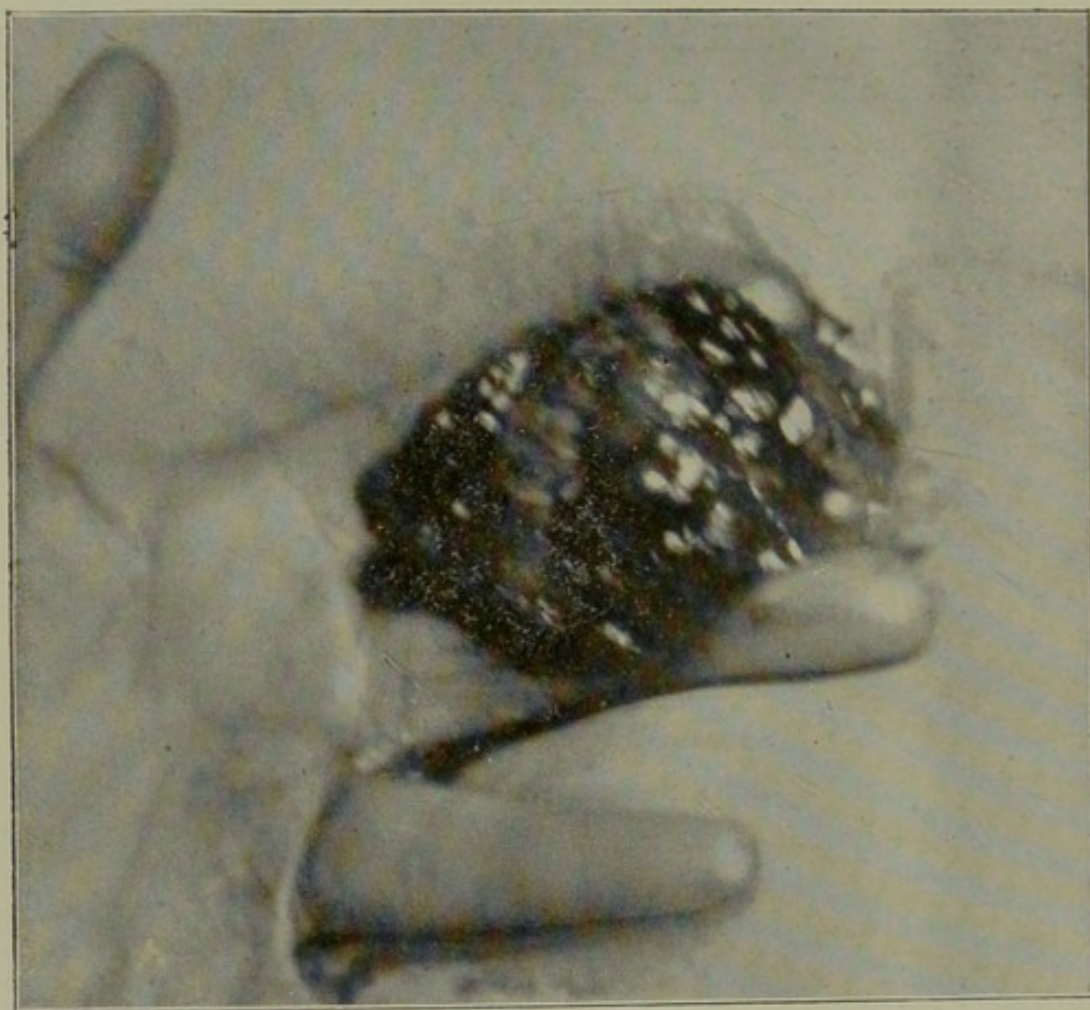


FIG. 40.—A VILLOUS TUMOUR DRAWN DOWN THROUGH THE ANAL ORIFICE.

growth to be protruded through the anal aperture. The accompanying illustration, depicts such a protrusion from the anus (see fig. 40). These tumours may be classed as benign, since they seldom show a tendency to recur after complete removal, and do not infiltrate the rectal wall. At the same



time it should be remembered that a carcinomatous change may take place in part of the growth, just in the same way as a simple adenoma of the breast may eventuate in true cancer. Two of our cases ultimately became carcinomatous. The specimen of one of these cases is now in the Museum of St. Bartholomew's Hospital, and was removed from a man aged fifty-five by Mr. Goodsall at the Metropolitan Hospital.\* This growth, when examined microscopically, was found to be undergoing carcinomatous change in one part of its surface.

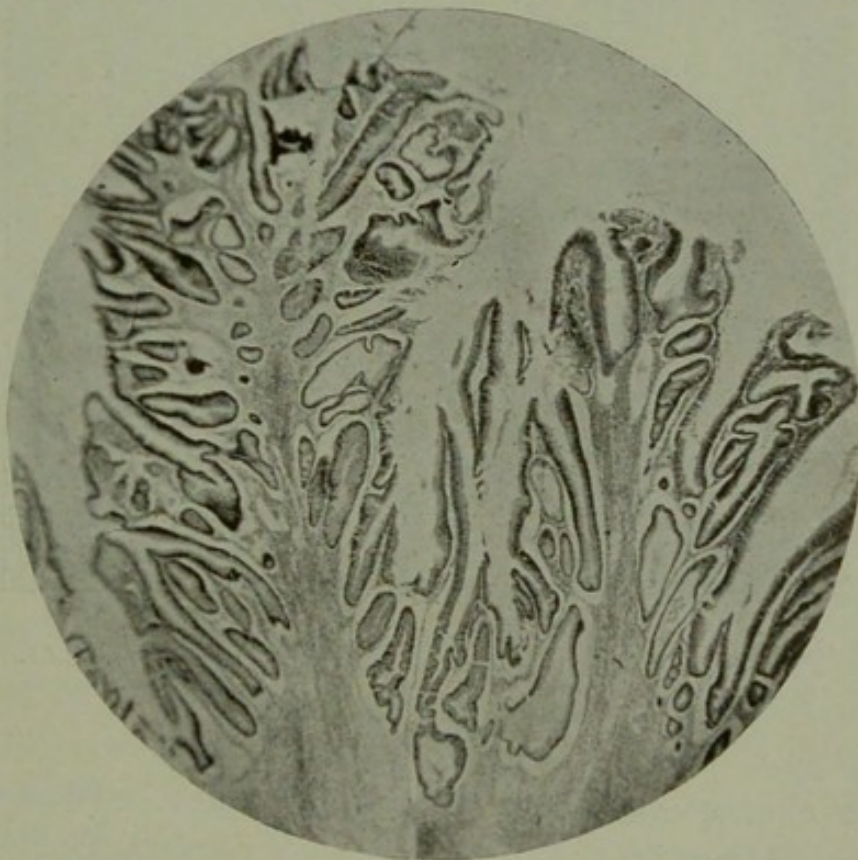


FIG. 41.—SHOWING THE MICROSCOPICAL APPEARANCE OF A VILLOUS TUMOUR.

#### *Etiology.*

In the present state of our knowledge no light can be thrown upon the determining factor in the causation of this disease. Pathologically the growth appears to consist of villous processes arising from the mucous membrane (see figs. 41 and 42). Sex seems to have no influence, since males

\* This patient left the hospital eleven weeks after the operation. Efforts to obtain the subsequent history of the patient have failed.



and females are affected with almost equal frequency—our own cases, however, show eight males and four females. In both sexes the age at which the growth appears is beyond middle life.

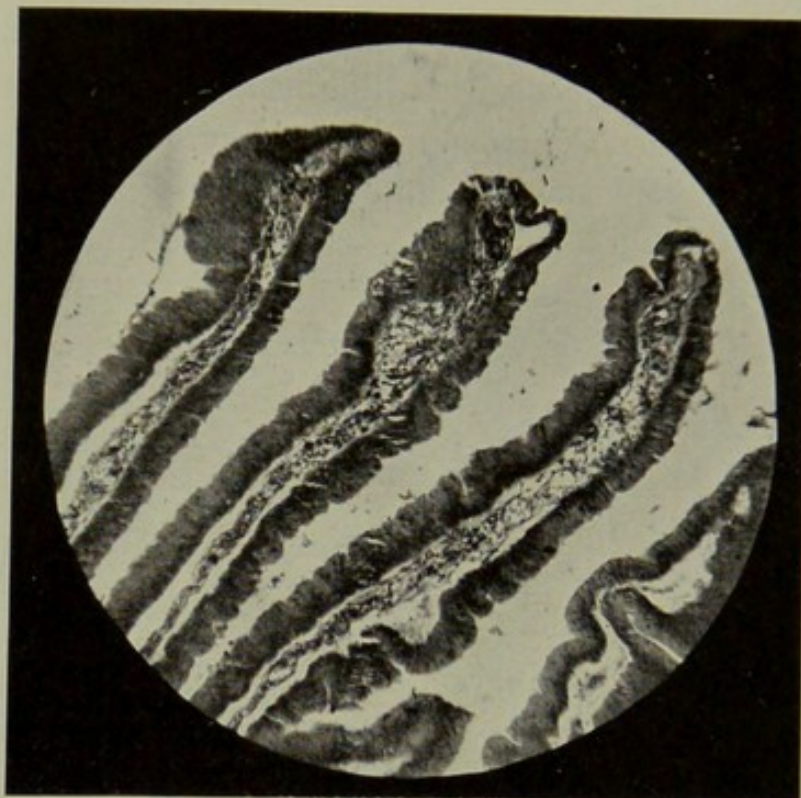


FIG. 42.—SHOWING THE STRUCTURE OF THE VILLI.

### *Symptoms.*

The characteristic symptom of a typical villous growth in the rectum is the frequent escape of a thin watery fluid from the bowel, necessitating the patient going to stool many times during the day and night. This prominent symptom, for which the sufferer seeks relief, is described as continuing diarrhœa. It would be erroneous, however, to suppose that all cases of villous growth present this single and characteristic symptom. There are others which make their appearance insidiously, their duration extending over many months if not for several years (in our cases from ten months to over five years).



These are pains of a dull and aching character both in the rectum itself and over the sacrum, at first intermittent, but later becoming constant; hæmorrhage from the bowel, usually slight, but occasionally severe, especially when internal hæmorrhoids co-exist; loss of appetite; gradual and increasing diminution in weight; a general cachectic look, the skin assuming a pale and waxy appearance; and, lastly, obstinate constipation, alternating with diarrhœa.

In the earlier stages of the disease, while the growth is yet small, none of the symptoms are well marked, beyond the escape of watery fluid, tinged or not with blood, but as it increases in bulk, the watery discharge to which it gives rise, increases largely in quantity, and obliges the patient to evacuate the bowel many times during the twenty-four hours. This discharge is usually described as consisting of mucus, but such is not the case. From a case in which the growth protruded from the anus, Mr. Goodsall collected a considerable quantity of this fluid in a comparatively short space of time. The fluid was pale and watery in appearance, and contained only a few shreds of mucus. It is the rapid secretion of this watery fluid which occasions such frequent action of the bowels, and close inquiry will elicit from the patient that a natural faecal evacuation takes place only once or, at most, twice in the course of twenty-four hours.

Bleeding from the rectum occurs with sufficient frequency in cases of villous tumour to warrant its inclusion as a symptom, but it is very questionable whether the blood emanates from the growth itself. So long as the growth remains inside the rectum, very little bleeding from its surface is noticed, and it is rare to find the exploring finger streaked with blood, as is the case in most instances of carcinoma. Should the growth, however, become prolapsed, bleeding readily takes place from its surface, but this ceases almost directly when it has been returned into the rectum. It



is of course possible that abrasions of the surface of the growth, produced either by local examination or by the passage of hardened fæces over it, may cause some hæmorrhage. The point, however, that we wish to emphasize is that villous tumours rarely bleed unless protruded, and we are of opinion that when bleeding exists, its cause must be looked for elsewhere than as an exudation from the tumour. So far as our observations go, we have found that several of the patients suffering from villous growth had internal hæmorrhoids, which in their cases were the source of the hæmorrhage. In one of our cases the patient, who was aged fifty-seven, had three of the largest piles that we have ever seen.

The pain complained of is readily explained by the constant dragging upon the rectal wall by the traction of the growth, and is referred to the rectum itself and through the sacral nerves to the skin over the sacrum. It is a noteworthy fact that pain is felt in the growth itself, so long as it is protruded through the anus, but ceases as soon as the tumour has been returned into the rectum.

The loss of flesh and general cachectic appearance is undoubtedly due to the constant discharge and accompanying mental anxiety.

It is rare to meet with complete intestinal obstruction caused by a growth of this kind, as the patient usually seeks relief long before it has attained sufficient size to occlude the lumen of the bowel.

#### *Physical Examination.*

On inspection, the anus is generally found to present a sodden appearance, and there is an absence of folds of redundant skin unless well-developed internal piles co-exist. The anal orifice is somewhat loosely closed by the sphincters, marked relaxation being present only when there is a history that the growth protrudes at times from the anus.



When the growth is protruded at the time of the examination it will be found to be attached by a distinct pedicle, which passes into the bowel, the pedicle being so much smaller in circumference than the growth itself that the fingers can be placed behind the growth as shown in Fig. 40. When there is no protrusion a digital exploration of the rectum should be next proceeded with. When there has been well marked hæmorrhage the right anterior pile, and perhaps others, is usually present. On introducing the finger to its full length and sweeping it round the interior of the rectal cavity a soft, slippery growth will be found occupying the rectum, and feeling very much like a redundancy of healthy mucous membrane. Careful manipulation will now show that the growth is attached to some part of the circumference of the bowel by a broad fold of mucous membrane, which generally extends obliquely or transversely to its longitudinal axis, unless the growth involves the anal canal, in which case it has not a well marked pedicle. In order that a more exhaustive examination may be made, it will be necessary to place the patient under the influence of an anæsthetic. When this has been done the sphincters can, if necessary, be thoroughly dilated, and the growth brought down through the anal orifice, unless the pedicle is too short or the growth situated too high up to allow of this. In this manner the exact size of the tumour can be ascertained, and an idea formed as to the measures to be adopted for its removal. When the growth is seen, its colour is of a brighter red than the surrounding mucous membrane. There is no induration of its seat of attachment. The growth is as a rule single, though we have notes of one case in which there were two distinct growths. If the tumour is undergoing carcinomatous change, there will be alteration in its consistency, with, perhaps, ulceration of its surface, induration of its base, and a marked tendency to bleed freely when touched.



*Treatment.*

Palliative measures are of no avail in the treatment of this kind of growth and should not be resorted to. As soon as its presence has been detected, early removal by operation should be advised, firstly, because the free, watery excretion from the growth gives rise to frequent actions of the bowels, and the constitutional depression consequent thereon; secondly, because of the possibility of either invagination or procidentia of the rectum being produced by the downward traction of the growth; and lastly, because the growth may ultimately undergo carcinomatous degeneration and so infiltrate the muscular coat of the bowel or even the peri-rectal structures. We have already stated that nearly all the primary villous growths of the rectum are furnished with a distinct pedicle and are therefore amenable to being drawn down and made to protrude from the anal orifice. In one of our cases, however, the pedicle was attached so high up as to render this impracticable. When so situated removal of the growth from within the rectum is a matter of extreme difficulty, and it is better either to perform left inguinal colostomy and subsequently remove the rectum itself or in suitable cases to resect the portion of the bowel containing the growth and perform end-to-end anastomosis.

*Method of Operating.*

The sphincters should, if necessary, be thoroughly stretched. The growth is now drawn down by the fingers and made to protrude through the anal orifice. A suitable clamp is then placed on the pedicle about half an inch from the margin of the tumour. The pedicle is then transfixed, on the proximal side of the clamp, in one or more places according to its breadth and ligatured in sections, as described on page 15 for dealing with a fold of prolapsed mucous



membrane. The pedicle is then divided on the distal side of the clamp. The ligatures are cut short, the clamp removed and the stump allowed to retract into the rectum.

### *After Treatment.*

The bowels should be kept confined for four days and then an injection of olive-oil ( $\frac{3}{4}$  i.) night and morning should be employed to make them act. Until the bowels have commenced to act freely, only a light diet should be allowed.

### *Recurrence of the growth after removal.*

A recurrence of this kind of tumour occurs with sufficient frequency to render it advisable for the patient to present himself for examination at least once in every six months after the operation. The recurrent growth generally commences at the margin of the scar of the previous operation, which is invariably adherent to the muscular coat of the bowel. The recurrent growth is, therefore, nearly always sessile. If it be undergoing carcinomatous degeneration, infiltration of the muscular coat also occurs and this may be suspected to have taken place if there be much attendant induration of the base of the tumour.

### *Treatment of the recurrent growth.*

As there is practically no pedicle, the growth cannot be completely removed without excising part of the muscular coat of the bowel as well. Accordingly the case should be treated as one of carcinoma pure and simple and excision of the rectum should be performed subsequent to left iliac colostomy.

### *(d) The myxoma or myxomatous polypus.*

The pure myxoma is very rarely met with in the rectum. Gant\* mentions one case in which the diagnosis of the

---

\* "Diseases of the Rectum and Anus," 2nd Ed., page 494.



pathological nature of the growth was verified by microscopical examination.

Growths consisting of a combination of mucoid and fibrous tissue (*fibro-myxoma*), however, are occasionally met with and may attain large size. There is an excellent specimen of this kind of tumour in the Museum of St. Bartholomew's Hospital. It was removed from the rectum of a woman, aged twenty-four years, and weighed, when fresh, nearly two pounds.

In structure the fibro-myxoma consists of bundles of loose gelatinous connective tissue containing spaces which are filled with fluid. The surface of the tumour is smooth or slightly lobulated. It grows slowly and may exist for a considerable time before giving rise to symptoms referable to its presence.

### *Symptoms.*

The growth gradually increases in size until it may almost completely fill the cavity of the rectum. Consequently the first symptom noticed is a steadily increasing difficulty in obtaining an action of the bowels and a sense of incomplete relief after defæcation. If the growth is attached near the anal orifice, protrusion during straining at stool may occur. The protruded mass, when of large size, may be so firmly gripped by the sphincters that reduction becomes impossible.

### *Treatment.*

This consists in removing the tumour by transfixion of the pedicle and ligaturing it in two, three or more portions according to its breadth. There is no tendency to recurrence after removal.



## CHAPTER VII.

### FOREIGN BODIES IN THE RECTUM.

The foreign bodies met with in the rectum include  
*(a) those that have been introduced through the anal orifice,*  
and *(b) those that have been swallowed.*

*(a) Foreign bodies that have been introduced into the  
Rectum.*

Examples of this class are seldom met with and have generally been introduced into the rectum by persons of weak intellect or by lunatics. We have met with two cases of this nature. Both patients were lunatics. One had introduced a piece of stick five and a half inches long and half an inch in diameter; the other had secreted in his rectum a few gold and silver coins, wrapped up in a piece of paper, which he had stolen. When the article that has been introduced into the rectum is of large size, it may become retained by the spasmodic action of the sphincters and levatores ani and in the course of time either cause intestinal obstruction or produce ulceration of the wall of the rectum from pressure.

In the Museum of St. Bartholomew's Hospital there is a gallipot which had been introduced into the rectum by the patient. This caused extensive ulceration of the rectum.



The galley-pot was removed by operation but the patient succumbed to subsequent peritonitis.

(b) *Foreign bodies that have been swallowed.*

To this category belong the majority of the foreign bodies met with in the rectum. They consist of fish-bones, pins, needles, splinters of bone and wood, etc. These articles are accidentally swallowed, as a rule, in the later decades of life and do not appear to give rise to any trouble during their passage through the alimentary canal until they have reached the rectum. When the rectum has been reached, the foreign body may be voided in the fæces without harm resulting provided that the anal orifice expands readily during defæcation and offers no impediment to the escape of the fæcal mass. If, however, the external sphincter muscle be hypertrophied and indurated, and particularly if the anal canal be the *seat of one or more small fibromata* (see page 228) so much spasm of the sphincters and levatores ani may be set up by the passage of fæces through the anal canal, that a foreign body, when present, may either become impacted in the anal canal or may perforate the rectal wall and set up peri-rectal suppuration. Hence it happens that a considerable number of the pelvi-rectal abscesses met with in practice and also a small percentage of ischio-rectal abscesses and fistulæ are produced by a fish-bone or similar sharp-pointed foreign body puncturing the rectal wall. We append the notes of twenty-three cases in order that the possible presence of a foreign body in the cavity of a pelvi-rectal or ischio-rectal abscess or in the track of a fistula resulting therefrom, may be constantly borne in mind in the treatment of such cases, because, unless the foreign body be discovered and removed complete healing will not take place. The accompanying illustration (see fig. 43, page 258) shows the foreign bodies which were removed in these cases and they are numbered accordingly.



*Symptoms.*

The symptoms produced by a foreign body in the rectum that has been swallowed depend in great measure upon whether (a) *it has become impacted in the anal canal* or (b) *it has perforated the rectal wall.*

(a) *When it is impacted in the anal canal.*—At the moment of the impaction, usually during defæcation, a sharp, lancinating pain is experienced in the anus causing severe spasm of the muscles. Any subsequent act of defæcation temporarily increases the pain, which at other times is continuous.

Should one of the hæmorrhoidal veins be lacerated, free hæmorrhage may occur. In one of our cases the colon contained a large quantity of blood clot when the patient presented himself at the hospital for treatment. In his case, the concomitant signs of severe internal hæmorrhage were added to the local symptoms.

(b) *When the foreign body has perforated the rectal wall.*—A severe and sudden attack of pain supervenes at the moment of puncture, which usually takes place during defæcation. The pain partially subsides after a few minutes, but the patient is never quite free from it or some discomfort until the foreign body has been removed. Several days or even weeks after the commencement of the pain and discomfort, a sense of weight is noticed in the bowel and perhaps a dull aching sensation over the sacrum, indicating that an abscess is forming. In one of our cases, persistent pain along the course of one sciatic nerve lasted for two months before a pelvi-rectal abscess was diagnosed. Sooner or later, a swelling, with all the characteristics of an acute abscess, appears in the ischio-rectal fossa, which, unless opened, finally bursts and discharges freely, a fistula being thus established.



*Treatment.*

When a case of foreign body in the rectum is seen soon after the puncture has taken place, it may be successfully treated in the following manner :—

An anæsthetic should be given, then the sphincters should be forcibly stretched short of tearing them. The largest bone we have yet seen measured one and three-eighths of an inch (Case 17) and was thus removed without any tearing of those muscles. The foreign body should then be removed, either from the rectum or by an external incision. After the foreign body has been removed, about ʒ ii. of Ung. cetacei or other simple ointment should be introduced into the rectum. The bowels should then be kept confined for three or four days, when they should be relieved by an enema of olive-oil, not by aperients. One or two ounces of olive-oil are quite sufficient for each injection. The enemata of oil should be used every night and morning for the two or three weeks after the foreign body has been removed. Should an abscess begin to form, it cannot be opened too soon.

THE NOTES OF CASES OF FOREIGN BODIES IN THE  
RECTUM.

CASE I.—St. Mark's Hospital. J. R., æt. 41, a traveller.

December 20, 1876.—Fish-bone (No. 1) removed from the anterior wall of rectum about an inch above the anus.

CASE II.—Metropolitan Hospital. G. C., æt. 50, a secretary.

November 13, 1877, 11.30 A.M.—At 9 A.M., while his bowels were acting, he was suddenly seized with pain in the rectum, and with a severe shooting pain in both hips and down both thighs. These pains have not ceased since they began; sitting greatly increases the pain in the rectum. The bone (No. 2) was removed without an anæsthetic. It had been forced into the rectal wall on its left side about three-fourths



to one inch above the anus. After the bone had been removed, about an ounce of enema opii was injected. The bowels were kept confined for ninety-six hours, and then they were relieved by an enema of olive-oil and water. On November 19th the bowels acted naturally without causing any pain or discomfort. No further trouble followed from the accident. The bone was swallowed probably about nine days before it was forced into the rectal wall.

This patient died in November, 1886, and during the nine years that followed the accident he had no further trouble from it.

CASE III.—St. Mark's Hospital. J. H., æt. 41, drayman.

January 22, 1879.—Fish-bone (No. 3) removed from the anterior wall of rectum. He attended for a month as an out-patient after the bone had been removed. During that period he injected about one ounce of olive-oil into his rectum every night at bed-time. Before the bone was removed he had had for some time constant pain in the rectum and a stiffness and numbness in the left leg.

August 28, 1887.—The patient says he has not had any further rectal trouble since the bone was removed.

CASE IV.—Metropolitan Hospital. S. E., æt. 70, iron-founder.

May 28, 1880.—On May 16th he swallowed a bone. On May 24th he had pain in passing a motion, and removed the bone (No. 4) from the rectum with his finger. On May 28th he attended the Hospital with a blind internal fistula on the right anterior side of the rectum. He was admitted as an in-patient, and the blind internal fistula was converted into a complete fistula with a T-shaped external opening. He left the ward on June 18th with the fistula almost healed. On July 9th he was discharged as an out-patient, the wound and fistula being soundly healed. The internal opening was small, and was situated about three-quarters of an inch above the anus on the right anterior side of the rectum.



CASE V.—St. Mark's Hospital. W. P., æt. 39, pianoforte-maker.

February 22, 1882.—In November, 1881, after a long walk, he felt pain in the rectum and anus; his bowels at that time were constipated. The pain or discomfort continued for about a month, and then a swelling formed on the left anterior side of the anus, and is still there. On examination a blind internal fistula was diagnosed, and was converted into a complete fistula with a large external T-shaped opening.

March 15.—The fish-bone (No. 5) was removed from the external opening. The removal of the bone gave him complete relief from pain. The T-shaped opening made on February 22nd had not done so.

April 22.—The fistula had soundly healed, and there was no tenderness on pressure over its track. This patient was treated throughout as an out-patient.

August 27, 1887.—He has had no further trouble from the fistula. Its track cannot be felt.

CASE VI.—St. Mark's Hospital. H. B., æt. 33, hatter.

June 21, 1882.—Fish-bone (No. 6) embedded in left side of rectum about one inch above the anus. The bone was removed per rectum.

CASE VII.—St. Mark's Hospital. W. B., æt. 47, cabman.

August 2, 1882.—Fish-bone (No. 7) removed from a complete fistula. The external opening was on the right anterior side of the anus, about  $1\frac{1}{2}$  inches from the rectum. The track of the fistula extended beyond the external opening to a point about two inches from the anus. The internal opening was situated on the right anterior side of the rectum, about a quarter of an inch above the anus. The external opening was enlarged with a T-shaped incision, and the bone removed.

CASE VIII.—St. Mark's Hospital. W. M., æt. 52, engineer's labourer.

September 6, 1882.—In March, 1882, he swallowed a bone.



A few days after he felt a pricking pain near the anus when walking. On April 24th an abscess which had been gathering for several days on the right posterior side of the anus broke of itself, and has discharged constantly ever since then. On May 17th he was admitted into a hospital, where the abscess was freely laid open with a single straight incision. He was in that hospital till August 28th, eleven weeks. He left there because they intended to operate again on him. On September 6th he attended as an out-patient at St. Mark's. His condition then was that he had an incomplete horse-shoe fistula, the external opening on the right side being one inch from the anus, and on the left posterior side  $1\frac{1}{2}$  inches, the track of the fistula extending for an inch beyond the external opening on this side. No internal opening could be detected. There probably had been one in the middle line posteriorly between the external and internal sphincters. The external opening on the left posterior side was freely enlarged with a T-shaped incision. On September 7th the fish-bone (No. 8) came away with the plug of cotton-wool placed in the opening on the 6th to arrest the bleeding. Before the bone came away he was quite unable to sit properly, because of the pricking pain in the anus. A few days after the bone had come away all discomfort or pain when sitting ceased. In three months the fistula had soundly healed. He was treated only as an out-patient.

October 3, 1887.—The scar of the T-shaped incision made at St. Mark's is now  $3\frac{1}{2}$  inches by  $1\frac{1}{2}$  inches. He has not had any pain or discomfort in the part since he ceased attending at St. Mark's in December, 1882.

CASE IX.—St. Mark's Hospital. G. T., æt. 49, caulker.

May 23, 1883.—About November 4th, 1882, he felt a sharp pain in the rectum; his bowels were being relieved at the time. Since then he has not been free from pain in the rectum, or able to sit properly. The patient has a blind internal fistula, the opening being on the left anterior side of



the rectum, about half an inch above the anus. The bone (No. 9), which was partly out of the opening, was removed from the fistula per rectum. No anæsthetic was given. The patient would not allow an external opening to be made to the fistula. On June 14th the blind internal fistula opened of itself externally. After that he could sit properly.

On September 19, 1885, the fistula being still unhealed, the patient was admitted into the wards and operated on in the usual manner. On October 24th (five weeks) he was discharged cured.

CASE X.—St. Mark's Hospital. P. P., æt. 70, bookbinder.

July 4, 1883.—The pin (No. 10) was removed from a blind internal fistula situated on the right posterior side of the anus, the opening being on the right posterior side of the rectum, about half an inch above the anus. The blind internal fistula was made into a complete fistula with a T-shaped external opening; the pin was removed through that opening, its point being directed towards the rectum.

November 14.—The patient was discharged cured. He was treated throughout as an out-patient.

CASE XI.—Metropolitan Hospital. T. W., æt. 23, soldier.

August 20, 1883.—Early in 1882, while trying to pass a motion, he felt a severe pricking pain in the rectum, and was unable to pass the motion. He kept on guard till relieved, and then went to the doctor of his regiment, who prescribed castor-oil, which quickly relieved the bowels, but the pricking pain in the rectum continued, and a swelling, which had begun to form on the right side of the anus soon after the pain begun, rapidly increased; he was then ordered to poultice the swelling. After three days he was sent to Limerick Hospital, where, five days after the commencement of his illness, the abscess broke of itself. He was in this hospital for twenty days, and then returned to his regiment and continued on duty for about five months, the fistula constantly discharging. He was then in hospital again for



two months, and then went on furlough for two months. He again returned to his regiment, and was then sent to the hospital for about three months, when the fistula not having healed, he was sent (August 14th, 1883) before the Army Medical Board, who discharged him from the army as "medically unfit for further service." From the commencement of his illness he has been unable to sit properly. On applying at the hospital (Metropolitan), he had a complete fistula, the external opening being on the right anterior side of the anus, about  $1\frac{1}{2}$  inches from the anal orifice, the internal opening being on the right anterior side of the rectum, about half an inch above the anus. He was admitted, and on August 21st was operated on in the usual manner, and the bone (No. 11) was removed from the fistula; a lateral sinus running from the external opening for about  $1\frac{1}{2}$  inches towards the scrotum was also laid open. On September 7th (seventeen days after the operation) the wound was sufficiently healed for the patient to leave the hospital, and in another fourteen days it had soundly healed.

November 6, 1887.—He has had no further rectal trouble, and is in good health.

CASE XII.—St. Mark's Hospital. J. G., æt. 35, chair-maker.

April 9, 1884.—Fish-bone (No. 12) removed from the rectum. The pain began while passing a motion, and lasted continuously for four days, and then recurred only occasionally, and ceased soon after the bone had been removed. On May 21st he was discharged cured, having been treated throughout as an out-patient.

CASE XIII.—The Rev. A. R., æt. about 45. Under the care of Dr. John Hall.

March 29, 1885.—On March 23rd, 1885, while attempting to relieve the bowels, a severe pain in the rectum suddenly came on, and prevented him from passing the motion. After



this the rectum and anus were painful and uncomfortable until the 24th, when the bowels were relieved and the pain became less severe. He then went for a walk for about three miles; while walking the pain became worse. On the 25th an abscess appeared on the left anterior side of the anus. On the 26th this abscess broke of itself. On the 29th, when first seen by Mr. Goodsall, he had a complete fistula, the external opening being on the left anterior side of the anus, and about half an inch from it. The internal opening was on the left anterior side of the rectum, about half an inch above the anus. A lateral sinus had also formed, and extended towards the scrotum for  $2\frac{1}{2}$  to 3 inches from the external opening. This sinus was at once laid open to its end. From the history the case was diagnosed as due to a foreign body in the rectum. On April the 7th, as the track of the fistula between the external and internal openings showed no marked tendency to heal up, and as the internal opening was very large, the fistula was laid open into the rectum, and then a small piece of the foreign body (No. 13) was found in the track. On April 14th the wound was rapidly healing. On April 30th he left London for the seaside, but before doing so he sent in a claim for compensation for the fistula to the Railway Passengers Assurance Company, in which he was insured against accidents. His claim was allowed and paid by that Company.

CASE XIV.—Mr. H., æt. 32. Under the care of Mr. A. H. Brewer.

April 18, 1885.—On April 12th and 13th he took some turbot. On the 14th, when his bowels were being relieved, he had severe pain in the rectum. The motion in passing felt like gravel. Straining increased the pain and discomfort. From this time the pain was continuous, and he was unable to sit properly. At times the pain extended down the left thigh to the posterior and outer side of the left knee and ankle. On the 18th Mr. Goodsall saw the patient with



Mr. Brewer, who had on the 17th tried to remove a bone from the rectum, but the patient could not bear the pain. Chloroform was given, the sphincters were then forcibly stretched, and the bone (No. 14) removed per rectum from its puncture. The site of the puncture was on the left anterior wall of the rectum, about three-quarters of an inch above the anus. An abscess had already formed, and was opened externally with a T-shaped incision. After this the pain in the rectum and adjacent parts rapidly got better.

May 1.—The opening into the rectum not having closed, and showing no tendency to do so, and the patient's habits being far from temperate, the fistula was laid open into the rectum. On May 23rd he went to Margate.

November 15, 1887.—Mr. Brewer says the patient has had no rectal trouble since the fistula healed.

CASE XV.—Metropolitan Hospital. G. S., æt. 24, shoemaker.

May 1, 1885.—On April 15th, 1885, while passing a motion, he suddenly felt a pricking pain in the rectum, and was then unable to completely relieve the bowels. The pain in the rectum was continuous up to the 17th, when he was obliged by it to give up his work. On the 18th he applied Ung. gallæ comp., which diminished the pain. On May 1st, when he came to the hospital, he had a bone partly embedded in the right side of the rectum, about three-quarters of an inch above the anus. The bone (No. 15) was removed per rectum, and then the pain ceased. No further trouble followed the puncture.

CASE XVI.—St. Mark's Hospital. M. A. K., female, æt. 21, laundress.

May 6, 1880.—The pain in the rectum came on suddenly at the end of passing a motion, and has not ceased since it began. Occasionally the pain extends from the rectum down the front of both thighs, but not in both thighs at the same time. Sitting increases the pain. On examination, a foreign



body was felt in the ischio-rectal fossa. Ether was given, and the bone (No. 16) was then removed through a T-shaped opening. The wound quickly healed. No further trouble followed.

September 22, 1887.—The patient has continued quite well up to this date.

CASE XVII.—G. W., æt. 62, dispenser.

July 22, 1886.—On July 18th, just as he had finished passing a motion, he felt a sharp violent pain in the rectum. The pain has not ceased since it commenced. On the 20th he had pain in the left posterior side of the anus when the bowels were relieved, and that pain has increased with each subsequent action of the bowels. On July 22nd, when he came under Mr. Goodsall's care, he had a deeply-seated abscess about the size of a chestnut on the left posterior side of the rectum. The swelling could be distinctly felt between the finger and thumb when the index-finger was passed into the rectum. There was no discharge from the rectum, and no tear of the mucous membrane nor internal opening was detected. The abscess was opened externally with a T-shaped incision, and then two pieces of bone (No. 17), together measuring  $1\frac{5}{16}$ ths of an inch, and about one drachm of pus escaped from the abscess. On July 23rd all pain except soreness in the wound had ceased. There was no pain when the bowels were relieved.

August 12.—The part has soundly healed.

May 12, 1887.—He has remained perfectly well.

CASE XVIII.—H. G., M.D.

November 4, 1886, 7 p.m.—At 11 a.m. to-day he felt a sharp pain in the rectum when his bowels were being relieved. The pain has been continuous since it commenced. There is also a dull aching pain in the sacrum, but no pain nor numbness in either the buttocks or the thighs. Coughing increases the pain in the rectum. Yesterday he had some haddock for his breakfast.



The sphincters were moderately stretched, and the bone (No. 18) was then removed per rectum. The bone was partially embedded in the right posterior side of the rectum, about half an inch above the anus. Some Ung. cetacei (about 3 ii.) was then placed in the rectum, and a pad of cotton-wool and a T-shaped bandage were applied to the anus. When he had recovered from the ether he was free from pain. He was advised to keep the bowels confined for three days.

November 8.—The puncture in the rectal wall has soundly healed. There is no pain in passing a motion, and no tenderness on digital examination.

CASE XIX.—St. Mark's Hospital. A. H., female, æt. 28, book-keeper.

November 25, 1886.—On applying at the hospital the patient had a complete fistula, the external opening being about an inch from the anus on its right posterior side, the internal opening being on the right posterior side of the rectum, about half an inch above the anus. The end of a foreign body could be felt at the internal opening. Ether was given, the sphincters were then forcibly stretched, and the bone (No. 19) removed per rectum; the external opening was also enlarged with a T-shaped incision. The patient was then admitted into the hospital, and remained there as an in-patient for twenty-three days; during the last week or ten days Tr. iodi was injected into the external opening about every other day. When discharged, the internal opening had almost closed.

August 11, 1887.—The internal opening was closed, and the external opening was very small. The patient could sit without any discomfort; control perfect; and said she felt quite well. If the fistula in this case had been laid open in the usual manner, the whole of the external and the lower part of the internal sphincter would have been divided, and



although the patient would have been more quickly cured of her fistula, she would have had some permanent loss of control.

CASE XX.—St. Mark's Hospital. A. B., female, æt. 44, map-colourer.

March 10, 1887.—The patient has a complete fistula, the external opening being on the left anterior side of the anus, about one and a half inches from it, the internal opening being on the left anterior side of the rectum, about five-eighths to three-fourths of an inch above the anus. The internal opening was large, and a foreign body could be felt in it. Ether was given, the sphincters were forcibly stretched, and the bone (No. 20) was then removed per rectum, and some Ung. hyd. subchlor. passed into the rectum. The external opening was then enlarged with a T-shaped incision, and she was treated as an out-patient till October 25, 1887, when she was admitted as an in-patient, because the internal opening was still unclosed and was very tender on pressure, and the delay in the healing might be due to a part of the bone being still in the fistula.

October 27.—The track of the fistula between the external and internal openings was laid open, but no foreign body was found in it.

November 11.—The patient was discharged from the ward, the wound being almost healed. It was constantly poulticed from the 29th October to the 11th November.

November 17.—The fistula is soundly healed.

CASE XXI.—S. D., æt, 43, commission agent.

February 23, 1903.—Nine days ago when passing a motion pain began on the left side of the anus and it has been continuous since then. He has not been able to sit properly since the pain began. He cannot walk because of the severe pain in the left buttock, thigh and leg. Twenty-four hours ago difficulty in micturition began and now he has retention of urine.



On examining the rectum a smooth swelling was found on the left side above the level of the levator ani. This abscess was opened with a T-shaped incision through the ischio-rectal fossa and the fish bone (No. 21) removed.

February 24, 1903.—The patient is quite free from pain.

April 8, 1903.—The patient left London for Brighton the wound almost healed.

April 28, 1903.—The part is soundly healed.

December 2, 1903.—A small polypoid growth was removed from the rectum and the external sphincter divided, because the patient at times had difficulty in defæcation.

CASE XXII.—Metropolitan Hospital. A. C., æt, 48, carman.

April 25, 1903.—He was admitted into the Hospital with a pelvi-rectal abscess and an ischio-rectal fistula. The abscess had burrowed under the gluteus maximus on the right side.

The patient said he had not been free from pain for two years. The pain was always less for a short time after each action of the bowels.

April 29, 1903.—The fistula was laid open into the rectum and the opening through the levator ani on the right side was enlarged. The foreign body (No. 22) was then found in the abscess cavity and removed. A polypoid growth about one-fourth of an inch in diameter was then removed from the anal canal. A T-shaped opening was now made through the right buttock into the part of the abscess cavity under the gluteus maximus. Five days later the patient had quite lost the pain he had had for about two years.

June 12, 1903.—The patient was sent to the Convalescent Home.

CASE XXIII.—Gordon Hospital. M. R., æt, 50, male, sockmaker.

February 13, 1905.—Came as an out-patient complaining of pain in the anal region and inability to sit down. Upon examination he was found to have a large ischio-rectal abscess on the left side. A T-shaped incision was made into



the most fluctuating part of the swelling and a large quantity of foul-smelling pus evacuated. The patient stated that five days previously he felt a sharp pain in his rectum during defæcation, and that he had never been free from pain since. Four days after the pain began he noticed a painful swelling on the left side of the anus, and it has been rapidly getting worse.

February 19, 1905.—Operation.

Under anæsthesia the external burrowing of the abscess cavity was freely laid open. A track passed deeply in the left anterior quadrant and through the levator ani. On passing the finger into this a sharp foreign body was felt, which turned out to be an ordinary sewing needle (No. 23). During its extraction the point was broken off.

February 20.—All pain has ceased and he feels quite comfortable.

February 23.—The packing in the wound was removed and the cavity flushed with perchloride lotion (1.—500).

March 2.—Wound granulating well—very little discharge. No pain.

March 9.—The deep part of the wound (L.A.) is filling up from the bottom—wound healthy.

March 16.—Wound healing rapidly.

March 25.—Discharged from the wards, the wound being nearly healed.

In our more recent cases we have observed two local conditions, which we think must have considerable influence in causing foreign bodies which have been swallowed to puncture the rectal wall in the region of the anal canal—viz., (a) *small fibromata of the anal canal*; (b) *hypertrophy and induration of the external sphincter, with narrowing of the anal orifice*.

From an examination of the notes of the cases which are given below it appears—

1. That this form of accident is more commonly met with



after thirty-five years of age, the average age in the twenty-three cases being forty-three years.

2. That a bone takes from one to nine days to pass from the mouth to the rectum. Cases 2, 4, 14, 18.

3. That the pain in the rectum and adjacent parts comes on suddenly while the motion is being passed, or immediately after it has been passed.

4. That there is constant pain or discomfort in the rectum, and sometimes also in the adjacent parts, from the time of puncture until the foreign body has been removed.

5. That the site of the puncture is usually within the last inch or three-quarters of an inch of the anal canal.

6. That when an abscess follows the puncture, it begins to form within two or three days of the puncture. Cases 11, 13, 14, 17.

7. That when the case is seen early and the bone removed, no ill-effects follow the puncture. Cases 2 and 18.

8. That when a fistula has formed, the patient may, unless the internal opening is large, be cured by making only a free external opening. Cases 4, 5, 8, 17, 21.

9. That when it is necessary to lay open a fistula which has been caused by a foreign body, the wound heals much more rapidly than it does in non-traumatic cases of fistula. This fact to some extent supports the opinion that a non-traumatic ano-rectal fistula, which often heals very slowly, is an indication that the patient's general health is below par.

It is important to a candidate for life assurance who has had a fistula, that the cause should be ascertained. If of traumatic origin, no increase should be made in the rate of premium because of such a fistula.

It is only within recent years that accident insurance companies have recognised their liability for the results caused by foreign bodies accidentally swallowed. Case 13.



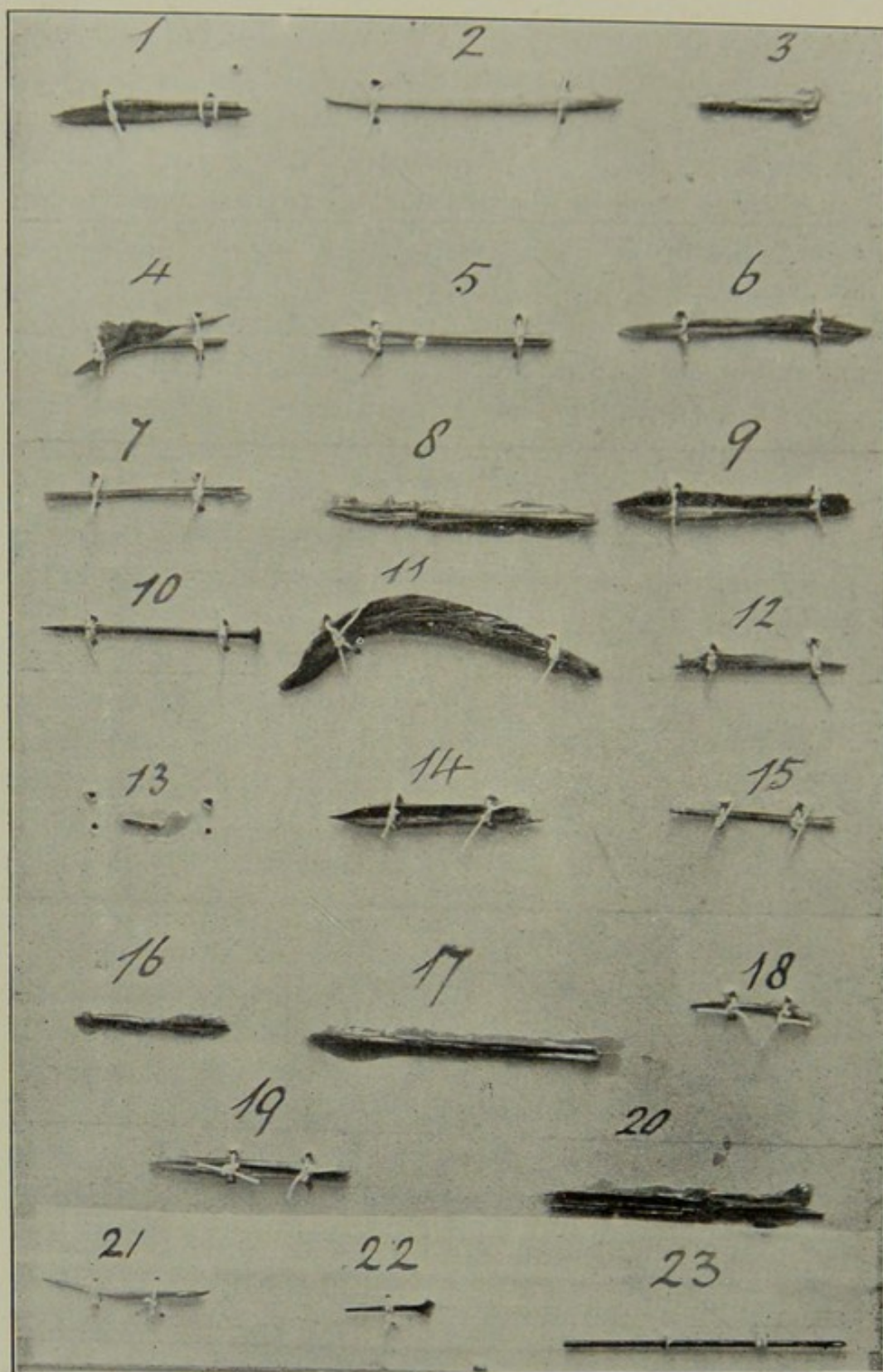


FIG. 43.—SHOWING THE SIZE AND CHARACTER OF THE FOREIGN BODIES REMOVED FROM THE TWENTY-THREE CASES.



## CHAPTER VIII.

### PRURITUS ANI.

Though the term *pruritus ani* simply means an itching of the anus, general usage has caused it to be indicative of a definite pathological change in the structure of the anal and peri-anal skin. This change is of an inflammatory nature and constitutes in reality a *dermatitis* pure and simple. In some individuals, especially in those who exhibit a tendency to gouty and eczematous disorders, the inflammatory process is somewhat acute and is then alluded to as *eczema ani*. In others, in whom no such tendency exists, the dermatitis is of a more chronic type and constitutes the variety known as *pruritus ani*. A simple itching sensation in the anus is not uncommonly met with as a symptom of such rectal diseases as fissure and fistula, but this should not be described under the head of pruritus unless some form of dermatitis be also present. In the acute form of the disease (*eczema ani*) the peri-anal skin is reddened for one, two or more inches around the anus (in very severe cases it extends to the scrotum and pubes), the natural rugæ are enlarged, sometimes œdematous, and here and there small excoriations of the surface are discernible. In the chronic form (*pruritus ani*) the skin immediately surrounding the anal orifice and also



that of the lower portion of the anal canal, loses its natural colour and presents a pearly-white or blanched appearance. Moreover, the skin itself is indurated, thickened and brittle, having lost much of its natural elasticity. The rugæ are enlarged and indurated and there are usually several distinct folds of redundant skin in addition. The skin of the anal canal cracks readily when put upon the stretch, such as happens when passing firm fæces and during a digital examination of the rectum. This is an important fact which should always be borne in mind when making a rectal examination in these cases, because the splitting of the anal margin causes severe pain to the patient.

### *Etiology.*

It may not always be possible to ascribe any definite cause in the production of pruritus ani. It appears that several pathological conditions of the anal canal and rectum may produce it in individuals who are predisposed to dermatitis generally. Some colour is lent to this supposition by the fact that the majority of patients suffering from pruritus ani, afford evidence of a gouty, rheumatic or eczematous diathesis and not uncommonly are affected with eczema in other parts of the body at the same time. Accordingly in persons thus predisposed, morbid conditions of the lower bowel are capable of producing pruritus ani, whereas, in otherwise healthy individuals, they would not do so.

Given the predisposition, therefore, the following may be considered to be the more common exciting causes, viz. : (a) want of cleanliness in the anal region, (b) rectal constipation, (c) hypertrophy and induration of the external sphincter, (d) the presence of small fibromata in the anal canal, (e) protruding internal piles, (f) prolapsus mucosæ recti and (g) blind internal fistula. Of these, the most important to our minds is imperfect cleansing of the anal region after defæcation. Even a slight degree of moisture of the peri-anal



skin and especially persistent faecal soiling of the region, is quite sufficient to produce dermatitis in persons predisposed to its occurrence. Next to this comes rectal constipation. The rectum, in such instances, is never free from faeces, a condition which not only causes a certain degree of venous congestion from direct pressure but necessitates the frequent voiding of flatus. Each time flatus is passed under these conditions, a small quantity of mucus escapes and renders the anal region moist, thus calling into operation the first cause mentioned above. In the same way the presence of protruding internal piles, prolapsus mucosæ recti and a blind internal fistula accounts for a constant dampness of the peri-anal skin. Finally, hypertrophy of the external sphincter and the presence of small fibromata in the anal canal produce rectal constipation and thus indirectly give rise to peri-anal dermatitis.

### *Symptoms.*

As indicated by the word pruritus, the chief symptom is itching of the anus and peri-anal region. If the dermatitis be acute (*eczema ani*) the itching is more or less continuous and is accompanied by smarting and burning sensations if excoriations have been produced by scratching or rubbing the part. The chronic dermatitis (*true pruritus ani*) gives rise to intermittent attacks of itching supervening: (1) *After an action of the bowels*; and, (2) *soon after the patient has become warm in bed*. These latter attacks are most distressing and often so disturb the patient's rest at night that his health begins to suffer from insomnia. When additional symptoms are manifested, they are attributable to the particular variety of the exciting cause and have already been described when dealing with those morbid conditions.

### *Treatment.*

The most important point in the treatment of this affection is to discover and eliminate the exciting cause. Thus the



hypertrophied external sphincter should be divided, fibromata of the anal canal, internal piles and a prolapsus mucosæ recti should be removed, or a blind internal fistula laid open. Rectal constipation, nearly always present in these cases, next demands our attention and should be thoroughly treated as follows:—A complete evacuation of the bowels should be obtained at least once during every period of twenty-four hours. To ensure this a suitable aperient should be given every night at bedtime and the rectum washed out with half-a-pint of plain water, tepid in winter and cold in summer, after the bowels have acted naturally. In our experience, such an enema invariably brings away a certain quantity of fæces, showing that even after a free natural action, some fæces are retained. Such retention is, we think, due to the spasmodic action of the sphincters and levatores ani reflexly set up by the irritable condition of the peri-anal skin, and unless the fæces remaining in the rectum be removed, the exciting cause of the dermatitis is still operative. Quite as important as the above, however, is the need to impress upon the patient the value of thoroughly cleansing the anal region after defæcation and keeping the part quite dry in the intervals. When the dermatitis is acute, he should be directed to wash the part, every night and morning as well as after each action of the bowels, with warm plain water and then to dry it thoroughly with a soft towel without undue rubbing. When the part has thus been thoroughly cleansed and dried, the following ointment should be applied upon a pad of cotton-wool and kept there until the next cleansing.

R Pulv. Zinci Oxidi  $\bar{\text{z}}$  iii.

Lin. Camphoræ  $\bar{\text{z}}$  ss.

Vasellini  $\bar{\text{z}}$  i.

Misce.

Before again washing the part, the remains of the ointment previously applied should be removed with olive-oil.

In those cases in which there is much œdema of the anal



skin, a lotion consisting of lactate of lead gives much relief, especially when there is severe nocturnal irritation. This can be conveniently prepared by mixing one drachm of the liquor plumbi subacetatis with seven drachms of fresh milk. A cream-like compound is thus formed which can be readily applied upon a pad of cotton wool. The lactate of lead thus prepared should not be kept longer than twenty-four hours.

In some cases, the unguentum hydrargyri subchloridi (B.Ph.) is very useful.

We have found the above plan of treatment to be particularly serviceable in treating these cases. In those instances in which a decided gouty or rheumatic diathesis is present, or when evidence of eczema in other parts of the body is manifest, the remedies and dietary suitable for those conditions should be prescribed in addition.

*For intractable cases* we have found the saturated solution of nitrate of silver useful as a caustic for destroying the superficial layers of the epidermis. It should be applied with a camel's hair brush to the surface, and should be left there for about ten minutes. It should then be neutralized with a solution of chloride of sodium, olive-oil being subsequently applied to the part. A re-application of the nitrate of silver is seldom necessary. We have successfully treated two of these cases with *pure formalin*. The application causes much pain and, therefore, it is desirable that the patient should be under the influence of an anæsthetic when the application is being made. After the formalin has been used, a strong solution of cocaine should also be applied. After an interval of four hours boracic fomentations should be commenced, and should be continued until the part has quite healed.



## CHAPTER IX.

### SYPHILIS OF THE ANUS AND RECTUM.

Syphilitic lesions of the anus and rectum are chiefly met with in hospital practice, and may be either of the congenital or the acquired type.

#### CONGENITAL SYPHILIS.

This is practically always a secondary manifestation, and is met with in young children, usually during the first two or three months of life. Radiating cracks or fissures at the anal margin or smooth, elevated and flat patches, varying in size from a pea to a threepenny-piece, situated in the peri-anal skin are the signs met with in the anal region. The exudation from these lesions is highly contagious. Great care should, therefore, be exercised during manipulation to avoid inoculation of the fingers. The diagnosis of congenital syphilis is confirmed when the child is found to be ill-developed, wasted and presenting syphilitic lesions in other parts of the body, such as snuffles, mucous patches in the mouth and eruptions on the skin.

#### *Treatment.*

A course of mercurial inunction and the local application of a dusting powder, such as starch and calomel in equal



parts, until the lesions have quite disappeared, should be persevered with. A mixture of equal parts of steel wine and cod-liver oil is most useful as a tonic during the above treatment.

#### ACQUIRED SYPHILIS.

The manifestations of acquired syphilis are met with in this region in all its forms, viz.: the primary, the secondary and the tertiary. The secondary are the most common.

#### *The Primary Lesion.*

The true chancre of the anus or of the rectum is seldom seen in England, but has been met with more often in the experience of continental surgeons. So far as our own observations are concerned, we have seen only one example of chancre of the anus among our patients at St. Mark's and at the Gordon Hospitals, a circumstance remarkable in itself since both institutions are set aside for the treatment of rectal diseases. According to Quénu and Hartmann\* the primary syphilitic sore cannot be regarded as a rare occurrence in the anal region. They quote statistics compiled by Péan and Malassez which show that of 1,237 primary syphilitic sores in men, 7 occurred at the anus, and of 175 similar lesions in women 14 were anal. The greater frequency in women is explained by the assumption that local infection may probably take place by contact during natural coition. In South America, according to Bumstead and Taylor† the anal chancre is not infrequently met with.

The chancre of the anus should be readily recognised. Its characters are identical with those presented by similar lesions on other parts of the body, and, therefore, a diagnosis can be made by a process of exclusion. We would suggest that in all doubtful cases, before active treatment is com-

---

\* "Chirurgie du Rectum," p. 76.

† "Venereal Diseases, 4th ed., p. 472.



menced, sufficient time should be allowed to elapse in order that the appearance of secondary eruptions may confirm the diagnosis.

The chancre of the rectum is rarely met with. We have never seen a case. But the possibility of its existence should be borne in mind.

### *Secondary Lesions*

In the region of the anus, the natural moist condition of the skin causes rapid proliferation of the epithelium surmounting the hyperæmic papillæ which constitute the earliest or macular syphilide. Consequently, when an eruption in the vicinity of the anus is seen, it appears as a raised, flat, irregularly rounded or oval patch upon the skin surface. In an early stage, before the superficial epithelial layers have been rubbed away, these patches are pearly-white in colour, and are spoken of as *mucous patches* or *tubercles* from their close resemblance to similar conditions met with upon mucous membrane, such as that of the mouth, vagina, etc. There may be a single patch, or several may be scattered about around the anus. When two or more patches become confluent, an irregularly-shaped continuous raised and flattened area is the result. When the surface becomes abraded a superficial ulcer with raised edges appears. From the ulcerated surface a thin offensive discharge exudes. That the mucous patch is one of the early secondary manifestations in the anal region is shown by the accompanying illustration (see fig. 44) in which a solitary mucous patch is seen on the left side of the anus, while the primary sore is still visible on the right labium majus. A later manifestation than the above is the appearance of multiple fissures at the anal margin. These usually appear during the first year after infection. This variety has been described in the chapter on Fissure (see Part I., page 228). These secondary manifestations are highly contagious. In



some instances they may be mistaken for eczema or pruritus, so that due care should be taken during the local examination of suspicious cases.

Secondary syphilitic lesions in the rectum itself probably occur, but are seldom seen.

### *Treatment.*

Constitutional treatment should be commenced forthwith and continued as in the treatment of secondary syphilis in

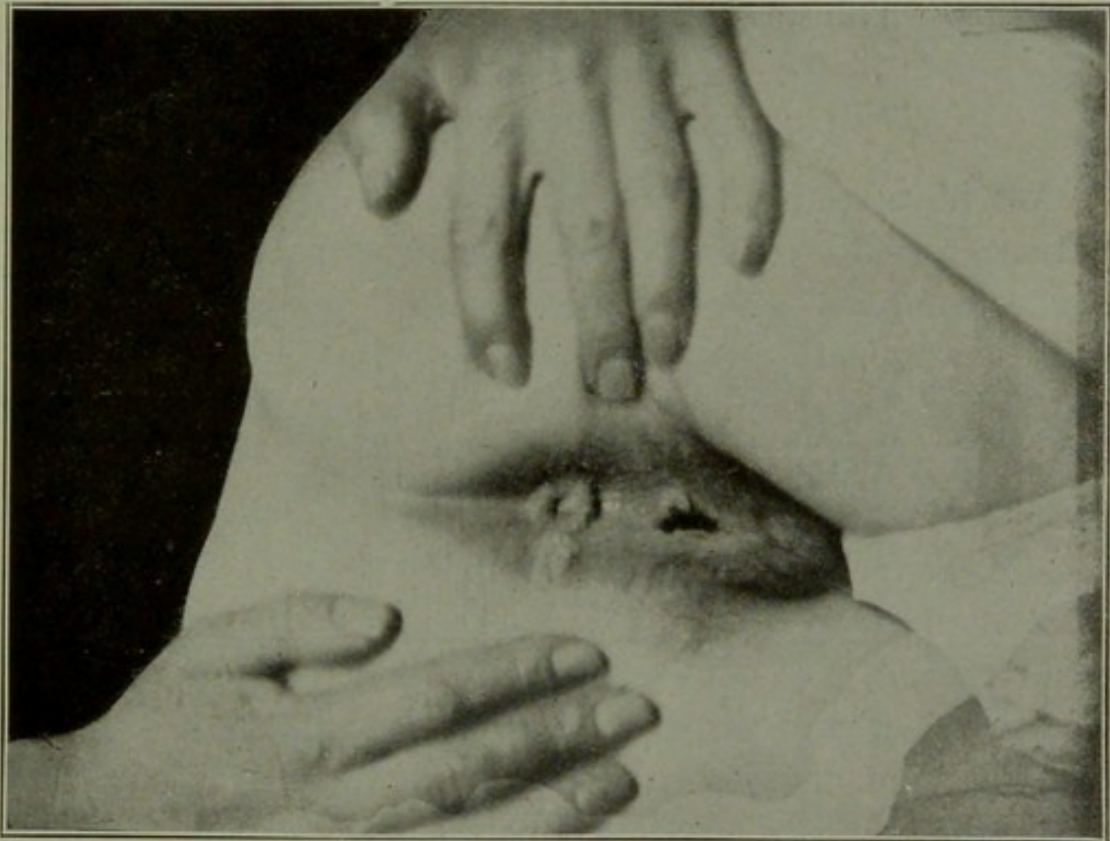


FIG. 44.— SHOWING A SINGLE MUCOUS PATCH ON THE LEFT SIDE OF THE ANUS, AND A CHANCRE ON THE RIGHT LABIUM MAJUS.

general. Locally, the peri-anal region should be frequently cleansed and then kept dry by the application of a powder consisting of calomel and starch or calomel and oxide of zinc in equal parts. Should the mucous patches disappear slowly, their resolution may be expedited by touching them with solid nitrate of silver.



*Tertiary Lesions.*

Tertiary manifestations of the anus and rectum are rare. They consist of gummatous deposits and may be seen in either of the three stages of their clinical course, viz.: tumefaction, ulceration, and cicatrization. When met with in the peri-anal region, these phases of the gummatous deposit present the usual characteristics and need no description here. When occurring in the rectum, however, certain peculiarities are presented which we shall now describe.

*The Gummatous Tumour of the Rectum.*

We have seen only one example of this condition. The patient, a male, experienced increasing difficulty in obtaining a complete action of the bowels, accompanied by a dull, boring pain in the rectum, particularly noticeable at night. Digital examination revealed a smooth, elastic, semi-fluctuating, globular swelling on the left side of the rectum, about an inch above the anal orifice. The swelling was painless to the touch, and, judging from the history obtained, had been slowly increasing in size. The mucous membrane over it was intact and there was no discharge. The patient had had syphilis, and there were evidences of the disease in other parts of his body. This tumour gradually disappeared under the influence of iodide of potassium.

In this case the diagnosis lay between three conditions: a gumma, an abscess and a malignant growth—possibly sarcoma. The absence of acute pain and tenderness on pressure, the gradual development of the swelling, the nocturnal character of the pain experienced, and the concomitant signs that the patient had had syphilis in other parts of the body negatived the diagnosis of an abscess, while the absence of spontaneous bleeding and friability of structure, and the gradual dis-



appearance of the tumour under the influence of iodide of potassium were not in favour of a malignant neoplasm.

*Gummatous Ulceration of the Rectum.*

This is the result of the breaking down of gummatous deposits in the coats of the rectum. We have seen two cases of this kind, in both of which the ulcerative process was extensive and had practically destroyed the anus and the lower part of the rectum, a huge, deep, sloughing ulcer with characteristic steep punched-out edges resulting. In both patients there was a history of syphilis, and other signs of the disease were evident. One of these cases died from exhaustion before any material benefit was obtained by anti-syphilitic remedies, and the other was lost sight of before healing of the ulcer had taken place, though considerable progress was made under that treatment.

*Cicatrization of a Gummatous Ulcer of the Rectum.*

Since a gummatous ulcer of the rectum means destruction of part or the whole of its circumference, ultimate repair must of necessity cause cicatricial stenosis. To this class of case, alone, should the term *syphilitic stricture of the rectum* be applied. Though we do not deny that such a form of stricture may exist, we nevertheless state that we have never seen an instance in which the syphilitic origin of a stricture was beyond dispute.

We have already mentioned (see page 98) that a large number of strictures of the rectum are set down as syphilitic when they are really due to infective ulceration, and have given our reasons for this opinion. Still there are many observers who support the opinion that the condition known as the *syphilôme ano-rectal* of Fournier\* is the most frequent cause of stricture of the rectum. To our minds, this opinion has been based entirely upon the analogical reasoning that because syphilis produces connective tissue hyperplasia in

---

\* "Lesions tertiares de l'anús et du rectum." Paris, 1875.



other organs such as the lungs, liver, etc., it must necessarily do so in the rectum.

### *Treatment.*

Gradually increasing doses of iodide of potassium, combined in some cases with small doses of mercury should be regularly and continuously given. Full attention should be paid to hygienic surroundings and to local cleanliness and antisepsis. The patient should be carefully dieted and very small quantities of stimulants should be allowed.

### SYNOPSIS OF THE NOTES OF FIFTY-FIVE CASES OF SYPHILIS.

From March 22nd, 1882, to November 1st, 1888, both dates inclusive, fifty-five cases of syphilis of the ano-rectal region were seen by Mr. Goodsall in the out-patient department at St. Mark's Hospital. Thirty-seven of the patients were males and eighteen females. The average age of the males was thirty-one years, the youngest eighteen years and the oldest fifty-seven years; and of the females the average age was twenty-four years, the youngest two years and the oldest forty-two years.

In twenty-nine cases the primary sore still existed.

In forty-three cases the glands in both groins were enlarged.

In fifteen cases there was a syphilitic rash on the body.

In thirty-three cases there were mucous tubercles or patches on the anal region.

In six cases there were syphilitic fissures.

In twelve cases there was ulceration of the anal region.

In one case there was a primary sore on the anal region.

In one case an ulcer of the rectum.

In one case a gummata on both sides of the anus.


In one case a gumma on one side causing a fistula.



The histories in fifty-three of the cases varied between four and eighteen months. The adult patients suffering from secondary syphilis were treated by the inunction of mercury, about half a drachm of the Unguentum Hydrargyri being used every night at bedtime. The perchloride, or the sulphate of iron was at the same time given as a tonic. The local applications used were equal parts of calomel and starch powder for the mucous tubercles, and the Ung. hydrargyri or Ung. hyd. subchlor. for the fissures and ulcerations.

The advantage of giving preparations of iron while inunctions of mercury are used, is that the patients lose their syphilitic symptoms, but do not get any ptyalism from the mercury.







## INDEX.

- Abdominal distension during operation for left iliac colostomy 201.  
Abscess, after excision of the rectum 172.  
Adenoma or glandular polypus in the rectum 222.  
Adults, causes of procidentia recti in, 22.  
ALLINGHAM on manner of operation for procidentia recti 33;  
    method of operation for perineal excision with formation of  
    an inter-ischial artificial anus 160; on operation by  
    cautery 35.  
Anal ulceration 47.  
Anus, abdominal, advantages of a preliminary, in operation for  
    carcinoma of the rectum 165.  
——, artificial, resulting from direct union of the colon to the  
    muscular parietes, illustration of, 185.  
——, resulting from inter-peritoneal adhesion, illustration of, 186;  
    showing the two distinct openings after removal of the  
    spur 192.  
——, benign tumours of the, 216; lipoma 220; symptoms and  
    treatment 221; papilloma 216; symptoms and treatment  
    219; soft fibroma or fibro-cellular tumour 219; symp-  
    toms and treatment 220.  
——, carcinoma of the, 114; treatment 115.  
——, chancre of the, 265.  
——, cæcal artificial, closure of the, 211; method of operation 212.  
——, dermatitis of the, 259; treatment 261.  
——, malignant growth in the, 114.



- , perineal excision with the formation of an inter-ischial artificial; Allingham's method 158; Cripps' method 155; various methods practised 155.
- , pruritus of the, 259.
- , syphilis of the, 264.
- Ascites in removal of malignant growths 215.
- BARDENHEUER'S operations for removal of lower part of the sacrum, and for excision of the rectum 162.
- Belt, for colostomy 193.
- Bryant villous tumour 231.
- Carcinoma of the anus 113; of the rectum 115; treatment 181.
- Cases of foreign bodies in the rectum 245; illustration of 258.
- Cases of syphilis seen by Mr. Goodsall at St. Mark's Hospital 270.
- Cautery, operation by the, for procidentia recti 35.
- Children, causes of procidentia in, 21.
- Cleanliness, want of, in the anal region, a cause of pruritus ani 260.
- Colostomy, left iliac, in carcinomata of the rectum 182; complication during and after operation and their treatment 198; method of dealing with the parietal peritoneum 184; operation 183; sigmoid colon 187; after treatment of 190; treatment when the symptoms of obstruction are present 202.
- Constipation, primary attack in connection with carcinoma of the rectum 124; rectal, a cause of pruritus ani 260.
- CRIPPS' method of operation for perineal excision, with formation of an inter-ischial artificial anus 155; on nitric acid in operation for procidentia recti 34; on operation by cautery 35.
- Delirium, iodoform after operation for removal of the rectum 175.
- Dermatitis, peri-anal, 259.
- Diagnosis, differential symptoms and signs:—
- Carcinoma of the rectum* 141.
- Invagination of the rectum*: before protrusion of the invaginated part 42; carcinoma 44; procidentia recti 45; prolapsus mucosæ recti 45; protruded intussusceptum coli 45; protrusion of the invaginated part 44; ulceration 43; villous growth 44.
- Procidentia recti*: prolapsus mucosæ recti 27; invagi



nation of upper part of the rectum 27; prolapse of the rectum 10.

Etiology of

infective ulceration 72; invagination of the rectum 39; malignant growths 118; procidentia recti 20; pruritus ani 259; tubular stricture 97; villous tumour 233.

Examination, physical, for

adenoma or glandular polypus 224; fibroma or fibrous polypus 229; villous tumour 236.

Infective ulceration 82.

Invagination of the rectum prior to and after protrusion has occurred 41.

Carcinoma recti 140.

Prolapse of the rectum 10.

Stricture 91.

Tuberculous ulcer 64.

Tubular stricture 104.

Traumatic ulcer 58.

Excision of the rectum, complications and their treatment 172.

Fibroma or fibro-cellular tumour of the anus 219.

———, symptoms and treatment 220.

Fibroma or fibrous polypus of the rectum 226.

———, symptoms 229; physical examination 229; treatment 230.

Fish-bones in the rectum 242.

Fistula, blind internal, a cause of pruritus ani 260.

———, recto-vesical or recto-vaginal 215.

———, urethral after operation for removal of the rectum 174.

FLEMING on use of nitric acid in the operation for procidentia recti 34.

*Foreign Bodies in the Rectum* 241.

Illustration of size and character of those removed from twenty-three cases 258.

Notes on cases 244.

Summary of probable results of, 257.

HARTMANN and QUÉNU on the primary lesion 265.

Hæmorrhage, a symptom in prolapse of the rectum 7.

———, as a result of carcinoma of the rectum 131, 135.



- , collapse from, after excision of the rectum 172.  
 —————, in removal of malignant growths 214.  
 Heart failure in carcinoma of the rectum 139.  
 Hypertrophy and induration of the external sphincter, a cause of pruritus ani 260.  
 Infective ulceration 65.  
 Intestinal obstruction in carcinoma of the rectum 181.  
 —————, the result of neglect of stricture of the rectum 111.  
 Iodoform delirium after operation for excision of the rectum 175.  
 Jaundice, appearance of, in carcinoma of the rectum 139.  
 JESSOP on manner of operation for procidentia recti 33.  
 Kidneys, amyloid degeneration of, the result of neglect of stricture 112.  
 KLEIN, Professor, report on infective ulceration 73.  
 KRASKE'S method of operation for excision of the rectum and for the removal of the lower part of the sacrum 161.  
 Ligature, operation by the, for procidentia recti 36.  
 Lipoma of the peri-anal region 220; symptoms and treatment 221.  
 Liver, enlargement of the, in carcinoma of the rectum 139.  
 Lupoid ulcer, characteristic features of, 52; treatment 52.  
*Malignant growths of the anus and rectum*: colostomy, how soon should it be performed 178; differential diagnosis 141; physical examination 140; treatment 145.  
 —————, cases unsuitable for removal of the growth 178.  
 —————, prior to the occurrence of obstruction 181.  
 —————, removal of growths: closure of the cæcal artificial anus 211; method of operation 212; signs of recurrence of the growth after removal 176.  
 —————, trans-sacral excision 161; Kraske's operation for removal of lower part of the sacrum 161; Bardenheuer's, operation for, 162.  
*Malignant Growths of the Anus and Rectum*:  
 treatment of cases unsuitable for removal of the primary growth 213; ascites 215; hæmorrhage 214; increase of secretion of rectal mucus 213; pain due to pressure upon or involvement of nerves of the sacral plexus 214; pelvi-



- rectal and ischio-rectal suppuration 215; recto-vesical or recto-vaginal fistula 215.
- Mercurial poisoning after the operation of excision of the rectum 175.
- Mortality after excision of the rectum 171.
- Mucus in prolapsus, escape of, 6.
- Myxoma or myxomatous polypus in the rectum, symptoms and treatment 239.
- Neoplasm, clinical course of the carcinomatous, 121.
- Operation by ligature for prolapse of the rectum 14.
- , cæcostomy in connection with excision of the rectum 206; after treatment 210; complications and their treatment 210.
- , choice of, for procidentia recti 31.
- for closure of the cæcal artificial anus 212; left iliac colostomy, preparation of patient for, 182; method of operating 183; after treatment 190.
- for excision of the rectum: Allingham's method 158; Bardenheuer's method 162; Cripps' method 155; Kraske's method 161; authors' method 166.
- for procidentia recti 30; after treatment 36; application of nitric acid 32; choice of operation 31; by cautery 35; by ligature 36.
- for villous tumour of the rectum 238.
- for resection of the rectum 149; treatment after 153.
- Operation, use of nitric acid in, 32.
- Operation, treatment for the traumatic ulcer 60.
- Palpation in prolapse of the rectum 9.
- Papilloma of the anus 216; symptoms and treatment 219.
- Parietal peritoneum in the operation for left iliac colostomy 184.
- Pelvi-rectal suppuration, the result of neglect of stricture 111.
- Peritonitis after operation for excision of the rectum 175.
- Pins and needles in the rectum 242.
- Poisoning, mercurial, after operation for removal of the rectum 175.
- Procidentia recti*: case of 18; causes in adults 22; causes in children 21; choice of operation 31; definition of 1; differential diagnosis 27; etiology 20;



# INDEX.

- exciting causes 21; meaning of the term 17;  
physical examination 26; predisposing causes  
20; symptoms 24; treatment 28.
- Prolapsus ani, definition of, 1.
- Prolapsus mucosæ recti, a cause of pruritus ani 260.
- , definition of, 2.
- Protrusion, reduction and prevention of, in prolapse of the  
rectum 12.
- Pruritus ani, definition 259; etiology 260; symptoms 261; treat-  
ment 261.
- QUÉNU and HARTMANN on the primary lesion of syphilis 265.
- Rectal tubes, illustration of, 108.
- ulceration 54.
- wall when foreign body has perforated 243.
- Recto-vesical or recto-vaginal fistula in removal of malignant  
growths 215.
- Rectum, Benign Tumours of the* 221.
- Adenoma or glandular polypus* 222; physical examination  
    224; symptoms 224; treatment and after treatment 225.
- Fibroma or fibrous polypus* 226; physical examination 229;  
    symptoms 229; treatment 230.
- Myxoma or myxomatous polypus* 239; symptoms 240;  
    treatment 240.
- Villous tumour* 231; etiology 233; symptoms 234;  
    physical examination 236; method of operating for 238;  
    recurrence of growth after removal 238; treatment 239.
- Rectum, Carcinoma of the*, 115: cases in which extirpation is  
    practicable 146; complications during and after the  
    operation for removal 198; etiology 118; extirpa-  
    tion of, subsequent to the establishment of an  
    abdominal anus (iliac colostomy) 164; operation for  
    removal of the growth 151; operation for resection  
    of the rectum 117; operation prior to occurrence of  
    obstruction 181; operation when symptoms of ob-  
    struction are present 202; pathological varieties 119.
- , *symptoms*: abdominal pain 135; abdominal distension  
    136; ascites 138; bowel affected 120; during the



- process of surface disintegration 128; intermittent hæmorrhage 135; prior to disintegration of the surface of the growth 124; rapid emaciation 136; tumour of the abdomen 138; when almost complete occlusion of the lumen of the bowel has supervened 132; when secondary deposits have occurred in the abdominal lymphatic glands and in the liver, lungs, pleuræ, etc., 137; when the growth has infiltrated the peri-rectal tissues and perforation of the rectal wall has supervened 131.
- , *treatment*, 151, 202.
- Rectum, chancre of the, 266.
- , excision of the, 154.
- cases unsuitable for operation 178; methods of operation practised 155.
- , excision of the, complications and their treatment; abscess 173; collapse from hæmorrhage 172; iodoform delirium 175; mercurial poisoning 175; peritonitis 175; shock 172; urethral fistula 174.
- , *foreign bodies in the*, 241: fish bones, pins and needles 242; introduced through the anal orifice 241; notes of cases 244; symptoms 243; that have been swallowed 242; treatment 244.
- , gummatous tumour of the, 268.
- , gummatous ulceration of the, 269.
- Rectum, *invagination of the*: differential diagnosis 42; etiology 38; symptoms 39; treatment 45.
- , malignant growths in the, 114.
- Rectum, *prolapse of the*: differential diagnosis 10; etiology 3; examination of the rectum 10; operation 14; sphincters 10; symptoms 5; treatment 12.
- Rectum, *prolapse of the*: procidentia recti, etiology 20; in adults 22; in children 21; exciting causes 21; predisposing causes 20.
- Rectum, *removal of the*: after treatment 170; cases unsuitable for removal 178; mortality from the operation 171; re-



# INDEX.

- currence of the growth after removal 176; treatment 177.
- Rectum, resection of the*, 147: description of the operation 149; after treatment 153.
- Rectum, syphilis of the, 264.
- Rodent ulcer of the anus, treatment of, 54.
- Sacrum, removal of the lower part of the*, 161: Kraske's operation 161; Bardenheuer's operation 162.
- Shot-bougie, illustration of, 109.
- Skin, redundant, in the prolapse of the rectum 9.
- Sphincters, loss of power and control in prolapse of the rectum 7; muscles, improving the tone of the, 13.
- Stricture of the anus and rectum* 88: cicatricial or fibrous 88; linear or annular 89; physical examination 91; results of 111; symptoms 90; treatment 92; varieties 89.
- Stricture, tubular, of the anus and rectum*: amyloid degeneration of the kidneys in 112; etiology 97; physical examination 104; treatment 105; results 111.
- Syphilis of the anus and rectum 264; acquired syphilis 265; congenital syphilis and treatment 264; gummatous tumour of the rectum 268; gummatous ulceration of the rectum and treatment 269; primary lesions 265; secondary lesions 266; synopsis of the notes of fifty-three cases of syphilis seen by Mr. Goodsall 270; tertiary lesions 268; treatment 267 and 270.
- Syphilitic ulcer 52.
- Trans-sacral excision with the formation of a sacral artificial anus 161.
- Traumatic ulcer 55; symptoms 56.
- Treatment after cæcostomy for carcinoma of the rectum 210.
- after operation for procidentia recti 28.
- left iliac colostomy 190.
- , benign tumours of the anus 219, 220, 221.
- *rectum*, adenoma or glandular polypus 224; fibroma or fibrous polypus 230; myxoma or myxomatous polypus 240; villous tumour 238.
- Treatment*: carcinoma of the anus 115.



*Treatment:* carcinoma of the rectum 145.

———— cases unsuitable for removal of the primary growth in carcinoma of the rectum 213; complications as a result of excision of the rectum 172.

*Treatment:* foreign bodies in the rectum 244.

———— infective ulceration of the rectum 85

———— lupoid ulcer 52.

———— primary and secondary syphilitic lesions 267.

———— prolapse of the rectum 12.

———— pruritus ani 261.

———— stricture of the anus and rectum 92.

———— syphilis of the anus 264.

———— syphilitic ulcer 52.

———— tertiary lesions 270.

———— tuberculous ulcer of the ano-rectal margin 50 and 64.

———— anus and rectum 59.

———— tubular stricture 105.

———— ulceration of the anus and rectum 59.

Tuberculous ulcer, variety and treatment 49.

———— of the ano-rectal margin 50.

Tumour in the abdomen 138.

*Tumours, benign, of the anus* 216: the lipoma 220; symptoms and treatment 221.

———— the papilloma 216; symptoms and treatment 219.

———— the soft fibroma or fibro-cellular 219; symptoms and treatment 220.

*Tumours, benign, of the Rectum* 221.

———— adenoma or glandular polypus 222; physical examination 224; symptoms 224; treatment and after treatment 225.

———— the fibroma or fibrous polypus 226; physical examination 229; symptoms 229; treatment 230.

———— the myxoma or myxomatous polypus 239.

———— the villous 231; etiology 233; method of operating 238; physical examination 236; recurrence of growth, after removal and treatment 239; symptoms 234; treatment 238.



INDEX.

- Ulcer, an adeno-carcinomatous, illustration of, 125.  
——, local contagions and treatment 48.  
——, lupoid 52.  
——, rodent of the anus 54.  
——, syphilitic 52.  
——, traumatic, physical examination 58; symptoms 56; treatment 59.  
Ulceration, anal, 47.  
——, gummatous, of the rectum 269.  
——, *of the anus and rectum*: circumscribed 54; symptoms 56; treatment 59.  
—— tuberculous 49; treatment 50.  
——, rectal 54.  
——, description of infective, 68; physical examination 82; symptoms 84; treatment 85; Professor Klein's report on 73; Professor Woodhead's report on 79.  
Urethral, fistula, after operation for excision of the rectum 174.  
VAN BUREN on nitric acid in operations for procidentia recti 34.  
Villous tumour 231.  
Weight, loss of, a symptom in prolapse of the rectum 7; in carcinoma 130.  
WOODHEAD, Professor, report on infective ulceration 74.







8

24



145











