

Diseases and injuries of the eye : a text-book for students and practitioners / by William George Sym.

Contributors

Sym William George.
Royal College of Physicians of Edinburgh

Publication/Creation

London : A. and C. Black, 1913.

Persistent URL

<https://wellcomecollection.org/works/dd2ahvwn>

Provider

Royal College of Physicians Edinburgh

License and attribution

This material has been provided by This material has been provided by the Royal College of Physicians of Edinburgh. The original may be consulted at the Royal College of Physicians of Edinburgh. where the originals may be consulted.

Conditions of use: it is possible this item is protected by copyright and/or related rights. You are free to use this item in any way that is permitted by the copyright and related rights legislation that applies to your use. For other uses you need to obtain permission from the rights-holder(s).



Wellcome Collection
183 Euston Road
London NW1 2BE UK
T +44 (0)20 7611 8722
E library@wellcomecollection.org
<https://wellcomecollection.org>





Presented by Dr.
R.W. Black.

Fc^{*} 3.41

7/6/61

R52113

P.A. *Healy*

The Edinburgh Medical Series

General Editor—JOHN D. COMRIE,
M.A., B.SC., M.D., F.R.C.P.E.

DISEASES AND
INJURIES OF THE EYE

IN THE SAME SERIES
TEXT-BOOK OF MIDWIFERY

BY

R. W. JOHNSTONE

M.A., M.D., F.R.C.S., M.R.C.P.E.

ASSISTANT TO THE PROFESSOR OF MIDWIFERY
AND TO THE LECTURER ON GYNECOLOGY
IN THE UNIVERSITY OF EDINBURGH

Crown 8vo, Cloth, containing 264 Illustrations.

Price 10s. 6d.

A. AND C. BLACK, 4 SOHO SQUARE, LONDON, W.

AGENTS

- AMERICA . . THE MACMILLAN COMPANY
64 & 66 FIFTH AVENUE, NEW YORK
- AUSTRALASIA THE OXFORD UNIVERSITY PRESS
205 FLINDERS LANE, MELBOURNE
- CANADA . . THE MACMILLAN COMPANY OF CANADA, LTD.
ST. MARTIN'S HOUSE, 70 BOND STREET, TORONTO
- INDIA . . . MACMILLAN & COMPANY, LTD.
MACMILLAN BUILDING, BOMBAY
309 BOW BAZAAR STREET, CALCUTTA

DISEASES AND INJURIES OF THE EYE

A TEXT-BOOK FOR
STUDENTS AND PRACTITIONERS

BY

WILLIAM GEORGE SYM

M.D., F.R.C.S.E.

OPHTHALMIC SURGEON, EDINBURGH ROYAL INFIRMARY
LECTURER ON DISEASES OF THE EYE IN THE UNIVERSITY OF EDINBURGH

WITH TWENTY-FIVE FULL-PAGE ILLUSTRATIONS, SIXTEEN OF THEM
IN COLOUR, AND EIGHTY-EIGHT FIGURES IN THE TEXT
ALSO A TYPE TEST-CARD AT END OF VOLUME

LONDON

ADAM AND CHARLES BLACK

1913

THE aim in this
clinical guide ra
points in Ophth
of the School
Practitioner hav
certain instances
so, I have given
as a rule I hav
accepted opinion

It is hoped t
tion for Injuries
necessarily so fre
the Practitioner.

I am indebted
in the Royal
Chapter XXIV.

EDINBURGH, A

PREFACE

THE aim in this little book has been to supply a useful clinical guide rather than to discuss obscure or disputed points in Ophthalmology. The needs of the Student, of the School Medical Officer, and of the General Practitioner have been kept in view throughout. In certain instances, in which I could hardly avoid doing so, I have given frank expression to my own views, but as a rule I have given prominence to the generally accepted opinion.

It is hoped that the chapter dealing with Compensation for Injuries may prove useful when the subject is necessarily so frequently brought under the attention of the Practitioner.

I am indebted to Miss Douglas, Sister of my Wards in the Royal Infirmary, for the major portion of Chapter XXIV.

WILLIAM GEORGE SYM, M.D.

EDINBURGH, *April* 1913.

PREFACE

The aim of this book is to provide a general
introduction to the study of the history of
the United States. It is not intended to be a
comprehensive history, but rather a guide to the
study of the subject. I have tried to make it
as simple and as clear as possible, and I hope
that it will be of some use to the student.

It is hoped that the student will find this
book of interest and value. I have tried to
make it as simple and as clear as possible,
and I hope that it will be of some use to
the student. I have also tried to make it
as interesting as possible, and I hope that
it will be of some use to the student.

WILLIAM G. SUMNER

CONTENTS

CHAPTER I

	PAGE
GENERAL EXAMINATION OF THE EYE	I
1. Pain	2
2. Deformity	8
3. Impairment of Sight	9

CHAPTER II

REFRACTION	36
Lenses	36
Refraction of the Eye itself	41
Ametropia or Faulty Refraction	46
Astigmatism	61
Objective Tests of Refraction	65
Subjective Tests of Ametropia	70
Asthenopia	73

CHAPTER III

THE EYELIDS	80
Affections of the Eyelids	82

CHAPTER IV

THE CONJUNCTIVA	98
Diseases of the Conjunctiva	100

CHAPTER V

THE CORNEA	PAGE 126
Ulcers of the Cornea	127
Non-ulcerative Affections of the Cornea	144
Non-inflammatory Affections of the Cornea	150

CHAPTER VI

THE SCLEROTIC	158
-------------------------	-----

CHAPTER VII

THE IRIS AND CILIARY BODY	162
The Iris	167
The Ciliary Body	179

CHAPTER VIII

THE CRYSTALLINE LENS	183
Hard or Senile Cataract	186
Soft or Cortical Cataract	205
Lamellar, Zonular, or "Congenital" Cataract	207
Anterior Polar Cataract	211
Posterior Polar Cataract	212
Degenerative or Complicated Cataract	213

CHAPTER IX

THE OPHTHALMOSCOPE AND OPHTHALMOSCOPY	217
---	-----

CHAPTER X

THE VITREOUS HUMOUR	235
-------------------------------	-----

CHAPTER XI

THE CHORIOID	239
Chorioiditis	240
Tumour of the Chorioid	246

CHAPTER XII

	PAGE
THE RETINA	251
1. Retinitis	252
2. Degenerative Changes	260
3. Detachment of the Retina	263
4. Tumour of the Retina	268

CHAPTER XIII

THE OPTIC NERVE	272
Optic Neuritis	272
Optic Atrophy	282

CHAPTER XIV

GLAUCOMA	293
--------------------	-----

CHAPTER XV

THE OCULAR MUSCLES	316
------------------------------	-----

CHAPTER XVI

CONCOMITANT STRABISMUS	339
Divergent Strabismus	339
Convergent Strabismus	342

CHAPTER XVII

THE LACHRYMAL APPARATUS	356
-----------------------------------	-----

CHAPTER XVIII

THE ORBIT	362
---------------------	-----

CHAPTER XIX

WOUNDS AND INJURIES	374
Sympathetic Ophthalmia	395

CHAPTER XX

MEDICO-LEGAL QUESTIONS.	PAGE 405
---------------------------------	-------------

CHAPTER XXI

OPERATIONS ON THE EYE AND ITS APPENDAGES	417
Operations on the Eyelids	422
Operations on the Cornea	430
Operations on the Iris	432
Operations on the Muscles	440
Operations on the Globe	444
Operations on the Lachrymal Apparatus	447
Operations on the Orbit	451

CHAPTER XXII

THE EXAMINATION OF THE EYE: POINTS IN GENERAL DIAGNOSIS	453
--	-----

CHAPTER XXIII

EYE SYMPTOMS IN DISEASES OF OTHER PARTS	463
---	-----

CHAPTER XXIV

POINTS IN THE NURSING OF PATIENTS SUFFERING FROM DISEASES OF THE EYE	468
---	-----

CHAPTER XXV

THERAPEUTIC AGENTS	479
------------------------------	-----

CHAPTER XXVI

REQUIREMENTS FOR THE PUBLIC SERVICES	485
--	-----

INDEX	487
-----------------	-----

LIST OF ILLUSTRATIONS

PRINTED SEPARATELY

PLATE	FACING PAGE
I. 1. Herpes Ophthalmicus. 2. Epicanthus . . .	84
II. 1. Panophthalmitis. 2. Acute Dacryocystitis. 3. Cicatricial Ectropion, secondary to Lupus. 4. Epithelioma, beginning at lid margin (<i>in colour</i>) . . .	97
III. Micro-organisms occurring in the Conjunctiva . . .	100
IV. 1. Mucopurulent Conjunctivitis. 2. Marginal Blepharitis with Ectropion. 3. Trachoma: aspect of patient (<i>in colour</i>)	104
V. 1. Pneumococcal Conjunctivitis: Petechiæ. 2. Diplobacillus (Morax-Axenfeld) Conjunctivitis. 3. Phlyctenules. 4. Subconjunctival Hæmorrhage. 5. Follicular Conjunctivitis. 6. Atropin Conjunctivitis. 7. Trachoma: Follicular type. 8. Trachoma: Cicatricial stage; with Pannus (<i>in colour</i>)	112
VI. 1. Phlyctenules: Tuberculous form. 2. Fascicular (superficial vascularised) Keratitis: "Strumous Pannus." 3. The same in more acute form. 4. Band-shaped Keratitis. 5. Interstitial Keratitis. 6. Hypopyon ulcer. 7. Hyphæma. 8. Pterygium (<i>in colour</i>)	129
VII. 1. Leucoma Adhærens. 2. Prolapse of Iris: partial Staphyloma. 3. Partial Staphyloma. 4. Keratitis Punctata. 5. Arcus Senilis. 6. Conical Cornea, from the front. 7. Conical Cornea, side view. 8. Buphthalmos (<i>in colour</i>) . . .	144
VIII. 1. Entropion of both lower eyelids. Shrunk globe (R.E.); Large eroded staphylomatous Cornea	

	(L.E.). 2. Heterochromia Iridis et Iridum.	
	3. Chemosis. 4. Rupture of globe at inner side (<i>in colour</i>).	161
IX.	1. Iritis. 2. Irregular pupil from posterior Synechiæ, the result of Iritis. 3. Iris bombé; anterior chamber shallow at periphery. 4. Anterior Synechiæ. 5. Iridodialysis. 6. Pupil drawn up to wound of Cornea. 7. Artificial pupil obtained by Iridotomy. 8. Coloboma of the Iris (<i>in colour</i>).	176
X.	1. Shrinking of Conjunctiva from Trachoma. 2. Xerosis of Conjunctiva. 3. Argyria: silver staining of Conjunctiva. 4. Mucocoele, inflamed. 5. Senile Cataract, "ripe." 6. Lamellar Cataract. 7. Traumatic Cataract. 8. Recent burn of Cornea and Conjunctiva: Symblepharon (<i>in colour</i>).	192
XI.	Ophthalmoscopy. 1. Indirect method. 2. Direct method: first step, placing the mirror	216-217
XII.	Ophthalmoscopy. Direct method: second step, position completed	
XIII.	1. Normal pupil as seen through ophthalmoscope mirror. 2. Glow from Albino fundus as seen through ophthalmoscope mirror. 3. Old Iritis: Synechiæ, some holding, some broken. 4. Iridodialysis. Edge of lens visible. 5. Cortical Cataract, as seen with mirror. 6. Sclerosis of Lens: early Nuclear Cataract. 7. Lamellar Cataract, with numerous spicules. 8. Lamellar Cataract. 9. Crescentic shadow in Conical Cornea. 10. Subluxation of Lens: congenital. 11. Cortical Cataract as seen by focal illumination. 12. Nuclear Cataract as seen by focal illumination (<i>in colour</i>).	225
XIV.	1. Average normal fundus: physiological cup. 2. Fundus of blonde: macular halo: some chorioidal vessels. 3. Fundus of brunette: slight "tiger-stripping." 4. Staphyloma downwards: "Fuchs's Coloboma" (<i>in colour</i>).	232
XV.	1. Disseminated Chorioiditis. 2. Staphyloma Posticum: scattered patches of atrophy. 3. Coloboma of Chorioid. 4. Rupture of Chorioid (<i>in colour</i>).	240

LIST OF ILLUSTRATIONS

xiii

PLATE	FACING PAGE
XVI. 1. Albuminuric Retinitis. 2. Diabetic Retinitis. 3. Opaque Nerve Fibres. 4. Subhyaloid Hæmorrhage (<i>in colour</i>)	257
XVII. 1. Chorioido-retinitis with pigmentation (syphilitic). 2. Retinitis pigmentosa. 3. Detachment of Retina. 4. Glaucoma cupping, ring, and pig- mentary changes (<i>in colour</i>)	264
XVIII. 1. Optic Neuritis (choked disc). 2. Embolism of central retinal artery. 3. Optic Atrophy following Neuritis. 4. Primary Optic Atrophy (<i>in colour</i>)	272
XIX. Six pathological specimens	288
XX. 1. Episcleritis. 2. Scleritis: the violet or purplish colour of the injection should be noticed, and the invasion of the cornea. 3. Ciliary Staphy- loma (usually slightly more anterior than in this instance). 4. Pigment spots on the Scler- otic; Cataract; Arcus senilis. 5. Results of severe Scleritis; thinning of sclerotic round the cornea; posterior synechiæ: Iridectomy has been performed. 6. Glaucoma: note the venous injection, the dulling of the cornea, and the shallowing of the anterior chamber. 7. Glaucoma: Iris much atrophied. 8. Tre- phining wound (<i>in colour</i>)	304
XXI. 1. Sinking of Caruncle after severe Tenotomy for Strabismus: right eye. 2. Ptosis—Bilateral: showing the exaggerated action of the Occipito- frontalis Muscle. 3. Paralysis of Right III. Nerve	336
XXII. 1. Convergent Strabismus: right eye. 2. Divergent Strabismus: right eye. 3. Hyperphoria: left eye	353
XXIII. Bilateral Proptosis from intra-cranial tumour. Ec- tropion from paralysis of the right facial nerve	360
XXIV. 1. Exophthalmos: left eye; showing the retraction of the upper lid. 2. Traumatic Paralysis of Right VI. and VII. Nerves, and Secondary Contracture of the Internal Rectus	368
XXV. To illustrate the colour-confusions of the colour- blind as brought out by Holmgren's tests (<i>in colour</i>)	467

IN THE TEXT

FIG.	PAGE
1. A letter of Bjerrum's type	12
2. A letter of Snellen's type	14
3. The visual angle	15
4. The average normal field of vision	18
5. Right homonymous hemianopsia	25
6. Course of visual fibres	27
7. Bitemporal hemianopsia	29
8. Action of a convex spherical lens	36
9. Action of a concave spherical lens	37
10. Action of a prism	39
11. The lens at rest, adapted for parallel rays	42
12. Graph showing amplitude of accommodation at intervals of 5 years	44
13. Amplitude of accommodation shown numerically	44
14. Myopic crescent to outer side of disc	49
15. To show the range of accommodation	59
16. Glasses as worn for distance	60
17. Glasses as worn for reading	60
18. Astigmatism	62
19. A cross as seen by an astigmatic eye, etc.	63
20. Astigmatic clock	64
21. Astigmatism	65
22. How to record a case of astigmatism	67
23. Retinoscopy with a plane mirror	69
24. Maddox rods	76
25. Hyperphoria corrected by a prism	77
26. Shows how a concave lens consists of two prisms with their apices together	78
26A. Shows how a convex lens consists of two prisms united at the bases	78
27. Epilation forceps	85
28. Spoon for destroying a tarsal cyst	87
29. Desmarres's elevator	108
30. Buller's shield	109
31. Knapp's roller forceps	115

LIST OF ILLUSTRATIONS

XV

FIG.	PAGE
32. Snell's cautery for the cornea	138
33. Dendritic keratitis	143
34. Hutchinson's teeth	145
35. Placido's disc	151
36. Various forms of cataract, in section	185
37. Unripe cataract	187
38. Speculum	194
39. Graefe knife	195
40. First and second positions of the knife in extraction	195
41. Cystotome	196
42. Spoon for expelling the lens	196
43. Capsule forceps	197
44. Nozzle of irrigator	197
45. Vectis	200
46. Lid elevator	200
47. Discission needle	210
48. Ophthalmoscopy : direct method	221
49. Ophthalmoscopy : indirect method	223
50. Determination of the position of an opacity in the media	226
51. Degree of inversion of the image in the indirect method	228
52. The three types of cup contrasted	232
53. Detached portion of the retina thrown into folds	247
54. One form of transilluminator	248
55. Chart of case of detached retina, etc.	266
56. Field of vision in a case of optic atrophy	284
57. Chart of central scotoma	286
58. Schiötz's tonometer	297
59. Field of vision in glaucoma	298
Chart showing actions of the various muscles	321
60. Typical relation between accommodation and convergence	345
61. Broad needle and grooved spud	378
62. Snell's portable electromagnet	390
63. The stitches in canthoplasty	425
64. Operation for ectropion	426
65. Entropion forceps	427
66. Operation for entropion	429

FIG.		PAGE
67.	Grooved tattooing needle	431
68.	Bundle of tattooing needles	431
69.	Fixation forceps	433
70.	Keratome for optical iridectomy, etc.	433
71.	Tyrrell's iris hook	434
72.	Iris forceps	435
73.	Very broad keratome for iridectomy in glaucoma	436
74.	Iridotomy scissors	438
75.	Strabismus hook	441
76.	Advancement forceps	442
77.	Needle-holder	443
78.	Eviscerator	446
79.	The stitches for closure of the sclerotic wound	447
80.	Weber's knife	447
81.	Speculum for the wound in excision of the lachrymal sac	448
82.	Dissector and sharp spoon for use in excision of the lachrymal sac	449
83.	Artificial eye	451
84.	Artificial eye in section	451
85.	Undine	468
86.	A good type of drop-bottle	469
87.	Wire shield for use after cataract operation	472
	Test-card for ascertaining the acuteness of vision	

At end of volume

DISEASES AND INJURIES OF THE EYE

CHAPTER I

GENERAL EXAMINATION OF THE EYE

THERE are two main reasons for which one may require to examine the eyes of a patient: the first, when we know or suspect the patient to be suffering from some more general ailment and we desire to settle the presence or absence of some eye symptom; the second, on account of some definitely ocular symptom which he presents. As examples of the former we may take three: A patient with declared Bright's disease should be watched lest retinitis occur; a patient suffering from headache should be examined for some error of refraction, for optic neuritis, and for glaucoma; a patient with vague pains in the lower limbs and with staggering gait should be examined for optic atrophy and Argyll Robertson pupils. These matters will be further dealt with later on.

It may, however, be some eye symptom which is complained of by the patient that calls for examination of the eyes; such an eye symptom may either be (1) *pain in one form or another*, (2) *deformity*, or (3) *some variety of interference with vision*. It is obvious that

2 GENERAL EXAMINATION OF THE EYE

these symptoms are not mutually exclusive ; the same patient may complain of two or even three of them. Thus a patient may complain both of squint as a deformity and of loss of sight of one eye ; or he may complain of a painful irido-cyclitis along with grave loss of visual power.

In order to make this book, so far as it is possible to do so, a clinical guide, it will be well to speak first of varieties of pain.

1. PAIN

All pains connected with the eye are liable to be rendered worse on use or attempted use of the organ ; this is more true of some forms than of others. One may speak of five varieties of pain :—

A. A sharp gritty sensation, as of a foreign body in the eye ; variously described according to its severity as itchy, stinging, or burning. It is always worse in the evening and in artificial light, and is apt to be aggravated by late hours, by cold winds, by heated air, by smoky rooms, or by tobacco smoke. This is the pain of conjunctivitis of all varieties save the most severe, and it is associated with sticky secretion and a particular type of injection. This sticky secretion glues the eyelashes into bundles, and may gum the lids together so that on waking the patient has to bathe the eyes before he can open the lids. The vessels injected are scarlet in colour, large in size ; the injection is most marked on the lids and in the cul-de-sac, least of all close to the corneal margin : the vessels are obviously superficial, because they can be emptied on gentle pressure, and can be made to slide over the sclerotic.

B. Pain of a shooting, darting, throbbing character, not so much in the eye as in the forehead, temple, side of nose, and upper teeth. It is often of the greatest severity, and is at its worst in the small hours of the morning.

The patient may sleep till 2 or 3 A.M., waken then with violent pain, and only get relief about 6 or 7 A.M. Along with this pain the injection of the globe is of a bright rose-pink colour: the actual vessels lie in the superficial layers of the sclera, cannot be emptied on gentle pressure or moved over the sclerotic, are small, crowded chiefly round the cornea, and arranged radially from it. The secretion from such an eye is watery, not sticky. This is the pain of iritis, and of all acute affections in which the ciliary tract is specially involved, including particularly hypopyon keratitis and glaucoma (in glaucoma the type of injection is apt to be slightly different, more venous and less arterial).

C. A feeling of weight and heaviness in, or rather behind, the eye: the patient feels "as if his eye would drop out." There is little or no secretion; the injection is limited to a part of the circumference of the cornea, and is of a violet or purplish tint. This is the pain of scleritis.

D. A peculiar form called **photophobia**, or dread of light, in which the patient manifests a desire to exclude light from the eye as much as possible. He closes the eyelids tightly, may cover the eye with hand or arm, with handkerchiefs or muffler; may creep into dark corners, under the bed-clothes or under the bed, and will resist vigorously any attempt to open the eye. Along with this there is copious lachrymation, "scalding" tears gushing out whenever the lids are opened in the least. This is the pain of superficial affections of the cornea, and is worse the more central and the more superficial the lesion is. It is present also, though to a less degree, in a number of cases of iritis and irido-cyclitis.

The question has been much discussed, Why should photophobia be present when the part affected has nothing to do with the perception of light? No very satisfactory conclusion has been arrived at. Some seek

4 GENERAL EXAMINATION OF THE EYE

to explain the symptom as being due to a cramp-like contraction of the iris.

E. A form of pain known as **asthenopia**, or **eye strain** — uncomfortable vision. This assumes many forms, the commonest being frontal headache: headache from this cause may, however, be temporal, hemicranial, occipital, or even vertical. There may be swimming in the head, giddiness, and other forms of bodily discomfort. Some surgeons, particularly in America, enlarge greatly the scope of asthenopia, believing that not merely the conditions mentioned, but many others, such as chronic constipation, epilepsy, and other neuroses, and other visceral affections, to say nothing of mental and even moral symptoms, may have their origin in some abnormality of the eyes. The special error which gives rise to asthenopia is usually an optical one, such as hypermetropia, but may also be muscular. The symptom is naturally most apt to come on when the eyes are used for some form of near work, but not by any means only then. It is very important to remember that vision may at the same time be perfectly good, and indeed often is so. The reason for this is that an eye which is almost normal and possesses good vision is kept by its owner constantly up to its duties, is constantly corrected and made to see; thus it becomes strained and fatigued. An eye, on the other hand, which is far from normal has but poor sight, and no constant effort is kept up to enable it to decipher everything correctly. What "strains" an eye is the continual use of a small effort of the ciliary muscle far more than the occasional demand for a large effort.

Of asthenopia there are three varieties, not very well named and not too logically classified as accommodative, muscular, and retinal. The first is produced by *errors of refraction*, and may consist of local pain, discomfort and redness of the eyes, generally worse after reading or other close use of them; this discomfort may be

immediate, that is, the patient may find that directly reading work is attempted the pain comes on, or he may feel it rather the next morning after he has read without much trouble the evening before. Another very common symptom is headache; this is usually frontal, "at the back of the eyes" as some patients express it, or temporal, but it is not infrequently occipital, or at the upper part of the neck; much more rarely it is vertical. There is considerable difference of opinion as to the relation between hemicrania (migraine) and asthenopia, some maintaining that all, or nearly all, the cases of migraine are asthenopic in origin, others that the opposite is true. Perhaps the two views might not appear so very divergent after all if it were realised that asthenopia may be in some cases the actual cause, in others merely the precipitating cause in an unstable nervous condition of the patient; in either of these types after optical correction much relief may be experienced by the patient in regard both to the frequency and to the severity of the attacks, even if a complete cure be not accomplished; but there certainly are cases in which the cure is complete, and that to an amazing degree; and it is just as true that there are cases in which the state of refraction appears to have no connection whatever with the headache, which has some entirely different origin, and which pursues its persistent course unaltered whether the refraction be corrected precisely or left untouched. The truth lies something like midway between the position of the monomaniac who regards every headache, including hemicrania, as a symptom of eye strain to be cured by means of spectacles alone, and that of the physician who administers drugs without end for years without inquiry as to the refraction. The attitude of the former, who refuses to recognise that, though many headaches are entirely curable by the correction of refraction, quite other may be the factors in

6 GENERAL EXAMINATION OF THE EYE

other cases into which the refraction question does not enter at all, is not any more scientific than that of the latter, who, from unfamiliarity with its true meaning, fails to perceive a fact which cries out to him. Let it be clearly grasped that many and many a case of headache may be cured, but not all, by correction of refraction, and that a physician has not done his duty to his patient who suffers from persistent or recurring headache unless and until that person's refraction has been examined and, if need be, treated; also, that the cases with low or moderate error and good vision are not less but more likely to receive benefit by this means than those in which the error is large, and that some of the most unlikely cases prove most amenable to this form of treatment.

How, it may be asked, does a small error of refraction produce headache? The answer probably should be that the constant effort on the part of the ciliary muscle to correct this error produces a wearing out of nerve force which leads to headache. It can hardly be that the cause lies in the dissociation of the accommodation and the convergence, for the degree of dissociation in the majority of such cases would be microscopic in amount, and this would not account for the astigmatic cases. The "wear and tear" theory accounts for the fact, well recognised by all who have studied the matter and have had practical experience, that asthenopia, or eye strain, is much more apt to affect the person with a small error than the person with a large error.

The same rules apply to *muscular asthenopia*. This arises when efforts are made to keep corrected a faulty position of one of the eyes, whose visual axis is not parallel to that of the other when the eyes are at rest. If one eye tends to turn outwards and has to be constantly brought into line again, the name *exophoria* is employed as being descriptive; should one tend to turn inwards, *esophoria*; if upwards, *hyperphoria* (right or left).

It is particularly to be noted that strabismus, which in a sense may be spoken of as eso- or exophoria as the case may be, produces no eye strain: eye strain is produced by the constant endeavour to prevent squint. It is to be noted too that the mere fact of one eye standing or appearing to stand higher than the other does not necessarily produce eye strain; provided the visual axes when the eyes are at rest are directed to the same point in space, there will be no asthenopia from this cause. It is an error into which many writers have fallen, to attribute the fault to the muscles, and to speak of want of muscular balance, or even, adding grammatical inaccuracy to incorrect diagnosis, "muscular imbalance"; for the fault lies, not in the muscles primarily, but in some of the other adnexa of the eye, fibrous or other tissues. The true fault is not want of balance of the muscles but of the fibrous tissue, necessitating possibly unequal exertion of two closely-correlated muscles. Thus, if there be esophoria, the external recti must be constantly innervated to overcome the fault; if exophoria, the internal recti; and if hyperphoria, the depressor muscles of one eye alone, and these are not at all accustomed to acting apart from those of the other eye. A very much smaller degree of hyperphoria is, for this reason, sufficient to account for asthenopia than would be required in the case of eso- or of exophoria. The symptoms are much the same as those of accommodative asthenopia, but perhaps the back of the head is more frequently affected than in the accommodative form.

Retinal asthenopia is much less common than either of the other forms; it probably occurs chiefly after exposure to very bright sunshine, snow-blindness, or lightning. The term implies that the retina is unable to bear without discomfort exposure to ordinary light or to endure use of the eyes, as in reading, there being at the same time no other cause of asthenopia. Chlorophyll

8 GENERAL EXAMINATION OF THE EYE

glasses, tonics, and the flight of time since the onset usually effect a complete cure.

Before we leave the subject of pain, it is important to direct attention to the fact that many of the most important affections of the eye, even such as are inflammatory, are entirely free from association with pain. It is very rare for a patient to complain of any pain or photophobia whatever when suffering, for example, from inflammation of either chorioid or retina: these symptoms are conspicuous by their absence, although these structures have to do with the actual reception of the light rays.

2. DEFORMITY

The question of deformity is of great importance in connection with eye disease, for when two persons meet the eyes are always the part looked at: if one has a deformity of foot, hand, ear, chin, or what not, he may manage more or less successfully to conceal it, but a deformity of the eye is not merely plain to all, but in particular to the person speaking to one. It seems to the sufferer to be painfully obvious. It is for this reason that the question of deformity bulks so largely in ophthalmology. Constant efforts may be made too to hide the error, if possible. For example, if a patient has a divergent position of the left eye he always tries to keep on his left side any one to whom he is speaking, because he can thus speak to him, looking towards his own left side, without displaying the fault at all.

The chief deformities with which we have to deal as such are ptosis, squint, and white opacities of the cornea. As each of these has, however, far more important bearings, it is better to postpone consideration of them meantime, noting here merely that it is often the consciousness of the deformity solely which forces the patient to come to consult one. More rarely there are such

congenital errors as dermoid of the cornea, coloboma of the iris, pinguecula, etc.

3. IMPAIRMENT OF SIGHT

This is by far the most important part of the subject, and in order that we may understand it thoroughly we must consider certain points in regard to the physiology of vision: this we shall do under the heads of *light sense*, *form sense* (*central vision*, *field of vision*), *colour vision*, and *binocular vision*.

A. Light Sense.—The light sense lies at the root of all vision; by it we mean the ability to perceive different quantities and variations of light and to contrast one with another.

The image received upon the macula of the healthy eye is the clearest and sharpest of all, but it is by no means the only image perceived, for from a large area images are received also which are of immense value, though they are less precise. Examination of the field then, or perimetry, consists in the discovery of the maximum angular separation from the visual line which will yet permit an object to be visible. It is not difficult to understand that the larger the object the greater may this angle be; but the degradation of vision from the central to the peripheral parts is not uniform. Three points have to be considered: light sense strictly so called, perception of an object, or form sense, and colour sense.

Light sense proper. The striking fact about this is that the light sense, that is, the perception of light, is as acute at the periphery of the field as it is at the centre. This can be tested in two ways; although a certain object may be too small to be actually seen at the periphery, that is, its form cannot be discerned, yet movement of it will be perceived with great accuracy, to the limits of the field. And further, diminution of the

illumination produces no diminution of the field of vision. Of course, if all light be excluded there can be no field of vision; but within all reasonable limits reduction of illumination has no influence upon the size of the field. It is obvious that this fact is one of enormous importance in practical life, for we guide ourselves largely by our peripheral vision, and we should become helpless after sundown were this not the case. This is the physiological condition, but in affections of the pigmentary coat this *light minimum*, as it is called (briefly, L.M.), is interfered with, and a more imperative stimulus is required to awaken the chemical processes in the pigment layers than is sufficient in the normal state.

If the L.M. is to be determined with precision some such instrument as Förster's photometer is required. This consists of a light-tight box, having at one side two apertures for the eyes, and a certain test object on the inner face of the opposite wall. Alongside the eye apertures, which must fit closely on the face, is a separate compartment containing a standard candle and communicating with the main part by one opening alone, which is capable of being altered in size, the opening being glazed with ground glass. The light of the candle, shining through the graduated opening, renders the test object visible: all that has to be done is to find the minimum size of aperture, and therefore the minimum amount of light, which will permit of this. In any test of the L.M. the influence of *Adaptation* is of great moment. If immediately previously to the application of the test the patient has been kept in relative darkness, his L.M. will give a reading very much lower than if he has been all the time in ordinary daylight. The L.M. rises in all affections of the physiochemical apparatus of the eye, and therefore in all affections of the pigmentary coat: it is high, for example, in chorioiditis, and even more typically in retinitis

pigmentosa; sometimes, but not always, it is raised in glaucoma. Those persons whose L.M. is abnormally raised accordingly see badly in imperfect light; with them diminution of light involves great deterioration of vision. It should be noted that normally the area of the retina which shows the extreme light minimum is not the macula, but lies close to it.

Note.—To express this condition of night-blindness two precisely opposite terms have been long in use, the sense in which they are employed varying according to the differing views as to the derivation of the terms (if no inferior motive). Thus, in this country Nyctalopia is employed to indicate night-blindness, and Hemeralopia the exact opposite, or day-blindness; but on the Continent the terms are exactly reversed, Hemeralopia indicating night- and Nyctalopia day-blindness. It is best, in these circumstances, to discard both terms and keep to Anglo-Saxon phrases which are beyond controversy.

There is another aspect of the light sense, and another way in which it should be tested. When we look at a letter printed in black ink on white paper, or at any object which contrasts strongly with its background, it stands out sharply and is easily seen, but let the contrast between the two be reduced, and there comes a stage when the letter or object can no longer be clearly differentiated. When applying this test we are examining the *light difference* (L.D.), or the minimum difference in illumination which will enable the eye to distinguish between two contiguous objects. The light difference is much most acute at the macula.

The light sense in the central area can in this way be tested by means of Bjerrum's test types. These are letters exactly similar to those of Snellen (*v. inf.*), but printed not black on white, but grey on grey, so as to form a feeble contrast to their background. On Snellen's cards $\frac{6}{8}$ corresponds to $\frac{6}{18}$ on Bjerrum. In certain pathological

states, especially in tobacco amblyopia and retro-ocular neuritis, where the L.D. is affected, vision of Bjerrum's types is very poor, though on Snellen's it may relatively be hardly affected at all.

The contrast between affections of the L.M. and the L.D. may be well illustrated thus: Two patients have $\frac{6}{24}$, of whom one suffers from retinitis pigmentosa, the other from tobacco amblyopia. Reduce the illumination, and the vision obtained by the former may be reduced 50 per




FIG. 1.—A letter of Bjerrum's type.

cent, while the latter sees as well as before, and perhaps better, for tobacco-amblyopia patients continually assert that they have actually better vision in the half-dark.

B. Form Sense.—In the examination of the visual capacity of an individual we must pay attention first of all to vision at the macula or **central vision**. The minimum degree of vision which a person can possess is mere perception of light, or "P.L." as it is often expressed. There are two ways of testing this: Either we may set the patient to face the light, and, unknown to him, interpose or remove a hand or card to screen the light from the eye,

when he should be able to tell whether light is obstructed or unobstructed. In doing this one must take care that neither from one's mode of questioning, nor from the touch or even the warmth of the hand, does he obtain any information; one ought to be testing sight and sight alone. Or one may place the patient in the dark room, and by means of the mirror reflect light into the eye, when he ought to be able to tell whether or not the light is falling on the eye. If he cannot do this, vision may be recorded as *nil*. If he can, but can do no more, $V. = P.L.$ The next degree of vision is "hand movements." The patient with his back to the daylight should be able to perceive the movements of a hand held before him. The next degree is counting fingers at so many metres or feet. Finally we come to the reading of test letters, or the interpretation of *form*. In this connection it is necessary to understand the term "visual angle," which may thus be explained: if we are to perceive two objects as discrete, separate objects, the size of picture which they form on the retina must obviously be larger than the diameter of one of the cones in the terminal layer of the retina. Imagine, then, two lines drawn from the nodal point of the eye to the retina, with an angle between them such that the two lines are just wider than one cone; these lines carried on forwards into space form together the visual angle, an angle of almost exactly $1''$. The manner of examining vision depends on this. We must know how wide an angle is required to enable distinct objects to be recognised as separate and distinct. It would not do to hold up a number of dots of different size and ask the patient, "Do you see this; do you see that?" What had to be done, and was done largely through the labours of Donders and Snellen, was to make up a series of tests in which certain objects of a certain definite size are displayed separated by an interval equal to the object. Take two

small squares and separate them on a board by an interval equal to one side of the square; if at the distance of 20 feet each of these squares subtends an angle of 1" the normal eye ought to perceive them as discrete. On this basis certain series of letters have been constructed, each letter (at its appropriate distance) subtending an angle of 5", each limb being one-fifth of the height or breadth of the whole letter, and the various portions separated by the same intervals. The patient, being placed at 6 metres (20 feet) from the board, is invited to read a line of letters each of which, as




FIG. 2.—A letter of Snellen's type.

mentioned, subtends an angle of 5". If he does this correctly we record his vision as $\frac{6}{6}$. This expression is sometimes, but not wisely, treated as though it were a vulgar fraction, and recorded as 1; but the phrase emphatically states that the person was tested at a distance of 6 m., which "1" may imply but does not assure one of.

One reason for the selection of 6 m. as the testing distance is that all the rays entering a pupil from a point at that distance are practically parallel; it is impossible to demonstrate any divergence between two rays which emanate from a point and enter the same pupil at a distance of 6 m. So far as parallelism of lines is con-

cerned 6 m. is as far away as infinity, the only place from which absolutely parallel rays can come.

Let two lines of 6 m. length be drawn from the nodal point of the eye, diverging 5", and therefore including within them one of the letters which should be read at 6 m., and continue these lines farther to 9, 12, 18, 24, 36, and 60 m., and they will include in this way a letter of each of the other rows; the patient who reads the top letter only would be recorded as possessing $\frac{6}{60}$; the next line, $\frac{6}{36}$; the next, $\frac{6}{24}$; the next, $\frac{6}{18}$; the next, $\frac{6}{12}$; the next $\frac{6}{9}$. We are thus provided with a complete and sufficient record of the degree of vision which a patient enjoys, from the normal $\frac{6}{6}$ to the minimum possible, P.L.

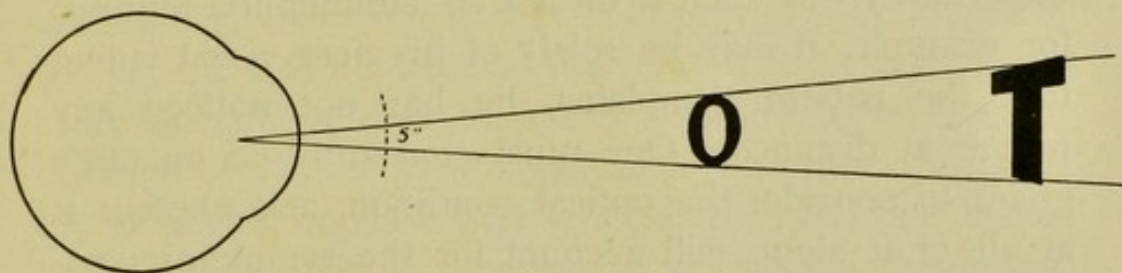


FIG. 3.—The visual angle.

A special form of this vision test is constructed for illiterate patients, but in Scotland this is practically never required.

It is most frequently on account of the acuteness of vision falling below the standard that one is consulted, though it must be clearly grasped that many persons whose distant vision is indifferent or poor do not seem to care much or to be inconvenienced thereby; it is very much a matter of custom and comparison with others.

But when we turn to the matter of near vision, of vision for objects held in the hand, vision for reading, etc., it is failure in this which drives many a person to seek advice. To leave out at present all questions as to discomfort or asthenopia—inability to see small print, sewing, music, fine lines, etc., is a great cause of incon-

venience and unhappiness ; this may be due to errors of refraction, to opacities of the cornea or irregularities of its surface, to opacity or imperfection of the lens, to diseases of the vitreous, chorioid, retina, or optic nerve. The student should understand that between the vision for distance and the vision for near there is not a rigid connection as understood by the ordinary patient, though to the instructed the matter may become simple enough. Thus, one complains of seeing badly at a distance and proudly boasts of his good near vision (myopia) ; another grumbles over difficulty in reading and brags about his distant vision, though it is no better than other people may enjoy (hypermetropia or presbyopia), and—more importantly—in such a disease as albuminuria retinitis, for example, it may be solely of his near vision failing that the patient complains, he has not noticed any failure at distance. One must constantly be on one's guard to consider the optical condition, and whether it at all, or it alone, will account for the symptoms complained of.

The point of maximum acuteness of vision is at the macula, though not that of the lowest L.M. To obtain its acutest sight the healthy eye must direct upon the object its macula or "centre." Unless, therefore, one enjoys *central fixation*, vision for objects falls far below the normal. An eye may possess central fixation, excentric fixation, or indifferent fixation. In testing this point as regards each eye one causes the patient to look at a fixation object (pencil, finger, etc.) having the other eye screened: if *central fixation* is present the eye looks directly at the object and follows any movement of it precisely, that is, the eye is necessarily so placed that the macula receives the image. If *excentric fixation* alone exists, the eye is directed above, or below, or to the side of the object, but always maintains the same relation to it. If *indifferent fixation*

is present the patient may either make no attempt to look at the object or else he moves the eye so as to cause the image to fall on several different points of the retina consecutively: the eye is not brought to rest at any special defined attitude.

Central fixation may be lost as a result of disease of the macular region of either chorioid or retina, or in retro-bulbar affections where the nerve fibres belonging to the macula are involved. It is also lost sometimes in cases of strabismus which has come on early in life. It is not lost in affections of the anterior part of the eye, if vision exists at all.

Field of Vision.—The simple clinical method of ascertaining the limits of the field of vision is to place the patient with his back to the light that he may have every advantage, and to stand opposite to him at a distance of 3 ft. or so while he fixes his right eye upon the surgeon's opposite (left) eye (his own left one being kept closed). He is then asked to indicate the limits of his field by saying whether he sees the movement of the surgeon's fingers as they are moved at the extreme limits of his field of vision above, below, etc., in a plane equidistant from the two. If these are perceived at the same moment that the surgeon perceives them himself, the field may be assumed to be normal.

The *perimeter* is an instrument for the more precise determination of the limits of the field. It consists essentially of a quadrant caused to describe a hemisphere by rotation about the visual axis of the eye under examination, a fixation spot being provided at the pivot on which the quadrant rotates. Along the quadrant a test object is caused to travel, and the exact point of its appearance when it is moved centripetally, or of disappearance when it is moved centrifugally, is recorded; the line joining the object at the critical point with the eye may form with the visual axis an angle of 60° to 90° or more. There are

18 GENERAL EXAMINATION OF THE EYE

various forms of the instrument. In testing, it is well to use sometimes a radial and sometimes a circular movement; information may be gained by one method which

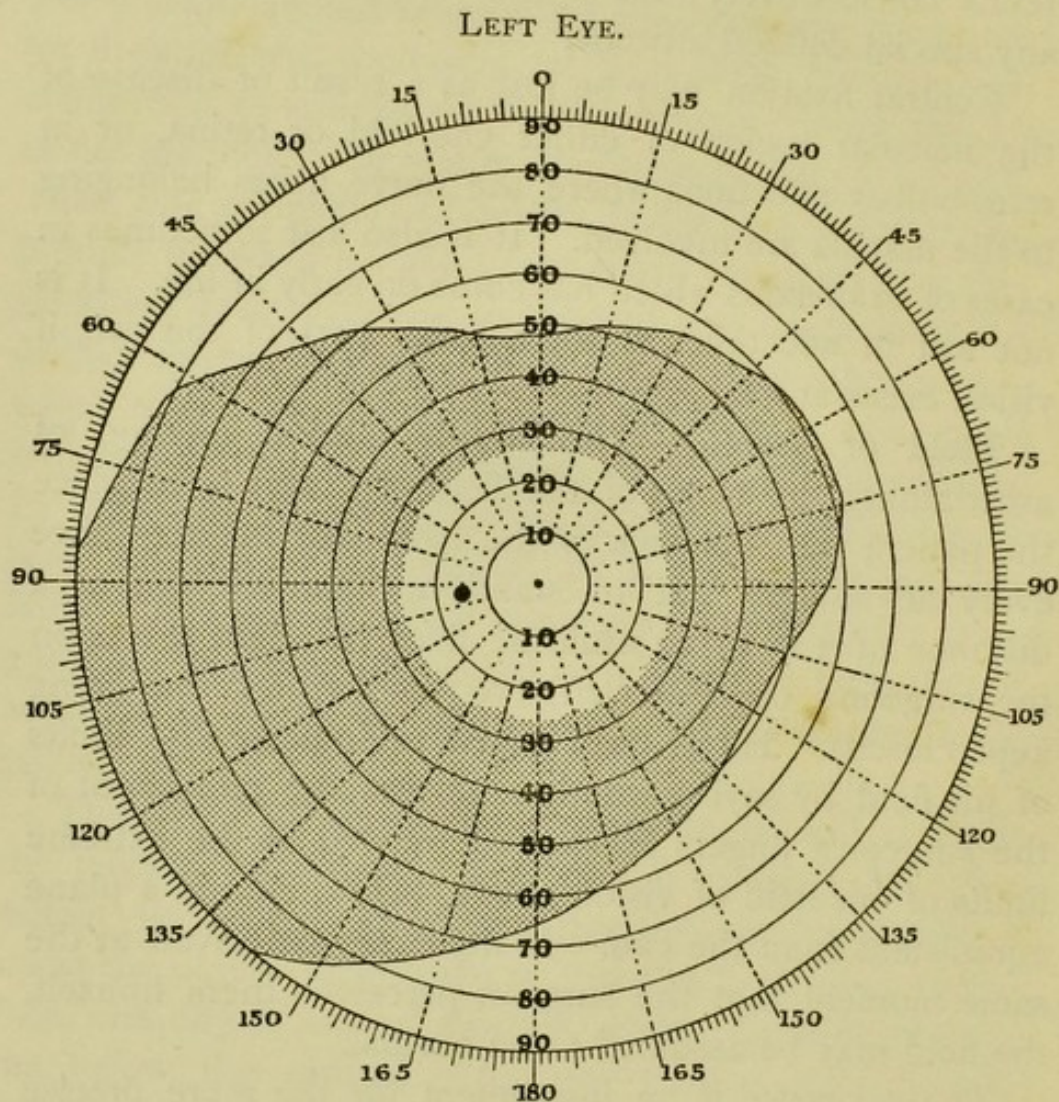


FIG. 4.—The average normal field of vision.

The grey shows the extent of the field with a $\frac{1}{300}$ object. The white shows the extent of the field with a $\frac{1}{2000}$ object. The small black circle is the normal blind spot.

would be passed over with the other. If one uses one of the forms of the ordinary perimeter with a test object some 10 mm. in diameter and the screen at the distance of $\frac{1}{3}$ m., the field extends to about 65° above, 75° below, 90° to the outer (temporal) side, and 65° to the inner (nasal) side, with intermediate limits at the oblique meri-

dians, a fact which is capable of being recorded in brief compass, for the purpose of note-keeping, thus :—

80 65 65	65 65 80
90 L. 65	65 R. 90
90 75 70	70 75 90

Gross errors of the field may be readily mapped out and recorded in this way, with either an automatic or a hand-worked perimeter-recording apparatus.

When using the perimeter, one must cause the patient to keep the eye strictly fixed upon the central fixation object, and to say *at once* when the travelling fixation object (a small white or coloured disc) appears or disappears according as one is moving it centripetally or centrifugally; it will generally be found that the field is slightly larger centrifugally than it is centripetally.

But the extent of the field of vision varies with the size of the test object, as one would naturally expect, and for examination of the finer errors about the central area the ordinary perimetric methods are too coarse, and it is more satisfactory to employ a large black velvet screen at a distance of 1 or even of 2 metres, and a test object which may be as small as 1 or 2 mm. The screen should be from four to seven feet square to afford the best results. In recording results thus gained one should mention $\frac{1}{1000}$, $\frac{3}{2000}$, etc., according to the size of the test object and its relation to the distance separating patient and screen. This special form of perimetry was largely introduced by Bjerrum of Copenhagen, who has done an immense amount of useful work in this connection. The curious fact comes out by the use of this method that for minute objects the field is circular or approximately so, occupying the central area of the retina, but it becomes less uniform as larger objects are employed

which can be seen by the more peripheral parts of the retina (Fig. 4).

Colour Fields.—It is to be feared that there is considerable lack of precision when colours and their fields are spoken of. But in the first instance it may be stated that for a field taken with a $\frac{10}{300}$ test object, *i.e.* in an ordinary perimeter such as McHardy's, the object being of moderate purity and fair intensity, the fields for red and for green are decidedly smaller than they are for yellow and for blue; properly speaking, one ought rather to say that the field for *a certain* blue (or other colour) of a certain size, against a black or a white background, is so-and-so. It is easy to prove to one's self that there is a peripheral area outside the field for red in which a red object can be seen as an object, but in which its colour is not perceptible; the peripheral colour-blind area for yellow or for blue is almost non-existent. It is as though the perception of red and green was possible only in the more highly evolved portions of the retina (see p. 30).

Of **Alterations of the field of vision** there are several types:—

(a) *Peripheral Restriction.*—The peripheral portions of the fields may be cut off, the more central alone remaining. This reduction is not necessarily uniform, for the blind portion eats into the seeing part here and there in great sectors in a large number of cases. This is a defect to be found typically in two conditions, namely, optic atrophy and retinitis pigmentosa. In both of these the restriction may be great, but there are two important distinctions between them. First, that if the light be reduced the optic atrophy field is quite unaffected, whereas in the other case even a small reduction has a most injurious influence. In other words, in pigmentary retinitis the L.M. is gravely disturbed, but is unaffected in optic atrophy. The other point is that, while in retinitis pigmentosa the central vision may be quite good though the

field is very greatly reduced, in optic atrophy this is never the case, but the central vision degenerates more or less *pari passu* with the peripheral.

(b) *Annular Scotoma*.—A *scotoma* is an island of lowered or lost vision surrounded by an area of better vision (*v. inf.*). In a number of cases of retinitis pigmentosa seen in the early stages the central field is good; outside that is a zone of good vision, then a zone of lost vision, an annular scotoma; outside that good vision again, and perhaps at the very periphery, a slight cutting off of the very extreme. This annular scotoma may be broken up into little islands or may be continuous, and as time goes on it merges itself into the peripheral loss, so that there only remains the central field, covering an area which may be very small.

(c) *Central Scotoma*.—The meaning of this term is that in the central region of the field there is an area of lost vision (absolute scotoma) or of gravely lowered vision (relative scotoma). Thus in a well-marked case a small test object, travelling centripetally, will, as it approaches the centre, pass into an area of lowered acuteness, and it may be into an area in which it completely disappears.

Scotoma is thus a condition in which the central (or paracentral) vision is reduced below that of the surrounding area—where, in fact, there is an island of defective sight in a region of relatively good vision. The scotoma is said to be *absolute* when within its area vision is entirely lost, when there is no perception of light; *relative* when vision is reduced but not lost; *positive* when the patient projects before him in the defective area a mist, cloud, fog, or dark spot; *negative* when he is not conscious of any such cloud. The best example of an absolute and also of a negative scotoma is the normal lacuna in the field produced by the disc—Mariotte's blind spot. A good example of a relative

and positive scotoma is furnished in tobacco amblyopia (p. 289). A positive scotoma is for the most part transitory, and may be due to an inflammatory or congestive affection of either the percipient apparatus (chorioiditis) or the conducting (retro-ocular neuritis, for example).

There are three conditions in particular in which a central scotoma is found, namely, (1) certain forms of optic atrophy, notably "Leber's" and the atrophy of disseminated sclerosis, or more rarely of tabes (the usual form of tabetic atrophy presents quite different symptoms); (2) tobacco amblyopia; and (3) retro-ocular or retro-bulbar neuritis. In tobacco amblyopia the scotoma is almost always relative, that is to say, not complete or absolute, while in the atrophy of class (1) it is most probably absolute; in retro-ocular neuritis it may or may not be absolute. The point of greatest saturation of a scotoma may be exactly on the centre (macula) or near to it, or may be between fixation point and the normal blind spot. In a number of cases of disseminated chorioiditis there are small scattered scotomata which are not central but correspond to the atrophic areas in the fundus, the perceptive apparatus being destroyed over these areas.

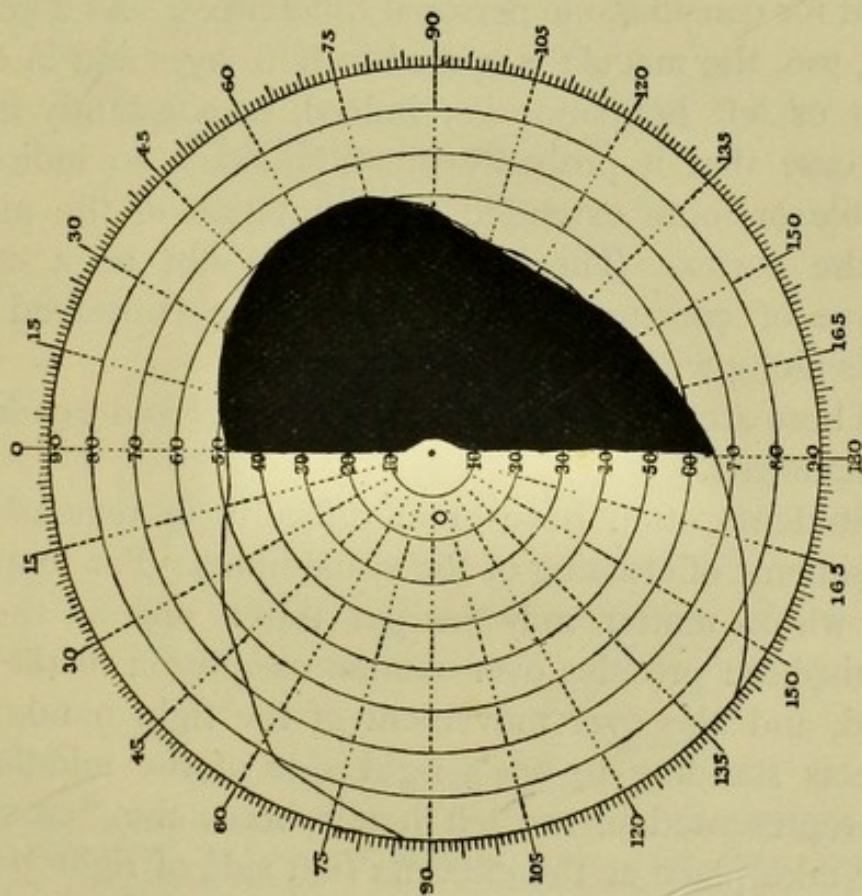
(d) *Irregular Alterations*.—Of these there are two in particular, the loss of a portion of the nasal and inferior fields, so common in glaucoma (Fig. 59), and that of the upper part of the field so characteristic of detachment of retina. Naturally, should the lower part of the retina not be the part detached (as, for example, in tumour of the chorioid), the field will suffer in a different portion.

In glaucoma there are two directions in which the field is affected; as shown by ordinary perimetric examination, there is apt to be a cutting off of a portion of the field to the nasal and lower region. It must not be understood that this is invariable, and particularly that the precise line of delimitation of the area of interference is always

the same ; in some patients, for example, it is the lower half alone, and that very extensively, which suffers. Next, on testing with a sufficiently fine test object, it is very frequently possible, if not always in favourable cases, to demonstrate the existence of a communication between the physiological blind spot of Mariotte and the peripheral portion which is blind to that size of test object. In applying the test, one places the patient at a distance of 1 or 2 m. from the black velvet screen and employs a test object just sufficiently large (perhaps 2 to 5 mm.) to carry the field a short way beyond the blind spot ; it will be found that the field does not surround the blind spot, making it into an island, but that the blind spot communicates with the peripheral blind area (see Fig. 59). One must be careful not to employ too large a test object, as the communication between peripheral blind area and blind spot may not be absolute and the test may fail ; on the other hand, a spot too small might not carry the field so far as to the blind spot, and again the test would fail. For rapid testing the most convenient plan is, having fixed the blind spot, to "walk round it" with the test object, which will be found to pass out of sight if this sign (which is known as Bjerrum's sign, from the Copenhagen surgeon who was the first to establish it) is positive. The same may be accomplished by means of a rotatory perimeter. A further point in the field is the existence of the "nasal step" ; this means that at the nasal side the field above the horizontal line may extend distinctly farther than that below the horizontal line, so that a "step" may exist at the junction. The symptom is due to a greater interference at the disc with the fibres escaping at its upper part than with those at its lower. The test is not a difficult one to apply qualitatively, and especially if the test object be made to travel in concentric circles rather than centrifugally and centripetally.

(e) *Homonymous Hemianopsia*, or loss of one-half of each field of vision—of the same-named half.—Up to this point the lesion which has produced the interference with the field has been an ocular one, but in hemianopsia that is not the case. The loss of field extends to the whole half-field, and very precisely so, the line of demarcation passing vertically above and below the fixation spot; and it is the half-field of each eye which is affected or lost (Fig. 5). No ocular lesion could cause this; it must lie, as a glance at Fig. 6, which shows the course of the nerve paths, will indicate, at some point superior to the chiasma. The fibres coming from the right (outer) side of the right retina travel up the right optic nerve to the chiasma; there they do not cross, but are joined on their own side by fibres from the inner (right) side of the left retina which reach the chiasma by way of the left optic nerve, and then cross to join those already mentioned. Should there be a destructive lesion of these two sets of fibres after they have joined, the result would be a left homonymous hemianopsia. The lesion is thus seen to be cerebral, and necessarily, in the case of left hemianopsia, on the right side of the cerebrum. It is even possible, in theory at least, to determine whether the lesion be in the optic tract or superior to it. The pupil-reaction fibres run with the true visual fibres along optic nerves, chiasma, and optic tracts; there they leave the others and run almost directly to the III. nerve nucleus, to return as motor nerves to the iris. Should a lesion take place in the nerve paths then, superior to the corpora quadrigemina—in the corona radiata, for example—while the visual fibres would be damaged, the pupil-reaction path would be unaffected; the effect of this would be that light thrown upon either the seeing or the blind half of the retina would set up pupil-reaction. On the other hand, if the lesion lie in the optic tract, both visual and pupil-reaction fibres would be cut

LEFT EYE.



RIGHT EYE.

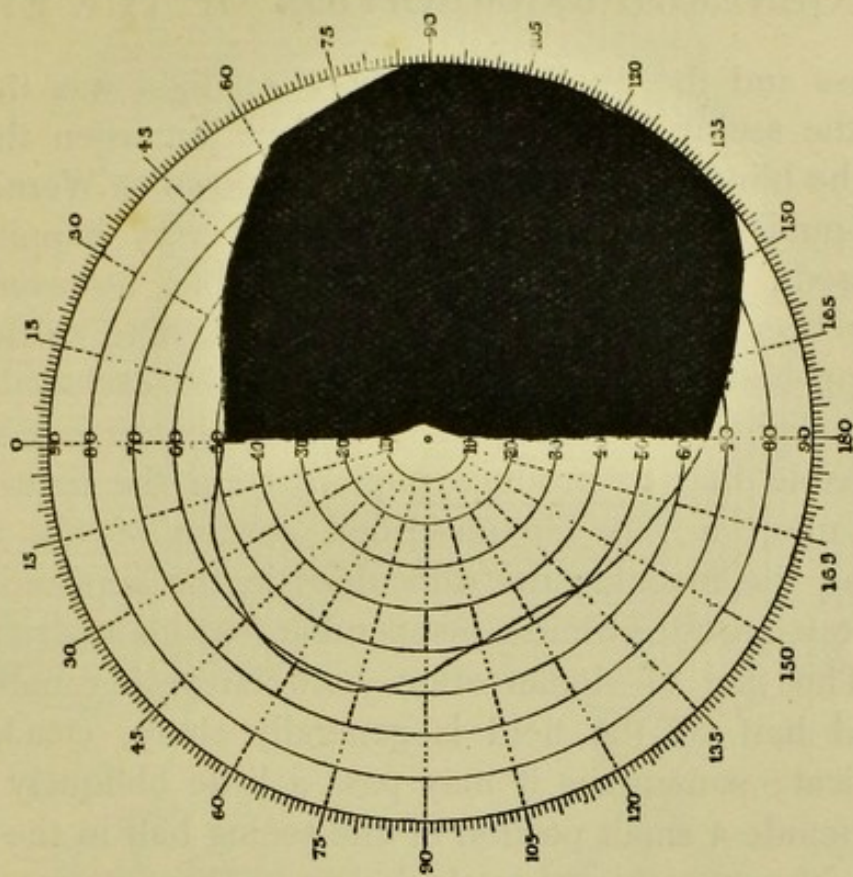


FIG. 5.—Right homonymous hemianopsia.

across and the pupil would act when light was thrown on the seeing half of the retina, but not when thrown on the blind half; this condition is known as Wernicke's half-pupil inaction sign (a name not very happily expressed). The test is not very reliable, however, not only because with the utmost care taken to shield the seeing half, internal reflection cannot be excluded, and some light must fall upon it, but also because it seems probable that to produce pupil-reaction the light must fall upon a very circumscribed portion of the retina round the macula; the difficulties in the application of the test are thus almost insuperable (see under Iris).

The line of demarcation between seeing half and blind half of the field is generally sharp, clean, and vertical; sometimes it may pass a little obliquely so as to include a small portion of the seeing half in the blind area above and conversely below. There seems to be room for considerable personal differences. As a general rule, too, the macula is spared in both eyes and in either right or left hemianopsia; indeed, so constantly is this the case that it probably must be taken to indicate a double or more extended representation of the macula in the cortex. There may or may not be a certain degree of concentric restriction of the conserved half-fields along with hemianopsia.

There are rare cases also of altitudinal and quadrantic hemianopsia.

Students often have great difficulty in remembering the scheme of crossing of the visual fibres. For simplicity the whole matter may be put thus: just as the left hemisphere presides over common sensation in the right hand, and also over movement of the right hand, so all objects standing to one's right side of the middle line are represented in the left hemisphere; the "crossing" may take place at the chiasma (left side of right retina), or it may take place in the air (left side of left retina),

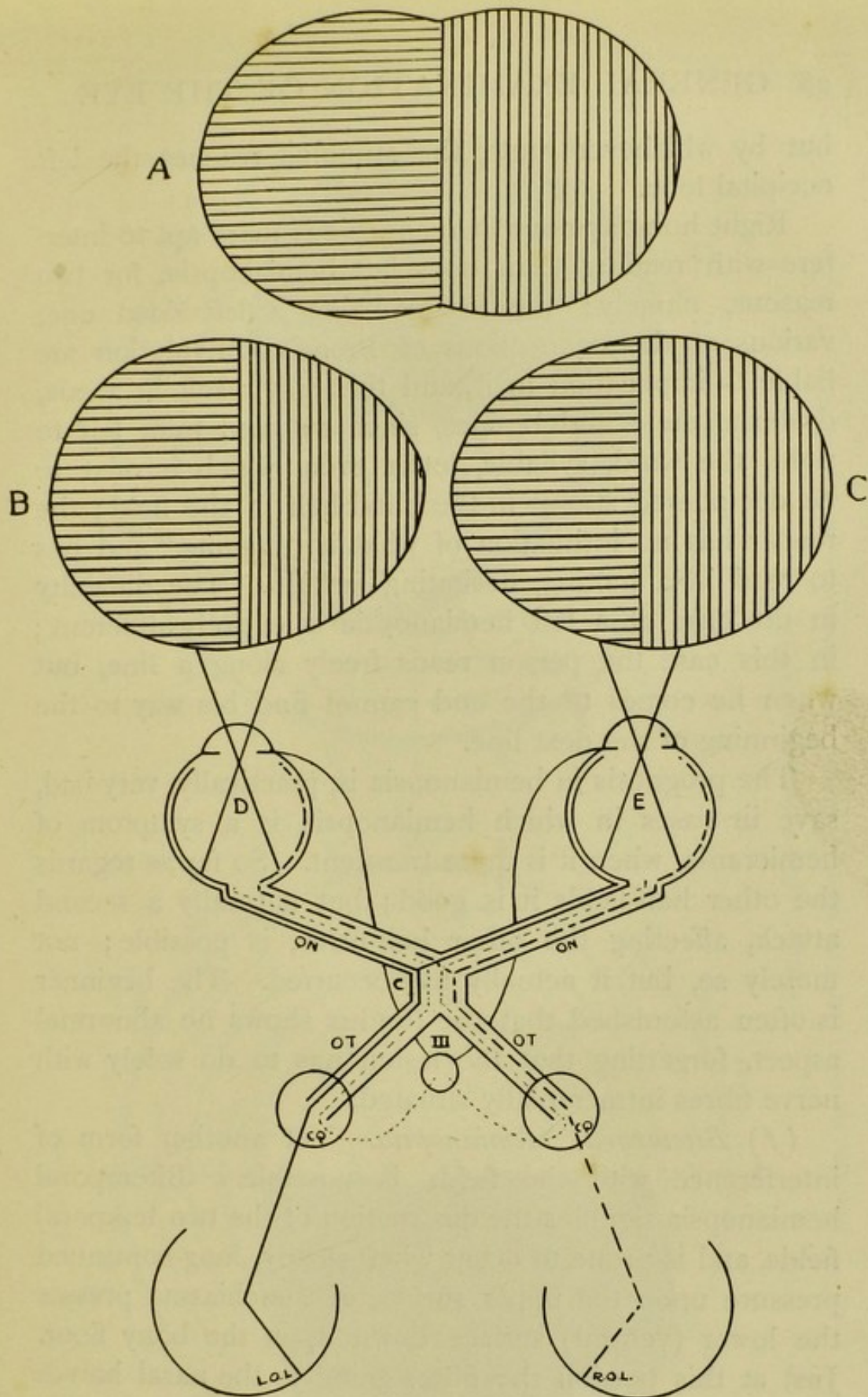


FIG. 6.—Course of visual fibres.

D. Left eye. E. Right eye. B. Field of vision of left eye. C. Field of vision of right eye. A. Combined binocular fields. O.N. Optic nerves. C. Chiasma. O.T. Optic tracts. O.L. Occipital lobes. III. Nucleus of III. nerve. C.Q. Corpora quadrigemina. A lesion at or above O.T. on left side will put out of action the fibres (continuous line) from the left sides of D and E, and prevent reception of images from (vertical line) right halves of the fields B, C, and A. If the lesion be in O.T. it will catch also the fibres (dotted line) which pass from C.Q. to III. and thence to the iris of each eye.

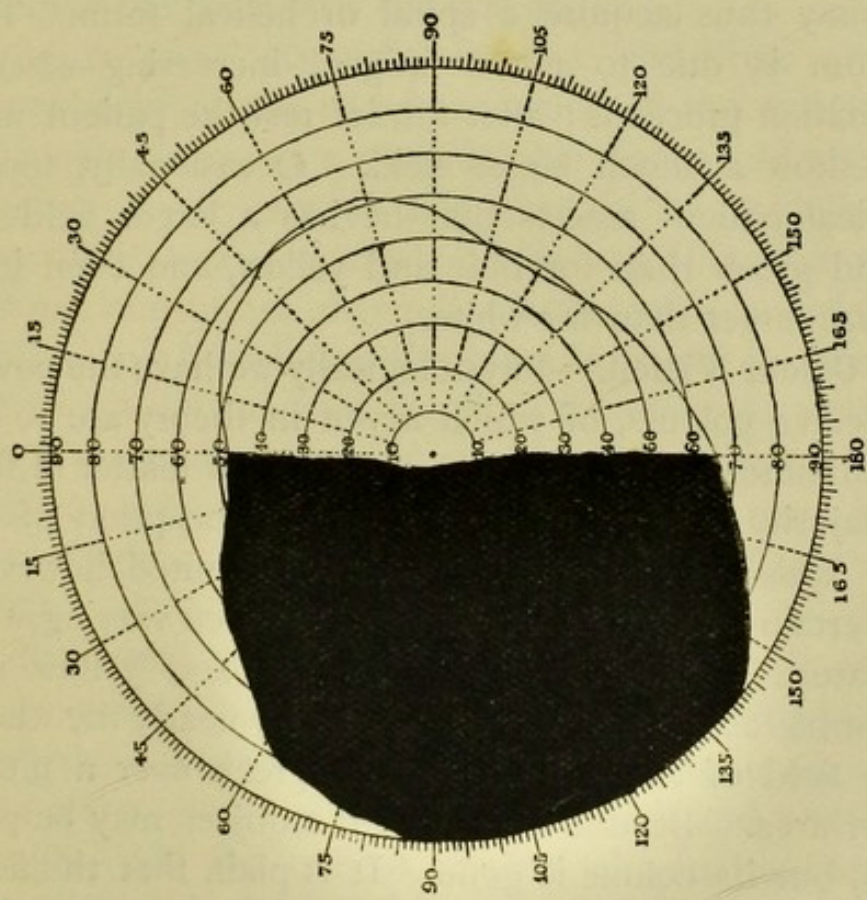
but by whichever route, the stimulus reaches the left occipital lobe.

Right homonymous hemianopsia is more apt to interfere with reading than does left hemianopsia, for two reasons, namely: the lesion being a left-sided one, various of the connections of Broca's convolution are liable to implication in it, and this may result in alexia, dyslexia, etc.; and besides, since we read from left to right, the word, syllable, letter even, which is next to be deciphered stands in the blind half of the field; the reader has no intimation of what is "coming," and has to read in a halting, hesitating fashion. The difficulty in the case of a left hemianopsia is entirely different; in this case the person reads freely along a line, but when he comes to the end cannot find his way to the beginning of the next line.

The prognosis in hemianopsia is, practically, very bad, save in cases in which hemianopsia is a symptom of hemicrania, when it is quite transient. So far as regards the other half-fields it is good; but naturally a second attack, affecting the other half-fields, is possible; not merely so, but it actually has occurred. The beginner is often astonished that the fundus shows no abnormal aspect, forgetting that the lesion has to do solely with nerve fibres intracranially situated.

(f) *Bitemporal Hemianopsia*.—Yet another form of interference with the fields is possible. Bitemporal hemianopsia signifies the destruction of the two temporal fields, and is prone to occur when steady, long-continued pressure upon the upper surface of the chiasma presses the lower (ventral) surface down upon the bony floor. Just at this portion the fibres going to the nasal halves of the retinae are understood to lie nearest to the bony surface, and consequently suffer the most readily. This misfortune is naturally apt to occur in acromegaly, where the enlarging pituitary body in some way com-

LEFT EYE.



RIGHT EYE.

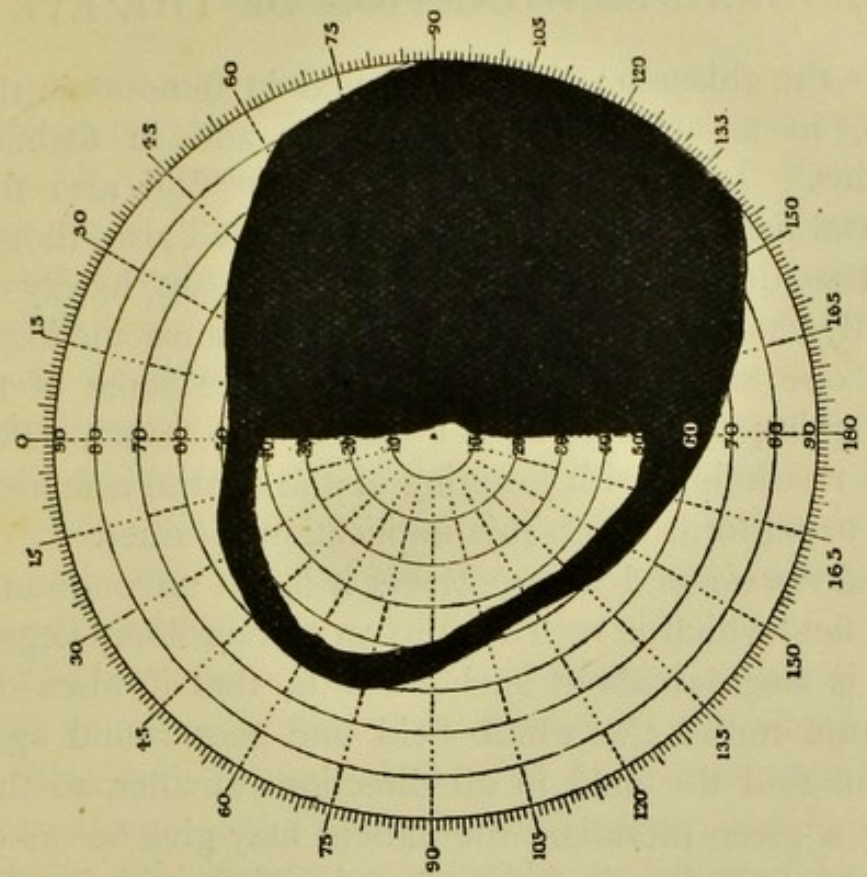


FIG. 7.—Bitemporal hemianopsia.

Note that the nasal half of the right field is partly encroached upon peripherally also.

presses the chiasma; it is also found in tumours in this region, in aneurism of the carotid, and in diabetes insipidus. In any case, it is usual to find also that the nasal field of one eye at least is affected also, though to a less degree, because the pressure can hardly be perfectly exactly in the middle line, but must incline so far to one side or the other as to injure some of the fibres going to the temporal side of the retina. Peripheral restriction, with lowering of the central acuteness, is the usual form which this implication assumes.

In *Hysteria* and *Neurasthenia* it is not uncommon to find a field which is restricted to an extraordinary degree. What is singular about such fields is, that if when one has gone round the whole field one goes round again one will find the field in all directions smaller, so that, taking a given meridian, the patient may give 60° as the limit the first time, 40° the second, 25° the third. The field may thus acquire a spiral or helical form. The symptom is due to nerve fatigue, increasing as the examination proceeds; after a brief rest the patient may again show a much larger field. Occasionally, too, a hysterical patient asserts that he has a larger field for red and green than for blue and yellow, and even in a bad case larger than for white.

C. Colour Vision.—Physiologically we have the power to perceive colours, of which seven in theory are to be differentiated in the spectrum, though as a matter of fact the majority of persons have a clear conception of six only. This power to perceive colour is limited, however, to a certain portion of the fundus, the area varying with the nature of the colour. Thus blue and yellow are perceptible as blue and yellow over very nearly the whole of the field of vision, but red and green over a much smaller area. Beyond that area the object may be perceived, but its colour is gone. It is plain that the field will vary also not only with the size of the test object but

also with its purity and its brightness. It is not sufficient to say that the field for green has such and such dimensions, we should state also the size of the test object and show its hue. It is to be hoped that standard colours will now be fixed upon, recognised, and utilised by all surgeons: hitherto there has been too much uncertainty, and every one is a law to himself. Consequently, records of any one else's results with a given patient are of little value to the surgeon.

Under the head of defects in colour vision there are two matters to consider, viz. *congenital* and *acquired colour-blindness*.

Congenital colour-blindness is an error which is much more common in men than in women, and which is apt to run in families. The eyes as a rule exhibit no external sign of the existence of the error, and it is more usually the friends or relatives or companions who discover the error than the doctor.

Apart from scientific interest and from personal inconvenience, the real importance of the existence of colour-blindness in a considerable portion of the community—5 per cent of men are said to be deficient—is a social one; for much of the signalling on railway systems and at sea depends on the swift, unerring perception and knowledge of colours from one another. In the two main transport services, therefore, as well as in the Navy and Army, knowledge of colours is rightly insisted upon. The lives of hundreds may at any moment depend on the colour perception of one or two men.

The usual method of testing is to employ a number of coloured wools (Holmgren's and Edridge-Green's methods). Three or four test skeins are used, a pale pure green, a rose pink, a good full red, and a yellow or orange. Ask the patient first to take in his hand the green skein and to select from the other wools any

which seem to him to have some of the same colour as the test. The colour should not be named by the examiner at all, and the patient should be made to understand clearly that among the general heap he will find no wool to *match* the test exactly; he has simply to look for others which possess some of the same colours. The examiner should watch him carefully while he does this with the successive test skeins, and will learn much from the manner in which a man with imperfect colour perception will pick up, compare, reject, accept, and re-examine the same skein.

There are only two forms of colour-blindness of much practical importance, the red-blindness and green-blindness. At the first test with Holmgren's wools a person with either form will place with the test skein stone-coloured, pale yellow, and cream-coloured skeins as well as more correct tints. The two forms diverge at the second test, when the patient is shown a rose-pink test skein. The red-blind, his red-perceiving apparatus not being stimulated by the red in the rose, will put beside it blues; the green-blind, because green as well as red excites his red-perceivers, will put greens beside it. At the third test, with a full red skein, the red-blind will place with the red skein greens and browns darker than the test skein; the green-blind will select browns lighter than the test (see Plate XXV.).

This classification, founded as it is upon a theory doubtful in itself, is, it must be confessed, not a little unsatisfactory in practice, and does not altogether adapt itself to facts. Edridge-Green's classification of the colour-blind according to their power of distinguishing colours in the spectrum is both more scientific and more satisfactory. He criticises the Holmgren's wool test very severely on the double ground that it may reject the (approximately) normal and let pass the distinctly and dangerously abnormal. He insists strongly and with

justice that *naming* of the colours should form an integral and vital part of the examination, not merely silently arranging them. He does so on the perfectly just contention that the engine-driver (we shall say) says to himself, "That is a green light," or "That is a red light." He has to name it to himself before he can decide what his duty is.

For this purpose Edridge-Green has devised a lantern by means of which a coloured light can be exhibited alone or modified in imitation of varying atmospheric and other conditions such as must present themselves to the mariner and the engine-driver. His correctness or his errors are thus plain for all to see ; and the very natural resentment of the worker on rejection after investigation by what he considers to be an unfair and unsuitable test is done away with.

A recent Departmental Committee has recommended that the Board of Trade should institute a lantern test with an instrument similar to Edridge-Green's, but not quite the same.

Acquired colour-blindness is well seen in cases of tobacco amblyopia. In this condition the patient has a relative scotoma, in which red and green perception is feeble. He may be tested by means of small discs of pale red and green brought near to the fixation point (especially to the outer side) against a black background. Colours over the central area of the field seem faded, and he may call green white and red yellow. It is easy to see that this failure may be a serious source of danger at sea, etc.

A further relationship of colour vision is in connection with the fields of vision. The fields for colours are necessarily smaller than is that for white, and the fields (in general terms) for red and for green are smaller than those for yellow and blue. In any case of optic atrophy as the field for white becomes smaller progressively so

do the fields for colours. Now it has been shown that if the fields for colours keep pace with that for white, and do not become reduced out of proportion to the white field, the prognosis is not so bad; but if there be a relatively greater loss on the colour fields, the prognosis as to rapid advance is decidedly less favourable. Rapidly or slowly colour vision becomes less both extensively and intensively so that finally colours cannot be made out at all, even though some perception of light and of objects still remains.

According to Bordley and Cushing, an anomalous alteration of the fields, whereby that for white may here and there be more reduced than that for green or red, while the limits of the field for blue may intertwine with those of the green and red fields, is to be found in some cases of optic neuritis from cerebral tumour. It may be so, but that is only in some cases; and their views have not received universal assent.

D. Binocular Vision.—It is not enough that one should see with each eye, one ought to see with both conjointly. The great benefit we derive from this power is stereoscopic vision, by means of which we fuse the different pictures simultaneously formed upon the two retinae into one solid figure, and so acquire knowledge of depth and projection of the relative situation of objects in space. Very few of the lower animals possess this power, their visual axes not being even approximately parallel. For the purposes of binocular vision the human muscular apparatus is co-ordinated with extreme precision, and it is absolutely impossible for any one to move one eye without moving the other also, whether in a vertical, horizontal, or intermediate direction. The movements also are conjugate and precisely equal, and that though the power of the muscles involved may be decidedly different. Thus the left internal rectus is a much more powerful muscle than the right external, yet on moving

the eyes to the right to follow an object they move together and absolutely equally. The only power we have to alter this relationship is in convergence, where we upset the conjugate movement, and by innervation of our two internal recti produce movement of an entirely different character. Any serious disturbance of our muscular relations is apt to produce double vision and a sensation of sickness and nausea, with faulty impression as to the position of objects. In the interests of binocular vision, too, the eyes have sometimes to make efforts resulting in much headache and discomfort, as when the rest-position is one not of parallelism but of convergence, divergence, etc.

CHAPTER II

REFRACTION

LENSES

THE action of a **convex** lens upon parallel rays of light is to cause them to become focussed at a point

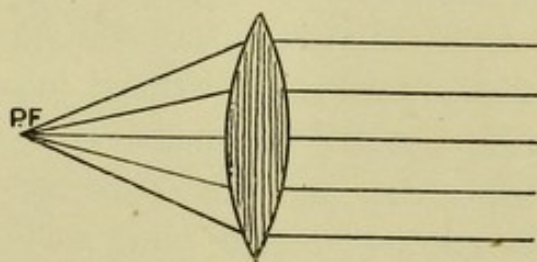


FIG. 8.—Action of a convex spherical lens.

P.F. is the principal focus.

which is called the Principal Focus of that lens; the distance separating lens and focus is called the Focal Distance of that lens. Rays which start, on the other hand, from a point, and strike, at its focal distance, upon

such a lens, are rendered parallel. Rays which strike upon a lens at a distance shorter than its focal distance are rendered less divergent, but not parallel; rays which strike upon a lens at a distance greater than its focal distance come to a focus again on the further side of the lens in a point called the Conjugate Focus of the first; rays starting from the second of these points are focussed at the first, hence the name Conjugate Foci. The conjugate focus of the principal focus is at infinity; for every point beyond the principal focus there is a conjugate focus at a distance less than infinity. When we turn to consider the refraction of the eye itself, the

importance of these elementary facts will become manifest.

Conversely, a **concave** lens renders divergent rays which were parallel, and these diverge as though they had proceeded from a certain (virtual) point called the Negative Focus of the lens. Similarly, rays which were converging towards that point are rendered parallel on encountering such a lens.

In the graduation of these convex (+) and concave (-) lenses two methods have been employed: the older method was to count by the focal length, and speak of a lens of 4 inches, 1 inch, etc. That plan has been superseded by another in which we count by the refractive power, and as a unit for this we take the power of a convex lens which focusses parallel rays at one metre; this is called a convex spherical lens of one Dioptre, or briefly + 1 D. A convex lens of one dioptre, then, is one whose focus is at one metre. A 2 D lens has twice the refractive power of the standard, a 10 D lens ten times, a 0.5 D lens has one-half the power. Two great advantages are gained by this method, for we are thus brought into line with the metrical system, and the unit lens having but feeble power we escape almost all trouble with fractions. As a rule (to which there are exceptions) it is not usual in this country to use other fractions than .25, .50, and .75.

A formula which must constantly be borne in mind is $D = \frac{1}{d}$; $d = \frac{1}{D}$. This means that the power of a lens, indicated by the number of dioptries, varies inversely as the focal distance. Thus the D, or refractive power, of a lens whose d (or focal length) is 2 M is 0.5; of a lens

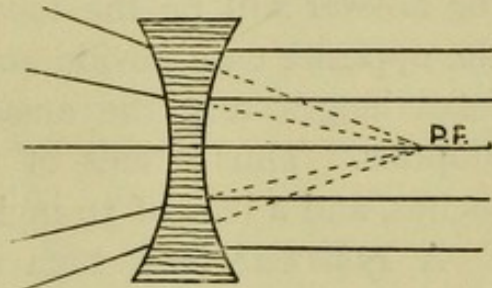


FIG. 9.—Action of a concave spherical lens upon parallel rays. P.F. is the (negative) principal focus.

whose d is $\frac{1}{5}M$, the D is 5.0; while the d of a lens of 8D is $\frac{1}{8}M$, or 12.5 cm., and so on. The value of this rule also will be very manifest when the correction of errors of refraction is considered.

Since in this country we are not in the daily habit of thinking in metres, centimetres, etc., but in inches, we require to be able to translate from D to inches. This is easily accomplished by regarding the metre as equal to 40 inches (which it approximately is) and writing the formulæ $d = \frac{1}{D}$ of 40, $= \frac{40}{D}$; and $D = \frac{1}{d}$ of 40, $= \frac{40}{d}$. In other words, divide 40 by the number of dioptries and the answer will be the focal distance in inches; or, in the opposite case, divide 40 by the number of inches of focal length and the answer will be the number of dioptries. Thus a lens of 8D has a focal length of 5 inches, and a lens of 10 inches focal length is one of 4D.

A *spherical* lens, such as those of which we have been speaking, has an equal curvature all over its surface, which is, as it were, a sphere of glass, or more usually a portion or slice cut off a sphere of glass, or two such, joined at their plane faces, and the rays of a pencil of light will be focussed by such a lens in one point; but we also have to do with cylindrical lenses. A *Cylindrical* lens may be a glass rod, or a slice cut from a glass rod. In one direction, viz. across the rod, it has curvature, while in the opposite, along the rod, it has none: the latter is called its axis,—the direction of no curvature. All rays of a pencil striking such a lens are therefore bent in towards a line parallel with the axis; its focus is this line, not a point. If we hold a convex cylindrical lens with its axis vertical, the rays of a pencil striking it will be focussed in a vertical line: *along* this line the rays will undergo no bending towards one another. These lenses are numbered in exactly the same way as the others; they are employed when we wish to influence one meridian and not another.

Of recent days improvements in the manufacture of spectacle lenses have enabled the optician to grind the curve of the lens surface upon a piece of glass already curved. Thus, up to a very short time ago, a convex sphero-cylindrical lens was prepared in this way: A flat piece of glass was taken, and on one face of it was ground the requisite spherical curvature, and on the other face the cylindrical curvature desired; it was then cut to the proper form with the axis of the cylinder in the correct axis. Now, this can all be done upon a piece of glass which already possesses a curvature of its own, a curva-

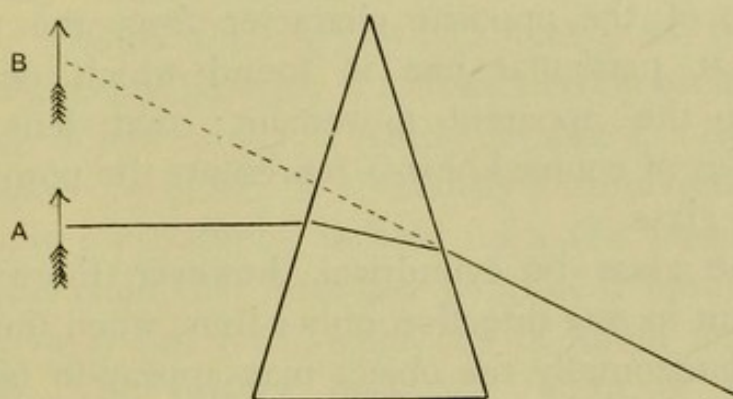


FIG. 10.—Action of a prism.

The image is displaced towards the apex of the prism; the image of the arrow A appears as though situated at B.

ture which adapts it to the form of the eye and to its movements.

Prismatic lenses are much less frequently employed. A prism deflects all rays passing through it towards its base; an object seen through it therefore appears as though displaced in the direction of its apex,—along the dotted line in Fig. 10. Prisms are usually numbered according to their physical angle, which is approximately double that of the efficiency angle: other modes of graduation in vogue need not be mentioned here; the matter is too abstruse for discussion in present circumstances.

Part of the necessary outfit of every ophthalmic surgeon is a case of test-lenses, concave and convex, spherical and cylindrical, besides prisms. It is very

important that he should be able at a moment's notice to decide the exact nature and strength of the lenses which a patient has been wearing. That is accomplished in the following manner: Hold up the glass to be examined so that through it you can see a fixed object, and move the glass from side to side, when the object will appear to move: according as this movement is "with" that of the lens or "against" it the lens is concave or convex. Let us assume that it appeared to move "against," and the lens was therefore convex; to find the strength you have only to superpose upon the lens one of the opposite character from the test-case until that particular one is found which neutralises precisely the apparent movement; that lens (whose strength is of course known) represents the power of the patient's glass.

If the glass be cylindrical, however, there will be movement in one direction only; thus, when the glass is moved horizontally the object may appear to move, but not when it is moved vertically. In such circumstances the lens which corrects the movement in the particular direction gives the strength of the cylinder. Or it may be that the lens is a compound, or sphero-cylindrical one; in such case one must discover the lens which neutralises movement in one meridian, then that which is required for the other meridian, say $-5D$ and $-6.5D$ respectively: the difference between these represents the cylindrical element in the glass. Another feature of a cylindrical (or sphero-cylindrical) glass is that when rotated about an antero-posterior axis it appears to distort the object regarded through it. A prismatic lens displaces bodily any object seen through it in the direction of its apex. An opposing prism will neutralise this.

It is essential to be able to discover the precise nature even of a complicated lens; it is best to be

independent of the special scientific instruments which are manufactured for the purpose.

REFRACTION OF THE EYE ITSELF

The normal, typical condition is that in which the eye at rest is capable of bringing to a focus, exactly on the retina, rays which before striking upon it were parallel. Thus a bundle or pencil of parallel rays impinges on the cornea; these are all focussed precisely in one point upon the retina. (Spherical aberration need not be considered.) This condition is spoken of as Emmetropia or "Em." Since the rays which reach us from all distant objects are parallel, it follows that by such an eye any distant object can be correctly focussed. But what is a "distant object"? If a brightly illuminated object, say a candle for example, is held up a few inches from the eye, it is plain that from any point of it innumerable scattering rays start forth, some few of which may enter the pupil. The further back the point of light is removed from the eye the fewer are the rays which enter the pupil, and the less is their divergence from one another. Place the light at 20 feet from the eye and trace two rays from any one point in it coming to the eye, the one entering the pupil at its extreme right side, the other at its extreme left. Between these it will be impossible to demonstrate any divergence, although theoretically, of course, such divergence does and must exist. Any object situated at a distance from the eye of not less than 15, or certainly 20, feet is, as far as parallelism of the rays coming from it is concerned, as far away as infinity itself and may properly be regarded as a "distant object."

The term *punctum remotum*, or *far point*, means the farthest distant point rays coming from which are brought to a focus correctly on the retina when accommodation is at rest; since the eye at rest in emmetropia is adapted

for parallel rays, it follows that the punctum remotum (or p.r. as it is frequently written) of the normal eye is at infinity. Another way of regarding that matter is to say that the punctum remotum lies at the position of the conjugate focus of the retina. This way of looking at the matter helps one much with the understanding of ametropia (incorrect refraction).

For the major part of life it is true to say that the refraction is normally emmetropic, and the p.r. at infinity; but in old age a peculiar change comes over the eye, in virtue of which it becomes to a slight degree

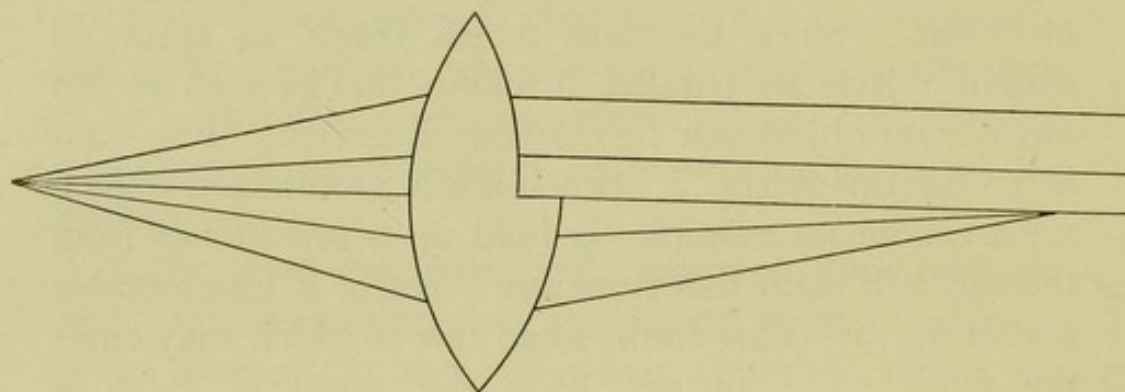


FIG. II.—The lens at rest, adapted for parallel rays (upper portion), the lens during accommodation (lower portion) bringing rays from a near point to the same focus as the upper portion.

hypermetropic (*v. infra*). At 80 years of age this may amount to as much as 2D or 2.5D.

It is not sufficient that the eye should be able merely to focus distant objects; we must have some means also of focussing near objects. This is supplied by the muscle of *accommodation*. By voluntary contraction of the ciliary muscles one alters the state of tension of the different parts of the lens, which then assumes greater convexity and therefore increased refractive power. In this way divergent, even highly divergent, rays may be focussed by an eye which, when at rest, is able to focus parallel rays alone.

As regards the actual mechanism by which accommodation is accomplished, there is still some

difference of opinion; but it is certain that this effect is produced by the action of the circular fibres of the ciliary muscle permitting or enforcing an increase in the convexity of the lens. There is no doubt further that this enhanced convexity is located chiefly in the central (pupillary) region of the anterior portion of the lens. It seems probable that the associated contraction of the pupil may be for the purpose of cutting off the rays which would pass through the more peripheral portions of the lens, for these would be very imperfectly focussed by them since they do not attain sufficient convexity.

Investigation shows that the amount or "*Amplitude of Accommodation*" diminishes steadily from the tenth year of a person's life till he is about 65 to 70, when, the lens having become quite hard and unable to undergo alteration of shape, accommodation is no longer possible. This is well brought out in the table. In the first column of this is the age at 5-year intervals; in the second the amplitude of accommodation for that age; in the third the near point. By this phrase "*near point*," or "*punctum proximum*" (p.p.) as some prefer to call it, is meant the nearest point to the eye at which an object can be focussed, the whole of the accommodative power being put in force. It will be noticed that the situation of the near point is arrived at by dividing 40 by the number of D of amplitude, and the p.p. is given in inches. The area in space between the p.r. and the p.p. is the *Range of Accommodation*. The distinct difference which exists (though only too often misunderstood) between amplitude and range of accommodation should be kept clearly in mind: the former is a certain number of dioptries, the other is an area in space. In a fourth column of the table is noted for convenience' sake the presbyopic correction, a phrase now to be explained.

The usual distance at which the average person holds a book to be read is approximately 10 inches. To focus

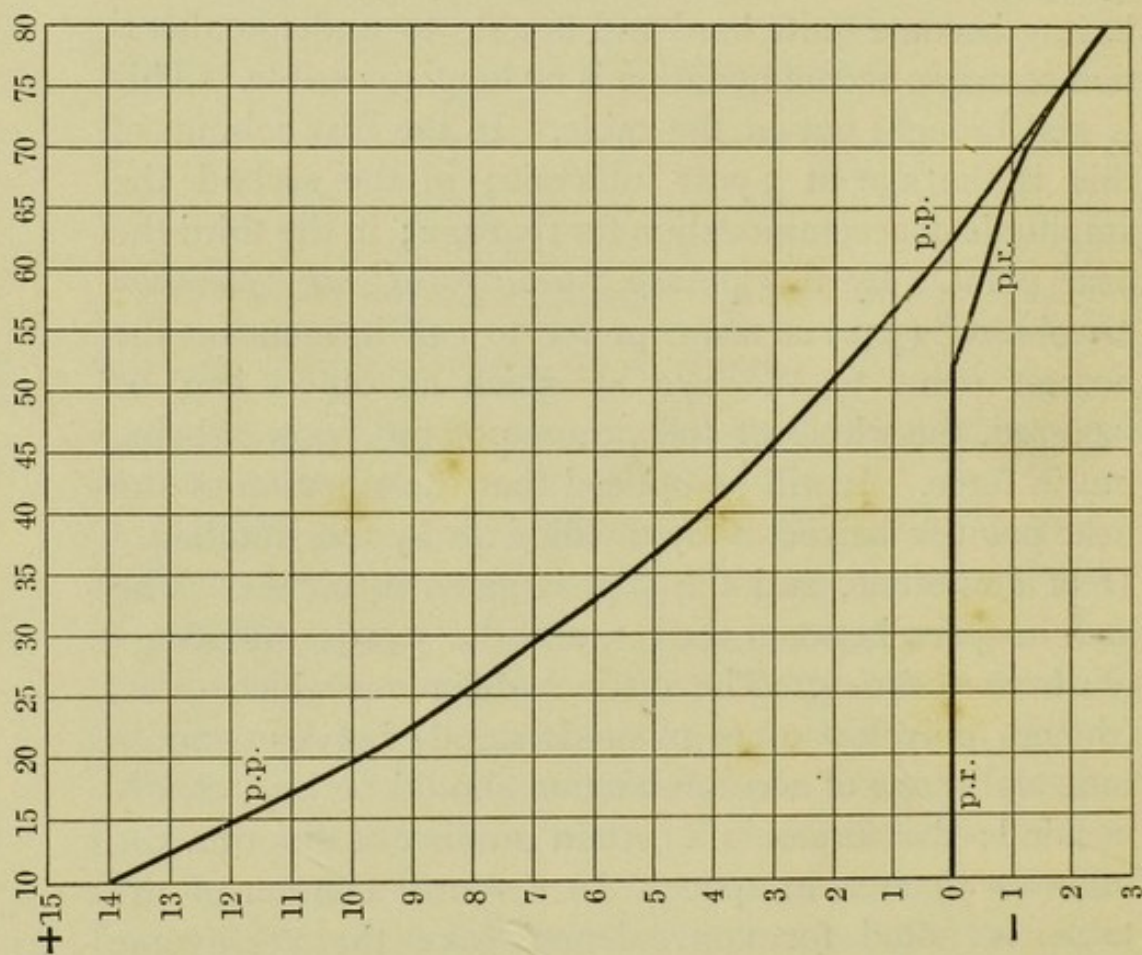


FIG. 12.—Graph showing amplitude of accommodation at intervals of 5 years.
The ordinates are dioptries.

Age	Amplitude of Accommodation	P.p. in Inches
10	14 D	2¾
15	12	3½
20	10	4
25	8.5	4¾
30	7	6
35	5.5	7¼
40	4.5	9
45	3.5	11¼
50	2.5	16
55	1.5	27
60	1.0	80
65	0.5	∞
70	nil	∞

FIG. 13.—Amplitude of accommodation shown numerically, and the "near point" in inches.

a normal eye for this distance requires the exercise of ($\frac{4.0}{10} =$) 4D of accommodation, and it will be seen in the table that shortly after the age of 40 years the amplitude falls below this. When the amount of accommodative power thus falls the strain to keep up accommodation becomes greater and the patient is on the horns of a dilemma. If he holds his book at the old place his accommodation gives out, he sees indistinctly after a time, and his eyes get painful and uneasy, or he has headache or other symptoms of eye strain; while if he holds his book farther away, the illumination obtained is feebler, which adds to the difficulty of accommodating and of deciphering the print. The average person about 40 to 45 then begins to have difficulty with small print, with time-tables, sewing, etc., requires brighter illumination to see near objects than formerly, and is apt to hold his book at greater distance from the eyes. This condition is called *presbyopia*, or old sight, because it physiologically happens to eyes when the person ceases to be young. The proper treatment is obvious: we must make up the deficiency in his accommodative power by means of a convex lens. The simplest rule is this: Look at the chart and you will see how much of amplitude he possesses; this will be below 4.0D. Give your patient the lens representing the difference between his own amplitude and 4.5D. The reason for making the standard higher than 4.0D is that the patient naturally is unable to exert constantly every scrap of the accommodative power he possesses; he must keep a little in reserve: that is why we leave a margin. A good rule of thumb is that a man requires + 1D at 45 and + 1D more for every five years after. The rule is not exact, for the estimate is too high, but it is very useful if one understands that that is so. Note that such correction is solely for use over near objects, such as reading and sewing; the lenses are not required for any other

purpose, and indeed would confuse at a distance. This has to be impressed on many patients who are just becoming presbyopic, for, not understanding that the fault is a dynamic one, they imagine they ought to see at a distance also with their glasses—which is, of course, a delusion.

The student must guard against supposing that presbyopia is a condition which comes on at 45 years of age: it comes on, or rather it prepares to come on, from the age of childhood. Symptoms of it come when the process, which has been going on all the patient's life, has advanced to an inconvenient degree—this occurs physiologically about that age. He must also recollect that a patient's work is not necessarily at 10 inches distance; he may be a violinist and require to see at 20 or 24 inches, for example, and his refraction must be adapted, but on the same lines as above, to suit that particular distance. Thus to see at 20 inches requires $E_m + 2D$, and the patient may not be able to supply the whole of this refractive power.

For the testing of near vision it is convenient to have a series of samples of print of various sizes; these are to be had ready made up in suitable form. It is not really necessary to aim at the same scientific precision in regard to near vision that is desirable in regard to distance, for in the latter case alone the eye is at physiological rest.

AMETROPIA OR FAULTY REFRACTION

If rays which were parallel ought to come to a focus on the retina, it is plain that on the face of it there may be two chief sources or forms of error, viz. rays may focus in front of the retina or may strike on the retina before focussing. The former of these types of fault is called Myopia (M.), the latter Hypermetropia (H.).

Myopia may be due (1) to the eye being too long from back to front (Axial myopia), (2) to the cornea

possessing too high a curvature (Curvature myopia), or (3) to the refractive index of the lens being higher than the normal (Index myopia); any of these causes is capable of producing myopia, and all exist. Since the refractive state of the myopic eye is such that rays formerly parallel are focussed in front of the retina, and divergent rays will be focussed further back from the chief refractive medium than its focus, there must be outside the eye a spot, rays starting from which have exactly the required degree of divergence to allow of their being focussed on the retina. This point is the conjugate focus of the retina, and consequently at it also will rays be focussed which start out from the retina; it is the far point, or p.r. of that eye, and all objects beyond it are more or less indistinct. The correct treatment for myopia is to cause the patient to wear in front of the eye a concave lens whose (negative) focus is situated just at that far point or p.r. Objects at a greater distance will have imparted to the parallel rays which start from them a divergence as if they had started from the p.r. of the eye; they will therefore be in focus. The instrument composed of eye and glass together has now its p.r. at infinity: it is an emmetropic apparatus. The patient without such a lens sees distant objects very imperfectly but nearer objects quite clearly (if there be no complication). We test the vision, as explained more fully in the chapter upon Examination of the Eye, by means of letters graduated upon a certain plan and capable of being used to record the precise degree of accuracy of sight up to the normal, which is $\frac{6}{8}$ (see page 15).

On testing with these letters the Myope is found to possess less, it may be very much less, than $\frac{6}{8}$, but to be able to read the smallest type of the reading tests easily at, but not beyond, a certain distance. This distance is the measure of the myopia. Thus, if the print cannot

be read till the book is brought to 10 inches (at most) from the eye, that eye has a myopia of ($\frac{40}{10} =$) 4.0D. It is in fact in the same position as an emmetropic eye which bears in front of it a + lens of 4D. It is good to get oneself into the habit of regarding a myopic eye (for this purpose) as one which possesses too much refractive power—as Em + so many D. Calculation is much simplified by this way of looking at the matter. This may be expressed in the example chosen as Em. + 4D. The correction for such an eye is obviously - 4D. It should be clearly understood that this method of testing must not be employed unchecked, as it is apt to give too high a reading in myopia (*v. infra*).

Myopia occupies this peculiar position that it is at once an error of refraction and a disease according to circumstances, for it is a physiological peculiarity in one person and a disease in another, while in a third it is both. The main risk is increase in the degree of error. There may be said to be **three main types**, which, be it understood, are not at all clearly marked off from one another, but merge by insensible gradations. There is *first* the type in which there is a low or very moderate degree, say up to four or five dioptries. The patient has reached full age, he has been known to be myopic since he was fifteen years old, and between that time and the present the myopia has increased. His mother and some relatives have been myopic. In his fundus there is not a trace of any pathological change and his vision is a full and sharp $\frac{6}{6}$ on correction.

The *second* type is that of a person of full age, with the same degree of myopia, but with a “myopic crescent” and a few weak points in the chorioid outside it. This myopic crescent arises as the result of the stretching of that weak point in the globe, and especially in the chorioid, where the nerve joins the globe. The posterior pole of the eye is slightly to the outer side of that point,

and as the globe increases in its antero-posterior diameter (this increase being the very essence of myopia) this weak point is drawn upon, it yields, and a narrow crescent of bared white sclerotic is seen at the outer margin of the disc. In time this stretching becomes greater, and now a low form of chronic sclero-chorioiditis affects the whole posterior polar area; its resisting power is lessened, it yields more, and little weak places in the chorioid, where pigment is absorbed and "dirty" looking sclerotic is seen, manifest themselves. When the crescent becomes broader and the posterior part of the eye has yielded at all one speaks of a *staphyloma posticum*, so called as being a protrusion of the coats analogous to the *staphyloma anticum*. This person has probably a family history of myopia, the degree in his own case being 5 to 10 D, and not having increased for a number of years. The staphyloma has a sharp, clean-cut border, though it may show signs of "lower tides" in former days. Such a patient as we have been describing as forming the second type is always in danger of further increase and of passing over into the third type.

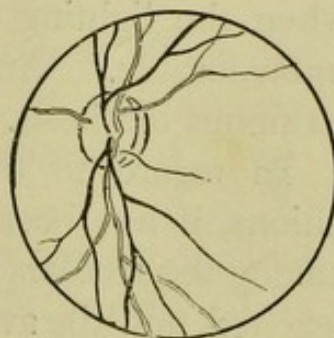


FIG. 14. — Myopic crescent to outer (macular) side of disc.

In the *third* type the staphyloma is wide, the degenerated area at the posterior part is wide also and not confined to the outer side of the disc, which may be seen in the midst of a large white area of atrophied chorioid; the margins of this staphyloma are no longer sharp and clean, but thinned out and irregular, and beyond them are many patches of atrophied chorioid; should these reach the macula and affect it, vision may be very bad indeed, but apart from that sight is poor, even when the person wears his full correction. In very many of these cases, where the myopia may amount to sixteen, twenty,

or even more dioptries, there is no family history of short sight whatever and the patient has never given his eyes hard or trying work. One sees them, for example, among the agricultural labourers, who do not tax their eyes at all, and who have never done so all their lives.

Many have been the theories propounded as to the causation of myopia, but the true answer, if there be a universally true answer, has not yet been discovered. One point is certain, it is certainly often hereditary; it is also caused to advance, even if it be not originated, by overuse of the eyes at near work, and particularly when the lighting and general hygienic conditions are unfavourable. Another cause is the tuberculous or strumous diathesis.

In regard to the matter of overwork and bad conditions, it has been shown that in schools the myopes among the scholars relatively increase as higher classes are reached, and the average degree of myopia increases also. This must not be accepted too readily as proof, for if the child had not been at school at all his myopia might have increased, since myopia seems to be one of those alterations in the dimensions of an organ which go on till full growth is attained a few years after 20. Still, what could be more likely to add to the myopia than hanging the head over books and thus inducing congestion of the chorioid, the prolonged accommodation, which tends to pull upon, and perhaps also to congest the chorioid, and the endeavour to decipher small and faint print in a bad light? Some find an additional cause in the persistent contraction of the oblique superior muscles, required, or supposed to be required, by the maintenance of the reading position, and in the supposed deficiency of elastic fibrous elements in the scleral tissue. To this last suggestion may be opposed the fact that this deficiency has not been proved to exist, and that the distension of globe affects the anterior portion, in front of

the line of insertion of the muscles, to a greater degree than the posterior.

The strumous or tuberculous diathesis acts in two ways, first by predisposing to a posterior sclero-chorioiditis which causes weakening and yielding of the parts, secondly by causing ulceration of the cornea and formation of nebulæ (see p. 153). These nebulæ interfere with clear vision, the book is drawn closer up to the eye, accommodation is strained to enable focussing to take place, and myopia is thus brought about. In many of these patients both factors are at work together.

There are four dangers in particular to which the myope is exposed, namely, increase in the myopia, chorioidal atrophy, detachment of retina, and divergent strabismus.

1. *Increase in the Myopia.*—Myopia is not a congenital condition, but one which comes on with growth. It is known that practically no child, not even if he be born of myopic parents, is myopic at birth; all who are myopic in later life become so. The age at which the fault first appears is usually about 10 to 12 years, though in bad cases it may be manifest at a much earlier period, and in very mild ones not till later. Increase of myopia may go on in any case up to 25 years or thereby, and we shall presently discuss what are the factors in this increase; for our present point of view the main fact is that if one take a group of myopes of low degree, another of myopes of somewhat higher degree, and so on, it will be found that the average vision possessed by each group diminishes as the myopia is higher. Thus the probability is that, even on careful correction of the error, any person having 6D of myopia will have worse vision than another whose myopia is of 3D, and a third person of 12D of myopia will have worse vision yet. Increase of myopia, then, is extremely apt to involve defect of sight, perhaps quite apart from complications, just as we shall see in

the opposite condition of refraction, where the greater the departure from normal the less the probable vision.

2. *Chorioidal Atrophy*.—Along with increase in the antero-posterior axis of the eye and consequent increasing myopia the thinned and stretched chorioid is apt to yield here and there ; grave defects in vision may result from this, depending chiefly upon the involvement or escape of the macular area. It is easy to believe that these harmful changes at the posterior portion of the globe are more likely to be present and to have a more injurious effect the higher the myopia. A myopic crescent may be present along with 3D of myopia, but it is much more probable along with 5D, and a staphyloma, which is unlikely with 4D, is almost certain with 12D. In the degrees above 8D the changes are almost invariably such as to preclude the obtaining of full vision. High error and chorioidal changes do not quite run on all fours, as might be erroneously imagined, and in a case of comparatively low myopia there may be degenerative changes which seriously reduce vision, while in a case of fairly high error, especially if there be a family history of myopia, there may be little change, and excellent sight on correction.

3. *Detachment of Retina*.—Separation of the retina from the chorioid is apt to happen in high myopia, because with the increase in size of the globe there is no corresponding increase in the solid contents, they become more fluid ; and the retina is very imperfectly supported against the chorioid. It is the lower part which is first and chiefly affected, for it is there that the fluid most readily collects which actually separates the retina from the chorioid.

4. *Divergent Strabismus* is a serious danger also for several reasons. (a) The patient has little need to accommodate, for his far point is so close to the eye at any

rate ; he therefore loses the associated convergence. (b) His eye is no longer globular, but ellipsoidal ; when it moves, therefore, it no longer moves without displacing any other structure ; it must displace orbital tissues. (c) His internal recti are less advantageously situated, owing to the different form of the eye, which is no longer strictly a "globe." (d) It is often the case in such persons that one eye possesses much worse vision than the other ; efforts to maintain binocular vision are therefore discounted. All these reasons then tend to discourage convergence and to promote divergence.

As just mentioned, the proper *treatment* of myopia is the wearing of the correcting lenses, which should never be an atom stronger than is necessary to produce the result ; but this general rule requires certain modifications. Various authorities differ as to particulars, but most agree that to the rule there are three exceptions, namely, (1) when the myopia is high with atrophic changes, when somewhat less than the full correction is safer ; (2) when the degree is low and the patient young, no correction need be constantly worn, except when there are indications of probable serious advance ; (3) when a patient with a moderate or high degree has reached adult life without wearing glasses. In the higher degrees it is best that the patient, even though he be not yet of presbyopic age, should wear a diminished strength for near work.

The beginner would do well to accustom himself to the elucidation of such simple problems in refraction as : A patient who is a violinist wishes to be able to read his music at 30 inches, but he is myopic to the extent of 5D. What lenses should he wear ? If his accommodative power be high he may of course wear the full - 5D, but if not he will require to employ a weaker lens. The problem should be worked out thus :

To see at 30 inches requires $Em + \frac{40D}{30} = Em + 1.5D$ nearly

The patient's refraction is $Em + 5.0D$

Therefore he should wear $-3.5D$

(This answer is approximately, but perhaps not absolutely, correct, for it takes no account of such matters as extent of convergence, breadth of fusion, etc.)

Examples such as this may easily be devised and practised with advantage.

It is a commonplace among the ignorant that "shortsightedness does not much matter because it comes all right again by and by." The meaning in this mistaken notion is that a myope does not become presbyopic; he does not become so obviously presbyopic as does an emmetrope, but he does so not less surely. A man becomes myopic to the extent of 6D, let us say; thereafter whether he is thirty years or seventy his far point is at 7 inches (approximately), and he can read at that distance without the aid of any glasses, but he has no more accommodative power at any age than an emmetrope, and if he wears his distance correction the failure of his accommodation becomes readily manifest. If he be sufficiently myopic he may never require to employ his accommodation at all, but if he have only a small degree of myopia he may even require convex reading glasses. Thus, a man who has 2D of myopia reaches the age of 60. To focus at 10 inches (the usual reading distance) requires $Em + 4.5D$, of which the normal person can supply by accommodation 0.5D. The myope of 2D = $Em + 2D$; at 60 he can supply 0.5D by accommodation; in all + 2.5.

$$Em + 4.5$$

$$Em + 2.5$$

+ 2.0 is the lens required to enable him to read.

For the purpose of reducing the excessive refrac-

tive power in myopia of over 20D, extraction of the clear lens is sometimes performed: the effect produced is approximately equal to that of a lens of 18 to 21D placed in the ordinary spectacle position. The operation should certainly never be undertaken unless the myopia reaches more than 17D, unless the fundus is at least fairly sound, and unless the patient has the use of both eyes. The chief dangers are sepsis, detachment of the retina, and glaucoma.

Hypermetropia or Hyperopia.—In Hypermetropia the rays which were parallel strike upon the retina before they have come to a focus, the eye is relatively or actually too short in its antero-posterior diameter. As in the analogous condition of myopia, this may arise in three ways, from the eye being actually smaller (axial hypermetropia), from the cornea having a flatter surface than it ought to have (curvature hypermetropia), and in addition from the absence of the lens either naturally or after its extraction (aphakia). If the eye is unable to focus parallel rays, *a fortiori* it is also unable to focus divergent rays: in other words, it can focus no object whether at or within infinity. It can focus only such objects as give out converging rays, of which there are of course none. It is capable when at rest of focussing those rays alone which have already had imparted to them a certain degree of convergence. The degree of convergence is such exactly that the rays would, if the eye were removed from their path, come to a focus at a definite point behind the situation of the retina; this point is the (negative) far point of the eye. Conversely, rays starting from it would, if the eye were placed in their path, emerge from it in parallel bundles. The point is the (negative) conjugate focus of the retina, and, as will be seen immediately, the correction is effected by means of a convex lens whose focus is at this point.

These statements apply to the eye in a state of complete rest, but as a matter of fact such an eye is not in general in such a state, for the patient employs some of his abundant accommodation to increase the refractive power of his eye. He accommodates for distant objects sufficiently to make up the deficit in his refraction.

Just as myopia is to be regarded as an excess of refractive power above the normal, or as $E_m + \times D$, so hypermetropia is a deficiency in refractive power, or $E_m - \times D$. The hypermetrope of (say) $2D$ ought to be regarded as having $E_m - 2D$: the deficit may be made up by employment of accommodation (or by means of a $+2D$ lens). This fact of the correction of hypermetropia by the accommodation enables the patient to obtain excellent vision, provided he is sufficiently young, and his hypermetropia is not too great; it compels us to draw distinctions also among certain classes of those possessing this error. A patient may have $\frac{6}{8}$ and maintain that his acuteness falls when a $+1D$ lens is held up before him; yet when we paralyse his accommodation with atropin he may be found to have $1.5D$ of error. This hypermetropia was *latent* (H_l); that is to say, it was concealed by him by means of the activity of his accommodation. In another case the patient's vision is $\frac{6}{24}$; on holding up a $+2D$ he obtains $\frac{6}{8}$: this hypermetropia was *manifest* (H_m); it was not concealed, but obvious as soon as a test was applied. Indeed it was *absolute manifest* (H_{ma}), because he could not obtain full vision till it was corrected. In the same case we may find that he still retains $\frac{6}{8}$ when wearing $+3D$. This extra hypermetropia ($1D$) is called *facultative manifest* (H_{mf}), because he can either exhibit or conceal it as he chooses. It must be evident that as age goes on a patient who started life with his H all latent, comes to have more and more of it manifest, until at last it is all absolute manifest or H_{ma} . The broad rule for the

correction of hypermetropia should be to correct the manifest, or even slightly to over-correct it. Different surgeons give different rules as to the amount of over-correction, but the broad rule is as above. It may be put in this other form: order for him the very strongest + lens with which he can obtain his best distant vision.

There are three conditions in which it may be advisable to correct more fully than in ordinary conditions. (1) While the vast majority of asthenopic patients obtain relief from the following of the rule given above, there is a residuum of cases in which relief of symptoms is not obtained till a lens is worn which decidedly over-corrects the Hm. (2) In patients with indications of glaucoma threatening it is probably best to correct very fully. (3) In cases of convergent strabismus. These cases will be discussed later under the head of Strabismus (p. 342): they cannot be profitably studied till certain other considerations have been examined into.

Hypermetropia may be low in degree, say up to 3 or 4D, or much higher; 10D one would regard as very high; and persons belonging to the two classes behave very differently. While the myope complains that his distant vision is bad, the hypermetrope complains that reading, writing, sewing, and such like occupations are trying and fatiguing. By exercising his accommodation he may obtain good distant vision, and generally does so, but he may complain of his eyes feeling tired as the result of this constant effort. Headache, especially frontal and temporal, is a frequent annoyance. Naturally these symptoms are more prone to give trouble in the young adult than before that stage in life. The high hypermetrope, on the other hand, is usually a child, for the acuteness of vision is often obviously lowered, and school work is a difficulty. He is, curiously enough, often mistaken for a myope, for he holds his book near the eyes and has but indifferent distant vision. He

holds the book near the eye in order to read, although one might expect him, in order to be able to focus, to hold it far away, and he does this because, since by no amount of accommodation can he obtain accurate vision, he prefers a large blurred image to a small, if less blurred, one. He often knows that he can improve the images obtained by a trick of looking at the book across his nose, utilising that member to cut off some of the "circles of diffusion" which would otherwise annoy him. In fact he uses his nose as the myope uses his eyelids, to sharpen the image.

In correcting hypermetropia as in correcting myopia the beginner will find a simple problem or two very helpful. Thus take a man of 20 years (therefore with an amplitude of 10D) who wishes to work at 13 inches, but has 3D of hypermetropia. His refractive power is too weak; it is $E_m - 3D$: to work at 13 inches requires $E_m + 3$: he being twenty years of age can supply 10D of accommodation for a moment, and perhaps 8 for a length of time. Theoretically his 8D is sufficient to meet the demand without any assistance from lenses if we paid no attention to the relation of accommodation and convergence (see below). As a matter of fact one would require to correct two-thirds of his error or thereby. Or again, a man of 50, with 1.5D of H, wishes to read at ordinary distance (10 in.). To do this requires $E_m + 4D$. His refraction is $E_m - 1.5D$, and he can supply 2.5D of accommodation, which would bring up refraction to $E_m - 1.5 + 2.5 = E_m + 1D$. He still therefore needs $+3D$: this is his correcting lens. It is not, of course, pretended that these examples are rigidly accurate, but if the student regards the problems from this point of view he will find much greater ease in dealing with cases.

It is very instructive to compare the amplitude and the range of accommodation in persons of the same age

but differing refraction. As an example, take the case of three persons aged 20, and therefore all possessing the same amplitude (10D), one of them, A, Emmetropic; B, Myopic 4D; and C, Hypermetropic 4D. Their amplitudes are the same, their ranges differ greatly.

A's range is from infinity, where his far point is

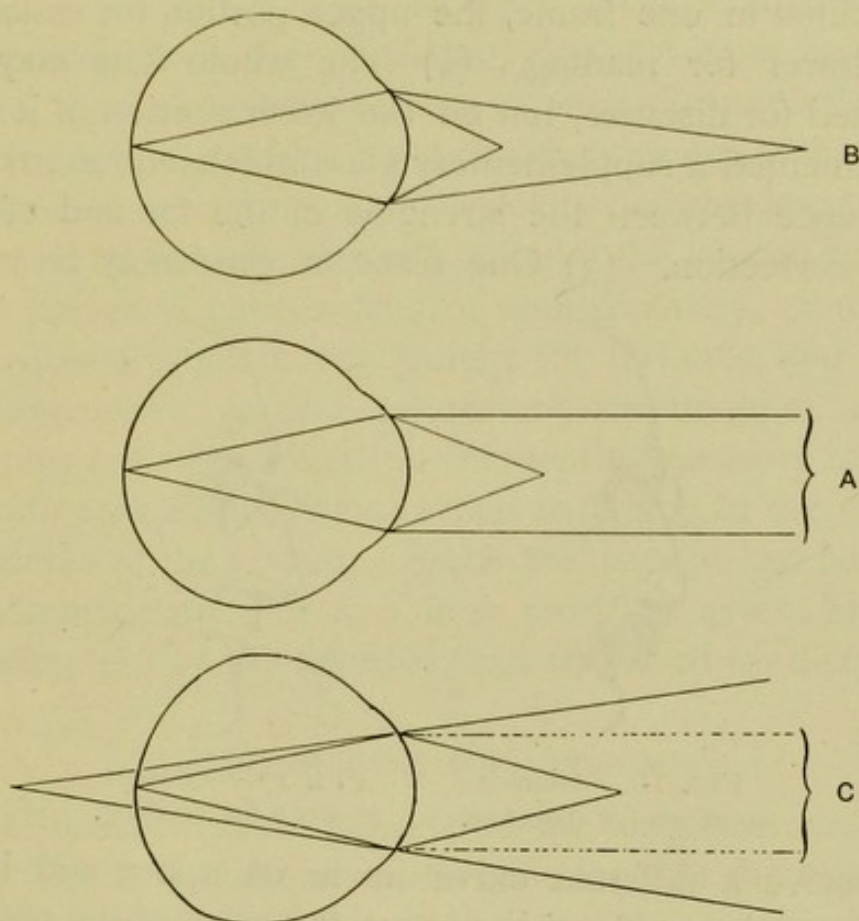


FIG. 15.—To show the range of accommodation.

A, An emmetropic eye at age of 20 years.

B, An eye myopic 4D at age of 20 years.

C, An eye hypermetropic 4D at age of 20 years.

to $(\frac{40}{10} =) 4$ inches. B's is from $(\frac{40}{4} =) 10$ inches to $(\frac{40}{4+10} =) 2\frac{3}{4}$ inches. C uses 4D of his amplitude to adapt himself for distance, and has therefore only $(10 - 4 =) 6$ D left with which to adapt himself for near work; his p.p. accordingly stands at $(\frac{40}{6} =) 7$ inches, and his range is from infinity to 7 inches.

It is manifest from the above that the hypermetrope appears to reach presbyopia early; the myope, who

does not use his concave glasses when reading, late or never.

When it becomes necessary for a patient to wear different glasses for distance and for reading, these can sometimes be combined in one; this can be done in three ways: (1) Two separate pieces of glass can be combined in one frame, the upper portion for distance, the lower for reading. (2) The whole lens may be adapted for distance, but on the lower portion of it may be cemented a supplementary glass which represents the difference between the strengths of the far and of the near correction. (3) One piece of glass may be made



FIG. 16.—Glasses
as worn for distance.



FIG. 17.—Glasses
as worn for reading.

to receive a different curvature in its upper and in its lower portions. In this respect the work of the optician has advanced wonderfully in recent years, and such glasses can be turned out with the greatest nicety. It is the case, however, that a good many patients prefer to have their glasses quite separate. The objections to the combined glasses are: (1) That when looking down one must look through one's reading glass, which is not convenient for stairs, etc. But this difficulty can be avoided by employing the second method of combining lenses and not carrying the cemented part quite to the lower edge of the lens. (2) That the interpupillary distance is different in distant gaze and in reading, and

the optical centres of the two parts should not be always the same. The skill of the optician may enable him to avoid this difficulty also. (3) That is, the pose of the glasses should be different for the two purposes; they should stand vertical for distance use, but be inclined to the face below when used with the down-looking eyes at reading or sewing (Figs. 16, 17). Even with these and other objections the combined glasses are an immense boon to persons who require to wear distinct lenses for far and for near work. In **Aphakia** (absence of the lens), whether due to congenital dislocation of the lens out of the line of sight or after extraction of the lens on account of cataract, a convex lens of approximately 10 to 12D is required to adapt the patient for distance, and in the post-operative cases a cylindrical correction of 2D or thereby (axis horizontal) is frequently necessary in addition to compensate for a certain flattening in the vertical meridian of the cornea. Since the patient can have no accommodative power, a lens must be given him for reading of 4 or 5D stronger than that used for distance.

ASTIGMATISM (OR ASTIGMIA)

Hitherto we have considered the simple errors of H and M. It may, however, be the case that the refraction in one meridian of the globe is not the same as that in another. The eye, when measured as to its vertical meridian, for example, may be found to have H of 3D, and in its horizontal H of 5D. It is plain that there may thus be five varieties of regular astigmatism as this condition is called :—

- One meridian may be H, and that at right angles to it
Em = Simple H As.
- One meridian may be M, and that at right angles to it
Em = Simple M As.
- One meridian may be H, and that at right angles to it
more H = Compound H As.
- One meridian may be M, and that at right angles to it
more M = Compound M As.

One meridian may be H, and that at right angles to it
M = Mixed As.

The source of nearly all astigmatism lies in the cornea, whose curvature in such cases is unequal; it may, like an egg or the bowl of a spoon, have in one direction a flatter, in another an acuter curve—this produces astigmatism. The name implies inability to focus to a point; when a pencil of rays strikes such an eye the rays entering by the cornea in its vertical diameter have their focus at a certain distance from the cornea, while

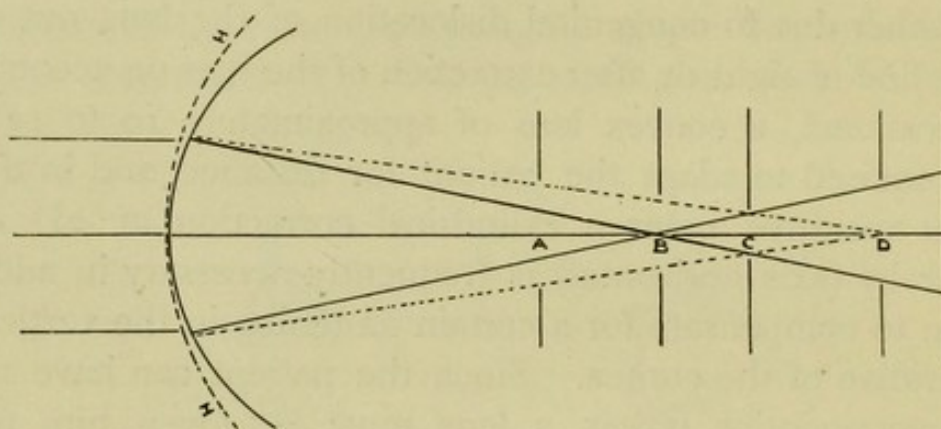


FIG. 18.—Astigmatism.

Continuous line, the vertical meridian; dotted line, the horizontal meridian.
If retina be situated at A there is compound hypermetropic astigmatism.
If retina be situated at B there is simple hypermetropic astigmatism.
If retina be situated at C there is mixed astigmatism.
If retina be situated at D there is simple myopic astigmatism.
If retina be beyond D there is compound myopic astigmatism.

those entering in the horizontal meridian have theirs at another; a point can therefore not be focussed as a point by such an eye. For the sake of convenience of demonstration one may for the moment assume (Fig. 18) that from any given point of illumination one central ray strikes the centre of the cornea and reaches the macula; above and below it there are two others forming a line in the vertical diameter: these come to a focus at a certain point B, which may be situated either in or behind the eye. Similarly in the horizontal meridian there are lines coming to a focus D, either in or behind the eye. According to the situation of A and B with

reference to the retina, there will be one form or another of astigmatism. If, for example, the retina lies between B and D, the case will be one of mixed astigmatism. If one should interpose a screen in the path of the rays, a cross would be seen to be formed with its limbs equal in certain positions, with the vertical limbs longer than the horizontal, with the horizontal longer than the vertical, with the vertical non-existent, and with the horizontal non-existent, each of these at a certain different spot. When an astigmatic eye looks at a fine line this imperfect focussing occurs in reference to all the points of which such a line is composed, with the result that if, for example, the horizontal meridian be correct or corrected and the line be placed vertical, the edges of that line will be correctly focussed, and the line will appear sharp and clear, no matter how incorrect the vertical meridian may be. A horizontal line would to the same eye appear blurred and dim. The student would do well to grasp the crude fact that *it is with one's vertical meridian that one sees a horizontal line.*

This is a point a little difficult for the beginner to grasp, but it can be made clear thus:

A line is composed of a number of dots or points arranged in a row in the direction of the line. From each point or dot comes a pencil of rays that the eye on which they fall attempts to focus. Should the eye have myopia or uncorrected hypermetropia, each of the points will form a circle on the



FIG. 19. — A cross as seen by an astigmatic eye normal (or corrected) as to its vertical diameter, ametropic in its horizontal.

fundus. Should the eye be correct, each will be focussed as a point. But should the eye be normal in its vertical meridian, each will be focussed as a dot, so far as the upper and lower sides of the dot are concerned, while, if the horizontal meridian is myopic or hypermetropic, each will be focussed imperfectly, *i.e.* not

as a dot, so far as the horizontal meridian is concerned. If the line lie horizontal, its upper and lower sides will, in the case assumed, be sharp and clear; while if it stand vertical, its lateral sides will be blurred and indistinct. This has a great effect in the success of an attempt to read the test letters, for these are composed of vertical and horizontal lines for the most part. Thus in the case we assumed, where a horizontal line could be clearly seen, but not a vertical, the letter D will appear as having a line at the top and another at the bottom, while between them is a blur; the letter may be mistaken for Z or S. A little practice enables one to detect the astigmatic at once by the manner in which he makes mistakes over the letters.

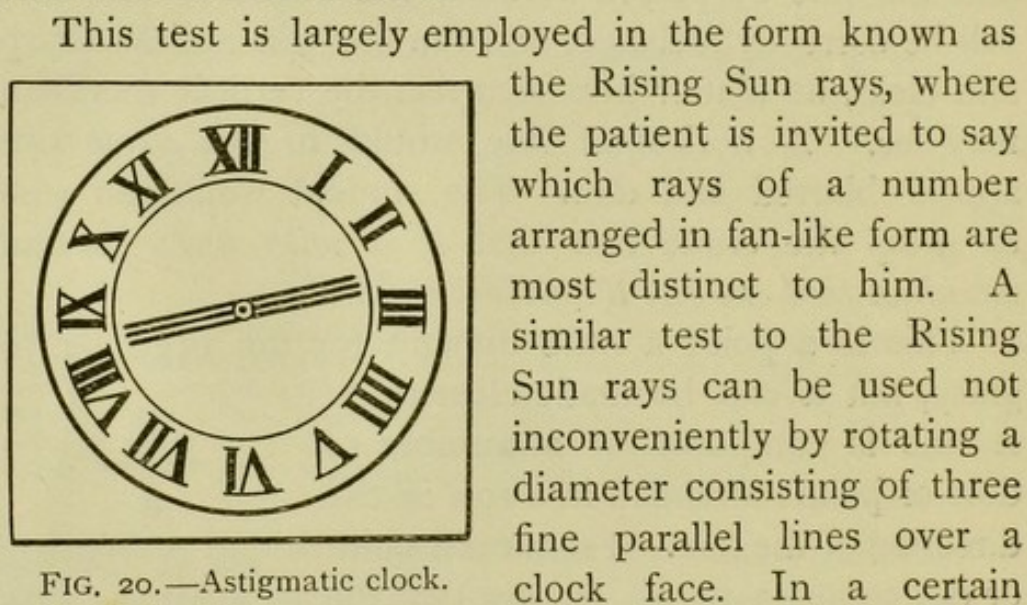


FIG. 20.—Astigmatic clock.

This test is largely employed in the form known as the Rising Sun rays, where the patient is invited to say which rays of a number arranged in fan-like form are most distinct to him. A similar test to the Rising Sun rays can be used not inconveniently by rotating a diameter consisting of three fine parallel lines over a clock face. In a certain position these lines will be sharp, black, and discrete; in the opposite, blurred. When in the latter position it may be cleared up by means of a cylindrical lens whose axis runs in the same direction. Thus the diameter is sharp when pointing to XII, VI: that indicates that the horizontal meridian is correct (or corrected); it is blurred when pointing to III, IX, indicating that the vertical meridian is faulty: the vertical meridian may be corrected, and the lines made sharp, when pointing to III, IX, by a cylindrical lens (+ or - as the case may be) lying with

its axis horizontal. It is for the correction of astigmatism that cylindrical lenses are employed. Thus if the refraction of the patient is $Em + 5$ in the vertical meridian and $Em + 3$ in the horizontal, he will require to wear a $-3D$ spherical supplemented by a $-2D$ cylinder, with its axis (of no curvature) horizontal.

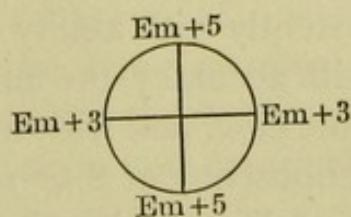


FIG. 21.—Astigmatism.

In mixed astigmatism, since any lens employed to correct one meridian makes the opposite meridian worse, we must order a cylindrical lens of the opposite type to the spherical and of sufficient strength to overcome both the original error and also that part of it produced by the spherical lens, *e.g.* $+2.0D$ Sph. $-3.75D$ Cyl. : axis 30° .

OBJECTIVE TESTS OF REFRACTION

Hitherto we have spoken merely of a patient "having" so many D of myopia, etc. Besides subjective testing, to be described immediately, there are in common use, not to mention others of less value, two methods of estimation, namely, direct estimation and retinoscopy, and one for the discovery of astigmatism alone by means of the ophthalmometer or astigmometer.

Of all the objective methods for the detection and estimation of errors of refraction there is none to equal **retinoscopy** or the **shadow test**, as it is called, in convenience, simplicity, and accuracy. When the patient is in the dark room at any rate, the method can be applied with no more apparatus than an ophthalmoscope mirror (or preferably a plane mirror), a spectacle frame, and a set of lenses. It is not necessary to dilate the pupil in the great majority of cases (see below). The surgeon should sit at a distance of about 4 feet from the patient at first, and when he is finishing the correction and finds the patient to be almost corrected by a certain

lens he may retreat even farther ; the farther off he is, consistently with ability to see the movements in the pupil with accuracy, the more exact will his results be. In a suitable case, and with a good plane mirror, one can perform retinoscopy at 8 or 10 feet quite well. It is assumed in the following description that a plane mirror is employed.

Reflect the light from the mirror into the pupil of the patient. Sometimes at a distance of three or more feet this is not easy for a beginner to do, but a very simple little device will help him : Hold the mirror to your own eye and reflect the light down upon your other (left) hand held below the level of the face. Then, keeping the light on the hand, raise your own face and with it the mirror, and also the left hand till the latter obscures your view of the patient's eye, slip away the hand, and there is the pupil illuminated. If the eye be approximately emmetropic a good red glow is obtained, if it be decidedly abnormal the light is poorer and duller. Now rotate the mirror so that the light travels across the pupil from side to side. As the light passes along it is of course succeeded by a shadow (hence the rather absurd name, shadow test), or rather by absence of light, for there is no true shadow of anything. It is this movement of light in which the test consists. The normal movement, if your distance from the patient be 4 feet or more, is one of extremely rapid movement in the same direction as the movement of the mirror, but so swift that it can hardly be seen ; in hypermetropia the shadow goes definitely *with* the mirror, in myopia *against* it ; the higher the degree of error the slower the movement. When the direction has been noted, lenses of the appropriate character should be put upon the patient in the spectacle frame, + for hypermetropia, - for myopia. The test is repeated with lenses of varying strength until (if the observer is a beginner) the direction of the shadow is reversed. Since the normal shadow is

with the movement, the weakest lens in the case of a myope may have to be supplemented by $0.25D$, while that of a hypermetrope will require the same amount of deduction. As a matter of fact, after some practice the surgeon works to the normal and does not invariably over-correct. If he is placed at a sufficiently great distance the degree of possible error and the necessary supplement or reduction become infinitesimal.

If the case be one of hypermetropia or myopia, the same lens will correct the error in all meridians, but if there be astigmatism the lens which is sufficient for one meridian will be found insufficient or incorrect for that at right angles to it. Retinoscopy will in such a case require to be conducted in two meridians, those of greatest and of least error, which will be found to be at right angles to one another, though they may not necessarily be vertical and horizontal. The difference between the two lenses thus required for correction is the measure of the astigmatism, and will be represented in the lenses ordered for the patient by the cylindrical element. Thus if the proper lens for the vertical meridian be $-5D$ and that for the horizontal $-3.5D$, the patient has $3.5D$ of myopia with $1.5D$ of astigmatism, and his prescription would run, $-3.5D$ Sph. with $-1.5D$ Cyl. : axis horizontal.

The beginner will find it most convenient to mark down his results somewhat thus :—

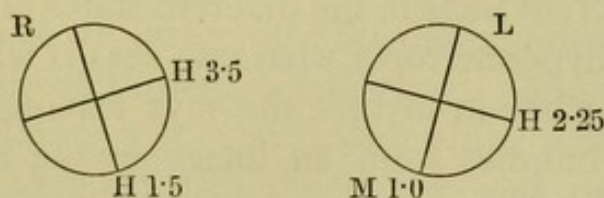


FIG. 22.—How to record a case of astigmatism.

This would mean : In the right eye compound hypermetropic astigmatism, in the left mixed. The prescriptions would run :—

R.E. $+1.5D$ Sph. with $+2.0D$ Cyl. : axis 75° .

L.R. $+2.25D$ Sph. with $-3.25D$ Cyl. : axis 150° .

In the case of the left eye the cylinder must be sufficiently strong to overcome the $+$ element in the sphere and to correct the myopia besides.

It is a mistake to mark the record chart with + and - signs, for no other person can know whether these represent the error or the lens required to correct it, or, if it be the lens, whether the number represents the correct lens or the lowest overmastering lens ; it is better to mark H or M. The beginner requires to be told that no lenses on his own face make any difference to the result, only those on the patient's. Any surgeon who requires to wear a correction for distance should wear it when performing retinoscopy.

The explanation of retinoscopy with the plane mirror may be put briefly thus : What illuminates the patient's eye is not the lamp or the mirror, but the aerial image of the lamp ; this image is situated as far behind the surgeon's head as the lamp is before it. A slight movement of the mirror means a relatively large movement of the source of light, all the greater the farther back the surgeon is from the lamp, hence the accuracy of this method. The light falls on the fundus which, being thus illumined, gives a red glow. The light moves across this, illuminating always a different portion as the mirror is moved, and what the surgeon watches is this procession of the light over the fundus, succeeded, as it leaves any spot, by darkness (the so-called shadow). This must obviously be true no matter what the refraction of the patient ; how, then, does the shadow appear to travel in different ways in the different states of refraction ? Because in hypermetropia what one sees is what actually takes place, while in myopia the rays leaving the eye in converging bundles form an image in the air between surgeon and patient, whose movement must necessarily be the reverse of the actual. It is this aerial image which is seen in myopia, hence the shadow appears to move against the movement of the mirror. Study of Fig. 23 will make this plain.

With the concave mirror the source of illumination is

the image found in the air between surgeon and patient ; since it is so situated all the terms are reversed : a shadow moves *with* in myopia and *against* in hypermetropia.

As the *Ophthalmometer* or *Astigmometer* is a "specialist's instrument," a very few words descriptive of its general principles will suffice. Every convex mirror gives back a reduced image of an illuminated object, the size of the image depending on the degree of curvature of the mirror. When the curve is flatter (longer radius of curvature) the image will be larger ; where it is more

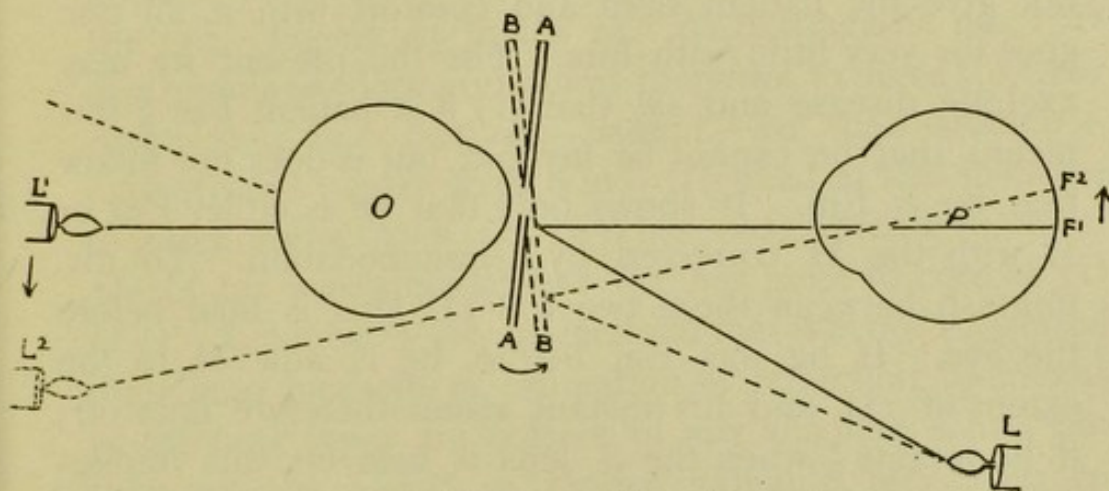


FIG. 23.—Retinoscopy with a plane mirror.

O=Observer. P=Patient. When the mirror stands at A the real source of light which falls on F^1 is at L^1 ; when the mirror moves from A to B, L^2 becomes the source of light and the illuminated area of the fundus is now F^2 . In other words, "the shadow travels *with* the mirror."

curved, smaller. Advantage is taken of the fact that the cornea is a convex mirror. A brightly lighted object is allowed to form an image on the corneal mirror, and the image is observed through a telescope. The tube of the telescope contains a special prism which affords to the examiner a duplication of the image, and by means of a screw arrangement the two images are placed in a certain fixed relation to one another. The object is next caused to throw its image in a direction at right angles to that direction in which it first stood. Should there be any difference in the curvature of the cornea, this will show itself in a greater separation or closer approximation

of the images. The instrument is so graduated that the difference in radii of curvatures is read off in numbers of dioptries of difference in refractive value.

SUBJECTIVE TESTS OF AMETROPIA

We can obtain much information, indeed in many cases we might obtain all we require, from the use of Snellen's test types, large and small, described on p. 14, and must never forget that the subjective result is the patient's final court of appeal. If our correction does not give the patient sight and comfort with it, all else goes for very little with him. For the present we may exclude disease and say that (1) if a patient has $\frac{6}{6}$ this means that he cannot be myopic, but it does not follow that he is Em. It shows only that he is either Em or H with the H corrected by accommodation. To distinguish between these two a + 1D lens is held before the eye. If he was Em before, he is now M to the extent of 1D, and his distant vision therefore falls off; if he retains $\frac{6}{6}$ when the + lens is held up, this implies that he is still Em, in other words, that he was H and we have merely relieved his ciliary muscle of (some part at least of) the work of supplementing his deficient refraction. The highest + lens with which he retains $\frac{6}{6}$ is the measure of his Hm. But (2) if he has less than $\frac{6}{6}$, say $\frac{6}{18}$, this means that he is not Em, but may be either H (uncorrected) or M. Again we put up a + lens; if he is H this will improve his vision, and we proceed as in the first case to find the amount of his Hm; but should the + lens make his vision worse, the patient must be M, when a - lens will correct his error. Should he be astigmatic we may find the Rising Sun test very useful, and he will make mistakes with the letters on account of seeing certain of their component lines clearly and others in a blurred fashion. Theoretically one might arrive at the astigmatic correction by

subjective testing alone; as a practical matter one requires some objective means as well, which must be checked by the subjective.

The *small test letters* are very useful as well as the large. If a patient requires to bring the smallest type nearer than 20 in. from his eye in order to read it, note the very farthest distant point at which he can hold it and read. This is approximately his far point; divide 40 by the distance and you know the - lens which will be required to correct his M. Or again, in the case of another patient who has difficulty with reading, inquire the age. Let us say this is 20. At that age he has 10D of accommodation, and ought therefore to have his near point at 4 in. But this patient—we shall assume—cannot read nearer than 6 in. To read at this distance requires $Em + (\frac{40}{6} =)7D$. What has become then of 3D of his accommodation? It has gone to correct 3D of H. Let it be clearly understood that it is not suggested that these methods of estimation of refraction by means of the near types are correct in any absolute sense, but they will be found to render valuable assistance in discovering the error.

In the statement made above, that it is not as a rule needful to employ a mydriatic in order to determine the refraction, I am aware that I have expressed a view at variance with that held by many surgeons; I hold this view strongly, however, and though anxious to avoid controversial matter in a work like this, I think it best to state plainly why I differ from some of my confrères. My reasons are briefly:—

1. In the case of hypermetropia it is as a rule not the total but the manifest error which gives the trouble. Assuming for the moment, then,—what I do not admit—that one does not discover the total hypermetropia without a mydriatic, one is yet able to give complete relief to the patient (see below).

2. In my experience nearly every patient above the age of actual childhood, whose intelligence is up to the average,

is able to show, and does show, a higher hypermetropia to retinoscopy than he shows subjectively. A good check is thus kept upon the subjective results.

The existence of "spasm of accommodation" is a hypothetical source of error which has in my opinion very little reality. If the patient understands what you wish, has a good dark room with only a dark uninteresting wall at which to look, and is given even a very little time, he will relax his accommodation. The hypothetical case of a patient of (say) 16 years, apparently myopic on subjective examination, but revealing himself as a hypermetrope after atropin is administered, is a figment of the imagination. It is true that cases do occur in which a tyro might be deceived; but that any reasonably expert clinician could thus be caught napping I simply do not believe. The theory that there are persons going about the world as myopes until some one administers atropin, when they become unmasked hypermetropes, may serve to frighten a beginner, but it is a mere "bogey."

3. Atropin is sometimes administered on the theory that it saves time. A conscientious worker, however, would require to see his patient three times in such a case; at the first he would learn the symptoms, etc., record the subjective results, and, if he is wise, the retinoscopic readings; at the second, the readings under the mydriatic; the third is in fairness to the patient required should the results at first and second differ, for the ability of the patient to bear the lenses prescribed under atropin may be doubted in these circumstances. Where, then, is the saving of time to the surgeon? And to the patient who has his bread to make by means of his near vision the delay and the period of incapacity are a cruel hardship. If the first and second readings do not frequently differ, the argument in favour of atropin falls to the ground.

4. With a reasonably good patient retinoscopy is more easy and quite as precise with a normal pupil as with a dilated one—easier in many cases, for one is not annoyed by the peripheral shadows and scissor movements which come in to disturb the important area. As to accuracy, it is possible, not merely in an isolated case but in many cases, to carry the retinoscopy without difficulty to eighth

parts of a dioptré without any mydriatic. This statement will perhaps astonish some who have never been in the custom of attempting the method without preliminary dilatation of the pupil. Let them try, and they will soon admit the accuracy of it.

My practice, therefore, founded upon satisfactory experience, is not to administer a mydriatic as a routine, but of course I may employ one in the case of children under the "intelligent" age, in patients whose accommodation is not under due control, and in those nervous persons who present various "distal" symptoms which may perhaps be due to some minute error which may possibly have escaped my observation.

ASTHENOPIA

Asthenopia is the name employed to indicate discomfort in the use of the eyes, or the too popular expression, eye-strain. Beyond the mere undue effort of a feeble accommodation in presbyopia, there are then three main causes of asthenopia in faults of refraction:—

1. The presence of astigmatism, largely because the attention constantly required to enable the person to interpret quickly images which are less clear than those which can be formed on the non-astigmatic eye, tires him mentally and fatigues the eye. The consequent effort and "wear and tear," or mental strain, causes headache, discomfort, mental dulness. Sometimes a child's "stupidity" is nothing else than the wastage of nerve energy due to his attempt to rise superior to his astigmatism, or the hopeless cessation of such an attempt as useless in face of his difficulties. If the hypermetropia or the myopia be high and the astigmatism low it is often best to correct the main error and leave the astigmatism uncorrected; in such a case the astigmatism can often be corrected by a slight alteration of the position of the spherical lens. Besides this the cost of the lens is so much augmented by the addition of a cylinder that in

the case of the poor, and especially of their children, a highly costly lens which is theoretically more precise is not obtained at all, while a simple one, less correct magisterially, might be obtained and employed with the greatest advantage.

Perverse astigmatism, or astigmatism against the rule, as it is sometimes called, gives much more distress and should be fully corrected. Astigmatism is "perverse" when the meridian of greatest refraction, that is, the more myopic or less hypermetropic, is horizontal or nearly so; that of least refraction, the less myopic or the more hypermetropic, vertical.

2. The want of relationship between accommodation and convergence. Without going into undue detail on this matter in this place, it is enough to say that along with a certain effort of accommodation there is normally associated a certain degree of convergence. If because of an error in the refraction the accommodation muscle requires to be exerted to a greater (or to a less) degree than the degree of convergence demanded by the position of the object in space, discomfort may arise; or if, owing to a fault in the apparatus of convergence, more effort (or too little) be required of that apparatus than of the accommodation demanded for the formation of a clear image, discomfort may arise. This relation is not rigid; it is somewhat elastic in all directions, else every error would necessarily entail discomfort, but it is fairly constant. The proper relationship is thus: with no accommodation there should be no convergence, and with no convergence no accommodation; that is, when our ciliary muscles are at rest, so should our internal recti be, and *vice versa*. If there be hypermetropia, however (to take an example), then the patient requires to accommodate to see well at a distance, yet he must not converge else his eyes will adopt a wrong position. On the other hand, if he has a

tendency to divergence of the optic axes (latent divergence), he must, when looking at a distance, exert his two internal recti so as to keep the axes straight, yet not exert his ciliary muscles else his focus would be incorrect. The perfect physiological condition is thus expressed: one metre-angle of convergence accompanies each dioptré of accommodation.

The meaning of "Metre-angle of Convergence" is the measure of the amount of convergence required to bring the visual axes from the parallel position to a convergence such that they would meet at a distance of 1 metre. With twice that exertion they would meet at 0.5 metre, with four times at one-fourth metre (0.25), and so on.

It is evident that this rule must tell hardly both on the hypermetrope and on the high myope, for the former requires to accommodate to a degree in excess of the necessary convergence, and the latter to converge without accommodating.

In the moderate degrees of hypermetropia the mere effort of accommodation to a degree sufficient to correct the error adds to the patient's troubles.

3. *Anisometropia* or unequal refraction of the two eyes. This is of all possible varieties—one eye myopic, the other hypermetropic, astigmatic or myopic to a degree greater or less; one eye astigmatic, the other also, but with different axes, and so on. But whatever the nature of the difference, the condition is one which is liable to cause much discomfort, though it does not always do so. In anisometropia the patient either

- (1) Uses one eye constantly, the other never;
- (2) Uses one eye for distance, the other for near work;
- (3) Uses both at all times, though at no time can more than one of them be quite correctly adapted.

If the patient is an adult, in the first condition it is generally best to legislate for the working eye only; in

the second to correct the reading eye for reading purposes, the "distance eye" for distance purposes; it may be wise in doing this to put a + glass before a myopic eye, but it can never be right in either the second or the third case to put a - lens before a hypermetropic eye or a higher - lens than corrects a myopic. As a rule of thumb it may be said: in dealing with the young one should try to correct the whole difference, to have *each* eye correctly adapted, but in dealing with the adult this is usually impossible, and as a matter of fact a difference of more than 2.5 or 3.0 dioptries can rarely be borne.

Next to errors of refraction the most potent source of asthenopia is a *fault in the attitude* of the two eyes towards one another. It may not be in accordance with strict sequence to explain the matter at this place, but it is convenient to group together the causes of asthenopia. If the attitude of the two eyes to one another is correct (orthophoria) the visual axes are parallel, if incorrect (heterophoria) they would intersect either in front of the

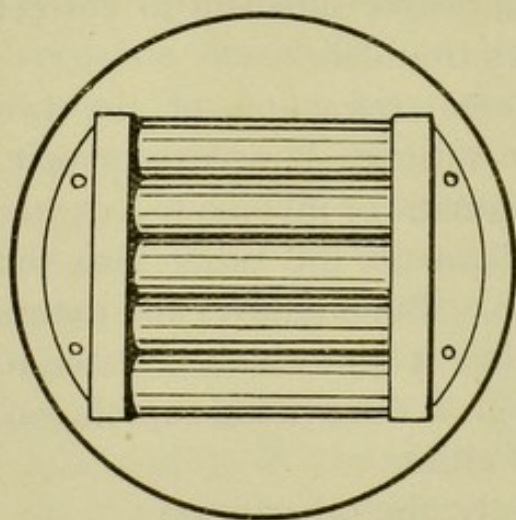


FIG. 24.—Maddox rods.

eyes or behind. The point may thus be tested: so long as the images of one object obtained by the two eyes are alike, the patient will use every effort to fuse them into one, owing to the ingrained intense dislike to double vision, but if we can render the image which falls on the right

eye different from that on the left, perhaps no effort will be made to fuse them and the eyes will be permitted to assume their rest-attitude. For this purpose Maddox has supplied us with the rod or rods known now by his name. The patient looks at a bright light with both

eyes open, but one of them bears in front of it a Maddox rod. This rod has the effect of so lengthening out the image of the light that it appears as a streak, not a point of light, so the patient has practically no impulse to fuse the two images; it does not appear to him that the point of light seen by one eye and the long streak seen by the other have anything in common, therefore no fusion-effort is made, and the eyes, as has just been said, assume their rest-position, and the patient is (if the expression may be excused) conscious of his unconscious diplopia. Whatever fault has been latent has now

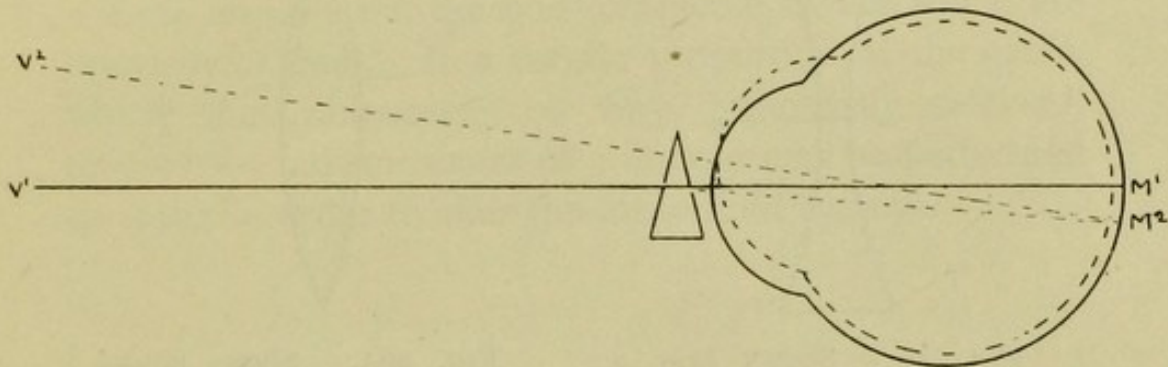


FIG. 25.—Hyperphoria corrected by a prism.

V^1M^1 is the visual axis of one eye; V^2M^2 that of the other. The object at V^1 throws its image at M^1 of the eye shown by the continuous line, but not at the macula of the dotted. The prism placed in front of the dotted-line eye diverts the image to reach the macula M^2 , thus neutralising the hyperphoria.

become manifest, and if that was divergence (exophoria) the patient has, without discomfort, crossed diplopia, if convergence (esophoria), homonymous diplopia, if one visual axis is directed higher than the other (hyperphoria) there is vertical diplopia. Since the muscles which move the eyes up or down are never under any circumstances employed for one eye alone, but invariably in conjugate fashion, a person has extremely little power of fusion, and a "trifling" amount of error of that type is capable of causing intense distress. With the lateral deviations, on the other hand, the "normal" must be regarded as having a somewhat elastic scope, and a slight degree of exophoria, and more particularly of

esophoria, must not be regarded at once as pathological and requiring treatment. The correction in each case is effected by means of prisms thus: esophoria by means of a prism, apex in ("the eye looks to the apex"); exophoria by a prism, apex outwards; hyperphoria by a prism with its apex upwards in front of the offending eye. The prism in any case can be divided between the two eyes in this fashion: there is, let us say, right hyperphoria requiring a prism of 3° before the right eye

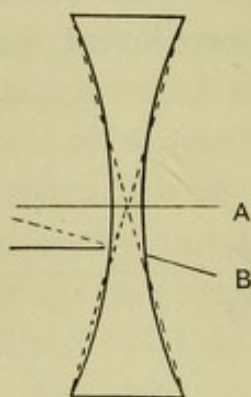


FIG. 26. — Shows how a concave lens consists of two prisms with their apices together.

If the eye looks through the optical centre there is no deviation, but if the lens be decentred to B, the image of an object will not fall on the macula unless the eye looks along the dotted line.

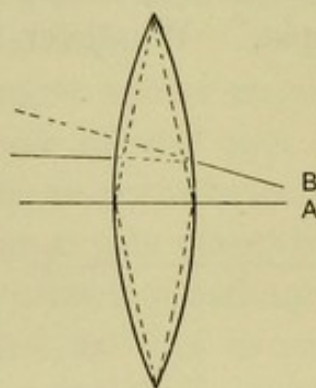


FIG. 26A. — Shows how a convex lens consists of two prisms united at the bases.

If the eye looks through the optical centre there is no deviation, but if the lens be decentred to B, the image of an object will not fall on the macula unless the eye looks along the dotted line.

apex upwards to correct it. It is much better than ordering the glass thus to order a prism of 1.5° before each eye, apex up before the right eye, apex down before the left. It is easy for the optician to combine the prism with any "optical" lens which the patient may require; indeed if the spherical lens which the patient uses is high and the prism required is low, the prismatic effect may be obtained by merely decentring the glass to a certain degree. Decentring a convex glass outwards, making the optical centre of the lens stand to the outer side of the visual axis, has the same effect as adding a

prism, apex inwards, and so on. Let it be remembered again that it is the low degrees of heterophoria which give trouble, because the patient makes constant efforts to fuse the images; the higher degrees give no trouble at all because the patient realises that such efforts must necessarily be futile and never attempts them.

The student must not confuse strabismus with heterophoria; strabismus is a frank adoption of a faulty position of the eyes, heterophoria implies that the fault is wilfully and constantly corrected in the interests of binocular vision. He must also grasp the fact that it is not the muscles but the non-contractile tissues which are primarily at fault. In a certain proportion of the cases, which must, however, be very judiciously selected, tenotomy or advancement of a muscle may be performed (p. 440), in order to alter the attitude of the eye.

CHAPTER III

THE EYELIDS

THE eyelids consist in the main of four structures—skin, tarsal cartilage, muscle, and conjunctiva. They cover, when closed, the whole base of the pyramid formed by the orbit, and form the first line of defence of the globe. The eyebrow consists of a slight thickening of the integument, covered with a growth of strong hairs, so disposed that the sweat, etc., from the forehead may be carried off from the eye and not allowed to obscure or injure that sensitive organ. From the eyebrow to the lid margin, and over the corresponding lower lid, the skin differs from the ordinary skin in being finer, in possessing almost no hairs and no sweat glands, and in being very lightly united to the underlying tissue; one effect of this is that hæmorrhage not merely easily occurs but also spreads with rapidity. At the edges of the lids are the cilia, with the glands of Moll opening into their follicles; these play a very important part in keeping the conjunctival sac free of foreign bodies and of fluid, and therefore of pathogenic organisms. It is an interesting exercise to place a drop of water on the outside of a person's upper eyelid and watch it lying on the eyelashes without entering the eye; it is a demonstration of the perfection of the screen formed by the lashes. Posterior to the eyelashes are the orifices of another set of glands, the Meibomian, whose oily or

waxy secretion plays an important part in keeping the conjunctiva moist, for it interposes a barrier to the escape of the tears from the conjunctival sac. Were it not for this secretion the tears would constantly run over the lid margins down the cheek. Between the line of cilia in front and the line of the orifices of these glands behind lies the "grey line," an important landmark in the edge of the eyelid.

The *Tarsal Cartilage* or *Tarsus* gives solidity to the eyelid, and permits the lids to be closed without being puckered on the side of the globe and without turning in upon the globe. The upper one is also the chief point of insertion of the levator palpebræ. Each, but more especially the upper, has a gentle lateral curve to adapt it to the form of the globe, and also a vertical one for the same purpose, which in the upper lid is slightly accentuated about 3 or 4 mm. above the margin—it is just at this bend that a foreign body under the upper lid is most apt to lodge.

There are two *muscles* of importance. The *Orbicularis* passes round both lids, exteriorly to the tarsus, and has the function of closing the lids; it is supplied from the VII. nerve. When this nerve is paralysed (Bell's paralysis), the lower lid being no longer kept pressed against the globe, the tears are sure to run over the cheek on account of the sagging of the lid (Plates XXIII. and XXIV.). So long as the lids are in proper position, contraction of the orbicularis closes them, but should they be everted seriously at their margins, contraction presses the upper edge of the upper cartilage against the globe and therefore everts the margin still further, and the lower lid in similar fashion. One sees this very markedly in certain cases of ectropion.

The *Levator Palpebræ Superioris*, innervated by the III. nerve, is attached to the upper margin of the tarsal cartilage, and also to the skin of the upper lid. The

tonic action of the muscle is released by reflex action at intervals that the moist conjunctival surface of the upper lid may sweep over the cornea and keep its epithelium from becoming dried by exposure to the air or injured by dust particles, etc. The voluntary closure and the involuntary wink are thus conducted by entirely different mechanisms. When the eyes are closed gently, as in sleep, the upper and lower lids meet in perfect apposition; the globe therefore never becomes dried by evaporation of the tears. At the same time the cornea is rotated upwards, both for the purpose of preservation from any possible injury and in order that, the cornea being turned towards the roof of the orbit, still less light can enter the eye than if it looked straight forwards. In very deep sleep, however, and in deep narcosis, the cornea is again directed forwards, changes of light not being capable of wakening the sleeper. This association of upward movement of the globe with downward droop of the upper lid is in very striking contrast to what is the case in waking life and in voluntary action. There is another muscle, but of unstriped fibres and supplied by the sympathetic, known as *Müller's*, which assists in elevation of the lid and no doubt in expression-changes. It has an important bearing in the symptoms of exophthalmic goitre (*q.v.*).

The conjunctiva of the lids and the lachrymal apparatus are dealt with under the appropriate headings.

AFFECTIONS OF THE EYELIDS

Inflammation of the Lids, Marginal Blepharitis.—

Any form of dermatitis which attacks the face may, of course, involve the eyelids, and in this way one is sometimes called upon to deal with erysipelas, etc. But, apart from these types, there is marginal blepharitis (called also blepharitis ciliaris). This condition is frequently seen in children, particularly in strumous

children. It does not often appear before the seventh year, and may last on till puberty or later ; its results may last throughout life, long after the inflammation proper has ceased. The margins of the eyelids are red and irritable ; there is a slight degree of photophobia, but the aspect of the patient is worse than his sensations. The small pustules along the edges of the lids break down, forming tiny ulcers, which heal up, only to break down again or to reappear at another part. The occurrence of these ulcers and their cicatrisation may lead to overgrowth of the eyelashes if the condition be very slight, to irregularity in the line of them, to inversion of the lashes upon the eye, to gaps in the row, and even to almost complete destruction of them. This is typically a strumous affection, which should be treated chiefly by attention to the general health. A stimulating ointment such as that of the yellow oxide of mercury does great good ; so does ichthyol ointment (2-3 per cent), or a mild sulphur ointment. The great difficulty is to get the patient to persevere ; perhaps he has had the disease for ten years, but unless your treatment cures him in a fortnight at most he neglects or reviles it. Some surgeons believe the condition to be frequently due to Morax's bacillus, and therefore employ preparations of zinc. This is certainly not always the case, though it not infrequently is. Two further points should be attended to, viz. to see that the lachrymal apparatus is in good order, and that some error of refraction is not responsible for keeping up the trouble.

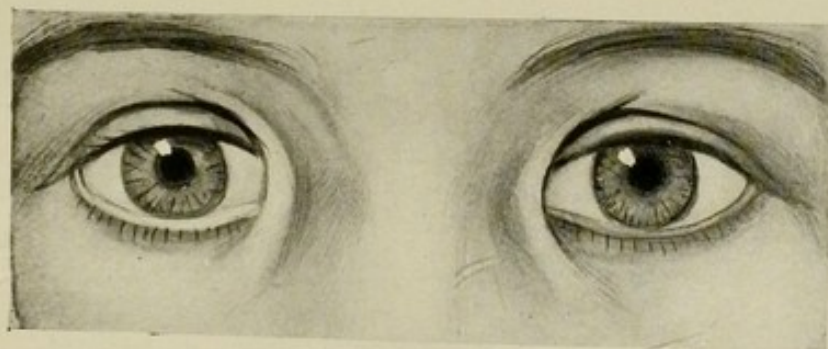
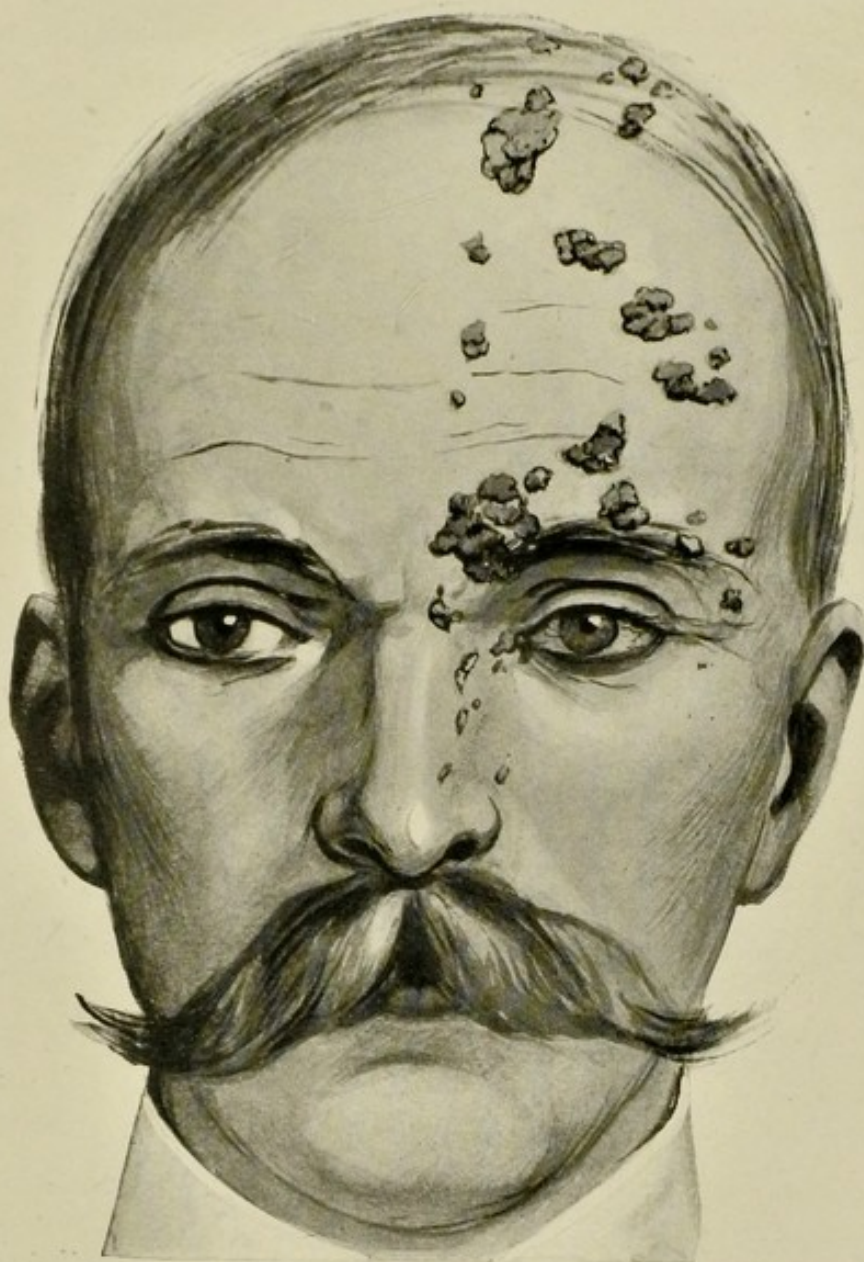
Sometimes blepharitis is a form of drug irritation. After long-continued use of atropin in a very considerable number of persons, and after one or two instillations in a few, an eczematous inflammation of the lids is apt to arise, the cause of which might not at first be obvious. If atropin be stopped and an ointment of ichthyol used, the inflammation rapidly subsides.

Iodoform, corrosive sublimate, and even boracic lotion have a similar local toxic effect in a few persons.


Inflammation of the lid margins, with consequent injury to the hair follicles, is apt to lead to four results, namely, a general overgrowth of lashes, which are long and "elegant" if the hyperæmia has been slight and persistent; stumpy, short, bristly lashes if the affection has been more severe and intermittent; misdirection of some of the lashes as the little ulcerated spots of lid margin heal and contract and so draw the eyelash out of line; and destruction of lashes. Two or more of these conditions are often fulfilled in the same eyelid, for here and there the lashes may be long and wavy, at another spot short and misdirected, and there may be gaps in the line. These faults have the inconvenience that the conjunctival sac is not so thoroughly protected from dust unless the lashes are regular; so the irritation is always kept up and the conjunctiva always inflamed. In the cases in which inversion of the eyelashes is present, this may lead to ulceration of the cornea from friction with the stumpy lashes—the condition known as trichiasis.

Persistent marginal *blepharitis* should then lead one to investigate the conjunctiva for trachoma, the margins for trichiasis, the cornea for erosion, the refraction for errors, the habits for alcohol, over-smoking, late hours, etc.

Distichiasis and *Trichiasis* are terms used to indicate respectively the existence of a duplicated row of eyelashes and a faulty position of the lashes. They are not quite the same, but are often associated. True distichiasis is a congenital anomaly, but a similar condition is often seen in trachoma where the persistent hyperæmia and irritation stimulate overgrowth of the extremely fine hair bulbs which may be situated posterior to the proper line; besides, the cicatricial contraction of the conjunctiva may lead to the drawing of the skin round the edge of



1. Herpes Ophthalmicus. 2. Epicanthus.



the lid, and so to the faulty position of a complete or partial row.

Trichiasis is one of the chief distresses of a trachoma patient, though the condition may arise under other circumstances also. In either of these conditions (distichiasis and trichiasis) the annoyance to the patient is very great, necessitating operative relief. Should there be only one or two faulty lashes, epilation is the simplest and best treatment, the hair being seized close to its root in flat-faced forceps and drawn out by a *straight* pull. If

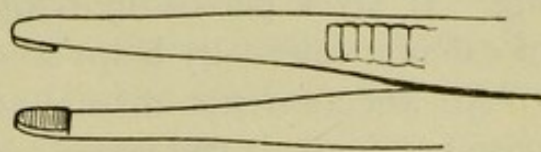


FIG. 27.—Epilation forceps.

there should be a few more, electrolysis may be employed and the offending bulbs destroyed. For this purpose the negative pole is attached to a fine needle which is passed into the follicle; the little operation is decidedly painful, even under cocain. If there are more still, a more extensive operation will be required, similar to those in use in entropion.

Tarsitis is the name fairly applicable to a more extensive and very chronic form of inflammation of the lid, not merely of the margin. The whole lid is thickened, heavy, swollen, and indolently inflamed; the patients are rather tuberculous children, and it is only very slowly that the affection yields to prolonged efforts at massage with ichthyol ointment (2-4 per cent) and internal tonics.

Hordeolum or **Stye** consists in the formation of a furuncle in one of the hair bulbs at the lid margin. Either upper or lower lid may be affected, and styes come in crops, now in one lid, now in another. The disease is a common one about puberty in either sex. It may occur in adult life too, however, and then is apt to be more painful, and to be attended with the formation of chemosis (œdema under the bulbar conjunctiva), which may cause much alarm to the patient. Local treatment should

consist in warm fomentations or even mild poulticing, but to prevent the formation of fresh styas as the result of the poultice the eyelids should be well anointed first, before each poultice, with an ointment of oxide of nitrate of mercury, and this application should be kept up even after all need for the poultice has passed away, the massage accompanying its employment having a good effect in keeping the contents of the glands from stagnating. If styas persist in returning, chloride or sulphide of calcium internally helps to check their formation.

An affection not dissimilar to hordeolum, and often mistaken for it, is **Chalazion**, or **Tarsal cyst**. One of the Meibomian ducts becomes blocked, forms a cyst by retention, and shows as a small protrusion like a pea on the eyelid, whether upper or lower. Some authorities assert that the retention is due to a preceding inflammatory change in the duct wall. At this stage the skin is entirely unaffected, for the little pea-like growth has taken its origin in a gland which lies posterior to the tarsal cartilage; on turning over the lid the surgeon will see a bluish inflamed part of the palpebral conjunctiva at the corresponding point. The cyst, now formed, is prone to be infected with septic organisms, with the result that it suppurates, discharges *via* the conjunctiva, and then dies down. After suppuration, however, there is apt to be the formation of some pouting granulations from the wall of the cyst thus laid open. The attempt has been made to assign tuberculosis as the cause of this condition, but the evidence is certainly not conclusive. A cyst may be mistaken for hordeolum, but the cyst does not affect the margin of the lid or a hair follicle, and does attack, or show upon, the mucous surface.

By way of *treatment* one may employ massage of the cyst with a slightly stimulating and antiseptic ointment such as nitrate of mercury ointment (B.P. diluted about eight times) or a weak iodine ointment; with these, if the

cyst be not too large and has not begun to suppurate, one may obtain resolution after some patience and time. A quicker, though in many cases not more successful, method is to incise the cyst, turn out its contents, and scrape the wall thoroughly with a small half-sharp spoon; the contents are somewhat pultaceous, but fairly clear. It is good to employ massage whether this be done or not, because, if blocking of the duct be the cause of the trouble, one may at least prevent others of the Meibomian ducts from becoming closed also; besides that, the thickened wall remains and takes long to soften and become reduced to normal dimensions.

When incision is decided upon the lid should be everted and the little cut made towards the lid margin; the offending duct is thus thoroughly laid open while



FIG. 28.—Spoon for destroying a tarsal cyst.

neighbouring ones are left intact, which is obviously not the case if the incision is made along the long axis of the lid. The operation, if the spoon is used with the proper degree of vigour, is somewhat painful, but an injection at the part of solution of cocain, or the introduction of a crystal or two of solid cocain, prevents it from being too severe.

When actual suppuration occurs, incision should be made and the contents, pultaceous and purulent, or pus entirely, thoroughly got rid of.

Herpes ophthalmicus (Plate I. 1) is a malady not very uncommon. The patient complains for a day or two of neuralgic pains over the area of distribution of the first division of the V. nerve, after which there suddenly appears a more or less copious crop of vesicles on the forehead and scalp as far as the jurisdiction of one V. nerve extends; more importantly for present purposes,

the vesicles form on the eyelids, down the skin of the nose on the same side, and even on the cornea. Accompanying the somewhat severe reaction which may be present if the cornea be attacked, there may be iritis, and should the cornea become secondarily infected, as it may readily enough do, the eye may suffer very severely and be left with an ugly opacity and with very indifferent vision. As far as concerns the cornea and iris, treatment is on the usual lines ; as far as concerns the skin, the best method is to keep the air and its sources of infection from the vesicles by means of a dusting powder copiously employed, or an ointment which may with advantage contain menthol and cocain. Internally, arsenic and salicin compounds are beneficial. Everything should be done to prevent scarring afterwards.

Œdema of the Lids, especially in the mornings, is always suggestive of Bright's disease, but a mild degree occurs in elderly persons from mere atony of the skin without any affection of the kidneys.

A curious affection of the lids is *Cold Œdema* ; this is a disease of whose nature little is known. It consists, as its name implies, in the development of an œdematous state of all four eyelids ; it is suggestive of erysipelas, but without redness or temperature ; it is much more copious and more permanent than the œdema which is not infrequent in cases of Bright's disease. The eyes become gradually almost closed up ; and, unfortunately, treatment, even to the removal of a "lump" of tissue, is of little permanent value. Injection of alcohol has been used with some success.

Emphysema.—Injury to certain of the bones containing the air spaces of the nose is sometimes followed by great puffing up of the eyelids, which on palpation give a peculiar crackling sensation, exactly resembling the sensation of touching a lung. This is due to the same cause, namely, the presence of air in the tissues, which

has escaped through the injured bony wall. This comes on when the patient first blows his nose after receipt of the injury. The only treatment required is to apply a firm bandage and prohibit use of the handkerchief for a couple of days.

Among the unfortunate occurrences which may befall the margin of an eyelid must be mentioned the implantation of a *Hard Chancre* and of a *Vaccine Pock*. In the one case the hard obstinate ulcer, in the other the pustular aspect, the enlarged glands under the angle of the jaw or in the præ-auricular region, according as the ulcer is at the inner or the outer portion of the lid, proclaims the nature of the lesion; but diagnosis may at first be extremely difficult.

Epithelioma and **Rodent ulcer** are prone to attack the eyelids. As in other situations where skin and mucous membrane join, so at the very margin of the eyelids conditions are favourable for the occurrence of this form of malignant disease. Epithelioma is perhaps a little more common towards the outer canthus than towards the inner, while rodent ulcer has two special seats—in the temporal region, soon making its way to the lids proper, and near the inner canthus on or close to the side of the nose. In this situation the epithelial neoplasm is not different from the type elsewhere, the dirty greyish-pink ulcer, not at first deep but persistent, with irregular, slightly-raised, hardened margins, scabbing over and breaking down again, bleeding at intervals, it may be, showing itself in a person of rather more than middle life, causing enlargement of the lymphatic glands or not according to circumstances and particularly according to its rapidity or its slowness of growth (Plate II. 4).

Of recent days surgery has received a powerful helpmeet in the X-rays and in radium, and without doubt many cases have been mitigated or cured by these means. Sometimes, however, no good is to be obtained from the

use of either of them, a great deal depending on the size of the ulcer, on the depth to which it has penetrated and the rapidity of destruction, and on the age of the patient. Should operation be required there is one great principle to guide one, namely, to cut clear of the disease; a second, but vastly less vital, rule is to cause as little deformity as possible. Where the malady has been diagnosed early, before there has been any very extensive destruction or invasion, a V-shaped incision, the open end of the V being at the lid margin, may be sufficient. It may, further, also be necessary to make an incision, as for canthoplasty, and slide the lid along so as to fill up the gap. There are numerous methods described for accomplishing this, and each case must be taken on its own merits and requirements. Skin may be borrowed from the temple, from the abundant integument of the upper lid to supply the deficiency of the lower, may be obtained by a tailed flap from the forehead, or may be brought from the arm or elsewhere to replace the lost tissue and form a new lid or lid margin. In this connection it is well to point out that grafts of the whole skin are much better suited for the face than Tiersch grafts, for the latter, containing as they do no glands, are unnaturally smooth and white, and do not present the natural velvetiness of the normal skin. Grafts of whole skin "take" very well on the face, the vascular supply being so copious. Two "dodges" are useful which might not occur to the uninitiated, namely, to unite the upper and lower eyelids temporarily by means of a stitch if the fresh graft can not otherwise be kept in good position: this stitch may be of horse-hair. Secondly, in order to avoid passing stitches through the graft, to take a long stitch of silk, and picking up a fold of healthy skin at one side of the graft, pass this through it, carry the thread across the graft to the other side, through a fold of skin there, and so on, forming with the thread a lattice-work

over the flap, the stitches being so placed as to lie across and upon the surface of the graft, keeping it in place without passing into it or in any way injuring its vitality.

Nævus of the lid is not uncommon ; its red or bluish-red appearance is characteristic ; when the child cries the area is apt to swell and assume a darker hue from the retention of venous blood. The proper methods of treatment are by means of electrolysis, radium rays, and excision, according to size and precise situation. The surgeon ought not to be too hasty about interference, however, as some disappear spontaneously as the child grows older.

Xanthelasma, or **Vitiligoidea**, occasionally gives alarm to nervous patients and distress to vain ones. It consists in the formation of a slightly-raised, irregular, yellowish patch in the skin, generally in the thin skin internal to and above the inner canthus in the angle between the root of the nose and the upper lid ; it is usually symmetrical, more or less. It does no harm, does not grow to more than unimportant size, and is quite painless, but if the patient is very desirous to have it excised, that can be done.

Molluscum contagiosum often appears in the eyelids ; there are numerous, white, slightly-raised spots, about the size of a pin-head, umbilicated, containing a minute quantity of pultaceous material. Each of the little masses should be incised, cleared out with a sharp spoon, touched with nitrate of silver, and an ointment of ammoniate (or other preparation) of mercury applied. Another method of treatment is to destroy each with a sharpened wooden match dipped in pure carbolic.

A small clear **cyst** in the skin of the eyelid is not infrequently observed ; it is of no importance, but may be emptied by a prick.

Warts of the surface and the formation of a curious horn of epithelial overgrowth are occasionally seen.

Entropion, or turning in of the lid (Plate VIII. 1), is a condition which gives rise to much trouble, for besides the mere pressure of the lid margin upon the eye the eyelashes are prone to rub upon the cornea and abrade its surface, the denuded portion being then liable to septic invasion. There are two varieties, not by any means mutually exclusive.

Cicatricial entropion occurs when some destructive process has removed a portion of conjunctiva. For example, a burn by hot lead may destroy a considerable part of the lower conjunctiva, and lead to turning in as the cicatricial process goes on ; or trachoma may have a similar effect, the shrinkage of conjunctival tissue causing the tarsal plate to bend its free margin inwards upon the globe. In attempting to relieve this condition it should always be borne in mind that it is deficiency of tissue which has caused the trouble. It is therefore wiser, whenever possible, to devote one's efforts to supplying what is lacking rather than to attempt to produce an opposing action. Transplantation of mucous membrane to the place of the lost conjunctiva is therefore a sounder procedure, from a surgical point of view, than excision of any exterior tissue. This, however, it is not always possible to avoid, because the contraction may have brought about a permanent incurving of the tarsal plate, which mere transplantation would do nothing to cure (Plate X. 1).

Spasmodic entropion is occasionally seen in babies, when it is due to an error in development, but is much more frequent in old or elderly persons, and in them the actually spasmodic element is not always very obvious. It is the lower lid which is attacked, and the occurrence is usually due to a senile laxity of the lid tissues which permits the lid to turn in and the eyelashes consequently to irritate the cornea ; then spasmodic contraction of the orbicularis naturally occurs and the

evil process is accentuated. Also if the eye be bandaged up for any length of time in an old person, the lower lid is very apt to turn in, consequently entropion is prone to occur in the practice of those surgeons who dress the eye for a considerable time after cataract operation.

Another form is a persistent *blepharospasm* which may be intermittent and due to reflex irritation, such as by bad teeth, a foreign body in the conjunctiva, annoyance of hypermetropia, or intestinal worms, or may be a feature of chorea, or may be constant and form a feature of photophobia in association with ulcer of the cornea.

Treatment.—It is sometimes sufficient to remove any dressing and encourage the patient to stroke the lid gently with the finger, pressing very gently at the lower limit of the cartilage, and to refrain from “blinking.” In other cases the application of a strip of plaster to draw down the lid, or of collodion, suffices. In a large number of the cases, however, operation is indicated. Removal of a strip of skin from the lower lid is apt to have but little permanency, though a certain degree of immediate improvement may be obtained. The old persons in whom the trouble occurs are, it should be remembered, likely to have lax tissues but not superfluous tissue; often enough they can, therefore, ill spare a strip of skin sufficiently wide to secure a good immediate effect. It is better to dissect up the skin and remove a strip of orbicularis rather than any skin. The old-fashioned Graefe method (p. 428) is a very good one. Gailliard’s stitches (p. 427) are sometimes very effective. Best of all, perhaps, is to make an incision along the length of the lid right down to the tarsal cartilage, and apply the cautery firmly but lightly to the depths of the wound and to the two “faces” of tissue. That persistent contractivity which is so characteristic of wounds by burning is thus enlisted on the side of cure. The immediate effect, in consequence of the complete division

of the tissues, is to intensify the entropion ; after a few days cicatricial contraction begins and the lid turns gradually out.

Ectropion, or turning out of the lid margins, is not uncommon ; it proclaims itself by its appearance. Here again there may be a spasmodic element, but this can only come into play after the lid has adopted a position of eversion, when contraction of the orbicularis can be seen to cause still further eversion of the everted lids.

We have to do with a propulsive form, in which the lid margins become everted on account of a hyperæmia of the conjunctiva pushing out the lid margin mechanically. This has the effect of pushing the punctum lachrymale out of place, and this structure can pick up the tears only when it is in contact with the moist conjunctiva. When the punctum is not acting properly the tears run over the lid margin and down the skin of the face, in which an eczematous condition is set up after a time, the skin becomes reddened, excoriated, and then contracts, drawing the lid margin farther away from the globe and accentuating the eversion (Plate IV. 3).

Of this type of ectropion, in which the main element is thickening of the mucous membrane, the chief treatment must consist in reducing this and thus allowing the lid to return to its normal relation to the globe. This may be accomplished by means of astringents, such as zinc, nitrate of silver, and tannic acid, or adrenalin. When there is decided *epiphora* (escape of tears over the cheek) cure is hastened by slitting up the lower canaliculus in such a manner that the lachrymal secretion can escape *via* the gutter thus made. The cautery applied deeply to the conjunctival surface is very effective in this form, just as it is successful when applied to the skin in entropion. Here again the trench should be deep, but narrow.

There is, next, the form of ectropion in which the

faulty position is brought about by the contraction of a cicatrix. Of these the commonest are caused by wounds or burns on the cheek, or by bone disease in that situation, and by lupus. The contracting cicatrix draws to itself from all directions, and as the lid has a free margin the effect is very noticeable there. The disease may affect either the upper lid or the lower; the latter is the more often attacked, but sometimes as the result of lupus or of a burn or of sinus trouble, etc., the upper lid is completely everted; when that is the case contraction of the orbicularis tends still more to evert the lid. But there is also a much milder variety of ectropion to be found in old persons whose whole lid tissue has become lax, allowing the lid to hang down, not keeping closely applied to the eye, and consequently permitting copious lachrymation. The bleary, watering eye of old age is due to a slight degree of senile ectropion.

Three **congenital abnormalities** of the lids require mention:—

(a) *Cryptophthalmos* is the term used when the lids have no separation at all, but are congenitally completely united over what is probably a minute and undeveloped globe.

(b) *Coloboma*, or cleft in the lid, appears as a deficiency in the margin of the lid in its inner third, or about the junction of the inner and middle thirds.


(c) *Epicanthus* is the name given to a fold of skin which covers over the inner angle of the lids and presents towards the outer side a concave or nearly straight margin. A minor degree is very common in children one of whose parents has a high bridge to the nose, and whom the child will in after years resemble (Plate I. 2). It is seldom that the deformity reaches dimensions sufficient to call for operation; if it should, a central ellipse of skin may be removed, giving a central linear scar, or a small piece of the redundant skin may be removed from each side of the nose.

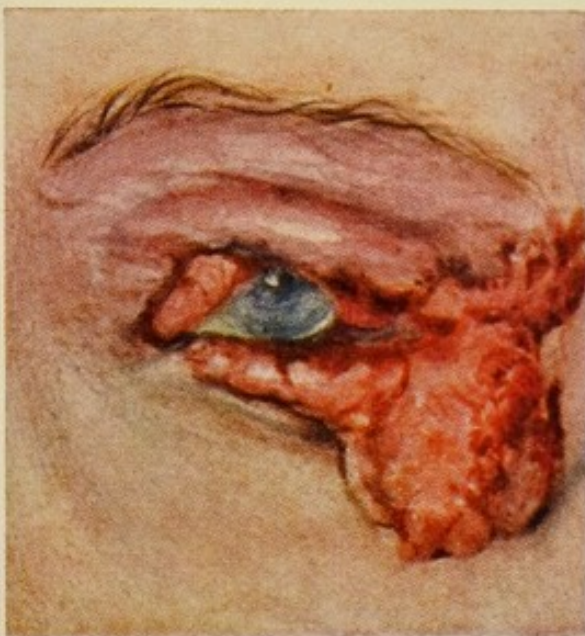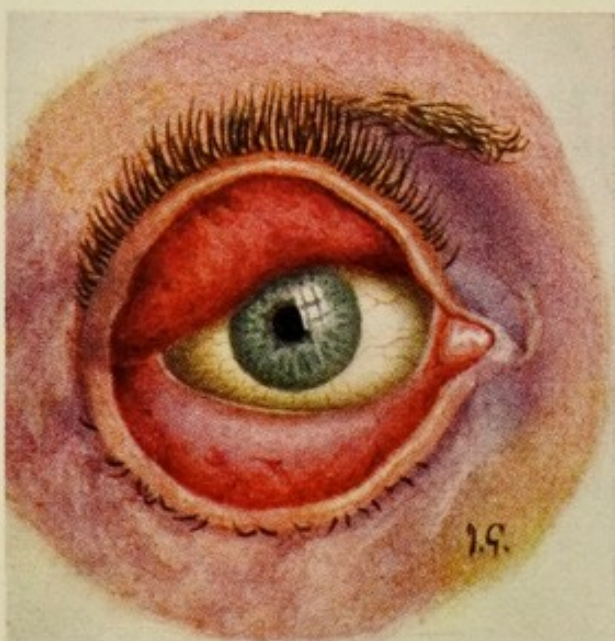
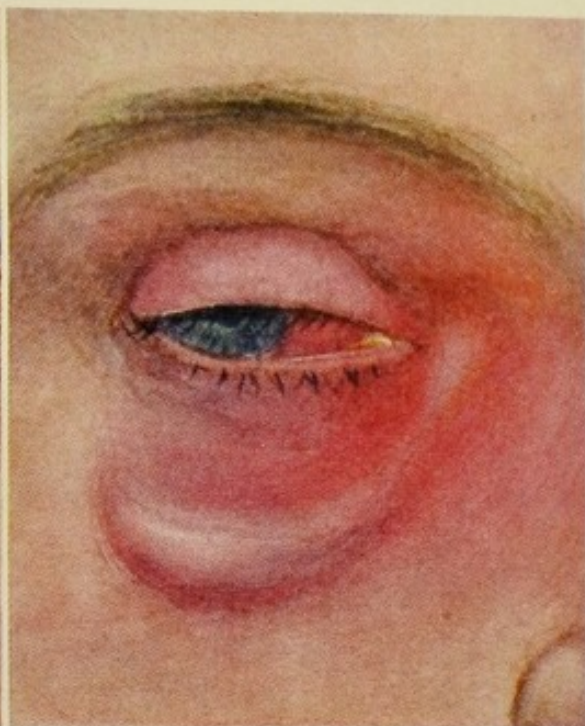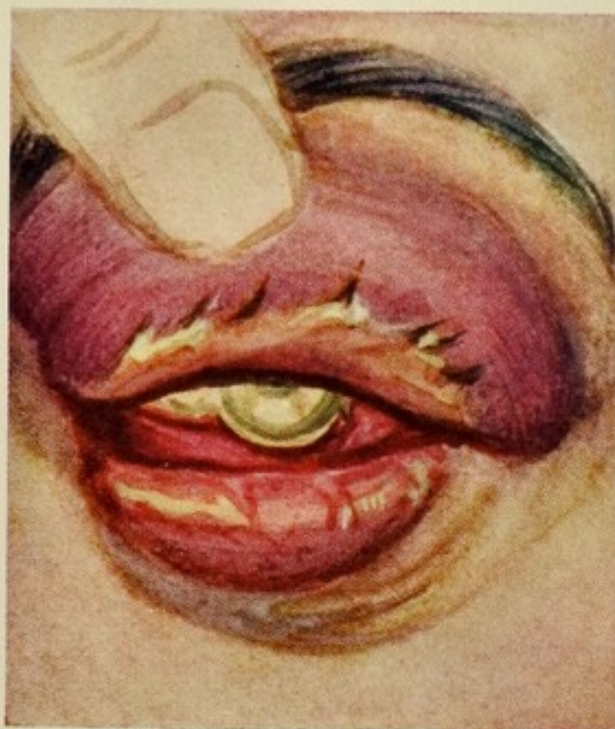Of faults in the motor apparatus of the eyelids (besides paralysis and spasm of the orbicularis above mentioned) there are several which require mention in this place.

Ptosis is the name given to the falling of the upper lid below its proper level ; it is produced by paralysis of the levator of the lid. There falls to be mentioned here, however, that there may be a false ptosis as well as a real. Thus, during, and in many instances for long time subsequent to, a prolonged attack of superficial keratitis the patient voluntarily keeps the upper eyelid low down over the eye in order to protect it from light, and this becomes so much a habit that it is difficult to relax, difficult to get the lid to occupy its proper position again ; it still hangs down, but that is not a real ptosis. Further, in cases of trachoma there is an added reason for this false ptosis, for the lid surface is rough and harsh, and the patient is unwilling to raise it any more than he can avoid. And still further, the infiltration of all the tissues of the lid incident to the pathological process of trachoma interferes with the action of the levator directly and increases the inability to raise the lid (Plate IV. 2).

True ptosis may be congenital, may be a definitely paralytic occurrence later in life, or may be senile ; it may be unilateral or bilateral.

Congenital ptosis may be present on one side or, more usually, on both ; it is sometimes found in several members of the same family. It may exist by itself or may be associated with other motor faults ; in particular it is common to find that the patient, even when the eyelid is lifted mechanically with the finger, is unable to direct the eye or eyes upwards ; there is, in fact, a congenital paralysis, or absence, of the apparatus of upward movement of lid and globe. In such a case it is impossible to assume that the fault is other than central in situation. Whether, when the other movements are free, the fault is central or the immobility due to non-





1. Panophthalmitis.

2. Cicatricial Ectropion, secondary to Lupus.

3. Acute Dacryocystitis.

4. Epithelioma, beginning at lid margin.

development of the muscle, is not easy to determine. The patient with congenital ptosis carries his head thrown back as far as possible in order to be able to see out below the lids, and for such elevation as he can accomplish he is dependent upon the occipito-frontalis ; this is shown by the wrinkling of the brow and the elevation of the eyebrow, and by the complete inability to effect any change in the position of the lid if the examiner's hand be placed firmly on the brow and the patient then endeavours to look up.

There is a curious class of cases in which the patient elevates the upper lid only when moving the jaw (*jaw-winking phenomenon*). This must be due to some error in the "coupling up" of the nerve-supply to the various muscles.

Paralysis occurring later in life may or may not be associated with paralysis of certain other or of all the other muscles supplied by the III. nerve. This may be unilateral or bilateral, and is probably due either to syphilis or to some exudation or new growth at the base of the brain, or to locomotor ataxia. It may also be part of ophthalmoplegia, whether complete or incomplete, which in the child is usually tuberculous and in the adult syphilitic (Plate XXI. 2).

Senile ptosis is quite a marked and definite occurrence in old age ; but in advanced years a slight degree of ptosis is usual from absorption of the orbital fat and sinking of the globe into the socket. Senile ptosis hardly lends itself to successful treatment.

CHAPTER IV

THE CONJUNCTIVA

THE conjunctiva is a modification of the integument, adapted to the peculiar conditions which prevail in the circumstances. It consists of a fine membrane, varying in thickness in different parts, and forming, when the lids are shut, a closed sac. The conjunctiva of the lids, or palpebral portion, is firmly attached to the other structures, is somewhat red and vascular, and is of absolute smoothness, so that the friction of the globe under the normal lid is reduced to *nil*; the lax portion which passes from the attached margin of the tarsus of the upper and lower eyelids to the globe itself is, especially in the case of the upper eyelid, thrown into numerous folds containing many mucous glands. This retrotarsal fold is necessarily very loose, that the movements of the globe may be unfettered, and it is about the fornix, or actual "arch of transition," that the vessels which are concerned in its nutrition for the most part enter the conjunctiva. The third, or ocular, portion is by contrast almost non-vascular, containing in health but few vessels and practically no glandular structures; it is firmly, but not closely, attached to the sclerotic, sliding over it easily at a touch. At the outer canthus there is a shallow cul-de-sac, but at the inner side the membrane ends in a semilunar fold and the *Caruncle*, a small fleshy elevation which con-

tains a few glands and some fine downy hairs. The conjunctiva does not end, properly speaking, at the edge of the cornea, rather it changes character and continues as the squamous epithelium of the cornea. The great vascularity of the conjunctiva and its constant exposure to the air, with all that that implies, render it very liable to attacks of inflammation.

It is, many times, useful to be able to come to a more or less immediate conclusion as to the presence of certain *organisms in the conjunctiva*, either in the course of examination of a case of conjunctivitis or in preparation for a serious operation such as extraction of cataract. It is generally, but not always, sufficient for this purpose to stain and examine a smear preparation. Here one can give only the barest outline of procedure. To collect a morsel of the secretion, sweep the lower fornix with a sterile platinum loop, paying special attention to the inner canthus, for it is here, just by the caruncle, that secretion can, if anywhere, be obtained. Great care must be taken that the lid margins and the skin have no chance to contaminate the little flocculent mass, which is spread out on a slide, dried in the air, and passed three times through a flame to fix it. For a simple aniline stain Axenfeld recommends Löffler's methylene blue and dilute carbol fuchsin, also thionin, and of course Gram. He gives a very convenient list of the organisms most usually found in ophthalmic work in two groups:

Those staining **positive** are sarcinae, staphylococci, streptococci, pneumococci, bacilli of the diphtheria and subtilis groups, bacillus perfringens of Chaillous, aspergillus fumigatus, streptothrix, and actinomyces.

Those staining **negative** are bacillus of Koch-Weeks, diplococcus of Morax-Axenfeld and of Petit, the coli group, gonococcus, meningococcus, micrococcus catarrhalis, bacillus pyocyaneus, and Friedländer's pneumobacillus (Plate III.).

DISEASES OF THE CONJUNCTIVA

1. INFLAMMATION.—Conjunctivitis takes a number of different forms, but the chief general characteristics are scarlet injection, sticky secretion, and smarting pain.

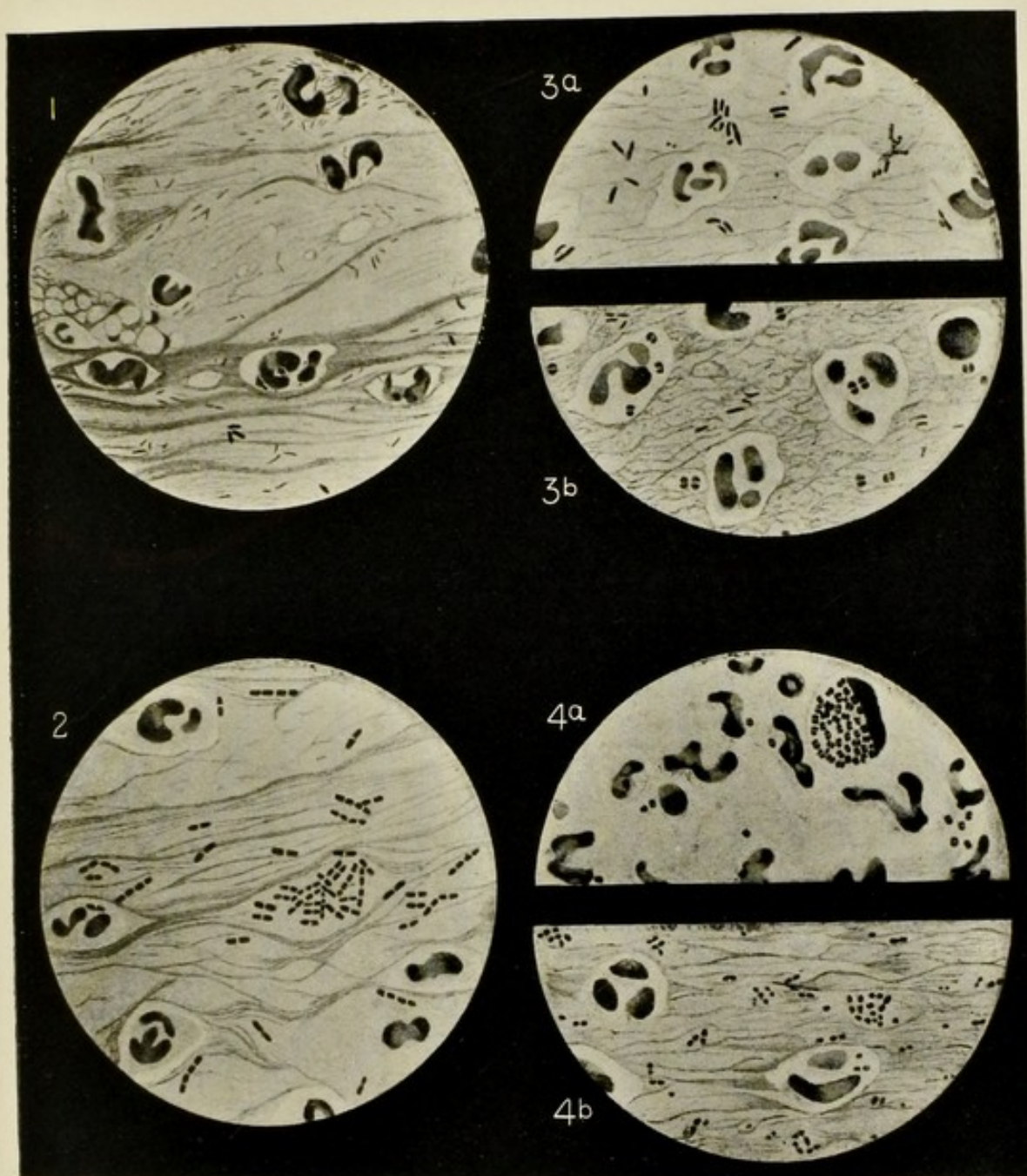
Scarlet *injection*: the vessels are large, tortuous, branching, most numerous towards the cul-de-sac; they are movable over the sclera and capable of being emptied on gentle pressure.

The *secretion* is sticky since it comes from a mucous surface; it glues eyelids and lashes together in the mornings unless it be too copious and too purulent; it forms a little collection at the inner canthus. Inflammation of cornea or of iris could not produce a sticky secretion, because these are not mucous surfaces.

The *pain* is usually described as smarting, scalding, itching, or slightly burning, as of a foreign body in the eye. It is worse in the evening, in artificial light, on use of the eyes, in smoky rooms, etc.


It is convenient to classify conjunctivitis provisionally on a bacteriological basis, but it must be clearly understood that the clinical appearances are not always the same for a certain organism, and that one form of organism may produce very different clinical appearances in different individuals.

(a) **Koch - Weeks Conjunctivitis.** — The causative organism is a very minute bacillus first described by Koch in Egypt, and later by Weeks in New York. This is the typical Catarrhal or acute Muco-purulent Conjunctivitis of the older authors. It is very contagious, so that both eyes are generally attacked, and the disease runs rapidly through a family, school, etc. The contagion is always by direct contact with infected fingers, or such articles as towels, handkerchiefs, etc.; it cannot be carried by the air, for drying quickly destroys the organism. The skin of the lids is reddened and a little



From Axenfeld's *Bakteriologie des Auges*.

- | | |
|---|-------------------------------------|
| 1. Koch-Weeks bacillus. | 3b. Xerosis bacillus with sarcinae. |
| 2. Morax-Axenfeld diplobacillus. | 4a. Gonococcus. |
| 3a. Diphtheria bacillus (short form) with streptococci. | 4b. Pneumococcus. |



swollen; their margins are red; the lashes and lids are glued together in the morning; the discharge lies in little hardened cakes at the inner canthus; the whole globe is covered with a scarlet injection. There is a little photophobia; in the child there is usually not much pain, but adults suffer more severely; the disease is self-limited, and in a good number of cases spontaneous recovery takes place in a few days to a couple of weeks; it never becomes chronic (Plate IV. 1).

Treatment consists in absolute cleanliness; the secretion must be frequently bathed away with a bland and mildly antiseptic lotion. Boracic (gr. iv. - \bar{z} i.), corrosive sublimate (1-6000), formalin (1-3000), and permanganate of potash (1-2000) are all useful. An antiseptic ointment serves the double purpose of preventing the gluing of the lids and of keeping up the antiseptic action of the lotion; for this purpose iodoform (gr. x. - \bar{z} ss.) and corrosive sublimate (1-10,000) are useful also. Diluted lanoline is preferable to vaseline as a base for the ointment.

(b) **Diplo-bacillary Conjunctivitis**, the form associated with the organism described by Morax and Axenfeld (Plate V. 2).—In this the injection is almost limited to the lid margins, and in particular to the inner and outer canthus, so much so that this particular form used sometimes to be described as Angular Conjunctivitis. There is little secretion, so little that it is occasionally difficult to obtain any for smear examination; the eyes feel hot and dry and uneasy, especially in artificial light, and are readily irritated by wind, smoke, etc. This form is comparatively rarely seen with us as an acute variety; there are great differences in this matter in different localities; on the other hand it is extremely chronic, because it is not a self-limited disease, but may continue for months or years uncured, now bad, now less severe, but never going away altogether. It is also very

insusceptible to treatment by the ordinary antiseptic lotions such as boracic and corrosive sublimate, but yields, however, very readily to treatment with zinc, which may be used in the form either of the sulphate in solution or of the oxide in ointment. Just because it is so chronic and so resistant, cases appear comparatively frequent.

(c) **Pneumococcus Conjunctivitis** is not, perhaps, so well defined in its aspect as either of the forms previously mentioned. The cases resemble pretty closely those of the Koch-Weeks variety, with the addition that small petechial hæmorrhages are frequent in the ocular mucous membrane. It is not suggested that this is pathognomonic of the presence of the pneumococcus; hæmorrhages may and do occur in other forms, but more constantly in this (Plate V. 1). The organism may be present, and indeed not seldom is, in conjunctivæ which exhibit little or nothing in the way of injection, etc., perhaps only a slight chronic hyperæmia. As treatment, perchloride lotion, formalin, permanganate are all useful, with iodoform ointment; sulphate of zinc is of good service also. Cases occur more rarely in which the only organisms found may be streptococci, staphylococci, bacterium coli, etc.; these are not known to possess any characteristic clinical features.

(d) **Purulent Conjunctivitis** is met with under two conditions, in the infant and in the adult.

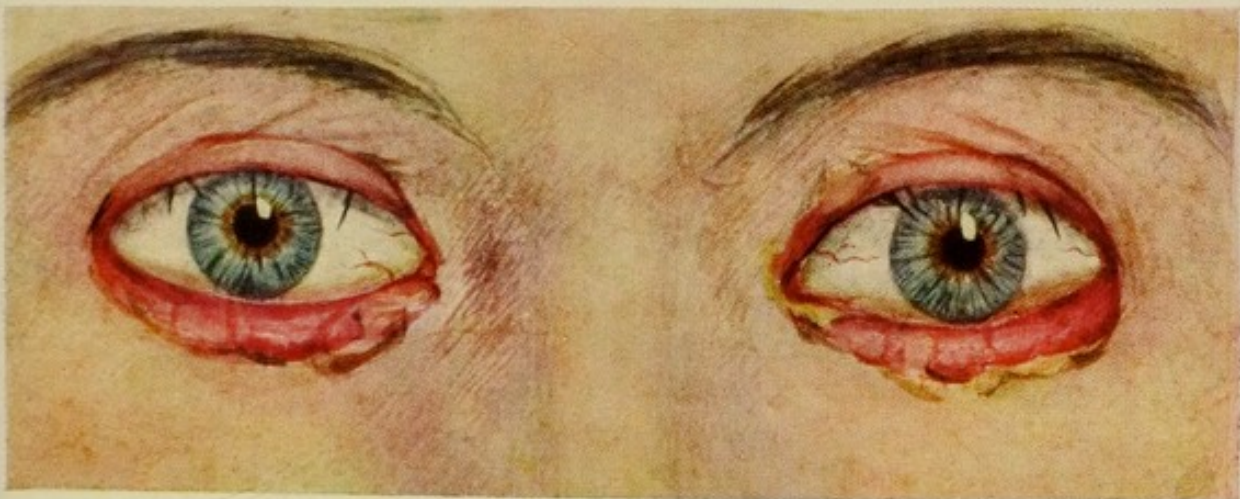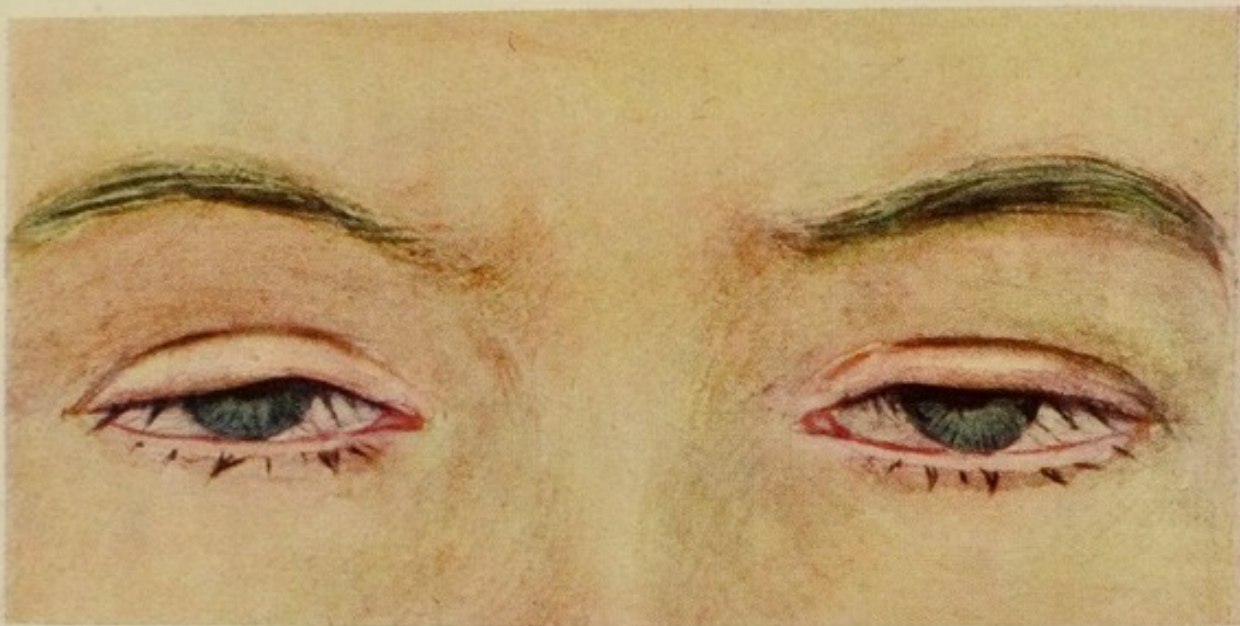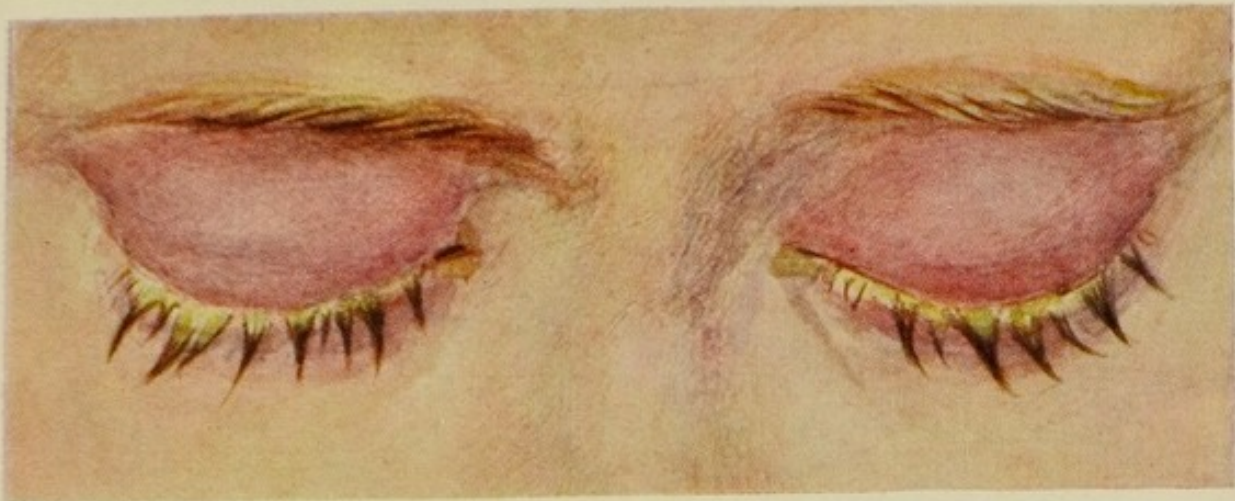(1) In the *infant* it appears from the third to the fifth day after birth, and is therefore spoken of as Ophthalmia Neonatorum; it has been a dreadful scourge in this and other countries in former days, and is even yet far from extinct among us, but is certainly less frequent than once it was. It has been calculated that this disease accounts for the presence in blind asylums of one-third to one-half of all the persons living in them, so destructive of sight is it. The name *Ophthalmia Neonatorum* has

been found fault with as archaic and not indicative of the precise pathological condition, but it is quite correctly descriptive in that the damage done is not limited to the conjunctiva, but extends to cornea, iris, and lens.


A few days after birth the infant's eyes are noticed to be slightly reddened, and a thin serous discharge is observed to be coming from them. Within a day the discharge has become purulent, the eyelids are swollen, thickened, bulging, red or purplish according to the degree of congestion, glazed on the surface, hard, almost incapable of being opened by the finger of the surgeon, while from between them escapes a copious purulent discharge. When the surgeon does succeed in getting the lids apart he finds the bulbar conjunctiva thickened also, swollen, livid or bright red, and often lifted up off the surface of the sclera by serous exudate—the condition known as *chemosis*. Should no other structure become involved, the discharge becomes less after some few days, the lids become softer and less swollen, and gradually all may return to normal again. Unfortunately, however, the cornea is exposed to very great danger and may suffer badly. When he opens the eyelids the surgeon should direct his attention specially to the cornea, watchful lest he see indications of mischief, which may occur in three forms: (*a*) a central clear ulcer; this is not always easy to see, but the altered and distorted reflection of the window-frame as seen reflected in the cornea will attract his attention. A superficial abrasion of the cornea such as this is almost certain to become infected with the organisms present in the conjunctival sac and lead to more serious destruction of tissue. (*b*) A central, infiltrated, semi-opaque area about the centre of the cornea without ulceration; this part of the cornea is in great danger of sloughing or melting away. (*c*) A more peripheral ulceration of cornea in the form of a furrow or crescentic

"ditch" involving a considerable part of the circumference. The explanation of these various forms of danger to the cornea may be given thus. The *first* is due to the macerating influence of the purulent discharge loosening and detaching the corneal epithelium; immediately that that has happened the organisms will invade the now unprotected corneal substance. The *second* is due largely to the interference with the nutrition of the more central parts of the cornea from the pressure of the chemosed bulbar conjunctiva, and of the hard thickened lids, upon the ciliary zone of vessels; these are situated just outside the corneo-scleral junction, and their vascular loops form the sole source of nutrient substances for the central region of the cornea; continued and severe pressure in that situation may bring about sloughing of the whole pupillary area of the cornea. The *third* danger to the cornea, the peripheral ulcer, takes its origin from the chemosis; when the conjunctiva is lifted off the globe by serum the loose fold lies upon the corneal margin; underneath this flap pus, organisms, and toxins accumulate, poisoning and macerating the epithelium, and permitting thus the entrance of injurious influences into the tissue itself.

It is the cornea which is the danger-point, by what way so ever it may be attacked, for if the "purulent conjunctivitis" cannot be prevented from becoming an "ophthalmia" the eye may be lost; if the cornea is preserved all is preserved, for however severe the inflammation of the conjunctiva may appear, it (the conjunctiva) never receives any permanent damage whatever, save in an extremely small proportion of cases. The possible *results* in a case of ophthalmia neonatorum may thus be considered. (1) Complete cure; the ulcer of cornea, should one ever form at all, heals up without perforation, the pus formation by the conjunctiva ceases gradually, the little patient begins once more to open the



1. Mucopurulent Conjunctivitis.
2. Trachoma : aspect of patient.
3. Marginal Blepharitis with Ectropion.



eyes and to look about him, and finally every part of the eye returns to its normal condition. (2) An opaque patch in the cornea remains permanently. Provided perforation has never occurred, it is really wonderful to how great a degree restitution of transparency may result, but an opaque patch (*leucoma* or *nebula*) may be left behind. This question of the clearing up of opacities in the cornea will be considered later under the head of the Cornea, p. 131. (3) Not only may an opaque area remain in the cornea, showing that perforation has taken place, but to this leucoma the iris may be attached, and indeed the two may be to some extent incorporated in the resulting scar. This is spoken of as *leucoma adhærens*. (4) There has been a perforation, and the scar tissue which is formed to supply the place of the sloughed-out corneal tissue is not sufficiently firm to resist successfully the intra-ocular pressure (which from a variety of causes may be increased) and now protrudes, forming a *staphyloma anticum* or *staphyloma of the cornea*. This staphyloma may be partial or complete; it may affect only a portion of the cornea, that is to say, or it may extend over its whole surface. In any case the amount of vision preserved is very poor and may be *nil*; the patient may by and by be able to count fingers at a few feet away or may be left with the barest perception of light. (5) If the loss of substance on the part of the cornea has been so severe as to permit of the escape of the lens from the eye, a probable result will be that the globe will become quite atrophic and shrunk; the "cornea" all dead-white with its surface epithelium degenerated and perhaps calcareous; perhaps with a few vessels straggling over it. (6) Occasionally it happens that the cornea clears up entirely or partially, but a small intensely white point of opacity is left on the anterior face of the lens—*anterior polar cataract*. (7) Along with this result, or even without it, *nystagmus* (see

p. 334) may remain, but only if the disease has more or less injured the sight of both eyes.

It should be mentioned here that it is an error, though a very common one, to assume that every case of ophthalmia neonatorum is due necessarily to the gonococcus; some 60 per cent or more have been shown to be, but various organisms other than the gonococcus are without doubt capable of producing, in the delicate tissues of the infant, a reaction similar to that just described. It is therefore an error, against which the general practitioner should be specially warned, to assume that the parents of such a child must have contracted gonorrhœa—an error which might lead to very serious consequences were expression given to it. Recently the opinion has been put forward that some of the cases are examples of trachoma, modified by existing in the infant, or some affection closely allied to trachoma (see p. 111).

Prophylaxis.—The leader in this matter was Credé of Leipzig, who reduced his percentage of incidence from 10.8 to 0.2 by means of nitrate of silver, and this remains the best method so far. The employment of nitrate of silver in every case of childbirth might, no doubt, prevent purulent conjunctivitis, but other points of view from which the matter might be regarded must also not be lost sight of, and on the whole it is best to say that in any case in which the physician has the smallest suspicion that vaginitis has been present nitrate of silver (gr. i.- $\frac{3}{4}$ ss.) should certainly be dropped into the eyes; there will follow a slight hyperæmia, but no genuine ophthalmia. In every case the rule should be: the baby's face to be wiped with dry absorbent cotton before any lotion or water is applied to the face at all, for it seems to be the case that until the vernix caseosa has been removed the eyes are perfectly safe, and the water with which the infant's face has been washed has

actually been the means of conveying the infection to the eye.

Treatment.—Perhaps the most important step of all in the treatment is to keep the eye as free as possible from the presence of pus. With a view to this the eyes should be washed frequently, even as often, if need be, as every hour, with a bland antiseptic lotion. There is no antiseptic which is absolutely bland, but permanganate solution comes nearer to the description than any other; boracic, gr. iv.- $\bar{3}$ i., will answer well also, or perchloride 1-6000. The discharge must be prevented, too, from caking and thus gumming the lids together, the effect of which would be to keep the conjunctiva soaked in pus; for this purpose it is well to keep the edges of the eyelids smeared with an ointment, which should at the least be capable of remaining aseptic, even if it have no great antiseptic power; iodoform ointment or one made with corrosive sublimate answers well. In addition it is necessary to apply from time to time a more powerful antiseptic to the conjunctiva, and this is best accomplished by painting the everted lids with nitrate of silver solution (gr. x.- $\bar{3}$ i.) every two days, or even every day. Recently, in consequence of the great activity in the manufacture of colloid preparations of silver by enterprising chemists, there has been much laudation of this or that preparation, but there is none of the organic salts which possesses the efficiency of the nitrate, one of the most active and powerful antiseptics we possess. When everting the lid for the purpose of painting the conjunctiva it is not necessary to do more than to draw upon the skin of the lid by means of a finger placed on the lower orbital margin, or to give the slightest push to the upper margin of the tarsal cartilage, when the corresponding lid will evert to a sufficient degree only too easily. If, when applying the nitrate of silver, one employs a camel's-hair pencil or a dressed probe, it is quite un-

necessary to neutralise with salt solution afterwards ; the abundant tears render any further addition of chloride of sodium (to throw down the silver by double decomposition) quite needless, but if actual drops of solution are applied, it is wiser to neutralise at once. If there should be serious difficulty in obtaining a view of the cornea, the surgeon must on no account use the smallest vehemence lest he rupture the thin base of an ulcer, an accident which may only too readily occur. To avoid any risk he should employ an elevator (Desmarres's pattern is the best)—an instrument with which the eyelids can be opened without pressure on the globe, and therefore without danger. A point of great importance in opening the eyes is to make sure that one is one's self

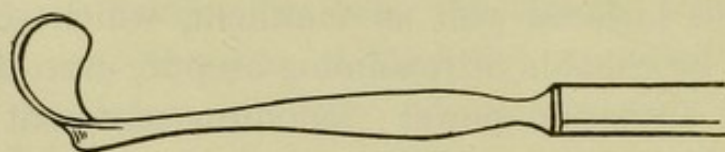


FIG. 29.—Desmarres's elevator.

protected should the cornea unfortunately give way ; for this reason also no pressure whatever should be exerted upon the globe, and the nurse or surgeon should not bend too closely over the patient and should wear glasses lest a spurt of the highly infective pus should reach his own eye.

(2) Dangerous as *purulent ophthalmia* is in infancy, it is much worse *in the adult*. It is difficult to say what the incubation period may be, for the moment of infection is usually quite unknown, but for obvious reasons the disease is to be found almost exclusively in young men, and it begins in the right eye. In some way or other a young man affected with gonorrhœa in a subacute or chronic stage infects his eye, whether by direct contamination with the fingers or not, and acute inflammation of the eye begins. For the first day or so there is little to be noticed but a certain degree of oedematous swelling

of the eyelids, some redness, and the discharge of a thin and perhaps blood-stained fluid ; but in a very short time the eye begins to discharge pus, in which myriads of gonococci may be found, the swelling of eyelids becomes much more severe, and marked constitutional disturbance manifests itself. So tense is the swollen lid that not a fold or wrinkle is seen in it ; it passes in one sweep from above the eyebrow to below the globe, livid, tense, board-like. The condition of the lids makes it very difficult or impossible to open the eye, but if this can be accomplished at all, the vessels on the globe will be found to show evidence of severe compression. The same dangers which menace the eye in the infant are enhanced in the firmer and less yielding tissues of the adult. The constitutional disturbance is often severe, and between this and the anxiety regarding his sight the patient is often in a pitiable state.

Treatment is in general terms similar to that employed for the infant, but with certain modifications. In the infant it is idle to expect to confine the disease to one eye ; in the adult every effort ought to be made to secure this. Besides warning the patient of the extreme danger of any carelessness in the matter of handkerchiefs, towels, fingers, etc., we ought to make a more determined and definite attempt to localise the disease to one eye by isolating the good eye. The best method of accomplishing this was introduced by Buller of Montreal, and is thus carried out. Take two rectangular pieces of adhesive plaster, one a little larger than the other, and near the centre of each cut a circular aperture. Apply

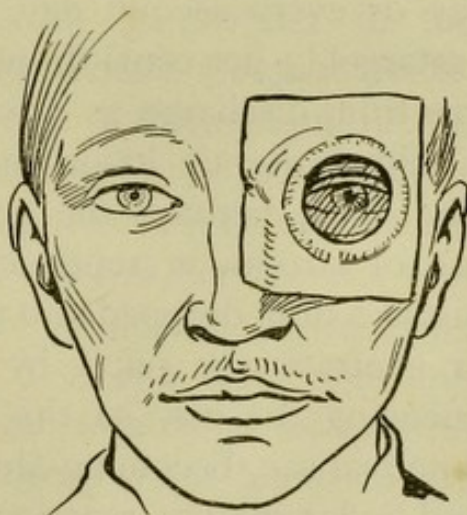


FIG. 30.—Buller's shield.

the larger piece to a watch-glass in such a manner that the margins of the aperture adhere firmly all round to the convex surface of the glass; then apply the smaller piece to the other side so that between them the glass is firmly held, while the smaller piece adheres to the larger right up to their margins on two of the four sides. There will thus be left exposed two contiguous marginal strips of the adhesive side of the plaster half an inch or so wide. These are to be made to adhere to the eyebrow and bridge of nose so that the *sound* eye is covered by the watch-glass. The lower and outer margins are left free for ventilation purposes, to prevent the glass becoming obscured by moisture. The condition of the healthy eye can thus be kept under constant supervision, the patient can see to get about, and the eye is not kept in a close, moist cell. The patient should be ordered to sleep upon his affected side in order that pus may not trickle over the nose to the other eye. The affected eye should be painted with nitrate of silver solution every day or every second day, and on the intervening days protargol (3 per cent) dropped in, the conjunctiva kept as free from discharge as possible by frequent bathing with a mild antiseptic lotion, and atropin should be instilled. The chief, perhaps the only, advantage gained by the use of atropin in septic conjunctivitis lies in this, that just as a drug dropped into the conjunctival sac may dilate or contract the pupil by becoming absorbed and influencing the iris, so the abundant toxins in the conjunctival sac, becoming absorbed, may set up congestion and inflammatory reaction in the iris; atropin, then, tends to prevent an attack and its worst results.

Whether the use of a gonorrhœal vaccine is going to prove really serviceable in cases of ophthalmia is not yet quite certain; the experiences of different surgeons are by no means uniform.

In gonorrhœal conjunctivitis in the adult one is

obliged to depend much less upon painting and lotions and more upon the antiphlogistic and antiseptic action of ointment than in the case of the infant; the patient also needs vigorous tonic treatment.

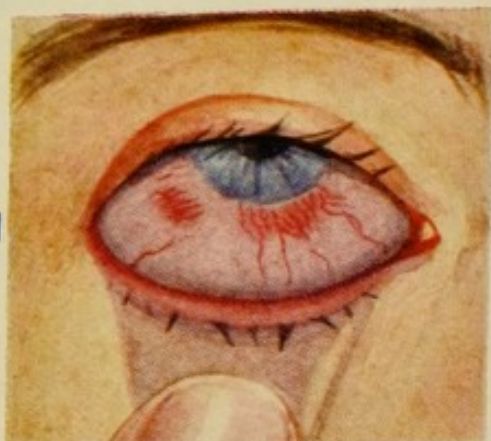The violence of the inflammation generally abates, even in the bad cases, as soon as perforation of the cornea has occurred, and in a case in which rupture is really imminent it may perhaps be good practice to puncture either through the base of the ulcer or elsewhere, but the point is doubtful and opinions are divided. Since the extreme pressure of the hard, swollen lids and of the chemosed conjunctiva is one chief cause of danger, it may be advisable to snip the chemosed conjunctiva or to slit open the outer canthus (see Canthoplasty) without sewing up the incision. Here, again, opinions differ, and the step should certainly not be taken unless it is clear that it is really the pressure which in the particular case in hand is the source of danger.

(e) It is necessary to mention a further connection which the conjunctiva has with gonorrhœa in the occurrence of **Metastatic Gonorrhœal Conjunctivitis**. This is a rare form of recurrent inflammation of the conjunctiva, with little discharge, with a moderate amount of pain, and with a slight tendency to invasion of the periphery of the cornea, which is found along with gonorrhœal rheumatism, the two conditions often varying together in the same patient. It is not dangerous, and generally yields to simple local treatment along with iodides internally. The gonococcus is not found in the discharge.

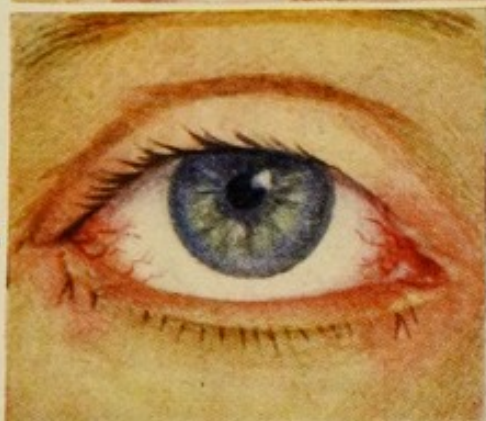(f) **Granular Conjunctivitis** or **Trachoma** is a disease of the conjunctiva which illustrates better than any other eye disease the influence of racial, climatic, and social distinctions. Its history is very singular, and as regards Western Europe might almost be said to have begun with the Napoleonic wars, for it was made a widespread

and frequent disease, though not really introduced, as some have mistakenly said, on the scattering of Napoleon's soldiers over Europe and the return of the British sailors after the great Corsican's Egyptian campaign. As regards this country at the present day it may be said to be a somewhat rare disease (very rare in the east of Scotland), at least in the indigenous population. In Ireland, however, it is vastly more common, and this is to some extent true of the associated Celtic populations of North-Western Scotland and of Wales. It is very common in the Jewish race, which, like the Irish, suffer from the affection in every quarter of the globe; it is very common in the Poles and the Mongolian race, but extremely rare, almost unknown, in the Negro, save in the North African. In countries which are partly low-lying and partly very elevated it is more frequent on the low ground, rare at the higher altitudes. In almost all countries in which it exists it attacks the lower classes to a much greater degree than those in more easy circumstances, but in certain parts of Egypt it is so excessively common that 92 per cent of the boys in the upper-class schools are stated to be affected by it; in such a region it cannot be much more common among the poor.

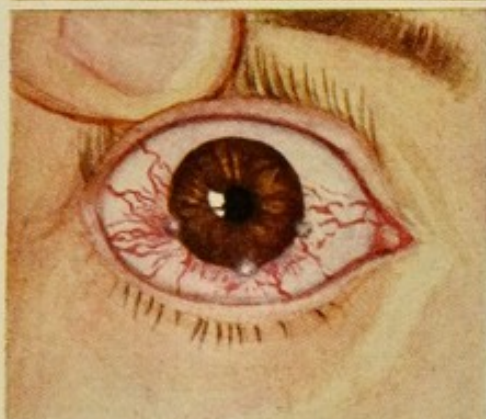The etiology of trachoma is not yet quite elucidated. That it is contagious, though not very readily so, is unquestionable, a fact which at once suggests a living or organismal prime cause, but so far no organism has been "found guilty." In the old-standing cases certainly the organisms found are merely accessory, whether before or after the fact, but not the cause; none is found with any regularity which is capable of producing the disease, though at one time or another many have been suspected, including even the gonococcus (see in this relation *Ophthalmia Neonatorum*). Of recent years, however, certain objects, of what precise nature is still unknown, have been found in the cells and extracellularly which



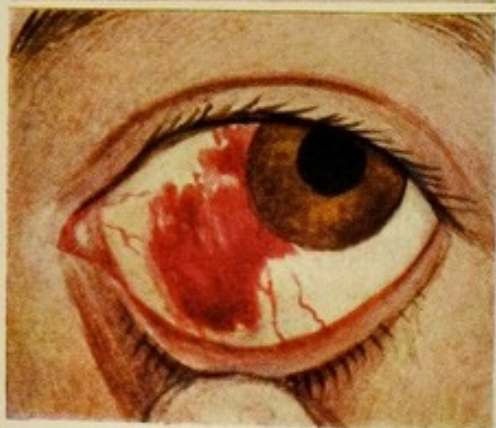1



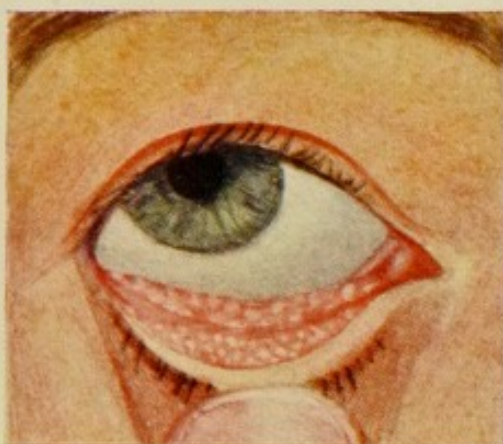2



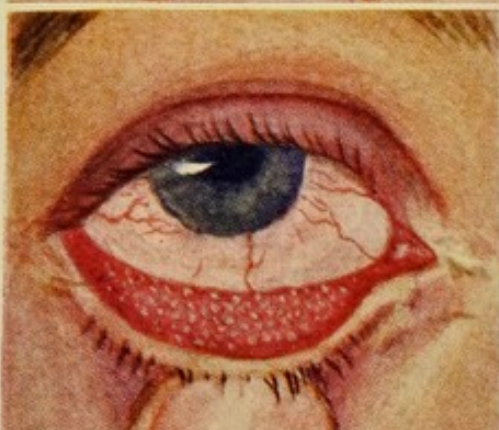3



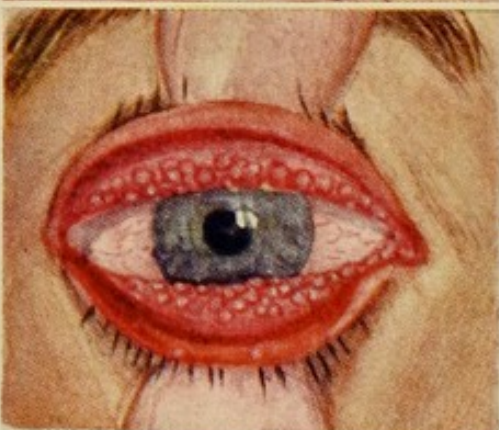
4



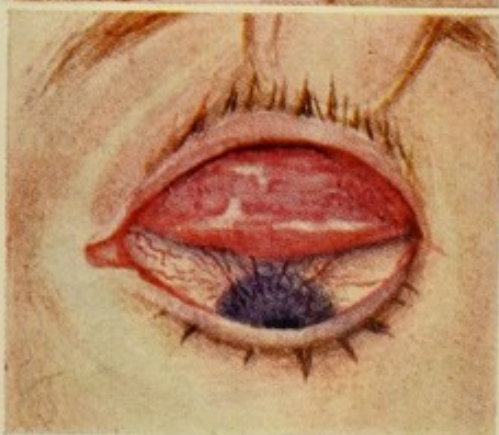
5



6




7



8

1. Pneumococcal Conjunctivitis: Petechiae.
2. Diplobacillus (Morax-Axenfeld) Conjunctivitis.
3. Phlyctenules.
4. Subconjunctival Hæmorrhage.

5. Follicular Conjunctivitis.
6. Atropin-Conjunctivitis.
7. Trachoma: Follicular type.
8. Trachoma: Cicatricial stage, with Pannus.



are tentatively known after the name of their discoverer as Prowazek's bodies. They are round, coccus-like bodies, which have, however, been found to occur also under certain conditions other than trachoma, and more particularly in ophthalmia neonatorum in cases which were not gonorrhœal; they have also been found in the vaginal cells of the mothers of such infants, and have even been recovered from the discharge from the male urethra in non-gonorrhœal urethritis. Whereas then it was at one time suggested that trachoma was actually a gonorrhœal conjunctivitis of a peculiar form (an explanation against the truth of which there was strong clinical evidence), the tables are now turned and a number at least of the cases of ophthalmia neonatorum, and possibly of preceding vaginitis, are attributed to trachoma, largely on the strength of the presence of these inclusion-bodies; these cases are described as "inclusion-blennorrhœa." At present, however, there is still much information lacking in regard to Prowazek's bodies and their distribution, and the etiology of trachoma is therefore not yet a closed subject. Indeed whether these bodies are or are not alive is not quite certain.

The essence of the disease is the development in the conjunctiva and subconjunctival tissue of the lids of newly-formed lymphoid bodies or aggregations. These are to be found principally in the upper lid at the upper limit of the cartilage and in the loose reflected tissue of the cul-de-sac, and to a less degree over the tarsal surface and in the lower lid. In these situations these masses show as "sago-grain bodies," a phrase which describes very well their small size and whitish clear aspect. After a varying length of time these particles give rise to persistent, if seldom very acute, irritation, with engorgement of vessels and hypertrophy of the papillary formations of the conjunctiva, and to overgrowth and contraction of the fibrous tissue elements in the mucous and submucous layers. The

conjunctiva at this stage shows, especially in the upper lid, a reddened, chronically inflamed, irregular, rough surface, from which project hard, tough papillæ, giving occasion to the name "papillary form" of trachoma. It is a matter of stage and of degree rather than of one form or another of the disease. It is not difficult to comprehend what some of the various results must be once this process is started; thus, the cicatricial development in the mucous membrane gradually must deprive the mucous glands of their nutriment and then of their existence, so that in an old-standing case the membrane is replaced by a cicatricial membrane containing no mucous glands, and which is therefore dry, moistened only by the lachrymal secretion, smooth indeed (for the papillæ have themselves been killed for lack of nourishment), but not "living," and with a smoothness which is treacherous (Plate V. 8). The cornea depends for the transparency of its superficial layers far more upon the mucous than upon the lachrymal secretion, and therefore when the mucous coat is destroyed it becomes semi-opaque, with small superficial "nutrition"-ulcers, and with vessels which have come from the conjunctiva of the globe to ramify over the superficial layer of the cornea—a condition known as *pannus*. Further, this cicatrization of the lid acts injuriously in two ways: first, by bending the tarsal cartilage to such a degree that the margin of the lid is turned in (backwards) upon the globe (*entropion*) and its eyelashes also (*trichiasis*). These conditions give rise to great injury to the cornea and to much discomfort on the part of the patient. Secondly, at the same time the whole lid aperture becomes narrowed in a horizontal sense; this results in greater pressure upon the cornea by the lids and more irritation by the eyelashes. The form of the palpebral aperture gradually becomes altered in a characteristic manner, for while it is narrow all along, its widest part is shifted nearer to the middle line, to a

point to the inner side of the mid-point of the lids. The cornea of such a patient suffers in two ways: ulcers form, small in size and usually superficial and central in position, and vessels belonging to the conjunctival series (*pannus*) invade its superficial and subepithelial layers (see Cornea, p. 143). The patient at this stage consults one, it may be on account of the photophobia in the subacute form, or of the deterioration of vision, or of the persistent irritability of the eye. On seeing the patient one is often struck at first by the hanging upper lid, a form of ptosis being present which owes its origin to photophobia, to the roughness of the lid, and to interference with the levator from infiltration of its fibres. At other times, when the disease has become quiescent, the patient presents himself usually in the hope of obtaining some improvement in sight.

Treatment must vary according to the stage at which the process happens to be. When the stage of lymph follicles is present our aim should be to rid them out of the conjunctiva. For this purpose expression by means of the forceps

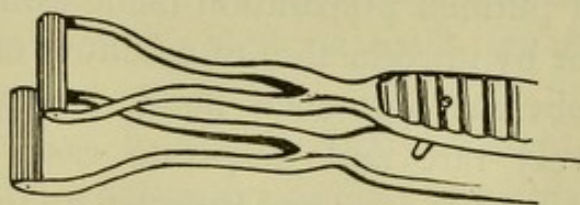


FIG. 31.—Knapp's roller forceps.

introduced by Knapp of New York is most effective. The patient should be under a general anæsthetic; the lids are then everted and the conjunctiva is picked up between the blades of a special pair of forceps, on which there are little fluted rollers, and the follicles are thoroughly squeezed out between the rollers. The amount of reaction following this apparently harsh treatment is wonderfully little. No dressing is required; the eyes should merely be bathed from time to time with lukewarm lotion. Graddy's forceps, which produce a similar effect by a different action, are well spoken of also. Another method, known as *brossage*, is

to attack the everted conjunctiva with a stiff tooth-brush dipped in a solution of perchloride of mercury (1-500). When the papillary overgrowth is the principal feature, such methods would be quite unsuitable, and astringent applications such as sulphate of copper in mitigated stick (greenstone), in crystals, in ointment, or as a lotion in solution, forms one of the best remedies. In all stages bathing with perchloride lotion is beneficial, while the special applications which have been recommended are simply without number; out of the hundreds iodine ointment and cuprocitrol may be mentioned as being very serviceable, while radium and X-rays seem to have done good in some cases. In the very severe cases of trachoma a method of treatment has occasionally been employed by which a very acute conjunctivitis is wilfully produced, of such severity that the offending follicles are killed by it and cast out. This is accomplished either by painting with an infusion of Jequirity (or by jequiritol, a purified preparation made from the *Abrus Precatorius*) or by introduction of a culture of gonorrhœal pus. It is obvious that such heroic treatment can be justified in very rare and desperate cases alone, and where the cornea is rendered vascular by the severity of the pannus. Treatment of the various complications of trachoma will be considered under the appropriate headings.

When the condition of affairs is a membrane wet with lachrymal secretion but destitute of the softening influence of mucus, the chief source of trouble is the condition of the cornea; so far as the conjunctiva is concerned diluted glycerine is the best application.

(g) **Follicular Conjunctivitis** rather closely resembles trachoma, but differs from it in being present entirely in young persons, in leaving no permanent evil results, and in the facts that the sago-grain bodies are smaller, affect the lower lid more than the upper, and give rise to the formation of no fibrous tissue or papillæ; also in that

there is no affection of the cornea. The condition sometimes gives rise to a little asthenopia, and often is present in children affected with adenoids. This asthenopia is sufficient at times to force the patient to seek advice, and the peculiar state of the conjunctiva is then discovered. It happens occasionally that an ordinary acute conjunctivitis is found in a boy or girl in whom this condition is also present, and the mistake may not unnaturally then be made of regarding the two conditions as constituting an example of genuine trachoma. This follicular enlargement is far from uncommon in minor degrees in children, and is often quite latent. It is fair to add that some writers regard the distinction between this and trachoma as a question rather of degree than of essential nature.

Expression gives complete relief if the case be at all a severe one; astringents, especially lead, are very useful in minor cases. Lead, it is to be remembered, must never be employed if the corneal epithelium be not intact, or it will form an indelible opaque patch on the cornea.

A very similar affection to the ordinary follicular conjunctivitis is found in *atropin irritation*; the treatment is to cease the use of atropin and apply an ichthyol ointment.

(h) **Diphtheritic and Membranous Conjunctivitis.**—It is convenient, though perhaps not strictly scientific, to group in one class a series of cases of conjunctivitis whose prominent feature from a clinical point of view is the formation upon the mucous surface, and especially upon the palpebral mucous surface, of a definite membrane such as is seen in genuine diphtheria. Not all of the cases are truly diphtheritic, it may be, but the determination in any case may be impossible without bacteriological examination, and even without culture and inoculation tests. True diphtheria of the conjunctiva

is a rare disease in this country, but in some others, North Germany and Belgium, for example, it seems to be more frequent. An acute inflammation of the eye occurs in a child, there is great constitutional disturbance, there is swelling of the præ-auricular and submaxillary glands, and on the conjunctival surface of the lids there lies a greyish, fine, but tough membrane, which can be lifted off with forceps, leaving a bleeding surface behind. In these really bad cases the cornea is extremely apt to slough or necrose and all sight to be lost. In other cases, more doubtful in their etiology, the membrane is whiter and less tenacious, and its removal does not necessarily induce hæmorrhage; in these cases the diphtheria bacillus may not be discoverable, and only some of the more common micro-organisms be found. Where there is abundance of an organism resembling the Klebs-Loeffler bacillus the difficulty in diagnosis may be great, since it is well-nigh impossible to distinguish with certainty between the genuine bacillus and the pseudo-diphtheritic or xerosis bacillus. In this connection two good rules should be borne in mind, namely, that one cannot expect a diphtheria patch in so aberrant a situation to behave in a typical normal manner; and "when in doubt, play trump." It is better to run the trifling risk involved in giving anti-toxin to a person who has not diphtheria than to allow the process to run on in the hope that after all it may turn out not to be diphtheria.

Apart from anti-toxin the best treatment is to keep the parts as clean as possible, pick off the membrane from time to time, and assist the general systemic resistance to the toxic process.

(i) **Pustular Conjunctivitis.**—This is one of the very commonest definite manifestations of what is still vaguely known as the "strumous diathesis" (Plate VI. 1). The disease occurs almost without exception in the young, most of the patients being between 7 and 15 years of age,

and when the patient does happen to be an adult it is usual to find that he had in former years suffered from the same trouble and that he has recently suffered from some debilitating illness. In connection with the etiology it is interesting to note that the patient is very rarely definitely tuberculous — pustular conjunctivitis is rare in the course of a progressive phthisis. Naturally, the patient generally exhibits some other signs of the diathesis, the thick lips, bleared (that is, blepharitic) eyes, the enlarged and perhaps discharging glands in the neck, and so on.

On the conjunctiva will be seen a certain amount of injection of the conjunctivitic type, the large blood-vessels of scarlet colour branching as they approach the cornea, but in this precise form these are apt to be more localised in one or two districts. Upon the conjunctiva, a few millimetres from the margin of the cornea, a small pustule, resembling one of acne, may be seen, but of course smaller, in the region of maximum injection. The favourite situation is to the outer side of the cornea, slightly below the horizontal meridian of the cornea, in the space of conjunctiva, in fact, which is most completely and most constantly exposed to air and dust. The pustule is almost unmistakable; the only condition for which one could mistake it is a patch of scleritis, but this latter is of a more bluish-red tint, gives rise to no discharge whatever (the mucous membrane not being affected), and is flatter on the surface, rising more gradually and to a flatter summit; the patient too is usually older.

(j) **Phlyctenular Conjunctivitis** differs from pustular conjunctivitis mainly in the situation of the lesion, not really so much in its nature. For in phlyctenular the little protrusion or phlycten is situated not in the conjunctiva proper but in the limbus corneæ, that "debateable land" where the relatively thick and vascular conjunctiva thins off rapidly to become the thin, fine,

non-vascular epithelial layers of the cornea. At first the true phlycten resembles a bleb or vesicle, and has been assumed by many to be such, but the so-called vesicle contains no fluid, only densely packed lymphocytes. After a short time the epithelium on the surface is apt to break down, when a small superficial ulcer is the result ; this as a rule becomes covered over with fresh epithelium after a brief delay, and no scar is left. But if it should become infected, as may readily enough happen, or if it be situated a little further over upon the true corneal surface, troublesome ulceration may result (see under Cornea, p. 128). It is often enough the case that the skin of the lid margins and round the orifices of the nose is red, eczematous, and excoriated. How much of this is cause and how much effect is not easy to say ; it was formerly supposed that the acrid secretions from the inflamed eye irritated the other parts to reaction ; recently the view has obtained more credence, especially among those who seek in bacteriology an explanation of every sign and symptom, that both skin and eye are infected with the staphylococcus, and that the eye has become infected from the skin. This theory does not quite explain why the affection occurs in a definite type of person, but the peculiar liability may be due to some susceptibility to that particular organism from some cause as yet unrecognised.

Though the patients are distinctly of the strumous type the tubercle bacillus has never been obtained from a pustule of the conjunctiva. Indeed no constant organism is to be found unless it be a few staphylococci. Yet staphylococci do not appear to be capable of causing the disease ; at all events cultures of them rubbed into the conjunctiva never set up pustular conjunctivitis—no observer has succeeded in accomplishing this experiment successfully. It has been suggested that the malady may be due to the toxins of (dead) tubercle bacilli, but

no definite pronouncement can be yet made to this effect.

Treatment.—There is nothing more effective than the nightly application of yellow oxide of mercury ointment; this has nowadays quite taken the place of an older-fashioned method of applying mercury locally, namely, by the dusting into the eye of an impalpable powder of calomel. This used to be accomplished by taking up a little of the powder on a camel's-hair pencil and "flicking" it into the eye—and excellent treatment it was from the point of view of mere efficacy, but it was difficult to apply, for the patient who had once had a powder puffed into the eye when he was persuaded to open it, was distinctly shy of affording facilities a second time. The ointment to which reference has been made is just as effectual and vastly more convenient. The *prognosis* is very good were it not for the great liability to recurrence till the patient is more grown up, and the possibility of an ulcer of the margin of the cornea should the pustule be or come up to the corneal margin.

At the same time a good tonic should be given, such as malt and cod-liver oil, or syrup of the iodide of iron; and the patient should be much in the open and constantly in fresh air. Diet generally requires to be looked to also and sweets forbidden. There is usually some gastro-intestinal trouble at the same time which yields to rhubarb or other stomachic. Encouraging the action of the skin by frequent baths is of much value.

There is a form of conjunctivitis for which it is difficult to find a niche in any classification; a form associated with no special organism, and which has no special distinctive feature. It can only be described as "Simple Conjunctivitis." The causes include any persistent irritation such as may be caused by irritating vapours or a dust-laden atmosphere, by heated and

vitiated air, late hours, or indulgence in alcohol ; it is apt to occur too where there is uncorrected error of refraction, or where the patient is exposed to too brilliant light, and in a number of conditions which could hardly be described as definitely pathological.

The line of treatment is sufficiently indicated by the description of the cause ; in addition mild, and particularly alkaline, lotions give relief.

Parinaud's Conjunctivitis is a rare form affecting persons who work among cattle and horses ; its chief features are granulations on the conjunctiva and enlargement of the submaxillary and præ-auricular glands.

2. Of the NON-INFLAMMATORY DISEASES of the conjunctiva three are sufficiently frequent to deserve mention.

Pterygium, so called from its fancied resemblance to an insect's wing, is a disease in which there spreads towards the centre of the cornea from its outer or inner margin a triangular web of fine semi-transparent fibrous tissue, ever slowly creeping towards the centre by its "head," while the wider portion or base is directed towards the canthus (Plate VI. 8). The "head" is firmly attached to cornea, but the point of conjunctiva from which it grows is very narrow, so that if two probes are taken and passed under the membrane, one from above and the other from below just at the corneo-scleral margin, they will almost meet under the membrane. The only proper treatment is to slice the head off from the cornea, over which the epithelium will soon be regenerated, and, dissecting back the conjunctival portion pretty freely, either cut it off in the shape of a diamond (lozenge), or, if this would entail too serious a loss of tissue, dissect up also a piece of healthy conjunctiva, cause the two to exchange places, and stitch them in their new positions. The disease, common enough in hot climates, is comparatively rare here, where it is seldom met with save among persons engaged in dusty occupations, such as millers or

stone-cutters. In the tropics the pterygium may become thick and fleshy (*Pterygium crassum*, as distinguished from the delicate membrane seen here, *P. tenue*). It is believed to take its origin always from previous pinguecula, and to be caused by the repeated erosion and healing between the pinguecula and the cornea.

Pinguecula indicates a small formation in the conjunctiva and sub-conjunctival tissue of a little yellowish mass at about 3 mm. to the outer or inner side of the corneal margin; it consists of elastic tissue, and is not fatty, though having that aspect. Except that it alarms a nervous patient, it is of no importance and should be left alone.

Spring Catarrh, or **Vernal Catarrh**, is among the less frequent diseases. The palpebral conjunctiva is covered with flattish elevations, closely resembling those of trachoma, but differing from the latter in being wider than they are tall, giving a "cobble-stone" aspect to the upper lid. They do not produce a reaction such as trachoma granulations do, and for months at a time the eye may be quite comfortable. Singularly enough, as soon as the weather begins to become warm again with the advent of spring, irritation begins, the eyes become red and itchy, and continue so all summer, varying with the rises and falls of the temperature. There is at the same time a curious thickening of the bulbar conjunctiva immediately surrounding the cornea, which may be slightly pigmented, and over the lid surface there is a pale, milky, filmy appearance. One striking feature in contradistinction to trachoma is that pannus is absent though the papillæ are hard and almost cartilaginous. Many methods of treatment have been suggested, but none are very satisfactory. Some surgeons shave off the masses, others disapprove of the knife and employ adrenalin, others recommend treatment by means of radium.

Tuberculosis of the conjunctiva is another rare affection ; it is usually seen in the form of persistent indolent ulceration of the palpebral conjunctiva (it rarely if ever attacks the ocular) with cock's-comb hypertrophic masses, and with enlargement of the lymphatic glands.

Lupus may spread from the neighbouring parts—skin or numerous nasal membranes.

Amyloid degeneration of the conjunctiva occurs in Russia alone, so far as has been observed ; the lids become hard and swollen with waxy-looking masses in the conjunctiva, which are repeated also on the globe.

Tumours of the conjunctiva, apart from those of the lids, are but rare ; sarcoma, usually pigmented, and carcinoma are occasionally met with.

Argyria or **Argyrosis** consists in the staining of the conjunctiva, which may be the result of too prolonged use of certain of the preparations of silver as local antiseptics in the treatment of conjunctivitis, etc. The tinting is of a dull, golden brown, and is most obvious in the lower cul-de-sac (Plate X. 3). It used to be much commoner than it is at the present day ; the statements of interested persons that this or that special preparation of silver never produces argyria should, however, be received (like some of their other assertions) with caution.

Xerosis of the conjunctiva is a curious change which is sometimes seen just at the corneo-scleral junction, especially at the outer limit of the cornea, in the angle between it and the lids. There is a dry, silvery, flaky-looking appearance, not unlike the sea-sand with ripple marks on it (Plate X. 2). The xerosis bacillus is present in abundance in such cases, but as a rule the patients have no uneasiness. It appears to be associated in a few cases with night-blindness, but why they should ever be associated, and why only in a few cases on each side of the association, is not known.

Lymphangeiectasis of the conjunctiva is another of

the little anomalies which give concern to some persons, but physical annoyance to none. The name signifies a distension of the lymph vessels here and there in a varicose fashion as tiny whitish or colourless elevations. Massage may remove the varicosity ; if not the tiny mass may be excised.

Essential shrinking or atrophy of the conjunctiva is a process whereby the membrane, losing all its moisture by destruction of its mucous glands, becomes shrivelled so that there is no longer any cul-de-sac ; the conjunctiva, or its atrophied remains, passes from the margin of the dull, intransparent, unprotected cornea to the margin of the lid. The disease, fortunately a rare one, is apt to occur in bad cases of trachoma, and apparently to follow pemphigus of the conjunctiva (Plate X. 1).

CHAPTER V

THE CORNEA

THE cornea is a perfectly transparent structure, devoid of any vascularity, and nourished entirely by means of the lymph-flow percolating through its structure, the pabulum coming from the loops of vessels at its extreme periphery in the corneo-scleral margin. The three essential parts are the *epithelium*, which is really a continuation of the conjunctiva, reduced to a minimum, covering it in front ; the *substance proper*, separated from the epithelium by the transparent membrane called Bowman's ; and the *endothelial lining* of the anterior chamber, separated from the substance proper by Descemet's membrane. The corneal structure consists of stratified layers of the essential substance, among which are large flat cells with branching processes which "anastomose" or join with those of neighbouring cells. The cornea is set into the sclerotic as a watch-glass is into its holder, overlapped exteriorly by the sclerotic, and encroaching on the latter interiorly. Its horizontal diameter is approximately 12 mm. Owing to its non-vascularity and its exposure the cornea is the coldest tissue in the body, its temperature being decidedly below that of any other. Its sensitiveness to touch is extremely active. In accordance with its anatomy the affections attacking the cornea may have their seat in the epithelium, the corneal tissue, or the endothelial layer.

It is convenient to classify affections of the cornea in the first instance according as they are ulcerative (destroying the epithelium) or not.

ULCERS OF THE CORNEA

An **ulcer of the cornea** may be shallow or deep, it may be central or peripheral, it may be clear or infiltrated, but whatever character it may possess, the point by which its existence is most surely demonstrated is the alteration in the aspect of the source of light as reflected from the surface whose curvature is altered; it may often, however, be directly observed as a loss of substance. If the window be the source of light, then one can see the reflection of the frame in the cornea distorted and twisted as its image falls upon the affected part—a sign of enormous value in some cases.

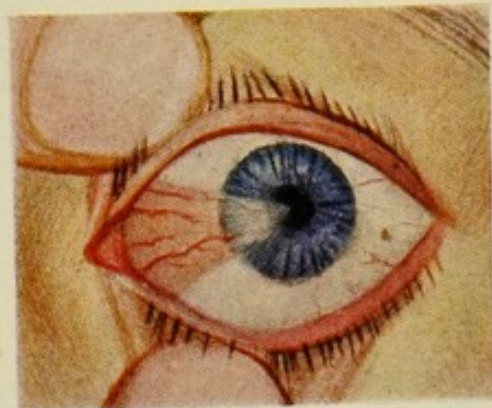
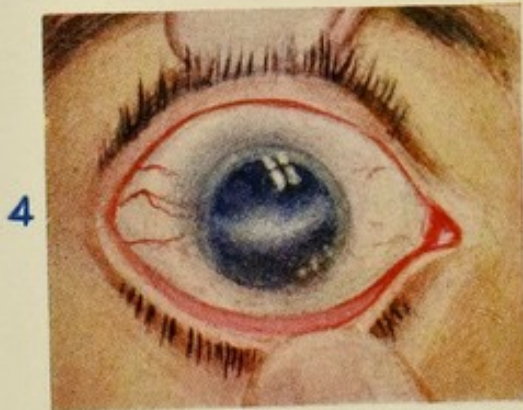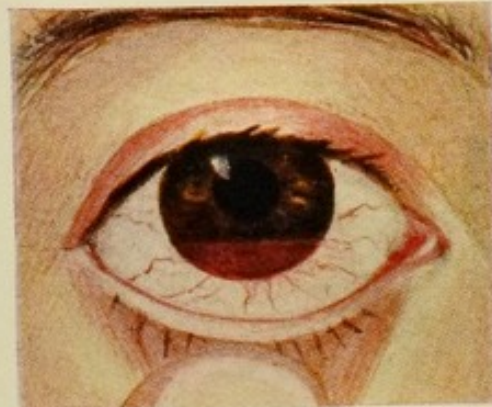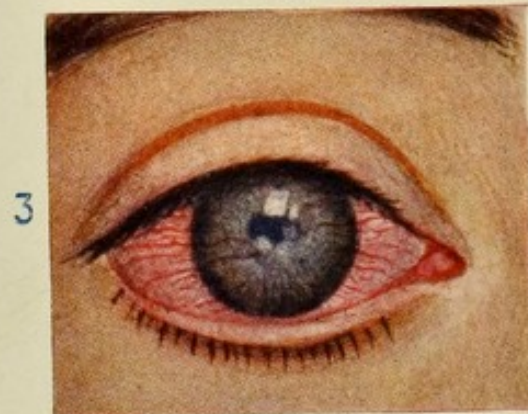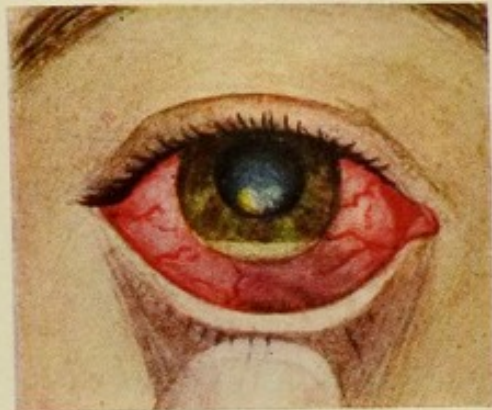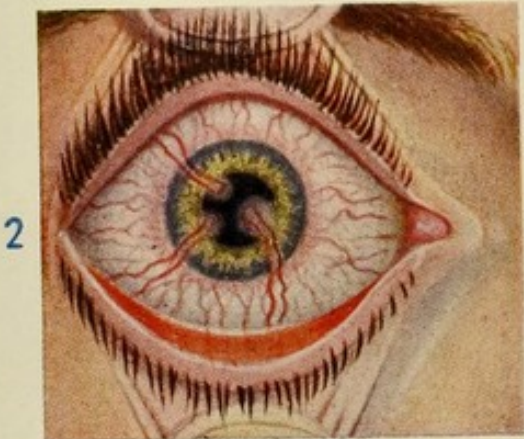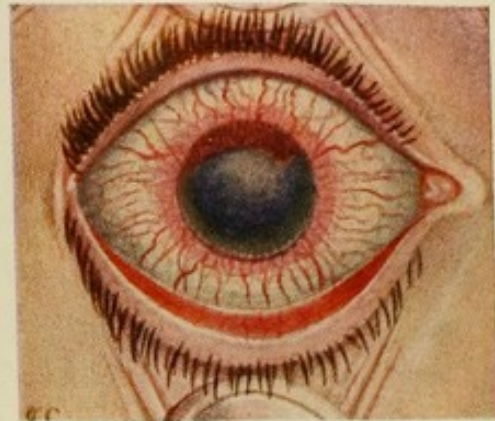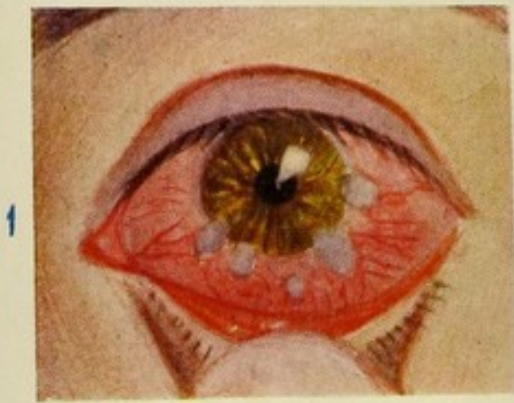Of ulcers of the cornea the chief varieties are the Strumous and the Septic.

The **Strumous Ulcer** varies considerably in aspect in different individuals, but as a general rule it has certain characteristics. It occurs in children for the most part; the child at the time of a first attack may be anything from 5 to 10 years of age; should it occur later it is more usually a recrudescence of a former attack. The prominent symptom is photophobia, or dread of light. The child may be found with a handkerchief over his eyes, holding down the head, or perhaps lying in or below the bed to escape the light. He struggles and fights to prevent any opening of the eyes, and even a child who has been bright and happy hides in corners and mopes, and will not play or interest himself in anything, for any attempt to use the eyes causes great distress. The eyelids are swollen, reddened, and painful, the skin of the lids often excoriated by the discharge from the eye; the patient resents the entrance

of light, but when the eye is examined it is found injected and watery. The vessels are for the most part those of the deeper set, pink, radially arranged, but in this form the more superficial ones are manifest also. The cornea itself may be bright and clear save at one part where the reflex is altered, and at this portion it is often dull, because the cells are swollen and tending to break down, greyish in colour and semi-opaque, and there may be a leash of vessels running to the spot over the surface of the cornea.

Of these strumous ulcers there are two methods of advance and fresh formation: a small vesicle, or what looks like a vesicle, though in reality it may be filled with small broken-down cells (as also in pustular conjunctivitis) forms near the centre of the cornea; there is intense photophobia, pain, and profuse lachrymation of "scalding," irritating tears, but after a few days the violence of the intensity diminishes, and when the eye is examined (though with difficulty, for it is still very painful and dreads the light) there will be seen at that edge of the cornea nearest to the little ulcer a leash of vessels. The vessels of this little leash are quite superficial, just under the epithelium; they are manifestly continuations of certain conjunctival twigs, and they make their way rapidly to the site of the ulcer. In other cases the ulcer forms close by the edge of the cornea; to it the conjunctival twigs come, then they push their way steadily into the cornea, always heading straight for the centre, the affected portion having in front a shallow crescentic ulcer where the epithelium is exfoliated, and drawing behind it a little leash of the vessels. This is therefore sometimes known as Fascicular Keratitis; it is merely one form of strumous inflammation of the cornea. Why the leash heads so definitely for the centre of the cornea, and why it stops there, are not explained (Plate VI. 1, 2, 3). It has actually





1. Phlyctenules : Tuberculous form.
2. Fascicular (superficial vascularized) Keratitis : "Strumous pannus."
3. The same in more acute form.
4. Band-shaped Keratitis.

5. Interstitial Keratitis.
6. Hypopyon Ulcer.
7. Hyphæma.
8. Pterygium.

been suggested by some that it is best to refrain from treatment till the centre is reached—a strange doctrine.

In some very long-continued cases the surface of the cornea becomes vascularised to a severe degree, and a condition known as *Strumous Pannus* (so called to distinguish it from the pannus of trachoma) becomes established, in which numerous superficial vessels ramify over the surface of the cornea. This is distinguishable from the trachomatous variety by the fact that it does not specially affect the upper portion of the cornea, as does the other. In very rare cases peritomy may do good; as a rule the condition yields in the end to the treatment outlined below. Some surgeons recommend sea air for patients suffering from strumous keratitis; I have always found the sea air to be rather injurious, and prefer to send the patient inland to the hills.

It is frequently the case that at the outer canthus there exists a *fissure* of the skin caused by the constant action of the orbicularis and the sodden condition of the skin; this adds materially to the pain and discomfort of the patient.

When there is much photophobia and the child resists examination to the danger of injuring the eye, it is best to lay him down on a couch rather than attempt to inspect the eye while he is standing on the floor or is in his mother's arms. The method of pinching the head between the knees of the surgeon as they are covered by a towel, while the body of the child rests on the lap of the mother or nurse, may do in hospital practice, but is not much to be commended.

In respect of *treatment* two local applications are very valuable, namely, atropin and yellow oxide of mercury ointment. The atropin does a great deal to remove the photophobia, a singular fact, since more light must enter the eye when one has succeeded in dilating the pupil. It is however a fact which points also to the conclusion

that the so-called "photophobia" is not in truth exactly a correct name for the symptom (see also page 3). Atropin may without disadvantage be mixed with the ointment. It is an interesting and important fact that though some authorities, perhaps rather on theoretical than on clinical grounds, disapprove of the use of atropin, yet so soon as the mydriatic has succeeded in dilating the pupil, photophobia becomes very much less; they explain this as due to relaxation of spasm of the sphincter and ciliary muscles. Another method of diminishing the lid spasm which used to be strongly recommended, though in our less strenuous days it has fallen somewhat into desuetude, is to plunge the child's face under water once or twice a day, and hold the little patient thus until the spasm relaxes with the urgent need for breath. Though "heroic," the treatment is not in any way injurious, and certainly has a wonderful effect in some obstinate cases. Cocain is sometimes employed to combat the photophobia, but cocain has the decided disadvantage that it interferes with the integrity of the corneal epithelium.

At the same time the patient's health should be attended to, and tonics administered if need be. Almost more important is the condition of the mucous membrane of the alimentary tract, it is generally out of order, and the child will be much improved by a course of rhubarb and soda, grey powder, or other "stomachic." Very important also is proper dieting, for often in these children the feeding has been most injudicious; sweet-meats should be strictly forbidden. The action of the skin should be ensured also by daily warm baths. In the case of the poor (among whose children the affection is most common) the proper feeding, cleansing, and regimen of a hospital often bring about a rapid improvement. The fissure at the outer canthus is best treated by touching with solid nitrate of silver. Adults do not

agree so well with yellow oxide ointment as do children ; with them it causes very much more irritation, and the mercury needs to be diluted still further or even omitted altogether and a simple bland ointment substituted.

The *prognosis* as a rule is quite good, but it should be borne in mind that these ulcers, while very rarely causing actual loss of the eye, are responsible for a great deal of deficiency of sight. The *nebulæ* or opaque scars which remain behind more or less permanently interfere with sight directly, since they are opaque, and indirectly because, being white, they break up the light, and, being irregular on the surface, they distort the images. Massage, especially with a stimulating ointment such as that spoken of, does much to improve tissue exchange and clear these up ; it should be continued, therefore, long after the acute stage has passed off, but it is often very difficult to induce the parents to persevere after the obvious symptoms have ceased.

The *prognosis* is not so good in the adult, and when there have been repeated attacks. Clove oil 2-5 per cent, turpentine 15-20 per cent, and in older days *vinum opii*, have all been recommended in obstinate cases. Caution must be observed in the use of them lest the irritation produced be too vehement for the feeble tissues. Dionine 2-10 per cent is safer, and though tolerance is early established the drug can be dropped for a time and resumed.

There are four different conditions in which the cornea suffers from formation of vesicles or blebs in addition to the simple strumous phlyctenule.

1. Vesicles or a vesicle may form on the cornea in the course of an attack of **Herpes Ophthalmicus**. It is said not to attack the cornea unless the nasal branch of the nerve is affected. After the vesicle has formed it soon gives way and the eroded surface very readily becomes infected, when a hypopyon ulcer may

easily arise. Even without so disastrous a result there is frequently a degree of inflammatory reaction more than might be expected, and a nebula may remain. The ulcer is treated on general principles, as above.

2. **Herpes Corneæ Febrilis** is a transitory affection of the cornea in which a crop of vesicles occurs, which may return after healing has taken place, coming out in crops. It is prone to occur during the course of a febrile attack, as, for example, when the patient has "caught cold." The risk again is septic infection of the numerous tiny areas denuded of their epithelium. One is tempted to employ cocain to allay the pain, but should remember that cocain may relieve the symptom but tends also to delay healing, less perhaps when administered in ointment than when in solution. Dressing with a bland aseptic or ointment, and quinine internally, makes the best treatment.

3. In old-standing cases of **Glaucoma** when the tension goes up it is not uncommon to find a large collapsed bleb on the cornea. This precise condition is perhaps never seen save when the tension is raised and has for some time been raised. It is attended with severe pain in the eye even although the cornea may at the time be actually anæsthetic to a high degree, as the cornea in glaucoma often is. The explanation probably is that it is due to some fault of nutrition taking its origin in the effects of pressure upon nerves and vessels at the corneo-scleral margin. It is not due to a transudation of fluid from the interior of the eye, for the bleb is slack, never tense, as it would be were that the explanation of its occurrence. The treatment for this painful affection is to reduce the tension; if the tension can be lowered the blebs will not recur. For the time being the bleb should be dissected off and the eye dressed.

4. After certain injuries of the surface of the cornea a **recurrent vesicle** formation is met with. The injury

has always been a superficial one—an abrasion of the epithelium, as by a scratch with a finger-nail, the corner of a piece of paper, or some such article. The patient has sharp pain at the time, but it does not last long; the little scratch heals up and he forgets about it. Perhaps a month later he awakens some morning with a severe pain in the eye and a rush of scalding tears, he is in agony for a couple of hours or as long as half a day, then he gets better again, and in a day all is well. After a few weeks the same process is again gone through, the excruciating pain on waking, and so on. The explanation is as follows: The regeneration of the epithelium is not quite satisfactory, and its cohesion with the superficial layers of the cornea proper is not complete, but merely sufficient for a time. Then a minute amount of fluid collects under the imperfectly attached epithelium and a tiny bleb forms. The first act of waking is to raise the lids, and just as this occurs for the first time in the morning, the feeble epithelium is dragged off the cornea by the lid, the nerve ends in the cornea are laid bare, and there is intense pain. Under bandaging and keeping quiet the epithelium is re-formed, again gives way, and so on. This may go on for many months, at intervals of about a month, and if one had not the clue such cases might be very puzzling. To obtain relief it may be necessary to pick off the remains of the bleb so as to prevent the edge from being dragged upon like a “rag-nail,” and certainly to bandage with an aseptic ointment. This ointment should be continued and the eye bandaged specially about the date at which the next attack is due, so that the bleb may be protected even if it should form. If this is done the recurrence ceases. It is not wise to use cocain, as it rather tends to interfere with the regeneration of the epithelium; if used at all it should be in ointment, not in aqueous solution.

The **Septic Ulcer** (**Ulcus Serpens**, **Hypopyon Ulcer**)

is of enormous importance from an economic point of view, for it is the most frequent cause of loss of sight among active workers with the hands. It consists, with exceptions, of an invasion of the cornea and its local destruction by the pneumococcus. The history is usually somewhat after this fashion: The patient has perhaps had a tendency on the part of one eye to watering; he receives a trifling injury to it—a foreign body striking the cornea, an abrasion of it by a twig, piece of coal, etc.; this is followed in a couple of days by severe, dull pain in the temple, inability to use the eye, watering, and a good deal, or a great deal, of pain in the temple of the corresponding side. This pain is worst at night, in the “small hours,” wearing the patient badly by depriving him of sleep. He perhaps sleeps until two A.M., “tramps the floor” till five or six, and then, the violence of the pain passing off, obtains another hour or two of rest. The pain is such that he complains but little of the loss of sight, indeed may hardly have noticed this amid his other troubles.

On looking at the eye one sees the lids a little congested and red round the edges, the whole conjunctiva deeply engorged, both conjunctival and iridic vessels distended; the cornea may be slightly dull all over, but certainly the ulcerated area is infiltrated, greyish at its base or yellowish; this yellow coloration is most marked at the margins, and it may be specially at one part of the margin where for the time being the progress of the ulcer is most active; the margins are just the least bit undermined, and outside them the cornea is semi-opaque and greyish in hue, this appearance fading gradually as the ulcer is receded from, so that the peripheral portions may even be clear. At the foot of the anterior chamber is a collection of “pus,” yellowish in colour, its upper margin horizontal. Especially when rapidly secreted this pus is very fluid, and has therefore

a horizontal upper margin, but when more slowly formed or when becoming absorbed it becomes thicker and convex above (Plate VI. 7). Sometimes some of this pus is embedded in the layers of the cornea, giving rise to the aspect which used to be called *onyx*, from its fancied resemblance to the lunule of the finger-nail.

The pus present in the anterior chamber has the peculiarity that it is sterile; the great question connected with it is: The ulcer to which it owes its existence is on the anterior face of the cornea, how does the pus reach the aqueous chamber? First and chiefly it is formed of the innumerable white cells attracted to the ciliary body by the cry of the corneal tissue injured by the toxins of the invading organism, that being the nearest vascular tissue to the injured part. Secondly, and not in all cases, it is possible that certain of the cells of the broken-down corneal tissue may pass through Descemet's membrane into the anterior chamber. This explanation is seriously doubted and even denied by some of the best authorities: it is certainly difficult to reconcile with the conduct of Descemet's membrane under other circumstances. Thirdly, a posterior abscess of the cornea may form, certain of the effete and dead cells from the ulcer make their way through the cornea to the posterior part and collect there anteriorly to Descemet's membrane, which, however, after a time gives way and allows them to fall down into the anterior chamber and add themselves to the collection at the foot of it.

Should the evil process be unchecked by treatment, the ulcer increases in depth, but to a still greater degree in superficial extent; this mode of advance is partly because of the physical conformation of the cornea, with its superimposed layers, which makes it easier for toxins and organisms to extend their influence superficially and along the canals of the lymph stream rather than deeply. At the same time the pus increases in quantity and may

half-fill or even nearly fill the anterior chamber. In a very bad case the ulcer will, ere that stage is reached, have eaten deeply into the corneal substance, and the thin floor will some day give way suddenly, causing the patient a spasm of intense agony, when the anterior chamber will empty itself.

The *pathology* of Hypopyon Ulcer, as this condition is often called, or *Ulcus Serpens Corneæ*, to employ another expression which conveys the idea of its frequent mode of progress over the cornea, has been the subject of much earnest and valuable work by many investigators. The *steps of the process* may be put thus: (a) The *presence of the pneumococcus* in the conjunctival sac. (It is true that other organisms are capable of setting up a not dissimilar reaction, but they do so much more rarely.) Now, the pneumococcus is a frequent inhabitant of the conjunctiva, but usually in an attenuated and non-virulent form; and whether or no, the organism is incapable of doing harm unless first of all it obtains access through an aperture in the epithelial armour to the substance of the cornea itself. In a chronically inflamed conjunctiva, however, with its folds, its crypts, and its excess of mucous secretion, the pneumococcus is actually protected from the inhibitory action of the lachrymal secretion, and therefore any condition of the conjunctiva which involves hyperæmia and extra secretion is favourable to the growth and the higher vitality of the coccus. Such a state of affairs is furnished very typically by two conditions—the presence of chronic mischief in the lachrymal sac, and the occupation of coal-mining,—the former because the conjunctiva is not, and cannot in the nature of things be, even approximately aseptic, and the latter because the constant irritation of the conjunctiva which must result from bad air, a heated atmosphere, and the incessant presence of foreign particles in the air, leads to the hyperæmia and attendant mucous discharge. For

this reason in this part of the country we see a very large number of cases of hypopyon ulcer in coal-miners,—far more than in men following any other trade. (*b*) The second step is the occurrence of an *abrasion* of the epithelium of the cornea, such as very readily follows the slight injury to an eye from a foreign body, from a touch with a finger-nail, chip of stone, or other substance. After the occurrence of this, but perhaps not before it, the exposed morsel of corneal tissue becomes infected with the pneumococcus, which is lying in wait ready to spring, and renders immensely serious what in other circumstances would be the merest trifle. The injury which produces a hypopyon ulcer usually occurs near to the centre of the cornea, both because that is the last part to be protected by the lids, and because, being farthest from the nutrient zone, that part is most likely to fall a victim to septic infection. (*c*) The third and final step is the *progressive formation* of the ulcer. The affected spot, poisoned by the toxins of the bacillus and attacked directly by it, becomes infiltrated, dull, clouded, and finally perishes and breaks down, and a breach has been formed in the parenchyma of the cornea. Round this the toxins spread, the organisms make their way among the layers, the epithelial cells exfoliate, perish, and are carried away, and always outside in the tissue hitherto healthy the same process is going on in ever-widening circles, the portions nearest to the dead part showing most of the change, most of the loss of transparency, the grey, dull cloudiness. By and by one of three things must happen: either the ulcer, penetrating deeply as well as extending laterally, eats through the whole thickness of cornea, and even through the tough and long-resisting Descemet's membrane, after which healing at once begins; or the destructive process causes loss of all the superficial layers of the cornea right up to the corneo-scleral junction, for it may be that it gradually

will destroy all the superficial parts without any perforation of the cornea ; or, lastly, the reparative processes get the upper hand over the destructive, the attacks of the organism are more successfully resisted, the toxins are less copious and less injurious, the ulcer begins to clean. As this goes on the dead cells are cleared away, those too deeply injured die and are removed, those less fatally affected recover and become clear again, fresh cells, capable of holding their own, are produced, and the aspect of the ulcer changes. From a dull grey with yellowish edges it alters to a clean clear base with colourless healthy margins over which the eager epithelium makes its way to cover in the denuded substance.

A very similar process of destruction of the cornea is apt to take place when the cornea from any reason is imperfectly covered by the eyelids. This may be when a lid is destroyed by epithelioma or by injury, when the globe is protruded too much by Graves' disease or by tumour in the orbit, when anæsthesia of the cornea is present, when a child is in a marasmic condition (this destruction may occur with the most extraordinary rapidity in what is called *keratomalacia*), and tropho-neurotically when the Gasserian ganglion is diseased or has been excised. (It is not necessary here to discuss the vexed question of the trophic influence of the sensory nerves.)

In the *treatment* of this progressive form of ulcer there are two chief indications, namely, to destroy the infected




FIG. 32.—Snell's cautery for the cornea.

margins and to prevent re-infection ; and in addition, to prevent certain co-incident processes from causing undesirable complications. The *first*

indication may be met by destroying the advancing margin with the actual cautery, or with a chemical caustic. If the cautery be used it is best employed

at just below red heat; a hotter point is very apt to lower the vitality of an unduly large area and thus cause a needlessly large cicatrix, and possibly even to favour the spread of the ulcerative process in some instances by diminishing the resisting power of a number of cells, which become re-infected. Various chemical destructive agents are used; none is better than pure carbolic. This can readily be applied if a wooden match is sharpened to a fairly fine point, dipped in the carbolic, and then employed somewhat vigorously to the edges of the ulcer, scraping away at the same time debris, broken-down and half-dead tissue. Other antiseptics may be substituted, but care must be taken that any such substance used should not diffuse itself over the cornea. It is one of the points in favour of the match dipped in pure carbolic that this can hardly occur.

As it is essential to apply the destructive agent to the ulcer, the whole ulcer, and nothing but the ulcer, it is a great advantage to be able to delineate in some way the area over which epithelium is lost. This can be accomplished readily by means of fluorescin. Fluorescin solution, in a strength of 1 or 2 per cent, dropped into the conjunctival sac and washed out again in a couple of minutes, does not stain epithelium but tints a bright green the corneal substance wherever it is denuded of epithelium. By employing this solution immediately before the curative application, one is enabled to see exactly what precise portions do and what do not require to be gone over. "Touch wherever the green colour is."

The *second* indication is not met by merely giving the patient an antiseptic lotion; any that we can use is too feeble for the purpose, and too transitory in its influence. It is better met by applying within the eyelids an antiseptic ointment and bandaging the eye immediately after its introduction. To apply a bandage after mere bathing, and without the permanent presence

of an antiseptic, may have some advantages, but it most assuredly is open to the very serious objection that the ulcerated cornea is kept in contact with a septic mucous membrane; an antiseptic ointment protects the ulcer from the germs and from fresh infection from the conjunctival sac. The bandage should be changed daily, or twice a day. Ciliary congestion being great and the iris being engorged also and threatening to form adhesions to the lens capsule, atropin should be administered in full strength once or oftener per diem. It is true that in a certain proportion of cases the tension is too high, but it is not very often that this indicates a contra-indication: eserine would be contra-indicated as tending to increase ciliary injection.

When the pneumococcus is the causative organism and in the less frequent cases in which the Morax-Axenfeld bacillus is largely present, zinc sulphate forms a useful collyrium, but is a little apt to irritate. I am accustomed to classify my hypopyon cases into three groups: the mild or early cases, in which, after perhaps three days, there is just a trace of pus in the anterior chamber, and a small dirty ulcer—in such cases atropin, scraping the ulcer clean, and applying corrosive sublimate ointment generally effect a cure; the medium, in which the ulcer is not large, the amount of pus in the anterior chamber does not amount to $\frac{1}{3}$ the height of the cornea, and the whole process has not been too rapid—in these cases the treatment above described seems to me to answer best; and the severe, in which the ulcer is larger superficially, and tends to spread deeply also, and the anterior chamber is more than $\frac{1}{3}$ full—in such cases I find Saemisch's section the most efficient mode of treatment. This little operative procedure consists in dividing the base of the ulcer, and is thus performed: The eye having been cocainised, a Graefe knife is introduced through sound cornea at the outer side of the

ulcer, passed across the anterior chamber with its edge forwards, to a corresponding point at the inner side of the ulcer—there the counter puncture is made and the knife is caused slowly to cut its way through the base of the ulcer directly forwards. Great care has to be taken that the lens be not injured and that the incision be not made too swiftly, as not only is the sudden reduction of tension in an inflamed eye extremely painful, but it is apt to be followed by internal hæmorrhage. After incision the eye should be bandaged again as before; the result is a dense but not extensive scar across the cornea, but to this the iris, unfortunately, is only too often adherent.

There are two *exceptions* to the rule that vigorous treatment should be applied in cases of hypopyon, namely, when the disease occurs at the extremes of life. In children hypopyon keratitis is found rather as a complication of strumous ulcer of the cornea, and it is quite uncalled for and quite unsuitable to apply to a juvenile cornea in a state of severe constitutional ulceration such vigorous remedies as the actual cautery or pure carbolic. In the aged, too, when hypopyon occurs, it does so rather as an expression of gravely lowered resisting power than of virulent invasion, and the patient ought to have nothing applied to his cornea which could possibly still further lower the vitality of a portion of it. It is rather upon internal tonics that one must rely in preference.

It is very important that during the healing process everything possible should be done to encourage tissue exchange and the clearing up of the scar tissue which replaces the true cornea; dionine ointment (2-5 per cent, or even stronger) with daily massage of the cornea is particularly beneficial. When the eye is sufficiently recovered to be able to stand it, massage should thus be applied: a small piece of ointment, the best base for

which is probably lanoline cream, and which may also contain dionine or yellow oxide of mercury in very small quantity, should be introduced into the conjunctival sac on a glass rod. The lids should be closed over this, and the thumb, resting gently on the closed eyelid, should be moved over lid and eye in a circular or rotatory fashion for thirty to sixty seconds with a light but firm pressure. The amount of improvement in nutrition of the partially opaque cornea, whether after hypopyon ulcer or strumous keratitis or interstitial keratitis, is more than might be expected.

One other method of treatment requires a word. Some surgeons, especially Professor Roemer, have recommended the use of pneumococcus cultures in the preparation of sera which, injected locally or into the circulation, may favourably affect the course of the disease. Whether or not it be because the area is so small and the susceptibility of the tissues of the eye so great is not known, but hitherto the success obtained by these means, so valuable in other parts of the body, has been very meagre. The time is certainly not ripe for employing sera in hypopyon ulcer to the exclusion of other remedial measures.

It remains to mention some less frequent types of ulcer.

Dendritic Ulcer of the cornea is an affection very apt to follow influenza and certain other debilitating illnesses. The cause is probably the development of some mycotic growth, which has not as yet been thoroughly identified, in the epithelial or sub-epithelial tissue of the cornea. The patient generally presents the history that one eye has been uneasy and troublesome, a little injected and somewhat painful, though not severely so, for a week or two, and that the condition, while not getting seriously worse, is not improving either. On examination by means of focal illumination, and especially after the

introduction of a drop or two of fluorescin, an irregular, budded streak of disturbed epithelium may be seen; the disease gets its name from the fact that this mode of spread is much like the arrangement of buds and branches. The ulceration is little more than a slight erosion of the epithelium, and in an uncomplicated case there is no purulent or other deposit at the foot of the anterior chamber. The branched aspect, the history, and the resistance to ordinary treatment make the diagnosis practically certain. The best method of treatment is to moisten a camel's-hair pencil in absolute alcohol and paint the ulcerated area thoroughly with it. Even when cocain has been given this is somewhat painful. Chlorine water (B.P. 1-5) or pyoktanin (*i.e.* methyl violet 1-2000) is the best application for home use. None of the ordinary antiseptics produce any effect upon this form of disease. Even at the best the recovery is often slow, and recurrences not uncommon. It is but seldom that anything worse than a fine thin scar is left, but should the eroded area become attacked by a pyogenic organism—which may readily enough occur—so good a result could not be looked for.

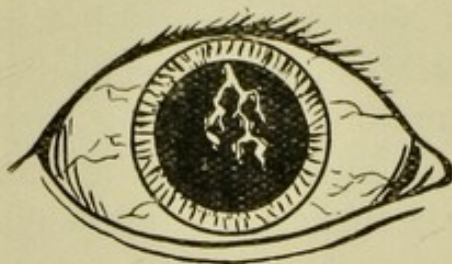

FIG. 33.—Dendritic keratitis.

Mooren's Ulcer or **Ulcus Rodens** is a destructive form of ulcer characterised by its overhanging edges and its habit of healing in one direction as it spreads in another. It occurs for the most part in old and enfeebled persons and always leaves damage behind it. Most surgeons consider the most effective treatment to be thorough cauterisation of the advancing margin, but certain cases resist even this treatment.

Among the superficial vascularised conditions of the cornea **Pannus** falls to be mentioned. Pannus means

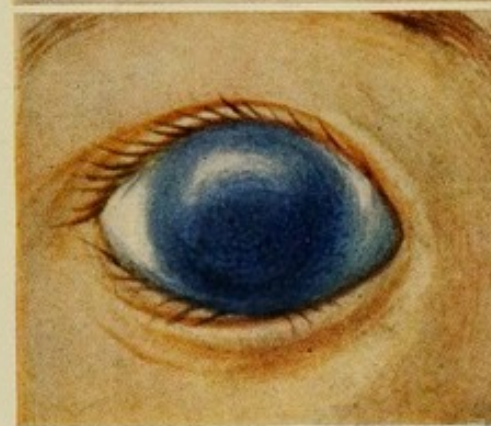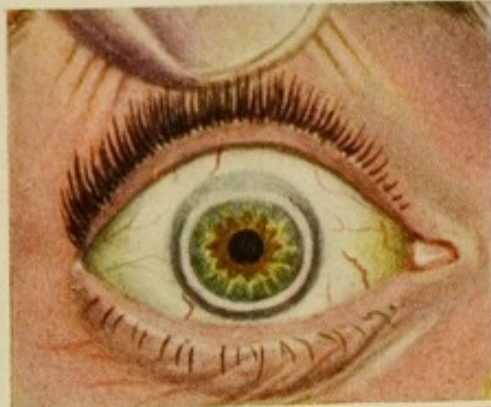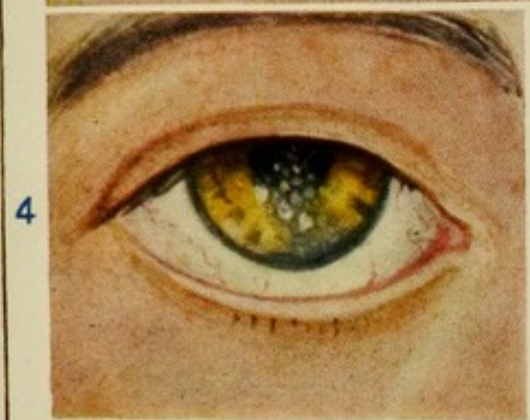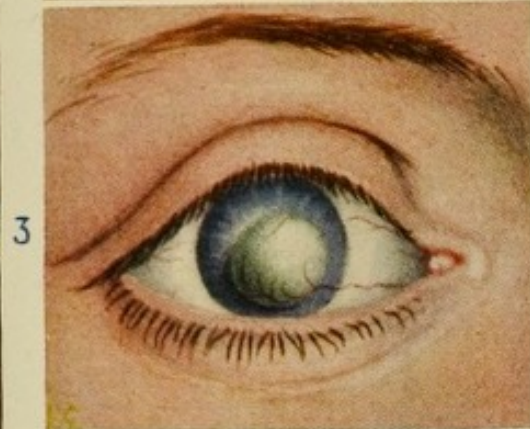
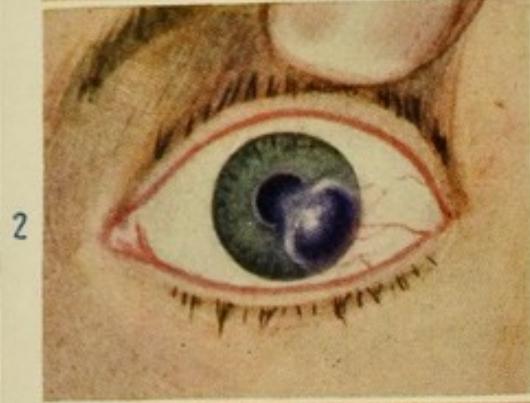that state in which a quantity of superficial conjunctival vessels push their way into the corneal region, ramifying over its surface. They lie for the most part in the sub-epithelial layers, but sometimes penetrate Bowman's membrane: between them there is some greyish infiltration, the degree varying with the severity of the affection, and there are numerous ulcers, small, superficial, or deep, healing and breaking down. What is very certain is that pannus proper is a disease of the cornea entirely dependent upon the presence of trachoma, whether it is caused by the mechanical irritation of the surface of the cornea by the rough and dry lids, or by an actual extension of the trachoma changes into the cornea: the true situation of pannus is always in the upper portion—say half or third—of the cornea, under the upper lid; it is the cause, when severe, of much trouble to the patient, and very serious loss of sight. It is also very striking that pannus is not to be found in cases of spring catarrh, though granulations not dissimilar to those of trachoma are present for many months in the upper lids.

“Strumous pannus” is a term not much employed nowadays: it signifies that superficial vascularised keratitis is present, with leashes of vessels running in here and there, but of strumous, not of trachomatous origin, and therefore not only, and indeed not probably, in the upper half of the cornea.

In the main the treatment of pannus is to attack and improve the condition of the lids, but sometimes the removal of a band of conjunctiva immediately round that portion of cornea which is affected is required (*Peritomy*), thus cutting across the vessels in their course.

NON-ULCERATIVE AFFECTIONS OF THE CORNEA

Of these the most important is **Interstitial** or **Parenchymatous Keratitis**. This disease is not primarily



1. Leucoma Adhærens.

2. Prolapse of Iris : partial Staphyloma.

3. Partial Staphyloma.


4. Keratitis Punctata.

5. Arcus Senilis.

6. Conical Cornea—from the front.

7. Conical Cornea—side view.

8. Buphthalmos.



a keratitis at all ; the signs exhibited in the cornea are in point of fact secondary to inflammatory and degenerative changes in the ciliary body, in the region of the zone on whose integrity depends the proper nutrition of the cornea. The precise nature of the changes in the ciliary body is indicated by the exactly similar processes visible with the ophthalmoscope in the anterior parts of the chorioid, and sometimes all over the chorioid, known as disseminated chorioiditis.

The disease affects the young, usually about puberty but often enough earlier, from the age of seven years onwards till twenty-two or so ; it is rather more frequent in girls than in boys, and it sometimes shows itself in more members of a family than one. It always affects both eyes, though there may be a little interval between the attacks, one eye being at or past its worst before the other begins to show signs of the disease. It is the most frequent hereditary manifestation of syphilis in connection with the eye. This statement should not be interpreted as meaning that the disease is invariably of syphilitic origin, for it is certainly strumous in some cases ; in a considerable number the evidence of syphilis is quite lacking. All authorities are agreed, however, in the opinion that in the great majority of cases syphilis in the parents is the true and real cause. Care should be taken to look for any other signs of hereditary taint, such as bossy forehead, rhagades, Hutchinson's teeth, deafness, flat bridge of the nose, and chronic enlargement of knee-joints.

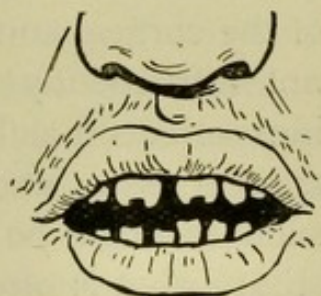


FIG. 34.
Hutchinson's teeth.

It is convenient to describe two types—*A mild form* : The patient complains that for a few days or even longer one eye has not seen so clearly, that things seem blurred, that the eye is easily tired ; but there is little or no pain, and on examination not much injection is

detected; what there is is of the ciliary type. The central area of the cornea is dull and has lost its lustre, invaded by a number of isolated little white or grey points of infiltration. This may exist for a few weeks in the central two-thirds or so of the cornea, and then gradually pass off, leaving the cornea again as sound and clear as it found it.

In the *severe type* matters are vastly different. The patient complains of some little pain in the eye, which sees indifferently, and which on inspection is found to be injected in the ciliary zone, and over the injected area the epithelium is dull, lacking in lustre, and greyish in colour. This state of things having existed for some few days, the injection becomes more pronounced and begins to invade the cornea itself; the invasion almost invariably begins at the upper part and consists of a broad bunch or group of vessels lying closely packed together in the peripheral part of the actual cornea itself, where under normal conditions there are of course no vessels whatever. These vessels, lying quite under the epithelium and actually in the substance of the cornea, and being so fine and so densely packed, not infrequently are misinterpreted by the unwary or inexperienced as being in reality a hæmorrhage into the corneal tissue, and certainly the aspect is frequently just such as might be accounted for in this way. They constitute what is often spoken of, from its peculiar appearance and colour, as a "salmon patch" in the cornea. In front of this band of vessels, *i.e.* centrally to it, is a narrower band of whitish infiltration, often very dense, which may appear to give rise to an actual distortion of the form of the cornea, as though the cornea were increased in thickness at that part, swollen by the copious infiltration and tissue change. As the weeks go on this vascular patch advances towards the centre of the cornea, preceded always by the infiltrated zone, which looks as if it were

being pushed along by the injected patch, and involves more and more of the periphery of the cornea (Plate VI. 5). Presently a precisely similar patch begins to appear at the lower margin of the cornea, repeating the aspect observed already at the upper, and gradually the two advance to meet one another, involving an ever-increasing portion of the periphery of the cornea, and working round laterally to meet one another, until at last the whole dull, whitish, semi-opaque or opaque central portion of the cornea is cut off and surrounded by a dense ciliary injection in the corneal tissue itself. The iris and pupil are almost or quite invisible, and the eye at this stage possesses very little vision indeed, sometimes only hand-movements or a little more; but presently matters begin to improve, the cornea to be not quite so densely injected, the central part not quite so opaque, and along with this evident improvement in the signs vision begins gradually to return. Up to this stage there has in a number of the cases been somewhat severe, and sometimes very acute, pain from time to time, but this now begins to abate. Slowly and gradually the cornea clears more and more, the vessels shrink in size and diminish in number, they occupy a smaller and smaller portion of the peripheral parts, and in a favourable case the eye may recover entirely, taking perhaps from six to ten months or even longer to do so. The cornea clears peripherally before the centre improves much, and during the regressive stage the tension of the eye may be somewhat below normal.

To understand the disease one must grasp the idea that it is not a corneal affection primarily at all but one taking its rise in the ciliary body. Since, as we shall see, the prognosis is usually favourable, very rarely does it happen that an eye is subjected to pathological examination during the active stages of the disease, but it appears from the study of such material as becomes

available that the actual lesion in the ciliary tract is closely analogous to that which we see in the chorioid under similar circumstances, namely, localised circinate patches of inflammation, accompanied by accumulation of round cells, absorption of some of the pigment, and increase in other places—chiefly surrounding the patch. The round-cell infiltration in the cornea is chiefly limited to the posterior layers, the part most entirely dependent upon the ciliary body. For this reason also ulceration practically never occurs, even when the crowding of cells in the central parts is very dense.

There can be no doubt that in a very large proportion indeed of the cases of genuine interstitial keratitis the ultimate cause lies in hereditary syphilis, but they go too far who regard the condition as conclusive proof of syphilis, and in a certain small proportion tubercle may be the cause. As with a certain number of other constitutional diseases, trauma has frequently enough the rôle of the exciting cause of interstitial keratitis. This happens too often to justify the theory of mere coincidence, and the possibility of an attack following upon injury is sometimes a serious matter in connection with questions as to compensation for injuries. In rare cases interstitial keratitis appears as a tertiary manifestation in acquired syphilis.

In the *treatment* one must in the first place give great attention to the general health; the great majority of the patients are badly in need of good wholesome food and better hygienic conditions. They are very apt to mope, to grow dull, spiritless, and indifferent to their own welfare, whereas they should be cheered up with the prospect that the vision, though failing daily, is eventually going to become better again, encouraged to walk out of doors, to take exercise, etc. When the vision has become so bad in both eyes that the patient is no longer able to guide himself, skipping in an

unoccupied room or on green grass will be found a highly beneficial form of exercise, it being one of the few for which sight is not required. Tonics are certainly indicated; some approve highly of administering mercury and other anti-syphilitic remedies. Locally one must put one's faith in atropin, which must be used somewhat freely. Atropin is of value because in the first place it puts at rest the inflamed ciliary body. It also has the power of reducing ciliary injection, and it also sets the iris at rest. Iritis is invariably present to a greater or less degree, and some of the bad results met with are as much due to the iritis as to the cyclitis.

The *prognosis* is, speaking generally, decidedly good. In the great majority of uncomplicated cases the cornea clears up again and vision returns to its former acuteness or nearly so. But there are dangers and *complications* which may prevent a result so satisfactory. (a) The cornea may fail to recover complete transparency; this is specially true of the central portions. (b) It may yield to the intra-ocular tension while in a weakened state, and partial staphyloma, myopia, irregularity of surface, be the consequence. (c) Iritis leads to adhesions between iris and lens and to deposits on the capsule of the lens. (d) Increased tension, which is often present to a slight degree and for a short time, may be too severe and too prolonged. (e) Other complications may preclude the recovery of good vision, notably the presence of a more extended disseminated chorioiditis, which may even attack and destroy the macula. (f) In a certain small percentage of cases the tension falls, the ciliary body degenerates more and more, the nutrition of the whole eye fails, and a very soft, shrunk, sightless eye is the result, with a completely opaque and degenerated cornea—that is, the lesions of the ciliary body have been too widespread and too destructive, and the tissue is unable to retain or regain its physiological functions and activity.

Certain other, less important, inflammatory affections of the cornea require brief mention :—

Keratitis profunda is the somewhat unsatisfactory name of a form of inflammation of the cornea which resembles interstitial in appearance, but in which the area of exudation and opacity is more restricted, one eye alone is affected, and the patients are usually older and have no syphilitic history.

Sclerotising keratitis is a term used to express certain changes which occur in the periphery of the cornea in the course of scleritis, *q.v.*

NON-INFLAMMATORY AFFECTIONS OF THE CORNEA

Kerato-globus or **Globular Cornea** is a somewhat rare affection in which the cornea becomes distended into a comparatively large protrusion, perfectly transparent, with a greatly increased depth of anterior chamber. This is really one of several forms of infantile glaucoma and is closely related to Buphthalmos, *q.v.*

Kerato-conus or **Conical Cornea** is more frequent. The essential feature of the disease is the conical protrusion of the cornea; in a well-marked case this is readily visible when the eye is viewed from the side; when the eye is seen in face the aspect is that of an abnormally "bright" eye, looking as though a tear-drop were lying on the surface of the cornea. The patient is usually a young person who may recently have suffered from some debilitating illness or depressing experience, and who finds that sight is failing both for near and for distant objects. The disease is more common in women than in men: it is said to begin about puberty, but certainly the average age of the patient at the time she presents herself must be about 25 or 26. One eye or (more frequently) both may be affected, but not necessarily to the same degree. It sometimes affects several members of one family. Visual power will be found to

be decidedly low on account of the enormous amount of astigmatism which cannot fail to be present, correction of which gives only a very limited degree of improvement (Plate VII. 6, 7).

The distortion of the convex mirror which is formed by the cornea causes an obvious distortion of object reflected from it, such as the window-frame. Use is made of this fact in observing the reflection of a Placido's disc (Fig. 35), a piece of cardboard bearing a series of concentric black and white rings, which is held in a good light before the cornea of the patient; the reflected images are observed through a central aperture in the card. A normal cornea gives a much reduced but perfect image, a conical cornea a misshapen and distorted image. With the ophthalmoscope mirror, and still more clearly with the retinoscopy plane mirror, the pupillary red glow shows a paracentral crescent of darkness which changes its place round the centre of the pupil with the slightest movement of the mirror or of the patient's eye. This appearance is due to the altered degree of obliquity at which the returning rays of light traverse the cornea (Plate XIII. 9).

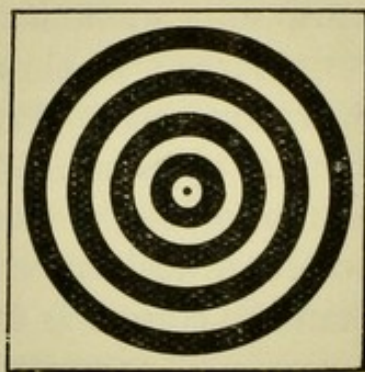


FIG. 35.
Placido's disc.

Treatment.—The patients generally are in need of tonic treatment; they are often anæmic and in lowered health. It is best if the condition be not too severe, and in the absence of any evidence of very active progress on the part of the disease, to delay any operative procedure till health is thoroughly recovered. One ought first to ascertain what is the best vision obtainable by optical correction, and not operate unless this is less than sufficient to enable the patient to make full use of the eye (or unless only one eye is affected). Formerly

hyperbolic glasses were regarded with favour, their form adapting them as closely as might be to the conicity of the cornea; but these have not been found to be very serviceable, for they are of benefit if the eye be very directly looking through in one exact position, and in no other—indeed in any other the vision is made worse. Contact lenses, applied directly to the cornea and lying inside the conjunctival sac, have been tried, but they cause unbearable irritation. But should the disease be very marked, or should it seem inclined to grow worse, operation ought certainly to be proceeded with. The aim of operation is to provide, at or near the centre of the cornea, a cicatrix which shall possess a greater power of resistance to the normal intra-ocular tension than the cornea as it is. No method of producing such a scar meets the case so well as the application of the cautery. With this at a temperature just above that of red heat a minute circular eschar is made at the summit of the cone; this is slightly below the centre of the cornea, for the weight of the upper lid (as it is believed) causes the point of maximum protrusion to be lower than the centre; thus the eventual nebula is not at the very centre of the pupil. Opinions are divided on the point, but it is probably best to penetrate the entire thickness of cornea and allow the aqueous to escape. A pressure bandage is kept on steadily for a number of days, that the cicatricial tissue may be well supported and the new curve of cornea be as flat as possible. It may be necessary to perform an optical iridectomy subsequently, but not usually, for the cautery, properly used, gives only a minute scar. When the high degree of astigmatism is corrected the subsequent result is not merely a great but a permanent improvement.

Another method of operating, well spoken of by some, is the excision of a narrow wedge of tissue at the

apex of the cone, but the surfaces which have to heal together are both narrow and of poor vitality.

Occasionally other morbid conditions of the eye are present along with conicity of the cornea, and these stand in the way of any decided improvement of sight.

The *pathology* of the condition consists in the gradual thinning and weakening of the substance of the cornea, so that it is no longer capable of resisting the normal tension. The tissue becomes more and more attenuated as the centre is approached, the peripheral portions being hardly affected at all. No changes of any very definite character have been constantly observed in the tissue elements themselves. Some writers would have one believe that the fault is really congenital, but fail to explain why, if that is the case, the disease first makes itself manifest at the most unlikely stage in life.

It is convenient to consider here in a group the various results which may follow ulcerative, inflammatory, or degenerative processes affecting the cornea.

Any ulcerative process of sufficient severity in a child, and any at all in the adult, leaves a scar behind ; it may be taken as certain that any loss of corneal substance in the adult will not be replaced by transparent tissue, whatever may be true of the child. If this injurious process be mild enough a fine thin opacity is left, which may be visible only under focal illumination, or, with varying degrees of severity of the original lesion, be a dense pure white cicatrix ; the milder form is called a *nebula*, the dense a *leucoma* ; the old term "albugo" has nearly dropped out of the language, and "macula" should never be used, as the word has another entirely different signification. It is convenient enough for the purposes of keeping records to have a scale of *nebulæ*—"1," barely visible ; "2," quite visible ; "3," "4," up to "5," an absolutely dense white intranslucent scar.

When perforation has occurred at some period of ulceration, the iris must have been in contact with the cornea, and pigment will be found in the scar; possibly the iris itself is still adherent and drawn forwards, in part, to the scar; such a condition is called *Leucoma adherens*. Protrusion of this scar brings anterior *Staphyloma*, the scar tissue being, at the time of formation, insufficiently firm to resist the intra-ocular tension, and being pushed outwards in consequence. This staphyloma may be complete or merely partial (Plate VII. 1, 2, 3). Of the staphylomata which so occur in this region there are three varieties, that of the cornea, as we have seen, ciliary, and intercalary. Ciliary staphyloma is prone to occur when there has been severe inflammation of the anterior parts of the sclerotic, leading to thinning of the coats there and consequent yielding to pressure, which may or may not be excessive. This is seen as a protrusion of a deep blue or purplish blue colour, streaked antero-posteriorly with white where certain of the scleral fibres are still holding their own against the thrust-out ciliary body. In very much less severe cases there may be little change of form but a decided slate-blue discoloration in the ciliary region. These forms are to be seen in some cases of slow, persistent cases of glaucoma in the young, cases in which there has been a long-standing and perhaps a constant raised tension, but never actually becoming an acute glaucoma.

The contents of the eye may to some extent escape when the cornea gives way, the aqueous and perhaps the vitreous rushing out, and perhaps the lens also, and a shrunk, shrivelled globe be the result (*phthisis bulbi*), which may have to be removed if troublesome. Finally in a very small number of cases the suppurative process spreads to the ciliary body and vitreous, acute panophthalmitis comes on, and the globe simply forms an abscess cavity. This is a much more rare result than the tyro might readily enough expect,

and is said not to occur if the pyogenic organism has been the pneumococcus; it has probably been the pneumobacillus or bacillus perfringens.

In the *treatment* of these various conditions one must of course be guided largely by the cause. In nebula, persistent massage with a stimulating ointment is useful, so is the application of alcohol (5-10 per cent), glycerine, oil of turpentine (10-30 per cent), but care must be taken that the reaction of tissues thus sought be not too severe. In the worse cases one may tattoo in order to mitigate the unpleasantness of the aspect.

In order that more direct improvement in vision may be secured it is often advisable to perform optical iridectomy (also called formation of artificial pupil), an operation of enormous value in many cases. The idea underlying it is, since the normal pupil is of no use, there being in front of it not clear cornea but opaque tissue, to remove a piece of iris opposite a clear or clearer portion of cornea, and thus to allow the patient to obtain fair or at the least improved vision. When the staphyloma is advancing, however, as it continues for some time to be very apt to do when the tension rises, iridectomy has another function, namely, the reduction of tension either permanently or for long enough to permit the new tissue to harden and resist that further protrusion which draws upon the iris, irritates it, causes congestion of parts thereby, and tends still further to increase of the staphyloma, in a vicious circle. In the large protruding staphylomata, such as one sees after bad ophthalmia neonatorum, for example, if distress is being caused, enucleation or evisceration is the right procedure; no half measures are safe or effective; in them the hideous white eroded mass, perhaps nearly as large in size as the remainder of the globe, stands out between the lids and is constantly exposed to injury.

In a case of ciliary staphyloma a broad iridectomy is

best, provided the state of the eye is such as to bear it and to obtain any benefit from it.

Arcus senilis or **Gerontoxon Corneæ** is, as its name implies, a senile or degenerative alteration of the corneal substance ; just within the corneo-scleral junction above there forms a greyish-white line of opacity which leaves between it and the corneal margin proper a narrow zone of transparent cornea. This opaque line, after advancing for a space concentrically with the margin, is found to be repeated at the lower margin of the cornea, and the two lines gradually lengthen till they meet at the sides. The change appears to have little or no influence upon the cornea ; at all events wounds passing through it heal just as quickly and well as if in normal tissue. The change is a form of fatty degeneration ; after encircling the cornea it advances no farther into it. The only difficulty in diagnosis is with sclerotising keratitis, but in the case of the latter the clear peripheral zone is not found, and there is further a history of inflammation. Treatment is not called for ; it should be remembered that though patients are sometimes alarmed on seeing arcus, the condition does no harm whatever, and that it is not so very infrequent among quite young persons, particularly in those of rheumatic tendency (Plates VII. 5, and XX. 4).

Calcareous Degeneration of the Cornea : called also Band- or Ribbon-shaped Degeneration of the Cornea.— This form of alteration of nutrition of the cornea consists in the formation just under the epithelium of deposits of whitish lime salts, giving the cornea in the affected region a rough and opaque aspect. The change is rarely seen save in eyes which have suffered from prolonged degeneration of the ciliary body with lowered tension. The deposition may begin either to the inner, or less frequently to the outer, end of a line drawn across the most constantly exposed portion of cornea, the part, in other words, just inferior to the horizontal meridian,

the two extremities advancing to meet one another. It is practically beyond treatment. Should there be pain, which is not always the case, soothing applications should be employed: picking off, or scraping off, or cutting off, or dissolving off the lime salts is of absolutely no use (Plate VI. 4).

Tumours of the cornea are very rare. *Dermoid* occurs as a congenital error in the form of a white, elevated mass on the corneo-scleral junction at the lower outer side, often with one or two large hairs growing from it. The explanation is that during the pre-natal separation of the tissue covering the globe into upper and lower lids, the line of cleavage has not been quite exact, with the result that a morsel of lid tissue is left stranded on the cornea. It can easily be dissected off and the scar tattooed.

CHAPTER VI

THE SCLEROTIC

THE sclerotic is one of the most inert tissues in the body, and is therefore but little liable to disease. It is practically exactly identical with the cornea, only that it is opaque while the cornea is transparent, and that it contains blood-vessels, which the cornea does not. The sclerotic is thickest at the posterior pole and gradually thins as it approaches the corneo-scleral junction, just outside which, where it covers the ciliary body, it is thinnest and most prone to give way, either as the result of a blow or from within when the tension keeps persistently high in a young patient. Although opaque and very resistant it is not so tough as the cornea, and will give way as the result of a blow rather than the latter. It is continuous with the dural sheath of the optic nerve, and is penetrated by numerous vessels, particularly the large venæ vorticosæ near the equator.

SCLERITIS or SCLEROTITIS, *i.e.* inflammation of the sclerotic, is apt to manifest itself in two parts particularly, viz. the area immediately surrounding the optic disc, more especially to its outer side, and anteriorly immediately peripherally to the corneo-scleral junction. In the former case the morbid condition, visible only by the aid of the ophthalmoscope, forms an important element in progressive myopia, and is chronic in its character; it is

dealt with in connection with myopia ; it is with the latter that we are dealing now.

The patient is more frequently a woman than a man ; she may complain of little discomfort, only the eye feels rather heavy and large, or, as some patients say, "as if it would fall out of the head." Vision is not in the first place interfered with, and the condition is annoying rather than actually painful. On examination at this stage there will be found, most usually under the upper eyelid just at the summit of the cornea, a flattish elevated area, violet-pink in colour, oedematous in aspect, with a somewhat reddened conjunctiva overlying the injected, deep-lying vessels. Under treatment this subsides, sometimes very slowly, but in many cases only to reappear again and again in a fresh part of the sclerotic just outside the corneo-sclerotic junction, until, it may be, it has circumnavigated the cornea.

There are two forms of inflammation of the sclerotic, a superficial and a deeper. The superficial, known as *episcleritis*, is most frequently a manifestation of gout. The patient is in most cases rather past the prime of life, rather stout and florid, and may often sum up his symptoms in the word that his eye feels "hot." This "hot eye," a feeling which may be very transitory (it is spoken of as *episcleritis fugax*), lasting only an hour or two after dinner, or half a day, is often mistaken for conjunctivitis and treated with astringents. This is wrong ; no astringent, unless adrenalin, should be used, but reduction in the stimulating elements of the food, abundant ingestion of water, administration of alkalies and depleting mineral waters, salicylates and aspirin are of use ; hot bathing, local depletion, and in more chronic cases judicious massage with a bland ointment : these form the best line of treatment (Plate XX. 1).

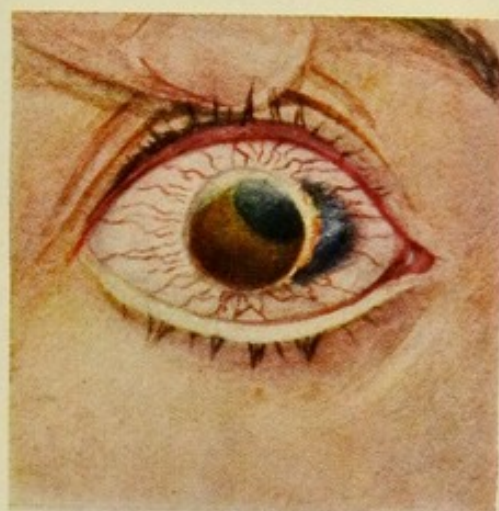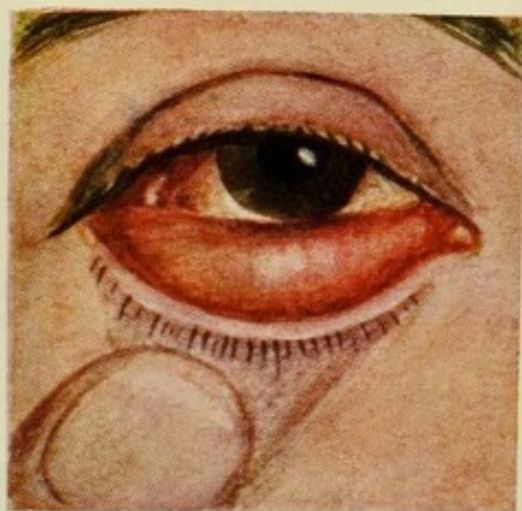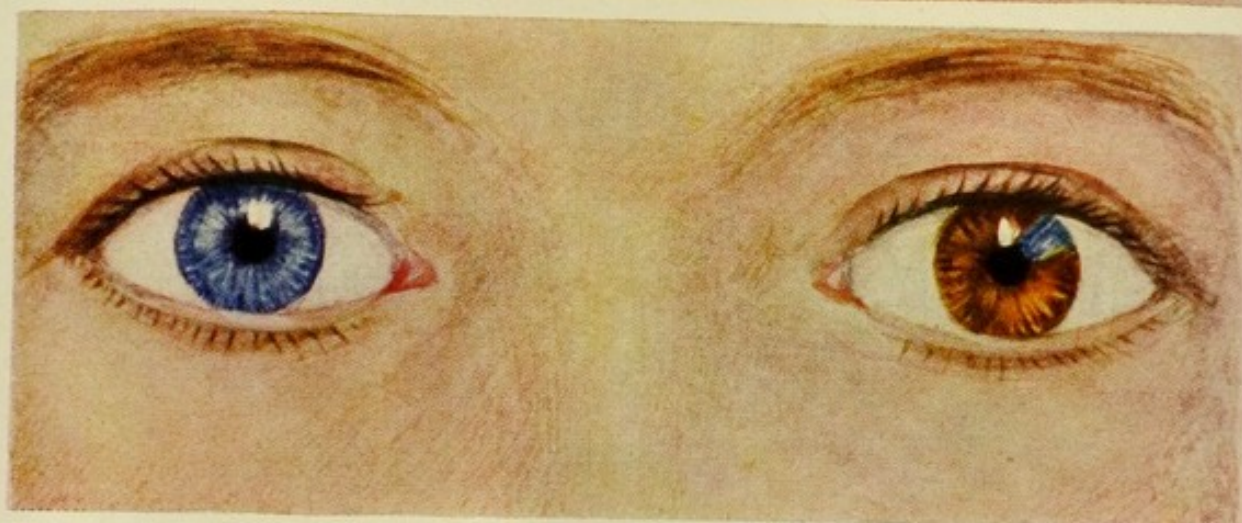
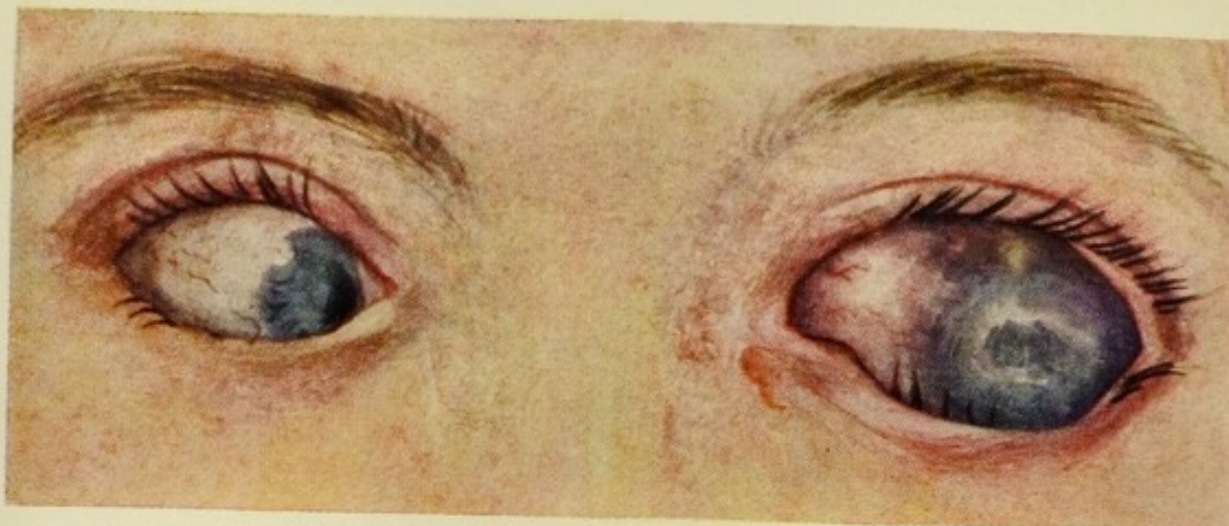The *deeper form* is more serious, for the part affected is the thinnest portion of the sclera and lies

over the ciliary body, which is apt to become involved in the inflammation, with disastrous results. For with the cyclitis in old-standing cases may come interference with the normal tension of the eye, the iris may become inflamed and adhesions form (posterior synechiæ), all the more that such "arthritic" subjects are liable to iritis at any rate. The cornea, too, is nourished from the vessel loops at the corneo-scleral junction, and if these are interfered with the cornea is apt to begin to become opaque in two ways: the central portion to exhibit soft-edged, deep-lying, whitish areas which resemble the opacities left after keratitis but are lying deeper, while peripherally the margin of the cornea appears almost to change into sclerotic (*sclerotising keratitis*); it looks as though the sclerotic tissue had encroached upon the cornea (Plate XX. 2, 5). This is distinguished from arcus senilis, which it closely resembles (see Plate VII. 4), by the fact of its not leaving any clear area between the periphery and the opacity as arcus senilis does, and by its being dead-white, like porcelain, not grey-white, and by being irregular. The deep form of scleritis is apt to be very persistent in returning, often making its way round the cornea in spite of all treatment, and ceasing spontaneously only when it has completed its circuit. Altogether a deep scleritis is a most dangerous and obstinate malady, and in really bad cases may lead to complete loss of sight.

The etiology of the scleritis is somewhat obscure, but when it is not a rheumatic affection, it is, in women, apt to occur about the menopause or, less frequently, about puberty, or at the time of some menstrual trouble, or amenorrhœic state. It seems as though in such persons some poisonous material were apt to accumulate in the system, and set up reaction at intervals. A few cases are probably tuberculous, and a very few may be syphilitic. The treatment has been sufficiently indicated;



PLATE VIII.



1. Entropion of both lower Eyelids : Shrunk Globe (R.E.) : Large eroded staphylocornal Cornea (L.E.).
2. Heterochromia Iridis et Iridum.
3. Chemosis.
4. Rupture of Globe at inner side.

eliminants, especially such as act by the skin, as do the salicylates, are very valuable, and should the patient's general condition suit it, Turkish baths. In bad cases hypodermic injections of pilocarpin as a vigorous sudorific have proved of great value.

In severe or long-standing cases the area which was affected acquires a blue or slate colour, in part probably from thinning of the sclera, permitting the deep colour of the ciliary body to shine through, and in part also from the wandering of pigment from the ciliary body into the sclerotic. In some cases this thinning is so serious as to permit the envelope to become stretched and staphyloma to form (Plate XX.).

Tumours of the sclerotic, because it is so inert, are very rare.

CHAPTER VII

THE IRIS AND CILIARY BODY

THE iris is the non-diaphanous curtain, containing a diaphragm, which hangs between the entering light and the perceptive mechanism and between certain parts of the dioptric media. It has therefore as its functions to regulate the amount of light entering the eye and, by shutting off aberrant rays, to enhance the precision of the image formed upon the fundus. It consists of three layers, the anterior endothelial, the muscular or stroma, and the posterior pigment layer, which is really the continuation of the anterior portion of the retina, with a limiting homogeneous membrane on each face of the iris stroma proper. The anterior endothelium is continuous with that which forms Descemet's membrane on the posterior aspect of the cornea, and through it there lead the crypts which form an important factor in absorption of fluid from the anterior chamber ; these crypts are open when the iris surface is fully spread out, *i.e.* when the pupil is contracted, but closed when the pupil is dilated. The stroma of the iris consists essentially of a framework of cells, of unstriated muscle, and of blood-vessels, which are particularly copious, the muscular tissue being for the most part grouped about the pupillary margin. In the stroma is abundant pigment, as there is also in the posterior layer, and the "colour of the eye" depends upon the relation between these two ; if there be little

in the stroma the eye will be light coloured, "blue," or "hazel," that in the posterior layer being almost constant. The pigmented posterior layer has a smaller aperture than the muscular, and when the pupil is white, as in cases of cataract, this exhibits itself as a narrow black ring which is not visible when the pupil is normal and black. Forming part of the posterior layer are certain peculiar cells which act as a dilatator muscle. In the albino the tissue is almost completely transparent (see Plate XIII.).

Seen from the front the iris presents a number of curious irregular markings according to the arrangement of its stroma, and often shows spots or marks of increased pigment deposit, which sometimes take singular forms.

The size of the pupil, which is not absolutely in the centre of the iris, depends upon the active contraction of the sphincter, the active contraction of the dilatator, and the tonicity of the vessel walls. The sphincter is under the command of the III. nerve, the dilatator and the muscular tissue of the vessel wall under that of the sympathetic. The pupil can therefore be *contracted* by active contraction of the sphincter, by paralysis of the dilatator, or by paralysis of the vaso-motor apparatus. *Dilatation* of the pupil can similarly be effected by active contraction of the dilatator, by constriction of the vessels, or by paralysis of the sphincter. The reactions of the pupil are thus of much importance as affording a visible indication of the state of nerve stability and activity in the two great nerve systems. Testing of the pupil reaction should be conducted in daylight, not in artificial light.

The **pupil** is **contracted** by (1) any circumstance which leads to domination of the voluntary cerebation over the sympathetic reactions. Persons who are cool, calm, and self-possessed have small pupils, while excitable, nervous persons have large ones. (2) Advancing

age : conditions in actual infancy excluded, the pupils of a child are large ; as age goes on they become smaller, till in old age they are minute ; this is probably, at least in part, a consequence of the inability of the vessels to alter readily their calibre and therefore the amount of their contents. The average size of the adult pupil is about 3 or 3.5 mm. (3) The light entering the eye : bright light causes contraction of the pupil, but it has been shown that it is from the neighbourhood of the macula alone that this reflex comes ; light, even bright light, thrown on the peripheral parts alone of the retina brings about no reaction. The importance of this fact has been noted in connection with Wernicke's sign (see p. 26). (4) Active accommodation. It is perhaps the case that it is the accompanying convergence which is mostly responsible for the pupil contraction, but there can be little doubt that it is largely due also to the necessity for shutting off any rays which do not pass through the heaped-up central parts of the lens during active accommodation, in the interests of accurate vision.

The **pupil** is **dilated** by mental excitement, such as anger, fear, pain, or indeed any condition which diminishes for the time being the cool mental balance. Emotional persons thus have large pupils ; they are large in a state of shock, of mental excitement, of pain, especially of abdominal pain. The pupils are small during sleep and small during chloroform narcosis ; if they suddenly enlarge during chloroform administration, that is a sign of acute danger—they are threatening, in fact, to assume the cadaveric attitude.

Certain drugs also, taken internally or applied locally, have the power of altering the pupil ; atropin is the classical dilatator, acting by paralysing the sphincter, but cocain, by stimulating the sympathetic, contracts the dilatator and reduces the size of the vessels ; while opium

internally, eserine and pilocarpin locally, contract the pupil.

From a medical point of view, apart from drugs, apart from shock, apart from temperament, there are many valuable indications afforded by the state of the pupils. The pupil is contracted, for example, in irritative cerebral lesions and in hæmorrhage into the pons; dilated in cerebral compression.

The pupils are always (physiologically) of the same size exactly, though in some quite healthy individuals inequality occurs as a mere peculiarity. They are of the same size although the amount of light entering one is quite different from that entering the other. Thus, if the right eye be shaded and a bright light allowed to fall upon the left, both pupils contract and remain equal; if this bright light is partly intercepted from falling on the left eye (what light may be falling upon the right one being left unaltered) both again dilate, and when the light is again allowed to fall upon the left eye both contract once more and to an equal degree; this is called, as regards the left eye, the *direct*, as regards the right, the *consensual*, pupil reaction. The reason for this is that each III. nerve nucleus is connected with each visual path, the light-reflex path diverging from the vision path at the corpora quadrigemina and passing to *both* III. nerve nuclei on the floor of the Aqueduct of Sylvius; light, therefore, which falls on one retina produces pupil reaction in both eyes. It is therefore true that even should one eye be quite blind, its pupil (unless there be some mechanical obstruction) remains the same as that of the other, and the two change precisely together. This fact may be a valuable one with which to be familiar even in connection with legal questions, for a man may claim that his left eye (we shall say) is blind, his pupil may be (artificially) dilated, he may deny all interference with the natural state of it on his part, and

assert that he does not know whether light is falling on it or not, but if the pupil of his other eye varies with light thrown on the "blind" one alone, he will find his contention difficult to establish.

But this pupil reaction to light is sometimes lost when sight is present, and that without loss of the accommodation reaction. This is the condition first described by the distinguished Edinburgh surgeon Argyll Robertson, and known throughout the world as the Argyll Robertson pupil. It is usually, but not necessarily, accompanied by contraction of the pupil, sometimes to a pin-point (spinal miosis), but the precise situation of the lesion is still not absolutely certain; some consider it to be in the immediate neighbourhood of the sphincter nucleus, others actually in the ciliary ganglion. It appears to be unknown in health, to be an almost infallible indication of syphilis, and to be one of the most absolute signs of locomotor ataxia and general paralysis of the insane. It is not in any way an indication of disseminated sclerosis, if it ever occurs in that disease.

The rule as to equality of the pupils is true also as regards accommodation and its accompanying reaction; it is impossible to accommodate with one eye to a greater or less degree, voluntarily, than with the other, therefore inequality in the refractive condition does not account for inequality of the pupils. A peculiar reaction of the pupil is to be seen in cases of central scotoma, namely, that when light is admitted the pupil promptly contracts but almost immediately dilates again to very nearly its former dimensions; it is an exaggeration of the normal swing of the pupil.

Hippus is the name given to the condition in which a pupil alternately dilates and contracts, and continues to do so after the withdrawal of the stimulus which initiated the movement.

In certain pathological states of the nervous system

the pupils are apt to be unequal; specially is this the case in general paralysis of the insane. When the pupils are observed to be unequal the case ought to be investigated in a dull and in a bright light. If the disparity between the pupils is most marked in a dull light, the fault almost surely lies with the sympathetic, whose action is too feeble; if the disparity is greater in a bright light, the III. nerve is to blame—its action is too feeble.

THE IRIS

If we now put aside these various alterations of the pupil which we have just discussed, diseases of the iris are found to be limited, one might almost say, to iritis and tumour formation, with the congenital error known as coloboma.

Iritis is one of the most important diseases affecting the eye, because it is so frequent, and so amenable to correct treatment, but liable, if unchecked, to lead to serious damage to the eye, and even to the destruction of its utility.

The symptoms are frequently so definite that a diagnosis might be based on them alone. There is a little dimness of vision, the degree depending rather on the degree of accompanying cyclitis than on the iritis itself; photophobia, readily enough explained by the pupillary action, carried through by a tender tissue compelled to contract and to undergo changes in vascular contents; and pain. This pain has certain features apt to be found more or less in all affections of the vascular coat of the eye; the pain is of a throbbing character, shooting up the temple and brow on the affected side, sometimes also attacking the upper teeth and the side of the nose; so decidedly is it located in those parts that sometimes the patient omits altogether to mention that the eye is affected at all. The pain has this feature further, that it is much worse at night-time, the hours

between 2 and 5 A.M. being often spent in agony by the patient. Vomiting is rarely present, a point of importance in the differential diagnosis.

The *signs* consist of injection of the eye, discoloration of the iris, immobility and irregularity of the pupil. The injection takes the form of numberless short, straight, pink, or rosy vessels, radially arranged round the cornea so that the area of the sclerotic showing the greatest injection is that immediately surrounding the cornea, the number of small vessels becoming less towards the equator of the globe. This is in accordance with the anatomical arrangement of the vessels which, under normal conditions, nourish the iris; these lie in the superficial *scleral* tissue overlying the ciliary body and run in straight lines towards the corneo-scleral margin, penetrating the hard coat above and below at a point nearer to the centre of the cornea than do those which are situated in the horizontal meridian. The result of this peculiarity is that at the sides of the cornea a narrow crescent of non-injected sclera is often seen interposed between the inflamed iris and the vessels of the inflamed globe (Plate IX. 1, 3). The vessels do not branch, are not tortuous, are only to be emptied by definite pressure, and cannot be made to move over the sclera. There is little or no secretion, save merely lachrymal. The iris is discoloured, a blue iris becoming brownish, and a brown one even of a greenish hue; at the same time the beautiful, bright, reflecting surface is lost and its aspect becomes dull, mossy, or velvety. The pupil is immobile and small, because the inflamed iris contains more blood than the normal, and it is prone to be irregular from the presence of adhesions which bind the iris to the lens. These adhesions, or posterior *synechiæ*, are of the most vital importance; the inflamed iris, resting upon the anterior capsule of the lens, gives forth an adhesive, lymph-containing exudate which binds iris and lens together.

These points of adhesion are not at first continuous round the pupil, and as the hyperæmia gradually passes off and the iris tissue returns to normal, the pupil again dilates, save at the points at which it is attached in this way. The effect is, of course, to produce irregularity of the pupillary ring (Plate XIII. 3). In a milder case the spots of exudate may leave a permanent deposit upon the lens capsule, stained with pigment from the iris, and showing in after days the former occurrence of iritis (Plate IX. 3). (See also Pupillary Membrane, p. 213.) The two principal dangers to the eye resulting from iritis take their rise in these very adhesions; these are spoken of as *occlusion* of the pupil and *exclusion* (or *seclusion*) respectively. When there has been exudation from the inflamed iris sufficient in amount to lie upon and cover up the whole pupillary area of the lens, there to organise, the pupil is said to be *occluded*, for this inflammatory exudate is non-transparent and obscures the pupil. When the adhesions between iris and lens have been sufficient in number and degree to attach the iris all round the circle, to shut off, in other words, the anterior chamber from the posterior, that is *exclusion* or *seclusion* of the pupil. Either may occur without the other, it is a question of circumstances, or they may be associated, and each is alike highly detrimental to the eye. Occlusion may render an eye practically entirely blind, and exclusion is almost necessarily followed by more or less complete blindness. One's chief aim in the treatment of iritis is to prevent the occurrence of either the one or the other.

The *etiology* of iritis is not invariably quickly settled. With certain varieties and types one becomes familiar, but there are many cases which do not lend themselves to water-tight classification, and some in which the cause is quite obscure. Putting aside, in the first instance, the traumatic cases and with them the sympathetic cases, we can recognise in the majority the result of some toxic

influence. This may be traced to certain definite diseases, such as rheumatism, gout, syphilis, diabetes, etc., or to some obscure absorption from the alimentary tract or elsewhere.

Take the following well-marked types:—

Rheumatic Iritis.—A frequent type. The affection is usually, but not by any means always, bilateral, and is often recurrent, especially apt to occur if a chronically rheumatic patient has been particularly free of his pains for some time. The exudate is sometimes purely serous, and the patient may have several attacks without a single synechia resulting, but they come by and by. In other cases the exudate is adhesive from the very first. The painfulness, too, varies greatly, for sometimes there is no pain, while in others it is very severe. An attack of fairly average severity may last for four to six weeks. An attack of iritis is very rare in association with genuine acute rheumatism. It is not infrequent in chronic rheumatoid arthritis.

Syphilitic iritis is a well-marked type. It is bilateral, causing very severe nocturnal pain, very plastic, not tending to recur, and manifests itself about the same time as the earlier secondaries. Some surgeons, who regard everything which happens to a patient as syphilitic, if they obtain a history of possible syphilis many years previously, would have one believe that the majority of cases of iritis take their origin in syphilis, and regard syphilitic iritis as very common; the fallacy is a pretty common one and is not confined to ophthalmology. One characteristic feature of the true syphilitic iritis is the presence of small rounded yellowish clots or deposits of yellowish organised lymph in the substance of the iris; these so-called gummata, being secondaries, are not, properly speaking, gummatous at all. Their favourite situation is at the pupillary margin. They consist merely of ordinary inflammatory exudate, but more apt

to run together and form small masses. When present these "gummata" are certainly indicative, but their absence indicates nothing; a definitely syphilitic iritis may show none of them.

Gonorrhœal iritis may arise at any time in the history of a case of gonorrhœa; it is said to occur only in cases in which gonorrhœal rheumatism is also present, but such a statement is too sweeping. The peculiar clinical feature of this form is the singular, massive, "lens-like" exudate lying in the anterior chamber; this is capable of rapid reabsorption. Cases of more ordinary "rheumatic" iritis are attributed by some to gonorrhœa contracted many years before, and which has been at rest and forgotten for decades.

Tuberculous iritis is fairly common; it probably accounts for a large number of the unexplained cases of double iritis in girls soon after puberty.

Iritis from auto-intoxication, having its origin in the abdomen or the mouth, occurs in a large number of cases. It has no known precisely characteristic features. Besides these forms iritis is to be met with in diabetes, gout, anæmia, Bright's disease, etc.

Iritis is *very rare in children*, unless traumatic, but is seen sometimes as a hereditary syphilitic manifestation apart from any keratitis: in such a case the patient is usually an infant of six to nine months.

Although as a nearly constant rule iritis is very painful, one meets with cases in which an eye shows evident signs of previous iritis of which the patient can remember little or nothing, the symptoms were so extremely slight. These are spoken of as cases of *quiet iritis*; they are probably never syphilitic.

In the diagnosis of iritis the following points will prove of moment. The two diseases for which iritis may readily enough be mistaken are conjunctivitis and glaucoma.

	Conjunctivitis.	Iritis.
Patient may be .	Of any age.	Usually young.
Secretion . . .	Sticky, adhesive.	Purely aqueous.
Vessels . . .	Large, branching, tortuous.	Small, straight.
Injection . . .	Worse at equator.	Worse round cornea.
Colour . . .	Scarlet.	Brick-red or pink.
Pain worst . . .	In evenings.	At nights (2 A.M.).
Iris	Unaffected, pupil reacts.	Small pupil, muddy and discoloured, sluggish, and irregular viro.

For the diagnosis from glaucoma see p. 302.

The *treatment* of iritis may almost be summed up in two words, viz. Constitutional and Atropin. Should the patient be rheumatic or syphilitic, should he have decaying teeth and unhealthy gums, should he have Bright's disease or diabetes, should he have gout or tuberculosis, these conditions must receive due and proper attention. There is a rather large residuum of cases, however, in which there is no evidence forthcoming as to the original cause of the attack. In these cases one is thrown back upon alternatives and intestinal antiseptics, potassium iodide, salicylates and aspirin, mercury, either in the form of hydrargyrum cum creta, calomel, or preparations for use by inunction, and sulphocarbolates. In certain cases vaccines have proved of decided value. Locally, there is one drug, and, one might almost say, one only, namely, atropin. Atropin acts in cases of iritis in several different directions, for it puts at rest the inflamed part, it empties the inflamed iris of blood (for naturally the more dilated the pupil the less blood exists in the vessels of the iris stroma), and it prevents adhesions. This last it accomplishes in virtue of the fact that while normally the iris rests upon the lens, when the pupil is dilated, the iris, owing to the recession of the equatorial portion of the anterior face of

the lens, hangs free; adhesion to the lens can then hardly occur. The most suitable concentration is gr. iv. to \bar{z} i., which may either be employed in aqueous solution or as an ointment, and should at first be employed three, four, five, or even six times a day. Once the pupil is dilated and free from adhesions a very much smaller number of applications will be sufficient to maintain the effect. In fact, give the atropin as often as may be required to effect the dilatation, and then as seldom as is sufficient to keep the iris so. The action of the atropin can be materially assisted, and the pain from which the patient is suffering greatly mitigated, by the application of heat, and particularly of dry heat, to the eye. A very convenient mode of accomplishing this is to apply a mass of cotton-wool or a silk handkerchief to a lamp chimney or to an incandescent globe till it is thoroughly heated and then hold it on the closed eye. It can be achieved also by means of a Japanese muff-warmer. Even greater relief is sometimes to be obtained in other cases by leeching; two, three, or four leeches are induced to attach themselves to the temple. Sometimes a pupil which has resisted atropin almost altogether will dilate considerably under this application. If preferred, the artificial leech may be substituted.

The rule that atropin should be employed vigorously and as early as possible is practically of universal application, but there are three *exceptions* which should be borne in memory: (1) Some persons possess an idiosyncrasy for atropin, and exhibit, after the drug has been used for a time, one form or another of "objection" to it. There may be mental symptoms, hallucinations, as well as flushed face, rapid heart, etc.; or there may be acute, even violent dermatitis, almost resembling erysipelas; or there may be a peculiar follicular form of conjunctivitis affecting chiefly the posterior surface of the lower lid, the lid somewhat thickened, the conjunc-

tival surface studded with numerous little raised whitish points, the "sago-grain" aspect (see Plate V. 6). In all such conditions the use of atropin must be discontinued. The most effective treatment for the local irritation is the application of ichthyol ointment.

(2) It is sometimes the case, though far from frequently, that along with true iritis there exists increased intra-ocular tension; when this is the case atropin must not be used, for it would aggravate the injury done by the increase of tension; of the two evils it is better to fail to dilate the pupil, and so permit the formation of adhesions, than to increase the tension further by the use of atropin.

(3) In recurrent iritis the adhesions resulting from previous attacks may effectually prevent any dilatation of the pupil, and the effect of using atropin would simply be to tug at the adhesions and irritate the inflamed iris; it is better, therefore, in such a case to confine one's self to hot applications and internal treatment.

A patient who has a fairly severe attack of iritis must make up his mind to an illness of four to six weeks' duration. In a case of iritis which has gone on well in which the question arises, "Dare I stop the atropin?" a good rule will be found to be: if the eye turns red again and injected while it is being examined, then it will not be safe or wise to cease the atropin. Never, under any circumstances, attempt to break adhesions by alternate use of atropin and eserine, as has actually been recommended by some; such procedure comes perilously near to malpraxis.

While, speaking generally, it is a good rule never to interfere surgically in a case of active iritis, there is a certain class of case in which persistent obstinate subacute inflammation is cut short by iridectomy when nothing else succeeds. In one type of iritis, that known as recurrent iritis, in which the patient has attack after attack at diminishing intervals of time, each attack

tending to leave the eye in a worse state than that in which it found the organ, a broad, free iridectomy acts like a charm, and the patient may remain free from molestation for many months or many years. It is best to choose a placid interval for the operation, if the patient can be persuaded to be so wise as to allow you, but when the acute attack passes off he is very apt to postpone his operation *sine die*, until the next finds him penitent but untreated.

For either of the two serious complications resulting from iritis, exclusion and occlusion of the pupil, iridectomy is unquestionably the best treatment. In occlusion, iridectomy enables the patient to have the advantage of a clear new pupil ; in exclusion of the pupil, iridectomy, by reopening the free passage from posterior chamber to anterior, cures the glaucoma which has arisen or is threatening to arise. This matter will be dealt with in the section on Secondary Glaucoma, and under the head of Iridectomy.

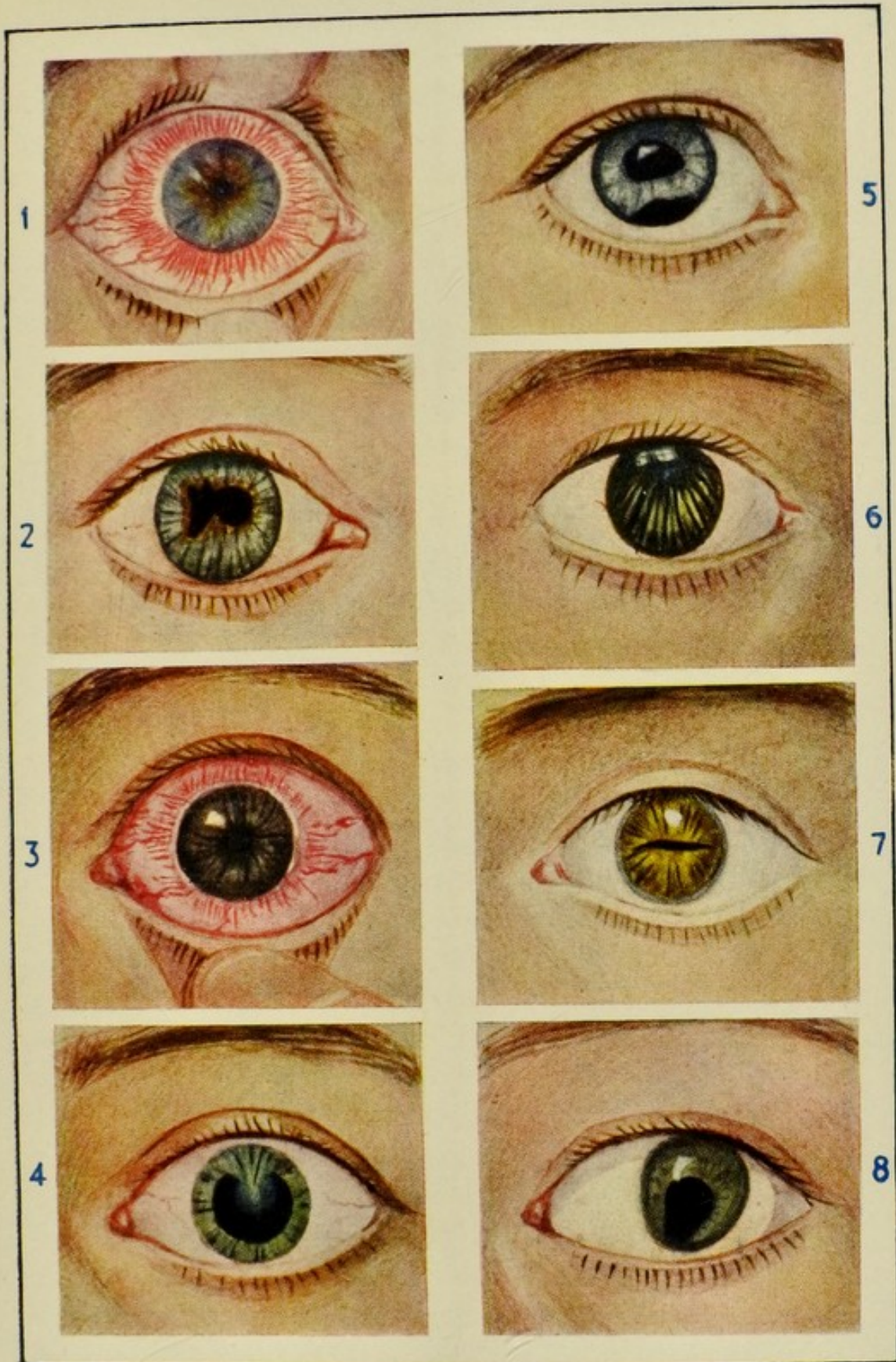There are two very serious *consequences* of the formation of *synechiæ*, namely, secondary glaucoma and universal adhesions. The former arises thus : An attack of iritis occurs and a few adhesions form. Each fresh attack tends to the formation of more adhesions because the pupil cannot be dilated, being fixed here and there by the synechiæ in a position of contraction. At last the ring of adhesions is complete, and there is no longer any means by which the aqueous humour can pass, as pass it must if the eye is to be maintained in health, from the posterior chamber between iris and lens into the anterior chamber, thence to be removed by way of the angle of the chamber. Fluid then accumulates behind the impervious iris and causes it to bulge forward and thus to encroach upon the vital angle ; this condition is known by the name of iris *bombé*, and is accompanied by increased tension (Plate IX. 3). If it is untreated and

is kept up, normal circulation of fluid having ceased, the ciliary secretion begins to diminish and the tension gradually falls below normal; if it be still untreated the nutrition of the whole eye becomes gravely interfered with, the vitreous loses transparency, the lens becomes opaque, the retina becomes detached by the shrinking of the vitreous, the badly nourished cornea degenerates, and the last stage of such an eye is a shrivelled, blind, unsightly mass. A timely iridectomy will save the situation; if it be performed during the stage of increased tension, when the arched (*bombé*) iris is still sound, the pent-up aqueous is let out, a permanent gateway is provided, the iris lies in its normal attitude, the pupil is no longer funnel-shaped, and the eye may recover and retain a great amount of useful sight. Even in the second stage, when the intra-ocular tension has begun to go down below normal, provided the degeneration has not advanced too far, a declining, failing eye may be changed into one which recovers a fair amount of sight.

Where universal adhesions occur, the prospects of the eye are very black. The phrase means that not the pupillary margin merely but the whole surface of iris which lies upon the lens has become glued down upon it. Iridectomy is the best procedure here too, but to one's great disappointment one sometimes finds that the nice black pupil which seems to have been secured is, in fact, a pupil covered by deep pigment; on the lens lies a dense pigmented felt, and extraction of the lens is urgently required.


Iridodonesis or **Tremulous Iris** is observed when the eye is quickly moved; it implies that the iris has lost the support of the lens, whether by extraction or dislocation, partial or complete; it may be seen, too, in some cases of abnormal fluidity of the vitreous humour.

Tumour of the iris is a rare condition; the new growth is practically always a sarcoma, whether melanotic



1. Iritis.
2. Irregular Pupil from posterior Synechia, the result of Iritis.
3. Iris bombé: anterior chamber shallow at periphery.
4. Anterior Synechia.

5. Iridodialysis.
6. Pupil drawn up to wound of Cornea.
7. Artificial Pupil obtained by Iridotomy.
8. Coloboma of the Iris.



or not; it may occur at almost any period of life, and is on the whole liable to occur at a distinctly lower average age than tumour of the chorioid. The little mass may be seen pushing forwards from the surface of the iris anteriorly towards the cornea and centrally into the pupillary area. By and by secondary glaucoma may occur from the increase of the tumour and the encroachment upon the angle of the chamber. In a very few cases it is possible to remove a very small tumour by means of iridectomy; it is generally necessary, and is probably always advisable, to enucleate as soon as the diagnosis is established.

Cysts of the iris occur as a rarity, sometimes spontaneously, sometimes secondarily to a wound (*e.g.* operation wound); the latter are implantation cysts taking their inception from epithelium carried into the wound.

Coloboma of the iris is one of the most frequent congenital malformations about the eye (Plate IX. 8). After the invagination of the ocular vesicle has lasted for a time the two horns coalesce to close in the interior vesicle, the mesoblastic tissue uniting to form the iris, the ciliary body, and the chorioid. Should the union of this mesoblastic tissue, which for a time is imperfect physiologically, continue so, a coloboma or deficiency in the uvea, or vascular coat of the eye, will result, which may exhibit itself in the chorioid, in the ciliary body, in the iris, or in the sheath of the optic nerve. Any one of these deficiencies may thus arise without a corresponding defect in the others. Thus coloboma of the iris does not imply a similar defect in the chorioid—either may exist without the other. Coloboma of the sheath of the optic nerve to a slight degree is known also as downward staphyloma and “Fuchs’s coloboma”; it is rare to find perfect vision in such an eye (Plate XIV. 4). Where there is a deficiency in the ciliary body a nick may

sometimes be observed in the corresponding portion of the lens—a coloboma of the lens.

Coloboma of the iris, then, is a deficiency in the iris at one part. This is all but invariably in the lower or lower-inner part, for it is at this point that the junction of the two horns ought to take place. The pupil is thus pear-shaped or clove-shaped, the thin end pointing downwards and slightly inwards. The condition is, of course, incurable, but fortunately the eye usually possesses at least fair sight. It has, however, a distinctly unpleasing aspect.

Congenital absence of the iris (Aniridia) is a rare abnormality. Other congenital abnormalities are polycoria, corectopia, and heterochromia.

Polycoria (multiple pupil) exists when there are more apertures than one in the iris screen. *Corectopia* indicates that the pupil, instead of being approximately in the centre of the iris, is unsymmetrically placed. As a matter of fact in the normal condition the pupil always lies nearer to the upper and inner portion of the iris than the actual mathematical centre. The band of iris round it is narrowest at the inner-upper portion.

Heterochromia iridis implies that a portion of one iris (or it may be of each) differs in colour from the rest; *Heterochromia iridum* that one iris is differently coloured from its fellow. (These two terms are only too frequently confounded.) These colour peculiarities are nearly always due to the marriage of persons of different iris-colour, and to the offspring assuming more or less the eye-character of both parents rather than that of one of them alone. They are believed to be more frequent in Britain than on the Continent, owing to the hybrid character of the Island race (Plate VIII. 2).

Tuberculous nodules in the iris, which may form during the course of inflammation of that membrane in a tuberculous subject, are generally to be distinguished

from the so-called gummata, which they resemble, by their smaller size and by their more peripheral situation : while a gumma is most likely to be found near the pupil margin, a tuberculous deposit is more usually near the periphery.

THE CILIARY BODY

The ciliary body is that part of the eye whose soundness is vital to every other part ; it is possible to have a good eye, but with separation of the retina or with a sarcoma of the chorioid, or with atrophy of the optic nerve, or with opacity of the cornea, but it is not possible to have a good eye while the ciliary body is unhealthy : it is the keystone of the arch.

The ciliary body consists essentially of three parts : (a) Muscular—the ciliary muscle is the most peripheral portion and is formed of two parts, that in which the fibres run in a meridional direction (Brücke) and that in which they run circularly ; (b) a very vascular connective tissue stroma ; and (c) the processes, which consist of a limiting membrane and the *pars ciliaris retinae*, the retina being here reduced to a mere layer of cubical cells and a deeply pigmented layer between it and the ciliary body. The retina passes across the ciliary tract to end as the posterior layer of the iris. The processes are about seventy in number.

So closely are the iris and ciliary body associated in vascular supply, structure, and function, that it is difficult to see how one of them could be inflamed without the other, and as a matter of fact such a thing hardly occurs ; but there are cases in which **cyclitis** (inflammation of the ciliary body) is the more important element, just as there are cases which are more properly described as iritis. It will be more easy to understand the disease if one bears in mind the several functions of the ciliary body : it is partly muscular, producing

accommodation ; it is partly secretory, and provides the aqueous humour and some at least of the nutrient fluid for the care of the vitreous humour, and thus presides over the tension of the eye ; and from it or through it come the vessels which give out from their loops at the corneo-sclerotic junction the lymph stream destined to nourish the deeper layers of the non-vascular cornea. Therefore, when the ciliary body is inflamed, accommodation becomes painful and difficult and attended with watering—an early symptom of great importance in the sympathetic form of the disease ; also the eye becomes tender to touch. Again, in cases of cyclitis the aqueous humour and the anterior parts of the vitreous become turbid, vision being affected therefore more than in true iritis ; and in later stages the vitreous may become quite opaque and disorganised, while the intra-ocular tension may fall much below the normal. And in at least certain classes of cyclitis the cornea may either become itself inflamed or may show evident signs of degeneration and malnutrition.

Irido-cyclitis, then, is chiefly a disease of early life, and apart from traumatism is associated with such general dyscrasiæ as syphilis, tubercle, Bright's disease, and diabetes. There is no more typical form than that which occurs in the tuberculous and anæmic young woman of 17 to 22, run down perhaps from hard work and poor living. The type of injection present is that of iritis, yet the iris may not be much affected, while vision is interfered with much more than in a case of more pure iritis. The fluid in the anterior chamber seems faintly turbid, and there is a cloud over the lower portion of the posterior part of the cornea. Not much pain is complained of, but there may be a little tenderness on pressure with the finger. On examination by focal illumination a few adhesions of the iris or deposits of exudate upon the anterior capsule of the lens,

browned by iris pigment, may be visible, and at the lower part of the cornea, on its posterior surface, may be seen a number of small greasy-looking dots, lying on the endothelium (Descemet's membrane). Hence the names "Descemetitis," "aquo-capsulitis," "keratitis punctata." These dots are arranged in a pyramid whose apex is upwards, reaching it may be as high as the centre of the cornea or higher, and having the larger dots at the base, the smaller towards the apex. These dots may have a feeble yellowish or brownish colour, and closely resemble the fat globules on gravy which is turning cold. The explanation of their peculiar arrangement is that the anterior chamber is a lake of warm fluid, kept heated by the vascular iris hanging in it, while the non-vascular, exposed, and therefore cold cornea tends always to lower its temperature. At the shallow margins of the "lake" the fluid, being there most heated, will tend to rise, falling again into the depths from the superior part of the chamber and carrying with it, suspended or in solution, exudated material, albuminous particles, which as they become precipitated in the cooler portions of the fluid will be deposited upon the sloping inferior portions of the cold cornea, there to lie as flakes and dots (Plate VII. 4).

The *treatment* consists in the use of atropin to reduce injection of the inflamed part and prevent adhesions, and to set the ciliary body at rest; and such alteratives as mercury with iron and arsenic. Care must be taken to watch the tension carefully. In older persons especially it is apt to rise, when atropin must be withheld. The process varies very greatly as to severity and duration, but often lasts a long time (many weeks), and is often bilateral.

As to the *prognosis*, this is fairly good if the health stands out well, but the corneal endothelium may take a very long time to clear up again, or may fail to do so

altogether. And the ciliary body in a certain proportion of the cases becomes quite disorganised, the tension of the eye falls lower, and the deposits remain permanently, or rather the endothelium on which they lay has itself become opaque. In these worse cases the vitreous also may have lost somewhat of its transparency, and the central portions of the cornea become nebulous, while in others a peculiar change comes over the anterior part of the cornea, just in the exposed band between the lids at and immediately below the horizontal diameter; this consists in a degeneration with deposit of lime salts just under the epithelium, called from its habit of spreading in a band from one side of the cornea to the other, band-shaped or ribbon-shaped keratitis. This band-shaped keratitis is an indication of grave degeneration of the ciliary body, and is incurable (see p. 156).

For sympathetic cyclitis, one of the most marked and characteristic features of sympathetic ophthalmia, see p. 395.

Tumours of the ciliary body are practically limited to sarcoma, either spreading from the iris or the chorioid, or involving the ciliary body from the first.

For affection of the ciliary muscle see under Accommodation and Muscular Apparatus.

CHAPTER VIII

THE CRYSTALLINE LENS

THE lens lies in a depression on the anterior aspect of the vitreous, the patellar fossa, slung there by the suspensory ligament or Zonule of Zinn, its margins reaching close to, but yet clear of, the ciliary processes; its anterior surface is laved by the aqueous humour, peripherally in the posterior chamber, centrally in the anterior, and the iris resting upon its surface for a short way forms a curtain between the two. It is an ectodermal growth, developed from an invagination which can be traced at a very early stage in the embryo. Its envelope or capsule is a homogeneous structure whose integrity is essential to preserve the lens from the action of the fluids in the anterior and the posterior portions of the globe, between which it lies. The anterior capsule is slightly thicker than the posterior, and it alone (the anterior) is lined with epithelial cells from which the lens has grown and is still growing. This point is of importance in connection with cataract operations and the question of treatment of the capsule in such a manner as to enable the surgeon to avoid the necessity of "needling." For "after-cataract" is almost entirely a product of the anterior capsule, and if this be removed, completely or partially, that annoying, and sometimes dangerous, little operation may often be avoided. These cells then form or "secrete" the lens, whose

fibres vary greatly in form according to their position with reference to the epithelium. The layers which they form are superimposed on one another like, as it is usually expressed, the leaves of a book or of an onion. The lens is unique among the bodily structures in this, that Nature makes for the lens no provision for the removal of effete cells, the capsule is an impervious membrane. The lens, therefore, increases all through life in size and in weight, so that, according to Priestley Smith, at sixty-five a man's lens is about one-third larger than it was at twenty-five. The increase would be much greater still were it not for the process of condensation which is also constantly going on. In childhood the lens is soft and perfectly homogeneous, and consequently a child's pupil looks absolutely black, but after middle life a certain change has reached a stage at which there is a distinct departure from homogeneity. This process consists in the condensation of the central parts into a nucleus while the more peripheral remain as they were (cortex). The process of differentiation has become quite unmistakable when the patient has reached thirty years of age, and it goes on becoming always more and more marked, more and more of the lens becoming nucleus, less and less remaining as cortex, till at last, say at the age of seventy, all is nucleus and there is no cortex at all. Accompanying this physical change is another, for as the nucleus hardens it changes its refractive index, one result of which is to throw back light when the eye is illuminated from the front or laterally. It is this which gives to the pupil of a person past middle life, especially when it is dilated, its grey or bluish-grey look, which may so readily be taken by the uninitiated to mean cataract. But though the pupil thus appears smoky and greyish there is no interference with the passage of light, and when the eye is illumined with the ophthalmoscope its red glow remains quite unaltered.

The lens up to middle life is perfectly colourless, but in age it acquires a distinct yellowish hue. The curvature of the anterior surface of the lens is somewhat flatter than that of the posterior, but during accommodation it becomes more acute at the central portion of the surface. As life goes on the lens in becoming harder becomes less amenable to the action of the ciliary muscle, and the amplitude of accommodation therefore gradually diminishes. The **diseases** to which the lens is liable are three, viz. opacity in its various forms, or "cataract," subluxation, and—very rarely—one or two congenital

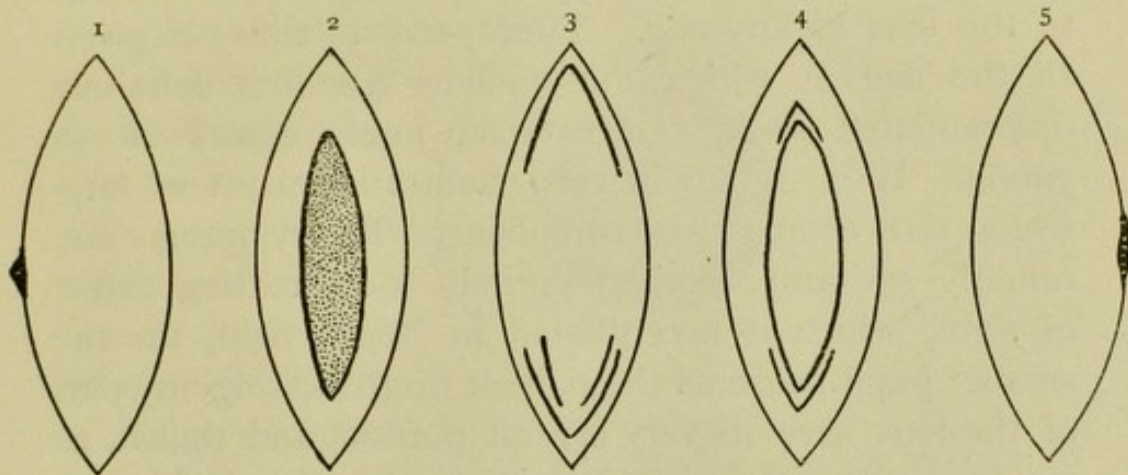


FIG. 36.—Various forms of cataract, in section.

(1) Anterior polar ; (2) nuclear ; (3) cortical ; (4) lamellar ; (5) posterior polar.

anomalies. The antique name of **cataract**, an opaque material which has flowed down into the pupil, is still retained in common acceptance, though our views as to the explanation of the appearances have somewhat altered. The explanatory term "opacity of the lens" is not, however, very much more correct, for the lens, though it loses its transparency, does not become opaque in the true scientific meaning of the phrase, but only intransparent. The word may be employed for all that, if its peculiar significance in connection with the lens be once clearly understood. Of the different forms of cataract it is convenient to recognise the following: hard or senile, soft, lamellar, anterior polar, posterior polar, and

degenerative; traumatic cataract is dealt with in the section on injuries.

HARD OR SENILE CATARACT

Hard or Senile Cataract is that form in which the nucleus, having, as the patient became older, separated itself off from the cortex more and more completely, has undergone further changes and become not merely hard but opaque as well. The reason for the fact of hard cataract occurring in senile individuals is thus obvious; it can hardly form save in persons who possess a nucleus to the lens at any rate. Twenty-five to thirty is given as the age at which the nucleus has first definitely differentiated itself, but cataract rarely comes on so young. It is usually in this country a patient of fifty-five to sixty or more who complains. The symptoms are, roughly speaking, limited entirely to increasing defect of sight, which is accentuated in bright light, for the smaller pupil prevents the patient from utilising any part of the lens save its very central portion, and that is, as we have seen, the site of the opacity. On looking at the patient in daylight and also when focal illumination is used, one must not assume too hastily that cataract is present merely because of a smoky reflex from the lens, for this, as we have seen, is physiological after middle life has come, and is due to the change in refractive index in the nucleus causing it to return the light somewhat from its surface when daylight or focussed lamplight is allowed to fall upon it. The mirror of the ophthalmoscope is the proper test, for if the appearance be due to real cataract, the red reflex will be broken up by opaque streaks, lines, or masses, while should it have been due merely to alteration of the index the reflex is uninterrupted. When any opacity exists in the eye in vitreous, lens, or cornea, the red glow returned by the fundus is interfered with over the area of the opaque

mass, which shows up against the red as a dull grey or black shadow, no matter what its own colour may be, just as a snowflake, looked at from below as it falls, looks black against the high illumination of the sky background. According to the area covered and the density of the darkness of the object one decides as to the amount of cataract present. Long before it is complete the red glow is entirely abolished. When the cataract is so far advanced that the red-glow test is no longer applicable one can decide upon the "ripeness" of the cataract by observing whether, under the use of focal illumination, the margin of the pupil passes abruptly into white, opaque lens or not. When the opacity is fully advanced and the eye is lighted up by focal illumination there is no change of level

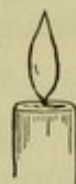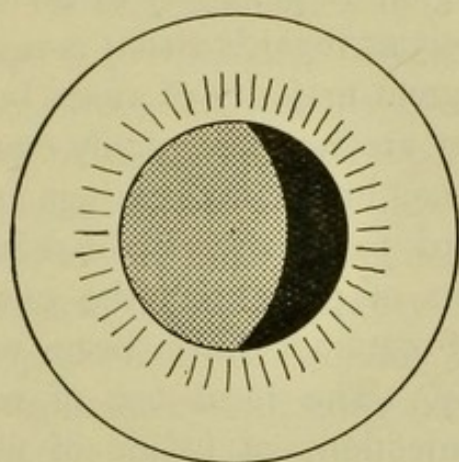


FIG. 37.—Shadow cast by opaque iris through semi-opaque anterior layers of lens upon deeper, more opaque, portions. Its presence indicates that the cataract is not ripe.

between iris and opaque lens, but should there remain some degree of transparency in the anterior layers of the lens just underlying the anterior capsule, then on the side on which the light is placed the opaque iris will cast a shadow upon the deeper-lying opacity; a crescentic shadow will thus be visible (Fig. 37). It is a very important matter to train one's self to acquire a fairly accurate notion how much vision a patient with a certain amount of cataract might be expected to possess, as it helps to enable one to judge as to the propriety of operating in any given case. Nothing but experience can bring this, and every opportunity should be seized

to acquire it. When quite ripe the lens has a whitish, faintly yellowish look, contrasting strongly with the colour of the iris (Plate X. 5, and XIII. 6, 12). Ripening takes a long time, sometimes measured by years; sometimes the process seems to remain stationary for a long period and the cataract may never ripen at all. It occasionally is the case that this yellowing of the nucleus proceeds to a much greater degree and the lens may be deeply pigmented, and become of a deep brownish black; in such a case the chorioidal pigment about the macular region is generally in an unhealthy state, and the prognosis as regards vision is not very good.

In the great majority of cases both eyes are affected, though they are not necessarily equally far advanced—a fact which has important bearings as regards treatment.

In regard to *treatment*, the efforts made to devise some means of preventing the onset and delaying the advance of cataract have been endless down to the present day. The local use of resorcin and subconjunctival injections of iodide of potassium are among the most recent, but they too are in all probability at the best futile, and may possibly be injurious. Extremely precise correction of any error of refraction is strongly recommended by some as tending to prevent cataract, but the evidence in favour of this is extremely weak; the same is also true of its influence in retarding the advance once cataract has begun, but here the difficulty of being certain in the presence of the irregular astigmatism caused by the incomplete formation of cataract is prohibitive of such meticulous accuracy. If one holds the view that very precise correction of the error prevents or retards the formation of cataract, then, to be logical, one must also consider that an incorrect lens will tend to hasten its advance, and since the refraction cannot be counted upon to remain exactly the same for any length of time, one runs the risk of doing at least as

much harm as good. The fact is, the patient should not be encouraged to throw away money upon spectacles which would do no good if they were correct, and may be correct only for an extremely brief space of time. There are two *palliative measures* worthy of consideration, atropin and iridectomy. When the central area of the lens is alone affected some relief may be obtained by the use of very weak atropin (gr. $\frac{1}{8}$ to $\frac{3}{16}$), but great care must be taken to ensure that the intra-ocular tension does not rise, as it is apt to do, in such a patient, for subacute or acute glaucoma might be readily induced in this way. Preliminary iridectomy was strongly advocated by Gunn, as well as by others, as tending to render the actual extraction operation less dangerous and as hastening the onset of a slowly ripening cataract. Most persons, however, would not unreasonably rather undergo one surgical operation than two, and the advantage gained by preliminary iridectomy is at least hypothetical, while if cataract is sufficiently far advanced to call for iridectomy the lens is certainly sufficiently consistent to justify extraction. No operation such as couching, by which the lens is allowed to remain in the eye but has its position shifted out of the "line of fire," is permissible, unless possibly in some rare and extraordinary concatenation of circumstances. No procedure such as massage of the lens with a view to hastening the repairing by mechanical friction is wise, or indeed justifiable.

But before operation is decided upon it is necessary to satisfy one's self that the patient is in reasonably good health, that the eye is so far at least sound in other respects, and to formulate one's policy in reference to the condition of the other eye.

(1) The patient should be fairly well, regard being had to the fact that the majority of those requiring cataract operation are well advanced in years. A large amount

of sugar in the urine, for example, is serious, though not necessarily prohibitive, while a trace is too common among old persons to have any very sinister significance. The presence of albumin in any quantity is serious too, or of eczema of the face; great feebleness may be a contra-indication, and any suggestion of tendency to unsoundness of mind must be carefully considered.

(2) The eye itself should be in other respects healthy, because otherwise some condition may be present which would itself destroy vision, and thus render an operation of no avail. It must be remembered that cataract appears to be consistent with perfect soundness of the eye in other respects. The points to which attention should thus specially be directed are five in number.

(a) The *amount of vision* should correspond reasonably well with the amount of opacity present. The decision of this point demands a good deal of experience. In even perfectly ripe cataract the patient is able to perceive promptly and with certainty a very small amount of light. This is best tested with the mirror of the ophthalmoscope; place a light behind the patient, reflect the light from it into the patient's eye from a distance so as to reduce the intensity of the light reaching his eye; the patient should be able to tell without a moment's hesitation that light is being thrown upon the eye. If there be less power than this there is something wrong.

(b) *Projection of light* should be good. This signifies that the patient must be able to locate exactly the source of light. Thus if one holds up the mirror, and thus pours the light downwards upon the eye, or to one side, he should know at once that the light is coming from above, from the right-hand side, and so on, and be able to point promptly to the correct spot. A diminution of the field towards the nasal side might indicate a tendency to glaucoma; restriction above might be due to detachment

of the retina, and so on: one must be careful to be satisfied as to the projection of light.

(c) The iris should *respond* readily to *light*: cataract never interferes with the response of the pupil. Should the iris not respond readily, that might indicate inability to perceive light, which cannot be due to cataract, and which therefore would indicate the presence of some complicating disease: or some binding down of the iris by previous iritis—a serious complication in the operation as tending to lead to difficulty in getting the lens out through the rigid iris, and to hæmorrhage, which would be absorbed slowly or imperfectly. The previous occurrence of iritis is, however, not necessarily a bar to operation.

(d) *Tension* should be normal. If increased (unless this may be due to rapid ripening of the lens, which swells as it ripens and may therefore cause increase of tension), glaucoma, with all its dangers, may have attacked the eye; if it be diminished, detachment of the retina is only too probable as a complication, because cataract is apt to follow detachment.

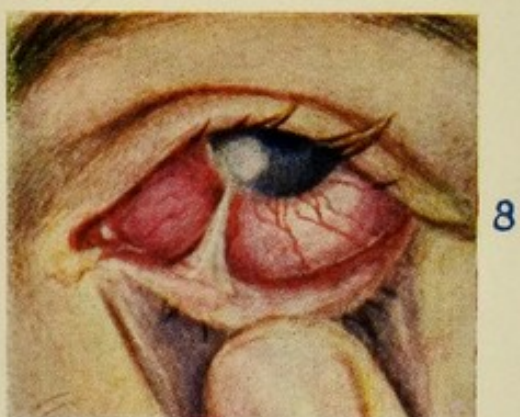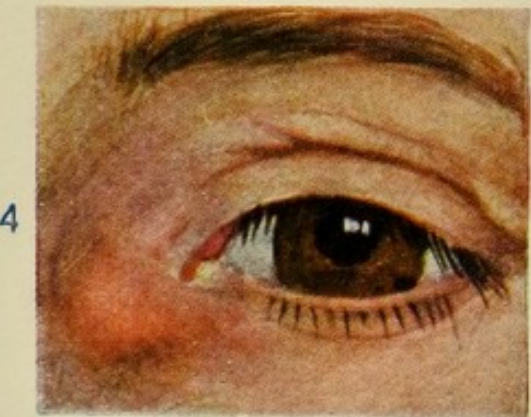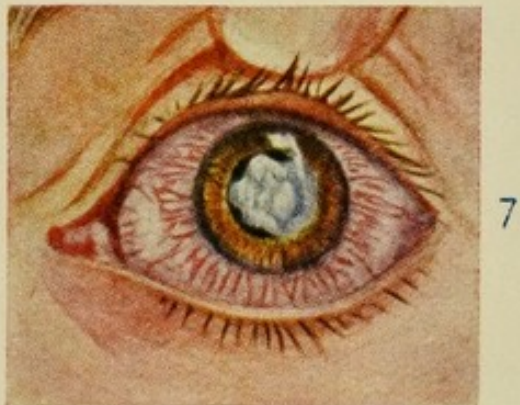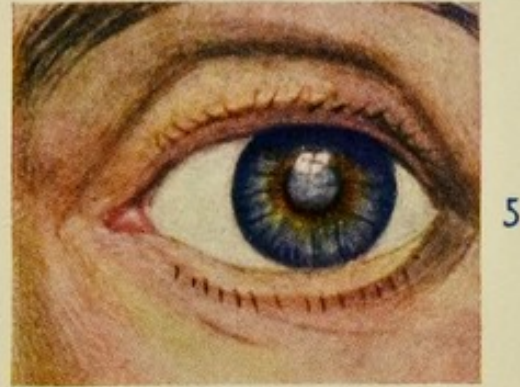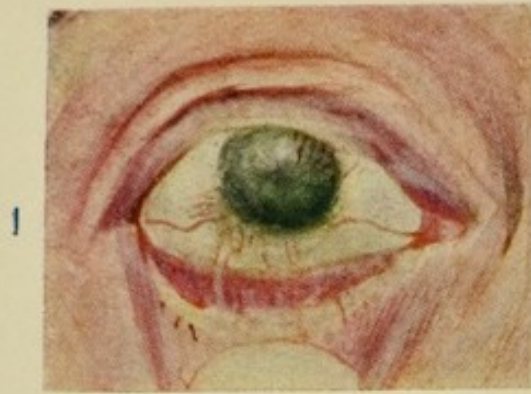(e) The *conjunctiva*, and still more the *lachrymal apparatus*, should be, as far as possible, *free from germs*. It is true that some organism or other may be found in nearly every conjunctiva, but these should be few in number, as they are feeble in vitality, and there should be no hyperæmia of the conjunctiva, and above all no chronic or acute septic condition of the sac. One should look with the greatest suspicion on a watery eye or one with blepharitis, or with muco-pus coming from the sac. When sac troubles are present the cataract operation ought not to be undertaken until the other condition has been cured, lest septic infection of the wound take place, as is extremely apt to occur. It is sound practice to examine a smear from the conjunctiva of every prospective cataract patient, and to put aside for preliminary treatment all

those in whom pneumococci, or indeed a copious growth of any organisms, are present.

At what stage in a case of ordinary senile cataract is it proper and right to operate? In this matter as in so many others the practice of different surgeons of wisdom and experience may differ very considerably. The chief points in the question are: (a) The age of the patient, for not only would it be absurd on general grounds to keep a man of 80 waiting unduly, but at great ages the changes are extremely slow. (b) The actual amount of vision present. Here in particular opinions differ much; one waits for full ripeness, another considers it sufficient that some inconvenience be present. Probably the best test is reading. If the patient has lost his reading power completely he had better be operated on and "take the risk." (c) The state of his general health, and any extraneous matters, such as excitability, or troublesome cough, or deafness (a very awkward complication of the operation), or uncomfortable home conditions, which may endanger success.


The originator and some of the advocates of a certain method of extraction confidently assert that their method of operating is the only one suitable for adoption in cases of unripe cataract, but this claim is not substantial; the ordinary methods are quite applicable if due care be taken.

The question of the *state of the other eye* is of some importance. Should both eyes be ripe, one eye should be operated on alone; for one never knows what complications may occur—hæmorrhage, pneumonia, insanity, etc.—and it is therefore unwise to expose both eyes to danger at the same time. If one eye be ready for operation, I take the view that it should be operated upon irrespective of the condition of the other, provided all indications are favourable. The objections to this course are that the patient may never require operation at all,



1. Shrinking of Conjunctiva from Trachoma.
2. Xerosis of Conjunctiva.
3. Angyria: silver staining of Conjunctiva.
4. Mucocoele, inflamed.

5. Senile Cataract, "ripe."
6. Lamellar Cataract.
7. Traumatic Cataract.
8. Recent burn of Cornea and Conjunctiva: Symblepharon.



as the other eye may "see him out," that you expose him to a certain risk, albeit a small one, by an operation which after all may not have been needful, and that the two eyes, being now greatly different in focus, will never act together. On the other hand, after it has become ripe a lens begins to undergo further degeneration, the capsule itself to become opaque, the lens to shrivel and perhaps to become dislocated from degeneration of the suspensory ligament, and the eye to diverge. The results of operation upon over-mature lenses are not by any means so satisfactory, and it is therefore not well to allow the proper moment to pass. Besides, it is better to have a surgical operation in the past than in the future, and most persons will be glad to be rid of the ugly appearance of the white pupil.

Assuming now that the results of all these investigations have proved satisfactory, one proceeds to operation. For several reasons it is better to describe this operation now rather than in the chapter on operations.

The operation of **extraction of cataract** as it is called, though the lens is not, properly speaking, extracted, is the chief operation of ophthalmic surgery, and one round the details of which controversy has raged and will rage for long. It will be best to describe the typical operation, leaving aside in the first instance all personal or peculiar modifications and deviations.

It is wise to administer a mild purge; but not to disturb the patient's food habits at all; he should have his breakfast just as usual on the morning of operation. On the previous day the eye should be well bathed with a mild antiseptic lotion, such as corrosive sublimate lotion (1 to 6000). In this connection it is essential to remember that there is no application which can be made to the eyes at once sufficiently powerful to possess a distinctly antiseptic action, and at the same time so bland as not to injure or excite unduly the delicate tissues

of the eye. A solution of corrosive sublimate more concentrated than 1 to 6000 is extremely apt to irritate the eye and cause acute reaction. For about ten to fifteen minutes before operation there should be dropped into the eye at intervals of a couple of minutes a few drops of cocain solution (4 per cent); there is nothing better than cocain, but some surgeons prefer one or another of the substitutes for it. On the table, on which the patient should lie in a good light with his feet towards the window, it is well to flush out the conjunctival sac

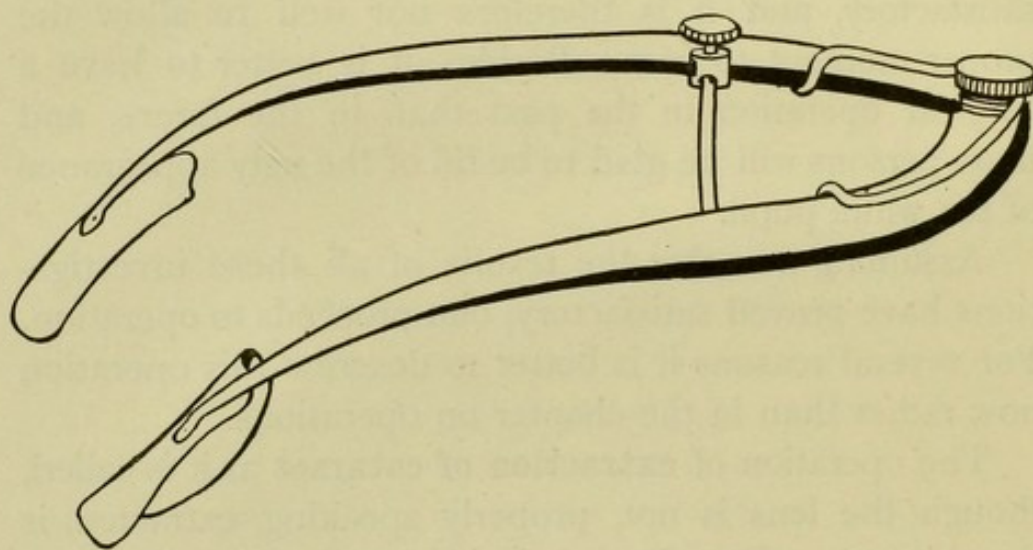


FIG. 38.—Speculum.

thoroughly with sterile water (or a weak antiseptic if preferred, but any antiseptic must be so feeble in its germicidal power that it acts chiefly or entirely mechanically). In the actual performance of the operation there are so many individual differences in the procedure of different surgeons that one must simply describe a general type, and one's own preferred modifications, and note very briefly the chief departures from the "normal" made by certain others also. The speculum having been inserted with due avoidance of injury to the corneal epithelium, the surgeon, standing at the head of the patient, and holding the Graefe's cataract knife in the right hand (for the right eye), seizes a firm hold of

conjunctiva at the lowest portion of the cornea in the fixation forceps, and encouraging the patient to look down, assists with the forceps the downward rotation of the globe, which he holds firmly but gently in position.




FIG. 39.—Graefe knife.

The exact spot at which to introduce the point of the knife may thus conveniently be determined: lay the blade flat across the cornea so that its edge coincides with the upper margin, then mark with the eye a spot half a knife-width lower than the back of the blade, at the corneo-scleral margin on the outer side; that is the best point. In order that it may pass through the true corneo-scleral junction the knife should be introduced at a point just exterior to the apparent corneo-scleral junction; it will then pass through that particular portion

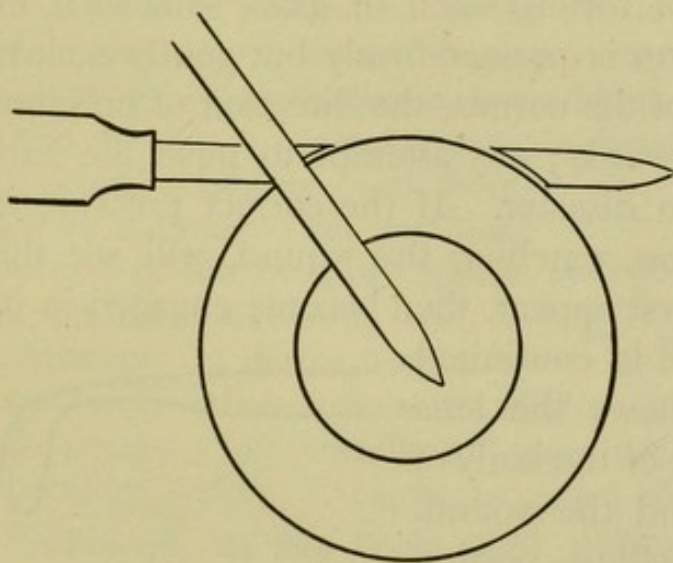


FIG. 40.—First and second positions of the knife in extraction.

(The section as shown in the figure would be much too small.)

of the coats when it enters the deeper tissues. The direction of the knife should at first be diametrical, but after a good piece of it has entered the anterior chamber the direction should be changed, and the point made to emerge through,

or rather just posterior to, the corneo-scleral junction at the inner side, at a point exactly corresponding to the point of entrance. Particular care must be taken that the counter-puncture be made before there is the slightest action of the knife: if not, aqueous

humour will escape and the iris will fall in front of the knife. With a few sweeping cuts, as few as possible, the knife should be caused to cut its way out above, again just exterior to the corneo-scleral junction. Into the anterior chamber, now empty, an instrument is intro-




FIG. 41.—Cystotome.

duced with which a small piece of the iris opposite to the centre of the wound is drawn out; it is then cut off

with scissors acting across the line of the wound in order that the pupil shall have the proper keyhole shape. The anterior capsule of the lens is now lacerated with a sharp-pointed instrument, called a cystotome, to allow free exit of the lens. The crucial stage in the operation is now reached, and on it all the surgeon's care, skill, and watchfulness must be concentrated. An instrument made of tortoise-shell or glass somewhat in the form of a spoon is pressed firmly but gently against the lower portion of the cornea, the direction of pressure being exactly backwards; any attempt to push the lens upwards will end in disaster. If the correct pressure is applied, the surgeon, watching the wound, will see the edge of the lens first appear, then become engaged in it, and as the pressure is continued and the spoon follows the lens up, more and more of the body of the lens will distend the wound.

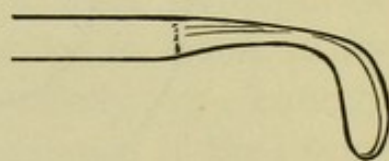


FIG. 42.—Spoon for expelling the lens.

As soon as the widest portion has passed the pressure should be cautiously relieved (not removed) and any cortical portions of lens which present themselves encouraged to escape along with the lens and after it. The horns of the iris should now be replaced in proper position with a repositor, and remains of cortex swept out from between the lips of the wound, which must be got into nice apposition, and the operation is over.

Most surgeons apply a simple bandage, some to one eye, some to both; the patient is put to bed and lies there for a few days. The practice of surgeons varies considerably as to dressing and undressing of the eyes, but most remove bandages finally about the fourth or sixth day, the patient thereafter wearing a shade or goggles, and being allowed up a day or two later. In the majority of cases atropin is required after the third day or so for a time, as in the process of healing there is apt to be a little congestion of the iris, or even a slight iritis, which must be kept within limits, but most surgeons agree that until the wound is healed superficially at least it is best to employ no mydriatic.

With all reserve, I may here mention the points in which my practice in regard to the operation differs from that of the majority. I cut a conjunctival flap as the knife emerges from the summit of the incision. In the course of the iridectomy I do not employ forceps, which cause pain and therefore unsteadiness, but a blunt hook, with which to seize the iris. I employ capsule forceps with their teeth directed backwards; with them I seize and remove the pupillary portion of the anterior capsule in place of lacerating with a cystotome. I derive from this plan the enormous advantage of almost complete relief from the necessity of "needling" (see below). I remove the speculum before I begin to expel the lens. For the removal of cortex, blood, and debris, and for general

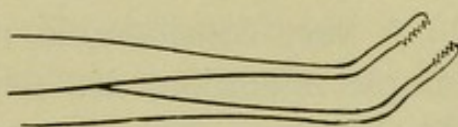


FIG. 43.—Capsule forceps.




FIG. 44.—Nozzle of irrigator.

cleanliness, I irrigate the anterior chamber with lukewarm normal saline, which runs into the eye from a vessel about 12 to 15 inches above the patient's head; the nozzle is provided with a long stem or handle, which renders it very much more convenient and agreeable in use than

M'Keown's original pattern ; I have two supplies of normal saline, one boiling, the other boiled but cold, and from one or other source I add till the temperature agreeable to the back of the hand is attained. This is much simpler and less troublesome than boiling on the spot the whole solution which is to be used, for then that is always either too hot or too cold. The head of water is also an arrangement which can never go wrong, while pumps are always liable to send the fluid too slowly or in dangerous gushes. I apply no bandage whatever, on the ground that it can only be applied on the outside of a mucous sac, in which the wound is situated ; to put a so-called antiseptic dressing on the outside of such a sac is to invite and encourage the growth of undesirable organisms inside it, and has no beneficial influence upon the healing of the wound. The conjunctival flap adheres to its base in, literally, a few minutes, holding the wound thus closed ; I therefore in the interests of conjunctival cleanliness encourage the patient to open the eyes from time to time after the first two hours or so are past. The only covering of the eyes which I put on is a pair of wire goggles, to protect from mechanical injury (Fig. 87, p. 472).

A very considerable number of surgeons prefer the simple operation, *i.e.* extraction without an iridectomy. The differences in the procedure are that the section should be larger and that either atropin or strong pilocarpin should be employed beforehand ; some favour one of these drugs, some the other. The great purpose served by either is that the iris, not being lax but stretched either in miosis or in mydriasis, has less tendency to prolapse, this being the chief danger where there is no gateway in the iris through which the aqueous humour may drain or gush out of the wound without carrying iris before it. Opinions differ as to the relative merits of the simple and the combined operation ; certainly the cosmetic result in the best of the simple cases excels the best of the combined, but whether the average apparent result is better, and whether the average

visual result is better, is more open to question. For comparatively young persons, with a small nucleus and a mobile iris, the simple is quite proper at all events, but the beginner should become expert before he tries it in the more aged.

In the course of the operation certain *complications* or *contretemps* may occur for which one should be prepared.

First, the *knife* may be found to have been introduced into the anterior chamber *upside down*, that is, with its edge downwards, when of course the incision cannot be completed. There are three courses open to the embarrassed operator. He may withdraw the knife and wait till the following day to complete the operation, by which time the aqueous will have re-collected; he may withdraw the knife and, using great care, re-introduce it through puncture and counter-puncture and proceed—a very delicate procedure; or he may, keeping the knife lying across the anterior chamber, swiftly twist it on its axis into the correct attitude and then proceed. The position of the surgeon under the circumstances is not one to be envied, and as the blame is entirely his own he must act entirely for the best interest of the patient, using the plan which he feels he can best follow.

Second, the *iris may fall in front* of the knife. The cause of this is either cutting before the counter-puncture is properly made, pressing the blade of the knife flat downwards against the tissues, cutting too slowly (one should never hurry, especially in one's early days, but it is quite possible to go too slowly), or some restless movement on the part of the patient. The best course is to halt for a moment, holding the whole blade of the knife well up, when the iris may slip off; if this fail, to turn the edge the least bit backwards and again it may slip off; and if these fail, to proceed as if all was right; the iris will be cut with the knife and the patient will thus

have a little pain, but it is the best which can be done. Any irregularity of the coloboma can be trimmed afterwards.

Third, the *lens may refuse to present*: this is generally due to the operator having made too small a section, and after he has made sure that the delay is not due to imperfect opening of the capsule, he should enlarge the wound in the manner indicated in the following paragraph.

Fourth, *vitreous humour may present* in the wound




FIG. 45.—Vectis.

with or without any obvious dislocation of the lens, or the lens may evidently be displaced even before vitreous

actually has made its appearance in the wound. There is all the difference in the world between the appearing of vitreous in the wound before and after the escape of the nucleus of the lens. Let us assume first that it appears before the escape of the nucleus; the operator should cease all attempts to express the lens, for according to natural law the fluid contents of the globe will all be expressed before the solid lens; he should remove the speculum if that has not yet been done, and introduce the vectis behind the lens. This is not quite easy to do, and perfect coolness and confidence in one's self (a very different thing from self-confidence) is required for a successful issue. There should be a good bend on the vectis, and the surgeon should begin to use it by placing his




FIG. 46.—Lid elevator.

hand well in front of the cornea, and introducing the vectis almost upwards; then, having got it well past the upper edge of the lens, swing the instrument swiftly but

deliberately round a bold curve, and, raising his hand, "pin" the lens between vectis and cornea, and slowly draw the lens upwards to the lip of the wound and so out. It will never do to attempt this hastily or any way but very coolly; he must be sure that he is behind the lens with the vectis, else it will be pushed further out of place. He should remember that the chief source of this accident is again his own fault for having made too small an incision to start with, through which the lens cannot pass, and if he has reason to think that this is true, he should enlarge the wound with the Graefe knife (scissors will hardly cut the cornea) before he touches the vectis. He should keep clearly in view that whatever happens the lens *must* be got out of the eye; if the lens be left in an eye that eye is infallibly lost, and perhaps the other one also.

Let us assume now that the vitreous has begun to escape after the lens is out—this is much less dangerous and the treatment is very simple, namely, to stop all attempts to clear out cortex or anything else; simply snip off the vitreous at the edge of the wound, close up the eye, and all will probably be well.

Fifth, a more dreadful accident is *expulsive hæmorrhage*. In rare cases it happens that the reduction of tension is more than the patient's vessels can stand, a large one gives way, and before one has time to know what is wrong, iris, lens, vitreous, retina, and everything are expelled through the wound, and the eye lost. Instant fastening of the eye in a less intensely rapid case, with administration of a dose of opium on the spot, I have seen successful, but that is very exceptional. There is really nothing to be done but enucleate when once it is certain that all is lost.

In the days after operation there are four unpleasant developments to watch against—suppuration, iridocyclitis, hæmorrhage, and delay in closure of the wound.

Threatened *suppuration* (panophthalmitis) is evident by the third day, as a rule, when it is going to occur; the eye is red, the patient has had a bad night, has probably been sick (a very bad piece of news to receive on a Wednesday or Thursday morning after Monday's extraction), the cornea is a little turbid, especially near the site of the wound, and its lymph-channels blocked, the wound margins are yellowish-white, the iris muddy, discoloured, and congested. The probability is that the eye will be lost altogether, but there is one method of treatment which is wonderfully effective, namely, the sub-conjunctival injection of cyanide of mercury. Three to five minims of a 1 in 6000 solution injected sub-conjunctivally will sometimes check the process promptly and convert disaster into victory; I have secured $\frac{6}{9}$ vision in a case in which all hope seemed to be gone.

Irido-cyclitis is a little later of coming on, which it does somewhat insidiously; the chief means of treatment are sub-conjunctival injection of cyanide; atropin; mercury internally; and bandaging. In all cases of iritis of whatever origin, preservation of the eye from changes of temperature, from draughts, etc., is productive of great benefit, and is most comforting to the patient.

Hæmorrhages from the ciliary body are a little prone to occur from restlessness on the part of the patient, from an accidental touch with bedclothes, etc., and also (apparently) quite spontaneously. Atropin, timely employed, helps to prevent them and to encourage absorption if they should take place. Blood-clot lying on the posterior capsule, and leaving there a deposit of fibrin, is a fruitful source of demand for needling.

Delay in closure of the wound, or rather of part of the wound, is occasionally seen; probably it is just through some tiny aperture that the aqueous continues to escape, and perhaps because there is some tag of capsule lying in or about the lips of the wound. It is a complication

which practically never occurs to those who do not bandage the eye; almost certainly, when it does occur under the bandage, leaving the eye undressed for a day will cause disappearance.

Another very distressing occurrence is the development of *insanity* after the operation. Probably this is due to mental perturbation and anxiety, and is largely contributed to by keeping the patient in the dark. At once all dressings should be removed and the patient kept quiet with bromide of potassium, and at the same time fed liberally and given tonics.

After-treatment.—When the patient is back to bed he should lie mostly on his back, certainly should not turn upon his wounded side; he must consent to be quite helpless for a few days and not attempt to assist himself, but to allow others to do everything for him. He should lie in a shaded but not dark room, opening the eyes from time to time but not keeping them open too long at a time. Food for the first few days must be of the simplest and least stimulating, and the bowels must not be allowed to become constipated, but it is wise to encourage no action for a couple of days after the operation, in order that the patient may rest undisturbed. After the second or third day the patient may sit up in bed without harm, and be out of bed on the fifth or seventh for some hours. The bed should be so placed that the patient looks away from the light, with the window behind him, a draught screen being fixed up round the head of the bed. Atropin is required in the majority of cases about the second to the fourth day; it is better to use it before any adhesions occur or any congestion of iris or ciliary body, such as *to a mild degree* comes on in very many of the patients during the healing process. At the end of a fortnight the patient may usually leave the hospital or nursing home in which he has been.

After-cataract is a great source of trouble to patient and surgeon. The meaning of it is that the majority of surgeons when they extract the lens do not extract the capsule, and this capsule, left behind, forms a fine veil which interferes with accurate vision on the part of the patient. It may be that vision has never been good since the operation, or that the good vision present at first has become clouded over. The blame for the occurrence rests chiefly upon the anterior capsule, for, as will be remembered, it is on the posterior surface of it that the cells lie which have originally secreted the lens, and which now, by throwing out a little fresh material, convert a transparent membrane into a fine veil. Next, the trouble may be due to portions of cortex left behind inside the sac of the capsule, and imperfectly absorbed. Lastly, to hæmorrhage or lymph formation upon the posterior capsule thickening it and rendering it semi-opaque. Removal of the pupillary portion of the anterior capsule with forceps at the time of extraction, and irrigation of the anterior chamber and capsule, do much to prevent any frequent necessity for the operation.

"*Needling*" is the name given to the little operation required to put matters right, from the fact that it used to be performed with a needle. It is much better, however, to employ a knife so that the capsule may be cut and not torn—the great secret of success. Either a small Graefe knife or one of Sichel's pattern should be introduced at the corneo-scleral junction and passed straight through the capsule about the middle of the pupillary area, and as it is drawn up again made to cut a small opening in the membrane, and then withdrawn. The two great rules to remember are, "Do as little as possible," and "Cut, do not tear." Should the membrane be too tough for this treatment it is best to divide it with iridotomy scissors (see p. 438). Should it be too hard

and calcareous for that it is sometimes possible to extract it by making a small incision, seizing it in capsule forceps, and cautiously drawing it out of the wound.

When the patient has recovered he requires a convex lens in front of the eye to compensate for the loss of the crystalline; in the average case the lens required is approximately $+10$ or $11D$. Since there is no possibility of accommodation he requires in addition a reading-glass of $+4$ or $5D$ stronger, viz. $+14$ to $+16D$. Owing to a certain flattening of the vertical meridian of the cornea from the effect of the wound at its upper part, there is in a considerable proportion of cases some astigmatism also, necessitating the addition of a $+$ cylinder of $2D$ or a little more.

SOFT OR CORTICAL CATARACT

In any person not in old age the nucleus does not form the whole of the crystalline; part is taken up with cortical matter, which, other things being equal, is softer and is more plentiful the younger the patient. Cortical cataract in its earlier stages is seen by daylight and in focal illumination as a number of streaks or striæ, some quite superficial in the lens, just posterior to the capsule, some lying far back, just in front of the posterior capsule. These are of a white or pearly grey colour, but when seen through the ophthalmoscope mirror against the lighted fundus appear as dark lines, since they catch the returning rays of light and stop them (Plate XIII. 5, 7, 11). As these begin to form the patient complains of two symptoms, besides that of defect of sight. He has trouble with a sort of partial diplopia or polyopia, from the breaking up of rays of entering light; and he may find that the presbyopia, for relief of which he had been wearing convex lenses, has now passed off so that he is able to read as well (it may be) without his glasses as with them. This obtaining of the "second sight," as the public sometimes call

it, is then an indication of commencing or threatening cataract. It may precede the actual onset by a very considerable time. In cortical or soft cataract, atropin can give no relief, even temporarily, for the reason that there is more opacity in the peripheral than in the central portions of the lens. As a constant rule, cortical cataract is more rapid in its development than is nuclear, but it is very capricious as to time. This is the form of cataract which is present in nearly all of the young persons who acquire the disease, and therefore it is found in diabetic patients, after lightning stroke, and indeed whenever cataract forms rapidly. To become ripe may take a very few months, a few weeks, or even only a few days. It will be plain from what has been said that in all persons above middle life cataract must be both cortical and nuclear, and that inasmuch as it is the nucleus which causes the difficulty in extraction, the procedure must be as for a nuclear cataract. In young persons, however, since there is no nucleus there is no need for a large incision, and the lens may be evacuated through that made by the introduction of a keratome, with or without an iridectomy as the case may be. The section should be made at the corneo-scleral junction above, so that, should iridectomy prove to be needful for the prevention of prolapse, this may be done at a part where it will cause no deformity. Gentle pressure on the posterior lip of the wound with a spatula will, after division of the anterior capsule, cause the escape of the major portion of the lens in a pultaceous, whitish mass; what remains may be fairly well cleared out by further pressure on the lower portion of the cornea, by the introduction of a guttered scoop into the lens along which the substance may pass out, by irrigation, or by means of a suction apparatus. This last is but rarely used now in this country, but is not altogether to be despised as antiquated. This operation of linear ex-

traction is used also in cases of lamellar and traumatic cataract (*v. inf.*).

LAMELLAR, ZONULAR, OR "CONGENITAL" CATARACT

Lamellar, Zonular, or "Congenital" Cataract, for it gets all these names, is often not diagnosed till school-days are begun, for it seldom is sufficiently bad to do more than hamper the patient, and it is—within limits—non-progressive. The patient, therefore, is very often a school child who has been found to be defective as to vision; he is supposed to be shortsighted because his distant vision is but indifferent or bad, and he holds his book near to the face in order to do his best in reading. The distance vision is not good because a portion of the lens in the pupillary area is intransparent, while the reading-book is brought close in accordance with a rule which is observed when vision is bad from any cause, namely, that if it is impossible for him to have clear images at any distance, the patient will prefer large though very blurred images to small, even if these should be somewhat less blurred. The patient often, but not always, shows signs of rickets, such as stumpy, irregular teeth, thickening of the ends of bones, etc. He often scowls and draws down the brows—has, in fact, a distinctly marked facies, in the attempt to reduce the entering light and so obtain dilatation of the pupil that he may utilise a clearer portion of lens. He often, but again not always, seems to have a little less than the normal endowment of mental activity—in the popular phrase, "wants twopence in the shilling."

On careful examination his pupils will be found to be greyish or faintly bluish, but not black, as they ought to be in a child. When focal illumination is employed this can be seen even more evidently. On using the mirror one sees that the central part of the pupil is occupied by a darkened glow, the redness is not so bright, but at

the periphery, beyond a darker circle which is often seen, the glow is quite normal. The outer margin of this dark ring is often somewhat dentated on account of the presence of what are described as Reiterchen or riders, small bifurcated opacities "riding upon" the main area (Plate XIII. 8).

The condition, which is always bilateral, is best understood by supposing that in infancy, or in the prenatal stage, a double layer of lens matter, one layer in front of the central point of the lens, the other behind it, has been "laid down" opaque instead of transparent, and the Reiterchen suggest that the next layer to be laid down was in some danger of a similar fate. Between the layers, in front of them, behind them, and peripherally to them the lens is perfectly transparent, the only opacity is in these layers alone. It seems probable that in the cases in which a very small central area is thus affected, the condition may be truly congenital and have occurred during foetal life, but where a larger, wider area is affected, the offending layer must have been laid down after birth. In some of the latter cases a history of fits in infancy has been obtained, and the suggestion made that the tetanic spasm has prejudiced the transparency of the part of the lens under construction at the time. In view of the fact that several members of a family may exhibit the defect, this theory seems unsatisfactory.

In the *treatment* of lamellar cataract the first point to be settled is, What is the amount of vision possessed by the eyes on careful correction of any existing refractive error? The next is, Other things being equal, can we fairly expect that the amount of vision to be obtained by operation will be so immensely greater than that now possessed by the eye as to justify running the risks of operation and accepting the inconveniences of absence of the lens? For the matter must be looked at thus:

the patient enjoys such-and-such an amount of vision at present, and that is obtained without any lenses; that can be raised to so-and-so by the use of glasses without operation. After operation one may fairly expect $\frac{6}{12}$ as an average minimum, *when the patient is wearing strong glasses*, but the vision without glasses will be decidedly worse than it is now. It is necessary to have a definite limit and say, "I will not operate if the corrected vision is equal to, say, $\frac{6}{18}$." What are the risks of which we speak? Principally septic infection and glaucoma, either of which may happen to the most careful surgeon; also detachment of retina after some time, and the incidental occurrence of intercurrent disease preventing proper treatment of the eye at some critical juncture. For certain positions in the world it may be wiser policy for the patient to keep poor vision and an undisturbed eye rather than seek better with spectacles and all the risks of operation. As instances one may suggest the actor and the domestic servant. In some cases it may be good policy to operate on one eye only; of course one never by any chance operates on both at the same time.

If vision is seriously interfered with by the cataract, what can be done for relief? (1) Continual dilatation of the pupil by means of a mild mydriatic, (2) Optical iridectomy, and (3) Extraction. The objections to the persistent use of a mydriatic are that if extraction should require to be performed, the younger (within limits) the patient is the better, and that continual use of atropin may give rise to atropin poisoning or to glaucoma, besides the risks of mishap from accidental ingestion of so active a drug. The objections to iridectomy are the possibility of accidental complications, the deformity, and the delay in perhaps needful extraction. On the whole, should operative interference be really necessary, extraction is the proper course.

There are different *methods of procedure*, of which that to be described now is perhaps best. Extraction of the clear lens is quite feasible and may be performed with decided advantage, but it is apt to be troublesome because the clear lens is not merely invisible but very adhesive; it may be well, therefore, to render the lens cataractous as a whole before extraction, both because one can see whether the pupil is becoming clear and because the lens ceases to be so cohesive. When aqueous humour is admitted to contact with the lens four results happen: the lens swells up from absorption of fluid, it becomes opaque, at the same time it becomes much less cohesive, and it is dissolved by the aqueous humour and carried off into the general circulation. These facts are utilised by breaking up the anterior




FIG. 47.—Discission needle.

capsule with a needle in the operation of discission or kerato-nyxis. The pupil is fully dilated with atropin, cocain administered, and by means of a stop-needle, introduced just within the corneo-scleral junction and passed into the pupillary area of the capsule, that membrane is thoroughly lacerated. The purpose, be it remembered, is not to break up the lens, but to open the capsule thoroughly. All the four results mentioned above occur, for the lens swells up, becomes opaque generally, less adhesive, and is (partly) absorbed. Should absorption go on smoothly and quickly nothing more need be done, unless a second needling should the process cease after a time. But if imbibition of aqueous by the lens be rapid the lens may swell up and block the angle of the anterior chamber, increased tension thus resulting. A sure sign that this is occurring will be found in the symptom of vomiting. If the patient who has been needled some two to five days previously begins vomiting, one may be certain that the tension has gone up and immediate relief is required. A linear

section is made as above (p. 206) described, and as much of the lens matter is removed as will readily come away on depression of the lip of the wound with a curette, and any remains left for spontaneous absorption. This is the method also employed when the lens is removed in the drastic treatment for excessive myopia.

Many think it best in the process of the operation to cause as much lens as possible to escape by gentle pressure, but to introduce no instrument, others freely ladle out lens with the scoop or curette, others wash out by means of the irrigation apparatus, others employ suction. The points to be specially remembered are: not to go on meddling and attempting too complete a clearance, and not to hesitate to perform iridectomy if the iris is not perfectly free from the wound at the close. An iridectomy is a vast deal preferable to a prolapse.

ANTERIOR POLAR CATARACT

Anterior Polar Cataract has an etiology quite different from the first three varieties of which we have spoken; the usual history is of ophthalmia neonatorum. In the majority of cases the eyes are affected with nystagmus, but the corneæ may be clear and one may then see lying in the pupillary area at its centre a small, very white, slightly projecting, hard-looking mass. Not merely does this mass protrude in the anterior chamber a little way, but, on further examination, an extension of it backwards into the lens substance can be made out, as though the opacity were spindle-shaped. The usual explanation of the condition is that there has occurred a violent suppurative conjunctivitis, with perforating ulcer of the cornea, though it must be admitted that an ulcer of the cornea is not an absolutely constant phenomenon. The moment a perforation occurs the posterior surface of the cornea must lie in contact with the anterior surface of the lens, lymph from the base

of the healing ulcer will be deposited on the lens also, and as the perforation closes and the aqueous again collects a minute pyramid of deposit is left on the anterior capsule. With this simple pathology there are some facts which do not agree; notably that in a number of the cases there is absolutely no evidence that perforation has ever taken place. In some of the cases where the opacity extends backwards into the lens substance, the anterior cell-layer has grown backwards also and shut off the true lens tissue from the new formation. Of itself anterior polar cataract never calls for treatment.

POSTERIOR POLAR CATARACT

Posterior Polar Cataract is usually a sign of some degenerated condition of the posterior parts of the eye; it may occur along with extensive atrophy of the chorioid, but its chief cause is that particular atrophic condition of retina known as retinitis pigmentosa. So decidedly is this the case that on observing posterior polar cataract it is well to look definitely for retinitis pigmentosa; it may occur without any such pigment change, however. The aspect is that of a small rounded flat area of opacity in the centre of the pupillary area, lying far back, and often showing lines radiating from it along the posterior layers of the lens, forming almost a cup-like arrangement (posterior capsular cataract). In the diagnosis of the deep position of the opacity attention should be given to the apparent movement of the dark disc (for so it looks when the ophthalmoscope mirror is used) as the eye is moved up or down.

For the means of recognition of the depth at which an opacity in the media lies see next chapter, p. 225.

In a small number of cases posterior polar cataract may be of congenital origin, associated with remains of the perforating artery of the vitreous and its termination

at the posterior pole of the lens. A posterior polar cataract interferes more with vision than does an anterior polar one, inasmuch as, the rays of light being more concentrated from passage through the lens, an opacity of a given size will cut off more of them.

DEGENERATIVE OR COMPLICATED CATARACT

Degenerative or Complicated Cataract means that form in which the change in the lens is entirely secondary to serious pathological processes in other tissues of the eye. These are chiefly atrophic changes in the ciliary body and vitreous humour, detachment of the retina, extensive chorioiditis, and glaucoma. The lens becomes white or yellowish-white, and sometimes hard, gritty, and calcareous, and is often shrunken and semi-luxated. Extraction is contra-indicated, for the loss of sight is due to causes other than the cataract, which is only one other sign of the progressive disorganisation of the eye.

There are other forms of cataract, but their differentiation is not of any immediate practical importance.

Three conditions are frequently mistaken for cataract :

(a) Persistent pupillary membrane. At a certain stage in foetal development the endothelium lining the anterior surface of the iris is continuous across the pupillary gap. This, or some remains of it, may persist into life. In the pupillary area of the lens there lies a fine patch of brownish threads, like a web, from which tenuous threads may pass to the anterior surface of the iris. These are distinguishable from inflammatory adhesions (*synechiæ*) by the facts that the pupillary movements are not impeded, and that the threads join the anterior (endothelial) layer of the iris, not the pigmentary posterior part.

(b) Lymph exuded from an iritis, covering the pupillary

region of the lens and occluding the pupil, is often mistaken for genuine cataract.

(c) The dull opalescent aspect through the pupil in subacute or chronic glaucoma is very frequently erroneously supposed to be cataract—a disastrous mistake which would be cleared up at once were the mirror used, for the red glow would be manifest.

To a less degree there is a risk of the uninitiated mistaking opacities in the cornea, and glioma or pseudoglioma, for cataract.

Dislocation or subluxation of the lens, or Ectopia Lentis, is of two varieties, congenital or acquired (traumatic); in the congenital form the condition is always bilateral and symmetrical; thus in the most common variety both lenses are dislocated upwards and somewhat inwards. This appears to be due to an imperfection in the suspensory ligament in foetal life; where the ligament is incomplete the lens is not anchored and becomes drawn away in the opposite direction. Attention is generally drawn to the matter when the child is of school age, for then the difficulty of focussing comes to light. On examination one notices first that the anterior chamber is deep, at least at some part, and the iris tremulous, for where it has lost the support of the lens the iris shakes (iridodonesis). The child has imperfect distant vision, and holds any book near to the eye in order to obtain large images.

The ophthalmoscope mirror indicates the diagnosis at once; the pupil appears as though divided by a dark curved line into two unequal parts, one of these being slightly lighter than the other. On the convex side of the line the pupil is aphakic, that is, the lens is absent; on the concave side is the lens, the line itself is the margin of the lens (Plate XIII. 10). The patient may be highly hypermetropic—if he uses the aphakic portion of his pupil, or myopic—if he uses the portion containing the lens, or

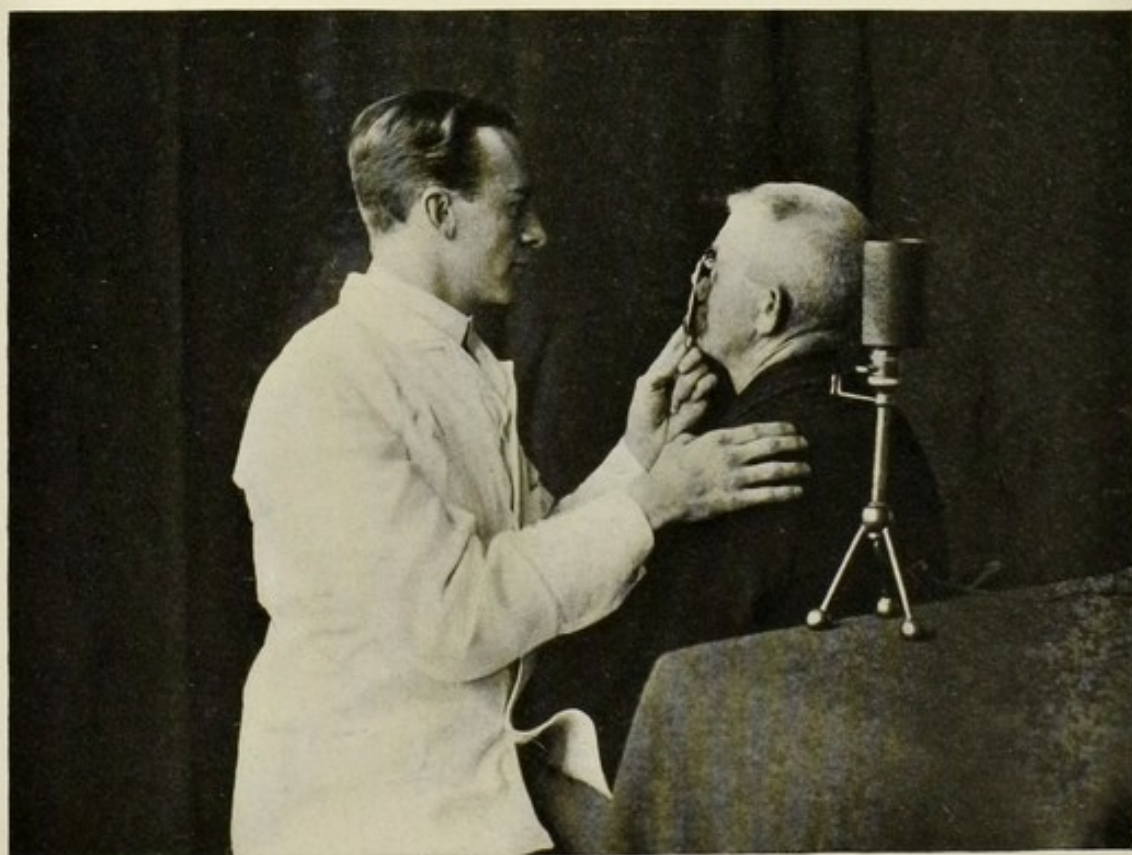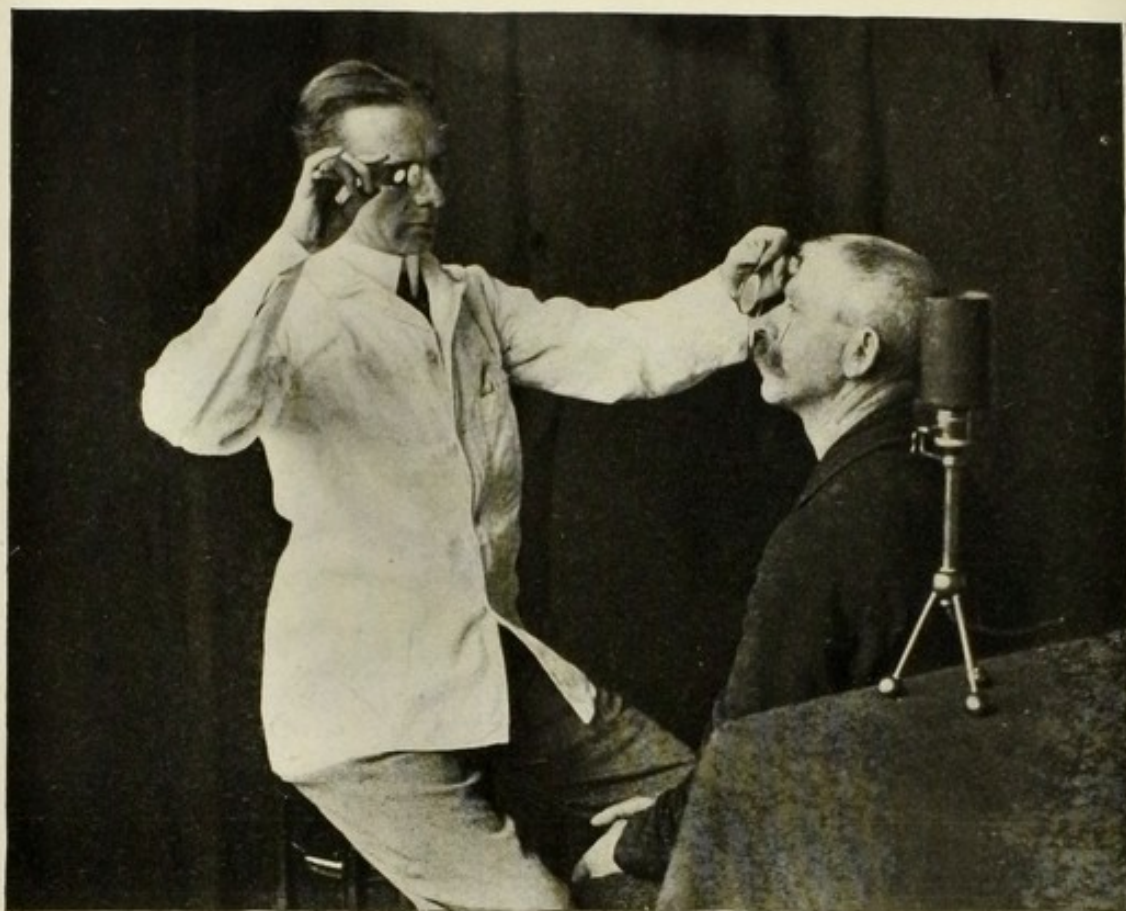even both as circumstances arise, vision improving when either a high plus or a moderate minus lens is presented. With the ophthalmoscope it is sometimes possible to see a double image of the disc at the same time, one seen through each portion of the pupil. The only way of *treatment* is to obtain as good vision as possible by plus or minus lenses, according to which gives the better result ; it will have to be borne in mind also that accommodation is impossible, and convergence has probably never been acquired. This being so, it is sometimes good practice to encourage the patient to employ one eye for distance, carrying a + 10D lens, it may be, while the other carries a + 15D lens, and is used for near work. Thus the patient does not require to carry two pairs of spectacles, and is always "ready." The danger to which eyes with ectopia lentis are exposed is that the lens may become more completely dislocated, and may pass through the pupil into the anterior chamber. This it is able to do because the ectopic lens, being highly elastic, is always smaller than the standard. When this accident happens, glaucoma at once arises, for reasons indicated in the section on glaucoma, and the danger to sight is acute. Should such an accident occur, what is to be done ? The rule as to giving a miotic in glaucoma does not hold good in these circumstances ; eserine will intensify the evil. The best plan, if the accident has been at all recent, is to give atropin, when the pupil will dilate, the lens will slip back into the vitreous chamber, and glaucoma will cease ; the pupil must then be kept small by weak eserine, until with the normal diminution with age the risk of any repetition becomes less and less. The only alternative is the highly dangerous one of extraction of the lens ; dangerous or not it must, however, be attempted, if the lens has been lying forwards for any length of time. The danger is that even during the making of the section the pressure of the knife may

force the lens back into the vitreous out of reach, vitreous may well out, and the section be made in vain. I have found it best under these conditions to begin the operation by fixing the lens *in situ* by means of a stop-needle introduced through the lower corneo-sclerotic junction, making the incision while the needle is in place, and extracting with the vectis, while with the other hand the needle is *pari passu* withdrawn. For traumatic dislocation of the lens see p. 383.

Coloboma or congenital cleft of the lens is seen in a very small proportion of the cases of coloboma of the iris, and presents an appearance as though a nick had been taken out of the lower margin, much like the lunule of the nail.

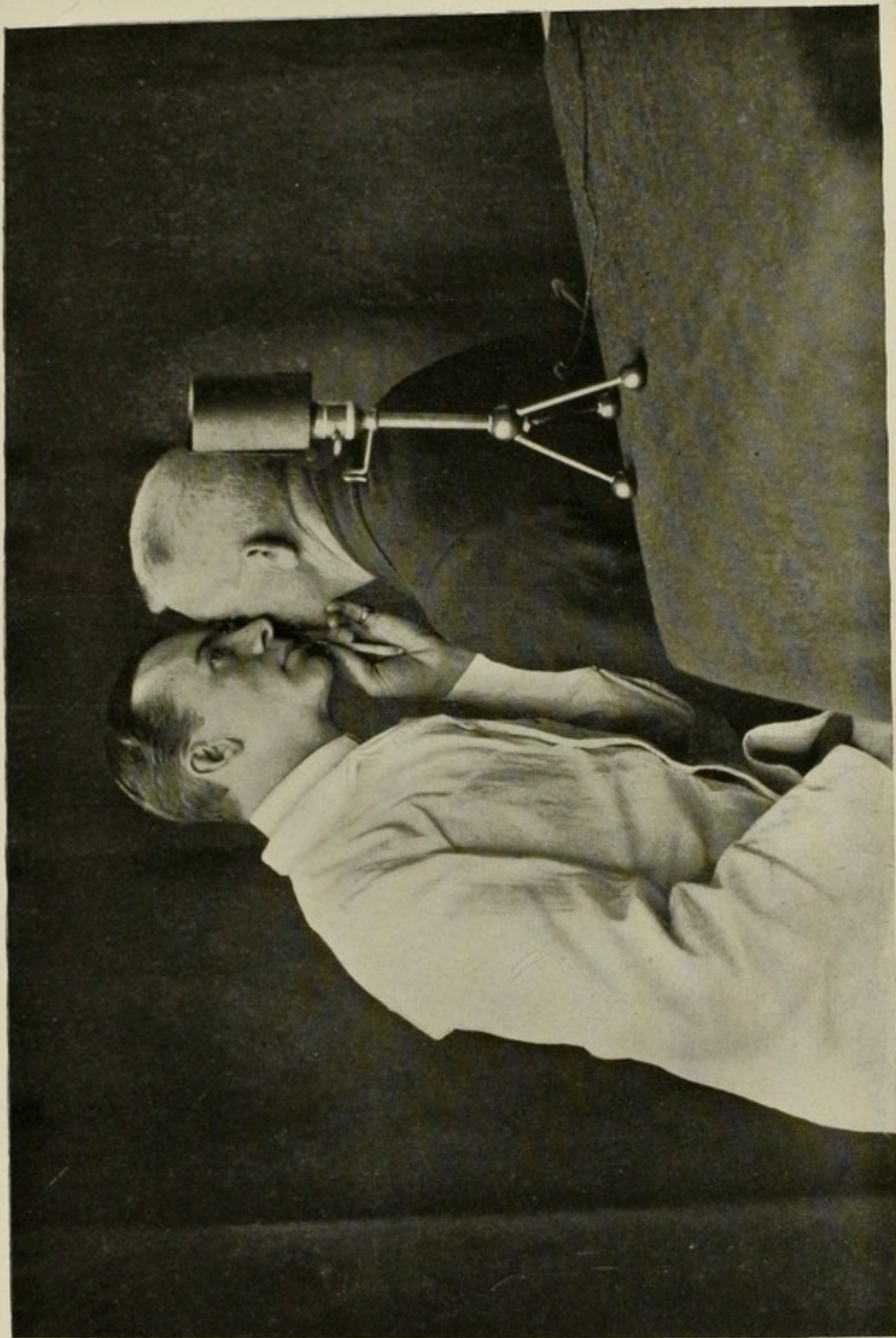
A rare disease of the lens consists in a localised area at the centre of the posterior part when the substance protrudes beyond the normal limit in the form of a minute heap or cone; the disease is known as *Lenticonus posterior*. It is probably a congenital fault, a want of perfect adjustment at the posterior pole of the lens. Vision is very seriously interfered with, and the condition is readily mistaken for posterior polar cataract.






Ophthalmoscopy.

1. Indirect method. 2. Direct method : First step, placing the mirror.



Ophthalmoscopy.

Direct method : Second step, position completed.



CHAPTER IX

THE OPHTHALMOSCOPE AND OPHTHALMOSCOPY

THE reason for which we are unable under ordinary conditions to see the fundus of an eye is that such light as is reflected from the fundus is sent back exactly in the line and direction by which it has entered the eye, or in other words, is sent back to the source of light, and unless one can make one's own eye the source of light one cannot gather to it the light from the fundus of another. It was their inability to accomplish this which prevented the surgeons before the days of Helmholtz, who invented the ophthalmoscope, from seeing the fundus. Helmholtz, the father of ocular physics, accomplished this feat in a certain way, and was able by this means to examine the living fundus. His apparatus consisted of two or three flat glass plates superposed and held together. Of the light of a candle reflected from these, that portion which was made to pass into the eye was returned to the plates; these being set at an angle allowed some of the light to be again reflected towards the original candle, but the rest passed through the plates, and entered the eye of the surgeon who looked through them. Thus Helmholtz was enabled to see what had never before been seen, namely, the fundus during life. The glass plates are no longer in use; a concave mirror, perforated so that the observer can look through it, is now employed instead. This

mirror is concave, and forms the rays which it receives from a lamp into an aerial focus lying a few inches in front of the observer's eye, between him and the patient. This actual image of the lamp thus becomes the source of light which illuminates the fundus, and to it are returned the rays which are reflected from the fundus. These pass on along the same path and are received by the observer, who holds the mirror with its aperture opposite his eye.

There are two systems in use in the examination, known as the Direct and the Indirect methods: the surgeon must be familiar with both methods.

In the **Direct Method**, or Erect Image, the surgeon practically requires to be expert with either eye, though, as we shall see, should only one of his eyes be available it is not impossible to use the other in the examination of either eye of a patient. The best method of procedure is that in a room which is otherwise dark; patient and surgeon sit opposite one another, the light from a lamp falling full upon the face of the latter, though screened from the former. Opposite the sight-hole of his ophthalmoscope the observer places his oblique mirror; the light should be at the same side of the patient as the eye to be examined, a little way behind but in a line as close as possible to the side of the head; the oblique mirror should have its face sloped towards the light. The mirror must be as near to the patient's eye as is possible; if the observer raises his mirror for a moment so that the light is reflected upon the patient's brow, he will see that about the central area of the patch of light reflected by the mirror there is a dark spot corresponding to the sight-hole of the mirror; unless this dark spot is brought over the pupillary area the fundus cannot be seen. Having thus adjusted his mirror, the observer brings his head down and close to the patient, so close that between the two there is no more than space for

the oblique mirror. It is much better for the observer to adjust the mirror to the patient's eye and then to bring his head to it than to adjust it to his own eye first. The surgeon uses his left eye for the patient's left eye, his right for the patient's right. (Should the observer be unable to use one eye and be obliged always to employ the other, say the right, he has to adopt a very inconvenient attitude when examining the left eye of a patient; he must keep the light at the patient's right side, and cause him to face towards it, but to turn both eyes to his (patient's) left. In this attitude it is not impossible to examine a patient's left eye with one's right one.) To achieve the best position it is well to incline the upper parts of the two heads towards one another to a slight degree. Should the observer put his head too much on one side, however—a mistake which many beginners make—he will see very little, because his nose instead of the mirror will catch the most part of the light from the lamp. And now comes the most difficult part of the observer's task, namely, to *refrain altogether from accommodating*. The reason for which this is necessary is that, assuming the refraction of each of the two eyes (patient's and observer's) to be emmetropic, each is adapted for the focussing of parallel rays only, and the rays which leave the fundus are, after passing through the media, collected into bundles of parallel rays. The eye of the observer is thus adapted for the focussing of parallel rays, and that of the patient is giving out parallel rays to meet it; if now the observer refrains from accommodating, an image of the patient's fundus will be formed upon the observer's; if he accommodates he is not adapted for parallel rays and no such image will be clearly formed. This power of not-accommodating is difficult to acquire, especially for some, but apart from actual practice with the ophthalmoscope some assistance may be obtained from the following exercises: Holding a book near the

eye, "let off" the accommodation and the print will all fade and become indistinct; this is more easy to accomplish if the book be held up on a level with the eyes rather than below them. Or stand opposite a window and, keeping one eye closed, hold up your ophthalmoscope mirror facing you so that you can see your own image in the glass of it; then look through the aperture at the scene outside the window, and so on alternately. In a short time it will become quite easy to hold up the mirror and look "distantly" at anything through the aperture without any attempt to accommodate. The same may be done with the handle of a small key, changing from accommodating for the key to adapting yourself for the scene visible through the ring of it. The beginner's temptation to accommodate is all the stronger that he knows that the object to be seen is close to his eye, but it must be overcome. One method of learning this seems very unwise, though some have recommended its employment, namely, to put behind the mirror a rather high concave glass, the effect of which will be to neutralise the evil effect of the accommodation and enable the observer to see the fundus. But as this plan encourages the beginner to do exactly what he ought not to do, and actually makes things easier for him when he does commit the fault, it is a plan to be avoided.

The image of the fundus seen by the direct method is magnified approximately sixteen times and is erect—it stands, that is to say, exactly as it appears.

When the refraction either of patient or observer is not normal, the correcting glass must be worn, and all modern ophthalmoscopes provide in some way a rapid means of sliding lenses of various strength behind the aperture in this mirror. To take a simple instance, a certain patient is myopic; from his cornea the rays cannot emerge in bundles all running parallel. A lens

is required which will render them so, for the surgeon's eye is adapted only for parallel rays, and except these are rendered parallel they cannot be focussed on his

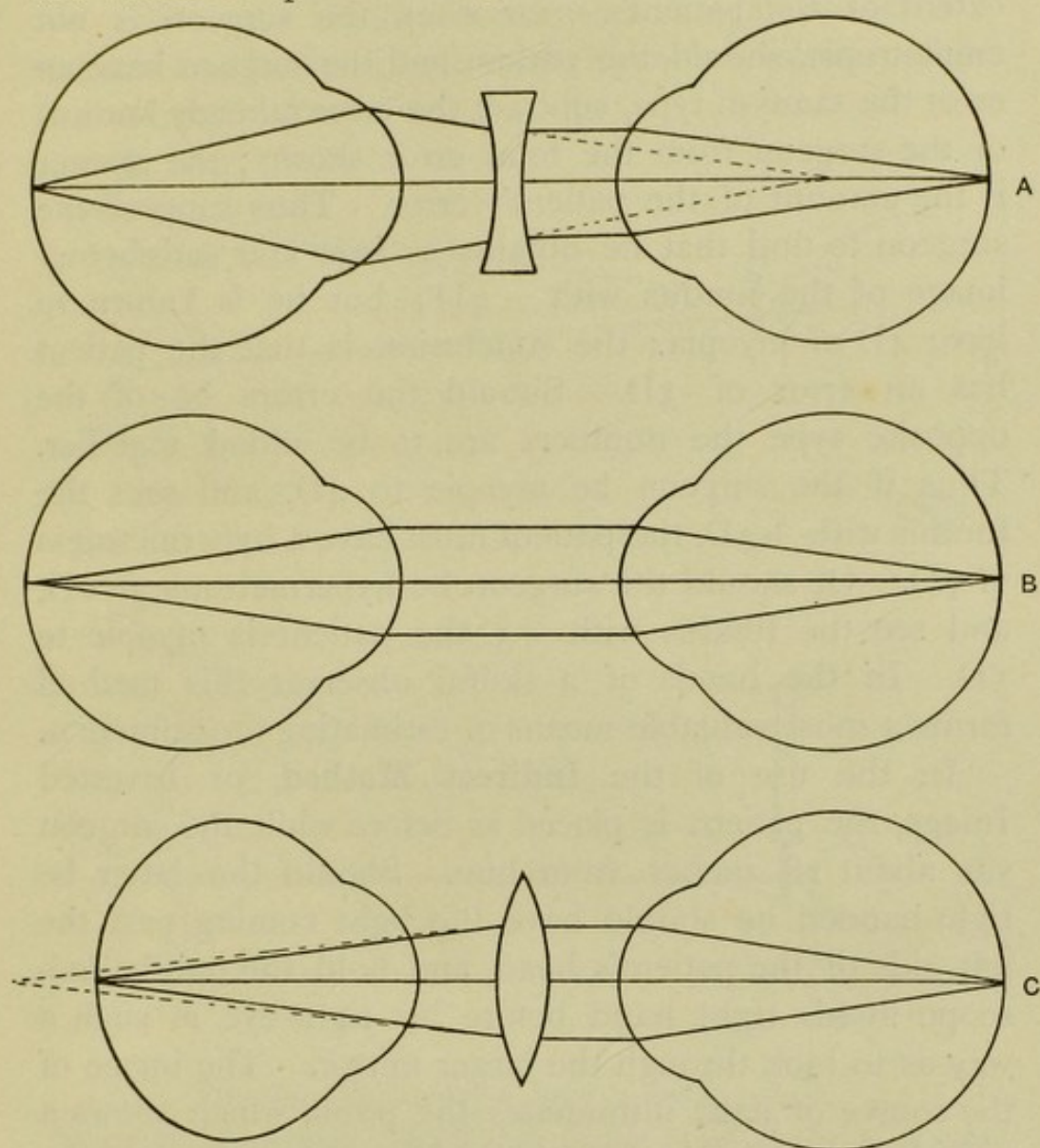


FIG. 48.—Ophthalmoscopy : direct method.

A. An emmetropic eye focussing rays from a myopic eye by the aid of a concave lens ; or *vice versa*. B. An emmetropic eye focussing rays from an emmetropic eye. C. An emmetropic eye focussing rays from a hypermetropic eye by the aid of a convex lens ; or *vice versa*.

retina. The very weakest concave lens with which a normal eye can see a myopic one is the measure of the myopia ; the strongest convex on the other hand is the measure of the hypermetropia. But should the surgeon be myopic he is not adapted for parallel rays, and must

wear the correcting glass which will cause such rays to acquire the degree of divergence requisite to adapt them for his eye. We find this rule then: To find the extent of the patient's error when the surgeon is not emmetropic, should the patient and the surgeon have an error the same in type, subtract the error (already known) of the surgeon from the total error shown; the answer is the amount of the patient's error. Thus suppose the surgeon to find that he obtains a large and satisfactory image of the fundus with $-7D$; but he is known to have $4D$ of myopia; the conclusion is that the patient has an error of $3D$. Should the errors be of the opposite type the numbers are to be added together. Thus if the surgeon be myopic to $4D$, and sees the fundus with $+3D$, the patient must have a hypermetropia of $7D$. Or should the surgeon be hypermetropic to $2D$, and see the fundus with -3 , the patient is myopic to $5D$. In the hands of a skilful observer this method forms a most valuable means of estimating the refraction.

In the use of the **Indirect Method**, or Inverted Image, the patient is placed as before while the surgeon sits about 18 inches from him. Should the latter be right-handed he should have the light coming past the left side of the patient's head, and hold the ophthalmoscope in his right hand before his right eye in such a way as to look through the larger mirror. The image of the source of light illuminates the pupil, which shows a red glow, and having secured this red glow through the pupil, he in his left hand holds up the strong convex lens supplied with every ophthalmoscope, and looking at *it*, as it were, he sees in the air an image of the fundus. It is, of course, difficult to realise that this image is aerial and not posterior to the pupil, but it is, for it is formed by the lens of the rays which, entering by the pupil, have been reflected from the fundus, have passed through the refractive media again and the lens in the

observer's hand, and are collected by it into an inverted image. The lens, which is of about $2\frac{1}{2}$ inches focus, should be held about that distance from the patient's eye. Since the image is aerial and stands between the surgeon and his lens, and about $2\frac{1}{2}$ inches from it, while

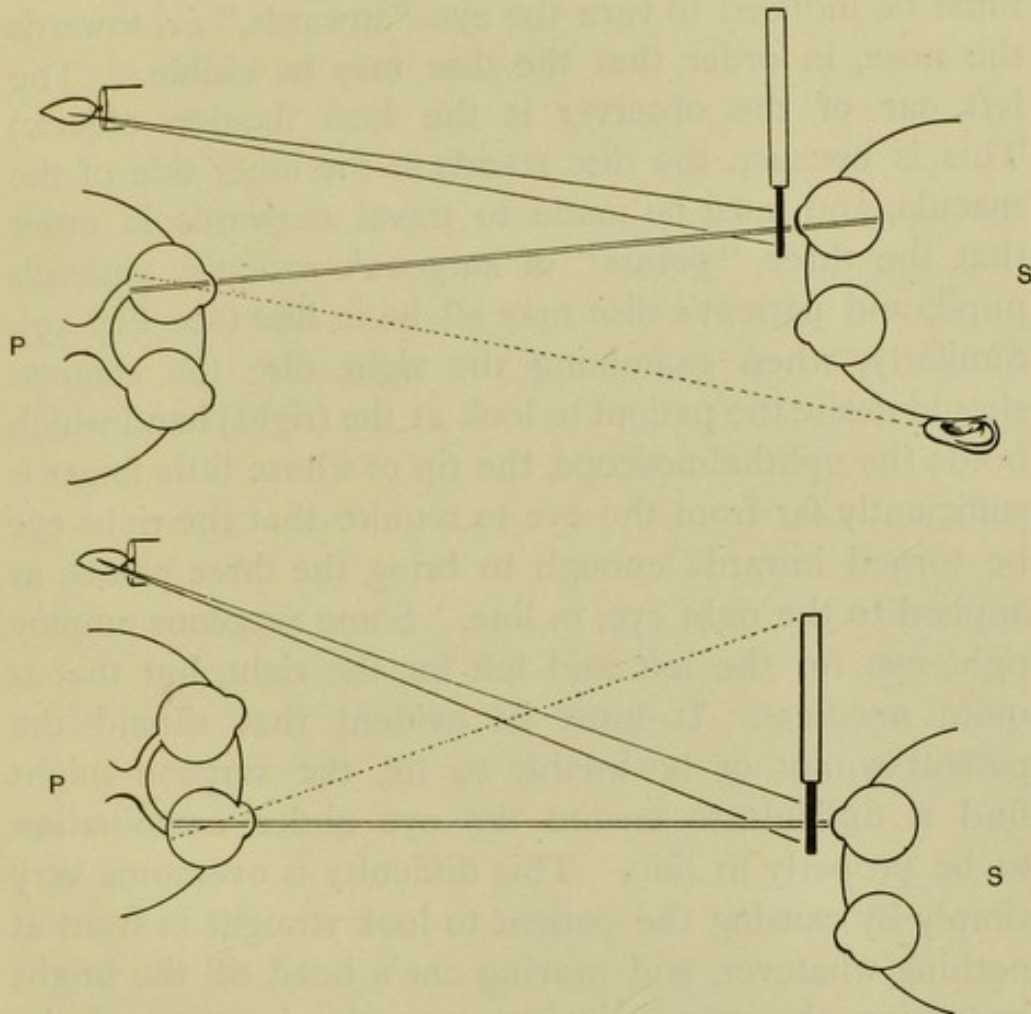


FIG. 49.—Ophthalmoscopy : indirect method.

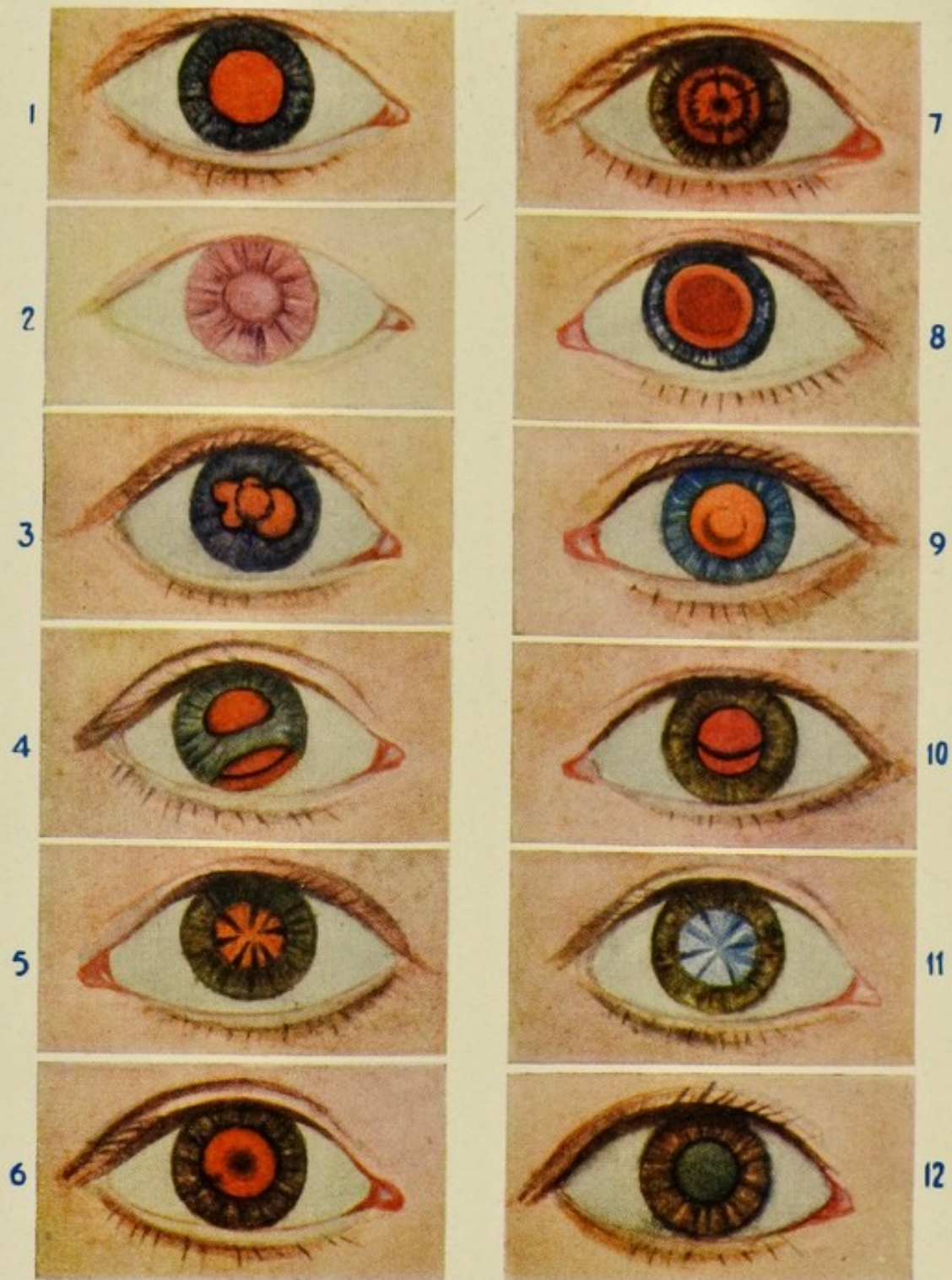P=patient. S=surgeon. Showing the fixation points adapted for a right-handed surgeon examining a patient's left disc (upper figure) and right disc (lower figure).

it is $2\frac{1}{2}$ inches from the eye, and the patient is some 15-18 inches from the surgeon, the image must be about reading distance from him; therefore, if he be in the custom of using lenses when reading, he should use them when employing the indirect method. Some surgeons prefer to use a rather high plus lens, +4D or so. The degree of magnification is about 4 or 5 times.

If we assume that the surgeon feels more expert with his right eye, he will find it best to place the light and the patient as has been suggested, whether he is about to examine the right or the left eye ; and to change solely the direction of the patient's gaze ; the patient must be induced to turn the eye "inwards," *i.e.* towards the nose, in order that the disc may be visible. (The left ear of the observer is the best fixation object.) This is because the disc stands to the inner side of the macula, and must be made to travel outwards in order that the three "points" of surgeon's macula, patient's pupil, and patient's disc may all be in line (see Fig. 49). Similarly, when examining the right disc the surgeon should desire the patient to look at the (right) hand which holds the ophthalmoscope, the tip of whose little finger is sufficiently far from the eye to require that the right eye be turned inwards enough to bring the three points, as applied to the right eye, in line. Some surgeons employ right eye for the left and left for the right, but that is quite needless. It must be evident that should the patient squint or be unable to fix, the surgeon might find it difficult to ensure the eye under examination to be properly in line. This difficulty is overcome very simply by causing the patient to look straight in front at nothing whatever, and moving one's head till the bright image on the cornea is just over the junction of the outer and middle thirds of the pupil ; when that is so the surgeon's eye is in line with the disc. This rule is equally true for the direct method, in carrying out which it is best to cause the patient to look straight before him ; the surgeon then so adapts his own attitude as to secure this position of the corneal reflex.

In using either method it should be a rule to *examine the media before the fundus is looked at at all* ; many a mistaken diagnosis would be avoided if this rule were observed ; vitreous opacities, spicules in the lens,





1. Normal pupil as seen through ophthalmoscope mirror.
2. Glow from Albino fundus as seen through ophthalmoscope mirror.
3. Old Iritis : Synechiæ, some holding, some broken.
4. Iridodialysis. Edge of lens visible.
5. Cortical Cataract, as seen with mirror.
6. Sclerosis of Lens: early Nuclear Cataract.

7. Lamellar Cataract, with numerous spicules.
8. Lamellar Cataract.
9. Crescentic shadow in Conical Cornea.
10. Subluxation of Lens : congenital.
11. Cortical Cataract as seen by focal illumination.
12. Nuclear Cataract as seen by focal illumination.

detachment of retina, etc., would be noticed with unfailing accuracy, and would not be "projected" upon the fundus, to the confusion of the true facts.

To settle **the exact position of an opacity** is a simple enough matter by means of the mirror. First, any opaque substance, whatever its own colour, appears dark against the lighted background of the fundus, and if it have any movement of its own apart from the movement of the eye it can only be in the vitreous humour; there is nowhere else that it could be. But if it is fixed, that is, if it move only along with the eye, one must settle exactly where it lies. The best plan of procedure is to keep one's own head and eye steady and cause the patient to look up and down as one desires, and watch the movement of the dark spot against the red glow. When a person "turns the eye up" he (of course) only elevates the anterior half of the eye, the posterior half goes downwards, the axis of movement passing just behind the posterior pole of the lens. An opacity lying immediately posterior to the centre of the posterior surface of the lens would therefore have no movement at all. Another point must be kept in view as well as the opaque particle, namely, the bright reflex on the cornea thrown back by it as a convex mirror; this must always be situated on the straight line joining the centre of movement with the portion of cornea which is at the moment presented towards the observer, the summit of the cornea. He sees this bright image in the centre of the cornea when the patient looks straight into the mirror, and when the patient looks up this point actually remains stationary, but relatively travels downwards, that is, approaches nearer to the lower margin of the cornea. Should the opacity be precisely at the centre of movement, then the bright spot will lie upon it, and the two will remain superposed in whatever position the eye is placed. They will become more and

more separated the further forward the opacity is situated. Thus a posterior polar cataract, when the patient looks high up or low down, will barely separate itself from the bright dot, while a small nuclear or lamellar cataract will distinctly do so, and a patch of deposit on the anterior surface of the lens will do so greatly. This method enables one to decide the situation with the greatest accuracy. The student is very apt to be led away by looking at the margin of the

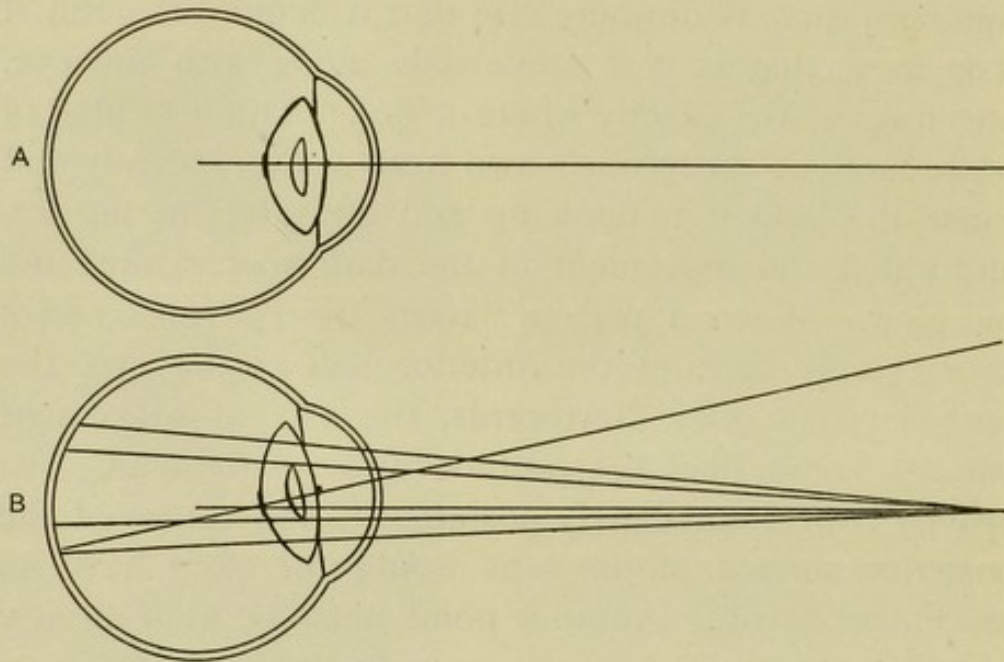


FIG. 50.—Determination of the position of an opacity in the media.

A. Patient looking straight forwards. The corneal reflex, anterior polar cataract, lamellar cataract, posterior polar cataract, and centre of rotation all in line. B. Patient looking up. Corneal reflex and centre of rotation in line. Posterior polar cataract has risen up slightly, lamellar cataract more, and anterior polar much.

pupil, and must guard against making a mistake by so doing. Thus a deep-lying opacity in the lens will appear to move downwards nearer to the lower edge of the pupil when the patient looks up, because its real upward excursion is so much less than that of the iris, since it (the iris) lies further forward (Fig. 50).

Some surgeons, it is true, prefer another method, but one which is much less precise: they regard as a fixed point the plane of the pupil, which of course appears red.

A dark spot anterior to that plane will appear to move "against" the movement of the observer's head across the red, while one posterior to the plane will appear to move "with" the observer.

It may be thought advisable to institute some comparison between the rival *merits of the two methods*. The advantages of the indirect are that, the magnification not being very high, a much larger area of fundus can be quickly examined than if the direct method be employed, and that, since the rays focussed do not require to be parallel but are gathered together by means of the lens, the observer is not so much interfered with by irregular refraction from changes in the lens, from high astigmatism, from conicity of the cornea, etc.; also, as there is a space of some eighteen inches or so between surgeon and patient, very sensitive persons are less likely to feel embarrassed, and unclean patients or those afflicted with ozæna give less offence to the surgeon than where very close approximation of heads is essential. The advantages of the direct method are that the larger magnification makes the examination more thorough and searching, and fine changes are less liable to escape notice; that one is particularly well able to detect differences of level in the fundus, such as may be caused by tumours, by exudates, by depression of the nerve head, etc.; that one can examine the fundus and correct the refraction at the same moment. On the whole, most surgeons find it best to utilise the Indirect method as their routine, and to apply the Direct in any doubtful or difficult case. In certain schools one method is specially favoured, in others the other. The Indirect method is certainly the more easily acquired.

A certain point in the use of the Indirect method gives trouble to the beginner: supposing he is examining a right eye with his right eye and the disc (or the special

portion under inspection at the moment) is not com-

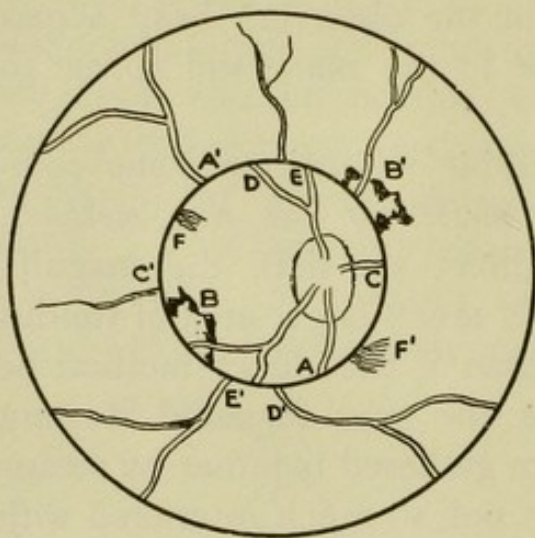


FIG. 51.—Degree of inversion of the image in the Indirect method.

The outer circle shows the limits of the visible part of the fundus; the inner circle, the extent of the portion visible at one time. The figure shows the inversion of the image; the vessel A is continued at A'; C, D, and E, at C', D', and E'; the chorioidal patch B is continued at B', and the hæmorrhage F at F'.

should therefore have inclined his head not to the left but to the right. Fig. 51 makes this plain.

Of the fundus it may illogically be said that there are three parts to examine—the disc, the macula, and the periphery—and no fundus has been really examined till all these have received attention.

The **fundus** generally has a finely granular surface of reddish or orange-red hue, the depth of tint varying within somewhat wide limits, according to the complexion of the individual, from the pale pinkish red of the lighter blonde to the dull brownish red of the dark brunette. The fundus may be very uniform, and in an averagely deeply pigmented eye may present very little variation, save where the disc stands and the vessels course, but in the lighter and in the darker types it is not uncommon to see also the chorioidal structure. The mistake is often made, even by those who are not strictly beginners,

completely disclosed at the (his) right side of the pupil. He is extremely apt naturally to incline his head to the left that he may see round the edge of the pupil—when the whole of the part at which he was looking disappears. He must remember that what appeared to him to be at the right side was, owing to the inversion of the image, at the left in reality, and “continued” beyond the left side of the pupil: he

of assuming that one sees the retina, but that is not so, for the real normal retina is absolutely transparent; what one does see is the inter-layer separating retina from chorioid, and the chorioid; under varying (but still physiological) circumstances one sees the chorioid itself. If the pigment be scanty one can see the chorioidal vessels as palish red strips coursing among lighter areas, like pale red canals in a lighter country; where the pigmentation is deep the chorioidal vessels, on the other hand, may appear as lighter red canals in a dark country; in this latter condition, where the chorioidal pigmentation is heavy, the appearance well described as "tiger-striping" is the result. Chorioidal vessels may always be known from retinal by the facts that they run "anyhow," *i.e.* they are not on their way to the disc, they have no double outline, and they appear like ribbons rather than cords. The retinal vessels are on their way to the disc; and in a troublesome case one can "find one's way" to the disc by following up a vessel as it becomes wider; and the vessels have a distinct double outline and in consequence look like cords. Arteries may be distinguished from veins by their lighter colour, their broader and more definite double outline, and by their light line between the double outlines being of a yellowish pink colour, not white. No pulsation is visible in the vessels, as a rule; venous pulsation depends upon the close approximation of artery and vein and is of no significance; arterial pulsation is always pathological.

The **Optic Disc**, which is nearly circular, owes its peculiarities of aspect to the two circumstances that at it there is a gap in the chorioid, and that it is the place of departure into the retina of the optic nerve fibres and the retinal vessels. In absolute measurement it is about $1\frac{3}{4}$ to $1\frac{1}{2}$ millimetres in width, and the disc-diameter is used as a convenient measure of objects in the fundus.

The absence of chorioid lightens the colour of the disc by depriving it of the pigment layers which are present over the remainder of the fundus ; the disc therefore has no colour save that which is imparted to it by its own vessels and by the shadows which its own recession may impart to it. The nerve fibres are in themselves absolutely invisible, yet their presence in great masses at the upper and lower margins of the disc gives to those parts a faint indistinctness, a diminished sharpness of outline which is not present on the two sides of the disc. For the nerve fibres do not run out from the disc like the spokes of a wheel, but chiefly above and below, curving round after leaving the disc so that large numbers reach the macula, yet so purged of their grosser parts that nothing exists at the macular region proper save the elements absolutely essential to vision. That this is so becomes very evident in the case of a congenital anomaly seen from time to time, where the nerve fibres retain or regain their myelin sheath at the disc margin and course over the fundus in curves sweeping round towards the macula (opaque nerve fibres).

The large vessels pursue the same course more or less and for the same reason, so that one may notice that at the upper and lower edge the vessels are large and numerous, at the inner side much fewer and very small, while at the outer (macular) side they are all but non-existent (Plates XIV.-XVIII.). Generally speaking, two arteries run upwards, which may branch off from one another either on the disc or after leaving it ; these are named the superior nasal and superior temporal arteries. A vein accompanies each artery, and a very similar arrangement occurs at the inferior half of the disc.

Round the outer limits of the disc the chorioid ceases abruptly, a fact which is sometimes indicated by the existence of a ring of increased chorioidal pigment just at the border ; it is not by any means always present

or always complete, but when present it is spoken of as the *Chorioidal Ring*. Within this there sometimes is a white or whitish ring, known as the *Scleral Ring*, where the sharp edge of the sclerotic suddenly becomes the nerve sheath. Within it is the disc proper, in the middle of which appear the retinal artery and vein as they emerge from the nerve itself to spread out in the retina. Whether or not one is able to see the trunk of the vessel depends largely upon the existence of a "cup." This *Cup* or *Pit* is present if the nerve fibres begin to separate out from one another before the actual nerve-head is reached. If this occurs one may well enough be able to see the vascular trunks in the depth of the cup before they break up. This cup may extend to the margin of the disc, but at one part only, namely, at the outer side; it does not often do so even in eyes in which quite a deep central cup exists. This cup or pit, if physiological, has certain characters which must be noted. The peripheral portion of the disc, which may be reduced to quite a narrow ring, is exactly on a level with the rest of the fundus, and is well coloured; the cup is abrupt, never sloping and never overhanging. The cup, as has been said, does not extend to the periphery of the disc. Vessels coursing over the fundus do not, on arriving at the disc margin, become "broken off," and appear to resume their course at a little distance from the fundus vessel; if that should take place at all it may do so at the edge of the cup, but not at the edge of the disc. The floor or bottom of the cup is often of a somewhat bluish hue, a circumstance which has considerable importance in regard to a point in diagnosis to be considered later, and which may be explained in this way: As the optic nerve reaches the disc the opaque sheaths of its various bundles of fibres cease abruptly, and the denuded fibres pass on to form the retina. An observer, looking down upon the ends of these opaque tubules,

thus sharply cut off, sees into them or down them an infinitesimal way, and then the bluish shadows cast by their walls cut off the deeper parts from sight. It is these shadows which give the bluish dotting or pitting to the disc.

Though such a course may not be strictly logical, it is convenient at this point to contrast with the physiological cup two forms of pathological cup, which must all be

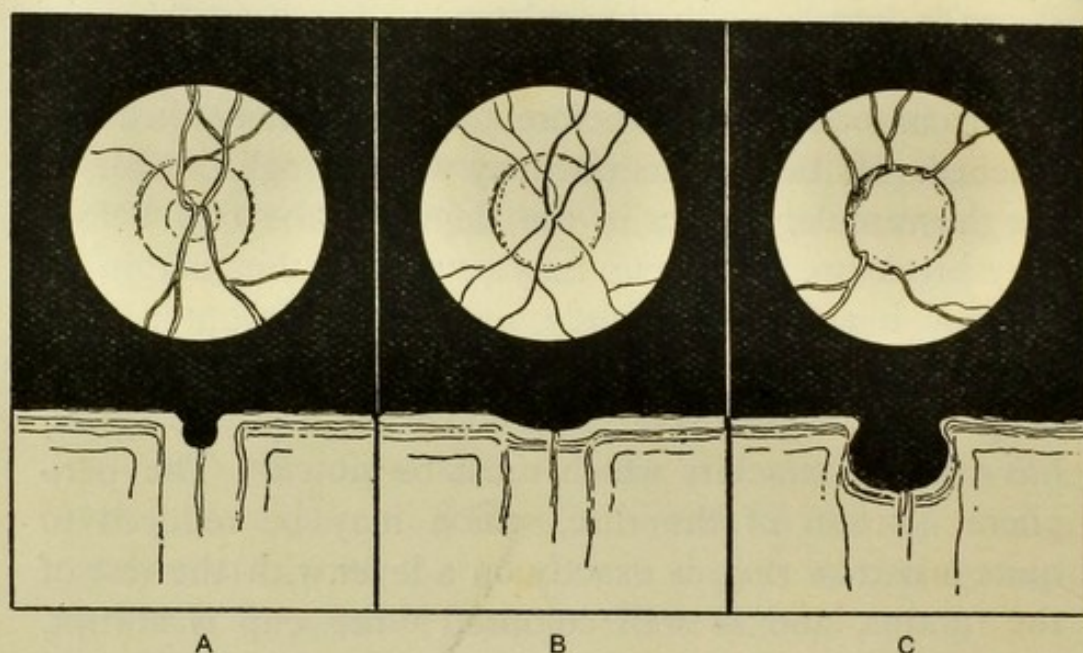
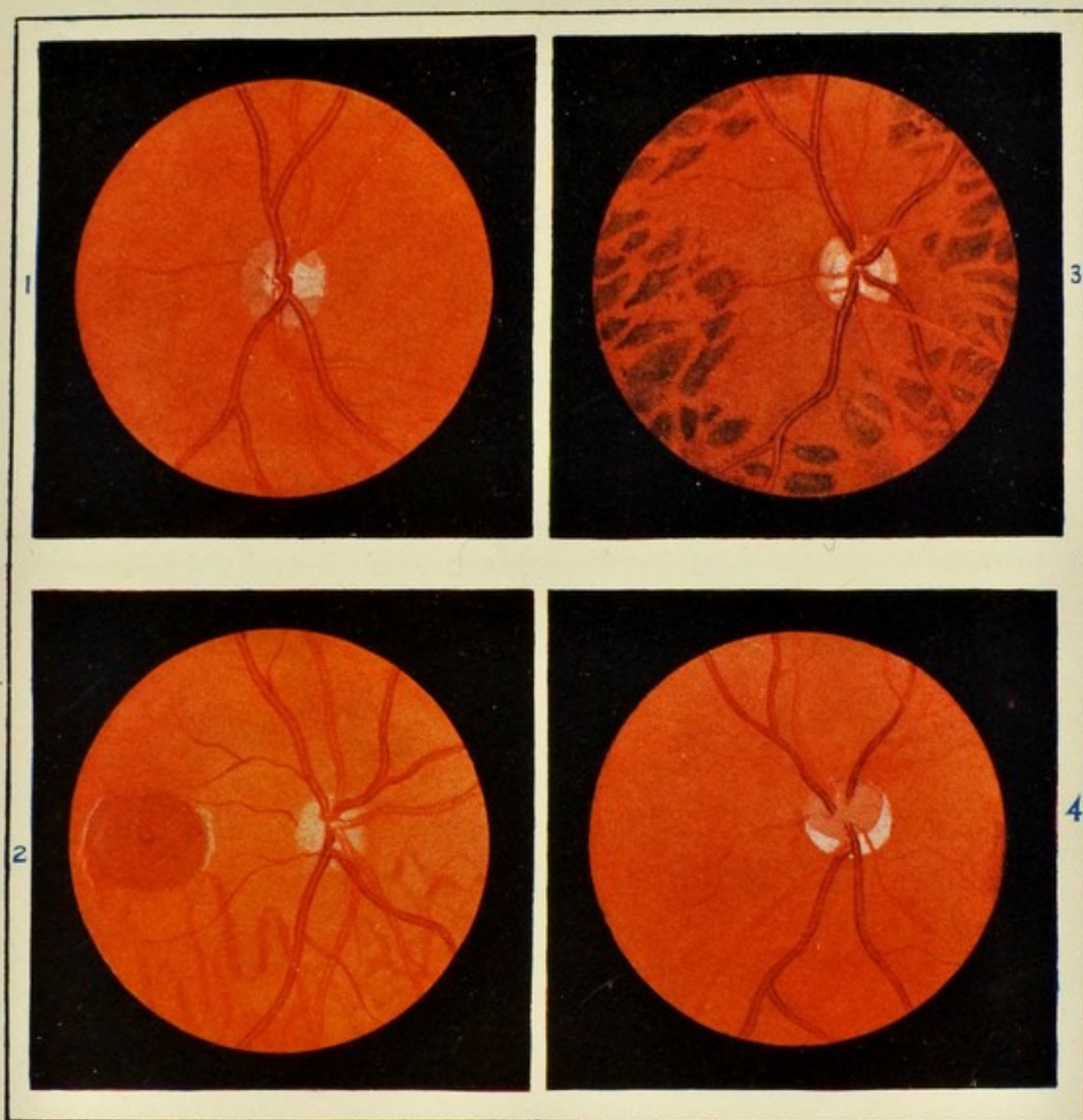


FIG. 52.—The three types of cup contrasted.

A. Physiological. B. Atrophic. C. Glaucomatous.

very precisely differentiated from one another. (1) The Atrophic cup. In cases of optic atrophy (atrophy of the optic nerve) the cup which may be exhibited is shallow, it affects the entire disc, it is gradual, the slope inclining gently down to the centre of the disc, which is also its point of deepest depression, and there is therefore no "broken vessel" phenomenon. (2) The Glaucoma cup affects the whole disc, the depression is most abrupt, so abrupt, it may be, that the form of the disc is rather a goblet than a cup, the vessels are pushed over to the nasal side of the disc, and the "broken vessel" phenomenon is well marked.




1. Average normal Fundus : Physiological Cup.

2. Fundus of Blonde : Macular Halo : Some chorioidal vessels.

3. Fundus of Brunette : slight "tiger-striping."

4. Staphyloma downwards : "Fuchs's Coloboma."



	Physiological Cup.	Atrophic Cup.	Glaucoma Cup.
Portion of disc affected	Central only.	All.	All.
Depression	Abrupt.	Sloping.	Abrupt.
"Broken" vessels	May be.	Never.	Always.
Vessels pushed to nasal side	Never.	Never.	Always.
Pulsation of arteries	No.	No.	Frequently.

The **Macula** presents, one might almost say, negative rather than positive features; it is situated at a distance approximately equal to two disc-diameters from the disc to its outer side, and is an area of about one and a half disc-diameters across, where there are no visible vessels, or where they are extremely small, and where the pigmentation is somewhat deeper than in the rest of the fundus. Surrounding it may be seen an oval light-ring, its long axis lying horizontally, the ring often incomplete at the side distant from the disc, its appearance changing with the least movement of the mirror; towards the central region the pigment becomes a little deeper still, and the appearance suggests an extremely slight elevation; at the centre of this, as it were upon the summit, is a bright, straw-coloured light-point which may appear almost triangular. These features are rarely to be seen in complete perfection save in the young brunette; the "ghostly" ring round the area, for example, is never seen in the myope, in the light-hued fundus, or in a person above thirty years of age, and an eye is certainly not necessarily pathological which exhibits few of these classical features. The **Fundus** generally, as one approaches its **periphery**, appears less accurately pigmented; the vessels are smaller, irregularities in the smoothness of the pigmentation, with weaker patches and spots of accumulated pigment, may be seen; it is as though Nature had done her work less carefully than for the more essential central regions. This is more particu-

larly the case in older persons. The periphery is a part of the fundus which requires careful examination when one may have to decide between what is a definite patch of chorioidal atrophy or enhanced pigmentation or senile degeneration, and what is mere want of regularity in the spread of the pigment.

The beginner often has much difficulty in deciding whether some visible change in the fundus has its seat in the retina or the chorioid ; a certain rule, not absolutely correct under all circumstances perhaps, will help : *white* patches alone may be in either, *black* patches alone are retinal, *black and white* together are in the chorioid.

CHAPTER X

THE VITREOUS HUMOUR

THE vitreous humour is that soft, almost fluid material which fills the chamber of the eye whose walls are formed by the sclerotic (lined with chorioid and retina), and the ciliary body, iris, and lens. The consistency of the normal vitreous is not unlike that of egg-albumen, which it also resembles in appearance. It can hardly be said to have any structure in adult life, but in the foetal state it may be demonstrated to be made up of fine, soft, tenuous fibrils, enclosing in their meshes a homogeneous, transparent substance ; in the foetus it is penetrated by a leash of vessels which run from the disc to the posterior pole of the lens—the perforating artery of the vitreous—but of this all trace in the normal state of affairs is gone before birth. The canal of Cloquet, through which the artery ran, if it can be said to persist at all, only serves as a lymph channel. Surrounding the vitreous is an absolutely transparent homogeneous membrane called the Hyaloid membrane.

Since the vitreous is non-vascular its nourishment is carried on with some difficulty, tissue exchange is not easy, and as the least possible opaque spot in it, however infinitesimally minute, must cast a shadow on the retina, it is not to be wondered at that in very many persons complaint is made of floating opacities in the air, which are simply the shadows

on the retina cast by these minute dots, "projected" into space. It will be seen how common these are when one adds that they are more frequent in myopes, because the vitreous is called upon to fill a larger space by the increase in the sagittal diameter of the globe; in hypermetropes and astigmatics, because of the congestion of the nutrient vessels of the chorioid; in dyspeptics, because the chemistry of the nutrient fluid in the meshes is imperfect; and so on. The lymph stream which passes through it, and from which it derives such pabulum as it requires, comes mostly from the ciliary body and chorioid; anything therefore which interferes with their normality tells upon the vitreous. Besides this, by the simple little manœuvre of looking at a bright light through a pin-hole in a card, any one can be made to see *muscæ*, as those fine opacities are called (*muscæ volitantes*). In fact, these minute opacities might almost be said to be physiological. They present two forms, one in which the *musca* is like a minute air-bell in a fluid, a dark circle with a slightly lighter interior; several of these may be like beads on a thread: those of the other type resemble nothing so much as tube-casts in a specimen of urine, only much less definite and decided; these may be shadows of some of the cells of the vitreous. They have these features also that while movable they have only a small area of movement; they float up when the patient looks quickly up to a brightly lighted cloud, and then gradually sink and disappear. They never come directly in the line of sight, but always a little to the side of the fixation line; consequently when the patient looks for them he cannot find them, they fly away before the eye, and are only seen in indirect vision. Further, they are never opaque, only a little intransparent; they never increase in number or size, and they are quite consistent with excellent sight. The worst thing a patient can do

is to watch them and to watch for them, for the more they are looked for the more surely will they swim into view. Many persons give themselves a great deal of unnecessary distress over these *muscæ*, looking for them on every bright cloud, and convinced that they indicate the approach of cataract. They are too small to be seen with the ophthalmoscope. The true treatment for the condition is first to reassure the patient; secondly, to remove any local cause, such as an error of refraction which is causing congestion; and thirdly, to ensure free and regular clearing out of all toxins from the *primæ viæ*.

Pathological *muscæ* are an exaggeration of the physiological, and may come from the ciliary body or the chorioid; thus they are a feature of cyclitis and chorioiditis, in their early stages, at any rate. The floating particles are larger, darker, vary in form and density, are more easily seen by the patient, and are visible also to the surgeon. They may be due to faulty nutrition of the vitreous, or to minute hæmorrhages from overcharged vessels. They are often to be seen by the ophthalmoscope as tiny dark specks floating in the substance of the vitreous. Since they do float in the vitreous one may fairly assume that in part at least the vitreous must be more fluid, less consistent, than normally it ought to be. They are usually irregular or shreddy in their form, and, floating up as the eye looks up, gradually sink down again into place. Two special matters for which one ought to search in a case in which these pathological *muscæ* are complained of are patches of chorioiditis and detachment of the retina, either of which may be more or less directly connected with the existence of these *muscæ*.

In regard to the *treatment* for *muscæ* there is little to be said. General good hygiene by prevention of constipation, by non-stimulating diet, by prohibition of all that congests the eyes, such as stooping, bending

over work, heavy meals, etc. ; correction of any error of refraction, temporary prohibition of reading, etc. Internally probably iodide of potassium is the most useful drug, apart from hepatics and mineral waters.

A rare *malformation* of the vitreous is the persistence of the perforating artery, which may be seen as a loop of vessels starting from the disc and protruding into the vitreous, perhaps actually reaching the posterior pole of the lens, where it forms a minute discoid opacity. Vision in such an eye may be quite good and the peculiarity discovered only accidentally ; more usually vision is much below standard.

Hæmorrhages may occur into the vitreous humour either as the result of trauma or of disease affecting the retina, the chorioid, or the ciliary body. They may also occur as a great rarity in the form of repeated bleedings into the vitreous in young men who apparently are quite healthy.

Apparently superficial to the retina a large circular effusion of blood may occur : the condition is known as a *Subhyaloid hæmorrhage*, though it is doubtful whether the term is as accurate as might be desired. The dark area becomes lighter above as the clot separates out, presenting a curious aspect (Plate XVI. 3) : the prognosis is fairly good.

A curious alteration of the vitreous sometimes occurs in the formation of *cholesterin*, which may be observed as bright, shining flakes moving in the vitreous ; these are visible with the ophthalmoscope, and may persist for long without doing much harm to the eye : *Synchysis Scintillans* is the name applied to the condition.

CHAPTER XI

THE CHORIOID

THE chorioid forms one of the three portions of the uveal or pigmented coat of the eye, and extends from the disc, where it is perforated to allow the optic nerve to pass through, to the ciliary processes. It is a highly vascular and highly pigmented structure; highly vascular because the nourishment of the interior of the eye is largely dependent upon transudation of lymph from its vessels, and highly pigmented so that light may alone reach the retina which has come through the pupillary aperture, and so that there may be provided a healthy black background on which the images may be formed. Its most outer layers contain the largest vessels, while the portion nearest the retina consists almost entirely of capillaries with a scanty but deeply pigmented framework of fibrous tissue.

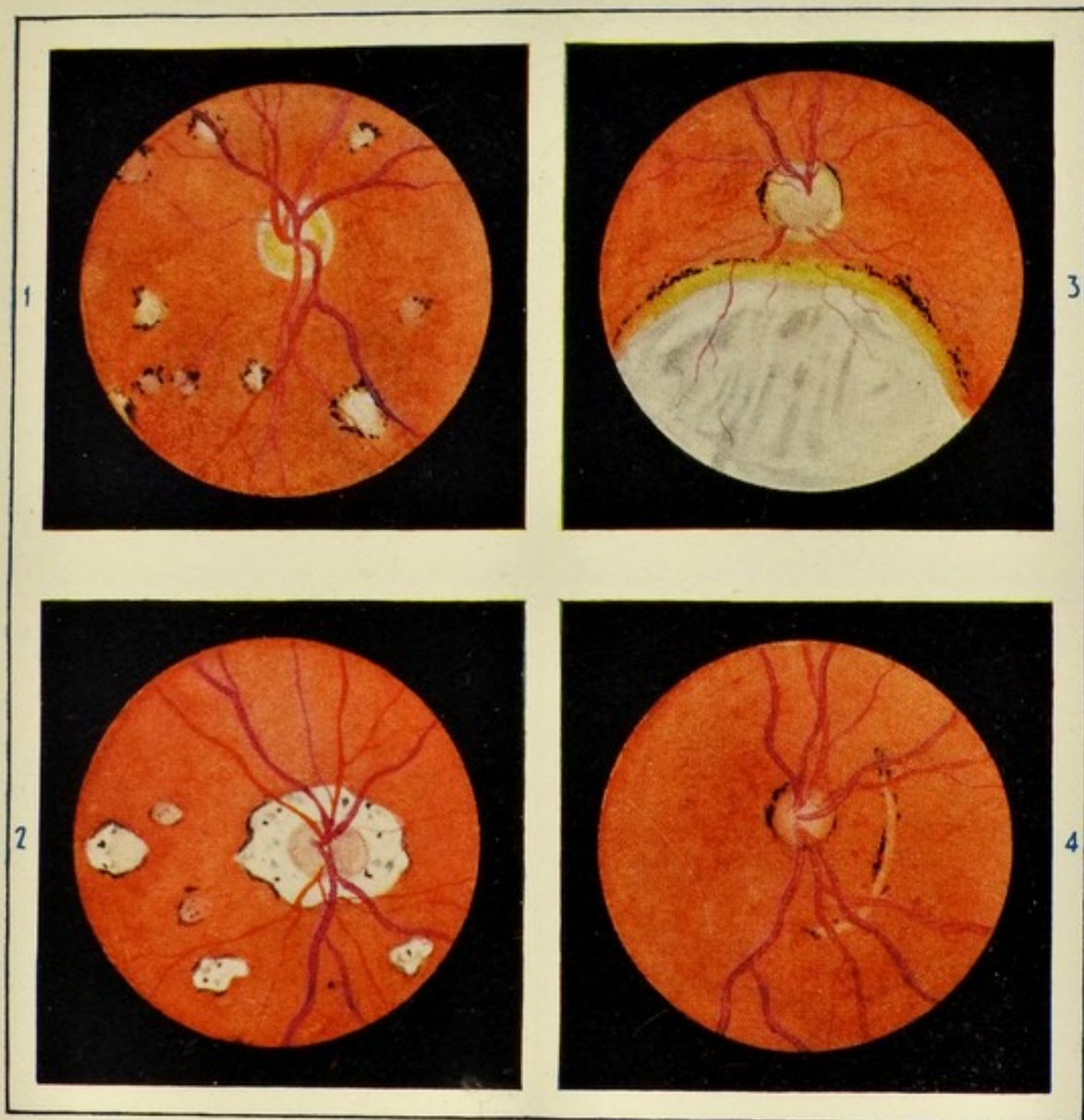
Congenital errors are limited to absence of the chorioid, an excessively rare anomaly, and **Coloboma** of the Chorioid (Plate XV. 3). This latter anomaly is explained by the imperfect closure of the foetal cleft in the tissue.

It is recognised as an area of a whitish hue, in place of the red granular structure normally visible, occupying more or less completely the whole of the portion of fundus lying directly inferior to the optic disc: in this area a few chorioidal vessels may be seen straggling, while the retinal arteries may or may not appear accord-

ing to the presence or absence of retina as well. The gap may be continuous from disc to periphery, may extend down from the disc but a short way, or may have a somewhat ovoid form and be separated both from disc and from periphery by normal tissue. It gives rise in itself to no symptoms and is usually discovered quite accidentally; as a rule the vision possessed by such an eye is considerably below the standard. Coloboma of the iris does not necessarily or even very frequently coincide with coloboma of the chorioid. In the minimal degree of the abnormality, when there is, attached to the disc at its lower margin, a small white area giving the disc a slight tilt on its horizontal axis, the condition is sometimes spoken of as *Fuchs's Coloboma* (Plate XIV. 4), because Fuchs was one of the first to describe it as a clinical entity. It is probable that in this coloboma the nerve sheath is also involved; the vision of such an eye rarely rises above $\frac{6}{12}$ even on correction of the astigmatism which is almost invariably present. Coloboma is almost invariably one-sided.


Chorioiditis (excluding for the meantime the cases of septic infection and metastasis) has five chief forms, the diffuse, the disseminated, central senile, the tuberculous, and the myopic. They all have this in common that the patient finds vision blurred, and feels as though all he saw were enveloped in a cloud or mist (positive scotoma). In some of the more acute varieties he discovers that he sees better in a bright light than in a dull (high L.M.), when there is much involvement of the pigment coat.

Diffuse chorioiditis, if acute, may follow upon an iritis, especially in the syphilitic cases, as though the inflammatory change had simply spread back along the uveal tract, but in many instances it occurs without any previous warning. On examination with the ophthalmoscope the vitreous is seen to be filled with a more or



1. Disseminated Chorioiditis.
2. Staphyloma Posticum: scattered patches of atrophy.

3. Coloboma of Choroid.
4. Rupture of Choroid.



less fine haze which prevents a clear and sharp view of the fundus details, indeed it may be so dense that the fundus cannot be made out at all. By the aid of a high power lens on the ophthalmoscope this haze may be made to resolve itself into an immense amount of the finest dust-like opacities floating in a relatively clear medium; according to circumstances this cloud may be far anterior or far posterior in the vitreous. The attack may clear up entirely or may leave patches of atrophy of the chorioid here or there in the fundus. These patches consist in their typical form of an area of atrophy through which one may see the sclera of a white or dirty white colour, often with little remnants of chorioidal pigment scattered through them, or lining their margins. They may be situated at any region in the fundus: in the diffuse form any patches left prefer the neighbourhood of the disc; in the disseminated form they are sprinkled anywhere on the fundus, but more especially towards the periphery; in the tuberculous form they may be found at any part, but with a preference for the posterior pole, and in the myopic chiefly round the disc; in the central senile guttate form they are at the macula. During the acute stage these spots are slightly raised, yellowish-white, soft-edged, but as the oedema diminishes and atrophy progresses they acquire a sharper contour, more defined margins, a whiter tint, because the sclerotic is visible through the aperture, and show indications of hypertrophy of the pigment about their margins. On careful testing with a very fine test-object a scotoma corresponding to each patch may be found, but unless the macula itself is attacked the patient may have very little sense of any failure of vision. This is specially true of the *disseminated* cases, where the fundus may be speckled over with round white-and-black atrophic areas, and yet, provided the macula has been spared, vision may be good and the patient unable to give any

account of an attack affecting sight. The special feature of the disseminated form is not merely the general distribution of the patches but their circular form; this is one of the commonest forms in which syphilis, hereditary or acquired, manifests itself in the eye. It is apt to come, in the acquired cases as a later or secondary, in the hereditary about puberty or earlier; it is always bilateral. The form which chorioiditis with atrophy is apt to take in advancing *myopia* is dealt with under the head of *Myopia*; it is in this place only necessary to point out that the first indication of advancing myopia may be the formation of the myopic crescent, that display of a crescentic area of sclerotic on the outer side of the disc produced by the stretching towards the posterior pole of the weak point in the chorioid where the entering nerve penetrates the globe, passes through the "button-hole" in the chorioid, and spreads out to form the retina. It is quite true, and should be kept in mind, that this so-called myopic crescent is in some cases a congenital condition, not one acquired as myopia comes on, and that it may be found in cases of emmetropia and even of hypermetropia. This crescent, as the myopia increases, widens, and the sclera behind it and to its outer side becomes further weakened, yielding to the internal tension; as this takes place weak spots are apt to form in the chorioid beyond the limits of the actual staphyloma posticum as the degenerating sclero-chorioidal atrophy proceeds and becomes more advanced; these weakened areas become merged in the main ectasia, and myopia steadily rises in degree. The dividing line between a physiological myopia and a progressive or malignant myopia can thus not be strictly or universally drawn, the two classes merge into one another.

In the *guttate* form we have to do with a simple degeneration and "failure" of the macular area in old

persons. In its typical form this rarely occurs before the age of 75 or so; it too is usually bilateral. The appearances in the fundus are as though the colour of the fundus at the macula had "run" in a number of fine, pale, yellow-pink dots; there is little if any inflammatory change, rather is it a mere wearing out of the essential pigment tissue. The disease produces a permanent central scotoma, but never deprives the patient of his peripheral field. He therefore retains vision which enables him to "get about."

In chorioiditis the *treatment* must depend upon the form which the disease takes. In the syphilitic forms antisppecific remedies are strongly indicated and should be pushed, as an eye attacked in this way can recover satisfactorily only if the original disease is neutralised with the very minimum of delay; it therefore behoves one to waste no time. In the cases associated with advancing myopia school work and reading, sewing, or writing should be reduced to a minimum, and dark goggles worn, for it is important to protect the affected chorioid from bright light, which makes such demands upon the integrity of the cells; mercury should be given as an alterative. Similarly in the tuberculous cases (and many of the cases of unilateral myopia, for example, are in reality cases of tuberculous chorioido-scleritis) work should be stopped and good tonics given.

Septic chorioiditis is a possible result of any injury to the eye which causes an external wound, occurs also as one of the rarer consequences of septic ulcer of the cornea, rarely as a primary disease, and sometimes as a metastatic manifestation, for example in acute rheumatism. A wound of the globe introducing septic infection into the vitreous infects a tissue which possesses low vitality, and no vessels, and is a fairly suitable nidus for the growth of organisms; acute abscess of the vitreous, septic chorioiditis, or *panophthalmitis*, as it is variously

called, is prone to occur. After an injury it may become evident about the second or third day. The pain becomes troublesome, vision worse or gone, the eyelids a little puffy and reddened, the cornea looks a little dull because of the loss of transparency in the vitreous, the fundus can no longer be illuminated, and there is increase in the general injection of the globe. Within a day or so the pain becomes excruciating on account of the formation of pus within the strong, tough, unyielding capsule of the globe, and in time, unless exit is artificially encouraged, the pent-up pus will at last find its way out by the sclerotic giving way at the site of the original wound or elsewhere. It is wonderful how seldom septic panophthalmitis occurs after purulent ulcer of the cornea, for the presence of pus in the anterior chamber suggests acute danger of such an occurrence, but in the first place the pus in the anterior chamber is sterile, and in the next the ciliary body appears to be powerfully resistant to the pneumococcus, which is the organism usually present in hypopyon ulcer; the uveal tract does not possess so effective resistance in the case of the bacillus pyocyaneus and one or two other rarer bacteria whose presence may bring on a very acute and rapid destruction. The metastatic form is due to transference of septic material, most likely by way of the blood stream, from such a site as the valves of the heart in endocarditis or the reproductive organs after childbirth.

When panophthalmitis has once set in, all attempt to save the eye is practically useless, though in a very few cases it may succeed. Thus injection of chlorine water into the vitreous has sometimes checked an attack when given early, but such cases are few and far between. Two or three minims may be injected through a puncture made with the blade of a Graefe knife; through this relatively large aperture the tip of a hypodermic needle

is inserted, and as the chlorine water passes in the excess of fluid escapes; otherwise the tension would rise and grave harm would result. (For a superior method of threatened ophthalmitis see chapter on Injuries, p. 374.) When there is evidence of definite presence of pus in the vitreous hot fomentations give the most relief, but these should be employed only until preparations have been made for the necessary operation. The pus must have free exit, and there are three methods of accomplishing this end—opening the globe as one might lay open a whitlow or any other abscess in a fibrous envelope, enucleation of the globe altogether, or evisceration. The first expedient is open to the objection that since it requires an anæsthetic and yet cannot be considered final, the patient has again to undergo operation unless a very ugly and somewhat dangerous stump is to be left behind; the second is liable to the danger involved in opening into the nerve sheath in the presence of a septic condition of tissues, and the consequent risk of meningitis; the third is undoubtedly the procedure to be preferred, as by its means one obtains all the advantages of enucleation, except rapid healing, without its dangers, and with a better stump in the end on which to fit the prothesis. It is of importance to note that after a process in one eye so definitely septic as panophthalmitis, sympathetic ophthalmia is practically unknown.

There is a class of cases confined to young children in which suppurative chorioiditis occurs secondarily to a meningitis, either indirectly or by direct transmission, but much less acute in character than the type just discussed. In this type a whitish yellow reflex is seen through the pupil, giving the aspect known to older writers as amaurotic cat's eye; this is often the first real indication of trouble. On inquiry one will be able to elicit a history of recent vague illness, but it

is rare that anything more severe is admitted. The aspect so closely resembles that (to be described under Retina) of glioma that it has received the name of *pseudo-glioma*, which is itself rather a confession of weakness on the part of the surgeon. There may be slight, but only very slight, injection of the eye. The yellowish mass increases in size for a time, on it the retinal vessels may sometimes be seen coursing, but by and by the globe begins to shrink, and if left to itself the end may be phthisis bulbi, a small, atrophied, useless globe, with a partially opaque cornea.

A very similar aspect may be produced by formation of a tuberculous mass in the chorioid.

It is stated that glioma may form in a pseudo-gliomatous shrunk eye; it seems more probable that a diseased and shrunk glioma may again take on active growth.

Tumour.—The only tumours of the chorioid known to occur are sarcoma, which in very rare cases is not pigmented but in the great majority contains much pigment, and occasionally true carcinoma, usually secondary to cancer elsewhere. Sarcoma may develop anywhere in the chorioid, but its chief seats of origin are about the posterior portion, close by the disc, and less frequently at the junction of chorioid and ciliary body. The first thing noticed by the patient, who is usually some fifty or more years of age, is that sight has partly gone from that eye, and on investigation it will very likely be discovered that while his central sight is good or fairly good, some part of his field of vision has been destroyed. Ophthalmoscopic examination at this stage will show detachment of the retina in the area corresponding to the lost portion of the field; but here a difficulty in diagnosis comes in, for a tumour is apt to cause detachment over a larger area than it actually occupies. Œdema surrounds it and the fluid thus exuded gravi-

tates and separates part, particularly the lower part, of the retina from the chorioid. On subsequent examination it will often be found that detachment of the retina over a large area has been caused by a tumour which is itself quite small. In regard to this matter the only particular points which one can make in the diagnosis are that the vision in the retained portion of the field is likely to be better in the case of tumour than in that of idiopathic detachment, and the line of demarcation between the two more sharp, and that the detachment may be elsewhere than below. In regard to the aspect of the detached area of the fundus, the loose retina, detached by fluid, tends to be thrown into folds, while that part which is separated by tumour rises towards the pupil like a bellying sail, and through it one can often make out something of the aspect of the new growth. At this time the tension of the eye

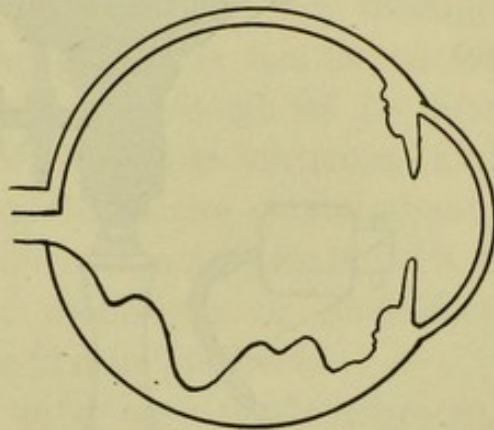


FIG. 53.

Shows how a loose detached portion of the retina is thrown into folds.

is likely (but not certain) to be increased should a tumour be present, but lowered if the separation be idiopathic. In the history of a sarcoma the eye is said to be in the *first stage* when detachment is present, but the tension is not seriously raised. The *second stage* is when the tension rises, as it is certain to do, and a definitely glaucomatous condition is reached. As a rule sight has been entirely lost before the patient enters on this stage, but he is not always aware of that. Therefore when an unknown person presents himself at an age anything above 50, having acute glaucoma in one eye, and that eye so affected that illumination is imperfect, it is well to bear in one's mind the possible presence of a tumour

as the cause of the glaucoma. Points which will assist in the diagnosis are that freedom of the other eye from any detachment is suggestive of tumour, so also is the absence of myopia in the patient and his relatives, because idiopathic detachment is closely associated with myopia; another point is that in the tumour cases vision has usually entirely failed before the glaucoma

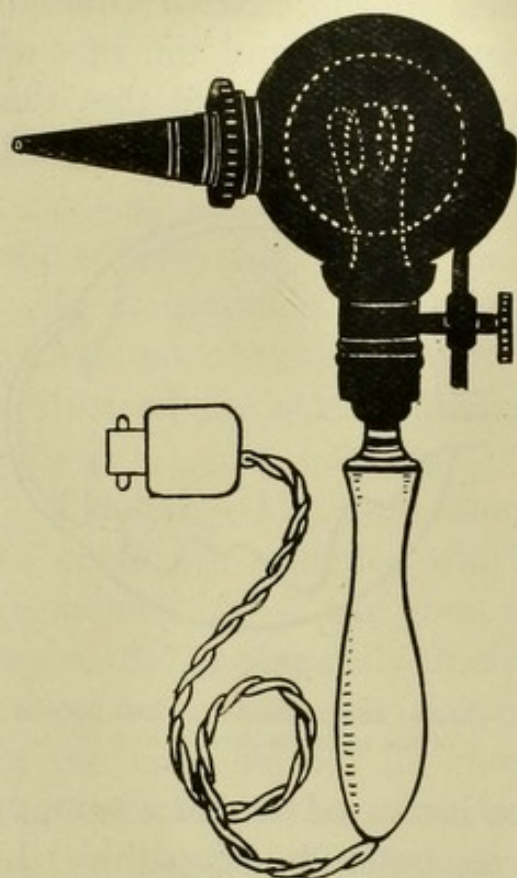


FIG. 54.—One form of transilluminator.

has come on, and that there are no remissions in the symptoms, no temporary lowering followed by increase of tension, no period of relief from the pain. Yet another indication is the presence in some of the tumour cases of a leash or bunch of engorged vessels on the sclerotic leading to the tumour itself. Both in this stage and the previous one valuable information may be obtained by transillumination. By means of the transilluminator a beam of strong light is caused to play upon differ-

ent portions of the sclerotic, the rest of the eye being kept in darkness. In the normal condition, or when the detachment is caused by fluid, a beam of strong concentrated light thrown under suitable conditions upon the sclerotic will penetrate to the interior of the eye and shine through the pupil, causing a red glow to be visible through it, but where a solid tumour is present this glow will not be obtainable when the point of the transilluminator is placed over the

situation of the detached portion of retina. This test is not so valuable in fact, however, as it appears in print, for a new growth is apt to lie so far towards the posterior pole as to be out of reach of the transilluminator, and, as has been indicated above, merely to find that *some* of the detachment is due to fluid does not by any means negative the existence of tumour. It is also theoretically possible that a flat tumour, such as occurs almost like a collar round the ciliary termination of the chorioïd, might not cut off all or nearly all of the transilluminator rays, and so might not show any departure from the normal.

By and by the tumour tissue makes its way through the coats of the eye after the glaucoma has lasted for some time, usually in the neighbourhood of its first formation or else round one of the *venæ vorticosæ*, and proceeds to grow outside the globe in the orbital tissue. This is the *third stage* of such a tumour (Plate XIX.). The *fourth stage* is that of metastatic or secondary growths, which usually appear first in the liver.

The diagnosis of tumour in a case of detachment, then, is not by any means always easy or certain. To recapitulate the points, the following indications are individually and collectively suggestive of tumour: the absence of myopia, of trauma, or of any other cause of detachment, increase of tension, good vision save over the lost portion of the field, a patient whose age is anything above 45, a rounded or bladder-like detachment, the presence of a leash or mass of vessels running over the sclerotic, no remission in the symptoms, and a positive indication from the transilluminator. When the last is all said it should be remembered that to have an eye removed which has been blinded by simple detachment is no great loss to the patient and no great fault on the part of the surgeon, but to leave an eye which contains a sarcoma is a very serious error.

The *treatment*, of course, must necessarily be early and

complete enucleation ; none of the substitutes such as evisceration are permissible. The earlier the enucleation the better the prognosis ; this is fairly good in the first stage, no more than fair in the second, bad in the third, and hopeless in the fourth.

A peculiar *degeneration* of the chorioid takes place in a certain number of cases of shrunk, useless eyes, the development, namely, of true bone in the substance. A patient who has had for years a small, shrivelled, sightless globe begins to complain of it being painful from time to time and tender to touch. This may, perhaps, be partly due to hæmorrhage from the diseased blood-vessels, partly to the deposition of lime salts and the formation of bone. It can sometimes be diagnosed definitely by the touch, but is more usually proved by circumstantial evidence. It is noteworthy that the bony plate, which is thickest at the nerve entrance, is never continuous across the disc, but remains perforated at that portion, there being no chorioidal tissue.

Detachment of the chorioid is stated to occur in a certain proportion of cases after extraction of the lens.

For *rupture* of the chorioid see p. 384.

CHAPTER XII

THE RETINA

IT might almost be said that the eye exists for the retina : all the apparatus of the eye leads up to the retina, in which its function is ultimately achieved. The eye is a complex machine, by means of which the retina is enabled to perform its duty. The refractive media are so arranged as to focus the light upon the retina, to which it is transmitted through them ; the chorioid forms the screen on which they form these images, which are then perceived and accepted by the retina. The retina is one of the most complex structures in the whole body, being composed of ten layers whose individual nature and whose precise functions are not yet by any means fully understood. It is attached very loosely to the chorioid, and indeed has only two fixed points, at the disc and at the *ora serrata* : at the former place it loses itself to become the optic nerve, at the latter to run forward as a fine membrane ending finally as the posterior layer of the iris. Over the chief part of its extent the retina might almost be said to be kept in place by the vitreous humour. There are certain striking features in regard to the retina, of which the first is that it is rather an extension of the brain than an end organ, for it contains in itself three neurons between the nerve-fibre layer next the vitreous and the rods and cones, applied to the chorioid. Another strange feature is that the actual percipient parts, the

rods and cones, are turned away from the entering light and rest upon the pigment inter-layer between retina and chorioid. The functions of the rods and the cones, those two terminals into which the nerve is finally distributed, have never been precisely differentiated, and there are numerous theories extant to explain the problem; but from the fact that at the macula there are no rods, but only cones crowded together, and that vision of objects is most acute there, it seems as though the latter (the cones) must be the organs of form vision, while the rods, absent at the macula where light perception is weak, may be the organs of light perception. It is with the macula alone that we have reading vision; "fixing" an object means directing the eye so that the image of that object shall fall upon the macula.

The retina is somewhat peculiar in this, that several of the more general diseases of the body which have no direct or immediate relation to the eye are liable to exhibit certain manifestations in the retina.

The morbid conditions to which the retina is liable are various inflammatory diseases, certain degenerative changes, separation from its attachment to the chorioid, and new growth.

I. RETINITIS

In all the forms under which retinitis is met with there are certain physical signs exhibited, more or less obvious, and more or less modified according to the etiology, which may conveniently be discussed in general terms before the various classes of cases are differentiated.

(a) *Increased Vascularity*.—This sign is shown in the overfilling and distension of the larger veins, which become tortuous and darker than normal. The word tortuous is used here in a sense different from merely sinuous; sinuous would indicate that a vessel, lying

always in a plane to which the line of the examiner's sight is perpendicular, never approaches the examiner or recedes from him, while tortuous would indicate that the vessel does not lie in any such plane all through its course, but pursues a course of which there is a sagittal, a coronal, and a vertical measurement; the difference, in fact, between the course of a river on a map and a corkscrew. The fact that the veins thus dip into and emerge from the retinal tissue implies also that the retinal tissue itself has become thickened and œdematous, as otherwise there could be no change in the plane in which they lie. The alteration is recognised with the ophthalmoscope by the loss of the light line on the vessel surface, and by the vessel becoming darker in hue wherever it is receding from the observer or approaching him; the reason for this is that the light from his ophthalmoscope mirror is not reflected back to him, but to another part of the eye. As is only to be expected, these changes are more obvious in the veins with their thinner walls than in the arteries.

(b) *Perivasculitis*.—The normal adventitia of the vessels is invisible, but when the retina and its vessels have been inflamed it becomes more or less opaque, so that here and there the vessels, both arteries and veins, are outlined in white. This may be very slight and very partial, and consist to all appearance of just a fine white line along each side of the vessel, or be so extreme that here and there an artery may be seen to have quite a broad "collar" of white round it, even in some cases hiding it from view in a part of its course, and looking as though it completely obstructed the vessel.

(c) *Hæmorrhages* are of frequent occurrence in different forms of retinitis. They are of two forms, according to the layer of retina in which they may occur. When in the superficial or fibrous layer of the retina they adopt the form imposed upon them by the radiating arrange-

ment of the fibres, and possess what is somewhat vaguely called a "flame" shape, the meaning of which phrase is that their sides are sharply outlined and slightly diverging at the end more remote from the disc, at that end the hæmorrhage has a somewhat ragged margin, as the blood penetrates further between the fibres at one point than it does at another. They vary in size, can never be very large, are often very minute, and may be extremely numerous. In the condition known as hæmorrhagic retinitis or thrombosis of the central retinal vein, the whole fundus may be covered with them. In albuminuric retinitis they are an important feature, though not an essential one. Hæmorrhage may, however, occur into the deeper layers of the retina, in which case, there being no firm fibres to impose a fixed figure upon the flowing or clotting blood, it breaks more equally into the softer tissue, and the form is roughly rounded. This is the form of hæmorrhage more frequently to be observed in diabetes.


(d) *Deposits in the retina* and degeneration of its elements. During or after an outbreak of retinitis certain of the tissue elements are prone to undergo peculiar degenerative changes, said to be principally of a fatty nature, the consequence of which is that in certain parts they become visible as white or whitish dots, or spots, or lines; these are sometimes intensely white and glistening, especially where a degeneration into cholesterol has occurred; this takes place chiefly in the nerve-fibre layer. At other times, and especially when they are quite recent, the outline is soft and fading, and the white by no means so intense. This is particularly the case in diabetic, and still more in albuminuric, retinitis, when the spots may be very numerous and arranged in a definite manner or pattern round the macula.

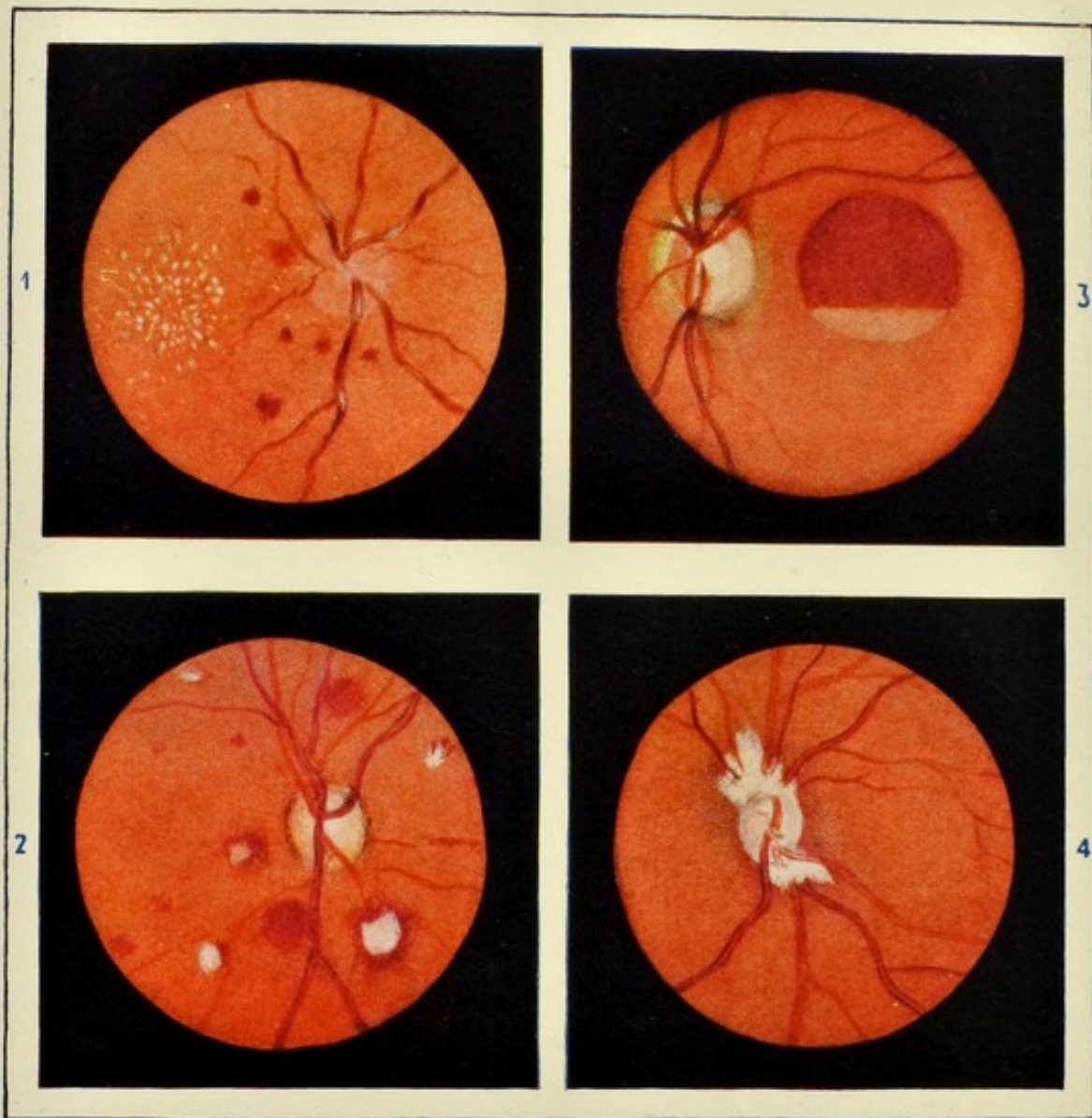
Varieties of Retinitis

1. **Albuminuric Retinitis.**—This is one of the most important of the diseases to which the eye is liable, certainly one of the most important of the ocular manifestations of general disease. The special aspect presented is generally that of a somewhat severe retinitis, always bilateral, with a good deal of involvement of the disc along with the retina, a neuro-retinitis, in fact; with numerous hæmorrhages of the so-called flame-shape, and with a large number of fine white spots or dots, arranged round the macula as a centre, formed into a pattern like a star or a cart wheel. Sometimes this star is complete, as though a bomb had burst exactly at the macula, scattering innumerable tiny white dots to an equal distance all round with great impartiality; at other times one or another part of the star may be wanting. The explanation of the star appears to be an acute œdematous condition of the macular portion of the retina, with consequent disorganisation and degeneration in parts, the tissue elements undergoing fatty degeneration (Plate XVI. 1). In a few cases actual detachment of the retina has been observed, as though the œdema had taken place behind the retina instead of, or as well as, into it; one requires, however, to be cautious in diagnosing detachment in such a case. When it does occur it suggests that the prognosis is even worse than usual. At the time of his first seeking advice the patient's vision is often $\frac{6}{18}$ or thereby and he is beginning to have a little difficulty with reading, and this amount of vision he may retain for a long time; but the really important point is that retinitis in a "kidney" patient indicates grave danger to life. It has been shown that of the men who exhibit this symptom almost all die within the year, and as nearly as possible all die within two years; for it indicates that his vessel walls are beginning

to give way, that degeneration of tissue is making serious progress, that certain toxic effete materials are not being excreted any longer by the kidney. In women the danger is, so to speak, not so acute, because in their case there have to be included the examples of transitory albuminuria during pregnancy, during which retinitis may occur; after parturition, spontaneous or induced, the kidney condition may be recovered from, the retinitis pass off, and the patient may live many years in the enjoyment of good or fairly good vision. These cases must not be confounded with those of eclamptic or uræmic blindness in which a patient, somewhat advanced in pregnancy, suddenly or rapidly loses sight completely which had up to that very day been quite good, who may have no change in the fundus whatsoever, although sight is reduced to zero. The two conditions may coincide, for they are both due to imperfect excretion from the kidneys; but one is a relatively slow degeneration of tissue, persistent and progressive, the other is an acute toxæmia with amblyopia from cerebral, not from peripheral, poisoning. The varieties of kidney affection in which retinitis is most apt to occur are those in which cirrhosis and contraction are going on. It happens occasionally that the first intimation which the patient has that his kidneys are not right is on the examination of the fundus, but naturally such an occurrence is not very common; a fact even more singular than that is that the albuminuric retinitis may precede by some months the appearance of albumin in the urine.

2. **Diabetic retinitis** bears a close resemblance to the appearances presented in the albuminuric variety, differing chiefly in three points, for the star formation at the macula does not occur, the hæmorrhages are larger and lie deeper in the retina, being therefore more rounded, and the areas of retinal degeneration are coarser, not so minute individually, and, like the





1. Albuminuric Retinitis.
2. Diabetic Retinitis.

3. Subhyaloid Hæmorrhage.
4. Opaque Nerve Fibres.

hæmorrhages, tend rather to occur between disc and macula. In a number of cases the patient has albumin as well as sugar in his urine. The expectation of life extends to two years or even more, and is thus distinctly a little better in diabetic than in albuminuric retinitis, the disease being in certain cases more amenable to treatment (Plate XVI. 2).

3. **Hæmorrhagic retinitis** is really in the majority of cases a more or less complete thrombosis of retinal vessels, or a serious sign that the vessel walls are no longer fit to stand the strain which the circulation puts upon them. It is therefore not infrequent in persons who are becoming advanced in years and who exhibit increased rigidity of artery walls—arterio-sclerosis. It may take the form of the formation of two or three medium-sized or very small hæmorrhages near to the disc or the macula; or the whole visible fundus may be simply infiltrated with blood escaped from a hundred small vessels; or, in the case of a more definite thrombosis, one of the larger veins may be seen to be grossly distended, tortuous and full, the retina round it œdematous and intransparent, and alongside, in its area of distribution, may be seen numerous flame-shaped hæmorrhages. Obviously, in many cases of so-called hæmorrhagic retinitis there is no true inflammatory change whatever.

The real importance of hæmorrhagic retinitis, whatever form it may take, is that it is a sure indication that the patient is in grave danger of the giving way of some vital vessel. In a number of old persons, if the patient is very careful and leads a very quiet, non-exciting, uneventful life, he may live a good while, though vision must always be impaired; but sooner or later, and generally before very long, some cerebral vessel gives way and hemiplegia or death is the result. Indeed, it is said that within a few months he will either have a

cerebral hæmorrhage or be the subject of glaucoma (p. 304).

Three minor varieties of retinitis fall to be mentioned, which are of very much less importance than those hitherto dealt with.

Leukæmic retinitis is a rare disease; in it the vessels are greatly distended and, owing to the peculiar condition of the blood, present a curious pale aspect. There are numerous hæmorrhages scattered all over the fundus, with patches of exudation besides.

Syphilitic retinitis is more correctly regarded as a chorioiditis (in which perhaps the retina takes part also).

Purulent retinitis occurs as a rare metastatic condition and as an integral part of panophthalmitis.

Retinitis circinata is a rare and peculiar form of disease closely resembling albuminuric retinitis in aspect, but having this peculiarity, that the areas of exudation group themselves in a wide circle enclosing disc and macula. It is only seen in aged persons, at the least 65 to 70 years of age. They often, as a matter of fact, have albuminuria at the time, and show signs of old hæmorrhages in various parts of the fundus. The condition is incurable, but does not as a rule completely destroy sight.

Embolism of the Central Retinal Artery is an occurrence not so infrequent as one might perhaps be apt to suppose. To be more accurate, it is the name given to a group of cases in some of which true embolism may be present, but in others, though the symptoms and indeed the signs are very similar, the actual lesion is somewhat different. The patient complains of sudden and complete loss of vision in one eye. He may be of any age, for the accident takes place in the young as well as in the adult, and only in a small proportion of the patients can any definite cardiac disease be shown to be present. The loss of sight takes place with curious

frequency just on rising in the morning, or at least is discovered at that time ; the patient goes to bed quite well, and just on the first exertion of the day the loss of sight occurs with startling suddenness. There remains only one little piece of field away to the outer side ; except for that small part the sight is entirely wiped out from that eye. Externally there is nothing to be seen, but on ophthalmoscopic examination the arteries are found to be very minute and thready, and if some hours have elapsed œdema has begun to show itself in the retina. This is most visible as a soft whitish obscuration all over the posterior part of the fundus, and particularly over an oval area including disc and macula. In the midst of this, just at the position of the macula, is a "cherry-red spot" regarding whose precise nature there is not complete agreement. The probable explanation is that there the retina is normally extremely thin, and therefore incapable of œdema ; the dark pigment therefore shows strongly there in marked contrast with the white, woolly, soft, thickened, semi-opaque retina. In certain cases the veins appear distended, especially towards the periphery, and there may be a few hæmorrhages there. There may also have been—a fact very disturbing to the theory of embolism—a history of previous abortive, less severe, but precisely similar attacks, from which recovery was complete. In some of the patients, too, there is evidence of Renaud's disease, hemicrania, etc. Altogether there appear to be four varieties of a very similar affection, not by any means necessarily mutually exclusive—first, genuine embolism ; second, thrombosis of the retinal vein ; third, chronic endarteritis and sclerosis of vessels, ending at last in permanent closure ; and fourth, spasmodic occlusion of the artery. As concerns *treatment*, the hope is put forward that by massage, or even by reduction of the pressure in front by means of iridectomy, one may

manage to induce the embolus to "move on," to leave the main trunk, and to settle down in one of the branches of the vessel. Otherwise treatment is of no avail, and the loss of vision is permanent.

2. DEGENERATIVE CHANGES

One of the most important of the degenerative diseases of the retina, and one which is frequently described as an inflammatory affection, is the so-called **Retinitis Pigmentosa**. The essential features of the disease are, however, neither any inflammatory reaction, which is conspicuously absent, nor pigmentation, which is not indispensable to the actuality of the malady.

The disease consists in a progressive sclerosis of the vessels of the retina, which shrink to the merest threads in far-advanced cases, along with, or followed by, degeneration and loss of function of the nerve elements; there is further atrophy of the pigment layer which intervenes between retina and chorioid, and, in typical cases, formation of pathological pigment in the superficial layers of the retina, and its deposit in certain well-defined areas. The disease, further, is often markedly a hereditary one, though it is not invariably so, is always bilateral, will affect either sex, and in its typical form is a youthful affection, though adult life may be reached before its slow progress has destroyed more than a proportion of sight. It is distinctly not a syphilitic disease, whether hereditary or acquired, but a spurious form of it, a chorioido-retinitis, in which (as the name implies) both retina and chorioid are involved, occurs as a syphilitic manifestation. Retinitis pigmentosa, too, is somewhat frequent among deaf-mutes, and, it is said, among the children of consanguineous parents.

Central vision may or may not be seriously affected; in far-advanced cases it is, but in some of the slow cases, even when the disease may be proved to have

been in existence many years and to have produced very serious effects, central vision may still be wonderfully good. Clinically there are two striking features, of which the first is that the patient complains of *Night-Blindness*, the condition in which the light minimum is unduly high. The light minimum is defined as the minimum amount of light sufficient to stimulate the retina, or more conveniently, though not more exactly, the minimum amount of light which will enable the retina to perceive a given test-object. This symptom of an increased L.M. is highly suggestive of torpor of the retina, or a sluggishness in the chemical processes which result in sight. Since those chemical processes take place in relation to the pigment layer which lies between retina and chorioid and belongs entirely to neither, it is only to be expected that the L.M. will be heightened in retinitis pigmentosa. (It is worth while to mention here that as an individual or family peculiarity, quite apart from actual disease, a certain degree of night-blindness is not at all very uncommon, and may be quite sufficient, though without any actual pathological changes, to cause serious inconvenience to its possessors, when they have occasion to be out after dark. Not unnaturally, along with heightened L.M., and for the same reason, after-images are apt to be readily produced and to last long.)

This symptom (night-blindness) it often is which the patient puts in the forefront of his complaint. He says he can get along quite well so long as daylight lasts, but directly the sun goes down he becomes nearly blind. The same inconvenience arises when he leaves a brightly lighted room for a darker passage ; at once he becomes almost helpless and must grope his way. In fact, he suffers from a great exaggeration of the normal restriction of adaptation. Another fact sometimes mentioned by the patient is that he cannot see the stars ; their feeble illumination is insufficient to awaken the sluggish or

imperfect chemical action which results in vision ; here again this is simply an exaggeration of a physiological condition, for there are multitudes of stars, invisible to the eye but demonstrable by the camera, whose illuminating power is insufficient to excite reaction in a normal retina.

The second great symptom is *Concentric Restriction of the Field of Vision*. The field of vision of any patient who complains of night-blindness should be examined, and if the case be one of retinitis pigmentosa, will be found restricted. It is affected in two ways. The extreme periphery may be slightly cut off all round ; then one will come upon an area of relatively good vision as one causes the test-object to move in a centripetal direction ; next upon small scotomata forming a more or less complete ring of lost vision, the so-called "annular scotoma" ; within that again is a central region of good vision. These scattered minute scotomata which coalesce to form the annular scotoma are situated, roughly speaking, about 30° or 40° from the centre, and are rarely to be found save in early cases. Not only do they coalesce, but as time goes on the seeing area between them and the periphery becomes eaten up, and all that remains is the central area of good vision : by and by it may go too, and complete, or almost complete, blindness result. So great is the restriction that the face of a person 2 to 3 feet away may occupy the whole of the field of vision. This condition is sometimes spoken of as tubular vision, for the field is as much reduced as though one were looking down a small tube. When this is the case a patient, even if he have good central vision, may be unable to guide himself on the street, since peripheral vision is almost more necessary when walking than central, to enable one to avoid obstacles.

Posterior polar cataract is particularly apt to form in patients who suffer from retinitis pigmentosa, and this,

even if it should not advance far, is yet sufficient to increase rather seriously their difficulty in vision, all the more that in this form of degeneration of the retina, for some unexplained reason, the pupil usually is and remains small.

Treatment is, in the great majority of cases, absolutely unavailing. In certain countries, for example in some parts of India, night-blindness takes an epidemic form, when feeding up, especially with liver, is considered to have a good influence, but there is no evidence of this in true retinitis pigmentosa. Strychnine, cod-liver oil, galvanism, have been recommended.

Prognosis is bad, but not absolutely so; that is, in many of the cases a certain amount of vision is vouchsafed to the patients for at least a good many years.

Retinitis proliferans is a disease regarding which but little is known. It consists in the formation of fibrous tissue bands which lie in the retina and stretch from it forwards into the vitreous. The disease is slowly progressive, and is supposed to take its origin from hæmorrhagic deposits in, and in front of, the retina.

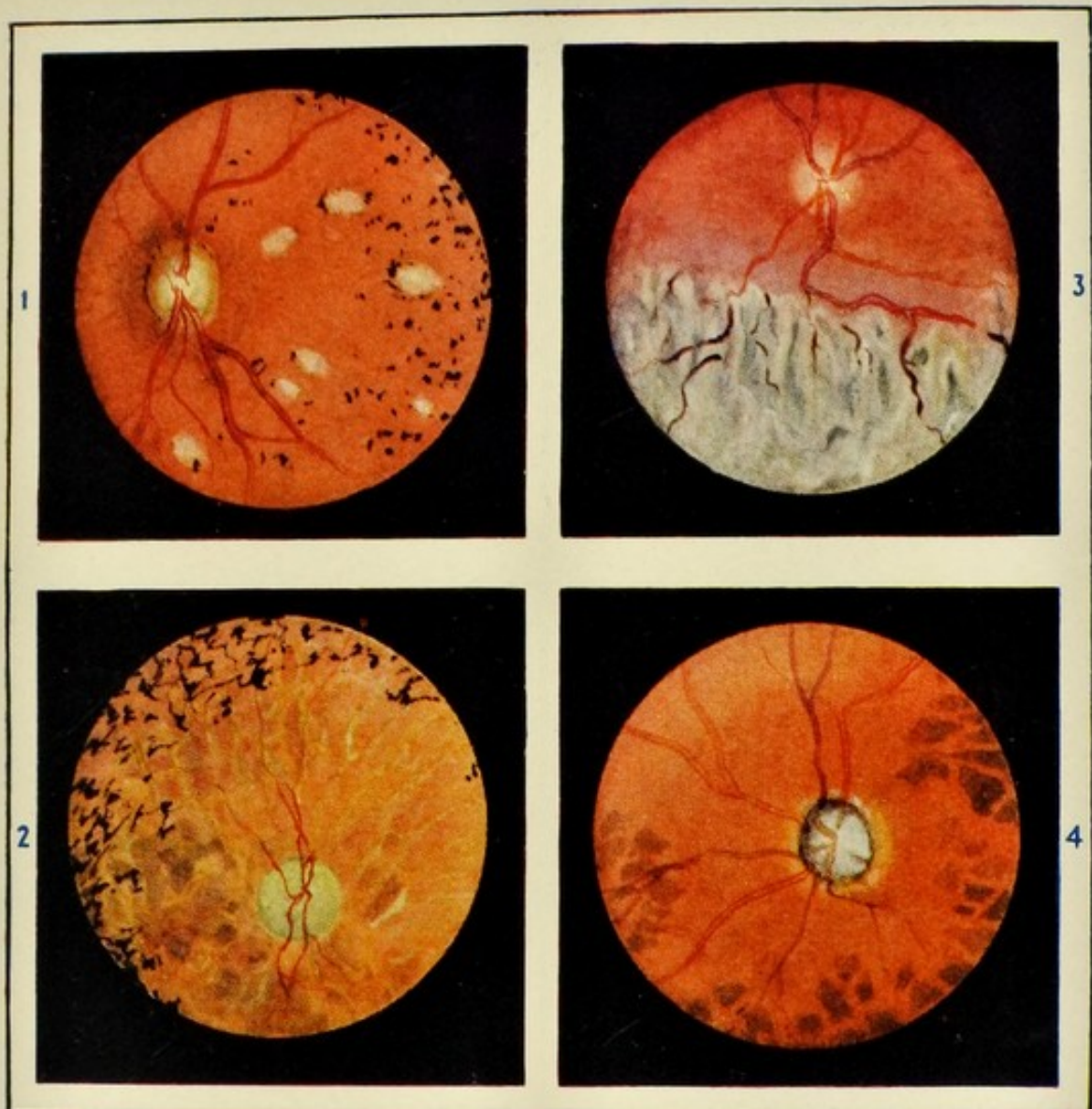
3. DETACHMENT OF THE RETINA

Detachment of the retina is one of the most important diseases to which the eye is liable, causing as it does a very considerable proportion of the blindness due to diseases of the eye proper. Many eyes, too, blinded from other causes, or at all events seriously affected by other diseases, take on detachment in their later stages, and so lose the last remnants of sight.

Pathology.—It must be mentioned at the outset that there are two chief varieties of detachment—that caused by tumour sprouting from the chorioid and mechanically separating the retina, and the idiopathic form in which the material separating retina from chorioid is fluid only. It is the latter alone which is under consideration at


this moment. There are two schools of thought in relation to detachment of the retina: one holds that the first step is the pouring out of blood or some exudate from the chorioid, between it and the retina, the retina being thus lifted from the chorioid by a *vis a tergo*; the other holds that the initial trouble is in the vitreous, which shrinks and, as it does so, "peels" the retina off the chorioid in virtue of nature's abhorrence of a vacuum, the fluid behind the retina being poured out secondarily to fill up the potential gap. The advocates of the exudate theory point to the rapid, almost instant, occurrence in certain cases, to its occasional traumatic origin, to the total absence in the majority of cases of any evidence of disease of the vitreous, and to the frequent occurrence of detachment in high myopia, where the chorioid is certainly abnormal. The "vitreous" faction point to the lowered tension which is usual, to the presence of vitreous changes which in some cases are obvious, and to the fact that in high myopia the vitreous must necessarily be more fluid than is normal, since it has a larger area to fill. Deutschmann, for example, the protagonist of operative treatment of detachment, is so convinced of the existence of bands in the vitreous, drawing upon the retina, that he endeavours to divide these in the course of his operation. It must be confessed that neither side has succeeded in altogether discrediting the claims of the other. It is to be noted that mere loss of vitreous, as from injury or in the course of extraction of cataract, is not necessarily or even probably followed by detachment.

Symptoms.—In a typical case the patient complains merely of gradual loss of vision, which may be slow, rapid, or alternately rapid and slow. He may complain further that objects appear distorted and misshapen or wavy and uncertain; he is almost sure to say that sight is better in the morning than after he has been up for



1. Chorioido-retinitis with pigmentation (syphilitic).
2. Retinitis pigmentosa.

3. Detachment of Retina.
4. Glaucoma cupping, ring, and pigmentary changes.



some hours. On examination he may be found to possess central vision still, but whether that be so or no the worst portion of his field of vision, the part in which vision is most sure to be lost, is the upper portion. For whether detachment begins or does not begin in the lower portion of the retina (corresponding to the upper part of the field), the detaching fluid always finds its way to that part sooner or later. Even if it be difficult to be certain of this fact in broad daylight, the relative inactivity of the lower portion of the retina will be readily demonstrated in a duller light, as by testing in the half-dark. The tension of the eye will almost certainly be found to be lowered. Additional points in aid will be the history of receipt of a blow on the eye, or still more probably on the head near the eye; or the existence of high myopia; or the fact that the other eye has already suffered from a similar loss of sight. The condition is absolutely painless.

Signs.—The ophthalmoscope will settle the question decisively, but the diagnosis is not in all cases easily made. When using the ophthalmoscope by the indirect method under any circumstances, it is a good routine, just because of the frequency of detachment (besides other reasons), to throw the light into the eye and cause the patient to look in various directions, up, down, etc., and note whether there is any difference in the reflex obtained. Assuming for the meantime the absence of any opacities in the lens, if one obtains a red glow when the patient looks up, but only a dull greyish one when he looks down, one should at once suspect the presence of detachment. The case stands thus: if detachment be present the eye must be more hypermetropic at that part in which the retina has come forward; there will therefore be a difference in the glow obtained; details will be visible at one part, on account of the alteration of refraction, which are invisible in another. Besides this, the fluid detaching the lower

portion of the retina may be opaque, and the membrane itself may have lost its transparency. In a typical case the lower part of the fundus presents a grey aspect, not a red; over this grey portion, which may show visible folds, the retinal vessels may be seen to course. These too are altered in appearance, have lost their double outline, look blackish, and are here and there lost to sight as the vessels pass over or behind a wave. The confirmatory test is to examine by the direct method, estimating the degree of hypermetropia here and there; this will be

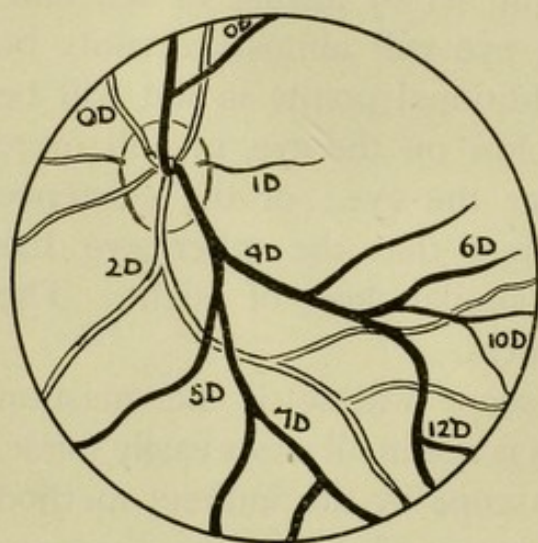


FIG. 55.—Chart of case of detached retina showing the varying amount of hypermetropia in different areas.

found to vary much, and it is good to keep a record in some such fashion as Fig. 55, by means of which changes and progress can be watched. It is an integral part of certain theories in regard to the onset of detachment that there should be a tear or rupture of the retina, and such is sometimes visible, but not by any means in

all cases; it is of course possible that the tear in the retina may be out of sight behind one of the billows into which it is thrown. The natural tendency of detachment, once started, is towards increase, and the fluid as it accumulates behind the retina tends to rise till after a time the macula itself becomes detached, when vision at once falls very low, and the patient will be noticed to direct his gaze above the object which he wishes to see, in order to cause its image to fall upon a part of the retina which is as yet above the high-water mark. This attitude is very characteristic, and will enable one sometimes to arrive at a diagnosis at the first glance at the patient.

Treatment.—Looking at the matter from a common-sense point of view, since the patient finds his vision worse after moving about, it will be well to keep him quiet, lying down, and in bed as much as possible. Since any movement of the eye will tend to cause the detaching fluid to move, and still further to peel off the retina, we have another indication for keeping the patient quiet. To promote absorption one may administer iodide internally, and perhaps pilocarpin and other eliminants, sudorifics and diuretics, and—to prevent straining also—cathartics. Locally one may keep the iris, etc., at rest by means of atropin and bandages, and may use various means to promote absorption; tapping of the post-retinal fluid; injection under the conjunctiva of strong solutions of chloride of sodium and other salts. Since the post-retinal fluid, coming directly from the blood, is likely to be more albuminous than the fluid of the vitreous, osmosis through the retina will tend rather to the increase of the detachment, and from this point of view a tear or rent on the retina would be a positive advantage; incision of the retina has therefore been recommended. Under the idea that there are contracting bands in the vitreous humour which tend to draw the retina off the chorioid, these have been divided with the knife. With the desire of fixing the retina to the chorioid by inflammatory adhesions the cautery has been applied to the sclera in the neighbourhood, and a minim of tincture of iodine has been injected behind the retina. One is obliged, however, reluctantly to confess that while in one case here and there some advantage may have been gained, and especially in the hands of the introducer of some new panacea, in the vast majority of the cases little good if any is achieved, and one is afraid lest actual harm may have been done. To tell the truth, in the very recent traumatic cases quiet and rest in bed may do a little good, and the prognosis is fair, but

no more than fair ; in all the other cases operative treatment is just about as likely to hasten as to hinder the advance of the detachment. It is well to remember that in some cases vision may be retained for many years, and after a time advance may altogether cease.

4. TUMOUR OF THE RETINA

Practically the only tumour of the retina is that particular form of cancer known as *Glioma*. The disease occurs in early childhood, and is said never to appear for the first time after the age of 5 years. There appears further to be a certain tendency to it in some families, in more than one member of which it has arisen. The first circumstance which the parents note is that as the child faces the light the pupil gives back a whitish or straw-coloured reflection instead of appearing black. Later this becomes more manifest till the whole pupil is occupied by a pale yellow mass over which the retinal vessels can be seen coursing, and on whose surface small hæmorrhages are often visible. This mass may come so far forward as to lie close behind the lens, and it is difficult for the uninitiated to believe that the condition is not cataract. By the time this stage is reached the child is probably suffering greatly from increased tension, in fact from an acute glaucoma, is sick, miserable, and in great pain.

Diagnosis.—When the aspect of affairs is as just indicated there is no great difficulty, but before the case reaches this stage there may be serious uncertainty. There are two conditions, vaguely spoken of as pseudoglioma (itself a term of ineptitude), with which it may be confused. These are a subacute inflammatory process in the chorioid and perhaps in the vitreous, and a tuberculous deposit in that situation. The chief points may thus be indicated. In true glioma the patient was well until after the yellowish glow, the “cat’s eye” aspect, was

observed, symptoms only coming on after that ; the mass observed is pale yellow with retinal vessels coursing over it ; the pupil is dilated, without adhesions, and though the iris may be somewhat atrophic there is no retraction of the angle ; the tension is increased. In the pseudo-gliomatous conditions there is generally a history of some more or less vague head-illness before the appearance of any abnormal aspect through the pupils—a time of sickness, of headache, of rise of temperature—and as the mass formed the patient rather improved in health than turned ill ; sometimes the yellow mass may have no vessels coursing over it, but may be merely a non-vascular exudate ; the pupil is rather prone to be small and irregular on account of old iritic adhesions (iritis accompanying the original uveitis) ; there is retraction of the angle on account of the cicatricial process going on in the chorioid and drawing upon the ciliary body and the iris where the two join ; the intra-ocular tension tends to be reduced. Even when all this is said it may well be understood that there are numerous instances in which an accurate diagnosis is well-nigh impossible, especially in view of the facts that apparently degeneration and disintegration may take place in a glioma on the one hand, and tumour-formation come on secondarily in an inflammatory or tuberculous mass on the other (Plate XIX.).

Treatment should consist in early and complete removal of the globe, care being taken to remove at the same time a good piece of the nerve behind the globe ; no substitute for enucleation should be adopted. Since it is by way of the nerve that the tumour is most likely to extend, gradually invading the cerebral tissue, it is wise to examine the nerve well at the moment of operation, so that, if its aspect suggests the necessity, one may remove even a little more of it from the depths of the orbit. When the diagnosis is seriously doubtful it is well to enucleate ; the old rule “When in doubt play trump” is

sound here too, for it is little to remove a blind, ugly, but harmless eye, while it is a dreadful error to allow a patient to keep a cancerous one for one day longer than is necessary.

The *prognosis* is fairly good if the operation be done early; recurrences are unpleasantly frequent, but a large proportion of the patients are permanently cured. This is true even in the cases of bilateral occurrence of glioma; the old idea was that the new growth had spread up one optic nerve and down the other, but it appears rather that it is the simultaneous expression of the same vice of development on both sides of the body at once, and while such a case is very distressing and unfavourable, it is not absolutely hopeless.

Pathology.—It is from the inner nuclear layer of the retina apparently that the tumour takes its rise: the cells of which it is composed contain an unusually large nucleus, and are best developed and most regular where they surround the fairly numerous blood-vessels, forming what have been called rosettes; but numbers of other cells of a less uniform type are found, degenerated and degraded examples of the normal constituents of the retina. The stroma is very scanty indeed, and in some of the cases the substance, in no case very firm, is so extremely soft as to be almost fluid.

A rare disease of the retina is known as **Amaurotic Family Idiocy**; it appears to be almost completely limited to male infants of Jewish descent, and so far has resisted all efforts at treatment. Ophthalmoscopically there is seen a circular lesion surrounding the macular region, bilateral, whose precise nature is not known. The child, who is usually under 3 years of age, becomes quite blind, and if he lives any length of time, appears to become imbecile. Several in a family or among near relatives are prone to be affected.

Blinding by direct sunlight, or *Eclipse Blindness*, is

apt to occur in those who recklessly look on at an eclipse of the sun without wearing protecting glasses or otherwise avoiding over-stimulation of the retina. A persistent, positive, wavering central scotoma may remain for a long time, or even, though lessened in degree, permanently. There may be nothing abnormal visible in the fundus, or a minute, yellowish-white, hard-looking dot at the macula. The fine tissues have been burned up by the excessive chemical action, and may never be restored in their integrity.

CHAPTER XIII

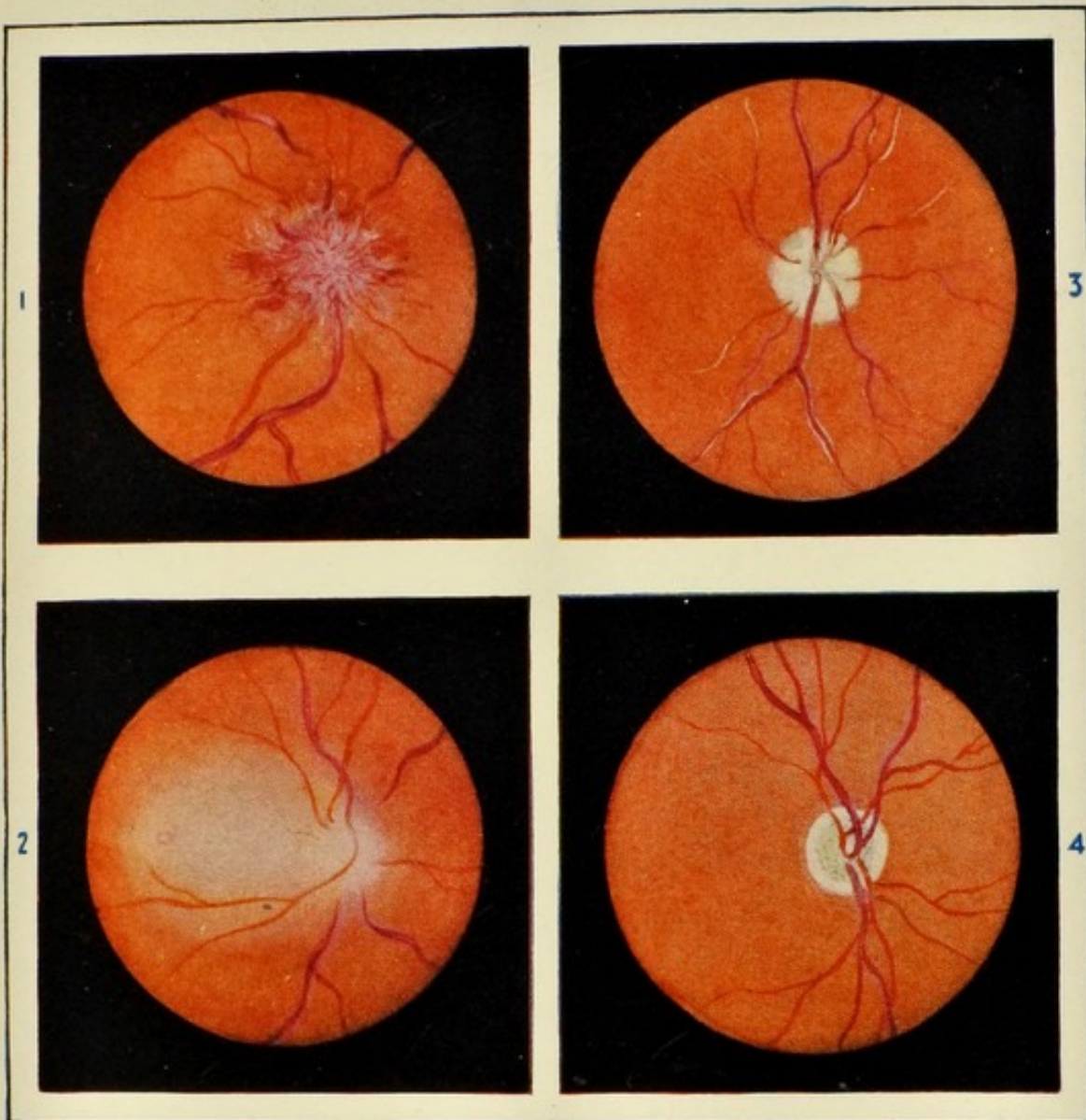
THE OPTIC NERVE

WHEN discussing the optic nerve it must be borne in mind that that structure is not a peripheral nerve in the sense in which the facial or the auditory nerve (for example) is, but on the contrary is actually, developmentally, physiologically, and pathologically part of the central nervous system, part of the cerebro-spinal tissues. The diseases to which the nerve is liable, namely, neuritis with its results, and atrophy, may or may not take their origin in more general conditions of the brain or cord.

OPTIC NEURITIS


A. **Associated with Intra-cranial Disease.**—For something like fifty years now it has been known that one of the most important indications of intra-cranial tumour is the presence of double optic neuritis; it is one of the triad of indications no one of which individually is of much diagnostic moment, but which, when all three are present, form a combination of almost certainly sinister moment—headache, vomiting, and optic neuritis. Recently it has become the fashion to discard the term optic neuritis in favour of papilloedema; but old names should not be too readily cast aside, and new ones have a trick of being found to imply more than is justified by our knowledge of facts.

Symptoms.—Strictly speaking, these are absolutely *nil*,



1. Optic Neuritis (choked disc).
2. Embolism of central retinal artery

3. Optic Atrophy following Neuritis.
4. Primary Optic Atrophy.



a fact which cannot be too thoroughly impressed upon the beginner. How often does one hear it implied, if not actually said—but not by the experienced—that as the patient complains of nothing about his eyes there cannot be much wrong there? Now it is essential that it should be clearly understood that a patient may not merely complain of nothing, but may on careful examination be found to be destitute of all symptoms in vision, field of vision, colour vision, etc., and yet present on ophthalmoscopic examination the most typical appearances of optic neuritis. Failure to grasp this fact has led to many a false and mistaken diagnosis. It is often the case that it is not until the actual neuritis is passing off into secondary atrophy that vision begins to suffer at all.

Symptoms may, however, be present; these are of three kinds. Flashes of light are complained of; from time to time the patient is annoyed by a sudden blaze, immediately succeeded by relative darkness. Sudden complete blindness may occur, the loss of sight lasting from a second or two to a minute, and passing suddenly away again. Inversion of the colour fields, as recently described by Bordley and Cushing, may be found. The phrase means that whereas in the normal condition the field of vision for blue exceeds in superficial area that for red and green, the order may be reversed and the limits of the field for blue may lie within those of the red and the green. This symptom is very uncertain in its behaviour, as are the other two, and it seems still doubtful whether much reliance can be placed upon it.

It is very noteworthy that though it is the optic nerve which is inflamed, photophobia is conspicuously absent.

Signs.—The early and slighter signs are often so fine and so slight, and the physiological variations in the aspect of the disc are so great, that it is no easy task to

be sure that the appearances presented are pathological at all. When matters have advanced further and the changes are gross it is a simple matter enough. While a person with but little practice in ophthalmoscopic work can readily make the diagnosis in the grosser cases, it at times taxes all the skill of the expert to detect the finer delicate alterations.

(a) **Changes in the Vessels.**—Increase in the number of fine vessels crossing the disc margin, particularly at the upper and lower extremities of the disc, is an early sign. As time goes on these become more numerous and impart a streaked aspect to the fundus immediately surrounding the disc. The arteries may be slightly enlarged at the very outset, but they soon cease to be so, and indeed become rather attenuated. This is not the case with the veins, which become greatly distended and tortuous, and dark coloured, losing their normal and very narrow light line and acquiring one more resembling that of the arteries, broader and not so pure white, as the vessels in consequence of their engorgement become more circular and less elliptical on section. Hæmorrhages are frequent after the very initial stage is past; these are usually of the “flame-shaped” pattern, and are situated on the disc itself and at the margin of the swollen area surrounding it.

(b) **Changes in the Disc.**—Loss of definition of the margins, especially at first the upper and lower, is a prominent feature. So very marked is this sign that in the more severe cases the margin is completely obscured, and as the disc swells and becomes more juicy-looking it appears larger than normal, for the œdema extends to the retina all round, and the false disc, that is, true disc *plus* the œdematous retina, has an area of perhaps twice the diameter of the true disc. It is at the margin of this false disc that hæmorrhages are frequent, just where the uplifted, engorged vessels

sink down suddenly to the true level of the retina. Another important sign is the filling up of the physiological cup with œdematous exudation in the earlier stages, and later with fine fibrous tissue. This conceals the origin of the vessels in the cup and forms a very important indication, especially in the early stages when the diagnosis is most difficult. Somewhat later, when the "inflammatory" changes are beginning to pass on into atrophy, certain white or whitish dots or slightly larger spots appear on the disc surface. These, which are soft in outline at first and later become more sharply defined, and in some instances glistening, are due to fatty(?) degeneration of the tissue elements of the retina. By the time they begin to form, vision is sure to have begun to fail (Plate XVIII. 1).

It is convenient to have some means of estimating the amount of swelling of the disc; this can be done with fair accuracy by direct estimation of the alteration in the refraction produced by the change in level. It is calculated that a difference of three dioptries indicates a difference of one millimetre of position; the refraction at a healthy part of the fundus is estimated, then that at the summit of the protruding disc. Supposing the first to be emmetropic, and the latter, being nearer to the lens, hypermetropic 4.5D, that would mean that the disc surface was swollen to the amount of 1.5 mm.—to a degree, in other words, equal to its own width.

(c) In some cases there occurs also the development of a **change at the macula** highly suggestive of that which forms the characteristic feature of albuminuric retinitis—the "star-formation" with its minute deposits and fattily degenerated areas arranged in "explosion form." In both conditions the explanation is probably the same, namely, an œdema of the retinal tissue throwing it into folds and streaks; but why this should occur only in a comparatively small proportion of the cases of optic

neuritis is not clear. It was at one time thought to be more closely associated with cerebellar than with cerebral tumours, but this is at least doubtful.

As time passes on the violence of the reaction in the nerve head passes off, and the aspect gradually becomes altered into one of atrophy. The disc ceases to swell and begins to "fall"; there are no fresh hæmorrhages; the margins begin slowly to clear; the greyish-pink or reddish aspect fades towards pallor; there is no physiological cup, for it is filled (if one was formerly present) with fibrous tissue; the exudate on the disc surface, on and among the vessels, partly is absorbed and partly becomes organised into fibrous tissue. Later still, the disc becomes of a dead white colour, the arteries narrow, but the veins remain dilated for a very long time, perhaps permanently, and where the retina surrounding the disc had been swollen and compressed there remains what is known as a high-water mark of partially absorbed chorioidal pigment, degenerated retina, and possibly remains of hæmorrhages. The disc margins, too, are often obscured at parts by fibrous white tissue, especially along the sides of the vessels where the adventitia has been partially organised.

As this stage is in progress vision is often failing rapidly, and may be entirely gone long before the disc has assumed its permanent appearance. As central vision fails so does the field contract; the contraction begins from periphery to centre, but is often somewhat irregular in its progress. After a severe neuritis of this type blindness is apt to be complete.

A very complicated and difficult question is that of the true *relationship between intra-cranial tumour and optic neuritis*; on this it will be necessary to lay down a few general propositions. There appears to be little if any doubt that for the production of optic neuritis in intra-cranial tumour increased intra-cranial tension is a

sine qua non, but an intra-cranial tumour may exist for a long time without the optic nerve showing any sign, and neuritis may "all at once" come on without any apparent reason. Tumours of any kind may cause neuritis, though the more infective are the more apt to do so. Tumour in any situation may cause it, but certain situations are more "dangerous" than others, and, roughly speaking, the more posterior the tumour the more certain is it to arouse this symptom. That is, it is very much more likely that a new growth about the cerebellum will cause neuritis than another of the same size, or even larger, but situated in the frontal lobes. Size alone is probably not a consideration of great moment; sometimes a minute new growth will cause neuritis while a much larger one does not.

The absence of optic neuritis is therefore not a certain indication of the absence of intra-cranial tumour, nor is its presence more than a strong point in favour of new growth in that area. Thus headache, vomiting, and optic neuritis, that sinister triad, may be due to causes quite other than tumour, but tumour is the most probable explanation of their presence.

The relation between optic neuritis and cerebral tumour is, then, not yet entirely clear. What appears to be true is that, either by virtue of the presence of the tumour or in consequence of meningitis, increased pressure is produced in the third ventricle; this causes increased intra-cranial pressure with engorgement and distension of the lymph spaces within the sheath of the optic nerve, and stasis of lymph there. It is possible further that this fluid, especially in the cases of certain forms of tumour, may possess some irritative quality, but even without that the intense oedema is considered to be the direct cause of the pathological changes in the optic nerve head; this condition it is proposed now to call not optic neuritis, nor choked disc, but papilloedema.

This change is almost invariably bilateral, but occasionally cases occur in which it is unilateral, and opinions are still divided as to whether a unilateral neuritis has any definite localising significance, some holding that it points to tumour, etc., on the same side as the neuritis; others do not agree; there is assuredly no absolute certainty in the indications to be attributed to the unilateral development or enhanced degree of the change.

In regard to the *treatment* of optic neuritis of intra-cranial origin, we are reduced to the treatment of the cause, which, as has been said, is for the most part the increased intra-cranial tension; we must reduce this pressure. In any case, then, of optic neuritis of this nature, it is of vital importance to sight (to say nothing of other matters) that pressure be reduced. There are but two methods of doing this, one might say—the administration of large doses of potassium iodide, and trephining. Should the former not be giving evident relief within a reasonable time, the latter should be urged. There are two difficulties which sometimes stand in the way, namely, the absence of localising symptoms indicative of the proper site for trephining, and the passive resistance of the physician in charge of the case. In regard to both it may become the duty of the ophthalmic surgeon to urge active interference; he knows that once atrophy sets in nothing will stop it. Therefore trephining should be performed for the sake of sight; the situation is of minor importance in this connection—"anywhere" that the surgeon may select as a convenient spot will serve so long as the tension is reduced; it is not always easy to persuade a keen diagnostician to "spoil" the localising symptoms which he expects to find by and by for the sake of sight which may not yet show any symptom of leaving the patient. He will frequently agree only when it is too late.

Optic neuritis may, however, arise from cerebral

causes other than tumour; it may be descending, from a basal or other meningitis, and may be a point of great importance in the diagnosis; when this is the case it is very apt to be associated with paralysis of one or another of the ocular muscles.

B. It may arise also from **causes quite apart from the nervous system altogether**, and in such cases the symptoms, and to some extent the appearances, may be quite different. For if, as in such conditions, the nerve in its course be inflamed, and not merely the nerve head, the fibres most prone to be attacked are those pertaining to the macula—they appear, from one cause or another, to be the most susceptible; the effect of this is the production of a central scotoma, a serious, perhaps a severe, interference with vision. The incidence of the attack upon the macular fibres may be explained either on the ground of the more exposed position of such fibres in the nerve posterior to the eye, or of the greater susceptibility to damage on the part of the more highly organised central fibres; the latter does not seem a very convincing hypothesis, for if it were true why should not the same hold good in regard to “intra-cranial” neuritis?

There are three great causes, namely, absorption of toxins after one of the exanthemata or from septic mouth or gastro-intestinal tract (see also Retinitis, p. 252); rheumatism; and spread from some source of inflammation at the apex of the orbit (periostitis, cellulitis) or in the neighbouring sinuses.

The *symptoms* consist of a central scotoma which may be complete or incomplete, extensive or limited to a small area of the field. Vision may thus be but little affected at first, or there may be a scotoma so large and so intense that sight is all but gone. At all events it is usual for the defect to increase rapidly, so rapidly in some cases that the loss of sight may be almost sudden.

Two other symptoms may be complained of by the

patient, but he may hardly notice them unless the disease be bilateral. These are, first, a curious shimmering before the eyes, similar to what one sees when looking at a field of grass in blazing sun, or when looking across the chimney of a burning lamp; this is supposed to be due to the less perfect insulation of the inflamed nerve fibres. Second, vision which is bad in bright light improves in the evening or on duller illumination; possibly this symptom may have a similar origin to the other. Along with this it is not infrequent to find that extreme movement of the eye in one direction or another is associated with pain deep in the orbit, and the same is true of gentle pressure of the globe backwards, but perhaps these should rather be regarded as signs of apical periostitis than of neuritis proper. Gentle percussion of the bones about the orbit sometimes elicits pain on the affected side.

The *ophthalmoscopic signs* may at first be very slight or absent altogether. The disc surface as a whole is apt to be rather pallid, but round the margins there may be a faint degree of hyperæmia and a slight veiling of the details. Then in the course of a few days the appearances become decidedly worse, there is marked general hyperæmia, more general œdema, more overfilling of the retinal veins, and more distinct attenuation of arteries. Thus one sees the singular coincidence of symptoms passing off while the signs grow more intense. It is but rarely that the picture is presented of a neuritis so intense as that with which one meets in the other variety, but the amount of change may be very considerable. *Treatment* must of course vary with the cause of the neuritis: protection of the inflamed nerve from light by means of dark glasses; anti-rheumatics, counter-irritation at the temple or blood-letting locally, and relief of pent-up pus, mucus, or other discharge in the accessory sinuses.

In cases of retro-ocular neuritis the toxins which are injuring the patient must be got rid of as quickly as possible. In Bright's disease, in rheumatism, in chronic stomatitis and gingivitis, etc., one knows what to do. In addition, one should protect the eyes from light by means of dark glasses, and should apply counter-irritation to the neighbourhood of the nerve by blisters applied to the temple. The patient should also be reduced to low and simple diet, and encouraged to produce more rapid elimination by drinking copiously of water. Later, after the period when alteratives such as iodide are suitable has passed, nerve tonics such as strychnine are required.

The *prognosis* is on the whole good; in the majority of cases the neuritis yields to treatment, vision improves, and that (in some instances) very rapidly, and the nerve recovers more or less completely its normal aspect. In a number of cases, however, even if vision appears to be completely restored, careful examination will reveal the permanent presence of a relative scotoma—an area can be mapped out in which colour perception is lost or diminished—the activity of the light-sense has not been recovered. And whether this be so or not, it is certainly frequent that the disc does not quite regain its former blush, but remains pale or even very white, and the vessels show signs of the perivasculitis which has existed. It is unfortunately the case, however, especially in some of the cases in which the neuritis follows the long-continued presence of foul pus in the sphenoidal or other sinuses, that the scotoma never clears up but remains permanently, and vision even becomes diminished below its first level (see also Hereditary Optic Atrophy, p. 287). One eye may be affected or both; or the same inflammation may attack one eye at a certain time and the other eye later.

With the fact in regard to diagnosis that it is easy to make the mistake of attributing the symptoms to

a hysterical condition, we shall deal when considering central scotoma from early retro-ocular atrophy.

OPTIC ATROPHY

Of this disastrous condition there are three varieties—simple atrophy, atrophy secondary to other changes in the fundus, and atrophy consecutive upon optic neuritis. These have in common the features of a progressive failure of vision (with certain exceptions to be mentioned presently) and pallor of the optic disc.

With the ophthalmoscope they all present the aspect of a white or greyish disc, which may be cupped in a particular way, and some reduction in the calibre of the vessels. To take these points in order. The *colour of the disc*: its whiteness or its greyness depends on three circumstances. (*a*) The original condition of the disc before the ailment came on. If formerly there had been but little physiological cupping, the colour of the nerve head will be more or less pure white according to the stage which the atrophy has reached; if formerly there was a deep cup with exposure of the lamina cribrosa, the bluish-looking pits in the floor will impart a grey tinge to the atrophied disc. (*b*) The presence or absence of any oedematous or fibrinous exudate upon the disc surface; thus if there has been no preceding inflammation of the disc, it will retain its former tint, only blanched and with the loss of rosiness, while if whitening exudate lies upon it and fills up the physiological cup, the hue will be much whiter and not grey at all, for the lamina cribrosa will be covered with a white screen. (*c*) The essential nature of the change in the nerve tissue itself; thus the particular type of change in the optic and other nerves of a tabetic is such as to impart a greyish hue—in the optic atrophy of tabes, then, for two reasons the disc is sure to be grey-white.

If *cupping* be present at all it is gradual, not abrupt.

There is a gentle, gradual fall in level from the margin of the disc on all sides to the centre (see chapter on the Ophthalmoscope, p. 217). This is present to a greater or less degree unless there has been preceding inflammation of nerve head with outpouring of fluid from the tissues, when this potential cup is filled up and does not exist. Reduction in the *size of the vessels* may not occur for a very long time in the cases of simple atrophy, because these are the vessels of the retina, not of the atrophying nerve, and the retina contains its own neurons, for which reason a disc may be dead white and the eye absolutely blind without much alteration of the size of the main vessels to be seen coursing over it. Where the atrophy is secondary to retinitis pigmentosa, to extensive chorioidal atrophy, or other grave changes in the fundus, the vessels shrivel markedly, especially should the macula be destroyed. In consecutive atrophy the arteries are usually minute while the veins may, as one indeed might expect, remain full-looking, dark and tortuous, for a very long time after the acute condition has passed away.

Clinically, then, the question may be presented to one, Is the optic atrophy in this case primary or consecutive? In resolving the problem one would lay stress upon (1) the colour of the disc: a white disc suggests (but does not prove) previous neuritis, a grey disc suggests (but does not prove) that the atrophy is primary. (2) Similarly cupping suggests primary, its absence consecutive atrophy, especially if there be white material filling up the physiological cup. (3) Small size of the arteries along with engorgement and tortuosity of veins almost proves the atrophy to be consecutive. (4) Indications of exudate into the vessel sheaths, and obscuration of a vessel anywhere, or of the margin of the disc anywhere, are strong points in favour of neuritis (see also p. 231).

Primary Optic Atrophy may occur in two forms.

In the first, the patient complains of slow, gradual loss of vision; he may be a man of 40 to 50, or younger, and there is a form present also in old age. On inquiry his central vision is found to be decidedly defective and his field of vision to be contracted peripherally, sometimes

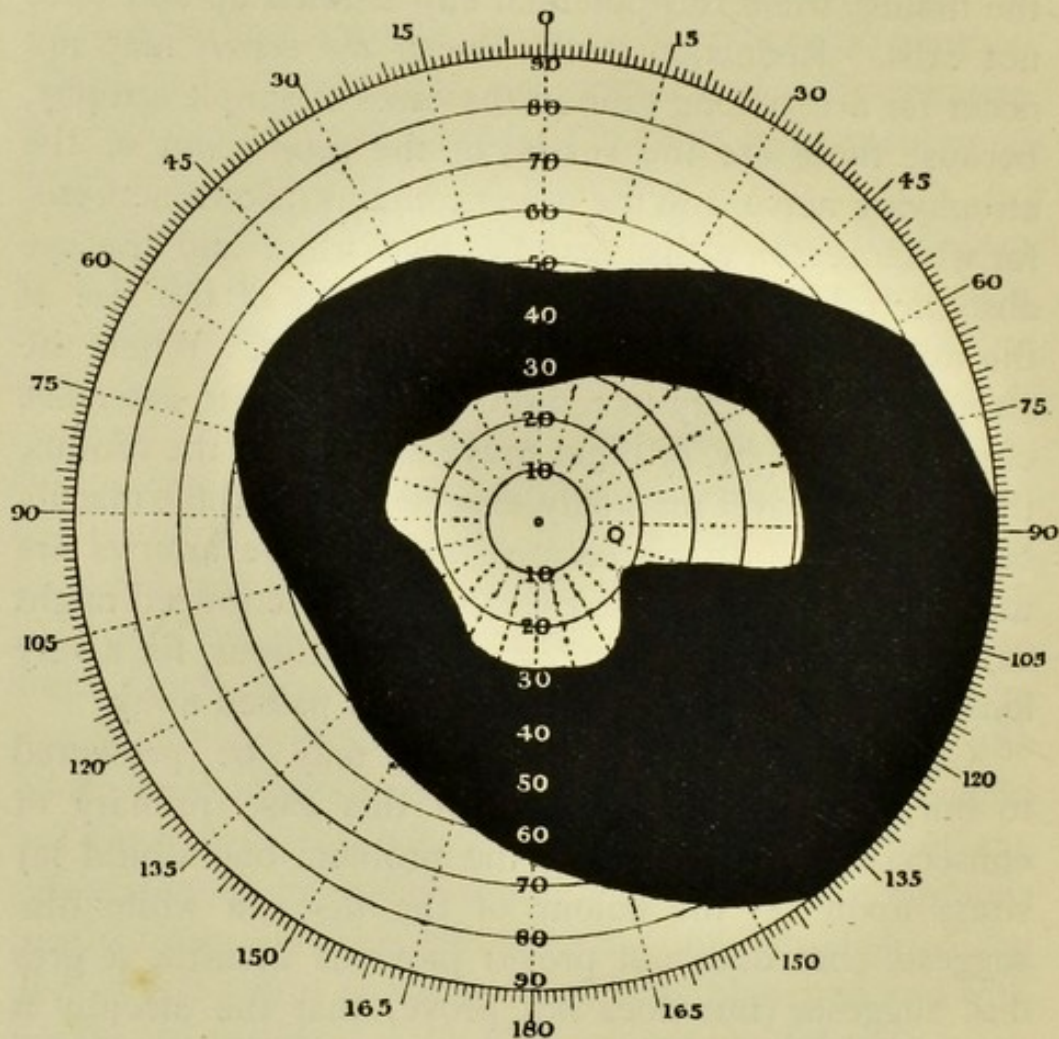


FIG. 56.—Field of vision in a case of optic atrophy. (Right Eye.)

in a very irregular fashion; the failure is usually bilateral, though not necessarily to the same degree. It is noteworthy that moderate reduction in the illumination of the testing room produces little or no change in the dimensions of the field, since the L.D. is not affected (see p. 11). The ophthalmoscopic changes have already been indicated. This atrophic state may or may not be associated with other morbid signs in the nervous system.

Thus one may find Argyll-Robertson pupils, absence of knee-jerks, Rombergism, and obtain a history of lightning pains, all pointing to a probable association with tabes. The singular point is that the signs of optic atrophy and those of other lesions of the nervous system seldom proceed *pari passu*; it is said indeed, but the statement is probably somewhat exaggerated, that other lesions remain stationary if the optic atrophy makes progress. In regard to the atrophy itself, the patient naturally is anxious to learn what the prognosis may be. This is always bad; the cases go on almost with absolute certainty to complete blindness, but not with equal rapidity. The relative condition of the field of vision for the ordinary test-object and for colours helps one to some extent. It is impossible that the field for white should be smaller than the field for a similar-sized coloured object (for the recognition of colour is a higher exercise of vision than the mere knowledge of the existence of an object), but should the field of vision for colours be reduced to a degree great in proportion to the reduction of the white field, one must regard that as an evil omen; it must indicate that the higher functions are failing in the intermediate portion of retina, and the lower will follow shortly. One may fairly give a better, though not a good prognosis, if the fields for colour and for white maintain their relative proportion to one another.

On the other hand, there may be no indication whatever of any morbidity of the nervous system otherwise along with the optic atrophy. It has sometimes been suggested that just as advance of the atrophy seems to retard the ataxia, so in this group of cases atrophy may come on far in advance of, or even to the exclusion of, other indications. This assumption is, however, to be received with some caution.

In another group of cases atrophy, in place of coming slowly and attacking first the peripheral field, comes, it

may be, more rapidly at first, and attacks the macular fibres, producing a central scotoma. Oftentimes this is far from easy to detect, and is, one fears, sometimes missed altogether, unless a very small test-object be employed and the patient placed at a distance from the

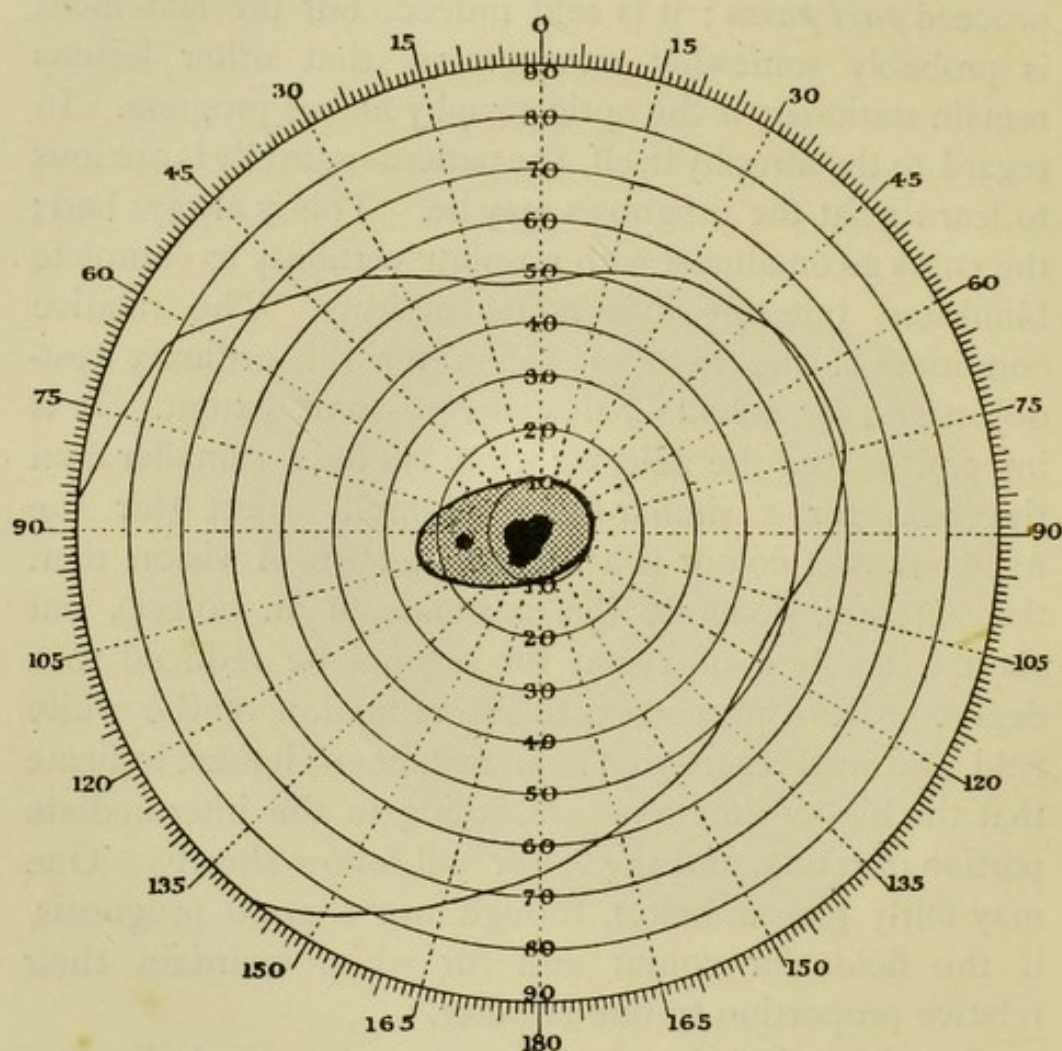


FIG. 57.—Chart of central scotoma.

The black area shows a true central scotoma. The stippled area shows the region of relative scotoma in tobacco amblyopia.

large screen, for the defect in the field may be far too fine to be exhibited in the ordinary perimeter examination, in which the test-object is relatively large and the distance short. Taking these cases of central scotoma as a group, there are **three types**:

A. A Progressively Advancing Optic Atrophy, beginning with a scotoma which becomes more dense

and more extensive with time, and along with this the disc becomes paler and whiter. Cases of this group may occur in association with tabes, but are much more closely associated with disseminated sclerosis; in every such case one should look specially for another eye symptom, namely, nystagmus. The existence of exaggerated knee-jerk, of tremor, of undue muscular fatigue and tremor, and of "hysterical" symptoms should make one very cautious. These cases are specially frequent among young women, but by no means confined to them.

B. It sometimes happens that a central scotoma of considerable size and density may display itself in each eye and remain stationary, making no advance through many years; this is a form spoken of as "**Stationary Scotomatous Atrophy**," and has probably had as its initial step a partial retro-bulbar neuritis.

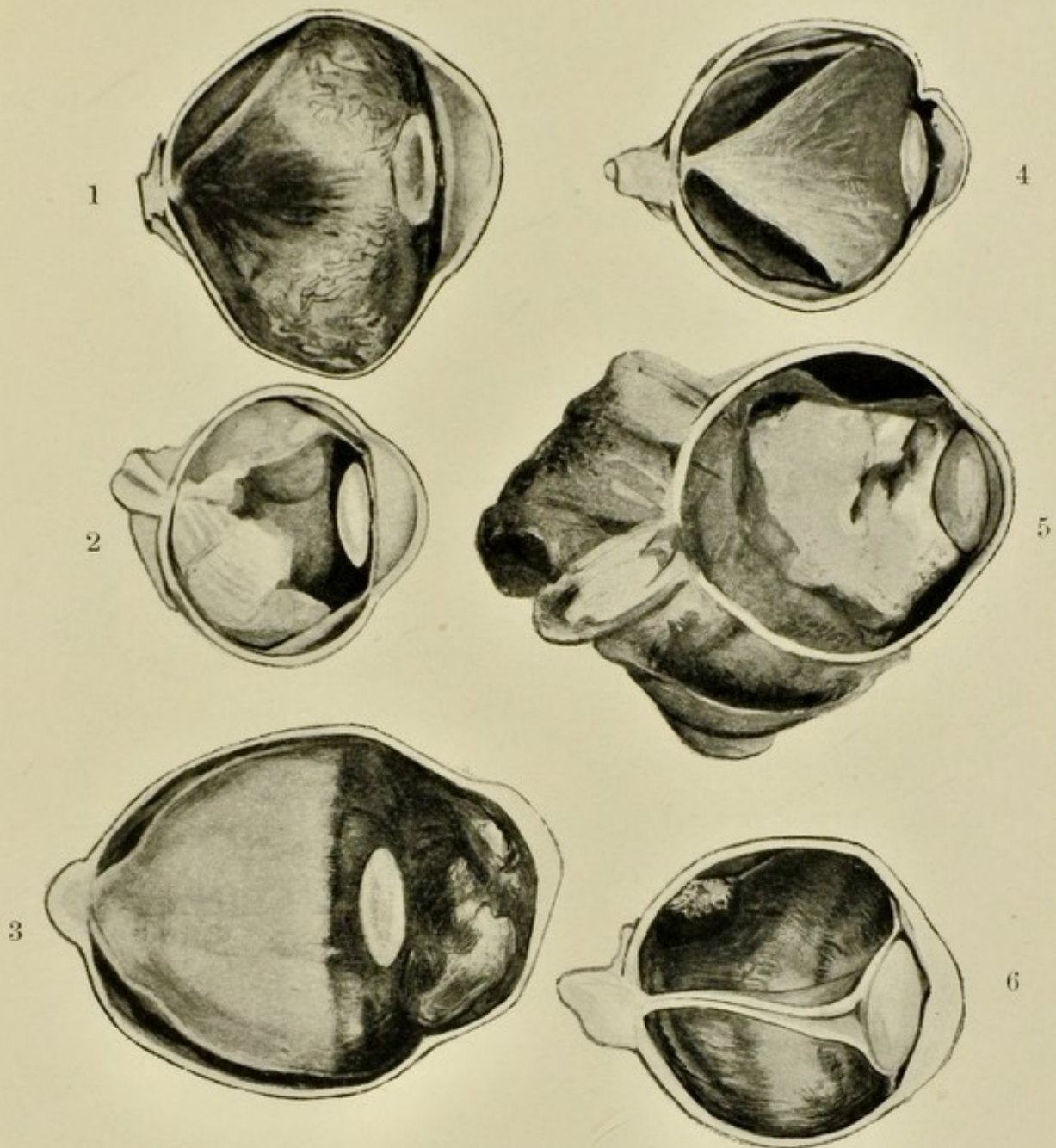
C. **Hereditary Optic Atrophy** or **Leber's Disease** forms the third variety, but in all probability this should be classed as an atrophy consecutive to a retro-ocular neuritis, and it differs from the preceding class chiefly in respect of its family character. The victims are young men of 18 to 25; very rarely does the disease affect women, and when it does the danger-time is rather about the menopause. The disease is in this sense hereditary that it attacks several men in one family, brothers or uncles; it appears not to be transmitted by the patients themselves, but to pass through the women of the family to their sons. After three generations it generally dies out. The patient complains of sudden or rapid loss of sight in one eye or both; if one eye only be affected at first, the other usually follows suit very shortly. He states that everything appears as in a mist or fog, and it is interesting that the subjective density of the mist bears no relation to the degree of loss of vision; thus the mist may appear to the patient merely as a bright, light haze, and yet there may be a

large absolute scotoma. With the ophthalmoscope there is little if anything to be made out, possibly a slight extra pallor of the outer quadrant of the disc; it is very rare indeed to find, either at the time or after the lapse of a few days, any hyperæmia of the disc, which becomes paler and paler till it assumes an aspect of dead whiteness. There is a scotoma, generally a large one, and as a rule either absolute or nearly so, but the periphery of the field is retained unaffected. The prognosis is very bad as regards central vision, which in the genuine cases is never restored, but favourable as regards further loss of sight; that is, after the disease reaches its worst, generally within a very few days, it remains stationary, and although central vision is permanently lost, peripheral sight is permanently retained. Individual cases, however, show considerable variations.

Treatment seems to be entirely unavailing: the natural course to pursue would be to blister, to give alteratives and absorbents, but results are very far indeed from encouraging.


So far as is known, this morbid condition is confined to the optic nerves, and the patients, though "nervous," do not fall into tabes or disseminated sclerosis. As an explanation of the disease, formation and absorption of some toxin connected with the sexual organs has been suggested, an explanation which leaves the mystery as dense as before.

Optic atrophy sometimes follows a severe blow on the margin of the orbit—from a severe fall, for example. The patient is rendered blind of that eye immediately, though the fact may not be noticed for some time, but no change is seen in the disc for a week or two, perhaps three; then complete atrophy comes on and the nerve becomes quite white. What has occurred has been a fracture along the roof of the orbit implicating or cutting across the optic nerve.



Six Pathological Specimens.

1. Equatorial distension of globe ; wide separation of lens from ciliary processes ; partial detachment of retina.
2. Glioma of the retina in a child of two years ; growing rapidly. Anterior chamber not shallow.
3. Enormous distension of globe antero-posteriorly and equatorially ; coats extremely thinned out ; cornea partly staphylomatous.
4. Large detachment of retina produced by small neoplasm.
5. Large soft sarcoma in a child. Posteriorly the tumour has penetrated the sclerotic and is growing outside the eye ; anteriorly the tumour is breaking down ; lens driven far forwards.
6. Complete detachment of the retina.



This will afford the most convenient opportunity to discuss the action of certain substances which produce, by their toxic action, various forms of loss of sight, even though they do not necessarily bring about any ophthalmoscopic changes. These substances divide themselves into two groups—those which affect the central portions of the field, and those which attack the field at the periphery.

Of those which produce a *central scotoma* the first and far the most important is **Tobacco**, though in many of the cases as they present themselves alcohol may be also playing an important rôle; indeed there may be an alcohol amblyopia (almost) indistinguishable from the tobacco, but in this country, hard drinkers though we may be, such cases are extremely rare. As being liable to produce a central scotoma bisulphide of carbon falls to be mentioned also, a substance employed in the manufacture of rubber goods. After forty the power of the system to resist the toxic influence seems seriously to diminish; and the sufferer from tobacco amblyopia is usually a man of 40 to 50 or more who smokes heavy tobacco to an amount exceeding 2 oz. per week; it is rare to find it in one who smokes less, while many smoke far more before the evil day comes. He is practically always a pipe-smoker, and generally uses a dirty clay. It is generally the case, too, that the patient is in the habit of smoking before food, when the system is naturally least favourably situated for resistance to toxic substances. But there is generally also some exciting cause, such as sleeplessness, anxiety, bodily illness, or distress, to arouse the outbreak by reducing the resisting power. The patient is said to have a peculiar odour by which he may actually be recognised, but I cannot say that I recognise it myself. He sees best, or believes he sees best, in the evening or in dull light, as the patient with retro-bulbar neuritis also does. He states

that his chief difficulty is to recognise faces ; he knows his friends by their figures or gait, not by their faces. This is because of the interference with the light-sense and the raising of the "light-difference" (L.D. ; see p. 11). We recognise the difference in faces by the differing degree of protrusion, etc., of features, which catch or lose the high lights, but the contrasts are fine and delicate, and when the nerve is inflamed these fine differences are not conveyed, and features are blurred and lose their characteristics. It is possible also that imperfect insulation of the fibres may account partly for the symptom. The most efficient test for this interference with the L.D. is with a coloured test object, which forms a less marked contrast to its surroundings than does a white one, or with Bjerrum's types, a series of test letters similar to Snellen's but printed in grey letters on a grey background, so as to offer but a feeble contrast. The patient's ability to read these letters should be contrasted with that of the normal individual, when his light-sense will be found inferior ; he will not be able to read a line which is readily visible to the other. There are numerous methods of applying the colour test ; one is to cause the patient to fix a small white mark on a black board, one eye being closed, and to place in the neighbourhood of the blind spot a small disc of red, green, or some other colour. It will then be found that red and green particularly are badly recognised, the former being called yellow or brass-coloured, the latter whitish. The point of greatest saturation of this scotoma is between the disc and macula, but it extends over an oval area including both disc and macula. The test can also be applied in a simple way by holding up two red-headed wax matches placed side by side ; if the patient, using the left eye alone, looks at the right-hand match, the colour at once fades out of the other.

The *pathology* of this condition is a little uncertain, since all the patients recover, or are supposed to do so; that is, if vision is not restored after treatment has been instituted, the case is no longer considered to be one of pure tobacco amblyopia. Opinions are divided as to whether the initial trouble is in the nerve or in the ganglion cells of the retina.

In *treatment* the essential point is cessation of the drug; if this is carried out recovery is almost certain. Cases of recurrence are occasionally seen in which the patients, having recovered in this way, have returned to former habits with unfortunate results. In such a case prognosis is not by any means so good. In the ordinary cases drugs are really unnecessary; more to please the patient than for any other reason one may give eliminants such as abundant water-drinking, open-air exercise, and potassium iodide; strychnine and other nerve tonics may be given later. A period of some weeks often elapses before the patient begins to feel any alleviation of symptoms, after which sight rapidly improves; the initial time of waiting is felt to be very irksome by the patient, who, however, may obtain some mitigation of his appetite by chewing gum.

Of those toxic substances which cause a *peripheral restriction* of the field, perhaps the most important is **quinine**, but in this country it is infinitely rare that quinine should be given in quantities sufficient to do any such mischief. The atrophy comes on rapidly after ingestion of the toxic dose of the drug, there is apt to be severe headache along with the increasing blindness, and on examination the nerves are found intensely pale and the arteries reduced to mere threads. The prognosis is not good. A very similar lesion is produced by **methyl alcohol** (wood spirit), which is occasionally drunk as an intoxicant.

It should be remembered that in several instances

atoxyl has induced blindness of this type, even complete and permanent.

A peculiar form of congenital fault in the nerve and its sheath is spoken of as a *Staphyloma downwards*, or sometimes as *Fuchs's coloboma*; the disc appears shortened vertically, and below it and in contact with it is a crescentic whitish or white area, the false staphyloma. The patients are often somewhat astigmatic, but practically never, even on careful correction of the optical error, obtain full vision (Plate XIV., 4).

Tumour of the optic nerve is a rare occurrence. Cases have been classified into intra-dural and extra-dural according to their seat of origin. Sarcoma in various modifications, endothelioma, and glioma seem to have been the principal forms observed. The cardinal symptoms are protrusion of the eye, loss of sight, and optic neuritis followed by atrophy. Loss of vision occurs early in the history of the case, indeed before the proptosis has reached more than a slight degree, and is often preceded or accompanied by neuritis. The protrusion is, as a rule, exactly in the line of the orbital axis, nearly straight forwards, that is to say, but a little outwards, and, since the tumour lies within the cone of muscles at the apex of the orbit, there is little if any restriction of movement. Sometimes the new growth can be felt with the fingers when the eye is sufficiently protruded. Removal may be effected either *via* the anterior part or by means of Krönlein's method of obtaining access to the orbit by removal of part of the outer wall; in a few of the cases of extra-dural tumour it may be possible to dissect the growth from the nerve and preserve both eye and sight; in some types of the intra-dural tumour a short healthy piece of nerve interposes between tumour and globe, and in such a case it may be possible to leave the eye (blind) *in situ* and remove the portion of nerve containing the tumour.

CHAPTER XIV

GLAUCOMA

THE subject of Glaucoma is one which presents many difficulties, because the disease not only varies so much in its clinical aspects, but also possesses a pathology which is in some points very obscure. The name, like that of a number of other diseases, has now little connection with the disease itself; it means the sea-green colour in the pupil—a feature absent in many cases of genuine glaucoma, but which may be present in conditions quite apart from that disease. There is, as a matter of fact, no one sign which is constantly and invariably present in glaucoma. If one were compelled to give a definition of glaucoma, perhaps the least objectionable would be—a disease whose most characteristic feature is a tendency to increased intra-ocular tension. One dare not say that there *is* increased intra-ocular tension.

There are numerous forms of glaucoma; but it is convenient in the first instance to classify the cases under the head of primary and secondary glaucoma, secondary signifying that there has been some other disease of the eye definitely present before the onset of glaucoma, and which is indeed the cause of the glaucomatous state; primary indicating that, so far at least as one can discover, there has been no such previous disease.

Primary glaucoma is again divided into simple and acute or subacute, according as there is slow onset and an absence of congestion, or a more rapid onset with congestion.

It will be most convenient, as affording the best general survey of the disease, to describe first a typical case of **acute glaucoma**. A woman (for this form is rather more common in women than in men) of fifty-five or so wakens in the night with severe pain, which she may describe as being located in the eye, but which is more certain to be present and more severe in the parts round about that organ. It will often be found that the pain is so definitely round the eye, in the temple and side of the head, and causing the upper teeth to "jump," that the patient may not refer the cause to the eye at all: she may consider it to be merely a very bad migraine. This pain is very severe, radiating all over one side of the head, and after it has lasted for a variable time vomiting comes on, a fact which has caused many a case of glaucoma to be regarded and treated as one of sick-headache.

On inquiry one will probably be informed that attacks, similar in character, though milder in degree, have occurred from time to time during the last few months or years; and should the patient be of an observant character she may have noticed that after each attack the vision has never quite reached the level on which it stood just prior to the outbreak, though of course much superior to what it was during the actual illness. The patient will further describe periods of dull or misty vision, a certain mild degree of night-blindness, and—a very characteristic sign when it is present—of seeing coloured rings like a circular rainbow round any light. The colours seen by various persons seem to vary somewhat; most patients appear to have their attention chiefly caught by the red and the yellow, but with others

the green and the blue are more obvious. Many also complain of the numerous and obtrusive rays which shoot out from any bright light; others remark upon the extreme darkness of the space which separates the light from the rings, which may be from one to three or more feet in diameter at a few paces' distance. It is not to be supposed that the presence of such rings is an absolutely certain diagnostic of glaucoma; some persons have them from childhood to age without a suggestion of glaucoma. They resemble the rings which may be seen round a light observed through a moist window-pane. The patient will very probably admit that presbyopia has increased with unusual rapidity, and that she has required to increase the strength of the reading-glasses too frequently. Another subjective sign is partial anæsthesia of the cornea,—a striking symptom, when the eye is at the moment intensely painful. This relative insensitiveness may easily be tested by touching the cornea very gently with a piece of blotting-paper, a hair, etc.

The objective signs which accompany an acute attack of glaucoma are often very marked and distinctive. There may be a little œdema of the upper lid, or even some slight chemosis, but there certainly will be a dusky injection of the globe. This is of the iritic or cyclitic type, only less inflammatory and more congestive, more venous. At the same time the pupil is semi-dilated and often departs markedly from the circle; it is oval, the long axis may be either vertical or horizontal. The cornea appears dull and steamy, like a glass which has been breathed on, the anterior chamber is shallow, and sometimes shallower at one part than at another. The iris itself appears dull, deficient in colour, and (at least if the process has lasted long or has recurred often) almost atrophic. On the sclera are two or three large venous trunks which dip into the deeper parts of the eye

and disappear about a couple of millimetres beyond the corneo-sclerotic junction.

Through the pupil comes the greyish, faintly yellowish, or greenish reflection to which the disease is indebted for its name "glaucoma," or the sea-green aspect of the pupil. It need hardly be said that this appearance is not pathognomonic; it may be present to some degree in any person of fifty-five onwards, whose pupil is dilated.

On palpation the *tension* of the eye will be found to be increased, perhaps very much so. The state of the tension may be ascertained by the skilled fingers. The patient is made to look downwards, and while he does so the surgeon places his two fore-fingers on the globe, or rather on the upper lid where it rests on the globe, and by gentle palpation endeavours to gauge the resistance offered by the globe to the dimpling in of its walls under his fingers, eliminating at the same time, as well as he can, the two disturbing elements in the test—the resistance offered by the upper lid and the varying rigidity of the sclerotic. It is impossible to put in words the normal feeling; one must learn to know it by practice. Three degrees of increase are generally recognised and represented graphically as $T + 1$, $T + 2$, and $T + 3$, normal tension being represented as T_n . $T + 1$ means that the eye is distinctly harder than normal; $T + 3$, as hard as a stone; $T + 2$, a degree intermediate between the others. (The terms $T - 1$, $T - 2$, $T - 3$ are also in use for representing abnormal degrees of softness.)

An instrument to record graphically and to test with greater accuracy than is possible for even the educated finger has long been eagerly sought, and seems now to have been discovered in the Tonometer of Schiötz. This beautiful instrument indicates the resistance offered to certain known weights which are employed to produce an impress upon the coats of the eye directly, and records

its results in millimetres of mercury (Fig. 58). The physiological pressure is considered to be not more than 25 mm.

In a case of any severity no reflex can be obtained from the fundus.

At the other end of the scale, representing a type so greatly differing from acute glaucoma that the two seem at first sight to have little in common, stands the case of **Glaucoma Simplex**, many of whose physical signs have to be indicated in the negative. In this form the patient is generally older, a man, say, of sixty-five or

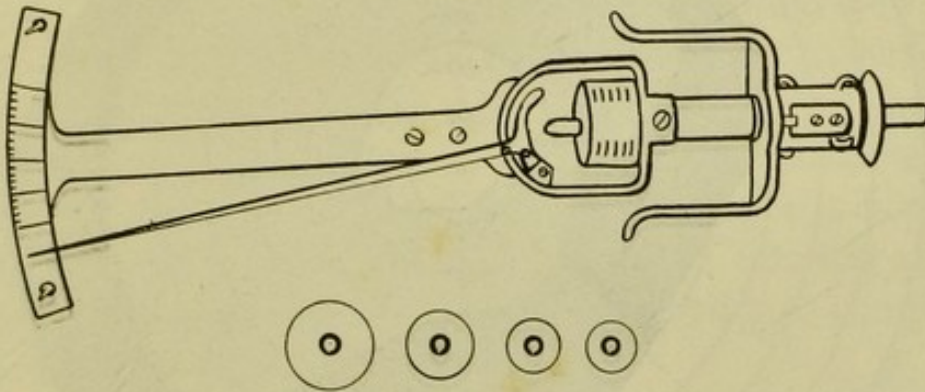


FIG. 58.—Schiötz's tonometer.

more, who complains of no pain, simply of gradual failure of sight. His vision is not appreciably worse at one time than at another, but he feels that he is gradually failing in sight; moreover, he has no coloured rings, no congestive attacks, no dilatation of veins, no hyperæmia, no dilated or unshapely pupil, no green reflex through the pupil, no shallowing of the anterior chamber, and perhaps, at least so far as the finger will guide one, no increase of intra-ocular tension.

Two features, however, these types have in common, the alteration of the field of vision and the ophthalmoscopic changes.

The alterations of the **field of vision** are threefold. *First*, in a well-marked case there is *reduction* of the field in the lower nasal portion. The field of vision, as

tested by means of the moving fingers, may be normal all over the field elsewhere; but at the nasal side, and particularly in the lower half of the nasal part, there will be found to be a restriction. At a later stage this

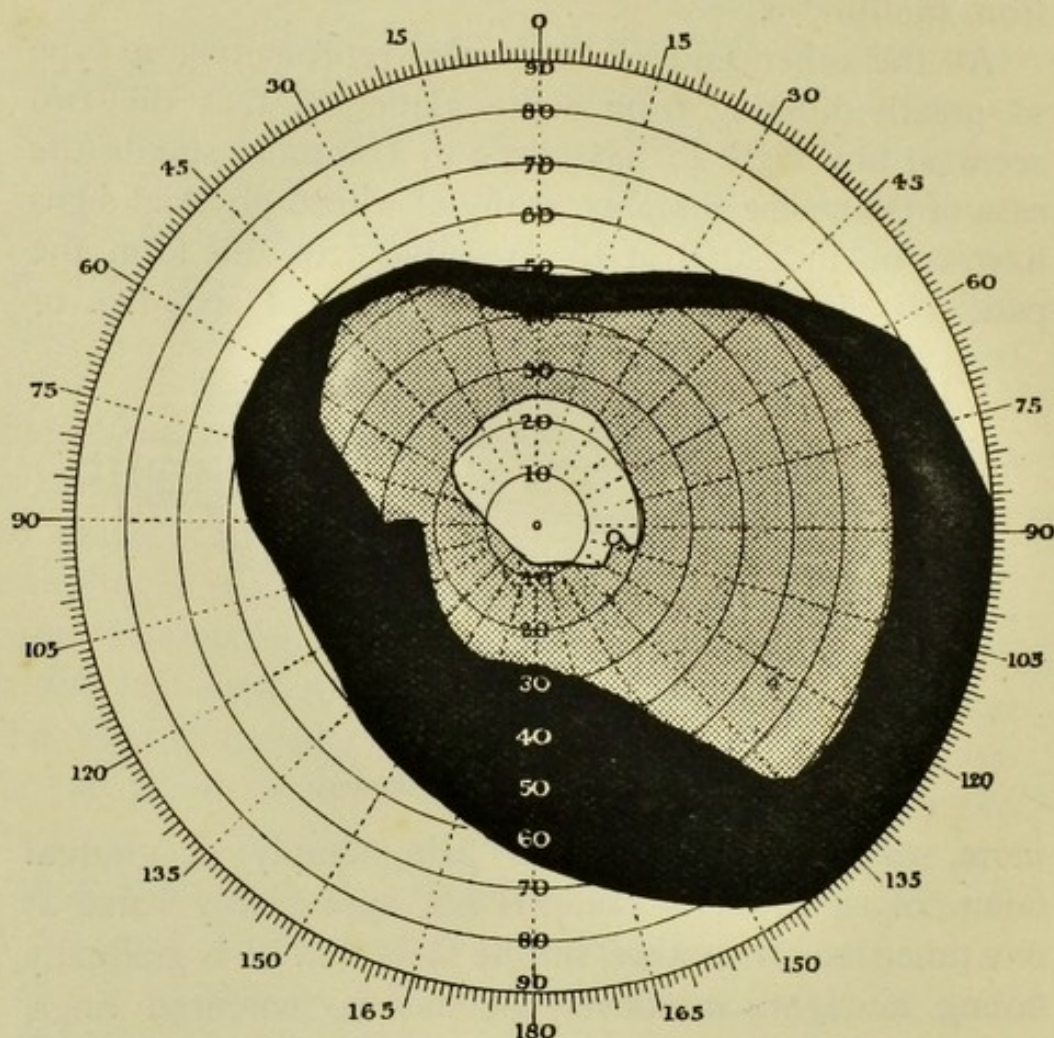


FIG. 59.—Field of vision in glaucoma.

The outer limit shows the normal field. The black shows the lost portion of field. The grey, the extent of the field with a $\frac{1}{300}$ object, the reduction being chiefly in the lower and nasal portions. The white, the extent of the field with a $\frac{1}{2000}$ object, the relatively blind area running into the physiological blind spot.

reduction of the field spreads to other portions. In some cases this restriction may be carried up to a point close to the fixation spot, a very important matter for the attention of the surgeon, for he must in such a case consider even more gravely than usual the question of operation or no operation. In some of the cases the restriction is less classical, more below, for example, than

to the inner side ; a chart of the field should always be secured before operation.

Secondly, on examination of the field by means of a very small test object a peculiarity may be detected which consists in the formation of a direct *continuity between the normal blind spot and the peripheral, pathologically blind, area*. To test this point one employs the large black velvet screen, from which the patient is placed at a distance of one metre or two as the case may indicate ; for test object a white spot, 1 to 5 mm. in diameter, is used. The size of spot to be employed is selected according to the visual power of the particular eye ; it must be large enough to carry the field a little beyond the blind spot, and small enough to carry it only a little way beyond. The characteristic feature is shown in this, that the blind spot is not now an island in a sea of vision, but that the tide has at one part or another receded and the "island" is in continuity somewhere with the shore.

Thirdly, there is the formation of the *nasal step*, a sudden, abrupt break in the line of margin of the field, exactly at the horizontal meridian on the nasal side. It takes its origin in this, that from the disc the fibres run upwards and downwards, and curve round to meet one another at the outer side of the retina in the horizontal meridian ; pressure on the upper fibres in excess of that upon the lower will manifest itself in a more decided diminution of the field in the corresponding area ; thus the step is formed. It may best be shown either by carrying the test object centrifugally 5° above and then 5° below the horizontal meridian to the nasal side, or circumferentially, just at the vision-limit in that situation.

An advantage which these field-of-vision tests just described all possess is that though they are no doubt best carried out on the black velvet screen, for diagnostic

purposes as distinguished from scientific, they really require no elaborate apparatus whatever.

The **ophthalmoscopic appearances** indicative of glaucoma are likewise threefold—cupping of the disc, pulsation of vessels, and general absorption of the retinal pigment.

Cupping of the disc, or excavation, as some, with a contempt of rigid accuracy, express it, implies that the surface of the disc is depressed below the general surface of the fundus. The essential points in the diagnosis of the glaucoma cup are: (*a*) that the vessels are pushed over to the nasal side of the disc; (*b*) that the cup extends over the entire disc, not merely the central part of it—the appearance of a break in the continuity of the vessels arises, therefore, at the very margin of the disc; and (*c*) that the plane is not inclined from the margin to the centre, but the whole surface is equally forced back into the sheath. Indeed, in some extreme cases, the disc is goblet-shaped rather than merely cupped (Fig. 52, p. 232). The depth of cup may actually be greater than is the width of the disc. This may be estimated thus: it is calculated that each millimetre of difference in level antero-posteriorly in the fundus makes a refractive difference of 3D. So then, if the refraction of the eye at the general fundus level is emmetropic, while a lens of -5 or -6 D is required to enable the vessels at the bottom of the cup to be brought into accurate focus, there must be a depression of the floor of the disc equal to 2 millimetres. Since the diameter of the disc is from 1.5 to 1.75 millimetres, the cup in a very severe case may thus be deeper than it is wide. This cupping gives rise to a phenomenon known as *parallactic displacement*, as seen with the ophthalmoscope. If, when examining by the indirect method, one causes the lens to move in a vertical plane in front of the eye, the objects in the fundus will appear to execute certain movements, the degree of movement depending on the distance separating the object from

the lens. Since objects in the fundus, as the edge of the disc and the floor of the cup, are not at the same but at distinctly varying distances from the lens, they will execute different degrees of movement, and will appear to slide or slip over one another in a striking way. Similarly, if when using the direct method, one fixes his gaze on the disc margin and moves the head, let us say, to the left, the floor of the disc, being more distant, will appear to move also to the left; if the examiner fixes the floor of the disc and moves his head to the left the disc margin will appear, being nearer to him, to move to the right. The student should familiarise himself with this parallax movement, which he can accomplish in a very simple way. Let him place upon a table two objects, say a candle and a tall book, the former near himself, and the latter at the end of the table; let him place his eye on a level with the table at one end of it, move his head slowly from side to side, and watch the apparent movement of the objects, and he will find that if he fixes the nearer one, that further off seems to move with his head, while if he fixes the further off, that nearer seems to move against the head.

Second, *pulsation of the retinal artery* may often be seen. When the intra-ocular tension is not high, blood enters the eye in a continuous stream, but when the tension rises above a certain degree blood can only enter at the systole; arterial pulsation may then become visible. It should be remembered that venous pulsation is of no significance whatever.

Third, *absorption* of the inter-layer of *pigment* between retina and chorioid, so that the chorioidal structure is laid bare, is quite common. The chorioidal pigment itself is often completely absorbed from a ring surrounding the disc margin—a fairly characteristic appearance of glaucoma.

Though at first sight it would almost seem as though

the two types were too entirely different to have a common nature and origin, as a matter of observation they are really formed into a series by innumerable cases which, altogether typical neither of the one nor of the other, present features belonging to both, one inclining to one end of the scale, another to the other. Farther, in many of the cases of so-called acute glaucoma, when the acute signs have passed off, it will be found that they have been merely ingrafted upon a glaucoma simplex, while in a good number of cases of glaucoma simplex careful inquiry will disclose a history of acute, or at least of subacute, exacerbations.

Diagnosis.—The only difficulty is in the diagnosis between acute glaucoma and iritis, and since the treatment appropriate in one of these diseases is absolutely contra-indicated in the other and may readily turn a bad but not hopeless eye into a dead loss, it is essential that the vital points should be clearly understood. In the two the type of injection is not dissimilar, but more arterial in iritis, more venous and dusky in glaucoma.

	Iritis.	Glaucoma.
Age . . .	Usually adult or younger.	About or after middle life.
History . . .	May have been previous attacks.	Usually previous attacks.
Vision . . .	Not very much affected.	Hazy, cloudy, much affected.
Halo round light .	None.	Present.
Field of vision .	Unaffected.	Somewhat restricted below and to nasal side.
Cornea. . . .	Clear.	Dull and steamy.
Anterior chamber .	Unaffected.	Shallow.
Pupil	Contracted.	Dilated.
Tension	Unaffected.	Raised.
Vomiting . . .	No.	Frequent.

It has actually been suggested that in a case of doubt

one might apply a mild mydriatic, which would leave the iritis patient uninfluenced, but would increase and emphasise the glaucoma. Such procedure is utterly unjustifiable.

The essence of glaucoma, then, is a tendency to prolonged periods of increased tension within the eye, a condition the existence of which will explain all the signs and symptoms.

Thus, assuming increase of intra-ocular tension to exist, the cornea may be anæsthetic because of pressure upon the nerve-fibres relating to the cornea; the pupil is semi-dilated for a similar reason, and also because the lens is pushed forwards a little; the exit of venous blood by the *venæ vorticosæ* is interfered with because the obliquity of their passage through the sclerotic exposes them to pressure-interference, and the ciliary body becomes congested, hence the dusky injection. Hence, also, the engorgement of the large veins on the anterior aspect of the sclerotic, for they become enlarged collaterally so as to take up the task of draining the eye. Increased pressure, by causing the lens to take a more anterior position, accounts again for the shallow anterior chamber and for the failure of accommodation, for the ciliary muscle is interfered with and the lens less amenable to its action, owing to the more anterior situation which the crystalline has assumed.

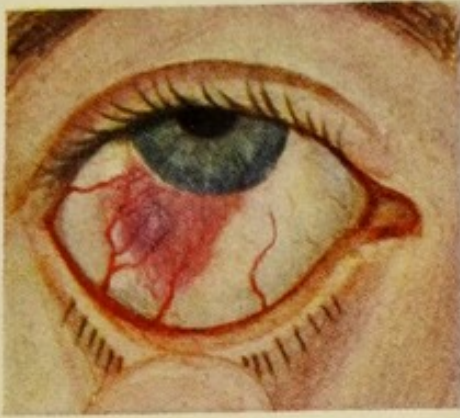Increase of the tension accounts even for the coloured rings which the patient sees, the glaucoma halo as it is called, for this is due to the imperfect removal of the lymph from the interstices of the cornea in which it is circulating, the fluid not being capable of being taken up by the vessels. The cupping of the disc and the peculiar alteration of the field are also explicable in the same way. Suffice it to say at present that one may fairly conclude that in the case of an acute glaucoma the pressure has led to encroachment of the lens or the

ciliary processes upon the space which ought to be open between them, and blockage has resulted : in the case of the glaucoma simplex there has been the slightest possible rise of tension ; this has become relieved by the recession of the disc, the nerve tissue in that region being perhaps feebler in resisting power than is normal ; cupping has thus resulted, the tension never rising except so slightly that complete relief could be obtained by this recession of the nerve into its sheath. Should a higher rise occur at any time, the lens is pushed forwards, the ciliary body engorged, the angle of the anterior chamber is blocked, and an acute exacerbation is the consequence.

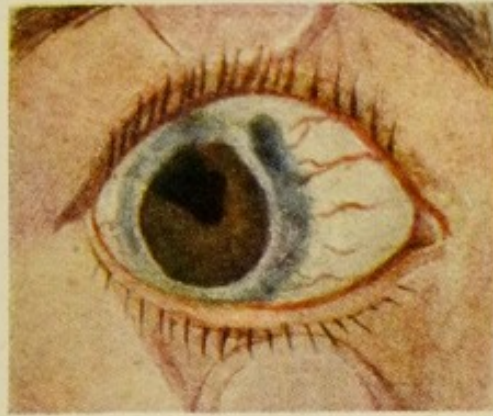
But what then is the original *cause* of the rise of tension? The suggested explanations are numerous, but probably no one cause is applicable to all cases. The case at issue being one of a want of due relationship between outflow and inflow, three possibilities present themselves, namely, *increased inflow*, *abnormal fluid*, and *diminished outflow*.

The old idea was that a "serous chorioiditis" came on, that the inflow was too great, and that the tension rose in consequence. There is, however, very little evidence in support of the theory. In regard to the second mode of origin, a point in its favour is the frequency with which one meets with vascular changes in glaucomatous eyes—hæmorrhages in the retina, etc. These changes suggest at least that the vessel walls are either unduly pervious or contain a fluid more prone to escape from them than is the normal blood. One of the difficulties about this theory is that if it were true the anterior chamber ought to be, not shallow, but deep.

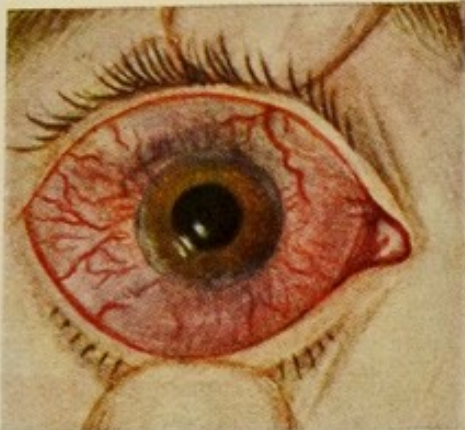The third suggested mode of origin is that which is in highest favour to-day. By far the most important exit-route for fluids from the eye is at the angle of the anterior chamber, that region where the root of the iris



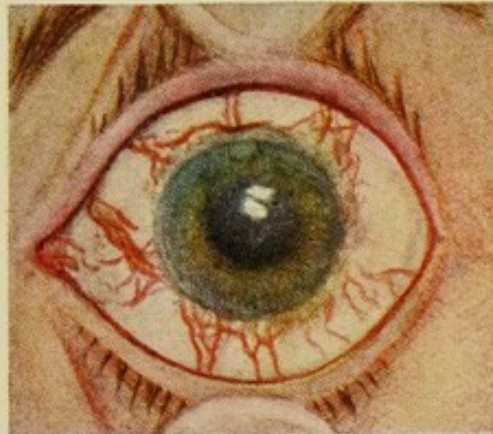1



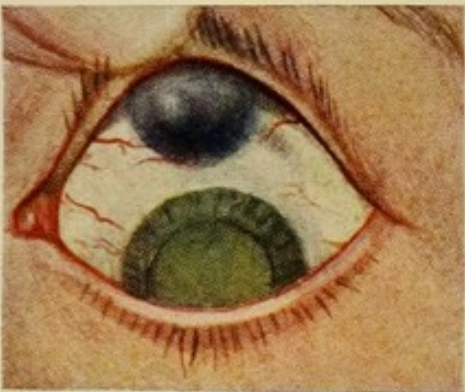5



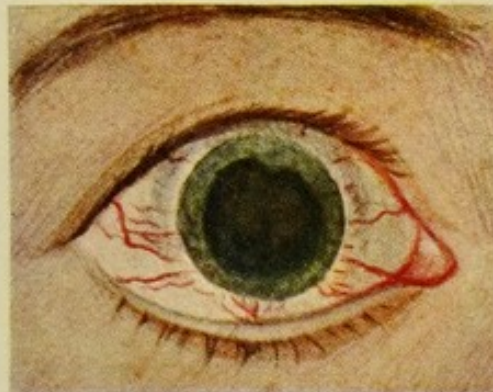2



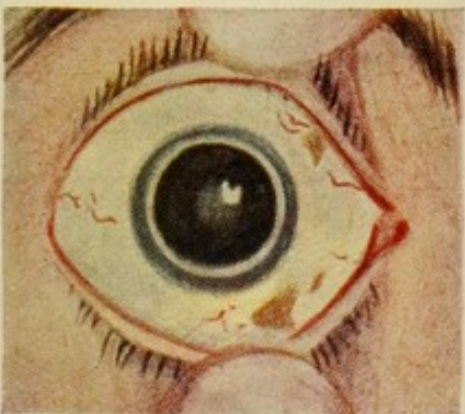6



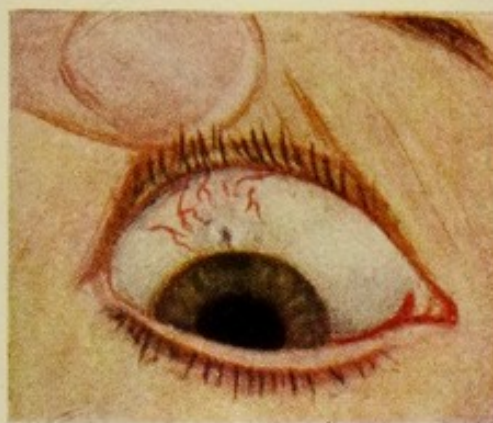3



7



4



8

1. Episcleritis.

2. Scleritis. The violet or purplish colour of the injection should be noticed, and the invasion of the cornea.

3. Ciliary Staphyloma (usually slightly more anterior than in this instance).


4. Pigment spots on the Sclerotic: Cataract: Arcus senilis.

5. Results of severe Scleritis: thinning of Sclerotic round the cornea: posterior synechiae. Iridectomy has been performed.

6. Glaucoma.—Note the venous injection, the dulling of the cornea, and the shallowing of the anterior chamber.

7. Glaucoma: Iris much atrophied.

8. Trephining Wound.



joins the periphery of the cornea in the immediate neighbourhood of the spaces of Fontana and of Schlemm's canal. There is no question that there must be diminished outflow in the old-standing cases, where the angle of the anterior chamber can be demonstrated to be non-existent, but that does not settle the matter; that might be merely a result of continued glaucoma, not a cause of it. Priestley Smith (Birmingham) has the credit of pointing out one reason for which older patients may be more exposed to glaucoma than younger, namely, the progressive increase in the dimensions of the crystalline lens as age advances. He calculates that the lens of a man of 65 is one-fifth larger than that of a man of 25; the free space between lens and ciliary body being but narrow at the best, how easily this larger lens may obliterate it altogether and block the passage. The same writer has shown that in glaucomatous eyes it is usual to find that the diameter of the cornea is shorter than the normal average; an eye with an average lens and a cornea below standard size would naturally therefore be even more exposed to blockage. It is quite certain, however, that these explanations cannot apply to all the cases, and among the more recently suggested causes is a sclerosis of the ligamentum pectinatum iridis, that meshwork of fibres forming one root of the iris, — a sclerosis which would interpose an obstacle to the intra-ocular fluids reaching the spaces of Fontana and the canal of Schlemm, and so becoming absorbed.

Whatever the original cause may be, it is admitted that once the rise of tension has become established the root of the iris will be pressed against the base of the cornea, may even become adherent there, and will thus shut off the true angle, where the absorptive apparatus lies, from the aqueous humour. Practically every case of old-standing glaucoma exhibits this feature on investigation, but it must not too hastily be assumed that it

necessarily was operative until late on in the morbid process.

Assuming that from some cause or another the outflow is obstructed, what will happen is that fluid will be unable to reach the true angle because the large lens presses against the congested ciliary body; the iris is pushed forwards and first narrows and later altogether obstructs the angle. The acute block becomes at once, and for the same reason, acuter still and more complete, and a threatened glaucoma becomes an actual congestive glaucoma. (Congestive glaucoma is a more accurate expression than "inflammatory," though the latter is often enough employed.) Excluding for the meantime secondary glaucoma, let us consider what causes might precipitate a primary attack. Any congestive condition of the ciliary vessels may do this, hence too generous or "inflammatory" diet, alcohol, over-exertion, etc. Any cause which dilates the pupil may have a similar effect, for the double reason that when the pupil is dilated the iris tissue is packed away into the angle of the anterior chamber, and that the iris crypts, those curious little open mouths on the anterior surface of the iris leading direct to the absorption-vessels, disappear and fail to be of any service. For this reason one must be very cautious in the use of mydriatics in any patient above middle life; dilatation of the pupil with atropin, etc., may be immediately followed by a sharp or even a violent attack. It is a good rule *never to give any mydriatic to any patient over 40 without first testing the tension of the eye.* Emotional excitement, such as anger, fear, grief, anxiety, and shock, is capable of bringing on an attack; so is want of sleep, for while during sleep the pupils are contracted, when sleep is not obtained they are, on account of fatigue, dilated by the action of the sympathetic. A patient, therefore, who has had threatenings of glaucoma ought to lead a very quiet,

uneventful, placid life, avoiding such excitements as gambling, racing, card-playing (except in a mild way), and whatever ministers to want of proper and sufficient rest of body and mind.

Treatment.—In the case of a person who complains of symptoms which prove to be *premonitory* of glaucoma, but in whom no definite or serious damage has yet been done, whose vision and whose field of vision have not been injured, but who is conscious of transitory attack of misty vision with slight congestion of the eye, and whose disc is as yet not cupped, probably the best treatment is to order pilocarpine or eserine to be employed locally, optical correction of any error of refraction to be worn, moderation in diet, a quiet life to be led, and abundance of sleep taken, and re-examination of vision and field to be made at intervals lest actual physical injury to the eye should be suffered to pass unheeded.

Next, in the case of a definite *acute glaucoma*, every endeavour must be made to lower the tension; the position of affairs is, as has often been pointed out, analogous to strangulation of a hernia, becoming, as time goes by, more and more acute in consequence of its own existence, and relief must be obtained immediately at all costs. A free purge, followed by a hypodermic of morphia, and accompanied by the use of eserine (gr. ii. to $\bar{3}$ ss.), is a good routine, and powdered dionine may give much relief. But though much relief may be experienced through these procedures, that is not enough, because behind the acute attack stands the permanent pathological state of the eye which will lead again and again, if unaltered, to fresh attacks, each more injurious and more destructive than the last. Something must be done permanently to alter this state of affairs. There is little doubt that the best procedure is to perform iridectomy promptly. It is not always easy to obtain permission to do this should the measures

first employed bring the patient much relief, for he is (not unnaturally) apt to say, "Well, that was a bad bout, but it is over now, and I have had nearly as bad before and yet got better." As a matter of fact, however, the improvement under mild measures should rather be looked upon as an encouragement that good will result from operation, and an additional reason for its performance. On the other hand, should the temporary mild measures bring no relief, the fact must not be looked upon as discouraging the idea of operation, the contrary rather; it means that the eye is in a state too abnormal for the success of gentle means, and will infallibly be lost unless operation is promptly performed. Whether then the purge, the morphia, and the eserine give relief or fail to give relief in an acute case of glaucoma, operation should be performed. If that be so, why use the preliminary measures at all? Because the lowering of tension they bring about places the eye in a better state for the actual operation, besides affording time to the surgeon and a little much-needed rest and repose to the distressed patient. The details of the actual operation will be found on p. 434.

How is it that the operation gives relief? Probably in several different ways, by tapping the anterior chamber, by local depletion, by opening up the angle of the anterior chamber, and by providing an open route for absorption. At first sight it seems singular that a disease which arises in virtue of diminished absorption, absorption depending partly, at least, on the crypts in the iris, and in which the iris is very prone to atrophy, should be treated by the artificial removal of a portion of this same iris; but clinical facts are too strong for theoretical speculative views, and Henderson has the credit of pointing out a possible means of reconciling them. For he has shown that after iridectomy the cut margins of the iris, anterior and posterior, do not heal to one

another at all, but the cut "edge" of iris never closes, no endothelium creeps round from anterior surface to posterior because the wound lies in a perfectly non-stimulating medium, and the aqueous humour which bathes it excludes all stimulus to cell-development. It may well enough be then that by these open gaps absorption takes place more freely than by the crypts on the anterior surface, closed or half-closed as these must be by the atrophy of the iris and the dilatation of the pupil. The old explanation of the filtration through a scar in the coats of the eye was not convincing, because one cannot regard scar tissue as well adapted for filtration, and no one of much experience can doubt that the most favourable of his cases of operation for glaucoma have been those in which a perfectly flat, firmly closed scar resulted, such being formed for the most part in eyes operated upon at a fairly early stage in the disease, while those in which a more open scar resulted, through which filtration could evidently take place readily enough, come in the second rank only, they mostly occurring in more advanced cases.

Experience has shown, however, that iridectomy, while still for most surgeons the operation of choice in the acute form of glaucoma, is not so satisfactory in the *chronic*. Not only is it less certain to keep the tension permanently near the normal level, and to prevent, therefore, the peculiar atrophy of the optic nerve which is an essential element in glaucoma simplex, but it is decidedly apt to leave the patient with vision less good than that which he enjoyed before it was performed. On this account surgeons have sought for a procedure which will secure lowering of tension, form a safety-valve to obviate subsequent rise of tension, and which will at the same time not lower the standard of vision. In other words, they have endeavoured to establish a "weak point" in the coats of the eye which will yield to the slightest

alteration of internal tension. Putting aside a multitude of minor modifications, four chief means of arriving at this result may be mentioned: entanglement of the iris in the wound, the scleral tongue operation of Herbert, Lagrange's operation, and trephining. (For description of various methods of operation see chapter on Operations.) Wilful entanglement of the iris, in order to secure that the scar be weak, does not strike one as good surgery, and the prolapsed iris, merely covered by a little thin fibrous tissue, may be the source of much mischief. In the three remaining methods a portion of tissue is removed from the cornea-sclerotic junction, in Herbert's plan by cutting the tip of a flap, in Lagrange's by removal of a slice, in trephining by cutting out a disc or "biscuit" of tissue. Without disparagement of other methods, it may fairly be said that trephining provides a method which has the advantage of simplicity with at least as encouraging a prospect of permanent efficiency as either of the others, but it is not so well adapted to the condition of acute glaucoma as it is to the non-congestive variety. In a book of this nature thus much may be said without prejudice to the other methods.

Prognosis.—Every case of genuine glaucoma should be regarded as one of danger, and it should further be borne in mind that behind the acute attack is often the chronic, slow, degenerative process, while each case of chronic glaucoma is capable of suddenly becoming an acute one. Given time, glaucoma will destroy all vision, but with varying rapidity. An acute "fulminating" glaucoma may destroy the sight beyond repair in a day, while a very chronic case may make little progress in twelve months. Roughly speaking, however, a moderately severe outbreak of acute glaucoma will destroy vision in a week or so, unless relief is obtained quickly. In recommending operation in any given case of acute glaucoma, one may hold out to the patient the expectation that

when all has quieted down vision will be slightly worse than it was just previous to the outbreak, and much better than it is during the acute stage, the degree of improvement varying with the actual severity and with the length of delay before operation. Every day lost, almost every hour lost, means diminution of the vision eventually to be obtained. Prognosis is not so cheerful in the chronic cases ; in them one can only say that the natural downward progress will be delayed, that vision will last the patient longer than would be the case were the operation not performed, and that vision after the operation will be a little worse than it is at the time of speaking. Naturally many patients prefer to leave matters to chance when so little can be promised, and naturally also many surgeons are reluctant to operate. Two factors are of much importance in the decision as to the line of treatment, namely, the age of the patient and the amount of vision remaining, and particularly the proportion of the field which is still retained. Thus one would certainly not be disposed to urge operation in a feebly nourished old man of 77 even if he showed unquestionable signs of glaucoma simplex ; and in a man of 60 whose field of vision was greatly reduced and whose limit of field came close up to the fixation spot, one would not urge operation. Taking a general survey, then, of the treatment of glaucoma, one might sum up thus:—In all cases of acute glaucoma, first employ a miotic and then operate by iridectomy. In glaucoma simplex, if vision is really being gradually lost, use miotics for a time and watch ; should progress not be arrested thus, trephine (or in some other way perform sclerectomy), unless the patient be very feeble or very old, or have a minute field, and especially if the other eye has already been lost.

The reason for putting so much stress upon the state of the field as assisting to guide one as to operation is

that it may happen that the portion of field adjoining the scotomatous area is lost as the immediate and permanent result of the operation, and should the boundary line come very close to the fixation spot, macular vision may at once and for ever depart, and the patient's sight may then fall from $\frac{6}{12}$ to counting fingers excentrically at 3 metres, a very distressing result of an operation.

Secondary Glaucoma is the term used when glaucoma is obviously the consequence of some recognised, previously existing disease of the eye. There are many such which can give rise to glaucoma, but there are seven of much greater moment than the others, namely, iritis, ulceration of the cornea, rapid ripening of cataract, dislocation of the lens, tumour in the posterior segment of the eye, the conditions after extraction of the lens and serosity of the aqueous. A few words about each of these in turn will suffice to explain matters.

Iritis leads to the formation of adhesions (synechiæ) between iris and lens; these block the route through the pupil by which fluids pass from the posterior chamber to the anterior; the fluid thus dammed up in the posterior chamber, accumulating there, pushes forward the iris; the iris, fixed naturally at the periphery, and adhering to the lens at its pupillary margin, becomes arched, or *bombé* (Plate IX. 3); the anterior chamber becomes shallow and its angle obstructed; the tension consequently rises and secondary glaucoma is produced. This, however, will yield to a timely iridectomy which opens the way from posterior chamber to anterior.

When an *ulcer* of the cornea perforates it, and the aqueous humour escapes, the iris must lie in contact with the cornea, even if it be not protruded through the gap left by the ulcer. The consequence of this is that iris tissue becomes involved in the scar tissue which replaces the lost corneal substance; the angle of the anterior chamber is—over a certain area—shallowed, or

may be altogether abolished, and glaucoma is established, being further aggravated by the dragging upon the root of the iris.

As a crystalline *lens* becomes cataractous it generally, if not always, absorbs moisture; as it swells it must push the iris forwards, narrowing the angle of the anterior chamber and thus interfering with absorption and leading to the establishment of glaucoma.

The crystalline *lens* may become *dislocated* in front of the iris; this is specially prone to occur in cases of congenital subluxation of the lens, for it is smaller than normal and can pass more readily through the pupil. When this happens the lens itself blocks a large part of the angle of the anterior chamber, and more yet is likely to be obstructed by the iris, since the rearrangement of the fluid contents of the eye forces it against the cornea. Glaucoma arises promptly when this accident happens.

When a *tumour* of the chorioid or a glioma of the retina has advanced to a considerable extent, it is certain to bring about the establishment of glaucoma. How this exactly is to be explained is not, however, quite certain: it may be merely the mechanical increase in the solid contents of the vitreous chamber in some cases, but in others glaucoma comes on while yet the tumour is minute; it may be that hæmorrhages or other exudates from the tumour have affected the absorption and tension-regulating apparatus, but for one reason or another by and by the tension rises to the actual development of glaucoma. Indeed this is a point which must be earnestly considered in some cases of unilateral glaucoma: Is there merely glaucoma, or is there a tumour here? Points in the diagnosis in such a case are that in the case of idiopathic glaucoma the pain and tension show some remission from time to time, and after palliative treatment, but when tumour is present there are no such remissions; also that in the idiopathic

form pain and loss of sight come on simultaneously, but in tumour the loss of sight precedes the onset of pain.

It might seem as though the *extraction* of the crystalline lens ought to secure the patient from any possibility of glaucoma, but this is not so. In a certain number of cases, while the operation has been recently passed, and the treatment barely finished, glaucoma sets in; in other cases it may be much later. The explanation probably lies in the deposition of fibrin along with the lens matter on the surface of the capsule of the lens, this mixed deposit becoming more firm, almost leathery, and the membrane "forming" right across from ciliary body on the one side to ciliary body on the other, and blocking the anterior chamber from the posterior as certainly as if the lens were there. In some instances inclusion of part of the capsule in the wound conduces also to this misfortune.

When, in consequence of some inflammatory change in the ciliary body, the *aqueous humour* contains an undue proportion of *serum*, glaucoma may come on; in such a case the anterior chamber may be not shallow but deep.

These form instances, probably the most important, of the development of glaucoma as a definite consequence of a distinct, precedent disease. In all, the line of treatment to be pursued is at all costs to re-establish the obstructed normal lymph-route, and especially its most vulnerable part, the angle of the anterior chamber. The particular means by which one endeavours to attain this in the various instances is considered for each under its own heading.

In this connection it is a fact worthy of careful note that mere increase in the intra-ocular contents does not appear to threaten glaucoma in all cases, for increase of tension does not arise in chorioiditis, choked disc, or retinitis, in all of which the vascular contents of the eye must be increased.

There is a congenital form of glaucoma called **Buphthalmos** or Ox-eye. In this condition the whole anterior half of the eye is distended, the cornea large, bluish, and only semi-transparent or nearly opaque; it is difficult, or it may even be impossible, to make out the details of the pupil and iris. The tension is hard, and the eye may be sightless or nearly so before advice is sought (Plate VII. 8). The most probable cause is a congenital fault in the formation of the tissues at and about Schlemm's canal, so that absorption of fluid from the interior of the eye into the veins cannot take place. The softer tissues of the child distend, and an acute rise of tension may thus be avoided, but the pressure destroys the sight by compression of the nerve-fibres at the sides of the enormously cupped disc. These eyes stand treatment very badly; they are ill-nourished and suppurate readily. Pilocarpine should be employed locally, and repeated sclerotomy may be practised, with decided benefit in some cases; iridectomy and sclerectomy are dangerous procedures. Since the eye is distended, the suspensory ligament of the lens is often imperfect, vitreous readily escapes, the coats are all very thin, and hæmorrhage to be dreaded; and septic infection is a more imminent danger than usual.

CHAPTER XV

THE OCULAR MUSCLES

THE muscles connected with the eye and its appendages are twelve in number, viz. the occipito-frontalis, the orbicularis palpebrarum, Müller's muscle, Horner's muscle, the Levator palpebræ Superioris, the ciliary muscle, and the six exterior muscles of the globe.

The *occipito-frontalis*, which is really rather a muscle of expression supplied by the VII. nerve, comes strongly into play in cases of ptosis, for it forms the only means by which in such a case the patient can elevate his upper lid. In these cases it will be seen exerting itself as well as possible, wrinkling the brows and drawing up the eyebrow, but having little effective action upon the lid itself. The *orbicularis*, also supplied by the facial, has a very important influence in keeping the lids in place ; when it is paralysed, the lower lid is apt to sag away from the globe, and the punctum to do likewise ; in consequence the tears are not able to enter the lachrymal passage, for they can do this only when the punctum rests upon the moist surface of the globe. Spasmodic contraction of the orbicularis leads to turning in of the eyelids (entropion), and singularly enough, if the lids are from mechanical causes turned out, contraction leads to increase of this (ectropion).

Müller's muscle, which runs backwards into the orbit from the tissues of upper and lower lids, has the effect

on contraction of bringing forward the globe, of causing exophthalmos or proptosis as it is variously called. It may also have the effect of drawing back the (upper) lid. It is supplied from the sympathetic system.

Horner's is a tiny muscle, described by an American surgeon (not the German of the same name), which has the effect of increasing the efficiency of the puncta in picking up the tears by holding them in position, and also of slightly compressing the lachrymal sac. It is really a portion of the orbicularis.

The action of the *levator* is well known ; paralysis of it produces a hanging down of the upper lid (ptosis).

Ptosis may form part of the symptoms of a paralysis of the III. nerve, or may exist by itself ; it is in this connection that we consider it at present. Ptosis may be bilateral or unilateral, congenital or acquired. It is very important, from the point of view of deciding upon the proper treatment, to discover whether certain conditions are present:—Place the palm of the hand flat upon the brow while the patient looks down, and then ask him to look up. The hand in that situation prevents any action of the occipito-frontalis ; if, therefore, there is no elevation of the lid, that will indicate that all previous movements had been accomplished by the frontal muscle. Next remove the hand, and, lifting the lid mechanically, ask the patient to look up. If he is able to do so, that will signify that the lesion causing the ptosis is not central (cortical). A patient with ptosis can hardly look up, because even if he should be able to raise his eye it would become hidden under the hanging lid ; in some cases when the lid is mechanically raised the eye will look up, in others it cannot ; in the latter case the lesion must practically with certainty be cortical, unless indeed it be due to defective development of several muscles. The primary consideration in regard to any operation for ptosis is to make sure that you are not so

zealous as to run the least risk of leaving the cornea exposed during sleep. One must, in other words, never completely cure ptosis. Naturally the bilateral cases afford the best scope for operation, for the patient is pleased with even a slight improvement in aspect and in ease.

For operations suitable see p. 440.

The function of the *ciliary muscle* is to increase the refractive power of the lens; this it accomplishes principally by causing protrusion of the central portion of the anterior surface of the lens. It has been abundantly proved that the two ciliary muscles act together with equal effect, and that astigmatism cannot be corrected at all by the action of the muscle. The ciliary muscle is perhaps unique among muscles in that its power diminishes constantly with age, and begins to do so long before adult life is reached. The reason for this lies in the constantly increasing hardness of the lens, which resists change of form to an ever-increasing degree.

When the ciliary muscle is paralysed accommodation becomes impossible and the static refraction becomes permanent. It is noteworthy that neither convergence nor the associated contraction of the pupil is interfered with. A patient whose refraction was normal will, on paralysis of accommodation, find that while distant vision remains as before, near vision (reading, sewing, etc.) is impossible. If he be hypermetropic distant vision is also reduced, while if he be myopic he may be conscious of no inconvenience or disability.

Apart from ciliary paralysis as an element in paralysis of the III. nerve, this affection occurs in diabetes, in early tabes, occasionally in syphilis apart from tabes, and as one of the most frequent sequelæ of diphtheria. When it occurs in a diabetic it should be looked upon as a somewhat serious symptom, pointing to an involvement of nuclei; it is liable to be followed by paralysis of more

vital nuclei. As a sequela of diphtheria it is, next to paralysis of the palate, the most frequent complication ; it comes on in about three weeks or so after the angina, and in the mild cases of diphtheria the patient may actually have returned to school ; it rapidly becomes worse, and then after the lapse of about two or three weeks passes off with great rapidity. The lesion is certainly a nuclear one, and questions of treatment, etc., will be found dealt with under the head of Nuclear Lesions.

The six **exterior muscles** of the globe divide themselves into the four recti and two obliques ; with the exception of convergence, which requires the simultaneous action of the two internal recti, all movements are strictly conjugate. I am convinced that though the deeper questions of the actions of the muscles individually and in groups are beset with extreme difficulty, the more commonplace matters of physiological action and of diagnosis of the nature of the paralysis which may be present (the questions which a student or practitioner will encounter) are really made more difficult rather than, less so by some teachers, and can be simplified.

It is necessary first to review rapidly the *physiological actions* of the various muscles. The internal rectus has a simple action, to turn the eye (*i.e.* the cornea) inwards. The external rectus similarly turns the eye outwards. The superior rectus has as its principal action to turn the cornea upwards, but it also turns it inwards and rotates the cornea about a sagittal axis, so that the upper end of the vertical meridian of the cornea is turned inwards. The inferior rectus turns the eye downwards (its chief action), but also turns it inwards, and rotates the upper end of the vertical meridian of the cornea outwards (by pulling the lower end inwards). The superior oblique, running from its pulley at the upper inner anterior angle of the orbit to the posterior, upper, outer quadrant of the globe, turns the cornea downwards ; owing to the posterior and

superior position of its insertion it at the same time turns the cornea outwards and rotates its upper part inwards. The inferior oblique, running more or less parallel to the superior, turns the cornea upwards and also, to a less degree, outwards, rotating its upper part outwards. It will thus be seen that, besides the internal rectus, two muscles turn the eye inwards, namely, the superior and inferior recti; two turn it outwards besides the external rectus, namely, the two obliques; two turn it upwards, the superior rectus and the inferior oblique; two turn it downwards, the superior oblique and the inferior rectus; two rotate the upper end of the vertical meridian of the cornea inwards, the superior oblique and the superior rectus; and two turn it outwards, the inferior rectus and the inferior oblique. Take any one of those pairs of muscles and it will be found that in one action they agree, while in two they differ; as a single example take the superior oblique and the superior rectus: though they both rotate in a similar sense, one turns the cornea down, the other up, one turns the cornea out, the other in. And even in the point in which a pair agree there is a difference, a difference of great importance from a diagnostic point of view, of which two illustrations are of much importance. The superior oblique and the inferior rectus both turn the eye down, but owing to the obliquity of each muscle—to the fact, that is, that its long axis is not at right angles to the axis of rotation—there is for each a position of the eye of maximum and one of minimum efficiency. When the eye is turned inwards the superior oblique acts with its maximum efficiency as a depressor and its minimum as a rotator; when the eye is turned outwards the inferior rectus acts with its maximum efficiency as a depressor, and consequently its minimum as a rotator. When the eye is looking inwards the inferior oblique acts with its maximum efficiency as an elevator, its minimum as a rotator, and

CHART SHOWING ACTIONS OF THE VARIOUS MUSCLES

Muscle.	Vertical Action.	Horizontal Action.	Rotatory Action.		For Maximum Vertical Action Cornea must be Turned.	Nerve.
	Cornea Moved.	Cornea Moved.	Upper End of Vertical Meridian of Cornea Moved.			
External Rectus	Outwards	VI
Internal Rectus	Inwards	III
Superior Rectus . . .	Upwards	Inwards	Inwards	Inwards	Outwards	III
Inferior Rectus . . .	Downwards	Inwards	Outwards	Outwards	Outwards	III
Superior Oblique . . .	Downwards	Outwards	Inwards	Inwards	Inwards	IV
Inferior Oblique . . .	Upwards	Outwards	Outwards	Outwards	Inwards	III

when the eye is looking outwards the superior rectus acts with its maximum efficiency as an elevator, its minimum as a rotator. The importance of these facts in the physiological actions of the muscles will appear when the diagnosis comes into consideration.

In the examination of the patient with paralysis of one muscle or another, four points are of much importance—the faulty position of the affected eye, its limitation of movement, the presence of double vision (diplopia), and of faulty projection.

(a) *The faulty position* of the affected eye. In many cases this is obvious, as when a high convergent attitude results from paralysis of either external rectus, but except in the case of the external and the internal rectus the squint may not be noticeable. When it is not obvious it may usually be brought out by covering one eye and the other alternately, and watching to see if any change in position is required to enable the patient to “keep” a fixation object.

(b) *Limitation of movement* is also usually manifest in the case of the external or the internal rectus, but not so obvious in the case of any of the other muscles. Take the case of paralysis of the left external rectus: if the fixation object is held in the middle line there may be good position; when it is moved to the patient's right side there is certainly no fault in position, but when it is moved along to his left, the left eye fails to follow its movement, the eye lags behind, and the further the object goes to the left the more obvious is the failure of the left eye to follow it and keep pace with the other. The squint, in fact, is not concomitant (see p. 339).

(c) *Diplopia*, or double vision, is due to the impression conveyed that two examples of an object are present when in reality only one is in view.

Unocular diplopia is not very common, and indicates almost certainly either an error in focus (usually a little

astigmatism) or irregularity of the refractive media, usually in the form of striæ of the lens : it does occur also as a great rarity apart from these conditions, no satisfactory explanation being forthcoming. When binocular, *i.e.* due to the simultaneous use of the two eyes, diplopia is due to paralysis of one or another of the muscles of the eye.

Diplopia, it should be mentioned, is never due to double pupil, even in the cases in which an artificial pupil is made in one eye away from the centre of the cornea—a mistaken idea which is somewhat prevalent. Any one can test the matter for himself: let him take a convex lens and fix it at its focal distance from a screen so that it forms a distinct image of some source of light. In front of it let him place a sheet of paper the size of the lens, in which he has cut one, two, or any number of apertures; no matter how many apertures there may be, or how placed, there is but one image upon the screen so long as the lens is kept at its focal distance from it. Spherical and chromatic aberration apart, which hardly come into consideration in the case of the eye, the images all fall upon the one spot. Double vision is therefore not produced by faulty situation of the pupil. If the lens is moved to a position within or beyond its focal distance there will be multiple images, but these are less distinct. Therefore, theoretically, an eye with two pupils may have diplopia, but only if its refraction is abnormal—when the images will be indistinct, and probably not observed.

Binocular double vision may be accounted for by either of two theories, neither of which, however, is entirely satisfactory. According to the (1) *Corresponding point* theory, there may be said to be in the left retina a series of points each of which corresponds to a similar point on the right retina, so that when the eyes are in a normal condition, if an object casts its image on certain points in the one retina, it casts them also on the corresponding points of the other, and the two images are then accepted as belonging to one and the same object. Indeed it is as though each cell in the visual centre gave forth a fibre which when it arrived at the

chiasma divided into two, one passing to the right retina, the other to the left in a precisely similar situation; whether either or both of these end-fibres be stimulated, the single impression is received by one cell only.

(2) *The muscle sense theory* means briefly that we estimate the attitude of an eye, and therefore the position in space of an object fixed by it, by our knowledge of the state of tonicity or of contraction of the muscles; if a muscle of one eye gives false information of its tonic condition, owing to paralysis of its contractility, we shall receive false information as to the situation of the object fixed.

(d) *Faulty projection* is the error which a paralysed eye makes as to the position of the object fixed by it. The error always consists in referring an object to a position towards which the offending muscle ought (but fails) to direct the eye. It is a cause of much discomfort and inconvenience to the patient; thus, should the muscle in question be one of the depressors of the eye, the patient, on looking down, will with his paralysed eye "project" the step of a stair to a position lower than its actual situation, and may stumble or fall.

Other symptoms exist, but these are of less importance. To save himself as far as he can from the inconvenience of double vision, the patient often inclines his head in such a way as to reduce to a minimum the defect due to the faulty attitude of the eye. This is not very obvious, though it exists, save in the case of paralysis of an external rectus, where it is plainly to be seen. Let us suppose that the case is one of paralysis of the left external rectus: the patient will turn his head to the left and his eyes to the right; in this position the left external rectus is thrown entirely out of use, is not called upon at all to act, and consequently the troublesome double vision is reduced to its lowest limits.

We now come to the *diagnosis*, in which there are

three steps, viz. What muscle is involved, Where the lesion is situated, and What is the nature of the lesion?

As test object a fairly tall lighted candle is the best, since it catches and holds the patient's attention, but a strip of white paper will serve the purpose. Before one eye of the patient should be placed a red glass, that he may be able readily to distinguish between the candle as seen by that eye and by the other. This difference may be enhanced by providing the other eye with a green glass.

The diagnosis will be made quite simple if attention is given to the three rules here laid down. Double vision will be greatest, that is, the separation of the images will be found to be increased, in one of the four principal directions, above, below, to right, or to left.

Rule 1. A muscle is involved whose duty it is to move one eye or the other in that direction. Thus, if the diplopia is most marked above, we know at once that an elevator of one eye is at fault, namely, the S.R. (superior rectus) or I.O. (inferior oblique) of one eye or the other.

Rule 2. The image which is furthest in the direction in which there is double vision is the "false" one, belongs, that is, to the faulty eye. This enables us to fix the blame upon a certain eye. Thus, in the example given above, we might find that with the red glass before the right eye the uncoloured image was the higher; the left in that case must be the paralysed eye.

Rule 3. The false image is deviated exactly in the directions of action of the muscle paralysed. This statement really includes the other two, but they are needed as leading up to this rule. Thus, in the case suggested above, we may find that when the object is moved to the patient's right, inwards, that is, with reference to the paralysed left eye, the difference in height between the two images is greater than when it is

moved to the left upper position ; we conclude that the paralysed muscle is that one which ought to turn the left eye upwards best when the eye is looking in, namely, the left inferior oblique. At the same time it will be found that the false image has its upper end tipped to the patient's left, and that the diplopia is homonymous. "Homonymous" means that the image to the left belongs to the left eye, and *vice versa*. The opposite condition is called crossed diplopia. To put the matter in another way, everything which the offending muscle ought to do and fails to do is done to the false image. This will be made plain by choosing any individual muscle, when it will be found that whatever that muscle ought to do to the eye happens to the false image when paralysis occurs. Take the L.S.O. as an illustration, and recall its actions. The L.S.O. turns the left eye downwards, turns it outwards, and rotates the upper end of the vertical meridian of the cornea inwards. In paralysis of the L.S.O. the double vision is in the lower part of the field ; the lower, and therefore the false, image is that belonging to the left eye ; the diplopia is homonymous ; the difference in height increases towards the patient's right (inwards with reference to the paralysed eye) ; and the upper end of the false image is twisted to the patient's right.

Let us work out an imaginary case as would be done in actual practice. A.B. complains of diplopia : any one of six muscles of either eye may be at fault. It appears that the double vision is worst on looking upwards ; at once we know that an elevator of one eye, either right or left, is involved. The images being readily distinguished from one another by means of the coloured glass before one eye, we find that the higher, and therefore the false, image belongs to the right eye ; the affected muscle must then be an elevator of the right eye, namely, either the superior rectus or the inferior

oblique. As the S.R. acts as an elevator chiefly when the eye is turned outwards, its failure will be most manifest when the eye is placed in that attitude, and conversely with the inferior oblique. We make the patient then follow the movement of the candle from the upper outer (right) to the upper inner (left) area. Should the height-difference between the two images be greater on looking to the outer side (and up) than on looking to the inner, we conclude at once that the faulty muscle is the right superior rectus. It is very much more safe to rely upon the variations of the height-difference than upon the crossed or homonymous character of the diplopia, or upon the character of the torsion. The reasons are that, owing to a pre-existing latent divergence or convergence, the theoretical lateral displacement of the images may be inverted; and that it is common enough for the patient to imagine the "tortioned" image to be the correct one, when the really normal one will appear to lean in an opposite direction, and the patient will then give misleading answers.

Another little matter upon which a warning should be given is the injudicious phrase so often employed that the two images incline "towards one another" or "from one another"; unless one qualifies such a statement by adding either the word "below" or "above," the phrase is ambiguous; and besides, should the diplopia be homonymous when it "ought to" be crossed, one is more at sea than before. Unquestionably the guide to which one ought to cling is the variation in the height-difference, and recollect that what happens to the false image ought to happen to the eye but does not; this promptly gives the clue to the muscle. One ought never to attempt to raise a mental picture of the retina with arrows delineated on it as used to be shown in some books—that way madness lies!

The beginner will find it a good plan to make three

charts of a case of diplopia, one showing the height-difference alone, one the lateral separation, and the third the torsion. In doing this he must be careful to make all his charts objective or all subjective, all, that is, (objective) as if the diplopia were projected on a screen held between patient and surgeon, while he stands behind the test object, or (subjective) as if he stood side by side with the patient and watched the diplopia from his point of view. It is a matter of no great moment which system he adopts, but to that one he must adhere.

Paralysis of the III. nerve gives rise to a combination of symptoms, for not only is the internus paralysed but both elevators, and though the superior oblique is unaffected (being innervated by the IV. nerve) the eye cannot be lowered, because that muscle can act as a depressor only when the eye is looking inwards, and inwards it cannot look since the internus is paralysed; the rotation action of the superior oblique can be demonstrated in many of these cases, being manifest as that muscle tries in vain to depress the eye. There are also ptosis, dilated pupil, and loss of accommodation (Plate XXI. 3).

The next point to be considered is the **situation of the lesion** which has given rise to the paralysis. There are in fact four possible situations, namely, the orbit, the base of the skull, the nuclei, and the supranuclear paths and centres.

1. *The orbit.* Strictly speaking, this might be divided up into muscle lesions and nerve lesions, but such is hardly necessary. The whole of the muscles may be involved, as in some cases of phlegmon of the orbit, or one nerve only may be caught, and there may be certain peculiar combinations, as the interior muscles along with the inferior oblique, for the nerves for these muscles come off by one twig. The external rectus is the muscle most frequently attacked.

2. Lesions *at the base* may affect one or both eyes; they may be sudden in their onset or gradual. Should the III. nerve be affected, it is to a high degree improbable that any of its muscles should escape if others are seriously implicated; it will be the whole nerve or none. The nerve most likely to suffer is again the VI., from its relatively long course over a bony floor; the two III. nerves may be involved at the same time as they emerge from the pons.

3. *Nuclear* lesions are characterised by their tendency to be either rapidly progressive or transitory; with the possible exception of some congenital forms, they are rarely stationary. They are frequently enough associated with certain other signs, such as polyuria and hebetude, indicative of implication of other nuclei; they tend also to decided diurnal variations, better after the night's rest and worse after the day's fatigue. Any group of muscles may be affected, but a not unusual association is the interior muscles of one eye—ophthalmoplegia interior—or the whole of the exterior muscles of one eye—ophthalmoplegia exterior—or the two muscles of accommodation (as after diphtheria). *Ophthalmoplegia completa* would result from destruction of all the centres on one side of the middle line of the floor of the fourth ventricle. (This question is complicated by the double crossing of the fibres of the IV. nerve—a complication of which there is no sufficient explanation.) In the onset of this condition it is not uncommon to find the nuclei affected from before backwards in the order in which they are described by Hensen and Völckers as being situated, the morbid change working its way more or less rapidly and more or less uniformly along the line of nuclei.

The nucleus of the VI. nerve has a preponderating influence over the III. nucleus of the other side, to which it sends a twig, so that lateral movements of the

two eyes are initiated from the VI. nucleus of the corresponding side. In a case of destruction of the VI. nucleus, then, there is paralysis both of the external rectus of the same side and of the internal rectus of the other which acts along with it in conjugate lateral movement, paralysis of that internal rectus *quoad* conjugate movement, but not paralysis of convergent movements, so that in destruction of the left VI. nucleus there is paralysis of the left E.R., and of the R.I.R.—paralysis of movement to the left—but the same I.R. will act readily along with its neighbour in the movement of convergence, which is initiated from the III. nucleus.

4. *Supranuclear* lesions must here be regarded in one group; their differentiation belongs rather to the domain of medicine. They have this feature that the paralysis is not so much one of muscles as of movements. Thus a cortical or subcortical lesion may produce paralysis of upward movements, and in some of the cases of congenital ptosis there is complete inability to raise the eyes (see Ptosis).

In cerebral hæmorrhage or thrombosis, paralysis of movement of the two eyes to one side is frequent enough as a temporary or permanent sign, and the eyes are then kept turned towards the opposite side; the phrase Conjugate Deviation to right (or to left) is employed to express this condition. Volitional movement of the eyes to the right is initiated in the left cortex; a destructive lesion of the left cerebrum may thus produce inability to turn the eyes to the right; they will then maintain an attitude of looking to the left, owing to the overmastering action of the opposing, unchecked muscles; the patient then "looks at his lesion." Should the lesion be an irritative one he will for similar reasons "look away from his lesion." But if the lesion be of the pons, after decussation has taken place, conditions are reversed, of course, and the patient with

a destructive lesion looks away from it, or towards an irritative lesion.

The next step in the diagnosis is the **nature of the lesion**.

In the *orbital* situation of paralysis "cold" plays an important part; one may naturally believe that there is behind this "cold" some vicious condition which permits the adverse influence to work the mischief, but that is not by any means always obvious, which exposure to draught, motor driving after being in a heated room, etc., may be. To scoff as some do at the influence of "cold" is to shut one's eyes to facts. *Rheumatism* is a frequent cause, whether muscle itself or its feeding nerve be primarily attacked. The transitory paralyses of ocular muscles which may mark the onset of *locomotor ataxia* are more probably nuclear than peripheral, but this one does not know for certain. Again, *inflammatory affections* of the orbit, notably cellulitis and periostitis at the apex, are causes; the latter may be accompanied by proptosis, pain on deep pressure, and a central scotoma from implication of the optic nerve. *Trauma* accounts for a certain number of cases, for the muscles may be directly injured by wounding instruments. It is said that isolated paralysis of the inferior oblique occurs in this way only, particularly in the hunting field, when a heavy fall may result in fracture of the superior maxilla with consequent injury to the muscle. A *tumour* of the orbit may destroy one muscle or more by pressure, as well as mechanically interfere with its action. One form of paralysis of the external rectus seen in infants is caused by intrapartum compression whether by a narrow pelvis or by forceps: it is usually permanent.

Lesions at the *base* are almost confined to pressure from tumour growth, gumma and aneurism, to involvement in inflammatory exudation (meningitis) or in blood-clot, and to fracture of the base.

The *nuclei* are liable to rapid degeneration in diphtheria, in diabetes, in syphilis, whether acquired or congenital, parasymphilitic states (general paralysis of the insane and tabes), and in tubercle; probably also in degeneration of vessel walls and imperfect blood supply. The paralysis of accommodation which occurs in diabetes is of nuclear origin and is a very serious sign of the patient's general state of faulty nutrition. Post-diphtheritic paralysis of accommodation must also be nuclear.

The discussion of the nature of supranuclear lesions would lead us too much into the regions of pure medicine; it may be left.

Treatment.—One must first endeavour to correct any vicious general condition which one may find to be present, such as diabetes, rheumatism, syphilis in one stage or another. In the orbital cases counter-irritation may help also, and where there is acute inflammation of the orbit, timely incision (p. 366).

In the diphtheritic cases general tonics, and particularly strychnine, are indicated; eserine used sometimes to be employed, but it is of no possible utility.

Mechanical traction in the line of the muscle by means of fixation forceps, and electrical stimulation, are both of some value.

The difficult cases are those in which a permanent paralysis of one or another muscle is left, and in which the diplopia persists, giving the patient great inconvenience. In such cases there are two methods of treatment which may prove useful: by prisms, and by means of operation. The *prism* is to be placed before the paralysed eye in such a position that it deflects upon the macula the image which has been falling upon a portion of the fundus other than the macula, though the same object has been casting its image upon the macula of the other eye. In the case of a simple muscle such as the

external rectus one has merely to discover what strength of prism will suffice to superpose the two images, which may be accomplished by means of a Maddox rod; that prism may then be worn over the offending eye, or its power may be divided and distributed over the two eyes; thus, if one prism of 8° is required to correct the error, this may be applied in the form of a prism of 4° before each eye, apices inwards. The most simple way of remembering how the prism should be placed is to keep in mind that the prism before the faulty eye should have its apex in the direction in which that eye looks. In the case assumed, the eyes stand in undue convergence; the apices of the prisms must then be directed inwards. When dealing with the more complex muscles, however, such as the superior oblique, the displacement of the false image is both vertical and lateral, and it will be found best to settle the degrees of these two errors separately and afterwards combine them in a prism placed obliquely.

Treatment by prisms is, however, open to two serious objections: because if the deviation is at all great the lens required for its correction is heavy, cumbrous, and unsightly, and because such a lens displaces *all* objects, no matter at what point of the compass they are situated, whereas it is only those lying towards certain points of the compass which appear to the patient displaced or duplicated. Prisms have therefore a very limited application.

Operative procedure should never be attempted until many months have elapsed since the onset of paralysis, for improvement may come on after a long period of resistance to treatment, and an operation might then turn out to have been unwise. The best method is by advancement of the weakened muscle, without tenotomy of its opponent if possible (for method see p. 442), but it is plain that all one can aim at must be to move the

diplopia which is present in mid-position; advancement can but put a weak muscle in a more advantageous position, it cannot infuse more activity into it. Still, in the case of a permanent paralysis of the external rectus the patient may be placed in a decidedly more comfortable position by a judicious advancement of his enfeebled external rectus. But what of the oblique muscles, whose insertion is out of reach? In such cases one may attempt advance of the origin of the muscle, or advancement of the other elevator (or depressor) of the same eye. Thus in permanent paralysis of the superior oblique it may be good surgery to strengthen the inferior rectus, with or without a mild tenotomy of the internus to prevent undue inversion.

Nystagmus is an affection of the ocular muscles presenting points of much interest and importance. The disease may be defined as a clonic involuntary spasm of the exterior muscles, or of certain of them. The direction of movement of the eyes may be vertical, lateral, rotatory, or a combination of these, but whatever the direction may be, both eyes are always affected, both move at the same time and to the same extent, and the movements are always conjugate; to these statements there are certain exceptions, as will be seen, but hardly such as to invalidate the rule. The rapidity of movement varies within pretty wide limits, from an incessant jerking movement through a small excursion to a slow wide sweep almost from canthus to canthus. Nystagmus may be divided into two great groups, the *congenital* (but this term is not strictly accurate) and the *acquired*. The former is prone to arise when from any cause arising prenatally, or within the very earliest time of infancy, circumstances prevent the education of the two maculae into becoming the seats of maximum efficiency of the two retinae. For it must be understood that the macula is at the time of birth only potentially the point of

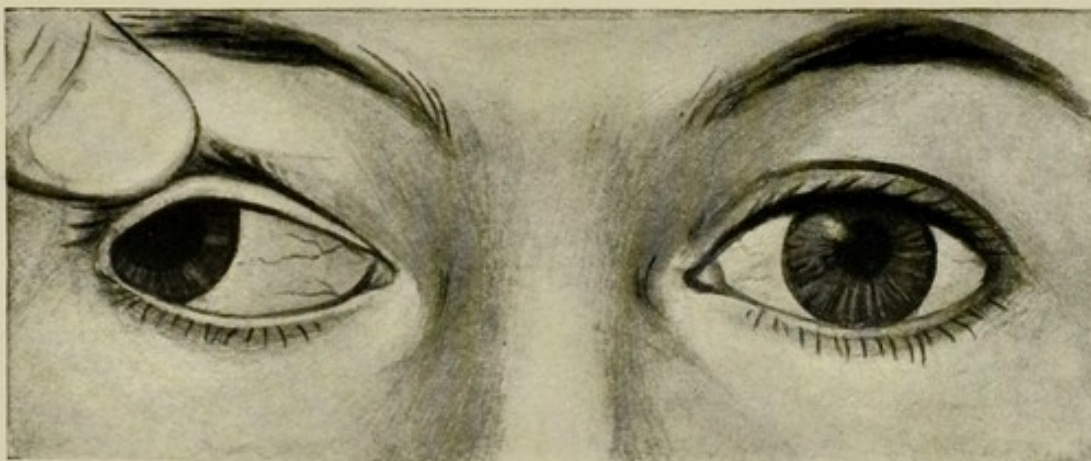
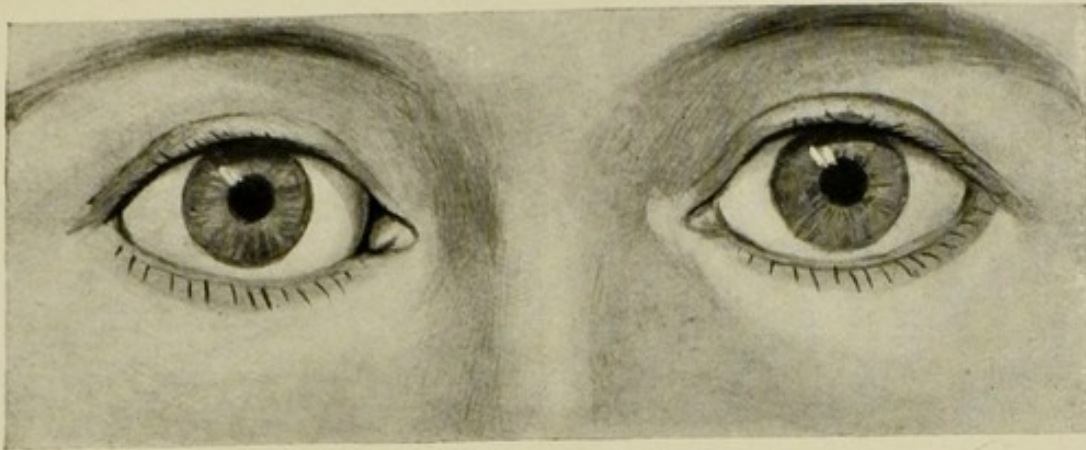
acutest visual power in the retina. This will be recognised if a child within the first week or two of life is examined; hold up a light before him and he may take an interest in it but will not "fix" it. The power and desire to fix with the macula are not developed for some weeks. If, then, there be prior to this date some pathological state preventing such fixation, the macula may not become superior in acuteness to the rest of the fundus and the neuro-muscular apparatus may not become so far educated as to command the muscles to keep the macula steady. The reason for which nystagmus is conjugate now comes out, for the conjugate movements are innate, while those of convergence are acquired *post partum*, and there is no power other than in convergence by means of which one eye may be moved in a direction other than along with the fellow.

The conditions then which can give rise to "congenital" nystagmus are in general terms those which, at a very early stage in the child's life, are capable of preventing the macula from receiving or interpreting images in a manner superior to other parts of the fundus. Thus among causes may be mentioned the severer degrees of lamellar cataract, other varieties of congenital cataract, ophthalmia neonatorum because of ulceration and subsequent opacity of the cornea, bilateral intra-uterine chorioiditis, very high degree of hypermetropia, albinism, and some forms of congenital optic atrophy. In every case the cause must be bilateral, for should one macula be capable of appreciating images well, the possession of that power will be sufficient to direct the fixation, and whether squint occurs or not, nystagmus will not.


The *nystagmus of adult life* is of two types, one associated with more definite disease of the nervous system, the other arising in connection with certain trades—an occupation-neurosis.

The chief nerve diseases with which nystagmus is associated are cerebellar disease and disseminated sclerosis. In the latter particularly the occurrence of nystagmus is a symptom of extreme importance from the diagnostic point of view. In both of these morbid states the direction of the nystagmus is apt to depend upon what muscles are voluntarily put in action at the moment, and to take the form of a violent and ill-regulated action of them. Thus, when the patient looks to the side, lateral nystagmus will arise ; when he looks upwards, vertical nystagmus. The movements are apt also to be coarser than in the congenital form.

Of the occupation-nystagmus the most typical example by far is that which occurs in miners. There are differences of opinion as to the ultimate cause of the nystagmus of miners, some holding that the deficiency of illumination is the essential element, others that the prolonged constrained attitude is the decisive factor. There can be little doubt that the two factors both enter into the question, in certain cases one preponderating, in others the other. Without entering into controversial matters one may say that, given a difficulty of fixation from any cause, it will be greatly enhanced by the lack of proper illumination, while that the attitude has much to do with it is demonstrable in many cases in which nystagmus comes on only, but at once, when the patient is placed in the attitude which he, in the exigencies of work, requires to adopt for hours. Indeed when a miner presents himself showing no unsteadiness of eyes, but complaining of the symptoms of such (fatigue of eyes, dull pain in eyes and forehead after a few hours of work, and so on), it is often easy to bring on the sign at once by the simple expedient of either diminishing the light or placing the patient in a constrained attitude, and particularly in that which he requires to adopt at work. Elevation of the eyes and convergence are not easy to



1. Sinking of Caruncle after severe Tenotomy for Strabismus. Right Eye.
2. Ptosis—Bilateral. Showing the exaggerated action of the Occipito-frontalis Muscle.
3. Paralysis of Right III. Nerve.



maintain at the same time, and nystagmus is therefore readily set up on the patient attempting to keep the gaze upon a finger held near to the eyes but on a higher level.

A symptom which is present in both these classes of case but never in the congenital variety is the impression that the object looked at is unsteady, that it appears to move.

In the *treatment* of nystagmus the chief point is, Can the original cause be removed? Thus in a case of congenital nystagmus, if better macular vision can be obtained, even in one eye, by iridectomy, extraction of the lens, correction of refraction, or other means, this should be done and done promptly; in the occupation-neurosis the work must be changed. Congenital nystagmus tends towards a gradual improvement, at any rate, even though it may never altogether disappear.

Two other varieties of nystagmus deserve mention. Along with the involuntary movement known as *head-nodding* of children a spurious nystagmus which is not conjugate is seen; the movements are of the nature of alternate convergence and divergence, a peculiarity never seen in the other forms; this is a development neurosis. Secondly, a slow uncertain sweeping movement is often to be observed in blind eyes. The movements vary a little in different cases, but frequently consist of a sweeping movement from right to left followed by a jerky progress from left to right; this may be due to persistence of the movements required in reading.

Spasm of Convergence or *Paralysis of Divergence* is a rare condition. It shows itself in homonymous diplopia beyond a short distance from the eye, and diminishing to either side. The condition may occur suddenly, but is usually recovered from.

Insufficiency of Convergence is more frequent; it may be part of general muscular weakness, as in Myasthenia

and Neurasthenia, or be due to a fault in the attitude of the eyes, which may be congenital or the result of a too severe tenotomy for internal strabismus. In the last case re-attachment of the divided muscle is required.

CHAPTER XVI

CONCOMITANT STRABISMUS

ERRORS of refraction are prone to be accompanied by Strabismus or Squint, divergent strabismus being more closely associated with myopia, convergent with hypermetropia, though opposite associations do occur. This strabismus is *concomitant*: that is, being dependent mainly on the state of refraction of the eye and not upon any muscular anomaly, it is (approximately) equal, whether the eyes be looking to the right hand or to the left.

DIVERGENT STRABISMUS

By this is meant that condition of the eyes in which, constantly or occasionally, the visual axes are not parallel but diverge from one another anteriorly (Plate XXII. 2). If the degree of divergence be high the condition is obvious on ordinary examination, but fallacies are more than possible and it is well to make sure. This may be accomplished in the following way: Cause the patient to regard a certain fixed object, whether near (as a pencil) or far away (as a chimney), keeping both eyes open; cover one eye, say the left, and the right remains stationary; uncover the left, cover the right, and the left may now have to execute a movement inwards (towards the nose) in order to take up fixation. If so, the left eye has been in a state of divergence—there was divergent strabismus. If the screened right eye be examined

while the left one is fixing, it will, in its turn, be found to be diverging. Sometimes it happens that both eyes are straight, and yet when one is screened from the fixation object it slowly turns away outwards: that is spoken of as *Latent Divergence*. Both these conditions, *i.e.* constant and latent divergence, are common in myopes, for the following reasons: (1) A myopic patient has little need to use his accommodation, and derives little advantage from doing so, particularly if his degree of error be high, unless he constantly wears his correcting lenses. Supposing his myopia to be of 7D, then his far point is at 6 inches approximately, and it is easier and more convenient for him to hold his book at that distance and read without the trouble of accommodating than to bring it nearer and have to accommodate. Now accommodation and convergence are very closely allied, so closely that it is difficult to converge much without accommodating; the patient therefore is likely to give up converging as well as accommodating, and to allow one eye to diverge relatively. The higher the error the more likely is this to occur.

(2) A myopic eye is elongated antero-posteriorly and tends therefore to adapt itself to the long axis of the orbit, and the axes of the orbits diverge from one another.

(3) Because the myopic eye is elongated, and not a portion of a sphere, it has to displace orbital tissue when it converges, which the normal eye does not do; an obstacle is thus placed in the way of convergence.

(4) Again, on account of the elongation, the internal rectus is placed at a mechanical disadvantage; this forms yet another obstacle to convergence.

(5) In the higher degrees of myopia the macula is exposed to serious danger of chorioidal degeneration; should such occur the patient's interest in binocular vision is gone, and he is indisposed to undergo the fatigue involved in convergence under difficulties. To some

extent this statement applies to all cases of loss of vision of one eye in adult life; that eye is very apt to diverge.

To relieve this troublesome and, if marked, very unpleasant-looking condition, the first indication is to enhance the patient's interest in binocular vision, to enable him to use the two eyes at once for all distances, and to encourage him, by forcing him to employ his accommodation, to use also his converging faculty; all these indications are met by causing him to wear constantly the full correction of his error of refraction, or at the least a fuller correction than he has hitherto employed. When the divergence is only latent or in the initial stage of development this will accomplish wonders. Where, however, the divergence is constant and marked this is not enough, and one must operate upon the muscles. Whatever views one may adopt regarding the relative propriety of advancement or tenotomy in other circumstances, there is no question that, in the condition with which we are dealing at present, shortening or "advancement" of the internal rectus of the offending eye is the proper line of treatment. Opinions are divided as to the propriety of associating with the advancement of the internus a tenotomy of the externus, some forbidding it altogether. In a fairly mild case it is quite good treatment at all events to advance first, and if after a few days the effect is not all that could be desired, to tenotomise then, before the new attachments are quite consolidated (see also p. 441). In more severe cases, indeed in nearly all cases of fixed divergence, it is better to divide the externus and advance the internus. The chief reason for which mere tenotomy of the externus is of little avail is that as we have, practically speaking, no function of divergence, and since the fault is a sin of omission rather than one of commission, weakening of the opposing function is not indicated so decidedly as strengthening of the inefficient one. When the divergence

is purely latent, that is, is present only when binocular vision is mechanically prevented, but in the interest of single vision is corrected when both eyes are open, it may give much trouble to the patient. In operating great care has to be taken not to overdo the convergence.

CONVERGENT STRABISMUS

By this is meant that the visual axes would meet if produced in front of the eyes. Here again the degree varies greatly from an amount which, under certain circumstances, is hardly visible, to an obvious and most unprepossessing deformity (Plate XXII. 1).

It is necessary in the first place to be quite sure that strabismus is present: that might seem a simple matter, but in certain circumstances an appearance of squint may be present without the reality. The primary test is to cause the patient to fix a certain object, such as your own finger, with both eyes open, then to cover one eye and see whether the other maintained its previous position or required to change it; the process should be repeated with the second eye. If there be no change of position, and each eye sees the object, there is no squint. The appearance without the reality exists in a number of cases of high myopia where the angle α is very small or negative, that is, where the visual line passes to the outer side of the apex of the corneal ellipse. A foolish mistake may be the result of carelessness in this matter.

It is convenient to have some handy means of measuring and recording the amount of squint present, and three simple methods may be mentioned, though others abound. (a) *Hirschberg's Method*.—A light held up before the eyes is reflected in each cornea, and if the two eyes are straight, and look at the light, its image will lie in the centre of each pupil. (This statement is not rigidly accurate, for several reasons, but is sufficiently exact for present purposes.) But should one eye, say the

left, be turned inwards, the light will throw its image upon a part of the cornea to the outer side of the centre, for the image is situated upon a line joining the light with the centre of rotation of the eye. The degree of departure from the centre of the cornea is in such case a handy measure of the amount of squint. Thus, should the reflected image of the light fall within the pupillary area, the amount of squint may be perhaps 10° ; if at the pupil margin, $12-15^{\circ}$; if between pupil margin and corneal margin, there may be 25° ; if at the margin, $45-50^{\circ}$. Occasionally, but obviously only in excessive degrees of squint ($60-80^{\circ}$), the image falls on the conjunctiva over the sclerotic.

(b) *Linear Deviation*.—A still simpler method is to mark with a pen or a pencil-point that precise spot on the lower lid which corresponds with the outer margin of the cornea of the strabismic eye, when the patient is looking straight to the observer, and has both eyes open; then to screen the fixing eye and cause him to fix with the squinting eye. This will necessitate a change in the position of the squinting eye, when again a mark should be made to indicate the new position of the outer edge of the cornea. The linear separation of these two points gives an indication of the amount of strabismus. The method is not very scientific or very accurate.

(c) *Priestley Smith's plan* depends, like the first method, upon the position of the reflected image on the cornea. Upon the back of an ordinary tape measure are marked those angles to which certain linear distances are the tangents, the radius of the circle being 1M. A lighted candle is held up by the surgeon on a level with his own and the patient's eyes, the two persons standing 1M apart. Let us assume again that the left is the squinting eye; the surgeon should hold the candle and the zero end of the tape measure in his left hand and notice that the image in the right eye falls upon the centre

of the pupil while in the left eye it falls excentrically. Sliding the tape between the first and second fingers of his right hand, he should then move it to his own right (patient's left), taking care that the hand is caused to come no nearer to the patient but to travel in a plane at right angles to his true visual axis. The patient, keeping both eyes open, fixes his gaze on the moving fingers, which the eye must strictly follow, while the head is kept still. As the eyes move to the (patient's) left the bright image on the left cornea will approach more and more nearly to the centre of the cornea. When it has reached that spot all that has to be done is to read off on the graduated tape the angular movement which was required to bring this about (to be more accurate, the tangent to the angle). This shows at once the movement required to bring into the straightforward position an eye which had been deviating—and is still. It shows, in other words, the angle formed by the visual axis in the faulty position, and in the position of looking straight forwards.

This faulty position of the eyes is closely associated with the existence of hypermetropia of moderate degree; the credit of being the first to point out the true relation between the two belongs to Donders. The explanation may be briefly put thus: When a hypermetrope wishes to see clearly, what he must do is to accommodate so as to overcome all his hypermetropia, and as much more as may be required to enable him to focus for the distance at which the object stands which he desires to see clearly. Now accommodation and convergence, as we have seen, are very closely associated, so closely that it is difficult to keep up accommodation without converging. Obviously, other things being equal, a necessity for constant or persistent accommodation, and for a greater degree of it than is physiological, will be all the more likely to entail convergence. In the case of the emmetrope no convergence and no accommodation are

required for infinite distance; 1D of accommodation and 1MA (metre-angle) of convergence for 1M distance, 8D of accommodation and 8MA of convergence for $\frac{1}{8}$ M (5 ins.), and so on; the two functions are associated, as we have seen, not rigidly but pretty closely. Supposing now that the patient is not emmetropic, but hypermetropic to the extent of 3D, then for a distant object he would require 3D of accommodation, and this amount of accommodation must be added to that which is physiologically excited. Thus, should the object be at $\frac{1}{2}$ M, this patient would require to use $3 + 2$ D of accommodation while exercising only 2MA of convergence, and when it is at 8 ins. ($\frac{1}{8}$ M) 5MA and $3 + 5$ D of accommodation. The patient is thus placed in a quandary: if he struggles to dissociate accommodation and convergence so far as to provide the necessary 8D with 5MA he is uncomfortable, perhaps has more or less severe headache; if he accommodates sufficiently and at the same time converges to the classically corresponding degree, the optic axes will cross at a point nearer to him than the situation of the object, and—in the first instance—neither eye will be fixed on it, but he is otherwise comfortable. His next step is to select his better eye, and turn both eyes by a conjugate movement towards the side of the eye selected so that *it* fixes the object and all the convergence is—apparently—thrown upon the other. The faulty position of a concomitantly squinting eye is

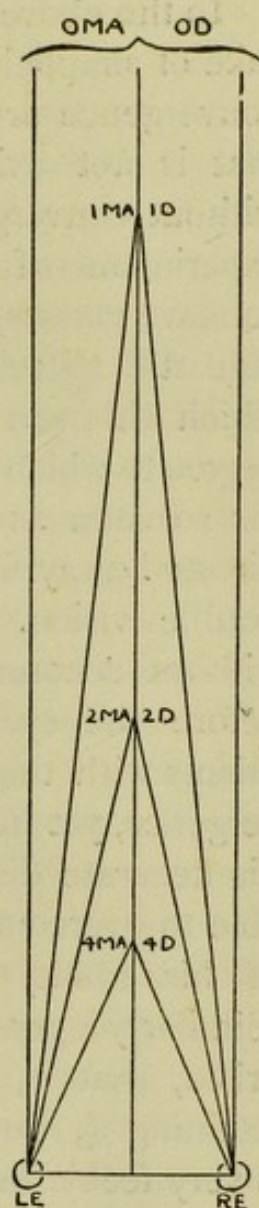


FIG. 60.—Typical relation between accommodation and convergence.

therefore the product of two elements, namely, undue convergence to suit the degree of accommodation, and a lateral movement to enable one eye to fix correctly.

In the above description it has been assumed for the sake of simplicity of explanation that accommodation and convergence are almost rigidly connected, but of course that is not strictly so. One is able to accommodate without converging. This can be shown by the simple experiment of causing an emmetrope to wear weak concave glasses, increasing their power so long as he is able still to retain single vision; the highest lens with which this can be accomplished is the measure of the degree to which he can accommodate without converging, for so soon as he converges, one eye at least must be directed away from the test types, and he will experience double vision. Similarly, it is possible to converge without accommodating, as can be proved by placing before the eyes of an emmetrope while he reads $\frac{6}{6}$, prisms with their apices inwards; these necessitate convergence, yet he must not accommodate else he will lose his accurate distant vision. The strongest prism he is able to overcome while retaining $\frac{6}{6}$ is then the measure of his ability to converge without accommodation. (Similarly a person may be induced to overcome diverging prism, that is, one with its apex outwards, while still retaining $\frac{6}{6}$, but the power to overcome such a prism is very feeble indeed.)

Again the classical relationship for emmetropia does not necessarily hold good for hypermetropia or myopia; thus it must not be assumed too hastily that a hypermetrope of 2D finds that to provide 2D of accommodation it is most comfortable to associate it with 2MA of convergence. In other words, as has already been said, the relationship is not strict, though it may be close.

There are three conditions in which a squint may be: Occasional, Permanent, or Alternating. *Occasional squint*

implies that the patient squints only when called upon to focus exactly. It often enough happens that a patient will go about with the eyes quite straight, but when he is asked to decipher the smaller of the distant types, or to read, or to fix a small object near to the eyes, the squint comes on at once—comes on, in fact, so soon as precise focussing is demanded. Sometimes the patient may have no squint for a couple of days or for half a day, but it comes when an effort is longer sustained. He is able, in short, to dissociate accommodation and convergence for a time, but not permanently. This is a stage through which most patients pass before the next is reached.

Permanent Strabismus.—This term explains itself. During all his waking life the patient squints, and always with the same eye. Whether the squint be present during sleep or no is largely a question of the length of time during which he has squinted.

Alternating strabismus indicates that the squint is permanent, but that the patient is indifferent with which eye he fixes and with which he squints. Some permanent squints pass through this stage, but not all, as we shall see. The facility with which a patient in this condition will change from fixing with one eye to fixing with the other is most amazing; the change can even be accomplished in some cases without the slightest movement of the eye, simply by “switching off” the attention from one eye and on to the other.

One or two points connected with strabismus require attention and explanation. The *degree of hypermetropia* present is usually small, about 3 or 4 dioptries, and one can hardly say that there is any real relation, certainly no close relation, between the amount of refractive error and the degree of strabismus. In the higher degrees of hypermetropia strabismus is much rarer, probably because the patient is quite unable to keep up constantly

the amount of accommodation which would be required to correct it, whether with or without convergence. It is quite rare to find 6D of hypermetropia in a "squinter." The patients almost never complain of diplopia. Sometimes they do, but we must remember that they are all very young and can hardly be expected to give an account of diplopia. In children, even in paralytic cases, double vision is quickly lost, the false image readily "suppressed" as it is called, a striking contrast to the persistence of diplopia, even for years, in the case of an adult.

The *choice of eye* to be the fixing one is sometimes determined by some trifling circumstance, but more often by a difference in the refraction, more hypermetropia or a little astigmatism, with consequent inferiority of visual power. It is usual to find either that the two eyes have an equal error, or that the squinting eye is the more abnormal in refraction. This raises the question: Is the amblyopia of the strabismic eye a cause or a consequence of the squint? That there is no ophthalmoscopic change in the amblyopic eye is neither here nor there; what can be seen with the ophthalmoscope must be relatively a somewhat gross lesion. It may further be pointed out that cases are seen from time to time in which vision is very poor in one eye, yet there is, and has been, no squint. Whether there may have been, in the cases of squint, a congenital amblyopia or not, there can be practically none of the existence of *amblyopia ex anopsia*, or amblyopia from non-use. This phrase hardly describes the condition of affairs, for it is active suppression of the image, active neglect of the impression received upon the retina which entails amblyopia; mere non-use in later life, as when an eye acquires cataract, is not employed, and becomes divergent, but yet is able to take up duty and central fixation as soon as the lens has been extracted—in such a case there is no amblyopia at

all. This amblyopia of the squinting eye in the child is recovered from only to a very limited extent, even should the eye be restored, either by natural processes or by artificial methods, to its true position. Almost certainly there is a slight degree of congenital inequality of vision in the two eyes, which is greatly accentuated by the disuse of one and the constant employment and education of the other.

The *age* at which convergent concomitant strabismus comes on is from three years to six, the time at which correct formation of images first begins to be of importance to the child ; rarely it may be later ; occasionally it is considerably earlier.

A question sometimes presented to the practitioner is whether the presence of a person who squints may induce squinting in a child hitherto unaffected. It is easy to scoff at the question and the idea of squint being contagious, but the wiser attitude is to realise that, should the patient have decided hypermetropia, he may quite possibly learn from a squinting nurse or relative that squinting just affords the relief he desires, enabling him to be comfortable and yet to see well. Should the child not have eyes of such build, it is difficult to imagine that evil could result. Strabismus can hardly be hereditary in any direct sense, but hypermetropia is, and perhaps other contributory circumstances are.

A book such as this is no place for controversy, but were all reference omitted to a theory of squint much spoken of to-day the fact might be misunderstood. The theory that squint is due not so much to hypermetropia as to "lack of fusion-sense" has been strongly advocated, but is open to certain objections. It does not, in the first place, account for squint at all ; it may permit strabismus to occur more readily, but it cannot bring it about. The theory certainly helps one to understand the anomalous cases of alternating strabismus. A serious objection to it is that one sees occurring in the child a deadly struggle between

the desire for binocular vision and that for ocular ease, in a child squinting one day and not another, fighting hard against paying the price of comfort, namely, the loss of binocular vision. Without the hypermetropia lack of fusion-sense will not account for strabismus (except in a few anomalous cases), with hypermetropia "lack of fusion-sense" is not required, and can be shown not to exist. In point of fact, it is often plain that the child is struggling hard to retain fusion, but may be obliged to relinquish it in order to secure the greater gain of peace and comfort.

There are a few cases in which there is strabismus but no hypermetropia; how do they arise? In such cases it may be that the classical relation between accommodation and convergence does not exist, but one departing from the normal very considerably. Also there may have been hypermetropia, but with the growth of the eye this has passed away, its results in the form of squint still, however, remaining behind.

It is essential to be able to distinguish with certainty between *paralytic strabismus* and *concomitant*; attention to the following points will enable this to be done:—

The essence of paralytic squint is that there is paralysis, that is, that there is (1) defective movement towards a certain direction, the direction in which the affected muscle should move the eye, but fails to do so. Put the eyes in a position to assume which calls for the active contraction of the affected muscle, and strabismus is obvious, while in the opposite direction squint is not present at all. Concomitant strabismus, on the other hand, is (for practical purposes) the same whether the eyes are looking to the right side, straight forwards, or to the left. (2) In paralytic strabismus double vision is almost certain to be present (though to this rule there are possible exceptions), while it is constantly absent in concomitant strabismus. (3) Concomitant (convergent) strabismus always comes on in childhood, though it may last for many years; paralytic squint may occur at any

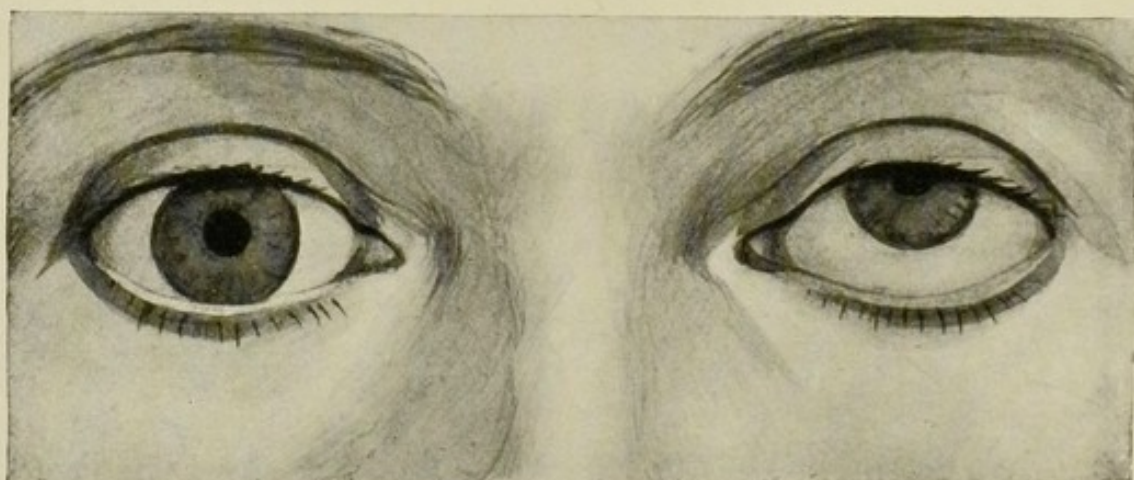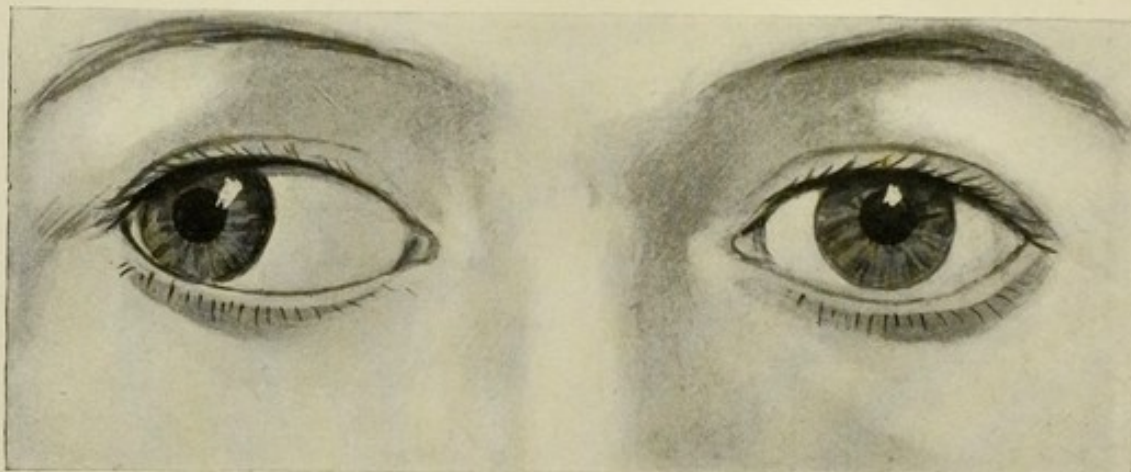
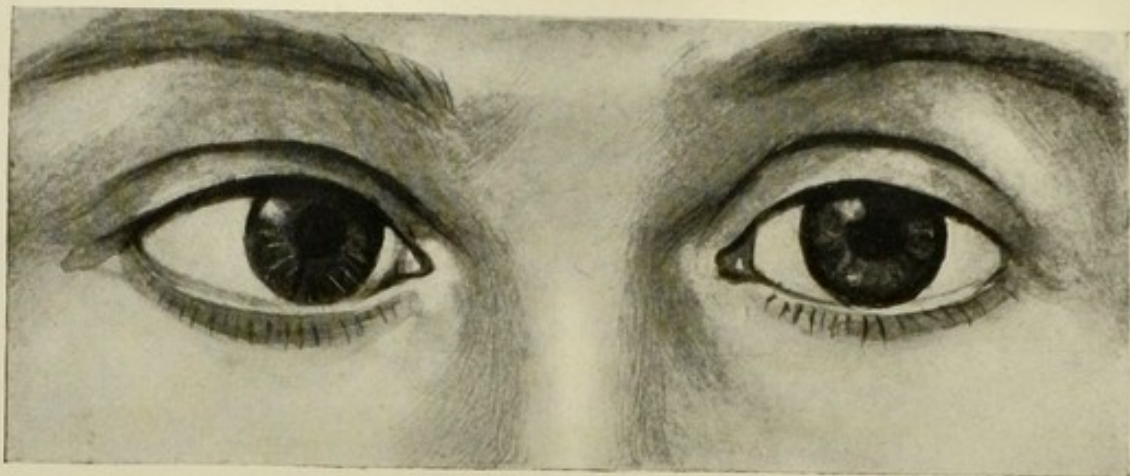
age. (4) Concomitant strabismus is associated with a certain type of refraction, while paralytic strabismus is not, but the association is not rigid, and there is no reason why a hypermetrope may not have paralysis of a muscle. (5) The position of the usually fixing eye when the usually squinting eye is made to fix an object is of much importance. Put in technical phrase, the secondary deviation is equal to the primary in concomitant strabismus, but is greater than the primary in paralytic. The explanation of its being greater in paralysis, or at least in paresis, is that the degree of movement of the shielded eye is determined, not by the *amount* of movement of the fixing one but by the *effort* put forth to enable the eye which is temporarily fixing to attain that position. A categorical example will make this more plain. A patient has convergent strabismus, the left eye being turned in; in ordinary conditions he fixes with the right eye and squints with the left. Note the amount of squint, then screen the right eye and make him fix with the left eye. If his case be one of concomitant squint, the secondary deviation, or false position of the right eye, will be equal to that formerly influencing the left eye; but the fault will be greater, the squint more intense, if he has required to exert a greater energy of conjugate lateral movement because the left eye was lame and less responsive to a stimulus. To bring the eyes to that position in health might require a force equal to x ; to do so when the necessary muscle is paretic might easily require a force equal to $3x$. The movement or excursion of the eye behind the screen is commensurate to the effort, not to the result.

Treatment of Convergent Strabismus.—The first line of treatment naturally is to correct the error of refraction which is the primary occasion of the onset of strabismus. In the young children who are brought to the surgeon

with this condition, and who cannot be expected to understand what is required, it is, as a rule, best to paralyse the accommodation with atropin, and it is well also to correct the error somewhat more fully than one might be disposed to do were squint not present ; but in this there is a little danger in this sense, that what should be aimed at is that the patient should wear without remonstrance as high a correction of his error as possible. If, however, one orders too full a correction, then when the effect of the atropin passes off the patient will find the glasses "too strong" as the tone of the ciliary muscle returns, and he will try to look above or round the glasses rather than through them. Thus too great an effort after precision will defeat itself. No case of concomitant convergent strabismus can be said to have been treated till correcting glasses have been worn, and worn steadily and constantly, for some months. In nearly all the cases of occasional strabismus, and in a good proportion of those of permanent strabismus, this is the sum and substance of the treatment. If, however, there is any degree of amblyopia, it is necessary to *educate the squinting eye*. There are different ways of accomplishing this, of which two may be mentioned : tying up the sound eye for so long (say an hour) each day, and forcing the child to use the other for feeding, playing, or what not ; and introducing atropin into the sound eye, which is thus rendered relatively useless for reading, etc., when the squinting one, into which no mydriatic has been instilled, is employed. Which is the better method to employ must depend largely upon the degree of amblyopia ; it is of no use, for example, to try to force a child to read with an eye which has only vision equal to finger-counting at 2M. An instrument has been devised, known as the Amblyoscope, for the purpose of educating the squinting eye and of re-awakening the acceptance of the simultaneous images of the two eyes whose



PLATE XXII.



1. Convergent Strabismus. Right Eye. 2. Divergent Strabismus. Right Eye.
3. Hyperphoria. Left Eye.

fusion results in binocular vision, but this must be looked upon rather as a scientific instrument than as a practical clinical aid, for the parents who have sufficient interest in their child's welfare and sufficient cash to purchase the instrument, and sufficient perseverance to employ it, rarely allow the child to drift into such a state that it could have much value; in the case of hospital patients there are few surgeons who have leisure or inclination to spend many hours daily in instructing the four-year-old child of a carter or a blacksmith in the art of binocular vision.

The exercise known as *bar-reading* may be useful if vision is sufficiently good. If a flat rod like a paper-cutter is held parallel to the page of a book, and pointing up it at a distance of three or four inches, certain of the words will be concealed from the right eye, certain others from the left. To train the eyes let the patient endeavour to read on without moving head or rod.

Should correction of the error of refraction, coupled with education of the squinting eye, fail of success, one must have recourse to *operative measures*. There are four classes of patients requiring operation, namely, those in whom correction of refraction alone has not proved sufficient; those in whom the degree of strabismus is large while the degree of hypermetropia is small; those who have come to adolescence or adult life yet continue to squint; and examples of alternating strabismus. In the young adult operation is required often because all the tissues, not merely the muscular, at the outer and inner sides of the eye have adopted a new position of rest; convergence is now their rest-position, not parallelism, and even if one corrects the refraction the faulty position-habit remains and is unaffected thereby. In the cases of alternating squint not only is there frequently little error of refraction, but the utter indifference to the position, and the absence of any desire for

fusion, so long as the eyes stand in their position of rest, all combine to force one to operate.

In regard to the *choice of operation* there are considerable differences of opinion ; it is open to one to divide (tenotomise) the internal rectus, or even the two internal recti, thus reducing the total convergence, to "advance" or shorten one external rectus or both, or to combine tenotomy with advancement. The advocates of tenotomy say that their operation reduces the degree of a functional action which is in exaggeration ; the advocates of advancement declare that it is surgically a false step to weaken any muscle, it is better to strengthen its opponent ; those who use a combination of the two in all their bad cases of strabismus dread "insufficiency of convergence" if double tenotomy is performed, and they deny that the results which they obtain are so unpleasing in aspect as their opponents maintain. To speak generally, my own inclination is in favour of tenotomy ; if the degree of squint be too great to be curable by a moderate tenotomy, of advancement *plus* tenotomy ; if still greater, of double advancement.

The chief difficulty which the specialist has in regard to convergent strabismus is threefold : (a) "The child will grow out of it." The case of some relative is adduced who used to squint as a boy but now is quite straight. This may quite well be, because as a matter of fact in many instances the squint gradually passes off as age goes on. But it is not realised that once amblyopia is established it is permanent, more or less, and the eye which squinted for a year or two, straight though it may be now, is amblyopic still. Had the matter been seen to, the squint would none the less have gone off and vision of the faulty eye been preserved. (b) Dread of the operation. It cannot be too deeply impressed upon the family practitioner, in whose hands so much power lies, and upon parents too, that the

earlier squint is treated optically the less likely is it that operation will be required. No surgeon wishes to operate on a case of convergent strabismus; he only does so if other treatment has not been timely employed, or having been employed has failed. Operation is the despair of the ophthalmic surgeon. (c) "The child is too young to wear glasses." There is an idea that a young child will necessarily resent glasses, but this is quite a delusion; a hypermetropic child will gladly wear the glasses if they relieve the error which gives him distress, though he may be unable to explain how or why. As a matter of fact one sees very young children obviously much happier in their spectacles than without them, children of four years, of three years, and even less. So far from wishing to take their spectacles off, they will demand to have them put on day by day.

CHAPTER XVII

THE LACHRYMAL APPARATUS

THE first element in the lachrymal apparatus is the Lachrymal Gland, which is situated in a small depression of the bone at the upper outer portion of the mouth of the orbit, under shelter of the frontal bone. The main part of the gland discharges by several tiny tubules into the fornix of the conjunctiva; these little tubules are surrounded by small masses of gland tissue which collectively form the palpebral portion of the gland. The fluid which comes from the gland consists of little other than a one per cent solution of chloride of sodium; it bathes and keeps moist and bright the anterior surface of the epithelium of the cornea. According to some observers it has a definite antiseptic value, but most consider that its action is diluent and inhibitory rather than actually bactericidal. From the conjunctival sac the fluid is again picked up by the two puncta, the open ends of two little ducts which lead into the lachrymal sac. These puncta are situated upon minute elevations immediately within (posterior to) the lid margins and lie with their open mouths touching the moist conjunctiva of the globe. It is in virtue of this fact that they are able to pick up the fluid from the sac by capillary action. The importance of recognising this fact is that one must thoroughly understand why watering of the eyes is apt to occur, and how to take care, in

the event of any surgical procedure being required, that the essentials of success are secured. Of these puncta the lower is much the more important; each leads into a canaliculus which forms a covered way in the lid tissue round the region of the caruncle into the lachrymal sac. The sac is relatively quite a large receptacle which lies immediately behind a slight protuberance on the lachrymal bone in a depression in the bony wall, and from the lower extremity of it the nasal duct leads down into the middle fossa of the nose.

Inflammation of the gland occurs but rarely; the symptoms of this are swelling, heat, and redness in the region of the gland, with tenderness on the slightest pressure, and some slight chemosis. Hot fomentation is generally sufficient to reduce the inflammation.

Subacute enlargement sometimes occurs in the course of certain of such febrile conditions as mumps.

Tumours of the gland, chiefly sarcomata, occur, and hypertrophy is not unknown. It is important to remember that the gland may be partially protruded from the orbit and become palpable in consequence of the growth of a tumour in the depths of the orbit, pushing it forward. Curiously enough, removal of the lachrymal gland seems to have practically no obvious injurious effect upon the eye; one might be apt to suppose that the corneal epithelium would suffer, but that structure is dependent for its transparency and integrity upon the mucus secreted by the conjunctiva rather than upon the lachrymal fluid. This is clearly shown in cases of trachoma, where destruction of the mucous glands of the conjunctiva leads to intransparency of the cornea.

Epiphora, or Lachrymation, or Watering of the eye, is frequently caused by malposition of one or both of the puncta. This may be produced by the dragging of a scar on the skin surface of the lids or cheek, or by

thrusting out of the margin by a swollen and thickened conjunctiva, as well as by congenital faulty position, paralysis of the VII nerve permitting the lid to sag away from the globe, etc. (Plates XXIII. 2, XXIV. 2). Apart from this it is often produced by the irritation of an inflammatory process in the eye, particularly keratitis and iritis, or by a foreign body irritating the eye, such as a particle of dust or an inverted eyelash. Hyperæmia of the conjunctiva may be accompanied by swelling of the membrane lining the canaliculi, obstructing the path for fluid and assisting to cause lachrymation.

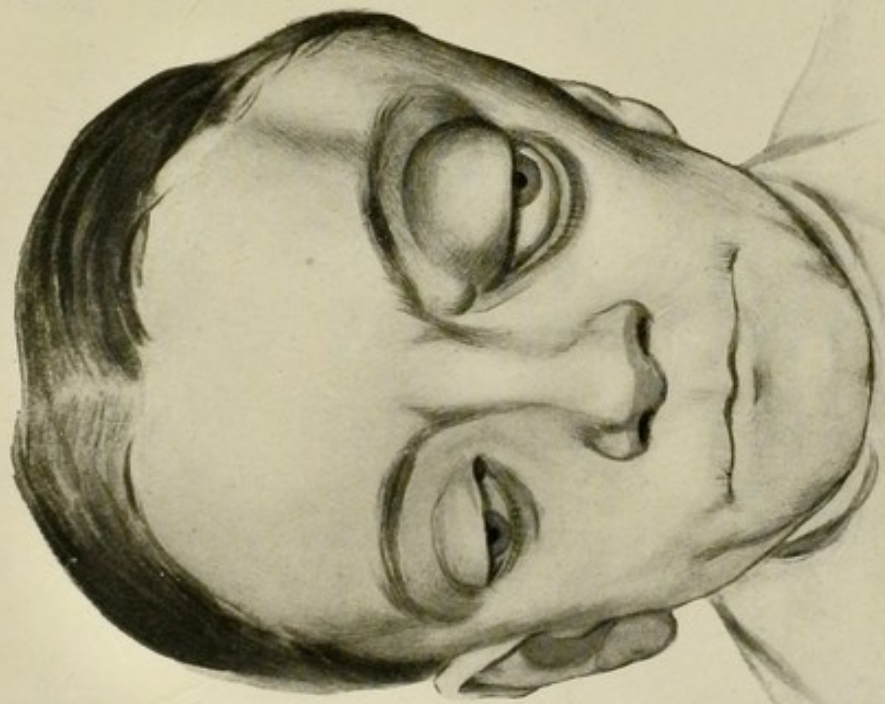
The **Lachrymal Sac** is liable to distension by mucus. If we assume a chronic catarrh of the mucous membrane with mucous discharge, we can readily understand the existence of a distension of the sac containing mucus—a *Mucocele*. This is generally of slow growth; the patient presents himself with a cushion-like swelling in the angle between nose and lower lid, just overlying the normal position of the sac. In the early stages it may be possible to empty the mucocele into the nose on pressure, but later on this becomes quite impossible. One reason for this is that as the sac distends it begins to overhang the upper end of the nasal duct, the entrance thus becoming valvular; pressure upon the sac then simply closes the entrance more completely. Sometimes after a sac has remained in this state for some time, sometimes without such a stage at all, an acute attack of *inflammation* of the sac (*dacryo-cystitis*) will occur. This is an acutely painful, indeed sometimes an intensely painful, affection, which is readily diagnosed. There is fiery redness of the region of the sac, a good deal of swelling round about, and intense tenderness in that position. The disease is very frequently diagnosed incorrectly as erysipelas of the face. After some few days it either dies down again or the abscess discharges through the skin at, or close to, the naso-palpebral fold. A patient may suffer many such

attacks, especially after exposure to cold, wetting, or when in a depressed state of health.


The *treatment* of affections of the lachrymal apparatus (other than the gland) is on the whole fairly satisfactory. To take first simple lachrymation : eliminate the presence of such a cause of irritation as a foreign body ; chronic conjunctivitis, leading not merely to partial obstruction of the passage, but to hypersecretion as well, must be treated with antiseptics and astringents ; eversion of the puncta, especially of the lower one, with astringents, and in bad cases with the cautery so applied as to leave a contracting scar internal to the punctum which will tend always to draw it towards the globe and thus enable it to resume its function. In a few of the cases it is well to open up the lower canaliculus (see p. 447) with a Weber's knife, but it is seldom if ever advisable to pass probes down the nasal duct, as some recommend almost as a routine (see below also). In the cases of chronic mucocele of small size or of chronic discharge of pus into the conjunctival sac on pressure over the lachrymal sac it is certainly best to slit up the (upper or lower) canaliculus, for the muco-pus or real pus must not be allowed to become dammed up, or an acute outbreak is almost certain. If this is done, and the patient encouraged to keep the sac constantly squeezed empty, he may go on for many years with a minimum of trouble. Failing this, the best course undoubtedly is to excise the sac entirely (p. 448). One is often asked how the tears are to be removed after excision of the sac, and whether the patient does not suffer as much as ever from lachrymation, and the answer is, that when once the source of constant irritation in the form of an inflamed sac is got rid of, a very much diminished quantity of tears is secreted, and evaporation is sufficient to account for a normal supply without trouble ; only when the patient goes out in a high or cold wind, etc., is there any watering.

It is very seldom indeed that removal of the lachrymal gland is required on account of persistent watering. Besides, the comparison should be, not between a normal condition and an excised sac, but between a constantly inflamed and irritable state on the one hand, and quietness with an excised sac on the other. The mistake is often made of assuming that there is a stricture of the nasal duct in such cases, and patients are often put to a very unpleasant amount of painful and futile treatment in the form of probing, largely because of a total misconception as to the real state of affairs. In the majority of the cases there is no stricture; the disease begins in the nasal mucous membrane and spreads to that of the sac, but there is no actual impassable stricture. Surgeons are also apt to be led away by the false analogy of the urethra, where the desired conditions are altogether different. There, one desires to have absolute closure of the passage, the fluid to be collected in a bladder, whence it is to be discharged at intervals through a channel as wide as possible. In the lachrymal canal one desires to have a potential passage through which the thin fluid shall percolate imperceptibly all day, and where there shall be no collection of fluid in the sac whatsoever. If a probe can go down at all, there is no need to pass one, for the channel required is merely potential; if the probe will not go down, fluid still may, and the ramming of a wire down has only the effect of further bruising an abnormal mucous membrane which wants soothing rather than crushing. Far superior to probing is the introduction of a bland oily antiseptic.


In **Acute Dacryo-cystitis**, if there is any hope of resolution, the abundant application of ichthyol, belladonna, and glycerine in ointment gives immense relief in many cases. But if abscess has actually formed, hot poulticing and free incision in the naso-palpebral fold, to



Bilateral Proptosis from Intracranial Tumour.



Ectropion from Paralysis of the Right Facial Nerve.



be followed, when all is quiet, by destruction of the sac, is the best form of treatment (Plates II. 3, and X. 3).

In children especially who suffer from acute sac troubles, and less frequently in adults too, bone disease is often at the bottom of the mischief, either of tuberculous or of syphilitic origin, and the sac trouble is in reality secondary to the caries. Such cases should be handled with much caution, lest in any operation one should find that one is led into too free a removal or destruction of bony tissue.

But there is another aspect of these cases of chronic lachrymal trouble, for chronic inflammation of the sac practically certainly implies the more or less abundant presence of active pneumococci in and about the conjunctival sac. When this is the case the slightest abrasion of the corneal epithelium becomes an acute and grave danger lest infection occur and an acute destructive abscess arise. Thus, should a patient who is found to have a chronic inflammation of the sac have also an abrasion or a cut of the cornea, it is not enough to treat the cornea; one must also destroy or excise the sac. Similarly if such a person suffers from ripe cataract, it is a wise policy to insist on excising the sac before any operation upon the globe itself is attempted.

The only **tumour** of the lachrymal apparatus, apart from the gland, which is met with is papilloma growing from the sac; it should be thoroughly removed, as it has a decided tendency to recur.

CHAPTER XVIII

THE ORBIT

THE orbit, or bony cavern in which the eye and its appendages are situated, is approximately 4 cm. in depth, its axis pointing slightly outwards as well as forwards. The open anterior part is nearly quadrilateral in form, its sides indicating roughly the existence of a roof, a floor, an outer, and an inner or nasal wall. The enormous advantage which man obtains, as compared with the vast majority of the lower animals, from the situation of the two orbits, is in the possession of binocular vision. By this is meant more than the mere fact—though even that is important enough—that the same object can be seen by the two eyes simultaneously; it implies also that the two images thus obtained can be fused into one solid image, conveying with the greatest possible accuracy the idea of depth, that is, of relative position. The degree of protrusion of the eye varies greatly under normal circumstances, and the impression that a person has large eyes or small eyes is chiefly derived from the amount of this protrusion and consequent exposure of the eye to view. Thus in old age all the fat about the orbit, and particularly the cushion behind the globe, becomes greatly diminished in quantity, with the result that the eyes sink deeper into the orbits, as they also do after any wasting disease. From injury with any large blunt instrument the eye is wonderfully

protected by the protruding roof, by the nose, and by the prominence of the superior maxilla, so that unless the direction of the blow is not merely from the front but also from below, the globe may escape uninjured. If the globe does receive part of the impact it is driven against the resilient cushion of fat in the apex of the orbit, and springs back to place again unharmed. On the outer side there is less protection, the bony wall having been "cut away" to allow a larger field of vision. Above, below, to the inner side, and posteriorly the orbit is in the most intimate relation with the accessory sinuses of the nose, disease in which may only too readily be communicated to the contents of the orbit. The globe itself might almost be said to be slung in the orbit by means of Tenon's capsule with its various offshoots. This structure is attached to the walls of the orbit all round, a short way posterior to the insertions of the recti muscles, and to the globe itself immediately anterior to their insertion. Each of the muscles is enclosed by Tenon's capsule, which splits to enclose it, reuniting again beyond it; and further, each muscle is inserted partly into Tenon's capsule itself, so that in point of fact no one muscle acts strictly by itself, all are united by strands into mutual assistance. This structure is, then, one of immense importance in the physiology and pathology of the eye, much more so than was at one time supposed to be the case.

The four rectus muscles, it will be remembered, take origin from the apex, just round the place of entrance of the optic nerve, and are inserted into the sclerotic outside the corneo-scleral junction, from which they are separated, in the case of the internus 4 mm., of the inferior 5, of the externus 6, and of the superior 7 mm. approximately. The superior oblique nominally takes its rise at the same place, but practically must be regarded as arising from the pulley at the upper, inner, anterior

corner of the orbit, passing thence to its insertion into the globe. The inferior oblique runs almost parallel to it, from its origin at the anterior inferior margin of the orbit.

The action of the recti, taken as a whole, must to some extent be to draw the globe backwards into the orbit (*enophthalmos*); the two obliques may possibly have a feeble influence in drawing the globe forwards, but this effect is produced rather by Müller's muscle (*v. infra*).

In persistent stimulation of the sympathetic, as in exophthalmic goitre, its action is well seen, but in that disease other influences are also at work increasing the protrusion (*exophthalmos* or *proptosis*).

The chief affections of the orbit are exophthalmos and enophthalmos, inflammation of Tenon's capsule, hæmorrhage, orbital cellulitis, aneurism and neoplasm, fracture, new growths, and involvement in tumours and inflammatory diseases taking origin in the accessory sinuses.

Exophthalmos or **proptosis** is the condition in which one eye or both becomes unduly protruded. When bilateral its chief cause is Graves' disease, which obtains its name of exophthalmic goitre from this circumstance. In Graves' disease it is not uncommon for the exophthalmos to be much more marked on one side, usually the right, and in the early stages especially, unless this is borne in mind, there is apt to be a difficulty in the diagnosis, since the protrusion may appear to be entirely unilateral. The precise mechanism of the protrusion is not quite simple; the veins at the apex of the orbit may be much distended, it is true, but were that the cause it should be easy on gentle pressure to push the eyes back again into their normal position, whereas this is not possible. The fault of position is largely due to the constant over-action of Müller's muscle, excited by the

over-acting sympathetic system. There must, however, be something more, for that muscle does not appear to be capable of the long, continuous, excessive action which the position would require. In a case of Graves' disease this exophthalmos may occupy a very important place in the symptoms, or may be comparatively insignificant as contrasted with the tachycardia and tremulousness. Three other symptoms are often present at the same time, known by the names of different observers. Graefe's sign: when the patient, who has been looking upwards, is caused to follow the movement of a descending finger, the globe keeps time with the object, but the upper lid lags behind, the effect of which is to allow a margin of white sclerotic to become visible above the summit of the cornea, between it and the upper lid; this is never seen in health. Dalrymple's sign consists in the abnormal widening of the palpebral aperture, more than the mere protrusion of the eye will account for; and Stellwag's sign is diminution of the frequency of the involuntary wink which lubricates and moistens the cornea. Darkening of the pigmentation of the skin of the upper and lower lids is a sign sometimes quite noticeable.

Unilateral proptosis (Plate XXIV. 1) may also be caused by cellulitis of the orbit, in which case there is obvious inflammatory reaction, and by tumour within or encroaching upon the orbit (*v. inf.*). It may be caused also by hæmorrhage into Tenon's capsule ("Tenonitis"), and by the presence of a foreign body in the orbit.

Enophthalmos is, as has been indicated, physiological to some extent in old age, and may occur whenever for any reason the orbital fat has become absorbed. It is thus seen to occur sometimes after an injury implicating the orbit. The explanation probably is that hæmorrhage deep in the orbit has, by pressure, caused absorption of the cushion of fat; as the effused blood is absorbed in its

turn the eye sinks into the orbit. A curious form of this is when exophthalmos and enophthalmos are to be seen in the same patient according as he hangs his head or lies on his back ; this peculiar condition, due no doubt to alterations in the quantity of blood contained in the deep orbital veins, is never found save after an injury to the orbit.

Inflammation of Tenon's capsule, or **Tenonitis** as it is sometimes called, is either due to direct infection of a wound in the parts, or to a rheumatic or gouty systemic state. The symptoms are just what one might expect : stiffness or fixity of the muscles, some proptosis, a general injection of the globe, and tenderness to touch. The best treatment consists in hot bathing or constant dry heat, bandaging to keep the eye at one temperature, and anti-arthritic remedies, such as aspirin, iodide, lithia, or colchicum.

Hæmorrhage into the deeper parts of the orbit is practically always traumatic ; it may occur as the result of an accidental wound, or in the operation for strabismus, when it is very alarming to patient and surgeon alike. Cold, firm bandaging, quietness, and patience are all that can be needful.

Cellulitis of the orbit, whether spontaneous, as may occur in the course of erysipelas ; metastatic, as may occur from a septic thrombus "landing" in the orbit ; or traumatic, is a sufficiently dangerous malady. The aspect becomes one of deep infiltration into the orbit, general severe injection of the whole globe, and fixation of all the muscles, so that the globe can execute no movements. There is generally a considerable degree of chemosis at the same time, and a thin and sometimes blood-stained discharge from the conjunctiva. The cornea is apt to become dull and hazy from lack of the proper secretion being wiped across it in the normal movements of the upper eyelid ; and in addition

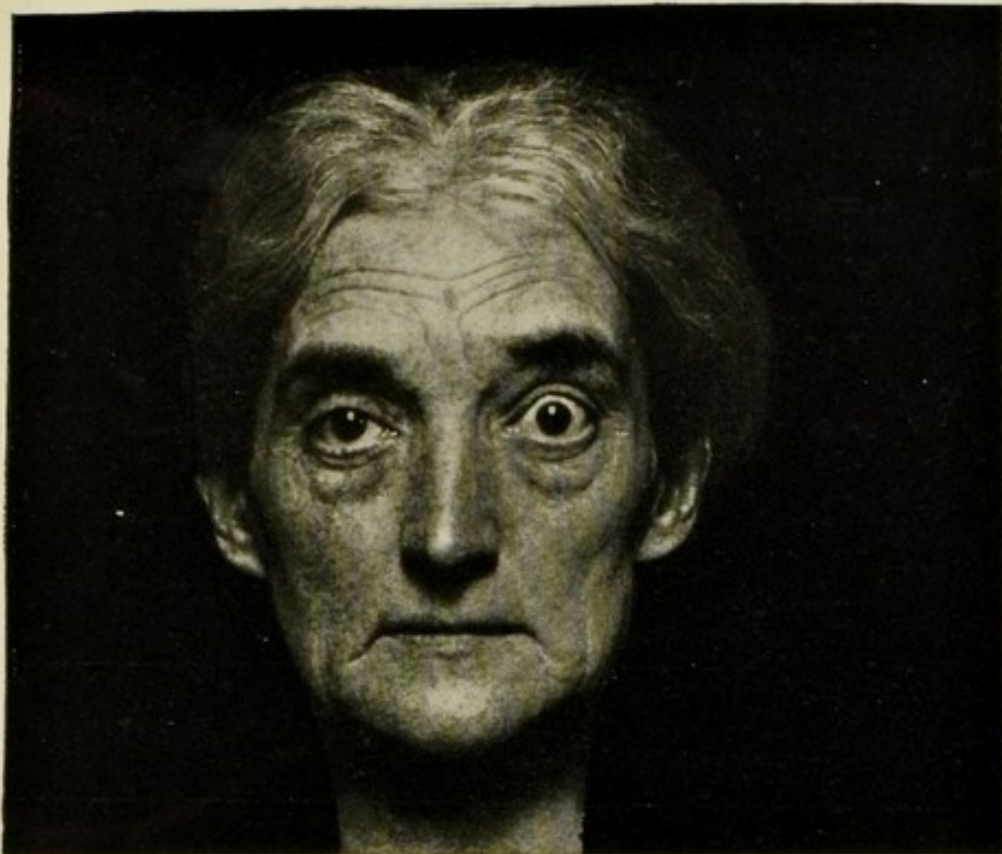there may be septic inflammation in the interior of the globe, when, of course, the pupil will be dull or yellowish, from infiltration into the vitreous. Even without such a complication the cornea is prone to suffer from the exposure and an ulcer to form, which necessarily becomes septic, spreads in extent and depth, and finally perforates the cornea, to the complete loss of the eye. Even should that not take place there is serious risk of loss of sight from implication of the optic nerve in the inflammation, leading to optic atrophy. This loss of sight may come gradually, it is true, but is rather apt to occur with abruptness, probably from interference in the first instance with the venous trunks which carry the blood from the interior. There may at the same time be very considerable fever and constitutional disturbance. It is very noteworthy that although the septic process is not so very infrequent in the orbit, it is very rarely that the process spreads to the brain or meninges; the orbit appears to be jealously cut off from the intra-cranial lymph spaces; for septic inflammations, whether acute or subacute, whether intra-orbital or intra-ocular, rarely develop into head mischief.

In *treatment* there are two good rules to remember, the first being that one should *incise early*, without waiting for definite evidence of pus. The reason for this is that in the interests both of cornea and of nerve it is important to relieve the tension and allow free exit of blood and lymph before the cornea has become ulcerated or the nerve too severely pressed on; and also because, though the risk *quoad vitam* may not be great, it is there, and because relief can in this way be given to the intolerable pain from which the patient is suffering. One should incise before there is any pointing, and the most convenient spot should be chosen, so that one may avoid the more important tissues. Through the lower lid at the lower outer angle of the orbit is the seat of


election, because one is least in danger of injuring important parts, and because, with the patient lying on the same side, if the incision is made there, drainage is best conducted. One should go boldly in through the skin, not opening the eyelids, or attempting to avoid subsequent scars by making the incision in conjunctiva.

The second good rule is *never to syringe* out the wound with the laudable idea of getting rid of more pus. The reason for this restraint is that one is much more likely to spread the pus or the organisms through the lax connective and fatty tissue of the apex of the orbit, which is of feeble resisting power, and thus to enhance the risk of further spread rather than diminish it. Having made a good deep incision (remembering that owing to the swelling one is apt to imagine that one has penetrated more deeply into the orbit than is actually the case) one should introduce a drain, but neither syringe nor attempt to press out fluid. The drain may be of gauze if pus has not yet formed, but should pus be seen, it is wise to employ a rubber tube, which may be shortened from time to time as the condition improves and the deeper parts of the wound cicatrise.

Aneurism of the orbit is invariably traumatic, is an arterio-venous anastomosis, and is a decidedly rare result of such an injury as a penetrating wound of the orbit, or a heavy fall. Within a short time of the accident, generally a few days only, the patient complains of a whirring or buzzing sound in the head, and the eye begins to protrude; at the same time the blood-vessels of the eyelids begin to be prominent and new trunks to make their appearance. A thrill may often be felt if the hand be gently laid on the globe, and a blowing or whirring sound heard if the ear be applied. The patient generally has a good deal of vague discomfort in the head, and sometimes violent headache. Ligature of the



1. Exophthalmos. Left Eye. Showing the Retraction of the Upper Lid.
2. Traumatic Paralysis of Right VI. and VII. Nerves, and Secondary Contracture of the Internal Rectus.



carotid is the treatment usually performed, but ligation of the angular vein has been found to be thoroughly satisfactory, and is less dangerous.

Neoplasm of the orbit generally consists, in reality, of a sarcoma, which may take its origin either in the wall of the orbit (periosteal) or from one or another of the soft tissues of the apex. (One is of course using the term "orbital" in this connection as excluding tumours connected with the globe itself.)

There are two chief signs, proptosis and limitation of movement. The nature and direction of the proptosis will naturally depend upon the precise position of the tumour, but assuming that it is situated in the apex, the general direction will be that of the axis of the orbit, namely, forwards and slightly outwards, with a downward tendency imposed upon it by the influence of the resistant upper eyelid. Should the tumour, however, be situated in the upper wall or roof, the direction will rather be more markedly downwards, and so on. From the direction alone one can frequently enough gain a fairly distinct idea as to the exact position of the new growth. The interference with the mobility is to be expected, but in the case of a tumour within the cone of muscles it is singular how large the dimensions are which a tumour may acquire before there is any appreciable difference. Where a neoplasm grows from one of the walls, however, say the inner, for example, not only will the globe be pushed outwards (as well as forwards), but its inward movement will be limited both mechanically and by interference with the internal rectus. In this way double vision may arise, a point which has always to be borne in mind when a case of diplopia meets one. Thus a case of paralysis of the internal rectus, with a little proptosis, not quite straight forwards, but with a tendency outwards also, may on investigation be discovered to be a neoplasm of the orbit at the inner

side, displacing the globe forwards and outwards, and interfering with movement inwards.

Some of these tumours are of very slow growth, even those which are not exostoses, and a peculiar feature is that a tumour which takes its origin outside of the globe may cause the most extraordinary amount of displacement, but will not actually attack the eyeball: the globe may be protruded quite out of the orbit, the cornea may be destroyed by ulceration consequent on exposure, the nerve may be pressed on so that the eye is quite blind, but there is no extension of the growth to the eye itself. The contrary is true of tumours which originate in the globe, for after a time such a growth will make its way through the sclera and begin to attack the other structures in the orbit. In tumours of the optic nerve (see p. 292), neuritis occurs quite early, before there is much proptosis at all, and the nerve then atrophies; this sometimes occurs while yet the protrusion is very slight; atrophy may possibly arise in tumours of other parts of the orbit, but rarely neuritis. In the case of a tumour within the cone of muscles, hypermetropia is frequently an important sign: it indicates that the posterior part of the globe is being driven in by the growth, and the eye flattened from back to front.

The tumours which occur within the orbit are most frequently sarcomatous, some being of very slow growth, others much more rapid; but fibrous and fatty growths also occur, and dermoid cysts. In the neighbourhood of the eye the favourite situation for a dermoid is outside the orbit, at the outer end of the eyebrow, but these growths also are found, though rarely, in the depths of the orbit, towards the inner side. The tumours of the optic nerve are fibrous, myxomatous, or a combination of the two.

Treatment.—Removal of the growth by surgical means is the only method we possess. It will easily be seen

that when the eye still has a reasonably healthy appearance, and still more while it retains sight, it is essential to use our utmost endeavours to prevent damage or loss of it, provided the efficiency of the operation is not thereby endangered. When the growth is far forward and to one side of the globe, the latter can be pushed aside, one muscle being, if necessary, divided (and its tendon transfixed with a thread so that it may be reattached in place at the close of the operation), but the greatest care has to be taken of the cornea, that its epithelium be not abraded or even allowed to become dried during the manipulations, else a destructive ulcer and a dense nebula, or worse, may be the result. When the tumour lies very deeply, attempts to enter the orbit from the front are apt to involve so much "knocking about" of the eye that it is certainly better to perform Krönlein's operation. The aim is to afford access to the orbit by way of the outer side rather than the front, the external wall being temporarily removed to permit free entrance. When the tumour arises from the optic nerve it may be possible, whether it be wise or no, to remove the nerve, dividing it deeply down at the very apex and again immediately behind the globe, and yet leave the globe itself; this has sometimes been successful, though it is hardly to be recommended. When the tumour is periosteal, and probably sarcomatous in nature, there is no need to perform Krönlein's operation, for the whole contents of the orbit must be cleared out—tumour, eye, muscles, everything down to the bone itself.

Fracture of the orbit is not a common accident; apart from cases in which extensive destruction of the cranial bones has occurred, it may take place when the base of the skull is fractured, though this is rare; it occurs occasionally, however, as the result of a heavy blow or fall on the outer side of the orbit. Practically the only

indication after a time is that vision of the corresponding eye is found to be lost, and after a week or two atrophy of the nerve begins to show itself on ophthalmoscopic examination. In such a case fracture has involved the sheath of the optic nerve, or the nerve, it may be, is torn across. Prognosis is, of course, absolutely bad, and no treatment can be of any avail.

Involvement of the orbit in disease of the accessory sinuses.—The chief danger to the orbit is when the ethmoidal or frontal sinus contains pus, which may endeavour to find egress by making its way into the orbit. A mucocele of the frontal sinus not infrequently points in the upper eyelid, about the middle of its length or perhaps a little nearer the inner extremity, and indeed in the case of any apparently superficial abscess in this locality one ought certainly to probe (with caution), when one may very probably find a communication with either frontal or ethmoidal sinus, or at least with necrosed bone forming part of the roof. It is to be noted that the spot at which the abscess forms and pus or mucus begins to escape is not so close to the nasal extremity of the eyelid as one might not unnaturally expect. After a long time, it may be, the mucus may become less in quantity and the scar be drawn in, causing a nasty fixing and drawing up of the upper lid, preventing it from covering the cornea properly and sometimes causing further trouble from inversion of eyelashes.

Treatment should rather be conducted from the rhinological point of view, and the mucocele either induced to drain *via* the nose, or the frontal sinus opened up and cleared out. From the strictly ophthalmological point of view it is well to remember never to be too impatient to operate for the improvement of the ugly cicatrization, for the whole affair is readily caused to break down again as the result of too early interference, and the mucus or muco-pus to begin again to flow and

destroy the careful plastic work which has been attempted too soon.

Abscess in the antrum of Highmore has been known to point in the floor of the orbit ; tumours originating in the sinuses may encroach upon the orbit or force their way into it.

A rare and singular disease is known as *Chloroma* : it consists in the development of multiple tumour formation in one or both orbits and in other portions of the body ; on section these tumours have a greenish or yellowish-green hue, hence the name. The development is accompanied by rapidly increasing weakness, anæmia, and inanition, and is quickly fatal.

CHAPTER XIX

WOUNDS AND INJURIES

THE eye is exposed to many dangers, and not merely are the accidents to it more numerous than its small size might lead one to expect, but the interests at stake are so enormous that it is necessary to dwell at some length upon the subject. An additional and very real reason for careful consideration of injuries is that immediate treatment is so very often of greater value by far than that which can be given after a lapse of time, that it is highly important that the family practitioner should have a clear understanding of the proper lines along which to work. Still another reason for special attention to injuries is—as will presently be seen—the appalling danger that blindness of both eyes may be the result of an injury to one of them.

Injuries of the lid are to be treated on ordinary surgical principles, due regard being had to the prevention, so far as possible, of subsequent deformity, as the part is more exposed to observation than others. In this connection a point of much importance is, that should the edge of the eyelid be cut or torn, it is to be sewn up again, with the utmost care taken so that there shall be no “nick” in the edge, which would give a most unpleasant aspect.

There is another source of trouble in injuries of the lower eyelid, viz. should the lid be cut, or, as more

frequently happens, torn away from its internal attachments, the lower canaliculus is almost sure to be cut across, and unless the two separated portions of it are slit up, and brought into correct apposition when the lid is being stitched in place, there is necessarily trouble with the tear-passage later on. This tearing away of the eyelid is an accident of not infrequent occurrence; a hook, the bracket of a lamp, the finger of an assailant, may hitch in the lower lid, and at once the head is drawn back suddenly; the inner end of the lid gives way and the lachrymal canal is torn.

Another injury to the lachrymal apparatus is apt to be the result of a blow with a rounded body, such as a fist, or the knee of a football player, in the situation of the sac; *rupture of the sac* itself or fracture of its bony wall is followed, on the first occasion of blowing the nose, by the escape of air under pressure among the loose connective tissue of the lids. At some point there has been established a potential continuity between the connective tissue and one or another of the accessory sinuses of the nose. The diagnosis is simple when the history is given, the only additional point of importance from the objective side being the feeling of crepitation beneath the fingers as one passes them over the blown-up, emphysematous eyelid. The only treatment required is to apply a firm bandage and to prohibit use of the handkerchief for a day or two.

Ecchymosis of the lids occurs very readily from blows in the neighbourhood of the eye because of the laxity and delicacy of the subcutaneous tissue.

In the case of any injury, and particularly of a burn of the eyelid, every care must be taken to avoid subsequent exposure of the globe; a cornea which cannot be covered completely by the eyelids is in constant and grave danger of ulceration, infection, and destruction.

Wounds and injuries of the globe are accidents of

high importance. The simplest is the planting of a foreign body, such as a particle of dust, under the upper eyelid. In this situation it usually lies two or three millimetres above the lid margin and about the middle of the lid as regards its length, where the concavity of the tarsal plate is most acute. In this situation it causes much watering and distress, as at every movement of the globe or eyelid the rough particle injures the epithelium of the cornea. From this position it is most satisfactorily removed by *Eversion of the Eyelid*, when the foreign body may be seen and picked or wiped off; to accomplish this one should cause the patient to look down, and place upon the upper margin of the tarsal cartilage a fine flat object such as a fruit-knife or the handle of a teaspoon; a little gentle backward pressure with this instrument will cause the lower edge of the lid to protrude from the globe; under this one should place the ball of the thumb, and as the instrument is gently pushed downwards the eyelid will turn over. The beginner's two mistakes are not causing the patient to look down, which is a *sine qua non*, and instead of pushing the upper edge of the tarsal plate down, trying to pull the lower margin upwards. A very nervous patient can often be relieved even without this unpleasant experience of eversion of the lid if one causes the lower edge of the lid to stand out as before, but instead of turning it over, pushes the lower lid up under the upper; as it descends again the eyelashes of the lower lid sweep clean the posterior surface of the upper and the foreign body is wiped away. After a little practice the first manœuvre becomes very simple and requires no apparatus at all, the forefinger taking the place of teaspoon or fruit-knife; while the second is perfectly simple to perform even on one's own person. In an extremely nervous and unruly patient the introduction of a drop of castor oil into the eye may cause the foreign body to become entangled and so removed.

In every case of causeless unilateral conjunctivitis it is well to exclude definitely the presence of a foreign body under the eyelid; often enough the patient is not aware of having received one, and may be sceptical as to its existence, thinking he has only "caught cold at an open window."

A *foreign body* may become lodged *in the cornea*; this is a common occurrence in such trades as that of the engineer or the miner, and occurs frequently also in ordinary daily life in high winds, in railway travelling, etc. Naturally the situation most probable for implantation of the foreign particle is the most exposed portion of the cornea, namely the lower half near the centre. There it can be easily seen against the background of the iris, but not so readily against the black pupil—a reason for employing as a local anæsthetic a drug which is not also a mydriatic. Having anæsthetised the cornea, one is able to lift off the foreign body with a spud, grooved or flat, or with the point of an ordinary surgical knife. Among the working classes it is made a great point to employ a "loded" (*i.e.* magnetised) knife, but it is doubtful whether there is any advantage in this. To remove the particle with the minimum damage to the corneal epithelium, which is of course one's aim, stand behind the patient as he sits on a rather low chair, let him lean his head against your chest, and steady the eye by placing the fore- and middle fingers of your left hand upon the globe above and below the cornea; by causing the patient to look first down while you push the upper lid out of the way and settle your forefinger, then up while you push aside the lower lid and settle your middle finger, you can fix the globe well without rubbing off any of the corneal epithelium. In using the knife or spud the great point is not to lay it as a tangent to the cornea, but to point it as though you were about to pierce the tissue; the particle can

then be lifted off, or dug out, with the least injury possible.

If the foreign body has been of steel and has been in the eye for a day or two, it is common to find it surrounded by a ring of rust-stained tissue; this should be lifted away also, provided it comes away readily, but, as a rule, not unless that is so.

In some cases the foreign body penetrates into corneal tissue so deeply that there is danger of it being pushed through into the anterior chamber by the point of the spud or broad needle; when this is the case it is best to pass a keratome into the anterior chamber close by the spot, and employ it as a firm unyielding base




FIG. 61.—Broad needle and grooved spud for removing foreign bodies.

against which to work the knife or spud. (Foreign bodies in the interior of the eye will be considered later.)

Two dangers primarily and very seriously affect our consideration of any **wound of the eye**, the dangers of primary suppuration and of sympathetic ophthalmia. They greatly influence the questions of treatment and prognosis.

It will be well to discuss very briefly a few points in regard to the danger of *primary infection* before considering individual types of injury. When dealing with non-vascular tissues, of which there are three in the eye, it might not unnaturally be supposed that non-resistance to the attacks of organisms, and consequent septic inflammation, was an almost certain result of injury. In the case of the cornea, however, the tissue is so very tough and elastic that the wound of entrance of a body is always smaller than the body itself; the consequence is that in a large number of cases the instrument is mechani-

cally cleaned as it enters, and sepsis does not follow. Secondly, should the anterior chamber be emptied as the result of a wound of the cornea there is a strong rush of fluid from the interior of the eye outwards, when the infective material is swept out. So long as the aqueous humour leaks away the stream is always running outwards. Thirdly, although the vitreous humour and the lens form, either alone or in combination, a fairly good "growing medium" in which to cultivate organisms, yet even they show some power of resistance and of self-preservation.

A wound of the *cornea* alone, that is without implication of the iris, is not dangerous; should it lie near the centre of the cornea, atropin ought to be given in the full strength; if it lie near the periphery, eserine is preferable. The meaning of the difference is that should there be an ulcer or wound near the centre of the cornea, it is well, in order that the iris should not be implicated in the healing, to dilate the pupil; but should the wound lie rather at the peripheral part, eserine or pilocarpin ought to be instilled, in order that the iris may be kept stretched, when it will not so readily be forced into the wound and caught there. Should the wound be already plugged with a knuckle of *iris*, an attempt may be made, after it has been thoroughly cleansed (so far as this can be done), to replace the prolapse; it is but seldom that this manœuvre can succeed, and it is generally better, especially should the wound be some hours old, to remove the prolapse. In doing this it should be a rule not merely to cut off the prolapsed part, but to seize the iris, *draw it out* of the wound a little, and then cut it across. The reason for this is that if the prolapsed portion alone is cut away, the portion of iris lying between the lips of the wound is not freed, pigmented tissue is incarcerated in the scar and forms a constant source of danger ever after.

A wound of the cornea may implicate the *ciliary region* of the sclerotic even if small, and almost certainly will if it be large. A wound in that situation permits the escape of vitreous humour, the amount varying not merely with the size but also with the direction of the cut. The uninitiated is apt to assume that the loss of vitreous may go on till the globe is emptied, but such is not the case: the intra-ocular pressure once relieved, there is no further escape unless the lips of the wound are subjected to pressure. It is desirable as soon as possible to transform the wound into a subconjunctival one. One would like to be able to sew up the scleral wound, but against this there is the difficulty that the extreme toughness of the sclerotic would necessitate the use of so much pressure upon the needles that these could not be passed from without inwards without great loss of vitreous humour, and would therefore require to be passed from within outwards; that the needles would have to wound also the pigmented coat, and that either permanently or temporarily a stitch must remain within the globe. It is true that a stitch may be passed through the superficial layers alone of the sclera, but one obtains just as much advantage, and more, by drawing the conjunctiva across the wound. The best plan is to wash the wound thoroughly; then remove a strip of conjunctiva all along one lip of the wound, and at the other lip undermine and loosen it. Silk stitches can then carry the edge of the loosened portion of conjunctiva across the wound to the raw surface on the other side, and attach it to the fixed margin. Under this protection the scleral wound heals rapidly. The same method can be employed even for wounds in the cornea, for the undermining can be so placed and adapted that an apron of conjunctiva can be dissected up and brought across the cornea, covering part of it temporarily; when the wound is healing the cells from the raw under-surface of the flap

greatly assist in bridging the gap, and when all is sound again the flap slips back into place exactly as it was before. There can be no question that the early and prompt treatment of a wounded eye has a very great influence in the prevention of sympathetic ophthalmia; the prompt cleansing, removal of pigmented tissue from the wound, closure of it and covering with conjunctiva possess a value which is truly enormous.

Should the weapon or foreign body penetrate more deeply, the next tissue to be wounded is the *lens*. The anterior capsule of the lens once opened, cataract immediately begins to form; in fact four changes begin, for the lens sops up the aqueous humour as a sponge would do, swelling as it does so; the lens becomes opaque; it loses to a large extent its adhesive character; and finally absorption of the lens matter takes place. The rapidity with which these changes proceed, and the degree to which they take place, depend on two factors, viz. the size of the rent in the capsule and the age of the patient. It stands to reason that the larger the rent in the capsule the more readily is aqueous taken up, and the more rapidly does the lens swell, and—other things being equal—the more speedy is the absorption. Also it is easy to comprehend that the younger the patient the more rapid will these changes be, the soft lens of youth undergoing physical alteration more readily than the harder lens of an older person. It is a good rule, then, in a case of traumatic cataract to stand by and watch the lens becoming more swollen and more of it becoming opaque, but to be ready to step in and assist nature whenever that may be necessary (Plate X. 7). One has to steer between two dangers: if one steps in too soon, the lens is not ready to come away, much cortex is left behind (because it is sticky and invisible), and is therefore apt to cause much irritation to the iris, etc., even should it not become definitely septic; on the other hand, if one delay too

long, the swelling may have led to glaucoma, and one has then to operate in very unfavourable circumstances.

A very important symptom for which to watch (and this applies with much force to that form of traumatic cataract also which one wilfully produces in the treatment of lamellar cataract) is vomiting. Vomiting coming on two or three days after an injury which has caused traumatic cataract is pretty sure to be due to increased intra-ocular tension caused by the swollen lens if it be not a sign of septic infection and impending panophthalmitis.

The *treatment*, then, of a case of traumatic cataract should be: Atropin to keep the iris out of the way of the wound in the lens capsule and preserve the iris from being pinched between cornea and swelling lens,—and expectancy. As has been mentioned above, if the lens be not injured, whether atropin should be used or eserine depends on the situation of the wound, but wherever the wound lies, if the lens be implicated, atropin should certainly be employed. In the event of the lens swelling rapidly, causing increased tension and perhaps vomiting, one should promptly extract the lens, or so much of it as is ready to come away. Should the ripening be slow, the form which operative interference might need to take would rather be breaking up of the lens with a needle (kerato-nyxis) to encourage fresh solution and absorption. The chief risk in cases of traumatic cataract being persistent rise of tension, and this evil being more serious the older the patient, this general rule should be followed:—Refrain from too early interference if the patient be young, but operate early if the patient be above middle life. In the latter case, as there is a nucleus of considerable size to be reckoned with, it is best to extract the lens in the same manner in which one would have proceeded had the cataract been idiopathic.

The eye is wonderfully protected from **injuries by blunt objects** such as a fist or ball, for the most of the force is usually received upon the frontal or malar bone, and even if the globe itself be struck, it has behind it a cushion of fat against which it is driven without harm. A blow which really injures the eye usually comes either from below as well as in front, or from the outer side, where the recession of the orbital margin to permit a larger field of vision and fixation constitutes a source of danger. In some such way the following types of injury (besides some of greater rarity) are liable to occur:—

(a) *Subluxation of the Lens*.—The lens is slightly tilted, and at one part the suspensory ligament may give way. This will be shown by an anterior chamber deeper at one part than at another, by a slight tremulousness of the lens on movement of the eye, and very often by some dilatation of the pupil and enfeeblement of accommodation. No treatment is required.

(b) *Traumatic Myopia*.—The precise etiology of this condition is a matter of disagreement, but probably a general stretching of the coats of the eye, the result of the impact, accounts for the symptom; it is possible too that the lens may have come too far forwards by a loosening of the suspensory ligament. The degree of myopia thus induced may even reach as high as 5D; it is usually transitory.

(c) *Dislocation of the Lens*.—The lens is dislocated downwards, freed from the restraint of the suspensory ligament. The anterior chamber appears deep, the iris, having lost the support of lens, not merely falls back a little, but is tremulous (iridodonesis); the pupil looks very black, and since, if the patient be no longer young, his lens ought to give a faint smoky-looking reflex, the pupil may form in this respect a distinct contrast to that of the other eye. The lens can be seen by means of the ophthalmoscope, the rounded dark line which marks

its convexity forming an important point in diagnosis. At the same time the refraction has become highly hypermetropic and accommodation is impossible. Here again treatment is out of the question unless the lens should slip into the anterior chamber; the patient may obtain much benefit from high convex spectacles.

(d) *Hæmorrhage* into the anterior chamber (*Hyphæma*), the blood coming either from the iris or from the ciliary body: it is quickly absorbed. (Plate VI. 7.)

(e) Dilatation of the pupil and *Paralysis of the Sphincter Pupillæ*; paralysis of the muscle of accommodation; separation of the iris from its ciliary attachment (*iridodialysis*). (Plates IX. 5 and XIII. 4.)

(f) *Rupture of the Chorioid*.—The degree of damage to visual acuteness varies a good deal, and indeed sometimes the existence of a rupture is not inconsistent with the presence of quite good vision (say $\frac{6}{18}$), but usually there is a more decided reduction. On examination with the ophthalmoscope one finds a whitish curved line concentric, more or less exactly, with the outer margin of the disc, from which it is separated about 1 to $1\frac{1}{2}$ disc diameters; the line tapers at its extremities, and at the maximum is about twice the width of the largest retinal veins; there is generally a little pigment scattered about the extremities of the line (Plate XV. 3). The situation in relation to the disc of this curved line of rupture depends on the direction of the violence which caused it; while its usual position is to the outer side of the disc, it may be above or below. In rare cases there are two concentric lines of rupture.

(g) *Commotio Retinæ*.—In a few cases, after a blow on the eye, vision is reduced for a time but returns again, and there is no pathological appearance to account for the loss of vision save a certain degree of œdema of the retina; for want of a better name the condition is spoken of as *commotio retinæ*.

(h) *Rupture of the Globe.*—The “seat of election” for rupture of the globe is above, in the ciliary region of the sclerotic, just about 2 mm. posterior to the apparent corneo-sclerotic junction. The cornea itself, if in a healthy state, never ruptures; the portion of sclerotic which gives way is the part at which it is not merely thinnest but is weakened by the passage through it of some ciliary vessels. There is another potent factor in the determination of the place of rupture, namely that the blow causing it is delivered from below as well as from in front; the upper portion of the corneo-sclerotic junction is therefore the most apt to give way, all the more that the whole portion of sclerotic posterior to the seat of rupture is supported against the roof of the orbit; but just at that situation the rounded globe leaves the line of the roof, a sharp bend occurs there as the blow is delivered, and the coats give way. At once the eye fills with blood, sight is lost, and there is very severe pain (Plate VIII. 4). Cases are classified into two groups according as the lens is, or is not, dislocated from the eye; if the conjunctiva holds, the lens probably remains *in situ*, but if it also should give way, the lens may be driven completely out of the globe. There is an intermediate class of cases in which the lens is driven outside the globe but remains under the intact conjunctiva, bulging it up at the side of the line of rupture. In the first of these groups, that in which the lens escapes, there is danger, it must be plain, of septic infection; where the conjunctiva remains intact this risk will not occur. In the decision as to the dislocation or not of the lens the absence or presence of the image reflected from the posterior surface of the lens is of much importance. In regard to treatment there is little to do but wait till the blood becomes absorbed and the eye quiets down, which it does after the lapse of a few weeks in the majority of cases. The eye often regains sufficient vision to have made it quite worth

while to save it ; it seldom is necessary to remove the eye, unless sepsis should occur. Should the lens be lying under the conjunctiva, it is best to leave it there until the rupture is healed and then remove it through a small opening in the membrane.

(i) *Detachment of Retina*.—This may come on at once or more gradually.

Even more serious from some points of view than either a cut or a blow is a **Punctured Wound**, or one in which a foreign particle has entered the eye. A punctured wound in which a foreign body has not been deposited within the eye may be made by a pin, fork, gimlet, etc., and is peculiarly apt to become septic, not merely on account of the nature of the instrument, but because no rush of aqueous or of vitreous humour through the wound can occur, cleaning it as it escapes. One is right to regard such cases with gravity as being very serious indeed, and to give a very doubtful prognosis. They are liable, of course, to acute septic inflammation, but worse than that to a slower septic sub-inflammatory cyclitis or irido-cyclitis leading on to a sympathetic involvement of the other eye. An eye cut with a knife, even through the ciliary region, may heal up soundly and be a very valuable organ in days to come, while one punctured by a gimlet or the prong of a fork, though the immediate aspect of the injury is much less alarming, is in reality in a vastly more unsatisfactory state.

All that may be said of punctured wounds may be said with even greater emphasis of cases of a **foreign body** lodging in the eye, for here we have an element of still greater danger added to those of the punctured wound. Assuming, in the first instance, that one sees the case within a very short time of the injury, there are certain points to be looked to in the determination of the presence or absence of a foreign

particle. These may be grouped under the following headings:—

(a) *Exact Mode of Occurrence*.—The nature of the work on which the patient was engaged at the moment of the accident is of great importance,—chipping a piece of metal, hammering, stone-cutting, etc. If, for example, he is able to state that the piece which struck him was an inch long it is obvious that it cannot be in the eye. But one must be careful, for patients are always ready to say without evidence that there “cannot possibly be anything in the eye”; presumably the wish is father to the thought.

(b) *The Nature of the Foreign Body*.—What is required in order that a foreign body may enter the globe is that it shall have sharp edges and considerable momentum. Other things being equal, a small foreign body will require to have great speed else it will not have sufficient momentum to cut its way through the cornea. A very important point, further, is the sharpness of its margins; a rounded body, or one with relatively obtuse edges will have less chance of entering the eye than if it had had a sharp edge. A particle of steel and of iron is thus more likely to pierce the cornea or sclerotic than is one of stone or of coal.

(c) *The Field of Vision* may supply most important information, for in the immediate vicinity (at all events) of a foreign body the retina is quite sure to have lost its function and there will be a corresponding loss of the field. Assume, for example, that while walking along in a factory a man receives a foreign body in the eye; it strikes the right eye on the outer side, there is a small wound which seems to indicate that something has actually penetrated. Should it have remained in the eye it must have lodged, from the direction in which it was travelling, in the nasal portion of the retina. If on examination we find that the corresponding outer portion

of the field of vision is cut off, we may fairly enough conclude that the foreign body has lodged in or injured the nasal side of the eye. In this matter there is a fallacy as regards the lower half of the retina, for blood effused into the vitreous at any part will lodge there and cut into the upper portion of the field.

(d) *Localised tenderness* is a point of some value also ; it is not by any means distinctive, but it points with some probability to the continued presence of a foreign body. In such a case as that to which reference has just been made, a tender localised area on the inner side of the globe would certainly be a sign not to be ignored.

(e) When the particle is of steel, *siderosis*, or staining with salts of iron comes on after a time ; the iris is the part which shows most alteration, adopting a reddish-brown tint which is very distinctive. Siderosis involves degeneration of tissue and gradual loss of vision.

(f) *The Röntgen rays* may exhibit the presence of a foreign body in the eye, and often enough are very useful in assisting the diagnosis, but two things should be remembered in this relation, namely, that the foreign body may be so small that it is difficult to be certain of a shadow cast by it at all, and that the eye is so hemmed in by bony tissue as to render somewhat uncertain the deductions one might attempt to draw from the circumstances of the case. This is true both positively and negatively, for a foreign body may appear from one's reading of the photograph to be in the eye when as a matter of fact there is none, and owing to its enclosure among bones, in another case a real foreign body may not show distinctively. Assuming now that a foreign body is certainly present, the Röntgen rays may give data from which the precise situation can be determined, but this requires somewhat elaborate apparatus. A simple plan, though one not so precise in its results

is to take two photographs, one immediately after the other, the patient being prevented from moving his head from the moment of beginning the first exposure till the second is complete, the only movement to be that in the first photograph he is looking up, in the second he is turning his glance downwards. If the position of the supposed foreign body in the two is different, it must be in the interior of the eye, when its precise position can be localised with quite sufficient accuracy; if it has not moved, it must be outwith the globe. For the working of the more elaborate methods, such as those of Sweet and of Davidson, an expert is required, whereas the simpler method just outlined can be followed by any X-ray operator without the necessity for costly apparatus.

There is another instrument, called the Sideroscope, intended to assist in precise localisation, but it has not come into general use at all. It is somewhat expensive and not infallible; the information afforded by the X-rays, which is more easily obtained, is not less valuable, but the method is highly praised by some.

So far as treatment is concerned, the essential point to be kept clearly before the mind is this: *You dare not leave a foreign body in the eye.* If a foreign body is present, out it must come at all risks and whatever be the difficulties. An eye with a foreign body in it is lost and so is the other eye. To this general statement there is but one exception, and that is very rare. The class of cases with which we have been dealing is that in which the injury is very recent; the rare exception is that one may meet with a case in which a foreign body has been encapsuled within the eye even for years, no changes are going on and the eye is quiet. Such an eye should be left alone, it being always understood that at any moment the intruder may, from some chemical changes or mechanical alteration, begin to

give trouble, when it or the eye — and probably the latter—will require to be removed. In reference to this removal of a foreign particle, one class of substance is much more favourable than any other, namely, the class of magnetisable metallic bodies. Should the morsel be of stone or of brass, for example, one must simply enlarge the wound of entrance or make a fresh incision at a more favourable situation, and introducing forceps catch and draw out the intruder, though in the process of executing this manœuvre much damage may be unavoidably done to the tissues. In the case of a morsel of steel, however, one can remove the particle either on




FIG. 62.—Snell's portable electromagnet with two points.

the tip of a soft iron extension of the core of an electromagnet, introduced into the eye and directed to the precise situation of the particle, or by means of a very powerful magnet outside the eye altogether. Opinions are divided among surgeons as to the relative merits of the two methods in the service of a large and well-equipped hospital, but for the use of the practitioner apart from a large hospital there can be no question which is the more valuable. The small magnet of Snell, or one of its modifications, can be worked either by a bichromate cell or by means of an accumulator or storage battery, and can be carried about from place to place.

Speaking generally, the particle entering the eye is aseptic, for the force applied to it which has caused a

small piece to fly with sufficient force to enter the eye has probably raised its temperature above bacteria-point, at least in the case of the smaller particles, so that unless there is a gaping wound with a large particle, immediate septic infection is not likely, but this is a hope upon which one must not place much reliance.

If the foreign body has injured the lens, it may either have remained embedded in the crystalline or have passed through it. In either case the question comes, Should one, while removing the foreign particle, remove also the lens? The answer depends largely upon the two elements—the size of the foreign body and the age of the patient; if the foreign body is large, the lens must be largely injured, will therefore swell up rapidly and ripen quickly, and accordingly the best course will be to extract as far as possible on the spot; while if the patient be of middle life or beyond, whatever the size of the foreign body, his eye bears the swelling of lens much worse, glaucoma is a more decided menace, the eye is wounded and must be incised at any rate, and on the whole the best policy again is to extract the lens at once.

If extraction of the lens is required, the question hardly crops up, but if not, should one enlarge the entrance wound to extract the foreign body, or make a fresh incision? It is essential to remember in this relation that the wound by which a foreign body has entered the eye is always smaller than the particle itself; this is on account of the elasticity of the coats of the eye. It follows that in the removal of the body one always has to make a larger wound than that which has sufficed for its entrance. It is impossible to lay down a hard and fast line, but as one wishes to have as little scarring of the cornea as may be, it is best to make a fresh incision in the sclerotic if the foreign body be lying deeply in the eye. It will be found, too, that the most favourable form of wound is the L-shape, for this gives

the maximum of opening capacity with the least possible injury. It is a great mistake, for example, to introduce the nozzle of a small magnet through a linear opening barely sufficient to let it through, for even if one might otherwise have been successful, the foreign body would certainly be wiped off as the magnet emerged, and one might thus never succeed in removing it from the eye at all.

In any case of wound of the eye sepsis may readily occur, though, as we have seen, that misfortune is less frequent than one might be tempted to expect. Should the process of suppuration begin, one of the first signs will be found to be swelling and œdema of the upper eyelid, and then slight chemosis. The onset of panophthalmitis will also be marked by increased pain in eye and head, with a dull pupil, immobile and muddy iris, complete loss of sight, and tenderness of the eye to touch (p. 243). Let it be borne in mind that the disaster of suppuration is not in every case a calamity, for it sometimes closes a controversy as to whether the patient can make up his mind to part with an eye which the surgeon feels it his duty to urge should be removed either for its own sake or for that of the other.

To be a good judge of whether an eye can be saved or not, requires a large amount of experience and judgment. Sometimes a very badly injured eye will heal up quite nicely and look well, while an eye which is, to all appearance, injured to a much less degree never recovers sight or beauty. There is as little kindness and as little wisdom in hastily deciding to attempt to save an eye which is hopelessly destroyed, can never see, and may be a serious danger, as in hastily deciding to remove an eye which is capable of being of service, or as in postponing the inevitable until evil signs arise which should never have been given the opportunity to develop.

Burns of the Eye.—An injury of a class quite different from the wounds which have been under

discussion is burning, which may occur from hot metal, from acids, and from other destructive chemical fluids.

A minor form is seen occasionally where a lady, using curling-tongs, accidentally permits them to touch the cornea. In such a case the pain is very severe, for it is upon the end organs of the nerves of the cornea that the injury is inflicted, and that with a cautery sufficiently heated to injure them, but not altogether to destroy them. The best treatment is to drop in a little atropin and dress with a bland ointment. Cocaine may do something to relieve pain, but it tends also to delay regeneration of epithelium, and should therefore be very sparingly employed.

The more serious burns are caused by lime or by a splash of hot metal, usually lead. These differ a little in this somewhat important clinical fact that in lead burns one generally sees pretty well at once what is going to be the full extent of the destruction, but in chemical burns the damage eventually done is always considerably greater than at first appears to be the case. The primary danger is to the cornea, which in a bad case of lime burn may be at once transformed into a dense white opaque tissue which never regains any transparency; this may be true of every particle of the cornea or of a limited area, but it is important to recollect that a cornea like that never regains transparency, and may slough out altogether. This accident is less common with lead, because the moisture on the surface, which affords no sort of protection against lime, causes the hot metal to slide off. Thus one often sees a cornea hardly damaged at all, yet a mass of solidified lead is lying in the conjunctival sac, clinging to the shreds of mucous membrane and to the eyelashes, having done much more destructive work in the conjunctival sac than on the cornea. The contrast is great, too, in regard to the sclerotic; after injury by either,

one may see the sclerotic white and dead-looking, but if the burn be by lead it will probably slowly recover and "live," while if it be by sulphuric acid or lime, the whitened portions will ultimately disappear or slough out, and the eye may be lost altogether. Just as in burns in other situations, a burn of the conjunctiva is succeeded by slow, protracted healing and in the end by a very contracting cicatrix; and union of lid to globe, known as *Symblepharon*, is common. This occurs because the destructive substance has lain in the lower *cul-de-sac* and destroyed the opposing surfaces of conjunctiva; as cicatrisation goes on, these two surfaces adhere and are merged in one scar, which may obliterate the fornix and may unite part, or even the whole, of the lower part of the sclerotic or even of the cornea to the lid (Plate X. 8).

For immediate treatment the most useful is some bland oil, which has the effect of covering over the burnt part and of interposing between the two opposed raw surfaces. Theoretically, one ought to apply weak alkalies when one meets with an acid burn, weak acids for a potash burn, but it is extremely improbable that one will see the case in time to allow of such theoretically correct treatment being of any value. In lime burns it does seem as if weak sugar and water was the best "first aid" treatment, followed later by oil. Later, while cicatrisation is going on, it is considered best to try to prevent union by passing a probe from time to time between the lid and the globe for the purpose of breaking down new adhesions; but the effect of this procedure is all but *nil*, and it is exquisitely painful. Recently, good accounts have been given of the value of "cargile tissue" in this connection.

In after days a patient may request one to cut down and separate from one another a united lid and globe, but this procedure should be undertaken only with caution, for it sometimes is the case that there is no lid

tissue and no sclerotic tissue left, and the skin forms practically the wall of the globe ; if in such circumstances an attempt to form a lid is made, the globe may at once be entered, the contents escape, and the last condition be worse than the first. Here again, if there be enough tissue to justify operation, ciliary tissue has been highly spoken of.

SYMPATHETIC OPHTHALMIA

In the case of the eye there is a risk in the event of injury which has no true counterpart in relation to any other part of the body—a tendency, namely, for the uninjured eye to be attacked by inflammation of a peculiar and very disastrous character as a definite consequence of the injury to the first eye.

Before studying the disease itself it is necessary to clear the ground a little. There are two distinct but related conditions which must not be confounded. A symptom is well known which, for want of a better name, we call "*Sympathetic Irritation*"; this occurs in all cases of injury, but is in itself harmless, though it may be annoying. When a foreign particle enters the right conjunctival sac, the left eye weeps and resents use, is uncomfortable, watery, and uneasy. The same symptom is true of more serious injuries, to a greater or less degree ; thus, let the left eye be injured by a knife, and the right eye cannot be employed for reading, etc., without much discomfort. This sympathetic irritation comes on at once and may last very long ; it is not in itself a source or even a certain indication of danger, but under some conditions it may prove to be a warning. It usually passes off as the wound heals ; its continued presence, and still more its reappearance after having passed off, is to be regarded as a very alarming sign.

Sympathetic inflammation is closely related no doubt, but is essentially different. It possesses three

marked features which must be studied individually, viz. :
(a) It only occurs after certain forms of injury ; (b) it does not make its appearance till an interval has elapsed from the date of injury ; and (c) it runs a definite course and has a definite pathology as regards both eyes.

(a) *The nature of the injury* producing it may be stated in very few words : the necessary feature is perforation of the coats of the eye from without. Perforation by spontaneous ulceration never produces sympathetic ophthalmia—it must come from an external wound ; an essential preliminary is a solution of continuity arising from without. Of all forms of injury which may cause sympathetic mischief the most certain to produce it is one in which a foreign body is carried into the eye and remains there ; it is hardly too much to say that a foreign body left in the injured eye will cause sympathetic ophthalmia almost without fail. Next in order of danger are the cases of punctured wound of the eye—wounds by a fork, a pen-nib, a brad-awl, a pair of scissors, and the like. A cut is dangerous, of course, but distinctly less so than a puncture. But there are differences also in regard to precise situation : the most dangerous situation of all is the ciliary region, that band, some 4 mm. wide, which surrounds the cornea. Next to that, the iris is most dangerous, and next to that the choroid. That is to say, as a practical matter there is no such thing as sympathetic ophthalmia unless the vascular, pigmentary coat of the eye has been injured, and of that coat the most dangerous portion by far is the ciliary body. (It appears to be true, however, that sympathetic ophthalmia may, as an extreme rarity, occur in cases of neoplasm of one eye.)

(b) *An interval of time* always elapses after the injury to the first or injured eye before the appearance of trouble in the second or “sympathising” eye. The time of real danger is from the third to the sixth week after

the injury, but it must not be supposed that after the sixth week there is no longer any danger, for though the probability of such an occurrence is less it is not non-existent. The truth is that, given the reception of an injury of a suitably dangerous character, the recipient is never quite safe. Cases have been observed in which without any subsequent injury to light up old quiescent mischief in the eye, sympathetic inflammation has suddenly developed many years after receipt of the wound. This is particularly true of the cases of encapsuled foreign body, but is not by any means confined to these cases. Another point is, that sympathetic ophthalmia may appear in the second eye even after the removal of the injured one, though naturally this is very uncommon. Thus an eye may be injured on a certain date, kept under observation for a time, removed as being dangerous before a single overt sign has shown itself in the second eye, and yet true sympathetic ophthalmia may subsequently, within a day or two, or a week or two, manifest itself in the second eye. It never happens that an eye, removed at once after receipt of a "dangerous" wound, causes sympathetic inflammation.

(c) *Its Course and Pathology.*—The mode of onset of a case of sympathetic ophthalmia is somewhat as follows: The right eye, let us say, receives a perforating wound; a morsel of steel has struck it near the corneo-scleral junction, there is some hæmorrhage into the vitreous chamber, but the lens remains transparent. However, the eye does not heal up well or soundly; the scar is puckered in slightly, and the *four cardinal danger-signals* are all present. These are (1) *Persistence of injection*: when an eye has been injured in any such way it naturally becomes somewhat injected, but this injection ought to pass gradually away; but in this case, let us assume, though ten weeks have elapsed since the receipt of the injury, the iridic and ciliary vessels are still injected,

and indeed the globe as a whole is somewhat reddened. (2) *Vision has not returned.* One might have expected that by this time the vision might have become somewhat clearer ; but no, vision is feebler and less clear than it was. In spite of all that has been done the patient can do no more than just count fingers at half a metre or a metre. (3) *The injured eye is tender to touch :* you advance to touch it and the patient at once shrinks back, dreading the least touch upon the eye ; this tenderness, to be looked for perhaps when the wound is fresh, ought to have passed away in a few days. (4) *The tension is low :* sympathetic ophthalmia is very, very rarely, if ever, initiated by an eye whose tension is above normal. These four signs, all attributable to some pathological process going on in the eye, have their origin in an inflammation of the ciliary body. Well, the fellow-eye, the left in the supposititious case in hand, has begun to be watery, uncomfortable, and tender to the light, vision is not distinct, and muscæ float before it and harass the patient. There is first a fine faint injection surrounding the cornea ; this becomes more decided, until a persistent, and rather acute, iritis with implication of the ciliary body, makes itself plainly felt. At first when this occurs the cornea is clear, then there begin to be deposited on it fine spots or dots ; these lie on its posterior surface, on Descemet's membrane, and present a characteristic arrangement, for they settle down upon the cornea in the form of a sector of a circle, the base below, the apex reaching to or towards the centre of the cornea ; the larger and coarser of the spots are nearer the base, the finer near the apex ; they are of a greasy aspect, sometimes faintly tinged with brown, and are spoken of as "mutton-fat deposits" from their resemblance to the cooling gravy of roast meat (Plate VII. 4). The iris shows adhesions to the lens, at first only a few in number, but soon becoming more numerous, till at last the whole margin is

adherent, and, indeed, in a bad case the whole posterior surface of the iris becomes adherent to the lens, a state of affairs which is rarely seen under other circumstances. The iris itself is thickened, spongy, soft, and completely disorganised : there is a severe and peculiar form of iridocyclitis. The tension may at this stage be increased, sometimes it is very highly raised, but in the end it sinks again, and, as the violence of the malady passes off, falls below normal and remains reduced, the eye becoming at last quite soft.

One marked feature of the iritis and cyclitis characteristic of sympathetic ophthalmia, as has just been mentioned, is the universality of the adhesions of the iris to the capsule of the lens. In a more ordinary case of iritis the pupillary margin is apt to form synechiæ, but in the sympathetic form the entire surface of iris becomes closely knit to the lens. One unfortunate result of this is that any attempt at iridectomy is almost certain to be unsuccessful, for the iris cannot be separated from the lens. This fact accounts readily for the shrinking, atrophy, and lowered tension which manifest themselves in the later stages of the disease ; for circulation of fluid through the eye is completely in abeyance.

Unless the process is checked by some means or other, the eye will become soft, blind, "box-shaped," square-ended (altered from its sphericity, in other words), and flattened above, below, and at the two sides by the pressure of the rectus muscles. The last stage of such an eye is a soft, perhaps slightly tender, globe, with a cornea which is flat, rather glassy in appearance, and semi-opaque, undergoing calcareous degeneration ; and with no sight whatever.

Microscopically the chief feature of sympathetic ophthalmia is the dense massing in the tissues of lymphocytes along with large collections of epithelioid cells and giant-cell formation. This sort of formation is,

so to speak, grafted on to the more ordinary inflammatory changes, and is believed by some to represent the true "sympathetic" element in the process. These changes are manifest in all parts of the uveal tract, but most copiously of all in the ciliary portion. The process is a copiously exudative iridocyclitis of exactly similar aspect in the sympathising and in the exciting eye.

Sympathetic ophthalmia has always presented a great difficulty as regards its pathology ; its nomenclature is a survival of a time when the morbid changes had not as yet been studied with the same opportunities and success which the present day affords. Although in the still earlier literature some references may be found which suggest that long ago there was a suspicion in the minds of our predecessors that injury to one eye was occasionally the real cause of loss of the sight of the other, the disease as a recognised malady dates only from early last century, and much of our early knowledge of it we owe to Mackenzie.

(It is well, for the sake of those who in reading the subject in foreign literature might be confused by a divergence in the terms, to say here that in this country we use only the terms first or injured eye, and second or sympathising eye ; abroad the first eye may be called the sympathising (that is, the eye which causes the other to be affected), and the second the sympathised.)

The first fact to grasp in connection with it is that it is a *disease of the uveal tract*, a uveitis, and that unless the uveal tract of the injured eye is inflamed, and that in a particular way, true inflammation of the sympathising eye will not occur. Sympathetic cataract, sympathetic conjunctivitis, etc., are figments of the imagination : they have no real existence.

This does not mean that other parts of the eye may not be attacked also, for the disc may be reddened and a little œdematous, for example ; nor does it imply that

the first eye is necessarily in a state of acute hyperæmia at the moment of the disease breaking out in the other ; but it does mean that without uveitis, present or past, in the injured eye, sympathetic inflammation will not occur, though irritation may and often does.

So far as one can see, there can be only three possibilities to account for so singular an event : that a form of inflammation, not essentially distinct from other similar processes of the kind, spreads up one nerve (optic) or set of nerves (ciliary), and comes down the corresponding nerve or nerves to the other eye ; that some special organism causes the disease in one eye, and thence makes its way somehow to the other ; or that some unexplained blood-condition of organismal origin, but not necessarily due to one definite bacterium, is established in the patient, which by " selective affinity " causes in the corresponding tissue of the second eye an outbreak similar to that in the first. The first of these theoretical suggestions is now abandoned, as it does not explain the facts, and, indeed, is not consistent with the facts ; the second would require conditions inherently impossible ; the third in one form or another at present holds the field without a rival.

What then is our duty in regard to an eye accidentally injured ? It must, in the first place, be obvious from what has been said above, that early removal of any and every eye which has received a perforating injury would do away with sympathetic ophthalmia, but we should thus sacrifice many an eye which is capable of good work. We need some *working rule* to guide such matters ; the following may be found useful :

(1) Any eye injured beyond possibility of useful sight should be enucleated promptly. There is no use in causing the patient to run risks for the sake of a certainly sightless and probably unsightly eye. If an eye be capable of being saved, it must be thoroughly cleansed, prolapse

removed, and if possible the wound closed by a conjunctival flap: immediate treatment is of the greatest moment.

(2) An eye which, having received a perforating injury, is at the end of a month still red, of soft tension, and tender to touch, should be enucleated, whether there be a little sight in it or no. If after the lapse of three to five weeks from the receipt of the injury, the eye still keeps up indications of inflammation of the ciliary body, it is a dangerous eye and should be away. The persistence of that quartet of symptoms mentioned above, namely, continued injection, tenderness to touch, lowered tension, and lost vision, after three weeks or so is more than sufficient ground for the performance of enucleation *before* any sign shows in the second eye. To wait longer for proof in the shape of injection or departing vision of the second eye is to invite misfortune. It is good practice in many cases to try to save an injured eye, and once one has begun to do so, it is unfortunate to have to remove it after all, but in every such case the best attitude is from the first to regard the effort to preserve as frankly tentative, and only to consent to make the attempt on the clear condition that beyond a certain point no further attempt will be made.

(3) An eye which, having at some previous time, it may be years before, received a perforating injury, has, after lying quiescent, again become painful, injected, and tender, should be enucleated, even should it still possess a little vision. The reason for this rule is that there is in fact no limit to the time which may elapse between the original injury and the evil consequences to the other eye. An eye may remain perfectly quiet for years and then, with or without some obvious reason, such as a trifling knock upon it, suddenly the peculiar form of iridocyclitis which leads to sympathetic inflammation becomes wakened up in it and the harm is done.

(4) If sympathetic irritation (not inflammation) appears in an eye several weeks or months after injury to the other, the injured eye should be removed. It is true that irritation *may* not be the precursor of genuine inflammation, but the danger that it will prove to be so is too serious to be neglected.

(5) When true sympathetic inflammation has appeared in the second eye the case becomes very difficult. Should there be any sight at all in the original eye, it ought emphatically not to be enucleated, because the ophthalmia of the second eye may readily be more completely destructive of vision than the accident was, and one would then have sacrificed the only eye which in the end would have retained any sight. If there be any sight then in the injured eye, do not remove it. The case is different if there be no sight in it, and opinions are divided; some advocate removal on the ground that one removes the focus of all the trouble; others say No, for you thus stir up the source of evil, and deluge the other eye with quantities of phlogogenic material. Probably enucleation is the wiser course, but there is no hard and fast rule.

The *treatment* of the sympathising eye itself is very far from encouraging. The malady is a uveitis, and therefore must be attacked by means of atropin primarily; hot applications give much relief, at any rate to the symptoms; mercury should be pushed. Recently certain writers have highly praised the giving of massive doses of salicylate of soda. The patient, whose health is always greatly below par, and whose mental distress is deplorable, requires most careful building up, open-air exercise, encouragement and cheering as far as possible.

It is essential that one should realise the necessity of *not touching the eye* in the hope of reducing the tension, etc. The tension may rise above normal on account of the binding down of the iris by adhesions, but nothing

should tempt one to operate until the eye has again become absolutely quiet and free of injection. What happens after an iridectomy performed too soon is that the gap simply closes up again with a sort of spongy mass of exudate, the wound pouts, and iris protrudes through it, and so far from doing good one has done unmixed evil. No matter how complete the adhesions, no matter how high the tension, not till the eye has been absolutely quiet for many months should it be opened by operation. Then, but not till then, some vision may be obtainable if one is able to make and keep clear a path for light through the spongy iris, opaque lens with its thick coat of plastic exudate from the inflamed iris and ciliary body, and the semi-opaque vitreous. This can really only be accomplished, if at all, by three operations: an iridectomy, then extraction of the lens (these two may be combined), and then cutting out a portion of the thick mass of fibrinous matted material occupying the situation of the former pupil.

CHAPTER XX

MEDICO-LEGAL QUESTIONS

THE eye is susceptible of severe and ready injury, and is essential to—practically—all kinds of work ; no wonder then that in regard to numerous cases, some of which reach the Law Courts and some are settled outside them, the surgeon is often consulted as to the amount of injury done and the genuineness of the claim made for compensation for injuries.

In the first place *occupations* may be classified into those for the proper conduct of which good vision in each eye and binocular vision are required ; those which require binocular vision but not necessarily good vision ; and those which cannot be said to necessitate either good vision or binocular (stereoscopic) vision. Of the first class may be mentioned as examples cabinet-makers and policemen ; the occupations of such men cannot be performed without good central vision, peripheral vision, and binocular vision. As examples of the second class may be mentioned masons and painters ; of the third class, labourers and gardeners. In estimating the degree of incapacity from which a man has been made to suffer as the result of an injury, the nature of his occupation must be taken very carefully into account, for an injury which incapacitates a mason might do little harm to a pavior. Three points have to be taken into special consideration, namely, central

(macular) vision, field of vision, and binocular vision. In regard to *macular or central vision* it is obvious that this must be retained in one eye at least for any occupation, and here there are certain fallacies and sources of error which are not sufficiently recognised. Notably this to begin with:—For the most of occupations, even of mechanical occupations, the average man is provided with accuracy of vision in excess of what is actually required; something very much less than $\frac{6}{6}$ is ample for a blacksmith, a lawyer, a book-binder, a farm-servant, a physician, an upholsterer, etc. Further, that in estimating vision by means of the distance types we are applying a fallacious standard. Thus, to take one of the examples given above, to an upholsterer as such, $\frac{6}{8}$ is a luxury rather than a necessity—what he wants is to see well at 10 to 30 inches, and so with many other occupations. The distance at which work is carried on should be carefully kept in view. Another point is that, in spite of what some say, one ought to disabuse one's mind of the idea that such an expression as $\frac{6}{12}$ implies that the person whose vision is represented by that symbol possesses only one-half of the normal amount of sight. Such an idea would be entirely fallacious. The cause of the reduction in vision is no less important: thus a nebula of the cornea which causes astigmatism and thus reduces vision to $\frac{6}{24}$ may be much worse for a paper-hanger than 4D of myopia would be with $\frac{6}{60}$ or even less. The previous condition of the eye hardly receives due attention: how different will the effect of traumatic paralysis of accommodation be upon a hypermetrope of 2D and a myope of 5D! Of the field and of binocular vision we shall have something to say presently.

It goes without saying that in testing the condition of a claimant for compensation one must approach the matter with an unbiassed mind, and be prepared to

meet with either a perfectly honest and just claim, an honest but mistaken claim, an honest claim intentionally magnified, or a false and dishonest claim.

The surgeon should note with precision the vision of each eye separately, taking that of the worse eye first as a rule, should observe with care the exact state of the injured and also of the other eye, should keep a record of any pathological condition found, such as a fine nebula, an irregular pupil, a subluxation of lens, etc., and should be specially careful to examine the uninjured eye for any similar appearance. He should also receive a precise account of the accident itself, its nature and date, and any details regarding it, that he may be in a position to decide whether the lesion as it appears to him could have been produced by the accident alleged. No hint should be neglected which the state of the other eye is capable of supplying. To give one or two examples,—evidence of old strumous ophthalmia, which most probably was bilateral even if not admitted by the claimant, or of myopia for a similar reason, or of spicules in the lens.

Putting aside meantime the question whether the exaggeration of the disability is involuntary or wilful, it is well to discuss what *errors* the claimant is apt to make in putting forward an exaggerated or false claim. It is seldom that any claim is made unless there be some external sign of injury, such as an opacity in the cornea. Three untenable claims are apt to be made in such a case:—(a) the *central vision* is often stated to be *worse* than the opacity will account for. It is difficult to lay down rules for such cases as there is no recognised standard of depth of opacity, and even if there were the amount of astigmatism accompanying the nebula varies greatly. The conduct of the client often, however, gives one much information: if he, having only a moderate opacity, denies ability to read the types, and

"looks for" the board, directing his eye any way except the correct way, or if he sees $\frac{6}{24}$ yet reads no more lines when, after a judicious interval, he is brought nearer the test-board, that should arouse suspicion. Or he may find much improvement in sight from two lenses in combination which, when superposed, neutralise one another. (b) He sometimes asserts that the *field of vision is very small*, although the injury is of such a nature that it could not affect the field. Thus it is not uncommon to "claim" to have a very small field as the result of a nebula. In such a case the reduction is often excessive, much greater than is ever the case apart from pigmentary retinitis or from atrophy, in which case the nerve head is very white. (c) The claim may be made that the injury to one eye has produced *sympathetic trouble* in the other. Now if there is one thing clear in the difficult subject of sympathetic trouble, it is that apart from penetration of the globe there is no sympathetic inflammation of traumatic origin. If it be sympathetic irritation merely (which of course may occur without an actual wound) of which complaint is made, there should be no restriction of the field of the second eye: this claim is often made however. In such ways the claimant is often apt to assert too much. Care must again be taken here to recognise a genuine traumatic hysteria which does occur even in very unlikely persons, and which is a true disease; it is not easy to distinguish between this and mere wilful exaggeration. One may be helped by inquiry as to the presence or absence of the helical field of hysteria, but that is not a symptom on which very much reliance can be placed.

Malingering and wilful exaggeration of admissible deficiency are only too common; "Ergophobia" is a very common disease; it is therefore necessary to have at hand a number of tests applicable to different degrees

of loss of vision. In the case of a person whose aspect of eye suggests that he might quite well read $\frac{6}{18}$, let us say, and Jæger 2 or 3, but who denies ability to read at all, Harman's modification of Remy's diploscope is occasionally very useful. The instrument consists of a rod about 16 inches long, one end of which is placed on the client's upper lip; the other bears a little carrier on which can be placed any of a series of cards bearing a few words of print, numbers, etc. Four inches from the card on the rod is a screen with a central aperture; through this the right eye can read the middle of the line of words and the left-hand words or numbers, the left eye can see the middle and the end of the line. The inexperienced person does not readily guess that what is over to one side is seen with the *other* eye, and is apt to commit himself to conflicting and impossible statements if he be a fraud. In using this test, as in all similar tests, it is necessary to keep a strict watch lest he close one eye momentarily in order to find out how much he may safely admit. In a case of similar type, a convenient plan is to place before the sound eye a strong convex lens (8D) and show him that he can read quite well provided the print be held at a short distance (5 inches or less); as he continues to read, gradually and unostentatiously the print should be drawn away from the eyes, and if this be read at a distance greater than 5 inches the reading must have been done by the "blind" eye, which has been furnished with a plane glass. The bar-reading test (p. 353) is very useful also.

The real integrity of a pretended-small *field* may sometimes be proved by the client's expertness in picking up a pin or small scrap of paper which the surgeon "carelessly" drops while speaking to him, by his skill in finding his cap placed in a position outside his field, avoiding obstacles in walking, etc.

The tests suggested above are such as may be carried out without the use of elaborate apparatus, such as the general surgeon is not likely to possess. There are numerous others, such as the coloured letter : A word is made up of alternate red and green letters in coloured glass ; this is hung up on a window, and the client is asked to read it while wearing a green glass before one eye and a red one before the other. Since the green glass will allow green rays alone to pass through it the red letters will be invisible through that glass, and the green letters invisible through the red glass. If, therefore, the claimant is still in possession of vision with each eye, he will read the whole word ; if not he will only read those letters of one colour. The word usually chosen is FRIEND, the first, third, and fifth letters of which make a known word, as do also the second, fourth, and sixth. It must be plain that a smart person can easily "dodge" this test. Letters of this sort, but printed on paper, have recently been also introduced, parts of which are rendered invisible by the use of certain coloured glasses.

When the client asserts a more "deep" loss of vision, other plans may have to be tried. A good and simple test for loss of binocular vision is to ask him to dip a pen in an ink-bottle, or to pour water into a cup ; to do these correctly binocular vision is required, at least until experience has taught a one-eyed man to become nearly as skilful as a two-eyed, a process which takes a period of six to twelve months. Another plan is to place a book or board so as to form a horizontal plane on a level with his eyes, and on it to drop a pin or small morsel of paper, not larger than a threepenny piece. A person with binocular vision has no difficulty whatever in touching this with his finger instantly and without hesitation or searching, while one who has recently lost binocular vision will certainly fail ; a malingerer will take

great care to fail, and will certainly show that he is doing so.

Another plan is to produce diplopia by placing a prism, apex or base upwards, before one eye; if it be placed apex inwards, the eye involuntarily executes a rapid correcting movement of convergence which the most expert swindler cannot prevent, but it is not always easy to be sure of this as the prism alters the apparent position of the eye as seen by the surgeon. The test is one soon learned by the expert claimant, but he can often be circumvented by a simple ruse:—Hold in front of the sound eye, while the “blind” one is closed, a prism, apex up, in such a manner as to cover half of the pupil only. The client will then readily admit (uniocular) diplopia, when the surgeon should ostentatiously withdraw his covering hand from the “blind” one and at the same time quietly slide the prism up so as to cover the whole pupil; the diplopia then becomes binocular without the client’s knowledge of the change.

The loss of *binocular vision* is serious, as must be admitted, whether the loss be due to high anisometropia (as when one eye acquires traumatic cataract) or to muscular lesions (from severance of a muscle or interference with its action). One of the serious inconveniences from which a man will suffer who *loses one eye* is the *loss of the sense of distance*. There are three principal factors in our knowledge of distance or the third dimension of space, namely, accommodation, convergence, and the difference between the two images. We form an idea of the position of an object, then, first from the estimate of the amount of accommodation required to give one a precise image of it, an effort which is greater the nearer the object is; second, from the estimate of the amount of convergence exercised in the endeavour to turn both maculæ upon it, which again is greater the nearer the object is; thirdly, from

the fact that the nearer an object is to one the more does the image obtained by the right eye differ from that of the left, their point of view is different. *Loss of binocular vision* manifests itself in inability to judge distance accurately, the patient missing his ink-bottle with his pen, putting down his cup short of the table instead of on it, and so on. This symptom may not be manifested at all if sight in one eye is lost slowly, but is always present if a good eye is lost suddenly or rapidly. It is however little short of marvellous that Nature manages to overcome even this difficulty, and after the lapse of nine to twelve months a man who has lost one eye is as little awkward, under normal conditions, as a two-eyed one. A great deal, however, depends on the age of the individual, and this is a point which should invariably receive consideration in one's estimate of the injury done, for a young person will adapt himself to the new conditions very much more rapidly and more completely than a man past middle life can do.

In these days of compensation for injuries received during work, it is often necessary for the surgeon to examine a claimant, to report upon his case, and, it may be, to give evidence regarding him in court. The surgeon to any hospital, too, must be ready to regard any of his patients as claimants; he will do well, in view of this fact, to keep a short jotting, however brief, of each patient who presents himself. It may be of immense value later to know regarding A.B. that when he first came to seek advice he attributed his condition (hypopyon keratitis, let us say) to "cold," and had received no injury; had once had inflamed eyes ten years ago, the condition had always been apt to return in the winter, or some such story; if he only "recollected" receiving an injury after going home and discussing the prospects with his friends, some doubt may not unnaturally be cast upon the genuineness of his claim.

The following pieces of advice to the examining surgeon may prove beneficial:—

Always keep a note, in regard to any suspicious condition, whether it arose of itself or not.

Approach any case in which you are asked to report with an unbiassed mind; be prepared to find perfect honesty or dishonest greed: both conditions exist. In the case of a person, one eye of whom has received an injury, always note the state of vision of the *other* eye immediately, at the first examination: the knowledge may be very useful subsequently.

Take pains in conducting your investigation; omit nothing which could throw light on the case. It puts a witness in a foolish position when he is asked, "Did you observe such and such a symptom in the case of A.B.?" and he is obliged to say, "No," even though he may be well aware that the motive of the question is not what it is meant to appear on the surface.

Let your report be couched in simple, untechnical terms; if any of these are required they should be explained. State your conclusions plainly, simply, in simple language, and avoid adjectives, such as "a desperate wound," "a fierce blow."

It may be that you are consulted regarding an eye which is quite quiet and free from any injection; if so (and, indeed, in any case) be cautious how you attribute the present condition, opacity of cornea, cataract, detachment of retina, or whatever it be, to some alleged accident regarding which you know nothing at all. The utmost you can safely say is that the condition at present is attributed by the litigant to such and such an injury which he is stated to have received, and that the present state is consistent with such a history.

In your report do not argue points, state them and your conclusions, introduce no speculations or irrelevant information, keep to the facts as they are, and take care

that you do not omit any which may bear upon the question.

In giving evidence, speak frankly and speak well out, conceal nothing, and (especially in presence of a jury) use the simplest possible expressions which will convey your meaning.

Recollect that your only right to be where you are is that you are called to tell the truth. You are called by the injured man, it may be, or by his employers, but you are called as a witness, not as a partisan ; it is not your business to argue the case.

When asked a question make sure you know exactly what the question means ; consider, and reply straightforwardly.

Never attempt to appear cleverer than you are, and never be funny. You are not called to a Court of Justice to make jokes ; it may be if you have a sense of humour that certain amusing ideas will come into your mind in the development of the case. Do not give utterance to them. And never lose your temper ; you may be asked annoying questions, but keep cool ; the man who loses his temper is apt to make statements which he cannot substantiate, and so to discount the value of all his evidence. Never argue with counsel ; even if you are right you and he are not on equal terms ; you are an amateur at controversy, he is a trained expert.

Remember that other considerations may enter into a case with which you have no real concern, but which may outweigh the value and importance of those with which you have to do. What seems to you a trifling and unimportant side issue may in the eyes of the law be far more serious than all that you have said in regard to your own province ; the scene is a Court of Law, not a Court of Medicine.

A very important consideration often forgotten both by surgeon and by client is that the law does not con-

template the granting of compensation for loss of an eye or a finger or a limb, but for loss of ability to earn a livelihood ; a man for example is not entitled to compensation because he has lost an eye if he can readily earn his former wage at his former trade with his other eye. This is a matter about which there is much misapprehension, and, it is to be feared, much disappointment. The legal aspect of the case is however not merely comprehensible, but perfectly sound and reasonable ; if the worker is deprived of his ability to make his living while working in the service of another, he should receive compensation, but if he is not deprived of this power, he can command his price as before. On consideration this will be seen to be quite as fair, quite as equitable to both parties, and not more liable to produce hardship in individual cases than if the law had been that an injured workman should receive so much percentage of his former wages for the loss of an eye, so much for the loss of a thumb, etc. ; and at any rate it is the *fact*.

Many and ingenious have been the attempts to devise a formula or formulæ by means of which to calculate the loss of efficiency incurred as the result of injury ; and much clever work has been expended in this relation by Magnus, Zehender, Berry, and others. But the factors are so numerous and conflicting that it is difficult to see how they can be made amenable to formulæ, and the sources of error are innumerable. Thus there should be taken into account not merely central vision, but also field of vision, binocular vision, the occupation of the person, his age, the nature of the lesion and—besides other matters—his personality, none of which are really capable of being expressed in figures almost any more than moral qualities could be. To take one illustration, the field of vision : A man receives a severe blow on the head, in consequence of which he is attacked by hemianopsia. This is complete, but non-progressive.

At first sight one might say that a man who had lost half his fields had lost half his sight, but that is not so, for he retains central vision, the most important part of sight.

Again, it is worse to lose the right half of the field than the left, because, as we have seen, the former loss interferes more with reading than the latter. Again, is the loss of the two half-fields equal to the loss of one eye? Is the condition of another man who acquires post-traumatic detachment of retina worse or better than the hemianope? The affection of the field is less in scope, but the prognosis is more gloomy.

These illustrations given above will suffice to show the complexity of the circumstances which must be taken into account, and the impossibility of reducing it all to a mathematical equation.

CHAPTER XXI

OPERATIONS ON THE EYE AND ITS APPENDAGES

THESE are legion ; one is tempted sometimes to wonder whether every ophthalmic surgeon has as the summit of his ambition — to have his name attached to some operation. In some cases they are but trifling modifications of the methods in use, required for a special purpose, and it would be impossible even to name (far more to describe) the various methods. Naturally this is specially true of the methods suggested for reparation of a lost eyelid ; for example, while one surgeon prefers to borrow from the cheek, another chooses the upper lid or forehead, and a third the arm. It will not be necessary to do more in regard to each type of operation than to describe a few methods which are in common use. There is no pretence that more than a few selected operations are described or even mentioned in this book.

In operating on the eye and its adnexa the surgeon should realise that the area in which he works is not capable of being made aseptic in the strict sense of the word. It is impossible in the case of the eye to employ such reagents as might have sufficient bactericidal power to rid the conjunctiva of its denizens. Even weaker solutions which might be regarded as bactericidal provided the contact be sufficiently long, are unsuited to the delicate tissues of the eye. So strongly do some surgeons feel impressed by this fact that, since they

dare use no lotion which could be fairly called "antiseptic," they have discarded all nominal antiseptics, and rely upon the cleansing effect of a stream of normal saline rather than risk irritation of an eye by a chemical substance which is incapable of doing good save mechanically, and yet is capable of producing serious injury to the delicate tissues. For it is a fact true of the eye even more certainly than of other parts that any substance which, when applied, is potent for good, is potent also for evil, because the tissues of the eye are naturally so delicate that their vitality is very readily lowered, which means that they will fall an easy prey to the pathogenic organisms which may have been "scotched but not killed." The familiar boracic lotion, for example, might be antiseptic if left for a good many minutes (or perhaps it might require some hours) in contact with the organisms of the conjunctiva; since this, in the nature of things, cannot be, it probably acts purely mechanically, and if that be so it appears to a number of surgeons that it is wiser to employ saline than boracic, since in at least a few cases considerable reaction follows its employment. To a still larger proportion of eyes corrosive sublimate lotion is inimical even in the extreme dilution in which it is used.

Few differences in the practice of different surgeons are more striking than the varying rules for the preparation of patients for operation; what one regards as vital another contemns; it is impossible to frame universal rules. One must endeavour to strike a mean between the happy faith of the man who considers elaborate precautions needless because necessarily ineffective on the one hand, and the meticulous faddiness of another who "leaves nothing to chance," and risks the success of his best efforts by harassing and irritating the eye on which he is about to operate.

Preparation of the Patient.—It ought to be laid to

heart more than is done that all needless preparation, all treatment which is not called for, all drugs which are not in point of fact required, all operations which can fairly be done without, all these constitute treatment in excess of what should be, treatment which is a source, therefore, not of strength, but of error and of danger. The preparations for operation ought then to be of the simplest, but one must not be too dogmatic in regard to details because opinions differ as to what may be considered the minimum necessary. To secure restfulness for the patient afterwards, and to "purge out the vile humours" which may be present and be hurtful, he should have a gentle aperient the day before. He should have a warm bath the night before, and the eyes should be well bathed out with one of the mild antiseptic lotions in common use (boracic, corrosive sublimate, permanganate of potass, etc.). The washing of the conjunctiva may be repeated in the morning. In Indian practice it seems to be not uncommon, at the hour of operation, to employ a solution of corrosive sublimate of a strength far greater than could be tolerated by the European conjunctiva, and that with advantage, or at least without obvious disadvantage; the disadvantages here would be very evident. The patient should breakfast much as usual, at all events take food a couple of hours before the operation; it is not good to be "empty" or to require food too soon after the operation.

Assuming that the operation is one of Extraction of Cataract, let your patient have dropped into the eye a solution of cocain, 4 per cent, a couple of drops at a time, at two or three minutes' intervals, for the last ten to fifteen minutes before the operation is to be begun. There is no special virtue in the particular strength named, some surgeons prefer it weaker, some employ it stronger, but whatever be the concentration employed the patient should keep the eye closed after each

instillation, otherwise the epithelium of the cornea is apt to become dried from exposure without the customary moistening by the upper lid (for the involuntary wink is in abeyance when cocain is instilled), and to peel off on the slightest touch. To epilate the eyelashes, as is done by some surgeons, is to be deprecated. At the operation itself the patient should be laid upon a table or couch (an ordinary sofa is perfectly suitable) with his feet to the window, dressed for bed, but well covered up. In this country it is usual always to stand above the patient's head, and to hold the knife in the right hand for the right eye, in the left hand for the left eye, but some, distrusting their left hands, prefer to operate on the left eye standing by the patient's left side. In certain continental schools the custom is entirely different. At the operation it is best to employ no antiseptic lotion, but normal saline only. In cataract operation one must have not merely the confidence but the co-operation of the patient; it is good, therefore, to speak a little to him beforehand, distracting his attention somewhat, encouraging him to be confident that the biddable patient feels no pain, that he has only to try calmly to do what is asked of him in the way of looking up or down. The antiseptic-soaked veil before the mouth may be good, but the placid confidence and prompt co-operation of your patient are much better. Some surgeons advocate the application of a bandage for one night (at least) before the operation in order that the reaction of the eye to dressings may be tested. No condemnation of such test-dressing of the night before is too strong; it necessarily raises the septicity of the conjunctival sac to a maximum or reduces its asepticity to a minimum just at the precise moment when the cleanliness of the conjunctiva is the most valuable asset the patient possesses; it can do no earthly good and may do much irreparable harm.

The **preparation of the surgeon** is not less important perhaps than that of the patient, but much more difficult to deal with. It is not suggested that anything less than perfect cleanliness is required, but since the hand never comes in contact with the wound that extreme ablution-ritual which is recommended for, say, abdominal operations, is not a necessity, and any procedure which tends to roughen and harden the hands or to make them less sensitive is to be deprecated. One thing is of vital importance—the surgeon must have full confidence in himself; this is not the same thing as self-confidence, rather the antithesis of it. He must feel that he knows what he is going to do and how to do it; he must know what difficulties are liable to crop up and how to meet them; he must have complete command of his own nerves and his own temper, and, if he is to be a skilful and successful operator, be perfectly cool, though not by any means indifferent, under all shocks. There can be few circumstances more alarming to a patient, and more calculated to produce disaster to him, than to find himself in the hands of a surgeon who has manifestly lost command of himself. In his early days a little shaking of the hand is no indication of inability on the part of the surgeon; he will get over that, while an abnormally steady hand at his first cataract operation may indicate that sort of over-confidence which goes before a fall. And for his comfort and encouragement let him know that there have been surgeons of vast experience and great skill whose hands, after many years of first-rate work, still have trembled like the traditional aspen leaf.

Preparation of the Instruments.—Than boiling there is no better means of preparation, but some are a little apt to forget that this does not cover all the ground, and instruments should be cleaned thoroughly as well; fragments of A's iris, even if carefully boiled, will do B's eye very little good even if they should by some

miracle do him no harm. But boiling is unsuited to the knives and other edged or pointed instruments, and unsuited likewise to such as may be made of tortoise-shell, caoutchouc, etc. Some surgeons, it is true, boil their knives, just as some boil their cocain, in spite of proof of the injury done to the instrument or the medicament. Perhaps the best method is to "strop" the knife very gently from handle to point, running always from back to edge, upon a pad of wool soaked in 1-20 carbolic or lysol and then to wash this off most thoroughly in alcohol and then in boiled water; soaking alone is not enough, for it does not clean the instrument of any greasy film which may have adhered to it. It is preferable to use all the instruments dry, lest water should run down into the wound, bearing with it one knows not what contamination.

OPERATIONS ON THE EYELIDS

I. For Ptosis.—For the relief of ptosis, whatever operation be selected, the principle must be clearly grasped that the condition must not be cured, for if it is—that is, if the patient's affected eye is so altered as to be wide open when he is looking straight before him—too much has been done, and the eye will not completely close during sleep; the result of this would be an exposure ulcer of the cornea and a nebula, if not worse. We must improve the condition but not anchor the lid so high that it will be unable to come down fully and easily. There are four lines along which one can work:—

1. By *removal of a piece of skin* and by insertion of long stitches subcutaneously to the eyebrow one may hope to excite sufficient tissue reaction to produce cicatricial contraction and draw up the lid. In the present day, however, this insertion of stitches is of no use; when antiseptics was unknown such a stitch did its work by exciting a considerable amount of suppuration and

consequent contraction in the tissues ; nowadays, what with asepsis and boiled threads, the foreign substance is introduced, lies a certain length of time in the tissues, and is then removed, without any reaction and consequently without beneficial result.

2. *By enlisting the services of the occipito-frontalis.* When the elevator is paralysed all elevation is done by the occipito-frontalis ; this is indicated by the elevation of the eyebrow, which is always present, and by the fact that if one puts the occipito-frontalis out of action, as one can readily do by placing the palm of the hand firmly on the forehead, the lid hangs down completely and cannot be elevated at all. Probably the best method of action along this line is that of Hess. A long incision is made along the eyebrow, and from this the lid is opened up like a bag right down to the ciliary margin. A double-needled stitch is then inserted, the two punctures about 3 mm. apart along the horizontal line, which is seen as a fold in the normal lid, almost on a level with the upper margin of the tarsal plate. The two threads pass up free inside this "bag" and are passed deeply into the tissues at the upper margin, passing close to the bony edge of the orbit and emerging just above the eyebrow. Three such stitches should be inserted in the length of the lid. When these are drawn tight over drainage-tubing they permit a large area of tissue to form new adhesions, and one is thus not dependent upon merely a linear new attachment but secures a broad area. The lid in this way is drawn into close association with the occipito-frontalis, which has thus much greater purchase upon it. The skin wound should be stitched before the special stitches are drawn tight, as much neater co-aptation is thus secured. The chief error into which a beginner is apt to fall is in not passing the stitches sufficiently deeply into the supra-orbital tissues, and thus losing grip. Needless to say, the large opening up of tissue through a

comparatively small incision affords a considerable risk of septic infection, but the precaution frequently taken of shaving the eyebrow is perfectly unnecessary and considerably hinders the patient's return to public life. It is better to paint the eyebrow with tincture of iodine.

3. *By enlisting the services of the superior rectus of the globe.* This operation, which was devised by Motais, proceeds upon the incorrect assumption that elevation of the lid is associated with elevation of the globe, and that by anchoring the lid to the superior rectus one meets the indication. The operation gives apparently a good enough immediate result, but the superior rectus is a weak muscle which must be still further weakened by withdrawing certain of its fibres for the benefit of the lid, and the considerable risk of producing diplopia thereby is sufficient to make one hesitate before accepting the operation as upon a sound method.

4. *By drawing forward the levator itself.* In this method one cuts down upon the expansion of the tendon as it spreads out to attach itself to the cartilage; this is then picked up in a series of three double stitches which are brought down to the margin of the lid, where they are knotted over beads or drainage-tubing. By this means the tendon is tucked on itself and shortened. The plan is fairly successful.

II. For Shortening of the Lid Aperture.—In chronic conjunctivitis of any origin, but most of all in cases of trachoma, narrowing of the palpebral aperture from end to end gives rise to much distress, causing pressure on the cornea, irritation by lashes, etc. For relief of this *canthoplasty*, or enlargement of the aperture, is performed, as well as in cases of violent and persistent blepharospasm. One blade of a pair of strong scissors is introduced into the conjunctival sac and pushed through the lid tissues precisely in line with the palpebral aperture; the scissors are then closed and a free

opening is obtained. Hæmorrhage is pretty free, and after it has been checked three stitches are inserted, one in the very angle, one in the upper, the other in the lower lid, each uniting conjunctiva to skin, the operation thus increasing the length of the palpebral aperture and diminishing the compression exercised by the orbicularis.

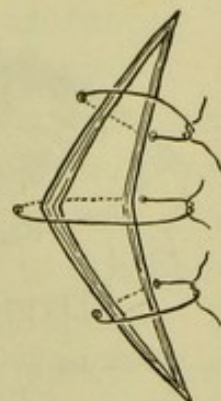


FIG. 63. —
The stitches in
canthoplasty.

III. For Ectropion.—Since the cause of ectropion, or turning out of the (lower) eyelid, may be either contraction of the skin of the lid drawing out the edge or redundancy of conjunctiva pushing it out, procedure may well differ according to circumstances. Should contraction be the cause massage without operation may sometimes effect a good deal, and if one has to operate, the question is of importance whether the whole lid is everted or only a part. If the whole be everted, as may arise from cicatricial contraction of a burn-scar or from caries of the bones in the neighbourhood, Wharton Jones's or the V Y method is useful. In this procedure one makes a deep V-shaped incision below the lower lid, the open base of the V towards the lid, and embracing most or all of it; the apical portion is dissected up so as to free all adhesions, so also are the sides of the V, the lid compelled to come into proper position, and if necessary stitched to the other lid to keep it so for a time, and then the margins of the V are drawn together so that the figure is transformed into a Y.

Where only a portion is everted, as happens often enough after caries in the malar bone, the lid margin will be found to be of exaggerated length, and the best procedure is to remove a wedge-shaped portion, the base of which is formed by the redundant edge, the apex being in the conjunctival portion and the fixed-down skin. When the gap is stitched up the position is much

improved. It is sometimes useful to place the offending lid in position and sew it thus, attaching it to the upper

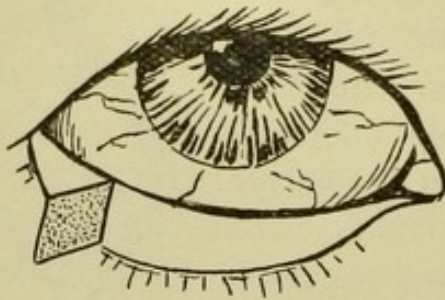


FIG. 64.—Operation for ectropion.

lid ; and to get it in position divide freely any bands or striæ which interfere, and on the raw surface thus prepared plant a skin graft.

When redundancy of the conjunctiva is the cause there are few methods superior to that of applying the cautery

along the inner side of the eyelid, right down to the cartilage, and not more than 4 mm. or so from the margin. The immediate effect of this procedure is naturally to take away any restraining influence which the tension of the tissues offered to the very disease which one is anxious to combat ; after a day or two cicatricial contraction however begins, and the firm contracting scar which one secures after a burn does much to hold the lid in good position.

Senile ectropion, the sagging and hanging out of the lower lids which is to be seen in old people, is really partly due to laxity of the orbicularis in particular and of the tissues generally, partly to chronic hyperæmia of the conjunctiva, partly to contraction of skin resulting from irritation produced by the lachrymal secretion, and the organisms contained in it, running over and not being properly taken up by the everted punctum. It may be treated by means of the cautery, as has been said, or by the introduction of Snellen's sutures. To introduce these take a couple of large half-curved needles on one stout thread, introduce each into the conjunctiva at the most elevated part, pass the needle down in the tissues of the cheek, and make it emerge on the cheek about an inch and a half below the lid margin. The second needle emerges close alongside the first, when the two are drawn

tight over a piece of drainage-tube. Two or even three such stitches may be introduced.

IV. For Entropion.—Senile entropion or turning in of the (lower) lid is often complicated by the existence of spasm of the orbicularis. The non-spasmodic element is frequently treated by excision of a strip of skin from the lower lid, a procedure which, if successful, is only so if too much precious skin is removed, and is often very transient in its good effect. Unless the incision be carried down to include the orbicularis muscle there need be little hope of permanency. This operation, just as in the case of ectropion, is best performed with

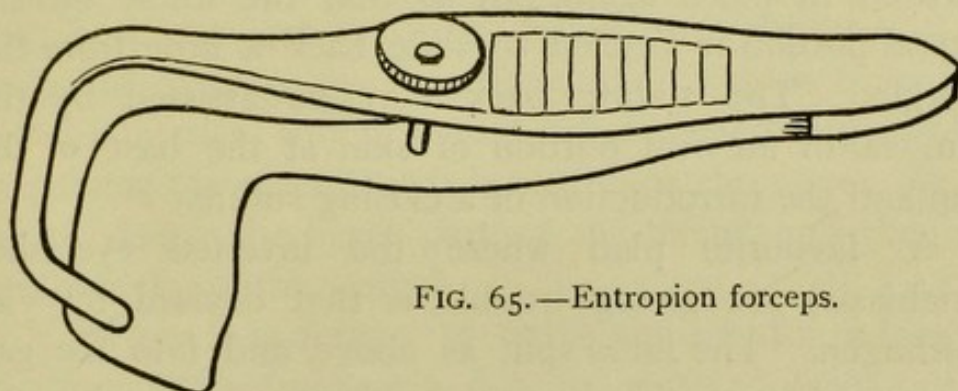


FIG. 65.—Entropion forceps.

the cautery, and for the same reasons. A milder measure is the insertion of stitches (Gaillard) which pass from the lid margin under the skin to emerge about three-quarters of an inch below, where they are tied over drainage-tubings. They are left in from four to seven days.

For organic entropion, such as is produced by the long-continued cicatrisation of trachoma, more elaborate methods are required. One needs to bear in mind three considerations, namely, the scantiness of tissue, the malign influence of the hairs upon the globe, and the incurving of the tarsal cartilage. Thus some operations fail because tissue is sacrificed, others because no account is taken of the faulty hairs, others because skin alone has been dealt with, and the firm unyielding

cartilage untouched. These different results of entropion may be met by different methods of operating.

Von Graefe's method continues to be much used, especially, perhaps, in cases in which only a portion of the lid requires treatment. The lid (or the offending portion of it) is split along the "white line" in such a manner that the anterior flap contains all the hair bulbs, the posterior consisting of cartilage and conjunctiva alone; this incision should be at least 4 mm. deep; failure in this point is a frequent cause of inefficiency. At each end of the split a short vertical incision is made in the anterior flap, and the corners of the flap thus made are sutured in place again, but so that the whole quadrilateral portion is caused to slide back a little from the margin. The sliding back may be assisted by the removal of an oval portion of skin at the base of the flap and the introduction of a closing suture.

A favourite plan where the inverted eyelashes (trichiasis) are giving trouble is that devised by Van Millingen. The lid is split as above, and into the gap is inserted a strip of mucous membrane taken from the lip. In obtaining this strip one or two points should be attended to: Touch the graft as little as possible with metal instruments; to secure this point, fix the lip in a lid-clamp, outline the flap desired with two parallel incisions, and instead of beginning at one end and stripping the graft off the submucous tissue while the delicate tissue is held in forceps, tunnel underneath at two or three places with a sharp knife, and the strip can then be removed with the greatest ease. Pass a stitch through each end before it is separated from the lip; this enables one to fix it in place instantly and without touching. Introduce only the minimum of stitches required to keep it in place. (Some advise that none at all be used.) Do not pull any stitch you use quite tight, and take into it a generous pad

of tissue; do not include merely the margin of the incision.

In the cases in which incurving of the tarsal cartilage is a factor of importance, as it is in many old-standing cases of trachoma, it is not enough to attack the soft parts and the cilia: one must attack the cartilage itself. A good method is, having fixed the lid in a clamp, to make two parallel incisions through the skin and muscle down to the cartilage, about 3 mm. apart, running the length of the lid; clear the tarsal cartilage of muscle fibres in that situation, and cut out a long prism or wedge of cartilage, its base forwards, its apex touching the conjunctiva, which should be respected if possible. In passing the stitches it is best to tack the upper lip of the incision to the lower part of the tarsus, and then to the lower lip of the wound.

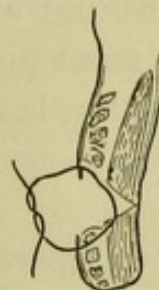


FIG. 66.—Operation for entropion.

Tarsal cartilage grooved and stitch introduced.

V. When it is desired to **unite the lids** for a length of time, or permanently (as in certain cases after enucleation, in severe proptosis of exophthalmic goitre, etc.), it is convenient to “raw” the middle portion of each lid for a few millimetres, just posterior to the line of the cilia; these raw surfaces are kept in contact by a horse-hair stitch for some days till they unite. By this means, after enucleation, one can prevent the falling in of the upper lid which entails so much irritation of the conjunctiva by the eyelashes, in a case in which for any reason an artificial eye is not to be worn; at any subsequent time the band can be divided if desired. In excessive exposure of the cornea one may be able thus also to preserve the eye from total loss.

VI. For Epicanthus.—The simplest procedure is to pinch up in the middle line enough skin to cause the two abnormal folds to disappear and to remove decidedly

less than that amount, suturing the wound thus made exactly in the middle line. Another plan, which is considered to be superior, is to remove from the side of the nose a piece of skin shaped like two triangles united; the wound when sewn up becomes linear and is invisible. The great point to remember in the rare cases in which operation is required is to under-correct the defect.

OPERATIONS ON THE CORNEA

Few operations are performed upon the cornea proper. Sometimes in the case of a badly-healing or persistent ulcer a plan suggested by Da Gama Pinto is useful: it consists of freshening the ulcer and drawing over it a loosened tongue of conjunctiva, which adheres and assists in the healing process. The operative treatment of *conical cornea* is referred to under that disease. *Tattooing* is indicated after certain forms of ulcer of the cornea which have left behind a dense white scar which is both unsightly and inimical to good sight. Before the surgeon decides to operate in this manner upon an opacity he ought to be satisfied that no milder measures are capable of producing benefit, and that the procedure is reasonably safe. So long as improvement can be obtained by the natural processes, assisted if need be by massage, by dionine, by slightly stimulating ointments, etc., tattooing ought to be put aside, temporarily, at all events. It should probably never be performed within a year from the time of ulceration. In this connection it is to be noted that tattooing, though really a cosmetic operation, does sometimes result in improved vision. The fact can be explained in this way: The dark pigment interferes less with the passage of rays than does a white nebula, and the introduction into the tissues of a foreign body brings about an enhanced tissue reaction; quickened and enlivened tissue interchange follows, and a long-standing opacity may be cleared somewhat.

Another point to be borne in mind is that tattooing is contra-indicated when there is any pigmented tissue embedded in the scar. Involvement of iris or ciliary body should be looked upon with great suspicion, for the reason that a state of irritation may be set up by the foreign particles introduced in tattooing which will end in sympathetic ophthalmia. Nor ought this treatment ever to be adopted in an eye with lowered tension; in such a case tattooing, however skilfully performed, becomes a very grave experiment. If all things are suitable, however, the improvement in appearance may be enormous. Cocain having been instilled, the surgeon should steady the eye between two fingers of the left




FIG. 67.—Grooved tattooing needle.

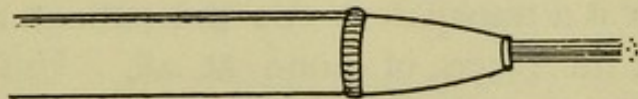


FIG. 68.—Bundle of tattooing needles.

hand, while with the other he introduces a grooved or guttered needle into the corneal tissue, the gutter holding in it a suspension of Indian ink, the minute particles of which are thus carried into the corneal tissue. Not too much should be attempted at one sitting, as one does not wish the eye to become in the least inflamed—that would spoil all; it is much safer and better to divide the operation into several sittings. It is best to introduce the needle very obliquely so as to prevent the suspended pigment grains from being at once removed. Some prefer to place a little of the suspension in the groove of the needle, others spread it over the cornea before beginning and work through it (this hides from one any good view of the parts which one wishes to darken). Should any blood appear, stop at once; fixation forceps must

not be employed, as the conjunctiva would be stained also.

In cases of large and complete or nearly complete staphyloma of the cornea **Critchett's operation** is still performed by some surgeons. In this operation one passes three large curved needles through the base of the staphyloma as close as may be to normal tissue; each of the needles is next drawn right through, bringing with it its tail of thread; these threads are then tied firmly. The operation has for the most part fallen into desuetude now, it not being in accordance with good surgical principles.

Transplantation of the Cornea.—There are many cases in which an eye is perfectly normal except for a large dense opacity of the cornea, and if one could only succeed in removing the opaque membrane and substituting for it a transparent one the patient might have good sight in place of none at all. Unfortunately, though many attempts have been made in this direction, no method has been devised which affords even a reasonable hope that the transplanted portion will become adherent and remain, or, if it should remain, will also retain its transparency.

OPERATIONS ON THE IRIS

Iridectomy or removal of a portion of the iris is performed under a considerable variety of circumstances. First, iridectomy may be *optical*, that is, may be primarily called for in order to enable the patient to make use of a new pupil because of some obstruction interfering with the old one; or *curative*, that is, required as a therapeutic agency.

In any case procedure is somewhat as follows: Cocain having been administered, the speculum is inserted, the eye is seized with forceps and kept steady, a keratome is introduced just outside the apparent corneo-scleral junc-

tion and introduced into the anterior chamber. This should be done as straight through the tissues as possible ; there should be no danger of splitting, as may readily happen to a beginner who uses his knife too obliquely. Directly the point has passed into the anterior chamber, a fact which one learns to recognise by an all but imperceptible alteration in the feeling of resistance offered, the direction of the keratome must instantly be changed, and the point directed forwards a little, so that it may pass in front of the iris and not wound it. The keratome having been passed into its maximum width, is now withdrawn, a portion of the iris is drawn out of the wound and cut off with a pair of scissors. When the

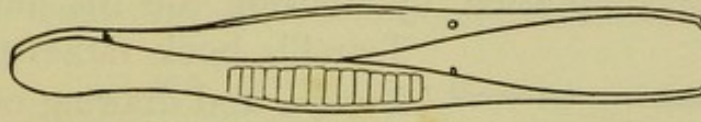


FIG. 69.—Fixation forceps.

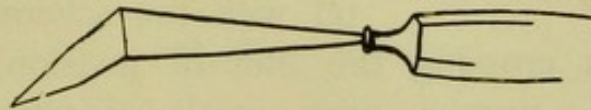


FIG. 70.—Keratome for optical iridectomy, etc.

edges of the iris have been replaced, should that be necessary, and stroked into good position and freedom from the lips of the wound, the operation is finished.

Optical iridectomy or formation of *artificial pupil* is required chiefly when either the cornea or the lens is occupied over the situation of the normal pupil by an opacity which prevents use of the eye. In regard to the latter condition, namely, when the lens is partly opaque, there is considerable difference of opinion as to whether treatment by iridectomy is a wise or an unwise method ; the cases are certainly very few in which one would be disposed to recommend it. In either case, too, there is a difference of opinion as to the best position for the new pupil, many surgeons recommending that if there be nothing to the contrary, the best part to select is down-

wards and inwards. This situation is open to the objection (among others) that it is very conspicuous, particularly if the iris should happen to be light in hue, and the aspect of the patient is injured thereby; it is more apt also to cause dazzling than if it be made upwards. The points in the selection of the direction in which the new pupil should be made are: to choose the most transparent portion of cornea available, to choose the part also whose curvature departs least from the normal, and to have it as near as possible to the centre of the cornea. With a view to this last point, the nearness to the centre, one should aim to make the widest part of the new pupil at the centre and the peripheral portion narrower. This is best accomplished by drawing the iris out with a




FIG. 71.—Tyrrell's iris hook.

Tyrrell's hook rather than with forceps, and drawing out a very small portion and snipping this off with the scissors held with their blades crossing the line of incision, not along it. In this way a neat, small iridectomy can be secured, whose widest portion is continuous with the old pupil, and which hardly extends beyond the normally exposed area at all. Look at any normal person and you will see that below the edge of the upper lid there is visible a distinct band of iris, below which again is the pupil. The most favourable situation of any for an optical iridectomy is through an opening in this band. It can at will be reduced in size by the action of the upper lid should errant rays or too bright light annoy, it is invisible, and it is as near as possible to the normal situation of the pupil. Let no one be beguiled into the belief that the best position is downwards and inwards, as some have said; it is not so.

Of the "curative" iridectomies the variety to be noted first is for *relief of increased tension* or glaucoma. The best mode of procedure has been and still is the

subject of much controversy, but most surgeons are agreed on three points, namely, that the incision ought to be peripheral, more so than in an optical iridectomy, that a somewhat larger portion of iris should be removed, and that this should be removed quite up to the periphery. The idea in the peripheral placing of the section is that the incision may lie as near as may be to the true angle of the anterior chamber and Schlemm's canal; therefore the incision should be made in white tissue ostensibly. The necessity for removal of a largish portion (it used to be set down at as much as one-fifth) of the iris is not quite clear. It is good to have a considerable size of iridectomy, but there has been a reaction from the old enormous iridectomies, to the

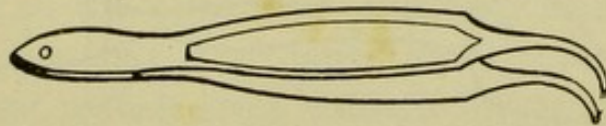

FIG. 72.—Iris forceps.

performance of which there are certain objections. A good deal must depend, among other things, on the physical condition of the iris; if it be atrophied, as it often becomes in old-standing cases, a freer iridectomy is probably better, but where it is still fairly healthy it is not good to lose the diaphragmatic action, the activity, and the crypts by means of which absorption can take place, unless for some reason more definite than a mere empirical tradition. The motive in securing that the iris be removed up to the periphery is the opening up of the true angle of the anterior chamber. Should a stump of iris be left it will lie in the angle, occupy space there, and perhaps become adherent (if it be not so already) to the cornea, and thus obliterate the true angle. Some surgeons used to advise that the iris be not cut from its ciliary attachment but torn off at its root; such a procedure is not quite in accordance with good surgical

procedure. It should be cut, but certainly peripherally ; and it is best to draw the iris out with forceps, and to cut it with the scissors, working along the wound, not across it.

It is a good rule in performing iridectomy in glaucoma to let your procedure be very deliberate, not to attempt to operate swiftly, but to lower the tension gradually and operate slowly. Whether a keratome or a Graefe knife should be employed is a subject of controversy ; some prefer the Graefe knife because they desire a larger incision, and because they dread injuring the lens with the point of a keratome in a case where the anterior chamber is very shallow ; to a good surgeon, however, it is not even difficult to pass a sharp keratome into an

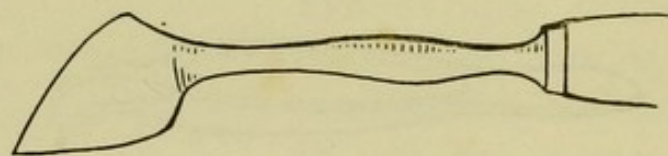


FIG. 73.—Very broad keratome for iridectomy in glaucoma.

anterior chamber which is all but non-existent without injury to the lens, while the wound made by the keratome is greatly to be preferred for its cleanness, smoothness, and its freedom from tearing or bruising. The matter is not one on which to be too dogmatic.

Iridectomy is required at times when a *perforating ulcer* has been present, a prolapse has occurred, and this is increasing and causing pain by dragging on the iris and raising the tension. In such a case the place for the iridectomy is as close as possible to the prolapse. Iridectomy in such conditions possesses two advantages: it frees the iris from being dragged upon, and it lowers the tension for the time being, and so permits the scar to consolidate, and not yield so readily to the intrusive iris.

Iridectomy is required in cases of *iritis* in which the iris has become largely or completely adherent at its

margin to the capsule of the lens (annular posterior synechiæ). In such a state there is no longer any passage from the posterior chamber to the anterior chamber, from which point the effete aqueous, etc., should escape into the venous circulation. The best time for the performance is during the stage of raised tension, with iris bombé, before any degenerative change has begun in the ciliary body and other tissues; but even after this stage has passed, and tension has begun to fall or has been for some time low, it is not too late to secure some benefit, if only there remain some vision, and the eye be not wholly dark. The iridectomy does not require to be very wide.

Iridectomy in *recurrent iritis* is of immense benefit in a large proportion of the cases. Nothing restrains the recurrence of the attacks so efficiently as a good iridectomy. There may have been attack after attack until the reluctant patient gives consent for an operation at a time when the eye is sufficiently free from inflammation to afford good prospect of a satisfactory result. It is often enough not difficult to persuade the patient during one of his attacks that he should have the iridectomy, but the time to perform it is not when the eye is inflamed—rather the contrary; then when he recovers from the actual attack he thinks, “Well, but I might never have another attack,” and postpones the operation *sine die*, returns contrite and in pain after some few weeks, but must be kept waiting for the injection to go down, and so the round goes on. The iridectomy should be fairly “free,” and should of course be made upwards.

Some surgeons approve also of iridectomy as a *preliminary operation* in a case of cataract; they consider it to be best to divide the main operation into two parts, the first, iridectomy, being followed at an interval of perhaps six weeks by extraction. The majority of

surgeons of experience do not consider this actually necessary, and there can be no doubt that the average patient will prefer one surgical operation to two, unless there should be some very grave reason for the separation.

Iridotomy is an operation of great utility under certain particular circumstances. It consists in cutting across the fibres of the iris by means of a pair of fine scissors introduced into the interior of the eye for this purpose. It has its chief indication in cases in which the lens has been extracted, but that operation has been followed by iritis, which has resulted in the iris being drawn up to the scar and forming an impervious membrane covering the site of the pupil, this veil being composed partly of stretched iris fibres, partly of inflammatory exudate,

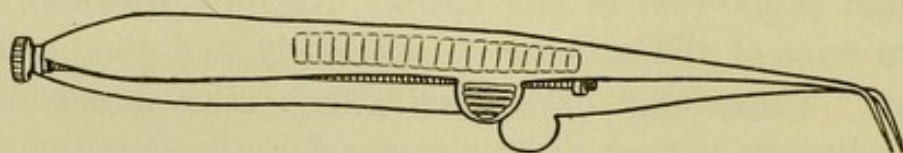


FIG. 74.—Iridotomy scissors.

matting the iris and the remains of lens and lens capsule into one intransparent mass (Plate IX. 6, 7). An incision is made at the outer or inner side of the cornea, and in doing so, for the purposes of this operation, it is quite good practice to thrust the keratome through this membrane also. The fine scissors are then introduced whose blades are shorter than the diameter of the cornea, the sharp-pointed of the two blades being passed through the aperture in the iris, and the blunt-pointed blade passed across the anterior chamber in front of the iris. The blades are then sharply closed, and the scissors in this way divide the fibres of the iris across their length, with the result that a (horizontal) pupil springs open through which really good vision may be obtained. If the operation is performed early, when there is still good contracting power in the iris tissue, and if the eye is in other ways healthy, and there is not too much lens

matter, the gain in vision is sometimes very striking. Obviously, it is out of the question to attempt it unless the lens is out of the eye.

In place of a small iridectomy for visual pupil a *præ-corneal iridotomy* may be performed; a small incision having been made in the region fixed upon, the iris is either caused to prolapse out of the wound or is brought out, and is then slit radially to the pupil. When the iris has slipped back into place the pupil will be seen to be clove-shaped, the very best form for an optical iridectomy, the pupil being small, its widest part just at the pupil margin.

There is much controversy nowadays as to the best operation in glaucoma. **Iridectomy** holds its place, and seems likely to continue to hold its place in the acute and congestive cases, the so-called "inflammatory glaucoma," but in the more chronic forms some method of procedure which will establish a *filtration scar* is becoming more adopted. The underlying idea in these operations is: Glaucoma is due to imperfect removal of effete fluids from the interior of the eye, probably on account of some fault at the angle of the anterior chamber; let us form therefore a weak point in the globe through which fluids can percolate independently of the angle. The main principle being granted, there are three ways in which the attempt is made. In Lagrange's operation an incision is made with a Graefe knife much as for iridectomy, but as the knife comes out it is made to cut a "slice" off the sclerotic, and then to form a conjunctival flap. The portion of sclerotic thus sliced off, which of course remains adherent to the conjunctival flap, is then wholly or partially removed with a pair of suitable scissors, the flap placed in position again, and as the wound heals up a weak point in the sclerotic or corneo-sclerotic junction is left, through which filtration may always go on

whenever the state of the tension renders this necessary. In **Herbert's** operation by a different procedure a tongue-like flap of sclera is formed.

A third method is to **trephine** out a portion of the corneo-sclerotic junction, leaving a round opening about 2 mm. in diameter, which fills up with loose, readily permeable tissue, thus forming a regular safety-valve for relief of tension. In the performance of this operation one first forms a flap of conjunctiva above; this is carefully dissected down till the flap can be dissected down no more without actually encroaching on corneal tissue; a minute trephine is then applied, and the 2 mm. piece of corneal and corneo-scleral tissue is cut out. The flap is then fixed in position, but some advise that before this is done a small peripheral iridectomy should be performed, a mere button-hole in the iris (Plate XX. 8).

Operations for relief of cataract will be found described in the chapter upon the Lens.

OPERATIONS ON THE MUSCLES

Tenotomy, or division of one of the muscles, is performed in a number of cases of strabismus, though of late years, partly owing to the greater conservatism of the surgeon and partly to the fact that children are more frequently brought in the earlier stages of squint, the proportion of cases considered to require operation has become much lower. The great point to be borne in mind is to make the division of the muscle as close as possible to the insertion of the tendon into the sclerotic, and further to restrict the division to the muscle itself, and not to interfere with the subsidiary attachments any more than can possibly be avoided. Under cocain the operation is practically painless. A speculum is inserted, and the conjunctiva over the muscle (usually the internal rectus) is picked up in fixation forceps and incised with scissors. The points of the scissors are passed through

the opening into the submucous tissue, and with them the surgeon snips on in the direction of the apex of the orbit, so that he may make his way through Tenon's capsule. When this has been accomplished the surgeon knows at once by the sensation that the points of his scissors are no longer held by the tissues, but have become more freely movable. Through the aperture in Tenon's capsule thus made a strabismus hook is inserted, and upon it the muscle is picked up and put on the stretch, and it is then divided with scissors as close as possible to the insertion. The conjunctival wound is then closed with a fine stitch; should the immediate effect be not too great the stitch is inserted in an almost vertical direction, taking up conjunctiva alone; should

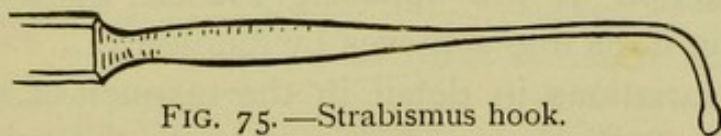


FIG. 75.—Strabismus hook.

there have been an over-effect, however, the stitch may be made to pass deeper and take up more tissue; it can be put in horizontally and thus diminish an undue primary effect. Some surgeons prefer to make the conjunctival incision quite away from the muscle, and perform the operation "subconjunctivally," as they believe that in this way they avoid more successfully that unpleasant sinking of the caruncle, which is so apt to proclaim an attempted cure of squint (Plate XXI. 1). By a judiciously performed tenotomy, strabismus may be reduced by 12-15 degrees.

Advancement of a muscle is the expression employed, though it may not be very accurately descriptive, for the operation intended to increase the power and diminish the length of an enfeebled muscle. By many it is now preferred to tenotomy: thus in a case of convergent strabismus requiring surgical treatment, one may either tenotomise the internal rectus (or recti) or advance

the external; it must be admitted that some of the arguments employed in favour of advancement as opposed to tenotomy are unsound, whether the conclusion be correct or incorrect. In a case of divergent strabismus there is no choice, for as there is practically speaking no function of divergence to be in a state of over-action, mere division of the external recti is as a matter of fact entirely without influence on the faulty position. It is sometimes asserted freely that it is unwise to tenotomise the opposing muscle and advance at the same "sitting," lest a number of hypothetical evils may occur; but with reasonable care these evils do not occur, and it is an enormous advantage in a case of advancement to prevent the new adhesions from being drawn upon and stretched by the action of the opposing muscle, by temporarily paralysing it, as one achieves by tenotomy.

The variations in detail in the manner of operating are legion, each surgeon being prone to the opinion that

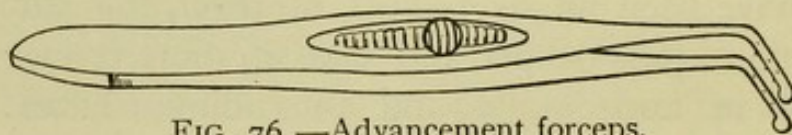


FIG. 76.—Advancement forceps.

the secret of success lies in some trifling modification or unimportant variation which he has invented, and which has no real significance whatever. A useful method may thus be described: Seize the conjunctiva over the muscle—say the internal rectus—and incise it with scissors; a small piece is then removed to prevent subsequent redundancy. The muscle is then picked up on the hook as if for tenotomy, and one blade of a pair of forceps fashioned like a strabismus hook passed underneath the muscle; the forceps are then closed firmly upon the portion grasped. Just how far back from the sclerotic attachment the forceps are made to clasp the muscle depends upon the amount of shortening which is considered to be requisite for correction of the fault

of position in the particular case. The tendon is now divided, while the muscle is firmly held, the subsidiary underlying attachments to the globe cleared thoroughly away, and a curved needle bearing a thread some eight or ten inches long is passed through the lower third of the muscle just behind the forceps. It is well to secure for this thread a firmer hold of the tendon than it could obtain by merely being passed once through (for the direction of traction would tend to pull it right out of the muscle), and perhaps the best way to accomplish this is to bring the thread round the edge of the muscle and pass it through again at a spot close to the original point of introduction. The thread may be of silk, but

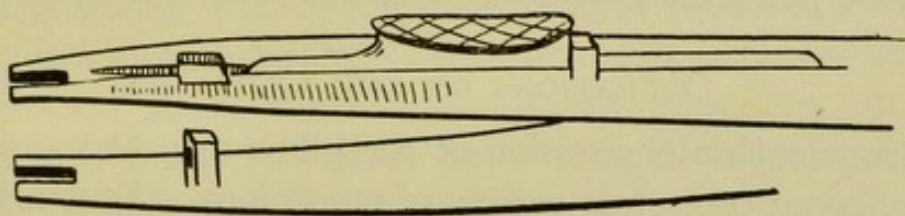


FIG. 77.—Needle-holder.

the disadvantage of silk is its "greasy" surface not allowing of a firm and non-slipping knot being made; there is nothing better than good strong linen thread—it can be boiled without harm, and does not slip or give at all when knotted. A similar stitch, similarly passed, is introduced at the upper third of the muscle. The piece of muscle held in the grip of the forceps is now cut off, great care being taken to avoid cutting any of the threads. The needle carrying the thread which is through the muscle is now passed through the stump of the muscle still attached to the sclerotic—this ensures a straight pull—and is then carried on, in one instance above the cornea, in the other below it, dipping into the superficial layers of the sclerotic so that it may obtain a good hold on firm tissue. While an assistant, holding the eye with forceps, rolls it to meet the stump of

muscle which is being advanced, the two stitches are now tied tightly, that in the lower part of the muscle to the thread which passes below the lower part of the cornea, and that in the upper to the other. If there be any gaping of the conjunctiva over the situation on the muscle, this also can be closed with a stitch. In order to minimise movement during the time of healing, it is best to keep both eyes constantly covered for some five days or so. After a few days the bandage is removed from both eyes, and the patient should be forbidden to keep the operated eye closed: he must keep both open.

One may look for an effect equal to 15-20 degrees as the result of advancement. If needful, the operation may be performed on both eyes.

OPERATIONS ON THE GLOBE

Enucleation or excision of the globe may be required on account of a great variety of conditions. Destructive injury, intra-ocular tumour, an eye which is from any cause (such as malignant glaucoma) both blind and painful, a shrunk and unsightly globe, etc., may be the determining cause of enucleation being required. The operation can be performed under local anæsthesia, but few surgeons care to undertake the operation save with a patient under a general anæsthetic. To perform the operation, introduce the speculum, and then with one pair of fixation forceps draw the eye down, and with another seize the conjunctiva close above the upper limit of the cornea; beginning from that point incise the conjunctiva with scissors all round the cornea, keeping as close to cornea as possible, thus preserving every particle of tissue which it is possible to leave. Next, burrowing more deeply with the scissors at the lower part, incise Tenon's capsule in that situation, and pass in a strabismus hook on which to catch up the inferior rectus muscle. This is then divided, and the other straight muscles

picked up one by one and treated similarly. The next step, division of the optic nerve, is the only point in the operation which presents any difficulty. It is best to hold a strong curved pair of scissors in the right hand like a pen, and pass them into the apex of the orbit, between globe and conjunctiva, and feel with them for the nerve. This will almost always be found to be above the point of the scissors, as one stands at the head of the patient; the grip of the scissors should then be changed to the ordinary firm hold, without their slipping from their place; they should be drawn slightly back to free the points and clear the nerve, then opened and passed deeply into the apex of the orbit; they then, on being closed, will divide the nerve, a procedure which requires a more vigorous effort than the beginner is apt to expect to be necessary. A few subsidiary attachments of connective tissue have to be divided as well as the two oblique muscles, and the operation is complete. The only real point of difficulty is to catch the optic nerve, as has been said, and to divide it without injury to the globe. It is very easy, especially in cases of soft shrunk globe, to lever the globe forwards on the blades of the scissors, and then when severing the nerve to cut in reality the posterior part of the sclerotic, and leave in the socket a piece of the posterior wall of the globe. To avoid any risk of this, which might be very disastrous, always, after identifying the nerve, pass the scissors deeply into the orbit and cut at the apex. This is a good rule, particularly in any case in which sympathetic ophthalmia is to be feared or in which a tumour is present. Hæmorrhage is pretty free and should be checked at once, as otherwise the tissues become much infiltrated with blood and healing is delayed. The best way to check this hæmorrhage is with a stream of very hot water; a pressure bandage is immediately applied and kept on for eight to twelve hours; thereafter no dressing

should be kept on, but the socket bathed out two or three times a day.

In certain circumstances one of the substitutes for enucleation may be employed. The most important of these is evisceration, which is also the operation of choice in cases of panophthalmitis, for in this condition it is desirable to give free exit to the pus, etc., but not to open into the nerve sheath or other posterior tissue of the globe, lest infection of it and even meningitis should occur. To perform **evisceration**, the first step is to incise the conjunctiva all round the cornea, but only for a short way at each spot; if the conjunctiva is dissected up needlessly freely, the subsequent œdema is very greatly increased. With a Graefe knife the whole

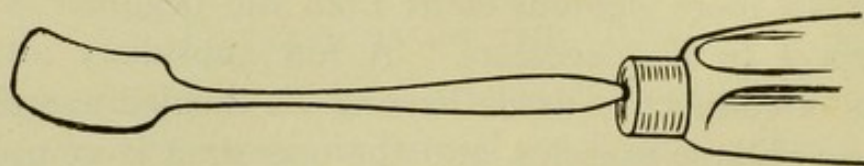


FIG. 78.—Eviscerator.

upper half of the corneo-scleral junction is incised; with scissors the remaining attachment of the cornea at the corneo-scleral junction is cut through, and the entire cornea lifted away with forceps. An instrument called an eviscerator, resembling a miniature spade but with rounded corners, is now introduced between the ciliary body and the sclerotic, and by means of a little manœuvring is made to turn out the whole contents of the sclerotic—iris, ciliary body, lens, vitreous, retina, and chorioid, at one swoop. The interior face of the sclerotic is now thoroughly but gently cleaned with a stream of weak boracic and swabs to make quite sure that no scraps of pigmented tissue have been left behind. The wound in the sclerotic, which may be trimmed at the angles for the purpose, is now sewn up, to form a vertical cicatrix, and then the conjunctiva is brought over the wound and sewn with a continuous or an interrupted

suture in a horizontal line, and the operation is complete. The stitches through the sclerotic should be so placed as to bring together not the edges of the wound but two surfaces of sclerotic, as in the diagram, for if this be done much sounder and firmer adhesion is secured. The needle, carrying a strong catgut suture, is passed from without inwards about three lines from the cut margin of the sclerotic to the right-hand side, from within outwards through the sclerotic at the other side of the wound, and again from within outwards close by the margin on the right side; in this way firm union is better secured. The conjunctival stitches may be of fine silk. No drain is required, and no dressing should be applied, as this would encourage œdema. A single layer of lint dipped in weak boracic is the best application; the boracic should on no account be iced. As a substitute for enucleation this operation may be employed in many conditions, but never in cases of intra-ocular tumour, nor when an injured eye requires removal on account of risk of sympathetic ophthalmia, unless the removal be performed immediately after receipt of the injury.

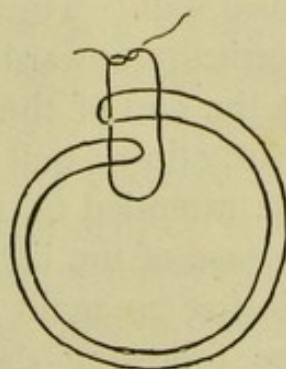


FIG. 79. — The stitches for closure of the sclerotic wound after evisceration.

OPERATIONS ON THE LACHRYMAL APPARATUS

To **incise the lower canaliculus**, take in the hand corresponding to the affected eye of the patient, as you




FIG. 80. — Weber's knife.

stand behind him, Weber's probe-pointed knife; draw down the lower eyelid with the unoccupied hand, and the punctum will thus be displayed; into it introduce the point of the knife, and, keeping the tissues on the

stretch with the fingers, slip the knife right along the canaliculus horizontally till it is brought up against the nasal wall. Turn the knife now so that the handle comes vertically upwards, and at the same time rotate it so that at the end of the incision its edge is forwards; push it gently down well into the sac. If these simple directions are attended to, the incision will lie against the globe on release of the lid; the incision should be prevented from closing up again by the passage of a probe along it on the following day. Unless the gutter thus made lies against the globe, it will not merely be visible but will fail to act in removing the lachrymal secretion.

Excision of the Lachrymal Sac may be a very simple operation, or one of insuperable difficulty, according as

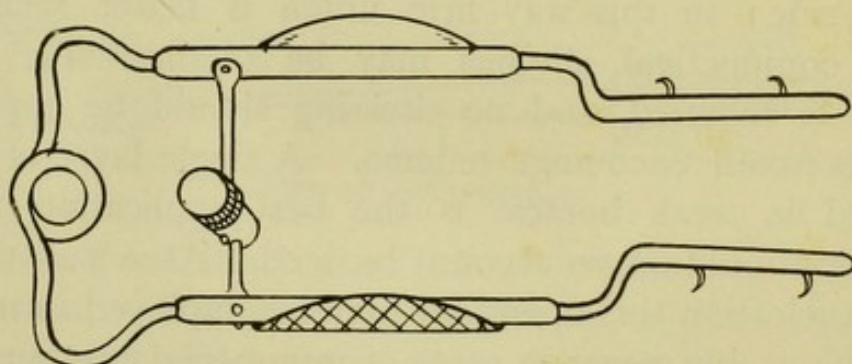


FIG. 81.—Speculum for the wound in excision of the lachrymal sac.

there has been freedom from inflammatory reaction in the surrounding tissues or not. When the mucocele or puro-mucocele is not, and has not been, the seat of inflammation, the excision can be quite well performed under local anæsthesia if desired (see p. 483), otherwise a general anæsthetic is very desirable. The operation is conducted in the following manner: Define with the finger or thumb nail the little ridge on the lachrymal bone under shelter of which (*i.e.* posterior to which) the sac normally lies, and make a straight or slightly curved incision right down to the periosteum there. The incision may be an inch in length; copious hæmorrhage may occur, but this

is greatly lessened if the tissues be promptly put on the stretch by a speculum, for the purpose of which there are several patterns in the market. (Previous injection of adrenalin is very advantageous also.) With a dissector one now proceeds to define the nasal side of the sac, then the dome, after which it is convenient to seize the sac in a pair of artery forceps, draw gently upon it, and divide its lower and then its outer attachments. It is, of course, possible to make a more elaborate and perhaps more elegant anatomical dissection, but that is hardly called for. The upper end of the nasal duct, cut across in the removal of the sac, is now cauterised or scraped thoroughly out to destroy its mucous membrane, and so prevent either direct septic infection or fresh ingrowth of




FIG. 82.—Dissector and sharp spoon for use in excision of the lachrymal sac.

membrane in an attempt to form a new sac. It is good also to destroy the canaliculi in a similar manner. One or two stitches should be introduced, one of which should be placed in the situation of the divided tendo oculi; no drain is required; but special care should be taken in the dressing so to pack the part with pieces of gauze or wool, that gentle but firm pressure is kept up over the bed of the sac, that the walls of the cavity in which the sac used formerly to lie be kept in close apposition. Re-formation of mucous membrane is thus prevented, either from canaliculus or from nasal duct, with attendant re-formation of mucus in the old situation.

Where the sac is the site of an abscess, and sometimes where it has been so though it may be so no longer, the simpler and better plan is, having determined one's landmarks as well as in the nature of things is possible, to cut right down, scrape out the sac walls thoroughly with a Volkmann's spoon, and pack with

iodoform gauze. When the disease occurs in children, and sometimes also in adults, the source of trouble is not the sac originally but the bones of the nose ; when such is the case it becomes all the more important to act along these lines. The two chief errors the beginner is apt to make are, first, not to get deep enough down ; he is apt to imagine that he is down to the sac when he has not yet reached it, being deceived by the swelling of the overlying tissues. His second error is in making his incision too far from the middle line and getting to the outer side of the sac. This is disastrous, for the sac is normally shut off from the rest of the orbital cavity by a strong fascia ; for this reason the operator should never see orbital fat ; if he goes too far out he may open this fascia, strike fat, among it pus from the sac may ooze, with a very serious orbital abscess as a consequence — a consequence which may be highly dangerous to sight and even to life, should the lowly organised tissue of the orbit be attacked by septic inflammation.

It is usual for a patient after enucleation has been performed to wear an **artificial eye** (prothesis). An artificial eye may generally be worn after four to six weeks, a good deal depending on the nature of the lesion which necessitated the enucleation ; if much inflammation preceded the operation, wearing of the prothesis would require to be delayed, while if the enucleation was performed on account of an injury received immediately before, or of an early sarcoma, the socket would be sufficiently "hard" to carry the eye in a shorter space of time. Also, the patient after enucleation should be encouraged as early as possible to expose the socket thoroughly to the open air, that the conjunctiva may become less irritable. The artificial eye is a shell of glass made to resemble the natural eye as closely as possible in colour of iris, size of pupil, exact hue of

sclerotic, and should be chosen with care, not only on the basis of its elegance, but of its fit in the orbit. It must be comfortable, and must not press the lower lid too far downwards. The patient is apt to desire an eye which is too large, as giving a more life-like appearance, but such an eye will move less freely than a smaller one with the movements of

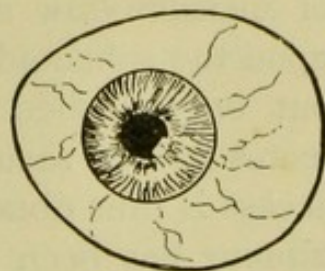


FIG. 83. —Artificial eye.

the other, and will thus be apt to draw attention. To insert the eye, take it between the finger and thumb, and introduce the outer (larger) portion of "sclerotic" under the upper lid, rotate it gently, drawing the lower lid

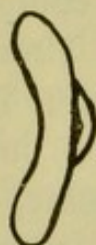


FIG. 84.
Artificial eye.
One variety
seen in section.

gently down as one does so, when the eye will slip into place. To remove it, draw down the lower lid and insert under the eye such an instrument as the bent part of a hair-pin; between this and the thumb the eye is held, and with a slight rotatory movement it is drawn out, the outer portion last. The patient generally finds it best to lean over a bed when removing the eye, which he ought to do every night; the eye should be well washed and dried (not left to soak in water). The action of the tears gradually dulls its surface, so that its life may be about a year before it requires re-polishing. Well-to-do patients generally find it pay best to have two or three eyes in constant use. Each night the socket should be well bathed and a weak astringent dropped in.

OPERATIONS ON THE ORBIT

When a tumour has to be removed from the orbit, and there is yet some hope of saving the eye, **Krönlein's operation** is most satisfactory. It consists in removing temporarily the outer wall of the orbit. An incision is made, following fairly exactly the outer wall of the

orbital margin; the soft parts are pushed thoroughly back, and the outer wall removed by means of two lines of incision (saw and forceps) in the bone, converging upon the sphenoidal fissure. The bone is not removed, but only pushed back out of the way; the external rectus may be secured with a stitch and divided, and free access is thus obtained to the orbital cavity. After the tumour has been removed, the external rectus, which has been secured by the stitch, is re-attached in its place, the bony wall slid into position again, and the soft parts replaced and stitched. Wonderfully little mark is left.

In cases of tumour affecting the orbital wall, or of malignant growths in the orbital tissues, complete **exenteration** of the orbit may be required. There is nothing mysterious in this dreadful operation; it is merely a process of patiently clearing everything out of the orbit. Hæmorrhage may give much trouble, but one may be greatly assisted by a light touch here or there with the cautery. If the skin of the lids can be left, that can be used to cover up the walls, they being simply allowed to fall in; but if they must go also (as in epithelioma for example), it is possible to cover the denuded bone with Tiersch grafts spread first on the back of the finger and "pieced" on to the walls. It is best to apply no dressing, and not to touch these with any wet either at the time or afterwards. Dust them merely with aseptic dusting powder, let no lotion come near them, and if fluid should try to collect at the apex, keep it removed by a strip of gauze acting as a syphon. If there be foetor, formidin powder is very beneficial: it reduces the odour very satisfactorily and causes no reaction.

CHAPTER XXII

THE EXAMINATION OF THE EYE: POINTS IN GENERAL DIAGNOSIS

THE object of this chapter is to afford to the beginner, by the discussion of a few of the general signs and symptoms of disease of the eye, a hint as to the probable nature of the trouble of which the patient complains. It may assist him on the way to a diagnosis: it is not suggested that, taken alone, it will enable him to make one. That there is repetition of matter already dealt with is unavoidable.

It is essential to good work that the surgeon should have a more or less definite system of examination of the eye on the nature of the pathological condition existing in which he is to deliver an opinion, though in no actual case may he find it essential to cover the whole ground. After some experience he learns to thread his way to his diagnosis, guided by signs and symptoms whose value time has taught him to grasp and use. It is not suggested that in the following brief survey all possible occurrences are considered,—rather it is meant as a help to the beginner in finding his way among the more usual diseases.

The *margins of the eyelids* should be neither inverted nor everted; the position of the puncta will indicate with great certainty whether or not they are so. The punctum ought not to be visible until the lower lid is

drawn down; it should lie touching the ocular conjunctiva, otherwise it cannot act by capillary attraction; a punctum which is visible without the lid being touched is not active functionally. If the edge of the lid be everted (ectropion) the skin becomes irritated and eczematous, the consequent contraction increasing the ectropion. The lashes of an inverted lid (entropion) rub against the cornea and cause it to inflame and to ulcerate.

A swelling of the lid near its margin is likely to be either a hordeolum or a tarsal cyst; the former is situated *at* the lid margin, the latter a little back from it. A definite, localised ulcer of the lid margin should be regarded with much suspicion: if chronic, it may be epithelioma; if acute, it may be a chancre or a vaccine pock.

Inflammatory swelling of the lids may be due to a local affection, to a sty (hordeolum) as yet in the stage of general swelling, to cellulitis, to inflammation of frontal or ethmoidal sinuses; should there be localised tenderness this may be either at the inner canthus, and be due to cystitis, or at the outer end of the eyebrow, and be due to periostitis. If this inflammatory swelling be accompanied by chemosis in the adult, there is probably a rather large hordeolum impending.

Injection of the globe should be examined carefully as to the precise position and nature of the vessels; if these are large, branching, scarlet, movable over the globe, and most marked towards the equator of the globe, and accompanied by sticky secretion, the case is one of conjunctivitis; if the vessels are somewhat similar but more localised to one part of the globe, with little secretion and a decided violet tint in the colour, it is probable that one has to do with a scleritis; if the vessels are small in size, radially arranged round the cornea, less marked towards the equator, pink in colour,

and not movable over the globe, the accompanying secretion being watery, the case is one of inflammation of the parts supplied by the ciliary stock of vessels, namely, the iris, deep substance of the cornea, and ciliary body. If along with this there is any injection of the cornea itself, or any decided haziness and deep-seated dimness of its substance, the case will probably turn out to be one of keratitis of the interstitial type; if there be much photophobia this is rendered more likely, but if pain in the head be a prominent feature, the iris or ciliary body is the more probable site; tenderness to touch in such a case is to be regarded as pointing rather to the ciliary body, especially should there be also a complaint of cloudy vision.

If, again, the injection be of the small-sized vessels, running radially, but more dusky and venous than in the cases above suggested, special attention should be given (*a*) to the pupil, (*b*) to the field of vision, and (*c*) to the tension of the eye; also careful inquiry should be made as to headache and vomiting. Should the pupil be dilated rather than contracted, the case is almost certainly one not of iritis, but of glaucoma. Confirmatory indications would be a field restricted at the lower nasal portion, and increased tension of the globe, with a history of headache and vomiting. The distinction is vital, for if the case be one of iritis, atropin is called for at once, while if the case be one of glaucoma a mydriatic is the last application which should be employed.

To turn to points in the subjective symptoms, if the patient complains at the age of 50 to 65 of seeing worse in good light than in dull, of being inconvenienced by the light shining on his face, the symptom will probably indicate the formation of a central opacity in his lens, which naturally will interfere more with vision when his pupil is small, as when the patient faces the

light. This is the more certain that persons at that age normally welcome brighter illumination, as producing more ready reaction in the visual functions.

If the patient of that age also says that whereas for some ten years or thereby he has been using glasses, but now so far from these being necessary for him he reads as well or even better without them, that should be taken to indicate the increase in the refractive index of the lens which so often accompanies or precedes cataract; this acquisition of "second sight," as these patients sometimes regard this symptom, is by no means a healthy sign. On the other hand, rapid increase of presbyopia, the patient requiring reading glasses of rapidly increasing strength, is probably an indication of glaucoma; for the rise of tension tells upon the nerves of supply of the ciliary muscle as they pass along within the scleral coat, and the lens, pushed forward as it is, is less amenable to the influence of the ciliary muscle, and in consequence the amplitude of accommodation falls quickly off.

A really sudden and complete loss of vision in both eyes is more likely to be due to uræmia than to anything else; sudden and complete loss of sight of one eye may be due to a large vitreous hæmorrhage, to "embolism" of the central retinal artery, or to retro-ocular neuritis. Strictly speaking, the loss in embolism of the central artery is not quite complete, for there remains, in almost every case, a portion of field, very peripherally, to the outer side. Loss as complete, if slower, no pathological condition being visible externally, may be due to glaucoma simplex, optic atrophy, detachment of retina, or retinitis pigmentosa.

Vision of both eyes reduced rapidly to $\frac{6}{24}$ or $\frac{6}{18}$ may be due to optic neuritis, retinitis albuminurica, acute chorioiditis, or tobacco amblyopia. In such circumstances, apart from other symptoms, diminution of the

light will injuriously affect the chorioiditis patient, while the toxic one sees better in a dull light, but in both there may be a positive scotoma. (It might also be due to uncorrected myopia or hypermetropia, but would not then be suddenly or rapidly acquired.)

A similar degree of rapid loss of sight, but unilateral, might not unlikely be due to commencing cataract, to glaucoma, to hæmorrhages in the retina, or to optic atrophy in an early stage. A more gradual loss of sight may be due to cataract in one of its varieties, to progressive disease of the chorioid, to glaucoma, to optic atrophy, to retinitis pigmentosa, or to detachment of retina. Should the cataract be central in situation, a small area of opacity will produce more interference with vision than will a number of spicules. This is particularly true of posterior polar cataract, for at the posterior pole of the lens the rays, having been (partially) refracted, are crowded into a smaller area. Testing the field of vision will help much to clear up the question. Should there be peripheral restriction, optic atrophy or retinitis pigmentosa becomes probable; should the lost portion of the field be above, detachment is almost certain, while if the lost portion be rather in the lower nasal area, glaucoma. Another helpful test is to diminish the illumination: this will injuriously affect those patients whose pigmentary coat is attacked (glaucoma, retinitis pigmentosa), and the patient with detachment of the retina; it will probably help rather than injure the cataractous patient.

The existence of a scotoma is an important point in the diagnosis. It may be due to a hæmorrhage in the vitreous, but to nothing anterior to the vitreous; or may be due to an acute chorioidal lesion, to a retro-ocular neuritis, or to tobacco amblyopia (if bilateral).

The condition of the **Tension** of the eye is a point of very great importance. Lowered tension occurs in a

number of degenerative conditions of the eye, notably cyclitis and detachment of retina, and is a sign of grave significance. Increased tension is chiefly found in glaucoma (but the two expressions should not be considered as exactly synonymous, though this is sometimes done), of which disease it forms a feature of primary importance.

Opacity visible to ordinary daylight examination. (Opacities visible by means of the ophthalmoscope solely are considered on p. 225.) The white opaque patch may lie in the cornea ; this is at once settled by observing, as the patient's eye moves, that the whitish patch moves over and conceals part of the coloured iris ; if the area is but faintly gray and semi-transparent it is called a *nebula* ; if more dense, a *leucoma* ; if it contains pigment from the iris, and if the iris is drawn up to lie at one point or another in contact with it, it is called a *leucoma adhærens* ; the old term *albugo* is now practically out of use. The examiner should note carefully whether the opacity affects the epithelium or lies subjacent to it, for prognosis may be much affected thereby. These opacities are the result of ulceration of the surface of the cornea or of dense infiltration into the substance as, for example, in severe interstitial keratitis. A *leucoma adhærens* infallibly implies a previous perforation of the cornea by wound or by ulcer. Opacity may lie in the posterior face of the cornea, in or on the endothelial lining of the anterior chamber, the result of inflammation of Descemet's membrane ; this is usually confined to the lowest sector of the cornea, the opaque area being more or less exactly pyramidal in shape.

Opacity in the pupillary area may be on the same level as the iris ; if so, it is due to exudate from an inflamed iris lying on the anterior aspect of the lens ; the pupil in such a case will very probably be immobile to light, and almost certainly irregular in outline from

adhesions of the iris to the lens. The colour is usually white, with or without flakes of pigment from the iris. Or it may be due to persistent pupillary membrane, or to anterior polar cataract.

Opacity lying behind the level of the iris is most probably in the lens, and has already been dealt with under the head of cataract ; but it sometimes happens that a very definite opacity lies posterior to the lens and yet shows to daylight examination. This is probably a tumour of the retina (Glioma), or sub-inflammatory exudate into the vitreous (pseudo-glioma), or a tuberculous mass in vitreous or chorioid. In such cases the opacity seems to come so far forwards that it is difficult to persuade one's self that the opacity is really posterior to the lens, all the more that the lens itself may be pushed a little farther forwards than its normal situation.

When a patient complains that he has suddenly lost the sight of one eye (the right eye, let us say), two matters require to be settled at the very first, namely,—Has he lost the sight of the right eye really, or has he right hemianopsia? A patient is very apt, on finding that he cannot see objects to his right, to imagine that he has lost his right eye ; to those who understand, the fallacy is obvious, but such a patient may mislead a novice. The second point is, Has this loss of the right eye actually come suddenly, or only been discovered suddenly? For it sometimes happens that a person loses the sight of one eye gradually, and it may be completely, without discovering the fact until he accidentally occludes one eye ; the same may be the case when one eye is congenitally defective. Even before he examines the eye to discover the nature of the lesion, the surgeon may obtain much information regarding the date of the loss, whether it be very recent or not, by inquiry regarding the state of binocular vision and projection. Should one lose one eye suddenly in

adult life, one loses one of the chief means by which one estimates distance, and consequently one is awkward and uncertain in movement. Thus, dipping a pen into an ink-bottle may be quite a difficult task, when pouring out tea, etc., one may miss the cup and pour past the edge of it, in place of setting a tumbler on a table one may drop it over the edge,—all for want of accurate projection, which demands either two eyes approximately equally good, or a long education of a single eye. Thus, should the person who complains of having recently and abruptly lost the sight of the right eye give no clear history of this awkwardness, absence of the symptom would rather indicate the probability of a more gradual and earlier loss. The point may be of much importance in regard to medico-legal questions (see p. 410 for tests, etc.). It might be thought impossible that a person should lose the sight of one eye and never be aware of its disappearance, but experience shows that such is undoubtedly the case.

Pain is a symptom of much value in diagnosis. One may readily distinguish six varieties of pain: (*a*) A smarting, burning, gritty feeling in the eye and lids, specially bad in the evenings, growing worse in bad or heated air; this is the pain of conjunctivitis, and is associated with sticky secretion, and injection of the superficial vessels. (*b*) A heavy, dull, weighty feeling in the eye, imparting a feeling, some patients say, as though the eye would drop out of the orbit if they bent forward, on the adoption of which attitude the pain is increased; the pain of scleritis. (*c*) A severe throbbing or bursting pain, complained of rather in the forehead and temple than in the eye itself, most severe in the middle period of the night, when it may become very intense. It is accompanied by watery secretion and injection of the circum-corneal, small radiating vessels of pink colour, and is the ciliary type of pain, present typically in iritis

and hypopyon ulcer of the cornea. (*d*) The same type, but with vomiting in addition; the pain of glaucoma. (*e*) Photophobia, or dread of light; the patient may merely prefer a somewhat shaded room, or the dislike to light may be intense, the patient covering up the eyes with the hands or arms, tying on handkerchiefs or towels, and retiring under the bedclothes or under the bed, screaming when an attempt is made to open the eyes for a moment; this is the pain of superficial ulceration of the cornea and, to a much less degree, of the iris. (*f*) A form of pain known as **Asthenopia** or **Eye-strain**, very common in these days of work under pressure. It may take the form of pains in and about the eyes, of headache or, according to some authors, of giddiness, constipation, to various physical ailments, and, according to others, of mental and moral changes for the worse, such as ill-temper, unreasonableness, loss of self-restraint, epilepsy. The beginner is very apt to make the mistake of looking for bad vision in cases of asthenopia, and deciding against the existence of asthenopia if vision should be good; this is quite wrong, for if vision be bad, little effort is made to force the retina to interpret the images, so no asthenopia results; but where accuracy of focus is just less than normal, the retina is forced to demand precision, and pain or asthenopia results.

The presence of *floating opacities* in the air (*muscæ volitantes*) causes much annoyance to some persons, and considerable disquiet to others. These may be definitely pathological or almost physiological. If the former, they are fairly large, rather black, and apt to come between the exact point looked at and the eye, and they are also likely to be constant; they may be due to minute hæmorrhages in the vitreous, to patches of chorioidal inflammation or degeneration, or to congestion of the retina. If the latter, they are inconstant as to presence and as to density, and rarely if ever come

directly between the macula and the point exactly fixed by it. They often take the form of beads on a string or of air-bubbles. The presence of these is a common enough accompaniment of eye-strain; they are more apt to be present at any rate in hypermetropes, for in them there is prone to be some congestion of the eye. In the myope, on the other hand, the pathological *muscæ* are for obvious reasons more frequent.

Alterations in the size of familiar objects is an occasional source of distress. It occurs under two conditions: first, it is not infrequent in neurotic children whose digestion is out of order,¹ and is due in their case to irregular action of the ciliary muscle, and is not in itself of much importance, though it is apt to alarm their parents. Secondly, micropsia (objects appearing smaller than they in fact are), when some exudation in the chorioid at the macula lifts up the retina from its bed, thus permitting an image of a given size to fall upon a smaller number of retinal elements than normally would be the case. Later on, when the exudation has been absorbed and perhaps the retina has suffered a good deal, the tissue-elements are drawn closer together; the same image would fall upon a larger number of retinal elements and would therefore be accepted as larger in size. This is known as macropsia.

¹ See R. L. Stevenson's poem, "The Sick Child."

CHAPTER XXIII

EYE SYMPTOMS IN DISEASES OF OTHER PARTS

THE student may find it convenient to have here a note of certain ocular manifestations of various systemic diseases; the list given below does not purport to be a list of all possible occurrences, but merely a note of what the practitioner should be prepared to watch for in his patients.

Diseases of the Nervous System.—In *Intra-cranial Tumour*, Optic Neuritis (choked disc) and consecutive atrophy are frequent and highly important. Ocular muscles may be paralysed; Nystagmus may be present, especially if the tumour be cerebellar; Hemianopsia is rare.

In *Disseminated Sclerosis* the classical eye signs are Central Scotoma, which may be the precursor of an actual scotomatous atrophy, and Nystagmus, increasing on physiological use of the muscles affected. Argyll Robertson pupil is not a sign of disseminated sclerosis.

In *Cerebral Hæmorrhage, Thrombosis and Embolism* Homonymous Hemianopsia may be present, the blind half of the fields being on the side opposite to the situation of the cerebral lesion. Conjugate deviation of the eyes is frequent also. In this connection a distinction must be drawn between cerebral lesions proper and those situated below the pons. In the case of a destructive (discharging) lesion of the cerebrum the patient is

unable to look towards his other side, and therefore "looks at his lesion." It is not difficult to remember the point in this way: sensation on the right side, let us say, of the body is experienced in the left hemisphere; an object to the right of the patient is seen by means of the left hemisphere, movement of the right limbs are originated in the left hemisphere, and just so movements of the eyes towards the right are innervated from or originated in the left hemisphere. It is plain, then, that if there be a destructive lesion in the left hemisphere, movement to the right may be rendered impossible, and the patient will look at his cerebral lesion, the balance of muscles and the balance of stimuli being no longer kept up. But if the lesion be one irritating but not paralysing the centres, the patient will "look away from" his lesion for similar reasons. If, on the other hand, the lesion occurs in the pons, below the crossing place of the fibres, the opposite will hold good in each case: the patient will "look away from" his lesion if it be a discharging one, and "at it" if irritative.

Word Blindness may be present also, the patient being able to decipher the letters of the word but incapable of combining them or of comprehending their meaning.

In *Epilepsy* careful examination of the refraction should be made; an error may be of much importance in determining the attacks.

In *Meningitis* of various forms, paralysis of one or another of the ocular muscles is a frequent sign, for which reason the fundus should be examined in the case of any child discovered to be squinting, because, it must be admitted, paralytic strabismus from compression of the VI. nerve is not always very readily to be distinguished from concomitant strabismus in a small child. Optic neuritis may be present at the same time—a highly suspicious association, if found. Tubercles in the

chorioid should be looked for. A particular form of head injury leading to paralysis which may be permanent is *compression* of the head *intra partum*, when paralysis of one or of both of the external recti may be produced.

In *Locomotor Ataxia* (Tabes) the classical signs are (1) the Argyll Robertson pupil, a pupil, that is, which acts to accommodation but not with light. On this point, too, some beginners are apt to be uncertain which way the test goes; but it is easy to recollect that the knee-jerk and other reflexes are lost, and so is the pupil reflex. The pupil reaction with accommodation is not a true reflex, and, therefore, is not likely to be interfered with. (2) The "grey atrophy" of the optic nerve is another characteristic sign. This atrophy is not preceded by neuritis, and consequently the disc is not "filled in" at all; the physiological cup (if there was one previously) remains unaffected in that way but merges into the atrophic shrinking. (3) Ptosis, watering of the eyes, and, still more, transitory paralysis of this or that ocular nerve, are strongly suggestive (but no more) of tabes.

When the Argyll Robertson pupil is present the pupils are usually, but are not necessarily, contracted (spinal miosis).

Urinary Disease.—The most important eye-manifestation by far is the Retinitis which is apt to accompany any of the chronic forms of *Bright's Disease* (much more rarely the acute), and especially the granular contracted kidney. Retinitis has been estimated to occur in approximately 7 per cent of cases of chronic Bright's Disease. The importance of the matter lies in the fact that the prognosis *quoad vitam* is very bad indeed when retinitis occurs (see p. 255). Patients with Bright's Disease are liable also to subconjunctival hæmorrhages; they are more liable also to iritis.


In *Diabetic* patients several eye symptoms are more or less frequent. (a) Retinitis, somewhat resembling that of albuminuria. The prognosis *quoad vitam*, though sufficiently serious, is not so bad as in albuminuric retinitis. (b) Cataract, which usually comes on with rapidity and in the young. (c) Paralysis of various ocular muscles, and especially the muscle of accommodation; this occurrence must be looked upon as decidedly serious, for its site is probably nuclear, and other nuclei more essential to life may just as readily be attacked also. (d) A scotoma much resembling tobacco amblyopia may be found even in those who are non-smokers, and it appears to be true that diabetics who smoke are more prone to tobacco amblyopia than the average.

Diseases of the Ductless Glands.—*Acromegaly*, leading to pressure upon the chiasma, is very prone to bring on bitemporal hemianopsia. It does not always do so, and in a number of cases the loss of vision in the temporal halves of the fields is merely relative, demonstrable only on the most careful examination. Optic atrophy comes on later as a rule, one eye being affected in advance of the other.

In *Leucocythæmia* and in profound *anæmia* small hæmorrhages are to be found in the retina in a certain proportion of cases, in the former disease there being a definite retinitis with some œdema of the retina and with very peculiar coloration.

Syphilis.—There is no part of the eye which syphilis may not and does not attack unless it might be the lens. Chancre occurs rarely on the lid; Interstitial Keratitis is one of the most frequent of the manifestations of hereditary syphilis, and is also a rare complication of the acquired form. Scleritis may be syphilitic. Iritis, almost always bilateral, is a common manifestation of the acquired form and more rarely of the inherited, occurring then in infants. Chorioiditis is frequent, retinitis somewhat rarer, optic neuritis more rare still as





To illustrate the colour-confusions of the colour-blind as brought out by Holmgren's test.

In the first test along with the green wool would be placed some of those shown underneath it.

In the second test, a Red-blind would place with the rose-pink, blues and purples (to left hand), while a Green-blind would select grays and greens (to right hand).

In the third test, along with the Red, a Red-blind may place greens and browns darker than the test, a Green-blind would choose shades lighter than the test.

This plate has been made by photographing canvas sewn with the correct shades of wool. If all the colours have not come out with equal precision, they at least show the types of error made by the colour-blind. See p. 31.

a direct result, though neuritis, either as a complication of intra-cranial gumma or of an apical periostitis in the orbit, is frequent enough; besides these varieties one must remember the atrophy in various parasymphilitic diseases such as tabes. Argyll Robertson pupil is regarded by some physicians as an incontestable proof of syphilis, and the varying pupils of General Paralysis of the Insane may be a valuable point in diagnosis. Gumma may occur in the ciliary body, or elsewhere; it may also attack the orbital walls and contents, simulating tumour. Periostitis too may give rise to protrusion of the eye and to optic neuritis.

Tubercle, like Syphilis, may attack any part of the eye. Pustular Conjunctivitis, Superficial and Interstitial Keratitis, Iritis (in adolescents chiefly), with or without definite deposit of a tuberculous mass, Cyclitis, and Chorioiditis, whether in the form of actual tubercle or of an anterior or a posterior Sclero-chorioiditis,—all these are frequent manifestations, besides affections of the walls of the Nasal Duct and the Sinuses.

There may be mentioned here a curious congenital cerebral defect, **Congenital Word Blindness**, which is to be found occasionally in children. The patient sees perfectly and can read letters quite well, but cannot combine them into words without much difficulty. There is no lack of intelligence, and the patient can grasp readily the meaning of a paragraph read to him, but will himself read out entirely wrong words which bear no resemblance to those printed,—will call duck "hen," road "street," and so on. To such a child, who is apt to be mistaken for a mere dullard or a fraud, reading is a perfect toil, but he is usually quite smart, perhaps exceptionally smart, with figures, with drawing, with any instruction received through the ear.

Colour Blindness is also a congenital anomaly, but this has been sufficiently dealt with already (p. 30).

CHAPTER XXIV

POINTS IN THE NURSING OF PATIENTS SUFFERING FROM DISEASES OF THE EYE

How to bathe the Eye.—For bathing, the lotion should be made tepid by the addition of hot sterile water, due care being taken that any lotion is not reduced thereby below the saturation ordered. Draw down the lower lid gently with the forefinger or thumb, at the same time asking the patient to look up. Then take a swab of cotton-wool or gauze soaked with lotion and let the contents drip gently on the exposed conjunctiva, using a scrap of dry cotton-wool to wipe up the moisture.

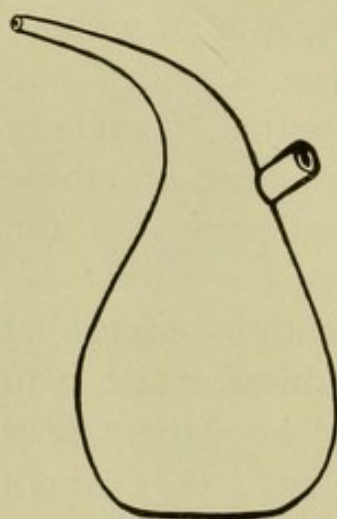

FIG. 85.—Undine.

The swab must be brought close to the eye, but, on the one hand, the lotion must not be splashed on the cornea, as this would prove very uncomfortable, and perhaps even painful, for the patient; and, on the other hand, the wool must not be allowed to touch the cornea or conjunctiva. Some surgeons prefer the use of the Undine, as the lotion is then untouched by the fingers. The nurse must be very careful when removing any crusts from the lashes not to press on the eyeball.

Drops are applied to the eye in much smaller quantities than lotion. To introduce drops, draw gently upon

the lower lid as for bathing, and put one or two drops from a dropper on the conjunctiva at the outer angle of the eye, taking care that the dropper does not come in contact with the lids or eyelashes, and thus become contaminated; and still more that it does not come in contact with the globe. "Chalk's" eye-dropper is one in frequent use; this consists of a flask which may be of a size from 2 drs. to 1 oz. It has a perforated glass stopper which reaches to the bottom of the flask, the stopper being covered at the top by a thin rubber cap. To pick up the drops, the cap is lightly pressed with the finger, and the pressure again relieved before the stopper is removed from the bottle, in order to draw the fluid into the glass tube. To release the drop for instillation the cap must again be gently pressed. If the patient has difficulty in looking up or in keeping the eye open, the upper lid may be gently lifted against the bone, but on no account must the nurse press against the eyeball. The dropper must be held vertically, or at least not so slantingly that the fluid can touch the cap and become infected by the rubber. The type of dropper and bottle shown in Fig. 86 is one in which there is no rubber at all; the stopper forms the dropper, and should it become accidentally contaminated it can be boiled at once before being replaced in the bottle, since it consists entirely of glass. In very cold weather the patient sometimes complains that the drops are cold. This can be remedied by holding the bottle containing the drops over

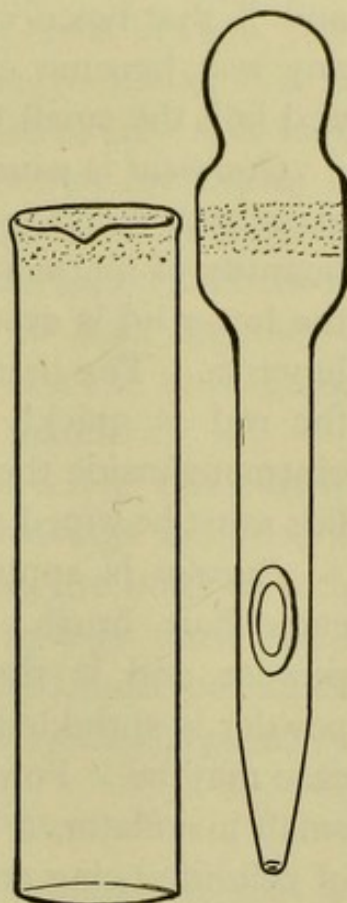


FIG. 86.—A good type of drop-bottle.

a spirit-lamp for a few seconds, or by plotting it in hot water, before applying the drops. Only a very small quantity of the drops must be taken from the stock-bottle into the flask at a time, as it is very apt to become turbid, flaky, and lose its strength. The nurse must keep watch lest the fluid should undergo any such change, and if that has occurred, or if the fluid should have in any way become contaminated, she must empty it out and boil the small bottle before refilling it.

Ointment is usually applied to the eye by means of a glass rod specially made for that purpose. A small quantity of ointment is picked up on the end of the rod, the lower lid is everted and the ointment laid on the conjunctiva. The patient is then told to close the eye, and the rod is quickly but gently withdrawn, leaving the ointment inside the lids. Any ointment left outside the lids must be wiped away with a small piece of cotton-wool.

Powder is applied to the eye by means of a small camel-hair brush. This is dipped quite dry in the powder and is then shaken or "flicked" so that the powder is sprinkled on the conjunctiva or cornea as the case may be. Powder may also be applied by using a small insufflator, a ball of rubber attached to a flask made of xylonite being employed to supply the puff of air.

Application of Heat may be carried out in various ways. Dry heat may be applied by means of the "Thermophor" and Charcoal Muff-warmer. The "Thermophor" is a small rubber bag filled with a substance which becomes pliable when heated. The bag or "thermophor" is dipped in hot water and then placed over the eye: it retains its heat for two to three hours. The Charcoal Muff-warmer is a small metal case covered with flannel or velvet, and perforated at the top. A piece of lighted charcoal is placed in it, which gives off the required heat. The patient does not bear well the weight of it pressing on the eye.

Heat by fomentation is perhaps more frequently employed. For this, make a pad of cotton-wool, lint, or domette, about 2 inches thick, and large enough to cover the eye and surrounding tissues ; wring out of very hot water and apply as hot as the patient can bear it. The heat must be kept up continually for twenty to thirty minutes, changing the pad before it cools. Then put a warm dry pad of cotton-wool or gamgee tissue over the area. This process is usually repeated every four hours.

Application of Cold is carried out by the use of ice. To make a small ice-bag take two pieces of gutta-percha tissue of the size required ; put some crushed ice between, and cause the edges of the tissue to stick together by wiping with a piece of wool wetted with a little chloroform, or by touching with a lighted match.

Another way is to put a piece of ice in the basin of lotion and wring out of this the dressings intended for application to the eye ; or by plotting the bowl of lotion in a basin containing ice. The dressings must not be allowed to become warm, and the cold must be kept up continuously for the time prescribed by the surgeon.

CATARACT PATIENTS

One of the first things to keep in mind is that the patient must be kept cheerful, as he is apt to become very down-hearted and depressed at the idea of being deprived of his sight for some time, and with the thought of an operation at hand. All undue fatigue and excitement must be avoided. Before operation the eyes are bathed twice or thrice daily for some days with a mild antiseptic lotion. The patient is given a warm bath the night before or morning of operation ; all precautions must be taken to prevent patient getting a chill. An aperient is given the day before operation, and as the majority of cataract patients are old people, it is a good plan to give such medicine as they have been

in the habit of taking, unless the surgeon should order any particular kind. As the operation is usually performed under a local anæsthetic, it is not necessary to evacuate the bowels by means of enema, but care must be taken to see that the bowels move satisfactorily after the dose. On the morning of the operation a light breakfast is given, consisting of tea or coffee and toast, with no accompaniments such as bacon and eggs or fish. The patient's face must be washed with soap and water and dried with a sterile towel. Sometimes an antiseptic soap is used, but this is not always suitable, as, in cases where the patient happens to have a tender skin, it is apt to peel in a few days after operation and occasion trouble.

Before operation the nurse must observe and report to the surgeon if there is anything abnormal, such as hernia, cough, secretion from the eye, or cutaneous disease.

The practice of surgeons varies in regard to dressings applied after the operation ; some surgeons do not put any dressing on the eye after extraction of cataract, and some bandage one eye only ; others again may bandage both eyes for some days. In the event of no dressing being applied to the eye, a shield made of wire gauze is placed over both eyes to prevent anything, such as the finger or the pillow, coming in contact with them. The



FIG. 87.—Wire shield for use after cataract operation.

patient is told by the surgeon to keep his eyes shut for a certain time ; until the effect of the cocain passes off the patient is very apt to open his eyes unthinkingly, and the nurse must watch against this.

When the patient has been brought back to bed after the operation, he should lie chiefly on his back. If he complains of pain from lying on his back for any length of time, the nurse may help him very much by turning him gently on the side opposite to the operated eye, or by raising his shoulders by means of an extra pillow. While thus being turned or raised the patient must not be allowed to exert or strain himself in any way, lest hæmorrhage should occur or the wound become reopened. The diet must be very light for the first few days—tea or coffee, milk, beef-tea, chicken soup, milk pudding, and bread and butter for the first three days. Then chicken or fish may be given, and by the end of a week ordinary diet is usually quite safe. An aperient is usually given on the third day after operation. The bed-pan must be employed for some days after operation, as the patient cannot be allowed to leave his bed. If all goes well, patient may be allowed to get out of bed on the sixth day.

The room should be moderately lighted and airy, but free from draughts. The old idea of dark rooms being necessary is now quite obsolete; all that is needed in an ordinary room is accomplished by drawing the blinds half-way down and turning the patient's bed so that he looks directly away from the window. In hospital it is often impossible to accomplish even this. To have the room too dark has the ill effect of depressing the patient seriously, and of adding to the difficulty of attending properly to his needs and of keeping the room and bed clean and tidy. If it is too dark he cannot be read to or fed easily, and it is very depressing both to himself and to his attendants. Patient's eyes may be shaded by means of a paper shade, while his surroundings can thus be kept more cheerful. Patient must be kept quiet on day of operation, but visitors "in moderation" may be allowed after the first or second day.

It is essential that a patient's head should be kept still and that his blood-pressure should not suddenly be raised, and coughing or sneezing might cause hyphæma or open the wound and so delay progress or endanger the recovery of sight.

The nurse must also take particular note if a patient after operation begins to refuse food or is sick, as that may be a sign of either increased tension or threatened suppuration.

It occasionally happens that cataract patients go "off their heads" the night of operation or after a few days. This may be due to various causes—such as having an eye bandaged, being kept in the dark, or the excitement of the operation. If the patient tries to get out of bed, it is best not to struggle with him; it is wiser to walk him gently round the room, as that will do far less damage to the eye than struggling to keep him in bed.

Patient must be warned against pulling up the bed-clothes in case of the hand coming in contact with the eye. A wire shield or goggles must be worn by the patient during bed-making, because a flick of the sheet or blanket on the eye might open the wound and cause prolapse of iris.

Patients must also be instructed not to put their hands near the face. In hospital it is the rule to feed the patients for the first three days after operation. Sometimes in the case of a child it is found necessary to bandage the hands; and in very refractory cases, hands have to be tied down to the sides of the crib, or a short splint may be applied at the elbows which will prevent the child from bringing up the hands.

In the case of an adult a bandage may be fastened to the wrist and to the foot of the bed, being left long enough to allow some movement but not sufficiently long to permit the hand to reach the face.

Music and Reading.—As the patient is not allowed

to use his eyes for himself, it is the nurse's duty to help to entertain him by reading the newspaper or a suitable book, or a little music where possible.

EYE DISEASE IN STRUMOUS CHILDREN

The child should be given a warm bath night and morning. His bowels must be attended to, and he should have as much fresh air as possible, though protected from light when there is much photophobia. The diet ought to be light in kind and contain plenty of milk. Tonics and cod-liver oil will no doubt be given. For the first few days the child frequently resents the treatment being carried out, and may fight against the washing of the eyes; great care must be taken at the opening of the eyes when bathing them so as not to injure the eyeball. It is a good plan to have the mydriatic or miotic (as the case may be) made up in the form of ointment, as it is not so easy for the child to squeeze an ointment out of the eye as drops; nor does the ointment suffer dilution by the tears. The child usually needs much persuasion to get him to look up, but a bunch of keys or a toy will generally induce him to open his lids; he may need this until he gets to know the nurse and to realise that he cannot intimidate her into giving him all his own way as his parents have—from mistaken kindness—probably done. The child must not be allowed to lie with his face buried in the bedclothes, as he so frequently tries to do.

OPHTHALMIA NEONATORUM

This is one of the most infectious of all eye diseases, and therefore very special care must be taken by the nurse, if she has more than one patient to attend to, in the way of sterilising. The nurse requires an assistant to hold the baby's head and to open the eyelids. As the quantity of discharge is so great, and must never be

allowed to collect, the bathing may require to be carried out every hour or half-hour. It is quite a common occurrence that before the bathing of the second eye is finished, the first eye is again pouring with pus. It is a good plan, instead of using swabs of cotton-wool or gauze, to employ an undine eye-douche, so that the flow of lotion may be more continual, using wool to mop up the lotion; the wool must be burnt immediately. When the lids are very swollen a retractor may require to be used to separate them, but this must not be done without the consent of the surgeon.

When the child's eyes are being bathed the pus sometimes comes out with a spirt; it is therefore advisable that the nurse should wear a pair of plain glass spectacles or goggles, as the result of infection might be very serious and have a disastrous effect on her own eyes.

The nurse must be familiar with the **strength of standard lotions and guttæ**. In hospital boric lotion is usually coloured pink, and is used as a saturated solution, to which a little hot sterile water has to be added.

Corrosive sublimate lotion is sometimes coloured yellow, but very often is used clear without colouring at all. The strength employed is from 1-5000 to 1-7000.

All lotions are used much weaker in ophthalmic cases than in ordinary surgical cases.

Atropin drops: grs. iv. to the oz. is the usual strength.

Weak atropin drops = grs. ii. to the oz. Extra strong atropin drops = grs. viii. to the oz., used in rare cases.

Pilocarpin is used in 1 and 4 per cent solutions.

Eserine sulphate, 1 per cent.

Cocain for corneal anæsthesia is used as a 4 per cent solution. Great care must be taken to see that the patient keeps his eyes closed between the instillations; otherwise the cornea would become glazed and the epithelium come off to the touch, and this might necessi-

tate postponement of the operation, besides giving the patient unnecessary pain.

Homatropin is used as a 1 per cent solution.

Protargol, from 2 to 5 per cent.

Argyrol is given from 5 to 20 per cent.

Nitrate of silver for *painting* the conjunctiva, grs. x. to the oz.

In hospital it is advisable that all septic cases should be kept apart from aseptic cases, and great care must be taken during the dressing and attending to patients so as not to carry any infection from one bed to the other. In some hospitals it is the rule, where there are several surgeons, to have separate wards for cataract patients, wards for other aseptic cases, and wards for septic cases only.

It very often falls to the nurse to see to the sterilising of the **instruments**. All the knives, before being sterilised, must be tested on the test-drum supplied for that purpose. Knives, scissors, and tortoise-shell instruments should not be boiled, but should be immersed in pure lysol. It is a good plan to have a piece of lint at the bottom of the tray on which to lay the knives and scissors, so that the edges of the instruments do not come in contact with the bottom or side of the dish and so become blunted. After lying in the lysol for a sufficient time, say five to fifteen minutes, instruments should be placed in alcohol to remove all trace of the lysol. From this they are put into sterile water or sterile normal saline. The other instruments are boiled immediately before using, and remain in the steriliser until the last moment, when they can be lifted out and put in sterile water or sterile normal saline. If the surgeon prefers to use the instruments dry, they must be laid on a dry sterile towel and covered with another sterile towel, which must not be removed until the surgeon is actually ready to use the instruments.

After operation, the instruments require special care in the cleaning of them. As is well known, eye instruments are very delicate and often require to have very sharp points. A tooth-brush should be used for scrubbing the teeth and joints of the instruments. Knives and scissors must be washed in warm water and then again immersed in the lysol and alcohol as before operation; only when they are taken from the alcohol, they must be dried with a soft cloth. This should be done by wiping the knife upon the cloth as a razor is stropped; no particle of the cloth must be allowed to come over the edge. The knives must again be tested on the test-drum before being put away. The other instruments are boiled in water to which a little soda has been added to prevent rusting and blackening. They must then be wiped thoroughly, care being taken to see that the instruments do not get sprained in any way during the drying process.

CHAPTER XXV

THERAPEUTIC AGENTS

Lotions.—The solutions most frequently employed are *Boracic Acid*, gr. iii. (to vi.) to \bar{z} i.; *Corrosive Sublimate* (Hydrarg. Bichlor.), 1 to 6000 or 8000; *Permanganate of Potass.* (1 per cent of official liquor); *Chinosol* (1 to 3000); *Collargol* (1 to 5 per cent). Alkaline lotions made with *Bicarbonate of Soda* or with *Glycothymoline* or *Thymoalkaline* (diluted 1 in 20) are comforting to many irritable eyes. The good custom of employing such substances as Fennel water or Cherry Laurel water has rather fallen aside lately.

Collyria.—“Drops” for the eye are generally prescribed to the amount of \bar{z} ss. Of *Atropin* (sulphate), of *Eserine* (sulphate), of *Homatropin* (hydrochlorate), of *Pilocarpin* (subnitrate), the usual strength is gr. ii. in half an ounce of distilled water or of normal saline. Apart from cases of iritis, etc., atropin is frequently used in half that concentration. Eserine of the full strength is sometimes painful to the patient, causing spasmodic action of the ciliary muscle, and often must be reduced in strength. All solutions of eserine must be protected from light, as they turn of a reddish hue after some exposure, at the same time undergoing some chemical changes calculated to interfere with their action. For long-continued use, as in cases of chronic glaucoma unsuited for operative interference, pilocarpin is frequently

employed at "half-strength," while for use at the close of an extraction of cataract where iridectomy has not been performed a solution of twice the power is valuable as giving an immediate, strong, and continued contraction. Where the watery solution of one of these drugs is found to produce an eczematous state of the lids and conjunctiva, it occasionally is useful to substitute an oily solution, but in such case the alkaloid itself must be employed, as the salts are not soluble in oil. Castor oil, or preferably olive oil or almond oil, forms the best base; the oil should be boiled first, and if this is done it will remain aseptic for a long time. Some surgeons prefer oily solutions for all purposes.

A solution which retains an honoured place in ophthalmology is *Nitrate of Silver*; if employed as drops it should not be stronger than one grain or perhaps two to the ounce, and its action should be checked by the immediate introduction of salt solution, which throws down the silver; but if applied by painting with a brush moistened in the solution, strengths of ten or even twenty grains to the ounce may be employed in the case of septic conjunctivitis. Many hard things have been said of nitrate of silver because its application is painful and because a fine pellicle forms where it has coagulated the albumin, but it is vastly the superior of any of the substitutes for it which have been proposed. Of these the best are probably *Collargol* and *Protargol* (2 to 5 per cent). *Argyrol*, though a good deal employed and strenuously advertised, has very little therapeutic value, and should not be relied upon; as a mild and rather soothing antiseptic it has a certain sphere of action.

*Adrenalin*¹ has some value in cases of chronic

¹ The term adrenalin is here used to indicate in a general way the active principle of the suprarenal bodies, not that substance as put on the market by any special firm of chemists.

watering of the eyes, in episcleritis, and according to some in spring catarrh; it may be combined if desired with weak cocain (gr. i.-ii.) and employed in the strength of 1-6000, or even weaker. (See below also.)

Adrenalin is also prepared synthetically: in this form it can be boiled without injury—treatment which destroys the glandular secretion.

Dionine is valuable as causing an effect exactly the opposite of Adrenalin, namely, increased lymph flow through a part. It is used in 2 or 5 per cent solution in cases of hypopyon ulcer to clear the toxins out of the cornea, in cases of cataract to hasten the absorption of cortical matter, and as an analgesic in iritis and other painful inflammatory conditions. In some persons the reaction is extreme; in others it is very transitory and tolerance is established very quickly.

Of astringent antiseptics may be mentioned *Sulphate of Zinc* (gr. i. ii. or even iv. to \bar{z} i.); *Acetate of Lead* (gr. $\frac{1}{2}$ -i. to \bar{z} i.), never to be used where there is any possibility of loss of corneal epithelium, as it might then leave a permanent opacity, but useful enough in follicular conjunctivitis; and *Tannic Acid* (gr. ii.-iv. to \bar{z} i.). Alum is rarely employed nowadays, but was formerly a great favourite. It appears to have an undesirable influence on the cornea, and if there be any ulceration there, should never be used.

Ointments.—The best base for ointments is Lanoline, which may be combined with vaseline and water to make it less sticky; pure vaseline is irritating to many eyes and should not be employed. *Yellow oxide of mercury* ointment has usually a strength of gr. iv. in half an ounce, but it can be employed in a higher concentration if desired; for adults, on the other hand, it must be diluted, for they do not bear it well. *Corrosive sublimate* ointment, 1-5000, is very valuable in many ulcera-

tive conditions of the cornea, and traumata especially. *Iodoform* ointment, too (gr. vi. to x. in half an ounce), is particularly valuable in septic states of conjunctiva, such as Koch-Weeks conjunctivitis, or of the cornea, such as hypopyon ulcer, as well as for the dressing after operations on the eyelids. Red oxide of mercury is not so much employed nowadays; it requires to be very much more dilute; it has considerable value, however, in chronic blepharitis. For this disease both *resorcin* (1 to 2 per cent) and *resinol* (a proprietary preparation) ointments are very helpful, especially the latter. Ointments of *iodine* (Ung. Iodi. B.P. 1-10) for chalazion, of nitrate of mercury (B.P. diluted eight times) for hordeolum, and of atropin where a child is apt to wash away a collyrium with tears, are all valuable. *Ichthyol* ointment is useful in many cases of blepharitis and conjunctivitis, especially if the skin be eczematous also, as well as in threatened abscess of the lachrymal sac; in the former case 2 per cent is strong enough, but in the latter, combined with extract of belladonna, and glycerine, five to ten times that concentration is not too much; in the mild form it is the best of applications for drug-eczema (atropin, etc.).

An ointment is best applied by picking up a little on a glass rod and smearing it off the rod into the eye.

Of local *Anæsthetics* a large number are in use, and of these the chief is *Cocain* (hydrochlorate). For instillation before an operation a 4 per cent solution is strong enough, and even with this strength the patient must keep the eyes shut between the instillations lest the epithelium suffer. For operations on the muscles, etc., subconjunctival injection of a few minims of a 1 per cent solution is of service, and where a tarsal cyst requires scraping out this may be injected first into the sac, a procedure preferable to that of applying powdered cocain to the spot. Solutions of cocain should never be

boiled ; they lose efficacy if this is done. Some surgeons prefer *Novocain* (3 to 5 per cent) when the interior of the eye is not to be opened ; novocain has but little penetrating power. *Holocain* (1 to 2 per cent) has an antiseptic as well as an anæsthetic action, and is well spoken of, but it is highly toxic. Even cocain causes a little smarting on first application ; some other anæsthetics cause much more. For subcutaneous injection Alypin (2 per cent) in association with Adrenalin is excellent—for example, in a case requiring excision of the lachrymal sac. The mistake which the young practitioner is apt to make is simply not giving the injection time enough to complete its action before he begins his operation ; twenty to thirty minutes should be allowed.

Internal Remedies need not be discussed here, as they do not differ from those employed under other circumstances. There are, however, two internal remedies of a somewhat outstanding character, mention of which cannot possibly be omitted ; these are Salvarsan (606) and Tuberculin. The principles underlying the use of these two drugs are the same as apply to their employment in affections of other parts of the body, and therefore need not be detailed here. In regard to **Salvarsan**, there was at one time a strong prejudice on the ground of a supposed risk of optic atrophy following its injection. So far as the most recent investigations and opinions go, however, it would appear that this fear is not justified, and that loss of vision, when it has followed the introduction, has not been due to that but to the disease for the treatment of which the drug was employed. **Neo-salvarsan** seems to be an even safer drug than 606, but it has not been so long on the market.

In regard to **Tuberculin**, the “old” is employed by some, while others prefer the “new” (T.R.), and some find that the results they obtain, in conjunctival and

corneal lesions particularly, with the bovine strain are more encouraging than those secured with the human. As a diagnostic test, *von Pirquet's* method is useful enough ; though it tells, it must be remembered, solely and only that this patient has at one time suffered from some tuberculous lesion ; it does not show that the deposit or infiltration, or whatever it be which is present at the moment, is itself tuberculous. It is difficult to imagine any circumstances in which the application of *Calmette's* reaction by an ophthalmic surgeon could be justified.

CHAPTER XXVI

REQUIREMENTS FOR THE PUBLIC SERVICES

Royal Navy. — A candidate for a Naval Cadetship must possess full normal vision ($\frac{6}{8}$ and Jaeger 1). His colour vision must be perfect, and he must suffer, or have suffered, from no fault of the eyes such as chronic Inflammation of Eyelids or Strabismus.

Army.—Candidates for Commissions are classified under three standards :—

Standard I.

Right eye $\frac{6}{8}$ and J1.

Left eye $\frac{6}{8}$ and J1.

Standard II.

Better eye $\frac{6}{8}$ and J1.

Worse eye $\frac{6}{10}$, corrigible to $\frac{6}{24}$, and J3.

Standard III.

Better eye $\frac{6}{24}$, corrigible to $\frac{6}{8}$, and J2.

Worse eye $\frac{6}{24}$, corrigible to $\frac{6}{12}$, and J3.

The amount of Myopia or of Myopic Astigmatism must not exceed 2.5D. Colour-blindness does not necessarily involve rejection.

Civil Service.—There are no definite regulations. Each case is decided “on its merits.”

British Mercantile Marine.—The regulations are not published in technical language; it is best to regard the required vision as $\frac{6}{8}$ with one eye and $\frac{6}{12}$ with the

other; no lenses permitted. Colour vision is tested by a modification of Holmgren's wools.

Indian Civil Service.—Vision (on correction if needed) must reach $\frac{6}{6}$ with one eye and $\frac{6}{9}$ with the other. There must be no morbid changes in the fundus, unless a posterior staphyloma (? rather a myopic crescent) with 2.5D of myopia as a maximum. Squint disqualifies.

Indian Medical Services.—Requirements as for Army Officers.

INDEX

- Accessory sinuses, 372
- Accommodation, 42
 - amplitude of, 43
 - and convergence, relation of, 344
 - range of, 43
- Acromegaly, 466
- Adaptation, 10
- Advancement of a muscle, 441
- After-cataract, 183
- Albuminuric retinitis, 255
- Alcohol amblyopia, 291
- " Amaurotic cat's eye," 245
 - family idiocy, 270
- Amblyopia, alcohol, 291
 - ex anopsia*, 348
 - quinine, 291
 - toxic, 289
- Amblyoscope, 352
- Ametropia, 46
 - subjective tests of, 70
- Amyloid degeneration of the conjunctiva, 124
- Anæsthetics, local, 482
- Aneurism of orbit, 368
- Aniridia, 178
- Anisometropia, 75
- Antiseptic lotions, 417
- Aphakia, 55
- Arcus senilis, 156
- Argyll Robertson pupils, 166, 465
- Argyria, 124
- Artificial eye, 450
- Asthenopia from astigmatism, 73
 - from error of refraction, 4
 - from heterophoria, 76
- Asthenopia, muscular, 6, 74
 - retinal, 7
- Astigmatism, 61
 - perverse, 74
- Astigmometer, 69
- Atrophy, optic. *See* Optic atrophy
- Atropin conjunctivitis, 117
 - in iritis, when unsuitable, 173
- Axenfeld's conjunctivitis, 101
- Bar-reading, 353, 416
- Bathing the eye, 468
- Band-shaped keratitis, 156
- Binocular vision, 34
 - tests for, 410
- Bjerrum's method of perimetry, 19
 - test letters, 11
- Blepharitis, marginal, 82
- Blepharospasm, 93
- Blind spot, Mariotte's, 21
- Bone-formation in the chorioid, 250
- Buller's shield, 109
- Buphthalmos, 315
- Burns of the eye, 392
- Calcareous degeneration of cornea, 156
- Canaliculus, injury to, 374
 - to incise, 447
- Canthoplasty, 424
- Caruncle, 98
- Cataract, anterior polar, 105, 211
 - complicated, 213
 - "congenital," 207
 - extraction of, 189, 193, 471

- Cataract, hard, 186
 lamellar, 207
 posterior polar, 212
 senile, 185
 soft or cortical, 205
 traumatic, 381
 "Cat's eye," 245
 Cautery for the cornea, 138, 141
 Cellulitis of orbit, 366
 Central vision, 12, 16
 Chalazion, 86
 Chancre of eyelid, 89
 Chemosis, 85
 Chloroma, 373
 Cholesterin in vitreous, 238
 Chorioid, 239
 coloboma of, 239
 formation of bone in, 250
 rupture of, 384
 tumour of, 245
 Chorioidal ring, 230
 Chorioiditis, 240
 Ciliary body, 179, 380
 tumours of, 182
 Ciliary muscle, 42, 318
 Clock, astigmatic, 64
 Cold, how to apply, 471
 Collyria, 478
 Coloboma, Fuchs's, 177, 240
 of chorioid, 239
 of iris, 177
 of lens, 216
 of lid, 95
 Colour-blindness, 31, 33, 467
 fields, 20
 vision, 30
 Commotio retinae, 384
 Compensation for injuries, 406
 Conical cornea, 150
 Conjugate deviation, 463
 Conjunctiva, 98
 organisms in, 99
 Conjunctivitis, 100
 Convergence, 342
 and accommodation, relation
 of, 344
 insufficiency of, 337
 metre-angles of, 75
 spasm of, 337
 Cornea, 126
 conical, 150
 Cornea, operations on, 429
 wound of, 379
 Cryptophthalmos, 95
 Cup of disc, three forms of, 231
 Cyclitis, 179
 Cyst of iris, 177
 of lids, 91
 Meibomian or tarsal, 86
 Cystitis, lachrymal, 358

 $D = \frac{1}{d}$, 37
 Dacryocystitis, 358
 Day-blindness, 11
 Decentring of lenses, 78
 Deformity, 8
 Dendritic ulcer, 142
 Dermoid of cornea, 157
 Descemetitis, 181
 Desmarres's elevator, 108
 Detachment of retina, 263
 Deviation, conjugate, 463
 Diabetes, 466
 Diabetic retinitis, 256
 Dioptre, 37
 Diphtheritic conjunctivitis, 117
 Diplo-bacillary conjunctivitis, 101
 Diplopia, 322
 Disc, optic, cupping of, 231
 optic, normal appearance of,
 228
 Discission, 210
 Dislocation of the lens, 214
 Distichiasis, 84
 Divergence, 339
 paralysis of, 337
 Drop-bottles, 469
 Drops for the eye, 478

 Ecchymosis of lids, 375
 Eclipse-blindness, 270
 Ectopia lentis, 214
 Ectropion, 94
 operation for, 425
 Electromagnet, 390
 Embolism of central retinal artery,
 258
 Emphysema of lids, 88
 Enophthalmos, 365
 Entropion, 92, 114
 operation for, 427

- Enuclation, 444
 Epicanthus, 95
 operation for, 429
 Epilation forceps, 85
 Epiphora, 94, 357
 Episcleritis, 159
 Epithelioma of lids, 89
 Errors made in claiming compensation, 407
 Esophoria, 77
 Essential shrinking of the conjunctiva, 125
 Evisceration, 446
 Excision of the globe, 444
 Exclusion of pupil, 169
 Exenteration of orbit, 452
 Exophoria, 77
 Exophthalmos, 364
 Exterior muscles of globe, actions of, 319
 Eye, general examination of, 453
 Eyelids. *See* Lid
 Eye-strain, 4, 73
 Eye symptoms in general disease, 463

 Fascicular keratitis, 128
 Field of vision, 17
 alterations of, 20
 in glaucoma, 22, 297
 in hysteria, 30
 Fixation, central, etc., 12, 16
 Fluorescin, 139
 Follicular conjunctivitis, 116
 Forceps, epilation, 85
 Knapp's roller, 115
 Foreign body in the cornea, 377
 penetrating eye, 378, 386
 under upper lid, 376
 Form sense, 12
 Fracture of orbit, 371
 Fuchs's coloboma, 177, 240
 Fundus, examination of, 227
 "Fusion-sense," 349

 Gerontoxon corneæ, 156
 Glaucoma, 293
 acute, 294
 field of vision in, 22, 297
 ophthalmoscopic appearances in, 300
 Glaucoma, secondary, 312
 simplex, 297
 theories of, 303
 vesicles on the cornea, 133
 Glioma of retina, 268
 Globe, injuries of, 375
 rupture of, 385
 Gonorrhœal conjunctivitis, 102
 metastatic, 111
 Granular conjunctivitis, 111

 Hæmorrhage into orbit, 366
 into vitreous, 238
 subhyaloid, 238
 Hæmorrhages in retina, 253
 Hæmorrhagic retinitis, 257
 Hard cataract, 186
 Hard chancre of lids, 89
 Headache, 4
 Head-nodding of children, 337
 Heat, how to apply, 470
 Hemianopsia, bitemporal, 28
 homonymous, 24
 Hemicrania, 4
 Hereditary optic atrophy, 287
 Herpes corneæ febrilis, 132
 Herpes ophthalmicus, 87, 131
 Heterochromia, 178
 Hippus, 166
 Hordeolum, 85
 Horner's muscle, 317
 "Hot eye," 159
 Hypermetropia, 55
 correction of, 58
 Hyperphoria, 77
 Hyphæma, 384
 Hypopyon ulcer, 133
 Hysteria, field of vision in, 28

 Idiocy, amaurotic family, 270
 Infection of eye, 378
 Instruments, care of, 477
 preparation of, 421
 Interstitial keratitis, 144
 Inversion, degree of, in indirect method, 227
 Iridectomy, 432
 Irido-cyclitis, 180, 398
 Irido-dialysis, 384
 Iridodonesis, 176
 Iridotomy, 438

- Iris, 162
 coloboma of, 177
 congenital absence of, 178
 cysts of, 177
 tremulous, 176
 tubercle of, 178
 tumours of, 176
- Iritis, 167
 different types of, 170
- Jaw-winking phenomenon, 97
- Keratitis, band-shaped, 156
 interstitial, 144
 profunda, 150
 punctata, 181
 sclerotising, 160
- Kerato-conus, 150,
 Kerato-globus, 150
 Keratomalacia, 138
 Knapp's roller forceps, 115
 Koch-Weeks conjunctivitis, 100
 Krönlein's operation, 371, 451
- L.D., 11
 L.M., 10, 261
 Lachrymal gland, 356
 Lachrymal sac, 358
 excision of, 448
 Leber's disease, 287
 Lens, coloboma of, 216
 concave, 37
 convex, 36
 crystalline, 183
 cylindrical, 38
 dislocation of, 214, 383
 prismatic, 39
 spherical, 38
 subluxation of, 214, 383
 testing an unknown, 39
 wound of, 381
- Lenses, 36
 bifocal, 60
 combined, 60
- Lenticonus posterior, 216
- Lesion causing paralysis of
 muscle, situation of, 328
- Leucoma, 105, 153
 Leucoma adhærens, 154
 Levator palpebræ, 81, 317
 Lid, coloboma of, 95
 Lid, cysts of, 91
 hard chancre of, 89
 injuries of, 374
 upper, how to evert, 376
- Lids, cold œdema of, 88
 congenital abnormalities of, 95
 emphysema of, 88
 epithelioma of, 89
 inflammation of, 82
 nævus of, 91
 rodent ulcer of, 89
 structure of, 80
 vaccine pock of, 89
 warts of, 91
- Light difference (L.D.), 11
 Light minimum (L.M.), 10, 261
 Light sense, 9
 Lime-burn of the eye, 393
 Lotions for the eye, 478
 Lupus of the conjunctiva, 124
 Lymphangeiectasis of the con-
 junctiva, 124
- Macula, normal appearance of,
 233
 Macular vision, 12, 16
 Maddox rod, 76
 Magnet for removing particles of
 steel, 390
 Meibomian ducts, 86
 Membranous conjunctivitis, 117
 Metastatic gonorrhœal conjunc-
 tivitis, 111
 Micro-organisms in conjunctiva,
 99
 Migraine, 4
 Miosis, 163
 Molluscum contagiosum, 91
 Mooren's ulcer, 143
 Morax - Axenfeld conjunctivitis,
 101
 Mucocoele, 358
 Müller's muscle, 82, 316, 364
 Muscæ volitantes, 235, 461
 Muscles, exterior, of globe,
 actions of, 319
 ocular, 316
 Mydriasis, 164
 Mydriatic, employment of, 71
 Myopia, 46
 dangers in, 51

- Myopia, traumatic, 383
treatment of, 53
Myopic crescent, 49
- Nævus of lids, 91
Nebula of cornea, 105, 153
Needling, 183
Neuritis, optic, 271
retrobulbar, 279
Night-blindness, 11, 261
Nuclear lesions, 329
Nursing, points in, 468
Nystagmus, 105, 334
- Occipito-frontalis, 316
Occlusion of pupil, 169
Occupations, requirements for various, 405
Ocular muscles, 316
Œdema, cold, of lids, 88
Ointments, 481
how to apply, 470
Onyx, 135
Opacity in media, to determine position of, 225
Opaque nerve fibres, 230
Operations on the eye, 417
Ophthalmia neonatorum, 102
how to bathe the eyes in, 475
Ophthalmometer, 69
Ophthalmoplegia, 329
Ophthalmoscopy, 218
Optic atrophy, 282
hereditary, 287
primary, 283
scotomatous, 287
Optic disc, normal appearance of, 228
Optic nerve, 271
tumour of, 292
Optic neuritis, 271
apart from tumour, 279
with intra-cranial tumour, 271
Orbicularis muscle, 81, 316
Orbit, 362
fracture of, 371
hæmorrhage into, 366
operations on, 451
- Pain, varieties of, 2, 460
Pannus, 114, 143
Pannus, strumous, 129
Panophthalmitis, 243
Paralysis of ocular muscles, 321
of pupil, 384
Parenchymatous keratitis, 144
Parinaud's conjunctivitis, 122
Patient, preparation of, for operation, 418, 471
Perforating artery of vitreous, 238
Perimeter, 17
Periphery of fundus, 233
Peritomy, 144
Perivasculitis, 253
Phlyctenular conjunctivitis, 119
Photophobia, 3
Phthisis bulbi, 154
Pinguecula, 123
Placido's disc, 151
Pneumococcus conjunctivitis, 102
Polycoria, 178
Presbyopia, 45
Prisms in ophthalmology, 39
Ptosis, 364
Prothesis, 450
Prowazek's bodies, 113
Pseudo-glioma, 245, 268
Pterygium, 122
Ptosis, 96, 317
operation for, 422
Punctum proximum, 43
remotum, 41
Punctured wound of eye, 386
Pupil, Argyll Robertson, 166
contraction of, 163
dilatation of, 164
exclusion of, 169
multiple, 178
occlusion of, 169
paralysis of, 384
reaction, 165
Pupillary membrane, 213
Purulent conjunctivitis, 102
Pustular conjunctivitis, 118
- Quinine amblyopia, 291
- Reading distance, 43
Refraction, 36
faulty, 46
objective tests of, 65
of the eye, 41

- Reports on claims for compensation, 411
 Retina, 251
 degenerative changes in, 260
 detachment of, 263
 embolism of central artery of, 258
 glioma of, 268
 hæmorrhages in, 253
 tumour of, 268
 Retinitis, 252
 albuminuric, 255
 circinata, 258
 diabetic, 256
 hæmorrhagic, 257
 pigmentosa, 260
 proliferans, 263
 Retinoscopy, 65
 Rodent ulcer of lids, 89
 Roller forceps, 115
 Röntgen rays as test for foreign body, 388
 Rules for diagnosis of muscle paralysed, 325
 Rupture of chorioid, 384
 of globe, 385
 of lachrymal sac, 375

 Sac, lachrymal, 358
 excision of, 448
 rupture of, 375
 Saemisch's section, 140
 Salmon patch, 146
 Salvarsan, 483
 Schools and myopia, 50
 Sclerectomy, 440
 Scleritis, 158
 Sclerotic, 158
 wound of, 380
 Sclerotising keratitis, 160
 Scotoma, annular, 21
 central, 21, 285
 "Second sight," 205
 Services, visual requirements for, 485
 Shadow test, 65
 Shield, Buller's, 109
 Shield for use after cataract operation, 472
 Sideroscope, 389
 Siderosis, 388

 Simple conjunctivitis, 121
 Sinuses, accessory, 372
 Skin grafts, means of attaching, 90
 Snellen's letters, 13, 70
 Spring catarrh of conjunctiva, 123
 Squint. *See* Strabismus
 Staphyloma anticum, 105, 154
 ciliary, 154
 posticum, 49
 Strabismus, alternating, 347
 concomitant, 339
 convergent, 342
 diagnosis between paralytic and concomitant, 350
 divergent, 339
 operation for, 440
 operation question, 353
 Strumous children, eye disease in, 475
 pannus, 129
 ulcer of cornea, 127
 Sty, 85
 Subhyaloid hæmorrhage, 238
 Subluxation of lens, 214
 Surgeon, preparation for operation, 421
 Symblepharon, 394
 Sympathetic inflammation, 395
 irritation, 395
 ophthalmia, 395
 Synchysis scintillans, 238
 Synechiæ, posterior, 168
 Syphilis, 466

 Tarsal cartilage, 81
 cyst, 86
 Tarsitis, 85
 Tattooing the cornea, 430
 Teeth, Hutchinson's, 145
 Tenonitis, 366
 Tenon's capsule, 363
 Tenotomy, 440
 Tension of the eye, 296
 Test letters, Snellen's, 13, 70
 small, 71
 Tobacco amblyopia, 289
 Tonometer, 296
 Toxic amblyopia, 289
 Trachoma, 111

- Transilluminator, 248
- Trephining the sclerotic, 440
- Trichiasis, 84, 114
 - operation for, 428
- Tubercle, 467
 - in chorioid, 243
 - in iris, 178
- Tuberculin, 482
- Tuberculosis of the conjunctiva, 124
- Tumour of chorioid, 245
 - of ciliary body, 182
 - of conjunctiva, 124
 - of cornea, 157
 - of iris, 176
 - of lachrymal gland, 357
 - of lachrymal sac, 357
 - of optic nerve, 292
 - of orbit, 369
 - of retina, 268
 - of sclerotic, 161
- Ulcer, dendritic, 142
 - hypopyon, 133
 - Mooren's, 143
- Ulcer of the cornea, 127
 - septic, of the cornea, 133
- Ulcus rodens corneæ, 143
- Ulcus serpens corneæ, 133
- Uveitis, sympathetic, 400
- Vaccine pock of lids, 89
- Vernal catarrh, 123
- Vesicle of the cornea, 131
- Vision, binocular, 34
 - central, 12, 16
- Vision, field of (*see* Field), 17
- Visual angle, 15
- Vitreous, cholesterin in, 238
 - hæmorrhage into, 238
 - humour, 235
- Warts of lids, 91
- Weeks conjunctivitis, 100
- Word-blindness, 464
- Wound of the eye, 378
- Xanthelasma, 91
- Xerosis of the conjunctiva, 124

THE END

1811. The first of the year was a very cold day.

The second day was a very cold day.

The third day was a very cold day.

The fourth day was a very cold day.

The fifth day was a very cold day.

The sixth day was a very cold day.

The seventh day was a very cold day.

The eighth day was a very cold day.

The ninth day was a very cold day.

The tenth day was a very cold day.

The eleventh day was a very cold day.

The twelfth day was a very cold day.

The thirteenth day was a very cold day.

The fourteenth day was a very cold day.

The fifteenth day was a very cold day.

The sixteenth day was a very cold day.

The seventeenth day was a very cold day.

The eighteenth day was a very cold day.

The nineteenth day was a very cold day.

The twentieth day was a very cold day.

The twenty-first day was a very cold day.

The twenty-second day was a very cold day.

The twenty-third day was a very cold day.

The twenty-fourth day was a very cold day.

The twenty-fifth day was a very cold day.

The twenty-sixth day was a very cold day.

The twenty-seventh day was a very cold day.

The twenty-eighth day was a very cold day.

The twenty-ninth day was a very cold day.

The thirtieth day was a very cold day.

The thirty-first day was a very cold day.

The thirty-second day was a very cold day.

The thirty-third day was a very cold day.

The thirty-fourth day was a very cold day.

The thirty-fifth day was a very cold day.

The thirty-sixth day was a very cold day.

The thirty-seventh day was a very cold day.

The thirty-eighth day was a very cold day.

The thirty-ninth day was a very cold day.

The fortieth day was a very cold day.

The forty-first day was a very cold day.

The forty-second day was a very cold day.

The forty-third day was a very cold day.

The forty-fourth day was a very cold day.

The forty-fifth day was a very cold day.

The forty-sixth day was a very cold day.

The forty-seventh day was a very cold day.

The forty-eighth day was a very cold day.

The forty-ninth day was a very cold day.

The fiftieth day was a very cold day.

TEXT-BOOK OF MIDWIFERY.

FOR STUDENTS AND PRACTITIONERS.

By R. W. JOHNSTONE, M.A., M.D., F.R.C.S., M.R.C.P.E.,
Assistant to the Professor of Midwifery and to the Lecturer on
Gynæcology in the University of Edinburgh; Extern Assistant
Physician, Royal Maternity Hospital; Obstetric Physician, New
Town Dispensary; University Clinical Tutor in Gynæcology,
Royal Infirmary; Gynæcologist, Livingstone Dispensary,
Edinburgh.

Crown 8vo, Cloth. With 264 Illustrations (3 coloured).

Price 10s. 6d. net.

This book has been designed primarily to supply students with a text-book of convenient size which contains all the information that they require. Special attention has been given to practical points, and to the discussion of the management of normal and abnormal cases, so that the book may be a guide to those actually engaged in the practice of midwifery. The anatomy and physiology of the female generative organs are fully described. The complicated subject of the development of the early embryo is simplified by the exclusion of comparative embryology, and by restricting the description to organs that have a direct bearing upon obstetrics. In the section on operative obstetrics particular attention is paid to operations which the general practitioner may be called upon to perform, while others that are only suited to hospital or special practice are more briefly described. A chapter on infant feeding contains simple instructions and prescriptions. The book is fully illustrated throughout, and many of the illustrations are new and original, whilst almost all have been specially drawn for this work.

THE LAWS OF HEALTH FOR SCHOOLS.

By A. M. MALCOLMSON, M.D. Small Crown 8vo, Cloth,
Illustrated.

Price 1s. 6d. net.

This book, intended for the teaching of the ordinary rules which guide one in the care of the general health, has been written specially for use in schools. Elementary anatomy and physiology have been described only in so far as these were deemed essential to a sufficient understanding of the methods used for the preservation of health. Technical words have been avoided as much as possible, and simplicity, both in subject-matter and in text, has been aimed at throughout. An endeavour has been made to divide the book into a number of short and approximately equal chapters, with the idea that each of these might make a complete lesson of reasonable length. There are numerous illustrations, many of which, for the sake of greater simplicity, are diagrammatic.

A chapter has also been included on the causes and prevention of infection. The book must prove altogether a concise and interesting instructor upon one of the most important subjects of present-day education for the young, the proper care and training of the body.

TEXT-BOOK OF OPERATIVE SURGERY.

By Dr. TH. KOCHER. Third English Edition, translated from
the Sixth German Edition, by HAROLD J. STILES, M.B.,
F.R.C.S. (Edin.). Containing over 300 illustrations, many with
colour introduced. Royal 8vo, Cloth.

Price 30s. net.

"It is quite out of place for any words of general praise to be bestowed upon this magnificent product from the pen of one of the world's greatest surgeons."—*Medical Record*.

"In our opinion it is without a rival."—*Edinburgh Medical Journal*.

Published by

A. AND C. BLACK, 4 SOHO SQUARE, LONDON, W.

Black's Medical Series.

HANDBOOK OF MEDICAL TREATMENT.

A GUIDE TO THERAPEUTICS FOR STUDENTS
AND PRACTITIONERS; WITH AN APPENDIX
ON DIET.

By JAMES BURNET, M.A., M.D., M.R.C.P. (Edin.). Fcap.
8vo, Cloth. **Price 3s. 6d. net.**

This is an unambitious attempt to supply the main facts of medical treatment within the compass of a small volume convenient to handle and to carry about. Purely surgical and gynæcological affections have been entirely omitted. Due attention has been paid to diet as an aid to treatment.

In a book of this kind it is very difficult to decide what ought to be included and what omitted. It is hoped, however, that the treatment recommended will in every case be found to be thoroughly sound, if at times somewhat dogmatically expressed.

MANUAL OF MEDICAL JURISPRUDENCE, TOXICOLOGY, AND PUBLIC HEALTH.

By W. G. AITCHISON ROBERTSON, M.D., D.Sc.,
F.R.C.P.E., F.R.S.E. Second Edition. With 39 Illustrations,
Crown 8vo, Cloth. **Price 8s. net.**

This small manual on Medical Jurisprudence, Toxicology, and Public Health has been written for the use of students who are studying for examination in these subjects. The author's endeavour has been to include all that the average student may be expected to know; the volume has no pretensions to compete with the many large and excellent text-books on these subjects, which are, however, as a rule, used only for reference by the practitioner and lawyer.

THE POCKET CLINICAL GUIDE.

By JAMES BURNET, M.A., M.D., M.R.C.P.E. Fcap. 16mo.
($4\frac{1}{8} \times 2\frac{3}{4}$ ins.), Cloth. **Price 1s. 6d. net.**
Or in padded leather with rounded corners and gilt edges.
Price 2s. net.

The object of this Guide is to aid students and practitioners in carrying out the simpler processes employed in everyday clinical work. It is convenient to have these methods brought together within the compass of a pocket volume. No attempt has been made to cover the whole field of laboratory investigation; only such processes as can be readily carried out are therefore referred to.

THE POCKET PRESCRIBER.

By JAMES BURNET, M.A., M.D., M.R.C.P.E. Third Edition.
Fcap. 16mo. ($4\frac{1}{8} \times 2\frac{3}{4}$ ins.), Cloth. **Price 1s. net.**

This small work is intended simply to aid students in their dispensary practice, and to encourage them to acquire the art of prescription writing. The author's aim throughout has been simplicity. Some of the less common diseases have been included, because had these been omitted certain critical readers might have found fault.

Published by

A. AND C. BLACK, 4 SOHO SQUARE, LONDON, W.

