

**Differential diagnosis of syphilitic and non-syphilitic affections of the skin, including tropical diseases : a survey for medical practioners and students / by George Pernet.**

**Contributors**

Pernet George.  
Royal College of Physicians of Edinburgh

**Publication/Creation**

London : Adlard, 1904.

**Persistent URL**

<https://wellcomecollection.org/works/fa4vbsw2>


**Provider**

Royal College of Physicians Edinburgh

**License and attribution**

This material has been provided by This material has been provided by the Royal College of Physicians of Edinburgh. The original may be consulted at the Royal College of Physicians of Edinburgh. where the originals may be consulted.

Conditions of use: it is possible this item is protected by copyright and/or related rights. You are free to use this item in any way that is permitted by the copyright and related rights legislation that applies to your use. For other uses you need to obtain permission from the rights-holder(s).



T. 5. 14.

R.C.P. EDINBURGH LIBRARY



R27722Y0236




Digitized by the Internet Archive  
in 2016

<https://archive.org/details/b21719937>

621

THE DIFFERENTIAL DIAGNOSIS  
OF  
SYPHILITIC AND NON-SYPHILITIC  
AFFECTIONS OF THE SKIN



THE DIFFERENTIAL DIAGNOSIS  
OF  
**SYPHILITIC AND NON-SYPHILITIC**  
AFFECTIONS OF THE SKIN  
INCLUDING TROPICAL DISEASES

A SURVEY  
FOR MEDICAL PRACTITIONERS AND STUDENTS

BY

**GEORGE PERNETZ**

ASSISTANT TO THE SKIN DEPARTMENT, UNIVERSITY COLLEGE HOSPITAL,  
LONDON; LATE PATHOLOGIST TO THE HOSPITAL FOR DISEASES  
OF THE SKIN, BLACKFRIARS.



London  
**ADLARD AND SON**

BARTHOLOMEW CLOSE, E.C.

1904

[ *All rights reserved.* ]



THE UNIVERSITY OF CHICAGO

SYMPTOMS AND NON-SYMPTOMATIC

TESTS OF THE SKIN

BY

THE UNIVERSITY OF CHICAGO

GEORGE F. HENKEL



CHICAGO, ILL.

1914

TO THE MEMORY

OF

A. & M. P.

THE END OF THE WORLD

1871

## PREFACE

IN January, 1900, I read a paper on "The Differential Diagnosis of Syphilitic and Non-Syphilitic Affections of the Skin" before the Medical Society of University College. The subject was one which I had long had in mind. Subsequently it was suggested to me that I should expand the paper and publish in book form. Other work has prevented my carrying this out sooner, but here is the book. I hope that the present survey will prove acceptable and useful to medical practitioners and students, for whom it is intended. I have, on second thoughts, left out names and bibliographical references in order to lighten the text, and also to keep it within bounds.

GEORGE PERNET.

152, HARLEY STREET, W.;

*July, 1904.*



# CONTENTS

## CHAPTER I

	PAGE
INTRODUCTORY—GENERAL DIAGNOSIS . . . . .	1

## CHAPTER II

THE PRIMARY CHANCRE—Maltreated Abrasions—The Soft Sore—Herpes Progenitalis—Scabies—Accidental Vaccinia—Epithelioma . . . . .	11
--	----

## CHAPTER III

EXTRA-GENITAL CHANCRES—General Remarks—Digital Chancres—Lips—Face—Nose—Eye—Scalp—Trunk and Limbs—Breast—Anus . . . . .	24
--	----

## CHAPTER IV

GENERAL REMARKS ON SECONDARY SYPHILIS—Histology of Syphilides—Aspect of the Patient—Distribution—Polymorphism—Arrangement—Individual Elements—Colour—Corroborative Signs and Symptoms—Lymphatic Glands—Itching—Mucous Patches—Throat—Loss of Hair—The Eyes—Headache—The Bones—Fever—Urine—Blood—Blood-vessels—Jaundice—Placenta . . . . .	39
---	----

## CHAPTER V

	PAGE
DIFFERENTIAL DIAGNOSIS OF SECONDARY SYPHILIDES— Roseola—Acute Exanthemata—Drug Rashes—Vaccina- tion Rashes—Tinea versicolor—Pityriasis rosea— Psoriasis—Seborrhœic dermatitis—Seborrhœa papulosa —Papulo-squamous Eczema—Mycosis fungoides—Dis- seminated Lupus erythematosus . . . . .	56

## CHAPTER VI

DIFFERENTIAL DIAGNOSIS OF SECONDARY SYPHILIDES ( <i>continued</i> )—Lichen planus—Syphilitic Lichen— Lichen scrofulosorum—Pityriasis rubra pilaris—Vesi- cular Syphilides—Varicelliform Syphilide—Erythema multiforme vesiculo-bullosum—Dermatitis herpeti- formis—Pemphigus vegetans—Bullous Iodide Eruption —Acute Pemphigus . . . . .	69
--	----

## CHAPTER VII

DIFFERENTIAL DIAGNOSIS OF SECONDARY SYPHILIDES ( <i>continued</i> )—Pustular Syphilide—Acne varioliformis— Acne vulgaris—Pediculosis—Scabies—Acne agminata —Acne scrofulosorum . . . . .	82
---	----

## CHAPTER VIII

TERTIARY SYPHILIS—General Remarks—History—Recur- rent Abortions—Sterility—Objective Signs—Types of the Tertiary Lesions—Corroborative Signs—Scars— Tongue—Mouth—Throat—Nose—Eyes—Headache— Fits—Bones and Joints—Viscera . . . . .	92
--	----

## CHAPTER IX

THE DIFFERENTIAL DIAGNOSIS OF TERTIARY SYPHILIS— Lupus vulgaris—Lupus erythematosus—Acne rosacea— Psoriasis—Seborrhœic dermatitis—Palmar and Plantar Eczema—Plantar Keratosis—Plantar Trichophytosis . . . . .	108
---	-----

## CHAPTER X

	PAGE
THE DIFFERENTIAL DIAGNOSIS OF TERTIARY SYPHILIS ( <i>continued</i> )—Lipomata—Carcinomata—Sarcomatosis cutis—Iodide of Potassium Indurations—Erythema in- duratum—Varicose Ulcers—Actinomycosis—Glanders —Rodent Ulcer—Ulcerating Granuloma of the Pudenda	122

## CHAPTER XI

DIFFERENTIAL DIAGNOSIS ( <i>continued</i> )—Leprosy—Yaws— Frambœsia Brasiliana . . . . .	139
---	-----

## CHAPTER XII

CONGENITAL SYPHILIS AND SYPHILIS IN CHILDREN— Congenital Syphilis—General Remarks—Placenta— Clinical Signs of Congenital Syphilis—Snuffles— Cranio-tabes . . . . .	160
---	-----

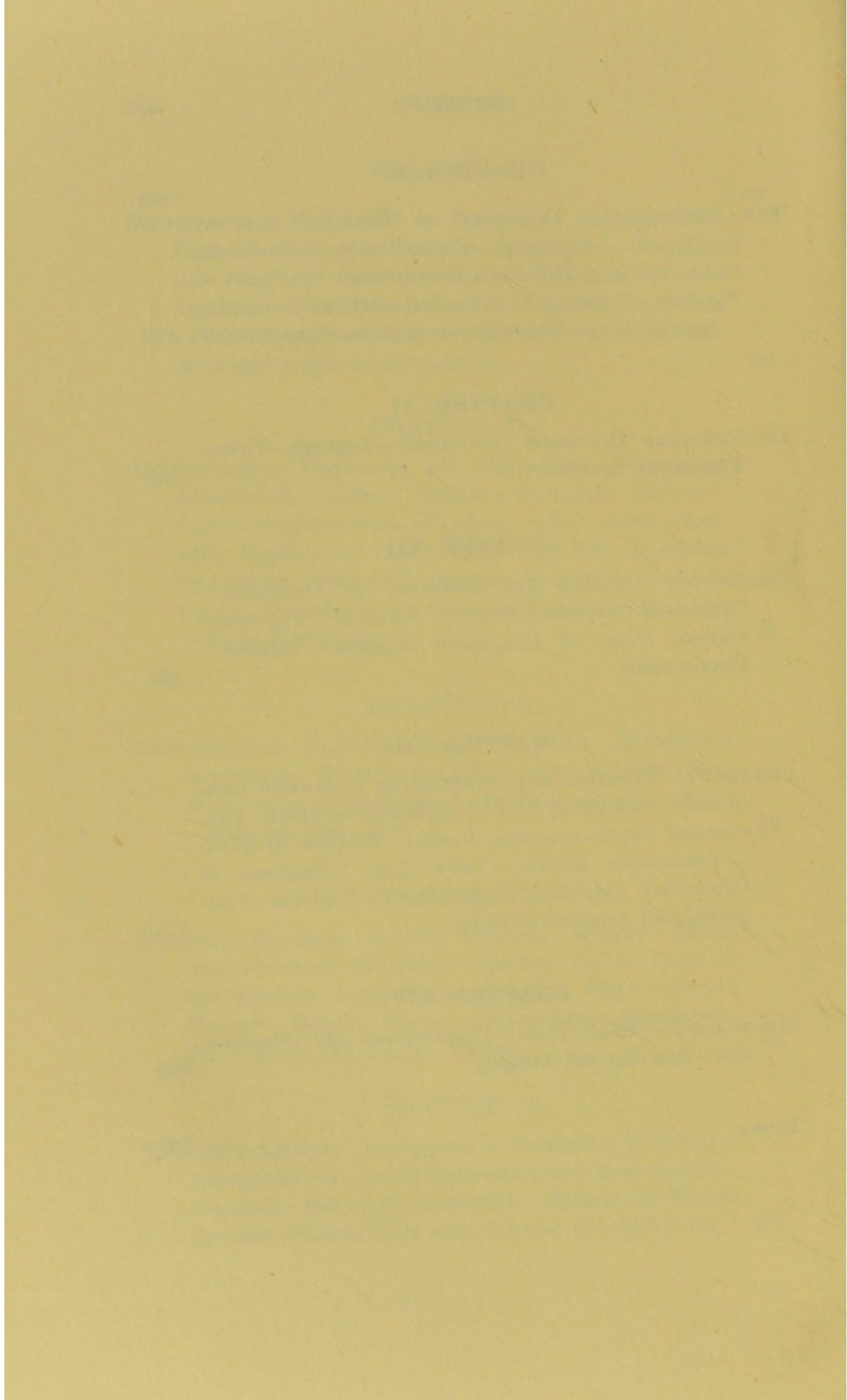
## CHAPTER XIII

CONGENITAL SYPHILIS AND SYPHILIS IN CHILDREN ( <i>con- tinued</i> )—Congenital Bullous Syphilide—Scabies—Pap- ular and Papulo-squamous Rashes—Bromide Eruption —Vaccination Rashes—Yaws—Late Symptoms of Congenital Syphilis—Eyes—Teeth—Deafness—Con- genital and Acquired Syphilis . . . . .	171
---	-----

## CHAPTER XIV

MISCELLANEA—Hair—Nails—Pigmentation and Discolora- tion—Scarring and Atrophy . . . . .	188
INDEX . . . . .	209





THE DIFFERENTIAL DIAGNOSIS  
OF  
SYPHILITIC AND NON-SYPHILITIC  
AFFECTIONS OF THE SKIN

57

CHAPTER I

INTRODUCTORY—GENERAL DIAGNOSIS

SYPHILIS, or not syphilis? That is the question which is constantly cropping up in practice, whatever the line of work. This is especially the case where sores and rashes of the skin are concerned, and it is here that mistakes are likely to be made. It is scarcely necessary to enlarge on the importance of accurate diagnosis from the point of view of prognosis, treatment, and prophylaxis. It is quite true that the differential diagnosis of syphilitic and non-syphilitic affections of the skin may be very difficult, as in the case of anomalous or ill-marked eruptions for instance. As a rule, however, with care a positive conclusion can be arrived at. It is important to take

to lean on any one sign or symptom, as is too often done. Prognosis, be it said, is frequently the thing about which the patient is most anxious. As to treatment, to be rational it must rest on the sure foundation of sound diagnosis. It must not be lost sight of that the effects of syphilis may be far-reaching, leading to serious cerebro-spinal and ocular complications, and even to death at times. And in pregnant women also, the effects of the poison on the foetus must be thought of. In exceptional cases, treatment may be a factor in diagnosis. Prophylaxis, again, is of vital moment in syphilis, for it behoves the medical man to do what he can to prevent its spread. This may be a delicate matter in some cases.

The positive diagnosis of syphilis plays a part in various ways in the law courts, in matters of life assurance, and so forth. It is very necessary, therefore, that all this should be borne in mind when giving an opinion. If there is any doubt in any particular case, it is important to be guarded, otherwise the consequences, quite unforeseen sometimes, may be the occasion of regrets and vexations.

On the other hand, it is equally important that morbid manifestations, which are not syphilitic in nature, should be carefully distinguished, else we shun Scylla and fall into Charybdis, the more so as there is a decided tendency in cases which present difficulties to go on the principle of when in doubt plump for syphilis. Such an attitude can only be corrected by a close attention to cutaneous diseases in general, inclusive of course of syphilis of the integument. Of recent years there has also been a

tendency to attribute to the bacillus tuberculosis lesions which are syphilitic. This error I have seen occur on several occasions.

Having outlined the importance of the subject and its practical bearings, I will now proceed to business and deal with general diagnosis.

I have noticed that students seem to think that diseases of the skin are, as it were, outside the pale of general medicine and surgery, and are not to be investigated on the usual lines. This is an error which it will be my endeavour to rectify. In the first place the patient's aspect and attitude should be rapidly noted. Much can be learned in a preliminary way by this habit of observation. Then come the name, age, occupation, and place of residence. The name frequently reveals nationality or race, a point of some importance in our present inquiry. As far as syphilis is concerned, the question of race to some minds amounts to the difference between the circumcised and the uncircumcised. I mention this because there is an exaggerated notion with regard to the immunity of the former. Circumcision by no means excludes syphilis. Again, certain affections of the skin are more frequent among the individuals of some nations and races, as will be seen further on.

Age in the case of women can be estimated without a direct question on the point, when the latter is not deemed advisable. Age is a factor which must be taken into account in skin diseases generally, but here again, as regards syphilis, infection may occur at any period of life, a point always to be

remembered. In this connexion accidental extragenital infection must never be lost sight of.

One word as to the social position and sex of the patient. It cannot be too frequently repeated that neither the one nor the other must lead to the *a priori* exclusion of syphilis.

Country of origin and place of residence also afford a clue, and indeed may be of the greatest value in arriving at a diagnosis. And this is especially the case in these days of travel and intercommunication. The geographical distribution of disease must be ever present in our mind.

These preliminaries having been elucidated, it is necessary to pursue a methodical course in dealing with the case, a course which must never be deviated from, and which must become an automatic habit as it were. The points to be noted now are :

1. The duration of the disease. This will be sufficient in many instances to exclude the acute exanthems, or slow chronic conditions, as the case may be.

2. How the disease commenced and how it has developed. This again is important.

3. General symptoms, such as fever, headaches, and so forth. When considered necessary, as in the case of a suspected acute exanthem, the temperature should be taken. The tongue and pulse must not be neglected; and what is of primary importance, it should be the rule to examine the urine.

4. Then comes inquiry as to previous treatment. Conditions are often modified or masked by drugs

and applications. In some cases, indeed, the eruption may be due entirely to the remedies.

This practically amounts to a history of the complaint. Of course, where possible accurate dates should be obtained, as in the case of the acute exanthemata for instance. As regards syphilis, however, it should be the great aim of us all to arrive at a positive diagnosis of that disease on the objective signs alone, without going into details. In the case of women, especially married women, it may be very important to avoid inquiry and cross-examination as to particulars. In the great majority of cases of syphilis, a corroborative history is unnecessary, indeed inquiry in this direction may be positively misleading, especially if relied on to the exclusion of objective facts. Here it may be as well to state that in the diagnosis of syphilis it is the positive points that count; negative assertions, either made in perfect good faith, be it said, or of set purpose, interfering but too frequently with the judgment and leading to erroneous conclusions.

The next step is to examine the sore or rash. In all cases every effort should be made to see as much of the complaint as possible. In men, this is not a difficult matter as a rule, but in women, for obvious reasons it may sometimes be necessary to see one part after the other. With tact and patience, obstacles to a complete examination will usually disappear one by one. It is important to avoid making a diagnosis on the appearances of any circumscribed portion of the integument, which the patient for various reasons may like to show you. Mistakes are

bound to be made if the medical man is weak enough to commit himself without a proper view of the trouble as a whole. Errors are often the result of insufficient examination, rather than of ignorance. The points now to be noted are :

1. Distribution—local or general, symmetrical, unilateral, and so forth. It is necessary to take a bird's-eye view of the eruption when wide-spread, back and front.

2. The arrangement of the elements making up the eruption. Grouping, for instance, is an important and striking feature at times of the syphilides.

3. The characters of the lesion or individual elements. The point of importance here is to make up one's mind as to the pathological nature of the morbid process. Examine not only with the eye, but also with the fingers. Are you dealing with hyperæmia, inflammation, hæmorrhage, hypertrophy, atrophy, an infiltration or a new growth? If the pathology be clearly grasped, a great stride is made towards differential diagnosis, as it leads at once to the exclusion of alternative diseases. In the case of crusted lesions, always remove the crust to see what is underneath.

It is very necessary to have a good light when viewing cutaneous affections; and daylight is best. Artificial light may make things very difficult; in that case, if there is any doubt, it is prudent not to give a decided opinion, but to see the patient again, if possible, under more favourable conditions.

In skin-work, a lens should always be used; a

two-inch bi-convex lens will answer most purposes, but it is well to have also a watchmaker's lens handy.

By glass pressure (the two-inch lens can be used for this) the blood can be driven out of Lupus vulgaris lesions, for instance, and the neoplastic foci will show up as brownish-yellow spots. But other granulomatous conditions, syphilides, for instance, may give very similar results.

Blue (cobalt) glass can also be used to view eruptions. It is held close to the eye, and certainly early macular syphilides scarce visible in the ordinary way are accentuated by this method. Its uses are limited.

4. Corroborative signs, such as glandular enlargement, state of the mucous membranes, of the eyes, and so forth.

One word as to the therapeutic test. In doubtful cases, the administration of mercury or iodide of potassium will be of assistance in diagnosis. Under mercury, for instance, the primary and secondary manifestations of syphilis clear up readily as a rule. Again, iodide of potassium will usually have a marked and immediate influence on tertiary symptoms. At other times both drugs combined will achieve good results. As to the latter mode of treatment, it is better adapted for tertiary than for primary and secondary syphilis, as the mercury, instead of being stored up in the tissues to exert there its specific action, is rapidly eliminated by the iodide of potassium, which acts as a diuretic. Another point which is frequently overlooked is the fact that mercury is necessary in all stages of the disease,



in the tertiary as well as in the other two periods. It is not infrequent to see syphilis excluded because iodide of potassium has had no beneficial effect. This is fallacious.

Again, there are some cases of syphilis that do not respond to mercury; indeed, the drug may be injurious. This may be so, for instance, in broken down cachectic or alcoholic individuals with severe ulcerating, so-called early malignant syphildes; or mercury and iodide of potassium may be ill-borne, the patients being very susceptible to the drugs, even in small doses, a state of affairs which makes the treatment one of great difficulty.

On the other hand, mercury is useful in conditions other than syphilis. Biniodide of mercury acts well, for example, in Lichen planus, especially in widespread more or less acute cases. This has led to Lichen planus being mistaken for syphilis; one observer has even erroneously contended on these grounds that Lichen planus was a syphilitic disease. Mercury also acts beneficially in some obstinate cases of psoriasis.

As to iodide of potassium, it has been recommended in large doses for psoriasis. This drug has also cleared some of the infiltration of malignant growths. Indeed, in ulcerating and extensive rodent ulcer it has acted so well at first as to lead to the diagnosis of syphilis, for a time, at least.

On the whole, therefore, the therapeutic test is not one to rely on entirely either one way or the other. It should be the endeavour of the practitioner to make a diagnosis, if possible, without its help,

reserving it only for doubtful cases. But even in them, the results must be taken with the other evidence.

All these points will be dealt with in their proper place.

To sum up so far, it may be said that in a general way everything depends on always investigating the case as a whole, and appraising the history given by the patient at its true value. If the latter clash with the objective facts before you, the history must go, and it is well to throw it overboard without compunction, or it may prove a troublesome piece of cargo. The attitude of mind should be that of scientific scepticism. Do not rely on the diagnosis of another; make one for yourself. Use the eyes first, then the hands carefully. The other senses are also useful: smell, and so forth. The thing to aim at is to diagnose syphilis without inquiring too closely into its origin. It is not worth while bringing a hornet's nest about one's ears if it can be avoided.

It is important to bear in mind that the combination of symptoms is liable to great variation; some of them may be but slightly marked or may even be absent altogether. Needless to repeat, it is the positive signs that must be taken into account first and foremost. There is also, generally speaking, a correlation between the severity of the rash and the concomitant signs. The more severe the onslaught on the skin in syphilis and the acute exanthemata, for instance, the more likely are the other symptoms to be marked.

The manufacture of future syphilophobes should also be avoided. Such a diagnosis as syphilitic wart, when venereal wart is meant, communicated to a patient may lead to the latter taking all sorts of normal things he discovers about his body, and every rash and so forth, for syphilis.

As the subject is a large one and somewhat complex, to render it as lucid as possible I will break it up on the lines usually followed in the study of syphilis, viz: (1) The primary sore; (2) the secondary eruptions; (3) the tertiary lesions; (4) congenital syphilis. These will be followed by chapters on special points, such as scars, pigmentation, and so forth.

I am well aware that the division of syphilis into primary, secondary, and tertiary may be criticized. Yet it is in the main a useful classification for the practical clinical objects I have in view. Moreover, it is one with which readers will be familiar, and these divisions will serve as finger-posts to them. Such an arrangement will necessitate some repetitions and overlapping here and there, but that will be no drawback, as some aspects will well bear emphasizing.

## CHAPTER II

### THE PRIMARY CHANCRE

MALTREATED ABRASIONS—THE SOFT SORE—HERPES  
PROGENITALIS—SCABIES—ACCIDENTAL VACCINIA—  
EPITHELIOMA

PATHOLOGICALLY, the formed SYPHILITIC CHANCRE (Hunterian chancre—chancre induré—Primäraffekt) is a new growth (granuloma), the primary change, however, being vascular. Its chief feature is the infiltration of the corium, mainly by plasma-cells: plasmoma—fibro-plasmoma. This infiltration with marked tendency to fibrous formation is the keynote to the primary infective change in syphilis, which ultimately leads to the induration. Migrated leucocytes play a small part in the process. It is important to bear the histological features in mind, as it is this which at once sharply differentiates the true chancre from some of the other local morbid processes I shall have to deal with. But the induration naturally depends on the texture of the part affected, and the arrangement and number of the blood-vessels supplying it, varying from a parchment-like to a hard nodular condition; sometimes it may feel cartilaginous. In some cases it

requires careful examination. Here it may be as well to say that as cracks and injuries about the fingers are not uncommon, the medical man should use precautions when carrying this out. The **primary sclerosis** (induration) is well defined to the feel, and more or less circular or oval in shape as a rule. On the labium majus the chancre may shade off into a diffuse thickening. It must not be forgotten either that the chancre may be a very insignificant lesion, a small solution of continuity, a harmless-looking erosion. This explains why the primary seat of infection may elude both the surgeon and the patient, a fact which has led to the misleading term **Syphilis d'emblée**. There is no *syphilis d'emblée* in the usual sense of the term, that is without a solution of continuity, however slight, somewhere in the tissues sufficient for the entrance of the syphilitic virus. But infection may occur directly into the blood-stream without the formation of a chancre (see Chapter III); in such a case the term would apply.

Among the well-to-do, who take a good deal of interest in their persons, it is essential not to overlook slight harmless-looking lesions about the genitalia, following sexual connection. In such cases, a decided opinion should not be given, but the patient be kept under observation. Corroborative symptoms of syphilis sometimes arise and justify the prudence of the practitioner.

**MALTREATED ABRASIONS.**—With regard to induration, the part played by previous local treatment of a sore must never be overlooked. The indiscrimi-

nate application of caustics (nitric acid, acid nitrate of mercury, etc.) to all and every sore about the genitalia is not as common as it used to be. Yet this cause of a reactive induration must be mentioned here from the point of view of differential diagnosis.

Another point to bear in mind is the possibility of primary syphilis occurring in a congenital syphilitic.

It would take me beyond the scope of this survey to describe minutely the variations in the clinical appearances of chancres. Suffice it to say here that they vary greatly. Phimosis may occur as a result of a chancre imprisoned under a long prepuce.

The next step is to investigate the condition of the corresponding lymphatic glands, that is for the moment, as I am dealing with chancres of the genitalia, the inguinal glands. In syphilis they are affected in a characteristic manner; they are multiple, hard (bullety), and indolent. French writers term the adenitis *Pléiade ganglionnaire* after the close group of stars.

The possibility of multiple syphilitic chancres is frequently overlooked. It is usual for the chancre to be single, but it is by no means a hard and fast rule. There may be two, three, four chancres, and exceptionally a much greater number about the genitalia, both male and female. I have lately seen four characteristic indurated chancres on the glans; and at the Hôpital Saint-Louis in Paris I saw as many as twelve in a man with scabies.

In this country insufficient attention is paid in a general way to chancres of the vulva. It is im-

portant to consider them briefly here. It is sometimes thought that they differ from those in the male. This is not so, for they are indurated and vary in their clinical appearances just as in the other sex. In women they mostly occur on the labia majora, and next in order of frequency on the labia minora and fourchette. The greatest amount of induration occurs on the labia majora, and it is often associated with a general hard œdematous enlargement of the affected labium, which may be painful. On the labia minora they are not so marked and may be more parchment-like. About the clitoris, the chancre may present itself as a small erosion; in this situation it is difficult to make out the induration. The peri-urethral chancre is indurated in women as in men, but in the former it is slow to heal. In women, too, hard chancres may be multiple about the vulva. As to the cervix, it is an error to suppose that the chancre is very rare in this situation. On the Continent, where women are examined more thoroughly than is the case with us, it is not uncommon. So that an examination with a speculum in a good light should not be neglected if it can possibly be managed when necessity arises.

In some special cases, confrontation may be of some assistance, that is, the suspected source of the infection may be investigated, male or female as the case may be. Of course the matter is a delicate one, and the suggestion should come from the patient. In making an examination of a woman, it is important to examine the cervix by means of a speculum, should there be no evidence about the vulva.

One word as to chancre of the genitalia in children. Apart from the possibility of accidental infection, cases of rape must be considered, especially from the medico-legal aspect. With regard to infants, syphilis is sometimes communicated to them among the Jews by the unclean instruments of the professional circumciser, the *mohel*, and in some instances by the filthy custom of sucking the wound after the prepuce has been sacrificed. In Morocco, the rabbi fills his mouth with *mahia*, an alcoholic drink, and sucks the wound three times. The same possibility of instrumental infection may arise among Muhammedans and other people who have adopted circumcision or slitting the prepuce. The infibulation of females which obtains in some quarters may be mentioned in this connexion, as also the ampallang custom among the male Dyaks.

A mother with recently acquired syphilis may communicate it to her children accidentally.

Again, chancres of the genitalia may themselves be accidental. Apart from what has already been said (see also Chapter III) syphilis may be contracted from a borrowed vaginal douche nozzle, for instance, and the disease communicated unconsciously to the husband. Such cases may lead to great difficulties in tracing the infection to its source, in the face of denials of the usual possibilities.

In natives of tropical and sub-tropical countries the chancre may attain a great size, and it has always a great tendency to become phagedænic, owing to their utter neglect of elementary cleanli-



ness and the application of such things as mud and so forth.

The primary chancre is not often seen in the early stages, owing to the indifference of natives as a rule to sores, unless pain be a symptom. In such neglected cases great deformity of the penis may ensue.

Among some native races, syphilis is so rife as to be the first thing to exclude before going any further.

The so-called **redux chancre** (or indurated pseudo-chancere) need be only mentioned here in passing. After healing, a chancre may apparently start again on the same area and after a time look very much like the original sore, but it is not really a lesion answering to the primary chancre. Syphilitic re-infection may occur, but it is extremely rare, yet it is well to bear this possibility in mind in differential diagnosis.

Among the non-syphilitic sores about the genitalia which most commonly lead to difficulties are :

THE SOFT SORE (ulcus molle, chancrelle, chancre mou, weicher Chancre, die venerisch-contagiöse Helkose). In sharp contra-distinction to the chancre, the soft sore is essentially an acute inflammatory process. Initially the former is not an ulcer. The soft sore occurs in the first few days following impure coitus, whereas the chancre has been found experimentally to have an incubation period varying from ten to forty-six days, but there are clinical cases on record of shorter and longer periods of incubation. It is very important to bear this in

mind, for although the usual incubation period is somewhere about three weeks, the range of variation is the thing to remember rather than the average, the latter being after all a mathematical abstraction. In one instance the incubation period is stated to have been ninety-seven days in the case of a patient who had passed through an attack of variola. With regard to the length of incubation in any particular case, so much depends too on the patient's statements, *bona fide* or otherwise, that it is difficult to exclude sources of error. Indeed, in some cases, cross-examination leads one into such a bog of complexities, especially when the possible sources of infection are many, that evidence elicited in this way is often worse than useless. Another point to be noticed in connexion with incubation is that when the patient comes before us the chancre has already reached a certain stage in development. But it must be remembered that histologically reactive changes occur very soon after inoculation of the virus. In chancres excised at an early period, the blood-vessels already exhibit changes in and about them.

As to the soft sore itself it is usually multiple, especially in women for obvious reasons, and in the uncleanly, the sore being auto-inoculable. Clinically the lesions consist of small, circular, shallow ulcers, with sharply cut borders, which may or may not be somewhat undermined. The floor is irregular and usually of a yellowish colour. It is surrounded by an inflammatory red areola. The local symptoms complained of are pain, heat, or itching. The soft sore is not indurated normally, but here again the applica-

tion of caustics may lead to an artificial induration. In connexion with the differential diagnosis, there is the possibility of mixed infection, that is both with the soft sore strepto-bacillus and the syphilitic poison. Soft sores in that case ultimately develop the characteristic induration of the chancre, and in due course the typical adenitis of the latter follows. It is well therefore to be on the look out for this and to be guarded as to the prognosis of what appears to be only a soft sore.

There may be no adenitis in the case of the soft sore, or a single acute bubo may form and go on to suppuration. On the other hand bubo may occur in association with a syphilitic chancre as a result of secondary infection by pus organisms.

In passing I may just allude to the sloughing and phagedænic complications which sometimes occur in soft sores from want of cleanliness and secondary infection from without. They are uncommon conditions in this country at the present time. Indeed, the soft sore is itself uncommon, at any rate that is my experience in London. International exhibitions, by bringing people together from many parts of the world, play a part in the increase of the soft sore. This was the experience in Paris in 1878, for in 1876 it had been remarked how rare the soft sore had become. In some countries this venereal condition is more frequently met with, as in Tokijo for instance, where it has been found that out of some 10,000 venereally affected prostitutes, 25 per cent. suffered from soft sores. In North Africa the soft sore is common.

The strepto-bacillus can be looked for in material curetted from the borders of the ulcer. It is important to go to some depth after drying the discharging surface to obtain the characteristic chain-like filaments of the bacilli in serried rows, an arrangement best seen in sections of excised tissues. The microorganism is polymorphous, a point to bear in mind. Even in smear preparations from the discharging surface, I have found the strepto-bacilli in large numbers, but not quite with the appearance just described. The bacilli varied in length, and were arranged end to end, forming longer or shorter filaments, sometimes two of which occurred side by side, or the bacilli were arranged in irregular bundles or in a fan-like manner. The strepto-bacillus stains well with Loeffler's methylene blue, and the stain can be fixed by means of a 10 per cent. tannic acid solution.

The strepto-bacillus, like the gonococcus, is decolorized by Gram's method of staining. A  $\frac{1}{2}$  oil immersion should be used.

It is only fair to add that, although Ducrey's bacillus (strepto-bacillus—*Bacterium ulceris cancrisi*) is generally admitted to be the cause of the soft sore, one authority at least does not accept its specificity.

When in doubt as to the diagnosis it is prudent to reserve your opinion and await developments.

This is especially important in delicate circumstances, which may lead to proceedings before a court of law. Even short of this, the precipitate diagnosis of syphilis has led to much unpleasantness and difficulties.

HERPES PROGENITALIS (*Herpes præputialis*) is a fairly common affection which sometimes causes patients much anxiety. Here again, in contradistinction to the syphilitic chancre, one has to deal with an acute inflammatory process, preceded by itching and burning. It often occurs as a single group of minute, pinhead-sized vesicles on a reddened base, but the groups may be many, the latter being the case chiefly in women according to my experience, when the eruption may involve many parts of the vulvar and adjacent areas. Difficulty arises when the herpetic vesicle is single or the vesicles are discrete instead of being in clusters. In both sexes the outbreak may be accompanied by swelling and œdema of the affected parts. The vesicles soon rupture, leaving polycyclic superficial erosions with geographical outlines, reminiscent at times of the islands of the Malay Archipelago. On the negative side there is neither the induration nor the characteristic adenitis of syphilis, although a slight reaction of the inguinal glands may occur, especially if the parts have been irritated by unsuitable applications, by vaginal discharges, or by want of cleanliness, leading in the male to accumulation of smegma and balanoposthitis. In herpes progenitalis some induration may be induced by caustics, just as in the case of the soft sore, and the diagnosis made difficult for the time being. Remember that herpes resents active treatment.

Another point to bear in mind is the possibility of herpes progenitalis being the forerunner of a hard chancre, the herpetic area becoming eventually indu-

rated and typical adenitis developing. This is not to be wondered at, seeing that patients with herpes progeneralis are very liable to recurrent attacks, and that the condition frequently follows on sexual connection. Moreover, syphilis may be contracted by a patient suffering from herpes, if exposed to contagion, and the result may be one or more chancres.

The glans may be also involved in **Herpes zoster** of the sacrum, perinæum, and genitalia.

In SCABIES, as is well known, the penis is frequently affected, in some cases large crusted sores forming on the glans. These at times much resemble the crusted form of primary chancre. Moreover, it has happened that a case of itch has been cured by suitable treatment, all but a well-defined crusted sore on the penis or genitalia, which has ultimately turned out to be a syphilitic chancre. Always remove the crusts to ascertain the kind of morbid process which is going on beneath them.

ACCIDENTAL VACCINIA, both of the male and female genitalia, has occurred by the conveyance of the virus from another recently vaccinated individual either by means of the fingers or by soiled linen. In one case a medical man inoculated a woman with vaccinia in this way by making a vaginal examination without washing his hands after dressing an infant's recently vaccinated arm. Here again differential diagnosis would come into play, but the real nature of the condition would be ascertained by carefully weighing all the points of the case—the duration and mode of development of the lesion or

lesions, the clinical appearances, the nature of the adenitis, and the fact of a recently vaccinated case in the family.

EPITHELIOMA of the penis generally begins in the sulcus behind the glans, and when imprisoned under a long or phimotic prepuce gives rise to the suspicion of hard chancre. The age of the patient, the duration of the disease, and the negative result of anti-syphilitic treatment would point in the right direction. Where there is phimosis, it is important in any case to slit up or remove the prepuce to make a thorough examination. Cancer of the penis in such a case gives rise to an offensive serous and bloody discharge from the preputial orifice. The glands are liable to become affected at an early stage, thus complicating the differential diagnosis. Age must not preclude the possibility of syphilis. Epithelioma in this situation is rare in this country, but in hot climates, such as Egypt for instance, it not infrequently occurs as a complication of neglected primary chancres. In women, epitheliomatous growths may develop on the labia majora.

I need only remind my readers of the so-called **Venereal Warts** (*condylomata acuminata*, *végétations vénériennes*) in both sexes, and of the inflammations and abscesses of Bartholin's glands in women, neither of which could well be mistaken for anything else.

One word as to syphilophobia. Neurotic individuals, and those with an uneasy conscience, are sometimes very troublesome and return again and again for the examination of slight and insignificant abrasions, or with balano-posthitis. Needless to say that such

cases should be examined patiently and thoroughly every time. They may contract syphilis in earnest eventually. In any case it is not good to pooh-pooh what they say; their tale must be listened to.

As to the differential diagnosis of syphilis, leprosy, and yaws see Chapter XI.



## CHAPTER III

### EXTRA-GENITAL CHANCRES

GENERAL REMARKS — DIGITAL CHANCRES — LIPS —  
FACE—NOSE—EYE—SCALP—TRUNK AND LIMBS—  
BREAST—ANUS

A MORE important subject from the point of view of this book than the genital chancre is the primary sore of syphilis as it occurs in other parts of the body, viz. the extra-genital chancre, to which the name of **Syphilis insontium** has been improperly applied in my opinion, for it implies that syphilis contracted by sexual intercourse is a syphilis of the guilty, an ethical point with which the surgeon has nothing to do. His part is to relieve and to point out the dangers of communicating the disease to others.

Notwithstanding all that has been written on the subject of extra-genital syphilis, the chancre frequently escapes diagnosis. It is rather the rule than the exception for a chancre of the finger, for instance, to be treated for weeks, and months sometimes, as a simple sore or whitlow, without the slightest suspicion as to its real nature. I have seen this occur in a case with an unmistakable generalized secondary eruption.

A point never to be lost sight of in practice is the possibility of a primary sore occurring on any part of the body. The primary chancre has been observed on the face, scalp, trunk, limbs and anus; and, as will be seen further on in the section on the differential diagnosis of the syphilides, on various mucous membranes. Moreover, the extra-genital chancre is not necessarily single; it may be multiple, a fact which is missed at times, and syphilis excluded on that account. I have been informed of a case in which a primary chancre developed on both thumbs, near the nails, as a result of attempts to reduce a paraphimosis.

Again, the extra-genital chancre is a common accident in those countries where syphilis is very rife, owing to overcrowding and a low grade of civilization, as in some parts of Russia for instance. This is also the case among native races, on account of scanty clothing, dirty sleeping mats, rice-sticks, the passing of the pipe from mouth to mouth, and so forth. The habit of passing round the loving cup at banquets might be responsible in a similar way, as also the use of a common communion cup.

It is a good rule to examine the patient generally; a syphilide or other secondary manifestation may already be present. This depends of course on the age of the chancre, but the duration is a thing about which some patients are not very precise. The examination should include the glands other than those corresponding to the extra-genital sore.

DIGITAL CHANCRES occurring in medical men themselves are not recognised as such for weeks

sometimes. The finger, or end of a finger, has been amputated for what turned out after all to be a syphilitic chancre. As serious consequences may result both to the individual and to others as a consequence of overlooking digital chancres, it is very necessary to insist on the importance of suspecting syphilis whenever a sore about the fingers does not respond quickly to appropriate local measures. Gynæcologists, accoucheurs, and midwives are especially liable to such accidental infections, as are also surgeons and nurses. It behoves them, therefore, to be careful to protect cracks, fissures, and injuries of the fingers, and this applies above all to men with a large midwifery practice, and to students attending cases in the maternity department of general hospitals. Indeed, it is advisable to give up midwifery practice altogether for a time when the hands are badly affected by diseases leaving raw surfaces behind, such as acute vesicular and eczematous eruptions and so forth. On the other hand, accoucheurs with a suspicious sore on the finger should refrain from midwifery practice. A few years ago an action came before the courts turning on the communication of syphilis in this way to a woman in labour. It is important, too, for medical men to bear in mind the possibility of chancres of the cervix uteri. Rectal examination has also led to accidental infection. Dental surgeons again may contract a digital chancre in the course of their work on the teeth of syphilitic subjects. It is well when sending on a syphilitic patient to a dentist to emphasize the importance of

the patient's mentioning the fact. Moreover, syphilis, as is well known, has been inoculated by means of unclean instruments: dental forceps, Eustachian catheters, etc.

Digital chancres may occur in other ways than those already mentioned: by bites, contaminated objects, and also as a result of wounds and abrasions of the fingers following blows on the mouth of syphilitic individuals.

Inquiries into the subject of digital chancres show that the incubation period may be frequently prolonged beyond four weeks; in some instances, however, this may be due to the non-recognition of the early stages. Further, such chancres are not necessarily followed by severe symptoms. When the latter do occur it may be that they are the result of a failure to diagnose the true nature of the complaint for several weeks, the patient being left without proper mercurial treatment. In the case of medical men, notwithstanding the fact that they have consulted medical friends, the possibility of syphilis has been, and will no doubt still be, often quite overlooked.

The middle and index fingers are the digits most frequently affected, then comes the thumb. A chancre is rare on the third finger, and extremely so on the little finger. The palmar or dorsal surface of the terminal phalanx is the usual part to be affected, the chancre being often situated at the edge of the nail, when it is extremely painful, a symptom which it is important to note. Patients sometimes present themselves for a rash, but with

dressings on the affected finger. These dressings should always be removed, notwithstanding the reluctance of the patient and the assertion that it is only a whitlow or a poisoned finger. In one case of this kind, in which the patient had had fomentations applied for some weeks, I discovered a characteristic chancre of the pulp of the finger when the bandages and lint were taken off.

Digital chancres may also be contracted in ways which need not be insisted on, but such a possibility must necessarily be borne in mind.

Chancres of the fingers are indurated much in the same way as elsewhere, but at the root of the nail this quality may not be marked, or may be absent.

The axillary and epitrochlear glands are enlarged, sometimes markedly so.

Taking all the foregoing points into account—duration, the negative results of local treatment, induration of the base of the sore, and the corresponding characteristic adenitis—the diagnosis of syphilis would be practically inevitable. Occupation and the digit involved would be facts to bear in mind. It is possible for inoculation of the finger to occur without marked local reaction, but the axillary adenitis may lead to an idea of malignancy. With regard to the latter one word of warning as to the histological diagnosis. No opinion should be given on microscopical examinations alone, but only with *all* the facts of the case before one.

As to the other nail affections which might come into the purview, they will be dealt with in the chapter on hair and nails (Chapter XIV).

LIPS.—Apart from the genitalia, this is one of the most common situations of the extra-genital chancre. Here it arises from kissing, contaminated glasses, cups, pipes, musical instruments, testing coins between the teeth, and by other means it is unnecessary to dwell upon here. Patients with active syphilitic ulcerations about the mouth should be warned of the dangers of kissing, as a slight crack or abrasion of the lip in a healthy individual may be the open door for the syphilitic virus.

Although it is very rare for the **soft sore** to occur away from the genitalia, it has been observed on various parts of the body (face, finger, trunk, and so forth). On the finger the soft sore may run an unfavourable course, owing to its escaping recognition. In such cases buboes may appear in the corresponding glands.

On the lip, differential diagnosis turns on the possibility of **epithelioma**. The points in favour of syphilis are the mode of development and duration, the character of the induration of the submaxillary adenitis, the latter being more frequently inflammatory than is the case with chancres in other situations; these contrast with the slow evolution of cancer, with delayed involvement of the glands. Here it is necessary to insist on the essential importance of not watching an epithelioma of the lip indefinitely, and waiting for glandular enlargement; such a course is unjustifiable. Again, the age and sex of the patient may afford a clue, as when a suspicious sore of the lip occurs in the young, cancer being more often a disease of middle and old age.

Men are more liable to cancer of the lip, but women may occasionally suffer. Smoking is not uncommon among women at both ends of the social scale in our own country. Some years ago in New Zealand I noticed that the Maori women smoked pipes a good deal, and I have observed the same thing among native women in other antipodean places. Clinically the cancerous growth of the lip has an irregular surface with elevated borders, and it bleeds readily.

**Accidental Vaccinia** may occur on the lip, as a result of pricking the lip with the broken end of a lymph-tube. Such an accident would be obviated by placing a little wool over the broken end of the tube before blowing out the contents. As to differential diagnosis, the characteristic evolution of the vaccine vesicle and the acute inflammatory reaction would point in the right direction.

Another possibility which may lead to confusion is the occurrence of a **tuberculous ulcer** about the lip. But if the case is gone into with care, and all the facts considered, including the absence of positive syphilitic signs, a mistake is not likely to be made. Tuberculous ulcers are rare. They may be acute or chronic, primary or secondary, and occur at the junction of skin and mucous membranes, about the lips, anus, and so forth. They are painful and present an irregular border, which slowly extends.

**FACE.**—On the face generally several conditions may be mistaken for a chancre. In the differential diagnosis I must repeat that the positive points in favour of the latter are the important ones; I need

not go over them again, but will merely call attention to the adenitis of the corresponding lymphatic glands, which is one of the first things to decide. This must be done as a matter of routine examination.

I will now consider the non-syphilitic manifestations which have given rise to the suspicion of syphilis. **Epithelioma**, as in the case of the lip, is one such condition; **rodent ulcer** is another. But with care as to the extremely slow development of the latter; its characteristic rolled border, with dilated vessels coursing over it, well seen with a lens; absence of adenitis, and so forth, it ought not to be taken for a chancre. Although rodent ulcer is in the main single, it may also be multiple occasionally. One form of epithelial growth, the so-called **crateriform ulcer**, may just be alluded to here: it grows rapidly, is of some size, breaks down at the summit, giving rise to a crater-like excavation. It may develop on an ordinary rodent ulcer. As to size, it must be noted that a chancre may sometimes become very large, the so-called hypertrophic chancre, *chancre géant*.

A patch of **Sycosis**, of the coccogenic variety (as opposed to the hyphogenic or *Tinea sycosis*), may be of large size and accompanied by fungation, crusting, and swelling of the parts, and occur about the moustache or beard region. Such a condition may look like a crusted hypertrophic chancre. As to **Tinea sycosis** (hyphogenic sycosis), the soft boggy nature of the suppurating lesions, their multiplicity to some extent, and the absence of corre-



sponding characteristic adenitis would be against syphilis. Moreover, the microscopical examination (with a  $\frac{1}{8}$ th objective, for it is a frequent mistake to search for fungus with a low power, which is useless) would reveal the fungus. Short stumps should be pulled out, cleared from fat with a little ether, and mounted in Liq. Potassæ B. P. (using a cover-slip, for I have seen men examine preparations without, and push the objective into the Liq. Potassæ). The fungus occurs in segmented mycelial filaments.

Again, an unusual condition, viz. a fungating **Molluscum contagiosum** growth of some size on the face may suggest syphilis. A careful examination of the affected area, with a lens if necessary, would probably show the presence of younger typical molluscum growths, for they are practically always multiple, pearly, solid, with a small central depression. The absence of induration and typical corresponding adenitis would also be points against syphilis.

**Accidental Vaccinia** of the face has also given rise to doubt. The characteristic mode of development and the markedly inflammatory aspect of the vaccinal lesion would preclude any possible error. Further, in the case of a woman with an infant in her arms or at the breast, it may be found, on personal examination (for patients do not always tell you these things spontaneously), that the child has been recently vaccinated. I have seen such a case, and on inquiry found the mother had never been vaccinated, as her parents were opposed to vaccination. Of course, in vaccinia the corresponding

glands would be affected, but not as in syphilis, for they would be inflamed and tender.

Accidental inoculation of **Horse-pox** (grease) may also occur (hand, forearm, face). The occupation and the inflammatory appearance would be sign-posts in the diagnosis.

**NOSE.**—Chancre of the nostril may be just mentioned here to remind readers of the possibility of its occurrence in this situation. Here its exuberant growth, in some cases making it project beyond the orifice, is a feature of importance. **Rhinoscleroma** will be dealt with later on (see Chapter X).

Primary syphilis of the nose has been mistaken for **Lupus vulgaris**—a mistake which, with care, should have been avoided.

**THE EYE.**—The chancre has been observed on the eyebrow, eyelids, and conjunctiva, both palpebral and ocular, inoculated by unclean fingers, a kiss, and in other ways. The inner canthus about the caruncle is one of the most common localisations. In such cases the corresponding glands, especially the pre-auricular and submaxillary, should be carefully examined, and the general directions followed. The chancre in this situation frequently occurs on the margin of one of the eyelids, and may be accompanied by marked swelling and hardness of the involved lid, which becomes tense and shiny.

**Tuberculous ulcers** would be excluded by their very different and slower mode of development, and their association possibly with tuberculosis of other organs (lungs). At the margin of the ulcer there are usually minute miliary translucent nodules;

these should be looked for with a lens. The pre-auricular glands, it should be noted, may be somewhat swollen. Scrapings from the ulcer should be examined for tubercle bacilli by the Ziehl-Neelsen or other method. They may be fairly numerous or few in number.

In this situation too as well as in others, **accidental Vaccinia** may occur, giving rise to much swelling and pain, with implication of lymphatic glands.

One of the favourite situations for **rodent ulcer** is in the neighbourhood of the eye, about the inner canthus.

Chancres have been observed on the SCALP as the result of bites, scratches from combs, and in one case it followed kissing.

Any part of the TRUNK and LIMBS may be attacked by the chancre, the infection occurring in a variety of ways: a wound sucked by a syphilitic mouth, accidental inoculation through sleeping with a syphilitic individual, dirty water-closets, from saliva applied to sticking-plaster, unclean caustic holders and hypodermic needles, dirty clothes, and so forth. As to infection through water-closets, although it is well to deal with this explanation on its merits and exercise due scepticism, there is no doubt that infection has occurred in this way. The wonder is that it does not take place more frequently considering the clientèle of some public lavatories.

Caution with regard to perfect cleanliness of hypodermic needles generally need scarcely be insisted on here. Hypodermic needles used for intra-muscular

injections in syphilitic subjects should be kept separately in a special tube for each patient.

It is not uncommon to see one or more hard chancres about the pubes in Arabs (North Africa), owing to their habit of shaving these parts. The small wounds inflicted by the razor become infected by the virus.

There are now a good many cases of **Tattoo-syphilis** on record, in some cases the primary chancres being multiple. As tattooing is rather fashionable in the upper walks of life, especially among visitors to the East (Burma, Japan), one must be on the look-out for such an untoward complication, the more so as syphilis is very rife in Asia.

Chancres of the BREAST require to be dealt with here in a more detailed way. In the case of wet-nurses the breasts should be carefully examined for any excoriations as well as for other reasons. On the other hand, medico-legal points may arise in connection with the infection of such a nurse by a congenitally syphilitic infant.

In this situation, the chancre is usually single, presenting itself in advanced stages as a punched-out lesion with a floor of a raw meat or beefy colour and somewhat raised borders. But it varies in aspect. In other cases, multiple chancres are present studded about the nipple: small, punched-out lesions with raised borders. The usual signs must be investigated, and in the latter case a secondary syphilide would have to be excluded by a general examination. Chancres of the female breast are not only com-

municated by infants, but also by adults with secondary syphilis of the mouth.

As to differential diagnosis, primary mammary chancres must be distinguished from tertiary syphilitic lesions, such as gummata. If all the facts be taken into account there should be no difficulty about this (see Chapter X).

The primary chancre of the breast may become phagedænic and form a horseshoe-like ulceration partly encircling the nipple. This would have to be distinguished from tertiary syphilis, in which a horseshoe-shaped breaking down of the tissues is often a diagnostic feature.

Chancre of the breast should not be confounded with cancer. Here as always all the points must be carefully considered, as a hasty examination might lead to excision of the breast. The latter suggestion actually occurred in one case, but fortunately the primary syphilitic nature of the condition was recognised in time.

**Paget's disease**, a malignant condition, could scarcely be taken for a chancre, but the reverse mistake has occurred. The fact is Paget's disease has now become so well known that primary syphilis is apt to be overlooked. Paget's disease has also been observed, be it said, on the scrotum and vulva (see Chapter X).

**Vaccinal syphilis** has been almost excluded by the use of calf-lymph. But a warning is not out of place here. A dirty lancet used for an actively syphilitic individual may transfer the virus to a healthy person, even though calf-lymph be employed.

This has happened. Lancets should always be thoroughly disinfected by wiping with an antiseptic solution, drying and passing through a flame, after and before using; or what is better, a new *lancette-plume* on a metallic holder should be employed for each individual case.

Chancre of the ANUS may be accidental or psychopathic. The latter is not uncommon in countries where Oriental customs prevail, such as Egypt. It may present itself in an unexpected way nearer home. It is well to bear in mind such a possibility, as a careless digital examination might infect the surgeon.

**Epithelioma** may also occur about the margin of the anus, giving rise to marked induration, which must not be mistaken for a primary sore.

**Sarcoma** about the anus, an extremely rare condition, has been mistaken for a large primary chancre.

The so-called **Oriental boil** or sore (Bagdad boil, Bouton de Biskra, de Gafsa, du Nil, Aleppo and Delhi boil, and other synonyms), which occurs in Northern Africa, many parts of Asia, Crete, Cyprus, etc., and is also said to be prevalent at Bahia, might be taken for an extra-genital chancre, the more so as the boil may be single. But like the chancre itself it may be multiple. It affects the uncovered parts usually, including the face, but the scalp, palms, and soles escape as a rule. I have been informed that intercourse with native women in Persia, where the boil is endemic, is one way in which Europeans may acquire the disease, but of

course it may be accidentally contracted in other ways. It begins as a small reddish spot, which becomes nodular, and slowly increases in size, with formation of scales. At a later stage, a crust forms, which after removal leaves a small ulcer behind. The latter discharges an ichorous material. The ulcer goes on increasing in size and crusts re-form, and so on, ultimately giving rise to a punched out sore with irregular borders, surrounded by a more or less inflammatory areola. The glands are enlarged. The evolution is slow, a matter of months, scarring ultimately taking place as a rule.

I have seen several cases of this disease in Europeans in Biskra. The lesions in them were mostly multiple. An Italian lad I met in the streets there had no less than five Biskra buttons scattered about the face. They were of the dry-crusted variety, the crusts being somewhat limpet-shaped. They had been present five months.

If all the facts of the case be taken into account, such as sojourn in an endemic area, duration, mode of development, and clinical appearances, there should be little difficulty in arriving at a right conclusion.

## CHAPTER IV

### GENERAL REMARKS ON SECONDARY SYPHILIS

HISTOLOGY OF SYPHILIDES—ASPECT OF THE PATIENT—  
DISTRIBUTION — POLYMORPHISM — ARRANGEMENT—  
INDIVIDUAL ELEMENTS — COLOUR—CORROBORATIVE  
SIGNS AND SYMPTOMS—LYMPHATIC GLANDS—ITCHING  
—MUCOUS PATCHES—THROAT—LOSS OF HAIR—THE  
EYES—HEADACHE—THE BONES—FEVER—URINE—  
BLOOD—BLOOD-VESSELS—JAUNDICE—PLACENTA

HISTOLOGY OF SYPHILIDES.—In dealing with the syphilides in a general way I must insist again on their HISTO-PATHOLOGICAL features. The morbid changes in syphilis are, to begin with, essentially vascular, and this is a fact which points to the blood as the important, perhaps the sole medium for the development of the specific poison. A specific parasite has not yet been definitely isolated, although there is more than one Richmond in the field. It is extremely likely, however, that a living organism or germ is at the bottom of syphilis, as in the case of other infectious diseases; everything points in that direction.

This primary histological vascular change may go



no further, as in roseola, in which the reactive tissue-changes are slight. But when a papular condition exists one finds proliferation of the connective tissue giving rise to an infiltration made up of plasma cells. It is, indeed, a plasmoma, like the chancre, but on a small scale and with less tendency to fibroma formation. If one takes a section of a lenticular (large papular) syphilide it will be seen that the infiltration pushes up the epidermis, which becomes flattened, the interpapillary down prolongations being effaced. Externally the new formation is raised above the level of the skin in a convex manner, like the surface of a lens; in the corium the downward convexity of the growth is more marked. If I have outlined the foregoing general microscopical features it is on account of their great importance in rational diagnosis. In approaching a case this conception of the morbid changes brought about by syphilis should be kept in the mind's eye, and the aid of the touch sense should never be neglected. The consistency of the elements of an eruption is an important factor, and, indeed, may serve to make an immediate preliminary diagnosis, which only needs confirming by further examination of all the available points of the case. The warning not to rely on one sign or symptom alone cannot be too often repeated, as it is this tendency which so frequently leads to mistakes.

Returning to the lenticular papule, it will be noted that it much resembles the primary chancre histologically. It is convenient here to make a generalization and to point out that the fundamental morbid

changes in syphilis are one and the same from the chancre to the mere roseola, and onwards through the many syphilides to the gumma, the clinical variations being a question of degree.

Secondary syphilides appear usually about six to seven weeks after the chancre, ten weeks or so after the infection. In this connexion again, variations in one direction or the other occur and must be borne in mind. When infection has occurred directly into the blood stream, the chancre and its incubation stage being missed, it has been found that the generalized eruption followed much more rapidly. In the case of two surgeons who accidentally inoculated themselves in this way at the same operation, the secondary rash appeared on the thirtieth and thirty-third day respectively, in both instances being preceded by febrile symptoms, viz. on the twenty-sixth and thirtieth day.

The GENERAL ASPECT of a syphilitic patient in the early and active secondary stage is often sufficient to make one suspect the disease. The patient looks ill and the face has an earthy hue, especially in women. But there are exceptions to this rule, depending on occupation and general nutrition. It is well to make a mental note of the general appearance when the patient enters the room. There is a look about syphilitic patients that is characteristic, especially when the headache is severe, in which case they look literally down in the mouth. The pallor of the face due to the anæmia brought about by the syphilitic intoxication has been diagnosed as simple anæmia and chlorosis in young women, owing to

insufficient examination, especially as the face is sometimes spared by the eruption.

After ascertaining the duration and evolution of the eruption, this should be looked at as a whole and its DISTRIBUTION noted. It is important to do this in a good light, and daylight is to be preferred. Indeed, artificial light may preclude a positive diagnosis in some cases, but this should be exceptional if all the facts be taken into consideration. The secondary syphilides are usually wide-spread and affect the body bilaterally, with more or less symmetry. They attack the following parts preferentially: the forehead at the margin of the scalp (*corona veneris*), the naso-oral region, the flexor aspects of the limbs, and the palms and soles. These parts should be inspected in a routine way. Indeed, taken with the general aspect, an eruption round the mouth is a valuable indication of the cause of the trouble. Syphilides are more likely to occur where there is congestion of the vessels, such as the waist in women where the corsets press.

I have also observed syphilides terminating abruptly and symmetrically on the flexor surfaces of the wrists.

As to the rash itself, an important point to notice is the POLYMORPHISM of the eruptive elements, which is so characteristic of syphilis. In some cases, the syphilide may be almost entirely of one type, as in the small follicular variety. Moreover, secondary rashes may succeed one another in the same individual, and vary each time in type, multiformity being attained by successive outbreaks.

The possibility of two totally different rashes being present at one and the same time, such as a secondary syphilide and psoriasis, for instance, must be alluded to here. At other times the syphilitic rash may be masked by an eczematous condition; the former is apt to be overlooked if an insufficient and cursory examination be made.

ARRANGEMENT.—The syphilides have a great tendency to form circles and especially segments of circles, small groups of similar lesions, or again clusters made up of a large papular (lenticular) element surrounded by smaller satellite papules arranged about it, sometimes in a circle or cluster. The term corymbose has been applied to the latter arrangements. It has occurred to more than one observer that the smaller satellites were secondary infections from the larger central lesion, this not only in syphilis but in other diseases of the skin. As to syphilis, however, the various elements of a corymbose system may come out simultaneously. Herpetiform (not in the sense of creeping) is another qualification applied to syphilides in large groups; it is usually applied to tertiary lesions. The segments of circles and circles found about the naso-oral area sometimes form very delicate circinate and gyrate arabesque-like patterns, which are very characteristic. Grouping is a most important and striking feature and at once strongly suggestive of syphilis.

The INDIVIDUAL ELEMENTS are circular or oval, and with few exceptions have no tendency to spread peripherally, and then only when some other process in addition to the syphilitic one is at work. The

elements come out in crops, and having gone through their pathological evolution *in situ*, remain unchanged in appearance until the involutionary process occurs, either spontaneous or as a result of treatment. So we get young and old elements mixed up. From the descriptive point of view, the rash may be macular, erythematous or roseolar; papular, papulo-squamous, papulo-vesicular, papulo-pustular; lenticular (that is large papular); follicular (arising about the hair-follicles), either of the large or small variety; nodular, bullous, rupial, ecthymatous. One point to bear in mind is, that secondary syphilides in bad cases may be gummatous (by some called early tertiary), but they are more superficially so than in the later tertiary period; in these markedly infiltrated lesions, liquefaction of tissue takes place, giving rise to ulcer-like looking areas, from a shilling to half-a-crown in diameter, which leave large scars on healing. These severe forms (called malignant syphilis, syphilis maligne précoce, and so forth, although it must be said such terms have led to discussion as to what was really implied by them) usually attack the scalp, the limbs, and to a less extent the trunk, the number of lesions being usually limited. They are met with in alcoholics, in tuberculous (strumous so-called) and in broken-down individuals. When they run together, as on the scalp, they lead to large areas of scarring. In old days, these severe forms were associated with necrosis of the bones of the skull, a very rare complication now in my experience. Soldiers from India and tropical countries were the chief sufferers,

as a result of other factors, such as climate, malaria, alcohol, etc. At the present time severe forms are not uncommonly met with in hot climes, such as India, China, etc., both in Europeans and natives. In the latter the skin and bones bear the brunt of the disease. But severe secondary forms are also met with in individuals who have never been out of this country. Instead of forming largish circular lesions with uniform destruction of tissue, the elements may be smaller, both oval and circular, and shallowed out after the style of the porcelain dishes in paint-boxes (*en godet* of the French), with reddish or greyish floors, secreting a thin puriform substance. These circular lesions are sometimes absolutely regular, as if outlined by compass, with slightly raised hard borders. This, again, is seen in broken-down individuals.

With regard to the secondary bullous syphilide in the acquired disease, it is extremely rare. Rupia is said to commence as a flat abortive bulla, but this is seldom seen; in this variety the necrotic process extends peripherally *pari passu* with the formation of crusts, which assume the well-known limpet-shell appearance.

Or again, we meet with rings, networks, and forms with a cockade-like play of colours (*en cocarde*); also pigmentary and hæmorrhagic lesions. In a word, the secondary eruptive elements are multiform, going through the whole gamut of possibilities in this way; and what is also of importance, imitate other skin rashes, very closely sometimes, hence the qualifying adjectives, such as

psoriasiform, varicelliform, varioliform, etc., which have been tacked on to some of the syphilides I shall have to describe presently.

As to nomenclature, be it said that nodular is a much better term than tuberculated. I have seen a secondary rash called a tuberculous syphilide—a most inappropriate way of putting it, and giving one no idea at all as to what was really meant. Again, syphilitic psoriasis should be sternly tabooed; it is misleading, as the latter name means a disease quite other than, and quite separate from, syphilis in every way. The same may be said of syphilitic lichen.

COLOUR is another point. Syphilides are more or less bright red at first, but a change in hue soon occurs, settling down into the characteristic tint, which has been called coppery, whatever that may mean to the individual using the word. It would be better, perhaps, to call it a dull red, reminiscent of raw ham. It is a point which one need not quarrel over, but what is important is to fix the usual colour of the syphilide on one's mind as a standard to judge by when examining rashes. If the blood be driven out of one of these dull red papules by means of a piece of glass—an ordinary lens will do or a glass tongue depressor—a brownish yellow area is left behind. (This procedure is called phaneroscopy and diascopy by the Germans.) This shows that the dull red tint is made up of the blood plus the new growth of the syphilitic process, or rather, perhaps, that the plasmoma is seen through a blood medium. Needless to add, after what I have said, that the

roseolar syphilide stands on a different footing *qua* colour, owing to the absence of new growth. In some cases, again, the colour of the papule has a tinge of blue in it, and this bluish tint, I have noticed, is well seen in the congested syphilides about the arms and legs of elderly women in the secondary stage of syphilis.

I have observed that in pale, anæmic young women the papules may be very little different in hue to the surrounding skin, or of a very pale brown, yellowish tint, the eruption being at the same time sparsely distributed about the trunk and arms.

The **pigmentary syphilide** (so-called leucoderma, but better perhaps, melanoderma syphiliticum) usually affects the neck, and is very characteristic when present. It will be dealt with later on (see Chapter XIV).

Before leaving the secondary eruption I must allude to one point which is made a good deal of, viz. ITCHING, which is supposed not to occur. This is fallacious, and to exclude syphilis merely because a rash does itch may lead to a serious error, for syphilides do itch at times, not usually it is true. In this respect much depends on the individual, and a syphilitic rash may be occasionally very pruritic. But a word of warning on this point. I have found in practice that where obvious scratch marks were mixed up with a secondary eruption the cause of the itching was due to scabies. This I have seen more frequently in women. It should be remembered that scabies is sometimes the result of promiscuous intercourse, and both diseases may be contracted at one



and the same time. Or the itching may be due to *Pediculosis vestimentorum*, or even to *Pediculosis capitis*, the latter especially in young women who wear the hair hanging down. *Pediculosis pubis*, as another cause of pruritus, must also be mentioned. Marked itching of the fauces has also been described.

As part of the rash, the so-called MUCOUS PATCHES or plaques (*plaques muqueuses*) or *Condylomata* (*condylomata lata*) of moist parts, and where friction of adjacent surfaces occurs, such as the vulva, anus, etc., must be mentioned here. The vulva may be a good deal affected in pregnant women. These lesions sometimes become hypertrophic and may attain a large size in the uncleanly. *Condylomata lata* are large papular lesions modified by position. *Condylomata acuminata*, on the other hand, are so-called venereal warts.

Pseudo-syphilitic ulcerated areas may occur about the anus of very dirty people: they clear up under simple treatment. In such cases there are no other signs or symptoms of syphilis. So much for the rash. Let us now turn to the CONCOMITANT AND CORROBORATIVE SIGNS AND SYMPTOMS of secondary syphilis. These must be investigated in a systematic way. First, by an examination of the LYMPHATIC GLANDS. In men, the groins are readily accessible, and at this stage the opportunity should be taken of examining the penis and genitalia generally. A primary chancre may be found, in some stage of evolution or involution. Secondary lesions in this situation, part and parcel of the generalized rash, must not be mistaken for chancres.

No chancre, or sign of one, may be present, but do not let this put you off syphilis if the other positive facts are in its favour. Negative evidence must be dismissed from the mind in such a case. A chancre may be intra-urethral, and the slight discharge it gives rise to mistaken for gonorrhœa. Syphilis has also been communicated by skin-grafting from a syphilitic subject. Then examine the sub-maxillary, post-sterno-mastoid, occipital, and other superficial glands, such as the epitrochlear.

In women, the readily accessible glands should be investigated, and in many cases, married women especially, an examination of the inguinal regions would be possible also if it should be necessary. As to a vulvar inspection, when there is doubt or the matter is serious, it should be carried out if possible. But when the rash and other corroborative symptoms are undoubted, such an examination may be omitted in the discretion of the surgeon, the condition and so forth of the patient being taken into consideration (virgo, catamenia, etc.). Adenitis, be it said, may be present for a long time after the primary sore has healed.

In women, secondary moist lesions, as well as mucous plaques, may be marked about the vulva.

The possibility of accidental chancre should not be overlooked when investigating a secondary rash, especially in children.

To return to the adenitis, that of the sub-occipital is of great value. Out of a series of 181 consecutive cases of secondary syphilis in women, I have noted the occurrence of this adenitis on both sides in ten,

on one side only in twenty-one. In a general way, I am inclined to agree with the statement that adenitis in this situation is not so frequently present in women as in men. I may add that in the aforementioned series, the sub-occipital adenitis was not related to scalp lesions, and indeed was present in cases where the scalp was entirely free.

With regard to glandular enlargement, it is said that it is an index to the future course of the disease, viz. that where adenitis is very marked, the prognosis is good. This is quite a mistake. The syphilitic virus may possibly get into the blood-stream directly from the chancre and not *via* the lymphatics and lymphatic glands. Pathological investigations carried out in an individual who had committed suicide in the very early stages of the disease, between the development of the chancre and the appearance of the rash, have shown that syphilitic changes had already occurred in various organs, such as the blood-vessels, cardiac muscle, etc. Further support is lent to the view that infection of the blood-stream takes place early by the fact that the excision of chancres in an early stage has not prevented the development of syphilis.

After the glands examine the THROAT, although the patient may not have complained of pain, for it is curious how painless syphilitic lesions in this situation may be; and at the same time, the tongue and buccal mucous membranes generally, for signs of syphilis. An examination of these parts may reveal an extra-genital chancre. Continued dysphagia is a symptom of tonsillar chancre. Bear in

mind, too, that chancres in the latter situation have been taken for diphtheria. Ulcerated cracks about the angles of the mouth are suggestive of syphilis.

The stomatitis of SPRUE (*Psilosis linguæ*, *Stomatitis intertropica*, etc.) should not lead to error if the general symptoms of that disease be borne in mind. Nor should it be confounded with mercurial stomatitis. Betel chewing, prevalent in the East, leads to inflammation of the mouth; the teeth are blackened by the practice.

LOSS OF HAIR.—The casual question so often put to patients, Are you losing your hair? really amounts to very little. Loss of hair is a common thing from causes quite other than syphilis. But it is well to examine the scalp, as certain forms of alopecia are due to, and are confirmatory of, syphilis. They will be dealt with further on (see Chapter XIV).

The EYES should be examined for *iritis syphilitica*, usually commencing in one eye and then attacking the other, even when the patient is under mercury. The symptoms are neuralgic pain and photophobia, with circumcorneal injection of the vessels and change of colour of the iris. Irregularity and sluggishness of the pupil are also points to note.

The importance of eye complications in syphilis must never be lost sight of. Anything unusual about the eyes (dimness of sight, photophobia, and so forth) should receive immediate attention, at the hands of an ophthalmic surgeon if need be; they are of greater moment than the rash, and may lead to the loss of the eye. In *iritis*, atropine is specially indicated to prevent posterior synechiæ. Syphilitic

involvement of the eye is indicative of a severe specific intoxication; such cases which have been followed up have demonstrated this clearly. Syphilitic iritis has occurred as an early symptom before the appearance of the rash. Early syphilitic optic neuritis has also been observed.

Among other corroborative symptoms, HEADACHE, especially at night (cephalalgia nocturna), is sometimes an important detail to fix the attention. It is sometimes intense, and when a patient who does not habitually suffer from headache complains of agonizing pains in the head, syphilis should be thought of. This specific headache occurs in both sexes, but in my experience it is more often seen in women, and points to a bad attack of syphilis, which may be difficult to treat. The attitude and gestures of the patient in describing these headaches show there is no deception about the sufferings experienced.

THE BONES.—In the secondary period there may also be marked bone-ache (osteocopic pains) with nocturnal exacerbations.

FEVER.—It is not sufficiently recognised that secondary syphilis may be accompanied by a marked rise of temperature. This has sometimes led to mistakes as to the true state of affairs. When a patient has sojourned in a malarious country, or one he considers malarious, although it may not be anything of the kind, a daily rise of temperature, really syphilitic in origin, has been taken for malaria. Here I may be allowed to say that the individual who has been in a malarious country puts down every febrile symptom to malaria. He is always very con-

fidant as to the correctness of his diagnosis and quite convinced that he knows more about malaria than any medical man practising in this country. Never take a patient's own diagnosis; that is the safe and only way.

Pyrexial cases of syphilis are sometimes extremely severe and may lead to a fatal issue (*vérole galopante*), usually in individuals with broken-down constitutions through other diseases or from want, alcoholism, etc. All the syphilitic manifestations are marked in degree, and the patients do not respond to mercury, indeed this may be worse than useless and aggravate the morbid manifestations. The symptoms may be typhus-like, with a mulberry-like (*framboesiform*) eruption about the body, sordes of the lips, much tremor, high temperature, and great weakness.

**THE URINE.**—In this connexion, **secondary syphilitic nephritis** must be alluded to. In bad cases the urine should be carefully examined. A good rule is to examine the urine always, as a matter of routine, whatever the case. Marked albuminuria is a serious symptom, and the issue may be fatal. Sugar in the urine may also occur. Another point about the urine is the increased elimination of mineral constituents, phosphorus, sulphur, lime, iron, etc., in syphilis.

**THE BLOOD.**—As in other intoxications, the blood is altered in syphilis in the following directions. There is a diminution of the hæmoglobin and of the red corpuscles. It is this which gives rise to the anæmia of secondary syphilis, which persists, usually

during the florid stage, in untreated cases especially, and is frequently a marked symptom in the ill-nourished. Women often exhibit this condition in a high degree, more so when nursing an infant at the breast or when suffering from menorrhagia, the latter occurring as a complication of syphilis. On the other hand, in well-fed individuals, leading healthy out-door lives, the complexion may be more or less ruddy. The conjunctivæ and mucous membranes should be examined to avoid overlooking anæmia, the pink apparently healthy-looking complexion in young women being at times misleading.

The test (Justus's), which consists in introducing a fairly large dose of mercury into a patient either by inunction or intra-muscular injection, is said to react in a specific manner in syphilitic subjects when the glands remote from the point of inoculation are affected and in all subsequent active relapses of the disease, viz. a rapid and characteristic sinking of the hæmoglobin ( $10^{\circ}$  to  $20^{\circ}$  of Fleischl's hæmometer). It is further stated that this reaction does not occur in healthy subjects, nor in those affected by other diseases. I mention this here as it is an interesting point, adding that independent investigations have not confirmed the aforesaid statements.

THE BLOOD-VESSELS.—It is a well-ascertained fact that syphilis leads to morbid vascular conditions. From the clinical point of view, which concerns us here, the occurrence of **phlebitis** in secondary syphilis must be mentioned. I have observed it several times now. In my experience women are chiefly affected; and it is the internal saphenous on one side that is

usually involved. A history of white-leg (phlegmasia alba dolens) is sometimes forthcoming.

The importance of being on the look-out for this condition need scarcely be insisted on *qua* treatment, which must be on general principles (physiological rest of the affected part, etc.) plus the exhibition of specific remedies.

JAUNDICE (*Icterus syphiliticus præcox*) is sometimes observed early in syphilis as part of the specific intoxication. It is a rare condition, and may disappear spontaneously, as in a slight but obvious jaundice which I observed in a case of primary chancre, before the eruption of a secondary rash.

ACUTE YELLOW ATROPHY OF THE LIVER has also been observed in the course of secondary syphilis, chiefly in women, with symptoms like those of phosphorus poisoning.

Among other complications of secondary syphilis I would also mention **joint affections** (synovitis), **myositis**, **orchitis**, and **epididymitis**. They are not common, and are usually observed in obstinate cases of secondary syphilis, which have been established for a year or two. I have also seen unilateral painful swelling over the parotid region occur in cases of this description.

The PLACENTA may be affected in syphilis. Changes (fatty, etc.) in it in parous women would make one bear syphilis in mind (see Chapter XII).

Before leaving this part of the subject, I would again call attention to the fact that the more marked the rash, the more marked are the other symptoms likely to be.



## CHAPTER V

### DIFFERENTIAL DIAGNOSIS OF SECONDARY SYPHILIDES

ROSEOLA — ACUTE EXANTHEMATA — DRUG RASHES —  
VACCINATION RASHES — TINEA VERSICOLOR — PITY-  
RIASIS ROSEA — PSORIASIS — SEBORRHŒIC DERMATITIS —  
SEBORRHŒA PAPULOSA — PAPULO-SQUAMOUS ECZEMA —  
MYCOSIS FUNGOIDES — DISSEMINATED LUPUS ERYTHE-  
MATOSUS

In this chapter it will not be necessary to repeat what has been said in the previous one as to the signs and symptoms which go to make up a diagnosis of syphilis.

ROSEOLA.—I have already called attention to the fact that although the **macular syphilide** (roséole, roseola syphilitica) looks like a simple erythema, histologically it is more than this, though the changes are slight in degree. The clinical aspect of this rash is characteristic, giving rise to a mottling of the skin of the trunk and flexor surfaces of the upper limbs especially; the face is seldom affected. The eruption consists of circular, oval, and irregularly contoured erythematous patches, roughly speaking from a lentil to a finger nail in size, and level with the skin; rosy red at first and disappearing on pressure, but later

becoming dusky and leaving a certain amount of staining behind. This staining remains for some time, and is an important diagnostic feature. At an early stage, when the macular condition is only just visible to the naked eye, the blue glass test certainly makes it much more obvious.

When the inflammatory reaction is more marked, œdema and migration of leucocytes occur, leading to **Roseola urticata** or **urticularial syphilide**, which differs from urticaria in that the "wheal-like" lesions develop gradually, do not itch as a rule, and involute slowly. But it is important not to make a diagnosis on the rash alone. All the factors must be taken into account, for there are cases of **Urticaria** (*Urticaria perstans*) in which the wheals do persist, in exceptional cases for a considerable time. Moreover, there is a disease known as **Urticaria pigmentosa** (*Xanthelasmaidea*) in which nodules or only slightly elevated lesions form, leaving marked pigmentation behind. Histologically, numerous mast-cells in rows are characteristic of this complaint. Both this condition and the wheal-like syphilide are uncommon. Bear in mind that the diagnosis of syphilis rests on positive facts.

The macular syphilide must not be confounded with the "marbled" appearance of the skin, **Cutis marmorata**, sometimes seen on undressing a patient in a cold room. In this condition a livid net-work makes its appearance, enclosing areas of healthy skin, whereas in the syphilitic roseola the erythematous or discoloured patches occur as islands surrounded by healthy skin.

When accompanied by febrile symptoms, acute and wide-spread, the syphilitic roseola may look like measles or r $\ddot{o}$ theln. Mistakes are not likely to be made if all the facts are taken into account. As far as the ACUTE EXANTHEMATA are concerned, their incubation, mode of invasion, and development would point in the right direction. It is important here, as always in such cases, to bear in mind the extreme periods of incubation and not trust to averages. In children the true nature of an acute exanthem is not likely to be overlooked, but difficulty may arise sometimes in older patients, especially as adenitis occurs in measles and r $\ddot{o}$ theln, especially in the latter.

DRUG RASHES.—Apart from various infectious disorders and toxic conditions (auto-intoxications) which may occasion erythematous rashes, the effects of drugs, either locally applied or given by the mouth, must be insisted on. **Belladonna** (atropine), **copaiba**, **quinine**, **chloral**, **antipyrin** may be mentioned here, but there are many others.

The **copaiba rash** is usually made up of rosy-red slightly elevated patches about the backs of the hands, the fronts of the knees, the elbows and abdomen. An error is more likely to be made, as the patient may have been treated elsewhere for venereal trouble—to wit, gonorrh $\ddot{o}$ ea. More complex is it when a copaiba rash and gonorrh $\ddot{o}$ ea are followed by a chancre and a secondary syphilide, as I have seen. The predilection of erythematous drug rashes for the backs of the hands and the neighbourhood of the joints is a point of importance. **Sandalwood oil** is another drug which may operate in the

same way ; the rash caused by it has been taken for and diagnosed as a syphilide. Such an error could only result from insufficient examination of the patient as a whole and from the inadequate weighing of evidence.

**Antipyrin** (and also other synthetic remedies of the same class) may give rise to an erythematous rash which has been taken for a syphilide. (See Chapter VI.)

**Antitoxin rashes** may be just mentioned here in connexion with the subject. An erythematous rash may also occur after the injection of hydrocele fluid used in the experimental treatment of syphilis.

VACCINATION RASHES must also be alluded to in passing. In the days of arm-to-arm vaccination, with the knowledge that syphilis could be communicated to the healthy in that way, such rashes have given rise to much anxiety. In this connexion I may add that arm-to-arm vaccination may in some circumstances still have to be resorted to ; and, moreover, with calf lymph dirty instruments may be sources of syphilitic infection, so that differential diagnosis is a matter of some importance. The erythematous vaccination rashes are in most cases evanescent. They may be urticarial, or again assume the form of an Erythema multiforme.

An extremely rare condition, the mottled, ill-defined erythematous rash which is seen in **Trypanosomiasis** (Congo) is merely mentioned here to remind readers of its existence, especially those who may be called to practise in certain areas of Africa where trypanosoma infection prevails.

Strange as it may appear, *TINEA VERSICOLOR* has been mistaken for a syphilide. The trunk is the part usually affected, more rarely the limbs (elbows, popliteal spaces), and quite exceptionally the face. In addition to the cases in which large areas of discoloration are present, there are some in which the lesions are small, discrete, and numerous. Moreover, instead of being of the usual fawn or brownish yellow hue they may be rather rosy red. It is these latter forms which are likely to lead to confusion. The points in favour of *Tinea versicolor* are the following: the discoloured areas can be scraped off, they are not in the skin like a true pigmentation, but on it, the discoloration being really an optical effect. In coloured races (Hawaiian Islands), they may appear whitish or greyish. Among some natives (Assam) the face is frequently affected. In the second place, the scrapings examined in Liq. Potassæ B.P. (with a  $\frac{1}{6}$ th objective) will immediately reveal the characteristic clumps of spores and mycelial elements of the specific fungus, *Microsporon furfur*. In doubt, it is wise to use the microscope. A syphilitic rash may occur in a patient with *Tinea versicolor*, the two conditions being mixed up. Here again the microscope would help.

*PITYRIASIS ROSEA* (*Pityriasis rosé de Gibert*) is another disease which frequently leads to an erroneous or a doubtful diagnosis. Some of the Viennese school still look upon this morbid entity as a ringworm of the body (*Herpes tonsurans disseminatus*), but no fungus has ever been discovered

by them in Pityriasis rosea, though they may have done so in instances of disseminated *Tinea circinata*, which they took to be the former condition. Here also the duration, mode of development, and distribution will point the way to a correct diagnosis. Pityriasis rosea usually commences as a large single patch (herald or primary patch) on the front of the trunk, but sometimes in other parts of the body; it may, however, escape observation on the part of the patient, but a large patch somewhere about the body will often be found if looked for. After remaining single for a week or ten days, generalization takes place, fresh patches appearing on the upper part of the chest and abdomen, and spreading thence to other parts of the body, but it is unusual for it to invade the limbs below the knees and elbows, being generally limited to the upper part of the thighs and arms. The face is rarely involved. The elements of the rash are pale rosy red (hence the name of Pityriasis rosea), almost level with the skin and either oval or circular, with a very delicate desquamation (scaly collarette), best seen with a lens. On the trunk, the elements of the rash follow the lines of cleavage, *i.e.* the direction of the ribs, with the long axis of the small finger-nail sized patches running parallel to the latter. A careful examination of the body will sometimes reveal the large primary patch, more or less circular or distinctly oval, mixed up with the smaller elements of the generalized rash, it may be on the back or elsewhere about the trunk. The primary patch will then often show a well-marked narrow border, about one-eighth of an

inch wide, with a clearing area within. If the parts be put on the stretch or glass pressure employed to drive out the blood, the border will appear of a pale yellowish tint. This tint is also seen when the small finger-tip sized elements are dealt with in the same way. The rash is in some cases extremely abundant, and the patchy elements more or less confluent, with discrete pin-point papules interspersed. In such the appearance is somewhat like that of measles, except for the general distribution and the non-involvement of the face. At other times the rash is made up of circinate elements, which may at first sight be mistaken for multiple *Tinea circinata*. The spots leave a fawn-tinted discoloration behind, another point which may mislead in the direction of syphilis.

The differential diagnosis is sometimes not an easy matter, especially as Pityriasis rosea may be ushered in by slight febrile disturbance and accompanied by adenitis, especially of the post-sterno-mastoid glands, and by some congestion of the throat. In some patients the inguinal and even the epitrochlear glands are decidedly enlarged, but instead of being hard as in syphilis, they are more inclined to be softish. To mistake this complaint for syphilis may be an unpleasant matter, as can well be imagined. It is necessary, therefore, to take all the facts carefully into consideration. Pityriasis rosea, in the majority of cases, gets well spontaneously in two or three weeks, but it may run a more protracted course. I would again remind my readers to diagnose syphilis on positive grounds only; and not on the rash alone.

An important point is to suspect syphilis when the flexor aspects of the forearms are affected, and also when the patient complains of severe recent headaches. In syphilis, corroborative evidence will be forthcoming if the case be thoroughly investigated, but now and then the *pros* and *cons* may be so evenly balanced as to require keeping the patient under further observation. In this connexion, there are **recurrent syphilitic roseolas**, which are at first sight something like Pityriasis rosea. The latter disease may, of course, occur in a syphilitic patient and be mistaken for a syphilitic rash.

PSORIASIS.—Among the squamous eruptions, Psoriasis deserves special mention. There is no doubt that at one time this disease was very frequently taken for syphilis. Among older writers the term **syphilitic Psoriasis** was in current use, a very bad one by the way, which leads to much confusion. Psoriasis is a disease *sui generis* and quite distinct from syphilis. Histologically, there is, roughly speaking, in the former condition dilatation of vessels with hypertrophied papillæ and imperfect cornification of the epidermis (parakeratosis). This leads clinically to the fine silvery scales, which can be scratched up with the nail in psoriasis lesions even when the latter present no apparent desquamation. When the silvery scales have been removed, a thin pellicle comes away, leaving behind minute bleeding-points, the tops of the elongated papillæ. All this is very characteristic of psoriasis, and must be borne in mind in making a diagnosis. I need not re-state here what I have already said concerning



the histological features of the syphilitic papule (see p. 40), which are quite different.

Clinically, the evolution of psoriasis differs from that of the secondary syphilides. In the former, the disease often commences as a single patch, which increases peripherally in size, and may remain for a longer or shorter time as such before generalization takes place. When this occurs the individual elements, which come out in crops, increase in size peripherally, giving rise to a multiform eruption consisting of very old and very young lesions. Now syphilis does not do this; in it the elements remain as such, that is do not spread peripherally once they are out; moreover, the scaling is scanty, and the scales are of a dirty hue and not silvery as in psoriasis. Syphilides come out in crops, and are polymorphous it is true, but it is not a continuous process, nor does one find very old patches mixed up with quite recent lesions as in psoriasis. The grouping of syphilides is another point. Again in psoriasis the extensor surfaces of the limbs are mainly involved, especially the elbows and the front of the knees, the face usually escaping; whereas in syphilis the flexor surfaces are more commonly affected. The foregoing is an outline of the general run of cases in the two diseases respectively. But there are exceptions and overlappings. The eruption in psoriasis may come out suddenly in the shape of small papules (*Psoriasis punctata*). Acute widespread outbreaks are observed in badly-fed suckling women, after shocks and frights, etc. Occasionally the palms and also the soles are affected; and

psoriasis may affect or even commence on the face. In syphilis, the palms and soles often suffer, and it is uncommon for the face to escape. Other differential features are that in psoriasis the patient often does look quite well, but this is not always the case, just as in syphilis the patient may have a florid aspect exceptionally, as in well-fed individuals leading healthy outdoor lives.

There is an uncommon form of psoriasis, viz. **Psoriasis rupioides**, which is very like syphilitic rupia, but a mistake will only be made if the investigation of the rash and patient as a whole is carried out carelessly. The limpet-shell crusting should be removed, when ulceration will be found in syphilitic rupia, but not in *Psoriasis rupioides*. Bear in mind that crusts should always be removed to see the state of things underneath.

Involuting psoriasis lesions may present a certain amount of discoloration reminiscent of syphilides, and this is more likely to be the case when arsenic has been exhibited. It is very important not to make a diagnosis on a limited area of eruption, as in some psoriasiform syphilides the imitation of psoriasis is so close at first sight as to be extremely misleading. This is the case with regard to the legs in the region of the knees. It is imperative, therefore, to see the rash as a whole, when in syphilis differences will be at once seen—perhaps an actual chancre or evidence of one discovered, together with adenitis and other positive symptoms about the mucous membranes, which I need not enumerate again. Moreover, the undermined horny layers of the epidermis, from

within outwards, giving rise to a ragged fringing with the free edges directed towards the centre at the borders of syphilitic lesions, are characteristic. This is especially well seen about the palms and soles. I would mention again that psoriasis and a syphilide may occur in the same patient. This possibility is a thing to bear in mind, but one rash does not influence the course of the other as a rule. In one case the occurrence of syphilis *appeared* to aggravate the psoriasis, but this may have been due to other causes.

The **nails** in psoriasis are frequently affected. They may be pitted or the sides undermined and discolored. This is not absolutely characteristic, but it is a point when taken with all the other symptoms (see Chapter XIV).

From the foregoing it will be seen that both in psoriasis and the psoriasiform syphilide there are positive facts to rely upon as far as the rash is concerned, but this should not lead to neglect of a thorough examination of the case as a whole. As to the therapeutic test, mercury has cleared up obstinate psoriasis which had resisted other means. Iodide of potassium, in large doses, has also been recommended in this disease. This is mentioned here as iodide of potassium has been put forward as a specific for syphilis in all its stages. Experience has shown, however, that mercury is the cornerstone of treatment.

A disseminated SEBORRHOIC DERMATITIS (Séborrhéides, Seborrhœa psoriasiformis, Eczema seborrhoicum, etc.) in the form of small discs scattered

about the body may lead to a suspicion of syphilis in those who are unfamiliar with skin diseases. In this condition the discs are from a quarter to half an inch in diameter (0.5 to about 1 centimetre), chiefly involving the trunk, where by coalescence they may form large irregular or more or less circular areas. They are usually yellowish or bright red colour, and the scales are more or less fatty. A seborrhœic condition of the scalp is often associated with this eruption. In some of these cases a reticulated arrangement may be observed, which is also assumed by syphilides in rare instances. The condition may look like a psoriasis that has been treated locally. A little care would readily differentiate it from a syphilide, and I mention it here only because I have seen the mistake occur, so firmly rooted is the idea with some that a rash on the body means syphilis, especially if it be circinate. I have seen most inoffensive rashes diagnosed as syphilitic merely because they were circinate.

The same may be said of SEBORRHŒA PAPULOSA (*Lichen circinatus*, *Pityriasis circiné*), in which small rings formed by bright pinhead-sized papules occur about the centre of the chest and in the interscapular region. By coalescence gyrately outlined patterns are formed with some yellowish discoloration in the central parts at times. Scurfiness of the scalp is also usually present.

There is also a generalized papulo-squamous form of ECZEMA (sweat eczema), which develops rapidly after profuse sweating. Numerous small papules form, more or less grouped, and these by

coalescence give rise to florid scaly patches. The trunk is the part mainly affected. The mode of onset and the appearance, together with the absence of corroborative symptoms of syphilis, would exclude the latter disease.

MYCOSIS FUNGOIDES, a rare condition, may commence in an insidious manner with the appearances of a seborrhœic dermatitis, generalized about the body and limbs. This chronic squamous pre-mycotic eruption needs to be distinguished from a syphilide. At a later period, infiltration takes place, for Mycosis fungoides is an infective granuloma. The duration and other features, together with the absence of concomitant syphilitic symptoms, would exclude syphilis (see Chapter XI).

Without going into details here, I would just mention that a generalized LUPUS ERYTHEMATOSUS, in disseminated small finger-nail sized lesions, a very rare condition, might lead some to suspect syphilis (see Chapter IX). Albuminuria is often present in these wide-spread cases.

## CHAPTER VI

### DIFFERENTIAL DIAGNOSIS OF SECONDARY SYPHILIDES (*continued*)

LICHEN PLANUS—SYPHILITIC LICHEN—LICHEN SCROFULOSORUM—PITYRIASIS RUBRA PILARIS—VESICULAR SYPHILIDES—VARICELLIFORM SYPHILIDE—ERYTHEMA MULTIFORME VESICULO-BULLOSUM—DERMATITIS HERPETIFORMIS—PEMPHIGUS VEGETANS—BULLOUS IODIDE ERUPTION—ACUTE PEMPHIGUS

LICHEN PLANUS is not infrequently mistaken for syphilis, and the reverse may also occur. As to the latter point, syphilis sometimes superficially imitates Lichen planus, especially if a small circumscribed area of skin only be examined and the diagnosis made on this alone, without taking the eruption as a whole and other factors into account.

Histologically a typical Lichen planus papule is made up of an infiltration of the corium plus a proliferation of the prickle-cell (acanthosis) and of the horny (keratosis) layers of the epidermis. Opinions differ as to the nature of the dermal infiltration, but the evidence is in favour of its being of a connective-tissue change. The clinical features are, however, the most important for our present

purpose. The typical Lichen planus papule is angular, raised, flat, shiny, and of a violaceous or bluish-lilac tint. These points are of primary importance. The colour is so suggestive that it should at once make one think of Lichen planus. Here again the necessity of using a lens must be insisted on, for in the generalized cases of Lichen planus, which concern us in this place and in which the elements differ in appearance in various parts, giving at times a distinctly polymorphous aspect to the rash, typical papules such as I have mentioned will be found. These will give a clue to the real nature of the malady. The eruption may have been interfered with by treatment, and this will sometimes mask the true state of affairs, which will only be discovered by a careful examination. As in Psoriasis and Pityriasis rosea, a generalized Lichen planus is often preceded by a primary patch of more or less standing. The seats of election of the disease are the inner sides of the knees and the flexor surfaces of the wrists. These regions should always be examined for typical papules. In the widespread conditions, the trunk and limbs generally are involved, but in contra-distinction to the syphilides, the palms and soles usually escape, and the face and scalp are only very exceptionally affected. The penis (glans, sheath) is often affected to a greater or less extent, an important fact to remember in connexion with differential diagnosis. The vulva may also be involved. In generalized Lichen planus the itching is marked as a rule; indeed, it may be so severe as to dominate the scene. And when this is

the case about the legs I have found the inguinal and femoral glands much enlarged, much as in the disease known as prurigo of Willan and Hebra (Prurigo mitis and Prurigo ferox). It is a point to bear in mind. I have already said that the generalized rash of Lichen planus is multiform. In addition to the typical papules, which are either discrete or coalesced into patches or arranged in lines or in circles, there are circular or somewhat oval erythematous softish lesions, slightly convex, which I have observed occur usually about the trunk mainly (abdomen, etc.); here some desquamation accompanies the process. Or instead of being flat and angular, the papules may be circular and acuminate. Mixed up with the general acute rash, there may be old warty thickened patches (Lichen planus verrucosus), especially on the fronts of the legs. When involution takes place, pigmentation is a feature which must not be mistaken for a syphilitic process; it is common in Lichen planus, quite apart from arsenic. In dark races, Lichen planus papules are pale and may be whitish in contrast with the pigmented skin. Another point of importance is the fact that the mucous membranes of the mouth are frequently affected in Lichen planus: the insides of the cheeks and lips, the tongue and palate. In these moist situations the lesions appear as small white spots and streaks. This outline taken with what has already been said with regard to syphilis should suffice to avoid error. It is well to recall here that biniodide of mercury has a good effect on generalized Lichen planus.



This fact is a point to remember, as it must not be taken as a proof of syphilis.

SYPHILITIC LICHEN (*Lichen syphiliticus*) is a term which is used in a loose way, and may mean anything according to the fancy of the speaker. It should be dropped. What concerns us here is the fact that there is a rare **small follicular syphilide** which requires to be differentiated from *Lichen scrofulosorum* (or *Folliculitis scrofulosorum*, which is a better name), and altogether unlike *Lichen planus*. In the former *Lichen* the rash is made up of closely aggregated small pin-head papules, situated at the hair-follicles; they are red at first, but gradually become paler, and may be practically of the same colour as the surrounding skin. They are arranged more or less in groups and circles, but the eruptive elements may be so abundant in places as to render it impossible to make out any arrangement. The appearance is that of inflammatory "goose-skin" (*cutis anserina*). The trunk, flanks, and neck are the parts mainly affected, but the limbs, especially the upper ones, may be involved. The disease affects children and young adults; it is most commonly met with among the former, and is usually associated with a tuberculous (clinically scrofulous) predisposition, an important point to bear in mind in the treatment of the case. The patients are in many instances pale and ill-nourished. The disease is a chronic one, fresh crops and recurrences making it go on sometimes for years, the more so as it gives little trouble, and therefore medical advice is not always sought. I must point out that I have seen conditions quite

other than Lichen scrofulosorum diagnosed as the latter.

Clinically, in some stages LICHEN SCROFULOSORUM is very like the small follicular syphilide, so that care is needed to avoid errors, especially where children are concerned. The syphilide is rare, it may occur at any age, and affect any part of the body, including the head and parts spared by Lichen scrofulosorum. The grouping of the elements in the small follicular syphilide is a significant feature; that alone should make one suspicious and lead to a search for corroborative signs and symptoms of syphilis, which would usually be forthcoming. A thorough examination should never be neglected, for to rely on a rash alone is to lean on a broken reed. As regards the duration and therapeutic test, it is well to state that the follicular syphilide does not respond readily to treatment. In both diseases staining results from involution, but it is more marked in the syphilide.

As to the histology of Lichen scrofulosorum, I have left it till now, as the knowledge of it is not of moment in the clinical differential diagnosis, and, moreover, observers differ about the structure of the lesions. Because giant-cells have been found is no reason for making the condition a tuberculosis of the skin, for at this time of day it should be thoroughly grasped that giant-cells are not pathognomonic of tuberculosis. It is true that the tubercle bacillus has been found in one or two instances, but here again a single rod-like structure staining by Gabbet's method is not sufficiently convincing.

Other observers have looked quite in vain for it. Histologically, the condition under discussion is quite different to Lichen planus. As far as experimental inoculation of guinea-pigs is concerned results have also varied. So that a clinical diagnosis must be relied on, but I would repeat that some descriptions of Lichen scrofulosorum do not apply to that disease at all (see Acne scrofulosorum). With regard to the histological details of the small follicular syphilide, they correspond to the plasmomatous structure of syphilitic lesions in general.

PITYRIASIS RUBRA PILARIS (Lichen acuminatus, Lichen ruber acuminatus) is another morbid condition which is partly follicular, but which would not be likely to be taken for syphilis, except as a result of insufficient examination or carelessness. In this disease the palms and soles are the seat at first of scaly patches, but gradually become diffusely red, scaly, and more or less thickened. On the backs of the hands and fingers the hair-follicles are the seat of hard, dry papules, which are rough to the touch. Other parts of the limbs are affected in a similar way, as also the trunk.

Going a step further it is now necessary to consider vesicular, bullous, and pustular rashes, which have led to errors.

Acquired VESICULAR SYPHILIDES are very rare, but if the general features of syphilis are kept in mind their recognition should offer no difficulty.

A VARICELLIFORM SYPHILIDE has been described. It would be distinguished from varicella by the fact of the vesicles developing on a well-marked papular

base, more definite grouping, slower evolution, together with polymorphism and concomitant symptoms of syphilis. Here, again, the mode of invasion and development of chicken-pox and the age of the patient would serve to differentiate the two conditions. The syphilide would be more likely to occur in an adult, but the possibility of acquired syphilis in children must not be overlooked, any more than the possibility of varicella after childhood. The difficulties as to diagnosis of varicella and some forms of variola need be only recalled here in passing.

I have already mentioned that a true secondary acquired **bullous syphilide** is a condition of extreme rarity, so much so that observers of wide experience have never seen a case. The **bullous iodide of potassium rash** is also uncommon. In the latter evidence of absorption of the drug should be sought for; the signs of syphilis would be absent.

On the other hand there are various non-syphilitic bullous eruptions which have been, or might be, taken for syphilis, chiefly because the mucous membranes of the mouth are often markedly affected in severe generalized cases.

In ERYTHEMA MULTIFORME VESICULO-BULLOSUM (Erythema or Herpes iris of the vesiculo-bullous type) the mouth, tongue, and palate may be severely implicated at the same time as the skin. In the latter situation bullæ occur not only on the extensor surfaces (backs of the hands and feet, etc.), but affect also the palms and soles to a high degree by coalescence of individual lesions. The iris appear-

ance of the skin lesions will usually be present, especially if the case be seen in the earlier stages. The concentric rings, varying in colour and appearance, are the distinguishing feature. It is a recurrent complaint, sometimes seasonal. Taking all the facts, together with the absence of corroboration of syphilis, would readily lead to a correct diagnosis. But in this connexion it is well to state that the recurrent vesicular eruption of the buccal mucous membranes may occur without concomitant skin lesions, for some time at any rate, when suddenly Erythema iris lesions will appear on the backs of the hands, giving a clue to the true state of things. Such cases, when limited to the mouth, are very likely to be taken for syphilis—indeed, such an error has occurred, and the patient dosed with mercury, leading to an aggravation of the symptoms (stomatitis). This so-called **Pemphigus of the mouth** may in other cases be part and parcel of a true pemphigus, either accompanying it or preceding it.

Erythema bullosum may also occur in vaccination, but in that connexion it is not likely to lead to error.

There is another group of cases, so-called **neurotic vesicular stomatitis**, which appears to be independent both of Erythema iris and Pemphigus, but which must not be taken for syphilis.

Again, there is the condition known as **DERMATITIS HERPETIFORMIS** (*Hydroa herpetiformis*, *Dermatites polymorphes douloureuses*, *Herpes vel Hydroa gestationis*), which is not likely to be mistaken for a syphilide, but I mention it here because I have seen a

case of the recurrent Herpes gestationis variety treated with iodide of potassium under the impression the disease was syphilitic. The drug was very detrimental to the woman in that instance, I may add, and I would here emphasize the importance of not giving iodide of potassium in bullous eruptions, as it is sure to aggravate the condition. In Herpes gestationis, a history of one or more previous attacks may be forthcoming, especially in multiparæ, no signs of syphilis are present, and the child is born healthy; but even supposing the infant presented symptoms of congenital syphilis, that would not exclude Herpes gestationis, as the mother might happen to be syphilitic as well. Dermatitis herpetiformis is typically made up of erythematous areas and grouped vesicles, the latter on an erythematous base, but it is a very polymorphous affection, as it is in some stages and in some individuals mixed up with pustules and crusted lesions. It is usually a very pruritic condition, but exceptionally the itching may be slight or absent. Bullæ may be the dominant feature, when it is sometimes difficult to distinguish it from pemphigus, indeed some writers consider it as such, and do not admit Dermatitis herpetiformis as a separate entity. Howbeit, the disease is one to bear in mind in diagnosis. The idea of syphilis may be suggested, too, by the fact that the mucous membranes of the mouth are not infrequently involved. Dermatitis herpetiformis has occurred after vaccination. There is a tendency in many minds to think that an ulcerative affection of the buccal cavity always spells syphilis, which is not the case.

This mistaken attitude is well brought out in the disease known as PEMPHIGUS VEGETANS (*Erythema bullosum vegetans*), the diagnosis of syphilis being almost always made by those little acquainted with dermatology generally, the more so as the condition is very rare. Indeed, before it was recognized as a morbid process distinct from syphilis, it had been labelled as a papillomatous cutaneous syphilide by an expert. The disease often commences in the mouth, accompanied by pain and difficulty in swallowing, and this region may present morbid appearances closely resembling syphilis. In anomalous cases, the mouth is the only part to be affected for some little time before the skin becomes involved, or again the latter may suffer little; this is a question of degree. In *Pemphigus vegetans* the bullæ do not dry up as in *Pemphigus*. Ulcerations and excoriations are left behind, and on these denuded surfaces, especially about the groins and axillæ, vegetating over-growth rapidly occurs (hence the name *Pemphigus vegetans*). This is accompanied by a fœtid sero-purulent secretion and followed by crusting. The affected areas slowly extend at the borders by the formation of fresh bullæ, more or less plump or flaccid. The disease is usually fatal, and it is a question if the cases on record, which got well without involvement of the skin, were really cases of *Pemphigus vegetans* at all. The ætiology has not been worked out, but in a case, which I recognized as *Pemphigus vegetans*, I obtained pure cultures of *Bacterium pyocyaneum* from the contents of one of the bullæ. The condition is no doubt an infective toxæmia, but whether

B. pyocyaneum is at the bottom of it is another matter. The differential diagnosis is also important from the point of view of treatment, for both mercury and iodide of potassium make Pempfigus vegetans worse. The diagnosis would rest on the consideration of the positive features of the disease, such as its onset, evolution, and the presence of bullæ, rather than on the exclusion of syphilis. Here I would repeat that the true secondary bullous syphilide is rare. The general features (distribution, etc.) would be quite against tertiary syphilis; although the ulcerating lesions of Pempfigus vegetans may spread serpigiously, but not in the manner of syphilis, and besides they should not be considered apart from the other morbid manifestations. Summing the matter up, it must be admitted that an error is very likely to be made by those not specially conversant with skin diseases, the first time a case of Pempfigus vegetans is seen, especially in the early period when the mouth may be the only part affected.

There is a bullous vegetating form of IODIDE ERUPTION which might be mistaken both for Pempfigus vegetans and a syphilide. I have already said that iodide of potassium aggravates bullous eruptions. If the idea of syphilis dominates the practitioner's mind the drug is likely to be pushed with unpleasant results to the patient. Previous treatment should be inquired into if iodide of potassium be suspected. Much-advertised mixtures for purifying the blood contain this drug (one of the best known contains about gr. vi ad ʒj); but whether the patient admits taking such remedies or not, it is well to hold



fast to facts. This form of iodide of potassium intoxication is a serious one, involving preferentially the backs of the hands, forearms, and face; but any part of the body may be affected, as also the tongue, a fact which favours the syphilitic view of the case. The general symptoms, among which albuminuria must be specially mentioned, may be so serious as to lead to a fatal issue; and here once again the importance of examining the urine may be mentioned. Indeed, drug eruptions indicate faulty elimination, due to renal disease or renal inadequacy, cardiac weakness, conditions of asthenia such as malnutrition, previous illness, and so forth. It must always be borne in mind, too, that small doses of the drug may lead in such circumstances to marked cutaneous manifestations. If pushed, necrosis of the parts affected may follow. Such cases are rare, but in this place they must be insisted on, as syphilis is so likely to suggest itself to the observer. Or again, a patient really suffering from syphilis may not tolerate iodide of potassium, the latter leading to cutaneous troubles on its own account or aggravating the syphilitic lesions. When mercury also is not well borne the treatment of the syphilis becomes a difficult matter. Another diagnostic point about the bullous iodide of potassium eruptions is the fact that lesions which to the eye appear to be bullous are found to be really solid when they are punctured.

In rare instances BROMIDE OF POTASSIUM has led to bullous eruptions resembling those produced by the iodide. The characteristic bromide rash will be dealt with further on (see Chapter VII).

Among the bullous eruptions there is a rare form of so-called ACUTE PEMPHIGUS, which I have shown to occur in butchers and those handling animal products. The wide-spread bullous eruption, though the striking feature, is only one of the symptoms of an acute general infection following a wound, and which is usually rapidly fatal. Although the name is not a good one, I do not propose to alter it, but would suggest that **acute pemphigus of butchers** would serve to separate it from other generalized bullous conditions. It is a very rare condition, but as the mouth is involved the idea of syphilis will occur. In the two cases I have seen, one of which was under my own observation, the palms and soles were not affected—a point of some differential diagnostic value, for in wide-spread syphilides these situations are not likely to escape. On the other hand, it would not be impossible for them to be involved in the acute pemphigus of butchers.

Before leaving the bullous rashes I would just allude in passing to **salipyrin**, a compound of salicylic acid and antipyrin, which has given rise to a herpes-like eruption about the buccal mucous membrane and the glans penis, accompanied by erythematous areas about the hands and upper limbs. This was, no doubt, due to the **antipyrin**, which is known to give rise to a bullous eruption which may leave some pigmentation of the skin behind. The latter might lead to the idea of syphilis (see Chapter XIV).

## CHAPTER VII

### DIFFERENTIAL DIAGNOSIS OF SECONDARY SYPHILIDES (*continued*)

PUSTULAR SYPHILIDE—ACNE VARIOLIFORMIS—ACNE  
VULGARIS—PEDICULOSIS—SCABIES—ACNE AGMINATA  
—ACNE SCROFULOSORUM

PUSTULAR SYPHILIDE.—Pustular eruptions may also lead to confusion. In the first place, the **pustular Syphilide** must be dealt with here, for it has been more than once mistaken for **Variola**, hence the name sometimes given to it of **Varioliform Syphilide**. Such cases have been sent on to small-pox hospitals. Compare also the names *petite vérole* (small-pox) and *grosse vérole* (syphilis, French pox). As I have already stated, the febrile symptoms in syphilis may be very marked, such as high temperature and severe headache, but a consideration of all the positive symptoms of syphilis would lead to a right diagnosis and to the exclusion of small-pox. But when the latter disease is epidemic, a pustular syphilide may be overlooked. This has occurred. The backache and other corroborative symptoms of the onset of variola may not be marked, or the patient may be vague and misleading about them.

On the other hand, as we have seen, syphilis may be ushered in by severe general symptoms. Duration would be of great importance. In variola the points would be the incubation, the mode of onset, the date of the appearance of the eruption (on the second to fourth day, usually third), and especially the mode of development of the rash, commencing on the face and wrists, and then involving the trunk and limbs, together with the evolution of the individual lesions from a shotty papule gradually becoming vesicular, and finally pustular. In the syphilide, pustulation occurs rapidly, and not by well-marked stages as in variola. Confirmatory of syphilis would be the polymorphism of the rash, together with the consistency and colour of the individual elements, the characteristic adenitis, possibly a primary sore and ulcerated throat. Modified variola would have to be diagnosed or excluded on similar lines.

In this place, **pustular vaccination** rashes must be alluded to in passing, as also **generalized Vaccinia**, but the fact of recent vaccination and absence of syphilitic symptoms would point in the right direction.

ACNE VARIOLIFORMIS (*Acné varioliforme* was the term originally given to *Molluscum contagiosum*, a totally different disease) is mentioned here because a superficial examination limited to the face and scalp may lead to error. The complaint has been called varioliform because it leaves pitted scars something like those of small-pox. It affects the forehead (*Acne frontalis*) about the margin of the hairy scalp, and what is important to note, the

lesions also go back into the latter region. Strictly speaking the process is not one of ordinary pustulation, but of necrosis about a hair-follicle (pilo-sebaceous system), leading to the formation of a tough crust. When the latter is removed, a small pit is left behind, which ultimately gives rise to a pitted scar, more or less circular. As the favourite seat of *Acne varioliformis* is the frontal region it is apt to be mistaken for the *corona veneris* of a syphilitic rash by those unfamiliar with, or commencing the study of, skin diseases. Except in very rare instances, the other parts are not affected, but the disease has been observed on the chest and on the scrotum. There may be a history of syphilis, and further, iodide of potassium acts beneficially: it is these two circumstances which have led to the idea of the syphilitic nature of this disease, which is considered, however, by the great majority as an entity and *sui generis*.

In the **pustular iodide of potassium** eruption, the lesions are observed about the face and limbs, with crusting, but the pustules are more superficial than in syphilis, and do not as a rule leave a scar. Besides, the concomitant symptoms of syphilis would be absent. Syphilophobes may be greatly concerned about this drug rash after taking iodide of potassium or some advertised blood mixture for a non-existent syphilis. At other times, owing to the vagueness of the history of previous professional advice and treatment it is difficult to tell whether such patients have really had syphilis or not. In any case, the diagnosis should not be accepted

unless there is definite corroboration in the retrospective account of the original trouble and in the objective signs which can be made out for oneself.

Another important drug eruption which has led to error in the direction of syphilis will now be dealt with, viz. **bromide eruptions**. In one case, for instance, a medical man was treated for three years for a supposed recurrent syphilitic rash, which turned out eventually to be really of bromide origin. This class of rash in infants will be referred to when I come to speak of congenital syphilis (see Chapter XIII). Here I propose to touch on its differential diagnosis from acquired secondary syphilis. Bromide of potassium is the salt most commonly used and also the one most potent for evil. It gives rise to pustular lesions, which may be discrete or confluent. The discrete or acneiform are observed on the face, back, chest, scalp, and about the limbs, especially the legs. The rash consists of yellow pustules, from about a hemp-seed to a pea in size, situated on an inflamed base. When the drug is persevered with there is increased severity of the eruptive manifestations; the individual elements become larger and confluent. In some instances ulceration may occur, with the formation of disfiguring scars, a state of affairs all the more likely to suggest syphilis.

But the characteristic lesions consisting of markedly raised, more or less convex elevations of a reddish or violaceous hue, generally round or oval in outline, or with a gyrate border, and topped by small, closely aggregated pustules, should suffice for a positive diagnosis. Moreover, the lesions are soft

and rather fluctuating to the touch, but they may also have a more solid feel. The diagnosis must sometimes be maintained in the face of denials, either intentional or otherwise, on the part of the patient as to drug-taking. An eruption such as that just described may look very formidable, but when the offending drug is left off the elevations gradually subside, leaving no scar but merely a stain, which is at first purplish, then brownish, and remaining behind for some time as a record. In some instances marked papillary hypertrophy of the elevated lesions occurs, with scabbing of the central parts. Scar tissue, such as vaccination scars, may be attacked. When there are only a few localized elevated patches the condition may be taken for tertiary syphilis.

The diagnosis of bromide rashes is important. They may occur in epileptics, who take the drug for long periods together. The numerous "I cure fits" remedies advertised in the papers contain bromide of potassium, and the drug is frequently prescribed for the menopause and other neuroses, menstrual troubles, and so forth. As regards children it is a favourite remedy for whooping cough, etc., or a single dose ordered by the medical attendant may be continued nightly by the parents without his knowledge. Inquiries in this direction will confirm the diagnosis made on the objective appearances alone. Another point is the fact that bromide lesions may go on coming out for some time after the drug is stopped. As in the case of iodide of potassium, the bromide is a diuretic. When diuresis no longer occurs, the toxic action of the drug continues.

I have said that in some cases the lesions are characteristic. On the other hand, in bromide eruption corroborative syphilitic evidence would be absent.

ACNE VULGARIS sometimes affects the trunk extensively in addition to the face, especially the chest and back. In the latter situation, the pustules and nodular abscesses may be numerous, and mixed up with scars of old lesions and comedones. In ill-fed and broken-down individuals the disease may also affect the limbs, the glands of the groin and axillæ being enlarged as a result of the wide-spread pustulation (*Acne cachecticorum*). This is sometimes well seen in individuals suffering from the effects of scurvy. The condition is apt to be taken for syphilis unless all the points are carefully considered. I need hardly add that mercury in such patients would be prejudicial.

Another pustular condition observed in those who are broken-down from privation, especially in the elderly, is **Ecthyma**. It is the result of local contagious pus infection (*staphylococcus*). It is really the same thing as *Impetigo contagiosa* (which some observers maintain is streptococcal in origin, and others staphylococcal), but in a higher degree, the process instead of remaining superficial leads to ulceration with much crusting, the lesions presenting an inflammatory areola. The class of patient affected in this way is often met with in poor-law infirmaries and among tramps. In addition to the wide-spread ecthyma, the corresponding glands are often enlarged, and as a good many of these in-



dividuals are the subject of chronic pediculosis, marked pigmentation is present also (vagabond's disease). Altogether the picture is one that has led to the erroneous diagnosis of syphilis. Ecthyma may sometimes have a rupia-like appearance.

On the other hand, I would emphasise the fact that the secondary ecthymatous syphilides are seen in the ill-fed and neglected, but here the concomitant signs of syphilis would serve to differentiate it from simple ecthyma.

Inveterate PEDICULOSIS VESTIMENTI (lousiness of the body) may occasion a good deal of pustulation about the upper part of the body (shoulders, and so forth). The distribution of the rash and the presence of the *Pediculus* in the vest or garment worn next the skin would decide the matter. The parasite has six legs and is therefore an insect. The minute blood-speck resulting from the insertion of the parasite's proboscis into the skin, just visible to a good eye and better seen with a lens, is a point of diagnostic value when it is present.

In SCABIES (itch, la gale, die Krätze), the multiplicity of the lesions has also led to suspicion of syphilis, in fact to the positive diagnosis of the latter disease, especially as in men the penis is frequently affected. The great points are the distribution of the rash, in males from about the transverse nipple line to the knees in front, including the genital area, and about the buttocks behind. Scratch marks and pustules on the buttocks and penis are always to be regarded from the point of view of scabies. In women, the arrangement of the clothing somewhat

modifies the distribution. In them the back and the breasts are often involved, especially the latter parts, which should be examined if possible in doubtful cases, for scabies may be very difficult to spot in the cleanly, and also in those whose occupation involves the frequent immersion of the hands in water (barmaids, laundresses, etc.). In bricklayers the same difficulty occurs. The hands, however, must always be closely scrutinized with a lens, especially the sides of the fingers and hands, the flexor aspects of the wrists, and also the palms, as the discovery of the typical burrow and picking out the *Acarus scabiei* will clinch the matter. Where the eruption is abundant, the glands will be enlarged as a result of the pus irritation and scratching. In contradistinction to syphilis, there is of course great itching, but be it remembered syphilides may itch sometimes, although in a mild degree as compared with scabies. Again, the occurrence of syphilis and scabies in the same individual must be thought of; and a syphilide that itches severely should make one suspect the *Acarus*. Among students, there is often a doubt about the acarus itself. To the naked eye it appears as a tiny globular body, just perceptible. Mounted in a drop of water and examined microscopically, with a low power, the female acarus, which forms the burrow, will be found to have eight legs, the two anterior pairs being provided with suckers, and the two posterior ones with a long bristle each. The parasite is not an insect, therefore, but belongs to the spider family (*Arachnida*).

Just as for syphilis, no one is above contracting

the itch. The social position does not exclude the possibility of either disease.

I have also seen a marked pustular and ecthymatous rash about the legs, which was thought to be syphilitic, but in reality due to the *Leptus autumnalis* or harvest bug, the six-legged larva of an acarus, *Trombidium holosericum*. The parasite abounds in some districts in July, August, and September.

A rare condition, ACNE AGMINATA (disseminated follicular Lupus, Acnitis), must be referred to in this place. It is a polymorphous eruption affecting chiefly the face, but coming out also on the limbs occasionally. The parts of the face mainly affected are the forehead, eyelids, the sides of the face, and the chin. The eruption consists of more or less grouped papules, about a hemp-seed in size, of a dull red, some being centred by a small pustule. The individual lesions commence deep in the skin, feeling like small shot, gradually coming to the surface, to form the papules and pustules just described. In the early stages they are better felt than seen. They come out in crops, and exacerbations occur when the patient is exposed to sunlight and sweats. This agrees with what I have found histologically, viz. an inflammatory leucocytic infiltration about the sweat-coils, leading to their disorganisation by supuration. This is consonant with one of the names proposed for the disease: **Hidradenitis suppurativa destruens**, which is too long for ordinary use. I did not find tubercle bacilli. In addition to the face the neck, shoulders, and the extensor surfaces of

the arms may also be involved. In these situations the lesions may be as large as a lentil, of a dull red tint reminiscent of the *Lupus vulgaris* apple-jelly appearance, hence perhaps the old name of **disseminated follicular Lupus**. When the blood is driven out by glass-pressure, a pale brownish discoloration is observed. A pigmented depression is left behind. A careful examination would show the real nature of the disease, and the absence of corroborative symptoms would exclude syphilis. A point to bear in mind here is that biniodide of mercury has given good results in some instances of *Acne agminata*, although I have not been able to confirm this, so that the therapeutic test might be fallacious.

Another condition which should be alluded to here is the *ACNE SCROFULOSORUM* of children, which is an altogether different thing clinically from **Lichen scrofulosorum**, but which has been taken for the latter by some observers. The usual areas of distribution are the sides and back of the thighs and the buttocks, but occasionally the arms may also be involved, the extensor aspects in preference to the flexor. The rash is made up of small, inflammatory pustules, follicular in situation usually but not always, varying from a large pin's head to about a hemp-seed in size. When they involute, they leave behind a small central scar, which can be well seen with a lens, surrounded by a pigmented ring. Young children mainly suffer from this disease. Attention to the foregoing points, and the absence of positive evidence as to syphilis, should suffice to differentiate it.

## CHAPTER VIII

### TERTIARY SYPHILIS

GENERAL REMARKS—HISTORY—RECURRENT ABORTIONS  
—STERILITY—OBJECTIVE SIGNS—TYPES OF THE  
TERTIARY LESIONS—CORROBORATIVE SIGNS—SCARS—  
TONGUE—MOUTH—THROAT—NOSE—EYES—HEAD-  
ACHE—FITS—BONES AND JOINTS—VISCERA

I WILL now take a general survey of the subject of tertiary syphilis before going into details of the morbid conditions that may be mistaken for it. I do not propose to repeat here what I have already stated at length in the first chapter. It will only be necessary to emphasize certain points.

In the first place the case must be investigated on the general lines indicated. Duration is a most important factor, and in some cases will at once exclude syphilis.

It is very necessary to remember that the history may not only be useless, but positively mischievous in forming an opinion of the case. A patient may stoutly deny in perfect good faith that he has ever had syphilis. Of course such a denial amounts to nothing in the face of positive objective signs. Again, tertiary syphilis may occur a great many

years after the primary infection, and both the primary and secondary manifestations may have been so slight that the whole business has been long forgotten or escaped recognition altogether. Sometimes, too, patients mislead in this matter of set purpose. As to women, a direct question cannot be put as in the case of men. Moreover, it is a matter of practical experience that in women there is often nothing corroborative when the patient is asked about a rash, a sore throat and loss of hair, the usual questions, which have come to be looked upon with a reverence that is almost touching. But supposing there has only been a faint macular rash years before the case is seen, and practically nothing else, is a patient, especially in certain walks of life, likely to have troubled about it or to recollect it?

As to "sore throat," ulceration of the tonsils, more or less marked, is not always observed in syphilis, whereas non-syphilitic sore throats of one kind and another are common, and most people have suffered in that way to a greater or less extent.

Loss of hair, again, is a common complaint, but it does not follow that all the buyers of advertised hair-restorers have suffered from lues. Some syphilitics have got plenty of hair, and many a non-syphilitic individual is bald. That the hair is affected in syphilis is undoubted, but not so commonly as is supposed.

My point in this matter is to call attention to the futility of this line of cross-examination in many cases.

RECURRENT ABORTIONS.—A factor of greater import

in the present connexion is the history of repeated abortions and miscarriages. I am quite aware that syphilis is not the only cause of such an occurrence. It is nothing to the purpose, either, to make a comparison with what takes place in cows, as is sometimes done. In them there is a form of **epizootic abortion** due probably to a specific micro-organism; in this condition repeated abortions are the exception. In syphilis morbid changes are found in the placenta, which may be adherent. It is not necessary to say more on the subject in this place, but I would insist on the value of a history of recurrent abortion in the retrospective diagnosis of syphilis, taken with other signs and symptoms of course. There are, moreover, features in the abortions of the latter disease which must be dealt with here briefly. First, then, is the fact of consecutive or of several abortions. In syphilis, again, there is a tendency for the miscarriages to occur at a later period of gestation as time goes on. After abortions in the early months a child may eventually be born at full time, either dead or living. This depends to some extent, too, on the specific treatment or otherwise of the mother. In the former case, a living child is not necessarily born; it may be dead or be born at seven months or so and not survive. If it survive, the child may show signs of syphilis or it may be apparently quite healthy. In a word, there are various possibilities, which must be borne in mind when questioning a woman on her parous history. In tuberculous mothers, on the other hand, there is a tendency for the miscarriages to occur earlier and earlier, owing

to the weakening effects of the disease, leading to increasing feebleness and malnutrition. But there are variations in this condition also, owing to improvement in the general health. Again, both infections, tuberculosis and syphilis, may occur in the same individual. Besides these, other causes, such as adhesions of the womb and so forth, may also give rise to repeated abortions. In estimating the evidence supplied by patients these various points need to be remembered. But it cannot be stated too often that the thing to aim at is to make the diagnosis of syphilis on the objective signs alone, without going into details of history, especially with women, as it may lead sometimes to complications, which are better avoided. For purposes of study and training, in appropriate circumstances, it is essential to go into all the facts of the case. The collection of such notes is, of course, of the highest educational value.

Another point is STERILITY in women who have had syphilis. This may be a coincidence. Just as repeated abortions do not always spell syphilis, neither does non-pregnancy. Sterility may be due to various conditions in the female. It is sometimes forgotten that males also may be sterile from one cause and another.

Having cleared off these preliminaries, I will now deal with the essential factors in diagnosis, viz. the objective signs. In the first place the skin lesions the patient complains about must be considered.

OBJECTIVE SIGNS.—The **distribution** is the first thing to note. The tertiary cutaneous manifestations



are asymmetrical and, most usually, unilateral. They may be bilateral, as, for instance, when they occur about the naso-oral region and spread to either side of the median line. When they affect both palms they may indeed be more or less symmetrical, but this is uncommon. Moreover, in contrast with the secondary eruptions, limited areas of the cutaneous surface are involved, and frequently, especially in the late tertiary stage, the lesions may be solitary or at any rate few in number.

**Histologically**, tertiary syphilides exhibit the same fundamental points as primary and secondary syphilis. Here also we have to deal with a mixed plasmomatous and fibromatous structure, a new growth. The true gumma, however, is not, as is generally supposed, the only type assumed by tertiary syphilis of the skin. When present it is, of course, distinctive of the last stage of the disease; compared with the primary induration it is at the other end of the chain. It must, however, be remembered that clinically, in point of time, the secondary and tertiary manifestations may merge into one another, hence the so-called late secondaries and early tertiaries. The clinical divisions adopted in syphilis I may repeat are convenient for purposes of orientation, but they are elastic and not hard and fast. It has been shown, histologically, that after syphilitic eruptions morbid products of the two first phases may remain dormant *in situ* for long periods, and spring up into activity under the stimulus of some external or internal irritant or injury, giving rise to tertiary lesions.

TYPES OF THE TERTIARY LESIONS.—The tertiary cutaneous types may be conveniently indicated here as the nodular, the circinate, the ulcerating, and the gummatous.

First as to the **nodular syphilide** or **cutaneous syphiloma** (das cutane Gumma, tubercular syphilide—the qualification tubercular is better dropped—tuberous syphilide). It looks very like a papule in its earliest phase. In course of time it becomes raised above the level of the skin, hemispherical in shape, firm and hard to the touch. The elements are well defined and more or less circular or oval, the latter occurring more especially on the trunk. They vary in size from a lentil to a pea and over, and may attain a diameter of three quarters of an inch (2 centimetres) and more. In colour they are of a deep dull red. One point about them is that they do not respond readily to treatment; they involute slowly, leading to an atrophic condition of the skin, whereas the simple papular and lenticular secondary syphilides are usually absorbed without leaving obvious traces behind. But this is not always the case, as I have seen a symmetrical secondary rash give rise to well-marked superficial atrophy of the areas that had been affected. Some of the syphilomata may become scaly and crusted, with ulceration.

The tertiary nodular syphilide usually occurs in groups and preferentially affects the nose and its neighbourhood, where they may be bilateral. Other parts of the face, such as the chin and forehead, may be involved. When they occur on the trunk or limbs, which is not infrequent, the groups have received the

name of **herpetiform syphilide**; not that they are vesicular or "creeping" (the latter is the true meaning of herpes), but merely because the syphilomata are multiple and irregularly grouped. At other times a corymbose-like pattern is produced reminiscent of what is seen in secondary syphilis (see p. 43). The smaller and harder the nodular elements the more numerous they are as a rule, and more closely aggregated, especially about the sides of the nose; whereas when the syphilomata are large they are fewer in number, discrete, and distributed over a larger area. In the latter case, too, the lesions are not so raised, the granuloma being more flattened out, so as scarcely to deserve the name of nodule sometimes given to it. The same kind of thing occurs in leprosy, in which disease the lepromata may be distinctly small and nodular or flattened out over a larger surface (see Chapter XI). Not only may the syphilomata under discussion become ulcerated and crusted, they may also fungate.

The **circinate syphilide** affects mainly the nape of the neck and the forehead near the border of the scalp. It appears as infiltrated segments of circles with their concavity directed towards the scalp, forming festoons. The condition commences as small nodular elements or infiltrations, which coalesce into a solid border. The latter pushes its way more or less convexly into the skin, clearing up as it goes. The infiltrated border and mode of spread are important diagnostic features. The circinate syphilide may remain dry or become ulcerated and crusted here and there.

There is also a late **circinate Erythema** (*Erythème circiné tertiaire, neuro-syphilide*), which appears in the shape of rings. This condition is characterized by the small number of the rings (or ovals) and their large diameter (from about two and a half inches to as much as six inches—6 to 16 centimetres). In this they differ from the **recurrent syphilitic roseolas** I have already mentioned (see p. 63). They are of a rosy hue at first, but later become brownish-red. They are very rebellious to treatment.

In connexion with the foregoing the **squamous syphiloma** may be referred to here. The tertiary new growth of the circinate type is often attended with scaling, especially about the margins of the scalp, in which case the desquamation may be more or less fatty (*seborrhœic*). On the face, the circinate bordered tertiary lesions are frequently also erythematous and finely squamous.

On the limbs squamous areas as big as the hand occur, but a careful examination reveals the granulomatous infiltration, especially at the borders, with more or less pronounced scar-like atrophy of the skin in the portions first affected, a point of great importance in diagnosis.

In the palm—for it is usual for one only to be affected—dry desquamation takes place, leading to the undermining of the horny layer of the epidermis from within out, an appearance which must be noted. Here the lesion commences as a small infiltration, which gradually extends and spreads over the palm and the flexor aspect of the wrist, leading to denudation of the upper epidermic layers. On

the sole a similar process goes on, often complicated, in those with sweaty feet (Hyperidrosis), by a thickening of the horny layers of the epidermis (Keratosi, Hyperkeratosis). Unilateral thickening in this region must always be investigated from the point of view of syphilis. A careful examination will usually show the existence of a circinately bordered spreading infiltration characteristic of the latter.

As to the **ulcerating syphilides**, they are a further development of the preceding forms. When the flat syphilomata break down, they may give rise to deep ulcers (Ecthyma profundum) especially in the ill-nourished individual. Or, again, pustules may form and lead to **Rupia** lesions by peripheral extension, accompanied by a *pari passu* formation of crusts. There can be no doubt that such complications are the result of syphilis plus secondary external microbial infection (Staphylococcus, etc.).

The **frambœsioid syphiloma** will be considered under yaws (Chapter XI).

But what requires a special word here is the **serpiginous ulcerating 'syphiloma**, which may involve large areas of the body, the sound parts being invaded by an ulcerative process extending in a convex manner, and giving rise to the kidney-shaped (reniform) and horseshoe-like ulcers, with formation of scar tissue within the spreading border. This is the so-called **Lupus syphiliticus**, a very bad name, for it is very misleading. It is true that the serpiginous ulcerating syphiloma may occur in those suffering from tuberculosis; indeed,

when it is extensive, the patients are usually broken down in constitution. But that the process is a syphilitic form of Lupus, that is Lupus vulgaris, as the name Lupus syphiliticus implies, is quite another matter. Although a mixed infection both by the tubercle bacillus and the syphilitic virus is not impossible, yet it has never been satisfactorily demonstrated. The existence of giant-cells would not prove that it was Lupus vulgaris. From the point of view of treatment, iodide of potassium and mercury have a decided effect on the serpiginous ulcerating syphilomata, but none on Lupus vulgaris. It must not be forgotten that cachectic patients require feeding up, and must be placed in hygienic surroundings before mercury is employed. I have dealt with this point already.

**Phagedæna** may also occur as a serious complication of tertiary ulcerating lesions, especially in the ill-fed, the alcoholic, and so forth. But apart from the diminished resistance of the individual, micro-organisms are no doubt responsible for such a condition. It is very rarely seen now, whereas in the days before antisepsis and asepsis, hospital gangrene was a common thing in hospital wards. In tropical countries, especially in areas where the climate is moist, phagedæna is common. The condition known as **tropical sloughing phagedæna** will be dealt with later on (Chapter X).

I come now to the **Gumma**. Objection has been made to the term on the ground of accuracy. It is retained here, however, as it has attained a definite clinical meaning. Histologically the gumma differs

from the other tertiary syphilitic lesions I have been dealing with, in that the fibromatous and plasmomatous changes are more individualized instead of being intermingled. In the gumma, the tough fibroma surrounds the soft contents, the latter undergoing liquefaction, which leads ultimately to the well-known breaking down of the growth. It is not a true suppuration as in the abscess. The gumma again develops preferentially in the hypoderm (subcutaneous gumma), but it may occur in the cutis itself. The former concerns us chiefly now.

It commences as a deep nodule, enlarges, and involves the superficial parts of the skin, which becomes red and soft. Finally the skin gives way, and the softened contents of the gumma are discharged, leaving an irregular cavity behind. The wet wash-leather look of the floor of this cavity is characteristic. Under appropriate treatment a gumma may be got rid of by absorption even when softening has taken place. Gummata may occur in any situation but, as far as the skin is concerned, the regions mainly affected are the limbs, especially the front of the knees, and to a less extent the elbows. Gummata also occur in the testicles, which, in rare instances, break down, involving the skin of the scrotum. In the mamma they are uncommon, but the possibility of such a thing must be borne in mind. Over bones, the periosteum may also become affected; and periosteal gummata may break through the skin.

In point of time, the gumma may occur many

years after the primary infection, or may be an early manifestation and rapidly follow the secondary rash.

I have observed that when the cutaneous areas affected are multiple, the type of the tertiary lesion is usually the same everywhere. And also that recurrences in the same patient usually affect the same type of lesion. An individual, for instance, who has started early gummata, will sometimes have gumma after gumma. Another patient will have circinately bordered squamous lesions time after time.

**CORROBORATIVE SIGNS.**—Having briefly reviewed the various kinds of tertiary lesions met with, it remains for me to mention the corroborative signs furnished by a further examination of the patient.

**SCARS.**—In addition to recent scarring or atrophy about the actual lesion the patient complains about, the presence of old scars either in the neighbourhood, or in other parts of the body, is a valuable indication. Definitely circular scars about the size of sixpence or so— $1\frac{1}{2}$  to 2 centimetres—are often found about the patellar region; this is especially the case in women. They are the remains of previous syphilitic manifestations. In other cases larger circular scars from a shilling to a florin in size—2 to 3 centimetres—may occur scattered about the limbs chiefly, trunk and scalp, as a record of a severe secondary ulcerative eruption.

**THE TONGUE.**—The buccal mucous membranes and tongue should always be examined in a routine way for scars. As to the latter, the edges or dorsum



will often show changes of that kind, best seen after drying the parts with a towel. **Leukoplakia** of the tongue is very significant, but not absolutely diagnostic. I would again take this opportunity of insisting on the fallacy of relying on one sign alone. Scars will be dealt with further on (see Chapter XIV).

Gummata may also occur in the tongue and in the mucous membranes of the mouth, and break down, as elsewhere.

With regard to this region, **Sprue** (Psilosis) (Malay Archipelago, etc.) needs mentioning. It leads to erosions and denudation of the epithelium of the tongue.

**THE MOUTH.**—Looking into the mouth, the loss of the uvula or a perforation of the palate may be observed.

**THROAT.**—As to the throat, or more properly the tonsils, it is astonishing how little record is left behind in this situation after prolonged and severe ulceration. Unless a good deal of deep destruction occurred at the time of the active throat symptoms, or as a result of an unrecognized and neglected tonsillar chancre, the examination of the throat may show but little evidence of past trouble.

Going further down, **Laryngitis syphilitica** must be mentioned.

Hoarseness of voice may sometimes be a clue. Here it may be stated again, that the case should be taken as a whole and every abnormal symptom noted. Syphilitic laryngitis may necessitate tracheotomy, and a patient may have to wear a tube for years.

THE NOSE may also exhibit signs of the destructive effects of the disease: necrosis of bone, loss of cartilage, and maybe that most offensive, evil smelling condition **Ozæna syphilitica**.

The well-known deformity of syphilis, "down with the nose, down with it flat," need scarcely be emphasized in this place.

THE EYES must also be carefully examined. The pupils may exhibit irregularity of outline pointing to posterior synechiæ following syphilitic iritis. They may be pin-point, and on testing them as to light and accommodation the Argyll-Robertson phenomenon may be demonstrated, viz. no reaction to light, but reaction to accommodation. In this connexion the knee-jerks should be tried; they may be found to be absent. Other symptoms of tabes may be present, such as lightning pains, gastric crises, girdle sensation, Romberg's symptom, etc. It is generally admitted, although there are some dissentients still, that locomotor ataxy (Tabes dorsalis) is mainly of syphilitic origin, although no doubt other factors are at work. Those who oppose the syphilitic theory point to the absence of tabes in some parts of the world where syphilis is rife (Turkey in Asia, tropical countries, etc.).

The pupils may be unequal, a condition observed in general paralysis of the insane, a disease all evidence points to as being syphilitic in origin also, but this again is not accepted by some writers. Tabes and general paralysis are included among the so-called para-syphilitic conditions.

A closer examination of the eye may reveal minute

black specks on the lens, the remains of torn-off portions of iris, the result of iritic adhesions treated by means of atropine.

Optic neuritis and optic atrophy—more rarely, too, blindness of one or both eyes, or even the loss of sight, from syphilitic retinitis, especially the central variety—may be referred to in passing.

Interstitial keratitis occurs not only in congenital syphilis, but may follow in the train of the acquired disease. It will be dealt with later on (Chapter XIII).

Paralysis of the oculo-motor (third cranial nerve), abducens (sixth), trochlear (fourth), and facial (seventh), in order of frequency, is not an uncommon late syphilitic manifestation. The third nerve is by far the most frequently involved. Unilateral ophthalmoplegia interna, in which reaction to accommodation as well as to light is abolished, is also observed in syphilis.

From what I have said it will be seen that the eye is an important indicator of syphilis, both past and present. It should never be neglected in the retrospective diagnosis.

HEADACHE.—Occipital headache may be very severe especially at night in the late gummatous stage.

FITS.—A patient with marked breaking-down tertiary cutaneous manifestations may give a history of a fit a short time previously. It should be remembered that epileptiform attacks occur in, and are due to, syphilis. The fit may be like one of epilepsy—this I have seen in an alcoholic syphilitic woman—or it may be Jacksonian in type.

Needless to add that indications of cerebral mischief are of much greater importance than the skin lesions and call for energetic treatment.

THE BONES and JOINTS should also be examined. In the former periostitis and nodes may occur with marked nocturnal pain (osteocopic). It is when at rest that pain is felt, and not while the patient is getting about. As to the joints, these structures are often overlooked as far as syphilis is concerned, but this is a mistake, as they are affected by inflammatory and gummatous changes of syphilitic origin.

THE VISCERA.—I cannot go into details of the viscera, but in a general way it should be pointed out that syphilis may involve any of them. The liver, for instance, may be found on palpation to be irregular on the surface as a result of syphilitic growths. Again, and in my experience in women chiefly, more or less stricture of the rectum may be discovered, associated with broken-down cutaneous gummata. Or a gumma of the testicle may be present. The epididymis, *i. e.* the globus major, is rarely affected; when it is the enlargement may be stony hard.

The nails too may exhibit changes in structure, but these will be referred to in detail further on (see Chapter XIV).

## CHAPTER IX

### THE DIFFERENTIAL DIAGNOSIS OF TERTIARY SYPHILIS

LUPUS VULGARIS — LUPUS ERYTHEMATOSUS — ACNE  
ROSACEA — PSORIASIS — SEBORRHŒIC DERMATITIS —  
PALMAR AND PLANTAR ECZEMA—PLANTAR KERATOSIS  
—PLANTAR TRICHOPHYTOSIS

AMONG the non-syphilitic morbid conditions which may be taken for syphilis, LUPUS VULGARIS will be noticed first. Like syphilis, Lupus vulgaris belongs to the infective granulomata. In the latter disease the growth results from the reaction of the skin to the tubercle bacillus. The micro-organism is not easy to find, however, and a number of sections have to be stained to be successful in this direction. Histologically, a section of skin shows foci of disease consisting of large giant-cells with excentric nuclei, and beyond these a zone of plasma-cells. The bacillus is found in the giant-cells. This is a mere outline, but it will help to give a fundamental notion of the process for clinical purposes.

There are several types of Lupus vulgaris, but the main ones are the nodular, the diffuse, the ulcerating, and hypertrophic.

Now as to differential diagnosis. The age of the patient is a valuable index. Lupus vulgaris usually begins early in life; on the other hand tertiary syphilis is met with in adults and the elderly, except of course the late congenital lesions or those of syphilis acquired in early childhood. It is rare for Lupus vulgaris to begin late in life, but exceptionally it does.

The next point to draw attention to is the great difference in mode of development. Lupus vulgaris takes years where syphilis takes only months; the question of duration is therefore of the greatest importance, as it will at once point to the exclusion of one or the other.

As to distribution, Lupus vulgaris, like tertiary syphilis, is asymmetrical, but on the face by spreading from the middle line, the nose for instance, it may eventually become very symmetrical and closely imitate another condition, viz. Lupus erythematosus. Usually Lupus vulgaris begins from one focus, but it is not uncommon for it to affect several parts of the cutaneous surface, in which case it is the rule for the multiple lesions to come out simultaneously, but there are exceptions to this.

The scalp is very rarely affected in Lupus vulgaris except by extension from adjacent areas of the face and neck, but it may be involved independently.

Age, duration and distribution having been considered, it remains to deal with the lesions themselves. When there is a small single circumscribed nodule, that is in the very early stage of the disease, the idea of syphilis would not arise. But the early

nodule is the type of the later ones, which occur at the spreading border of the adult growth. The nodule is embedded in the skin, is translucent, of a brownish-red which has been compared with "apple-jelly." If glass-pressure be employed, as it should be, a brownish discoloration remains. The result of the glass-pressure test is not absolutely diagnostic, but must be taken with the other evidence already alluded to. Clinically, *Lupus vulgaris* of any duration usually presents diffuse redness, with infiltrated nodular border, and small satellite nodules beyond, thrown out like scouts in advance of the main body of the disease. When the blood is driven out of the reddened patches by making the part taut or by means of glass-pressure, the nodules show up as brownish areas. Ulceration may also be present, but it is more superficial than that of tertiary syphilis, and the kidney and horse-shoe shape of the broken-down part so distinctive in the latter disease is not seen. Mixed up with the redness, nodulation and ulceration, there will be in advanced cases atrophy or scarring of the parts already swept by the morbid process, that is in the central portions.

Syphilis, again, in bad cases, involves the bones, but *Lupus vulgaris* spares them.

There is an erythematous form of *Lupus vulgaris*, the so-called **Lupus erythematodes**, in which the plasmoma is ill-developed, but the hyperæmia accentuated and persistent.

It is well to remind readers that there are warty-looking forms due to epithelial hypertrophy—**Lupus**

**verrucosus**—and that epithelioma may complicate Lupus vulgaris. The induration of such a malignant development must be distinguished from syphilis, so as to lose no time in dealing with it thoroughly.

Another type which must not be confused with tertiary syphilis is acutely spreading Lupus vulgaris, which breaks down very readily, and resents radical local measures, a *noli me tangere* lupus.

Lupus vulgaris not infrequently affects the mucous membranes, mainly of the mouth, palate and gums. In this situation it is not likely to be confounded with syphilitic lesions if the case be taken on its merits as a whole, for it is very unusual to see it in these situations without involvement of the skin of the face. This may, however, occur, especially about the nasal mucous membranes. The absence of corroborative syphilitic signs would exclude lues.

As excluding syphilis there would further be the absence of corroborative signs, but as far as this is concerned the possibility of Lupus vulgaris attacking a syphilitic patient must be borne in mind.

The so-called **Post-mortem Wart** (Tuberculosis verrucosa cutis, Verruca necrogenica), which is observed about the hands of post-mortem porters, butchers, medical men, etc., needs to be distinguished from syphilis. It is due to the Bacillus tuberculosis. The duration, mode of development, appearance, and resistance to drugs given by the mouth would be differential points.

Again in the syphiloma, the existence of granular and ulcerating separate foci in the vicinity of the main lesion, and also the existence of previous



circumscribed scars, would be further evidence as to the true nature of the disease.

Allied to *Lupus vulgaris* is the condition called **Scrofulodermia**, also due to the Tubercle bacillus. As the name indicates it occurs usually in so-called scrofula or struma—clinical terms which are convenient, although it is well understood at this time of day that tuberculosis is meant by them.

In scrofulodermia, the skin over suppurating, breaking-down lymphatic glands becomes involved, about the neck for instance, leading to chronic ulceration with much crusting, which slowly spreads. Or this may occur over tuberculous growths in the skin, scrofulous or tuberculous gummata, the latter term being employed quite apart from syphilis, and merely indicating a clinical resemblance to the true gumma. The backs of the hands and feet are sometimes extensively affected, and in some instances *Lupus vulgaris* nodules may be present beyond the margin of the scrofulodermia area. If these clinical features be kept in mind there is little fear of mistaking it for anything else. But if there should be doubt the therapeutic test would be indicated. Iodide of potassium would influence syphilitic lesions, leading to improvement usually in the course of a week, whereas the tuberculous skin diseases would show no change. Large doses of the drug in *Lupus vulgaris* administered for long periods have had no beneficial effect.

In connexion with this portion of the subject it should be stated that where there is infiltration with ulceration and atrophy or scarring, Syphilis, *Lupus*

vulgaris, and Scrofuloderma are the common conditions to think of. Where leprosy is endemic that disease would also come into the purview; it will be dealt with in another chapter.

It is convenient here for purposes of differential diagnosis to touch on LUPUS ERYTHEMATOSUS. This is not a tuberculous affection of the skin, although it may be found associated with enlarged or broken down lymphatic glands. Further, there is often a history of pulmonary tuberculosis in the patient's family. It is only fair to add that some writers insist on its tuberculous nature. The disease is observed mainly in young and middle-aged adults, children and the old being usually spared. This age factor is important. Moreover it affects females more than males.

The main features of Lupus erythematosus are its symmetry. The seats of election are the nose, the cheeks, the ears, the scalp, and the back of the hands and fingers. On the face, the cheek and nose patches may coalesce to form the well-known bat's wing or butterfly pattern. It is associated with a poor or so-called chilblain circulation. The patches are chronic in their course, spreading at the periphery and involuting in the centre; this leads to atrophy of the parts affected, but not to true scar formation such as follows ulceration and destruction of the tissues. This is an important difference as far as syphilis is concerned, for ulceration in Lupus erythematosus is quite the exception. The discoid slightly depressed atrophic areas of the scalp should be examined with a lens, when in many cases a definite horny plugging of the follicles will be

apparent. The lesions sometimes present very adherent crust-like accumulations formed by the coalescence of the plugs before mentioned, but there is no ulceration underneath as in syphilis.

Lupus erythematosus may affect the scalp alone, or it may become generalized. In the latter form albuminuria is frequently present. Remarkable bat's wing patterns may occur on the back. Rarely, the mucous membranes of the mouth may be affected, and then in a more or less symmetrical manner.

There are superficial forms of erythematous, gyrately bordered tertiary syphilomata, which, when present about the naso-oral region, may look something like Lupus erythematosus. In the former, the condition may begin on one side of the face and gradually spread to the other, giving rise to a bilateral distribution, but not to the characteristic symmetry of Lupus erythematosus.

The small hard discrete tertiary syphilitic nodules of the central parts of the face must not be mistaken for ACNE ROSACEA. The positive characters of the former, which I need not repeat here, would be sufficient to show the way (see page 97). At the same time, Acne rosacea may be present as well, and indeed be a predisposing cause for the other. In Acne rosacea, the middle third of the face including the forehead is mainly affected; there are dilated vessels, pustules, and also sometimes deeper nodular-like lesions in the skin, which may lead to the suspicion of syphilis. Indeed in some cases it requires careful investigation to discriminate. In the latter there would be in most cases some corro-

borative evidence to guide one, but this may not be forthcoming. In men, the history of syphilis might mislead, as I have seen in cases under iodide of potassium, which gives rise to pustules about the face, especially if there be a pre-existing *Acne rosacea*. This would have to be excluded, or the exhibition of more iodide would make matters worse. This I have seen in a patient who diagnosed his own case as syphilis and increased the iodide in the hope of curing his trouble. In women, it may not be wise to go into details, and in them it is imperative to look carefully for the corroborative signs I have enumerated in my general remarks (see page 92).

***Acne necrotisans et exulcerans serpiginosa nasi*** (*Folliculitis necrotica*, etc.) is a rare condition, which requires to be differentiated from syphilis. It occurs acutely about the end of the nose as small papules, which become purulent or necrotic, leading to numerous scars. Fresh papules form at the borders and so on.

***Acne keloid*** (*Dermatitis papillaris capillitii*), which affects the nucha, must be distinguished from syphilis, especially when of some standing. It is found in men, in whom irritation due to the edge of stiff collars plays a part as a factor. The disease commences with papules, later becoming nodular and by coalescing form transverse band-like elevations, made up of granulation and scar tissue, with tufts of hairs here and there on the growths. The parts may become undermined and pocketed with pus. The whole process is slowly chronic.

The **herpetiform syphilide** may be closely imitated

by some of the eruptive areas of **Acne agminata** (see page 90), if taken alone and apart from the eruption as a whole—a thing which should never be done. It may again be insisted on here that the mind should not concentrate itself on a limited area of an eruption, a common source of error.

The evolution of **Herpes zoster** (Zona) is so characteristic that it could scarcely be taken for syphilis, yet when the scalp has been involved and the eruption severe, this mistake has occurred. In elderly people especially there may be necrotic and crusted areas, which, when seen some time after the acute vesicular outbreak, have been thought to be syphilitic.

The festooned **squamous** and **circinate syphilides** about the margin of the scalp, forehead, and nape especially, must be distinguished from Psoriasis and Seborrhœic dermatitis.

Exceptionally, PSORIASIS may commence on the scalp, and be limited to it for a time before generalizing to other parts of the body, but it would be very unlikely in the usual run of cases for the elbows or knees or other parts to be quite free from the characteristic lesions. But when affecting the scalp only, the more or less pronounced discoid arrangement of the eruption on the central parts of the scalp, with heaped-up scales forming crusts, and absence of ulceration about the spreading festooned border should prevent error.

As to the SEBORRHŒIC DERMATITIS of the border of the scalp the eruption may at first sight offer some difficulty. Here the positive infiltrated border of

the syphilide, with perhaps here and there a little ulceration and crusting, together with the existence of scars recording previous syphilitic eruptions somewhere about the body, and also other corroborative signs, would build up the diagnosis. It must be mentioned, too, that seborrhœa may play a part in the development of a syphilide at the borders of the hairy scalp. The latter should be examined generally for evidence of seborrhœa. In circinate seborrhœic conditions, again, the fatty scales would be of some assistance, but these may occur in the syphilide, owing to the grafting of the one process on the other. Seborrhœides (Pityriasis) may also exist on the trunk as well as on the scalp. It must be borne in mind that the diagnosis of syphilis must rest on positive grounds.

SEBORRHÆIDES (Pityriasis) may occur in large rings on the denuded scalp of the bald and on the chest, and may be suggestive of some late ringed forms of syphilis, especially if there be corroborative lesions of the latter about the patient. After a time, rings may appear more or less symmetrically on other parts of the body. The seborrhœides are pale red in colour, and the process is a superficial one. This, taken with the ineffectual anti-syphilitic treatment, would decide in favour of a seborrhœic (pityriasic) eruption.

PALMAR ECZEMA (Eczema palmare) will be distinguished from the late tertiary palmar syphiloma, sometimes still improperly called palmar psoriasis, by the fact that the eczematous condition is bilateral in the great majority of cases, and occurs in those whose occupation entails handling irritating bodies,

and soaking the hands in various fluids. The backs of the hands are usually affected to a greater or less extent as well as the palms. In the latter situation, the well-known painful fissures arise in the lines of flexion from loss of elasticity of the parts leading to the condition known as **Eczema rimosum**. I have seen fissuring of the palms in chronic, unrecognized, and therefore untreated, palmar syphilis, in women who had house work to do. The squamous syphiloma may be very like eczema, but the well-defined spreading border of the former, with denudation of the horny layers of the epidermis and the undermined edge, would serve to avoid confusion with eczema. The syphiloma moreover is in the main unilateral, commences in the palm and gradually increases in size by serpiginous extension. Small satellite circular areas may accompany the main patch, exhibiting on a small scale the denudation and undermining which are so characteristic. In cabmen, golfers, and those who expose both palms to friction, I have seen it in both palms, but always much more accentuated in one palm than the other. But here again this bilateral distribution may be observed in those whose palms are not exposed to any particular friction, although on one side it may be very limited in extent. Again, in the syphilitic cases, a characteristic circinately bordered syphilide may be present about the face, or some other positive objective sign may be discovered on further examination of the patient. The palmar syphiloma is a late manifestation, and it may therefore be difficult to find corroborative evidence. In one instance I saw a

typical unilateral palmar syphilide in a woman suffering from locomotor ataxy (*Tabes dorsalis*).

As to the feet, eczema will be diagnosed on the same grounds as in the case of the hands. There is also a condition of KERATOSIS affecting both soles, and usually preceded or accompanied by marked sweating of the parts (*hyperidrosis*), which would be differentiated from syphilis by its bilaterality or symmetry, and the absence of the distinctive points of the syphiloma, especially the infiltrated border and frequently a certain amount of ulceration at the spreading edge. In syphilis, unilaterality is the rule. Some keratosis (*hyperkeratosis*) may also be present in some portion of the affected part in syphilis, especially where there is *hyperidrosis*.

Another point to be considered in this connexion is the possibility of secondary eczema supervening, and also of an eczematous condition determining the occurrence of the syphiloma. This may lead to difficulties sometimes, which would be cleared up by the exhibition of mercury.

Very exceptionally PLANTAR TRICHOPHYTOSIS (ring-worm of the sole) may occur on the sole, with clinical appearances very like those of syphilis. The examination of scrapings for fungus and the discovery of mycelial elements would establish the diagnosis, but more than one microscopical examination might be necessary.

In this connexion the two forms of **Sycosis**, **coccogenic** and **hyphogenic**, may be dealt with here. As regards the former, which used to bear the incorrect name of non-parasitic sycosis, pus



cocci (staphylococci) are the cause; they may lead to a circumscribed, raised area of inflammatory folliculitis, accompanied by swelling and crusting, especially about the upper lip near the nostrils. It is these fungating severe forms of coccogenic sycosis which require to be differentiated from tertiary syphilis. The crusts should be removed, when in the former disease the process will be found to be follicular, whereas in the latter a sinuously outlined ulceration would be present. Corroborative evidence of syphilis would be forthcoming if looked for, at any rate in the majority of cases, such as scars in the neighbourhood of the lesions, or other signs in various situations, which I need not detail again.

In hypogonic sycosis, also called **Tinea sycosis** and **Tinea barbæ** (Barber's itch), the foci of disease are generally multiple and do not usually attain the dimensions of the single coccogenic sycosis mass (one inch and more, 3 centimetres or so) just described, but in neglected and improperly-treated cases they may. The lesions are lumpy and suppurate. Hairs should be pulled out from the affected areas and examined microscopically. Fungus is generally discovered with a little care, but repeated examination may be necessary. It is well to let the hairs soak thoroughly in Liq. Potassæ B. P. It is no use looking for the sporulated mycelium with a low power, as I have often seen students do; a  $\frac{1}{6}$ th objective should be used. The fungus is *Trichophyton megalosporon ectothrix*: at any rate that is my experience.

Instead of lumpy suppurating lesions, rings may occur in the beard region (**Tinea circinata barbæ**). These would not be likely to be taken for syphilis if the mode of development and the appearances are taken into account. The possibility of *Tinea circinata* in this region is, however, sometimes forgotten, that is why it is mentioned here. Scrapings should be examined in Liq. Potassæ.

This naturally leads me to the consideration of the pustular form of **Tinea circinata**, which is usually found about the forearms and the backs of the hands. It is made up of a well-defined circular patch of closely aggregated pustules on an inflammatory base, usually single. This appearance is very characteristic, but when altered by maltreatment it has suggested the idea of syphilis to those unacquainted with it. The fungus here is *Trichophyton megalosporon ectothrix*, which is pyogenic on its own account, quite apart from pus cocci.

Some obstinate forms of **Tinea tropica** contracted in the East may involve large areas of the trunk. They should be thought of in arriving at a conclusion. It is so common to see the idea of syphilis dominant when unusual conditions crop up. Here, again, the microscope should be used. In these tropical ringworms I have usually found long slender mycelium, more or less segmented. The appearances vary, however, as do also the cultures.

**Biskra sores** have already been dealt with (pages 37, 38).

## CHAPTER X

### THE DIFFERENTIAL DIAGNOSIS OF TERTIARY SYPHILIS (*continued*)

LIPOMATA — CARCINOMATA — SARCOMATOSIS CUTIS —  
IODIDE OF POTASSIUM INDURATIONS—ERYTHEMA IN-  
DURATUM — VARICOSE ULCERS — ACTINOMYCOSIS —  
GLANDERS—RODENT ULCER—ULCERATING GRANU-  
LOMA OF THE PUDENDA

WITH regard to the differential diagnosis of gummata, several kinds of new growth will have to be dealt with.

In the first place, LIPOMATA would be readily recognised by their lobulation and the dimpling of the skin when pinched up.

Subcutaneous CARCINOMATA may occur as the result of a generalized infection secondary to cancer of the liver or stomach. This occurs in the last stages of the disease, when the patient has reached an extreme degree of cachexia. The growths may be very numerous. The diagnosis should offer no difficulty as far as syphilis is concerned.

In this place, another morbid condition, **Cysticercus cellulosæ cutis**, consisting of multiple subcutaneous growths must be mentioned. These

growths, which are formed by the encysted cysticercus of *Tænia solium*, vary usually from a large pea to a marble in size, and are firm and elastic to the touch. They are sometimes very numerous, chiefly affecting the trunk, but other parts of the integument may also be involved. These cysts may occur in the mucous membranes of the mouth, which should always be examined; and also in the eye. Associated with the tumours, there may be the history of epileptiform attacks due to cysts forming in the brain. The affection is a rare one in this country, but is more common in those countries (Germany) where raw pork is a staple article of food. With the multiplication of shops in London dealing in German articles of food, the disease may become more common with us. The growths must not be mistaken for gummata. This is not likely if the possibility of cysticercus and the features of gummata be borne in mind. If any doubt, a small growth should be excised and the contents examined for the hooklets characteristic of the parasite.

SARCOMATOSIS of the skin may assume various aspects. The growths may be primary or secondary.

As to the former class, the **idiopathic multiple hæmorrhagic Sarcomatosis cutis** is so characteristic that it could not well be taken for syphilitic growths. In the first place, the condition is symmetrical, commencing about the feet and hands, and gradually invading the legs and forearms, arms and thighs; sometimes spreading on to the trunk and face, and even involving the mucous membranes. The

growths vary in size up to a cherry or so; they may coalesce or remain discrete, and are purplish in hue. The disease is very rare in this country, and then is imported from abroad (Galician Jew, etc.). It is observed mainly in Austria and Italy.

Another primary type occurs subcutaneously, commencing in a small way about the trunk, and then generalizing, but the hands and feet escape.

**Fungating Sarcomata** may arise in localized areas of the cutaneous surface, on a nævus for instance, and attain to the size of a small orange.

**Secondary Sarcomata** are also observed subcutaneously as a result of general infection from within.

All these conditions are rare. The diagnosis would rest on the general view of the case, the mode of development, and, if necessary, microscopical examination of the growths.

The syphilitic gumma differs in that it is more rapid in its progress, soon presenting redness of the skin, softening and breaking down in the characteristic way. Moreover, in the case of syphilis, the granulomata respond to specific treatment. Corroborative evidence of syphilis would also be forthcoming, but of course sarcomata might occur in a syphilitic subject. In the differential diagnosis the positive data would be the guiding factors. Gummata would not be likely to be taken for anything else, but sarcomata might possibly suggest syphilis.

**IODIDE OF POTASSIUM INDURATIONS** of the skin and subcutaneous tissues may exceptionally suggest gummata. They occur as hard rounded subcu-

taneous swellings, which gradually involve the skin, leading to violaceous redness of the latter. At a later stage, growths more or less circular and flattish, raised above the level of the skin, make their appearance. The legs and trunk are mainly affected, especially the former. Lesions in various stages of development may occur at one and the same time. That they should occur in a syphilitic individual is not to be wondered at, and would give a clue to the use of iodide of potassium or of some blood-purifying nostrum. Active syphilitic lesions may also be present. A consideration of the development, which differs from that of the syphilitic gumma, would serve to point in the right direction, at any rate away from syphilis, and to lead to further investigation on the aforesaid lines.

ERYTHEMA INDURATUM (Erythème induré des scrofuleux, Bazin's disease) is very likely to be mistaken for syphilis unless all the facts are carefully taken into consideration. The nodular indurations begin deep in the skin of the calves of the leg mainly; at first they can be better felt than seen. Gradually the skin becomes reddened and then livid over them. Here the process may end by slow absorption. But it is when the growths go on to ulceration of the skin and break down with sloughing that the likeness to syphilitic gummata is so great as to lead to error. When seen in this condition by those unfamiliar with the disease the diagnosis of syphilis is sure to be made. This will be avoided if the following circumstances are noted. Erythema induratum occurs mostly in young women,

and chiefly in those of scrofulous (tuberculous) habit, who have a good deal of standing to do. It is bilateral in distribution and attacks the backs of the legs. Further, anti-syphilitic treatment, which has often been tried under the impression the condition was syphilitic, does not influence the disease. Iodide of potassium makes matters worse.

VARICOSE ULCERS are sometimes mistaken for tertiary syphilis. This I have found to happen in youngish women with varicose ulcers which have formed rapidly. The fallaciousness of the history in women has already been insisted on as far as evidence in favour of syphilis is concerned. The presence of varicose veins and the superficial irregular ulceration with the purplish colour of the surrounding tissues would be the points to consider. The occupation (much standing) and the history of precedent injury *in loco* would help. The appearances of a breaking down tertiary syphilitic infiltration have been described; these and additional evidence of syphilis in other parts of the patient's body would lead to a correct diagnosis. In the case of varicose ulcer, simple appropriate treatment of that condition would lead to repair without anti-syphilitic remedies. It must be remarked, however, that in old chronic cases, varicose ulcers may present a punched-out appearance very suggestive of syphilis. Indeed, when this is the case, and there is a good deal of surrounding infiltration, corroborative evidence of lues should be sought for. Even when nothing results from inquiry and examination in this direction, it is well to exhibit anti-syphilitic

remedies. The latter will in some cases rapidly lead to improvement in the ulcers, which had been hitherto hanging fire and remaining more or less *in statu quo*, notwithstanding the ordinary local measures.

Syphilitic infiltration of the skin of the lower part of the leg, violaceous in colour, with multiple circular deep ulcerations, exuding a serous or sero-purulent fluid with crusting, has been mistaken for tuberculosis. This mistake should not occur with care.

This is a good opportunity for calling attention to **Malingering** (Dermatitis artefacta). Lesions very like broken-down syphilitic gummata are sometimes produced, in young women chiefly, by the application of destructive agents; they are usually on one side only, but they may occur on both legs, for instance, when the possibility of syphilis or tuberculosis would have to be discussed. Such sloughing lesions are sometimes very deep. Circular ulcers may be produced in this way on the arms or trunk, but more on one side than the other according to the right or left-handedness of the malingerer. In the diagnosis the general impression of the patient's appearance and manner would make one suspicious from the first. It is often to avoid work or to attract attention and sympathy that such things are done. In young women, hysterical stigmata, such as supra-mammary or ovarian tenderness, hemianæsthesia, pharyngeal anæsthesia, contraction of the field of vision, and so forth, are frequently present. An indication may be forthcoming about the lesions themselves, either angularity in outline of some of



them, linear marks due to the trickling of caustic fluids, etc. The absence of confirmatory evidence of syphilis, either acquired or congenital (see Chapter XIII as to latter), would be of help. The patient may require to be kept under strict observation, when the lesions will be found to heal up rapidly under simple treatment.

A marked ulcerated condition due to the coalescence of unhealthy or secondarily infected **Vaccination** pustules may give rise to a suspicion of syphilis, but the facts would point in the right direction.

Accidental **Horse-pox** in man might also lead to error (see page 33).

There is a form of tertiary syphilis which attacks the angle of the mouth on one side, leading to a deeply excavated ulceration of the mucous membrane of the corresponding cheek. The idea of a primary broken-down chancre may be suggested, as there is a good deal of surrounding hard infiltration, but the corresponding glands are not affected, a fact which clears the ground. There may or may not be corroborative syphilitic changes in the patient. As to history, it may be utterly negative. In such a case, when the condition occurs in young adults, it has struck me that the syphilis may have been acquired in infancy or early childhood, leaving practically no visible trace behind.

**ACTINOMYCOSIS** rarely affects the skin primarily, but spreads to it secondarily from subjacent tissues (bone, liver, etc.). It is usually observed about the skin of the neck or lower jaw, commencing as hard

nodular swellings, which slowly become softened in parts and break down here and there, giving issue to a puriform fluid, containing small yellow grains made up of the ray fungus (*Actinomyces*, *Oospora bovis*). The characteristic rosettes of clubs can be made out in glycerine, the cover-glass being gently pressed on to the slide. The fungus can be stained by Gram's method, and counter-stained with a watery eosin solution. The differential diagnosis from syphilis may offer difficulties at first sight. A source of fallacy is the therapeutic test, by means of iodide of potassium, for this drug acts also in practically a specific manner in Actinomycosis.

Allied to the preceding is **Mycetoma** (Fungus foot of India, Madura foot), most commonly observed in India (Madura), and also seen in Algeria and Senegal, the United States, etc., but as far as Europe is concerned, only in Italy and Constantinople. The foot is mainly involved (bare-footed natives), but it has been noted in other parts (knee, hand, etc.). It is a very slowly progressive disease, leading to the formation of nodular swellings, which break down and give issue to a sero-purulent discharge containing variously coloured grains: greyish, yellowish, reddish, or black. The grains have been compared with fish roe and gunpowder. The disease leads to great deformity of the foot, with degeneration and softening of the tissues. There are two clinical varieties of the condition, one with pale grains and the other with black. The former is due to a ray fungus, which has had various names given to it (*Discomyces Maduræ*, *Streptothrix Maduræ*). There

are variations in the accounts published, which may be explained by the fact that the micro-organism is polymorphic. The "black grained" variety is also due apparently to a specific fungus. Fungus-foot is, however, so characteristic when of some standing, that the idea of syphilis would only occur to those unacquainted with the condition. The geographical distribution is of importance. An imported case might lead to difficulties, however. The knowledge that the patient came from a country where the condition was endemic would be valuable.

**Blastomycosis** must be mentioned here briefly, although the general aspect is more like that of Scrofuloderma or of a Lupus verrucosus. It occurs chiefly in the United States. The parts mainly affected are the face and neck. The disease commences as pea-sized nodules which break down and ulcerate, leading to a verrucose or more or less fungating condition. In the pus that can be squeezed out, budding yeast-like bodies (the so-called blastomycetes) are found (examine in Liq. Potassæ). Allied to this, or more probably the same thing, is the fungus disease originally named **Protozoic dermatitis**, because it was thought to be due to an animal (coccidial) parasite. The clinical appearances are much the same. It has been observed in California and Argentina.

GLANDERS (Farcy, Morve, Rotz) in the acute form, which would not be likely to be taken for syphilis, need not detain me. But the destructive chronic form (Farcinoma cutis, Farcinose mutilante de la face) is another matter, and may closely simulate

syphilis. It is very rare, but when it does occur about the nose and lips, it is very suggestive of tertiary syphilis. This variety has been found to commence in the mucous membranes of the nose and mouth, and to spread to the skin, subsequently infiltrating it and leading to destruction of the invaded tissues by a process of ulceration and breaking down much as in syphilis. The development of small farcy nodules on a livid infiltrated base, which disintegrate in their central parts with issue of a puriform secretion ultimately leading to ulcerated areas, the latter increasing in size and coalescing, produces a clinical picture very like tertiary syphilis. It may happen that a breaking-down syphiloma in this situation may be taken for chronic glanders, as I have seen. The therapeutic test would be valuable here, for in the former disease the effects of iodide of potassium, followed up by mercury, would be decisive.

**Anthrax** (malignant Pustule, Charbon, Milzbrand) (on the Continent anthrax is improperly employed as a synonym of carbuncle, and the use of anthrax in this sense in translations is very misleading). This serious disease attacks those who have to do with hides, slaughtering, and so forth, but sometimes it attacks persons who are not employed in such a way. Malignant pustule develops on the hands, neck, or face, viz. the exposed parts, usually, but it may occur on covered parts quite away from these situations. In the latter case a mistake is very likely to be made and much precious time lost. At the seat of inoculation a bulla

or pustule first forms, and this is followed by a localized gangrenous condition surrounded by brawny infiltration. This is briefly the condition that needs to be dealt with without delay, wide excision being best. It could scarcely be taken for syphilis. The *Bacillus anthracis* being very large is readily found even without staining, but the latter is easily carried out.

I have already alluded to a fungating **Molluscum contagiosum** lesion on the face as being liable to be taken for a primary chancre (see page 32). Exceptionally, a more or less general fungating condition of the scalp may occur as a result of this disease passing unrecognized. At the margins discrete typical Molluscum contagiosum solid growths with central depression would in such a case be forthcoming and give a clue to the nature of the fungating areas.

RODENT ULCER (*Ulcus rodens*) has also been referred to in connexion with primary syphilis (see page 31). When small and single, with its typical rolled waxy-looking border, over which course dilated vessels, and accompanied by scarring and ulceration, it should not be mistaken for tertiary syphilis. But this error has been made by leaning unduly on the duration. Now although as a rule the development of rodent ulcer is very slow, a matter of years, it may occasionally be much more rapid. The latter I have observed to be the case in the comparatively younger patients, in contrast with the usual slow course in old people. When the rodent ulcer is more extensive and ulcerated, unless

special attention is paid to all the facts taken as a whole, a tertiary syphiloma may be diagnosed. This mistake I have seen occur, and what is more the administration of iodide of potassium have a decidedly beneficial effect for a time and up to a certain point. Subsequent events showed the growth was not syphilitic, much time having been lost. This was in the days before X-rays, and the rodent ulcer, notwithstanding operative interference, became too formidable for further radical treatment. Clinically rodent ulcer varies in appearance. There may sometimes be a certain amount of fungation. It must be remembered that rodent ulcer may attack the bones and lead to great deformity. Again, this growth is not limited to the neighbourhood of the nose and eye, its favourite situations; it may start in other parts of the body, such as the back, where it is much more likely to be taken for syphilis. Again, a rodent ulcer may occur as a palm-sized superficial succulent ulcer, well-defined, but the borders will exhibit the features of the disease.

The histological appearances of rodent ulcer are characteristic, viz.: irregularly outlined islands of epithelial growth just under the epidermis, which separates it at once from the syphiloma.

The **Crateriform ulcer** is another epithelial growth, which affects the upper part of the face and may develop on a precedent rodent ulcer. It is rapid in its development and attains a large size. It breaks down at the apex, giving rise to a crater-like cavity. Histologically it has been found to be an epithelioma in structure.

**Epithelioma** of the lip or margin of the anus is more likely to be taken for a primary chancre (see page 37) than for a tertiary syphiloma. Epitheliomatous ulceration is painful and the infiltrating hardness more or less characteristic according to the experience of the observer. The age of the patient would be helpful, as epithelioma occurs in the middle-aged and old. When in the skin proper, the growth usually develops more slowly than when situated at the junction of skin and mucous membranes. The diagnosis may not be at all an easy one; it must, however, be made without delay to prevent the infection of the lymphatic glands. It is bad practice to watch the case indefinitely without coming to a conclusion, as is sometimes done. Of course, if the patient be seen when the glands are already implicated, that would be a help. Again, bear in mind that iodide of potassium gets rid of infiltration up to a certain point in cases of epithelioma, of the tongue for instance, so the therapeutic test may be fallacious. Should there be any doubt after all-round consideration, a microscopical examination of a portion of the growth would decide; no time should be lost if epithelioma be reasonably suspected.

Again, epitheliomatous nodular growths may develop in the neighbourhood of a scar, the result of a previous operation for cancer (breast, etc.). In rare cases, after removal of a small primary cancer, epitheliomatous nodules may develop acutely in the neighbourhood. They are exquisitely tender, commence as small papular-looking lesions, which increase rapidly in size and number, and are quite

different to tertiary syphilitic growths. It is a very rare condition. Microscopical examination would show the epithelial nature of the growths.

**Paget's disease** was first described as affecting the nipple only, but subsequent observation has shown that it may occur on the penis, vulva, scrotum, and pubes. The female breast, however, is the usual seat of this malignant process; the patients are elderly, usually somewhere about fifty. It has been compared with eczema, not very aptly perhaps, for the red, raw surface, with well-defined border, and distinct induration on palpation between the fingers, is totally different. Its progress is slow, and the glands may not be involved even when the disease has been present some years. The true nature of the disease is not so likely to be overlooked when situated about the female nipple as it is when it occurs elsewhere: vulva, scrotum, etc. As the condition is malignant (cancerous), diagnosis is important. Crusts should be removed, and the fingers should be used. The latter is often neglected, especially by students. Even in the earlier stages of Paget's disease, some superficial induration can be made out, which has been compared to a penny felt through a cloth. The positive evidence would exclude syphilis. On the other hand, a breaking-down gumma about the nipple would present the characteristic features which have been already frequently insisted on. It was thought at one time that Paget's disease was due to psorosperms (sporozoa, coccidia), but this view has been practically given up, the so-called parasites being looked upon now as nothing



more than altered epithelial cells. The latter (pseudoporosperms) can be demonstrated in the scrapings taken from the red granular surface, after soaking in Liquor Potassæ and mounting in glycerine jelly. The degenerated cells may be round with a double contour and be very suggestive of parasites, or they may be irregular in shape.

**Rhinoscleroma** is a very rare disease in this country. It occurs in various parts of the world, but has been observed chiefly in Austria. The disease usually commences in the mucous membrane of the anterior nares as a stony-hard infiltration, either diffuse or nodular, which slowly but surely spreads to the adjacent parts. It is only in the later stages that some superficial breaking down with crusting takes place. As it grows outwards the aspect of the nose at first sight is very suggestive of syphilis. The duration (years), evolution, and hardness would point to the true nature of the disease. Tertiary syphilis, in addition to its characteristic clinical features, would usually rapidly respond to iodide of potassium. As regards the employment of mercury, it should be pointed out that improvement has followed with this drug in one or two cases of rhinoscleroma, at any rate at first. This may be a source of error.

A short bacillus with rounded ends has been constantly found in the sclerosed tissues, and is looked upon as the essential cause of the disease.

There is another uncommon disease, viz. **Xerodermia pigmentosa** (Kaposi's disease), in which atrophic areas, crusted ulcerations, and growths occur

about the face, but these changes should not be mistaken for syphilis if the general features of the disease are borne in mind. These are freckle-like pigmentations about the face, neck, and upper part of thorax, and also of the forearms and lower two-thirds of the arms. Interspersed among the pigmented areas are atrophic spots, small warty-looking growths, and telangiectases, in addition to the ulcerated and neoplastic lesions.

ULCERATING GRANULOMA OF THE PUDENDA (groin ulceration, *Granuloma inguinale tropicum*) is a morbid condition which is very likely to be taken for tertiary syphilis, with which it has no doubt frequently been confused. It is mainly observed in negroes, but it is not limited to them, as other dark-skinned races and even whites may also suffer. The disease occurs in British Guiana, Fiji, India, and China. A similar condition has also been observed in Europe and the United States. It commences in the groin or about the genitalia, male and female, as a nodular thickening, which breaks down and gradually extends by a process of serpiginous ulceration. The warmth and moisture of the inguinal, genito-crural, and genito-anal regions, combined with neglect of cleanliness, favour its development. The groins and greater part of the male genitalia may be ultimately involved, with offensive discharge and overgrowth of the irritated surface. It is then that syphilis is the first thing that suggests itself, especially as the disease is in some cases apparently contracted by sexual intercourse. In women, the disease may spread from

the labia to the vagina and adjacent inner surfaces of the thighs. Unchecked, large areas of skin may become involved by peripheral extension. It would be differentiated from syphilis by its occurrence mainly in dark-skinned races, its localization to the groins and genitalia and adjacent parts, its long duration without impairment of the general health, and its resistance to mercury and iodide of potassium. Clinically, too, the exuberant granulation-look of the discharging surface differs from the serpiginous tertiary syphilide, whose features have already been insisted on more than once. The latter condition affecting the groin and genitalia is to say the least of it uncommon, but it does occur.

**Tropical sloughing Phagedæna** is a common disease among the natives in various tropical areas of Africa, Asia, and America. It follows abrasions, stings, and wounds of the skin, and appears as serpiginous, stinking, sloughing ulcers, which are very destructive to the deeper tissues. The ulcer begins frequently as a bulla, which breaks down. The mode of development and appearance would serve to differentiate this condition from syphilis.

## CHAPTER XI

### DIFFERENTIAL DIAGNOSIS (*continued*)

#### LEPROSY—YAWS—FRAMBESIA BRASILIANA

LEPROSY (*Elephantiasis græcorum*, *Lepra arabum*, *Lepra*, *la Lèpre*, *der Aussatz*, *Spedalskhed*). There is no doubt that in past times a variety of disfiguring and repulsive morbid skin conditions used to be labelled leprosy and the unfortunate sufferers treated as outcasts. This confusion obtains even at the present day, in Morocco for instance.

In this place it is only necessary to call attention to the differential diagnosis of leprosy and syphilis. Although at the present moment it is generally held that syphilis existed in the old world before the return of Columbus and his companions from American seas, there are still some who support the view that the disease was introduced into Europe at that time. The epidemic outbreak of syphilis at the end of the fifteenth century is explained by them on the latter assumption. On the other hand, it has been pointed out that the outbreak coincided with the relaxation of the rules for the segregation of lepers. Further, that syphilis was mistaken for leprosy, and that many syphilitics were confined in

leper hospitals. Leprosy is undoubtedly an infective contagious disease, but in a very slight degree as compared with syphilis. In mediæval times leprosy was considered to be very contagious, an idea which possibly arose as a result of the confusion of the two diseases. At the end of the fifteenth and the beginning of the sixteenth century, attention was mainly directed to syphilis, and leprosy receded into the background, so much so that knowledge of the latter complaint became vague or entirely lost by the medical profession of those countries in which leper hospitals had ceased to exist by the sixteenth, or at latest the seventeenth century. The discovery of the specific properties of mercury gradually robbed syphilis of many of its terrors, but it may be said in passing that the serious complications attributed to syphilis were often undoubtedly due to the reckless manner in which quicksilver was administered to the panic-stricken sufferers in the early sixteenth century. Howbeit, this is by the way only, as the history of syphilis cannot be discussed here. The fact remains that syphilis and leprosy are mistaken for one another at the present day. One observer has gone so far as to contend that leprosy was the fourth stage of syphilis, but that view it is needless to say is quite erroneous, for syphilis and leprosy are two distinct diseases.

The differential diagnosis is a matter of the greatest importance. In the first place, from the point of view of treatment, to which syphilis is as a rule very amenable; in the second, from that of the sufferer and his friends, to whom the positive dia-

gnosis of leprosy must come as a shock. In some circumstances, it need hardly be said that the latter is best withheld from the patient. Further, in some countries, in Cape Colony and New South Wales for instance, to mention two of our own possessions, leprosy is a notifiable disease and means segregation (Cape Colony), or at least isolation and supervision (New South Wales).

No opportunity should be lost of seeing and studying leprosy, whenever a chance offers, either in this country, or where the disease is endemic, as in many parts of the British Empire. Even medical men, practising among Europeans in places where leprosy prevails, have been known to confess they had never seen a case of the disease. It is hoped that readers of this survey will not imitate such an apathetic and unmedical attitude, which must be rare at the present time.

The diagnosis of leprosy and syphilis respectively must be based on positive grounds, and not arrived at by a process of exclusion. In a book of this kind, it is impossible to deal exhaustively with leprosy; moreover, our immediate concern is the integument.

In a general way, the race the patient belongs to will often be a valuable preliminary point. Leprosy prevails not only in warm and tropical countries as is commonly supposed, but is also met with in temperate and cold regions. Here the knowledge of its geographical distribution is of importance. The disease is widespread, occurring in Asia, Africa, America, and Australia. In Europe, the chief foci

are in Iceland, Norway, Spain, Russia, Roumania, etc.

In the case of Europeans, and those of European descent generally, the fact that they have sojourned in leprous areas or countries will put the observer on his guard. This is a factor which must be taken into account.

It is well to bear in mind that leprosy may involve the glans penis. In this situation leprous nodules (lepromata) may simulate primary chancres, especially as in the former some induration may be felt, and the inguinal glands become enlarged. The primary chancre is usually single, but the leprous nodules are mostly multiple. When phimosi is present, leprous lesions of the glans may at first lead to doubt. But here again, as always, the case must be investigated as a whole, when in leprosy further symptoms of that disease would be forthcoming. Of course, a leper may contract syphilis, although it must be remembered that sexual feeling becomes lost in many instances owing to involvement of the testes, a fact which is against the opinion so long held that lepers were very depraved (satyriasis). On the other hand, this designation may have arisen on account of the facial aspect of bad cases of leprosy.

The manifestations of leprosy are protean. The skin may be mainly affected (nodular Leprosy, *Lepra tuberosa*—it is better to employ the term nodule than tubercle, to avoid confusion with tuberculosis), or the nerves may be mainly involved (Nerve Leprosy, *Lepra anæsthetica vel maculo-anæsthetica*). In

addition to these two clinical forms, there are also mixed cases, in which both skin and nerves are affected (mixed Leprosy). But it must be well understood that these three forms are only distinguished for the sake of convenience, for leprosy, whatever its manifestations, is one. Indeed, the division into the three varieties usually recognized ignores the fact that the viscera and tissues generally may suffer from the attacks of the *Bacillus lepræ* (Hansen's bacillus), the essential cause of the disease.

The skin manifestations of leprosy may assume many aspects, such as erythematous patches, rosy red or somewhat violaceous at first, then settling down to some shade of sepia, the macular leprides. Such an exanthem in the early stage may look like a **macular syphilide** (roseola). This form of lepride is usually symmetrical, may be generalized, mainly affecting the face, the extensor surfaces of the limbs and the backs of the hands and feet, whereas in syphilis the rash often mainly involves the flexor surfaces. In such cases, there may be an elevation of temperature. It is in non-leprous countries that leprosy would not be thought of, but the knowledge that the patient had lived where the disease was endemic, should bring it to mind, in the face of the absence of evidence of syphilis. It must be mentioned here that early leprous exanthems also simulate skin diseases other than syphilis, such as *Erythema multiforme*, for instance.

These leprides vary greatly in size and shape. They may be individually much larger than the macular syphilide, increase in size peripherally,



clearing in the central parts and forming large rings, and by coalescence, gyrate patterns. The central parts may become slightly depressed and pale. The annular border is superficially but distinctly infiltrated. At other times, the affected areas are more diffuse enclosing circular areas of normal skin, a very important diagnostic feature, which is sometimes observed in another disease, *Mycosis fungoides*.

The macules or annular elements may also be limited in number.

Again, superficial infiltrated areas may be surrounded by a broad halo. Leprides are sometimes very like a papulo-squamous syphilide.

But apart from the aspect, which is so suggestive of leprosy, the sensory condition of the eruptive elements is of the greatest assistance in arriving at a conclusion. Sensation to pain, touch, and temperature should always be tested. Anæsthesia is significant. The thermic sense should also be tested in the usual way by means of two test-tubes, one containing cold, the other hot water. It will be found either much diminished or entirely abolished (thermo-anæsthesia). It may be remarked in passing that in the early stage of the eruption, hyperæsthesia may be present.

In connexion with the sensory condition of the macules, the longitudinal ribbon-like areas of anæsthesia of the ulnar borders of the upper limbs, of the outer parts of the thighs, and especially of the inner borders of the hands and feet, in which situations the anæsthesia commences, gradually extending

upwards, must be referred to. Later, the areas of anæsthesia become segmental from below upwards, and more or less dissociation of sensation can be made out. In practice it will be found that the latter may be difficult to ascertain with accuracy in some cases.

All the factors must be taken into account, and to distinguish from syphilis, the positive signs and symptoms of that disease sought for.

After one or more of the leprous eruptive attacks which have been mentioned, nodular outbreaks occur, commencing as small papules which gradually enlarge, eventually becoming nodular. It is in the early stages of a nodular outbreak that the disease may be confused with syphilis.

When the nodular period of leprosy is well established, the facial aspect of a patient becomes so characteristic that confusion with syphilis would appear impossible. Nevertheless, it is well to avoid a snap-shot diagnosis, except as a preliminary to thorough investigation. The parts which chiefly exhibit the nodular infiltrations (lepromata) are the face and extremities, so much so that the trunk may be practically spared. The lobes of the ears, the forehead, the lips, and chin are seats of election for the development of the nodules, which commence in a small way, become as large as peas, nuts, and so forth. The nose becomes sunken at the junction of the cartilages and the bones, an appearance which is reminiscent of syphilis, but in the latter it is the bones that suffer. The eyebrows are lost, the conjunctival vessels become injected, the skin of the

face generally is of a cyanotic bronzed or leaden hue, the whole giving rise to the so-called leonine aspect, the hair of the head being preserved. There is a curious family likeness about the facial aspect of lepers in the advanced nodular stage, that one might almost be tempted to say *ex uno disce omnes*.

As to the eyes, they are frequently affected in leprosy, and morbid conditions of these organs must not be attributed to syphilis, such as interstitial keratitis, a likely error if the leprous symptoms in other parts are overlooked. Indeed, the state of the eyes may lead to a diagnosis of syphilis, as some of the lepromatous manifestations, especially when ulcerated, the depressed nose, and the nodular condition of the tongue and soft palate, so frequently present in advanced leprosy, may be taken as corroborative of such a diagnosis. Laryngeal changes modifying the voice may also lead in the same direction.

*Pari passu* with the facial infiltrations, the hands and feet are affected, the digits ultimately becoming sausage-like and exhibiting ulcerations about the joints. On the extensor surfaces, chiefly, of the forearms and legs, lepromatous infiltrations and nodules develop.

The nodular eruption in an early stage may very well be mistaken for syphilis. In the latter, the nodules run a more acute course, and confirmatory evidence of syphilis would be forthcoming. Moreover, they differ usually in their distribution from those of leprosy, which chiefly affect certain parts, as we have seen. The scalp in leprosy is so rarely

involved that one may almost say, for practical purposes, that it is never affected; it is very exceptional. I have seen it once. In syphilis, however, it is quite otherwise.

There is a characteristic greasy feel about the skin of lepers, when the disease has existed for some time.

Corroborative of leprosy is the fusiform thickening of the ulnar nerve between the olecranon and inner condyle of the humerus. In suspected cases this should always be carefully felt for. An enlarged epitrochlear gland should not be mistaken for the nerve. The great auricular as it passes over the sterno-mastoid, and the external popliteal below the head of the fibula, should also be examined for any thickening; in the case of the former nerve it is an important feature in diagnosis.

Perforating ulcer of the sole of the foot, together with bullous lesions about the hands and feet, elbows, and knees, are helpful factors in arriving at a conclusion. The bullæ leave behind atrophic and scar-like areas.

In leprosy, too, various mutilating deformities of the toes and fingers occur, which, with care and taken with other symptoms, could not well be mistaken for syphilis. An ulcerating leproma may look very like a breaking-down syphilitic gumma. What has been said with regard to diagnosis of the latter need not be repeated here. As to the former, there would be corroborative evidence of leprosy.

In doubtful cases, the specific parasite must be looked for.

As the bacillus plays an important part in the positive diagnosis of the disease, it must be briefly dealt with. It resembles that of tuberculosis both in appearance, being somewhat smaller, however, and in its staining properties. Both bacilli are acid-fast, that is resist the decolorizing effects of mineral acids when previously stained by certain dyes. But the leprosy bacillus differs from that of tuberculosis in being extremely abundant in the skin, especially in the nodules, and some of the discharges, such as the nasal mucus. In sections of the skin, even in the so-called macular lesions, but which are really, in most cases at any rate, flat superficial infiltrations, the bacilli can readily be found. In nodules, they occur in enormous numbers both inside and between the tissue-cells, in groups and colonies (glœal masses), and play an important part in the structure of the granulomatous new-growth as far as total bulk goes. Plasma-cells are also present of course. The glœal masses have been looked upon as involution products, but I consider they are a phase in the life-history of the parasite, a resting-stage during which it prepares by multiplication for a further invasion of its host.

The clinical evidence in favour of leprosy may be so obvious that the microscopical examination for the specific bacilli may not be necessary, although always useful, but it should never be neglected in doubtful cases. For this purpose, the nasal mucus, scrapings from mouth lesions, discharges from breaking-down lepromata, excised pieces of skin (macules,

nodules), etc., can be used. A good method is to examine serum squeezed out of a nodule. This is carried out by clamping the nodule, which is incised with the point of a sharp scalpel, the serum being caught on cover slips or slides. Special clamps have been devised, but it can be done quite well with a pair of curved forceps. Films can thus be prepared in the usual manner and rapidly stained by the Ziehl-Neelsen, Gram, or other method.

One word as to the therapeutic test. Mercury in the shape of intra-muscular injections of soluble salts leads to improvement in leprosy. In one instance, this beneficial result led to the giving up of the suspicion of leprosy and the firm diagnosis of syphilis. The patient was therefore discharged from the leper hospital and left the country. The case was really one of leprosy.

It must be insisted on in this place that iodide of potassium is contra-indicated in leprosy. In one instance, which came under my notice, this known fact was disregarded by a medical attendant unacquainted with leprosy, the case being looked upon as syphilis notwithstanding undoubted evidence to the contrary. The result was a severe purpuric eruption.

Much confusion has resulted from the use of the word *Lepra* as a synonym of *Psoriasis*; the former term should be employed for *Leprosy* only. It must also be mentioned here that *Elephantiasis græcorum* and *Lepra arabum* are synonyms of *Leprosy*; whereas *Lepra græcorum* and *Elephantiasis arabum* are totally different conditions, the

former being Psoriasis and the latter meaning the enlargement of leg (Barbadoes leg), scrotum, etc., due to *Filaria sanguinis hominis* (*Filaria nocturna*).

In the foregoing remarks on Leprosy I have only touched on some of its features which might be mistaken for syphilis in accordance with the title of this survey. It is in countries where leprosy is an imported disease that the idea of syphilis will suggest itself. On the other hand where the former disease is endemic and common, syphilis may be overlooked.

There is a chronic ulceration of the foot observed in Egypt, the so-called **Pilgrim's ulcer**, which is generally single and situated over the heel, but two may occur. It is superficial, with a heaped-up border, and apparently quite painless. The foot is deformed in other ways, the whole being very suggestive of leprosy, but the ulcers in the latter disease extend more deeply. One feature of Pilgrim's ulcer is the resistance to treatment. Various things have been tried, but among them mercury and iodide of potassium are not mentioned in the account of the condition, from which I have taken the foregoing details. In any case if it be not syphilis, Pilgrim's ulcer merits a passing reference here.

**Mycosis fungoides** (*Granuloma fungoides*—*Pian fungoide*) (the name does not imply a fungus origin. It is descriptive: fungating mushroom-like. Another name is *Granuloma fungoides*). It is necessary to touch on this disease here, for in some cases it may be taken for syphilis, especially when there is clear evidence, or a possibility, of syphilitic infection at

some earlier period of the patient's life. There are two main types of Mycosis fungoides: the cases of slow development, in which infiltrations and tumours of the skin are late manifestations, the outcome of a dermatitis that has been present maybe for years (pre-mycotic stage); and those, in which tumours are the first signs of the disease. In the former class the duration, the marked constant itching, and the failure of treatment would be points of diagnostic importance. When the disease has become firmly established the cutaneous surface is extensively involved, presenting numerous infiltrated areas, more or less circular, of a bluish or plum-coloured hue, softish to the feel, with a tendency to ulcerate superficially. Mixed up with this there may be diffuse infiltrated patches, with scarring and atrophy, for in Mycosis fungoides the granulomatous lesions may involute spontaneously. In addition to this, pigmentation may also occur. When the nose and scalp are affected and are the seat of ulcerations, crusts, and scars, the idea of syphilis suggests itself. But if the disease be taken as a whole and all the factors carefully considered, its true nature will become apparent.

In the tumour cases, the growths vary greatly in size and colour. They are from a pea to an orange in size, and of a bright red or bluish tint. As I have already stated, the growths may disappear spontaneously. On the other hand, many break down and ulcerate, becoming excavated and fungating, and it is then that they may be taken for syphilitic manifestations, the more so as the ulcera-



tion may be horse-shoe shaped. The error is also likely to occur when the tumours are few in number or the fungating growths localized.

In passing it may be mentioned that some cases have to some extent suggested leprosy (hence the name of *Lèpre indigène* given it by Bazin).

*Mycosis fungoides* does not respond to anti-syphilitic remedies, but the X-rays exert a decidedly beneficial effect on the infiltrations.

YAWS (*Framboesia*—*le Pian* of French writers—*Polypapilloma tropicum*) is another disease about which there has been a good deal of discussion. At one time it was held by many that yaws and syphilis were one and the same disease, although some observers had maintained the two conditions were different. Now this position is reversed, and there are but few who believe in the former view. The subject is one, however, that requires further elucidation, for the matter is complicated by other factors. Yaws is mainly a disease of the tropics, but it has been observed in Assam, that is North of the Tropic of Cancer. Its chief haunts are the West Coast of Africa, Mozambique and Madagascar; Ceylon (where it is called *Parangi*); Java; the Malay States (*Purru*); French Indo-China; Cambodia; the West Indies, Guiana, the Fiji Islands (*Koko*), New Caledonia (*Tonga*), and other Pacific Islands, also New Guinea. Yaws and *koko* are considered to be the same disease, but this has been disputed. As to *koko* of Fiji again, it has been stated that the Fijians do not suffer from syphilis. This is made much of by those who look upon syphilis and yaws

as identical. On the other hand, it may be that concurrent manifestations of syphilis and yaws may have been attributed to the latter. It seems rather difficult to believe that the Fijians are immune to syphilis, or have been able to escape it, notwithstanding their fierceness, customs, and cannibal habits. Thirty years ago yaws and syphilis occurred side by side in New Caledonia. From my own knowledge of some of the South Sea islands (Hawaiian group and New Caledonia, but not Fiji), I cannot help feeling sceptical about the absence of syphilis among the natives of Fiji. From an opinion I heard expressed once by a medical man, who had practised in the latter group, with regard to a case of undoubted tertiary syphilis, I came to the conclusion that syphilitic lesions were perhaps labelled as yaws out there, the two conditions being probably mixed up together. On the other hand, the non-existence of syphilis among the Fijians has been stated as a fact by very competent observers. In New Guinea recent observation has shown that yaws is prevalent among the natives, but they are free from syphilis. Now the place is becoming settled, I have no doubt that the latter disease will sooner or later attack the New Guineans. As to parangi of Ceylon the question has arisen as to whether it was yaws at all, or covered yaws and other diseases, including syphilis. It is generally admitted that parangi corresponds mainly to yaws.

In this matter, those who insist on the identity of syphilis and yaws rely on the Columbian theory of the importation of syphilis in support of their con-

tention. As I have already stated, this origin of syphilis is not generally admitted. However interesting the discussion of the *pros* and *cons*, they cannot be gone into here. The foregoing outline must suffice as introductory to the subject which concerns us more immediately, viz. differential diagnosis.

Briefly, yaws may be defined as a contagious and inoculable disease with an incubation period, which may vary from a fortnight to several months. In yaws experimentally produced the incubation varied from twelve to twenty days. There may, or may not be, a primary papule before the generalized outbreak occurs. As to distribution, the eruption may be limited or widespread. General constitutional symptoms, such as fever and pains, may be severe, or may be practically absent. The skin becomes harsh, and also scaly in patches, a condition which precedes the characteristic papular eruption. The eruptive papular element is a very minute conical elevation at first, which soon presents a yellow point of necrosis at its apex which is not pus, but a cheesy-looking substance. The papules may involute, or go on to form the typical yaw or framboesial lesion by increasing in size and eventually becoming capped by a crust. When the latter is removed, the raspberry-like appearance (hence Framboesia from the French *Framboise*, which by the way comes from the Dutch *Braambezie*, Old High German *Brâmberi*, and so forth, our English *Bramble-berry*), to which it has been compared. The fully-developed hemispherical framboesial lesion is usually about half

to three-quarters of an inch in diameter (about 1 to 2 centimetres), but occasionally the yaw attains a much larger size. When the central part heals and flattens, leaving a peripheral circinate raised border, the condition is called "Ringworm Yaws" in some places. Gyrate forms are also observed. As a result of involution, achromic and hyperchromic areas are left about the body, but they disappear in time. Superficial scars may also be left behind.

Yaw lesions at the junction of the mucous membranes and skin (lips, anus, etc.), and also where two skin surfaces are in contact (genito-crural region, etc., etc.), are moist and vegetating, looking very much like syphilitic manifestations (mucous plaques, etc.).

The mucous membranes themselves are not affected, but on this point, it is fair to add, there is also a difference of opinion, some observers maintaining that destructive ulceration of the soft palate or of the lining membrane and cartilage of the nose may occur in patients who have passed through yaws years before, whereas others consider such complications are due to syphilis.

When they occur on the palms and soles, the yaws are painful owing to the resistance of the thick epidermis. They break through eventually, leading to ulcerations, which may sometimes look like perforating ulcers.

The eyes and viscera are also said to escape in yaws. As to the bones, morbid changes have been observed, but here again the possibility of concurrent syphilis has been suggested.

That the lymphatic glands are enlarged is not to be wondered at in an infection like yaws.

Another point about yaws is the fact that the disease responds to mercury and iodide of potassium.

Altogether it will be seen that the differential diagnosis of yaws from syphilis may present difficulties, for superficially the objective symptoms of both have much in common. Yet the differences outweigh the resemblances. Yaws is very contagious, but it is not transmitted to the foetus as is syphilis. Where yaws is prevalent children are nearly all attacked, much as in the case of such a disease as measles with us. Mothers even inoculate children so as to get over the inevitable without delay. The primary yaw when present does not differ from the characteristic elements which go to make up the eruption of yaws, but it does differ from the primary chancre. In syphilis the eruptive elements are essentially polymorphic, whereas in yaws they are of one type, viz. the characteristic papule going on to a yaw. The iritis and changes observed in the permanent teeth in syphilis are not seen in yaws. Another point is the auto-inoculability of yaws for some time after the generalized outbreak, whereas auto-inoculation of syphilis in florid syphilitic subjects has failed. It has been shown too that syphilis could be contracted by patients suffering from yaws; and also that an antecedent attack of syphilis did not protect against yaws. Both diseases may be present at one and the same time in the same individual. In a district

where syphilis has existed for many years, with manifestations differing in no way from those observed in other countries, a single case of yaws occurs and very shortly after affects many persons, the eruption breeding true in every case. Again, yaws dies out in a community, but syphilis remains. Such facts are in favour of yaws and syphilis being specifically two different diseases.

This is also supported by the histological appearances in the case of yaws and of syphilis respectively. Both are granulomata, but in the former disease the growth is ill-developed, and the plasma-cells are not arranged in a sheath-like manner round the blood-vessels as is usually the case in syphilis. But a point of more importance is the marked down-growth of the epithelial inter-papillary processes, accompanied by an imperfect development of the cells of the horny layers (parakeratosis) leading to the formation of a stratified crust, the component parts of which are held together by micrococci, leucocytes, exudation, etc. These appearances in sections I have cut are suggestive of secondary microbic infection from without.

Yaws may be contracted by Europeans, but this is uncommon owing to the difference in habits, hygiene, dress, and so forth, as compared with the natives of the various countries where the disease flourishes.

Sometimes a syphilide may assume a framboësi-form appearance, that is, some of the eruptive lesions are raised, more or less hemispherical, from a quarter to half an inch (from about 0.5 to 1.5 centi-

metres) in diameter, and surmounted by a crust, which on removal reveals a moist, more or less raspberry-like, mamillated, papillated, or warty-looking growth. Other cutaneous syphilitic changes also exist, such as macular, pigmented, and squamous lesions, infiltrated areas, and so forth. Corroborative symptoms would be present. The term papilloma, that is, a morbid condition due to proliferation of the papillæ, is, strictly speaking, a misnomer and had better be dropped. The framboesiod syphilides are probably due to secondary microbial invasion; a somewhat similar complication occurs sometimes in *Lupus vulgaris* and coccogenic Sycosis. If this view be correct the characteristic yaw lesion may be an epiphenomenon. This is borne out by the statement made by one observer, viz. that if the primary papulo-necrotic eruptive elements of yaws be not subjected to irritation, they involute spontaneously. The numerous sources of irritation and secondary microbial infection from without in natives need not be insisted on here.

As to the chronic ulcerations and ugly scars which follow an attack of yaws, it is likely that they also may be the result of phagedænic processes, which are so apt to occur in ulcers and abrasions of all kinds among natives of the tropics. Or they may be, as some contend, of syphilitic origin. The latter may account for some of the bone lesions observed associated with yaws. Lately, it has been sought to connect yaws with Goundou (West Africa), that is a congenital morbid condition consisting of symmetrical bony growths affecting the superior maxillary bones.

One of the early names of *Mycosis fungoides* was *Pian fongoide* on the assumption that it was related to yaws. Moreover, a case of the former was described as yaws by a very competent observer of the tropical disease.

A brief reference must be made in this place to another condition called **Verruga Peruana** (Carrion's disease), which is met with in Peru (Western Andes valleys). This disease has been considered to be yaws modified by malaria. It is mentioned here as the lesions of *Verruga Peruana* vary in appearance, and the fungating tumours sometimes observed might possibly be taken for syphilis. Histologically it has been shown that the growths (nodules) of this Peruvian disease are neither warts nor granulomata.

Under the name of *FRAMBÆSIA BRASILIANA* or *Boubas*, a disease has been described as occurring in Italians who had resided in Brazil. It is a chronic condition consisting of ulcerations of the skin and mucous membranes. On the skin the lesions commence as bullæ or pustules, which break down leading to the chronic punched out ulcers with indurated borders. The disease appears to be neither syphilis nor yaws.

From the foregoing remarks on the subject of yaws and syphilis it will be seen that it is one of great interest, and will well repay further investigation and study at the hands of those with opportunities.



## CHAPTER XII

### CONGENITAL SYPHILIS AND SYPHILIS IN CHILDREN

CONGENITAL SYPHILIS—GENERAL REMARKS—PLACENTA  
—CLINICAL SIGNS OF CONGENITAL SYPHILIS—  
SNUFFLES—CRANIOTABES

CONGENITAL SYPHILIS (*Syphilis héréditaire*—hereditäre Syphilis). At the outset it may be remarked that true **heredity** of syphilis is by no means a proved fact. In the light of recent research and of a critical examination of the hypotheses put forward, many points require further investigation, contrary to what is generally supposed. The great majority believe that as far as syphilis is concerned there is no doubt about it being hereditary, whereas the truth is that the problems connected with heredity are highly complex and far from settled or even understood. The study of immunity, and also that of the germ-cells from the embryological point of view will, no doubt, eventually throw light on the subject. But little progress can be made as long as the essential causative agent of syphilis, presumably a living parasite, has not been isolated.

At the moment, our English way of putting it,

viz. : congenital Syphilis, is therefore better than the one generally adopted abroad of using the adjective "hereditary."

In connexion with congenital syphilis, it is worth while to allude to two other points of interest, about which there has been, and still is, a good deal of discussion. In the first place, **Colles's law** (called *loi de Baumès* by the French) has been impugned, but apparently on insufficient grounds. When the exceptions are critically examined, they are found to be not absolutely convincing. The facts are in favour of the truth of the conclusion arrived at by Colles, viz. : that the mother of a congenitally syphilitic infant may suckle it with impunity. Some observers consider the risk to the mother is not absolutely excluded. But the possibility of accidentally acquired syphilis in infants and subsequent infection of the mother must ever be remembered.

On the other hand, Profeta's original statement (formulated also by Behrend) that a healthy child born of a syphilitic mother could be suckled by her, or by a syphilitic wet nurse, without risk to the child, which subsequently became **Profeta's law** (so-called), viz. : that a healthy child born of a syphilitic mother was not susceptible of syphilitic infection, which is quite another story. Though temporary immunity is admittedly possible, there is no enduring immunity.

In the foregoing remarks, I have touched but very briefly on these two important points, which play a part in differential diagnosis. They must be borne in mind in practice, otherwise one is liable to

be thrown off the scent. In the diagnosis of syphilis, congenital or acquired, in infants and children, the objective symptoms and signs must not be swept aside by considerations of a hypothetical nature. It is the former that must weigh in arriving at a conclusion. The mind must not be influenced by mere statements. In the case of congenital syphilis and of acquired infantile syphilis, or of rashes thought to be syphilitic, it is important to stick to what we can see and find out for ourselves. Another point here is the fact that things may not be as they seem. After all this is a human world. The fact that the real parent may not be the supposed parent is a possibility which cannot be lost sight of in some cases which appear puzzling or anomalous. Such a possibility makes it imperative that the positive diagnosis of syphilis in infants should be made on good grounds.

Cases have been brought forward to show that syphilis could affect the third generation (including the original syphilitic—second generation would be a more appropriate designation) by way of heredity. But there are objections to such a view. In the first place, the handing of syphilis to direct descendants (first generation strictly) through the maternal ovum or the paternal spermatozoon is not proven. Another source of fallacy I have already insisted on. Until the parasite of syphilis is discovered much must needs remain in obscurity. But at present evidence points to syphilis of the foetus being derived from the mother.

I have alluded to the repeated abortions which

occur in syphilitic women. When the dead foetus is expelled before term, so-call **foetal syphilis**, the skin, which concerns us chiefly, may exhibit little or no morbid change. In such cases, the diagnosis of syphilis would rest on an examination of the placenta and of the foetal viscera. The mother should also be examined for corroborative evidence. Hydramnios in the mother and maceration of the foetus are in favour of syphilis, but are not absolutely pathognomonic of that disease. **Ichthyosis foetalis** must not be confounded with syphilis. The former is characterized by thickening of the skin, forming epidermic plates separated from each other by fissures (harlequin foetus). It varies in degree. Other deformities are usually present. In most cases there is no evidence of syphilis in the parents. The syphilitic foetus may exhibit changes in the skin of a desquamative nature, which are not to be confused with the true ichthyotic condition.

An examination of the PLACENTA should never be omitted where opportunity offers, as its appearance may afford assistance in the diagnosis of congenital syphilis. In some cases when the child is born apparently healthy, the appearances of the placenta may enable one to anticipate the probable development of syphilitic symptoms later on. The placenta is larger than usual and of a pale rosy-red. It may be firm and leathery to the feel, or friable and soft. Hæmorrhagic foci may be present, and are very suggestive. The gross morbid changes vary, therefore, and are not pathognomonic of syphilis, but any

variation in the above directions from the normal placenta should make one suspicious.

It must be clearly understood that the syphilitic infant may be born to all appearances healthy and only develop symptoms after some weeks. It is erroneous to suppose that it must necessarily exhibit the wizened, old-mannish appearance described in most books dealing with the subject. Such cases do occur, of course, and when they do there can be no mistake about them.

Apart from those uncommon cases in which the infant is born with a rash, such as a bullous syphilide, a condition which may also develop in the first few days of life, the symptoms of congenital syphilis usually become manifest about the third week after birth. There are variations in this respect, but the rule is for them to appear within the first three months. When they are observed later than this, the question arises as to whether the syphilis may be acquired, and not be congenital at all. The limit is put at six months by some observers. In this connexion it should be pointed out that there is a great tendency to overlook the possibility of syphilis being acquired accidentally by infants and very young children. It is more common than, or rather not so rare as, is generally supposed. When the habits of some classes are considered, such as one woman nursing another's infant, and even suckling it in a neighbourly way, infectious syphilitic individuals sharing the same bed as infants and children, the promiscuous use of spoons, feeding-bottles, etc., in common, and so forth, it is rather astonishing that

it is not of more common occurrence. Higher in the social scale, syphilis contracted by the young from nurses and servants is a possibility that must not be lost sight of. Again, although the acquirement of syphilis by the infant at the time of birth by infection from recent genital lesions of the mother has been doubted, writers have noted the development of chancres about the face of infants four weeks after birth, which were apparently contracted in the aforesaid way.

CLINICAL SIGNS OF CONGENITAL SYPHILIS.—To clear the ground and avoid repetitions, it is necessary here to give a short general description of congenital syphilis as it occurs in infants (*Syphilis congenitalis neonatorum*). Congenital syphilis of children will be considered later on. The rashes observed may be papular or papulo-squamous; or appear clinically as diffuse, superficially infiltrated areas of greater or less extent, sheet-like at times (*en nappe*), and improperly called erythema. Or again, when the attack on the tissues is more severe, and the tissues more vulnerable, the eruption may be in an ascending scale, vesicular, bullous, hæmorrhagic, in the same way as we have seen is the case in acquired syphilis and in non-syphilitic toxic conditions. It should be stated at once that a roseolar rash is very rare in infants, although such a thing has been described. When present the possibility of acquired syphilis would occur to one.

Mucous patches are prone to form about the mouth and anus. The latter part should always be inspected. When it is affected, mothers, among the

people, say "the thrush has gone through" the child. Round the mouth, rhagades are frequently present, especially about the angles. In bad cutaneous cases moist lesions (mucous plaques so-called) occur in the post-auricular sulcus, in the cervical and genito-crural folds, etc. The correct diagnosis of mucous patches about the vulva of an infant led in one case to the breaking down of an unjustifiable attempt at a criminal prosecution. This in passing as to medico-legal aspect of the subject before us.

Apart from the skin changes, which will be dealt with in detail further on, there are corroborative signs of congenital syphilis which must be looked for systematically, as much may depend on their existence when the integumentary lesions are slight or anomalous-looking.

The general aspect of the infant in typical bad cases is at once suggestive of syphilis. The prematurely aged and wrinkled face, and the puny, wasted frame, together with the persistent hoarse cry of the patient when disturbed, are so characteristic that once observed they are not readily forgotten. In other instances the child, as I have said, may be fairly well nourished, but in them there is often a pallor of the skin or a slightly yellowish tint about the face that puts one on the track.

SNUFFLES or syphilitic coryza is a most valuable confirmatory symptom. It often precedes other manifestations and its significance must not be overlooked from the point of view of treatment or prognosis. Syphilitic snuffles is readily differentiated

from mere nasal catarrh (simple coryza). It is characterized by swelling of the mucous membrane and submucosa of the nose, no doubt due to infiltration of the tissues in this situation comparable to the infiltrations observed in the skin itself. This swelling leads to obstruction, which is often aggravated by the formation of crusts. Taking it altogether, the discharge from the nose is slight in degree. The interference with suckling which results leads to the characteristic noise which the child makes when it is at the breast or feeding bottle, hence the name snuffles. This leads to difficulty in feeding and is responsible for much of the wasting so frequently observed in infants suffering from congenital syphilis. The condition is so different from a simple coryza that a mistake as to its real nature is very unlikely. In the latter, the discharge is clear and copious. Simple coryza does not last long, a fortnight or less, whereas snuffles is a chronic obstinate condition of long duration.

CRANIO-TABES is another significant morbid condition which has led to much discussion. This is the name given to a thinning of the bones of the skull, chiefly affecting the parietals and occipitals. The condition is usually symmetrical, but it is sometimes more marked on one side than the other, and more rarely it may be practically unilateral. When the skull is taken bilaterally between the thumb and fingers, the localized thinning of the bones is felt giving the sensation of parchment. Much discussion has taken place as to whether the change was due to rickets or syphilis. The fact is it may be found in



both conditions, but when present it is strongly suggestive of congenital syphilis. In many instances it is found with other undoubted signs and symptoms of the latter, in cases where there is no confirmatory evidence of rickets. Cranio-tabes must not be taken alone, as diagnosis must not rest, as I have already frequently pointed out, on any one single sign or symptom. In adults, syphilis leads to demineralization (page 53) as shown by the examination of the urine. May not similar changes be at the bottom of cranio-tabes in infants?

Bony THICKENINGS may also occur, about the anterior fontanelle for instance, giving rise to the hot-cross bun or natiform "bosses" sometimes felt in that part.

The SPLEEN in congenital syphilis is frequently enlarged (splenomegaly), and should be examined as a matter of routine; this is important, when there is any doubt about the diagnosis.

The LIVER may also be enlarged. When syphilis affects the liver, jaundice may occur (*Icterus syphiliticus neonatorum*), although it is rare. Some observers deny its existence altogether. It differs from the simple jaundice of the new-born in that the latter is first usually seen about the second day and soon disappears. In the syphilitic variety, other signs of the disease are present, the discolouration is chronic, and may appear some weeks after birth. When the infant succumbs, confirmatory evidence of syphilis about the viscera (liver, etc.) and bones, (*osteo-chondritis*) have been found.

Indeed all the viscera and organs may suffer in

congenital syphilis: lungs, pancreas, kidneys, the adrenals, thymus, and so forth, but these would only be available after death. They should be examined in fatal cases, where the skin lesions and other signs were but slightly marked or anomalous.

**Epiphysitis syphilitica** (Osteo-chondritis syphilitica) affords confirmatory evidence in some cases. The epiphyses usually affected are those of the lower end of the femur, the upper end of the tibia, and the lower end of the radius; but the other long bones are also liable to suffer. The epiphysis may become separated and suppuration occur as a result of secondary infection, and lead to helplessness of the affected part (hence so-called pseudo-paralysis). The elbow-joint on one side is the most usual seat of this condition.

**Dactylitis** and **onychitis** may also be observed as concurrent symptoms.

**Iritis** is also seen in congenital syphilis, just as it is in the acquired form, but in my experience it is very uncommon, although I have looked for it in many cases. It is well, however, to examine the eyes in a routine way, as unless specially sought for it may be overlooked owing to the mildness of the local symptoms as compared with what is observed in adult syphilitic iritis. It has been shown that the pupils of infants do not respond readily to atropine and homatropine, so that the existence of adhesions must not be too precipitately diagnosed.

The **blood** also undergoes changes, leading to a condition of secondary anæmia. There is a diminution in the number of red blood-corpuscles and in

the quantity of hæmoglobin, accompanied by nucleated erythrocytes, poikilocytosis, and so forth. But the aforesaid changes are not pathognomonic of syphilis. They must be taken with other facts. The blood changes resemble those observed in pseudo-leukæmic anæmia (splenic anæmia). An interesting point about the anæmia of congenital syphilis is that it does not always readily respond to specific treatment.

In unusual or anomalous congenital syphilides, corroborative evidence may be obtained by an examination of the mother, who may exhibit florid and undoubted symptoms of the disease. In one case, the mother felt ill and presented marked syphilitic alopecia. The father is not so frequently available. It may happen that pricks of conscience may induce him to suggest the possibility of syphilis in his child. But this sort of assistance must be received with caution. In one instance in my experience the case turned out to be, when I saw it, one of undoubted non-syphilitic eruption, notwithstanding the paternal misgivings.

**Histologically**, the syphilitic poison leads to changes in the foetal and infantile tissues, which differ to some extent from those observed in the acquired syphilis of a later period. This is due to the circumstance of active growth in the former, the viscera and bones being chiefly affected. But these need not detain us as our concern is the skin, and here the appearances are much the same fundamentally as in the acquired form.

## CHAPTER XIII

### CONGENITAL SYPHILIS AND SYPHILIS IN CHILDREN (*continued*)

CONGENITAL BULLOUS SYPHILIDE—SCABIES—PAPULAR AND PAPULO-SQUAMOUS RASHES—BROMIDE ERUPTION—VACCINATION RASHES—YAWS—LATE SYMPTOMS OF CONGENITAL SYPHILIS—EYES—TEETH—DEAFNESS—CONGENITAL AND ACQUIRED SYPHILIS

THE CONGENITAL BULLOUS SYPHILIDE.—Passing on to a later period, the infant may be born, dead or alive, with a bullous rash, the so-called **syphilitic Pemphigus**, a better designation for which is **congenital bullous syphilide**. This condition has been observed in a seven months' child associated with many other syphilitic changes in the viscera and bones. On the other hand, the eruption may appear in the first week of life. In addition to the foregoing points, the distribution of the rash is of the greatest importance in diagnosis, for the bullous syphilide attacks the extremities of the limbs preferentially, involving the palms and soles. The blebs may also affect the face, but the trunk is often spared, except in bad cases. As to the bullæ, they

are more usually flaccid than plump and tense, with sero-purulent contents, or they may be hæmorrhagic. They are situated on an inflammatory base. When they dry up, crusts form, or excoriated areas are left behind. On the palms and soles, the blebs may become confluent and large portions of the epidermis become detached, looking something like what is observed in the macerated fœtus.

In addition to this, such infants are ill-developed, feeble, with a weak cry, and altogether, though they may be full-term, look more like the prematurely born. The bullous syphilide denotes great severity of the infection, combined with the loose condition of the infantile epidermis. The termination is usually fatal, although immediate active anti-syphilitic treatment may save life occasionally. The condition fortunately is not common.

The clinical appearances of the congenital bullous syphilide are so characteristic that it is difficult to understand how it is that the totally different infantile condition, **Pemphigus neonatorum**, should be so frequently mistaken for it. Over and over again this error has been, and still is, made, so great is the tyranny exercised by the idea of syphilis. In *Pemphigus neonatorum*, which attacks infants in the first few weeks of life, the bullæ are plump and tense, with clear contents and without an inflammatory areola. Moreover, they are scattered mainly about the trunk, thighs, and buttocks. The palms and soles are not involved. The infant often looks healthy and well nourished. The disease rapidly improves under simple, mildly antiseptic local applications.

*Pemphigus neonatorum* comes into the category of *Impetigo contagiosa*, the bullous formation being favoured by the more delicate condition of the infantile epidermis. In a case of *Pemphigus neonatorum*, which had been taken for a bullous syphilide, I found the family occupied one room, and the three other young children all suffering from marked *Impetigo contagiosa* of the face. In *Pemphigus neonatorum* the bullæ may become sero-purulent and develop a faint areola. This I have observed in weakly, ill-nourished infants. In such, the disease may lead to death by septic absorption, but this is a very rare complication. I have never seen *Pemphigus neonatorum* affect the palms and soles, but it has been observed exceptionally. Even then there should usually be no difficulty in arriving at a diagnosis. All the facts of the case should be taken into account. In syphilis, corroborative evidence would be forthcoming. In fatal cases, a necropsy should be made, and the viscera and bones examined.

In connexion with internal purulent collections and visceral abscesses, a non-syphilitic hæmorrhagic vesiculo-bullous eruption may occur in infants, involving the trunk and limbs, and also the palms and soles, terminating fatally, but it is extremely uncommon. In such cases the possibility of syphilis should not be overlooked.

**Dermatitis exfoliativa neonatorum** is of rare occurrence. In this condition, which has some resemblances to *Pemphigus neonatorum*, the epidermis is raised in a diffuse manner instead of in the form of circumscribed bullæ. Lamellar exfoliation

follows. The mucous membranes of the mouth may be affected, with fissuring at the angles. This might suggest syphilis, but if the clinical picture were viewed as a whole, an error in this direction would be avoided. It may be added that some writers consider the disease is a separate entity, whilst others include it under *Pemphigus neonatorum*.

A severe condition, so-called **Pemphigus gangræn-  
nusus**, which soon leads to death, has also been described as occurring in infants. The bullæ formed are hæmorrhagic, break down, leaving deep ulcerations, which take on a gangrenous look, the whole being accompanied by marked constitutional symptoms. Possibly this condition may be the same thing as *VARICELLA GANGRÆNOSA* and *DERMATITIS GANGRÆNOSA INFANTUM*; or it may have been in some cases an infantile form of **Acute Pemphigus**, that is an acute toxæmia accompanied by a severe bullous eruption as the dominating clinical feature.

**Dermatitis gangrænosa infantum** (*Ecthyma térébrant*, *Ecthyma gangrænosum*) is another condition whose diagnostic features must be briefly referred to here. It may occur as a complication of **Varicella**, hence **Varicella gangrænosa**, and of **Vaccinia**, but also independently of these. Ulcers form as a result of the vesicular or bullous lesion, and spread in depth and peripherally, becoming punched out and gangrenous, with the formation of a black slough. These necrotic circular lesions may attain a size of an inch or more. This condition, which varies in severity and number of lesions, is mainly seen in the first year of life, but it may occur later, up to four years of age

or so. The appearances are very characteristic. It has been observed in a case of congenital syphilis, but that was an accidental association.

There is another and totally different bullous condition, viz. **Epidermolysis bullosa** (Congenital Pemphigus), which commences in infancy. In an infant of six weeks which came under my observation it had been first noticed the third day after birth. Slight injuries lead to the formation of bullæ and excoriations about the hands and feet. Several members of a family may be affected (hence the designation *Epidermolysis bullosa hereditaria* sometimes employed). The nails are frequently involved, but this is usually observed later on in life. It will be distinguished from the bullous syphilide by the chronicity, mode of development of the lesions, the tendency to run in the family, and the absence of any corroborative signs and symptoms of syphilis. *Epidermolysis bullosa* appears to be a congenital deformity. In this condition the mucous membranes of the lips and the eyes may also be involved.

**Congenital Multiple Sarcoma cutis** is very rare indeed, but as it has occurred in the new-born, it must be mentioned here in connexion with our subject. Numerous purplish nodules from a pea to a bean in size may be scattered about the body, or the growths may be larger and few in number.

SCABIES.—The hands and feet, including the palms and soles, are the favourite parts to be affected in infants suffering from SCABIES or ITCH. The diagnosis of syphilis is sometimes erroneously made in infantile itch just as it is in the adult. The



distribution and the multiformity of the lesions from scratches to blebs caused by pus infection should at once suggest itch. In bad cases the excoriations and crusted pus inoculation lesions may also be present on other parts of the body. When extensive the infant may be very ill from septic absorption and even die, should the scabies origin of the condition be overlooked or recognized too late. Burrows should be looked for about the hands and feet, and if found the acarus should be picked out to clinch the diagnosis. If this should prove unsuccessful, evidence of scabies in the mother or other member of the family might be forthcoming. Except in severe, neglected, and dirty cases, and among the children of the poor and ill-nourished, the infant does not look ill as a rule. There are no corroborative signs of syphilis such as have been described. But in this connexion the possibility of scabies complicating congenital syphilis must be mentioned. Rational local treatment soon leads to improvement in scabies.

The PAPULAR and PAPULO-SQUAMOUS CONGENITAL SYPHILIDES are observed mainly about the buttocks and thighs, face, neck, and trunk. They vary in size up to about three-eighths of an inch (1 centimetre) and are of a dull or yellowish red, becoming of a brownish hue as they involute. Other signs of syphilis would be present.

**Congenital vesicular syphilides** are rare. In an instance that came under my observation, there were papulo-vesicles from a pin's head in size to the diameter of a split pea and larger scattered about

the chin, wrists, and palms, about the anus and vulva, thighs, etc. Some of the papules were shiny. There were as corroborative symptoms: snuffles, cracks at the angles of the mouth, and hoarse cry.

Syphilitic infants frequently present reddened, dry, diffuse areas of **superficial infiltration** starting from the anus and buttocks and spreading down the back of the lower limbs in a sheet-like manner, in a good many cases involving the heels and soles. This rash is practically pathognomonic of syphilis. A characteristic feature about it is the shiny appearance, with faint wrinkling of the surface when the affected part is pinched up between the fingers. When the infiltrated parts are put on the stretch and the blood driven out thereby, the yellowish-brown tint of the infiltration is brought out. This condition is improperly called *Erythema syphiliticum*. Beyond the borders of the diffuse infiltrated sheets, there may be here and there outlying small satellite circular areas of infiltration or papular lesions. The diagnosis is confirmed by snuffles, ulcerated cracks at the angles of the mouth, a papular rash about the naso-oral region, the hoarse cry, mucous patches about the anus, and so forth. It is most usually mistaken for simple **Intertrigo**, but in the latter the area involved corresponds more or less to the napkin region, the affected parts are not infiltrated and dry, but erythematous and more or less moist according to the amount of irritation caused by urine and fæces. There are no mucous patches about the anus, but in Intertrigo, when marked and of some duration, slight superficial

excoriations may be present here and there. Intertrigo does not spread down the legs and involve the soles as does the diffuse syphilide. Moreover in the former removal of the sources of irritation combined with appropriate simple soothing treatment rapidly leads to improvement.

Diffuse syphilitic infiltration may also affect the face, especially the naso-oral region, and be accompanied by desquamation and fissuring. A superficial careless examination might lead to the condition being taken for **Eczema**. Nor must the sheet-like infiltrations of the buttocks and lower limbs which I have just described be labelled eczema. In the latter disease the pathological change is not an infiltration as in syphilis. Moreover, in syphilis there would be corroborative evidence of the nature of the disease. Eczema is a very common disease in infants. In appearance it varies greatly in degree and extent. It may be erythematous, papular, vesicular, and pustular; moist, scaly, or crusted. The face, scalp, and flexures suffer most. With care a mistake is not likely to occur; it is well to bear in mind that eczema in infants may lead to fissures and cracks, and that the folds of the skin in fat children may be markedly involved.

On the other hand, a **Seborrhœic dermatitis**, which is so common in infants, usually commencing on the scalp and spreading to the face and neck, should not be regarded as syphilitic. The greasy scales of the former, which occur in the scalp, and the superficial nature of the dermatitis, point in the right direction. Besides, such infants are often well

nourished and plump enough. When there is redness and oozing of the affected parts, the condition merges into eczema. The condition generally is also sometimes labelled ECZEMA SEBORRHOICUM, but, whatever the terminology employed, the clinical facts are the things to hold on to. I need scarcely again insist on the point that the diagnosis of congenital syphilis must be based on positive facts, and here no evidence of the kind would be found.

BROMIDE ERUPTIONS.—I have already dealt with BROMIDE eruptions (see page 85), but it is necessary to refer in this place to the fact that in infants this drug rash has been mistaken for congenital syphilis. The appearances have been described, so need not be again alluded to here. The diagnosis of syphilis is sometimes persisted in, notwithstanding ocular evidence to the contrary in the shape of characteristic lesions, but chiefly perhaps because there is no history of any drug having been given to the child. In one case I was able to show how worthless as evidence such a negative history can be. I found firstly, that the mother suckled the infant, and, after a good deal of trouble, secondly, that the mother was taking medicine for epilepsy. The bromide had got to the infant *via* the milk. It must be borne in mind that various drugs are eliminated by the milk. But, apart from the milk, bromides are frequently exhibited in infantile conditions. Moreover, the mothers in some walks of life are not very accurate in their statements.

**Furunculosis neonatorum** is sometimes observed in the first few weeks of life, and according to some

observers is often associated with syphilis. I have seen it where the latter could be certainly excluded, but it is a point to bear in mind and evidence of congenital syphilis sought for, as there is no doubt that the latter morbid condition may pave the way for secondary pus infection. On the other hand, a neglected umbilical cord may be the *fons et origo mali*, or the furunculosis may follow Pemphigus neonatorum.

**Urticaria pigmentosa** is a rare chronic condition which commences in the first few months of life, and may for that reason be mistaken for congenital syphilis. The condition commences as wheals, which are very pruritic and become permanent instead of rapidly subsiding. In this way nodular lesions of a yellow or buff colour are formed; or the wheals may be flatter and assume some shade of fawn or sepia pigmentation. The trunk is mainly affected, but the face and scalp may also be involved. The wheals come out in crops, and when they are scratched firmly with the nail they become more prominent. **Urticaria factitia**, more or less pronounced, can be produced in non-affected areas of the skin. The disease is so characteristic in its onset and development that it could not be taken for anything else. It is referred to here, however, because unusual rashes in infants and pigmentation in general are so frequently diagnosed as syphilis.

In infants, VACCINATION RASHES are not uncommon. It is important not to mistake them for syphilitic eruptions. They are usually urticarial or erythematous, and in most cases evanescent. Occasionally

they are vesicular or pustular or even bullous. A common rash consists of numerous pin-point, red conical papules, which come out in crops, the so-called **Vaccine Lichen**. Another complication is extensive **Impetigo contagiosa** with much crusting, which looks very formidable, but which soon clears up under appropriate treatment. Another post-vaccinal rash is **generalized Vaccinia**. In this condition the lesions resemble vaccination vesicles. The diagnosis would be helped by the fact of recent vaccination in the infant and the absence of congenital syphilitic symptoms. A vaccination rash may of course occur in an infant suffering from congenital syphilitic symptoms. A further source of fallacy, *post hoc propter hoc*, is the possibility of the syphilitic signs becoming manifest after vaccination, when the latter is carried out early. As to the inoculation of syphilis at the time of vaccination I have dealt with the point already (page 36).

Congenital syphilis is common among some native races in various parts of the world, especially in the East. The mortality from this cause is large.

Where YAWS is prevalent that disease will have to be distinguished from syphilis. It is frequently seen in children at the breast, bearing in mind that the period of suckling is prolonged among primitive peoples much beyond the time limits which usually obtain in England. In some areas scarcely a child escapes—the parents even encourage the infection to get it over, just as some people with us take no precaution against the spread of measles, looking upon it as an inevitable illness of childhood.

I need not repeat here what I have said with regard to differential diagnosis, which may offer some difficulties (page 152).

LATE SYMPTOMS OF CONGENITAL SYPHILIS.—Leaving the early manifestations of congenital syphilis, it is now necessary to consider the late symptoms, **Syphilis hereditaria tarda**) Syphilis héréditaire tardive). It may be said at once that as far as the skin is concerned they are very uncommon, as the integument suffers much less than the teeth, eyes, and bones.

Gummatous indurations of the skin are observed, often over bones, and indeed occasionally connected with an underlying chronic periostitis or node, on the front of the shin for instance, as I have seen. Ultimately the growth breaks down, leading to an excavated ulcer with more or less surrounding infiltration. Clinically the aspect is that of the breaking-down gumma as it occurs in tertiary acquired syphilis.

The history in such cases may or may not be helpful; it may be misleading. Miscarriages and abortions in the patient's mother would be of some weight, if such evidence were obtainable. It is advisable, however, in the majority of cases to direct the attention to the lesions themselves, and to avoid mistaking them for a tuberculous condition, an error which, in my experience, is not infrequently made. For it is a fact that the diagnosis of tuberculosis is sometimes made on insufficient evidence, the possibility and probability of syphilis being entirely overlooked.

The next thing to do is to examine the patient

carefully for corroborative evidence of congenital syphilis. Sometimes it is writ large on the patient's face. The saddle-shaped nose, the bossy forehead, the clouded corneæ, the radiating scars about the mouth, giving it a pursed appearance, are signs that he who runs may read. In other cases some of these morbid changes are less accentuated and must be looked for at closer quarters.

THE EYES should always be examined, with a lens if necessary, for **interstitial Keratitis** or the remains of that condition; or a history of eye trouble may be forthcoming. The diagnostic significance of interstitial keratitis is so great that the main points about it may be briefly mentioned here. It is a late complication, occurring at any time from about five to about twenty years of age, rarely later; but in most cases it develops somewhere about twelve. Girls are more prone to it than boys. As to the keratitis itself it varies in degree, and an important feature about it is that both eyes are usually affected, one after the other, much as is the case in acquired syphilitic iritis. Interstitial keratitis is generally complicated by more or less iritis and synechiæ may result; it may lead to blindness or leave behind permanent opacities, or again clear up eventually, especially under appropriate treatment. It is stated that interstitial keratitis may commence in the intra-uterine period of life and the infant be born with clouding of the cornea. I have already stated that interstitial keratitis has been observed in acquired syphilis, but it is rare. In a marked case of congenital Pemphigus (*Epidermolysis bullosa*)



which came under my notice, both corneæ were hazy, a very rare complication; the condition was quite different, however, to what is seen in syphilis. In congenital syphilis other morbid conditions of the eye may be found such as choroiditis, retinitis (pigmentosa), and optic atrophy.

Radiating scars at the angles of the mouth should be looked for and will rarely be absent.

THE TEETH.—Then the teeth should be inspected. The characteristic teeth of congenital syphilis are the two upper incisors; the crescentic notching, with narrowing of the distal free extremity, is typical. It must be remembered, however, that the eyes, nose, and borders of the mouth may be markedly affected and significant, and yet the particular teeth alluded to not typically notched, indeed the teeth may be normal in appearance. Various combinations are possible: there may be typical notching of the teeth and no other sign about the face to speak of. In some cases, the permanent teeth are frequently interfered with: spaced, pegged, and so forth. On the Continent I have seen transversely striated and eroded upper incisors quite erroneously demonstrated as characteristic of congenital syphilis, that is shown as Hutchinson's teeth. This was some years ago, it may be said. The diagnostic significance of the typically notched teeth has been disputed, but I think on insufficient grounds. It is a most important deformity from the point of view which concerns us here. Notching of the milk teeth has also been noted by some observers. In one case that came under my own observation there

was notching of the two upper central incisors very like what is observed in the permanent set of congenital syphilitics. There was no other evidence of syphilis in that patient.

Again, DEAFNESS may occur as a result of congenital syphilis. Taken with other signs, it is of import.

**Nodes** in connection with the bones, especially the tibia, and scars of previous ulcerated lesions of the skin would be confirmatory points.

Of recent years there has been a tendency in some quarters to put down a number of heterogeneous developmental abnormalities and morbid conditions to syphilis. These have been placed in a category labelled **Para-syphilis**. I mention this here, as they must not be leant upon for purposes of diagnosis in the absence of the positive objective signs I have reviewed. However interesting they may be from a general medical point of view, a discussion of Para-syphilis would take me beyond the scope of this book. General paralysis of the insane may be mentioned, however, as having been repeatedly observed in congenital syphilitics.

CONGENITAL AND ACQUIRED SYPHILIS.—With regard to the differential diagnosis of congenital and acquired syphilis, it is necessary to insist on the importance of a thorough and careful examination. Syphilis may be contracted at any period of life. In the great majority of cases in children, infection is accidental in one of the many ways I have mentioned. It must not be lost sight of, however, that the criminal and unnatural communication of

the disease to children may occur. Man is a superstitious animal, and there is a disgusting belief prevalent among mankind, including civilized communities, that a venereal disorder can be effectually got rid of by carnal knowledge of the innocent. On the other hand, and also from the medico-legal aspect, it is highly important to exercise the greatest care in cases of syphilis occurring in children, and to take all the circumstances into account, thus avoiding the possibility of innocent men becoming the victims of blackmailers, working through untruthful children, well-coached in the ways of perjury. One thing to be remembered is the unreliability of statements made by young children in such circumstances. Further, boys have also become infected with syphilis through the instrumentality of dissolute women, a possibility which is sometimes forgotten. Again, the habits which obtain in some countries, and among some races more than others (North Africa and the East, for instance), must be taken into account, as I have already pointed out.

I would insist here on the importance, too, of care in the selection of wet nurses. In this connexion, the communication of syphilis to the wet nurse by a syphilitic infant must also be considered. From both points of view the necessity of accurate diagnosis need not be emphasized.

On the whole, syphilis acquired in early life gives rise to the same kind of primary sore and to much the same skin rashes as I have dealt with in preceding chapters, to which I must refer the reader. One feature about acquired syphilis in young children is that it

responds readily to mercury, and in the majority of cases runs a favourable course. The appearance of late manifestations, it may be years after such an infection, about which the patient would know nothing, would have to be diagnosed on their merits alone, as I have many times insisted upon, notwithstanding the age of the patient and a denial of syphilis if the patient were a man. In the case of a young unmarried woman, no questions could be asked of course. When the parents can be questioned, some corroborative evidence as to a sore, a rash, and so forth may be obtainable, or it may not. In any case, it would be more a question of satisfying the enquiring mind than anything else, unless the parents introduced the subject of syphilis of their own accord.

As I have dealt at length with the differential diagnosis of a number of non-syphilitic eruptions in another place, it is not necessary to go over the ground again here. Suffice it to say that such diseases as Itch, Psoriasis, Urticaria papulosa, widespread *Tinea circinata*, and so forth, in young children, apart from infants, have been erroneously taken for syphilis. *Pityriasis rosea* occurring in children may imitate a syphilide so closely as to necessitate the greatest care in arriving at a conclusion, the more so as glandular enlargement and congestion of the fauces are generally found to be present in the former, which may also be so widespread as to involve the forearms and legs (see page 60).

## CHAPTER XIV

### MISCELLANEA

#### HAIR—NAILS—PIGMENTATION AND DISCOLORATION— SCARRING AND ATROPHY

I HAVE already incidentally touched on some of the conditions with which I propose to deal in this chapter in a more detailed way from the point of view of differential diagnosis.

THE HAIR.—This will first claim our attention. **Defluvium pilorum** has long played a part as a fundamental symptom of *lues venerea*, and this tradition still obtains with many at the present time, for nothing is more common than the idea that loss of hair spells syphilis. There is no doubt whatever that syphilis does affect the hair, but what is important is to distinguish those conditions which arise from quite other causes. On the other hand, it is important to avoid overlooking cases which are undoubtedly syphilitic.

Just as in other severe toxæmic conditions the hair may suffer in a general way in syphilis. On the scalp there may be general thinning with falling of the hair, **Defluvium capillorum**, which may be practically the only symptom of syphilis observable at the

time. In such cases, the patient should be examined carefully for other signs of syphilis. In one marked instance, the fact that the patient was suckling a syphilitic child pointed to the real state of affairs, although there was nothing corroborative of syphilis about the mother at the time, but she had had a rash some months before.

Rapid denudation of the scalp may follow erysipelas, enteric, and so forth, and should not be mistaken for syphilis. In the latter disease, the hair of other parts of the body may be affected as well as that of the scalp.

Generally speaking **syphilitic Alopecia** occurs somewhere about the first eighteen months after infection, and usually not earlier than the fifth or sixth month of the disease.

At one time **Thallium acetate** was used for the sweats of pulmonary phthisis, and it may be used again. It is mentioned here because its use leads to falling of the hair, generalized alopecia, not only of the scalp but of the body generally. The hair returns when the drug is left off.

**Alopecia areata** may occur acutely, and lead rapidly to a general loss of hair. In some cases the scalp may present numerous point of exclamation stumps (!), the thick distal portion being the normal diameter of the hair, and the thin proximal one the atrophied root-end, which is gradually extruded from the follicle. This ! appearance is very significant, and should be well impressed on the mind. In the case of well-defined, bald, smooth, circular areas of Alopecia areata, these stumps should be

looked for at the borders. At other times, it may be associated with circular bald areas elsewhere on the scalp, there is band-form denudation extending round the head (OPHIASIS of Celsus), a condition which occurs both in children and adults.

It is rare to see bald areas simulating Alopecia areata in secondary syphilis, but such may occur. The presence of other secondary signs and symptoms would assist in the diagnosis, and mercurial treatment would lead to growth of hair on the patches, although it should be borne in mind that syphilitic loss of hair has a tendency to get well spontaneously. Of course ordinary Alopecia areata and syphilis may be accidentally associated in the same individual.

Again, loss of hair associated with a **seborrhœic** or **pityriasic** condition of the scalp, which is so common, must not be put down to syphilis, as it sometimes is. Nor must the baldness of the vertex and the receding of the hair from the temples and forehead lead to the same error. In syphilis there is a tendency for the hair to return spontaneously, an event which is sometimes attributed to the effects of an advertised nostrum.

In **Myxœdema**, the hair of the scalp becomes poor in quality and small in quantity. The characteristic features of that disease would be a sufficient sign-post.

There is a condition of the hair of the scalp which is extremely significant of syphilis, almost pathognomonic, and that is the existence of small, finger-tip sized, fairly well defined areas of thinning

scattered about the scalp generally, but in some cases more marked about the back of the head. The appearance is moth-eaten. The French call it *alopécie en clairières*. The aforesaid areas are seen to be not quite bald if examined closely. In such cases other signs of syphilis must be looked for and will usually be forthcoming. The condition does not always respond readily to specific treatment. This may depend on the age of the patient and other factors. The point is mentioned here as it might possibly lead to the idea that the loss of hair was not syphilitic in origin after all, and put the observer off the scent.

In children, loss of hair in patches is in the great majority of cases due to **Ringworm**. It would be scarcely possible to mistake the condition for syphilis. Stumps should be examined microscopically for fungus.

**Ulceration of the scalp** with formation of scar leads to destruction of hair, and the same thing occurs as a result of certain atrophic conditions. These will be considered further on, when I have to speak of scars and atrophy.

The **eyebrows** are also liable to be affected in syphilis, leading to a characteristic loss of hair in transverse narrow bands, which divides up the eyebrows into three or four portions (*sourcils sabrés* of French writers).

In the rapidly generalizing forms of Alopecia areata, the eyebrows as well as the eyelashes and the hair of other parts of the face and body are frequently involved.



I have already alluded to the denudation of the eyebrows in **Leprosy** (see page 145).

**THE NAILS.**—In a general way, it may be premised that much the same nail-changes may occur in different diseases, and that one and the same disease may give rise to a variety of nail-changes. Therefore in making a diagnosis all the observable and ascertainable facts of the case must be carefully considered, such as the state of the nail or nails and the number of nails affected, including the toe-nails; the symmetry or otherwise; the duration and the mode of development. Then the patient must be examined generally for past or present eruptions, and so forth. With regard to the syphilitic nail-affections, they are more or less characteristic in some instances, or at the least very suggestive of syphilis.

The **primary chancre** about the nail I have already alluded to (see page 27). But I may say this condition has been overlooked more than once, and unfortunately treated as if it were a simple local affection. A sore about a finger-nail, especially one which has resisted ordinary simple local treatment, should always excite the suspicion of syphilis. Both the sore and the patient should be thoroughly examined, and kept under observation, from that point of view. It is important for the patient, and for others too, that a primary chancre should be diagnosed as promptly as possible, as the consequences may be serious. That is why I insist so strongly on this point. Over and over again such sores have been treated as whitlows, especially as pain is sometimes very severe.

After a primary chancre about the nail, the latter is more or less deformed, with transverse furrows and ridges, or it may be permanently destroyed to a greater or less extent. Years after a digital chancre of this kind, the changes about the finger-nail may be of assistance in treatment by suggesting the possibility of past syphilis.

Whitlows and injuries (crushes, cuts, and burns) may lead to similar changes.

**Malignant disease** of the nail is extremely rare. It is only necessary to point out here that **Epithelioma** undermining the nail and involving the subjacent bone has been recorded.

The nutrition of the nails, it may be said in passing, is much interfered with in those who are constantly using the **X-rays**. The amount of destruction and deformity may be very marked in such cases. The diagnosis should offer no difficulty.

The nails may become involved in the secondary eruptive stage of syphilis, leading to thinning, brittleness, furrowing, pitting, and so forth.

In this stage of syphilis a papule may form about the matrix or in the nail-bed, leading to faulty, or absence of, nail-formation in that situation, which may lay bare the nail-bed. This lacuna in the nail progresses from behind forwards *pari passu* with the growth of the nail.

In **Psoriasis**, the nails are sometimes markedly involved, being pitted, a condition well seen if a lens be used; or what is more characteristic, but not absolutely pathognomonic, the nails are undermined, dirty, and loosened at the corners of their free

edge and down the sides. Evidence of psoriasis in other parts of the body would usually be forthcoming.

Again, with regard to **Eczema** about the nails, there should be no difficulty if all the points of the case be taken into account.

The same may be said of **Lupus erythematosus**, when the back of the finger ends are involved.

Ulcerating syphilitic lesions of the nails, **Paronychia vel Perionychia syphilitica** (Syphilitic perionyxis, Syphilis ulcerosa unguium) occurring in the course of the secondary stage are rare. Several nails are usually affected, and the finger-nails are more liable to suffer than the toe-nails. In other cases the margins of the nails are red and swollen, looking like a whitlow, but differing from the latter by the fact that it may go on for months. There is no pain to speak of, and suppuration may not occur.

At a later stage, the ulceration, which is deep usually, affects the matrix and sides of the nail. It is accompanied by pus formation, and results in the shedding of the nail in bad cases. The affection varies in degree, of course. In the severe forms there is much swelling and redness of the soft parts, but there is much less pain than one would expect. The big toe-nails suffer most frequently, but any of the finger- or toe-nails may be affected. Ulceration, with infiltration of the tissues, and maybe scarring in parts, in this situation is suggestive of syphilis, and the case should be investigated for corroborative evidence in the way I have already more than once indicated.

**Onychia maligna** (Onyxis des scrofuleux) is a rare condition of ulceration, accompanied by marked

swelling and tumefaction of the surrounding soft parts, which usually involves the big toes or the thumbs. The patients are in most cases young. It is considered by some to be tuberculous (scrofulous) in nature, but the syphilitic origin of the condition is insisted on by others. That there is a tuberculous onychia is undoubted; on the other hand, cases have been erroneously diagnosed as such which were really syphilitic. Mercurial treatment should be tried when there is any doubt.

There is another syphilitic nail-affection, **Onychia sicca syphilitica** (*Onyxis craquelé*), in which the nails become very brittle, crack, shell off readily and break at the distal free border. In addition to this areas of deficient growth may be present, as also furrows, ridges, and discolorations. It is a very rare complication, but this may be accounted for by the fact that in the working classes such nail-alterations would not be bothered about, and so escape observation. On the other hand, the well-to-do, who are careful about their nails, are less prone to suffer. But it is they who are likely to consult for the relief of such a nail-condition, and for that alone. It is important to bear syphilis in mind when such a case comes under observation. Women are more subject to **Syphilonychia sicca** than men, and the fingernails are more commonly affected. The nails may be involved in this way at various periods, but the changes usually occur some years after the primary infection. Corroborative signs should be looked for. The onychia has also been observed in cases of long-standing palmar and plantar syphilides. The

condition does not readily respond to anti-syphilitic treatment.

On the other hand, the nail proper may become thickened and very tough in syphilitic subjects.

Among the affections of the nails which should not be mistaken for the Syphilonychia sicca are those which occur in Psoriasis and Eczema, to which I have already referred.

**Tinea Unguium** (Onychomycosis) is an uncommon disease, in which one or more nails may exhibit chronic deformity and discoloration. The true nature of the case is in most cases overlooked because a microscopical examination of nail-scrapings is omitted. The affected nails should be scraped with the sharp edge of a glass slide and the scrapings well soaked in 40 per cent. Liquor Potassæ. The examination must be made with a  $\frac{1}{6}$ th objective. Pressing the cover slip firmly on to the preparation will be of assistance. It takes time for the fungus, in the shape of mycelial filaments, plain or segmented, to become apparent. If the search is not successful at first, the preparations should be put on one side and examined again after some hours or the next day, a little Liq. Potassæ being added to moisten them. The fungus may then be readily found. In that case, there could be no doubt about the diagnosis.

The nails are generally more or less affected in advanced nodular **Leprosy**, and also in the nerve forms.

The rule to remember is to avoid making a diagnosis on insufficient evidence. Errors will not occur if all the facts taken as a whole be considered.

It is not possible here to go into the details of the numerous general morbid conditions in which nail affections are observed, such as the acute exanthemata, typhoid, influenza, diseases of the nervous system, arsenical poisoning, and so forth. For these details I must refer readers to my article on "Diseases of the Nails" in *The Encyclopædia Medica*, vol. viii.

In **congenital syphilis** of infants, the nails are sometimes affected, exhibiting ulcerations and suppuration, **perionychia**. In the **congenital bullous syphilide**, the nails are very liable to be involved to a greater or less extent. In such cases the general symptoms of syphilis would allow of no alternative diagnosis. In **Epidermolysis bullosa** (hereditaria), the nails may be reduced to horny pegs or be absent altogether (see page 175).

**Onychia** and **perionychia** limited to one or two nails in young children should make one think of the possibility of syphilis. In one case for instance, a boy of four, the depressed bridge of the nose and a history of snuffles led me to the diagnosis of syphilitic perionychia (and onychia). The nails rapidly improved on mercury.

**Syphilonychia sicca** has also been described as occurring in the subjects of congenital syphilis.

PIGMENTATION AND DISCOLORATION.—It is a common error to look upon pigmentation as pathognomonic of syphilis. Of course secondary syphilitic eruptions do leave pigmentation behind, but so do non-syphilitic eruptions. Very marked pigmentation (Syphilide papuleuse nigricante) may follow a papular syphilide.

LICHEN PLANUS, especially when generalized, leaves

much staining of the skin as a record, and this is sometimes very dark in hue.

**Psoriasis** may do the same, but the discoloration mainly occurs when arsenic has been administered.

The pigmentation brought about by the long-continued exhibition of arsenic on its own account must be alluded to here in connexion with the subject. This **arsenical pigmentation** has been very specially brought home to many owing to the recent Manchester beer-poisoning epidemic. It is frequently observed in epileptics, who have in a careless way been taking arsenic with their bromide. But arsenic is often given, or taken by patients, for long periods. Arsenical pigmentation usually affects the covered parts of the body. It is observed about the neck, but also involves the abdomen and other parts of the trunk. In the early stage, the follicles are spared, giving rise to a characteristic appearance of white dots on a dark ground. Associated with it in some cases is a keratosis of the palms and soles. In the former situation the thickening about the sweat orifices can be made out with a lens.

Again, a fawn-coloured discoloration is often met with in involuting **Pityriasis rosea**. This fact, taken with the appearances of the rash and the enlargement of glands, may be very misleading in diagnosis.

In passing it should be mentioned that **Antipyrin** leads to eruptions which may leave behind permanently pigmented areas (Eruption érythémato-pigmentaire fixe). These occur as roundish or oval patches up to a crown in size, at first pale red, but soon becoming deeper in tint, of a brownish-red or

even blackish. The rash caused by antipyrin is of the *Erythema multiforme bullosum* type, and mainly affects the backs of the hands, but the face and other parts of the body may also suffer. Phenacetin and other synthetic remedies of the coal-tar series are said to act in a similar way.

The **bullous Iodide of Potassium** rash also leaves a certain amount of staining behind.

Other discolorations and pigmentations, such as **Chloasma**, **chronic Pediculosis** (vagabond's disease), **Addison's disease**, and so forth, have to be distinguished, and could scarcely be taken for syphilis if any care be exercised. **Tinea versicolor** has already been dealt with (page 60).

Discoloured areas, which have been called **coffee-stain** patches, occur on the legs. They may be found in those who have had syphilis, but that they are syphilitic is quite another matter. In some cases there is no such association.

In patients who have suffered from long-standing dermatitis associated with **varicose ulcers**, a great deal of staining of the legs may be present.

Pigmentation, of the legs especially, is also observed in cases of recurrent **Purpura**. Again, some staining is left behind in the condition known as **Erythema purpuricum**.

**Melano-leucoderma**, involving the backs of the hands, the forearms, the face, and other parts in a more or less symmetrical manner, should not be taken for syphilis. Here, again, the condition may be present in those who have had syphilis. **Melano-leucoderma** frequently affects the penis and scrotum,



and also the parts about the anus. This I have seen relied upon as corroborative evidence of syphilis, quite unjustifiably, in a case of early general paralysis.

The **pigmentary Syphilide** (sometimes also called *Leucoderma syphiliticum*, but improperly) is of great significance in the diagnosis of syphilis. Its favourite situation is the neck (*collier de Vénus*, so called), and women are much more liable to it than men, but I have seen it in the latter also. In two male cases it was associated with some of the secondary female sexual characters. In addition to the neck I have seen it affect at the same time the perinæum (a female) and the lower part of the abdominal region (male). In the latter case there was also an *alopécie en clairières* (like the glades in a wood). It is made up of pale circular areas on a pigmented background, or the pigmented portions may form an irregular network. The pale areas are of the same hue as the normal skin, and are not the result of involuted syphilitic lesions, as some have maintained. The condition is rebellious to treatment, and therefore becomes an important feature in retrospective diagnosis, all other facts being taken into consideration. Yet its presence about the neck is so strongly suggestive as to be almost pathognomonic, but not quite, as somewhat similar pigmentations have been described as depending on tuberculosis. On the other hand, syphilitic papulo-squamous lesions about the neck may leave pale areas behind (achromia, hypochromia) which by contrast may simulate the true pigmentary syphilide.

URTICARIA PIGMENTOSA has already been touched

upon more than once, and need not detain us again (see pp. 57, 180).

In some cases of **Urticaria**, quite apart from *Urticaria pigmentosa*, a certain amount of staining may be left behind. It occurs in cases in which the wheals, instead of subsiding rapidly, persist for some time, **Urticaria perstans**.

In the case of ulcerative syphilitic lesions, the resulting scar exhibits a zone of pigmentation round its margins. This is very characteristic. It is specially well marked in severe secondary syphilis with numerous circular ulcerating lesions. The existence of a pigmented border to scars should at once suggest syphilis. I may add that I have seen it about scars on the fronts of the shins apparently due to injuries. The diagnosis of syphilis would be borne out by the presence of multiple scars about the limbs, and in most cases on the scalp, together with other evidence.

SCARRING AND ATROPHY.—This leads me to say a few words about the importance of scars as aids to the diagnosis, retrospective and otherwise, of syphilis.

In the first place the scars of primary chancres must be mentioned. The examination of the genitalia will sometimes reveal one or more scars of this kind. In other situations such a scar may be of great value in diagnosis, as for instance on the lip of a child with signs of syphilis. This would indicate the extragenital point of infection, and perhaps be of great importance in a medico-legal case.

It should be remembered that accidental VACCINA-

TION of the lip by means of the broken end of a lymph-tube may occur and leave a scar very like that of a past primary chancre.

**Gummatous** infiltration of the lip, observed in tertiary syphilis, will sometimes be immediately recognised by the occurrence of scarring about the affected part.

Well-defined circular scars about the knees are very characteristic. I have observed them more frequently in women than in men. In the former they may afford important assistance in arriving at a conclusion, and therefore be valuable sign-posts in the matter of treatment.

Again there are the circular scars surrounded by a pigmented border to which I have just alluded.

An interesting feature about these circular syphilitic scars is that they are in some cases mathematical circles.

On the legs, and mainly on the calves, the scars left by old necrotic **Erythema induratum** lesions would have to be distinguished from syphilis (see page 125).

The scars resulting from **varicose ulcers** need only to be mentioned.

A very characteristic grouping of scars and atrophied areas are left behind by the **herpetiform syphilides** I have described (see page 115). As a rule there are only one or two such groups, more or less oval in shape, but there may be five or six of them. The scars are usually from a lentil to a bean in size, circular and oval. The back is a favourite situation, but other parts may be affected (shoulders,

etc.). They often affect one side of the trunk, sloping away from the median dorsal line, so that the term herpetiform, that is reminiscent of Herpes zoster, is useful for descriptive purposes. The aforesaid condition is practically pathognomonic, but there is a disease, **Acnitis**, or **Acne agminata** (see page 90), in which somewhat similar grouped scars occur, but this is exceptional. In the latter, the involvement of the face would point in the right direction. Under treatment some of the herpetiform syphilide elements involute without ulceration or suppuration, leaving an atrophic condition behind.

The scarring of **Acne varioliformis** has already been referred to (page 83).

In searching for evidence about the body, apart from the scars left by past broken-down gummata (buttocks, thighs, and other parts), irregular scars associated with infiltration and ulceration at the spreading edge may be found. I have already insisted on the foregoing association in the diagnosis of syphilis, but a similar association is seen in **Lupus vulgaris**, **Scrofulodermia**, and also it may be added in **Rodent Ulcer**.

In long-standing cases of **coccogenic Sycosis barbæ**, scarring may occur in the whiskers-region as a result of the folliculitis. The hairs are destroyed over the affected area, in a more or less irregularly oval or quadrilateral manner. At the margin there is redness, and maybe active folliculitis. At any rate, separate foci of active sycosis and infiltration will usually be present elsewhere. The condition has been called

**Lupoid Sycosis**, and also more recently, **Ulerythema sycosiforme**. It is really a form of cocco-genic sycosis. It has been taken for syphilis, and this is a mistake very likely to be made, unless the clinical condition is investigated with care.

The scars about the neck so common in the so-called scrofulous (tuberculous) would be of assistance in distinguishing LUPUS VULGARIS from syphilis.

As to the face, the radiating scars about the mouth, especially the angles, have already been insisted upon when dealing with the diagnosis of secondary and congenital syphilis. From the retrospective point of view they are important, as are also the analogous conditions about the tongue in syphilis. But this I have already dealt with.

Circular scars of the scalp, with destruction of the hair in the affected areas, are extremely significant. In this situation they must be distinguished chiefly from the lesions produced by **Lupus vulgaris**, **Lupus erythematosus**, and **Favus**.

As to **Lupus vulgaris**, it is very rare for it to affect the scalp in the shape of a separate patch, for it is usually as one single patch that it is observed there. Other parts of the face or body would be affected (multiple Lupus vulgaris). The rule is for the scalp patch to appear at the same time as the Lupus lesions elsewhere. But in a case of my own, the scalp patch, perhaps by auto-inoculation, only appeared after the disease had existed for many years on the face. In addition to the corroborative evidence of the disease elsewhere, the slow evolution, with the formation of nodules at the margin, the

small amount of ulceration as a rule, unless irritated, and resistance to treatment would also help. The scalp may be ultimately invaded in *Lupus vulgaris* by extension from the face, but even that is unusual.

In **Lupus erythematosus** the scalp is frequently involved. It is not a true scarring such as results from ulcerative or necrotic destruction, but an atrophic condition. The patches are usually multiple, and there would be symmetrical lesions about the nose, cheek, ears, or hands in most cases. Exceptionally there may be a single circular patch on the scalp and no sign whatever of *Lupus erythematosus* elsewhere. The patches are denuded of hair, reddened, more or less depressed, and the follicles are picked out, a point well seen with a lens. In rare instances, *Lupus erythematosus* may affect the arms acutely, the small patches becoming markedly white and atrophic in their central parts, surrounded by a narrow zone of redness.

In **Favus**, more or less depressed and circular denuded areas are left behind in the scalp as a result of pressure of the favus masses, especially in neglected cases. In such a condition the microscopical examination should never be omitted. This can be readily carried out as for ringworm. The disease is rare in London, occurring much more frequently in Jews from Poland than among the native population. But in Scotland it is much more frequent.

In **Mycosis fungoides**, the greater part of the scalp may become denuded of hair and exhibit a scarred condition which must not be taken for syphilis.

In the occipital region a condition known as **Acne keloid** (*Dermatitis papillaris capillitii*) occurs, which might be mistaken for syphilis (see page 115). The disease is very chronic. Ultimately hypertrophied scar tissue forms, accompanied by baldness of the area involved, but exhibiting here and there characteristic tufts of hair. In so-called **Folliculitis decalvans**, irregular cicatricial areas are formed about the scalp.

As a result of secondary syphilitic eruptions, **hypertrophic scarring** may occur occasionally in severe cases, as a result of ulcerative or rupia-like lesions. Such a complication no doubt results from secondary pyogenic infection. This hypertrophic scarring must be distinguished from true keloid. Hypertrophied scarring has also been noted in **Acne vulgaris**, **Sycosis**, **Variola**, **Scrofulodermia**, and after **Vaccination**. On the other hand the papular eruptive elements may subside leaving an atrophic condition behind. Both possibilities must be borne in mind.

In shoeing-smiths, small circular scars may occur about the flexor aspects of the forearms, above and below the bend of the elbows, as a result of burns from the sparks as they fly upwards. These should not be taken for syphilis.

With regard to the more or less superficial atrophic scar-like conditions, those left behind about the backs of the hands and fingers by **Lupus erythematosus**, and also by **Erythema iris**, the latter very faint, may be just mentioned. The superficial scarring and atrophy observed about the hands and knees and

elbows in **Epidermolysis bullosa** is also a point to bear in mind.

**Leprosy** has been dealt with in detail elsewhere (see page 137), but the superficial cicatricial changes observed about the sites of bullæ (elbows, etc.) must be recalled here.

In conclusion, the scars resulting from **X-ray burns** may be mentioned. These burns are very obstinate to treatment.





## INDEX

- Abducens, paralysis of, 106  
 Abortion, epizootic, 94  
   " recurrent, in syphilis, 93  
   " " tuberculosis,  
     94
- Abrasions, maltreated, 12  
 Acanthosis, 69  
 Acarus scabiei, 89  
 Accidental syphilis, 15  
   " vaccinia, 21, 30  
 Acne agminata, 90, 116, 203  
   " cacheticorum, 87  
   " frontalis, 83  
   " keloid, 115, 205  
   " necrotisans et exulcerans serpi-  
     ginosa nasi, 115  
   " rosacea, 114  
   " scrofulosorum, 91  
   " varioliformis, 83  
   " " scars after, 83,  
     203  
   " vulgaris, 87  
 Acné varioliforme, 83  
 Acnitis, 90  
   " scars after, 203  
 Actinomyces, 129  
 Actinomycosis, 128  
 Addison's disease, 199  
 Adenitis, 13, 48, 49, 62, 71, 87, 142  
   " suboccipital, 49  
 Age, 3  
 Albuminuria in iodide eruption, 80  
   " " Lupus erythemato-  
     sus, 68
- Albuminuria in syphilis, 53  
 Aleppo boil, 37  
 Alopecia areata, 189  
   " " generalizing, 191  
   " syphilitic, 189  
 Alopécie en clairières, 191, 200  
 Ampallang, 15  
 Anæmia in congenital syphilis, 169  
   " secondary syphilis, 53  
   " syphilis, 41  
 Anæsthesia in leprosy, 144  
 Anthrax, 131  
 Antipyrin rash, 58, 59, 81  
   " " pigmentation after,  
     198  
 Antitoxin rashes, 59  
 Anus, chancres of the, 37  
   " epithelioma of the, 37  
   " sarcoma of the, 37  
 Arabs, chancres of the pubes in, 35  
 Argyll-Robertson phenomenon, 105  
 Arrangement of eruptive elements  
   in syphilis, 6  
 Arsenical pigmentation, 198  
 Atrophy, 201  
   " of the skin in Epidermoly-  
     sis bullosa, 206  
   " of the skin in Erythema  
     iris, 206  
   " of the skin in Favus, 205  
   " " " Leprosy, 207  
   " " " Lupus erythe-  
     matusus, 205,  
     207

- Atropine rash, 58  
 Aussatz, der, 139  
 Auto-intoxications, 58
- Bacillus anthracis, 132  
 „ lepræ, 148  
 „ of rhinoscleroma, 136  
 „ pyocyaneus in Pemphigus vegetans, 78  
 „ tuberculosis, 108, 111, 112
- Bacterium pyocyaneum in Pemphigus vegetans, 78  
 „ ulceris cancrisi, 19
- Bagdad boil, 37  
 Balano-posthitis, 22  
 Barbados leg, 150  
 Barber's itch, 120  
 Bartholin's glands, 22  
 Baumès, loi de, 161  
 Bazin's disease, 125  
 Behrend on congenital syphilis, 161
- Belladonna rash, 58  
 Betel chewing, 51  
 Biskra, bouton de, 37, 38  
 Blastomycetes, 130  
 Blastomycosis, 130  
 Blood in congenital syphilis, 169  
 „ syphilis, 53  
 Blood-vessels in syphilis, 54  
 Blue-glass test, 7, 57  
 Boil, Oriental, 37  
 Bones in congenital syphilis, 167, 168  
 „ syphilis, 52, 107
- Boubas, 159  
 Bouton de Biskra, 37  
 „ „ Gafsa, 37  
 „ du Nil, 37
- Breast, chancres of the, 35  
 Bromide eruptions, 80, 83  
 „ „ in infants, 179
- Bubo, 18  
 Bullous syphilide, 45  
 „ „ congenital, 171
- Cape Colony, segregation of lepers in, 141  
 Carbuncle, anthrax as a synonym of, 131  
 Carcinomata, subcutaneous, 122  
 Carrion's disease, 159  
 Cephalalgia nocturna, 52  
 Cervix uteri, chancres of the, 14  
 Chancre, accidental, 49  
 „ digital, 25  
 „ excision of, 50  
 „ extra-genital, 25  
 „ géant, 31  
 „ Hunterian, 11  
 „ hypertrophic, 31  
 „ in children, 15  
 „ incubation of, 16  
 „ induré, 11  
 „ in natives, 15, 16  
 „ intra-urethral, 49  
 „ mou, 16  
 „ of the anus, 37  
 „ „ breast, 35  
 „ „ cervix uteri, 14, 26  
 „ „ eye, 33  
 „ „ face, 30  
 „ „ limbs, 34  
 „ „ lip, 29  
 „ „ nail, 192  
 „ „ nose, 33  
 „ „ pubes, 35  
 „ „ scalp, 34  
 „ „ trunk, 34  
 „ „ vulva, 13, 14  
 „ phagedænic, 15  
 „ primary, 11, 48  
 „ pseudo-, indurated, 16  
 „ redux, 16  
 „ tonsillar, 50  
 „ weicher, 16
- Chancrelle, 16  
 Chancres, multiple, 13  
 Charbon, 131  
 Chicken-pox, 75  
 Children, chancres in, 15

- China, syphilis in, 45  
 Chloasma, 199  
 Chloral rash, 58  
 Circumcision, 3, 15  
 Coccidia, 135  
 Coffee-stain patches, 199  
 Colles's law, 161  
 Columbian theory of syphilis, 139, 154  
 Condylomata acuminata, 22, 48  
   "  lata, 48  
 Confrontation, 14  
 Congenital syphilis, 160  
 Copaiba rash, 58  
 Corona veneris, 84  
 Corymbose syphilide, 43  
 Coryza, syphilitic, 166  
 Cranio-tabes, 167  
 Crateriform ulcer, 31, 133  
 Cutis anserina, 72  
   "  marmorata, 57  
 Cysticercus cellulosæ cutis, 122  
  
 Dactylitis in congenital syphilis, 169  
 Deafness in congenital syphilis, 185  
 Defluvium pilorum, 188  
   "  capillorum, 188  
 Delhi boil, 37  
 Dermatitis polymorphes douloureuses, 76  
 Dermatitis artefacta, 127  
   "  exfoliativa neonatorum, 173  
   "  gangrænosa infantum, 174  
   "  herpetiformis, 76  
   "  papillaris capillitii, 115, 205  
   "  seborrhœic, 116, 178  
 Development, 4  
 Diagnosis, 2  
 Diascopy, 46  
 Digital chancres, 25  
 Discomyces Maduræ, 129  
 Distribution, 6  
  
 Drug rashes, 58  
 Ducrey's bacillus, 19  
 Duration, 4  
 Dyaks, 15  
 Dysphagia and tonsillar chancre, 50  
  
 Ecthyma, 87  
   "  gangrænosum, 174  
   "  profundum, 100  
   "  térébrant, 174  
 Eczema, 67, 178  
   "  of nares, 194  
   "  palmar, 117  
   "  palmare, 117  
   "  rimosum, 118  
   "  seborrhœicum, 66, 179  
   "  sweat, 67  
 Egypt, chancres of anus in, 37  
   "  epithelioma of penis in, 22  
 Elephantiasis arabum, 149  
   "  græcorum, 139  
 Epidermolysis bullosa (hereditaria), 175, 183  
 Epididymitis in syphilis, 55, 107  
 Epileptiform attacks in syphilis, 106  
 Epiphysitis syphilitica, 169  
 Epithelioma of anus, 37, 134  
   "  face, 31  
   "  labia majora, 22  
   "  lip, 29, 134  
   "  penis, 22  
 Epitheliomata, acute, 134  
 Eruption érythémato-pigmentaire fixe, 198  
 Erythema induratum, 125  
   "  "  scars after, 202  
   "  iris, 75  
   "  multiforme, 143  
   "  "  vesiculo-bullosum, 75  
   "  purpuricum, 199  
   "  tertiary circinate, 99  
 Erythème circiné tertiaire, 99  
   "  induré des scrofuleux, 125  
 Exanthemata, the acute, 58

- Exhibitions, the soft sore and international, 18
- Extra-genital chancres, 24
- Eye, chancre of the, 33
- Eye brows in syphilis, 191  
 „ leprosy, 145, 191
- Eyes in syphilis, 51, 105
- Face, chancres of the, 25
- Facial nerve, paralysis of, in syphilis, 106
- Farcinoma cutis, 130
- Farcinose mutilante de la face, 130
- Farcy, 130
- Favus, 205
- Fever in syphilis, 52
- Fibro-plasmoma, 11
- Filaria nocturna, 150  
 „ sanguinis hominis, 150
- Fingers, chancres of the, 25
- Fits in syphilis, 106
- Fleischl's hæmometer, 54
- Folliculitis decalvans, 206  
 „ scrofulosorum, 72
- Fourth nerve, paralysis of, in syphilis, 106
- Framboesia, 152  
 „ brasiliiana, 159
- Fungus-foot of India, 129
- Furunculosis neonatorum, 179
- Gafsa, bouton de, 37
- Gale, la, 88
- General paralysis of the insane, 105
- Giant-cells, 73, 108
- Glands, lymphatic, 13, 48, 49, 62, 71, 87, 142
- Glanders, 130
- Glass-pressure test, 7, 62, 110
- Gonorrhœa, 49, 58
- Goose-skin, 72
- Goundou, 158
- Granuloma, 11, 68  
 „ fungoides, 150  
 „ inguinale tropicum, 137
- Granuloma, ulcerating, of the pudenda, 137
- Grease, 33
- Groin ulceration, 137
- Grouping of syphilitic lesions, 6
- Gumma, das cutane, 97  
 „ the syphilitic, 101, 124, 127
- Gummata, scarring after, 202  
 „ tuberculous, 112
- Hæmoglobin, diminution of, in syphilis, 53, 54
- Hair in syphilis, 188  
 „ loss of, 51, 93
- Hansen's bacillus, 143
- Harlequin fœtus, 163
- Headache in syphilis, 41, 52, 106
- Helkose, die venerisch-contagiöse, 16
- Heredity in syphilis, 160
- Herpes gestationis, 76  
 „ iris, 75  
 „ preputialis, 20  
 „ progenitalis, 20  
 „ „ a forerunner of hard chancre, 20  
 „ tonsurans disseminatus, 60  
 „ zoster, 21, 116
- Hidradenitis suppurativa destruens, 90
- Histology of acnitis, 90  
 „ congenital syphilis, 96  
 „ gumma, 102  
 „ Lichen planus, 69  
 „ Lichen scrofulosorum, 73  
 „ Lupus vulgaris, 108  
 „ primary chancre, 11  
 „ psoriasis, 63  
 „ rodent ulcer, 133  
 „ syphilides, 39  
 „ tertiary syphilis, 96  
 „ yaws, 157
- History, 9
- Hoarseness of cry in congenital syphilis, 104

- Horse-pox in man, 33, 128  
 Hunterian chancre, 11  
 Hutchinson's teeth, 184  
 Hydramnios, 163  
 Hydroa gestationis, 76  
   "  herpetiformis, 76  
 Hydrocele fluid rash, 59  
 Hyperidrosis, 100, 119  
 Hyperkeratosis, 100, 119  
 Hypodermic needles, 34  
 Hysterical stigmata, 128  
  
 Ichthyosis foetalis, 163  
 Icterus syphiliticus neonatorum, 168  
   "      "      præcox, 55  
 Impetigo contagiosa, 87, 181  
 Incubation of primary chancre, 16, 17  
 India, syphilis in, 45  
 Induration, 12  
 Infibulation, 15  
 Infiltration, 11  
   "      congenital superficial  
           syphilitic, 177  
   "      syphilitic, taken for  
           tuberculosis, 127  
 Intertrigo, 177  
 Intra-urethral chancre, 49  
 Introductory, 1  
 Iodide eruption, vegetating, 79  
   "      of potassium in leprosy, 149  
   "      "      in Lupus vul-  
           garis, 112  
   "      "      in rodent ulcer,  
           133  
   "      "      induration, 124  
   "      "      rash, bullous, 75  
   "      "      "      "      dis-  
           coloration  
           after, 199  
   "      "      "      "      pustular, 84  
 Iritis in congenital syphilis, 169  
   "      syphilitica, 51  
 Itch, the, 88, 175  
 Itching in syphilis, 47  
   "      of fauces in syphilis, 48  
  
 Japan, soft sore in, 18  
 Jaundice, early, in secondary syphi-  
           lis, 55  
   "      in congenital syphilis, 168  
 Jews, 15  
 Joint affections in syphilis, 55, 107  
 Justus's test in syphilis, 54  
  
 Kaposi's disease, 136  
 Keratitis, interstitial, 106, 183  
 Keratosis, 69, 100, 119  
 Knee-jerks in syphilis, 105  
 Koko, 152  
 Krätze, die, 88  
  
 Laryngitis syphilitica, 104  
 Lens, 6, 7  
 Lepra, 139  
   "      anæsthetica, 142  
   "      arabum, 139, 149  
   "      græcorum, 149  
   "      maculo-anæsthetica, 142  
   "      tuberosa, 142  
 Lèpre, 139  
   "      indigène, as a synonym of  
           Mycosis fungoides, 152  
 Leprides, macular, 143  
 Lepromata, 142  
 Leprosy, 139  
   "      anæsthetic, 142  
   "      maculo-anæsthetic, 142  
   "      mixed, 143  
   "      nails in, 196  
   "      nodular, 142  
   "      nodules, 142  
   "      of glans penis, 142  
 Leptus autumnalis, 90  
 Leucoderma syphiliticum, 47  
 Leukoplakia, 104  
 Lichen acuminatus, 74  
   "      circinatus, 67  
   "      planus, 8, 69  
   "      "      generalized, 70  
   "      "      in dark races, 71  
   "      "      mercury in, 8

- Lichen planus, mucous membranes  
in, 71  
" " pigmentation after,  
197  
" " verrucosus, 71  
" ruber acuminatus, 74  
" scrofulosorum, 72, 91  
" syphilitic, 72  
" syphiliticus, 72  
Limbs, chancres of the, 34  
Lip, chancres of the, 29  
" epithelioma of the, 29  
Lipomata, 122  
Liver, acute yellow atrophy of, in  
secondary syphilis, 55  
" in congenital syphilis, 168  
Locomotor ataxy, 105, 119  
Lousiness of the body, 88  
Lupoid sycolosis, 203  
Lupus, disseminated follicular, 90, 91  
" erythematodes, 110  
" erythematosus, 68, 109, 113,  
205  
" " nails in, 194  
" syphiliticus, 100  
" verrucosus, 110, 130  
" vulgaris, 33, 101, 108, 112  
Lymphatic glands, 13, 48, 49, 62, 71,  
87, 142  
  
Maceration of the fœtus, 163  
Madura foot, 129  
Mahia, 15  
Malaria and syphilis, 52  
" in *Verruga peruana*, 159  
" syphilis mistaken for, 52  
Malignant disease of the nail, 193  
" pustule, 131  
Malingering, 127  
Marbled skin, 57  
Measles, 58  
Melanoderma syphiliticum, 47  
Melano-leucoderma, 199  
Menorrhagia in syphilis, 54  
Microsporon furfur, 60  
  
Milk, bromide eruption through the  
mother's, 179  
Milzbrand, 131  
Miscarriages, 94  
Mohel, 15  
Molluscum contagiosum, 32, 83, 132  
Morocco, circumcision among Jews  
in, 15  
Morve, 130  
Mucous patches, 48  
" plaques, 48  
Muhammedans, 15  
Mycetoma, 129  
Mycosis fungoides, 68, 144, 150, 159,  
205  
Myositis in syphilis, 55  
Myxœdema, 190  
  
Nail, epithelioma of, 193  
" malignant disease of, 193  
" primary chancre about the nail,  
192  
Nails, affections of the, 192  
" and X-rays, 193  
" in congenital syphilis, 197  
" in eczema, 194  
" in Epidermolysis bullosa, 197  
" in leprosy, 196  
" in Lupus erythematosus, 194  
" in psoriasis, 66, 193  
" in syphilis, 107  
" ringworm of, 196  
Nationality, 3  
Natives, chancres in, 15  
Nephritis, secondary syphilitic, 53  
Nerve leprosy, 142  
Nerves in leprosy, 147  
Neuro-syphilide, 99  
New South Wales, leper law of, 141  
Nil, bouton du, 37  
Nile sore, 37  
Nodes in congenital syphilis, 185  
Noli me tangere Lupus, 111  
Nose, chancres of, 33  
" in syphilis, 105

- Oculo-motor, paralysis of, in syphilis, 106
- Onychia in congenital syphilis, 169  
197  
„ maligna, 194  
„ sicca syphilitica, 195
- Onychitis in congenital syphilis, 169, 197
- Onyxis craquelé, 195  
„ des scrofuleux, 194
- Oospora bovis, 129
- Ophiasis of Celsus, 190
- Ophthalmoplegia interna, 106
- Optic atrophy, 106  
„ neuritis, 52, 106
- Orchitis in syphilis, 55
- Oriental boil, 37
- Osteochondritis syphilitica, 169
- Osteocopic pains, 52, 107
- Ozæna syphilitica, 105
- Paget's disease, 36, 135
- Palate, 104
- Paralysis of cranial nerves in syphilis, 106
- Parakeratosis, 63
- Parangi of Ceylon, 152
- Parasyphilis, 105, 185
- Paronychia syphilitica, 194
- Parotid, swelling over, in syphilis, 55
- Pediculosis capitis, 48  
„ pigmentation in chronic, 198  
„ pubis, 48  
„ vestimenti, 88  
„ vestimentorum, 48
- Pediculus, 88
- Pemphigus, 77  
„ acute, 174  
„ „ of butchers, 81  
„ congenital, 175, 183  
„ gangrænosus, 174  
„ neonatorum, 172, 180
- Pemphigus neonatorum and Impetigo contagiosa, 173  
„ of the mouth, 76  
„ syphilitic, 171  
„ vegetans, 78
- Perionychia in congenital syphilis, 197  
„ syphilitica, 194
- Persia, Oriental boil in, 37
- Phagedæna in syphilis, 101  
„ tropical sloughing, 138
- Phagedænic primary chancres, 15  
„ soft sores, 18
- Phaneroseopy, 46
- Phimosis, 13, 22
- Phlebitis in secondary syphilis, 54
- Phlegmasia alba dolens, 55
- Pian, 152  
„ fongoïde, 150, 159
- Pigmentary syphilide, 47
- Pigmentation after antipyrin rash, 198  
„ „ psoriasis, 198  
„ in Lichen planus, 71, 197  
„ „ syphilis, 197  
„ „ vagabond's disease, 88
- Pilgrim's ulcer of Egypt, 150
- Pityriasis, 117  
„ capitis, 190  
„ circiné, 67  
„ rosé de Gibert, 60  
„ rosea, 60, 187, 198  
„ rubra pilaris, 74
- Placenta in syphilis, 55, 163
- Plaques muqueuses, 48
- Plasma-cells, 11, 108, 148
- Plasmoma, 11, 40, 110
- Pléiade ganglionnaire, 13
- Polymorphism of secondary syphilides, 42
- Polypapilloma tropicum, 152
- Post-mortem wart, 111




- Pre-mycosis stage, 151  
 Primäraffekt, 11  
 Primary chancre, 11  
     „ sclerosis, 12  
 Profeta's law (so-called), 161  
 Prognosis, 50  
 Protozoic dermatitis, 130  
 Prurigo ferox, 71  
     „ mitis, 71  
     „ of Hebra, 71  
     „ of Willan, 71  
 Pseudo-chancere, indurated, 16  
 Pseudo-leukæmic anæmia, 170  
 Pseudo-paralysis in congenital syphi-  
     lis, 52, 53  
 Pseudo-psorosperms, 136  
 Pseudo-syphilitic ulceration, 48  
 Psilosis linguæ, 51, 104  
 Psoriasis, 63  
     „ Lepra as a synonym, 149  
     „ of scalp, 116  
     „ pigmentation after, 198  
     „ punctata, 64  
     „ rupioides, 65  
     „ syphilitic, 63  
     „ the nails in, 193  
 Psorosperms, 135  
 Pubes, chancres of the, 35  
 Pupils in syphilis, 105  
 Purpura, 199  
 Purru, 152  
 Pyrexia in syphilis, 52, 53  
  
 Quinine rash, 58  
  
 Race, 3  
 Ray-fungus, 129  
 Redux chancre, 16  
 Re-infection, syphilitic, 16  
 Retinitis, syphilitic, 106  
 Rhagades in congenital syphilis, 166  
 Rhinoscleroma, 33, 136  
 Rickets and cranio-tabes, 167  
 Ringworm of the sole, 119  
 Ringworm yaws, 155  
 Rodent ulcer, 31, 34, 132  
 Roseola in congenital syphilis, 165  
     „ syphilitic, 56, 143  
     „ „ recurrent, 63, 99  
     „ urticata, 57  
 Roséole, 56  
 Rötheln, 58  
 Rotz, 130  
 Rupia, 45, 100  
 Russia, frequency of extra-genital  
     chancres in, 25  
  
 Salipyrin eruption, 81  
 Sandal-wood oil rash, 58  
 Sarcoma of the anus, 37  
 Sarcomata, fungating, 124  
     „ secondary, 124  
 Sarcomatosis cutis, 123  
     „ „ congenital mul-  
         tiple, 175  
     „ „ idiopathic mul-  
         tiple hæmor-  
         rhagic, 123  
 Satyriasis, 142  
 Scabies, 13, 21, 47, 88, 175  
 Scalp, chancres of the, 34  
 Scarring, 201  
     „ hypertrophic, 206  
     „ „ in Acne vul-  
         garis, 206  
     „ „ in scrofulo-  
         dermia, 206  
     „ „ in sycosis,  
         206  
     „ „ in vaccina-  
         tion, 206  
     „ „ in variola,  
         206  
     „ in accidental vaccinia, 201  
     „ in Acne agminata, 203  
     „ „ varioliformis, 82,  
         203  
     „ in Acnitis, 203

- Scarring in coccogenic Sycosis barbæ, 203  
 „ in Erythema induratum, 202  
 „ in gummatous infiltrations, 202  
 „ in herpetiform syphilide, 202  
 „ in Lupus vulgaris, 203, 204  
 „ in Mycosis fungoides, 205  
 „ in rodent ulcer, 203  
 „ in Scrofuloderma, 203, 206  
 „ in varicose ulcers, 202
- Scars, 103, 201  
 „ from X-ray burns, 207  
 „ in shoeing-smiths, 206
- Scrofula, 112
- Scrofuloderma, 112, 130
- Seborrhœa capitis, 190  
 „ papulosa, 67  
 „ psoriasiformis, 66
- Seborrhœic dermatitis, 66
- Séborrhéides, 66, 117
- Secondary syphilis, 39
- Seventh nerve, paralysis of, in syphilis, 106
- Signs, corroborative, in congenital syphilis, 166, 182  
 „ „ in primary syphilis, 7  
 „ „ in secondary syphilis, 48  
 „ „ in tertiary syphilis, 103
- Sixth nerve, paralysis of, in syphilis, 106
- Skin-grafting communicating syphilis, 49
- Snuffles, 166
- Soft sore, 16, 17  
 „ „ extra-genital, 29  
 „ „ in London, 18  
 „ „ in North Africa, 18
- Soft sore in Paris, 18  
 „ „ in Tokijo, 18
- Sore, soft, 16, 17
- Sourcils sabrés, 191
- Spedalskhed, 139
- Spleen in congenital syphilis, 168
- Splenic anæmia, 170
- Sporozoa, 135
- Spine, 51, 104
- Staphylococcus, 87, 120
- Sterility, 95
- Stomatitis, 76  
 „ intertropica, 51  
 „ mercurial, 51  
 „ neurotic vesicular, 76  
 „ syphilitic, 51
- Strepto-bacillus, 18, 19
- Streptothrix Maduræ, 129
- Stricture of the rectum, syphilitic, 107
- Struma, 112
- Sugar in the urine in syphilis, 53
- Superstition as to syphilis, 186
- Sweat eczema, 67
- Sycosis, coccogenic, 31, 119  
 „ hyphogenic, 31, 119, 120  
 „ non-parasitic, 119
- Synechiæ, posterior, 51
- Syphilide, acquired vesicular, 74  
 „ bullous, 75  
 „ circinate, 98, 116  
 „ congenital bullous, 171, 197  
 „ „ papular, 176  
 „ „ papulo-squamous, 176  
 „ „ vesicular, 176  
 „ corymbose, 43  
 „ ecthymatous, 88  
 „ en cocarde, 45  
 „ en godet, 45  
 „ frambœsiform, 158  
 „ herpetiform, 43, 98, 115  
 „ „ scarring after 202

- Syphilide, macular, 56, 143  
 „ nodular, 46  
 „ papuleuse nigricante, 197  
 „ pigmentary, 47  
 „ psoriasiform, 65  
 „ pustular, 82  
 „ secondary ecthymatous, 88  
 „ small follicular, 72  
 „ tertiary nodular, 97  
 „ tubercular, 97  
 „ tuberculated, 46  
 „ urticarial, 57  
 „ varicelliform, 74  
 „ varioliform, 82  
 Syphilides, histology of, 39  
 „ secondary, 41  
 „ „ arrangement of, 43  
 „ „ colour of, 46  
 „ „ distribution of, 42  
 „ „ itching of, 47  
 „ „ polymorphism, 42  
 „ ulcerating, 100  
 Syphilis, accidental, 24  
 „ acquired in infants and children, 164, 185  
 „ and cranio-tabes, 167  
 „ and Fijians, 153  
 „ and New Guineans, 153  
 „ congenital, 160  
 „ d'emblée, 12  
 „ foetal, 163  
 „ hereditaria tarda, 182  
 „ héréditaire, 160  
 „ héréditaire tardive, 182  
 „ hereditäre, 160  
 „ insontium, 24  
 „ late symptoms of congenital, 182  
 „ malignant, 44  
 „ maligne précocce, 44  
 „ nails in, 194  
 Syphilis, nails in congenital syphilis, 197  
 „ of third generation, 162  
 „ primary, 10  
 „ re-infection in, 16  
 „ secondary, 39  
 „ tattoo-, 35  
 „ tertiary, 92  
 „ vaccinal, 36  
 Syphiloma, cutaneous, 97  
 „ frambœsioid, 100  
 „ palmar, 118  
 „ squamous, 99, 116  
 Syphilonychia sicca, 195  
 „ „ in congenital syphilis, 197  
 Syphilophobes, 10, 84  
 Syphilophobia, 22  
 Symptoms, general, 4  
  
 Tabes dorsalis, 105, 119  
 Tattoo-syphilis, 35  
 Tænia solium, 123  
 Teeth in congenital syphilis, 184  
 Temperature, 4  
 Tertiary syphilis, 92  
 Testicle, gumma of, 107  
 Thallium acetate, 189  
 Therapeutic test, 7, 149  
 Third nerve, paralysis of, in syphilis, 106  
 Throat, the, in syphilis, 50  
 Thrush in congenital syphilis, 166  
 Tinea barbæ, 120  
 „ circinata barbæ, 121  
 „ „ disseminated, 61, 62  
 „ „ pustular, 121  
 „ sycosis, 20, 31  
 „ tropica, 121  
 „ unguium, 196  
 „ versicolor, 60, 199  
 „ „ among Hawaiians, 60  
 „ „ in Assam, 60  
 Tonga, 152

- Tongue, the, in secondary syphilis, 50  
 „ „ in tertiary syphilis, 103  
 Tona (Tonga), 152  
 Tracheotomy in syphilis, 104  
 Treatment, 4  
 Trichophyton megalosporon ectothrix, 120, 121  
 Trichophytosis, palmar, 119  
 Trochlear nerve, paralysis of, in syphilis, 106  
 Trombidium holosericum, 90  
 Tropical ringworm, 121  
 Trunk, chancres of the, 34  
 Trypanosomiasis rash, 59  
 Tuberculosis verrucosa cutis, 111  
 Tuberculous ulcers, 30, 33  
 Turkey in Asia, endemic syphilis in, 105  
 Typhus-like symptoms in syphilis, 53
- Ulcer, crateriform, 31  
 „ perforating, of the foot in leprosy, 147  
 „ rodent, 31, 34  
 „ tuberculous, 30, 33  
 Ulceration of the scalp, 191  
 Ulcus molle, 16  
 „ rodens, 132  
 Ulerythema sycosiforme, 203  
 Urine in drug eruptions, 80  
 „ syphilis, 53  
 Urticaria, 57  
 „ factitia, 180  
 „ perstans, 57, 201  
 „ pigmentosa, 57, 180, 200  
 Urticarial syphilide, 57  
 Uvula, 104
- Vaccinal syphilis, 36  
 Vaccination pustules, 128  
 Vaccination rashes, 59, 180  
 „ „ pustular, 83  
 Vaccine Lichen, 181  
 Vaccinia, 174  
 „ accidental, 21, 30, 32, 34  
 „ „ generalised, 83, 181  
 „ „ scars, 201  
 Vagabond's disease, 88, 199  
 Varicella, 75, 174  
 „ gangrenosa, 174  
 Varicose ulcers, 126, 199  
 „ „ scars after, 202  
 Variola, 75, 82  
 „ modified, 83  
 Végétations vénériennes, 22  
 Venereal warts, 22  
 Vérole galopante, 53  
 „ grosse, 82  
 „ petite, 82  
 Verruca necrogenica, 111  
 Verruga Peruana, 159  
 Viscera in syphilis, 107  
 Vulva, chancres of the, 13, 14
- Warts, venereal, 22  
 Wet-nurses and syphilis, 186  
 Women, diagnosis in, 5, 93, 115  
 „ examination of, 49  
 „ sub-occipital adenitis in, 49
- X-ray burns, scars from, 136, 207  
 X-rays, 133, 152  
 „ and the nails, 193  
 Xanthelasmaïdea, 57  
 Xerodermia pigmentosa, 136
- Yaws, 152, 181  
 Zona, 21, 116



14/12



