

## **Caries of the tarsus and ankle-joint.**

### **Contributors**

Royal College of Physicians of Edinburgh

### **Publication/Creation**

[Edinburgh?] : [publisher not identified], [1845?]

### **Persistent URL**

<https://wellcomecollection.org/works/efsw7g7f>

### **Provider**

Royal College of Physicians Edinburgh

### **License and attribution**

This material has been provided by This material has been provided by the Royal College of Physicians of Edinburgh. The original may be consulted at the Royal College of Physicians of Edinburgh. where the originals may be consulted.

This work has been identified as being free of known restrictions under copyright law, including all related and neighbouring rights and is being made available under the Creative Commons, Public Domain Mark.

You can copy, modify, distribute and perform the work, even for commercial purposes, without asking permission.



Wellcome Collection  
183 Euston Road  
London NW1 2BE UK  
T +44 (0)20 7611 8722  
E [library@wellcomecollection.org](mailto:library@wellcomecollection.org)  
<https://wellcomecollection.org>

#### IV.—CARIES OF THE TARSUS AND ANKLE-JOINT.

The following Cases illustrate well the improvement which has been lately made in the treatment of disease of the bones of the tarsus and ankle-joint; and they may also assist in forming an estimate as to the relative merits of the operations of amputation below the knee and at the ankle-joint. Some of the Cases, at the same time that they add instances in proof of the advantages and safety of the latter operation, point out an important modification in its mode of performance.

CASE 1. *Amputation through the Leg. Recovery.*—Elisabeth Hutton, aged 12, from Dunfermline, was admitted into the Royal Infirmary, under Dr Handyside, on March 30, 1841, on account of disease of the right ankle-joint. The soft parts around the joint were much swollen. Several openings existed on each side beneath the malleoli, through which the probe passed readily into carious bone. The discharge was not profuse, but the patient was becoming hectic. Two years and a half before admission, the joint became swollen without any assignable cause. Six months afterwards it became very painful, and continued in this condition for a year, when the openings formed, and matter was discharged.

On the 12th of April, a consultation of the Surgeons was held on the case, when it was agreed to amputate through the leg. Next day the operation was performed through the middle of the leg. The flaps were made by cutting from without inwards. Seven vessels required ligature.

After the operation, the hectic declined rapidly; the flaps united by the first intention, except at their margins merely; and the patient was dismissed, cured, on the 30th of April.

CASE 2. *Amputation below the Knee. Recovery.*—Cecilia Grant, aged 15, was admitted on March 22, 1842, on account of disease of the left foot. There was considerable pain, redness, and swelling over the ankle and tarsus; and, on the inner aspect of the latter, fluctuation was perceptible, but no opening then existed. About thirteen months before admission, the ankle and foot became swollen and painful, and had continued so, notwithstanding appropriate treatment. Openings were made by Dr Handyside to evacuate the matter, and through these the bones of the tarsus were found, on examination by the probe, to be in a carious condition. The patient became hectic, and, as this increased, it was agreed, at a consultation of the Surgeons, that amputation below the knee should be performed. This was done, on the 25th of April, by Mr Miller, in the absence of Dr Handyside. The flaps had healed partially by the first intention, when, on the fourth day after the operation, they became inflamed, and were attacked on their margins by phagedenic action, which was at that time prevalent in the hospital.



Powerful escharotics were applied, after which the stump again became healthy; and the patient was dismissed, cured, on the 28th of May.

CASE 3. *Amputation through the Leg. Recovery.*—Caroline Hamilton, aged 18, was admitted on March 6, 1843, with disease of the left ankle-joint. The joint was stiff and immovable, the soft parts around it were much thickened and swollen; over it there were several ulcers, leading into sinuses, and also several unhealthy cicatrices. On passing the probe through the sinuses, the bones of the ankle-joint were found to be quite carious, and the lower extremity of the tibia seemed to be diseased for a short way above the ankle. The disease had existed for about twelve years, and the patient had formerly refused to submit to amputation when proposed to her in the Royal Infirmary by Mr Liston. She continued in the hospital under palliative treatment till the month of August, when she consented to submit to amputation.

At first sight, the case appeared to be one fitted for the operation at the ankle-joint, which had been performed some time previously by Dr Handyside, in the case next related; but, from the disease appearing to affect the tibia for some way above the joint, from the great swelling of the soft parts, and from the ulcerated and otherwise unhealthy condition of the integument all around the joint, it was thought advisable to amputate some inches higher up. Accordingly, on the 1st of August, Dr Handyside performed amputation somewhat below the middle of the leg. The posterior flap was formed by transfixion, and by cutting from within, and an ample covering for the bones was formed. Five vessels required ligature.

After the operation, the patient's health improved rapidly, the flaps united by the first intention, except at their margins; and the patient was dismissed, cured, on the 22d of September.

CASE 4. *Amputation at the Ankle-joint. Recovery.*—George Macdonald, aged 19, from Lanark, was admitted on April 25, 1843, on account of disease of the right foot and ankle. There was considerable swelling of the soft parts around the joint, and the latter was the seat of acute pain. Sinuses existed on each side of the joint, through which the os calcis and astragalus could be felt to be in a carious condition.

The disease was of two years' standing, and was originally caused by a severe sprain. The patient refused to submit to amputation till the month of July, when the pain became more severe, and hectic had set in.

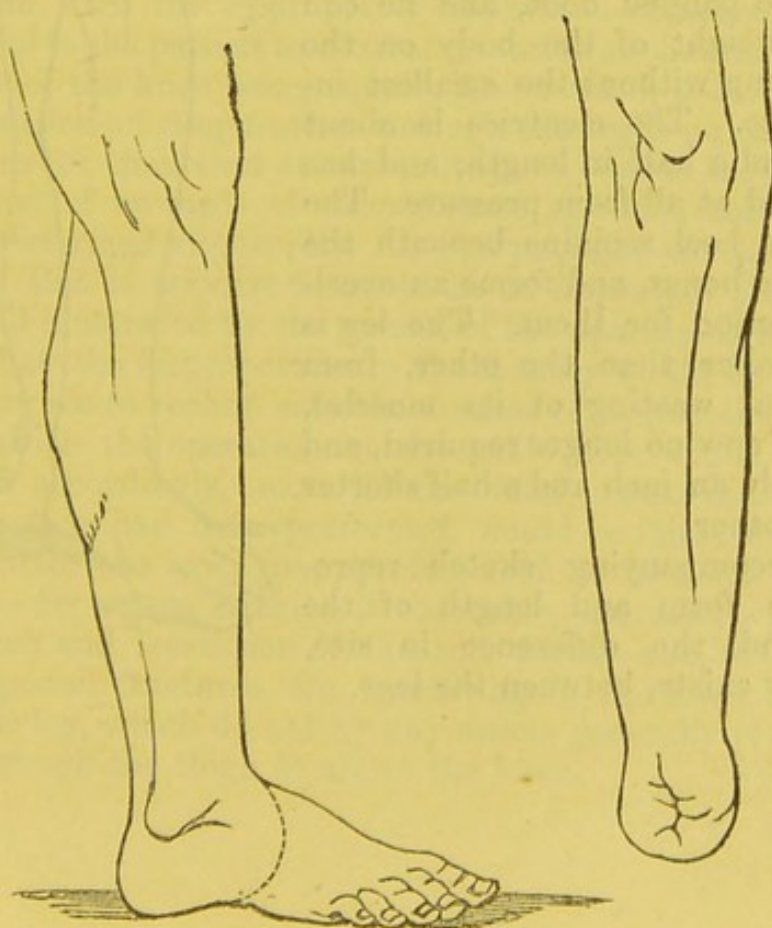
The case was reckoned favourable for the operation of amputation at the ankle-joint, which was accordingly performed by Dr Handyside, on July 11th, in the following manner:—A strong bistoury was entered in front of the joint, and midway between the malleoli. From this point an incision was carried forwards over



the side of the instep in a semicircular direction, and then downwards to the middle line of the foot, terminating immediately in front of the ball of the heel. The extremities of this incision were met by another and a similar one on the outer aspect of the joint, the second one terminating where the first had been commenced. The flaps were then dissected backwards,—the tendo Achillis was easily divided at its attachment to the os calcis,—and the separation of the foot was readily accomplished. The malleoli were removed by the saw, and along with them about one-eighth of an inch of the lower end of the tibia, although the cartilaginous surface of the latter was not diseased. Two vessels were tied, these being the anterior tibial and external plantar arteries. After the introduction of the sutures, which were five in number, the flaps covered the bone completely, and the ball of the heel was situated, as in the antero-posterior flap operation, below the extremities of the bones. A bandage was then applied to support the stump.

The flaps united almost entirely by the first intention, and a month afterwards the patient could rest his weight on the stump. The ball of the heel continued to form an excellent cushion beneath the ends of the bones. The cicatrice was situated vertically on the fore part of the stump, and it did not exceed two inches in length. The leg was only an inch and a half shorter than the other, so that the patient could walk easily with a high heeled padded shoe.

The accompanying sketches represent the line of one of the two similar incisions made in this case, and the form of the stump and leg, as copied from a cast taken upwards of two months after the operation.





CASE 5. *Amputation at the Ankle-joint.—Recovery.*—Andrew Scott, aged 8, from Leith, was admitted on June 4, 1843, on account of disease of the left ankle. The joint was enlarged, painful, and distorted. An opening existed below the inner malleolus, through which the probe passed readily into the joint, and detected a carious condition of the astragalus. The affection arose, it was stated, from a sprain which he received six years before admission.

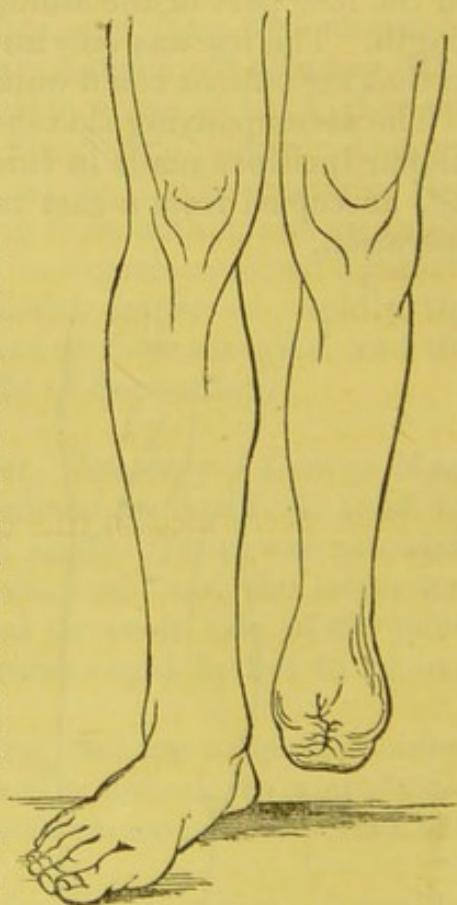
On the 11th of June a sequestrum was felt loose beneath the inner malleolus, and it was removed easily by dilating the opening. The sequestrum was found to be part of the astragalus, which was again felt to be quite carious. A consultation of the Surgeons was held on the case, when it was recommended to delay amputation, and to try the application of the red oxide of mercury.

On July 26th, he was sent out of the Hospital by Dr Handyside; and as the case did not improve, but still appeared to him to be one requiring amputation, he then performed the operation. This was done on the 14th of August, and exactly in the same manner as in the case last described. Two vessels only required ligature. The flaps united by the first intention, and a month afterwards the patient was walking freely on the stump.

On examination afterwards the astragalus was found to be almost entirely destroyed by disease, and a large carious cavity existed in the upper portion of the os calcis.

At present the boy walks with perfect ease and freedom with a high heeled and padded boot, and he can rest the weight of the body on the naked stump without the smallest inconvenience. The cicatrice is about an inch and a half in length, and has not suffered at all from pressure. The ball of the heel remains beneath the ends of the bones, and forms an excellent protection for them. The leg is much smaller than the other, from the partial wasting of its muscles, which are now no longer required, and it is exactly an inch and a half shorter than the other.

The accompanying sketch represents the form and length of the stump, and the difference in size, which now exists, between the legs.





REMARKS.—The two cases first related occurred at a period when, for caries of the tarsus and ankle-joint, amputation through the leg was regarded as the established practice here as elsewhere.

In Cases 1 and 3, amputation was performed not immediately below the knee, as most surgeons recommend, but in accordance with the recommendation of Professor Fergusson of London, through, or rather below, the middle of the leg; as in my opinion, also, this part should be selected in preference to the former, when the surgeon has his choice. The danger to life is thus less, the stump, if well formed, is equally comfortable, and afterwards the limb is more serviceable, owing to the patient having free use of the knee-joint.

In Case 3, although previously the importance of amputation at the ankle-joint for caries occurring there, had been demonstrated by Professor Syme, and although the latter operation had been, as already stated, previously performed by myself, I preferred, for reasons already given, amputating a few inches higher up. It was afterwards seen that, as far as the bones were concerned, the operation at the ankle-joint might have been performed, but previously the efficacy of it seemed to me so doubtful, as not to warrant the attempt. Moreover, the danger attending the operation which was performed, though greater than that incurred by the operation at the ankle-joint, is not, I believe, as already stated, nearly so great as that which attends amputation immediately below the knee, which operation most surgeons would have regarded as the alternative in these circumstances; and I regretted the less being obliged to amputate through the middle of the leg, as after the latter operation the limb, with the appropriate apparatus attached to it, is equally useful to the patient as after amputation at the ankle-joint,—the motions of the knee being equally preserved in both.

The operation of amputation through the leg is no doubt more dangerous to life than that at the ankle-joint,—as is shown by the fact, that out of upwards of twenty cases in which the operation has been performed in this city, all the patients except one have recovered. But it appears to me to be an important observation, which is well illustrated by the results of the operations in Cases 1, 2, and 3, that the disproportion in the fatality would be much decreased, were we to reckon *only* those cases of amputation through the leg in which the operation at the ankle-joint might have sufficed. And accordingly, most of the fatal cases in which the former operation had been performed, would be found to be those where the latter was quite inapplicable, such as for acute gangrene of the foot—for severe injuries at the ankle, attended with extensive contusion and laceration of the soft parts—and for necrosis, severe compound fractures, &c., occurring in the lower or middle thirds of the leg, which do not by any means generally require amputation through the thigh or above the knee.



It follows, therefore, that the operation of amputation below the knee will still not unfrequently be required,—as amputation at the ankle-joint cannot supersede it in nearly all cases, and as the operation of amputation through the condyles of the thigh-bone, as lately recommended by Mr Syme,<sup>1</sup> cannot properly supersede it in the remaining ones.

The greater safety of amputation at the ankle-joint over that through any part of the leg, is sufficiently accounted for by the comparatively small extent of the part removed by the former operation, and by the consequent slightness of the shock,—in accordance with the still established rule in surgery, that the danger is diminished proportionally as the amputation is distant from the trunk. It has lately, however, been conjectured by Mr Syme,<sup>2</sup> that much of the safety attending the operation at the ankle, as well as near other joints, is due to the circumstance, that the cancellated texture only of the bone is divided by the saw, and that the medullary canal is not opened into. This would be an observation of considerable importance in surgery, were it established. But the reasons which I have given above for the greater safety attending the ankle-joint operation are so obviously sufficient, that it is quite unnecessary to have recourse to any theoretical explanation in addition.

It may be that there is less risk incurred by the division of a bone through its cancellated texture than through its shaft; but we are still in great want of statistics sufficient to prove this. The results of amputation at the ankle-joint, as compared with that through the leg, cannot prove it, for reasons already given; neither for like reasons would it be proved, although the operation through the condyles of the thigh-bone was found to be less dangerous than that through its shaft; and it will be difficult to find those who will believe that, *cæteris paribus*, amputation below the knee is more dangerous than amputation through the condyles of the thigh-bone,<sup>3</sup> or that amputation through the trochanters of the latter is more safe than amputation through its shaft, until it should be proved by the evidence of statistics.

The operation of amputation at the ankle-joint was performed many years ago by various surgeons in France,<sup>4</sup> by the formation of antero-posterior as well as of lateral flaps, but generally in such a manner as not to afford a sufficient covering for the ends of the bones.

The projection of the malleoli formed one of the chief obstacles, but this difficulty was overcome by M. Baudens,<sup>5</sup> who practised

<sup>1</sup> See MONTHLY JOURNAL for May 1845.

<sup>2</sup> See MONTHLY JOURNAL for August 1844 and for May 1845.

<sup>3</sup> See MONTHLY JOURNAL for May 1845.

<sup>4</sup> See Médecine Opératoire, by Velpeau, 1832.

<sup>5</sup> See Médecine Opératoire, by Bourguery, 1840.



and recommends removing them by the saw, and along with them part of the articular surface of the tibia.

A still greater improvement, however,—that of taking the covering flap from behind, so as to make the soft parts of the heel cover and protect the ends of the bones,—seems also to have been first practised in France. This method is described by Dr T. King of London.<sup>1</sup> “The operation,” says he, “might be performed by making a short flap in front, by a semicircular incision, extending from one malleole to the other. As the internal malleole descends less than the outer one, the joint should be opened on that side; the astragalus being luxated, the covering flap should be carved out of the soft parts of the heel.

The removal of the malleoles would allow an ample covering for the stump. Lisfranc, in his lectures, mentions a man on whom this amputation had been performed, who could walk ten or twelve miles a-day with great ease.”<sup>2</sup>

The merit, however, of introducing this operation into regular practice is more especially due to Professor Syme, of this city. He was, I believe, the first surgeon who performed it in this country,<sup>3</sup>—who showed the importance of the operation,—and how it ought, in many cases, to supersede the operation of amputation through the leg.

According to the method practised by Mr Syme,<sup>4</sup> the soft parts of the heel are included in the posterior flap, and the flaps meet transversely in front of the anterior margin of the lower end of the tibia. The cicatrice, however, is thus necessarily exposed to the pressure of the latter part, and of the bases of the malleoli, and also to the front of the boot or shoe. According to the method described in Case 4, the ball of the heel is also included, but the flaps are so formed as to meet vertically in front. The cicatrice thus—which afterwards does not exceed from an inch and a half to two inches and a half in length—lies between the soft part of

<sup>1</sup> Cyclopædia of Practical Surgery, article “Amputation,” 1837.

<sup>2</sup> Since writing the above, my attention has been directed to some observations on this subject, in the *Periscope of the Northern Journal of Medicine* for September 1844, among which there is an interesting quotation from M. Malgaigne’s *Manuel de Médecine Opératoire*, 1834, which the above quotation very much resembles, and which also goes to prove, that the practice of including the soft parts of the heel in the posterior flap was at least recommended first in France. M. Malgaigne writes as follows, page 247:—“Nous ferions donc un très-court lambeau en avant, par une incision demicirculaire aboutissant au bord postérieur de chaque malléole. Puis l’articulation serait attaquée par le côté interne dont la malléole descend moins de quatre lignes que l’autre, et, la désarticulation achevée, on taillerait le lambeau aux dépens de la peau du talon, plus propre que tout autre, après la guérison, à soutenir le poids du corps. Et si les malléoles faisaient trop obstacle à la réunion, nous ne verrions aucun inconvénient à les retrancher et à obtenir ainsi le moignon le mieux conformé et le mieux revêtu, de tous ceux qui résultent d’amputations faites à la jambe et à la cuisse. M. Lisfranc dit dans ses cours, qu’il a pu examiner un homme amputé dans cette articulation qui avait conservé la flexion de la jambe, et qui pouvait, sans inconvénient, faire quatre à cinq lieues par jour.”

<sup>3</sup> See MONTHLY JOURNAL for Feb. 1843.

<sup>4</sup> See MONTHLY JOURNAL for August 1844.



the stump and the soft padding of the boot. By the latter method, also, there is no danger of sloughing of any part of the stump, as the posterior tibial artery is not divided, so as to cut off the principal vascular supply, but only its divisions into the two plantar arteries; whereas, by the former method, the trunk of the posterior tibial artery may be divided, and thus give rise to the serious consequence of at least partial sloughing of the posterior flap,—as happened in two cases related by Mr Syme,<sup>1</sup>—the vessel having been divided accidentally in the one case, and intentionally in the other.

The operation can be much more easily and rapidly performed by the method of antero-lateral flaps, as the dissection of the os calcis from the soft parts of the heel is thus much more easily effected;—the great bruising and twisting of the soft parts which occurs in the other method of disarticulation is thus happily avoided, and primary union is thus more likely to take place. The operation could, if necessary, be still farther facilitated also by incising the pad of the heel backwards from the point where the two antero-lateral incisions meet. This would not interfere much with the subsequent usefulness of the stump.

In the method by antero-lateral flaps, moreover, should union by the first intention not be complete, the matter is allowed to drain off freely from the lower commissure of the flaps, so as to render quite unnecessary the establishment of an opening through the integument of the heel,—the formation of which is recommended by Mr Syme,<sup>2</sup> in the method by antero-posterior flaps,—if, indeed, it has not been formed accidentally or unavoidably<sup>3</sup> during the tedious and difficult dissection which is required to separate the os calcis from its attachments.

In removing the malleoli, it is better to employ the saw than the cutting pliers; as, along with these points of bone, a thin slice of the lower end of the tibia ought always, in my opinion, to be removed. When the articular extremity of the tibia is diseased, this evidently must be done,—the surgeon then has no choice;<sup>4</sup> but even when the cartilage of the tibia is sound, as in Case 4, I would advise its removal, as it will accelerate the healing process, more especially if union by the first intention should fail.

<sup>1</sup> See MONTHLY JOURNAL for August 1844.

<sup>2</sup> Ibid. for April 1843.

<sup>3</sup> Ibid.

<sup>4</sup> See *ibid.* for a case by Mr Syme, in which he first seems to have removed part of the lower end of the tibia.

*(To be continued.)*