

## **Diseases of the anus and rectum / by D.H. Goodsall and W. Ernest Miles.**

### **Contributors**

Royal College of Physicians of Edinburgh

### **Publication/Creation**

London : Longmans, Green, 1900-1905.

### **Persistent URL**

<https://wellcomecollection.org/works/gf6thzjg>

### **Provider**

Royal College of Physicians Edinburgh

### **License and attribution**


This material has been provided by This material has been provided by the Royal College of Physicians of Edinburgh. The original may be consulted at the Royal College of Physicians of Edinburgh. where the originals may be consulted.

Conditions of use: it is possible this item is protected by copyright and/or related rights. You are free to use this item in any way that is permitted by the copyright and related rights legislation that applies to your use. For other uses you need to obtain permission from the rights-holder(s).



Wellcome Collection  
183 Euston Road  
London NW1 2BE UK  
T +44 (0)20 7611 8722  
E [library@wellcomecollection.org](mailto:library@wellcomecollection.org)  
<https://wellcomecollection.org>







*ms*  
*HC* # 6. 55

R52355













\* [The second part is in preparation and will contain chapters on—  
ULCERATION — STRICTURE — SYPHILIS — TUBERCULOSIS — NEW GROWTHS  
(BENIGN AND MALIGNANT) — PROLAPSE AND PROCIDENTIA OF THE  
RECTUM.]



DISEASES  
OF THE  
ANUS AND RECTUM,

BY

D. H. GOODSALL, F.R.C.S. (ENG.),

*Senior Surgeon (late House Surgeon) to St. Mark's Hospital for  
Fistula and other Diseases of the Rectum; Senior Surgeon to the  
Metropolitan Hospital.*

AND

W. ERNEST MILES, F.R.C.S. (ENG.),

*Surgeon (out-patients) to the Gordon Hospital for Diseases of the  
Rectum; Assistant Surgeon to the Cancer Hospital, Brompton;  
late Senior Assistant Demonstrator of Anatomy at St. Bartholomew's  
Hospital Medical School, and House Surgeon to St. Mark's  
Hospital for Fistula and other Diseases of the Rectum, etc.*

IN TWO PARTS (*Illustrated*).

---

PART I.\*

---



LONGMANS, GREEN & CO.,

39, PATERNOSTER ROW, LONDON

NEW YORK AND BOMBAY

1900.

[ALL RIGHTS RESERVED.]





## P R E F A C E .

This work on the diseases of the anus and rectum is the outcome of our personal experience of the subject extending over periods of thirty years and six years respectively.

The conclusions drawn are the results of the observation of many cases of which we have kept records. We have endeavoured to convey to the reader the clinical features of the various forms of disease described, and also to set forth those methods of treatment which we have found to be most successful.

This volume contains 91 illustrations, of which 15 are not original. These latter have been made use of for illustrating the chapter on Anatomy. For permission to reproduce the illustrations from the works of other authors, our best thanks are due to Messrs. Young J. Pentland, of Edinburgh, for figures 1 and 6 from Cunningham's Manual of Anatomy ; to Charles Griffin & Co. for figure 3 from Macalister's text-book of Human Anatomy ; and to Messrs. Longmans, Green, & Co. for figures 4, 5, 7, 9, 10, 13 and 18 from Quain's Anatomy.

We have taken figures 8, 11, 14, 15 and 17 from MM. Quénu and Hartmann's most excellent and elaborate work entitled "Chirurgie du Rectum," published by G. Steinheil of Paris.

The remaining 76 illustrations are original and, with the exception of the diagrammatic figures 21, 23, 25—28, 30, 32—39, and figures 12 and 16, have been made from photographs of cases under our care.

For some of these photographs we are much indebted to Messrs. P. G. Harvey and L. Galsworthy of St. Bartholomew's Hospital, who took the greatest interest in making them as perfect as possible.

To Dr. Hugh Walsham, for his observations upon the relation of ano-rectal abscess and fistula to phthisis (see page 131), and also for making the skiagrams reproduced in figures 64 and 66, our very best thanks are given.

Finally we thank Mr. W. R. Hall, Registrar of the Medical Society of London, for his kindness in reading the proof sheets with so much care, and for preparing the index.

D. H. GOODSALL.

W. ERNEST MILES.



## TABLE OF CONTENTS.

### CHAPTER I.

#### ANATOMY.

The Perineal Space—The Rectal Triangle—The Skin—The Superficial Fascia—The Sphincter Ani Externus—The Ischio-rectal Fossa—The Levator Ani Muscle—The Rectum—The Upper Portion of the Rectum—The Middle Portion of the Rectum—The Lower Portion of the Rectum—Structure of the Rectum—The Serous Coat—The Muscular Coat—The Internal Sphincter—The Submucous Tissue—The Mucous Membrane—Anal Papillæ—Blood-vessels of the Rectum and Anus—Arteries—Veins—The Lymphatics of the Rectum and Anus—The Nerves of the Rectum and Anus ... I

### CHAPTER II.

#### GENERAL DIAGNOSIS.

Pain—Hæmorrhage—Discharge—Constipation—Diarrhœa—Difficulty in Defæcation—Protrusion from the Anal Orifice—Loss of Weight—Influence of Heredity—Method of Examination for Rectal Disease—Sub-division of the Anal Region—Inspection—Examination of the Rectum ... .. 39

### CHAPTER III.

#### ABSCESS.

Etiology—Varieties of Abscess in this Region—Subcutaneous Abscess—Ischio-rectal Abscess—Submucous Abscess—Pelvi-rectal Abscess—Labial Abscess—Treatment—Palliative Treatment—Operative Treatment—Operation—The Method of Operating—After Treatment ... .. 55

CONTENTS.

CHAPTER IV.

ANO-RECTAL FISTULA.

Varieties of Fistula—The Complete Fistula—The Blind External Fistula—The Blind Internal Fistula—The Position of a Fistula—The Multiplicity of *Fistulæ*—Etiology—Fistula due to Traumatism—Fistula due to Fissure—Fistula due to Polypoid Growths—Fistula due to Internal Piles—Fistula due to Ulceration—Fistula due to Stricture—Fistula due to Carcinoma—Symptoms—Pus—Pain—Passage of Flatus and Fæces—Hæmorrhage—Physical Examination—The External Opening—Primary and Secondary Openings—The Internal Opening—The Position of the Internal Openings—The Number of Internal Openings—The Main Track: (*a*) In Complete Fistula; (*b*) In Blind External Fistula; (*c*) In Blind Internal Fistula—Lateral Burrowing: (*a*) External; (*b*) Internal—Morbid Conditions Complicating Fistula—Constitutional Effects of Fistula—Treatment—Choice of Operation—Operation by Incision—General Rules—Method of Operating in Complete Fistula—In *Fistulæ* Posterior to the Transverse Anal Line—In Posterior Horse-shoe *Fistulæ*—In *Fistulæ* Anterior to the Transverse Anal Line—In Anterior Horse-shoe *Fistulæ*—In Blind External *Fistulæ*—In Blind Internal *Fistulæ*—After Treatment and Diet—Average Duration of the Healing Process—Complications after the Operation and their Treatment—Advisability of Operating upon an Ano-Rectal Fistula complicated by Pulmonary Tuberculosis—Cases—Treatment after the Operation—Perineal Urethral Fistula simulating Ano-rectal Fistula—Etiology—Differential Diagnosis—Treatment ... .. 92

CHAPTER V.

RECTO-URETHRAL, RECTO-VESICAL, AND RECTO-VAGINAL FISTULÆ.

Recto-urethral Fistula—Etiology—Symptoms—Treatment—Operation—After Treatment—Comparison of the advantages in the use of the saturated solution of Nitrate of Silver and the Cautery.



## CONTENTS.

Recto-vesical Fistula—Etiology—Symptoms—Treatment—Operation—After Treatment.	
Recto-vaginal Fistula — Etiology — Symptoms — Treatment—Operation—After Treatment ... ..	174

### CHAPTER VI.

#### SINUS OVER THE SACRUM AND COCCYX.

Literature of the Subject—Characteristics—Etiology—Symptoms—Treatment—Cases ... ..	187
--	-----

### CHAPTER VII.

#### ANAL FISSURE.

Description--Position of a Fissure—Etiology—Constipation — Dr. Ball's Views — Incidence of Age, Heredity, and Occupation—Symptoms—Pain—Muscular Spasm — Alteration in Size of the Motion Passed—Hæmorrhage—Physical Examination—Inspection—Condition of the Anal Skin—Condition of the Sphincters—Presence of Discharge—Exploration of the Rectum — Diagnosis — Differential Diagnosis — Morbid Conditions complicating Fissure — Treatment : Palliative, Operative—Operation by (1) Incision (2) Stretching the Sphincters—Method of Operating—After Treatment—Diet after the Operation—Complications after the Operation and their Treatment ... ..	208
---	-----

### CHAPTER VIII.

#### HÆMORRHOIDS OR PILES.

Definition—External Piles—Circumscribed Blood Extravasation at the Anal Margin — Etiology — Symptoms — Physical Examination—Natural Termination—Treatment—Method of Operating—Redundant Folds of Peri-anal Skin—Etiology—Symptoms—Physical Examination — Treatment—Dilated Peri-anal Veins - Etiology—Symptoms—Physical Examination—Treatment—Operation — After Treatment — Internal Piles — Structure — Position in reference to the Rectal Wall—The Various Combinations of Individual Piles	
--	--

CONTENTS.

with each other—Etiology—Symptoms—Hæmorrhage—Pain  
Protrusion—Discharge of Mucus—Physical Examination—  
Anal Inspection—Condition of the Sphincters—Examination  
of the Rectum—Treatment: (1) Palliative (2) Operative—  
Choice of Operation—Modification of Salmon's preferred—  
Method of Operating—After Treatment and Diet—Complica-  
tions after the Operation and their Treatment—Authors'  
objections to other methods of Operation—Strangulated  
Internal Piles—Treatment—Cases unsuitable for Operation—  
Constitutional Defects associated with Internal Piles—Com-  
plications with other Anal and Rectal Diseases—Mortality  
after Operation—Causes of Death     ...     ...     ...     ... 251



## LIST OF ILLUSTRATIONS.

FIG.	PAGE.
I.—Outlet of Pelvis ... ..	2
II.—The Peri-Anal Region ... ..	3
III.—Muscles of the Perineum, diagrammatically represented ... ..	5
IV.—Muscles of the Perineum in the Female ... ..	7
V.—Superficial Muscles of the Perineum in the Male ...	9
VI.—Ischio-Rectal Fossa ... ..	11
VII.—Levator Ani and Coccygeus Muscles of the Right Side, from within... ..	12
VIII.—Curves of the Rectum ... ..	15
IX.—Median Section of the Pelvis and its Viscera in an Adult Male ... ..	17
X.—Median Section of the Pelvis of a Female aged about 30 years ... ..	19
XI.—Plaster-of-Paris Cast of the Rectal Cavity ... ..	23
XII.—The Lower Part of the Rectum laid open at the middle line anteriorly showing the Valves of Morgagni ... ..	24
XIII.—Dissection of the Perineum in the Male ... ..	28
XIV.—Inferior Hæmorrhoidal Veins ... ..	30
XV.—Superior Hæmorrhoidal Veins and Arteries ...	32
XVI.—Dilated Tufts of Veins beneath the Mucous Membrane, constituting the early stage of Internal Piles ... ..	33
XVII.—Lymphatic Vessels of the Anus in the Infant ...	35
XVIII.—Dissection of the Perineum of the Male to show the distribution of the Pudic and other Nerves ...	37
XIX.—Showing the Position recommended for the Examination of Male Patients ... ..	50

LIST OF ILLUSTRATIONS.

FIG.	PAGE.
XX.—Showing the Position recommended for the Examination of Female Patients ... ..	51
XXI.—Illustrating the Method recommended for Mapping out the Anal Region ... ..	52
XXII.—An Ischio-Rectal Abscess resulting from the burrowing of a Subgluteal Abscess through the Great Sacro-sciatic Foramen ... ..	60
XXIII.—Diagrammatic Representation of the Lower Part of the Rectum and its immediate surroundings... ..	61
XXIV.—Showing the Extensive Subcutaneous burrowing caused by Adjacent Follicular Abscesses	63
XXV.—Diagrammatic Representation of an Ischio-rectal Abscess ... ..	66
XXVI.—Diagrammatic Representation of a Submucous Abscess ... ..	70
XXVII.—Diagrammatic Representation of a Pelvi-rectal Abscess ... ..	72
XXVIII.—Diagrammatic Representation of a Pelvi-rectal Abscess which has invaded the Ischio-rectal Fossa ... ..	74
XXIX.—Showing the Wound made by a T-shaped Incision ... ..	80
XXX.—Illustrating the extent of the T-shaped Incision	81
XXXI.—Showing the T-shaped Wound partially healed	83
XXXII.—Diagram of a T-shaped Incision into an Ischio-rectal Abscess ... ..	85
XXXIII.—Diagram of a T-shaped Incision into a Pelvi-rectal Abscess situated posteriorly to the Transverse Anal Line ... ..	88
XXXIV.—A Complete Fistula diagrammatically represented ... ..	93
XXXV.—A Blind External Fistula diagrammatically represented ... ..	95
XXXVI.—A Blind Internal Fistula diagrammatically represented ... ..	97
XXXVII.—Diagrammatic Representation of a Complete Subcutaneous Fistula resulting from a Fissure	100



## LIST OF ILLUSTRATIONS.

FIG.	PAGE.
XXXVIII.—Diagrammatic Representation of a Complete Submuscular Fistula resulting from a Fissure	102
XXXIX.—Diagrammatic Representation of a Submucous Blind Internal Fistula resulting from a Fissure	103
XL.—Showing an External Opening on or just anterior to the Transverse Anal Line ... ..	112
XLI.—Showing Extensive Burrowing of a Fistula in which forty-three External Openings were found at the Operation ... ..	113
XLII.—The same Case as in Fig. XLI., showing the Burrowing laid open ... ..	115
XLIII.—The same Case as in Figs. XLI. and XLII., showing Cicatrisation nearly completed ... ..	116
XLIV.—The same Case as in Figs. XLI.—XLIII., showing the appearance of the Cicatrices three years after the Operation ... ..	117
XLV.—Showing Extensive Subcutaneous Burrowing from a Fistula posterior to the Transverse Anal Line ... ..	123
XLVI.—Showing the Subcutaneous Burrowing of a Fistula posterior to the Transverse Anal Line	124
XLVII.—Showing the Burrowing of an Ischio-rectal Fistula limited to one side ... ..	125
XLVIII.—The T-shaped Wounds of Two Distinct Fistulæ caused by a Foreign Body ... ..	126
XLIX.—The same Case as in Fig. XLVIII., after the Wounds had healed ... ..	127
L.—An Anterior Horse-shoe Fistula partially laid open	129
LI.—An Anterior Horse-shoe Fistula, of which the whole of the External Burrowing has been laid open ... ..	130
LII.—Showing the Subcutaneous Burrowing of a Fistula confined to one side laid open ... ..	141
LIII.—A Fistula passing under the External Sphincter into the Rectum, laid open together with its Lateral Burrowing ... ..	142
LIV.—Appearance of Wound made by the H-shaped Incision ... ..	143




LIST OF ILLUSTRATIONS.

FIG.	PAGE.
LV.—Posterior Horse-shoe Fistula ... ..	144
LVI.—The same Case as in Fig LV., with the wound almost healed ... ..	145
LVII.—Anterior Horse-shoe Fistula ... ..	146
LVIII.—The same Case as in Fig. LVII., showing the External Burrowing laid open ... ..	147
LIX.—Anterior Horse-shoe Fistula (in a Female) ...	148
LX.—The same Case as in Fig. LIX., showing the External Lateral Burrowing laid open... ..	149
LXI.—A Blind Internal Fistula cured by a T-shaped External Incision... ..	151
LXII.—The Partially Healed Wound in Case I., showing the Bilateral Burrowing of a Typical Horse-shoe Fistula ... ..	161
LXIII.—The same Case as in Fig. LXII., showing the wound soundly healed ... ..	162
LXIV.—Skiagram of the Chest in the same Patient as in Figs. LXII.—LXIII., showing the presence of Tuberculous Deposit in the Lungs ... ..	163
LXV.—The Appearance of the partly healed Wound in Case II.... ..	164
LXVI.—Skiagram of the Chest in the same Patient as in Fig. LXV., showing the Tuberculous Deposit in the Lungs ... ..	165
LXVII.—Showing the Burrowing laid open of a Perineal Urethral Fistula, involving both Superficial Perineal Triangles and the Scrotum ... ..	168
LXVIII.—Showing Unilateral Backward and Outward Burrowing in a Case of Perineal Urethral Fistula	171
LXIX.—The External Appearance of a Typical Case of Sinus over the Sacrum and Coccyx ... ..	188
LXX.—Showing an External Opening placed well to the left of the Sacro-coccygeal Articulation ...	189
LXXI.—The same Case as in Fig. LXIX. showing the extent of the Lateral Borrowing ... ..	192
LXXII.—Showing the appearance of the Scar two years after the Operation in Case I. ... ..	194



LIST OF ILLUSTRATIONS.

FIG.	PAGE.
LXXIII.—Appearance of the Scar fourteen months after the Operation in Case II. ... ..	195
LXXIV.—Showing the position of the Scar in Case III. ...	197
LXXV.—Showing the Appearance of the External Opening in Case IV. ... ..	199
LXXVI.—Showing the Appearance of the Wound in Case IV. immediately after the Operation ... ..	200
LXXVII.—Showing the Two External Openings in Case V., both of which were on the left side ... ..	201
LXXVIII.—Showing the Scar in Case V. ... ..	202
LXXIX.—Showing the extent of the Wound in Case VI., after the Burrowing under the Gluteus Maximus had been laid open ... ..	203
LXXX.—The same Case as in Fig. LXXIX., showing the Wound almost completely healed ... ..	204
LXXXI.—Showing the Bi-lateral Burrowing in Case IX. ..	206
LXXXII.—Showing a Typical Fissure . . . . .	210
LXXXIII.—Showing the method of grasping the External Sphincter and everting the Fissure ... ..	239
LXXXIV.—Showing a Single Circumscribed Blood Extravasation at the Anal Margin ... ..	255
LXXXV.—Showing Two Circumscribed Blood Extravasations at the Anal Margin ... ..	256
LXXXVI.—Showing the alteration in the character of the Epithelium in a Pile in the Third Stage of its Development ... ..	277
LXXXVII.—Showing the R.A. Internal Pile protruded ...	278
LXXXVIII.—Showing the R.P. Internal Pile protruded ...	279
LXXXIX.—Showing both the R.A. and the R.P. Internal Piles protruded ... ..	280
XC.—Showing the Œdema of the Peri-anal Skin in a case of Strangulated Internal Piles ... ..	281
XCI.—Showing the A. Internal Pile protruded by the aid of the Finger in the Vagina ... ..	383





# DISEASES OF THE ANUS AND RECTUM.

---

## CHAPTER I.

### ANATOMY.

As a preliminary to the study of the diseases of the rectum and anus, it is essential that we should possess an accurate knowledge of the anatomy of the perineum, first, because diseased conditions can only be accurately determined by comparison with the normal; and, secondly, because intimacy with the relative position and importance of the several structures met with in the region enables us to carry out operative procedures with such precision as will ensure that our interference is extensive enough for the complete cure of the disease, and just so limited that no more damage than is absolutely necessary for the purpose is inflicted upon the structure concerned. To this end, we propose to review the anatomy of that part of the perineum which contains the anal aperture, and to draw attention to the structure and pelvic relations of the rectum.

#### *The Perineal Space.*

The perineal space, as is well known, corresponds to the pelvic outlet of the skeleton, and when the pelvis is examined with its ligaments "*in situ*" it is found to

have the following boundaries (see fig. 1). In front is the symphysis pubis and the sub-pubic ligament; behind lies the tip of the coccyx; while from before backwards, the rami of the pubis and ischium, the ischial tuberosity and the great sacro-sciatic ligament, form the lateral boundary on either side. The above space, which is somewhat diamond-

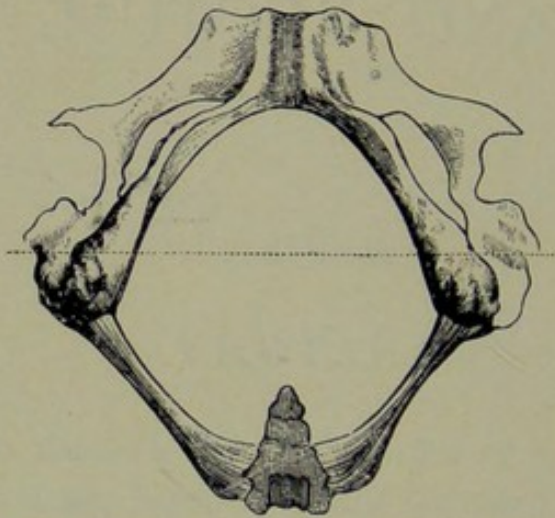


FIG. 1.—OUTLET OF PELVIS. (Cunningham.)

shaped, is subdivided by an imaginary line drawn from the anterior margin of one ischial tuberosity to the other, into an anterior or uro-genital triangle and a posterior or rectal triangle. The latter, since it contains the anus, is the one with which we have to deal, and accordingly we shall call attention to the anatomy of the several structures contained therein.

### *The Rectal Triangle.*

Midway between the tuberosities of the ischia and slightly behind a line drawn between their most prominent points, the anus is situated. This aperture is firmly closed by the sphincter muscles, the skin at the anal margin being thrown into small radiating folds or rugæ. Passing backwards from the posterior margin of the anus to the tip of the coccyx there is a well marked furrow corresponding to a firm band of tissue, known as the ano-coccygeal



ligament (see figure 2). Anterior to the anus and midway between its anterior margin and the bulb of the urethra in the male or the fourchette in the female, is the central point of the perineum, consisting of an indefinite mass of fibrous and muscular tissue. On either side, between the anus and the tuber ischii is the ischio-rectal fossa.

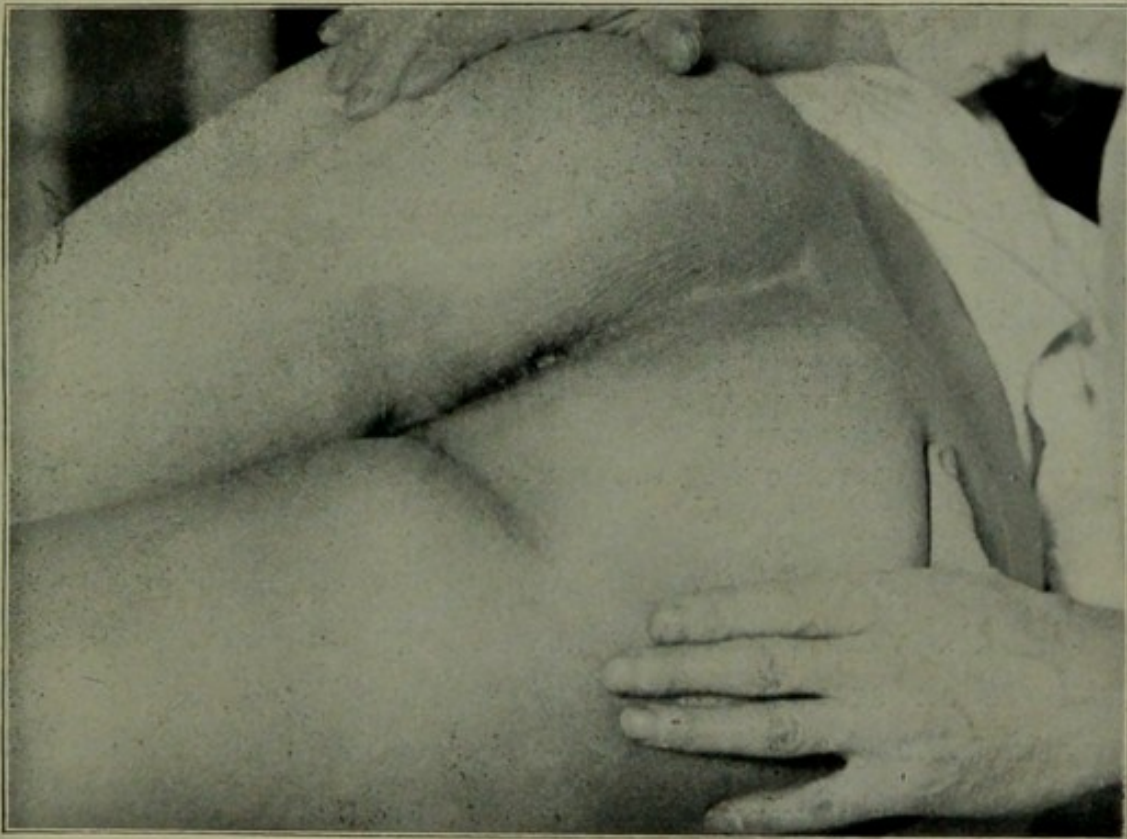


FIG. 2.—THE PERI-ANAL REGION.

### *The Skin.*

In this region the skin is thick and closely bound down to the underlying fascia, this being especially well marked over the tubera ischii. The epidermis is deeply pigmented. There are few papillae in the corium, but close to the margin of the anus they become more numerous and are arranged in clusters. In the skin over the external



sphincter muscle, scattered bundles of unstriped muscular tissue are found radially disposed, constituting the *corrugator cutis ani muscle*. Sweat and sebaceous glands are few and small, except in the vicinity of the anus, where they are numerous and large.

*Surgical Importance.*—In some individuals the skin is tightly stretched over this region, while in others it is much more loosely attached so that it can be readily lifted up between the finger and thumb. This circumstance is of importance in operations about the region, and serves as an indication as to the quantity of skin in the neighbourhood of the anus that may be removed without incurring the risk of ultimate contraction. It is well to bear this fact in mind, especially when removing redundant folds of skin round the anus, such as are met with in cases of piles. It should be noted too, that the more soft and elastic the skin is, the greater is the risk of removing too much, because of the readiness with which the skin can be lifted off the subcutaneous tissue.

#### *The Superficial Fascia.*

In the vicinity of the anus, the superficial fascia consists of an areolar meshwork containing lobules of fat in considerable quantity. The fat thus contained is directly continuous with that occupying the ischio-rectal fossa, there being no definite stratum of deep fascia separating the superficial from the deeper fatty tissue as in other regions of the body. Over the tubera ischii, the superficial fascia becomes more dense in texture, strong fibrous septa intervening between the lobules of fat and binding the skin down to the subjacent bone. Between the fascia and the bone, in this locality, a well developed bursa exists. Anteriorly to the anus, the adipose tissue becomes more scanty and disappears entirely in the scrotum.

*Surgical Importance.*—Abscesses in this tissue often burrow extensively, and, by reason of the fibrous septa existing between the lobules of fat, the burrowing is tortuous. It is



important to remember this fact when operating upon a fistula in this situation, careful probing being necessary to discover the lateral offshoots from the main track.

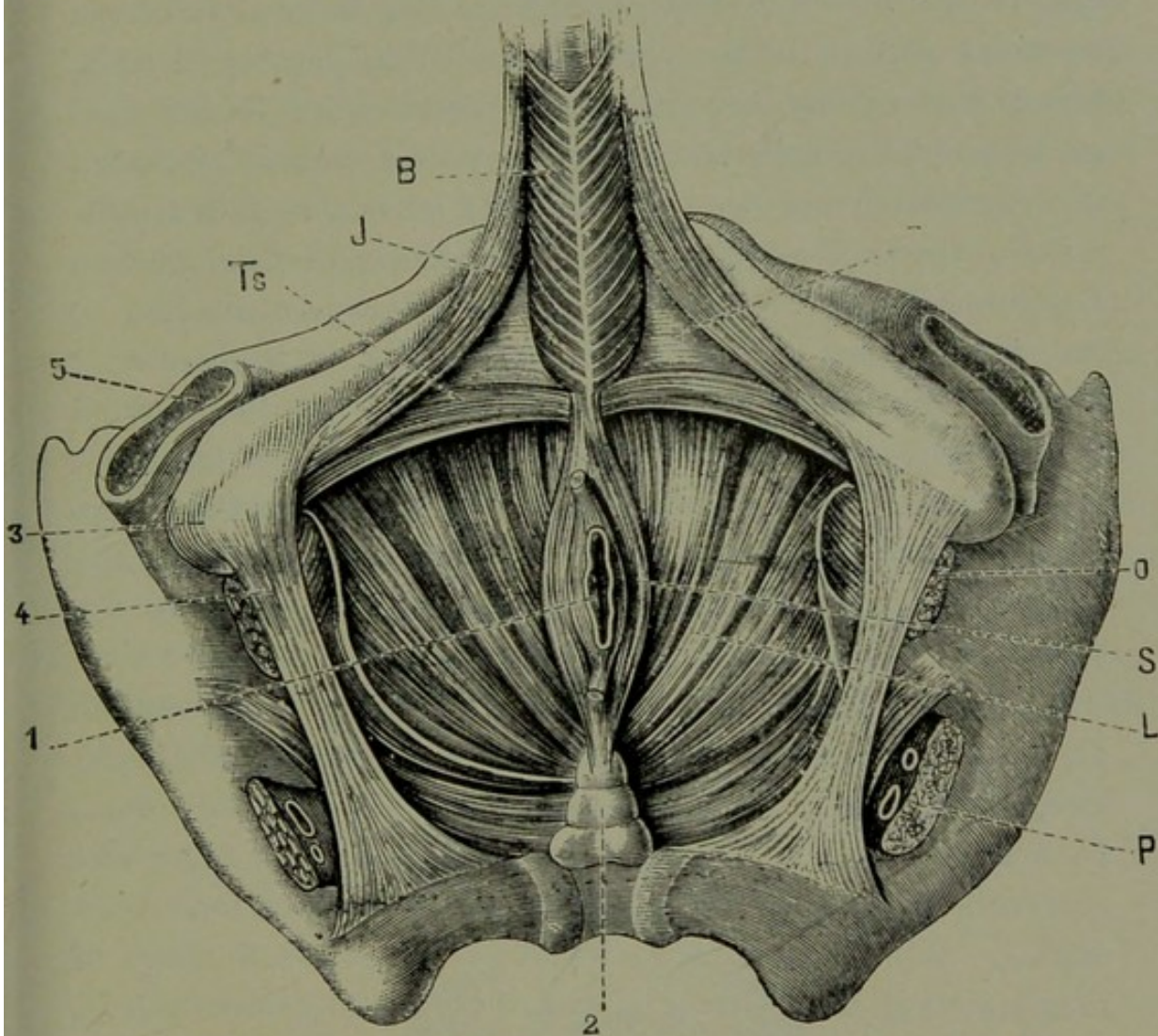


FIG. 3.—MUSCLES OF THE PERINEUM, DIAGRAMMATICALLY REPRESENTED.

1 anus; 2 coccyx; 3 tuber-ischii; 4 greater sciatic ligament; 5 acetabulum;  
 B bulbo-cavernosus; Ts transversus perinei; J ischio-cavernosus;  
 F anterior layer of the triangular ligament; O obturator internus;  
 S sphincter ani; L levator ani; P pyriformis. (A. MACALISTER.)

### *The Sphincter Ani Externus.*

This is a true sphincter muscle and embraces the terminal portion of the rectum. It arises from the dorsal aspect of the tip of the coccyx and also from the ano-coccygeal ligament; and, after dividing to surround the anus, is inserted into the central point of the perineum. Careful dissection will show that on each side the muscle consists



of two distinct strata, one superficial and the other deep (see fig. 3). The former is subcutaneous and its fibres arise from, and are inserted, for the most part, into the skin. The deeper portion is closely applied to the outer coat of the terminal portion of the rectum, immediately external to it, being covered by the tendinous insertion of longitudinal muscular fibres of the bowel, as they pass downwards between the superficial and deep parts of the muscle to gain attachment to the skin of the anus. Thus, the superficial portion lies immediately beneath the skin of the anus, internal to the termination of the longitudinal coat of the rectum; whereas the deep part is placed outside the longitudinal fibres. The nerve supply of this muscle is derived from two sources, viz., the inferior hæmorrhoidal branch of the pudic, and the perineal branch of the fourth sacral nerve; the former being distributed to the superficial part, while the latter supplies the deeper portion.

*Surgical Importance.*—Upon the external sphincter muscle depends the voluntary closure of the anal orifice, and, therefore, this muscle is of the utmost importance to the individual. In health, it relaxes readily during the passage of fæces and contracts as soon as the contents of the rectum have been voided. When hypertrophied and indurated, as a result of long standing constipation or fissure (which may have healed), the muscle is more or less physically, as well as tonically, contracted and is incapable of complete healthy relaxation, so that it offers resistance to the expulsion of solid fæces. For this reason, it frequently has to be divided, in order that the overaction of the muscle may be temporarily suspended, and the induration of its fibres given time to be absorbed. Complete division of the external sphincter, at one or even two places, does not permanently diminish its power of control, at any rate unless the main trunk of its nerve is divided; an accident that can hardly occur provided that the division is done with care, since the nerve is situated very deeply, running along the



inferior surface of the levator ani to its destination. When dividing the external sphincter for fissure, the incision should include the whole thickness of the muscle, the section being carefully carried out, bundle by bundle, until the lower margin of the internal sphincter has been reached, but on no account should that muscle be in any way damaged. Should a less complete division of the external sphincter be made, the healing will be more tedious, extending over months instead of weeks, and occasionally the fissure will not be cured.

In those cases in which a fistula results from a fissure, the fistulous track is sometimes seen to pass only beneath the superficial portion of the external sphincter, the longitudinal fibres of the muscular coat of the rectum preventing it from burrowing beneath the deeper portion. Fistulæ which originate from abscesses in the ischio-rectal fossa enter the bowel beneath the deep portion of the external sphincter, between it and the internal sphincter; so that in such a case it would be necessary to divide both parts of the external sphincter in laying open the sinus of the fistula.

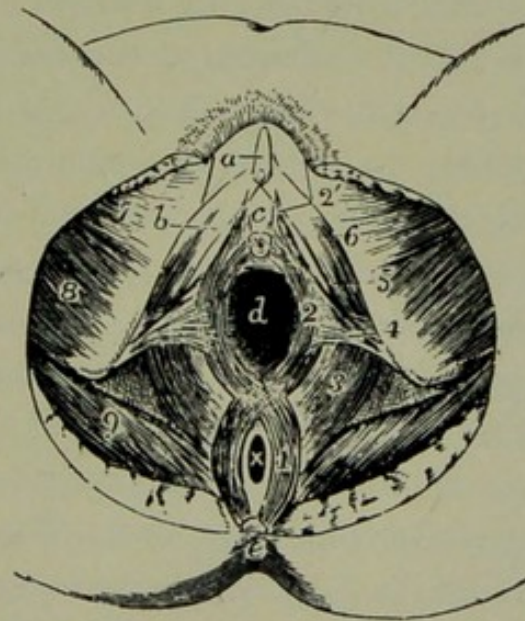


FIG. 4.—MUSCLES OF THE PERINEUM IN THE FEMALE. (Allen Thomson.)

*a* clitoris; *b* crus clitoridis; *c* is placed in the vestibule above the orifice of the urethra; *d* vagina; *x* anus; *e* coccyx; 1 external sphincter of the anus; 2 sphincter vaginae; 2' some of its fibres prolonged to the clitoris; 3 levator ani; 4 on the left ischial tuberosity points to the transversus perinei (the inner portion of this muscle is represented too far forwards in the figure); 5, 6 ischio-cavernosus; 7 gracilis, 8 adductor magnus, semitendinosus, etc. 9 gluteus-maximus. (QUAIN.)



In women, since the fibres of the external sphincter are continued into those of the sphincter vaginae (see fig. 4), any division of them at the point of interlacement tends to weaken the support of the pelvic floor. Consequently, when opening a labial abscess which passes from one side to the other between the anus and the fourchette, or when operating upon an anterior horse-shoe fistula, the track running in front of the anus should not be laid open unless it is quite clear that it passes superficial to the muscular fibres.

### *The Ischio-rectal Fossa.*

The ischio-rectal fossa is the space between the ischial tuberosity and the rectum, and contains a large quantity of fat which forms a compressible pad to allow of the rectum being distended prior to and during the process of defæcation. The space has the shape of a pyramid, the apex being directed upwards towards the pelvic cavity and situated at the junction of the obturator and anal fasciæ. Its base corresponds to the surface covered by skin. It is usual to describe an internal, an external, and a posterior wall to this space, but a glance at the accompanying illustration (see fig. 5) will show that such a description is inaccurate and that we should rather speak of an antero-external, a postero-external, and an internal wall or boundary.

Thus the antero-external wall is formed from without inwards by the body of the ischium, the obturator internus muscle and the obturator fascia below its junction with the anal fascia. The postero-external wall consists of the gluteus maximus muscle, the great sacro-sciatic ligament, and the portion of pelvic fascia covering that ligament. The internal wall is made up of the rectum itself, the levator ani muscle, and the anal fascia. From the above description it will be seen that the true boundaries of the fossa are fascial, namely, the obturator and anal fasciæ and part of the pelvic fascia proper, the apex of the space being formed by the meeting of the anal and obturator



fasciæ at the point where the levator ani takes its origin from the pelvic wall.

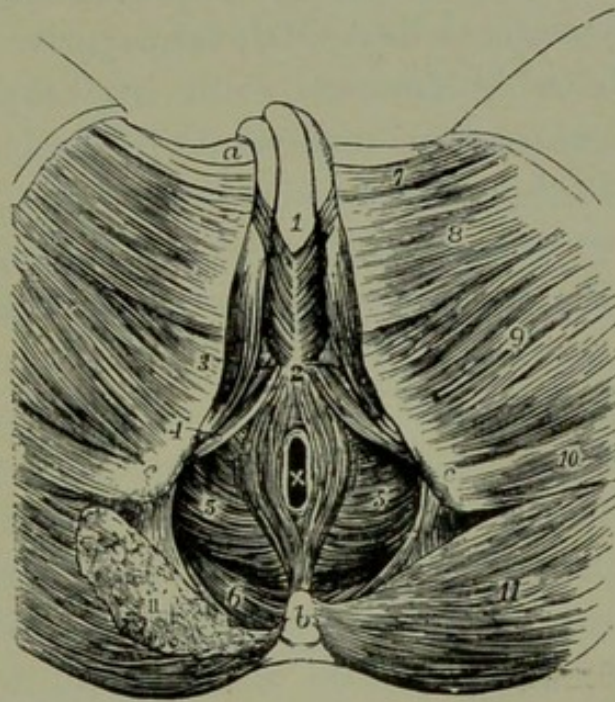


FIG. 5.—SUPERFICIAL MUSCLES OF THE PERINEUM IN THE MALE.

(Allen Thomson, after Bourguery.)

*a* Spine of the pubis; *b* coccyx; *c* placed on the tuberosity of the ischium, points by a line to the great sacro-sciatic ligament; *x* anus; 1 placed on the corpus spongiosum uretræ in front of the bulbo-cavernosi muscles; 2 central point of the perineum; 3 ischio-cavernosus; 4 transversus perinei; 5 levator ani; from 2 to *b*, external sphincter of the anus; surrounding *x* is the internal sphincter; 6 coccygeus; 7 adductor longus; 10 semitendinosus and biceps; 11 on the left side, the gluteus maximus entire; 11' the same cut on the right side, so as to expose a part of the coccygeus muscle. (QUAIN.)

In addition to the fatty tissue contained in the ischio-rectal fossa, there are numerous vessels and nerves. The arteries are the inferior hæmorrhoidal branches of the internal pudic, which, after piercing the inner wall of Alcock's canal, run forwards and inwards through the ischio-rectal fat and supply the terminal portion of the rectum, the superficial and deep portions of the external sphincter, and the circum-anal skin. One or more of these branches pass through the plane of separation between the two portions of the external sphincter. Those branches that are distributed to the rectal wall form loops of communication with the offsets from the middle hæmorrhoidal branch of the internal iliac and the superior hæmorrhoidal branch of the inferior mesenteric. The inferior hæmorrhoidal veins follow the same course as the arteries of



the same name, and after collecting blood from the peri-anal skin, external sphincter, and the terminal portion of the rectum where they communicate with the superior hæmorrhoidal plexus, cross the ischio-rectal fossa in company with the arteries, and piercing the inner wall of Alcock's canal, empty themselves into the internal pudic vein.

The inferior hæmorrhoidal nerve also accompanies the vessels and arises, either as a separate branch from the sacral plexus, or from the pudic nerve. Leaving Alcock's canal, it breaks up into muscular and cutaneous branches, the former being distributed to the superficial portion of the external sphincter muscle, the latter terminating in the integument and skin of the anus as far as the mucocutaneous junction. This nerve also communicates with the long pudendal branch of the small sciatic nerve and with the superficial perineal branches of the pudic, which are found in the anterior part of the fossa close to the base of the triangular ligament.

The perineal division of the fourth sacral nerve, after piercing the levator ani or issuing between it and the coccygeus, supplies that structure and running along its perineal surface from behind forwards enters the deep portion of the external sphincter behind the *transverse anal line*.\* This nerve also supplies the integument between the anus and coccyx.

*Surgical Importance.*—The frequency with which abscess is met with in the ischio-rectal fossa renders its anatomy particularly interesting. A reference to fig. 6 shows that, above and internally, the anal fascia and the levator ani muscle alone intervene between this fossa and the superior pelvi-rectal space, from which it may be readily understood how a purulent collection in the latter situation can make its way into the ischio-rectal fossa, between the fasciculi of the levator ani muscle and thence breaking through the delicate

---

\*See page 51.



anal fascia, appear as an ischio-rectal abscess. This circumstance explains the comparative frequency with which septic cellulitis, in the neighbourhood of the broad ligament and uterus, is apt to terminate in an ischio-rectal abscess.

When the confines of the ischio rectal fossa are examined posteriorly, it will be observed that the fossa on one side is separated from that of the opposite side merely by the attachment of the posterior fibres of the levator ani muscle to the

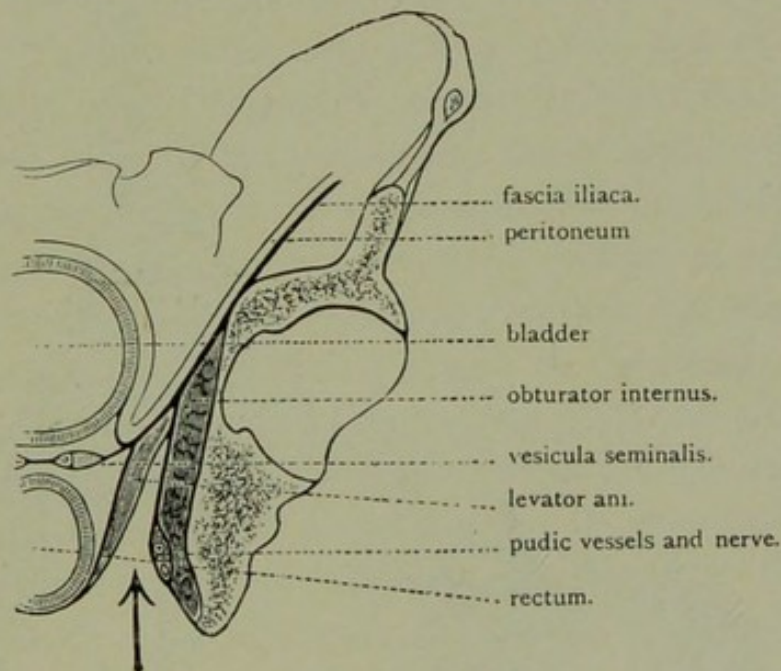


FIG. 6.—The arrow is directed upwards into the ischio-rectal fossa. The parietal pelvic fascia is seen upon the inner surface of the obturator internus. Observe also the anal fascia clothing the outer surface of the levator ani and the rectal fascia upon its inner surface. (CUNNINGHAM.)

ano-coccygeal ligament, so that it is possible for an abscess in one ischio-rectal fossa to make its way to the opposite side by insinuating itself between the levator ani and the ano-coccygeal ligament. This is precisely what happens in the variety of fistula known as the "posterior horse-shoe," the connecting track, between the abscess cavity on either side, passing deep to the ano-coccygeal ligament behind the rectum. Unless this fact be kept in mind when operating on a posterior horse-shoe fistula, the connecting track between the two abscess cavities is apt to be overlooked and the fistula in consequence may probably remain uncured despite repeated operations.



*The Levator Ani Muscle.*

The levator ani muscle constitutes the greater part of the so called pelvic diaphragm. Its superior surface is covered by the recto-vesical layer of the pelvic fascia, while its

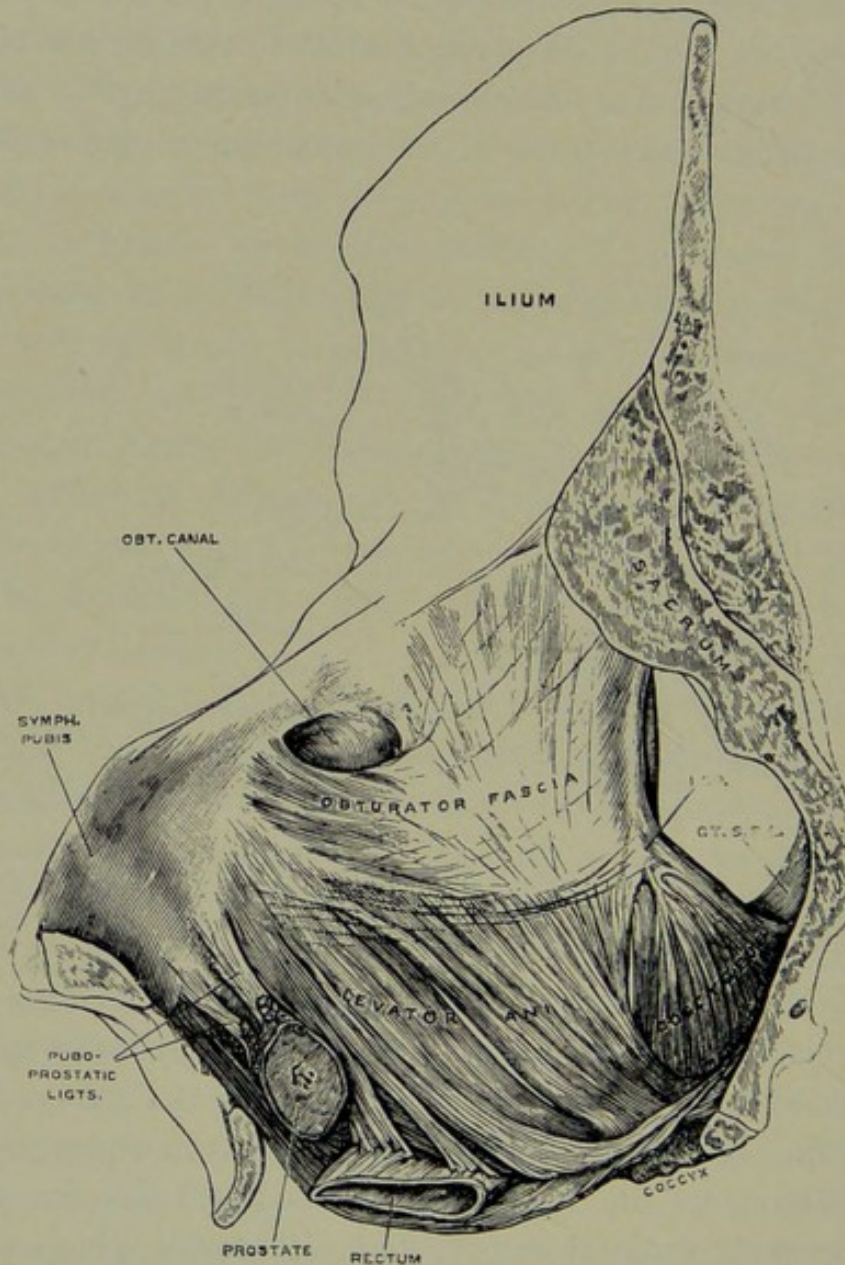


FIG. 7.—LEVATOR ANI AND COCCYGEUS MUSCLES OF THE RIGHT SIDE, FROM WITHIN. (Drawn by T. W. P. Lawrence.)

i.sp., ischial spine; gt.s-s.l., great sacro-sciatic ligament. (QUAIN.)

inferior or perineal aspect is lined by the delicate anal fascia, which, as we have already seen, forms the inner boundary of



the ischio-rectal fossa. The levator ani has an extensive origin from the anterior and lateral aspects of the pelvic wall, from which its fibres pass obliquely downwards, backwards and inwards towards the middle line (see fig. 7). Superiorly, it is attached (*a*) to the pelvic aspect of the body of the os pubis in the angle formed between the obturator and recto-vesical fasciæ; (*b*) to the pelvic fascia along the so called white line and (*c*) to the spine of the ischium. From the above extensive origin, its fibres are inserted in the following manner. Those arising from the os pubis and the anterior part of the white line, pass almost straight backwards to the central point of the perineum; those taking origin from the remainder of the white line are directed downwards, backwards, and inwards to the terminal portion of the rectum and to the ano-coccygeal ligament; while the posterior fibres find insertion into the lateral aspect of the coccyx. Of the fibres which embrace the lower portion of the rectum, the superficial are arranged circularly just above the deep part of the external sphincter, while the deeper ones pass inwards between the external and internal sphincters to become incorporated with the longitudinal fibres of the muscular coat of the rectum itself.

In a carefully dissected specimen of this muscle (see fig. 3). it will be noticed that several intervals exist between the muscular fasciculi, through which the recto-vesical fascia can be seen.

The action of the levator ani is somewhat complicated. When the two muscles act together as a whole, they chiefly support and tend to raise the pelvic floor. This action can be well seen in a subject whose terminal portion of the rectum has been extirpated. On making an effort to close the aperture, the whole pelvic floor is found to recede and to be drawn upwards. The fibres which surround the rectum act by compressing that viscus and so assist in the expulsion of fæces; while those fibres which pass between the external and



internal sphincters to blend with the longitudinal coat of the rectum, expand the anal orifice as a preliminary to expulsion. During the act of defæcation, the contraction of the levator ani compresses the neck of the bladder and closes the urethra while the fæces are being passed from the rectum.

The levator ani receives its nerve supply from the perineal branch of the fourth sacral nerve and from the deep branch of the perineal division of the pudic nerve.

*Surgical Importance.*—By its insertion into the terminal portion of the rectum, the levator ani maintains that viscus in position, so preventing it from being protruded. Therefore in extirpation of the lower part of the rectum, it is necessary to completely sever the attachments of the muscle to the rectal wall, in order that the bowel may be drawn out of the wound. It is expedient that the muscular fibres of the levator ani be divided, in this operation, close to the rectum, so that the support of the pelvic floor may be interfered with as little as possible. In all other operations upon the lower part of the rectum, the fibres of the levator should not, if possible, be damaged lest the power of expulsion be impaired.

### *The Rectum.*

The terminal eight or nine inches of the large intestine constitute the rectum. Contained entirely within the cavity of the true pelvis, the rectum extends from the left sacroiliac synchondrosis, at a point where it is continuous with the sigmoid flexure of the colon, to the anal aperture. This portion of the bowel does not run a straight course, but presents three distinct curves. Starting from the left sacroiliac synchondrosis, it is first directed downwards, backwards, and to the right, then it curves forwards lying in the concavity of the sacrum, and, finally changing its direction at a point corresponding to the tip of the coccyx, bends backwards to terminate at the anus (see figure 8). It is important to



bear these curves in mind when introducing instruments into the rectum. The upper half of the rectum is closely bound down to the sacrum by the meso-rectum, and is, therefore, more or less fixed, while the lower half has no peritoneal investment and is more freely movable.



FIG. 8.—CURVES OF THE RECTUM. (Quénu and Hartmann.)

In order to facilitate the description, it is usual to subdivide the rectum into three portions, viz., the upper segment extending from the left sacro-iliac synchondrosis to the middle of the third piece of the sacrum; the second segment extending from the middle of the third sacral vertebra to the level of the tip of the coccyx; and a terminal portion extending from the tip of the coccyx to the anal aperture.

#### *The Upper Portion of the Rectum.*

This measures from four to five inches in length in the adult, and is completely invested by peritoneum, which forms a distinct meso-rectum by means of which it is attached to the posterior aspect of the pelvic cavity. It is directed



downwards, backwards, and to the right, and ends in the middle line opposite the middle of the third piece of the sacrum, and at this point the meso-rectum usually ceases to exist. The first portion of the rectum is very similar in outward appearance to the sigmoid colon, and has well marked sacculi and appendices epiploicæ. For this reason some authors, notably Huguier, consider that this part of the large intestine does not belong to the rectum at all, and should be included in the description of the sigmoid colon.

*Relations :—*

*In front* are some convolutions of the small intestine, the bladder in the male when distended, and the uterus in the female when enlarged.

*Behind* lie the first three pieces of the sacrum; the pyriformis muscle; and the meso-rectum containing the superior hæmorrhoidal vessels.

*On its left side* are the ureter and the branches of the internal iliac artery.

*On the right side* are coils of small intestine.

*Variations.*—In recently born infants, the first part of the rectum is situated in the abdominal cavity because of the shallowness of the pelvis, and the rectum appears to enter the pelvis to the right of the middle line. In an adult subject examined by Mr. Miles in the dissecting room at St. Bartholomew's Hospital, the first portion of the rectum passed transversely across the promontory of the sacrum from the left to the right sacro-iliac synchondrosis, from whence it dipped down into the pelvic cavity. In those rare cases of complete transposition of viscera, the rectum enters the pelvis on the right side.

*The Middle Portion of the Rectum.*

This portion of the bowel measures about two and a half inches in length, and extends from the middle of the third piece of the sacrum to the level of the tip of the coccyx. The



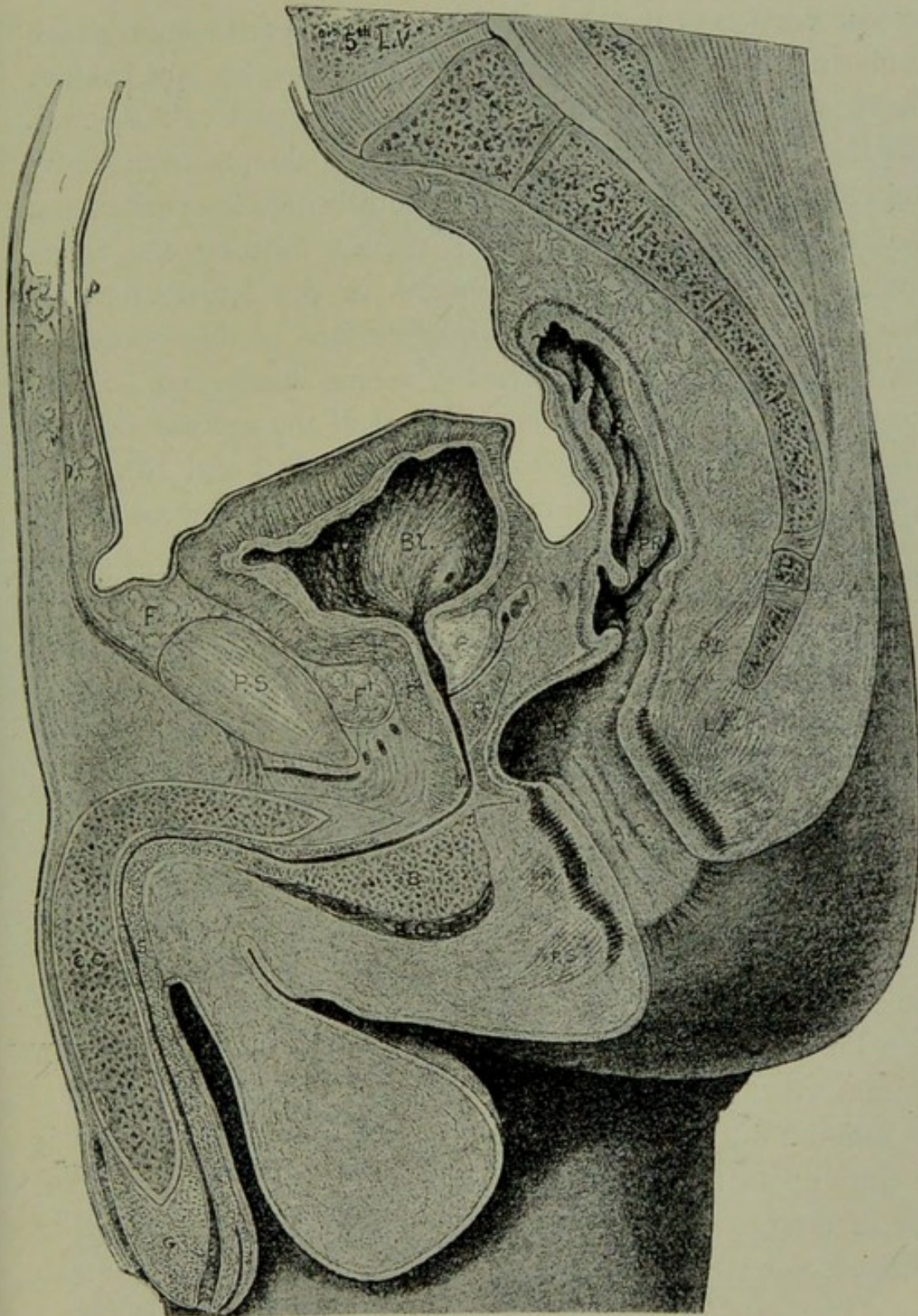


FIG. 9.—MEDIAN SECTION OF THE PELVIS AND ITS VISCERA IN AN ADULT MALE. (J. S.)

The bladder contained about three ounces of urine, and there were some feces in the lower part of the rectum 5th L.V., body of 5th lumbar vertebra; S. on body of second sacral vertebra; P.S. pubic symphysis; R.R. rectum; P.R. plica dextra recti; A.C. anal canal with its longitudinal folds of mucous membrane—the columns of Morgagni; the tissue between the anal canal and the coccyx constitutes the ano-coccygeal body; I.S. internal sphincter; E.S. external sphincter; L.A. levator ani; R.A. rectoccygeus muscle; Bl. bladder; P. P<sub>1</sub> P<sub>2</sub> prostate gland, P. its middle lobe; between P. and P<sub>1</sub> the common ejaculatory duct; M. membranous part of urethra; S. spongy part of urethra; C.C. corpus cavernosum; G. glans penis; B. bulb of corpus spongiosum; B.C. bulbo cavernosus muscle; F. supra-pubic pad of fat; F<sub>1</sub> retro-pubic pad; P. peritoneum. (QUAIN.)



greater portion of it is in relation with the peritoneum, which forms an investment in front and at the sides, but not behind. There is, therefore, no meso-rectum to this part of the bowel. The line of reflection of the peritoneum is oblique from above and behind forwards, so that at the point where the peritoneum passes on to the bladder in the male forming the recto-vesical pouch, or on to the vagina in the female forming Douglas's pouch, only the anterior surface of this portion of the rectum is in relation with the serous membrane. Below the point of reflection the second part of the rectum receives no covering from the peritoneum (see figs. 9 and 10). The extent of this uncovered portion varies with the degree of distension of the bladder in the male and the enlargement of the uterus in the female. This disposition of the peritoneum, in its relation to the second portion of the rectum, has led Quénu and Hartmann\* to subdivide it into two portions, namely, an upper or peritoneal portion, and a lower or non-peritoneal part, which latter measures about one inch in length.

*Relations :—*

*In front.*—In the male subject will be found the recto-vesical pouch of the peritoneum; the base of the bladder corresponding to the trigonum vesicæ; the vasa deferentia; the vesiculæ seminales and the prostate gland. In the female, Douglas's pouch and the posterior wall of the vagina are in contact with this portion of the rectum.

*Behind.*—In both males and females the middle portion is in close apposition to the concave surface of the lower portion of the sacrum and the coccyx, being separated from them by loose areolar tissue, containing one or more lymphatic glands.

*The Lower Portion of the Rectum.*

This measures about one inch and a half in length, and corresponds to that part of the bowel which is embraced by the levatores ani, the internal sphincter and the external

---

\* Chirurgie du Rectum, 1895 page 3.



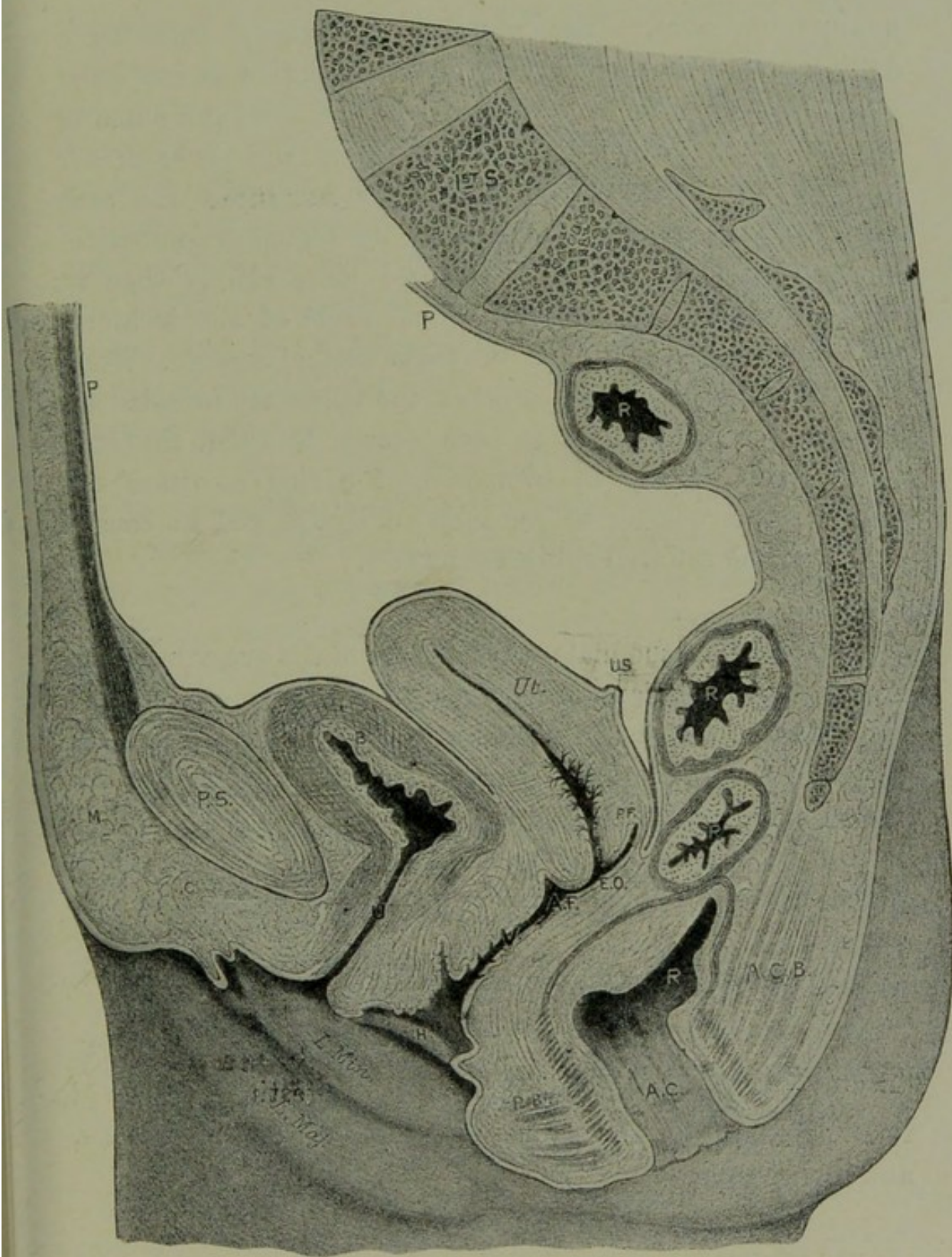


FIG. 10.—MEDIAN SECTION OF THE PELVIS OF A FEMALE AGED ABOUT 30 YEARS. (J. S.)

1st S. body of 1st sacral vertebra; P.S. pubic symphysis; B. bladder; U. urethra; Ut. uterus; O. external os uteri; U.S. utero-sacral ligaments, which are united with one another on posterior aspect of uterus; V. vagina; A.F. anterior vaginal fornix; P.F. posterior vaginal fornix; H. hymen; R. rectum; A.C. anal canal; L. Min. labium minus; L. Maj. labium majus; C. clitoris; M. fat of mons pubis; P. peritoneum; P.B. perineal body; A.C.B. ano-coccygeal body.

"This section was made after hardening the body by an injection of a 1 p.c. solution of chromic acid, and the distension of the abdominal vessels with this fluid probably depressed somewhat the vic viscera." (QUAIN.)



sphincter muscles. These muscles, in virtue of their tonic contraction, make this part of the rectum into a narrow canal or passage, and, for this reason, it has received the name of *the anal canal*. When the rectum is empty, and the sphincter muscles are tonically contracted, the length of the anal canal can be readily appreciated by digital examination. In women, this can be determined more readily than in men, by making a combined examination of the levatores ani and sphincters through the recto-vaginal septum. When the rectum is distended, or when the sphincter muscles are relaxed, the anal canal as such ceases to exist, the anal outlet being felt to be composed of a ring of tissue not more than a quarter of an inch in depth, and to consist chiefly of the external sphincter muscle.

*Relations :—*

*In front.*—In the male, are the apex of the prostate gland, the base of the triangular ligament, and the mass of muscular and fibrous tissue representing the perineal body. In the female, are the lower part of the posterior wall of the vagina and the perineal body.

*Behind.*—The ano-coccygeal ligament, the posterior fibres of the levatores ani, and the origin of the external sphincter muscle.

*Laterally.*—The ischio-rectal fossa and its contents.

*Structure of the Rectum.*

The rectum, like the rest of the large intestine, consists of four coats, namely, the serous, the muscular, the submucous, and the mucous.

*The Serous Coat.*

This exists as a complete investment in the upper part of the rectum only. In the middle part, it forms but a partial covering, and is entirely absent from its posterior surface. On its lateral aspects, the serous covering is partial, the line of reflection being oblique from above and behind



downwards and forwards until the anterior surface alone is covered. In the male, at a point situated about one inch above the upper border of the prostate, the peritoneum leaves the anterior surface of the rectum, and is reflected on to the bladder. In the female, about two inches above the rectal attachment of the levatores ani, the peritoneum is reflected on to the upper part of the vagina and the uterus. The distance of the point of reflection from the anal orifice, in the male sex, is about two inches and a half when the bladder is empty, and three inches and a half when that viscus is distended.

#### *The Muscular Coat.*

The muscular fibres of the rectal wall are arranged in two distinct layers, namely, an outer or longitudinal and an inner or circular stratum. The longitudinal fibres are evenly distributed and are no longer divided into three distinct bands, as they are in the colon. These longitudinal fibres, according to Sappey,\* terminate in the following manner. The outermost are inserted into the layer of pelvic fascia lining the upper surface of the levatores ani; the middle blend with those of the levatores ani; while the innermost pass between the internal and external sphincters to be inserted by a series of fine tendons into the skin of the anal margin. These tendons can, according to our observations, be seen to pass also between the superficial and deep portions of the external sphincter before terminating in the skin. The origin of the tendons takes place between the lower margin of the internal and the upper margin of the external sphincter. The circular fibres are, for the most part, uniformly disposed and form a complete layer. At the termination of the rectum, these circular fibres are aggregated into a thick band, constituting the internal sphincter, which is situated immediately above the upper border of the external sphincter, and separated from it by an interval, which has

---

\*Quoted by Quain.



received the name of the *white line of Hilton*. In the upper portion of the rectum, the circular fibres form distinct bands between the sacculations (Quain).

### *The Internal Sphincter*

Is an hypertrophy of the lowermost circular fibres of the rectum and consists entirely of unstriped muscular tissue. The limits of this band can be made out by digital examination of the interior of the rectum. It has been estimated by Sappey to be from 4 to 6 cm. wide, and from 3 to 4 mm. thick. The internal sphincter muscle embraces the greater part of the anal canal, and upon its integrity the involuntary closure of the anal orifice depends.

*Surgical importance.*—Partial injury to this muscle causes great impairment of the power of control; while complete division, even on one side, frequently leads to permanent rectal incontinence.

### *The Submucous Tissue*

Consists of an areolar meshwork forming a bed for vessels, nerves and lymphatics. It is more abundant and of looser texture than in other regions of the intestine, thereby allowing of much freedom of movement of the mucous membrane upon the subjacent muscular coat.

### *The Mucous Membrane.*

This is more vascular than that of the colon and is also of greater thickness. On account of the looseness of the submucous tissue, it is capable of free movement over the muscular coat. When the rectum is empty, the mucous membrane is thrown into folds but these, for the most part, disappear during distension. When the rectum is distended, however, certain folds do not become effaced. These have been described under the name of the folds of *Houston*. These folds vary both in number and in position. That they exist is shown by figure 11 illustrating a Plaster-of-



Paris-cast of the rectal cavity (Quénu & Hartmann).\* The largest of these folds is situated, in front and to the right side, at the level of the reflection of the peritoneum from the rectum to the bladder or vagina. Two other folds may be present but are less constant. When existing, they are situated on the left side, one above and the other below, the main fold (this is well shown in fig. 11). The mucous membrane of the anal canal, immediately above the muco-cutaneous junction or *white line of Hilton*, is thrown




FIG. 11.—PLASTER-OF-PARIS-CAST OF THE RECTAL CAVITY.  
(Quénu and Hartmann).

into longitudinal folds, three or four on each side, which are known as the *Columns of Morgagni*. These are undoubtedly caused by the constricting effect of the internal sphincter, of which they are the natural consequence. According to Treitz, these folds contain longitudinal muscular fibres. Between these folds, and situated about 3 to 9 mm above *Hilton's white line*, well marked pockets or semi-lunar valves are to be seen. These are known as the *Valves of Morgagni* and are best seen in young individuals and new born infants. In the adult, they

\* Op. cit., page 21.



are not so distinct. The accompanying illustration (fig. 12), taken from the rectum of a boy 9 years of age, shows these valves. So far as our observations on this point are concerned, they seem to have a constant arrangement. Thus in the middle line posteriorly there is no valve, but on each side of it there is a large one; then follows an interval corresponding to the lower part of a column of Morgagni;

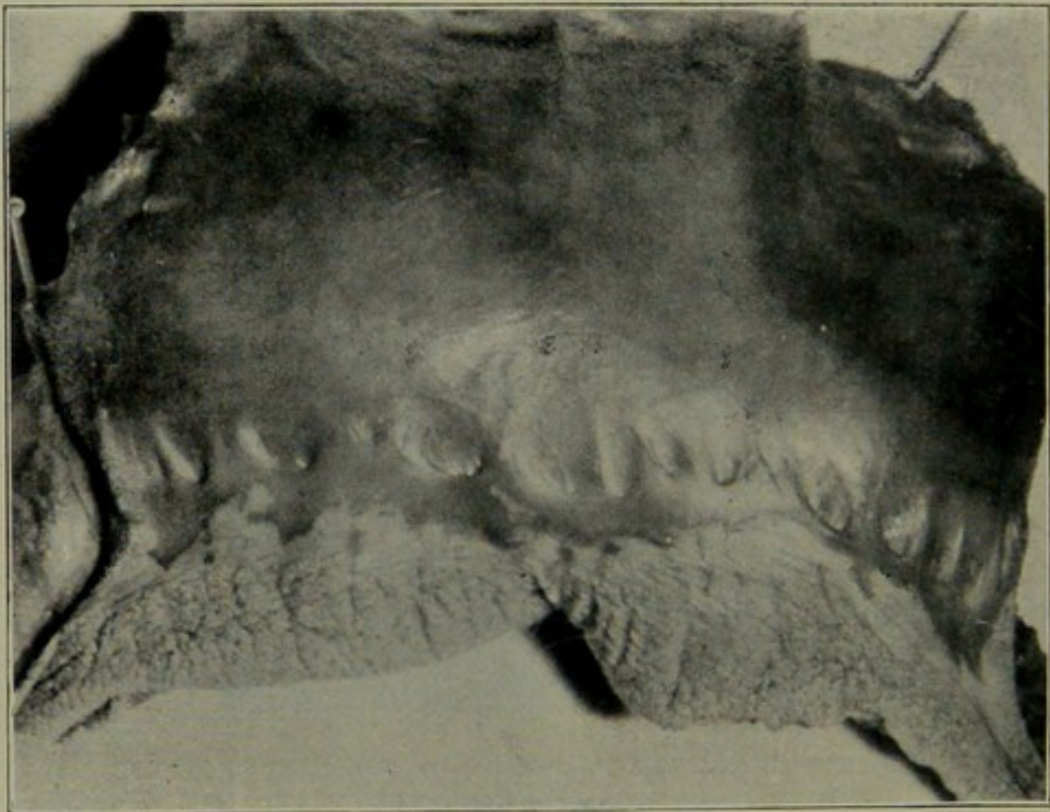


FIG. 12.—THE LOWER PART OF THE RECTUM LAID OPEN AT THE MIDDLE LINE ANTERIORLY SHOWING THE VALVES OF MORGAGNI.

then there is another valve followed also by an interval. Anteriorly there is no valve. Each valve limits a small saccule or pocket into which a probe may be introduced in a downward direction for a distance varying from a quarter to three-eighths of an inch. The use of these valves is a matter of conjecture. Some consider that they serve as reservoirs for rectal mucus. Ball, of Dublin, attaches



great importance to them, as he considers that they may be torn down during the passage of a hard motion and so give rise to fissure.

The epithelium of the rectal mucous membrane is of the columnar variety and, in this respect, is similar to that of the remainder of the intestine. Just above the muco-cutaneous junction, the columnar epithelium undergoes a change becoming stratified in character. This transition occupies a narrow zone, situated immediately above Hilton's white line and between it and the line of Morgagni's valves. To this zone the name of *pecten* has been given (Stroud).† The surface of the pecten is smooth and has a glistening appearance. Its colour is intermediate between that of the mucous membrane and the skin, and is almost devoid of sweat glands. The stratified epithelium found in this region is richly supplied with nerve endings. The epithelium covering the surfaces of the valves of Morgagni consists of oval or fusiform cells placed close together.

### *Anal Papillae.*

In a certain number of cases small papillae will be found to arise either from the margins or from the surfaces of the valves of Morgagni. According to Stroud\* these papillae are not constant but, when existing, are found to consist of a small quantity of connective tissue containing nerve fibres and ganglion cells, and having a lining of epithelium identical with that of the pecten. These papillae are peculiar to man. Stroud considers them to be "accessory sense organs of a higher degree of development than the major part of the pecten and not pathologic outgrowths." According to our own observations, they can readily be made out by the exploring finger. They not infrequently become hypertrophied and constitute one form of polypoid growth.

† Annals of Surgery, 1896, vol. 24, p. 1.

\* Loc. cit.



*Blood-vessels of the Rectum and Anus.**Arteries.*

The arterial blood supply is derived from three sources, viz., a superior hæmorrhoidal which is the terminal branch of the inferior mesenteric; a middle hæmorrhoidal from the internal iliac; and an inferior hæmorrhoidal from the internal pudic.

*The superior hæmorrhoidal artery* enters the meso-rectum and soon divides into two primary branches, a right and a left, the former being distributed to the posterior and right lateral aspects of the upper half of the rectum, and the latter to its anterior and left lateral aspects. Both these primary divisions give off several branches which ramify on the external surface of the bowel and form loops of anastomosis. From these loops several branches arise which pierce the muscular coat at different levels and, entering the sub-mucous tissue, the majority of them break up for the supply of the mucous membrane; while others, six or seven in number, take a longitudinal course downwards beneath the mucous membrane. These latter branches, which are terminal, may be traced as far as the saccules of Morgagni, one lying in each column of Morgagni accompanied by a corresponding vein (see fig. 15).

*Surgical importance.*—The pulsation of these terminal arteries can be felt by the finger in the rectum and their exact position so made out. When internal piles are well developed, they may be considerably enlarged and will give rise to severe recurrent hæmorrhage should a ligature slip or otherwise become detached. Such hæmorrhage is difficult to control since the divided artery usually retracts to a considerable extent. It is important also to bear in mind the position and arrangement of these vessels when laying open the submucous burrowing of a fistula. Fortunately such burrowing usually takes place in the interval between neighbouring



vessels, so that if the incision be limited to the mucous wall of the submucous burrowing they will be avoided. Occasionally, however, the burrowing may take a somewhat oblique course and cross the line of one of these arteries. When this happens, the track passes superficial to the vessel which remains in contact with the muscular coat and, therefore, if the probe-director be kept close to the mucous membrane during its introduction along the track, the danger of including the artery will be diminished. In excision of the rectum, these vessels are necessarily divided and must be secured. They should be secured separately when excision is the primary operation, but, when a preliminary colotomy has been performed, they are best secured *en masse* by transfixion of the bowel above the point of section and ligaturing in two halves.

*The middle hæmorrhoidal artery* arises from the anterior division of the internal iliac. It is distributed to that part of the rectum situated between the peritoneal reflection and the levatores ani and inosculates freely with branches of the superior hæmorrhoidal. In the female, this artery is usually absent, its place being taken by branches from the vaginal. In the male, the middle hæmorrhoidal furnishes several branches to the prostate. The main distribution of this artery is to the muscular coat of the bowel, a few small branches extending to the submucous coat where they form communications with branches of the superior and inferior hæmorrhoidal arteries.

*The inferior hæmorrhoidal artery* arises from the internal pudic as it lies in Alcock's canal. Piercing the inner wall of that space, the vessel divides into several branches which traverse the ischio-rectal fat on their way to the anus. In the ischio-rectal fossa, several branches are given off to the fatty tissue and others, becoming cutaneous, are distributed to the skin of the peri-anal region. The terminal branches enter the substance of the external sphincter muscle which they supply (see fig. 13). A few pass between the superficial and deep



portions of the external sphincter and also between the internal and external sphincters, and ramify beneath the

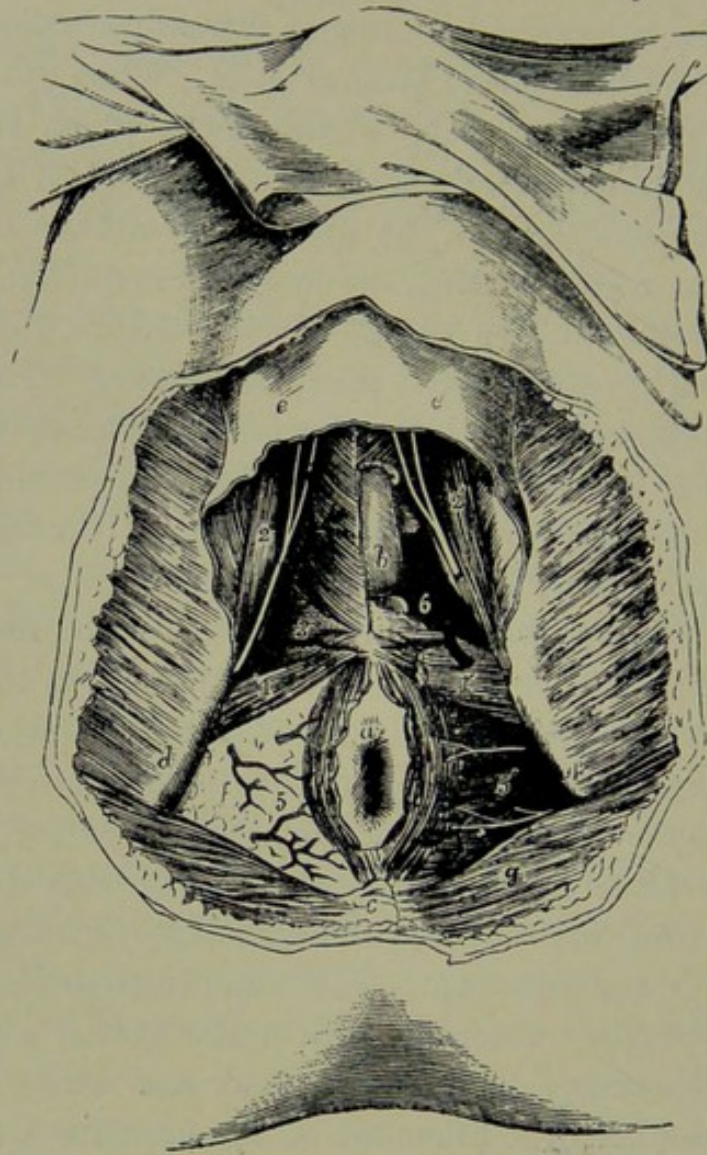


FIG. 13.—DISSECTION OF THE PERINEUM IN THE MALE. (Allen Thomson.)

The right side shows a superficial, the left a deeper view. *a.* anus, with a part of the integument surrounding it; *b.* left half of the bulb of the corpus spongiosum, exposed by the removal of the bulbo cavernosus muscle; *c.* coccyx; *d.* right ischial tuberosity; *e.e.* superficial perineal fascia; *f.* fat occupying the right ischio-rectal fossa; *g.* gluteus maximus muscle: 1, on the right transversus perinei muscle points to the superficial perineal artery as it emerges in front (in this case) of the muscle; 1', on the left side, on the surface of the triangular ligament, points to the superficial perineal artery cut short; 2, on the right ischio-cavernosus muscle, points to the superficial perineal artery and nerves passing forwards; 2', on the left side, the same vessels and nerves divided; 3, on the right half of the triangular ligament, points to the transverse perineal artery; 4, on the left ischial tuberosity points to the pudic artery deep in the ischio-rectal fossa; 5, 5', inferior hæmorrhoidal branches of the pudic arteries and nerves; 6, on the left side placed in a recess, from which the inferior layer of the triangular ligament has been removed, in order to show the continuation of the pudic artery, its branches to the bulb, and Cowper's gland. (QUAIN.)

mucous membrane of the anal canal, where they form communications with the middle hæmorrhoidal.



*Surgical importance.*—The branches of the inferior hæmorrhoidal artery are frequently divided when operating upon abscess or fistula in the ischio-rectal fossa. The bleeding is at first free but soon stops, so that it is seldom necessary to apply a ligature. The burrowing of a fistula in the ischio-rectal fossa often circumvents branches of the inferior hæmorrhoidal artery and the tissue in which they are imbedded. Accordingly, when the subcutaneous burrowing has been laid open, a careful search should be made for a track dipping down beneath these branches.

### *Veins.*

The veins of the lower half of the rectum and of the anus are very numerous and form a close meshwork, known as the hæmorrhoidal plexus, of which there are three distinct zones, viz., an inferior, a middle, and a superior, corresponding to the distribution of the hæmorrhoidal arteries. The plexuses of the superior and inferior zones communicate freely with one another, but that of the middle zone is in the main distinct, there being but slight communication with the others. Since the blood from the superior hæmorrhoidal plexus passes into the rootlets of the portal vein, and that of the inferior hæmorrhoidal plexus into the internal iliac vein, there is a free communication in this region between the portal and caval systems.

*The inferior hæmorrhoidal plexus* is arranged subcutaneously round the anus along the outer border of the external sphincter. This venous ring receives numerous small branches from the sub-muco-cutaneous tissue of that part of the anal canal situated below Hilton's white line. The majority of these pass superficially to the external sphincter and, therefore, are entirely subcutaneous, while others find their way between the superficial and deep portions of the external sphincter. These branches constitute the communication between the superior and inferior hæmorrhoidal plexuses. From the



venous ring, efferent branches pass in three directions,\* viz., anteriorly, one or more veins pass along the cruro-scrotal fold

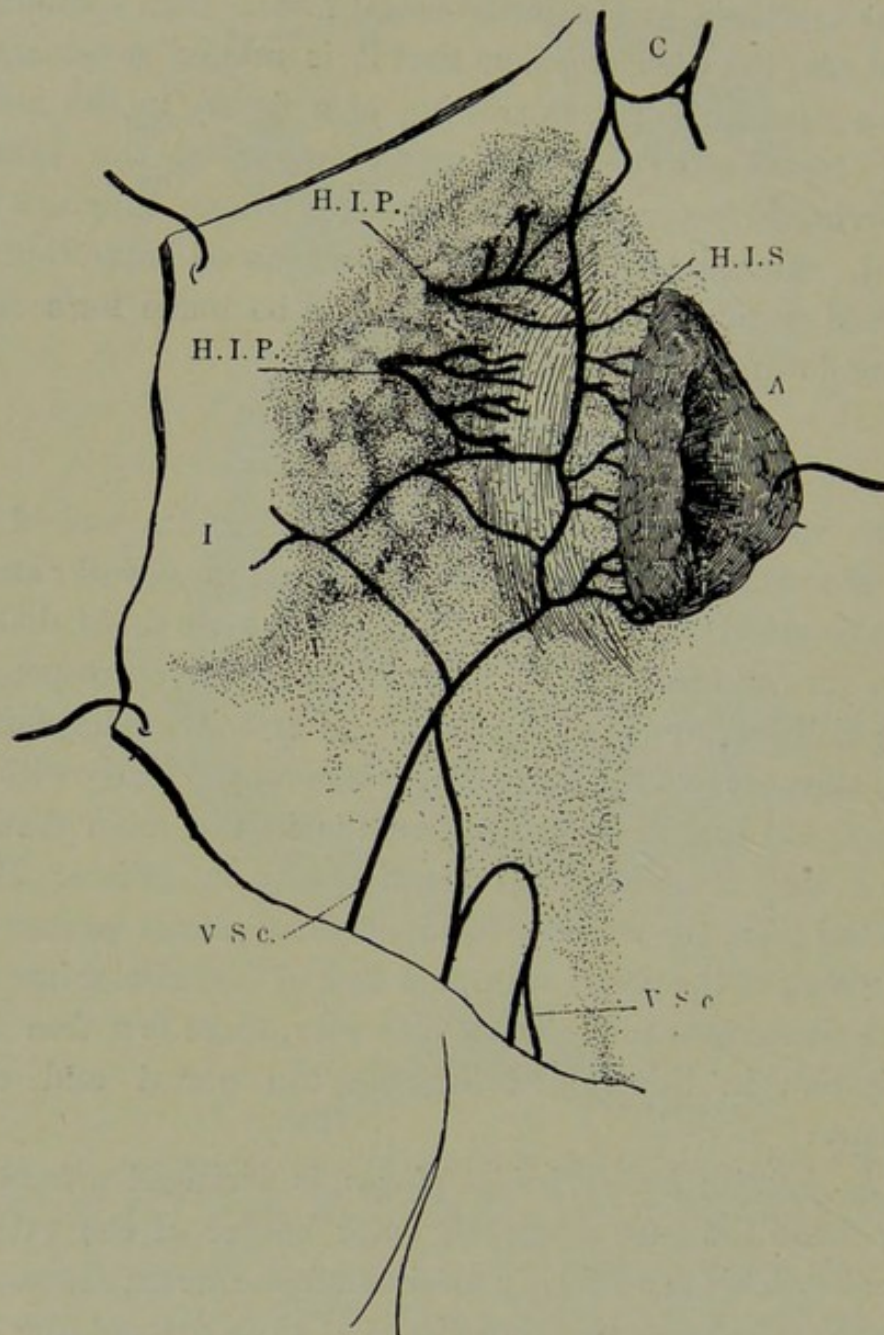


FIG. 14.—INFERIOR HÆMORRHOIDAL VEINS. (Quénu and Hartmann.)

A. anus; C. coccyx; I. ischium; H.I.P. inferior hæmorrhoidal trunks running outwards in the fat of the ischio-rectal fossa; H.I.S. veins emerging from beneath the superficial part of the external sphincter; V.Sc. sub-cutaneous veins in the cruro-scrotal furrow.

to join the internal saphena in the femoral region; posteriorly, a few branches pass backwards to join the plexus round the

\* Quénu and Hartmann. Op. cit



coccyx; whilst, laterally, several large trunks, the inferior hæmorrhoidal veins proper, traverse the ischio-rectal fossa with the arteries of the same name and empty themselves into the internal pudic vein as it lies in Alcock's canal (see fig. 13).

*Surgical importance.*—The small veins passing subcutaneously from the anal canal to the venous ring round the external sphincter, are apt to become dilated by constant straining at stool and are occasionally ruptured. The localized extravasation, in such cases, gives rise to the so-called venous or thrombotic pile. Those branches, which pass between the superficial and deep portions of the external sphincter, probably account for the fact that a fistulous track sometimes takes this course, especially when it results from a fissure, either from the burrowing extending by the side of the veins or because the veins become thrombosed and the seat of suppuration. In a similar manner, the disposition of the venous ring round the outer margin of the external sphincter possibly accounts for some of the subcutaneous forward and backward burrowing so often observed in peri-anal fistula.

*The middle hæmorrhoidal plexus* is disposed as a close network of vessels on the outer surface of the rectum immediately above the levatores ani. It receives blood from the muscular coat of the bowel and also, to a small extent, from the mucous membrane, but its communication with the other parts of the hæmorrhoidal plexus is very slight. Anteriorly, there is a free communication with the prostatic plexus, in the male, and with the vaginal plexus, in the female. Laterally, in both sexes, two or more middle hæmorrhoidal veins arise which convey the blood to the internal iliac vein.

*Surgical importance.*—As the middle hæmorrhoidal plexus is disposed on the external surface of the bowel, it is the source of the more or less free bleeding which takes place when the rectum is being freed from its surrounding attachments during the operation for excision.



*The superior hæmorrhoidal plexus.*—This is confined to the submucous coat of the lower four or five inches of the rectum, and commences as clusters of small vessels situated beneath the mucous membrane of the *pecten* between the saccules of

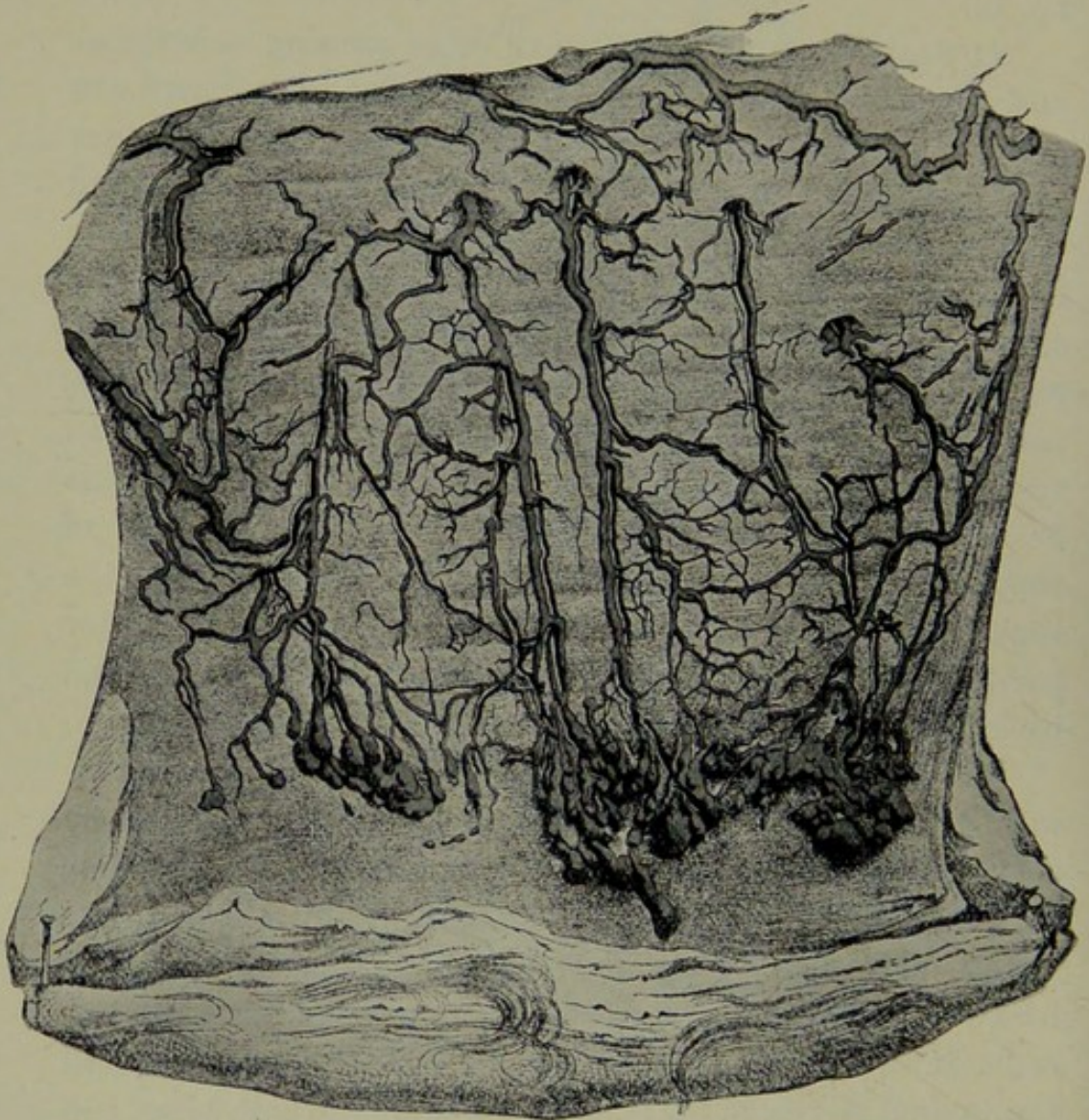


FIG. 15.—SUPERIOR HÆMORRHOIDAL VEINS AND ARTERIES.  
(Quénu and Hartmann).

N.B.—The sacculated condition of the tufts of veins is well shown. The darker lines represent the arteries.

Morgagni. The small veins comprising these tufts, except in recently born infants, show distinct sacculations, so that the general appearance is one of cavernous tissue (see fig. 15). From each of these tufts a main trunk arises which passes up-



wards in a corresponding column of Morgagni in company with a terminal branch of the superior hæmorrhoidal artery. There are, as a rule, six or seven of these main trunks arranged parallel to one another around the circumference of the bowel. As they pass upwards, they receive numerous branches from the plexus in the intervals between them, so that a free communication between neighbouring trunks is

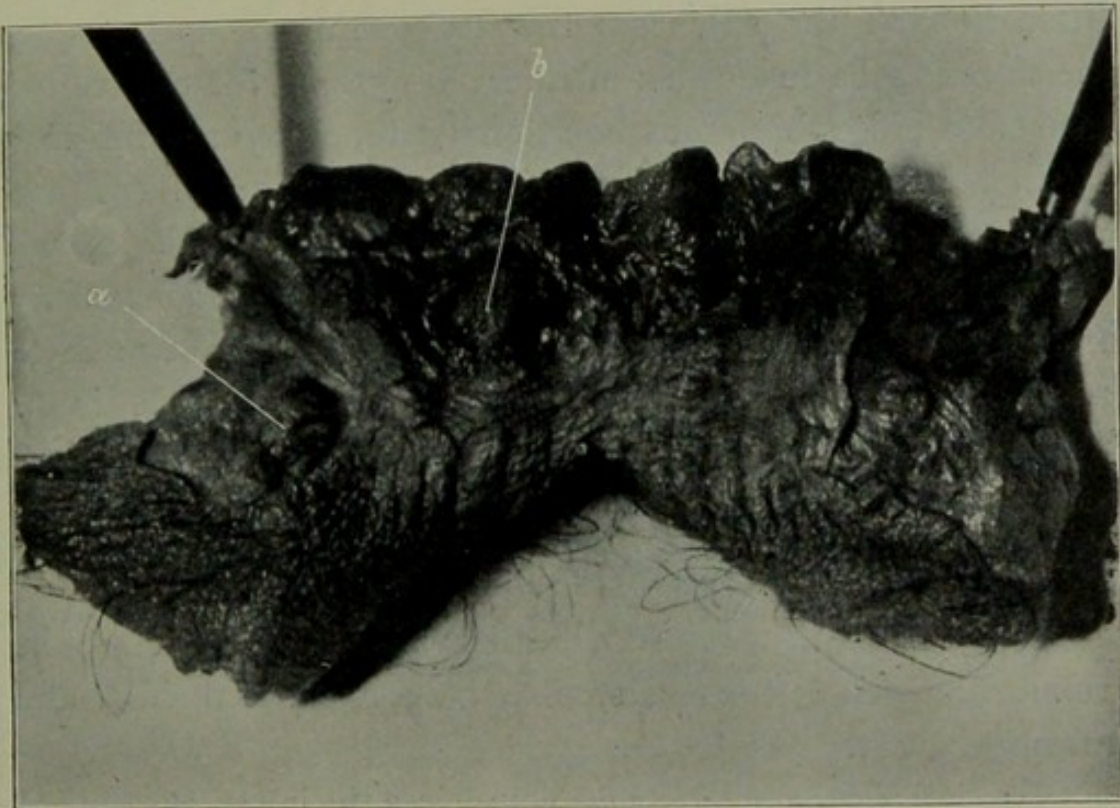


FIG. 16.—DILATED TUFTS OF VEINS BENEATH THE MUCOUS MEMBRANE, CONSTITUTING THE EARLY STAGE OF INTERNAL PILES.

*a*, the R.A. Internal Pile; *b*, the R.P. Internal Pile.

established. These trunks pierce the rectal wall at a distance varying from four to five inches above the level of the anus, and, after forming communications on the lateral and posterior aspects of the bowel, end in a right and a left trunk which unite in the meso-rectum to form the superior hæmorrhoidal vein. A somewhat free communication exists between the superior and the inferior hæmorrhoidal plexuses in the neighbourhood



of Hilton's white line, but there is very little communication with the middle hæmorrhoidal plexus (Quénu and Hartmann).\*

*Surgical importance.*—The tufts of veins situated beneath the mucous membrane of the pecten in the intervals between the saccules of Morgagni, when varicose, constitute the internal pile (see fig. 16). The lower margin of the pile is at Hilton's white line, *i.e.*, at the muco-cutaneous junction. When operating upon an internal pile, the tumour should be lifted well off the subjacent internal sphincter, so that the incision can be made in the intervening layer of connective tissue. Unless this point be attended to, either the internal sphincter will be wounded or some of the veins of the pile will be divided. Since the varicose condition extends beyond the tuft into the lower part of the venous trunk emanating from it, the ligature should be carried as high up as possible so as to include this also. If only the tuft be included in the ligature, the varicose condition of the vein above it may lead to a partial further development of the pile.

#### *The Lymphatics of the Rectum and Anus.*

The lymphatics in this locality are arranged, like the veins, in three distinct sets, *viz.*, a superior, a middle, and an inferior set.

*The inferior lymphatic zone* comprises the lower portion of the anal canal, the anal margin, and the peri-anal skin, from which the vessels conveying the lymph pass forwards on both sides along the cruro-scrotal fold to enter the horizontal set of inguinal glands (see fig. 17).

*The middle lymphatics* draw their lymph from the muscular coat of the lower part of the rectum, and pass into the glands in relation with the internal iliac vessels.

*The superior lymphatics* are those of the rectal mucous membrane, including that of the upper part of the anal canal. The lymphatic trunks have the same arrangement as the

---

\* *Op. cit.*, page 39.



superior hæmorrhoidal veins, and pass with them through the rectal wall to enter the meso-rectum, where they terminate in the glands met with in that situation.

*Surgical importance.*—It is important to bear in mind the three groups of lymphatic glands which receive lymph from the ano-rectal region when dealing with carcinoma, syphilis, and ulceration of those parts. When the anus is involved, the inguinal glands will sooner or later be affected. If a carcinoma

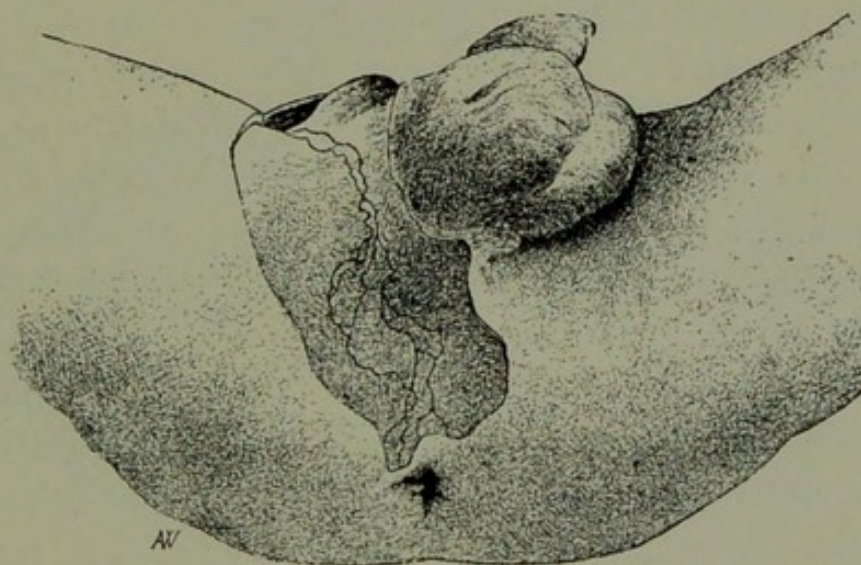


FIG. 17.—LYMPHATIC VESSELS OF THE ANUS IN THE INFANT.  
(Quénu and Hartmann).

be limited to the rectum, so long as nothing but the mucous membrane is involved, the glands in the meso-rectum will probably alone be implicated, but, when infiltration of the muscular coat has occurred, the internal iliac glands are likely to be the seat of secondary deposit.

#### *The Nerves of the Rectum and Anus.*

These have their origin from two distinct sources, viz., the sympathetic and the spinal nerves.

*The sympathetic fibres* are derived from the inferior mesenteric and hypogastric plexuses, and are distributed to the muscular coat (including the internal sphincter) and the mucous membrane of the rectum. Their mode of termination is identical with that met with in other parts of the intestine.



They form a close gangliated plexus between the longitudinal and circular muscular fibres (Auerbach's plexus), and a second gangliated plexus (Meissner's plexus) in the submucous tissue.

*The spinal fibres* are derived from the 3rd and 4th sacral nerves and the pudic nerve. These branches are chiefly destined for the supply of the anal mucous membrane and, according to Hilton\*, enter the anal canal through the interval between the internal and external sphincters. Having reached the submucous layer, the fibres break up into upper and lower filaments, the former supplying a narrow zone of mucous membrane immediately above the white line (the pecten), while the latter descend and are distributed to the skin of the anus. The mode of termination of these fibres in the mucous membrane has been determined by Stroud.† According to his observations, the nerve fibres break up in the submucous tissue into a fine plexus containing many large and small ganglionic cells which anastomose freely. From this plexus, fine fibrils enter the epithelial layer and form a plexus containing numerous small nerve cells, from whose peripheral ends dendrites arise which interlace with neighbouring dendrites. Each papilla met with in the region of the pecten contains a small nerve trunk, upon which a ganglionic enlargement exists.

*Surgical importance.* The abundant nerve supply of the mucous membrane of the anal canal accounts for its great sensibility. Operations in the anal region are among the most painful of any in surgery, and, consequently, deep anæsthesia is often required during their performance. The nerves that supply the anal mucous membrane also supply the external sphincter and the levatores ani—hence it is that irritation of their peripheral terminations in the mucous membrane calls forth reflex spasm of those muscles (see fig. 18). This phenomenon is well observed in a case of anal fissure. The mucous membrane of the rectum above

\* Rest and Pain, p. 289, 4th ed.

† Annals of Surgery, 1896, vol. xxiv., page 1.



the internal sphincter is much less sensitive—even extensive ulceration or carcinomatous infiltration causing little pain unless the anal mucous membrane also be involved or the lumen of the rectum be narrowed by the growth. The fact that the pudic nerve supplies the compressor urethræ; that the 3rd and 4th sacral nerves give branches to the

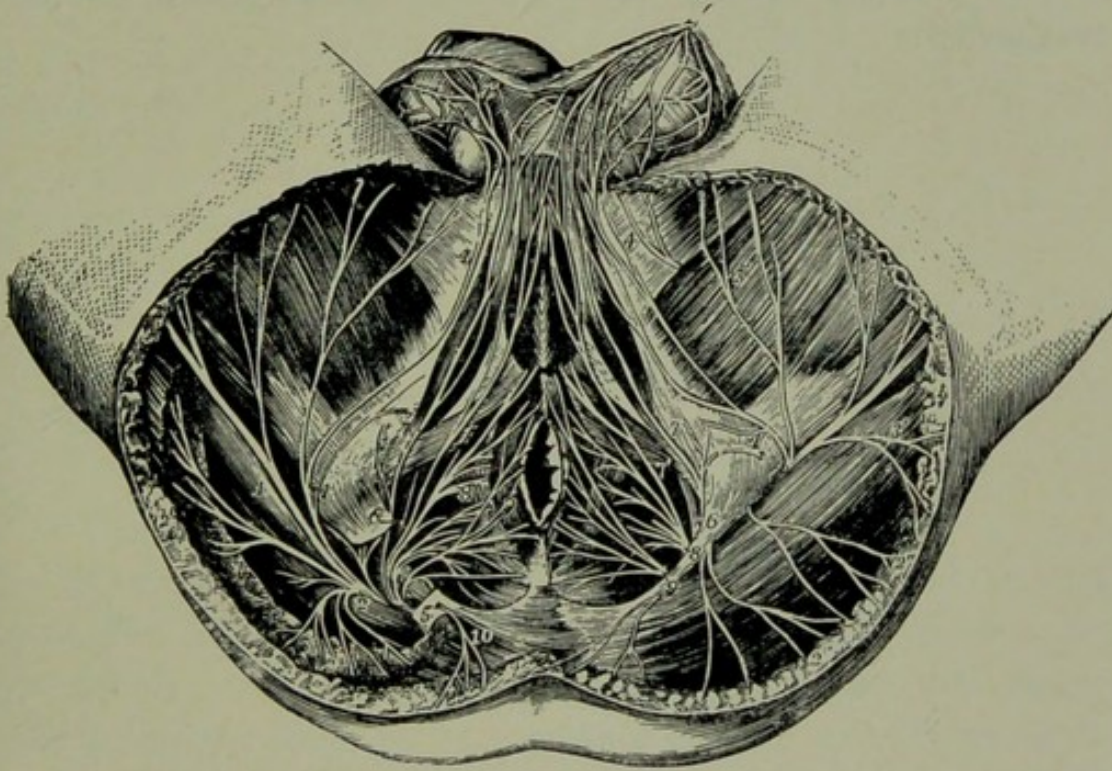


FIG. 18.—DISSECTION OF THE PERINEUM OF THE MALE TO SHOW THE DISTRIBUTION OF THE PUDIC AND OTHER NERVES. (Hirschfeld and Leveillé).

On the right side a part of the gluteus maximus muscle and the great sacro-sciatic ligament have been removed: 1, great sciatic nerve of the right side; 2, 2', on the right side, inferior gluteal nerve; 2'', on the left side, gluteal cutaneous branches of the small sciatic; 3, small sciatic nerve in the thigh; 4, 4, inferior pudendal nerve; 4', network of this and the superficial perineal nerves in the scrotum; 5, right pudic nerve; 6, superior branch or dorsal nerve to the penis; 7, external superficial perineal branch; 7', internal superficial perineal branch; 8, deep or musculo-bulbal branches; 9, inferior hæmorrhoidal nerve; 10, perforating cutaneous nerve. (QUAIN.)

bladder, prostate, and vagina; and that all these nerves are associated with others arising from the lumbar enlargement of the cord, such for instance as the lumbar, the great and small sciatic, readily explains upon anatomical grounds alone, the pains in the loin, over the crest of the ilium and sacrum, and down the backs of the thighs and calves; and also accounts for the occasional attacks of retention of urine

sometimes observed as a reflex accompaniment of anal fissure and also of fistula when situated in the middle line posteriorly. By the same reasoning we can understand how symptoms referable to the rectum may be the expression of disease of neighbouring viscera, such as the uterus, vagina, prostate, and bladder. Consequently the possible co-existence of such diseases in any case of rectal disease should not be overlooked.



## CHAPTER II.

### GENERAL DIAGNOSIS.

Much information may be obtained in regard to the probable nature of a case of anal or rectal disease by questioning the patient about certain symptoms and signs, which, either alone or in combination, are usually present. Of these the most important are (*a*) pain, (*b*) hæmorrhage, (*c*) discharge, (*d*) constipation, (*e*) diarrhœa, (*f*) difficulty in defæcation, (*g*) protrusion from the anal orifice, (*h*) loss of weight, and (*i*) influence of heredity.

#### (*a*) *Pain.*

The pain complained of may be either intermittent or continuous. In character, it may be smarting, throbbing, shooting, lancinating, aching, burning, or bearing down.

*Intermittent pain.*—When of an intermittent character, the following questions should be asked :—

(1) *When did you first have this pain?* If pain was the first symptom noticed, the time of commencement of the disease may thus be settled. When the pain dates back for some months or even years, it may be assumed that the

disease is not of an inflammatory nature such as an abscess. The most probable cause of pain recurring over a lengthened period is fissure. When of recent appearance it may be due to fissure, complete fistula with a large internal opening, blind internal fistula, internal piles sufficiently prolapsed to come within the grasp of the external sphincter, stricture, or new growth.

(2) *How long does an attack usually last?* When due to fissure, it varies from a few minutes to several hours. In blind internal fistulæ, it may continue for several hours or days. In complete fistula with a large internal opening, it may last for several hours. With stricture, it quickly ceases after an action of the bowels. In carcinoma, the duration varies from a few minutes to an hour or two. In other new growths, and also in piles, the pain persists so long as the protruded mass is gripped by the external sphincter.

(3) *To what cause did you attribute its onset?* When the pain supervenes upon the passage of a large and hard mass of fæces, a fissure, an ulcer or ulceration in the lower inch of the anal canal, is often its cause. When the pain follows the passage of soft or fluid fæces, a blind internal fistula should be suspected. When the pain precedes, persists during, and ceases soon after, the passage of hard or soft fæces or discharge with or without blood, carcinoma or stricture of the rectum should be sought for.

(4) *Have subsequent attacks in any way varied from the first, e.g., are they longer in duration, greater in intensity or otherwise altered in character?* An increase in the duration and intensity of the subsequent attacks is met with in cases of fissure, so that, whereas the attack of pain at first lasted for but a few minutes, after the lapse of months or years it may persist for six or eight hours or even become continuous. An increase in intensity, together with alteration in character, is met with in carcinoma when the growth has extended downwards to



within the lower inch of the anal canal. This phenomenon is also met with in simple stricture of the rectum, when it becomes complicated by the formation of a fistula.

(5) *What effect has defæcation or constipation upon it?* When defæcation is followed by an attack of pain, fissure, blind internal fistula, prolapsed internal piles, protruded polypus or polypoid growth, simple stricture, or partial occlusion by cancerous growth may be present. When pain comes on while the bowels are confined and increases in intensity while that condition persists, ulcer, stricture, cancer or impaction of fæces (especially when complicated by retention of urine) is probably present.

(6) *What is the duration of the longest interval between succeeding attacks?* In cases of fissure, internal piles, polypus or polypoid growths, there may be intervals of days, weeks, or months between attacks.

(7) *Does the pain supervene independently of defæcation, the passing of flatus or micturition?* When the pain commences so soon as the patient goes to bed, or comes on during the night, either eczema or syphilis of the anal region should be looked for.

*Continuous pain.*—When the pain is continuous the following points in regard to it should be ascertained:—

(1) *When did it begin?* When the pain has its onset during defæcation, it may be due to the puncture of the rectal wall by a foreign body such as a fish-bone, or to localized blood extravasation at the anal margin. If it begin soon after defæcation, it may be due to strangulated prolapsed internal piles, the pain persisting until they have been mechanically reduced, or have sloughed off, or have ceased to be gripped by the sphincters. When the pain begins independently of defæcation and, especially, when it commences during the night-time, its probable cause is suppuration.



(2) *What were you doing when it began?* The pain produced by a puncture of the rectal wall by a foreign body always begins during the actual passage of fæces. When caused by extravasation of blood, it frequently occurs during the act of defæcation, but sometimes during a straining effort, such as lifting heavy weights, &c., or during a severe fit of coughing.

(3) *Has it in any way varied since its commencement?* When there is a progressive increase in intensity, followed by a more or less sudden diminution, after which the pain again becomes more pronounced, suppuration is the most likely cause.

(4) *What are its characters?* Pain of a throbbing character is met with in abscess, strangulated internal piles, and in the early stage of extravasated blood. When a puncture by a foreign body takes place, the pain consists of a pricking or stabbing sensation in the rectum, and of much discomfort when sitting.

(5) *What do you think caused it?* When due to a foreign body it will be ascertained that the pain began during or soon after defæcation. When the pain is the result of a fall, it may entirely subside after a definite period. Occasionally, after the actual pain has subsided, there will be the history that the injured part never felt quite comfortable and after a varying interval, sometimes extending over many months, acute throbbing pain begins at the seat of the injury. Under these circumstances, the pain for which the patient seeks relief is almost always due to suppuration.

(6) *What effect has constipation or diarrhœa upon it?* When the bowels are either confined or relaxed, the pain caused by a foreign body is increased by defæcation. When the pain is due to extravasated blood, an abscess, or to strangulated piles, constipation increases it. When the perianal skin is in an eczematous condition, diarrhœa always increases the attendant pain.



*(b) Hæmorrhage.*

Hæmorrhage from the anus is a frequent symptom of ano-rectal disease. It may be intermittent or continuous.

*Intermittent hæmorrhage.* Hæmorrhages may succeed each other at short or long intervals and, therefore, we should ascertain the following facts in regard to them.

(1) *Are the hæmorrhages always associated with defæcation?* Bleeding from internal piles is frequently associated with the actual passage of fæces. In the first stage of the development of internal piles, the bleeding may recur at intervals of several days or weeks, but each succeeding attack is usually brought on by defæcation. During the second stage of internal piles, the attacks of bleeding in time become more frequent, so that at length there is scarcely an action of the bowels without attendant loss of blood which may be more or less copious. A slight loss of blood during defæcation, especially when repeated at irregular intervals, is indicative of uncomplicated fissure or a tear in the mucous membrane of the anal canal due to a foreign body which has been evacuated. In these cases, the quantity of blood lost may be only sufficient to smear the motion, and the material used for subsequent cleansing. When the motion passed is smeared and a few drops of blood terminate the act of defæcation, there is often present a fissure complicated by internal piles; or a circumscribed ulcer in the lower part of the rectum. Profuse hæmorrhage accompanied by a protrusion from the rectum after defæcation, is indicative of internal piles in the second or, occasionally, in the third stage of development. When the loss of blood accompanying the protrusion is slight, either procidentia recti, prolapsed mucous membrane, polypus, polypoid growth, or villous growth will be found to exist.

(2) *Do the hæmorrhages occur independently of defæcation?* When bleeding occurs at other times than during defæcation,



a fissure may be excluded, the common cause being internal piles in the first or second stage of their development and, occasionally, carcinoma. When such bleeding is accompanied by a protrusion from the anus, it may be due to procidentia recti, prolapse of mucous membrane, prolapsed internal piles, polypus, or polypoid growth.

*Continuous hæmorrhage* very rarely lasts more than twenty-four hours, unless it be the recurrent or secondary hæmorrhage following an operation. When the hæmorrhage follows soon after an operation, it may be due either to the omission to secure a divided vessel or to an inefficient ligature. When occurring two or three days after an operation, it is usually due to a premature action of the bowels having caused detachment of a ligature. At the end of the eighth or ninth day secondary hæmorrhage may occasionally occur with the separation of a slough. The most severe cases of this form of hæmorrhage are met with when the sloughs are due to the application of nitric acid.

The chief cause of spontaneous hæmorrhage is carcinoma, especially when situated low down in the rectum and in the late stage of its growth.

When continuous hæmorrhage does not follow an operation the following points should be elicited.

(1) *Is it the first attack?* When there has been no previous attack of hæmorrhage, a laceration or puncture caused by a foreign body; or the erosion of a vessel due to ulceration may be its cause.

(2) *What other attacks have occurred?* When there have been previous attacks, lasting for a day or two at a time, the probability is that the bleeding is due to carcinoma, though, in some instances, it may be caused by the giving way through the mucous membrane of a vessel in an internal pile (see Internal piles).



(c) *Discharge.*

Discharges from the ano-rectal region should be subdivided into (1) those issuing from the skin surface and (2) those escaping from the rectum.

(1) The discharges met with from the skin surface are pus, serum, sero-pus and blood. Pus is always due to either an abscess or a fistula, and escapes from one or more external openings which can be easily seen. A serous discharge is due to an eczematous condition of the peri-anal skin. When the discharge is sero-purulent, it is usually due to tuberculous ulceration. When there is blood, it is nearly always caused by either lacerations due to scratching to relieve irritation or to a peri-anal blood clot which has ulcerated through the skin.

(2) The discharges which escape from the rectum are mucus, pus, muco-pus, and watery fluid. All of these may be more or less tinged or mixed with blood or fæculent matter.

*Mucus* may be due to internal piles in their third stage of development, prolapsed mucous membrane, invagination of the rectum, procidentia of the rectum, and colitis.

*Pus* is due either to an abscess which has ruptured into the rectum or to a fistula.

*Muco-pus* is met with in ulceration, non-malignant stricture, and carcinoma, in which perforation of the rectal coat has taken place and caused an ischio-rectal abscess.

*Watery fluid* is met with in cases of villous tumour.

It is essential in all cases to see, if possible, the discharge that escapes from the rectum and, for this purpose, the patient's linen should be examined. When however the actual discharge or its stains cannot be seen, much information as to its probable nature and causes may be obtained by the following questions.

(1) *What is the character of the discharge?* Mucus is often readily recognised by the patient as being like the white part



of an uncooked egg; pus, as a liquid custard; muco-pus, as a jelly-like substance mixed with blood; and the watery fluid from a villous tumour, as diarrhœa with bleeding.

(2) *Was the appearance of the discharge preceded by pain?*

When pain, which had been continuous for several days, suddenly ceased or became greatly diminished with the escape of the discharge, a ruptured abscess may be diagnosed. When there is a history of a bearing down pain preceding and subsiding soon after the evacuation of the discharge, ulceration or stricture, with or without fistula, should be searched for.

(d) *Constipation.*

In rectal disease, the question whether the patient suffers from constipation should not be considered settled until a digital examination of the rectum has been made. The rectum is often found to be partially or fully distended with fæces in those who say that their bowels are relieved regularly and properly every day, such a condition of fæcal accumulation being observed even when the examination is made only an hour or two after the bowels are said to have been freely relieved. In these cases, it is clear, that the rectum is habitually, either in part or fully, distended with fæces, and that an evacuation consists of the descent of motion from the sigmoid colon into the upper part of the rectum driving out an equal quantity of fæces from its lower part. Such an evacuation is not natural, because in this way the rectum is converted into a fæcal reservoir, instead of being, as functionally intended, an expelling apparatus.

A condition of fæcal accumulation, as above described, is almost invariably met with in eczema of the anus, circumscribed blood extravasation at the anal margin, fissure, hypertrophy with induration of the external sphincter, and internal piles.

When constipation is observed in the early stage of carcinoma of the rectum, the bowel below the disease is



empty, the fæcal accumulation being confined to the part above it. A similar condition exists in fibrous stricture of the rectum.

(e) *Diarrhœa.*

Diarrhœa is often supposed to exist when the only symptom is a frequent escape of a small quantity of solid or semi-solid fæces combined with mucus, blood, pus, or a combination of them. A true diarrhœa is not often met with in rectal disease, so that, when there is prolonged frequent action of the bowels, the evacuated material should be examined and a digital exploration of the rectum made.

When the motion passed is found to be in short pieces of small calibre, with more or less mucus, blood and mucus, or pus and blood, a fibrous stricture is probably present. If there be an admixture of blood in considerable quantity, the motion not being in short pieces, carcinoma of the rectum may be suspected. When the motion is scybalous, the pieces being covered with much mucus, a little blood also being present, the case is probably either one of invagination of the upper part of the rectum, prolapse of the rectal mucous membrane, or procidentia recti. When a considerable quantity of pus is mixed with the fæces, there is probably extensive ulceration.

(f) *Difficulty in defæcation.*

Difficulty in defæcation must not be confused with constipation. With this condition, there is a more or less constant desire to empty the rectum but there is an inability to obtain complete relief, either from dread of pain caused by an evacuation or from a direct impediment to the passage of a motion. The following questions should be asked with a view to determining the cause of the difficulty.

(1) *Is it pain?* When this is the reason, a fissure, ulcer, tear in the mucous membrane, or the partly torn through attachment of a polypoid growth probably exists. All of these conditions often occasion so much reflex spasm of the



sphincters and levatores ani, that a physical obstruction at the anal outlet is produced. This spasm is so strong in some cases that the patient is obliged to assist expulsion by removing the fæces from the anal canal with his finger.

(2) *Is there a feeling of tightness at the anus accompanied by irritation after the motion has been passed?* When this is so, marked hypertrophy and diminished dilatibility of the external sphincter will be found to exist.

(3) *Is each action of the bowels preceded by bearing down pain which continues during the act of defæcation and ceases almost immediately afterwards, leaving a sense of only partial relief?* Under these circumstances a fibrous stricture or carcinoma of the rectum should be looked for.

(g) *Protrusion from the anal orifice.*

A protrusion from the anus occurs in the following diseases—internal piles, polypus, polypoid growth, prolapse of mucous membrane, carcinoma extending downwards beyond the anal orifice, procidentia of the rectum, invagination of the rectum, intussusception and villous tumour. In order to distinguish between these conditions, an actual inspection of the protrusion should be made whenever possible. The following questions, however, will assist in elucidating the cause of the protrusion.

(1) *Is it associated with defæcation?* When the protrusion occurs during the passage of fæces and returns into the rectum immediately or soon after the evacuation is terminated, internal piles in the second stage of their development, polypus with a short pedicle, polypoid growth, slight cases of procidentia or villous tumour may be present. When the protrusion remains down for a period varying from several minutes to hours, internal piles which have nearly completed the second stage of development, polypus with a long pedicle, fully developed procidentia, intussusception or villous tumour may be met with.



When the protrusion remains permanently down until artificially replaced, internal piles which have reached the third or last stage of development, strangulated internal piles, prolapsed mucous membrane, carcinoma involving the anal canal or a large villous growth probably exist.

(2) *Does it recur when standing or during exercise?* A protrusion occurring under these conditions is most probably due to internal piles in the third stage, prolapsed mucous membrane, procidentia of the rectum, large polypoid growth or large villous tumour.

(h) *Loss of weight.*

A loss of body-weight usually takes place in cases of internal piles which have given rise to profuse and frequent hæmorrhage, in many cases of fistula, especially those of a tuberculous nature, sometimes in fibrous stricture, in villous tumour, occasionally in long standing fissure and in all cases of malignant disease in its later stage.

(i) *Influence of heredity.*

Internal piles are distinctly hereditary. In almost all cases of this disease which are met with under the age of twenty-five years, a history of the disease having occurred in other members of the family can almost always be obtained. In carcinoma, also, hereditary influence can sometimes be traced but in other ano-rectal diseases it is by no means well marked.

*Method of Examination for Rectal Disease.*

*Position of Patient.*—The patient should be placed upon a couch of convenient height and in the best light obtainable. If a male, he should support himself upon his elbows and knees, resting on the same level, the chin being supported by the palms of the hands. When this position is adopted it will be found that owing to flexure of the lumbar portion of the vertebral column, the pelvis is tilted backwards, thus fully



exposing the anal region to view (see fig. 19). In this position the rectum can be more readily explored by the examining finger owing to the downward direction of the passage. Moreover, when a speculum is being used, the rays of light are directed straight into it from above, and the mucous membrane falls away from the margins and extremity of the speculum, rather than over its end, and into the gap in its side which almost always happens when the patient is placed in the lateral and semi-prone position.

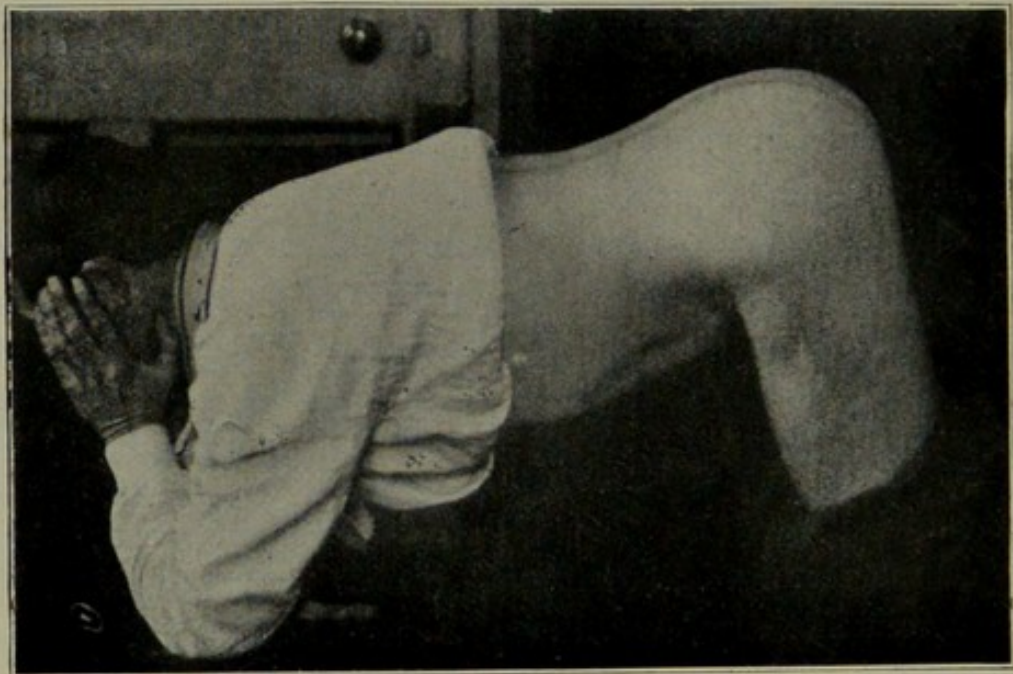


FIG. 19.—SHOWING THE POSITION RECOMMENDED FOR THE EXAMINATION OF MALE PATIENTS.

In female subjects the position recommended is the right lateral and semi-prone with the right arm and hand drawn completely behind the back and both knees flexed, the left more so than the right (see fig. 20). When it is necessary to examine the rectum with a speculum, a pillow should be placed under the right hip in order to raise the pelvis and



cause the rectum to fall forwards and to the right side of the pelvis, and therefore away from the end of the speculum.

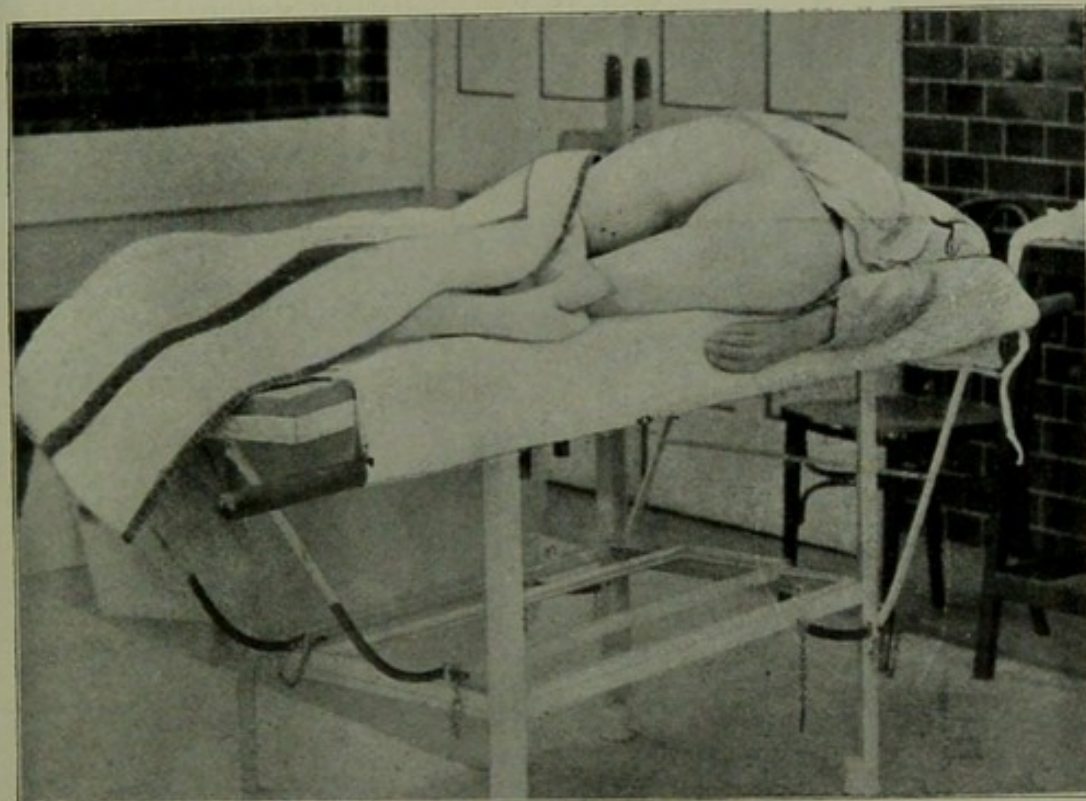


FIG. 20.—SHOWING THE POSITION RECOMMENDED FOR THE EXAMINATION OF FEMALE PATIENTS.

### *Sub-division of the Anal Region.*

For convenience in describing the exact position of diseased conditions in relation to the anal margin and rectal wall, we have adopted the scheme of subdividing the perineal space into quadrants by two imaginary straight lines intersecting at right angles in the centre of the anal aperture. The first line is drawn from the most prominent part of one tuber ischii to the other. This line we have termed *the transverse anal line* and, by it, the anal ring is divided into an anterior and a posterior half. When dealing with the various diseases met with in the rectum and anus, we shall endeavour to show that this line is of much clinical importance. The second line runs



along the median raphé from the tip of the coccyx to the symphysis pubis and intersects the transverse line at its centre. We have designated the extremities of these lines by the letters A, L, P and R representing respectively the anterior, left, posterior and right points of the circumference of the ano-rectal region.

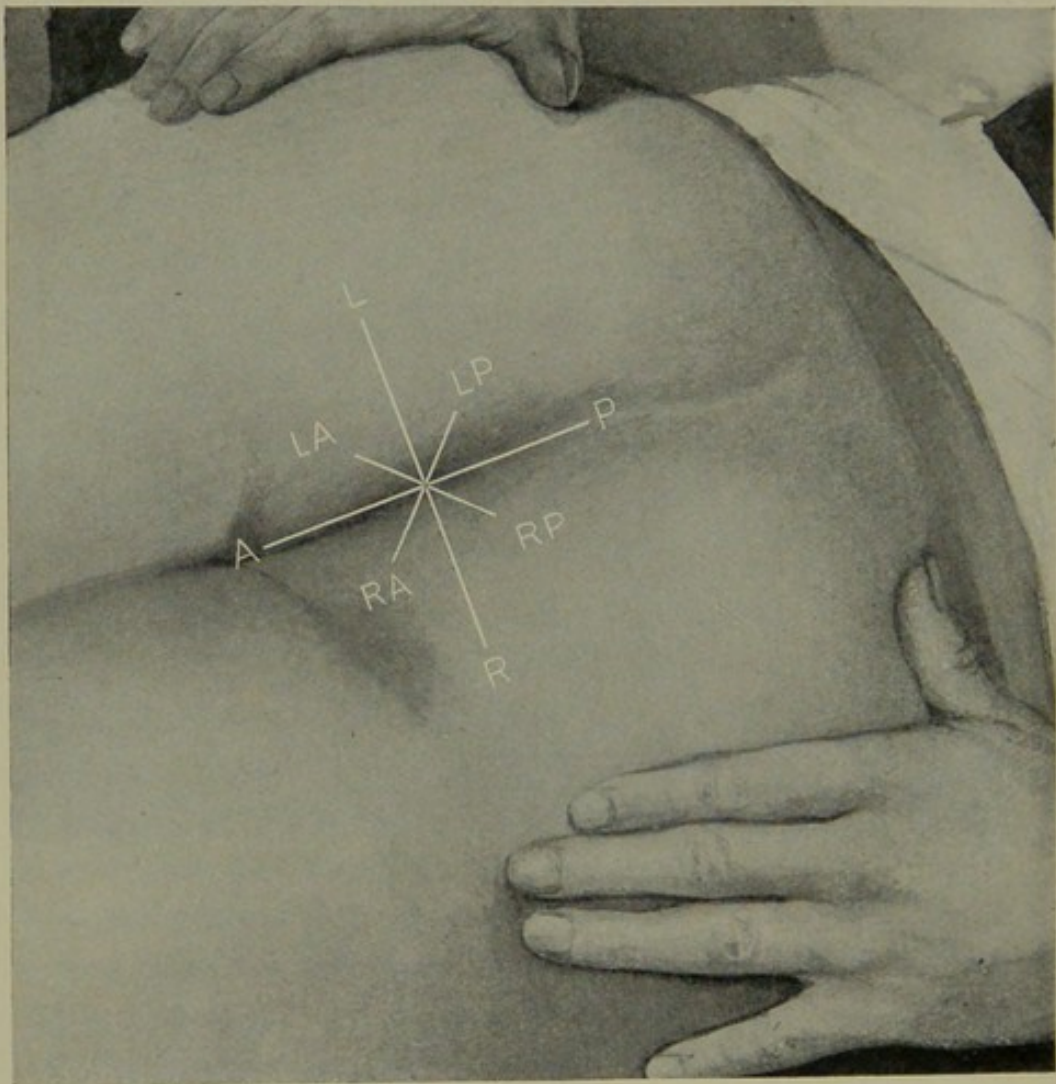


FIG. 21.—ILLUSTRATING THE METHOD RECOMMENDED FOR MAPPING OUT THE ANAL REGION.

Each of the quadrants is again bisected by two additional lines drawn at right angles to each other and intersecting at



the point of section of the lines AP and RL. The extremities of these lines are designated by the signs LA, LP, RP and RA, representing the left anterior, the left posterior, the right posterior, and the right anterior quadrants (see fig. 21).

By adopting this scheme, the exact position of the disease can be definitely indicated. Thus an internal pile situated in the right anterior quadrant of the rectum can be briefly described as the RA internal pile; and, similarly, the external opening of a fistula situated posterior to the transverse line on the right side and distant from the anal margin, say one inch, may be readily described thus—external opening=RP 1 inch. This abbreviated and concise method of description is applicable to all other forms of disease met with in the region and will be adopted by us in our descriptions throughout the work.

### *Inspection.*

Having exposed the anal region to a good light, a systematic examination of the following structures should be made, viz., the peri-anal skin, the external sphincter, and the anal margin.

(1) *Peri-anal skin.*—The points to be observed in connection with the peri-anal and adjacent skin are: (a) discoloration; (b) redundant folds of skin; (c) external openings of fistulæ; (d) obstructed sebaceous follicles; (e) ulceration; (f) warty outgrowths, innocent or malignant; (g) skin lesions of syphilis and tubercle; (h) œdema of the anus; (i) extravasated blood; (j) eczema; (k) pruritus.

(2) *The external sphincter.*—The condition of this muscle is best determined by the resistance it offers to the pressure made upon it with the examining index finger. Much information may be obtained as to its irritability and development in this way.

(3) *The anal margin.*—The points to be observed are, the presence of a fissure or the lower margin of an ulcer, the internal opening of a fistula, prolapsed internal piles, proci-



dentia, the protrusion of growths from the rectum, the presence of purulent, mucous, or bloody discharge or ascarides.

*Examination of the Rectum.*

In all examinations of the rectum the left index finger should be used, because by doing so the right hand is free for manipulative and operative purposes. Before introducing the finger, soap should be placed beneath the nail and also around its margin, in order to prevent faecal matter from getting there during the examination. Vaseline should then be placed on the anus, and the finger introduced into the bowel while the patient is straining as much as possible. This bearing down on the part of the patient minimizes the discomfort sometimes attending the introduction of the finger. More than half of the diseases of the rectum will be found situated within two inches of the anus. The most common error in making a digital examination is to introduce the finger too far at first, it being often passed up at once to its full extent. By doing so, the presence of diseased conditions close to the anus is missed. It is advisable, therefore, to introduce the finger at first only as far as the distal joint, and to examine the whole inner surface of the lowest inch of the bowel before introducing the finger any further. The examination, however, should never be terminated until the finger has been introduced to its full length, if possible, and every portion of the rectal wall within reach, together with the sacrum, coccyx, tuberosities of the ischia, the ischio-rectal fossæ, and the adjacent viscera have been thoroughly explored. It is a fact, which should be borne in mind, that disease of adjacent structures causes discomfort in the rectum and anus when no rectal disease exists.



## CHAPTER III.

### ABSCESS.

The immediate neighbourhood of the anus and the lower part of the rectum is frequently the seat of suppuration, which, though most often circumscribed, may, in a few instances, be diffuse. Abscesses in this locality, when burrowing, extend along the lines of least resistance, being guided between planes of fascia and passing round those blood vessels which are of sufficient size to resist thrombosis and dissolution. This law as regards extension holds good, whether the primary suppurative focus originates beneath the skin, under the neighbouring muscles, or in the submucous connective tissue of the rectum itself, the result being that the original abscess cavity, when left alone, will be found to have offshoots or diverticula. Such an abscess, unless artificially opened, extends until either a mucous, a cutaneous, or a serous surface is reached, through which it can discharge itself. Thus a collection of pus in the ischio-rectal fossa ultimately makes its way between the internal and external sphincters, and perforating the mucous membrane discharges into the cavity



of the rectum. Later on, if this has not already occurred, it breaks through the skin in one or more places. In this way, an abscess in the neighbourhood of the anus or rectum terminates in a fistula. Every fistula begins as an abscess, and the offshoots from it constitute the lateral burrowings of the fistula. Even after a fistula has formed, a retrogression to the abscess state frequently takes place by the temporary closure of the external and internal openings. When this occurs, extension by lateral burrowing sooner or later continues. A reference to the anatomy of this region by bringing to mind the numerous planes of more or less dense connective tissue, which join and intersect one another, together with the arteries which cross the ischio-rectal fossa, will readily explain the complex burrowings of a peri-anal or peri-rectal abscess when it is allowed to continue without surgical interference. All abscesses met with in this region usually pursue a very regular and definite course, which varies with the seat of origin of the abscess.

#### *Etiology.*

The cause of abscess in this locality, as elsewhere, may be divided into (a) *the predisposing* and (b) *the exciting or determining*.

(a) *Predisposing Causes.*—Any condition favouring the invasion of bacteria, either locally or through the blood stream, may be considered to predispose to the formation of an abscess. Locally any lesion of the rectum, such as ulcer, stricture, fissure, internal pile, extravasated blood, tear in the mucous membrane, or disintegrating new growth, opens up the path for infection. Also laceration by foreign bodies, especially when they penetrate the entire thickness of the rectal wall, is occasionally a source of infection. Of the last we have the evidence in the fact that a foreign body, such as a fish bone, is sometimes found in the cavity of an ischio-rectal abscess or in the main sinus of a fistula.



*Age.*—In regard to the age at which abscess occurs, our observations show that in 114 cases among hospital patients the average age was 30 years. Of these, 107 males gave an average age of 29 years and in 7 females the average was 41 years. The youngest male subject was 7 months whilst the oldest was 76 years. The youngest female was 34 years and the oldest 55 years. The above statistics have been compiled from cases of abscess seen at St. Mark's Hospital during a period of six years. Our experience in regard to the age at which abscess may be met with is, that it occurs at any period of life in the male; but in the female it appears to be exceedingly rare during the first and second decades of life. We have never seen a case in a female under 15 years of age.

*Sex.*—Abscess is much more prevalent in male than in female patients, the proportion in hospital cases being 15 males to 1 female and in private cases 6 to 1. This we think clearly shows that the rougher life led by males has much to do with the far greater frequency with which abscess is met with in them.

*Occupation.*—The following occupations appear to predispose to the formation of abscess in the neighbourhood of the anus and rectum, viz., those of brewer's draymen and servants, bricklayers, carpenters, clerks, packers, printers and publicans, all of which involve a good deal of sitting or standing. Boating and, especially, riding on a wet saddle are particularly prone to cause such an abscess.

(b) *The exciting causes.*—Modern pathology teaches us that every true suppurative focus is due to the agency of pus-producing organisms. Admitting this to be true, the question at issue is to determine, so far as we are able, the species of bacteria and the route by which they invade the peri-anal and peri-rectal tissues. So far as the bacteria responsible for suppuration in this region are concerned, much light has been thrown on the subject by the investigations of



Quénu and Hartmann.\* Of twelve cases of abscess in the neighbourhood of the anus, in which culture experiments were carried out by these investigators, the following results were obtained. In seven abscesses the presence of the tubercle bacillus was clearly demonstrated. Of these seven the tubercle bacillus was found alone in two; in four it was associated with the bacillus coli communis, and in one with strepto and staphylo-cocci. In the remaining five cases no evidence of the tubercle bacillus was forthcoming, the staphylo-coccus alone being found in two; in one the staphylo-coccus was associated with the bacillus coli, and in two the bacillus coli was found by itself. From the above researches it would appear that the bacteria usually causing abscess in connection with the anus and the rectum are the bacillus coli communis, the tubercle bacillus, the strepto-coccus pyogenes, and the staphylo-coccus pyogenes. According to the above quoted authors, the tubercle bacillus also plays an important part in the production of these abscesses, even in subjects in whom there is no other evidence of the tuberculous diathesis. These bacteria may gain access to the peri-anal or peri-rectal connective tissue, either locally or through the blood stream.

The above mentioned sources of infection operate from within the rectum, but there are also others which operate from without. Of these, traumatism of any kind, such as kicks upon the anal region, falls upon the buttocks, riding upon a badly fitting saddle, either upon a horse or a cycle, or the constant joltings of a long and tedious drive in a cart, or sitting on a wet, damp, or cold seat, predisposes to the formation of an abscess.

Apart, however, from these local lesions, the constitutional condition of the patient exerts considerable determining influence on the possibility of pus formation, the bacteria being probably conveyed to the damaged tissue by the blood stream. A healthy individual, in whom tissue change is active, and

---

\* Chirurgie du Rectum, p. 130.



whose physiological resistance is normal, may receive even severe injuries and suffer no ill-effect in consequence. Whereas, in one whose constitution is impaired by disease, want, or exposure, similar injuries will be followed by far reaching effects. Pathology inclines us to the belief that the condition understood by a good or a bad constitution, is really the power or the disability to resist the invasion of micro-organisms. Given an individual with impaired physiological integrity, it matters not whether the bacterial invasion takes place locally or by means of the blood stream, the result is the same, manifestation of bacterial activity and supremacy. By this argument alone can we reconcile the frequent experience that there are many individuals who suffer from lesions of the rectum and anus, or receive such injuries to those parts as have been mentioned above, and yet in whom no suppurative phenomena develop. We have notes of several cases in which an abscess supervened many months after an injury was received in the locality. We think the explanation of this is that, in the interval between the receipt of the injury and the appearance of the abscess, some depressed condition of the constitution occurred, which permitted the advection, through the blood stream, of the infective agent to the damaged tissue, and we may take it that in these instances, had not the physiological integrity been impaired no suppuration would have ensued.

#### *Varieties of Abscess in this Region.*

The different forms of abscess that may be met with are :

- (a) the subcutaneous,
- (b) the ischio-rectal,
- (c) the submucous,
- (d) the pelvi-rectal,
- (e) the labial.



In addition to the above varieties, abscesses in this region are occasionally met with which have their origin in suppurative conditions of the prostate, the urethra, Cowper's or Bartholin's glands. Also a subgluteal abscess may find its way into the pelvis through the great sacro-sciatic foramen and thence passing through the levator ani, appear in the ischio-rectal fossa (see fig. 22).

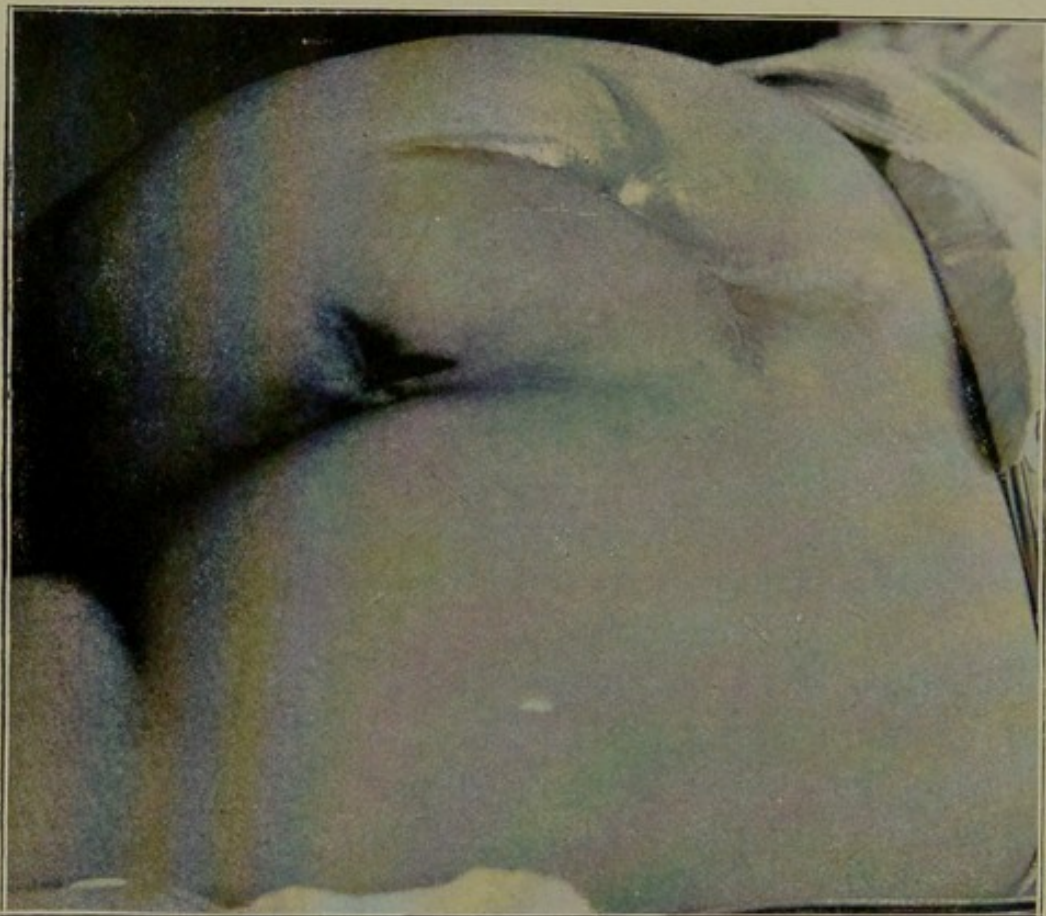


FIG. 22.—AN ISCHIO-RECTAL ABSCESS RESULTING FROM THE BURROWING OF A SUBGLUTEAL ABSCESS THROUGH THE GREAT SACRO-SCIATIC FORAMEN.

The scar on the buttock shows the extensive burrowing beneath the gluteus maximus. The scar in the ischio-rectal fossa shows where the pus pointed after its course through the pelvis. No track connecting these two openings outside the pelvis could be found. Thickening in the posterior part of the pelvi-rectal region was marked.

The accompanying diagrammatic representation of the rectum and its immediate surroundings will enable us to follow the course taken by these abscesses by bringing to



mind the several structures which either impede or guide extension in different directions (see fig. 23).

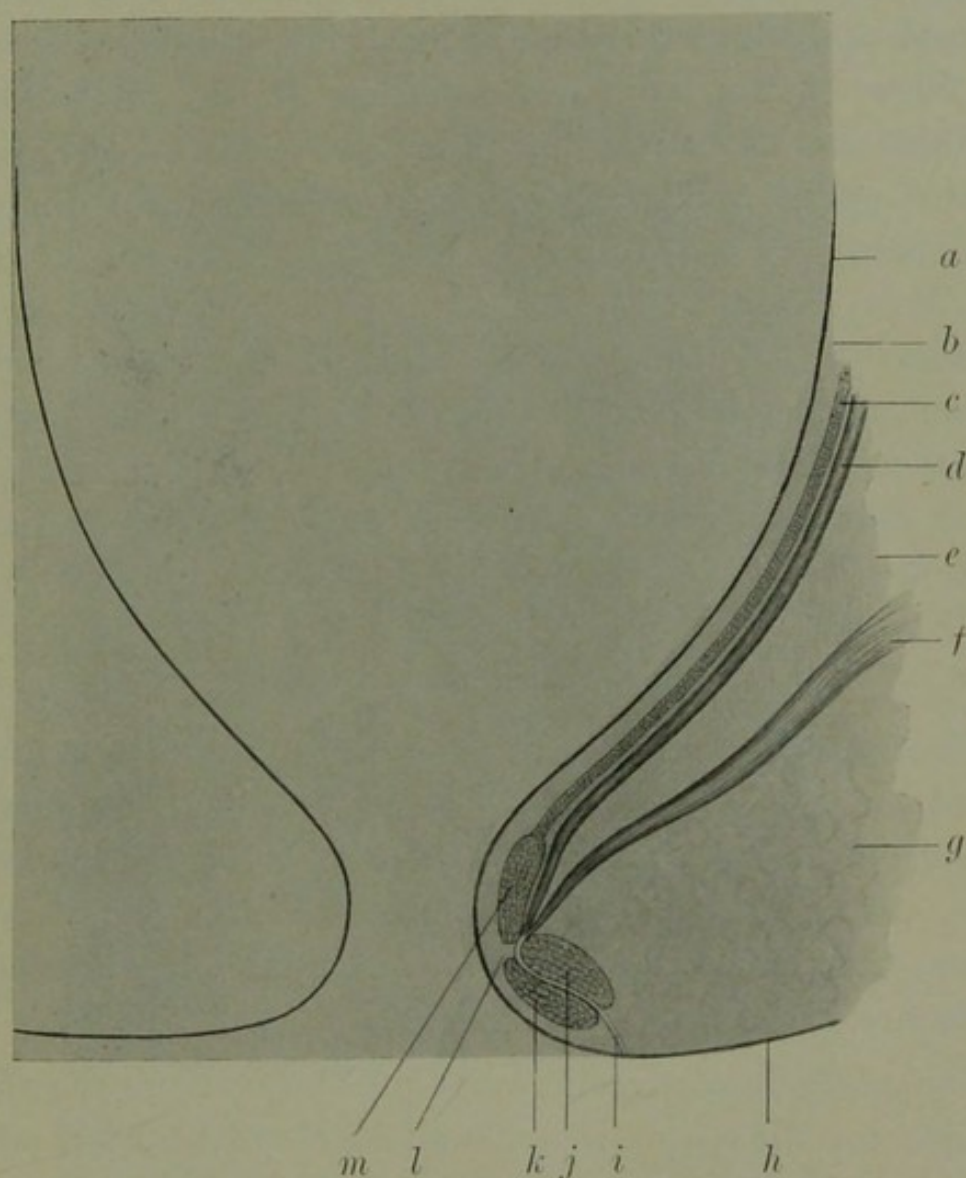


FIG. 23.—DIAGRAMMATIC REPRESENTATION OF THE LOWER PART OF THE RECTUM AND ITS IMMEDIATE SURROUNDINGS.

*a* mucous membrane; *b* submucous tissue; *c* circular muscular fibres; *d* longitudinal muscular fibres; *e* pelvi-rectal space; *f* levator ani; *g* ischio-rectal fossa; *h* integument; *i* tendinous insertion of the longitudinal muscular fibres; *j* deep portion of the external sphincter; *k* superficial portion of the external sphincter; *l* interval between the internal and the external sphincters; *m* the internal sphincter.

Thus it will be seen that an abscess starting in the subcutaneous tissue will find a ready outlet through the integument and will have no occasion to extend into the ischio-rectal fossa or to rupture into the rectum. The ischio-



rectal abscess being situated beneath the stratum of deep fascia will, in addition to finding an exit on the surface, be liable to make its way into the rectum between the internal and the external sphincters by passing between the fibres of the tendinous insertion of the longitudinal muscular coat of the rectum. The pelvi-rectal abscess being situated above the levator ani will either remain confined to the pelvi-rectal space, or by passing downwards between the fibres of the levator ani invade the ischio-rectal fossa secondarily. The submucous abscess, being located beneath the mucous membrane, will either find an exit by perforating the mucous membrane at the level of its seat of origin or extend downwards, until it reaches the subcutaneous tissue at the anal margin and perforates there.

#### (a) *Subcutaneous Abscess.*

The Subcutaneous Abscess is superficial to the deep fascia and to the planes of muscular tissue, with the exception of the corrugator cutis ani which belongs to the subcutaneous tissue. It may originate in a sebaceous follicle, *the follicular abscess*; from extravasated blood, or from the lower extremity of a fissure, *the marginal abscess*.

*The follicular abscess* may be single but is more generally multiple, for the reason that a number of neighbouring sebaceous follicles become infected at the same time or soon after each other. It is usually met with within a radius of two inches from the anal margin. Occasionally several abscesses may develop, the whole series extending over a period of several weeks or months. It is more prevalent in the summer and autumn months than during the other seasons of the year. In size it is small as a rule, and shows no tendency to open into the rectum, but rather to burrow away from it. Neighbouring abscesses of this nature are especially liable to coalesce with one another, causing in



such cases considerable subcutaneous burrowing (see fig. 24). Frequently they are confined to one side of the rectum only. However extensive such burrowing may be, there is rarely any communication with the rectum, and, therefore, a fistula seldom results.

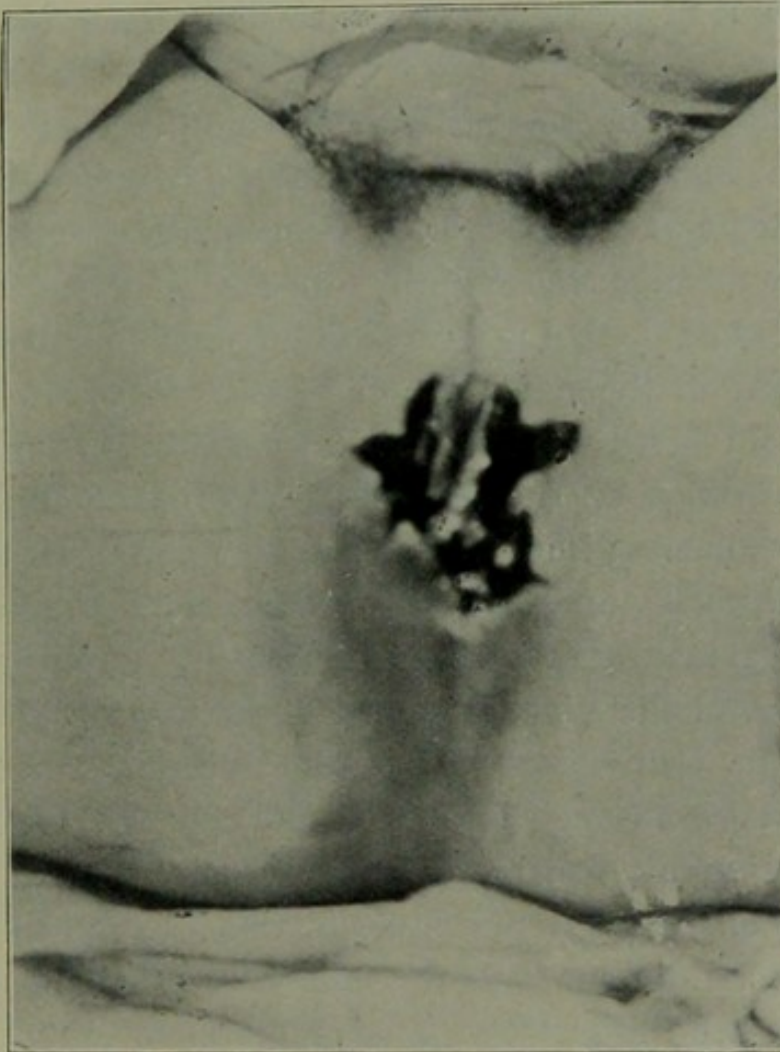


FIG. 24.—SHOWING THE EXTENSIVE SUBCUTANEOUS BURROWING CAUSED BY ADJACENT FOLLICULAR ABSCESSSES.

The photograph was taken soon after the burrowing had been laid open. It will be noticed that the rectum has not been interfered with.

*Symptoms.*—A follicular abscess manifests itself by itching, soreness and pain in the anal region, inability to sit and difficulty in walking. When touched great pain is complained of.

*Physical examination.*—In the early stage of its existence the abscess is small, superficial, circumscribed and freely



movable over subjacent tissues, enabling it to be lifted up between the fingers and thumb. The overlying skin in the earlier stage is often, but not invariably, reddened. When seen at a later stage both the overlying and the surrounding skin are intensely congested, and there is central softening with surrounding œdema. Very often, if the abscess is on the point of breaking, the pus can be seen beneath the epidermis.

*The Marginal Abscess*, as its name implies, is situated close to the anal margin. It originates from septic infection of an extravasated clot of blood or as a localized cellulitis in the immediate neighbourhood of the lower extremity of a fissure. This variety of abscess is always single, and may be situated at any point in the anal circumference. When the abscess results from blood extravasation, it may burrow towards the rectum, passing superficially to the external sphincter, and ultimately opening into the rectum. The burrowing also extends outwardly and opens on to the surface from a half to one inch distant from the anal margin, thus forming a complete fistula of the simplest kind. When the abscess supervenes upon a fissure, it usually opens externally from a quarter of an inch to one inch from the anal margin, the internal opening being situated at the lower extremity of the fissure. The sinus of the resulting fistula in this case is wholly subcutaneous, and differs from the preceding in that it does not extend beneath the rectal mucous membrane.

*Symptoms.*—The marginal abscess being situated near the anal verge is accompanied by constant pain. By being continuous the pain differs from that attending fissure, which supervenes at, or soon after, each action of the bowels and lasts for a definite period (see fissure). The pain is often of a throbbing character, and is intensified by each act of defæcation as well as during sitting and walking. There is also a sense of fulness at the anus.

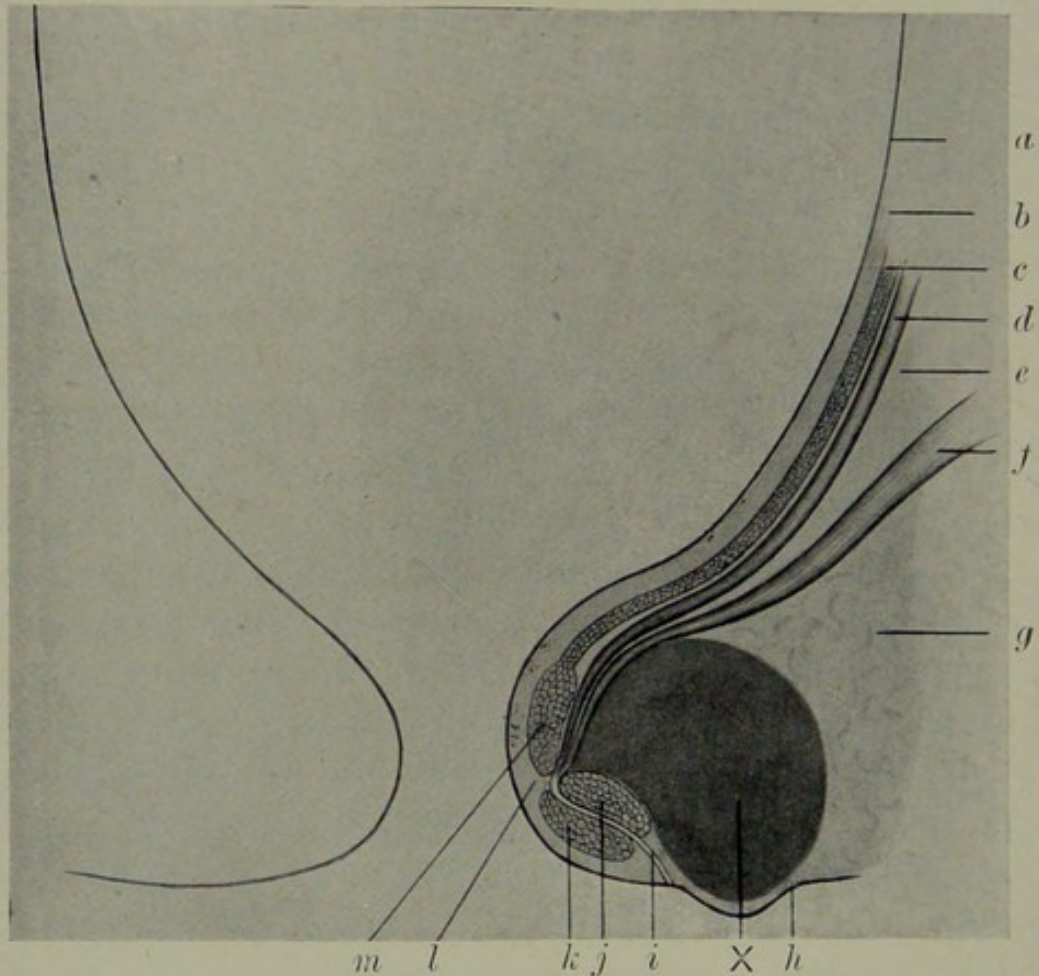


*Physical Examination.*—On separating the nates a swelling is found close to the anal margin, which is more prominent when the abscess is due to an extravasated clot of blood than when it has been caused by a fissure. In the former case the pus has to make its way through intact and healthy skin, a process taking several days or a week or two to accomplish, whereas, when an abscess forms in the neighbourhood of a fissure, there is but connective tissue intervening between the abscess cavity and the fissure, so that in two or three days after the appearance of the abscess this barrier of connective tissue is broken through, the pus finding a ready exit through the fissure, and consequently the abscess has no need to become much distended and prominent. On this account also the blind internal fistula thus formed may exist for several weeks before ulceration through the skin takes place. The anus should now be carefully examined by requesting the patient to strain down while its margins are being drawn apart. In this way the presence of a pre-existing fissure can be detected and the question, whether the swelling extends into the rectum beneath the mucous membrane, decided. The finger should now be passed into the rectum, care being exercised to exert the pressure necessary for its introduction upon the side opposite to that on which the abscess exists, so that the pain caused by the introduction of the finger may be lessened as much as possible. A thorough exploration of the rectum can now be carried out without the infliction of much pain, and the presence or absence of other diseased conditions determined. As we shall see further on, an abscess may start entirely within the rectum as a submucous abscess and eventually point beneath the skin at the anal margin, thus simulating the appearance of the marginal abscess. Digital exploration will at once make the diagnosis clear as to whether a marginal abscess is or is not part of a submucous abscess, and thus indicate the method of treatment to be adopted (see pages 84 and 86).



*(b) Ischio-rectal Abscess.*

The Ischio-rectal Abscess starts as a focus of septic inflammation in the adipose tissue of the ischio-rectal fossa. The fat in this locality being but sparsely supplied by blood vessels favours the septic process, with the result that sooner



**FIG. 25.—**DIAGRAMMATIC REPRESENTATION OF AN ISCHIO-RECTAL ABSCESS.

*a* Mucous membrane; *b* submucous tissue; *c* circular muscular fibres; *d* longitudinal muscular fibres; *e* pelvi-rectal space; *f* levator ani; *g* ischio-rectal fossa; *h* integument; *i* tendinous insertion of the longitudinal muscular fibres; *j* deep portion of the external sphincter; *k* superficial portion of the external sphincter; *l* interval between the internal and external sphincters, *m* the internal sphincter; *x* the abscess cavity

The diagram of the abscess is intended to show the pointing under the integument, the bulging between the external and internal sphincters, and the pressing inwards of the whole thickness of the rectal wall over the abscess.

or later pus is formed. The resistance offered by the fatty tissue is so slight that the whole ischio-rectal fossa may soon become occupied by the purulent collection (see fig. 25). A reference to the anatomy of this fossa (see page 8) will show



that the pus is closely hemmed in on all sides by strata of fascia and muscle, which offer a considerable impediment to further extension. The weak points in the region are (1) the interval between the sphincters, (2) the incomplete stratum of deep fascia separating the fat of the fossa from that of the subcutaneous tissue, and (3) the incomplete attachment of the levatores ani to the ano-coccygeal ligament. In the young, the line of separation between the two sphincters, though existing, is not necessarily a weak point; but as age advances the interval between these muscles becomes more pronounced, especially in the middle line posteriorly. Not only does this increased separation take place between the internal and external sphincters, but it is also found between the superficial and deep portions of the external sphincter. The reason for this increased separation between the internal and external sphincter is, we think, prolonged straining during defæcation. The separation is more marked in the middle line posteriorly on account of the attachment of the external sphincter to the ano-coccygeal ligament being its most fixed point, and, therefore, at this point the greatest force is exercised by the levatores ani when they contract. Accordingly the attenuation of the tissue between the sphincters in the middle line posteriorly constitutes one of the weakest points in the wall of an ischio-rectal abscess. Moreover, the increased strain thrown upon the attachment of the levatores ani to the upper surface of the ano-coccygeal ligament causes this bond of union to be weakened and in this way a vulnerable point is produced posteriorly in the tissues separating one ischio-rectal fossa from the other. Bearing these facts in mind it is easy to follow the course of the extension of an abscess situated in the ischio-rectal fossa. Thus, having completely filled the fossa, further increase of the pus finds out the weak points in its walls. Consequently the abscess may burst into the rectum through the interval between the sphincters posteriorly, or it may make its way



between the attachment of the levatores ani and the ano-coccygeal ligament and so gain access to the ischio-rectal fossa of the opposite side. Also, either before or after the above has happened, the pus may find its way to the surface through the deep fascia and appear beneath the skin, tracking both forwards and backwards in this situation. When both ischio-rectal fossæ have become invaded and subcutaneous burrowing has taken place on one or both sides, with rupture into the rectum in the middle line posteriorly between the sphincters, a typical *posterior horse-shoe fistula* is established.

In women, on account of the looser texture of the ischio-rectal adipose tissue, an abscess starting *posteriorly* to the rectum may extend forwards in the ischio-rectal fossa on one or both sides, and discharge into the vagina before opening through the skin. In this way, the lower part of the rectum may be almost completely surrounded by the abscess cavity before any pointing on the surface takes place. Should such an abscess not have discharged itself in the middle line posteriorly between the sphincters, an event which would be recognised by the escape of pus from the anus, a digital examination of the rectum would render the diagnosis of the existing abscess an easy matter.

Abscesses which start in the ischio-rectal fossa *anteriorly* to the *transverse anal line* are more superficial in their course than those starting *posteriorly* to that line. In these, the pus reaches the subcutaneous tissue at the outer margin of the external sphincter muscle and then extends forwards beneath the skin towards and along the cruro-scrotal or cruro-labial fold. At the same time burrowing takes place in an outward and backward direction, usually, superficial to the inferior hæmorrhoidal artery. The pus reaches the rectum between the internal and external sphincters at a point situated midway between the transverse anal line and the anterior margin of the anus, on the side on which the abscess exists. The internal opening may be situated at a point correspond-



ing to the interval between the sphincters, but sometimes it may be quite an inch or even more above this point, in consequence of the burrowing having extended upwards beneath the mucous membrane before bursting into the rectum. In such cases the burrowing may also extend even higher than this opening, a pocket being formed beyond it. Occasionally the forward burrowing passes subcutaneously in front of the anus to the opposite side, thus forming a subcutaneous *anterior horse-shoe fistula*.

*Symptoms.*—The usual symptoms attending an ischio-rectal abscess are pain in the ischio-rectal fossa, inability to sit in comfort, difficulty and pain during defæcation and sometimes retention of urine. To these may be added more or less constitutional disturbance, especially in the early stages. The pain may take the form of a feeling of weight in the part or it may be of a dull aching or throbbing character. When the abscess bursts into the rectum or discharges externally, all the above symptoms are suddenly relieved. Should the opening temporarily become closed, the abscess cavity refills, and all the symptoms, with the exception of retention of urine, may recur. This cycle may be and usually is repeated more than once, and is often attended by additional burrowing.

*Physical Examination.*—When the abscess is situated *posteriorly* to the *transverse anal line*, by introducing the finger into the rectum a more or less globular swelling can be felt in the ischio-rectal fossa between that finger and the thumb of the same hand outside. In this way not only the main abscess cavity, but also the lateral burrowing from it on one or both sides of the rectum, can be readily made out, although externally there may be no indication of the presence of an abscess. When the abscess is situated *anteriorly* to the *transverse anal line*, it is usually so superficial that it quickly points under the skin, and a digital exploration of the rectum is, therefore, not necessary for the recognition of its presence. Still, the intro-



duction of the finger into the rectum should never be omitted, as by this means much additional information may be obtained in regard to the starting point of the abscess and the extent of its lateral burrowing.

(c) *Submucous Abscess.*

This variety of abscess originates in the submucous tissue, usually in the lower three inches of the rectum, and is gener-

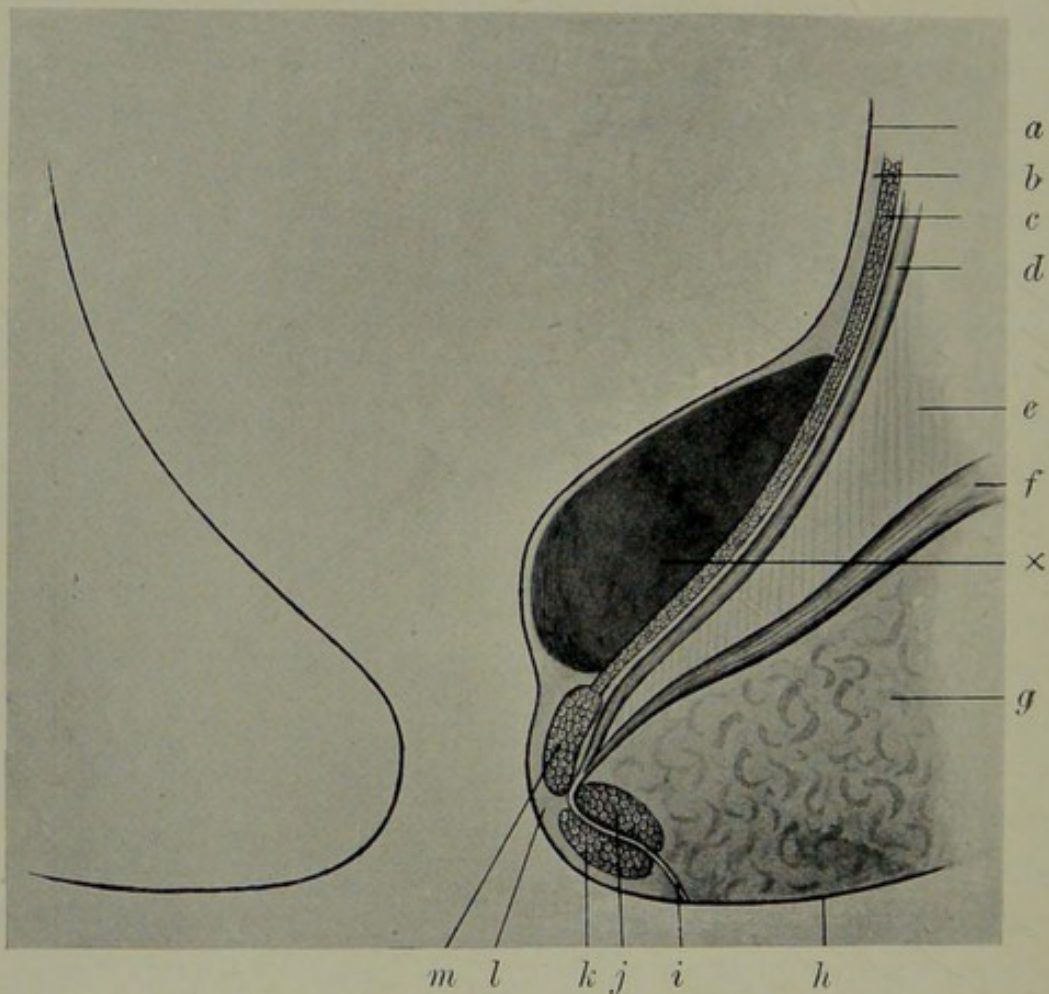


FIG. 23.—DIAGRAMMATIC REPRESENTATION OF A SUBMUCOUS ABSCESS.

*a* Mucous membrane; *b* submucous tissue; *c* circular muscular fibres; *d* longitudinal muscular fibres; *e* pelvi-rectal space; *f* levator ani; *g* ischio-rectal fossa; *h* integument; *i* tendinous insertion of the longitudinal muscular fibres; *j* deep portion of the external sphincter; *k* superficial portion of the external sphincter; *l* interval between the internal and external sphincters; *m* the internal sphincter; *x* the abscess cavity.

The diagram is intended to show that the swelling caused by the abscess projects only into the cavity of the rectum, and cannot therefore be felt externally.

ally confined to one side of the bowel (see fig. 26). It shows a marked tendency to burrow downwards towards the anal



orifice. Lateral extension also takes place horizontally and in a slightly upward direction. We have never seen it extend all round inside the muscular wall of the rectum as the ischio-rectal abscess posterior to the *transverse anal line* occasionally does outside of it. When the burrowing has reached the margin of the anus, the pus is usually discharged through an opening situated either at the anal margin itself or about a quarter of an inch external to that point. A second opening may form at the upper extremity of the abscess cavity, but usually it is somewhere in the upper part of the abscess area. It is exceptional for openings to be met with at the extremities of the lateral burrowings, there being sufficient drainage established by the openings in connection with the main abscess cavity to prevent their formation.

*Symptoms.*—The most prominent symptom of a submucous abscess is acute pain before, during, and after defæcation. There is also a constant feeling of weight and throbbing in the rectum which is from time to time temporarily relieved by the escape of pus from the abscess cavity. Difficulty in micturition is sometimes experienced. Constitutional disturbance, when it exists, is not so marked as in ischio-rectal abscess.

*Physical Examination.*—On introducing the finger into the rectum, a procedure which will, unless very carefully and gently carried out, cause great suffering to the patient, a more or less elongated, smooth, tense or semi-elastic swelling will be felt in the rectal wall. This swelling cannot be pressed down towards the surface so as to be felt between the exploring finger and the thumb outside. When the abscess has burst before the examination, or the rupture has been caused by the examination, the examining finger, when withdrawn, will be found covered or streaked with pus. The sensation imparted to the examining finger in a case of recent abscess is similar to that imparted to the tongue by a gumboil. An abscess that has already discharged and is quite emptied of



its contents, feels like a nodule or a haricot bean in the submucous tissue.

(d) *Pelvi-rectal Abscess.*

The pelvi-rectal abscess originates in the loose connective tissues existing between the levatores ani below and the reflection of the peritoneum above. This space, varying in

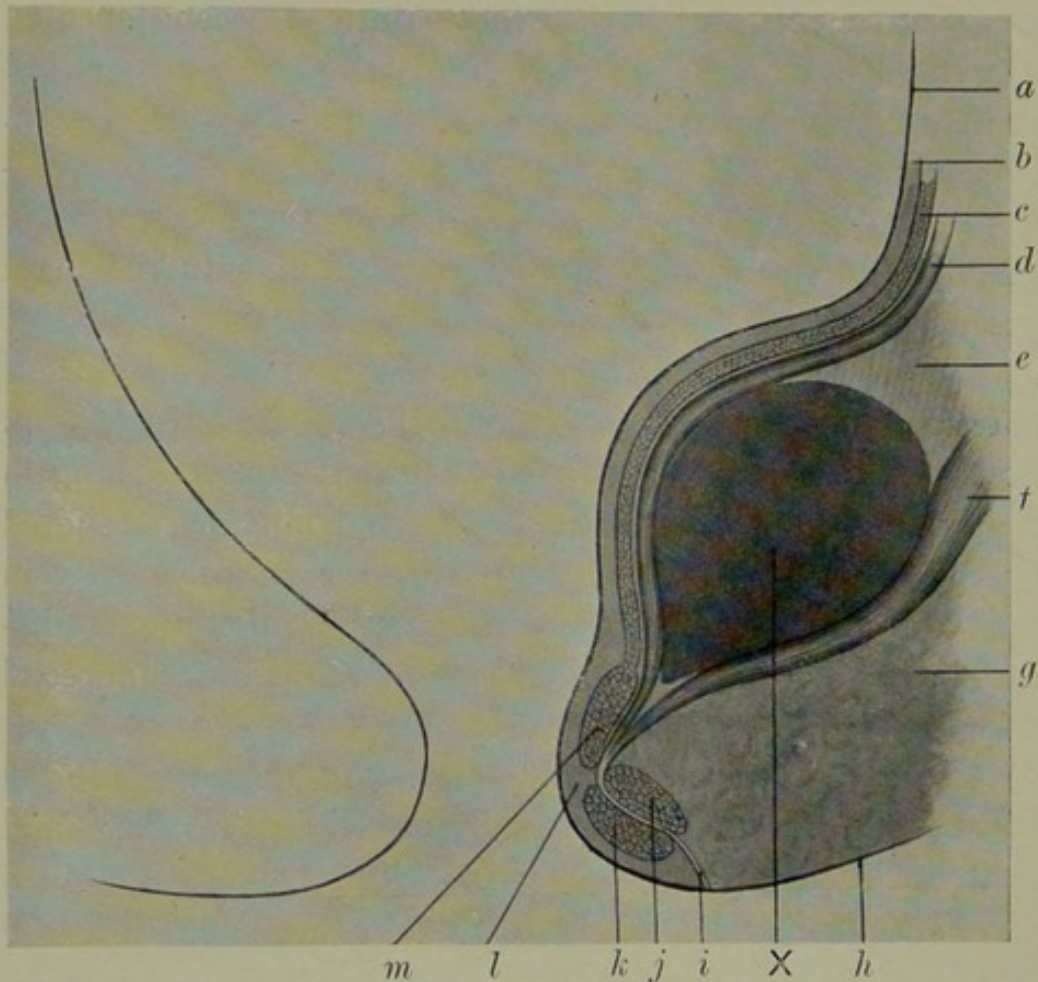


FIG. 27.—DIAGRAMMATIC REPRESENTATION OF A PELVI-RECTAL ABSCESS.

*a* Mucous membrane: *b* submucous tissue: *c* circular muscular fibres: *d* longitudinal muscular fibres: *e* pelvi-rectal space: *f* levator ani: *g* ischio-rectal fossa; *h* integument; *i* tendinous insertion of the longitudinal muscular fibres: *j* deep portion of the external sphincter: *k* superficial portion of the external sphincter: *l* interval between the internal and the external sphincters: *m* the internal sphincter; *x* the abscess cavity.

The projection inwards of the whole thickness of the rectal wall and the bulging downwards of the levator ani are here shown. This abscess can therefore be felt from the rectum and sometimes externally on deep pressure.

depth in different subjects, is known as the superior pelvi-rectal space, and was first described by Richet\* (see fig. 27).

\* *Traité pratique d'Anat. med-chirurg.* 4th Ed. Paris 1873, p. 93, quoted by Van Buren.



The connective tissue of this region is continuous with that of the meso-rectum, and of the broad ligaments in the female, and also with that surrounding the prostate gland and neck of the bladder in the male. Hence it follows that septic processes, starting in any of those situations, spread to the superior pelvi-rectal space, and therefore are not *primâ facie* connected with the rectum. However, there are instances in which the pelvi-rectal abscess owes its origin to the rectum itself; such, for instance, as those supervening upon perforation of the rectum above the level of the internal sphincter. Foreign bodies in the rectum, *e.g.*, fish bones, &c., may, though rarely, puncture the bowel above the level of the internal sphincter and so set up an abscess. Ulcerative processes extending up the rectum followed by stricture below its upper limit; the partial tearing through of the attachment of a polypoid growth situated above the level of the upper border of the internal sphincter; and also advanced malignant disease of the lower part of the bowel, may lead to perforation and the formation of a pelvi-rectal abscess. Suppuration resulting from any of the above causes readily extends in the plane of connective tissue, and it is easy to understand how widespread the resulting burrowing may be. A diffuse cellulitis in this situation is fraught with great danger to life, as the pus may make its way into the general peritoneal cavity and so induce septic peritonitis. This termination is more likely to occur in the acute forms of the disease. When the abscess runs a more chronic course, thickening of the abscess wall, especially on the peritoneal side, affords protection against perforation in that direction. Sooner or later, however, in these cases the pus finds its way through the fasciculi of the levatores ani and so reaches the ischio-rectal fossa, appearing there as an ischio-rectal abscess (see fig. 28). It is this kind of abscess which causes the *deep anterior horse-shoe fistula*, the *recto-urethral fistula*, and sometimes the much more common *posterior horse-shoe fistula*, the burrowing having, to a greater or lesser



extent, encircled the rectum, before it extended to the ischio-rectal fossa, where it follows the usual course of burrowing in that situation (see page 67). A well marked case of pelvi-

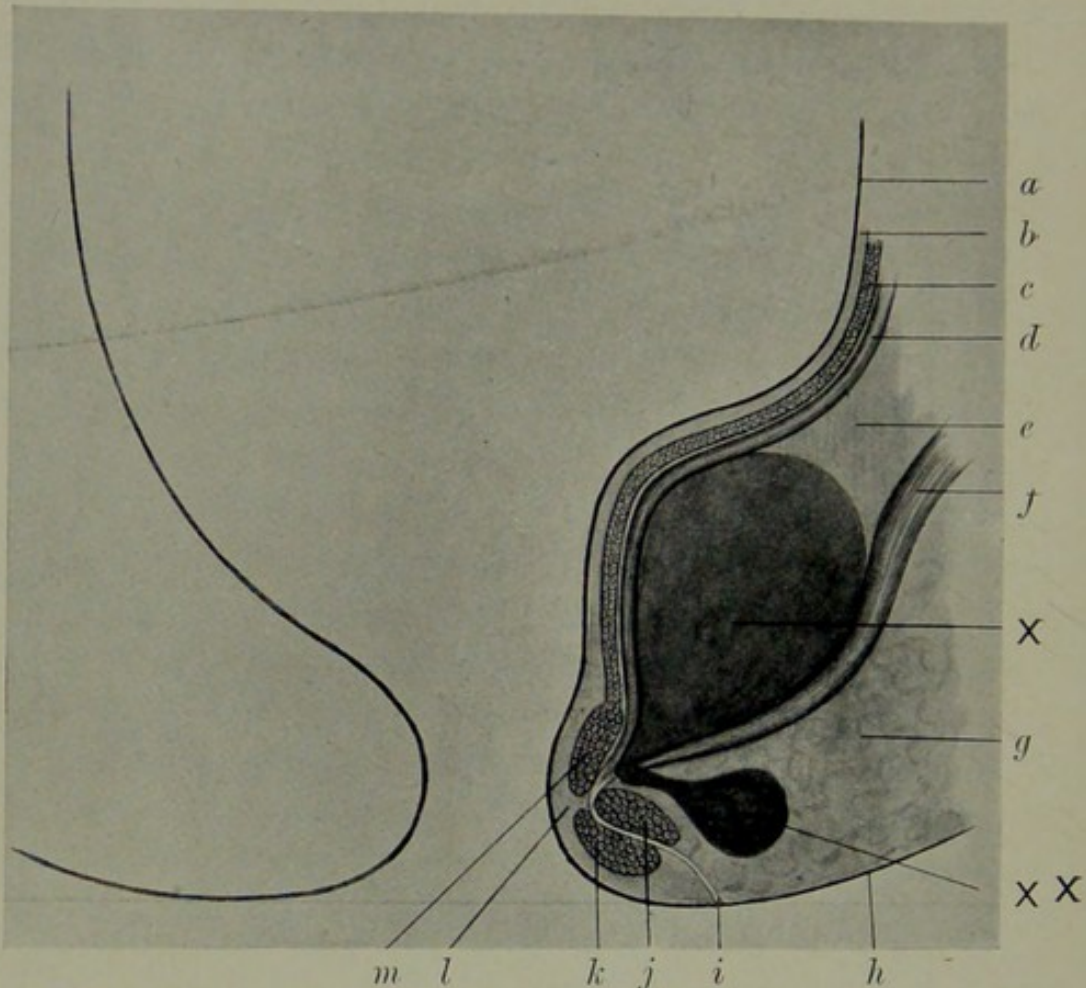


FIG. 28.—DIAGRAMMATIC REPRESENTATION OF A PELVI-RECTAL ABSCESS WHICH HAS INVADDED THE ISCHIO-RECTAL FOSSA.

*a* Mucous membrane; *b* submucous tissue; *c* circular muscular fibres; *d* longitudinal muscular fibres; *e* pelvi-rectal space; *f* levator ani; *g* ischio-rectal fossa; *h* integument; *i* tendinous insertion of the longitudinal muscular fibres; *j* deep portion of the external sphincter; *k* superficial portion of the external sphincter; *l* interval between the internal and the external sphincters; *m* the internal sphincter; *X* the abscess cavity; *X X* its extension into the ischio-rectal fossa.

The perforation of the levator ani usually takes place, as shown in the diagram, close to its junction with the longitudinal muscular coat of the rectum. Soon after the ischio-rectal fossa has been invaded there will be external evidence of an abscess in that locality.

rectal abscess invading the ischio-rectal fossa on both sides, was recently under our care. The abscess undoubtedly started as a localized tuberculosis of the lymphatic glands in the mesorectum. At the operation, when the burrowing in the ischio-rectal fossæ was laid open, an aperture was found in the



interval between the levatores ani posteriorly, which led into a second abscess cavity above the level of the levatores. Into this second abscess a probe passed readily for a distance of four inches, directly in front of the sacrum, showing clearly that the upper limit of the cavity was situated between the layers of the meso-rectum. The diagnosis of the tuberculous nature of the abscess was strengthened by the co-existence of well marked tuberculous ulceration of the larynx, which had developed several months before the abscess manifested itself.

*Symptoms.*—The initial symptoms marking the onset of an abscess in the superior pelvi-rectal space are those of an ordinary case of pelvic cellulitis. In the acute forms, these symptoms are well marked, there being great constitutional disturbance with pain, of a more or less acute character in the pelvis, which may also radiate to the lumbar and sacral regions and, in some instances, extend down the thighs. In the more chronic cases, these symptoms, or some of them, are less pronounced, and, in fact, may be absent. Until, however, symptoms definitely referable to the rectum develop, these cases may be readily overlooked, unless caused by cancer or benign stricture of the rectum. The appearance of the abscess in the peri-anal region should at once lead to the correct diagnosis of the case. In addition to the existence of an abscess in the ischio-rectal fossa, other symptoms, such as pain and difficulty during defæcation, persistent passage of pus by itself or with either fæces or flatus, a sensation of weight and bearing down in the rectum and difficulty in micturition or even retention of urine, are usually present. So soon as the ischio-rectal fossa becomes implicated, all the local symptoms of abscess in that locality manifest themselves (see page 69).

*Physical examination.*—In the earlier stage there may be no external indication of an abscess in the peri-anal region, the ischio-rectal fossæ preserving their usual appearance. On



introducing the finger into the rectum, however, a distinct fulness or swelling, encroaching upon the lumen of the bowel and extending upwards beyond the reach of the finger, can be felt. The lower margin of the swelling may be above the upper border of the internal sphincter, indicating that the abscess has not yet found its way into the ischio-rectal fossa. It must be remembered, however, that there are other localities to which a pelvi-rectal abscess may extend, namely, the iliac fossa, the lumbar region, and also the gluteal region *viâ* the great sacro-sciatic foramen. Accordingly, if the swelling felt from within the rectum be found to extend upwards beyond the reach of the finger, these localities also should be carefully examined. When a pelvi-rectal abscess has invaded the ischio-rectal fossa, the external signs are those of an ischio-rectal abscess, if only one fossa is involved; or those of an anterior or posterior horse-shoe fistula, when both fossæ are implicated. Under these circumstances, digital exploration of the interior of the rectum will throw much light upon the seat of origin of the suppuration, and should always be made in order to ascertain whether the swelling seen externally extends beyond the uppermost limit of the ischio-rectal fossa.

(e) *Labial Abscess.*

An abscess originating in the labium majus remains confined in most instances to the labium. Occasionally, however, it may extend backwards subcutaneously into the rectal triangle, burrowing in this direction by the side of and beyond the anus. A lateral offshoot may also pass transversely across between the anus and the fourchette to the opposite side, thus simulating a subcutaneous anterior horse-shoe fistula but differing from it in not having an opening into the rectum, though an external opening in the peri-anal region may exist. Occasionally, there is an opening into the vagina on its posterior wall, varying in position from half an inch to an inch above the introitus. We have seen one case



in which an abscess, starting in the left labium majus, extended into the rectal triangle, and passing backwards deeper than the left inferior hæmorrhoidal artery, burrowed beneath the ano-coccygeal ligament and pointed in the ischio-rectal region of the opposite side, where an incision was made into it. Fortunately for the patient, no rupture into the rectum had taken place, although a marked bulging could be felt in the middle line posteriorly between the internal and external sphincters, one of the weak spots to which we have already drawn attention (see page 67). This burrowing healed without any division of the external sphincter being required.

*Symptoms.*—These are identical with those of the ordinary peri-anal or ischio-rectal abscess. Careful inquiry should elicit the fact that the abscess started in, and was for a time confined to, the labium majus; and that the appearance of the abscess in the peri-anal or ischio-rectal region, with its attendant symptoms, was subsequent to the labial trouble.

*Physical examination.*—In the female, attention should be paid in all cases to the direction of the forward burrowing from an abscess in the peri-anal region. When the abscess originates in the anal or ischio-rectal region, the forward burrowing is found subcutaneously in the cruro-labial fold. When the burrowing does not extend into the cruro-labial fold but takes a course internal to it, it may be found to extend into the labium. Accordingly, in these cases, the labium should always be examined for induration or swelling. The point we wish to emphasize is, that an abscess originating in the labium does sometimes extend backwards into the rectal triangle and appear as a peri-anal or ischio-rectal abscess, whereas the abscess starting primarily in the rectal triangle usually advances forward in the cruro-labial fold and does not extend into the labium. The recognition of this fact may be all important in the subsequent treatment of the case. Digital exploration of both rectum and vagina will greatly assist in making the diagnosis.



*Treatment.*

Abscess in the neighbourhood of the rectum and anus should be treated like abscess in other situations, *i.e.*, by *free evacuation*. As a rule, when a case of abscess in this part of the body is seen by the surgeon, either the abscess is pointing or has already burst through the skin, the patient having wasted time by applying poultices, &c. Occasionally a case is seen in the presuppurative stage, there being an absence of softening and fluctuation. Whenever an inflammatory swelling is present in the anal region or in the neighbourhood of the rectum, and it is probable that the formation of pus will ensue, a free incision should be made into the swelling with as little delay as possible. When pus has formed, an evacuation of the abscess cavity relieves tension and so prevents the burrowing which is certain to take place should it be left unopened. In those instances where the presuppurative stage only has been reached, an early and free incision may ward off the impending tissue necrosis, so that resolution, more or less complete, follows. Such a result is very rarely obtainable because tissue destruction has probably taken place to a certain extent even before pus has formed: but if the incision be made early, the extent of necrosed tissue may be so small that the resulting abscess cavity quickly heals. It is our opinion that, if peri-anal and perirectal abscesses were efficiently treated as soon as they made their appearance, fistula would be an extremely rare form of disease.

*Palliative Treatment.*

This should only be resorted to when the patient absolutely refuses to have an incision made, or when other conditions render an operation inadvisable. But we can hardly conceive conditions in which a simple incision into an inflammatory swelling in this part of the body could be productive of any harm. Palliative measures con-



sist of rest in the recumbent position; hot fomentations frequently applied; and warm sitz baths at short intervals. The bowels should be freely relieved by gentle laxatives, aided by the injection of an ounce of olive oil at night to soften any hardened masses of feces that may be present. The diet should be light and nutritious.

The above treatment certainly relieves the patient of a good deal of pain and also facilitates the pointing of the abscess; but it must be remembered that until the pus reaches the surface and discharges, the risk of lateral burrowing taking place from the main abscess cavity is constantly present, and, should simultaneous rupture into the rectum and on to the surface take place, a complete fistula will be at once established. There are cases of abscess in the peri-anal region which, having been left to themselves, have broken spontaneously and yet no fistula resulted; but these are few and far between.

### *Operative Treatment.*

We would strongly urge that every abscess in this locality be freely incised as soon as it is seen. In this way the probability of a fistula resulting is immensely diminished. Some abscesses terminate in a fistula in spite of being freely incised even in their quite early stages, but these are the exception. In such cases it is possible that the constant movement in the sphincters is the cause of the non-closure. The incision will, however, have relieved the tension and prevented further lateral burrowing. In this way it may reduce the resulting fistula to a straight sinus, which will need but a simple operation for its cure.

### *Operation.*

When operating upon an abscess in the peri-anal region, the incision into it should be sufficiently free to extend from one extremity of the surrounding induration to



the other. It is not sufficient to limit the incision to the area in which pus has formed because, the tension being relieved, the margins of the wound will fall together and good drainage will not be established. Even when the incision extends well beyond the limits of the abscess cavity, we recommend that a second incision be made at right angles from the centre of the first in order to ensure gaping of the opening (see fig. 29).

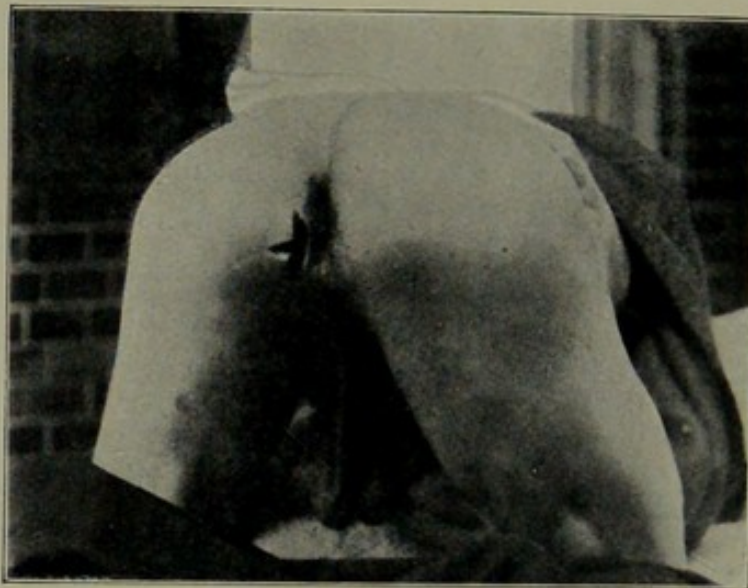


FIG. 29.—SHOWING THE WOUND MADE BY A T-SHAPED INCISION.

It will be observed that the T-shaped opening widely gapes although no manual traction is being made on its sides.

Accordingly we always make use of a T-shaped or a crucial incision, as by this means the wound is given the best chance of healing from the bottom. Having made these incisions, all septa that are found to exist, should be gently broken down by the finger. When lateral burrowing has taken place, it should not be laid open, unless it is extensive, as the greater part of it will disappear with the filling in of the abscess cavity, and unnecessary incisions may thus be avoided. Even extensive abscesses which, if left to themselves, would lead to a complex fistula, will often



contract down into a single sinus, if freely opened by a T incision. In making use of the T-shaped or the crucial incision, care should be taken that all their extremities extend beyond the indurated area into healthy tissue so far as the skin is concerned (see fig. 30).

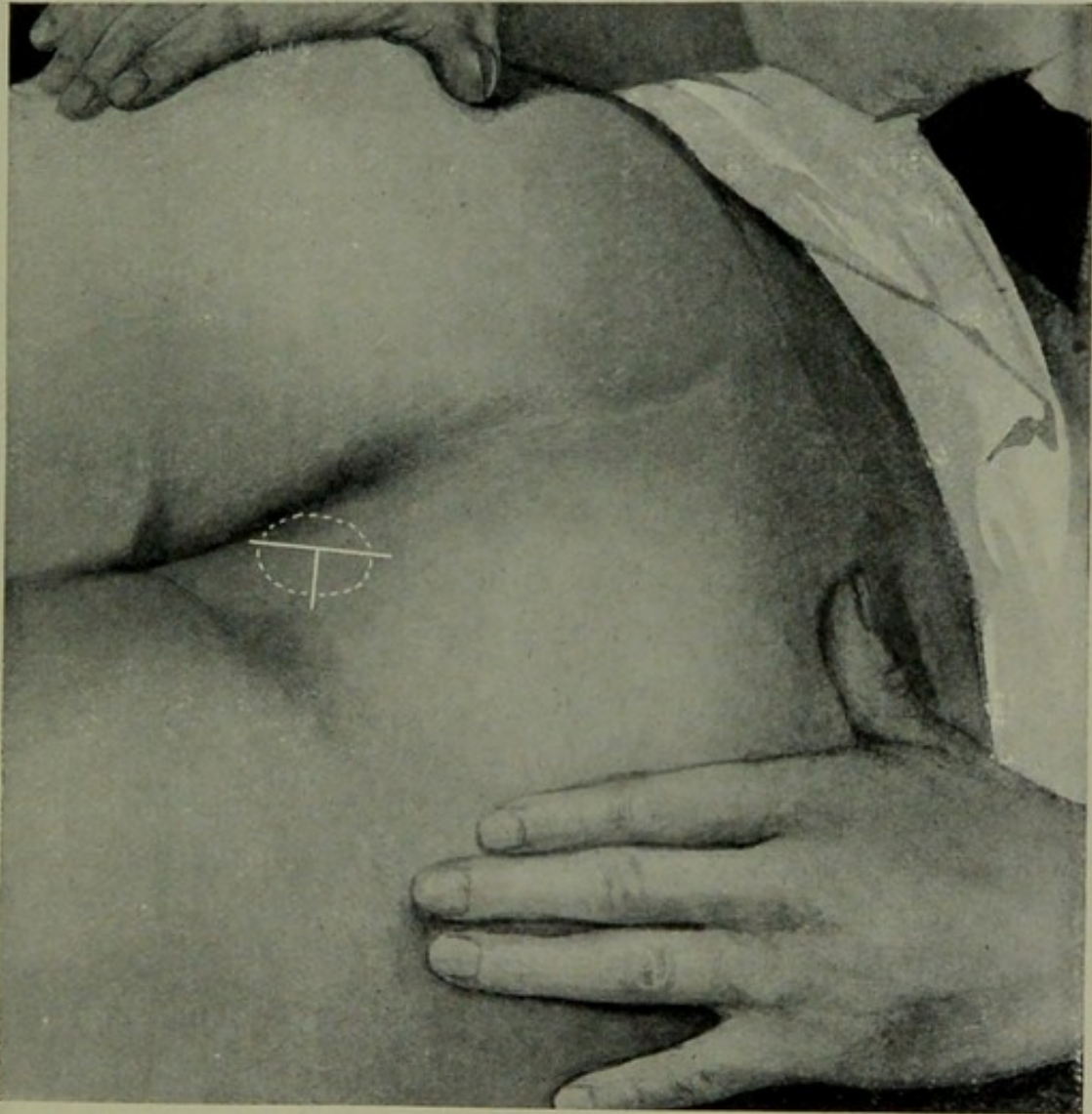


FIG. 30.—ILLUSTRATING THE EXTENT OF THE T INCISION.

The dotted line represents the limit of the area of inflammation.

The points to be observed in opening a peri-anal abscess are:—

- (1) To adopt the T-shaped or crucial incision, where permissible.



- (2) To extend each extremity of the T-shaped or crucial incision, so far as the skin is concerned, slightly beyond the inflammatory zone.\*
- (3) To break down all septa in the main abscess cavity.
- (4) To ignore limited lateral burrowing until an opportunity has been given for it to close without incision.

If these suggestions be carried out, and the abscess is seen before it has burst into the rectum, a fistula will seldom follow. The reason why fistula so frequently follows an abscess is, we feel sure, due to the following causes:—

- (1) The opening of the abscess is delayed too long.
- (2) When the opening is made, the incision is frequently far too small.
- (3) The form of the incision is linear, usually radiating from or parallel to the anus.

It must be borne in mind that all incisions into an abscess are shortened with the contraction of its cavity, and, therefore, an incision which appeared to be sufficiently long when it was made, very soon becomes too small to allow of good drainage. The incision being small, its edges readily come together, and may unite during the healing process before the abscess cavity has been obliterated. In consequence of this, the abscess may refill and lateral burrowing take place, with the result that, sooner or later, a fistula is formed, either with or without an opening into the rectum. A linear incision, therefore, is often insufficient to secure free drainage of an abscess in this part of the body. When, however, the T-shaped or crucial incision is adopted on the lines we have suggested

---

\* The limits of the inflammatory zone can sometimes be clearly seen when the patient is under the influence of ether, on account of the lividity produced in the overlying skin.



above, the margins of the wound gape and remain apart until the abscess cavity has been obliterated (see fig. 31).

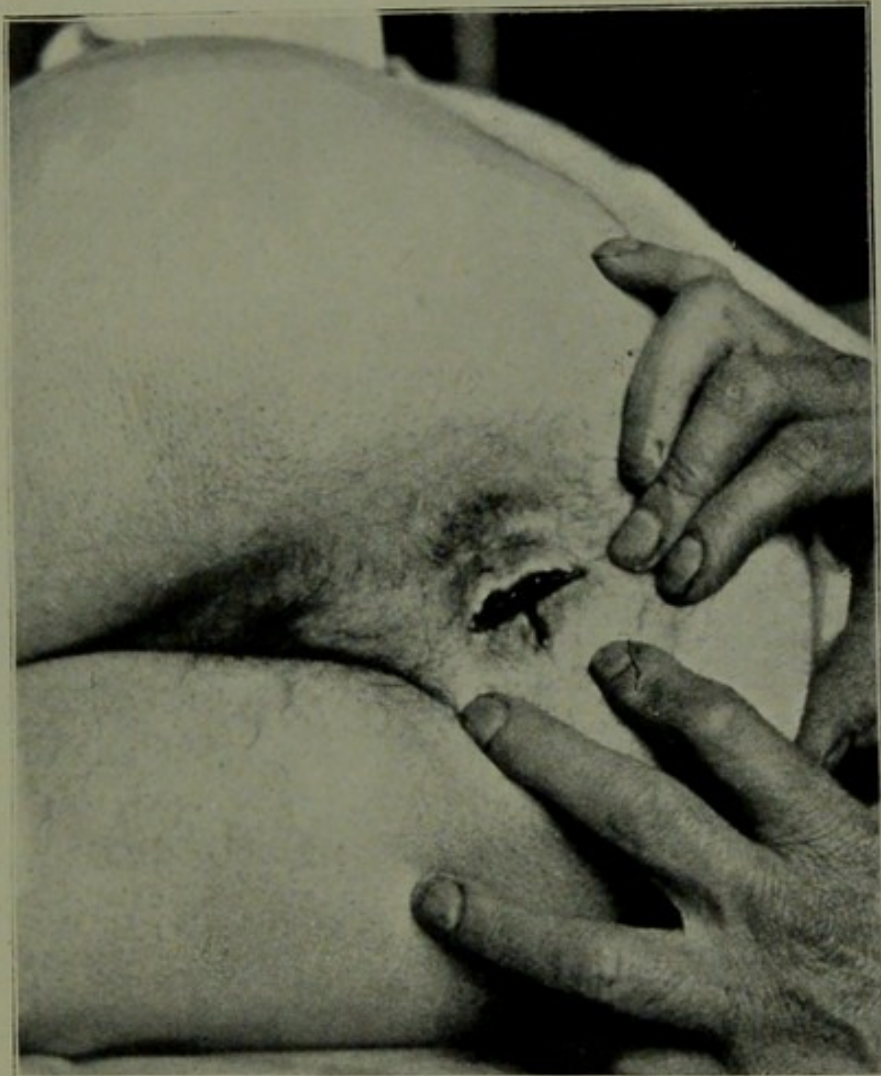

FIG. 31.—SHOWING THE T-SHAPED WOUND PARTIALLY HEALED.

### *The Method of Operating.*

The method to be adopted varies with the particular form of abscess to be dealt with.

*The follicular abscess.*—These abscesses should always be opened with a crucial incision. When met with in an early stage, the whole of the abscess may be lifted off the subjacent tissues between the finger and thumb, and, while held in this position, the bistoury should be passed through the whole length of the abscess. A second incision should then



be made at right angles to the first, the centre of the incisions passing through the deepest part of the induration. As a rule, there is very little bleeding, and it quickly ceases. As soon as the opening has been completed, a hot boracic fomentation should be applied.

*The marginal abscess* may also be opened by a crucial incision (we almost invariably adopt the T-shaped incision), care being taken not to damage the external sphincter. In order to make the incision, the index finger of the left hand should be introduced into the rectum and the abscess grasped between it and the thumb outside. The first incision should be made parallel to the anus; while the second is made at right angles to the first by introducing the point of the knife beyond the outer margin of the abscess cavity, opposite the centre of the preceding incision, and bringing it out at the centre when a T incision is desired, or carrying it on through the opposite margin when a crucial incision is to be made. The objection to the use of the crucial incision, in a marginal abscess, is that the external sphincter may be damaged. The pus having been evacuated and the cavity washed out with some perchloride of mercury solution, a small plug of cotton wool should be passed into the cavity and retained in position by a bandage.

*The ischio-rectal abscess.*—When this form of abscess is pointing on the surface, it should be freely opened by means of a T-shaped incision, the horizontal limb of the T being parallel to the anus, and the vertical limb running outwards from its centre (see fig. 32). It is not necessary to introduce the finger into the rectum in order to make this incision. When this is done a good deal of unnecessary pain is inflicted upon the patient, unless he is under the influence of a general anæsthetic. The abscess having been opened, all septa should be broken down by the finger, and the wound freely irrigated and then plugged with cotton wool. There



is generally free bleeding for a few minutes after the incisions have been made, but the divided vessels seldom require a ligature, as the plugging readily stops the hæmorrhage.

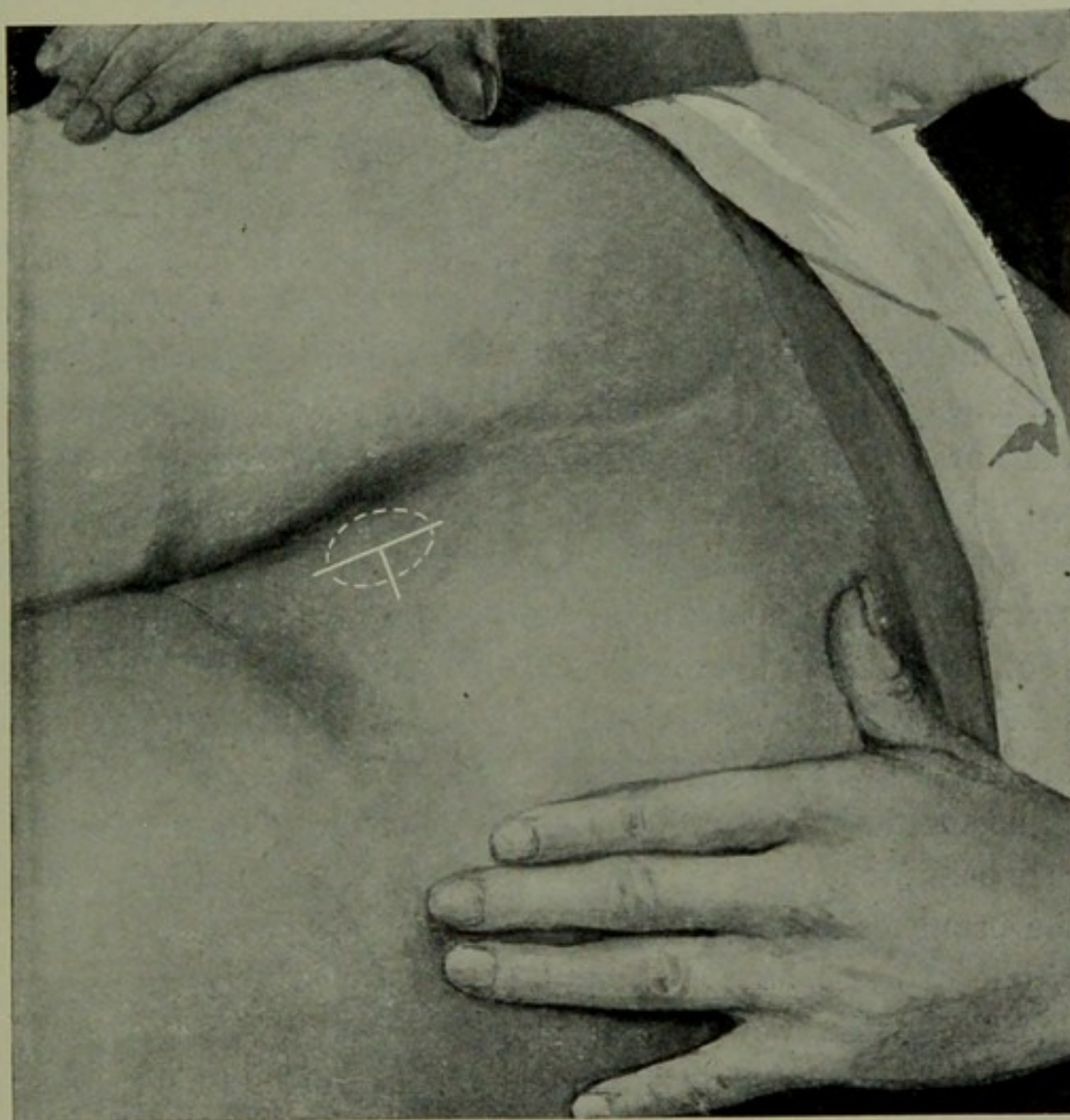


FIG. 32.—DIAGRAM OF A T-SHAPED INCISION INTO AN ISCHIO-RECTAL ABSCESS.

The dotted line represents the outer margin of the indurated area.

When the abscess is situated deep in the ischio-rectal fossa and is not yet pointing beneath the skin, the index finger of the left hand should be introduced into the rectum and the abscess pressed down towards the surface by this means. The finger in the rectum also enables the surgeon to define the



exact limits of the abscess and to determine the direction in which the knife should pass to its cavity. The first incision should be as large as possible, care being taken that the neighbouring muscular structures are not damaged. The T-shaped incision is then completed, and the wound irrigated and plugged. As this manipulation causes considerable pain, the operation should be performed under the influence of a general anæsthetic.

*The submucous abscess.*—The finger should be introduced into the rectum, and the wall of the abscess carefully examined with a view to determining the position of neighbouring branches of the superior hæmorrhoidal artery. If the abscess has burst into the rectum, a fact which will be recognised by the presence of pus in the rectum, the opening will probably be found at its lower extremity and should not be enlarged, because we have generally found that an injection of an ounce of olive oil, night and morning, and rest in bed, with light diet, suffices for its ultimate closure. If healing does not take place within two or three weeks, the abscess cavity or resulting sinus should be laid open from end to end by a linear incision, care being taken, when introducing the director, not to include the branches of the superior hæmorrhoidal artery (see p. 26). If one of these branches be divided a plug should be introduced into the wound, a pad placed outside the anus, and a T bandage applied. This is, as a rule, all that is necessary for the arrest of the bleeding, but, sometimes, it may be necessary to introduce a speculum and apply a ligature to the bleeding point.

Occasionally a submucous abscess is met with before rupture into the rectum has occurred. Under these circumstances, a small T-shaped opening should be made into the lower margin of the wall of the abscess and enlarged with a pair of dressing forceps. In making this opening, the horizontal part of the T should be parallel to the anal margin with the vertical



part extending upwards. If much hæmorrhage follows this procedure, pressure forceps should be applied to the bleeding points. By making an opening at the dependent part of the abscess, we are simply imitating the course usually followed by a submucous abscess when left to itself, and, therefore, the subsequent treatment should be the same as that indicated for an abscess that has burst spontaneously.

When the lower margin of an unbroken submucous abscess is found to be situated more than an inch above the anal verge, the abscess should not, we think, be opened in this position on account of the difficulty that might be experienced in arresting hæmorrhage. In these cases we always wait until the abscess has worked its way downwards to within an inch of the anal margin before opening it, because, in this situation, hæmorrhage, should it take place, can easily be arrested. After a submucous abscess has been opened, a plug of cotton wool should be inserted into the wound.

*The Pelvi-rectal abscess.* The method of operating upon a pelvi-rectal abscess depends upon whether the abscess has involved the ischio-rectal fossa or not.

When the ischio-rectal fossa has *not* been invaded and the exploring finger can be passed well above the lower margin of an abscess situated *posteriorly to the transverse anal line*, a long straight bistoury with its back towards the rectum should be passed through the skin in the right posterior (R.P.) quadrant and onwards into the abscess cavity, the finger in the rectum acting as a guide both as to the direction which the knife should take and also as to the depth to which it should be introduced. So soon as resistance to its onward progress ceases, the knife should be withdrawn, the wound at the same time being enlarged in the R.P. direction. A pair of dressing forceps should now be passed into the abscess cavity, then widely opened and withdrawn. The linear incision which has so far been made should



now be converted into a T-shaped incision by making another across its inner extremity care being taken, in doing so, not to damage the sphincter muscles (see fig. 33).

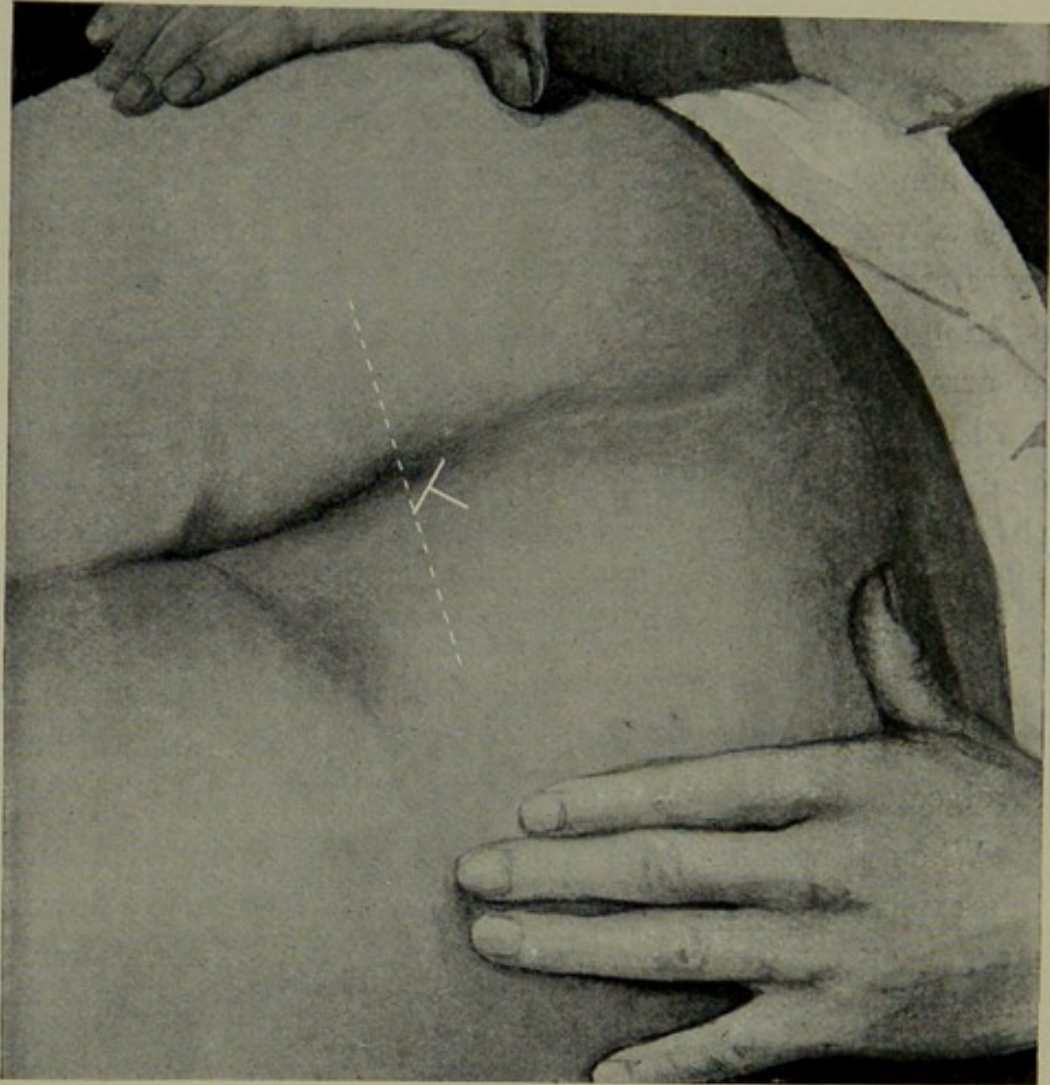


FIG. 33.—DIAGRAM OF A T-SHAPED INCISION INTO A PELVI-RECTAL ABSCESS SITUATED POSTERIORLY TO THE TRANSVERSE ANAL LINE.

The dotted line represents the transverse anal line and the continuous line extending in the R.P. direction indicates the first incision made in opening the abscess.

When the abscess is situated *anteriorly to the transverse anal line*, it should be allowed to burrow downwards to within an inch of the surface before it is opened. When it has reached this point, it may be easily and safely opened by a T incision.



When the ischio-rectal fossa *has* been invaded by the pelvi-rectal abscess before the case comes under observation, it should be opened as an ordinary ischio-rectal abscess and then a pair of dressing forceps should be passed into the cavity of the pelvi-rectal abscess through the aperture in the levator ani, which should be enlarged freely by withdrawing the widely opened forceps. When the abscess burrows into the ischio-rectal fossa *posteriorly to the transverse anal line*, the aperture leading from the pelvi-rectal abscess to the ischio-rectal fossa is usually found near the middle line. When it burrows *anteriorly to the transverse anal line* it is, as a rule, situated laterally at the anterior part of the ischio-rectal fossa and *not* in the middle line anteriorly.

In all cases of abscess in the ischio-rectal fossa, the condition of the rectum above the abscess should be carefully examined in order to ascertain whether the abscess originated in the pelvi-rectal space. This possibility should be borne in mind, when, on laying open an abscess in the ischio-rectal fossa, an unusual quantity of pus is evacuated. The pelvi-rectal origin of the abscess should also be suspected and the opening through the levator ani searched for, when, after operating upon an ischio-rectal abscess, the discharge of pus remains plentiful and shows little, if any, tendency to diminish.

*The labial abscess.*—When the abscess is confined to one labium it should be opened freely by a T incision, the horizontal part of the T being in the long axis of the labium and the vertical part running outwards. When the abscess has extended beyond the labium and points in the ischio-rectal fossa, that part of the abscess should be opened by another T incision. The intervening track between the openings should not be laid open, except when superficial to the muscular fibres, lest the sphincter vaginae be divided. When the abscess has extended into the opposite labium, a T incision should be made in that situation, but the track, unless subcutaneous, should not be opened.



*After Treatment.*

Too much attention cannot be paid to the details of the after treatment of an ano-rectal abscess. Although the operation may have been thoroughly performed, a fistula may result; but such a termination can, in many cases, be averted by constant care during the whole of the process of repair, especially when the abscess has been laid open in the earlier stages of its formation.

About four hours after the operation has been performed, by which time all bleeding will have ceased, the patient should be placed in a sitz bath for about 20 minutes, the temperature of the water being such as he can comfortably bear, and maintained at that degree during the period. The bath should be repeated night and morning until healing has taken place. In the interval between the baths, hot boracic fomentations should be applied every two hours while the discharge is profuse, and every four or six hours as soon as the reparative process is thoroughly established and the quantity of discharge is steadily diminishing. At least once in twenty-four hours the wound and abscess cavity should be irrigated or syringed out with a solution of Hyd. Perchlor (1—500), and any partially detached slough removed. As granulation, proceeds irregular healing should be carefully prevented. The surface of the wound should be sponged by a small piece of cotton wool, twisted on to the end of a probe, in order to break down any bridging over of the granulations. This important detail in the after treatment should always receive attention, because, in this way, much may be done to prevent the abscess resulting in a fistula.

The patient should be kept in bed or on a couch until the abscess has almost healed. Many abscesses will heal without the patient resting during the day time, but the process of healing takes longer, and more often fails than when con-



tinuous rest is enforced. For the first two or three days after the operation the diet should be light, but, as soon as healing is going on satisfactorily, plenty of good plain food should be given. The bowels should be kept confined for about forty-eight hours and then freely relieved, after which a daily evacuation should be obtained. The nightly injection of an ounce of olive oil is certainly most useful for this purpose, because it lubricates and softens the motion, thus preventing it from being passed in large masses. The passage of a large and hard mass of fæces may, by over-stretching the rectum and anal canal, irritate the abscess cavity, and so predispose to the formation of an internal opening.



## CHAPTER IV.

## ANO-RECTAL FISTULA.

The term fistula is derived from the Latin word *fistula*, a reed or pipe, and has been applied to the disease in question on account of flatus escaping from the rectum through the track of a complete fistula. A fistula is always preceded by an abscess and is a contracted, but unobliterated, abscess cavity which has been prevented from completely closing by the constant action of the sphincter muscles, combined with the continual movement of the part during deep respiration, micturition, the passage of flatus or fæces, and muscular effort such as running, walking, or lifting heavy weights. A typical complete fistula consists of a sinus opening externally on to the skin surface in the anal region or adjacent thereto, and internally into the rectal cavity. There are several deviations from this simple form of fistula. One internal opening to a fistula is the rule, a multiplicity of internal openings being the exception. In all but the simplest forms of fistula a single external opening is exceptional. The single fistula is the rule, the multiple the exception.



*Varieties of Fistula.*

There are three forms of fistula recognised by all surgeons, viz., (1) *the complete*; (2) *the blind external*; (3) *the blind internal*. It may be accepted as a fact that all fistulæ are at first incomplete.

*(1) The Complete Fistula.*

In a complete fistula there is an external opening through the skin and an internal opening through the rectal

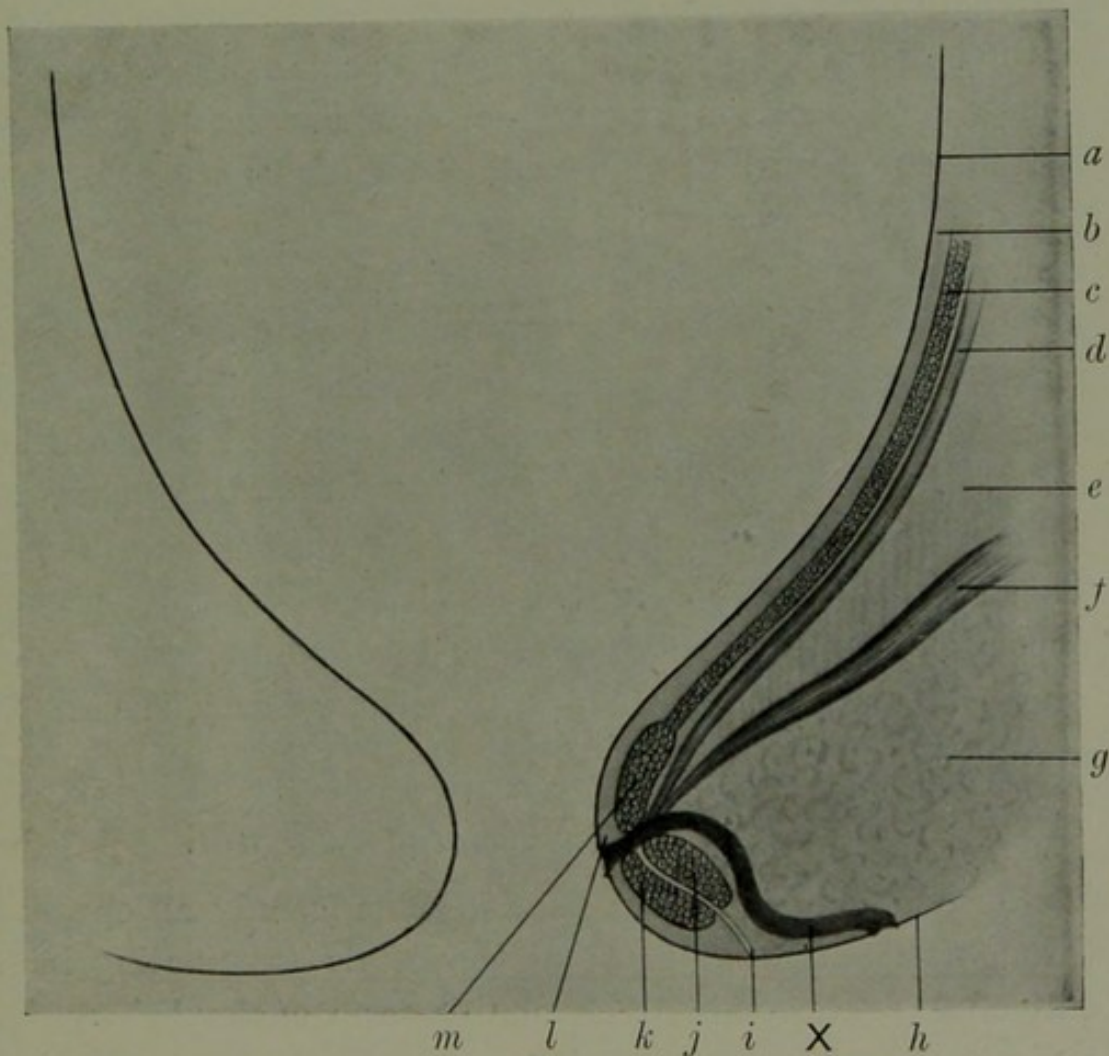


FIG. 34.—A COMPLETE FISTULA DIAGRAMMATICALLY REPRESENTED.

*a* Mucous membrane; *b* submucous tissue; *c* circular muscular fibre; *d* longitudinal muscular fibres; *e* pelvi-rectal space; *f* levator ani; *g* ischio-rectal fossa; *h* integument; *i* tendinous insertion of the longitudinal muscular fibres; *j* deep portion of the external sphincter; *k* superficial portion of the external sphincter; *l* interval between the internal and the external sphincters; *m* the internal sphincter; *x* main track of fistula.

The course taken by the track is well shown. Starting from the external opening, it first passes subcutaneously, then it dips down beneath the external sphincter, and, finally, passing between it and the internal sphincter perforates the mucous membrane exactly opposite the interval between the sphincters.



wall, these two apertures being connected by an intervening track or sinus. When the main track is in the ischio-rectal fossa, it generally passes between the internal and external sphincters to open into the rectum. In order to do this, when starting as an ischio-rectal abscess, it insinuates itself between the tendinous fibres of insertion of the longitudinal muscular coat (see fig. 34). When the main track is not in the ischio-rectal fossa, and has arisen from a pre-existing fissure, it may pass subcutaneously throughout (see fig. 37); or it may insinuate itself between the superficial and the deep portions of the external sphincter before opening externally, the tendinous insertion of the longitudinal muscular coat preventing it from entering the ischio-rectal fossa (see fig. 38). From the outer extremity of the main track one or more lateral sinuses may pass off, either ending in a cul-de-sac or opening on the skin surface by a secondary aperture. In some instances a lateral off-shoot may arise from the inner extremity of the main track after it has passed through the interval between the sphincters, and then it usually takes an obliquely upward course beneath the mucous membrane. The internal opening of a complete fistula is usually exactly opposite the interval between the sphincters, but occasionally, when there is submucous lateral burrowing, it may be situated at a higher level.

### (2) *The Blind External Fistula.*

(2) In a blind external fistula, there is only an opening through the skin, the track of the fistula terminating in a cul-de-sac. The main track of this form of fistula may be entirely subcutaneous, especially when it is the result of a follicular abscess. When the track extends into the ischio-rectal fossa, it may be simply the unobliterated portion of a previously existing complete fistula, the internal opening of which has become temporarily or permanently closed. This supposition is substantiated by the fact that the blind ex-



tremity of a track in the ischio-rectal fossa is nearly always directed towards the interval between the sphincters (see fig. 35), and very often passes between them, only denuded mucous membrane separating the inner end of the track from the cavity of the rectum.

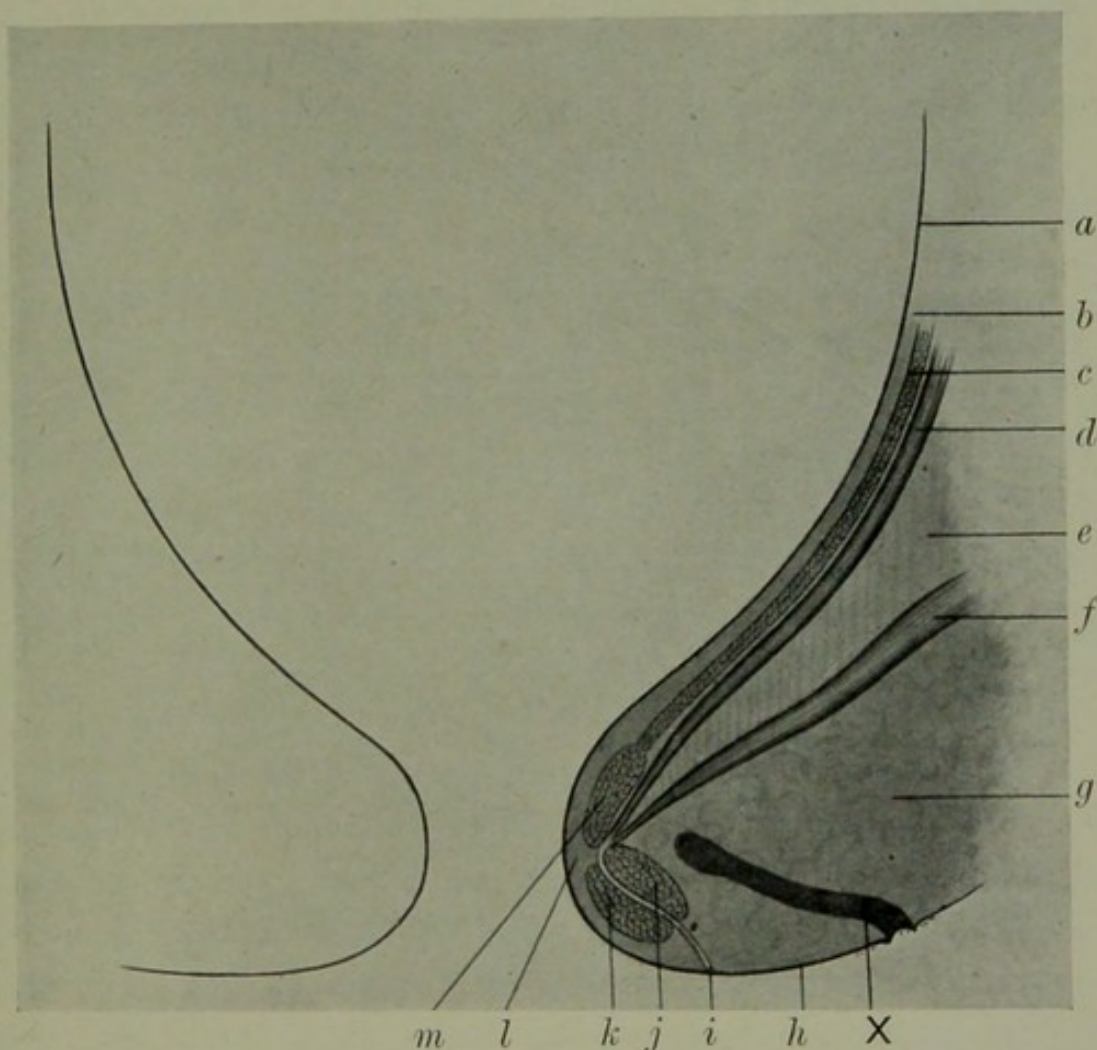


FIG. 35.—A BLIND EXTERNAL FISTULA DIAGRAMMATICALLY REPRESENTED.

*a* Mucous membrane; *b* submucous tissue; *c* circular muscular fibres; *d* longitudinal muscular fibres; *e* pelvi-rectal space; *f* levator ani; *g* ischio-rectal fossa; *h* integument; *i* tendinous insertion of the longitudinal muscular fibres; *j* deep portion of the external sphincter; *k* superficial portion of the external sphincter; *l* interval between the internal and the external sphincters; *m* the internal sphincter; *x* main track of fistula.

The main track is here shown in the ischio-rectal fossa, its blind extremity being directed towards the interval between the sphincters.

### (3) *The Blind Internal Fistula.*

(3) In a blind internal fistula, an opening exists only in the rectum. There is no opening on the skin surface. The



track of the fistula may be (a) subcutaneous, (b) submuscular or (c) submucous.

(a) *Subcutaneous*.—In this variety the track is confined to the subcutaneous tissue and passes superficially to the external sphincter. It usually takes a radial course from the anal margin, and seldom exceeds an inch and-a-half in length. As a rule it is about half-an-inch long. There is seldom any lateral burrowing. The internal opening will usually be found in the floor of a fissure or in a circumscribed ulcer at the anal margin.

(b) *Submuscular*.—When the track takes a submuscular course it may pass either between the two portions of the external sphincter or between the internal and external sphincters. When the fistula has been caused by the puncture of a foreign body, or by ulceration through the rectal wall, above the internal sphincter, the track is situated in the pelvi-rectal space. If the track pass between the superficial and the deep portions of the external sphincter, it is usually the result of a fissure, its blind extremity producing a small swelling at the outer border of the external sphincter. If the track pass between the internal and external sphincters, it involves the ischio-rectal fossa, and may have caused considerable burrowing in that situation (see fig. 36). A blind internal fistula of this nature may have originated in the ischio-rectal fossa, or it may be the result of burrowing from a fissure, in which latter case the internal opening will be found to be situated in the floor of the fissure. When the track passes through the rectal wall above the internal sphincter, there is usually extensive burrowing in the pelvi-rectal space, from whence the ischio-rectal fossa may be secondarily invaded. As we have already stated, this variety of blind internal fistula is usually the result of puncture of the rectal wall by a foreign body, or of perforation due to ulceration or carcinomatous infiltration. The frequency with



which the track from the internal opening passes between the internal and the external sphincters, appears to us to be strong evidence that the majority of fistulæ are in the first instance of the *blind internal* variety.

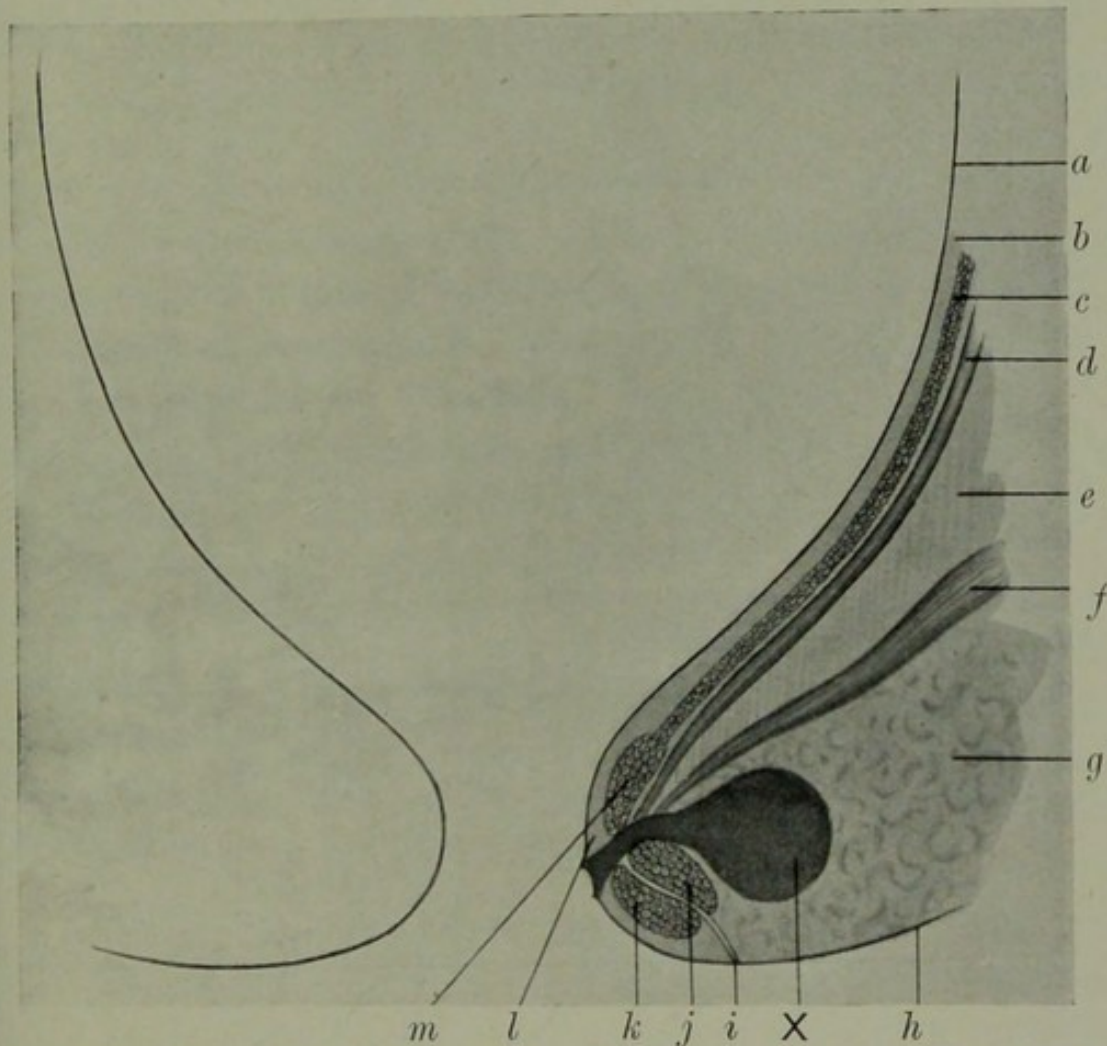


FIG. 36.—A BLIND INTERNAL FISTULA DIAGRAMMATICALLY REPRESENTED.

*a* Mucous membrane; *b* submucous tissue; *c* circular muscular fibres; *d* longitudinal muscular fibres; *e* pelvi-rectal space; *f* levator ani; *g* ischio-rectal fossa; *h* integument; *i* tendinous insertion of the longitudinal muscular fibres; *j* deep portion of the external sphincter; *k* superficial portion of the external sphincter; *l* interval between the internal and the external sphincters; *m* the internal sphincter; *x* main track of fistula.

The blind internal fistula here represented is the result of an ischio-rectal abscess, the track passing between the internal and external sphincters to open into the rectum.

(*c*) *Submucous*.—In this variety the track and its lateral off-shoots are confined to the submucous tissue. In a well-marked instance the track can be distinctly felt as a cord-like thickening beneath the mucous membrane, though occasionally, if the preceding abscess has been small and circumscribed,



it may feel like a bean or indurated lymphatic gland. A blind internal fistula thus located, is usually the result of a fissure or of an ulcer in which perforation has only involved the mucous membrane. When due to fissure, the course taken by the track is, as a rule, obliquely upwards; but when it is the sequel of an ulcer, the track may extend in any direction, though usually it approaches the muco-cutaneous junction.

#### *The Position of a Fistula.*

A fistula of either of these varieties may be met with in any part of the anal or ischio-rectal region, but there is a marked difference in the extent and course taken by the burrowing in those situated anteriorly to the *transverse anal line*, and in those situated posteriorly to that line. First, fistulæ starting posteriorly to the *transverse anal line*, generally burrow more extensively than those met with anteriorly to it. Secondly, blind internal fistulæ are met with more frequently posteriorly to the line than anteriorly to it. Thirdly, fistulæ in tuberculous patients are met with more frequently anteriorly than posteriorly to the line, and very rarely on that line.

#### *The Multiplicity of Fistulæ.*

Two or three distinct fistulæ may be met with in the same patient. We have seen as many as four quite separate and distinct fistulæ in the same individual. When more than one fistula is met with in the same patient, the cause may have been either ulcers in the rectum or the laceration of the walls of the rectum close to the anal orifice by a foreign body, such as a fish-bone, which, after having transfixed opposite sides of the bowel, may ultimately have been passed from the rectum during the passage of a motion (see fig. 48.) In cases of stricture of the rectum, several fistulæ sometimes exist, the smaller fistulæ communicating with the rectum below the lower end of the stricture, and the larger fistulæ doing so in the area of the stricture or above its upper limit.



*Etiology.*

The conditions that cause a fistula are identical with those that lead to the formation of an abscess in this region (see page 56), since every fistula is the result of an abscess.

*Age.*—Fistula may be met with at any age in males. We have seen cases in male infants under one year and, beyond that, at all ages up to 80 years. In females it is a very rare disease under 20 years, although beyond that age, sex appears to have no influence in preventing it. The average age at which fistula is met with in males is 40 years, and, in females, 36 years.

*Sex.*—Cases of fistula, in patients above 20 years, are met with in the proportion of seven males to one female, and almost exclusively in males under 20 years.

*Constitution.*—Constitutional conditions predisposing to fistula and placed in the order of frequency in which they are met with, are overwork, the want of proper food, bad hygienic surroundings, intemperance, phthisis, diabetes, and such debilitating diseases as typhoid fever, etc.

*Parentage.*—Fistula is not hereditary. In some cases of fistula it may be found that the father or the mother or other member of the family has had fistula, but this occurs so seldom that it appears to be only a coincidence.

*Constipation,* when it is extremely obstinate, does undoubtedly sometimes cause an abscess from which a fistula may result. In most cases of fistula not due to fissure or associated with piles the rectum is found almost, if not quite, empty after a recent evacuation, and, as a rule, patients suffering from fistula, uncomplicated by piles or fissure, do not also suffer from constipation.

*Pregnancy* does not, in our experience, predispose to or influence the formation of a fistula.



*Traumatism, fissure, polypoid growths, internal piles, ulceration, stricture and carcinoma,* may, under certain conditions, act as exciting causes.

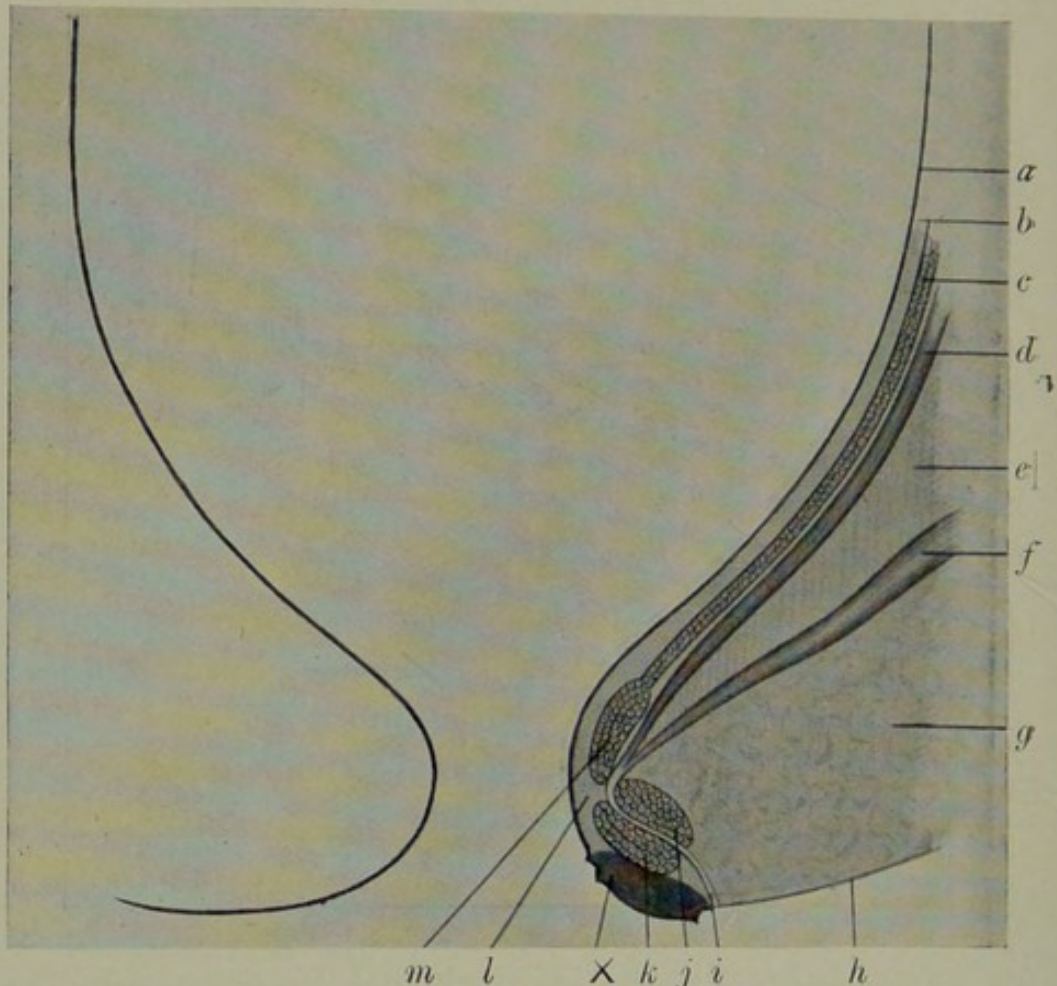


FIG. 37.—DIAGRAMMATIC REPRESENTATION OF A COMPLETE SUBCUTANEOUS FISTULA RESULTING FROM A FISSURE.

*a* Mucous membrane; *b* submucous tissue; *c* circular muscular fibres; *d* longitudinal muscular fibres; *e* pelvi-rectal space; *f* levator ani; *g* ischio-rectal fossa; *h* integument; *i* tendinous insertion of the longitudinal muscular fibres; *j* deep portion of the external sphincter; *k* superficial portion of the external sphincter; *l* interval between the internal and the external sphincter; *m* the internal sphincter; *x* main track of fistula.

The inner of the two openings is situated at the lower extremity of the fissure, while the external opening is just beyond the outer margin of the external sphincter.

#### *Fistula due to Traumatism.*

Blows, kicks, or falls upon the buttock occasion localized blood extravasation which may, under the influence of constitutional depression, result in suppuration and finally terminate in fistula.



When a fistula results from the puncture of the rectal wall by a foreign body, such as a fish-bone, there are sometimes two distinct fistulæ, one on one side of the anus and the other almost opposite to it (see fig. 48). This position of the fistulæ is due to the fact that the foreign body when pointed at both ends, usually transfixes both sides of the rectum during its transit of the anal canal. These fistulæ are primarily of the blind internal variety, but sooner or later may become complete. The internal openings correspond to the position of the original punctures, and they are not necessarily opposite the interval between the sphincters.

*Fistula due to Fissure.*

*Fissure*, when situated posteriorly, may be, and frequently is, the cause of the following three forms of fistula, the subcutaneous, the submuscular, and the submucous, the form of fistula depending upon the position of its internal opening.

(1) *The subcutaneous fistula* is usually of the complete variety. The internal opening is situated at the lower margin of the fissure, the sinus of the fistula running either slightly to the right or left of the median line and opening externally at a distance of about half an inch to one inch from the anus (see fig. 37).

(2) *The submuscular fistula* is usually of the complete variety. When the central part of the floor of the fissure extends through the submucous tissue exposing the fibres of the external sphincter, a fistula may form, the track of which may pass either between the superficial and deep portions of the external sphincter (see fig. 38) or between the external and internal sphincters. In either case, the fistula will open externally about one inch to one inch and-a-half from the anus on its R.P. or L.P. side. It is important to bear in mind the fact, when operating, that the main track of a fistula may pass between the superficial and deep portions of the external sphincter. If the superficial portion only of the



muscle has been divided, the wound may heal very slowly on account of the deep portion being intact and in a state of constant spasm, especially in healthy, muscular patients.

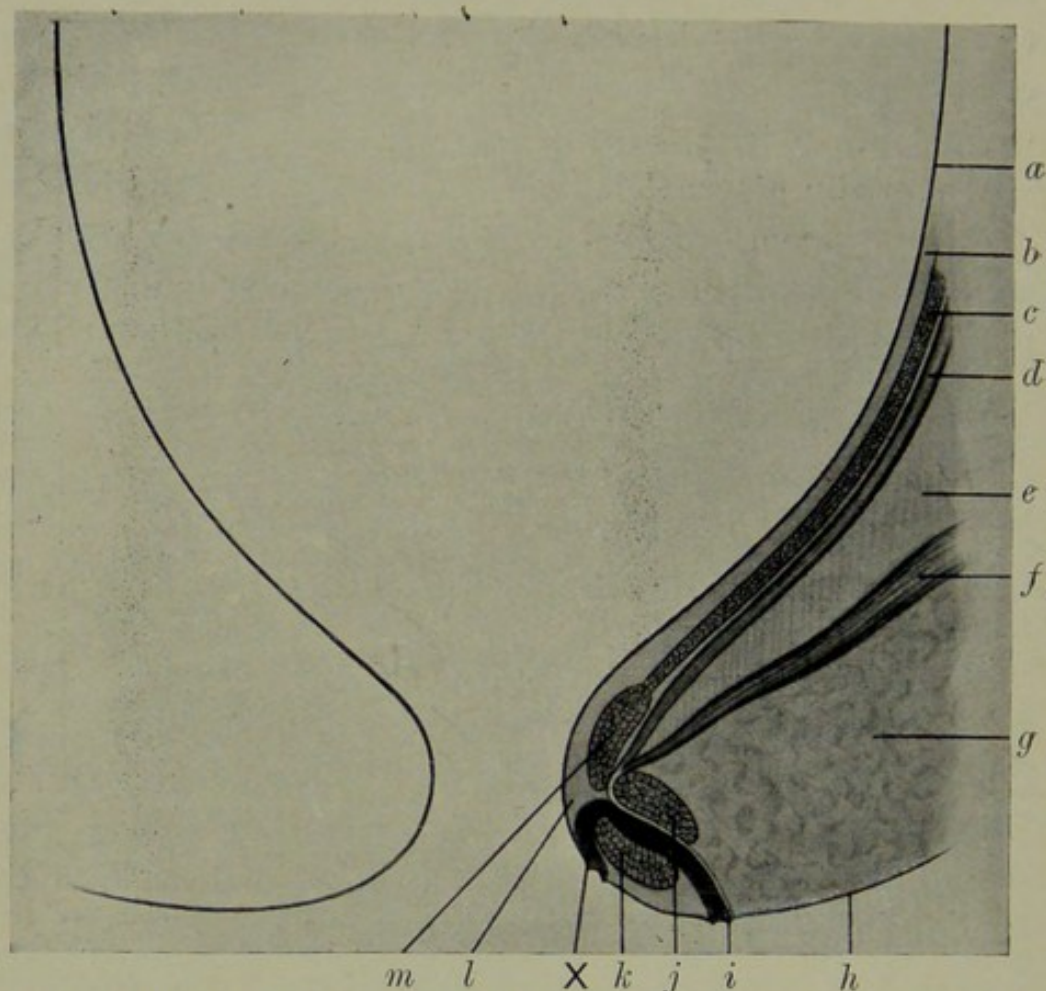


FIG. 38.—DIAGRAMMATIC REPRESENTATION OF A COMPLETE SUBMUSCULAR FISTULA RESULTING FROM A FISSURE.

*a* Mucous membrane; *b* submucous tissue; *c* circular muscular fibres; *d* longitudinal muscular fibres; *e* pelvi-rectal space; *f* levator ani; *g* ischio-rectal fossa; *h* integument; *i* tendinous insertion of the longitudinal muscular fibres; *j* deep portion of the external sphincter; *k* superficial portion of the external sphincter; *l* interval between the internal and external sphincters; *m* the internal sphincter; *x* main track of fistula.

The internal opening is situated in the floor of the fissure from which the main track first ascends and then bends round the upper border of the superficial portion of the external sphincter.

This circumstance, we think, led the late Mr. Salmon to adopt his *back cut*, by which procedure he ensured complete division of the deep portion of the external sphincter.

(3) *The submucous fistula* is usually of the blind internal variety. The internal opening of the fistula is situated at



or near the upper end of the fissure, and its track is usually confined to the submucous tissue, extending either directly upwards beneath the mucous membrane or obliquely up-

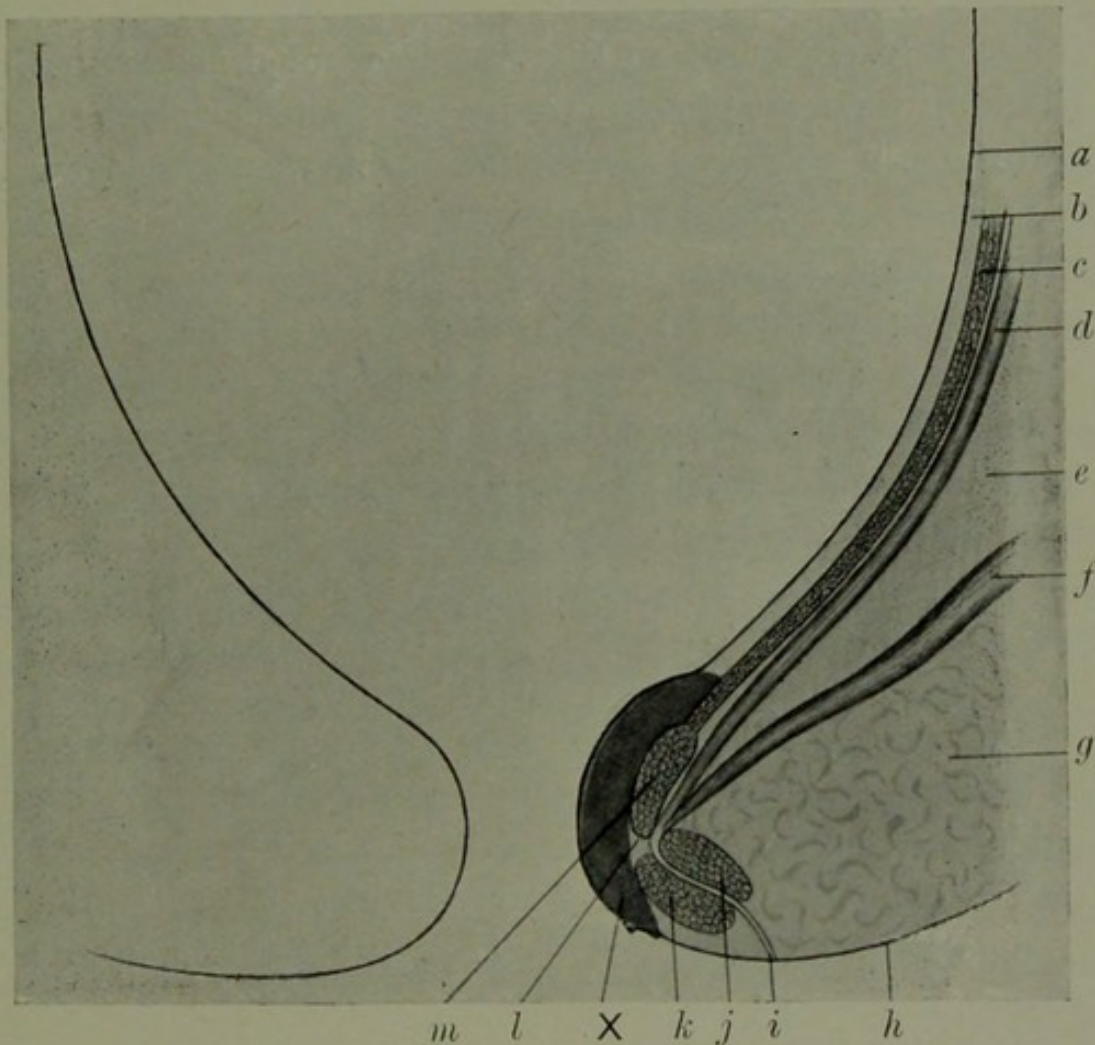


FIG. 39.—DIAGRAMMATIC REPRESENTATION OF A SUBMUCOUS BLIND INTERNAL FISTULA RESULTING FROM A FISSURE.

*a* Mucous membrane; *b* submucous tissue; *c* circular muscular fibres; *d* longitudinal muscular fibres; *e* pelvi-rectal space; *f* levator ani; *g* ischio-rectal fossa; *h* integument; *i* tendinous insertion of the longitudinal muscular fibres; *j* deep portion of the external sphincter; *k* superficial portion of the external sphincter; *l* interval between the internal and external sphincters; *m* the internal sphincter; *x* main track of fistula.

The internal opening is usually situated at the upper extremity of the fissure from which the track extends upwards beneath the mucous membrane to a variable distance.

wards either to the right or to the left side of the rectum, forming a cul-de-sac under its mucous coat (see fig. 39). This form of fistula resulting from a fissure may give rise to a somewhat copious discharge of pus.



*Fistula due to Polypoid Growths.*

Polypoid growths in the rectum are sometimes found associated with extensive fistulæ, the internal opening of the fistula being in close proximity to the growth. The growth is probably concerned in the production of a fistula in the following way: the seat of attachment of the polypoid growth is frequently partially torn through during the passage over it of a firm mass of fæces, and, when the tear in the mucous membrane extends completely through it, fæcal material can be and often is extravasated in the submucous tissue, thus giving rise to an abscess which may become a fistula. When a fistula has formed, each succeeding evacuation of firm fæces, by traction upon the growth, may re-open the tear and allow further fæcal extravasation to take place, with the result that sooner or later a very extensive fistula is formed (see figs. 57 and 58.)

*Fistula due to Internal Piles.*

Occasionally a fistula may supervene upon the protrusion and partial strangulation of internal piles. When the strangulation is complete, the mass sloughs off and there is an end of the trouble. But when the protruded piles are only partially strangulated, and they are subsequently returned into the rectum, the blood extravasation which has taken place, though usually absorbed, sometimes becomes the seat of septic infection, and an abscess results which produces a blind internal fistula.

*Fistula due to Ulceration.*

When a fistula follows ulceration of the rectum, it is primarily of the blind internal variety. If the ulcerated surface be confined to a limited portion of the circumference of the lower half-inch or inch of the rectum, the resulting fistula is usually single, the internal opening being situated in the ulcerated patch and the external opening being placed from half an inch to one inch and a half from the anus. When, on



the other hand, the whole of the circumference of the lower part of the rectum is ulcerated, two or more fistulæ may be formed, either on the same or on both sides of the rectum. In the latter case, when the ulceration extends upwards for three or four inches above the anus, the external openings may be situated at a distance of two or more inches from the anus. These results are due to perforation of the rectum taking place, in the first case, between the external and internal sphincters, and, in the second case, above the internal sphincter, *i.e.*, in the superior pelvi-rectal space (see page 72).

*Fistula due to Stricture.*

Two distinct varieties of complete fistula, both commencing as blind internal fistulæ, follow stricture of the rectum, viz. :—

(1) Those in which the internal opening is situated below the lower margin of the stricture, the external opening being situated either through or by the side of an œdematous fold of skin close to the anus, or through the skin at a distance of from one inch to one inch and-a-half from the anus.

(2) Those in which the internal opening is situated in the strictured portion of the bowel or above the upper margin of the stricture, when the external opening will be found at least two or three inches from the anus and usually in the R.P. or L.P. direction. In women, this form of fistula may be of the recto-vaginal variety. In such cases, the opening into the vagina will be found to be situated in the upper part of its posterior wall either to the right or to the left of the middle line.

*Fistula due to Carcinoma.*

Fistula is an occasional result of carcinoma of the rectum, especially when that disease is limited to the lower two or three inches of the bowel. The infiltration and disintegration of the entire thickness of the rectal wall permit of the escape of fæcal matter into the surrounding connective tissue. Accordingly an abscess, either in the pelvi-rectal space or in



the ischio-rectal fossa ensues, and usually becomes a fistula. When the carcinomatous deposit is situated within the peritoneal region of the rectum, perforation into the peritoneal cavity speedily ends the patient's life. In these cases, however, if a colotomy have been performed in the earlier stages of the disease, such perforation is not likely to happen, because the intestine immediately above the disease, being no longer distended by faecal accumulation, does not readily give way on account of the plastic exudate formed on its peritoneal surface. As time goes on, however, the extension of the growth may involve the non-peritoneal portion of the rectum where disintegration of its coats will allow of septic infection of the surrounding connective tissue taking place. In such cases, there is usually widespread peri-rectal burrowing, and the resulting fistulae are consequently extensive. In some cases, this burrowing will extend beneath the gluteus maximus by leaving the pelvis through the great sacro-sciatic foramen. We have seen this occur on both sides in the same patient.

### *Symptoms.*

The prodromal symptoms of fistula are those of abscess and have been fully considered under that head (see page 63). So soon as a fistula has become established, its existence is made manifest by a discharge of pus, either from an opening on the skin surface, or inside the rectum, or from both of these simultaneously. As remarked under "abscess," a fistula may, by closure of its openings, return to its former state and then the symptoms of abscess are resumed for a time, but they subside when either the original openings break down again or fresh ones appear.

Though a persistent discharge of pus, supervening upon the symptoms of an abscess, is characteristic of the establishment of a fistula, there are other symptoms that may be present, depending in great measure upon the variety of fistula which has resulted. These symptoms are pain, the



passage of flatus or fæces through the fistulous track, and hæmorrhage.

*Pus.*

The discharge of pus marking the appearance of a fistula may take place from the skin surface or from the rectum. When taking place externally, the fistula is primarily of the blind external variety, and when the pus escapes exclusively from the rectum, a blind internal fistula is present. Sooner or later, either of these forms of fistula may become complete, and then the discharge of pus issues from both localities. So soon as the initial discharge of pus has taken place, and especially if the opening by which it issued is free, the abscess cavity collapses and contracts into a track or sinus. The lining membrane of this track continues to secrete purulent material which may escape through the opening continuously in small quantity or collect, for a time, during which interval there is no escape of pus. In this way, the discharge of pus becomes intermittent. When the discharge takes place at intervals, the openings become temporarily closed and the abscess cavity is reformed. Extension by lateral burrowing is thus promoted. Some of these lateral offshoots sooner or later reach the surface and open there, when additional external openings are established, the appearance of each being marked by a discharge of pus from it.

The pus from different cases of fistula varies both in character and quantity.

Its *character* varies with the variety of the fistula, and also with the extent of the lateral burrowing. In the blind external fistula, the pus is always yellowish, being thick in the early, and thin or watery in the later stages of the fistula's existence. In the complete variety it may be thick and yellowish, especially when the internal opening is small, but it usually has a brownish tint, when the internal opening is large, owing to admixture of fæcal material with the pus. In the latter case too, it may occasionally be blood-stained. In



the blind internal variety, the pus is often brown in colour from admixture with fæces but sometimes it is mixed with blood.

The *quantity* of pus in a given case, varies with the extent of the lateral burrowing of the fistula. In the simplest form of fistula, *i.e.*, when there is only a single track, the quantity is often very small, there being as a rule no indication of it unless the track of the fistula is compressed, when a small bead of pus may escape from the external opening. In those instances in which extensive lateral burrowing has occurred, the anal region is always more or less smeared with pus, even when but one or two external openings are present. The presence of much pus should be taken as a most reliable indication that extensive burrowing exists and, therefore, during the operation, too much care cannot be exercised to discover the lateral off-shoots of the fistula, in order that they may all be, if possible, freely laid open at the one operation.

In cases of fistula occurring in tuberculous patients, the discharge is sero-purulent during the quiescent period.

#### *Pain.*

The abscess preceding the formation of a fistula is nearly always attended by much pain, which sometimes is most severe. So soon as the abscess has been opened or, as generally happens, has been allowed to open spontaneously, all pain quickly ceases, unless the resulting fistula is of the blind internal variety. In the latter form of fistula pain is experienced at and after each act of defæcation when the internal opening is of large size. All three forms of fistula become painful when their openings are temporarily closed and the escape of discharge prevented. A traumatic fistula, caused by a foreign body which remains *in situ*, is always more or less painful, even when discharging freely;



and, in this respect, is the exception to the general rule that a free discharge from a fistula means exemption from pain.

#### *Passage of Flatus and Fæces.*

In a complete fistula, flatus sometimes escapes through the external opening, causing much annoyance and discomfort to the patient. In some cases of blind internal fistula, flatus may enter the track, causing it to become distended and painful. In such a case when the swelling is recognisable externally, there will be resonance to percussion.

#### *Hæmorrhage.*

There is seldom any bleeding in cases of fistula, unless the patient also suffers from internal hæmorrhoids. When there is a large internal opening, the granulations around its margin may bleed to a slight extent, especially after the passage of a hard motion or after digital exploration, and thus cause a small loss of blood from the rectum or from the external opening of the fistula. Other causes of hæmorrhage in cases of fistula are, polypus, polypoid growth near the margin of the internal opening, ulcer, or malignant growth in the rectum. In all cases of fistula where there are frequent attacks of profuse hæmorrhage, malignant disease should be looked for.

#### *Physical Examination.*

The examination should be systematically carried out. Actual inspection is absolutely necessary and should always be made before any treatment is adopted. For this purpose the patient, if a male, should be instructed to rest upon his elbows and knees upon a couch with his chin supported by his hands, the buttocks facing the best light obtainable. In women the lateral and semi-prone position should be adopted (see figs. 19 and 20). In making an examination in



a case of fistula, five distinct points should receive consideration, namely,

- (1) The external opening or openings.
- (2) The internal opening.
- (3) The main track between the external and internal openings, when the fistula is of the complete variety, or that leading from the external opening or from the internal opening, in the incomplete varieties.
- (4) The lateral burrowings from the main track.
- (5) The presence of other diseases complicating the fistula.

#### (1) *The External Opening.*

*Its Characteristics.*—These depend first upon whether the preceding abscess has been opened, or whether the abscess or the blind internal fistula resulting therefrom has been allowed to break externally. When the abscess has been freely opened the external opening is, as a rule, smaller than when the abscess has broken spontaneously, and its margins are less undermined. When the abscess is of a tuberculous nature and has been allowed to open spontaneously, the external opening is always large and its margins are irregular and undermined, the surrounding skin having a reddish-purple hue. When not of a tuberculous nature, the patient being otherwise in good health, a nipple-like mass of granulations often covers or surrounds the external opening, the orifice being either in the centre or at one side of the mass of granulations. In such an instance, there may be difficulty in finding the external opening on account of its being obscured by the granulations. This difficulty may be overcome in one of two ways; either by passing the index finger into the rectum and compressing the fistulous track between it and the thumb outside, when a small drop of discharge will exude and dis-



close the opening; or by cutting off the redundant granulations close to the skin surface, when the outline of the external opening will at once be revealed.

In patients of debilitated constitution, not necessarily tuberculous, the external opening may be so small that it cannot readily be detected. In such a case, a useful method for discovering the external opening is to take the anal region between the forefinger in the rectum, and the thumb externally, when by gentle pressure thus applied, a small bead of pus will usually escape through the opening, and so disclosing its position.

#### *Primary and Secondary Openings.*

External openings may be divided into (a) primary and (b) secondary. By a primary external opening we mean either the opening made when the original abscess was incised, or the aperture caused by spontaneous rupture of the abscess. By a secondary opening we mean any opening that has formed or has been made subsequent to the primary opening.

(a) *Primary openings.*—It is of great importance to recognise the primary opening in all cases of fistula in which there are multiple openings. It may be accepted as a general rule that the primary opening is situated at the distal extremity of the main track, and that all the other openings are in the course of, or at the extremities of, the lateral burrowings from the main track. A careful history obtained from the patient is the best means we can recommend for determining which is the primary opening, because a patient can generally remember the position of the original abscess. When the fistula has involved both ischio-rectal fossæ, the patient's history with reference to the side on which the abscess first appeared is of the greatest value. In cases in which a history is not obtainable we have to rely upon our experience in regard to the



usual position of primary openings in the various forms of fistula. Our observations upon this point are as follows:—The external opening of a fistula which has resulted from a tuberculous abscess, is almost invariably situated within an inch of the anal orifice. In other forms of fistula in which the external opening exists anterior to the *transverse anal line*, its distance from the anal orifice is generally about one inch to one inch and a half. External openings situated

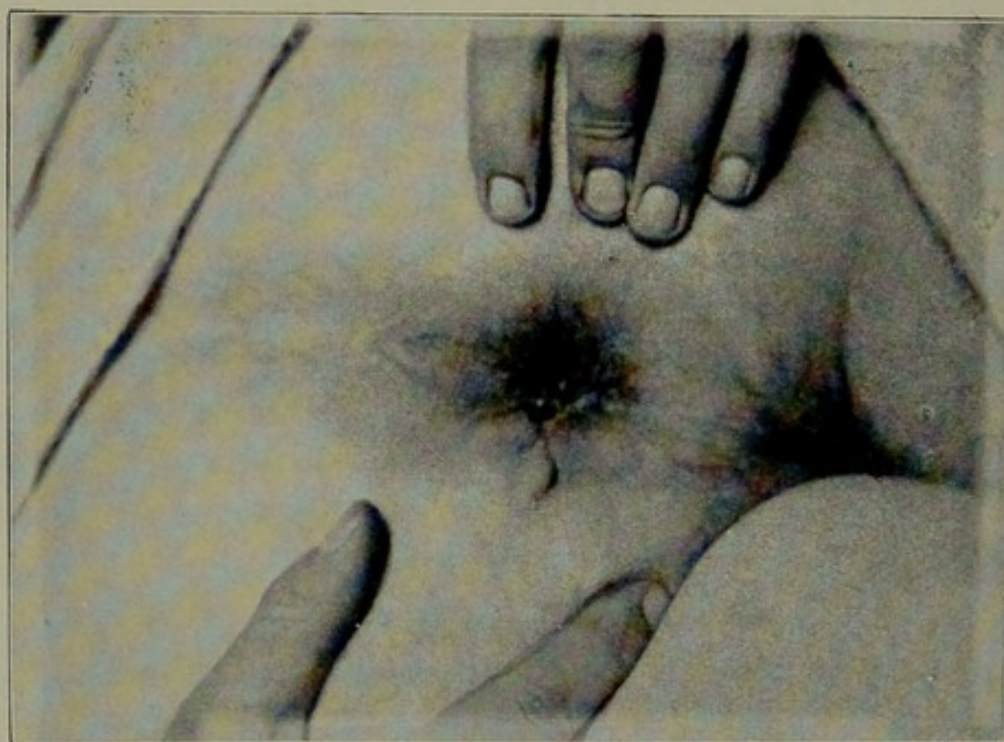


FIG. 40.—SHOWING AN EXTERNAL OPENING ON OR JUST ANTERIOR TO THE *Transverse Anal Line*.

posterior to the *transverse anal line*, are generally one to two inches distant from the anal margin but we have seen instances in which they were as much as four inches from it. External orifices posterior to the *transverse anal line* in fistulæ which have resulted from a fissure, are usually not more than an inch from the anal orifice. When they are situated on the *transverse anal line* either to the right or left of the anus, they are usually within one inch to one inch and a half of the anal orifice (see fig. 40).



(b) *Secondary openings*.—These vary considerably in number in different cases, the greatest number that we have seen in a single case being forty-two (see fig. 41).

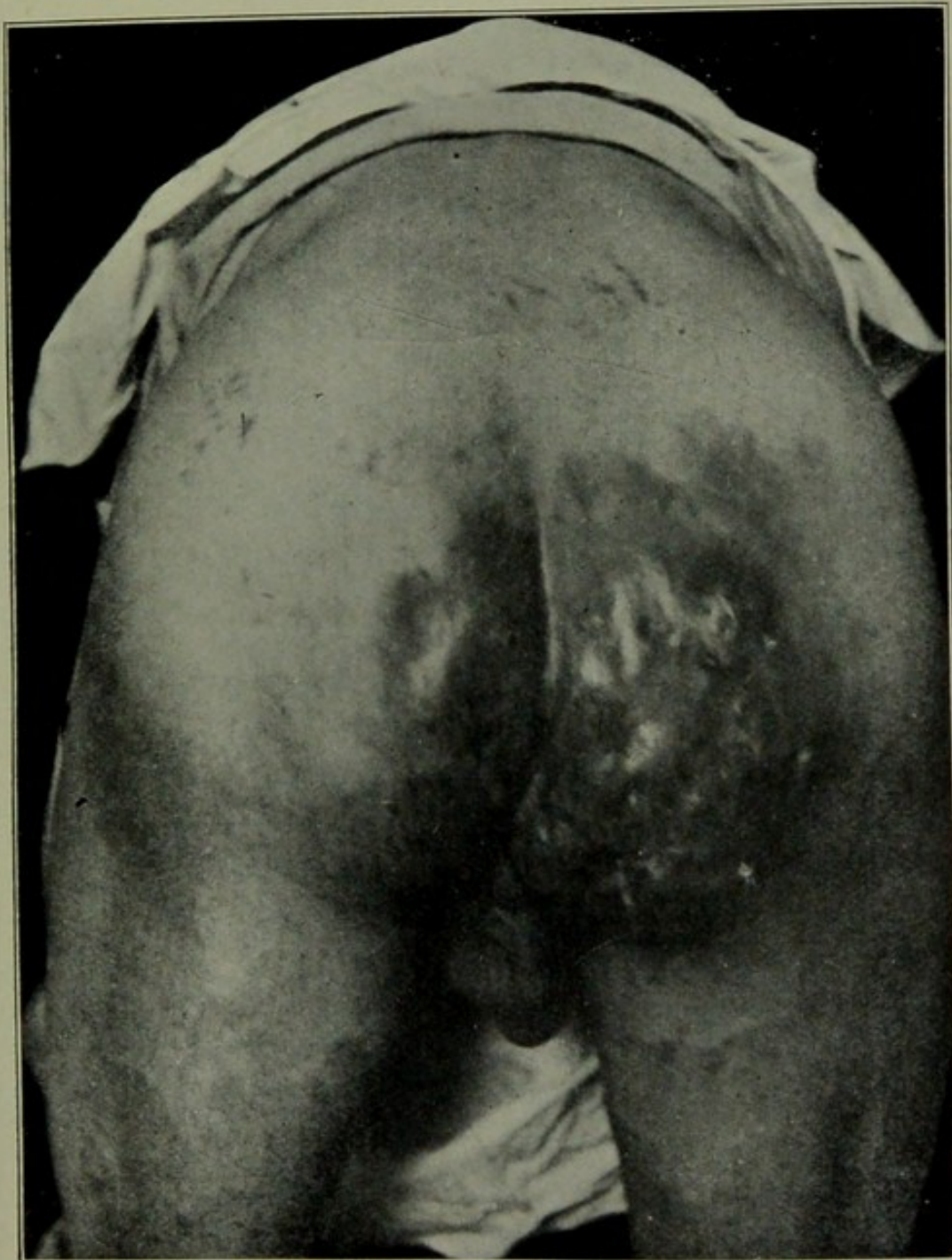

FIG. 41.—SHOWING EXTENSIVE BURROWING OF A FISTULA IN WHICH FORTY-THREE EXTERNAL OPENINGS WERE FOUND AT THE OPERATION

The skin of the area involved was of a purple colour, tense, shining and constantly covered with discharge which readily escaped from many openings.

[Photo taken before the operation.]



As this case is so exceptional, we cannot do better than append the notes in detail.

F. W. G., æt. 54, accountant, was admitted into St. Mark's Hospital under the care of Mr Goodsall on May 1st, 1897.

*History.*—In 1877 an abscess appeared in the ischio-rectal fossa in the R. P. quadrant and spontaneously broke externally. The resulting fistula continued to discharge, but did not increase in size until 1892, when it began to burrow, extending into the L.P quadrant. After this extension, the lateral burrowing steadily progressed on both sides of the anus. On the right side the burrowing ultimately extended outwards on to the buttock, and forwards along the cruro-scrotal fold. On the left side, similar burrowing took place to a lesser extent on the buttock and, to a greater extent, along the cruro-scrotal fold into the subcutaneous tissue of the scrotum, as figs. 41 and 42 clearly show.

*Symptoms.*—Absolute inability to sit; almost constant pain; continuous and copious discharge; considerable difficulty in walking, and great emaciation.

*Examination.*—External openings 43. Internal opening, single and situated opposite the interval between the external and the internal sphincters, in the middle line posteriorly. Skin of peri-anal region and nates very livid in colour and extensively undermined. All the external lateral burrowing is subcutaneous, with the exception of that part of it which passes beneath the ano-coccygeal ligament to the left ischio-rectal fossa. Internal lateral burrowing extends forwards on both sides from the internal opening.

*Operation, May 3rd, 1897.*—The burrowing beneath the ano-coccygeal ligament was first laid open. Then all the subcutaneous burrowing on both sides was similarly dealt with, care being taken to leave as many islets of skin as possible. When this had been done, the main track passing into the rectum between the external and the internal sphincters was laid open from the centre of the first incision. Finally, the internal lateral burrowing was opened up and the wounds dressed in the usual manner.

*Subsequent Progress.*—May 9th, 1897. Wounds healing well. June 12th. Wounds almost healed (see fig. 43). Patient leaves the hospital to-day, *i.e.*, 40 days after the operation.

July 16th, 1900.—Present weight, 11st. 11lbs. 8oz.; height, 5ft. 5in. Since the operation the patient says his weight has been above twelve stone. Urine (report of the Clinical Research Association, Limited), "Acid, S.G. 1023. Albumen a very small amount. Sugar absent. "*Microscopical examination of centrifugalised deposit.* This contains a "small number of hyaline and granular casts. There are a few tubal "cells and red blood discs free in the deposit, and leucocytes are slightly "increased in number."



*Remarks.*—The rapid healing was undoubtedly due, in great measure, to the fact that about fifteen islets of skin were left from which cicatrization took place. In this unusually extensive case it will be noted that there was only one internal opening; that the external lateral burrowing first extended into the opposite ischio-rectal fossa, and then subcutaneously on both sides. This case also shows that a fistula, though quiescent for several years, may ultimately extend rapidly.

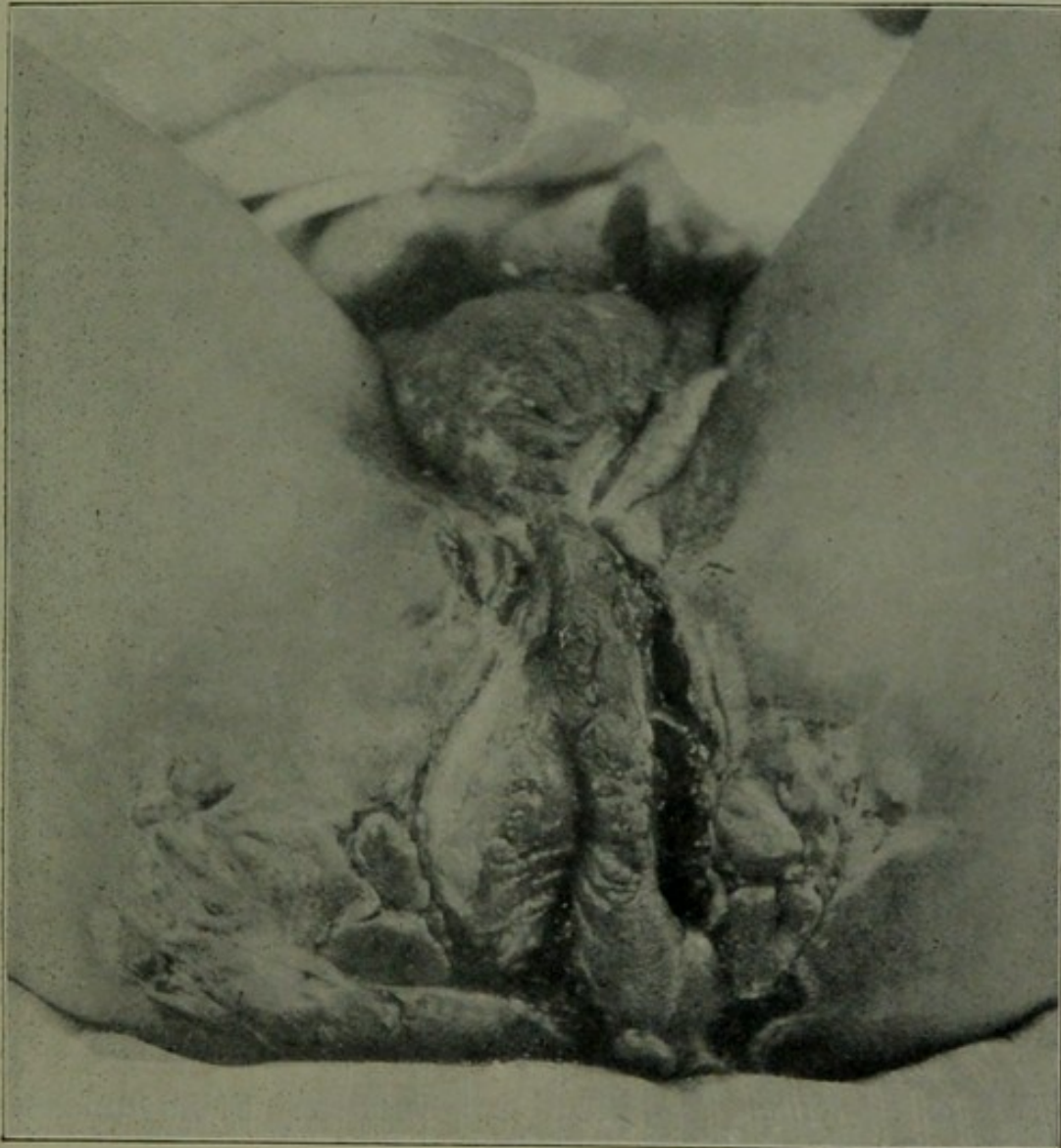


FIG. 42.—THE SAME CASE AS IN FIG. 41, SHOWING THE BURROWING LAID OPEN.

There was only one internal opening which was situated in the middle line posteriorly opposite the interval between the external and internal sphincters. The burrowing forward on the left side extended into the subcutaneous tissue of the scrotum and is clearly shown, as are also the many islets of skin which were surrounded by the subcutaneous burrowing.

[Photo taken three weeks after the operation.]



The number of secondary openings depends, to a great extent, upon the following three causes. First, upon the size of the internal opening. When large (in some cases, especially if situated in the middle line posteriorly, it is large enough to admit the tip of the index finger) liquid fæces readily pass into such an opening during the straining at

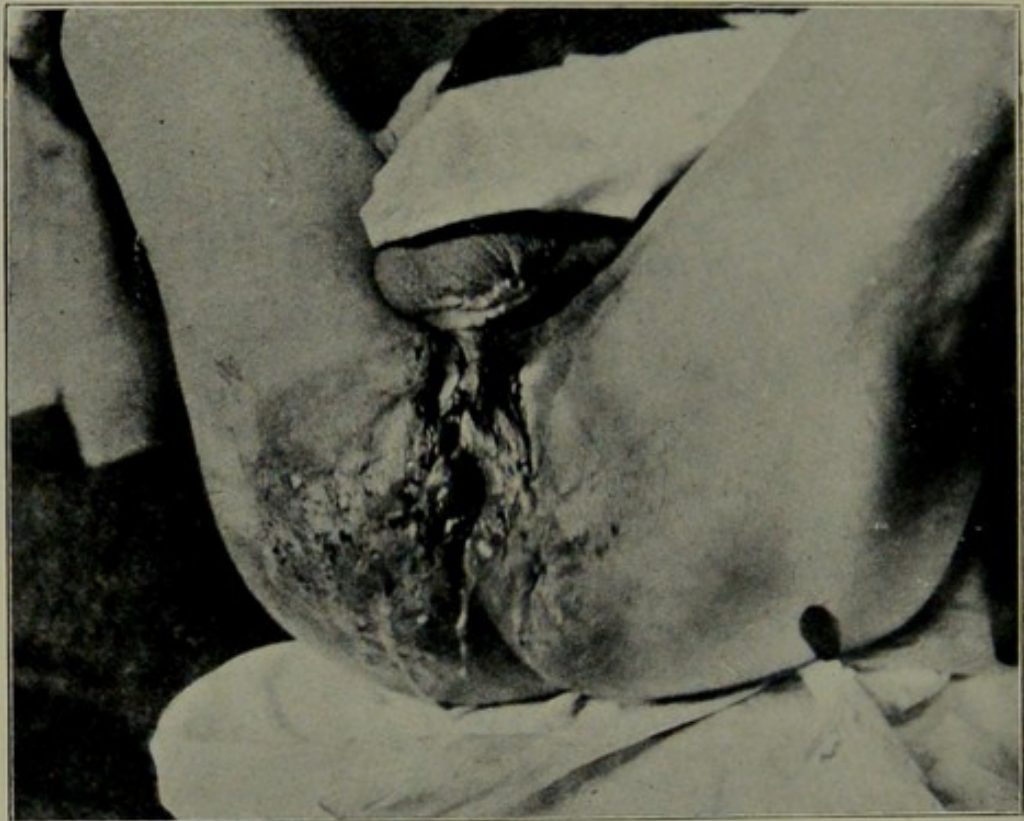


FIG. 43.—THE SAME CASE AS IN FIGS. 41, 42, SHOWING CICATRISATION NEARLY COMPLETED.

It will be noticed that only one incision has been made into the anal canal, viz., in the R. P. direction, and that the discoloration of the skin is fading.

[Photo taken five weeks after the operation.]

defæcation. When this fæcal extravasation is of frequent occurrence, although the quantity extravasated may be very small, it is sufficient to keep up active suppuration in the subcutaneous connective tissue. Secondly, upon the constitutional condition of the patient. In those subjects who are broken down in health, either as a result of intemperance or debilitating disease, the original abscess, unless it has been



freely opened externally, often burrows extensively and ultimately discharges itself by several external openings. Thirdly, upon the duration of the fistula. The longer a fistula is allowed to remain untreated, the greater is the probability that multiple external openings will result. This is especially likely to occur in fistulæ, the internal openings of which are situated between the internal and external sphincters.

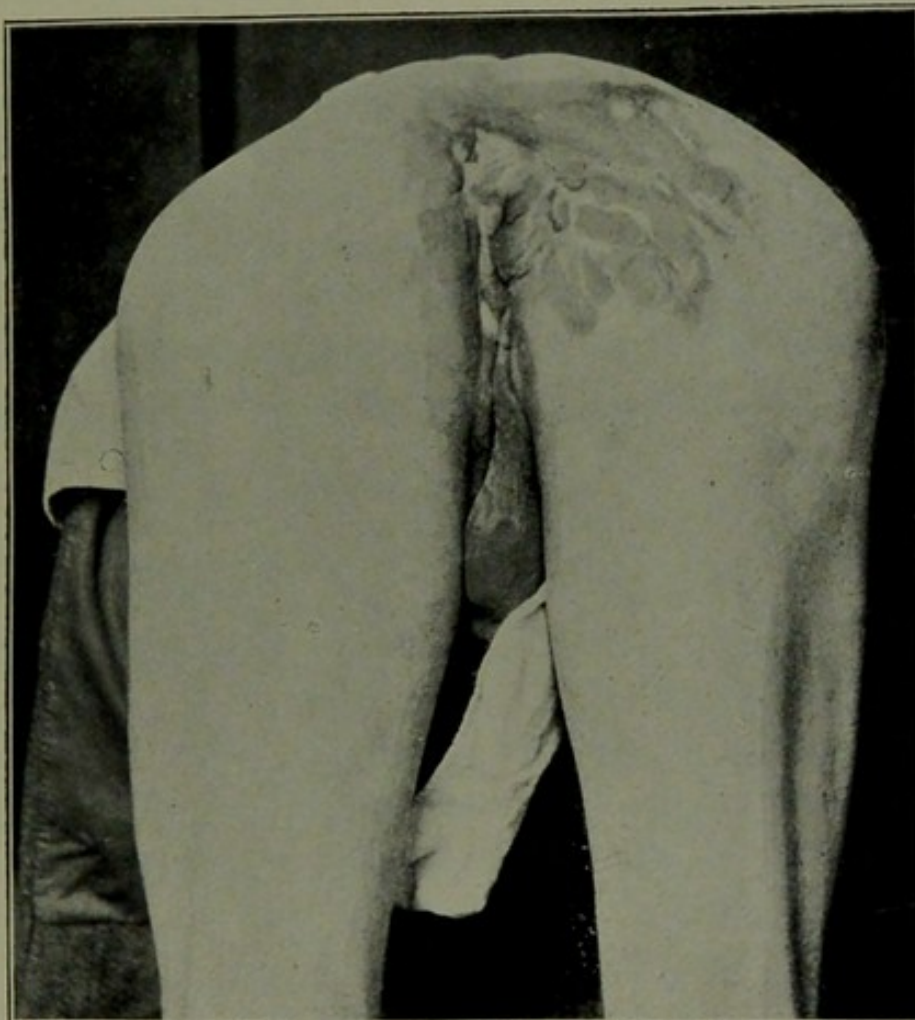


FIG. 44.—THE SAME CASE AS IN FIGS 41, 42, 43, SHOWING THE APPEARANCE OF THE CICATRICES THREE YEARS AFTER THE OPERATION.

The discoloration of the skin has entirely disappeared. The islets of skin surrounded by cicatrices are very distinct. The cicatrix in the scrotum is clearly shown.

[Photo taken 16th July, 1900.]

### (2) *The Internal Opening.*

*Its characteristics.*—The internal opening of a fistula has been described as a small pit or slight depression in the



mucous membrane; it has also been likened to the impression imparted to the finger when placed on the top of a pencil-case after the pencil has been drawn into its sheath. Generally the opening is more or less circular in shape, except when it has been started from a tear in the mucous membrane, produced either by a foreign body or by the partial tearing down of the seat of attachment of a polypoid growth. In such cases, the internal opening will have the shape of the torn surface. In size, internal openings vary considerably and, in tuberculous subjects, are often exceptionally large. If the internal opening be situated posteriorly to the *transverse anal line*, and especially when placed in the middle line posteriorly between the internal and external sphincters, it is sometimes of large size. Those met with anterior to the *transverse anal line* are usually small, and very often may easily be passed over during a digital exploration.

*The Position of the Internal Openings.*

There are three positions in which the internal opening of a fistula, following an abscess which has opened into the rectum spontaneously, may generally be found.

- (1) In the middle line posteriorly, either immediately above the inner margin of the external sphincter or in Hilton's white line, *i.e.*, at a spot corresponding to the interval between the internal and external sphincters.
- (2) On the right anterior (RA) side of the rectum, between the internal and external sphincters.
- (3) On the left anterior (LA) side of the rectum, between the internal and external sphincters.

When the fistula has originated from a pre-existing fissure, the internal opening is usually found at the lower margin of the fissure. It may also be situated near the middle of the floor of the fissure, or at its upper margin (see page 101).



When the fistula has been caused by an ulcer, by the puncture of a foreign body, or by the partial tearing through of the attachment of a polypoid growth, the internal opening may be situated at any part of the circumference of the rectum, but usually in the terminal inch or two inches of the bowel.

When the fistula has been caused by a stricture, the internal opening may be situated

- (a) At the lower margin of the stricture.
- (b) In the strictured zone.
- (c) Just above the stricture.

Of these, the first mentioned is the most common.

When the fistula has been caused by a submucous abscess, the internal opening, except in the case of a fissure, is usually found at or near the muco-cutaneous junction.

#### *The Number of Internal Openings.*

It may be taken as a rule, that there is but one internal opening to each complete or blind internal fistula. When a second internal opening is present, it is nearly always situated at a higher level in the bowel, either directly above, or above and to the right or left of the lower opening. This higher opening is almost invariably in the course of, or at the extremity of, the submucous track leading upwards from the lower opening. When more than one internal opening is met with on the same level, they are usually the internal openings of *separate* fistulæ. In an ulcerated condition of the lower part of the rectum, there may be several internal openings; careful examination usually showing that each opening, when occurring at the same level, indicates a distinct fistula. In one such case which came under our observation, four distinct fistulæ were present. As a result of puncture of the opposite sides of the rectal wall by a foreign body (*e.g.* a fish bone), we have seen a complete fistula on one side, and



opposite—but totally distinct from it—a blind internal fistula. Such a case as the one above described, has led to the assumption that the two internal openings were connected with the track of the fistula which opened externally, the blind internal fistula not having been recognised as a separate fistula. It is easy, even when no fistulous track exists, to insinuate a probe beneath healthy mucous membrane entirely round the lower part of the rectum; but this procedure may lead to error in diagnosis, and cause much unnecessary damage to the anal region.

### (3) *The Main Track.*

*Characteristics.*—A fistulous track can be recognised as a cord-like thickening under the skin or deeper tissues, running from the external opening towards the rectum in blind external fistulæ, and extending to the internal opening in complete fistulæ. In blind internal fistulæ, the track, when external to the rectum, is usually globular in shape, and varies in size from that of a small pea to a large plum. This swelling can readily be felt by introducing the index finger into the rectum, placing it over the internal opening or above it, and compressing the tissues between the finger and the thumb outside. In this way the exact outline and extent of the fistula can readily be felt. When the track of a blind internal fistula is confined to the submucous tissue alone, it gives the impression to the exploring finger of an elongated fulness or gumboil-like swelling beneath the mucous membrane.

*Its Course.*—The course taken by the main track depends in great measure upon the form of fistula. Thus:—

#### (a) *In complete fistula.*

The main track may be either *subcutaneous* or *submuscular*.

*Subcutaneous.*—In subcutaneous complete fistulæ, whether anterior or posterior to the *transverse anal line*, the direction



taken by the track is almost, if not invariably, straight outwards from the internal opening, *i.e.*, along a line radiating from the anus.

*Submuscular.*—When the main track is submuscular, it may be situated either in the ischio-rectal fossa or superficial to it.

When *superficial to the ischio-rectal fossa*, it takes a straight course towards the rectum from the external opening and passes between the superficial and the deep portions of the external sphincter. This form of fistula usually results from a fissure (see page 102), and is seldom met with anteriorly to the *transverse anal line*.

When *in the ischio-rectal fossa*, the course of the main track is curved when posterior to the *transverse anal line*, and straight when anterior to that line. When *posterior* to the line, the external opening usually is R.P. or L.P., the internal opening being situated in the middle line posteriorly between the external and internal sphincters. When *anterior* to the line, the external opening is in the same radial line as the internal opening, either R.A. or L.A., the main track often making a sharp bend round the upper border of the external sphincter before it enters the rectum.

(b) *In blind external fistula.*

When the blind external fistula is caused by a follicular abscess, the main track towards the rectum is usually superficial to the external sphincter, and, therefore, is entirely subcutaneous in its course. When the track passes through or dips beneath the external sphincter, it follows the course of an ordinary complete fistula; that is to say, when situated anterior to the *transverse anal line*, the track runs straight towards the rectum, and when placed posterior to that *line*, it pursues a curved direction towards the middle line posteriorly. When the external opening is on the *transverse anal line*, the track, as a rule, follows the *line* towards the rectum.



(c) *In blind internal fistula.*

The course taken by the main track of a blind internal fistula, when the internal opening is in the middle line posteriorly and deeper than the external sphincter, is towards the surface in the right or the left posterior quadrant. In those cases in which the internal opening is superficial to the external sphincter, its course is towards the surface in the middle line posteriorly or slightly to the right or left of that line. When it passes by the side of the rectum deeper than the inferior hæmorrhoidal artery of the same side, it points under the skin in front of and somewhat outside the anal orifice. When the pointing is situated in this position, *i.e.*, in front of the *transverse anal line*, it might reasonably be assumed, from what we have said above, that the internal opening would be found on the R.A. or L.A. side of the rectum exactly opposite the place of pointing. But in such a case, the fact that the first noticeable sign of the fistula is an escape of pus from the rectum, proves it to be a blind internal fistula, and should at once prompt a digital examination, with the object of discovering the exact position of the internal opening. Should the internal opening be found in the middle line posteriorly, there will be no difficulty in tracing the thickening, which always exists in such cases, as it passes from the internal opening round the lower part of the rectum to the place of pointing. By following this simple procedure the mistake may be avoided, while operating, of making an artificial internal opening, and so leaving the greater part of the main track of the fistula, together with the internal opening, untouched. In those cases of blind internal fistula which are confined to the submucous tissue, the main track is directed either obliquely or vertically upwards for a distance varying from one inch to two inches or more above the internal opening.



(4) *Lateral Burrowing.*

By this term is meant the passing off of the branch sinuses from either end of the main track or from some part of its course. Lateral burrowing may be external or internal.

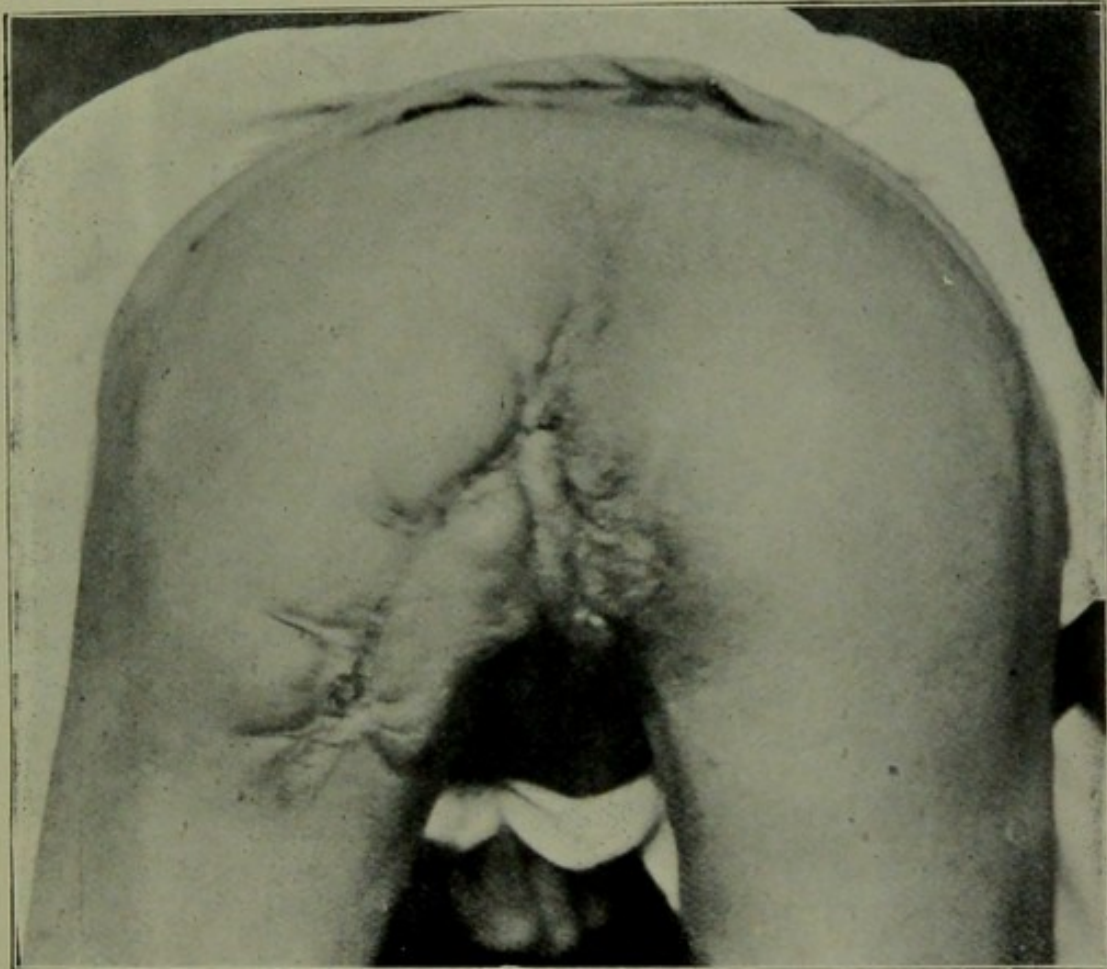


FIG. 45.—SHOWING EXTENSIVE SUBCUTANEOUS BURROWING FROM A FISTULA POSTERIOR TO THE *Transverse Anal Line*.

The burrowing has extended outwards and downwards on the posterior aspect of the left thigh and also forwards in the right cruro-scrotal fold.

[Photo taken when the wounds were nearly healed.]

*External lateral burrowing.*

External lateral burrowing may be (a) subcutaneous, *i.e.*, superficial to the ischio-rectal fossa, and (b) submuscular, *i.e.*, in the ischio-rectal fossa.

(a) *Subcutaneous*.—The external lateral burrowing is subcutaneous when found in connection with a fistula whose



main track is entirely subcutaneous, and it is continued, away from the anus, in almost the same straight line as that taken by the track. Hence, should a second opening appear it will

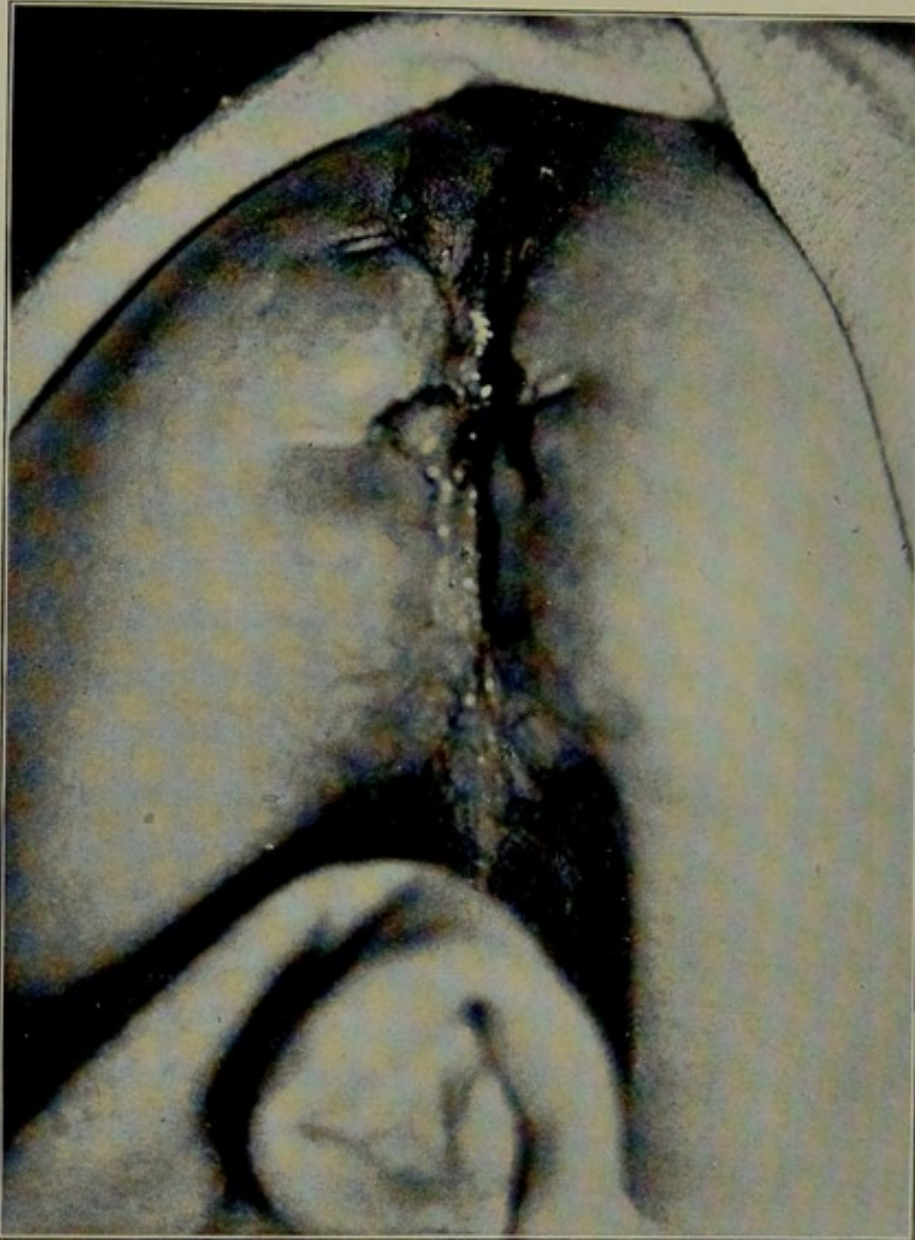


FIG. 46.—SHOWING THE SUBCUTANEOUS BURROWING OF A FISTULA POSTERIOR TO THE *Transverse Anal Line*.

The chief part of the burrowing is over the coccyx and sacrum, but it has also extended outwards on both sides of the anus.

usually be found in a direct line with the first, and still further from the anus. But when the main track of a fistula is submuscular, the burrowing that takes place superficial to



the ischio-rectal fossa, is entirely subcutaneous. So far as we know, the subcutaneous burrowing from such a fistula follows no definite course, but may extend in any direction. When, however, the main track is posterior to the *transverse anal line* (see figs. 45 and 46), the course usually taken is away from the anus—forwards, backwards, or outwards—and, sometimes, in all three directions.

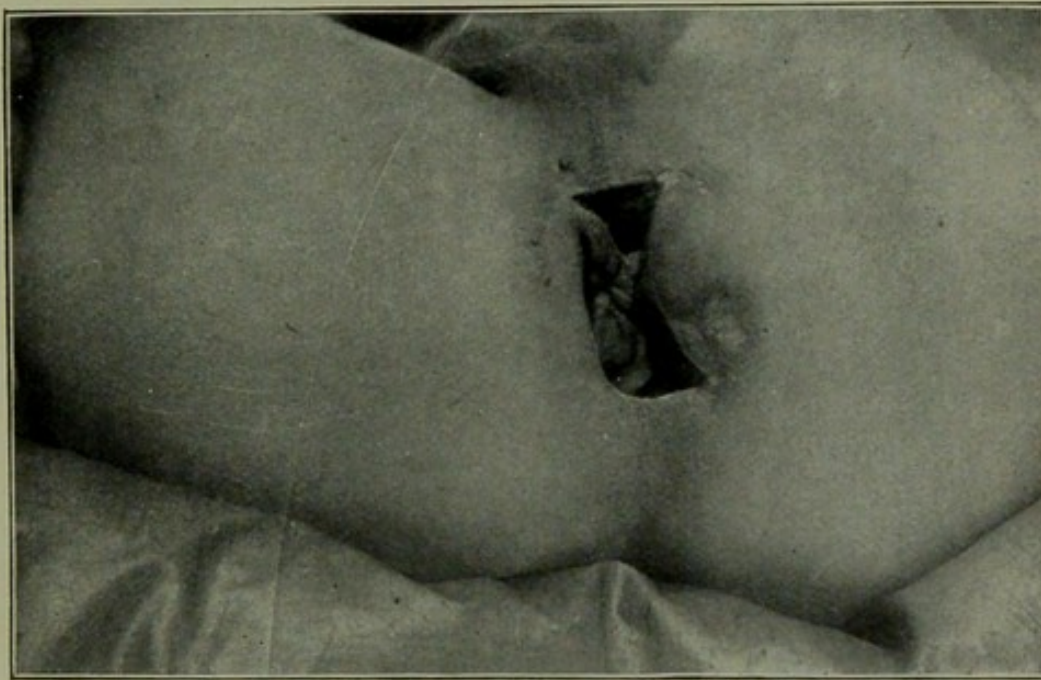


FIG. 47.—SHOWING THE BURROWING OF AN ISCHIO-RECTAL FISTULA LIMITED TO ONE SIDE.

The Fistula originated posteriorly to the *transverse anal line*, and burrowed forward under the inferior hæmorrhoidal artery, pointing in front of, and about one inch to the left of, the anus. It also extended nearly across the middle line anteriorly.

When the main track is anterior to the *transverse anal line*, the subcutaneous burrowing may also extend in any direction, but that usually met with is forward towards the cruro-scrotal furrow, occasionally extending even as far as the groin.

(b) *Sub-muscular*.—When the internal opening is situated in the middle line posteriorly between the superficial and the deep portions of the external sphincter the burrowing is not extensive. But, when the opening is between the external and the internal sphincters, the extent of the burrowing that may take place seems to be quite unlimited.



The primary external opening, in such a case, is usually from about one inch to one inch and a half from the anal orifice; occasionally, its distance is as much as three to four inches or even more. It is usually situated midway between the middle line posteriorly and the right or left side of the anus, *i.e.*, in the R.P. or L.P. direction. The burrowing in

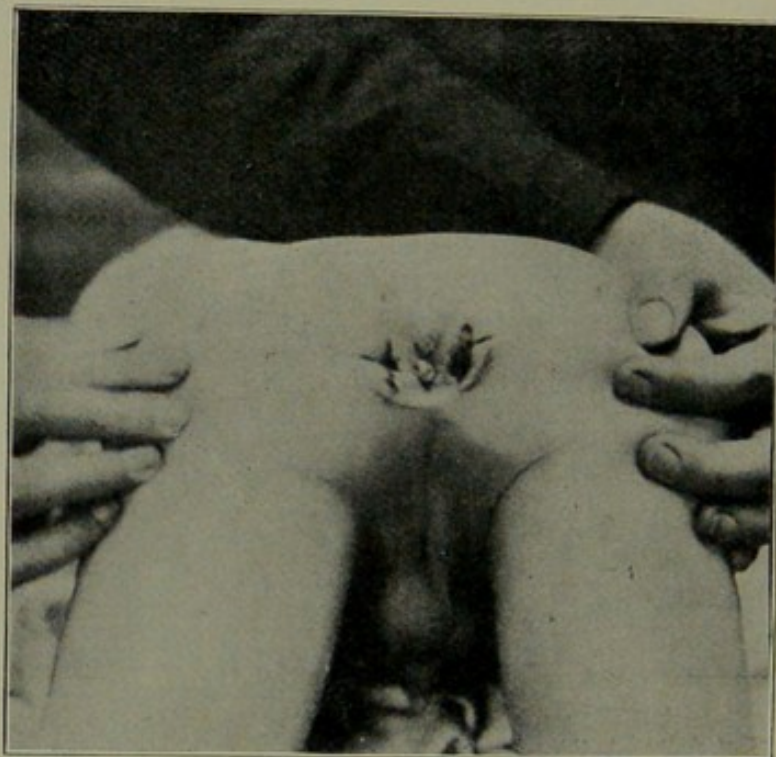


FIG. 48.—THE T-SHAPED WOUNDS OF TWO DISTINCT FISTULÆ CAUSED BY A FOREIGN BODY.

It will be seen that there has been no division of the external sphincter. A small roll of cotton wool has been placed in the anal canal with the object of showing that the anal margin is intact.

[Photo taken soon after the operation.]

such a fistula takes place primarily in two directions. First, it may burrow from the side on which the primary external opening is situated to the opposite side, the track passing beneath the ano-coccygeal ligament (see page 11) and eventually perforating the skin nearly opposite the primary external opening. Secondly, the burrowing may extend forwards in two ways on the same side passing either superficially to the branches of the inferior hæmorrhoidal artery (in which case



this secondary external opening is usually situated on or near the *transverse anal line* and about one inch and a half distant from the anal orifice), or beneath the branches of that artery and continuing parallel to the outer border of the external sphincter, perforate the skin in front of the anterior margin of the anus about one inch to one inch and a half distant from it. In women it may extend even into the

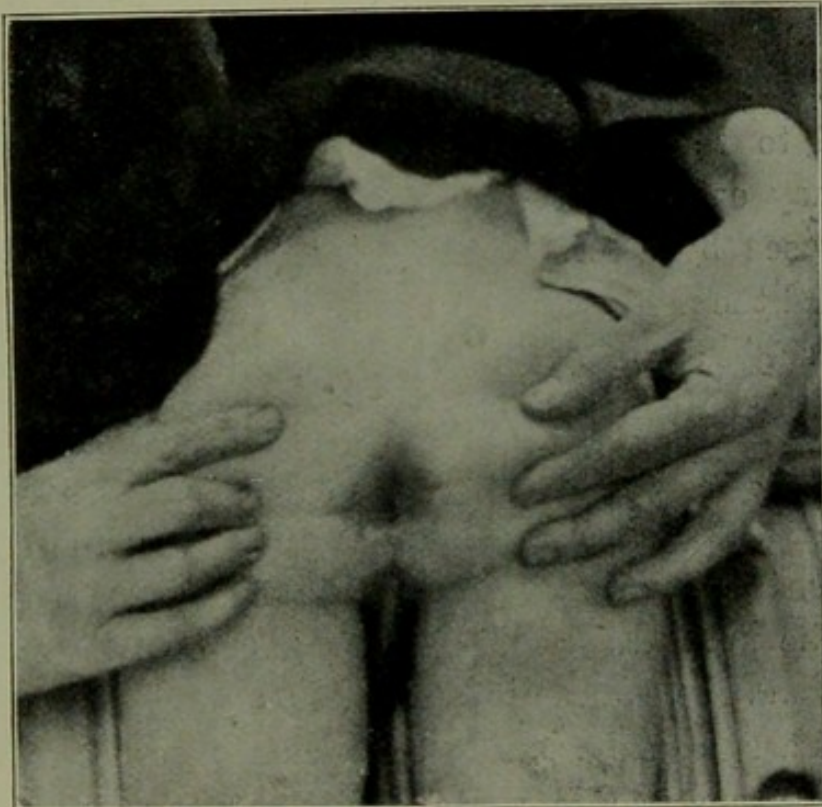


FIG 49.—THE SAME CASE AS IN FIG. 48, AFTER THE WOUNDS HAD HEALED.

This case illustrates our contention that the external sphincter need not always be divided to cure a fistula

cruro-labial fold. This deeper burrowing may take place on both sides, in women, thus producing the most complete form of posterior horse-shoe fistula, the connecting track passing beneath the ano-coccygeal ligament as above described. In men, lateral burrowing extending forward under the inferior hæmorrhoidal artery on both sides of the rectum, occurs less frequently. A still further burrowing, that may be met with in these cases, is directed both forwards and



backwards subcutaneously on either side; so that, when such a fistula has been completely laid open, the wound has the form of the letter H (see fig. 54).

When the internal opening is situated on the *transverse anal line*, either to the right or the left of the anus between the sphincters, the lateral burrowing is usually directed outwards and the skin is perforated at a point from one inch to one inch and a half from the anus, further burrowing continuing subcutaneously beyond the external opening, outwardly as well as in a forward and backward direction, parallel to the anus. Such fistulæ are rarely extensive. They may exist on both sides and, when they do, are probably caused by a foreign body, such as a fish bone, having transfixed the anal canal on opposite sides during defæcation. Two T shaped wounds (see fig. 48) result when these fistulæ are operated upon by the method which we shall describe below (see page 150).

When the external opening is anterior to the *transverse anal line*, the burrowing takes place outwardly in the direct line of the main track for one quarter of an inch to half an inch beyond the external opening and laterally on either side of it; as a rule, from one to two inches in a posterior direction and from two to three inches, or even for a greater distance, in an anterior direction, that is, along the cruro-scrotal fold. The posterior burrowing has a tendency to pass outwards as well as backwards, while the burrowing anteriorly tends to approach the middle line as it passes forwards (see figs. 50 and 58). The course taken by the burrowing in some of these cases is well seen in fig. 50, in which the burrowing on the left side has been laid open. After a short interval, during which repair was rapidly progressing; a swelling appeared on the opposite side (distinctly shown in the photograph) clearly demonstrating that the original abscess had burrowed across the middle line in front



of the anus. At the time of the operation there was no indication of this. The plugging of the wound and the healing process closed up the exit for the discharge from the right side, and thus caused the lateral burrowing in this locality to appear as a secondary abscess.

Occasionally, from the anterior lateral burrowing, a subcutaneous track may pass off at right angles to it, and, crossing the middle line in front of the anus about midway between it and the scrotum, perforate the skin on the opposite side

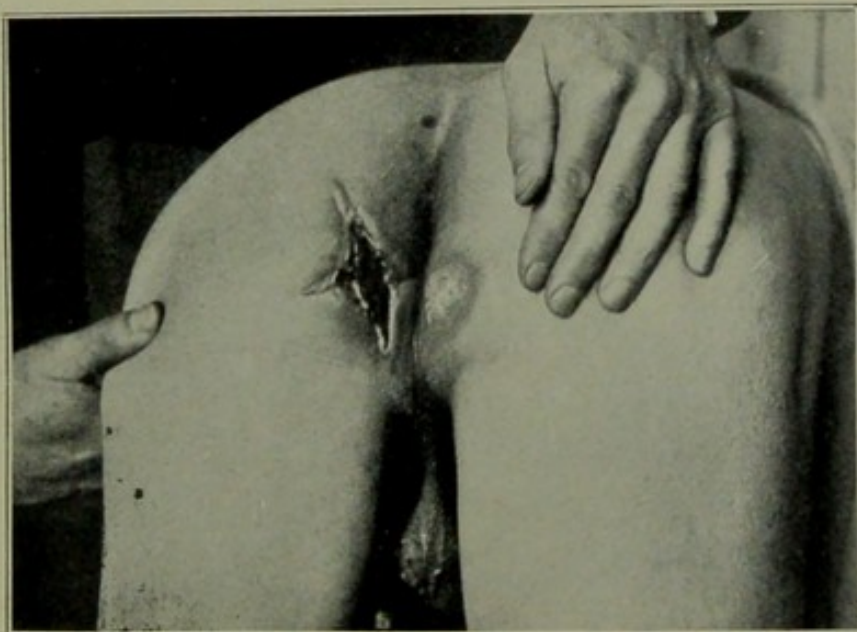


FIG. 50.—AN ANTERIOR HORSE-SHOE FISTULA PARTIALLY LAID OPEN.

The part of the fistula on the left side had been laid open. The wound was rapidly healing before the burrowing on the right showed itself.

[Photo taken about a fortnight after the operation].

of the perineum. The burrowing having then reached the opposite side, anterior and posterior lateral burrowing on that side may take place, and form an *anterior horse-shoe fistula* (see figs. 51, 58 and 60).

In anterior horse-shoe fistulæ, the internal opening is very rarely situated in the middle line anteriorly, but is usually placed between the external and the internal sphincters in either the R.A. or the L.A. quadrant.



*Internal Lateral Burrowing.*

Internal lateral burrowing is always confined to the submucous tissue, but may extend upwards vertically, or, as is more usually the case, obliquely. Extensive submucous burrowing is far more frequently met with anterior to the *transverse anal line* than posterior to it. In every case of complete fistula and also of blind internal fistula, this internal lateral burrowing should *always* be carefully sought for. Incomplete cure of a fistula is more often due to overlooking the presence of a submucous sinus than to any

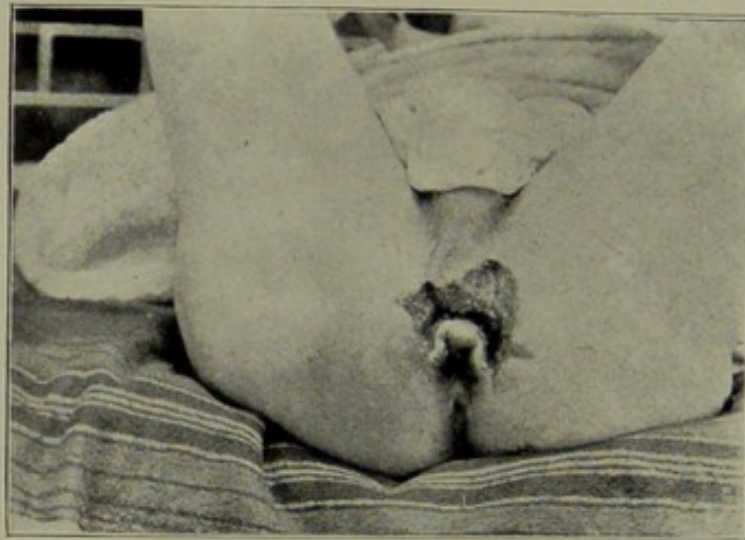


FIG. 51.—AN ANTERIOR HORSE SHOE FISTULA OF WHICH THE WHOLE OF THE EXTERNAL BURROWING HAS BEEN LAID OPEN.

In this case the anal canal was not interfered with. The wound subsequently healed without division of the external sphincter.

[Photo taken about one week after the operation].

other cause; although the failure to effect a cure in such cases is generally attributed to defects in the patient's constitution, and *not* to the incompleteness of the operation. A case illustrating this point and showing the persistency of the submucous burrowing above the internal opening, came under our observation in a patient who had been operated upon for fistula, in Australia, thirty years previously. Since that operation the patient had never been free from a purulent discharge from the rectum. The main track of the fistula,



together with the external lateral burrowing, had been laid open and was soundly healed; but the submucous burrowing, about one inch long and extending vertically upwards, had been left and had kept up the subsequent continuous discharge. This case was cured in three weeks by simply laying open the submucous burrowing.

(5) *The Morbid Conditions Complicating Fistula.*

These may be divided into (a) *constitutional* and (b) *local*.

(a) *Constitutional*.—Phthisis and diabetes predispose to fistula, as we have already remarked in discussing the causation of fistula. Therefore, in a case of fistula occurring in a debilitated subject, the presence or absence of either of these diseases should be carefully ascertained.

Phthisis, in our experience, is not so common a cause of fistula as some authors have stated. This experience is confirmed by Dr. Hugh Walsham\* who has kindly made the following observations for us.

*Clinical Cases*.—" Out of 891 cases of pulmonary tuberculosis that have been under treatment in my outpatient room during the last three years, I have had five cases of fistula-in-ano and two cases of ischio-rectal abscess, all in males aged 55, 49, 52, 41, 37, 42, and 41 respectively."

" In the two with ischio-rectal abscess, the physical signs in the chest were slight. Of the five with fistula-in-ano, in two the physical signs were slight, in the other three the disease in the lungs was far advanced."

*Post-Mortem Cases*.—" Out of 133 post-mortem examinations, made by myself on persons dead of pulmonary tuberculosis, I found fistula-in-ano in only one case."

" In four other cases there was extensive tuberculous ulceration of the rectum but no fistulæ."

" The above statistics are, I think, sufficient to show that ano-rectal fistula is not a common complication of pulmonary

\* Assistant Physician (late Pathologist) City of London Hospital for Diseases of the Chest.



“ tuberculosis. Even when it does occur in connection with  
“ phthisis, it by no means follows that the fistula is tubercu-  
“ lous, although it may become so if left untreated. Tuber-  
“ culous ulceration of the rectum is confessedly rare; as above  
“ stated, there were only four cases of this condition in 133  
“ post-mortem examinations of tuberculous subjects. The  
“ tuberculous or non-tuberculous nature of the fistula can  
“ only be determined by the discovery or non-discovery of the  
“ tubercle bacillus in a scraping from the wall of the sinus.  
“ Cases in which operative interference is contra-indicated  
“ must be few. The contention of the older physicians, that  
“ by curing the fistula we might possibly increase or accel-  
“ erate the pulmonary mischief, must be given up as fallacious.  
“ I know of no facts in support of it. By operation, the patient  
“ is at once relieved of much acute suffering every time the  
“ bowels are moved, and of much distress of mind, both of  
“ which, while they last, must necessarily have a tendency to  
“ aggravate the pulmonary mischief.”

(b) *Local*.—Of the local complications, the co-existence of internal piles is most frequently met with. The other diseases, given in the order of their frequency, are fissure, ulcer and ulceration of the rectum, stricture, polypoid growths and carcinoma. All these should be systematically looked for in every case, and will, if they exist, be found, so far as our experience goes, within the lower two inches of the rectum, except stricture or carcinoma which may be situated at a considerably higher level, though seldom beyond the terminal six inches of the bowel.

#### *Constitutional Effects of Fistula.*

In cases of simple fistula in previously healthy persons, the body weight of the patient is maintained or even increased, although the fistula may have existed for many years. In one case that came under our observation, although the fistula had existed for thirty-four years, the patient's weight



was far in excess of the average. In all cases of fistula in which there is extensive lateral burrowing and consequent copious suppuration, the body weight steadily decreases and the patient's constitutional powers gradually become much impaired. In those whose constitution has been debilitated from any cause, and especially in the tuberculous, the loss of weight during the existence of the fistula is sometimes very rapid. We have observed in these cases, even when of long standing, that the urine is nearly always free from albumen, showing that prolonged suppuration due to a fistula does not appear to have any ill effect upon the kidneys. Many of the subjects of fistula appear to suffer from considerable mental depression, occasionally culminating in suicidal tendencies. Such mental depression is, according to our experience, more frequently met with in cases of recto-urethral and urethral fistulæ, but speedily disappears after the fistula has been cured.

#### *Treatment.*

The treatment of fistula may be divided into (a) palliative and (b) operative.

(a) *Palliative treatment*, though it may frequently succeed in making a fistula quiescent, is rarely sufficient for its permanent cure. It should always be adopted when the patient's constitutional condition contra-indicates an operation, unless the fistula is causing much pain, or is attended by copious discharge, or the lateral burrowing is extending. In any of these conditions, an operation cannot be performed too soon. Palliative treatment consists of constitutional and local measures. The constitutional treatment comprises change of air, rest, plain wholesome food, and the avoidance of stimulants, especially malt liquors. Boating, horse-riding, and cycling should be forbidden. Local treatment consists of the use of warm sitz baths of ten to fifteen minutes duration, night and morning, and the constant application in the



intervals of hot boracic fomentations. Pressing the fistulous track gently with the fingers, while the part is in the sitz bath, is useful for emptying the sinuses of discharge. The bowels should be relieved at least once during the twenty-four hours. The injection of an ounce of olive oil at night greatly facilitates this. It is undesirable to procure fluid motions, because some of the liquid fæcal matter may pass into the track of the fistula through the internal opening, even when small, and so set up increased inflammation. Tonics, such as strychnine, iron and quinine, are extremely useful, not only during the palliative treatment, but also after the operation.

In blind internal fistulæ, palliative treatment should not be adopted.

(b) *Operative treatment* can nearly always be relied upon to effect a permanent cure.

The recognized operative measures that have been adopted for the cure of a fistula are as follow:—

- (1) Incision.
- (2) Dissecting out the fistulous track.
- (3) The elastic ligature.
- (4) The silk ligature.
- (5) The injection or application of nitrate of silver.

#### *Choice of Operation.*

The operation that we invariably adopt for the cure of all cases of ano-rectal fistula is that by incision.

(1) *Incision*.—By this method the main track, as well as all the lateral burrowing arising from it, can be freely laid open at a single operation, and, therefore, the discharge and pain are at once diminished. Moreover, so long as the internal sphincter is not divided either completely or partially, the patient does not run any risk of incontinence or sustain any loss of control over the contents of the rectum. In those



cases in which the complete laying open of the lateral burrowing would involve injury to the internal sphincter, an effort may judiciously be made to secure the healing of such sinuses as pass above and external to the internal sphincter, by the injection of solutions of nitrate of silver and the like; but this must be considered as an adjunct to the operation by incision, and need never be resorted to unless the internal sphincter is involved in the burrowing.

(2) *Dissecting out the fistulous track.*—This operation should only be used in those cases of fistula in which no lateral burrowing exists and in which the internal opening of the fistula is close to the verge of the anus.

(3) *The elastic ligature* is suitable only for small cases of fistula without any lateral burrowing. Since for the performance of this operation it is necessary to incise the skin over the track of the fistula and at the same time to lay open any lateral burrowing whether internal or external, the procedure is really one of incision combined with the slow cutting through, by a ligature, of the external sphincter and the wall of the main track, together with the overlying subcutaneous tissue. The only advantage, to our minds, that this operation possesses over that of incision alone is that the patient is enabled to get about and, to some extent, follow his usual occupation during the treatment.

(4) *The silk ligature* was in vogue many years ago but, at the present time, is rarely used. It was then frequently applied owing to the general conviction that a fistula should not be cured too quickly lest the onset of pulmonary phthisis should follow its healing. We never recommend this procedure, and think that it should be abandoned because of its tediousness and of the pain and discomfort at times attending its use.

(5) *The Injection or application of Nitrate of Silver.*—This method may be useful in treating rectal fistulæ in which the sinus runs outside the internal sphincter, deep in the



ischio-rectal fossa, and shows no tendency to heal. In such a case, the sinus quickly heals after division of the internal sphincter, with the result that, though the fistula has been cured, incontinence of fæces probably takes its place, leaving the patient totally unfit for many occupations, and in a deplorable condition so far as his personal comfort is concerned. It is, therefore, most desirable that a deep sinus passing outside the internal sphincter should be cured without recourse to division of that muscle. The free application of a stick of nitrate of silver, or still better the injection of a saturated solution (*i.e.*, 960 grains to 1 oz.) often brings about sloughing of the main sinus wall and also that of any lateral burrowing, and so leads to their ultimate closure by healthy granulation tissue. The advantage of using a solution is that the liquid is able to enter every part of the fistula, whereas when the solid nitrate of silver is employed, it is in most cases impossible to introduce it into the whole of the main track and its lateral burrowings. When an internal opening exists above the internal sphincter, some of the solution, if applied, will pass into the rectum, and can readily be recognised as a whitish coagulum. The nitrate of silver apparently does no harm to the mucous membrane, and the internal opening itself often closes quickly after being thus treated. About five minutes after using the solution, an ounce of olive oil should be injected into the rectum to prevent any further action of the nitrate of silver upon the mucous membrane. As soon as the injection has been completed, the external opening should be enlarged by a crucial incision so as to afford free drainage. The resulting slough of the lining of the sinus will usually completely separate by the sixth day, when healthy granulation tissue will be found to have taken the place of the sinus tissue. Boracic fomentations should be applied constantly until all the slough has separated and the sinus has healed. If, after the lapse of two or three weeks subsequent



to the injection, the sinus show no marked tendency to close, the injection should be repeated as before. We have known cases to require three or four applications before a successful result was attained and, therefore, this method should not be abandoned even after one or two failures. When, after repeated applications, the sinus still remains unhealed, it is better to leave it alone than to incur the risk of probable incontinence by division of the internal sphincter for the cure of the fistula. In fact, the patient should be urged to tolerate the persistence of his fistula rather than take the risk of the loss of power of control over the contents of the rectum.

### *The Operation by Incision.*

*Instruments required.*—A large and a small soft steel probe-pointed director; a director with the groove running out at the end; a round probe  $5\frac{1}{2}$  inches in length and  $\frac{3}{16}$  of an inch in diameter throughout; a sharp-pointed curved bistoury; a blunt-pointed curved bistoury; a scalpel; pressure forceps; fenestrated artery forceps; dissecting forceps; straight scissors; curved scissors; and ligatures (No. 6 plaited silk).

*Position of the patient.*—This varies with the position of the main track of the fistula. When the fistula is posterior to the *transverse anal line* or situated on the right side anteriorly to that *line*, the patient should be placed in the right lateral and semi-prone position. When the main track is situated on the left side anteriorly to the *transverse anal line*, the position of the patient should be the left lateral and semi-prone. When operating upon an anterior horse-shoe fistula, the lithotomy position is best adapted for the purpose and most convenient for the operator, but the patient's knees should not be drawn up so far as to make the skin in front of the anus tense.

### *General Rules for the Operation.*

There are certain general rules to be observed in operating upon all varieties of fistulæ, viz. :—



(1) Subcutaneous burrowing should be laid open for at least a quarter to half an inch beyond its extreme limit, so that complete laying open of the sinuses may be secured.

(2) Care should be taken, by gentle manipulation, not to make a passage for the probe where one does not already exist.

(3) The internal sphincter should not be damaged to any extent, or not at all if possible.

(4) Should there be any difficulty in finding the internal opening, all the external lateral burrowing should be operated upon before the main track is dealt with. It is important that the whole of the main track should be laid open from end to end, unless by doing so the internal sphincter would be divided. Laying open only part of the main track, leaving the internal opening untouched, is always followed by much delay in the healing process, and very often by failure to cure the fistula.

(5) After laying open all the burrowing, all angles of overhanging skin, especially if discoloured or undermined, should be removed with scissors. Occasionally it will be found that a piece of skin has been isolated by the laying open of subcutaneous sinuses passing all round it. Any overhanging portions of this islet of skin should be removed, but the main portion should be left *in situ* (see figs. 42 and 43). The reason why such an islet of skin has not been undermined is that a small artery passes directly into it and so maintains its nutrition. If the islet be left, cicatrisation will take place readily from the whole of its circumference, and will, therefore, diminish the time required for the healing of the wound.

The above rules hold good when operating upon any form of fistula, excepting anterior and posterior horse-shoe fistulæ with small internal openings, as well as upon some fistulæ on or close to *the transverse anal line* (see figs. 48 and 49).



*Method of Operating in Complete Fistula.*

The patient having been thoroughly anæsthetised, the left forefinger is introduced into the rectum in order to feel the position of the internal opening. The course taken by the main track, and the extent of the lateral burrowing, should then be made out by compressing the peri-anal and the perirectal tissues between the finger in the rectum and the thumb of the same hand placed on the skin surface. The point of a probe-director should now be introduced into the main track through the external opening. In some cases, the orifice is so contracted that difficulty will be experienced in inserting even the smallest probe through it. Under such circumstances, the orifice should be enlarged by making a small incision across it at right angles to the direction of the main track. When two or more external openings exist the one considered to be the primary (see page 111) should be selected. As soon as the probe-director has fairly entered the main track, it should be gently passed along it in a direction towards the internal opening. No force should be used during the transit, lest a false passage be made. Should the main track take a straight course towards the rectum, the point of the probe-director will, as a rule, readily protrude through the internal opening, where it will be felt to impinge upon the index finger. In those cases in which the main track takes a curved or indirect course, some difficulty may be experienced in reaching the internal opening on account of the inability of the probe to adapt itself to the curves of the track. When this difficulty presents itself, the index finger should be withdrawn from the rectum and the point of the probe should be forced through the skin at the spot where its further progress is arrested. The bridge of tissue covering the probe-director should then be divided, care being taken that the point of the bistoury is maintained in close contact with the groove in the director. In this way the first part of the main track will have been laid open. The incision thus made will nearly



always permit of the probe-director being passed through the remainder of the track in the required direction. The left index finger should now be again introduced into the rectum, and the probe-director then passed along the track towards the internal opening. If the passage of the probe still be impeded the manœuvre, above described, should be repeated. It may, though rarely, be necessary to do this a second time before the internal opening can be reached. As soon as the point of the probe-director is felt in the rectum, a little gentle manipulation will suffice to make its point pass through the internal opening. When the probe-director has entered the rectum, its point should be hooked down by the index finger and brought out through the anus. The probe-director should then be passed onwards until its groove appears beyond the internal opening. The bridge of tissue (containing the external sphincter, or part of it, in all sub-muscular fistulæ) which covers the probe-director, is then divided and the probe thus liberated. The index finger is again introduced into the rectum, and then by everting the anal margin at the spot where the incision has been made, the floor of the main track in its entirety will be exposed to view. A careful search should now be made along the floor and sides of the main track, by the aid of the point of the probe-director, for any apertures leading into lateral burrowing. If lateral burrowing be found, the probe-director should be passed along it to its extremity, and forced through the skin at this point if no secondary external opening be situated there. The bridge of tissue over the probe-director should then be divided and a further search made for lateral burrowing. When the lateral burrowing has been thoroughly laid open, all incisions, which terminate abruptly, should be extended for half an inch so as to ensure good drainage. Overhanging or undermined edges of skin should be removed, and the wound carefully cleansed. When all bleeding has been arrested, the wound should be packed with cotton wool



wrung out of perchloride of mercury solution, especial care being devoted to the part which passes into the rectum. An external dressing should then be applied and a T bandage adjusted.

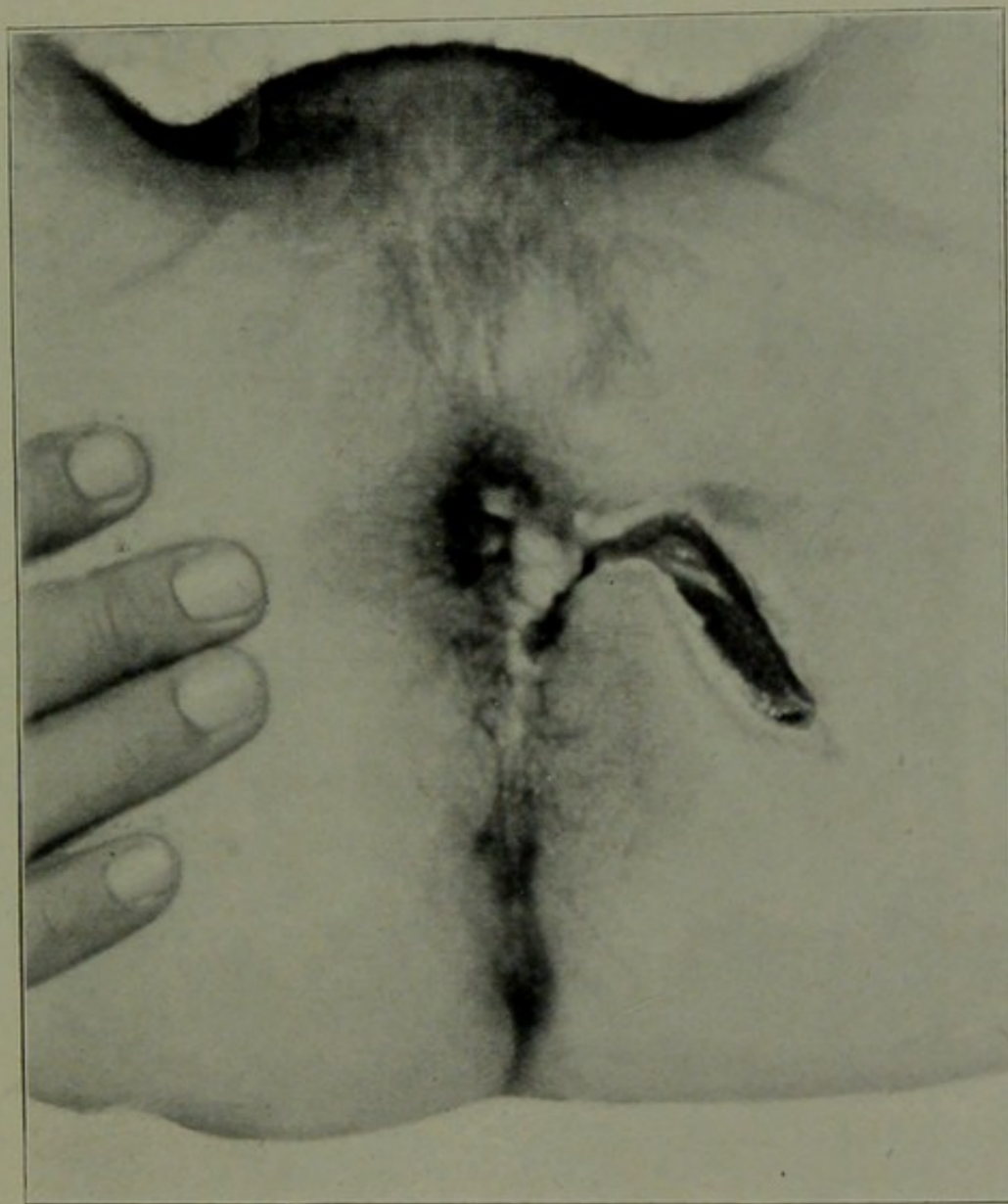


FIG. 52.—SHOWING THE SUBCUTANEOUS BURROWING OF A FISTULA CONFINED TO ONE SIDE LAID OPEN.

The healing is taking place throughout the whole wound.

*The differences in the method of procedure required by complete fistula posterior to the transverse anal line as compared with complete fistula anterior to that line.*



As we have already pointed out (see page 125), the lateral burrowing of a fistula situated posterior to the transverse anal line takes a different course to that of a fistula anterior to that line, and, therefore, the operation must be modified accordingly.

*In Fistulae Posterior to the Transverse Anal Line.*

In cases of fistula confined to either side of the anus, the mode of procedure which we recommend differs according

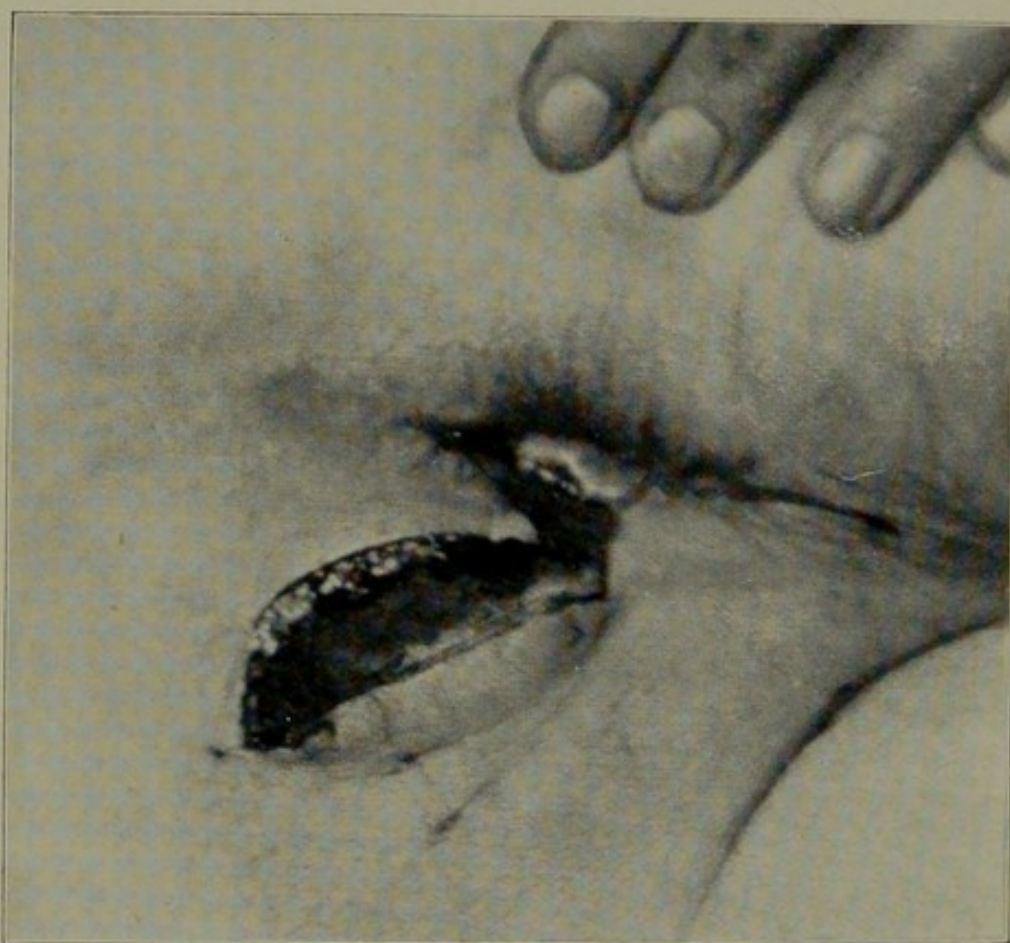


FIG. 53.—A FISTULA PASSING UNDER THE EXTERNAL SPHINCTER INTO THE RECTUM LAID OPEN TOGETHER WITH ITS LATERAL BURROWING.

as the main track is subcutaneous or submuscular. When only subcutaneous, it should be laid open from end to end, together with all the lateral burrowing (see fig. 52). When the main sinus is submuscular and passes either between the superficial and deep portions of the external sphincter, or



between the internal and external sphincters on its way into the rectum, it should be laid open into the rectum, together with all the subcutaneous and submucous burrowing (see fig. 53). When, however, a lateral burrowing, as is sometimes the case, passes either upwards outside the internal sphincter or forwards beneath the branches of the inferior

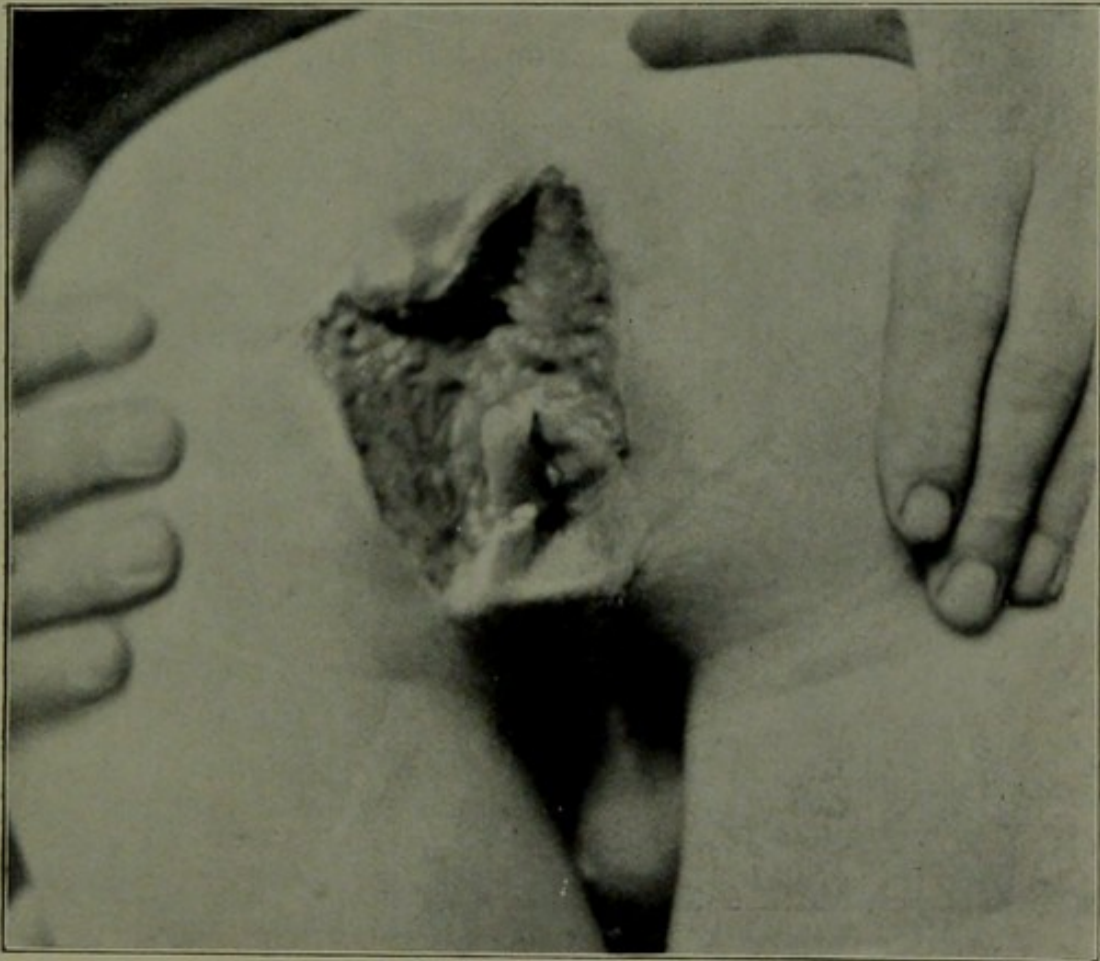


FIG. 54.—APPEARANCE OF WOUND MADE BY THE H-SHAPED INCISION.

The sinus leading into the rectum was not laid open, the external sphincter was not divided. The thorough gaping of the wound prevented any retention of pus.

hæmorrhoidal artery, neither the one nor the other of these tracks should be laid open until an attempt has been made to get it to close by other means (see page 135).

*Posterior horse-shoe fistula.*

In those cases in which the internal opening is situated in the middle line posteriorly between the two sphincters and the



burrowing has extended to both sides—the *typical posterior horse-shoe fistula*—all the subcutaneous burrowing on both sides should be laid open first, and afterwards the sinus passing beneath the ano-coccygeal ligament from one side to the other, and the vessels divided by this incision secured. If the internal opening be small, the resulting H shaped wound may be firmly plugged with cotton wool wrung out of a solution of Hyd. Perchlor (1 in 500), and the sinus in

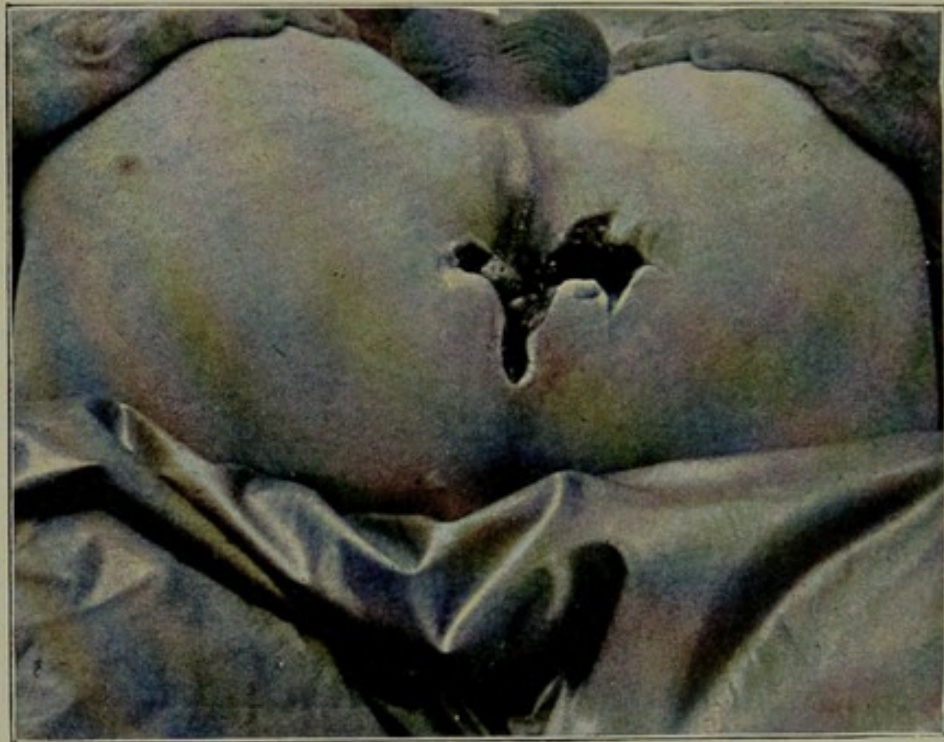

FIG. 55.—POSTERIOR HORSE-SHOE FISTULA.

The external lateral burrowing was laid open.

[Photo taken within a fortnight of the operation.]

connection with the internal opening left for subsequent treatment, if necessary (see figs. 51, 55, and 63). This may be all that is required to cure the fistula, but in the majority of cases it does not succeed. Operating in this way, *i.e.*, by not laying open the main track into the bowel, has three great advantages:—

(1) That all hæmorrhage can be readily controlled by plugging the wound.



(2) That when the bowels are relieved neither flatus nor fæces will pass into the wound, as occurs when the external sphincter has been divided.

(3) Should the fistula be cured without division of the external sphincter, there can be no loss of power even in that muscle.

When the internal opening is large, it is well to postpone laying open the main track into the rectum, until the greater part of the wound has healed. When a part of the main track passes up above the level of and external to the in-

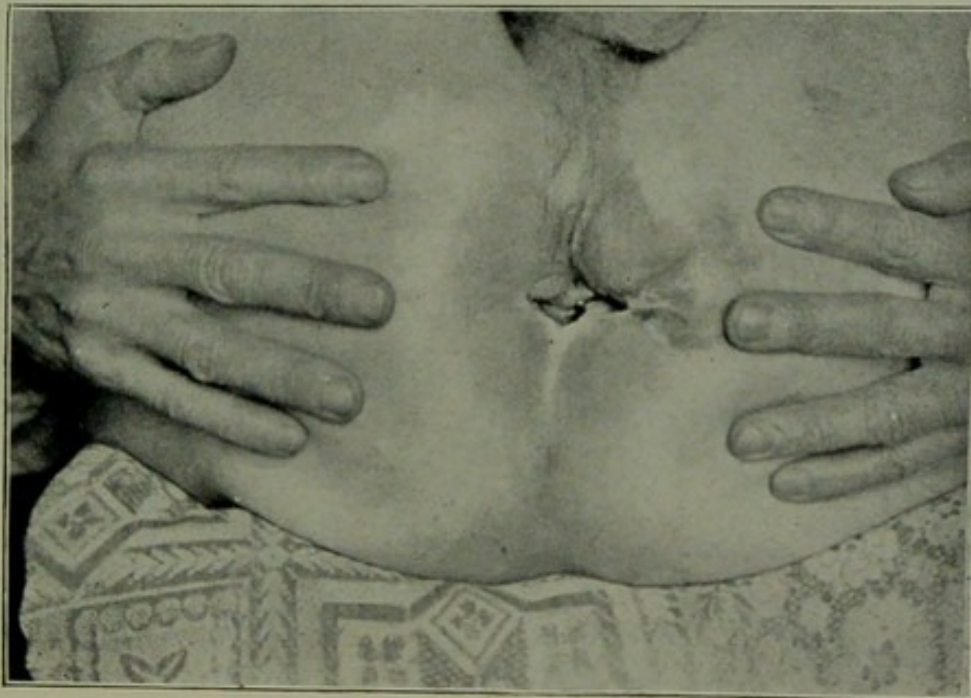


FIG. 56.—THE SAME CASE AS IN FIG. 55.  
The wound almost healed.

ternal sphincter, it should be subsequently dealt with by the injection of nitrate of silver (see page 135). This treatment should be commenced during the second or third week after the primary operation has been performed.

In those cases of posterior horse-shoe fistula in which there is burrowing forwards on one or both sides of the rectum beneath the branches of the inferior hæmorrhoidal artery, such burrowing should not be laid open at the primary operation,



as, if left to itself, it will frequently close, on account of the free drainage established by the H-shaped incision (see figs. 54, 55 and 63).

*In fistulæ anterior to the transverse anal line.*

When the fistula is confined to either the right or the left side of the anus, the main sinus, when subcutaneous, should be laid open from end to end together with all

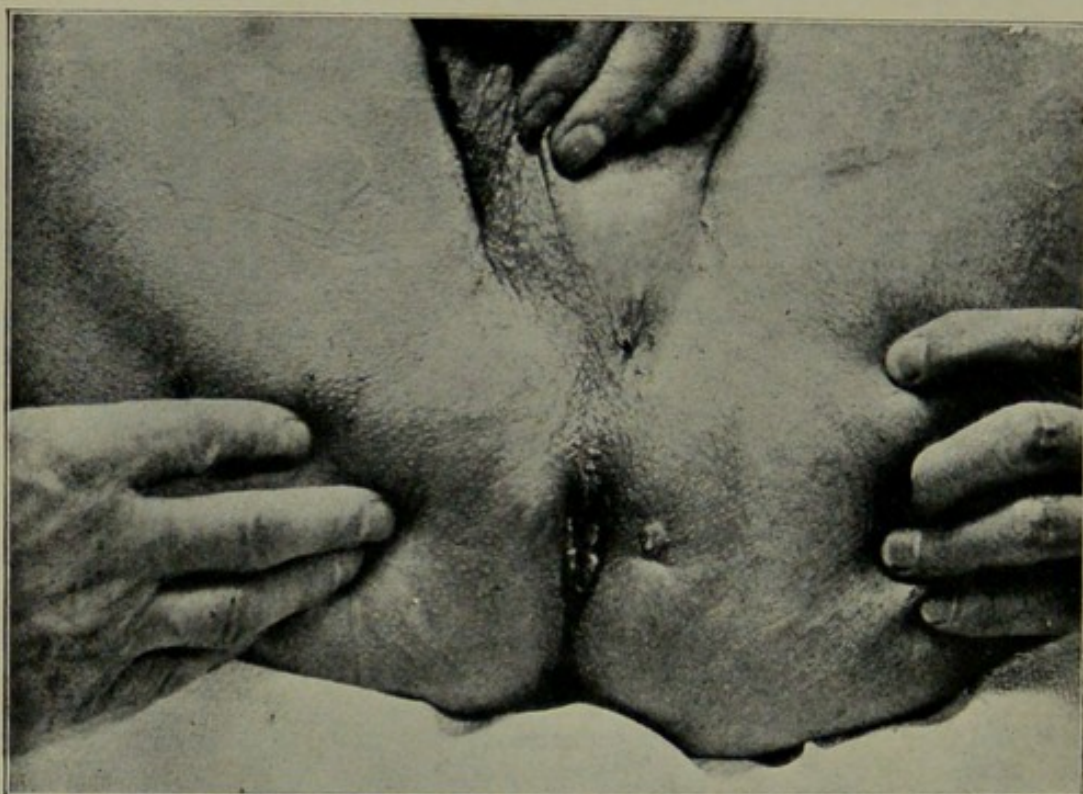


FIG. 57.—AN ANTERIOR HORSE-SHOE FISTULA.

In this case a polypoid growth was found partially attached to the side of the internal opening, which was situated about two inches above the anus on the LA side.

lateral burrowing, if any. When the main sinus is sub-muscular and passes no deeper than the external sphincter, it should be laid open from end to end together with all subcutaneous and submucous burrowing. Occasionally, a lateral sinus may pass upwards external to the internal sphincter. This should be treated by injection with nitrate of silver solution with the object of inducing it to close. In such a case, division of the internal sphincter always



produces some permanent loss of power, and, in women, will be followed by permanent rectal incontinence and, later on in life, by procidentia of the rectum.

*Anterior horse-shoe fistula.*—As we have already pointed out, the position of the internal opening in a case of posterior horse-shoe fistula, is in the middle line posteriorly between the internal and the external sphincters. In an anterior

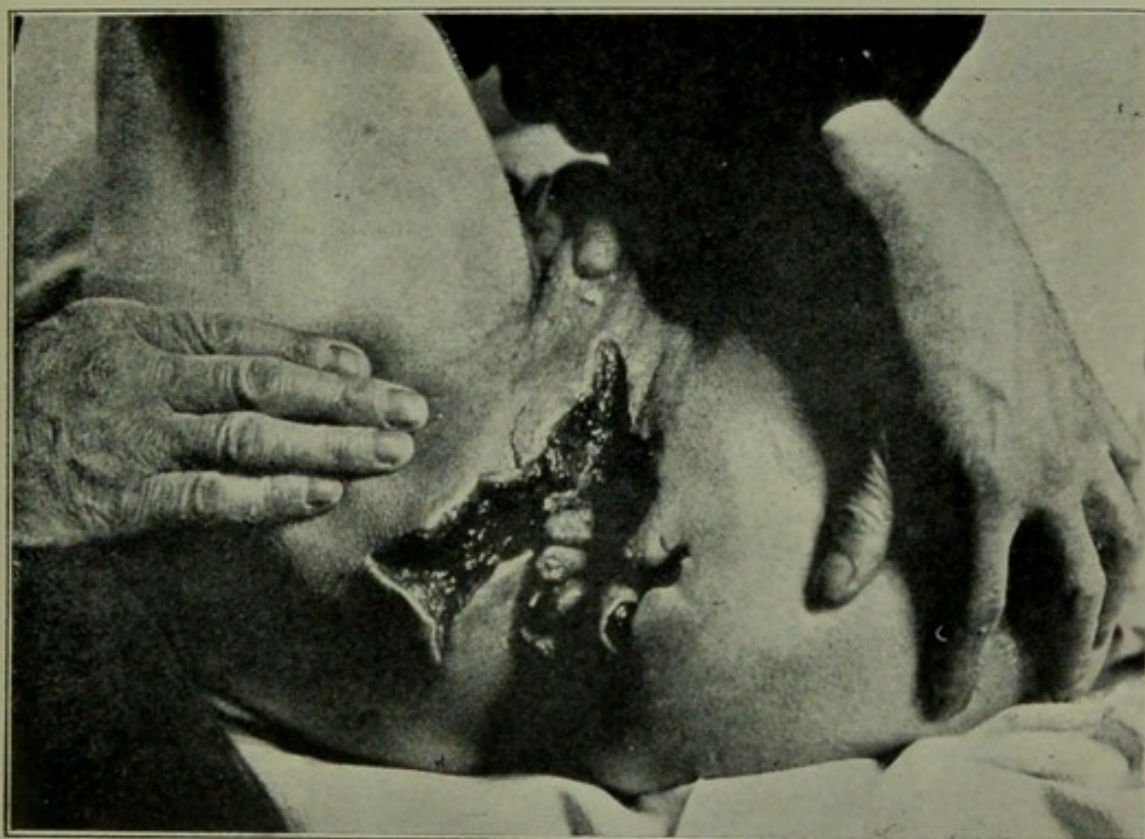


FIG. 58.—THE SAME CASE AS IN FIG. 57, SHOWING THE EXTERNAL BURROWING LAID OPEN.

The extensive burrowing on the right side passed off from the anterior of the two external openings.

[Photo taken about a fortnight after the operation.]

horse-shoe fistula, however, the internal opening is usually found between the internal and the external sphincters (occasionally also above the internal sphincter) either on the RA or the LA side of the rectum. In some instances the internal opening may be met with in the middle line anteriorly, but this is extremely rare. In operating upon a case of anterior horse-shoe fistula, all the subcutaneous



burrowing should be laid open first, and then the main sinus passing into the rectum between the external and the internal sphincters (see figs. 57, 58, 59 and 60). Should a polypoid growth be found to co-exist, its base must be ligatured and the growth removed. When the main sinus passes into the rectum through or deeper than the internal sphincter it should not be laid open. Should the internal sphincter be divided, the patient will certainly have more or less permanent loss of control over the contents of the rectum.

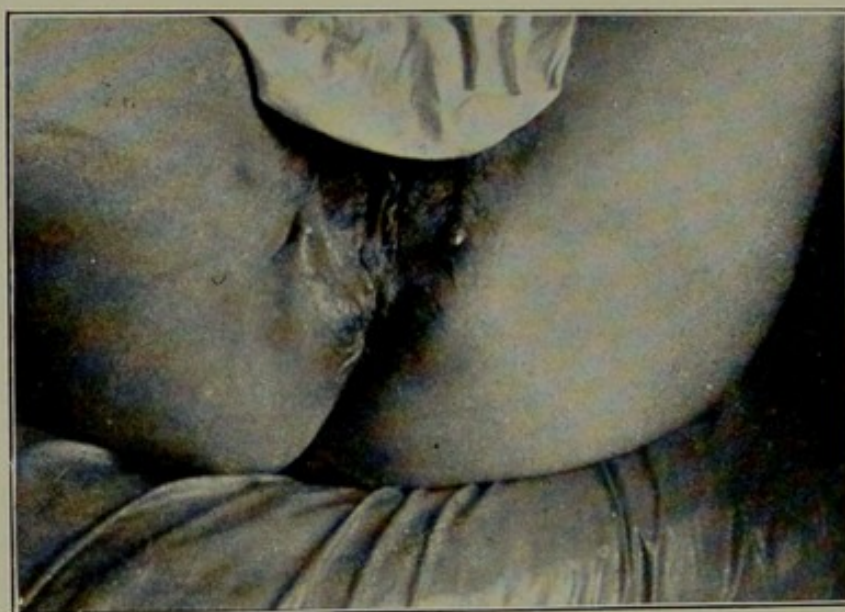

FIG. 59.—AN ANTERIOR HORSE-SHOE FISTULA (IN A FEMALE)

The only external opening was L.A. one inch. The lateral burrowing was subcutaneous only.

[Photo taken immediately before the operation.]

In some instances, the lateral burrowing of an anterior horse-shoe fistula will extend backwards beneath the branches of the inferior hæmorrhoidal artery. This burrowing should be laid open at the time of the primary operation because, in our experience, if left alone it will not close, as often does the forward burrowing beneath the branches of the inferior hæmorrhoidal artery in connection with fistulæ posterior to the line. We think the following is the explanation of this difference. When fæces are being expelled from the rectum,



the mass is at first driven downwards and forwards against the anterior rectal wall, until it reaches a point from one to two inches from the anus when it changes direction and is expelled downwards and backwards. Accordingly, in the backward burrowing of a fistula anterior to the transverse line, the discharge in the sinus is driven backwards, thereby distending the sinus and so preventing it from healing. On the other hand, in the forward burrowing of a fistula posterior to the transverse line, the onward passage of fæces has the beneficial

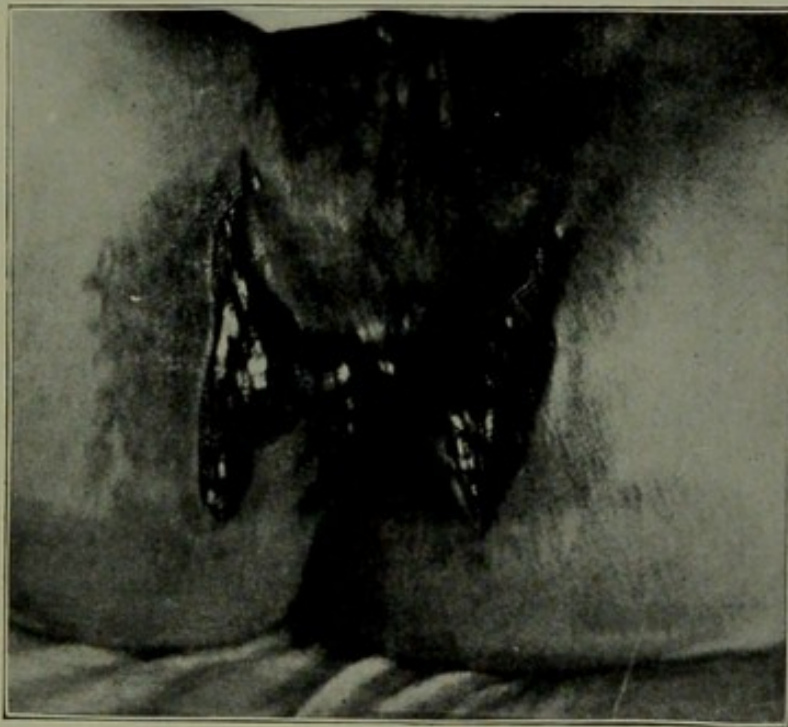


FIG. 60.—THE SAME CASE AS IN FIG. 59, SHOWING THE EXTERNAL LATERAL BURROWING LAID OPEN.

The H-shaped wound is perfectly illustrated in this case.

[Photo taken soon after the operation.]

effect of emptying the sinus and preventing its distension, thus promoting healing, especially when a free external opening through the skin has been provided.

#### *Method of Operating in Blind External Fistulae.*

When the patient is fully under the influence of an anæsthetic, the left index finger should be introduced into the



rectum and the point of a probe-director should be passed through the external opening (there are, as a rule, no secondary external openings in a blind external fistula unless they are the result of the confluence of adjacent follicular abscesses) into the main track and gently passed onwards, the finger in the rectum following the point of the instrument in its progress. When the probe-director is found to pass between the external and the internal sphincters, its point should be forced through the mucous membrane in order to convert the blind external fistula into a complete fistula. The operation should then be completed as detailed under that head (see page 139).

When the point of the probe-director does not pass between the external and the internal sphincters but goes deeply in the ischio-rectal fossa external to the internal sphincter, it should not, on any account, be made to perforate the rectal wall, as otherwise the internal sphincter would be involved in the subsequent incision. Accordingly, when the main track takes this deep course, we must be contented with simply enlarging the external opening freely by a T incision and trusting to the resulting wound healing from the bottom (see figs. 48 and 49) (see page 135).

#### *Method of Operating in Blind Internal Fistulæ.*

The usual method adopted in operating upon these cases, after discovering the position of the internal opening, is to pass a speculum into the rectum and then to introduce the bent extremity of a probe-pointed director into the internal opening of the fistula. The probe being retained *in situ*, the speculum is withdrawn, and the point of the probe made prominent under the skin near the anal margin. The skin over the end of the probe is now divided, thus converting the blind internal into a complete fistula, which can be easily laid open into the rectum on the director. The objections to this method are :—



1. Part, or the whole, of the internal sphincter will be divided when the track leading from the internal opening passes through or above the internal sphincter.

2. The probe may, soon after its entrance into the track of the fistula, pass out of it again, and thus, when the intervening tissue is divided, a considerable portion of the track may be left untouched.

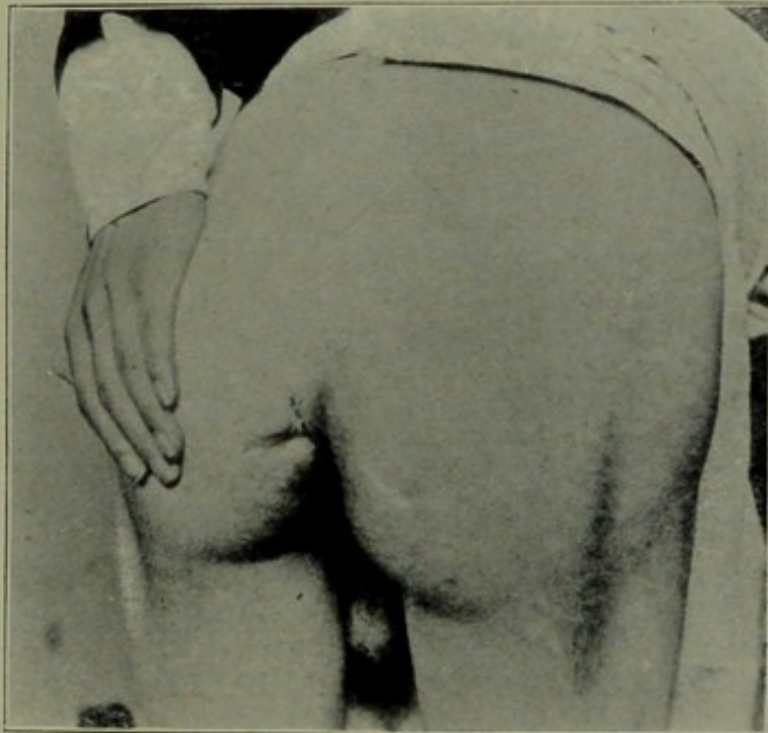


FIG. 61.—A BLIND INTERNAL FISTULA CURED BY A T-SHAPED EXTERNAL INCISION.

The sphincters were not in any way interfered with. The internal opening was in the middle line posteriorly between the sphincters.

The exact procedure to be adopted depends upon the position of the main track of the fistula, that is, whether it is situated in the ischio-rectal fossa or entirely beneath the mucous membrane.

The method that we always adopt when the fistula is in the ischio-rectal fossa (see fig. 36), is to introduce the left index finger into the rectum, and, after finding the internal opening, to carefully examine, both to the right and left of it in the ischio-rectal fossa, for any induration indicating the



lateral burrowing of the fistula. When this has been made out, the index finger is passed onwards for at least an inch beyond the internal opening, unless the latter is situated very high up. The finger in the rectum is then semi-flexed, and the swelling due to the fistula is pressed downwards, and so made prominent beneath the skin by the side of the rectum. In this way, the extent of the more superficial part of the swelling can be felt between the index finger in the rectum and the left thumb outside. A crucial or T-shaped incision should now be made into the centre of the swelling, thus converting the blind internal fistula into a complete fistula, and, at the same time, affording a free exit for the pus (see fig. 61). When the track to the internal opening passes between the external and the internal sphincter, the sinus into the rectum should be laid open. But when the track passes through or above the internal sphincter, in its course to the internal opening, it should not be interfered with, as by doing so the internal sphincter would be either partially or completely divided by the incision. In such a case, the external opening should be freely enlarged and, should the sinus not readily heal, a nitrate of silver injection should be used (see page 135).

When the main track is entirely *submucous* (see fig. 39) the probe-director, guided by the left index finger should be introduced into the internal opening and gently passed along the track to its extremity. Care should be taken to keep the point of the probe-director in contact with the mucous membrane, so that it may be passed superficially to any artery crossing the direction of the track. When the upper extremity of the track has been reached, the point of the probe-director should be made to perforate the mucous membrane in that situation. The instrument should then be passed onwards until its groove can be felt beyond the aperture. Since free hæmorrhage may follow the laying open of a submucous track, it is necessary to ascertain whether one of the branches of the superior hæmorrhoidal artery



passes superficially to the probe-director. This may be determined by carefully palpating the mucous membrane beneath which the instrument has been passed, the tension upon the mucous coat being relaxed by pressing the probe-director firmly against the muscular coat of the rectum. If no vessel be found to cross the probe-director, the intervening tissue should be completely divided. Should one of the branches of the superior hæmorrhoidal artery be found to pass superficial to the probe director, one of two methods may be adopted. Either a ligature may be passed along the track and tied tightly, or the artery should be clamped on both sides of the probe director and then the track may safely be laid open. The tissue held by the pressure forceps should be ligatured.

*After Treatment.*

After all operations upon fistulæ, the following routine treatment should be carried out. Immediately after recovery from the effects of the anæsthetic has taken place, 15 to 30 minims of liq. opii sed. should be given in a small quantity of water, this dose should be followed in four hours by a mixture of catechu and opium as given below.

℞			
Liq. Ammoniæ Acetatis ...	...	...	ʒ ss
Tinct. Catechu ...	...	...	ʒ ss
Tinct. Opii...	...	...	m., x
Tinct. Cardamomi Comp.	...	...	ʒ i
Aquæ ...	...	...	ʒ vi

℥

This draught should be repeated every four hours during the first sixteen, and every eight hours during the succeeding forty-eight. About twenty-four hours after the operation, all the external dressings should be removed and the surrounding skin gently washed with an antiseptic lotion, but the cotton wool, with which the wound has been packed, should not be disturbed. Hot boracic fomentations should



now be commenced, and their use continued until the bowels have been freely relieved. The fomentations may then be discarded, unless the condition of the wound renders their continuance for a longer period desirable. The bowels should be freely relieved about ninety-six hours after the operation by administering the two following pills to be taken at bed time:—

R

Hydrargyri Subchloridi	...	...	gr. ij
Ext. Colocynthis Comp.	...	...	gr. v
Ext. Hyoscyami	...	...	gr. ij

℞

On the following morning the draught given below should be taken.

R

Magnesiae Sulphatis	...	...	ʒ iiss
Tinct. Sennæ	...	...	ʒ ij
Tinct. Jalapæ	...	...	ʒ ij
Aquæ Menthæ Pip.	...	...	ʒ xij

These purgatives will almost invariably secure a complete evacuation of the contents of the colon and rectum and there will, therefore, be no need for enemata. After this preliminary clearance, a free action of the bowels should be obtained, at least once in every twenty-four hours, until the wound is quite healed.

The first action of the bowels usually brings away the packing in the wound. If any portion remain in the wound after this, it should be removed. The wound should be carefully cleansed, after the bowels have acted, and irrigated with a solution of sublimate of mercury (1 in 500). The cavity of the wound, especially when there is any tendency to overlapping or approximation of adjacent surfaces, should be lightly packed with pieces of cotton wool wrung out of the sublimate solution. This dressing should be changed once in twenty-four hours, and more often when



there is much discharge. Whenever the dressing is changed, the whole surface of the wound should be carefully sponged, to prevent either irregular healing or bridging taking place. Occasionally the granulations become exuberant, a condition indicating tardiness in healing. In such cases, the following lotion will be found useful in restoring the wound to a healthy state:—

℞			
	Zinci Sulphatis	... gr.	ij
	Aluminis	... gr.	iiij
	Aquæ destillatæ	... ℥	i
℥			

*The Diet after the Operation.*

Until the bowels have been freely relieved, a milk diet should be enjoined. After this, the patient may resume his ordinary diet, provided that there is no contra-indication in his general condition.

*Average Duration of the Healing Process.*

When a fistula is uncomplicated by other rectal disease or by general diseases, the duration of the healing process varies according to the variety of the fistula and the depth of its lateral burrowing.

A subcutaneous fistula usually heals within a fortnight. A fistula consisting of a main track (without lateral burrowing) which enters the rectum either between the superficial and the deep portions of the external sphincter or between the external and internal sphincters, generally requires from four to five weeks for complete cicatrisation. Cases of fistula in which there is, in addition, extensive subcutaneous lateral burrowing, will, as a rule, not be healed in less than from six to nine weeks. The healing process in cases of anterior or posterior horse-shoe fistulæ, may extend over three or four months and, even longer, should the patient's constitution be debilitated by the preceding suppuration.



*Complications after the Operation and their  
Treatment.*

The complications that may supervene after an operation upon a fistula may be divided into (a) *the immediate*, that arise within the first twenty-four hours; and (b) *the remote*, that supervene at a later period.

(a) *Immediate.* Under this head are comprised hæmorrhage, an action of the bowels soon after the completion of the operation, and retention of urine.

*Hæmorrhage.*—When recurrent bleeding occurs after an operation upon a fistula, it usually shows itself within three or four hours, and is due to one of the following causes:—

- (1).—Bleeding from a vessel which escaped ligature.
- (2).—The slipping of a ligature.
- (3).—Insufficient packing of the wound.

When recurrent hæmorrhage is found to have taken place, all dressings should be removed and the bleeding point secured. Should there be a general oozing from the surface of the wound, cotton wool, soaked in the stronger solution of perchloride of iron, should be packed in its cavity, with a pad of cotton wool and a T bandage carefully and firmly applied.

*An action of the bowels soon after the completion of the operation.*—This is almost always due to the fact that the bowels were not thoroughly relieved before the operation. Purgatives should be given at least twelve hours before the time fixed for the operation, so that their full effect may be completed before then. When an action of the bowels takes place after the operation has been finished, all the external dressings should be removed and the surrounding skin cleansed. The packing of the wound should not be disturbed, as such a procedure will cause much pain and may require an anæsthetic for the re-introduction of the plug. So far as we have seen, the passage of fæcal material over the surface of a recent wound in the ano-rectal region does not appear



to exert any deleterious effect. There is usually not more than one action of the bowels immediately after the operation, because, as soon as the patient is under the influence of the opium and catechu, the intestinal irritability ceases.

*Retention of urine.*—There is seldom any difficulty with micturition after an operation upon an uncomplicated fistula. When internal piles or fissure complicate the case, difficulty with micturition sometimes occurs. The best way to avoid having to pass a catheter after these operations is to allow very little fluid to be taken by the patient during the first twenty-four hours, at the end of which period the reflex spasm of the sphincter vesicæ will have subsided. When retention of urine occurs, the patient should first be made to sit in a warm hip bath. If this fail, a catheter should then be passed. This subject is more fully considered under Internal Piles.

(b) *The remote complications* are irregularity in the healing, extension of burrowing, persistence of the discharge, prolapse of mucous membrane or of an internal pile or piles into the wound, and the impaction of fæces.

*Irregularity in healing* is due to the more superficial parts of the wound being allowed to come into contact before healing has taken place at the deepest part. The resulting union at the points of contact leads to the re-establishment of a part, or even the whole, of the fistula. The only way to prevent these adhesions taking place is by thoroughly sponging the whole surface of the wound at least once a day, and afterwards placing pledgets of cotton wool between the contiguous surfaces. When irregular healing is found to have occurred, the adhesions should be broken down with a probe or divided with a bistoury.

*Extension of burrowing* occasionally occurs owing to a lateral offshoot from the main track having escaped notice at the operation. In such a case, the packing of the wound shuts up the pus in the undetected track and burrowing continues from it. This extension of burrowing manifests itself by the



supervention of pain of a throbbing character and by the appearance, in some cases, of a swelling in the neighbourhood of the wound (see fig. 50). The onset of pain in the wound, after the first eighteen hours following an operation upon an uncomplicated fistula, is always suggestive of extension of burrowing. Under these circumstances, the packing of the wound should be removed and the additional burrowing fully laid open. The fresh wounds should then be packed and fomentations applied to the part.

*Persistence of the discharge.*—In some cases it will be found that, although the wound is slowly diminishing in size day by day, the quantity of pus generated does not show a corresponding diminution. The most usual cause for the maintenance of the purulent discharge is the existence of a track extending beyond the part laid open into the rectum, either beneath the mucous membrane or external to the rectum in the ischio-rectal fossa.

In those cases in which the fistula has resulted from a pelvi-rectal abscess which has extended into the ischio-rectal fossa, the discharge may show no progressive decrease in quantity, because the operation has been limited to the ischio-rectal fossa, and, therefore, the opening into the pelvi-rectal abscess has been overlooked and left undilated. The discharge may also be maintained, or even increased in quantity, by the wound becoming unhealthy.

The treatment of this condition depends on its cause.

*When due to a sinus.*—The sinus, when submucous, should be laid open forthwith ; if external to the internal sphincter, it should be treated as mentioned on page 135 ; if caused by a pelvi-rectal abscess, careful search should be made for the aperture in the levator ani and the treatment described on page 87 adopted.

*When the wound is unhealthy.*—When the continuance of the discharge is due to an unhealthy condition of the wound, the whole of its surface should be destroyed by



the application of either sulphate of copper, Vienna paste, nitric acid or a forty per centum solution of formalin. Both before and after the application of any of these substances, the wound should be rendered insensitive by a twenty per centum solution of cocaine. Boracic fomentations should be commenced three or four hours after the application, and repeated every four hours until the wound assumes a healthy state. In some instances more than one application may be necessary. The margin of the wound should be carefully destroyed.

*Prolapse of mucous membrane or of an internal pile or piles.*—As one of the results of the division of the external sphincter in an operation for fistula, internal piles, when existing, will become prolapsed after the second or third action of the bowels subsequent to the operation. In those cases in which the internal sphincter has been either partially or wholly divided in addition to the external sphincter, folds of mucous membrane will be prolapsed, even when internal piles do not exist. Such a protrusion, whether consisting of internal piles or mucous membrane, will, unless removed, greatly retard the healing of the wound. Accordingly, in these cases, we always remove the protrusion by the ligature about fourteen days after the primary operation. Our reason for postponing the removal until after this interval has elapsed, is to insure that the prolapsed tissue will have attained its maximum, and that no further protrusion will follow.

Knowing how readily existing piles will become prolapsed after division of the external sphincter, we make it a rule, in a case of fistula, to ascertain whether they are present; if they are, we ligature them before completing the operation, taking care that the mucous membrane is not too freely removed.

*Impaction of feces.*—On account of the division of the external sphincter, fecal impaction is rarely met with after an operation upon an uncomplicated fistula. When several



internal piles have co-existed and have been removed, it may occasionally occur on account of the narrowing of the passage which is apt to follow a too free removal of the piles. For the symptoms and treatment of this condition see "Internal Piles."

*The Advisability of Operating upon an Ano-Rectal Fistula complicated by Pulmonary Tuberculosis.*

At one time, it was the general opinion in our profession that when a fistula was complicated by pulmonary tuberculosis an operation should not be performed. In recent years a great change in this opinion has taken place and, at the present time, these patients are often recommended to have a fistula cured by operative measures in order that one source of weakness may be removed. So far as our experience goes, we consider that every case of fistula, occurring in a subject of pulmonary tuberculosis, which is causing discomfort or much discharge, should be operated upon, unless the pulmonary disease is so advanced that the life of the patient would be jeopardised by the operation. We know of no instance in which the activity of the pulmonary disease has been definitely increased by the curing of the fistula.

Fistula, in phthisical subjects, sometimes causes so much pain and difficulty in defæcation that the bowels act several times during the day on account of the incomplete emptying of the rectum. The real explanation of these symptoms is often not appreciated and, consequently, the patient is treated for diarrhœa that does not exist. There is often also much discharge which constitutes a continuous drain upon the patient's strength.

The pain and difficulty in defæcation are due to the following causes:—

(1) The large internal opening which usually exists in tuberculous fistulæ.



(2) The spasmodic contraction of the external sphincter met with in some cases (the external sphincter is usually relaxed in phthisical patients).

(3) The retention of fæcal material in the track and lateral burrowing of the fistula.

The comparatively large quantity of discharge is due to the extensive undermining of the skin around the primary and secondary external openings, which favours the retention of

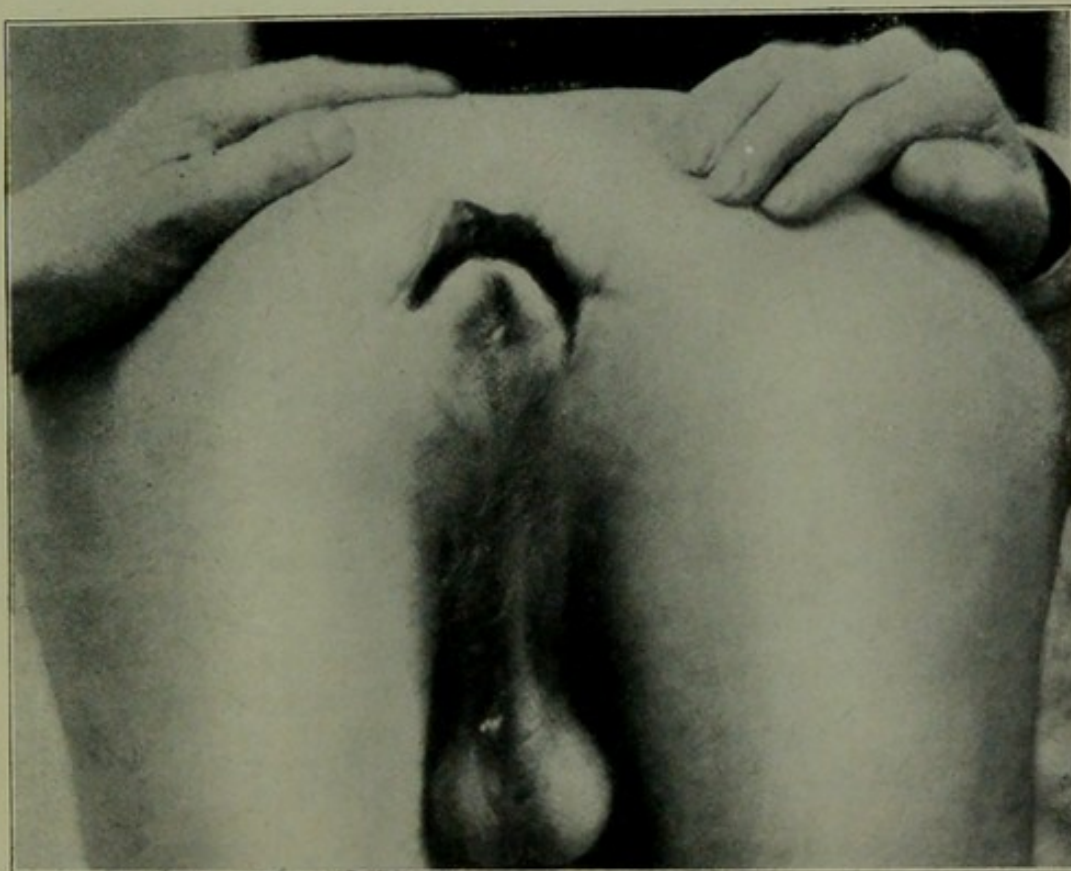


FIG. 62.—THE PARTIALLY HEALED WOUND IN CASE I. SHOWING THE BILATERAL BURROWING OF A TYPICAL POSTERIOR HORSE-SHOE FISTULA.

[Photo taken fourteen days after the operation.]

All the external burrowing in both ischio-rectal fossæ has been laid open together with the communicating track between the ano-coccygeal ligament and the attachment of the levatores ani. That part of the fistula opening into the rectum has been left untouched, so that there has been no division of the external sphincter.

fæcal material in the main track and the lateral burrowing. All these symptoms can be effectually removed by an operation. Their disappearance is always followed by a great improvement in the comfort of the patient, and also by an



increase in his body weight. The wounds heal soundly, though less rapidly than in a healthy patient.

In illustration of our views on this subject, we have appended the notes of the two following typical cases, in both of which there was extensive pulmonary tuberculosis in active progress during the healing of the wound, as Figs. 64 and 66 distinctly show.

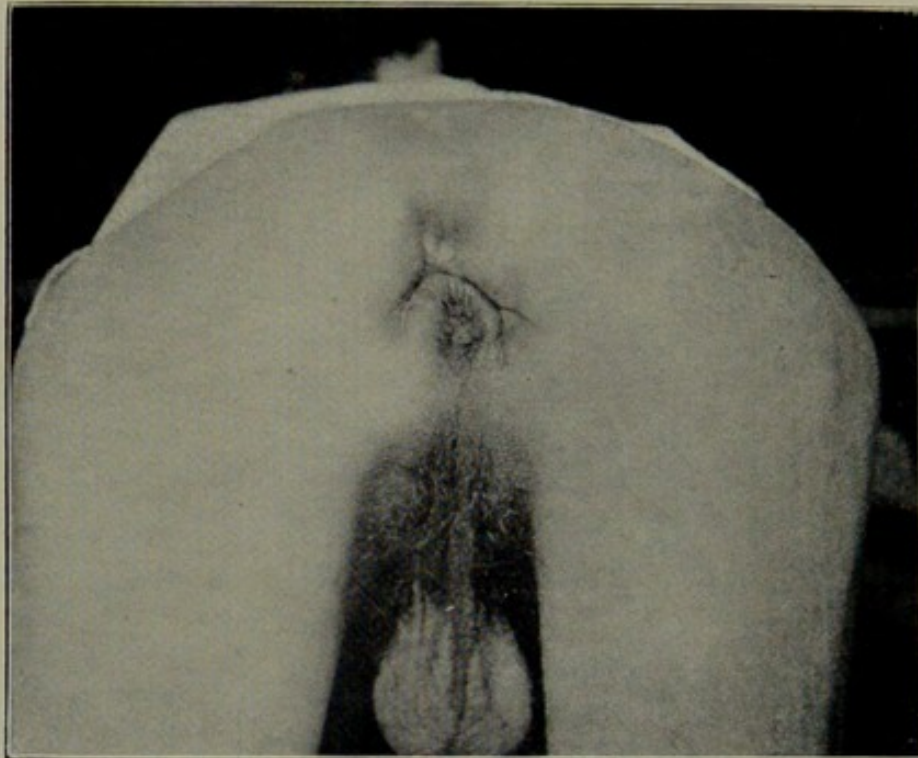


FIG. 63 —THE SAME CASE AS IN FIG. 62, SHOWING THE WOUND SOUNDLY HEALED.

*[Photo taken nine weeks after the operation.]*

This case is an excellent example of the cure of an extensive posterior horse-shoe fistula without division of the external sphincter. Fig. 64 shows that this patient had well marked pulmonary tuberculosis, the skiagram having been taken during the healing process.

Another point to be borne in mind in connection with fistulæ in tuberculous patients, is the readiness with which a small fistula may, in two or three days, become converted into a most extensive one. We, therefore, recommend that these fistulæ should not be examined with a probe until the operation is about to be performed, because we have seen such a procedure lead to extensive increase in the dimensions of a fistula.



## CASE I.

J. G., æt 42, a waiter.

*History.*—Hæmoptysis five years previously. In July, 1897, an abscess appeared in the right posterior quadrant of the peri-anal region which was opened at a general hospital in London. In March, 1898, when an in-patient at a hospital for diseases of the chest, an abscess appeared in the left posterior quadrant and broke spontaneously. In July, 1899, he was admitted for fistula into another general hospital in London, but was not operated upon on account of the condition of his lungs.

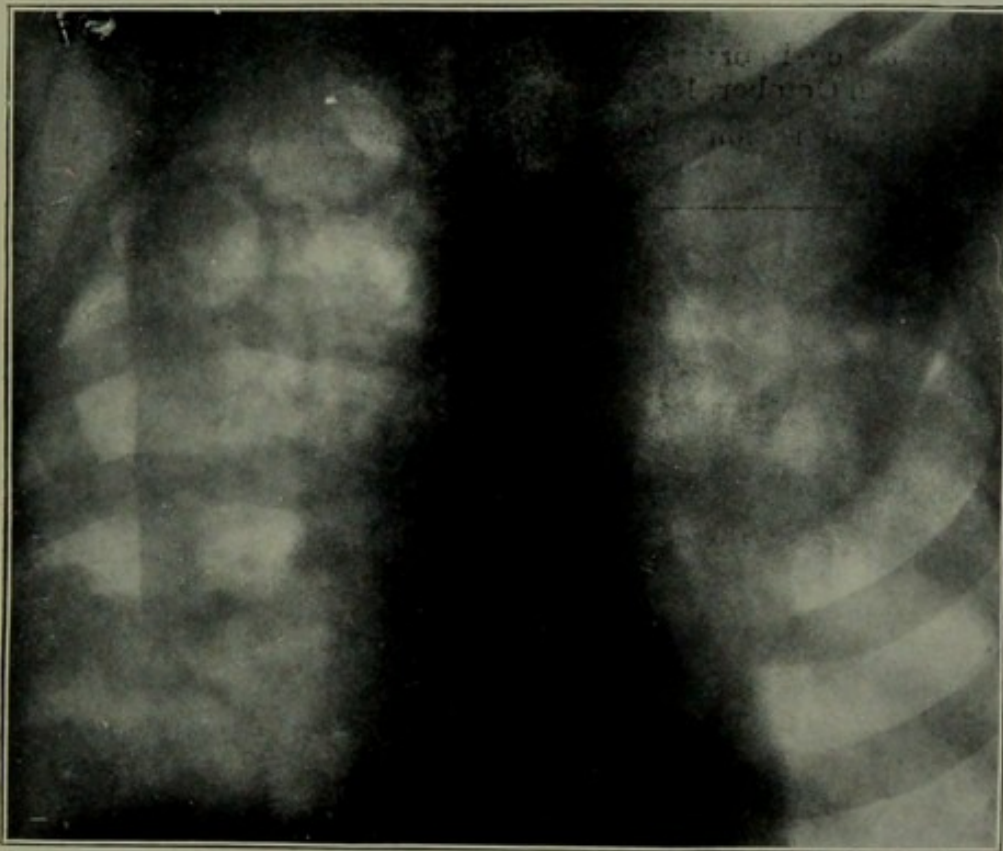


FIG. 64.—THE SKIAGRAM OF THE CHEST IN THE SAME PATIENT AS IN FIG. 62, 63, SHOWING THE PRESENCE OF TUBERCULOUS DEPOSIT IN THE LUNGS.

*Description of Skiagram by Dr. Hugh Walsham.*

Neglecting the shadows formed by the axillary fold on each side, the skiagram shows a well marked and advanced case of chronic pulmonary tuberculosis. There are seen to be two cavities situated at the apex of the right upper lobe, and general tuberculous infiltration of both upper lobes on each side. The tuberculous stippling on the left side follows fairly closely the division between the upper and lower lobes. The left lower lobe being apparently clear of tubercle.

On February 26, 1900, he was admitted into St. Mark's Hospital under the care of Mr. Goodsall, and was operated upon on March 1.

*Operation.*—When the external lateral burrowing and the main track, except that part of the latter which entered the rectum between the external and internal sphincters in the middle line posteriorly, had



been laid open, the wound presented the appearance of a horse-shoe (see fig. 62).

*Result.*—The healing of the wound was slow but steady, and on May 9, 1900, *i.e.*, 68 days after the operation, the patient left the hospital cured (see fig. 63). A week before his discharge a skiagram was taken of his chest (see fig. 64).

*Temperature.*—On admission, 99 F.; the following day, 100 F.; the third day, 101 F.; the fourth day (after operation), 99·4 F. During the remainder of his stay in the hospital, the temperature never rose above 99·6 F., generally being below 99 F.

#### CASE II.

J. R. æt 38, coal porter.

*History.*—In October, 1899, an abscess appeared in the R. P. quadrant of the peri-anal region, while he was attending as an out-patient at

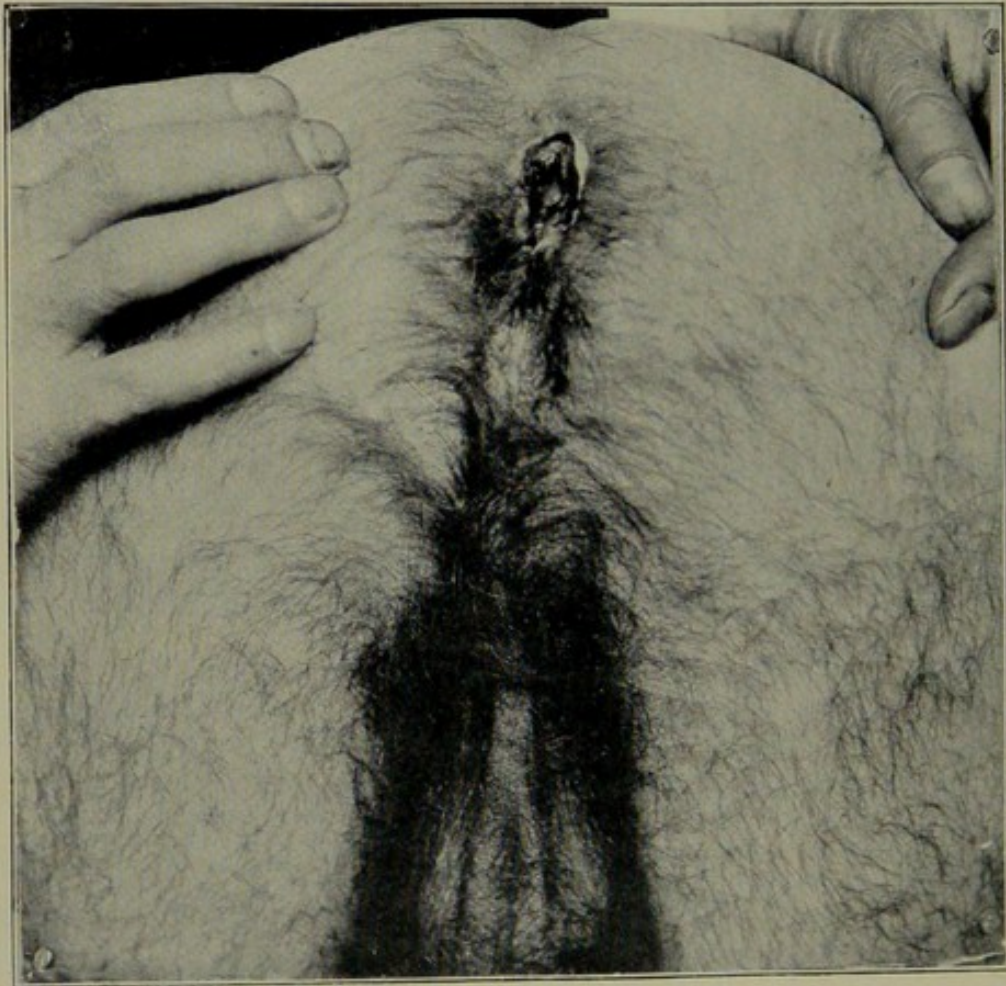

FIG. 65.—THE APPEARANCE OF THE PARTLY HEALED WOUND IN CASE II.

[Photo taken thirty days after the operation.]

The photograph shows the thickened or œdematous overhanging margins of the wound, the excessive hairiness of the anal and scrotal regions, and the relaxed scrotum conditions which are usually met with in phthisical patients.



one of the London hospitals for diseases of the chest. The abscess broke spontaneously soon after its appearance. On April 7, 1900, he went to St. Mark's Hospital and was admitted under Mr. Goodsall on May 7.

*Operation, May 10.*—The main track of the fistula between the external and the internal openings was laid open, together with all lateral burrowing. The undermined edges of skin were completely

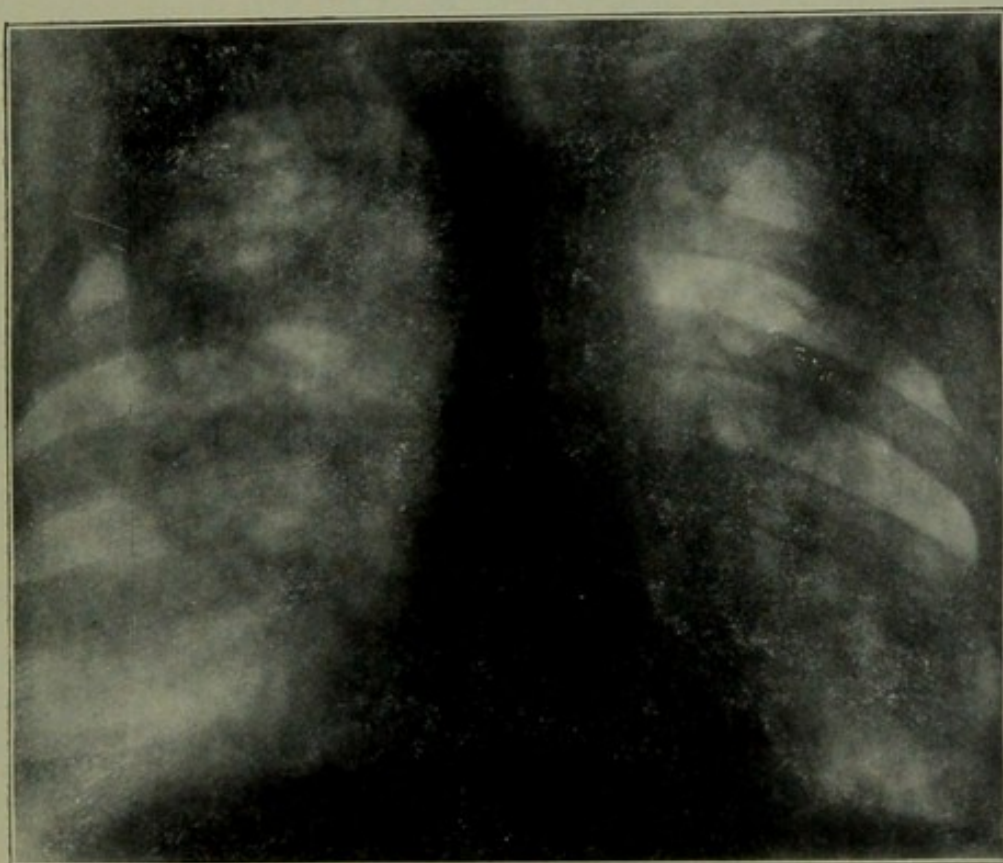


FIG. 66.—THE SKIAGRAM OF THE CHEST IN THE SAME PATIENT AS IN FIG. 65, SHOWING THE TUBERCULOUS DEPOSIT IN THE LUNGS.

[Photo taken three weeks after the operation.]

*Description of Skiagram by Dr. Hugh Walsham.*

The chest is viewed from the front. The skiagram shows advanced tuberculous disease of both lungs. There is a well marked cavity in the left upper lobe. The vertical lines seen on each side must be disregarded. They are caused by the axillary fold, the patient being skiagraphed with the sternum towards the sensitive photographic plate.

removed, so that the resulting wound gaped widely (see fig. 65). The internal opening was of large size and was situated in the middle line posteriorly opposite the interval, between the external and the internal sphincters. The external sphincter was completely divided when the main track was laid open into the rectum.

*Result.*—The healing process was slow and steady. On June 15, *i.e.*, 36 days after the operation, the patient left the hospital being desirous of returning to work.



*Temperature*—On admission into St. Mark's, 99·4 F. ; May 10 (after the operation), 98·2 F. During the succeeding seven days the temperature did not rise above 99·2 F. May 18, 100·2 F. After this and up to the date of his discharge, the temperature varied between 97·4 and 102. F.

*Treatment after the Operation.*

The wounds, in tuberculous patients, will often heal more rapidly with the free application of iodoform than under any other kind of dressing. In Case I. the wound was dressed only once in every twenty-four hours during the last five weeks, the cavity being insufflated with iodoform ; in other respects the local treatment adopted was as recommended on page 153.

Much more attention must be given to the treatment of the patient's general health, in cases of tuberculous fistula, than to the constitutional treatment in cases of fistula not complicated by tuberculosis.

Cod liver oil and tonics, such as strychnine, quinine and iron, are extremely useful for promoting repair.

A nutritious and easily assimilated diet should be ordered. In tuberculous patients, the healing process, under any kind of treatment, is always slow. It may be greatly accelerated by dry country or sea air. As soon as granulation has been satisfactorily established the patient may, so far as the wound is concerned, safely travel.

*Perineal urethral fistula simulating ano-rectal fistula.*

A perineal urethral fistula is an abnormal communication between the bulbous portion of the urethra on the one hand, and the skin surface in the urethral triangle on the other. As a rule, the communicating track of a perineal urethral fistula is short and direct, so that urine readily escapes during micturition through the aperture in the perineum. On this account, the nature of the fistula is sufficiently obvious, and it can be at once relegated to the sphere of urethral surgery. Still, there are fistulæ which, arising in connection



with the urethra, simulate very closely an ano-rectal fistula situated anteriorly to the *transverse anal line* (see fig. 68). From these fistulæ, urine seldom escapes during micturition, except perhaps in such small quantity as to be scarcely recognisable, and, consequently, the urethral origin of the fistula is, at first sight, by no means clear. The importance of being able to distinguish between these two forms of fistula cannot be over-estimated, when the question of treatment arises. The distinction lies in the fact that a perineal urethral fistula seldom invades the ischio-rectal fossa, and, therefore, rarely communicates with the rectum. In order that we may understand the course taken by this form of fistula, it is necessary to call to mind the anatomy of the urethral triangle. It will be remembered that this space is bounded, in front, by the sub-pubic ligament; at the sides, by the rami of the pubis and ischium; and, posteriorly, by an imaginary line drawn from the anterior border of one tuber ischii to the other (see fig. 1). Stretching across and filling up this space is the triangular ligament, the posterior border of which corresponds to the imaginary line above alluded to. The triangular ligament is pierced in the middle line by the urethra, the bulbous and the commencement of the spongy portions of which are attached to its superficial aspect along the middle line. By this arrangement the urethral triangle is sub-divided by the urethra into a right and a left superficial perineal triangle (see fig. 3). These triangles contain muscles, vessels and nerves, and are covered by a stratum of fascia, known as the superficial perineal fascia of *Colles* (see fig. 13). This structure has the following attachments: On each side, it is attached to the rami of the pubis and ischium; behind, it curves round the transversus perinei muscle to blend with the posterior border of the triangular ligament; while, anteriorly, it becomes continuous with the fascia covering the scrotum and penis. In the middle line, *Colles's* fascia is bound down to the median raphe



in the bulbo-cavernosus muscle, by a septum, which, though complete behind, is deficient in front. Bearing these facts in mind, it will be readily appreciated that the lateral burrowing of a fistula, originating in the superficial perineal space, will take the same course as urine extravasated in that locality. Thus, commencing on one side of the middle line, it cannot extend backwards into the rectal triangle on account of the

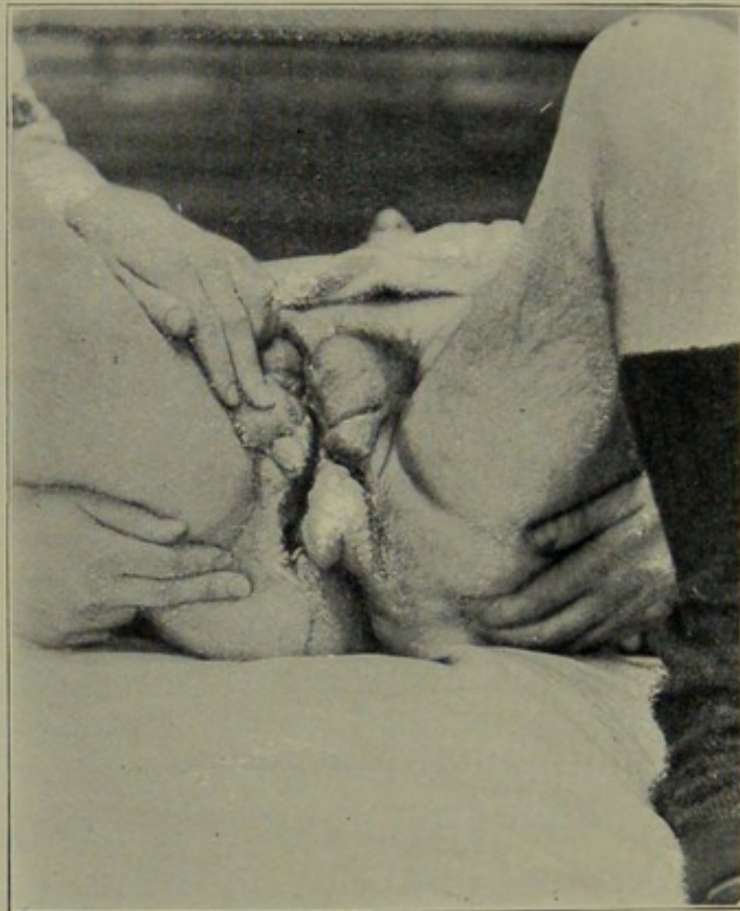

FIG. 67.—SHOWING THE BURROWING LAID OPEN OF A PERINEAL URETHRAL FISTULA, INVOLVING BOTH SUPERFICIAL PERINEAL TRIANGLES AND THE SCROTUM.

The Y-shaped appearance of the wound is well shown, the posterior extremities of which correspond to the level of the base of the triangular ligament.

union between *Colles's* fascia and the posterior border of the triangular ligament; neither can it extend into the thigh on account of the attachment of the same fascia to the rami of the pubis and ischium. Accordingly, extension can only



take place forwards towards the scrotum. Either before or after reaching the scrotum, however, it may extend into the superficial perineal triangle of the opposite side by crossing at the point where the median septum is deficient. Having occupied both superficial perineal triangles, further extension can only take place through the scrotum. External openings may be found at any point along its route, but the position of the primary opening is generally on one or other side of the middle line at the level of the base of the triangular ligament, and, therefore, in front of the *transverse anal line* either in the RA or the LA quadrant. When the lateral burrowing has involved both superficial perineal triangles as well as the scrotum, the appearance of the wound, resulting from the complete laying open of the fistula, is Y-shaped, the extremities of the fork being directed towards the rectal triangle (see fig. 67).

### *Etiology.*

A perineal urethral fistula is due either to suppurative processes, arising in connection with the bulbous portion of the urethra and its immediate vicinity, or to traumatism. In those instances of non-traumatic fistula in which urine escapes readily through the fistula during micturition, an organic stricture of the urethra almost invariably exists, the urethra having partially given way behind the stricture.

In those cases of fistula in the neighbourhood of the bulbous portion of the urethra in which urine does not escape through the fistulous track, the abscess, from which the fistula resulted, most probably originated in Cowper's gland. Acute suppuration in this gland is met with as a sequel to urethritis, especially when of a gonorrhœal nature. The abscess thus formed may either discharge itself into the urethra and subsequently close, or it may extend into the peri-urethral tissue and by gaining access to the urethral triangle cause a fistula. When taking the latter course, an



aperture communicating with the interior of the urethra seldom exists, and, consequently, there is no extravasation of urine. Tuberculous disease of Cowper's gland may give rise to a chronic abscess terminating sometimes in a perineal urethral fistula.

### *Differential Diagnosis.*

A perineal urethral fistula in which extensive lateral burrowing has taken place, may, from the proximity of the burrowing to the anus, very closely resemble an ano-rectal fistula situated anteriorly to the *transverse anal line* and indeed has been mistaken for it. Consequently, it is of great importance that these two kinds of fistula should be distinguished from one another. Each begins as a painful swelling, in front of the *transverse anal line*, which increases in size and ultimately discharges through one or more external openings. The subcutaneous burrowing of both may extend in any direction, and is, therefore, of little value for diagnostic purposes. The situation of the deep burrowing, however, is of much value, because in the ano-rectal fistula it is found in the ischio-rectal fossa, whereas in fistulæ in the urethral triangle it never extends further backwards than the base of the triangular ligament (see fig. 67). Accordingly, the knowledge of the situation of this part of the burrowing is of great importance, and can readily be acquired by passing the left index finger into the rectum and compressing the peri-rectal tissues between it and the thumb of the same hand placed on the skin surface. In the ano-rectal fistula, the main track can be followed continuously from the external opening to the rectal wall, and, if the fistula be complete, the internal opening can be readily felt (see page 117). In the perineal urethral fistula, no such main track can be felt by the finger in the rectum and there is no communication with the bowel. Through the external opening of an ano-rectal fistula, pus, fæculent material and flatus may



escape, but not urine. Through the external opening of a perineal urethral fistula, pus or urine may issue but not flatus or fæces. Unless these points be borne in mind, a mistake in diagnosis may occur, especially if external appearances only are relied upon. In the accompanying illustration (see fig. 68), it will be noticed from the scar that the subcutaneous burrowing extended backwards into the rectal

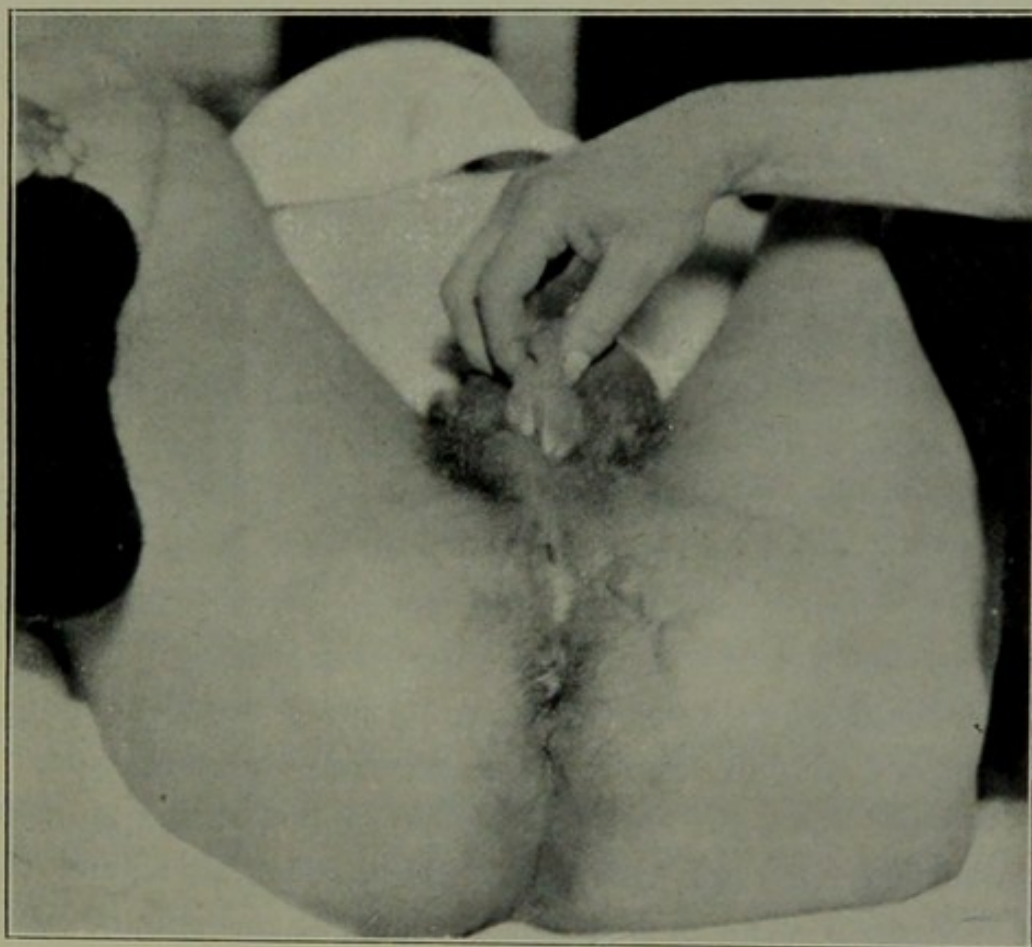


FIG. 68. - SHOWING UNILATERAL BACKWARD AND OUTWARD BURROWING IN A CASE OF PERINEAL URETHRAL FISTULA.

[Photo taken when the wound was healed.]

The scar in the scrotum indicates that the burrowing had extended forwards on both sides. There was no burrowing in the right superficial perineal triangle. The foramen-like aperture shown in the photograph is a depression in the scar, and not an external opening.

triangle, a circumstance which caused the case to be wrongly diagnosed as an ano-rectal fistula. When the urethral origin of the fistula has been determined, the next point to be settled is whether a stricture of the urethra is present or not. This



is an important point, because it directly influences the subsequent treatment. If a stricture be found, the cause of the fistula is probably the giving way of the urethra, resulting in the formation of an abscess primarily in the peri-urethral tissue. When a stricture is not present, the fistula probably originated as an abscess in Cowper's gland and a communication with the urethra is not, therefore, likely to exist. The existence of a communication with the urethra is clearly demonstrated, if urine escape through the fistula.

#### *Treatment.*

When there is a stricture of the urethra, it should be dilated up to the diameter of the meatus. We do not think that there is anything to be gained by dilating the stricture beyond this. When this extent of dilatation has been secured, we recommend that fifteen minims of a saturated solution of nitrate of silver (see page 135) should be injected through the external opening of the fistula. A silver catheter should be introduced into the bladder and retained while the injection is being made. As soon as the injection has been completed the catheter should be withdrawn. The external opening of the fistula should then be freely enlarged by a crucial or T-shaped incision, with the object of converting it into a funnel-like opening. All the lateral burrowing should then be laid open from end to end. The patient should not, if possible, pass urine during the first twelve hours after the injection. The urine should be drawn off with an india-rubber catheter as often as the patient may desire to have the bladder emptied. The bladder itself should be washed out, at least once in every twenty-four hours, with a weak solution of Condy's fluid. This catheterization and washing out should be continued until the fistula has been healed for four or five weeks. During the healing process, the patient should be directed to sit in warm water every night and morning,



and at all other times boracic fomentations should be constantly applied to the wound. In other respects, the after treatment is identical with that described on page 153.

As a result of the action of the saturated solution of nitrate of silver, the wall of the fistula sloughs and usually separates in from four to six days.

When these cases have been treated according to the method described above, a satisfactory result has been, almost invariably, attained (see fig. 68).



## CHAPTER V.

### RECTO-URETHRAL, RECTO-VESICAL AND RECTO-VAGINAL FISTULÆ.

Communications between the rectum and the prostatic urethra, the urinary bladder and the vagina, though not of common occurrence, are sufficiently often met with to justify their inclusion in a work of this kind. Excluding congenital malformation, they are the result either of disease or of traumatism and give rise to symptoms which may make the patient's existence utterly miserable. When they are neglected they may become a source of danger to life.

#### *RECTO-URETHRAL FISTULA.*

This form of fistula, fortunately seldom met with, consists of a main track communicating, so far as we have seen, on the one hand with the anterior wall of the rectum, either on a level with, or immediately below the area in contact with the prostate, and on the other hand with the prostatic urethra. In our experience we have seen but five



cases, excluding those that were due to malignant disease and traumatism. In all of these, the rectal aperture was situated in the anterior wall of the rectum, either to the right or to the left of the middle line and within a distance varying from one and a half to three inches from the anus. The urethral aperture was probably situated either in the floor or in the lateral walls of the prostatic urethra. We are led to this conclusion in regard to the situation of the urethral aperture, from a case of prostatic abscess which terminated in a pelvi-rectal abscess and secondarily invaded the ischio-rectal fossa. The patient ultimately died from exhaustion induced by the prolonged suppuration, and at the autopsy an opening was found in the floor of the prostatic urethra. Quénu and Hartmann\* state that the prostatic urethra and, in very rare instances, the membranous portion of the urethra, are the seats of the urethral opening.

#### *Etiology.*

In each of the five cases of recto-urethral fistula referred to above, the cause was a prostatic abscess supervening upon neglected gonorrhœa.

Segond† collected 43 examples of prostatic abscess, which discharged into the rectum, and of these 21 opened also into the prostatic urethra.

Among other causes which have been mentioned are tuberculous disease, carcinomatous ulceration, and traumatism. In the days of perineal lithotomy, the rectum was occasionally wounded when the incision into the prostatic urethra was being made, with the result that a recto-urethral fistula supervened. Falls upon sharp pointed substances, inflicting penetrating wounds in the perineum, are said to occasionally establish a communication between the rectum and the urethra.

---

\* *Chirurgie du Rectum*, 1895, p. 238.

† *Des abcès chauds de la prostate*. Th. de Paris, 1880, pp. 89-90, quoted by Quénu and Hartmann.



*Symptoms.*

These consist of the escape of urine into the rectum during micturition, and of the occasional passage of flatus and fluid fæces through the urethra during defæcation, when the rectal opening is large. The escape of flatus and liquid fæces through the urethra is not so marked in this form of fistula as it is in the recto-vesical variety, the reason probably being, that in the latter the apertures are larger and the communicating track is shorter and more direct. When the fistula is active, pus may escape both from the rectum and from the urethra, and lateral burrowing may also appear in the perineum, *anteriorly* to the *transverse anal line*, establishing a secondary opening on the skin surface. From such an opening, urine may escape and lead to much irritation of the surrounding skin. In addition to these symptoms, others referable to the rectum and to the urethra are usually present.

So far as the rectum is concerned, the mucous membrane becomes congested and a degree of rectitis is induced by contact with urine. This inflammatory condition of the rectal mucous membrane gives rise to a frequent desire to evacuate the contents of the bowel, and also to some rectal tenesmus. As a result of the burrowing beneath the rectal mucous membrane in the prostatic area, more or less puckering and thickening of that structure is established, and its mobility over subjacent tissues is lost. The seat of the rectal aperture can be felt as a depression in the thickened mucous membrane. The sensation imparted to the exploring finger by the altered mucous membrane is similar to that experienced when examining an evacuated submucous abscess. As a result of the burrowing of the peri-prostatic suppuration, a pelvi-rectal abscess (see page 72) may result, either prior to or subsequent to rupture into the rectum. In a case which we now have under observation, the induration produced by the burrowing into the pelvi-rectal space is well



marked on both sides of the rectum, though it does not extend all round it, the posterior fourth of the circumference being quite free from inflammatory thickening.

In regard to the urethral symptoms, a slight purulent discharge (quite enough to stain the patient's linen) appears to be nearly always present in cases which are not due either to carcinoma or to traumatism. So far as our experience goes, stricture of the urethra and cystitis are always present in these cases, the result being that frequency of micturition is a prominent symptom.

#### *Treatment.*

Sir Henry Thompson\* recommends that, in these cases, all the urine should be drawn off by a catheter each time the patient desires to empty the bladder, and also just before the bowels act. We fully agree with this excellent practice. It certainly serves two desirable purposes--first, it keeps the stricture well dilated; and secondly, while the catheterization is persevered with, further extension of the lateral burrowing of the fistula does not take place.

The above quoted author, in addition to the catheterization, employed the galvanic cautery with success. We have never applied the cautery in these cases.

Several forms of plastic operation have been suggested for the cure of recto-urethral fistula, all of which are said to have been successful in certain cases. For a full resumé of these operations we refer the reader to MM. Quénu and Hartmann's work.†

The method of treatment which we have found to be successful is as follows:—First of all, the urethral stricture is dilated up to the diameter of the meatus. This dilatation should be gradual. As soon as the state of the stricture permits, all the urine should be regularly drawn off by a catheter. This procedure, if adequately carried out, should

\* Diseases of the urinary organs, 4th Ed., 1876, p. 147.

† Op. cit., pp. 240-242.



prevent any urine passing through the fistulous track. The bladder should be washed out every night and morning with a weak solution of Condy's fluid, in order to diminish the cystitis and the consequent frequency of micturition.

#### *Operation.*

When the full dilatation of the stricture and the relief of the cystitis have been attained, the track of the fistula should be injected with 20—30 minims of a saturated solution of nitrate of silver. This injection should be made through the opening in the perineum, when one exists (it was present in all our cases), or through the rectal aperture when no perineal opening is present. When the injection is made through the rectal aperture, a bi-valve speculum should be introduced into the rectum in order to facilitate the procedure. Before the injection is made, a silver catheter should be passed into the bladder so that the urethral opening may be stretched, and any of the solution that has escaped into the urethra may be partially or completely decomposed by contact with the instrument. When a perineal opening is present, it should be freely enlarged, after the injection, by a crucial or a T-shaped incision, so that a funnel-like wound, leading down to the rectal and the urethral orifices, may be established. The wound is then packed with dry cotton wool, and the catheter withdrawn after the bladder has been emptied. A vulcanite rectal tube (three inches long and half-an-inch in diameter) is finally introduced into the rectum, in order that flatus may readily escape.

#### *After Treatment.*

The after treatment consists in keeping the patient under the influence of opium for the first twenty-four hours. During that period urine should not be passed nor a catheter used. At the expiration of that time, a soft rubber catheter (No. 7 or 8) should be introduced to empty the bladder. The rectal



tube should now be withdrawn. In order to prevent the necessity for emptying the bladder during the first twenty-four hours, only a very small quantity of fluid, say ten ounces, should be given until that period has expired. During the remainder of the after treatment, all the urine should be drawn off at four-hourly intervals or more often if necessary. The bladder should be washed out, at least once in every twenty-four hours, with a weak solution of Condy's fluid. The patient should be directed to use a sitz-bath every night and morning (from 15 to 20 minutes in duration), and at other times hot boracic fomentations should be kept constantly applied to the wound. The packing in the wound should be allowed to come away spontaneously and need not be renewed. As soon as the packing has come away (it usually does so in three or four days), the wound should be carefully wiped out, at least once in twenty-four hours, with cotton wool soaked in corrosive sublimate solution (1—500). It is most important that the rectum should not be over distended until the fistula has completely healed. The distension by flatus can be effectively avoided by the use of the rectal tube during the day time. The fæces can be kept soft and broken up by the injection into the rectum of one ounce of olive oil every night at bed time. The oil should be retained all night if possible. While it is retained the vulcanite tube should not be used.

*Comparison of the advantages in the use of the saturated solution of nitrate of silver and the cautery.*

We think that the saturated solution of nitrate of silver possesses great advantages over the actual cautery for destroying sinus-tissue, as it destroys the whole thickness of the wall of the main sinus together with that of its lateral burrowing. The vitality of the fibrous tissue of the sinus is so low that it is unable to resist the destructive power of this caustic. The healthy tissue surrounding the fibrous wall is, however, able



to resist the action of the nitrate of silver, and consequently destruction is limited to the sinus-tissue. This point, we think, is borne out by the fact that we have never observed any undue contraction to follow the application. Another advantage which a liquid caustic has over the cautery is that it can penetrate every branch or pocket of the sinus. The actual cautery, however, destroys all the tissue, either diseased or healthy, with which it is brought into contact, the depth of the destruction depending directly upon the duration of the contact and the temperature of the cautery. In this way, much more tissue-necrosis than is necessary may result at the point of contact, while other parts of the main sinus, as well as the lateral burrowing, may entirely escape cauterisation. Accordingly, we think that the cautery is doubly defective—first, it is difficult to destroy the sinus-tissue of the whole fistula by its means; secondly, the destruction may be so great, where contact has been made, that unnecessary contraction may be, and often is, produced.

#### *RECTO-VESICAL FISTULA.*

A communication between the urinary bladder and the rectum, though by no means of common occurrence, is much more frequently met with than the preceding form of fistula. The communication is generally situated in the region of the trigone of the bladder, that is to say, where the bladder and rectum are in relation with each other, and it is usually direct, the recto-vesical septum being merely perforated. This condition is usually the result of traumatism or of ulcerative processes. When it is the result of an abscess which has burst into both rectum and bladder, the intervening track may be long and sinuous and the two apertures may consequently be situated at different levels. When there is an intervening track, the rectal and vesical orifices are usually small and the condition of the rectum is very similar to that observed in the recto-urethral variety. When, however, the



communication is direct, the aperture in the rectum is usually large, because it is generally the result of either tuberculous ulceration or carcinoma.

### *Etiology.*

By far the greater number of recto-vesical fistulae are due to traumatism. Some years ago, when it was the practice to relieve a distended bladder by tapping through the rectum, catheterization being for some reason or another impracticable, a permanent communication between the rectum and bladder was by no means of uncommon occurrence, more especially if the canula had been left *in situ* for any length of time. An excellent example of this condition is to be found in the Museum of the Royal College of Surgeons of England (see specimen No. 3744).

Gun-shot wounds penetrating both viscera, and also perforation by fragments of bone in extensive fractures of the pelvis, may also establish a permanent communication between the rectum and bladder.

Of the non-traumatic causes, the most important are, pelvi-rectal abscess, tuberculous ulceration of the bladder, ulceration of the rectum, and carcinoma of either viscus, the infiltration in the last disease gradually extending through the recto-vesical septum and terminating in perforation. That simple ulceration of the rectum may cause a recto-vesical fistula, is shown by specimen No. 2589 in the above-mentioned Museum.

### *Symptoms.*

The symptoms directly due to a recto-vesical fistula depend, in great measure, upon the size of the openings. When these are small, all the symptoms closely resemble those of recto-urethral fistula and have been detailed under that head (see page 176). When, however, the openings are large and the communication is direct, the effects are much more pronounced. In these instances, urine is continually passing



into the rectum from the bladder, and, consequently, the rectum habitually contains urine, a circumstance which, in addition to being extremely discomforting to the patient, exerts a considerable irritating effect upon the rectal mucous membrane. More important than this, however, is the passage of flatus and fæces into the bladder. As a result, flatus is continually escaping through the urethra. The presence of fæces in the bladder sets up intense cystitis, causing much pain and frequency of micturition. When small masses of firm fæcal material pass through the urethra, symptoms are produced which very closely resemble the passage of a small calculus. As a consequence of the cystitis, suppuration in the kidneys sooner or later ensues and terminates the patient's life.

#### *Treatment.*

This also depends upon the size and cause of the rectal opening. When due to traumatism, even when the aperture is large, much can be accomplished by tying a catheter in the bladder and inserting a rectal tube, in order to prevent distension of the rectum by flatus. By this means, the opening either diminishes in size or closes altogether.

Should the above treatment fail, a plastic operation can be performed with some prospect of success. The method of procedure sometimes adopted is as follows:—

#### *Operation.*

The external sphincter is thoroughly stretched, and the anus is kept dilated by means of retractors or a suitable speculum. The margins of the aperture are then pared and deep sutures inserted, care being taken not to include the vesical mucous membrane. The sutures should be inserted about one-eighth of an inch apart, and the line of sutures should extend well beyond the angles of the wound. The suturing having been completed, a catheter should be passed into the bladder, and a rectal tube inserted into the rectum.



*After Treatment.*

The catheter should be gently withdrawn at the end of twenty-four hours and repassed, at short intervals, to guard against hyper-distension of the bladder. The use of the rectal tube should be persevered with for some time. The sutures may be removed at the end of five or six days.

In those cases in which the communication between the rectum and bladder is due to tuberculous disease, or to carcinoma, inguinal colotomy should be performed without delay.

*RECTO-VAGINAL FISTULA.*

This form of fistula consists of a communication between the rectum and the vagina. The fistulous track is either short and direct, when it is due to a loss of substance in the recto-vaginal septum; or it may be of some length and more or less tortuous in its course, when the fistula is the result of pre-existing suppuration. In the former variety, the rectal and vaginal orifices practically coincide with one another and can readily be made out, but, in the latter, the two orifices may be situated at different levels and, therefore, are not so readily discovered. When the fistula is due to an abscess which has ruptured into both passages, the vaginal orifice can be felt and it may be seen during an examination with the vaginal speculum; but the rectal orifice, on account of smaller calibre and the reduplication of the rectal mucous membrane, is far less easily discernible.

The position of the vaginal opening in the recto-vaginal septum depends upon the cause of the fistula *e.g.*:—When due to an imperfectly closed lacerated perineum, the orifice is usually situated about an inch from the introitus. When due to the prolonged pressure of the foetal head during the second stage of labour, the loss of substance in the recto-vaginal septum occurs within three inches from the fourchette. When due to stricture of the rectum or to a



pelvi-rectal abscess, the opening is situated at the upper extremity of the vagina slightly to either side of the middle line. Lastly, when the fistula is a sequel to ulceration of the rectum or to carcinoma of the vagina or rectum, the orifice is situated according to the seat of the disease in the recto-vaginal septum.

#### *Etiology.*

Sloughing of the recto-vaginal septum from pressure, ulceration of the rectum, carcinoma of the rectum or vagina, stricture of the rectum, suppuration in Douglas's pouch or in the pelvi-rectal space, and traumatism may all give rise to a recto-vaginal fistula.

#### *Symptoms.*

The chief symptoms are the escape of flatus or flatus and fæces through the vagina. In addition to these there is a constant sero-purulent discharge from the vagina which, together with the escape of the rectal contents, produces irritation and excoriation of the vulva.

#### *Treatment.*

The method of procedure in the treatment of this disease depends upon the cause and position of the fistula and the size of the openings.

(a) When the communication is direct and the orifices are not too large, such as when the fistula is due to an imperfectly closed ruptured perineum, it may be readily cured by the application of the solid nitrate of silver to the whole track.

(b) When the fistula is due to stricture of the rectum, the stricture should be gradually dilated to three-quarters of an inch in diameter, and a rectal tube worn as continuously as possible, in order that distension by flatus cannot occur. Under this treatment, the fistulous track will contract considerably, and may even close without any further treatment.

(c) When the perforation of the recto-vaginal septum is large, and is situated within two inches and a half of the anus



the operation which we have found to be successful in closing the aperture is as follows:—

*Operation.*

The external and the internal sphincters are gently stretched without tearing the mucous membrane, and a sponge or plug of cotton wool is inserted well above the seat of the fistula to prevent the descent of fæces during the operation. A bi-valve rectal speculum is then passed into the rectum and the margin of the aperture in the recto-vaginal septum is dissected away, the greatest care being exercised to remove as little tissue as is compatible with thorough vivification. This having been done, the whole rectal wall is then separated from that of the vagina for the space of a quarter of an inch round the circumference of the opening. This separation is easily effected by means of dissecting forceps and blunt pointed scissors. When this step in the operation has been completed, the aperture in the rectal wall is closed vertically by silk worm gut sutures inserted transversely. The sutures should pass through the entire thickness of the rectal wall at a distance of a quarter of an inch from the margin of the aperture, and should be three-sixteenths of an inch apart. The upper and lower angles of the wound should be further protected by a suture placed about a quarter of an inch beyond the aperture. When the sutures are tied, the margin of the wound will be inverted and a surface of a quarter of an inch in depth will be in apposition for firm union to take place. Before the margins of the wound are approximated, the whole area should be made as aseptic as possible by careful sponging. The rectal part of the operation now being completed the speculum and the plug in the rectum should be removed.

The closure of the vaginal portion of the fistula is now proceeded with. A duck-bill speculum having been introduced, the field of operation is carefully cleansed and sutures inserted



as in the rectal part of the operation, and, as soon as the wound is closed, the speculum should be removed.

A vulcanite rectal tube (three inches and a half long and half an inch in diameter) should be passed into the rectum and left there.

By this operation, the rectal and the vaginal orifices are closed separately and the margins of each are inverted for the space of a quarter of an inch. As a consequence, there is a broad surface of more than half an inch in extent upon which union can take place.

The subsequent treatment consists in confining the bowels for ninety-six hours and giving the patient a light nutritious diet. The rectal tube should be removed at the end of twenty-four hours for the purpose of being cleansed and then reinserted. The vagina should, at the same time, be gently irrigated with a solution of corrosive sublimate (1—2,000). After this, the rectal tube should be removed and cleansed once every day and discarded altogether on the third day. When the use of the rectal tube has been dispensed with, an ounce of olive oil should be injected into the rectum every night and morning for the purpose of softening the motions, and securing an easy action of the bowels. On, or about, the seventh day all the rectal sutures should be removed, but those in the vagina may be left for a fortnight unless they are causing irritation.

(*d*) When the fistula is the result of ulceration, involving the lower part of the rectum, an attempt should first be made to cure the ulceration, then the aperture, if situated low down, can be closed by suture.

(*e*) When perforation at the upper part of the recto-vaginal septum is due to ulceration of the rectum or to carcinoma, the treatment which affords the greatest relief to the patient's suffering is inguinal colotomy.



## CHAPTER VI.

# SINUS OVER THE SACRUM AND COCCYX.

As one of the results of suppuration in the neighbourhood of the rectum, a sinus is sometimes formed over or near the sacro-coccygeal articulation. In most of these cases there is, as a rule, no connection whatever with the rectum, but occasionally the burrowing may extend to the rectum and open there. An opening through the skin in the neighbourhood of the sacro-coccygeal articulation is always either present or indicated by a scar (see fig. 69.)

The literature on this subject is extremely limited.

Curling\* says:—"A fistula connected with a carious state of the ischium or coccyx is unfit for operation unless the surgeon can reach the diseased bone, and, if necessary, gouge it."

Solly,† in a clinical lecture, delivered in 1855, refers to a case of "fistula dependent on carious sacrum," and says he believes such cases are rare. His case, which had been in the hospital for a year, was relieved by a free incision over the sacrum.

That these cases are not so rare as the literature of the subject shows is, we think, proved by the fact that seventeen cases have come under our observation within a period of fourteen years.

\*Curling "On the Rectum," 4th edit., 1876, p. 107.      †"Lancet," 1855, vol. ii., p. 461.



*Characteristics.*

The disease consists of one or two external openings, a main sinus, and lateral burrowing.

*The external opening* closely resembles that of an ordinary ano-rectal fistula, and has been mistaken for it (see fig. 70).

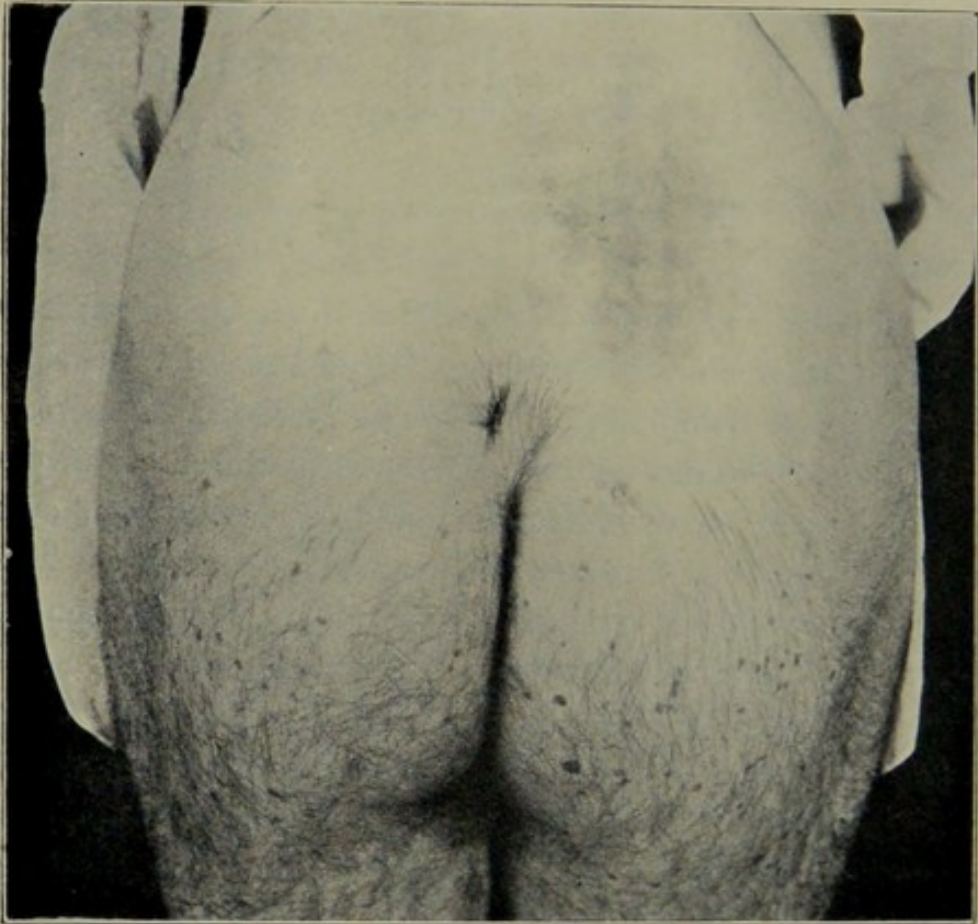


FIG. 69.—THE EXTERNAL APPEARANCE OF A TYPICAL CASE OF SINUS OVER THE SACRUM AND COCCYX.

Though in outward appearance the external opening often closely resembles that of an ano-rectal fistula, it will be observed that it is situated on a level with or higher than the base of the coccyx.

The usual seat of the primary opening is from half an inch to one inch to the left of the sacro-coccygeal articulation, though sometimes it may be exactly over it. In other cases, it may be situated quite an inch above the articulation (see fig. 69). The second opening, when present, is usually from one to two inches nearer the anus than the first opening (see fig. 77).



*The main sinus* passes both upwards and downwards from the external opening. It may extend upwards to the level of the posterior superior spine of the left ilium, and downwards

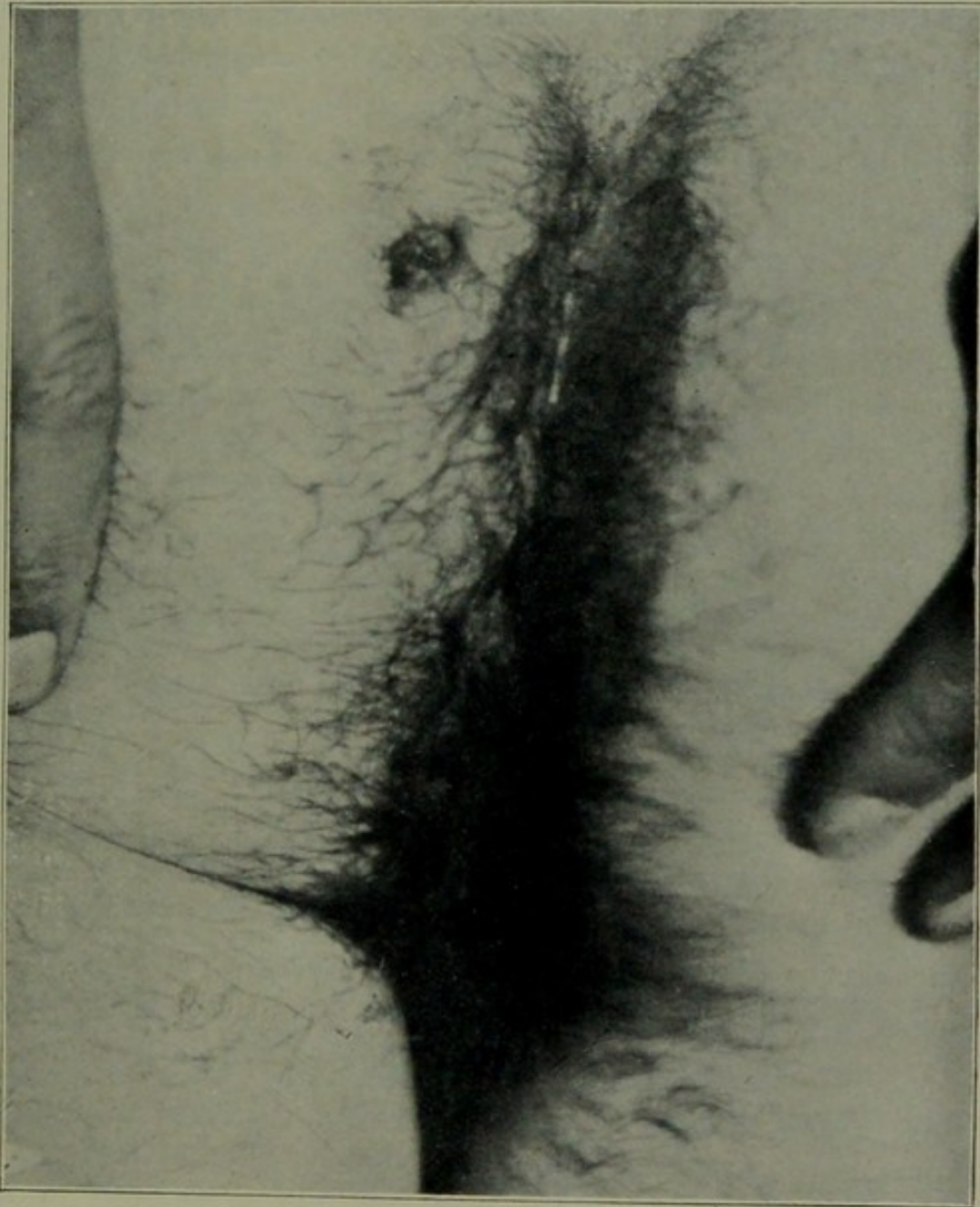


FIG. 70.—SHOWING AN EXTERNAL OPENING PLACED WELL TO THE LEFT OF THE SACRO-COCCYGEAL ARTICULATION.

[Photo taken March 12, 1893.]

as far as a point midway between the anus and the tip of the coccyx. From the main sinus, *lateral burrowing* usually takes place. The offshoots are generally about an inch in length,



and extend outwards, either transversely or obliquely, towards the buttock. They are chiefly, if not entirely, confined to the left side of the middle line (see figs. 71, 76 and 80). In only one case (see fig. 81) was there well-marked lateral burrowing on the right side. Occasionally, lateral burrowing may extend beneath the gluteus maximus as far as the greater sciatic notch, and pass through it into the pelvis, ultimately burrowing downwards, and pointing between the anus and the coccyx (see fig. 80). We believe this was the course the burrowing took in the case referred to by Mr. Solly. The main sinus is usually subcutaneous, except when it has extended into the ischio-rectal fossa. The lateral burrowing is subcutaneous except when it passes under the gluteus maximus. When the main sinus communicates with the rectum, it probably passes between the internal and external sphincters. A probe passed into the main sinus, or the lateral burrowings from it, is felt to grate against the dense ligamentous structures in this region. This grating sensation, we think, has given rise to the erroneous belief that bare or dead bone existed.

### *Etiology.*

There is nearly always a clear history of an injury to the part, such as a blow or a fall.\* This may have preceded the appearance of the abscess by many weeks, months, or even years, the part having been more or less stiff or tender from the date of the injury until the abscess had been opened or had broken of itself. In the majority of cases, the abscess appears to have been allowed to break spontaneously. The prevalent idea, that these cases are due to necrosis of the sacrum or the coccyx, has not been confirmed by our experience. All our cases have been cured without the removal of any dead bone, which, in fact, did not exist. In two of these cases, portions of bone had been removed by other surgeons

\* The receipt of an injury is recorded in eight of the ten cases of which the notes are given in this chapter.



with no good result, the disease having existed for five years in one, and three and a half years in the other. In a third case, the disease had existed for seven years, showing great persistency, although no dead bone existed. We have never seen a case of true necrosis of the sacro-coccygeal articulation in connection with this disease. The reason for the lateral burrowing being so frequently on the left side only, has never been elucidated.

*Age.*—So far as we have observed, this disease occurs during the third and fourth decades of life. We have not met with a case in a woman which began after the age of thirty years.

*Sex.*—In our seventeen cases, eight occurred in women and nine in men. It would appear, therefore, that sex does not influence the disease. At one time we thought the disease was more frequently met with in women than in men, but a wider experience has shown this conclusion was erroneous.

### *Symptoms.*

The early symptoms are similar to those of an abscess which has been allowed to break of its own accord. Closure of the orifice sometimes takes place, and, when it does, the abscess reappears and discharges again, either at the same or through a fresh opening. After several months the discharge becomes continuous, and then the part is often more or less painful and inflamed, and sometimes œdematous. Occasionally, the orifice will heal and remain closed for several weeks or months before the abscess reappears. While the abscess is quiescent, the part always feels stiff, and is tender when touched.

The temporary closure of the opening and the apparent disappearance of the sinus for comparatively long periods, are direct evidence against necrosis being the cause of the disease. The persistence of the feeling of stiffness, and the tenderness



to pressure in the neighbourhood of the sacro-coccygeal articulation, serve to show that the disease is then only quiescent and not completely cured.

### *Treatment.*

The only method of treatment, which we have found to be uniformly successful, is to freely lay open the main sinus from end to end, together with all the lateral offshoots (see fig. 71).

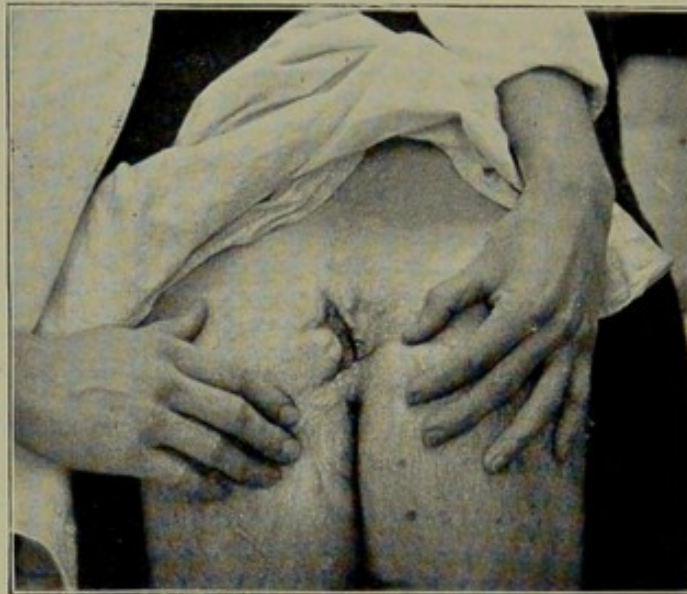


FIG. 71.—THE SAME CASE AS FIG. 69, SHOWING THE EXTENT OF THE LATERAL BURROWING.

[Photo taken about three weeks after the operation.]

In this case there were four lateral off-shoots all situated on the left side of the middle line.

Care should be taken that the incisions are carried well into healthy tissue beyond the extremities of the burrowing. The existence of any offshoots should be carefully sought for with the probe, because, should one be missed, the healing of the wound will be delayed, or partly arrested. After the main sinus and its lateral offshoots have been laid open, the resulting wound should be carefully irrigated with sublimate of mercury solution (1-500), and afterwards firmly packed with cotton wool wrung out of some of the same lotion. The packing should be allowed to come away spontaneously. Hot



boracic fomentations should be commenced on the morning following the operation, and continued at four-hourly intervals until the wound has healed. During the early part of the healing process, the wound should be carefully sponged, at least once in every twenty-four hours, in order to prevent bridging over by the granulations as well as to avoid irregular healing. There is no advantage in repacking the wound, but, where adjacent margins are inclined to come into contact, a small piece of cotton wool should be inserted between them. Should the surgeon operate and remove the part of the bone supposed to be bare or dead, leaving the main sinus and the lateral burrowings, if any, not laid open to their ends, the patient, so far as we have seen, will not get well (see Cases III. and V.), owing to the fact that the main sinus is not caused by necrosis, but by the anatomical structure of the part, which prevents the walls of the main sinus, or of any part of its lateral burrowing, from uniting permanently until all tension has been removed.

In order to fully illustrate this subject we append the notes of the more typical of our cases in detail, from which it will be seen that the patients were quickly cured by laying open the main sinuses and their lateral burrowings from end to end. The granulation tissue in the main sinuses and lateral burrowing was removed by scraping and sponging; the fibrous walls, in our later cases, were not removed, because we found this to be unnecessary. The wounds were filled with dry cotton-wool. No attempt was made in any of the cases, to find either dead or bare bone, nor was any to be seen or felt.

#### CASE I.

St. Mark's Hospital. E. A. W., æt. 25, married, pregnant. Family history good.

September 11, 1886.—Admitted as an in-patient. In 1879 an abscess about the size of a hen's egg formed close to the sacro-coccygeal articulation. It gathered for about three weeks, and then broke spontaneously. The patient did not know what caused the abscess. It quickly



disappeared and gave her no trouble until Easter, 1882. The abscess then re-formed and, after being poulticed for about a week, was broken by a blow from a fellow-servant. The abscess again quickly disappeared, and gave her no further trouble until February, 1886, when she was confined with her second child, and was then unable to lie on her back because of the aching pain over the lower part of the sacrum. From this date the part gradually became more and more painful, and at times it discharged. On July 29, 1886, she went to St. Mark's Hospital where the opening of the sinus was enlarged. On September 11, 1886, she was admitted into the hospital and, on the 13th the sinus, which extended from about two inches below the posterior

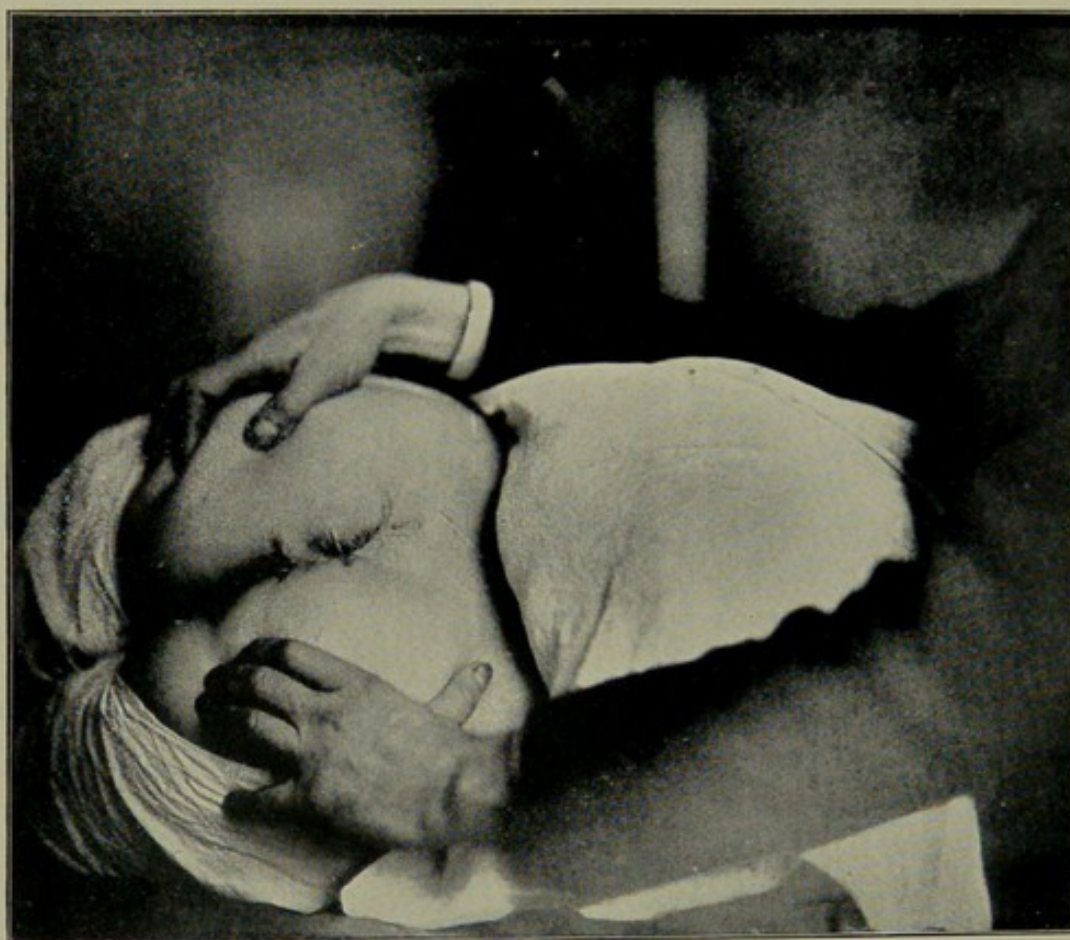

FIG. 72—SHOWING THE APPEARANCE OF THE SCAR TWO YEARS AFTER THE OPERATION IN CASE I.

[*Photograph taken 8th November, 1888.*]

It will be noticed that the lateral burrowing was limited to the left side.

superior spine of the left ilium to half an inch below the tip of the coccyx, was laid open from end to end. Four lateral pockets were also laid open. The granulations, lining the sinus, were removed, and the wound was then filled with dry cotton-wool. No dead or bare bone was either seen or felt during the operation.



On September 14 the wound was poulticed. This treatment was continued until the part had quite healed.

November 5, 1886.—Patient discharged cured.

October 26, 1888.—The part had kept perfectly well since she was discharged from the hospital. Her third child was born eight months after the operation.

November 8, 1888.—Wound remained soundly healed (see fig. 72).

## CASE II.

St. Mark's Hospital. C. H., æt, 20, shopwoman. Family history good.

August 23, 1887.—Admitted as an in-patient. In 1883 the lower part of the sacrum was injured by a fall off a stool. The part was stiff and painful for about a year, and then a swelling, about the size of a small marble, formed over the site of the injury. From this date the

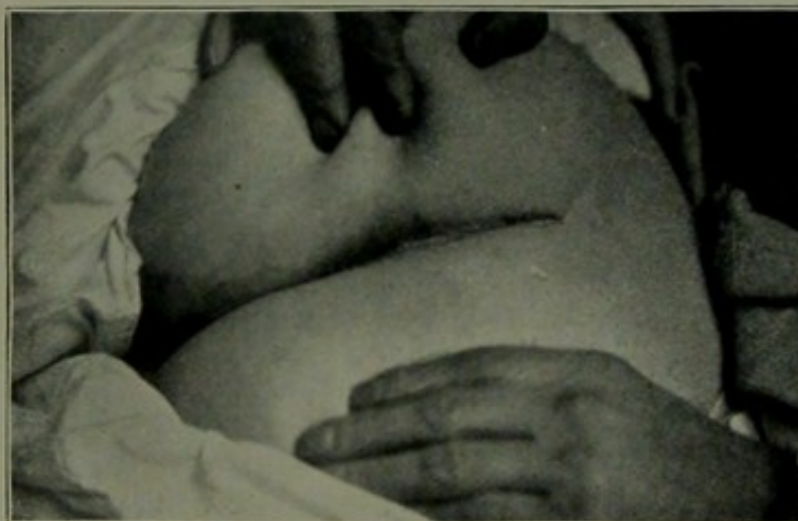


FIG. 73.—APPEARANCE OF THE SCAR FOURTEEN MONTHS AFTER THE OPERATION IN CASE II.

[Photo taken 8th November, 1887].

In this case there was not any lateral burrowing, consequently the scar is limited to the natal cleft.

part continued unchanged until April, 1886, when she was thrown from a cart and severely shaken. After this accident the part became more painful. On December 26, 1886, while skating, she fell backwards and again injured herself over the lower part of the sacrum. Three or four days after this fall, the medical attendant opened the swelling over the sacrum in two places, letting out about a teaspoonful of pus. The pain in the abscess was much increased by the fall on December 26. About January 10, 1887, she slipped downstairs, and again injured herself over the lower part of the sacrum. From this date until her admission into St. Mark's, August 23, 1887, the sinus was nearly always discharging. On August 25 the sinus was laid open from end to end. It



extended from about two or three inches from the posterior superior spine of the left ilium to a point about midway between the anus and the tip of the coccyx. A transverse incision was made on the left side of the sinus and about an inch on the sacral side of the sacro-coccygeal articulation. All the granulations in the sinus were removed, but not the fibrous wall. The wound was filled with dry cotton-wool. On September 17 (twenty-three days after the operation) she was made an out-patient. On December 1 the wound was healed, and a few days later she was married.

January 12, 1888.—The part of the scar over the coccyx had broken down for about an inch. On this date, and again on January 26, nitrate of silver was applied to the broken-down part of the scar. On February 26 the scar was again sound, and continued to keep so until July 12, when it broke down for about three-quarters of an inch over the coccyx; nitrate of silver was again applied. On July 19 the scar was once more sound.

November 8.—The scar had remained perfectly sound since June 19. Her first child was born at the end of last September. There was now neither stiffness nor tenderness over either the sacrum or the coccyx.

### CASE III.

St. Mark's Hospital. F. M., æt. 28, domestic servant. Family history good.

March 24, 1888.—Admitted as an in-patient. In 1882, when romping with a fellow-servant, she fell on a stone floor, injuring herself over the coccyx and the lower part of the sacrum. About eleven months after the fall, an abscess formed over the injured part, and broke spontaneously in about a month. Two months later she went into a hospital, where the surgeon enlarged the opening of the abscess. After being there for two months she was discharged, and told to come in again at the end of three months, when the diseased bone would be removed. The patient did not do so, but went into another hospital, where she was an in-patient for six months. While there, she was twice operated on, a piece of bone being removed at both operations. She then went to her home in Dorsetshire until May 25, 1885, when she was admitted into a third hospital. From the date of leaving the second hospital, the sinus had been constantly discharging. During the last four months, the middle third of the inner side of the right thigh had become swollen and painful. At this time, the sinus extended on the sacral side of the sacro-coccygeal articulation for about three inches from the opening.

June 20.—About three ounces of pus were removed, with an aspirator needle, from the abscess in the right thigh.

November 17.—The abscess in the right thigh was laid open by an incision about three inches in length. Several ounces of thick curdy pus were let out.



January 7, 1886.—Left the hospital at her own request, and returned to her home. The sinus over the sacrum and the coccyx, and the sinus in the right thigh were still discharging.

October 27.—The patient was re-admitted into the third hospital, the sinus over the coccyx still discharging continuously.

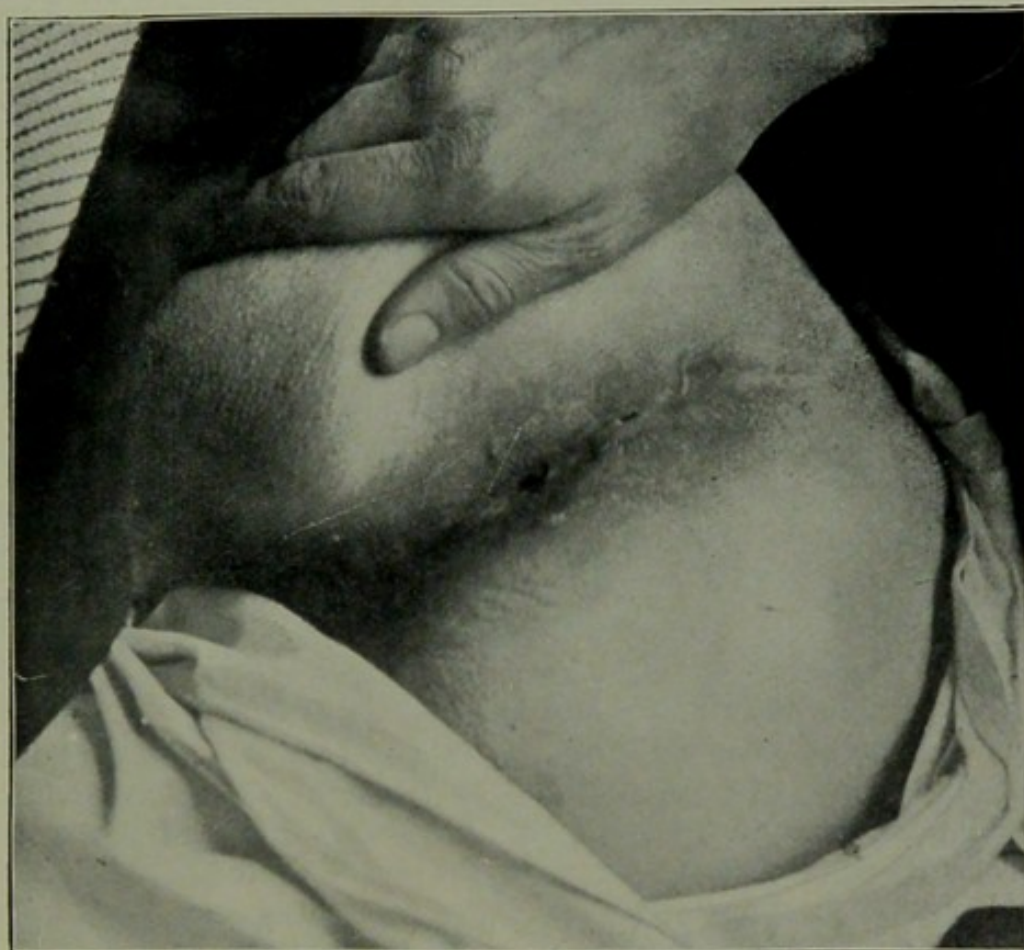


FIG. 74.—SHOWING THE POSITION OF THE SCAR IN CASE III.

[Photo taken April 4, 1891, i. e., three years after the operation at St. Mark's Hospital.]

It will be noticed that the greater part of the cicatrix is confined to the left side. At the upper extremity, however, it extends to the right side. The foramen-like spot in the scar is merely a depression, and not an external opening.

April 20, 1887 —The abscess cavity over the sacrum and the coccyx was laid open for about four inches in an upward direction. The coccyx was found depressed, and the upper part denuded of periosteum. All exposed pieces of bone were removed.

April 27.—Fæces were present in the wound.

July.—Wound healed, with exception of a small sinus leading into the rectum.

August 21.—Sinus leading into the rectum kept about the same.

The patient again returned to her home, and while there an abscess formed over the left hip, and broke spontaneously.



November 10.—The patient was re-admitted into the third hospital, and remained there for about five weeks. No active treatment was adopted on this occasion.\*

She again returned to her home, and remained there till March 24, 1888, when she was admitted into St. Mark's Hospital with a sinus over the sacrum and coccyx, which had been discharging continuously for the previous five years. Leading from the opening of the sinus, which was situated close to the left side of the sacro-coccygeal articulation, there was a direct communication with the left dorsal side of the rectum about two and a half inches above its lower end. The orifice in the rectum was about a quarter of an inch in diameter, with a well-defined margin. This fistula allowed a large quantity of motion to escape externally. The sinus extended on the coccygeal side of the sacro-coccygeal articulation to about a quarter of an inch beyond the tip of the coccyx, and on the sacral side of that articulation for about two inches in the direction of the posterior superior spine of the left ilium. As the passage of fæces through the fistula caused intense pain, it was decided to lay open the fistula as well as the burrowings of the sinus. This was done on March 26. Neither dead nor bare bone was seen or felt during the operation. On May 14 (seven weeks after the operation) the patient was discharged, with the fistula and sinus soundly healed, but with complete loss of control over the contents of the rectum.

September 15.—The patient was re-admitted into St. Mark's, the sinus and fistula continuing soundly healed, but she had very little increase in her power of control over the contents of the rectum. On September 28, about one-third of the anal orifice of the rectum was closed by an operation similar to that for lacerated perineum. On October 23, the patient was discharged with the power of control much increased, although still far from being perfect.

The patient died of bronchitis on December 6, 1897. There had been no return of the sinus.

#### CASE IV.

St. Mark's Hospital. M. P., æt. 26, housemaid. Her mother died of phthisis.

May 5, 1888.—Admitted as an in-patient. In 1879, she fell and cut herself near the sacro-coccygeal articulation. The wound quickly healed, but the scar was always tender. In 1885, an abscess formed close to the scar and, after gathering for a month, broke of itself, and discharged constantly until she was admitted into St. Mark's Hospital on May 5, 1888.

On May 10, the sinus was laid open from end to end, as well as

\* We are indebted to the House-Surgeon of the third hospital for the notes of this case, made between May 25, 1885, and November 10, 1887.



a short lateral burrowing on the left side of it. The granulations were removed. The wound was filled with dry cotton-wool. No dead or bare bone was to be seen or felt during the operation. On

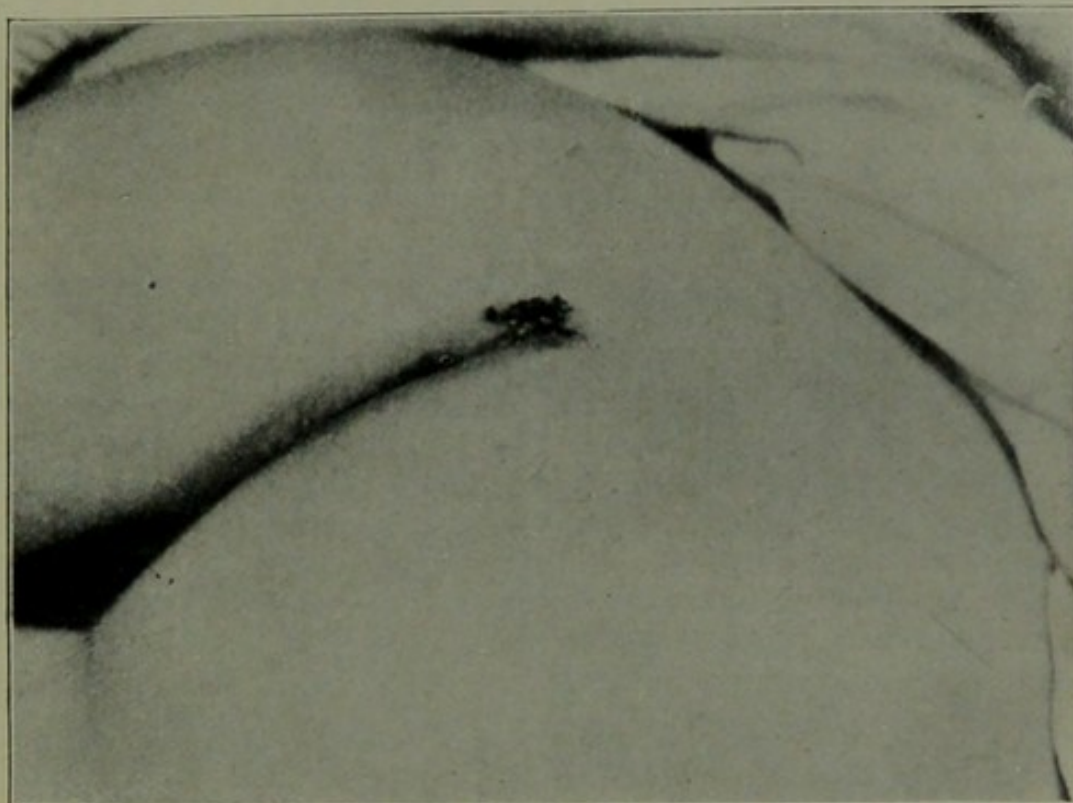


FIG. 75.—SHOWING THE APPEARANCE OF THE EXTERNAL OPENING IN CASE IV.

[Photo taken immediately before the operation.]

The external opening is confined to the left side. The granulations are more exuberant round the orifice than in an ano-rectal fistula. This exuberance of the granulations and the great length of time that the disease had existed might have led to the assumption that carious bone existed.

May 27, the wound was soundly healed. On June 2, the patient was discharged. After the operation the wound was constantly poulticed from day to day until it had healed.

#### CASE V.

St. Mark's Hospital. E. L., æt. 23, servant. Family history good.

In 1884 she fell down the coal-cellar stairs, striking herself near the sacro-coccygeal articulation against a wooden box. She was able to get up the stairs without assistance, and went on with her work. Subsequently the part struck was always tender. About five months after the fall, a small swelling formed over the injured part, and, two months later, began to discharge. The patient was then admitted into a hospital where she remained about four weeks. While there the abscess closed. No other treatment than rest and poulticing was



followed there. Two or three days after she had left that hospital a second opening formed, about one to one and a-half inches nearer the anus than the first and this had always discharged more or less freely. In December, 1887, the patient was admitted into a second hospital, where the sinus on the coccygeal side of the second opening was laid open. She remained in that hospital for six weeks. On her discharge the part of the sinus which had been laid open had healed. The remainder of the sinus on the sacral side of the second opening was still discharging.

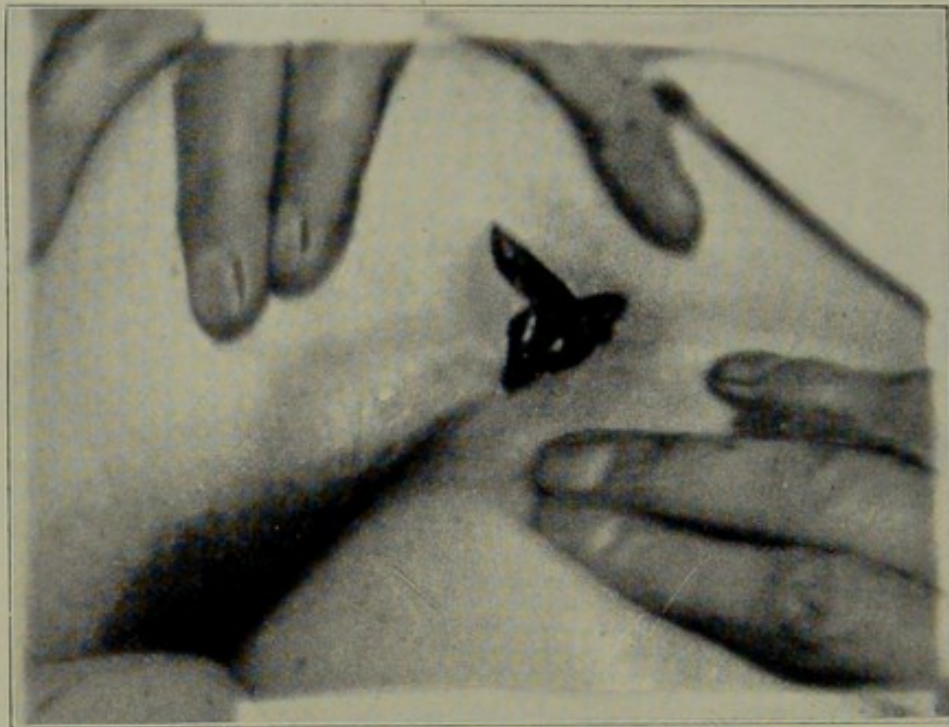

FIG. 76.—SHOWING THE APPEARANCE OF THE WOUND IN CASE IV.  
IMMEDIATELY AFTER THE OPERATION.

In this case the lateral burrowing is shown to be entirely confined to the left side.

September 3, 1888.—The patient was admitted into St. Mark's Hospital with a sinus over the left side of the sacro coccygeal articulation. The first opening was about three-quarters of an inch on the sacral side of the sacro-coccygeal articulation; the second being about an inch on the coccygeal side of that articulation. The sinus extended for about half an inch on the sacral side of the first opening and to the left of the middle line. The greater part of the coccyx had been removed.

September 7.—The remainder of the main sinus and the lateral burrowing on the left side of it, were laid open from end to end. The granulations were removed, and the wound filled with dry cotton-wool. Neither dead nor bare bone was seen or felt during the operation.



September 22.—Discharged as an in-patient, the greater part of the wound having healed.

November 8.—Wound healed.

June 7, 1893.—The part remained soundly healed until December, 1891, when the patient slipped on the frozen pathway and fell, striking the coccygeal region against a step. For two days after this accident she was unable to walk because of the pain in the injured part, which, however, gradually disappeared. On May 28, 1893, an abscess formed and broke spontaneously in two or three days and was still discharging.

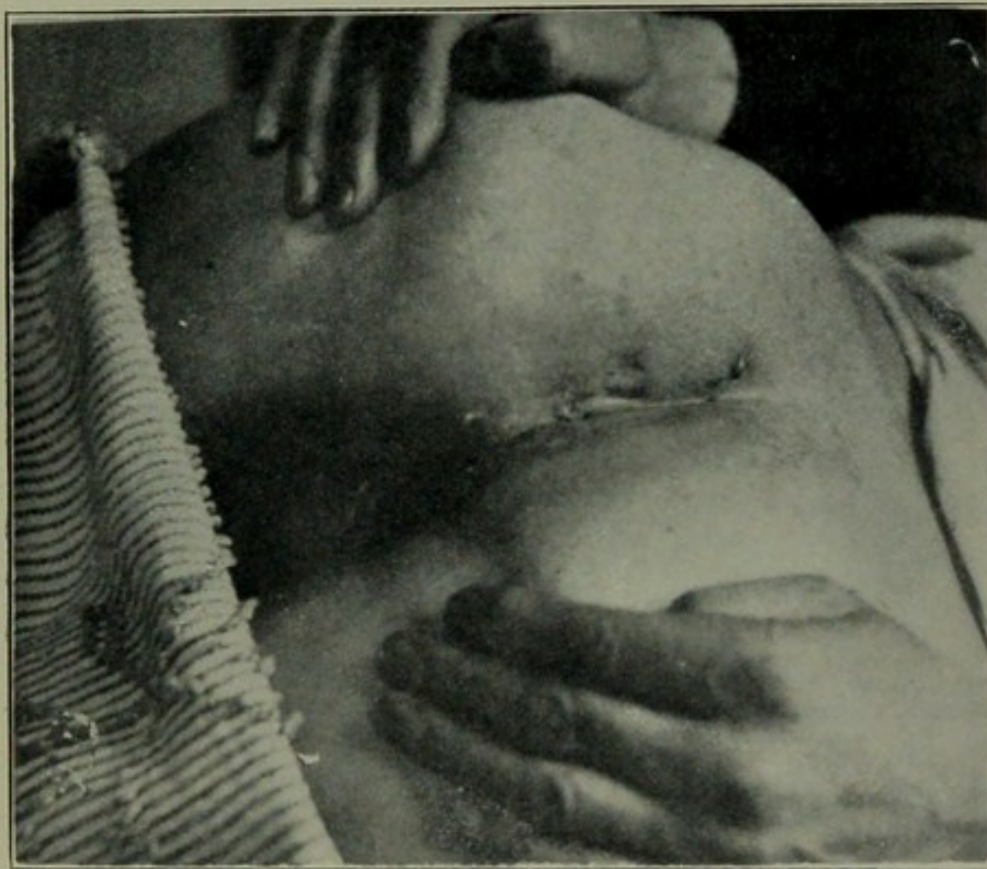


FIG. 77.—SHOWING THE TWO EXTERNAL OPENINGS IN CASE V., BOTH OF WHICH WERE ON THE LEFT SIDE.

[Photo taken before the operation.]

It may be noticed that one of the two openings is situated below the level of the tip of the coccyx. This is the secondary opening, the primary being to the left side of the sacro-coccygeal articulation.

The opening was enlarged with a crucial incision.

March 7, 1894.—The part was still discharging. It sometimes remained healed for a month or two and then broke down again.

April 18.—The sinus was laid open completely, the three wounds being on the left side of the middle line.

July 18.—Part soundly healed.



September 19.—Part soundly healed, scars freely movable.

August 28, 1900.—The part had remained soundly healed since September 19, 1894.

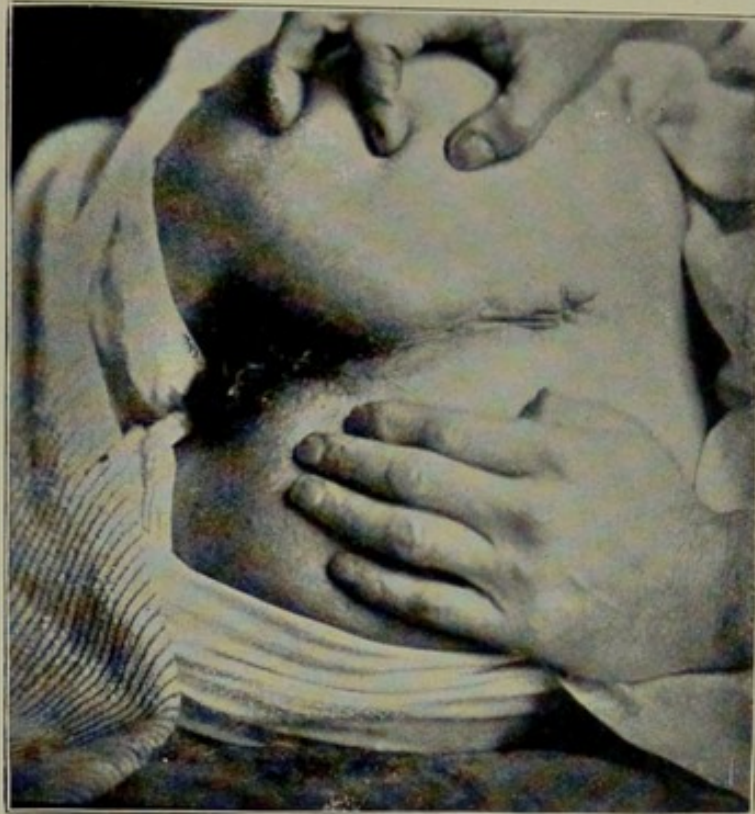

FIG. 78.—SHOWING THE SCAR IN CASE V.

The scar in this case shows that the burrowing extended slightly to the right side, but the greater part of it was confined to the left.

[Photo taken November 8, 1888, i.e., two months after the operation.]

#### CASE VI.

St. Mark's Hospital. W. T., æt. 37, baker.

September 14, 1888.—Admitted as an in-patient. In April, 1887, his horse suddenly bolted, and he was thrown back, "striking the end of his backbone against the box of his cart." For a short time the fall rendered him insensible, but two or three weeks after he felt no discomfort from the accident.

Early in April, 1888, an attack of rheumatic fever came on, and he was laid up by it for several weeks.

About July 10 an abscess began to form over the sacrum and coccyx, which, after gathering for about five weeks, was lanced and about a pint of pus let out. The abscess had discharged continuously since then. Since April, 1888, he had lost considerably in weight,

On admission into the hospital the opening of the abscess or sinus was about three-quarters of an inch on the left side, and from three-



quarters to one inch on the sacral side of the sacro-coccygeal articulation. The opening was about three-sixteenths of an inch in diameter. A probe could be easily passed for two and a-half inches downwards, two inches upwards, and from three and a-half to four inches towards the posterior superior spine of the left ilium. On the left side of the posterior part of the ischio-rectal fossa, the tissues were hard, though neither red nor tender on pressure. The tissues over the sacrum were swollen, especially on its left side, but not tender on moderate pressure, and the skin was of normal colour. No pus escaped from the rectum. The discharge from the opening over the sacrum was very profuse.

September 17.—The burrowing of the sinus over the sacrum was laid open, the incision on the left side extending as far outwards as the sacro-sciatic notch.

All the granulation tissue was removed from the parts of the sinus laid open, and several of the tendinous points of origin of the gluteus maximus were broken down.

A counter-opening was also made in the induration on the left side of the ischio-rectal fossa, midway between the anus and the coccyx. A probe could be passed through this opening for upwards of three inches in the direction of the left sacro-sciatic notch (see fig. 79).

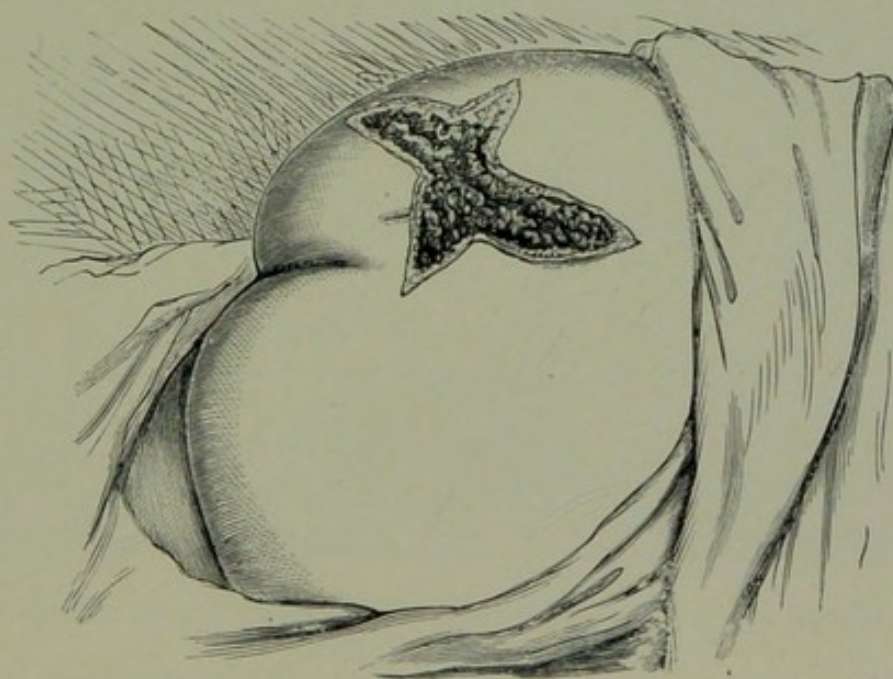


FIG. 79. — SHOWING THE EXTENT OF THE WOUND IN CASE VI. AFTER THE BURROWING UNDER THE GLUTEUS MAXIMUS HAD BEEN LAID OPEN. ;

[Woodcut made from the photograph taken after the operation.]

The incision was made through the whole thickness of the gluteus maximus. The resulting hæmorrhage, though free, was readily controlled.

November 8, 1888.—The patient was discharged as an in-patient, and advised to go to his home at Ipswich for two or three months, to



see whether the remainder of the sinus between the sacro-sciatic foramen and the counter-opening, made on September 17, would not close. The whole of the wound made over the posterior surface of the sacrum had healed, excepting the outer part of the incision over the posterior surface of the left sacro-sciatic notch. The quantity of discharge from this part of the wound and from the counter opening was very small, and was slowly diminishing.

The patient, about a year later, reported that the wounds were healed and that he had gained forty pounds in weight since the operation.

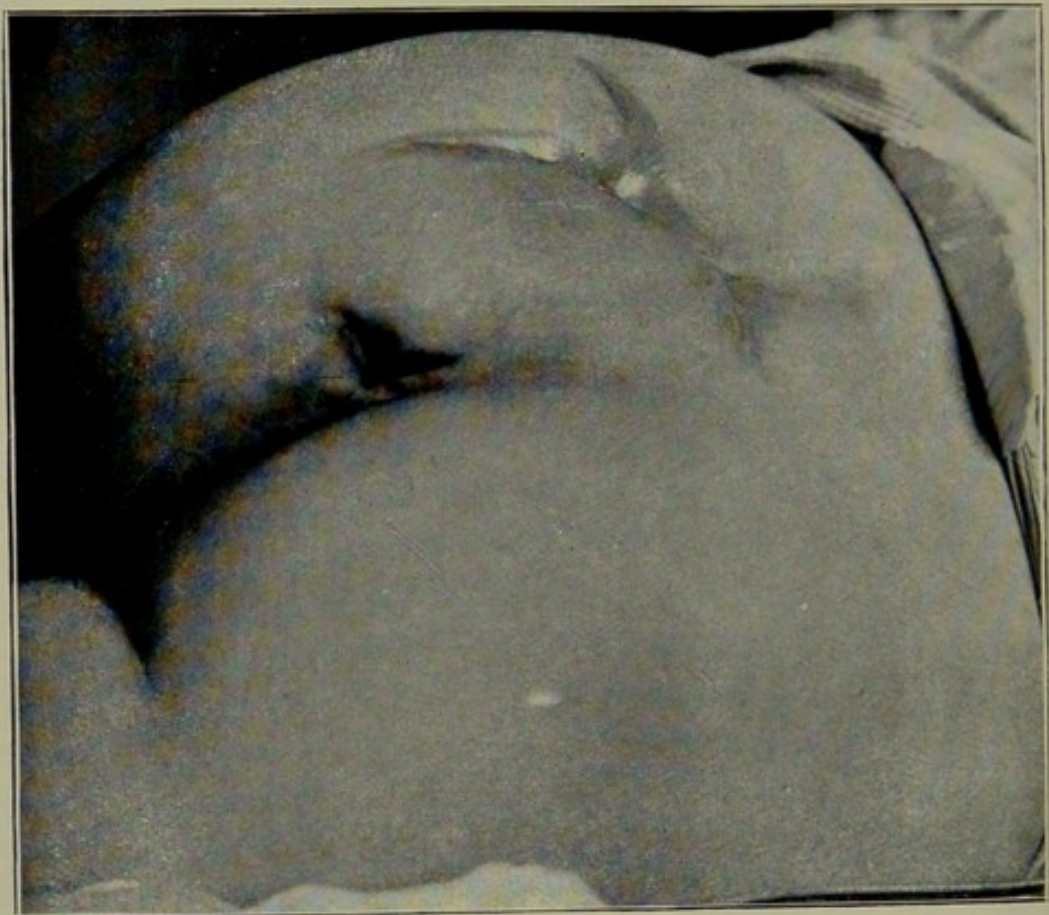


FIG. 80.—THE SAME PATIENT AS IN FIG. 79 SHOWING THE WOUND ALMOST COMPLETELY HEALED.

*[Photo taken fifty-two days after the operation.]*

The position of the external opening made into the ischio-rectal part of the burrowing is clearly shown.

#### CASE VII.

A. K., æt. 52, domestic servant. Family history good.

May 14, 1895.—When fifteen years old she fell backwards and struck the lower part of her back against a chair. The accident did not incapacitate her for work, but the injured region was painful for a



time and had been tender to pressure ever since the accident. In 1885, *i. e.* twenty-seven years after the receipt of the injury, an abscess appeared to the left of the sacro-coccygeal articulation and was opened. The wound closed in a fortnight, and remained healed until five years ago, when the abscess reappeared and discharged intermittently during the succeeding five years. It then healed for a time. In February, 1895, the abscess again reappeared, broke spontaneously and has continuously discharged since then.

On examination, an external opening was found three-quarters of an inch to the left of the sacro-coccygeal articulation. The main sinus was an inch and a half long, extending one inch to the left and half an inch to the right of the middle line.

May 21, 1895.—The sinus was laid open from end to end and the wound packed with dry cotton wool.

June 21, 1900.—The part had remained well since the wound healed from the operation on May 21, 1895.

#### CASE VIII.

X. X, *æt.* 32, Surgeon R.N. Family history very good.

July 1, 1895.—Early in April, 1895, when on board a gunboat, he received repeated contusions whilst endeavouring to keep his seat during a storm. On April 19 an abscess, which appeared five days previously over the sacro-coccygeal articulation, was incised and about an ounce of pus let out. During the formation of the abscess, he had no difficulty with micturition. At a hospital at the Cape of Good Hope a drainage tube was inserted, and three weeks later the abscess had healed. A week later the abscess reformed, and had discharged continuously since then.

On examination an external opening was found over the sacro-coccygeal articulation, from which a main sinus extended, on the left side of the middle line, towards the anus for a distance of one inch and a quarter.

July 2.—The main sinus was laid open from end to end, together with a lateral offshoot, half an inch in length, extending towards the left buttock. No vessels were ligatured. The wound was packed with dry cotton wool, and a pad applied.

July 15.—The Patient went to Margate, the wound having almost healed.

December 7.—A letter was received from him stating that he had returned to his duty and was quite well.

September 21, 1900.—Was still doing his duty and reported to be quite well.

#### CASE IX.

St. Mark's Hospital. M. A, *æt.* 22, domestic servant. Family history bad.



June 17, 1893.—Admitted as an in-patient. In July, 1891, she slipped down a flight of twelve stone steps, striking the sacro coccygeal region. The pain in the part was very severe, and she fainted, being unable to return to work for several hours. The pain continued, and a week after the accident an abscess had formed at the injured part and had broken spontaneously. As the abscess did not heal, it was lanced four weeks after the date of the injury. It had never healed or closed up temporarily. The quantity of discharge had varied from time to time

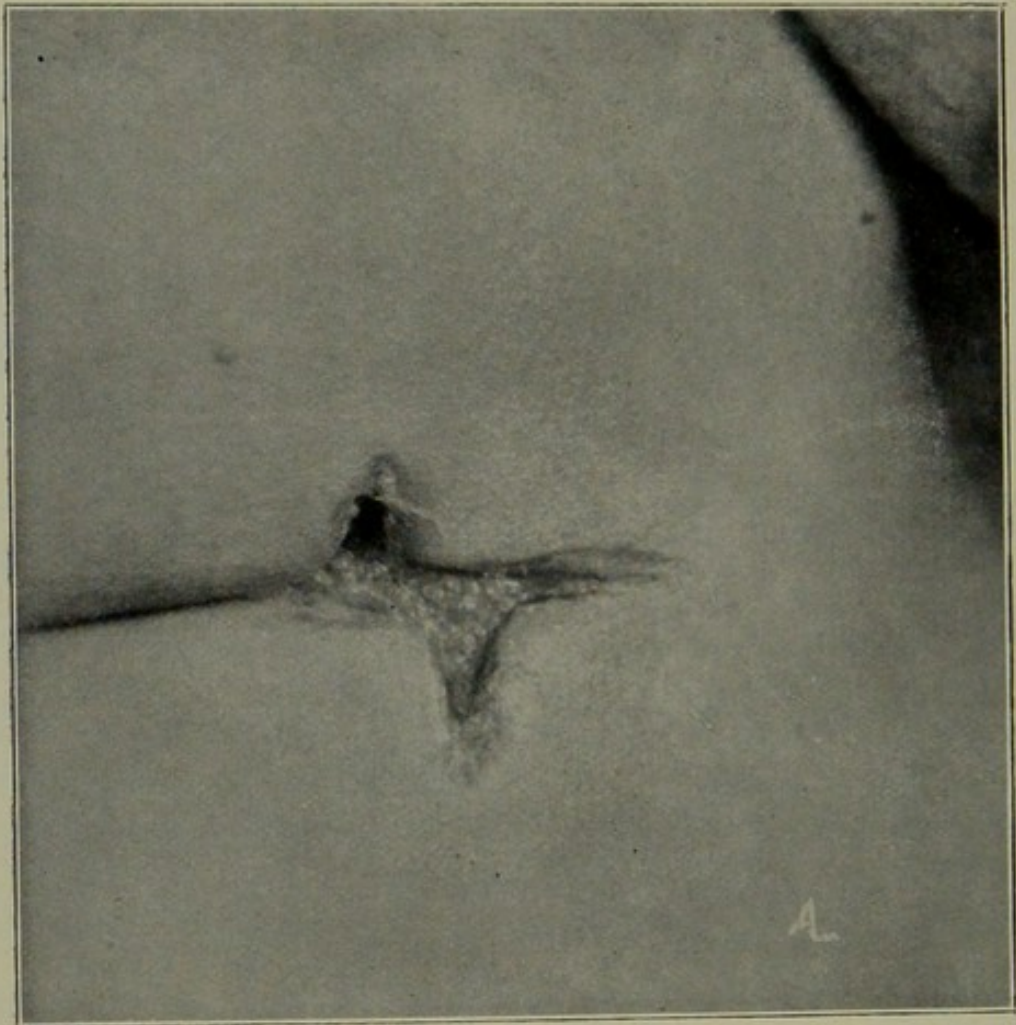


FIG. 81.—SHOWING THE BI-LATERAL BURROWING IN CASE IX.

This is the only case we have seen showing well marked lateral burrowing on the right side.

[Photo taken July 7, 1893, i.e. 18 days after the operation.]

On examination, an external opening was found over the sacro-coccygeal articulation. From this opening, the main sinus passed directly upwards for two inches and a-half, and downwards for one



inch. There was lateral burrowing on both the right and the left side of the main sinus for about three-quarters of an inch.

June 19.—The main sinus and the lateral burrowings were completely laid open, and the wound was subsequently packed with cotton-wool.

June 26.—The wound was granulating steadily.

July 16.—The wound almost healed. Patient discharged from the wards.

#### CASE X.

Metropolitan Hospital. C. T., æt. 23, clerk. Family history good.

March 11, 1894. Fifteen months ago, an abscess appeared on the left side of the sacro-coccygeal articulation and broke spontaneously. Since that time, the abscess had healed and broken down on four occasions. Primarily it took the form of a boil. No history of an injury could be obtained.

On examination, an external opening was found on the left side of the sacro-coccygeal articulation (see fig. 70). Lateral burrowing extended from the main sinus on the left side only (see fig. 71).

March 14, 1894.—The main sinus together with all the lateral burrowing was laid open, and the resulting wound packed with dry cotton wool.

April 5, 1894.—The patient left the hospital, the wound having almost healed.

July 16, 1894.—The wound was soundly healed.

June 24, 1895.—The scar remained sound and was freely movable.

October 5, 1900.—The part had remained soundly healed since July 16, 1894.



## CHAPTER VII.

### ANAL FISSURE.

By the term *fissure* we should understand the lesion to consist of a small ulcer situated at the verge of the anus. For this reason the prefix *anal* should be used to distinguish this particular ulcer from one situated in the rectum itself, *the rectal ulcer*. This distinction is reasonable when we recognise the fact that an anal ulcer or fissure, coming as it does almost entirely within the sphere of influence of the external sphincter, is a most distressingly painful affection, whereas the purely rectal ulcer, situated above the region of both external and internal sphincters, is often attended with but little pain, and at times with none at all.

In the majority of cases a single fissure exists, but occasionally two or even three may be present in the same patient. Of the 221 examples of fissure which occurred among hospital patients, a single lesion existed in 208; in 12, there were two fissures; and only in 1 (a female) were three present.

In connection with the subject of fissure, the conclusions that we shall endeavour to draw, are based upon the actual observance, and clinical records of 221 examples of the disease which occurred in Mr. Goodsall's practice at St. Mark's Hospital, together with 108 cases collected from his private case books.



Of the 221 hospital cases, 132 were males and 89 were females; whilst of the private cases, 58 were males, and 50 females.

The total number of cases then was 329, of which 190 were males and 139 females.

### *Description.*

A typical anal fissure may be described as a small, more or less superficial ulcer, situated just within the verge of the anus at the bottom of one of the rugæ into which the anal orifice is thrown by the contraction of the external sphincter. The ulcer is, as a rule, pear-shaped or triangular in form and extends upwards in the longitudinal axis of the anal canal to a distance varying from three-eighths to seven-eighths of an inch in length. The narrowest part or apex of the ulcer is usually situated over the lower border of the internal sphincter, while its base usually reaches downwards as far as the lower margin of the external sphincter. This position of the ulcer is the most common, but the ulcer may be located entirely within the inner surface of the external sphincter. The usual breadth of an anal fissure when its sides have been separated, is from a quarter to half an inch at the broadest part. In the more common form, the lower part is situated in the skin of the anus and the upper part in the mucous membrane (see fig. 82). The ulcer varies in depth in different instances; in some, the floor consists of the partially torn through mucous membrane, and, in others, it consists of the submucous and subcutaneous connective tissue through which the muscular fibres of the external sphincter can be seen. In yet another variety, especially those of long standing, the pale fibres of the external sphincter muscle are exposed and form the floor of the fissure. These fibres may be observed to cross at right angles to its long axis. The margin of the fissure is well defined and regular in outline. Owing to the contraction of the external sphincter,



the lateral borders overlap the floor of the fissure, so that its full width cannot be seen unless they are first drawn apart. At the lower border of the fissure, or on one side of it, there is sometimes a small fold of skin, the *sentinel pile* of some authors, varying in length from less than an eighth to three-quarters of an inch, and in breadth from less than an eighth to half an inch. To this fold of skin we shall again refer.

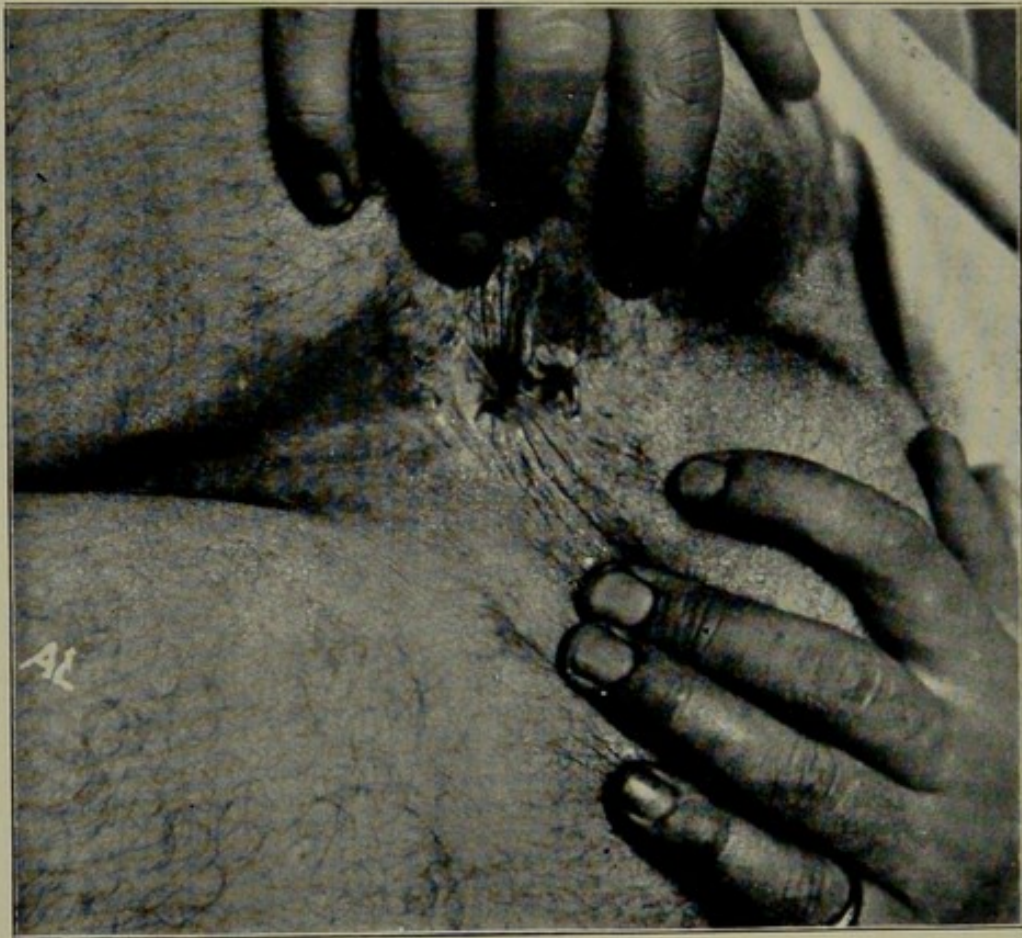

FIG. 82.—SHOWING A TYPICAL FISSURE.

It will be seen that the lower end of the fissure extends well into the skin of the anal margin, and that the perianal skin is corrugated

The most characteristic feature of a fissure, however, is its extreme sensitiveness, the merest touch causing intense suffering and invoking spasmodic contraction of the sphincters and levatores ani. The exact location of the sensitive spot varies in different cases. In some, the floor of the ulcer is its seat,



a circumstance that is attributable to the mucous membrane and skin of the anus being but partially torn through, thereby exposing the delicate nerve terminations which abound in this situation (see page 36). In those instances in which the fibres of the external sphincter are exposed to view, the floor itself is insensitive or nearly so, while the edges of the ulcer contain the sensitive nerve-endings.

### *Position of a Fissure.*

A fissure may be located at any point in the circumference of the anal orifice, but in the great majority of the cases, the lesion will be found on the posterior margin of the anus, and to the immediate right or left of the middle line. The next most common situation is slightly to the right or left of the middle line anteriorly. It is interesting to note that whereas the posterior position occurs with almost equal frequency in both males and females, the anterior position is more often met with in women than in the opposite sex. In this connexion an analysis of our cases gives the following results—of 89 cases of fissure in females the lesion was found to be placed near the middle line posteriorly in 58, in the middle line anteriorly in 12, in the left posterior quadrant in 4, and in the right posterior quadrant in 3. In 4 cases there was a fissure located in the middle line posteriorly, and another in the middle line anteriorly; in 2 cases there was a fissure in the middle line anteriorly with a second in the left posterior quadrant; in 1 case a fissure was situated in the right posterior quadrant with another in the left anterior quadrant, while in only a single instance were there three lesions, one in the middle line posteriorly, another in the middle line anteriorly, and a third on the right side midway between the others. In the remaining four cases the position was not recorded. Of 132 cases of fissure in male subjects, the posterior position was observed in 109, the middle line anteriorly in 1,



the left posterior quadrant in 6, the right posterior quadrant in 3, the left side in 1. In 4 instances a fissure in the middle line posteriorly accompanied one in the middle line anteriorly; in 1 a fissure in the middle line anteriorly was coexistent with another in the left posterior quadrant, and in the 7 remaining cases the locality of the fissure was not recorded. The above statistics strikingly illustrate the fact that, whereas in males the middle line anteriorly was the seat of fissure in less than one per centum of the cases, the lesion was found there in more than eight per centum in females. A possible explanation of this may be found in the fact that the anal mucous membrane may be over-stretched, and so rendered susceptible to fissure during parturition. The question may be asked—Why should there be such a preponderance of the posterior position of fissure? It is, perhaps, not an easy matter to give a satisfactory answer. It may be that the posterior margin of the anus being more fixed by its attachment to the ano-coccygeal ligament, is therefore unyielding, and more likely to be torn during the passage of a large and hard motion than other parts of its circumference. Or by reason of the backward direction of the lower segment of the rectum, a greater strain is thrown, during distension, upon the posterior margin of the anal ring. Neither of these hypotheses, however, accounts for the occasional presence of fissure in other situations. If, on the other hand, we accept Ball's theory that fissures are due to the tearing down of a valve of Morgagni, a ready explanation is at hand, which would at the same time account for the fact that a posterior fissure is very seldom situated exactly in the middle line, but rather to one or other side of it. If a reference be made to the anatomy of the lower part of the rectum (see page 24), it will be seen that in the middle line posteriorly there is no valve of Morgagni, but that a large one exists on either side of it, and as these are more developed than those in other situations, they may be more liable to be torn



down during the act of defæcation, especially when the fæces are hard, and are passed in large masses.

### *Etiology.*

Constipation may be regarded as the potential cause of fissure. Physiologically, the rectum is not meant to serve as a reservoir for the prolonged sojourn of fæcal matter, and yet how often is this condition met with, even in those whose bowels act regularly every day! The effect of such retention is that the fæces lose a considerable quantity of moisture by absorption and become hard. This dryness, or increased firmness, prevents the wall of the rectum and the sphincters from moulding the mass to the capacity of the outlet, and when it is voided, the delicate mucous membrane of the anal canal is over-stretched and frequently torn. When the mucous membrane is so torn, the repeated passage of similar masses prevents the tear from healing, or may even increase the rent, and a fissure is thus established. We have no doubt that the majority of fissures are caused in this way, but the question may well be asked—Why does not laceration take place in the majority of adults, who at some time or another void hardened masses of fæces?—To such a question we reply that other factors are operative, and contend that much depends upon the degree of dilatibility of the anal orifice and on structural changes in the skin and mucous membrane. In those who are but occasionally constipated, the natural condition of the parts is not necessarily disturbed, but with those who suffer from habitual constipation the case is different. A perfectly healthy anus is capable of being dilated to a considerable extent, and by that means can adapt itself to the size of the motion to be passed. But in an individual who has suffered from habitual constipation, and whose rectum, therefore, is always loaded, the sphincter muscles from over-exercise and excessive strain become hypertrophied and indurated, with the result that they do not readily



dilate and are apt to contract spasmodically during the passage of a motion. The skin of the anus becomes thickened from the irritation produced by small quantities of mucus being frequently expelled during the passage of flatus, and thereby loses its natural elasticity. This statement is confirmed by observation of the stools of constipated persons. The contents of the rectum are voided in pieces which are found to taper distinctly at one end, showing that such a piece has been nipped off from the main mass, by the spasmodic and premature contraction of the sphincters, during its passage through the anal canal. That such nipping off of pieces of motion from the mass in the rectum does take place, can be verified by making a digital examination of the rectum in constipated individuals immediately after an action of the bowels, when, in the majority of cases, the rectum will still be found to contain some faeces. In our opinion, it is this inability of the anal orifice to expand readily during the passage of a large and hardened motion, together with the liability of the indurated sphincters to contract spasmodically during its transit that cause laceration of the mucous membrane. Although we consider that this is the chief operative factor, it is possible also that the structural condition of the anal mucous membrane may have some influence. The continued presence of motion in the rectum, may to some extent, interfere with the secretion of the mucous glands, rendering the mucous membrane itself drier and less pliable. We might compare this condition of the anal mucous membrane to that of the lips, which are prone to become dry in cold weather and liable to crack when the mouth is suddenly opened.

Ball, of Dublin,\* is of opinion that the vast majority of fissures are produced by the tearing down, during the passage of a hard motion, of the lateral attachments of one of the valves of Morgagni. In support of this he points out that the torn-down valve is to be found at the lower end of the fissure,

---

\* The Rectum and Anus, p. 138.



constituting the so-called *sentinel pile*. Of this he says, "The torn-down anal valve could always be demonstrated, and, although it is in some cases very small and apparently insignificant, in the vast majority it was much hypertrophied and œdematous." This ingenious explanation may be correct in some cases, but that the anal valve is instrumental in causing a fissure in all cases, we cannot believe. In the first place, in our experience, the so-called sentinel pile is by no means so frequent an accompaniment of fissure as Dr. Ball has observed. The result of the investigation of our cases conclusively proves that the presence of the sentinel pile is the exception rather than the rule. Thus of 89 cases of fissure in females a sentinel pile was present in 7 and a similar number was recorded among 132 males, or 14 examples of the sentinel pile in a total of 221 cases—a very small percentage indeed! As mentioned above, when speaking of the position of fissure, the theory of the torn down valve would certainly explain the frequency of the fissure being found just to one or other side of the middle line posteriorly, but here again—what about the sentinel pile? Surely if the fissure were dependent upon the tearing down of the large valve in this position, the sentinel pile should be still more frequently in evidence; but this observation we are unable to confirm. So far as the production of the sentinel pile is concerned, we think that a much more likely reason for its occasional presence is that one of the small veins passing from the skin around the anus into the anal canal has become obliterated by the fissure, with the result that that portion of the skin from whence came the vein has been rendered œdematous, partly by impediment to venous return and partly by lymphatic obstruction. In support of this argument we may mention that, in some cases, œdematous folds of skin corresponding exactly in character and appearance to the sentinel pile are found round the anus in positions other than the site of a fissure. Such folds of skin have



nothing whatever to do with a torn-down valve and are found in other conditions than fissure, such as piles, pruritus and eczema of long standing, when they are undoubtedly due to venous and lymphatic obstruction. Such instances of œdematous folds of skin, away from the site of the fissure, were observed by us in four of the 89 cases of fissure in females, and in ten of the 132 males.

Boyer considers that spasm of the sphincters is the cause of fissure, and is always antecedent to it. The exact *modus operandi* he does not mention, but if he means that the lesion is produced by an hypertrophied and indurated sphincter contracting spasmodically upon a hardened fœcal mass during its transit through the anal orifice, we agree with him. Speaking of the causes of fissure, Kelsey remarks: "Although these ulcers are generally stated to be due to an act of laceration of the mucous membrane, or to its abrasion from some irritation, they not infrequently originate within the sinuses of Morgagni, and a true fissure may be entirely concealed from view within one of these pouches." Quènu and Hartmann\* sum up the subject with the statement that constipation and the tendency to piles may be considered as the real and constant causes of fissure. They contend that piles, which they estimate are present in 70 to 80 per cent. of fissure cases, act by predisposing to constipation and that they so modify the structure of the mucous membrane that the slightest injury, such as is caused by passing a hard motion, causes an ulcer. With this we totally disagree, as our observations on this point show that piles are only present in a very small number of cases of fissure.

Besides constipation, the following may be mentioned among the causes of fissure, viz., congenital narrowing of the anal orifice, eczema and herpes ani, rectal polypi, uterine enlargements and displacements, pelvic inflammations, syphilis, and the tuberculous diathesis, but even in these con-

---

\* Chirurgie du Rectum, p. 421



ditions, the bowels are almost invariably constipated, so it may be assumed that they are only indirect causative factors by predisposing to the constipated habit. Lastly, very occasionally fissure is met with in patients who say that their bowels always act two or three times a day without aperient medicine. On making a digital rectal examination in such cases, in our experience, motion is always found in the rectum, the two or three evacuations being due to the dividing up of one healthy action of the bowels into two or three partial evacuations. It is a fact that patients suffering from fissure always have some motion in the rectum, unless the bowels have been relieved either by a purgative or an enema.

*Age.*—Fissure may be said to be a disease of adult life, children very rarely suffering from it, except in cases of hereditary syphilis. The age records of our hospital cases show that fissure may be met with in both sexes at any time of life between puberty and old age. Of the females, the youngest was 20, the oldest 60, and among the males the ages ranged between 15 and 68. We have no record of, nor can we recollect seeing an example of simple fissure in a child, and we venture to think that, if fissures of syphilitic origin be rigidly excluded, this disease in the early years of life is a particularly rare one. Such a conclusion as the above, however, is not in accordance with the experience of other authors. Allingham\* records a case in a baby in arms. Koplik† speaks of fissure in infants existing in a vast number of cases in which constipation is the symptom complained of. Mathews‡ cites a case in which he treated a fissure in an infant in arms. Quénu and Hartmann§ also regard the disease in children as comparatively rare, but quote cases in which they have had occasion to treat quite young children. Be this as it may, it seems to us a significant fact,

\* Diseases of the Rectum, sixth edition, page 260.

† Mathews' Medical Quarterly, vol. 1, 1894.

‡ Diseases of Rectum, Anus, and Sigmoid Flexure, p. 271. § *op. cit.*, page 420.



that, of 221 cases of fissure attending the out-patient practice of St. Mark's Hospital for Diseases of the Rectum, not a single example of fissure was observed under the age of 15 years. It is possible that children living in France and the United States of America may be more liable to fissure than, so far as our experience goes, is the case in England.

*Sex.*—It is very generally accepted as a fact that fissure is more frequently met with in females than in males. Of 221 cases of this disease of which we have notes, and which occurred in the out-patient practice at St. Mark's Hospital, 89 were females and 132 were males, giving a proportion of about two females to three males.

In a paper on fissure contributed by Mr. Goodsall to St. Bartholomew's Hospital Reports in 1893, it was found that in 600 cases of fissure taken consecutively from the out-patient register of St. Mark's Hospital, the proportion was three females to five males, whereas in cases of the disease met with in his private practice, they stood in the relation of five females to six males.

According to St. Bartholomew's Hospital Reports during the ten years, ended December 31st, 1890, 46 females and 31 males were admitted suffering from fissure, *i.e.*, in the proportion of three females to two males. St. Thomas's Hospital Reports during the same period show that 20 females and 11 males were registered as in-patients, *i.e.*, in the proportion of two females to one male. Westminster Hospital Reports during a period of seven years, ended December 31st, 1890, show a proportion of ten females to nine males. By adding these totals together, it will be seen that in the practice of these three general hospitals, 51 males and 76 females were admitted for fissure, the proportion being three females to two males, which is the converse of our own statistics. The weight of this *in-patient* evidence tends to show that the disease is more prevalent among women than men, but it should be borne in mind that the result obtained from the reports of the



general hospitals quoted, might, in all likelihood, depend upon the fact that poor women are better able to afford the time required for in-patient treatment than are men of their own class, who, unless absolutely incapacitated for work, would be obliged to seek only out-patient relief.

*Parentage.*—We have not been able to obtain sufficient reliable information to enable us to say whether heredity has, or has not, any influence in the causation of fissure.

*Occupation.*—Fissure is found to be much more prevalent in those who lead sedentary or indoor lives than among persons whose occupation is of an active nature, and associated with outdoor exercise. For this reason clerks, tailors, shoemakers, &c., among men, are much more likely to suffer from fissure at some period of their lives than are their more active confrères such as postmen, farm-labourers, soldiers, and the like. In women, such distinction in occupation cannot so well be made as most of them lead indoor lives, occupied, as the majority of them are, with household duties. An analysis of our cases gives the following results:—Of 132 males, sedentary lives were led by 105, the occupations of the remaining 27 being either active or unrecorded. In women, the preponderance of the sedentary occupation is still more marked; thus of 89 females, 26 earned their living by sedentary occupation, such as milliners or machinists; 60 were concerned in household duties, while only 3 came under the category of active or unrecorded. The reason for this influence of occupation in the production of fissure is no doubt to be found in the fact that those who lead indoor or sedentary lives are much more prone to suffer from constipation, which, we believe, is undoubtedly the exciting cause in all cases of fissure.

### *Symptoms.*

The symptoms of fissure are in nearly all cases well marked and characteristic. They are expressed by pain both local and reflex, by spasm of the muscles controlling the lower portion



of the rectum, and by alteration in the size of the motion passed. To these may be added the occasional loss of blood in small quantities, unless piles are also present, when the hæmorrhage may be considerable.

*Pain.*

The pain is generally well marked in cases of fissure and may be described as its most definite symptom. Though varying considerably in intensity and duration in different individuals, a circumstance no doubt influenced to some extent by individual capacity for enduring pain, it causes distress out of all proportion to the size of the lesion. Moreover this pain, in addition to being confined to the seat of disease, may be reflected to distant parts, producing more or less general distress which may perhaps totally incapacitate the sufferer from following his occupation while the pain continues or lead him to imagine that he must be afflicted with a more grave disease than fissure.

The local pain is generally described by patients as a burning, aching, or shooting and throbbing sensation, situated just within the anus; or as an intense itching of the part. It usually commences either while the motion is being passed, or, in less than half the cases, within half-an-hour to an hour after defæcation, and persists from half-an-hour to six or eight hours, or even longer, and in a few cases until the next action of the bowels takes place. The pain often ceases almost suddenly, and when it has disappeared, it rarely recurs until the next action of the bowels, except in syphilitic fissures, when it frequently returns at night. Our observations in regard to the duration of the pain show that in females it varies from half-an-hour to continuous pain, that is until the next motion is passed, and that the average duration in them is from five to six hours. In male subjects the average duration of the pain is between two and three hours; in a few it persists for but ten minutes, being followed by itching in the anal



region, which sometimes lasts for several hours, whilst in others the pain continues as long as twelve hours, occasionally being unremitting. When the pain, which has hitherto been intermittent, becomes continuous, an abscess in connection with the fissure should be looked for. It may be said then that the pain accompanying a fissure is sometimes paroxysmal and, at other times, more or less continuous.

In well-marked cases of fissure these painful phenomena are repeated with each action of the bowels, and it cannot be wondered at that the patient dreads the time when he must perforce relieve the loaded rectum. Thus he is induced to put off the act of defæcation as long as possible, and so aggravates his former constipated habit with the result that each passage of hardened fæces further tears the wound in the mucous membrane, or, at all events, stretches it and precludes its repair. At length, worn out by repeated attacks of pain, and losing flesh from disorder of digestion invoked by chronic constipation, he is driven to seek relief.

It is indeed surprising, when we reflect upon the extreme discomfort and pain caused by a fissure, that patients endure the distress for such a length of time before seeking surgical aid. Our experience on this point, so far as hospital patients are concerned, is that the average time for seeking relief, after the initial symptoms of fissure have manifested themselves, is about three years in men, and five to six years in women. In some instances the disease was endured for as long as twenty years, and in one private patient for thirty years.

#### *Muscular Spasm.*

The existence of spasmodic contraction of the external and also of the internal sphincter muscles, together with the levatores ani, may be looked upon as a constant accompaniment of fissure. The severity of the spasmodic action certainly varies from an increased irritability, as evinced by sudden spasmodic action of the sphincter following stimuli



such as the introduction of the finger into the anus, to habitual tonic spasm in which the external sphincter feels abnormally firm and indurated. In some instances the levatores ani muscles also participate in the spasmodic closure of the lower part of the rectum, when the analogy to the allied condition of vaginismus becomes strikingly evident. In respect of this latter condition, pathology has taught us that the spasm of the muscles of the pelvic outlet is induced by irritation of exposed nerve fibres in the remains of a lacerated hymen, and it is possible that an identical condition obtains in fissure. The exposed nerve filament in the floor and edges of a fissure call forth undue and excessive action of the sphincter muscles, which is in some cases so complete that the patient cannot for a time pass even flatus. The physiological rôle of the muscles guarding the anal orifice is one of tonic contraction to prevent the involuntary escape of flatus and fæces from the bowel, and, to ensure this, a highly developed nervous mechanism must exist. The minute anatomy of this part shows us that not only are the nerves supplying the mucous membrane and skin of the anal canal very numerous, but that their individual fibres terminate in specially developed nerve-endings or tactile corpuscles (see page 36). In fact the mode of termination of the nerve fibres sufficiently warrants the idea that a special rectal sense is here developed, the duty of which is to warn the sphincter muscles, through the agency of a special centre in the lumbar region of the spinal cord, of the presence of flatus or fæcal matter in the rectum. This being so, it is easy to understand how undue and excessive action of the sphincters may be called forth when these nerve terminations are exposed by a laceration of the anal mucous membrane. Thus it happens that the pain evoked by the passage of a hardened mass of fæces over an abraded surface in the mucous membrane induces spasmodic contraction of the sphincters and levatores ani; and the spasm, by compressing the wound, maintains the pain, thus rendering the patient



incapable of passing any more motion for a time even though aided by violent straining and, in some instances, by the introduction of his finger. The pain persists so long as the spasm lasts and there is no respite in the patient's suffering until the muscles are exhausted and the damage caused to the fissure by the passage of firm fæces over it has been repaired. The pain may be re-awakened in all its intensity at the next act of defæcation.

*Alteration in the size of the motion passed.*

An alteration in the size of the motion passed may always be observed in fissure cases, on account of the spasm of the sphincters and levatores ani, which is a constant accompaniment of fissure, the anal orifice is considerably narrowed, and consequently the diameter of the motion passed is diminished, and sometimes the motions are flattened or tape-like. This is not a characteristic sign of the disease, as other conditions, such as stricture, polypoid growths, ulcers over the internal sphincter, or malignant disease have the same effect.

*Hæmorrhage.*

Bleeding in cases of fissure does not often take place. At the moment when the actual tearing of the mucous membrane occurs, a small quantity of blood may be passed (not more than a drop or two) sufficient perhaps to streak the motion, and this may be repeated from time to time when additional laceration is produced by the passage of hardened fæces, but it is exceedingly rare, unless piles are also present, for blood to be lost in any quantity from a case of fissure alone. In this respect there is a striking contrast between fissure and piles, and it seems to us highly probable that in those cases of fissure in which a free flow of blood has been recorded that piles in the first stage of development had existed as well and had been overlooked. Our experience leads us to the belief that, if a patient is suffering from uncomplicated



fissure, the quantity of blood lost seldom exceeds one or two drops, and generally no blood at all is lost unless the fæces are exceptionally firm.

The most characteristic symptoms then of anal fissure are pain, or irritation of the anus, and spasm of the sphincters, which may be considered as pathognomonic of the disease. These symptoms vary in different cases, the one or the other being more pronounced in all cases. Still it should be borne in mind that occasionally, even with a well marked fissure, the prominent symptom is only irritation of the anus, coming on usually after passing a motion, and occasionally after passing flatus. In most cases of uncomplicated fissure, the patient when asked to strain the anus out is unable, from the spasmodic action of the levatores ani, to make the anus descend much beyond its natural level, certainly not to the level of the tuber ischii which is always possible in a healthy patient.

#### *Physical Examination.*

In a case of suspected fissure a local examination is indispensable. For the purpose of examination a good light is essential and the most convenient position for the patient is the right lateral and semi-prone (see fig. 20).

#### *Inspection.*

On separating the buttocks, the anus is fully exposed to view and the condition of the surrounding skin can then be seen. Sometimes evidence of pruritus, eczema, or secondary syphilis will be forthcoming, which will materially assist in the subsequent treatment.

#### *The Condition of the Anal Skin.*

The anal skin in these cases is not infrequently redundant and thrown into numerous folds; when such exist, it is well to examine systematically the furrows between adjacent folds lest excoriation should escape observation. In a few cases



an isolated œdematous fold of skin, *the sentinel pile*, may be observed (see page 215), and, when present, forms a valuable guide to the position of the fissure.

*The Condition of the Sphincters.*

This should form the next subject of inquiry. By placing the tip of the index finger upon the external sphincter, any undue firmness or induration may at once be detected. The degree of spasmodic contraction of the sphincters and the levatores ani may also be approximately estimated by requesting the patient to strain down, when, if spasm exist, he will be unable to force the anus outwards in spite of repeated attempts to do so. The reason for this is that the attempt at straining down causes pain in the fissure, which, in turn, evokes spasmodic contraction of the sphincters and the levatores ani, and thus prevents protrusion of the anus and even the escape of flatus. Some patients are able to force the anus outwards to a greater extent than others, even when suffering from fissure, but it may be accepted as a clinical fact that, in all cases of fissure, this power is considerably diminished, when compared with the normal; and its degree may be taken to some extent as a measure of the severity of the lesion. Of the eighty-nine cases of fissure in females of which we have records, this inability to force the anus outwards was well marked in seven, and among one hundred and thirty-two males a similar condition was observed in twenty-three.

*The Presence of Discharge.*

The external examination can now be completed by observing the presence or absence of discharge from the anus, such as mucus, blood, pus or fœculent material. When either mucus or blood, or both of these are present, internal piles should be looked for. When pus is present, a blind internal fistula probably coexists; and when fœculent material is present, there is probably a fœcal accumulation in the rectum.



*The Exploration of the Rectum.*

We now come to the most important point of the local examination in cases of fissure, that is, digital exploration of the rectum. This procedure is always attended by more or less pain. We cannot emphasize too strongly, that a digital exploration should always be made, and, if desired by the patient, under an anæsthetic. Such an examination we hold to be important, not for the mere purpose of making a diagnosis of fissure, as this conclusion may already have been arrived at from the symptoms described by the patient and from the external examination, but, in order to enable us to state correctly whether there are or are not other diseased conditions of the rectum coexistent with the fissure. The omission of an examination for the presence of coexistent disease, may, and often does, result in the over-looking of some important complication of the fissure, *e.g.*, polypoid growths, piles, blind internal fistula, polypus and submucous abscess. The introduction of the finger into the rectum should not, therefore, be dispensed with; but in order to gain the confidence of the patient, and to avoid causing him unnecessary pain, the utmost gentleness in carrying out the procedure should be exercised. If the situation of the fissure can be made out, as is usually the case, by separating the sides of the anus and so exposing the lower margin of the fissure, the exploring finger should be pressed well against the opposite margin of the anal ring, as it is being introduced into the rectum, so as to avoid touching the fissure. If this manœuvre be carried out, very little pain, in the majority of cases, will be caused by the passage of the finger into the rectum.

When the finger is in the rectum, the spasmodic contraction of the external and internal sphincters can be felt, and often the levatores ani will be found to be in a more or less irritable condition. The next thing that will be noticed, in nearly all cases, is the presence of fæces in the rectum,



despite the fact that the bowels may have acted but recently. If the rectum be loaded, an enema should be administered in order to facilitate the further examination. The bowels having been fully relieved, a careful search should be made for any coexistent disease. In men, it is well to inquire also into the condition of the prostate, and, in women, into the state of the uterus and its appendages. In women also, the condition of the coccyx should be made the subject of inquiry, as coccygodynia may occasionally, though rarely, be also present. We have seen cases which have been operated on for fissure, in which the real cause of the patient's symptoms was the condition of the coccyx. When the finger is removed from the rectum the anus is often spasmodically drawn upwards, showing that the spasm is set up by the local stimulation. The rectal complications of fissure will usually be met with in the lower inch of the bowel. Some authors advocate the use of the speculum, but we think this unnecessary and its use is certainly attended by considerable pain. The speculum itself may also prevent the full extent of the disease from being observed. We always rely on digital examination only.

### *Diagnosis.*

The diagnosis of anal fissure is in most cases easily made, the symptoms being so characteristic that it is possible to arrive at a correct conclusion even without recourse to local examination. Still, however certain we may feel that a fissure exists, a thorough local investigation, for reasons pointed out above, should be urged in all cases. If then a patient presents himself with a history of having felt a tearing sensation at the anus, with a slight loss of blood when passing a hard motion, and of this having been followed by intense pain which set in either at the time of defæcation or after a short interval and persisted for a considerable time afterwards, eventually ceasing almost suddenly, and not recurring until the next action of the bowels, the presumption is strongly in



favour of fissure being present, either alone or complicated with other rectal disease. When this cycle of events has been repeated on several occasions after the act of defæcation, the diagnosis is corroborated. If, on local examination, more or less marked spasm of the sphincters and the levatores ani exists, as evidenced by the patient being unable to force the anus outwards; and more especially if on separating the sides of the anus, the lower extremity of a triangular or oval ulcer is brought into view, the edges of which are well defined, and the floor covered by reddish or greyish granulations, or consisting of the muscular fibres of the external sphincter, the diagnosis of fissure is confirmed. Moreover, if, on introducing the finger into the rectum, the upper limit of the ulcer can be defined and no other disease of the rectum be found, the diagnosis of an uncomplicated fissure should be made. If, on the other hand, such conditions as polypoid growths, piles, polypi, blind internal fistula or abscess are also found to be present, the case is one of complicated fissure.

#### *Differential Diagnosis.*

There are three conditions from which it is most important that a fissure should be differentiated, viz.:—(a) Syphilitic Fissure; (b) Blind Internal Fistula; (c) Disease of neighbouring Pelvic Viscera.

(a) *From Syphilitic Fissure.*—Having come to the conclusion that a fissure is present, we must next decide whether it is simple in character or of syphilitic origin. The following considerations will aid us: Syphilitic fissures are usually multiple and are generally situated either on the right or the left side of the anus. In shape, they are not so triangular or oval as non-syphilitic fissures, and they bleed readily when their edges are separated. They differ, too, in the character of the pain to which they give rise. The pain commences during an action of the bowels, and seldom persists for longer than half an hour. The pain may recur, and often



does, at night when the patient is in bed, although the bowels have not been relieved for several hours—a very exceptional occurrence in fissures of non-syphilitic origin. In all cases of syphilitic fissure, either the inguinal or the femoral lymphatic glands, or both sets of glands, will be found to be enlarged, hard, freely movable, and painless. Besides the enlarged glands, other signs of syphilis will generally be found, such as mucous patches in the mouth and fauces or one or other of the syphilodermata, with a history of exposure to contagion within the previous six or eight months.

(b) *From Blind Internal Fistula.*—Another condition that may be confounded with fissure is a blind internal fistula. Both are attended by pain associated with defæcation and by spasm of the sphincters, but attention to the following points will serve to discriminate between them. In blind internal fistula, there is a history of continuous pain which, though increased at the time of defæcation, does not pass off. This variation in the intensity of the pain has been repeated with each succeeding action of the bowels until, at the end of a few days, or a longer period, a discharge of pus from the anus has been noticed, after which the pain disappeared except during, and for a variable time after, an action of the bowels. At intervals, pus has been discharged from the anus, the discharge being often preceded by pain which has supervened occasionally without an action of the bowels. On examining the anus, some purulent discharge can generally be seen issuing from the bowel, or can be squeezed out or made to issue by compressing the margins of the anus together while the patient also bears down. When the finger is introduced into the rectum, its surface, on withdrawal, will probably be found to be smeared with a streak of purulent discharge. When in the rectum, the finger cannot detect the roughened patch on the mucous membrane, so typical of fissure, but may make out a localized induration by carefully manipulating the lower two inches of the rectum between the forefinger in the rectum



and the thumb outside. An induration, due to the fistula, can always be felt in this way. In many cases, a distinct internal opening, which feels like a dimple or small pit, or a roughness in the mucous membrane may be detected. It should be observed that this rough surface is never so sensitive as are always the floor and margins of a fissure, unless it is the cause of the fistula. If this spot be examined with a silver probe bent to a half circle of half an inch diameter, its point may, with a little careful manipulation, be inserted into the cavity or track of the fistula. The distinctive feature, however, of blind internal fistula is the presence of pus which is never noticed in fissure. It may be well to draw attention, in this place, to the fact that a fissure is not uncommonly the starting point of a blind internal fistula (see page 101), which may, and does when of the subcutaneous variety, soon become complete. Both lesions may, therefore, coexist, in which case the internal opening of the fistula will be found in the floor or at the lower margin of the fissure.

(c) *From disease of neighbouring Pelvic Viscera.*—Finally, in some instances, though symptoms indicating fissure are present, no lesion can be found even after careful exploration with both finger and speculum. In such cases as these, it is well not to express an opinion until a careful examination of the pelvic organs has also been made. In women, a retroflexed and retroverted uterus, or a prolapsed and inflamed ovary in Douglas's pouch, by pressing upon the rectum, may cause pain and difficulty in defæcation, and so simulate fissure; while in men, disease of the prostate, or vesiculæ seminales, or even of the base of the bladder, may be the cause of the symptoms complained of.

#### *Morbid Conditions complicating Fissure.*

Placed in the order in which they most frequently occur, the morbid conditions in the rectum, which may be met with concurrently with fissure, are polypoid growths, internal



piles, polypi, and blind internal fistula (subcutaneous or ischio-rectal).

*Polypoid growths* are so frequently met with, in cases of fissure, that it is possible they exert considerable predisposing influence in its production. The growths are usually multiple, there being generally two or three, though probably there is no limit to the number which may be present. We have, on one occasion, seen as many as twenty-two in the same individual. Their size varies considerably, the length being from less than a quarter to one-and-a-half or two inches, and the breadth from one-eighth to half or three-quarters of an inch. They are met with in the terminal two inches of the rectum, being generally situated within an inch of the anus. These growths are met with, in male subjects, in at least 11 per centum, and, in females, in 22 per centum of cases of fissure. They are often situated either at the side of, or opposite the fissure. The recognition of their presence is all important because, unless they are removed at the time when the fissure is operated upon, it is extremely improbable that any operation will permanently cure the patient. Moreover, if the operation should be successful, the healing will be much slower than it would have been had the growth or growths been removed.

*Internal Piles* are met with, in cases of fissure, in at least 20 per centum in males, and in upwards of 16 per centum in females. According to Quénu and Hartmann\* as many as 80 per centum of adults suffering from fissure, either have piles or are predisposed to them. We cannot confirm this statement, and we think that the percentage given by these authors is much too high, at any rate, as regards this country. There is no doubt that in many cases of fissure, piles do coexist, and they are then the cause of the severe hæmorrhage sometimes met with. As we have already said, a fissure, uncomplicated by piles, seldom bleeds beyond an

---

\* Op. cit., p. 421.



occasional drop or two. We have observed that when only a single pile is present in a case of fissure, it is always the right anterior (R.A.) pile. Fissure is not found with piles in the third stage of their development, because of the stretching which the sphincters undergo from the frequent prolapse of the piles in such cases. The scar of a pre-existent fissure may, however, sometimes be detected in such cases.

*Polypus.*—A well-marked polypus is seldom found associated with a fissure. When met with, its pedicle should be ligatured, and the growth removed at the same time that the external sphincter is divided.

*Blind internal fistula* is met with, in cases of fissure in males, in about 8 per centum, and, in females, in about 2 per centum. It is usually found in connection with a fissure situated posteriorly. It may be only subcutaneous or may track into the ischio-rectal fossa, or extend beneath the mucous membrane above the upper margin of the fissure (see figs. 34, 37, 38, 39). The particular course that the fistula may follow depends upon the part of the fissure from which it starts. When the burrowing begins at the lower margin of the fissure, the fistulous track lies beneath the peri-anal skin and soon becomes a complete fistula by opening externally. When the burrowing starts from the centre of the floor of the fissure, two courses are open to it, either it will track beneath the superficial part of the external sphincter opening on to the surface at the outer margin of that structure, *i.e.*, about three-quarters to one inch from the anus, and a little to the right or left of the middle line posteriorly; or the fistulous track may pass through between the deep portion of the external sphincter, and the lower border of the internal sphincter and so gain access to the ischio-rectal fossa. In such cases as the last, we have seen most extensive burrowing, almost completely encircling the lower part of the rectum, result from delay in opening the blind internal fistula. In one case, the fistula had discharged itself into the



vagina. Lastly, when the fistulous track starts from the upper margin of the fissure, it makes its way in an oblique direction upwards beneath the mucous membrane only.

### *Treatment.*

The treatment of anal fissure may be divided into the *palliative* and the *operative*.

Some cases will be found to yield to the former, chiefly, if not entirely, the uncomplicated cases. In all complicated cases, and in simple ones of long standing, there is so much spasm of the sphincters, generally with attendant hypertrophy and induration (more especially of the external sphincter), and the pain is at times so severe, that operative measures should be proceeded with as soon as convenient to the patient. Each case, however, should be treated upon its own merits. In all cases palliative treatment may be tried for two or three weeks, at the end of which period, unless marked relief has been obtained and the fissure is healing, an operation should be performed. We have observed that, in cases of uncomplicated fissure, when the ulcer is of slight extent and not deep; when it has not existed for any length of time; when there is no marked spasm or hypertrophy of the sphincters, and also when occurring in patients above 60 years of age, success is likely to follow palliative treatment, and the cure to be permanent. While on the other hand, if the fissure is complicated by other rectal disease; if it is well marked and deep, especially when the muscular fibres of the external sphincter can be seen in its floor; if the edges are thickened and hard, indicating chronicity; if the sphincters are hypertrophied and feel indurated, and there is well marked spasm of the musculature of the pelvic outlet; if either polypoid growths or polypi are present; and, lastly, if the patient has been losing flesh and is worn out by constantly recurring and excessive pain, operative interference is undoubtedly indicated. It is well in these cases to thoroughly explain



beforehand to the patient the proposed method of treating the disease, and also to lay particular stress on the fact that palliative treatment, though successful in some cases, and, therefore, worthy of a fair trial, cannot be considered so certain and permanent in its curative effect as an operation. Palliative treatment is often successful while it is continued, but a few weeks of neglect, in a complicated case, nearly always leads to a recurrence of the symptoms of fissure. All complicated cases of fissure, that is when well marked polypi or polypoid growths exist, or when the patient also suffers from internal piles or fistula, should be operated upon as soon as possible.

### *Palliative Treatment.*

This consists of, measures for preventing constipation; attention to local cleanliness; and the application of local remedies.

*Constipation.*—A free evacuation of the bowels should be obtained at least once in 24 hours. To ensure a daily action of the bowels, aperients suited to the patient's constitution should be taken every night at bed-time. The best aperient is the one which acts without causing general discomfort and depression, and at the same time ensures free relief of the bowels. The motions should be always kept soft. The injection of olive oil at bed-time, to be retained all night, has an excellent local effect, and will also often cause the bowels to act freely without an aperient.

*Cleanliness.*—Cleanliness of the part is an absolute necessity, since accumulation of fæcal matter in the fissure or between the folds of skin round the anus is apt to cause irritation, and may excite spasm of the sphincters. The anus should be carefully bathed with warm water every night and morning, and also after each evacuation, the part being afterwards thoroughly dried with a soft towel.

*Local remedies.*—When the anal mucous membrane is dry



and inclined to crack on slight dilatation, the lower part of the bowel should be lubricated frequently. For this purpose, the unguentum hydrargyri subchloridi is very beneficial when applied immediately after the part has been dried, or cacao-butter suppositories, introduced at bed-time, help the patient very much by lubricating the passage and the first part of the motion. Unguentum resinæ, either alone or mixed with an equal quantity of vaseline, is a most useful application for protecting the fissure and accelerating its healing. When there is much attendant pain, this may be allayed by the introduction of suppositories containing cocaine (grs. 2) or morphia (gr.  $\frac{1}{4}$ ).

In the majority of cases amenable to palliative treatment, relief and cure can often be obtained in the way we have described. The local application of nitrate of silver which has found favour with some authors, is thus made. The sides of the anus being held apart, the fissure is exposed to view and a pointed stick of nitrate of silver is rubbed over the whole of its surface. A small pledget of cotton wool is then placed over the fissure and kept in position by a T bandage. By this procedure, the superficial granulations are destroyed and the tissues stimulated to repair. By destroying the exposed nerve endings, reflex spasm of the sphincters is diminished or abated, and the raw and exposed tissues are protected for a brief period from subsequent injury by a coating of insoluble albuminate of silver. This form of treatment we cannot recommend, because of the intense pain sometimes caused by it. It can be successful only in uncomplicated cases, and occasionally is so. When adopted, a twenty per centum solution of cocaine should be applied to the fissure before the application of the nitrate of silver.

#### *Operative Treatment.*

The methods at present in vogue for the operative treatment of fissure are two—*incision* and *stretching of the sphincters*.



The method of incision, known as Boyer's operation, is the one usually practised by English surgeons, and is generally adopted at St. Mark's and the Gordon Hospitals; while that of stretching the sphincters finds almost universal favour among French surgeons, being known as Récamier's operation, he having been the first to describe this plan of treatment. Both of these operative procedures have the same object in view—to eliminate the spasmodic action of the sphincters, in fact, to paralyze them for a time and thus ensure the physiological rest so essential for the repair of the fissure. It is clear that, since the sphincters are called into action through reflex stimulation of afferent nerves passing to the centre in the lumbar enlargement of the cord, the means at our disposal for preventing reflex action are either to dissolve the continuity of the muscular fibres or to prevent afferent or efferent impulses passing along the nerves concerned. The former of these is effected by Boyer's operation, and the latter by the method of Récamier.

#### *The Operation by Incision.*

By this method, division of some of the muscular structures surrounding the anal orifice is effected. We have seen that spasmodic action of the musculature of the pelvic outlet, comprising the external and internal sphincters and the levatores ani, constitutes the impediment to the healing of the fissure, causing the pain to be of long duration and affording the wound no rest while it persists. The question of practical importance arises—*How much of this muscular structure must we divide to ensure cessation of spasmodic narrowing of the anal outlet, compatible with doing the least possible permanent harm to the part in regard to its functional activity?* Our guide in this matter is based upon anatomical considerations. Of the muscles concerned, the levatores ani, when contracting, draw the lower part of the rectum upwards



and forwards, and have a dilating effect rather than one of constriction, and, therefore, a division of their fibres would be futile. The internal and external sphincters constrict the anal canal, and, therefore, the point to be determined is whether both of them are concerned in the spasmodic action. Now the internal sphincter is composed of involuntary fibres, being supplied by nerves derived from the same source as those supplying the muscular coat of the rectum itself, and, therefore, it is not directly called into action by stimulation of the peripheral terminations of the nerves supplying the lining membrane of the anal canal, which we have seen are derived from the pudic and the 3rd and 4th sacral. It is true that stimulation of these nerves will bring about reflex contraction of the internal sphincter; but this can be explained by reflex radiation along other nerves emanating from the lower portion of the cord, just in the same manner as we account for pain manifesting itself in the loins and down the backs of the thighs. On the other hand, the external sphincter is supplied by the identical nerves which give sensory filaments to the anal mucous membrane and skin, and, therefore, this muscle is much more directly concerned in the reflex arc, and responds much more readily to stimulation of the anal margin. If these deductions are correct, the fact that it is only necessary to divide the external sphincter for the cure of fissure should be borne out by clinical observation. On this subject we can say, unreservedly, that such has been our experience, and that we have never found it necessary to divide more than the external sphincter to cure a fissure. It remains to us now to consider the manner in which division of the external sphincter effects a cure. This muscle, arising as it does from the ano-coccygeal ligament, and being inserted into the central point of the perineum, must of necessity contract towards the centre, thus closing the anal orifice. When divided on one side, it is no longer capable of doing this, as each portion contracts towards its fixed point. In



this way constriction of the anal ring is rendered impossible, with the result that the fissure is no longer pressed against the fæces when the bowels are being relieved. To all intents and purposes, such division of the muscle causes a temporary loss of function, but this is resumed as soon as the breach of continuity has been repaired by scar tissue. In the interim, however, the fissure has had the advantage of complete physiological rest, and Nature has been afforded the opportunity of repairing the lesion, so that by the time the ends of the muscle have been joined together, the fissure no longer exists. That division of the external sphincter is instrumental in healing the fissure, is proved by the fact that repair takes places equally well if the muscle be divided at a point away from the seat of the fissure, and also that a single division suffices to cure two or more fissures existing at the same time. To divide more than the external sphincter is never necessary, and indeed can only be productive of harm. It is a clinical fact worth remembering, that division of the internal sphincter is invariably followed by a material diminution of the power of control, or by absolute incontinence. The reflection that, when the internal sphincter has been divided, the levatores ani tend to drag the margins of the wound apart, thus preventing approximation during the process of repair, sufficiently explains why permanent loss of power should result therefrom.

The foregoing considerations set forth the object and limits of the operation which we advocate, viz. :—the complete division of the fibres of the external sphincter and *only the external sphincter*. Of the efficacy of this operation we have had abundant proof.

*Instruments Required.*—Scalpel, straight probe, pair of strong sharp scissors, pile hooks, fenestrated artery forceps, pressure forceps, grooved probe-pointed director, and silk ligatures.



*Method of operating.*

When fully anæsthetised, the patient is placed in the right lateral and semi-prone position, the knees being drawn up, the left more so than the right. The left index finger

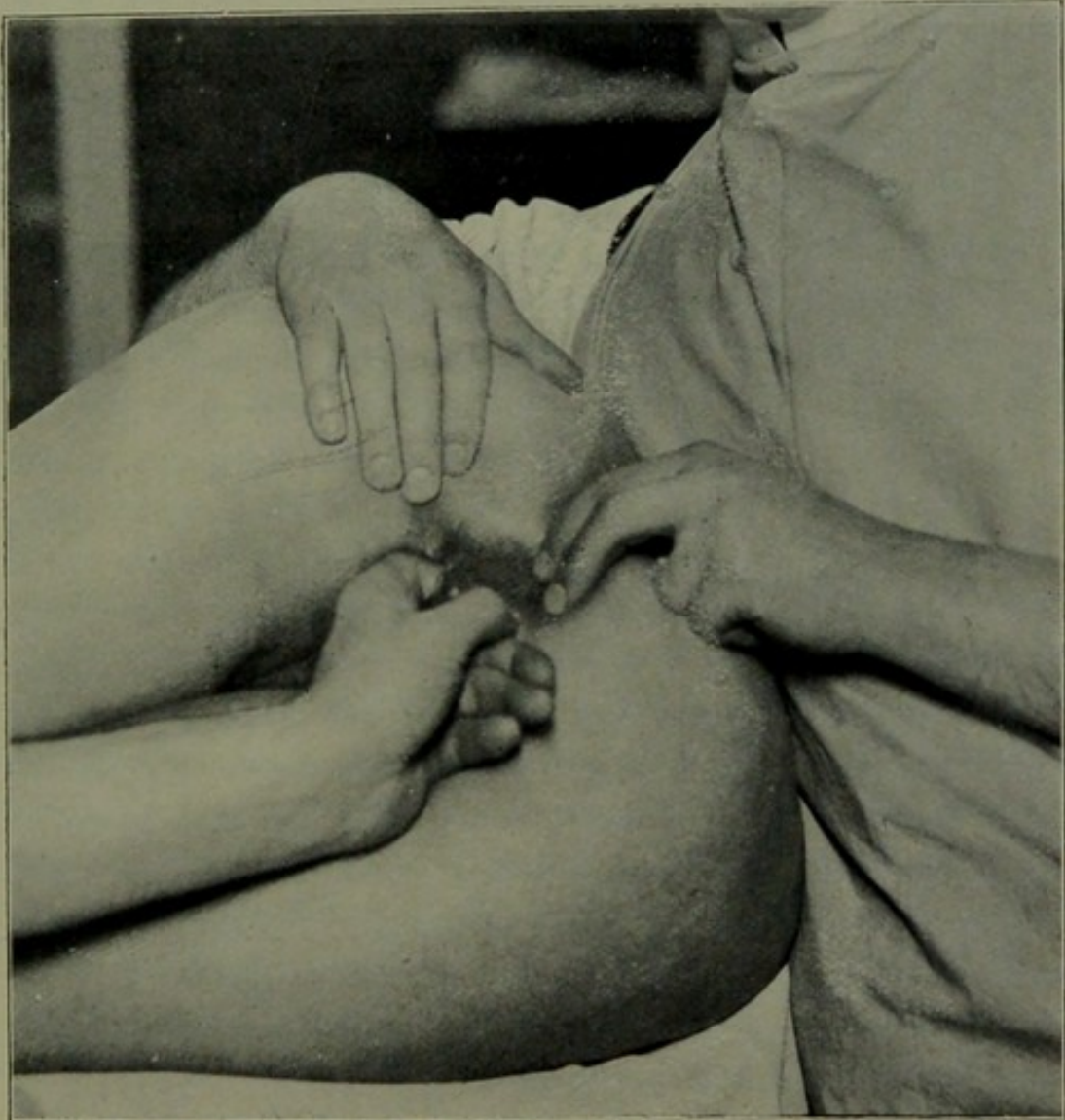


FIG. 83.—SHOWING THE METHOD OF GRASPING THE EXTERNAL SPHINCTER AND EVERTING THE FISSURE.

This manipulation not only renders the external sphincter prominent for division, but enables the operator to see when all the fibres of that muscle have been divided.

is now passed into the rectum, and the external sphincter grasped between it and the left thumb which opposes the index finger from the outside. By this means the external



sphincter can be rendered prominent and the margin of the anus sufficiently everted to expose the fissure to view (see fig. 83). By means of a scalpel or fissure knife, all the fibres of the external sphincter are now cautiously divided. On no account should the internal sphincter be damaged. This division may be effected either through the floor of the fissure itself or at a point midway between the posterior margin and the right side of the anus (R.P.), irrespective of the position of the fissure. A single division of the external sphincter is sufficient to effect a cure, even when the patient has two distinct fissures. When the division has been completed, a careful search should be made for any polypus, polypoid growth, internal pile or blind internal fistula that may be present, and require to be appropriately dealt with. A small piece of cotton wool, wrung out in some perchloride of mercury solution (1 to 500), should then be placed in the wound and a T bandage adjusted. This operation, simple as it appears, is eminently satisfactory and we venture to assert that any case of fissure can be cured in this way, and that the cure will be permanent. Its advantages are that; it leaves no permanent loss of power in the part; it completely cures the fissure; and the patient is not liable to a return of the disease. The only objection that can be urged against its use, is the very long time occasionally required for healing, but this at most is a minor consideration, as after the first week there is very little, if any, discomfort caused by the wound.

Before quitting the subject of incision, it would be interesting, perhaps, to follow up briefly the historical evolution of the operation. Boyer, in the early part of this century, observed that if a fissure was converted into a simple wound by incision, all the symptoms ceased, and that, with the healing of the wound, the fissure disappeared also. Accordingly, he was in the habit of passing a blunt-pointed bistoury along his finger, previously introduced into the rectum, and on its withdrawal



dividing the mucous membrane, both sphincters and adjacent subcutaneous tissue, and skin. This extensive incision, though it was effective in curing the fissure, does not appear to have met with much approval from other surgeons, probably on account of the serious impairment of control to which it undoubtedly gave rise. Accordingly we find Curling,\* Copeland, Dupuytren and others advocating a superficial incision, by which the mucous membrane only, or at most a few of the more superficial fibres of the external sphincter, were divided; while others, among whom may be mentioned Blandin and Demarquay†, practised the submucous division of the external sphincter. These modifications of Boyer's operation, however, proved unsatisfactory and fell rapidly into disuse; and it would appear that just as Boyer did too much and conferred the misery of incontinence upon his patients, so his opponents did too little and failed to cure the disease.

*The Operation by Stretching the Sphincters.*

By this method the contractile power of the sphincters is temporarily suspended, an atony of the muscular fibres being engendered by the process. After an interval of several days or weeks, the muscles nearly always regain their normal tone, and are capable of closing the anal canal; but, in the interim, the fissure has had the opportunity of healing under the enforced conditions of brief rest. This method was first suggested by Récamier in 1829, in lieu of a cutting operation. The first time he made use of stretching he did not intend to cure the fissure by its means, but merely performed this operation with the object of facilitating the application of nitrate of silver; and, indeed, in this instance, apparently it did not strike him that the stretching might have had some part in effecting the cure. Subsequently he endeavoured to cure by stretching alone. The method he first employed was to introduce

\* Dublin Hosp. Gaz., 1855.

† Arch. Gén. de Méd., 1846.



two or more fingers into the rectum, and, with the thumb outside, to pinch up and knead the sphincter muscles from one end to the other. By this means the contractile power of the sphincters was temporarily suspended, but, as the operation had to be performed several times and caused a great deal of pain, the method was abandoned. Still, the desire to cure a fissure without resort to division of the sphincters, no doubt due to the disastrous consequences of Boyer's operation, occupied the minds of the surgeons of the day, and we find Maisonneuve accomplishing this object by introducing the whole hand into the rectum, closing the fist and then withdrawing it. At a later date,\* he abandoned this rough and ready measure, and substituted in its stead a simple stretching of the sphincters by inserting the index fingers and forcibly separating them, at first in the antero-posterior direction, and then laterally. Much success, however, does not appear to have been achieved by this modification, and consequently the method of stretching the sphincters seems to have been entirely given up until Van Buren† in 1864 published a series of successful cases. At the present day, the operation has numerous advocates, especially among French surgeons,‡ by whom the method of incision is employed solely for those cases in which stretching has failed. Our experience of stretching the sphincters is much more limited than that of division of the external sphincter; but we have made use of it in a sufficient number of cases to enable us to conclude that by its means a cure can be effected, though not with the certainty that complete division of the external sphincter gives.

*Method of Operating.*

The bowels having been previously emptied by aperients, the patient, when fully anæsthetised, is placed in the right lateral and semi-prone position. The surgeon then introduces

\* Gaz. des hôpitaux, 1849, p. 220.

† Transactions of the New York Academy of Medicine, vol. 11, p. 180, quoted by Ball.

‡ Quénu and Hartmann, loc. cit., p. 441.



first one index finger and then the other into the rectum, and placing them back to back steadily and strongly draws them apart in the antero-posterior axis. While this is being done, the terminal phalanges must not be flexed completely lest laceration of the rectal mucous membrane should occur. The traction should be steadily persevered with until the resistance of the sphincters is felt to yield. A similar traction should then be made laterally, that is, in a direction at right angles to the first. Some surgeons use the thumbs instead of the index fingers, while others again utilize instruments for the purpose; but, as Duplay\* points out, the fingers are more suitable than these, because the surgeon can appreciate precisely, through muscular sense, the exact moment when resistance is being overcome. If the dilatation has been effectual, the anus will be seen to be quite flaccid, and the orifice will gape, the rectal mucous membrane protruding slightly through the anal ring. In nearly all cases the fissure will be torn during the process of stretching, but this is not followed by permanent damage to the patient. After the stretching has been firmly continued for a few seconds, blood is usually extravasated under the skin posteriorly to the anus, and should not be interfered with as it is generally absorbed in about nine days. Should a polypus or polypoid growth coexist, it should now be removed but not before the stretching has been carried out, otherwise a tear through the mucous coat of the bowel may take place at the site of the growth. A small piece of absorbent wool, wrung out in perchloride of mercury solution, should now be introduced partly into the rectum, and a pad of cotton wool and a T bandage adjusted. The immediate effect of this operation, as we have stated above, is to temporarily suspend the contractile power of the sphincters; in fact, it reduces them to a state of atony, from which, however, they recover after an interval varying from a few days to several

---

\* Gaz. des hôpitaux, 1891, p. 445.



weeks. The object attained is similar to that arrived at by division of the external sphincter, but the result differs in this respect—that the power of contraction returns much sooner after stretching. The question of interest which now presents itself is—By what means is the power of contraction of the sphincters abolished? Is it due to some disturbance in the structure of the muscular fibres themselves, such as laceration or hyper-elongation, which makes them no longer capable of contraction; or is it that the nerves, either afferent, efferent or both, are so injured by the stretching of their fibres that they are unable to convey impressions to or from the centre in the spinal cord? For the purpose of elucidating this point, Quénu and Hartmann† have conducted some very interesting experiments upon dogs. Having performed the operation of stretching upon seven animals, and subsequently dissected the parts, they arrived at the following conclusions—(a) *in regard to muscles*; that blood extravasation does not take place within the sheaths of the muscles; that the muscular fibres are neither lacerated nor torn from their insertions; that the contractility of the muscular fibres is not impaired, the muscles contracting readily to direct stimuli. In fact, no appreciable structural alteration could be discerned in them by microscopical examination. (b) *So far as the nerves were concerned*; it was observed that stimulation of the nerves supplying the muscles caused contraction, thus indicating that their power of conduction remained intact. From these observations, the sole conclusion that could be arrived at was that the sensory nerves were affected, and did not convey afferent stimuli. No direct evidence of this hypothesis could be obtained, but the investigators compared the condition of the anus, after stretching, to the relaxed and patulous state of the anus which they observed in a patient who was under an anæsthetic for the operation of scraping the uterus.

---

† loc. cit., p. 444.



*After Treatment.*

This is a most important part in the treatment of fissure and varies in detail with the operation that has been performed.

*After the Operation by Incision.*

As soon as possible after the operation liq. opii sed.  $\text{m m xxx}$  should be given. Commencing four hours later, a mixture of catechu and opium (see page 153) should be given every four hours for the first 16, and every eight hours during the succeeding 48. The part should be dressed for the first time on the morning following the operation, all the original dressings being removed with the exception of the piece of cotton wool in the wound. The surrounding skin should be carefully cleansed with perchloride of mercury solution (1 to 500), and afterwards a pad of cotton wool, wrung out in solution of the same strength, should be applied. The dressing should be repeated every night and morning until healing has taken place, unless it should be found that the surrounding skin is irritated by the solution. In cases of irritation due to this cause, the strength of the solution employed should be diminished to 1 to 2000. On the fourth day after the operation, the piece of cotton wool in the wound should be removed by gently twisting it on its axis as it is being withdrawn. The removal of this plug enables the patient to void flatus more easily. About ninety-six hours after the operation, the bowels should be freely relieved by an aperient (see p. 154). As a consequence of the bowels having been confined for such a long period, there is always a considerable accumulation of fæces in the colon, and, consequently, the first action of the bowels should be copious. Owing to division of the external sphincter, impaction of fæces is not so likely to occur, after an operation for fissure, as after that for internal hæmorrhoids with no division of that muscle. It should be borne in mind, however, that impaction of fæces may occur



after any rectal operation if the first two or three actions of the bowels are not sufficiently free.

The patient should be kept lying in bed for from ten to fourteen days after the operation, and should be allowed to get out of bed only for purposes of micturition or defæcation during that period. In cases of fissure, the wound resulting from division of the external sphincter nearly always heals slowly, usually in about four or five weeks. In some cases, the healing process may extend over a period of ten or twelve weeks, the patient being unaware that the wound persists, and complaining only of a slight dampness of, or itching in, the anus. This delay in healing is caused most frequently by the R. margin of the wound, when the incision is on the R.P. side, or the L. margin when on the L.P. side, becoming œdematous and falling into the wound. Another cause of retarded healing is the formation of exuberant granulations at the bottom of the wound. These sometimes may vary in length from a half to three-fourths or even one inch. They act as a foreign body in the wound, and cannot be removed too soon. Under the influence of cocaine or eucaine, they should be scraped away with a Volkmann's spoon. When the delay is due to the œdematous state of the margin of the wound, this may be removed by applying a ligature to it. This step, however, is not imperative, because the wound will ultimately heal if left to itself, the patient suffering neither pain nor discomfort from the œdema or from the delay in healing. If removal be decided upon an anæsthetic should be given, since this little operation is quite as painful as that for internal hæmorrhoids. It is essential that the œdematous fold be removed by ligature, as otherwise very free bleeding may take place.

*After the Operation by Stretching.*

As soon as the patient has sufficiently recovered from the anæsthetic, liq. opii sed.  $\mathfrak{m}$  xx should be given, and followed,



after an interval of four hours, by a catechu and opium mixture which should be repeated every four hours until sleep has been induced, after which it should be given every night and morning for the succeeding three days. About ninety-six hours after the operation, the bowels should be freely relieved by an aperient. In other respects, the treatment should be the same as that detailed above under "incision," except that the patient may get about at the expiration of a week from the operation. As we have already stated, a somewhat extensive extravasation of blood, chiefly posterior to the *transverse anal line*, follows the stretching. The discolouration of the surrounding skin becomes most marked during the first three days; but this need give no cause for anxiety as, in our experience, it becomes absorbed in about nine days and requires no additional treatment.

*Diet after the Operation.*

During the first twenty-four hours after the operation only a little water, not more than one pint, should be allowed. During the succeeding eighty hours one pint of milk, one pint of beef tea, with bread and butter, and water *ad libitum* should be given during each twenty-four hours. As soon as the bowels have been freely relieved, ordinary diet should be resumed, provided that the temperature is normal and the general health satisfactory.

*Complications after the Operation and their treatment.*

The complications following an operation for fissure may be divided into (a) *immediate*, or those manifesting themselves during the first twenty-four hours and (b) *remote*, those occurring after that period.

(a) *The immediate* complications are retention of urine, and diarrhœa.

*Retention of urine* is more frequently met with in women than in men, and may be avoided altogether by allowing the



patient to take but very little fluid during the first twenty-four hours after the operation. In this way, there is not sufficient urine secreted to cause hyper-distension of the bladder during the period of reflex spasm of the sphincter vesicæ. The reflex spasm induced by the operation usually subsides within eighteen to twenty-four hours, and then there is, almost invariably, no impediment to normal micturition. Should the patient be allowed to try to micturate during the period of reflex spasm, he will generally fail, but the attempt will have increased the vesical irritability. Accordingly, we always urge our patients to resist the desire to micturate during the twenty-four hours following the operation, and, in order to prevent a free secretion of urine during this period, we advise that as little fluid as possible should be taken. If, however, any difficulty be experienced in voiding urine after the first twenty-four hours, the patient should be placed in a warm hip-bath for 10—15 minutes. This treatment is almost invariably successful, but in the event of its not proving so, the patient should be kept warm in bed for an additional six hours. When, after this further period, urine cannot be voided, a soft rubber catheter must be passed under aseptic precautions. It should be borne in mind that, having once passed a catheter, its use may have to be continued every eight hours, for perhaps, several days before natural micturition is re-established. On the other hand, when the patient has once passed urine naturally, even after waiting for thirty hours, there is rarely any subsequent difficulty in micturition during the remainder of the after treatment, unless impaction of fæces is allowed to take place.

*Diarrhœa.*—When occurring soon after the operation, is probably due to delay in administering the aperient and the consequent incompleteness of the preparatory emptying of the colon. Although this complication is undesirable in every way, it appears to exert no deleterious effect upon the healing of the wound. When an action of the bowels takes



place soon after the operation, all the external dressings should be changed and the part gently cleansed but, on no account, should the plug of cotton wool in the wound be removed.

(b) *The remote complications are*—Cystitis; descent of internal piles; abscess; impaction of fæces; ulceration; pyæmia.

*Cystitis* is seldom met with after operations for fissure, but does occasionally occur.

*Descent of Internal Piles.*—After an operation for fissure, more especially by incision, it is not at all uncommon for internal hæmorrhoids, which, although existing at the time of the operation, had hitherto been kept *in situ* by the spasm of the sphincters and so escaped diagnosis, to make their appearance within a week or ten days. Should their presence retard the healing of the wound, they should be removed without delay. Such piles may be considered, however, to be in the first stage of their development and, therefore, they are amenable to palliative treatment, which should always be adopted, unless they interfere with the healing process. In any case the piles will come down less readily after cicatrization has occurred, than during the healing of the wound.

*Abscess.*—The formation of an abscess occasionally follows the operation of stretching, but this is by no means a frequent complication. The inflammatory swelling cannot be opened too soon, as it may quickly lead to the development of a blind internal fistula. We have never met with an abscess following the operation by incision.

*Impaction of Fæces* sometimes occurs after both the operation of stretching and that by incision. It should be looked for when the patient complains of constant bearing down pain in the rectum and aching in the sacral region, in addition to a discharge of liquid fæces from the anus. When these symptoms are observed, a rectal examination should be



made and the impacted mass of fæces, if present, at once removed.

*Ulceration* may be suspected to have ensued when there is persistent discharge of a purulent nature, which increases in quantity instead of steadily diminishing, as it should do, when the fissure wound is progressing favourably. The peri-anal skin and, especially, both margins of the wound become continuously painful. The bowels also, instead of acting once or twice in the morning, act many times during the twenty-four hours, both by day and night. It should be borne in mind that, when a fissure wound is healing well, a nocturnal action of the bowels is extremely rare. At the onset of these symptoms, the rectum should at once be examined under an anæsthetic. If the wound be found in an ulcerated condition, the surface should be dried and a 40 per centum solution of formalin carefully applied by means of a piece of cotton wool twisted round the end of a probe, not only to the base of the ulcer, but also to every portion of its edges, especially where undermined. When this has been done, the surface should again be dried and a small piece of cotton wool, wrung out of a 20 per centum solution of cocaine, placed over the ulcer, after which an external dressing should be applied.

*Pyæmia* is very rarely met with after an operation for fissure. We have never seen this complication, but the late Mr. P. Y. Gowlland recorded one case which occurred in his practice. The patient ultimately recovered.



## CHAPTER VIII.

### HÆMORRHOIDS OR PILES.

The terms, *hæmorrhoids* and *piles*, are popularly understood to denote a form of disease which owes its origin to a varicose and altered condition of the veins of the lower part of the rectum and of the anus. So far as nomenclature is concerned the terms are ill-chosen, because they each refer to a symptom rather than to a pathological condition—thus the word *hæmorrhoid* is derived from the Greek, *αἷμα*, blood, and *ῥέω* I flow, the compound word denoting *a flow of blood*, which is a characteristic symptom of the disease but by no means a constant one. Again the word *pile* is derived from the Latin *pila*, *a swelling*, and therefore only indicates another symptom of the disease. However, both these terms have been so long in use, and their meanings are so generally understood, that it would be unwise to alter them. To the general public, these terms have a more comprehensive meaning and are, as a rule, used to denote any form of ano-rectal disease, from which they may be suffering. To the surgeon, they should signify that the veins of the lower part of the rectum and of the anus have undergone some change, which enables them to be recognised in their altered condition as a particular form of disease. The nature of this change is not merely one of dilatation or varicosity and nothing else. In addition to the dilatation, there is always some thickening of the wall



of the vein and a considerable increase of the connective tissue elements between adjacent veins. Though the dilatation of the veins gives rise to a more or less distinct swelling, this alone is scarcely sufficient to account for the whole of the bulk of these tumours. Indeed, a histological section of a pile shows that there is a large admixture of connective tissue between and around the dilated veins (see fig. 86). This increase in the connective tissue is always more marked when piles are of long standing or have been the seat of repeated attacks of inflammation, the resulting plastic exudation leading to induration and thickening. In some cases the exudation has been so abundant that the veins have become partially obliterated, the greater part of the piles consisting purely of fibrous tissue.

Since the time of Hippocrates, piles have been arranged into two chief classes, viz., *the external* and *the internal*; according as they are respectively found *outside* the anal orifice, or *inside* the rectum.

#### EXTERNAL PILES.

The following two distinct conditions are usually described as external piles or hæmorrhoids, though neither of them should, in our opinion, be so named. These conditions are (a) *a circumscribed blood extravasation at the anal margin*, and (b) *a redundant fold of peri-anal skin*. It is true that in both conditions there is a distinct swelling to be seen, which may perhaps justify the term "pile"; but as neither contains dilated veins, nor gives rise to a flow of blood, the term "hæmorrhoid" is inappropriate.

There is, however, a third form (c) *dilated peri-anal veins*, to which the term "external pile" may reasonably, we think, be applied. In this, the morbid condition shows itself as a more or less distinct fulness around the anal orifice. Combined with this condition of the peri-anal veins, there are always present hypertrophy and induration of the external sphincter,



together with consequent narrowing of the anal aperture. Internal piles may be associated with any of these three conditions. Constipation always accompanies the first two varieties, and constipation or diarrhœa is invariably met with in the third.

(a) *Circumscribed blood extravasation at the anal margin.*

This condition is usually referred to under the name of the *venous* or *thrombotic pile*, and is supposed to be due to thrombosis taking place in a previously dilated or varicose vein at the anal margin. With this opinion we do not concur, because in the cases which we have examined the blood clot has always been outside the vein. Hence, we consider that the condition is due to a rupture taking place in one of the peri-anal veins, which is followed by a limited extravasation of blood into the surrounding connective tissue. If a case of this kind is seen soon after the swelling has made its appearance, that is before coagulation of the extravasated blood has taken place, the tumour is found to be tense and soft, but if some days have elapsed, the sensation imparted to the examining finger is that of a pea or bean beneath the skin. At this later stage the blood has coagulated, and the surrounding connective tissue is becoming condensed, by round cell exudation, into a true capsule. If an incision be made into the tumour at this stage, the clot can be enucleated, while the capsule is left behind, or the capsule together with its contained clot can also be removed as a distinct tumour. The longer the duration of the extravasation, the more distinct will be the capsule, and we presume that this circumstance has led to the belief that the capsule consisted of the wall of a dilated vein.

*Etiology.*

The rupture of a peri-anal vein, resulting in blood extravasation, is most commonly caused by violent straining during



defæcation, by over-exertion in lifting heavy weights, or by a severe fit of coughing.

The following table, prepared from 104 consecutive cases which came under our observation, shows the influence exerted by sex, age, occupation, and the constipated habit :—

<i>No. of cases.</i>	<i>Males.</i>	<i>Females.</i>
104	86	18
<i>Age in years—</i>		
Average ... ..	35½	40½
Oldest ... ..	66	62
Youngest ... ..	6	21
<i>Occupation—</i>		
Active ... ..	27	—
Sedentary .. ..	57	17
Unstated ... ..	2	1
<i>Constipation—</i>		
Fæces in Rectum...	63	16
Rectum empty ...	2	—
Unstated ... ..	21	2

#### *Symptoms.*

During straining at stool, while lifting a heavy weight, or when coughing violently, there is a sensation that something has given way in the anal region, and a painful swelling is found to have suddenly appeared at the margin of the anus. The pain in the anus persists for some time afterwards. The swelling is also tender to the touch, and the patient is unable to sit in comfort. Defæcation is rendered exceedingly painful, and difficulty is experienced in emptying the bowel of its contents owing to the induced spasm of the sphincters and levatores ani. These painful phenomena usually begin to abate after two or three days, and disappear entirely by the end of a week, unless further straining has caused the rupture of a vein at some other part of the anal circumference.



*Physical examination.*

A swelling, varying in size from one-sixteenth of an inch to one inch in diameter, is found situated at the anal margin, its inner border extending into the anal canal, and its outer margin extending beneath the skin covering the external sphincter. Although usually single (see fig. 84), and located

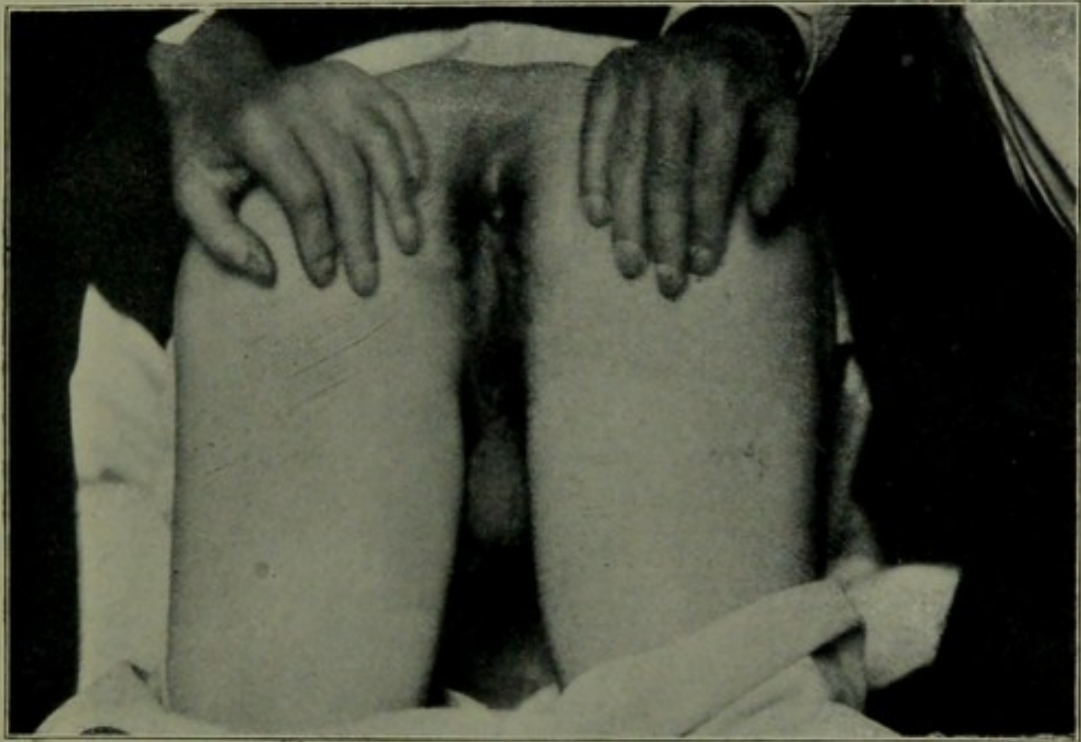

FIG. 84.—SHOWING A SINGLE CIRCUMSCRIBED BLOOD EXTRAVASATION AT THE ANAL MARGIN.

Patient, aged 30. His bowels were habitually constipated. The extravasation was completely absorbed in five weeks from the commencement of the palliative treatment.

at any point in the anal circumference, there may be two (see fig. 85), or, very rarely, three present.

*Table of single and multiple clots in 104 cases.*

	Males.	Females.
Single clot ... ..	78	16
Two clots ... ..	7	2
Three clots ... ..	1	—

In shape, the swelling is either circular or oval. When the skin over it is tense, the colour is bluish purple, but when



the skin is loose there may be no discolouration at all. When seen immediately after its appearance, the swelling is tense and cystic in character, but after the lapse of some days it feels like a pea or bean beneath the skin. In the latter condition, it is freely movable beneath the overlying skin and upon the subjacent tissues, and can be easily lifted up

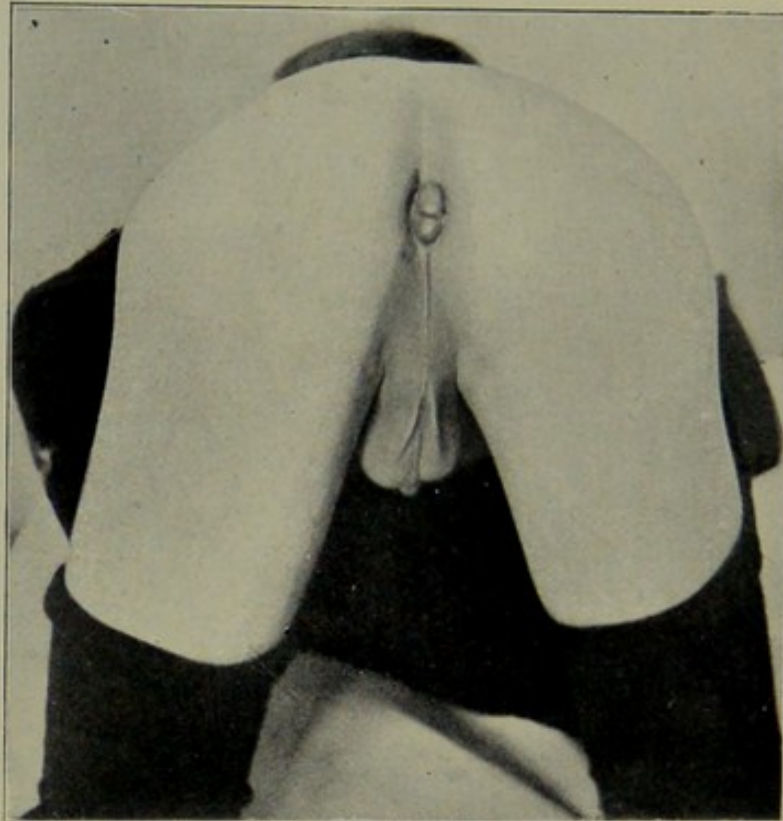


FIG. 85.—SHOWING TWO CIRCUMSCRIBED BLOOD EXTRAVASATIONS AT THE ANAL MARGIN.

The patient, aged 8 years, had impaction of fæces. The extravasation occurred during straining at defæcation. The sphincters were spasmodically contracted. The extravasation was completely absorbed in five weeks from the commencement of the palliative treatment.

[Photo taken ten days after the extravasation occurred.]

from the latter. When the clot is the seat of inflammation and impending suppuration, it becomes adherent to surrounding structures. In many cases of extravasated blood clot, the sphincters will be found to be hypertrophied, and, in the majority of them, the rectum is loaded with hardened fæces.



*Natural Termination.*

If these local extravasations are not irritated, and constipation is prevented, the blood will be completely absorbed in four or five weeks, and leave no trace of its ever having existed. When the primary extravasation has been so extensive that the skin covering it is tightly stretched, ulceration occurs on the surface (this happened in six of the 104 cases), and the blood clot is spontaneously extruded, leaving a cavity which will often slowly contract and heal, but occasionally a blind external fistula will result. When subjected to irritation, or when occurring in debilitated subjects, infection of the blood clot by pyogenic organisms is apt to take place, and suppuration to ensue (this happened in only one of the 104 cases) resulting in a marginal abscess which has been already described (see page 64).

*Treatment.*

The majority of these blood extravasations can be completely cured without any operative treatment, but, in whatever way the cure is effected, succeeding extravasations may take place should the cause again become effective. The probable reason for the extravasation should, therefore, be clearly explained to the patient, in order that he may avoid the risk of its recurrence. All cases, in which the skin over the extravasated blood is not tense or in which inflammation has not already supervened, may be successfully treated in the following manner. An aperient, of sufficient strength to ensure that the bowels will be relieved at least once or twice daily, should be given every night at bed-time. A lotion consisting of—

℞	
	Liq. Plumbi Subacetatis. ʒ ss
	Spiritus Vini Rectificati ʒ i
	Glycerini ʒ ss
	Aquæ Rosæ ʒ x

℥

should be kept constantly applied to the anal region by means



of a piece of lint or a pad of cotton wool, squeezed nearly dry and retained in position by a T-bandage. This application should be renewed every two hours for the first three days, and subsequently every four hours until absorption of the blood clot has taken place. Within forty-eight hours after the commencement of this treatment, all pain and discomfort will usually have disappeared and the swelling will be found to be much reduced in size. The patient need not be confined either to a bed or a couch, though he should, as much as possible, avoid sitting for the first few days. Under this treatment, the extravasated blood will be completely absorbed in from three to five weeks.

Another way in which these cases may be treated, is by making an incision into the tumour and turning out the coagulum, under the influence of a local anæsthetic. This is most conveniently done by introducing the left forefinger into the rectum, and rendering the seat of the extravasation prominent by compressing it between the finger and the thumb outside, in the same way as when operating for fissure (see fig. 83). While the part is held in this position, the incision should be made through the centre of the swelling, commencing at its outer margin along a line radiating from the anus. When the coagulum has been pressed out, the cavity should be sponged with some sublimate solution and plugged with a small piece of cotton wool. This plug should be allowed to come away of its own accord, and should not be renewed. An external dressing should be kept applied until the wound has healed. The objection to this operation is, that the part is painful for a week or ten days and healing of the wound is not completed under a fortnight.

When operative interference has been decided upon, and when there is no suppuration, we think that the best method is to administer a general anæsthetic, and to excise an elliptical piece of the skin over the most prominent part of the swelling.



*Method of Operating.*

The piece of skin to be removed should be about one quarter of an inch wide, and three-fourths of the length of the tumour. The excision is best effected by lifting up the skin from the surface of the tumour with a pair of dressing forceps, and removing the required piece with curved scissors. Through the opening thus made, the blood clot, in its capsule, can be readily protruded and completely removed with the scissors. All bleeding should now be arrested by pressure, and, when it has ceased (this may take twenty or thirty minutes), the edges of the wound should be carefully adjusted, without sutures, and kept in position by an external dressing.

Healing will, almost invariably, be completed within forty-eight hours after the operation. The only objection to this method is that a general anæsthetic is required. Occasionally, it is not possible to raise the piece of skin required to be removed, in which case it should be mapped out and dissected off. In doing this, there is some risk of puncturing the cyst wall, and this, should it occur, will increase the difficulty of enucleation.

In those cases in which inflammatory action has begun, the tumour should be freely laid open by either a T-shaped or crucial incision, as recommended for a marginal abscess (see page 84).

*(b) Redundant folds of peri-anal skin.*

These cutaneous outgrowths are exaggerated peri-anal folds or rugæ. They vary both in size and shape, being sometimes distinctly pedunculated, but generally sessile. In length, these folds measure, as a rule, from one quarter to three-quarters of an inch, though they may be longer. There is a certain quantity of connective tissue contained within the fold, but usually there are no distinctly dilated veins. The connective tissue is frequently the seat of inflammation, which,



when it subsides, leaves more or less induration. In this way the soft, pliant character of the fold is more or less lost, so that it ultimately stands out prominently from the surface. In the intervals between neighbouring folds, follicular secretion collects and causes excoriation and dermatitis, which may spread to the whole of the peri-anal area. The lodgment of fæcal matter between the folds also increases the irritation.

#### *Etiology.*

The most frequent primary cause of this redundancy of peri-anal skin is constipation. The over-stretching of the skin round the anal aperture, during the passage of a large and hard mass of fæces, causes the normal folds or rugæ to be slightly torn, and thus opens up the path for septic infection. As a result of this, the folds become inflamed and œdematous. When the inflammation has subsided, they do not contract to their former size and, in addition, lose some of their natural elasticity. This sequence of events is sometimes repeated with each subsequent constipated action of the bowels, and gradually leads to a marked increase in the size of one or more of the rugæ. Consequently, the crevices between adjacent folds are deeper and permit of an accumulation of follicular secretion therein. This secretion decomposes and causes additional irritation. In all cases of constipation, flatus is frequently voided and, with it, often a small quantity of rectal mucus. This mucus lodges between and around the folds and irritates them. Fæculent matter readily lodges between these folds when they have attained a certain size, and thus becomes a source of irritation. Later on, the more or less constant irritation in the anal region from the above causes, makes the patient frequently rub the part in order to allay the itching and discomfort. The rubbing still further congests the region and tends to increase the size of the folds of skin.



*Symptoms.*

If not the seat of inflammation, these folds, even when large, cause very little inconvenience beyond the difficulty experienced in cleansing the anal region after defæcation. At times there may be slight itching, especially after the passage of flatus. When inflamed, the constant smarting, irritation, and swelling induced render sitting uncomfortable, and walking painful. When the inflammation terminates in suppuration, the symptoms become those of a subcutaneous abscess (see page 62).

*Physical Examination.*

In the earlier stages, nothing more than an exaggeration of one or more of the normal rugæ will be observed. On separating adjacent folds, retained secretion or fæcal matter will be found between them. When this is wiped away, the surface under it will be found to be red, glistening, and perhaps excoriated. Sometimes the separation of the folds may cause tearing at the bottom or sides of the sulcus. In the later stages, the folds will be found much larger and, when inflamed, they will be red, œdematous, and glistening. The surrounding skin is thickened, and sometimes inflamed and excoriated in places, especially in the middle line posteriorly and also anteriorly on one or both sides. Occasionally the surrounding skin is blanched, much of its natural pigmentation having quite disappeared. This blanching may also extend into the anal canal. In any stage of the existence of these folds, it will be frequently noticed that the external sphincter is hypertrophied; that both sphincters and the levatores ani are irritable; and that the rectum is nearly always more or less distended with firm fæces.

*Treatment.*

The constipation should receive careful attention. When there are not more than two or three folds, they should be removed by scissors, the point of section being about one-



eighth of an inch above the bottom of the sulcus. This will allow the sides of the wound to come together without causing contraction of the peri-anal skin. When the folds are numerous, only two or three of the more prominent should be removed at first, lest contraction of the anal aperture should result. If, after these wounds have healed, there is no tendency to contraction, additional folds may be removed, if thought expedient. In all cases, if the external sphincter be much hypertrophied or thickened, that muscle should be carefully and completely divided on one side only (see page 239).

Should an operation not be adopted, the following method of treatment will be found useful. After thoroughly cleansing the region with warm water (without soap), it should be dried and then carefully wiped over with cotton wool which has been dipped in olive oil. By the use of the oil all the adherent secretion, as well as any ointment that may have been previously applied can be completely removed, and the subsequent remedial application can then be placed in actual contact with the irritated surface. As soon as the cleansing has been completed the following ointment should be smeared over the surface.

R		
	Zinci oxidi vel Bismuthi Carbonatis	ʒ iij
	Linimenti Camphoræ	ʒ ss
	Vaselini	ʒ i

Fiat unguentum

We usually recommend that this ointment be used as a nocturnal application, and that during the day the following powder be applied:—

R		
	Zinci oxidi vel Bismuthi Carbonatis	ʒ ss
	Pulv. Camphoræ	ʒ ij
	Pulv. Amyli	ʒ x

Fiat pulverem



In some instances the camphor is objectionable to the patient, and, if so, a corresponding quantity of starch should be added in the place of it.

(c) *Dilated peri-anal veins.*

The superficial veins of the anal margin, forming the communication between the superior and inferior hæmorrhoidal venous plexuses, occasionally become dilated, and involve the whole circumference of the anus. To this condition of dilated peri-anal veins, we consider the term *external piles* should be alone applied. During a straining effort, when the veins are distended with blood, there is a subcutaneous, compressible, and more or less uniform swelling surrounding the anal orifice, the skin becoming stretched but not œdematous. After the straining has ceased for some time, the swelling almost completely subsides, leaving the skin round the anus loose and redundant, but not thrown into distinct folds. There is no induration or excoriation of this redundant skin.

*Etiology.*

This condition is due to difficulty in defæcation, caused by hypertrophy and irritability of the sphincters. The constant straining thus engendered causes turgescence of these veins, while the spasmodic action of the sphincters impedes the venous return, with the result that the walls of the veins become over stretched and remain permanently dilated.

*Symptoms.*

The mere dilatation of the peri-anal veins gives rise to little or no inconvenience, beyond the swelling and a feeling of fulness at the anus. Consequently the patient seldom seeks relief solely for this condition. His chief complaint is the constant difficulty experienced in defæcation. Feeling that his bowels should be relieved, he cannot, even by persistent straining, void the whole of the contents of the rectum, and is sometimes obliged to make several attempts before obtain-



ing complete relief. Often he is driven to aid expulsion by introducing a finger into the rectum. Much soreness and discomfort are generally complained of after the bowels have acted. There is also a dull aching sensation, together with a feeling of fulness in the part, after an unsuccessful effort has been made to secure an evacuation.

*Physical Examination.*

When the patient is not straining but resting quietly on his side, the anal skin is observed to be loose and redundant and the anal orifice firmly closed.

When a straining effort is made, the patient being on his side, the anus becomes prominent and is forced down to the level of, and in some instances beyond, the plane of the ischial tuberosities; and then the anal skin becomes distended, creating a distinct fulness round the whole circumference of the anal margin. The anal orifice is now seen to be firmly contracted, and to form the apex of a cone-like prominence. During the straining, a small quantity of flatus and rectal mucus may escape, but, on account of the spasmodic action of the sphincters, we have never seen any solid fæces passed.

When the finger is introduced into the rectum, the sphincters grip it tightly and impede its easy introduction. When the finger is fully inserted, the extent of the hypertrophy and thickening of the sphincters can be easily appreciated. The rectum will be found to be dilated, and often filled with a large quantity of firm fæces as well as flatus, constituting the condition known as *ballooning* of the rectum. In women, the chronic distension of the rectum caused by the spasmodic action of the sphincters, sometimes produces a rectocele, which should be looked for at the time of examination.

It must be borne in mind that these external piles are often complicated by the presence of internal piles, which should in all instances be carefully looked for. Even though



internal piles may have attained some size and have existed for a considerable time, they generally afford no external indication of their presence, because prolapse seldom occurs on account of the spasmodic contraction of the sphincters and consequent narrowing of the anal orifice. Hæmorrhage, occurring during the period of difficulty in defæcation, is an almost certain sign that internal piles are developing, and should be regarded as an additional indication of their probable presence. The recognition of the presence of internal piles in these cases is very important, because, after division of the external sphincter, the undue narrowing of the anal canal will have been remedied and the obstacle to their prolapse removed. Consequently the patient, though relieved of the symptoms for which he sought relief, will soon experience discomfort from the protrusion of the internal piles, and will have to undergo a second operation, which could have been easily performed as a part of the first.

#### *Treatment.*

The only method that will permanently cure this condition is an operation. When, from any cause, an operation cannot be performed, an injection of one ounce of olive oil (to be retained all night) will greatly facilitate defæcation. The motions also should be kept soft by gentle aperients and by attention to diet.

#### *Operation.*

Under the influence of a general anæsthetic, the external sphincter should be completely divided in the right posterior (R.P.) quadrant. The effect of the division of the external sphincter is to suspend its action, for the time being, and bring about absorption of the induration between the muscular fibres. Should an internal pile be present, it should be removed by ligature (see p. 290). Finally, the anterior margin of the wound, made by dividing the external sphincter, should be treated in the following way. An



incision, involving nothing but the skin, should be commenced three-eighths of an inch in front of the wound at the mucocutaneous junction. From this point, the incision should be carried, outwards and backwards in a slightly curved direction, so as to end in the outer extremity of the incision through the external sphincter. The piece of skin thus mapped out, together with the corresponding piece of mucous membrane above it and the dilated veins under it, should be included in a ligature and tightly strangulated. It is not absolutely necessary to remove this margin of the wound, but as it will, if left, become œdematous and fall into the wound, healing will be considerably delayed, and, therefore, time will be gained by its removal. The wound should now be plugged, so that healing by granulation may be obtained.

When cicatrisation has taken place, it will be found that a motion can be easily passed without undue straining, and that the circum-anal veins no longer become so greatly distended. If, after an interval of two or three months from the operation, it be found that the skin of the anal margin is inconveniently redundant, portions of it, together with the subjacent veins, should be removed.

#### *After Treatment.*

The details of the after treatment are the same as those for internal piles (see page 292).

### INTERNAL PILES.

By the term "internal piles" we understand that the veins of the sub-mucous tissue of the lower portion of the rectum, usually, if not invariably, of the last two inches and a half, are in a varicose condition, the rootlets of each venule being elongated and tortuous, so as to form distinct and localised clusters beneath the mucous membrane, which is distended over them. The vein emanating from each cluster passes upwards in the sub-mucous tissue, and soon losing its



varicosity, causes no further swelling under the mucous membrane. From this arrangement it is clear that the swelling beneath the mucous membrane is more or less pear-shaped, the lower end of the bulbous extremity being situated at the muco-cutaneous junction, while the tapering end is directed upwards, and usually extends for about one and a-half inches, so that a pile is usually of corresponding length.

In the right anterior quadrant, the varicose condition usually extends upwards for from one and a-half to two and a-half inches from the muco-cutaneous junction and, so far as our experience goes, this particular pile extends further up the bowel than any other associated with it in the same patient. In most cases of internal piles, several of these tumours co-exist, arranged more or less parallel to one another, the number varying with the duration of the disease. It has been said that a second ring of internal piles may exist at some little distance up the bowel, above that which we have described, forming, in such instances, a double ring. We have no recollection of having seen such a case, though we agree that the mucous membrane of the upper part of the lower half of the rectum may become so movable over the muscular coat, as to be invaginated into the portion of the bowel below it, and at times, even to be protruded at the anus. In such cases, a careful examination will show that the upper ring consists only of a reduplication of mucous membrane, with nothing more than normal connective tissue existing between the layers, there being an absence of compressible veins, such as can be always felt in a internal pile. Moreover, it will be noticed that the colour of this invaginated portion is similar to that of the rest of the mucous membrane of the bowel, or, when there is congestion of the minute vessels of this part of the mucous membrane, even brighter in colour. In other words, in an internal pile, the disease exists in the veins of the



submucous tissue ; whereas, in invaginated mucous membrane, any pathological change is in the mucous membrane itself. This upper ring of mucous membrane cannot, therefore, be described as internal piles.

### *Structure of an Internal Pile.*

If an internal pile be removed and dissected, it will be found to consist of a central artery, a mass of dilated veins, and a quantity of connective tissue. The central artery is one of the terminal branches of the superior hæmorrhoidal and is usually greatly increased in size, its magnitude occasionally being as great as that of the radial at the wrist. The veins are dilated branches of the venous tufts (see page 32), from which the rootlets of the superior hæmorrhoidal vein arise and form the greater part of the bulk of the tumour. The dilatation does not always involve the entire circumference of the venule, as in simple varicosity, but more often consists of saccular bulgings at one or more points. Accordingly, the naked-eye appearance is one of a number of saccules\* communicating with veins by minute apertures. Occasionally, the blood contained in a saccule coagulates, and the clot becoming organized is eventually transformed into fibrous tissue. Such coagulation and subsequent fibrous transformation occur when the pile is of long standing and has been the seat of inflammation, with the result that all the veins become obliterated, and the bulk of the tumour consists of fibrous tissue.

The connective tissue is disposed between and around the veins, and is nearly always much increased (hyperplasia) by the round-cell exudation resulting from the impeded venous return. The connective tissue elements are further increased by inflammation and by the organisation of thrombi.

---

\* A good example of this condition can be seen in specimen No. 2594 at the Museum of the Royal College of Surgeons of England.



*Stages of Development.*

In the development of an internal pile, three well marked stages may be observed.

*In the first stage*, the hæmorrhoidal tumour is not protruded through the anal canal, although its presence, as a pile, can be readily recognised, either by digital examination or with a speculum.

*In the second stage*, owing either to increase in bulk or the stretching of its attachment to the wall of the rectum, the pile is protruded through the anal orifice during defæcation, returning spontaneously into the bowel as soon as the expulsive effort has ceased.

*In the third stage*, the increase in size and the elongation of its attachment, result in the pile being constantly protruded, unless the patient remains recumbent for some time.

*Position of Internal Piles in Reference to the Rectal Wall.*

Referring to the description of our method of sub-dividing the anal margin into fixed points for convenience of description (see page 51), we find that piles may be situated in any of the following positions, viz. : R.A., R., R.P., P., L.P., L., L.A., and A.

The R.A. pile usually stands alone, the R. and R.P. are very often coalesced, the P. may be distinct, the L.P. and L. are, as a rule, coalesced, the L.A. is sometimes coalesced with the L., while the P., a very rare form of pile, is almost constantly, in our experience, distinct.

The number of piles met with in a given case may vary from one to seven.

*The Various Combinations of Individual Piles with each other.*

In all patients below the age of twenty years who have internal piles, the R.A. pile is invariably met with, and



usually alone. Should other piles be present at such an age they will probably be the R. and R.P., or, if the case be one of exceptional severity, the L. or the L. and L.P. may also co-exist. In patients above the age of twenty years, the R.A. may exist either alone or with any number of others up to seven. When seven are met with, they take the following order: R.A., R. and R.P. (coalesced), L.P. and L. (coalesced), while the single piles, P. and L.A., remain distinct as two small piles wedged in between their larger neighbours. The A. pile is very seldom met with. When it exists, it is either distinct or coalesced with the L.A., or even partly attached to the R.A.

### *Etiology.*

There are various causes that may lead to the formation of internal piles, and of these the most important are:—

*Occupation.*—A sedentary occupation appears to have the greatest influence in causing piles, both in the male and the female sex. Of 504 cases in males, 323 were sedentary; while among 176 female patients, as many as 162 led a sedentary life. These 680 cases were met with in hospital practice.

A laborious occupation, often involving great straining, especially when intermittent, is a potent factor in the causation of piles.

The following special occupations were followed by 96 of the 504 male patients:—

Clerks	26	} Sedentary = 76		Sailors	10	} Active = 20
Publicans	11			Travellers	10	
Tailors	16					
Bootmakers	23					

*Age.*—The average age compiled from 504 males was forty years, the youngest being thirteen and the oldest eighty-four. Of 176 females, the average age was thirty-eight years, the youngest being two and the oldest seventy-two. The following table, arranged in the decades of life, shows very well



the time of life in males and females at which piles are most commonly met with.

*The table showing the relative frequency with which Internal Piles are met with in the various decades of life.*

	Hospital Cases.		Private Cases.	
	Males.	Females.	Males.	Females.
1st decade	0	1	0	0
2nd „	12	4	0	1
3rd „	72	45	8	4
4th „	146	47	20	16
5th „	145	44	23	10
6th „	79	26	21	4
7th „	41	8	6	2
8th „	8	1	1	1
9th „	1	0	0	0
	504	176	79	38

*Sex.*—In our experience, internal piles are met with three times more frequently in males than in females; thus, in 797 cases taken from hospital and private practice, 73 per centum were met with among males and 27 per centum among females. Among private patients 68 per centum were males and 32 per centum females, and in hospital patients 74 per centum were males and 26 per centum females.

*Constipation.*—The greater prevalence of internal piles in the male sex is most probably due to the fact that men, by reason of their occupations, are less able to devote attention to daily defæcation than women. It is obvious that a man who is obliged to take a long journey to his work, at an early hour in the morning, must often have to leave home before an evacuation takes place. The result is that the rectum is frequently converted into a temporary reservoir in which, the longer the fæces remain, the harder the mass becomes from absorption of moisture, and therefore the greater is the difficulty in expulsion when an opportunity offers. The



increased straining required to expel such retained and hardened fæces, in addition to the obstruction to the venous blood caused by the presence of fæcal masses in the rectum, must have considerable influence in promoting the development of internal piles.

The rectum is physiologically intended to act, not as a reservoir, but as an expelling apparatus. In long standing cases of constipation, and in all cases of piles which have been associated with constipation, fæces are always found in the rectum unless the bowels have recently been completely relieved by an aperient or an enema. This proves that if the rectum be often made use of as a reservoir, it loses its natural intolerance of the presence of fæces, and through atony of its muscular coat due to hyper-distension, becomes less and less able to completely expel its contents. It must have come within the experience of many, that when the act of defæcation has been postponed, the volume of flatus voided is greatly increased during the period of retention of fæces, and, therefore, in addition to the venous congestion caused by the presence of fæces in the rectum, there is also added the frequent bearing down to pass flatus.

Those who suffer from internal piles nearly always give a history of having had either constipation or diarrhœa. In this country, habitual constipation almost invariably precedes their appearance. We have seen a few cases which have been caused by diarrhœa, but this is rare in England, though in tropical climates diarrhœa is said to be the frequent exciting cause. Before hæmorrhoids make their appearance, constipation often exists for ten or twenty years, during which period an action of the bowels has probably taken place naturally only once or twice a week, with the result that the rectum has never been quite free from fæcal accumulation. The fæces retained in the rectum become hard, and necessitate considerable straining before anything can be passed, but as the rectum is over-distended and cannot mould the



fæces, the anal canal has to be either greatly stretched or torn before the rectum can be emptied. In some subjects this repeated hyper-dilatation of the anal canal leads to one of two things—either to a fissure and subsequent hypertrophy of the sphincters (notably the external), or to over-stretching of the sphincters and diminution of their contractile power. When a fissure results, the constipation is for a time voluntarily increased, because the patient soon discovers that each action of the bowels is followed by more or less pain or irritation, and that a day without an action is one free from both pain and discomfort. Accordingly, this aggravated constipated state and the increased difficulty in obtaining an evacuation have a powerful influence in the production of hæmorrhoids. The recollection of pain is fortunately short-lived in the human mind, and, therefore, when a patient gives the history of piles he frequently ignores the period when pain was the predominant symptom; while the constipation which still continues, the hæmorrhage, and the pile itself are alone present in his mind. In support of this observation, we would suggest that the anal region should be carefully examined in every case of internal piles in the third stage of their development, because the cicatrix of a pre-existent fissure will be frequently found, the fissure having been permitted to heal by the almost continuous stretching of the sphincters produced by the constantly protruded internal piles.

*Parentage.*—Heredity appears to have considerable influence in the causation of internal piles in the first three decades of life. In such young patients, it is by no means unusual to find that one or both parents have been operated upon for piles. Under the age of twenty years, the disease appears nearly always to have been predisposed to by heredity; and, indeed, it is our experience that in such instances a careful inquiry will nearly always elicit the history of the prevalence of piles in other members of the family.



*Pregnancy* frequently operates as a causative factor of internal piles. A reference to the table on page 271 will show that they are more prevalent among women during the child-bearing period, than either before or after it. It has occasionally come under our notice that patients, advanced in life and suffering from constipation and pruritus ani, have stated that at the time when they were bearing children they had suffered from internal hæmorrhoids, though at our examination there was no evidence, beyond the constipation, that they had suffered from them. This fact should be borne in mind in making a prognosis upon a case of hæmorrhoids, seen either during a pregnancy or soon after it. Any abdominal distension, causing much downward pressure, will have a similar effect in producing temporary piles; so that when we see a patient, during or soon after pregnancy, suffering from internal piles we usually, unless these are constantly prolapsed, advise her to postpone any operative treatment until after the child-bearing period, when, in many instances, the need for an operation will have completely disappeared.

*Disease of Pelvic Viscera.*—Affections of the bladder and urethra, such as enlarged prostate and stricture, by reason of the straining during micturition, lead to engorgement of the hæmorrhoidal viens. Prostatic enlargement accounts, we think, for piles being frequently met with in males above the age of fifty years, especially if they did not begin to make their appearance before that age.

### *Symptoms.*

The symptoms of internal piles are hæmorrhage, pain, protrusion, and discharge of mucus. In the majority of cases, bleeding is the first symptom observed by the patient.

### *Hæmorrhage.*

Hæmorrhage occurs primarily only when the bowels are relieved, and may vary in quantity from a few drops to a



considerable loss of blood. In cases of slight bleeding, the motion passed may be found to be streaked with blood, or the material used in cleansing the anus may be smeared with it. The quantity lost depends in a great measure upon the consistence of the excrement, scybala causing far more hæmorrhage than softer fæces, while a liquid motion may be passed without any loss of blood. The above is the condition of things met with in cases in which hæmorrhoids do not descend outside the rectum, that is to say, in the first stage of their existence. In the second stage of hæmorrhoidal development, *i.e.*, when the piles protrude from the anus at each act of defæcation, but spontaneously return into the rectum, the hæmorrhage may be profuse, especially when the fæces are scybalous, necessitating the patient straining very much to complete the action of the bowels, and thereby forcing the piles down in front of the mass to be voided. It is in this, the second stage, that, in our experience, the most severe hæmorrhage from piles is observed. The reason for this, we think, is that the rectal mucous membrane, still retaining much of its natural delicate structure, is easily torn through by the straining or is abraded by the scybala. In such cases, or, indeed, in any case of hæmorrhage from piles in which the loss of blood does not cease either immediately or very soon after they have been returned into the rectum, careful search should be made to ascertain whether the hæmorrhage is coming from a single point on the surface of one of them. We have, on several occasions, observed this to be the case in severe and continued bleeding. In this connexion, we may observe that, from a clinical point of view, hæmorrhage may take place from prolapsed piles in two distinct ways, which can be observed by watching the result when the patient is requested to strain down forcibly. In the majority of cases, the blood will be found to gently ooze from the surface of one or more piles as long as they are protruded, the constricting influence of the sphincters impeding venous return. This



form of bleeding ceases almost immediately after the piles have been returned into the rectum, the hæmorrhage returning with the next protrusion of the piles. In other instances, the bleeding will be found to take place from a spot on the surface of one of the piles, flowing in a small continuous stream, the trajectory of which may measure from three to nine inches in length. This form of bleeding may not, for some time, be arrested by merely returning the pile into the rectum. The vessel may continue to bleed into the rectal cavity. This circumstance explains the clinical fact that sometimes, after a good action of the bowels, a patient suffering from hæmorrhoids complains that the desire for defæcation recurs in the course of a period varying from a few minutes to half an hour, and finds that the second action consists chiefly, if not entirely, of pure blood. These patients are usually very pale and thin.

In the third stage of hæmorrhoidal formation—*i.e.*, when the piles do not spontaneously return into the rectum but require manual reduction, the prolapse again taking place on slight exertion, such as standing or walking, as well as with every act of defæcation—bleeding is the exception, a discharge of rectal mucus taking its place. When the surfaces of these piles are examined, the mucous membrane will be found to have undergone considerable structural change at its lower part, the epithelial covering being greatly thickened, so as closely to resemble epidermis. This altered mucous membrane is very much paler in colour than the normal, and, when dried, its surface does not readily become moist again. Moreover, gently rubbing the surface will not always cause bleeding, as would happen in the case of a pile covered with normal mucous membrane. Microscopically the epithelium of the altered mucous membrane is seen to have become metamorphosed, the single layer of columnar cells having been changed into several layers of stratified epithelium (see fig. 86).



*Pain.*

Pain is a frequent accompaniment of piles, and is generally of the referred character, being situated over the dorsal aspect of the sacrum, or in the lower lumbar region. As such it may exist whether the piles are prolapsed or not.

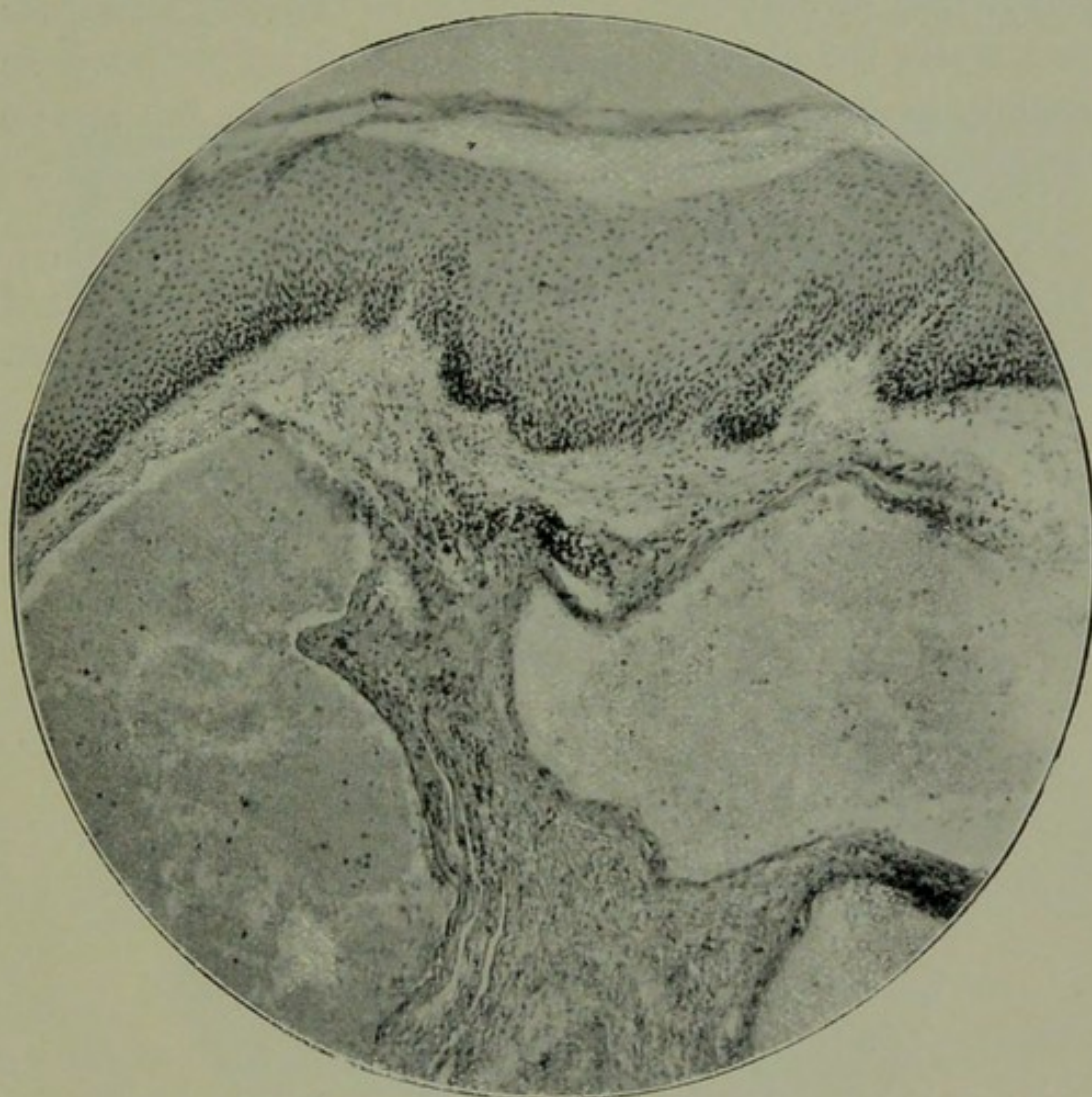


FIG. 86.—SHOWING THE ALTERATION IN THE CHARACTER OF THE EPITHELIUM IN A PILE IN THE THIRD STAGE OF ITS DEVELOPMENT.

The section shows two dilated veins with an increase in the intervening connective tissue. The metamorphosis of the columnar into stratified epithelium is well shown.

[*Micro-photograph.*]

Local pain is present when they are prolapsed, and is then of a throbbing character, ceasing almost immediately after reduction, if no other disease, such as fissure, ulcer, fistula, or malignant growth, complicates the case. When complicated



by other disease, local pain is present both when the piles are prolapsed, and also for some time after they have been reduced. When of an intermittent character, it will be found that either a fissure or an ulcer coexists; but when the pain is of a continuous or bearing-down nature, a malignant growth may be suspected, and should be carefully sought for by carrying the digital exploration as high up the bowel as possible, in order not only to examine the rectum, but also to ascertain the condition of adjacent pelvic viscera.

*Protrusion.*

Protrusion of an internal pile through the anus does not occur during the first stage, although it may be the first

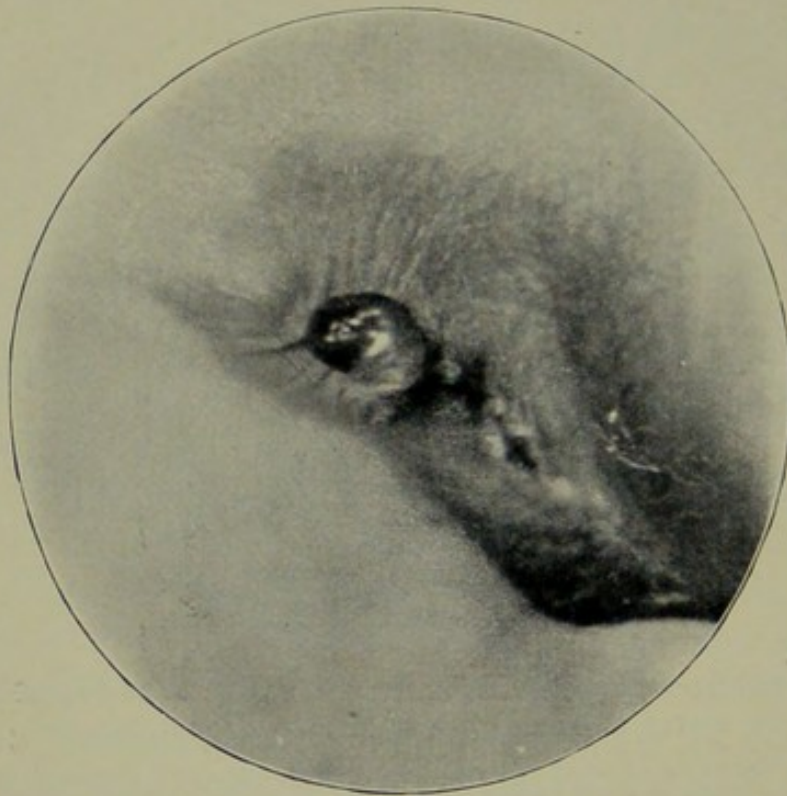


FIG. 87.—SHOWING THE R.A. INTERNAL PILE PROTRUDED.

symptom observed by the patient. When protrusion actually takes place, the second stage may be said to have been reached, and from that time the symptom becomes more and more pronounced until the third stage is arrived at, when the



piles invariably protrude during defæcation, active exercise, or prolonged standing. The R.A. pile is usually the first to protrude (see fig. 87), and may always be observed in a case of protrusion unless it has previously been removed by operation, or has sloughed away as the result of spontaneous strangulation. The protrusion next affects the R.P. or the L.P. pile (see fig. 89). During the second stage of internal

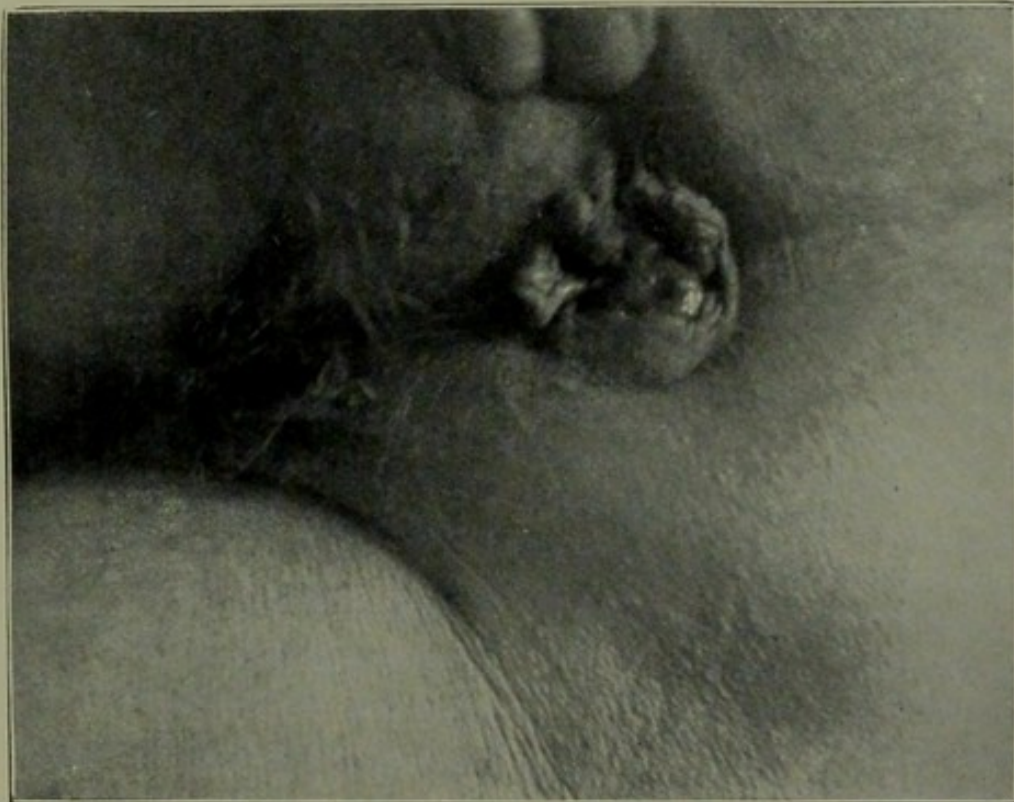


FIG. 88.—SHOWING THE R.P. INTERNAL PILE PROTRUDED.

The R.A. internal pile is absent. There is a polypoid growth attached to the R.P. internal pile. The peri-anal skin is redundant throughout.

piles, the protrusion is reduced spontaneously and, therefore, causes little inconvenience unless it becomes strangulated by the spasmodic action of the sphincters when, if not artificially reduced, it will become gangrenous and either partially or completely slough. During the third stage, on account of the relaxed condition of the sphincters, the protrusion is almost continuous so long as the patient is not recumbent.



*Discharge of Mucus.*

This symptom of piles is met with chiefly in their third stage. Owing to the piles being almost continuously protruded during the day time, the sphincters become relaxed and allow mucus to escape from the bowel. The quantity

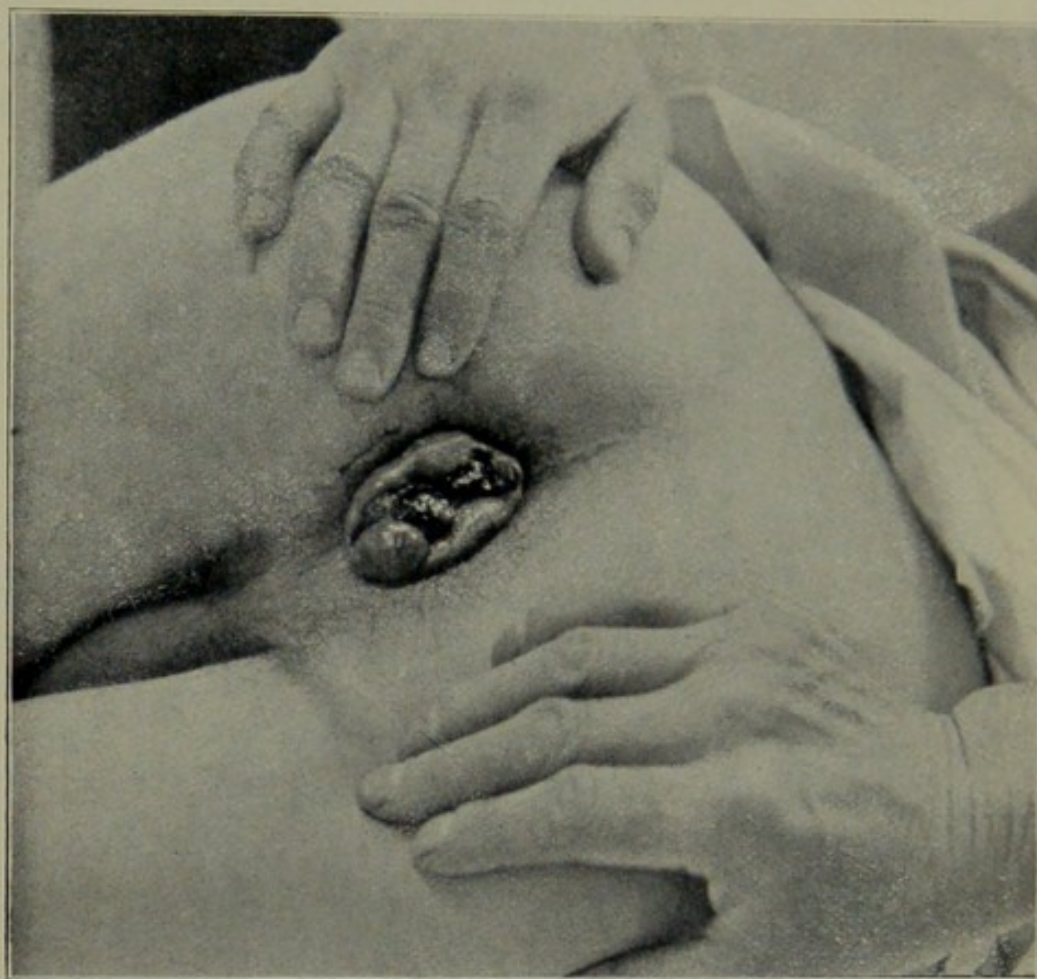


FIG. 89.—SHOWING BOTH THE R.A. AND THE R.P. INTERNAL PILES PROTRUDED.

The whole of the peri-anal skin is œdematous on account of the obstruction to venous return which was produced by prolonged straining during defæcation. The internal piles are not strangulated. The R.A. portion of the peri-anal skin is well defined.

of mucus discharged, in these cases, is much in excess of the normal secretion, as during the digital examination of a healthy rectum no appreciable quantity can usually be detected, nor can much be expelled when the patient strains



down. This increase of the secretion, during the third stage of haemorrhoids, is no doubt due to reflex hypersecretion consequent upon the irritation and congestion of their mucous coat when protruded. In support of this view we have on many occasions observed that the copious dis-

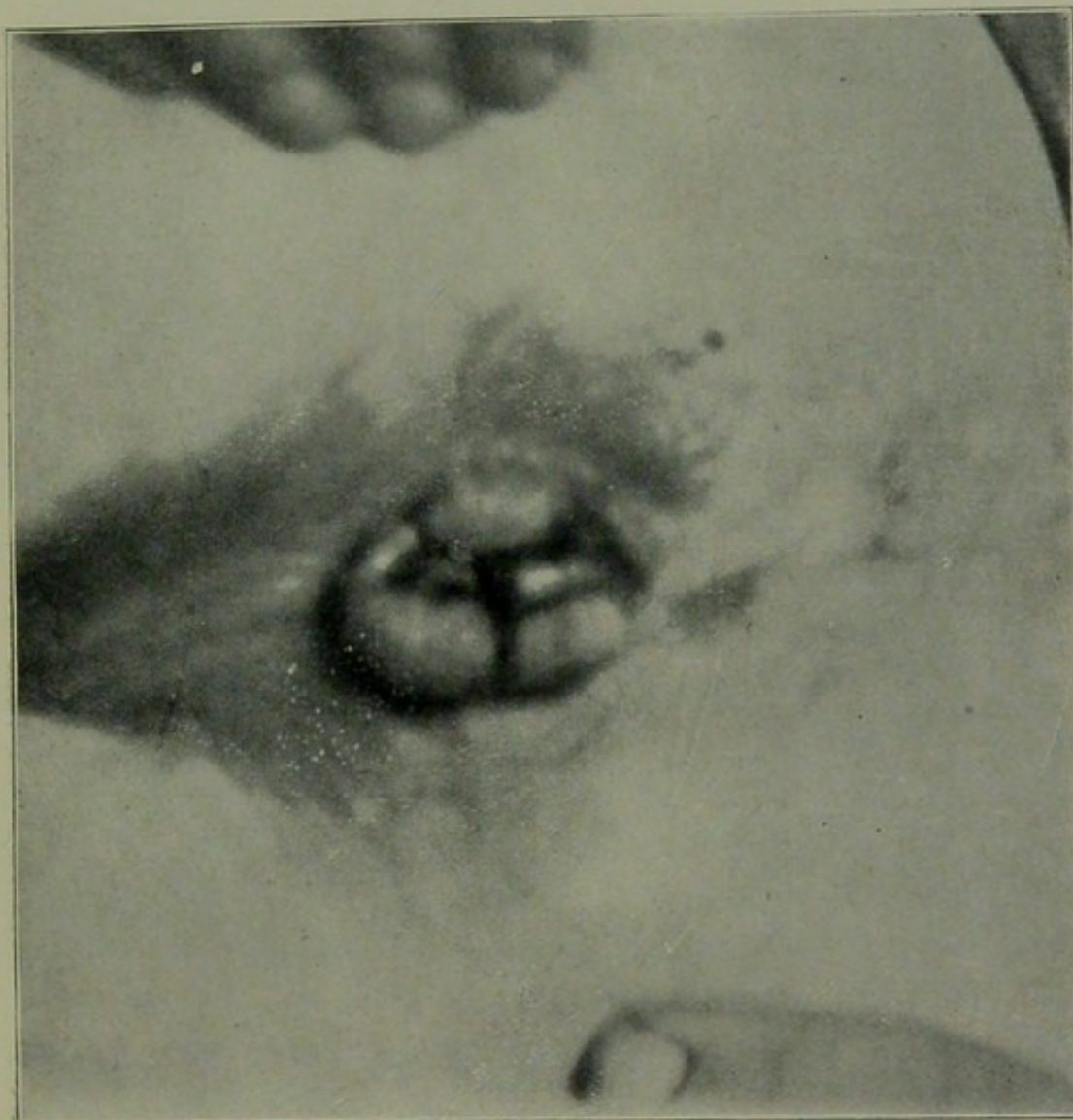


FIG. 90.—SHOWING THE ŒDEMA OF THE PERI-ANAL SKIN IN A CASE OF STRANGULATED INTERNAL PILES.

In this case, the divisions between the œdematous folds of peri-anal skin are well shown, that on the right side being especially well marked. The R.A., the R.P. and the L. folds are clearly defined. The R.A. and the R.P. internal piles can also be distinctly seen, but the L. internal pile is not sufficiently protruded to come into view.

charge of mucus entirely ceased soon after the piles had been removed. When this hyper-secretion exists, the discomfort caused to the patient by the underclothing adhering



to the anus is very great, and frequently is the chief object for which he seeks relief. The prolapsed piles themselves cause little or no inconvenience, except, perhaps, that they interfere with the cleansing of the part after defæcation, and sometimes diminish the power of walking. In some instances, as a result of the constant escape of rectal mucus, the perianal skin becomes much irritated. This condition also disappears within a few weeks after the removal of the piles.

#### *Physical Examination.*

When examining a patient for internal piles, attention should first be paid to such morbid signs as can be seen externally, then the condition of the sphincters should be inquired into, and, finally, a thorough exploration of the rectum and neighbouring pelvi-viscera should be made.

#### *Anal Inspection.*

In cases of internal piles, one or more folds of skin, soft, elastic, and sessile, are nearly always met with round the anal margin, the fold situated in the R.A. quadrant of the anus being most constant. Such folds, owing to their elasticity, if lifted from the surface of the external sphincter between the finger and thumb, return to their original size and shape when the traction upon them has been removed. The extent to which such folds can be enlarged is well illustrated in a case of strangulated internal piles of about twenty-four hours duration (see fig. 90). This œdema is due to the obstructed venous return, and not to inflammation. On separating the buttocks and requesting the patient to strain down, the anus is forced below its natural position, the sphincters relax, and the piles, when they have reached the second and third stages of their development, come into view. In women, the R.A., the L.A. and the A. internal piles, if developed, may be easily protruded through the anus by



inserting the index finger into the vagina and pressing upon the part of its posterior wall (see fig. 91).

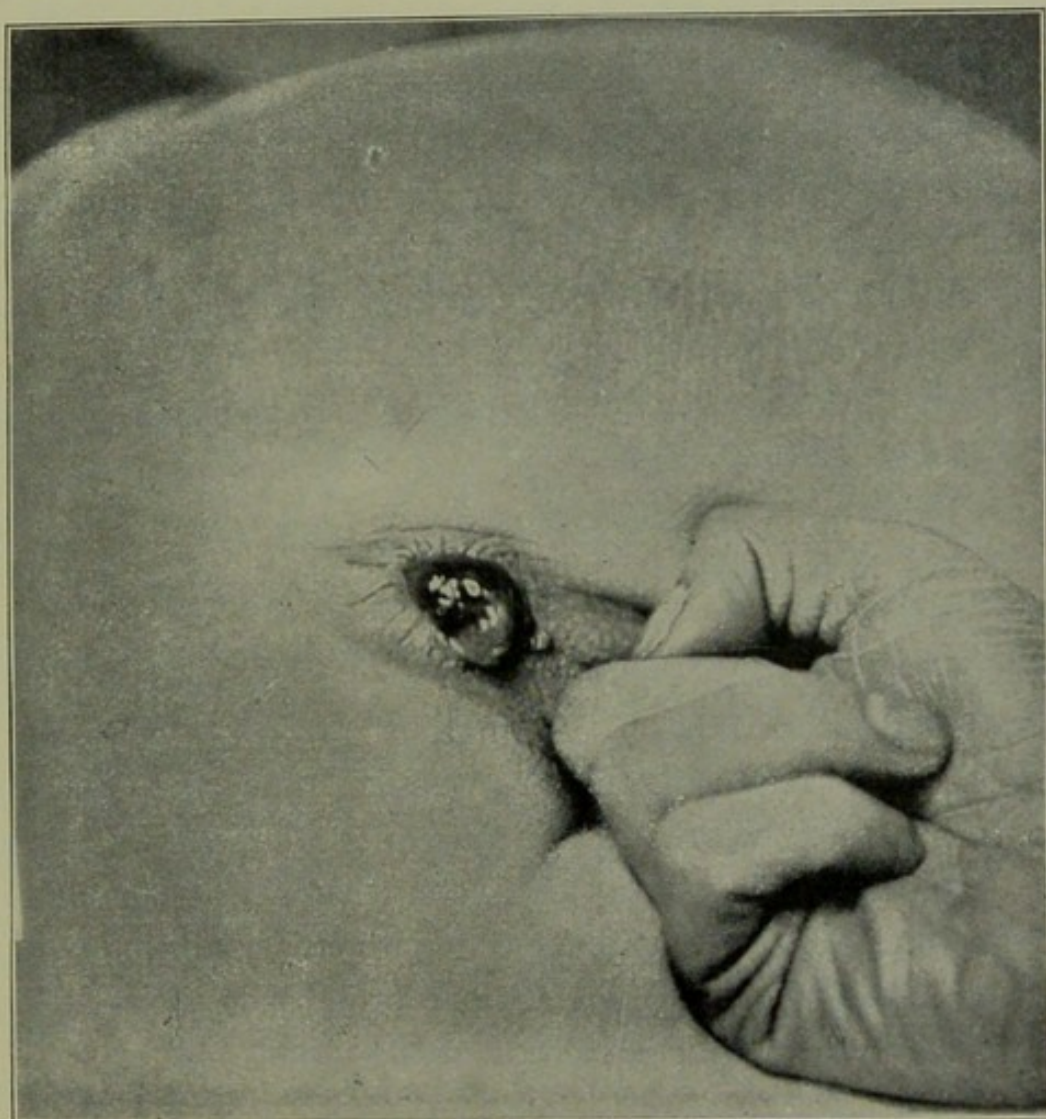


FIG. 91.—SHOWING THE A. INTERNAL PILE PROTRUDED BY THE AID OF THE FINGER IN THE VAGINA.

This is a very good example of the A. internal pile which is, as we have already said seldom developed.

In a few cases, the anus will be forced outwards beyond the level of the ischial tuberosities, the anal region becoming cone-shaped prior to the dilatation of the anal orifice, which forms the apex of the cone. In such a case, the sphincters (notably the external), will be found much hypertrophied and more or less rigid, thus preventing the natural expansion of the anal orifice. The piles are not, under these



circumstances, readily protruded, parts only of one or two of them being visible after much straining.

*Condition of the Sphincters.*

In long-standing cases of piles, especially when in the third stage of their existence and in those without any previous history of a fissure or an ulcer, the sphincters do not close spasmodically under the stimulus of digital examination, and, in fact, do not appear to possess the normal standard of contractile power.

When hæmorrhoids are complicated by a fissure or an ulcer of the rectum, any attempt at making a digital examination immediately excites spasmodic contraction of the sphincters, and renders the examination extremely painful to the patient.

In those cases in which a fissure or an ulcer has previously existed, but at the time of examination is found to be soundly cicatrised, the exploring finger, when introduced to its full extent, may meet with so much resistance from the thickened and hypertrophied external sphincter that it will completely fill or even stretch the anal canal. With this condition of the external sphincter, the piles are not prolapsed, though they may bleed freely with each action of the bowels.

*The Examination of the Rectum.*

On introducing the finger into the rectum in the usual manner, no hæmorrhoid will be felt, the mucous membrane being equally soft and movable in all directions, as far upwards as the finger can reach. If now the finger be partly withdrawn, so that only the terminal phalanx remains in the bowel, and if this be swept from side to side, maintaining gentle pressure upon the rectal wall, the existence of the piles may be readily appreciated as redundancies of the inner coat of the rectum. The R A. pile is most easily recognised because it extends further up the rectum, and is usually more



developed than the rest. The R. and the L. piles can also be made out in the later, but not in the early, stage of their formation.

So far as our experience goes, piles cannot with certainty be detected by the finger in any other way than in the manner above described. If the finger be now re-introduced to its full extent, some fæces will always be found in the rectum, unless the bowels have been recently emptied by a very efficient saline aperient or an enema. In fact, the usual condition of the cavity of the rectum, in cases of hæmorrhoids, appears to be that of partial distension with fæces. In order to establish this fact, we have examined several patients within an hour or so after a natural evacuation of the bowels had taken place, and have invariably found fæces in the rectum, the lower portion of the bowel being found free from fæcal accumulation, while the upper part was considerably distended, showing that the ordinary act of defæcation simply served to get rid of the overflow from the fæcal reservoir. This habitual presence of fæces in the rectum must have considerable influence in producing varicosity of the hæmorrhoidal veins.

### *Treatment.*

The treatment of internal piles may be either *palliative* or *operative*.

#### *Palliative treatment.*

This treatment should always be tried in the early stage of hæmorrhoidal disease—certainly in all cases in which the piles are never protruded; and also in the second stage when protrusion takes place only at the time of defæcation, and the piles return into the rectum, of their own accord, directly the act has been completed. In both these stages of hæmorrhoidal formation, hæmorrhage is the chief symptom for which patients seek advice, although constipation, in this country, at any rate, is almost invariably present. Should



the case be complicated by stricture of the urethra, prostatic enlargement, vesical calculus, or neoplasm, these conditions must be attended to as the first step in the treatment of the piles. It is not uncommonly found that they are caused or aggravated by those conditions, and, therefore, they may be relieved or even cured by the alleviation of the exciting cause, and thus render an operation quite unnecessary. In women, also, it should be borne in mind, that piles are not infrequently produced or, at any rate, aggravated during the later stages of gestation, and also during parturition. If such cases are watched and treated with mild aperients and the nightly injection of olive oil, it will be frequently found that the hæmorrhoids either completely disappear or become so far relieved that no surgical treatment whatever is desirable.

*Constipation* should receive the first consideration, and at least one daily evacuation should be ensured.

*Hæmorrhage* is most efficiently relieved by the administration of preparations of iron, the sulphate being, perhaps, most satisfactory. This should be prescribed in doses of (gr. i.-iii.), combined with sulphate of magnesia (gr. xx.-xl.), to be taken three times during the day. When the hæmorrhage takes the form of a general oozing from the surface of the piles, the following preparations may be used for local application, viz.: Perchloride of iron, nitric acid, hazeline, or carbolic acid. When the hæmorrhage is seen to take place from a single spot upon the surface of one of the piles, the bleeding point should be ligatured just in the same manner as one would apply a ligature to an artery. The ligature then should be cut short and the pile returned into the rectum. An anæsthetic need not be given for this little operation. All that is necessary for the after treatment is to keep the bowels confined for about ninety-six hours, at the end of which period they should be freely relieved by



aperients, so that a full evacuation is obtained then and every twenty-four hours afterwards.

Applications of a lubricant nature, such, for instance, as the injection of one ounce of olive oil at night and its retention until the following morning, are extremely useful in preventing hæmorrhage, because by thus softening the fæces and preventing the cohesion of scybala, engorgement of the hæmorrhoidal veins is avoided, and the surface of the piles is not abraded by the passage of hard motion during defæcation. An ointment of sub-chloride of mercury or suppositories of cacao butter, when passed into the rectum immediately after defæcation, are especially beneficial as their use ensures the complete reduction of any prolapsed pile above the grip of the external sphincter. Continuance of the hæmorrhage is thus avoided by preventing the prolapsed pile from remaining within the constricting influence of the external sphincter.

*Pain.*—Lead lotion (see page 257) is useful when there is much throbbing sensation in the piles, or when the folds of the skin of the anus are swollen, and it should be kept continuously applied to the anus for a week or more.

*The Diet* should be arranged by eliminating from it all substances which tend to constipate the patient's bowels. Rice, or any of the various preparations derived from it, should always be avoided. Alcohol in any form, we are of opinion, should not be ordered in cases of piles; and if a patient be in the habit of taking it habitually he should be directed to discontinue its use, as we have observed that progress is much more satisfactory without the aid of stimulants than with them.

### *Operative Treatment.*

Various methods for the operative cure of hæmorrhoids have been from time to time adopted, among which the following may be mentioned, viz. :—

(a) *The application of nitric acid.*



- (b) *Transfixion by needles and subsequent ligature.*
- (c) *Operation by clamp and cauterly (Henry Smith's operation).*
- (d) *Operation by clamping and removing with a fine saw (Gowlland's operation).*
- (e) *Operation by crushing (Pollock's operation).*
- (f) *Injection of carbolic acid, hazeline, &c.*
- (g) *Operation by ligature (Salmon's operation).*
- (h) *Operation by excision of the pile-bearing area and suturing the rectal mucous membrane to the skin (Whitehead's operation).*

#### *Choice of Operation.*

We always make use of the *ligature*, and have no hesitation in urging other surgeons to adopt it as the best operation for all cases of internal piles. Our reasons for so doing are that the pile and only the pile need be removed by it; that the quantity of blood lost during the operation is very small, a most important consideration for the patient who may be anæmic from previous loss of blood; that when the ligature has been properly applied there is absolutely no risk of hæmorrhage; that the time required for its application, even in a severe case, is short—as a rule but a few minutes; that the convalescence is short—on an average from seventeen days to three weeks; and that the operation is not followed by recurrence, if all the piles present are completely removed in a patient above 40 years of age. When the patient is under 40 years, all the piles may not have developed, so that later on in life a second operation may be required for the removal of piles matured in the interval.

*Operation by ligature (Salmon's operation) as modified by the late Mr. P. Y. Gowlland, and also by Mr. Goodsall.*

*Preparation of the Patient.*—The bowels should be freely relieved on each of the three days prior to the operation



by aperients given every twenty-four hours, and also by the administration of a copious enema of warm water (2-3 pints) about three or four hours before the time appointed for the operation. As one of the results of the enema, the piles will be forced down outside the anus, but should be immediately returned into the rectum after the bowels have ceased to act. The patient should be instructed to void urine, and also to get the bowels finally relieved a few minutes before the time fixed for the operation. After this final action of the bowels the piles, if prolapsed, should not be returned. The advantage of this last action of the bowels is that the rectum as well as the bladder is quite emptied immediately before the operation. When the time appointed for the operation is before noon, no food should be allowed later than 10 p.m. on the previous evening. In the event of the hour of operation being after mid-day, no food, liquid or solid, should be given during the previous six hours. Those patients who are in the habit of taking alcohol in any form should be advised, especially if they are accustomed to take it freely, to discontinue its use for at least a week before the operation, as by doing so they will take the anæsthetic much more satisfactorily.

*Instruments and ligatures required.*—Salmon's scissors and pile hooks, a pair of dissecting forceps, two pairs of pressure forceps, one pair of fenestrated artery forceps, a round probe and silk ligatures (No. 16 plaited silk cut into lengths of eighteen inches for ligaturing the piles, and No. 6 plaited silk in ordinary lengths for securing small vessels).

*Position of the Patient and of the Operator.*—The patient should be placed in the right lateral and semi-prone position, with the right arm and hand well behind the back, and the left thigh flexed upon the abdomen (see fig. 20). The anal region should then be exposed to the best light obtainable. The assistant should stand above the patient's nates, using his right hand to raise the left buttock and leaving his left



hand free. The surgeon stands below the nates, facing the anal region, which should be on a level with his chest.

### *Method of Operating.*

*Estimation of Redundant Skin.*—When the patient has been fully anæsthetised, it is necessary to decide how much of the skin of the anus is redundant. As a rule, there are folds of redundant skin corresponding to the R.A., the R.P. and the L. or L.P. internal piles (see fig. 89).

*Stretching the Sphincters and the estimation of their elasticity.*—Both index fingers should be introduced into the rectum, and the sphincters moderately stretched with those two fingers only. Should the external sphincter be found to be too rigid and thickened to readily yield, it should be completely divided in the R.P. quadrant. When the piles are protruded, the condition of the external sphincter should still be ascertained, and if rigid and thickened, the muscle should be divided.

*The order in which Internal Piles should be ligatured.*—They should be ligatured in the following order: the R.A. pile should be included in the first ligature; the R. and the R.P. piles (usually coalesced) in the second ligature; the L., or the L.P. and L. coalesced, in the third ligature; the P. in the fourth ligature; and the L.A., the A., or the L.A. and A. coalesced, in the fifth and last ligature. By applying the ligatures in this manner, we have not found it necessary, in any case to make use of more than five ligatures for strangulating the internal piles. In the majority of cases three suffice. In some instances, it may be found that the R.A. pile is not present, its absence being due either to its having sloughed in consequence of previous strangulation, or to its having been removed by operation at a time when it was the only pile sufficiently developed to require attention. In other cases too, the L.A., the A., or the P. piles are not developed. A word is necessary in regard to the L.A. pile,



which is very often small, and unless specially looked for, may escape observation and later on require removal.

*The application of the Ligatures.*—Each pile should be hooked, drawn out of the rectum and lifted upwards when on the right, and carried downwards when on the left side. An incision, from an eighth to a quarter of an inch in depth, should then be made, with a pair of Salmon's pile scissors, at the muco-cutaneous junction of the pile. This incision should involve the whole of the muco-cutaneous border of the pile. The assistant then takes the handle of the pile hook from the surgeon, and as soon as the middle part of the ligature has been placed in the incision by the latter, the assistant should draw out and *depress* the handle of the Salmon's hook when the pile is on the right side, or draw out and *raise* the handle when the pile is on the left side of the rectum. As the R.A. pile usually extends higher than any other pile met with in the same case, it should be ligatured first. The ligature should be carried as far as possible above the hook in the pile, and should then be tied tightly (*it cannot be tied too tightly*) so that the included tissue may be lifted off the muscular coat of the rectum and completely strangulated.

*The restoration of the Lumen of the Anal Canal.*—When more than two internal piles have been ligatured, the left forefinger should be introduced to its full length into the rectum, because it may be found that the lumen of the *anal canal* has been nearly obliterated. The introduction of the finger will be facilitated by turning it backwards and forwards on its axis, at the same time that it is slowly pressed onward into the rectum. Should the passage be found contracted, the digital dilatation will prevent any permanent contraction remaining after the wounds have healed.

*Removal of the lower part of the Ligatured Piles and the completion of the operation.*—After the finger has been withdrawn, the lower part of each pile may be removed, care being



taken to leave a sufficient length of stump for the constricting ligature to retain its hold. The remaining portions of the piles should now be returned into the rectum. Then the folds of redundant skin should be removed by simply snipping them off with Salmon's scissors. Not more skin than is clearly redundant should be removed. The removal of each fold is followed by free general bleeding from the surface of the wound. This hæmorrhage is easily arrested by taking up, with a pair of fenestrated artery forceps, the centre of the bleeding surface and applying a ligature to it. The ends of these ligatures should be left about a quarter of an inch long. When all the hæmorrhage has been arrested, a small piece of cotton wool, wetted with a twenty per centum solution of hydrochlorate of cocaine or a ten per centum solution of eucaine, should be carefully introduced into the *anal canal* for about one inch and-a-half, and left there. The ligatures on the piles should now be cut off on a level with the anus, and a pad of cotton wool, wrung out with sublimate solution (1—500), placed outside the pledget of cotton wool wetted with cocaine or eucaine and the whole kept *in situ* with a T bandage.

*A further modification of Salmon's Operation.*

We have recently further modified Salmon's operation by making the incision for the ligature at the outer margin of the fold of redundant skin which corresponds to the internal pile to be removed, instead of making it at the mucocutaneous junction. The incision is made through the skin only and is U-shaped, the ends of the U being in the mucocutaneous junction on each side of the internal pile to be removed. The ligature when thus applied includes both the internal pile and its corresponding fold of skin. The advantages of this modification are that one ligature answers for both the skin and the internal pile, that often it is not necessary to remove any skin subsequently to the operation, and that the operation is much shorter. After the ligatures



have been applied as tightly as possible the left index finger is passed for its full length into the rectum, and then withdrawn. The ligatures are now cut short and then the internal piles together with the folds of redundant skin are passed into the *anal canal* and retained there with a pledget of cotton wool wetted with the solution of cocaine or eucaine, the whole being kept *in situ* with a pad wetted with the sublimate solution and a T bandage.

This further modification of Salmon's operation greatly reduces the risk of recurrent hæmorrhage,

#### *After Treatment.*

As soon as possible after the operation, half a drachm of liq. opii sed. should be given, and a catechu and opium mixture (see page 153) should be administered every four hours for the first sixteen, and every eight hours during the succeeding forty-eight. The part should be dressed for the first time about twenty-four hours after the operation, when all dressings, except the pledget of cotton wool in the rectum, should be removed. The anal region should be carefully sponged with a sublimate solution (1—500), and a pad of cotton wool, wrung out in the same solution, should be placed on the wounded surface and covered by a pad of dry cotton wool and a T bandage. This dressing should be repeated every night and morning until the wounds are healed. On the fourth day after the operation, the piece of cotton wool in the anal canal should be removed by twisting it gently on its axis as it is being withdrawn. After the plug has been removed, the patient is able to pass flatus more easily. On the fifth day, or about ninety-six hours after the operation, the bowels should be freely relieved either by an aperient, or by an enema of three pints of warm water. Should the injected water fail to thoroughly relieve the bowels, it should be immediately repeated. There is always an accumulation of fæces in the colon, in these cases, after the bowels have



been confined for ninety-six hours, and it is most necessary that this should be got rid of at the first relief of the bowels after the operation. It is sometimes, but not often necessary to repeat the enema more than once; when required it should be repeated. If fæces be allowed to accumulate in the rectum at this stage of the after treatment, impaction is likely to ensue in the course of a few days. After having obtained a satisfactory preliminary action of the bowels, they should be freely relieved once daily until healing has completely taken place. The patient should remain in bed for the first fourteen or fifteen days after the operation. The healing of both external and internal wounds in healthy patients takes from seventeen days to three weeks.

*Separation of Ligatures.*—The ligatures used for tying the piles, if applied sufficiently tightly to completely strangulate the included tissue, usually come away spontaneously in from eight to twelve days. They should on no account be forcibly removed. When the ligatures have not been tied sufficiently tightly, and have thereby failed to completely strangulate the included tissue, a longer time will be required for their separation; and when they come away, a digital examination will often show that a non-strangulated piece of tissue remains as a polypoid excrescence, from a quarter to half an inch long, and from one to three-eighths of an inch wide. In this manner polypoid excrescences are left in the place of the piles, and may subsequently cause considerable discomfort. When found to exist, they should be removed by applying a ligature to their base, care being taken that it is tied tightly enough to completely strangulate the included tissue. The ligatures applied to vessels in the wounds made by the removal of the redundant folds of skin, usually separate within a week, when they have been tied sufficiently tightly. If their separation has not been effected by the eighth day, they should be removed, by gentle traction on the ends, as, if left, they are apt to become partially



imbedded in the granulations and thus retard the healing process. We have seen one case in which these ligatures remained imbedded for two months, but the non-closure of the wound was attributed to the patient's constitutional defects and not to the retained ligatures.

*The Diet after the Operation.*

During the sixteen hours succeeding the operation no food should be given, a little water (not more than one pint) being allowed during that period. Afterwards one pint of milk and one pint of beef tea, with bread and butter and water *ad libitum* may be given during each twenty-four hours until the bowels have acted freely, and, as soon as this occurs ordinary diet may be resumed, provided the general health is satisfactory.

*Complications after the Operation and their Treatment.*

These may be divided into (a) the *immediate*, or those that supervene during the first twenty-four hours, and (b) the *remote*, or those that manifest themselves after that period.

(a.) *The Immediate Complications.*

These are: *hæmorrhage*; *diarrhœa*; and *retention of urine*.

*Hæmorrhage* may recur from cutaneous vessels divided when the redundant folds of skin were removed. This is always arterial, and may soak through the dressings. When it occurs the dressings should be removed, and the bleeding vessel secured by a pair of fenestrated forceps and then ligatured.

Hæmorrhage into the rectum, from defective ligation of an internal pile, first manifests itself by pallor and faintness, with perhaps cramps in the lower extremities and sweating. Colicky pain in the abdomen and a desire to evacuate the contents of the rectum ensue, but there may be no external evidence of bleeding having taken place, as the dressings may remain unstained. This last circumstance may lead the nurse,



or even the surgeon, to think that the symptoms presented are not due to hæmorrhage. In these cases, the dressings should be removed, and the patient should afterwards be requested to strain down. When hæmorrhage has taken place, a sudden gush of dark-coloured blood, with clots, will follow, occasionally in a very considerable quantity. As patients have bled to death from this form of hæmorrhage, it is necessary that it should be arrested as speedily as possible. If the patient's condition permit, an attempt should be made to secure the bleeding vessel. This procedure, however, may be one of considerable difficulty, because, as these cases are usually met with from eight to twelve hours after the operation, artificial light has generally to be used. The part is then swollen and tender, and the bleeding vessel has in all probability been retracted to a considerable height up the rectum, and the services of an anæsthetist may not be at hand. For these reasons, it has been found far more desirable to pass a small vaginal speculum or a vulcanite rectal tube into the rectum for three or four inches, and to pack strips of gauze, or cotton wool, between the speculum or tube and the rectal wall. The pressure thus made upon the bleeding vessel is quite sufficient to stop further hæmorrhage. We have never found this method fail.\* Another advantage of the tube, beyond its facility of use, is that the rectum and colon cannot be distended with flatus while it is in position; and, therefore, the rectum is enabled to contract upon the tube and so exert additional pressure upon the bleeding vessel. Moreover, if any blood clots still remain in the rectum, they can be washed out through the tube by irrigation with hot water. The tube should not be removed for forty-eight hours, after which it may be left out.

*Diarrhœa*, when met with soon after the operation, is in the majority of cases, due to an incomplete emptying of the colon

---

\* We believe that the late Mr. P. Y. Gowlland was the first to treat hæmorrhage from the rectum in this manner.



prior to the operation. Either the aperient was administered too late to act thoroughly before the operation, or it was not sufficiently powerful to produce a complete evacuation of the colon. Although this complication of diarrhœa is in every way undesirable, it appears to exert no deleterious influence upon the healing of the wounds, unless it is due to ulceration or malignant disease. Two other causes of diarrhœa at this stage may be mentioned, viz. :—pre-existing ulceration of the rectum or colon ; or malignant growth in those parts.

Should an action of the bowels take place soon after the operation has been completed, all the external dressings should be changed, and the part gently cleansed. On no account should the pledget of cotton wool in the rectum be removed. Considerable pain would be experienced if it were removed, and also during and after its re-introduction.

*Retention of Urine.*—This complication can, almost invariably, be prevented by insisting on the bladder being emptied immediately before the operation, by limiting as much as possible the quantity of fluid taken during the first sixteen or twenty-four hours after it, and by not permitting any attempt to pass urine during the first twenty-four hours. Reflex irritation may induce a desire to micturate within an hour or so after the operation, but should an attempt to void urine at this time be made, it will almost invariably fail, and the vesical irritability will thus be considerably aggravated. This inclination should be resisted and then the irritability of the bladder will soon pass off. When the first attempt to micturate is made, the T bandage should be removed in order that the urethra may not be compressed by it. It is not necessary to insist upon the urine being passed in the recumbent position, because it is much more readily voided in the ordinary way. If, at this stage of the after treatment, the urine cannot be passed naturally, the wound should be dressed and the attempt at micturition postponed for two or three hours, when, in all probability, the difficulty experi-



enced will have disappeared. Should the second attempt fail (it seldom does), the penis should be bathed with water as hot as can be borne; or a warm sitz-bath may be ordered.

If these directions be observed, retention of urine, necessitating catheterization, will rarely be met with after operations upon the rectum. It should be borne in mind that when a catheter is used for relieving retention after an operation upon the rectum, catheterization will in most cases, almost invariably in women, have to be continued perhaps for several days before natural micturition is re-established; whereas if urine is voided in a natural manner primarily, there will be no difficulty in this respect, unless impaction of fæces is subsequently allowed to take place. It is agreed that the more frequently a catheter is introduced into the bladder, the greater is the possibility of the supervention of cystitis.

(b) *The Remote Complications.*

These are *œdematous folds of skin; impaction of fæces; cystitis; delirium tremens; tetanus; abscess; fistula; narrowing of the rectal passage; stricture of the anus; ulceration of the lower part of the rectum; fibrous stricture; pyæma; and peritonitis.*

*œdematous folds of skin* usually make their appearance with the first action of the bowels, and are certainly aggravated, both by subsequent incomplete evacuation and by fæcal impaction. They are met with in almost every case of internal piles after operation, their extent varying with the difficulty experienced in emptying the rectum during the first act of defæcation. On the eighth or ninth day, the œdema begins to subside and, at the thirteenth or fourteenth day, will have disappeared sufficiently to permit of an estimate being formed of the extent of the permanent redundancy of skin. At this time, not earlier, in the after treatment, such folds as are clearly redundant should be snipped off with a pair of Salmon's scissors, under the influence of local anæsthesia. It is far better to leave behind too much skin



than to take away even one fold too much. Should these folds of skin be removed before the œdema has had time to subside, there is the serious risk of removing more tissue than is necessary.

It must be borne in mind that a very tight anal stricture is sometimes caused by the too free removal of œdematous folds of skin, and we, therefore, urge that the greatest care be taken not to remove too much. It is much better to leave such folds as are doubtfully redundant. No vessels need be ligatured at this operation, though, for a few minutes after removal, there may be free hæmorrhage from the wounds. After the bleeding has ceased a pad of cotton wool wrung out of a sublimate solution (1—500) should be placed over the wounds and a T bandage applied. The bleeding ceases in about half-an hour, or sooner when adequate pressure is maintained. These wounds, as a rule, heal in about forty-eight hours, especially if their margins are carefully approximated after all bleeding has ceased.

*Impaction of fæces* may be met with at the time of the first action of the bowels, and may be caused in any of the following three ways. By failure in the complete emptying of the colon prior to the operation; by solid food being taken before the bowels have been relieved; by the administration of preparations of chalk to confine the bowels during the first ninety-six hours. When met with subsequently to the first action, it may be due to the fact that the bowels have not been fully relieved each day; to narrowing of either the anal orifice or the anal canal, produced by a too free removal of tissues at the time of the operation; and, lastly, to postponement of defæcation on the part of the patient through dread of the pain which might attend the passage of formed fæces. This last cause cannot come into operation if, as we have already urged, a thorough evacuation be secured daily by the injection of olive oil, by enemata of water, or by an aperient. The first indication of the presence of fæcal



impaction is the escape of small quantities of liquid fæces from the anus, necessitating frequent changing of the dressings. This condition is not one of true diarrhœa, although astringent medicines and, occasionally, opiates are sometimes given to check it. The next symptom complained of, is a constant feeling of fulness and discomfort in the lower part of the rectum, with pain over the sacrum. Later on, there may be difficulty in micturition or even retention of urine. There is also much flatulent distention with the frequent passing of small quantities of flatus. When any of the above symptoms are present after an operation upon the rectum, a digital exploration should be carried out forthwith. It may then be found that an accumulation of firm fæces, sometimes moulded at its lower end into the shape of a cricket ball, is acting like a ball valve and blocking up the passage, so that only a small quantity of liquid fæces can, from time to time, pass down by its side. This fæcal accumulation can be readily and safely removed by the index finger, under the influence, if possible, of an anæsthetic. Within two or three hours after the removal of the mass, all discomfort will have ceased. Constant care should be taken to prevent the recurrence of the impaction.

*Cystitis* may supervene as a result of catheterization, or it may be caused either by retention of urine or by impaction of fæces. For its treatment, we recommend that the bladder be washed out every eight hours with Condy's fluid (thirty minims to one pint of warm boiled water). The washing out should be continued on each occasion until the solution returns unchanged in colour. Combined with the washing out of the bladder the following mixture should be given every six hours:—

R

Tinct. Belladonnæ ...	...	m. x.
Sodii carbonatis ...	...	gr. v.
Pulv. Acaciæ ...	...	gr. xxv.
Aquæ ...	...	℥ i



or urotropin (gr. v.—x.) every four hours. The patient should be allowed only milk and water in addition to his solid food.

*Delirium tremens* is occasionally met with after an operation for internal piles. We have treated all the cases which have occurred in our practice with hydrate of chloral (gr. xx.) every hour until sleep was procured. Liquid food, consisting of milk, eggs, and beef tea, was given at hourly intervals between the doses of the medicine. One hundred and twenty grains is the largest quantity we have had to administer before sleep was procured.

*Tetanus*.—Of this, fortunately unusual, complication, we have been able to collect eleven cases, four of which occurred in the practice of St. Mark's Hospital during March and April, 1858, at a time when tetanus was prevalent at other London Hospitals.\* Of the remaining seven cases, one occurred in the practice of the late Mr. P. Y. Gowlland one in that of Mr. Goodsall; and one each in those of five other surgeons. All these cases occurred in patients who had been operated upon for internal piles only, and all terminated fatally.

*Abscess*.—This may be either of the sub-mucous or of the ischio-rectal variety. The abscess may result from wounding the muscular coat of the rectum by a too deep incision at the muco-cutaneous junction of the internal pile at the time of the operation, or it may follow impaction of fæces. Its presence should be suspected when there is a return of the pain; or when there is difficulty in defæcation about the eighth or ninth day after the operation, that is to say, at the time when the sloughs are separating. For the treatment of this condition (see pages 78-79).

*Fistula*.—When following an operation for internal piles, fistula is always preceded by the formation of an abscess, and is of the blind internal variety (see page 95).

---

\* See Curling, Observations on the Diseases of the Rectum, fourth edition, page 63.



*Narrowing of the Anal Canal.*—When this occurs, it usually shows itself by the twelfth day after the operation.

Constriction of the lower part of the anal canal, following an operation for internal piles, sometimes takes place when more than two piles have been removed. When the operation has been limited, as it should be, to the removal of mucous membrane and sub-mucous tissue only, then any constriction which may occur can easily be overcome. After an operation for internal piles, the rectum should be examined on the twelfth day by gently passing the index finger to its full length into the rectum. If no constriction be met with at this examination, it is most improbable that there will be any when the part is soundly healed. If any be met with, the index finger should be passed to its full extent once in forty-eight hours for a fortnight, or less frequently when the passage shows no signs of recontraction after the first stretching. On the other hand, should the recontraction be marked, a rectal tube (half to three-quarters of an inch in diameter) should be worn for one or two hours every other night, at bedtime, until the contraction has been overcome.

*Stricture of the anus* sometimes results from a too free removal of the peri-anal skin. It begins to cause inconvenience about two or three weeks after the operation, though it may do so earlier. When met with, the anal margin, together with the external sphincter, should be incised in the R.P. quadrant. Constant care should be exercised to make the scar as wide as possible, so that at least from one quarter to half an inch may be let into the margin of the anal circumference.

*Ulceration of the lower part of the rectum*, following an operation upon internal piles, may be caused by a neglected faecal impaction, or by some infective process, not necessarily syphilitic.

*Fibrous stricture*, involving the whole rectal wall, is always



preceded by ulceration, and may, therefore, be considered as a possible complication of operations upon internal piles.

*Pyæmia.*—This complication is seldom met with after an operation for internal piles. Curling\* mentions one case in a man, aged 52, upon whom he had operated for piles and fistula. He was seized with pyæmia, and died from multiple abscesses in the lungs five months afterwards.

Van Buren† also mentions two cases.

Mr. Goodsall has seen one case, a male 52, who was operated upon at St. Mark's Hospital in 1870 for piles, and developed pyæmia, dying twelve days afterwards. An abscess appeared in his left groin. No autopsy was allowed.

*Peritonitis.*—We have never seen this complication following an operation for internal piles. Bushe‡ in his work mentions one such case, but this is the only one that we have been able to find recorded in the literature of the subject as occurring after an operation for internal piles.

*Our objections to the other methods for the operative treatment of internal piles are the following :*

(a) *To the application of nitric acid.*

Nitric acid is extremely uncertain in its action, and it is very difficult, if not impossible, to limit the extent of destruction of tissue following its use. We have known of a case in which the application was followed by such severe hæmorrhage that the patient nearly bled to death, and a tube had to be inserted into the rectum in order to arrest the bleeding. In another, extensive suppuration in the peri-rectal connective tissue resulted from two applications of this acid, within an interval of two or three days, and, when we saw this case, the whole of the lower four or five inches of the rectum had completely sloughed.

\* Observations on the Diseases of the Rectum, 4th ed. p. 63.

† Diseases of the Rectum, p. 56, New York, 1880.

‡ Rectal Diseases, 1st ed., 1837.



(b) *To the transfixion by needles and subsequent ligature.*

There is much to be said in favour of this operation which, to our minds, comes next to Salmon's. Our objections to it are, that more time is required for its performance; that, as the needles may lacerate the pile tissue during the process of tying, there is some danger of hæmorrhage; and also that a portion of the pile, in consequence of the tearing action of the needle, may not be included in the ligature. Moreover, it is necessary to make an incision at the mucocutaneous junction so as to prevent inclusion of the sensitive skin of the anus in the ligature, and the operation then becomes a slight and very tedious modification of that of Salmon.

(c and e) *To the operations by clamp and cauterly (Henry Smith's operation), and by crushing (Pollock's operation).*

The objection to Henry Smith's operation is that the whole of the pile cannot be removed without including more or less healthy mucous membrane with it. The same objection applies to the crushing operation with Benham's or Allingham's clamp.

(d) *To the operation by clamping and removing by a fine saw (Gowlland's operation).*

Although this operation is easily and speedily performed, a serious objection to it is that the removal of the clamped pile, by the saw, does not always arrest the bleeding from the stump.

(f) *To the method of injection of carbolic acid or hazeline.*

This form of operation does not permanently cure the pile, is quite unsuitable for cases in which several piles are present, and may be followed by abscess and fistula.

(h) *Operation by removing the pile-bearing area and suturing the rectal mucous membrane to the skin (Whitehead's Operation).*

To this operation we think the chief objections are, the



severe loss of blood attending it, the length of time required for its execution, the tardiness in subsequent healing, and the risk of ultimate contraction of the lower part of the rectum.

### *Strangulated Internal Piles.*

During the later part of the second stage of hæmorrhoidal disease, the piles, when protruded for some length of time, may be so engorged from passive congestion that they ultimately become tightly constricted by the external sphincter. This constricting influence of the sphincter increases the congestion by at first impeding only the venous circulation, the arterial blood supply not being much interfered with. Later, the engorgement of the veins leads to their rupture, and blood is extravasated into the connective tissue of the pile. Later, still, the additional pressure thus produced is sufficient to arrest the arterial circulation also, when gangrene or sloughing takes place. Such a condition of things constitutes what is known as *an attack of piles*, and is really the natural process of cure, which the surgeon only imitates *by means of the ligature*. When all the piles present in a given case are strangulated, and slough, the resulting cure, is most satisfactory, as no redundant skin, no constriction of the anus, no diminution in the calibre of the anal canal is left. In the majority of instances, only one or two of the larger piles with perhaps the more dependent parts of one or two others will be found to have sloughed completely. After the lapse of two or more years, in consequence of this incomplete sloughing, the parts of those piles that have escaped the process may develope and so cause further trouble. The sloughing process supervenes usually within forty-eight hours of the descent of the piles, and the healing process is generally completed within three weeks, that is, in about the time required by Salmon's operation. The complete subsidence of the œdema, in these cases, shows that the swelling is not due to varicose veins under the peri-anal skin.



We have never seen a fatal result follow this natural process of cure.

*Treatment.*

When such a case presents itself, we suggest the following plan of treatment. The strangulated internal piles should be carefully cleansed with a sublimate solution (1—500), and should then be returned into the rectum under the influence of an anæsthetic. To effect the reduction, the patient should be placed in the right lateral and semi-prone position (see fig. 20). A piece of dry cotton wool having been placed over the piles, the thumb of the right hand should be slowly introduced into the rectum, the protrusion being at the same time pressed together by the thumb and index finger of the left hand. When all the piles, together with the œdematous folds of skin, have been thus pressed into the rectum, the right thumb should be carefully withdrawn, and the sides of the anus firmly pressed together by the left thumb and index finger to prevent re-protrusion, while the thumb is being withdrawn. The piece of cotton wool should now be twisted on its axis and, when converted into a cord, carefully withdrawn. A vulcanite tube ( $2\frac{1}{2}$  inches long, and  $\frac{1}{2}$ — $\frac{5}{8}$  inch in diameter), should then be introduced into the rectum and retained *in situ* by a pad of cotton wool wrung out of the sublimate solution and a T bandage. The tube should be left in for at least forty-eight hours, the pad of cotton wool being changed as often as may be necessary. The bowels should be confined for ninety-six hours and then be freely relieved by an aperient at least once in every twenty-four hours. A pad, wrung out with the sublimate solution, should be kept almost constantly applied to the anus.

*Cases that are Unsuited for Operation.*

*Age.*—Patients above the age of seventy years, if in good health, may be successfully operated upon for piles; but if their general condition be not satisfactory, no operation



should be undertaken. The necessarily prolonged confinement in bed after the operation, and their impaired reparative power, due to age, render the time required for recovery a great tax upon the vitality of such patients. Much relief can be given by palliative treatment alone in these cases.

*Plethoric Conditions.*—In those patients in whom there is a well-marked tendency to a plethoric habit of body, where frequent headache is complained of, though it completely disappears after a loss of blood from the hæmorrhoids, the removal of the piles is inadvisable, as by their removal this safety-valve would be closed to the patient. We have known such subjects to die of cerebral symptoms, within two or three years after the operation.

*Locomotor Ataxy.*—The subjects of this disease when suffering also from internal piles, should not, in our opinion, be operated upon, because, in such cases the probable duration of life after the onset of internal piles is only a few months, or at the most a year or two. The chief inconvenience, in these cases, is due to the protrusion, and the consequent escape of rectal mucus, symptoms which can be relieved by palliative measures. Hæmorrhage is never severe in ataxic patients nor is there any severe pain, so that some of the chief indications for operative interference are absent. The above remarks refer only to cases of hæmorrhoids which have supervened as one of the results of the ataxic condition. When the piles have existed for some years prior to the onset of *Tabes Dorsalis*, the hæmorrhage and the protrusion are often aggravated by it. In this class of cases, the question of operation must be decided on its merits. In one such case we performed the operation, and the patient's general condition was thereby improved.

*Paraplegia.*—As a result of the obstinate constipation met with in paraplegic patients, internal piles are apt to supervene, combined with much œdema of the circum-anal folds of skin. We have never operated upon such a patient, but from our



experience of this complication, we secure all possible relief by a full daily evacuation and strict cleanliness of the part.

*Hemiplegia.* — We think that patients suffering from hemiplegia, or who have partially recovered from it, should not be operated upon for piles. Care should be taken that the bowels are relieved everyday. Unless this be done the protrusion and hæmorrhage may be very troublesome, and so still further curtail outdoor exercise.

*Malignant Disease of the Rectum.* — Internal piles complicated with malignant disease of the rectum or colon should not be operated upon. Malignant disease may be suspected to exist when the bowels become frequently relaxed, though the patient in the earlier part of his history had suffered from constipation.

*Abdominal Tumours.* — When internal piles are present in patients suffering from abdominal tumours which are amenable to surgical treatment, no operation upon them should be entertained until the graver disease has been removed; when it will often be found that the internal piles give no further trouble.

*Pregnancy.* — As we have already mentioned pregnancy is frequently one of the exciting causes of piles. We agree with Allingham\* and others, that it is possible to successfully operate upon such cases, especially during the first four months of gestation. Nevertheless, we do not advise the operation because of the longer time required for convalescence, the difficulty of ensuring the contraction of the scars, and further, the probability that with the termination of the pregnancy all need for an operation may disappear. Another contra-indication for operating in these cases is that an abortion or a miscarriage may result therefrom.

#### *Constitutional Defects associated with Internal Piles.*

That the appearance of internal piles is generally associated with an atonic condition of tissue, or want of natural

\* Diseases of the Rectum, sixth edition, page 129.



tone, is supported by the observation that many patients suffering from hæmorrhoids, are also the subjects of hernia, varicose veins of the extremities, and a relaxed condition of the soft palate and uvula.

*Internal Piles complicated with other Diseases of the Anus and Rectum.*

*Internal Piles Complicated by a Fissure.*

When these exist the fissure usually precedes the appearance of the internal piles. When operating upon such a case, the external sphincter should be divided either at the seat of the fissure or in the right posterior quadrant, and then the internal piles should be ligatured, care being taken *not* to remove any of the mucous membrane beyond the limit of the internal pile or piles. This is an important point and should receive attention before the operation as, after dividing the external sphincter, the mucous membrane is more readily drawn down than is possible before such division, and so may be included in the ligature as part of the internal pile. The question, therefore, as to the number and extent of the internal piles to be removed should be decided prior to, not after, the division of the sphincter.

*Internal Piles complicated by an Ulcer.*

When a patient suffering from piles complains of much pain, not only during the state of protrusion but lasting perhaps for many hours afterwards, the presence of an ulcer may be suspected and should be carefully looked for. The ulcer may be found either on the surface of one of the piles or at the side of it. When placed on one side, it may, unless carefully looked for, be completely hidden from view in the furrow between two adjacent piles and so escape detection and treatment. When operating upon piles complicated with ulcer, if the latter occur on the surface of the pile, both should be included in a single ligature and removed. In those instances in which the ulcer is found to be situated



between two piles, its base and lower margin should be divided by an incision carried also through the entire thickness of the external sphincter, and then the piles should be ligatured with the same precautions referred to in the previous paragraph.

*Internal Piles complicated by Fistula.*

This complication has already been discussed on page 159.

*Internal Piles complicated with diseases of the Pelvic Viscera.*

Displacement of the uterus and ovaries, sub-peritoneal fibro-myoma, and uterine subinvolution are sometimes met with in patients who seek relief from piles. The piles may have been successfully removed, but the patient still complains of many of her former symptoms, and regards the operation as only a partial success. We have seen several such cases, the patient complaining of inability to walk, of pain in the lumbar and sacral regions, and of a general feeling of lassitude, though at the same time acknowledging that the hæmorrhage together with the protrusion has disappeared, while difficulty in defæcation, but not the attendant pain, has ceased. When such cases are met with, a thorough examination of the pelvic viscera should be made so that abnormal conditions of the neighbouring viscera, if found to exist, may be appropriately dealt with.

*The Mortality after the Operation.*

*Mortality.*—The mortality after the operation by ligature for internal piles, we estimate, is not more than  $\cdot 25$  or  $\cdot 2$  per cent., so that this method of treatment may be considered one of the safest in surgery. When the great benefits resulting from the removal of piles are borne in mind, there should be no hesitation in recommending healthy and otherwise suitable patients to submit to the operation. After it, the patient's general health is materially improved, his weight is increased, and the listlessness, mental depression, and want of energy, so commonly met with in the subjects of advanced hæmor-



rhoidal disease, completely disappear. After the lapse of two or three years, the patient's vitality is greatly increased, provided that during such period he has led a healthy life.

### *Causes of Death.*

*Hæmorrhage.*—Severe bleeding, after an operation for hæmorrhoids, was more commonly met with when the operation by excision was in vogue than at the present time. With the ligature, hæmorrhage, either primary or recurrent should not occur if it has been properly applied, and has not been dragged down after the pile has been secured. On no account should the ends of the ligature on one pile be made use of for dragging down other piles for inspection, more especially after a part of the strangulated pile has been cut off. The operation itself should not be considered to have been completed until all the bleeding has been arrested. If these points are kept in mind and acted upon, hæmorrhage, as a subsequent complication and as a cause of death, should not be met with.

*Tetanus.*—This disease when it has followed the operation for piles, as we have mentioned above (see p. 301) has always, as far as we know, been fatal.

*Pyæmia.*—In the few recorded cases where this disease has followed hæmorrhoidal operations, the result has been fatal. If strict attention be paid to the sterilization of all instruments, ligatures &c., used at the operation, if all other aseptic precautions be adopted throughout, and if the part be kept as clean as possible during the after treatment, no septic infection of the wound should take place.



1870  
No. 10

...

...

...

...

...

...

...

...



## I N D E X.

- Abdominal tumours complicating internal piles 308.
- Abscess : following fissure 249 and internal piles 301 ; etiology 56 ;  
lines of extension 55 ; treatment—after operation 90,  
operative 79, palliative 78 ; varieties—ischio-rectal 66 :  
labial 76 ; pelvi-rectal 72 ; subcutaneous—follicular 62,  
marginal 64 ; sub-gluteal 60 ; submucous 70.
- , ischio-rectal : operation 84 ; physical examination 69 ;  
symptoms 69.
- , labial : operation 89 ; physical examination 77 ;  
symptoms 77.
- , pelvi-rectal : operation 87 ; physical examination 75 ;  
symptoms 75.
- , sub-cutaneous : follicular — operation 83 ; physical  
examination 63 ; symptoms 63.
- , ——— ——— marginal — operation 84 ; physical  
examination 65 ; operation 84.
- , sub-gluteal 60.
- , submucous : operation 86 ; physical examination 71 ;  
symptoms 71.
- Age, incidence of, in the etiology of abscess 57 ; fissure 217 ;  
fistula 99 ; piles 253, 270 ; sinus over the sacrum and  
coccyx 191.
- Age—limit for operation for internal piles 306.
- ALCOCK, canal of 27.
- ALLINGHAM on infantile fissure 217.



INDEX.

- Anal canal, constriction of, 302.  
 ---- line, transverse, defined 51.  
 — margin, points for observation 53.  
 — papillæ, anatomy of, 25.  
 — region, authors' imaginary sub-division for descriptive purposes 51.
- Anatomy of arteries 26 ; blood-vessels 26 ; coats—muscular 21, serous 20 ; fascia, superficial 4 ; fossa, ischio-rectal 8 ; lymphatics 34 ; mucous membrane 22 ; muscle, levator ani 12 ; nerves 35 ; papillæ 25 ; perineal space 1 ; plexus, hæmorrhoidal—inferior 29, middle 31, superior 32 ; rectum—lower portion 18, middle 16, upper 15 ; skin, peri-anal, 4 ; sphincters—external 5, internal 22 ; tissue, submucous 22 ; triangle, rectal 2 ; veins 29.
- Arteries, hæmorrhoidal, anatomy and surgical importance of, 26—29.
- AUERBACH, plexus of 36.
- Bacillus coli communis in abscess 58.
- Bacterial infection in abscess 57.
- BALL on causation of fissure 2, 12, 214 ; on valves of Morgagni 24.
- BARTHOLIN'S glands in the causation of abscess 60.
- BLANDIN on division of the sphincters 241.
- Blood extravasation in the causation of abscess 56.
- Blood-vessels, anatomy of 26.
- Boracic fomentations in the treatment of fistula 136.
- BOYER on causation of fissure 216 ; operation for fissure 236, 240, 242.
- Burrowing, lateral—external 123, internal 130.
- BUSHE, unique case of peritonitis after operation for internal piles 303.
- Carcinoma complicating fistula 105, 132.
- Canal, anal, constriction after operation for internal piles 302.
- Carbolic acid injection for internal piles 304.
- Cases, authors', fistula with 43 external openings 114 ; two of fistulæ in tuberculous subjects 163, 164 ; ten of sinus over the sacrum and coccyx 193—207.



INDEX.

- Cautery and saturated solution of nitrate of silver, their advantages compared, 179.
- Cleanliness importance of, 234.
- Colotomy, inguinal, indicated 183, 186.
- Complications after operation for fistula 156, fissure 247, piles 295.
- Constipation, as a diagnostic symptom 46, 271; as a causation factor 99, 216, 253, 260; treatment for, 234, 286.
- Constitutional condition as a predisposing cause of disease, 59, 99.
- COPELAND on incision for fissure 241.
- COWPER'S glands in the causation of abscess 60, 170.
- CURLING on fistulæ in the sacro-coccygeal articulation 187, on incision for fissure 241, case of pyæmia after operation for internal piles 303.
- Cystitis following operation for fissure 249, for internal piles 300.
- Defæcation, difficulty in, as diagnostic symptom 47, 69, 71, 75, 77, 254, 263.
- Delirium tremens after operation for internal piles 301.
- DEMARQUAY on division of the sphincters 241.
- Diabetes in relation to fistula 131.
- Diagnosis, differential, of fissure 228.
- Diagnostic symptoms and signs :—
- general : constipation 46; diarrhœa 47; difficulty in defæcation 47; discharge 45; hæmorrhage 43; heredity 49; loss of weight 49; pain 39; protrusion from anal orifice 48.
  - of abscess : pain 64, 69, 71, 75, 77; difficulty in defæcation 69, 71, 75, 77; difficulty in micturition 71, 75; discharge 75; discomfort in sitting 69, 77; retention of urine 69, 75, 77.
  - of fissure : alteration in size of motion passed 223; hæmorrhage 223; muscular spasm 221; pain 220.
  - of fistula : discharge 107; hæmorrhage 109; pain 108; passage of flatus and fæces 109;



## INDEX.

Diagnostic symptoms and signs :—

of piles, external : difficulty in defæcation 254, 263 ; discomfort in walking or sitting 261 ; itching 261 ; pain 254.

of piles, internal : discharge 280 ; hæmorrhage 275 ; pain 277 ; protrusion 278.

of sinus over the sacrum and coccyx 191.

Diarrhœa, diagnostic significance of, 47, 272 ; following operation for fissure 248 and for internal piles 296.

Diet during treatment 287, after operation 155, 295.

Digital examination, 49—54.

Discharge of pus 45, 107, 158, 225, 280.

DUPLAY on digital dilatation of the sphincters 243.

DUPUYTREN on incision for fissure 241.

Etiology of

abscess 56 ; fissure 213 ; fistula 99—perineal urethral 169, recto-urethral 174, recto-vaginal 184, recto-vesical 181 ; piles, external—dilated peri-anal veins 263, redundant folds of anal skin 263, venous 253, piles, internal 270.

Examination, digital, generally 49—54.

Examination, physical, for

abscess : follicular 63 ; ischio-rectal 68 ; labial 77 ; marginal 65 ; pelvi-rectal 75 ; submucous 71.

fissure : 224.

fistula : 109.

piles : external, 255, 261, 264 ; internal, 282.

Excreta, in fissure cases 223.

Exercise, physical, to be avoided by fistula patients 133

Extension of abscess along lines of least resistance 55.

Exacuation, free, in treatment of abscess 78.

Fæces, escape of, in fistula cases 109 ; impaction of, after operation 159, 249, 299.

Fascia, superficial, anatomy and surgical importance of 4.

Fish-bone found in abscess and fistula cases 56.

Fissure : causing abscess 56, and fistula 101 ; complicating fistula 101, 132, and internal piles 309 ; complications—morbid 230, after operation 247 ; definition 208 ; descrip-



INDEX.

tion 209 ; diagnosis 227, differential 228 ; diet after operation 247 ; etiology 213 ; infantile 217 ; method of operating 239, 242 ; physical examination 224 ; position 211 ; operation—by incision 236, by stretching the sphincters 241 ; symptoms 219 ; treatment—after 245, 246, operative 235, palliative 234.

Fissure, syphilitic, differential diagnosis, 228.

istula, ano-rectal ; complicating internal piles 159 ; complications, before operation 131, after 156 ; constitutional effects 132 ; duration of healing process 155 ; etiology 99 ; following operation for internal piles 301 ; lateral burrowings—external 123, internal 130 ; main track 120 ; multiplicity 98 ; openings 110 ; operation—by incision 134, 137, by other methods 135, in tuberculous cases 160 ; position 98 ; simulated by perineal urethral fistula 169 ; symptoms 106 ; treatment—after operation 153, 166, operative 134, palliative 133 ; varieties — blind external 94, internal 95, complete 93 ; horse-shoe, anterior 147, posterior 143, sub-cutaneous 101, submucous 102, sub-muscular 101.

———, perineal urethral simulating ano-rectal ; characteristics 166 ; etiology 169 ; differential diagnosis 170 ; treatment 172.

———, recto-urethral : characteristics 174 ; etiology 175 ; operation 178 ; symptoms 176 ; treatment 177 ; after operation 178.

———, recto-vaginal : characteristics 183 ; etiology 184 ; operation 185 ; symptoms 184 ; treatment 184, after operation 186.

———, recto-vesical : characteristics 180 ; etiology 181 ; operation 182 ; symptoms 181 ; treatment 182 ; after operation 183.

Fistulous track, characteristics and course 120 ; operation of dissecting out 135



## INDEX.

- Flatus, escape of, in fistula cases, 109.
- Foreign bodies in rectum 56, 73, 96.
- Fossa, ischio-rectal, anatomy and surgical importance of 8, 9.
- GOWLLAND, case of pyæmia after operation for fissure 250, case of tetanus after operation for internal piles 301, clamping operation for internal piles 304 ; modification of Salmon's operation for internal piles 288, 292.
- Hæmorrhage, diagnostic significance of, 43 ; following operation 156, 295, fatal 311 ; with internal piles 274, 286 ; rare in fissure, 223, and fistula 109.
- Hæmorrhoids, see " Piles."
- HARTMANN, see " Quénu and Hartmann."
- Hazeline injection for internal piles 304.
- Heredity, influence of in the causation of disease 49, 99, 219, 273.
- Impaction of fæces after operation 159, 249, 299.
- Incision, the best operation for fistula 135 ; for fissure 236 ; for internal piles 288.
- Infantile fissure 217.
- Iron indicated 134.
- Instruments for operation by incision 137.
- KELSEY on causation of fissure 216.
- Kidneys not affected by fistula 133.
- KOPLIK on infantile fissure 217.
- Laceration of mucous membrane causing abscess 56.
- Levator ani muscle, anatomy and surgical importance of 12, 14.
- Ligatures in fistula operations 135.
- Locomotor ataxy cases unsuitable for operation for internal piles 307.
- Loss of weight, diagnostic significance of 49 ; non-occurrence in simple fistula cases, 133.
- Lymphatics, anatomy and surgical importance of 34, 35.
- MAISONNEUVE on stretching the sphincters 242.
- Malignant disease complicating abscess 73, and internal piles 308.
- Mapping out anal region, method recommended for 52.
- Margin, anal, points for observation 53.
- MATHEWS on infantile fissure 217.
- MEISSNER, plexus of 36.



## INDEX.

- Membrane, mucous, anatomy of 22 ; prolapse of 159.
- Mental depression in fistula cases 133.
- MORGAGNI'S columns 23, saccules 26, valves 23.
- Muscle, levator ani, anatomy and surgical importance of 12, 14.
- Nerves, anatomy and surgical importance of, 35, 36.
- Nitric acid, objections to its use in the treatment of internal piles 287, 303.
- Nitrate of silver treatment 135, 173, 179, 235.
- , saturated solution compared with cautery 179.
- Occupation, incidence of, in etiology of abscess 57, piles 254, 270.
- Œdematous folds of skin after operation for internal piles 298.
- Olive-oil as a lubricant 91, 134.
- Openings in fistulæ 110.
- Operation for abscess : ischio-rectal 84, labial 89, pelvi-rectal 87, sub-cutaneous 83, submucous 86.
- fissure : by incision 236, by stretching the sphincters 247.
- fistula : ano-rectal 134, 160 ; anterior 146, posterior 142, to transverse anal line ; blind external 149, internal 150 ; complete 139, horse-shoe, anterior 147, posterior 142 ; perineal urethral 172, recto-urethral 178, recto-vaginal 185, recto-vesical 182 ; by dissecting out the track 135, by elastic ligature 135, by incision 137, by injection of nitrate of silver 135.
- piles, external, 259, 261, 265 ; internal, by incision 288, by other methods 303.
- sinus over the sacrum and coccyx 192.
- Pain, diagnostic significance of, 39, 64, 71, 75, 77, 108, 220, 254, 277, 287.
- Papillæ, anal, anatomy of, 25.
- Paraplegic patients unsuitable for operation for internal piles 307.
- Patient's position for physical examination, females 51, males 49.
- Pecten-zone, so named by Stroud, 25.
- Pelvic viscera, disease of, a factor in the causation of internal piles 274 ; differential diagnosis of, 230.



INDEX.

- Perineal space, anatomy of, 1.
- Peritonitis, very rare after operation for external piles 303.
- Phthisis in relation to fistula 131.
- Piles, definition of term, 25.
- Piles, external : differentiation 252 ; etiology 263 ; operation 265 ; physical examination 264 ; symptoms 263 ; treatment 265 ; see also "*skin, peri-anal,*" redundant folds of, 259.
- , internal : causing abscess 56, and fistula 104 ; combinations 269 ; complicating fissure 231 ; complications 295, 309 ; development 269 ; descent after operation for fissure 249 ; etiology 270 ; physical examination 282 ; position in reference to rectal wall 269 ; prolapse after operation 159 ; structure 268 ; symptoms 274 ; treatment — after 293, operative 287, palliative 285 ; operation—choice of 288, methods objected to 303, mortality following 310.
- , internal strangulated : causation 305 ; constitutional defects associated with 308 ; operation, when contra-indicated 306 ; treatment 306.
- , *sentinel*, 215.
- , thrombotic or venous : causation 253 ; etiology 253 ; natural termination 257 ; operation 259 ; physical examination 255 ; treatment 257.
- Plethoric subjects unsuitable for operation for internal piles 307.
- Plexus of Auerback 36 ; hæmorrhoidal 29—34 ; of Meissner 36.
- Polypoid growths complicating fissure 231, 232, and fistula 104, 132.
- Position of disease, method adopted by authors for indicating 53.
- Position of patient for examination, males 49, females 51.
- Pregnancy, a factor in the causation of internal piles 274, not of fistula 99 ; a contra-indication for operation for internal piles 308.
- Prescriptions in after treatment of fistula 153—5 ; in palliative treatment of cystitis 300, of fissure 235, of external piles 257, 262, 265, of internal piles 286, 306.



INDEX.

- Prostate, suppuration of, causing abscess 60.
- Protrusion from anal orifice, diagnostic significance of 48, 278.
- Pus discharge 107, 158.
- Pyæmia, after operation, 250, 303.
- QUÉNU AND HARTMANN on bacterial infection in abscess 58 ;  
causation of fissure 216 ; infantile fissure 217 ; piles  
complicating fissure 231 ; recto-urethral fistula 175, 177 ;  
stretching the sphincters 242, 244.
- Quinine indicated 135.
- RÉCAMIER on operation for fissure 236 ; stretching the sphincters  
241.
- Rectocele, occurrence of, 264.
- Rectum, anatomy of upper, middle and lower portions 15—18, of  
coats 20 ; digital examination of 54.
- RICHET on the superior pelvi-rectal space 72.
- Rules, general, for operation by incision 137.
- SALMON'S *back cut* 102 ; operation for internal piles as modified  
by the late Mr. Gowlland and by Mr. Goodsall 282, 292.
- SAPPEY on anatomy of muscular coat 21, and internal sphincter  
22.
- SEGOND on prostatic abscess 175.
- Sentinel* pile, the, 215.
- Sex, incidence of, in the etiology of abscess 57 ; fissure 218 ;  
fistula 99 ; internal piles 271 ; sinus over the sacrum and  
coccyx 191.
- Silver, nitrate of, in fistula 135, 173, 179 ; advantages of saturated  
solution compared with cautery 179.
- Sinus over the sacrum and coccyx : bibliography 187 ; cases 193 ;  
characteristics 188 : etiology 190 ; operation 192 ;  
symptoms 191.
- Sitz-bath treatment 90, 133.
- Skin, peri-anal ; anatomy and surgical importance of 3, 4 ; points  
for observation 53 ; condition in fissure cases 224 ; redun-  
dant folds of 259.
- SMITH'S (Henry) operation for internal piles 304.
- SOLLY on fistula dependent on carious sacrum 187, 190.
- Spasm, muscular, symptoms in fissure 221.



INDEX.

- Sphincter, external, anatomy and surgical importance of 5, 6 ;  
 points for observation 53.
- , internal, anatomy and surgical importance of 22.
- Sphincters, condition of, in fissure 225, in internal piles 284 ;  
 operation by stretching 241.
- Staphylococci in abscess 58.
- Stimulants contra-indicated in treatment of fistula 133.
- Streptococci in abscess 58.
- Stricture: a causation factor in abscess 56, in fistula 105 ; com-  
 plicating fistula 132 ; after operation for internal piles  
 302, 303.
- STROUD on anal papillæ 25 ; on pecten zone 25, 36.
- Strychnine indicated 134.
- Syphilitic fissure, differential diagnosis of, 228.
- Tetanus after operation for internal piles 301, 311.
- THOMPSON (Sir Henry) on stricture of the urethra 177.
- Tissue, submucous anatomy of 22.
- Tonics indicated 134.
- Track, fistulous, characteristics and course 120 ; operation of  
 dissecting out 135.
- Transfixion by needles, objections to 304.
- Traumatic infection 58, 100, 190.
- Treatment, operative, see "operation"
- , palliative for abscess 78, fissure 234, fistula 133,  
 internal piles 285.
- , after operation for abscess 90 ; fissure 245, fistula 153,  
 178, 183, 186 ; piles 262, 293.
- TREITZ on anatomy of mucous membrane 23.
- Triangle, rectal, anatomy of 2.
- T-shaped incision 80.
- Tubercle bacillus in abscess 58.
- Tuberculosis, pulmonary, complicating fistula 108, 160 ; cases 163.
- Ulcer causing abscess 56 and fistula 104 ; complicating internal  
 piles 309.
- Ulceration complicating fistula 132 ; following operation for  
 fissure 250, and for internal piles 302.



INDEX.

- Urethra, fistulæ in connection with, 167, 174 ; suppuration of, causing abscess 60.
- Urine, retention of, after operation 157, 297.
- VAN BUREN, case of pyæmia after operation for internal piles 303 ; on stretching the sphincters 212.
- Veins, peri-anal, anatomy of 29.
- WALSHAM (Hugh) on phthisis and fistula 131.
- Weight of patient : diagnostic significance of loss of, 49 ; maintained in simple fistula.
- WHITEHEAD'S operation, objections to 304.
- Women, abscess in 57, 68, 77, fistula in 105 ; peculiarities of lateral burrowing in 127 ; position for physical examination 51 ; pregnant 99, 274, 308.



LONDON :  
THE BLACKFRIARS PRINTERS, LIMITED,  
WALTER HOUSE,  
DEAN STREET, FETTER LANE, E.C.



$\frac{R}{L}$   
 $\frac{L}{R}$



