

Atlas of the external diseases of the eye : including a brief treatise on the pathology and treatment / by O. Haab ; Authorized translation from the German, edited by G.E. de Schweinitz.

Contributors

Haab O. 1850-1931.
Royal College of Physicians of Edinburgh

Publication/Creation

London : Rebman, 1899.

Persistent URL

<https://wellcomecollection.org/works/bt4vzghz>

Provider

Royal College of Physicians Edinburgh

License and attribution

This material has been provided by This material has been provided by the Royal College of Physicians of Edinburgh. The original may be consulted at the Royal College of Physicians of Edinburgh. where the originals may be consulted.

This work has been identified as being free of known restrictions under copyright law, including all related and neighbouring rights and is being made available under the Creative Commons, Public Domain Mark.

You can copy, modify, distribute and perform the work, even for commercial purposes, without asking permission.



Wellcome Collection
183 Euston Road
London NW1 2BE UK
T +44 (0)20 7611 8722
E library@wellcomecollection.org
<https://wellcomecollection.org>

ATLAS OF THE
EXTERNAL DISEASES
OF THE EYE


HAAB

2 3. 58

R.C.P. EDINBURGH LIBRARY



R26584M0236



Digitized by the Internet Archive
in 2015

ATLAS
OF THE
EXTERNAL DISEASES OF THE EYE
INCLUDING A BRIEF TREATISE
ON THE
PATHOLOGY AND TREATMENT.

BY
PROF. DR. O. HAAB,
Of Zürich.



AUTHORIZED TRANSLATION FROM THE GERMAN.

EDITED BY
G. E. DE SCHWEINITZ, A.M., M.D.,
Professor of Ophthalmology in the Jefferson Medical College, Philadelphia;
Consulting Ophthalmologist to the Philadelphia Polyclinic; Ophthalmic Surgeon to the Philadelphia Hospital and to the Orthopedic Hospital and Infirmary for Nervous Diseases.

With 76 Colored Plates and 6 Engravings.

LONDON:
REBMAN, LIMITED,
129, SHAFTESBURY AVENUE, CAMBRIDGE CIRCUS, W.C.

PHILADELPHIA, U. S. A.:
W. B. SAUNDERS,
925 WALNUT STREET.

1899.

PRINTED IN AMERICA.

All rights reserved.

EDITOR'S PREFACE.

THIS volume forms an excellent companion-book to Professor Haab's "Atlas of Ophthalmoscopy and Ophthalmoscopic Diagnosis," and is exactly what might be expected from an author of such wide clinical experience and trained observation. Beginning with the examination of the eye—that is, with functional testing—the student is easily and gradually led from one examination to another, and made familiar with the best methods of investigating the organ of sight for the detection of morbid processes. Following this are the chapters on diseases of the eye, the most important of which are clearly described and the best therapeutic measures briefly recorded. As Professor Haab himself has pointed out, there is much difficulty in portraying in colors the external diseases of the eye; but, in spite of this, he has succeeded in furnishing an admirable series of plates, to each one of which a brief clinical history is appended, which thoroughly illustrate the text. Perhaps it is not too much to say that while one is reading this manual he distinctly feels that he is in the atmosphere of a large clinic.

The Editor has compared the translation with the original, and can testify that although it is not precisely literal, it is none the less singularly accurate, and always conveys with faithfulness the author's meaning. Occasional editorial comments are placed in brackets. It is hoped that this book will prove of use not only to physicians whose opportunities do not permit them to see large numbers of external ocular disorders, but also to teachers and students of ophthalmology.

PREFACE.

AT the request of the publisher I undertook the task of preparing the present atlas and accompanying treatise, although at the time I fully appreciated how difficult it is to give a faithful reproduction of the external diseases of the eye. But after seeing the work of Mr. J. Fink, of Munich, at my clinic last summer, I became convinced of his ability to accomplish anything within the range of the illustrator's art.

With the exception of a few pictures which I already had in my collection, the illustrations were all painted from nature, the artist utilizing any suitable cases that happened to come to the clinic. We therefore had to depend largely on chance for a complete collection of suitable clinical pictures ; but we were fortunate enough to obtain and commit to canvas the most important of such diseases as lend themselves to illustration.

Some things which cannot be satisfactorily reproduced on paper—as, for instance, certain corneal lesions—were not even attempted ; while other deficiencies in the collection are explained by failure to secure the necessary clinical material.

In the treatise on pathology and treatment which accompanies the plates I have confined myself to essentials—above all, to a detailed description of methods of examination, which I deemed most important to students and practising physicians. For this reason less space has been devoted to operative technique and more to the pathology and to non-operative treatment.

I wish to express my sincere appreciation of the publisher's efforts to bring the atlas up to the standard of the excellent series of which it forms a part.


O. HAAB.

CONTENTS.

	PAGE
Examination of the Eye in Disease	17
1. External Inspection by Daylight	20
2. Tension of the Eyeball	36
3. Testing Acuteness of Vision	38
4. Examination with Lateral Illumination	46
5. Examination by Transmitted Light	48
6. Examination with the Inverted Image	50
7. Examination with the Upright Image	50
8. Accommodation	50
9. Measuring the Field of Vision	55
10. Measuring the Light-sense	59
11. Testing the Color-sense	60
12. Examination for Disturbances of Mobility	62
Detection of Malingerers	74
 Diseases of the Lachrymal Apparatus (PLATES 1-3)	 78
Dacryostenosis, Dacryocystitis, Ectasia of Lachrymal Sac.	
 Diseases of the Eyelids (PLATES 4-10)	 92
1. Inflammations.	
Herpes Zoster and Erysipelas	92
Eczema	94
Seborrhea	97
Hordeolum	100
Chalazion	102
2. Anomalies in the Shape and Position of the Eyelids	104
Congenital Ptosis	104
Ectropion	105
Entropion	106
3. Injuries of the Eyelids	107
4. Tumors of the Eyelids	108

	PAGE
Diseases of the Conjunctiva (PLATES 11-19)	109
A. Confluent Inflammations.	
1. Simple Catarrhal Conjunctivitis	109
2. Follicular Conjunctivitis	112
3. Gonorrheal Conjunctivitis	113
4. Diphtheritic Conjunctivitis	119
5. Trachoma	121
6. Spring-conjunctivitis	126
B. Circumscribed Inflammations.	
7. Eczematous, Phlyctenular, or Scrofulous Conjunctivitis	129
8. Pemphigus	134
9. Variola	135
10. Acne	135
11. Scleritis	135
12. Tuberculosis	136
13. Syphilomata and Leprosy	138
Injuries of the Conjunctiva.	
1. Foreign Bodies	138
2. Ecchymoses	139
3. Burns	139
Pterygium	140
Tumors of the Conjunctiva	141
 Diseases of the Cornea (PLATES 20-28)	 143
A. Diffuse Inflammations.	
1. Parenchymatous Keratitis	143
B. Circumscribed Inflammations.	
2. Eczematous Keratitis	149
3. Herpes Corneæ	155
Herpes Zoster	155
Herpes Febrilis	156
4. Hypopyon Keratitis	159
5. Catarrhal Ulcer	167
Injuries of the Cornea	168
Malformations of the Cornea	169
 Diseases of the Sclera (PLATE 29)	 171
1. Inflammations of the Sclera	171
2. Injuries of the Sclera	173
 Diseases of the Iris and Ciliary Body (PLATES 30 and 31)	 177
1. Inflammations	177
Symptoms of Iritis	177

	PAGE
Symptoms of Cyclitis	179
Causes of Iritis	181
Sympathetic Ophthalmitis	184
2. Injuries of the Iris	187
3. Tumors of the Iris and Ciliary Body	188
Diseases of the Lens (PLATES 32-34)	188
Cataract	189
a. Partial Stationary Cataracts.	
1. Anterior Polar Cataract	191
2. Posterior Polar Cataract	191
3. Perinuclear, Lamellar Cataract	192
b. Progressive Cataracts.	
1. Senile Cataract	193
2. Congenital Cataract	195
3. Traumatic Cataract	195
4. Complicated Cataract	196
Dislocation of the Lens	197
Diseases of the Vitreous Body (PLATE 35)	199
Glaucoma (PLATE 36)	203
1. Primary Glaucoma	203
a. Inflammatory Glaucoma	204
b. Non-inflammatory or Simple Glaucoma	207
Infantile Glaucoma	208
2. Secondary Glaucoma	211
Diseases of the Orbit (PLATES 37-40; FIGS. C, D, E, F)	211
1. Inflammations	211
2. Injuries of the Orbit	215
3. Tumors of the Orbit	216



LIST OF ILLUSTRATIONS.

- PLATE 1. Dacryocystitis.
- PLATE 2. Dacryocystitis with Rupture of the Abscess through the Skin.
- PLATE 3. Lachrymal Fistula on the Right Side; Ectasia of the Lachrymal Sac on the Left; Bilateral Epicanthus.
- PLATE 4, *a*. Papular Syphilide.
- PLATE 4, *b*. Eczematous Blepharitis.
- PLATE 5. Meibomian or Internal Hordeolum.
- PLATE 6, *a*. Eczematous Blepharitis.
- PLATE 6, *b*. Molluscum Contagiosum and External Hordeolum.
- PLATE 7, *a-c*. Multiple Chalazion.
- PLATE 8. Blepharochalasis on both Sides.
- PLATE 9. Blepharochalasis. Ptosis. Epicanthus.
- PLATE 10. Subcutaneous Hemorrhage in the Lids after Fracture of the Base of the Skull.
- PLATE 11, *a, b*. Dermoid Tumor.
- PLATE 12. Gonorrheal Conjunctivitis in the New-born.
- PLATE 13, *a, b*. Diphtheritic Conjunctivitis.
- PLATE 14, *a*. Trachoma of the Lower Lid.
- PLATE 14, *b*. Subconjunctival Ecchymoses (*Hyphæma Conjunctivæ*).
- PLATE 15, *a-d*. Spring-conjunctivitis.
- PLATE 16, *a*. Chaff-particle at the Corneal Margin.
- PLATE 16, *b*. Pterygium.
- PLATE 17. Eczema of the Conjunctiva and of the Face.
- PLATE 18, *a*. Marginal Eczema-pustule.
- PLATE 18, *b*. Epithelioma of Cornea and Conjunctiva.
- PLATE 19, *a, b*. Lime-burn of the Conjunctiva and Cornea.
- PLATE 20. Herpes Zoster Ophthalmicus.
- PLATE 21. Foreign Body on the Cornea and Dermoid Cyst of the Orbit.
- PLATE 22. Eczema of the Cornea and Conjunctiva on Both Sides.
- PLATE 23, *a*. Perforation of the Cornea by an Eczematous Ulcer, with Adhesion of the Iris.

PLATE 23, <i>b</i> .	Macula of the Cornea.
PLATE 24.	Herpes Corneæ Febrilis.
PLATE 25, <i>a</i> .	Herpes Corneæ Febrilis.
PLATE 25, <i>b</i> .	Hypopyon-keratitis.
PLATE 26, <i>a, b</i> .	Serpiginous Ulcer of the Cornea; Pterygium.
PLATE 27.	Suppuration of the Cornea from Serpiginous Ulcer; Panophthalmitis.
PLATE 28, <i>a</i> .	Trachoma, with Pannus of the Cornea.
PLATE 28, <i>b</i> .	Phthisis Bulbi Anterior; Calcareous Degeneration of the Cornea.
PLATE 28, <i>c</i> .	Parenchymatous Keratitis.
PLATE 29, <i>a</i> .	Scleritis.
PLATE 29, <i>b</i> .	Sequelæ of Scleritis and Sclerotizing Keratitis.
PLATE 30, <i>a</i> .	Sarcoma of the Iris.
PLATE 30, <i>b</i> .	Syphilitic Iritis.
PLATE 31.	Syphilitic Condylomatous Iritis.
PLATE 32, <i>a</i> .	Senile Cataract.
PLATE 32, <i>b</i> .	Traumatic Cataract.
PLATE 33, <i>a, b</i> .	Zonular Cataract.
PLATE 33.	Incipient Senile Cataract.
PLATE 34, <i>a</i> .	Anterior Polar Cataract.
PLATE 34, <i>b</i> .	Subconjunctival Displacement of the Lens.
PLATE 35, <i>a</i> .	Suppuration in the Vitreous, caused by a Piece of Iron.
PLATE 35, <i>b</i> .	Panophthalmitis from the Entrance of a Piece of Iron into the Vitreous.
PLATE 36, <i>a</i> .	Acute Glaucoma.
PLATE 36, <i>b</i> .	Laceration of the Iris and Lens by a Spicule of Iron.
PLATE 37.	Sarcoma of the Choroid.
PLATE 38, <i>a, b</i> .	Glioma of the Retina.
PLATE 39.	Exophthalmos.
PLATE 40.	Pulsating Exophthalmos of the Left Eye.

FIGURES IN TEXT.

	PAGE
FIG. A. Diagram showing Action of External Eye-muscles	63
FIG. B. Diagram showing Double Images in Paralysis of the Superior Rectus, Inferior Oblique, Inferior Rectus, and Superior Oblique of the Left Eye	70
FIG. C. Dermoid Cyst of the Orbit	216
FIG. D. Bone-cyst, due to Ectasia of the Ethmoid Cells, Frontal Sinus, and Nasal Cavity	218
FIG. E. Angioma of the Orbit	220
FIG. F. Cancer of the Upper Maxilla and Orbit	223

EXTERNAL DISEASES OF THE EYE.

EXAMINATION OF THE EYE IN DISEASE.

IN ophthalmology, as in other fields of medical activity, success in diagnosis depends, above all, upon the experience of the diagnostician. Only second in importance, however, is a definite, systematic routine in examination, the faithful observance of which will eventually become second nature to the surgeon, so that he will almost instinctively apply all the various methods of examination one after the other in their proper order.

Owing to the ease with which both the exterior and the interior of the eyeball can be seen, the great majority of its external as well as its internal alterations and diseases can be determined with absolute certainty, usually at the first examination. Those cases in which the diagnosis must be confirmed or corrected by observing the course of the disease or the effect of treatment (*ex juvantibus*) form a small minority; and in only a very few disease-processes is the true interpretation obtained from the autopsy. The ophthalmic surgeon is rarely forced to conclude his diagnosis with the phrase "*sectio docebit*"—a virtual admission of failure.

Nevertheless the practice of ophthalmology, if based on the proper recognition of disease, is by no means without its difficulties. The physician is confronted and perhaps misled by a multitude of processes differing but slightly from each other, by a rich variety of clinical pictures, and by the difficulty of recognizing many important pathologic conditions in the eye, either because the lesions to be looked for are very small or because they are apparently unimportant—that is, they present well-nigh imperceptible deviations from the normal.

To this diversity of phenomena, on the one hand, and to the extraordinary demands on the observer's eyesight, on the other, must be attributed the many cases of mistaken diagnosis which, in spite of the ease and clearness with which both the exterior and the interior of the eye can be seen, unfortunately occur in this, as in other branches of medicine. The most deplorable result of such diagnostic error is blindness, which occurs only too frequently, as, for instance, in cases of glaucoma.

It is therefore important for the student of medicine to familiarize himself as much as possible with ophthalmology, as he is likely at any time, as a practising physician, to be obliged to resort to ophthalmic surgery, which he will then realize is as vital a branch of medicine as surgery or obstetrics, for to many people blindness is as great a calamity as death itself.

The student will readily appreciate the importance of a thorough training in ophthalmology if he will reflect for a moment that it is often impossible to refer an eye-patient to a specialist, unless one happens to reside in the same place or in the immediate neighborhood. To be sure, eye-patients are often transportable—*i. e.*, able to travel—but not always, when it happens that the morbid process, as, for example, in certain forms of glaucoma, has much debilitated the subject by pain, vomiting, etc.; or when a new-born infant is concerned, whom the parents object to send on a journey; or when certain external conditions, such as advanced age, poverty, etc., make travel impossible; or, finally, when the ocular disorder is accompanied by other grave disturbances which put travelling out of the question.

In many cases the loss of time alone incurred by consulting a specialist residing at a distance might entail irreparable injury on account of the fatal delay in applying the proper remedies and the consequent ravages of the disease in the delicate organ, which the most skilful hand is unable afterward to remedy.

Mention has been made of the great demands on the

examiner's eyesight in the study of ocular affections; the same remark applies to the actual practice of ophthalmology. It is therefore quite in order, before beginning a detailed description of the most efficient method of examination, to devote a few words to the most essential requisite in such an examination—the visual apparatus of the observer. I have often observed that medical men take up ophthalmology as a specialty without fully realizing the prime importance of good eyesight in this branch of medicine.

Although the use of a lens (corneal loupe) may to some extent correct defective eyesight in the examination of the anterior portion of the eye, yet in working with the ophthalmoscope imperfect visual acuity is always a distinct disadvantage. A person with marked astigmatism suffers most in this respect both in examining the exterior and the fundus of a diseased eyeball; it is only with the greatest difficulty that he is able to see the most essential points, if they do not escape him altogether.

A moderate degree of myopia (1–3 D) is less troublesome than hypermetropia. As age advances the hypermetropic eye requires convex glasses, which are a great obstacle to delicacy in examining and operating; or, at least, are very unpleasant and multiply the difficulties of the task.

Binocular vision, the power to see with both eyes at once, is, of course, essential for obtaining a correct stereoscopic picture; and as the diagnosis of many pathologic changes in the eye depends on a correct understanding of the appearances in the fundus, one who is able to study them with one eye only is thereby deprived of a very important aid, especially when a rapid survey of a given phenomenon in all its dimensions is desired. Again the lens can throw itself into the breach and make up for the absence of binocular vision; but in operating its use is out of the question, or is at least a disadvantage. By long practice he who has but one sound eye at his disposal, or whose eyes do not work together properly, may pos-

sibly overcome the defect to some extent; but he will almost certainly be outstripped in the race by better equipped competitors. Even if he has succeeded, after much trouble, in correcting the defect by long practice and by the use of various appliances, cases of unusual difficulty either in operating or exploring will always present themselves, in which he will be more or less at a disadvantage compared with one whose eyesight is perfect.

Although I have known oculists who practised their profession successfully in spite of aggravated astigmatism or the virtual loss of one eye, my advice to a medical man who contemplates devoting himself to ophthalmology is no less emphatic, not to do so, unless, upon careful examination, it is found that each eye has at least 1.5 the visual acuity of the average normal eye, that binocular vision is perfect, and that he is not color-blind. Any one who, lacking these requisites, takes up ophthalmology as a specialty, will find it difficult to attain proficiency and will be in constant danger of being distanced by men who are better equipped by nature.

To introduce the student to the study of ophthalmology we shall first give a detailed description of the *methods* which lie at the foundation of the examination for diagnostic purposes. After that the plan of study will consist chiefly of accurate descriptions, with illustrations, of pathologic processes and their numerous varieties.

The first step in the examination of an eye-patient, be the disease external or internal, is

1. External Inspection by Daylight.

The patient is placed on a chair facing a window, in a strong light, the observer standing with his back to the window. It is better not to take the history until after the examination, except the most necessary points or such as the patient cannot be prevented from giving, as the correct interpretation of objective signs would be dis-

turbed by incorrect data and explanations on the part of the patient.

The entire person is first rapidly inspected, and any departure from the normal noted. Abnormal appearance of the face—pallor, redness, or yellow, cachectic discoloration—the signs of rapid loss of flesh, etc., must be carefully noted. It is especially important to look for traces of disease in the exposed parts of the skin, the face, the neck and throat, and the hands. This examination should include a search for recent or old exanthemata, especially eczema, syphilitic eruptions, etc.; or the scars of such skin-lesions. Next the examiner looks for signs of injury to the integument, as abrasions, contusions, subcutaneous hemorrhages, or wounds of any description, and should be careful not to forget them, if found, especially when the eye is said to have been injured. This examination must never be neglected in cases which from the beginning come to the notice of courts of law, or in which an actionable accident is alleged as the cause of the disorder.

The condition of glands under the jaw and at the angle, at the back of the neck, and in front of the ear should be investigated to determine if there is any swelling or any scars or fistulæ. Joint-affections and old ankyloses should also claim attention.

Alopecia, if of recent development, is important as pointing to the possible presence of *syphilis*, which so often plays a part in diseases of the eye. Eczema and seborrhea of the hairy scalp are also valuable diagnostic signs, as will be explained more in detail later on.

The result of this preliminary inspection of the exposed portions of the skin and of the glandular system, etc., will determine whether it is necessary to examine the skin of the entire body; in any case this examination, as well as that of the body in general, can wait; and attention is next directed to the exterior of the eye. It is advisable not to examine the eye at short range at first, as certain general appearances, such as traces of eruptions, slight differences between the right and left sides of the

face, differences in the palpebral fissures of the two eyes and in the size and shape of the eyeballs, are best appreciated from a distance.

If there is a *squint* of one eye, we test the *mobility of the eyeball* by making the patient look to either side and up and down. The same examination is repeated if one eye is more prominent than its fellow, a condition called *protrusion*. Under certain circumstances testing the mobility may have to be postponed, and inspection is continued.

The region of the lachrymal sac (to the nasal side of the inner canthus) is first examined. If the least degree of swelling, and especially if redness, is observed, it ought to suggest catarrh or inflammation of the lachrymal sac—in short, *dacryostenosis*, which must then be borne in mind. The abnormal contents of the sac can often be squeezed out by pressure with the finger through the lachrymal puncta, even when there is no visible swelling of the lachrymal sac, and only a slight increase of fluid in the eye—so-called “swimming” of the eye—to suggest defective discharge of the lachrymal fluid.

Dacryostenosis cannot be diagnosed with certainty without flushing the lachrymal duct, a procedure which is best undertaken at the end of the examination. We shall discuss this point in detail when we come to treat of disease of the lachrymal apparatus.

Before proceeding to the study of the eye itself and any defects there may be in it, a rapid inspection is made of the *eyelids* for the purpose of noting any abnormal conditions, such as misplaced cilia or deformed or diseased palpebral margins; for these structures are frequently the seat of disease. It should be carefully noted whether the lachrymal puncta are in their proper places (at the nasal extremity of the lid) and whether they communicate with the tear-lake (*lacus lacrimalis*).

If the eye is opened naturally, the region of the palpebral fissure is inspected without touching the lids. If the palpebral fissure is too narrow, the lids may be gently drawn apart and the inner surface of the lower lid ex-

amined by drawing the lid downward, if the previously found conditions make it desirable.

The inner surface of the upper lid may also be examined at this point by everting the lid. Often, however, it is advisable to defer this procedure or even to omit it altogether, since it may not be necessary, if the disease is internal, and would interfere with the tests for visual acuity, or at any rate unnecessarily distress the patient. In deep wounds of the eyeball the act may be downright harmful.

Eversion of the eyelid is effected as follows: The left thumb, held with its volar surface nearly in a horizontal plane, is pressed on the eyelid a little below the eyebrow so as to draw the skin gently upward, enough to obliterate the wrinkles (in elderly people), and at the same time to separate the palpebral margin from the eyeball. Next the lid is seized with the thumb and index-finger of the right hand, either by the cilia, or, if there are none, by a fold of skin near the margin, and drawn downward, while the patient is told to look down as much as possible. The lid is now taut and can be turned over the left thumb, which is at the same time moved downward, pressing the upper edge of the tarsus back and down, while the right hand draws the lower margin of the lid forward and upward. If it is found impossible to evert the lid in this way, a probe or glass rod may be substituted for the left thumb. This will enable one to accomplish it even when the patient is awkward and fails to look down, or shuts his eyes convulsively. The more gentle the operation the better it will succeed; and the clumsier the hand of the operator the more violent will be the struggles and the greater the difficulties. The lid can also be everted with one hand; but this method is not to be recommended, as it is too severe.

While the inspection of the eyeball and of the inner surfaces of the eyelids usually presents no special difficulties in the adult, it is a much more troublesome matter in the case of new-born infants and children, and requires

certain special precautions which merit particular description. I have often observed unsatisfactory results in the examination and treatment of children which were due solely to the inexperience and want of skill of the operator, ignorant of the proper methods of overcoming the resistance which the little sufferers usually offer to the manipulations. Here again the rule is to conduct the examination with firmness indeed, but with all possible forbearance, not only because the struggles increase in proportion to the want of delicacy, but also because a sudden wrenching apart of the convulsively closed eyelids is apt to result in serious injury to the cornea and in lacerations of the outer canthus; or the fissures in the outer canthus caused by the action of the lachrymal fluid, a frequent cause of blepharospasm in children, are aggravated and thereby tend to enhance the spasm, which in turn delays recovery.

In order to examine and treat with comfort, safety, and despatch children up to the age of ten years, the first step is to put them into the proper posture. The operator takes his position so that he has the window or lamp to his right or left; the nurse or, if she is a sensible woman, the mother sits opposite him, holding the child's legs under one arm. The child's back is supported on the nurse's lap and its head rests on, or is held between, the operator's knees (which he has previously covered with a towel). (In the case of new-born children care must be taken not to exert too great pressure on the head.) After the nurse has secured both the child's hands the examination can proceed quietly and without distressing the little one, the light falling full on its face.

First, the eyes are carefully dried with absorbent cotton. Wet, slippery eyelids cannot be separated either in adults or in children, because the fingers cannot secure a hold without the use of such force as to provoke spasm. In many cases it is an advantage to wrap the fingers with gauze before attempting to separate the eyelids. If with all these precautions it is found impossible to separate the lids on account of swelling or spasm, or both, they should

be gently and carefully drawn apart with Desmarre's lid-elevator, care being taken that the surface opposed to the eyeball is perfectly smooth, so as to avoid injuring the cornea. The instrument must, of course, be absolutely clean. One elevator for the upper lid is usually all that is needed. If, as often happens in private practice, there is no elevator at hand, the physician can easily improvise one from an ordinary hairpin by bending the closed end so as to form a hook about 1 cm. long, which may then be carefully inserted under the eyelid. The hairpin must be perfectly smooth, and cleaned by heating before it is used. It is much better to resort to this primitive device than to force the lids apart with the unaided fingers, for it requires a very skilful hand to separate such tightly closed eyelids in a struggling child without an instrument and without injuring the cornea.

Eversion of the eyelid, on the other hand, is very easy in such children; indeed, it often occurs when it is not desired. One of the chief uses of the elevator is to prevent eversion, as the object of the examination is usually to inspect the cornea and surrounding parts, rather than the inner surfaces of the lids, and if the latter are everted inspection of the cornea is impossible.

It is often necessary to evert the upper eyelid in the examination and treatment of ophthalmia neonatorum. In such cases any injury to the cornea by the finger-nail would be fatal; the least scratch or the slightest loss of tissue might entail the loss of the eye. Hence the holder should always be used when the eyeball is inspected, especially if the lids are swollen. As has been pointed out, inspection of the inner surface of the lids in such cases is quite easy, because the upper lid usually turns over as soon as the skin is drawn upward. If it fails to do so, however, the operator should wait until the baby cries, when the lid can easily be everted, even in the later stages after the swelling has subsided. Gentle traction of the outer canthus toward the temple assists the eversion and tends to fix the lid in the everted position (ectropion).

In treating children with severe blepharospasm the following must be borne in mind: Even after the operator has finally succeeded in opening the lids the cornea cannot always be seen, because it is convulsively rolled upward. Scolding the child only makes matters worse; the only thing to do is to wait patiently, avoiding all pressure on the parts to be examined and encouraging the child by speaking to it kindly. Usually the eyeball is rolled downward sooner or later, if only for a short time, so that the cornea can be inspected. If the spasm is so severe that the eye fails to rotate downward of its own accord, a few drops of cocain should be instilled and the result awaited. Forceps should be used only as a last resort; the parts are first thoroughly cocainized and the instruments must be handled as gently as possible.

Always insist on making a thorough examination of the cornea and surrounding parts until a clear view of the entire corneal region has been obtained, no matter how much the child cries and struggles. The greatest care is necessary not to exert undue pressure on the eyeball, for such children often have deep ulcers of the cornea, which are liable to burst from the slightest pressure on the eye, causing permanent injuries by incarceration of the iris, distortion of the pupil, etc. Indeed, rupture of the floor of the ulcer may result in loss of the eye through infection, especially if the crystalline lens is forced through the perforation, an accident which quite easily may happen.

So much for the technic of the external examination of the eye in children, the importance of which cannot be overestimated.

In the **inspection of the eyeball**, to which we now turn our attention, the following precautions are to be observed: If there is redness, its nature—*i. e.*, first, its situation and, second, its color—affords an important clue to the seat of the disease, and therefore to the diagnosis. The following points are to be noted:

A practised eye readily distinguishes between inflammation of the conjunctiva, in which the conjunctival vessels are congested, and inflammation of the cornea or iris, although both conditions produce a redness of the eye. The first condition is called *conjunctival*, the second *ciliary*, congestion. The first, or conjunctival congestion, is characterized by the fact that it is most intense where the blood-vessels are most marked—*i. e.*, at the fornix and in its immediate neighborhood—and decreases in intensity as it approaches the corneal margin, being absent in the immediate neighborhood of the cornea, so that there is a zone about 5 mm. broad in which the blood-vessels are very pale (see Plate 14, *a*). This centripetal increase in the intensity of the congestion also appears in the marked redness of the caruncle, situated at the inner canthus, and of the plica semilunaris next to it on the temporal side, which is very conspicuous in conjunctival inflammation, and even at a distance betrays the congestion of the conjunctival vessels, as, for instance, in acute conjunctival catarrh.

Ciliary or *circumcorneal* congestion, on the contrary, increases as the corneal margin is approached, is most distinct at the corneal margin, and diminishes uniformly at every point as the periphery of the anterior segment of the globe is approached (see Plate 21). The most distinctly congested corneal zone is from 3 to 7 mm. wide, and corresponds approximately to the zone least involved in pure conjunctival congestion. Hence, whereas conjunctival congestion decreases in intensity as it approaches the corneal margin, ciliary congestion diminishes in intensity as it recedes from the corneal margin. The blood-vessels concerned in ciliary inflammation are so deeply placed and, in part, so minute that they cannot be seen as well as the conjunctival vessels.

Disregarding the question of localization, quite a difference in the *color* of the two forms of congestion may be observed, if one has a good eye for color. The color of a conjunctival congestion is yellowish or “brick-red;” that

of a ciliary congestion is more bluish, "pink," "scarlet," or "crushed raspberry" (Plates 21 and 30, *b*).

The differences in color and in localization are readily explained by the arrangement and distribution of the blood-vessels concerned in each form of congestion.

Conjunctival congestion is due to abnormal distention of the conjunctival vessels, barely visible in the normal eye on account of their tenuity. The vessels in the sclerotic portion of the conjunctiva make their appearance at the fornix, and from all sides radiate forward and outward toward the cornea, breaking up into arborizations as they proceed and thereby becoming more and more minute. This enlargement furnishes the anatomical explanation of the diminution of the intensity of a conjunctival congestion as it approaches the cornea. As these vessels are very superficial, they show the true color of the blood when overfilled, which in thin layers is a *yellowish-red*. Moreover, the conjunctival vessels can be recognized by their mobility with the shifting of the conjunctiva, which is but loosely attached to the sclerotic, especially at some distance from the cornea. This mobility is often of service to clear up any doubts about the nature of such a blood-vessel.

The vessels that are responsible for ciliary or circumcorneal congestion are very different in their arrangement and distribution. In the first place, they are situated *beneath* the conjunctiva. They also are but faintly visible in the normal eye; in fact, only the arterioles are visible, their accompanying venules becoming manifest only when the eye is inflamed. These arterioles proceed from the tendons of the recti muscles, either singly or in pairs, pursue a very tortuous course in radiating lines to the cornea, and suddenly disappear at points several millimeters distant from the corneal margin, by entering the sclerotic, in which they ramify, and contribute largely to the blood-supply of the ciliary body and iris (ciliary region). Their points of entrance into the sclerotic are often distinctly tinted and plainly visible. They are

called the *anterior ciliary vessels*, while those which enter the choroid at the back of the eyeball are known as the *posterior ciliary vessels*. The anterior ciliary vessels, before entering the sclerotic, form ramifications, the branches of which anastomose with one another and form a dense plexus of capillary loops around the cornea. Since both the larger arterial trunks and their more minute branches about the cornea lie *beneath the conjunctiva*, between it and the sclerotic,¹ they do not move with the shifting of the conjunctiva, and present a bluish (lilac or violaceous) coloration, for the simple reason that the conjunctiva acts as a turbid medium, through which the blood has a bluish tint. If a thin layer of milk is spread over a black surface, the milk appears blue, and in a similar way the bluish tint which we observe in the ciliary vessels is formed.

It must be borne in mind that the superficial conjunctival vessels and the deeper ones of the episclera communicate with each other at the corneal margin, so that the conjunctiva receives some of its blood-supply from the ciliary region, through certain small branches which enter it from the episcleral, pericorneal plexus, and which in it (usually in straight lines) run backward (anterior conjunctival vessels). This explains why a ciliary congestion of some duration gradually produces more or less hyperemia of the conjunctival system also, resulting in a combination of the two forms of congestion. The converse, however, is not true: So long as the cornea is not affected a long-continued conjunctival congestion is not apt to induce ciliary congestion.

The cornea possesses the peculiarity that as soon as it suffers the least injury from a scratch-wound, the entrance of a foreign body, or inflammation from any cause, the characteristic uniform circumcorneal congestion immedi-

¹ Occasionally a ciliary artery, running from without and below, or from without (temporal) inward toward the cornea, is seen lying in part within the conjunctiva and movable with it. Such a branch is derived from the palpebral arteries.

ately makes its appearance and thus brings the lesion promptly to the surgeon's notice. The injury or inflammation may be very slight and much time and care may be required for its detection; hence, in every case of ciliary congestion the cornea should be subjected to a thorough examination. If nothing abnormal is found in the cornea by the methods presently to be described in detail, the cause of the circumcorneal congestion must be sought in irritation or inflammation of the iris or ciliary body (iritis, cyclitis).

The foregoing description applies to general congestions affecting the entire area of distribution of each system of blood-vessels; in addition, we have to consider the local or circumscribed congestions which occur in both systems and which may be limited to a small area. This happens, in the case of the conjunctiva, when there is a *local, circumscribed* lesion—for example, a slight wound or localized inflammation in the form of an eczema-pustule (phlyctenule)—instead of a general process affecting the entire mucous membrane, as, for instance, in acute catarrh. Under such circumstances the hyperemia, which is superficial and *yellowish-red* in color, is limited to the immediate neighborhood of the injury or inflammatory center; or, to be accurate, to the system of vessels in the affected area.

In a *localized ciliary* congestion the appearance is different. The color is darker and more bluish; the vessels can scarcely be made out; and the color does not disappear upon pressure with the finger on the eyelid as readily as in conjunctival congestion. Circumscribed ciliary congestion is caused by inflammation of the sclera, which usually is circumscribed, or by a deep wound of long standing in the sclera.

It is this accurate knowledge of the differences between the various forms of congestion which enables the practised examiner to diagnose a given case with a rapidity which astonishes the beginner. For instance, he recognizes conjunctival catarrh at a glance by the abnormal color at the inner canthus, in the region of the caruncle, plica semi-

lunaris, and adjoining conjunctiva. In another case, guided solely by the ciliary congestion, he promptly locates the seat of the inflammation or injury in the cornea, although the injured spot is barely visible. He then looks for further signs of the morbid process, and in a short time the diagnosis is formulated and even the etiology determined. For instance, a patient enters the room with the characteristic alopecia and red blotches on the forehead, along the line of the hair, strongly suggestive of syphilis. There is a ciliary congestion in one eye; on further inspection the pupil is found to be irregular in outline (instead of round) from serrations which encroach on the papillary border, and in the iris there are yellowish-red, thickened areas. The diagnosis of syphilitic iritis is reached in less time than it takes to read this example. Not to anticipate, however, we will proceed to describe the method of examining that important structure, the cornea, which is such a frequent seat of disease.

Examination of the Cornea.—We determine two things: First, the *condition* of the *surface*; and, second, the *transparency*.

The surface of the normal cornea acts like a small convex mirror in reflecting a sharply defined, small upright image of objects placed in front of it with the usual distortions incident to convex mirrors. Thus the image of window-bars reflected from the corneal mirror of a patient seated before the surgeon appears slightly bent (convex), but clear-cut and distinct. This image of the window-bars is utilized to test the condition of the corneal surface, by allowing it to fall consecutively on different parts of the cornea. The patient is required to follow the uplifted finger as it is moved up and down and to either side while the surgeon watches the reflection in the cornea and is able to detect the slightest inequality in its surface. Such slight irregularities are not uncommon, and may be of several kinds:

1. The image in one part of the cornea, without being at all distorted, may appear somewhat indistinct; the

surface is evidently opaque at this point, it looks as if it had been breathed upon, and, like a moist window-pane, is a poor reflector. Opacities of this kind usually correspond to inflammatory areas. Opacity of the entire cornea indicates either a general inflammation or glaucoma. The precise nature of such an opacity will be described later; for the present, suffice it to say that in many cases this opacity alone should lead us at least to suspect glaucoma, and may point the way to a correct diagnosis; we therefore emphasize the importance of noting accurately the reflecting powers of the cornea.

2. The image of the window-bars may be perfectly clear and distinct, but the distortion may be greater than normal. It may be limited to a portion of the image, or it may be general. In the first case the distorted portion of the image is usually found to correspond to an area which, although smooth, is either depressed below, or elevated above the general level, or presents a plane surface. The latter condition is sometimes called a *facet*.

The distortion may be general. Two conditions are possible. Either the entire surface is rough and irregular, or beset with numerous facets, as, for instance, after repeated ulcerations; or, more rarely, the general distortion of the image is due to incorrect curvature of the entire cornea, giving it a more or less conical shape, a condition termed *keratoconus*. The image is very small at the *apex* of the cone and increases in width as it approaches the corneal margin, where the lateral portions of the membrane (between the center and the margin) take part in the reflection. Keratoconus is a serious disturbance to vision; it is most surely recognized by observing the nature of the corneal image—another reason for training the eye in the study of corneal changes.

3. Under certain circumstances opacity may be combined with irregularity of the surface, as, for example, more or less rough depressions from recent ulcers, or opaque elevations from imprisoned foreign bodies, or a

rough prominence due to an epithelial neoplasm. Foreign bodies embedded in the cornea are a very common occurrence in practice; their presence can always be discovered by the disturbance they cause in the corneal reflections. The following precaution is needful in many cases: Slight irregularities of the cornea, such as follow eczema, for instance, are more easily detected if the flow of tears is checked for a moment; hence, if it is very copious, the lids must be held open and the fluid allowed to run off, before the inspection is begun.

After the condition of the corneal surface has been determined in this manner, we proceed to test its *transparency*. This is often disturbed in morbid processes, notably in inflammations. Colorless blood-corpuscles invading the corneal tissue produce a general or local opacity, ranging, according to the kind and degree of inflammation, from an almost imperceptible, bluish-gray film to complete opacity, grayish-white, or, if the inflammation is purulent, even distinctly yellow in color. The eye should be carefully trained to recognize the slightest degree of yellowish discoloration, as it indicates that the disease has assumed a distinctly purulent character and the prognosis is proportionately grave. The yellow color of such an infiltration can be seen better by daylight than by artificial light.

Other colorations of a more reddish hue on a gray background sometimes occur in the cornea. Newly formed blood-vessels enter the inflammatory area from the corneal margin and form a delicate plexus which produces a faint reddish sheen. Usually at least the larger branches can be seen with the naked eye.

Another form of opacity, with or without blood-vessels, is produced by the scars left by former infiltrations which ended in ulceration. Sometimes these cicatricial opacities are distinctly whitish or grayish-white, so that we speak of white spots or *leukomata*. When the dots are not very pronounced their grayish color is so like that of a recent infiltration that a beginner finds it difficult to distinguish

between the two forms; not so the experienced practitioner, however, for *he knows that a recent inflammatory infiltration, whether it is localized or diffuse, always has a dull surface, whereas an old macula possesses a good reflecting surface.* Once more the value of studying the reflecting properties of the cornea is exemplified, since it is important to be able to distinguish between an old opacity and a recent corneal inflammation. Opacities of long standing usually have a bluish tint, but the surest way to recognize them is by their smooth surface.

With the growth of accident-insurance the ability to determine the *age* of a corneal opacity becomes more and more desirable. It frequently happens that holders of accident-insurance policies attempt to ascribe to a recent accident an opacity which has existed for some time, in the hope of obtaining damages for it along with the recent injury. The following example may serve to illustrate the importance of carefully examining for corneal opacities: A patient exhibits ciliary congestion, suggesting the probability of corneal disease. There is, in fact, a circumscribed corneal opacity, and the diagnosis of keratitis seems plausible, especially as he complains of pain in the eye; but on inspection the opaque area is found to be perfectly smooth; further examination shows that the pupil is not quite round and that the iris is dull and discolored; in short, it turns out to be a case of iritis. The corneal opacity is due to a former inflammation which the patient had in his youth, and he is, of course, much impressed when we tell him that he had inflammation once before in the same eye.

In persons with blue or gray irides, corneal opacities, being practically of the same color as the iris, cannot be readily distinguished except over the black pupil. Artificial light, presently to be described, is needed—indeed, the information afforded by lateral illumination is so valuable that it must never be omitted, even in the examination of persons with dark irides.

In the mean time, we continue the examination by day-

light, examining the anterior chamber and its posterior boundaries, the iris, and the crystalline lens.

First we note whether the *anterior chamber* is of normal depth, abnormal depth, or shallow, by ascertaining the distance of the iris from the cornea in each eye and comparing one with the other. For example, the temporal half of the anterior chamber may be quite shallow, while the nasal half is abnormally deep. This usually indicates that the lens is displaced outward toward the temporal side. If this is the case, a slight *tremor* of the nasal portion of the iris is observed when the eye is moved. The tremor may extend over the entire iris, especially if the lens is absent, as, for example, when it is dislocated into the vitreous body.

Abnormal contents of the anterior chamber, such as a grayish-yellow or yellow exudate, blood, etc., must not be overlooked. A narrow, yellowish band, or mere line in the lowest portion of the anterior chamber, indicates the presence of pus and is considered a serious symptom. The phenomenon is called *hypopyon*. Foreign bodies are occasionally met with in the anterior chamber.

Pathologic discolorations of the iris—in inflammation, for instance—can be seen much better by daylight than by artificial light, which is always more or less yellow. The normal color of the two eyes must be compared, as the color of the two irides may differ in health, although rarely.

Comparison of the two pupils in respect to size, shape, and reaction to light is of the highest importance. As is well known, difference in the size of the two pupils may be a very grave symptom, indicating disease which may involve much more than the eye alone; for example, paresis or tabes.

The size of the pupil is also affected by light and convergence. A preliminary examination may be made by alternately illuminating and shading the eye with the hand; but in most cases this must be supplemented by an examination with artificial light. To obtain a correct idea

of the shape of the pupils they must be examined in a dark room.

Abnormal coloration of the pupil, crystalline lens, and vitreous body is best seen by daylight. Bluish-gray or grayish-white dots and streaks in the pupillary region indicate cataract. In elderly people a slight, grayish filminess is sometimes observed, apparently in the depths of the lens, which has often led inexperienced men to diagnose cataract; the phenomenon is produced by the increased reflecting power of the lens, due to the sclerosis of age. Cataract cannot positively be said to exist unless examination with artificial light, in the manner to be described, reveals distinct opacities in the substance of the lens.

Finally, the appearances in the deepest portion of the eye, the vitreous body, are noted in the examination by daylight. Every shade of yellow, red, brown, gray, or blue may be seen reflected in its substance. These reflections are often of grave significance, as, for example, in the condition shown in Plate 38, *a*, where they indicate the presence of a very malignant tumor on the retina. Similar clinical appearances may be due to inflammatory exudates in the vitreous body or to severe hemorrhages, in which case the color of the blood is more or less pronounced.

So much for the examination of the eye by daylight. We may conclude it by testing the

2. Tension of the Eyeball.

The degree of intraocular pressure is tested with the finger-tips, just as we test the consistency or fluctuation of a tumor. The patient is told to look *straight* before him or very slightly downward, so that the tips of the two index-fingers can be placed close together on the upper lid, over the region between the upper margin of the cornea and the equator of the eyeball. Gentle pressure is exerted alternately with each finger, the other preventing the globe from rolling or moving to one side. The arms should be held in an easy and perfectly sym-

metrical position, so that the muscular tension is the same in both arms, and to do this the operator must stand in front of the patient, not to one side. For similar reasons it is better to use the two index-fingers, instead of the index and middle fingers of the same hand.

The patient must be careful to avoid extreme downward rotation of the eyeball, as it might have the effect of raising the tension by increasing the pressure of the external eye-muscles. In rotating the globe downward the inferior rectus and superior oblique exert a direct pressure upon it, and the elevators (superior rectus and inferior oblique) do likewise, because they are put on the stretch and thereby brought into close contact with the eye. Slight as it is, this increase in the tension is enough to affect the accuracy of the test.

It is not possible to obtain trustworthy results in patients who during the examination tightly close the lids, especially in screaming children. By persuasive and careful examination it is usually possible to accomplish the end in the case of an adult, even when the eyeball is sensitive to the touch. With children it is different, and in cases of suspected increased intraocular tension narcosis may be needed before the examination is satisfactory.

The beginner will do well to practise this important part of the examination as much as possible on normal eyes, so as to become thoroughly familiar with the resistance of a normal eyeball.

This method of estimating intraocular tension with the fingers is, of course, not very accurate, depending, as it necessarily does, on the subjective feeling of the surgeon, which is largely a matter of experience. When the tension is excessively high or excessively low there can, of course, be no doubt that the eye is abnormal; but slight departures from the normal are not always so easy of detection, especially as there are individual variations within physiologic limits. Thus the eyes in youth are usually less resistant to the touch than in old age, when the sclera has become rigid. Here again "practice makes perfect," and the experienced can, as a rule, dispense with the instruments that have been devised to measure intraocular tension, except in very unusual cases. These instruments, called *tonometers*, have their fallacies; some are very complicated and it is not always convenient to use them. The most serviceable, as far as my experience goes, are those designed by A. Fick and Maklakow, both of which yield fairly accurate results if properly

handled. To obtain accurate results with Fick's tonometer an assistant is needed, and great care is necessary. Maklakow's method is easier and simpler.

The ideal way to express the tension would be by the number of millimeters in a column of mercury corresponding to the intraocular pressure in each case. Instead, however, as the tension is tested with the finger-tips, we designate increased resistance by $T + 1$, $T + 2$, $T + 3$, and decreased resistance by $T - 1$, $T - 2$, $T - 3$, where $T + 3$ denotes that the finger is unable to produce any appreciable depression in the eyeball, and $T - 3$, that the finger feels no resistance whatever—the globe is “as soft as mush.”

The examination is now continued either by artificial light or the examiner proceeds to the functional testing of the eye. The choice will depend on whether the employment of the latter is necessary, or even possible. If, on account of spasm in the lids, tears, violent pain, or serious injury, it is impossible to test the acuteness of vision, it must, of course, be postponed. In medicolegal cases, however, it is advisable to test the vision of each eye if it is at all possible. Holders of accident-insurance policies do not, as a rule, mangle at the first examination, though they may do so later on, and it is often very useful (in such cases) to know in time the acuteness of vision of the uninjured eye.

The functional test is also called the *subjective* examination, as distinguished from the *objective*, with which we have been dealing so far, because the examiner relies on the data obtained from the patient. If it is decided to apply this test, the first step consists in

3. Testing Acuteness of Vision.

The test is first applied to each eye separately ; later, to both at once.

It is well to form the habit of examining the right eye first, and to preserve the same order in writing the history, as it makes it easier to understand at any future reading.

As the acuteness of vision is usually tested for the purpose of correcting errors of refraction, myopia, hypermetropia, or astigmatism, a set of lenses should be at hand.

The first requisite is a good light, to insure sufficient illumination of the signs—usually letters—by the reading of which the acuteness of vision is determined. The type-card is therefore hung in a strong light opposite, or next to a window. If the examiner is able to discern with ease the letters which correspond to his own visual power the light is sufficiently strong. This control-test should never be omitted, as any diminution of the light affects the visual acuity unfavorably. As Schweigger aptly says, the improvement in a patient's eyesight which we observe at successive examinations is very often an improvement in the weather rather than in the disease. If, therefore, the daylight is not strong enough to illuminate the type-card properly, artificial light must be used. The source of light may be the same as that used for the ophthalmoscopic examination later on, care being taken to protect the patient's eyes with a shade, so that the light falls only on the type-card.

A transparent type-card may also be employed to insure a good illumination of the test-letters. The card is fastened to the window and a mirror is placed opposite at the proper distance, the patient reading the letters as they are reflected in the mirror. This arrangement has the advantage of enabling the examiner to stand near the patient and the type-card at the same time, so as to point to the letters he is to read. In a small room the necessary distance from patient to type-card can best be obtained by this device.

The test for acuteness of vision is based on the following considerations: Suppose we were to test the vision by the simplest possible means, by asking the patient to tell, for instance, how many fingers we had stretched out on the background of our black coat. A normal eye would be able to distinguish such large objects at a great distance; in fact, we should have to move away 50 meters before the

fingers would appear indistinct. This would be the limit ; at a greater distance than 50 meters a person with normal eyes could no longer recognize the fingers with certainty. Now, if another person were unable to count the same fingers when placed more than 25 meters away, that person would possess only half the visual power, or $\frac{25}{50}$, because the object to be perceived by him would have to be brought nearer by one-half the distance. If the distance had to be reduced to 10 meters, to enable a person to count the fingers, his vision would evidently be equal to one-fifth the normal, or $\frac{10}{50}$; and at 5 meters the visual acuity would be $\frac{5}{50}$, or $\frac{1}{10}$. *The acuteness of vision can therefore be expressed by a fraction in which the numerator indicates the greatest distance at which the person examined is able to recognize an object, and the denominator the greatest distance at which a normal eye can recognize the same object—* in other words, the *normal distance* for that object. For the outstretched fingers this distance is 50 meters. Normal vision is therefore represented by $\frac{50}{50}$, or 1 ; abnormal vision, by some fraction of 1.

Now, if we were actually to adopt this plan of testing the acuteness of vision we should find this running backward and forward with outstretched fingers over a distance of 50 meters rather troublesome. Therefore, instead of varying the distance from the patient to the object, we vary the size of the object. We use test-objects of varying normal distances. Suppose, for instance, we choose 5 meters once for all as the distance for applying the test ; it is evident that an object 10 times smaller than the outstretched fingers will have to be used as the standard. Such an object would be, for instance, a letter 7.5 mm. in height. Letters of this size can just be discerned by a normal eye at a distance of 5 meters ; their normal distance, therefore, is 5 meters ; and we place the number 5 over a row of letters of this size which form the lowest line on the type-card.

In the next line above, the letters are twice as large ; a normal eye should therefore be able to read them at twice

the distance, or 10 meters. This row of letters is designated by the number 10, which is their normal distance. If no smaller letters than these can be discerned, vision is $\frac{1}{2}$, or, keeping the same fraction, $\frac{5}{10}$.

The letters in the third row are three times as large as those in the first row (which are 7.5 mm. high); a normal eye should therefore be able to read them at three times the distance, or 15 meters. This row is marked 15, its normal distance. If an individual cannot read any letters smaller than these, his vision is evidently $\frac{1}{3}$, or, keeping the same fraction, $\frac{5}{15}$.

The letters in the fourth row are four times as large as those in the first row, and are designated by their normal distance, 20 meters. If these letters, which a normal eye can read at four times the distance, or 20 meters, are the smallest that can be discerned, vision is evidently $\frac{1}{4}$, or $\frac{5}{20}$.

The letters in the fifth row are six times as large as those in the first row, and above them is a single large letter, ten times as large as the first, which correspond respectively to visions of $\frac{1}{6}$ (or $\frac{5}{30}$) and $\frac{1}{10}$ (or $\frac{5}{50}$). The normal distance at which the sixth row should be read is 6×5 , or 30, and it is accordingly marked 30; similarly, the large, single letter at the top is marked 50. The large-letter test is equivalent to the finger-test.

Now we can measure visual acuities ranging from $\frac{5}{10}$ (or $\frac{1}{2}$) to $\frac{5}{50}$ (or $\frac{1}{10}$) without changing the position of the type-card, which remains fixed at a distance of 5 meters. Or, the type-card may be fixed at a distance of 10 meters, in which case the readings would be $\frac{10}{10}=1$, $\frac{10}{15}=\frac{2}{3}$, $\frac{10}{20}=\frac{1}{2}$, $\frac{10}{30}=\frac{1}{3}$, according to the letters the patient is able to read.

It appears therefore that the numerator in the fraction corresponds to the distance in meters of the patient from the type-card, and the denominator corresponds to the distance at which the type should be read normally. Example: The distance of the patient from the card is 5 meters; if the type marked 15 is discerned the vision is $\frac{5}{15}$, or $\frac{1}{3}$.

A simpler way of stating the rule is: *Above the line*

put the distance that suits the patient ; below the line, the distance that suits the normal eye.

In the example given above, the patient reads the type which a normal eye discerns at 15 meters, at no greater distance than 5 meters—that is, at a distance equal to $\frac{1}{3}$ the normal distance ; hence his visual acuity is only $\frac{1}{3}$.

This extremely practical system of testing the acuteness of vision we owe to Snellen, and his type-cards, which we have just described (and which can be bought in any bookstore), are now universally used ; at least his system is always followed, whether his own type-cards or others constructed on the same principle by other authors be used. Some type-cards are designed for even smaller fractions, or decimals are substituted for common fractions, etc.

When a transparent type-card is used it is placed beside the patient, and the mirror 5 meters away ; the row of letters marked 10 therefore represents the normal type, and the numerator is 10, instead of 5, since the letters are actually 10 meters distant from the patient.

For children and illiterate persons *fork-like figures*, **E W M**, in various positions, of the same size as the letters, are used. These figures possess the additional advantage of being uniform in shape, whereas some letters, as **V O L**, are easier to read than others, like **B R Z N**. On the other hand, this quality of not being equally legible is useful in the examination of malingerers. For if a patient reads all the letters in one row easily and without hesitation, he is always able to discern one or more of the easier ones in the next row also ; and if he fails to do this, malingering, or at least exaggeration of his condition, may be suspected. As a control-test, the vision is tried at various distances. If the answers are given honestly the result will always be *approximately* the same ; for instance, $\frac{3}{15}$, $\frac{2}{10}$, $\frac{1}{5}$, when the test is made at the distances of 3, 2, and 1 meter respectively. The malingerer, on the other hand, is apt to claim better, or at least the same, visual acuteness as the type-card is brought nearer ; hence

a suspected malingerer should always be tested at various distances.

The same plan may be adopted if the patient fails to read even the largest letter, although it is better in such a case to ask him to count the outstretched fingers, the result being recorded as "Counts fingers at 0.2, or 2, or 4 meters," etc. If he is unable to count fingers, we try if he can see movements of the hand at 0.2, 0.5 meter, etc., and record: "Perceives movement of the hand at . . . meters."

When even this power no longer exists, the *perception of light* should be tested in a dark room, by alternately covering and uncovering a lamp or candle, noting the distance at which the light is perceived. It is only when (qualitative) light-perception is absent that we speak of blindness or amaurosis.

In testing the *accommodation* for the purpose of selecting glasses, etc., consecutive texts in varying sizes of type are substituted for the letters. The type-cards (after Snellen) are provided with these texts, which are compiled on the same principle as the letters.

The foregoing description has been made as easy as possible, and differs somewhat from that usually given, which reads simply: Acuteness of vision is determined by finding the smallest subtended angle in which the eye can recognize the shape of a given object. For objects at the same distance this angle is assumed proportional to the size of the object, which is sufficiently accurate for small angles. *For larger angles the size of the object must be taken as equal to twice the tangent of half the angle.* Hence the respective letters on the type-card are not exactly 3, or 5, or 10 times as large as the letters which are 7.5 mm. long, but only approximately. In order to express the visual angle in commensurable terms a conventional unit has been selected. For this purpose an angle of 5' (minutes) is taken for the recognition of letters *the thickness of which is one-fifth the height.* In the formula $V = \frac{d}{D}$, d stands for the distance at which the letter can be distinctly recognized; D , for the distance at which the letter subtends an angle of 5' (minutes); and V , the visual acuity.

The angle 5' is arbitrary; it corresponds to the average normal vision. Many persons see quite clearly at a smaller visual angle; thus, the letters numbered 5 may be discerned at a distance of 7.5, or even 10 meters. Such persons would possess a vision equal to $1\frac{1}{2}$ and double the normal respectively.

It is important to observe the following precaution in testing the acuteness of vision. When, in the examination of the right eye, for instance, the left eye is to be excluded from the visual field, it must not be covered with the hand or fingers, except possibly with the hollow of the hand, so that the eye can remain open. It is better to use a pair of testing-spectacles in which the left lens is replaced by a disk of tin or pasteboard, which cuts off the view without closing the eye. Pressure on the eye with the hand or finger, even for a short time, disturbs vision by altering the normal outline of the cornea, so that the acuteness of vision obtained is incorrect. Any one can convince himself of the truth of this statement by pressing upon his eye for a short time.

Now, suppose the right eye, for example, is to be tested. We first note the visual acuity without glasses—in other words, the uncorrected vision. If this is found to be less than 1, the effect of concave or convex lenses of varying strengths is tried. The weakest concave or strongest convex lens that produces the best vision indicates the degree of subjective myopia or apparent hypermetropia. If spherical glasses fail to bring the vision up to 1, cylindrical glasses must be tried. Cylindrical lenses, plus or minus 1 (or even other cylindrical lenses), are held in front of the eye, in a horizontal, vertical, or either of the two oblique directions, to see whether a combination of spherical and cylindrical lenses, or cylindrical lenses alone, produce the best vision. The direction of the axis of the cylinder is best recorded as follows: Axis vertical, or A. v. or, simply, \parallel ; Axis horizontal, or A. h. or $=$; axis x degrees temporal or nasal above—*i. e.*, the upper end of the axis deviates x degrees from the perpendicular to the temporal or nasal side.

The notes of the test for visual acuity would then read something like this:

R. $\frac{5}{30}$ — 1.5 sph. $\frac{5}{10}$ \subset cyl. — 0.75 \parallel V = 1.
 L. $\frac{5}{50}$. No improvement with glasses.

[Ordinarily, in this country, this record would be as follows: R. E. $V = \frac{5}{30}$ without correction; with — 1.5 D sph., \ominus — 0.75 D cyl., axis 90° $V = \frac{5}{5}$ or 1. L. E. $V = \frac{5}{50}$; no improvement with glasses.—E.D.]

In this patient's left eye we may have noticed a central corneal opacity, which explains the low visual acuity of $\frac{1}{10}$; or we may find, in another case, upon continuing the examination, that the amblyopia is caused by disease in the fundus.

In the above record of the right eye (R.) the uncorrected vision is $\frac{1}{6}$; with a spherical lens the visual power is raised to $\frac{1}{2}$; and finally the effect of the cylindrical lens is to bring the vision up to 1.

Ophthalmologists have their own system of numbering spectacle-lenses. Ordinarily a lens is designated by its focal length; but spectacle-lenses are numbered according to their refractive power. A lens of 1 meter focus is taken as the unit, and, with the exception of lenses 0.5 and 0.75, all others are multiples of the *meter-lens*, or *dioptr*, as it is also called. A lens of 2 D therefore has a refractive power twice as great as a lens of 1 D, and consequently half the focal length, or 0.5 meter; a lens of 3 D has three times the refractive power and one-third the focal length of a lens of 1 D (meter-lens or ml), etc., for the refractive power of a lens is the inverse of its focal length. The smaller the focal length the greater the refractive power.

To find the focal length of a lens in the dioptric system divide 100 by the number of dioptr. Thus, the focal length of a lens of 3 D is $\frac{100}{3} = 33.3$ cm.; that of a lens of 8 D, 12.5 cm. To find the number of dioptr. for a given focal length—10 cm., for example—divide 100 by the number of cm. in the focal length: $\frac{100}{10} = 10$ D; for 20 cm. the number of dioptr. is 5, etc.

In the old system a lens of 1 inch focus was the unit, and all the lenses in use were fractions of this unit. No. $\frac{1}{2}$ had a focal distance of 2 inches; No. $\frac{1}{3}$, a focal distance of 3 inches, etc. The number of the lens gave the focal

distance (more correctly, the radius of curvature) and the refractive power at the same time, and consequently took the form of a fraction. The diopter (Ml) corresponds to lens $\frac{1}{40}$ in the old system. To change from the new system to the old, divide the number 40 by the number of diopters; to change from the old system to the new, divide the same number (40) by the denominator of the fraction. For example, a lens of 2 D, new system, is No. $\frac{1}{20}$ in the old; lens No. $\frac{1}{8}$, old system, corresponds to a lens of 5 D in the new system. The lenses in the two systems are practically the same, the nomenclature only being different.

The refractive power of the eye, as determined with spectacle-lenses by the so-called subjective test, is not always quite accurate, because accommodation comes into play, whereby myopia may be exaggerated or hypermetropia diminished. Absolutely correct results can be obtained only by objective examination with the ophthalmoscope, or by the *Schmidt-Rimpler* method, or with the shadow-test.¹

After the acuteness of vision has been ascertained the examination is continued by artificial light in a dark room, the first step being

4. Examination with Lateral Illumination.

This part of the examination is important on account of the information it affords as to the condition of the anterior segment of the eyeball, which cannot be obtained at all, or but imperfectly, in any other way, especially if a good *corneal loupe* is employed.

The lamp is placed on a table to the right and a little in front of the surgeon, who sits facing the patient. With a convex lens of 15–20 D, which is found in the ophthalmoscope-case, the light is thrown into the eye under observation so as to focus on the parts which it is desired to examine with special care. The rays collected by the

¹ For a full description of the objective methods of testing the refracting power of the eye, see the author's *Grundriss und Atlas der Ophthalmoskopie*.

lens form a small brilliant image of the flame of the lamp at this point. The parts of the cornea, iris, etc., illuminated in this way are thus brought into a bright light and stand out in strong relief against the dark background of their surroundings. Suppose, for example, the iris to be discolored, so that a gray opacity in the overlying cornea cannot be seen; if only the cornea is illuminated, the iris, being in shadow, forms a good background for the opacities in the cornea and they at once become visible. Or, if the cornea is left in shadow and the iris only illuminated, any changes in the latter and in the pupil can be seen. The most minute alterations in the cornea, iris, and crystalline lens, which would escape detection in the strongest daylight, can be discerned by this method.

To obtain the best results with lateral illumination a loupe is necessary. *Hartnack's* spherical loupe is the best, as it covers a fairly large field. The loupe is held in the left hand, the right manipulating the illuminating-lens. The proper coöperation of the two lenses, on which the success of the method largely depends, is no easy matter to accomplish and requires a great deal of practice. Among other things, this method enables us to locate accurately certain minute depositions on the posterior surface of the cornea which occur in iritis and in cyclitis, and which cannot be detected in any other way. Similar small gray dots occur in the crystalline lens; but they can readily be distinguished from the former with the aid of a loupe. For when the depositions on the cornea are clear and distinct, the crystalline lens must be out of focus; and, on the other hand, to make a close examination of the lens the loupe must be held nearer the eye, whereupon the cornea necessarily disappears from the field. (Hence, if depositions on the cornea and grayish dots in the pupil are present at the same time, we can study the two conditions separately, which may be of great value.) If even by using the loupe the surgeon finds it difficult to see the depositions on the cornea, let him move his head to and fro (after he has focussed the cornea with a strong light

shining on it), and the spots will be seen to follow the motions of the head and become perfectly distinct. Sometimes it is difficult to distinguish the depositions from minute dots on the anterior surface of the cornea. In that case a few particles of calomel are applied to the cornea with a camel's-hair brush. The patient will not be inconvenienced if only a very little calomel is applied, which can be accomplished by tapping the brush with the finger after it has been dipped in the calomel. Now the dots on the anterior surface of the cornea can easily be seen distinct from those on the posterior surface, especially if the surgeon moves his head from side to side as before, or the particles of calomel are put in motion by the act of winking.

If the pupil can be dilated, it is possible with lateral illumination to look into the vitreous body. The light must enter the eye as nearly as possible in perpendicular lines, and the surgeon, standing close to the lamp, directs his gaze along the entering beam of light. In this way foreign bodies, hemorrhages, neoplasms, and detachments of the retina in the anterior portion of the vitreous can be detected and their color studied.

The next procedure is the

5. Examination by Transmitted Light.

This important part of the examination serves to confirm and show even more clearly some of the results obtained by lateral illumination. It also reveals the faintest *reaction* of the pupil to light. For the rest, its chief object is to detect opacities in the refracting media, the cornea, lens, and vitreous body.

The lamp being placed a little behind and to one side of the patient, the surgeon throws the reflection of the lamp into the eye by means of the ophthalmoscope, illuminating the pupil so that it appears bright red against the dark background of the eye, which is in shadow. The pupil contracts as soon as the light strikes it, unless

there is pupillary paralysis from any cause. By noting the character of the beam of light as it emerges from the pupil, after being reflected from the fundus, we can detect any opacities there may be in the pupillary area, manifesting themselves as more or less intense shadows which intercept the light—especially if they are located in the cornea, lens, or vitreous body. Opacities due to cataract are brought out very distinctly in this way (*see* Plate 33, *b*, *c*), particularly the fainter opacities of lamellar cataract, which often occur in a rudimentary form only. Opacities in the anterior or posterior poles of the crystalline lens can also be seen, whether the nucleus be clear or opaque. If the patient, while the pupil-area is steadily illuminated, is directed to look up or to one side, an opacity in the anterior pole will move with the pupil, in the center of which it remains fixed. An opacity in the posterior pole, on the contrary, remains stationary, and appears to move downward when the gaze is directed upward, because the pupil moves upward in front of it. A posterior opacity from pigmentary degeneration of the retina can be distinctly seen only by transmitted light. It always lies close to the corneal reflex.

To study minute changes in the cornea, anterior chamber, and iris a strong convex lens may be used with advantage in the examination by transmitted light. The delicate blood-vessels, which often persist for some time in the cornea after parenchymatous keratitis, are best seen with a "loupe-mirror;" they appear as fine, dark lines against the red background of the pupil, which has previously been dilated, if possible. Deposits on the posterior layer of the cornea also become visible. In these examinations a strong convex lens, such as is used under certain circumstances in the later stages of ophthalmoscopic examination, is fixed behind the sight-hole of the ophthalmoscope, and the surgeon approaches so close to the eye under examination that its cornea lies within the focal distance of this convex lens. The lens need not be very powerful (+6 or +8 D), or a lens of +15 D to

+18 D will answer if the ophthalmoscope happens to contain such a one.

[An ophthalmoscope should always be provided with a +16 or +20 D lens in its series. Examination of the transparent media with such a lens is most important, particularly in the study of late corneal lesions.—ED.]

When the examination by means of transmitted illumination has been completed, and not till then, we proceed to the ophthalmoscopic examination proper, beginning with

6. Examination with the Inverted Image,

which is followed by

7. Examination with the Upright Image.

A detailed description of these two methods is found in my *Grundriss und Atlas der Ophthalmoskopie*, to which reference has been made.

This ends the examination for most, though not for all, patients. It may now be necessary, for instance, to measure the

8. Accommodation.

In practice, accommodation is measured by finding the nearest point, P (punctum proximum), at which the smallest readable print can be deciphered. Each eye is first tested separately, by bringing the test-type closer and closer, until the letters become blurred and illegible. This shortest reading-distance is then measured with a rule, the zero-point being held opposite the sclerocorneal junction. When the accommodation is good, as in young eyes, and the test-card can be held very close to the eye, a successively smaller type must be used as the distance is diminished, because large print can be read even without proper accommodation in "diffusion-circles." The smallest readable type should therefore be selected for the test.

In measuring the accommodation the refractive power of the eye must be accurately known, as the formula

$$A = P - R$$

is used in the calculation, in which P and R (punctum remotum) are expressed in diopters. The number of diopters for P is found by taking the number of the lens whose focal length equals the distance of P from the cornea. If, for example, the distance from the near point to the cornea is found to be 20 cm., P is expressed by 5 D, the number of the lens which has a focal length of 20 cm. That we are justified in expressing the distance of the near point from the cornea by the number of a lens appears from the following considerations: Suppose the case of an emmetropic eye having no power of accommodation. If an object is placed 20 cm. distant from the cornea no distinct image will be formed on the retina, since the rays of light will be brought to a focus behind the retina, for the shorter the distance of an object from a convex lens or a combination of two convex lenses (such as is formed in the eye by the cornea and the aqueous humor and crystalline lens), the greater the distance from the lens to the image on the other side. In order, therefore, to obtain a distinct retinal image of an object 20 cm. in front of an eye incapable of accommodation, the rays of light coming from the object must be rendered parallel, since only parallel rays entering the resting, emmetropic eye are collected on the retina. This would be accomplished by holding a lens of 20 cm. focal length close in front of the eye, since rays coming from the focal point of a convex lens emerge in parallel lines on the other side. A distinct image of the object would, therefore, be formed on the retina; and the eye is said to be "adjusted" or accommodated for such an object by a lens of 20 cm. focal length. In other words, an emmetropic eye is accommodated for near objects by a lens whose focal length is equal to the distance of the object from the eye, the lens

being assumed to be in contact with the cornea. If an eye has the power of adjusting itself to a near object without the aid of such a lens, it does so by increasing the refractive power of its crystalline lens, through the act called accommodation, by an amount equal to the refractive power of the artificial lens that would be required.

For an emmetropic eye the number of the lens which expresses P at the same time gives the value of A . For, since the distance of R is infinite, $R = 0$ D; hence, in the above example, $A = 5$ D.

In myopic and hypermetropic eyes, on the other hand, R represents a certain number of diopters, corresponding to the degree of myopia or hypermetropia present. For ametropic eyes, therefore, the refractive power must first be ascertained by one of the objective methods before the accommodation can be determined.

For myopic eyes the number of diopters which express the degree of myopia must be subtracted from the number of diopters which correspond to the distance of the near point. For example: If P is found at 8 cm., $= 12.5$ D, and myopia $= 3$ D, then $A = 9.5$ D.

For hypermetropic eyes, on the other hand, the number of diopters which express the total hypermetropia is added to the number of diopters corresponding to P . If, therefore, the near point for an eye of 4 D hypermetropia is found at 10 cm., the accommodation is 14 D.

The exact state of affairs in hypermetropia is as follows: In facultative hypermetropia, in which R is virtually behind and P in front of the eye, the formula reads: $A = P - (-R) = P + R$. In absolute hypermetropia, in which both P and R lie behind the eye—*i. e.*, both are negative—the formula reads: $A = -P - (-R) = R - P$; or, in other words, A diminishes the hypermetropia by the amount of P .

To ascertain whether a patient has normal accommodation, it is needful to know the amplitude of accommodation corresponding to his age; for the range of accommodation decreases from year to year, because the

elasticity of the lens gradually diminishes. The following table supplies this information :

Table of the Range of Accommodation for the Different Ages.

Age.	Near point (P. p.) in meters.	Far point (P. r.) in meters.	Range of accommodation in diopters.		
10 . . .	0.07	∞	14		
15 . . .	0.08	—	12		
20 . . .	0.1	—	10		
25 . . .	0.12	—	8.5		
30 . . .	0.14	—	7.		
35 . . .	0.18	—	5.5		
40 . . .	0.22	—	4.5	Pr.	
45 . . .	0.28	—	3.5	0.5	
50 . . .	0.4	—	2.5	1.5	
55 . . .	0.66	—4 (H. 0.25)	1.75	2.5	(2.25)
60 . . .	2	—2 (H. 0.5)	1.0	3.5	(3.0)
65 . . .	—4	—1.3 (H. 0.75)	0.5	4.25	(3.5)
70 . . .	—1	—0.8 (H. 1.25)	0.25	5.0	(3.75)
75 . . .	—0.5	—0.57 (H. 1.75)	0	5.75	(4.0)
0 . . .	—0.4	—0.4 (H. 2.5)	0	6.5	(4.0)

We have two reasons for wishing to know the normal range of accommodation : *First*, because it enables us to compute the loss of accommodation in disease ; and, second, because when the physiologic decrease in the power of accommodation has reached a certain point it interferes with the power of seeing near objects, a condition termed *presbyopia*. As age advances civilized man is forced to resort to the use of convex glasses. As long as vision is distinct at a distance of 25–33 cm.—that is, so long as A equals 4–3 D—no appreciable inconvenience is noticed ; but beyond that point the reading of fine print begins to be troublesome, because the book cannot be held close to the eye. Either the individual chooses larger and larger type and a better light, or gives up fine needlework, or the aid of spectacles is invoked to supply the defective accommodation. The strength of the glasses must be regulated according to the kind of work for which they are intended. A cobbler, whose working-distance is 40

cm., needs only half as strong glasses as does a draughtsman who works at a range of 20 cm.

In the table presbyopia is assumed to begin when the near point has receded to a distance of 25 cm. from the cornea; or, in other words, when A begins to be less than 4 D. The degree of presbyopia and the number of the lens necessary to correct it are readily found by subtracting the existing power of accommodation, expressed in diopters, from the working-distance desired. Example: Distance desired, 33 cm. (= 3 D); existing accommodation, 2 D; number of spectacle-lens required, 1 D.

The foregoing applies to the emmetropic eye, and in this connection the following facts must be borne in mind: The above table shows that hypermetropic change begins at the age of 55, on account of the lessened refractive power of the crystalline lens. This tendency of the emmetropic eye to become hypermetropic must be taken into account when glasses are prescribed, by increasing the strength of the lenses in proportion to the degree of hypermetropia present. The necessary correction is indicated in the column of numbers marked Pr. But if cataract is present, the refractive power of the lens is at first increased, thereby compensating for the hypermetropia due to age. For such cases the numbers in the second column, or even lower ones, must be used.

For eyes that were originally hypermetropic the spectacles prescribed for presbyopia must, of course, be corrected for the degree of hypermetropia normally present; while for myopic eyes the degree of myopia must be subtracted from the number of the presbyopia-glasses. Presbyopia makes itself felt later in short-sighted persons than in those who possess normal vision. [If the patient is astigmatic this refractive defect must be properly neutralized.—ED.]

In measuring normal accommodation, or the decrease in accommodation due to disease, the following facts are to be remembered: When the accommodation is very slight, and the distance of the near point correspondingly great,

the patient is unable to read print of any kind, and we have to produce an artificial near point by means of convex glasses. If, for example, it is found that the patient can read fine print with a 6 D lens at a distance of 10 cm., his accommodation is equal to 10 D (the number of diopters which are equivalent to 10 cm.) less the power of the lens, or 4 D. If the patient is 10 years old, his accommodation ought to be 14 D, and he therefore lacks 10 D.

9. Measuring the Field of Vision.

In many diseases of the eye and in a number of nervous affections it is necessary to measure the field of vision. Whereas visual acuity depends on the functioning power of the center of the retina only, the limits of the field of vision are determined by testing the perceptive powers of the entire surface of the retina, and particularly of its peripheral portions. With perfectly good visual acuity there may coexist gaps in the field of vision, so-called *scotomata*; or there may be regular or irregular concentric *contractions*—irregular when the field is contracted more in one part than in others. One-half of the visual field may be wanting, usually on both sides, a condition termed *hemianopsia*; or there may be so-called *homonymous defects*, dark areas of the same size and shape occupying symmetrical portions of both halves of the visual field (for example, absence of the left upper quadrant on both sides).

The limits of the field of vision can be roughly ascertained by very simple means, and it is better always to make at least such a superficial examination rather than omit it altogether because no suitable instrument of precision happens to be at hand.

The simplest way is the following: The patient, either sitting or lying down—for the examination sometimes has to be made on a patient in bed—is placed opposite the surgeon, at a distance of about 0.5 meter, so that the faces

of the two are in parallel planes. The patient is then required to fix his *left* eye, the other being covered, upon the surgeon's *right* eye, which is directly opposite. Keeping his eye steadily fixed on the patient's, the surgeon then gradually brings his outstretched fingers nearer and nearer to the line joining his own eye and the patient's, in a plane midway between them. If, for instance, the right hand is extended with two fingers held up, the fingers can be seen and counted by indirect vision, without diverting the gaze from the patient's face. If the fingers are gradually brought nearer to the line of vision, both surgeon and patient can keep them in sight, supposing both to possess a normal field of vision; but if the patient's field of vision is small, or much restricted on the temporal side, he will not be able to see the fingers until they are quite near the connecting line. To make sure that the patient really sees the fingers, the surgeon may alternately move them and hold them still and ask the patient to tell him whether they have moved or not. In this way the surgeon ascertains how far the visual field extends in all directions, by comparing it with the limits of his own field, although, of course, the result cannot be set down in figures.

In many cases of very defective vision this simple method is the only one available, as the patient is unable to see any but the coarsest test-objects.

If the lens is blurred by cataract the flame of a candle in a dark room, which is a more intense stimulus to the retina, must be used for a test-object. The surgeon screens the light with his hand and brings it successively into the different regions of the field, and, after removing his hand, asks the patient to tell which direction the light comes from. This *projection-test*, as it is called in contradistinction to the ordinary method, may also be performed with the ophthalmoscope by throwing on the eye to be examined the reflection of the lamp from various directions. It forms a very important part of the examination in cataract, as it reveals any pathologic changes in the

eye-ground which had been obscured by the disease. If, for instance, the patient fails to locate the light promptly in the upper segment when it is held opposite the upper part of the eye, operation for cataract is not advisable, as there are probably some detachments in the lower portion of the retina.

In the exact measurement of the visual field the limits are accurately noted in angular degrees by means of an instrument designed for the purpose. This instrument, called a *perimeter*, also affords a means of testing the power to perceive colors (*color-sense*). The perimeter shows us that the normal eye does not distinguish colors clearly in the peripheral portions of the field, where black and white are still perceptible. The limit for black and white forms the outer boundary of the visual field; next, proceeding toward the center, comes the limit for blue. The power of recognizing blue therefore extends furthest toward the periphery, while the limits for red and green lie successively nearer the center.

In using the perimeter the following rules must be borne in mind, or the result will be of no value:

1. The test-objects must be sufficiently illuminated, as in testing the acuity of vision; white objects must be a pure white, and the color of colored objects perfectly clear and distinct, not soiled nor faded by use. Hence the test-objects are to be made of white or colored paper, about 2 cm. in diameter, and renewed from time to time; they are then pasted on a small card affixed to a carrier, which can be moved on the arc of the perimeter from the periphery toward the center.

2. It is necessary to keep a strict watch on the patient to see that his eye remains constantly fixed on the center or zero-mark of the perimeter. Unless the patient is unusually intelligent or accustomed to the examination, his eye will have a tendency to swerve from the zero-point and turn toward the approaching test-object, and he will announce that he sees it. It is manifest, however, that he has seen it by direct, not by indirect, vision; his

statement is therefore worthless, and the test has to be applied anew for that meridian. To overcome this troublesome and time-consuming tendency on the part of the patient the surgeon must take his stand behind the perimeter, and face the patient and control him with his gaze.

3. When the color-limits are to be determined the patient must not be told the color of the test-object beforehand; but he is to name the color as soon as he sees the object. When the white mark is used, however, he should be told to pay no attention to the color, but to say "Now" as soon as he sees anything moving.

4. The measurement is not to be made while the patient is tired; and should therefore occupy as short a time as possible. When the eyes are fatigued the examination is apt to show a narrower field than really exists.

A record-chart (after Förster), with the outline of a normal field of vision printed on it, is used to record the result of the examination.

A great variety of perimeters have been devised. The one recommended and first introduced into practice by Förster is both simple and serviceable. It consists of a semicircle, rotating around a central pivot, with a chin-rest at the center of curvature for the support of the patient's chin. A very good instrument, in my opinion, has lately been constructed by Ascher. It possesses the advantage that the field of vision can be projected and directly outlined on a real hemisphere, without the surgeon's being obliged to give up control of the patient's eyes, as is the case with other hemispheres. The hemisphere, which is not very large and easy to handle, is made of transparent celluloid. The test-objects are moved about on the outside of the hemisphere and the limits of the field immediately marked out with soft chalk, the patient holding the instrument himself in a comfortable position. [A self-registering perimeter—for example, McHardy's—is most useful.—ED.]

Abnormalities in the field of vision are often of great significance. Besides indicating functional disturbance in certain parts of the retina, they may lead to the discovery of interruptions in the optic nerve or in any part of the visual tract as far as the cerebral cortex in the occipital lobe, or of disease of the cortex itself.

Among eye-affections, separation of the retina from the choroid is a frequent cause of disturbances in the visual

field. Constrictions in the field correspond to the areas of separation, a detachment in the upper portion of the retina producing a constriction in the lower part of the visual field. Pigmentary degeneration of the retina, under certain circumstances, produces marked concentric constrictions. Disseminated scotomata are found in diffuse choroiditis; central scotomata in disease of the macula lutea, etc. Atrophy of the optic nerve from any cause is also followed by constriction of the visual field, more particularly of the color-limits, and especially the limit for green. Disease of the papillomacular bundle gives rise to central scotoma. Obscuration of the same half of each visual field (hemianopsia) points to a disturbance behind the chiasm, in the domain of the right tractus, or in the pathway to the right cortex, or in the cortex itself. Speaking generally, homonymous defects in the field of vision indicate disease of the opposite hemisphere, at some point posterior to the chiasm.¹

10. Measuring the Light-sense.

The practice of measuring the light-sense, which is necessary in a limited number of cases, was also introduced by Förster, who designed a suitable instrument for the purpose, the photometer.²

Whereas a normal eye can read the letters on a type-card even when the light is comparatively poor, there are certain diseases in which reading is possible only in a good, strong light. These diseases chiefly affect, not the nervous pathway behind the retina and in the course of the optic nerve, but the perceptive layer itself, the specialized epithelium, whether they originate in the retina or are secondary to disease of the choroid. In syphilitic choroiditis or in the active stage of simple choroiditis, in

¹ A brief survey of the most important disturbances in the field of vision, for clinicians, practising physicians and students, fully described and illustrated, will be found in my *Augenärztliche Unterrichtungstafeln*, Magnus Heft v., Breslau, 1893.

² More correctly, "photoptometer," as the term photometer is applied to instruments for measuring the intensity of a source of light.

pigmentary degeneration, or in detachment of the retina, the light-sense often diminishes to a hundredth of the normal. The same is true in so-called idiopathic night-blindness (nyctalopia), the cause of which is probably to be sought in the retina, but is not well understood.

Förster's photometer consists of an oblong box (30 cm. long, 22 cm. wide, and 17 cm. high), painted black on the inside. One of the short sides is pierced by two sight-holes for the patient's eyes, and a third opening, through which the interior is illuminated by a standard candle enclosed in a case. The size of the opening can be regulated by means of a shutter and screw. On the opposite side of the box are a number of vertical black lines of varying thickness on a white background, on which the light can be thrown with varying intensity by the aid of the shutter. The smaller the opening, and consequently the less the amount of light needed to recognize the vertical lines, the better the light-sense. The size of the opening is read off on a scale and the light-sense computed from it. If, for example, a patient requires an opening 10 times as large as suffices for a normal eye to distinguish the marks, his light-sense is 10 times less, or $\frac{1}{10}$ of the normal.

It is an essential condition of trustworthy results that the patient's eyes be thoroughly rested and accustomed to the dim light. He should therefore be in a dark room at least ten minutes before the examination is begun.

II. Testing the Color-sense.

It has been found that among men from 4 to 5 per cent. are color-blind, although among women the percentage is almost zero. As the most usual form is red-green color-blindness, which disqualifies a man for service as a sailor or railroad employee, it is necessary to test with scientific accuracy the power of perceiving color. Many color-blind persons have learned by practice to conceal their infirmity, and are able to name any given color correctly

without really seeing it; hence certain precautions are needful in making an accurate test of the color-sense. If, for example, a color-blind person is given a red and a green object he will, as a rule, be able to distinguish between them by the difference in the amount of light they reflect; but if the confusion-colors are added he will find it very difficult, if not impossible, to pick out the required color. As red and green appear to a color-blind person like shades of gray, yellow, and blue, he is apt to confuse them with those shades. The following methods of examination are employed:

1. A large number of variously colored skeins, about as large as the little finger, are prepared, comprising the colors of the spectrum and numerous shades of gray, brown, and rose. The yarns being heaped up before the subject in a confused mass, a light-green test-skein is first laid down beside them in good daylight, on a colorless background (such as a black table). If the subject under examination is blind for red and green he will choose some confusion-colors [*i. e.*, with or without the greens—grays, drabs, stone-colors, fawns, pinks, yellows]. Next a rose skein is laid on the table: A person with red-green blindness will now choose blue shades, because he does not see the red in the rose skein; while one who is blind for blue and yellow will choose red skeins, because he does not see the blue in the rose. This method was first proposed by Seebeck and more fully developed by Holmgren; but it fails to detect many cases of color-blindness in individuals who have trained themselves to recognize colors.

2. The so-called *tissue-paper contrast-test* may be used. If a black or gray letter, on a colored background, is covered with tissue-paper, it appears to have the complementary color of the background; green, for example, if the background is bright red. The greenish tint, however, is very delicate and cannot be perceived by a color-blind person. The thickness of the tissue-paper must be accurately regulated, and none but an expert can be trusted to perform the test. [This test is not of much practical

value.—ED.] Pflüger's tablets for the detection of color-blindness are constructed on this principle.

3. Another method of detecting color-blindness consists in the use of colored figures on a colored background, confusion-colors being used for both figures and background, and the shape of the figures obscured as much as possible by a mosaic arrangement of dots, so that only the color can be plainly perceived. The dots forming the figures must be of the same color as the background. Stilling has utilized this method in his "pseudoisochromatic plates for the detection of color-blindness." The test is a delicate one and quite simple in its application, so that it need not be performed by an expert. By its aid we can detect any diminution in the color-sense for a particular color, as well as total color-blindness. The plates also contain figures for the detection of persons who pretend color-blindness. They are to be commended for the accurate determination of disturbances of the color-sense.

12. Examination for Disturbances of Mobility.

In paralysis of the eye-muscles the ordinary test of requiring the patient to look up and down and to either side is not sufficiently accurate, and must be supplemented by a careful study of the double images which occur. Obviously, if the left abducens, for instance, is completely paralyzed, it is easy enough to demonstrate that the left eye fails to move to the left when the patient is told to fix an object held in front of him and a little to the left side. In this case there will also be a deviation of the eye toward the nasal side, because the internal rectus preponderates (convergent squint); but if the paralysis is only partial, we must investigate the double images before we can make an accurate diagnosis, especially if, as frequently happens, several muscles are involved.

If the paralysis is recent, the patient usually consults an oculist for the diplopia and accompanying visual vertigo; but as the paralysis progresses, the diplopia becomes less

noticeable, although it is possible even in old cases to detect its presence by using suitable means—holding a red glass in front of the eye, or producing vertical diplopia with an appropriate prism.

In order to understand the various forms of diplopia which occur in paralyses of the ocular muscles it is only necessary to remember the origins and insertions of the external eye-muscles. The accompanying diagram (Fig. A), which the student can at any time sketch for himself, will help to make the matter clear.

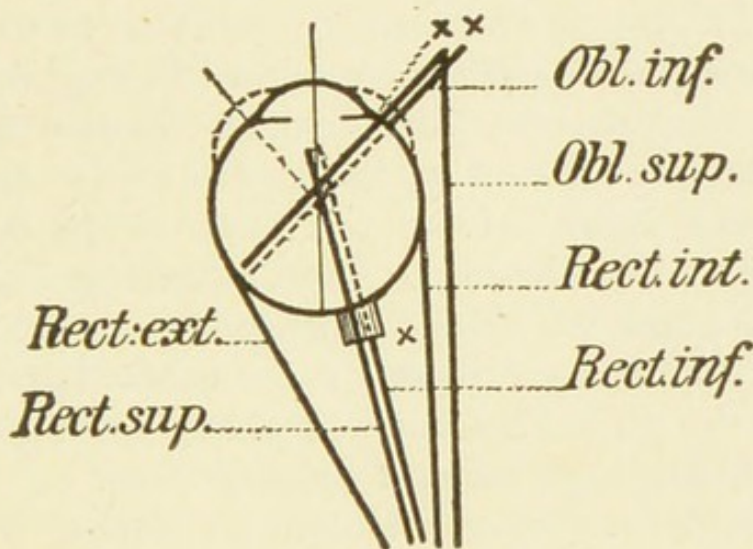


FIG. A.

The course of the recti muscles is easily remembered by bearing in mind that they all arise at the apex of the orbit, around the optic foramen, and are inserted into the sclera 7–8 mm. behind the sclerocorneal junction. The plane of the internal and external recti coincides with the horizontal meridian; while the plane of the superior and inferior recti forms an acute angle with the vertical meridian of the globe, as their insertion is a little more temporal than their origin.

The superior oblique (or trochlear) also takes its origin at the optic foramen and proceeds forward parallel to, and a little above the internal rectus until it reaches the trochlea, or pulley of the superior oblique, from which point its direction, backward and outward, really begins.

Practically, therefore, it passes around the globe in that direction (backward, outward, and downward), beneath the superior rectus, and is inserted behind that muscle, near the horizontal meridian, and a little behind the equator.

The inferior oblique arises in front, on the inner floor of the orbit, opposite the lower extremity of the lachrymal crest of the lachrymal bone. It embraces the globe from below, in the same plane with the superior oblique, and is inserted behind and above, on the outer aspect of the globe, between the insertion of the external rectus and the optic nerve.

If we imagine a gigantic orbit with a globe of such dimensions that we can just encircle it with both arms, we can imitate the action of the recti muscles by taking a position to the nasal side of the optic-nerve entrance, at the point *x* on the diagram. By embracing the globe in a horizontal plane we should imitate the action of the internal and external recti; if, on the other hand, we were to embrace the globe in a vertical plane, we should imitate the action of the superior and inferior recti. Incidentally we should notice that the globe had a tendency to slip sideways, as, from our position on one side, we should be holding it obliquely.

To imitate the action of the oblique muscles we should have to take our stand on the inner portion of the orbit, in front, at the point *xx* in the diagram, and grasp the globe in a direction from before outward and backward, so that our hands would almost meet on the outer and posterior portion.

If we further imagine this gigantic eye to be easily movable about its axis we shall obtain a clear idea of the actions of the various muscles by turning it in imagination with our hands, as described. If we imagine ourselves, with our hands on the insertions of the muscles, turning the globe from the three points mentioned, we note the following effects:

In the first position, with our arms embracing the globe

in the horizontal meridian, we simply turn it to and fro, the cornea moving from one canthus to the other in a horizontal plane. If we imitate the action of the superior and inferior recti, we note that when we tilt the globe upward the cornea does not move directly upward, but, owing to our somewhat nasal position, slightly inward as well, and the upper extremity of the vertical meridian is inclined slightly inward (toward the nose). If, on the other hand, we exert a downward pull with the arm which represents the inferior rectus, the globe is rotated downward, the cornea is drawn slightly inward, and the lower extremity of the vertical meridian is brought nearer the center of the eye—*i. e.*, inclined inward (toward the nose).

If we imitate the action of the oblique muscles (from the position *x x*), the eye being in the primary position, the pull of the superior oblique gives the cornea an outward and downward direction, because the globe is elevated behind; and the pull of the inferior oblique gives the cornea an outward and upward direction, because the globe is depressed behind.

But if we suppose the eye to be looking outward (toward the temple) (compare Fig. A), so that the cornea is in the outer canthus, we can readily appreciate that the oblique muscles will have an almost exclusively rotatory action, with very little elevation or depression. If, on the contrary, we suppose the eye to be turned inward (toward the nose) and looking directly at us, the oblique muscles will act almost exclusively as elevators or depressors.

As to the direction in which the oblique muscles rotate the eyeball, the effect of the superior oblique is to incline the upper, that of the inferior oblique the lower, extremity of the vertical median inward. By rotation is meant turning of the eye about any axis running from before backward through the lobe.

Returning once more to the superior and inferior recti, we can readily understand that this pair is also capable of rotating the eye when it is directed inward, but not as much as the oblique muscles. When the eye is directed

outward (toward the temple), the superior and inferior recti act exclusively as elevators or depressors.

Evidently, then, we need only to know the course of the various muscles in order to understand their actions and the position they give to the cornea.

The internal rectus is an adductor, the external an abductor of the cornea.

The superior rectus elevates the cornea and inclines the upper extremity of the vertical meridian inward when the eye is in the primary position.

The inferior rectus depresses and slightly adducts the cornea and inclines the lower extremity of the vertical meridian inward when the eye is in the primary position.

The superior oblique depresses and abducts the cornea (rotating it downward and outward) and inclines the upper extremity of the vertical meridian inward.

The inferior oblique elevates and abducts the cornea (rotating it upward and outward) and inclines the lower extremity of the vertical meridian inward.

To draw the cornea directly upward from the primary position, the superior rectus and inferior oblique must coöperate; to turn the gaze directly downward, the coöperation of the inferior rectus and superior oblique is required; while adduction and abduction from the primary position are effected solely by the action of the internal rectus and external rectus respectively.

Having now firmly fixed the actions of the muscles in our mind, we are ready to take up the analysis of the double images which occur in paralysis. Let us again suppose the left external rectus (abducens) to be paralyzed. If a test-object—a candle, for instance—is held before the patient in a dark room, in such a position that he must turn his eyes to the left in order to fix it without turning his head, he will tell us that he sees two images of the flame side by side on the same level. This may be explained as follows: The normal right eye fixes the flame correctly; but the left eye cannot be turned to the left far enough for the image of

the flame to be formed on the fovea centralis (as in the right eye), and the image falls instead on a point of the retina a little to the nasal side of the fovea centralis. An image formed to the nasal side of the fovea centralis will be projected outward—*i. e.*, to the temporal side of the visual line. It is situated in the visual field, on the temporal side of the fixation-point, the deviation toward the temple in the visual field being proportional to the deviation of the retinal image from the fovea centralis toward the nose. If the light is moved still further toward the left, the right eye will follow it; while, on the other hand, only the retinal image of the left eye will move nasalward and its false image correspondingly temporalward—*i. e.*, to the left. The false image (image of the affected eye) is so called because it is indistinct, for images formed outside the macula lutea are faint, becoming more and more indistinct as the periphery is approached. In the case before us the patient sees the image of the right eye in its proper place; that of the left eye, on the contrary, to the left or temporal side—there is homonymous or simple diplopia.

If the candle is moved back toward the right on the same level, the two images begin to approach each other; and when a point directly opposite, or slightly to the nasal side of the center of the eye has been reached, the patient sees single, as he also does when looking still further to the right. It appears, therefore, that diplopia occurs only when the test-object is brought within the field of action of the palsied muscle; the error can be corrected by turning the head (instead of the eyes) to the left.

In paralysis of the left external rectus abducens, which under normal conditions controls the outward movement of the cornea, the false image lies to the left of the real image. For similar reasons, on the other hand, if the internal rectus of the left eye is paralyzed, the false image is displaced to the right—in that case there is heteronymous or crossed diplopia.

If the superior rectus is affected, the eye lags in eleva-

tion and slightly in abduction, so that the retinal image is formed below, and a little to the outer side of the fovea centralis. Hence the image of the left or affected eye lies above, and a little to the inner side of that of the right or sound eye, its upper extremity being inclined slightly inward from failure of the superior rectus to rotate the eyeball. The absence of rotation becomes more marked as the eye is turned further inward, because the pull of the superior rectus is more oblique in adduction and therefore exercises a more pronounced torsion-effect. If, on the contrary, the eye is turned outward, the torsion-effect of the muscle does not come into play at all, its only effect being to elevate the cornea, and the vertical distance between the two images is therefore increased. Lateral separation of the images, which is not great, is most pronounced when the eye is in the primary position.

If we were to investigate the double images in paralysis of the oblique muscles in the same way, we should arrive at the following general conclusion: The direction in which the false image separates from the true image always corresponds to the direction in which the eye is moved by the affected muscle; or, better: *The image of the affected eye is always projected in the direction toward which (if it were able to perform its function) the paralyzed muscle would rotate the cornea; and the image is inclined in the direction toward which the affected muscle in the sound state would incline the vertical meridian.*

Let us take another example: Suppose the left superior oblique is paralyzed. Its unaided action on the eye in the primary position is to rotate the cornea outward and downward and to tilt the upper end of the vertical meridian inward. This is precisely the direction toward which the image of the left eye is projected: it is found to the outer (temporal) side of, and below, the image of the right eye, with its upper end inclined inward, toward the nose (compare Fig. B). The double images in paralysis of the superior oblique are, of course, found in the lower portion of the field of fixation, since the muscle is a depressor of

the cornea, its depressing action being most marked when the eye is directed inward. Hence, when the light is held low and toward the right, the vertical distance between the images is greater than it is when the eye is forced to turn outward and downward. When the eye is directed outward and downward, the superior oblique rotates the vertical meridian inward; hence the image of the left eye exhibits a greater nasal inclination above and the vertical separation is at the same time diminished. The image of the left eye therefore always remains to the left of that of the right; in other words, there is homonymous diplopia, because the superior oblique is an abductor.

In paralysis of the inferior oblique, which, when it normally acts alone, rotates the cornea outward and upward and tilts the upper extremity of the vertical meridian toward the temporal side, the image of the affected eye is found to the outer side and above its fellow, with a temporal inclination in its upper extremity. Again, the vertical separation of the double images is greatest when the eye is turned inward, and their obliquity most pronounced when the eye is turned toward the temporal side. The double images are homonymous, and the diplopia must be sought in the upper portion of the field of fixation.

In paralysis of the superior rectus, which normally rotates the cornea upward and inward and tilts the upper extremity of the vertical meridian toward the nose, the image of the affected eye is found above and somewhat to the inner side of its fellow, with a slight nasal inclination above. In abduction the nasal inclination is diminished and the vertical separation of the images increased.

In paralysis of the inferior rectus, which normally rotates the cornea downward and slightly inward and tilts the lower extremity of the vertical meridian toward the nose, the image of the affected eye is found below and a little to the inner side of its fellow, with a slight nasal inclination in the lower extremity. The nasal inclination

is distinct only when the gaze is directed inward ; it diminishes when the eye is turned toward the temple, while the vertical separation of the images increases.

To determine with certainty which of the two images belongs to the right and which to the left eye, a red lens is held before one of them. The image of the eye that has the red lens before it appears red, while the other has its normal color.

It is essential to determine in which eye the paralysis exists, or whether both eyes are affected. This is determined by the following rule : *That image is false and belongs to the diseased eye which travels away from the other image in approximately the same direction as that in which the test-light is moved ;* for the hurrying onward of the image and the lagging of the eye from paralysis are correlated phenomena.

If, for example, we find that the image of the left eye travels faster than that of the right in the same direction as the light when it is moved toward the left, the paralysis is in the left eye and the left external rectus (abducens) is paralyzed. If we now move the light toward the right—possibly in the examination of the same patient—and the image of the right eye travels faster than that of the left, we conclude that the right external rectus (abducens) is also paralyzed.

If, when the light is raised, one of the double images also moves upward, and moreover still higher upward, we conclude that the higher the light is elevated this image, travelling in advance upward, belongs to the paralyzed eye, etc.

In order to make an accurate analysis of the double images in a given case it is essential that their positions should be indicated on a diagram—for example, like the one shown in Fig. B—which is intended to illustrate paralysis of the oblique muscles and of the superior and inferior recti. For this purpose a cross is constructed of two lines and the position of the double images is sought for in nine places with the aid of the test-light and marked

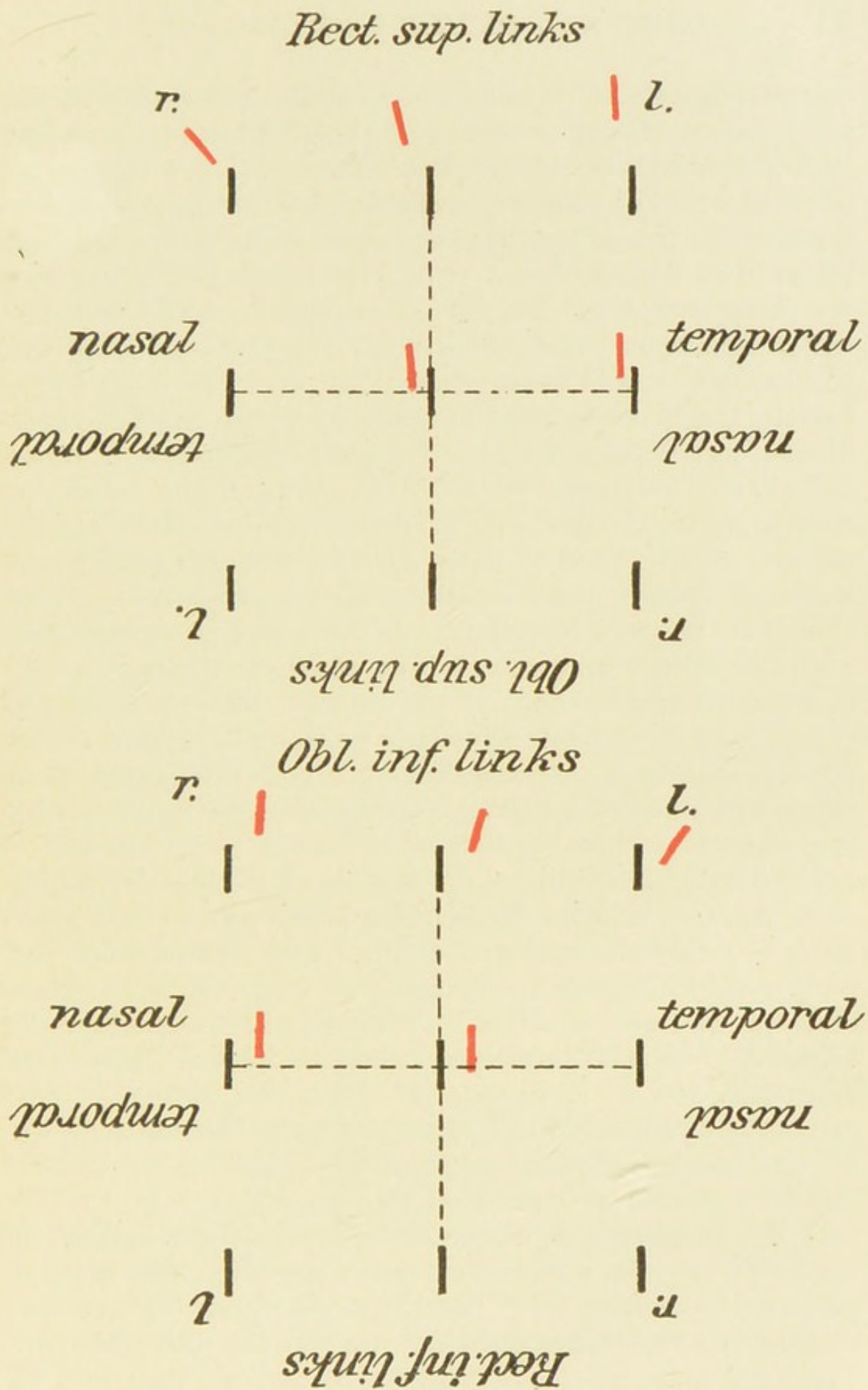


FIG. B.

on the diagram as follows : First, in the center, then above and below and right and left, corresponding to the cross, and then again right, and the left above and right and left below. It is better for the surgeon to mark the positions of the images as they are given him by the patient, who sits in front of him. Thus, the image of the left eye, which separates to the left in paralysis of the external rectus (abducens), is marked in the diagram to the right as the surgeon stands facing the patient, etc. Sometimes the patient is asked to mark the positions of the double images himself; the appearance of the chart in that case is quite different, the image of the left eye (in the example) appearing on the left side of the chart, instead of on the right. Hence it is necessary to know how the diagram was made, and it must never be neglected to mark which side is right and which left. If the surgeon records the positions of the images, *r.* (right) must be written in the upper left-hand corner; if the patient does the marking, *r.* is put in the upper right-hand corner. A glance at the position of the letters *r.* and *l.* in Fig. B informs us that the positions of the double images were recorded by the surgeon.

Woinow¹ has followed this method in his tables showing the double images in paralyses of the eye-muscles; these tables are much to be commended for purposes of diagnosis, especially in cases in which several muscles are involved. Woinow gives a number of examples of such multiple paralyses to facilitate their diagnosis.

I have emphasized this matter of the different methods of recording the phenomena of diplopia because it is a frequent source of confusion to the beginner.

When the paralysis has existed for some time it is often very difficult to make a correct diagnosis, because the patients have learnt by practice to suppress one of the double images. Nevertheless they often complain of

¹ Woinow, *Ueber das Verhalten der Doppelbilder bei Augenmuskellähmungen*, in 15 Tafeln dargestellt, Vienna, 1870.

visual disturbances, because in certain rotations of the eyeball the diplopia still confuses them. For this reason one must examine with especial care in these directions, down and in, for example, in paralysis of the superior oblique; and by holding a prism in the appropriate position in front of the eye the diplopia in such cases may be developed. Suppose there is an old paralysis of the left external rectus (abducens). The patient does not see double with a red glass, even in the region of diplopia (to the left of the median line); but if a prism of about 10° is placed before the eye, with the base up or down, so as to produce vertical diplopia, he at once becomes conscious of a double image, because the image which has been displaced by the prism now appears in an unusual location on the retina and is at once perceived by the patient. A glass rod has been suggested for such cases by Maddox; it may also be used for recent cases. Such a rod, or a series of rods, lying side by side and colored red, makes the flame of a candle appear like a long red line, which impresses itself more sharply on the patient's consciousness and brings out the exact position and obliquity of the double image.

The study of the double images enables us to distinguish between *paralytic* and *concomitant* squint. Concomitant or ordinary squint depends upon not a paralysis, but an abnormal position of the eye which is not limited in its rotations. In convergent squint, for instance, the power of adduction may be increased beyond the normal, the excess corresponding to the amount by which abduction is diminished, resulting sometimes in the complete disappearance of the cornea in the inner canthus during vigorous adduction. The eye does not lag behind its fellow nor fail to accompany it in all its movements; always, however, maintaining the same abnormal position. The double images, if there be any at first, correspond to these conditions; the distance between them remains constant in whatever direction the eye be turned, and in a short time the diplopia disappears altogether, as the squinting eye learns to suppress its image.

Detection of Malingerers.**Examination for (Simulated) Amblyopia.—**

The detection of pretended amblyopia, or exaggeration of defective eyesight, is a task requiring some skill on the part of the examiner.

As some responsibility attaches to the performance of the test, a review of the methods employed will not be amiss. Either to escape military service, or, more frequently, to establish a claim for damages, the subject under examination attempts, by giving wrong answers, to make his eyesight appear worse than it really is. A claimant for damages exaggerates the injury in the hope of obtaining more damages; the recruit wishes to escape conscription on account of defective eyesight; the statements of hysterical patients are often proved to be incorrect.

It is natural to suspect malingering if the result of the subjective examination fails to agree with the result obtained by objective tests—*i. e.*, if function is claimed by the patient to be abnormal where nothing structurally abnormal is found. But it must not be forgotten that *congenital amblyopia* occurs with perfectly normal anatomic conditions. Unilateral or bilateral amblyopia is met with particularly in hypermetropic persons, with otherwise healthy eyes, and even appropriate lenses fail to effect any improvement.

Complete blindness of both eyes is rarely simulated; but frequently blindness of one eye is. In the latter case the simulation is more easily exposed than if defective vision only is claimed for one or both eyes. If blindness of one eye is claimed, pupil-contraction to direct light-stimulus and the consensual contraction of the other eye (contraction of the pupil of the other eye when light falls on the eye under examination) can be investigated with great care; but there are rare cases of pupillary reaction to light in both eyes, although one of them is absolutely sightless. On the other hand, a pupil may fail to contract on exposure to light, though vision is perfect,

because the iris is paralyzed or fixed by synechiæ. For these reasons it is better to adopt the following methods :

1. The patient is asked to read while a card is held vertically against the book in the median plane in such a way as to divide the page into two columns. If the subject is really blind of one eye he will read only the column opposite his sound eye ; but if he is pretending he will read both columns. Sometimes a pencil or a ruler held against the page suffices to convict the malingerer, for it does not disturb his reading ; while if he were really blind of one eye he would leave out the words covered by the pencil. An experienced malingerer often betrays himself at the very beginning of the examination by rapidly closing the eye he claims to be blind, in order to get his bearings. The examiner should be constantly on the lookout for this maneuver, whatever method be used.

2. The subject is taken into a dark room and a lighted candle is slowly moved from the sound eye toward its fellow. If the patient perceives the light after it has become hidden from the sound eye by the intervening bridge of the nose—as seen by the shadow cast by the latter—it is proof that he sees it with the eye he claims to be blind. This method often fails to expose a clever cheat.

3. The tests performed with prisms are more trustworthy in their results ; they have been the means of exposing many frauds. If a prism is held, with the base toward the temple, before a person with normal vision, and he is asked to fix a test-object, usually the flame of a candle, a slight movement of adduction will be observed in the eye behind the prism. It is the natural result of the effort to achieve single vision ; for the prism produces lateral diplopia which is immediately and without difficulty overcome by adduction. The impulse to bring the double images together is so strong that the test rarely fails. The prism must be placed before the supposedly blind eye. [The same test, as pointed out by Priestley Smith and E. Jackson, may be used to detect feigned binocular blind-

ness: A lighted candle is placed before the subject in a dark room. He is not required to "look" at the candle, being nominally blind; but the candle is placed about where he appears to be looking. A prism 6° – 8° is then placed before one eye, its base, for example, toward the temple. If the patient sees, the eye will rotate inward, and when the prism is removed, a movement of "recovery" outward will take place.—ED.]

Another plan is to place the prism, base down, before the admittedly sound eye and ask the patient whether he sees one or two candles. If both eyes are sound, the image of the eye behind the prism is above that of its fellow. If, therefore, the subject acknowledges that he sees two images it is a proof that both eyes are sound. As many malingerers, however, are aware that admission of binocular vision would expose them, the test must occasionally be varied by producing diplopia in the admittedly sound eye. For this purpose a strong prism (about 15°), with the base up, is gradually carried up from below in front of the eye. As soon as the lower half of the pupil is covered by the edge of the prism diplopia begins, because those rays which have passed through the prism are refracted, while the others enter the pupil directly. By covering the other eye we convince the subject that it is possible to see double with one eye. Now the supposedly blind eye is uncovered and the prism at the same time carried a little higher, so as to cover the entire pupil. If the subject again acknowledges binocular vision, it is evident that he is malingering, and the visual acuity of the pretended blind eye may even be tested with a type-card without his suspecting it. The higher of the two images in the case described corresponds to the supposedly blind eye. A naked prism is the best for this test.

4. A high convex glass of about 6 D is placed before the sound eye, which is thereby rendered (artificially) myopic and cannot read fine print at a greater distance than about 17 cm. The book is first held within that dis-

tance, and then gradually moved further away. If the act of reading is found to be possible at a distance greater than 17 cm., it must have been performed by the other eye.

Detection is somewhat more difficult when defective vision only is pretended, or when, as is frequently done in suits for damages, an attempt is made to exaggerate an existing defect, as when a subject with a visual acuity of $\frac{1}{3}$ claims to possess only $\frac{1}{10}$. In such cases it should be borne in mind that malingerers, as we have already pointed out, are very apt to give contradictory answers when the test for visual acuity is applied at different distances. [Any refractive error should be corrected by objective methods and tests for acuity of sight made with the proper lenses.—ED.] The cleverest malingerer will find it difficult always to pick out the letters which correspond to his true visual acuity, if the distance of the type-card is rapidly changed, or if he is asked to read the test-letters in a mirror. Besides, he will show an inclination to stop at the end of a line and claim that he cannot read any letters in the following line, whereas really, if all the letters, even the most difficult ones, in one line are read without difficulty, one or two of the easiest letters in the following line can always be made out. As we have said before, this should at least excite a suspicion of malingering.

Another plan is to exclude the admittedly sound eye from vision, without the patient's knowledge, by placing an appropriate lens before it, as described under 4. With the type-card some distance off, lenses of successively higher degrees of concavity are placed before the sound eye; with the weaker glasses the eye is still able to see the distant type-card; as soon, however, as a lens of about 10 D is used, distant vision is impossible. If reading is still performed it must be by the other eye, which was claimed to be blind. The acuteness of vision of the supposedly blind eye can thus be measured at the same time.

A very useful device for the detection of expert malingerers is the stereoscope, especially as constructed and

equipped with plates by M. Burchardt.¹ By this method, which I have practised for many years, the cleverest malingerers can be exposed and their true visual acuity ascertained. The stereoscopic plates are so arranged that the subject under examination is quite unable to tell with which eye he is reading the test-letters.

To ascertain the true condition of affairs when an already existing defect has been aggravated by an accidental injury, a complete examination is usually needful. The method of the erect image furnishes the most trustworthy information as to the effects of corneal opacities or cataract on the visual acuity. The fact that a distinct inverted image is obtained does not necessarily prove that vision is good, for it may be obtained in cases in which vision is considerably impaired by astigmatism, due to corneal opacities, or by a partial cataract. The visual acuity must, therefore, be judged solely by the distinctness of the *erect* image.

DISEASES OF THE LACHRYMAL APPARATUS.

The source of the lachrymal secretion, the lachrymal gland, which is situated in the upper outer angle of the orbit, close to the orbital margin, is rarely attacked by disease (inflammation, carcinoma, sarcoma, adenoma, etc.). On the other hand, the surgeon's skill and patience are often invoked for the relief of disturbances in the drainage-system, usually in the form of stenoses.

Excessive flow of tears (epiphora) is rarely due primarily to malposition of the inferior punctum lachrymale (from eversion or ectropion of the lower lid). In most cases *dacryostenosis* is the basic evil, the obstruction sometimes occurring as high up as the canaliculi. Not infrequently occlusion of the lower canaliculus is caused by

¹ M. Burchardt, *Praktische Diagnostik der Simulation von Gefühlslähmung von Schwerhörigkeit und von Schwachsichtigkeit*, Berlin, 1878, Gutmann'sche Buchhandlung. Mit Stereoscop, Tafeln, und genauer Gebrauchsanweisung.

traumatism. If the lower lid is torn at the inner canthus by a blow with the fist or a stick, the lower canaliculus is usually divided. In rare cases epiphora is due to the presence of a concretion, usually a mass of fungus, in the lower canaliculus; but in the great majority of cases the primary cause is a *stricture in the lachrymonasal duct*, which forms the communication between the lachrymal sac and the inferior meatus of the nose.

The lachrymal sac, to the nasal side of the inner canthus, lies partially embedded in a groove of the lachrymal bone (*fossa sacci lacrimalis*), which is bridged over in front by the internal palpebral ligament. This structure can be brought plainly into view as a tense, horizontal band by drawing the eyelid outward, toward the temple.

The lachrymonasal duct is lodged within a bony canal, the narrowest portion of which corresponds to the opening of the lachrymal sac into the duct; this point is therefore the most frequent seat of stricture. Stricture or occlusion also occurs in the lower extremity of the canal, being caused by swelling of the mucous membrane either of the nose (usually temporary) or of the duct itself. In order to understand the occurrence of obstructions in the drainage-system, which are particularly common in the early stages of the disease and are often only temporary, it must be remembered that the lachrymonasal duct (like the inferior meatus of the nose) contains a venous plexus resembling cellular tissue, which from its great liability to congestion is very apt to produce a temporary occlusion. This also explains the excessive flow of tears in coryza. Unlike the lachrymal sac, the nasal duct is surrounded by bone and cannot expand when the secretion accumulates in excess, so that swelling of its vascular lining rapidly produces a stenosis which may eventually become permanent.

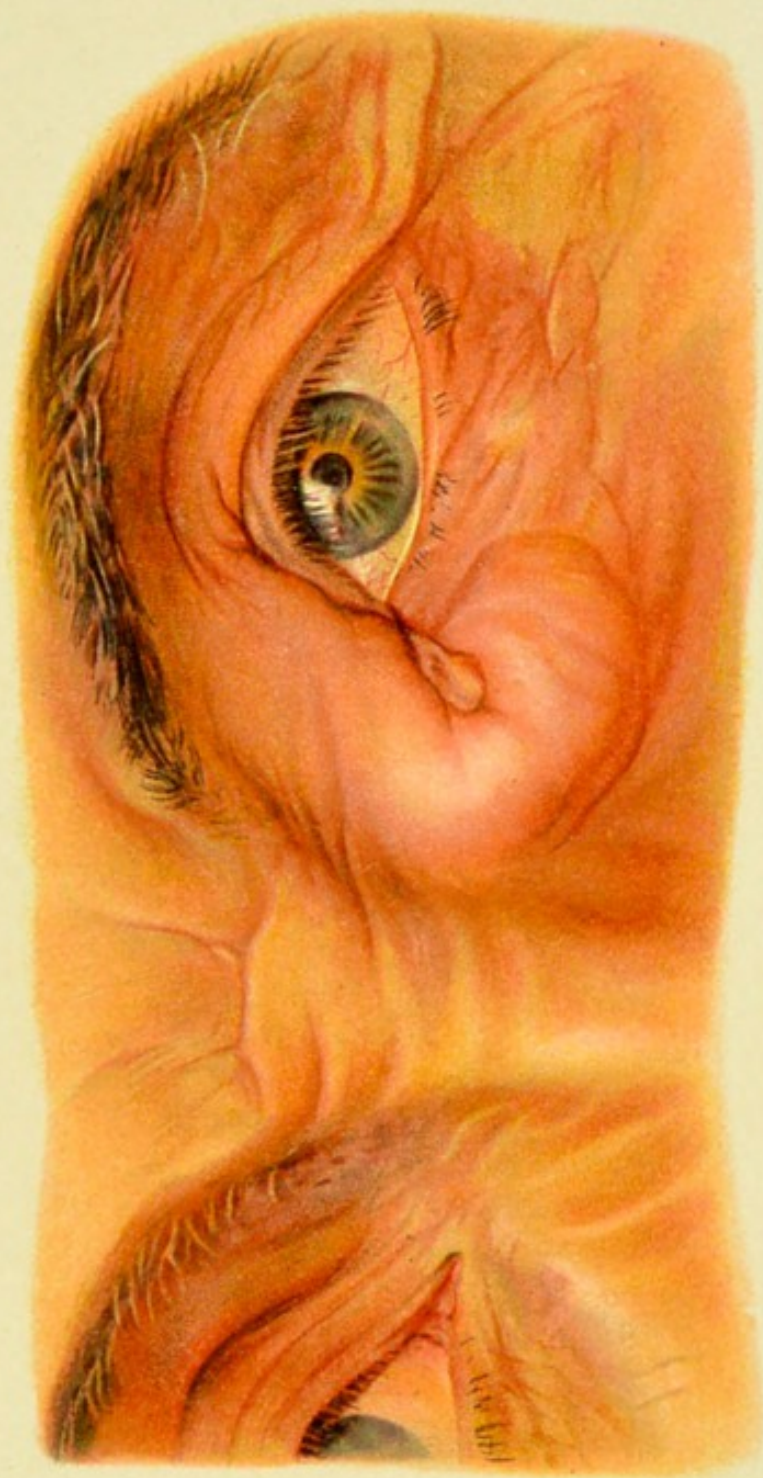For these reasons catarrh of the lachrymonasal duct usually forms the first stage of a long and tedious process which may drag on for years. The catarrhal condition either originates in the nose and extends into the nasal duct, or it begins in the lachrymal sac and spreads down-

Plate 1.

Dacryocystitis.—The region of the left lachrymal sac bulges forward; there are inflammation and pain on pressure; the adjacent portions of the lid are edematous. A slight fluctuation is felt at the apex of the tumor. A tear is seen in the furrow running from the inner canthus toward the swelling. The patient, who is 57 years old, has been in the habit of expressing the mucus and pus in the sac at regular intervals for the past fifteen years. Inflammation began a week ago. Subsequent course: Rupture of the abscess outward, without formation of a fistula.

ward. The aggravation of the epiphora which is observed to follow a fresh attack of nasal catarrh speaks for the first view; while, on the other hand, it happens not infrequently that the lachrymal sac is filled with a mucous secretion when there is no obstruction in the duct and the contents of the sac can be expressed through it into the nose. But the chief factor in the etiology of epiphora is *hereditary predisposition*. [This observation is not in accord with the Editor's experience, although no doubt heredity plays a part.] The family history must be carefully investigated. Most patients are reluctant to admit any hereditary taint, and prefer to give a "cold" as the cause of their trouble, just as they do for so many other diseases. Arrested or defective development of the bones of the skull, especially of the nose and adjacent parts, may possibly constitute a predisposing condition. Thus, stenosis of the lachrymal canal is sometimes met with in subjects with *flat noses* or asymmetric facial development. If we consider, however, that children are less subject to the complaint than adults, in spite of the fact that they have smaller ducts and suffer more frequently from coryza, we are forced to the conclusion that something else besides mechanical conditions is responsible, probably a natural predisposition favoring the growth of pathogenic fungi in the lachrymal sac and lachrymonasal duct. Such a predisposition is simply an individual peculiarity, which, like other dispositions, may be inherited.

That the lachrymal sac is often the abode of the most virulent pathogenic germs is one of the earliest discoveries of the bacteriologic study of the eye. Whether the presence of these fungi is the cause or the





effect of the catarrhal condition is still an open question. But if we consider that suppuration of the eyeball occasionally follows an operation for cataract, even when the lachrymal sac contained practically no secretion, showing [in the most unpleasant manner] that such noxious germs must have been originally present in the sac, we shall incline to the opinion that the germs are primary, not secondary, to the catarrh. These fungus-colonies reveal their presence in other ways, for I cannot conceive how a simple catarrh should be able to occlude the nasal duct in places, narrow as it is, while it is quite easy to understand that the mucous membrane could be eroded and made to ulcerate by the action of germs and the toxin they produce, leading eventually to strictures and adhesions.

The infectious nature of the contents of the lachrymal sac in epiphora is further proved by the fact that the slightest injuries are followed by suppuration and by the occurrence, in most cases, of conjunctivitis and blepharitis. In itself the epiphora is hardly serious enough to induce either the surgeon or the patient to undertake treatment; but the complications that are likely to follow are of such grave significance that treatment is imperatively demanded.

Epiphora is always the first symptom to appear. The lachrymal fluid is increased in quantity and accumulates in the palpebral fissure without overflowing, or it overflows and necessitates constant wiping of the eyes. The condition is aggravated by exposure to wind, smoke, or dust. In addition to the inconvenience caused by the constant necessity of drying the eyes, there is the more serious disturbance to vision, because the accumulated fluid forms a layer over the cornea which acts as an incorrect refracting medium through which the optical image appears distorted, especially when the gaze is directed downward. When both eyes are affected the visual disturbance is particularly troublesome.

In spite of all these inconveniences the patient very often neglects his condition, especially if he knows what an unpleasant treatment is before him, so that the secondary results of dacryostenosis rarely fail to appear. On the other hand, there are extraordinary cases in which a stenosis occasions but little inconvenience, and is, in fact, overlooked until accidentally discovered by the intro-

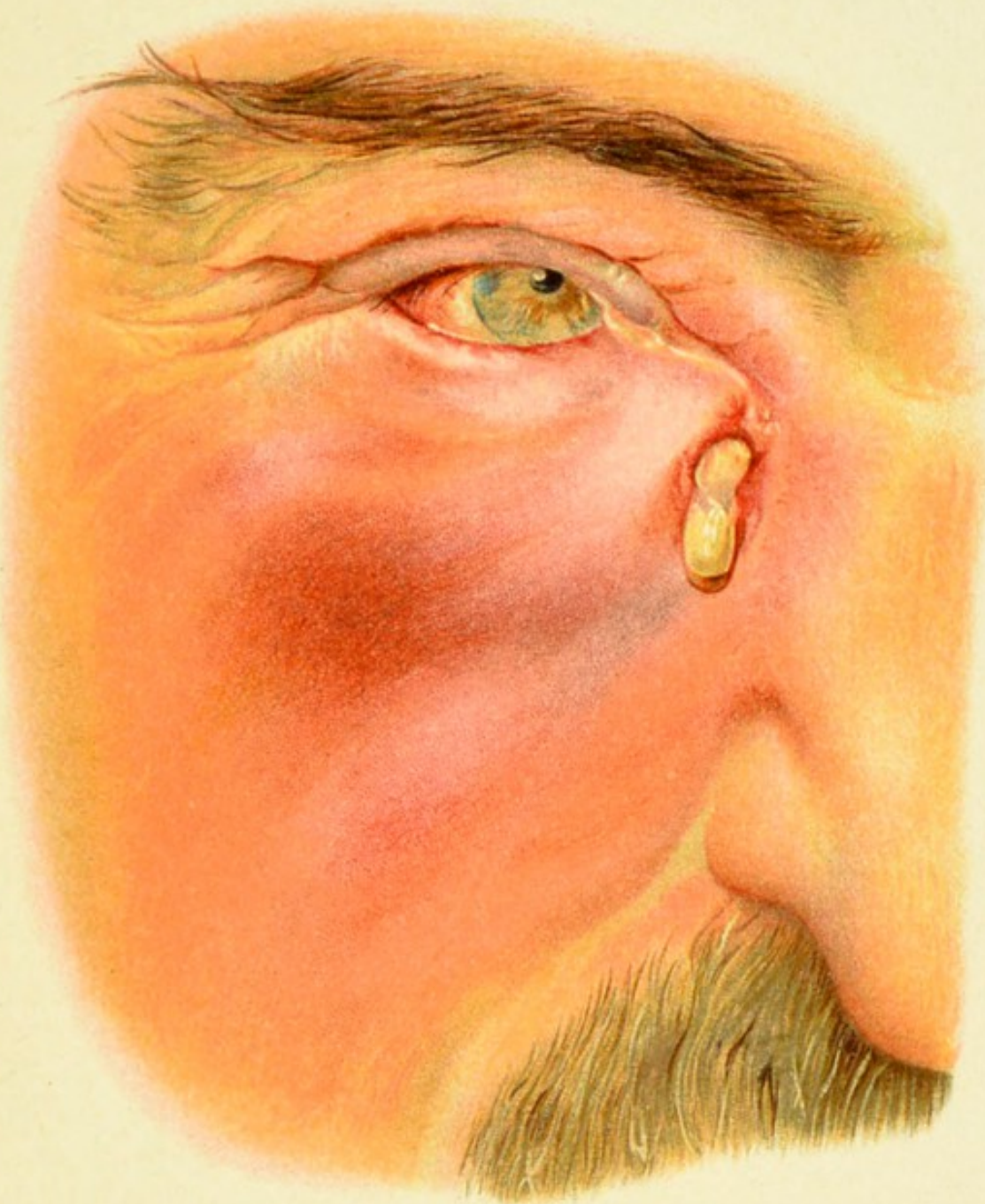Plate 2.


Dacryocystitis with Rupture of the Abscess through the Skin.—

The redness and swelling in the region of the lachrymal sac have abated somewhat, but the upper lid still exhibits some inflammatory edema. The patient is 64 years old; he has been troubled for some time with epiphora of the right eye. On May 1, 1897, a few drops of fluid were injected into the nasal duct, and it was found that permeability was not entirely lost. Inflammation set in on May 10, and two days later the abscess ruptured and pus was discharged, after which the inflammation subsided without the formation of a fistula. On May 20 another attempt was made to inject a few drops of bichlorid solution into the nasal duct, and proved successful. Since then the probe was used for some time, and finally a style was left in position.

duction of a syringe, preparatory to an operation for cataract, for instance. In most cases, however, epiphora is present from the beginning and is soon followed by conjunctivitis and blepharitis. The patient wakes up in the morning to find his eyelids glued together; the eye grows more and more sensitive to smoke and dust, and conjunctival congestion occasionally makes its appearance. The itching and burning of the inflamed palpebral margins from eczema cause the patient intense annoyance, and deformity sometimes results. If the cornea is abraded in the slightest degree and the lachrymal sac contains infectious material, hypopyon-keratitis may develop and threaten the patient's eyesight. This happens because as soon as the normal outflow of the lachrymal fluid is interfered with, the pathogenic germs readily find their way into the conjunctival sac and set up suppuration.

The active interchange of germs which has been experimentally proven to take place between the conjunctiva and the palpebral margin explains why the process so frequently extends to the lids, which, in addition, offer many snug recesses for the growth of bacteria in their numerous glands and gland-ducts. It may be that the growth of the microorganisms is further facilitated by the constant irrigation of the parts. Many patients are driven to consult the surgeon by intense inflammation of the lachrymal sac and its contents.





By some process which is not well understood the infectious material finds its way from the lachrymal sac into the surrounding tissues and sets up an intense phlegmonous inflammation resembling erysipelas, for which it is sometimes mistaken. The skin is very much inflamed, in places edematous (on the lids), and very tender to the touch (see Plates 1 and 2); but the lachrymal sac can be distinctly felt at the center of the inflammatory area; and as the disease progresses, the lachrymal abscess ruptures and a purulent secretion is discharged. Sometimes the abscess points from 1 to 2 cm. below the internal palpebral ligament, instead of at the position of the sac. This so-called **dacryocystitis** nearly always involves the surrounding tissues as well as the sac itself; the permeability of the lachrymonasal duct may persist in spite of the inflammatory process, the intensity of which depends more on the presence of infectious material and its entrance into the surrounding tissue, than on the degree of stricture, although the condition is always preceded by more or less epiphora and obstruction of the duct.

If, as is usually, but not invariably, the case, the abscess ruptures through the skin (Plate 2), a *lachrymal fistula* may be formed (Plate 3). Fortunately this is a comparatively rare occurrence, from which it may be argued that the accumulation of pus is probably more marked in the tissues surrounding the sac than in the sac itself.

Quite often the fistulous opening in the abscess, after discharging pus for a time, closes of its own accord and the inflammation disappears without leaving a trace. If a lachrymal fistula is formed, it usually persists as a very fine opening which eventually exudes pure lachrymal fluid (Plate 3). If the condition has lasted a long time, chronic distention of the lachrymal sac (ectasia) is sometimes associated with the fistula. [Lachrymal fistula may be mistaken for a *buccal fistula* below the margin of the orbit. —ED.]

Ectasia of the lachrymal sac (also called *mucocoele*, *lachrymal tumor*) may develop in the later stages of the

Plate 3.

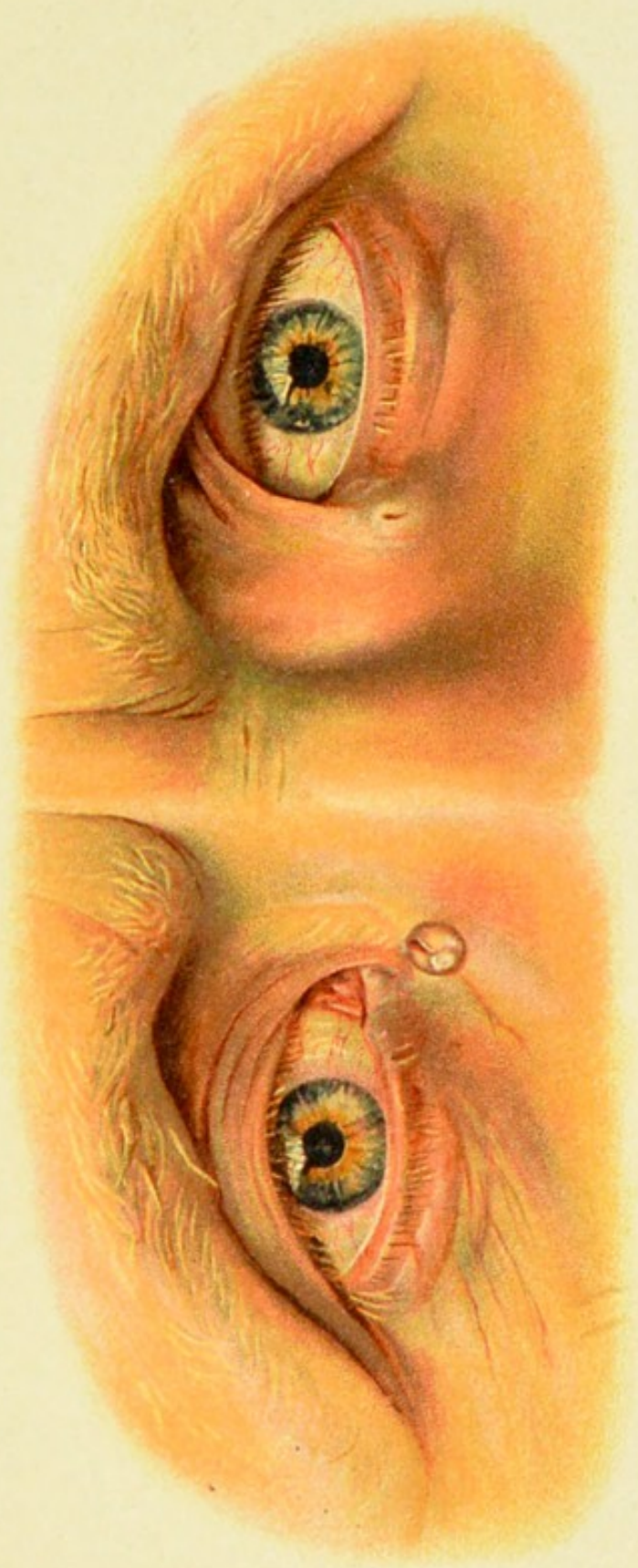
Lachrymal Fistula on the Right Side; Ectasia of the Lachrymal Sac on the Left; Bilateral Epicanthus.—A tear-drop is seen at the opening of the fistula on the right. On the left side the fistulous opening does not extend as far as the sac. The right eye shows some ciliary congestion, due to a slight degree of keratitis (not visible in the picture). Patient, a man, 29 years old, has been troubled with watering of the eyes since his thirteenth year. In 1884 he was admitted to the clinic for dacryocystitis on the left side; the sac was incised and a probe passed, but the flow of pus could not be arrested. At the time a scar was noticed on the right side, where he had been treated for dacryocystitis before, in some other clinic. At present, impermeable stricture of the nasal duct on both sides. On June 12, 1897, both lachrymal sacs were extirpated.


process, with or without the formation of a fistula. It is at once recognized by noting that the normal depression at the nasal side of the inner canthus has disappeared or has given place to more or less prominence (Plate 3), and by the absence of inflammation in the skin. Pressure upon the swollen sac expresses the contents, consisting of viscid, glairy mucus or a mucopurulent mixture, through the canaliculi or into the nose; many patients themselves discover this method of obtaining relief. There is always danger that the ectasia may turn into a dacryocystitis.

When the accumulation of mucopus in the lachrymal sac is very great, *dacryocystitis blennorrhœica* results. This is really nothing but the result of an active purulent catarrh of the mucous membrane of the lachrymal sac. It often leads to inflammation of the conjunctival sac, the eyelids, and possibly even of the cornea, not to mention the lachrymal sac itself and its surroundings. The catarrhal secretion is mucous or purulent, depending on the kind of microorganisms present in the sac.

A catarrhal condition once established in the lachrymal sac, even though the secretion be only mucous and the nasal duct not obstructed, epiphora still persists because the opening from the sac into the duct is stopped up with mucus.

Tab. 3.





Diagnosis.—In the diagnosis the following points must be borne in mind :

Simple epiphora may be due to a nervous disturbance or to abnormal irritability of the nasal mucous membrane [and to refractive error and insufficiency of convergence or to exophora.—ED.].

An abnormal accumulation of fluid in the lachrymal sac is detected by pressing on the sac with the finger in an outward direction, from the nose toward the eye.

In order to ascertain whether the epiphora is caused by a stricture in the nasal duct, a few drops of liquid are injected into the lower canaliculus. The lower canaliculus is chosen because it is somewhat wider than the upper and admits the nozzle of the syringe more easily. Sometimes the canaliculus has to be dilated with a blunt probe (or a straightened hairpin) before the syringe can be introduced. The nozzle of the syringe should not be larger than that of an Anel syringe, or about 0.7 mm. in diameter. A Pravaz syringe, made entirely of glass, including the nozzle, and holding 2 grams, is the best for the purpose. I consider the use of an ordinary syringe, whether the piston be made of leather or asbestos, inadmissible, even for the nasal duct, on account of the extreme difficulty of sterilizing it and the consequent danger of infecting the canal. As a rule, the same syringe is used for everybody, whether the stenosis is aseptic or not.

As the injection of a neutral fluid (0.8 per cent. saline solution) is practically painless, it may be performed in all cases without risk of deterring the patient from continuing the treatment, as frequently happens if a probe is introduced for purposes of diagnosis.

If the fluid is slowly injected into the lower canaliculus in this way, while the head is bent slightly forward, it will pass out through the corresponding nostril, if the duct is patulous. If the patient is lying down, as is the case sometimes in the examination of children, the liquid trickles into the throat and the act of swallowing announces the permeability of the duct. If the lumen is

only partially occluded, part of the liquid flows back through the upper canaliculus; if occlusion is complete, the entire dose is forced out in a fine stream.

In the diagnosis of phlegmonous inflammation it is to be remembered that two other diseases present similar clinical pictures:

1. *Furuncle* is not uncommon in the region of the lachrymal sac, and is readily distinguished by the fact that it is never preceded by epiphora, and by the permeability of the nasal duct, although some difficulty may be experienced in introducing the syringe on account of swelling about the punctum lachrymale.

2. *Alveolar abscess* may very closely simulate a dacryocystitis. Suppuration at the root of a tooth, especially the upper canine, sometimes produces an abscess in the region of the lachrymal sac, which may rupture in the same spot as a true lachrymal abscess. If an alveolar abscess exists, the upper alveolar border on the corresponding side is swollen and tender to the touch. [A track of suppuration leading to the anterior frontal or ethmoidal cells and opening just above the inner canthal ligament may be mistaken for chronic lachrymonasal disease.—ED.]

From *erysipelas* the affection is easily distinguished if the tenderness on pressure and swelling of the lachrymal sac are considered.

The differential diagnosis from *tubercular* or *syphilitic* inflammatory processes in the bones about the sac and nasal duct is somewhat more difficult. The general habit must be taken into account, glandular swelling at the maxillary angle looked for, and the condition of the bone ascertained by means of a sound. If it is learnt that a probe has already been introduced, especially during the inflammatory stage of the process, the possibility of *injury* to the bone must be considered. The bone does not become inflamed spontaneously in simple stenosis, even when followed by dacryocystitis.

Finally, we may mention that *carcinoma* and *sarcoma* of the *upper maxillary bone* sometimes encroach on the

region of the lachrymal sac and produce a swelling which bears some resemblance to a phlegmon. The fatal error of mistaking a malignant growth for an affection of the lachrymal sac can be avoided by noting the diffuse swelling below the sac and the permeability of the nasal duct, and by observing that there is less sensitiveness to pressure than in phlegmonous affections. [A cyst in front of the lachrymal sac (prelachrymal cyst) or a solid growth in the same region may simulate dacryocystitis. Prelachrymal abscess also occurs, and may result in a fistula in front of, but not communicating with, the lachrymal sac. —ED.]

A distended lachrymal sac, without inflammation (Plate 3), is sometimes mistaken for a *dermoid* cyst of the orbit (Plate 21 and Fig. C) or an *osteoma* of the ethmoid bone (Fig. D). We shall return to this subject in the section devoted to diseases of the orbit.

Prognosis.—The prognosis in dacryostenosis is always grave, as even apparently mild cases often refuse to heal. Not that simple epiphora or the associated conjunctivitis and blepharitis, troublesome though they be, are to be feared; the gravity of the disease lies in the danger to the cornea and hence to the eyesight. In three-fourths of all the cases of hypopyon-keratitis, which works such havoc in the entire visual apparatus, the corneal infection is primarily caused by an obstruction in the lachrymonasal canal.

The prospect of recovery is brightest when the proper treatment has been applied from the beginning of the malady and there are no false passages made by previous unskilful use of the probe. Under the most skilful treatment the result will depend on the duration of the disease, the condition of the contents of the sac, and the number and permeability of the strictures. If the sac has once lost its elasticity through excessive distention, there is small hope of checking the epiphora, even if the nasal duct is clear, for the draining-mechanism is irremediably injured. A normal sac acts like a pump by forcing the fluid into

the lachrymonasal duct; its anterior wall is drawn forward during closure of the lid by the action of the orbicularis palpebrarum, to which the internal lateral ligament is attached, and when the muscle relaxes the wall returns to its original position by virtue of its own elasticity, expressing the contents of the sac into the canal. This maneuver is impossible when the anterior wall is permanently distended.

The prognosis is on the whole favorable in certain cases of obstruction in infants, which are due to deficient communication between the lachrymal canal and the nasal duct, and disappear when continuity is established. The anomaly usually disappears of its own accord in a few weeks, even when a considerable degree of purulent catarrh has developed in the lachrymal sac, provided the condition is not aggravated by the introduction of a probe.

Treatment.—The treatment of the diseases of the lachrymal apparatus that have been described has two main objects: 1. Removal of the obstruction in the duct; 2. Removal of the germs which cause the morbid secretion in the lachrymal passages.

In many cases a cure is effected by merely complying with the second indication, treatment being directed solely against the catarrh of the sac and duct. There are cases in which the permeability of the duct is not entirely lost, and the obstruction produced by swelling and accumulations of mucus is only temporary. In such cases—they are usually of recent origin—simple irrigation with an antiseptic fluid answers every purpose, as a rule. From 5 to 10 c.c. of a disinfectant or astringent solution are injected with a so-called glass syringe every day, or every few days. A 1:5000 solution of mercuric chlorid (even 1:1000 is very well borne) is recommended as a disinfectant; for an astringent, a 1 per cent. solution of silver nitrate or a weak zinc solution is used.

In every case the catarrh and swelling in the nasal cavities must receive appropriate treatment (nasal douche, cauterization, etc.). I have seen cases of epiphora perma-

nently cured by cauterization in the nose, which had stubbornly resisted treatment with probes.

If the obstruction is due to syphilitic processes in the nose, ulcerations, etc., general antisyphilitic treatment must be inaugurated at once.

The injections should be kept up for some time, even if the fluid at first fails to pass into the nose, as a few repetitions of the procedure sometimes suffice to remove the obstruction. The lachrymal sac must always be thoroughly washed at the very outset, especially if a probe is to be introduced into the canal for the purpose of removing a stricture, in order to avoid aggravating the condition by scattering the germs contained in the sac when the probe is passed.

In many cases the use of probes to remove the strictures is unavoidable. But in my opinion (other specialists may differ with me on this point) the use of a probe is to be recommended only in recent cases, where it can be introduced without much difficulty. If the strictures are numerous and offer so much resistance that a considerable effort is needed to effect an entrance, especially if the sac is already distended, it is better to spare the patients the hardship of the procedure, which even cocain cannot render painless. Their description of the "horrors" of the operation may deter many others from subjecting themselves to the treatment, who then put off the dreaded interview with the surgeon until driven to it by the very complications which make the treatment hopeless. If some permeability still exists, and a few drops of a 5 per cent. solution of cocain can be injected into the duct, the introduction of a probe is not very painful, and its use in such cases is to be recommended; but if the stricture is impermeable, cocain is of little use, since it fails to reach the desired spot.

The following suggestions, based on a large experience in the use of the probe, may not be unwelcome:

It is much better to introduce the probe through the upper canaliculus, because, when the instrument is raised

to the vertical position, as it must be in order to glide into the duct, the distortion is less severe than in the lower canaliculus. This distortion sometimes has the disagreeable effect of obliterating the opening of the canaliculus into the sac, making it absolutely impossible to pass the probe into the sac; and when afterward the upper canaliculus is incised in order to continue the treatment, its opening is also found to be obliterated, or soon becomes so. The upper canaliculus is not much harder to split than the lower one. If the operator experiences the least difficulty in this part of the operation, he would better give up the treatment altogether; for the proper introduction of a probe is a far more delicate matter, and should only be attempted by a practised hand, or it does more harm than good. In my opinion the introduction of a probe requires the skill of a specialist and is quite as difficult as any of the larger operations on the eye.

The maneuver will undoubtedly be attended with less pain and better results, if a few days are allowed to elapse after the slitting of the canaliculus, the incision being prevented from healing. The following rules must not be neglected on any account: The probe used at the first trial should not be smaller than Bowman's No. 3 or 4; these two sizes, in fact, suffice for the entire treatment. Before raising the instrument to the vertical position, preparatory to pushing it into the duct, the operator should make sure that the point is in contact with the anterior wall of the sac; he determines this by the increased resistance of the bone. Strong pressure should never be used. When further advance becomes impossible, the instrument should be left in place a quarter of an hour, and further attempts postponed until the next *séance*, two or three days later. In this way it is often possible to gain a little ground at each successive trial, without using undue force, until finally permeability is established at the third or fourth visit. To make sure that the probe has really entered the nose, a few drops of liquid are then injected with a de Wecker's cannula-syringe, with which the canal should

be irrigated at every subsequent introduction of the probe. The syringe is provided with a bulb, and in using it the contents (1:5000 mercuric chloride) are gradually squeezed out as the syringe is withdrawn. If the probe cannot be passed or withdrawn without using force, it is better, in my opinion, to abandon the treatment with probes, which, it is true, is quite feasible, but mostly does not furnish permanent cures, because the strictures constantly form anew and the hardships of the treatment are out of all proportion to the results obtained. If, after one or two trials, the liquid injected with the syringe preparatory to another attempt with the probe fails to pass into the nose, the treatment with sounds is best abandoned. Whether self-retaining sounds or styles will then furnish better results remains to be seen. I have never seen any permanent good results in such cases; the original state of affairs never failed to return after their removal.

If the lachrymal sac is the source of the secretion in these old cases, it is best to extirpate it. If it contains but little secretion, it may be cleansed as well as possible by repeated injections and then disinfected, after which the canaliculi are to be closed by electrolysis (with a platinum wire).

If the sac is much distended, extirpation is indicated at once, as in that case even permeability of the duct, if it could be established, would not check the excessive flow nor obviate the danger to the cornea.

For new-born infants the treatment should be limited to regular evacuation of the sac by pressure with the finger until communication with the nose is established; this may take several weeks. In addition a $\frac{1}{2}$ per cent. zinc solution is dropped into the eye once a day, for the purposing of controlling the conjunctival catarrh.

I am aware that my views on the treatment of eye-diseases differ from those usually advanced, particularly in the limited field accorded to the use of probes. These views are the result of twenty years' careful observation of patients and a study of their subsequent history. Because a patient has stopped coming for treatment is no reason to assume that he is cured. In *recent* cases the passing of probes, if performed with

the proper technic and as gently as possible, is often followed by good, permanent results. It is for old cases that I wish to combat the routine application of this therapeutic method. One of my patients, on whom I performed extirpation of the sac on both sides, later had a probe passed by a colleague who knew nothing of the operation. The patient had consulted him for a different eye-trouble, and as the eye, of course, watered a good deal, a probe was immediately introduced and forced through in spite of the resistance encountered.

[While the Editor agrees with the author as to the necessity of avoiding the indiscriminate use of probes, as to the value of antiseptic irrigation of the lachrymonasal canal and the paramount importance of intranasal treatment, he regards his views on lachrymal treatment in general as too pessimistic. It should be remembered that distinguished authorities—*e. g.*, Theobald and Snell—regard many failures to cure lachrymal disease as due to inadequate size of the probes, and advocate probes 3–4 mm. in diameter.]

DISEASES OF THE EYELIDS.

1. Inflammations.

The skin of the eyelids is subject to the same diseases as the skin covering the rest of the body. The eyelids alone may be affected, or the eye-affection may simply form part of a general process involving other portions of the body. Acute diseases, such as erysipelas, herpes zoster, variola, furuncle, anthrax, etc., are met with, as well as chronic processes, among which eczema in its various forms and seborrhea deserve special mention.

Erysipelas and **herpes zoster** of the lids are occasionally mistaken one for the other; a careful inspection, however, at once reveals the real nature of the disease. In herpes zoster the inflamed area is confined to one side of the face (Plate 20), because the skin-lesion is caused by disease of the trigeminus, and therefore corresponds to the area supplied by that nerve. The first branch is most frequently attacked, the second much less frequently, and the

third very rarely, if ever. If the first branch of the nerve is diseased, the eruption appears on the forehead, as far as the median line, on the upper lid and its immediate surroundings, on the side of the nose (corresponding to the distribution of the nasociliary nerve), and on that part of the hairy scalp supplied by the nerve. In erysipelas the eruption is, of course, not confined within such limits. Moreover, the vesicles in erysipelas are large, while in herpes zoster they are small and coalesce in patches, corresponding to the terminal distributions of the nerves. They at first contain a clear fluid which later becomes purulent, and in a short time they dry up and form scabs. From admixture with hemoglobin the scabs are usually of a dark-brown or black color (Plate 20), giving the disease its characteristic appearance which lasts for several days. The edges of these scabs are indented, in accordance with the irregular patches of vesicles from which they are formed, and have been described as resembling a geographical map. The same irregularity of outline characterizes the scars, which are slightly depressed (at first red, later becoming white), and remain visible for years, showing that the corium is involved in the vesicular eruption, which is not the case in erysipelas or herpes febrilis.

Herpes zoster ophthalmicus, like herpes zoster in other parts of the body (*e. g.*, in the area supplied by the intercostal nerves, so-called "rose-girdle"), is further characterized by the occurrence of severe neuralgic pains, both before and during the eruptive stage, and even during the period of convalescence, many patients complaining of pain in the region supplied by the affected nerve for weeks after subsidence of the eruption. In many cases, on the other hand, there is anesthesia of the affected area during convalescence. The morbid process quite frequently involves the cornea; we shall speak of this again in the section devoted to inflammations of the cornea.

The **treatment** of the skin-lesion in herpes zoster consists in fostering the healing of the scabs; for this purpose either a dusting-powder, consisting of white zinc oxid

and rice-starch, or vaselin, may be used. For the relief of the neuralgia the uninterrupted current of electricity has been advocated.

Eczema occupies a prominent place among diseases of the eyelids.

The dry form, *eczema squamosum*, attacks the surface of the lids and contiguous areas. The skin is rough and somewhat inflamed; the patient complains of itching. A speedy cure is usually effected with oil of cade (which must not be allowed to enter the eye) or with 5 per cent. ichthyol-ointment.

The *moist* or vesicular variety is much more common, both on the surface of the lids and particularly on the ciliary margin, where it leads to the disease called *blepharitis ulcerosa*. Eczema on the surface of the lids is usually associated with the same disease on adjoining areas, the hairy scalp, the ears, etc.; the treatment consists in cleanliness and the application of Hebra's ointment.

Blepharitis eczematosa often occurs in combination with this process, although it also occurs independently, and in that case is apt to be very refractory. It is also observed secondary to conjunctival catarrh or to keratitis, from maceration of the lids by the conjunctival secretion or the excessive flow of tears; and, finally, it is met with as a concomitant to a form of eczema which, as we shall see later, frequently attacks the conjunctiva and cornea in scrofulous and anemic subjects. Children are particularly liable to this trilogy, and frequently afford us an opportunity of observing the *simultaneous* occurrence of the process on the lids, the conjunctiva, and the cornea, associated often with eczema of the nose, mouth, ears, and hairy scalp. It would appear, therefore, as Horner no doubt correctly thinks, that *clinically* at least there is a connection between these three different manifestations of eczema (blepharitis, conjunctivitis, and keratitis eczematosa), although we still lack anatomic or bacteriologic proof of their identity. Upon closer inspection we observe that the individual vesicles possess a *circular* outline

and soon produce ulcers of varying depth, which on the cutaneous surface of the lids become covered with scabs, while, of course, on the conjunctival mucous membrane and on the cornea no such scab-formation can take place.

Marginal eczema presents various clinical pictures, according to the type and intensity of the process. Solitary, flat, round pustules, of a yellowish color, may be scattered among the tufts of matted cilia, or pierced by a single cilium (Plate 4, *b*) ; or the yellow pustules are replaced by the well-known eczema-scabs, removal of which with the cilium-forceps reveals the small round ulcer beneath, with the discharge of a few drops of thin pus. The ulcers sometimes form a continuous series, or several of them coalesce. If they penetrate to the deeper layers of the corium, as a result of suppuration, the roots of the cilia are destroyed and the characteristic *gaps in the eyelashes* appear (Plates 4, *b* ; 6, *a* ; and 23, *b*). In severe types of pustular eczema, such as occur in children of marked scrofulous habit or after *measles*, the four lids may become involved. The surface of the lids becomes edematous, the edges thickened and inflamed, and the entire palpebral margin is covered with crusts, through which the tufts of matted cilia are seen projecting. On careful inspection of the upper lid small pustules, still covered with epidermis, may be seen underneath the crusts. When the latter are removed, part of the cilia usually come away with them, exposing the moist and bleeding surface of the palpebral margin covered with deep ulcers.

If the inflammatory process is protracted, the cilia drop out in ever-increasing numbers or become misplaced inward by the cicatricial contractions which follow the healing of the ulcers, and cause abrasions on the cornea (*trichiasis*). The palpebral margin becomes permanently thickened and a squamous form of eczema continues for some time to torment and disfigure the patient. Eventually either *entropion* or *ectropion* may result : the former in consequence of the cicatricial contractions on the inner surface of the lid-margins ; the latter on account of the

Plate 4.

a. **Papular syphilide** (from Mracek, *Atlas of Syphilis and the Venereal Diseases*, Plate 22).

b. **Blepharitis eczematosa**, associated with slight eczematous keratitis (whence the ciliary congestion) and eczema of the ear. The patient, who had been suffering for some time from inflammatory eczema of the eyes, had earrings put in his ears, with the sole result that the ears also became eczematous and the lobe inflamed. About the middle of the lower lid there is a gap in the lashes from a previous attack of eczema; on the upper lid recent eczematous ulcers are seen.

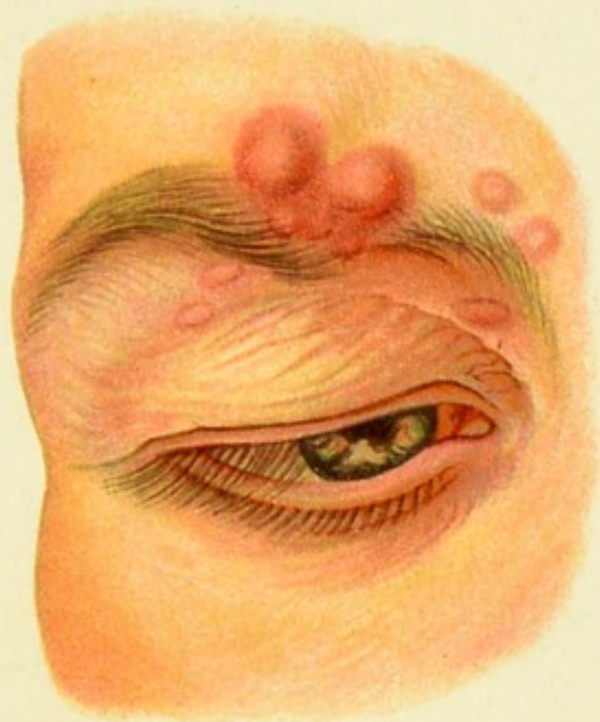
cicatrization which is ultimately brought about on the outer surface by the incessant maceration. In the case of the lower lid the development of ectropion is also fostered by the mechanical drawing down of the margin when the eye is wiped.

The eczema which follows a dacryostenosis may, in view of its etiology, be classed as a special form. Chronic conjunctival catarrh from any cause usually leads to the development of marginal eczema in the end.

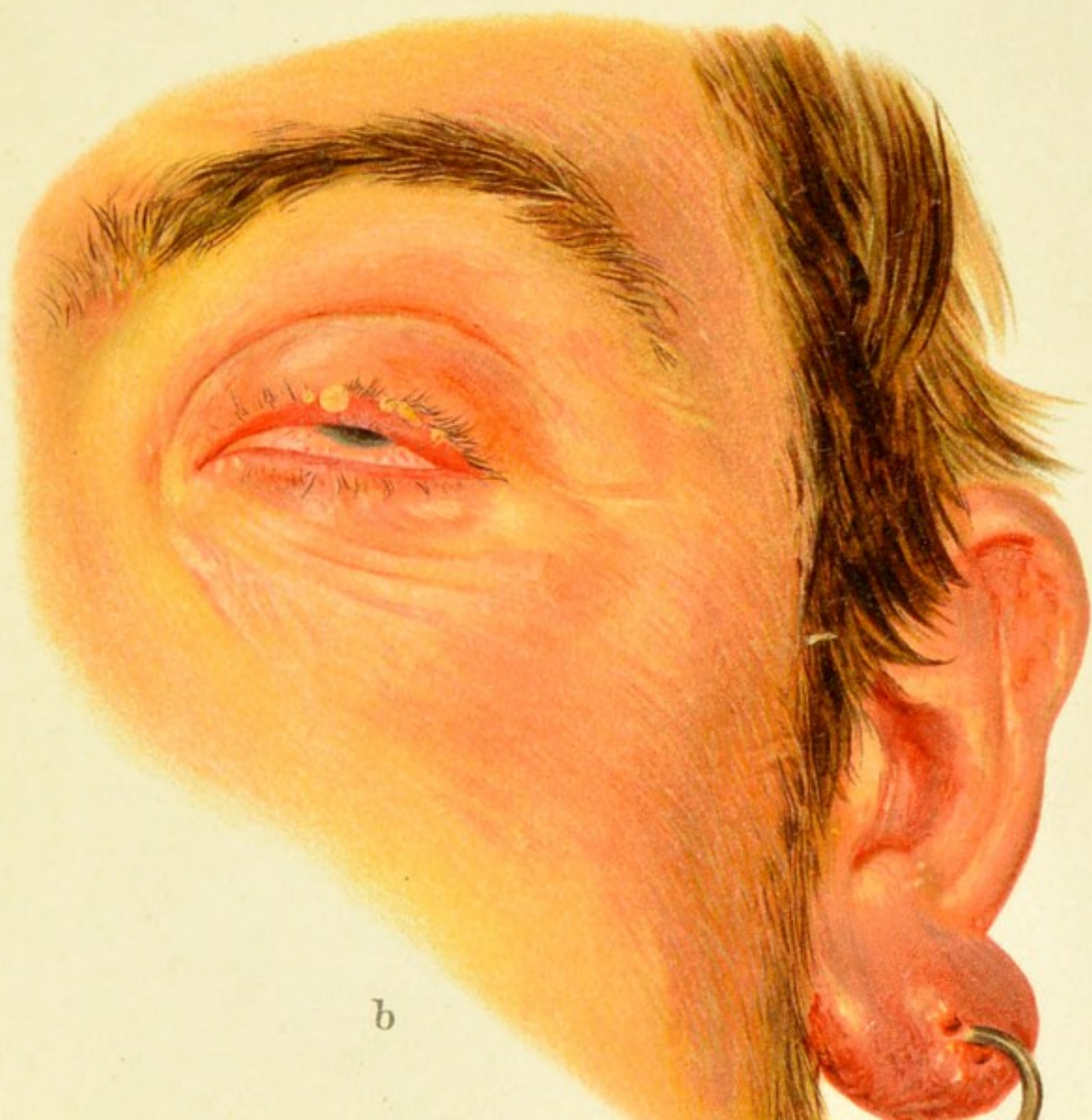From a clinical point of view eczema of the lids should be classed with diseases due to dirt, especially in children. A few chronic cases may perhaps be explained on the theory of natural predisposition. In other cases the disease is fostered by a debilitated condition of the organism, in children especially by scrofula, anemia, and acute diseases like measles, whooping-cough, etc.

The **diagnosis** in marginal eczema presents no great difficulties; the differential diagnosis from squamous blepharitis or seborrhea of the lids will be discussed in the section devoted to that disease. The **prognosis** in acute cases is correspondingly favorable; in chronic eczema among adults, which is, on the whole, a rarer occurrence, it is less favorable.


The **treatment** should be both general and local, based on a careful consideration of the etiologic conditions. Scrupulous cleanliness and general supporting remedies are the first requisites. The local treatment is directed



a



b



principally toward the removal of such causal conditions as dacryostenosis and conjunctival catarrh.

Eczema in contiguous areas must also be subjected to vigorous treatment. The scabs are to be first softened with Hebra's or with white precipitate ointment, 1 per cent., in the form of a plaster, and then removed. The exposed ulcers are then covered with the same ointment or painted with a 2 per cent. solution of silver nitrate, or even touched lightly with the mitigated stick. The cauterization-scab must not be disturbed, and when it comes away of its own accord the application is repeated, and so on until no more ulcers appear.

Children should have their eyes bandaged after the ointment has been applied, to prevent rubbing with the hands. Compresses steeped in bichlorid solution have been recommended to keep the parts perfectly clean, particularly if eczema of the cornea is present. A 1:5000 solution is used. In a very few individuals a bichlorid dressing induces eczema; if so, it is at once detected; in all other cases this form of wet dressing does *not* produce eczema.

Extraction of the cilia is to be recommended only in chronic eczema in adults, and should be followed by an application of tincture of iodine to the palpebral margin; the tincture must not be allowed to enter the conjunctival sac. The same remedy is employed in all cases of chronic thickening and inflammation of the palpebral margins. If the moist form changes into the squamous variety, oil of cade is substituted for tincture of iodine.

Seborrhea of the palpebral margins (Horner), also known as *squamous blepharitis*, is an affection which is often confounded with eczema. The differential diagnosis is not difficult, if the following points are borne in mind:

Marginal seborrhea very often follows in the wake of similar disease in the hairy scalp, characterized by falling out of the hair, the formation of dry scales, and a fatty secretion. The lashes gradually drop out, the itching becomes intense, and the patient is finally driven to consult

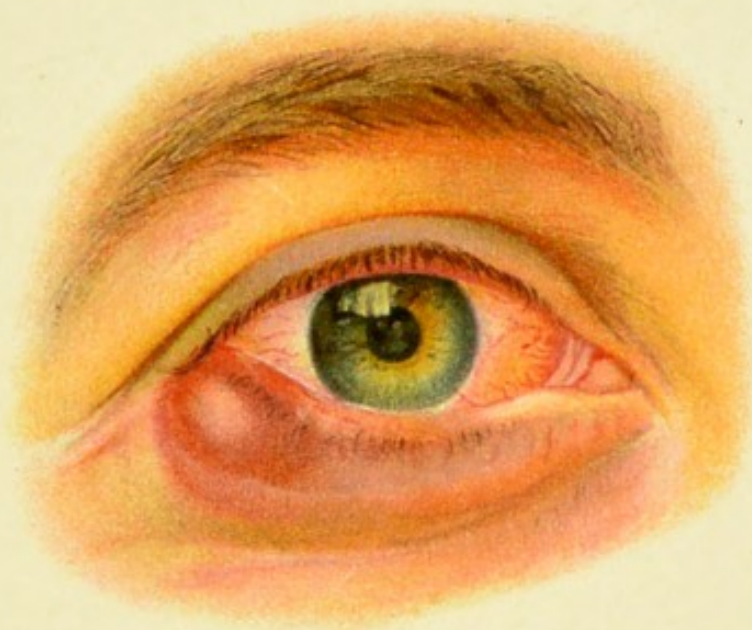Plate 5.


Meibomian or **internal hordeolum** in the temporal third of the right upper lid, of four days' duration. Mild conjunctival catarrh has existed for some time, hence the conjunctival congestion. Course: Spontaneous evacuation of pus through the conjunctiva. Treatment of catarrh undertaken to prevent recurrence of the inflammatory process in the lid.

a doctor when his eyes have become more and more sensitive to radiating heat and can no longer stand the strain of continuous use, especially if, as often happens, conjunctival catarrh and hordeolum add their quota to his discomforts. The inflamed and, in chronic cases, thickened margins exhibit the cardinal symptom of the disease: Scales, appearing either as a fine white powder among the cilia, or of a more pronounced branny character, in rare cases mixed with a fatty secretion to form larger scabs, presenting a certain likeness to the crusts in eczema; but on removal of the scabs with the cilium-forceps no ulcers are found on the skin, which is red and smooth and covered with thin epidermis. The cilia also are characteristic in this disease: the longer the process has lasted the shorter, thinner, and more sparsely distributed will be the eyelashes, robbing the eye of its chief ornament. The inflamed and thickened margins take on a deeper red at each fresh irritation or congestion, and the eyelashes are ultimately reduced to a thinly scattered row of almost colorless hairs. In eczema we have normally developed cilia alternating with areas entirely denuded of hair; in seborrhea, on the contrary, the cilia are uniformly sparse and poorly developed, showing that we have to deal with a skin-disease which directs its attacks principally against the hair-follicles.

Heredity plays an important rôle in this form of blepharitis. The disease often begins in youth, and many people suffer from it all their lives. Although we have, as yet, no proof that the disease is due to a microorganism, there are many reasons for thinking that it is contagious.

Diagnosis.—In addition to eczema, phthiriasis—*i. e.*,





the presence of lice among the eyelashes—may be mistaken for this affection. The parasites usually belong to the variety *phthirius inguinalis*, or crab-louse; head-lice rarely attack this region. The disease may be mistaken for *molluscum contagiosum* (Plate 6, *b*) if the nodules are small and the examination has been very superficial.

Prognosis.—The disease is a serious one. Not only is the eye disfigured and its usefulness impaired; but if the cilia are lost, the conjunctival catarrh which ensues is apt to resist all treatment, and may in the course of years produce ectropion, which, in turn, brings on disease of the cornea and other more serious complications. The disease can only be cured in youth. In later life the evil may be palliated or temporarily checked; but it recurs as soon as the conditions are favorable: radiated heat, night-work, etc.

The treatment should match the disease in stubbornness. Other hairy parts of the body, if the seat of seborrhea, must be treated with lotions of: Carbol, 5 per cent.; sulph. precip., 2 per cent., mixed with equal parts of alcohol and eau de Cologne, or with sulphur ointment. The eyes must be thoroughly cleansed every morning with a fine linen cloth, after having been carefully rubbed the night before with an ointment consisting of turpeth mineral (basic mercuric sulphate), or

White precipitate (hydrarg. ammoniat.),	0.05
Vaselin,	
Lanolin,	āā 5.0

The ointment is to be applied immediately before going to sleep. Salves which tend to become rancid only aggravate the evil. In winter the eyes should be washed with warm water. This treatment must be prescribed for several months from the very outset. In chronic cases tincture of iodine may be used with advantage. [An excellent ointment for squamous blepharitis is one composed of 3 per cent. of milk of sulphur and 3 per cent. of resorcin.

Plate 6.

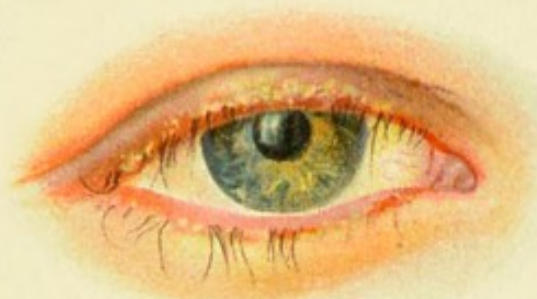a. **Eczematous blepharitis** of long standing, so that on one side numerous gaps, on the other only the squamous form of the disease, are seen.

b. **Molluscum contagiosum and external hordeolum** in a girl, 17 years old. The uniformly small nodules are most numerous in the region of the eyes; a few isolated ones are also seen on the rest of the face and on the upper part of the body; but they have not as yet spread to the lower portions. The nodules show the characteristic central opening or depression. The external hordeolum which is seen on the lower lid, a little to the nasal side of the center, is merely an accidental complication.

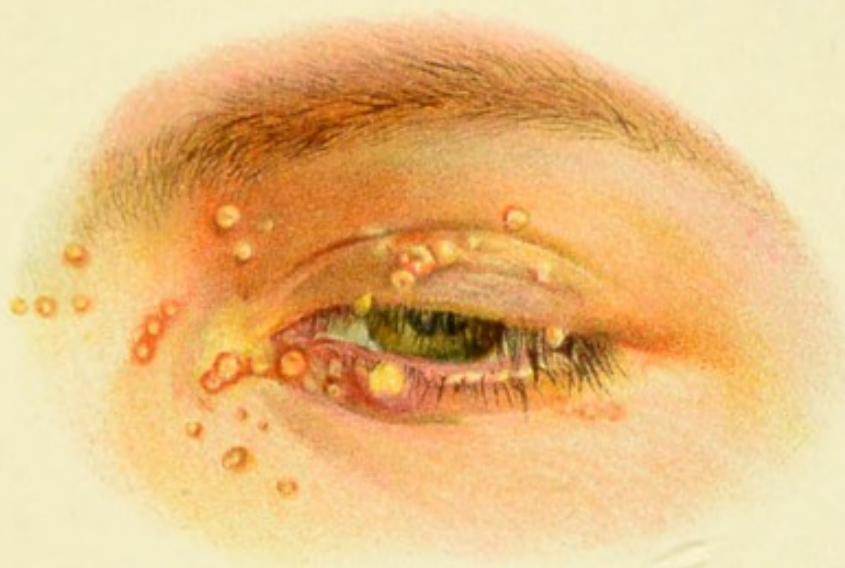The scales should first be removed with a 5 per cent. solution of chloral (Gradle) or with a solution of sodium bicarbonate. Pagenstecher's ointment (yellow oxid of mercury) is useful in ulcerated and eczematous blepharitis, as is also aristol ointment. In *all* cases of blepharitis an essential part of the treatment is the thorough correction of any existing refractive error. This alone will suffice to cure many mild cases.—ED.]

The various glands in the lids frequently become the seat of inflammation. We have two varieties to deal with: 1. About 600 sebaceous glands, which accompany the cilia on both the upper and the lower margins, the so-called glands of Zeiss; 2. The long, acinous Meibomian glands, which lie closely packed in the tarsus, in perpendicular lines to the palpebral margin. They are practically enlarged sebaceous glands, opening on the free border of the lid and by their oily secretion preventing the tears overflowing.


Hordeolum.—Suppuration of a sebaceous gland leads to the formation of the well-known sty or *external hordeolum* (Plate 6, *b*, lower lid, to nasal side of center); while the same process in one or more Meibomian glands produces the so-called *internal hordeolum*, a much more serious disturbance, the inflammation being more extensive and the pain proportionately greater. The redness and swelling of surrounding parts are so great as to simulate the picture of erysipelas or ophthalmic blennorrhoea. The lids



a



b



and the conjunctivæ may be edematous, especially if the purulent focus is situated near the outer canthus. This is easily found by palpating the inflamed lid, as it is extremely painful; sometimes it corresponds with a small yellow pustule on the margin of the lid. It marks the opening of the duct of the inflamed Meibomian gland or glands. If the patient can bear the discomforts of the procedure, it is sometimes possible to inspect the inner surface of the lid and note the accumulated pus shining through the conjunctiva. For the small abscess which forms in a short time is more likely to rupture through the conjunctiva than through the skin. With the bursting of the abscess the pain and discomfort cease and the swelling subsides.

Both the internal and the external hordeolum, but especially the latter, may recur for weeks or even months, first in one and then in another of the four palpebral margins. The process is fostered by seborrhea and chronic conjunctival catarrh; but the first fundamental condition is the presence of *pyogenic microorganisms*. I once had occasion to observe how the introduction into the conjunctival sac of a virulent culture of *staphylococcus aureus* caused the occurrence of hordeola.

There is every justification for classifying these two forms of gland-inflammation, as well as chalazion (to be described), under the head of *acne*, as Horner has suggested.

Neither variety of hordeolum produces permanent injury, and the treatment is quite simple. Active poulticing with linseed-meal is recommended, both to alleviate the suffering and to shorten the process by bringing the abscess to the point of spontaneous evacuation or incision. [Repeatedly applied compresses soaked in hot carbolized solution or in hot water containing 33 per cent. of fluid extract of hamamelis is preferable.—ED.] The knife should be used as soon as a distinct purulent focus is seen through the conjunctiva, the incision being made from within, perpendicular to the margin.

Plate 7.

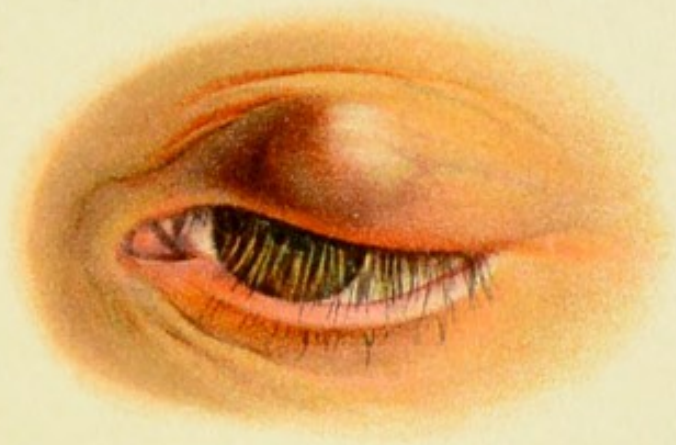a. **Chalazion** on the upper lid of a young man; developed during the last two months. Incision from within and evacuation resulted in cure.

b. **Multiple chalazion**, on the right eye of a young woman; developed gradually during the last six months.

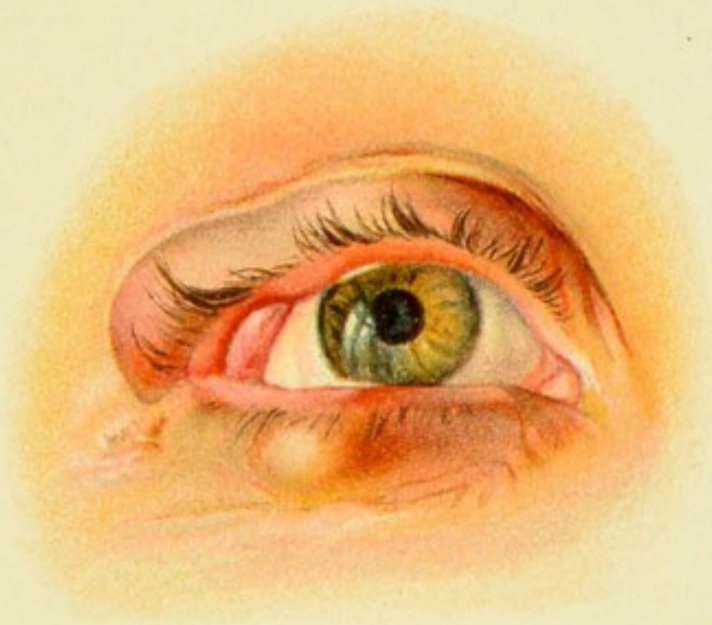c. The lower lid of the same side, seen from within. Conjunctiva shows proliferation resembling granulation. Evacuation from within. Cure.

To prevent the recurrence of hordeola I have found it advisable to prescribe a collyrium for several weeks after the subsidence of the inflammation. This is composed as follows: Zinc sulphate, 0.1 to 20.0 of a solution of sublimate, 1:5000 or 1:10,000. Seborrhea, if present, must be treated.

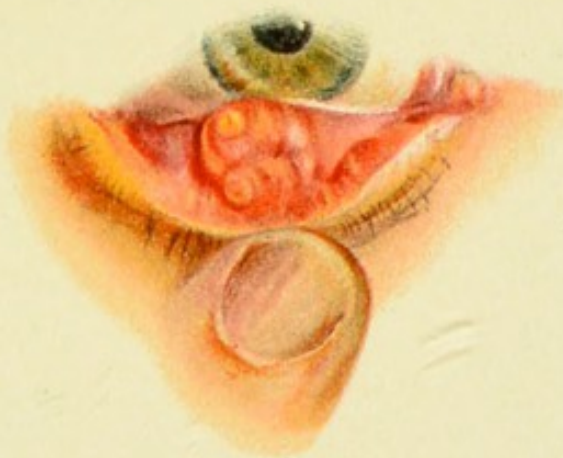
From what has been said it is evident that **chalazion** and hordeolum are more or less related. In most cases the chalazion develops slowly, without giving rise to inflammatory symptoms; occasionally, however, its inception or subsequent course is attended with inflammation. The nodule in the course of weeks or months may attain the size of a pea or half a cherry (Plate 7, *a*); quite frequently it is multiple (Plate 7, *b*), in which case its favorite seat is in the upper lid. The skin is not inflamed at first, and, whether the growth be single or multiple, always moves with the shifting of the swelling, which is only movable with the tarsus. The conjunctiva on the inner surface of the lid is red and swollen, and sometimes hypertrophied, as if it were the seat of granulations (Plate 7, *c*). This is more particularly the case when the tumor is preparing to burst or has already done so. The contents of the nodule are grayish and can often be seen through the walls. Anatomic examination shows that the tumor is situated within the tarsus, and therefore originates in one or more Meibomian glands. The contents consist of a soft, grayish-red mass of granulations, more or less liquid in the center. The walls of the tumor are formed by the dense connective tissue of the tarsus. Microscopic




a



b



c



examination reveals that the chalazion begins with a proliferation of the epithelium in the acini of a Meibomian gland, the acini becoming surrounded by an ever-increasing inflammatory infiltration of the tarsus. As the glands are destroyed the small-cell infiltration increases and forms granulation-tissue, with a few giant cells, so that the entire growth comes to resemble a tubercular proliferation, although the process has nothing whatever to do with tuberculosis. On the contrary, this chronic inflammation of the Meibomian glands is probably due to another bacillus, which I found in several cases in small numbers. It was difficult to stain. Perhaps it is identical with that described later by Deyl.

One argument in support of the specific nature of chalazion is the fact that it is always preceded by mild, chronic catarrh of the conjunctiva, and that the formation of other chalazia is best prevented by checking the conjunctival catarrh by means of the preparation of zinc referred to in connection with hordeolum. We also know that chronic conjunctival catarrh favors the growth of pathogenic microbes in the conjunctival sac.

Chalazia must be removed as soon as they have attained a certain size; very small ones need no treatment. A large conjunctival incision is made running vertically to the palpebral margin and the contents scraped out with a curet. The capsule is allowed to take care of itself, so that the swelling does not subside until one or two weeks after the operation. If the operation is properly performed, the tumor will not recur. If the growth is nearer the skin and threatens to burst, a horizontal incision may be made through the skin parallel to the lid-margin and the contents removed in that way. A chalazion must never be cauterized from the conjunctival side, as the resulting cicatrization leads to trichiasis and entropion. [The conjunctival hyperemia induced by *eye-strain* is a constant cause of chalazia and hordeola; therefore the necessity of correcting the refraction of the eye if it is anomalous.—ED.]

Plate 8.

Blepharochalasis on Both Sides.—The patient is 31 years old; otherwise quite well; no sugar or albumin in the urine. The disease began eleven years ago; the eyes are much disfigured by the redness and swelling of the lids. Dilated veins are seen in the inflamed skin. In this case, as in the last, there is a suggestion of epicanthus, the skin of the upper lid being overlapped by the fold of epicanthus, more so on the right than on the left side. The results of operative removal were very satisfactory. Only a narrow strip of skin and orbicularis was excised; the lower lip of the wound was firmly attached to the upper margin of the tarsus by means of eight sutures.

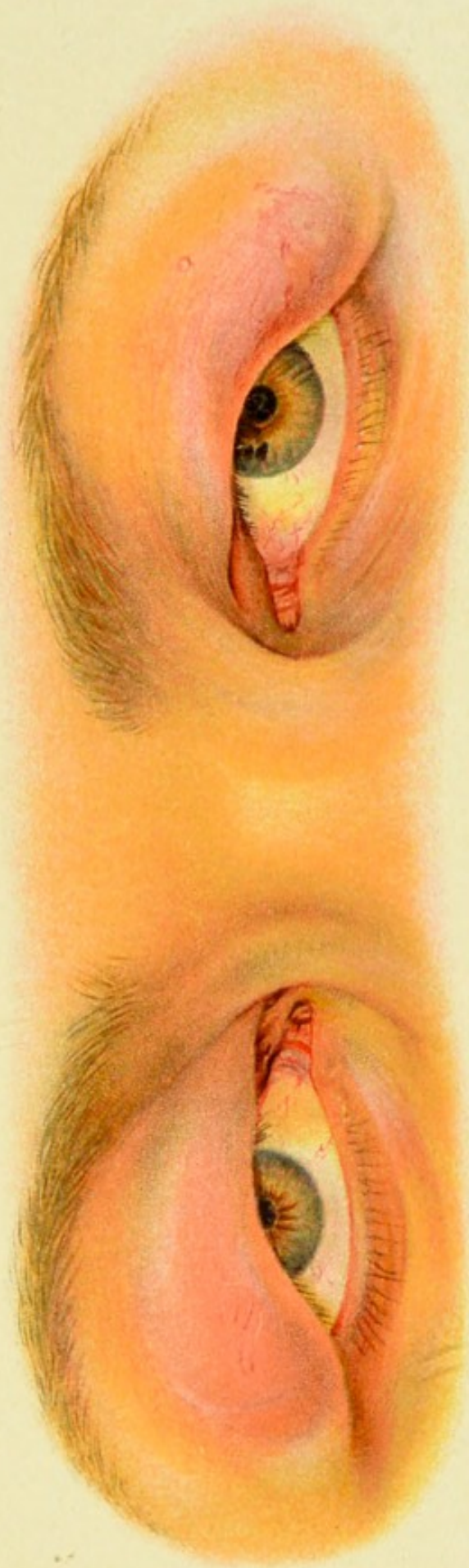2. Anomalies in the Shape and Position of the Eyelids.


Congenital ptosis (Plate 9), or drooping of the upper lids, from paralysis or defective development of the levator palpebræ superioris, is usually bilateral, while the *acquired* form commonly occurs only on one side. Acquired ptosis often follows paralysis of the sympathetic, being directly caused by paralysis of the involuntary Müller's muscle, an accessory of the levator palpebræ. The condition is characterized by *contracted* pupil and vasomotor paralysis on the affected side of the face. Ptosis due to paralysis of the oculomotor nerve is more marked and the pupil of the affected eye is usually *dilated*.

The congenital anomaly known as *epicanthus* (Plates 3 and 9) consists of a crescentic fold of skin which surrounds and partially covers the internal canthus. The condition is normal in the Mongolian race and in many new-born infants of the Caucasian race, gradually disappearing among the latter as the bridge of the nose is more fully developed. If the fold persists to adult age, it must be removed by direct excision; the practice of excising an elliptical piece of skin from the bridge of the nose is unsatisfactory, in my opinion.

Ptosis adiposa (lipomatosis) and *blepharochalasis* (Plates 8 and 9) are two congenital anomalies primarily due to defective attachment of the integument to the upper margin of the tarsus and the tendon of the levator. The

Tab. 8.





skin cannot be raised with the lid, and hangs down like a pouch over the palpebral margin, producing a marked deformity. According to Fuchs, the skin is very thin and slightly hyperemic. The two anomalies may be corrected by excising a portion of the redundant skin and attaching it by means of sutures to the upper margin of the tarsus (Hotz's operation).

The foregoing anomalies are rare compared with the conditions termed ectropion and entropion.

Ectropion (also called *eversion* of the lid-margin when very slight) occurs in the lower lid when the skin and tarsus become relaxed—*senile ectropion*; or in consequence of cicatricial contraction of the skin after traumatism—*cicatricial ectropion*. The cicatricial form develops in caries of the orbital margin, after burns, scalds, ulcerations, etc., or through the gradual cicatrization attending the repeated excoriations and eczematous eruptions brought on by constant maceration and wiping of the eyes in dacryostenosis and chronic catarrh.

The *paralytic* form is produced by palsy of the facial nerve which supplies the orbicularis palpebrarum. The lower lid only is everted, the upper lid being drawn upward by the preponderance of the levator and Müller's muscle. The direct result is *lagophthalmos*, or inability to close the eye, especially during sleep, which is apt to produce conjunctival catarrh. Another important form of *lagophthalmos* is due to protrusion of the eye from tumors of the orbit and exophthalmic goiter.

Spastic ectropion is sometimes met with in young persons, due to abnormal contraction of the orbicularis palpebrarum. It is corrected by replacement and a suitable bandage.

The remaining varieties of ectropion demand surgical treatment, by means of which, above all things, the elongation of the lid that is often present must be corrected by excising a wedge-shaped portion of the tarsus and conjunctiva (after the method of Kuhnt or Dimmer's modification of his operation). If the ectropion is slight, Snellen's

Plate 9.

Blepharochalasis in the Later Stages; Congenital Ptosis; Epicanthus.—The patient, 26 years old, is terribly disfigured by the malady. It could not be definitely ascertained whether the ptosis was congenital. The characteristic wrinkles are seen on the forehead. The epicanthus is partly congenital and partly caused by the blepharochalasis; deep, ugly looking pits are concealed under the folds. The skin of the upper lids is relaxed and hangs down in folds. In the upper portion of the right upper lid a few vertical folds are seen. The same swelling of the lids, seen in the preceding case, was formerly present. The malady began spontaneously with swelling and inflammation, when the patient was five years old. The redness and swelling gradually disappeared in his thirteenth year and gave place to the present condition. The results of operative treatment were very satisfactory. A larger piece of skin was cut away than in the preceding case, mostly from the nasal portion of the upper lid, for the purpose of correcting the epicanthus. In placing the sutures the needle was introduced through the lower margin of the wound, then through the upper margin of the tarsus, and passed out through the tendon of the levator about 5 mm. higher up, and finally through the upper margin of the wound. Eight stitches were put in on each side. The action of the lid was materially improved and the cosmetic result excellent.

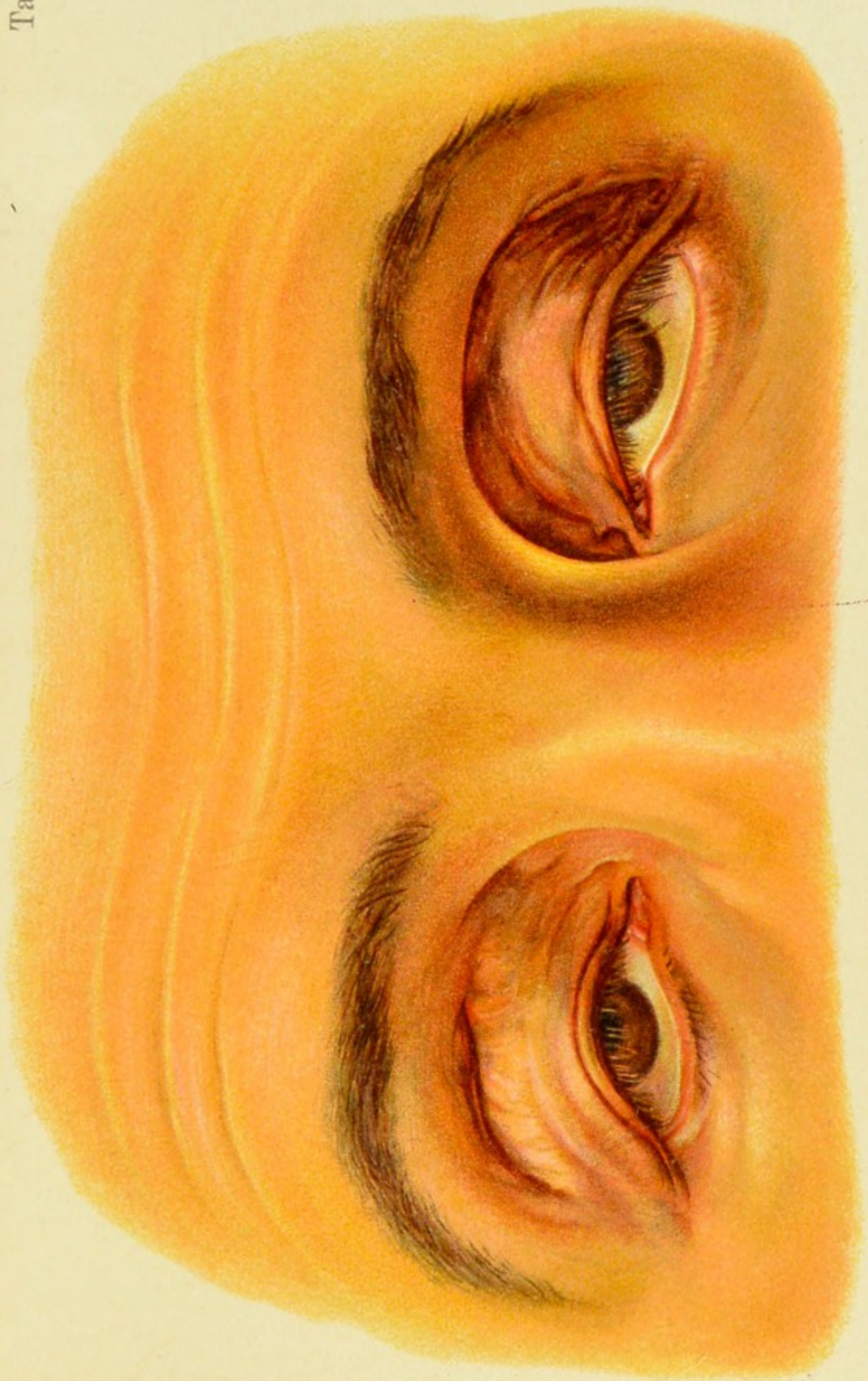
suture suffices; the patient should be advised to wipe the eye from below upward.


Entropion, especially of the lower lid, may also be caused by spastic contractions of the muscular fibers. It is seen most frequently in elderly people with relaxed eyelids and small, deep-set, or deficient eyeballs, associated usually with blepharospasm. The condition is usually temporary and can be corrected by simply drawing the skin away from the palpebral fissure and securing it with adhesive plaster or a Gaillard suture.

Cicatricial entropion is a more serious injury and generally requires operative treatment. It is caused by cicatricial shortening of the conjunctiva after trachoma, diphtheritic conjunctivitis, burning or scalding of the conjunctiva, and not infrequently after excessive therapeutic cauterization.

Symblepharon is a cohesion between the eyelids and the

Tab. 9.





ball which sometimes develops as the result of burns and ulceration.

Sometimes the free edges of the lids become adherent to each other, in which case the condition is called *ankyloblepharon*.

The term *blepharophimosis* is applied to a condition in which the palpebral fissure is apparently shortened by the passage of a vertical fold of skin over the outer canthus. The commissure is normal underneath the fold of skin, which can be made to disappear by outward traction with the finger. If the palpebral margins have actually grown together at the outer commissure, the condition is more correctly designated as *ankyloblepharon*.

3. Injuries of the Eyelids.

Injuries of the eyelids are very common. The skin in this region is loosely attached to the underlying tissues and very extensible, favoring the development of severe subcutaneous hemorrhages which cause various discolorations, ranging from red to dark blue or black. The lids are swollen, particularly if there is subcutaneous *emphysema*, as in fractures or fissures of the orbital bones, which permit the escape of air from the nasal and other cavities (sinus frontalis, etc.). The thin, nasal wall of the orbit is particularly liable to fracture, especially the cribriform plate of the ethmoid bone, and the escaping air distends the lids so that they feel like an emphysematous lung. Sometimes there is protrusion of the eyeball. These symptoms, however, look more alarming than they really are and the patient usually escapes with nothing worse than a "black eye." A far greater significance attaches to the subcutaneous hemorrhages caused by fracture of the base of the skull (Plate 10). In this accident the blood sometimes is forced forward as far as the eyelids, and the resulting ecchymosis in the lower part of the ocular conjunctiva and in the lower lid (rarely also in the upper) constitutes an important symptom.

Plate 10.

Subcutaneous Hemorrhage in the Lids after Fracture of the Base of the Skull.—The hemorrhage is more marked in the upper than in the lower lid, which is the opposite of what is usually observed. Patient is 24 years old, male. Four days before, he jumped from a moving car and struck on the back of his head. He was unconscious twenty-four hours and complained of headache for a long time afterward. No other lesion was found. Cured after a rest of several weeks, part of the time in bed. No permanent injuries.

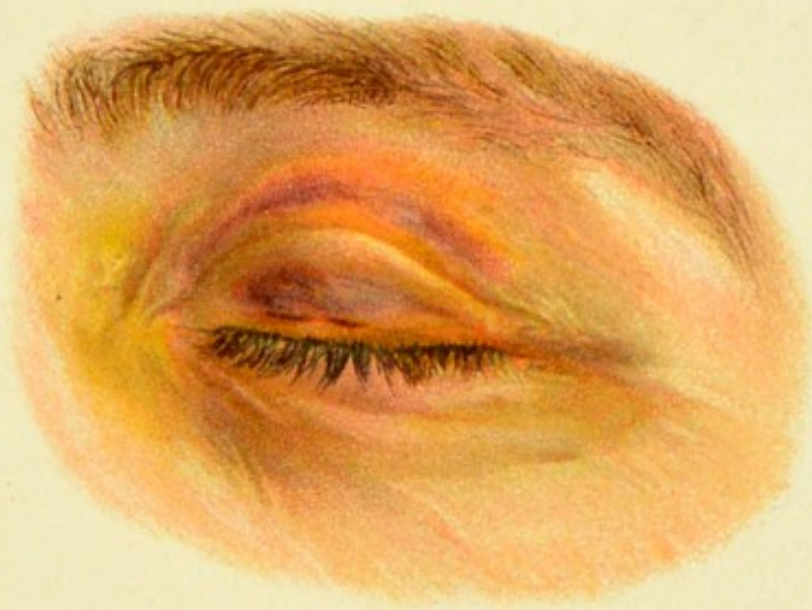Permanent injuries may result from a cut severing the upper lid or dividing one or the other lid in a vertical line, unless the wound is promptly and carefully sutured. Especial care must be taken to bring the edges of the wound together accurately at the free border of the lids. If the lower lid is torn at the inner canthus, permanent interruption of the lower canaliculus usually results in spite of the most careful application of sutures; this has been referred to on p. 79. Fortunately, the upper canaliculus under ordinary conditions is able to carry off the lachrymal fluid.


In powder-burns the particles of powder are best removed by burning with the electric cautery after the wound has healed.

4. Tumors of the Eyelids.

Benign Tumors.—*Xanthelasma* occurs in middle-aged persons, especially women, and occasionally requires operative treatment on account of the deformity. The patches are of a yellowish-brown color and slightly raised above the surrounding skin. Both eyes are usually affected, the patches being symmetrically distributed above and below the inner canthus.

Molluscum contagiosum, as its name implies, is apt to spread over the body of the patient and infect those who come in contact with him. The papules are as large as a pea or a cherry, and appear in large numbers, preferably on the lids and their surroundings. In proof of the con-





tagious nature of the disease I may state that I inoculated myself with it successfully about twelve years ago, that being one of the earliest successful inoculations on record. The growth, which was taken from the eyelid of a child, took six months to develop. Epidemics of the disease have been observed in schools.

Milium, or an occluded sebaceous gland, appears as a small elevation which is sometimes confounded with molluscum contagiosum in its first stages. The shallow central depression, however, through which the milky contents of the molluscum can be expressed, is not seen in the milium. With the microscope certain peculiar, shining, spherical bodies are found in mollusca which establish the diagnosis.

Each nodule must be removed with the galvanocautery, curet, etc.

Fibroma molluscum, or *molluscum simplex*, warts, and *cutaneous corns* are occasionally seen; also *angiomas*, *telangiectatic* and *cavernous tumors*. The latter are usually congenital, and should be removed as early as possible.

Malignant Tumors.—*Carcinoma* and *sarcoma*, the former preferably on the palpebral margin, the latter often melanotic, usually begin in the tarsus.

DISEASES OF THE CONJUNCTIVA.

A. CONFLUENT INFLAMMATIONS.

1. Simple Catarrhal Conjunctivitis.

We distinguish an acute and a chronic form. In acute conjunctivitis the inflammatory symptoms are more pronounced and the bulbar conjunctiva is involved, while catarrh, especially the chronic form, is usually limited to the palpebral conjunctiva.

The objective symptoms are: Abnormal secretion of mucus or pus, congestion, swelling of the mucous membrane producing a roughness in the tarsal conjunctiva,

the formation of folds in the region of the fornix, and swelling of the semilunar fold and caruncle. In purulent catarrh there may be edema of the bulbar conjunctiva and the lids themselves are more or less swollen.

The lids are glued together in the morning; the patient complains of burning and itching and a gritty feeling. Owing to a film of mucus on the cornea there is a temporary haziness, which disappears as soon as the patient wipes his eyes. If the layer of mucus is very thin, the patient sees colored rings around the lamp (iridescent vision), as in glaucoma. Photophobia, blepharospasm, and pain are not marked as long as the cornea is not involved, so that the lids are more easily separated than is the case in corneal inflammations. Later in the course of chronic catarrh the lid-margins and the cornea may become inflamed, especially in elderly people, giving rise to the so-called *marginal* or *catarrhal ulcer*, or to purulent ulcers.

Etiology.—A variety of pathogenic microörganisms are found in the conjunctival sac during catarrh. Among those which are known to produce conjunctivitis are: (1) the *gonococcus* (see gonorrheal conjunctivitis); (2) the *pneumococcus* of *Fränkel-Weichselbaum*, which causes a mild and not necessarily contagious form of catarrh, and is found oftener in children than in adults;¹ (3) the *strep-tococcus*, which produces either simple or pseudomembranous diphtheritic inflammation. Whether the *staphylococci* which are often found in the conjunctival sac are capable of causing conjunctivitis or not, is still an open question.

The following *bacilli* may give rise to conjunctivitis: (1) the *diphtheritic bacillus* (see diphtheritic conjunctivitis); (2) the *Koch-Weeks' bacillus*, which under certain conditions sets up a severe, contagious inflammation in children

¹ [There are a number of observations on record, particularly those of Harold Gifford, which indicate that pneumococcus-conjunctivitis may also be an affection which is distinctly contagious, which attacks adults, which passes from one eye to another, and which clinically is difficult to differentiate from Koch-Weeks bacillus conjunctivitis.—ED.]

and adults [acute contagious conjunctivitis, vulgarly known as "pink eye."—ED.]; (3) the *diplobacillus* of *Morax* and *Axenfeld*, the occasional cause of a slow, protracted form of conjunctivitis. [It is not infrequently found in stubborn cases of subacute conjunctivitis.—ED.]

As far as our present knowledge of simple catarrhal conjunctivitis goes, different bacilli may be found in clinically identical forms; and, conversely, the same bacilli may give rise to different clinical appearances (Bach).

Among other causes which produce, or at least aggravate, conjunctivitis may be named: Bad ventilation, dust, smoke, alcoholic abuse, blepharitis, dacryostenosis, foreign bodies in the conjunctival sac, etc.

Diagnosis.—This is based on the symptoms described. Corneal complications may be detected by observing ciliary congestion and irregularities in the surface of the membrane.

Prognosis.—This is excellent in young subjects, although in elderly people and in cases in which the exciting causes cannot be removed, the treatment may present some difficulties.

Treatment.—This is primarily concerned with the removal of the exciting causes: Locally, astringents, either applied by the surgeon himself, or in the form of eye-drops or ointment entrusted to the patient. The mucous surfaces may be painted with a 1 per cent. to 2 per cent. solution of argentic nitrate according to the degree of purulent secretion. For a collyrium prescribe zinc sulphate 0.05–0.1 in 10.0 of distilled water, or 1 : 10,000 sublimate solution; the latter solution remains sterile longer. If the cornea is not involved, lead acetate 0.1–0.2 in 10.0 of distilled water, or ung. amylo-glycerini (glyceritum amyli), may be useful; but if the cornea is involved, incrustations of lead may follow its use and retard the healing of the corneal injury. In obstinate cases a variety of remedies must be tried: Copper sulphate, tannin, alum (0.5 per cent.). Collyria are to be used once or twice a day; ointments are

Plate II.

a. **Dermoid tumor** in a child, aged 1 year. The growth is congenital and is growing very slowly.

b. The same in a man, aged 21 years. The characteristic hairs, often seen in a dermoid tumor, are present. The tumor in this case also has grown very little since birth. After removal a small, gray spot appeared on the cornea.

applied once a day with a glass rod. Atropin is quite unnecessary unless there is a corneal complication. [Frequent cleansing of the conjunctival sacs with saturated boric-acid solution, or with boric acid and saline solution, is advantageous. If reaction is high, iced compresses are useful. Zinc is especially valuable in diplobacillus conjunctivitis.—ED.]

2. Follicular Conjunctivitis.

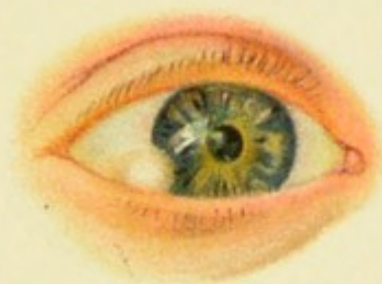A chronic form of catarrh, characterized by the formation of numerous granulations on the conjunctiva, more particularly in the retrotarsal folds (Plate 14, *a*). The nodules appear singly or in rows, are of a pinkish-gray color, and vary in size from 1 to 3 mm.; the larger ones are more or less transparent.

The disease belongs to childhood and early adult life, and may run its course without marked subjective symptoms; or the child may be troubled with blinking (*nictitatio*) and inability to continue at close work. As a rule, there is little or no secretion.

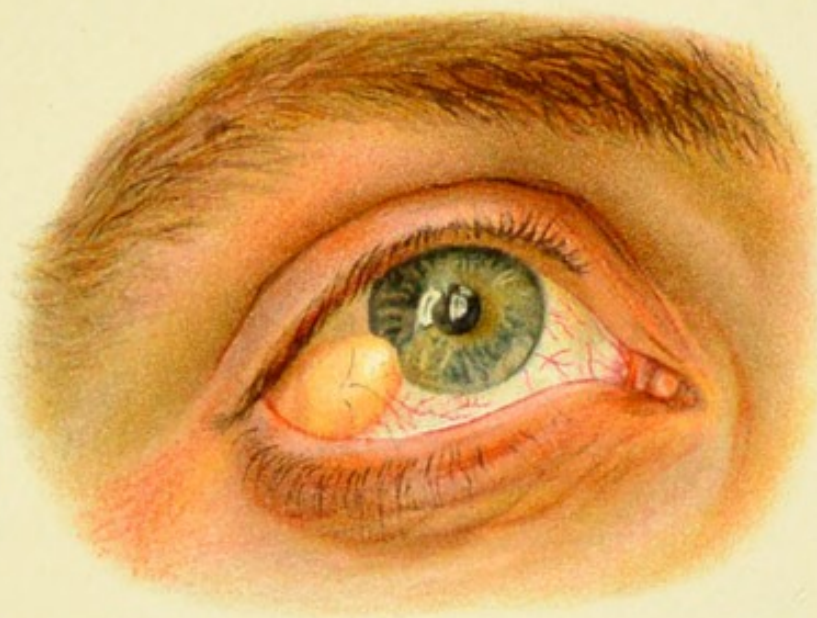Diagnosis.—Follicular conjunctivitis is often confounded with trachoma; but the distinction may be made by observing that the granulations are most numerous in the lower retrotarsal fold, while in trachoma they are found chiefly in the upper curve of the fornix.

Prognosis.—The disorder may run a slow and tedious course; or it may disappear without leaving a trace.


Treatment.—Lead, either as an ointment or in solution, as a collyrium (Plumb. acet. 0.1–0.2 to 10.0, aquæ destill. or ung. amylo-glycerini). [Excellent collyria also



a



b



are : Boric-acid solution to which a few minims of alcohol to the ounce have been added, and boric acid in saturated solution ; applications of moderate astringents like tannin and glycerin (5 per cent.) are suitable ; but if the disease is stubborn, the follicles should be expressed with suitable forceps.—ED.]

3. Gonorrheal Conjunctivitis.

Gonorrheal conjunctivitis is caused by infection of the conjunctival sac with Neisser's gonococcus ; and, while it may occur at all ages, is most frequently seen in infants, in whom it is due to the entrance of genital secretion into the eye at the time of birth, or later to contact with the mother's soiled fingers. Later in life the genitalia (now and then also in very young girls who suffer from a virulent leukorrhea) or another eye similarly affected are the source of infection. Doctors and nurses are constantly exposed to infection from this source.

The importance of this disease cannot be overrated ; it is the direct cause of blindness in one-third of all the cases, being surpassed in this respect only by small-pox in countries where vaccination is not sufficiently enforced. Most cases of blindness are caused by *ophthalmia neonatorum*, which, in spite of the higher standard of midwifery and more competent medical treatment of the present day, defies all efforts to eradicate it, because of the negligence on the part of the persons in attendance in not seeking medical assistance early enough, and because the disease is and always will be dangerous in spite of the improved methods of treatment. It is therefore much to be desired that the prophylactic measures advocated by Credé might meet with more general adoption, especially in the quarters of the poor and thoughtless, who now furnish the great majority of virulent cases.

Ophthalmia, or *blennorrhœa neonatorum* [conjunctivitis neonatorum], usually begins on the third day after birth, with swelling and redness of the lids, and a discharge con-

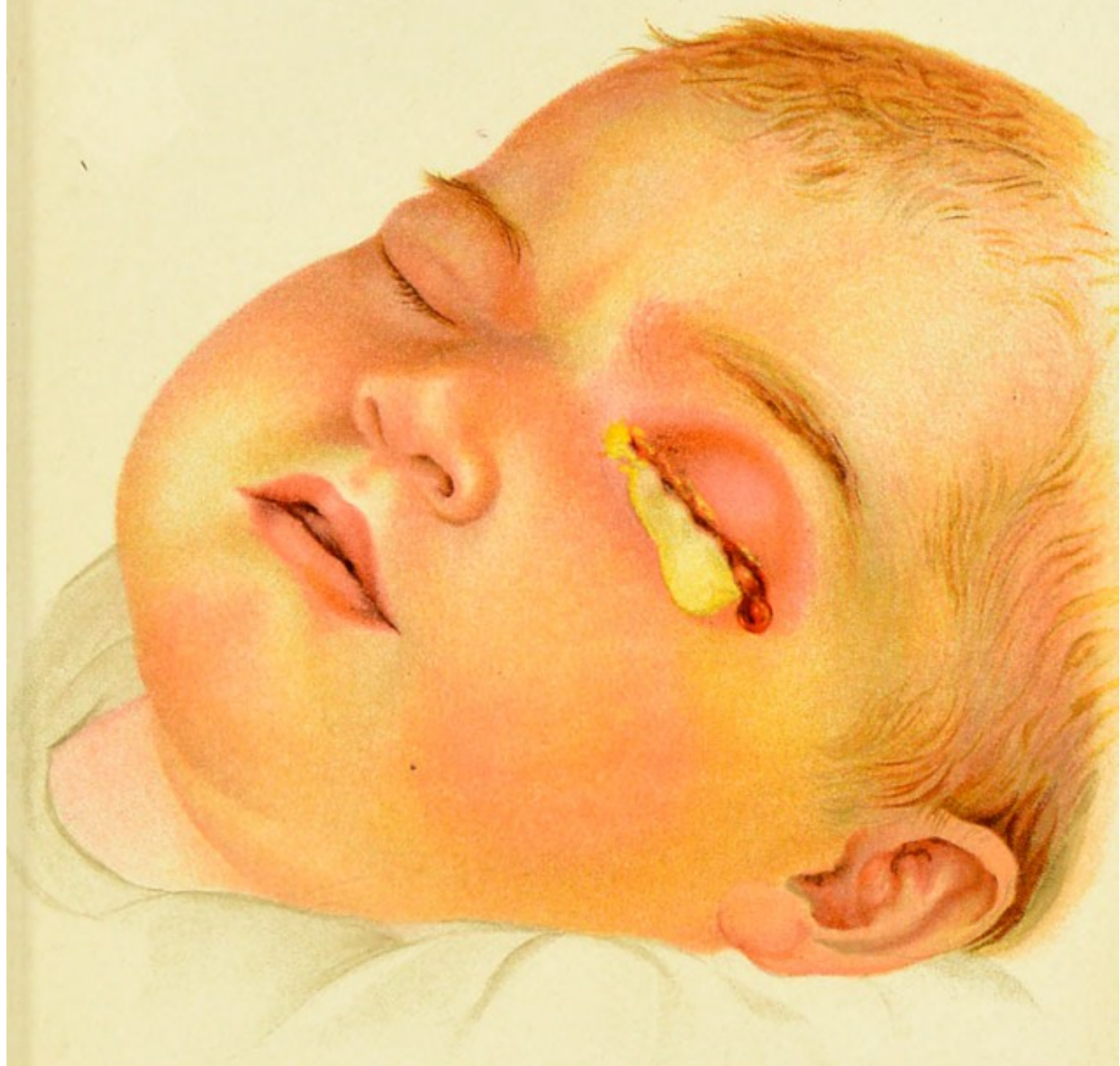Plate 12.

Gonorrheal Conjunctivitis in the New-born.

sisting of blood and serum, which has been likened to bouillon. Both eyes are usually affected, one a little later than its fellow. The conjunctiva in the first stage is red and swollen, but smooth. Edema is usually absent in infants.

After a few days the secretions become more purulent, the swelling of the lids diminishes, and the skin over the lids appears wrinkled; the conjunctiva is soft and puckered into folds, the color deepens to a dark red, the surface is rough and velvety, and longitudinal folds appear in the region of the fornix. At this time thick, yellow pus is secreted in large quantities and oozes out of the palpebral fissure (Plate 12) or collects in the folds of the conjunctival cul-de-sac.

During this second, or true gonorrheal stage, which may last for weeks, the cornea is in the greatest danger. The secretion, if not removed from the conjunctival sac, attacks the cornea; at first a small, gray patch appears at, or a little below, the center of the membrane; it increases rapidly in size and is soon converted into a *suppurating ulcer*, which spreads over the entire surface and may lead to perforation. If perforation takes place, the suppurative process invades the deeper tissues and gives rise to virulent inflammation in the anterior portion of the eye, or even to *panophthalmitis*. Sloughing of the entire cornea may easily lead to prolapse of the lens; in smaller perforations there is more or less adhesion of the iris to the opening, and a *staphyloma* may result. If the perforation is very small and centrally situated, the cornea may escape with a *central macula*; but in this case the lens may suffer from the prolonged contact with the ulcerated portion of the cornea, the endothelial cells of the anterior capsule proliferate, and an *anterior capsular* or *pyramidal cataract* results (Plate 34, *a*). The resulting corneal opacity may be much less than the lenticular; but not infrequently





large white spots, or *leukomata*, remain and interfere materially with vision.

In older children and in adults the inflammation runs a more acute course. The swelling and infiltration of lids and conjunctiva are much more marked, and there is severe edema of the bulbar conjunctiva, the edges of the cornea being covered by the overhanging folds of the chemotic membrane. The corneal tissue is in constant danger of being eroded by the masses of pus accumulated under these folds, and marginal ulcers of the cornea are consequently more frequent in adults than in children. Their detection is often difficult, because they develop unseen under the shadow of the swollen conjunctiva. These marginal ulcers are characterized by rapid spread, and often result in extensive sloughing of the cornea. Under certain conditions an ulcer may develop in the center.

In some instances where the infiltration in the palpebral conjunctiva, especially of the upper lid, is very great, the tissues assume a yellowish-gray color, resembling a diphtheritic membrane. These cases are fraught with great danger to the cornea.

Diagnosis.—This cannot be definitely established without a microscopic examination of the secretion and the detection in it of gonococci, although the severity of the process, in adults at least, is such as to leave no doubt of the virulent nature of the inflammation. It must be remembered, however, that both infants and adults are liable to occasional attacks of non-virulent purulent catarrh which closely resemble a light attack of gonorrhea. Moreover, it is particularly desirable that the disease be recognized before it has become fully developed, in order that the proper precautions may be taken to protect the unaffected eye. For ordinary purposes a cover-glass preparation, stained with fuchsin, will give all the necessary information; if diplococci are found congregated about the nuclei of pus-corpuscles, the diag-

nosis may be considered established. For accurate demonstration of the gonococci cultures are necessary.

The **prognosis** is somewhat more favorable in infants than in adult patients. If a new-born infant is seen early enough, there is no reason why the eye should not be saved, if the proper treatment is employed, with two reservations: If it is not tainted with hereditary syphilis, or very much enfeebled by other disease. In older patients recovery is always very doubtful; total or partial destruction of the cornea is to be feared even with the most careful management. It is one of the most dangerous diseases to which the eye is subject. I have repeatedly seen the loss of both eyes take place in spite of the most energetic and painstaking treatment.

Prophylaxis is a matter of the greatest importance in purulent ophthalmia. Credé's method is a practically certain preventive of its occurrence in the new-born, and may materially influence the severity of the process in the adult. It consists in the instillation of one drop of a 2 per cent. solution of silver nitrate into the eye immediately after the first bath. No other measures are necessary except the proper precautions against subsequent infection. This method has proved very successful and demonstrates conclusively that silver nitrate is the most effective remedy against gonococci, a very small quantity sufficing to check their further growth.

All gonorrheal patients, and those who come in contact with them or with patients suffering from gonorrheal conjunctivitis, must be carefully warned of the great danger of infection. If one eye only is affected, as frequently happens in adults, the sound eye should be protected from contact with the infectious secretion by a collodion shield as soon as the diagnosis is definitely settled. The eye is covered with a thin pad of cotton over which a piece of linen is fitted, and the edges glued to the skin with collodion, after which the entire dressing is given a second coat of collodion. To make sure that infection has been successfully warded off, the shield must be loosened every

day, for the first few days, and the eye thoroughly inspected. [Buller's shield, or a watch-crystal fastened over the sound eye with strips of gauze and collodion, is a more easily managed dressing and permits ready inspection of the eye.—ED.] In infants the application of such a shield is not practicable, nor is it often necessary, as both eyes are usually affected from the beginning.

Treatment.—During the entire course of a gonorrheal conjunctivitis the first duty of the attendant is to keep the conjunctival sac absolutely clean by constant removal of the discharge. To reduce the swelling and inflammation ice-cold compresses are applied at short intervals, the eye being carefully wiped with a pledget of cotton every time the compress is changed. The compresses must be washed in a 1 per cent. solution of potassium permanganate before they are put back on the ice, and the same solution should be used by the surgeon in cleansing the eye at each examination. In the beginning, while the inflammation is at its height, cold compresses should be applied day and night; later, the cleansing process at least must be kept up during the entire night. If the secretion is very abundant, the attendant should separate the lids every quarter of an hour, so as to allow the pus to run off; but in no case is he to wipe the conjunctival sac. That duty must be performed by the surgeon himself, from one to three times a day or oftener, as the severity of the process demands. [As collyria in purulent ophthalmia the Editor prefers a saturated boric-acid solution, or mercuric chlorid, 1 : 8000, or formaldehyd, 1 : 6000. He has also had excellent results with potassium-permanganate solution (1 : 2000) used in copious irrigations— $\frac{1}{2}$ liter at a time. Vaseline rubbed on the lids and introduced into the conjunctival sac is of great advantage. Recently, protargol and argonin have been advocated in place of silver nitrate in purulent ophthalmia. They may be used in from 2 to 5 per cent. solutions.

Silver nitrate is the best remedy for checking the secretion. As a strong caustic solution would endanger the

Plate 13.

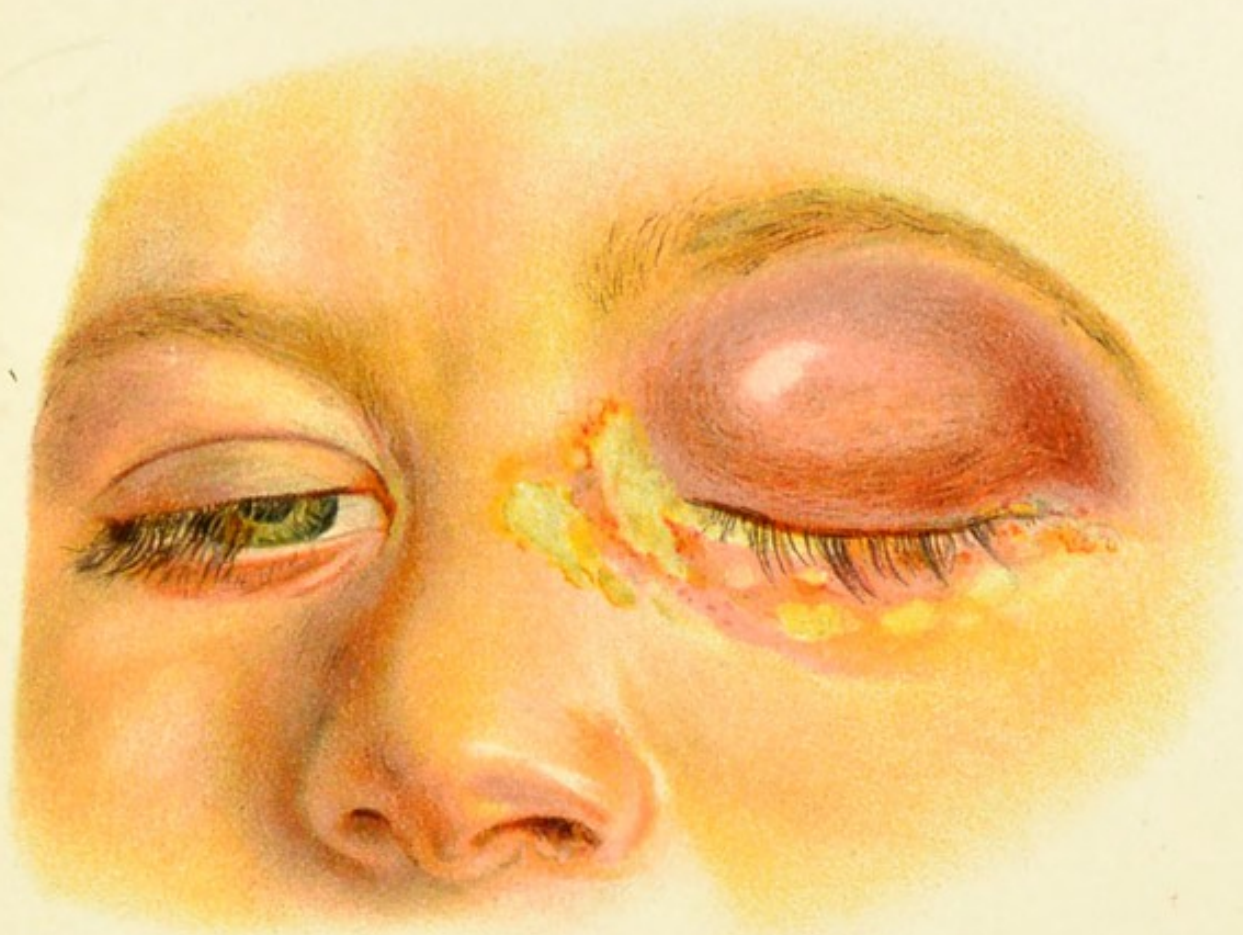a. **Diphtheritic conjunctivitis** in a small boy. This picture shows a higher degree of inflammatory swelling and injection of the conjunctiva than the last. The skin of the lower lid and the region about the inner canthus are infiltrated and eroded in places by the purulent discharge.

b. The everted upper lid of the same patient, showing the deep diphtheritic infiltration of the conjunctiva, which is of a yellowish-gray color.

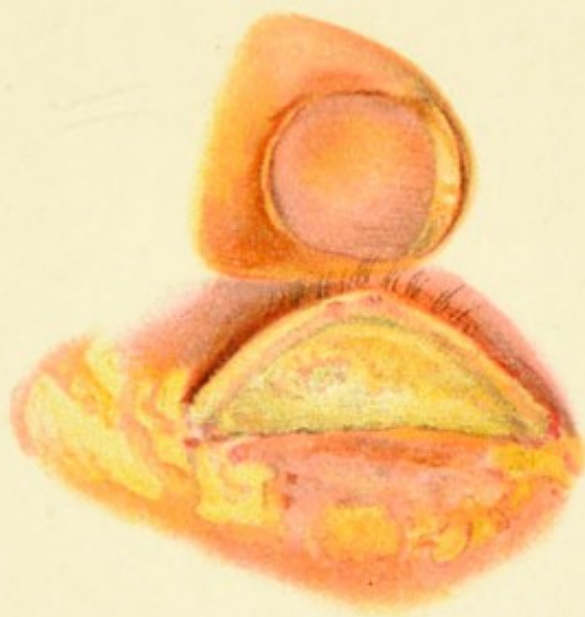
vitality of the cornea, a 2 per cent. solution is usually employed; but in neglected cases, in which the swelling of the conjunctiva is unusually great, it may be necessary to use the solid stick. The more active the purulent secretion the more frequent should be the applications; in adults two brushings a day may be needed; in fact, the nitrate should be applied as soon as the eschar has separated, and that, in turn, depends on the amount of discharge. The important point to be remembered in cauterizing the conjunctiva is that it must not be practised until there is a free discharge of pus; in other words, not before the second or gonorrheal stage. As long as the conjunctiva is tense and swollen and there are fibrinous deposits and discolored areas cauterization is harmful.

When the silver nitrate is to be applied, the child is made to assume the position described on p. 24. Each lid, in infants and adults, is to be everted separately and thoroughly painted with the solution, but in such a way as to avoid contact with the cornea. The retrotarsal folds, which are always the seat of greatest swelling, should receive special attention. After the desired eschar is formed, the excess of nitrate is to be washed away with water, or, if the mitigated stick has been used, with a saline solution, to prevent injury to the cornea. Protargol has lately been recommended for this purpose, but its efficacy still remains to be proved.


Ulceration of the cornea is not a contraindication for silver nitrate; on the contrary, it is then the only available remedy and must be applied with all the more thoroughness. The conjunctival sac should be carefully freed



a



b



from adherent particles of secretion before silver nitrate is applied.

In adults it is advisable in severe cases to divide the outer canthus by a horizontal incision with scissors. It facilitates eversion of the lid, allows the conjunctival sac to be cleansed more readily, and relieves the pressure on the bulb which is so dangerous to the cornea.

4. Diphtheritic Conjunctivitis.

This disease, which is caused by the Löffler bacillus, produces alterations of varying degrees and clinical appearances. In one case the diphtheritic symptoms are most conspicuous—intense inflammation, swelling of the lids, deep infiltration of the conjunctiva (Plate 13, *b*), producing a grayish-yellow discoloration and followed by partial necrosis. Another case may simulate the *croupous form* of inflammation: the exudation is superficial and leads to the formation of a grayish-white or yellowish, fibrinous membrane containing few cellular elements, which is detached with more or less difficulty and reappears again and again for several days, without inflicting any more serious injury on the mucous membrane than a slight bleeding. The false membrane usually does not extend over the bulbar conjunctiva. The clinical picture in both the croupous and the diphtheritic forms varies widely according to the extent and intensity of the process.

In severe diphtheritic conjunctivitis the infiltration involves the bulbar conjunctiva and may threaten the cornea; the danger to vision in such cases is very great, total blindness often resulting from sloughing of the cornea. Sometimes the skin of the adjacent area shows diphtheritic symptoms (Plate 13), the neighboring lymph-glands are swollen, and there is general prostration with fever. The necrosis may be so extensive that the conjunctiva looks like a piece of yellow rubber. In the course of ten to fourteen days the diphtheritic inflammation undergoes

resolution, the secretions of blood and serum give place to a more and more purulent discharge, the ulcers in the conjunctiva heal, and the resulting cicatricial contraction may produce entropion. The greater the intensity of the diphtheritic or croupous inflammation the more abundant the discharge of pus in the second stage, so that the latter is sometimes spoken of as the gonorrheal stage.

Diagnosis.—Now that the diphtheria-bacillus is known, the diagnosis presents less difficulties than formerly. The diphtheritic nature of croupous conjunctivitis, first demonstrated by bacteriologic methods, is clinically confirmed by the observation that simple laryngeal diphtheria may be contracted from a patient suffering from diphtheritic conjunctivitis. In addition, bacteriology teaches us that other pathogenic microorganisms, such as *staphylococci*, *pneumococci*, and especially *streptococci*, are capable of producing both the superficial, pseudomembranous, and the deep, necrotic form of conjunctivitis. Staphylococci and streptococci are nearly always found associated with the diphtheritic bacillus. The Ernst-Neisser method of staining affords the readiest means of testing the virulence of the bacilli found. The fact that fibrinous deposits and suspicious areas are sometimes seen in gonorrheal conjunctivitis renders a bacteriologic examination imperative.

The **prognosis** depends on the severity of the inflammatory process. It is materially better since the introduction of diphtheria-antitoxin, except when streptococci form the principal exciting cause, as these microorganisms appear to be specially dangerous to the cornea. If extensive sloughing of the cornea has set in, even antitoxin is unable to stay the process.

Treatment.—Subcutaneous injections of Behring's diphtheria-antitoxin should be practised as early as possible. In light cases scrupulous cleanliness is usually all that is needed. In the gonorrheal stage painting with a 1-2 per cent. solution of silver nitrate is indicated. Cold compresses may be used with some advantage in the

initial stages ; in the infiltrative form hot applications are more suitable. As the disease is extremely infectious the patient must be kept in strict isolation.

5. Trachoma (Granular Conjunctivitis).

This disease, which is also known as *Egyptian* or *granular ophthalmia*, arises by infection, the acute form, characterized by the presence of a more or less purulent secretion, being particularly contagious. For this reason both eyes are usually affected. The disease often lasts for years ; in the chronic form, which is the most common by far, there is little or no secretion.

Trachoma is often so insidious in its onset that it escapes detection for a long time. When it is well established the palpebral conjunctiva and retrotarsal folds become uniformly swollen and present a rough, uneven appearance.

Two varieties of granulations are distinguished :

1. The so-called *papillary granulations* ; the papillæ which are normally discernible in the tarsal conjunctiva and produce the peculiar velvety appearance seen in all forms of chronic catarrh, become enormously hypertrophied and form raspberry-like elevations. They are, as a rule, more numerous in the upper than in the lower tarsal conjunctiva.

2. *Follicular granulations*, most abundant in the retro-tarsal folds, forcing their way through the superficial layers of the mucous membrane in the form of hemispherical, semitransparent bodies of a grayish-pink color, arranged in dense parallel rows and converting the retro-tarsal folds into a thick, unyielding mass. The granulations are less conspicuous in the tarsal conjunctivæ, because they are smaller and less numerous and completely buried in the swollen, papillary mucous membrane ; but even in this situation they may sometimes be seen as small, bright, circular spots of a yellowish color.

A characteristic feature of the disorder is the appear-

Plate 14.

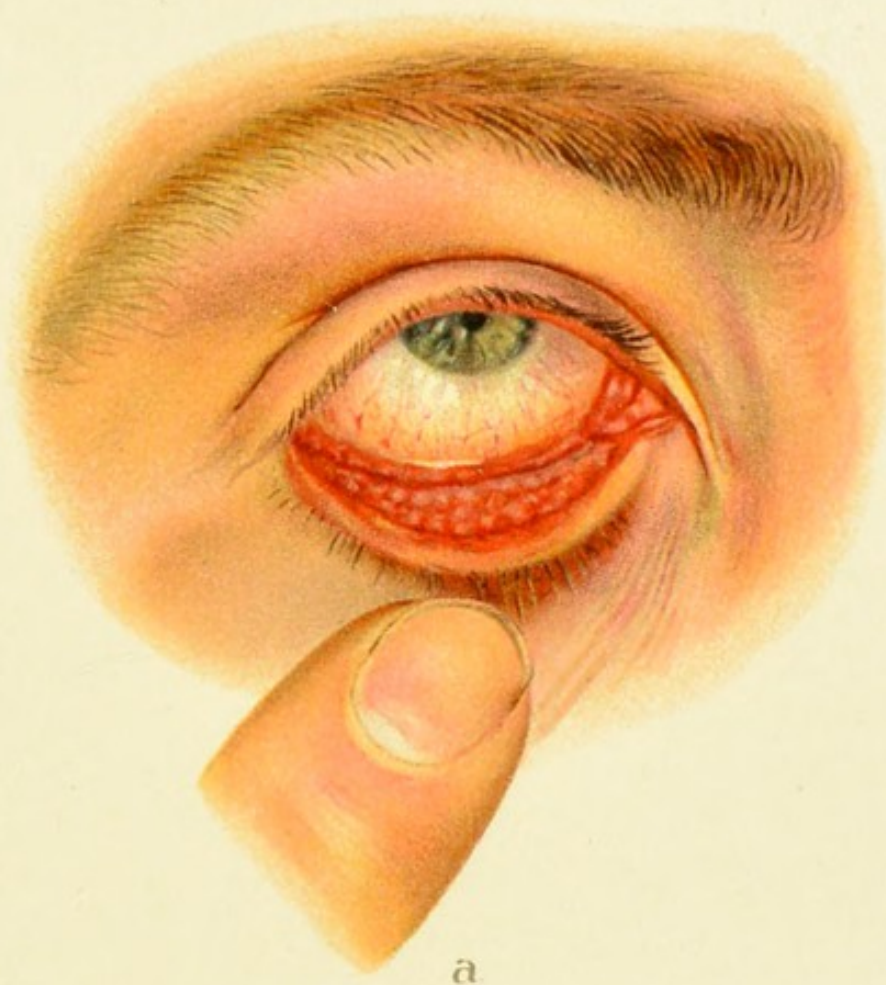
a. Trachoma of the Lower Lid.—Male, aged 24 years. A few granulations are seen in the retrotarsal fold of the upper lid. His occupation (carpentry) obliges him to work in a dusty atmosphere, and no doubt is partly responsible for the disease. We observe the conjunctival injection characteristic of conjunctival catarrh.

b. Subconjunctival Ecchymoses (Hyphæma Conjunctivæ).—The hemorrhage in this case was caused by a slight injury, but the same symptom sometimes occurs in whooping-cough.

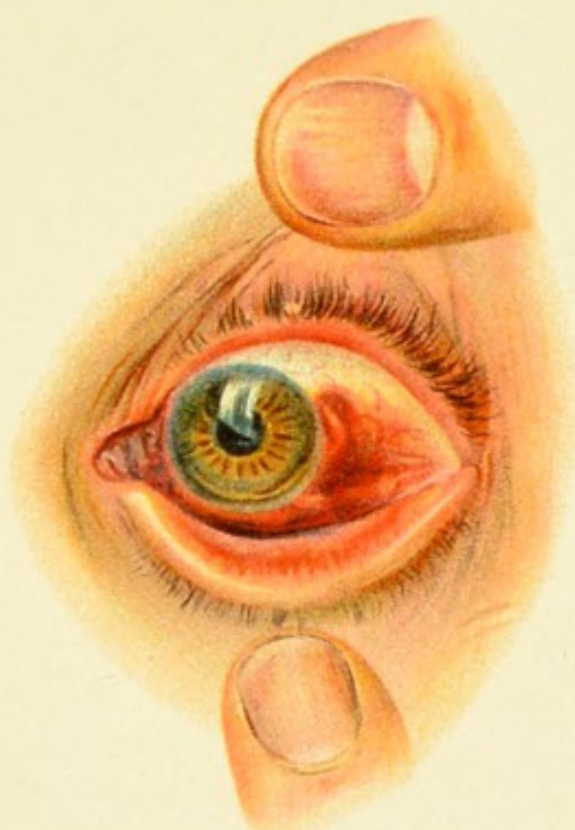ance, in most cases, of the corneal complication known as *pannus* (see Plate 28, *a*). This consists of a grayish-pink, granular deposit of vascular tissue, which usually begins at the upper margin of the cornea and gradually extends downward to end in a fairly well-defined horizontal boundary. The blood-vessels forming the pannus communicate with the conjunctival vessels and form a venous plexus in the cellular tissue of the deposit, which during the greater part of the process is limited to the space between the corneal epithelium and Bowman's membrane, but may in the later stages penetrate more deeply. Pannus is in every respect analogous to trachomatous disease of the conjunctiva, and is therefore more than a simple mechanical irritation due to friction of the granulations. It may cause more or less visual disturbance, or even total blindness.

Cicatrization is a conspicuous feature of the last stages of trachoma. As the retrotarsal folds regain their normal thickness, the mucous membrane covering them contracts as it is gradually converted into connective tissue, and a network of grayish-white scar-lines makes its appearance on the tarsal conjunctiva. These cicatricial changes and the atrophy which occurs in the tarsal plates give rise to *entropion*, and the friction of the cilia on the cornea in turn aggravates the pannus, so that *ulceration of the cornea* not infrequently results.

Trachoma is a veritable curse to the countries where the disease is endemic; its victims suffer for years and



a



b



are usually incapacitated for work most of the time ; many of them become blind.

Fortunately, its geographical distribution is limited. It occurs most frequently in Arabia and in Egypt ; in Europe the inhabitants of low-lying regions (Belgium, Holland, Hungary, the countries bordering on the lower Danube, and Italy) suffer most, the higher regions being exempt from the disease. The poorer classes are usually attacked.

The subjective symptoms are essentially the same as those of catarrh. Ptosis is a more or less constant symptom in the early stages and gives the patient a characteristic appearance. As the cornea becomes involved the discomfort of the patient increases, and if the pannus invades the pupil, vision is affected.

The **course** varies widely, according to the severity of the process and its tendency to acute exacerbations or chronicity ; the most unpleasant feature is the constant occurrence of relapses, even after recovery seems to be established, although they are partly due to the patient's neglect in abandoning the treatment too soon. In some cases papillary granulations are more conspicuous ; in others the follicular type preponderates ; in a third class of cases the two forms are found associated. During the last stages cicatricial trachoma and its disastrous sequelæ are often observed. The latter include entropion, trichiasis, xerosis of the conjunctiva, connective-tissue change of the cornea, and, finally, a general devastation of the conjunctival cul-de-sac by symblepharon. On the other hand, the pannus may disappear under appropriate treatment, and regeneration of the conjunctiva take place if cicatrization has not been too extensive.

The **cause** of trachoma is a specific poison, the exact nature of which we do not know as yet, although specific microorganisms of trachoma have been described by more than one observer. Certain external conditions, such as crowded quarters, poverty, bad air, and a low altitude, undoubtedly tend to foster the disorder. An interesting fact in connection with the relation of trachoma to alti-

tude is that the inhabitants of Switzerland have so far escaped infection, although numbers of Italian laborers suffering from the disease come into the country every year and live in tolerable proximity to the natives. It has also been observed that recovery from the disease is hastened by sojourn in the mountainous regions of Switzerland and the Caucasus. [According to Burnett, trachoma may occur at an altitude of 4700 feet. Van Millengen denies the influence of altitude and the immunity of certain races. Nevertheless the disease is almost unknown in pure negroes.—ED.]

The **diagnosis** in the initial stage is often very difficult; indeed, it may be impossible at first to distinguish the disease from follicular conjunctivitis. Generally speaking, the granulations in trachoma are most numerous in the upper retrotarsal fold, which, like its fellow behind the lower lid, soon becomes thickened and assumes a reddish-yellow tint. Sometimes trachoma is confounded with spring-conjunctivitis, although it has nothing whatever in common with that disorder. In spring-conjunctivitis the nodules are more flattened than in trachoma, and slightly pedunculated, while the rest of the tarsal conjunctiva is covered with a peculiar milky film. If, in addition, the characteristic proliferations about the corneal margin are present, the distinction is easily made; moreover, there are no granulations in spring-conjunctivitis. Acute trachoma may be mistaken for gonorrheal conjunctivitis.

Prognosis.—It follows from what has been said that the prognosis is exceedingly grave; at least in respect to a speedy recovery, especially if the patient is not in good circumstances and unable to follow the protracted course of treatment necessary to effect a cure.

Treatment.—As the disease is a long and tedious one, the treatment must be proportionately assiduous. It may be divided into three methods: Local medication, mechanical treatment, and operative procedures. Recovery

is materially assisted by favorable external conditions, especially pure air, if possible in a mountainous region.

Among local remedies silver nitrate in 2 per cent. solution, and copper sulphate, in the form of a stick or a crystal (the end of which has been rounded off by rubbing it on a wet cloth), or in the form of an ointment, are recommended. Both remedies are usually applied once a day; in severe inflammation with active secretion silver nitrate is imperatively demanded. (The greater the secretion the more energetically the nitrate should be applied.) After the discharge has ceased, treatment with copper-sulphate crystal is to be begun and continued for months or even years. The conjunctiva is carefully gone over with the crystal as often as once a day at first, later at longer intervals, until the swelling has entirely subsided and the mucous membrane appears white and smooth. Later on the patient may be directed to paint his eyes himself with an amylo-glycerin salve containing $\frac{1}{2}$ –1 per cent. copper sulphate. Some patients even learn to use the crystal. [Excellent applications which may be used at home are tannin and glycerin (5 per cent.), or boroglycerid (20 per cent.).—ED.] If a relapse occurs, with renewed secretion, the silver-nitrate solution is again resorted to, unless the irritation is too great, in which case a weak sublimate solution may be substituted. A few drops are instilled into the conjunctival sac and wet compresses applied to allay the inflammation.

The granulations are best removed by mechanical means: By picking them out one by one with a needle and expressing their contents between the thumb-nails, or by squeezing them out with Knapp's roller-forceps. They may also be destroyed with the galvanocautery. Keining's method of brushing the granulations daily with a 1 : 2000 sublimate solution combines mechanical removal with medicinal action. Excision of the diseased retro-tarsal folds is apt to be followed by grave cicatricial changes in the conjunctiva and is not to be recommended.

On the other hand, the deformities of the lids which often result must be corrected by surgical means.

Pannus usually requires no special treatment. If the vascular tissue is unusually thick, cauterization may be practised with great care. If ulcers develop in the cornea, copper sulphate must be used instead of silver nitrate [and the treatment suitable for corneal ulcer instituted.—ED.]. The patient and his attendants should be duly impressed with the importance of observing proper precautions against the spread of the disease. If possible the patient should be isolated, especially if the disease appears in large bodies of men, as in an army.

6. Spring-conjunctivitis (Fruehjahr's Catarrh).

Spring-catarrh is the only process in the human body, with the exception of freckles, that is exclusively dependent on atmospheric heat, so much so that it does not attain its full development in cool seasons. It is a diffuse inflammation, involving the entire conjunctiva, although localized deposits are sometimes observed.

The disease is quite rare in some localities, and occurs most frequently in young men, giving them a strikingly pale and languid appearance and often lasting for years. Owing to the slight degree of ptosis which is usually present the patients have the same dull, sleepy look that is seen in trachoma.

One characteristic symptom is a peculiar yellowish-red discoloration of the conjunctiva on either side of the cornea (Plate 15, *d*). The remaining objective phenomena may be divided into three groups:

1. *Hypertrophy* at the sclerocorneal junction, consisting of smooth, semitransparent nodules, of pinkish color and waxy appearance, found chiefly on either side of the cornea, but occasionally encroaching on the upper and lower segments of the limbus (Plate 15, *a* and *d*). These nodules never undergo degeneration.

2. The so-called *tessellated* or *pavement-granulations* on the tarsal conjunctiva (so called on account of their resem-

blance to street-pavement). They consist of hard, flattened masses, pinkish in color, and upon close inspection are seen to be slightly pedunculated (Plate 15, *b*). The surface of these granulations often exhibits a bluish tint, which may extend over the rest of the tarsal conjunctiva, constituting the third symptom, viz.:

3. *Milky opacity*, in some places like a delicate cauterization-film, in others resembling a plate of smooth, bluish-white enamel (Plate 15, *c*).

These symptoms are not always found associated in every case. Any one of the three groups may be wanting, or they may be present in varying degrees of intensity. The hypertrophied limbus may encroach upon and practically conceal the cornea on all sides; or this symptom may be absent altogether and the granulations on the tarsal conjunctiva may attain such proportions as to cause ulcerations in the cornea by their friction (rarely). In other cases they may be very few in number, scattered here and there in small groups, while the intervening tissue exhibits the milky opacity which has been described.

The limbus-form is often followed by the formation of a small crescentic opacity in the cornea, running parallel to the periphery and resembling a segment of arcus senilis; it often persists for years after the disease has run its course.

A more or less constant symptom is found in the mucous or mucopurulent secretions which collect in threads on the retrotarsal folds and surrounding tissues. This gives rise to some of the symptoms seen in catarrh, as itching, stinging and burning pains, inability to do fine work, and gluing of the lids in the morning. General aggravation of the symptoms usually follows exposure to excessive heat. The disorder appears to be influenced more by heat than by the direct action of the sun, the patients suffering less severely in high altitudes in spite of the greater power of the sun's rays.

The **diagnosis** is based on the state of the weather and the pathologic changes described. The disease is some-

Plate 15.

Spring-conjunctivitis.—*a.* Patient is a robust and otherwise healthy farmer, 24 years old. In winter and during a protracted spell of cool weather in summer the disease practically disappears; moderate amount of secretion. The conjunctiva of the lower lid is covered with a milky film; that of the upper is normal. The tissues about the corneal margin are hypertrophied and encroach to the extent of from 1 to 2 mm. on the membrane.

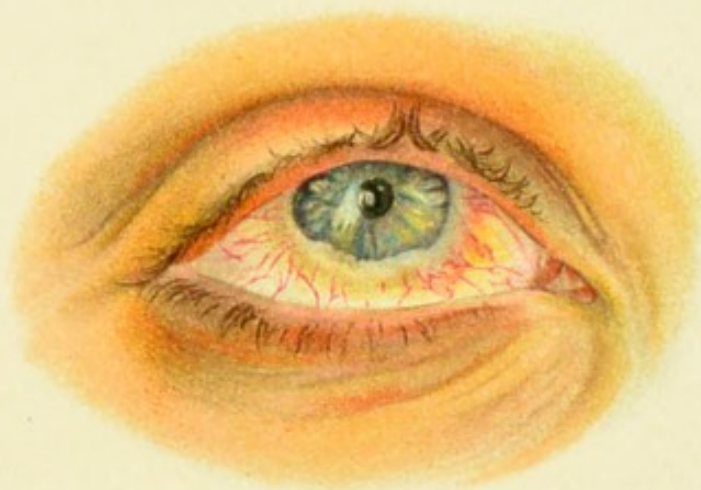b and *c.* Clerk, aged 19 years. For the last three years the inflammation has regularly made its appearance in May, and lasted the entire summer. There are no follicular granulations to be seen anywhere. The right upper lid shows the tessellated appearance of the hypertrophied tissues; on the left lower lid the milky opacity is illustrated.

d. In this patient (male, aged 14 years) the characteristic yellowish injection is clearly seen to the temporal side of the cornea, merging into the marginal hypertrophy, which is also well marked.

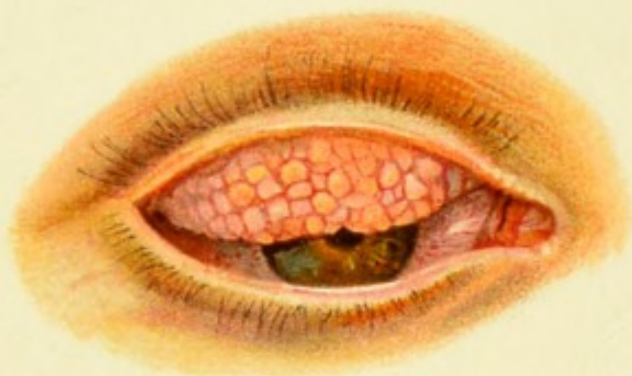times mistaken for trachoma (*q. v.*) and marginal eczema of the cornea (marginal keratitis). The latter can always be recognized by the ensuing ulceration in the cornea. When the disease occurs in elderly people, as it occasionally does, some difficulty may be experienced in distinguishing it from an incipient cancer. Even a microscopic examination of the hyperplastic tissue about the limbus does not always clear up the diagnosis, since the same abnormal preponderance of epithelial elements and tendency to send out long villous processes into the subjacent connective tissue (which also shows marked hypertrophy) are seen in spring-conjunctivitis. Neither granulations nor follicle-formation can be detected with the microscope.

Prognosis.—Two factors combine to render the prognosis unfavorable: Our inability to control the chief exciting cause, the weather, and the want of a specific remedy.

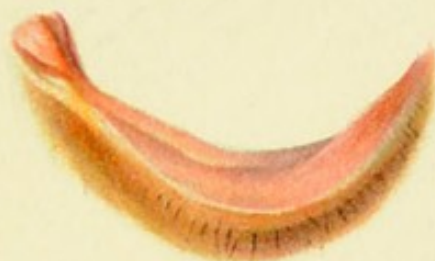Treatment.—Although all kinds of remedies, new and old, have been suggested, the treatment is still essentially palliative. A 1 per cent. lead ointment may be used, providing there is no corneal ulceration. Good results have been obtained in some cases by inunctions and massage with 1–2 per cent. yellow mercuric-oxid ointment, or



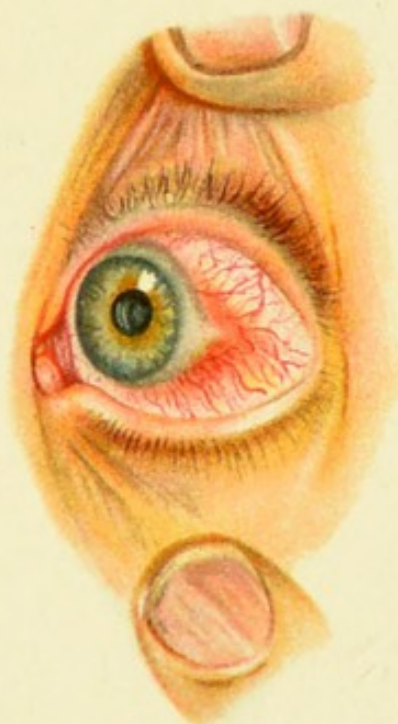a



b



c



d



with dilute acetic acid, 1 drop to 10–20 drops of water, as a collyrium. Relief is sometimes obtained from surgical removal of the larger nodules. [Boroglycerid acts well; the internal administration of arsenic has some repute.—ED.]

B. CIRCUMSCRIBED INFLAMMATIONS OF THE CONJUNCTIVA.

In contradistinction to the confluent forms of inflammation, in which the palpebral conjunctivæ are chiefly involved, we find that in the circumscribed varieties the pupillary region is the principal seat of the lesion. The most important representative of the group is

7. Eczematous, Phlyctenular, or Scrofulous Conjunctivitis.

This is absolutely the commonest form of all inflammations of the conjunctiva, general or circumscribed. Horner gave it the name of eczema. Its dermoid character becomes manifest by the distinct clinical association with eczema of the lids, face, and head, on the one hand, and of the cornea itself, on the other, and by its appearance, in common with all other forms of eczema, in scrofulous subjects. In the absence of a scrofulous habit, some reduced condition of health and nutrition, either from anemia or as a result of measles, scarlatina, pertussis, etc., will usually be recognized as the predisposing cause. The disease occurs most frequently during the scrofulous period—*i. e.*, in childhood; rarely in the first year of life or after puberty. It rarely appears for the first time in adult life, but is sometimes seen in persons who have had an attack in their childhood.

Like other diseases of the eye, phlyctenular conjunctivitis chiefly attacks the ill-fed and ill-kept children of the poor. We find associated with it swollen submaxillary and cervical glands, chronic nasal catarrh and eczema of the nasal mucous membrane, and eczema of the upper lip. [The rhinopharyngeal lesions are always present in

these cases, and if they are not actually the cause of many attacks, certainly aggravate them ; in short, they must be cured if the disease is to be eradicated.—ED.] The lip and the nose eventually become the seat of an unsightly swelling, which combines with the general puffiness of the face to form a characteristic clinical picture in cases of long standing. If the cornea is involved in the infiltrative process, the excessive lachrymation, by its constant irrigation of the lids, produces marginal eczema and, later, spasm and photophobia, on account of which the children hold their dirty hands over their eyes or bury their faces in the pillow and thereby aggravate the condition.

Although *eczema of the conjunctiva* and *corneal eczema* occur together or within a short interval of each other, and are therefore parts of the same process, we shall discuss the two conditions separately, because prognosis and treatment are materially different in the two affections.

Unless the pustules are very numerous, eczema of the conjunctiva does not produce any marked irritation, as the general appearance of the patient shows. Lachrymation may be somewhat excessive, and some photophobia may be present ; but, as a rule, the eye can be opened without much difficulty. If the patient complains of irritation, the cornea must be carefully examined for eczema.

The seat of predilection is the circumcorneal zone, especially the limbus or sclerocorneal junction. This so-called "marginal eczema" [marginal phlyctenular keratitis] is the commonest manifestation of the process in the cornea and in the conjunctiva. The more remote portions of the conjunctiva are less subject to the disease. The retrotarsal folds and tarsal conjunctivæ are exempt or, at most, exhibit catarrhal symptoms.

The size of the pustules is inversely proportional to their number ; usually they measure from 1 to 2 mm. ; but if they are very few in number they may attain twice that size (3 to 4 mm.). Sometimes the pustules are so minute that they can be recognized as elevations only by the disturbance of reflection which they produce ; the

conjunctiva and the cornea look as if they were sprinkled with glass-dust. As each individual pustule, whether large or small, is surrounded by a zone of inflammatory tissue, the appearance in this form—when the pustules are very minute—resembles the red injection and swelling of catarrh, so that the term *eczematous catarrh* is used with great propriety. From the fact that the lids become much swollen and inflamed, these cases are also designated as *catarrh* with swelling. Eczematous catarrh sometimes occurs in combination with a more discrete eruption of larger pustules.

The typical *eczema-pustule* or *phlyctenule* is circular in form, and, when recent, appears as a small, reddish-gray elevation capped with a layer of smooth epithelium. It is surrounded by a zone of marked conjunctival injection. On the second day after its appearance the covering separates and is replaced by a small, circular mass of gray or yellow necrotic tissue (Plates 17 and 18). The yellow spot gradually encroaches on the body of the pustule, so that the larger ones are eventually converted into small round *ulcers*, only slightly raised above the level of the conjunctiva. As the healing process goes on the pustules become more and more flattened, the inflammatory zone contracts, and the site of the ulcer is covered with new epithelium. The disease lasts from one to two weeks and never attacks the sclera.

The cornea is very often affected, either alone or in association with the conjunctiva. In some cases only the cornea is attacked in one eye, and the conjunctiva, without the cornea, in the other. The cornea is most liable to be involved in the multiple form, characterized by the presence of innumerable granular elevations.

As in other parts of the body, the eczema is distinguished by its occurrence in *successive crops*; pustules in all stages of development are seen at the same time with the scars of a former attack.

The corneal eczema may be primary, or secondary to marginal eczema of the conjunctiva. The secondary form

is observed as a (1) simple marginal irritation, to be discussed later; (2) the excavated or funnel-shaped ulcer; (3) fascicular keratitis; (4) phlyctenular (eczematous) marginal pannus; and (5) marginal ring-ulcer (annular ulcer).

Eczema of the conjunctiva causes little discomfort, as the general appearance of the patient shows; he usually seeks relief for a slight stinging-pain during the eruptive stage and the feeling as if the eye contained a foreign body; occasionally the lids are glued together in the morning.

The **diagnosis** is readily made if it is borne in mind that eczema preferably attacks young subjects, while carcinoma, which in its initial stage resembles an eczema-pustule and also begins at the corneal margin, occurs only in elderly persons. Another fundamental difference is, that carcinomatous nodules never undergo the rapid degeneration which puts a speedy end to the life of an eczema-pustule. Cancer displays the general characters of a solid growth, and ulceration, if it occurs at all, is delayed a much longer time. Nevertheless I have seen several cases of carcinoma which were at first diagnosed and treated as eczema by the family physician, and the loss of precious time occasioned by this error led to a fatal termination.

Scleritis, which is characterized by the formation of flat, circular elevations from 3 to 5 mm. in diameter, may in its initial stage be confounded with eczema. An old case of scleritis can be recognized by the slate-colored tint of the sclera remaining from an earlier attack, while in recent cases the diagnosis is established by observing that the epithelial covering of the nodules is intact and does not undergo necrotic change. The scleritic focus, moreover, is surrounded by a bluish injection, while in eczema the congestion is of the conjunctival type and is more superficial. Finally, there is much more pain, both spontaneous and on pressure, in scleritis.

A superficial observer might mistake a case of marginal eczema of the conjunctiva for *spring-conjunctivitis*; but

the nodules in the latter disease do not begin to degenerate at the top like eczema-pustules. In doubtful cases it is only necessary to remember that circumscribed eruptions and their ulcers are always approximately *circular* in shape.

The **prognosis** in simple conjunctival eczema is always favorable, whether the pustules be large or small. The disease is never dangerous, although it may occasion a good deal of discomfort if it is protracted. As an index of the scrofulous habit or debilitated condition of the patient, it is always of some significance, because the cornea in such cases may at any time become involved and endanger the integrity of the visual apparatus.

The **treatment** is quite simple. The pustules might with propriety be allowed to heal spontaneously ; but it is better to assist the healing process by dusting the affected areas with powdered calomel, as a more radical cure is thereby effected and the danger of recurrence is reduced to a minimum. For the latter reason the treatment should be continued for two weeks after the ulcers have healed.

Experience has taught the value of the following precautions in the use of calomel as a dusting-powder : It should not be employed if there is a recent corneal lesion or any general irritative condition ; hence it is contraindicated in "catarrh with swelling." The drug must be perfectly pure and as finely powdered as possible by being sifted through a cloth. The applications should be made with a camel's-hair brush (the excess being removed by tapping against the finger), at the same hour every day, either directly on the pustule or on the lower retrotarsal fold. If the patient is taking large doses of potassium iodid at the time of treatment calomel is contraindicated, as the caustic effect on the conjunctiva would be too great. Iodin is eliminated by the conjunctiva as by other mucous membranes—that of the nose, for instance (hence potassium-iodid catarrh of the conjunctiva, nose, etc.)—and combines with calomel to form iodids of mercury, which act as severe caustics. I have seen eschars due to this chemical

reaction as thick as a diphtheritic membrane covering the entire conjunctiva.

If eczema is complicated with severe catarrh, the secretion must be controlled by painting the conjunctiva with a 1-2 per cent. solution of silver nitrate before calomel is applied ; but if there is much inflammatory swelling, the irritation should first be allayed by the application of hot compresses steeped in lead-water.

Atropin is usually quite unnecessary in conjunctival eczema, as the pain is not severe enough to demand its use [a warm collyrium of boric acid is valuable.—ED.].

The local applications should always be supplemented by general medicinal treatment of the fundamental disease and by tonics to improve the patient's general health. This matter will be referred to again in connection with the treatment of corneal eczema. [In all these cases the rhinopharynx is always more or less diseased and requires assiduous care.—ED.]

Other localized eruptions are rare in the conjunctiva compared with eczema ; we may mention, however, *pemphigus*, *variola*, and *acne*. In rare instances macular and papular *syphilides*, *pityriasis*, *psoriasis*, *ichthyosis*, etc., are met with, usually as forming part of a general process.

8. Pemphigus.

Pemphigus gradually leads to the condition formerly termed "essential shrinking of the conjunctiva." The conjunctival sac in the course of years becomes completely obliterated, the lids are immovably fixed to the eyeball, and the cornea, owing to the loss of nictitation, becomes ulcerated and thrown into folds. Bullæ are rarely seen, owing, probably, to the delicate structure of the membrane ; instead, the conjunctiva is covered with gray patches, deprived of epithelium and covered with a lardaceous secretion, which later are converted into cicatrices, while fresh lesions appear in other situations. In some cases the mucous membrane of the mouth is similarly

affected, or there is pemphigus of the general integument to indicate the nature of the conjunctival lesion.

The prognosis is gloomy, as no effective treatment has as yet been discovered.

9. Variola.

There is grave danger that the pustules about the lower corneal margin may give rise to a secondary corneal affection in the form of marginal ulcers or deep purulent infiltration, resulting in perforation-staphyloma, purulent iridochoroiditis, and panophthalmia. These sequelæ, which are not noticed until the conjunctival disease has subsided, are the most frequent causes of blindness after small-pox.

10. Acne.

Acne may produce nodules about the corneal margin which closely resemble eczema-pustules. The eruption is frequently seen on the cornea of patients the subjects of aggravated acne rosacea. The infiltration resembles that seen in eczema; it is gray in color, slightly raised above the surrounding level, is more persistent, and leaves a more pronounced opacity than the eczema-pustule. I have known it to produce almost complete opacity of both corneæ in the course of years.

11. Scleritis.

In scleritis I have sometimes seen the conjunctiva in the diseased area dotted with a number of round, flat nodules, from 1 to 2 mm. in diameter, which were distinguished from eczema-pustules by the absence of conjunctival congestion and by the fact that they did not degenerate, but persisted for days and weeks and were gradually absorbed. Under the microscope they were seen to consist of masses of growing connective tissue, fairly rich in cellular elements. I have never been able satisfactorily to explain the relation of these nodules to the scleritic process.

Finally, we must include among the circumscribed inflammatory processes in the conjunctiva the various forms of infectious granular tumors, chief among which is

12. Tuberculosis.

Tuberculosis is always chronic, and occurs either independently or in association with lupus of the face. In nearly every case the nature of the disease manifests itself by swelling, and occasionally by cheesy and purulent degeneration of the preauricular and submaxillary lymph-glands. Sometimes the process is purely local, or at least no signs of tuberculosis are found in other organs of the body. In other instances the patient exhibits signs of a general tubercular infection in lungs, lymphatic glands, joints, etc. Occasionally the process begins in the nose and the infection is carried to the eye through the lachrymal duct. In the conjunctiva it appears first as a more or less circumscribed focus of tubercular infiltration, or as a single nodule, or the tubercles are scattered over a larger area. The tuberculous growth is more or less completely enclosed in a capsule of granulation-tissue, which materially increases the extent of the focus; neither tubercular nodules nor bacilli are to be found in the excised growth. These are only found in the deeper layers of the hypertrophied tissue, if they are found at all; the bacilli are never present in large numbers any more than in other forms of chronic tuberculosis.

The tubercles rapidly become cheesy and break down, and the conjunctiva becomes covered with *tuberculous ulcers* with purulent or cheesy floors and surrounded by granulation-tissue. In the intervals between the ulcers, which may be quite numerous if the process becomes extensive, miliary tubercles are occasionally seen, and sometimes true follicles, resembling trachomatous granulations. In protracted cases the entire palpebral conjunctiva of both lids eventually becomes diseased, gradually the process encroaches on the pupillary region, and the

cornea may be completely obscured by the formation of a dense pannus. The scars which sometimes form in the conjunctiva often produce a condition which closely simulates trachoma, especially if both eyes are affected, as occasionally happens.

Pain is usually inconsiderable and depends chiefly on the accompanying catarrh; later, if keratitis develops, the patients may suffer some discomfort.

The **diagnosis** is based on the swelling of the preauricular lymph-gland and on the formation of ulcers with purulent floors, phenomena which do not occur in trachoma. Under certain conditions, if the process is confined to the tarsal region, a round nodule closely resembling a chalazion may be formed on the lid; even Baumgarten once mistook a tubercular nodule in this situation for a chalazion. In doubtful cases the diagnosis should be confirmed by inoculation, if tubercle-bacilli cannot be demonstrated.

The **prognosis** in all cases is very grave, as the growth may recur after the most careful excision. If the focus is very small, a cure may be effected by the radical removal of the proliferations; but if there is general involvement of the conjunctiva and of the lids, it is difficult to arrest the process. In the case of two young men of marked tubercular habit who came to me late in the disease, the sight of both eyes was destroyed; and in another case, that of a young woman, one eye became entirely blind and the other very nearly, in the course of years.

The **treatment** consists in the thorough removal, as far as possible, of the diseased tissues by operative means, and in the application of iodoform. Unfortunately the drug cannot always be brought into close contact with the tuberculous nodules. I have never seen any good results follow the use of either the old or the new (modified) tuberculin preparation; the latter was tried lately in a case with lupus of the face, and neither the tuberculous nor the lupous process showed any improvement. Gen-

Plate 16.

a. **Chaff-particle** at the corneal margin. The patient, a peasant-girl, does not know how long the foreign body has been in the eye, but the vascular development of the cornea shows that it must have been there for some time.

b. **Pterygium** in an elderly man. It has spread over the cornea gradually during the last few months. The obliteration of the plica semilunaris is well shown.

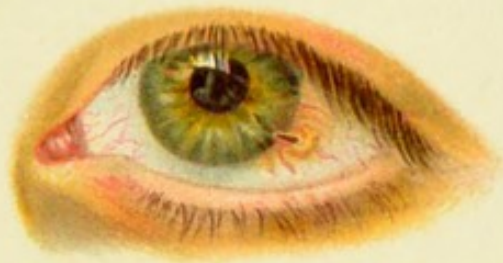eral constitutional remedies should, of course, be added to the local treatment.

13. Syphilomata and Leprosy.

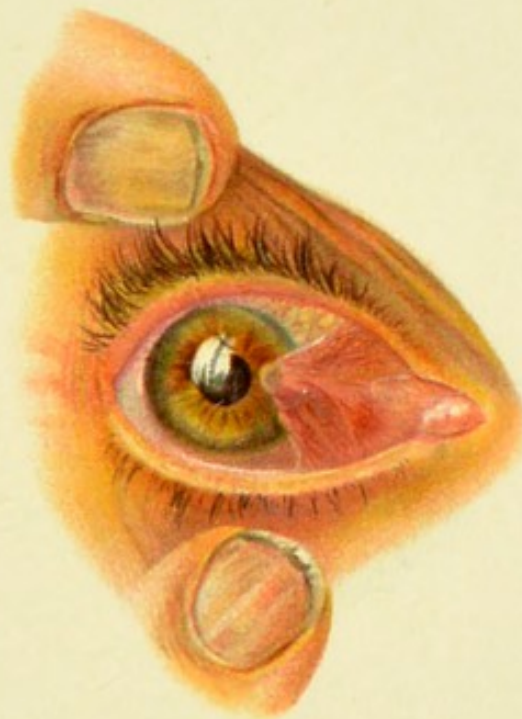
Syphilomata and leprosy are occasionally met with, the former very rarely. In leprosy the region about the corneal margin becomes the seat of yellowish, semitransparent tubercles, with few blood-vessels, which may penetrate into the sclera or spread over the surface of the cornea. The breaking down of the tubercles is followed by extensive tissue-destruction. In addition, the tubercles appear in the iris and produce iritis and cyclitis, which cause further injury to the eye.

INJURIES OF THE CONJUNCTIVA.

1. Foreign bodies are frequently found in the conjunctival sac. A small body usually lodges on the inner surface of the upper lid, near the margin; larger ones often find their way under the upper retrotarsal fold, where they may remain for some time and give rise to granulations and catarrhal secretion. The fold in such cases must be carefully scraped out and cleansed with a probe. Agricultural patients occasionally present themselves with a particle of chaff (Plate 16, *a*) or the wing of an insect firmly embedded near the corneal margin. The concave border of the foreign body is usually directed toward the eye, so that it gets a firm hold of the tissues and often remains for weeks, and may cause new blood-



a



b



vessel formation and even granulations. Sometimes it is found on the cornea itself.

2. Ecchymoses of the conjunctiva (hyphæma conjunctivæ, Plate 14, *b*) are quite common, either as the result of injuries, such as scratches or cut-wounds, or from stasis of the blood during a paroxysm of whooping-cough, or ordinary cough in elderly people with weak vessel-walls. It has been observed especially in persons who are the subjects of marked arteriosclerosis with or without nephritis, and who usually die of apoplexy; hence the phenomenon is significant from a diagnostic point of view. Wounds of the conjunctiva should be closed with sutures as soon as possible.

3. Burns, caused by molten lead or iron, hot ashes, etc., or by acids and alkaline lyes, and particularly by slaked or unslaked lime (mortar), are among the commonest accidents. The usual seats are the lower portion of the conjunctival sac and the lower segment of the cornea (Plate 19). The epithelium is destroyed and the necrotic tissue appears grayish or bluish-white, while the adjacent conjunctiva is intensely swollen and inflamed, and occasionally suffused with blood. Burns on the cornea give rise to similar whitish spots; these soon lose their epithelial covering (Plate 19, *b*), ulcers are formed, and a cicatricial opacity results, which, if situated in the center, may interfere seriously with visual acuity. In the conjunctiva the injury is followed by cicatricial contractions, shortening of the mucous membrane, general shrinking of the conjunctival sac, and the development of *symblepharon*.

In the cornea the eroded area sometimes becomes covered by a process of conjunctiva, forming a so-called *pseudopterygium*.

Treatment.—The ultimate effects of a lime-burn are much more serious than appears at the first glance, and great care is therefore necessary in the treatment. The injured eye must not be washed with water, as such a proceeding would dissolve more of the caustic material and diffuse it over the conjunctival sac. The cleansing is best

Plate 17.

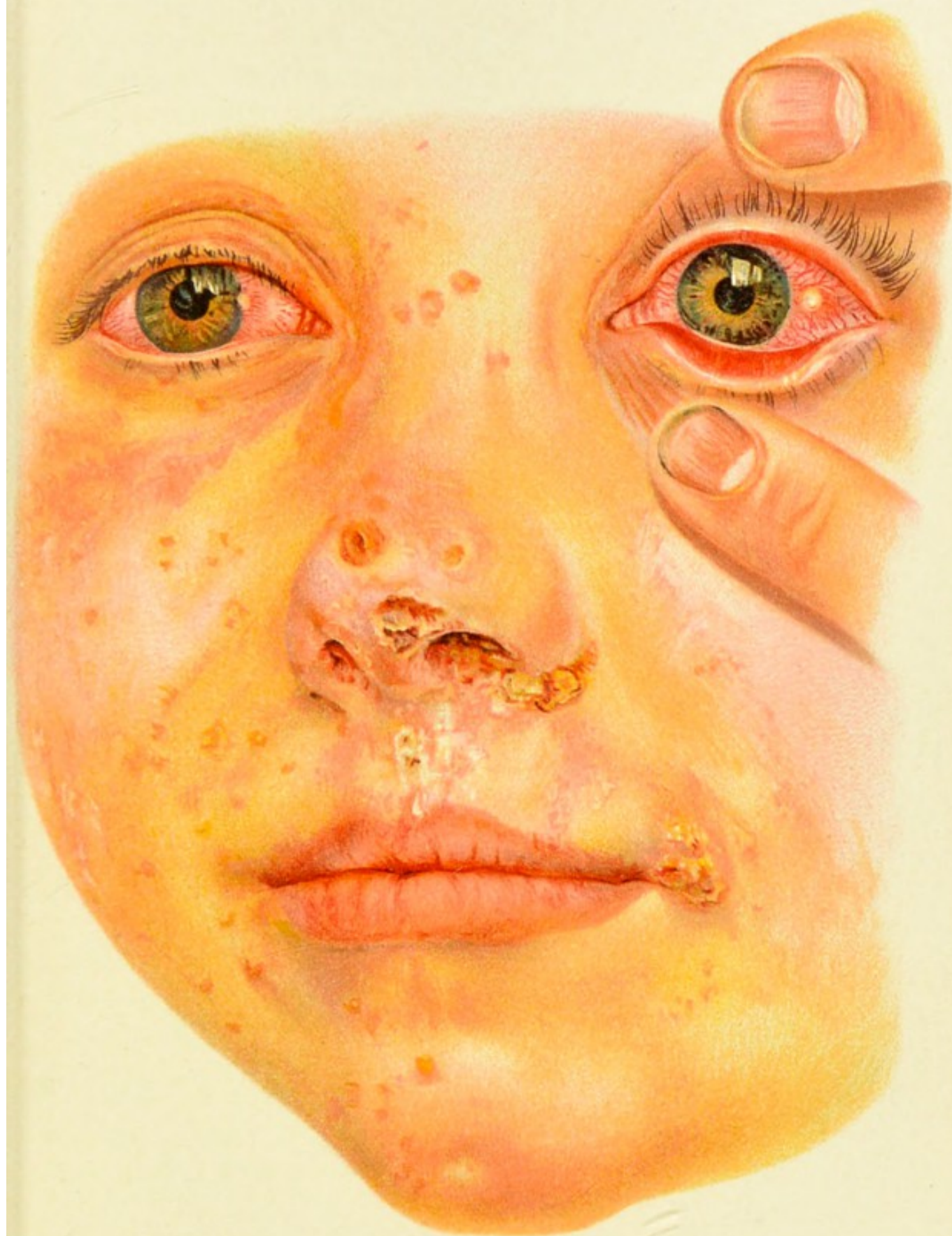Eczema of the Conjunctiva, associated with Severe Eczema of the Face.—An ill-nourished factory-girl, 15 years old, with sallow, puffy face, afflicted with chronic rhinitis, eczema of the nose and face, and eczematous catarrh of both eyes, with considerable secretion. At the nasal border of the cornea, in the right eye, a pustule is seen, situated partly on the conjunctiva and partly on the cornea. In the left eye there is a single pustule on the bulbar conjunctiva, to the temporal side of the cornea, the margin of which is also beset with minute pustules (not seen in the picture). The facial eczema was subjected to suitable treatment, the conjunctiva painted with silver nitrate, and later dusted with calomel. The patient was subjected to diaphoresis. After a two months' course of treatment, which was marked by many relapses, a complete cure was effected without injury to the eyes.

effected with a brush dipped in oil, after which a concentrated solution of sugar, which combines with lime to form an insoluble compound, may be instilled into the eye. If the burn was caused by an acid or by an alkali, use a substance which will neutralize the caustic agent. To allay the pain and isolate the injured tissue as much as possible, vaselin containing 1 per cent. of atropin may be rubbed in; this also has a tendency to prevent adhesions between the lids and bulb. But it is not always possible to prevent the development of symblepharon, and an operation subsequently becomes necessary.

PTERYGIUM.

This anomaly consists of a triangular flap of conjunctiva, which by a very gradual process, lasting months or years, encroaches on the cornea either from the nasal or the temporal side (Plates 16, *b*, and 26, *a*). In severe cases the growth eventually covers the pupil and causes permanent diminution of vision. Wherever the pterygium becomes adherent to the cornea a permanent superficial opacity remains.

The pterygium develops from a *pinguecula*, a yellowish elevation not infrequently seen in elderly people on either the nasal or the temporal side of the cornea. It is often





caused by exposure to wind and dust. The yellow color, which gave origin to the name, is not due to fat, but to hyaline degeneration and an overgrowth of elastic fibers. The mechanism involved in the movement of the pinguecula and adjacent conjunctiva toward the cornea is not well understood.

Two forms of pterygium are distinguished, the *progressive* and the *stationary*. The latter is smooth and light in texture, non-inflammatory, with a flattened, fibrous apex; it gives little pain. The progressive pterygium, on the other hand, is succulent and inflamed; the apex or the entire central border is swollen and grayish-red in color. A large pterygium exerts a good deal of traction on the conjunctiva, so that the semilunar fold is often obliterated (Plate 16, *b*).

The sequelæ of pterygium are conjunctival catarrh, deformity, and eventually diminished vision by obscuration of the pupil or diplopia from motor disturbances in the globe.

The **treatment** consists in operative removal of the growth and reposition of the conjunctiva; cauterization is usually of no avail. The growth, however, is liable to recur even after radical surgical removal.

TUMORS OF THE CONJUNCTIVA.

Benign Tumors.—The commonest form is the *dermoid growth* (Plate 11, *a* and *b*). The cornea is usually involved to a greater extent than the illustrations show. The tumor is always congenital, and chiefly troublesome on account of the deformity it produces. Its usual seat is the external or the inferior margin of the cornea. Structurally it is neither more nor less than a piece of aberrant skin, supplied with hairs and sebaceous and sudorific glands. Associated with it we often find malformation of the lids, iris, etc.

In removing the tumor great care is necessary to avoid making an opening in the cornea.

Plate 18.

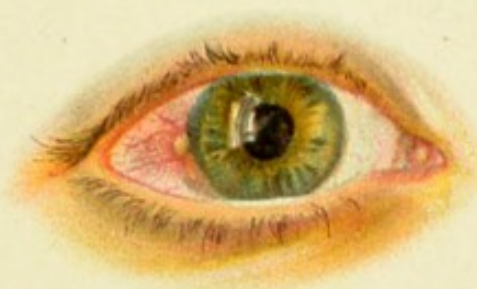a. **Marginal eczema-pustule** in a scrofulous boy, 12 years old ; three days after the beginning of the disease.

b. **Epithelioma involving both cornea and conjunctiva**, in a man, aged 36 years. The tumor has been growing steadily for three years ; but the patient felt no inconvenience until quite recently, when it began to cause itching and stabbing-pains and some diminution of vision. The growth is not painful on pressure. The adjacent portion of the cornea is thick and opaque, its surface rough and uneven ; the rest of the cornea is covered with a cloudy and highly vascular film, so that direct inspection of the eye is impossible. Vision is practically abolished, the movements of the hand being discerned only at a very short distance. Enucleation. Examination shows that the cornea is largely involved, and even the sclera has been attacked by the tumor.

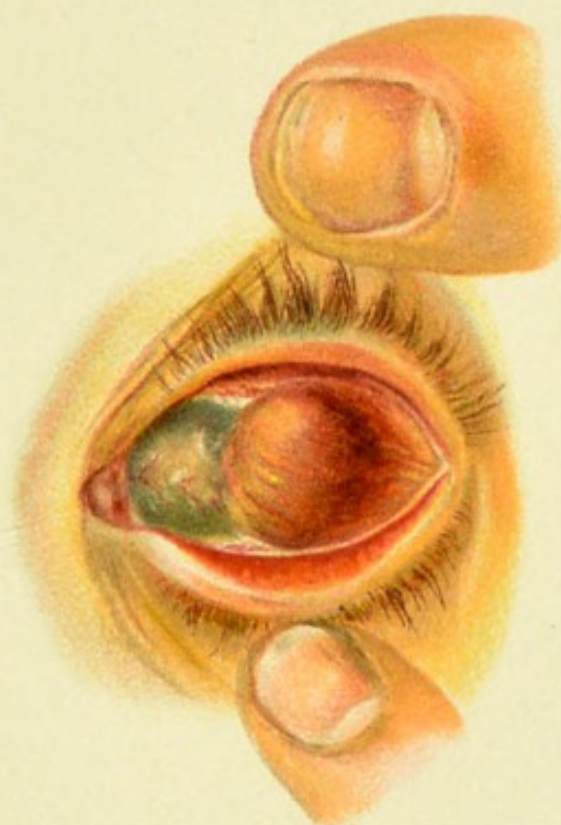
Simple polypi (small fibromas) occur rarely ; their favorite seat is the inner canthus. Papillomata are occasionally seen in the same situation.

Malignant tumors include *carcinoma* (epithelioma) and *sarcoma*. Both tumors preferably begin at the corneal margin. Epithelioma originates as a small, non-pigmented, flat elevation, not unlike an eczema-pustule, which for a long time retains its superficial character, but eventually becomes larger and penetrates more deeply into the subconjunctival tissue (Plate 18, *b*). While cancerous growths are seated on a broad base and tend to spread superficially, the tendency of a sarcoma is rather to grow in height, overhanging the cornea without involving its structure. Sarcoma is usually *pigmented*.

Both carcinoma and sarcoma are exceedingly malignant and demand immediate radical excision, to protect both the eye and the life of the patient. If the tumor is firmly embedded in the tissues of the eye, enucleation is unavoidable.



a



b



DISEASES OF THE CORNEA.

A. DIFFUSE INFLAMMATIONS.

1. Parenchymatous Keratitis (Interstitial or Diffuse Keratitis).

This disease is important, not so much on account of its frequency as of the grave symptoms to which it gives rise. The great majority of cases (90 per cent.) occur in children between the ages of five and sixteen. The course of the disease has been so admirably described by Horner¹ that it seems to us we cannot do better than quote his exact words :

“In these children a faint, gray haze, accompanied by slight ciliary congestion, slowly creeps into the periphery of the cornea. At first it occupies a narrow band along the margin ; but gradually it includes wider portions of the periphery and sends out tongue-like processes toward the center (see Plate 28, *c*), which soon coalesce and cover the entire marginal zone with a cloudy film, leaving only the central portion free. The lids are spasmodically closed, and when we force them apart we observe that the surface of the cornea is cloudy and the epithelium has a steamy, stippled appearance (in rare cases it is puckered into folds), as in cases of increased intraocular pressure. With lateral illumination the stripe-like and net-like opacities are seen to occupy the deeper layers of the membrane. The film gradually advances from all directions toward the center, where it contracts and increases more and more in density, forming a serious obstacle to vision, while *pari passu* the marginal zone begins to regain its transparency. Now the central opacity gradually begins to change, and the surface relaxes and breaks up, showing areas of greater transparency among the gray spots. The vascular changes vary widely during this process of migration. In some cases the centripetal migration is not followed by any pathologic changes in the blood-vessels ;

¹ Horner, “Die Krankheiten des Auges im Kindesalter,” *Handb. der Kinderkrankheiten*, 5 Bd., ii. Abt., p. 320.

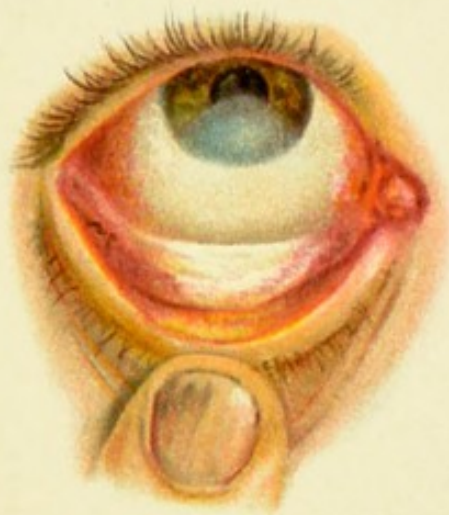Plate 19.

a. Lime-burn of the conjunctiva and cornea, recent, in a boy, 13 years old. The injury was caused by the explosion of a bottle which the patient was filling with water and unslaked lime. The skin of the lids, on the right, shows the marks of glass fragments. The conjunctiva of the upper and lower lid is badly excoriated; also the bulbar conjunctiva below the cornea and the lower segment of the cornea itself, which is dim and bluish-white. Satisfactory cure was obtained with practically normal vision, although a rather dense cicatricial opacity remained about the lower corneal margin and the conjunctiva covering the lower retrotarsal fold was somewhat shortened.

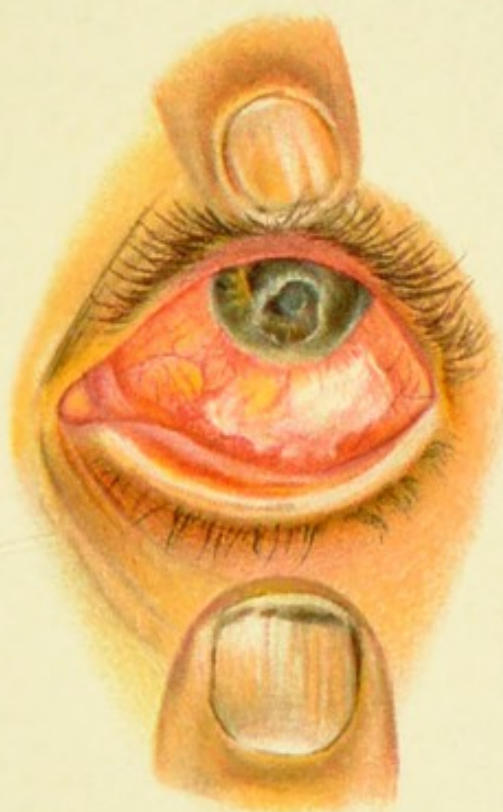b. Lime-burn of the conjunctiva and cornea, of longer standing than the preceding, in a mason, 18 years old. A week ago, while the patient was mixing mortar with lime that had been slaked two days before, some of the material entered the left eye. The eschar is seen in process of separation, and the corresponding spot on the cornea has lost its epithelium and is surrounded by a gray border. The center of the injured spot is slightly depressed from the loss of tissue. Healing was followed by only slight scar-formation and vision was not diminished.

in others a few small vessels appear in the deeper layers of the cornea, but not until some time after the formation of the central opacity. In a few rare cases, however, a very characteristic vessel-formation is observed to accompany the advance of the process from the sclera into the cornea. Short, densely packed blood-vessels, terminating abruptly at the center, appear to push the opacity before them and in a sense constrict the corneal field. These vessels are sometimes so thickly crowded that they look like an ecchymosis.

“The corneal disease does not end with the completion of the centripetal migration and breaking up of the central opacity. Irregular gray spots and nebulæ make their appearance in the substance of the cornea and combine with the resolution of the central opacity to give the membrane a speckled appearance. This secondary stage is sometimes interpreted as a primary corneal lesion, and the special name *keratitis punctata* is given to it. The error is readily explained by the fact that the patients do not



a



b



usually present themselves for treatment until after the centripetal migration is completed.

“When iritis occurs as a complication the precipitates on the posterior lamina of the cornea and the secondary changes in the more anterior portions of the membrane tend to accentuate the punctate appearance of the opacity and thus form another source of error. In about 30 per cent. of all cases of interstitial keratitis the deep structures of the eye become involved early in the course of the disease; but in most cases this complication appears much later. Iritis usually takes the serous form; it is attended with the deposition of heavy precipitates on the posterior lamina of the cornea and ligamentum pectinatum, slight exudation into the pupil, and variable pressure-symptoms—usually subnormal tension. As serous iritis itself is a form of *uveitis*, we are often able, after the center of the cornea has cleared up, to establish the existence of opacities in the vitreous, equatorial foci of chorioiditis, and uveal neuritis; we may find polar and posterior cortical cataract—in short, all the signs of a diffuse morbid process, which from its conspicuous feature has been called diffuse keratitis, but is very often a panophthalmia.

“The disease usually affects both eyes, the second being attacked days, weeks, or even months after its fellow. I myself have been able to establish bilateral involvement in 80 per cent. of my cases, in spite of the obvious fact that the patient hails the appearance of disease in the second eye as a proof of inefficient treatment and seeks advice elsewhere. It is always advisable to predict the probable occurrence of the disorder in the other eye, and to warn the patient that it is very apt to run a slow and tedious course. The most favorable cases last from six to eight weeks; secondary opacities, iritic complications, and their consequences protract the duration of the disease to months and years. Relapses are frequent, even after long intervals of freedom from the disease. These relapses do not, as a rule, exhibit the same character as the original

attack ; the participation of the sclera is more pronounced or a true scleritis develops ; and the corneal haze is not so diffuse, but appears in patches, while the vascular changes in the superficial and deep layers are more irregular."

The ultimate fate of the corneal maculæ varies widely. In some cases transparency is completely regained ; in others, marked by frequent relapses, the center is irremediably obscured by fine, nebular opacities and vision is permanently injured. In almost every case of interstitial keratitis minute vessels can be detected with a loupe and lateral illumination, or with the ophthalmoscope and direct light. They can be seen twenty years after an attack, and may be utilized as a diagnostic sign of syphilis.

The **cause** in two-thirds of the cases is hereditary syphilis, and the classical signs of this condition should always be looked for ; they are : Flat upper jaws, sunken nasal bridge, scars at the angles of the mouth, and Hutchinson's teeth, characterized by diminished size with fairly good enamel and shapely outline, and, usually, wide intervals, especially between the incisors. The central incisors of the upper jaw are wedge-shaped at the expense of the free cutting-surface, which is often marked with a small circular notch. The significance of the deformity is limited to the permanent teeth. We also look for ulcers or scars in the palate, for tissue-destruction of the pillars of the fauces, or adhesions of these structures to the pharyngeal wall. Deafness not infrequently develops in the later stages of the disease ; the cervical glands are enlarged ; there are chronic periostitis of the tibiæ and painless synovial effusions in the knee-joint. Upon inquiring into the family history we learn of a large mortality among the children, and of abortions and stillborn infants. In some cases, if the refracting media are not too much obscured by the opacity, it may be possible, during the healing-stage, to make out minute light or dark blotches on the eyeground, which I have illustrated in my *Atlas of Ophthalmoscopy*, vol. vii. of this series, and which I consider positive signs of hereditary lues. The larger foci of

choroiditis which sometimes appear during the later stages of the disease have no significance.

The **diagnosis** is materially simplified by the fact that parenchymatous keratitis never undergoes ulceration, differing in this respect from eczematous inflammation of the cornea. It is of the highest importance to be able to distinguish the disease from glaucoma, which in rare instances occurs in childhood; an error in this respect might entail fatal consequences. In both diseases there is a faint cloudiness of the cornea; but in keratitis the opacity is irregularly distributed in spots, while the haze of glaucoma is uniform and diffuse, and usually less marked than in keratitis. Definite information can be obtained by testing the tension, if necessary under anesthesia.

Prognosis.—This is unfavorable in so far as we are unable to remove the inflammation or prevent its occurrence in the other eye. The prospect of vision being eventually restored is, however, fairly good, recovery is practically perfect in many cases, and almost always a serviceable degree of visual acuity is regained.

Treatment.—This, in the first place and in all cases, must include a tonic regimen; in the second place, provided they do not interfere with digestion, the milder iodids, and finally the careful use of mercury; the latter drug, however, is not so efficacious as in the inflammations of acquired syphilis. The local treatment in the early stages should consist of atropin and dark glasses to relieve the irritative symptoms. Later hot fomentations are to be applied; and if it is tolerated, after a time yellow oxid of mercury salve may be rubbed into the eye. The oxid can be incorporated with ungt. amylo-glycerin, 0.1–0.2 in 10.0, or with vaselin, 0.2–0.5 in 10.0, applied with a glass rod and well rubbed over the surface of the cornea with the closed lid, once a day or every other day. It may not be borne until late in the disease, but its continued use materially hastens the clearing of the opacity. [In addition to the tonic regimen, which should include cod-liver oil, arsenic, iron, etc., according to the

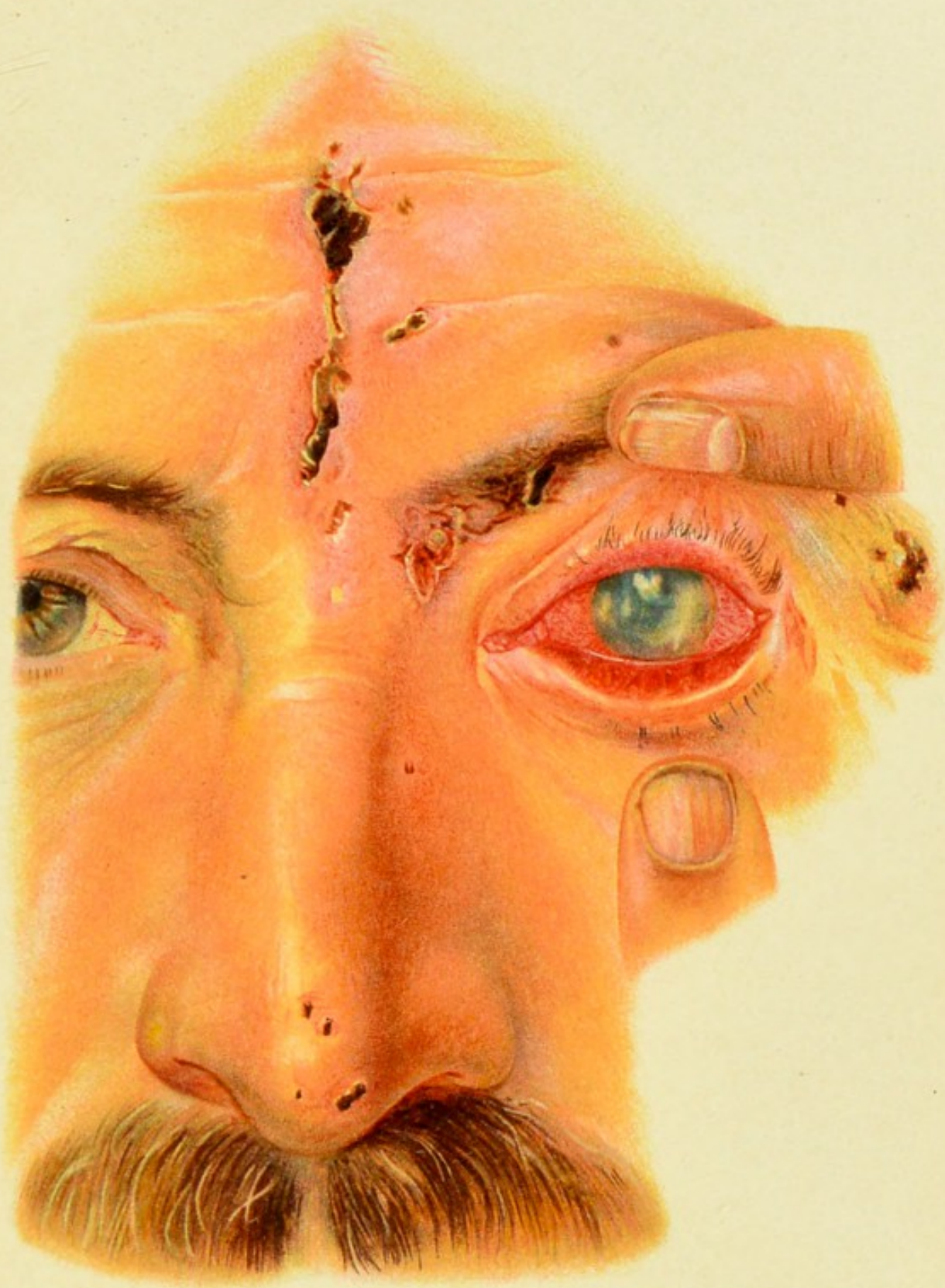Plate 20.

Herpes zoster ophthalmicus, taken on the sixth day of the disease. The patient, a healthy man, of 48 years, at that time complained of pain and the sensation of a foreign body in the left eye. The next day he had a slight chill, followed by nausea and lassitude, so that he went to bed. When he woke up the following morning forehead and nose were covered with an eruption which caused burning pain. The left eye also became violently inflamed and he could not see well with it. The doctor ordered lead-water compresses (a mistake, on account of the corneal affection), whereupon vision became worse. At the time of admission the vesicles had already dried up and formed crusts, as seen in the picture. The lids are somewhat edematous; conjunctiva very red and swollen, and covered with secretion; the entire cornea, with the exception of the periphery, is denuded of epithelium, and where any exists it is grayish-white and opaque. The corneal tissue shows diffuse turbidity, and the pupil, which is moderately dilated, is barely visible. Sensibility is diminished in the distribution of the ophthalmic branch of the fifth nerve and entirely lost in the cornea except at the periphery. Under a bandage the corneal epithelium gradually regenerated in two weeks and the surface cleared somewhat. When the patient was dismissed, six weeks after the beginning of the attack, sensibility had not been restored in the cornea; the surface was uneven, though capable of reflection, but the tissues were obscured by maculæ, so that the pupil was barely visible. In this case the cornea was attacked primarily, at the same time as the skin.

indications, suitable diet, regular exercise, massage, etc., the Editor has much faith in the daily inunction of mercurial ointment, which may be kept up for weeks at a time.]

In rare instances parenchymatous keratitis is met with in *acquired* syphilis, usually in association with iritis. It is somewhat more common in *rheumatic* subjects, forming in such cases part of a general *scleritis*. Portions of the cornea near the scleritic focus become opaque and, in the course of time, as white as the sclera (*sclerotizing keratitis*); the cornea loses its circular outline and appears to be encroached upon by the sclera (Plate 29, *b*). [The disease is also attributed to rachitis, scrofula, malaria, and depressed nutrition. Rarely it may begin *in utero*.—ED.]

Slight injuries may give rise to extensive parenchyma-





tous infiltration of the cornea, which usually disappears rapidly, but occasionally persists for some time and only partially disappears. It is therefore important to observe the greatest care in the treatment of slight injuries, either from scratches or the entrance of foreign bodies; often it may be necessary to use protecting bandages. Deep diffuse infiltration of the cornea may also be caused by iridocyclitis.

B. CIRCUMSCRIBED INFLAMMATIONS OF THE CORNEA.

These forms are more frequent than the diffuse, and the most frequent of them is

2. Eczematous Keratitis,

also called *phlyctenular* or *scrofulous keratitis* [phlyctenular keratoconjunctivitis.] The corneal affection may occur independently or in combination with *eczema of the conjunctiva*, the predisposing causes being the same for both forms.

The pustules vary quite as much in size and number in the *independent* corneal disease as in conjunctival eczema; but here also each individual focus has a distinctly circular contour. The smaller vesicles, which appear as minute grayish elevations and are rapidly converted into small, superficial depressions by the loss of their epithelial covering, heal in from eight to ten days, without causing congestion or leaving any appreciable permanent opacity. The healing of *larger ulcers* takes place much more slowly and involves a greater loss of substance; ulcers with purulent floors are formed; a few thickened blood-vessels appear at the edge of the cornea and gradually work their way toward the ulcer, underneath the epithelium. Unless secondary infection takes place, the ulcer clears up and regenerates under its fresh epithelial covering, as may be seen by its reflective properties and failure to stain with fluorescein. The normal transparency is not completely restored, but a permanent

Plate 21.

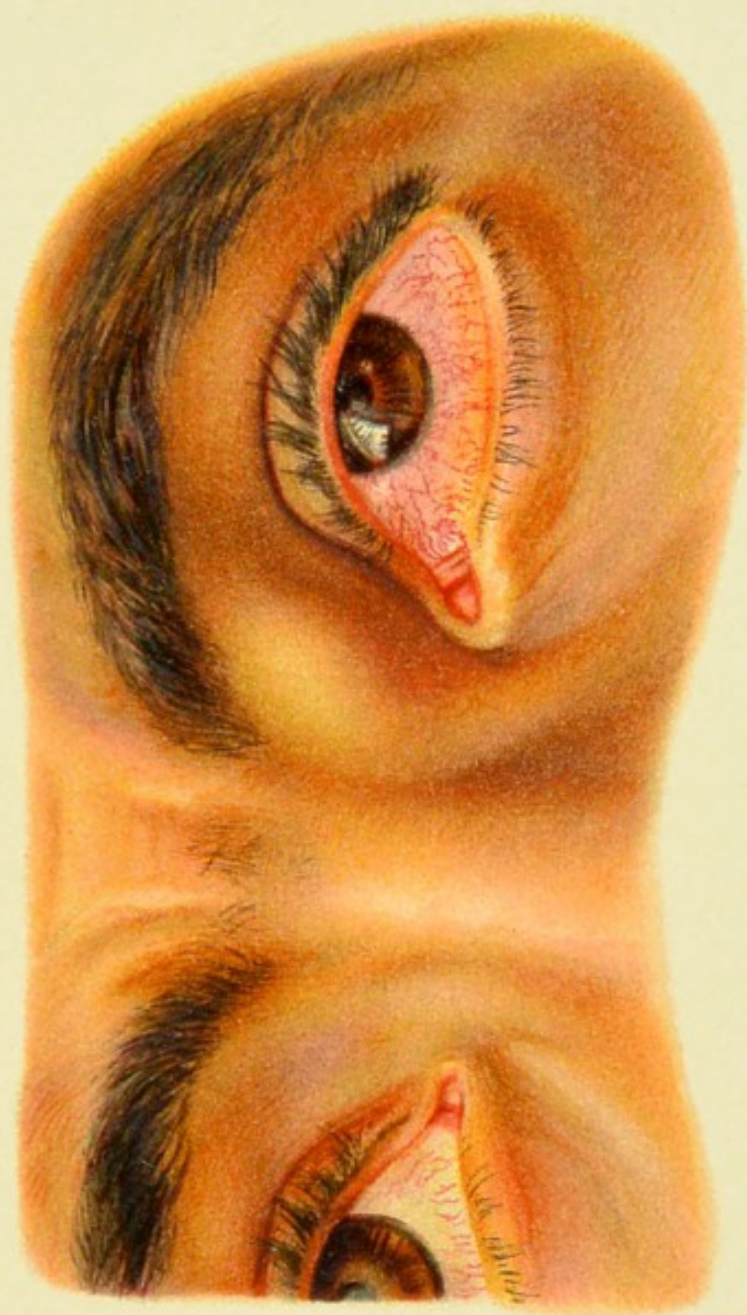Foreign Body on the Cornea and Dermoid Cyst of the Orbit.—An Italian marble-cutter, 18 years old, yesterday received a splinter in his left eye, which appears as a small brown particle surrounded by a yellow infiltration, a little to the temporal side of the center. Patient refuses to have the dermoid cyst removed. The swelling above the left lachrymal sac has existed since childhood, and has increased very little in the last few years.

macula remains, especially after a centrally situated ulcer (Plate 23, *b*); the circular shape indicates its eczematous origin. Large pustules may penetrate deeply into the corneal tissue and eventually cause a perforation, usually after the development of iritis and turbidity in the anterior chamber. Large single ulcers near the corneal margin are more apt to perforate than central ulcers. Perforation is usually followed by attachment of the iris to the wound, where it becomes incarcerated in the healing process (Plate 23, *a*).

If the perforation is very large the iris is apt to slip through the opening (*prolapse of the iris*), and if there is extensive purulent infiltration from secondary infection, the corneal tissues may break down and a *staphyloma* result. This is formed as follows: The iris which closes the perforation, although reinforced by granulation- and scar-tissue, is unable to withstand the intraocular pressure, which is usually increased by secondary glaucoma, and gradually bulges forward. In a few weeks or months the staphyloma is completed—a hemispherical, grayish-white or bluish protrusion, which causes a marked deformity. Vision is usually destroyed much earlier.

If the disease is protracted and the eruptions constantly recur, accompanied by vascularization, so-called *eczematous* or *scrofulous pannus* (Plate 22) results. Numerous superficial blood-vessels unite with new and old foci and their maculæ to form a grayish-red coating over the face of the cornea and, of course, interfere greatly with vision. If the condition persists for any length of time an extensive

Tab. 21.





opacity may result and cause permanent diminution of visual acuity.

Corneal eczema very often occurs secondarily to eczema of the conjunctiva. Pustules appear directly on the corneoscleral junction, partly on the cornea and partly on the conjunctiva. The adjacent corneal area becomes cloudy, and a few blood-vessels make their appearance. This is the so-called *marginal keratitis*. If the marginal phlyctenulæ are large (1.5–2 mm.) the corneal half is often converted into a *deep* (excavated) ulcer, with strong tendency to perforation (Plate 23, *a*); or the phlyctenular ulcer may leave the periphery and creep toward the center of the cornea, forming the so-called *migratory pustule* or *fascicular keratitis*. The mechanism of this process is not well understood. Most cases do not come under observation until after the process is completed, weeks or months after the beginning of the inflammation, when the following picture is seen: A bundle of minute blood-vessels, from 1 to 2 mm. broad, extends from some portion of the periphery toward the center of the cornea, running beneath the surface in a straight or slightly curved line and terminating in a crescentic, grayish elevation. When the process is kept under observation for some time the blood-vessels appear to push before them the crescentic infiltration in which they end; the latter gradually wanders toward the center or across the face of the cornea, between the center and the periphery, its convex border presenting toward the center. The process is attended with severe irritation and blepharospasm; children evince a constant desire to bury their heads in pillows or creep into dark corners. Whenever the disease is seen at its inception, the original cause is always found to be a marginal pustule. Occasionally several fasciculæ are seen in the same cornea, or one in each eye. The entire course of the fascicular keratitis across the cornea is marked by a stripe-like opacity, which remains for years as evidence of the disease, and usually produces permanent diminution of vision, as it preferably affects the pupillary region.

Plate 22.

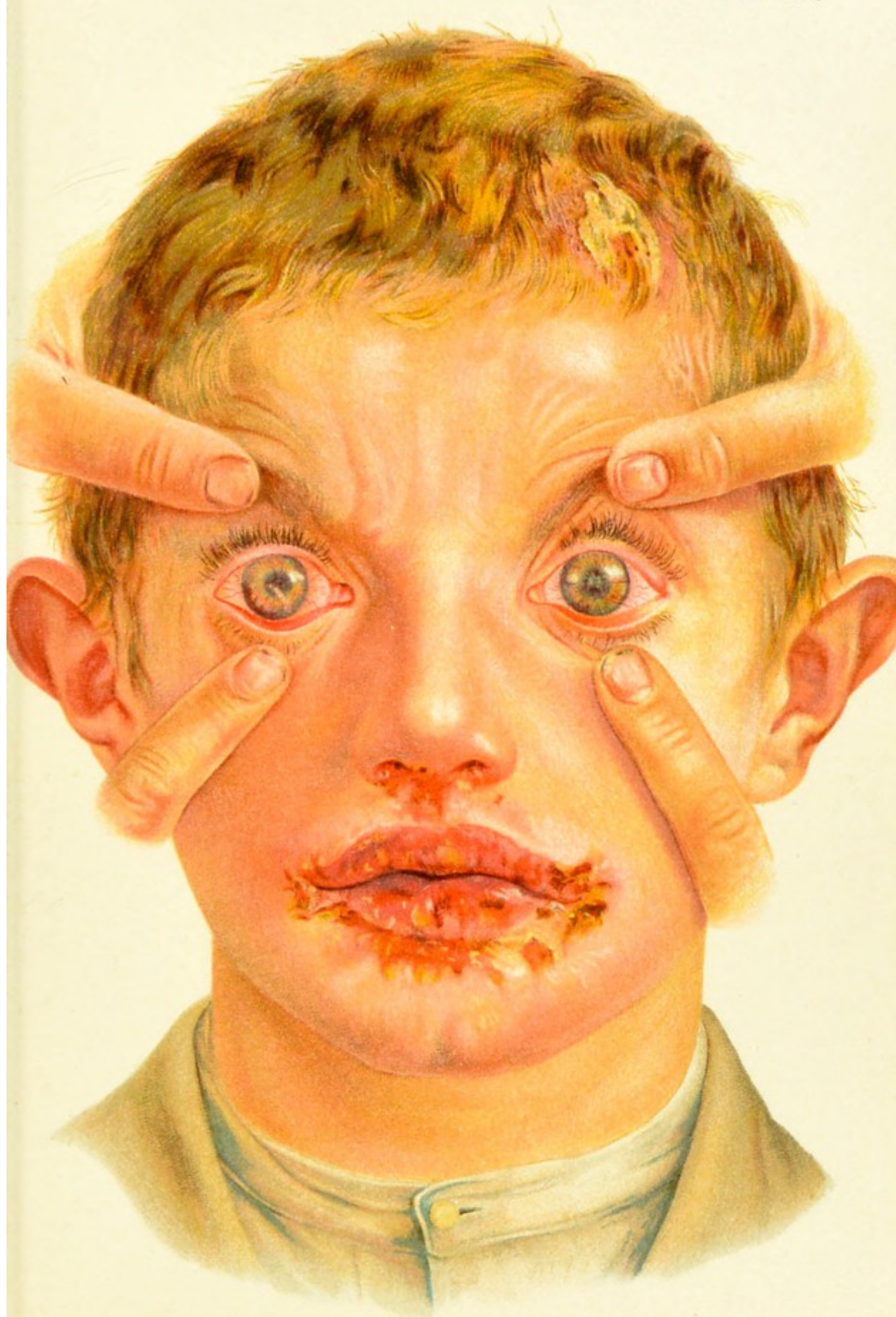Eczema of the Cornea and Conjunctiva on Both Sides, with Eczema of the Hairy Scalp, Nose, and Mouth.—The patient, a delicate, undersized boy of 11 years, very pale, has suffered from inflamed eyes for the past two years. There is conjunctivitis of both eyes, with copious secretion and eczematous pannus over both corneæ, which are covered with infiltrates of various sizes, fresh pustules, and macules of long standing. A recent pustule is to be seen in the nasal half of the cornea in the left eye; in the right eye a crescentic opacity in the lower segment betrays the former occurrence of fascicular keratitis. The cutaneous eczema proves the common origin of the various manifestations.

Marginal phlyctenulæ sometimes lead to the development of eczematous, marginal pannus, or, which is worse, to a long marginal ulcer, by the coalescence of several adjacent pustules. The adjacent portions of the cornea become the seat of extensive infiltration, and perforation is very apt to result.

While in the conjunctiva the process is attended with only a moderate degree of irritation, eczema of the cornea gives rise to marked subjective symptoms, pain, a feeling of grittiness, as if the eye contained a foreign body, difficulty in opening the lids, or even blepharospasm, and excessive lachrymation. Vision is affected as soon as the process invades the pupillary region.

Diagnosis.—The circular shape of the individual pustules and the presence of eczema in other parts of the body are the chief diagnostic points (Plate 22). In addition much information may be gained by observing the ciliary congestion and the reflecting properties of the corneal surface. If many old and recent opacities are present, associated with pronounced vascularization, the picture of parenchymatous keratitis may be simulated. The latter condition, however, is never productive of tissue-destruction, and the circular opacities which sometimes develop in the later stages are less sharply defined than are the maculæ of eczema, which, in addition, are characterized by a constant central depression.

The **prognosis** is influenced by the unfortunate ten-





dency to relapses, which threaten to protract the disease indefinitely. If a large pustule develops in the center of the pupil, permanent impairment of vision is the unavoidable result. In strumous subjects external conditions, such as food, living-quarters, cleanliness, etc., have a marked effect on the outcome of the disease.

Treatment.—General measures to neutralize the evil effects of the strumous habit are the first requisite. If the patient's surroundings as to food, lodging, and cleanliness are unsatisfactory, every effort should be made to get him into a hospital, where his diet can be carefully regulated. Iron (*ferr. sacch. solub.* [the Editor prefers the iodids of iron, to which Fowler's solution may be added]) has a stimulating effect on the appetite, especially for meats, and acts as a general tonic. This should be supplemented by saline baths, and during the winter with cod-liver oil; in obstinate cases good results are sometimes obtained by a course of sweating.

Locally, atropin in sufficient quantities (3–8 drops of a sterile 1 per cent. solution or several applications of atropin-vaselin) to check the pain is indicated. A compress-bandage, which in itself tends to allay the pain, is then applied to guard against secondary infection and purulent infiltration of the abrasions, which are very apt to occur in eczema. The best form of bandage consists of one wound over a pad of cotton, which is kept moist with a 1:5000 solution of mercuric chlorid, more particularly if there is catarrh. The dressing must not be removed until every single abrasion is sufficiently covered with epithelium. To check the catarrhal secretion, which does not contraindicate the bandage, the tarsal conjunctiva should be painted once every day with a 1 to 2 per cent. solution of silver nitrate.

If purulent infiltration has set in around the pustules, near the corneal margin, for instance, the bandage should be tightly drawn. This is the only condition in which pressure is desirable in the application of the dressings.

Before the caustic treatment of fascicular keratitis was

Plate 23.

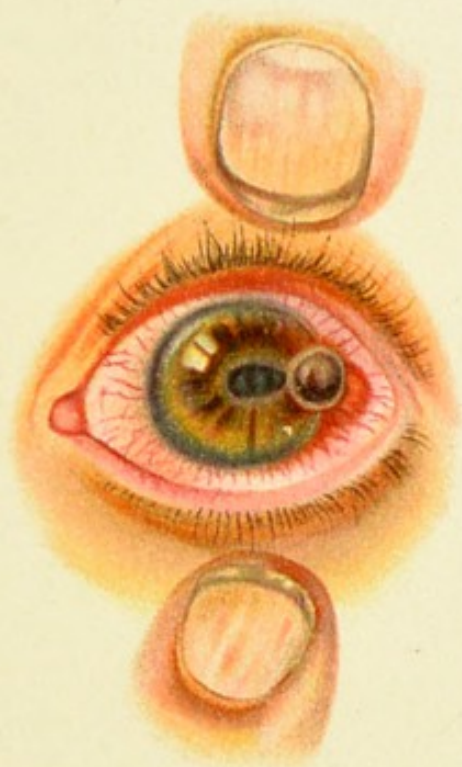a. Perforation of the Cornea by an Eczematous Ulcer, with Adhesion of the Iris.—Patient is a scrofulous boy, 10 years old, who had been treated outside of the hospital for the past four weeks, and was admitted at the time of this recent perforation. It is evident from the shape of the perforation that it is due to an eczema-pustule, even without the evidence of eczema in the other eye. There is typical ciliary congestion. The pupil, owing to the adhesion of the iris, is displaced toward the temporal side. A compressing bandage was applied for two weeks, and the perforation healed, leaving a smooth, slightly pigmented scar. The pupillary distortion is permanent. After a few weeks vision was practically restored.

b. Macula of the cornea of long standing, the remains of an eczematous ulcer. The circular outline of the scar and the loss of cilia indicate that eczema is the causal agent. The eye at the present time is free from irritation.

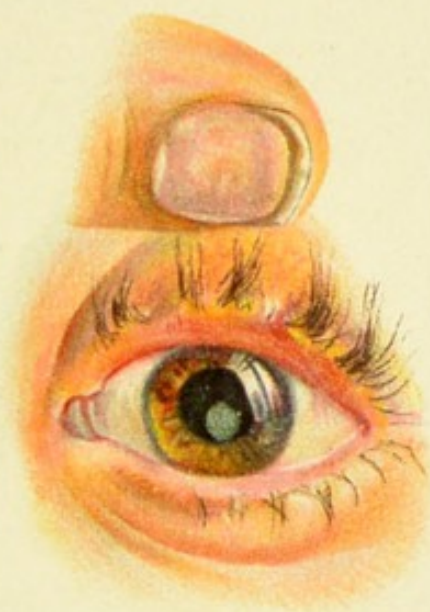introduced, the malady was most distressing to the patient and a great trial to the physician. Now we resort to cauterization, usually with the mitigated stick, well drawn out to a point, under local anesthesia with cocain. It is important to have the patient under good control, so as to avoid injuring the healthy tissues, hence the services of a capable assistant are indispensable. If the first application fails to arrest the process a second should be tried. The destruction of the advancing crescent is speedily followed by cure, as the rich vascularity of the tissues is most favorable to regeneration.

It is most important in all forms of eczematous keratitis to apply a stimulating remedy at the most favorable moment for hastening the reparative process. For this purpose a 1 to 2 per cent. salve of yellow oxid of mercury (well mixed and comminuted) usually suffices. Its use is indicated as soon as the inflammation has begun to subside, when the ulcers are usually clean and vessel-formation has begun. The salve fulfils the double purpose of clearing up the opacities and preventing relapses, and its application must be persevered in for some time.

[The treatment of the rhinopharynx is essential in all these cases, and always there will be found rhinitis, hyper-



a



b



trophied turbinals, adenoid vegetations, etc. The lachrymonasal duct should be kept patulous. Severe corneal ulcers are managed on general principles.—ED.]

3. Herpes Corneæ.

Herpes is another form of keratitis of a dermoid character and occurs as herpes zoster or as herpes febrilis.

Herpes zoster (see p. 92) produces various lesions in the cornea :

1. The vesicular eruption may appear primarily in the cornea at the same time as on the skin (Plate 20). The vesicles appear in groups, rapidly break down, and form an irregular, shallow ulcer, which sometimes becomes deeper and gives rise to extensive purulent infiltration of the cornea. In the mildest cases the site of the vesicular eruption is marked by a more or less permanent opacity (Plate 20). Iritis occurs in some instances as a complication. The most conspicuous symptom in this and in the following forms of herpes zoster is lessening or abolition of the sensibility, which is determined by touching the eye with a twist of cotton.

2. In some cases anesthesia occurs in circumscribed areas, and upon careful examination delicate *nebulæ*, often composed of numerous, small round dots, are seen in these areas and sometimes produce shallow ulcers, but in most cases persist for some time without breaking down and eventually disappear entirely. These opaque spots appear to be directly dependent upon the anesthesia or disease of the trifacial, which is the original cause of herpes.

3. Paralysis of the trifacial may give rise to *neuro-paralytic keratitis*, a dangerous form of inflammation caused by pyogenic micrococci, which may lead to extensive ulceration or purulent (colliquative) necrosis of the corneal tissues.

The treatment of herpes zoster consists in the careful and continued application of a protective (sealed) bandage, which, if persevered in, may possibly ward off neuro-paralytic keratitis. For this reason it should be employed

Plate 24.

Herpes Corneæ Febrilis.—These eighteen outline drawings show various shapes and positions of herpes-ulcers, taken from thirteen cases under my observation during the epidemic of influenza in 1890-91. (They are also to be found in the work of Dr. Hagnauer, who was at that time my assistant.¹) In Figs. 1, 5, 6, 7, 13, and 17 we see macules from former attacks of herpes, recognized by their irregular outline, resembling a geographical map. Figs. 10 and 15 show the macules which resulted from the ulcers seen in 7 and in 9 and 12. Figs. 12 and 14 illustrate the coalescence of a discrete eruption, and Fig. 17 a magnified picture of the original ulcer. In Figs. 11 and 12 slight vascularization is beginning to show itself.

even when anesthesia is the only symptom, and is imperatively demanded when there is destruction of the corneal tissue.

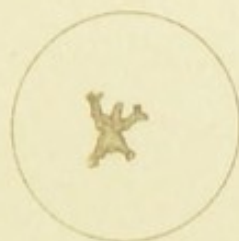
Herpes corneæ febrilis (Horner) should engage our interest if only because it proves conclusively that processes can occur in the cornea in every respect analogous to cutaneous diseases, and that the individual foci possess the same shape, on a very much reduced scale, as in the skin.

It is important to note that the vesicles on the cornea are much more delicate in structure, and therefore break down and disappear more rapidly than on the skin; hence the diagnosis is usually made from the characteristic shape of the subsequent loss of substance, the herpetic ulcer and its peculiarities. After the vesicles burst (in from one to two days) the cornea for the next week or two looks as if it had been scratched with a sharp splinter. The irritation is moderate, and the injured spot as well as its immediate surroundings, only slightly opaque. In a week, or from one to two weeks after the first appearance of the eruption, the last shreds of the vesicle-walls separate and the ulcers present their typical *sinuous* outline and clear-cut edges. The contour can be very clearly brought out by *staining with fluorescin*, a procedure of the greatest

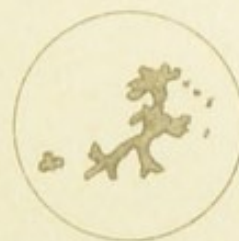¹ *Die Misdeutungen des Herpes Corneæ Febrilis*, Inaug. Dissert. Zürich, 1891.



1



2



3



4



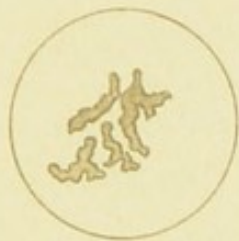5



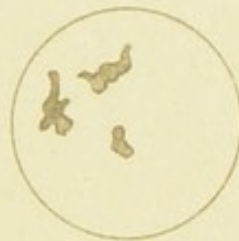6



7



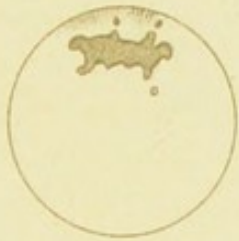8



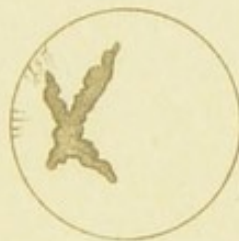9



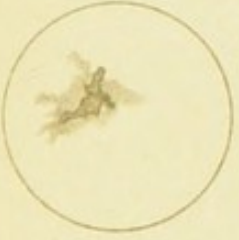10



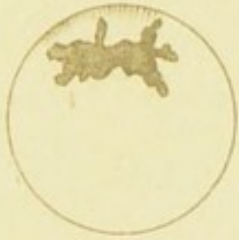11



12



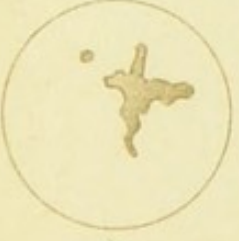13



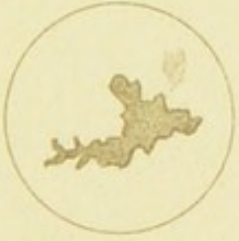14



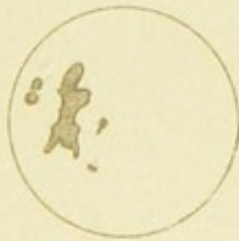15



16



17



18



diagnostic value in doubtful cases. [As pointed out by Veasey, toluidin-blue will also stain the cornea when it is deprived of epithelium.—ED.] Before the stain is introduced, a few drops of a 2 per cent. solution of cocain are instilled into the eye, which has the incidental advantage of intensifying the color. One drop of an alkaline solution of fluorescin (fluorescin, 0.2; sod. carb., 0.3; aqua destill., 10.0) is then applied to the cornea and the eye kept closed for half a minute, after which it is thoroughly washed with a 1 : 5000 bichlorid solution. The peculiar shape of the ulcer at once becomes manifest (Plates 24 and 25, *a*). Occasionally more than one ulcer is to be seen. As a rule, the original outline is retained throughout the course of the disease; in exceptional cases, however, small extensions make their appearance after a few days, due to deeper-lying ulcers whose epithelial covering has just separated. Of course, if secondary infection and infiltration of the surrounding tissue supervene, the ulcer may assume any size, and may even result in a true *hypopyon*. The distinguishing feature of herpetic ulcer is the exceedingly slow healing process, requiring from four to eight weeks for its completion, which is probably due to the scant and sluggish vessel-formation.

The explanation may be found in the fact that the nerves are diseased in herpes febrilis as well as in herpes zoster; this is shown by the diminished sensibility of the cornea observed in many cases. As in all forms of corneal ulcer, regeneration begins at the edges; a new epithelial covering overspreads the floor of the ulcer, so that it recovers its reflecting power and does not stain with fluorescin. The original level is very gradually restored, although a more or less pronounced macula always remains and for years afterward retains the shape of the original ulcer (Plate 24).

Herpes corneæ does not appear in successive crops, like eczema; but it is prone to recur in the same eye, or, by way of variety, in the other eye, whenever the individual happens to have fever. An ordinary cold or a short attack

Plate 25.

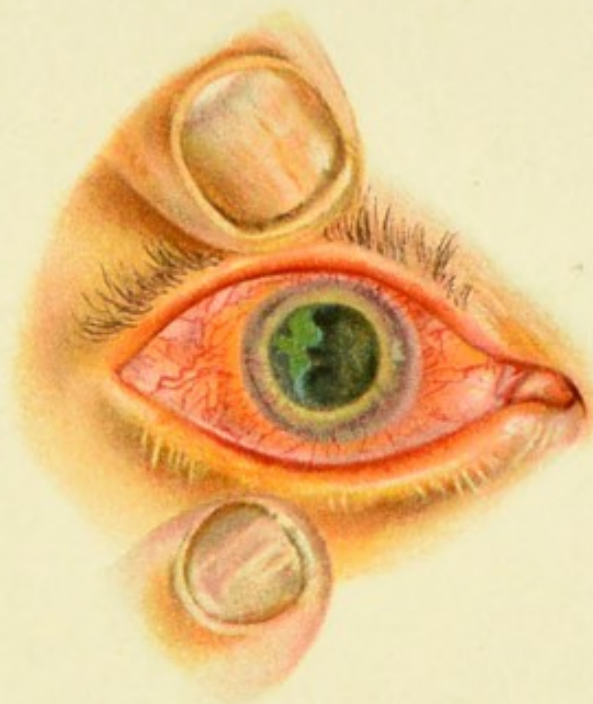a. Herpes corneæ febrilis, three weeks after the beginning of the disease, stained with **fluorescin**, showing a green ulcer, of irregular, sinuous shape, in the temporal half of the cornea. (The green color is a little too light in the figure.) A slight degree of vessel-formation may be seen at the temporal margin of the cornea. The conjunctiva is stained yellow by the fluorescin and, in addition, shows marked ciliary congestion. The pupil is dilated with atropin.

b. Hypopyon-keratitis.—Just below the center of the cornea is a purulent infiltration which developed in the course of a few days. The limit of the infiltration remains stationary. The hypopyon in the anterior chamber is 2 mm. high. No history of traumatism. There are moderate dacryostenosis and chronic conjunctival catarrh. Satisfactory cure after several applications of pure carbolic acid. Visual acuity $\frac{6}{60}$.

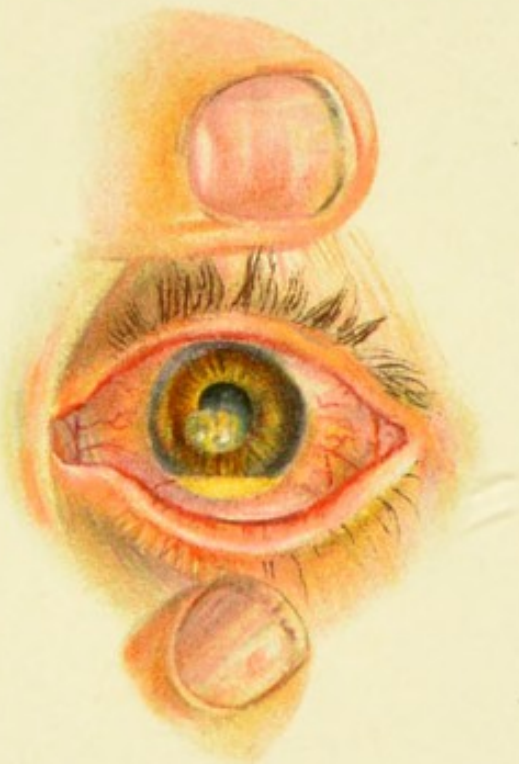of gastric fever suffices to bring it out. The malady is particularly common after influenza. In spite of the long duration of the process, the iris rarely becomes involved, unless a secondary infection takes place.

The diagnosis is readily made from the symptoms described, and especially from the color obtained with fluorescin. Sometimes a herpetic ulcer fails to show the typical sinuous contour (resembling a geographical map), in which case we base our diagnosis on the slow process of repair. At first the diseased spots may easily be mistaken for scratches, except for the absence of a history of traumatism. It is often difficult to determine the febrile nature of the disease, because the patients usually present themselves long after they have forgotten any feverish symptoms they may have had. Occasionally a herpetic macula from a former attack is detected and helps to clear up the diagnosis.

Prognosis.—We should emphasize the probability of a long duration, and, if the lesion is centrally situated, the unavoidable permanent impairment of vision. On the other hand, if the ulcer is properly treated there is little danger of its spreading. Relapses are not infrequent, and little or nothing can be done to prevent their occurrence.



a



b



The treatment is the same as for corneal ulcer; it consists in atropin and the constant use of a bandage, to be worn until the reflex is restored in every part of the ulcer (for its chief object is to guard the ulcer against contamination of any kind, especially of an infectious nature). The bandage also serves to diminish the pain by keeping the lids quiet, and allows the process of tissue-repair to go on undisturbed. When at last a firm epithelial covering has been formed, the bandage may be dispensed with, and yellow oxid of mercury salve (see p. 147) may then be used for from three to four weeks, to complete the cure. In the beginning of the disease one or two applications of sublimate solution with a cotton pledget (under cocain anesthesia) are of advantage.

4. Hypopyon-keratitis, or Purulent Ulcer of the Cornea.

The slightest abrasion on the corneal surface may open a way for the entrance of pyogenic microorganisms, providing some infectious material containing them is present and the cornea at the time affords a favorable culture-medium. The second condition is satisfied in individuals weakened by disease, bad food, or senile decay. The diseases which produce such a condition are measles, scarlet fever, typhoid fever, whooping-cough, variola, etc. Infectious material is especially abundant in catarrh of the lachrymal sac or of the conjunctiva. Farmers often suffer from purulent keratitis, probably because their hands are soiled with earth, although the unhygienic conditions under which they live are no doubt partly responsible. I have often found a perceptible reduction of the hemoglobin in patients of this class. Then, too, the heat which prevails at harvest-time probably favors the occurrence of infection.

The lesions are usually of a *traumatic* nature, sometimes only slight abrasions made by a straw, a finger-nail, or a twig, which create entering-points for infection. These may be established by foreign bodies. Sometimes the

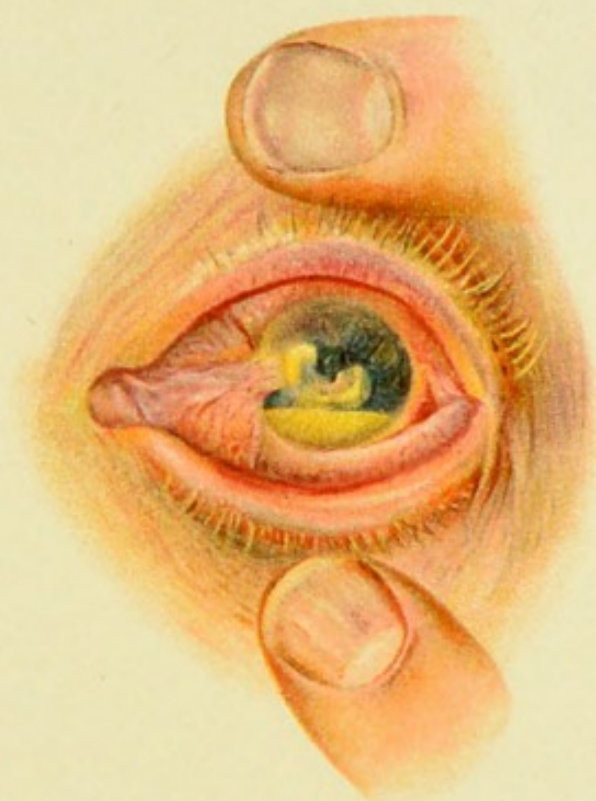
Plate 26.

a. Serpiginous Ulcer of the Cornea ; Pterygium.—Laborer, 65 years old. Five days ago, while patient was chopping wood, a twig struck him in the left eye. He now presents a large growing ulcer, with suppurating edges, while the center is already in process of regeneration. He says he has been troubled with excessive lachrymation in both eyes for six or seven years. The lachrymal canaliculi are occluded. A fairly large pterygium has been present for some time. Below the cornea the ocular conjunctiva shows a moderate degree of edema. An hypopyon, 1 mm. in depth, increased during the next few days in spite of repeated cleansing of the ulcer with pure carbolic acid, and finally filled two-thirds of the anterior chamber, so that it was decided to evacuate the pus by puncture. The ulcer eventually healed completely. A large central leukoma remained. Visual acuity: movements of the hand.

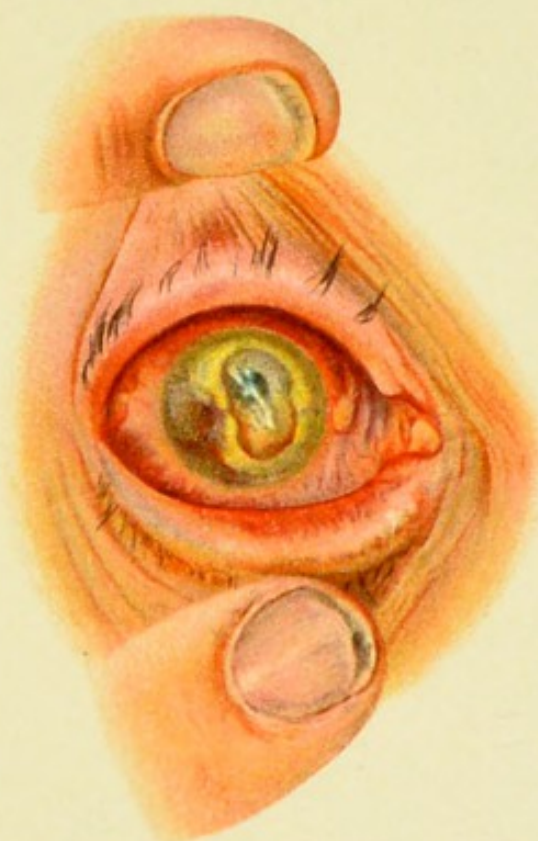
b. Serpiginous ulcer of the cornea, in an advanced stage. The patient is a farmer, 75 years old. He has felt stabbing- and burning-pains in the eye for two weeks; his friends noticed a spot and inflammation. Three days ago he consulted a doctor, who sent him to the clinic. Marked senile. symptoms; hemoglobin, 80 per cent. The eye has watered for some time; canaliculi are impervious. The eye is very red; in the upper nasal portion of the cornea is a large ulcer with broad, greenish-yellow edges and attenuated, bulging center, through which the dark anterior chamber is dimly seen. Hypopyon $2\frac{1}{2}$ mm. deep; the aqueous humor is turbid. The use of the thermocautery is followed by perforation of the ulcer and evacuation of the hypopyon. Two days later the edges again suppurate, especially about the lower portion of the ulcer. Cauterization with carbolic acid. On the next day the ulcer had progressed, especially below. At this time the picture was taken. Another application of the galvanocautery arrested the process. In five days the ulcer cleared up. Cure after one month, with the formation of a smooth scar, but no staphyloma. $V = \frac{1}{50}$.

offending object is the direct cause of the infection, if it happens to be contaminated.

Aseptic wounds of the cornea, even if quite large, heal rapidly and take on a new covering of epithelium in a very short time; but if they become infected, they first turn gray and then yellow, and the discoloration spreads to the immediate surroundings; an infiltration develops by the migration of leukocytes toward the injured spot, where they accumulate in the corneal substance in ever-increasing numbers. The purulent nature



a



b



of the infiltration betrays itself in the yellow discoloration. Now, the same process may take place if a simple ulcer—caused by eczema or herpes, for instance—becomes infected. In proportion as the inflammation and the consequent accumulation of leukocytes increase, the rest of the cornea becomes covered with a delicate, diffuse cloudiness and its reflex is lost. As soon as the purulent focus attains a certain size, iritis supervenes; the aqueous humor becomes turbid, synechiæ are formed around the pupillary margin, and pus collects in the anterior chamber, at first a mere yellow line along the lower margin of the chamber, later increasing to a segment (Plates 25, *b*, and 26, *a*), which may occupy one-half or three-fourths of the anterior chamber.

This purulent iritis is caused by a toxin, elaborated by the microorganisms in the cornea, finding its way into the anterior chamber (just as atropin does, for instance) and setting up an inflammatory process. The pathogenic bacteria themselves are not likely to penetrate so far, unless there has been a very deep-reaching infiltration and perforation into the anterior chamber; hence a hypopyon is usually free from bacteria.

As the purulent inflammation increases, inflammatory edema develops in the bulbar conjunctiva and eventually in the lids. The edema becomes very marked and involves the orbital contents (giving rise to protrusion); if extensive destruction of the corneal substance takes place, the suppurative process, penetrating into the iris and deeper coats of the eye, gives rise to *panophthalmitis* (Plate 27).

It must be remembered that a purulent infiltration of the cornea is very likely to result in general sloughing; the primary focus, which is usually circular in shape, breaks down in the center and an ulcer is formed, the floor and margins of which exhibit a grayish-yellow discoloration. The patient usually complains of pain in the eye, headache, and dimness of vision, if the ulcer is situated within the pupillary region. There are, however,

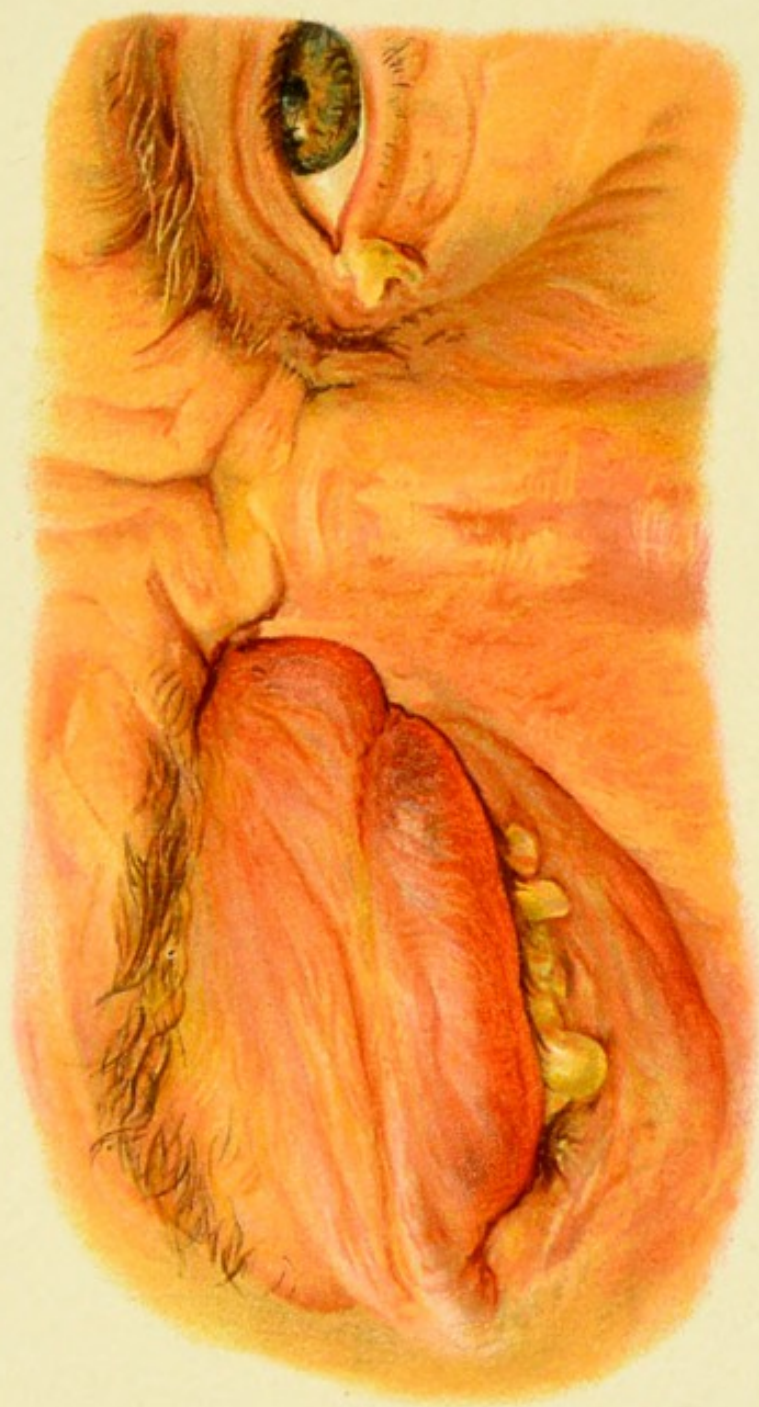Plate 27.

Suppuration of the Cornea from Serpiginous Ulcer ; Panophthalmitis.

—The patient, who is 73 years old and a farmer by occupation, was treated in this clinic a year ago for conjunctival catarrh, which is now present, as may be seen by the dried secretion at the inner canthus of the left eye. The tear-duct is patulous on both sides. Four days ago the patient noticed a burning sensation in the right eye, but paid no attention to it until yesterday, when he found that he could not see clearly. He does not know of any injury. In the right eye the lids are glued fast with secretion, the conjunctiva is red and swollen, and there is ciliary congestion; the cornea is clear except at the center, which is occupied by a circular, shallow ulcer, 2 mm. in diameter, not serpiginous, but of a uniform greenish or yellow color. Small hypopyon. Behind and a little below the ulcer in the anterior chamber a strip of purulent exudate is adherent to the cornea. Aqueous humor turbid. The ulcer was immediately incised after the method of Saemisch. The exudate behind the ulcer was extracted, and brought with it a membrane which lined almost the entire anterior chamber. The next day the sloughing of the cornea had increased, and the incision was opened once more. On the following day the purulent ulcer was much larger, a large amount of pus had collected in the anterior chamber, and there was incipient panophthalmitis, with edema of the lids and copious purulent discharge from the conjunctiva (see Plate). On the fifth day after treatment was begun the entire cornea was converted into a greenish-yellow purulent infiltrate, and in the course of the next few days sloughed away more and more, while panophthalmia increased *pari passu*.

so-called *torpid ulcers* of this kind, which give little pain (perhaps because the sensitive fibers are paralyzed by the toxin), but are none the less serious.

The most frequent, as well as the most dangerous, type of hypopyon-keratitis is the *serpiginous ulcer*, one of the most malignant forms of corneal disease, which is attended with great danger to the eyesight from the fact that it preferably affects the central portions of the cornea. The ulcer spreads rapidly by one or more of its margins advancing in the form of an elevated curve of yellow infiltration (see Plate 26), while the parts of the ulcer lying behind this propagating arc, as it is called, show more or less tendency to repair. Hypopyon soon develops. Left to itself, the lesion at first produces extensive destruction





of the superficial tissues, and later penetrates more deeply, so that perforation often occurs, followed by prolapse of the iris and, finally, panophthalmitis.

It appears from the investigations of Uhthoff, Axenfeld, and others that the serpiginous ulcer is almost always caused by the *Fränkel-Weichselbaum pneumococcus*, while the other purulent ulcers of the cornea are due to the action of *staphylococci* and *streptococci* (much less frequently to *aspergillus*), and only in rare instances to pneumococci.

Among these other forms of hypopyon-keratitis we include the purulent ulcerations which occur in the course of gonorrheal and diphtheritic conjunctivitis, and in malarasmic infants who are afflicted with, and eventually die of, grave digestive disturbances; also *keratitis neuroparalytica*, caused by paralysis of the trifacial nerve. These forms of purulent keratitis are capable of causing quite as extensive destruction in the eye as the serpiginous ulcer.

The invariable termination of all purulent ulcers, be they large or small, is a dense, cloudy scar or *leukoma*, which usually produces a permanent visual disturbance, as it is situated wholly or partly within the pupillary region. If the perforation is small, the result is a mere adhesion of the iris (*adherent leukoma*); on the other hand, the scar of a large perforation may become distended and even give rise to a *partial* or *total corneal staphyloma*. Small ulcers sometimes leave a membrane of inflammatory exudate in the pupil, which interferes with vision. If adhesion of the iris to the capsule takes place along the entire pupillary margin, *secondary glaucoma* is apt to develop and iridectomy becomes necessary; in fact, any adherent leukoma may give rise sooner or later to secondary glaucoma. Sloughing of the entire cornea is usually followed by prolapse of the lens, *panophthalmitis* and, finally, *phthisis bulbi*.

The **prognosis** in all forms of hypopyon-keratitis, and especially in serpiginous ulcer, is always exceedingly grave,

since the entire cornea is threatened with destruction. Unless appropriate measures are taken at the proper time, the process usually leads to total or virtual blindness.

Treatment.—As a prophylactic measure, dacryostenosis and conjunctival catarrh occurring in elderly people should be treated with special care, and the subjects warned of the danger that threatens them. Most cases are presented too late for general treatment to have much effect; but for all that it must not be neglected in protracted cases. The chief aim in the management of the disease should be the thorough destruction of the pathogenic colonies in the cornea—in other words, disinfection. At the same time the greatest care should be exercised not to destroy any more corneal tissue than is needful, because extensive corneal cicatrices, even if they do perforate, are very apt to undergo distention. The first step in this procedure is direct disinfection of the ulcer itself; the second, the injection of a saline solution under the conjunctiva, cauterization of the retrotarsal folds, etc., for such is the rapidity with which the ulcer tends to spread that the most energetic measures are demanded. Still, every case must be treated on its individual merits. If the case is seen at the very beginning of hypopyon-keratitis and presents no more than a yellowish infiltration with a slight tendency to ulceration at the center, painting with carbolic acid is usually sufficient, or even when there is a somewhat more extensive infiltration, about as large, say, as the one represented on Plate 25, *b*, which had already produced hypopyon. The eye is cocainized for this purpose, and the carbolic acid, after being slightly warmed in order to melt it, applied to the corneal focus by means of a sharp probe wrapped with cotton, until a whitish eschar is formed, limited strictly to the diseased area. The eye is then treated with atropin and covered with a sealed bandage. If after one or two days the infiltration is still found to be progressing, the caustic agent must again be applied.

If the infiltration is larger than the one shown in the

figure, it is fair to assume that the bacteria have penetrated into the deeper layers of the corneal tissue, where they cannot be reached by the carbolic acid, which only acts on the surface. A galvanocautery, drawn out to a point, affords the best means of cauterizing in this case, or a heated knitting-needle will answer the purpose in an emergency. If one margin of the ulcer has already progressed further than the others, cauterization should be particularly vigorous at that point. If the situation of the ulcer or of the arc of propagation is such as to justify somewhat less heroic measures, the infiltrated tissue may be scraped out as thoroughly with a sharp-pointed knife, or a small sharp curette, and the site touched with carbolic acid; but if on the next or on the third day any part of the infiltration is found to have progressed, the thermocautery must be brought into requisition after all. This procedure may be employed in such cases as are illustrated on Plate 26, for example. [Other antiseptic and caustic substances which may be applied to check the spread of purulent ulcers are: silver nitrate (2 per cent.), tincture of iodine, formaldehyd (1 : 50). After curetting an ulcer an excellent practice is to dust iodoform upon its surface and apply a dry sterile bandage.—ED.]

Another method of treating these cases is that advocated by Saemisch, which consists in splitting the ulcer. The eye is first thoroughly cocainized and securely fixed with the forceps; a Graefe knife is inserted into the sound tissue on one side of the ulcer, with its cutting-edge directed forward, carried across the anterior chamber behind the ulcer, and brought out on the other side of the ulcer in the sound tissue, so as to divide it from behind forward. The incision should pass through the center of the propagating arc. Thus in the case illustrated in Plate 26, *a*, the section would be made from the outer and lower, to the inner and upper side of the cornea, dividing both propagating arcs. As soon as the aqueous humor, and with it the hypopyon, is evacuated, the greatly inflamed iris comes in contact with the posterior surface of the

cornea and causes violent pain, which lasts for some time. If the hypopyon is tenacious and does not come away entirely of its own accord, it must be removed with a pair of forceps. If pus remains in the anterior chamber, it need not be removed, as it is usually free from germs. In performing this operation the greatest care is necessary to avoid injuring the lens with the knife. After the first incision the wound must be reopened every day with a blunt, slender probe, until the ulcer begins to heal. The advantage of this method is that good results are often obtained at the smallest possible sacrifice of corneal tissue; on the other hand, it cannot be denied that the operation is almost always followed by extensive anterior synechiæ of the iris, which in turn may give rise to secondary glaucoma. Even Saemisch's section is inadequate in malignant cases and when the ulcer has reached a large size (see Plate 27).

This operation is entirely analogous to a section carried through a phlegmon or furuncle, from sound tissue on one side to sound tissue on the other, and depends for its good effects on the same conditions, namely, relaxation of the tissues and the opening of a channel for the lymph-stream to reach the wound and check the further progress of microorganisms—in other words, self-drainage.

The treatment may be supplemented by injecting from $\frac{1}{2}$ to 1 c.c. of a 2 to 5 per cent. saline solution under the conjunctiva, every day or every few days—a procedure which is supposed to have a stimulating effect on the lymph-stream. Above all, dacryostenosis and conjunctival catarrh must receive careful treatment, the latter by means of daily applications of a 2 per cent. solution of silver nitrate; the former by daily irrigation of the tear-sac with a 1:1000 sublimate solution, and, if necessary, by passing a sound or extirpating the sac. Atropin is also indicated to combat as soon and as vigorously as possible the iritis which is usually present. [A collyrium of mercuric chlorid (1:1000) is, in the judgment of the

Editor, too strong; 1:5000 is sufficient. Formaldehyd (1:3000) is useful.]

5. The Catarrhal Ulcer.

This is the most important representative of the non-purulent group of ulcers, and is of interest on account of its comparative frequency. As its name indicates, it is a sequel of conjunctival catarrh, and usually occurs in old people. It occupies the peripheral portion of the cornea, forming a shallow sulcus of variable length along the corneal margin. As the ulcer presents very little infiltration, either at the base or along the edges, its position and extent are often difficult to determine without an examination of the reflecting properties of the corneal surface or the behavior with fluorescein staining. Pain is usually moderate, the flow of tears and circumcorneal redness are not excessive, and the ulcer on the whole shows a tendency to heal of itself. On the other hand, if there is much purulent secretion, a neglected ulcer may develop into one of a purulent type and threaten perforation. This is a grave complication on account of the large extent and peripheral position of the ulcer, and is very apt to be followed by extensive prolapse of the iris.

The **diagnosis** is suggested by the presence of ciliary congestion. The discovery of this type of congestion during an attack of catarrh should be immediately followed by a close scrutiny of the cornea for the presence of such catarrhal ulcers. To this end the reflecting power of the membrane is tested and an examination made by lateral illumination, which affords the surest means of detecting the grayish opacity (of the diseased cornea) during the initial stage.

The **prognosis** is favorable. The ulcer heals rapidly with appropriate treatment, and, owing to its peripheral position, does not affect the eyesight.

Treatment.—This is usually limited to the conjunctiva. If infiltration makes its appearance, local disinfect-

ants are indicated, one application of sublimate being usually sufficient.

INJURIES OF THE CORNEA.

Injuries of the cornea demand the most careful consideration, not so much on account of their frequency as of the vital consequences which they may entail. The slightest abrasion of the surface may open the way to infection and set up a morbid process which the surgeon is afterward unable to control. Foreign bodies frequently become embedded in the corneal surface. They may be so minute as to be detected with great difficulty, and yet set up an inflammation which by surrounding it with an area of grayish discoloration betrays the site of the foreign body. When this is a spicule of iron it has a brown or brownish-black color. If the iris is brown, such a body is at first difficult to detect; later it is brought out more clearly by the area of infiltration, before described, which surrounds it. Similarly a white substance (grain of sand, etc.) where the iris is light colored can at first only be detected by testing the reflection of the corneal surface or with the aid of lateral illumination.

Occasionally a non-irritant body, such as a grain of powder, for example, which has penetrated below the surface, may become permanently embedded.

Stab- and cut-wounds, if deep enough, lead to perforation and prolapse of the iris, or at least to adhesion of the iris to the scar.

The **treatment** in all injuries of the cornea consists in guarding against infection by means of a compressing bandage. Foreign bodies are carefully removed with a sharp instrument, a cataract-needle, etc., or with a cotton pledget dipped in a sublimate solution, if they are situated on the surface.

After the removal of a foreign body the cornea should be carefully examined with a loupe and lateral illumination for any stray particles that may have been over-

looked. If the intruder was a spicule of hot iron, the brown spot which often remains (see Plate 21) must be carefully scraped out (a matter of some difficulty during the first few days, as the substance clings tenaciously). Atropin is not necessary in fresh, non-inflammatory cases; but a compressing bandage is always to be applied and kept on until the reflex has become normal, or at least until the site of the injury becomes covered with epithelium and fails to take the fluorescein stain. If this precaution is neglected, a protracted case of diffuse or hypopyon-keratitis is apt to result.

Large wounds of the cornea, especially perforating wounds, must also be dressed with a compressing bandage, and the patient must be put to bed. In case of prolapse of the iris, if the injury is quite fresh, replacement with a suitable instrument (spatula) may be attempted, after disinfecting with a 1:5000 sublimate solution. The operation is usually a failure. If the prolapse is one or two days old, infection has very probably taken place, and replacement would be followed by a dangerous iritis which would imperil the other eye. In such a case it is better, therefore, to excise the prolapsed iris, replacing only the ciliary attachments, so as to leave as little iris-tissue as possible in the wound and relieve the tension of the pupil.

MALFORMATIONS OF THE CORNEA.

These are of interest because they interfere with vision. The most frequent anomaly is unequal horizontal and vertical curvature, and forms one of the causes of astigmatism.

Megalocornea (*cornea globosa*) may be congenital and sometimes hereditary; the cornea may retain its transparency throughout the life of the individual. A similar anomaly occurs after *infantile glaucoma*; but the cornea in this form early presents the characteristic glaucomatous haze and later becomes covered with irregular opacities which materially impair its transparency. The bulb

Plate 28.

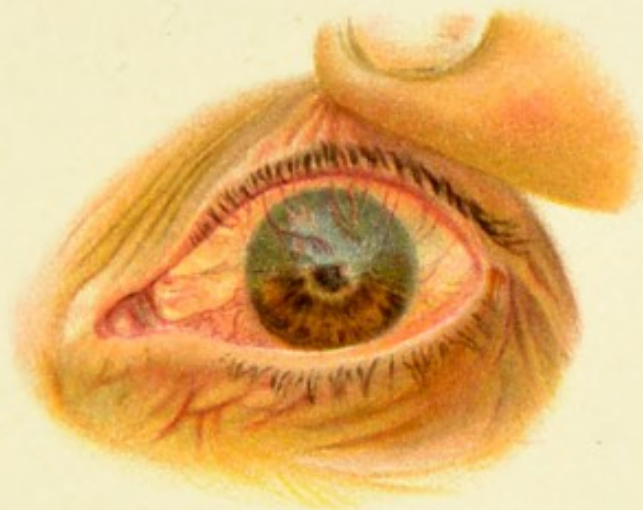a. Trachoma, with Pannus of the Cornea.—The patient, an Italian woman, 37 years old, has suffered for years from inflammation of both eyes. One eye shows incipient cicatricial trachoma, with a number of papillary granulations on the upper lid. (The patient unfortunately declined to sit any longer after the first illustration, and it was impossible to obtain a picture of the inner surface of the upper lid, as had been intended.)

b. Phthisis Bulbi Anterior ; Calcareous Degeneration of the Cornea.—The woman, who is 26 years old, sustained a stab-wound in the right eye when she was five years old ; the scar is plainly seen, running obliquely toward the corneal margin. She does not remember ever to have been able to see with this eye. The contraction of the anterior portion of the eyeball suggests that traumatic cyclitis occurred at the time. As the remains of iritis are to be seen in the other eye, it is quite likely that there was also sympathetic iritis, which, strangely enough, appears to have healed spontaneously, for the patient does not remember to have suffered from inflammation in the left eye. The cornea of the right eye was shrunken, and badly disfigured with whitish epithelial scales. Tattooing was employed with very good results and without doing any damage.

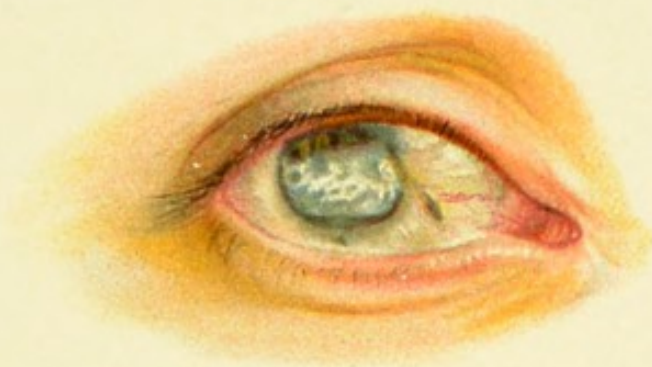c. Parenchymatous Keratitis.—The inflammation began three weeks ago, and the cornea is already to a large extent covered with an opacity which began at the upper and outer margin. The opacity was soon followed by marked vascularization. That the keratitis is diffuse is recognized by the ill-defined delimitation of the infiltrated area. Cause, hereditary syphilis.

gradually yields to the increased tension, and unless the latter is relieved the condition usually ends in blindness.

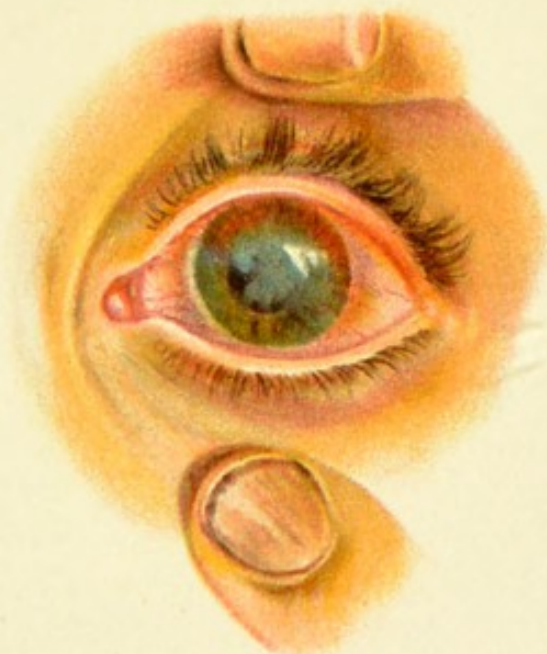Keratoconus is an acquired anomaly, in which the cornea assumes a conical shape. The center of the cornea becomes thinner and is gradually bulged forward by the intraocular pressure. A severe grade of keratoconus is at once recognized by the altered reflex, which lends a peculiar flashing-look to the eye. The light is concentrated on the apex of the cone ; the reflex is smaller and brighter than in the normal eye, and surrounded by a halo. Doubtful cases are best examined with a Placido disc, the black and white concentric rings of which show a peculiar distortion. Similar distortions and illusive movements are also observed in the ophthal-



a



b



c



moscopic image. In advanced cases of keratoconus the apex becomes opaque and another disturbing element is added to the abnormal refractive phenomena. Both eyes are usually affected, and the condition is met with most frequently among women. It is rarely possible to correct the optical error with glasses. I once saw the process arrested by *sclerotomy*, supported by general constitutional treatment. [High grades of conical cornea cannot be helped much if at all with glasses; but intermediate grades, and even cases of considerable conicity, may be markedly benefited and vision greatly improved with high cylinders or spherocylindrical combinations. The best operative procedure is cauterization of the apex of the cone with the galvanocautery and later, if necessary, an optical iridectomy.—ED.]

Staphyloma may develop in consequence of extensive ulceration of the cornea and lead to grave impairment of the visual power. The deformity is caused by the distention of scar-tissue and is almost always associated with heightened intraocular tension—secondary glaucoma. Irremediable blindness is the usual result, and the only treatment is a surgical operation.

DISEASES OF THE SCLERA.

1. Inflammation of the Sclera.

Inflammatory processes are much less common in the sclera than in the cornea, and are always localized in the anterior segment. Two forms are distinguished: *superficial*, or *episcleritis*, and *deep scleritis*. Many transitional forms are also met with, and it is often difficult to determine to what depth the inflammation has penetrated. Both forms are characterized by the formation of circular, hypertrophic nodules; in deep scleritis, however, the inflammatory process is prone to diffuse itself over a larger area, surrounding the cornea on all sides and producing

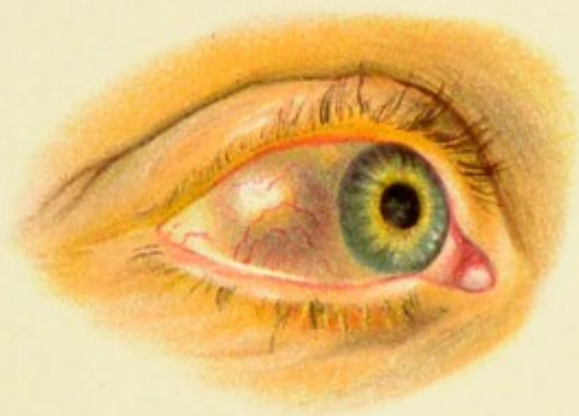Plate 29.

a. Scleritis, recent—*i. e.*, three weeks old. The back-shaped elevation, which is plainly visible to the temporal side of the cornea, is very sensitive to pressure. The disease was probably rheumatic in character and took two months to heal, leaving a slaty discoloration at the site of the elevation, which may be seen over the cornea in the next figure.

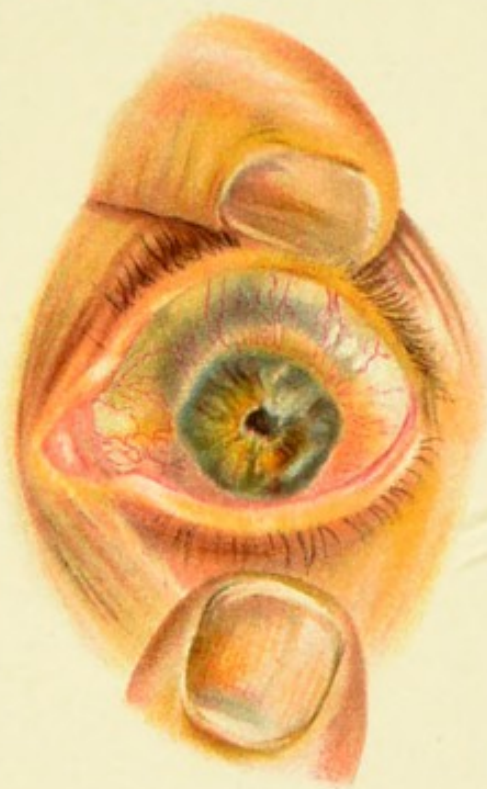b. Sequelæ of Scleritis and Sclerotizing Keratitis.—It is quite evident, from the pronounced slaty discoloration and reduced density of the sclera above the cornea, that the patient (a woman, 37 years old) has suffered for years from scleritis. The actual presence of scleritis at that point and to the temporal side of the cornea may be inferred from the inflammatory opacity in the cornea and corresponding ciliary congestion. It is also evident from the haziness of the corneal margin that the cornea has suffered frequent encroachments during former attacks of scleritis (sclerotizing keratitis). Finally, we see signs of a former plastic iritis in the irregular outline of the pupil, which is attached to the lens by numerous synechiæ. The only abnormality in the other eye is a broad synechia in the inner and lower portion. The cause of the process is difficult to determine. The irritative symptoms began when the patient was fourteen years old. She has eight healthy children; two of her brothers died of phthisis. Eleven years ago she had a short attack of articular rheumatism without fever. Her eyes had not troubled her for the past three years; the present inflammation began six weeks ago after confinement. Not a trace of albumin in the urine. Iridectomy. Discharged with visual acuity of the left eye equal to $\frac{3}{60}$.

first a bluish-red, and later a pale violet, porcelain-like discoloration (Plate 29, *b*). A deep scleritis often encroaches on the cornea, where it produces infiltrations in the deeper layers which do not break down, but usually leave a permanent opacity (*sclerotizing keratitis*). Besides the cornea, the iris and choroid coat are very liable to become involved; opacities are formed in the vitreous body and threaten to destroy the eyesight. Finally, not to mention iritic exudates, circular synechiæ, or pupillary membranes, the process may eventually lead to cataract and ectasia scleræ, when the membrane is weakened by a prolonged attack of the disease.

We speak of a *scleral staphyloma*. This form of scleritis usually attacks both eyes, preferably those of young individuals of the female sex. Such patients are often



a



b



tuberculous or the subjects of hereditary or acquired syphilis. The disease, which usually lasts for years, is rarely amenable to treatment.

Episcleritis is more common than the deep form, and is characterized by the scleritic hump (Plate 29, *a*) which betrays its site by a deep, bluish-red injection underneath, which is not movable with the conjunctiva. The inflammatory foci never ulcerate, but gradually disappear in from five to ten weeks or later, leaving a dull gray spot due to the attenuation of the scleral tissue. Episcleritis is also refractory to treatment, especially the migrating form, which tends to encircle the cornea wholly or partially—*scleritis migrans*.

The elevations in the sclera, which represent a true round-cell infiltration, vary in size from 3 to 8 mm.; several may be present in the same eye. They are usually very sensitive to pressure, but not painful if undisturbed, except in a few cases, when the pain is said to be very distressing. The process is very apt to recur, and, in course of time, attacks both eyes. Episcleritis is, on the whole, less dangerous than the deep form, and is followed by fewer complications.

Tuberculosis and syphilis are predisposing causes; but the affection is more often observed in connection with the rheumatic diathesis, and the treatment in most cases should consist of active antirheumatic remedies: sweating and a long-continued use of sodium salicylate.

2. Injuries of the Sclera.

In addition to stab- and cut-wounds, which are quite common, we occasionally see the more serious injury of *rupture of the sclera*, caused by the application of violent external force—a blow with the fist or a stick, or a cow's horn, or collision with any blunt object. Rupture of the sclera is, of course, a perforating wound, and therefore endangers the contents of the globe; the same is true, however, of most stab- and cut-wounds. Besides causing

the loss of more or less vitreous body, such perforating wounds are the means of introducing infectious material into the interior of the globe, and as the latter is an excellent culture-medium, the purulent inflammation rapidly spreads to the retina and uveal tract. In exceptional cases rupture of the sclera takes place without tearing the conjunctiva, so that the rent does not communicate with the outside. In such cases the lens, instead of being forced completely through the rent, as it usually is, may only prolapse as far as the conjunctiva (Plate 34, *b*). Rupture usually takes place above the cornea, in a line parallel to the margin; sometimes to one side of the cornea (Plate 34, *b*). The accident is very often followed by a large hemorrhage into the vitreous—hemophthalmos—the retina becomes seriously involved (retinitis proliferans), and total or partial blindness usually results. A large escape of vitreous, especially if mixed with blood, is followed sooner or later by separation of the retina and total blindness.

Wounds inflicted with a knife, scissors, or broken glass may heal satisfactorily, if they do not become septic; they are not attended with as great a loss of vitreous as is a rupture caused by compression of the bulb.

A *foreign body* is not as likely to bury itself in the sclera as it is in the cornea; it usually penetrates into the globe and lodges in the vitreous or on the retina. This is particularly the case with pieces of iron, which acquire sufficient momentum to pierce the tissues of the sclera. Pieces of copper also, from exploding dynamite caps, chips of stone scattered by powder or dynamite blasting, and glass splinters from the explosion of glass vessels in laboratory work, etc., often penetrate the sclera. If the splinter is large, it may inflict a considerable wound without remaining in the globe; these cases are rare, however, compared with those in which the splinter penetrates into the interior of the globe; and the latter event is always to be considered the most likely in making a diagnosis.

A perforating wound of the sclera, if extensive and before the edges have become united, reveals itself by re-

duction in the tension of the globe. The ophthalmoscope shows more or less hemorrhage and inflammatory turbidity in the vitreous body. If the wound is situated along the equator, a bright band may be seen in the ophthalmoscopic image, indicating a lesion of the choroid. The presence of a foreign body in the interior of the globe demands a thorough ophthalmoscopic examination. If the suspected substance is iron, it is advisable to use the *sideroscope*, a very delicate magnetic needle provided with a device which permits its deviations to be read off with a telescope, or the large electromagnet, proposed by me, which either attracts the splinter toward the iris or at least indicates the presence of iron by the pain it produces. [The Röntgen rays furnish a means by which the presence and position of a foreign body in the eye can be determined with accuracy. Of the many methods suggested for employing the X-rays under these circumstances, that one proposed by W. M. Sweet seems to the Editor, who speaks from experience, to be the best.]

Never explore a wound in the sclera with a probe, either for the purpose of detecting a suspected foreign body or to determine whether the wound is really a perforating one. For in doing so there is great danger of introducing pathogenic germs, which may be present on the exterior of the wound, into the vitreous body and setting up a fatal inflammatory process in the interior of the globe.

The *treatment* of scleral wounds demands absolute rest in bed, at least for some time. If the wound is large, both eyes must be bandaged. If the wound is already closed, it is better not to disturb it; gaping wounds may be carefully closed with sutures passing through the conjunctiva and episcleral tissue; it is not usually advisable to include the sclera itself in the sutures.

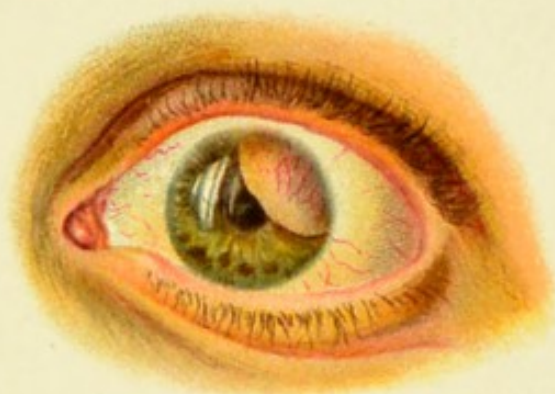Only when the piece of iron which has penetrated the sclera is very large should the attempt be made to extract it through the scleral wound with an electromagnet; small splinters should be drawn into the anterior chamber and

Plate 30.

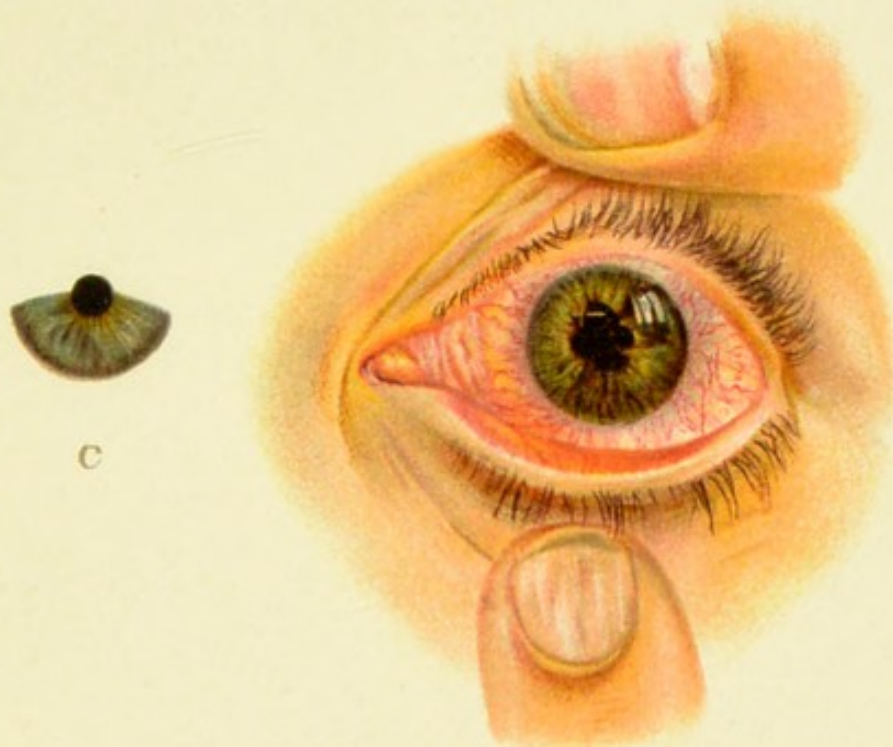a. Sarcoma of the Iris.—I am indebted for this picture to the kindness of my colleague, Dr. Mayweg, of Hagen, who made the following report of the case before the Ophthalmologic Society of Heidelberg, at the meeting of the society in 1897. As long ago as 1870 the patient, a factory-hand, 53 years old, had his attention called to a small yellowish-brown elevation, as large as a pinhead, in the temporal third of the iris, near the outer rim. A year later he noticed a change in the spot; it gradually became larger, without causing diminution of vision, which at the time of his admission was perfectly normal. The tumor was completely removed in two sittings and the wound healed in three weeks. Examination of the tumor revealed a moderately pigmented, spindle-cell sarcoma. The pigment-spots on the lower portion of the iris are not pathologic; such spots are often seen on the iris; occasionally, however, they develop into sarcoma.

b. Syphilitic Iritis.—There is marked ciliary congestion. The hyperemia in the iris has changed the original blue-gray color (as seen in the other eye in Fig. C) to a greenish tint. The pupil is dilated with atropin and shows the projecting synechiæ. The patient complains of pain and a moderate degree of photophobia; he was infected a few years ago.

removed through an incision in the cornea. When the eye is brought near the electromagnet, if there is a loose piece of iron in any part of the vitreous body it will be drawn around the lens against the iris and cause it to bulge forward. As soon as this is observed the patient's head is at once thrown back, or the electric current interrupted, lest the substance become fixed in the posterior surface of the iris. If the eye is now turned toward the site of the intruder, it can usually be drawn through the pupillary opening into the anterior chamber, if the precaution has been taken to dilate the pupil before beginning the operation. If the substance is lodged in the retina or choroid coat, some time may elapse before the magnet becomes effective, hence the attempt must not be abandoned too soon and may be repeated if necessary. The smaller the particle of iron the greater must be the power of the magnet, and *vice versa*. If there is no large magnet at hand, an attempt must be made to find and extract the foreign body with the small magnetic probe, either through the original scleral wound, or through a fresh in-



a



b

c



cision. [If the foreign substance, steel or iron, is properly located by means of skiagraphic examination, the Editor believes that its extraction through a suitably placed incision by means of the extension point of a Hirschberg or similar magnet is an eminently proper surgical procedure.]

DISEASES OF THE IRIS AND CILIARY BODY.

1. Inflammation.

As a rule, the anterior segments of the uvea, the iris, and the ciliary body all participate in the inflammatory process, so that inflammation of the iris alone (*iritis*) or of the ciliary body (*cyclitis*) is not very common; in severe grades of inflammation even the choroid becomes involved, and we speak of *uveitis*.

The **symptoms** of iritis are very characteristic. There is pericorneal injection, and the pain, lachrymation, and photophobia are so severe that the patient finds it difficult or impossible to open his eyes in a bright light. Hyperemia is a conspicuous symptom, which manifests itself in chromatic alterations in the iris; a blue iris becomes green, gray changes to a reddish tint, a light brown or green color is somewhat darker and more muddy than that of the normal eye (Plate 30, *b*). The striations are partially obscured; the tissues are somewhat turbid and puckered or thickened from the inflammatory infiltration. The increase in the volume of the iris causes shrinking and partial loss of mobility in the pupil. The latter symptom is aggravated by the inflammatory irritation in the muscle-fibers, and eventually the pupil fails to react promptly to light on account of attachments between the pupillary margin and the lens capsule. At first certain portions only of the pupillary margin become attached, which, after dilatation of the pupil with a mydriatic (atropin, hyoscin, cocain, homatropin), appear as tongue-shaped

projections of varying width (Plate 30, *b*) and mar the circular outline of the pupil. These attachments are called *posterior synechiæ*, to distinguish them from anterior synechiæ between the iris and the cornea, which occur in perforations of the cornea. If the case is seen late, the entire pupillary margin may be bound down and the pupil may fail to dilate altogether under the influence of a mydriatic. Sometimes the pupil begins to dilate at various points after a long application of the drug, by the freshly formed synechiæ giving way, and if the attachments are not too old it is sometimes possible to loosen them all in this way and restore the contour of the pupil. The attachment of the whole pupillary margin by an annular synechia is termed *exclusion of the pupil* (*seclusio pupillæ*), because the space behind the iris, the posterior chamber, is excluded from the anterior chamber.

If numerous synechiæ are formed, they are usually associated with exudation into the pupillary region and the formation of a false membrane which completely occludes the pupil; this is called *occlusion of the pupil* (*occlusio pupillæ*). The interference with vision is directly proportional to the thickness of the membrane. At the same time a similar exudation takes place in the aqueous humor, which becomes turbid with leukocytes and fibrin, and leads to still greater obscuration of the iris and pupil. In severe grades the leukocytes may collect at the bottom of the anterior chamber, forming a *hypopyon* and thus indicating the purulent nature of the iritis. In other cases the exudate consists principally of fibrin and forms a semitransparent grayish opacity in the anterior chamber. High grades of iritis usually give rise to a diffuse haziness of the cornea, due partly to fine deposits on its posterior surface, and partly to direct participation in the inflammatory process in the form of an infiltration of migratory leukocytes.

The pain in severe iritis is often very great, and spreads from the eye to the brow and temple; it becomes almost unbearable if the eye is exposed to the light; but may

also be very severe at night, when it gives rise to excessive lachrymation.

On the other hand, there are insidious cases of iritis, in which the patient is hardly conscious of inflammation; persons are sometimes found to have synechiæ who do not remember ever to have had inflamed eyes.

Iritis may be present in one eye only; and, if it recurs, attacks the same eye; or it may show a tendency to affect both eyes, so that the second eye becomes involved sooner or later.

Cyclitis presents other manifestations of inflammatory exudation:

1. Precipitates on the posterior lamina of the cornea, ranging in size from a mere point to 2 mm., consisting of circular accumulations of round cells, mixed with pigment or fibrin, gray or brown in color, according to the nature of the pigment. They are seen chiefly on the lower portion of the cornea and may be so minute as to be detected only with the aid of a loupe and lateral illumination, or with the ophthalmoscope under direct light. They are often limited to the inferior quadrant of the cornea—*i. e.*, to a triangular area, the apex of which lies in the pupil. The exudation in cyclitis may also take the form of hypopyon or deposit grayish-white masses which appear floating in the inferior and lateral portions of the anterior chamber.

2. The exudation may be principally into the posterior chamber and produce a general attachment of the surface of the iris to the lens-capsule by a complete posterior synechia. This is recognized by the gradual retraction of the iris against the border of the lens as the exudate contracts, and the deepening of the anterior chamber at its periphery. In this form of ciliary attachment dilatation of the pupil is complete, or absent altogether.

3. The exudate may occupy the vitreous chamber, especially the anterior portion, and, if extensive, produce more or less marked impairment of the visual power. The exudate behind the lens in course of time becomes

organized into masses of inflammatory tissue which gradually contract, while the continuous irritation of the ciliary body and progressive obscuration of the vitreous finally lead to atrophy of the eyeball (phthisis bulbi).

In severe grades of cyclitis the three forms of exudation may be combined, and severe inflammatory symptoms, especially pain and congestion, are present. On the other hand, a simple cyclitis may run its course without giving rise to pain and congestion, being recognized only by the presence of precipitates and turbidity of the vitreous and by the interference with vision which these alterations produce. The term *serous iritis* was formerly given to this variety; but the name is incorrect and now obsolete.

Alteration of the intraocular pressure is an important symptom of cyclitis. It may be abnormally high, in the form characterized by the deposition of precipitates, or it may fall below the normal, especially in severe grades of the disease and in the later stages. Associated with abnormally diminished tension we often have the important subjective symptom of extreme sensitiveness to pressure in the ciliary region, the patient immediately drawing his head back when we attempt to touch this region. Another ominous symptom of cyclitis is edema of the upper lid.

Iridocyclitis, or the association of cyclitis and iritis, constitutes a dangerous and very intractable disease, owing to the permanent injuries to the eye inflicted by the cyclitic exudates in the posterior chamber and in the vitreous, which are absorbed with great difficulty and cannot be removed by surgical means. The cyclitis shows a decided disinclination to heal, and may torture the patient for months and years. But even a simple, chronic cyclitis, producing mere punctiform precipitates on the cornea and a moderate degree of turbidity in the vitreous, may run a slow and tedious course. When primary it usually attacks both eyes. In cases of long duration the choroid usually becomes involved.

While, therefore, even an *acute* iritis or iridocyclitis may be protracted for weeks, the duration of the

chronic form must be expressed in months or years, and the final result is but too often practical or total blindness, the more so if the disease shows a tendency to relapses, as it often does. Chronic iritis and iridocyclitis eventually lead to atrophy of the iris, cataract, atrophy of the bulb, either of its anterior portion (*phthisis anterior*) or of its entire volume (*phthisis bulbi*).

The **causes** of iritis and iridocyclitis are manifold. We distinguish between *primary* and *secondary* iritis. The latter occurs in keratitis, especially in the purulent form, and after scleritis, choroiditis, retinal detachments, intraocular tumors, etc.

The primary form may follow in the train of various constitutional diseases, or it may occur as a localized disorder, as in traumatism. Syphilis is by far the commonest cause of iritis and iridocyclitis (in about one-half of all the cases).

Syphilitic iritis may assume the form of a simple iritis with synechiæ (Plate 30, *b*); or it may be attended with more or less extensive deposits on the cornea, or both these forms may be combined. Not uncommonly the disease presents a characteristic picture by the formation of nodules in the tissues of the iris (Plate 31). The color of these nodules when they are small (1 mm.) is grayish-red; when they are large (3 or 4 mm.) yellowish-red, and the surrounding portion of the iris is usually congested and reddened. They preferably select the pupillary, more rarely the ciliary, margin, and grow quite rapidly. Occasionally several appear together, and by coalescing convert portions of the pupillary margin into a thick fold. The site of such a syphiloma is invariably marked by a synechia, which persists even after the nodules have become absorbed. Any marked thickening of the pupillary margin, associated with an extensive synechiæ, should arouse a suspicion of the specific nature of the inflammation, even if the nodules are not plainly visible, as they often require the microscope for their detection.

Iritis, with or without the formation of nodules, usually

Plate 31.

Syphilitic Condylomatous Iritis.—L. P., 23 years old, footman. The patient complains of pains in the right temporal region and in the right eye for the past five days. Ciliary injection; cornea and aqueous humor normal; pupil dilates in the form of a kidney upon instillation of atropin, owing to a synechia at the outer lower portion. At this point a reddish tumor as large as a hemp-seed projects into the pupil. On the raphe of the penis, about the middle of the pendulous portion, is a moderately infiltrated, pigmented scar of a livid coppery hue, about as large as a bean. Inguinal, cervical, and axillary glands swollen. Diffuse pustular syphilide.

Cured with inunctions and subconjunctival injections of sublimate.

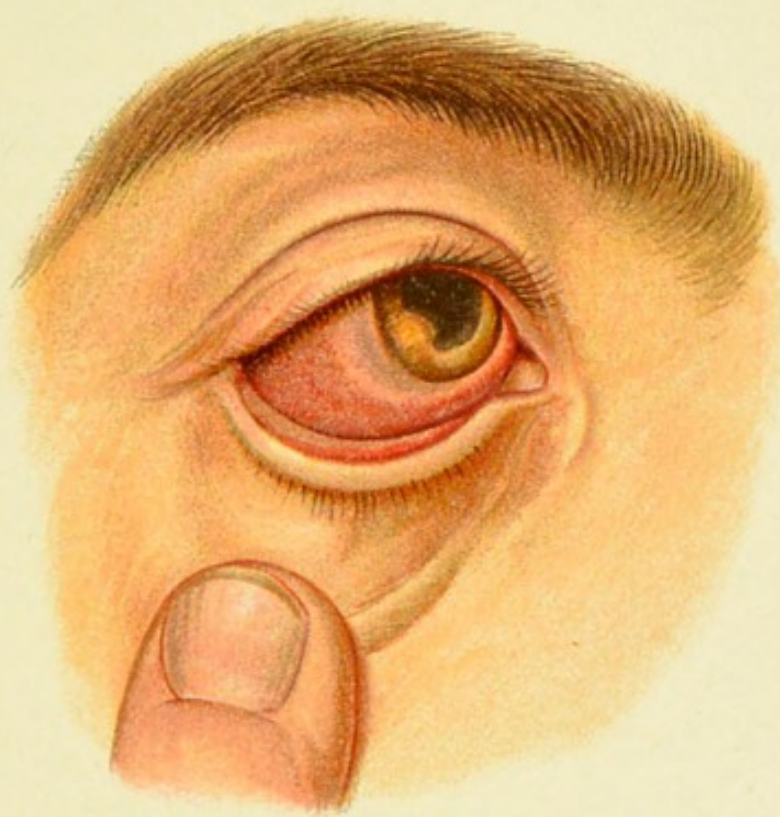
appears in the secondary stage of syphilis, so that the syphilomata might with propriety be termed *papules*. If, as rarely happens, it appears after the first year of the disease, the nodules may be wanting, or they may appear during the tertiary stage, when they should be designated as *gummata*. They may attain to a considerable size and involve the ciliary body.

In the course of a syphilitic infection iritis is very apt to develop in both eyes; it is prone to recur, and is often accompanied by disease of the choroid, retina, and optic nerve.

Iritis may be attributable to hereditary syphilis. Chronic, bilateral iritis, occurring in a child, always suggests hereditary syphilis.

Rheumatic iritis is quite common in certain districts. It presents no characteristic symptoms, and the diagnosis must be based on evidences of rheumatic disease in other parts of the body, on the history, and on the effect of drugs. Relapses are frequent; they often follow relapses of articular rheumatism.

Gonorrheal iritis, occurring as it does in gonorrheal subjects who are apt to suffer from so-called gonorrheal rheumatism, is often difficult to distinguish from the rheumatic form. The same tendency to appear in association with articular rheumatism, or with relapses of the same, is observed in this type. It often proves very intractable.





Among the rarer forms of iritis may be mentioned *tuberculous* and *scrofulous iritis*, which occurs in tuberculous subjects either as a simple iritis with posterior precipitates, or as a chronic tubercular process with the formation of nodules in the tissues of the iris. The latter somewhat resemble syphilomata; but they are situated at the periphery, instead of at the pupillary margin, and their color is more gray or grayish-red. Their growth is less rapid than that of syphilomata and is attended with less inflammatory symptoms; usually they are associated with large precipitates on the posterior layer of the cornea. A number of smaller nodules often coalesce and form an irregular, lumpy mass, which partially fills the anterior chamber. The process preferably begins in the lower portion of the anterior chamber. The presence of miliary tubercles among the larger spherical proliferations in the iris sometimes helps to clear up the diagnosis. Small nodules resembling tubercles may also be caused by the entrance of cilia into the anterior chamber and, rarely, by leukemia and pseudoleukemia.

Iritis is occasionally met with in *diabetes* and *albuminuria*, or in connection with *recurrent fever*.

Idiopathic iritis, or one in which no primary disease can be discovered, is not attended with marked inflammatory symptoms. It occurs usually in the form of a chronic iridochoroiditis with synechiæ, deposits, and disease of the deep layers of the vitreous, which becomes more and more turbid. It leads to obscuration of the lens and atrophy of the choroid and retina, and may in the course of years result in complete blindness. Idiopathic iritis is a grave disease, which usually affects both eyes, although at first one eye may be more seriously involved than the other.

The most important of those forms not due to a constitutional disease is *traumatic iridocyclitis*, because it is apt to be followed by *sympathetic ophthalmitis* of the other eye. Destruction of the affected eye at least is the usual outcome. Traumatic iridocyclitis occurs when a perforat-

ing wound becomes infected; aseptic wounds of the iris and ciliary body heal without inflammation. The complication may be caused by operative (as in cataract-extraction, for example), as well as by accidental injuries. Whenever a wound penetrates to the ciliary body, or a foreign body is allowed to remain in the eye, there is danger of iridocyclitis and inflammation of the other eye.

Sympathetic ophthalmitis sometimes follows an acute purulent iridocyclitis, which will eventuate in panophthalmitis, but is much more likely to develop into the chronic, insidious form of iridocyclitis, which at first does not appear to be at all alarming. The visual acuity of the injured eye may not be materially affected, and no more serious symptoms may be noted than a slight congestion, diminished tension, and a few punctate precipitates on the posterior surface of the cornea, so that the surgeon hesitates to sacrifice the eye. On the other hand, if a phthisical bulb, in which the primary inflammation has already subsided, again becomes inflamed, either spontaneously or as the result of a second traumatism, sympathetic ophthalmitis may develop, while non-inflammatory, painless atrophy of the globe is unable to produce the condition. In most cases the sympathetic inflammation makes its appearance while the primary iridocyclitis is still active, say from four to eight weeks after the injury. Its coming is heralded by prodromata which are designated *sympathetic irritation*, because they are not actually inflammatory in character; they are defective accommodation, photophobia, and beginning ciliary congestion. These are soon followed by the objective inflammatory symptoms, distinct ciliary congestion, pupillary contraction and synechiæ, opacities on the posterior surface of the cornea, and all the other signs of iridocyclitis. Sympathetic iritis is one of the most malignant forms of inflammation and often goes on to total blindness. The route of transmission from the affected to the unaffected eye has not as yet been discovered. [Sympathetic ophthalmitis may sometimes arise in the wake of an attack of sympathetic irritation,

may sometimes coexist with it, but frequently, indeed usually, develops without any premonition or association of this character. Therefore it would seem to be safer to regard sympathetic irritation and sympathetic inflammation as two essentially different conditions.—ED.]

Diagnosis of Iritis.—It is of vital importance to be able to distinguish iritis and iridocyclitis from glaucoma, because remedies appropriate for the treatment of iritis have the most disastrous effects in glaucoma, and the error might easily lead to total blindness. In iritis the pupil is contracted; in glaucoma dilated. The intraocular tension (which is markedly elevated in glaucoma) affords valuable information, and its investigation must not be neglected in any case declared to be iritis. The former occurrence of iritis may have an important bearing on the diagnosis, as it throws light on the question of syphilitic disease; hence a persistent pupillary membrane must not be mistaken for the remains of synechiæ. A persistent pupillary membrane is not infrequently seen in the form of gray dots or threads in the pupillary region, passing from the iris to the lens-capsule. But while the remains of synechiæ originate at the pupillary margin and form a wreath or wreath-like patches, the threads of a persistent pupillary membrane are attached to the small circle of the iris and appear in the form of irregular groups.

The **treatment of iritis and iridocyclitis** includes local remedies and general constitutional medication for the removal of the primary disease. In every case mydriasis must be maintained with atropin or hyoscin, supplemented with a few drops of cocain in refractory pupils. If intraocular tension is increased, atropin must be withdrawn for a time. The eye must be protected from light, either with dark glasses or by keeping the patient in a dark room, according to the severity of the iridocyclitis. Atropin and dark glasses not only diminish the pain by keeping the iris quiet, but also tend to check the inflammatory process by lessening the entrance of blood into the contracted iris. Mydriasis also renders the

formation of synechiæ difficult. In simple iritis, showing mere punctate opacities, one to two drops of a 1 per cent. solution are usually sufficient; in acute iritis five to eight drops per day, with, if necessary, the same dose of a 2 per cent. solution of cocain. Absolute rest for the eyes and abstinence from alcohol in any form should be strictly enforced in acute iritis.

Syphilitic iritis demands vigorous antispecific treatment in the form of inunctions, 2 to 4 gm. per day, and potassium iodid, 2 to 5 gm. per day. In obstinate cases a course of sweating is recommended, which, with sodium salicylate internally, is also applicable to the rheumatic form.

Tubercular iritis can only be treated by general constitutional medication; excision of the nodules is not of much avail. On the other hand, I have seen good results in several instances follow the introduction of sterilized iodoform into the anterior chamber.

In traumatic iritis prophylaxis plays an important part. The strictest asepsis is to be observed in all operations within the eyeball; infected wounds should be sterilized as well as possible with carbolic acid, with the thermocautery, or in any other appropriate way. For this purpose iodoform may be again recommended; I once saw, in the case of a suppurating cataract-wound, an apparently hopeless eye saved by the introduction of iodoform into the wound and into the anterior chamber. Cold compresses, so popular among the laity, are to be absolutely forbidden in all wounds of the eyeball, on account of their great liability to infection. [The Editor has the greatest confidence in sterilized ice compresses in non-infected wounds of the eyeball. Naturally great care is exercised that the compresses themselves shall not carry infection.] If the wound is already infected, cold compresses, as well as leeches, are as useless as would be the "singing of hymns at a fire" (Hirschberg).

Most important is the prophylaxis of so dangerous a disease as sympathetic iritis. Therefore, all injuries likely

to produce this affection must be treated and watched with the utmost care, and such eyes must be enucleated which threaten sympathetic iritis, especially such as have badly healing wounds in the ciliary region. If the scars in such eyes begin to contract, they usually are ready for enucleation, especially if to other indications are added abnormally low tension, persistent ciliary congestion, and tenderness on pressure. The prevention and cure of traumatic iritis demand the removal of any foreign body which may be within the globe, a procedure still more earnestly demanded if sympathetic iritis threatens.

If sympathetic inflammation has already set in, immediate enucleation of the eye originally affected is usually indicated. This is to be followed by long-continued mydriasis (with atropin) in a dark room and a course ofunctions with blue ointment.

In order to guard against the occurrence of traumatic, and especially sympathetic iritis, it is well never to operate on an inflamed eye except for the removal of a foreign body or for other imperative reasons. Operation on a sympathetically affected eye is never advisable until some time after the subsidence of all inflammatory symptoms, when an attempt may be made to improve the visual power by an iridectomy.

If occlusion takes place after iritis, iridectomy must be performed early, to prevent the occurrence of glaucoma.

2. Injuries of the Iris.

Injuries of medicolegal significance, caused by violent external force are sometimes met with in the iris. Such are fissures in the pupillary margin and rupture of the sphincter, which destroy the circular outline of the pupil, and, by producing partial or total paralysis, give rise to *traumatic mydriasis*, although the latter is also caused by simple contusion of the nerves. *Iridodialysis* is the term applied to a rupture of the ciliary attachment, in which a dark crescentic opening is formed in the periphery of the

anterior chamber ; the pupillary margin at this point is straight instead of circular and does not react. The iris may be completely or partially detached in ruptures of the sclerotic coat, a condition termed *traumatic irideremia* or *aniridia* ; or the iris may be folded back on itself (Plate 34, *b*). All these injuries of the iris may be attended with hemorrhage into the anterior chamber and dislocation of the lens.

3. Tumors of the Iris and Ciliary Body.

Cysts usually develop after perforating wounds of the anterior chamber. They are generally benign, though somewhat difficult to remove. Operation should not be delayed, because there is danger of glaucoma and consequent loss of vision.

Sarcoma occasionally occurs in the iris and ciliary body. It is usually pigmented, the color ranging from gray to dark-brown or black, and very malignant. A sarcoma sometimes develops from small pigment-spots in the iris which have been present a long time ; the growth is at first very slow, but gradually a large mass is formed (Plate 30, *a*), which, if left to itself, breaks through the outer coat. Sarcoma of the ciliary body may escape detection a long time, until finally it emerges on the periphery of the anterior chamber. If the sarcoma is limited to the iris and is very small, it may be excised ; but if the sarcoma is large, or situated in the ciliary body, enucleation is necessary to save the patient's life. Tubercular tumors have been referred to under Iritis.

DISEASES OF THE LENS.

The crystalline lens, being a non-vascular structure, is not subject to inflammation ; at the most it may be invaded secondarily by pus-corpuscles after rupture of the capsule by traumatism or suppuration.

Cataract is practically the only disease, whether primary or secondary to other disease or injury of the eye, that occurs in the lens.

The color of the opacity is gray or bluish-white by direct light, and black on a red background by transmitted light (Plates 32 and 33). As the opacity is often situated at the periphery of the lens, it is necessary to dilate the pupil to bring it clearly into view. If this is done and the eye is examined by lateral illumination, the position of the opacities is readily seen. Depending on the arrangement of the lens-fibers, an incipient cataract appears in the form of radial lines, streaks, or wedge-shaped opacities (Plate 33, *b* and *c*) running from the anterior or posterior cortical layer toward the anterior or posterior pole, and, if long enough, encroaching on the pupillary region. In addition a number of punctate opacities are scattered here and there. The opacities are always in the fibers of the lens or in the epithelium covering the posterior surface of the anterior lens-capsule, never in the capsule itself. When we speak of *capsular cataract* we mean opacities due to proliferation of the capsular epithelium, which are found exclusively in the central portions of the anterior lens-surface, are sometimes bright yellow, sharply defined, and in some cases projecting (Plate 34). This form consists of a dense accumulation of epithelial cells, while the other varieties of cataract are due to degenerative changes, being produced by the lens-fibers between the nucleus and the cortex in the region of the equator separating and leaving open spaces, which become filled with transparent granular masses. The fibers in the equatorial region swell up and become turbid, and eventually break down, forming a viscid mass containing fat-granules, droplets of myelin, cholesterol-crystals, and débris. The distinct swelling which occurs in the lens during the formation of a cataract would appear to indicate that the degenerative process is associated with an increased amount of fluid in the lenticular substance. The swelling can be recognized by the less-

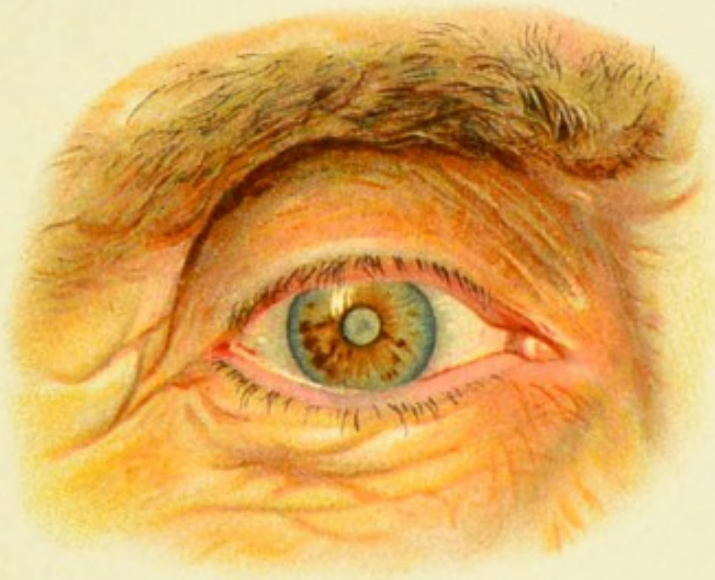Plate 32.

a. Senile cataract, mature—i. e., the opacity has extended as far as the capsule, and therefore the pupillary margin. The patient, a woman of 72 years, is otherwise in good health.

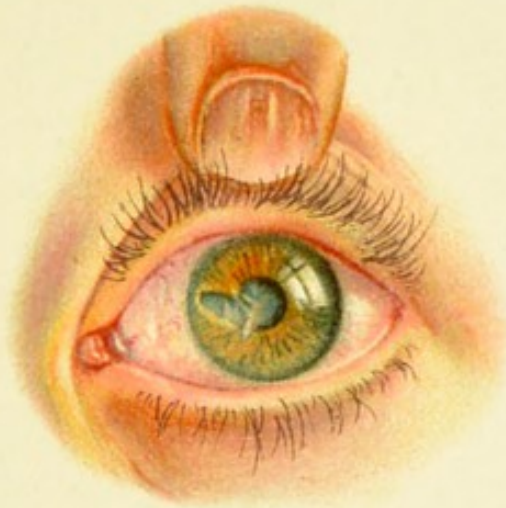b. Traumatic Cataract.—The patient, a boy of 14 years, stepped into a large box with one foot and struck his left eye against the edge. The eye was probably injured by a nail or a sharp splinter, for we see in the lower portion of the cornea (a little to the nasal side of the center) a freshly healed wound about 2 mm. long, appearing as a grayish streak, with a corresponding wound in the nasal half of the iris and in the anterior lens-capsule. The opacity has spread from the anterior cortex, where it surrounds the wound in the capsule, to the posterior cortex, forming a delicate rosette, which is only seen by transmitted light. There is some ciliary injection. Visual acuity, $\frac{6}{36}$. Two weeks later the opacity in the posterior cortex had diminished, while that in the anterior was more pronounced, and the lens began to swell. In the course of the next two weeks the entire lens became opaque. The unabsorbed portion of the cataract was then removed by repeated discission, and after a few months the visual acuity was found to be $\frac{6}{8}$, with a hypermetropia of 12 D.

ened depth of the anterior chamber from forward dislocation of the iris. The entrance of aqueous humor into the lens from any cause, such as injury to the anterior capsule, is followed by swelling and turbidity of the lens, and what is known as traumatic cataract (Plate 32, *b*).

Subjective symptoms—that is to say, impairment of vision—are present only when the cataract affects the axis of the lens; a peripheral opacity may be present a long time without being discovered. A central cataract soon betrays itself by the appearance of dark spots and streaks, “*muscæ*,” in the field of vision, and by diplopia, which is particularly noticeable when the patient looks at a light. If the entire surface of the lens becomes turbid, the visual deterioration is, of course, greater than it is when a few rays of light can still find their way through streaks of opacity. As the cataract progresses the visual acuity decreases more and more, although in an otherwise healthy eye some degree of vision is always preserved in simple cataract, enabling the patient to discern movements of the hand at 20 to 30 cm. and to locate a candle in the dark



a



b



correctly in any direction (see p. 43). The flame of a candle can always be seen in a dark room at a distance of 3 meters at least. If even this power is lost, we must assume the existence of morbid changes in the deeper coats of the eye, retinal detachments, atrophy of the optic nerve, diffuse choroiditis, etc. Sometimes the beginning of senile cataract can be inferred from the development of myopia or from the increase in an already existing myopia, due to the fact that the swelling of the lens increases its refractive power. The various forms of cataract are classified clinically as follows :

a. Partial Stationary Cataract.

Under this head are included :

1. Anterior Polar Cataract.—A small white spot or pyramidal mass is formed at the anterior pole of the lens, and sometimes drawn out to a point (Plate 34, *a*). It is a so-called capsular cataract—*i. e.*, the opacity consists of proliferating capsular epithelium. It may be congenital, and is in that case usually bilateral ; or it may be acquired. A central corneal ulcer perforates, the aqueous humor escapes, and the lens is brought against the site of the ulcer, exciting proliferation of the capsular epithelium. Hence a macule is always seen in the center of the cornea in such cases. The process just described occurs only in childhood, usually after gonorrheal conjunctivitis. An anterior polar cataract is always behind the lens-capsule, and cannot therefore be detached from the lens without opening the capsule and producing traumatic cataract. If the opacity is small, the visual disturbance is slight, but increases in a strong light with the contraction of the pupil.

2. Posterior polar cataract forms an opacity on the posterior pole, and may be congenital (rarely), when it is caused by remains of the fetal tunica vasculosa lentis and of the hyaloid artery ; or acquired, after pigmentary degeneration of the retina, choroiditis, or degeneration of

Plate 33.

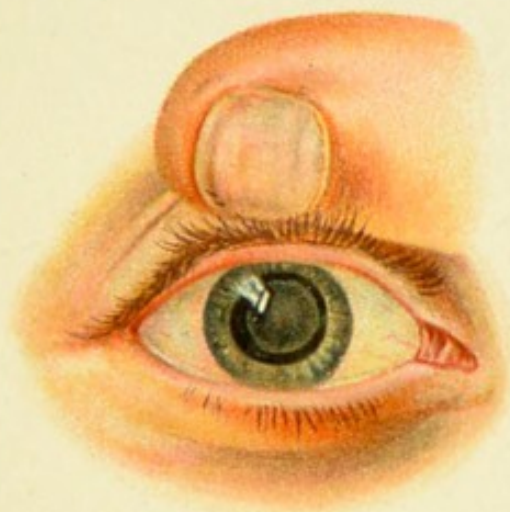
a. Zonular Cataract.—The patient is 7 years old, and has had lamellar cataract in both eyes since infancy. His visual acuity, which was never quite normal, is now $\frac{1}{4}$ in the eye represented in the plate, the defect becoming more noticeable on his being sent to school. The lens was removed, as the eyes are in other respects normal.

b. The same eye by transmitted light. The pupil is dilated, showing fine, radiating lines surrounding the central opacity (an unusual condition).

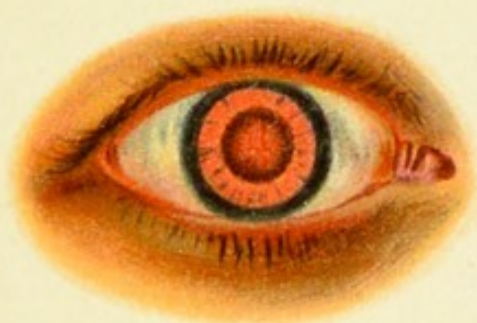c. Incipient senile cataract in transmitted light, showing the radiating streaks of opacity to the best advantage, after dilatation of the pupil. In other respects the eye is normal. The slight degree of ciliary congestion is caused by a trifling abrasion of the cornea, not shown in the picture.

the vitreous. The last two diseases usually produce somewhat greater opacity on the posterior cortex, and, with the exception of the congenital form, this posterior cataract shows a tendency to progress. The opacity caused by pigmentary degeneration, on the other hand, remains stationary for a long time. It can be detected only with the ophthalmoscope by transmitted light, and is one of the signs of this retinal disease.

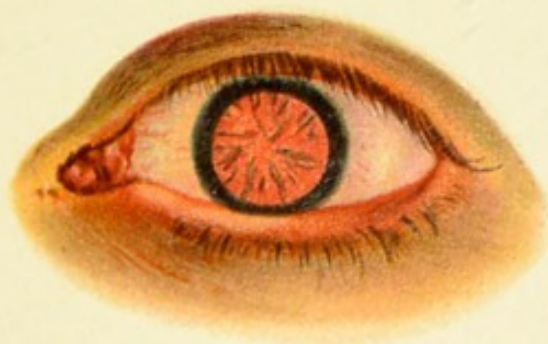3. Perinuclear, zonular, or lamellar cataract, is the most frequent form of cataract in childhood, and is supposed to have something to do with rhachitis (Horner). It consists of two cup-shaped opacities, enclosing the transparent nucleus between them. The size of the nucleus and of the cataract varies; the one shown in Plate 33, *a*, for example, is quite small. It is usually larger, and appears by lateral or transmitted light like a round disk, which by lateral illumination shows a distinct convexity; and if the light (in lateral illumination) is thrown on the posterior half of the lens the posterior opacity is seen with its concavity directed forward. Sometimes the margin of a lamellar cataract is seen by transmitted light to be covered with small projections, corresponding to slender strips of opacity placed on the edge of the cataract, and therefore called "riders." In other



a



b



c



cases short streaks are seen nearer the periphery (Plate 33, *b*). Occasionally we meet with a case in which the lamellar cataract remains rudimentary and the disks are represented by fine disseminated dots. The visual disturbance is, of course, correspondingly slight, while in severe cases it is extreme, especially when the pupil is contracted, not a ray of light being able to get past the cataract and reach the retina. Lamellar cataract is usually bilateral and stationary, but later in life may become complete.

In the **treatment** of the first-named varieties of cataract operative interference is indicated only when the cataract is extensive; lamellar cataract, however, usually requires operative removal sooner or later. Simple iridectomy (at the lower, inner angle) may allow some light to enter past the cataract in mild cases; but, as a rule, removal of the lens by discission is indicated.

b. Progressive Cataracts.

This group comprises the more frequent forms of cataract, the most important of which is

I. Senile Cataract.—It begins as a spoke-like arrangement of lines, streaks, or wedges, radiating from the pole of the lens, *incipient cataract*, goes on developing as *cataracta intumescens*, and becomes complete, *cataracta matura*, when the opacity reaches the capsule, so that the iris does not throw a shadow on the opacity by lateral illumination (Plate 32, *a*). The cataract is called “ripe” at this stage, because it is in the best condition for operative removal, the soft consistency of the cortex permitting its complete separation from the capsule. In a strong light the yellowish nucleus may be seen shining through the grayish cortical layers. The nucleus may be colorless. Senile cataract is caused by the physiologic sclerosis of the lens due to age, which is the cause of diminished accommodation (see p. 53) and serves to protect the nucleus from cataractous change, as shown by the fact that it retains its

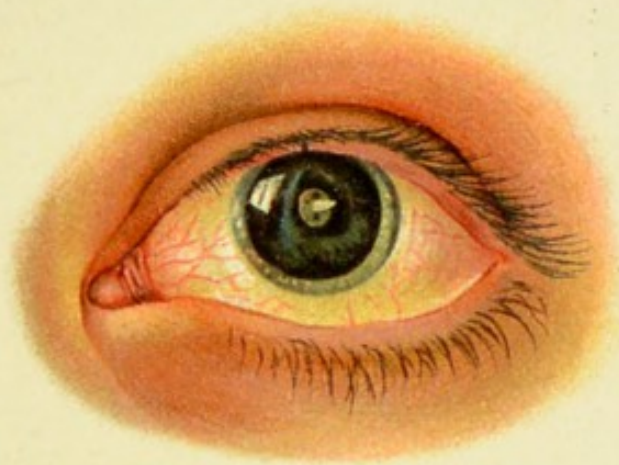Plate 34.

a. Anterior polar cataract, so-called pyramidal cataract. The boy, who is 15 years old, did not have any purulent discharge at birth; but six months later he was seized with convulsions. The physician who was called at the time discovered a spot in the eye. Hereditary syphilis is suspected, as there were two premature births in the family and eight children died at ages ranging from eight to ten weeks. There are only three children living. No other signs of syphilis are to be found; the cornea is perfectly transparent and the fundus of both eyes normal. Visual acuity on both sides is only $\frac{1}{4}$, as the centrally situated opacity, of course, produces marked disturbance, especially with contracted pupil. On both sides a small pointed cone is seen on a round, grayish-white base 2.5 mm. in diameter, projecting into the anterior chamber. The remaining portions of the lens are clear. In performing discission a circular section was made around the polar opacity and the latter extracted. Microscopic examination shows it to be a so-called capsular cataract, situated under the capsule. The operative removal of the lens was successful, and resulted in a visual acuity on both sides of $\frac{1}{2}$, with hypermetropia of 13 D.

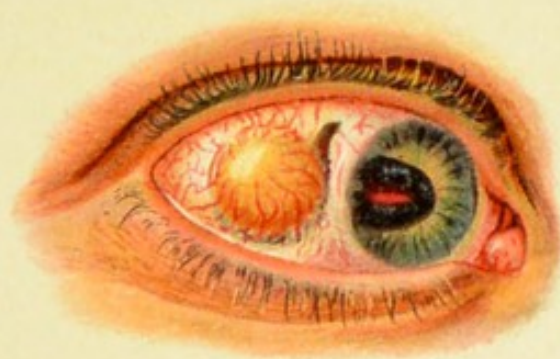b. Subconjunctival Displacement of the Lens.—Three months and a half ago the patient, a man of 56 years, struck his eye against the limb of a tree. The accident was immediately followed by marked reduction of visual acuity; at present the patient is just able to count fingers at $2\frac{1}{2}$ meters. Convex glasses have no effect; the left eye is normal. The scar in the sclera, through which the lens escaped, is plainly seen on the temporal side of the cornea. The pupil is displaced outward, having evidently been turned backward by the force of the blow. Streaks of injected vitreous are seen running toward the seat of rupture. The posterior layers are so turbid with blood that the fundus is barely visible; but a rent in the choroid coat can be seen on the temporal side. The conjunctiva was divided and the lens, which had become adherent and annoyed the patient, removed without injury to the original rupture or escape of the vitreous. Complete cure in ten days.

transparency more or less perfectly within the turbid cortex. After the seventieth year the sclerosis extends almost to the capsule, the usual gray color of the opacity is wanting, and it may happen that the lens remains semi-transparent, with a dark reflex due to the absence of cortical substance and the yellowish-brown discoloration of the nucleus—*cataracta nigra*.

The stage of maturity is followed by that of "over-ripeness," during which the volume of the lens gradually



a



b



diminishes, the anterior chamber becomes abnormally deep, and an anterior capsular cataract not infrequently appears in the shape of small white dots. Shining cholesterol-crystals are seen suspended in the liquefied cataract. As the cataract continues to shrink, it becomes tremulous, and, finally, the zonula may give way and produce luxation of the cataract.

2. Congenital cataract is much less frequent than the senile form ; it is usually bilateral and soft, as there is no nucleus. In very exceptional cases congenital total cataract is hard, for reasons that are not understood as yet.

3. Traumatic Cataract.—This is nearly always progressive. Any laceration of the lens-capsule, which admits the aqueous humor or vitreous body to the substance of the lens, is followed by cataract. The injury may be direct, caused by some perforating instrument (knife, scissors, foreign body, etc.) ; or indirect, from concussion of the entire globe, the capsule probably becoming ruptured at the equator. In rare instances cataract may be produced by mere concussion of the lens without solution of continuity in the capsular structures. In large wounds of the anterior capsule the greater part of the lens may become turbid within twenty-four hours ; in smaller wounds the cataract develops more gradually. A grayish or bluish-white discoloration at first appears about the injured spot (Plate 32, *b*) ; the lens-substance swells and projects into the anterior chamber in the form of a cone. Particles of the lens-substance separate and sink to the bottom. In small wounds the swelling is inconsiderable, and absorption of the cataract in the anterior chamber, which is usually quite rapid in young people, takes place more slowly in consequence. If the communication between the aqueous humor and the lens is maintained, swelling and absorption continue until all of the lens-substance except the capsule is removed. A small rent in the capsule may be enlarged by the swelling of the cataract ; or, if it is very small, it may be closed, either by the proliferation of capsular epithelium or by adhesion of the iris.

Such minute lacerations often produce a delicate rosette-like opacity (seen by transmitted light) in the posterior cortex of the lens, and the cataract may remain stationary for a time, or even diminish; but, as a rule, it becomes progressive and goes on to total opacity.

Secondary glaucoma is an important complication of traumatic cataract. As soon as the swelling of the lens becomes excessive there is danger of glaucoma, especially in old people. The increase in tension is at once indicated by cloudiness of the cornea, and, unless the pressure is relieved by paracentesis corneæ and evacuation of the cataractous mass, vision is gradually destroyed.

Cataract is sometimes attended with inflammation, the anterior chamber becoming contaminated at the time of the injury and setting up an iritis or iridocyclitis. Adhesions are formed between the lens and the iris or ciliary body, giving rise to *cataracta accreta*, which does not lend itself readily to operation.

4. Complicated cataract occurs in consequence of other diseases of the eye, such as acute iritis and iridocyclitis, especially the purulent forms (creeping ulcer); chronic iridochoroiditis with opacities in the vitreous, separation and pigmentary degeneration of the retina, and the end-stage of glaucoma. Persons with a high degree of myopia show a certain tendency to cataract, especially in advanced life. Complicated cataract is recognized by its abnormal, dirty-yellow or, if calcification has taken place, chalky color, by adherence of the iris, by thickening of the capsule, tremulousness, etc., and especially by the loss of function. In normal cataract, as has been stated (see p. 57), the power of locating a candle in the dark is always retained.

In addition to the **causes** of cataract which have been mentioned (senility, traumatism, etc.), we recognize diabetes and albuminuria and hereditary disposition.

In the **diagnosis** the following points are to be borne in mind: Incipient cataract must never be diagnosed until the eye has been examined by transmitted light.

The sclerosis incident to old age often produces an intense gray reflex in the pupil, which may be mistaken for a cataractous lens. By transmitted light, however, the pupil exhibits a beautiful red reflex, and the streaks of opacity which characterize incipient cataract are absent (Plate 33, c). In traumatic cataract, if the lens becomes opaque rapidly, a bright metallic reflex is sometimes seen in the posterior layers by lateral illumination; and must not be mistaken for a foreign body. The latter appears black by transmitted light, which is not the case with the reflex referred to.

The **treatment** of all forms of cataract, except the complicated, is essentially surgical. Partial juvenile cataracts are treated by discission, and the semifluid mass is evacuated through an incision in the cornea. Complete soft cataracts can also be removed by means of a short incision through the cornea and capsule. To remove a senile nuclear cataract a semicircular incision must be made concentric with the corneal margin and involving more than one-third of the circumference. If, after the delivery of the cataract through the pupil and corneal wound, it is found difficult to replace the iris, a small section must be removed by means of iridectomy. It is sometimes advisable in slowly ripening cataracts to operate before the stage of maturity has been reached. In such cases iridectomy is performed before the cataract is delivered, in order to make more room for the egress of the lens-substance and prevent an increase in tension from swelling of the cortical remains.

In traumatic cataract the intraocular tension must be carefully watched and a part of the lens-substance removed by paracentesis of the cornea, if the pressure rises. If the swelling is great, the pupil must be well dilated to allow the cataractous mass free access to the anterior chamber.

Dislocation of the Lens.

This is due to anomalies in the zonula. Owing to congenital unequal development, decentration of the lens to-

ward the shorter zonula takes place : *Ectopia lentis congenita*. If the upper zonula is shorter than the lower, the lens is displaced upward and the dislocation increases as the lower zonula gradually atrophies and disappears. Such a dislocation upward results in diminution of the upper angle of the anterior chamber and tremulousness of the iris, which loses the support of the lens. The same phenomena are observed after rupture of the zonula by a blow on the eye, a not infrequent accident. The lens may suffer only partial dislocation to one side, so that the margin is seen as a sharp circular line within the pupil (*subluxatio lentis*), or it may be thrown into the vitreous body (*luxatio lentis*). In the latter case the normal gray color of the pupillary reflex is changed to black, the entire iris is tremulous, and the lens is seen, by lateral illumination or with the ophthalmoscope, as a spherical body freely movable within the vitreous. In favorable cases it becomes fixed after a time by adhesions, cataract develops, and the lens contracts ; usually, however, a movable lens gives rise to *glaucoma*, probably by irritating the ciliary processes which secrete the aqueous humor. Even subluxation may have this effect.

A partial dislocation, whether congenital or traumatic, is very apt to become complete. Complete luxation may be anterior (although rarely), and a shrunken and turbid, or a semitransparent, lens is sometimes found in the anterior chamber. If the lens is transparent, the yellowish luster of its margin gives the impression of a large drop of oil in the anterior chamber. In violent contusions with rupture of the sclera the lens is sometimes bodily ejected from the eye, and the same accident may occur in perforation of the cornea by extensive ulcerations if the patient strains during the examination.

Spontaneous luxation into the vitreous chamber is caused by atrophy of the zonula in consequence of liquefaction of the vitreous humor occurring in severe myopia, anterior choroiditis, or retinal separation. Atrophy of the zonula sometimes occurs through the shrinking of an

over-ripe cataract, and luxation may be induced by the slightest shock, a blow, or the momentary congestion caused by bending over or sneezing.

The greater the dislocation of the lens, the greater the visual disturbance. Subluxation gives rise to myopia and astigmatism, and, later, to more marked disturbances from obscuration of the lens. Complete dislocation of the lens from the pupillary area has the same effect on vision as absence of the lens, or *aphakia*, and causes a reduction in the refractive power, which in emmetropic eyes amounts to 10 D. If the lens becomes fixed in the vitreous body and causes no further disturbance, the patient can see quite well with cataract-glasses. Such cases are, however, exceptional. Usually the condition is very painful and gradually leads to glaucoma and total blindness.

The **prognosis** in dislocation of the lens is very grave. The eye is always in great danger and in many cases its loss is unavoidable.

Treatment.—In a very few cases the aphakia may be corrected by the use of suitable convex glasses. In partial dislocations, especially in young persons, the lens should be removed by discission; in fresh luxations into the vitreous chamber an attempt may be made to induce fixation by rest in bed, any intercurrent rise in tension to be met by the instillation of myotics (physostigmin, pilocarpin), or the glaucoma may be checked by repeated sclerotomy. Extraction of the lens is usually attended with a dangerous escape of vitreous humor. Glaucoma not infrequently necessitates removal of the globe.

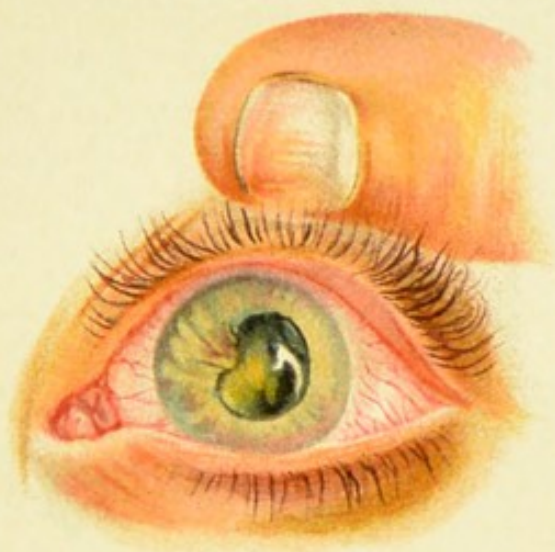DISEASES OF THE VITREOUS BODY.

Disease of the vitreous, in the large majority of cases, is secondary to inflammation of the ciliary body, choroid, and retina, and manifests itself in turbidity, due to the entrance of inflammatory material, and in degeneration,

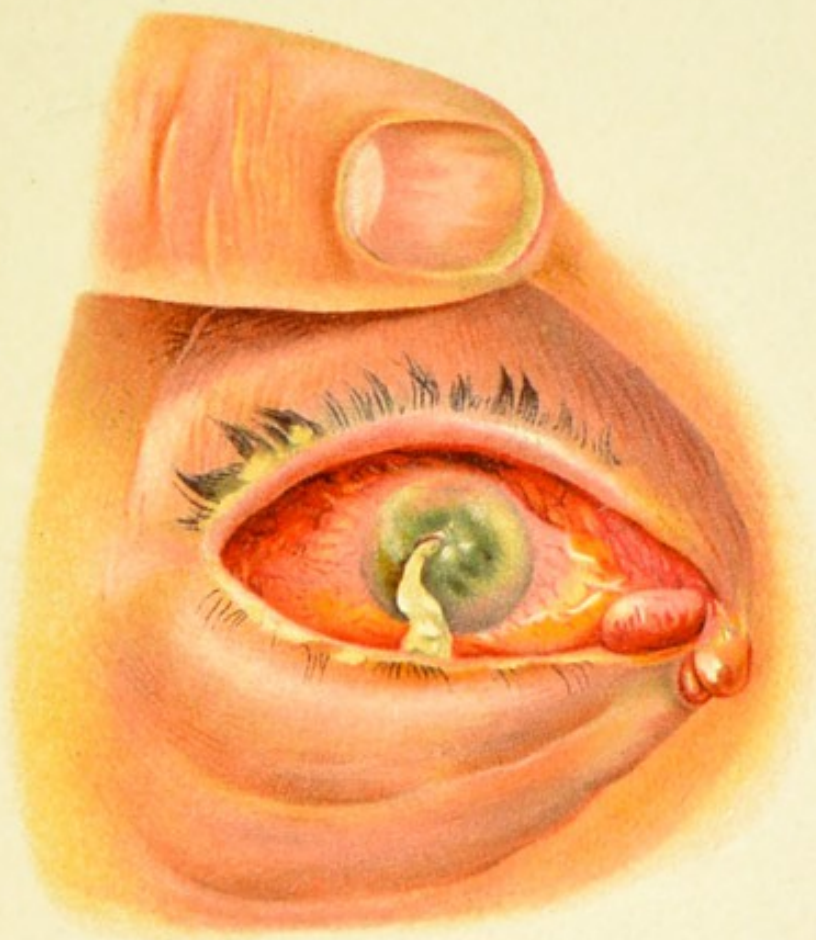Plate 35.

a. Suppuration in the Vitreous, Caused by a Piece of Iron.—B. H., aged 9 years, while digging with a small hoe on April 17, 1897, suddenly felt something enter her left eye. On April 20 she was admitted to the clinic, the eye having meanwhile become inflamed and vision impaired. The cornea was covered with a diffuse haze, and by lateral illumination a fine gray scar, about 1.5 mm. in length, was seen in the inner upper quadrant where the substance had entered the eye. There was a broad adhesion between the lens and the iris. Hypopyon of 2 mm. in the anterior chamber; large exudate in the pupil, making it difficult to determine the condition of the lens. It was found impossible to extract the piece of iron with the large electromagnet. Six days later (when the picture was taken) the edema and redness of the conjunctiva had subsided, the anterior chamber was clear, and the pupillary exudate had shrunk to a mere shred. The lens was not distinctly cataractous, but displayed a greenish-yellow reflex, indicating suppuration in the vitreous. Visual acuity reduced to light-perception at 20 cm. On May 12 enucleation was performed. The piece of iron was found embedded in the nasal portion of the vitreous, surrounded by pus. Normal recovery.

b. Panophthalmitis from the Entrance of a Piece of Iron into the Vitreous.—B. M., a peasant-woman, 41 years old, got something in her right eye while hoeing potatoes. At first she felt only a sensation of grittiness; but vision at once became dim, and during the night she had violent pains in the eye and on the right side of the brow. The next day the lids were swollen and somewhat inflamed, the eyeball protruding and less movable than normal, and moderate chemosis developed. No dacryostenosis or conjunctivitis. Cornea uniformly opaque, with a sharp linear wound, 1.5 mm. in length, in the outer upper quadrant. The iris was barely visible. Small hypopyon and exudate in the pupil. No reflex could be observed. When the eye was brought near the large electromagnet, the piece of iron at once emerged through the opening. The panophthalmitis, however, continued and the condition seen in the picture developed: Marked exophthalmos, edema of the conjunctiva (chemosis), and grayish-green discoloration of the cornea. A shred of necrotic tissue adheres to the wound, evidently a portion of vitreous which has undergone liquefaction-necrosis and escaped through the wound, as it is found impossible to wipe it off. *Enucleation* was performed twelve days after the accident, complete panophthalmitis having developed. The globe was filled with a yellowish-brown lardaceous mass, from which three colonies of streptococci and one colony of multiarticular, vacuolated bacilli, resembling the "Wurzell bacillus," were obtained. The wound healed without further complications.



a



b



leading to liquefaction or to the formation of fibrillar, flake-like opacities. As the vitreous possesses a feebleregenerative power than any other tissue in the body, the slightest escape of vitreous humor through a traumatic or operative wound, or any interference with its structure by the introduction of instruments, is likely to produce opacity and separation of the retina.

The suppuration caused by the entrance of a foreign body deserves special mention. What has been said in this connection about injuries of the sclera may be supplemented by the following: A foreign body which penetrates as far as the vitreous and retina is more likely to enter through the cornea than through the sclera; it may pass through the iris and the lens (Plate 36, *b*), or through the lens only, and sink to the bottom or continue its flight to the retina, depending upon the amount of momentum it has acquired. Having reached the retina the intruder either buries itself in its tissues or recoils and lodges somewhere in the lower anterior part of the vitreous, where it cannot well be detected even with the ophthalmoscope, so that its presence has to be inferred from the lesion in the retina.

If traumatic cataract develops, detection is even more difficult, although its probable course can be approximately determined by the position of the wound in the cornea, iris, and lens. [The Röntgen rays may always be utilized to locate foreign bodies within the eyeball.—ED.] If the wound remains aseptic, the piece of iron can usually be extracted by means of the large electromagnet (see p. 175), which may also be utilized to determine the nature of the foreign body. Unfortunately, however, such particles of iron usually set up a violent suppurative inflammation, which results either in suppuration of the vitreous (Plate 35, *a*) or in panophthalmitis (Plate 35, *b*). This is particularly the case when the particle of iron is derived from a hoe or similar digging tool. Panophthalmitis may declare itself within forty-eight hours. The infection is probably carried by the substance itself, since

a piece of a hoe, which is contaminated with dirt, is more likely to produce a severe purulent inflammation than a spicule of forged iron, a glass splinter, grain of powder, or other foreign body. It may be that in some cases infection occurs secondarily through the wound.

Occasionally the entrance of a foreign body into the vitreous chamber gives rise to an insidious attack of iridocyclitis, which is no less dangerous to the life of the eye than an acute, purulent inflammation. Enucleation is usually necessary to save the other eye, for sympathetic ophthalmitis is particularly apt to develop in such cases. Even if no inflammatory process of any kind develops after the entrance of a spicule of iron, the eyesight may eventually be destroyed by *siderosis*—*i. e.*, gradual chemical solution of the iron which is deposited on the retina. In a few rare instances the presence of iron-particles has been tolerated without detriment to the eye. Aseptic particles of copper are at first tolerated, but eventually injure the retina; although, if they become encapsuled in the anterior portion of the vitreous, a serviceable degree of visual acuity may be retained for some time.

Enucleation is indicated in most cases of suppuration in the vitreous and of panophthalmitis. The latter is recognized by edema of the lids, the conjunctiva, Tenon's space, and the adjacent orbital tissue, which produces exophthalmos. The inflammatory edema in the orbit is caused by the toxins elaborated by the pyogenic microörganisms in the interior of the bulb, and not by the microbes themselves, since they cannot well penetrate beyond the bulb. For this reason enucleation may be performed during the height of the panophthalmitis without danger of the inflammation spreading downward and to the brain, providing the eyeball does not become infected during the operation by soiled fingers or instruments.

In these cases of injury to the eye by a particle of iron, sustained while the patient is hoeing in the fields or doing any work in which iron is made to strike iron, as in cutting with a chisel, for example, the surgeon should not allow

himself to be influenced by the statement that the substance merely hit the eye without entering. It is quite common to be told by the patient that he saw a stone as big as his fist strike him on the eye and fly off, and then to find a piece of iron in the depths of the eyeball. The illusion may be explained by the fact that the patient sees the foreign body entoptically magnified during its passage through the vitreous, and projects its flight outward. In all such cases, therefore, it is of the utmost importance to make a thorough search for particles of iron, and to remove the intruder as quickly as possible. By prompt removal the eye may be saved even when the particle of iron is from a hoe; but every minute of delay makes the prognosis more doubtful. The best method to pursue is the one described on p. 175.

GLAUCOMA.

Increased intraocular tension, increased hardness of the eyeball, or glaucoma, is one of the most important diseases of the eye, and every practising physician should be perfectly familiar with its symptoms, as the integrity of the affected eye depends on prompt application of the proper treatment.

There are two varieties: *primary* and *secondary glaucoma*.

I. Primary Glaucoma.

Primary glaucoma is spontaneous, usually bilateral, and may be acute or chronic, with a varying increase of intraocular tension. In the acute form we have all the external signs of *inflammation*: Redness, pain, edema of the conjunctiva and iris; in the chronic form these are absent most or all of the time. Primary glaucoma is therefore subdivided into *inflammatory* and *non-inflammatory* or *simple glaucoma*, although the latter may at any time change to the inflammatory form.

a. Inflammatory Glaucoma.—We subdivide this again into *acute* and *chronic* inflammatory glaucoma, bearing in mind that the acute form often changes to the chronic.

Inflammatory glaucoma is usually preceded by prodromata, such as headache, dragging and pain in the temple, and occipital neuralgia; the visual acuity is variable, and the patient complains of a haziness before his eyes, as if he were surrounded by smoke or fog. If he looks at a light during one of these prodromal attacks, it appears to him surrounded by an iridescent halo, the cause of which is found, on examination, to be a slight haziness of the corneal surface. The cloudiness is most pronounced in the central portion, which resembles the appearance of glass the surface of which has been breathed upon. There is also some shallowing of the anterior chamber—*i. e.*, the iris and lens are displaced forward; the pupil is somewhat dilated and reacts slowly to light. Sometimes there is ciliary congestion. A prodromal attack of this kind may last several hours, the eye becoming quite normal again afterward. The intervals between the attacks become progressively shorter. They may be induced in various ways, by emotional excitement of any kind, pleasurable or painful, by a hearty meal, by bending over, etc.; or they may occur without any demonstrable cause. The prodromal stage may be protracted for weeks, months, or even years; but in the last case permanent alterations result—congestion of the anterior ciliary vessels, excavation of the nerve-head, and impaired vision.

An outbreak of fully developed glaucoma (*glaucoma evolutum*) is characterized by the following symptoms: Violent pain in the eye and headache, which soon become unbearable and rob the sufferer of sleep and appetite, accompanied by intense congestion of the eyeball. Edema of the lids occurs, and in severe cases of the bulbar conjunctiva. There is rapid loss of vision, which is almost absolute in the affected eye. If the attack is a severe one,

the patient vomits as long as it lasts and usually takes to his bed, with every appearance of severe illness. The characteristic objective signs are diffuse haziness of the cornea; shallowing of the anterior chamber; alteration in the shape of the pupil, which is dilated and may be irregular, oval with its long axis vertical or obliquely placed, or decentered; reaction to light imperfect or absent. A greenish reflex is seen in the depths of the pupil (Plate 36, *a*), from which the name of the disease is taken (green cataract), although there is nothing characteristic about it, since it is observed in most elderly people when the pupil is dilated. Its presence in glaucoma becomes apparent on account of the dilatation incident to the disease, and is due chiefly to sclerosis of the lens, complicated in some cases with a slight turbidity of the vitreous. Upon inspection with the ophthalmoscope the eye-ground is seen imperfectly or not at all, owing to the opacity of the cornea and the turbidity of the vitreous referred to. Upon palpation the tension of the eyeball is found to be increased.

If treatment is delayed, an attack of this kind may last for days and weeks, and subside very gradually, leaving the visual acuity permanently impaired and followed by chronic congestion of the anterior ciliary veins, dilatation of the pupil, immobility and atrophy of the iris, and reduction in the depth of the anterior chamber (Plate 36, *a*). In many cases the visual field shows marked restriction on the nasal side. The optic nerve is more or less excavated and discolored from atrophy, particularly in the temporal half.

Hemorrhagic glaucoma, a most malignant form of the disease, gives rise to hemorrhages in the retina, which are detected with the ophthalmoscope, and sometimes into the anterior chamber and into the vitreous.

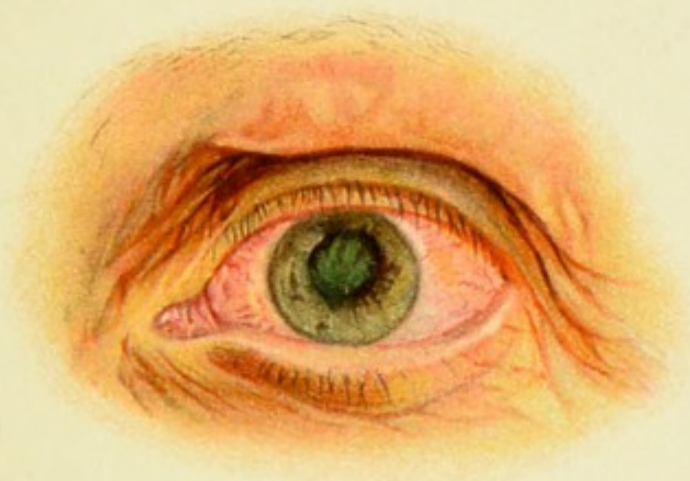When the glaucomatous habit is once established, the attacks occur again and again in slightly decreasing severity. Each successive attack increases the deterioration of vision and damage to the optic nerve, until finally perma-

Plate 36.

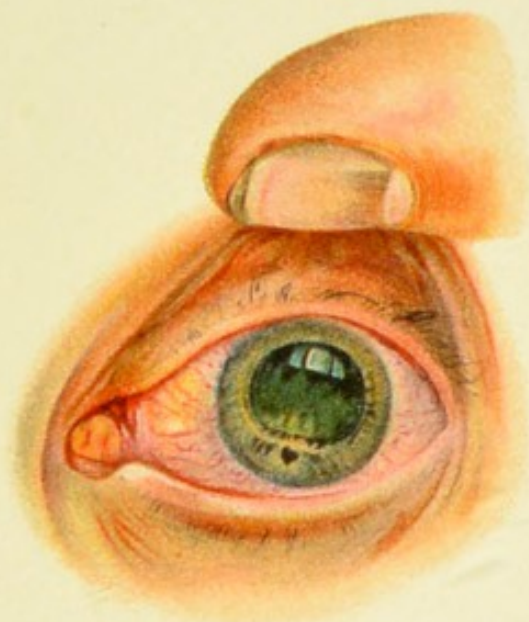
a. Acute Glaucoma.—E. B., a woman of 71 years, underwent an operation for cataract in the left eye seven years ago (without iridectomy), and since that time enjoyed perfectly good vision, the posterior capsule having been removed by discission shortly after the operation. The pupil was round and movable. Two days ago she was suddenly seized with pain in the eye and dimness of vision, without apparent cause. Her condition improved at first after the administration of myotics, and visual acuity returned to $\frac{1}{2}$. Another acute attack occurred in the clinic, with tension of T + 2, redness of the eye, and dilatation of the pupil (see illustration), which was displaced slightly upward, as frequently happens in glaucoma. The surface of the eyeball was cloudy, and a grayish-green reflex was observed in the deep portions of the eye. Sclerotomy and thorough discission were performed, and by continued use of physostigmin and pilocarpin the patient was finally cured, with a visual acuity of $\frac{1}{3}$.

b. Spicule of Iron in the Vitreous (Extracted) ; Laceration of the Iris, Traumatic Cataract, and Turbidity of the Vitreous.—V. Sch., a peasant-woman, 60 years old, got a piece of iron in her left eye while hoeing potatoes on June 14, 1897. The next day she went to a doctor, who pronounced the wound superficial and of no consequence. The patient did not feel pain at any time, but complained of a thick haziness immediately after the injury. When she was admitted to my private hospital, on the 17th, the eye was inflamed and the channel of the wound plainly seen (see figure). The wound consisted of a rent in the cornea (where the foreign body had entered), a little below the center, appearing as a fine, gray line 1.5 mm. in length; a laceration in the iris, traumatic cataract, and a triangular wound in the posterior capsule. The iris was adherent to the wound in the anterior capsule. The pupillary reflex was greenish, and by lateral illumination a metallic luster was seen in the opacity of the posterior cortex. The foreign body was not visible, although undoubtedly present in the vitreous. On approaching the large electromagnet it was at once drawn into the anterior chamber, from which it was removed through the original point of entrance (June 17). On the 27th the inflammation had practically disappeared, and on the 29th the woman was discharged. All inflammatory symptoms had subsided and the patient was able to count fingers at 2 meters. On July 9 the visual acuity was still the same and the cataract had not progressed; the fundus also was plainly visible.

nent, absolute blindness supervenes and the eye presents the appearances characteristic of *absolute glaucoma*: The cornea is less opaque than in the early stages, and is surrounded by a wreath of dilated blood-vessels; the anterior



a



b



chamber is excessively shallow; the iris reduced to a narrow ribbon or completely obliterated in places (Plate 40). The pupil is widely dilated and immovable, and shows a greenish reflex shining through. The papilla of the optic nerve is deeply excavated in its entire circumference and the eyeball is as hard as stone. From time to time the eye is quite painful, and eventually degenerates, while the cornea becomes permanently obscured and covered with glassy deposits and hypertrophied folds. The sclera may exhibit ectasia about the cornea or in the equatorial region. The lens becomes cataractous.

The course of chronic inflammatory glaucoma is slower than that of the acute variety, which sometimes takes the form of *fulminating glaucoma* and utterly destroys the eyesight in a few hours.

b. Non-inflammatory or Simple Glaucoma.—

In this treacherous form of glaucoma the visual deterioration imperceptibly goes on to complete blindness without the patient's being aware of distinct attacks or of pain and inflammation. The examining surgeon often finds one eye irremediably injured or absolutely blind, and the other more or less amblyopic; rise in tension is barely perceptible or even absent; but the optic nerve is found to be excavated. By testing the tension repeatedly at various times of the day, however, especially early in the morning, the cardinal symptom can usually be obtained, and on careful inquiry the patient admits that he has had slight pain and dimness of vision. The loss of vision usually begins at the circumference of the field of vision, the restriction being most noticeable at first on the nasal side. Central vision is also affected to a corresponding extent, although it is relatively better up to a certain period in the disease. The disease always affects both eyes, and may be protracted for years, eventually passing into the inflammatory or the hemorrhagic form. In some cases of simple glaucoma the degeneration of the optic nerve is probably hastened by the abnormal loss of rigidity of the lamina cribrosa.

Generally speaking, glaucoma is a disease of advanced life. Inflammatory glaucoma is rare before the fiftieth year; simple glaucoma sometimes occurs before that age. Occasionally the process is met with in children.

Infantile Glaucoma.—The changes produced by glaucoma in the growing eye include abnormal enlargement, which is never observed in the adult (if we except the ectasiæ which occur in the degenerative stage), no matter how long the rise in tension continues. *Buphthalmos* or *hydrophthalmos* develops if the process is not arrested. The first symptom observed is the characteristic cloudiness of the surface of the cornea, followed shortly by diffuse opacity of the entire membrane, which becomes enlarged and covered with spots. Upon careful examination a peculiar network of ribbon-like streaks is seen in the depths of the corneal tissue. This phenomenon persists after the tension has returned to the normal, and furnishes, in the writer's opinion, an important, albeit somewhat tardy, support to the diagnosis. The dilatation of the pupil and shallowing of the anterior chamber are less marked than in the adult form, and, if the cornea has become enlarged, the anterior chamber will appear abnormally deep. Excavation of the optic nerve is not slow to develop in most cases. The disease usually affects both eyes. The children exhibit photophobia and usually appear to feel some pain, so that considerable difficulty is experienced in making an examination. As it is quite impossible to make a satisfactory test of the tension if the infant struggles and cries, anesthesia is usually employed for the entire examination, including inspection with the ophthalmoscope. In rare instances the disease tends to spontaneous cure; but, as a rule, it goes on to complete destruction if not checked by the proper treatment. Sooner or later the child strikes against some object in his surroundings, and the weakened membranes burst and shrivel up.

Glaucoma occurs shortly after birth or during the first few years of life. It is unknown in later childhood.

It may be stated, in general, that myopic eyes almost never become affected with inflammatory glaucoma, but may be attacked by the simple form. Arterial sclerosis and cardiac weakness are predisposing causes. The mechanism of glaucoma is not well understood. The rise in tension is thought to be caused by increased secretion of fluid within the eye (von Graefe's serous choroiditis) and by obstruction to the normal outflow from changes in the eye (obstruction to the outflow in the anterior chamber in the form of circular adhesions between the periphery of the iris and the cornea, Knies and Weber theory).

Dilatation of the pupil with atropin is positively known to bring on glaucoma if the eye is predisposed to the disease or has already suffered an attack.

Diagnosis.—Inflammatory glaucoma is very apt to be confounded with iritis; and the differential diagnosis is of the highest importance, as the two conditions demand radically different treatment. It should be made a rule of practice never to use atropin until the tension has been accurately determined. In iritis the pupil is contracted; in inflammatory glaucoma, dilated. The recognition of simple glaucoma depends on an ophthalmoscopic examination. A fatal error is to mistake infantile glaucoma for parenchymatous keratitis; the two conditions are very similar in their external appearances during the initial stage. The distinction is made by observing the tension.

The **prognosis** is always grave. Simple glaucoma is more difficult to cure than the inflammatory variety; but the hemorrhagic form is the most hopeless of all. The more precarious the condition of the heart and blood-vessels, the more dubious will be the prognosis in a given case of glaucoma.

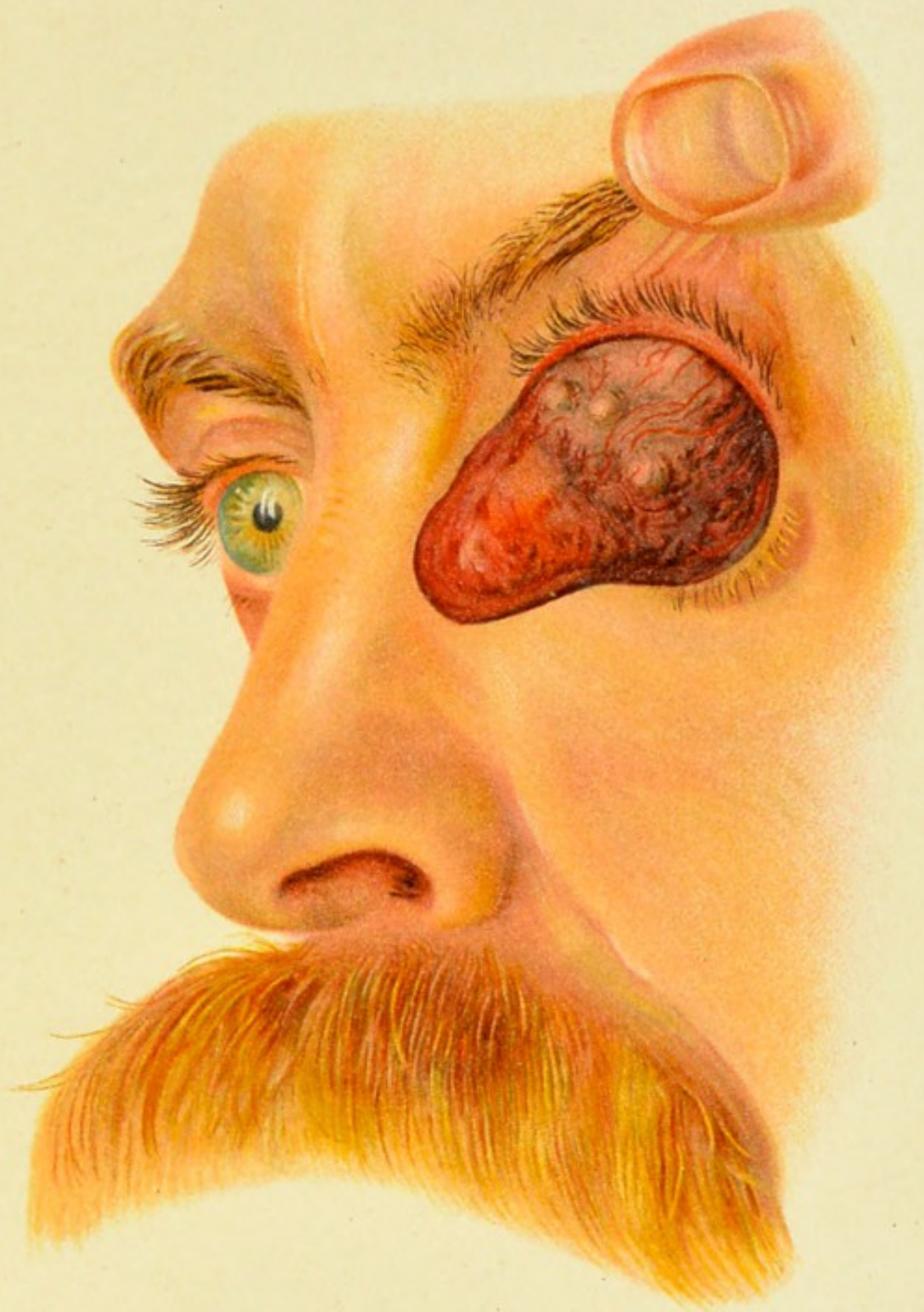
The **treatment** consists in the local use of myotics, physostigmin or pilocarpin, and in most cases surgical operation. Medicinal treatment must be begun at once: 3 to 5 drops of a $\frac{1}{2}$ per cent. solution of physostigmin (eserin), or 5 to 10 drops of a 2 per cent. solution of pilocarpin,

Plate 37.

Sarcoma of the choroid, which has ruptured anteriorly. The patient, who is 53 years old, says he received a severe blow on the left eye eleven years ago, by running against a beam, and that since then vision gradually deteriorated and the eye sometimes gave him pain. About six months ago the eye began to increase in size. A large conical tumor projects through the palpebral fissure, and is seen to be covered with a number of smaller nodules (hidden in part under the upper lid). A small, bluish segment of the cornea is seen below. The growth is imperious to sunlight even when a lens is used. In places it feels hard to the touch. No pulsation in the tumor. No glandular swelling on the left side of the head. The whole contents of the orbit were immediately extirpated and the diagnosis of sarcoma confirmed by examination of the specimen (moderately pigmented spindle-cell sarcoma) and by the subsequent course, for the man died a year later of a large sarcoma involving the left half of the pelvis and the inguinal glands on both sides, and of a sarcoma in the right deltoid muscle. The tumor did not recur *in situ*.

instilled into the eye every day. Pilocarpin is the milder of the two, and is well adapted for long-continued use and after an operation. This is supplemented by subcutaneous injections of morphin, which has the double advantage of inducing sleep and assisting in the production of myosis. Atropin is to be strictly avoided in glaucoma.

The success of an operation for glaucoma depends altogether on its being performed early in the disease. Iridectomy is the best operation in inflammatory, and sclerotomy in simple, glaucoma in an advanced stage. In the early stages of simple glaucoma iridectomy may also be employed. It is often advisable to combine the two operations, and many cases require repeated sclerotomies at varying intervals, the myosis meanwhile being steadily maintained. The course of the disease is in most cases marked by frequent relapses, which readily yield to proper treatment. But in no case should a patient be left to himself without observation after the performance of an iridectomy. In hemorrhagic glaucoma, not iridectomy, but sclerotomy is indicated, combined with active myosis and cardiac stimulants. Infantile glaucoma can be cured by repeated sclerotomy, if begun early enough.





2. Secondary Glaucoma.

This form of glaucoma may occur at any age and as a complication of various diseases. It manifests itself by cloudiness of the cornea, dilatation of the pupil (unless there are annular adhesions), and pain. Like the primary form, it may lead to loss of vision through excavation of the nerve-head.

Secondary glaucoma is induced by the following conditions:

1. Any condition tending to draw or push the iris forward; anterior synechiæ with corneal wounds, especially such as bulge forward, or pressure by swelling or subluxation of the lens.

2. Posterior displacement of the iris by a lens which has entered the anterior chamber.

3. Pupillary occlusion.

4. Iridocyclitis with precipitates on the posterior surface of the cornea.

5. Mechanical irritation of the ciliary body by a lens in luxation or subluxation.

6. Intraocular tumors, sarcoma and glioma in the second stage (before rupture outward has occurred).

The **treatment** of secondary glaucoma is chiefly directed to the relief of the condition which produced the rise in tension. Anterior synechiæ must be separated or the attached portion of the iris excised (iridectomy). A dislocated lens in the anterior chamber is to be removed. Occlusion of the pupil demands an iridectomy to restore communication between the anterior and posterior chambers. In iritis combined with increased tension sclerotomy is indicated and often suffices to restore the normal pressure.

DISEASES OF THE ORBIT.

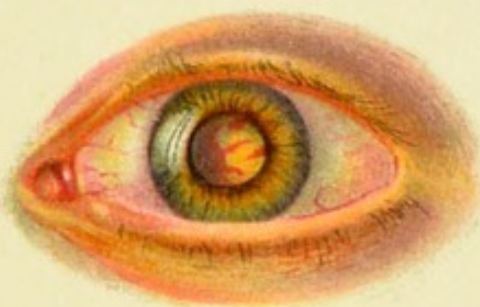1. Inflammations.

Inflammation may originate in the periosteum of the orbit, or it may attack the contents of the orbit primarily.

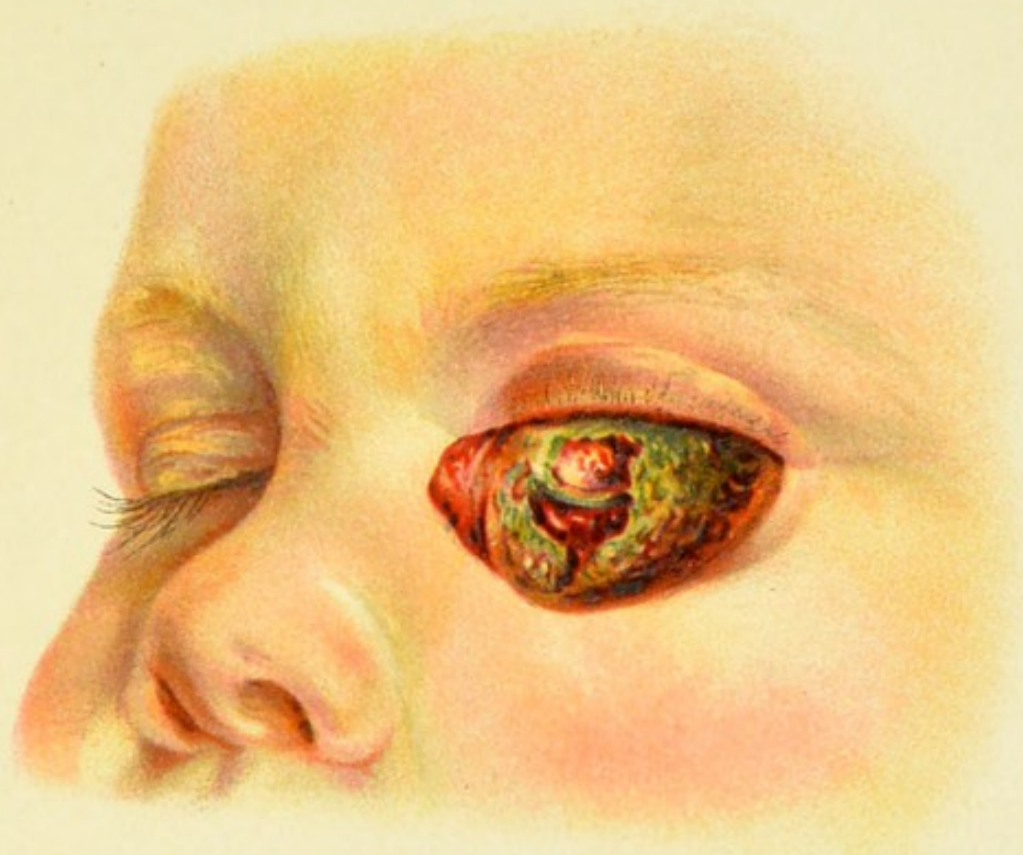Plate 38.

a and *b*. **Glioma of the Retina.**—The infant was quite well up to the sixth month of its existence, at which time she began to squint with the left eye. When she was one year old her mother noticed a yellowish reflex in the pupil, which appeared more and more distinct as the pupil dilated. A few weeks ago (the child is now twenty months old) the right eye began to show signs of failing vision. The left eye was somewhat inflamed, hard ($T + 1$), and larger than the right. The left iris brown, the right blue. Left pupil dilated and rigid, transmitting a bright reflex (see Fig. *a*) corresponding to several nodules which appeared to occupy the greater portion of the vitreous. The surface of the tumor streaked with red, partly blood-vessels and partly, no doubt, hemorrhages. In the right eye, in which tension was normal, the pupil was dilated and there was a complete, funnel-shaped retinal separation; the eye appeared to be nearly blind. Enucleation of both eyeballs was proposed and refused; but the child was brought back one year later to have the operations performed. At this time there was marked protrusion of the left eye; the cornea was increased to twice its normal size and was opaque; two days after admission it ruptured and large masses of the tumor protruded through the opening (Fig. *b*). Four days after admission, enucleation on the right side and extirpation of the contents of the orbit on the left were performed. On account of severe hemorrhage, however, it was impossible to sterilize the orbit thoroughly in the region of the optic foramen; on the next day fever set in, and on the day following, *scarlet fever*. Death two weeks after the operation, from purulent meningitis.

Periostitis of the orbit is quite frequently met with. Its usual seat is the margin, where it produces thickening and tenderness on pressure. The thickened masses of bone are not movable. Often there is edematous swelling of the lids. An inflammation situated in the posterior portion of the orbit is less easily recognized and often very difficult to distinguish from orbital cellulitis. It manifests itself by protrusion, with more or less pain, and lessened mobility of the eyeball (Plate 39). Sometimes the nature of the process is not recognized until a deep-seated periostitis leads to suppuration and the abscess ruptures anteriorly, when the roughness of the bone is felt with the probe. The suppurative process may spread to the cranium and cause meningitis or cerebral abscess. This complication is particularly apt to follow periostitis of the



a



b



roof of the orbit. A periostitic abscess at the orbital margin produces marked swelling and redness of the superjacent area, and ruptures externally. A fistula is often formed, through which the roughened bone can be felt with a sound; after discharging pus for some time the fistula becomes closed by the characteristically contracted adherent scar seen in bone-suppurative. There is usually a defect at the corresponding point on the bone, caused by the caries. Ectropion of the upper or lower lid sometimes develops from adhesion with the fistula.

Orbital periostitis develops after injuries and in the course of tuberculosis, the immediate cause of the process being usually traumatic, hence the upper outer and lower inner margins of the orbit are most liable to be attacked by tuberculous caries. Children commonly suffer from this form, which is comparatively frequent; while in adults syphilis is more likely to be the causal factor. In the tertiary stage the bones become thickened from periostitis; suppuration is less common.

The treatment of suppurative forms of inflammation has for its first object to provide evacuation of the pus through the skin. This is best accomplished by making an incision 2 to 3 cm. long through the periosteum to the bony margin, at the point of greatest swelling. The periosteum is then separated from the bone by means of a curet and the wound extended between the periosteum and the bone, so as to afford a good view of the injury. A drainage-tube or strip of iodoform-gauze is then introduced into the wound to allow the pus to discharge freely. Caries of the orbital margin requires general supporting treatment and, if necessary, removal of the necrotic bone with a sharp curet.

Syphilitic periostitis can usually be made to disappear by a vigorous course of blue ointment and potassium iodid.

Inflammation of the cellular tissue of the orbit leads to **phlegmon of the orbit**, or **retrobulbar abscess**, and manifests itself by severe external symptoms, as

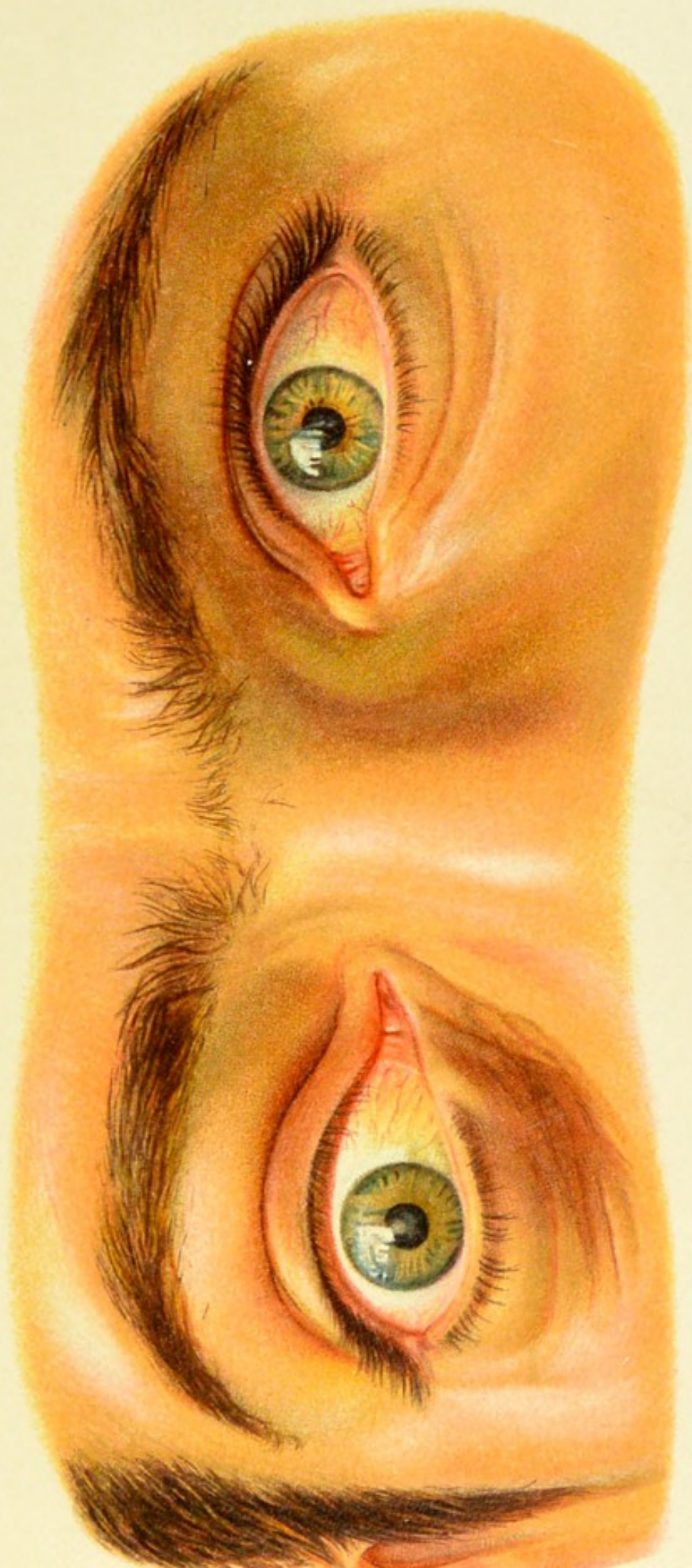Plate 39.

Exophthalmos of the right eye, probably due to periostitis of the orbit. Patient is a baker, 20 years old, and was admitted to the clinic on account of grave symptoms in the right eye, which he first noticed two weeks ago. After violent cold and headache the eye became so swollen that he could not open it. On raising the lid with the finger he found that he saw double. The swelling soon subsided, but the diplopia remained, and the patient has to keep the right eye closed when he walks. The eyeball is displaced forward and downward, about 8 mm. in each direction. The movements are much restricted in every direction, especially upward. When the eye is turned to the right, there is right diplopia; when to the left, crossed diplopia (diminished abduction and adduction). When the gaze is directed upward the image of the right eye is also displaced upward. Visual acuity and eye-ground normal. On palpating between the orbital margin and the globe a tumor-like resistance is felt. The rhinopharynx is normal. No signs of syphilis.

The patient's condition continued for two weeks without change, and then disappeared entirely without treatment, first the protrusion and then the dislocation downward. The cause is probably to be sought in a periostitis, secondary to catarrh of the frontal sinus.

marked edematous swelling of the lids and ocular conjunctiva (chemosis) and exophthalmos. The movements of the eyeball soon suffer restriction and vision is often impaired or utterly destroyed. The subjective symptoms are even more severe than in periostitis: Violent pain, vomiting, prostration, and slow pulse—together a very alarming clinical picture. The abscess may rupture and discharge its contents through a point on the lids, marked by intense redness and swelling and by fluctuation. After the pus is evacuated the inflammatory symptoms may subside rapidly; but a permanent visual deterioration usually remains, because orbital phlegmons are very apt to produce inflammation and atrophy of the optic nerve. The bulbus itself may suffer permanent injury in the form of retinal separation. If the inflammation is very severe, panophthalmitis may result, and, as in the case of periostitis, lead to fatal purulent meningitis and cerebral abscess.

Among the causes of orbital abscess may be mentioned:





1. Wounds which have become secondarily infected (traumatic or operative) and foreign bodies in the orbit.

2. Purulent catarrh of the bony cavities communicating with the orbit (frontal sinus, nasal cavities, ethmoid cells, antrum). Periostitis of the orbit first develops and transmits the infection to the orbital contents.

3. Erysipelas of the face, by the inflammatory poison penetrating to the deeper structure and setting up an inflammation in the cellular tissue of the orbit.

4. Metastasis in pyemia, typhoid, scarlet fever, influenza, etc.

The treatment consists in removing the pus in the depths of the orbit, which may endanger the eye and even the life of the patient. Access is obtained by the same method as that described in periostitis, and after the periosteum has been separated from the bone an incision is made in it from behind forward, over the point where the pus is supposed to be, and a drainage-tube introduced.

2. Injuries of the Orbit.

Either the soft parts or the bone may be injured. Fracture of the bone under certain circumstances gives rise to emphysema of the lids (see p. 107) and of the cellular tissue in the orbit, showing itself in protrusion of the eyeball. The latter can be replaced, but exophthalmos reappears as soon as the patient blows his nose. The partial or total loss of vision following a blow on the bones of the orbit or the entire cranium is important from a practical and medicolegal standpoint. Holder and Berlin have shown, by their valuable investigations, that a fracture of the base of the skull, even when the blow is received on the back or side of the head, is capable of producing fissures in the roof of the orbit and optic canal. The corresponding nerve is often so badly damaged by contusion or hemorrhage that the nervous pathway is interrupted and total loss of vision results. The patient on recovering consciousness is blind in one or both eyes, and

Fig. C.

Dermoid Cyst of the Orbit.—S. M., 58 years old. In her twenty-eighth year a tumor developed in the inner canthus of the left eye, attaining a considerable size within three months and then diminishing again. The growth of the tumor was attended with moderate pain and inflammation. Two months ago the neoplasm again began to grow, and has increased rapidly in size during the past three weeks, so that the globe is now displaced far to the temporal side, and the woman often complains of (crossed) diplopia. The tumor is smooth, the size of a pigeon's egg, and resilient to the touch; the lower portion is visible in the palpebral fissure under the bulbar conjunctiva, and can be felt for some distance backward along the bulb. It is freely movable, not adherent to the bone, does not diminish on pressure, and shows no pulsation. Left lachrymal duct patulous. Nasal cavity normal. Ophthalmoscopic examination: On the nasal side the wall of the globe is turned in so as to simulate a slight retinal separation; at the periphery the posterior portion of the ciliary body is seen (large, dark-brown projections). The diagnosis of dermoid cyst was confirmed after extirpation. The cyst extended along the nasal wall to the posterior pole of the orbit, and contained the characteristic mushy material, with numbers of cilia. The eyeball returned to its normal position and movement was restored. Cure in seventeen days.

a few weeks later the atrophy of the nerve is demonstrable with the ophthalmoscope. Fracture of the orbital roof and optic canal may also be caused by a severe blow on the upper or outer portion of the orbital margin. The resulting blindness in these cases is incurable.

3. Tumors of the Orbit.

Orbital tumors sooner or later have the effect of displacing the eye forward. A tumor situated within the cone of the recti muscles, surrounding the optic nerve, causes a displacement in the direction of the orbital axis; the movements of the eye are somewhat restricted, but equally strong in all directions, if the tumor is benign (Fig. E), whereas malignant tumors very early interfere with the action of the muscles. If a tumor develops outside the cone of the muscles from one of the orbital walls, the eyeball will be displaced toward the opposite side. Thus, a tumor beginning on the floor of the orbit causes

protrusion and upward displacement (Fig. F); one in the nasal portion of the orbit, protrusion and outward displacement (Figs. C and D). A deep-seated tumor can sometimes be located by palpation with the little finger between the globe and the orbital margin. The nature of

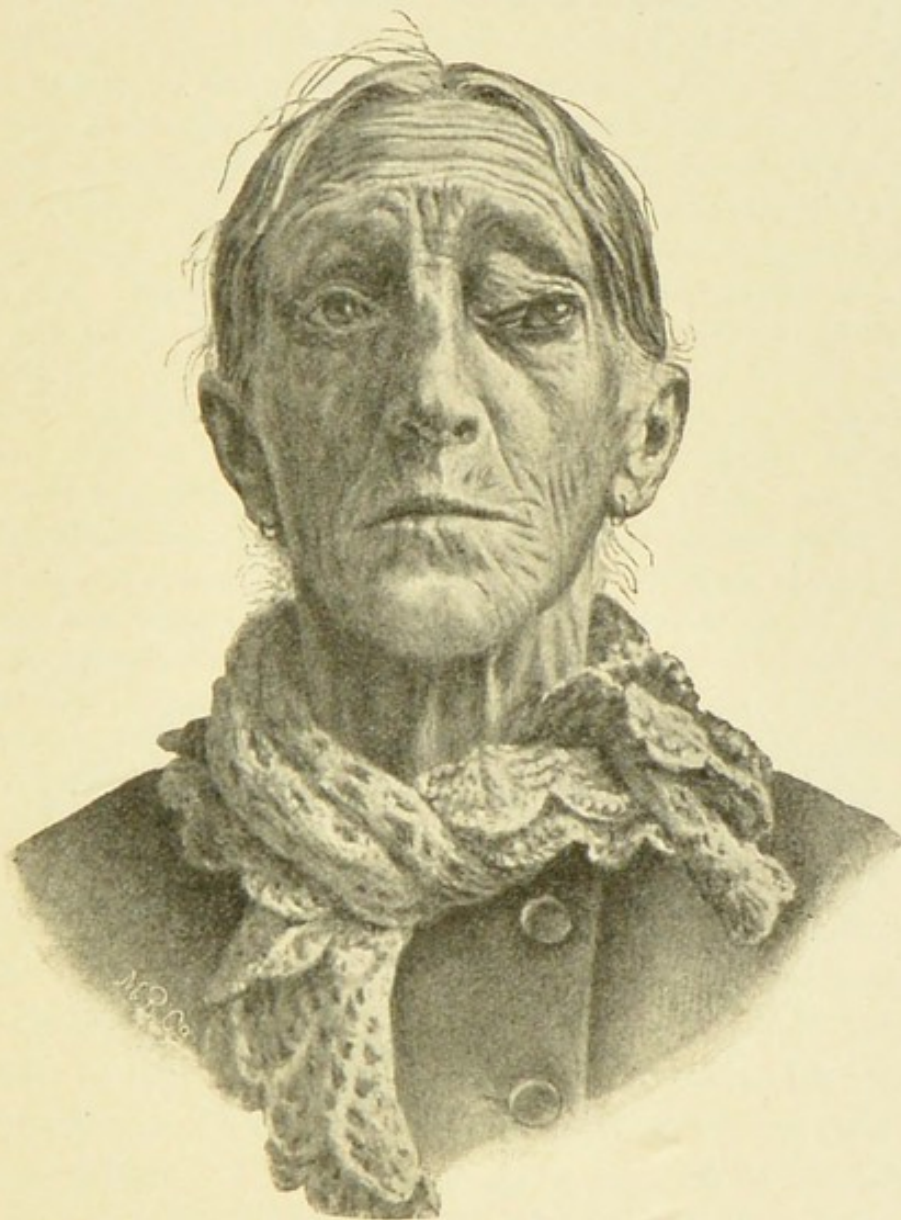


FIG. C.

the tumor in most cases can only be surmised; but it may be assumed that a tumor which grows slowly and causes little pain and limitation of movement is benign; while malignant growths develop more rapidly and occasion a higher degree of pain and functional disturbance.

Dermoid cyst (Plate 21 and Fig. C) is one of the more

Fig. D.

Bone-cyst Due to Ectasia of the Ethmoid Cells, the Frontal Sinus, and the Nasal Cavity.—M. F., carpenter, 24 years old. The tumor first made its appearance seven years ago, above the inner canthus of the left eye, and increased gradually, attaining its present size two years ago. No pain at any time; but last winter there was excessive lachrymation from time to time.

At present there are no signs of inflammation and the left lachrymal duct is patulous. The tumor is about the size of a pigeon's egg, the greater portion situated above the internal lateral ligament, which forms a slight constriction in its lower portion. In the region of the root of the nose it is impossible to differentiate by palpation between the supra-orbital margin and the tumor; but along the upper outer border the tumor can be felt extending some distance into the orbit. The tumor is tense, elastic, and fluctuating; no pulsation. Crossed diplopia. Visual acuity and fundus normal. Upon extirpation of what was thought to be a dermoid cyst, a fibrous sac of connective tissue was found, which could not be dissected out, being firmly adherent to the bone on its upper and nasal sides, and limited on the outer side by a thin plate of bone, the nasal wall of the orbit. The bony plate is displaced toward the orbit and is slightly movable. The sac contained a mass of thick, greenish or brownish gelatinous material. After this was removed, a cavity the size of a pigeon's egg was exposed, communicating above with the frontal sinus and below with the nasal cavity, and limited on the orbital side partly by the plate of bone and partly by connective tissue. Cure was effected in three weeks. The plate of bone and the eyeball gradually assumed a more nasal position.

frequent benign tumors. The disposition to dermoid cyst is congenital, but the growth usually does not develop sufficiently to inconvenience the patient until quite late in life. Its favorite seat is the anterior portion of the orbit, a little above either the inner or the outer canthus; but a large cyst may fill the greater part of the orbit and cause lateral displacement of the bulb. Care must be exercised not to incise the cyst during the operation. In exceptional cases I have done this purposely, when the cyst was very large and partly situated behind the globe. I made a small incision in the anterior pole and closed it again after part of the contents had escaped, so that the cyst, while retaining a moderate degree of tension, was quite easily removed *in toto* from behind the bulb.

A dermoid cyst may be difficult to distinguish from a cystoid dilatation of the ethmoid cells, the frontal sinus, or the nasal cavity, an example of which is shown in Fig. D. The differential diagnosis is based on the presence of a thin plate of bone between the cyst and the globe, corresponding to the nasal wall of the orbit.

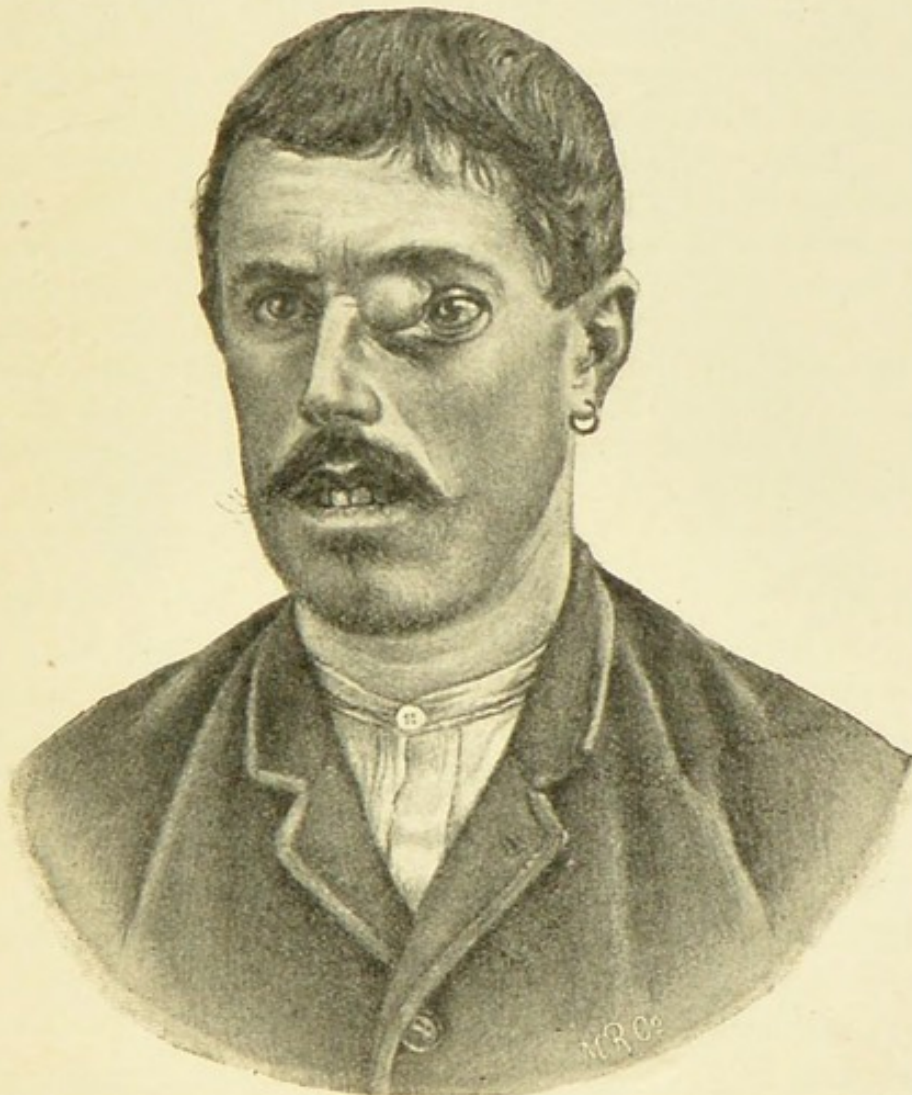


FIG. D.

An orbital cyst appearing shortly after birth should always suggest *encephalocele* or *meningocele*, which consists of a hernia-like protrusion of the dura mater into the orbit. If the sac contains brain-tissue, it is called *encephalocele*; if only cerebrospinal fluid, *meningocele*. The lesion usually develops along the line of a bone-suture. The most frequent seat in the orbit is the suture between

Fig. E.

Angioma of the Orbit.—This tumor developed in the course of ten years, without giving rise to pain or inflammation, in the center of the orbit, and caused such enormous protrusion of the eyeball that the woman, who was then 41 years old, finally consented to have it removed. Unfortunately the tumor, which was evidently benign, had by this time (1891) become so large that enucleation of the globe had to be performed at the same time. The visual acuity of the affected eye had been diminishing for some time and was then reduced to $\frac{2}{5}$. This visual deterioration was chiefly due to a macula, which I observed in its initial stages, six months after the first appearance of protrusion, and which is illustrated in Fig. 52, *a*, Lehmann's *Atlases*, vol. vii., second edition, which shows the ophthalmoscopic image as it appeared in 1888, and in Fig. 48, *a*, showing a transverse section of the macula. In addition there existed for some time a moderate degree of papillitis (choked disk), which eventually passed into optic-nerve atrophy. At the time of operation the lids could not be closed, the palpebral fissure remaining open to the extent of 3 mm. Ectropion had begun in the lower lid. To the outer and lower side of the globe a moderately hard, lobulated tumor was felt, not fluctuating and not sensitive on pressure.

the ethmoid and frontal bones, hence the anomaly is found usually in the upper inner portion of the orbit. The tumor is covered with normal skin, diminishes on pressure, sometimes with symptoms of cerebral tension, and may exhibit both circulatory and respiratory pulsation, transmitted by the brain. It is firmly attached to the bone.

Vascular tumors are occasionally seen in the orbit, sometimes they take the form of an angioma, less frequently that of aneurysm. A cavernous tumor may attain a considerable size (Fig. E).

Malignant tumors of the orbit are of the greatest importance, as they threaten the patient's life. Sarcoma in its various forms is the tumor that occurs most frequently. It may originate in the bone, the periosteum, the muscles, the lachrymal gland, the connective tissue in the orbit, or the sheath of the optic nerve. A sarcoma in the choroid may break through into the orbit and continue to grow toward the front of the eye (Plate 37).

The rare cases of primary orbital carcinoma usually begin in the lachrymal gland. On the other hand, carci-

noma of the lids or of the conjunctiva may extend into the orbit, or it may break through from the adjacent bony cavities, especially the antrum of Highmore (Fig. F). Early recognition of the last-named condition is most important, as operation very soon becomes impossible if the cancer is allowed to grow for any length of time. The nasal cavity should also be carefully examined, in

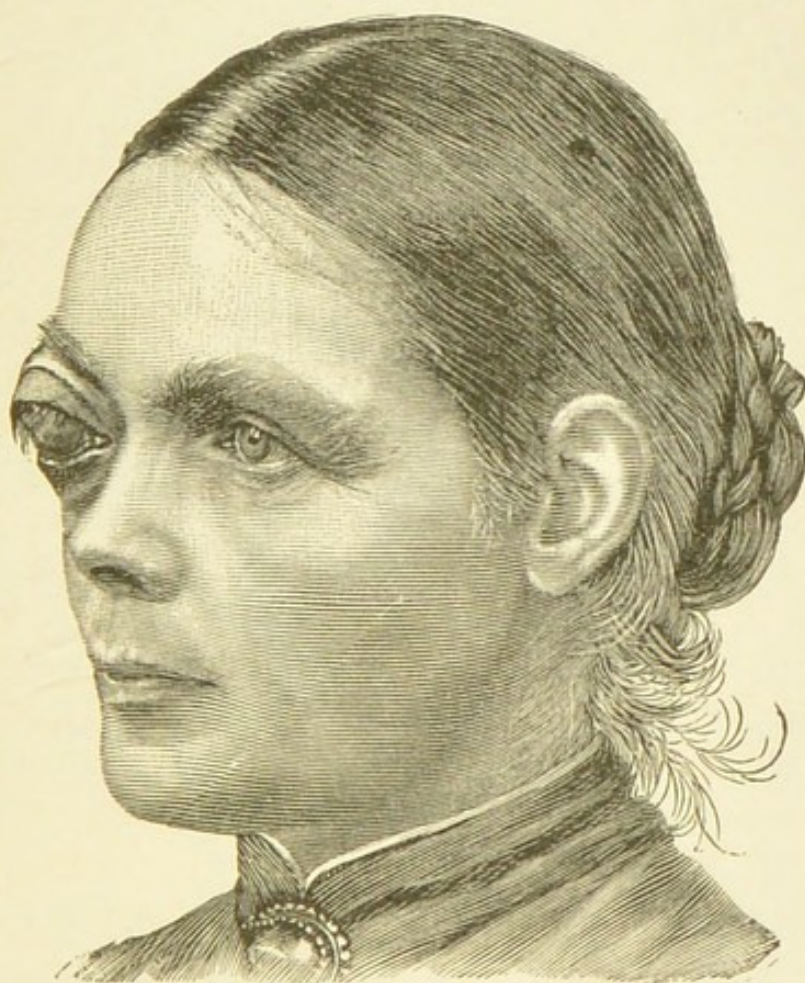

FIG. E.

such cases, for possible exostoses below the lachrymal sac or the lower orbital margin and in the temporal region (see Fig. F). If the antrum of Highmore is filled with cancerous tissue, the respiratory murmur will be heard much better with the stethoscope at that point than over the sound side.

Malignant tumors must be extirpated as soon as possible. Krönlein's method, which consists in temporary resection

Fig. F.

Cancer of the Upper Maxilla and Orbit.—Mrs. A. W., 53 years old. Four months before her first visit to the clinic the patient had violent toothache on the right side, and although she had several teeth extracted the pains increased in severity and spread to the right eye and temple. As we see in the picture, there was even at that time a slight swelling in the region of the right upper jaw and temple, and the right eyeball was displaced forward and upward. The movements of the eye were restricted in every direction, but especially downward. The patient was referred to the surgical clinic, and extirpation of the tumor was performed by my colleague, Dr. Krönlein. The whole upper jaw, with the exception of part of the palatine process, and the greater part of the zygoma were resected. It was then found that the growth was much more extensive than was to be expected; it extended some distance backward on the base of the skull and was laid bare as far as the middle meningeal artery. The eyeball had to be removed, as it was in close relation with the cancerous tissue. Externally the tumor had broken through the bone and invaded the masseter muscle. On microscopic examination it proved to be a squamous epithelioma. The woman became extremely emaciated and died three months later in collapse. There was no recurrence of the tumor.

of the temporal wall of the orbit, affords the best means of access. The flap of bone and soft tissues is replaced after the tumor has been removed and secured with sutures. A small tumor in the temporal portion of the orbit can often be removed by this method without sacrificing the globe. In extensive malignant growths the entire contents of the orbit must be extirpated.

An interesting and not very common affection of the orbit has received the name *pulsating exophthalmos* (Plate 40). It may develop spontaneously (rarely) or after a severe blow on the skull. Pulsation can be felt at the inner upper portion of the bulb, and the patient complains of a noise in his head like the pounding of a steam-engine. A bruit can be distinctly heard on auscultation in the region about the eye and more faintly as far back as the occiput, on both the affected and the unaffected sides. It is a characteristic sign that the noise and pulsation disappear on compression of the carotid. Upon close inspection a large pulsating vein is usually detected in the

inner upper portion of the bulb. The protrusion can be slightly reduced by continued pressure. If the condition is neglected, the conjunctiva eventually becomes puckered into large, edematous folds, the superficial vessels in the anterior portion of the globe become more and more dilated, until finally the lids are unable to close and the

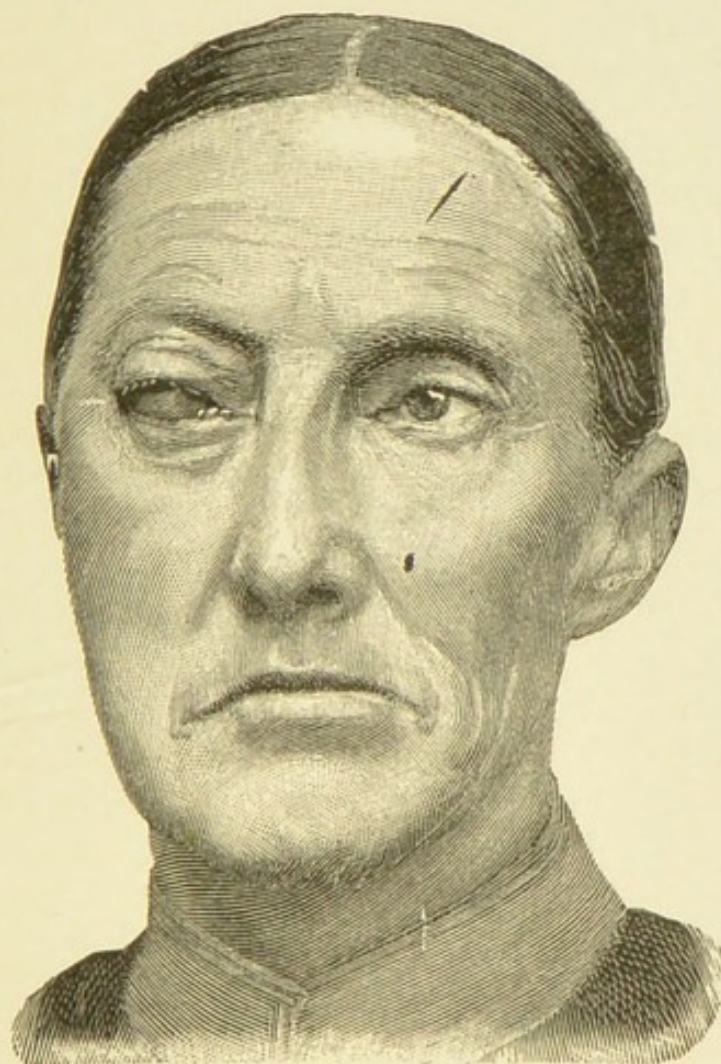


FIG. F.

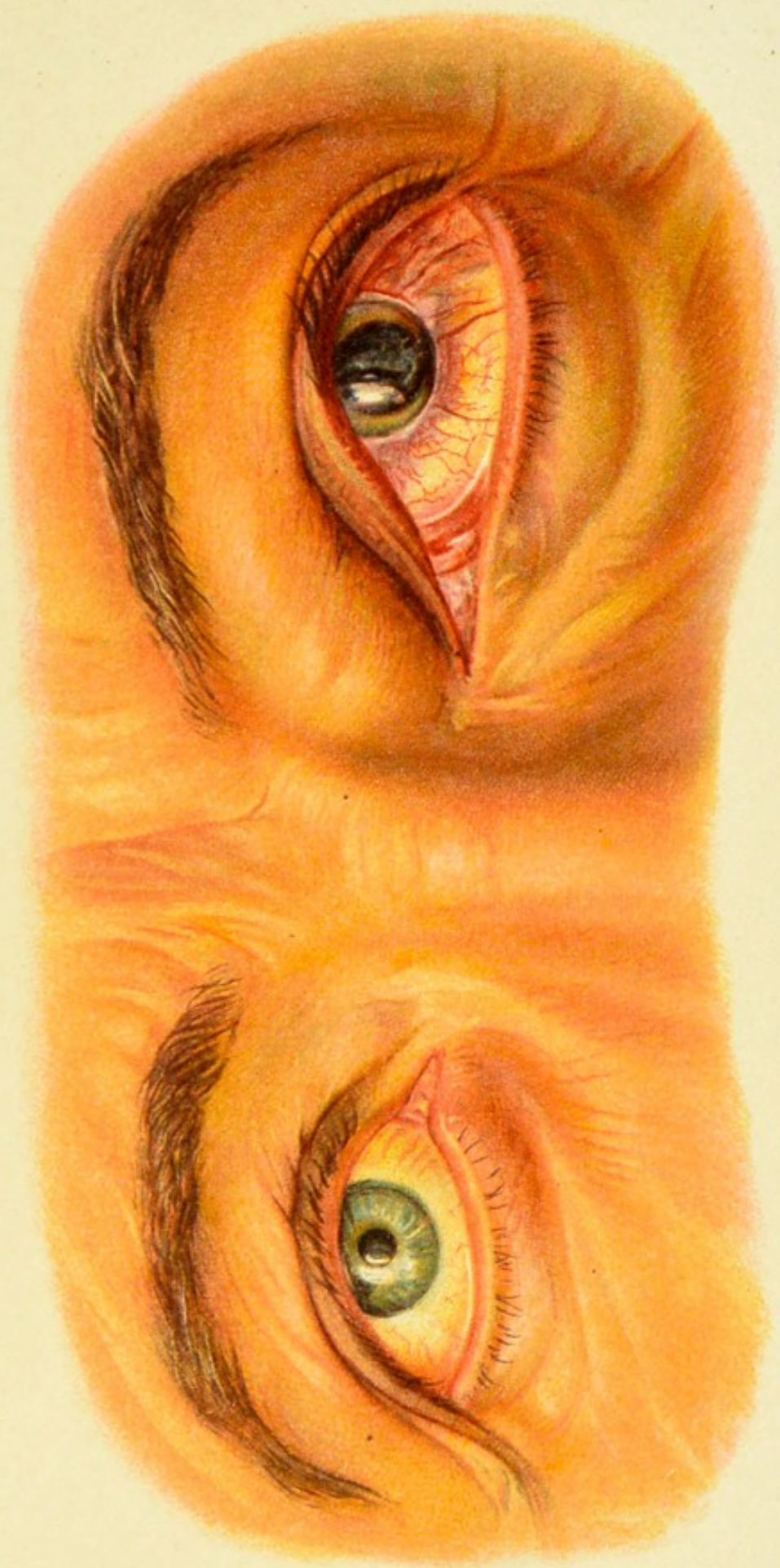
cornea is endangered. The disease is caused by traumatic fracture of the base of the skull or spontaneous rupture of the internal carotid within the cavernous sinus. The veins which carry the blood from the orbit into the sinus thus become engorged with arterial blood from the carotid and pulsate.


The surest treatment is ligation of the common carotid

Plate 40.

Pulsating Exophthalmos and Glaucoma of the Left Eye.—The patient is 38 years old, and a farmer by occupation. On August 14, 1896, he fell from a load of grain; did not lose consciousness, but bled freely from the nose and at once became stone-deaf. On September 13 the left eyeball began to protrude, visual acuity and mobility diminished, and by the middle of October, when he was admitted to the clinic, all the symptoms of pulsating exophthalmos had developed, except that the patient did not complain of noise in the head, although a pulsating bruit could be heard with the stethoscope all over the head. The increasing protrusion of the globe, however, became more and more distressing (at one time a small corneal ulcer developed), and the patient consented to ligation of the carotid, which was performed by Dr. Krönlein on November 20. At first the result appeared to be favorable; but in the course of the next six months marked exophthalmos again developed and became further complicated with glaucoma. The latter is responsible for the dilatation of the pupil and disappearance of the iris under the lower margin of the cornea, seen in the picture. The anterior chamber is shallow and contains a small hyphema. Fundus not visible, only red light. T + 2. As the region of the supraorbital vein (above the inner canthus) was much swollen and the vein itself exhibited pulsation and bruit, I advised the patient to have the other carotid ligated, which was done by Dr. Krönlein on July 30. The exophthalmos subsided almost completely and the subjective condition improved, although the glaucoma remained. The vision of the left eye and hearing are permanently destroyed, but the man is able to work.

of the same, and if necessary of the opposite, side. In some cases digital compression of the carotid suffices to effect a cure.





INDEX.

- ABSCESS of lachrymal sac, 86
 retrobulbar, 213
 Accommodation, method of measuring, 43, 50
 table of range of, 53
 Acne of conjunctiva, 135
 Acuteness of vision, 38
 Amblyopia, 74
 Aniridia, 188
 Ankyloblepharon, 107
 Anterior chamber, examination of, 35
 Aphakia, 199
 Atrophy of optic nerve, 59

 BACTERIA in conjunctival sac, 110
 in lachrymal sac, 80
 Blennorrhœa neonatorum, 113. See *Conjunctivitis, gonorrheal*.
 Blepharitis, eczematous, 94; Pls. 4, 6
 squamous, 97
 Blepharochalasis, 104; Pls. 8, 9
 Blepharophimosis, 107
 Buphthalmos, 208

 CATARACT, 189
 anterior polar, 191; Pl. 34
 capsular, 114, 189; Pl. 34
 complicated, 196
 congenital, 195
 diagnosis of, 196
 incipient, 193
 partial stationary, 191
 perinuclear, zonular, or lamellar, 192; Pl. 33
 posterior polar, 191
 progressive, 193
 senile, 193, 194; Pls. 32, 33
 traumatic, 195; Pls. 32, 36
 treatment of, 197
 Cataracta accreta, 196
 intumescens, 193
 matura, 193
 nigra, 194

 Catarrh, eczematous, 131
 Chalazion, 102; Pl. 7
 Choroid, sarcoma of, Pl. 37
 Ciliary body, diseases of, 177
 gummata of, 182
 tumors of, 188
 Color-blindness, 60
 detection of, 62
 Color-sense, contrast-test for, 61
 perimeter-test for, 57
 Congestion, ciliary or circumcorneal, 27
 conjunctival, 27
 diagnostic value of, 30
 localized ciliary, 30
 Conjunctiva, acne of, 135
 burns of, 139; Pl. 19
 diseases of, 110
 ecchymoses of, 139
 eczema of, 129, 132; Pls. 17, 18
 essential shrinking of, 134. See *Pemphigus*.
 foreign bodies in, 138
 hyphæma conjunctivæ, Pl. 14
 ichthyosis of, 134
 in leprosy, 138
 in scleritis, 135
 in variola, 135
 syphilomata of, 138
 tuberculosis of, 136
 tumors of, 141
 ulcers of, 110, 114, 132, 136
 Conjunctivitis, diphtheritic, 119;
 Pl. 13
 eczematous, 129, 132
 etiology of, 110
 follicular, 112
 gonorrheal, 113; Pl. 12
 treatment of, 117
 granular, 121, 123, 128
 phlyctenular, 129
 scrofulous, 129
 simple catarrhal, 109, 111
 spring-, 126, 132; Pl. 15

- Cornea, burns of, Pl. 19
 diseases of, 143
 examination of, 31
 injuries of, 168
 leukomata of, 33, 115
 maculæ of, 34, 114; Pl. 23
 malformations of, 169
 milky opacity of, in spring-conjunctivitis, 127
 opacities of, 34, 114
 transparency of, 33
 ulcers of, 159, 162
 Corneal deposits, 49, 179
 loupe, 46
 Credé's prophylactic method, 113
 Cyclitis, 177, 179
 Cysts, dermoid, 87, 150, 217
 prelachrymal, 87
- DACRYOCYSTITIS, 83; Pls. 1, 2
 blennorrhœica, 84
 treatment of, 88
 Dacryostenosis, 78, 79
 symptoms of, 22
 Deposits, corneal, 49, 179
 Diffusion-circles, 50
 Diopter, 45
 Diplopia, 63, 67
 Double images, 66, 72
- ECTASIA of lachrymal sac, 83; Pl. 3
 Ectopia lentis congenita, 198
 Ectropion, 95, 105
 Eczema, 21, 94
 marginal, 95, 128, 130
 of conjunctiva, 130; Pls. 17, 22
 of cornea, 130; Pls. 22, 23
 of eyelids, 94
 pustule or phlyctenule, 131
 Emmetropia 52
 Encephalocele, 219
 Entropion, 95, 122; Pl. 9
 Epicanthus, 104; Pls. 3, 9
 Epiphora, 78
 hypopyon-keratitis, 82
 Episcleritis 173
 Erysipelas of eyelids, 92
 of lachrymal sac, 86
 Eversion, 23, 24
 Examination of anterior chamber, 35
 of eye by lateral illumination, 46
 by transmitted light, 48
 Exophthalmos, Pl. 39
 pulsating, 222; Pl. 40
- Eyeball, inspection of, 26
 tension of, 36
 Eyelids, anomalies of, 104
 diseases of, 92
 eczema of, 94
 erysipelas of, 92
 eversion of, 23
 herpes zoster of, 92
 injuries of, 107
 seborrhea of, 97
 tumors of, 108
- FACETS in cornea, 32
 False images, 70
 Field of vision, 55. See *Visual field*.
 Fistula, lachrymal, 83; Pl. 3
 Foreign bodies in conjunctiva, 138; Pl. 16
 in cornea, 33; Pl. 21
 in sclera, 174
 Fruejahr's catarrh, 126, 132. See *Conjunctivitis, spring-*.
- GLAUCOMA, 198; Pl. 40
 fulminating, 207
 hemorrhagic, 205
 infantile, 169, 208
 primary, 203
 absolute, 206
 acute, Pl. 36
 evolutum, 204
 inflammatory, 204
 secondary, 163, 196, 211
 simple, 207
 Glioma of retina, Pl. 38
 Granulations, follicular, 121
 papillary, 121
 pavement or tessellated, 126
- HEMIANOPSIA, 55, 59
 Herpes corneæ febrilis, Pls. 24, 25
 zoster corneæ, 155
 of eyelids, 92
 ophthalmicus, Pl. 20
 Hordeolum, 100; Pls. 5, 6
 Hydrophthalmos, 208
 Hypopyon, 35, 178
 Hypopyon-keratitis, 82; Pl. 25
- ICHTHYOSIS of conjunctiva, 134
 Images, double, in paralysis, 66, 72
 false, 70
 Irideremia, 188
 Iridocyclitis, 180

- Iridocyclitis, traumatic, 183
 treatment of, 187
 Iridodialysis, 187
 Iris, adhesions of, 154
 diseases of, 177
 injuries of, 187
 lacerations of, Pl. 36
 prolapse of, 150
 tremor of, 35
 tumors of, Pl. 30
 Iritis, 117
 diagnosis of, 185
 gonorrheal, 182
 idiopathic, 183
 rheumatic, 182
 serous, 180
 syphilitic, 176, 181; Pl. 31
 treatment of, 185
- KERATITIS**, eczematous or phlyctenular, 149
 fascicular, 132, 151
 marginal, 128, 130, 151
 neuroparalytic, 155, 163
 parenchymatous, 143; Pl. 28
 sclerotizing, 148, 172; Pl. 29
 scrofulous, 149
 Keratoconus, 32, 170
- LACHRYMAL APPARATUS**, diseases of, 78
 sac, abscess of, 86
 bacteria in, 80
 ectasia of, 83; Pl. 3
 furuncle of, 86
 tumor, 83
 Lens, abnormal coloration of, 36
 diseases of, 188
 dislocation of, 198; Pl. 34
 subluxation of, 198
 Leprosy of conjunctiva, 138
 Leukomata, 33
 Light-perception, 43
 Light-sense, 59
 Lipomatosis, 104
 Loupes, corneal, 46, 49
 Luxatio lentis, 198
- MALINGERERS**, detection of, 74
 Megalocornea, 169
 Membrane, persistent pupillary, 185
 Meningocele, 219
 Meter-lens, 45
 Migratory pustule, 132, 151. See *Keratitis, fascicular.*
- Miliun, 109
 Mobility, disturbances of, 62
 Molluscum contagiosum, 108; Pl. 6
 Mucocele, 83
 Muscæ, 190
 Muscles, ocular, action of, 63
 paralyses of, 62, 68, 69
 Mydriasis, traumatic, 187
 Myopia, 52
- NICTITATIO**, 112
 Nyctalopia, 60
- OPACITIES** of cornea, 34, 114
 Ophthalmia, Egyptian or granular, 121. See *Trachoma.*
 neonatorum, 113. See *Conjunctivitis, gonorrheal.*
 Ophthalmitis, sympathetic, 184
 Optic-nerve atrophy, 59
 Orbit, abscess of, 213
 diseases of, 211
 injuries of, 215
 tumors of, 150, 216, 217, 220
 Osteoma of ethmoid, 87
- PANNUS**, 122; Pl. 28
 eczematous or scrofulous, 150
 phlyctenular marginal, 132
 treatment of, 126
 Panophthalmitis, 114, 163, 201; Pl. 35
 Papillomacular bundle, disease of, 59
 Paralyses, 66, 68, 69
 false images in, 66
 Pemphigus of conjunctiva, 134
 Perimeter, 57
 Photometer, 60
 Phthisis bulbi, 163, 180, 181; Pl. 28
 Pinguecula, 140
 Pityriasis of conjunctiva, 134
 Presbyopia, 53
 Protrusion, 22
 Pseudopterygium, 139
 Psoriasis of conjunctiva, 134
 Pterygium, 140; Pls. 16, 26
 Ptosis, 104
 congenital, 106
 Pupil, abnormal coloration of, 36
 occlusion and exclusion of, 178
 reaction of, to light, 48
 Pupillary membrane, persistent, 185
- REACTION** to light, 48

- Retina, detachments of, 59
glioma of, Pl. 38
pigmentary degeneration of, 59
Retrobulbar abscess, 213
- SCLERA, diseases of, 171
foreign bodies in, 174
injuries of, 173
Scleritis, 132, 135, 171 ; Pl. 29
Scotomata, 55, 59
Seborrhea, 21
marginal, 98
Siderosis, 202
Squint, 73
test for, 22
Staphyloma, 114, 163, 171
scleral, 172
Subluxatio lentis, 198
Symblepharon, 106, 139
Synechiæ, 178
Syphilides, 96, 134
Syphilomata, 138
- TENSION of eyeball, 36
Tonometer, 37
Trachoma, 121, 123, 128 ; Pls. 14, 28
Transparency of cornea, 33
Trichiasis, 95
Type-cards, 39, 42
- ULCERS, marginal or catarrhal, 110
of conjunctiva, 136
of cornea, 159, 162, 167 ; Pls. 26, 27
Uveitis, 177
- VARIOLA of conjunctiva, 135
Visual acuity, test for, 38
field, abnormalities of, 59
methods of measuring, 55-57
Vitreous body, abnormal coloration
of, 36
diseases of, 199
foreign bodies in, Pls. 35, 36
suppuration of, 201
turbidity of, Pl. 36

$$\frac{8/\kappa}{80/R}$$

