

## **The anatomy of the lymphatic system / by E. Klein.**

### **Contributors**

Klein E. 1844-1925.  
Royal College of Physicians of Edinburgh

### **Publication/Creation**

London : Smith, Elder, 1873-1875.

### **Persistent URL**

<https://wellcomecollection.org/works/zqjcht4e>

### **Provider**

Royal College of Physicians Edinburgh

### **License and attribution**

This material has been provided by This material has been provided by the Royal College of Physicians of Edinburgh. The original may be consulted at the Royal College of Physicians of Edinburgh. where the originals may be consulted.

This work has been identified as being free of known restrictions under copyright law, including all related and neighbouring rights and is being made available under the Creative Commons, Public Domain Mark.

You can copy, modify, distribute and perform the work, even for commercial purposes, without asking permission.

**wellcome  
collection**

Wellcome Collection  
183 Euston Road  
London NW1 2BE UK  
T +44 (0)20 7611 8722  
E [library@wellcomecollection.org](mailto:library@wellcomecollection.org)  
<https://wellcomecollection.org>

THE ANATOMY  
OF THE  
LYMPHATIC SYSTEM  
—  
KLEIN.

—  
THE SEROUS MEMBRANES.

Y 6. 28


\* y. 7. ~~28.~~  
29



THE ANATOMY  
OF THE  
LYMPHATIC SYSTEM.

BY  
E. KLEIN, M.D.

ASSISTANT-PROFESSOR AT THE LABORATORY OF THE  
BROWN INSTITUTION, LONDON.




---

I.—THE SEROUS MEMBRANES.

---

LONDON:  
SMITH, ELDER, & CO., 15 WATERLOO PLACE.  
1873.



# CONTENTS.

---

## SECTION I.

### *NORMAL CONDITIONS.*

CHAPTER	PAGE
INTRODUCTION . . . . .	1
I. THE ENDOTHELIUM OF THE FREE SURFACE OF THE SEROUS MEMBRANES	3
II. THE CELLULAR ELEMENTS OF THE GROUND-SUBSTANCE . . . . .	11
III. THE LYMPHATIC VESSELS OF THE SEROUS MEMBRANES . . . . .	31
<i>a.</i> Lymphatics of the Omentum and the Pleura Mediastini . . . . .	31
<i>b.</i> The Lymphatic System of the Centrum Tendineum of the Diaphragm . . . . .	41
<i>c.</i> The Lymphatic Vessels of the Mesentery . . . . .	47
<i>d.</i> Relation of the Lymphatic Vessels to the Surface of the Serosus Membranes . . . . .	49
<i>e.</i> Development of Lymphatic Capillaries . . . . .	54
IV. BLOOD-VESSELS OF THE SEROUS MEMBRANES . . . . .	58


---

## SECTION II.

### *PATHOLOGICAL CONDITIONS.*

INTRODUCTION . . . . .	62
1. THE CHANGES OF THE SUPERFICIAL ENDOTHELIUM . . . . .	63
2. ALTERATION OF THE CELLULAR ELEMENTS OF THE MATRIX . . . . .	73
3. THE BLOOD-VESSELS AND LYMPHATIC VESSELS . . . . .	81
BIBLIOGRAPHY . . . . .	82
EXPLANATION OF PLATES . . . . .	83





# ANATOMY OF THE LYMPHATIC SYSTEM.

---

## I. THE SEROUS MEMBRANES.<sup>1</sup>

---

### SECTION I.—*THE NORMAL CONDITIONS.*

SINCE the important discovery of injecting the lymphatic vessels of the diaphragm from the peritoneal cavity by Recklinghausen, and since this author has shown that the serous cavities represent great lymphatic sacs, the serous membranes have become a favourite object of study. A long series of excellent researches has highly amplified our knowledge of the normal and pathological histology of the serous membranes in a relatively short time. The staining with solution of nitrate of silver, first employed by Recklinghausen, plays a great part in this advance.

As regards the normal conditions, the attention of histologists has been chiefly if not wholly directed to three questions: 1. The distribution of the lymphatic vessels in the serous membranes; 2. The origin of the lymphatic capillaries from the lymph-canalicular system

<sup>1</sup> The results of the observations I intend to describe in this memoir have been partly published by Dr. Burdon-Sanderson and myself, as a preliminary publication, in the *Centralblatt für medicin. Wissensch.* 1872, January 2, 3, and 4. Since that time I have made a series of observations, which in many respects complete those there described, in such a way that the anatomy of the serous membrane, in so far as it refers to the lymphatic system, may be regarded as complete. I shall have, many times, occasion to restate what has been already put down in that preliminary publication, together with observations of a later date.

These researches were undertaken at the request of Dr. Burdon-Sanderson in connection with the Pathological Inquiries conducted by him for the Medical Department of the Privy Council. They are published with the sanction and approval of the medical officer of the Privy Council, Mr. Simon.

of Recklinghausen; and 3. The free communication between the lymphatic vessels and the serous cavity by means of stomata.

The following description refers to the minute structure of the omentum, the centrum tendineum of the diaphragm and the pleura mediastini. In dealing with these membranes we shall be able, besides other important facts, to instruct ourselves about the three questions above mentioned.

In this Section I. we shall treat separately (1) of the endothelium of the free surface, (2) of the cellular elements of the ground-substance, (3) of the lymphatic vessels, their distribution and relation to the tissue and the surface, as well as their development, and (4) of the blood-vessels.

## CHAPTER I.

## THE ENDOTHELIUM OF THE FREE SURFACE OF THE SEROUS MEMBRANES.

A GENERAL description of the endothelium of the free surface of the serous membranes is hardly necessary after those given by Recklinghausen, Auerbach, Ludwig and Schweigger-Seidel, Dybkovsky and others.

Some points only will be treated of in this chapter, which have not yet been sufficiently appreciated.

The endothelium of the free surface is in the normal condition not everywhere a layer of flattened more or less hyaline cell-plates, but possesses in many places a different character, which may be described as follows: the individual cells are polyhedral, club-shaped, or even short columnar, their substance is distinctly granular, even in the fresh condition, their nucleus is for the most part, like that of the ordinary endothelial plates, ovoid, sometimes spherical, clear, sharp-outlined, with a large shining nucleolus. In many cells, however, the nucleus is marked by a constriction, or is even perfectly divided into two.

A portion of the fenestrated part of the fresh omentum of a full-grown guinea-pig, cat, dog or monkey, mounted in an indifferent fluid, such as one-half per cent. saline solution, peritoneal fluid, etc., or after having been stained in one-quarter or one-half per cent. solution of nitrate of silver and mounted in glycerine, shows often enough on the surface of the thin trabeculæ small groups of club-shaped or polyhedral granular cells, projecting from the surface of the trabeculæ like buds. If one follows a large trabecula, which contains either large blood vessels only, or besides those, also tracts of fat-tissue, one can always find smaller or larger areae, generally on one surface only, the

endothelium of which areæ possesses the above-mentioned characters. As these chief trabeculæ project in many instances like folds or fringes, they afford the best opportunity of studying this *germinating* or *young* endothelium—(we shall use this expression always afterwards)—from the surface as well as in profile. Especially in the latter case, one is sure to find, where a large area of germinating endothelium is focussed, numbers of cells which are raised from the general surface by means of a stalk, and which possess in their peripheral spherical portion two nuclei or a nucleus in a state of division; and further, one is sure to find there spherical cells just like lymphoid corpuscles, which are either simply attached to the general surface or are in a state of separating themselves from young endothelial cells. The same character is possessed by the endothelium of the surface of certain nodular or cord-like structures, which are either isolated or in connection with the chief trabeculæ of the fenestrated part of the omentum, in which larger blood-vessels or fat are contained. I have come across, several times in the normal as well as in the chronically inflamed omentum, endothelial cells which presented the characters of giant-cells—myeloplaxes, that is protoplasmic masses containing five to ten nuclei. These masses were attached to the surface by means of a shorter or longer protoplasmic stalk.

A very rich distribution of germinating endothelium is to be found on the omentum of rabbits. As we shall afterwards see, the omentum of the rabbit shows remarkable differences as regards the distribution of the lymphatic and blood-system. These differences are, however, in general merely differences of development, which are to be explained by differences of age. Always, however, there are to be found on the delicate portion of the omentum covering the left part of the stomach, as well as on the denser part covering the pyloric portion of the stomach, numerous places, either in the form of more or less isolated islands of different size or of cords, the surface endothelium of which possesses the above-mentioned characters, viz. is germinating. Seen from the surface such areæ appear to be covered with cells, which are raised like buds, with shorter or longer stalks. The upper parts of these buds appear in many instances to undergo division. That the germination on these places goes on with some rapidity can be

deduced from the fact that besides the appearances of constriction and division of the polyhedral or club-shaped endothelial cells, there are always numbers of smaller spherical lymphoid elements to be found amongst them, which are detached from the surface, that is to say, which have become perfectly separated.

Germinating endothelium is to be found just as richly on the omentum of the dog, especially in the non-fenestrated portion, where it is to be met with in the form of isolated smaller or larger groups.

The pleura mediastini of dogs, cats and monkeys is a very good object for studying germinating endothelium. On the trabeculæ of that membrane, as well as on the complicated system of tracts which extends freely over the surface, there exist numbers of lateral or intercalated nodular swellings of various size, the surface of which is covered abundantly with young endothelium. From the great number of club-shaped and pedunculated two-nucleated endothelial cells, and from the number of spherical cells which are more or less loosely attached to the surface of the above-mentioned swellings, we cannot but deduce that there is going on a very abundant production of lymphoid cells.

Not less instructive is the mesogastrium of the frog. If this membrane of a female frog during the winter months is examined in an indifferent fluid or after staining with silver solution, one recognises on the surface of the dense portion, especially on the trabeculæ of the fenestrated portion, numbers of places where the endothelium possesses the germinating character: they appear either in small groups or as nodules which project freely on the surface of the trabeculæ.

This germinating endothelium, which is similar to that described in mammals as regards its substance, shape, and nucleus, possesses the peculiarity that the surface of the endothelial cells is provided with a bunch of cilia. If the membrane is mounted in serum, and the cover glass supported by small strips of paper, the ciliary movement can be observed during three hours and more with equal rapidity. The proliferation of this ciliated endothelial cells takes place in the following way: one finds not rarely a ciliated cell of a columnar shape which possesses two nuclei, situated above each other in the longitudinal axis

of the cell ; the cell possesses in some cases a more or less distinct constriction between the two nuclei, and the cilia of the surface have become very delicate and short.

Finally, there may be seen endothelial cells without cilia, which consist of two nearly spherical portions held together by a short neck ; each portion possesses a spherical, sharp-outlined nucleus, with clear contents and a shining nucleolus.

Mr. Francis Darwin showed to me a preparation of the mesogastrium of *Rana temporaria*, where there were to be seen germinating endothelial cells that perform distinct amœboid movements. Fig. 52 shows such young endothelial cells, which bud from a freely-projecting knob ; the cells are in amœboid movement.

A similar, but not quite so abundant, germination may be observed on the peritoneal surface of the septum cisternæ lymphaticæ magnæ of the frog, especially on the endothelial cells which surround, or more correctly speaking, which line the stomata first described by Dogiel and Schweigger-Seidel.

These authors found on the peritoneal surface of the septum of female frogs, during the spawning season, ciliated endothelial cells of a nearly cylindrical shape, in small groups near the stomata. I shall turn to the stomata afterwards. At present I wish only to mention that during the winter months, in some septa besides the germinating mostly ciliated endothelial cells, there exist shorter or longer tracts, which project more or less freely on the peritoneal surface, and which are covered with polyhedral, sometimes ciliated endothelial cells.

Ludwig and Schweigger-Seidel first called attention to the difference which exists as regards the endothelium of different portions of the peritoneal surface of the centrum tendineum of the diaphragm of rabbits. These authors have shown that the endothelial cells, which are situated over the straight lymphatic channels, between the tendon bundles, are of a smaller size than the endothelial cells which lie over the tendon bundles themselves.

They assert also that there exist sometimes groups of lymphoid corpuscles, which are continuous with, or properly speaking, derived from, those stripes of small endothelial cells previously mentioned. I am able not only to confirm this latter observation, but also to

complete it to the extent that there exist groups or tracts of germinating endothelium in rabbits as well as in guinea-pigs, cats, dogs, and monkeys, which, as we shall see afterwards, stand in an intimate relation to lymphatic vessels.

Somewhat different in its arrangement is the germinating endothelium of the mesentery of frogs, cats, dogs, and monkeys, viz. in these membranes they occur only in groups of less than five endothelial cells, mostly two or three. They are also of a polyhedral shape, consisting of a distinctly granular protoplasm, with a constricted or double vesicular nucleus; their size is considerably smaller than that of the common endothelial plates surrounding them. On fresh preparations, which have been mounted in serum with great care, they appear as granular bodies projecting from the surface like buds; on preparations stained with silver solution, they appear generally beset with brownish granules. There exists a great variety as regards the number of such groups in a given field. Searching the surface of the membrane under a magnifying power of about 200, one passes two or three fields where there are no groups; whereas, in a neighbouring field one meets with half-a-dozen or even a dozen of them. They are to be found over those parts which contain large blood-vessels quite as often as over the intermediate portions.

These structures are not to be confounded with those very small figures which occur on silver-stained preparations, isolated or in small groups, amongst the large endothelial fields: a part of those small fields may correspond to young endothelial cells if they are distinctly granular.

If one examines carefully the surface of a silver-stained mesentery of the frog, one will find that the large common endothelial plates, which in intensely-stained preparations show a clear nucleus in a brownish cell substance, do not touch each other everywhere by means of the well-known more or less wavy lines, but that these silver lines in some places appear to be replaced by a branched corpuscle, the body of which is situated at the point of junction of a number of endothelial cells, and the processes of which stretch between these endothelial cells so as to become identified with their silver lines.



In some of these branched corpuscles a distinct clear nucleus is to be seen. It is farther to be noticed, on careful examination, that these branched corpuscles, or let us say at once these branched cells, exhibit apparently great differences as regards shape, size, processes, and nucleus, for at one place a corpuscle is like the above-mentioned, at a neighbouring place the corpuscle has a spindle-shaped form, the nucleus staff-shaped, and at still another place it is somewhat elongated, and is provided with a very few processes.

In some preparations, slightly stained with silver, I have been able to make out with high powers that in some instances the body of these branched corpuscles lies somewhat deeper than the endothelium, whereas one or the other of the finely granular processes stretches itself perfectly superficially between the endothelial cells.

The same relations are to be found on the mesentery of cats and monkeys, over large trabeculæ containing large blood-vessels as well as on the pleural surface of the centrum tendineum. We shall see afterwards that they are easier to be found in the inflamed condition. Most abundantly, however, and chiefly, they are seen to exist on the omentum of rabbits, on the omentum and pleura mediastini of the guinea-pig, cat, dog, and monkey, especially on those places where, as we have seen, the germinating endothelium occurs, viz. on the above-mentioned nodules and patches, as well as on the tracts which contain large blood-vessels and fat.

At present I will not describe the minute relations of these branched corpuscles which project partly or wholly between the endothelium of the surface, as we shall return to them repeatedly afterwards.

Before leaving this chapter, I wish to say a few words about the method of investigation by which I have arrived at the foregoing results. The examination of fresh preparations in serum or other indifferent fluids is of great importance. The membrane, after being excised with the greatest precautions against pulling or tearing, is placed in a capsule with somewhat diluted serum or one-half per cent. saline solution; after being spread out by slight movement to and fro, a portion of it is separated with sharp scissors; a glass slide is brought in the capsule, and the portion is floated on it, so as to be

perfectly spread out; the glass slide is raised out of the fluid, and the preparation is covered with a cover glass.

Equally important are preparations stained with nitrate of silver solution; the membrane is excised, together with the organs to which it is attached, *e.g.* intestine for the mesentery, sternum and pericardium for the pleura mediastini, costal muscles with their corresponding ribs for the centrum tendineum, stomach spleen and pancreas for the omentum of guinea-pigs and rabbits (for the omentum of the cat, dog, and monkey, this is unnecessary). The excised organs are placed in a large quantity of quarter or half per cent. solution of nitrate of silver for a few minutes, and then treated in the ordinary way. In mounting the preparations in glycerine the same precautions are necessary as in mounting the fresh preparations, as above mentioned, *viz.* those portions which are to be mounted are spread out on the glass slide under water, and covered afterwards with a cover glass, on the under surface of which a drop of glycerine has been previously applied. A good plan is to pour over the membranes diluted serum before staining with silver. The risk of mechanical injury is best avoided by pouring the silver solution on the membranes *in situ*, and then cutting them out with their corresponding attachments, so as to transfer them to water. We may mention at present that in our farther investigations, especially in those of the cellular structures of the tissue and of the lymphatics, we have always found that the treatment of the serous membranes requires very great precautions against even slight mechanical injuries, for only then can the appearances of irregularities be avoided, which, especially in silver stained preparations, are apt to confuse the observer. In the contrary cases, there may be found appearances of not pre-existing structures, even with some regularity.

It may not be unnecessary to make some remarks about the dark lines which appear on silver-stained preparations, as the boundaries of the endothelial cells. Some authors have tried to show that these lines correspond to a precipitation in a serous fluid which is accumulated in furrows on the surface of the endothelium, the individual endothelial cells being somewhat convex on their upper surface. There will scarcely be anyone who will not admit that (1) there

exist such furrows; (2) that the surface of the serous membranes is always moistened by a serous fluid, and consequently that fluid is accumulated mostly in the above-mentioned furrows; (3) that the silver-salt produces precipitations in albuminous substances. If, however, anyone concludes from these three circumstances the silver lines correspond to precipitations in the serous fluid of the surface, the conclusion is decidedly wrong, as the silver lines do not correspond only and exclusively to these precipitations, for there exists a number of facts which show that the existence of the silver lines depends also and chiefly on precipitations in an intercellular albuminous substance, which holds together the individual endothelial cells. The chief argument of Schweigger-Seidel, who first expressed the above-mentioned erroneous opinion, and who defended it with great constancy, was, that the appearance of the silver lines is prevented by rinsing the surface of a serous membrane with diluted glycerine, or with diluted sugar-solution. This assertion, however, I must contradict most decidedly, as it is not the case either after rinsing with glycerine or sugar-solution, nor even with water, provided that the membrane has not been rinsed so much as to remove the endothelium altogether. Of course, one can hardly expect that the silver lines should be of great thickness in those instances in which the membrane has been rinsed, as there exist no precipitations in a serous fluid of the surface which would increase the precipitations in the intercellular substance. The presence of various other lines on the surface of the silver-stained membranes cannot be regarded from what has been said above by any means as a proof against the silver lines being chiefly dependent on the intercellular substance. We may mention here as well the very regular system of silver lines corresponding to intercellular substances in silver-stained sections of any mucous membrane covered with laminated epithelium, *e.g.* cornea, conjunctiva, mucous membrane of the mouth, œsophagus, larynx, vagina, &c., in silver-stained sections) through masses of smooth muscular fibres, in the muscular coat of silver-stained arteries, and so on. It remains, therefore, for the antagonists of the intercellular lines only to deny the intercellular substance of the endothelium altogether, as it has been done by Robinski, whose assertion it is scarcely necessary to discuss.

## CHAPTER II.

## THE CELLULAR ELEMENTS OF THE GROUND-SUBSTANCE.

THE following description of the cellular elements will be incomplete, as they will be considered in many ways in the chapter on lymphatic and blood-vessels. The most instructive and simple object for the investigation of the cellular elements of the ground-substance is the omentum of rabbits, this being flatter, and, for the most part, very slightly fenestrated compared with that of the guinea-pig, dog, cat, and monkey.

If one compares the omenta of various rabbits, one finds, on microscopical observation, some not immaterial differences. One finds, namely, a great number of omenta of full-grown animals in which there are richly distributed opaque tracts of different breadth, forming a network: some of these tracts consist of a row of patches of different size, mostly oblong, sometimes roundish, which coalesce with each other more or less.

There are numerous patches which are situated laterally to these tracts, as well as perfectly isolated ones. Seen under a lens, the tracts generally follow the course of the larger blood-vessels. In young animals the network of opaque tracts is less developed than the isolated patches. But also, on the same omentum, there exists a difference between different parts; while that part of the omentum which lies upon the anterior wall of the stomach, viz. between the large and small curvature, contains very abundantly isolated patches up to such a size that they are hardly visible to the naked eye, we find on those portions which lie along the great curvature and upon the pylorus, besides these, also large tracts of fused patches. It may be said in general, the younger the animal the more isolated small patches are to be met with; the older the animal the larger they are, and the more confluent to tracts. It must not be understood, however,

that in full-grown animals there exist only tracts and large patches, as there exist also here, as has been already mentioned, smaller patches situated laterally to the tracts. It may be deduced from this that in the omentum there is going on a continuous growth and new-growth of opaque patches, which, by growing in length and coalescing in the direction of their longitudinal axis, form tracts.

A portion of the fresh omentum is a very unfit object for the study of the cellular elements of the ground-substance: besides the above-mentioned germinating endothelium, only more or less numerous migratory cells can be seen on and in the patches and tracts. There is only one mode of preparing that gave me good results, that is, the mode of staining the fresh omentum with silver solution after having pencilled it gently on one surface. I proceed in the following way: a rabbit is killed by bleeding, the stomach is exposed; after having pushed the intestine to the right side, the free surface of the omentum is pencilled several times, from the large curvature towards the diaphragm, with a fine camel's hair pencil moistened with fluid of the abdominal cavity. After that, a quarter or half per cent. solution of nitrate of silver is allowed to flow over the omentum from a large capillary tube, until the membrane has become slightly milky (one to two minutes are generally sufficient); after that, the stomach, together with the omentum, spleen, pancreas, and a portion of the duodenum is cut out and transferred to a large capsule with distilled water; after some time the water is renewed, and the omentum is separated under water, together with the spleen and pancreas, from the stomach with scissors and is transferred to common water. Those portions of the omentum which are seen to contain small patches are cut out and mounted, as has been already described. A failure is more frequent than a success: either the surface has not been pencilled enough, and then the endothelium of both the surfaces is coloured, and consequently, hardly anything is to be seen of the cellular elements of the ground-substance; or the surface has been pencilled too hard, and then the arrangement of the ground-substance is altered, its bundles appear considerably stretched and distinctly fibrillar. Successful preparations become only slightly yellowish brown, and can be preserved without alteration for a very long time.

Omitting at present everything except the cellular elements of the ground-substance, let us direct our attention to the very smallest isolated patches recognisable as such under the microscope, and let us anticipate that there are no capillary blood-vessels in them, and that the ground-substance is perfectly unstained. The first thing that strikes one are brownish-coloured structures of an irregular shape, that is to say, structures which contain larger and smaller brownish granules; in most of them an ovoid sharply-outlined nucleus, sometimes with a nucleolus, or a constricted nucleus, or even a few small nuclei, are to be seen. These brownish cells are of a different size, but always much larger than colourless blood corpuscles. Their shape is irregular, as has been already stated: their body is beset with a variable number of smaller or larger blunt or roundish prominences. Some of these cells are sharply defined, others are on one side more or less distinctly continuous with the basis on which they lie. It is clear that they correspond, as regards shape, to migratory cells. Besides these cells, there is to be found a limited number of small granular corpuscles, with one or two small nuclei, which are perfectly like lymphoid corpuscles. In some places they are in such a close connection with the above-mentioned large cells that they resemble knobs which are in a state of separation from them.

As we have already mentioned, the ground-substance is unstained. In it we find a network of a finely granular substance, which is stained slightly yellowish. This network consists of large plates, connected with each other by shorter or longer tracts of different breadth. In the plate-like enlargements one recognises a sharp-outlined oblong nucleus, with one or two nucleoli, or a constricted nucleus, or a nucleus which has almost divided into two. In the latter instances, the granular matrix is darker stained in the immediate neighbourhood of the nuclei. I will refer the reader to Fig. 30, which represents such a small patch: *a* represents the network of the finely granular substance (as this network is represented only in one layer, all of the processes which join the plate-like enlargements are not represented in the figure); *b* represents the above-mentioned irregular-shaped, large, coarsely granular cells. It is evident from this figure that we have before us a network of branched, more or less flattened, cells,

which, on the one hand, undergo division, as at F, and from which, on the other hand, grow up large coarsely-granular elements.

If we direct our attention to a small patch which is provided with a system of capillary blood-vessels (see Figs. 24 and 29), we see that nearly the whole matrix is occupied by a network of finely-granular, nucleated branched cells, which network is in communication with the isolated branched cells of the surrounding tissue.

In the same preparation from which Fig. 29 is taken there exist also patches the ground-substance of which has not remained unstained, but is of a slightly brownish colour; in this ground-substance we see a rich system of clear lacunæ, which communicate with each other by numerous branched and unbranched canaliculi of different breadth and length. Under a high power, we recognise in many of the lacunæ and canaliculi the finely-granular nucleated branched cells above described, besides small lymphoid corpuscles. We need not render it especially prominent that this system of lacunæ and canaliculi corresponds to the well-known lymph-canalicular system of Recklinghausen, and that it represents the spaces in which the above-mentioned system of branched cells lies. The Fig. 30 may be regarded as a combination of the negative, viz. the clear lymph-canalicular system, and the positive, viz. the system of branched cells, the outlines of the former as well as the nucleated protoplasm of the latter being distinctly recognisable.

In preparations of the dense part of the omentum, *e.g.* the pyloric part, prepared in the same way as above, one finds numerous places quite superficially under the endothelium, where the branched cellular elements and also the lymph-canalicular system show a somewhat different arrangement, the cells being arranged in small groups, and the individuals of one group being situated round a common centre. In these cases the cells are either very little branched towards this centre, or they touch each other even in a straight line, whereas they are provided with processes in the opposite direction, so as to join the neighbouring cells. In silver preparations the ground-substance of which is stained there are consequently to be found superficial groups of clear lacunæ, which are separated from each other by silver lines, and which send off canaliculi in the opposite direction. This, to a

great extent, resembles a group of endothelial plates branching outwards. We shall return to these structures afterwards, in the chapter on lymphatic vessels.<sup>1</sup>

Besides the above-mentioned small young patches, we find patches of the following various structure: a smaller or greater number of capillary blood-vessels are imbedded in a matrix, which contains besides a limited number of spherical lymphoid cells of different sizes, branched cells, lying more or less closely by each other; in some places, the matrix appears to be completely supplanted by these latter ones. Where they are not crowded together it is distinctly to be seen that they are provided with processes which join each other and those of the neighbouring cells. In the intermediate portions between the latter and the former the cells become less branched, their processes much shorter.

On negative silver-stained preparations, viz. in which the lymph-canalicular system has remained clear, the lacunæ of those cells appear to be separated from each other merely by lines in those places where the cells lie crowded together. From the fact that in positive silver-stained preparations the cells of the intermediate portions possess, instead of the single ovoid clear nucleus, a constricted or even a completely divided nucleus, and secondly, that the cell bodies themselves exhibit sometimes furrows like marks of

<sup>1</sup> As the reader may have already observed, I have, as regards the cellular elements of the omentum, quite the same opinion as Rollett has of those of the cornea. In both cases the branched cells are more or less flattened parallel to the surface, and in both cases the lymph-canalicular system corresponds to those cells. In the omentum, as well as in the cornea, the migratory cells are always found in the lymph-canalicular system, and, as we shall see afterwards, in the œdematous omentum the lacunæ and canaliculi may be distended by serous fluid and lymphoid corpuscles, which find their way through the lymph-canalicular system to the lymphatic vessels. Rollett has treated in his paper the branched corpuscles of the cornea and their lymph-canalicular system in such an exhaustive manner that it is hardly necessary to enter again into a controversy about the nature of the connective tissue corpuscles and the lymph-canalicular system of Recklinghausen. As regards the serous membranes, there cannot be the slightest doubt about the cellular elements of the ground-substance being more or less flattened branched-nucleated protoplasmic cells, and the lymph-canalicular system representing merely the spaces in the ground-substance for those cells; and I cannot agree by any means with the assertion of Schweigger-Seidel and Boll that the connective tissue corpuscles in general represent elastic plates which play only a passive part. We shall see afterwards that the protoplasmic nature of the connective tissue cells of the serous membranes plays an important part in the normal condition, and still more in chronic inflammation.



division, we are justified in saying that the fact of the cells being in some parts of those patches more crowded, smaller, and less branched, is due to a division of the branched cells, and that in this way such a patch increases in breadth and thickness.

From what has been said just now it is evident that the last mentioned patches are, as regards their structure, similar to those above mentioned, and that they are only further developed.

As regards the spherical cells of different sizes previously mentioned, it can be stated: first, that they lie in the lymph-canalicular system, as may be deduced from the negative silver-stained portions of these patches; secondly, that there exist all intermediate sizes between where a rounded nucleus is surrounded only by a very thin zone of protoplasm, up to cells which are twice as large as a common colourless blood-corpuscle. From what has been said at the commencement of this chapter we must claim also here, for at least some of the lymphoid cells, that they are derived from the branched cells of the matrix.

Besides these patches, there exist in the omentum of rabbits a few other structures, which, although under a lens they do not seem to differ much from those previously mentioned, yet under a higher power they exhibit between a network of capillary blood-vessels a number of lymphoid corpuscles held together by a delicate reticulum of branched corpuscles, similar to the reticulum of adenoid tissue.

A last form, which is also very interesting, and which is not very often to be found, is the following: from a tract which, besides a rich system of blood-vessels, shows the same structure as the one just before mentioned, or which tract contains only a larger artery and vein, a small artery comes off, dissolves itself into a network of capillary vessels, which join again into venous vessels, which return to the previously mentioned tract. The matrix in which these capillaries lie consists merely of a regular beautiful reticulum of nucleated-branched cells, without having any visible intercellular substance. Amongst the cells of the reticulum there are to be seen cells which are apparently spindle-shaped. These are situated generally in a row, accompanying the capillary vessels; by lateral branches they seem to join the branched cells of the reticulum. Looking at these apparently

spindle-shaped cells carefully under a high power, one soon finds out that they are only the profile of somewhat flattened branched cells, exactly the same as the other cells of the reticulum. The meshes of the reticulum appear perfectly clear, and contain only here and there a lymphoid corpuscle. We shall return in the chapter on lymphatic vessels to these patches and cords, where we shall be able to recognise and understand better their intimate structure.

We will, however, anticipate, by calling the patches and tracts which we have been considering up to the present *lymphangial patches (nodules) and lymphangial tracts*.

We may therefore say that there exist in the omentum of the rabbit two kinds of lymphangial structures :

*a. Patches, the matrix of which consists of groups of ordinary, more or less flattened, more or less branched cells, which on the one hand multiply by division, in which way the patch increases in size, and from which, on the other hand, grow up lymphoid cells. The branched cells lie in the lymph-canalicular system, together with the lymphoid cells. At an early stage of development these patches do not contain a special system of blood-vessels; at a later time they possess a special rich system of mostly capillary blood-vessels. By growing in length these patches join so as to form whole tracts.*

*b. Patches and tracts, the matrix of which consists of a reticulum, the meshes of which contain a variable number of lymphoid corpuscles: they are generally provided with more or less abundant blood-vessels.*

We come now to deal with the omentum of the guinea-pig, cat, dog, and monkey, the omentum of which animals is of a very similar structure, and at the same time perfectly analogous to that of the pleura-mediastini. Consequently, what will be said of the former holds good also for the latter.

In the tissue of the omentum of these animals similar lymphangial structures are to be met with, which, owing to their greater diameter in thickness, we shall not name patches, but nodules. By their size we may distinguish them as nodes and nodules, and we may say as well here as in the rabbit's omentum that they join so as

to form tracts, and that they project generally only over one surface of the membrane. The larger ones are provided with a special system of more or less numerous capillary blood-vessels. They are to be met with also here, either along the larger blood-vessels, or isolated at those points to which a number of thin connective-tissue trabeculæ radiate. The older the animal the larger and more numerous nodules are to be found, and the thicker and longer are the tracts they form. In young animals, their number is very limited, and they are of so small a size that they are to be recognised only under the microscope.

Before considering their minute structure, we wish to call the attention of the reader to the following points:—All these nodular and cord-like structures we have referred to in this chapter belong, if I may so say, to the proper ground-substance of the membrane. We have seen in the first chapter that the germinating endothelium may form small nodular bodies on the surface of the membrane, besides being found on the surface of the nodular structures previously mentioned.

If we look at a very small, that is a very young nodule, which can only be discovered under the microscope as such, and is isolated in the fenestrated membrane, we find in a pencilled silver-stained preparation, in which, like in those we have described in the rabbit's omentum, the ground-substance has remained nearly perfectly unstained, whereas the cellular elements are distinctly visible by their yellowish or brownish granules, we find, I say, also here, that the ground-substance contains more or less flat branched-protoplasmic cells with oblong nuclei. These cells are more or less crowded together, and join one another by their processes to form a network. The nucleus is generally single, and contains one or two nucleoli; sometimes the nucleus is constricted, or even divided into two. Migratory cells are also to be found in these places, which either resemble lymphoid cells, or which are large and coarsely granular. There is one point which we need merely allude to here, having entered into it fully in speaking of the rabbit's omentum, viz. that some of the larger migratory cells form a distinct continuum with one of those branched cells, by means of a longer or shorter neck, that

is to say, that some of the larger migratory cells have originated from a branched cell. In negative silver preparations of a corresponding young nodule it can be made out also that the clear lymph-canalicular system contains not only the network of branched cells, but also the migratory cells. Besides the latter, we find also larger isolated nodules in the fenestrated part of the omentum; they are already provided with a system of capillary blood-vessels. As regards their minute structure, one can determine with certainty in positive silver preparations that their matrix is occupied by more or less flattened cells, which, in the same way as in the rabbit's omentum, are the more branched the nearer they are to the borders of the nodules. In negative silver preparations we find the lymph-canalicular system accordingly so transformed that in the central parts of the nodule the lacunæ communicate with each other only by a few short canaliculi or even touch each other in lines; whereas in the peripheral parts of the nodule the number and the length of those canaliculi become greater. We need only add that from those more or less branched cells of the matrix migratory cells may be seen to grow up like knobs and become separated.

Besides the nodules just mentioned, we find also here, especially in the pleura mediastini of the cat, smaller nodules of an elongated shape, which consist of a delicate reticulum of nucleated branched cells, the meshes of which are perfectly filled with lymphoid corpuscles. Finally, we find nodules, and shorter or longer tracts, which possess a very rich system of capillary blood-vessels. Between these capillary blood-vessels extends a reticulum of pretty large branched cells, the meshes of which are either perfectly clear and empty, viz. contain nothing but fluid, or they contain here and there a smaller or larger lymphoid cell, which in some instances may be seen to grow up from those branched cells, viz. we find in one place that from a branched cell of the reticulum a nucleated rounded knob projects into the space of an adjacent mesh; and not far from that we find a similar appearance, with this difference, that the nucleated knob is raised from its branched cell by a more or less deep furrow. In a third case we find the nucleated knob previously mentioned connected with the branched cell by means of a thin peduncle. From these facts we

are justified in concluding that the lymphoid corpuscles which are to be found in the spaces of the reticulum are offsprings of the cells of that reticulum.

If we examine one of the above-mentioned membranes without special preparation we often find nodules and tracts marked only as an accumulation of lymphoid corpuscles. After what we have stated in the foregoing pages it would be perfectly erroneous to say that the nodules and tracts of the omentum represent only accumulations of lymphoid corpuscles (Knauff, Recklinghausen); and it would be not less incorrect to say that they resemble follicular tracts of lymphatic glands, viz. consist of adenoid tissue (Sanderson). We have seen, namely, that there exist several marked varieties in the nodules: *a.* Simple accumulations of germinating endothelium of the surface; *b.* Accumulation of more or less flat branched cells, or what comes to the same, accumulation of lymph-canalicular systems, the lacunæ of which become by the gradual division of their cells nearer to each other, and become provided in this way with less numerous and shorter canaliculi. Further, we have seen: *c.* Nodules which perfectly resemble adenoid tissue; and finally, (*d*) we have found vascularised nodules, the matrix of which consists of a reticulum of large more or less flat branched cells, the spaces of which are generally occupied by fluid, or by a very limited number of lymphoid corpuscles; that is to say, the matrix is replaced by a space filled with fluid, which space is subdivided into a number of small spaces by a reticulum of branched cells.

As we shall see in the chapter on the lymphatic vessels, the varieties *c* and *d* form one category of nodules and tracts, which, as they develop *in* lymphatic vessels, may be called endolymphangial nodules and tracts, whereas the nodules included in variety *b* lie outside lymphatic vessels, but in close connection with their wall, and may therefore be called perilymphangial nodules and tracts.

We must, however, add that we do not intend to draw a hard line as regards structure between *c* and *d* on the one hand and *b* on the other hand, at least not for the guinea-pig, cat, dog, or monkey; for we have not unfrequently seen nodules and tracts, the peripheral parts of which consisted of large more or less flat branched cells, which

were distinctly situated in the lymph-canalicular system, whereas in the central parts the branched cells were transformed into a delicate reticulum of cells, the bodies of which had become considerably smaller, and the processes very thin and delicate. The meshes were filled out nearly completely by lymphoid corpuscles; and there was nothing to be seen of an intercellular matrix.

After what has been said about the distribution of those nodules and tracts it is scarcely necessary to draw the special attention of the reader to the fact that from their topographical arrangement they are analogues of the fat tissue of the omentum. We will, therefore, consider in the following paragraph the structure and the development of the fat tissue in so far as it is necessary to show the very intimate relation between the above-mentioned perilymphangial structures and the fat tissue of the omentum. Before doing so we will describe first an organ which is situated in the fossa infra-orbitalis of young rabbits and guinea-pigs, the structure of which is able to throw some light on our discussion about the relation of the fat tissue and the perilymphangial structures.

By the side of the glandula infra-orbitalis lies a mass of fat, which appears sometimes to be more or less isolated from the gland as a separate structure, and sometimes to represent only an envelope of that gland. In young and half-grown animals it is generally found to consist for the most part of a perfectly hyaline matrix, and to contain only a few small fat lobules. The older the animal gets the more fat lobules and the less hyaline substance are to be found in it.

The best method of preparing this structure for examination is the following: the skin and subcutaneous tissue are first removed, and the fascia which bridges over the fossa of the infra-orbital gland is then slit up. A small portion of the hyaline body, which now protrudes through the opening, can be snipped off with fine curved scissors, and mounted in aqueous humor. The following appearances will then be found under the microscope: in some places, there are a very few thin, isolated, wavy, shining connective tissue bundles, with here and there an amœboid corpuscle; in other portions very little is to be seen in the perfectly hyaline matrix, while elsewhere the matrix contains a

not very limited number of isolated coarsely-granular spindle-shaped looking elements, of a considerable length. They show sometimes in their thick portion an oblong compressed nucleus; their extremities are very delicate, and are seen sometimes to be branched. If the preparation is protected from evaporation, and if one observes the hyaline matrix previously mentioned, put under a high power, one is able to make out after some time has elapsed that granular fields come into view in which a more or less distinct large oval clear nucleus-like body may be just perceived. Still later, these granular fields become more or less distinctly outlined; it is possible to make out that they represent plates of different sizes. Gradually, also, the previously-mentioned nucleus-like body becomes sharply outlined, and is seen sometimes to contain a distinct nucleolus. If the observation is still continued, a various number of different processes come into view, which spring from those plates, and which become in their course so delicate that they can hardly be followed. The outlines become gradually more defined, and it is possible to make out that the greater part of the plate is made of a more or less distinctly fibrillar substance, and between the fibrils lie single granules, which are continuous with the masses of granules which surround the nucleus. We can farther see distinctly that the processes, too, are very finely fibrillated, and that they are sometimes branched and join those of neighbouring cells after a longer or shorter course. A connection between those processes and the above-mentioned isolated, wavy, shining connective tissue bundles is not to be found. Such a connection is already *a priori* improbable, from the perfectly different aspect and course of those connective tissue bundles, provided that the preparation has been made with the necessary care, and that all rough handling has been avoided. In a portion which contains only a very few connective tissue bundles the contrast between the processes of the above-mentioned cell plates and the connective tissue bundles is very striking as regards thickness, course, and aspect; by careful examination it is hardly possible to imagine how the very delicate processes of the cell-plates could possibly be transformed into such a connective tissue-bundle. We need not mention that in those preparations in which the number of connective tissue-bundles is very large it is very difficult to come to a decided conclusion.

The system of cell-plates, with their processes, can be brought into view very distinctly, and without great loss of time, by mounting the preparation in diluted Müller's fluid, instead of in serum or humor aqueus, and they there become visible in fifteen minutes, or even less.

Not all of the cells which we have designated above as being branched are flat and of the same size; generally they are in some degree flattened. The largest of these latter cover nearly the third part of a field (Hastnack  $\frac{3}{8}$ ), but there are many which are smaller. The question arises now, in what relation do the first-mentioned granular spindle-shaped cells stand to those branched more or less flattened elements.

If one compares a number of preparations it is obvious that in some of them the number of spindle-shaped elements is a very great one, and that they mostly run in one direction, whereas in some other ones there are only few to be found. As regards their aspect, these spindle-shaped cells resemble perfectly those which are to be found in embryonal connective-tissue. If a preparation of the above-mentioned substance, containing a great number of spindle-shaped elements, is mounted in a large drop of serum or humor aqueus, and if that edge of the covering glass which lies parallel to the longitudinal axis of a certain number of the spindle-shaped elements is pushed slightly by a needle one can observe the remarkable fact that the coarsely granular spindle-shaped elements become all converted into pale, branched, partly finely-granular partly striated, plates, each of which contains a large flat ovoid nucleus. If, then, the cover-glass is again allowed to float back, the plates become again converted into spindle-shaped elements.

In preparations which had been mounted only shortly before, the placoids which appear instead of the spindle-shaped elements are very faint, exactly as we saw them previously in fresh preparations, mounted only a very short time. This manipulation proves that the coarsely-granular spindle-shaped elements are not, in fact, spindle-shaped, but are perfectly identical with the above-mentioned placoids seen edgewise. Under a high power, and using sufficient care, one can easily observe by the above-mentioned manipulation how an in-



dividual spindle-shaped element rolls on its broadside so as to appear as a placoid, and *vice versâ*. Having so determined that all the elements of this gelatinous hyaline body are of the same nature, a further question arises, What is the significance of those elements?

From what has been said until now, it is plain that this gelatinous body is perfectly analogous with what is called 'Schleimgewebe,' namely, what is regarded as embryonal connective tissue; but we must venture to repeat again that we have not been able to discover a transition of the cellular elements of that gelatinous body into connective tissue bundles. The significance of the placoid cellular elements of it is to become transformed into fat cells.

If we examine a preparation taken from the perfectly hyaline part of the neighbourhood of a fat lobule we find the nearer we approach to the fat lobule the more numerous are the branched placoids, which contain fat globules, either one large one, or several small ones. First they appear only isolated, the protoplasmic part and the processes of the cell are very distinctly recognisable, the nucleus is situated somewhat peripherally; then we find them lying in groups, they are still provided with processes, but contain a very large fat globule. Here the protoplasm of the cell-body is reduced to a more or less thin covering of the fat globule. Where cells of that kind lie close beside each other, their processes can hardly be made out; but where these are met with as isolated ones it does not require any high power to convince one's self that they are still provided with processes.

Where these new fat cells lie in groups a great number of blood-vessels are to be met with: they form in such places a special system, which is perfectly analogous to that found in fat lobules. But there exist similar systems of blood-vessels in groups which do not contain fat cells, which contain only clusters of the previously-mentioned placoids: here they are, however, provided only with fewer and shorter processes. One finds, for instance, an arterial branch breaking up into a bunch of capillary vessels, which, after anastomosing with each other, collect themselves into a venous vessel. The hyaline matrix in which this system of blood-vessels is imbedded contains a great number of branched placoids. In such places it can be further made

out, that these placoids undergo rapid divisions; one finds, namely, not only cells the nucleus of which is either constricted, or even divided, but the cells themselves show very distinct notches, and more or less deep furrows, by which they become separated into two parts of nearly equal size.

From these facts we can deduce that by division of these placoids groups of cells result, which lie more or less close to each other, and which possess shorter and fewer processes than those which are to be met with in isolated ones.

There are, finally, to be found intermediate stages between such vascularised lobules, the cells of which are not transformed into fat cells, and those above-mentioned vascularised true fat lobules. There can be, consequently, no doubt whatever that this hyaline body becomes transformed into fat tissue in the way that its branched flat placoids become transformed into ordinary fat cells, and that while doing so they proliferate by division, and that these groups are provided with a special system of blood-vessels. The latter may already be found even when the cells of the matrix have not yet transformed into fat cells.

After having described the development of fat tissue in the gelatinous body of the infra-orbital fossa, we shall be able to deal with that of the omentum and of the mesentery more briefly than we could otherwise have done, as we find in these membranes exactly the same relations. As regards the formation of fat cells, we find here the same relations. We have had the opportunity to remark that perilymphangial vascularised nodules develop from, and consist of, accumulations of more or less flat and branched cells. We had further remarked that these nodules join so as to form whole tracts, which generally follow the course of the larger blood-vessels. We need now only add that if the branched cells which represent the matrix of those tracts become converted into fat cells as above described the result would be what is generally called a vascularised tract of fat cells. That the tracts of fat cells, as well as the more or less isolated fat lobules or fat nodules, are only transformed perilymphangial nodules can be very easily recognised by following a perilymphangial tract along a large blood-vessel up to a neighbouring fat tract.

In that way one will be sure to find smaller or larger nodules, which are in all stages of conversion into fat tissue. [From this it is also evident that the fat tracts show here the same relations to the surface endothelium as the perilymphangial nodules in general]. It is remarkable that the distribution of the perilymphangial nodules stands in an opposite relation to that of the fat tracts. The more perilymphangial nodules and tracts an omentum contains the smaller is the number of the fat tracts, and *vice versâ*. In well-fed half and full-grown dogs, and still more in cats and white rats, the omentum shows only fat tracts and very few lymphangial nodules of a very small size, in a state where the capillary system is just developing, whereas, in the omentum of rabbits, seldom, and then only to a limited extent, fat tracts appear. In the omentum of guinea-pigs and that of the monkey the lymphangial nodules and fat tracts are pretty equal, even in the most favourable conditions. In the pleura mediastini there is a very much smaller tendency for the lymphangial nodules to become converted into fat tracts, whereas in the mesentery, even of the rabbit, the tendency is great; from which it is evident that the conversion of lymphangial nodules into fat tissue does not take place equally in all serous membranes, nor in all animals—the mesentery has the greatest, the pleura mediastini the smallest tendency. In cats, dogs, and rats there is a much greater tendency than in guinea-pigs or monkeys, and the smallest is to be found in rabbits.

There are two other points with regard to the fat tracts still to be mentioned, namely: 1. That as long as a lymphangial nodule does not become converted into a fat nodule there are always, as we have seen, numerous lymphoid cells to be found in it, which, as we have pointed out, are at least partly to be considered as offsprings of the branched cells of the stroma of the nodule. But as soon as a lymphangial nodule becomes converted into a fat nodule the lymphoid cells become fewer, or, at any rate, are not to be found in the same number as before. We must therefore conclude that the surplus of nourishment which the cells of the matrix are provided with is all consumed in the production of the fat, whereas, previously, it had been employed for the production of lymph-corpuses. After what

has been said above about the transformation of the branched cells of the stroma into fat cells, it is unnecessary for me to warn the reader against the possible assumption that in the transformation of lymphangial nodules into fat nodules the lymph-corpuses are the elements which become converted into fat-cells—according to the previous assertions of histologists—and consequently we could easily understand why the number of these lymph-corpuses decreases as this transformation is going on. For in contradiction to such assertions we have the above stated fact that the fat cells are transformed branched cells of the stroma of the nodule. Besides, the decrease of the lymph-corpuses can easily be explained in another way. We have seen that the branched cells of the stroma of the nodule lie in the corresponding lymph-canalicular system, together with the lymph-corpuses. Under ordinary circumstances, one must suppose that the lymphoid corpuses, after they have detached, viz. constricted, themselves from those branched cells, are carried away into the lymphatic vessels, into which, as we shall see afterwards, that lymph-canalicular system leads. As soon as the branched cells of the matrix become converted into fat cells the production of new lymph-corpuses is diminished to a very great extent, and, consequently, there is very little here that can be carried away.

2. The second point we wish to call attention to is the following: the lymphangial nodules and tracts grow relatively quicker when they are going to become converted into fat tracts. That is seen best in the mesentery. Here, for example, in cats and in rabbits it is very easy to find that the number and size of lymphangial nodules and cords increases very much in the neighbourhood of fat tracts.

It is plain, therefore, after all we have said about the fat tracts, that we are in agreement with Fleming in saying that fat cells are transformed branched cells, but that we are not in agreement with that observer in saying that fat tissue develops in the adventitia of arteries. What we have already pointed out is that the formation and growth of the lymphangial nodules is generally, not always though, closely related to the larger blood-vessels, and we shall see in one of the following chapters that the development of the lymphangial nodules, and consequently also that of the fat nodules and fat

tracts stands only in so far in a relation to the blood system as a very active growth of capillary blood-vessels takes place in the lymphangial nodules. We may say, further, that we consider fat tissue, in agreement with Toldt, to be a special sort of glandular tissue, for it develops from a special tissue, *i.e.* from lymphangial nodules, which, as we have seen, have very much to do with the formation of lymph-corpuses, just as a lymphatic gland has.

We have still to make a few remarks about the mesogastrium of frogs. There are not seldom nodules to be found in the ground-substance, which are of a spherical shape, sometimes situated so closely to each other that they almost coalesce, so as to form a cord, and which are not always near the large blood-vessels. They have a structure which resembles in all respects that of lymphatic follicles.

As regards the mesentery, there is very little remaining to be said, partly because we have already discussed the cellular elements of the omentum, and partly because we shall return to the subject of the cellular elements of the mesentery in the chapter on inflammation, the cellular elements in the inflamed state being very much easier to study than in the normal. This is especially true of frogs and cats, in which animals chronic inflammation occurs accidentally, in consequence of parasites which find their way from the intestine, through the lymphatics of the mesentery, to the mesenteric glands.

The cellular elements of the ground-substance of the mesentery are in general more or less flat branched; in their structure, size, and nucleus they are not different from those in other serous membranes. In frogs and monkeys, as well as in cats and dogs, I have not unfrequently seen, on pencilled silver preparations, places where the branched cells of the lymph-canalicular system appeared to undergo division. In some the nucleus is divided; in others the body of the cells itself exhibits a cross mark between the two nuclei, so that then the body of the cell consists of two halves, touching each other in a straight line. Sometimes a group of three or four of them were touching each other in straight lines, either situated all round a common centre, or arranged in a chain one after the other. In general, these phenomena are seen to take place near the large blood-vessels. There, also, we

sometimes find elements which appear like nobs on the branched cells of the lymph-canalicular system, and which perfectly resemble lymph corpuscles. A fact we have had already opportunity to refer to is that near the large blood-vessels similar smaller or larger masses of branched cells are to be found which mostly form oblong nodules and cords, which begin now to have a special system of blood-vessels of their own. These nodules and cords are exactly like those described in the omentum, namely, those which we described under the name of perilymphangial nodules and tracts. Their intimate structure, their migratory cells, the relation of these to the branched cells of the matrix, the relation of these nodules to fat tissue, is here exactly the same as in the omentum. Especially worthy of notice is the fact that in guinea-pigs I have met with mesenteries which exhibited an immense development of these perilymphangial tracts, whereas in cats and dogs the perilymphangial tracts have a great tendency to convert themselves into fat tracts.

As regards the cellular elements of the abdominal serosa of the centrum tendineum, there is very little to be said. They differ in no respect from those we have found in the mesentery: where the larger blood-vessels branch, and where, as we shall see, lymph-capillaries are to be found forming a network, there we find also that the branched cells of the serosa are situated nearer to each other. Amongst those we find also here groups of flattened cells, which are connected with each other only by very few short processes, or even touch each other end to end. In correspondence with this arrangement, the lymph-canalicular system also becomes modified, namely, contains groups of lacunæ, which communicate with each other by a few very short canaliculi. The cells of the pleural serosa of the centrum tendineum can be recognised more easily on pencilled silver preparations than those of the abdominal serosa. We there see, close under the endothelium of the surface, a layer of very large flat, branched cells, which lie mostly isolated, but in the neighbourhood of those places where the vena-cava and aorta pass through the diaphragm, and also in the median portions of the centrum tendineum, are found in larger groups closely together, so that in many places there

appears under the endothelium of the general surface a second layer of large flat cells, arranged very similarly to an endothelium. The cells consist of an almost hyaline substance, and possess a large clear ovoid nucleus: the cells which lie deeper in the proper substance of the serosa are more or less flat and branched. In preparations which have been stained with nitrate of silver after being pencilled from the pleural surface, the branched cells of the serosa are not easily recognisable, the lymph-canalicular system of the branched cells being the chief thing that comes into view; but by using a high power and examining a preparation which has been deeply stained in many places, one is able to distinguish the bodies as well as the processes of the branched cells, the former occupying the lacunæ, the latter the canaliculi of the lymph-canalicular system. The cell substance is very pale, distinctly granular round the oblong or spherical sharp outlined nucleus.

The cells of the islands of the serosa, which are surrounded by lymphatic vessels (see the following chapter), are very instructive as regards the processes of division of the branched cells of the lymph-canalicular system we have already mentioned in a former place. One finds in the central parts, as well as in the peripheral parts of those islands, numerous places where the branched cells lie in groups, as if round a common centre or in chains: there the individual cells are very little or not at all branched where they touch each other, whereas they are provided with processes on their outer sides. These cells of the serosa come out very distinctly when the serosa has been slightly affected by inflammation. Under those circumstances their relation towards each other and the surrounding parts is much more distinct. We call the attention of the reader to the figures 14, 16, 17, which will render our meaning easier to understand than any long description.

## CHAPTER III.

## THE LYMPHATIC VESSELS OF THE SEROUS MEMBRANES.

*a. Lymphatics of the Omentum and the Pleura Mediastini.*

IN the rabbit's omentum the lymphatics are easily demonstrated. Following the above-mentioned method, it is necessary only to pencil *in situ* the surface of the fresh omentum and then to stain it in silver. Different portions of the omentum are differently circumstanced as regards lymphatics. In the neighbourhood of the greater curvature of the stomach, and in the portion of omentum covering its pyloric end, there occurs a rich network of lymphatics: they are related to the large blood-vessels in such a way that a group of the latter has a lymphatic running along both sides and communicating with one another by transverse and oblique lateral branches. The lymphatics are also distributed independently of large blood-vessels, chiefly between and around the lymphatic patches which, as mentioned above, are met with in great abundance in this part (the pylorus and greater curvature). Concerning their structure, there is little to add to what is already known. They are wide vessels, the walls of which consist only of one layer of endothelial plates; the latter, in the large lymphatics accompanying the blood-vessels, being of a short spindle shape, almost sinuous. These possess also valves and sacculated dilatations corresponding to them, and are to be considered as the main lymphatic trunks.

The other class, running apart in the tissue, are not different in calibre, and have also a sinuous endothelium; but they are either without valves or have them only in a very few places, while they are provided with sinus-like dilatations springing from their sides. These are to be considered as the lymphatic capillaries.



In the portion of omentum covering the anterior wall of the stomach the conditions are somewhat different. There it will be seen that the lymphatics run only in company with the blood-vessels; large blood vessels, again, are rare in that part, the vessels of common occurrence being the smaller arteries and veins, which, however, run quite isolated, often for a considerable distance. The arrangement of the lymphatics is as follows. Either a single lymphatic vessel is accompanied on one side frequently by a vein and sometimes also by an artery: the lymphatic keeps close to the blood vessel, possesses at certain points sacciform dilatations, and receives also sometimes a branch laterally. These are vessels that have mostly a sinuous endothelium. Or, secondly, it may happen that a blood-vessel is accompanied on both sides by a lymphatic: these are disposed exactly as in the former case, and communicate by cross branches.

Finally, it occurs not unfrequently that the blood vessel runs within a lymphatic—that the blood-vessel is invaginated. There cannot be the slightest doubt that such invaginations occur. They are of various kinds. One case, for example, which is quite easy to make out, is that of a vein invaginated for a considerable part of its course, while, at the same time all its branches, so long as they are not capillaries, are also invaginated. The chief lymphatic, containing the venous trunk, leaves the latter, after a long course, at a point where this vein opens into a larger trunk, and then unites with the lymphatic that accompanies this principal venous trunk. It may also happen, secondly, that the lymphatic leaves the blood-vessel long before the latter opens into a large trunk: in this case the vein and lymphatic run side by side to the latter point. Finally, there is a third case, which, however, in the omentum is much rarer, viz. where the lymphatic accompanying a blood-vessel (and invaginating it) suddenly acquires an extensive dilatation, through which the blood-vessel penetrates, breaking off at an angle, while the lymphatic can be traced a long way beyond the dilatation.

All these descriptions are drawn from preparations that have been pencilled and silvered. I have in my possession preparations of rabbit's omentum where such perivascular lymphatics present themselves as large tubes, the walls of them showing the sinuous endothe-

lium distinctly coloured; in the tube lies the blood-vessel, the wall of which shows the spindle-shaped endothelium on its inner surface.

In this case, where the lymphatic appears, not, as in the common silver preparations, in the form of a clear space showing endothelial markings on a dark ground, but as a wide tube, there is hardly any possible room for mistake, inasmuch as one can see, even with a low power, that the blood-vessel is contained, as if it were a thin rod, within the wide tube. In the first case, also, where the lymphatic shows itself as a clear space with endothelial markings, a mistake will not readily be made if one has before him an invagination extending over a long tract; for in that case it can be seen that the lymphatic makes certain bends, which affect both sides of it together—that is, the impression on one side of the vessel has its corresponding and complementary deflection on the other. The importance of this as a criterion will appear from the following considerations. The blood-vessel lying in a lymphatic has that surface which is directed towards the lumen of the lymphatic also covered by an endothelium. There appears, therefore, in the optical longitudinal section on each side of the vessel, an endothelial membrane, i.e. a membrane with oblong nuclei disposed at regular intervals—the endothelium being seen of course in profile. It presents, therefore, the appearance as if a lymphatic ran on each side of the vessel. In this manner the above-mentioned condition, viz. that the bendings of the lymphatic on both sides of the blood-vessel correspond to and complement each other, is of importance for deciding whether we have before us one lymphatic in which the blood-vessel is invaginated, or a pair of lymphatics.

The lymphatics are also to be seen in the fresh omentum, provided that the part is mounted in serum and has not been subjected to any mechanical injury. After having studied the lymphatics in well-silvered preparations, both those accompanying the blood-vessels as well as the invaginating variety of them, one may recognise them also in fresh objects. They present themselves as broad tracts which appear to be bounded by a membrane with oblong nuclei disposed at regular intervals; that is, one sees the endothelial membrane in profile.

In the lumen of the lymphatic there swim a number of lymph-corpuscles of various sizes, exhibiting amœboid movements. How easy it is to fail to see the lymphatics in the fresh omentum is shown by the circumstance that, if the membrane is subjected to only a very slight stretching, the lymphatics collapse completely, and appear as nothing else than rows of spindle-shaped elements, between which migratory cells lie here and there. Even in silvered preparations the same source of error exists. I have seen it happen, in a considerable number of silver preparations in which the lymphatics were plainly visible, although their endothelium was only faintly coloured, that, on removing the preparation from one object-glass to another (necessitated by an accident), the lymphatics were no longer to be seen. It is only in the rarest cases that a lymphatic will be seen, unless the omentum be treated *in situ* with the proper reagents. And, in my opinion, this will not appear astonishing, when it is borne in mind, on the one hand, how delicate and flaccid the lymphatics in this situation are, and on the other hand, how tender and thin is the ground-substance itself. How easily, therefore, the lymphatics collapse when the membrane is cut out and the circulation of lymph has ceased. Thus, as regards the mesentery, there is no possibility of failure in the demonstration of the large lymphatics running from the intestine to the mesenteric glands and accompanying the blood-vessels, and which possess muscular walls; for in their case, collapse to the extent of their disappearance cannot occur. On the other hand, demonstration of the lymphatic proper in the mesentery invariably fails if the mesentery is not treated *in situ* with the greatest care. In like manner, it is hard to fail in demonstrating the lymphatics of the pleural side of the *centrum tendineum*, because here the serous membrane is prevented from shrinking too much by the subjacent tendinous tissue. On the other hand, want of success in demonstrating the lymphatics of the mediastinal pleura is easily intelligible on the same grounds as in the case of the omentum.

From the circumstances just now mentioned, it follows that one should be very careful in asserting the existence, in an omentum whose lymphatics are not apparent, of spindle-shaped elements—and among them a greater or less number of migratory cells—ranged

along the sides of the blood-vessels. For it is easy to understand that this appearance might simply be due to the folded walls of the collapsed lymphatics, and the migratory cells be actually in the lumen of the lymphatics. That there actually occur near the vascular trunks occasional aggregation of lymph-canalicular cells and migratory cells is another and different fact to which we have already directed attention.

We come now to the important questions—Do the lymphatics in the rabbit's omentum form a closed vascular system, or do they take origin among the tissues? and, In what way do the lymphatics stand related to the above-mentioned patches and cords? The answer to the first question will become obvious when we have first considered the second question attentively.

We have already mentioned that in negative-pencilled preparations, as well as in positive, one can convince himself that at certain points the lacunæ, or lymph-canalicular cells respectively, are so closely pressed together that they come to be arranged in lines; that is, they are not united by canals or processes in their respective cases, but simply joined to one another like the cells of an endothelium. This appearance we shall call that of simple lacunæ, understanding thereby the larger lacunæ formed by the fusion of a group of lacunar spaces of the lymph-canalicular system, and lined, therefore, on one side with cell-plates arranged like an endothelium. We have already stated, however, that these isolated simple lymph-lacunæ are connected by means of canals with the isolated lacunæ of the adjoining lymph-canalicular system (and the outermost cells, respectively, by processes with the adjoining cells;) and we shall now add that those simple lymph-lacunæ are situated quite superficially—that is, under the endothelium of the surface—and are but seldom met with in the ground-tissue itself. We may at the same time mention, in connection with those isolated lacunæ, also the simple lymph-lacunæ that occur in the large-sized patches, concerning which we have already stated that they consist only of an agglomeration of more or less branched cells, with the young cells belonging to them and lying with them in the lymph-canalicular system. In this same kind of patches and cords there is illustrated yet another interesting relation in which

they stand to the actual lymphatic vessels. We have already stated that the larger patches are provided with a system of blood-vessels. Disregarding at present the exact details, we shall merely mention that this system consists of an afferent arteriole, efferent veins, and intermediate capillaries. Regarding, now, the lymphatic system of these patches, it is always to be observed that the efferent vein, more seldom also the afferent artery, is accompanied by at least one capillary lymphatic, or is even invaginated in one such. At the point where the vein becomes the capillary—that is, where it enters the patch—the lymphatic as such terminates, that is to say, its hitherto sharply-defined wall and covering of sinuous endothelium ceases, and only the lymph-canalicular system appears in its place.

There can be no doubt whatever, if a favourable point is closely observed, that at the point the lumen of the lymphatic vessel on the one hand loses itself in reality in a labyrinth of spaces, which consist of lacunæ with uniting canals, representing the lymph-canalicular system, and, on the other hand, the endothelial plates of the lymphatic are continued as branched cell-plates.

The appearances just now mentioned correspond to what Recklinghausen first described as to the origin of the lymphatic capillaries in the centrum tendineum of the rabbit, with the addition of the fact that the endothelium continues itself in the lymph-canalicular system as branched cell-plates. We call, therefore, these patches or nodules peri-lymphangial nodules. When the lymphatic capillary issuing from the nodule is of the invaginating kind, as in Fig. 40, one may see at any time several points at which the lymphatic vessel throws out one or the other of its branches to the lymph-canalicular system of the surrounding tissue.

We come now to the consideration of the important relation of that kind of nodules which we have described in Chapter II. under *c*.

We find, for example, a wide lymphatic vessel invaginating a venous trunk; the vein collects a small number of capillaries, which come off from a small arterial branch. The lymphatic vessel, however, does not cease to exist as such at the point where the capillaries debouch in the vein, as in the former case, but continues on to the

artery in such a way that the whole system of the capillaries is invaginated in a sacciform dilatation of the lymphatic vessel. Not till the root of the artery is reached does the lymphatic as such cease to exist, at which point it loses itself in the lymph-canalicular system accompanying the artery. Thus we have before us here a case where a vein is invaginated in a lymphatic vessel, while the system of capillaries belonging to it hangs freely in a lymph-sac, which is a direct continuation of the lymphatic tube. A modification of this form is the following:—A lymphatic vessel that simply accompanies a vein possesses a blind sacciform dilatation, in which the system of capillaries belonging to the vein is inserted like the glomerulus of a Malphigian corpuscle of the kidney. We have already mentioned that in the case where a blood-vessel is invaginated the blood-vessel itself possesses on its outer wall, viz. on that diverted towards the lumen of the lymphatic, an endothelial covering, which exactly resembles that forming the outer wall of the invaginating lymphatic. On the invaginated capillaries the same is to be seen, that is to say, besides the endothelium forming the outer wall of the common lymph-sac, there is an endothelial covering outside the capillaries. From this it is clear that the two kinds enumerated of invaginated capillary network are identical. In both cases we have an outer wall of endothelium for the lymph-sac, and an endothelial wall around the capillaries.

The second case of invagination of the capillary system is more frequent than the first, for the reason that the case of a lymphatic vessel simply accompanying a vein is more frequent than the case in which the vein is invaginated. So long as the system of capillary blood-vessels is small there is nothing further in the lymph-sac to be seen, except here and there a migratory cell. Besides these, however, one finds nodular structures which resemble those just mentioned in some respects, but differ from them in other respects. We will direct the attention of the reader to Fig. 50 on Plate X. and Fig. 43 on Plate VIII.

In Fig. 50 we see that from the endothelial outer wall of a capillary vessel branched nucleated protoplasmic bodies extend to that of a neighbouring capillary; these occur, therefore, in the lumen of

the lymph-sac, and the lumen is thereby partitioned into a number of spaces. While at one point this proliferation occurs sparingly, at a neighbouring point the lumen of the lymphatic-sac may be quite free, or these branched cells may be so plentiful as to form a tolerably close network, which differs from a young adenoid reticulum only in respect of the somewhat greater amount of protoplasm which occurs round the nuclei at the nodes of the network. From what has been said, only this conclusion can be drawn, that the growth of a network of branched cells proceeds from the endothelium of the lymphatic sac, whereby the lymphatic vessel is transformed into a cavernous or sinuous structure. It is very easy to make out at all points and in all stages of development, with great clearness, that not only from the endothelium of the wall of the lymphatic vessel, but also from the branched cells extending across its lumen, lymph corpuscles originate, which become finally detached and lie in the meshes of the reticulum, or in fact in the lumen of the previous lymphatic vessel. In a completely formed nodule of this sort, which we designate as endo-lymphangial nodules, one cannot of course any longer determine its origin; all that one sees is a delicate reticulum, with lymphoid cells in its meshes, and supplied with a more or less rich capillary network. For the same reason, also, in the case of a fully developed nodule or cord of the first form, i.e. a peri-lymphangial nodule or cord, which owes its origin to an aggregation of lymph-canalicular cells, it is not easy to distinguish it from an endo-lymphangial nodule or cord, inasmuch as, as we have already mentioned above, the at first more or less flat cells gradually transform into an adenoid reticulum, in the meshes of which lymphoid corpuscles lie, while at the same time the fibrillar ground-substance disappears. We wish to add here, for the better understanding, two other points, namely, 1. That those lymphatic nodules and cords which are surrounded by a distinct semicircular lymphatic vessel, and whose reticulum is continuous with the endothelium of the lymphatic vessel, correspond to a peri-lymphangial nodule; and 2. That the proliferation of an endo-lymphangial nodule extends more and more into the lymphatic vessel invaginating or accompanying a large blood-vessel, so that, therefore, the large blood-vessel seems to be enclosed in a lymphatic cord. This then comes to resemble

the form of cords which originate in the fusion of several peri-lymphangial nodules.

To summarise the preceding statements, we may divide the lymphatic nodules into peri- and endo-lymphangial: the former constitute isolated nodules or patches, and, by fusion, cords; the latter form patches and nodules, and, by continuous outgrowth, cords. From what I have seen in the omentum and pleura mediastini of guinea-pigs, dogs, cats and monkeys, I am inclined to think that along one lymphatic vessel several endo-lymphangial nodules may originate, isolated, which afterwards become fused together, so as to form a cord.

It seems to me that the development of the peri-lymphangial nodules follows more the arterial vessels, whereas that of the endo-lymphangial nodules the venous vessels. My researches have, however, not been carried out so far as to enable me to state this with certainty.

We come now to the lymphatic system of the omentum and pleura mediastini of the animals just mentioned. We are able to treat this part more briefly, since we have stated the essential points in detail in the preceding, where, in the omentum of the rabbit namely, the proof of the facts brought forward is considerably easier to adduce than for the first-named animals. The lymphatics in the normal state are here much more difficult to demonstrate than in the rabbit.

It is desirable to select for studying preparations mounted quite fresh in serum, and subjected to the least possible tearing. One may be prepared for ill-success in many cases of staining the omentum with silver. It is very difficult to pencil accurately the extremely delicate fenestrated portion of the omentum. The best preparations are obtained from the guinea-pig, from that part of the omentum in which the pancreas lies enveloped. It is less difficult to pencil the omentum of the cat, the rabbit, or the ape, because here the omentum lies on the small intestine like an apron. It is equally difficult to obtain a successful preparation of the pleura mediastini of the guinea-pig as well as of the cat, there being in the latter case an unusual number of trabeculæ, running in all directions free on the surface, bearing the lymphatic nodules, which trabeculæ interfere to a great



extent with the pencilling. In the puppy, the pencilling is easier: the membrane is not too tender, and therefore one succeeds much better in obtaining a silver preparation in which the lymphatic system may be successfully studied.

What I shall describe hereafter refers only to a small extent to silver preparations of the normal membranes; to a greater extent it refers to the investigation of fresh normal membranes, and chiefly to the investigation of membranes—either fresh or silvered—that have been slightly chronically inflamed. The latter, if the chronic inflammation has not reached too high a degree, are especially well adapted for the study of the lymphatic system, for the simple reason that here the lymphatics are held distended, either by the fluid of œdema or by lymphoid corpuscles. Thus the tuberculous omentum and pleura mediastini of the guinea-pig and ape have been of great service in many cases in consequence of the œdematous condition.

The lymphatic vessels which accompany the larger blood-vessels have quite the same relation as we have found them to have in the rabbit, i.e. they accompany each vessel either singly, or more frequently in pairs, and are in a few cases of an invaginating character; the latter condition, however, being, on the whole, not very frequent. Concerning their structure, there is to be made out only a wall composed of endothelium; they follow exactly the course of the venous branches; here and there also a lymphatic is seen beside an artery. As regards those nodules and cords which, by their stroma, may be interpreted as peri-lymphangial nodules and cords, there exists quite the same condition as we have already determined for the omentum of the rabbit; namely, the lymphatic vessel terminates as such and loses itself into the densely-aggregated lymph-canalicular system, while the corresponding system of branched cells is in direct continuity with the endothelium of the lymphatic vessel. Here, also, we find amongst the tracts of lymph-canalicular cells which accompany sometimes a small vascular trunk simple lymph-lacunæ, that is, a fusion of several lymph-canaliculi. As in the rabbit, such simple lymph-lacunæ occur also quite superficially in the omentum and pleura mediastini of the before-mentioned animals. Considerably often, also, lymph-sinuses, viz. sacciform dilatations of lymphatic vessels are

to be met with. Most generally it is the case where a lymphatic vessel accompanying a vein gives off a short side-branch, which ends blindly in the form of a sac. Into this terminal lymph-sac there exists an invagination of a system of blood capillaries belonging to that venous trunk. There may occur a growth of the endothelium of the one wall of the lymph-sac towards the wall of the opposite side in the form of a cellular network, from which, on the one hand, young cells become separated, and which, on the other hand, gradually comes to resemble an adenoid reticulum. In this manner an endo-lymphangial nodule is consequently produced. The other form of development of endo-lymphangial nodules and cords is also tolerably frequent, the form, namely, where a lymphatic vessel accompanying a large blood-vessel possesses a sacciform dilatation in which a number of capillary blood-vessels lie. By the outgrowth of the endothelial wall of the lymphatic, in form of a cell network, towards the lumen of the sac, an endo-lymphangial nodule or cord is formed.

(b.) *The Lymphatic System of the Centrum Tendineum of the Diaphragm.*

Recklinghausen was the first to assign to the lymphatic vascular system of the centrum tendineum an adequate importance, having there previously demonstrated the lymphatics by silver and by natural filling of these from the peritoneal cavity. Ludwig and Schweigger-Seidel have amplified the results of Recklinghausen. My researches do not only confirm those of the authors just mentioned, but complete them to a considerable extent.

I will first describe the methods by which the lymphatic vessels of the diaphragm may be demonstrated. First, the method employed by Recklinghausen, that is, pencilling the pleural surface of the centrum tendineum with a fine camel's-hair brush dipped into serum, and subsequent staining the centrum tendineum with half per cent. of silver-solution. By this method the lymphatic vessels of the pleura serosa are shown.

To obtain perfect preparations of these lymphatics, the following

is the best plan: the anterior wall of the chest of a just-killed rabbit or guinea-pig having been removed, the vena cava ascendens is ligatured near its entrance into the auricel, the pleura separated from the diaphragm, and the lungs and heart cut out. In this way the pleural surface of the diaphragm can be exposed without being smeared with blood. After this, each half of the centrum tendineum is pencilled separately two or three times with a fine camel's-hair brush dipped in serum, commencing in the middle line, and carrying the brush outwards; a quarter or half per cent. solution of nitrate of silver is poured on the pencilled surface, and is allowed to remain there for three to five minutes, after which it is replaced by distilled water: this is changed two or three times. After that the whole diaphragm, together with the ring of cartilage and bone to which it is attached, is cut out, brought into a large capsule with water. As soon as the pleural surface assumes a yellowish-brown colour, the centrum tendineum is divided into a number of pieces, which are floated on object glasses and mounted in glycerine. In a similar way one proceeds if it is intended to demonstrate the lymphatics of the abdominal surface of the centrum tendineum; the abdominal surface, having been exposed, is pencilled and treated as above.

The lymphatics of the diaphragm may be also injected, either by Recklinghausen's method, that is, by injecting a few c.c. of milk into the abdominal cavity of a living rabbit or guinea-pig, and by killing the animal after 12 to 24 hours (it is desirable to stain afterwards the centrum tendineum with silver); or by the method of Ludwig and Schweigger-Seidel, viz. by pouring on the abdominal surface of the diaphragm of a fresh-killed rabbit a few c.c. of a watery solution of Berlin blue, in which a fine precipitate of Berlin blue granules had been effected by the addition of a small quantity of alcohol, and by carrying an artificial respiration on for 15 to 30 minutes. A more simple method, which gives better results, is the following: into the abdominal cavity of a living middle-sized rabbit or guinea-pig, which had been left without food for 24 hours, 5 to 10 c.c. of a five per cent. solution of Brücke's Berlin blue are injected; after 4 to 8 hours the animal is killed by bleeding from the crural artery or by strangulation, and is allowed to become perfectly cool. In exposing the pleural surface of

the diaphragm, we find in most cases a complete injection of the lymphatics. In healthy guinea-pigs the injection is hardly ever so complete as in rabbits.

From Recklinghausen it is well known that the very abundant lymphatics of the centrum tendineum are distinguishable into lymphatic trunks and lymphatic capillaries, the former being provided with valves and lined by spindle-shaped endothelium, the latter by their variable lumen, the numerous excavations, their want of valves, and their sinuous endothelium. Recklinghausen states that some of the lymphatic capillaries of the pleural serosa terminate blindly, like a horn curved inwards, and that they dissolve themselves at these places in the lymph-canalicular system. Ludwig and Schweigger-Seidel have further shown that the lymphatics of the pleural serosa of the centrum tendineum of the rabbit stand in communication with lymphatic vessels, which run between the tendon-bundles; these being arranged in an abdominal radiating and a pleural circular layer, the lymphatics which run between them have, consequently, a radiating and circular course, and the former are called by L. and S.S. superficial, the latter, deep lymphatic channels. My researches teach me the following as regards the distribution of the lymphatics in the rabbit: the lymphatics of the centrum tendineum are for each half arranged in two systems, an anterior and posterior. The vessels of the anterior system are distributed upon the outer and anterior (that is larger) portion of the anterior quadrant, and upon the outer (that is smaller) portion of the posterior quadrant. Those of the posterior system are distributed upon the inner posterior (that is smaller) portion of the anterior and upon the inner (that is larger) portion of the posterior quadrant. (The relative number of lymphatics is greater in the posterior quadrant than in the anterior). The efferent trunks of the anterior system course along the pars costalis of the diaphragm, and unite on the posterior surface of the xiphoid cartilage on each side, usually to one or two large vessels, which run along with the mammary vessels towards the sternal gland. On their way they join with those lymphatics that come from the intercostal spaces. It may be mentioned that the sternal gland is found gene-

rally completely injected after the natural injection with five per cent. Berlin blue, as described above.

The efferent trunk of the posterior system is single on each side; it mounts obliquely towards the middle line, and opens into the thoracic duct near the point where the latter emerges from the diaphragm. Each system communicates with the corresponding one of the other side by a few larger vessels. The vessels of each system have the following characters: the large vessels possess valves and a wall consisting of spindle-shaped endothelium; they are situated chiefly between the pleural serosa and the tendons, or in the depth of that serosa. The capillaries that run into those vessels have no valves, are provided with irregular excavations, and their wall consists of sinuous endothelium. There are two kinds of capillaries: *a*, such ones that chiefly lie in the pleural serosa, and are of a variable breadth; *b*, capillaries that lie only between the tendinous tissue. They run, consequently, in a straight course, in two directions, so that we may distinguish deep straight capillaries running in a circular direction and superficial straight capillaries running in a radial direction. These two kinds of straight lymphatic capillaries communicate with each other generally at those points where they cross each other in such a way that an extremely short communication-branch exists where their walls come in contact; or it is not seldom seen that a superficial straight capillary bends under a right angle, so as to continue its course as a deep straight capillary. The deep straight capillaries represent the vessels of communication between the superficial straight capillaries and the lymphatic vessels that lie in the pleural serosa. As a rule, the deep straight capillaries, before they join a lymphatic trunk, run a short distance, in a more or less wavy course, between the tendon and the pleural serosa.

The relation between the straight lymphatic capillaries and those that lie between the tendon and the pleural serosa, or in the latter, can also be very clearly demonstrated in preparations prepared in the following way: the abdominal surface of the centrum tendineum of a rabbit just killed, after having been exposed, is pencilled and covered with water for a few seconds; after that, the concavity of the centrum tendineum is covered with a quarter or half per cent. solution of

nitrate of silver, and artificial respiration is carried on for fifteen to twenty minutes, the animal being suspended head downwards. The centrum tendineum, having been sufficiently washed with water, is cut out and prepared for microscopic preparations, as mentioned above. In such preparations the lymphatics present themselves as dilated sacs and tubes, the endothelial wall of which comes out with great distinctness. Fig. 36 is taken from such a preparation.

The fact that lymphatic vessels which have a winding course sink down at once between the tendon-bundles, to continue their course as straight vessels, is here very obvious.

It can be further made out in such preparations that the horn-like terminations of lymphatic capillaries, as represented by Recklinghausen, are only apparent, for they correspond to such points where a lymphatic vessel curves round so as to sink down between tendon-bundles and to become a straight vessel. In silver preparations prepared in the ordinary way after pencilling, such horn-like terminations are sometimes pretty common, and can easily be mistaken for true terminations.

The question presents itself now, What is the physiological value of the straight lymphatic vessels? Ludwig and Schweigger-Seidel already attributed to these straight lymphatics an important part in the absorption. According to those authors they are widely dilated during the inspiration position of the diaphragm, corresponding to the action of the muscles and tendons of this latter, whereas they are compressed during the respiration, the lymphatics of the pleural surface of the diaphragm being quite the reverse. Consequently, the respiratory movement of the diaphragm acts like a pump on its lymphatics. (The free communication of the lymphatics with the peritoneal cavity, by means of stomata, will be discussed hereafter.) This, however, is not the only way in which the straight lymphatics act. We have mentioned before that the lymphatics of the diaphragm are arranged in an anterior and posterior system, the former discharging itself in trunks that run towards a gland, the latter in a wide short trunk that runs directly into the thoracic duct. Now the straight lymphatic capillaries are the vessels which perform the communication of those two systems, and this is their chief action. As the

deep straight lymphatic capillaries and the superficial ones represent, as we have seen, only one category of vessels, we are justified in saying that this category of lymphatic capillaries discharges itself in two directions: one freely in the thoracic duct, and a second less freely towards the sternal gland. In a following chapter we shall see that the straight lymphatic capillaries, the deep ones as well as the superficial ones, stand in free communication with the peritoneal cavity, by means of vertical lymphatic canals (stomata of the authors); consequently, we have to substitute for the diagram of L. and S.S. representing the lymphatics as a single pump, a diagram of a pump with two cylinders, the one cylinder corresponding to the pleural vessels of the anterior system, the other to those of the posterior system, while the pipe connecting the two cylinders is represented by the straight capillaries, and the piston tube by the vertical lymphatic canals. It must be borne in mind, however, that the two cylinders act simultaneously.

The superficial straight lymphatic capillaries are not the only capillaries that are to be met with on the abdominal surface of the centrum tendineum of the diaphragm of rabbits and guinea-pigs. Near the median line of the anterior quadrants, and near the large blood-vessels that pass through the diaphragm, there exist lymphatic capillaries of a winding course, and provided with numerous dilatation-sinuses. They stand in communication with the straight lymphatic capillaries.

In some places two neighbouring superficial straight capillaries anastomose with each other by means of a transverse branch provided with sinuses, which belong to the peritoneal serosa.

After what has been said about the relation of the lymphatic capillaries to the lymph-canalicular system in the omentum, there remains very little to be said as regards that in the centrum tendineum. We may mention that the continuity of the endothelium of the pleural lymphatic capillaries with the branched cells of the lymph-canalicular system of the pleural serosa can be demonstrated very easily in the centrum tendineum of rabbits and guinea-pigs. We refer the reader simply to the Figs. 14, 16, and 17, on Plate IV.

These figures, together with their explanation, will undoubtedly make these relations sufficiently clear.

(c.) *The Lymphatic Vessels of the Mesentery.*

The mesentery possesses, as it is known, two kinds of lymphatic vessels; first, vessels which run from the intestine to the roots of the mesentery into the mesenteric glands; and, secondly, vessels which belong to the mesentery itself. The vessels of the first kind run in a radiatory direction and are situated in the chief trabeculæ of the mesentery, together with the large blood-vessels, which run to and from the intestine. These lymphatic vessels are distinguished by their numerous valves and by their continuous rich circular muscular coat. Their endothelium is spindle-shaped, like that in the lymphatic trunks in general. The vessels of the second kind are: (a) large lymphatic vessels, which accompany also, like those of the first kind, the larger blood-vessels. They are either single or, generally, double: in the former case the lymphatic is situated between the arterial and the venous trunk; in the latter the artery and the vein lie both between the two lymphatics. They are anastomosing with each other by a few wide branches. Here and there they possess a valve; they have no muscular coat; their coat consists only of one layer of endothelium, which is more or less elongated, spindle-shaped. In many places the breadth of the endothelial cells is not much inferior to the longitudinal diameter. The lymphatic vessels of this kind are very often found to invaginate the arterious or venous trunk for a longer or shorter distance, especially with their large sacciform dilatations. These dilatation-sinuses are constantly to be found on the lymphatics of mammals, as well as in those of frogs. Especially in *rana temporaria*, and in *bufo*, I have come across not a few mesenteries where, instead of lymphatic vessels which accompany the blood-vessels, there was a system of lymph-sinuses, situated behind each other and communicating with each other by small openings. This depends very much upon the arrangement of the ground-substance, for in these latter cases there were large trabeculæ in which the large blood-vessels and nerve-trunks were imbedded, from which



(trabeculæ) small branches sprang in regular intervals, anastomosing with each other and forming a mesh work. Seen from the surface it looked exactly like a fenestrated membrane. The meshes were occupied by those above-mentioned lymph-sinuses.

In frogs the invagination does happen not only in that way, that one of the blood-vessels or the nerve-trunk is invaginated in a lymphatic vessel, but sometimes the whole trabecula which contains the blood-vessels and the nerve-trunk is invaginated in a lymphatic vessel.

( $\beta$ ) Besides those lymphatics which are to be found in and near the chief trabeculæ of the mesentery, there exist other lymphatic vessels, which belong to that portion of the membrane which stretches between the chief trabeculæ.

These are more or less wide vessels, provided with no valves; their wall is a single layer of rhombic endothelium with sinuous outlines. They correspond to what is generally called lymphatic capillaries. They accompany generally the smaller veins. In the pencilled silver-stained mesentery of the dog, cat, monkey and frog they are very easy to demonstrate. They are anastomosing with each other to a wide net-work, and are also, like those previously-mentioned vessels, provided with dilatation-sinuses. In those mesenteries where there is little fat tissue, and consequently the lymphangial plaques and tracts are clearly seen to consist of branched cells, it is also evident that these patches and tracts have always on one or both their sides lymphatic vessels.

In the mesentery of living curarized toads prepared for Cohnheim's experiment one can very often distinguish the lymphatic vessels with great ease. In some places they form a rather scarce net-work of vessels, which run along the blood-vessels; in some other places they break up in a dense system of lacunæ. In several instances I have found knobs of different size projecting into the lumen of the lymphatic vessels from their endothelial wall. These knobs were seen to consist of an accumulation of germinating endothelial cells; and, in fact, I have been able in one instance to observe that these germinating endothelial cells detach themselves, and are carried away by the lymph-current. I conclude from this that here a local germination of lymphoid cor-

puscles is going on from the endothelium of the lymphatics directly into the lumen of this latter.

(d.) *Relation of the Lymphatic Vessels to the Surface of the Serous Membranes.*

It is held by many histologists that there exist in many serous membranes discontinuities between the endothelium of the surface, by which discontinuities—stomata—a superficial lymphatic vessel may communicate with the free surface. That there must exist stomata on the abdominal surface of the centrum tendineum has been proved by the well-known experiments of Recklinghausen. After Recklinghausen, several observers have shown the absorption of dissolved and undissolved substances, injected into the serous cavity, from the lymphatics of the serous membrane. There have been also several observers who tried to show on silver-stained preparations those stomata. They have, namely, shown that there exist small circular or angular dark or light fields between the common large polygonal endothelial cells. These small fields were either single or in small groups not very far apart from each other; they were of different size, and where they appeared to be regularly distributed they were found to represent the centre of a larger or smaller group of endothelial cells, radiating towards that centre.

That in many serous membranes stained with nitrate of silver such figures occur there can be no doubt whatever, but it is a quite different question whether they correspond really to holes. For, on the one hand, it can be shown that these figures are sometimes to be found on places, and not very rarely, where there are no lymphatic vessels just below that part, *e.g.* on the centrum tendineum: on the other hand, in the same preparation, they are not to be found where they ought to be, namely, below where a superficial lymphatic vessel lies. Besides, from their irregular distribution, their irregular shape and size, one would be more inclined to take them as accidental than as anatomical structures.

The histological proof that lymphatic vessels stand freely in communication with the surface has been brought forward until now,

as far as I can see, only by Dybkovski for the pleura costalis. Dybkovski has shown on that membrane, after having injected the lymphatics, that the superficial lymphatic vessels lead freely between the endothelium of the surface by short vertical branches. Close to that comes the assertion of Dogiel and Schweigger-Seidel, that the septum cystemæ lymph. magnæ in frog is perforated by a number of canals—stomata—that is to say, that the cystema lymph. magna is in free communication with the peritoneal cavity. According to these observers, large flat endothelial cells on both surfaces of the septum have a radiating arrangement round those stomata; the nucleus of these radiating endothelial cells lies peripherally in that portion with which the cells border the stoma, so that each nucleus causes a roundish projection of the cell into the stoma. We shall see hereafter that these assertions do not correspond perfectly to the facts. Finally, Ludwig and Schweigger-Seidel have drawn attention to the important fact that the peritoneum of the centrum tendineum has a fenestrated arrangement in those parts which cover the straight lymphatics. This fact, together with the experience of Recklinghausen, brought many authors to the assumption that those small irregularly distributed figures amongst the endothelium above the straight lymphatic channels in silver preparations represent stomata.

We come now to deal with the results of our own researches. We distinguish two kinds of stomata on the surface of the serous membranes, namely, stomata vera and stomata spuria or pseudo-stomata. The stomata vera are again of two kinds: *a*. They represent the mouth of a vertical lymphatic channel, which is lined by a special layer of endothelium, and which channel leads into the lumen of a superficial lymphatic vessel; *b*. They represent a discontinuity between the endothelium of the surface, leading into a simple lymphatic sinus near the surface, which, as we have seen, represents a cavity lined only on one side with an endothelium. Both kinds of stomata vera are bordered by endothelial elements of a more or less distinct germinating character, namely, the cells are smaller, polyhedral, distinctly granular, they stain more readily in silver solution, and possess a single, or a constricted, or a divided nucleus. As regards the dis-

tribution of the first kind of stomata vera, the following is to be noticed :

In great numbers they are to be met with on the peritoneal surface of the centrum tendineum. We have had the opportunity to mention that the straight lymphatic capillaries, the deep ones as well as the superficial ones, stand in free communication with the peritoneal cavity by means of vertical lymphatic channels. The free mouths of these are the stomata in question. These vertical lymphatic channels are generally situated in chains behind each other; they are more numerous and shorter for the superficial straight lymphatics than for the deep ones. The vertical lymphatic channels of the latter exhibit in some rare cases a peculiarity, which consists in this: if from the deep, straight lymphatic capillary a vertical lymphatic channel is given off just at the point where the former is covered by a superficial lymph-capillary, then we see that the vertical lymphatic channel passes simply through the superficial straight vessel, that is to say, the vertical lymphatic channel appears to be invaginated in the straight lymphatic vessel.

In the vertical channels of the deep straight lymphatic capillaries, having a considerable length, it is very easy to recognise that they are lined by a special layer of endothelium, which in the most cases, exactly like that of the corresponding stoma, consists of polyhedral germinating elements. The layer of endothelium which lines the vertical channel is also distinguishable in those of the superficial straight vessels if they are not collapsed. Adjusting from the peritoneal surface, one sees first the germinating endothelium of the stoma, then a similar layer of polyhedral endothelial elements surrounding the vertical channel like a corona.

Over the above-mentioned excavations and sinuses of the lymphatic capillaries of the peritoneal serosa of the centrum tendineum there exist also stomata vera, *i.e.* vertical lymphatic channels which, like those of the superficial straight capillaries, are only of a very limited length. The endothelium does not differ in any respect from that of the latter. Quite as numerous are the stomata vera, *viz.* the vertical lymphatic canals in the omentum and pleura; we find them on the lymphatic capillaries and lymph-sinuses in the omen-

tum and pleura of all animals. They are not quite as numerous to be seen on the lymphatic capillaries of the mesentery of cat, monkey, and dog; but they occur relatively often in that of frog and toad. They are naturally extremely short, in consequence of the superficial position of the lymphatic capillaries, the membrane being very thin; but they are in every case lined by a special layer of endothelium, which in every respect resembles that of those above mentioned.

In these membranes—omentum, pleura mediastini and mesentery—stomata vera occur on lymphatic capillaries which accompany or invaginate the blood-vessels, as well as on those which have no such relation to the blood-vessels. It is necessary to mention that these stomata are generally not so very easy to demonstrate in the normal omentum, pleura mediastini, and mesentery (except that of the frog and toad), the lymphatic capillaries not being so easy to demonstrate. If, however, these membranes are slightly affected with chronic inflammation, their demonstration does not require any great skill; by spreading out the fresh membranes carefully in serum they may be seen without further preparation. Exactly like the vertical lymphatic canals, *i.e.* stomata vera, just mentioned, are those of the septum cysternæ lymphaticæ magnæ of frogs and toads, described by Dogiel and Schweigger-Seidel. Different from the description given by these observers, I must mention *that the vertical lymphatic canals are lined by a special layer of more or less polyhedral endothelial cells, which consist of a granular protoplasm.* According to D. and S. S., these stomata are bordered by the nuclei of the common flat large endothelial plates, both on the peritoneal surface and on that of the cysterna, which nuclei project into the stoma; but these projections represent that special lining layer of polyhedral endothelial cells seen in profile, as it is easily to be recognised on membranes carefully spread out in the fresh state, and still better after staining with nitrate of silver. I refer the reader to Figure 3, on Plate I. In female frogs and toads the endothelial lining of these vertical lymphatic canals is provided with ciliæ.

In several female frogs and toads during the winter months I have found the endothelium of the stomata of the septum, as well as

of the mesentery, in a very active state of germination, the animals suffering from chronic peritonitis.

A second kind of stoma verum represents a simple discontinuity of the endothelium of the surface. They lead into a simple lymphatic lacuna, situated superficially beneath the endothelium, and, as we have seen, lined only on one surface, the lower surface, with an endothelium. The endothelium of the surface which borders such a stoma has very often also a germinating character. This kind of stoma verum is to be found in the omentum of rabbits and the mesentery of frogs and toads. They are also very much easier to demonstrate when these membranes are affected with slight chronic inflammation.

We have already mentioned, at the beginning of this Essay, that there exist superficial branched cells in the serous membranes which lie either totally or partially between the endothelium of the surface, or, as is more commonly the case, only reach the surface by a process which projects between the superficial endothelium. In the peri-lymphangial nodules and cords described as occurring in the omentum and pleura this is the case in an extraordinary degree. We find here a large number of such perpendicular processes, projecting freely between the endothelium of the surface, which proceed from the superficial cells of the cell-network of the matrix of these lymphatic structures. This may be seen both in the young and old structures, in true or optical sections, as well as in surface preparations. As we have stated that the branched cells which constitute the matrix of these peri-lymphangial nodules, as well as those of the ground-tissue of any given part, lie in the lymph-canalicular system,<sup>1</sup> it is a necessary conclusion that the lymph-canalicular system opens

<sup>1</sup> We must again repeat here that by this we only mean the negative picture whose position is formed by the branched lymph-canalicular cells themselves, with their processes. We are therefore not in precise agreement with the views of Lavdovsky and Afonassiew. These authors consider that in the serous membranes a superficial lymph-canalicular system exists as such, *i.e.* without the lymph-canalicular cells; and that this quasi empty lymph-canalicular system opens freely on the surface by a number of fine perpendicular canals. We, on the contrary, consider that the branched lymph-canalicular cells reach the surface through processes; and as we deny the existence of a lymph-canalicular system without cells, and rather consider it only as a negative picture of the latter, the statement, that the lymph-canalicular system opens freely on the surface by canals, is

freely on the surface, between the endothelium, by perpendicular canals.

We shall show in the pathological part what great importance must be ascribed to these freely-projecting cell-processes; we call them pseudo-stomata. A peculiar relation exists between these pseudo-stomata and the young endothelium of the surface of those lymphatic structures, which consists in the fact that the cell-process representing the pseudo-stoma buds forth quite distinctly as a young cell. Of this I have convinced myself in such structures, chiefly in the omentum of the rabbit, but also in the omentum and pleura of the guinea-pig, cat, and dog, both in surface aspects and also especially in profile views. The nucleated buds, which, in form, size, and appearance, are not to be distinguished from young endothelial cells, are seen to project over the surface by a long thin peduncle. From the frequency with which we see these bud-like young endothelial cells sending a fine process vertically downwards between the surrounding young endothelial cells, we may conclude that a not inconsiderable part of the young cells which bud forth from the surface of a lymphangial nodule owe their origin to the pseudo-stomata. This process, as we shall see, plays an important part in chronic inflammation.

*(e.) Development of Lymphatic Capillaries.*

We intend here to consider the development of lymphatic capillaries only in so far as this takes place normally and to a relatively limited extent in serous membranes; in chronic inflammation we shall see that this development takes place in a far greater degree. We shall

only correct in so far as negative pictures are meant by it. There was consequently no extreme necessity for Lavdovsky to claim priority for the discovery that the surface of serous membranes possesses a number of minute openings, which communicate with the lymph-canalicular system, since we contradict this statement when made with the meaning he applies to it. Least of all can Lavdovsky claim priority for the perpendicular lymphatic canals, of which we spoke on p. 19 of the preliminary communication of E. Klein and Burdon-Sanderson, and to which Lavdovsky chiefly referred, as we have seen that this is something radically different from his own views. What we designated perpendicular lymphatic canals were branches of lymphatic vessels lined by endothelium, and opening freely on the surface.

examine the development of lymphatic capillaries in the omentum of the rabbit, and in the mesogastrium of the frog, as it may be easily observed in those places. We have already become acquainted with the fact that accumulations of branched lymph-canalicular cells form the foundation of those peri-lymphangial patches and nodules which are supplied with blood-vessels, as also of those which as yet are without a blood supply. If we examine a number of such patches in successful pencilled and silvered preparations, in which the number of migratory cells is still inconsiderable, we may find, both amongst the buds which spring from the lymph-canalicular cells, but still remain connected with them, as also amongst the lymph-canalicular cells themselves, some individuals in whose interior a vacuole is contained. They are to be found of the most various size, and in every transitional stage, from some in which the granular protoplasmic body, besides the vacuole, contains only a single oblong nucleus, which is somewhat pushed to one side, to other large elements in which the protoplasmic body is spread out to form a thin granular mantle, in which at one point a constricted nucleus lies, or two nuclei, or even a number of nuclei at equal distances from each other. In the latter case, the wall appears on optical section to consist of spindle cells fused together by their extremities. Finally, when these intermediate forms have been observed, we can easily understand the large spherical vesicles, whose wall is distinctly differentiated into separate endothelial plates. Further, it admits of no doubt that while a cell grows into such an endothelial vesicle, buds grow out from the protoplasm of the cell towards its interior, *i.e.* towards the vacuole, which become separated off as young cells. In general, such endothelial vesicles are formed from lumps which bud from the lymph-canalicular cells, but in many cases also directly from the lymph-canalicular cells themselves. In the latter case, we can still recognise, even in those elements which have already become transformed into vesicles of considerable size, processes through which the protoplasmic mantle is connected with the neighbouring lymph-canalicular cells. We have, therefore, here before us, *in optimâ formâ*, the conversion of lymph-canalicular cells into endothelial vesicles, quite on the same principle which was shown by me to obtain in the developing blood-vessels of the embryo chick.



Further, it is easy to make out that the endothelial vesicles whose wall shows distinct endothelial plates after treatment with silver occur chiefly in the immediate neighbourhood of lymphatic capillaries, and not only solitary, but sometimes scattered in groups, and sometimes arranged in a linear series, close behind each other. It is already probable, from what has preceded, that the endothelial vesicles finally communicate with each other either by fusion, or by extension of the vacuoles through the protoplasmic processes which connect their walls; and also that they communicate in a similar manner with the lumen of neighbouring lymphatic capillaries, because, as we already know, the endothelium of the lymphatic capillaries is in direct communication with the lymph-canalicular cells. It is therefore only necessary that the vacuole of the lymph-canalicular cell should extend along the process which connects it with the endothelial cell in order that it should open into the lymphatic capillary. In this manner, first, a lymphatic capillary may become longer, and secondly, lateral sinuses or dilatations may be formed. I have not observed these processes in the normal omentum of the rabbit, because, as may be easily conceived, they do not occur with sufficient frequency; but in chronic inflammation, on the other hand, I have followed them out in *all serous membranes* to so great an extent, and with such intensity, that I do not hesitate to accept them also as the final result in the case of the above-described endothelial vesicles.

These endothelial vesicles show a peculiar relation in the mesogastrium of the frog. I have described their development in the 'Quarterly Microscopical Journal,' and have there stated that in female frogs, in winter, they may be sometimes observed in a very considerable number, owing to the presence of slight chronic peritonitis. I have also said that the young vesicles bear cilia, which are directed to their interior, and that this is sometimes still the case when their wall is already distinctly differentiated into endothelial plates. So far as their development is concerned, I have nothing to add to what I have already said. In many vesicles the development of young cells towards the lumen is very marked, while in others nothing is to be seen of this process. I have also shown that these vesicles are not simple cysts, as stated by Remak, but that they stand in the closest

relation to the development of lymphatic sinuses and capillaries; indeed, in a mesogastrium in which there is a sufficient number of such endothelial vesicles in different stages of development, their connection with lymphatic capillaries may be easily shown. I have also shown that in a later stage they lose their cilia. Finally, I have said that an endothelial vesicle may open freely on the surface, and that in that case a *true stoma* is formed. There is no difficulty in understanding this, if we remember what has been said about pseudo-stomata; it is only necessary to imagine that if, for instance, a lymph-canalicular cell, one of whose processes projects freely on the surface, *i.e.* forms a pseudo-stoma, becomes converted by vacuolation into an endothelial vesicle, and the vacuole extends along the process forming the pseudo-stoma, the process must finally result in the formation of a true stoma. I may add here that I have observed such endothelial vesicles also in male frogs and in toads.

We shall see that the new formation of such true stomata takes place to a very great extent in chronic inflammation of the various serous membranes of mammals.

According to what we know of the development of endothelial vesicles, we must express the view that they always ultimately become connected with lymphatic capillaries.

## CHAPTER IV.

*THE BLOOD-VESSELS OF THE SEROUS MEMBRANES.*

THIS is the last subject we shall have to treat of in the section concerning normal structure. We shall pass over the *distribution of the blood-vessels in general*, as this is so well known and so simple that we should only weary the reader were we to bring it forward here. We shall only consider two points in this chapter; first, the distribution of blood-vessels in the lymphangial nodules and cords; and second, the development of blood-capillaries. It is especially the latter to which we desire to draw the attention of the reader. We have already mentioned, at the commencement, that in the omentum and pleura a growth and new formation of lymphatic nodules takes place, all of which gradually become furnished with a distinct blood-vascular system, which itself grows with the growth of the nodules, and in which the capillaries especially are very richly distributed. We can therefore observe in these places a continuous increase and new formation of vessels in the adult organism in the normal state. Concerning the first point, viz. the distribution of blood-vessels in the lymphatic nodules and cords, we have to say what follows. Wherever in a nodule or cord a blood-vascular system can be observed, it consists in general of an afferent small arterial branch, and one or even two small efferent veins, between which is a network of capillaries, which is more or less close, according to the size of the nodule. In isolated cases only a variation may be noticed, where there are two small arteries and only one vein. I refer the reader to the figures, which although they represent pathological preparations, are completely identical so far as the distribution of blood-vessels is concerned, with full-grown normal nodules. We may often see, coming off from a small artery which is distributed to such a cord or nodule, a capillary

which, without joining the other capillaries of the nodule, forms a pool and passes into a vein. The part to which this capillary loop belongs may already be clearly recognised to be a young developing nodule. Now, between this simple capillary loop and the above-mentioned completely developed blood-vascular system, the most various intermediate stages may be found; and it becomes a question whether in time a part of the afferent limb of such a capillary loop becomes an artery as the growth of the nodule goes on, and whether a portion of the afferent limb becomes developed into a vein. My researches on this point have led to no positive result. I could find no stand-point from which I might arrive at a positive conclusion, for instance, that the artery of a young nodule had been developed from what was originally a capillary vessel. I cannot, however, give a decidedly negative answer, since one is forced to assume, partly from the comparison of nodules in different stages of development, and partly from general embryology, that this really is the case.

We now pass to the consideration of the second point, viz. the development of capillary blood-vessels in the nodules.

Absolutely the best object for study is the omentum of the rabbit. Both fresh objects examined in serum, and pencilled preparations slightly impregnated with silver, give excellent results. If attention be given to a series of young patches, in which the branched cells of the matrix are clearly recognisable, and not obscured by the presence of migratory cells; and in which, moreover, only a very limited number of capillaries is formed, we see immediately that the wall of these capillaries is protoplasmic to a very great extent; and we can also see, when we have before us a nucleus on the upper or lower wall of the capillary, that the part immediately surrounding the nucleus is distinctly granular, the neighbouring portions gradually less so, until finally the wall becomes hyaline. In good silvered objects we can follow the endothelial markings of such capillaries of young nodules only for a short distance at their commencement and termination, *i.e.* at the parts nearest to the artery and vein. In fully-developed patches the endothelial marking is distinctly to be recognised in the capillaries. Accordingly, we must consider those capillaries whose walls still distinctly retain their protoplasmic character as young

capillaries. But on closer observation another much more important fact is brought to light; namely, that the branched cells of the matrix stand in direct continuity with the protoplasmic wall of these young capillaries, by their processes. From the extraordinarily common occurrence of the above fact in various modifications, and from the clearness with which it may be observed, no error is possible. I must especially insist upon this now, because in any figure, however successful, apart from the suspicion one may always feel of a drawing, this can never be so clearly recognised as it appears *de facto* under the microscope.

We need not seek long in a patch in which the number of such young capillaries is considerable in order to come upon a capillary which ends cæcally. This is either a short lateral branch or a longer capillary which makes a loop-like bend. At the cæcal end we can recognise very clearly the protoplasmic character of the wall. The lumen becomes more or less suddenly narrowed, the wall finally becomes solid, and passes into a perfectly ordinary nucleated branched cell of the matrix. We find all forms of this hollowing out of the branched cells; at one time only in a thicker process of a cell, at another even in the body of the cell itself.

A very common occurrence is, further, that the branched cells, as we have already had occasion to state, show vacuoles, both in the body and also in thicker processes. The vacuoles become elongated towards a capillary branch which is being hollowed out, and finally fused with it. Capillaries, therefore, are not only formed from previously existing capillaries by continuous excavation of the branched cells connected with their walls, but are also formed isolated in the branched cells themselves, becoming ultimately united with the former. Isolated vacuolation for the purpose of the formation of blood-capillaries is a perfectly distinct process from vacuolation for the purpose of the development of lymphatic capillaries; for in the latter case *vesicles* are developed whose wall almost immediately shows an endothelial differentiation, even when these vesicles have not yet come into communication with lymphatic vessels; in the former case, on the contrary, this differentiation into endothelial plates does not take place for a considerable time.

The principle according to which the formation of capillaries takes place is similar to that which was first pointed out by Stricker in the new formation of blood-vessels in the tadpole and in inflammation, and which was afterwards confirmed in every detail by Arnold. But we must here remark that in our lymphangial nodules, patches, and cords, the new formation of blood-capillaries does not take place by the sending forth of protoplasmic buds from the wall of a capillary, which are then excavated, starting from the vessel; but this excavation goes on both from the already formed vessel, and also isolated in the branched lymph-canalicular cells, which are in direct continuity with the endothelium of the blood-vessels.

Precisely the same mode of development may be shown in the previously-mentioned gelatinous body of the infra-orbital fossa. Here a number of places may be found in the neighbourhood of the fat-body where there is as yet no formation of fat in the groups of branched cells, and where, nevertheless, an active development of capillaries is going on. From place to place we find such accumulations of branched cells and young capillaries, in which, on the one hand, the direct connection of the former with the wall of the latter may be easily seen, and, on the other hand, the excavation of already formed capillaries into those cells as well as the isolated vacuolation of the branched cells may be followed through all stages. It seems, from what has been said of this hyaline body, and of the development of fat-tissue in the omentum and the mesentery, to be the general rule, that the transformation of the branched cells of those cords and nodules into fat cells is preceded by the development of a corresponding system of capillary blood-vessels.

SECTION II.—*PATHOLOGICAL CONDITIONS.*

MUCH less attention has been paid to the study of the serous membranes in pathological respects. As regards the changes which the endothelium of the surface undergoes under morbid conditions, we meet with the assertions of Rindfleisch, Ranvier and Kundrat. The two last authors confirm the germination of the endothelium in inflammation of the serous membranes. The process of germination is, according to them, exactly the same as it occurs otherwise, and as we had occasion to see in the normal state; the cells increase in size, become more polyhedral, the nuclei are observed to divide, and then the cells themselves. According to Kundrat the miliary nodules on the serous membrane in tuberculosis are derived from germinating endothelium.

According to Sanderson there is a pre-existing adenoid tissue in the omentum in the form of nodules and cords, which increases to an extraordinary extent in chronic inflammation, so that the nodules and cords of tubercle which occur in artificial tuberculosis are nothing but hyperplastic adenoid tissue. According to Knauff small knots and cords are present even under normal conditions, consisting of a collection of lymphoid elements. These small knots play the most important part in tuberculosis; it is these that grow and multiply, and represent the miliary tubercles.

Finally, in respect of the lymphatic vessels, Klebs has declared that the lymphatic vessels play an important part in artificial tuberculosis; since the endothelium of the lymphatic vessels proliferates; the young cells originating thus compose the tubercle-knot.

We have already had an opportunity of pointing out in the first chapter, that on the serous membranes in certain regions, there is

normally to be seen a germinating endothelium, a condition, it seems, overlooked by Ranvier and Kundrat. We have further shown, in the second chapter, that the knots and cords are not exactly to be regarded as pre-existing adenoid tissue, nor as collections of lymph-corpuseles, but that they are developed for the most part out of ordinary branched cells of the tissue—in fact, as peri-lymphangial knots and cords; and more, that the farther the development is advanced the more numerous are the lymph-corpuseles at the spot—the more does the cellular network assume the character of an adenoid network.

Finally, we have pointed out, in the third chapter, that normally, in the omentum and the mediastinal pleura, knots and cords originate by the outgrowth of the endothelium of the lymphatic capillaries as a network of branched cells, from which young cells spring.

Thus we see that all the views of the authors are applicable to a certain extent to the normal serous membranes—the views of Kundrat and Ranvier, of Knauff and Sanderson, and finally of Klebs. We shall now show in this section how far these views are applicable in pathological relations.

### 1. *The Changes of the Superficial Endothelium.*

*a.* When severe acute peritonitis is produced in a rabbit, guinea-pig, dog, or cat, for example, by the introduction of ammonia, of a solution of iodine in hydro-iodic acid, or of toxic pyæmic fluids, which latter kill the animals in a period varying from twelve to forty-eight hours, into the peritoneal cavity, the mesentery, the intestinal serosa, the omentum, and the peritoneum of the centrum tendineum appear extraordinarily hyperæmic, if an opportunity is afforded of examining the animal during the first twenty-four or forty-eight hours. The abdominal cavity contains mostly, but not always, a greater or smaller quantity of bloody-coloured fluid, with abundant separation of fibrine. In these cases of severe acute peritonitis, the endothelium of the surface exhibits a common character—it appears, that is to say, loosened and removed over great parts. The fluid contains, accordingly, an abundance of isolated membranes composed of endothelial cells, and the surface of many parts is deprived of its endothelium. Many of the endothelial



cells, not only those found free in the fluid, but also those still on the peritoneum, exhibit, in so far, a morphological change, as they appear larger, as if swelled up, and their protoplasm is occupied by a greater or smaller number of variously-sized granules. If the fresh membrane is examined microscopically we may recognise that in the circumference of those parts which have become deprived of their endothelium, the individual endothelial cells are distinctly granular, even in the surface view. On silver preparations these spots are distinguished by the endothelial cells becoming more deeply coloured (*cæteris paribus*), *i.e.* exhibit a dark granular precipitate. Corresponding to the endothelial cells being more or less loose, we find instead of the well-known sharply-defined silver lines, *i.e.* instead of the stained intercellular lines, variously-sized, roundish or oblong, dark-coloured, drop-shaped elements. What appear as cell elements are accordingly separated from each other by broad or narrow spaces, in which the above-described bodies lie. I have just said that this substance which appears as black-coloured drops takes the position in which the cementing substance should be found. In fact, nothing is easier than to discover the gradual transition of those broad spaces, filled with the drop-shaped bodies, into the simple dark silver lines.

The shape, the colouring, the want of every structure, admits of no other interpretation than that just given, namely, that the individual endothelial cells become loosened, and that there is a more or less fluid substance between them, which has become stained by the nitrate of silver. Whether these drop-like bodies are offsprings of the original cementing substance, or whether they belong to the transudation, would be an idle discussion. From the rapid and abundant transudation from the blood-vessels the loosening of the endothelial cells is quite well conceivable as a simply mechanical result.

A further important fact is that the nuclei of the endothelial cells exhibit distinct appearances of division, and this sometimes very extensively. Not only do we find a great number of flat endothelial cells in the fluid, in which the nucleus presents the most various appearances of division, but we especially find, for example, in the centrum tendineum and mesentery, quite extensive places on which we should

have suspected nothing of the kind in the healthy condition; thus, for example, there is seen on the endothelium, which covers the peritoneal side of that portion of the serosa which lies upon the tracts of tendons, and on which, as we have seen in the first part, proliferation is not to be observed in the normal condition, an active alteration of the nuclei over extensive spaces, from the simple constriction to the division into two or three small nuclei. In the case of the omentum it is more difficult to furnish a decided opinion, for there, as we have seen, an extensive proliferation goes on in the normal condition.

Should, however, the inflammation be of a less degree, *e.g.* in the case of peritonitis, consequent on the entrance of air after larger or smaller abdominal wounds by which we expose the peritoneum to the atmosphere, or by the insertion of threads, of small solid bodies, as starch (1-2 c.c. of a tolerably concentrated mixture of starch and water), 5-10 c.c. of a five per cent. Berlin blue solution, a few c.c. of oil or oil and starch, or any similar fluid which acts readily as a foreign body—in these cases, we obtain an appearance somewhat different from the preceding. Here, indeed, there are also seen, after twenty-four or forty-eight hours and later, isolated detached endothelial plates in the exudation. The peritoneum, however, exhibits only a few places where the endothelium is loosened or has disappeared in masses. On silver-stained preparations the endothelium is more strongly coloured; we recognise, in many regions, as on the centrum tendineum, that the endothelial cells have become granular, are somewhat swollen in diameter, the nucleus has become more prominent; in short, they possess more the appearance of epithelium: the nucleus of many of the cells is in the state of division. On the omentum, and especially on the fenestrated portion, there may be demonstrated more easily polyhedral endothelial cells whose nuclei are in the state of division. What is most worthy of observation is, that where we have met with germinating endothelium in the normal condition a very active proliferation has taken place. It extends over the abdominal surface of the centrum tendineum, as well as over the pseudo-stomata and stomata of the omentum and the mesentery. In some places the germination of the endothelium is of a very remarkable extent. Not only occur there bud-like processes which

consist of young endothelial cells, but the endothelial cells so proliferating arrange themselves into a cord, which stretches freely over the surface. In the exudation we find a great number of cells, which, on account of their size, their granulation, and their nucleus, are very sharply distinguished from the small pale blood or lymph-corpuscles. In consideration of what we have said above, it will, I think, not meet any opposition if we consider those corpuscles, reminding one of endothelial cells, which occur in the exudation, as the products of the endothelium. Besides, there can be no mistake that also a large number of cells which are to be found in the exudation, rather smaller, more or less pale, originate by the division of the former, for there may be observed on the warm stage amœboid movements and division in those larger cells furnished with constricted or double nucleus.

There are intermediate stages between the forms first cited and that of acute peritonitis of more moderate degree, just as there is a complete gradation between acute peritonitis of the severest degree and of the mildest; and this depends, as is known, upon the intensity and extent of the irritation employed, upon the animal itself, and upon circumstances which we cannot enter upon in detail in this place, as they lie quite without the boundaries of this description. What we wish to show is the variety which exists in respect of the changes of the endothelium that occur when we have to do with a very intense acute peritonitis, viz. intense hyperæmia, abundant emigration of colourless blood corpuscles, and abundant thin exudation fluid; or with slight acute peritonitis, viz. slight hyperæmia, generally limited to the omentum, peritoneum of the centrum tendineum and intestinal covering, and no marked emigration of colourless blood corpuscles. For in the latter case it may be observed that a lively germination of the endothelial cells takes place, limited chiefly to those places where a germination could be made out already under normal circumstances, namely, on the centrum tendineum around the stomata over the lymphatic capillaries of the peritoneal surface, on the lymphangial knots and cords of the omentum and of the mesentery, where we have met with pseudo-stomata and true stomata in numbers, and, lastly, on the fenestrated parts of

the omentum, where we have become acquainted with isolated pseudo-stomata in the normal state.

(b.) *Chronic Peritonitis*.—Still more does the condition of limited endothelial proliferation come into view in chronic inflammation. If we tuberculise<sup>1</sup> a guinea-pig by the well-known method of injecting material of an indurated lymphatic gland into the abdominal cavity, the most instructive appearances result, as regards germination of the endothelium, round and about the stomata, especially on the omentum, on the parietal peritoneum, on the centrum tendineum, and on the mesentery. The process is most intense on the omentum. Here we find, as long as the tuberculous process has not yet advanced very extensively, a very active germination of the endothelium on the knots and cords frequently mentioned, and whose number and size have decidedly increased. Under these circumstances the true stomata can be made out in many cases much easier in fresh preparations and silver-treated objects than in the normal condition. Their number, compared with that of the pseudo-stomata, is decidedly smaller. We shall limit ourselves to the smaller lymphatic knots, for on the larger the process of germination of the endothelium has already advanced so far that it even comprises the endothelium of the thin connective-tissue trabeculæ of the neighbourhood.

I do not think it necessary for understanding the matter that I should once more enumerate all those appearances which indicate an active germination of the endothelium. The germination of the endothelium on the fenestrated portions in the form of small buds consisting of young endothelium, is also a very active one; here we are able to perceive, on account of the great number of such buds, the presence of a protoplasmic stalk emerging from the matrix, and representing the centre of these little buds. This protoplasmic central stalk corresponds completely to a pseudo-stoma. The germination of young endothelial-looking cells is to be observed on the pseudo-stomata themselves in great numbers. If we trace, in a preparation mounted in serum, a thin cord usually projecting towards

<sup>1</sup> We refer the reader to the detailed account of artificial tuberculosis by Burdon-Sanderson; in the same place a detailed account is given of the macroscopic conditions of the affected organs.

one side like a fold, we may convince ourselves, searching at the edge of this cord, that the germinating polyhedral, or even conical cells of the surface, are to be referred almost as abundantly to the pseudo-stomata as to the endothelium of the general surface. At least, I have often met with appearances, not only in these cords, but also on the small knots, where, in a given profile view, whether optical-profile or section-profile, a young endothelium cell of the surface alternated with an endothelial-like bud of a pseudo-stoma. This distinction in an optical-profile view, such as on a fold, is sometimes combined with great difficulties. I myself considered all these young endothelial cells of the surface for a long time simply as the surface endothelium, until, by the frequency of pseudo-stomata on the lymphatic knots of the rabbit's omentum, and by the discovery that numerous young cells of the surface, quite resembling endothelial cells, stand in direct connection with the pseudo-stomata, I became aware of the inaccuracy of that view. I submitted, therefore, the young endothelium of the surface of these knots and cords to a subsequent exact examination. I have accordingly studied this relation especially, first upon sections through the large knots and cords of the pleura of the cat, through the knots and cords of the tuberculous omentum of the guinea-pig, and have so discovered that, in the first place, the distribution of pseudo-stomata upon these lymphatic knots is a very extensive one, by far more extensive than I was at first inclined to accept, and secondly, that a great number of the young endothelial-looking cells are in continuity with the pseudo-stomata, that is, with the protoplasmic processes which usually represent the pseudo-stoma. Once acquainted with the fact itself, I came speedily into a position to confirm, under all conditions, the fact previously mentioned, that the proliferation affects not only the endothelium which surrounds a pseudo-stoma, but that the pseudo-stoma itself takes part in it. It is clear that there is no necessity to make a distinction between those young cells which originate from the superficial endothelium surrounding a pseudo-stoma, and those of the latter themselves, since there exists no morphological difference; they are quite alike in their appearance, nucleus, form, and size;

they are both situated on the surface of the membrane, and one can properly speak only of young endothelium.

As has been already indicated, the proliferation of the endothelium surrounding a true stoma is an active one. Not only do these endothelial cells enlarge, become distinctly granular, and present nuclei in the act of division, not only do these cells germinate and produce lymphoid cells, but this change gradually spreads out on the one hand over the endothelial cells of the surface which are in the neighbourhood, as well as over those of the vertical lymph-canals, and further over those of the lymphatic capillaries into which these lymph-canals open. If we search the abdominal surface of a diaphragm furnished with abundant knots of tubercle, we shall recognise the most various appearances of development as regards the proliferation of the endothelium of the stomata. As the youngest stages, those are most undoubtedly to be taken where the stoma is surrounded by a projecting zone of young endothelial cells at both ends, that is to say, not only at the entrance into the vertical canal, but also at the exit of the latter into the straight lymphatic capillary.

Besides these, we find other places where this zone has become already several cells high; this has then the appearance of a short cone. Other stages are these: the cone of cells is longer, and at the same time somewhat thinner and solid; further, broad, long cones, which, although the stoma is collapsed, still show a central cavity; and, finally, where only a large and broad patch is to be seen, formed of young endothelial cells. In the latter, the diagnosis that we have to do with a germination of endothelium round a stoma is generally not easy. Sometimes it is rendered easy by the following circumstances: first, one finds an indication of the opening, close round which the germination-process has become most intense, for the smallest cells are found there; secondly, if the opening itself be not visible, we can still recognise the spot where the stoma is to be looked for, from the presence of an amorphous central fibrinous plug very darkly coloured in silver. Close to this, the smallest elements lie; finally, a thick cord of fibrine, which, becoming gradually thinner, is seen to dip into the point around which the smallest elements lie, thus indicating the direction and the place of the current of absorp-

tion. When all these conditions are absent, we may perhaps, as long as the growth has not reached too great an intensity, be able from its distribution and position to conclude that we have to do with a germination around the stomata. We shall, however, not undertake to make such a diagnosis where we find a large patch of germinating endothelium raised considerably over the surface, and covering nearly a whole field under the microscope. On a preparation which presents the appearances previously described there are to be seen many lymphatic vessels of the peritoneal surface of the centrum tendineum more or less filled with young cells, and widely distended. In a vessel of this kind, provided it is only partly filled with cells, we may recognise some of the latter as being products of endothelial cells on account of their size, nucleus, and granulation. At the same time it can be made out, in one place or another, that a growth of the endothelium of a stoma is going on into the lumen of the lymphatic capillary in the form of a cone of young cells projecting free into its lumen, whereas the endothelial cells which represent the wall of the lymphatic are seen to be enlarged, distinctly granular, and their nuclei in the act of division. There cannot be the least doubt that (1) the changes and the growth of the endothelium round the stomata spread over the endothelium of that portion of the lymphatic vessel to which the stoma corresponds, and (2) that the young cells which result from the growth of the endothelium of the stoma fall partly into the corresponding lymphatic vessel, and partly into the abdominal cavity.

I may now briefly describe the germination of the endothelium round the true stomata of the omentum of the guinea-pig. We have previously mentioned that those stomata occur abundantly on the lymphatic vessels of the omentum, and it may be simply stated in this place that the germination of their endothelium in animals which have become tuberculised from the abdominal cavity proceeds in the same way as in the centrum tendineum. I refer to Figs. 42 and 45, where undoubtedly the fact comes out that the young cells become detached into the lymphatic vessels. In order to become acquainted with these conditions, it is necessary not to confine one's self to parts far advanced in the morbid process, because on them the

diagnosis is rendered more difficult by the abundance of new growth, and by the lymphatics being filled with young cells. The same occurs as regards the germination of the endothelium round the stomata when the guinea-pigs are suffering from chronic inflammation of the peritoneum, whether this be the result of the introduction of solid bodies (pieces of gutta-percha, according to Cohnheim and Fränkel), or of the injection of pyæmic fluids and consequent chronic pyæmia (see Dr. Sanderson's Report, 1872) into the abdominal cavity.

A fact worth noticing is; that guinea-pigs in which the tuberculization was induced by subcutaneous injection, or by direct injection into the blood-vessels, exhibit a marked difference, viz. whereas in those cases in which the tuberculization has been induced by the peritoneum, and in which, the peritoneum being more advanced in the tubercular process than the internal organs (as the lymphatic glands, spleen, liver, and lungs), the germination of the endothelium round the stomata or pseudo-stomata is the first and chief change to be made out at a time when the tubercular process has made very little progress, one does not find this to be the case when the tuberculization has been induced subcutaneously or by the vessels, for a marked growth of the endothelium round the stomata does not take place until the tuberculosis in general is very advanced.

The same conditions with which we have become acquainted in the preceding as regards the omentum and centrum tendineum are to be observed on the mesentery. In those cases, where the mesentery exhibits moderately far-advanced tuberculous affection, the growth of the endothelium around the true stomata occurs in a very striking manner. Figs. 9 and 12 are taken from such a mesentery; here, over the greatest part of the mesentery, there could be demonstrated with great ease the stomata vera themselves, as well as the germination of their endothelium. Besides this, the germination of the endothelium round the pseudo-stomata and the budding of young cells from the pseudo-stomata themselves was quite distinct.

What had been said in reference to the change of the endothelium surrounding true and pseudo-stomata in the guinea-pig, I have found to be also true of the mesentery and omentum of monkeys which



died in consequence of tuberculosis. The liver, spleen, lungs, and lymphatic glands contained very numerous tubercles, while the omentum and the mesentery were disproportionately little affected, and the centrum tendineum least of all. The same conditions were found on the mesentery and omentum of cats, which presented the macroscopic appearances of tuberculosis, viz. grey nodules disseminated over these membranes, especially over the mesentery. These were cases of chronic inflammation of the mesentery and omentum in consequence of a parasitic immigration from the alimentary canal.

Similarly I have found the abnormal germination of the endothelium round the stomata, especially round those of the omentum of the rabbit whose omentum exhibited signs of chronic inflammation in consequence of the presence of parasites in the lymphatics.

I have, however, also induced artificially the abnormal germination of the endothelium on true stomata and pseudo-stomata on the omentum and centrum tendineum of the rabbit. If a few c.c. of starch and oil or starch and water are injected into the abdominal cavity of a well-nourished rabbit, and if the examination of the omentum and centrum tendineum is undertaken not earlier than four to eight weeks, we shall find that the alteration of the endothelium is now limited to those places only where we have become acquainted with stomata and pseudo-stomata, the germination of the endothelium being here very considerable.

Lastly, I must mention the germination of the endothelium round the stomata of the mesentery and mesogastrium of a comparatively large number of female frogs during the winter months. In these cases there appeared also on the septum of the cisterna-lymphatica-magna abundant germination of the endothelium round the stomata on the peritoneal surface, as well as a germination of the endothelium spreading from these points. It may be remarked by the way that the peritoneum of the ovaries and oviducts, and that in the neighbourhood of the liver, were in these cases covered with more or less numerous false membranes.

## 2. *Alteration of the Cellular Elements of the Matrix.*

(a.) *Acute Inflammation.*—The object most suited for the study of the cells of the lymph-canalicular system is afforded by the serous membranes in the inflamed state, and, above all, the omentum minus and mesentery in the condition of acute œdema. I have had the opportunity of examining these membranes in a very large number of guinea-pigs, rabbits, and dogs, in a condition where they were swollen by œdema to five times their normal thickness or more; and here the best results attended the examination, both in the fresh condition and after treatment with silver. In guinea-pigs, as well as in dogs, I induced septicæmia by injecting into the abdominal cavity peritoneal and pleural exudation fluids, which were obtained by certain pyæmic processes of an extremely acute process (compare the Report for the Privy Council by Dr. Sanderson, 1872). In rabbits I have seen in some cases œdema of the omentum coming on after the injection of diluted ammonia into the abdominal cavity, and once after the injection of starch.

After the first twelve to seventy-two hours, œdematous mesenteries presented on those places where the œdema was very considerable, the connective tissue bundles much separated from each other; the cells of the matrix very distinct and isolated. The latter were recognisable in fresh preparations on account of their protoplasm being granular: they were distinctly branched, and connected with each other by processes of extraordinary length. Many appeared in profile, and presented themselves as granular spindle-shaped cells. On the spots where the œdema was not very considerable, the investigation was even more instructive, for there the connective tissue bundles of the matrix were not separated much from each other. They were only transparent to an extraordinary degree, whereas the lymph-canalicular system was recognisable as unusually dilated in its lacunæ and connecting canals. Here also there were met with appearances which correspond to those represented by Schweigger-Seidel on transverse vertical sections through the cornea, namely, the dilated inter-

fascicular spaces covered on one side only by a spindle-shaped granular cell, that is by a flat-cell seen in profile; in other places the latter was seen to extend through the middle of the space. Besides these there were also spaces whose cells were seen from the surface provided with a number of processes.

In many of the spaces there were found migratory cells in addition to the branched cells; and on one preparation I have observed a migratory cell migrating freely out of such a lymph lacuna into a neighbouring lymphatic vessel widely dilated and easily recognisable by its endothelium.

In mesenteries only a little swollen by œdema the appearance of the dilated lymph-canalicular system could be fixed very easily by silver, by first pencilling the membrane carefully on one side, and then pouring the silver solution over this surface *in situ*; after having been washed with water, the omentum was kept *in situ* until the yellow-brown colour appeared.

The examination of the œdematous omentum proved of great value for judging of the normal relations, especially those of the peri-lymphangial nodules and the fat-tissue. In the former, one may very easily recognise the network of branched cells which form the matrix of the nodule; farther, that this stands in direct continuity with the wall of a lymphatic vessel which exists on the border of the nodule, and is widely dilated. The endo-lymphangial nodules are also easily recognisable, their lymphatic vessel, viz. the lymphatic vessel in which they lie, being dilated by the presence of œdematous fluid.

We now turn to the question whether the lymph-canalicular cells exhibit any alteration in acute inflammation, and if so, what that change is.

I have had the opportunity on several occasions of examining the centrum tendineum of rabbits after forty-eight hours, in which peritonitis had been set up by the injection of several minims of dilute ammonia into the abdominal cavity; and on whose centrum tendineum the endothelium of the abdominal surface had quite disappeared over tracts of various size. These were simply treated with silver. The lymph-canalicular system of the abdominal serosa

presented itself here with the greatest distinctness on those spots where the endothelium had become detached. Here one had to do with a centrum tendineum quasi-pencilled.

In many places the system of lymph-canalculi of the peritoneal serosa contained migratory cells; on other places the branched cells were also very distinct, besides that the outlines of the lymph-canalicular system were recognisable.

On places such as these one could perceive a striking difference in the individual parts of the lymph-canalicular system in reference to that of other places. First, it was clear that the lacunæ were larger, the canals were not branched and not so abundant, and secondly, they appeared wider at many places. When one directed one's attention to one of the widest of the canals, one could discover on them one or even several small dilatations. As for the branched cells of the lymph-canalicular system, it is to be noticed that they are distinctly recognisable by their granular appearance, and by the presence of their nucleus. In many of them it was possible to trace the protoplasm of the cell body, which lay in the lacuna, into the canals; in the wide canals which, as above described, were furnished with lacunæ-form bulgings, a swelling corresponding to this bulging could also be demonstrated on the protoplasm or on the protoplasmic processes. As for the nuclei, constrictions could be remarked upon them, and some of the cells were furnished with two nuclei.

From this appearance one is able without doubt to draw the conclusion that both the lymph-canalicular system and also its contents, viz. the branched cells, have undergone changes: the lacunæ and canals, or the cell body and cell processes respectively, were swollen, the canals or cell processes reduced in number, less branched, and finally, the nuclei of the cells in the act of division. An objection against these deductions can be made all the less as we have to do here with a change of the lymph-canalicular system and of the cells which cannot be attributed to any cause of the method of preparation. If we pass from the places just described to places where the endothelium of the surface is also removed, and where consequently colouration of the matrix has occurred, but where the lymph canalicular system contains migratory cells, the

difference in the lymph-canalicular system is even more striking. If the number of migratory cells is large, then one requires some time before one is able to interpret such spots; with a high magnifying power (obj. 8), however, and with somewhat more attention, one can recognise the lacunæ of the lymph-canalicular system as being provided only with a few wide canals. Both in the former and in the latter, we can recognise lymphoid corpuscles. We shall also be able to discover here and there in such a dilated canal a smaller or larger protoplasmic mass surrounding a nucleus, and forming a continuity with a protoplasmic process, which can be traced into the corresponding lacuna. This nucleated mass of protoplasm appears either as a terminal or as a lateral bud of a cell process. In the same manner, one can find one lymph-canalicular cell or another in which the division of the nucleus has so far advanced that instead of the large ovoid nucleus one comes upon two or three small nuclei, or that the cells of the lymph-canalicular system have a swelling placed on one side, so that the lacuna forms a projection: this swelling is still in distinct connection with the rest of the cell. We have to do here, therefore, with a change of the branched lymph-canalicular cells, as was described of the cornea-corpuscles by Stricker and Norris, and confirmed by Rollett. It is unnecessary for me to state that an exudation both of the colourless and coloured corpuscles had taken place from the blood-vessels, inasmuch as the vessels, especially the small veins, were to be seen sheathed in compact cords of these; they could be followed even into the lymph-canalicular system.

The omentum of such rabbits as these proved to be not less instructive. On the cells of the lymph-canalicular system which presented themselves isolated in the tissue, one could demonstrate on some places exactly the same change as was described on the centrum tendineum, namely, the lacuna being larger, the number of the canals fewer, the canals wider, the cells of the lymph-canalicular system presenting themselves as granular bodies with processes, and their nucleus here and there in the act of division. In the neighbourhood of the blood-vessels numerous migratory cells were met with in the lymph-canalicular system. If we examine carefully the lymphatic nodules, a distinct increase of migratory cells could be

made out, especially of small finely-granular cells, which may be taken in all probability as emigrated colourless blood corpuscles.

In lymphatic nodules which lie in the neighbourhood of a vessel, and which possess either a scanty system of vessels or even none whatever, and which, according to the description given in Section I., are to be regarded as being in an early stage of development, we are likely to find a number of the lymph-canalicular cells which possess on their body or on a process, buds of various sizes in such a number as is not to be found in the uninflamed state; the condition of their nucleus is usually that of division, sometimes it is divided into two or three small nuclei. From these appearances we may conclude that here also an active inflammatory change had taken place.

Of the greatest importance as regards the changes of the branched cells of the lymph-canalicular system of the mesentery and omentum of the guinea-pig and dog was the examination of these membranes in the œdematous condition during the second or third day of the inflammation. If, after what I had seen on the centrum tendineum and omentum of the rabbit, I had had still any doubt about the active participation of the cells of the lymph-canalicular system in the production of young cells, the study of the œdematous mesentery of those animals just mentioned would have cleared up completely every doubt.

(b.) *Chronic Inflammation.*—The most important changes in branched cells of the lymph-canalicular system occur in chronic inflammation, which may arise from the most various causes. We will commence with the centrum tendineum.

*Centrum Tendineum.*—If we prepare a centrum tendineum of a guinea-pig which has tubercular nodules on the centrum tendineum, by pencilling its pleural surface and subsequent staining with silver solution, we shall obtain a satisfactory understanding of the changes of the cells of the lymph-canalicular system if the preparation is a successful one, that is, if the system of lymphatic vessels and lymph canals is plainly and beautifully to be seen. Besides places where the lymphatic vessels and the system of lymph-canals, as well as the cells of these, present no deviation from the normal condition, there are spots to be met with where a distinct change has occurred, the

branched cells being decidedly more abundant, less branched, their processes uncommonly broad. In some places the cells are so closely situated by each other that they resemble an endothelium; in this case they are separated from each other by linear intercellular substance. In Fig. 14 this change is very distinctly to be seen.

This figure is taken from a silver-stained preparation of centrum tendineum of a guinea-pig suffering from slight chronic inflammation. At *b* an important change of the branched lymph-canalicular cells has taken place, the same being arranged like an endothelium after having undergone division. To the greatest extent this change is to be found in the tubercular nodules which have their seat in the serosa of the pleural surface. Fig. 22 is a silver preparation of a tuberculous diaphragm of a guinea-pig. The branched lymph-canalicular cells have all undergone the above-mentioned change, being now arranged like an endothelium, with the difference, however, that the cells are for the most part separated by thicker tracts of intercellular material.

I may mention here that I have frequently succeeded in injecting the lymph-canalicular system of the peritoneal serosa, as well as of the tendons of the centrum tendineum, in some cases also that of the mesentery and the peritoneum parietale, with colouring material; namely, in guinea-pigs which suffered from artificial tuberculosis, and in rabbits in the peritoneal cavity of which starch and water had been injected several weeks before. In these cases anilin and milk (an alcoholic solution of anilin is mixed with so much water that the anilin is precipitated in form of very fine granules), has been introduced into the peritoneal cavity of the affected animals in a quantity of about 4 c.c.; after twenty-four to forty-eight hours the animals were killed. On microscopical preparation of the centrum tendineum there were many places to be found in which the inflammatory changes of the branched lymph-canalicular cells were very slight, and on which places not only the protoplasm of the branched cells and that of the migratory cells, but also the lymph-canaliculi themselves, contained more or less numerous anilin granules. To a very great extent that was the case in a rabbit which suffered from chronic

peritonitis in consequence of starch-injection into the peritoneum, many of the straight lymphatic capillaries of whose centrum tendineum were plugged up by lymph-corpuses.

As regards the peri- and endo-lymphangial nodules and cords of the omentum, it is to be noticed that in chronic inflammation a very active proliferation of the elements of those structures takes place. The best example to ascertain this fact is to be found in the omentum of guinea-pigs in different stages of the tuberculous process. Here it can be shown that those structures increase not only in size, but, what is of greater importance, also in number. Not only the branched cells of the matrix, but also the lymphoid corpuses that are in direct or indirect connection with it, undergo very active proliferation. The branched cells of the matrix become very much more abundant by growing into the neighbouring tissue; they are first large in their body as well as in their processes, but gradually become transformed into a delicate reticulum. It is very common to find such branched cells of the matrix whose body is provided with a number of small constricted nuclei, and amongst the lymphoid corpuses of the matrix, multinuclear large elements are oftener to be met with than in the normal condition.

By the out-growth of the branched cells of the matrix very often secondary nodules and cords are formed, which in some instances project over the general surface of the omentum like bridges, villi or papillæ; they are, as has been stated previously, more or less covered with germinating endothelium.

After having discovered the pseudo-stomata on the omentum, my attention was directed to the question, whether in chronic inflammation the proliferation of the protoplasmic elements representing the pseudo-stomata plays any part in the development of those smaller and larger villous projections that are so often to be found on the omentum as well as on other portions of the peritoneum.

It was soon ascertained that the pseudo-stomata do not only proliferate in the way above stated, viz. budding lymphoid cells to the surface, which resemble young endothelial elements, but also that they grow out over the general surface as protoplasmic masses, which carry with them the surrounding zone of the endothelial cells. As



long as these villi are small, one recognises a pale granular matrix, containing two or more nuclei, covered by a layer of endothelial plates, somewhat thicker than common endothelial cells. In a still later stage the matrix contains, besides the corpuscles just mentioned, a substance which is first hyaline, but afterwards becomes finely striated connective tissue. In some omenta many villi are to be found, which consist of a fully-developed connective tissue matrix, with the corresponding lymph-canalicular system and their branched cells. The question arises where this connective tissue matrix originates. Kundrat asserts, that the connective tissue matrix of those projections and villi of the omentum in chronic inflammation take their origin from endothelial elements, which, having become elongated, become transformed into bundles of connective tissue. I cannot confirm this statement, for I must on the contrary mention that the bundles of connective tissue that make their appearance in these villi are always first hyaline thin bands, which gradually increase in thickness, whereas the cells of the matrix never show any transition into these bundles. I possess preparations of the mesogastrium and the septum cysternæ lymphaticæ of a female frog, which suffered from chronic peritonitis, where the development of villi with a connective tissue matrix can be followed through all its intermediate stages; and here it is more likely that the connective tissue bands are mere excretions, either of pseudo-stomata cells or, as it is oftener the case, of the superficial endothelial cells.

I have come across innumerable preparations of mesenteries of guinea-pigs suffering from chronic peritonitis, where the connective tissue bands of the matrix of the above-mentioned villi and projections must be taken as excretions of the cells; in not one single instance was there to be seen a transformation of cellular substance into these bands. They always appear as thin hyaline bands of equal diameter, which gradually increase in thickness, and in a later stage show a fibrillar structure. I am, therefore, in agreement with Rollett, who states that in the serous membranes connective-tissue bundles develop from an inter-cellular substance. We come now to deal with a point, the significance of which has been until the present completely overlooked—we mean the significance of vacuolation

of cells in inflammation. We have had already the opportunity to mention the occurrence and the changes of vacuolated cells in the normal omentum. We have here only to add that in chronic inflammation very numerous cells of the matrix of the serous membranes become vacuolated, and change either into lymphatic vessels in the way previously described, or they become elongated and join a capillary blood-vessel. As regards the former case I had frequently occasion to see that in some of them a formation of lymphoid corpuscles takes place from the wall of the vesicle into its cavity. Further, I have met with large multi-nucleated cells (myeloplaxes), in which there was to be seen the transformation of the central portion into a number of lymphoid corpuscles, that of the peripheral part into the nucleated wall of a vesicle—endothelial vesicle.

I refer the reader to Figures 18, 20, 23, 25, 27, 31, 33, and 53.

The most interesting fact as regards the vacuolation of cells I have observed in the cells of the pseudo-stomata in chronic inflammation. It occurs, namely, that in one of these a vacuolation takes place, and the vacuole opens on one side free on the surface through the process that stretches to the surface between the endothelium, whereas towards the opposite side it becomes connected with a lymphatic capillary, so that we have then before us the case that a lymphatic capillary opens freely on the surface of the membrane by a vertical canal, the entrance opening of which represents a true stoma. See Figures 27, 33A, 53, and 54.

In Fig. 54, mesogastrium of a common frog, an endo-lymphangial growth of a branched network is to be noticed in such an isolated vacuolated cell, from which it can be inferred that endo-lymphangial nodules develop in lymphatics in their earliest stage.

### 3. *The Blood-Vessels and Lymphatic Vessels.*

What has been said as regards the development of blood capillaries in the normal serous membranes is true also for chronic inflammation, of course with greater extensity and intensity.

Finally, we have to notice the intensive growth of a branched reticulum from the endothelial wall into the lumen of lymphatic

capillaries, viz. the formation of endo-lymphangial nodules and cords in chronic inflammation, as it occurs in the omentum and pleura mediastini of tuberculised guinea-pigs, in the mesentery of tuberculous monkeys, in the omentum of rabbits, some of the lymphatics of which were plugged up by parasites (ova of cysticercus), and in the mesentery of cats, some of the lymphatics of which contained ova of nematodes.

---

### BIBLIOGRAPHY.

- Recklinghausen*: On the Resorption of Fat. Virchow's Archiv, vol. 36.  
*Recklinghausen*: The Lymphatics and their Relation to the Connective Tissue. Berlin, 1862.  
*Schweigger-Seidel and Dogiel*: On the Peritoneal Cavity in Frogs, and their Connection with the Lymphatic System; in 'Arbeiten aus der physiolog. Anstalt zu Leipzig,' 1866.  
*Ludwig and Schweigger-Seidel*: On the Centrum Tendineum of the Diaphragm. Ibidem.  
*Schweigger-Seidel*: On the Treatment of Animal Tissues with Nitrate of Silver, etc. Ibidem.  
*Rollett*: Article Cornea in Stricker's Handbook.  
*Schweigger-Seidel*: On the Cornea, in 'Arbeiten aus der physiolog. Anstalt zu Leipzig,' 1869.  
*Boll*: On the Structure and Development of the Tissues, in Max Schultze's Archiv, vol. vii., part 4.  
*Knauff*: Centralblatt für medicin. Wissenschaften, August 1867.  
*Recklinghausen*: Article Lymphatics, in Stricker's Handbook.  
*Flemming*: On the Development of Fat-cells. Max Schultze's Archiv, vol. vii., part 1.  
*Toldt*: On the Histology and Physiology of Fat-tissue. Sitzungsber. d. Wiener k. Academie d. Wissensch., vol. lxii., part 4, 1870.  
*Lavdovsky*: Centralblatt für medicin. Wissensch., 1872.  
*Afonassiew*: Virchow's Archiv, vol. xlv.  
*Stricker*: See Stricker's Handbook, chap. xxxviii.  
*Arnold*: Virchow's Archiv, vol. liii.  
*Rindfleisch*: Pathologische Histologie.  
*Ranvier*: Corveil and Ranvier's Normal and Pathological Histology.  
*Kundrat*: Medicin. Jahrbücher in Vienna; ed. by Stricker, vol. i., part 1.  
*Burdon-Sanderson*: Report of the medical officer of the Privy Council, 1867 and 1868.  
*Klebs*: Virchow's Archiv, vol. xlv.  
*E. Klein*: Quarterly Journal of Microscopical Science, January 1872.

## EXPLANATION OF PLATES.

---

I have to offer my sincere thanks to the Government Grant Committee of the Royal Society for having furnished the means for the execution of the following plates :—

### PLATE I.

FIG. 1. Germinating Endothelium of tracts freely projecting over the surface of the pleura mediastini of a healthy cat. Preparation stained with nitrate of silver.

M. p. Hastnark, E. p. No. III. Obj. 7.

FIG. 2. Surface of a mesentery of frog, stained with nitrate of silver.

M. p. E. p. III. Obj. 5.

*a.* Common flat endothelial cells of the surface, amongst which six couples of cells are to be found, which have stained deeply with the reagent, and which consist of a granular protoplasm; these cells are not flat, but more or less polyhedral—germinating or young endothelial cells. Between the cells of these couples more or less distinct openings are to be seen—stomata vera, which lead into a lymphatic space below; they are exactly like the stomata of the epidermis of plants.

FIG. 3. Silver-stained preparation of the septum cystemæ lymphaticæ-magnæ of frog.

M. p. III. Obj. 5.

A. Peritoneal surface of that membrane.

B. The surface directed towards the cystema shows amongst the common flat endothelial cells, the size and shape of which are obviously different on the two surfaces, openings of canals, by which that septum is penetrated. The openings, viz. the canals are lined with a special layer of polyhedral cells, which have the character of young germinating endothelial cells.

FIG. 4. Silver-stained preparation of slightly œdematous mesentery of guinea-pig, suffering from chronic infective peritonitis.

M. p. III. 5.

- a.* The endothelium of the general surface ; below the endothelium close to the surface a large dilated lymphatic vessel *c* is to be seen, through which passes an artery *d* and a nerve trunk *e* (Invagination) ; the lymphatic vessel stands in free communication with free surface, viz. the peritoneal cavity, by a number of stomata vera, which are lined with young endothelium.

FIG. 5. Silver-stained preparation of the omentum majus of dog.

M. p. III. 8. (Tube drawn in.)

Shows amongst the flat endothelium of the surface small and large groups of germinating endothelium, between which numbers of small stomata are to be seen.

## PLATE II.

FIG. 6. Silver-stained preparation of the omentum of rabbit.

M. p. II. 7. (Tube half drawn out.)

- a.* Common flat endothelium of the general surface.  
*b.* A tract projecting somewhat over the surface, covered with an endothelium, the cells of which are of smaller size ; amongst these smaller or larger groups of small cells are to be seen, which are not flat but polyhedral, which consist of a distinctly granular protoplasm, and which are arranged more or less regularly round stomata.

FIG. 7. Silver preparation of centrum tendineum of rabbit. Peritoneal surface.

M. p. III. 7.

- a.* Common flat endothelium of the peritoneal serosa, which covers the tendon-bundles.  
*b.* Smaller endothelium, which covers straight lymphatic vessels which lie between the tendon-bundles.  
*c.* Stomata vera, some widely open, some collapsed, which lead to those straight lymphatic vessels ; these stomata are lined

with endothelial cells, which, as in Fig. 6, are of a germinating character.

*d.* Represent sinuses of those straight lymphatic vessels.

FIG. 8. Peritoneal surface of a silver preparation of a centrum tendineum of a guinea-pig which suffered from chronic infect. peritonitis (artificial tuberculosis.)

M. p. III. 7.

*a— $a_1$*  and  *$a_1— $a_1$$*  Indicate the straight lymphatic vessels between the tendon bundles, as in Fig. 7.

*b.* Represent stomata which are plugged up by a substance which has become darkly stained by the reagent (fibrinous plug); the endothelium which surrounds the stomata is in a state of intensive germination, forming buds and villi, freely projecting over the surface; on the latter ones cells are seen to be in the state of detaching themselves by constriction (lymphoid cells).

FIG. 9. Silver preparation of the mesentery of guinea-pig in the same morbid condition as that of Fig. 8.

M. p. III. 7.

*a.* Common endothelium of the surface.

*d.* The upper wall of a lymphatic sinus, which has become freely exposed to the surface; the endothelial marking of that wall is clearly to be seen.

*b.* Stomata, which lead obliquely into the cavity of the lymphatic sinus.

*c.* Germinating endothelium round these stomata, forming buds, which project over the free surface.

### PLATE III.

FIG. 10. Silver preparation of the omentum of a guinea-pig suffering from chronic infective inflammation.

M. p. III. 7.

*a.* The trabeculæ of the fenestrated portion of the omentum, with its endothelial covering.

*b.* Freely-projecting villi, the top of which is covered with *c* germinating endothelium.

FIG. 11. Silver preparation of the peritoneal surface of the centrum tendineum of the diaphragm of rabbit, as in Fig. 7.

M. p. III. 5.

- t.* Endothelium which covers the serosa over the tendon-bundles.
- s.* Stomata over the straight lymphatic vessels, some of them open, some collapsed; the surrounding endothelium of a germinating character.

FIG. 12. Silver preparation from the same mesentery as Fig. 9.

M. p. III. 5.

- a.* Stomata, the surrounding endothelium *c* of which, as well as of lymphatic sinuses *b*, is intensively germinating.
- b.* The endothelium of lymphatic sinuses, the stomata of which are widely open, so that the endothelium of their bottom can be seen.
- d.* Common flat endothelium of the general surface.

FIG. 13. Silver preparation of the fenestrated portion of omentum of guinea-pig suffering from chronic peritonitis.

M. p. III. 7.

- a.* Thin trabeculæ covered with common flat endothelium.
- b.* Abundant germination of endothelium, springing off from the surface of a larger trabecula *c*, and continuing on the smaller secondary trabeculæ.

#### PLATE IV.

FIG. 14. Silver preparation of the pencilled pleural surface of the centrum tendineum of a guinea-pig suffering from slight chronic inflammation of the serous membranes.

M. p. III. 7.

- a.* The endothelium of lymphatic-capillaries.
  - c.* The lymph-canalicular system of the pleural-serosa; the branched cells, which occupy that l. c. system, are in some places distinctly to be seen.
- At *b*, these cells (respectively the lacunæ of the l. c. system) have become more numerous by division.
- At *d*, the continuation of the endothelium of the lymphatic capillaries with the cells of the l. c. system is clearly to be seen.

FIG. 15. From a preparation similar to that shown in Fig. 14; there was a little more inflammation in the serous membranes.

M. p. III. 7. (Tube half drawn out).

- a.* Endothelium of lymphatic capillaries.
- b.* The same somewhat altered.
- c.* Continuation between it and the cells of the lymph-canalicular system.

FIG. 16. A preparation similar to that shown in Fig. 14.

M. p. III. 7.

*a, b, and c* as in Fig. 14.

FIG. 17. Silver preparation of the pencilled pleural-surface of the normal centrum tendineum of rabbit.

M. p. III. 7.

- l.* Endothelium of lymphatic capillaries.
- c.* Lymph-canalicular system of the serosa.
- s.* The same, in which only the nuclei of the branched cells are to be seen.

At *t*, continuation of the endothelium of the lymphatic vessels with the lymph-canalicular system, or, properly speaking, with their branched cells.

FIG. 18. From a silver-stained preparation of the mesogastrium of a frog, representing a node projecting freely from the surface of a large trabecula *t*.

M. p. III. 8.

- a.* Ciliated endothelium which covers the surface of that node.
- b.* A vacuolated cell of the matrix of the node; fine ciliæ are projecting into the vacuole.
- c.* A vacuolated cell, the wall of which has already differentiated in individual endothelial plates.
- d.* A vacuolated cell filled with nucleated young cells.

FIG. 19. From a silver preparation of a pencilled mesentery of ape suffering from chronic peritonitis.

M. p. III. 8.

*M.* Connective-tissue matrix not represented.

- a.* The lymph-canalicular system, with its corresponding branched cells.
- b.* Large migratory cells which lie in that l. c. system beside the branched cells.



FIG. 20. From the lumbar portion of the peritoneum parietale of a rabbit suffering from chronic peritonitis.

M. p. III. 8.

- a.* Enlarged branched cells of the ground-substance, provided with a vacuole *c*, in which lie fat globules *d*, and young (lymph) cells *e*.
- b.* The nuclei of the branched cells.

FIG. 21. From the mesentery of ape suffering from chronic peritonitis.

M. p. III. 8.

- a.* Enlarged branched cells of the ground-substance, filled with fat globules *b*. The ground-substance *M* is not represented.

#### PLATE V.

FIG. 22. From the centrum tendineum of a guinea-pig suffering from artificial tuberculosis of the serous membranes (including the centrum tendineum). The preparation had been pencilled from the pleural surface and stained with nitrate of silver.

M. p. III. 7. (Tube not drawn out.)

Showing a patch in pleural serosa (young tubercle), which owes its origin to an intensive proliferation of the branched cells of the lymph-canalicular system.

At *A*, the connection of that patch with the lymphatic capillaries, which bend in another layer than that represented in the figure.

FIG. 23. From a silver-stained omentum of a guinea-pig suffering from chronic infective peritonitis.

M. p. III. 7.

*F.* Ground-substance of the fenestrated portion of the omentum, over the surface of which a villus is projecting freely: *A* its radix, by which it is connected with the membrane; *B* its summit.

- a.* Common flat endothelium of the general surface of the villus.
- b.* Germinating endothelium.
- c.* Vacuolated cells in the ground-substance of the villus.
- d.* The same, containing young cells.

FIG. 24. From a silver-stained preparation of normal omentum of rabbit, representing a vascular patch, the ground-substance of which F has remained unstained by the silver, whereas the very rich network of the branched cells *e* have become very distinct.

M. p. III. 7.

- a.* Capillary blood-vessels.
- b.* Growing capillaries; the growth takes place by hollowing of the branched cells which are in connection with the wall of the capillary vessels *d*.
- c.* Vacuolation in the branched cells, as the first step of becoming hollowed out and afterwards to become continuous with the lumen of a capillary vessel.

FIG. 25. From a silver-stained preparation of the mesentery of a monkey suffering from chronic peritonitis.

M. p. II. 7.

F. Ground-substance not represented.

- a.* Different stages of vacuolation of apparently not branched cells of the matrix. Such vacuolated cells becoming united from tubes, the wall of which becomes differentiated in endothelial plates *a*.
- b.* Small, *c* larger nucleated elements of the matrix.

FIG. 26. From a silver-stained preparation of the omentum of a guinea-pig, as in Fig. 23, representing a villus which projects freely over the surface. Optical longitudinal section.

M. p. III. 10 à l'immersion.

- a.* Ground substance of the villus, consisting of finely fibrillated connective tissue, containing large granular spindle-shaped looking cells, which in many places, *c*, are projecting between the enlarged and germinating endothelium *b* and *c* freely up to the surface—Pseudo-stomata; from them also young cells grow up, *d*.

FIG. 27. From a silver-stained preparation of the centrum tendineum of a guinea-pig as in Fig. 22. Pleural surface.

M. p. III. 5.

- a.* Common endothelium of the general surface; below it a vacuolated cell, which forms a stoma verum with the surface.

FIG. 28. From the same mesentery of monkey as Fig. 25.

M. p. III. 8.

F. Ground-substance not represented.

*a.* Large, coarsely-granular nucleated elements, which contain a various number of spherical or irregular globules of different sizes, which are homogeneous in structure, and are somewhat similar to fat globules, although they refract light differently.

#### PLATE VI.

FIG. 29. A preparation similar to that shown in Fig. 24.

A vascularised patch of the normal omentum of rabbit.

M. p. III. 8.

*a.* Capillary blood-vessels.

At *b*, their connection with the branched cells of the ground-substance; these places represent at the same time where young capillaries are formed.

*c.* The branched cells of the matrix.

*d.* Similar ones of the ground-substance of the neighbourhood of the patch.

FIG. 30. From a pencilled silver-stained normal omentum of rabbit.

M. p. IV. 8.

Representing a young patch, the ground-substance of which *M* is unstained.

*a.* The lymph-canalicular system, with the corresponding branched nucleated cells.

*b.* Migratory cells, either perfectly detached from those branched cells or in a state of growing from them.

*c.* Vacuolated element, which is a mere knob of a branched cell.

In *d* the vacuolation has gone so far that a vesicle is formed, the wall of which has differentiated in endothelial plates.  
(Development of a lymphatic vessel.)

At *F* division of the branched cells.

FIG. 31. From a silver-stained mesentery of a monkey suffering from chronic infective peritonitis. Representing a sprout freely projecting over the surface.

- a.* Pedunculus of the sprout.
- b.* Summit of it. The endothelium which covers this sprout, especially that of the summit, is of a germinating character.
- c.* A vacuolated cell of the matrix.
- d.* Young cells of the matrix.

FIG. 32. From a pencilled portion of the mesentery of the same monkey as Fig. 31.

M. p. IV. 8.

- a.* Migratory cells not yet perfectly detached from the nucleated branched cells, which lie in the lymph-canalicular system *b.*
- c.* The nuclei of those branched cells. There are numbers of small elements and particles in the lymph-canalicular system to be seen, which owe their origin probably to the nuclei of the branched cells as well as to the migratory cells.
- F. Matrix unstained.

FIG. 33. From the silver-stained mesentery of the same monkey.

M. p. II. 7.

In A a vacuolated cell is to be seen which lies below the endothelium of the surface: its wall has already become differentiated into endothelial plates *a*, and at the same time its cavity has opened, so as to communicate with the free surface of the mesentery by a stoma verum *b*.

In B a sprout is to be seen, which projects between the endothelium of the general surface *a* freely outwards: it stands in communication with the tissue below the endothelium of the surface by means of a protoplasmic pedunculus *c*; its body is formed by a vacuolated cell *b*, which in fact represents only the cell of a pseudo-stoma.

FIG. 34. From a pencilled silver-stained preparation of normal omentum of rabbit.

M. p. III. 7.

- a.* Lymphatic-capillary vessel, showing the endothelial markings of its walls.
- b.* An artery.
- c.* Capillary blood-vessels; and *d*, branched cells of a surrounding patch.
- e.* A place where the endothelium of the lymphatic vessel becomes continuous with those branched cells.
- f.* Migratory cells.

## PLATE VII.

FIG. 35. Silver-stained preparation of a pencilled centrum tendineum of normal rabbit.

M. p. III. 2.

- a.* Large lymphatic vessels, with valve.
- b.* Lymphatic capillaries.
- c.* Lymphatic capillaries, which dip down between tendons.

FIG. 36. Preparation of centrum tendineum (normal) of rabbit, the diaphragm of which had been injected with nitrate of silver by Ludwig's experiment, the ground-substance nearly unstained.

M. p. III. 5.

- a.* Large lymphatics of the pleural side.
- b.* Lymphatic capillaries which run between the tendon-bundles, straight lymphatic capillaries.

FIG. 37. Natural injection of the lymphatics of the centrum tendineum of rabbit with five per cent. Berlin-blue solution ; seen from the abdominal side.

M. p. III. 4.

- a.* Large lymphatics of the pleural side.
- b.* Straight lymphatic capillaries.

FIG. 39. From a pencilled silver preparation of the omentum of rabbit.

M. p. III. 5.

- a.* Lymphatic vessels showing their endothelium.
- b.* Valves of the lymphatics.
- c.* A large trabecula containing large blood-vessels (not represented).
- d.* Ground-substance (not represented).

## PLATE VIII.

FIG. 38. Silver preparation of a centrum tendineum (pencilled from the abdominal surface) of rabbit.

M. p. III. 4.

Showing lymphatic capillaries of the peritoneal surface.

FIG. 40. Silver preparation of a pencilled omentum of rabbit.

M. p. II. 7.

- a.* A vein filled with blood.
- b.* Capillary blood-vessel.
- c.* Lymphatic capillary vessels showing their endothelium; the blood-vessels are invaginated in these lymphatics.
- d.* Branches of the lymphatic vessel, which are in communication with the lymph-canalicular system of the ground-substance *e.*
- f.* The lymph-canalicular system of a lymphatic patch, which system is also in communication with the lymphatic vessel at *g.*

FIG. 41. Fresh preparation of an œdematous omentum of a guinea-pig suffering from chronic peritonitis.

M. p. III. 7.

- a.* A lymphatic vessel.
- b.* A portion of a peri-lymphangial nodule.
- c.* The endothelial wall of the lymphatic vessel seen in profile.
- d.* Blood capillaries of the nodule.
- e.* Lymph corpuscles. It is seen that the reticulum of nucleated branched cells which forms the stroma of that nodule is in continuation with the endothelial wall of the lymphatic vessel.

FIG. 42. Silver preparation of omentum of guinea-pig suffering from chronic peritonitis.

M. p. III. 7

The figure represents a large trabecula, which projects over the general surface like a fringe.

- a.* A venous blood-vessel, its endothelium distinctly to be seen.
- d.* Accumulation of lymph-corpuscles, probably in lymphatic vessels which accompany the vein.
- b.* An open stoma verum, surrounded by germinating endothelium; the stoma leads into a lymphatic space, which, as far as it can be traced, shows its endothelial wall in profile; the lymphatic space is, except a few large lymph-corpuscles, filled with clear fluid; it is probable that the lymph-corpuscles which project to the right and left side of this lymphatic space lie in the continuation of it.
- c.* A sprout of germinating endothelium, round a stoma, which

is plugged up by a darkly-stained substance (fibrin); it is probable that also here this stoma leads to a lymphatic vessel, which is filled with lymph-corpuscles.

*f.* Endothelium of the general surface.

*e.* Enlarged endothelium seen in profile at the edge of the fringe.

FIG. 43. Fresh preparation of the same omentum as Fig. 41.

M. p. III. 7.

*a.* A venous capillary vessel, filled with blood.

*b.* An invaginating lymphatic vessel.

*c.* Outer endothelial wall.

*e.* Inner (covering the blood-vessel) endothelial wall of the lymphatic vessel.

*d.* Endo-lymphangial reticulum, which is continuous with the endothelial wall of the lymphatic vessel. In this way endo-lymphangial nodules and tracts are formed.

FIG. 44. From an œdematous omentum of a monkey suffering from chronic peritonitis.

M. p. III. 7.

*a.* An artery

*b.* A vein filled with blood (not fully represented).

*c.* A lymphatic vessel in which both the veins and the artery are invaginated. Many of the endothelial cells of the wall of the lymphatic vessel are seen to be enlarged.

*d.* Lymph-corpuscles which nearly have plugged up the lymphatic vessel.

#### PLATE IX.

FIG. 45. A silver preparation of the centrum tendineum of a guinea-pig, suffering from chronic infective inflammation of the serous membranes.

M. p. III. 5.

Surface view of a portion of the peritoneal surface.

*a.* The upper endothelial wall of a sacciform dilatation of a superficial straight lymphatic capillary vessel; the endothelium of the general surface of the serosa is somehow removed.

*b.* Large open stomata vera.

- c.* Germinating endothelium; at *b* a sprout of germinating endothelium *c* is growing into the cavity of the lymphatic vessel.
- d.* Common endothelium of the general surface.

FIG. 46. From an omentum of a guinea-pig suffering from chronic infective peritonitis. The omentum had been kept in spirit and stained with carmine.

M. p. II. 8.

- a.* A capillary vein.
- b.* Matrix of the fenestrated portion, containing numerous nucleated cells. About the intimate relation of these nucleated cells nothing can be made out distinctly.

FIG. 47. From the fenestrated portion of an injected omentum of guinea-pig suffering from slight chronic infective peritonitis.

M. p. III. 5.

To show the distribution of blood-vessels in the lymphatic nodules.

- a.* Arteries.
- v.* Veins.
- c.* Capillary vessels.
- d.* Matrix of the fenestrated portion of the membrane.
- e.* Germinating endothelium covering a freely-projecting nodule.
- f.* Holes of the membrane.

FIG. 48. From the same omentum as Fig. 47.

M. p. III. 5.

A freely-projecting large lymphatic nodule.

- a.* Arteries.
- b.* Veins.
- c.* Capillary vessels.
- d.* Matrix.
- e.* Holes of the latter.



## PLATE X.

FIG. 49. From a pencilled silver-stained mesentery of frog; slight chronic peritonitis.

M. p. III. 7.

- a.* Small blood-vessels, showing distinctly their endothelium.
- b.* Lymphatic vessels, showing their endothelial wall; the lumen of the vessels contains numerous colourless corpuscles *c.*

At *d*, and towards the left side of the preparation, a lymphatic vessel is seen to be in continuity with the lymph-canalicular system of the ground-substance, in which system also numerous colourless corpuscles are to be found. To the left-hand side of the preparation, where the drawing is taken from, an abundant emigration of colourless blood-corpuscles can be seen to have taken place from the appearance in which the blood-vessels and the surrounding tissue is found: these colourless corpuscles are seen to pass through the lymph-canalicular system into the lymphatic vessels towards the right-hand side.

- f.* Ground-substance, not represented.

FIG. 50. From the same omentum as Fig. 43.

M. p. III. 7.

- a.* Vein.
- b.* Artery.
- c.* Capillaries.
- d.* A lymphatic vessel, in which this whole system of blood-vessels is invaginated.
- e.* Reticulum of nucleated branched cells growing from the endothelial wall of the lymphatic vessel into the cavity of the vessel.

FIG. 51. From a fresh preparation of œdematous pleura mediastini of cat, representing a lymphatic cord in profile.

M. p. III. 7.

- a.* Germinating endothelium of the surface of the cords.
- b.* Nucleated buds which are direct offsprings of the reticulum of the matrix. There are seen numbers of such protoplasmic

processes which project from the reticulated-branched cells of the matrix up to the free surface between the endothelium of the latter (Pseudo-stomata).

- c. Branched cells of the reticulum, which form, so to speak, the matrix of the chord.
- d. Lymph-corpuscles occupying the meshes of the reticulum.

FIG. 52. From a fresh mesogastrium of *rana temporaria*.

M. p. III. 8.

A. A knob freely projecting over the surface of the membrane, consisting of a clear matrix, *in which* some granular cellular elements are to be seen; the knob is covered with an endothelium *c*, which is not so flat as the endothelium in general.

a. The root of the knob. With the endothelial covering of this knob there are in direct continuity four cells, which spring from a common protoplasmic peduncle by means of long thin protoplasmic filaments.

The cells *b* have shown for a considerable length of time active amœboid movements.

The cell *d* was also in continuity with the endothelium *a* of a fold of the membrane.

There cannot be any doubt that these cells are endothelial cells, and consequently that they are in a state where they are already amœboid cells (lymph corpuscles), although they have not yet perfectly separated from the endothelial matrix.

FIG. 53. From a fresh mesogastrium of *rana temporaria*.

M. p. III. 7.

1, 2, and 3. Vesicles of the tissues, the interior of which is lined with ciliæ; the wall consists of a nucleated protoplasm; each of these vesicles develops from one cell of the tissue by vacuolation; in 3, three granular cells are to be seen two of which are provided with ciliæ. These could only have been brought into the cavity of the vesicles from outside, because some of the germinating endothelial cells of the surface are provided with ciliæ.

In 4 the summit of such a vesicle is adjusted, which shows a stoma; so that the interior of the vesicle communicates with the free surface of the mesogastrium. This stoma is

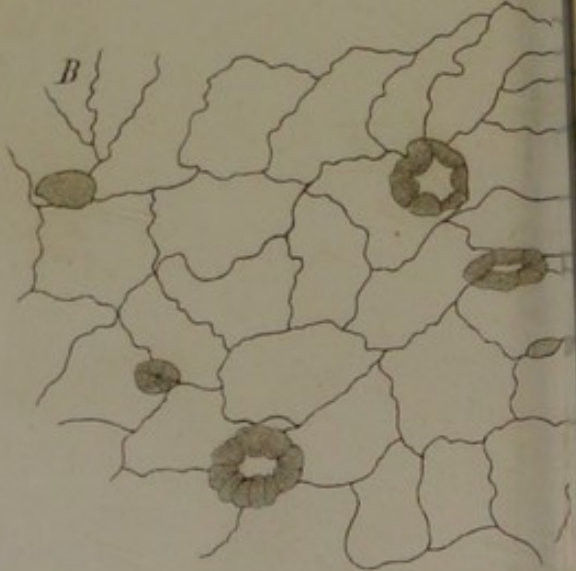
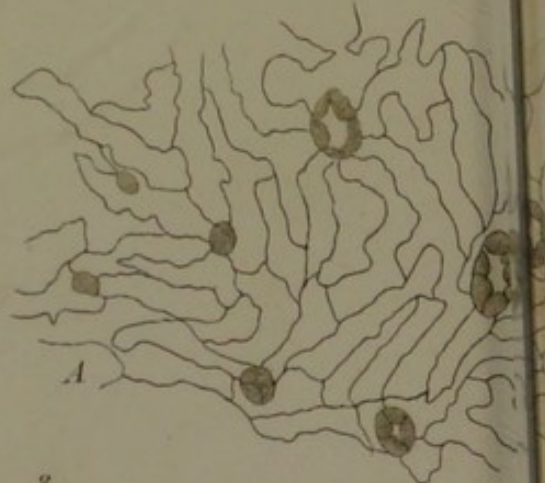
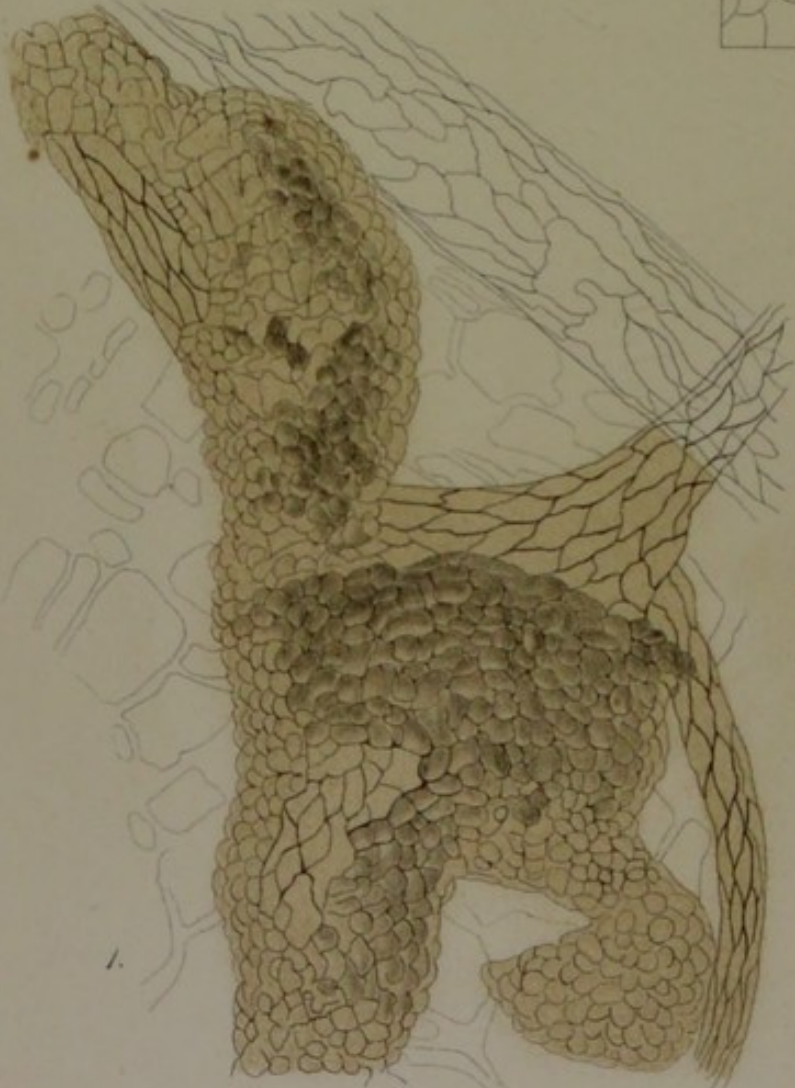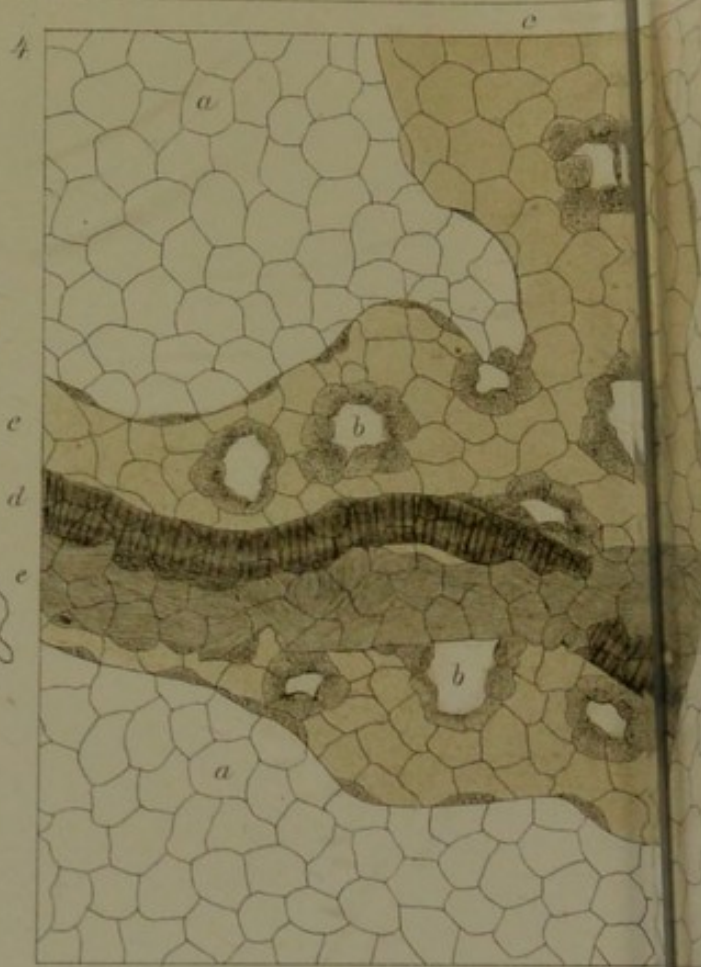
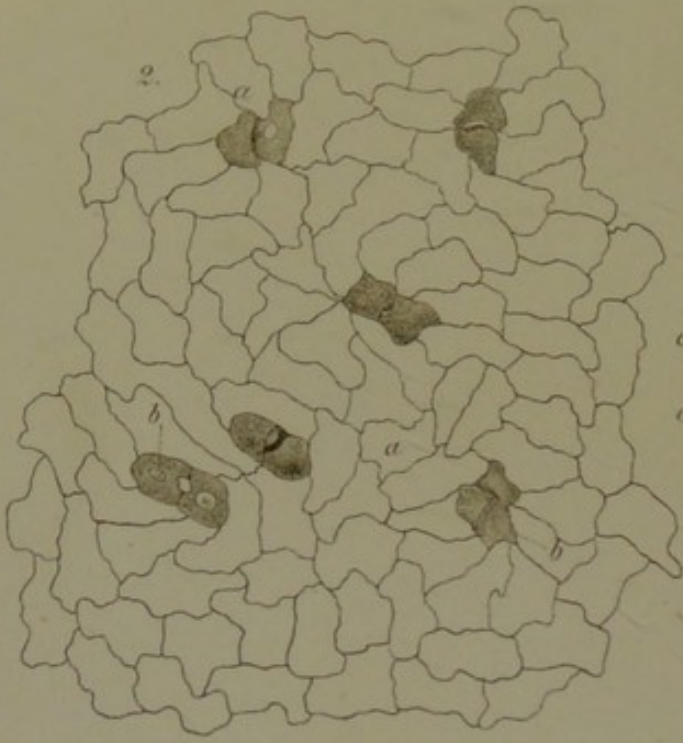
also lined with ciliæ. It is very probable that such a ciliated vesicle opens towards the free surface in the course of its development.


FIG. 54. From the same preparation as Fig. 53.


M. p. III. 8.

A vesicle which has already lost its ciliary lining. The protoplasmic wall of the vesicle grows towards the cavity in form of a protoplasmic reticulum like that in Fig. 50. In that way gradually a nodule may result which possesses the structure of a lymph-follicle—endo-lymphangial nodule.





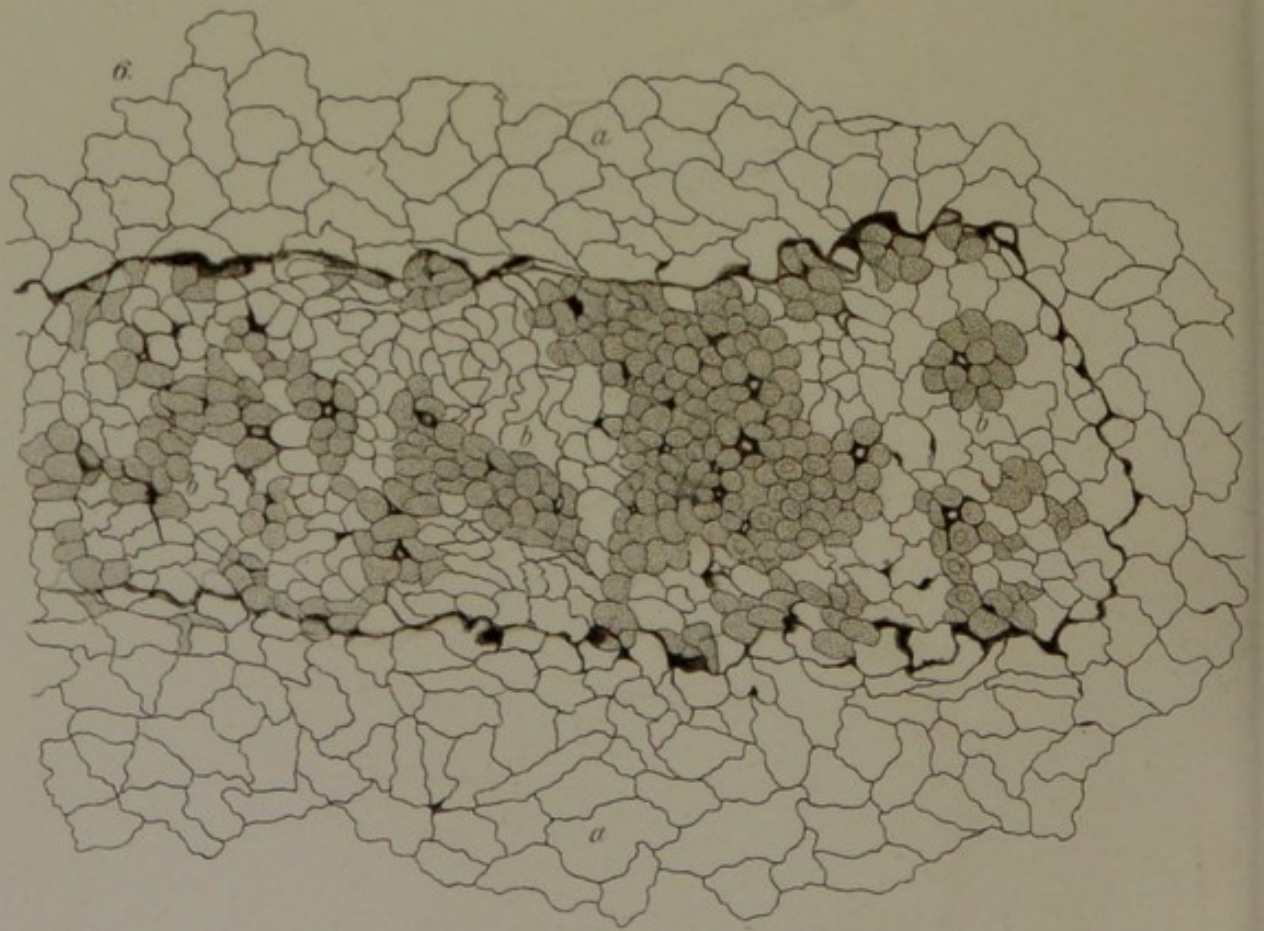
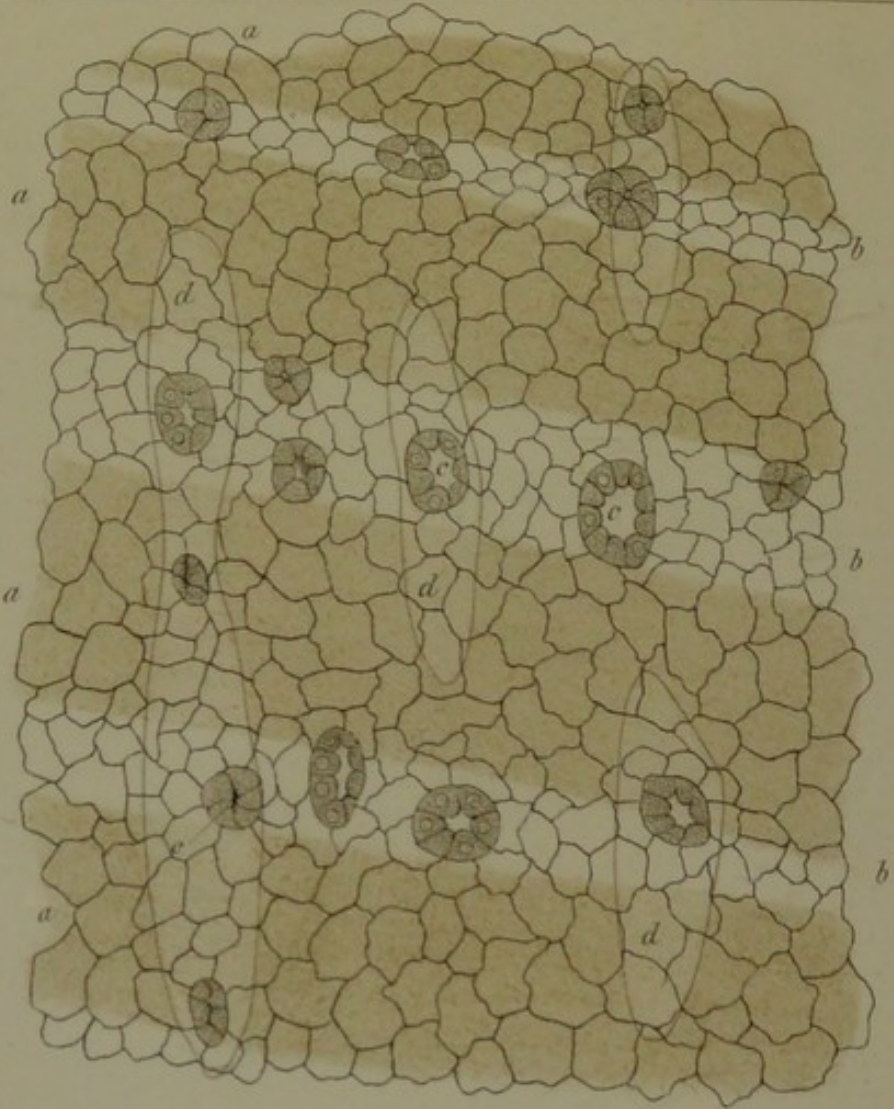




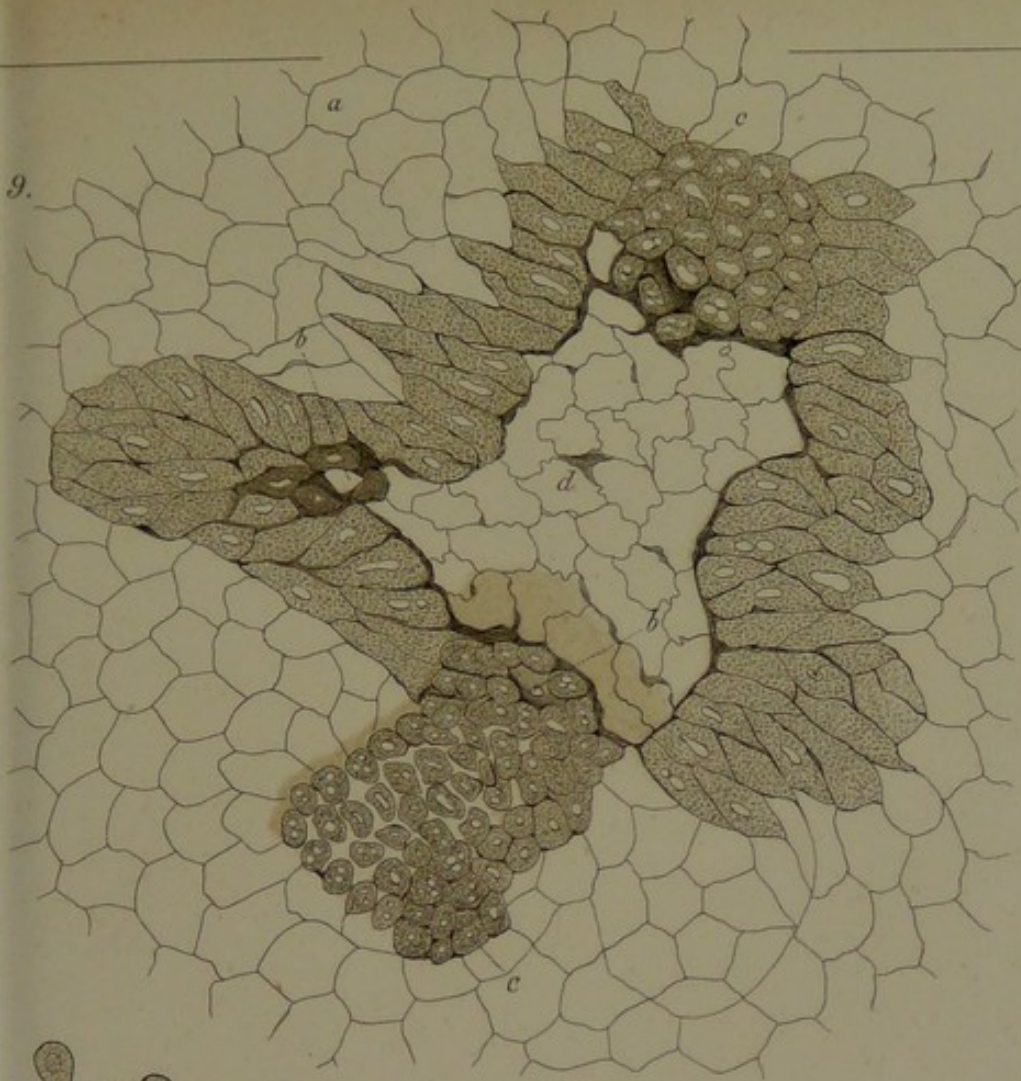




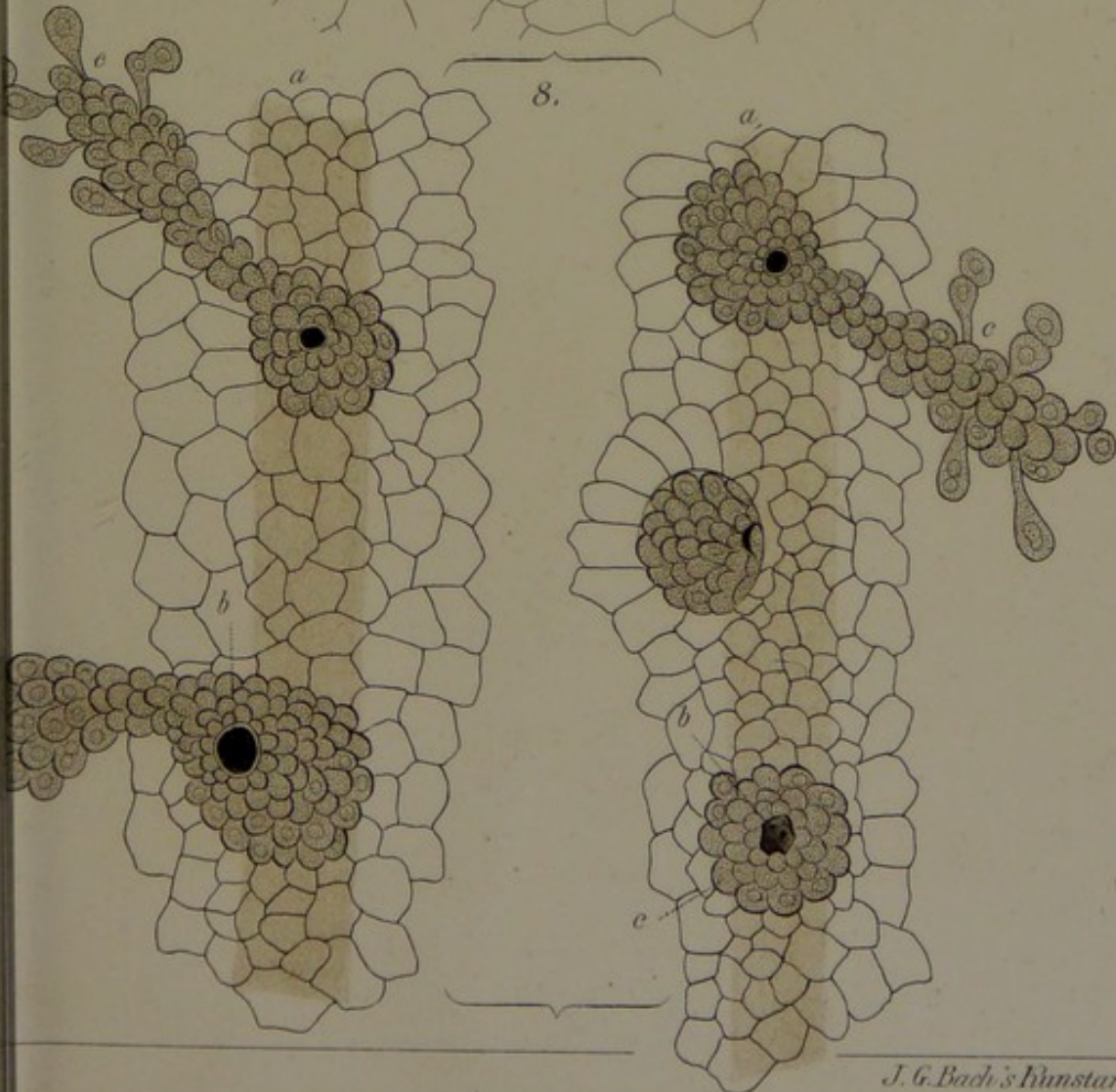
7.




9.



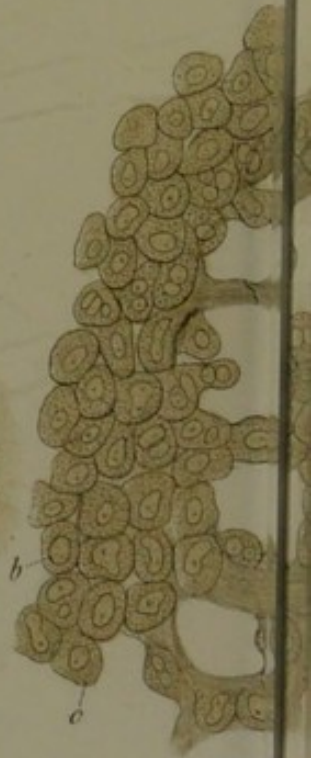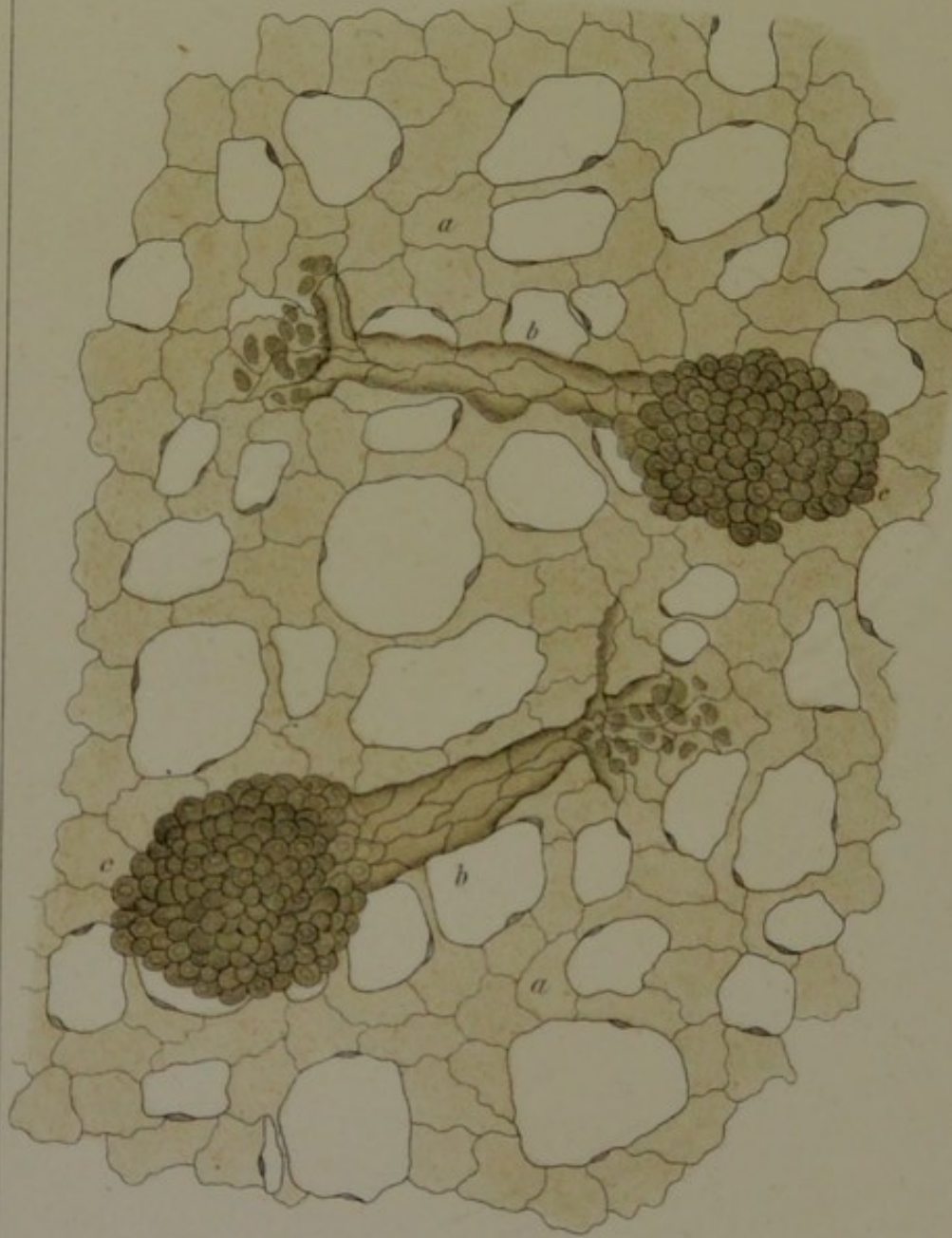
8.



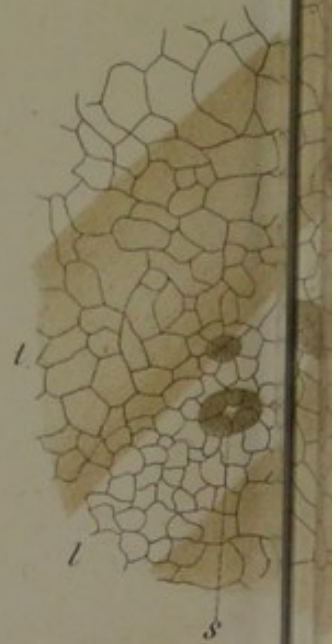



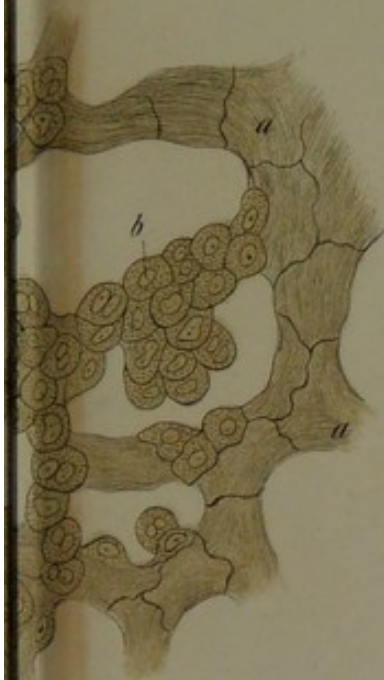10.



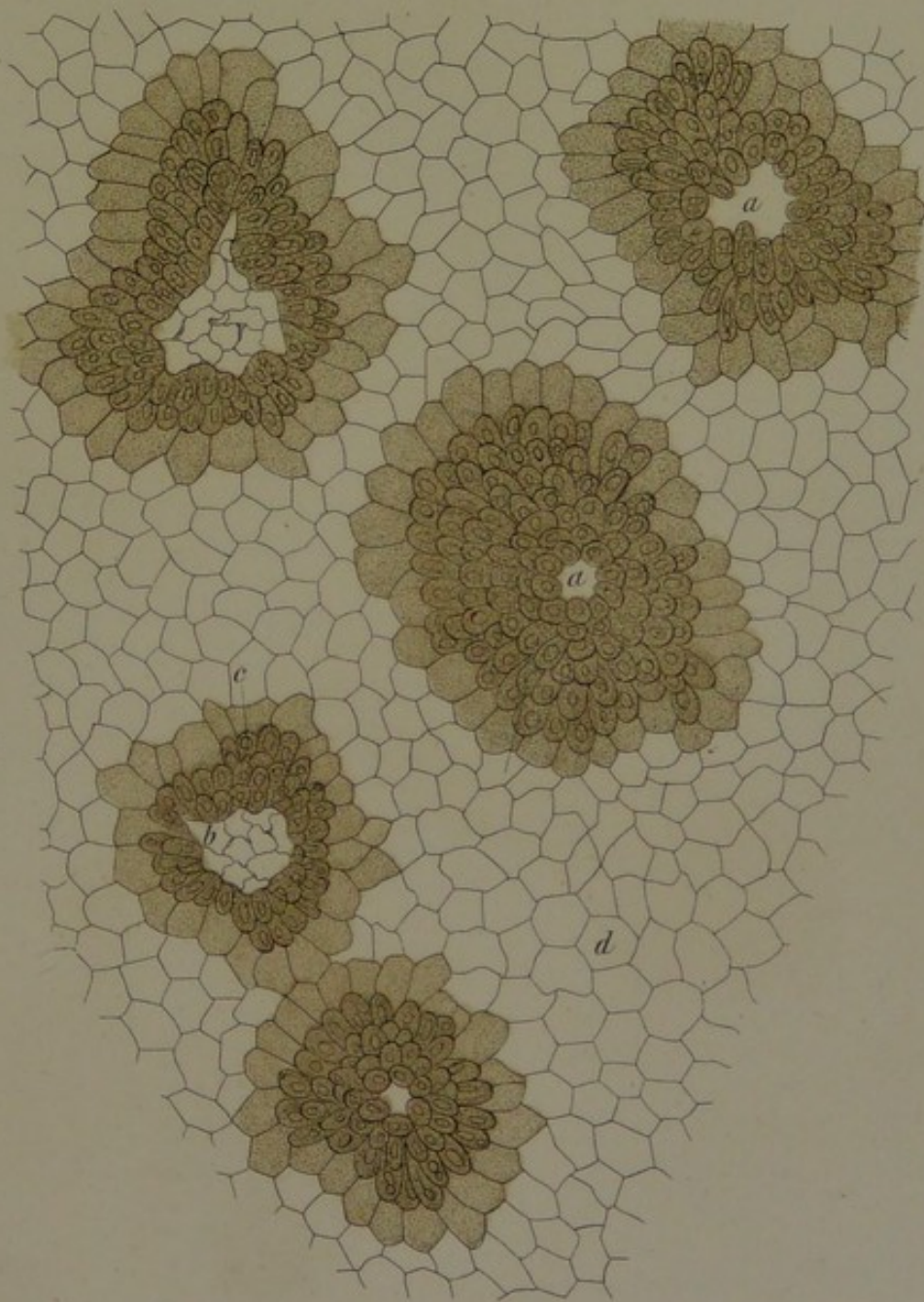
11.

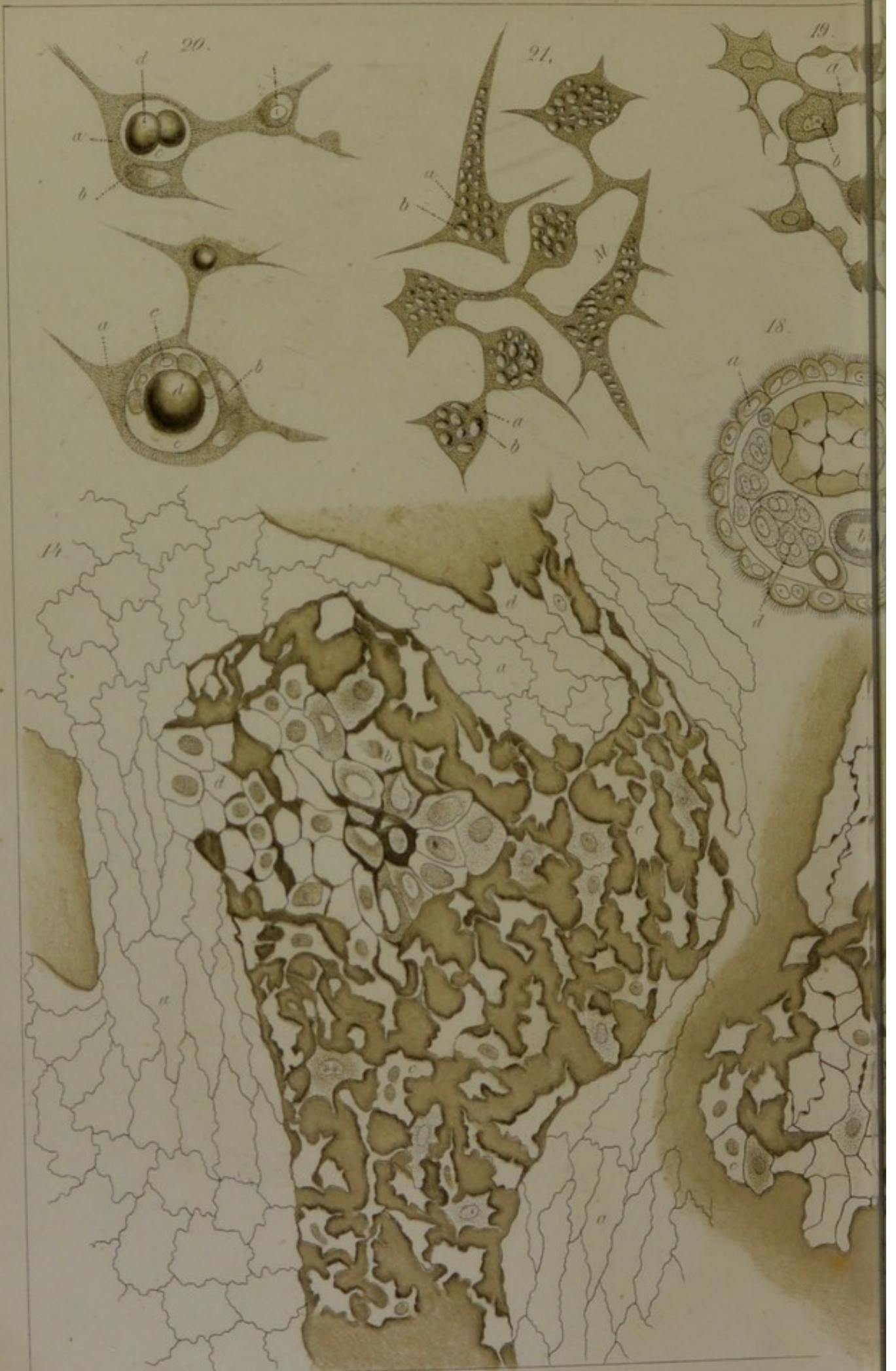

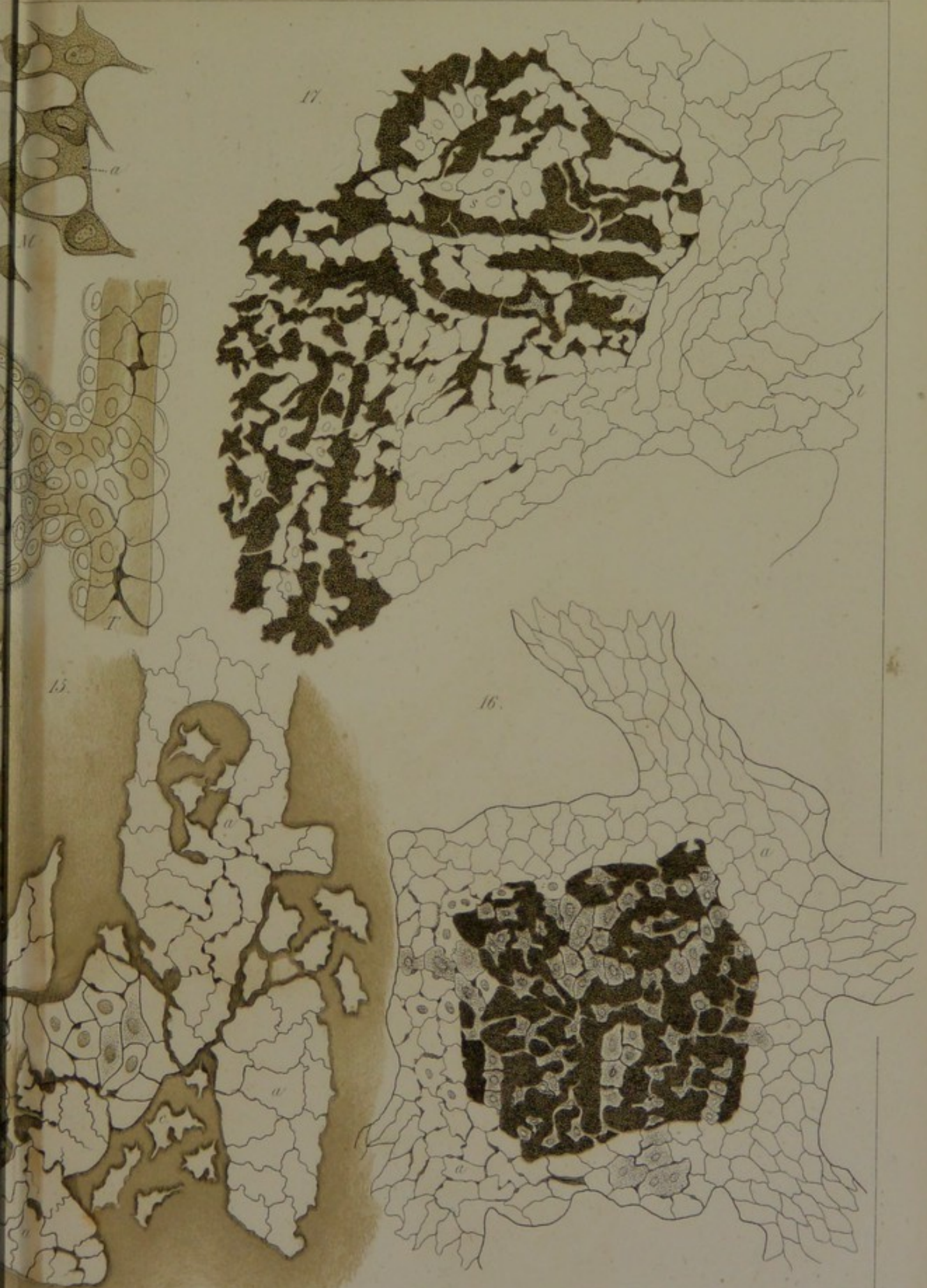13.




12.



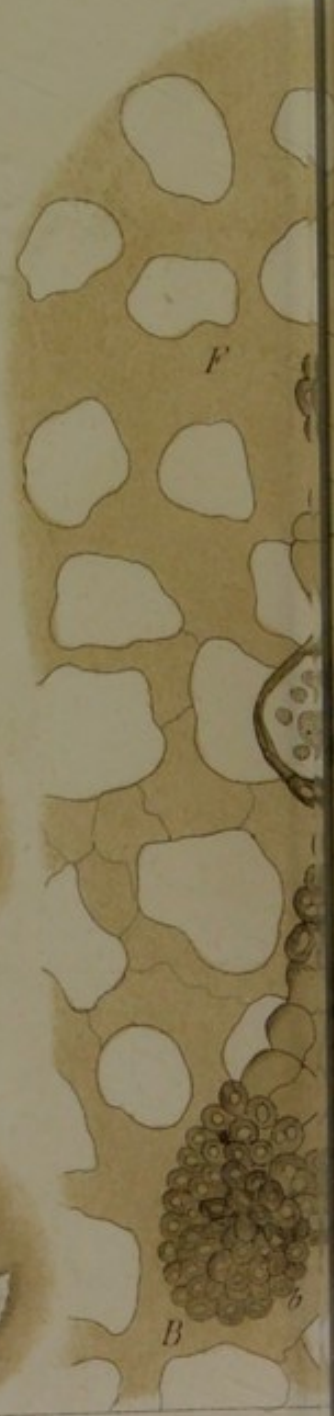
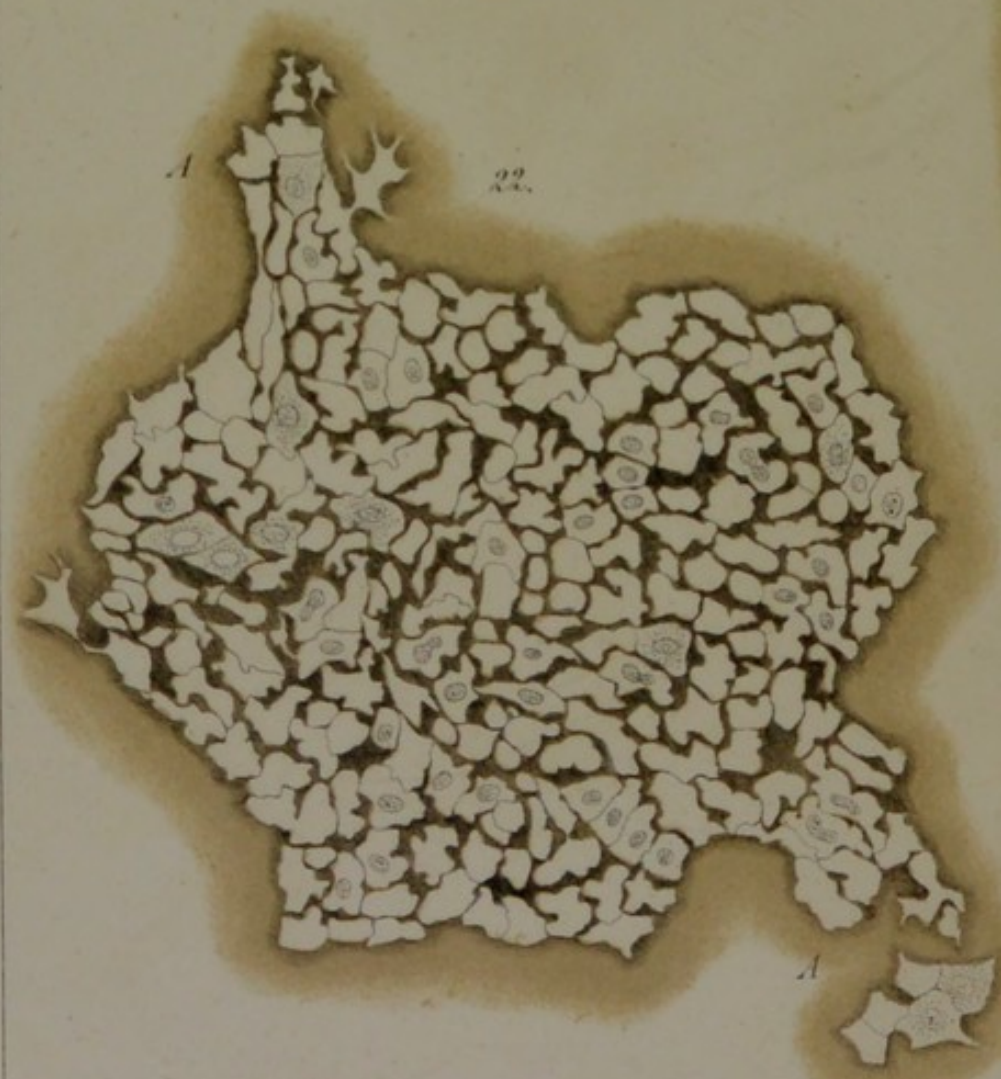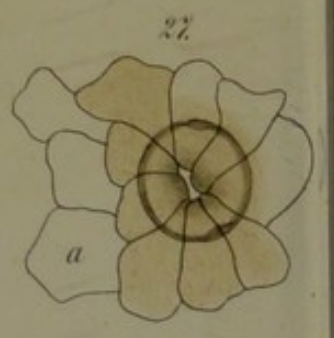

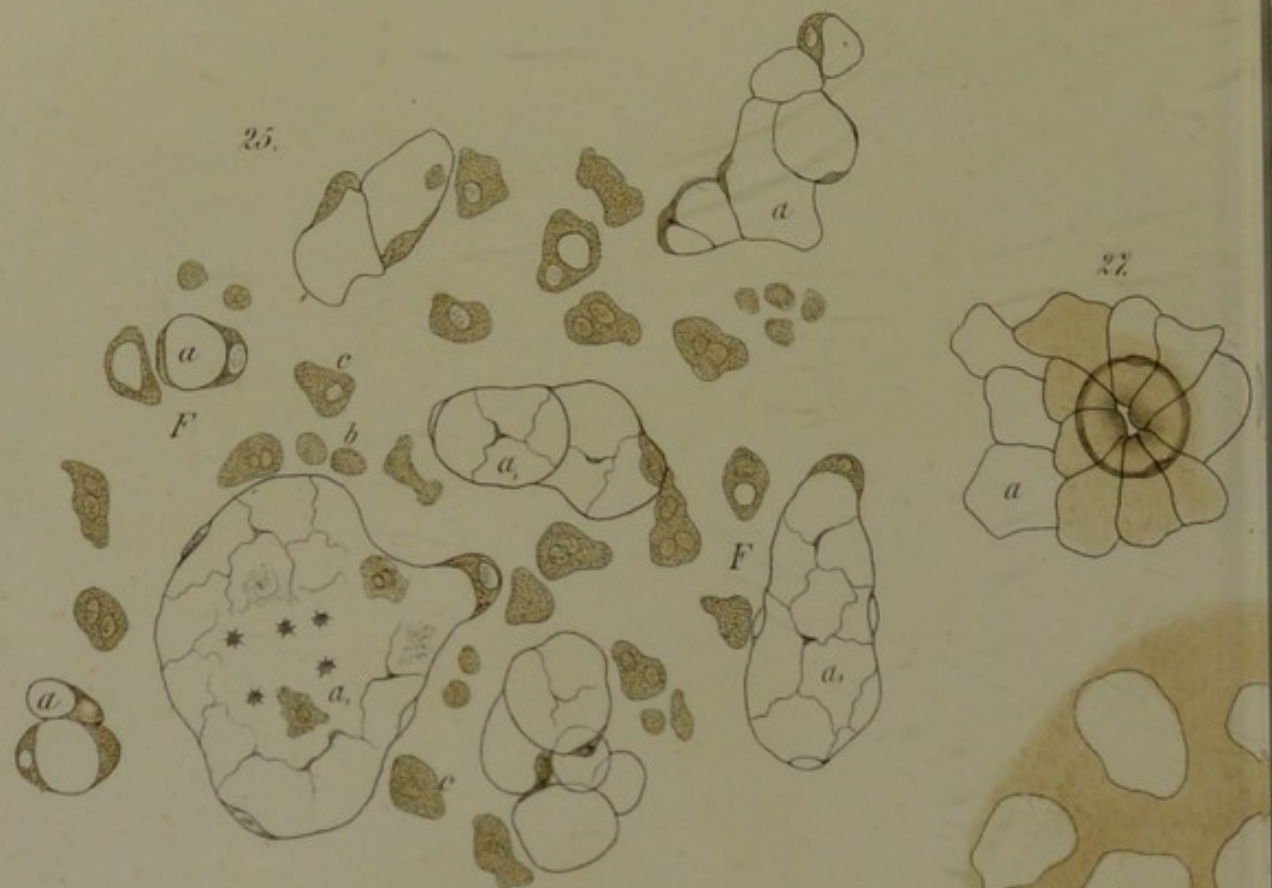
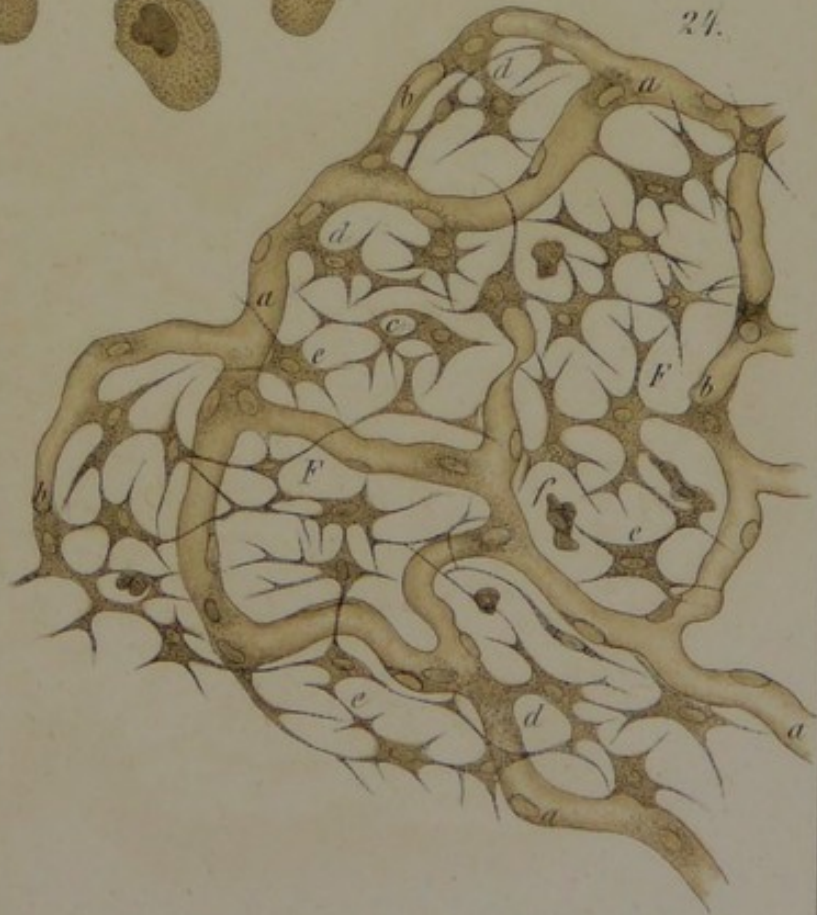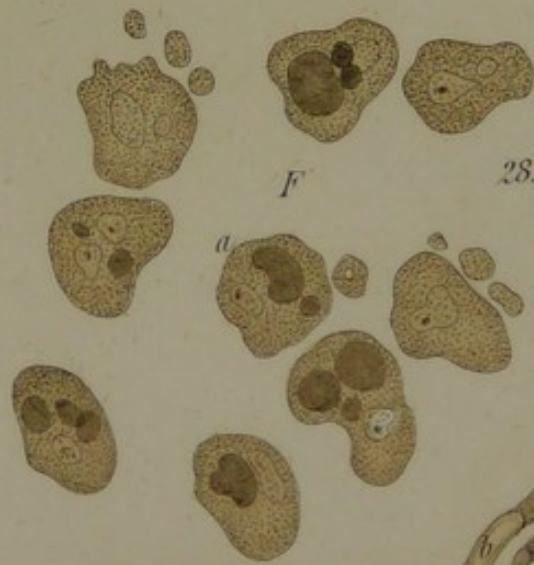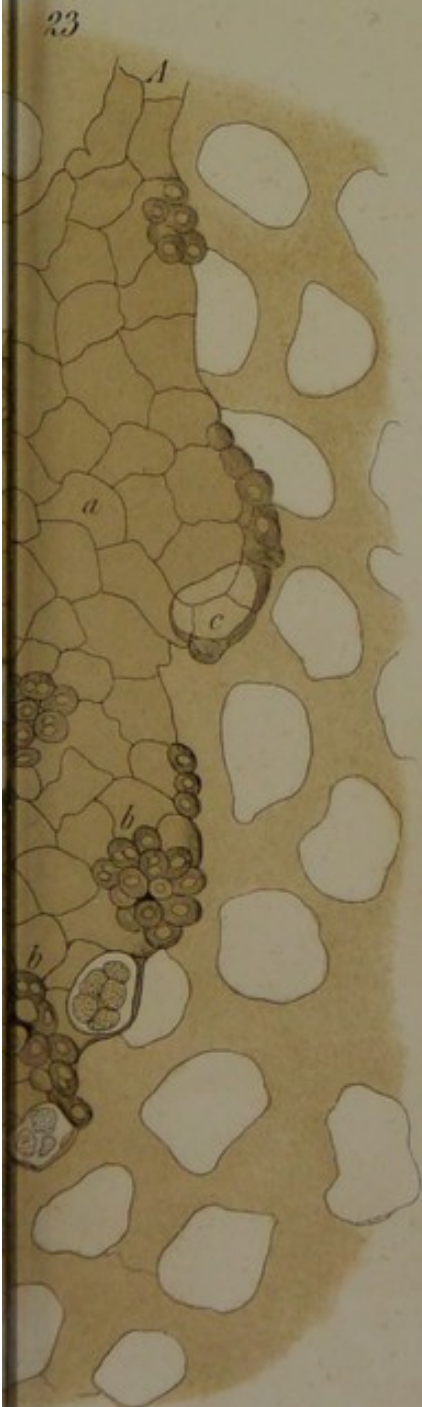




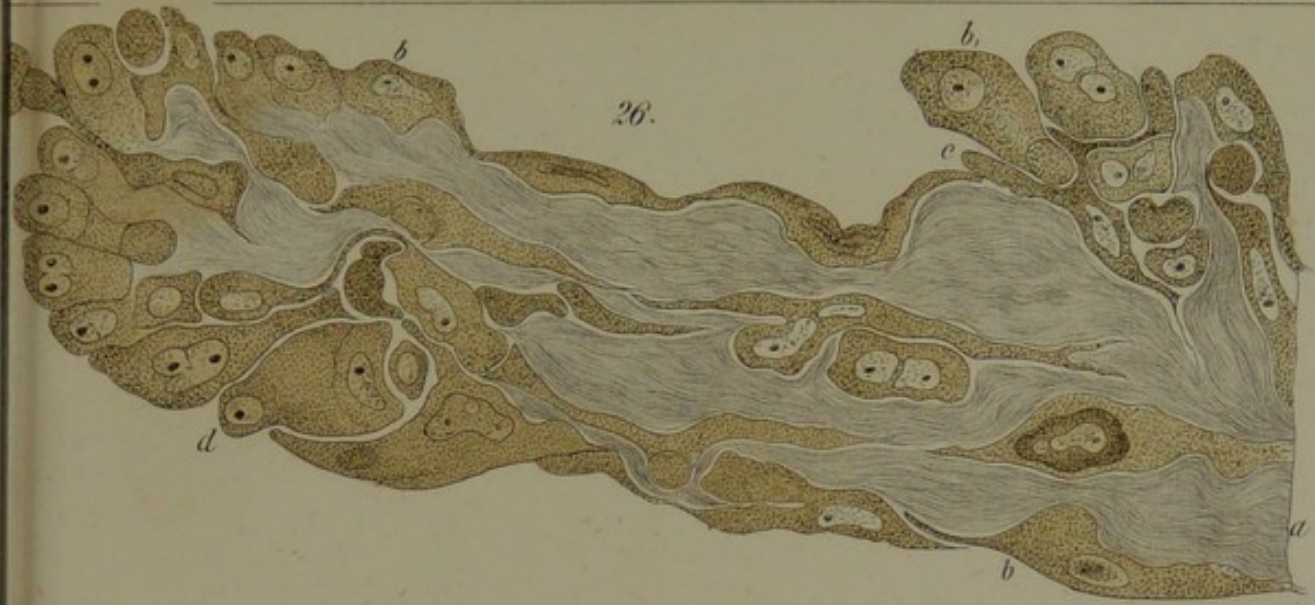



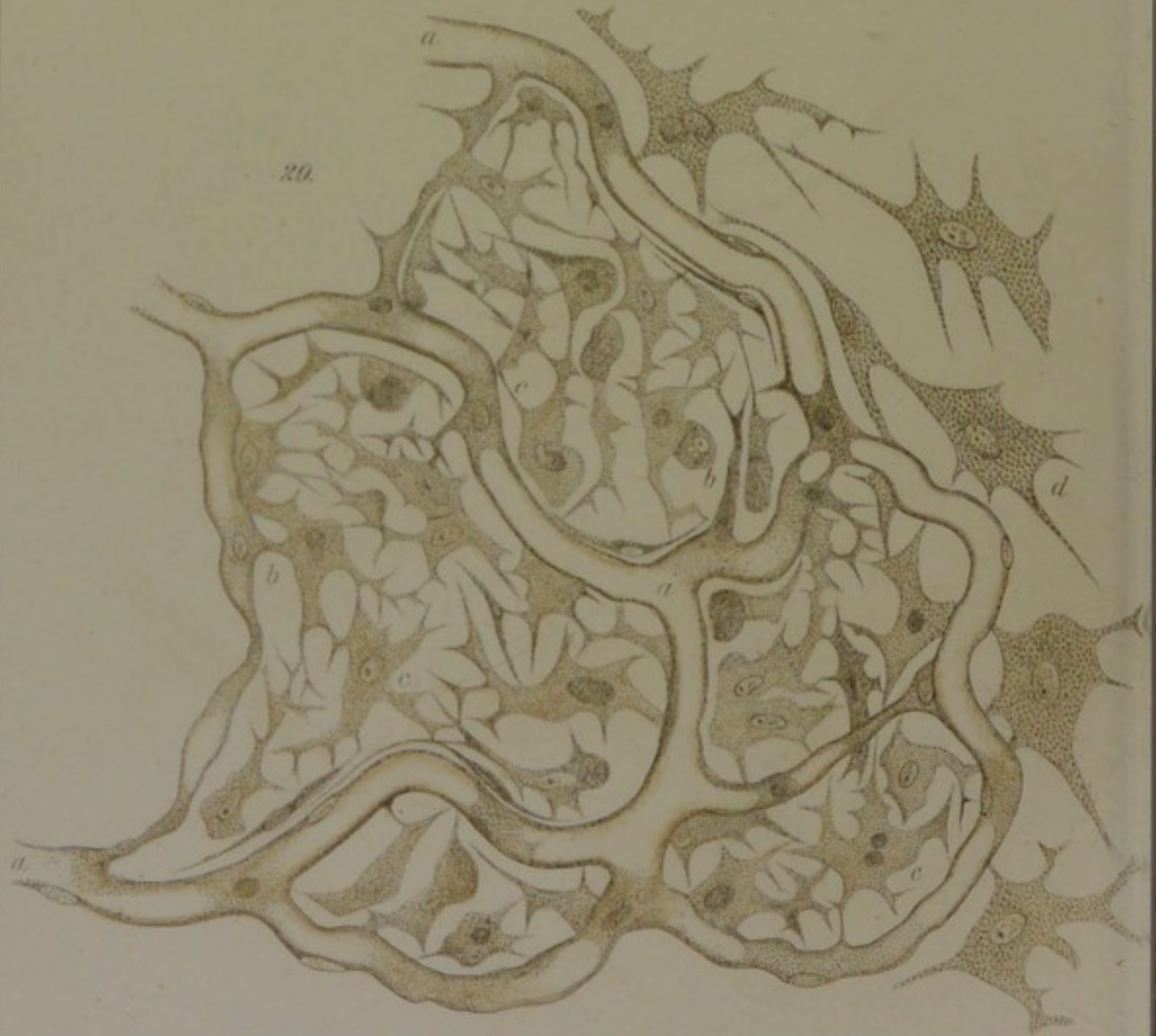
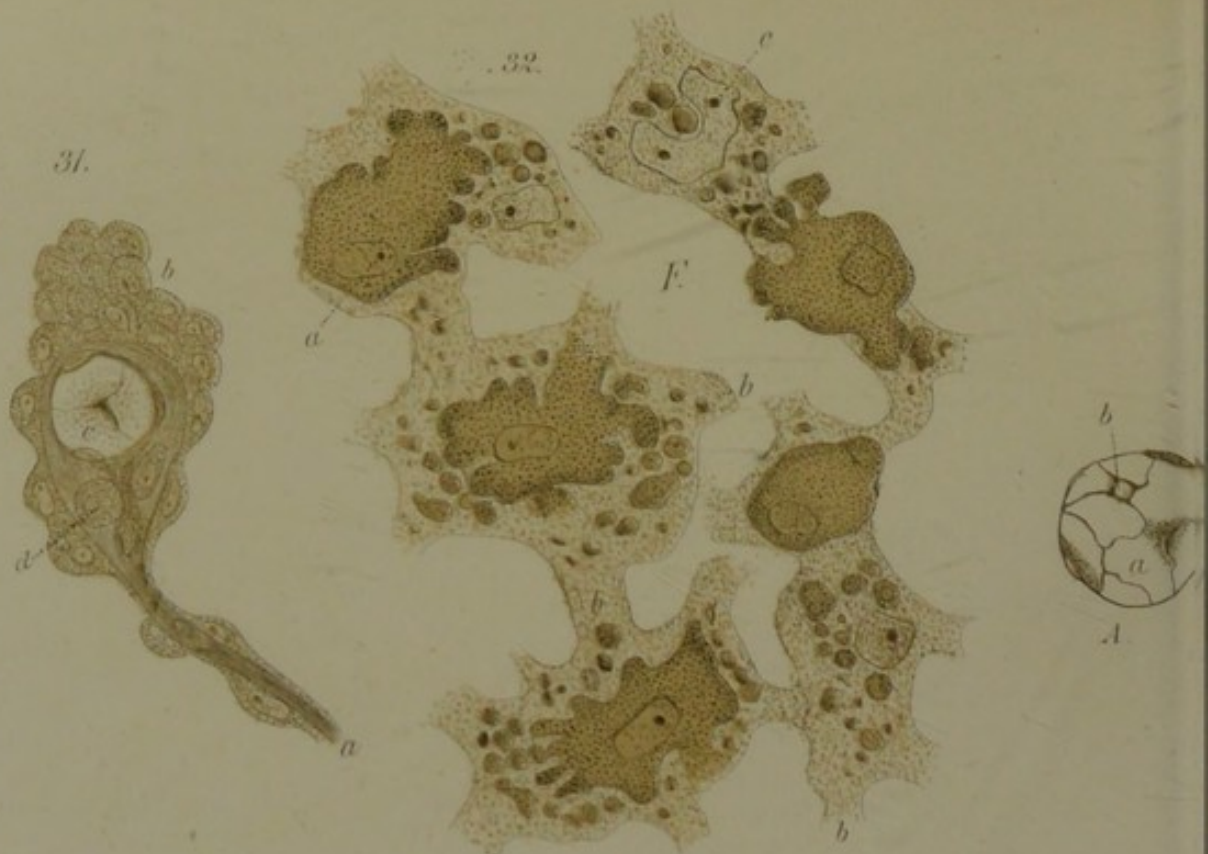




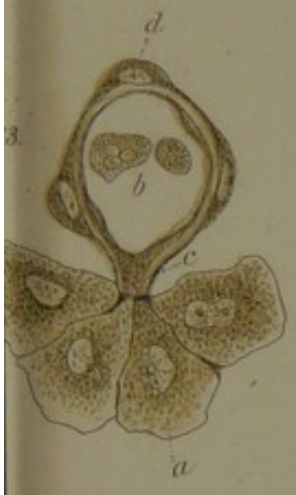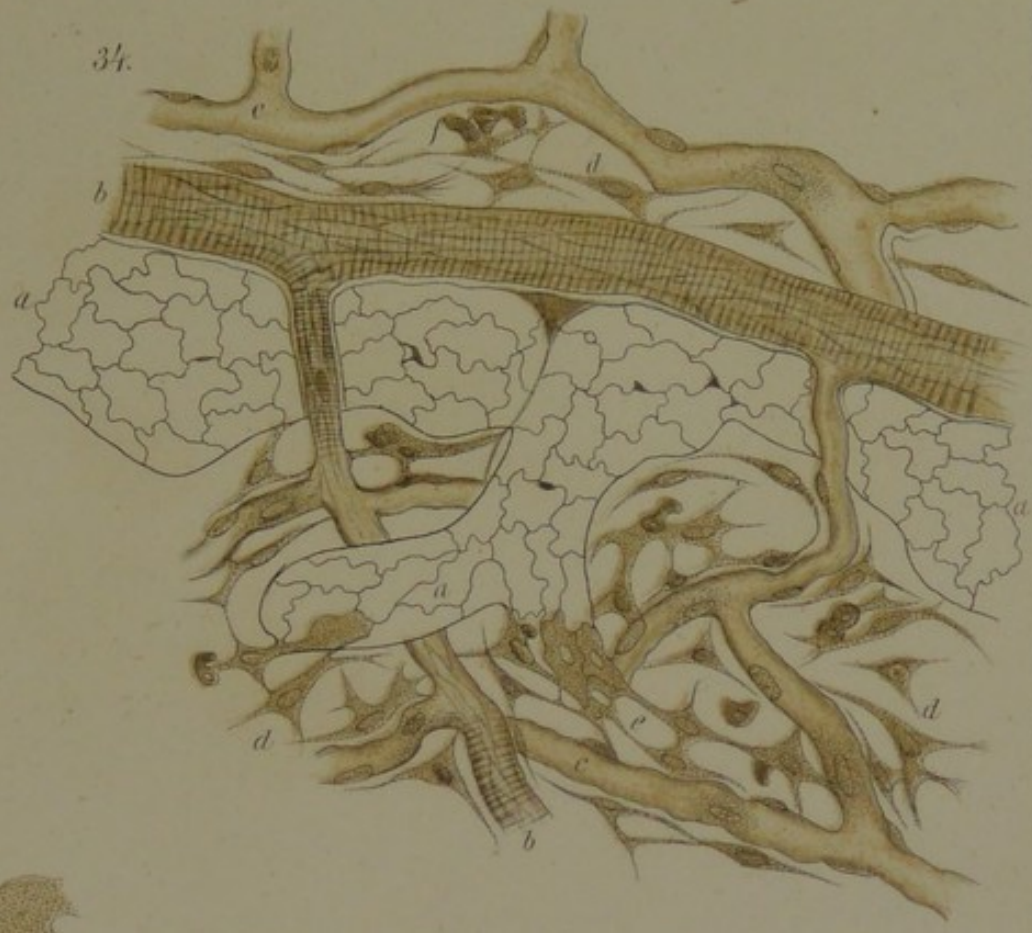








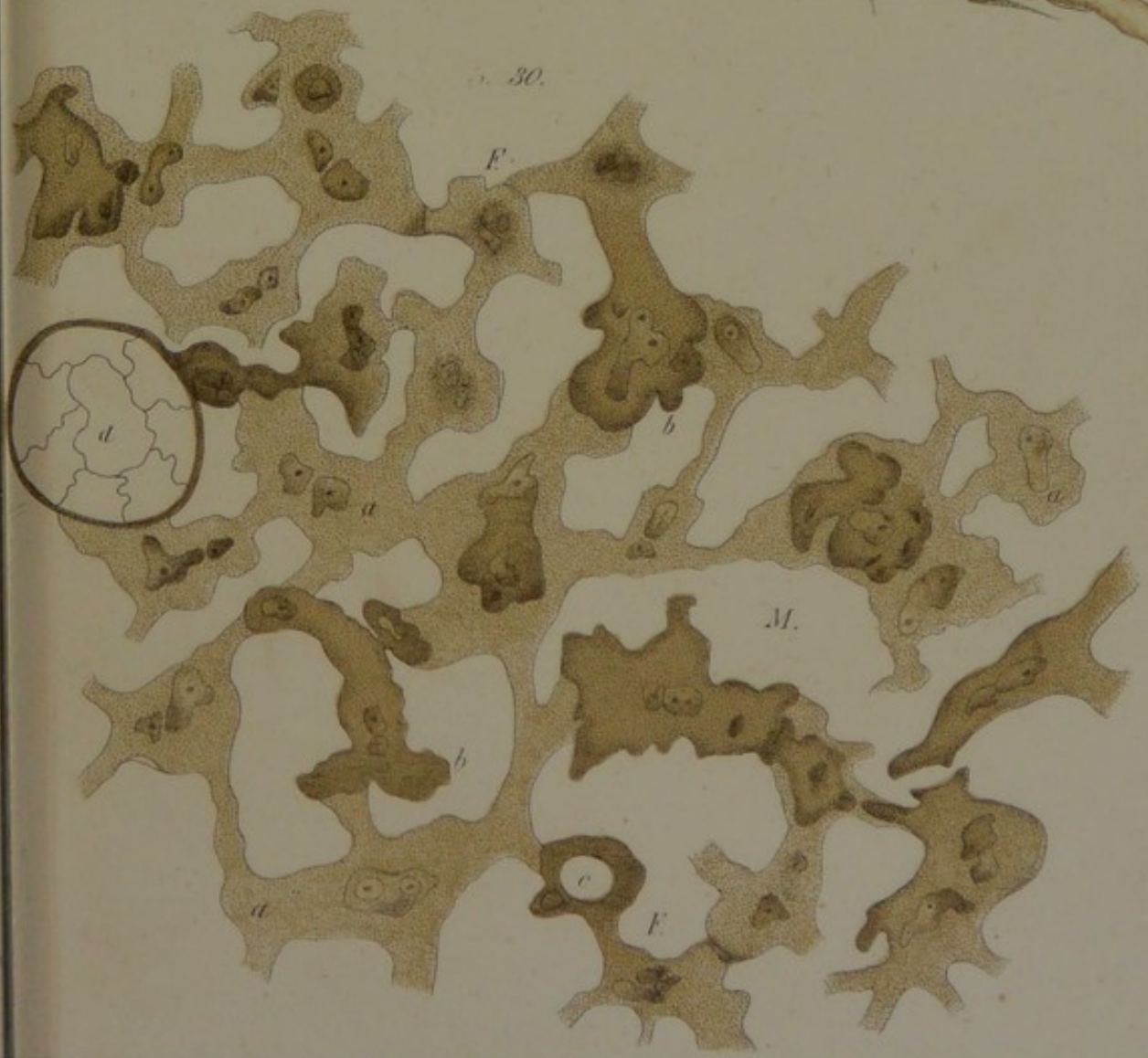
34.




30.





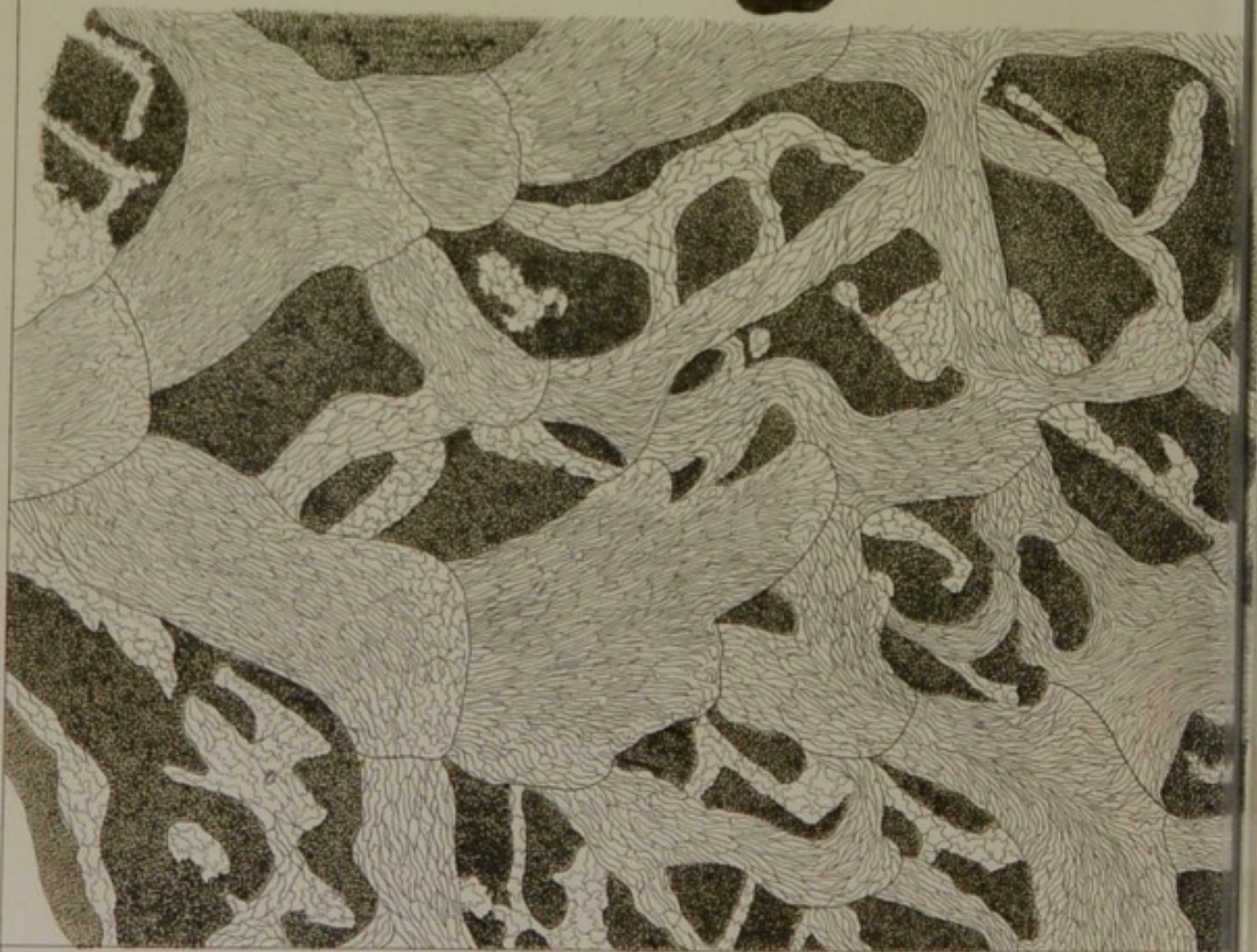




37.

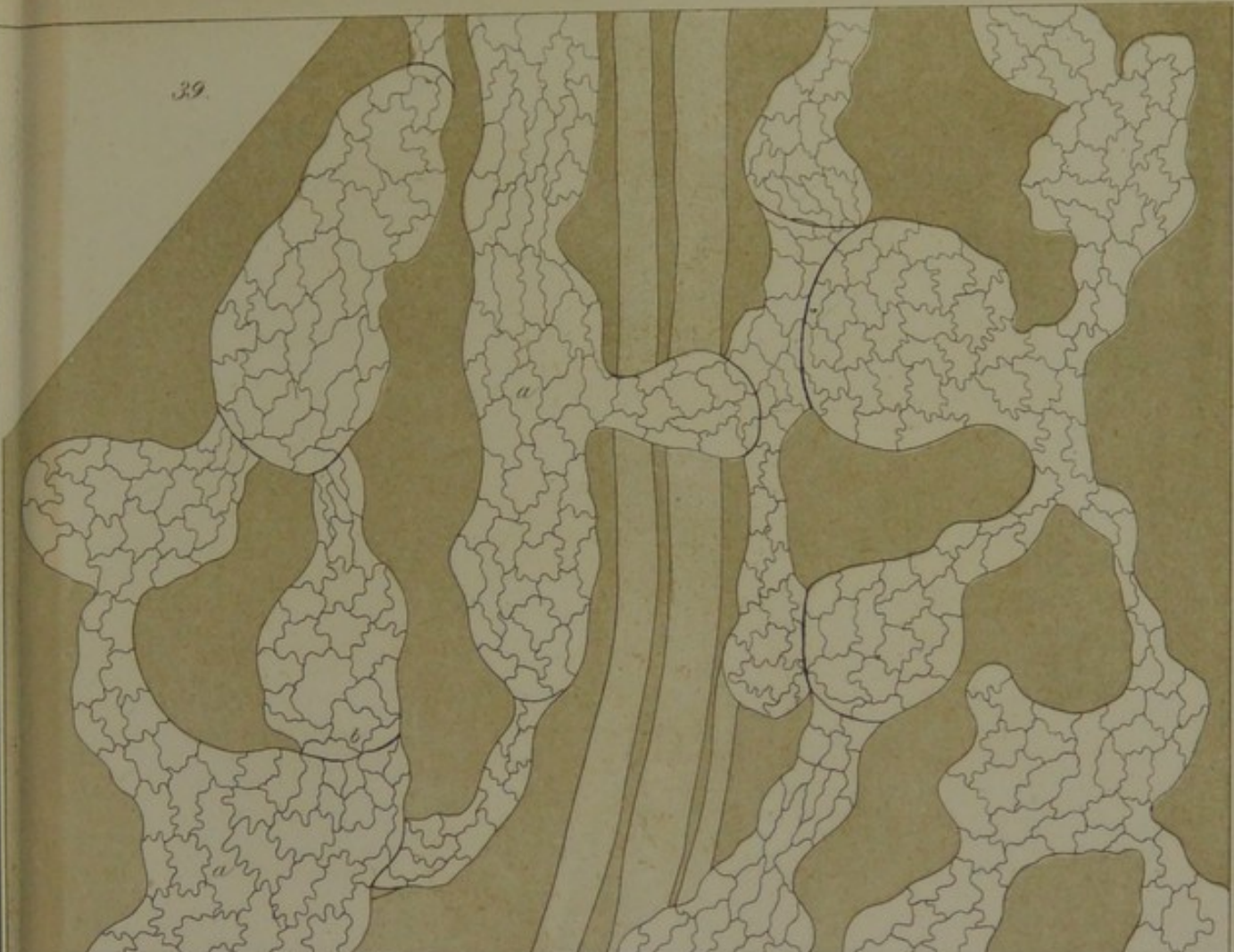


35.

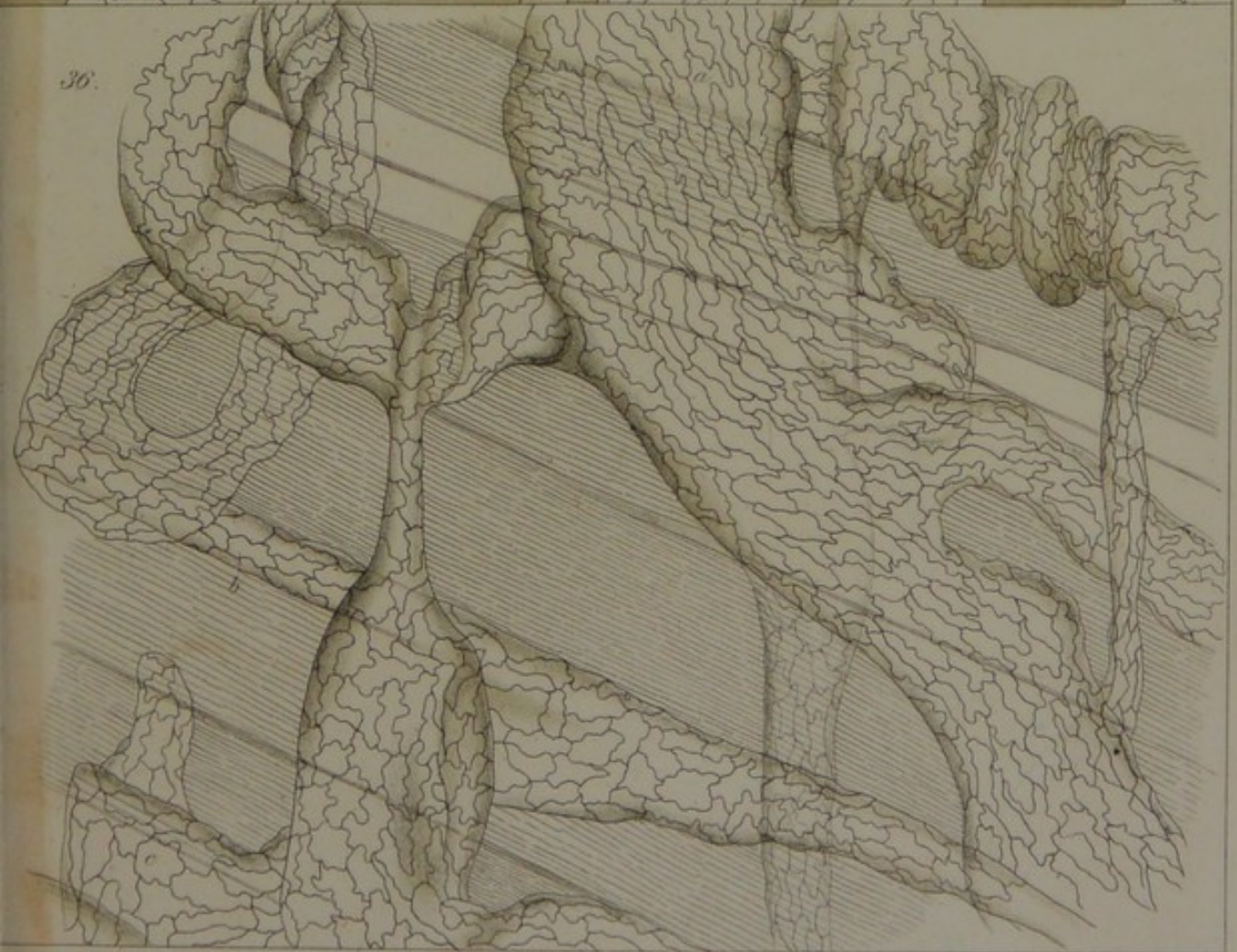


*E. Klein del.*


39.

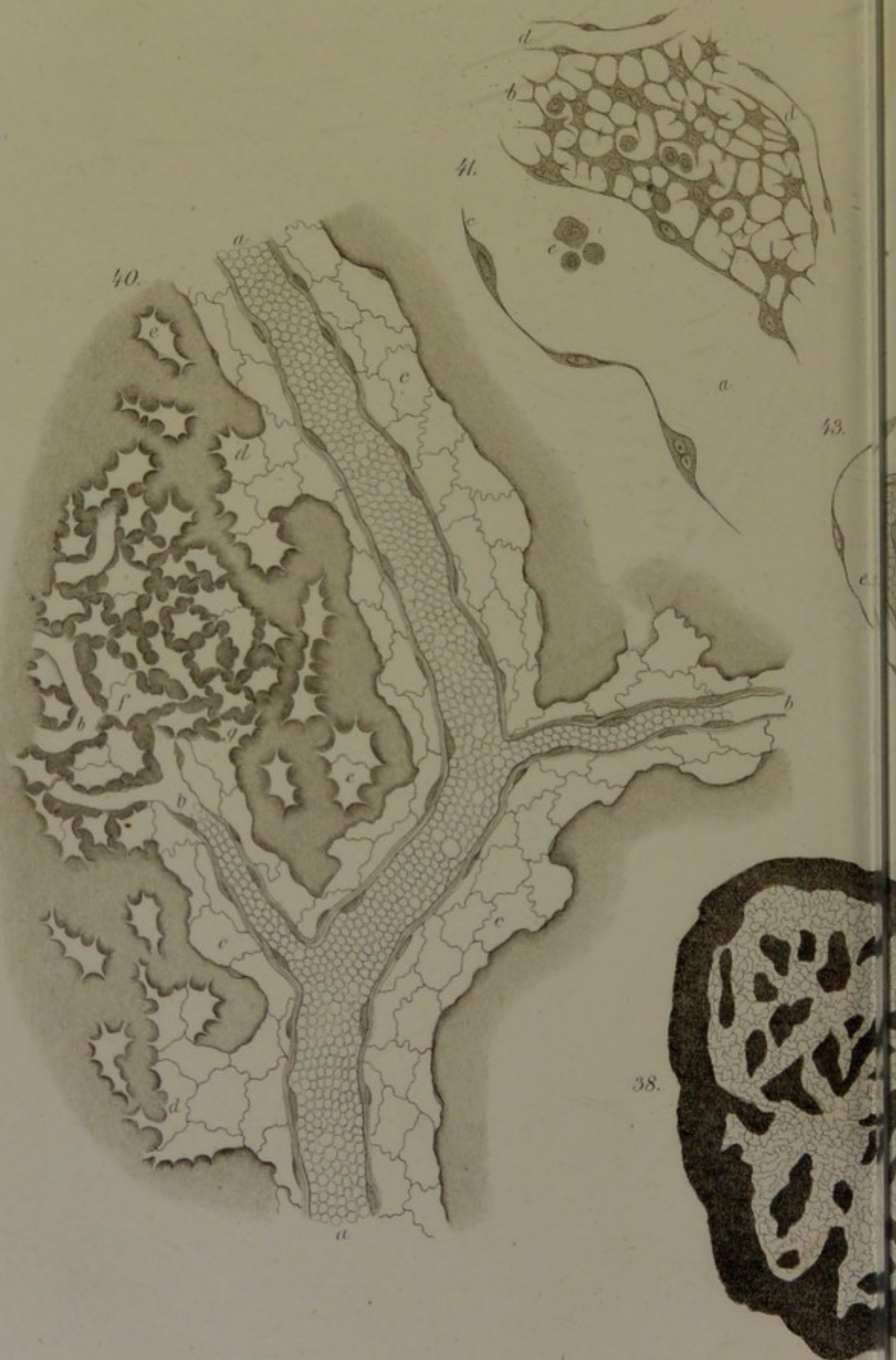

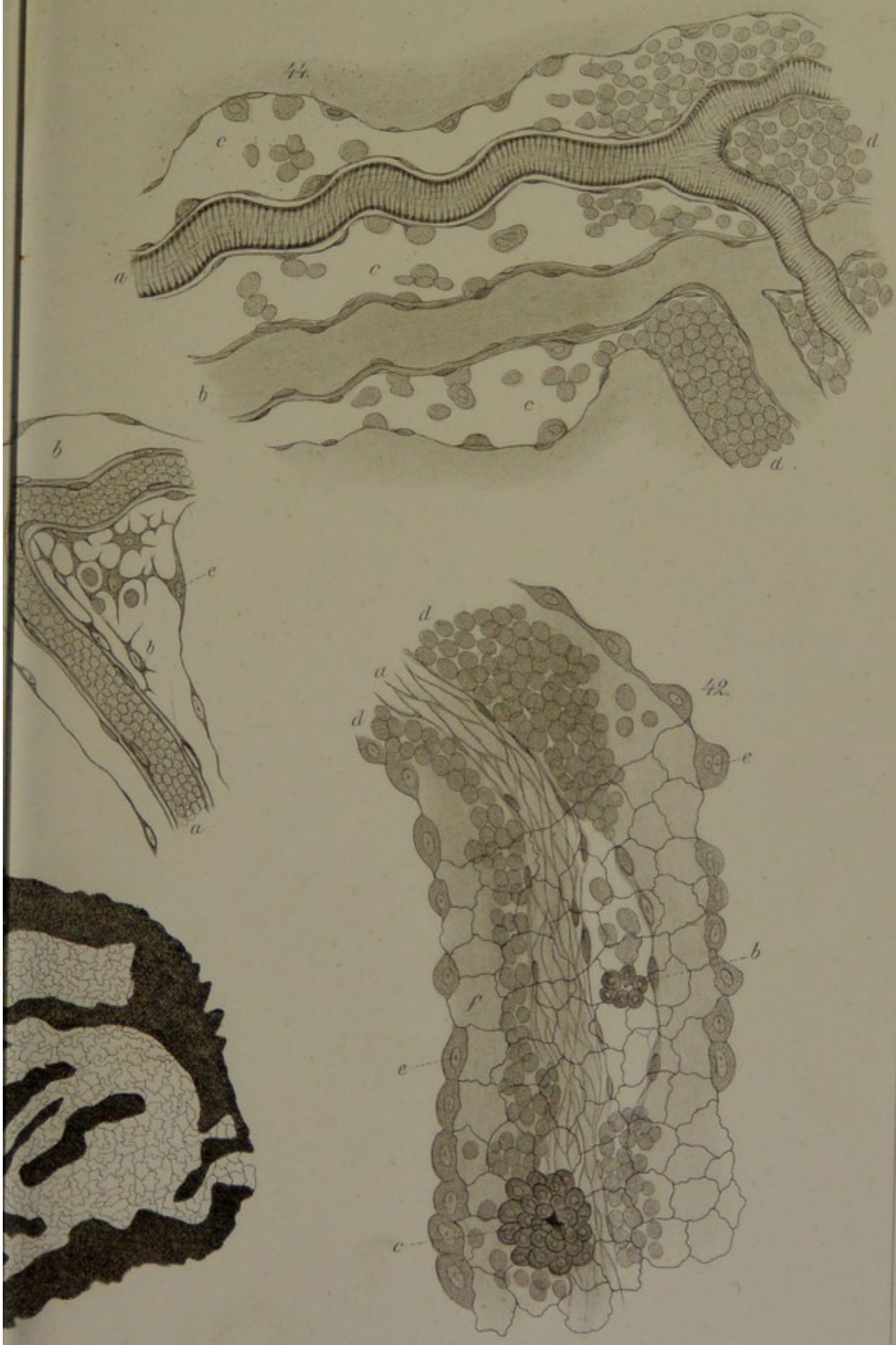30.










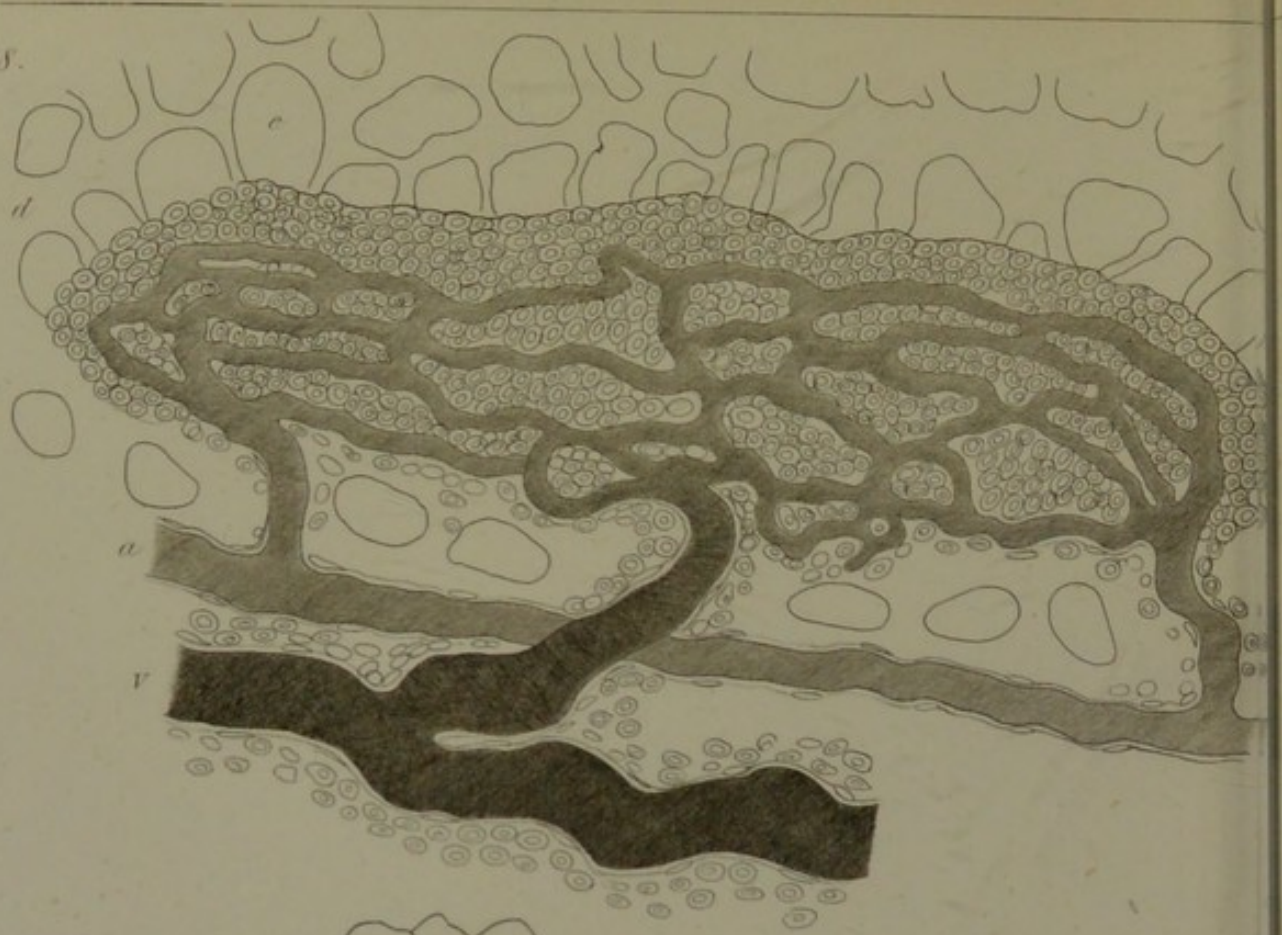




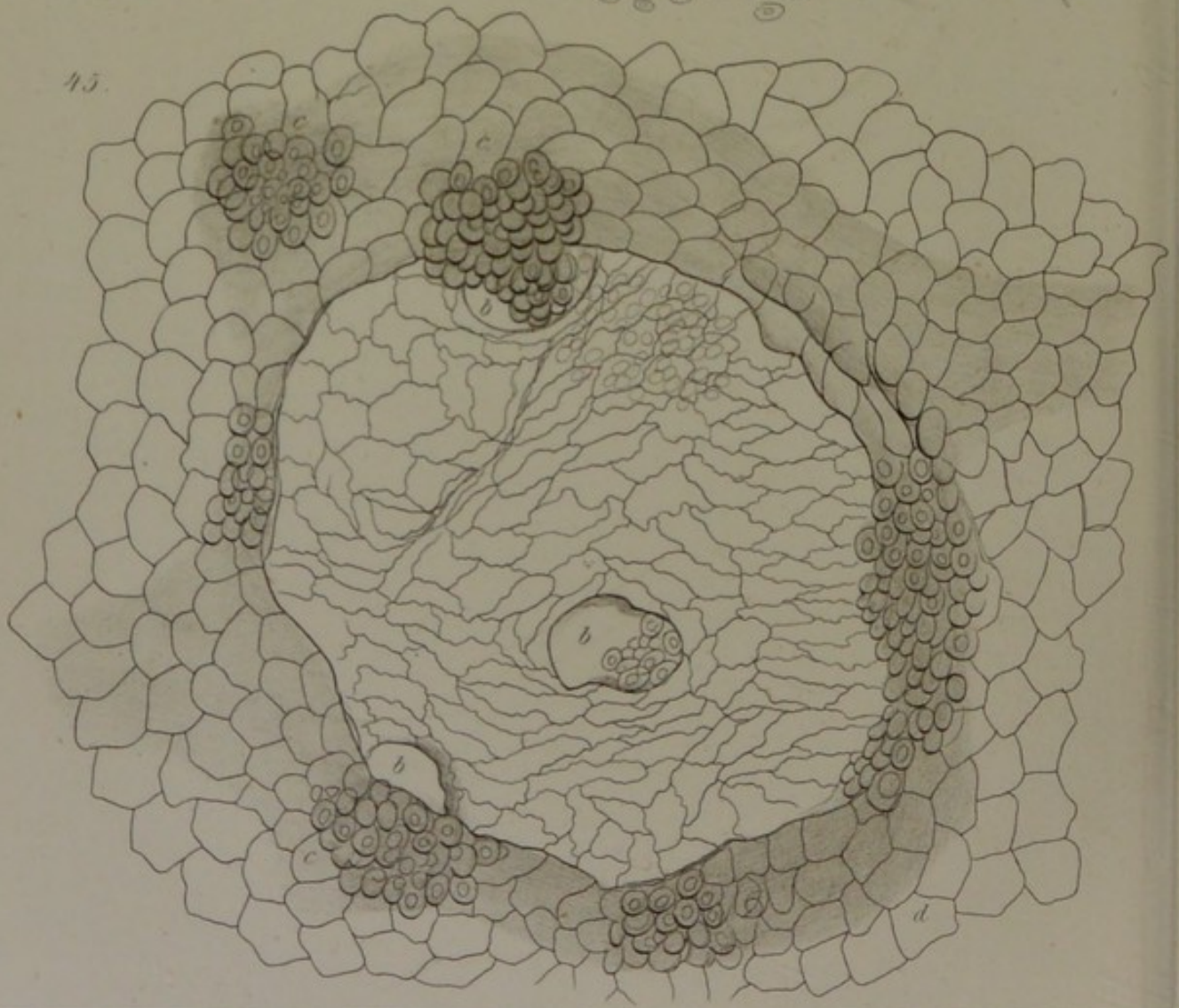




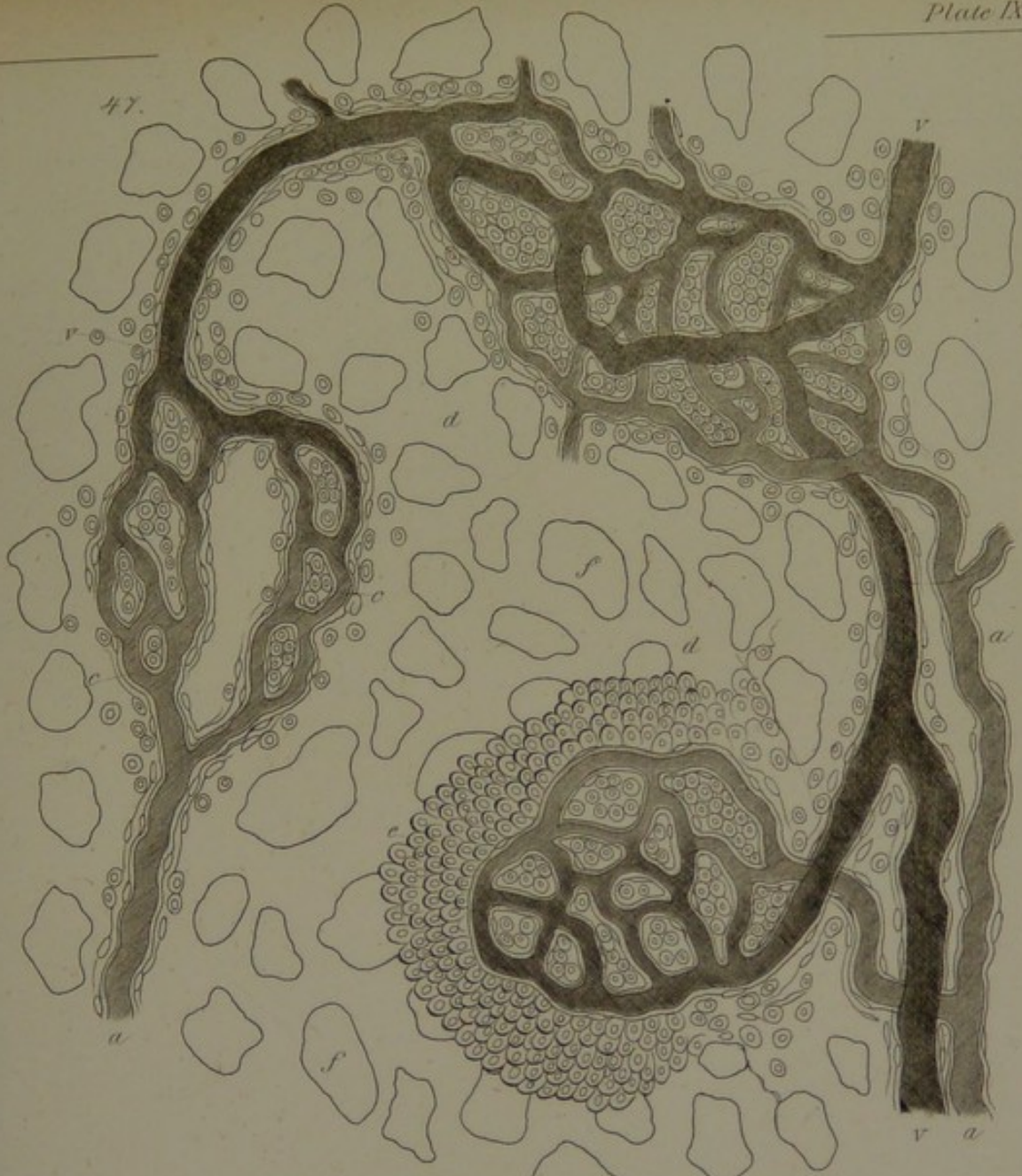
48.



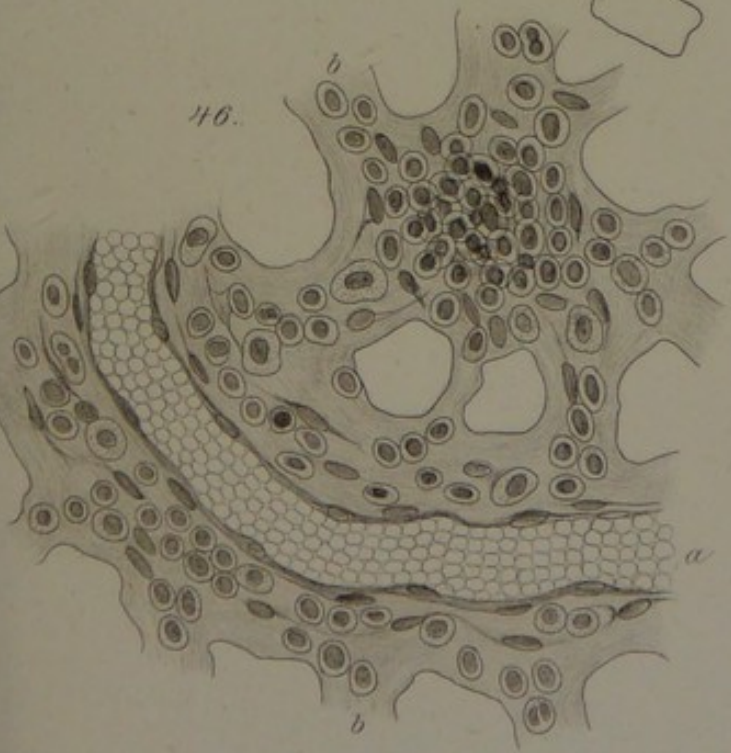
45.




47.

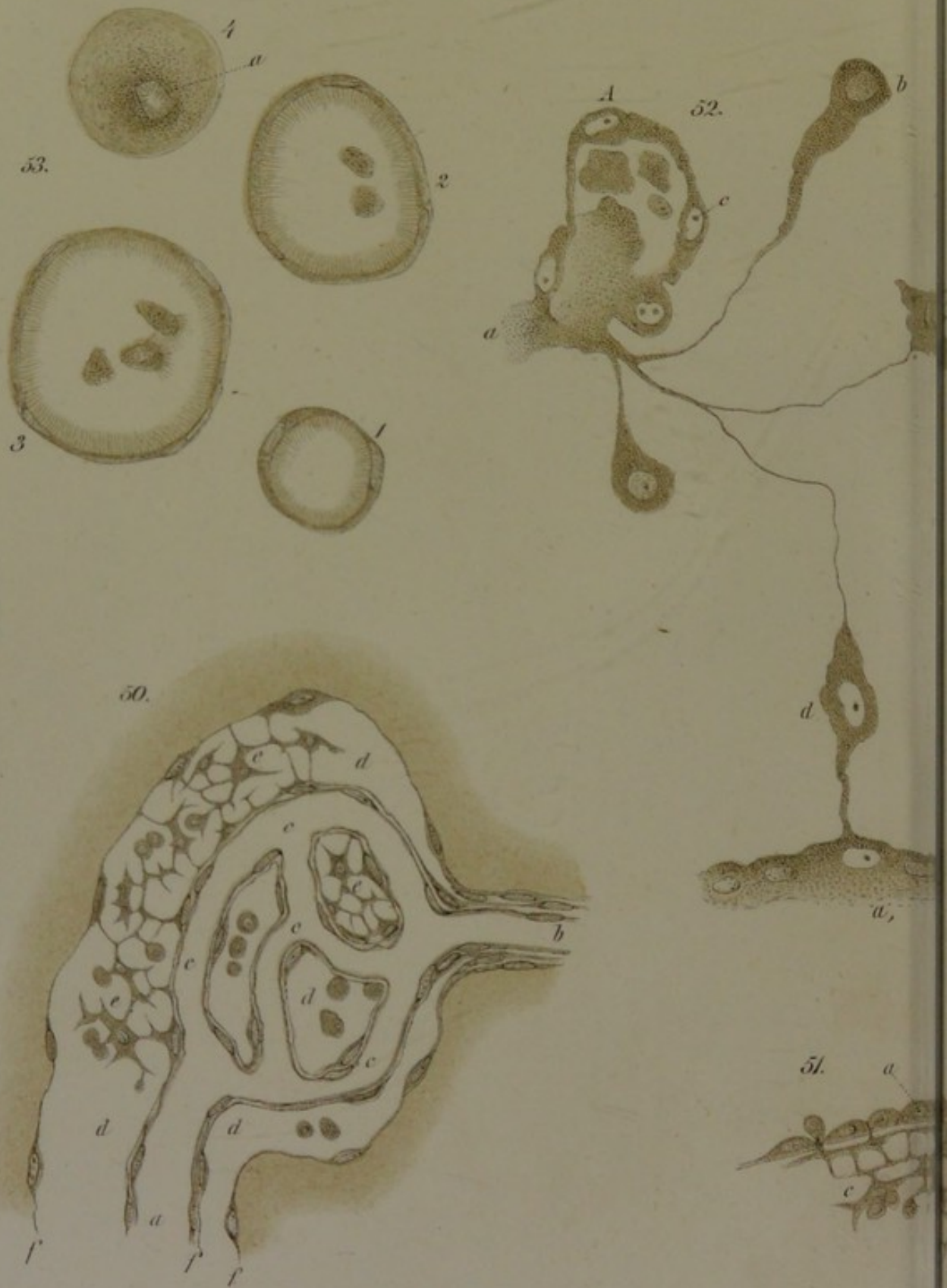


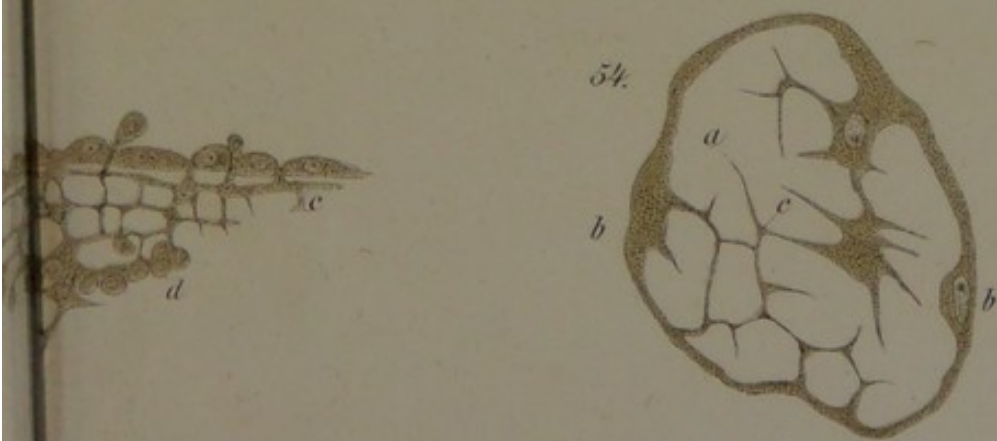
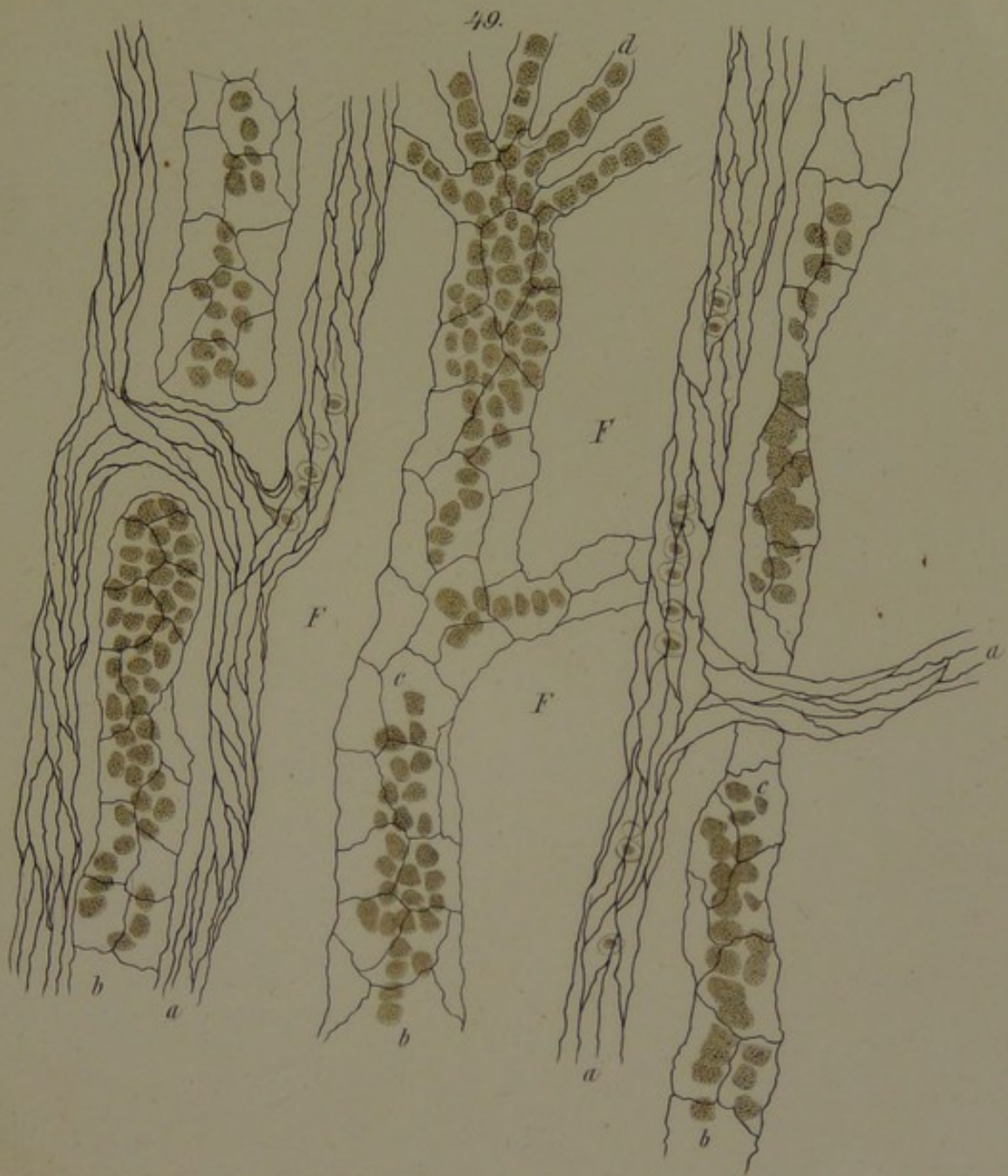46.



















M/E

