

Frozen sections of a child / by Thomas Dwight ; fifteen drawings from nature, by H.P. Quincy.

Contributors

Dwight, Thomas, 1843-1911.
Quincy, Henry Parker, -1899.
Thane, George Dancer, 1850-1930
University College, London. Library Services

Publication/Creation

New York : W. Wood, 1881.

Persistent URL

<https://wellcomecollection.org/works/pqnpf9yy>

Provider

University College London

License and attribution

This material has been provided by This material has been provided by UCL Library Services. The original may be consulted at UCL (University College London) where the originals may be consulted.

This work has been identified as being free of known restrictions under copyright law, including all related and neighbouring rights and is being made available under the Creative Commons, Public Domain Mark.

You can copy, modify, distribute and perform the work, even for commercial purposes, without asking permission.



Wellcome Collection
183 Euston Road
London NW1 2BE UK
T +44 (0)20 7611 8722
E library@wellcomecollection.org
<https://wellcomecollection.org>

FROZEN SECTIONS

OF A

CHILD

DWIGHT



The
child
first
and
always

The Friends of the Children
of Great Ormond Street

LIBRARY

1535629

Institute of Child Health

University College London
30 Guilford Street
London WC1N 1EH

CAMBRIDGE PHILOSOPHICAL

LIBRARY.

Presented by Prof. Humphrey



2809606491





Digitized by the Internet Archive
in 2014



D. 2. 7.
*Philosophy: Librarian
for Smith*

FROZEN SECTIONS

OF A

CHILD

BY

THOMAS DWIGHT, M.D.

Parkman Prof. of Anatomy of Harvard University
~~INSTRUCTOR IN TOPOGRAPHICAL ANATOMY AND PHYSIOLOGY IN HARVARD UNIVERSITY~~ FELLOW OF THE AMERICAN ACADEMY
OF ARTS AND SCIENCES; SURGEON AT THE CARNEY HOSPITAL

FIFTEEN DRAWINGS FROM NATURE

BY

H. P. QUINCY, M.D.

NEW YORK
WILLIAM WOOD & COMPANY

1881

COPYRIGHT
WILLIAM WOOD & COMPANY

1881

TROW'S
PRINTING AND BOOKBINDING COMPANY
201-213 *East 12th Street*
NEW YORK

PREFACE.

THE sections that form the basis of this little work were made, with many others, during the winter of 1880-81, to illustrate my lectures at the Harvard Medical School. The sections were so instructive, and the series so perfect, that I was very anxious to have them drawn and published. The subject was the body of a girl, said to be three years old. The length was thirty-three inches. At this age the proportions of the body, and of the organs, are no longer those of the infant, and not yet those of the adult. The anatomy of this age has received little attention, and I hope that this work may therefore be of use. It will serve, also, for the study of the adult relations, as the peculiarities due to the age of the subject are carefully noticed in the text. I have endeavored to call attention to the most important inferences to be drawn from the plates, and have mentioned, incidentally, many points of anatomy which the student will not find in the text-books. The reader is urged, however, to study the plates carefully for himself. They are of life-size, and drawn from the sections with great care and patience. The arteries were injected.

Believing, as I do, that frozen sections will play an important part in the anatomical teaching of the future, I shall say nothing of their

advantages, which speak for themselves, but will mention some of their shortcomings. One would expect that they would be very well suited for the study of fasciæ; and so they are if you destroy the specimen by removing the tissues between the fasciæ. Otherwise you see little or nothing of them, for few fasciæ are thick enough to be easily distinguished when seen in section. Small vessels that have not been injected—the thoracic duct, for instance, and nerves that are cut across—are often made out only with great difficulty. I feel it my duty to admit that there is serious doubt whether in all the plates the pneumogastrics and the thoracic duct are placed quite accurately in the posterior mediastinum.

My experience with frozen sections enables me to offer the following directions for making them. First, be very sure that the body, or part, to be frozen is in precisely the position you desire, and that there are no folds or indentations in the skin. I always use natural cold when possible. Weather much above zero (Fahrenheit) is unsatisfactory; but if the part is thoroughly chilled by several days' exposure to a pretty low temperature, a night of 10° may possibly finish it. Salt and ice, or snow, no doubt, will answer the purpose, but much time and patience are required. It is essential that the melted ice should have a chance to run off. The body should be frozen like a rock—so much so that the operator cannot tell whether he is cutting bone or muscle. Tooth is the only tissue he should be able to recognize. The sections should be made in a cold room, with a very sharp saw that has been chilled. When a section is cut, its surface is obscured by a thick half-frozen saw-dust, which is doubly thick if the freezing is not quite sufficient. It is wisest, if time allows, to remove this at once, which is done by pouring a little hot water


over the section and brushing or scraping it off rapidly and carefully. This is a very delicate part of the process, and its successful performance has much to do with the beauty of the specimen. If it is to be kept, it should be laid on a piece of glass or wood, and placed at once, while still frozen, in *cold* alcohol.

The specimens from which these plates are made are preserved at the Harvard Medical School, and are at hand to solve any doubts that may arise.

To study the plates turn the book so that the vertebra is nearest to you and imagine that you are looking down into your own body.

70 BEACON STREET, BOSTON,

July, 1881.



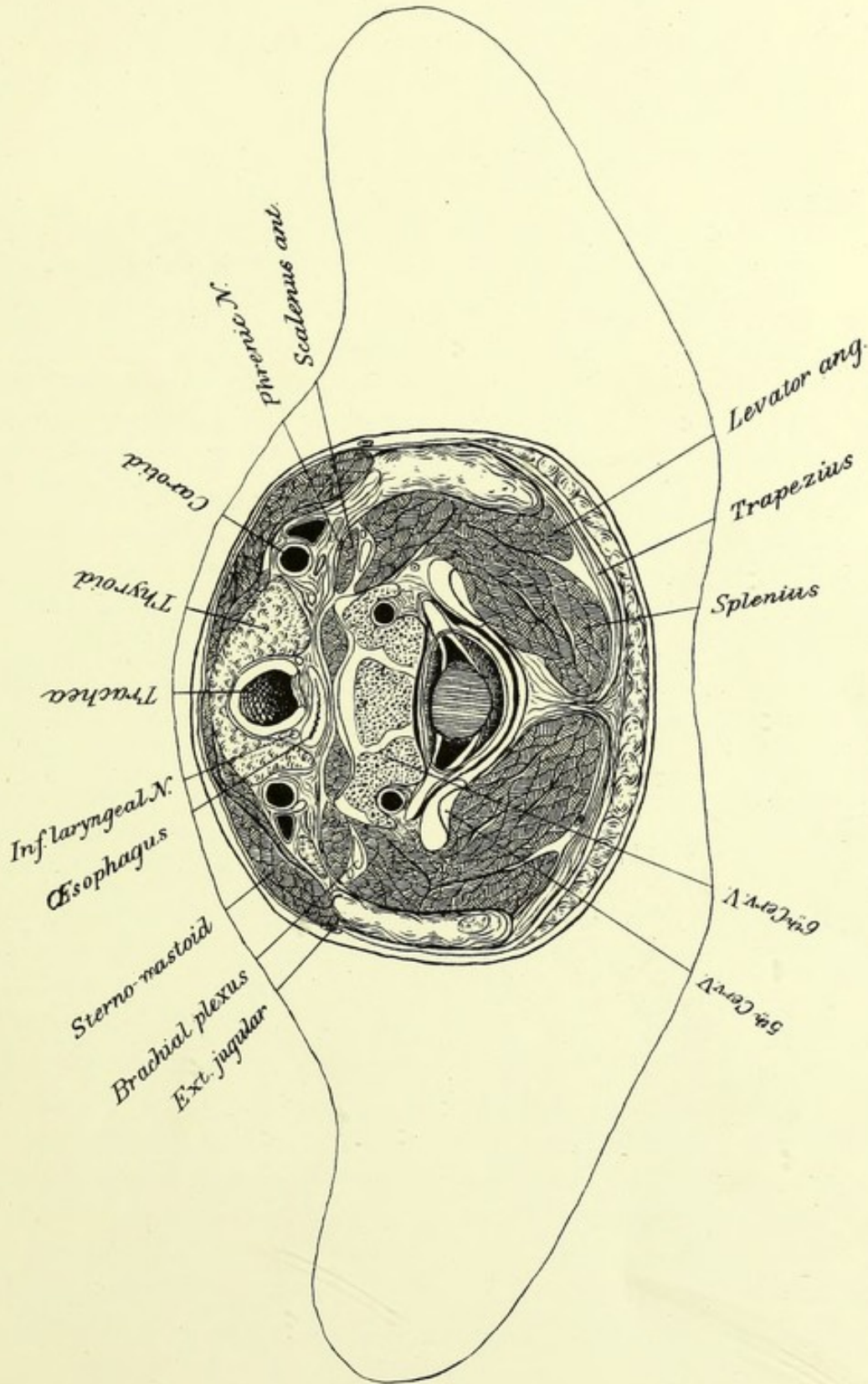


PLATE I.

THE plane of this section inclines somewhat forward. The limits of the neck are not easily defined: for, in front, the upper part is hidden by the lower half of the face, and behind, the lower part of the neck is indistinguishable from the back. Thus, there is but a very small part of the body that is clearly neck and nothing else, and this condition is particularly marked in infancy and early childhood. The cut passes through the body of the sixth cervical vertebra, striking it in front near its upper border, where it is still cartilaginous. The articular processes of the fifth cervical are seen resting against those of the sixth. The essential centres of ossification of a vertebra are one for the body and one for each half of the arch. They are separated by the neuro-central sutures. The direction of these sutures is modified by the presence of a double transverse process in the cervical region. A more correct idea of them is obtained from PLATE V., where they cut off merely the posterior angles of the body. They disappear from the fourth to the sixth year. A glance at PLATE X. will show that ossification is completed sooner in the lower part of the column. The vertebral artery is seen in its foramen. In front of it is the projection known as the tubercle of Chassaignac, which is a characteristic of the sixth vertebra, and sometimes used as a guide to the carotid.

The intervertebral discs form 41.9 per cent. of the length of the cervical region of the adult spine, the mean length of this region being 13.6 cm. It forms 22.5 per cent. of the length of the column above the sacrum. In the very young embryo, the neck forms one-third of the spinal column (above the sacrum) and the lumbar region one-fifth. In the adult these proportions are pretty nearly reversed. This change begins very early, for at birth the lumbar region is longer than the cervical. At three years the proportionate length of the cervical region is a little greater and that of the lumbar a little less than in

the adult.¹ The shortness of the neck in infancy does not, therefore, depend on that of the cervical region of the spine, but on the largeness of the head, the high position of the sternum, and the abundance of fat.

The sixth cervical nerve is seen leaving the spinal canal, which is broad to contain the cervical enlargement. It is well to remember, that as there are eight cervical nerves and only seven vertebræ, each of the first seven passes above the vertebra of the corresponding number, and in the other regions the nerve passes under its vertebra. The nerves do not arise from the cord opposite their points of exit, but somewhat higher; suffice it to say, for the cervical region, that the eight nerves are all given off above the fifth, or certainly the sixth, spine, which is about on a level with the body of its vertebra. The fifth nerve and a branch of the fourth are seen between the scalenus anticus and medius on their way to the brachial plexus. The phrenic is just in front of the former muscle, which it follows down to the thorax. This nerve arises from the fourth cervical, but almost always receives fibres from the fifth, though at very uncertain points.

The trachea is divided a little below the cricoid, probably through the first ring. This, therefore, is the important region of tracheotomy. The isthmus of the thyroid appears to be rather large; usually it covers the three rings after the first,² but it is extremely variable, and may be wanting. The left lobe reaches to the œsophagus, and slightly overlaps the carotid. It is easy to see how, if enlarged, it might make its way between the artery and the vein, as is said sometimes to be the case. The œsophagus, cut just below its origin, already inclines to the left. The recurrent laryngeal nerves lie in the angles between it and the trachea.


The muscular masses and the general arrangement of the fasciæ are easily understood. The superficial muscular layer, omitting the platysma, consists of the sterno-mastoids and the trapezii. They are both supplied by the spinal-accessory nerve, with some assistance from the spinal nerves. It is a mistake to suppose that the sterno-mastoids bow the head. As they are attached behind the transverse axis of the occipital joints, they would tend to throw the face upward. The action of one of them is to turn the face to the other side. They

¹ Aeby : *Archiv. für Anatomie und Entwicklungsgeschichte*, 1879.

² Pilcher : *Annals of Anatomy and Surgery*, April, 1881.

are very powerful muscles, and their chief work probably is to hold the head and neck firm. The trapezii and the sterno-mastoids are both inclosed in the cervical fascia, which extends from the ligamentum nuchæ to the median line, and splits to receive them. From the deep surface of this fascia, in the anterior region, there pass off a number of layers, making sheaths for the smaller muscles, joining the capsule of the thyroid and the sheaths of the great vessels. The sheath of the carotid must not be considered as a membranous tube, but rather as a collection of dense areolar tissue surrounding the artery, vein, and nerve, and running in between them. The vein is seen at the outside of the artery, and the nerve behind; on the left, between them. The small size of the vein compared to that of the artery is due to the latter being injected and the former empty. The omo-hyoid lies at this level on the outside of the vessels. The pre-vertebral fascia, binding down the longi colli, and passing over the scaleni, is a very distinct structure. The levator anguli scapulæ lies behind the scalenus medius, beneath the fat at the side of the neck. It slightly overlaps the splenius. In rotary motions of the head each splenius may act with the sterno-mastoid of the opposite side. It is very likely, however, that slight rotary motions are made chiefly by the group of small muscles below the occiput.

The external jugular veins are seen at the rear edge of the sterno-mastoids, outside of the fascia. The anterior jugular is normally outside of the fascia: it may be single or double. It opens into the subclavian vein, or, especially in the latter case, may be connected with both by a transverse vein just above the sternum. The deep plexus of veins in front of the trachea, somewhat below this level, comes from the thyroid body, and empties into the left innominate vein.



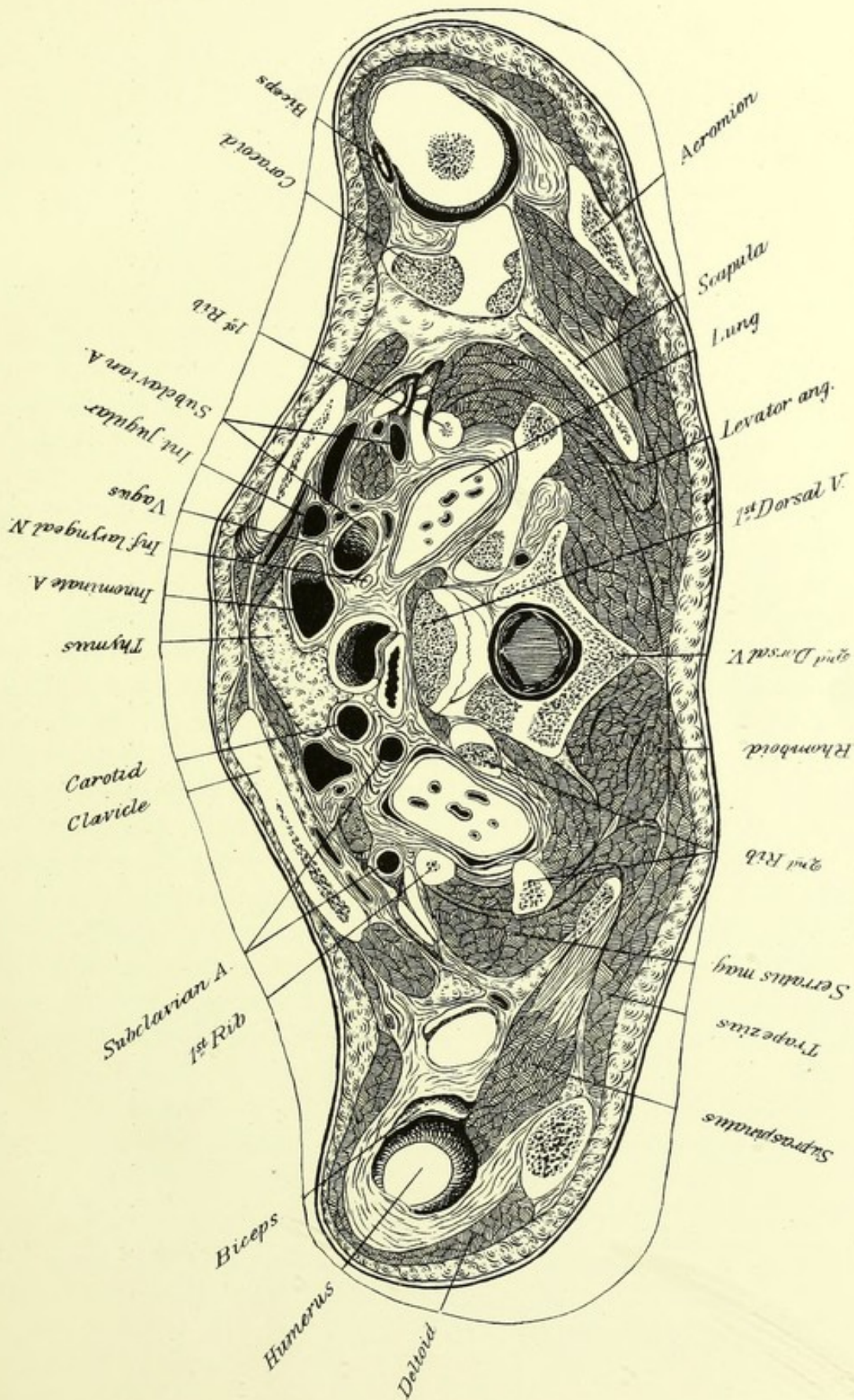


PLATE II.

THIS plane is nearly level antero-posteriorly, though perhaps the front is still a little the lower, its distance below the preceding plate being about 2 ctm. We see the lower part of the first dorsal vertebra, and, apparently behind it, owing to the curve of the spine, a part of the intervertebral disc. The arch and pedicles belong to the second dorsal. By remembering that two ribs rest, in part at least, against the first dorsal, we know that till we approach the lower end of the dorsal region the head of each rib touches the upper border of the corresponding dorsal vertebra. Thus we see the beginning of the second rib on both sides at its origin, and the first rib cut obliquely as it descends to the sternum. The relations may fairly be called normal, even for the adult, as there is a great deal of variation in the height of the top of the sternum and in the consequent inclination of the plane of the top of the thorax. In this case the upper end of the sternum is opposite the lower part of the second dorsal vertebra. This is, perhaps, higher than usual. The lungs are seen rising above the clavicles; the left one appears the larger, although the section is a little higher on that side. They reach to about the level of the head of the first rib. Usually there is little difference in the height of the apices which lie far back in the cage formed for them by the upper ribs. The general course of the first rib to the sternum, from the point at which it is divided, can easily be imagined. The pleura extends obliquely forward to the margin of the rib beneath the structures which appear between the lungs and the clavicles. The *scaleni antici*¹ are important landmarks. They reach the first rib a little below this section. The

¹ They are not named in the plate, but are to be seen on each side between the two lines that converge from different parts of the subclavian artery.

phrenic nerve is still in front of each, but gradually working its way to the inner side of the muscle. The subclavian vein is seen in front of the muscle on the right side, but on the left it is just too deep. The subclavian artery and the brachial plexus cross the first rib behind this muscle and before the scalenus medius. According to Zuckerkandl¹ the artery and the plexus are generally separated by the scalenus minimus (long known as an anomaly), which arises from the transverse processes of the sixth and seventh cervical vertebræ, or the latter only, and from the upper border of the first rib. It runs to be inserted into the same rib between the structures just mentioned, but it is attached also to the top of the pleura. Its chief purpose apparently is to strengthen and tighten the latter. Sometimes the place of the muscle is taken by fibrous bands, which, indeed, had been observed by Sibson.

The cervical portion of the thymus, which often reaches to the thyroid, lies in front of the trachea and great vessels. The innominate divides just below the surface of this section, rather above the right sterno-clavicular joint. The left carotid is on the left of the trachea, and the left subclavian far back beside the œsophagus. The cut ends of both subclavian arteries show clearly how they arch over the lung, resting on the pleura. The internal mammary artery and vein lie in the angle between the right subclavian and the scalenus anticus. On the left, only the artery is seen beside the muscle. The internal jugular appears on both sides, but the subclavian vein only on the right. The innominate veins begin just below the section. The right pneumogastric nerve runs directly before the subclavian artery, being still behind and between the carotid and jugular. The left one is nearly in front of the carotid. The left recurrent laryngeal nerve runs in the angle between the trachea and œsophagus, but the right one, which is given off just in front of the subclavian, has not yet had time to get there, and is seen behind the artery.

We can now resume the study of the cervical fasciæ. The anterior layer splits below the thyroid into one going to the front of the sternum, and into a stronger one passing to its posterior surface. It is seen separating the sterno-hyoids and thyroids from the sternal insertions of the sterno-mastoids. This deeper layer gives off the important expansion that passes from the posterior belly of the omo-

¹ Zeitschrift für Anatomie und Entwicklungsgeschichte, Band II.

hyoid to the clavicle and the first rib. It then invests the subclavius (which is seen on the outer side of both clavicles), and extends from the first rib to the coracoid process. This well-defined fascia is called the costo-coracoid membrane. It is continued into the axilla, forming the front portion of the sheath of the axillary vessels; the remainder is formed by another prolongation of the deep cervical fascia. The pre-vertebral fascia is very dense in this region. Strong prolongations arise from it opposite the lower cervical and the upper dorsal vertebræ and are attached to the roots of the lungs, but more particularly to the front and back of the pericardium, and thus indirectly to the diaphragm. They may be called its suspensory ligaments, and prevent any serious sinking of its tendinous centre.¹ The pericardium is attached also to the sternum by areolar tissue, among which certain bands may be distinguished, named by Luschka the superior and inferior sterno-pericardiac ligaments.

The upper part of the left shoulder-joint is opened, and but a small piece is taken off from the head of the humerus. The beginning of the acromion is behind it, and on the inner side the upper surface of the root of the coracoid is seen. The superior angle of the scapula is behind the angle of the second rib, and its posterior border ends immediately above PLATE V. Its relations, therefore, are the same as in the adult: it covers the ribs from the second to the seventh inclusive. On the right the cut falls decidedly lower, striking the glenoid cavity, the coracoid, and the greater tuberosity of the humerus. The long head of the biceps runs on this side through its sheath in the wall of the capsule, but on the left it is seen inside the joint running over the head of the humerus. The trapezius, deltoid, and pectoralis major, are all parts of one muscular layer. On the left, the cephalic vein is seen just after it has pierced the fascia between the two latter. This plate and the next show how liable the deltoid is to injury in severe blows or falls on the shoulder. It is quite as likely that its very frequent wasting in such cases is due to direct injury to the muscle as to the circumflex nerve that supplies it. The supra-spinatus is seen on both sides, divided before its insertion. In the specimen, though not in the plate, fibres of the infra-spinatus may be distinguished mingling with the capsule of the right shoulder. It is worth while to remember how high up on the greater tuberosity these rotators are inserted.

¹ Teutleben : *Archiv für Anatomie und Entwicklungsgeschichte*, 1877.

The serratus magnus is well shown beneath the scapula, which it holds firmly in place. It is supplied by the long thoracic nerve. Its paralysis allows the posterior border of the scapula to fall outward—"angel palsy." A somewhat similar result follows paralysis of the trapezius, but the eversion of the shoulder is less marked and its falling greater. The supra-scapular artery is seen on the left, passing over the upper border of the scapula.

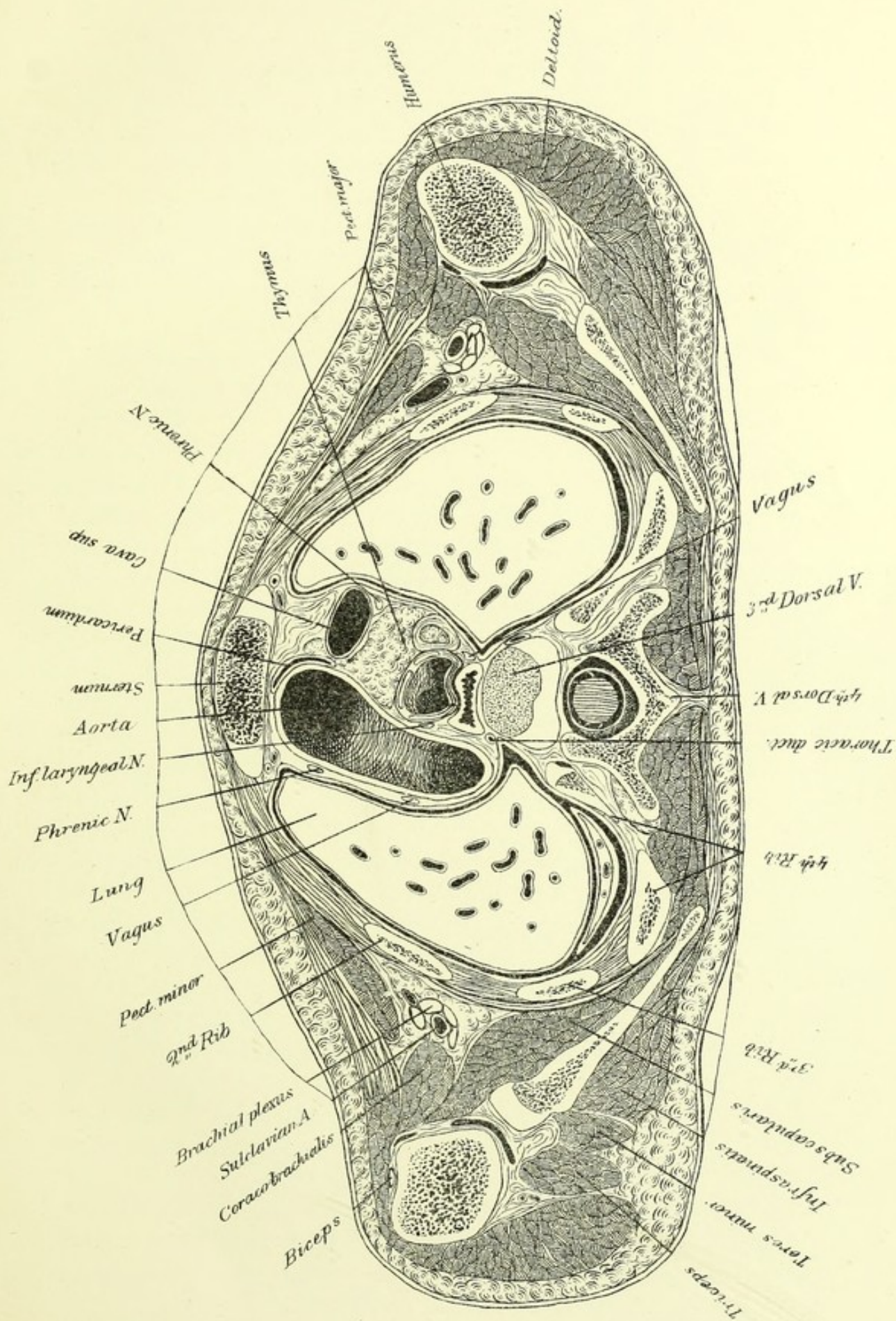


PLATE III.

THIS is a little less than 2 ctm. below the preceding, and very nearly level. The reader is referred to the plate for the identification of the vertebræ and ribs. The cartilage on the side of the sternum is an expansion from that of the first rib, which in children may reach nearly to the cartilage of the rib below it. The manubrium is divided in its lower half. The second rib, bone and cartilage, continues nearly horizontally from the point at which it is divided to its insertion. The cartilages of the following ribs, excepting the last two, have both a falling and a rising portion. Braune states that at about this level the antero-posterior diameter of the chest equals one-third of its breadth, while in the new-born child it is one-half. In a man of fifty, however, he found the proportion 1 to 2.5, which is very nearly that of this subject. That, however, was probably an individual peculiarity, and the shape of the thorax at three, seems to be intermediate between that of the infant and the adult.

A great deal more lung-tissue is seen here than in the preceding plate. The pleuræ are still far apart, not quite reaching the borders of the sternum. Between them we have the anterior mediastinum filled with areolar tissue, bounded by the sternum in front and the aorta and vena cava behind. Between the latter and the trachea is found a large part of the thymus, which is peculiarly situated, as it is not common for it to extend so far back. It is seen again in PLATE IV. in the anterior mediastinum. This organ is not rarely found in the young adult. According to Rüdinger, its involution does not begin till the fifteenth year. The great fissure of the lungs begins on the left, a little above this section, and on the right just below it. The bifurcation of the trachea is seen opposite the lower border of the fourth dorsal. This is practically its adult position in regard to the spine, though it is often said to be higher. In this child it must be rather below than above the junction of the first and second pieces of the sternum. The thoracic duct lies on the left of the œsophagus; it arches forward a little above this, and was not found in the preceding

sections. It may rise as high as the thyroid body before returning to its end at the junction of the left jugular and subclavian veins, or it may rise hardly at all above that point. The innominate veins are not seen, as they run in the thickness of the slice above this plate, and unite to form the vena cava superior opposite the lower half of the cartilage of the first rib, at the right border of the sternum behind the thymus. As the cava descends, it inclines backward, so that in PLATE IV. it is behind the aorta, but, owing to the spiral course of the latter, it is beside it again at its termination just above the level of PLATE V.

The course of the œsophagus deserves a special description. Just below its origin it begins to incline to the left, as is shown in PLATE I. The deviation is more marked in PLATE II., but in the next, opposite the third and fourth dorsal vertebræ, it is driven back toward the middle by the arch of the aorta. It continues for some distance near the median line. Opposite the ninth dorsal it is well to the right, but it then begins to sweep forward and to the left. It ends opposite the lower part of the tenth dorsal.

In another child, of about the same age, examined by means of similar sections, the gullet at the top of the first dorsal was completely on the left of the trachea, which rested against the prevertebral fascia. It continued on the left, passing behind the left bronchus, till it regained the middle line opposite the seventh dorsal. It then ran to the left again, in front of the descending aorta, and ended at about the upper border of the eleventh dorsal. In this case there was an effusion in the right pleural cavity. Braune states that the greatest deviation to the left is in the region of the second and third dorsals; Tillaux, that the general direction is to the left, but that it is slightly deflected to the right, opposite the third dorsal, by the arch of the aorta. An examination of sections by Pirogoff, Braune, Rüdinger, and Henke, shows that there is great individual variation. Whether pleuritic effusions can displace the gullet, is important, but unsettled. One point seems reasonably certain, that at the bifurcation of the trachea it usually passes behind the left bronchus, and, as far as I know, never behind the right one, excepting when all the viscera are transposed. Muscular fibres frequently pass from the left bronchus to the œsophagus, and in nine cases in which Gruber¹ found a muscle arising from the right bronchus, in every one its fibres ran from the bronchus di-

¹ Reichert und Du Bois Reymond's Archiv., 1869.


rectly or obliquely to the left. Various other irregular muscular bundles connect the gullet with the pleuræ and pericardium. The aorta is in close connection with the œsophagus for a great part of its course. This we shall return to. PLATE V. shows the relations to the left auricle and right pulmonary vein to the œsophagus.

The views of the intra-thoracic nerves in Plate III. are very instructive. The phrenics are seen far forward, especially the left one, which lies between the opposed surfaces of the pericardium and pleura. The right, which has not yet reached a corresponding position, lies behind the vena cava. The right pneumogastric has joined the œsophagus; the left one, at the left of the arch of the aorta, gives off the recurrent laryngeal, which emerges between the aorta and trachea. The phrenics pass in front of the roots of the lungs; the pneumogastrics behind them, as is clearly shown in PLATE IV. The pericardium is seen covering the right anterior surface of the ascending aorta. The course of that vessel is left for the next chapter.

The left scapula is cut just under the glenoid cavity, the right one lower still. In both cases the joint is opened where the capsule hangs down in a fold, which is obliterated when the arm is raised. A small bursa is found on each side between the humerus and the pectoralis minor. The subscapularis and the infra-spinatus, separated by the body of the scapula, are easily known. The teres minor lies against the latter muscle. On the right, the long head of the triceps, represented too much like fibrous tissue, runs along the anterior border of the scapula. On the left it becomes muscular at once, and is seen outside of the teres minor.

The axilla is shown as a small space, containing the large vessels and nerves, surrounded by areolar and fatty tissue. It is bounded on the inside by the chest-wall, in front by the lesser pectoral, on the outside by the coraco-brachialis, and behind by the subscapularis. Its lower wall is formed by the skin, which is held close up by the axillary fascia. The axilla ends above by the convergence of its walls (PLATE II.).

The trapezius is slightly shaded in this plate. Below are the rhomboids, running to the posterior border of the scapula. It is important to know that there is a small space under the scapula, usually containing a little fat, bounded by the chest-wall, the rhomboid, and the serratus. Pus occasionally is found in it, and as the serratus does not allow the abscess to point in the axilla, it may attain a large size and give much pain before it is recognized.



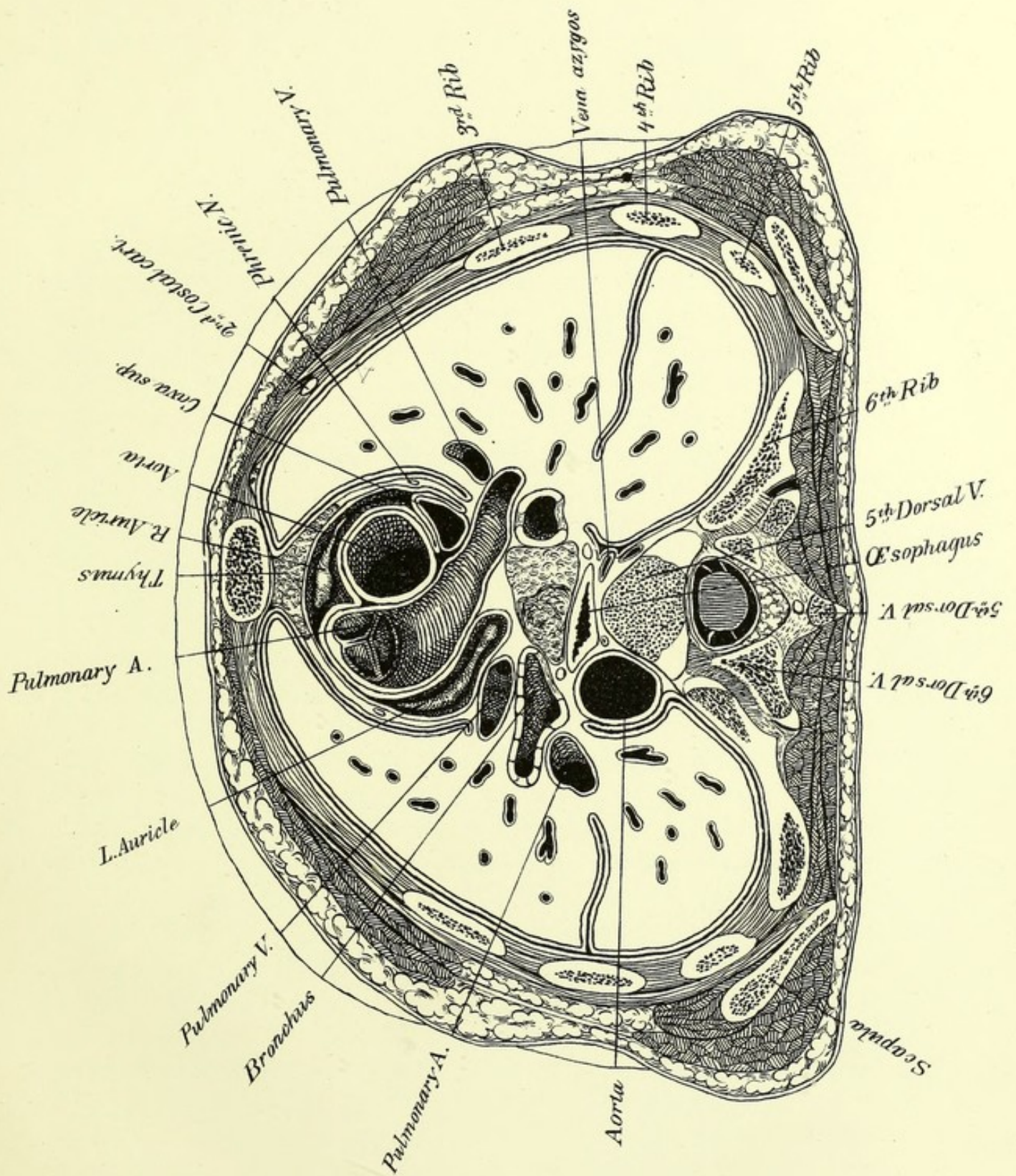


PLATE IV.

THIS is about 1.8 cm. below the preceding surface, and slightly nearer to it in front than behind. It is, however, practically horizontal, and falls just below the axillæ. The apex of the spine of the fifth dorsal appears on a level with the lower part of the body of that vertebra. The second piece of the sternum is divided just above the third cartilage. The cartilage of the second rib just touches this plane, showing that in this instance, at least, it describes a curve, though a slight one.

This plate and its two neighbors show admirably the relations of the great vessels and of the roots of the lungs. The pleuræ nearly meet behind the sternum, where they overlap the thymus. The pericardium is opened widely above the auricles. It is folded in between the aorta and the vena cava, follows the former till it begins to turn backward, and passes round the front and side of the pulmonary artery.

The pulmonary artery and the aorta are twisted round one another. The former arises not quite in front of the latter, as is sometimes taught, but a little more to the left, behind the left border of the sternum at the lower edge of the third cartilage. The auricular appendages hang on either side of it. One of its valves is behind, two in front. The vessel runs upward, backward, and slightly to the left, dividing beneath the aortic arch opposite the junction of the cartilage of the second rib to the sternum. The right division is seen in this plate, the left is higher. The aorta arises lower, the central point of its lumen at its origin being a little above the plane of PLATE V., behind the sternum, on a level with the upper border of the fourth cartilage. This is a very little lower than it is usually placed, namely, opposite the third intercostal space, or even the third cartilages. The aortic valves have been described in various ways. There are two behind and one in front. The right one of the former and the

greater part of the latter are seen in PLATE V. The third is at a higher level. I have followed Sibson's¹ nomenclature, but it seems as if it would be quite as well to say that there is a superior one on the left, and two inferior on the right. One of the sinuses of Valsalva corresponds with each flap. The superior sinus is the largest; it gives off the left coronary artery. The right artery springs from the anterior sinus. The aorta runs forward, upward, and to the right. In PLATE IV. the pulmonary artery is on its left, and the superior cava almost behind it. At this plane it changes its direction and runs more distinctly forward and to the left. In PLATE III. it is behind the sternum at the height of the first intercostal space. It is seen in this section arching over the root of the left lung, and we may infer that the highest point of the arch is opposite the top of the third dorsal vertebra and below the top of the sternum. Inasmuch as these two points are in no constant relation to each other, we must consider what is the proper position of the top of the arch with regard to each. Sibson² found the top of the arch in one instance one and one-half inch below the top of the manubrium, and in another one-half inch above it. In five cases he found it above, and in six on a level with the top of the sternum, while in seven it was quite an inch below it. "In two-thirds of the instances (thirty in forty-eight), however, the top of the aorta occupied an intermediate place behind the upper half of the manubrium, its average position being half an inch below the top of the bone." The position of the highest point of the arch on a level with the upper part of the third dorsal vertebra is rather higher than is normal in the adult,³ although good text-books place it as high as the second. The rapid decrease in size of the arch of the aorta is partly real and partly apparent. It becomes smaller after giving off the great arterial branches, and, moreover, the section strikes it below its greatest diameter. The descending aorta proper begins between PLATES III. and IV., say between the fourth and fifth dorsals. The close relation of the aorta to the œsophagus from this point to the diaphragm should be carefully noticed. The aorta, which in PLATE IV. is quite on the side of the spinal column, gradually passes

¹ The Position and Form of the Heart and Great Vessels. Reynolds' System of Medicine. Vol. IV.

² Loc. cit.

³ Mr. J. Wood: The Topographical Relations of the Arch of the Aorta and the Posterior Mediastinum to the Spinal Column. Journal of Anatomy and Physiology. Vol. III.

in front of it, getting behind the gullet, as is shown in PLATES VI. and VII. It runs through the diaphragm below PLATE VIII., opposite the twelfth dorsal vertebra.

The root of the lung is composed of the bronchus, blood-vessels, nerves, and lymphatics. The most important of these structures are seen in PLATE IV. The right bronchus is larger than its fellow, which is normal, and appears to descend more rapidly, which is not. On the right, the right branch of the artery is in front of the bronchus, and a branch of the superior vein before that. On the left the vein is in front of the bronchus, and the artery behind; but if the section had been made a little higher the story would have been different, for the left pulmonary artery would have been seen arching over the bronchus, and but little of the vein would have been seen. PLATE V. shows the lower right pulmonary vein opening into the left auricle. The left one is cut while it is rising toward the heart. In fact, each of the left pulmonary veins opens into the heart somewhat above its fellow. According to the usual description, the order from above downward is as follows: on the right, bronchus, artery, veins; on the left, artery, bronchus, veins; and from before backward on both sides, veins, artery, bronchus. This order from above downward is in the main correct, but in the other direction it can include only the superior pulmonary veins, for PLATE V. shows clearly that the inferior ones cannot be in a plane anterior to that of the arteries.

A mass of enlarged and degenerated glands lies beneath the bifurcation of the trachea. This, together with the bronchi, forms at this level the front wall of the posterior mediastinum. The lateral walls are formed by folds of the pleuræ. The contents are the aorta, the œsophagus, with the pneumogastric nerves, the thoracic duct, and the vena azygos. It contains, also, sympathetic nerves, but they were not recognized. The vena azygos arches over the root of the right lung to join the vena cava just above the pericardium. It constitutes a very important connection between the systems of the upper and lower venæ cavæ.

Faint, illegible text, possibly bleed-through from the reverse side of the page. The text is arranged in several paragraphs and is too light to transcribe accurately.

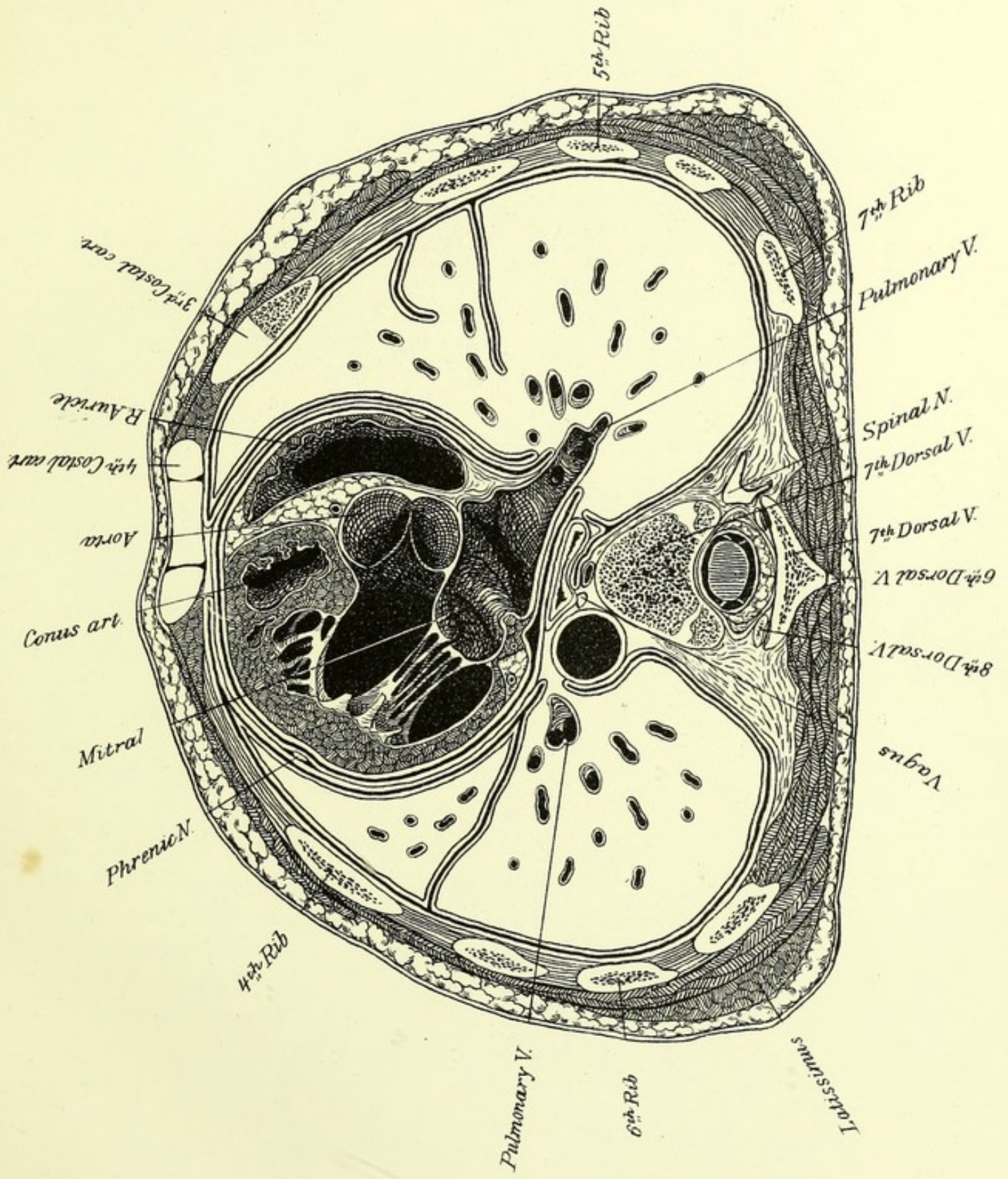


PLATE V.

THIS represents a pretty even section, 1.8 cm. below the preceding one. Three vertebræ are shown. The body of the seventh dorsal is cut about the middle. The arch belongs to the same vertebra, but the articular processes of the eighth appear before it; and behind is the tip of the spinous process of the sixth.

The dorsal region forms 47.6 per cent. of the spine above the sacrum, and keeps very nearly the same relative length in the embryo and throughout life. Its mean length in the adult is 28.5 cm. The intervertebral discs constitute a little more than a quarter—26.4 per cent.—of the dorsal region. The eighth rib is just below the plane of the section on the left, and still deeper on the right. The third rib is shown on the right just where it joins its cartilage. The latter rises very rapidly as it approaches the sternum. This bone is cut where the fourth cartilages join it between its third and fourth pieces. The scapulæ end just above this plane. The differences between the relations of the antero-posterior and the transverse diameters of the thorax of the child and of the adult are much more marked at about this level than at the highest part of the cavity. Thus, in this plate, the former diameter is to the latter about as 1 to 2, while in the adult it varies from as 1 to 2.5 to as 1 to 3. At birth it is nearly as 2 to 3. The nipple is on the front wall of this slice opposite the fourth rib on both sides. Luschka found it in the fourth intercostal space forty-four times out of sixty in males. In women it is said to be opposite the fifth rib; but, owing to the great variety of forms and sizes of the breast, it is of no constant value as a landmark in women.

This cut is a remarkably fortunate one, for it has struck the heart so as to open its four cavities, and to show both the valves of the left ventricle. Three-fourths of the heart, as seen in this plate, belong

to the left side, and both this view and the next show how this appears to be the important side of the heart, and the right merely an addition to it; yet before birth the two sides are of about equal strength. The conus arteriosus, a prolongation upward of the right ventricle to the pulmonary artery, is nearly in front of the aortic valves, two of which appear in this plate. Behind them is the mitral valve, consisting of two segments—an anterior one on the right, a posterior one on the left. The valve is closed; it lies behind the left border of the sternum, and at this level is opposite the fourth cartilage. There was some difficulty in defining its limits quite accurately, but they seem to correspond very well with the normal ones of the adult, namely, from the third space to the fifth cartilage. The pulmonary valves are higher than the aortic, which are higher than the mitral, and the tricuspid is the lowest. No one of these valves, however, is completely above the one next below it—they all overlap. The left auricle appears in this plate to deserve to be called the posterior one, but *PLATE IV.* shows it extending forward on the left.

The pleural cavities are about as near together behind the sternum as in the preceding plate, but the left lung makes way for the heart. Usually, a needle thrust through the fifth or sixth intercostal space, and sometimes through the fourth at the left border of the sternum, will pierce the pericardium and not the pleura. The great fissure of the left lung begins rather above the head of the fourth rib, that of the right rather below it. The third, or middle, lobe of the right lung is shown in *PLATE V.* It varies in size and shape, according as the fissure that forms its upper boundary runs upward from the main fissure from which it springs, directly forward, or downward, as in this case. As a rule, the main fissure usually strikes the lower surface of the lung, so that the front of the lung is formed entirely by the upper lobe, or by the upper and middle lobe on the right.¹ In this case the middle lobe is a tongue-shaped body of little consequence, and the upper lobes form but a very small part of the base of both lungs.


An extra lobe of the right lung may be formed by the abnormal course of the vena azygos, which makes a groove in the top of the

¹ Dr. Cilley, of Cincinnati, has the credit, I believe, of being the first to call attention to this in any publication in English. Vide Cincinnati Lancet and Clinic, 1881. The fact was, however, already known to German anatomists.

lung as it runs to open into the superior cava near its beginning instead of near its end.¹ Chiene describes a case in which the vena azygos left the spine at the fifth dorsal vertebræ, and, running in the edge of a fold of pleura, cut out an extra pear-shaped lobe in the right lung, which had its origin in the angle formed by the junction of the upper lobe with the root of the lung.²

¹ Gruber : Bulletin de l'Académie de St. Petersburg. Vol. XV. 1871.

² Journal of Anatomy and Physiology. Vol. IV.



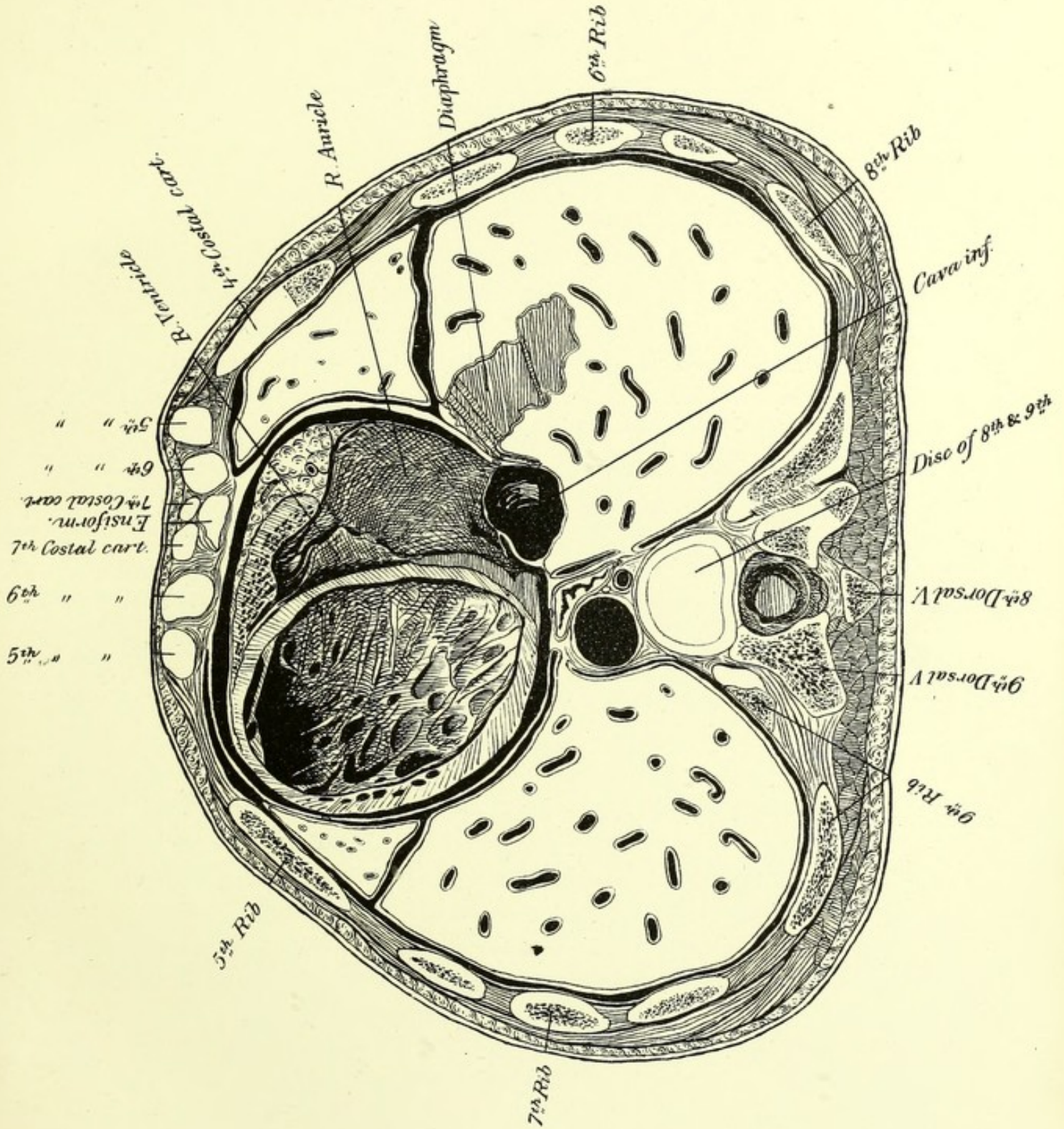


PLATE VI.

THIS is 1.8 ctm. below the preceding. The cut runs, perhaps, a little obliquely, so as to strike the front wall of the chest a little higher than it should. There, however, is no serious error in assuming that the section is a true one. We are struck at once with a peculiarity depending on the age of the subject. The disc between the eighth and ninth dorsal vertebræ appears on a level with the beginning of the ensiform cartilage, which is seen just behind the cartilages of the seventh ribs, which are about to meet. In the adult of either sex the sternal end of the seventh pair of ribs would be found opposite a lower point. Luschka places them opposite the vertebral end of the eleventh pair. A horizontal section by Braune, through the upper part of the ninth dorsal vertebræ, strikes the sternum at the sixth intercostal space. A comparison with other sections leads to the belief that the latter is a more usual relation than Luschka's. The relations of the sternum in this child correspond remarkably with those of the adult till we reach the lower part of the body of the sternum, which is smaller than it should be, so that the fifth, sixth, and seventh ribs are crowded together at their sternal ends.

The sternum varies extremely in length and in the relative size of its parts. Tillaux states that it increases with the height of the body, but that many exceptions occur—both of which statements agree with my observations. Hyrtl states very certainly that “the manubrium of the female sternum exceeds half the length of the body, while the body of the male sternum is at least twice as long as the manubrium.” I found that this did not apply to the breastbones of twelve men out of thirty, nor to those of fourteen out of twenty-six women. The male sternum is usually decidedly larger than the female. The above-mentioned measurements give a mean of 5.18 ctm. for the male manubrium, and of 4.67 ctm. for the female; of 10.59 ctm. for the body

of the male sternum, and of 8.94 ctm. for the female.¹ The history of the development of the sternum has not been thoroughly studied. I believe that the lower part of the body of the bone is proportionally small in early childhood, which occasions discrepancies with the relations of the adult, as occurs in this subject.

The upper surface of the diaphragm, separating the right lung from the liver, is just grazed in this section. The view of the heart shows the right auricle resting on the liver, the right ventricle, and the lower posterior wall of the left one. The apex is seen in *PLATE VII*. In the section before us, the lower segment of the tricuspid is seen lying on the lower wall. The other two are placed higher, one attached to the front wall, the other to the septum. It is not easy to define accurately the position of the valve, but we may say that it lies behind the lower fourth of the sternum, and that its upper border probably does not quite reach the level of the fourth cartilage, as it should. The floor of the right auricle presents nothing of interest, excepting the remains of the Eustachian valve, the edge of which appears as a line in front of the orifice of the vena cava inferior. It is easy to see, by looking at *PLATE V.*, how this valve, when more developed, as in intra-uterine life, would direct the current toward the fenestra ovalis, which must have been in the oblique inter-auricular septum, the top of which is seen in that plate. The vena cava inferior passes through the tendinous part of the diaphragm opposite the lower part of the body of the ninth dorsal vertebra. It is kept widely distended by its firm attachments to the diaphragm. Thus, even at this age this vein exists as a distinct vessel above the diaphragm. At birth it opens into the heart almost immediately after passing the foramen. In the adult the vessel runs upward and bends toward the left. As the foramen through the diaphragm is about horizontal, and the opening into the heart nearly vertical, it follows that the posterior and right surface of the vein is longer than its anterior and left one. According to Luschka, the former is 3.8 ctm., the latter 2.2 ctm. The vein contains no muscular fibres above the diaphragm, but fibres from the heart end tendinously in its walls, apparently to expand, not to constrict it. It is covered by the pericardium in its upper two-thirds.

We will now endeavor to define the position of the heart. The apex is on a level with the upper border of the cartilage of the sixth


¹ *Journal of Anatomy and Physiology.* Vol. XV. 1881.

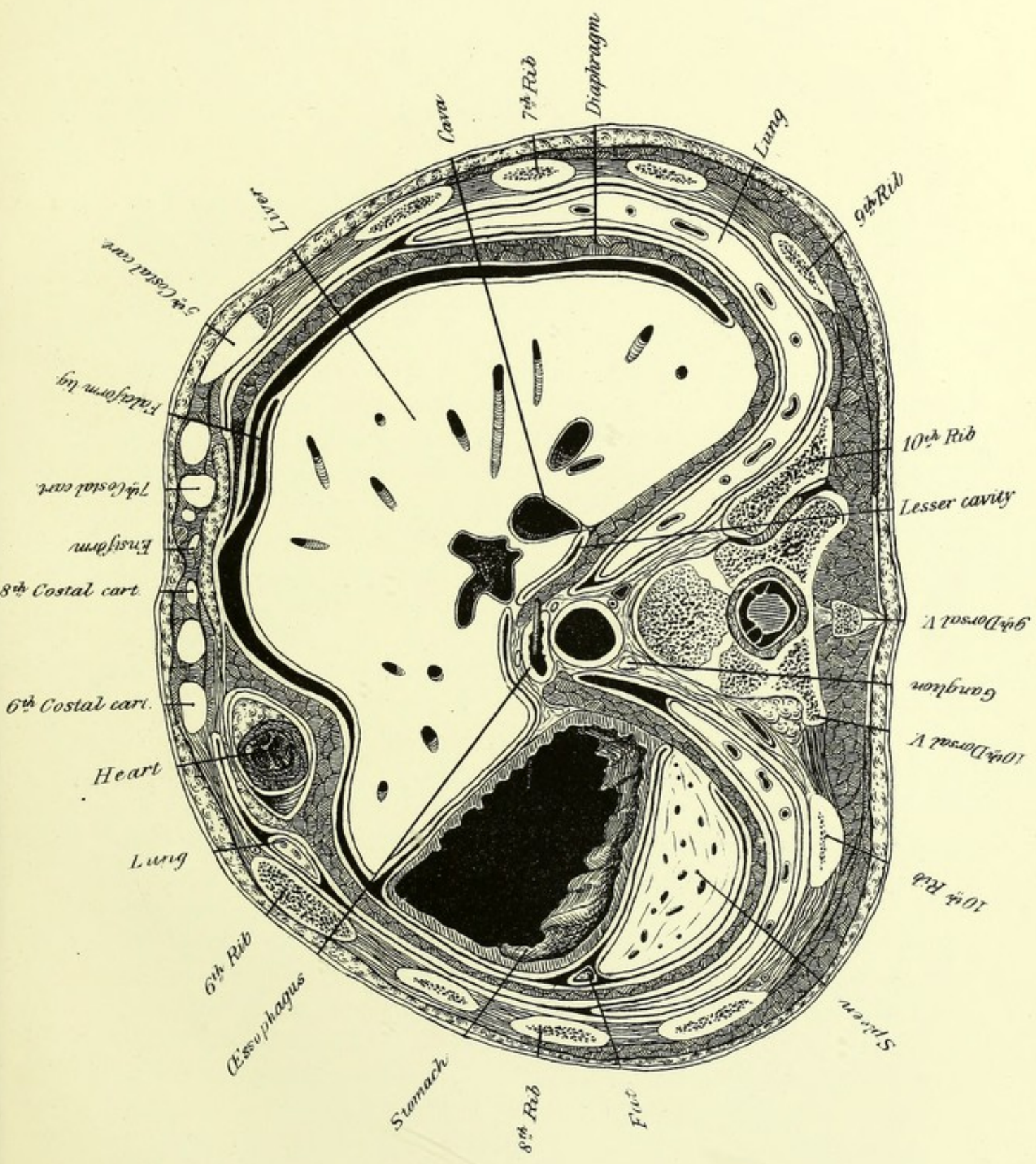
rib at its most dependent part, 3.2 cm. below the nipple, and at least 1 cm. inside of it. The lower end of the auriculo-ventricular groove is at the right of the base of the ensiform cartilage, opposite the cartilage of the sixth rib as it rises to join the sternum, and about 1 cm. to the right of the median line. The lower border of the heart would be represented by a slightly curved line connecting these points. The auriculo-ventricular groove runs upward to the middle of the line between the cartilages of the third ribs. The right auricular appendage is seen rather above that level in PLATE IV., and in the same plate the left auricle, which constitutes, perhaps, the highest point of the heart, is opposite the lowest part of the second intercostal space at the side of the sternum. The position of the heart is, therefore, practically normal, even for the adult. The apex¹ is rather lower than usual in relation to the ribs, but possibly this would have been corrected as the lower part of the sternum became more developed. The greatest breadth of the heart is seen in PLATE VI., and more of the heart lies in contact with the chest than at the level of any other plate.

The pericardium rests upon the central tendon of the diaphragm, but it extends over on to the muscular part both to the right and the left. The attachment of the front wall of the pericardium to the diaphragm is particularly firm.

This plate shows a change in the shape of the posterior mediastinum, which is caused by the aorta having made its way to the front of the column, crowding the œsophagus and the vena azygos to the right.

¹“The lower edge of the apex was on a level with the lower edge of the left fifth cartilage in one-seventh of the instances observed (six in sixty-nine); it was below that edge in two-fifths of them (twenty-six in sixty-nine); and it was above that edge in almost one-half of them (thirty-four in sixty-nine). In five instances the lower boundary of the apex was situated one inch above the lower edge of the fifth cartilage, and in four it was fully one inch below that edge.”—Sibson: loc. cit.








PLATE VII.

AN even section about 1.6 ctm. below the last. It shows important relations in both the thoracic and abdominal regions. The diaphragm is seen separating the cavities, except in front, where it passes for a short space above this section. The œsophagus, now in front of the aorta, opens just below the level of this section, opposite the lower half of the tenth dorsal. In the adult its termination is placed from the ninth to the eleventh. The apex of the heart is divided just at the lowest point of the cavity of the left ventricle. Only a very small pericardial cavity is seen around it. The lower edge of the right lung is seen behind the liver, and that of the left behind the spleen. A very small piece of the left lung appears also, outside of the apex of the heart, under cover of the sixth rib. The posterior borders of the lungs extend about 6 mm. below this plane. They are, therefore, below the tenth rib at its angle. In the mammillary and axillary lines they end very near the level of PLATE VII. The lungs are, of course, in a state of complete expiration, and smaller than they probably can be during life, but one of the merits of a frozen section is that it shows them in much more normal relations than they would present if the chest were opened in the usual way, which would occasion their collapse. The pleural cavities extend considerably lower. They do not, however, follow the diaphragm into the angle which it forms with the cartilages of the six lower ribs; the very lowest part of this space is filled with areolar tissue. The pleura is described as reaching in the mammillary line to the cartilage of the sixth, sometimes of the seventh rib; and in the axillary line, to the lower border of the ninth rib on the right, and of the tenth on the left. It does not touch the cartilages of the four or five lower ribs. Let us compare this general description with this individual case. In PLATE VIII. the front of the pleural cavity reaches about to the mammillary line. On the left, it lies against the seventh cartilage

near its lowest point. On the right it lies against the bony part of the same rib. (The right of this section is higher than the left.) In PLATE IX. it reaches the tenth rib on both sides, at a point not far from the axillary line. It lies behind both kidneys, but covers more of the right one. On both sides, the pleura reaches the upper border of the last rib, near its beginning, but the rib very soon runs away from it, as may be inferred from PLATE IX. A case has been reported in which a surgeon operating in the lumbar region to reach the kidney, mistook the eleventh rib for the twelfth, and by carrying the incision toward its lower border, opened the pleura. PLATE IX. shows that at that level such an incision opposite the kidney would certainly open the pleura on the right, and perhaps on the left. The length of the twelfth rib is important in this connection, for the rib is by no means always easy to recognize. Dr. Holl¹ examined sixty skeletons of all ages to ascertain the absolute and relative length of the twelfth rib. As there are two sides to each subject, and the ribs are not necessarily symmetrical, this gives one hundred and twenty observations. The longest twelfth rib measured 16.0 cm. (giants and children being omitted), and the shortest, 2.0 cm. The twelfth was three-fourths of the length of the eleventh in thirty-three cases; one-half in forty-four; one-third in eighteen; one-fourth in fifteen; one-sixth in three, and one-eighth in one. This shows how very variable it may be. Holl points out as a fact of great surgical importance that the pleura descends just as far as usual when the twelfth rib is wanting, or but slightly developed.

The pleura is attached rather loosely to the walls of the chest by a layer of areolar tissue, which accounts for the slightness of the injury it usually suffers in fractures of the ribs.

For all practical purposes, we may consider the diaphragm as a circular muscle whose fibres converge to the central tendon. This, as stated above, is firmly attached to the pericardium, and through this, to the vertebral column at the top of the thorax, and less firmly to the cervical fascia and to the sternum. The bearing of these points on the mechanism of respiration deserves careful study. The thoracic cavity can be enlarged by the raising of the upper ribs and of the sternum, which together with some slight rotation of the ribs, in-

¹ Die Bedeutung der Zwölften Rippe bei der Nephrotomie. Archiv für klinische Chirurgie. Band xxv., 1880.

creases both the vertical and the transverse diameters. An important part of the process, however, is the contraction of the diaphragm, by which the tendinous centre is made tense, and the abdominal viscera depressed. Now, for the muscle to act effectively, its lateral points of origin must be fixed, and this is done by the muscles that pull the lower ribs downward and backward. Such are the quadratus lumborum, the serratus posticus inferior, and many of the small lateral bellies of the great erector spinæ. The ribs, therefore, may be pulled both upward and downward in vigorous inspiration, or at least the lower ones may be drawn rather backward and held fast. This question has been confused by those who use the words "inspiratory" as applied to a muscle as synonymous with "raising the ribs," which involves, if the above view be correct, a serious error. Mechanical toys, like Hamberger's bars are quite misleading. The vexed and very complicated question of the action of the intercostals is much simplified by this theory. If the movements of all the ribs are not free and in the same direction, these muscles cannot have a common effect on all parts of the thorax. This is true whether applied to both the external and internal intercostals, or to either set separately. In point of fact the action of both is simply to draw the more movable ribs toward the more fixed. Those in the upper part of the chest pull upward, those in the lower downward, and the action of almost any set of them must vary with circumstances. There is, however, another point to be considered, namely, the effect of the inspiratory movement on the great veins that lead to the heart.¹ The opening of the cava inferior through the tendinous portion is made as large as possible by the contraction of that muscle, and the suction power, both of the inspiratory enlargement of the chest and of the relaxing auricle, act very strongly on the contents of the vena cava and on the portal circulation. Two large branches of the hepatic vein are seen in PLATE VII. on their way to the cava, which they enter just below the diaphragm. A similar effect is, no doubt, produced on the great veins at the root of the neck.

Leaving the liver and stomach for the next chapter, we will discuss the spleen. It reaches nearly, if not quite as high, as the stomach, that is, somewhat below the level of the head of the ninth rib. It extends to the lower half of the first lumbar. It is evident that the

¹ Forbes on the Diaphragm. The American Journal of Medical Science, July, 1880.

upper part is nearer the spine than the lower. It is entirely under cover of the ribs. Luschka describes it as following the ninth, tenth, and eleventh ribs, a description that would apply very tolerably to this case. The great peculiarity of the spleen in this instance is its relation to the peritoneum. Usually it is entirely covered, except near the hylus, with a prolongation from the lining of the great peritoneal cavity, though it is stated that at least in the young subject a portion of the lower and posterior surface derives its covering from the lesser cavity. Here, however, a large part of the organ is without any serous covering. The anterior layer of the gastro-splenic omentum may be seen in PLATE VIII., running backward from the outer surface of the stomach to the inner one of the spleen, but the posterior layer does not exist, because the fold of peritoneum, which ought to be carried around the back of the spleen to form it, is seen stopping short between that organ and the kidney.

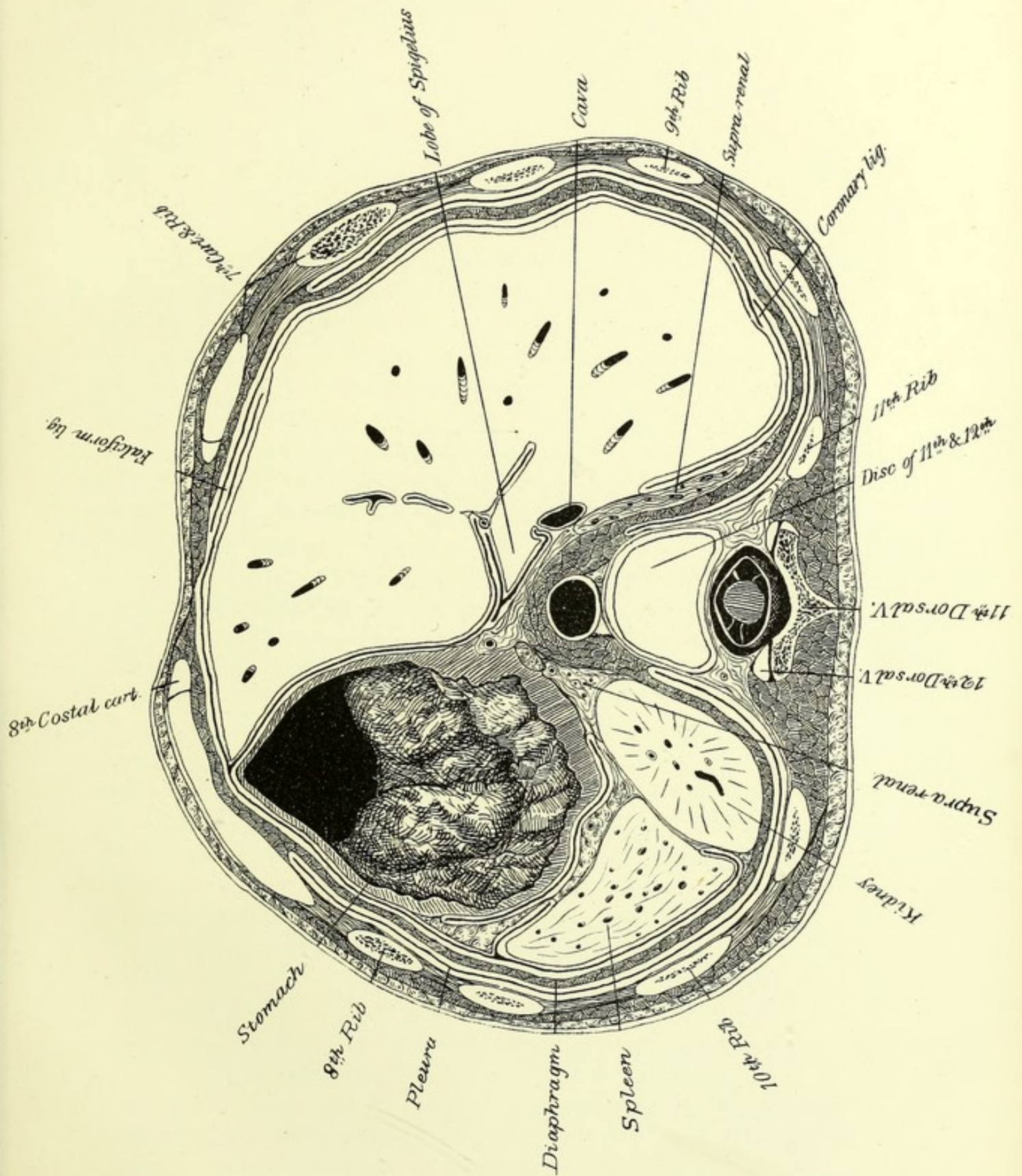


PLATE VIII.

THIS section, on an average 2 ctm. below the last, is unfortunately uneven from side to side. The left side is perhaps as much as 5 mm. below the right. The column is divided at the disc below the eleventh dorsal. The ribs are not very unsymmetrical, but the cartilage of the seventh is divided at its lowest part on the left, while on the right it passes below the section. We do not see the head of a rib opposite the intervertebral cartilage, as the eleventh and twelfth ribs arise from their respective vertebræ. The tenth usually arises from the tenth vertebra and a part of the cartilage above it, without reaching the ninth.

The liver fills a much larger part of the abdomen than in the adult, though proportionally smaller than in the fœtus. The greatest transverse diameter is shown in PLATE VII., but that is not so great as is sometimes considered normal for the adult. The great increase of size is due to the depth. It almost reaches the level of PLATE VI., from which it is separated only by the diaphragm, and it extends downward below PLATE X. to the third lumbar vertebra. The outline of the anterior edge can be readily deduced from the plates. It rises gradually to PLATE IX., and then more rapidly. The liver of a healthy adult lying on his back should not descend below the border of the ribs, except in the region of the ensiform cartilage. It is evident that in this case the liver considerably exceeds these limits. This is not the result of disease, but a characteristic of the age of the child.

The liver is usually described as having an upper and a lower surface, an anterior border, which is thin, and a posterior one, which is thick, especially on the right. The lobe of Spigelius is marked off on the under surface by the fissure of the vena cava on the right, the transverse one in front, and that of the obliterated ductus venosus on the left. How the inferior cava comes to be lying along the under sur-


face is not explained. His¹ has the merit of showing that this description applies to the liver removed from the body, drained of its blood, and distorted by its own weight. When *in situ* the liver has not a posterior border, but a posterior surface. The vena cava makes a deep groove in the rear, as is seen in PLATES VII. and VIII.; indeed, in the former it is almost surrounded by the liver. The lobe of Spigelius lies to the left of it, and is, at least, as much on the hind as on the lower surface of the liver. The transverse fissure, which forms its anterior boundary, cuts through to the level of PLATE VIII., and shows the outline of this lobe very clearly. The œsophagus often makes a slight groove in the liver. To the left of this the posterior surface passes into the posterior border. The impression from the right kidney is also in part on the posterior surface, as is shown in PLATE IX. The tissue of the liver is very yielding; it resembles a sponge filled with blood, and very probably can undergo slight temporary changes of form by the pressure of neighboring parts. That long-continued pressure will make permanent changes is well known. Hence it is very likely that the liver, which in early foetal life filled a great part of the abdomen, is reduced to its proper shape and size by the pressure of the growing organs around it. The right coronary ligament is opposite the tenth rib. To understand its formation, remember that a part of the back of the liver has no peritoneal covering. The serous membrane of the top of the liver is reflected upward and forward under the diaphragm; that of the lower surface of the right lobe downward over the posterior wall. These two folds approach one another at the right side of the liver, and at last meet back to back, forming the triangular ligament. The falciform ligament is seen in front, running very obliquely to reach the umbilical fissure which appears in PLATE IX. The aorta is about passing through the diaphragm at this level. Immediately after this it gives off the cœliac axis, of which all three branches are seen in this plate. The splenic is seen near the front surface of the spleen, the coronary of the stomach between that organ and the liver, and the hepatic in the transverse fissure. A branch of the portal vein lies in the right division of this fissure. Both the supra-renal capsules are shown, presenting, however, quite different outlines. In front of the left one lies a ganglion of the sympathetic system.

¹ Archiv für Anatomie und Entwicklungsgeschichte. 1878.

The views of the stomach are very instructive. They confirm entirely Luschka's statement that the fundus points upward, and that the lesser curvature is essentially vertical. It is astonishing to find it still described as the upper border of the stomach. The fundus reaches nearly as high as the liver. In the axillary line it is opposite the seventh rib. In PLATE VII. it is seen cut transversely. The next view shows the stomach changing its position, running at first forward, and then turning to the right beneath the liver. The lowest part of the greater curvature is seen in PLATE X. This shows also precisely how far it extends to the right. Certainly five-sixths of the stomach are on the left of the median line, as Luschka states. The pylorus is seen in PLATE IX., opposite the first lumbar vertebra. By comparing this plate with the two preceding, the direction of the lesser curvature can be made out. The pylorus is usually found between the ensiform cartilage and the right costal arch.¹

Some important relations of the peritoneum can be studied in PLATE VIII. The space behind the stomach, which extends down into the great omentum, is a part of the lesser peritoneal cavity and communicates with the general cavity by the foramen of Winslow. Remembering that this foramen is bounded below by the duodenum, in front by the portal vessels, behind by the vena cava, and above by the lobe of Spigelius, we see that a line drawn directly forward in this section, from the vena cava to the transverse fissure, would indicate its position, and, indeed, be separated from it only by a thin layer of liver. The < shaped peritoneal cavity, which we see to the left of the lobe of Spigelius, also belongs to the cavity of the omentum. Its anterior wall in this place is formed by the gastro-hepatic omentum, a double layer of peritoneum running from the transverse fissure to the lesser curvature. A considerable part of the spleen is shown at this level without peritoneal covering.

¹ If I remember rightly, the stomach contained frozen milk when the section was made. It was very moderately distended. The fact that the lowest part of the stomach is contracted and the upper dilated is easily understood when it is remembered that the body was frozen lying on its back; so that the contents of the stomach would naturally gravitate toward the fundus.



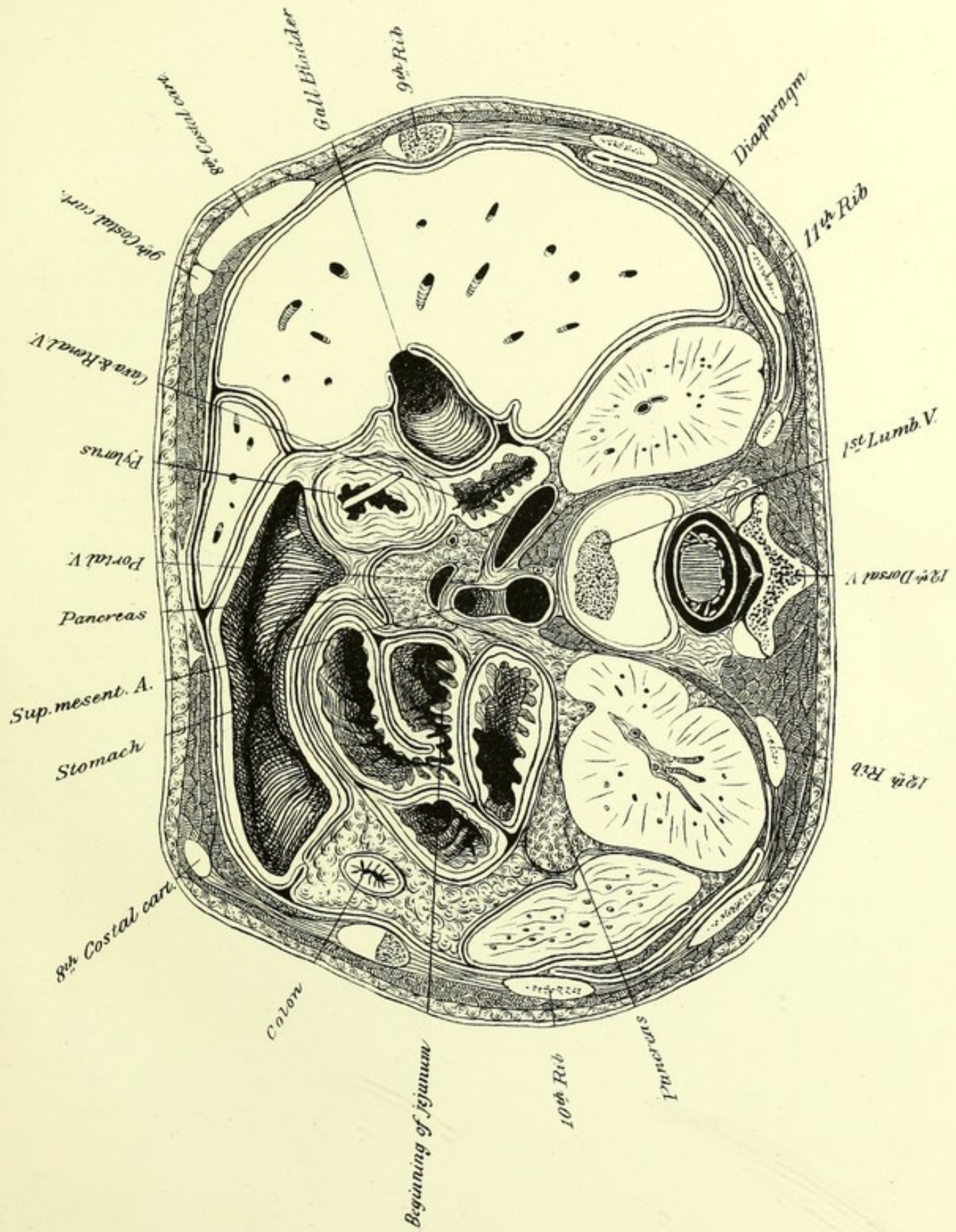


PLATE IX.

THIS section is, perhaps, on the average, 1.8 ctm. below the preceding, and is practically level. The cancellated tissue of the first lumbar vertebra is just nicked at its highest point. The relations correspond remarkably well with those shown in one of Braune's sections through the middle of the same vertebra, the chief difference being that this plate shows more of the liver and stomach. The last four ribs are shown on both sides, and each ninth rib is cut at its junction with its cartilage. In Braune's plate the lowest part of the seventh is shown on one side pretty much as it is shown in PLATE VIII. From this we may infer that not only are the stomach and liver proportionally larger in the child, but also that the lower part of the front of the thorax does not descend so low as in the adult. The lowest part of the pleura is seen on each side. The umbilical fissure, containing the falciform ligament, cuts off the left lobe of the liver. The gall-bladder is opened. It does not extend so far forward as in the adult. The kidneys lie on each side of the spinal column. The left one is divided near its middle, the right one above it. The aorta, lying between the vertebral origins of the diaphragm, is seen giving off the superior mesenteric artery. The portal vein is directly before it, below the pancreas. This is formed by the junction of the splenic and superior mesenteric veins. The inferior mesenteric is a tributary of the former. The vena cava appears immense in this section, which is due to the fact that the right renal vein is laid open at its entrance into it, so that they are shown as one. Valves at or near the mouth of each renal vein and those of the spermatic veins have been alluded to, but the slight descriptions given of them do not agree. Mr. Rivington,¹ who has carefully examined a small number of cases, thinks more extended observations would be likely to establish the existence of valves at the orifices of both the right and left spermatic veins with few exceptions. When no valves exist at the

¹ Valves of the Renal Veins. *Journal of Anatomy and Physiology.* Vol. VI.

opening of the left spermatic vein, some are generally found near it in the renal vein. He found several instances of valves at or near the mouths of the renal veins and also of the semilunar fold at the lower part of the orifice of the renal vein which had been described before.

Perhaps the most important feature of this plate is the view of the beginning and the end of the duodenum. A probe is passed through the pylorus. The thickening of the muscular layer at this point is very striking. The opening looks almost directly backward. The inferior wall of the duodenum is seen in this plate, but the cavity of the gut rises above this level as it passes between the gall-bladder and the head of the pancreas. It then turns abruptly downward, and we see it descending between the gall-bladder and the renal vein. In *PLATE X.* it is seen, having again changed its direction, running from right to left across the body of the second lumbar vertebra behind the mesentery, in which branches of the superior mesenteric artery are seen. It then rises and inclines forward to end in the fold shown in *PLATE IX.* Thus we see both ends of the duodenum at about the same level. They are both, to a certain extent, fixed points; the former being attached to the stomach, and the latter suspended by muscular fibres coming from the cœliac axis and the crus of the diaphragm. The remainder of the duodenum—to wit, all but the ends—is pretty freely movable. It has been compared to a horse-shoe, and to a ring not quite completed.¹ The plates show its peritoneal relations very fairly. In *PLATE IX.* we see its first part covered by peritoneum on the right from the general cavity, on the left from the lesser, both being prolonged from the front and the back of the stomach respectively. In *PLATE X.* the peritoneum is seen covering the front of the transverse portion, excepting where it is behind the mesentery. On the left, it begins to be surrounded again by the peritoneum. In *PLATE IX.* the colon appears in a mass of fat between the liver and spleen. Its apparently minute size and the absence of all peritoneal attachment will be accounted for when it is known that the very highest point of the colon is barely touched. A considerable part of the pancreas appears in this plate, in front of the first lumbar vertebra. The head lies against the duodenum, the tail in front of the left kidney. The peritoneum passes over its anterior surface.

¹ Braune : *Archiv für Anatomie und Entwicklungsgeschichte.* 1877.

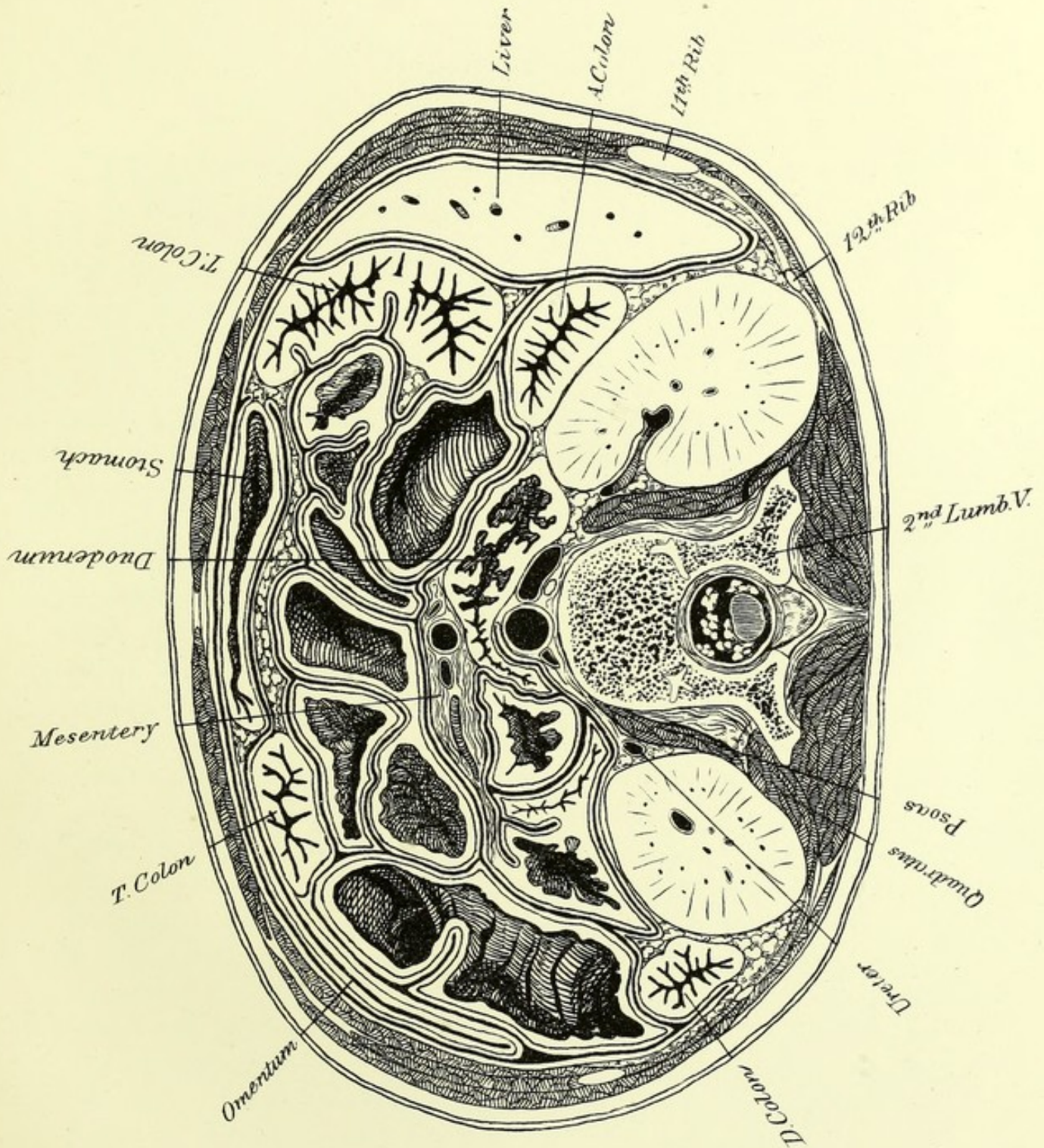


PLATE X.

THE slice above this section, as well as the remainder, are rather thicker than those through the upper part of the body; thus, the level of this plate is nearly 2.3 ctm. below that of the preceding. The second lumbar vertebræ is divided in its lower half. The cartilages of the eleventh and twelfth ribs are cut near their tips; they are now quite out of the thoracic region, and end between the abdominal muscles. The cartilage of the tenth rib is missed on the right by a hair's breadth. The lumbar region of the spine has a mean length in the adult of 17.2 ctm., forming 29.84 per cent. of the movable portion of the spine. The intervertebral disks represent 44.6 per cent. of it. The diameter of the abdomen from before backward is less compared with the breadth than in the last plate, probably on account of the small piece of the liver that is found in this section. The lowest part of the stomach lies in front, and on either side of it a piece of the colon is seen. A piece of the colon appears by each kidney. The transverse colon, as may be inferred from this plate, is a loop or festoon attached at two points to the back of the abdomen, and hanging both downward and forward. The relations of the peritoneum to the colon are interesting, though more important in other parts of it than in those shown in this plate. The parts of the ascending and descending colon lying by either kidney are but partially covered. The great omentum is seen prolonged from the left of the stomach across a piece of the transverse colon. Let it be remembered that the cavity of the omentum is behind the stomach and above the transverse meso-colon, and then is prolonged downward in a fold of peritoneum attached to the stomach above and passing over the front of the colon, and inseparably united to the upper anterior surface of the meso-colon, from which it originally was distinct. The descending portion of the omentum was necessarily drawn in a conventional manner, which makes it appear thicker than it really is at this age. It may become

loaded with fat in the adult. The mesentery lies in front of the duodenum, just below the origin of the transverse meso-colon, and contains the greater part of the ramifications of the superior mesenteric artery in its folds.

The kidneys present, in this plate, pretty nearly the reverse of their relative sizes, as shown in PLATE IX. The right one is here divided at about its middle, and the left one below it. PLATE VIII. shows the left kidney at the disk between the eleventh and twelfth vertebræ, in an angle bounded by the stomach in front and the spleen on the left. The diaphragm and pleura overlap it behind. The left kidney is the higher, though PLATE VIII. unfortunately makes it appear a little higher than it should, owing to the obliquity of the cut. The right one, which is seen alone in PLATE XI., is clearly the lower. The left kidney is said to reach to the upper border of the eleventh rib, and the right half a rib's breadth lower. It is very possible that the difference between the two is more marked in this case, and that the left one is a trifle higher; but this account is not far wrong. About half of the right kidney appears below the ribs, and rather less of the left. The diaphragm, as already stated, covers the back of their upper ends, and lower down they rest against the quadratus lumborum behind and the psoas on their inner side. The peritoneum rests against them to a varying extent, but normally never surrounds them. A kidney may be movable from either one of two causes: 1st, it may have a peritoneal covering and a true mesentery; 2d, and, more commonly, the areolar tissue that surrounds it may become less firm than before, especially by the loss of fat, and thus leave the kidney without support.

The three muscular layers bounding the sides of the abdomen present some features that call for notice. It is interesting to see that the external and internal oblique run in the same direction, and are in the same planes as the external and internal intercostals, respectively, and that the triangularis sterni appears to be a continuation of the transversalis. As to the action of these muscles and the purpose of their arrangement, it is evident that they protect the contents of the abdomen more effectually than if their fibres all ran in one direction. There is, I think, no evidence that they can contract independently, and their close connection makes it improbable. They are essentially compressors of the abdomen; they help to extrude its excretions, and they are sometimes antagonists of the diaphragm. They

assist to give it a firm support for contraction by steadying the thorax. Carried further, their action is to flex the body forward, and, it may be, when one side acts alone, to twist it.

The posterior border of the external oblique does not pass off into any fascia, but is a distinct line running from the last rib to the crest of the ilium, forming the front of a triangle, the base of which is a small portion of the crest, the posterior border being formed by the front edge of the latissimus dorsi. This is the triangle of Petit. The latissimus may reach the external oblique, or even overlap it, as, I think, is the case on the left side of PLATE X. In either case, of course the triangle does not exist; it is usually to be found in adults, and not in infants. Lesshaft¹ found it eighty-four times in one hundred and eight bodies of adults, and only nine times in thirty-five bodies of new-born children and fœtuses. The floor of this triangle is formed by the posterior fibres of the internal oblique. It is a weak point in the abdominal wall. The muscular belly of the great erector spinæ is seen in this plate, but more developed in the following. It is a very powerful muscle, and with the gluteus maximus is the most important in maintaining the erect position. The nomenclature of English anatomists is very clumsy—that of Henle very simple and explanatory instead of confusing. In English we have it divided into seven pieces. The innermost is the spinalis dorsi, which runs between the spines of the upper lumbar and lower dorsal vertebræ and those of the upper dorsal region. Then comes the longissimus dorsi, prolonged by the transversalis cervicis to the neck, and that, in turn, by the trachelo-mastoid to the head. Outside of this column lies the ilio-costalis, its accessory muscle, and finally the cervicalis ascendens, ending at the transverse processes of the neck. Henle very properly omits the spinalis dorsi, treating it as a separate muscle. There then remains the great muscular mass derived from the ilium, the lumbar fascia, and sacrum, which divides into two main columns, composed—the inner of the longissimus dorsi, cervicis, and capitis; the outer of the ilio-costalis lumborum, dorsi, and cervicis, respectively.

¹ Die Lumbalgegend in anatomisch-chirurgischer Hinsicht. Archiv für Anatomie, Physiologie und wissenschaftliche Medicin. (Reichert and Du Bois Reymond.) 1870.

The first part of the document discusses the importance of maintaining accurate records of all transactions. It emphasizes that every entry should be supported by a valid receipt or invoice. This ensures transparency and allows for easy verification of the data.

In the second section, the author outlines the various methods used to collect and analyze the data. This includes both primary and secondary data collection techniques. The primary data was gathered through direct observation and interviews, while secondary data was obtained from existing reports and databases.

The third part of the document details the statistical analysis performed on the collected data. It describes the use of descriptive statistics to summarize the data and inferential statistics to test hypotheses. The results of these analyses are presented in a clear and concise manner, highlighting the key findings of the study.

Finally, the document concludes with a discussion of the implications of the findings. It suggests that the results have significant implications for the field of study and provides recommendations for further research. The author also acknowledges the limitations of the study and offers suggestions for how these can be addressed in future work.

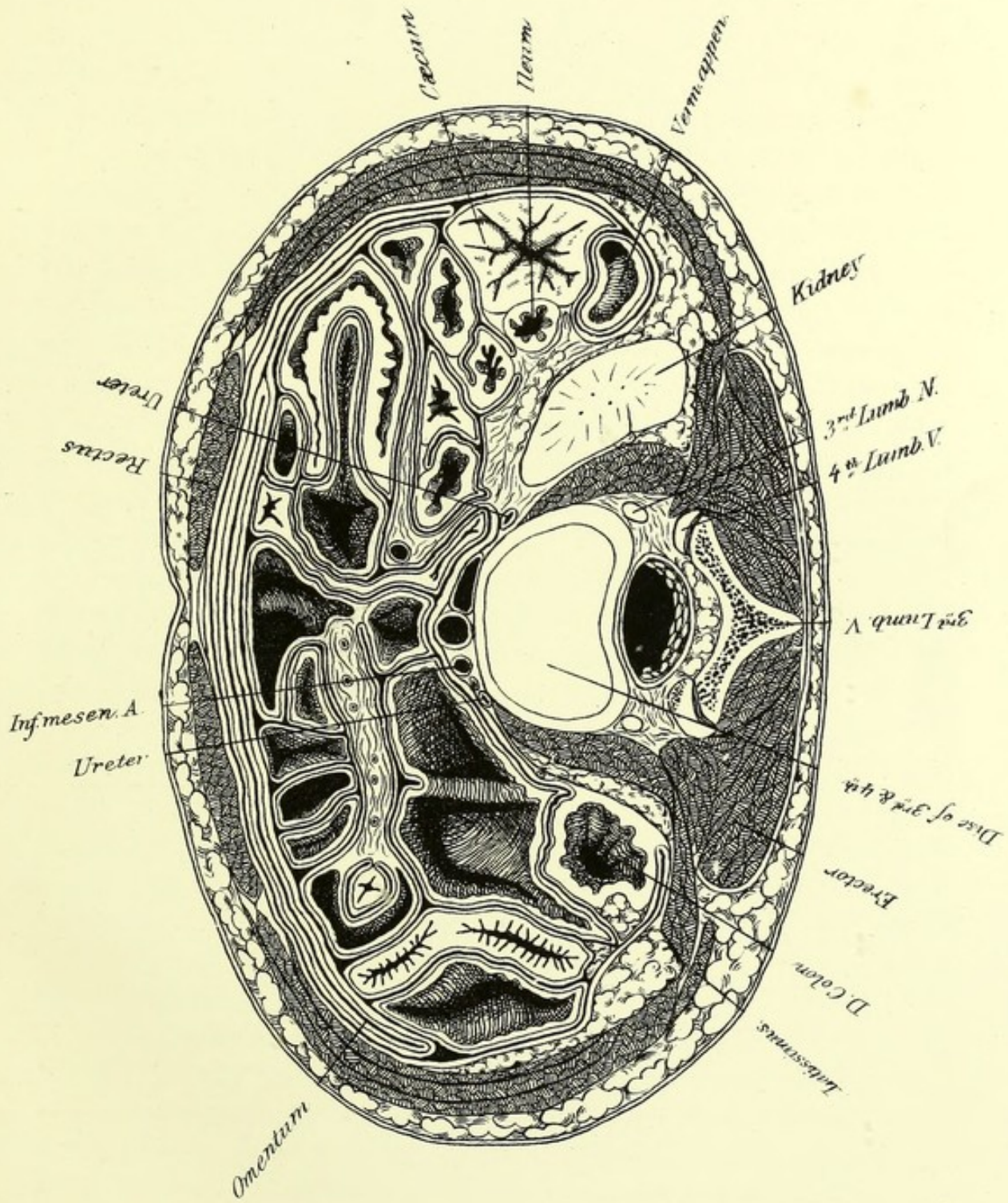


PLATE XI.

THIS section is about 2.4 ctm. below the last. It passes through the intervertebral disk between the third and fourth lumbar vertebræ, showing the spine and arch of the former, embraced by the articular processes of the latter. The breadth of the vertebral column is apparent. The spinal cord has come to an end in the thickness of the slice above, probably near the top of the third lumbar. At birth it is said to approach the fourth lumbar, but owing to the more rapid growth of the spinal column, it subsequently is not found so low. In man it ends at about the lower border of the first, and in woman, perhaps half way down the second. Nevertheless, according to Ravenel,¹ the female cord is relatively shorter than the male. In this subject the cord is still relatively long. In the adult the origins of the nerves of the lumbar plexus are opposite the space from the eleventh to the twelfth dorsal spine, or a little lower, and those of the sacral plexus extend from the latter point to the first lumbar spine. They are, of course, lower here, but they cannot easily be placed.

The umbilicus is rather below the level of this cut, opposite the fourth lumbar. Holden places it opposite the third lumbar, and Luschka opposite the lower edge of that vertebra. If I may differ from such authorities, I should say that it is more frequently below than above the disk between the third and fourth lumbar vertebræ, and near the level of the highest point of the crest of the ilium. I do not think that in this instance it is far from the adult position, though still rather lower.

The great omentum lies in front of the intestines. Two pieces of the mesentery are seen, one of which runs transversely, and the other forward toward the right rectus. In the right anterior part of the abdomen there is an appearance somewhat resembling a diverticulum, such as is sometimes found in the lower part of the ilium. It is not one, however, but a true invagination of the intestine. There

¹ Zeitschrift für Anatomie and Entwicklungsgeschichte. Band II.

is no sign of inflammation around it. It is probable that small invaginations occur not rarely in children, and reduce themselves without giving rise to symptoms.

The cæcum is seen in this plate lying on the right side of the abdomen. More than one-half of it is below the surface of this section, so that we may with sufficient accuracy say that it is on a level with the umbilicus. The ilium lies on the left of the cæcum as it descends to open into it lower down. The vermiform appendix, which arises from the rear of the cæcum at a still lower point, appears behind it. It pursues a twisted course, in the main, upward and inward. To understand this position of the cæcum, we must remember that in the early part of fœtal life the cæcum, which is a little diverticulum of the intestine, lies below the liver near the median line. The future large intestine runs from this point to the left, and then downward. Gradually, however, the cæcum moves to the right above the mesentery, thus forming the transverse colon. It then descends along the right side of the abdomen, forming the ascending colon. According to Dr. Allen Thomson,¹ the parts are in the same positions as in the adult in the fourth or fifth month of fœtal life. Kölliker² states that they descend toward the iliac fossa in the latter half of fœtal life. It is evident that in this child the cæcum has made very little progress in its descent from the right hypochondrium. My observations lead me to believe that the wanderings of the cæcum are not completed as soon as these authorities state. I doubt very much if, as a rule, it has reached its permanent position at birth, and think that not very rarely it does not reach it for a year or two afterward.


The ascending colon, what there is of it, runs upward in front of the right kidney, in the angle between it and the lowest part of the liver, as is shown in PLATE X. It rises a little above this level, but soon turns down to reappear in the same plate as the transverse colon, which is traced to the side of the stomach. It reappears on the left of that organ, and rises higher than on the right. Its highest point is just opened in PLATE IX. beside the beginning of the cartilage of the ninth rib. The descending colon is seen in Plate X. outside of the kidney. It follows the surface of the organ, so that below the kidney in PLATE XI. we see it further in, just opposite the border of the erector spinæ. In PLATE XII. it is making its way forward, lying

¹ Quain's Anatomy. Eighth edition. Vol. II. ² Entwicklungsgeschichte.

in the angle between the psoas and iliacus. In the next plate it has reached the abdominal walls, and a little later begins to form the sigmoid flexure, which we will leave for the present. Two points of comparison with the adult arrangement must be mentioned. The right colon of the adult passes in front of the right kidney, as is the case with its rudiment here.¹ The left colon on the other hand, lies on the outer side of the left kidney. The transverse colon in the adult not uncommonly hangs down in front as low as the umbilicus. Both the ascending and descending colon are but partly covered by peritoneum at the level of PLATE X. The descending one, however, is more covered in the next plate, and has a true mesentery in the iliac fossa. The relation of the peritoneum to the colon, especially on the left, is of much surgical importance. The extent to which the gut is covered varies extremely, and at all ages. Lesshaft found that on the average the left colon had a mesentery, usually a very short one, once in six subjects.

The lumbar fascia deserves notice. The superficial layer is a very strong diamond-shaped aponeurosis, extending high up in the dorsal region, down toward the coccyx, and laterally on to the ilia. The latissimus dorsi arises from it above, as does also the serratus inferior, and the gluteus maximus springs from it below. The erector spinæ which it bridges over has a part of its origin from the deep surface of this fascia. In short, the muscles that straighten the body, by drawing both the upper and under halves backward, spring from it. This arrangement shows the necessity of the thickness of the anterior portion of the capsule of the hip-joint. At the outer margin of the erector spinæ the fascia above described is joined by the middle layer of the lumbar fascia, which runs to the transverse processes of the lumbar vertebræ. This is continuous with the transversalis muscle, and some fibres of the internal oblique arise from its posterior surface. In front of this fascia lies the quadratus lumborum, which extends beyond the outer edge of the erector. Covering the anterior surface of the quadratus is the inner layer of the lumbar fascia, extending from the roots of the transverse processes outward to join also the transversalis muscle. Below it is attached to the crest of the ilium, and it ends above as the ligamenta arcuata. The superficial layer of the lumbar fascia, which is very dense is shown in PLATE XI., turning round the outer borders of the erectores.

¹ Lesshaft, loc. cit. This rule does not seem to be quite without exceptions.



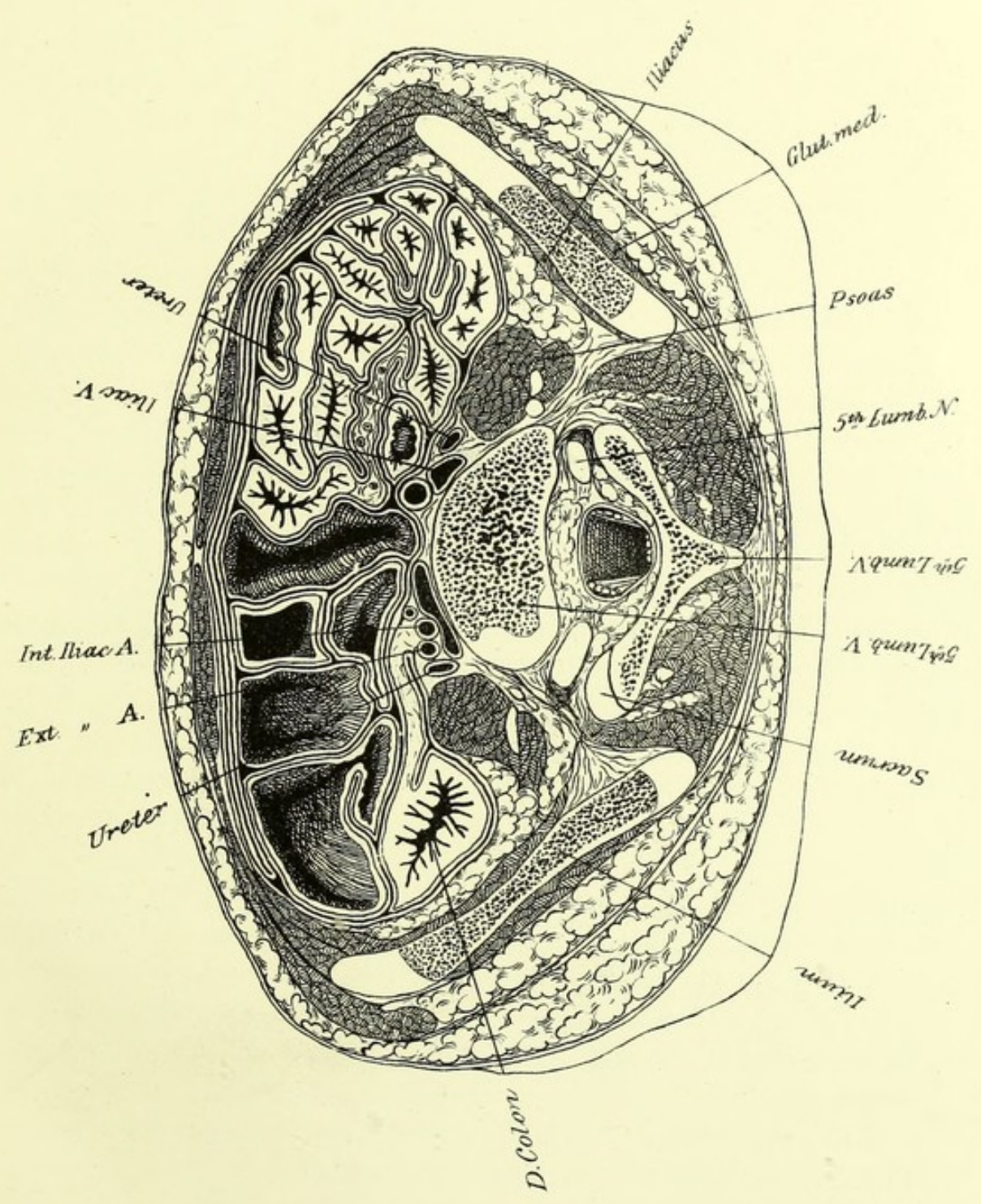


PLATE XII.

THIS section, about 2.4 ctm. below the last, is not quite even, the right side being the higher. Though the difference is slight, it is sufficient to occasion considerable discrepancy between the lateral halves which otherwise would be nearly symmetrical. The right ilium, of course, seems not only shorter, but more cartilaginous than the other. The fifth lumbar vertebra shows an asymmetry that is really only apparent, for on the left it is struck at its prominent lower border, and on the right in the concavity which its surface presents. The articular process of the sacrum appears on the left, but not on the right. The fifth lumbar is shown enclosed by the ilia, which project above it and behind all of it except the spinous process. The ilio-lumbar ligament, running from the transverse process of the last lumbar to the crest of the ilium, is above this section, but strong bands of fibres, running more or less obliquely between different points of the vertebral column and the ilium, are seen on both sides. It is well to remember that the spine of the fourth lumbar vertebra is on a level with the highest point of the crest of the ilium.

Having reached the lower end of the movable portion of the spinal column something may be said of its curves, and first of those in the adult. There is no absolute standard; all people do not have the same curve. Apart from the peculiarities of the figure of each individual, the curve is modified by the profession, the age, various diseases, by fatigue, and by position. Mr. Wood¹ gives a rule which, though it is not confirmed by my observations, is, no doubt, approximately correct, and is certainly simple: it is that a line from the centre of the body of the axis to that of the last lumbar vertebra at its articulation with the sacrum passes through the body of the first dor-

¹ Topographical Relations of Arch of Aorta, etc. *Journal of Anatomy and Physiology*. Vol. III.

sal and second lumbar. He adds that it "would indicate the line of gravity of the head and trunk in a perfectly upright and balanced position, traversing the pelvis midway between the cotylo-femoral joints and falling between the bases of support." It should be stated that these remarks of Mr. Wood apply especially to the young adult male. Henle's rule that the middle of a line from the top of the atlas to the end of the coccyx is opposite the eleventh dorsal, that the first quarter ends opposite the lower border of the third dorsal, and the third quarter opposite the lower edge of the fourth lumbar, has seemed to me remarkably accurate. At birth the spinal column is very nearly straight; indeed, the line of the spinous processes may be perfectly so, but the bodies of the vertebræ show a curve in the cervical and dorsal regions.¹ According to Ballandin² the normal curve of the neck does not appear till the third month after birth. It soon becomes more stable, as does also the dorsal one. The lumbar curve does not appear till the child begins to walk, and it is stated that it can be obliterated by traction on the detached spine till the twentieth year. Ballandin's views on the production of the lumbar curve are interesting and plausible, and agree well with what was said in the last chapter concerning the powerful muscles of the back that maintain the upright position and the strength of the front part of the capsule of the hip. Ballandin states that if a very young child be laid on its back, with the lumbar and dorsal spinous processes resting on the table, the legs naturally assume the position of outward rotation, the knees usually being somewhat bent. If the knees are brought together, they at once spring up farther from the table; but if they be pressed down and made to touch it, the abdomen becomes prominent and the spinal column bends forward in the lumbar region. The same thing occurs after the removal of the viscera, and can be shown to depend on the shortness of the ilio-femoral ligaments. As the child learns to stand and walk, and the great erector muscles are raising the body, they are constantly resisted by this ligament (assisted probably by the iliacus and psoas), and thus the obliquity of the pelvis is increased and the lumbar region of the spine pulled forward.

Returning to this plate we find little worthy of notice in the abdominal viscera. The colon is seen between the left iliacus and psoas,

¹ Bouland: Robin's *Journal de l'Anatomie et de la Physiologie*. 1872.

² Virchow's *Archives*. Vol. LVII.

the omentum is still in front, and the remainder of the space is filled by folds of small intestine, which are distended on the left and contracted on the right. The psoas makes a bold projection on either side of the vertebra. Nerves of the lumbar plexus are seen within it. A considerable amount of fat lies between the psoas and iliacus behind the peritoneum. The aorta has divided in the thickness of the slice above this plate, presumably at about the normal position opposite the middle of the fourth lumbar vertebra. It is much more likely to divide below than above this point. The common iliac artery and vein are seen on the right, while on the left, at a somewhat lower level, the external and internal iliac arteries lie, just after their origin, in front of the common iliac vein, which is running very obliquely at this point. The iliac arteries usually divide near the lower border of the last lumbar vertebra. The right one is usually the longer. Their relations to veins differ materially. At their lower ends each has the vein at its inner side, but the left vein inclines to the right, as does also the right one, which gets behind its artery, and the two unite to form the vena cava behind the right iliac at a point below the bifurcation of the aorta.

Nothing has been said of the ureters, which, indeed, call for little comment till they reach the bladder. They descend along the psoas behind the peritoneum. In this plate they are still on the outside of the iliac vessels, which they usually cross near the division of the common iliacs. In *PLATE XIII.* they pass near the outer angles of the promontory of the sacrum. It is not uncommon for the ureter to be double at its origin, but the two roots almost always unite before opening into the bladder.



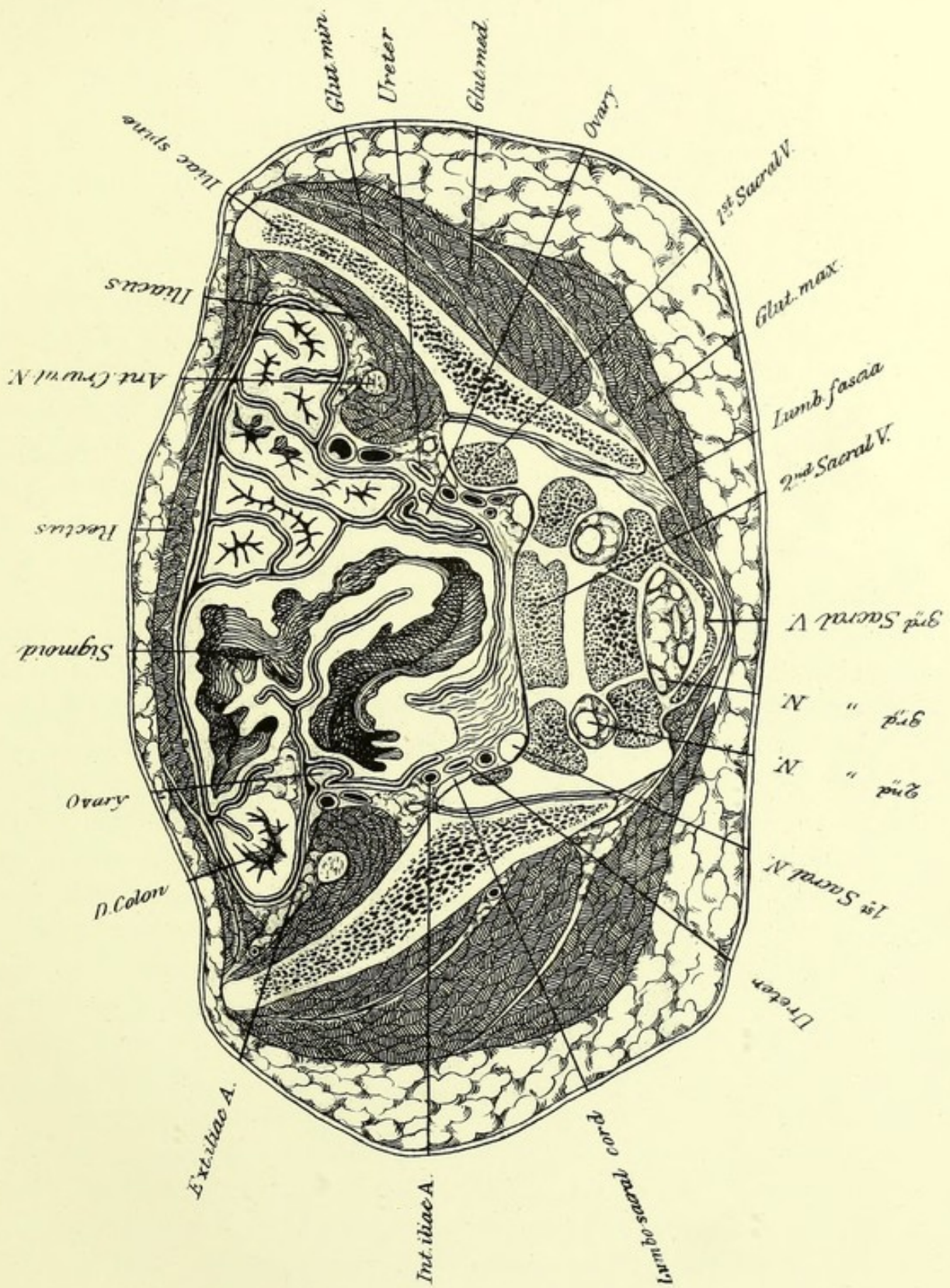


PLATE XIII.

THIS is an interesting but, at first, a very confusing section. It is nearly 2.5 ctm. below the last, and rather higher on the right than on the left. The very curious view of the sacrum suggests that the cut slants backward, but it does so, at most, to a very slight extent. The anterior superior spinous processes of the ilia are struck pretty evenly on both sides. The articular surface of the ilium is separated from the expanded portion that forms the wall of the false pelvis by a well-marked angle which represents the beginning of the ilio-pectineal line at the edge of the promontory of the sacrum. On account of the relations of the great sacral nerves to the vertebræ it will be convenient to consider both together. The fifth lumbar nerve is seen in PLATE XII. leaving the spinal canal; it is seen again in this plate, close by the promontory, as the lumbo-sacral cord, a name it assumes after it is joined by a branch from the fourth lumbar, which probably has occurred before it has reached this level. The first sacral nerve appears just as it leaves the anterior sacral foramen. The bodies and the lateral masses of the second and third sacral vertebræ are seen farther back, cut very obliquely. The second sacral nerve lies in the foramen between them. The arch of the third vertebra is very accurately hit. The third sacral nerve, much smaller than the preceding ones, lies in the canal, which it is just about to leave. The sacral plexus, be it remembered, is formed by the lumbo-sacral cord, the first three sacral nerves, and a branch of the fourth. It is a broad nervous band, reaching toward the lower part of the great sacro-sciatic foramen, which its direct continuation, the great sciatic nerve, leaves below the pyriformis. The view of the process of ossification is a very instructive one. The inclination of the pelvis must be very considerable to account for this view of the sacrum. To place the pelvis in its proper position, the normal conjugata of Hermann Meyer should form an angle of 30° with the horizon. This conjugata is a line run-

ning from the top of the symphysis to a transverse line across the body of the third sacral vertebra. The anterior superior spines of the ilia should be in the same vertical plane as the spines of the pubes, and perhaps even a little in front of it. Very different views are expressed as to the difference in the curve of the male and female sacrum. I agree with Ward that the male sacrum is the more curved, and that the curve is more regular. The female sacrum is more distinctly divided into two parts, the upper of which is smooth and the lower curved, by the line just mentioned, which crosses the third vertebra. This line, I believe, was first described by Hermann Meyer. It is not rare to find the sacrum composed of six vertebræ. Sometimes it seems as if there were an extra piece, intermediate in character and position, between the lumbar and sacral vertebræ, or the number of the latter is evidently increased. Bacarisse¹ gives a rule for determining whether a mutilated sacrum is one of five or six pieces. If a line connecting the lower ends of the auricular surfaces pass above the middle of the third vertebra, there are five pieces; if below it, six. The sacro-iliac synchondrosis is one of the strongest in the body, but great additional strength is gained by the very strong ligaments passing from the sides of the sacrum and the back of the ilia, so as to oppose the separation of the latter by the weight of the body on the sacrum. The psoas and iliacus lying on the inner side of the ilium encroach a good deal on the abdominal cavity. The tendon of the psoas, at first inside the muscle, has now reached its outer border. It receives fibres from the iliacus as well as from the psoas. The viscera that are shown in this plate are, for the most part, either in or above the cavity of the true pelvis. The descending colon, and some folds of the small intestine, occupy the iliac fossæ, and the anterior wall of the abdomen is distended so as to project in front of the pubes. Most of the remaining cavity is occupied by the sigmoid flexure of the colon. The point where the descending colon ends and the sigmoid flexure begins is not a very definitely placed one. In this instance it is in the thickness of the slice below PLATE XIII. We see the descending colon cut transversely. It passes to the right, turns suddenly, and reappears behind the left rectus as the sigmoid. Luschka places the beginning opposite the highest point of the crest of the ilium, where the colon begins to be surrounded by peritoneum.

¹ Inaugural Thesis. Paris. 1873.

It must be remembered that the whole descending colon may be so covered, and there seems no reason for having the change of name precede the change of direction. The sigmoid flexure in this case forms a very respectable "S," ending opposite the left sacro-iliac synchondrosis, where the rectum begins. This flexure is attached to a pretty long mesentery that allows it to move very freely. Its position varies not only with the degree of its distention, but with that also of the bladder and of the other folds of intestine. It may be found in the right iliac fossa. In new-born children it very frequently extends into the right inguinal region; indeed, it is always there at that age according to some authorities.

The ovaries are seen in this plate occupying very different positions from those they assume later. The right one is situated at the margin of the true pelvis opposite the outer part of the promontory. The left one is much farther forward, opposite the external iliac vessels and entirely above the true pelvis, for this section strikes its lower end. They are both placed with the end nearest the uterus below, and with their flat surfaces looking sideways. They are covered by a fold of peritoneum. The ovaries, in fact, are descending into the pelvis in a manner perfectly analogous to the descent of the testes, only in a different direction. In the adult the ovaries are in the true pelvis. It is very doubtful if they are always in the same position.

The right external iliac artery appears much larger than the left, which is probably due to the injection having been made from the right femoral. The branches of the internal iliac vessels are much behind them, making their way downward to the back of the pelvis. The gluteal muscles are well shown, but require no special comment.



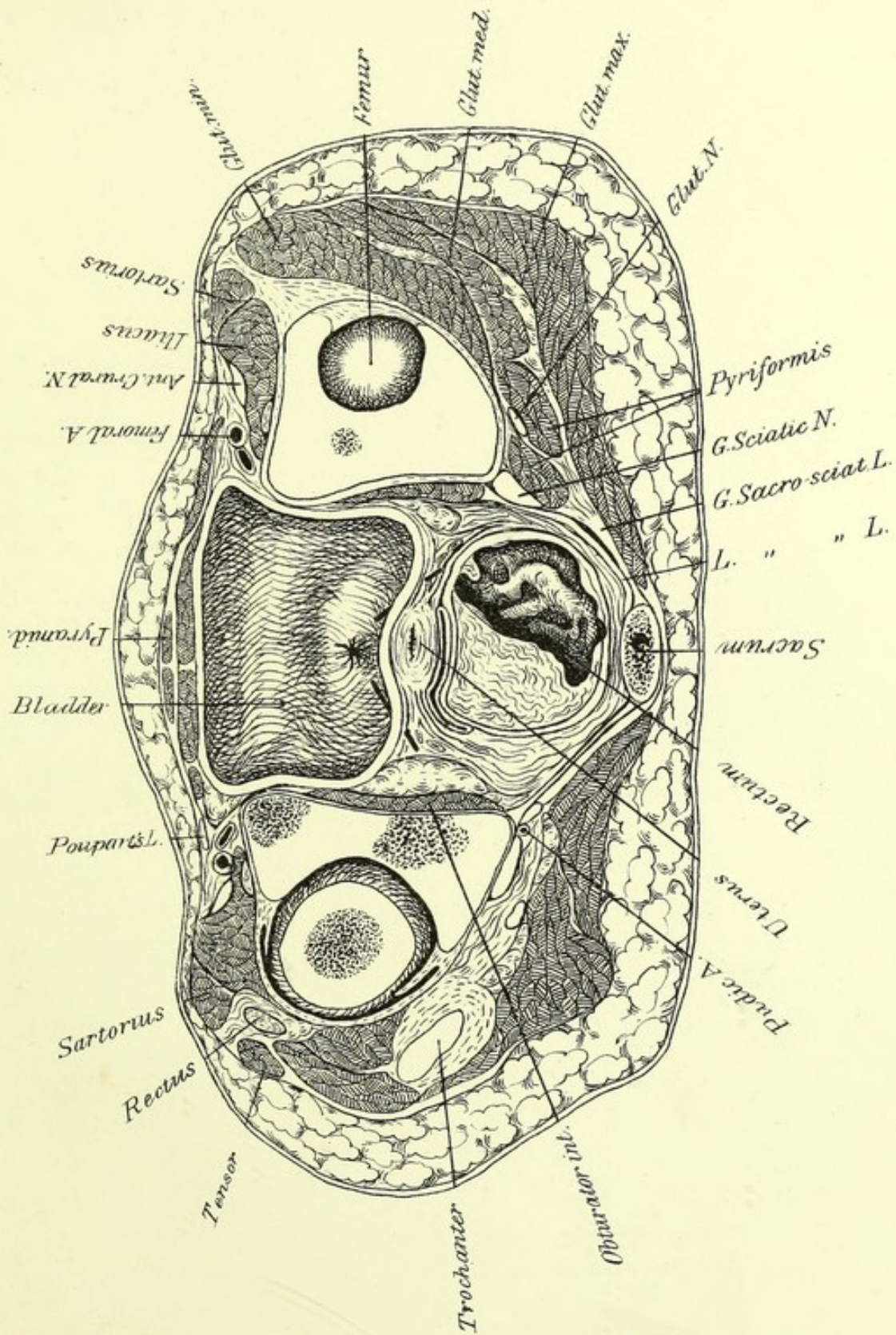


PLATE XIV.

THE plane of this section is about 2.2 ctm. below that of the one above. It passes 7 mm. above the symphysis of the pubis and strikes the last piece of the sacrum. It is higher on the right than on the left, but about level from before backward. Hence it is evident that, in this case at least, the pelvis has reached its full inclination. One is struck by the length of the antero-posterior diameter compared with the transverse one; but sections by Braune, Pirogoff, and Rüdinger show very nearly the same proportions in similar sections of the adult pelvis. The prominence of the front of the abdomen, though caused in part by the distended bladder, is due even more to the accumulation of subcutaneous fat above the pubes. At least half the cavity is filled by the bladder, which was moderately distended with urine. The cut divided it very nearly evenly. It is not pointed above, as in infancy, but is irregularly globular and somewhat compressed from before backward, which often is the case with the female bladder, as is also, according to Luschka, the lateral asymmetry which is seen in this instance. The lightly shaded part of the bladder shows the place at which it bulges forward over the pubes. The summit of the bladder is at the anterior border, where it extends upward between the intestines and the abdominal wall. The posterior wall of the bladder is thicker than the front one. The lowest point is at the opening of the urethra, which is very sudden, if the expression is allowable. There is the merest trace of a funnel-like narrowing, constituting the so-called neck of the bladder. This, if it exist at all, is, at all events, much less developed in the female than in the male. Straws have been passed through the terminations of the ureters, which are not themselves visible, as they open in the posterior wall of the bladder. The *trigonum vesicæ* is a triangle formed by the openings of the ureters and the urethra, the mucous membrane covering it being smooth instead of in folds, as elsewhere. The wall below it is thickened

by muscular fibres from the ureters, and a band running between their orifices may cause a ridge in the bladder. Accounts of the position of the trigonum do not agree. It is usually described as being at the lowest part of the bladder, its posterior angles being somewhat raised. Richet, however, states that the lowest part of the bladder is the "*bas fond*" situated behind the trigonum. The openings of the ureters in this case, however, are distinctly in the posterior wall. In another girl, a little larger than this one, examined also by frozen sections, they have very nearly the same position. In a boy of about the same age, examined by opening the abdomen, the bladder was found nearly empty, and the trigonum was in the lower wall, though the ends of the ureters were higher than the urethra. There was a pouch formed by the posterior wall behind the ridge, at the base of the triangle. It seemed as if distention of the bladder would have raised the orifices of the ureters. In Braune's sagittal section of a young male (twenty-one years), they are in the posterior wall. It is probable that this is their normal position in youth, and that, with advancing years, they gradually sink lower, especially in the male, in whom the base of the bladder is larger, and in whom the bladder is with more difficulty completely emptied from various causes, and in whom, chiefly on account of the enlarging prostate, a depression or pouch behind the trigonum is very frequently developed in the latter part of life. In the female, this does not occur. The peritoneum covering the bladder approaches the plane of this section very closely at the anterior angles of the organ, and behind it, where it is reflected over the uterus. In the median line it does not come within 1.5 ctm. of the pubes.

This plate shows the lowest part of the body of the uterus. It is not over two centimeters in length, measured as well as circumstances permit along the posterior surface. It is less expanded at the upper portion than in the adult. It inclines forward, resting against the back of the bladder. The broad ligaments are seen on the under surface of the slice above, running to the sides of the pelvis. The Fallopian tubes run much more upward than in the adult, so that the ovaries are seen in the preceding section. The folds of the broad ligament contain, even at this age, many veins which later form a series of very rich plexuses, which communicate both with the system of the iliac veins, and also by the *plexus pampiniformis* and ovarian veins, with the vena cava on the right and the renal vein on the left. These veins may become largely dilated and varicose, forming a true varicocele in

the female.¹ The diagnosis cannot be made with certainty, but it is very probable that this state would account for some of the obscure pains felt in the left side only at the menstrual period. The rectum is described elsewhere. Suffice it, therefore, to say that it is struck just as it is completing a curve with its convexity to the right. Below the fold, seen on the left, it expands to its greatest dimensions. This plate shows the lowest part of the peritoneal pouch between it and the uterus, which extends here as in the adult, behind the upper part of the vagina. The distance of this from the anus is in this subject approximatively 2.5 cm. According to Tillaux, in the adult male this distance is 5 cm. with an empty bladder and 6 cm. for a full one. There may be a variation, however, of 2 cm. It is well known that when the bladder is distended, a greater extent of it lies above the symphysis uncovered by peritoneum. Dr. Garson² has shown that a distended rectum materially changes the relations both of the bladder and of the peritoneum. His observations apply only to the male. He has shown that by distending the rectum the bladder may be pushed bodily upward, carrying the peritoneum farther from the symphysis, and raising it also between the bladder and rectum. This displacement of the bladder is due to stretching of the urethra, chiefly in the prostatic and somewhat in the membranous portion.

The greater and the lesser sacro-sciatic ligaments are seen most distinctly on the right side. The latter lies inside of the former. With the aid of the muscles they supply the deficiency in the walls of the pelvis caused by the sciatic notch. The obturator internus is seen inside the pelvis, in the chamber formed by the bone and the obturator fascia. A mass of fat occupies the ischio-rectal fossa between this and the pelvic fascia which passes to the sides of the bladder, vagina, and rectum. The left ischium is divided just at the spine, to which the lesser ligament separating the two foramina is attached. The pudic artery and nerve (the latter drawn rather large) are seen as they turn round it. The glutei muscles are shown most clearly on the right. On

¹ Some years ago, while injecting the system of the vena cava inferior from the common iliac vein in a woman of at least middle age, I was surprised to see a very rich plexus of veins appear in the left broad ligament and send a branch across the uterus. I found that this had occurred by the passage of the injection from the left renal vein downward through the ovarian vein, which was as large as my little finger. *Vide* Boston Medical and Surgical Journal, Vol. 96. I subsequently found that this condition had been described in Richet's *Anatomie Médico-Chirurgicale*.

² *Edinburgh Medical Journal*, October, 1878.

the left the top of the great trochanter appears. Its position shows that the leg had rolled outward as the body lay on its back to be frozen. The pyriformis, in two parts, is seen on the right. The great sciatic nerve, which leaves the pelvis below it, appears in front of it. On the left, where the plane is lower, this nerve has already made its way outward, so as to lie behind the ischium. The lower branch of the great or superior gluteal nerve is seen on both sides. The main trunk leaves the pelvis above the pyriformis; it then divides into two branches, of which the lower may be seen more distinctly on the right side tending toward the space between the gluteus medius and minimus.

The right hip-joint is opened so high up that but a very small piece is taken from the head of the femur. Curiously enough, this plate shows the three centres of ossification of the acetabulum; that of the ilium, which is the highest on the right, those of the pubes and ischium on the left. The socket is not thoroughly solidified till the seventeenth or eighteenth year.

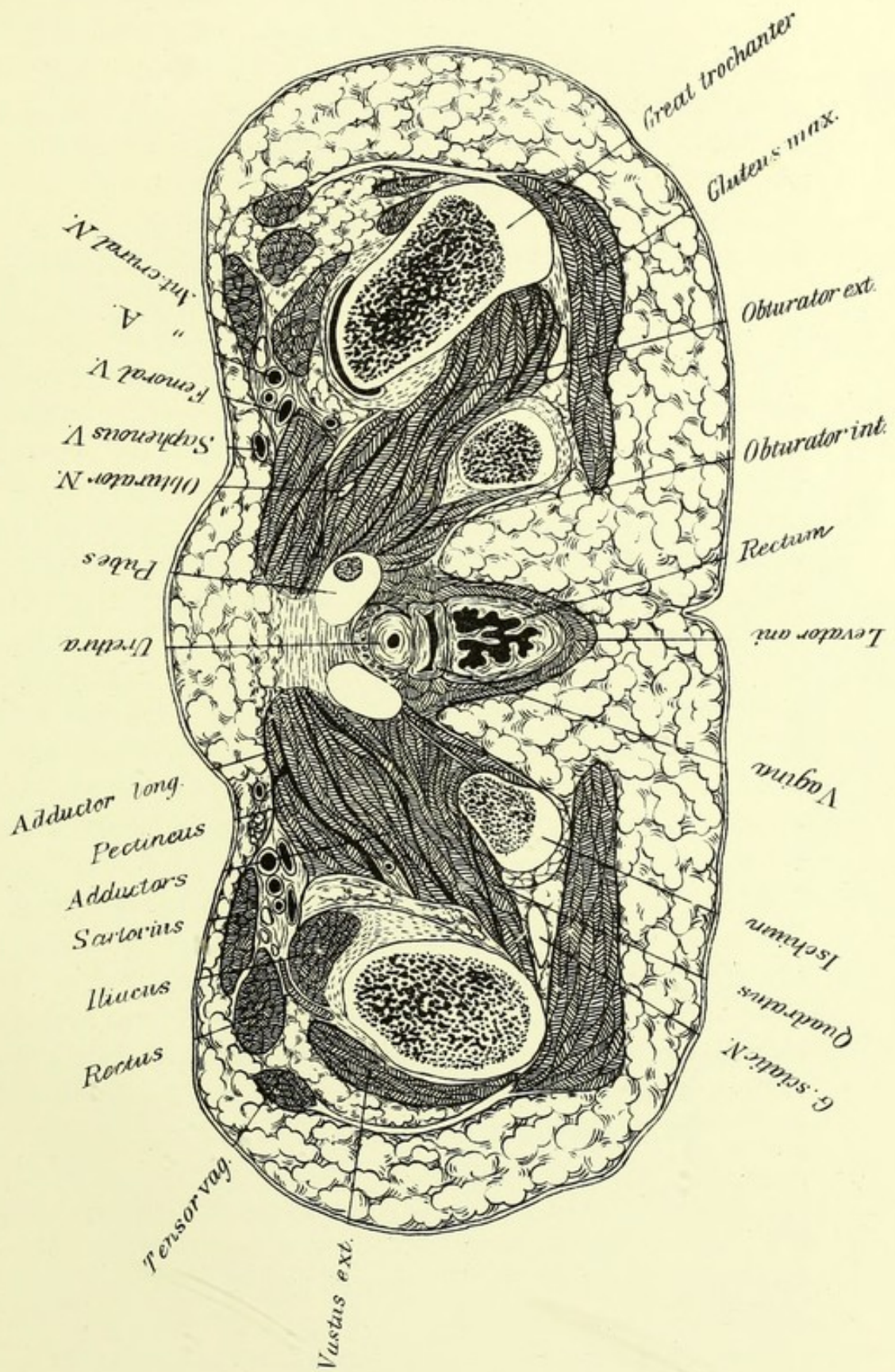


PLATE XV.

THIS section is about 2.2 ctm. below the last. It passes just below the symphysis in front, and misses by a very little the tip of the coccyx. These two points, therefore, are about on a level, if the section is straight. There is, however, a suspicion that it may slant a little backward. The tuberosities of the ischia with the pieces of the pubes map out the lateral outlines of the pelvis, which appears triangular. If the section had been a little higher, so as to strike the tip of the coccyx and the great sacro-sciatic ligament, it would have been irregularly diamond-shaped. As it is, we see the obturator internus on either side, in its case formed by the obturator membrane and the obturator fascia; and in the middle the urethra, vagina, and rectum, enclosed by muscle which appears to be the lower part of the levator ani. On either side of this is the fat of the ischio-rectal fossa, which runs up between the levator and the obturator fascia, and is continuous below with the fat of the thighs and buttocks. The coccygeus, which runs from the spine of the ischium to the side of the coccyx, is in the same plane as the levator ani, and what in the male is called the levator prostatae, and in the female runs to the sides of the vagina, is really a part of the same.

We will now follow the rectum from its beginning, opposite the left sacro-iliac synchondrosis, which appears in PLATE XIII. It then sweeps downward, backward, and to the right, frequently, at least, crossing the middle, and then describing another curve with its convexity to the right, resumes its median position. PLATE XIV. shows the last mentioned curve. On the left is seen a sharp fold formed by the bowel which falls on the line of the section, below it the rectum expands into a pouch opposite the last piece of the sacrum. The rectum then runs forward and at last turns distinctly downward and backward. This last curve exists in both sexes, and it is very important that it should not be forgotten when introducing instruments.

PLATE XV. shows the rectum at the beginning of the last curve and below the expansion which it presented at the level of the preceding plate. The folds of the mucous membrane of the rectum are mostly vertical near the anus, this plate shows a well-marked anterior one; higher up they are transverse or oblique. The external sphincter deserves its name, not only because it is below the internal, but because it surrounds it also. The fibres of the levator ani reach the gut at the upper border of the external sphincter and mingle with those of that muscle. Some 8 ctm. above the anus, there is very commonly a thickening of the circular muscular fibres, called the third sphincter. It is of little consequence and does not deserve the attention it has received. The mechanism of defecation is probably pretty much as follows: The fæces accumulate in the sigmoid flexure, only a small part descending into the rectum between operations, except in cases of habitual constipation. When the mass passes into the rectum in sufficient quantity, the need of an evacuation is felt, but the process is started by the voluntary muscles, such as the diaphragm and those of the abdomen which compress the abdominal contents. This compression is increased by the contraction of the levator ani, which at the same time tends to pull open the anus. The sphincters yield before the pressure. Just how great a share of the work is done by the muscles of the intestine proper can hardly be ascertained. It is probable, however, that their assistance is necessary to completely empty the rectum. Doubtless sometimes they play the chief part, and sometimes a very subordinate one. The upper part of the rectum has a true mesentery, which permits moderate displacement. It has been demonstrated that the whole hand can be introduced into the rectum, and also that it had much better not be, unless the information to be gained is of sufficient value to justify risking the patient's life to obtain it. A wedge-shaped space between the lower parts of the rectum and vagina, which bend respectively backward and forward, is filled in part by the sphincter muscles and the remainder by areolar tissue. This is the perinæum. The urethra is seen just in front of the vagina.

The right femur is struck at the great trochanter. The lowest part of the cavity of the joint is opened on that side, but on the left the cut passes lower, a little above the trochanter minor. The psoas and iliacus, now united, are seen on both sides, on the left, just above their insertion. They lie in front of the hip-joint, and send some

fibres to the capsule, which is thus drawn out of the way by the same muscle that flexes the thigh. A bursa is placed on the anterior surface of the capsule, which sometimes opens into the joint. Pus from a psoas abscess can in this way enter its cavity. The views of the muscles are very nearly the same on both sides, the chief difference being that much more of the vastus externus is seen on the left. The gluteus maximus and the tensor vaginae femoris are seen inserted into the fascia lata, a part of which passes uninterruptedly from the crest of the ilium to the tibia. The rectus lies beside the tensor, and the sartorius is seen in front. On the left leg the last overlaps the femoral vessels, which lie on the pectineus, the adductor longus being between the latter and the median line. The obturator externus can be easily identified on both sides by its relation to the obturator membrane. Behind it is seen the quadratus femoris, running from the tuberosity of the ischium to the femur. The great sciatic nerve lies between the quadratus and the gluteus maximus in the space between the tuberosity and the trochanter. The remainder of the muscular mass between the pelvis and femur belongs to the adductor group, but as often happens, the divisions are so irregular that the individual muscles cannot be certainly distinguished. The femoral vessels are named on the right side and require no comment. On the left the section passes below the origin of the profunda, and consequently the relations are less simple. The femoral vein has already passed behind the artery. The profunda artery and vein are situated on their outer side. The external circumflex artery is seen winding round the femur between the iliacus and the rectus.

Faint, illegible text, likely bleed-through from the reverse side of the page. The text is too light to transcribe accurately.

INDEX.

- Aorta, p. 19
 arch of, 20
 division of, 51
- Artery, carotid, 9, 12
 cœliac, 36
 iliac, 51
 pulmonary, 19, 20, 21
 subclavian, 12
- Axilla, 17
- Bladder, 57
 displacement of, 59
- Cæcum, 46
- Chassaignac, tubercle of, 7
- Colon, 40, 41, 46, 47, 54
- Conus arteriosus, 23
- Costal cartilages, 15
- Defecation, mechanism of, 62
- Diaphragm, action of, 32
- Duodenum, 40
- Fallopian tubes, 58
- Fascia, cervical, 9, 12
 lumbar, 47
- Fossa, ischio-rectal, 59, 61
- Heart, 23, 28
- Kidney, 39, 42
- Ligament, coronary, of liver, 36
 sacro-sciatic, 59
 suspensory, of diaphragm, 13
- Liver, 35
- Lung, apex of, 11
 extra lobe of, 24
 fissure of, 24
 lower border of, 31
 root of, 21
- Mediastinum, anterior, 15
 posterior, 21
- Membrane, costo-coracoid, 13
- Mesentery, 42
- Muscle, abdominal, 42
 deltoid, 13
 erector spinæ, 43
 levator ani, 61
 psoas, 54
 scalenus, anterior, 11
 minor, 12
 serratus magnus, 14
 sphincter ani, 62
 sterno-mastoid, 8
 trapezius, 14
- Nerve, cervical, 8
 lumbar, 45
 phrenic, 8, 12, 17
 pneumogastric, 9, 17
 recurrent laryngeal, 8, 12
 sacral, 53
- Nipple, 23

- Oesophagus, course of, 16
 end of, 31
 Omentum, cavity of, 37, 41
 gastro-splenic, 34
 great, 41
 Ovaries, 55
- Pelvis, inclination of, 53
 Pericardium, 19, 29
 Perinæum, 62
 Peritoneum of bladder, 58, 59
 colon, 41
 liver, 36
 spleen, 34
 rectum, 59
 Petit, triangle of, 43
 Pleura, 15, 24, 31, 32, 39
 Pylorus, 37
- Rectum, 61
 Respiration, mechanism of, 32
 Rib, length of twelfth, 32
 Ribs, relations to vertebræ, 11
- Sacrum, 54
 Scapula, 13
 space beneath, 17
 Sheath of carotid, 9
 Sigmoid flexure, 54
 Spigelius, lobe of, 37
 Spinal cord, 45
 Spine, cervical region of, 7
 curves of, 49, 50
 dorsal region of, 23
- Spine, lumbar region of, 41
 proportions of, 50
 Spleen, 33, 34
 Sternum, 27
 position of top of, 11
 Stomach, 37
 Suture, neuro-central, 7
- Thoracic duct, 15
 Thorax, diameters of, 15, 23
 Thymus, 15
 Thyroid, 8
 Trachea, division of, 15
- Umbilicus, 45
 Ureter, 51, 58
 Uterus, 58
- Valve, aortic, 19, 24
 Eustachian, 28
 mitral, 24
 pulmonary, 19, 24
 of renal veins, 39
 tricuspid, 24, 28
 Varicocele in the female, 59
 Vein, jugular, 9
 portal, 39
 pulmonary, 21
 Vena azygos, 21, 25
 cava inferior, 28, 36
 superior, 16
- Winslow, foramen of, 37



