

Discolouration of the cornea with blood-pigment / by E. Treacher Collins.

Contributors

Collins, E. Treacher 1862-1937.
University College, London. Library Services

Publication/Creation

[London] : [Ophthalmological Society of the United Kingdom], [1895]

Persistent URL

<https://wellcomecollection.org/works/unhx6mus>

Provider

University College London

License and attribution

This material has been provided by This material has been provided by UCL Library Services. The original may be consulted at UCL (University College London) where the originals may be consulted.

This work has been identified as being free of known restrictions under copyright law, including all related and neighbouring rights and is being made available under the Creative Commons, Public Domain Mark.

You can copy, modify, distribute and perform the work, even for commercial purposes, without asking permission.



Wellcome Collection
183 Euston Road
London NW1 2BE UK
T +44 (0)20 7611 8722
E library@wellcomecollection.org
<https://wellcomecollection.org>

Discoloration of the cornea with blood-pigment.

By E. TREACHER COLLINS.

(With Plate IV, fig. 1.)

IN October, 1890, I brought before this Society two cases of a peculiar form of discoloration of the cornea with blood-pigment. Three cases of a similar description had been previously published by Vossius, and one by Lawford; since then two others have been recorded by Weeks of New York, and John Griffith. I have now the notes of nine more to add to these. A study of the seventeen cases has enabled me to write a fairly complete account of the affection, and as a description of it has not yet found its way into the text-books on eye disease, I think it will be interesting to members of this Society, to read to them the result of my extended inquiries into it this evening.

The cases so far recorded have all been brought forward by those to some extent engaged in microscopical work, but it must not, therefore, be thought that the condition is only a pathological curiosity. It is one which frequently involves, as all those who have written on it have mentioned, a very nice point in diagnosis; the curious fact being that the difficulty consists in distinguishing it from a condition of a widely different nature. Those who have not seen this form of discoloration of the cornea would hardly believe it possible that it could be confused with a lens dislocated into the anterior chamber, and yet I have seen some of the best observers doubtful in deciding between these two conditions.

The discoloration in all but two of the cases involved the whole cornea, except a narrow ring varying in width

from 1 to 1.5 mm. at its extreme periphery, which remained clear and uncoloured.

In one of the exceptional cases, a coloured picture of which is figured in vol. xi of our 'Transactions,' the discoloured area, though central, is much smaller in extent, and of a very bright hue. This case also presented another point of difference, which I shall have to refer to later on; it is doubtful if it should be included in the same category with the others, though it may be that it is merely a later stage of the same affection.

In the other exceptional case there was a wound in the lower half of the cornea, the discoloration was confined to its upper and inner two thirds, the lower third being entirely clear and unstained, as also was the extreme periphery in the whole circumference.

The colour of the stained portion of the cornea has been described in different cases clinically as greenish black, greenish brown, greenish, rusty brown, and reddish brown. In eyes in which it has looked greenish clinically I have found that it had on section a reddish-brown hue. In one case the section of the cornea was of a bright orange colour. I detached the cornea in one of the specimens from the rest of the globe, and found it presented the same discoloured appearances as when *in situ*.

In all the cases there was blood-clot in the anterior chamber, and in most of them, and probably in all at one time, the clot completely filled the chamber, which was so distended that the lens and iris were displaced backwards, and the angle of the chamber widely opened out.

In some cases, in which the eye had been previously blind for several years with detachment of the retina, the hæmorrhage into the anterior chamber had apparently occurred spontaneously. In others it had followed on injuries of different sorts, in four having been occasioned by the removal of a prolapsed iris.

In nine of the seventeen cases the tension was definitely

increased; in six others, in which it was either normal or *minus* at the time the patient came under observation, the possibility of its having been increased at the time of the hæmorrhage into the anterior chamber cannot be excluded: it is not only possible, but highly probable, for in two of the cases in which it was increased, while they remained under observation it became decreased. Pathological examination of the eyes shows that the increase of tension is evidently brought about by the filling up of the widely opened angle of the anterior chamber with blood-clot, which effectually prevents the exit of intra-ocular fluids at this part.

The discoloration of the cornea is known in one case to have been certainly present eight days after the hæmorrhage into the anterior chamber; in another it was seen thirteen days after; and in a third, fourteen days after.

Through the kindness of Mr. Silcock, who has allowed me to watch one of his cases, in which the discoloration came on after hæmorrhage into the anterior chamber incident on the removal of a prolapsed iris, and where it was not found necessary to remove the eye, I am able to record the rate at which the staining disappears. The cornea in this case cleared from the periphery towards the centre, but the stained area always had a sharply defined edge. It was first definitely noted to be present eight days after the operation. Fifteen days after, the extreme periphery of the cornea in its entire circumference was quite clear. Twenty-five days after, the lower margin of the pupil, dilated with atropine, was just visible below the staining. Two months after, there was still a large central opaque area. Nine months after, the centre of the cornea was still discoloured, but much less densely so. A year after, the central patch was of a grey colour, and measured 4 mm. in diameter. The patient was not seen again until two years and three months after, when the cornea was quite clear.

The discoloration may occur at any age, as shown by

these cases, from fourteen months up to fifty-six years. That it is not altogether of such rare occurrence as the little notice it has up to the present attracted would seem to imply, is shown by the fact that during three years at Moorfields Hospital I met with nine cases of the affection. I find in all of these corneæ, which I have examined microscopically, in the discoloured area a number of highly refracting particles.

In connection with it the following questions present themselves for consideration :

- (1) What is the nature of the pigment ?
- (2) How does it get into the cornea ?
- (3) Why is it found located in a large circular patch in the centre of the cornea, and why is the extreme periphery left clear ?

With regard to the nature of the pigment, Virchow has taught us that in old blood-clots retained in the interior of the body, such as are found in aneurisms, or in the brain after cerebral hæmorrhage, small crystals of a rhomboidal shape and bright red colour are often met with, also an amorphous deposit of the same colour and nature. This substance he has termed hæmatoidin. The size of these hæmatoidin crystals varies considerably, and I have found the size of the highly refracting particles met with in the discoloured corneæ to vary in different cases. In some they have the appearance of little rhomboidal crystals, and in others of the finest dust-like particles. Dr. Halliburton, in his text-book of 'Chemical Physiology and Pathology,' describes hæmatoidin as insoluble in water, alcohol, ether, acetic acid, dilute mineral acids, and alkalies. I have found that sections of the cornea with this peculiar form of staining, after having been immersed in these different solutions, still contain the highly refracting granules as before.

He goes on to state that hæmatoidin is soluble in concentrated acids and caustic alkalies, and that when treated with fuming nitric acid the crystals give the same colour reaction as the bile-pigment does (Gmelin's reaction).

Salkowski found hæmatoidin to be identical chemically with bilirubin. I have not been able to determine if the particles in the discoloured cornea are present after treatment with strong acids or alkalies, because these reagents cause such changes of the tissue as to prevent any further satisfactory examination. With pieces of the cornea from two of the cases and a drop of fuming nitric acid I obtained a beautiful play of colours, passing from green to blue, to red, and then to a bright yellow. The varying colour of the bile-pigment or hæmatoidin in Gmelin's test depends on the different degrees of its oxidation. Supposing this staining of the cornea to be due to the presence of hæmatoidin, as I think I am about conclusively to prove, then we have a satisfactory explanation of the difference in the colour of the stain which has been described in different cases, and also why corneæ, which appeared greenish clinically, on section after hardening were of a yellowish or reddish hue. Halliburton reports that neither hæmatoidin nor bilirubin shows bands spectroscopically, but both possess a strong absorption power for the violet end of the spectrum. I have examined with the micro-spectroscope the stained portion of the cornea from two cases, and there were no bands of absorption whatever to be seen, only absorption of the violet end of the spectrum.

Hæmatoidin is a derivative of hæmoglobin, and is free from iron. I have tested sections of the cornea from four of these cases with ferrocyanide of potassium and hydrochloric acid, and also with ammonium sulphide; the highly refracting granules were not stained black with the former or dark green with the latter test. In two of them, however, though the granules were not stained green, a substance which seemed to be confined to the interspaces between the laminae of the corneæ was. In the logwood and eosin stained sections of these two corneæ this substance did not show up very definitely, but seemed to stain rather more with eosin, and less with logwood than the surrounding fibrous tissue of the cornea.

Vossius in one of his cases got a reaction with ammonium sulphate, and in the other with cyanide of potash, indicating the presence of iron. Weeks applied to the sections of the cornea from the case he recorded the ferrocyanide test, and states that there appeared to be a faint reaction.

There occurs often, Halliburton says, in connection with blood extravasations and associated with hæmatoidin a substance containing iron, to which Neumann has given the name hæmosiderin. I conclude, then, from microscopical, chemical, and spectroscopical examination of these corneæ that the discoloration is mainly due to hæmatoidin, but that in some of them it is associated with hæmosiderin.

With reference to the second point, the mode of entrance of the pigment into the cornea, Vossius was of opinion that there was direct hæmorrhage into its substance, the blood coming from the vessels at the sclero-corneal margin. If this was the case red blood-corpuscles would be found in the cornea, and the discoloration would occur from the periphery towards the centre. In none of the corneæ I have examined microscopically have I found any blood-corpuscles, and in two cases which were under observation while the discoloration came on, it was noticed as soon in the centre as anywhere else. In none of the corneæ I have examined microscopically were any blood-vessels to be seen, but in the case already referred to as an exceptional one, where the discoloured patch was small and very bright, the lines of old blood-vessels could be seen with the ophthalmoscope and a high *plus* lens, as they are after an attack of interstitial keratitis. The fact of the presence in all the cases of blood-clot in the anterior chamber, alone renders it highly probable that it is the source from which the pigment is derived. Weeks says that it is probable that the pigment entered the substance of the cornea in the soluble form of hæmoglobin, and was there transformed into a salt not soluble in the fluids of the cornea. With this I quite agree, for it is obvious that there is no circulation of fluid in the cornea of sufficient force to

disseminate the particles of hæmatoidin, which are insoluble in water and weak alkalies, throughout its substance. Weeks is of opinion that this hæmoglobin-containing fluid entered the cornea through the spaces of Fontana. Seeing, however, that there is generally increase of tension in these eyes, due to the exit of fluids at the angle of the anterior chamber being obstructed, and also, as I have just mentioned, that the discoloration appears as soon in the centre of the cornea as elsewhere, I think it is more probable that the hæmoglobin enters the cornea by a process of diffusion through Descemet's membrane.

The third point in connection with these cases I wish to deal with is the shape of the discoloured area, and why a narrow ring at the periphery is usually found clear. The explanation is a very simple one. It is that when the whole cornea is discoloured the real nature of the case is not recognised; it is then thought to be one in which the blood entirely fills the anterior chamber. Absorption of the hæmatoidin granules commences at the periphery equally in all directions, and it is not until this part of the cornea has become cleared of them that the fact that the discoloration is really in the cornea itself can be recognised. In the eighth case appended to this paper this point is well brought out. Paracentesis was twice performed, with the idea of evacuating the blood from the anterior chamber, but on neither occasion was any alteration produced in the appearance presented by the eye. Subsequently the entire periphery of the cornea cleared, and the typical appearance which has attracted attention in these cases was produced.

The process of clearing in the cornea gradually proceeds from the periphery to the centre, becoming slower and slower the further removed the discoloration is from the vascular channels at the sclero-corneal margin. We can easily understand that the process is a slow one when we consider that the substance which has to be removed, hæmatoidin, is insoluble in the fluid of

the cornea, and that each particle has to be taken up by a migratory leucocyte.

In conclusion I may point out that this discoloration in the centre of the cornea causes a considerable defect in vision, and that the case I have mentioned in which in the course of about two years it completely disappeared is a very valuable one, for it enables us to prognose ultimate recovery should the other part of the eye not be permanently damaged.

Articles referred to in the paper.

VOSSIUS.—Archiv f. Ophthal., Bd. xxxv, Abth. ii, s. 207.

LAWFORD.—Trans. Ophth. Soc., vol. viii, p. 60.

TREACHER COLLINS.—Trans. Ophth. Soc., vol. xi, p. 43.

WEEKS.—New York Eye and Ear Infirmary Reports, vol. i, pt. 1, p. 37.

JOHN GRIFFITH.—Trans. Ophth. Soc., vol. xiv, p. 74.

CASE 1.—Annie B—, æt. 14 months, was admitted to the Moorfields Hospital under the care of Mr. Couper on September 17th, 1891. Her left eye had been struck by a stone three weeks previously.

On examination two nebulae were seen in the lower half of the cornea, and the scar of a punctured wound in the sclerotic three millimetres below its lower margin. The whole of the cornea, except a ring 1·5 mm. wide at its margin, was of a dull uniform greenish colour; the peripheral ring was clear, and a brownish reflex was seen from behind it. The tension was normal, and as far as could be made out the child was unable to distinguish light from dark with the eye. The following day it was excised.

Pathological examination.—After the eye had been hardened in Müller's fluid it was opened by an antero-posterior vertical section. The anterior chamber was then found to be markedly deepened and full of blood-

clot. The lens and iris were displaced backwards, the angle of the anterior chamber being widely open. The vitreous was of good consistency, but slightly detached antero-laterally. The retina was *in situ*. On section the central portion of the cornea appeared of a rusty-brown colour.

Microscopical appearances.—Scattered throughout the substance of the cornea are seen a number of fine dust-like particles; these do not extend quite as far forwards as Bowman's membrane. Descemet's membrane appears intact. No blood-vessels or blood-corpuscles are seen in the substance of the cornea. There are numbers of red blood-corpuscles in the mesh of the ligamentum pectinatum. The angle of the anterior chamber is widely open.

CASE 2.—Thomas G—, æt. 26, was admitted to the Moorfields Hospital on April 10th, 1888, with a wound at the sclero-corneal margin of his left eye from a chip of iron, through which the iris prolapsed. An iridectomy was performed at the seat of the wound, after which there was free bleeding into the anterior chamber. The eye afterwards quieted down, and the blood in the anterior chamber became completely absorbed. A white mass was, however, seen ophthalmoscopically, and it was uncertain whether this was an organised blood-clot or a detached retina; he had no perception of light with the eye.

On May 21st, 1892, he came stating that for the last four days the eye had been painful, though he had had no fresh injury to it. The condition of it at that time was as follows:—The tension was increased; there was a small cicatrix at the upper and inner margin of the cornea. The whole cornea except its extreme periphery was of a greenish-brown colour. Its appearance simulated very much that of a lens displaced into the anterior chamber. There was a small red-coloured hyphæma.

Pathological examination.—The iris was found to be

extremely shrunken, and the pupil widely dilated. A large portion of the anterior surface of the iris was adherent to the periphery of the cornea. There was marked ectropion of the uveal pigment, most of the anterior surface which is left free being covered by the displaced pigment epithelium. The anterior chamber contained some blood-clot and discoloured opaque fluid. The central portion of the cornea, on section, could be seen to have a faint brownish colour. The vitreous was shrunken, and the retina detached from the ora serrata up to the optic disc.

Microscopical appearances.—Scattered in small patches throughout the central portion of the cornea are numerous little highly refracting, fawn-coloured, granules. They are most abundant amongst the anterior layers, and some of them are situated between the laminae.

In sections treated with ammonium sulphide the granules are not stained, but a substance situated between the laminae takes on a dark greenish colour. In the logwood eosin stained specimens this substance is stained pink with the eosin. No blood-vessels or blood-corpuscles are seen in the cornea. The root of the iris is much atrophied, and intimately adherent to the periphery of the cornea.

CASE 3.—Jane T—, æt. 14, was admitted to the Moorfields Hospital, under the care of Mr. Tweedy, on July 12th, 1892. The evening before she had been struck on her left eye by a hammer. There was a small wound in the upper part of the cornea, with a prolapse of the iris and an hypopyon. The prolapsing iris was cut off, after which the anterior chamber filled with blood.

On the 26th it was noted that the eye was still much injected, and that the blood was not being absorbed. The eye-ball was then excised.

Pathological examination.—The tension of the eye immediately after removal was normal. There was a small partly healed wound in the upper half of the cornea. The anterior chamber was full of blood-clot.* The central portion of the cornea was of a rusty-brown colour on section; the

extreme periphery of it was clear. The lens was *in situ*. There was some blood-clot between the iris and lens. There was extensive diffuse purulent infiltration throughout the vitreous. The retina was in position, but thickened.

Microscopical appearances of the cornea.—In the central portions of the cornea are numerous, highly refracting, granules which stain darker than the corneal tissue with eosin. They are thickest amongst its posterior layers; none are found situated quite as far forwards as Bowman's membrane. No blood-vessels can be seen in the cornea in the sections examined. Between the layers of the cornea at its extreme periphery, and between the fibres of the anterior part of the sclerotic, are some red blood-corpuscles. The granules are much smaller than the blood-corpuscles. They do not stain black with potassium ferrocyanide and hydrochloric acid, nor dark green with ammonium sulphide. They are still present in sections which have been soaked in alcohol, ether, acetic acid, weak alkalies, and acid.

On applying a drop of fuming nitric acid to a small piece of the discoloured cornea a play of colours was produced.

CASE 4.—George S—, æt. 5, was admitted to the Moorfields Hospital, under the care of Mr. Gunn, on November 16th, 1892. Three weeks previously he had fallen down, striking his left eye against a tin whistle. The tension of the globe was *minus*. In the sclerotic, on the inner side of the cornea, was a puckered cicatrix. The cornea itself was of a greenish colour throughout except at its margin, which in its entire circumference was clear. The eye was excised the same day.

Pathological examination.—After hardening in Müller's fluid an equatorial section of the globe was made, and the cornea and sclerotic were peeled off the front half. The ciliary body was found to be intimately adherent to the sclerotic at the seat of the scar. There was a large blood-clot in the anterior chamber, and the lens was wounded.

The retina was *in situ*. The cornea, when entirely separated from the rest of the globe, presented the same discoloration as it did in the intact eyeball. When examined with the micro-spectroscope no absorption bands could be seen; there was only absorption of the violet end of the spectrum.

CASE 5.—William B—, æt. 39, was admitted to the Moorfields Hospital under the care of Mr. Lawford on June 15th, 1893. About half an hour previous to admission he was struck on his right eye by a piece of cast iron. On examination a horizontal transverse wound was seen in the outer half of the cornea, and lying in the lower part of the anterior chamber was a large piece of metal. There was no hyphæma. The lens appeared to be wounded.

The eye was at once cocainised, and, after several unsuccessful attempts with the magnet and forceps, the foreign body was removed. Its withdrawal was followed by the prolapse of a large portion of iris, which became torn away from its opposite attachment; the prolapsed portion was cut off. The anterior chamber at once became filled with blood.

On June 21st the following note was made:—Right eye: V. = p. l. Tension slightly more than left. Anterior chamber filled with blood-clot and lens matter; cornea hazy; wound fairly flat; no pain.

On June 26th the tension of the right eye was found to be lower than the left, and it gradually became less.

On the 28th, thirteen days after the injury and operation, the cornea was noted to have a greenish appearance. The eye was excised on July 1st.

Pathological examination.—There was a partially healed wound in the outer half of the cornea. The upper and inner two thirds of the cornea were of a greenish colour; the lower third was unstained, and the iris could be seen through it in that position. The discoloration nowhere extended right up to the corneal margin, but ended by a sharply

defined margin a little short of it. After hardening in Müller's fluid the stained part of the cornea appeared on section of an orange colour, the discoloration extending uniformly from its anterior to its posterior surface. There were blood-clots in the upper and outer part of the anterior chamber. The iris and lens capsule were adherent to the wound; part of the iris and the greater part of the lens was absent. The vitreous was of fairly good consistency, but slightly turbid. The retina was *in situ*.

Microscopical appearances of the cornea.—Numerous fine, highly refracting, granules are seen scattered throughout the substance of the cornea. These granules stain with eosin rather more deeply than the surrounding fibrous tissue; they do not stain with logwood. They do not appear to bear any definite relation to the spaces between the fibrous laminae, some seeming to lie on the fibres of the cornea. Some are situated between Descemet's membrane and the stroma, and some between the anterior epithelium and Bowman's membrane. A piece of the cornea separated from the rest of the globe was examined with the micro-spectroscope, but no absorption bands could be detected; there was only absorption of the violet end of the spectrum. The granules are not stained by ammonium sulphide, but in sections treated with this reagent a substance between the laminae of the cornea takes on a dark greenish colour. In the logwood and eosin stained specimen this substance is seen to be stained pink by the eosin.

CASE 6.—Patrick K—, æt. 47, was admitted to the Moorfields Hospital, under the care of Mr. Tay, on June 26th, 1893. He stated that for the past five years he had been subject to attacks of inflammation in his eyes, more especially in the right. About three weeks ago he discovered he was unable to see anything with the right eye; he had had no injury to it, and complained of no particular pain in the eye, but had pain at night over the

right frontal region. He had never suffered from gout or rheumatism.

On examination of the eye there was seen to be much injection of the superficial conjunctival vessels. The central portion of the cornea was of a dark greenish-black colour. This discoloured part ended about 2 mm. distance from the sclero-corneal junction by a very sharply defined margin. The extreme periphery of the cornea in its entire circumference was clear. The iris could not be distinctly seen. He was only able to distinguish light from dark with the eye, and the tension was +1. His left eye appeared healthy; $V. = \frac{6}{18}$, Hm. 1 D. = $\frac{6}{9}$.

The tension in the right increased to +2; it became very painful, and on July 6th, 1893, was excised.

Pathological examination.—The central part of the cornea showed on section a uniform yellowish-brown discoloration extending throughout it. The anterior chamber was full of bright red blood-clot; it was considerably deepened, the lens and iris being displaced somewhat backwards: its angle was widely open. The vitreous was thin in consistency, and had some opaque filmy streaks in it. The retina was *in situ*, and the optic disc was cupped.

Microscopical appearances.—In the substance of the cornea in its central part are seen numerous highly refracting particles, bearing no definite relation to the spaces between the fibrous laminae. They are more numerous in the posterior than in the anterior half of the cornea. They are not altered in colour when treated with potassium ferrocyanide and hydrochloric acid, or with ammonium sulphide. There are no blood-vessels or blood-corpuscles to be seen in the cornea. The angle of the anterior chamber is widely open, the iris being displaced backwards. Blood-clot completely fills the anterior chamber, and red blood-corpuscles are seen in the mesh of the ligamentum pectinatum.

CASE 7.—Frederick I—, æt. 31, was admitted to the

Moorfields Hospital, under the care of Mr. Morton, on July 24th, 1893. He stated that he had been short-sighted in both eyes for many years. Seven or eight years ago his left was struck with a piece of wood from a lathe, and shortly after went blind. He then attended as an out-patient, and the note on his letter says he had detachment of the retina. Six months ago he had a fresh injury to the same eye from a piece of wood; since then it has been very painful.

On examination of the left eye there was found to be intense injection of both the palpebral and ocular conjunctiva. There was a deep brown discoloration of the central portion of the cornea; the extreme periphery was clear, though a dark reflex was seen from behind it. The tension of the eye was + 1, and with it he could only distinguish light from dark.

Pathological examination of the eyeball after it had been hardened in 50 per cent. spirit.—The anterior chamber was distended with bright red blood-clot. On section of the cornea, the deeper part of it appeared more discoloured than the superficial. The lens was calcareous throughout. The retina was detached from the optic disc up to the ora serrata; it had a cyst protruding from its outer surface. At the upper part, between the detached retina and the choroid, was an opaque gelatinous substance.

Microscopical appearances.—Scattered throughout the central portion of the cornea corresponding to the discoloured area are numerous highly refracting particles, which stain darker than the surrounding tissue with eosin; they cannot be made out to bear any definite relation to the spaces between the laminæ of fibrous tissue. They are most thickly located in the posterior half of the cornea; the position at which they cease in the periphery of the cornea is very sharply defined.

No blood-vessels or blood-corpuscles are seen in the sections of the cornea. The angle of the anterior chamber is widely open, but is completely filled, as is the

whole of the anterior chamber, by blood-clot. On applying a drop of fuming nitric acid to a piece of the discoloured cornea a beautiful play of colours was obtained, passing from green to blue, to red, and then to a bright yellow.

CASE 8.—William B—, æt. 17, was admitted to the Moorfields Hospital, under the care of Mr. Silcock, on November 17th, 1892. Two days previously a piece of rivet which he was cutting flew up and struck his right eye. On examination a wound was found in the cornea close to its outer margin, through which the iris, coated with lymph, was protruding.

The patient was at once placed under an anæsthetic, the prolapsed iris was then drawn out as far as possible and snipped off, after which the anterior chamber became immediately filled with blood.

The following are the notes on the course of the case after the operation.

November 19th.—The patient has been sick. The anterior chamber is full of blood ; T. + 3. A paracentesis was performed, and repeated the following day, but on neither occasion was much blood evacuated.


25th.—The tension of the eye is now less than normal. A dull, greyish-yellow opacity, the upper border of which is sharply defined, hides the iris from view ; it is doubtful if it is due to blood-clot in the anterior chamber, or to staining of the posterior layers of the cornea.

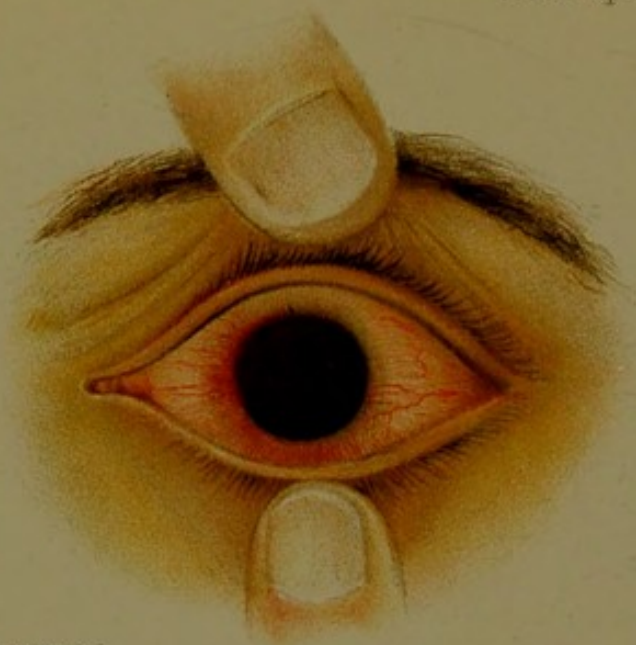27th.—The opaque yellowish material, which is apparently in the cornea, appears to be clearing off. The iris can be seen above it. The anterior chamber as far as can be seen is clear. T. —.

30th.—The discoloration of the cornea is changing to a dull greenish-brown hue.

December 2nd.—The periphery of the cornea is clear, the staining is less dense ; T. —.

7th.—The stained area in the cornea is slowly diminishing peripherally ; its edge remains very sharply defined.





Mary. H. Brooks del.

Fig 1.

12th.—The stained area is less extensive, though still occupying the greater part of the cornea. The lower margin of the pupil, dilated with atropine, is now just visible below the staining. The stain is less dense than it was, especially at the periphery. The wound has healed. T. n. V. = hand movement. He was then discharged from the hospital.

January 12th, 1893.—The eye remains quiet; a large central portion of the cornea is still opaque.

August 24th, 1893.—The centre of the cornea is still pigmented, but much less densely so. V. = $\frac{6}{24}$.

November 19th, 1893.—The patch in the centre of the cornea is now of a grey colour, and measures 4 mm. in diameter. V. = $\frac{6}{12}$. T. n.

February 14th, 1895.—The cornea is quite clear.

CASE 9.—William J. M—, æt. 30, came as an out-patient to the Moorfields Hospital on March 26th, 1895. He stated that fifteen years previously he had received an injury to his left eye from a clothes-line. A cataract formed in it, which five years afterwards was operated on. He was able to see with the eye for a few years after the operation; the sight of it then gradually failed, and for the last three or four years it had been quite blind. A fortnight ago, without any apparent cause, the eye suddenly became painful, and has remained so ever since.

On examination the whole of the left cornea, with the exception of a narrow ring at the periphery 1 mm. wide, is found to be of a dark red colour. The peripheral ring is clear, but there is a dark reflex from behind it (see Pl. IV). T. n. V. no p. l. Some ciliary and conjunctival injection. Right eye healthy.

April 9th.—The ring of clear cornea at the periphery is slightly larger. The discoloured area is now more of a rusty-brown than a red hue. This circular brown patch with its sharply defined margin looks very like an amber-coloured lens displaced into the anterior chamber. T. n.

May 2nd.—The eye still keeps slightly injected, and is at times painful. The discoloured area in the cornea is smaller and less dense than it was; red blood-clots can be seen in the anterior chamber.

(*May 2nd, 1895.*)