

**Endophthalmos : a paper read in the section of ophthalmology at the annual meeting of the British Medical Association held at Portsmouth, August, 1899 / by E. Treacher Collins.**

**Contributors**

Collins, E. Treacher 1862-1937.  
University College, London. Library Services

**Publication/Creation**

[London] : [British Medical Association], [1899]

**Persistent URL**

<https://wellcomecollection.org/works/jjputcs9e>

**Provider**

University College London

**License and attribution**


This material has been provided by This material has been provided by UCL Library Services. The original may be consulted at UCL (University College London) where the originals may be consulted.

This work has been identified as being free of known restrictions under copyright law, including all related and neighbouring rights and is being made available under the Creative Commons, Public Domain Mark.

You can copy, modify, distribute and perform the work, even for commercial purposes, without asking permission.

**wellcome  
collection**

Wellcome Collection  
183 Euston Road  
London NW1 2BE UK  
T +44 (0)20 7611 8722  
E [library@wellcomecollection.org](mailto:library@wellcomecollection.org)  
<https://wellcomecollection.org>





14  
#  
22

## ENOPHTHALMOS.

*A Paper read in the Section of Ophthalmology at the Annual Meeting of the British Medical Association held at Portsmouth, August, 1899.*

By E. TREACHER COLLINS, F.R.C.S.,

Assistant Surgeon, Royal Ophthalmic Hospital, Moorfields.

ENOPHTHALMOS, or displacement of the eyeball backwards in the orbit, is a symptom which, though not frequently met with, may be brought about in a variety of ways. Having during the last few years had several cases in which it was present come under my observation, some of them exceptional ones, I thought it would be interesting to bring them together and compare them with the various theories which have been put forward to account for its causation.

First of all, the cases may be divided into those in which the sinking of the eyeball has resulted from some severe injury to the face and those in which no history of such injury could be obtained. I will consider the latter cases first.

### NON-TRAUMATIC CASES.

In paralysis of the cervical sympathetic, together with contraction of the pupil and slight drooping of the lid, there is sometimes sinking of the eyeball in the orbit. I have met with 3 cases presenting the pupillary and lid symptoms of paresis of the cervical sympathetic; in 2 enophthalmos was present, but had to be carefully looked for before it was noticed. In the other cases no displacement of the eye backwards could be detected. The cases are of interest in that in none of them could any very definite cause for the affection of the sympathetic be discovered.

CASE I.—F. B., aged 22, came first as an out-patient to the Moorfields Hospital on March 11th, 1896, complaining that for the last twelve months her left eye had looked smaller than her right. On examination the palpebral aperture on the left side was seen to be narrower than on the right, due to drooping of the upper lid. The left pupil was smaller than the right; both acted well to light and accommodation. When excited or nervous she sweated profusely on the left side of the forehead, the area over which the sweating occurred being limited by a very well-defined line in the centre. Enophthalmos was at this time not specially looked for or noted. When she again attended a year later it was found to be present to a slight extent. V.—R.  $\frac{1}{2}$  Hm. 1.25  $\frac{1}{2}$  J. 1, L.  $\frac{1}{2}$  Hm. 1.25 J. 1. The right pupil measured 5 mm., the left 3 mm. Application of cocaine to the left eye did not produce any dilatation of the pupil or any alteration in the position of the upper lid. When a child she had swellings on both sides of the neck, and two years ago had some swollen glands on the right side. She states that when she eats she feels something slip down from near the condyle of the jaw on the left side. On pressure behind the ramus on this side a tender spot is detected. Twelve years ago she had diphtheria, after which when she swallowed fluid it came through her nose. For a time also her sight was defective and she had to wear glasses; as she got stronger she gave up using them. I have seen her at intervals since she first came; there has been no alteration in her condition.

1946575

CASE II.—Mr. T., aged 35, came to consult me in June, 1890. His left eye had been watery since 1895. He had been treated by several surgeons with various antiseptic and astringent lotions without benefit. He had noticed that his left upper lid drooped, more so sometimes than at others. On examination there was seen to be slight ptosis on the left side, the lid moving, however, with the globe. The left pupil was smaller than the right: both acted normally to light and accommodation. The eyeball was displaced slightly backwards in the orbit. There was some congestion of the palpebral conjunctiva. The application of cocaine produced no dilatation of the left pupil or retraction of the upper lid. V = R  $\frac{2}{3}$  no Hm. L.  $\frac{2}{3}$  Hm.  $\frac{5}{8}$ . No history of injury to neck or of any swelling there could be elicited. Patient had had an attack of syphilis eight years ago.

The next case which I have to bring to your notice is one which has for several years been under the care of my friend Dr. Galloway, suffering from morphœa in the course of the right fifth nerve. He has kindly permitted me to make use of his notes concerning her.



Case 3.—Morphœa in the course of the right fifth nerve, accompanied by enophthalmos.

CASE III.—E. G. came first under the care of Dr. Galloway as a patient at the Great Northern Hospital, on May 29<sup>th</sup>, 1889. She was then 22 years old, and suffering from morphœa which affected the right median side of the scalp, the cheek, and the side of the nose. She stated that the disease had commenced eight years previously, just above the right eyebrow, and at a spot 7 inches vertically behind it. The two patches gradually extended, the one forwards and the other backwards, until in about a year's time they met. About four years ago a patch began to form on the right side of the nose, and subsequently one below the eye in the region of the infraorbital nerve. The patch on the brow, at the time she came under observation, measured 7 inches in length and 1 inch in breadth. It extended backwards from above the right eyebrow in the course of the longer branch of the supraorbital nerve. The affected area was quite hairless, and below the level of the surrounding hairy scalp, it seemed hard and adherent to the periosteum. There was some capillary dilatation in the patch, as well as its margins. Sensation over the patch seemed

unaltered. When she first attended in 1889 it was noticed that her right eye was sunken deeper in the orbit than the left. Since then the amount of depression has increased. The patches of scleroderma have not altered in size since 1889; they have, however, become somewhat less firmly adherent to the subjacent structures. On January 14th, 1899, V. of R. eye =  $\frac{1}{2}$  Hm. 3.5 $\frac{1}{2}$ . L. eye =  $\frac{1}{2}$  Hm. 3.5 $\frac{1}{2}$ . There was marked displacement of the right eye backwards in the orbit. On looking upwards as far as possible the lower margin of the right cornea appeared slightly lower than the left. On looking to the left she had crossed diplopia, on looking up the image seen with the right eye was higher than that seen with the left.

In this case I think there can be little doubt that the process of sclerosis, which had affected the skin and its subjacent tissue, had likewise affected the cellular tissue of the orbit, and so caused the sinking back of the eyeball. I have been unable to find any case recorded that is quite like it. It is tempting to assume that the change is the result of some loss of trophic nerve influence, but on this point I believe dermatologists are as yet not agreed.



Case 4.—Analgesia of right fifth nerve, accompanied by enophthalmos.

As another case of enophthalmos arising without injury, and in connection with an affection of the fifth nerve, I may mention one which I recorded with Dr. Mott in the Ophthalmological Society's *Transactions*, vol. xvi, p. 354.

CASE IV.—A man, aged 31, had analgesia of the right fifth cranial nerve and enophthalmos with slight drooping of the upper lid on the same side. He gave a definite history of a chancre and secondary symptoms four years previously. A year before coming under observation he had a "stroke," after which for some time his eye was turned inwards, and the right side of his mouth was drawn downwards to the right side. He also had great difficulty in swallowing, and a feeling of numbness in the

right hand and foot. Dr. Mott diagnosed that there had been syphilitic thrombosis of the pontine vessels. The pupils of the two eyes were equal, and acted normally to light and accommodation. The right pupil dilated with cocaine to the same extent as the left. There was no defect in the movement of the eyes, but there was slight rotatory nystagmus in each, most marked in the right.

In this case the accompaniment of the enophthalmos with slight drooping of the lid suggests at first that there was paresis of the sympathetic, the absence of any alteration in the pupil, and its dilatation on the application of cocaine is, however, opposed to such an explanation. There was some affection of the fifth nerve, as shown by the analgesia, and it might be suggested that there was atrophy of the contents of the orbit through loss of trophic nerve influence. If such was the case it is peculiar that enophthalmos is not a more frequent accompaniment of fifth nerve palsy.

I have met with one case, of which now several have been recorded, where one eye was displaced backwards in the orbit, but when the patient stooped or when his jugular vein was compressed it became exophthalmic. My case, which is recorded in full in the *Transactions* of the Ophthalmological Society, vol. xv, p. 240, is briefly as follows :

CASE V.—A youth, aged 17, had noticed for a year that "on stooping his left eye seemed to give and bulge out." There was no history of injury to the eye, but he had received a blow on the top of his head from a cricket ball five years previously. Enophthalmos on left side when standing erect, on stooping for a minute left eye becomes more prominent than the right, and the upper lid droops over the eyeball. Vision of the two eyes equal. No tumour or abnormal pulsation to be felt in the orbit. Protrusion of the eye can also be produced by compression of the jugular vein on the left side.

A similar case without any history of traumatism has been recorded by Lang and A. H. Thompson in the *Transactions* of the Ophthalmological Society, vol. xvii, p. 250, where references to several others will be found.

There seems to be a general consensus of opinion that the symptoms in these cases are best explained by the presence of a new growth of the nature of an angioma, which has caused absorption of orbital contents and sinking of the eyeball, and that when the growth becomes engorged with blood by stooping or compression of the jugular vein the eyeball becomes proptosed.

In the *Transactions* of the Ophthalmological Society for 1896, Mr. Macle hose describes one of a series of cases which he has seen presenting the following symptoms :


Inability to move one eye outwards (usually the left); narrowing of palpebral fissure; retraction of the globe when the patient looks away from the paralysed side, and in some of the cases slight weakness of the internal rectus. In one of his cases the retraction of the globe (enophthalmos) was permanent. The condition was apparently congenital, and Mr. Macle hose said he was unable to offer any satisfactory explanation of the symptoms.

The following case is one of a similar character.

CASE VI.—H. P., aged 20, came as an out-patient to the Moorfields Hospital on May 26th, 1898. He stated that his left eye had always appeared smaller than his right, and that he saw double on looking to his left. He was quite certain that the condition of his eye was not of recent origin but had been present since birth. Six years previously he had a blow from a stone on his left eye, which has left two superficial scars of the skin under the brow. The palpebral fissure on the two sides appear equal, but the integument between the left eyebrow and the left upper lid



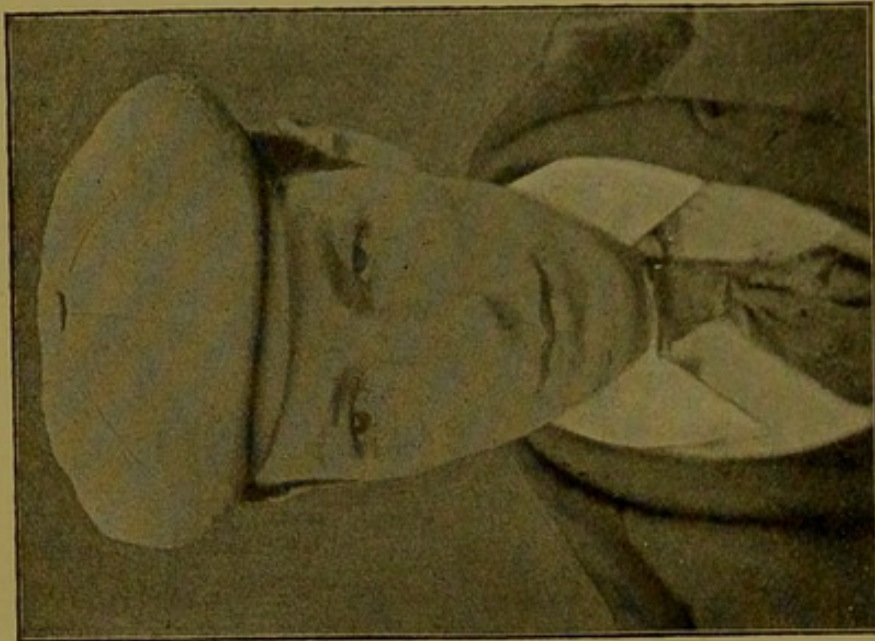
(A)




(B)

Case 5.—Enophthalmos of left eye which became exophthalmos on stooping ; A, patient in erect posture ; B, patient directly after stooping.





(D)



(C)

Case 6.—Congenitally defective movements of left eye, with enophthalmos; C, patient looking to his right, showing narrowing of left palpebral aperture and retraction of eyeball.

has a relatively full and puffy appearance. The left eyeball is more deeply situated in the cavity of the orbit than the right. On the patient being directed to look to the left there is only the very slightest movement outwards of the left eye. On being directed to look to the right, the left eye moves inwards a certain distance, and then turns somewhat upwards with a wheel movement of the vertical axis of the cornea outwards; at the same time the eye becomes sunk a little deeper in the orbit, and drawn away a short distance from contact with the inner surface of the lids; the palpebral fissure also becoming slightly narrowed. The movements of the left eye upwards and downwards are unrestricted, and appear, on account of the sunken condition of the eye, a little more extensive than those of the right, a larger part of the left cornea being brought under cover of the lids. On looking to the left of the median plane the patient has homonymous diplopia, and to the right crossed diplopia. In the extreme upward position the false image (that seen with the left eye) is scarcely so high as the true image, and in the extreme downward position the false image is scarcely so low as the true one, but in no position is there any inclination of either image from the vertical plane. The levator palpebræ acts normally, there is no facial paresis, no anæsthesia of the face, and the tongue is protruded in the middle line. There is no marked difference between the two sides of the face; if anything, the right is the more prominent of the two, and the bridge of the nose projects decidedly more on the right side than on the left. The pupils of the two eyes are equal, and act normally. V. of each eye =  $\frac{2}{3}$  and J. 1, from 5 to  $\infty$  mm. Nothing abnormal detected in the fundus of either eye. The patient's general health has always been good, and there is nothing in the family history of importance.

In these cases the enophthalmos is apparently congenital and associated with a congenital defect in the movement of the eye. Heuck had the opportunity of making a dissection in a child who had congenital defective movement of the eyes, complete double ptosis, loss of upward and downward movement, and defective lateral movement. He found that the defective movements of the globe were due to the abnormal shortness of the muscles and to their insertion too far back in the sclerotic, some of them being displaced back as much as 2.5 mm. The defective movement of the eyes in the cases now under consideration is probably due to the same cause.

The recti muscles arising from the apex of the orbit and inserted into the globe in front of its equator would on contraction tend to draw the eyeball back into the orbit, were it not for the resistance offered by expansions of Tenon's capsule passing between the sheaths of the muscles and the walls of the orbit, which are termed the check ligaments.

Dr. Thomas Dwight, in Oliver and Norris's *System of Diseases of the Eye*, vol. i, p. 100, says, in speaking of these expansions of Tenon's capsule: "Their effect is partly to steady the eyeball, and to resist the backward pull of the recti."

Maddox, in his book on the *Ocular Muscles*, says, p. 14: "It is evident that the check ligaments, by acting on the posterior hemisphere of Tenon's capsule, help to draw the eye forward against the backward traction of the recti." And again: "By their direct attachments to the recti they moderate the power of backward traction, even with respect to the muscular tone in the absence of voluntary contraction."

Now in the absence of any definite anatomical evidence to show the cause of the enophthalmos in these cases.

I would suggest that, in addition to there being a congenital shortness of the muscle and insertion of it too far back into the sclerotic, there is an absence, or insertion too far back, into the walls of the orbit of the check ligaments; so that the unrestricted muscular tone causes some permanent retraction of the globe, which is much increased on contraction of the unsupported muscle.

## TRAUMATIC CASES.

I have met with 5 cases of traumatic enophthalmos, the notes of which are appended. I propose to compare these with the different theories which have been put forward to account for the symptom.

Schapringer<sup>1</sup> suggested that some of the cases might be due to a lesion of the cervical sympathetic, and he records one case in which this seems probable. It was that of a little girl, aged 7, who struck her right temple against an iron grating. She did not lose consciousness, but bled from the nose and ear. Two hours later drooping of the upper lid and a sunken appearance of the eye were noticed.

The ptosis was not due to paralysis of the levator, as the lid moved upwards in association with the globe. The pupil of the right eye was round, active, and equal to its fellow. The tension was diminished. The sensibility of the skin, its capillary circulation, and its temperature showed no difference on the two sides of the face.

The day following the accident the symptoms had partly subsided, and two days later had entirely disappeared. The immediate onset of the enophthalmos and ptosis after the injury in this case, and its rapid disappearance, certainly suggest a temporary muscular paresis.

Schapringer says a small hæmorrhage involving the sympathetic root of the ciliary ganglion would explain all the symptoms. The diminished tension he attributes to secretory disturbance in the eye; and the non-affection of the pupil to the fact that the pupil dilator fibres do not pass through the sympathetic root of the ganglion. In none of my cases is it known that the enophthalmos came on directly after the injury, and in all of them it was permanent.

In two there was ptosis due to paralysis of the levator palpebræ muscle (Cases x and xi), and in one of the others there was slight drooping of the upper lid (Case viii). In Case x the pupil is noted as being inactive to light, and only feebly active to accommodation. In all the other cases the pupils were active and equal.

Beer, who has recorded 2 cases of traumatic enophthalmos<sup>2</sup> attributes the symptom to atrophy of the orbital tissues from lesion of the sympathetic or fifth nerves. In 2 of my 5 traumatic cases (Cases viii and xi) defect in sensation in the course of the fifth nerve was present. In Case xi, which I was able to watch for some time, the anæsthesia over the face and brow, at first complete, gradually disappeared. If we accept this explanation as the cause of the sinking of the eye, as I have already said in speaking of the non-traumatic cases, it is strange that enophthalmos is not a frequent accompaniment of lesions of the fifth nerve.

Gessner<sup>3</sup> recorded from Nieden's clinic 3 cases of enophthalmos of traumatic origin, in all of which there had been penetrating wounds into the orbit, leaving scars at its margin. He suggests that the wound in these cases gave rise to inflammation of the cellular tissue and periosteum of the orbit, which led to contraction of its contents and consequent displacement backwards of the eyeball. The defective movements of the eye in some of the cases might also be accounted for by the implication of the muscles and formation of adhesions. Gessner, however, thinks they are more likely the result of laxity of the muscles due to the sinking of the globe.

In 3 (Cases IX, X, and XI) out of my 5 traumatic cases there were scars at the margin of the orbit, and had evidently been wounds penetrating the orbital tissues.

In Case VIII, though there was no external wound, it is noted that extensive swelling followed the blow, which was a very severe one, against a pony's head.

It is very probable that fracture of the walls of the orbit occurred, causing a communication between it and one of the neighbouring air sinuses, which resulted in an orbital cellulitis. The same explanation might possibly apply in Case VII, which is a very exceptional one, in that the blow was received on the cheek of the side opposite to that on which the sinking of the eye subsequently occurred. The patient's statements on this point are very definite. I have several times questioned her on the matter and she always adheres to it that the blow was on the opposite side.

In Cases VII and X there was obvious defect in the movement of the eyeball, in Case VII outwards and in Case X in all directions. In Cases VIII and XI, though there was no apparent defect of movement, in certain positions the patient saw double.



Case 7.—Enophthalmos on right side, following blow on left cheek.

Lang attributes traumatic enophthalmos to depressed fracture of the wall of the orbit allowing of increased space for the orbital contents, the eyeball becoming depressed back by the pressure of the external air.

In two cases recorded by Becker and Tweedy an injury with a cow's horn seems to have driven the eyeball through the floor of the orbit into the antrum of Highmore.

In none of my 5 cases can the presence of fracture be excluded. In Case x there certainly was some fracture of the margins of the orbit, for several pieces of bone were removed. In Case VII it is difficult to conceive how a blow on the right cheek could produce a depressed fracture of the wall of the left orbit.


In conclusion I may add that though it is unnecessary to assume that in traumatic enophthalmos the sinking of the eye is always brought about in the same way, it seems to me that the 5 cases I have met with are best explained by the theory which attributes the sinking of the eye to the contraction of inflammatory products the result of an orbital cellulitis.

CASE VII.—S. R., aged 37, came to the Moorfields Hospital on February 2nd, 1894. Her right eye was then seen to be much less prominent than the left. It had the sunken appearance of a glass eye. She was unable to move the right eye outwards; its movements in other directions were normal, as also were those of the left eye. There was no difference in sensation of the skin of the face or brow of the two sides. V. = R.  $\frac{5}{8}$  Hm. 1  $\frac{1}{2}$ , L.  $\frac{5}{8}$  Hm. 1  $\frac{1}{2}$ . She stated that she was "cross-eyed" when a child, but that it passed off as she grew up. Three years before she had had a severe blow from a stick on the left cheek bone, after which the left eye was discoloured and swollen for about three weeks. Some weeks after the blow she noticed a twitching sensation in the right eye, and she thought the sight of it became defective. Twelve months after the blow her friends noticed that her right eye appeared sunken: the amount of sinking she thinks has increased since then. She has suffered a good deal from headaches, and did so for many years before the blow. She has never seen double. She has been married nineteen years, and had five children and one miscarriage. Four of the children are living and in good health; one died of croup. Her menstrual periods are frequent, and she loses much at them. I have seen her at intervals since she first attended, and her condition has remained unchanged. She complains of some trouble from the collection and overflow of tears caused by the want of close apposition of the lachrymal puncta to the sunken globe.

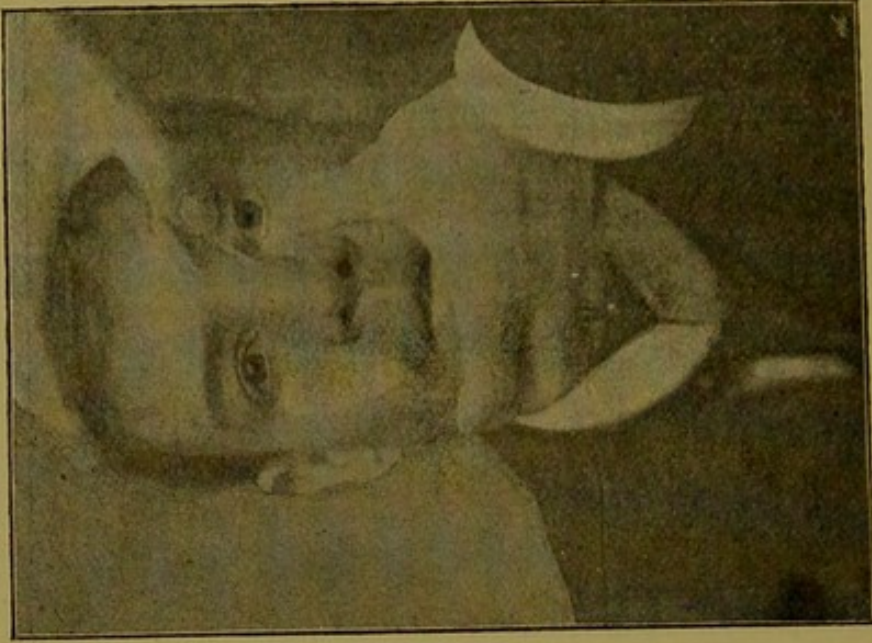

CASE VIII.—Captain G., an officer in the Indian army, on January 17th 1895, while playing polo received a severe blow from his pony's head on his right eye. This was followed by much swelling of the lids and discoloration of the skin. After the swelling subsided the eye seemed to sink and at times he found he saw double. He came to consult me on July 6th, 1895. The palpebral fissure on the right side was then seen to be narrower than on the left, due to slight drooping of the upper lid. The right eyeball was less prominent than the left, being displaced backwards. The pupils of the two eyes were equal and acted normally to light and accommodation. There was no apparent limitation in the movements of the eyes, but the patient had crossed diplopia on looking upwards and to the right. There was numbness of the skin over the right brow and right side of the face, sensation being less acute there than on the opposite side. On pressure of the two eyeballs back into the orbit less resistance was offered by the right than the left V. = R.  $\frac{5}{8}$  J. 1, L.  $\frac{5}{8}$  J. 1. Ophthalmoscopically the right fundus appeared healthy.

CASE IX.—Miss D., aged 23, came to consult me on December 30th, 1896. For a considerable time both she and her friends had noticed, that there was a dissimilarity in the appearance of her two eyes. She had always been shortsighted, but had never worn glasses. When four years old she had a severe blow on the left eye from falling against the handle of a saucepan, which had left a scar. This scar was about an inch in length, and extended vertically downwards from about the outer extremity of the left brow to a little below the outer canthus. The left eyeball was displaced backwards in the orbit to a slightly deeper level than the right. The palpebral fissures on the two sides were equal in size. There was no defect in the movements of the eyes; she did not complain of diplopia, and none could be detected. The pupils of the two eyes were equal and active to both light and accommodation. Ophthalmoscopically the fundus of each eye appeared normal. V. = R.  $\frac{1}{2}$  J. 1,  $\bar{c}$  — 0.75  $\frac{1}{2}$ ; L.  $\frac{3}{8}$  J. 1,  $\bar{c}$  — 1  $\frac{1}{2}$ .

CASE X.—H. M., aged 26, a marine, was on February 3rd, 1896, struck in the face, on board a man-of-war, by an armoured hatchway weighing 15 cwt. It caused an extensive wound of his right upper lid, nose, and lip. Subsequently three operations were performed for the removal of bone. He came as an out-patient to the Moorfields Hospital on August 20th, 1896, when his condition was follows: There was extensive scarring of the upper lip, right side of the nose, and right upper eyelid. The scar in the upper eyelid extended right across it parallel with and just beneath the upper margin of the orbit. There was complete ptosis. On the lid



Case 10.—Traumatic enophthalmos and ptosis, with scars at margin of orbit.



Case 11.—Traumatic enophthalmos and ptosis, with scars at the margin of orbit.

being raised he saw double. The right eyeball was much displaced backwards in the orbit; he was unable to move it outwards. There was marked defect in the vertical movements, and slight limitation in the movement inwards. The pupil was inactive to light, and only acted feebly to accommodation. In other respects the right eye appeared healthy; the left eye was normal. V. = R.  $\frac{2}{3}$  Hm. 1.5  $\frac{2}{3}$  J. 1; L.  $\frac{2}{3}$  J. 1. I saw him again on January 10th, 1898. His condition was then much the same. He had developed some entropion of the lower lid, and he complained of a swelling forming in the region of the lacrymal sac, which was due to its distension with fluid, and which on pressure emptied itself down his nose. That there had been considerable loss of bone at the upper angle of the orbit could be distinctly felt. There was no difference in sensation on the two sides of the face.

CASE XI.—H H, aged 30, came to the Moorfields Hospital on March 30th, 1899. He stated that five weeks previously his face had been injured by the explosion of a copper cylinder containing gas. For twenty-four hours after the accident he was unconscious. His nose and left upper lid were cut. Since the injury he had been unable to raise the left upper lid. At first he had loss of sensation over the whole of the left side of his face this has since partly returned. On examination a triradiate scar was seen starting on the left side of the nose and extending across the bridge, downwards to the left ala, upwards to the inner side of the left eye, and more than half way across the left upper lid. His left upper lid drooped over the eye, and he was unable to raise it except by the use of his occipitofrontalis muscle. He had complete anæsthesia over his left brow; he could feel when touched on the left cheek, but said it was numb, and different to when he was touched on the other side. When his left upper eyelid was raised his left eyeball was seen to be displaced backwards in the orbit, being at a distinctly deeper level than his right. No defect in the movement of the eye could be detected, but on looking to his left side he had homonymous diplopia. The pupils of the two eyes were equal and acted normally. I have seen him at intervals of a month since his first visit. On July 17th he had acquired considerable power in raising the upper lid. The diplopia had entirely disappeared, and he had acquired normal sensation over the left side of the face and brow. The eyeball was still displaced backwards in the orbit.

#### REFERENCES.

- <sup>1</sup> *New York med. Monatschrift*, June, 1890; and *Ophthalmic Review*, vol. ix, p. 294. <sup>2</sup> *Arch. of Ophth.*, vol. xxii, 1. <sup>3</sup> *Arch. f. Augenheilk.*, Bd. xviii, Hft. 3.



