

**An atlas of ophthalmoscopy : with an introduction to the use of the ophthalmoscope / by O. Haab ; translated and edited by Ernest Clarke.**

**Contributors**

Haab, O. 1850-1931.  
Clarke, Ernest, 1857-1932  
Still, D. C.  
University College, London. Library Services

**Publication/Creation**

London : Baillière, Tindall & Cox, 1895.

**Persistent URL**

<https://wellcomecollection.org/works/q684gt2y>

**Provider**

University College London

**License and attribution**

This material has been provided by This material has been provided by UCL Library Services. The original may be consulted at UCL (University College London) where the originals may be consulted.

This work has been identified as being free of known restrictions under copyright law, including all related and neighbouring rights and is being made available under the Creative Commons, Public Domain Mark.

You can copy, modify, distribute and perform the work, even for commercial purposes, without asking permission.

**wellcome  
collection**

Wellcome Collection  
183 Euston Road  
London NW1 2BE UK  
T +44 (0)20 7611 8722  
E [library@wellcomecollection.org](mailto:library@wellcomecollection.org)  
<https://wellcomecollection.org>

HAAB'S ATLAS  
OF  
OPHTHALMOSCOPY

---

*ERNEST CLARKE*

Douglas C. Still,  
34, Sutton Lane,  
Chiswick,  
W. 4.

OPHTHALMOLOGY HC266A HAAD

AN ATLAS  
OF  
OPHTHALMOSCOPY.

WITH AN INTRODUCTION  
TO THE USE OF  
THE OPHTHALMOSCOPE


BY  
DR. O. HAAB,  
PROFESSOR OF OPHTHALMOLOGY, UNIVERSITY OF ZURICH.

Translated and Edited by  
ERNEST CLARKE, M.D., B.S. (LOND.),  
FELLOW OF THE ROYAL COLLEGE OF SURGEONS,  
SURGEON TO THE CENTRAL LONDON OPHTHALMIC HOSPITAL, OPHTHALMIC  
SURGEON TO THE MILLER HOSPITAL, ETC.



LONDON :  
BAILLIÈRE, TINDALL & COX,  
20 & 21, KING WILLIAM STREET, STRAND.  
1895.

[All rights reserved.]



WORK BY ERNEST CLARKE, M.D., B.S.



## EYESTRAIN (commonly called Asthenopia).

*Pp. 168, with 22 Illustrations.*

'Apart from all other considerations, Dr. Clarke's monograph is of definite value to those engaged in ophthalmic practice in that the teaching of a large number of scattered writings upon the subject of asthenopia is therein presented, compactly and carefully arranged.'—*British Medical Journal*, June 24th, 1893.

'In this little volume, Dr. Ernest Clarke . . . has placed the well-known features of excessive work of the eyes, especially in the case of patients who are affected with some error of refraction, or who suffer from muscular or nervous debility, in a clear and easily intelligible form.'—*Lancet*, January 7th, 1893.

'We commend Dr. Clarke's investigations on Eyestrain to the attention of the profession.'—*The Medical Press*, March 15th, 1893.

'The treatment of Eyestrain is very sensibly discussed, and much stress is laid on the proper observance of truly hygienic habits, both in work and relaxation.'—*The Medical Magazine*, February, 1893.

'Our author has evidently consulted many authorities, and the book shows evidence of care in its preparation.'—*The Practitioner*, January, 1893.

'This book shows its author to be a man of most persevering research, and may be said to contain an exceedingly good summation of our present state of knowledge on this important condition.'—*Glasgow Medical Journal*, February, 1893.

'The author has elaborated his subject in a most scientific and scholarly fashion, which makes the work all the more useful for reference.'—*The Optician*, January 26th, 1893.

867103

## TRANSLATOR'S PREFACE.



AT the request of the publishers, I willingly undertook the translating and editing of this little work, recognising that it supplied a distinct want. To the student it will, I hope, prove a useful guide, and the busy practitioner will be able to refresh his memory by consulting the plates, most of which are very accurately drawn.

With the exception of the addition of four diagrams (Figs. B, C, E, and F) taken from my book on Eyestrain, no alterations of any importance have been made from the German edition.


ERNEST CLARKE.

3, CHANDOS STREET,  
CAVENDISH SQUARE, W.  
*September, 1895.*



Digitized by the Internet Archive  
in 2015

## CONTENTS



	PAGE
INTRODUCTION . . . . .	9
EXPLANATION OF THE OPHTHALMOSCOPE . . . . .	12
THE DIRECT METHOD OF EXAMINATION . . . . .	16
EXAMINATION OF A MYOPIC EYE BY THE DIRECT METHOD . . . . .	18
MEASUREMENT OF HYPERMETROPIA . . . . .	22
MEASUREMENT OF ASTIGMATISM . . . . .	27
THE SIZE OF THE OPHTHALMOSCOPIC IMAGE . . . . .	31
EXAMINATION OF THE FUNDUS BY THE INDIRECT METHOD . . . . .	32
THE MAGNIFYING POWER WITH THE DIRECT AND IN- DIRECT METHODS . . . . .	36
THE DETERMINATION OF INEQUALITIES IN THE FUNDUS . . . . .	37
THE SHADOW TEST . . . . .	39
THE QUALITIES OF A GOOD OPHTHALMOSCOPE . . . . .	42
THE METHOD OF CONDUCTING AN OPHTHALMOSCOPIC EXAMINATION . . . . .	44
THE OPHTHALMOSCOPIC APPEARANCE OF THE NORMAL FUNDUS . . . . .	50



---

**FIGURES.**
**THE NORMAL FUNDUS.**

- 1.—NORMAL FUNDUS WITH MODERATE PIGMENTATION.
- 2.—NORMAL FUNDUS WITH SLIGHT PIGMENTATION.
- 3*a*.—A DEEPLY PIGMENTED FUNDUS WITH RETINAL REFLEX.
- 3*b*.—A DEEPLY PIGMENTED CHOROID.
- 4*a*.—FUNDUS OF A RABBIT.
- 4*b* & 4*c*.—OPAQUE NERVE-FIBRES IN MAN.

**CONGENITAL MALFORMATION.**

- 5.—COLOBOMA OF CHOROID.
- 6*a*.—COLOBOMA OF CHOROID AND OPTIC NERVE.
- 6*b*.—COLOBOMA OF CHOROID AT MACULA.
- 7*a*.—COLOBOMA OF CHOROID AT OUTER PART OF FUNDUS.
- 7*b*.—COLOBOMA OF CHOROID AT NASAL SIDE OF FUNDUS.
- 8*a*.—COLOBOMA OF CHOROID AT POSTERIOR POLE.
- 8*b*.—ALBINISM.
- 9.—CONGENITAL DISLOCATION OF LENS.

**DISEASES OF THE OPTIC NERVE.**

- 10*a*.—EARLY STAGE OF OPTIC NEURITIS.
- 10*b*.—LATER STAGE OF OPTIC NEURITIS.
- 11*a* & 11*b*.—DOUBLE OPTIC NEURITIS—CHOKED DISC.
- 12.—SYPHILITIC NEURO-RETINITIS.
- 13.—PAPILLITIS FOLLOWING MENINGITIS.
- 14.—PAPILLITIS FOLLOWING TUMOUR OF BRAIN.
- 15*a*.—OPTIC ATROPHY FOLLOWING NEURITIS.
- 15*b*.—OPTIC ATROPHY FOLLOWING DIVISION OF NERVE.
- 16*a*.—EARLY STAGE OF GREY ATROPHY.
- 16*b*.—LATE STAGE OF GREY ATROPHY.

- 
- 17.—OPTIC ATROPHY FOLLOWING GLAUCOMA.  
18*a*.—EARLY STAGE OF GLAUCOMATOUS CUPPING.  
18*b*.—LATE STAGE OF GLAUCOMATOUS CUPPING.

#### DISEASES OF THE RETINA.

- 19*a* & 19*b*.—ALBUMINURIC RETINITIS.  
20*a* & 20*b*.—ALBUMINURIC RETINITIS.  
21*a* & 21*b*.—ALBUMINURIC RETINITIS.  
22*a* & 22*b*.—DIABETIC RETINITIS.  
23.—RETINITIS ACCOMPANYING PERNICIOUS ANÆMIA.  
24.—EMBOLISM OF THE ARTERIA CENTRALIS RETINÆ.  
25*a* & 25*b*.—RETINITIS HÆMORRHAGICA.  
26.—EMBOLISM OF THE ARTERIA TEMPORALIS SUPERIOR.  
27.—SUBHYALOID HÆMORRHAGE.  
28.—SYPHILITIC ARTERITIS IN THE RETINA.  
29.—RETINITIS PIGMENTOSA.  
30.—RETINITIS PIGMENTOSA, LATER STAGE.  
31.—CHANGES IN FUNDUS IN CONGENITAL SYPHILIS.  
32.—CHANGES IN FUNDUS IN CONGENITAL SYPHILIS.  
33.—CHANGES IN FUNDUS IN CONGENITAL SYPHILIS.  
34.—CHOROIDO-RETINITIS.  
35*a* & 35*b*.—CHANGES AT MACULA IN HIGH MYOPIA.  
36*a*, 36*b*, & 36*c*.—CHANGES AT MACULA IN HIGH MYOPIA.  
37.—CHANGES AT MACULA IN ADVANCED AGE.  
38.—CHANGES AT MACULA FOLLOWING A BLOW ON EYE.  
39.—CONCUSSION OF THE RETINA.  
40.—CONCUSSION OF THE RETINA.  
41.—CHANGES AT MACULA CAUSED BY FOREIGN BODY.  
42.—CHANGES AT MACULA CAUSED BY PRESSURE ON EYE.  
43*a* & 43*b*.—RETINITIS FOLLOWING FOREIGN BODY IN EYE.  
44.—RETINITIS FOLLOWING FOREIGN BODY IN EYE.  
45.—RETINITIS FOLLOWING FOREIGN BODY IN EYE.

- 46.—RETINAL DETACHMENT FOLLOWING PUNCTURED WOUND.  
47.—RETINAL DETACHMENT IN MYOPIA.  
48.—RETINAL DETACHMENT WITH A RENT.  
49.—HÆMORRHAGIC RETINITIS DURING PREGNANCY.  
50.—RETINITIS PROLIFERANS.

#### DISEASES OF THE CHOROID.

- 51.—CHOROIDITIS DISSEMINATA, EARLY.  
52.—CHOROIDITIS DISSEMINATA, OLD STANDING.  
53.—CHOROIDITIS DISSEMINATA, RECENT.  
54.—COLLOID DEGENERATION OF THE CHOROID.  
55*a*.—CHOROIDO-RETINITIS AND NEURITIS.  
55*b*.—CHOROIDITIS DISSEMINATA, CHRONIC.  
56.—CHRONIC CHOROIDITIS FOLLOWING FOREIGN BODY IN  
EYE.  
57.—TUBERCLE OF CHOROID.  
58.—CHRONIC TUBERCULOSIS OF THE CHOROID.  
59.—SARCOMA OF CHOROID.  
60.—SARCOMA OF CHOROID.  
61.—RUPTURE OF CHOROID.  
62.—SCLEROSIS OF CHOROIDAL VESSELS.  
63.—CHOROIDAL ATROPHY IN MYOPIA.  
64*a* & 64*b*.—CHOROIDAL ATROPHY IN MYOPIA.

## INTRODUCTION.

THE examination of the fundus by means of the ophthalmoscope is not only of the greatest importance in the diagnosis of diseases of the eye, but it further affords most useful information concerning the diseases of other organs, such as the brain and kidneys, and enables us to detect the presence of such general affections as syphilis and tubercle. Although, therefore, ophthalmoscopy may claim to be one of the most important methods of examination, it is unfortunately one of the most difficult, for a clear view of the fundus can sometimes only be obtained by those most skilled in the art; and even if a view is obtained, it is very often far from easy to interpret it correctly.

The chief difficulty a beginner has to encounter is to diagnose between a healthy and diseased fundus. That this is a real difficulty we recognise when we realize the enormous number of varieties the normal fundus may assume.

An ophthalmoscopic examination may appear simple enough to those who, through ignorance

or carelessness, only attempt to observe the grosser changes in the fundus; but it is difficult, often most difficult, even for a skilled ophthalmoscopist to observe and interpret all the finer changes that disease produces.

Practice and experience are our best teachers, and we may be materially helped by the experience of others in the shape of written descriptions and accurately-drawn pictures of the fundus. Written descriptions of any part are, in all departments of medicine, of doubtful utility, because it is always difficult to explain to another, in words, what we ourselves see, especially if that other is ignorant of the subject; and this applies more particularly perhaps to ophthalmoscopy, for how can we accurately describe the topography of a fundus in words? how give the exact situation of a certain change? And when we come to describe the colour, we are met by almost insuperable difficulties. A little more white, or red, or grey may change the picture in so important a manner that the experienced oculist will recognise serious changes, which the beginner may think are normal or of no consequence, and *vice versâ*.

It is a good education for the eye, to produce a coloured drawing of the fundus; it trains us to observe correctly the finest changes in the colour tones; and even if we are poor artists, any attempt is better than none. A large number of such

coloured pictures of the fundus are already published in well-known atlases, treatises and hand-books; but in many cases these pictures are mixed up with the text, and many of them are representations of rare diseases, while those which show the different stages of some common complaint are omitted. For instance, very little information can be given to a beginner by two pictures showing the changes produced by Albuminuric Retinitis or Chronic Choroiditis. These errors have been avoided in this book; such rare diseases as *Cysticercus Sub-retinalis* have been omitted, and replaced by drawings of greater practical importance. Many of the drawings were taken at different periods of the disease, so that the changes can be compared. The drawings were all made by the indirect method, and the important details supplied by the direct method; consequently, such unimportant details as the light reflex from the vessels and the peculiar irregular mosaic-like pigmentation of the fundus are not represented. As a matter of fact, they are most bewildering to the beginner, and are, moreover, most difficult to reproduce faithfully in a picture. The pictures are intended to be viewed by daylight; this has necessitated a slight alteration of the colour of the original sketches, which were of course taken by artificial light, and are too yellow for daylight.

## EXPLANATION OF THE OPHTHALMOSCOPE.

Before the discovery of the ophthalmoscope by Helmholtz in 1851 the aspect of the inside of the eye in the living subject was as dark as the pupil appeared to be. Not only were surgeons ignorant of the exquisite coloured pictures which this useful instrument discloses, but most of the changes produced in the fundus by disease were not even dreamt of. Why must we have a special instrument to enable us to see the back of the eye? Why does the inside of the eye and the pupil appear black in everyone but albinos? The answer is: for the same reason that the inside of a photographic camera, prepared to take a photograph, appears black if we look through the uncovered lens. If we raise the focussing-cloth and look at the back of the camera, we see on the ground-glass screen a perfect coloured image of the view in front of the camera, provided it is properly focussed; but if we go to the front and look through the lens, we see nothing on the screen—all appears dark, and we only see a small image of ourselves reflected from the lens, just as we see the same reflected from the cornea, when looking at another person's eye. We have the same optical arrangement in the eye as in the camera. The rays of light passing through the crystalline lens form an inverted small

image on the retina, just as they do on the ground-glass screen or photographic plate in the camera. One of the first laws of optics in dealing with lenses is that the object and its image stand in a definite relation to one another; they are reciprocal, so that, provided the dioptric system remains unchanged and the distance is not altered, they may be substituted for each other. For instance, suppose we take a camera in a dark room and place in front of the uncovered lens a lighted candle, say at a distance of one metre, and focus this light on the ground-glass screen; if now we remove the screen and put the light in its place, and hold the screen one metre in front of the lens, we shall get a sharp inverted image of the candle on the screen, as before. Thus, preserving the same distance, we may substitute the object for the image, and although the object in one case is in front of the lens and in the other behind, we get the same image. Just as the rays of light proceeding from the candle pass through the camera to the image, so the rays of light coming from the image pass back through the camera to the candle. If we substitute our eye for the candle, as no rays of light are passing from our eye, no rays will return, and the inside of the camera will appear dark, just as the inside of the eye does.

Now, if by some contrivance we manage to send rays of light from our eye into another eye, we shall



get some of these rays back again, and the pupil, instead of appearing black, will give a red reflex. We can do this in the simplest manner with a piece of glass plate. If we place a light at the side of the head of the person whose eye we propose to examine, by holding up this glass to our eye we can reflect some of the light into the eye, and we shall get some of the returning rays passing through the glass into our own eye, and this will give us a view of the part of the fundus that is

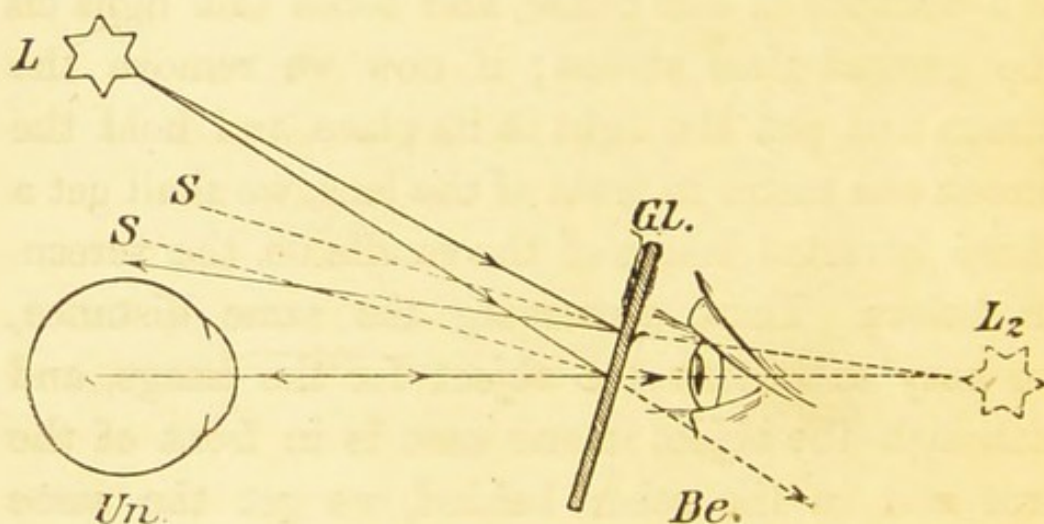


FIG. A.

illuminated, and the pupil will appear red. By referring to Fig. A we can see how this takes place. Some of the rays coming from the light, *L*, are reflected from the surface of the glass, *Gl.*, into the eye that is being examined, *Un.* These rays appear to come from *L<sub>2</sub>*, a point behind the observer's eye, and if the eye *Un.* is focussed for this distance (*Un.—L<sub>2</sub>*), a sharp image of the candle will be formed on its retina. Anyhow, a portion of the

fundus of Un. will be illuminated, and will be capable of reflecting light. Most of this reflected light returns to the candle L, being reflected from the surface of Gl. ; but as this surface is transparent, some of these reflected rays pass through it into the observer's eye, which can thus see the fundus of Un. As only a few rays reach the eye, the lighting is feeble. Helmholtz improved this by using *several* plates of glass. Now, if we substitute for the glass a mirror with a hole in its centre (either produced by perforation in the glass or scratching away the silver), more light can be sent into the eye, and a much larger number of the returning rays will pass through the hole in the mirror into the observer's eye, and consequently a better and brighter image of the fundus will be obtained. By using a concave mirror, and so concentrating the light, a still better result is obtained. With certain sights, in order to get a clear view of the fundus, lenses must be used with the ophthalmoscope. For instance, if either the observer or the observed is myopic, a concave lens must be used.

This method of examining the eye is called the *direct method*, and the image is an upright one and enlarged.

NOTE.—Before the invention of the ophthalmoscope it was wrongly supposed that the pigment on the fundus of the eye absorbed all the light, and

that this was the reason why a pigmented eye appeared dark and an albino's eye red. If we place an albino's eye under the same conditions as a normal pigmented eye, we shall find it will behave in the same way, and the pupil will appear black. The absence of pigment in the albino's eye allows the light to enter through all parts—through the sclerotic, iris, and choroid; but if this light is shut off by placing over the eye a card with a small perforation corresponding with the pupil, we shall see that the pupil appears black instead of red.

### THE DIRECT METHOD OF EXAMINATION.

This method of examining the fundus only allows a small portion to be seen at one time; but this portion is considerably magnified (about fifteen diameters), and consequently the minutest details are visible.

We can, moreover, by its aid estimate the refraction of an eye, which, as an objective method, has of course a distinct advantage, and enables us to be independent of the patient's answers. The first thing the observer has to do, and most beginners find this very difficult—is to relax his accommodation. The person whose eye is being examined must also be made to relax his accommodation, which can be done by directing him to look at

some object five or six metres off with the other eye. If, then, both the observer's and the observed eye are emmetropic, all the details of the fundus will be clearly seen. We can easily understand this when we remember that rays passing from the mirror to the back of the eye that is being examined are reflected as parallel rays if the eye is not accommodating and is emmetropic, and that parallel rays must be focussed on the fundus of the observing eye if it also be emmetropic and its accommodation be relaxed. If, on the other hand, the observer's eye under these circumstances accommodates, the image, instead of being sharp, is blurred and indistinct. But it is not only necessary to observe these rules in order to get a good picture of the fundus, but it is of paramount importance if we wish to estimate correctly the refraction of the eye we are examining. For this reason it is important that the observer should estimate his own refraction, and if there is any error correct it.

If the observer is myopic, the fundus will be indistinct, just as is the case with all distant objects, for the rays coming from the observed eye are parallel—that is, as if coming from a distant object. In order, therefore, to obtain a clear view of the fundus the myope must use a concave glass, and the weakest concave glass he can see distinctly with, will be the measure of his myopia, if his accommodation is relaxed.

A hypermetropic observer is in a somewhat better position, because he can see the fundus if he accommodates; but as he must relax his accommodation in order to estimate the refraction of the eye he is examining, he must first find his own refractive defect and correct it. Unless he had his defect properly corrected in early youth, he has become so accustomed to use his accommodation that it will be most difficult—almost impossible—for him to relax it; and the probability is that, although the convex glass he uses corrects his defect, he, nevertheless, cannot help using some accommodation, and will thus over-correct himself, rendering himself myopic.

It necessarily follows, therefore, that it is most difficult for a hypermetrope to estimate the refraction of an eye correctly by this method. He should use some other method, such as the 'shadow test,' which will be explained later.

We have supposed up to now that the observed eye was emmetropic. We will proceed to examine the conditions that exist when the observed eye is myopic or hypermetropic.

### EXAMINATION OF A MYOPIC EYE BY THE DIRECT METHOD.

The myopic eye at rest is focussed for some point at finite distance, and the higher the myopia the nearer is this point (the *punctum remotum*) to the

eye. It is the greatest distance at which any object can be seen clearly by the eye, and beyond this point everything is blurred. By using its accommodation

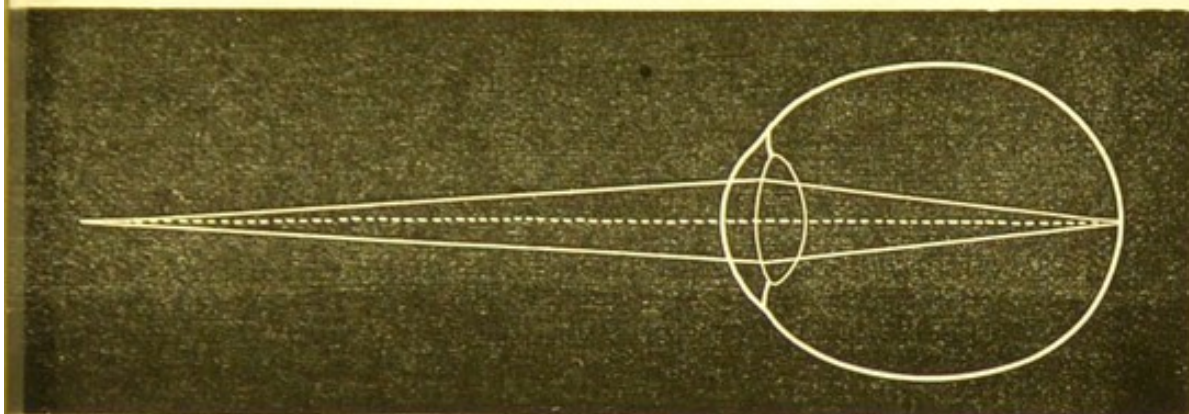


FIG. B.

the myopic eye can see distinctly any object nearer than the punctum remotum and as near as the punctum proximum, or near point. Only divergent rays are focussed on the retina of a myopic eye

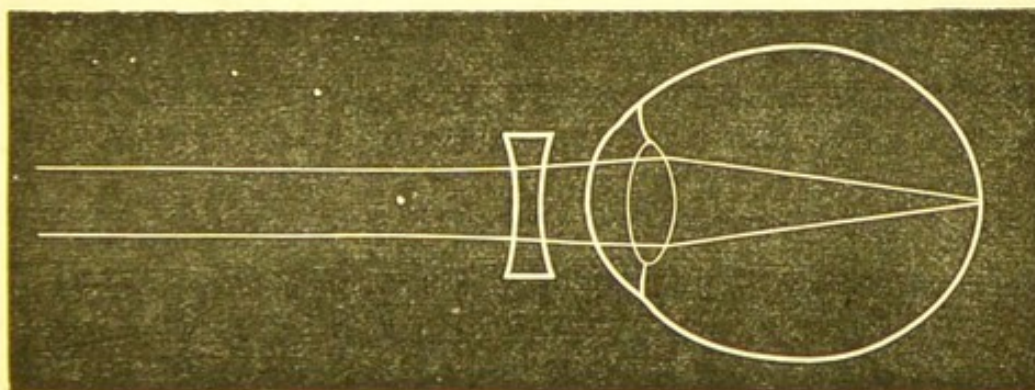


FIG. C.

(see Fig. B); rays coming from a point beyond the far point—that is, less divergent rays—or parallel rays coming from a distance, are focussed in front of the retina; and on the retina itself we have only a blurred image, and to obtain a clear image on the retina a concave glass must be put up in front of the eye (see Fig. C).

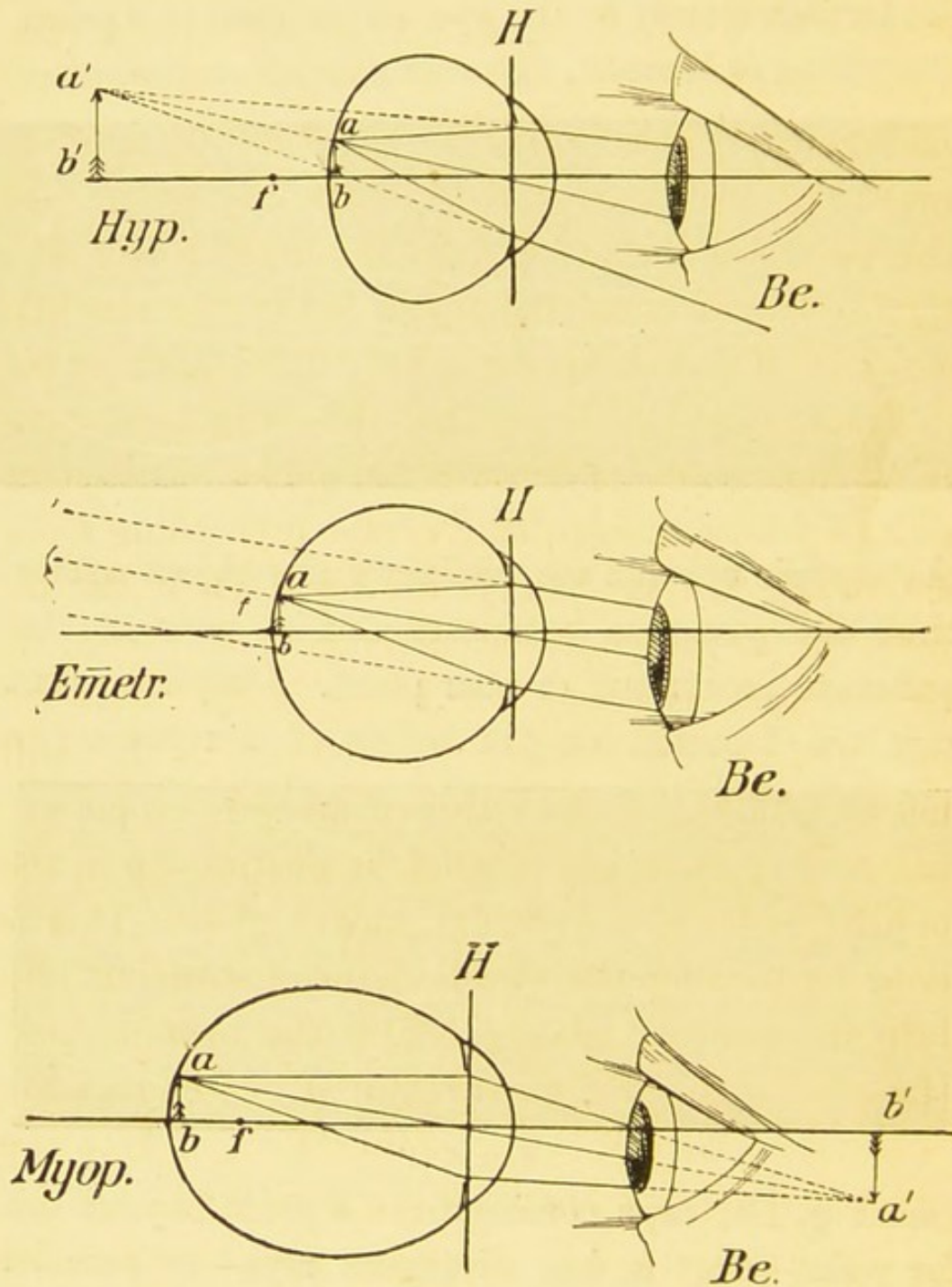


FIG. D.—Examination by the direct method of a hypermetropic, emmetropic, and myopic eye. In each eye these rays are shown proceeding from an illuminated point (*a*) in the fundus. These rays pass out as divergent in the hypermetropic, parallel in the emmetropic, and convergent in the myopic eye. *Be.* is the observer's eye. The mirror has been omitted from the figure.

The myope's eye is too long in the antero-posterior diameter; roughly speaking, every dioptré of myopia means a lengthening of the antero-posterior axis by about one-third of a millimetre. The amount of the myopia is measured by the distance of the far point. If the point is 1 metre off, then the myopia is 1 D.; if  $\cdot 5$  metre off, then the myopia is twice as much—*i.e.*, 2 D.; if one-third of a metre off, 3 D., and so on.

From the above we see that the retina in myopia is at the conjugate focus of an object situated at finite distance; consequently, rays proceeding *from* the retina of a myopic eye are focussed at the far point if the accommodation is relaxed. Now, as this far point is at finite distance—in fact, near the eye—the rays are convergent, consequently they will not be focussed on the retina of an emmetropic eye unless they are made parallel by putting up in the ophthalmoscope a suitable concave glass. This is done by turning the wheel of the instrument and bringing concave glasses before the opening, and the *weakest* concave glass required is the measure of the refraction (if the accommodation of both the observer's and the observed eye is relaxed).

The observer will of course be able, by using his accommodation, to see the fundus with a stronger concave glass than is required, but he will not then be able to measure the amount of myopia. If the observer is a myope, and his myopia is not corrected



with glasses, to ascertain the refraction of the observed eye he must deduct from the concave glass he requires the amount of his own myopia. If, for instance, the weakest concave glass he can see the retina of the myopic eye clearly with, is  $-5$  D., and he himself is  $-2$  D., then the observed eye is  $-3$  D. If he is hypermetropic, he must *add* the amount of his hypermetropia; *i.e.*, if he has hypermetropia of  $2$  D., and the weakest glass he sees the retina well with is  $-5$  D., the amount of myopia in the observed eye is  $-7$  D.

## MEASUREMENT OF HYPERMETROPIA.

The hypermetropic eye is the flat, undeveloped eye, in which, with the accommodation at rest, divergent or parallel rays come to focus beyond the

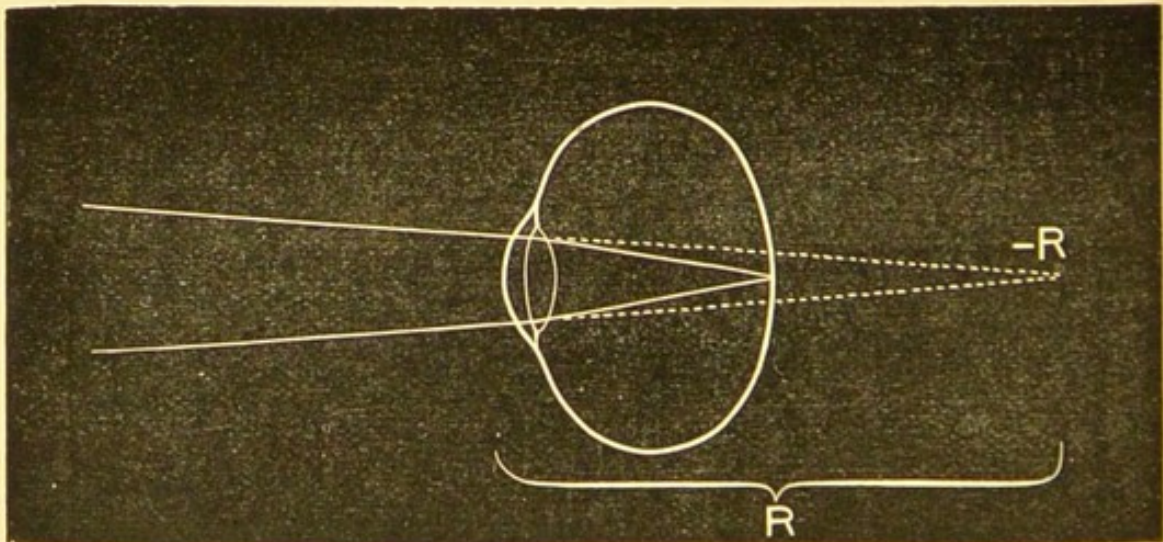


FIG. E.—Showing the punctum remotum of a hypermetropic eye. retina, and only convergent rays focus on the retina (see Fig. E); but as in nature all rays are parallel or

divergent, the hypermetropic eye at *rest* sees everything indistinctly. The hypermetrope has the advantage of the myope in that he can more or less, according to the amount of the hypermetropia, correct his defect by accommodation. He makes his lens more convex, and this causes the rays as they pass through the eye to be more convergent and to focus on the retina. The punctum remotum of a hypermetropic eye is beyond infinity; the part




FIG. F.—Showing parallel rays focussed on the retina of a hypermetropic eye by means of a convex lens.

towards which the luminous rays ought to converge in order to be focussed on the retina is behind the eye, and is the virtual and not the actual focus of the distant rays, and is called the negative punctum remotum (see Fig. E).

A hypermetrope will not stand the full correction of his defect; this is especially so in youth, when the accommodation is very active. The amount he will allow to be corrected is called

manifest hypermetropia, and the remainder is the latent hypermetropia. With advancing years the latent hypermetropia becomes gradually (and finally, at about the age of forty, entirely) manifest. Just as in myopia the distance of the far point in *front* of the eye gives us the measurement of the myopia, so in hypermetropia the distance of the far point (virtual) behind the eye gives us the amount of hypermetropia. If the far point is 1 metre behind the eye, +1 D. represents the hypermetropia; if  $\cdot 5$  metre, then the hypermetropia is doubled, and is corrected by a lens whose focal point is  $\cdot 5$  metre off—*i.e.*, +2 D., and so on. If an emmetrope is examining ophthalmoscopically an eye that is hypermetropic to the extent of 4 D., then, in order to see the fundus clearly, he must make the rays proceeding from the eye, which are divergent, parallel, and this is done by putting up a convex glass of 4 D. The fundus could be seen clearly without a glass by accommodation; but, then, as it would be impossible to measure the amount of accommodation used, so would it be impossible to estimate the amount of hypermetropia in the observed eye. A hypermetrope who is examining a hypermetropic eye with the ophthalmoscope must deduct the amount of his own hypermetropia from the strongest lens he requires to see the fundus with; *i.e.*, if he is hypermetropic to the extent of 3 D., and the strongest convex glass he

can clearly see the fundus with is  $+6$  D., the observed eye has 3 D. of hypermetropia.

A myope, on the other hand, as he requires a weaker correcting-glass, must add in dioptries the amount of the defect; thus, supposing he is myopic to the extent of 5 D., and requires no glass to see the fundus well with, the eye that is being examined is then hypermetropic to the extent of 5 D. Again, if his myopia is 3 D., and the strength of the convex glass he can use is 2 D., then the amount of hypermetropia present in the observed eye is 5 D.; or if he has myopia of 7, and he cannot then see the fundus clearly with any glass less concave than 3 D., the amount of hypermetropia present is  $7 + (-3)$ , *i.e.*, 4 D.

To put the matter a little more clearly, we may say that if an ametropes, to clearly see the fundus of an eye with the ophthalmoscope, and to correctly estimate its refraction, requires (1) a glass of the same kind as his own ametropia but stronger, he must deduct the number of his own from that glass; (2) a glass of the same kind, but from one to ten dioptries weaker than his own ametropia, then the eye that is being examined has an ametropia of from one to ten dioptries of the opposite kind.

*Example.* — He has 6 D. myopia, and requires  $-5$  D., the refractive defect of the observed eye is  $+1$  D.; if he requires  $-4$ , it is  $+2$  D., and so on. He has hypermetropia  $+4$ , and requires  $+3$  D.;

then the refractive error of the observed eye is  $-1$  D.

(3) If the glass required in the ophthalmoscope is not of the same kind and strength, then the refraction of the observed eye is the opposite to that of the observer's, and the amount is equal to the addition of the number of dioptries of each.

*Example.*—He has myopia of 5 D., and requires  $+3$  D.; the eye then is  $+8$  D. He has  $+3$  D., and requires  $-2$ ; the eye is then  $-5$  D.

It should be borne in mind that to ensure that we have the exact measurement of the patient's refraction by means of the ophthalmoscope we ought to look at the yellow spot. If the patient is not under the influence of a mydriatic this is not always easy, for not only does the pupil contract when the examined eye is turned towards the mirror, but the light reflex from the cornea interferes very much with our view; and, further, the absence of any large structure, such as the retinal vessels, makes it difficult to see when we have really accomplished our object. As a rule, all we see at the macula is a slight stippling, produced by the irregular deposit of retinal pigment, and when this pigment is specially pronounced we get a bright ring or crescent at the fovea. This is the fovea reflex, and although the reflex is slightly in front of the retina, the distance is so small that it can be ignored, and this fovea reflex can be focussed

and made use of in this manner for ascertaining the refraction. If it cannot be used in this way through being too faint, then we must try and focus a small retinal vessel passing from the disc to the macula.

The beginner will find that the easiest part to focus is the temporal side of the disc, for its margin there is generally very well defined; and if the vessels passing from here towards the macula be focussed separately, we may get the refraction of the different meridians of the eye, and by that means we can estimate the

## MEASUREMENT OF ASTIGMATISM.

Astigmatism (from  $\acute{\alpha}$ , privative, and  $\sigma\tau\acute{\iota}\gamma\mu\alpha$ , a point), as its name implies, is a condition of the eye in which the rays passing through it are not all focussed at one spot.

*Irregular astigmatism* is a difference of refraction in different parts of the same meridian, and is due to change in the lens, cornea, or nebulæ, etc. The latter are recognised by oblique illumination. Irregular astigmatism cannot be corrected by glasses, nor can it be estimated by the ophthalmoscope.

*Regular astigmatism* is a difference of refraction in different meridians of the same eye, the maximum and minimum being at right angles to one another. Parallel rays passing through the centre of a convex spherical lens unite at a point, the principal

focus, if the curvatures of the lens are all uniform ; but if this is not the case—if, for instance, the vertical curvature is greater than the horizontal, the rays passing through the former will unite sooner than those passing through the latter. This is what we find in regular astigmatism. The result is that we get, instead of a sharp image on the retina, a more or less blurred one. The seat of astigmatism is chiefly in the cornea, but a small amount of corneal astigmatism can be corrected by an unequal contraction of the ciliary muscle, which produces an astigmatism of the lens the converse of that of the cornea.

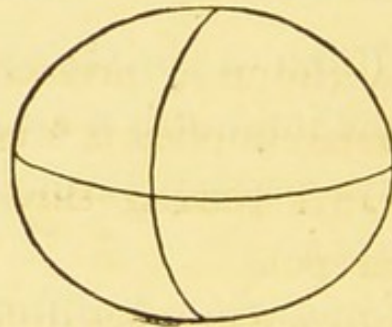


FIG. G.—A spherical surface, showing the vertical meridian more strongly curved than the horizontal.

Astigmatism is corrected by cylindrical lenses, which have the property of only acting on rays that pass at right angles to their axis ; consequently, the axis of the glass must be placed at right angles to the meridian it is intended to correct. For instance, supposing the eye is emmetropic in its horizontal meridian, but hypermetropic in its vertical, then the axis of the glass required to

correct the hypermetropia must be placed horizontally.

Ophthalmoscopically astigmatism is revealed by a more or less partially blurred view of the fundus details, such as disc, vessels, etc., and by our inability to improve matters by using the spherical lenses in an ophthalmoscope. Some ophthalmoscopes have cylindrical glasses fixed in them, but this is not at all necessary, as the astigmatism can be approximately estimated without much difficulty by measuring the refraction of the meridians at right angles to each other in the following manner: Focus, for instance, the vessels that pass in a horizontal direction from the disc to the macula, and note the glass in the ophthalmoscope (the weakest concave and strongest convex) that is required to give them a clear definition; this will give us the refraction of the meridian at right angles to the horizontal one—viz., the vertical. Then focus the vessels that pass vertically upwards and downwards from the disc; this will give us the refraction of the horizontal meridian, and the difference between the two glasses (if any) is the astigmatism (if any).

If the chief meridians are not vertical and horizontal but oblique, we can then, say, focus the vessels passing upwards and outwards from the disc; and when we have got these vessels into focus, if astigmatism exists the vessels passing downwards and outwards will not be in focus, but



will be either blurred or invisible, and we proceed to find the glass that is necessary to bring these latter vessels into focus, and so on. If the correcting glass is a large one we must be careful to look through the centre, for if we look through the glass obliquely we shall get an appearance as if produced by astigmatism, which might not be present.

It is hardly necessary to say that it is of paramount importance that the accommodation of both the examined and examining eye should be as much as possible relaxed. In young people we should make certain of this by putting the eyes under atropine.

In estimating the refraction by means of the ophthalmoscope, as above explained, the observer should approximate his eye as much as possible to the eye that is being examined, as the value of the lens is altered by altering the distance; a concave glass is weakened and a convex glass strengthened by removal from the eye. It is for this reason that old people are often seen to wear their glasses low down on the nose, the strength of the convex glass being slightly increased. This, of course, specially refers to lenses of high power. Therefore, the further away we hold the ophthalmoscope the more shall we over-correct in myopia and under-correct in hypermetropia; *i.e.*, the myopia of the eye being examined will be less and the hypermetropia more than that represented by the ophthalmoscope glass.

## THE SIZE OF THE OPHTHALMOSCOPIC IMAGE.

Another very important reason for holding the ophthalmoscope as near as possible to the eyes is that a view of the fundus is obtained thus much more easily through a small pupil, and without altering the position of the eyes a much larger surface of the fundus can be observed. [If the pupillary opening is very small, we must try and enlarge it by darkening the other eye; and if this does not do it, we must instil a drop of homatropine (2 per cent. solution with 4 per cent. sol. of cocaine in ol. ricini); or, what is better, smear the inside of the lower lid with vaseline and homatropine (2 per cent.). In about twenty to thirty minutes the pupil will have enlarged sufficiently to enable us to make a careful examination of the fundus.]

It is not advisable to use atropine in such cases, as the effect takes much longer to pass off, and in old people may be the cause of glaucoma. An experienced oculist very rarely has to resort to artificial dilatation of the pupil if the eye is normal, unless he wishes to thoroughly examine the macula region, and in such a case it is almost indispensable, especially in old people, whose pupils are notably smaller than those of younger people.

For the same reason the opening in the ophthal-

moscopic mirror should not be too small; 3.5 mm. is about the right size.

The extent of the fundus which can be compassed in one view depends on the refraction of the observed eye. It is larger in hypermetropia, smaller in emmetropia, and smallest of all in myopia. The amount of fundus seen also depends on the size of the light we are employing. If we are using a gas or candle flame we see the inverted image of the flame on the fundus when using a concave mirror in an ophthalmoscope, and the fundus is clearly defined only in this region, and therefore beginners should use as bright and broad a light as they can procure.

If we want to light up a larger extent of the fundus we can do so by using a mirror of greater concavity. For lighting up the macula region, which, owing to its deeper pigmentation, requires more light, we should use a mirror of 16 cm. focal length. A plane mirror in the ophthalmoscope gives less illuminating power, but because of this it has the advantage of not causing so much contraction of the pupil as a concave one.

## EXAMINATION OF THE FUNDUS BY THE INDIRECT METHOD.

This method was first suggested by Ruete. It consists in lighting up the fundus with a concave

mirror held some little distance from the eye that is being examined, and holding from 5 to 7.5 cm. in front of that eye a strong convex glass of from 13 to 20 dioptries. The rays of light proceeding from the examined eye pass through this lens and form a *real inverted* image of the fundus (see Fig. H), and the observer looking through the aperture of the mirror can see this image by

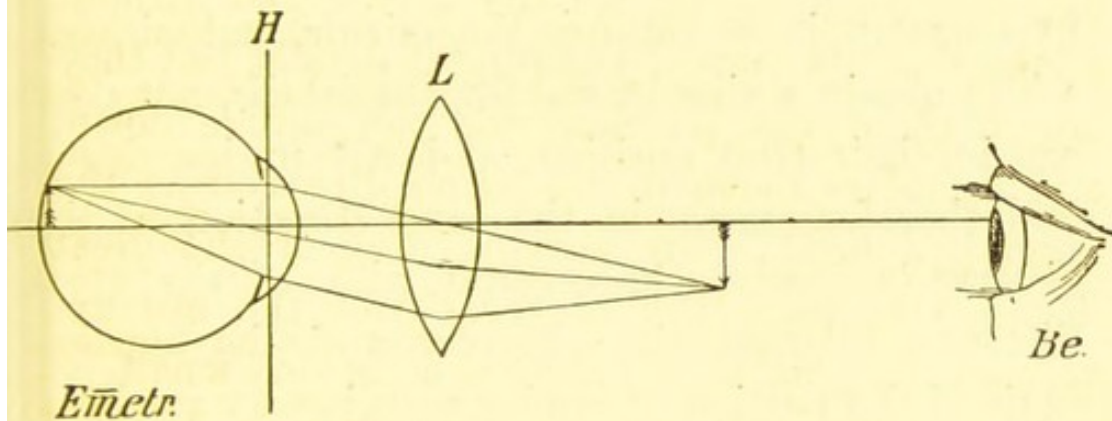


FIG. H.—Examination of an emmetropic eye by the indirect method. The parallel rays leaving the observed eye (*Emetr.*) are focussed by the convex lens *L* to form a real inverted image at a point between *L* and the observer's eye (*Be.*), which is nearer the lens *L* if the observed eye is myopic, and nearer the observer's eye if hypermetropic.

accommodating. (Note.—In this figure both eyes are represented too near the lens.)

In high degrees of myopia no lens is required to see the inverted image of the fundus. The rays proceeding from such an eye are so convergent that they come to focus at punctum remotum, and form the inverted image.

We always know that we are dealing with a high

myopia if we can see some details of the fundus upside down when using only our mirror.

The observer recognises that the picture is inverted by slightly moving his head, and finding that the image moves in the opposite direction to his head; when it moves to the right the image moves to the left, and so on. It is important to recognise that the picture is inverted, because on this depends the diagnosis of myopia, for in high hypermetropia we can use the mirror, and without a lens obtain a view of the fundus details, but they are in their true position, and *not* upside down, and therefore move in the same direction as the observer's head. On account, also, of the great distance between the observer and the eye examined the portion of fundus seen is very small.

We see, then, that the lens we place in front of the eye we are examining by the indirect method makes the eye myopic, and according to the refraction of the eye, so the inverted image will be nearer or further from the lens used. If the eye is emmetropic, then, as the rays proceeding from it are parallel, they will be focused by the lens at its focal point; if the eye is myopic, as the rays coming from it are convergent, then the image will be focused *nearer* than its focal point, and in hypermetropia, with its divergent rays, *further*; consequently, in high hypermetropia the observer will either have to move his head back in order to get a view of the inverted image, or he will have to accommodate more.

The convex glass we use by this method must be held so that it is nearer to the pupil than its focal point; in this way we get no view of the iris, etc., but the picture of the fundus occupies the whole surface of the lens. The larger the size of this glass, the more extensive will be the fundus view.

The size of the inverted picture does not only depend on this, but also on its focal power and on the refraction of the eye examined. The higher the myopia, the larger the fundus picture; the higher the hypermetropia, the smaller it is. The nearer the focussing lens can be approached to the observed eye—that is, the more powerful it is—the larger will be the fundus picture.

The size of the fundus picture also of course depends on the surface illuminated by the light. This surface is larger than that we get with the same light with the direct method, and the illumination is, moreover, stronger if we use a concave mirror. As before remarked, if the pupil is very small, we can get a good view of the fundus much better by this method than by the direct; but, of course, it is hardly necessary to say that even by this method the smaller the pupil the less light gets into the eye, and the more indistinct our view.

To sum up, the indirect method has the following advantages over the direct method:

1. The examiner is further from the patient,

which is a distinct advantage in some cases, and makes the examination easier for the former.

2. A larger view of the fundus seen at one time.

3. No necessity for correcting glasses in the ophthalmoscope.

4. Possibility of seeing the fundus with a smaller pupil.

On the other hand, the details of the fundus are very much more magnified, and consequently much better seen by the direct method (and changes can be seen that can very easily be missed by the indirect method).

### THE MAGNIFYING POWER WITH THE DIRECT AND INDIRECT METHODS.

According to Fick, with the direct method the fundus is magnified seventeen times in emmetropia, twenty times in myopia of 5 D., and fifteen times in hypermetropia of 5 D. In hypermetropia and myopia the further removed (from the eye that is being examined) the correcting glass is, the more we lose in magnifying power.

In the indirect method the magnification depends entirely on the strength of the lens we use. The stronger it is, the less is the magnifying power; but, on the other hand, the larger is the view we get. If the lens is 13 D., the image is enlarged in emmetropia to a little over five times (Schweizer); whereas

if the lens is 20 D., only a little over three times (Fick). If myopia is present in the observed eye the enlargement of the image is slightly less, and if hypermetropia slightly more.

## THE DETERMINATION OF INEQUALITIES IN THE FUNDUS.

This can be done by the direct or indirect method, and by the former method the amount of unevenness can be measured.

The disc may be excavated or cupped, or may be more or less swollen, or a new growth may be present, or a foreign body be projecting into the vitreous. In emmetropia, if the disc is cupped the bottom of the cup will be out of focus, and a concave glass must be used to see it. If the optic nerve is swollen, the summit of the swelling will be also out of focus, and if the accommodation is not used, will require a convex glass in the ophthalmoscope to see it distinctly.

We can measure the depth of any excavation or the height of a swollen disc by counting  $\cdot34$  mm. for every dioptré required in the ophthalmoscope—*i.e.*, about 1 mm. for every 3 D. For instance, a cupped disc is  $\cdot5$  mm. deep if it requires  $-1\cdot5$  D. to see the bottom of the cup, the rest of the eye being emmetropic.

With the indirect method we determine these



conditions in a different way. Keeping our eye fixed on a part of the fundus, say the disc, and moving the focusing lens from side to side, if the disc is excavated we shall see the edge of the hollow moving from side to side with the lens movement, projecting over or leaving uncovered the bottom of the cup. If the disc is swollen, the summit of the swelling appears to move to and fro as we move the lens.

This appearance of movement of these inequalities on the fundus is produced by a decentring of the eye that is being examined and the convex glass, causing a divergence of the rays coming from the two parts—*i.e.*, the bottom of the cup and its edge, or the top of the swelling and its base.

By means of the ophthalmoscope we can detect opacities in cornea, aqueous humour, lens, or vitreous; the returning rays impinging on them cause them to appear dark against the red background. This method is very much helped by putting up a high convex glass, as +20 D., in the ophthalmoscope. This especially refers to spots on the cornea, and deposits on its posterior surface, left by iritis and cyclitis; in such cases the instrument must be held very close to the eye.

Vitreous opacities can best be detected (with a faint light) with a plane mirror. The patient is told to move his eye up or down, and the opaque floating opacities are seen to move even after the movement of the eye itself has ceased.

## THE SHADOW TEST.

This method of estimating the refraction of the eye has been called pupiloscopy, keratoscopy, retinoscopy, and skiascopy. It is fairly easy after a little practice, and it is by far the best objective method, especially in estimating astigmatism, and the rapidity and accuracy by which it can be performed are most marked.

We examine the patient in the same manner as by the indirect method, but without the focusing-glass, and we can use either a plane or concave mirror. The observer, who should be a little over one metre from the eye he is examining, throws the light from the mirror into the eye, and if there is no obstruction he will see the red reflex from the fundus. If he rotates his mirror in any direction, this light passes off the fundus, and a shadow takes its place, and the manner in which this shadow acts gives him the information by which he estimates the refraction of the eye.

Suppose he uses a *concave* mirror: if he is *beyond* the far point of the eye, as in myopia of over 1 D., the shadow will move across in the same direction as the mirror is rotated; that is, if the right eye is being examined, if the mirror is rotated so that the light first falls on the right eye, and moves off it to the left eye, the shadow will move from the

temporal to the nasal side of the eye. If the observer is *within* the far point of the eye, as in emmetropia and hypermetropia, the shadow moves *against*; that is, if the mirror is rotated so that the light falls first on the right eye and moves towards the left eye, then the shadow passes from the nasal to the temporal side of the right eye.

Suppose the shadow is found to move *with*, indicating myopia, concave glasses of increasing strength are put up in front of the eye being examined, until the shadow moves in the opposite direction. This indicates that the eye is now overcorrected, and the number of this glass, with 1 D. added to it (for the observer is a metre away from the eye), gives the refraction of the eye for this (horizontal) meridian. In the same way the refraction of the vertical meridian is found; and if both meridians are alike, the refraction of the eye is a simple myopia; if they are unlike, astigmatism is present, and the amount of astigmatism is represented by the difference between the refraction of these two meridians.

If the shadow moves *against*, the eye is emmetropic, hypermetropic, or has a myopia of less than 1 D., and convex glasses are put up of increasing strength until a glass is reached which just overcorrects—that is, causes the shadow to move *with*. The strength of this glass is noted, and 1 D. is deducted from it, and the result is the refraction of

the meridian that was being estimated. If oblique astigmatism is present, the shadow will move obliquely; in this case the refraction of this oblique meridian is found, and then that of the meridian at right angles to it.

If the shadow moves *with* in one meridian and *against* in the meridian at right angles, mixed astigmatism is present.

The shadows move with a plane mirror in the opposite direction to what they do with a concave one—viz., *against* in myopia of over 1 D., and *with* in emmetropia, hypermetropia, and myopia of less than 1 D.

In using the shadow test the pupil ought to be fairly dilated, for if it is too small it will be most difficult, if not impossible, to see the shadow; and, secondly, because it is very important to get the refraction of the macula.

Again, the same remarks with reference to the relaxing of the accommodation apply here as much as in the other methods. [Hence, whenever it can be done without harm—and certainly in all under twenty years—atropine or homatropine should be used before attempting the shadow test; we get thereby the double benefit of a dilated pupil and a paralysed ciliary muscle.]

## THE QUALITIES OF A GOOD OPHTHALMOSCOPE.

It is impossible in so small a compass to give a detailed description of how an ophthalmoscope should be made; but it will suffice here to mention what the important qualities are that we should look for when providing ourselves with the instrument.

*The Mirror.*—This should be concave, with a focus of from 14 to 17 cm., and should be set obliquely and capable of being turned round, so that it can be used for either eye. This obliquity of the mirror enables us to approach very near the eye we are examining, and, moreover, enables us to look straight through the correcting lens which we may be using; whereas if the mirror is not set obliquely, the instrument has to be held obliquely, and we consequently look obliquely through the correcting lens, and thereby change a spherical lens into a cylindrical one, and obtain an incorrect estimate of the refraction.

Some ophthalmoscopes have the mirror so arranged that it can be made oblique or not, as we wish; but when we do not require to use the oblique mirror, as in the indirect method and in the shadow test, it is best to use a separate mirror. Some instruments, also, have both concave and

plane mirrors, the latter for use in the shadow test and when examining for vitreous opacities; but here again it is better not to complicate the instrument, but have a separate plane mirror. One of the chief disadvantages of a changeable mirror is that it is so liable to drop out and be broken or lost.

The mirror should be perforated: imperforate mirrors are not so good, as the glass reflects some of the light. The hole in the mirror should not be too small, for if it is, too little light will reach the eye of the observer; its diameter should be about 3 mm. anteriorly (the glass side), and somewhat wider behind, and the sides of the tube should be well blackened. The correcting lenses of the ophthalmoscope should not be too small; they should have a diameter of not less than 5 mm. There should not be too many of them, and never more than two should be used together.

The best plan is to have the glasses ordinarily used set round the rim of one disc, say 1 to 8 concave and 1 to 7 convex, and those less used arranged either on another disc or movable quadrant. Supposing in this quadrant we have four glasses, 16 concave and convex and .5 concave and convex; we can then by combining the glasses get from .5 to 24 concave, and from .5 to 23 convex, and this is quite sufficient for all practical purposes.

Another important point is the selection of the focusing-glass used in the indirect method. This

should have a focus of about 6 cm.—*i.e.*, be about 17 D.—and should have a diameter of about 4 cm. The focusing lenses usually supplied with ophthalmoscopes are much too small and handicap the beginner, because the picture of the fundus is so small. The glass should be kept clean and free from scratches.

### THE METHOD OF CONDUCTING AN OPHTHALMOSCOPIC EXAMINATION.

The patient should be in a darkened room. The light used, whether gas or lamp, should have as broad a flame as possible, and should be placed on the same level as the eye that is to be examined and on the same side of the head, to obtain which it is advisable either to have the patient sitting on a revolving stool, or, what is better, the light should be capable of being adjusted by means of a bracket. The incandescent gas-light gives an admirable illumination, but the observer must remember that it gives a greenish tinge to the fundus. The ordinary incandescent electric lamp is inferior to the above, because an image of the wire is thrown on to the fundus, and only a small surface is illuminated. [But if the globe, instead of being made of clear glass, is of ground glass, these defects are removed, and it is then perhaps the very best form of illumination.] The observer sits facing the patient, about 40 to 60 cm. off.

Before actually commencing the ophthalmoscopic examination the first thing to do is to thoroughly examine the eye by the oblique or focal illumination. How often a beginner wastes time in trying to get a view of the fundus which all the time is obscured by corneal or lens opacities, which latter defects he could have discovered had he first examined the eye by the oblique light!

The lamp being removed a short distance from the patient's head, a convex lens of about 17 D. to 20 D. (in fact, the focusing-glass used in the indirect method) is so held at the side of the eye that the light is focused as a luminous spot on the cornea, and by moving the lens about the whole surface of the cornea is thoroughly examined, and not only the cornea, but the anterior chamber, the iris, and the crystalline lens. This examination is further aided by viewing the illuminated spot through a strong magnifying-glass.

We now proceed to examine the eye with the ophthalmoscope, and for this purpose we place the light nearer the patient's head and a little behind, so that the only light that reaches the eye shall be from the ophthalmoscope. We throw the light on to the eye by means of the concave mirror and light up the fundus, making the pupil appear red; we are thus able to detect opacities, not only in the cornea, but also in the lens and vitreous. [The latter are best seen with a plane mirror and a faint



light.] We must not be content to simply examine one spot, but by making the patient move his eye about in all directions, we must thoroughly examine all parts of the media.

How often the grey and slightly opaque appearance of the lens in people advancing in years has been wrongly diagnosed as cataract by an observer who has contented himself with the oblique illumination, and has omitted this necessary second part!

The third part of the examination is by the *indirect method*, which gives us by means of the inverted image a more extensive view of the whole fundus. Still using the concave mirror, and throwing the light on the eye, we hold up before the eye the focusing-glass, a convex glass of about 17 D. or 20 D. This lens should be held between the index-finger and thumb, and should be steadied by resting the tips of the remaining fingers lightly on the patient's forehead, at the same time taking care that we do not cover up the eye we are not examining, and thus prevent the patient from fixing some object. If we always use the mirror with the right hand, this can only happen when examining the left eye. For instance, if we are examining the left disc and tell the patient to look at our left ear, we must take care our left hand that is holding the focusing-glass does not obscure the patient's right eye. The inverted image which

we get by this method is between the focusing-glass and the mirror (see Fig. H, p. 33), and the observer has to accommodate in order to make this image sharp. Beginners generally find some difficulty in doing this, and at first cannot help accommodating for the patient's eye or the focusing-glass, but a little practice conducted in the following manner will soon enable them to remedy this. If some small picture, say one of the plates in this book, is held about 60 cm. from the eye, and the focussing-glass is held about 20 cm. in front of this, a small inverted image of the plate is projected in front of the glass, which after a little practice can be seen as a clear image. At the same time, by tilting the glass slightly he will find out the way to avoid the light reflex from the lens, and when he has once learnt this he will be better able to ignore the light reflexes from the cornea, which are so bewildering to him at first.

Having succeeded in getting a clear inverted image of the fundus, the next difficulty is in making the patient keep his eyes fixed on a certain point in order that a particular part of the fundus may be seen. Some patients have very little control over their eyes, and seem to have the greatest difficulty in fixing any particular spot for long. Of course, this is especially the case with children. If there is any difficulty in getting the patient to raise his upper lid sufficiently, the

observer must do this by pressing the lid gently upwards with the tip of his ring-finger. We should not be satisfied with only a view of the disc and its neighbourhood, but should thoroughly examine the whole periphery.

If we wish to look at the right disc, we must direct the patient to look past our right ear at the wall beyond, for the disc is about  $15^{\circ}$  on the nasal side of the posterior pole of the eye.

The examination of the macula is the most difficult, but at the same time the most important. The difficulty lies in the fact that when we examine this part we are obstructed by the corneal reflex, and the contraction of the pupil that takes place in the eye when not under the influence of a mydriatic; and as this region is more pigmented as a rule, the image is fainter.

The best way to get over this difficulty is, if, for instance, we are examining the left macula, to instruct the patient to look at our left eye; we then proceed to find the disc on the temporal side of the focusing-glass, and turn the mirror slightly towards the nose. An inverted image of the macula will then be seen on the nasal side of the glass, and the corneal reflex vanishes towards the temporal side.

If we wish to look at the *right* macula, we instruct the patient to look at our right ear and proceed in the same manner.

We must be particularly careful to prevent any

light from reaching the eye that is not being examined, as it will cause the pupils to contract even more. The focussing-glass should be perfectly clean and free from scratches; otherwise, the marks on the glass might be mistaken for spots on the fundus.

The fourth part of the examination consists in examining the eye by the *direct method*. This gives us an upright enlarged picture, but of only a very small portion of the fundus. The light is quite close to the patient's head and slightly behind, and the observer sits on the same side of the patient as the eye he wishes to examine, using his right eye for the right eye and left for the left. The light should then be focussed on the eye with the ophthalmoscope, and without allowing the light to leave the eye the instrument should be approached as near as possible to the eye. The observer must not accommodate, but look as if trying to see through the patient's head into distance. If the patient looks horizontally and slightly to the left when examining the right eye the disc will easily be seen, or can be easily found by following one of the larger bloodvessels to its source.

If any error of refraction has to be corrected, this should be done without moving the ophthalmoscope by turning the wheel until a suitable glass is found; if this is done, it will be found easier to keep the

accommodation relaxed. A rabbit's eye is very good to practise on (the fundus is given in Fig. 4a), for the eyeball is prominent and quiet, the pupil is wide, and the rays are divergent.

### THE OPHTHALMOSCOPIC APPEARANCE OF THE NORMAL FUNDUS.

Before studying the changes produced in the fundus by disease it is very important that the beginner should learn to recognise the numerous varieties of the *normal* fundus.

The red colour of the fundus is chiefly produced by the bloodvessels of the choroid. The network of these vessels is closest at the posterior pole. To some, although trifling, extent the retinal vessels contribute to the red appearance, and in a very minor degree the visual purple is supposed to help; but this can only be recognised in a very few eyes, the effect produced being as if a delicate rose were added to a bright red.

The fundus varies in colour in different parts and in different people. In some the colour is a bright yellowish-red, in others a dark or brown red, and these differences are due to the varying quantity of pigment present. Dark people have, as a rule, a darker fundus than blondes.

The situation of the pigment has also a good deal to do with the appearance of the fundus. If the

preponderance of pigment is in the retinal epithelium, the fundus has a general dark-red colour; the red of the choroid is very slightly visible, and its vessels are invisible. On the other hand, if the pigment is chiefly in the choroid—*i e.*, in the intervascular spaces—and the retinal pigment is scanty, we find the colour is light-red, the choroidal vessels are more or less visible, and between them we see the dark-coloured network of the pigment (see Figs. 1, 4*a*, 7*a*, and 7*c*), and sometimes the whole network of choroidal vessels is plainly visible (Fig. 3*b*).

If the pigment is scanty or absent in both retina and choroid, as in albinos, the fundus is much lighter in colour and the choroidal vessels are red on a whitish background (Fig. 8*b*), the whiteness being due to the sclerotic, rendered visible by the absence of the pigment. In those who are not quite albinos, but very fair and deficient in pigment, the choroidal vessels are often seen very plainly on a faint-red background (Fig. 2).

The posterior pole of the eye, that is the region of the disc and macula, is, as a rule, darker than the rest of the fundus. The choroid is darkest in the neighbourhood of the disc, and immediately round the disc it often forms a black ring—the *choroidal ring*. Sometimes within this ring, between it and the disc, a white ring is seen. This is the scleral or connective-tissue ring, and is the white sclerotic appearing between the nerve and the

choroid. The optic nerve has a delicate greyish-red colour when viewed with the ophthalmoscope; the nasal side is redder than the temporal, due to a larger number of nerve fibres collected on the nasal side. Very often, but not always, the centre of the disc is lightest in colour. This is caused by a funnel-shaped depression in the centre of the nerve, and the deeper this depression is the more conspicuous does the lamina cribrosa become, and consequently the whiter is this spot.

When this depression is at all marked in man it is called a 'physiological cup.' In the rabbit it is very conspicuous (see Fig. 4*a*). The lamina cribrosa is recognised by the grey spots on the white ground at the bottom of the cup, and in descending to this spot the vessels are seen to bend over the rim of the excavation.

The disc is not always circular. It may be oval, horizontally or vertically; and normally it does not project from the retina, or only occasionally, and then very slightly on the nasal side, so that the name of 'papilla' that is sometimes given to it is erroneous. With the exception of the hexagonal layer of pigment epithelium the retina is perfectly transparent, and is scarcely, if at all, seen by the ophthalmoscope. Now and then we see a fine radiating striated appearance, due to nerve fibres, in the retina round the disc, chiefly at its upper and lower part, and in young individuals who have a

strongly pigmented fundus we sometimes get a bright reflex from the retina, round the disc and macula (see Fig. 3a). These retinal reflexes appear as bright greyish-white irregular patches between the bloodvessels, and form bright lines along the vessels and (even in later years) a ring round the fovea centralis, and a small ring or crescent at the centre of the fovea. We recognise these as light reflexes, for by moving the mirror and thus moving the light we change their position and appearance, and they exhibit a peculiar glistening sheen. They are best seen by the indirect method when the pupil is not too widely dilated.\*

In eyes that are not too deeply pigmented we see in the macula region, chiefly in the middle near the dark fovea, a stippling of the fundus caused by the irregular pigmentation of the retinal epithelium. This stippling is seen more or less over the whole fundus, if there is not too much pigment.

We now turn our attention to the bloodvessels of the retina. The retina gets its blood-supply from the arteria centralis retinae, which, passing in the optic nerve, divides when it reaches the disc (sometimes before) into branches which spread out over the whole fundus. The blood is collected by the retinal veins, which all pass to the disc and

\* For an explanation of these light reflexes see Dimmer: 'Die ophthalmoskopischen Licht Reflexe der Netzhaut.' 1891.



unite as the vena centralis retinae entering the nerve with the artery.


The arteries are lighter in colour than the veins (and the blood column is narrower), and the light reflex, which forms a band down their centre, is broad and light red in colour, whereas that in the vein is narrower and whiter. This difference is, of course, best seen in the larger vessels and by the direct method. According to Dimmer the light streak is due, in the arteries, to reflection from the blood corpuscles of the axial current; while in the veins it is caused by reflection from the convex surface of the blood column. The arteries generally run a straighter course than the veins, which are more tortuous.


The central artery and vein first divide into two main branches, one going to the upper and the other to the lower portion of the fundus. These again divide, and we get an arteria and vena temporalis and nasalis superior, and also an arteria and vena temporalis and nasalis inferior. Sometimes there is an arteria and vena nasalis. The macula region is partly supplied by very fine and, as a rule, invisible vessels, branches of the temporal vessels which form an arch above and below, and partly by small vessels which come direct from the disc. The vessels supplying the macula appear to cease at the inner border of the macula reflex, but that they actually reach the centre of the fovea is

---

certain from the well-known entoptic figure of the vessels produced by moving to and fro a lighted taper at the side of the eye, in the dark. At the periphery of the fundus the vessels are very small and scanty, and are arranged in a radiating manner.

Pulsation in the arteries and veins is very rarely seen under normal conditions, but may be visible in a vein close to its termination at the disc. The blood column is seen to move to and fro, the termination of the vein appearing to be alternately filled and emptied. Pulsation in the artery may occasionally be seen by careful examination. It is more a wave than a pulsation, and is seen at the spot where a large vessel is bent or forked.





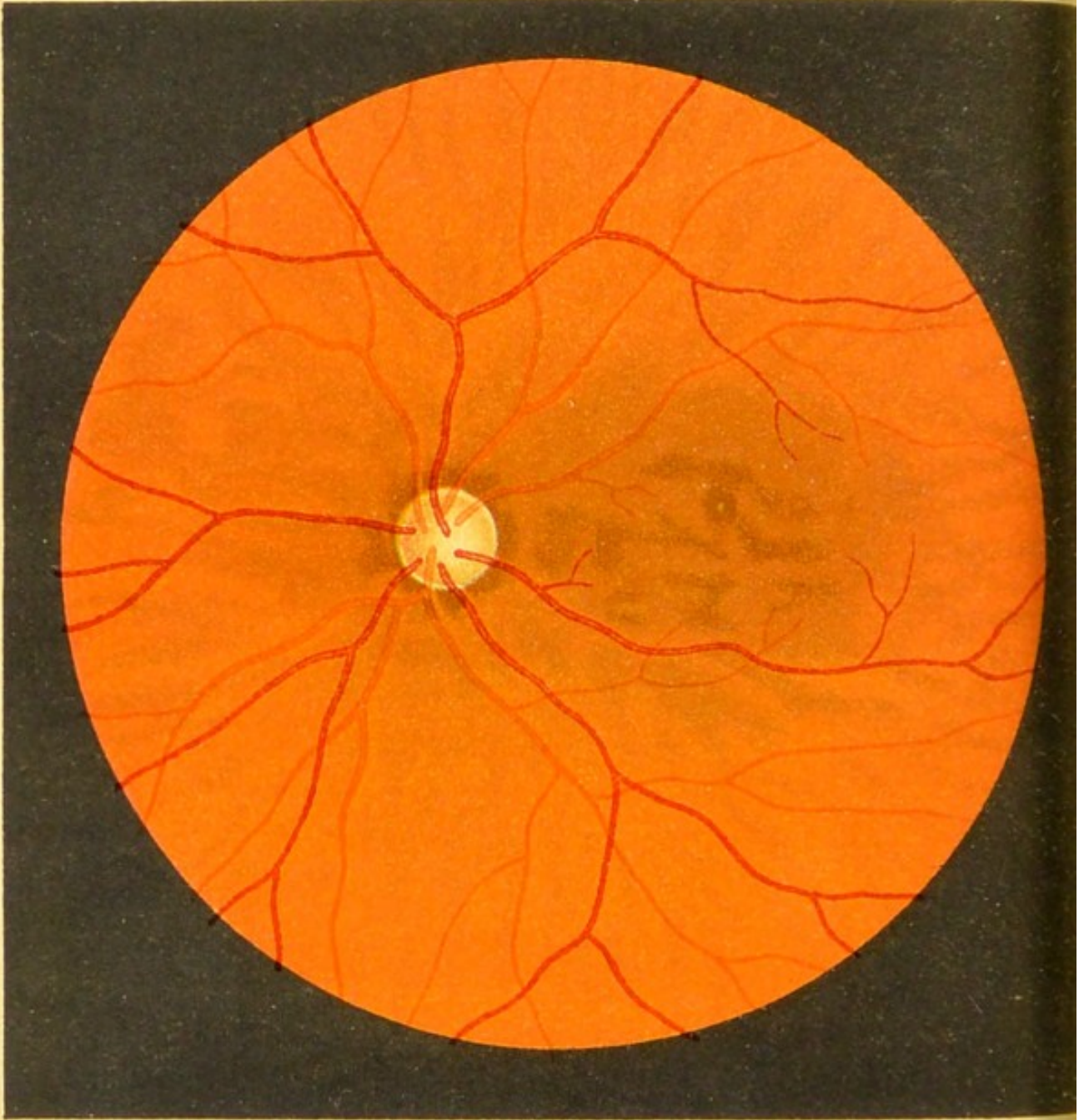


Fig1

FIG. 1.—Ophthalmoscopic Appearances of the  
Normal Fundus.

The fundus represented here has a moderate pigmentation, most marked round the disc and all over the region of the macula lutea. The mottled appearance at the periphery is caused by the more strongly pigmented intervascular spaces of the choroid with the lighter-coloured choroidal vessels between them, rendered visible by the scantiness of the pigment in the hexagonal cells of the retina.

The vessels of the retina lie in front of the latter, and some of them show the light streak.

The fovea centralis is seen as a glittering white spot in the centre of a dark ring of pigment.

The disc has a well-marked funnel-shaped depression in the centre, which is whiter than the rest of the nerve, and the scleral and choroidal rings are both visible.

FIG. 2.—Ophthalmoscopic Appearances of the  
Normal Fundus.

The eye of a fair man, showing much less pigmentation than Fig. 1.

Not only is the pigment deficient in the retina (as in Fig. 1), allowing the vascular layer of the choroid to be plainly visible, but the choroid itself is lacking in pigment, so that its vessels appear darker than the intervascular spaces. (Contrast this with Fig. 1.)

The fovea is red, and the bright reflex from its centre is absent.

The funnel-shaped depression at the centre of the disc and the scleral and choroidal rings are very distinct.

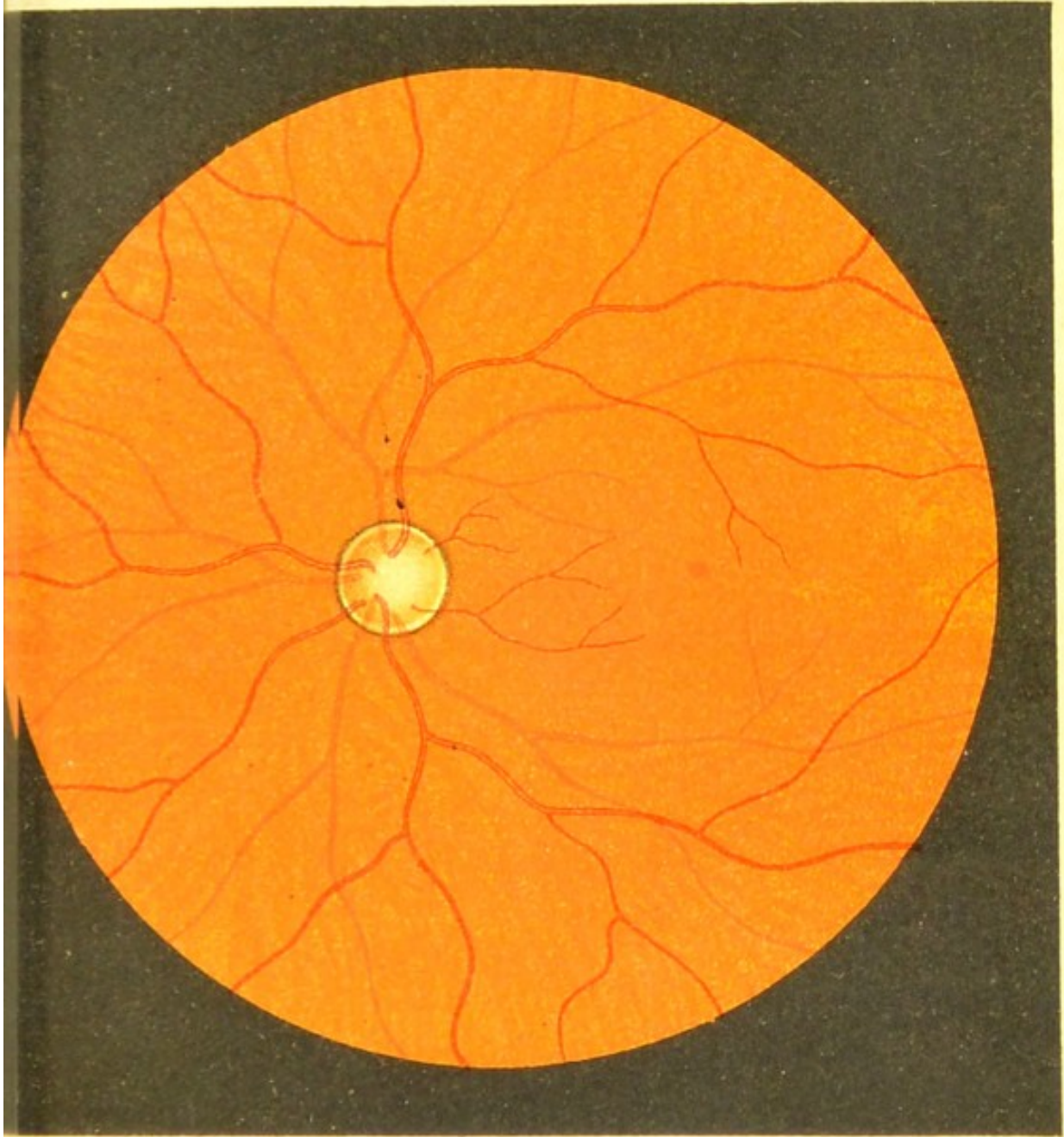
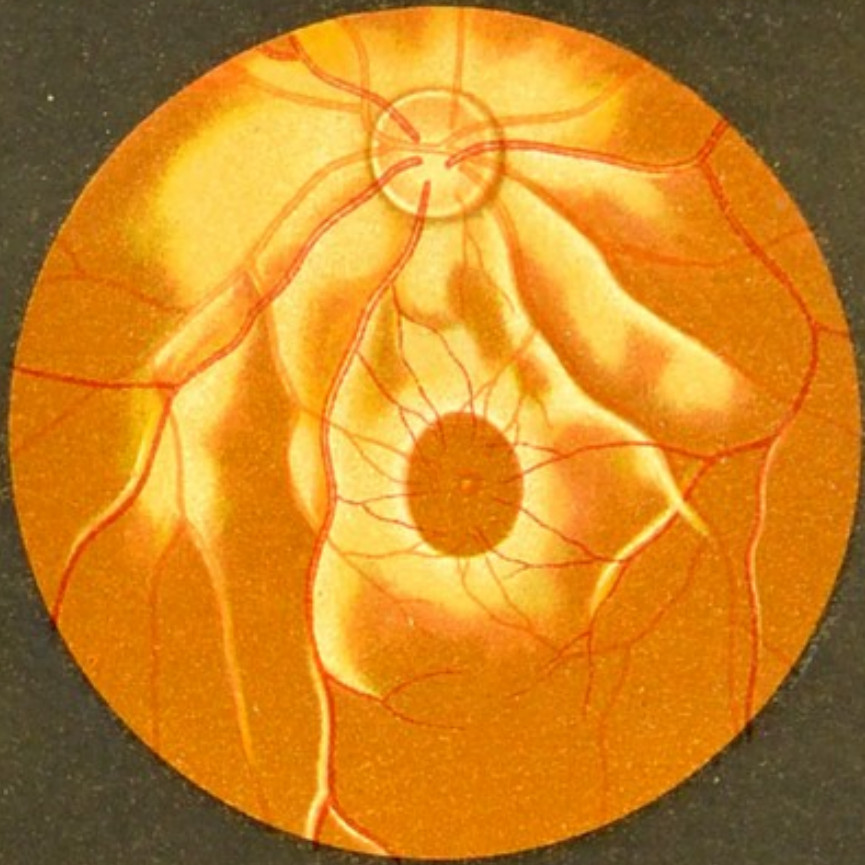



Fig. 2










a



b

Fig 3

**Figs. 3a. and 3b.—Ophthalmoscopic Appearances of the Normal Fundus.**

A deeply-pigmented fundus, showing the bright reflex from the retina (shot-silk retina) commonly seen in young individuals with a dark-coloured fundus [and especially in hypermetropes]. The macula is oval horizontally, and is surrounded by a broad halo of reflected light—the macula reflex. The fovea reflex is seen as a bright whitish spot at the fovea centralis. The retinal epithelium is so loaded with pigment that the choroid is only seen as a general redness, no details being visible.

Fig. 3b.—A fundus containing a quantity of pigment, which, however, is not in the retinal epithelium, but in the choroid. The choroidal vessels are plainly seen through the transparent retina, and their light colour is very conspicuous contrasted with deep pigmentation of the intervacular spaces.

This condition is chiefly seen in old people.

The disc is excavated—a 'physiological cup'; at the bottom of the excavation the lamina cribrosa is plainly seen.

## OPAQUE NERVE-FIBRES.

### FIG. 4*a*.—Opaque Nerve-Fibres in a Rabbit.

In the rabbit opaque nerve-fibres are generally present, and the appearance seldom varies from the representation given here. The nerve-fibres spread out chiefly in a horizontal direction on both sides of the disc; they are pearly white in colour, finely striated, and terminate in brush-like extremities. The retinal vessels are seen passing over the surface of the nerve-fibres, and the difference in colour between the arteries and veins is much less marked than in man. The pigment and vessels of the choroid are entirely hidden by the opaque fibres. The disc in rabbits is oval horizontally, and its funnel-shaped appearance is very marked.

### FIGS. 4*b* and 4*c*.—Opaque Nerve-Fibres in Man.

In man opaque nerve-fibres are not common, and they vary greatly in their arrangement, and also in the amount visible. They are generally seen at the upper and lower margins of the disc, sometimes more or less covering these margins, and passing out into the retina as pearly-white striated patches—sometimes small, as in Fig. 4*c*, and sometimes much larger, as in Fig. 4*b*, terminating in brush-like extremities. Sometimes a patch of opaque fibres is seen at some distance from the disc, as in Fig. 4*b*. The retinal vessels pass over the fibres, although sometimes they are partly covered by them. The brush-like manner in which the patches terminate is always seen, and is most characteristic, and serves to distinguish this condition—which is physiological, and is due to the persistence of the medullary sheath of the nerves—from pathological changes, such as we see in Albuminuric Retinitis.

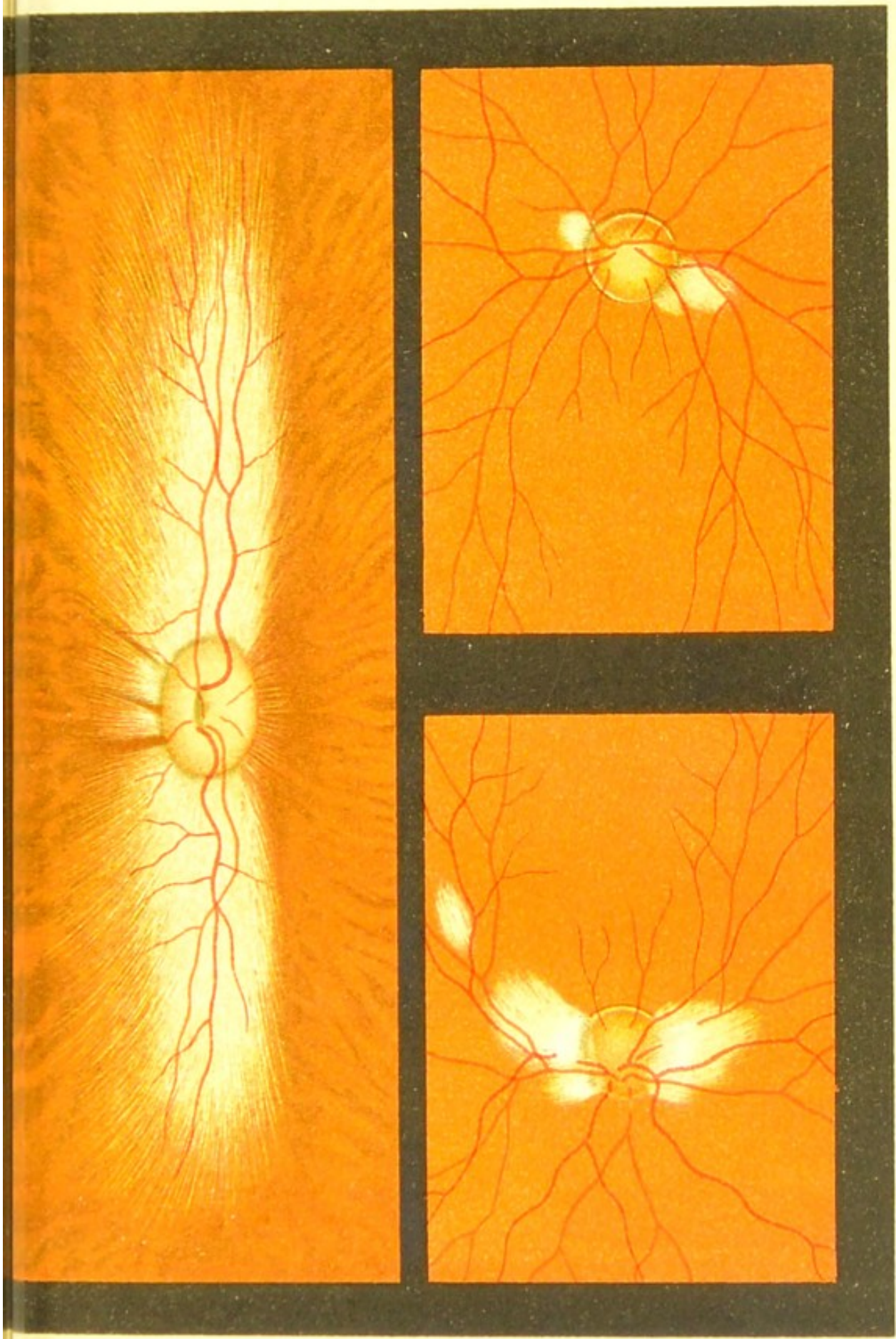




Fig 4

c

b







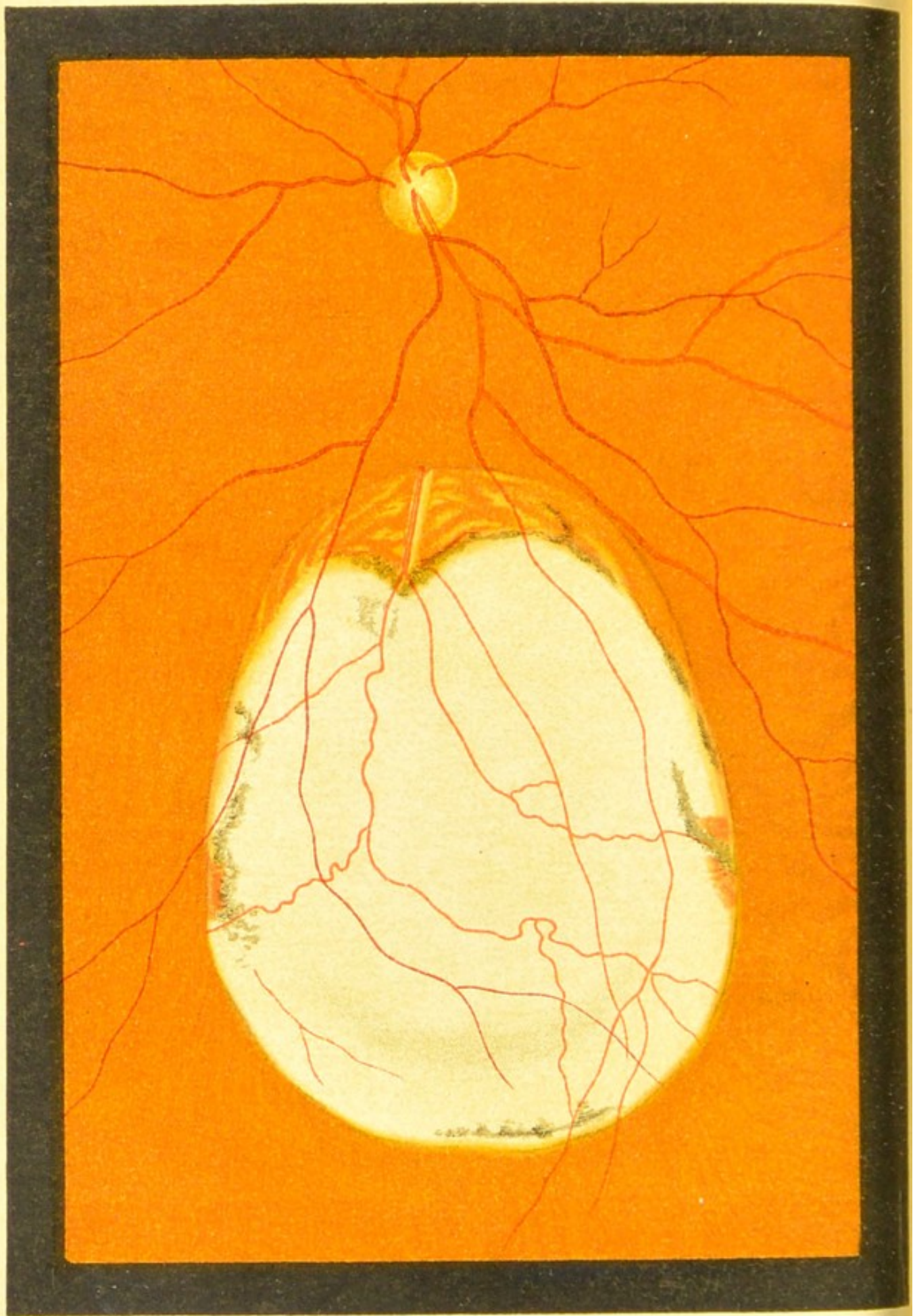


Fig.5.

## CONGENITAL MALFORMATIONS

(FIGS. 5 to 9).

### FIG. 5.—Coloboma of the Choroid.

A large oval patch is seen in the lower part of the fundus. It is distant from the disc about three disc-diameters, and at its upper margin some choroid is visible; but, with the exception of some remains of this tunic in the shape of deposits of pigment and a few vessels (at each side), it is deficient over the rest of the patch, and the sclerotic is exposed.

The retinal vessels are seen passing over the patch.

The rest of the fundus is normal.

[True coloboma is always downwards, or downwards and inwards, and it is due to the arrest of development of the tunica vasculosa of the choroid.]

FIG. 6a.—Coloboma of Choroid and Optic Nerve.

In this case the coloboma is unusually broad, and it embraces the disc, which is very much enlarged.

The retinal vessels are normal.

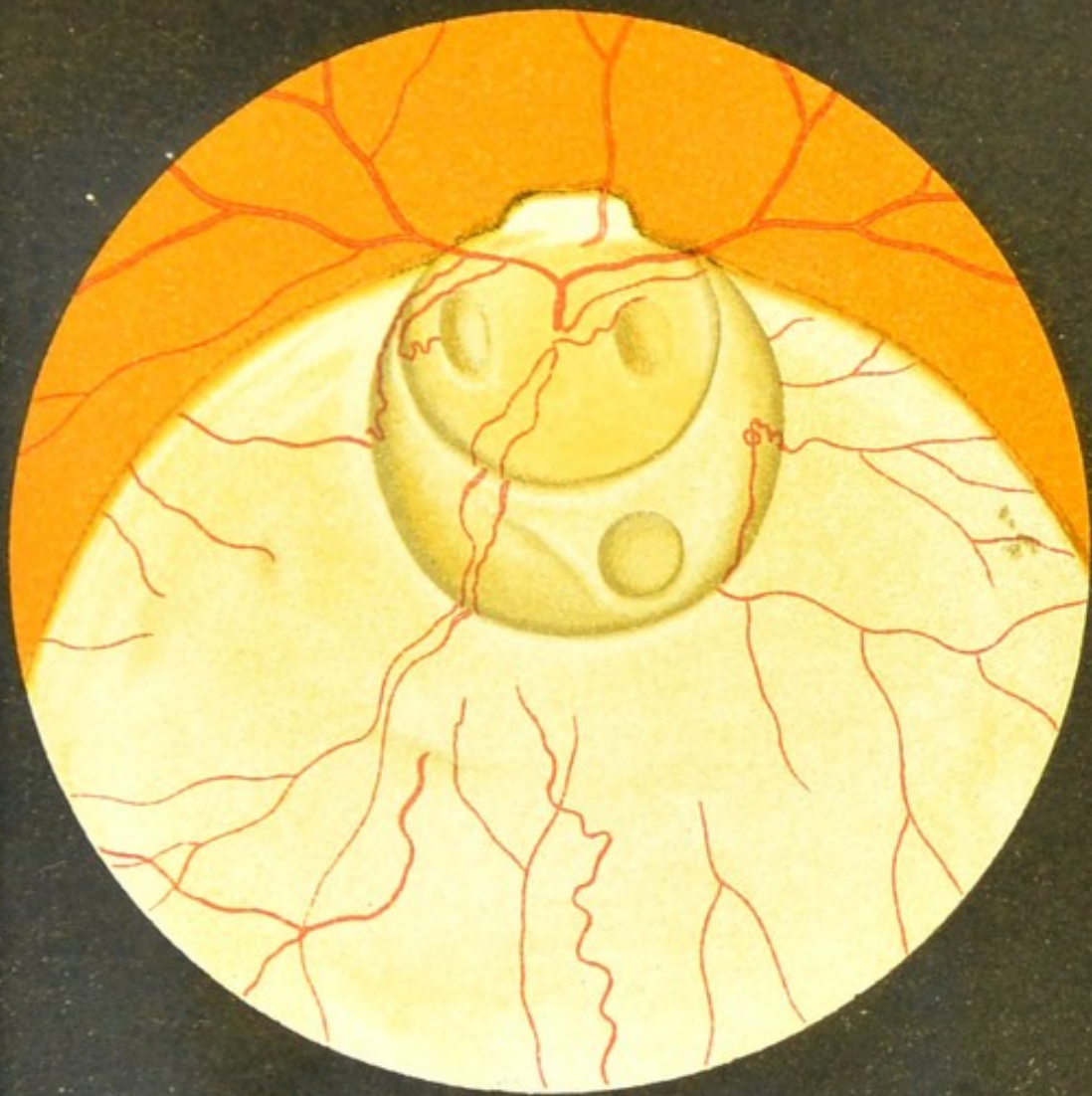The disc and the portion of sclerotic which surrounds its lower border are excavated. In this larger excavation or staphyloma we see three smaller ones; two on the disc are oval, and that on the sclerotic is round. Some retinal and choroidal vessels are seen on the coloboma.

The choroidal vessels are distinguished by passing from view on reaching the margin of the coloboma. The staphyloma of the sclerotic is due to a thinning of this portion of the tunic which has participated in the defect.

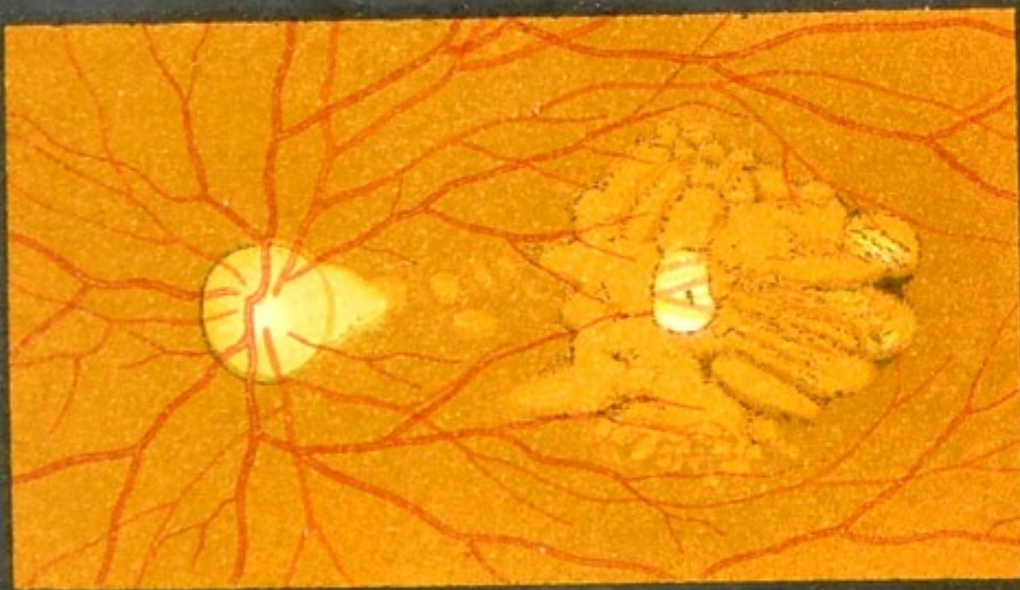FIG. 6b.—Coloboma of the Choroid at the  
Macula.

In this case the region of the macula is light red in colour, due to a congenital absence of the retinal pigment, and scattered over its surface are irregular streaks of pigment. At its centre the choroid is only represented by a few bloodvessels passing across the white sclerotic.

On the temporal side of the disc there is a triangular yellowish patch, showing that the choroid is here also somewhat deficient; the rest of the fundus is normal. The same changes were seen in the fellow eye.




a

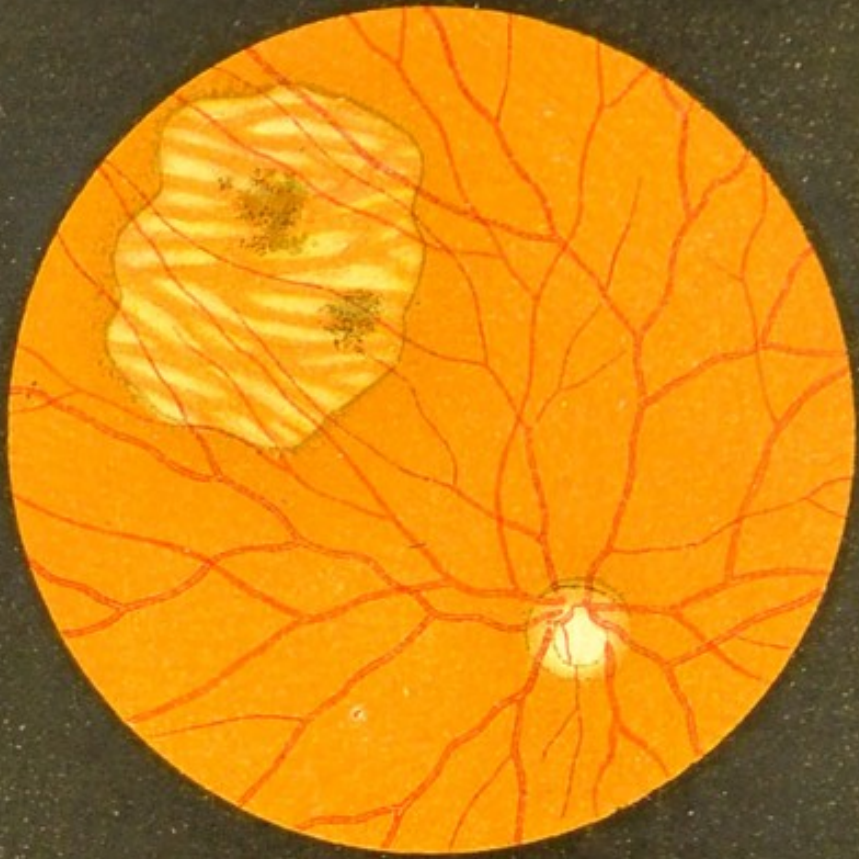


b

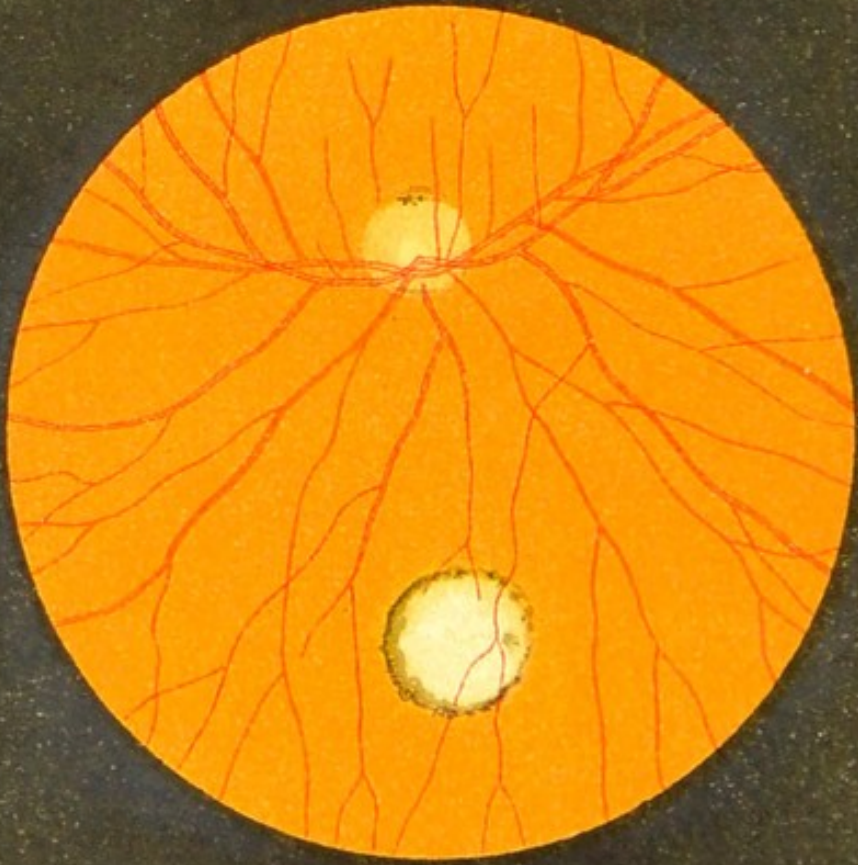
Fig 6.







a



b

Fig 7

FIG. 7a.—Circumscribed Congenital Absence of the Retinal Pigment and Choroid at the Upper and Outer Part of the Fundus (*inverted image*).

The patch, over which the retinal vessels pass uninterruptedly, has a well-defined margin of increased pigmentation. The choroidal vessels are seen clearly over the whole surface, but the pigment is absent from the intervacular spaces.

The remains of the retinal pigment are collected together in the form of two blackish patches.

The rest of the fundus is normal, and the fellow eye is normal.

FIG. 7b.—Coloboma of the Choroid on the Nasal Side of the Disc (*inverted image*).

The coloboma is almost circular, and its margin is well defined by pigment. At this part the choroid is entirely absent, and the retinal vessels are seen passing across the white sclerotic.

The rest of the fundus is normal. The fellow eye is quite normal.



FIG. 8a.—Coloboma of the Choroid at the Upper Part of the Posterior Pole  
of the Eye (*inverted image*).

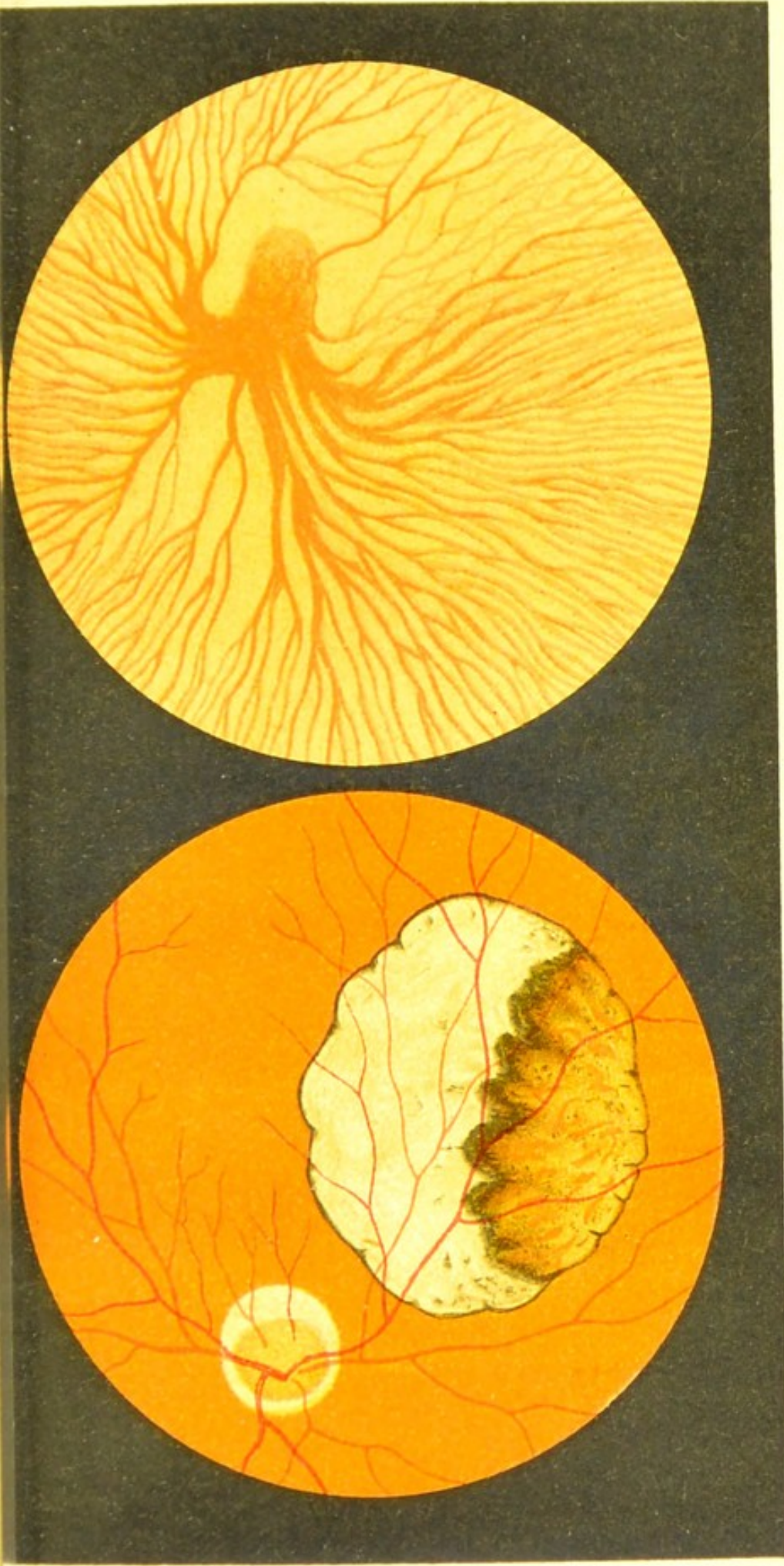
The patch is bordered by a sinuous line of pigment. At its upper part some portion of the choroid remains, but below this it is entirely absent, and only the white sclerotic is visible. The retinal vessels pass unchanged across this abnormal patch. The patient is myopic, and the disc is surrounded by a ring of choroidal atrophy.

The fellow eye presented an exactly similar defect at the upper part of the fundus, above the posterior pole.

FIG. 8b.—Congenital Absence of Pigment of the Eye—Albinism.

This picture only represents a small portion of the lower and outer part of the fundus at the periphery, and it shows one of the venæ vorticosaë, with its branches. The absence of pigment both from the retina and choroid shows up the choroidal vessels very plainly against the white background of sclerotic.


No retinal vessels are seen, for they are very small in size and scanty in number in this region.




b

Fig 8.

a








Fig 9.

FIG. 9.—Congenital Dislocation of the Lens—  
Ectopia lentis congenita (*inverted image*).

The figure represents the fundus of the right eye seen with the ophthalmoscope by the indirect method.

The dislocation is outwards and downwards, and by suitably adjusting the focusing-glass the margin of the lens is seen passing across the middle of the field, and the disc is duplicated, the smaller image being that which is seen through the lens. The disc shows a well-marked myopic crescent.

## DISEASES OF THE OPTIC NERVE (FIGS. 10 to 18).

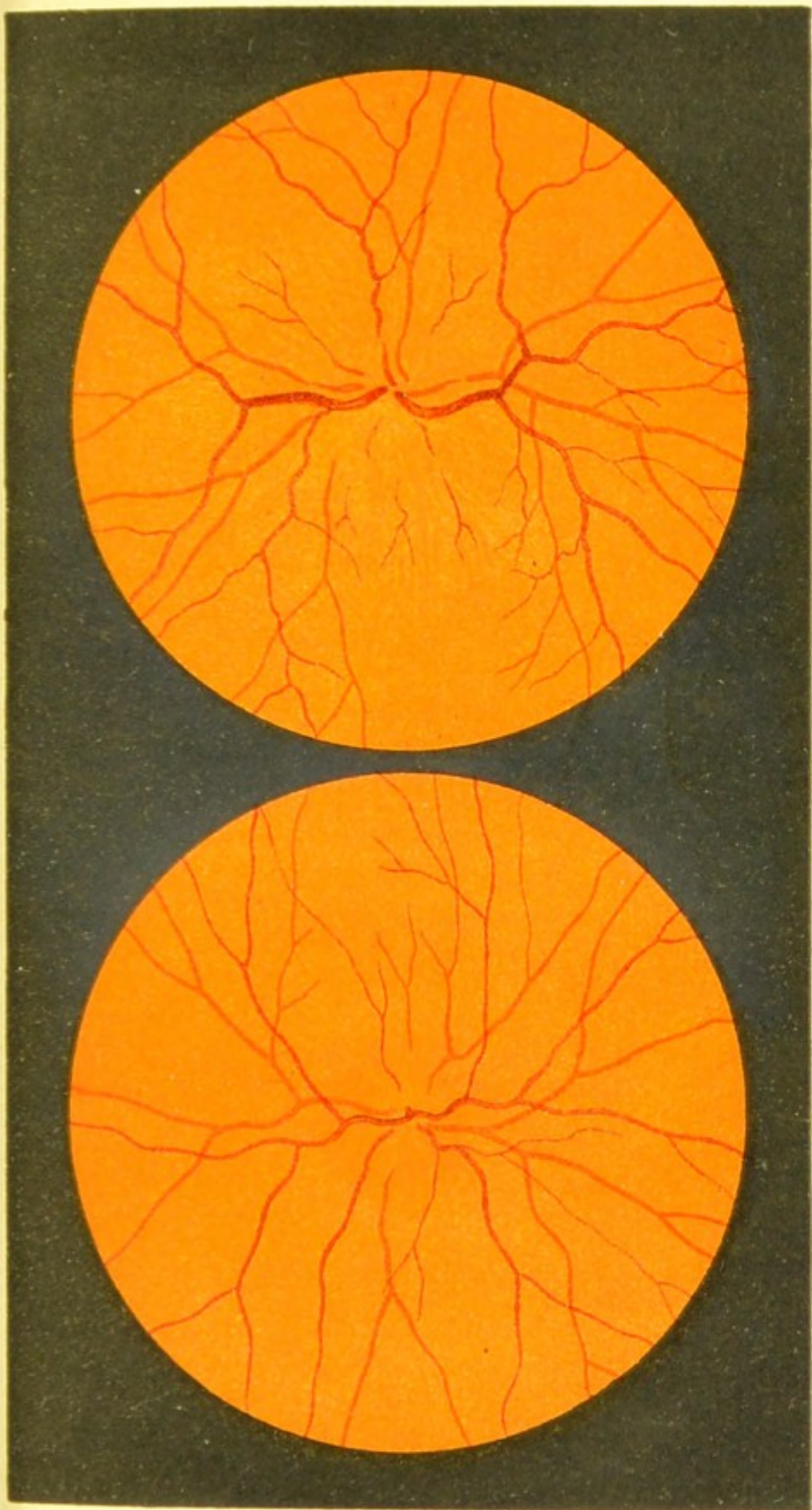
### FIG. 10a.—Optic Neuritis—Early Stage.

The disc is so congested and its margins so obscure, that it is difficult to distinguish it from the rest of the fundus.

By means of the parallaxic movement (see Introduction) and the direct examination it was seen to be slightly swollen. The retinal vessels and the rest of the fundus appear normal.

### FIG. 10b.—Optic Neuritis—Later Stage.

The disc is swollen and enlarged. The venous engorgement is well marked. The arteries are narrowed.




b

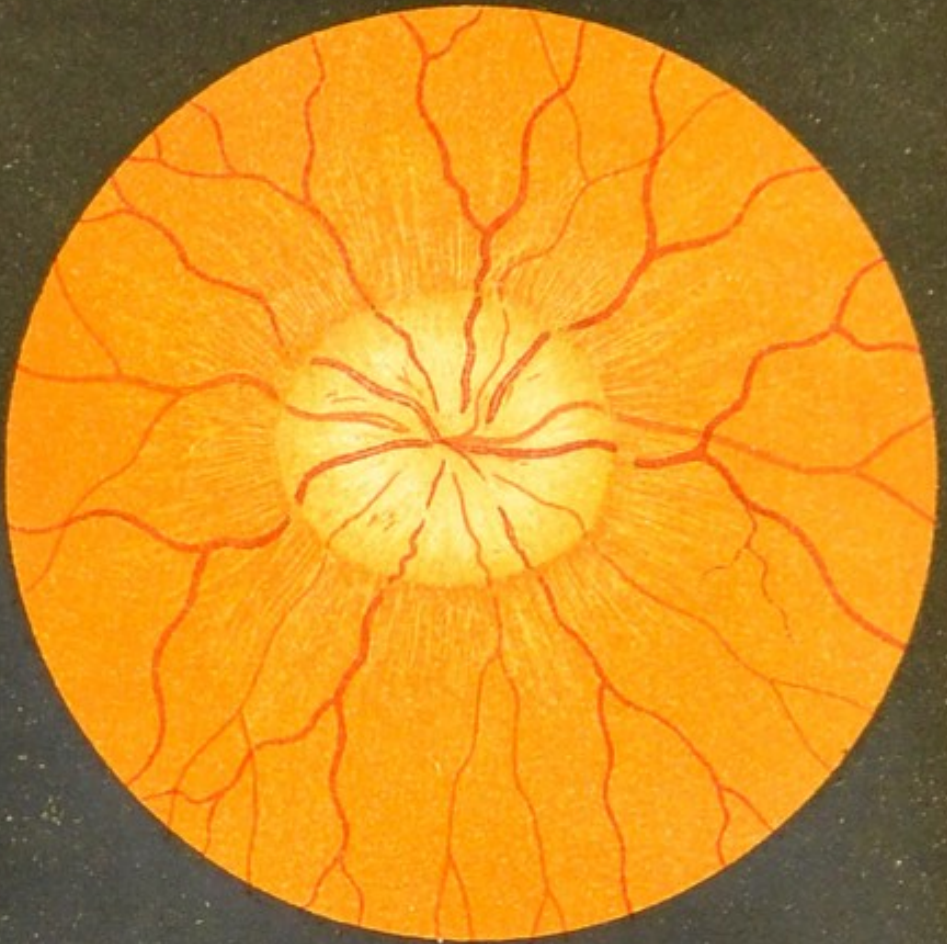
Fig 10.

a



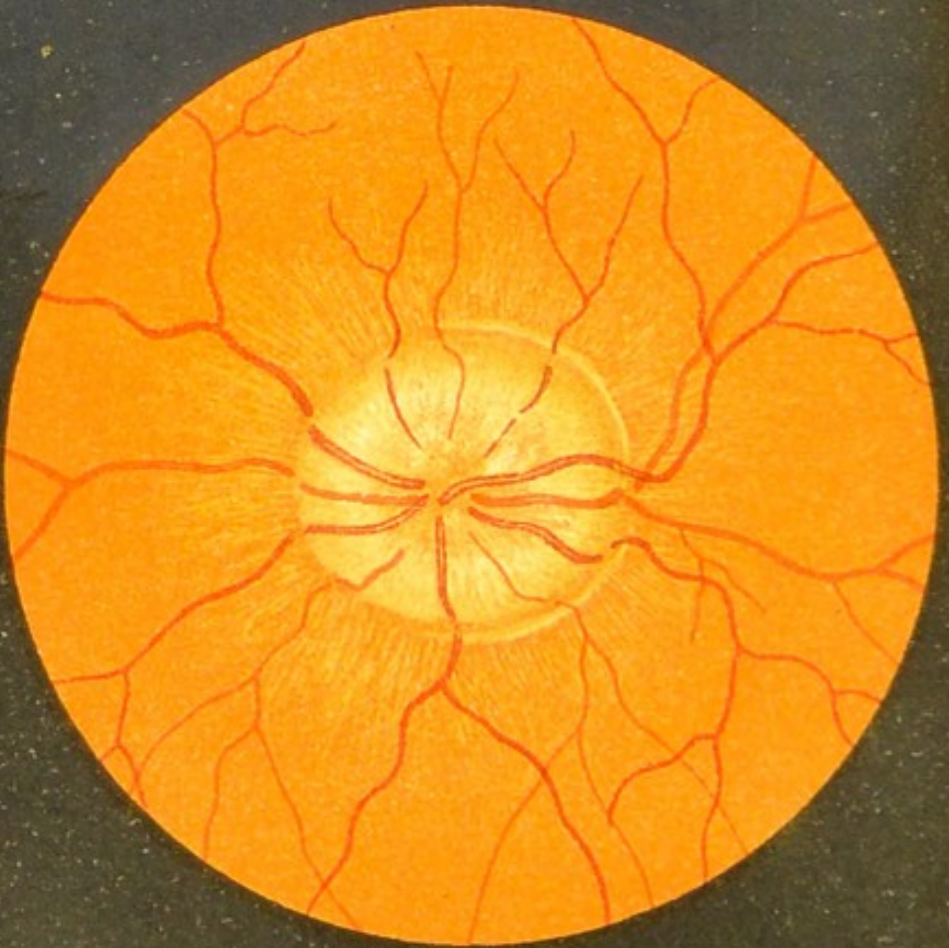






a

Fig. 11.



b

FIGS. 11*a* and 11*b*.—Double Optic Neuritis accompanying Tumour of Brain—  
'Choked Disc.'

The disc is enlarged, and is so swollen by œdema and inflammation that it projects forward considerably, and the vessels in passing to the retina have to dip abruptly at its margin. The veins are engorged and tortuous.

The retina in the neighbourhood of the papilla is slightly infiltrated, and has a striated appearance.

In the left eye a white crescentic line is seen close to the margin of the disc; this is probably a wrinkling of the retina. (From the clinic of Professor Eichhorst.)

FIG. 12.—Syphilitic Neuro-Retinitis.

The disc and surrounding part of the retina are intensely blurred. Part of this blurring is due to a diffuse central haziness of the vitreous.

In this case the periphery of the fundus is unaffected, although sometimes patches of old-standing or recent disseminated choroiditis may be seen there.

This picture is very characteristic of syphilis.

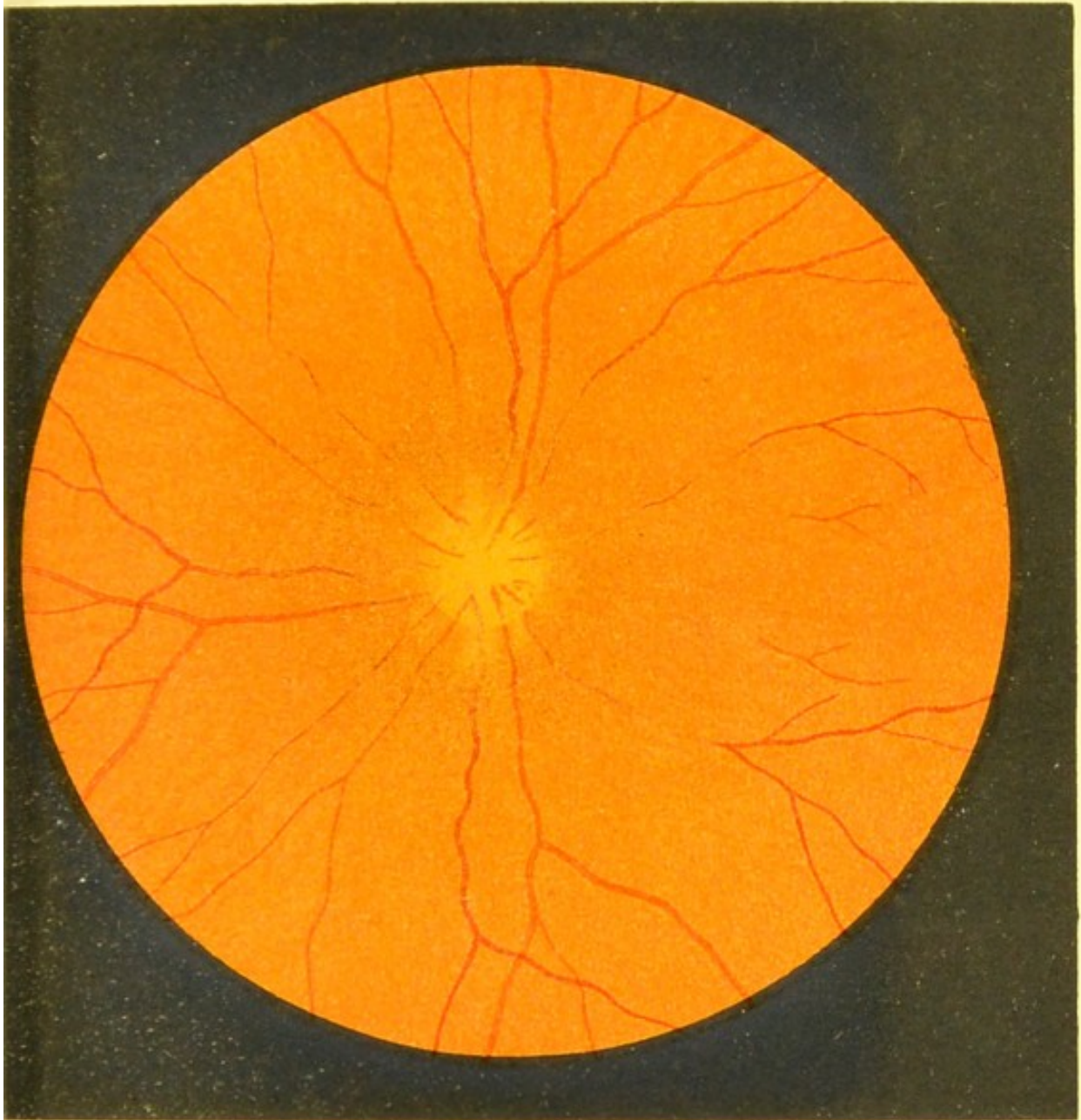



Fig.12.







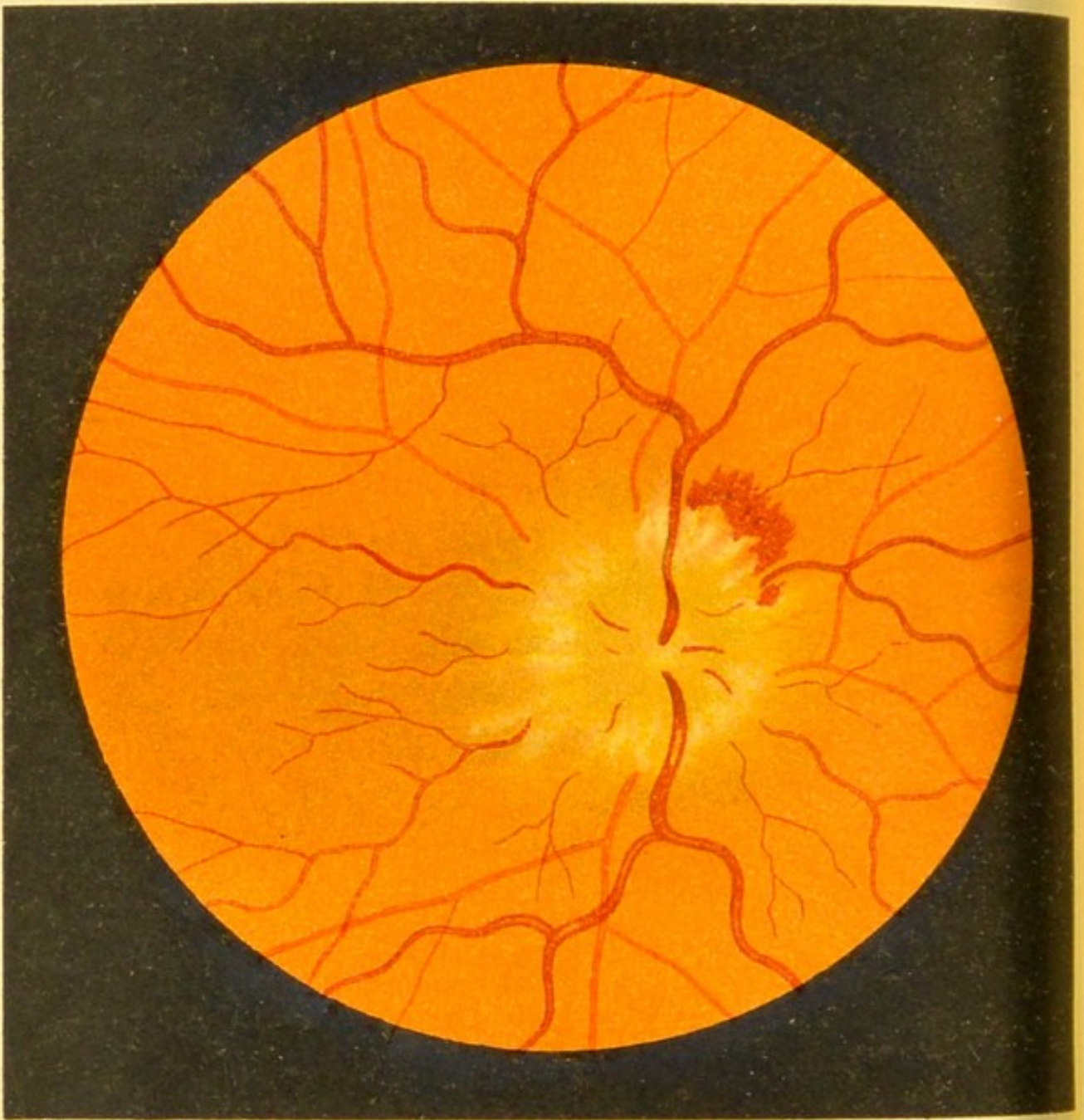


Fig. 13.

FIG. 13.—Severe Papillitis (*inverted image*).

This condition was due to meningitis, the result of a blow on the head. It was present in both eyes.

The inflammation has led to well-marked infiltration of the optic nerve, shown by the whitish spots and striæ on the disc and the neighbouring parts of the retina, and the hæmorrhages adjoining the lower and outer margin. The disc is enlarged, very swollen, and prominent.

The infiltration of inflammatory products in the optic nerve impedes the outflow of blood from the retinal veins, which are consequently engorged and tortuous. (From the clinic of Professor Eichhorst.)

FIG. 14.—Inflammation and Choking of the Disc  
accompanying an Orbital Tumour.

The eye was proptosed.

The disc is intensely inflamed and œdematous, and is covered by white striated patches of exudation.

The retinal veins are very much engorged and numerous hæmorrhages are scattered over the fundus.

The retinal arteries are moderately full.

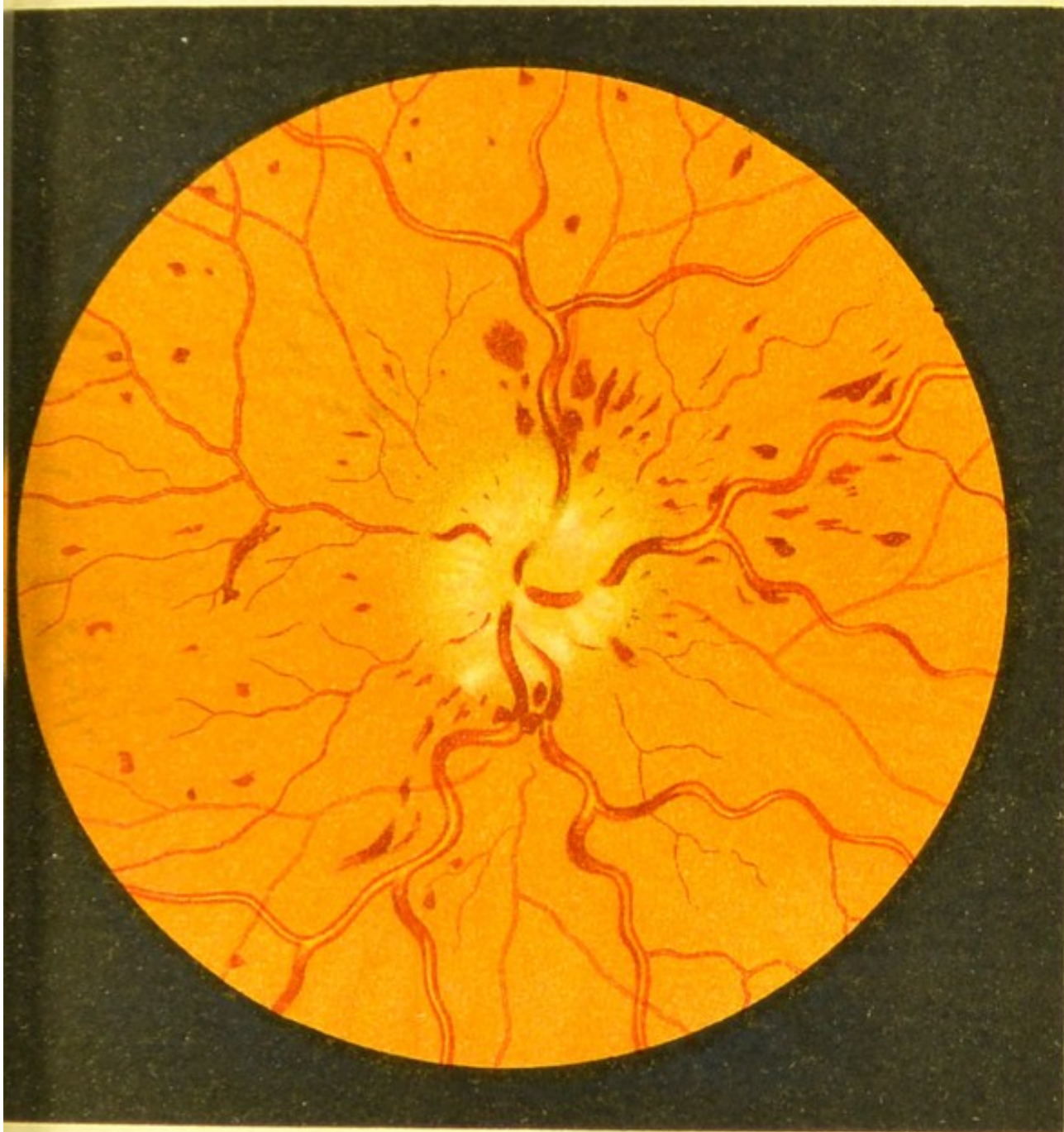


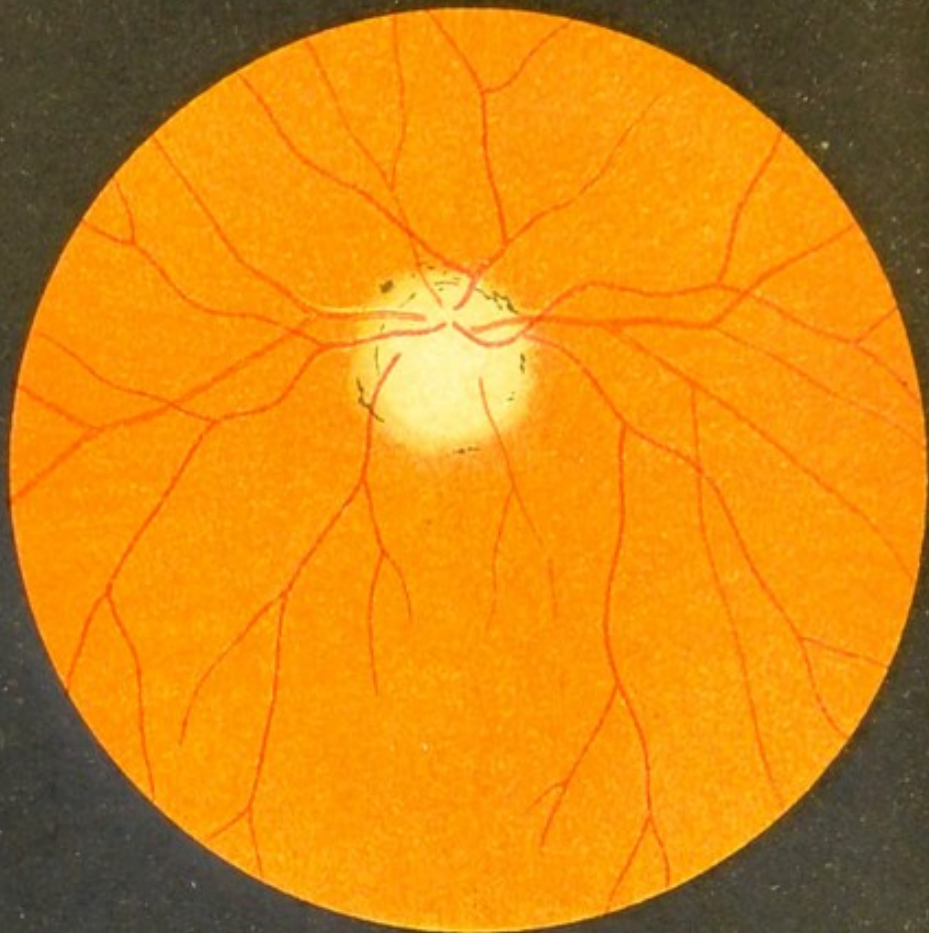



Fig 14.







a



b

Fig. 15.

FIG. 15a.—Optic Atrophy following Neuritis.

The disc is very pale, its margins rather indistinct, and the lamina cribrosa is invisible. The whiteness of the disc is partly due to the lessened blood supply and partly to the connective tissue, increased in amount by the previous inflammation. Along some of the vessels white lines are seen; they are due to the thickening of the arterial walls (peri-arteritis). Around the disc we see some pigment deposits and a narrow ring of choroidal atrophy, also a sequel of the neuritis. The retinal vessels appear normal in size; at a later stage they become smaller.

FIG. 15b.—Atrophy of the Optic Nerve following Division of the Nerve, caused by Fracture of the Optic Canal, the Result of a Blow on the Head.

With the exception of the whiteness of the disc, the appearances are normal.

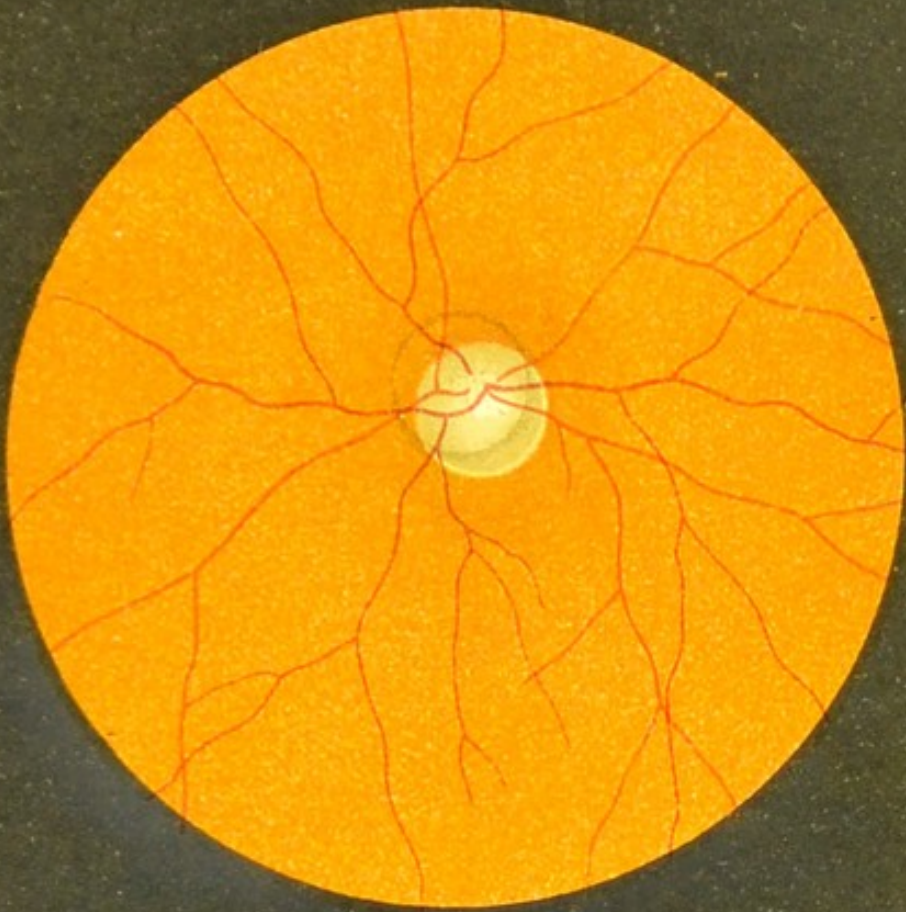


FIG. 16a.—Early Stage of Grey Atrophy of the Optic Nerve (*inverted image*).

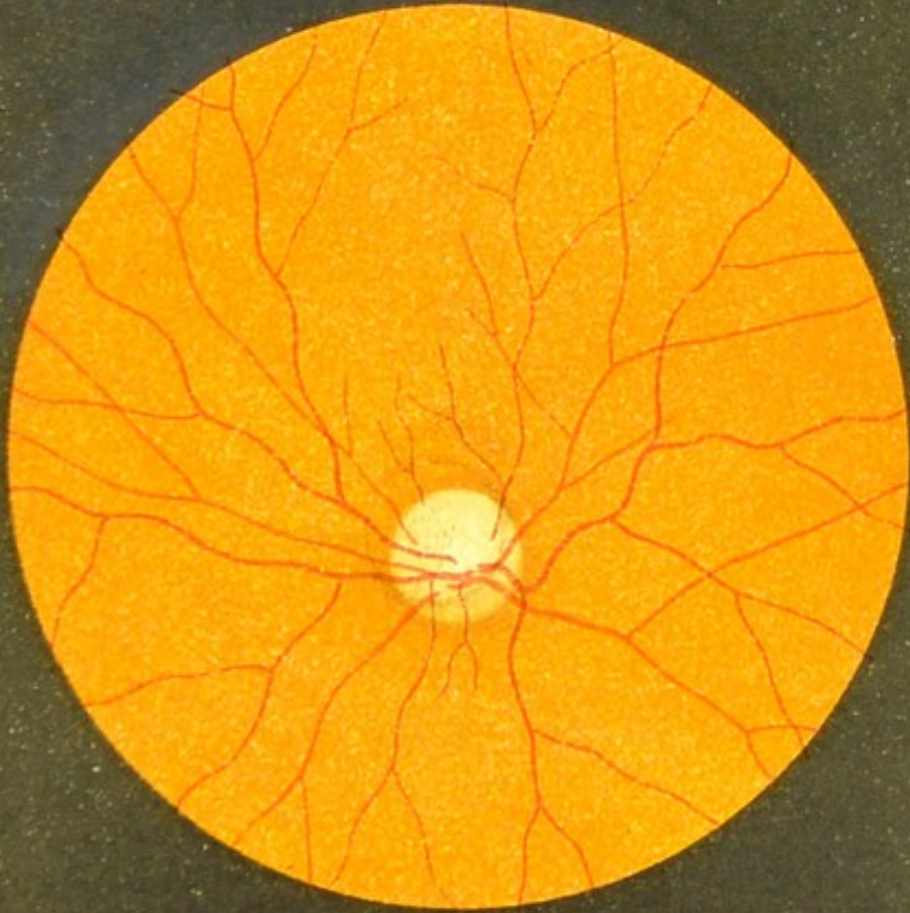
The change of colour is very marked on the temporal side, but less so on the nasal side. The lamina cribrosa in the centre of the disc is fairly distinct. The vessels even at this early stage are seen to be narrowed.

FIG. 16b.—Advanced Grey Atrophy of the Optic Nerve.

The change of colour is more marked than in the former case. The lamina cribrosa is plainer. This condition is produced by the exposure of the connective tissue, the result of atrophy of the nerve-sheaths. The margins of the disc remain perfectly distinct. The vessels are becoming narrower and narrower.





b



a

Fig.16.





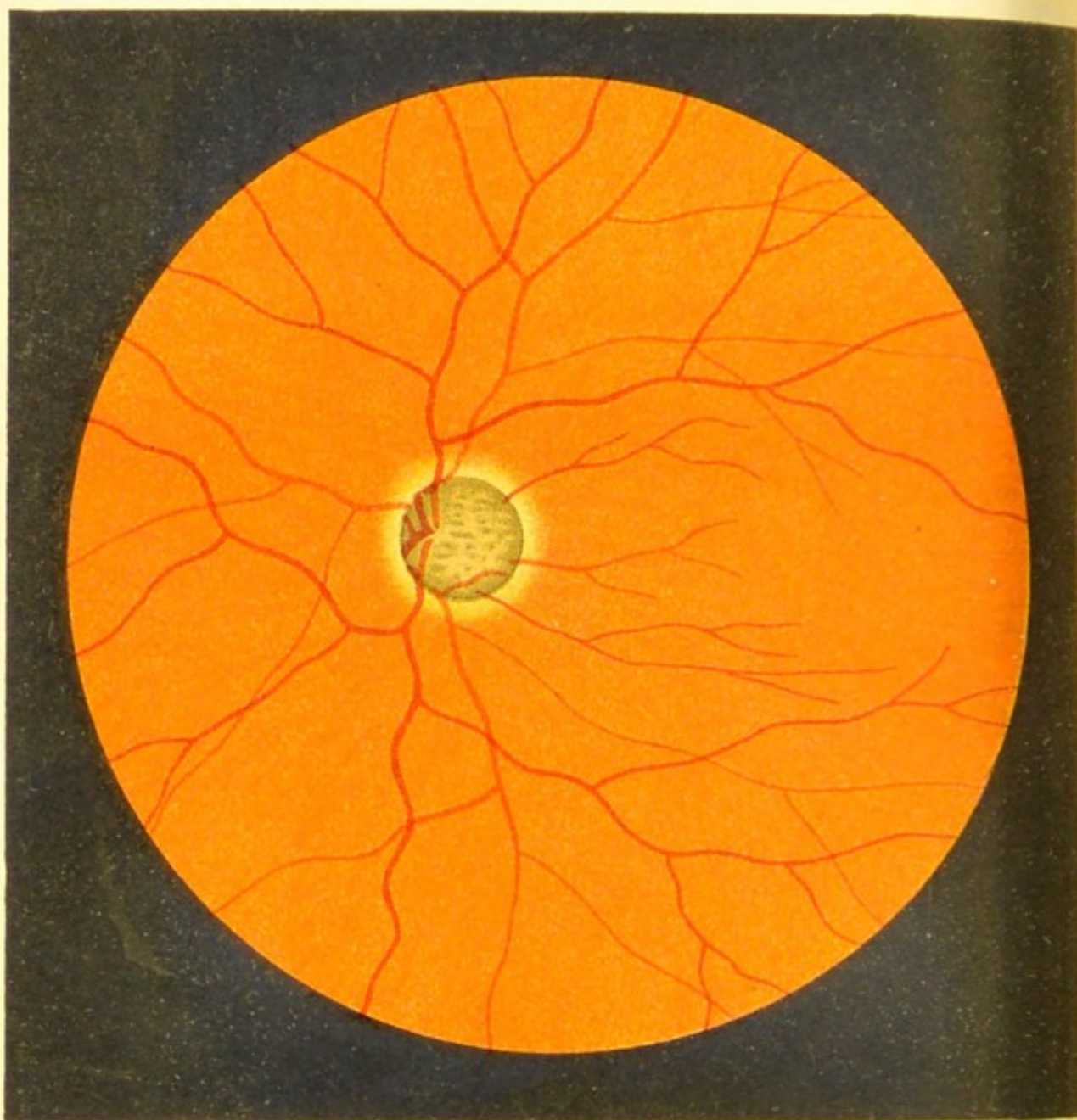


Fig.17.

FIG. 17.—Optic Atrophy following Glaucoma.

The whole of the disc is deeply cupped and very grey in colour. The depressed lamina cribrosa is very distinct, owing to the atrophy of the nerve-sheaths. The portion of the choroid that immediately surrounds the disc is atrophied and forms a bright ring, which has been called the glaucomatous halo.

If the vessels are followed from the retina to the disc, they are seen to dip down at the margin of the disc, and some of them quite disappear from view, reappearing as they pass to their exit from the nerve at the bottom of the cup.

The retinal veins are swollen, and the arteries are small.

The excavation of the disc can be diagnosed by the indirect method by moving the focussing lens to and fro, and obtaining the parallaxic movement of the edges of the disc over its centre. The amount of cupping can be estimated by the direct method by noting the difference of refraction between the upper rim and the bottom of the cup. In this case there was a difference of 6 D., showing that the cup was 2 mm. deep.

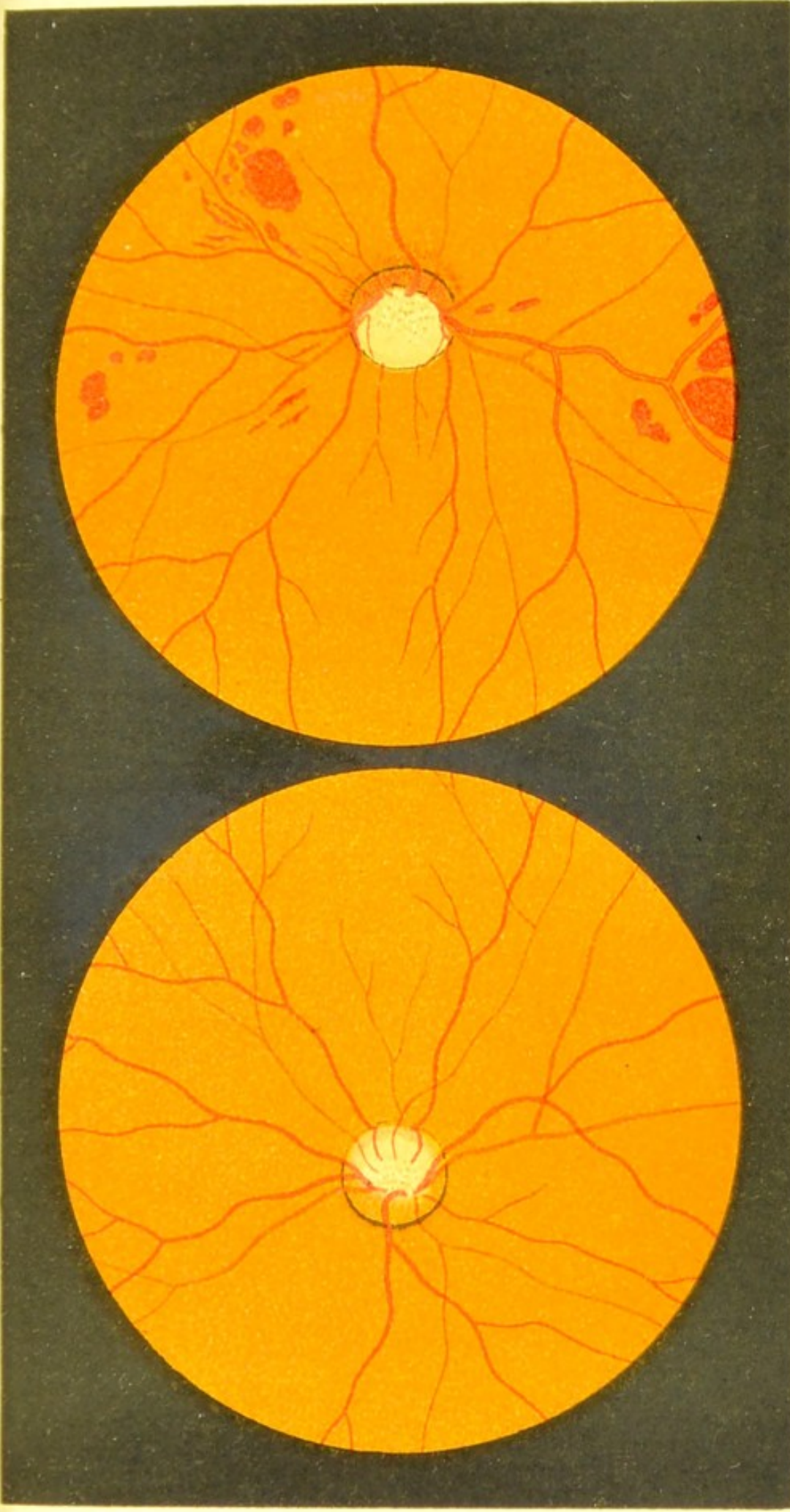
FIG. 18*a*.—Early Stage of Glaucomatous Cupping of the Disc.

Only half the disc, the temporal half, is up to the present excavated; the nasal half is reddened. The vessels are seen bending over the temporal margin as they dip down to the bottom of the cup. The lamina cribrosa is exposed, and the atrophic changes have already produced a greyish appearance in the excavated portion of the disc.

The above condition is distinguished from physiological cupping in that, in the latter, the excavation does not extend right up to the margin of the disc.

FIG. 18*b*.—Later Stage of Glaucomatous Cupping, with Hæmorrhages—  
Hæmorrhagic Glaucoma.

The nasal portion of the disc, which is very red, is the only part unaffected by the excavation. The remainder of the disc is deeply cupped, and exhibits grey atrophy. The lamina cribrosa is visible throughout the greater part of its extent. The veins are engorged, which is partly due to the blocking caused by the bending back of the vessels as they pass over the margins of the cup.





b

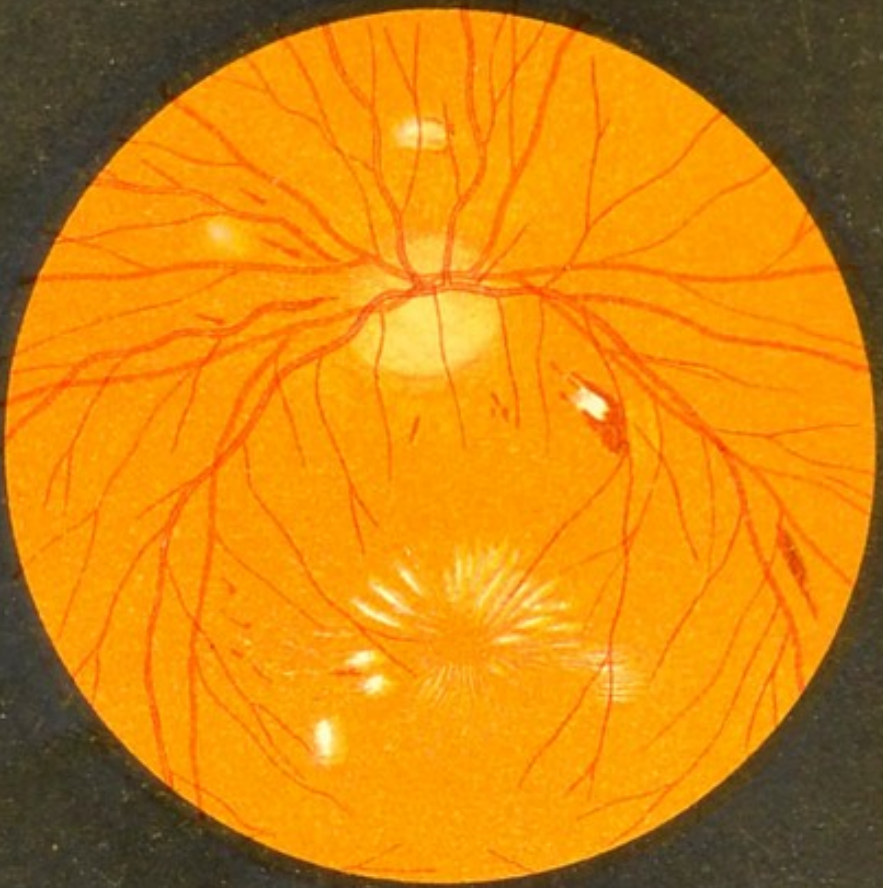
Fig.18.

a

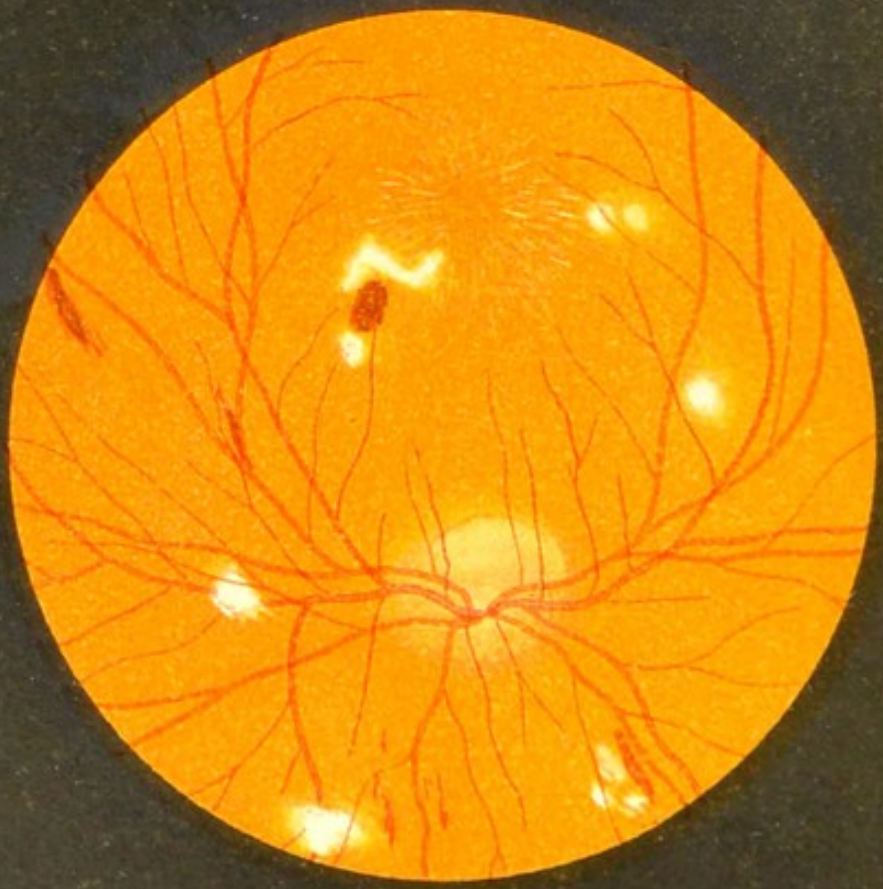







a



b

Fig. 19.

DISEASES OF THE RETINA (FIGS. 19 TO 50).

FIGS. 19a and 19b.—Neuro-Retinitis Albuminurica. (*Both eyes of the same patient.*)

The presence of optic neuritis is shown by the congestion of the disc and the blurring of its margins. The retinitis is evidenced by the changes seen in the immediate neighbourhood of the disc, and by the scattered hemorrhages over the rest of the fundus. Round white degenerative patches are seen here and there [some are crossed by the vessels, and others are superficial and completely hide that portion of the vessel they cover], and at the macula these white spots are small and linear, and are arranged in the form of a star, at the centre of which we see the fovea considerably darker in colour than the rest of the fundus.

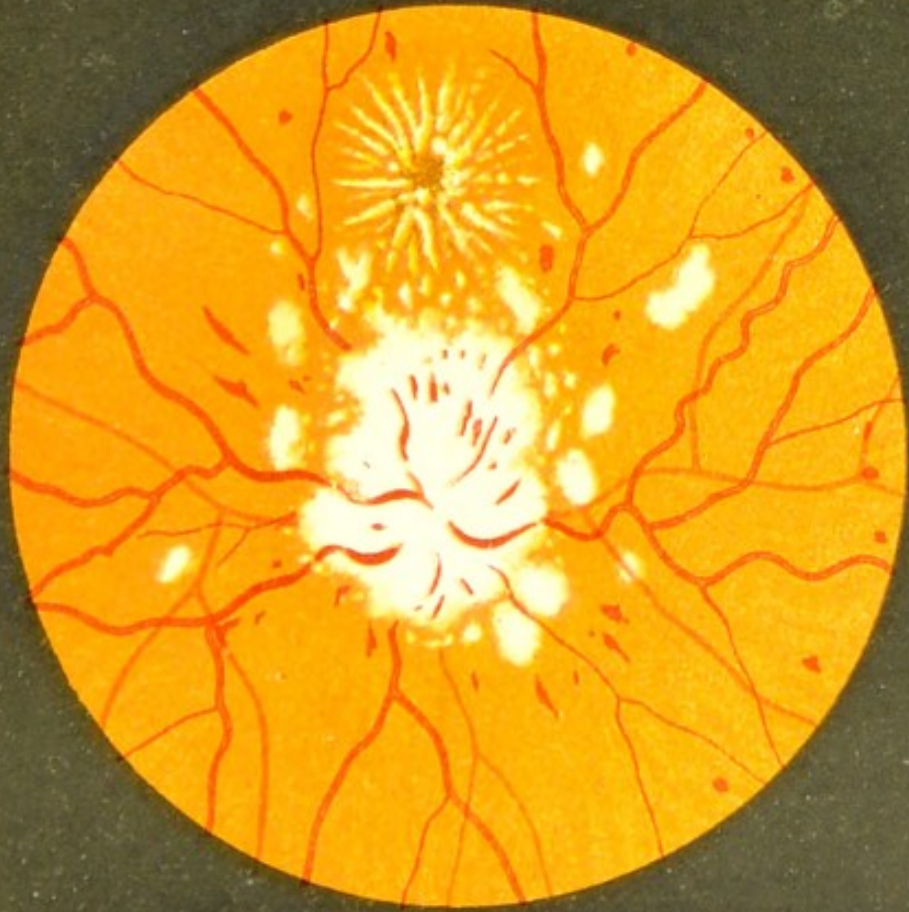FIG. 20*a*.—Retinitis Albuminurica: More Advanced Stage.

The white atrophic patches and the star-shaped figure at the macula have become more marked. The situation of the disc is only recognised by observing the spot to which the engorged veins are directed. All the retinal arteries are narrowed, and some of them are obliterated. Numerous small hæmorrhages are seen scattered over the fundus.

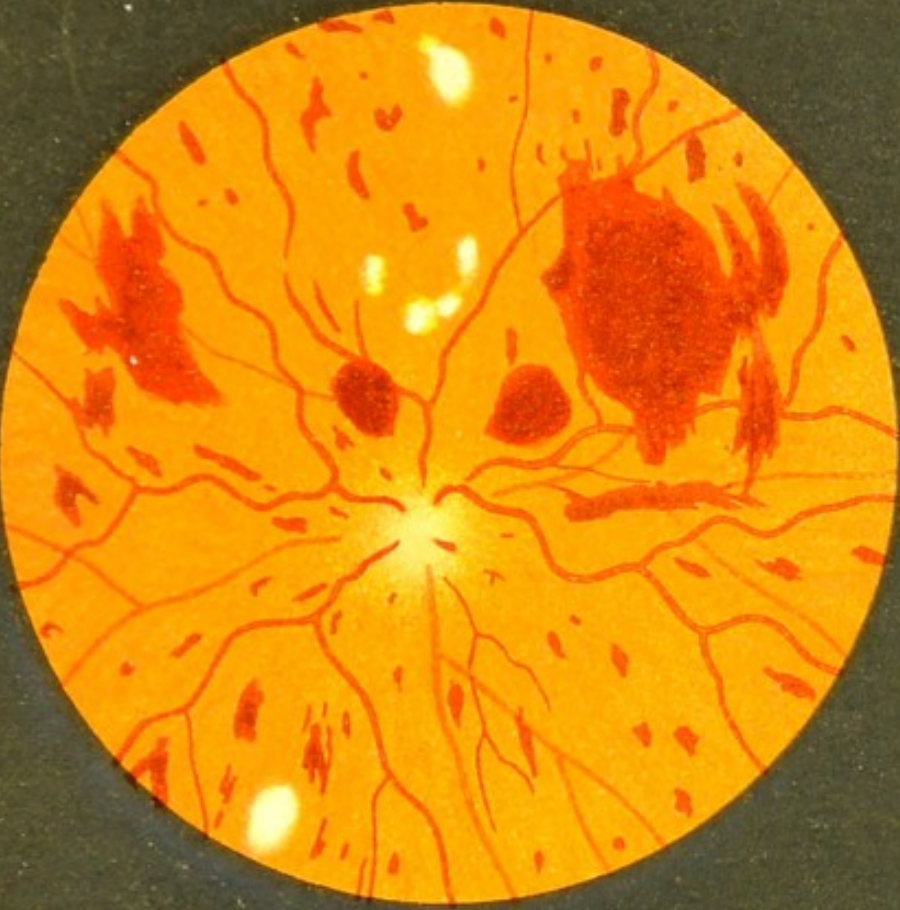FIG. 20*b*.—Retinitis Albuminurica.

In this case the hæmorrhages, some of which are very large, far outnumber the atrophic patches, and optic neuritis is present. The veins are engorged and tortuous, and the star-shaped figure so characteristic of this disease is absent.

The appearances of the fundus are more like those of Retinitis Hæmorrhagica due to thrombosis of the central vein; but the neuritis rather points to albuminuria as being the cause.





a



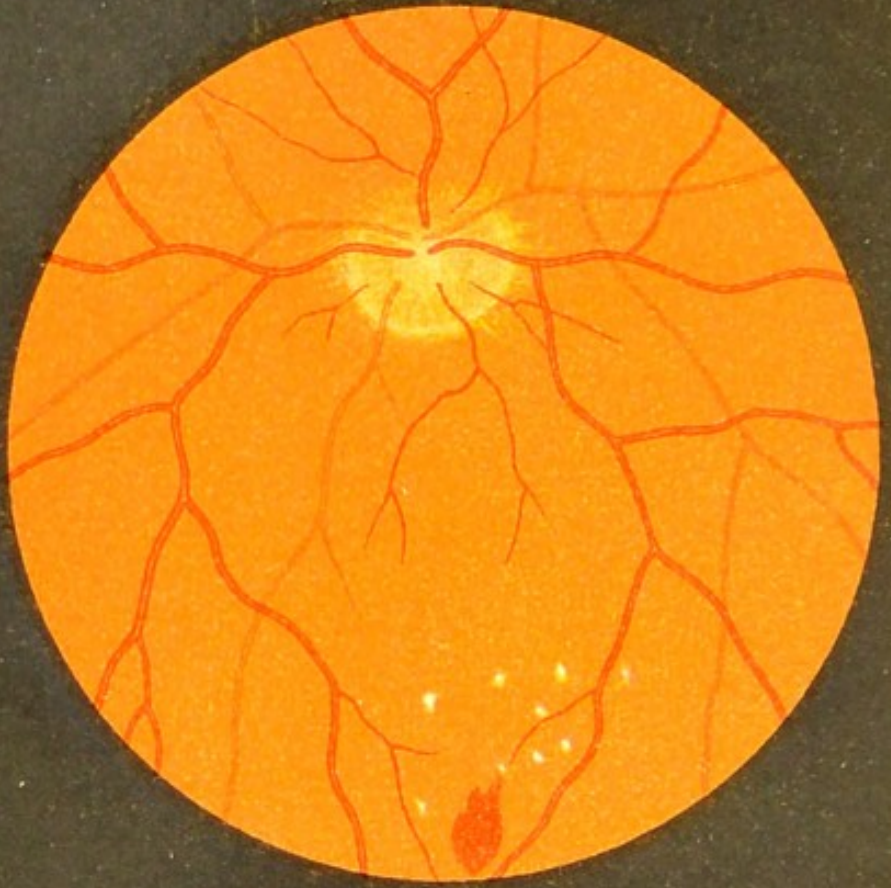
b

Fig.20.

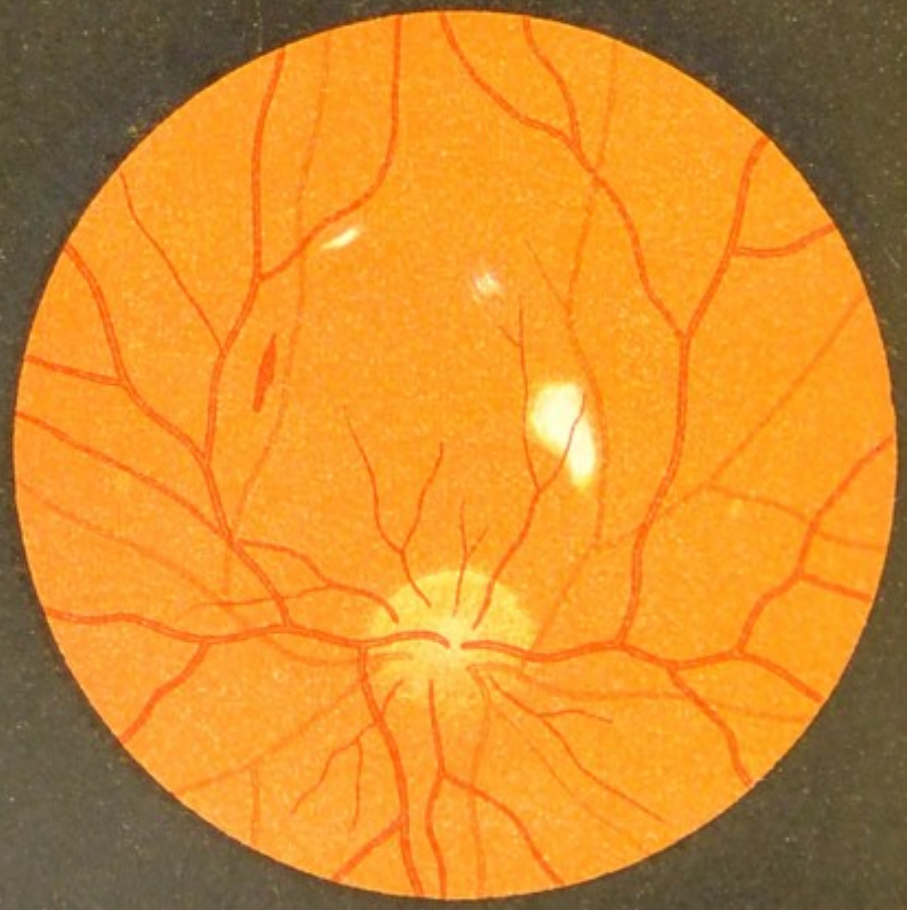







a



b

Fig. 21.

FIGS. 21*a* and 21*b*.—The Fundus of both Eyes from a Patient suffering from  
a Mild Form of Neuro-Retinitis Albuminurica (*inverted image*).

The nasal and upper and lower margins of both discs are blurred, showing the commencement of optic neuritis. A few hemorrhages and white spots are seen near the macula, but no star-shaped figure. This condition is more commonly seen by the ophthalmic surgeon than that represented in the former figures (19 and 20).

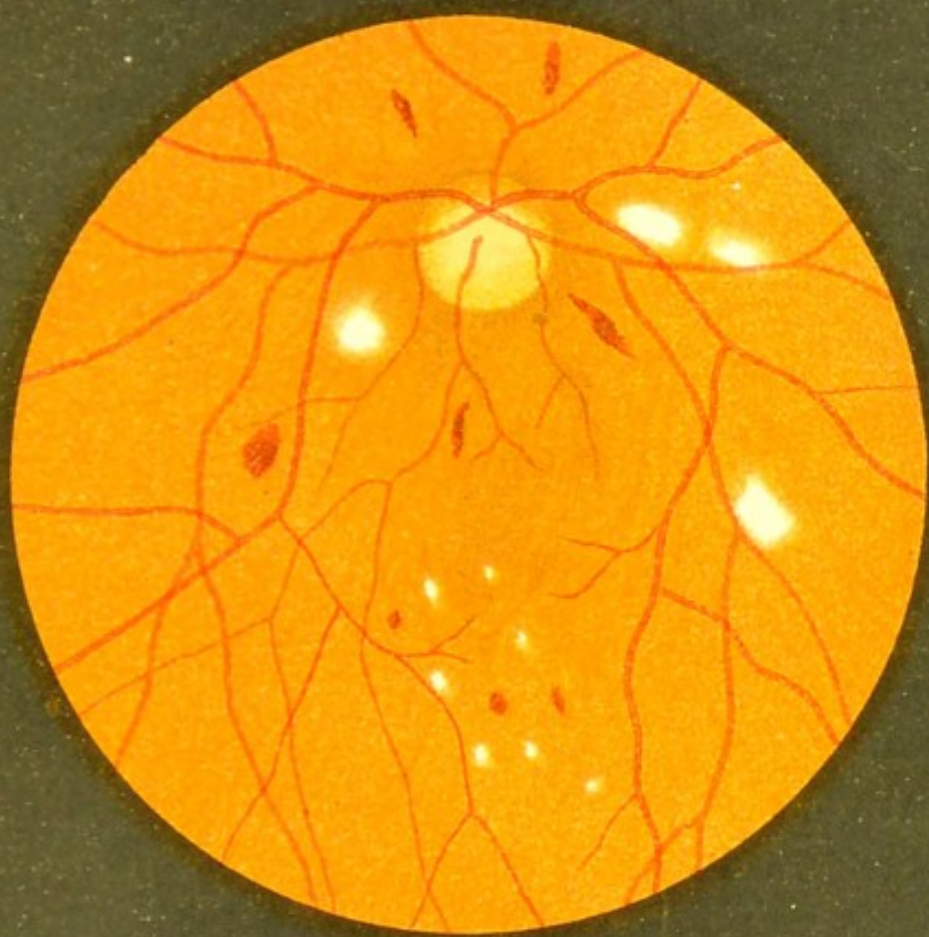
It is most important to bear in mind that in every case where we find white or red patches on the fundus the urine should be examined.

As we shall see in the following figure, the fundus in Diabetic Retinitis may be very similar to this.

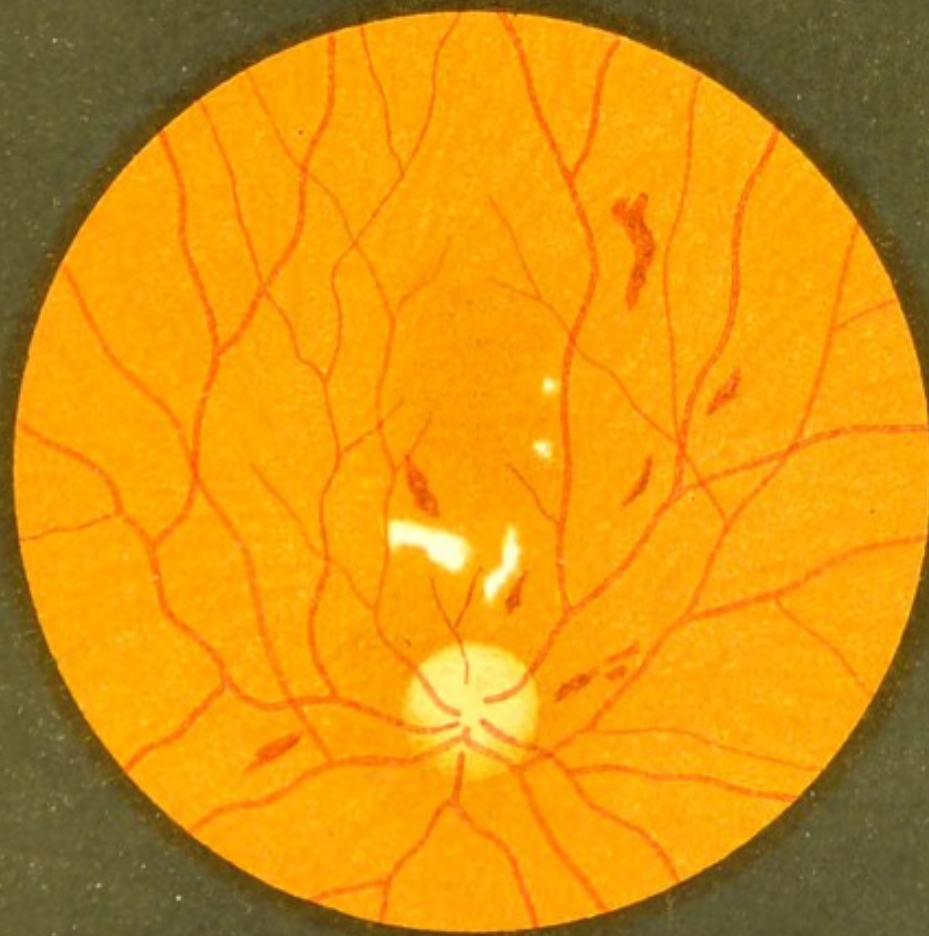FIGS. 22*a* and 22*b*.—Diabetic Retinitis.

The fundi of both eyes.

The appearance here only differs from that in the previous figure in the greater number of the hæmorrhages that are present.





b



a

Fig. 22.





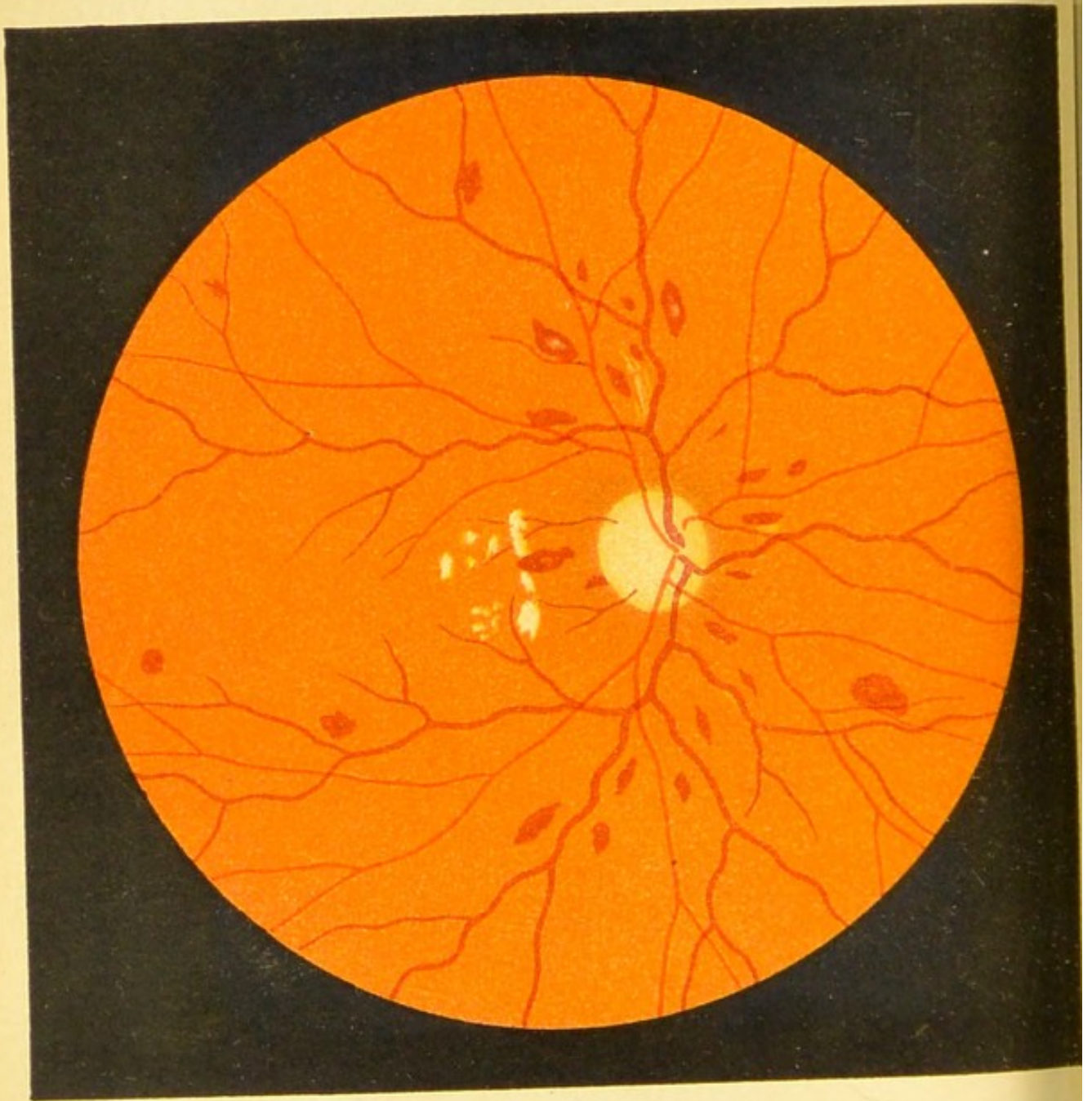


Fig. 23

FIG. 23.—Changes in the Fundus accompanying  
Pernicious Anæmia.

The anæmia shows itself in the extreme whiteness of the disc and the paleness of the fundus.

The arteries are narrowed and the veins swollen.

Numerous hæmorrhages are scattered over the retina; some of these contain a whitish centre.

There are some white atrophic patches in the neighbourhood of the disc.

(The patient was from Professor Eichhorst's clinic, and died shortly after this picture was taken.)



FIG. 24.—Embolism of the Central Artery of the  
Retina.

There is marked paleness of the retina round the disc and over the whole posterior pole of the eye, the margins of the disc being consequently very ill defined.

Many of the vessels in this region are obliterated in parts, and the white background shows up very plainly some of the finer vessels at the macula that are normally invisible.

The fovea centralis is seen as a cherry-red round spot, which resembles a hæmorrhage. This appearance is caused partly by the choroid being seen through the thin retina, and partly by contrast.

The retinal vessels, which at first are somewhat narrowed, are here normal in size. The column of blood is, in places, broken up in the arteries.

The retina is normally transparent at the periphery, and allows the pigmented intervascular spaces to be well seen.

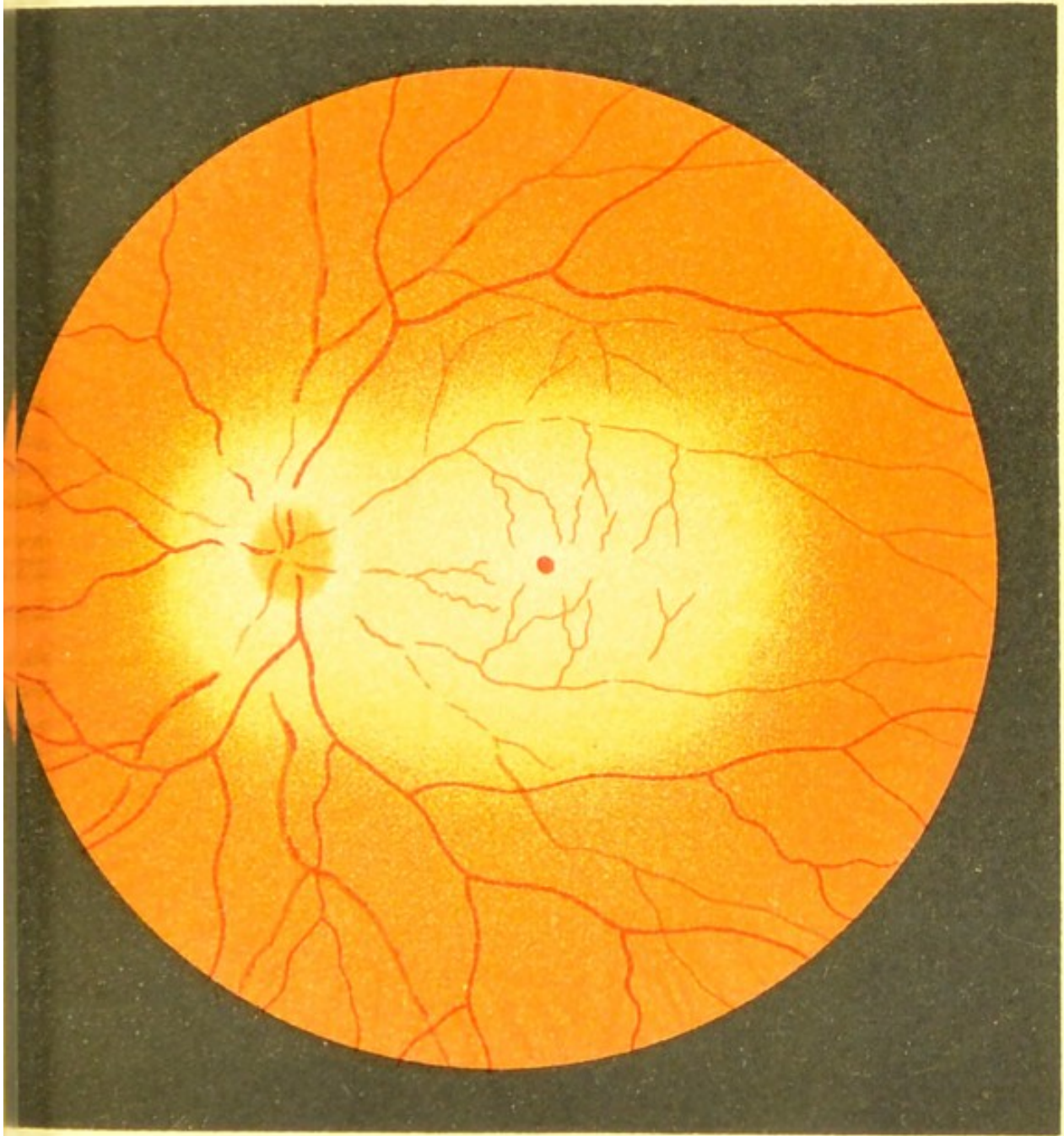
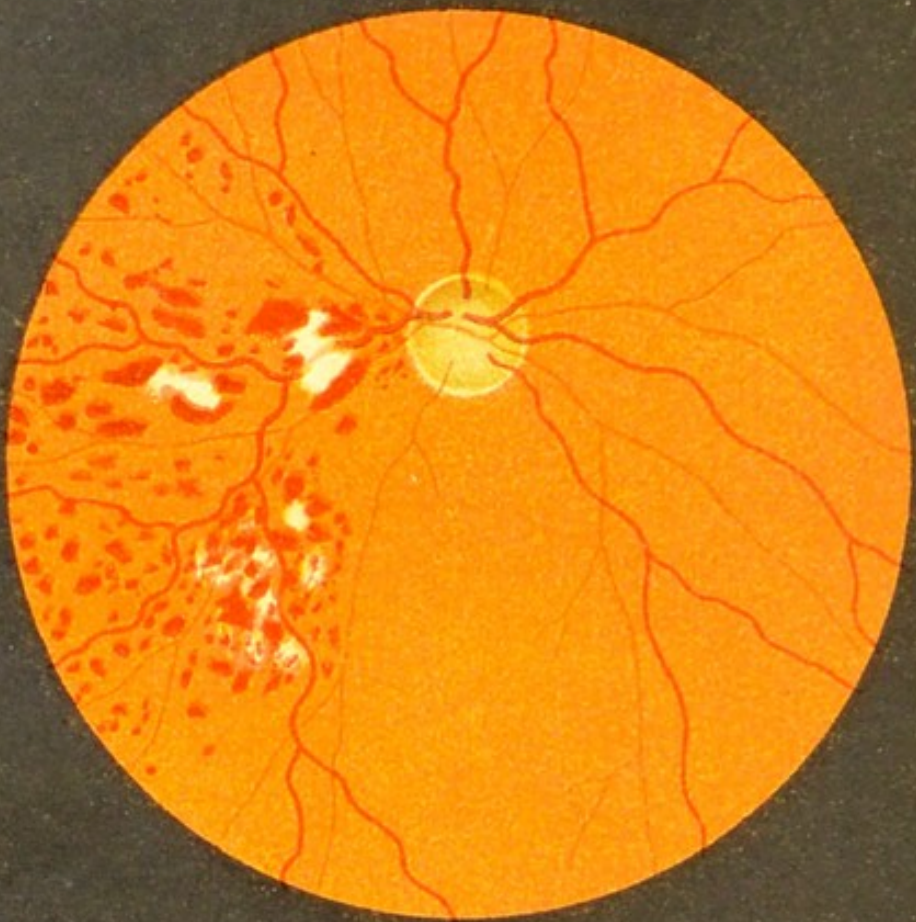


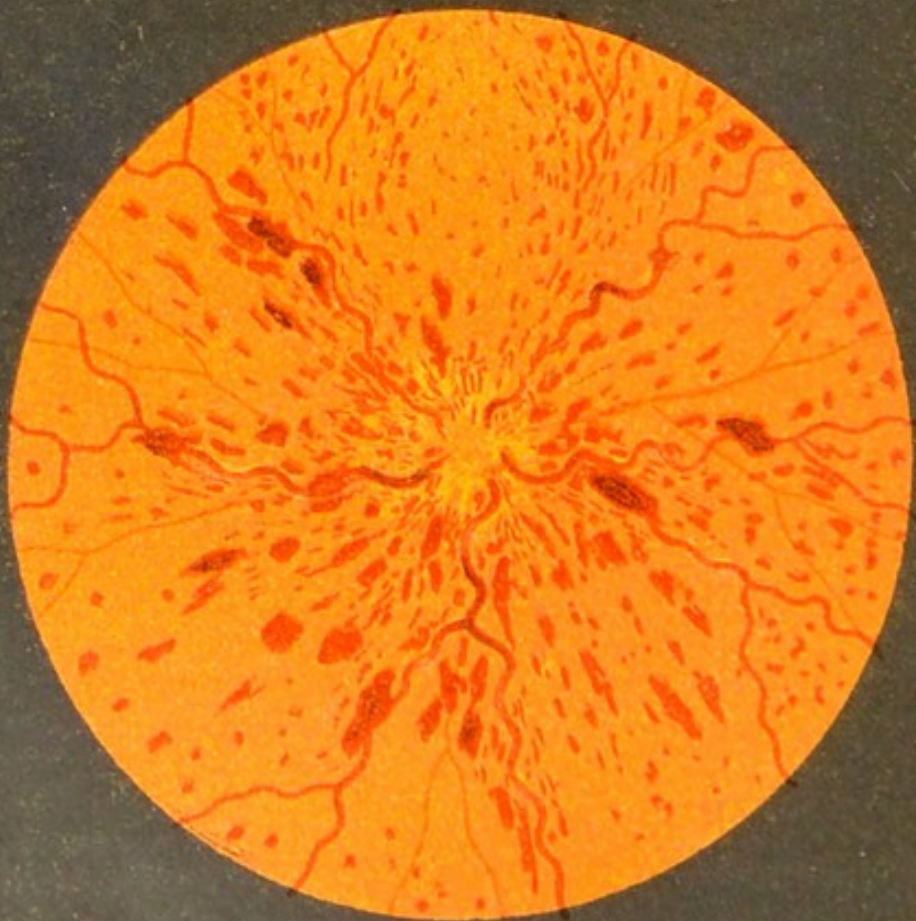Fig. 24.







a



b

Fig. 25.

FIG. 25*a*.—Thrombosis of the Vena Temporalis Superior—Retinitis Hæmorrhagica (*inverted image*).

Numerous hæmorrhages are seen covering the area of distribution of this branch of the retinal vein. Some of them are oval and some round, and several white atrophic patches are interspersed with them. The portion of vein that is plugged is close to the papilla, but is not shown in the drawing.

FIG. 25*b*.—Thrombosis of the Central Vein of the Retina—Retinitis Hæmorrhagica.

The hæmorrhages are very numerous and are scattered over the whole fundus. The veins are engorged and tortuous; the arteries are small and barely visible round the disc, which latter condition is partly due to their being covered by the hæmorrhages, and partly to the œdematous state of the retina.

The direction of the nerve-fibres in the macula region is shown by the arc-like arrangement of the hæmorrhages. The long flame-shaped hæmorrhages lie in the nerve-fibre layer, and the round ones in the deeper layers of the retina. The former acquire their striated appearance through the blood-clot being split up by the nerve-fibres. The disc is very indistinct; it is reddened and œdematous, and in parts covered with small finely-striated hæmorrhages. Although no white atrophic spots are seen in this case, they may appear at a later stage. (See Fig. 25*a*.)

FIG. 26. — Embolism, or Thrombosis of the  
Arteria Temporalis Superior (*inverted image*).

The retina is affected all over the area of distribution of this branch of the retinal artery.

The plugged artery appears to be normal in calibre.

The whitish appearance of the affected retina is due to œdema, the result of interference with the circulation. It is sharply limited near the macula, and, as we saw in embolism of the central artery, it is also most intense in this region.

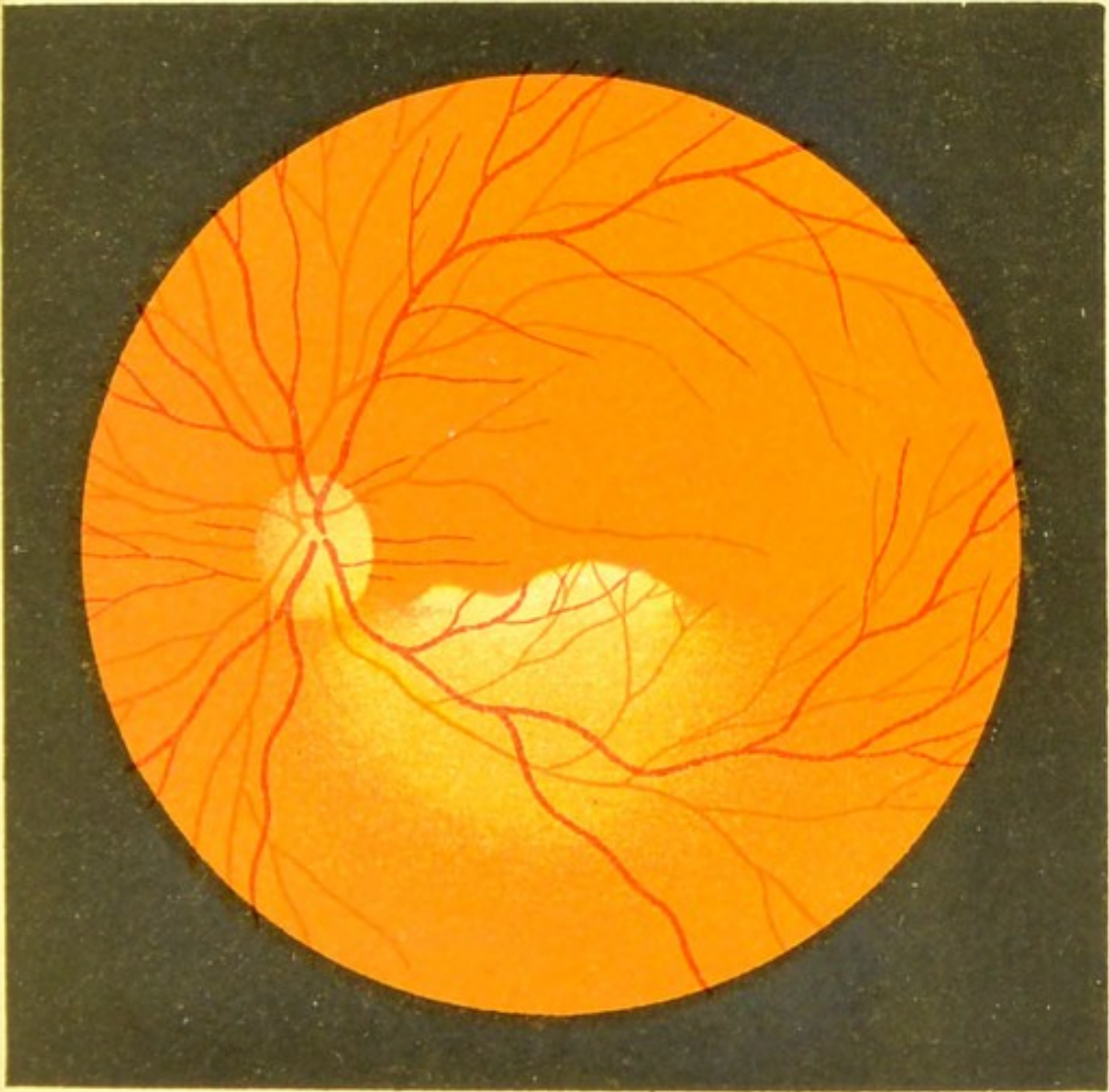



Fig.26.







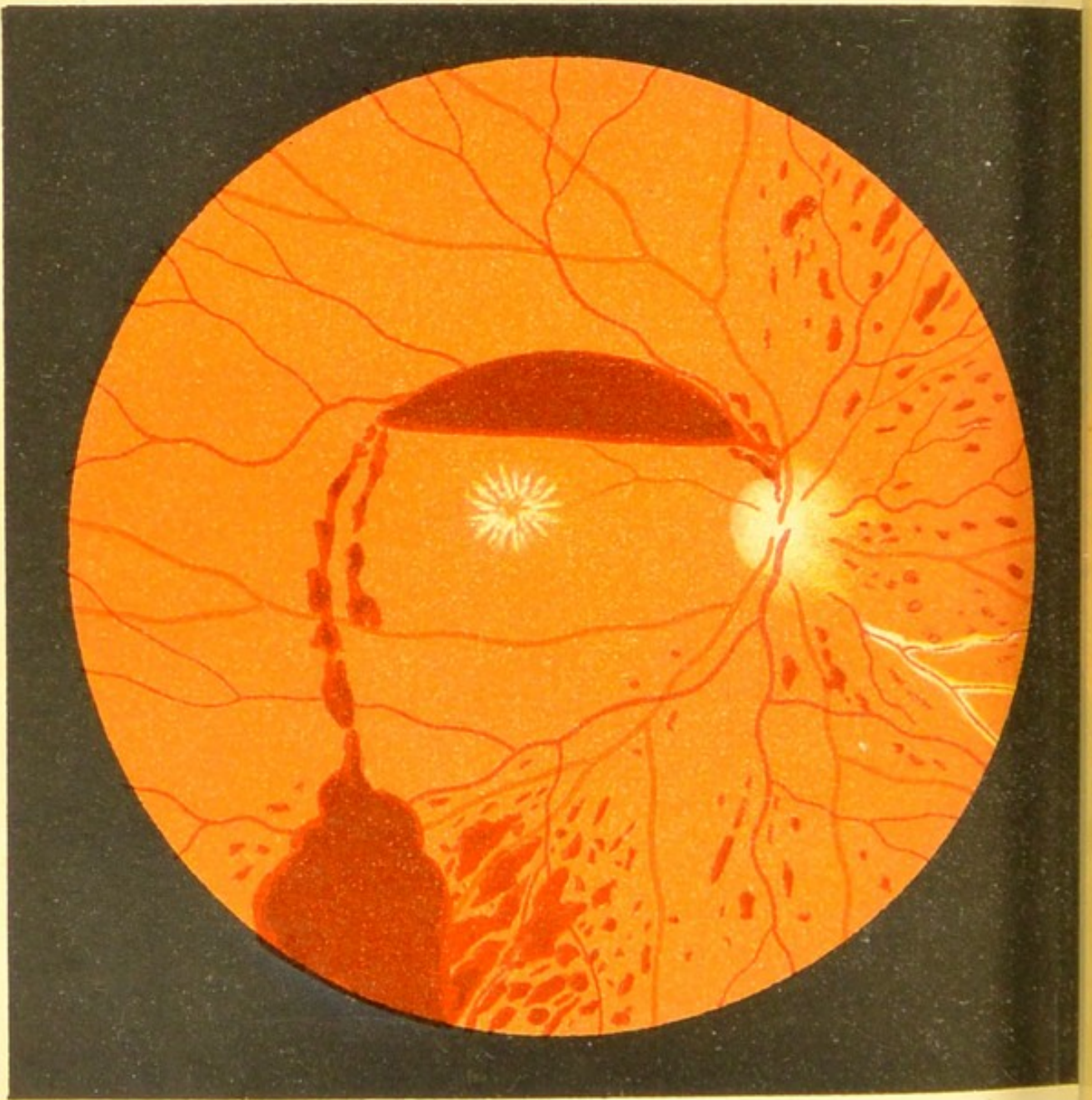


Fig. 27.

FIG. 27.—Subhyaloid Hæmorrhage in a Young Man (*inverted image*).

This is an effusion of blood from the retina between the latter membrane and the vitreous. The blood does not as a rule pass *into* the vitreous, but in this case, at a later stage, blood was found in the vitreous, which considerably masked the view of the fundus.

The hæmorrhage is on the upper part of the fundus, and the blood is seen to be passing down from here to the macula, where it forms a large dark-red patch, with a sharply-defined curved lower margin and a straight upper margin, which latter, as the blood is fluid, changes its position according to the position of the patient's head.

Numerous smaller hæmorrhages are seen scattered over the nasal and upper part of the fundus, and a vein with thickened white coats is seen at the upper nasal corner.

Although the star-shaped figure is present at the macula, no albumen was found in the urine, and the cause of the trouble was undetermined.

FIG. 28.—Syphilitic Arteritis in the Retina.

At the lower part of the drawing on the left the area of distribution of an affected artery is covered with numerous hæmorrhages, and the retina is inflamed.

The diseased arterial coats appear as white lines, and the column of blood is distinctly seen between the lines, except in places where the coat has become so thickened that it is nontransparent.

Below on the right side we see numerous hæmorrhages, but the retina and arteries are unaffected; and, again, at the upper part of the field on the left the arteritis is very marked, but the retina appears normal, and there are no hæmorrhages.

These various conditions are explained thus: At the commencement of the arteritis, although the vessels appear normal, still they may be plugged; and if there is no outlet for the blood through collateral vessels, hæmorrhages will appear. And, again, the arteries may have thickened white coats and yet be patent, and consequently there is no interference with the circulation.

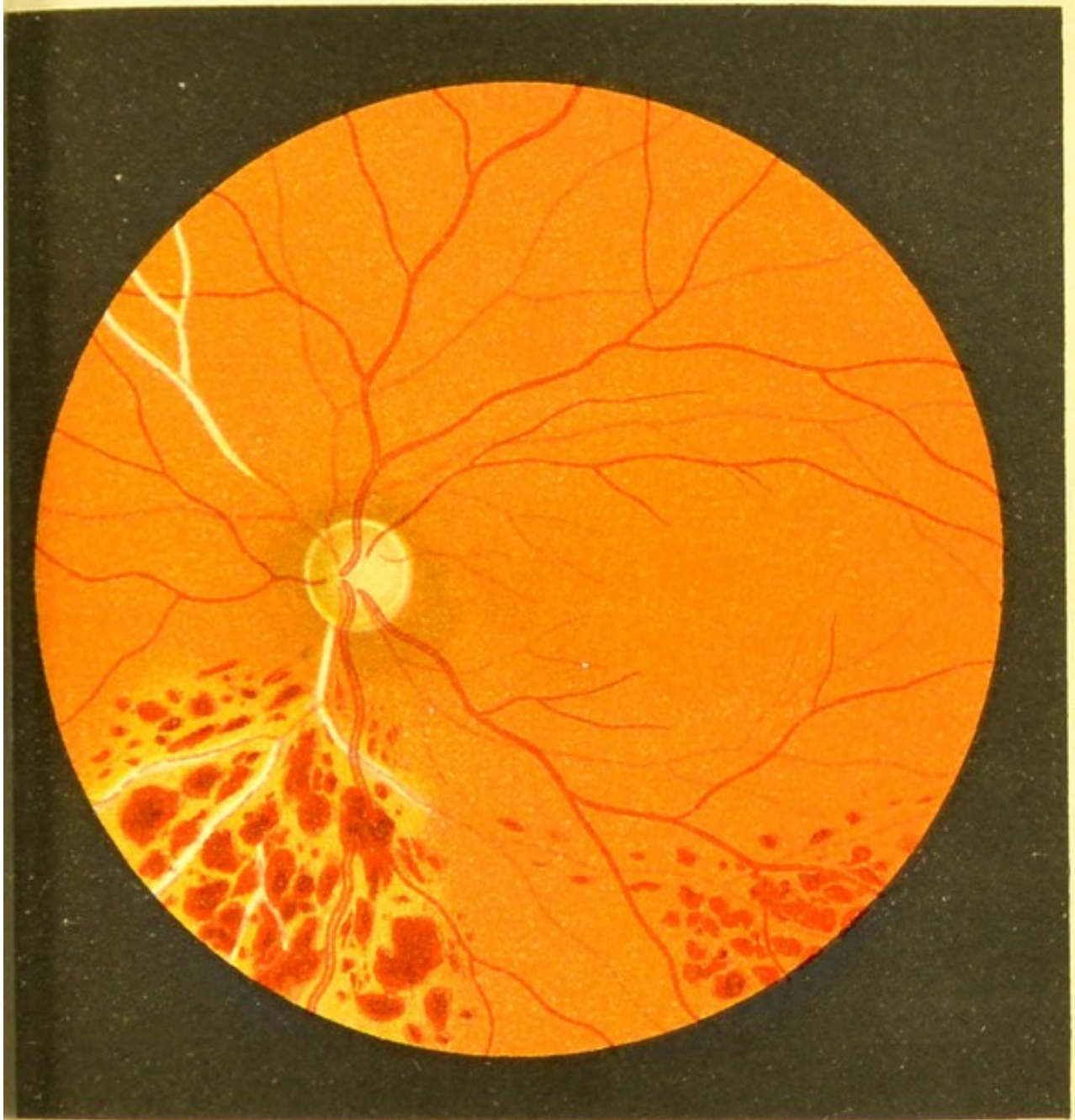



Fig.28







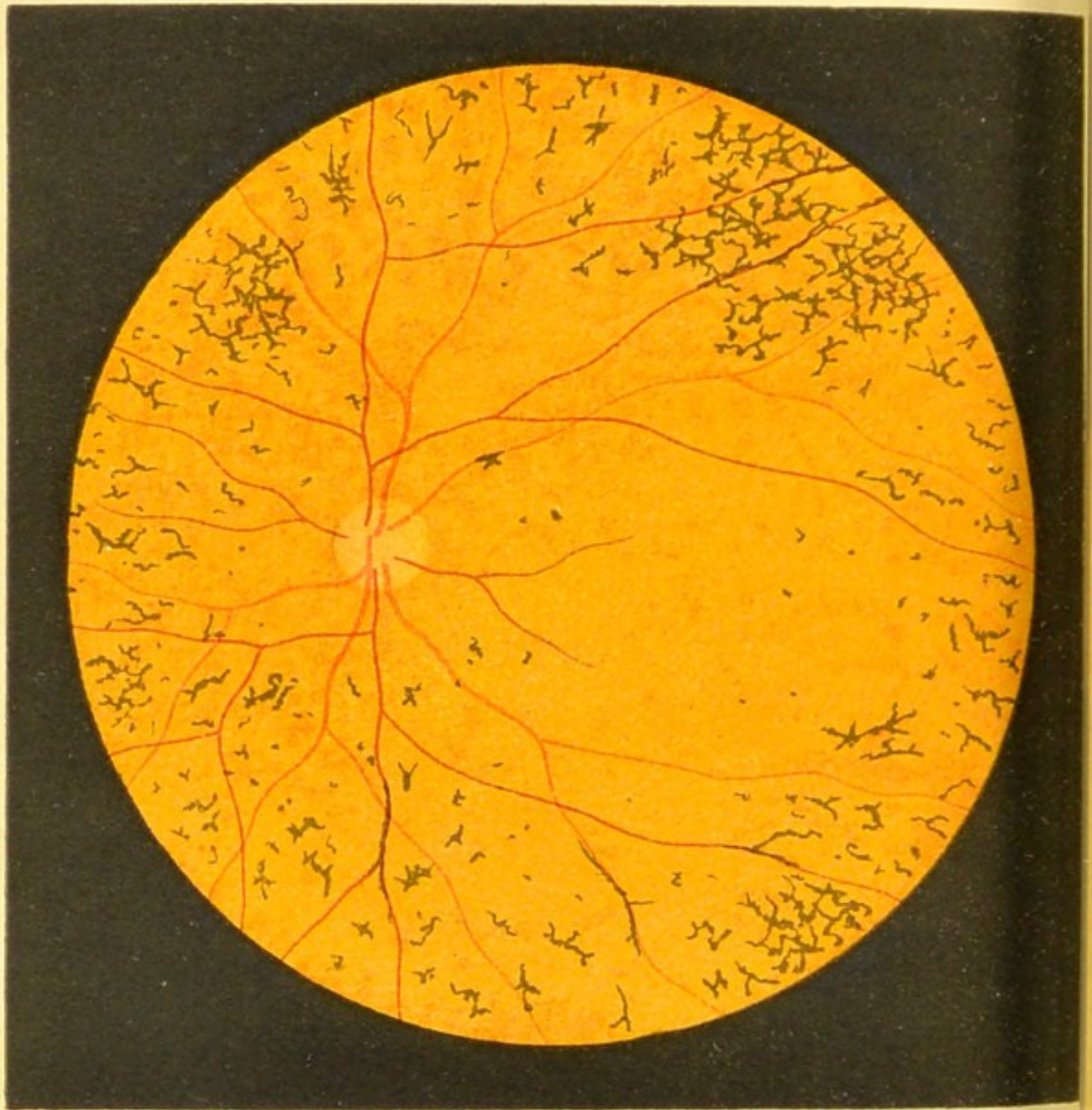


Fig. 29.

FIG. 29. — Pigmentary Degeneration of the  
Retina—Retinitis Pigmentosa.

The changes in this disease are more degenerative than inflammatory, and as a rule both eyes are affected.

In the early stage of the disease the degenerative process is conspicuous by the marked diminution in the calibre of the vessels, and as it progresses both arteries and veins diminish more and more, and the disc assumes an atrophic yellowish-white appearance.

The whole fundus becomes paler, greyer, and often quite leaden in colour as the disease advances.

The characteristic pigment spots are at first seen only at the periphery, and are few in number; but they gradually increase in number, and in the later stages are sometimes seen covering the whole fundus. In this case the disease was fairly advanced. The pigment spots are of a deep-black colour, small, angular, and bone-corpuscle-shaped, sometimes by the side of, at other times covering, the vessels. The region of the macula and disc is the last to be affected. No white atrophic spots are to be seen, although in some cases at a later stage a few yellowish-white atrophic spots appear (at first at the periphery) in the choroid, and occasionally light-coloured spots are seen at the macula.

FIG. 30. — Pigmentary Degeneration of the  
Retina—Retinitis Pigmentosa : Later Stage.

The progress of the degenerative changes is shown by the greyer and more leaden hue of the fundus, by the closer and more marked network arrangement of the pigment, by the increased atrophy of the disc, and by the further diminution in the calibre of the vessels.

The peculiarity of this disease is that the field of vision gradually becomes more and more contracted as the disease advances, and is finally reduced to a minimum.

In this case the outermost zone of the fundus remained free from pigmentation, and a ring scotoma was present. This would show that the retina only fails in its function in the parts attacked by the disease. Nevertheless, it must be remembered that the pigmentation is a secondary process, and contraction of the visual field may occur without any such objective signs.

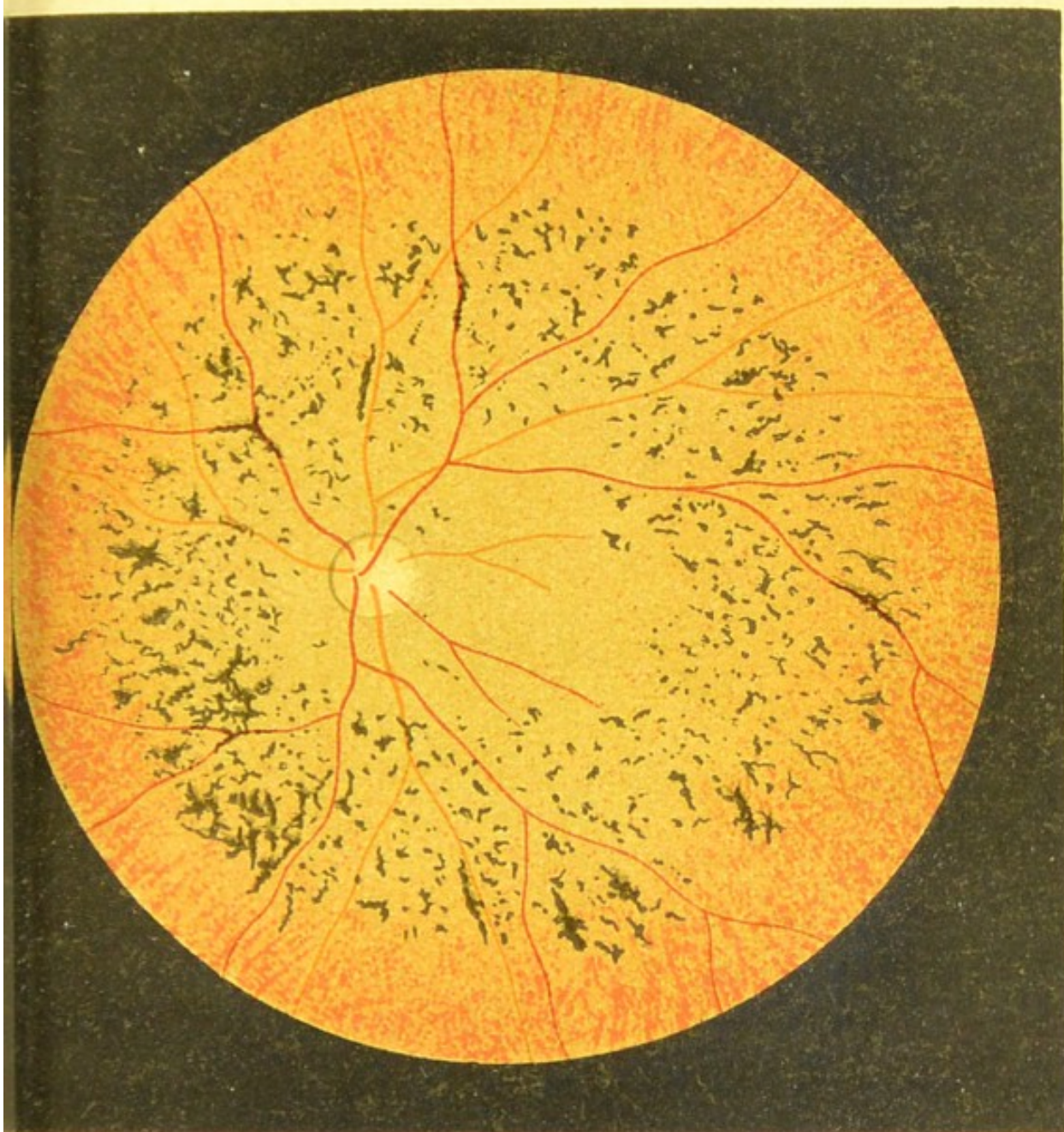




Fig.30.





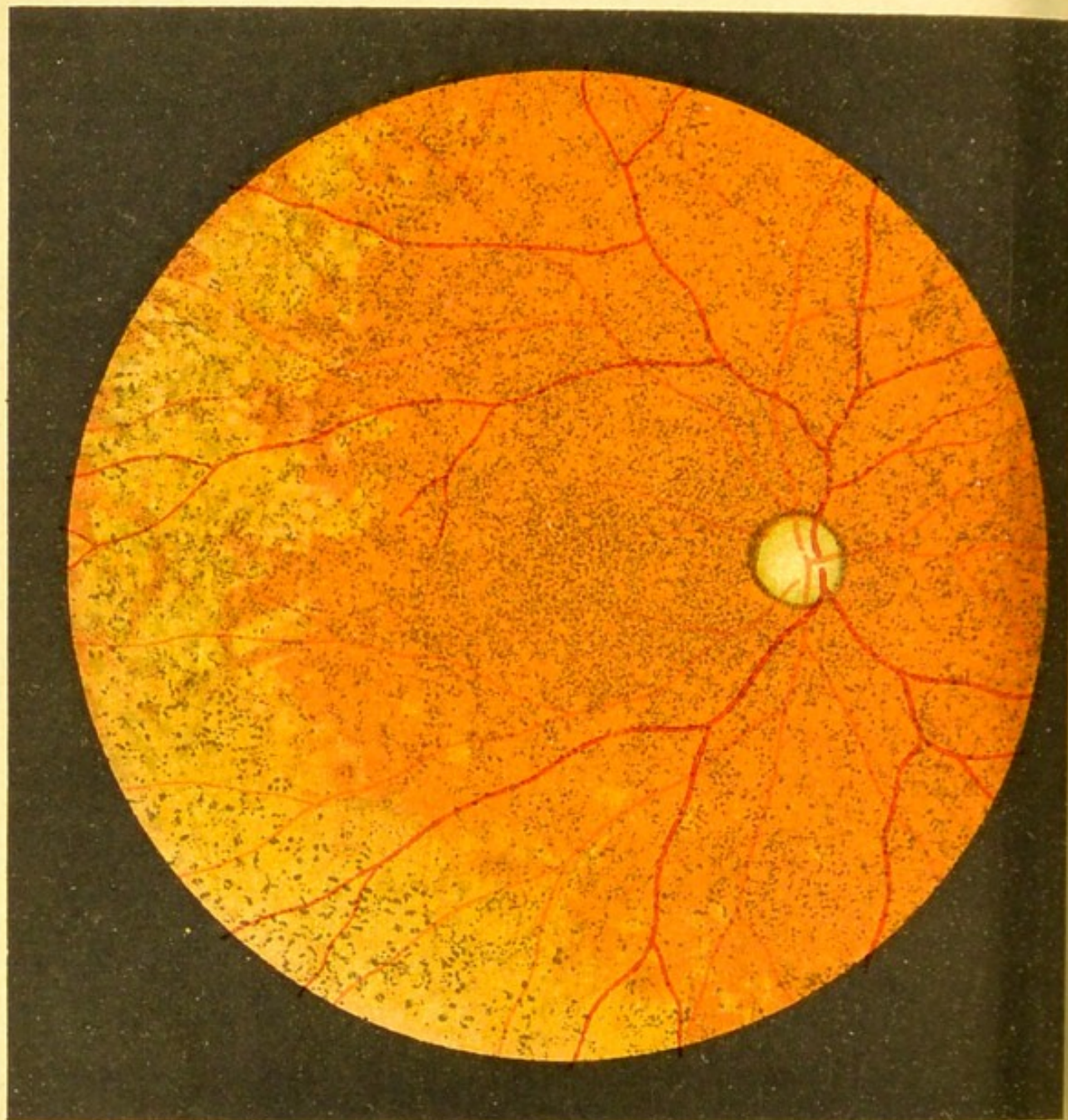


Fig.31.

FIG. 31.—Changes in the Fundus in Congenital Syphilis.

This and the two following figures represent different varieties of the same disease. It is a moot point whether this disease begins in the retina or the choroid, but it has been placed under the heading of Diseases of the Retina because the pigmentation which accompanies it appears to be in the retina, and in some cases the complaint bears a very strong resemblance to Retinitis Pigmentosa.

In Fig. 31, at the periphery, on the left side, the fundus has a bluish-grey coloration, and is covered by small round or angular black pigment spots.

The rest of the fundus has a yellowish-red mottled appearance, and over its surface are innumerable small brownish-black spots that give it the appearance of having been sprinkled with snuff. The vessels are narrowed, and the disc is pale.

Many cases are not so pronounced as this one, the speckled appearance being only seen at the periphery, but even then it is very characteristic of congenital syphilis.



FIG. 32. — Fundus Changes in Congenital Syphilis.

This is a milder form than the previous case, and the disease is limited to the periphery. The pigment patches are here also most probably in the retina, and owe their origin to an affection of the hexagonal pigment.

It is doubtful whether the light-yellowish round and oblong patches that are seen here are situated in the choroid or retinal epithelium.

This condition, and that shown in the following figure, are not unfrequently seen in the course of Interstitial Keratitis when the cornea has become transparent. Sometimes the changes are limited to one spot; sometimes they are more extensive. In this particular case there was a history of Keratitis.

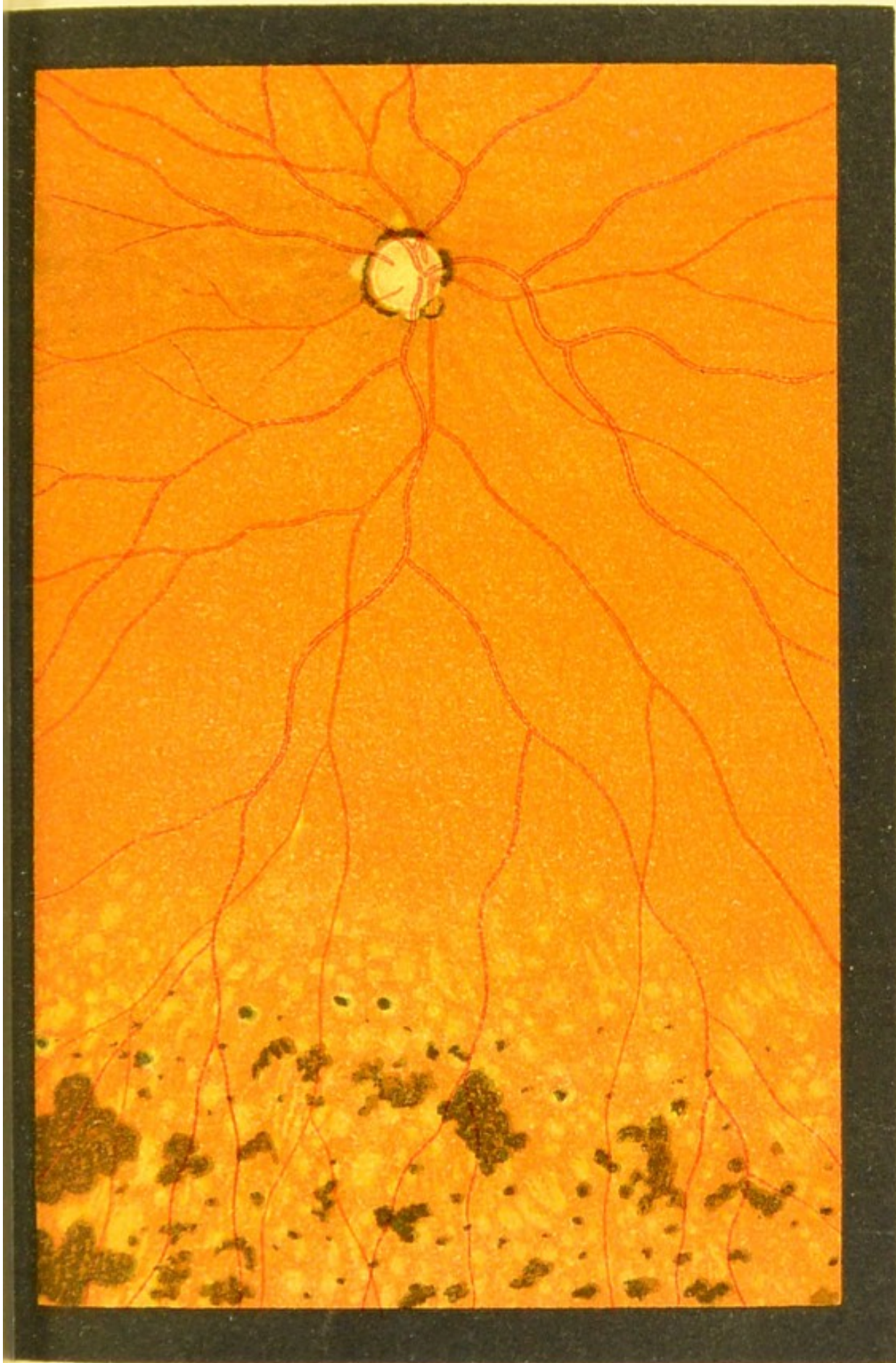




Fig. 32.





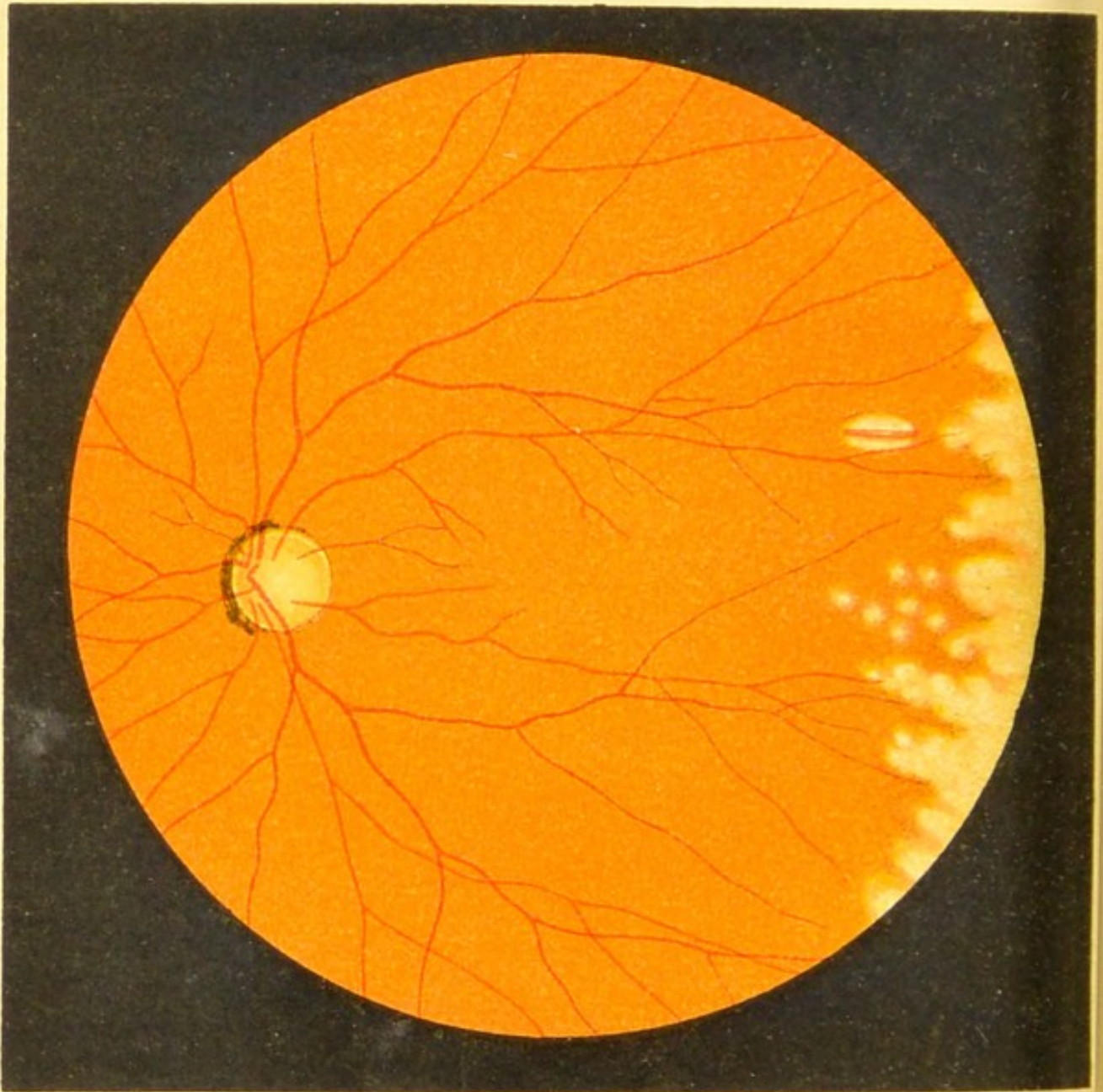


Fig.33.

FIG. 33. — Fundus Changes in Congenital Syphilis.

Whereas in the former case the pigment patches were most marked, we find them entirely absent in this case, and the only changes are a number of round whitish patches at the periphery. The larger of these spots are undoubtedly in the choroid, for one of them, isolated from the rest and oval, is seen to be crossed by a choroidal vessel, which is very conspicuous against the white background, which is produced by the atrophied choroid allowing the sclerotic to be visible.

The pigment epithelium of the retina has quite disappeared from the region of the patches, although it is slightly increased where the patches cease, and so gives them a darkish border.

There was a history of Interstitial Keratitis.

The changes seen in each of these figures (31, 32, and 33) are sometimes seen at the same time in different parts of the same fundus.

FIG. 34.—Pigmentary Changes in the Retina associated with Choroiditis Disseminata.

At the posterior pole of the eye the changes in the fundus very much resemble those of Retinitis Pigmentosa. The disc is somewhat pale, the vessels narrowed, and the general colour of the fundus lighter than usual, with a yellowish tinge, and scattered over the surface are a few pigment spots that closely resemble those seen in Retinitis Pigmentosa.

In addition to this, a number of fairly large round or oval yellowish-white patches are seen mostly at the periphery. In size they are about half the diameter of the disc, and most of them have a sharply-defined outline. The white colour is due to the reflection from the sclerotic, the retinal pigment and the stroma of the choroid being atrophied. Crossing some of them, the choroidal vessels are seen, as narrow red bands.

This case represents a fairly late stage of Choroido-Retinitis. It is often complicated with vitreous opacities, and is generally syphilitic in origin.

As we shall see later on, pigmentary changes in the retina accompany other forms of choroiditis.

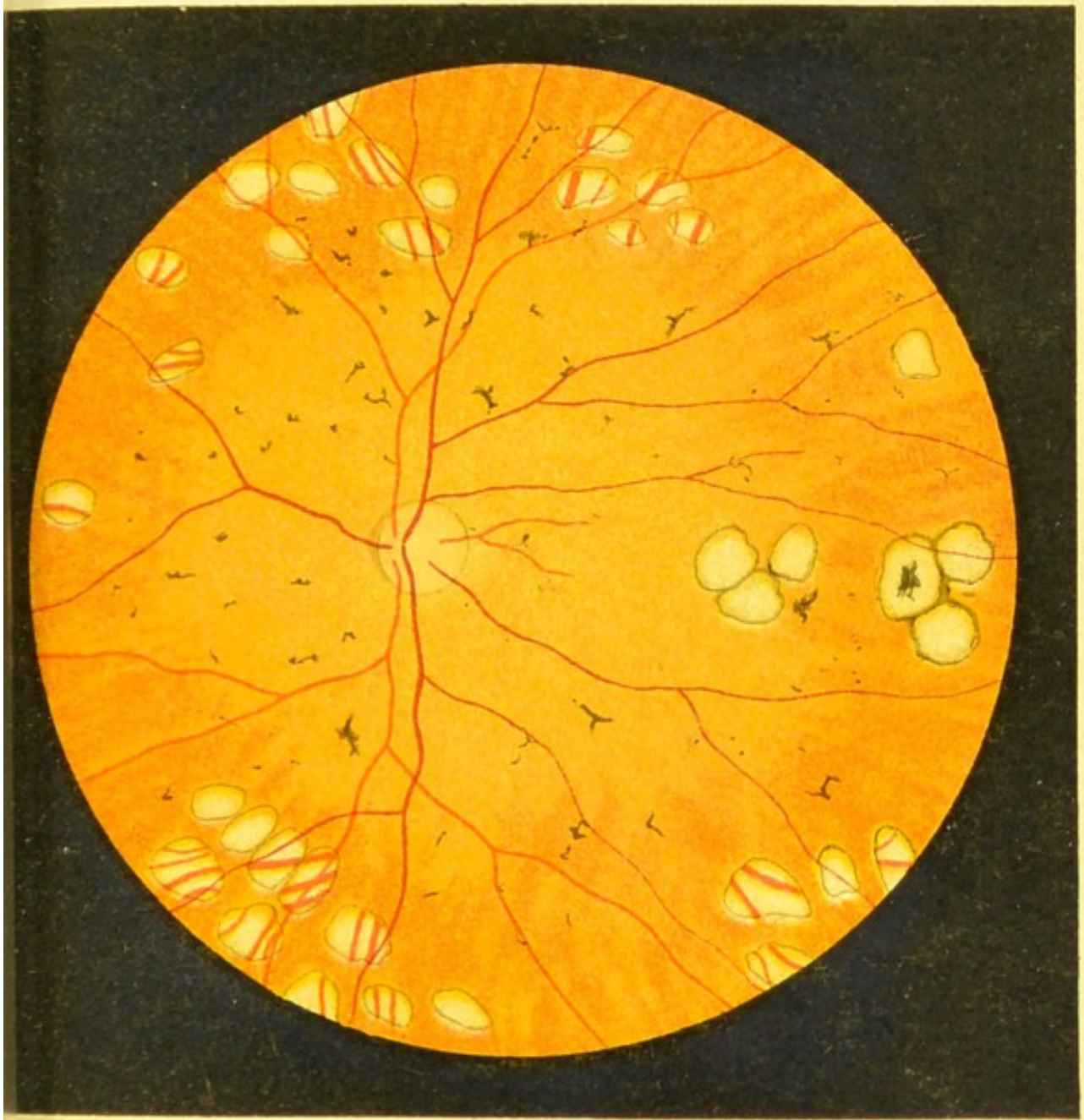
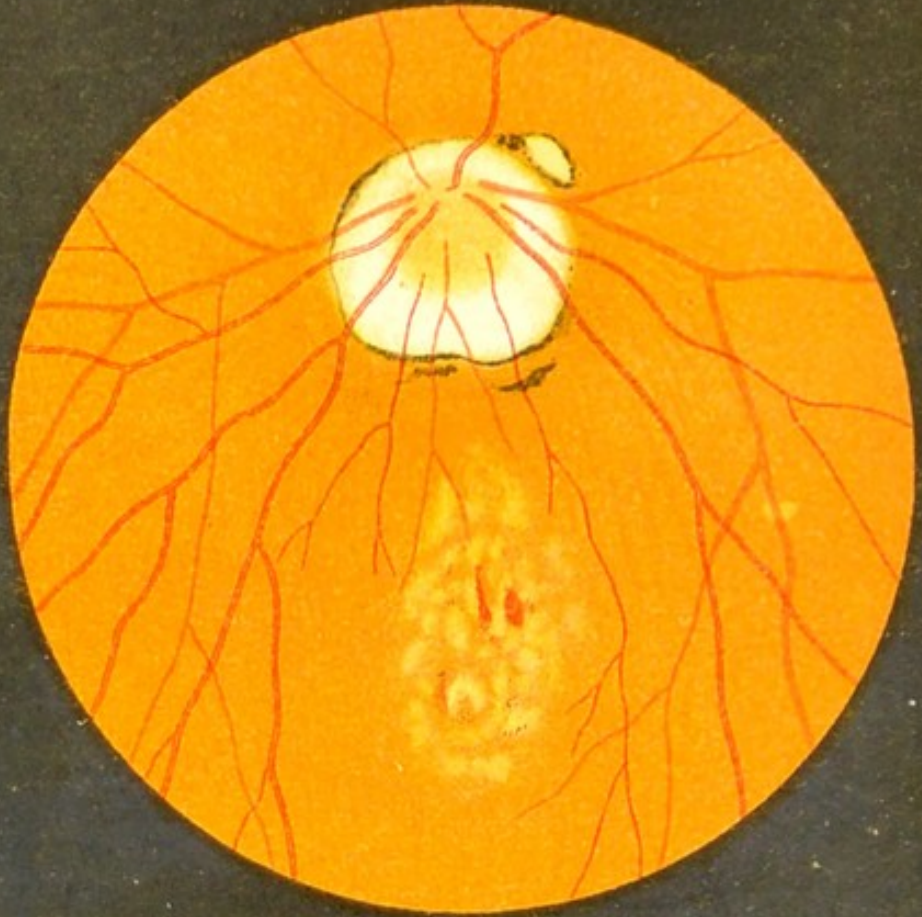

Fig. 34.









a



b

Fig. 35.

**Figs. 35a and 35b.—Changes at the Macula in High Myopia.**

It is doubtful whether the chief seat of this disease is in the choroid or in the deeper layers of the retina. The latter view is supported by the facts that apparently very slight changes at the macula in myopia are accompanied by very serious loss of vision; and, on the other hand, very marked changes are seen in the same region in Choroiditis Disseminata, with very little or no interference with the function of the retina. In some cases there is no doubt that the choroid is affected either primarily or secondarily. The changes at the macula are of extreme importance, because they are the cause of defective vision in so many myopic eyes. They assume all sorts of appearances. Figs. 35a, 35b, and 36a portray fairly recent changes. Both Figs. 35a and 35b exhibit the characteristic choroidal atrophy round the disc. In *a* this entirely surrounds the disc, while in *b* it forms a crescent on the outer side.

In Fig. 35a we see what is generally the first change at the macula in these cases—viz., a collection of yellowish-white spots, giving the patch a marbled appearance. There is a small amount of pigment here and there, and in the centre of the patch some slight hæmorrhages.

In Fig. 35b the appearance is more marbled, and there is much more pigment. In this case the rest of the fundus is rather deficient in pigment, and the light-coloured choroidal vessels with the dark intervacular spaces are very plain.

FIGS. 36*a*, 36*b*, and 36*c*.—Changes at the Macula  
in High Myopia.

Fig. 36*a*.—The nasal half of the disc is swollen and red, probably a functional hyperæmia, the result of eye strain, although by some considered inflammatory.

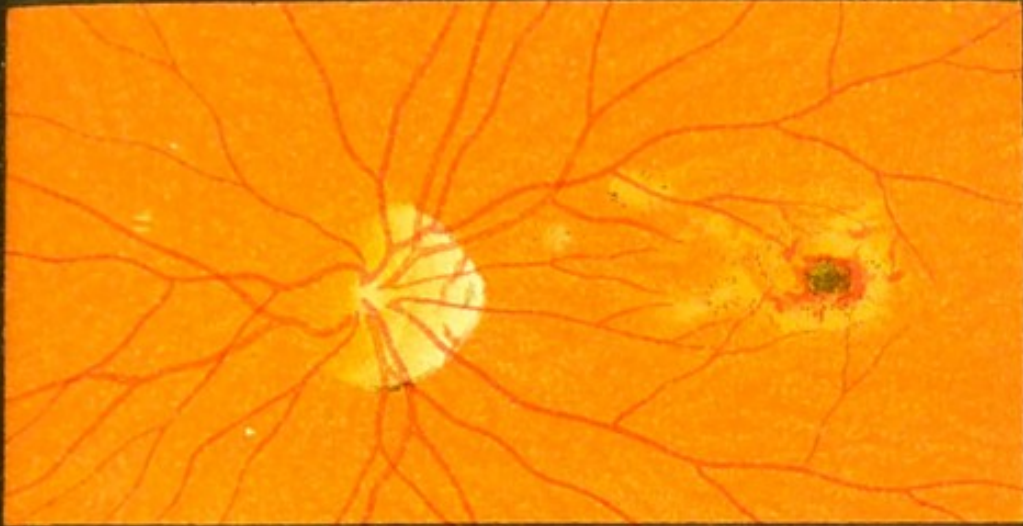An oblique appearance is given to the disc by the crescentic patch of choroidal atrophy at its outer side. The whole fundus is rather deficient in pigment, and the macula shows changes similar to those in the former case.

Fig. 36*b*.—The changes here are older; this is shown by the increase of pigment and the choroidal atrophy.

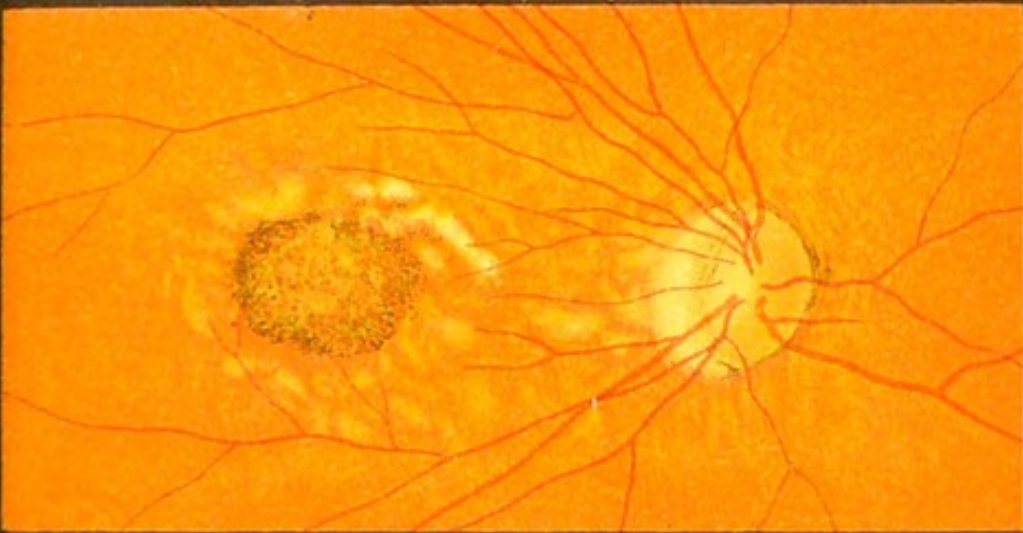In this case the changes are not limited to the macula region, but are scattered over the whole of the posterior pole of the eye.

Fig. 36*c* represents a still further advanced stage of the same disease.

The disc is surrounded by a large irregular choroidal atrophy, broader at its outer side. The macula is covered by a large white patch, deficient in choroid and bordered by pigment, and crossing this patch we see some choroidal vessels. On the outer side of this we see a larger irregular patch of retinal and choroidal atrophy, covered with irregular masses of pigment.



a





b



c

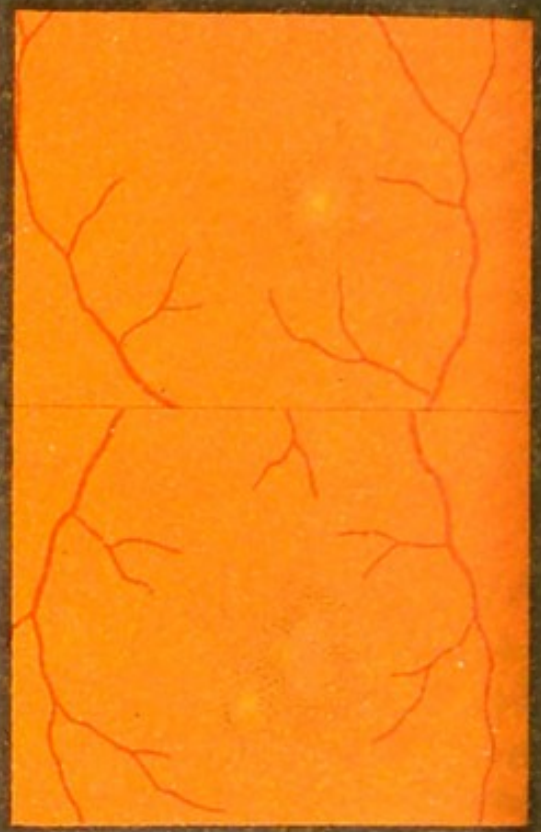Fig.36.



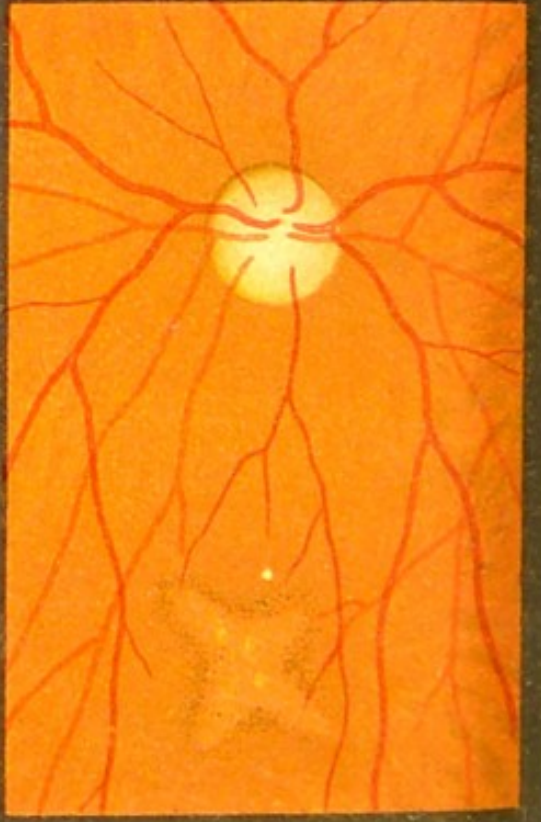



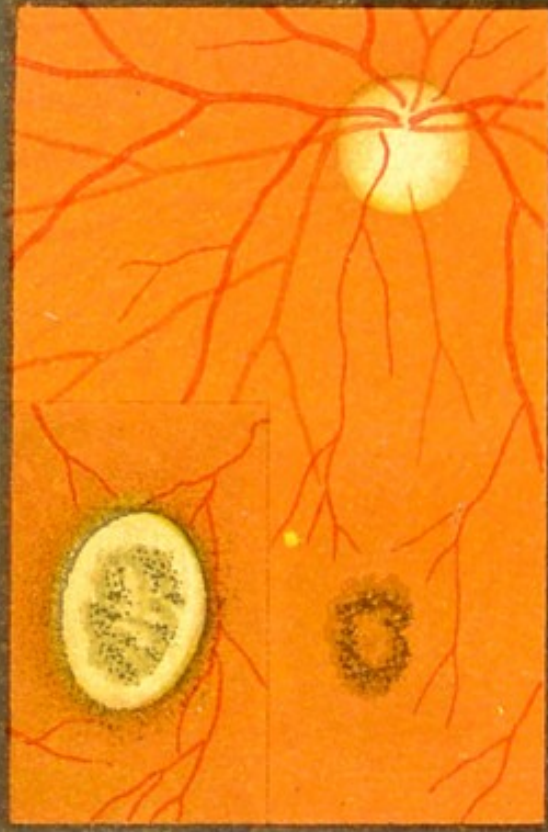
1



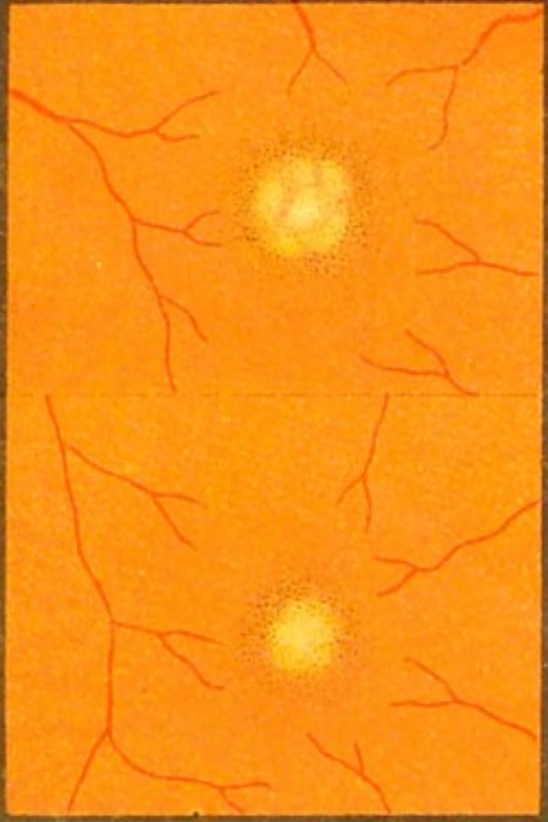
2



3



4



a

b

a

b

Fig. 37.

FIG. 37.—Changes at the Macula in Advanced Age.

These changes first begin in the retina, and if the disease progresses pass back to the choroid, as in Fig. 37 *1*, where *a* shows the appearance of the macula three months after the commencement of visual disturbance, and *b* the same six months later. Considerable diminution of vision may be accompanied by very slight changes.

The disease as a rule affects both eyes, and although it may assume many varieties of appearance (in some presenting a good deal of pigment, in others very little, the colour in some being a bright red, in others a whitish yellow, etc.), still they all agree in one characteristic—viz., the centre of the fovea is always the part most deeply affected. With the exception that in some cases there is a slight increase of pigment at the periphery, and perhaps a senile atrophy of the disc, the rest of the fundus is normal in all these cases. The changes at the macula must not be confused with the senile choroiditis shown in Fig. 54.

Fig. 37 *1*, *a* and *b* show the maculae of both eyes of a man aged seventy years; Fig. 37 *4*, *a* and *b* those of a woman aged seventy-four years.

FIG. 38.—Changes at the Macula following a Blow on the Eye.

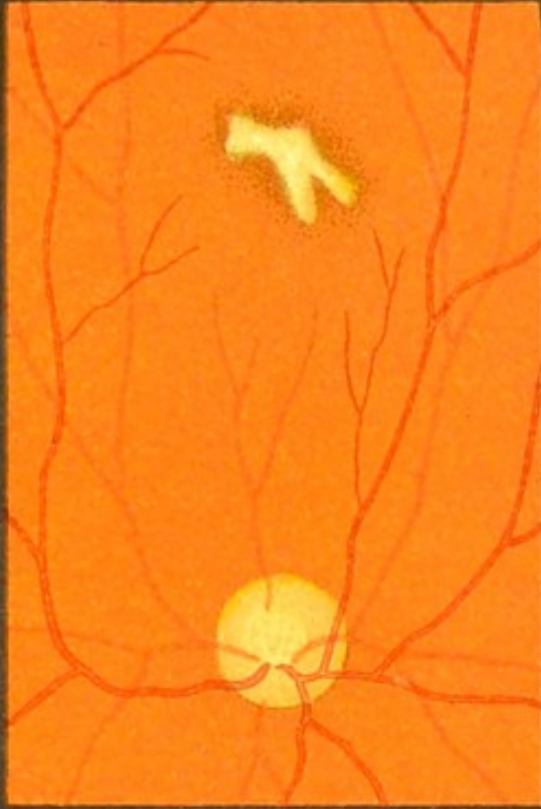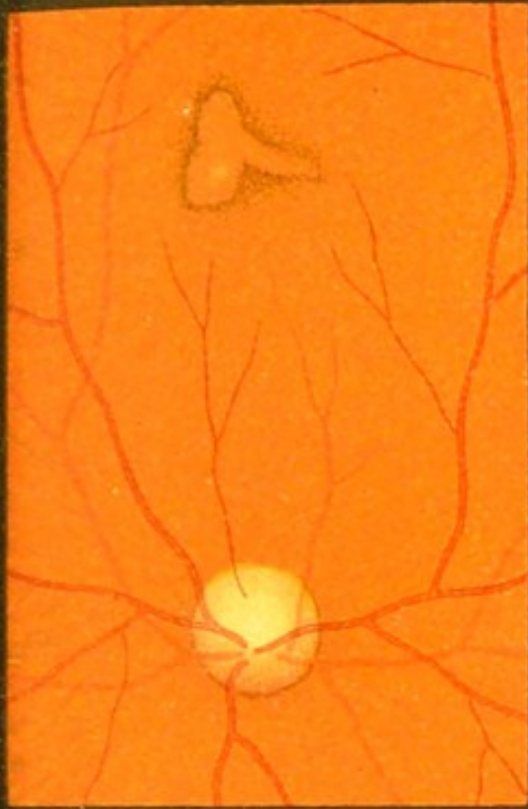It is not at all uncommon to find retinal changes at the macula after severe blows on the eye. The injury may be caused by a simple fall on the eye (Fig. 38 *I*); a blow from a fist (Fig. 38 *2* and *3*); a knock with a hammer (Fig. 38 *4*)—in the latter case the injury had been received twenty years previously—by a wad from a blank cartridge, an arrow, or a lash from a whip.

The changes at the macula resemble very much those that occur in myopia and old age. We may find only a slightly-increased deposit of pigment surrounding a more or less round or irregularly-shaped bright patch, or, if the disease has lasted some time, an atrophic patch, as in Fig. 38 *4*.

From a legal point of view these cases are often of the greatest importance. The changes sometimes take weeks to appear after the injury, and then perhaps are so slight that they seem to be out of all proportion to the great amount of visual disturbance that may be present. Before giving any opinion about such cases it behoves us to make a most thorough examination of the fundus by the direct method and with an artificially-dilated pupil, and also to keep the patient for some time under observation; otherwise we might be tempted to suspect the patient of malingering.

2

4





1

3

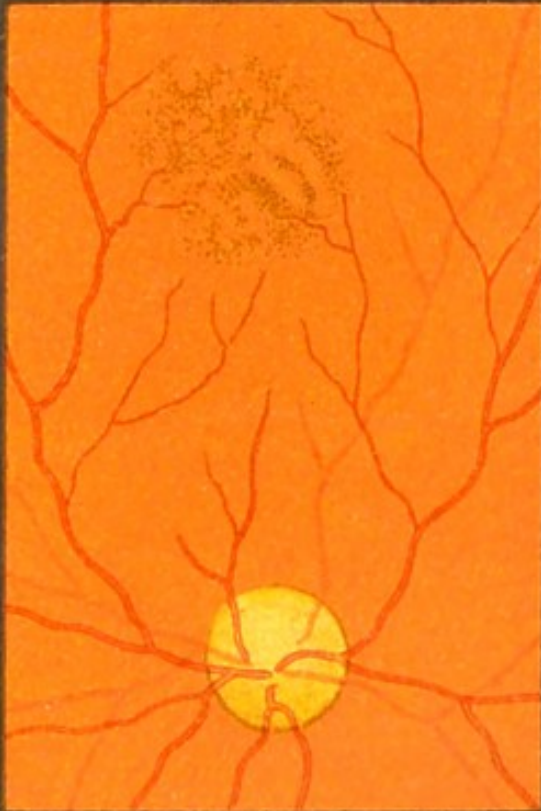
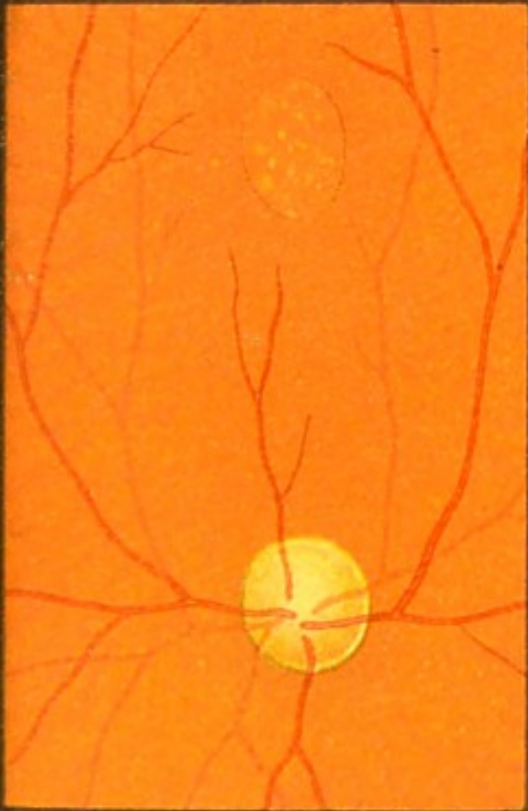
Fig.38.





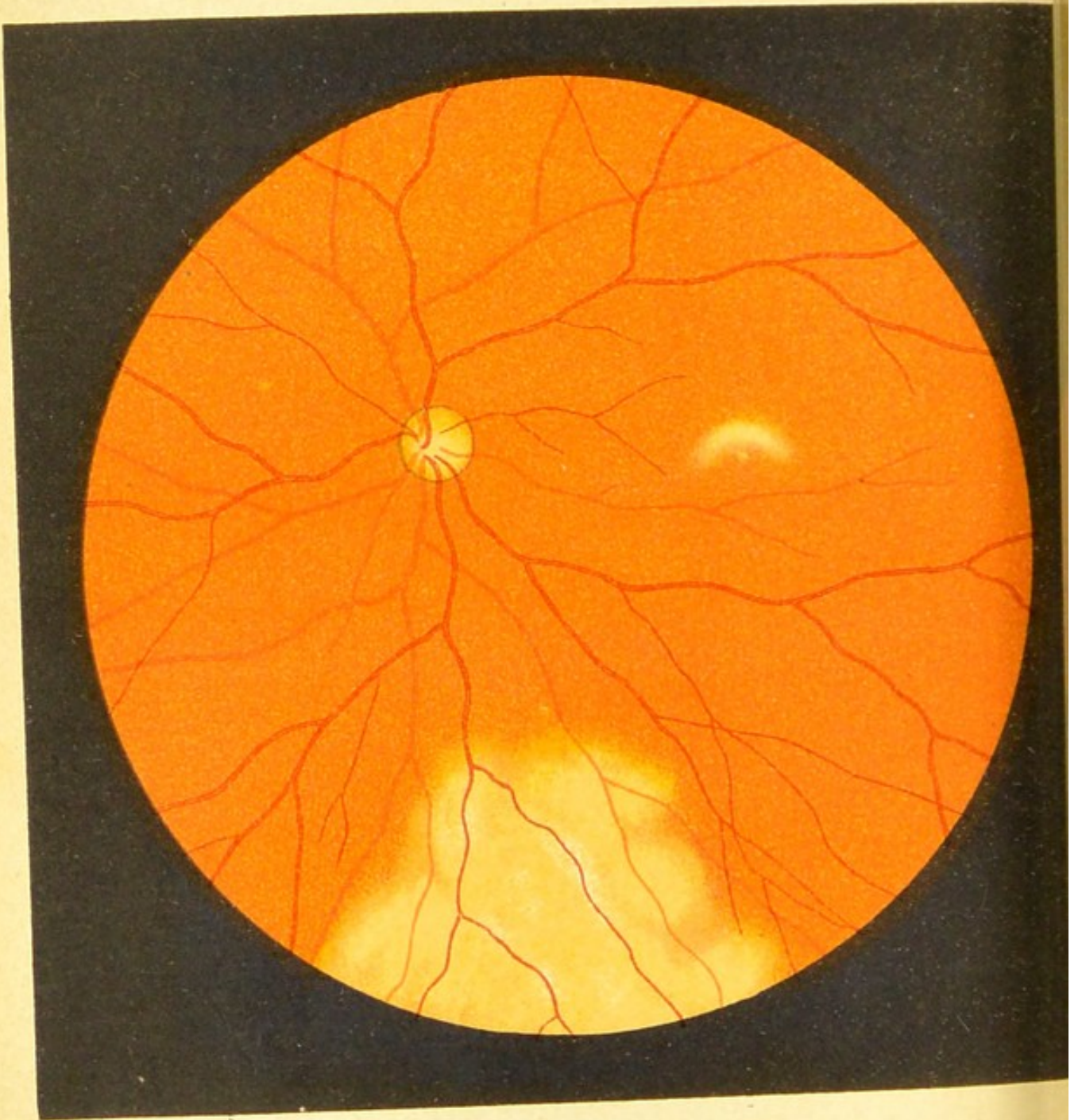


Fig.39.

FIG. 39.—Concussion of the Retina (*erect image reduced*).

These changes in the retina, which have been mistaken for detached retina, have been known to follow blows on the eye with a blunt instrument, such as a stick, stone, snowball, or the fist. They are very evanescent, and the sooner the fundus is examined after the injury the better they are seen.

At the lower part of the drawing we see a large whitish discoloration of the retina, spreading from the part of the eye where the blow was received, and over which the retinal vessels pass in a normal manner; and at the macula we see a second small patch of similar colour.

When two such patches are present, the one near the seat of injury is generally more extensive, more marked, and retains its milk-white colour longer than the second spot at the macula, which is smaller and more evanescent.

There may be no visual disturbance. The nature of these changes is not quite clear.

This drawing was taken a few hours after the eye had been hit by a snowball.



FIG. 40.—Concussion of the Retina (*inverted image*).

The eye in this case had received a very severe blow from a large piece of iron, and at the periphery, in the neighbourhood of the seat of the injury, we see there is a very severe retinitis, accompanied by several small hæmorrhages, and at the macula a crescentic white patch.

All these changes disappeared after a few days, that at the macula being the first to go. This traumatic retinitis is easily distinguished from detached retina by the following facts: A recent detachment is not so white and opaque, but much more transparent; in retinal concussion the course of the vessels is undisturbed, they show no parallactic movement and no increased hypermetropia, and, lastly, the folds of the retina which we see in detachment are absent.

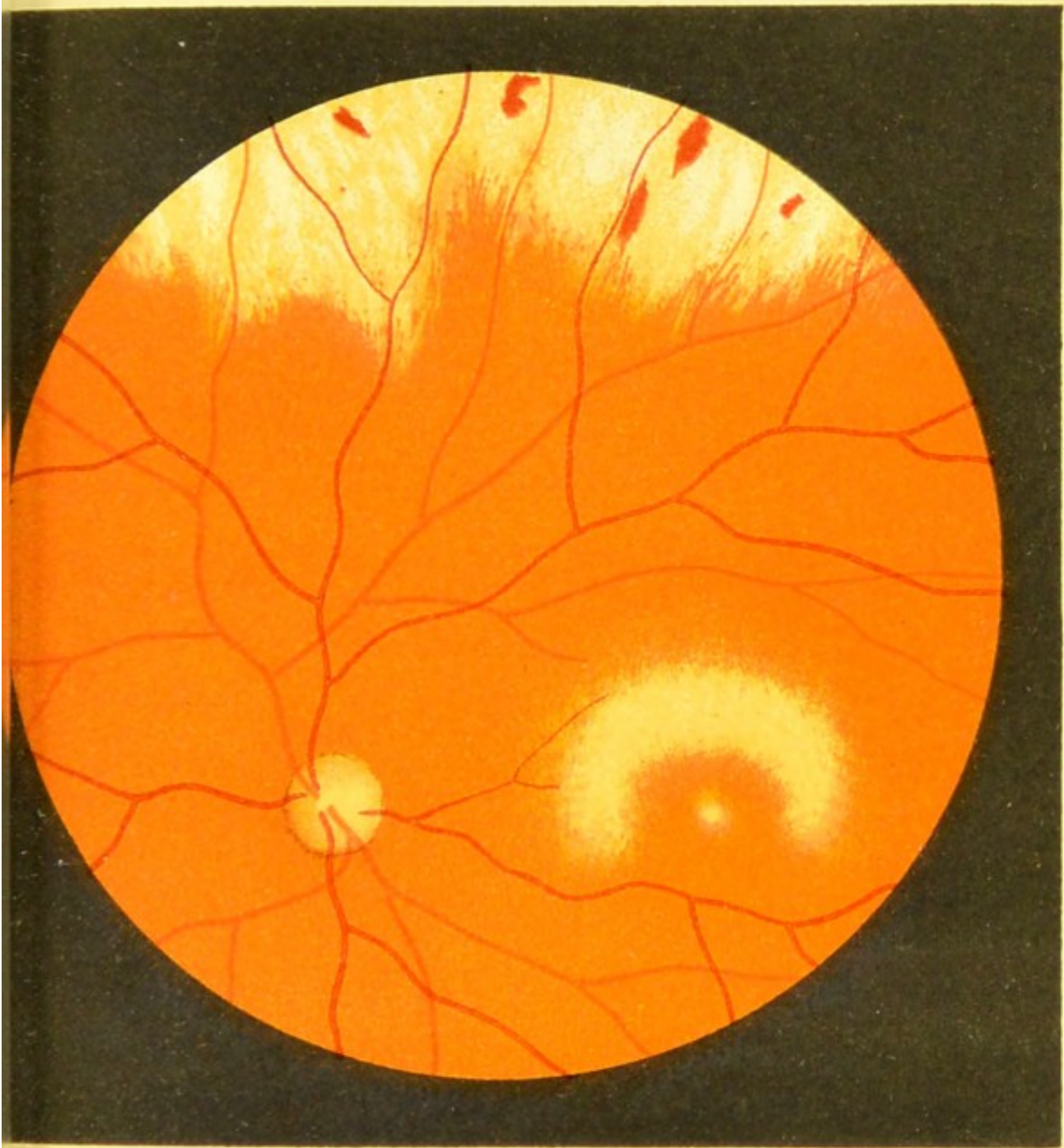
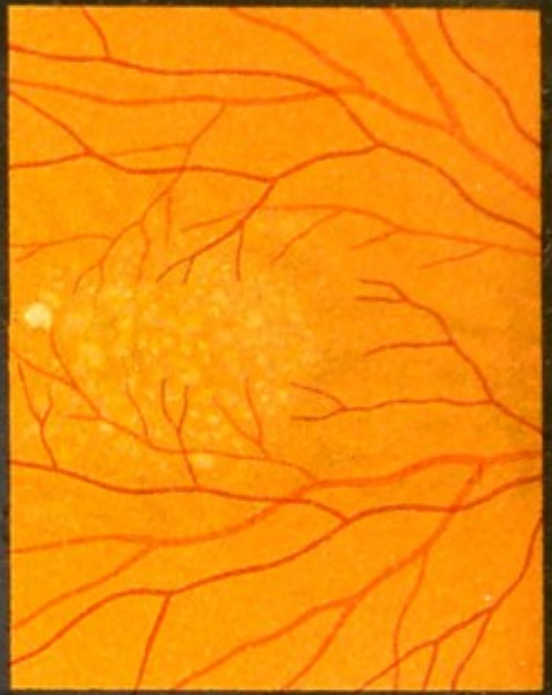
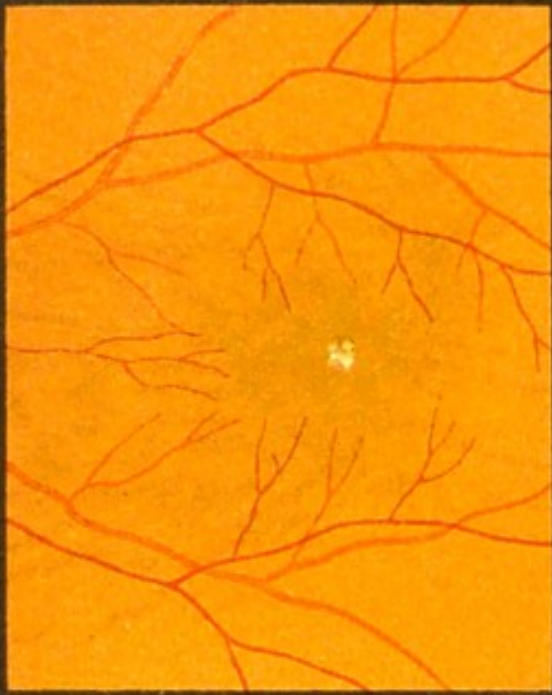


Fig.40.





a



c

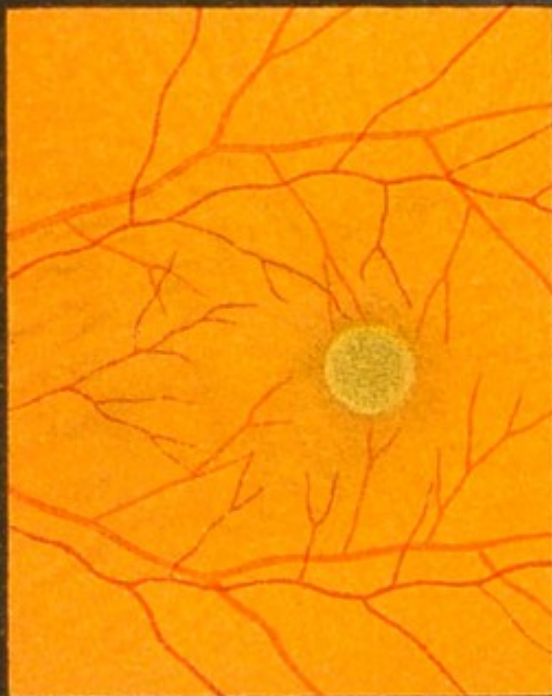


Fig. 41.

FIG. 41.—Changes at the Macula following the Presence of Foreign Bodies in the Vitreous.

The extreme sensitiveness of the macula is shown by the changes which take place there in a very short time, from the presence of an aseptic foreign body in the deeper parts of the eye, although the macula itself may not have been directly injured.

Fig. 41*a*.—In this case a piece of a copper percussion-cap had been in the vitreous for five days. The changes consist of some whitish spots at the fovea, which disappeared after the removal of the foreign body. Two and a half months afterwards the acuity of vision was found to be normal.

Fig. 41*b* shows the yellow spotty changes at the macula of an eye, in the front part of which a piece of a copper cap had remained for one year. The foreign body was not removed, and further changes took place (as shown in Fig. 56), which, however, became less marked at a later period, and, although it is now eleven years since the injury, the eye has an acuity of vision equal to one-third.

Fig. 41*c* shows the macula of a patient in whose retina a splinter of steel had remained embedded for twenty hours. The foreign body was removed by a powerful magnet. (It is seen *in situ* in Fig. 43*a*.) There was at first a yellow mottled appearance at the macula, and later the round grey spot appeared, as shown in the drawing (which was made three months after the injury).

The acuity of vision was only lessened by one-tenth.

The appearances represented by Fig. 41*d* were seen at the macula of an eye in whose vitreous a steel chip had remained eight days. The foreign body was removed by a powerful magnet introduced into the eye, and acuity of vision was only lessened by one-seventh.

FIG. 42.—Changes at the Macula following Pressure upon the Eye.

Fig. 42*a*.—A slow-growing angioma had in this case caused marked proptosis. The disc is swollen and red; the retinal veins are swollen and tortuous; and at the macula there is a yellowish-red patch, surrounded by pigment.

Fig. 42*b* represents the fundus of a left eye (inverted image) six days after the right had been destroyed by a revolver shot in the temple. The ball had passed through the back of the left orbit, and had concussed the left eye. The greatest changes are shown at the macula, in the shape of an irregular yellowish-white patch, with a hæmorrhage and some pigment deposit. Below the disc are seen a long yellowish patch and two hæmorrhages. At the first examination a small hæmorrhage was seen near the disc, but this was soon absorbed.

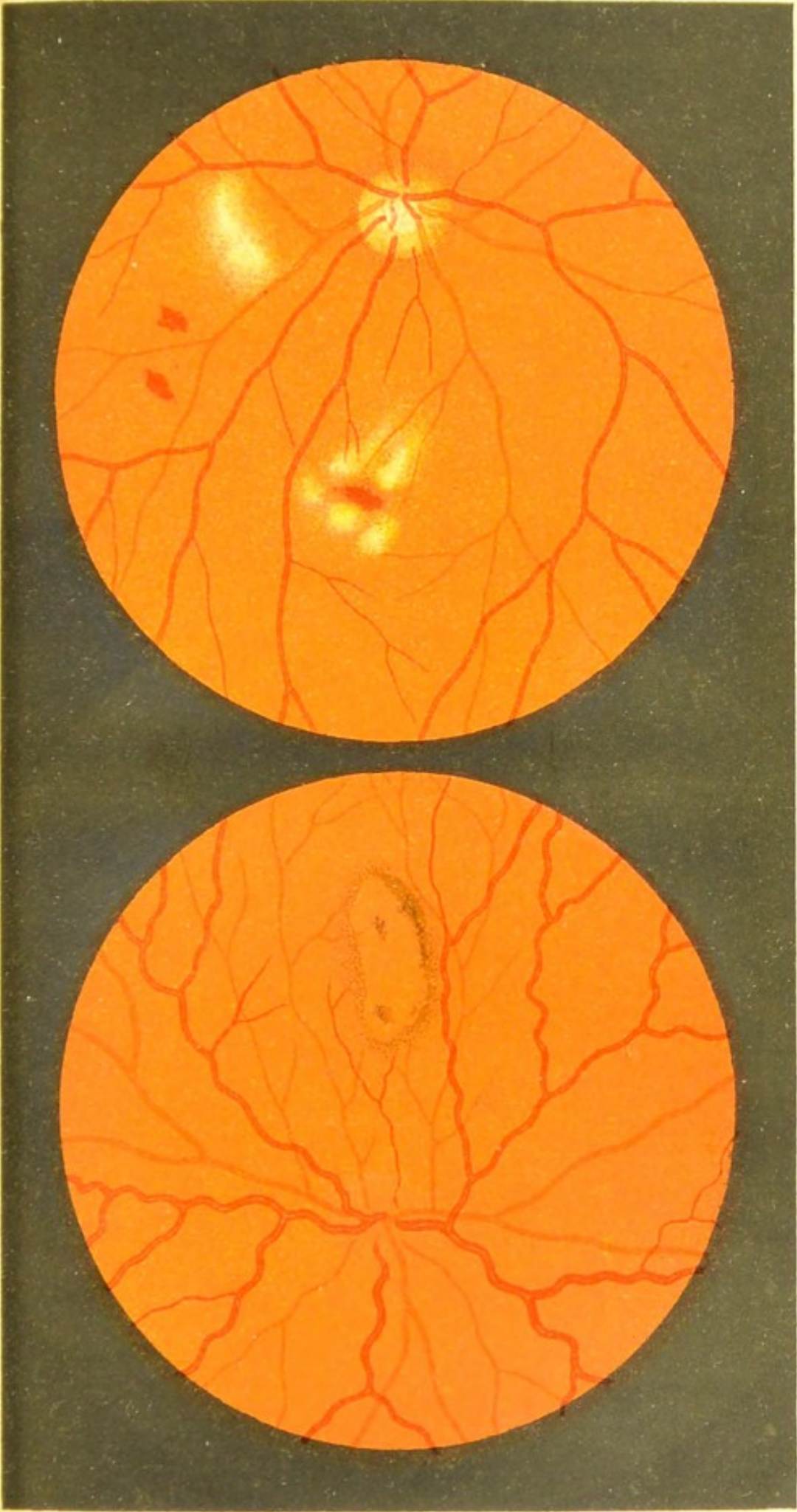




Fig.42.

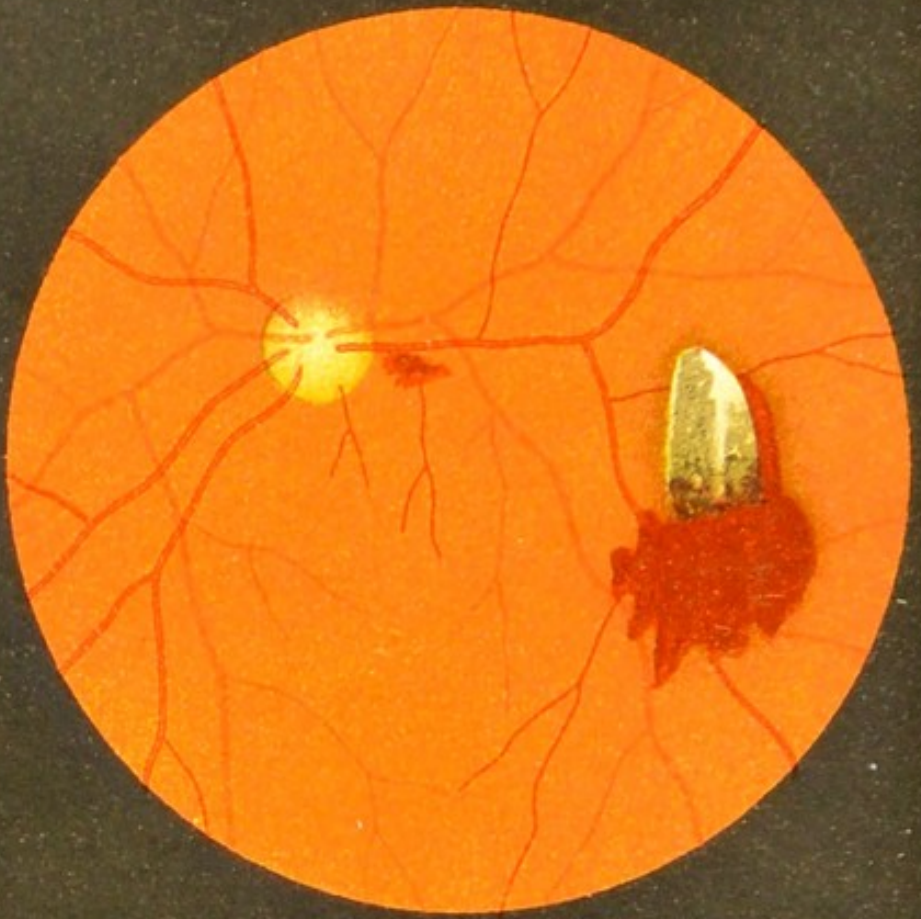
a

b










a

Fig.43.



b

FIG. 43.—Recent Injury to the Retina by a Chip of Iron.

In Fig. 43*a* we see a chip of iron embedded in the retina. The injury occurred twenty hours before the drawing was made. The chip had passed through the sclerotic close to the cornea.

The movements of the eye did not cause any change of position in the foreign body, which was removed by a powerful magnet. Although the chip of iron had gone nowhere near the macula, changes took place in this region, as shown in Fig. 41*c*.

Fig. 43*b* is a somewhat similar case. About two hours before the patient was seen, a chip of cast steel that was being chiselled passed through the cornea, iris, and lens, and embedded itself in the retina.

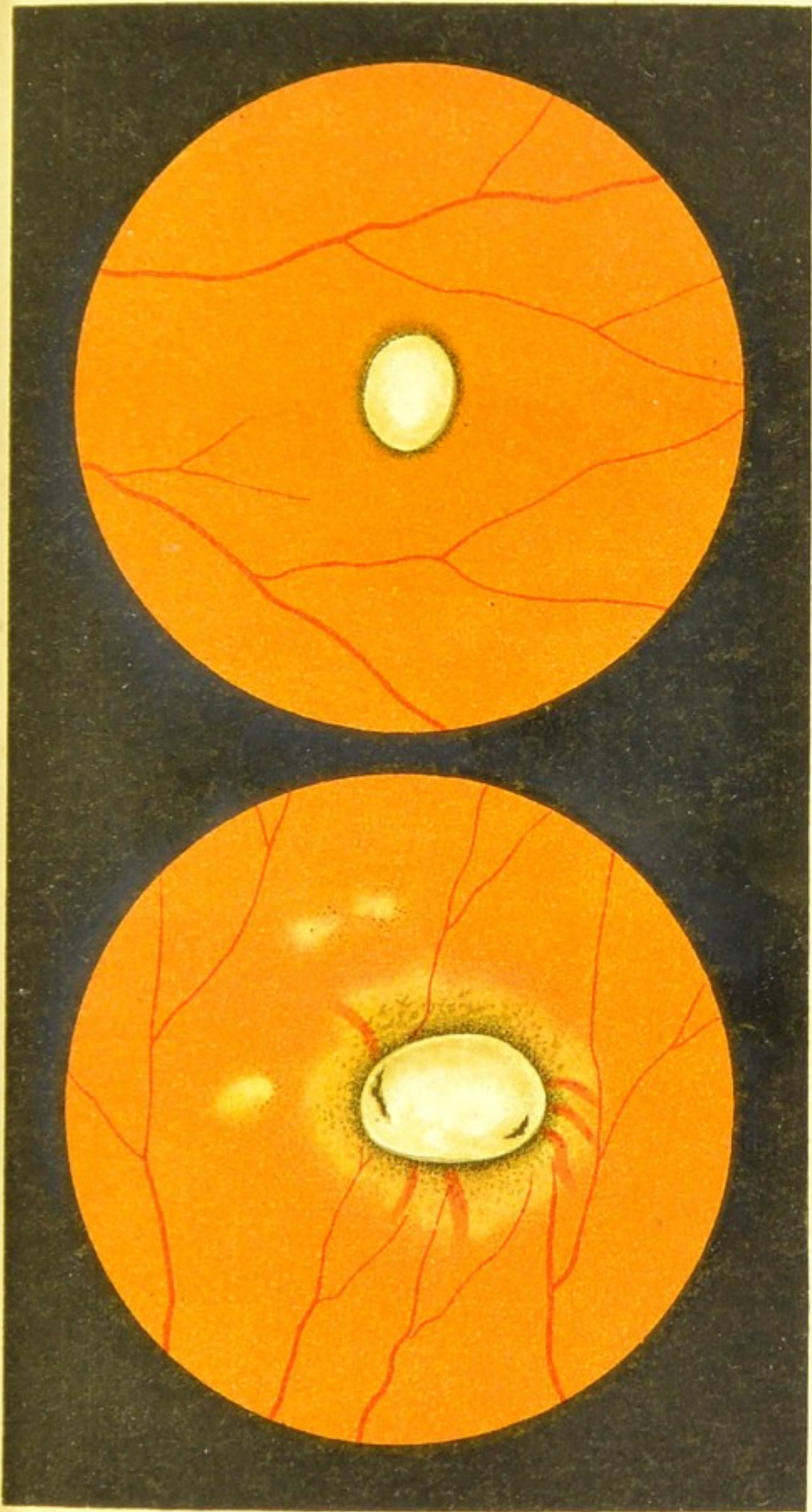
In both cases the seat of injury of the retina is covered with blood. The white patch is not an exudation, as in the following cases, but is meant to represent the metallic lustre of the steel, which was plainly seen by the ophthalmoscope.

The chip in the first case was oblong, 4 mm. long and 1.5 mm. thick, and that in the second case was a trifle shorter and weighed .016 gramme.

FIG. 44.—Old-standing Injury to the Retina caused by a Chip of Iron.

In the two former cases the foreign body had only been a short time in the eye, and, with the exception of the part that was embedded in the retina, was plainly visible; but in these two cases the chips of iron had remained *in situ* for a lengthy period, and, with the exception of two small portions of metal visible in Fig. 44a, they are entirely hidden by exudation. That in Fig. 44a had been in the eye for two months, and very characteristic changes are seen in its neighbourhood. The epithelial pigment has partly atrophied, allowing the choroidal vessels to be plainly visible in the bright ring that surrounds the foreign body, and in its immediate neighbourhood there is a large increase of pigment. Near the spot we see three small patches of choroidal atrophy. These patches have a blurred outline, and are partly surrounded by faint dots of pigment.


In Fig. 44b no changes have taken place round the foreign body, although six weeks had elapsed since the accident.




a

Fig. 44t.

b







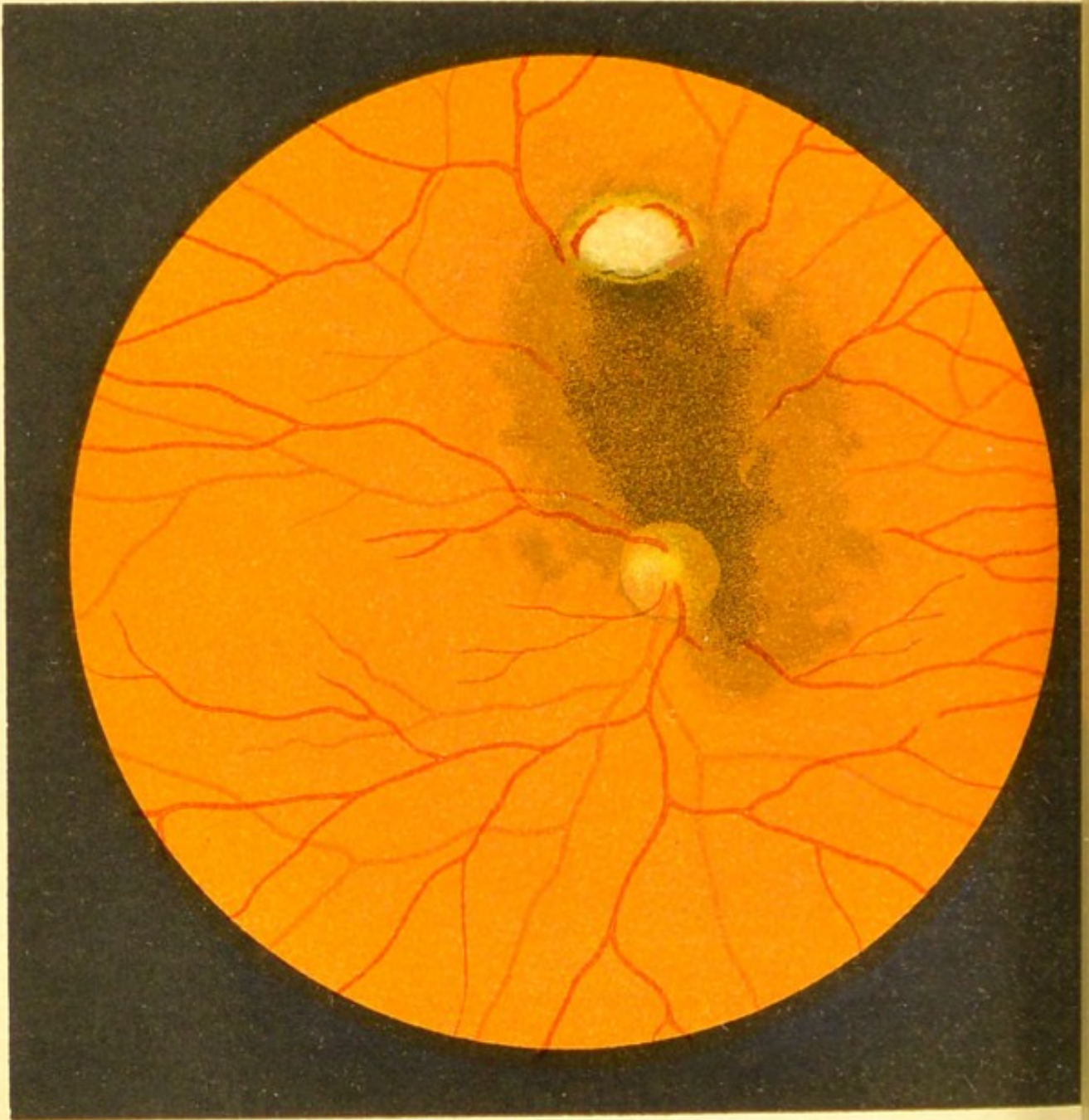


Fig. 45.

FIG. 45.—Injury to the Fundus by a Foreign Body penetrating the Eye (*erect image*).

If a foreign body enters the eye with great velocity, instead of becoming embedded in the tissues at the back, it may rebound and, passing forwards and downwards into the vitreous, lie concealed behind the ciliary body. In such a case the point on the fundus where the rebound took place is marked by definite changes, due to the injury.

In the accompanying drawing we see a roundish white spot above the disc, marking the point of impact of a chip of steel; the retina and choroid are torn, and the sclerotic is exposed, and at the margins of the wound there are some small hæmorrhages.

In some cases the hæmorrhage is more extensive and passes into the vitreous, and blurs or entirely conceals the fundus.

If we suspect the presence of a foreign body in the eye, and, after careful examination of the fundus, discover such a spot as is here drawn and described, we should be materially helped towards a correct diagnosis.

FIG. 46.—Detachment of the Retina following a Punctured Wound of the Eyeball (*inverted image*).

In this case gradual diminution of vision began to come on four years after a sharply-pointed piece of tin had penetrated the sclerotic on the temporal side of the cornea, and had apparently caused only a very trifling injury.

In the lower part of the drawing on the left side we see a round greyish-white mass of exudation, passing forward somewhat into the vitreous. Above this, and extending for some distance along the periphery, is a detachment of the retina.

The detached portion of retina is light in colour, wavy, and is crossed by irregular, tortuous vessels that appear darker in colour than normally. Stretching across between the upper part of this detachment (in the drawing) and the exudation we see a number of curious white streaks, some of them anastomosing together, and all running in the same direction. There is no sign of detachment of the retina in the immediate neighbourhood of these lines. They remained for many weeks unchanged. It is doubtful whether they bear any relation to those figured in Fig. 50.

Round the disc and at the macula there is a slight increase of pigmentation.

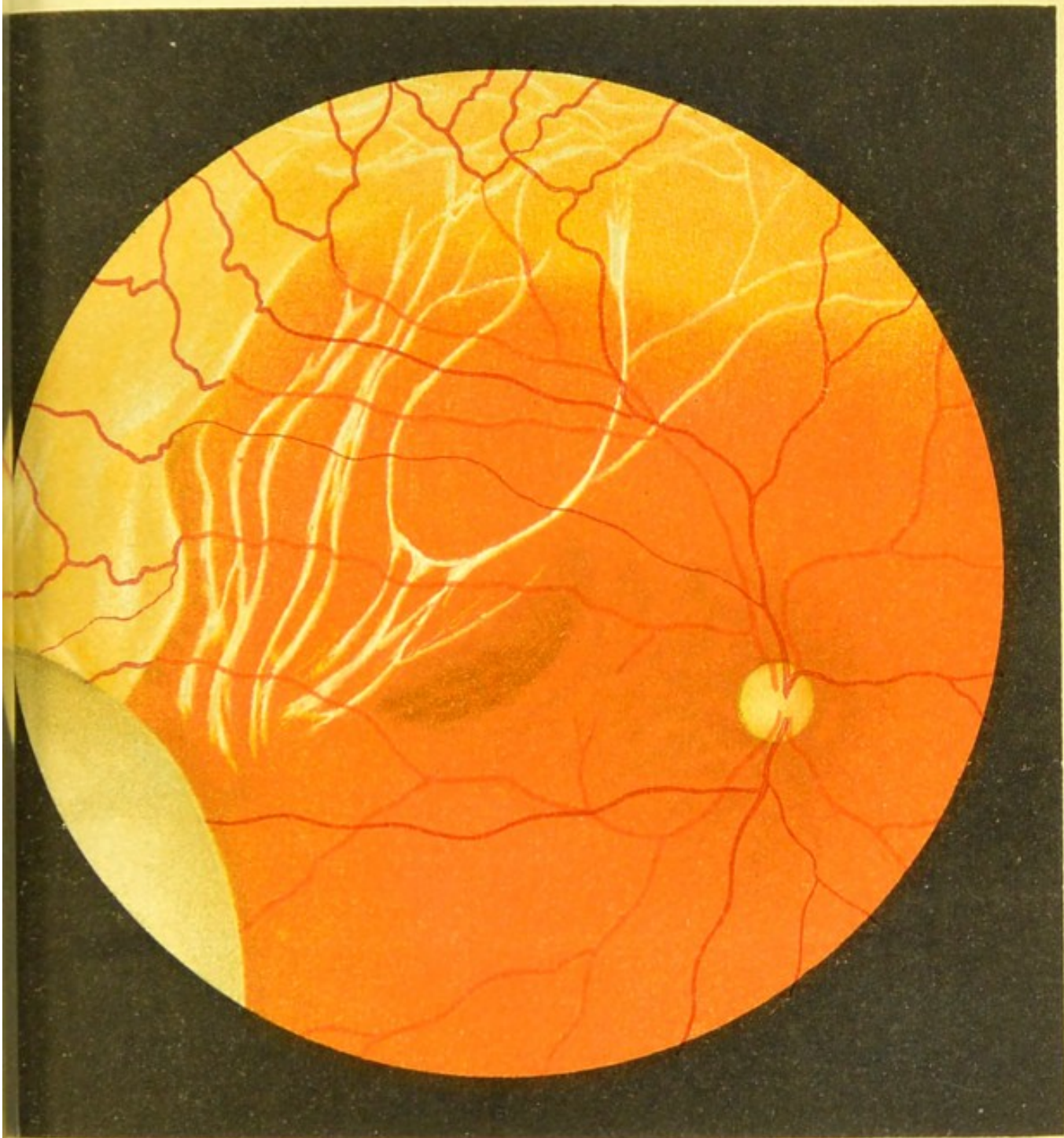



Fig.46





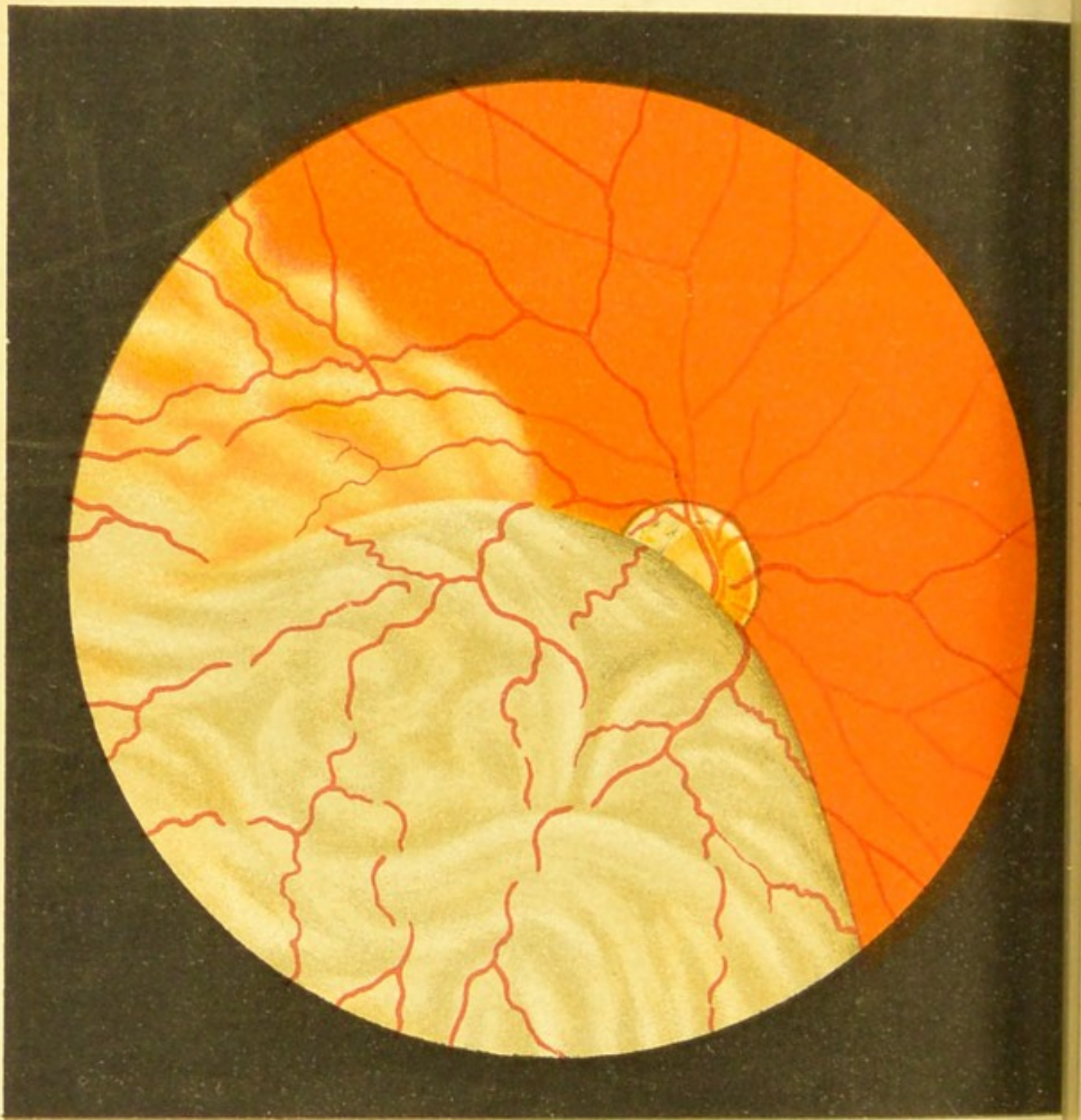


Fig.47.

FIG. 47.—Retinal Detachment in a Myopic  
Eye (*inverted image*).

The detached portion of the retina hangs down like a curtain, covering the upper part of the field and about half the myopic disc. It resembles a globular bladder bulging forward into the vitreous.

The detached retina is opaque, of an ashy-grey colour, and is thrown into folds. The vessels are tortuous and irregular, and here and there disappear between the folds, and they are mostly darker in colour. Below this we see another smaller detachment, where the retina has not yet the ashy-grey colour and where the folds are few.

The rest of the fundus is normal.



FIG. 48.—Detached Retina, with a Rent.

According to Leber, a shrinking vitreous, pulling away the anterior layers of the retina from the posterior hexagonal pigment layer, is the cause of idiopathic detachment of the retina; and when the connection between the vitreous and retina is more than usually intimate, a hole (or holes) is torn in the detached membrane, and one or more flaps turning forwards are seen at the margin of the rent.

Such a rent has occurred in the detached retina in this case, and a large flap is seen, turned downwards and forwards, at the lower margin of the square hole. The choroidal vessels are clearly seen through this hole, and also over the part of the fundus where the retina is normal and transparent. On the left of the drawing the detachment is very slight.

This drawing shows the fundus quite at the periphery; the disc is above and to the left, as shown by the course of the vessels.

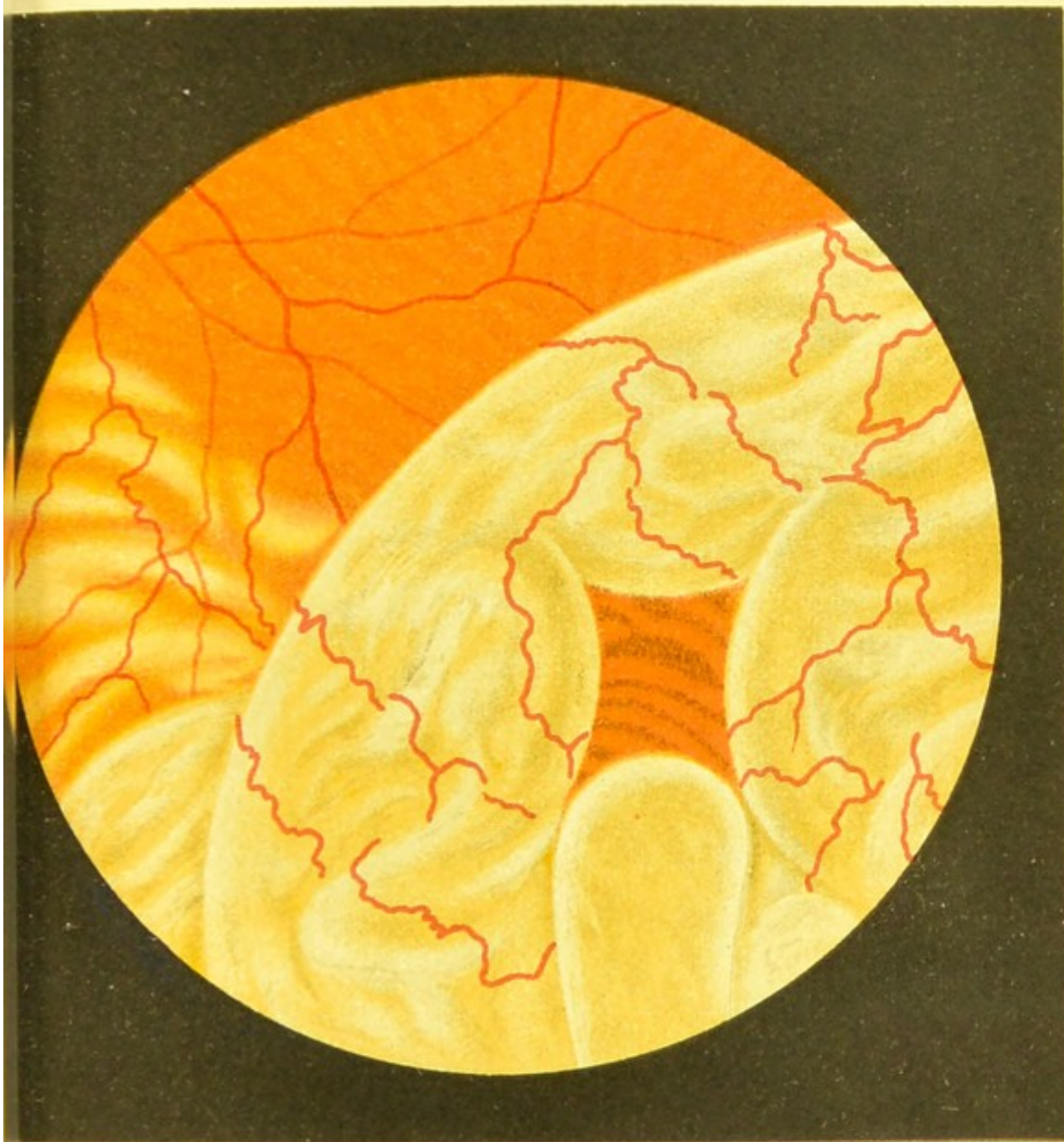


Fig.48.





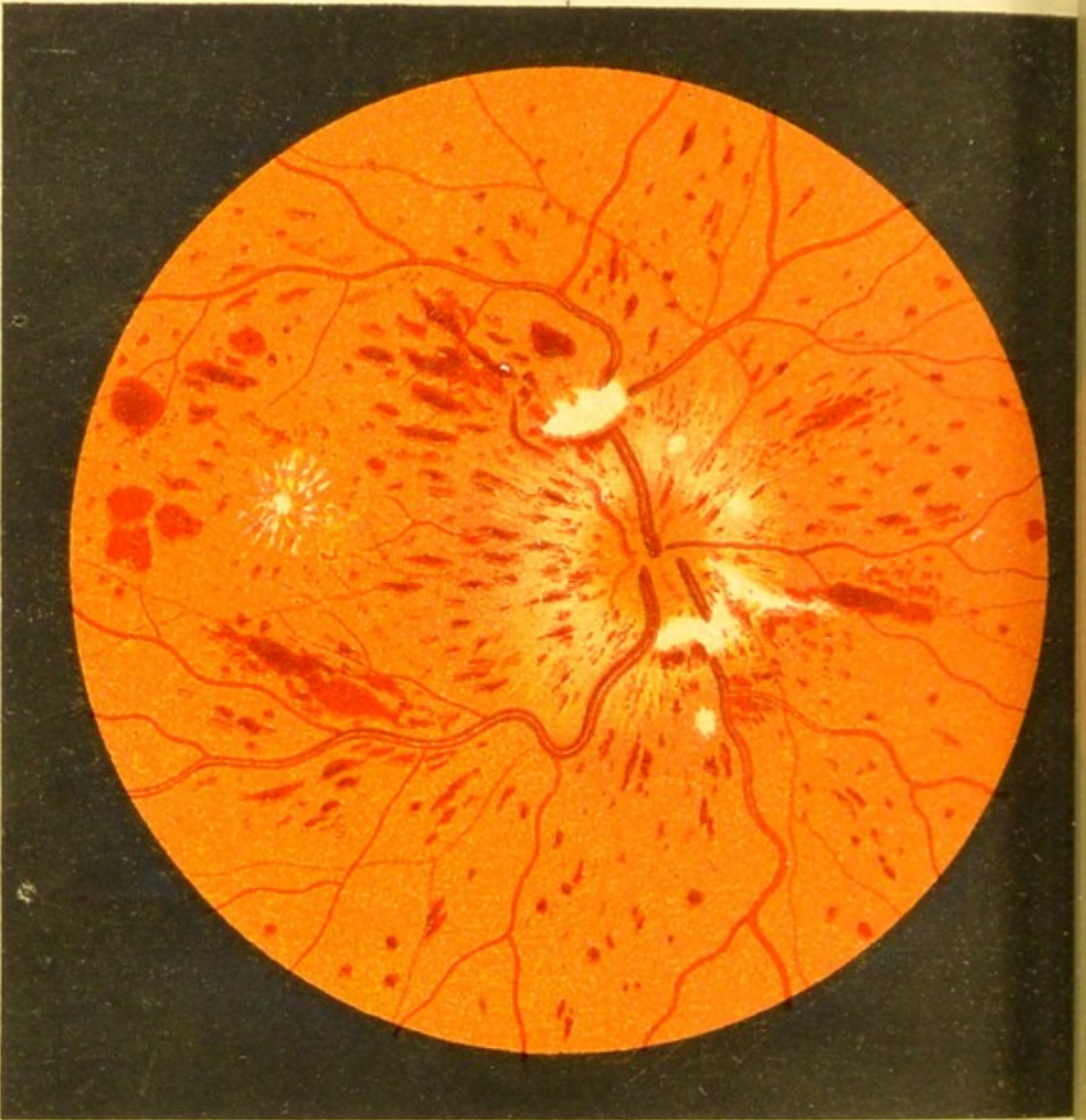


Fig. 49.

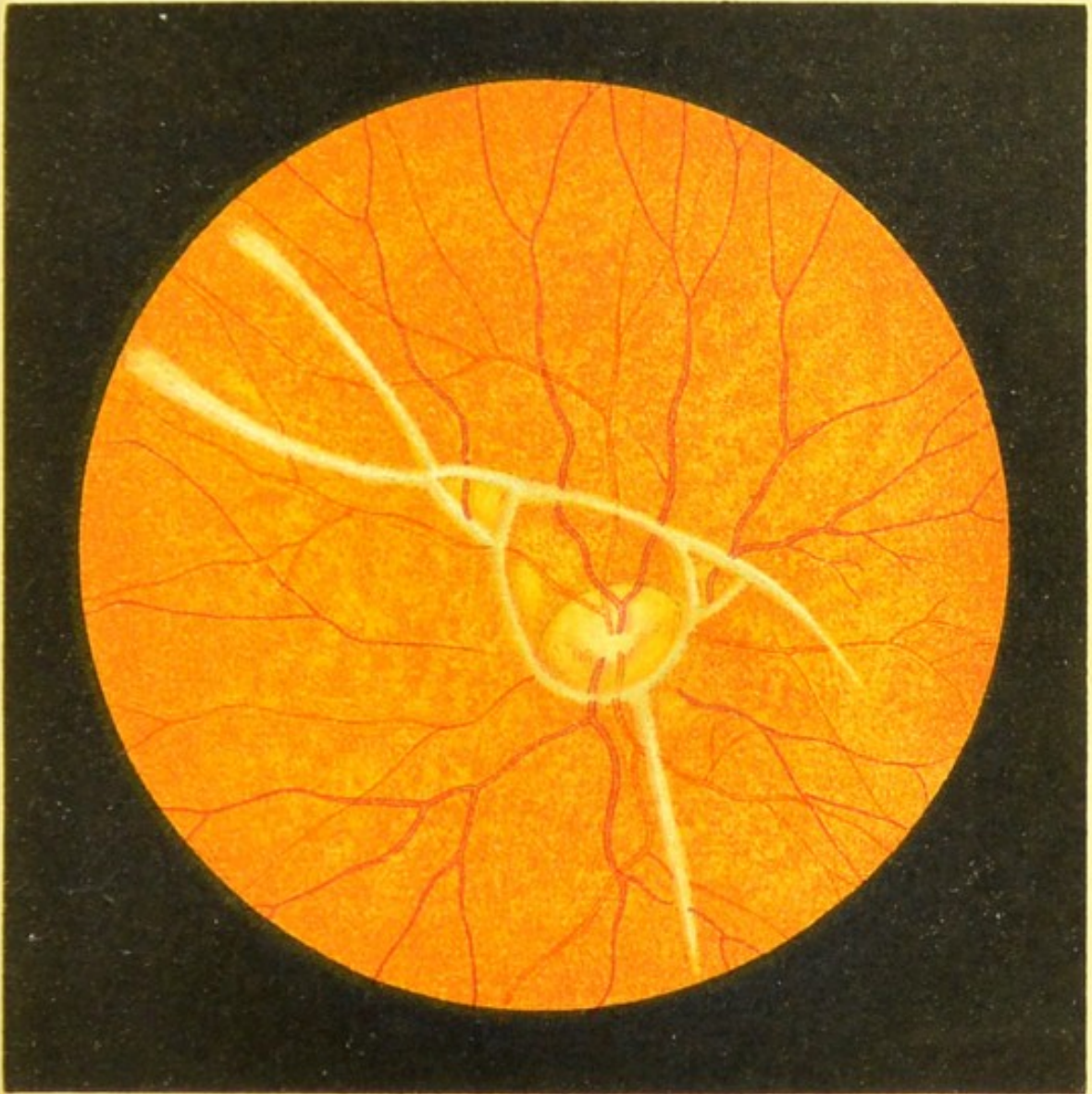
FIG. 49.—Hæmorrhagic Retinitis during  
Pregnancy.

In spite of the star-shaped figure at the macula, repeated examinations of the urine revealed no albumen. The patient was delivered at full term, and three weeks later most of the hæmorrhages and white patches had disappeared. She was very anæmic both before and after her confinement. Acuity of vision returned to normal, and the right eye was never affected.

FIG. 50.—Retinitis Proliferans.


In this case the sclerotic was ruptured on the nasal side of the cornea by a severe blow, the lens was expelled, and there was hæmorrhage into the vitreous, which, until it had disappeared prevented any examination of the fundus. Surrounding the disc and crossing the bloodvessels we see narrow greyish-white streaks, that disappear after running a short distance. There was no sign of detached retina.


A pathological examination made later, revealed the fact that these lines were due to a proliferation of fibrous tissue in the most superficial layers of the retina. (See 'Arch. f. Augenheilk.,' Bd. 25, S. 186.)



**Fig. 50.**







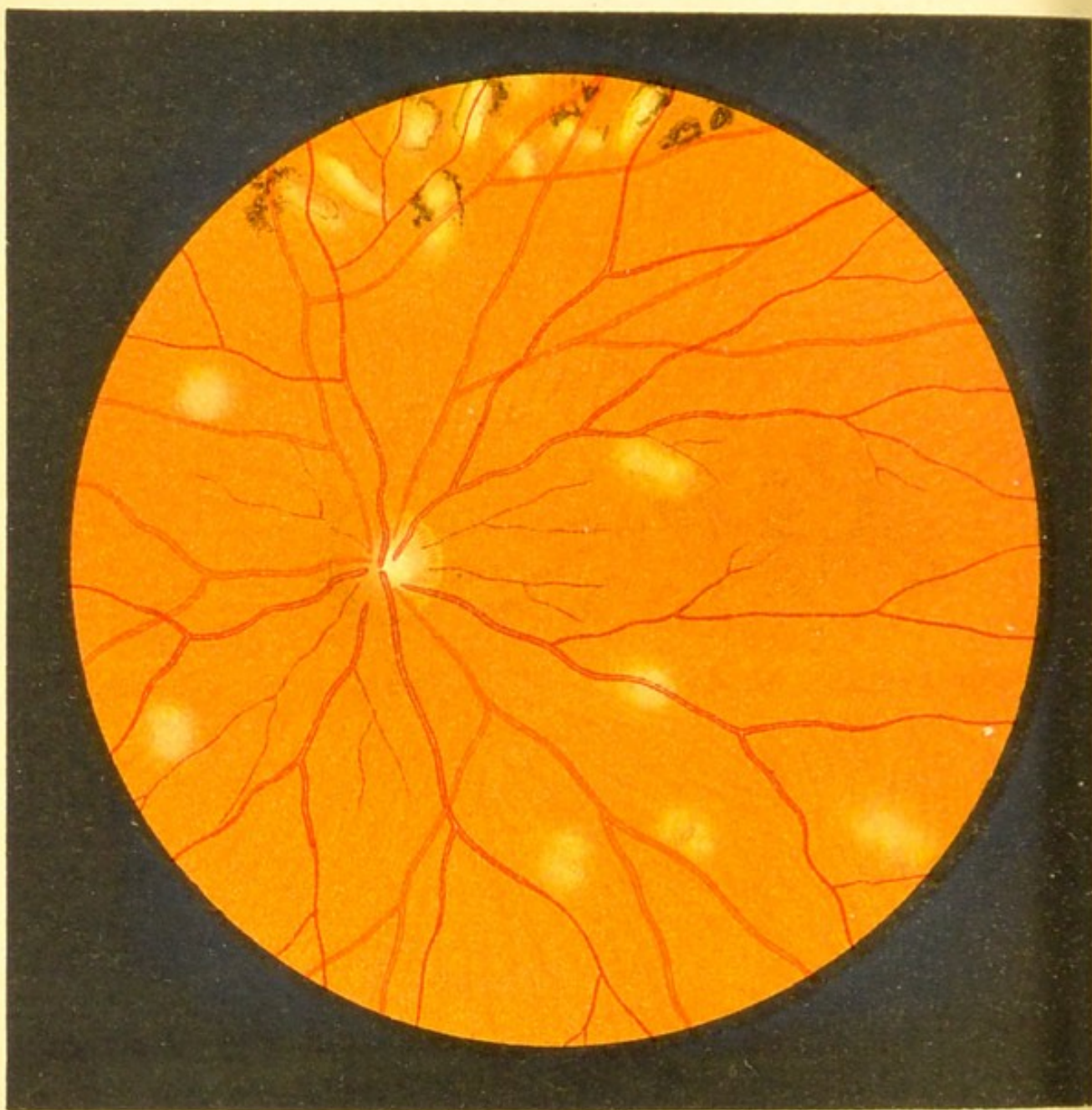


Fig.51.

## DISEASES OF THE CHOROID

(FIGS. 51 to 64).

### FIG. 51.—Choroiditis Disseminata : Early Stage.

We recognise these inflammatory patches as being in the choroid by observing that they are behind the retinal vessels.

The recent spots have a uniform yellowish-white appearance, with ill-defined margins, while older ones show marked pigmentary changes (as in the upper part of the figure); while later still these roundish spots may coalesce, and we get long irregular patches.

The disc is congested on its nasal side, and the retinal veins are somewhat enlarged.


FIG. 52.—Choroiditis Disseminata: Old-standing.


In this case both eyes were attacked by the disease, which had existed many years. In its early stage the appearance of the fundus was very similar to that shown in the foregoing figure. We see here an enormous increase of pigment; the black patches are irregular, often coalescing, and most abundant in the neighbourhood of the disc.

Towards the periphery we see many black spots surrounded by a bright halo, and here and there scattered over the field, patches exhibiting all the stages of choroidal atrophy, from the yellowish-white recent spots to those where the atrophy is complete, and which derive from the sclerotic their characteristic pearly-white appearance.

The choroidal vessels and normal pigmented intervascular spaces are seen in those parts where the disease is less dense. The retinal vessels appear to pass undisturbed over the whole fundus, but it has been shown microscopically, that in some cases, the retina itself has been attacked by this disease starting sometimes in the choroid and sometimes in the hexagonal pigment layer, and leading to increased deposit of pigment. As is very frequently the case, the cause of the disease in this and the foregoing case was undetermined.












Fig. 53.

FIG. 53.—Choroiditis Disseminata : Recent.

This case differs from the previous ones in being a very acute inflammation of the whole of the choroid. Only one eye was attacked, and the patient was a young girl with a tubercular history, but otherwise healthy.

The absence of pigment and the grey colour of the patches indicate that the disease is recent ; the light-coloured border round the patches shows that it is progressive. These patches are characterised by a rapid increase in size and number, the whole fundus assuming an appearance as if acted upon by some corrosive fluid. In some cases the choroid becomes entirely destroyed in a few weeks.

The intensity of the inflammatory process is manifested by the blurred appearance of the disc and surrounding retina. This blurring is partly due to a central haziness of the vitreous, but also partly to actual inflammation in the parts themselves. In this case the optic neuritis and retinitis after a short time yielded to treatment, and quite disappeared. The grey patches became black, and were bordered by a narrow bright line, which took the place of the broad halo shown in the drawing.

FIG. 54.—Colloid Degeneration of the Vitreous  
Basal Membrane of the Choroid.

This is a senile change, and does not impair vision.

The spots are as a rule round and yellowish-white in colour, although where the degeneration is very extensive they assume a greyer appearance.


The neighbourhood of the disc, especially above and below, is the part usually affected, the macula as a rule escaping.


Microscopically this disease is found to be a hyaline degeneration, which forms bead-like projections on the anterior surface of the vitreous lamina, sometimes pushing into the hexagonal epithelium of the retina.

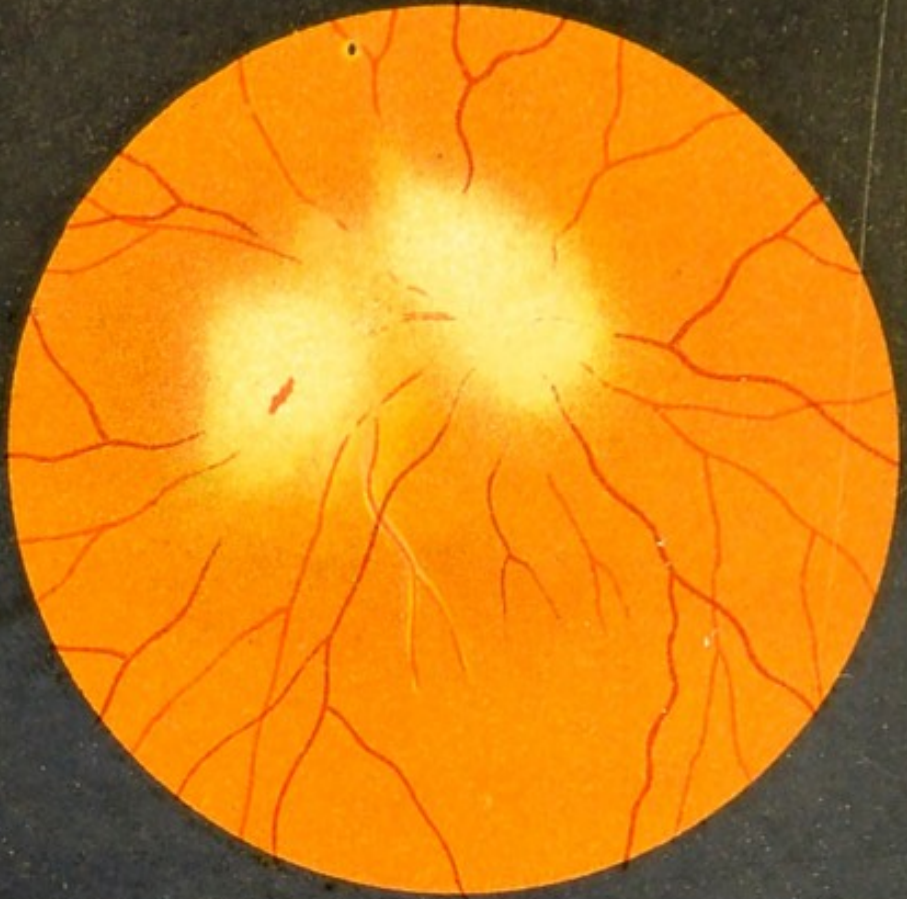
The disc in this case shows senile atrophy, which is frequently present in old people without causing any disturbance of vision.

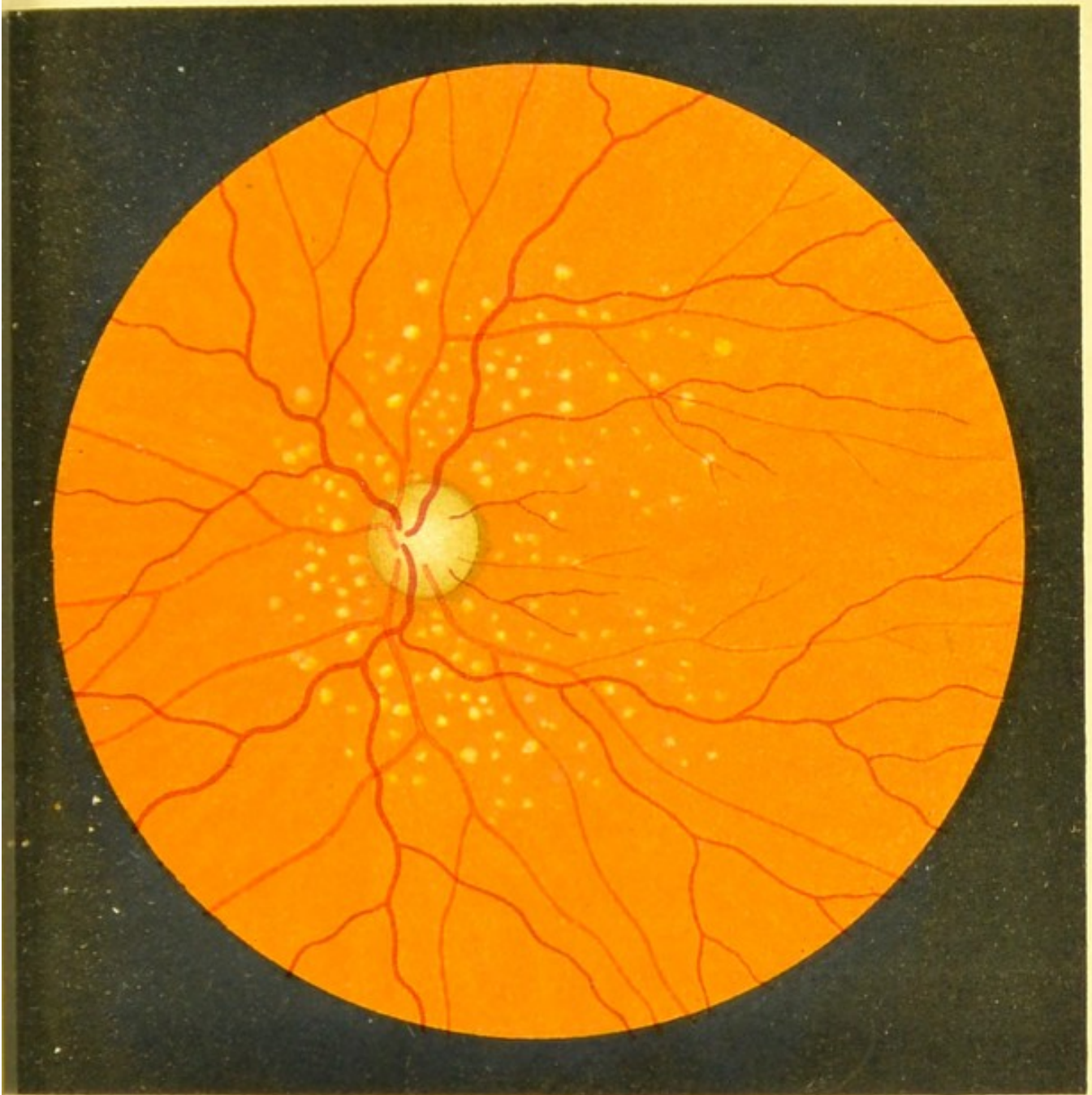

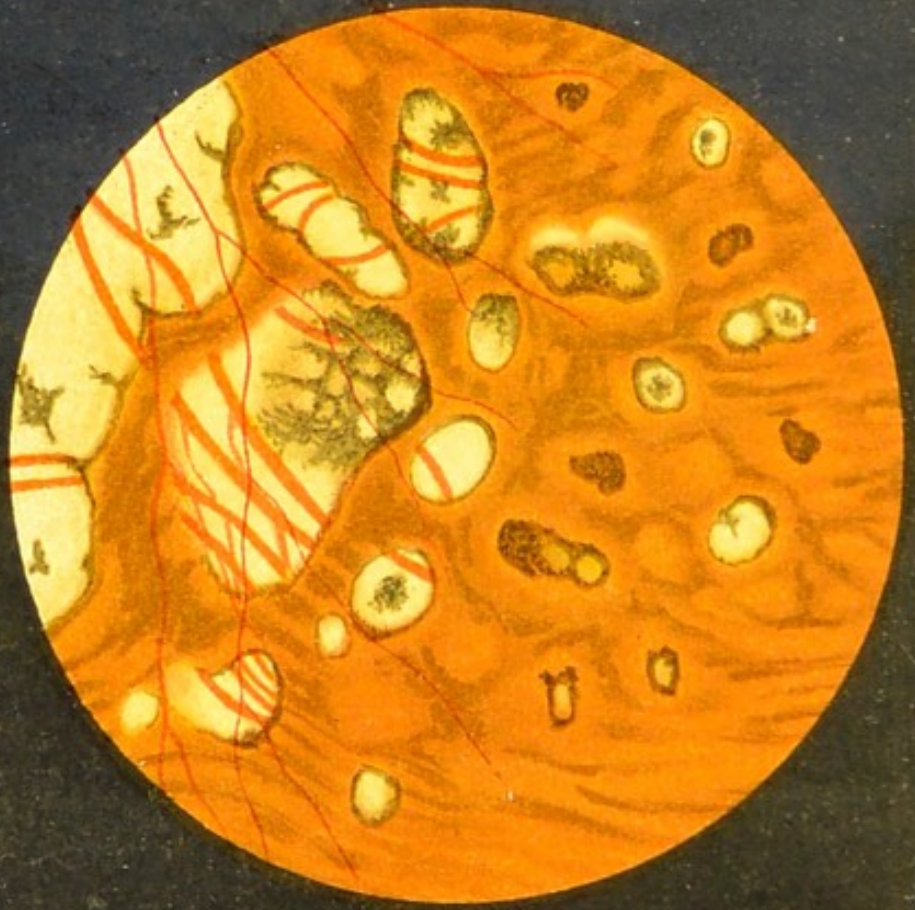Fig.54.







a



b

Fig. 55.

**FIG. 55a.—Choroido-Retinitis with Optic Neuritis : Recent.**

It is not uncommon to find the retina and optic nerve taking part in the inflammation of the choroid, which is as a rule more acute than in Choroiditis Disseminata. In this case we see a well-marked papillitis, the inflammatory patch spreading outwards and downwards (in the drawing) from the disc, and below this a second patch, about as large. Both patches have ill-defined outlines, and the retinitis is shown by the blurring of the vessels, and in the lower patch by a small linear hæmorrhage. A small artery running just below the macula has white thickened coats. At a later period the choroid was found to be atrophied in both patches, leaving white punched-out-looking spots, and the papillitis subsided, leaving slight atrophy of the disc.

**FIG. 55b.—Choroiditis Disseminata : Chronic.**

This case is an example of a fairly frequent form of chronic choroiditis, showing the great variety in the shape and colouring of the patches. The patient, a female, who was otherwise perfectly healthy, had suffered for some years from the disease, and the patches had been slowly increasing in size. The atrophy of the choroid has exposed the sclerotic, and many of these atrophic white patches are crossed by the larger choroidal vessels. The margins of these patches are more or less pigmented, and here and there deposits of pigment are seen, surrounded by a bright halo, as in Fig. 52. The portion of the fundus drawn here is at the periphery.



FIG. 56.—Chronic Choroiditis, with Secondary Pigmentation of the Retina, due to the Presence of a Foreign Body in the Eye (*erect image*).

A piece of a copper percussion-cap passed through the sclerotic close to the corneal margin, and was seen lying below, in the anterior part of the vitreous, at first concealed by inflammatory exudation which was greyish-white in colour and semispherical in shape (similar to the case pictured in Fig. 46).

Some slight detachment of the retina occurred near this spot, but this disappeared later on. The mass of exudation round the foreign body lessened somewhat in extent, but a string of exudation which passed from this mass right through the vitreous to the disc remained visible for a long time. Although the disc was normal when the drawing was made (a year and a half after the injury), there had been some papillitis shortly after the injury.

The changes at the macula which followed the papillitis are still very plainly visible, and scattered over the whole surface of the fundus there are numerous spots of a yellowish colour and blurred outline, and interspersed with these a number of black spots, which very much resemble the pigment spots in Retinitis Pigmentosa. The yellow spots are choroidal, while the black spots are mostly retinal.

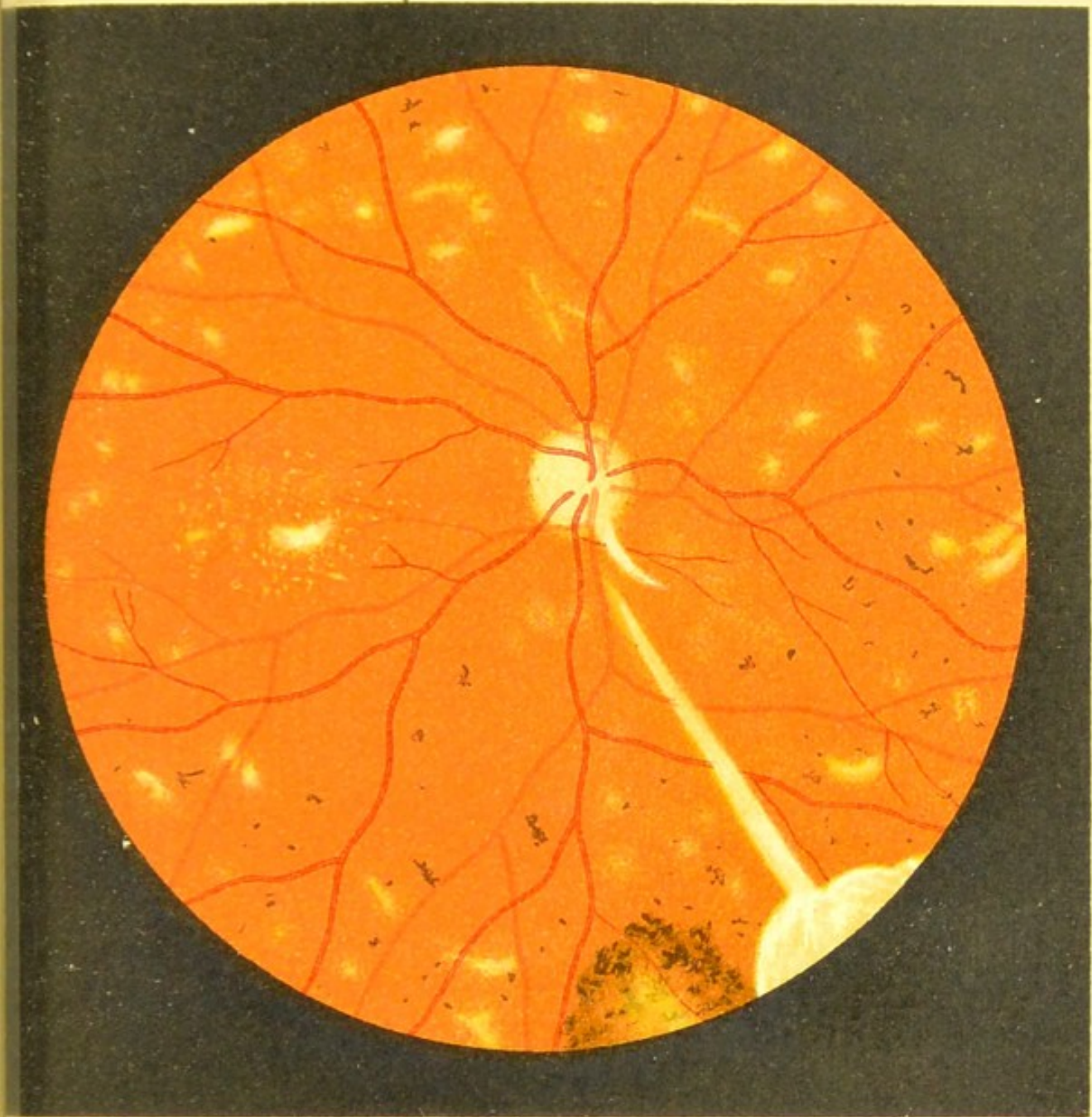




Fig.56





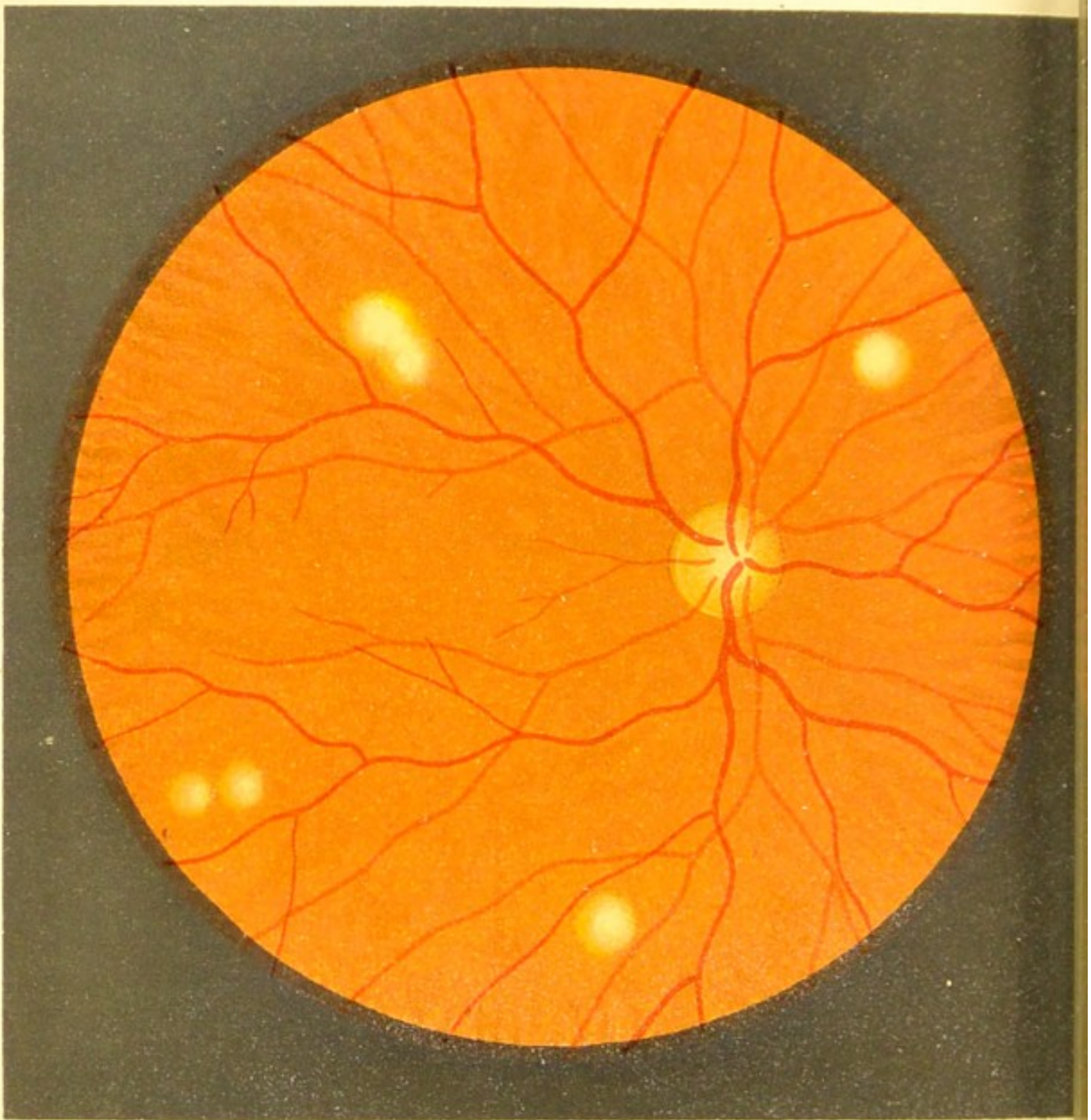


Fig.57.

FIG. 57.—Tubercle of the Choroid.

Miliary tubercle of the choroid is always acute and secondary, and seen sometimes only a short period before death.

At first these tubercle spots are small and partly covered by pigment, and are greyish-white in colour; but as they grow, they push the pigment on one side, and the colour changes to a reddish-yellow or yellowish-white. The spots are round, with an ill-defined edge, and two spots are sometimes seen to coalesce. Sometimes the nodule projects forwards and pushes the retina in front, in which case, if a vessel is passing over, it becomes bent.

It is sometimes difficult to differentiate between this condition and recent Choroiditis Disseminata, as shown in Fig. 51.

FIG. 58 — Chronic Tuberculosis of the Choroid  
[Chronic Tubercular Choroiditis] (*erect  
image*).

At the upper and outer part of the fundus, at the periphery, we see a largish tumour, which has been growing slowly and is the result of the coalescence of a large number of small tubercular nodules; these are indicated by the greyish round patches on the surface of the growth.

At the junction of this tubercular tumour with the choroid we see the latter actively inflamed. This is shown in the drawing by the irregular whitish coloration of the choroid and the numerous yellowish and white spots. This choroiditis in the immediate vicinity of the tumour serves to distinguish this growth from a sarcoma, which it resembles in all but this (see the following figure).

The optic neuritis which is present is probably caused by tubercle of the brain, which the patient (a young man) was suffering from at the same time.

This case, which was the first of its kind ever shown (by Horner), is more fully described in Graefe's 'Arch.,' Bd. 25.

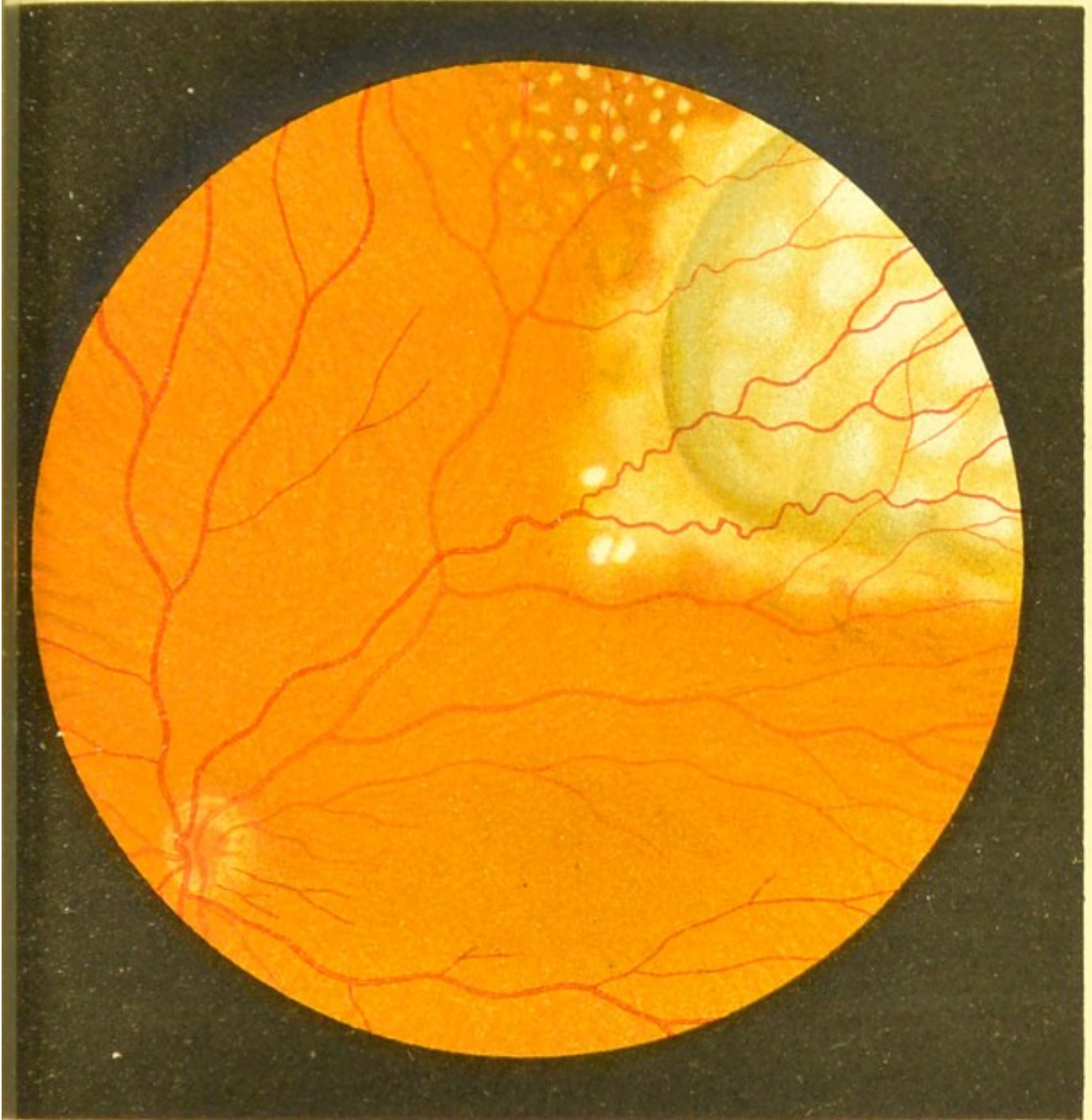



Fig.58.







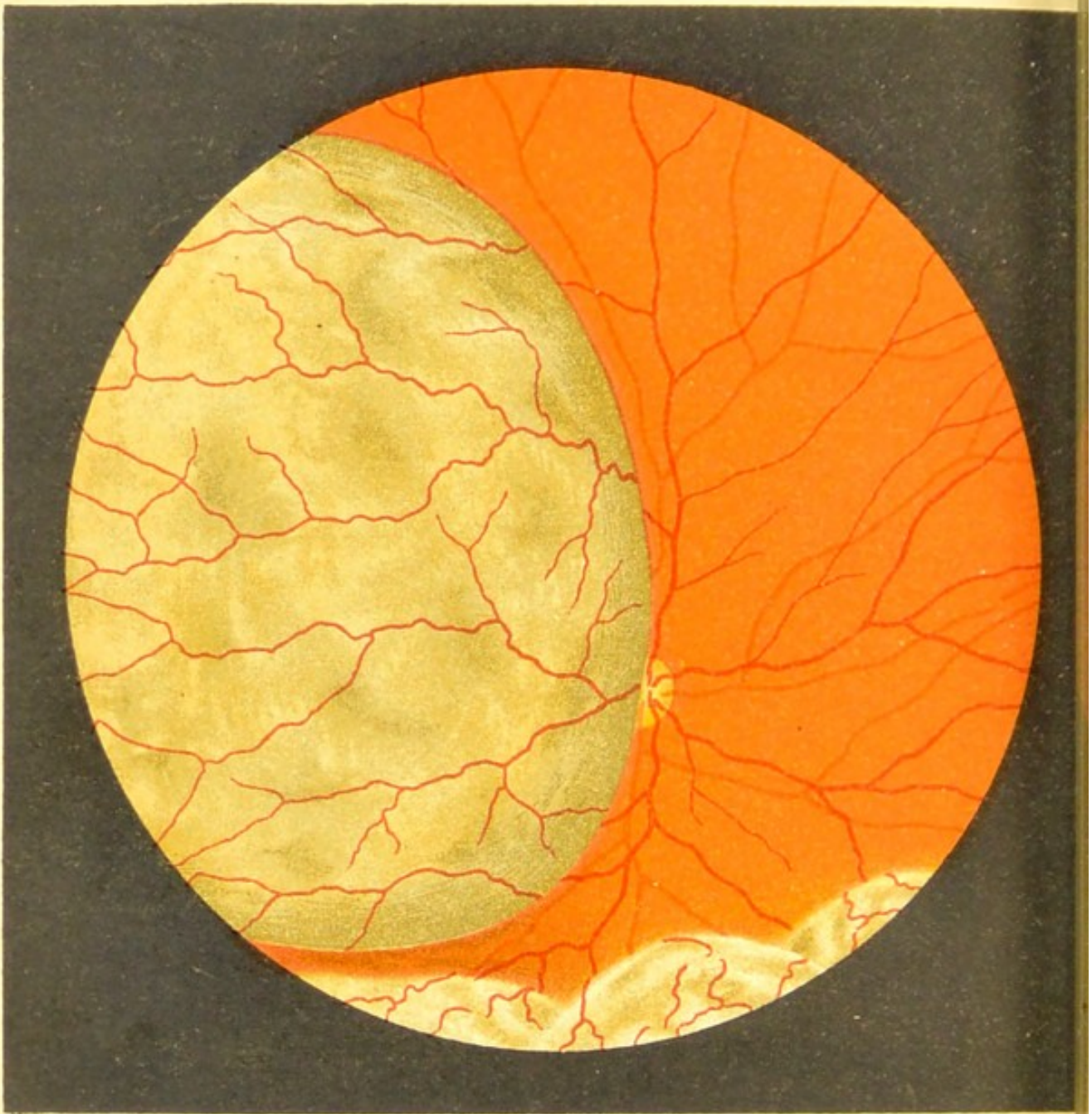


Fig.59.

FIG. 59.—Sarcoma of the Choroid.

The tumour is seen occupying the outer half of the field. It is bluish-grey in colour, has a slightly mottled surface, and projects forwards into the vitreous, partly concealing the disc. It is not actually covering the disc, but overlapping it; for by directing the patient to move his eye from side to side during the ophthalmoscopic examination, the amount of disc that was hidden was found to vary with the position.

We see by the arrangement of the vessels, which are slightly tortuous, that the retina is stretched over the tumour. We distinguish this condition from simple detachment, which is seen at the lower part of the picture and which commonly accompanies this disease, by the absence of folds and the uninterrupted course of the vessels.

The rest of the fundus was normal.

The growth was found to be a melanotic sarcoma.

FIG. 60.—Sarcoma of the Choroid.

This case differs from the former in the larger size of the growth and the absence of any simple detachment of the retina. There are also some slight changes visible at the macula.

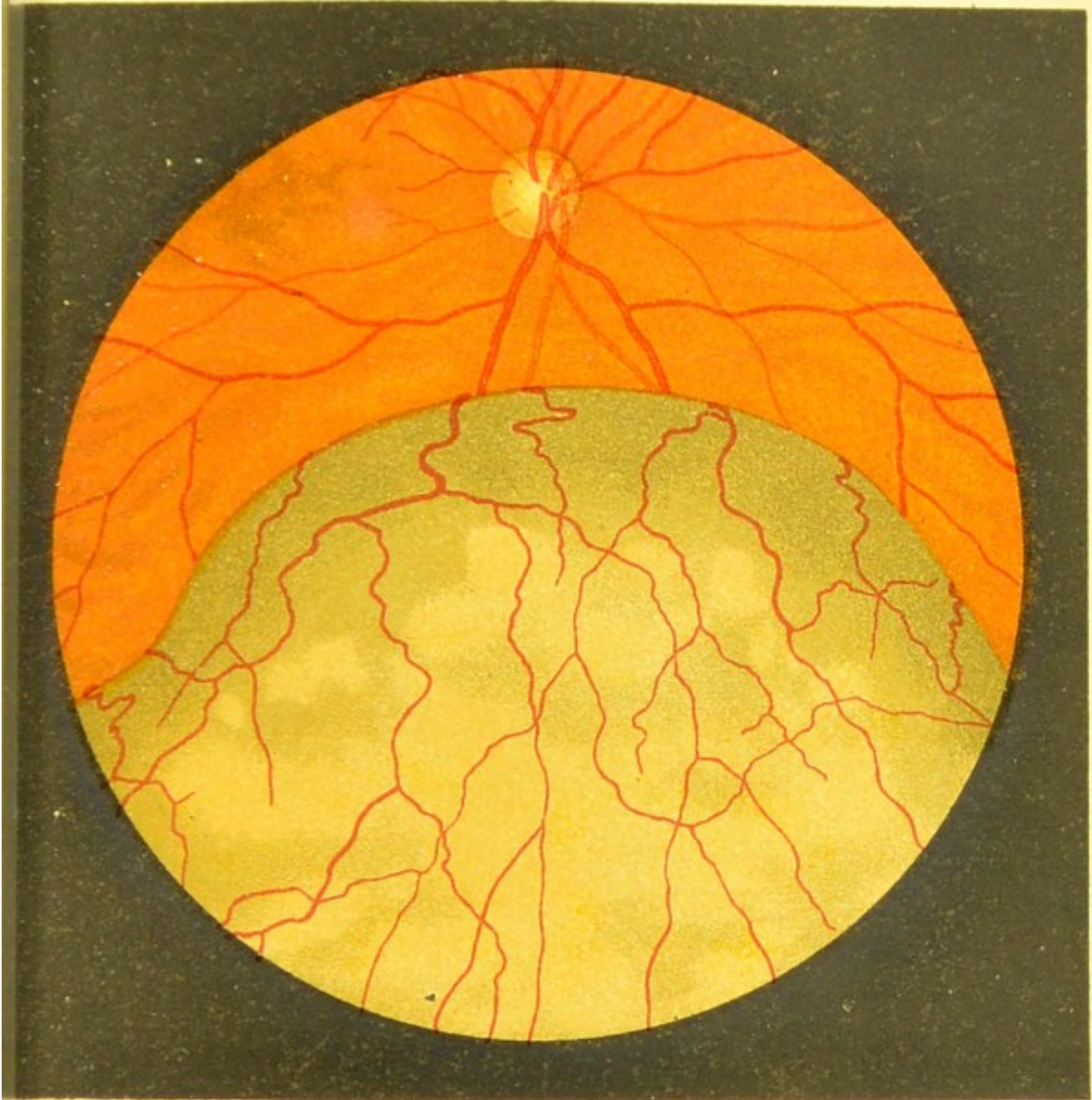




Fig.60.







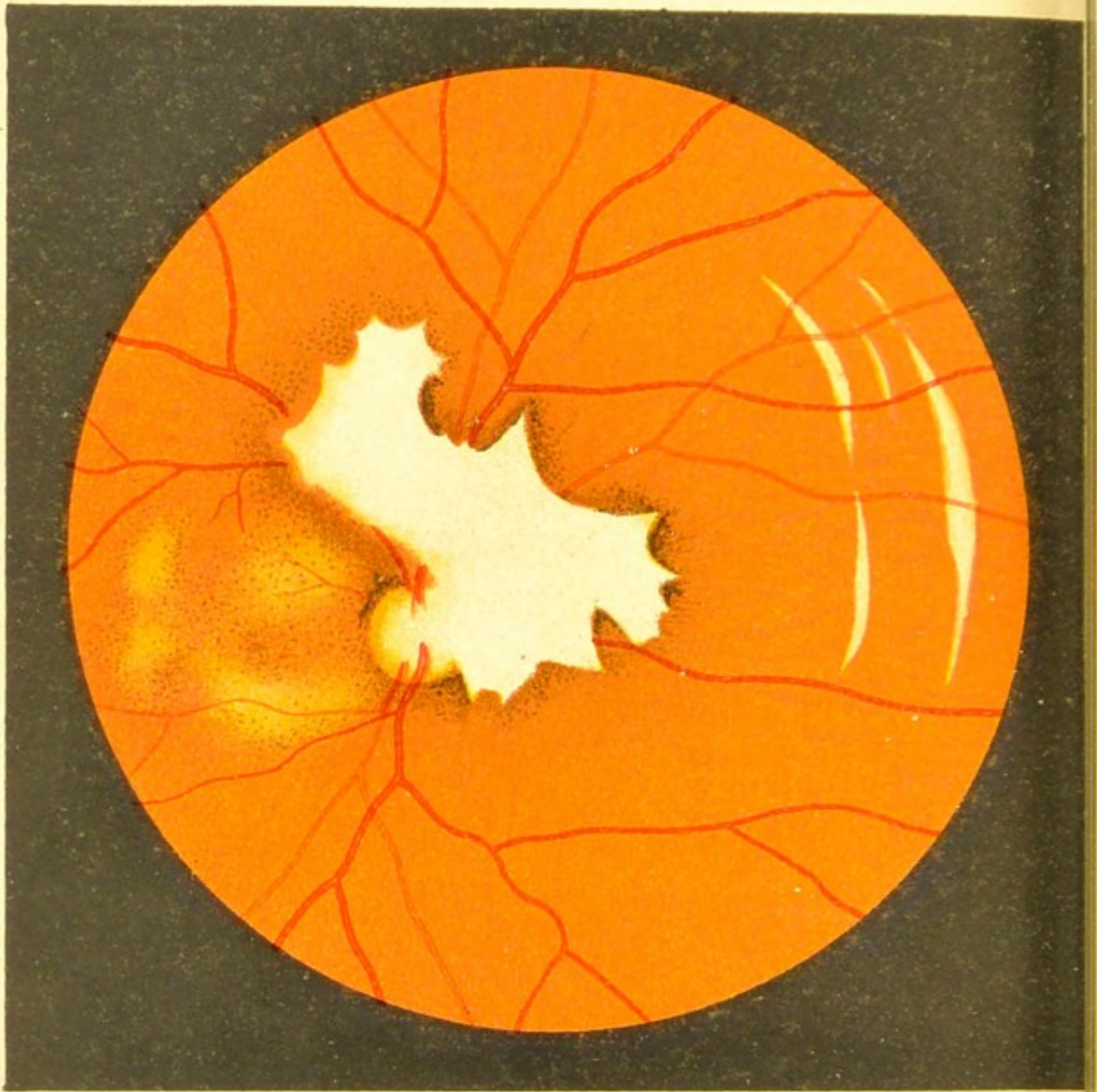


Fig.61.

FIG. 61. — Rupture of the Choroid (*inverted image*).

The eye had received a very severe blow from the paper plug of a blank cartridge.

Hæmorrhage occurred in the anterior chamber and vitreous, and when this was absorbed the following changes were seen: Partly covering the disc and retinal vessels, and extending downwards and inwards, we see a large irregular-shaped white fibrous patch; its margins are curved and in places pigmented.

Further removed inwards we see five ruptures of the choroid. These are characteristically curved, and their margins are well defined. They owe their whiteness of colour to the sclerotic that is visible. The retinal vessels pass uninterruptedly over them.

With the exception of some changes in the macula region, the rest of the fundus is normal.

FIG. 62.—Sclerosis of the Choroidal Vessels.  
Disseminated Choroiditis and Secondary  
Pigmentation of the Retina.

When this condition is seen only a small part of the fundus is, as a rule, attacked by the disease.

In this case the sclerosis of the choroidal vessels is accompanied by a deficiency of the retinal pigment, which allows the choroid to be plainly visible, and the white opaque coats of its vessels show up well against the dark pigmented background. The changes in the vessels are most marked at the posterior pole of the eye, and disappear towards the periphery.

Round this region of diseased vessels we see here and there white roundish spots of choroidal atrophy, some of them with a pigmented border, and scattered about in the same region several angular patches of retinal pigment.

The retinal vessels are normal.

The drawing was taken from an unusually well-marked example.

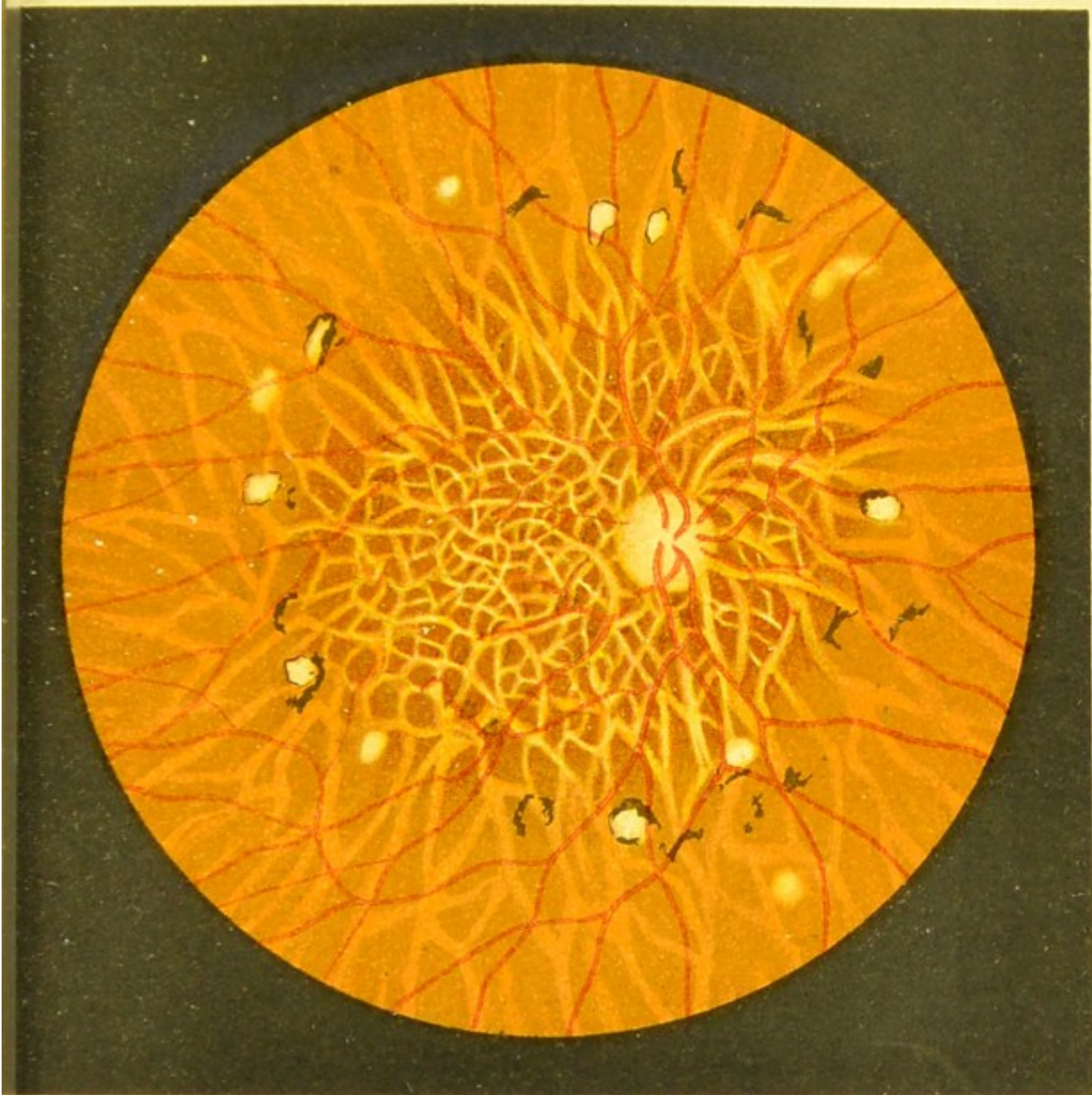
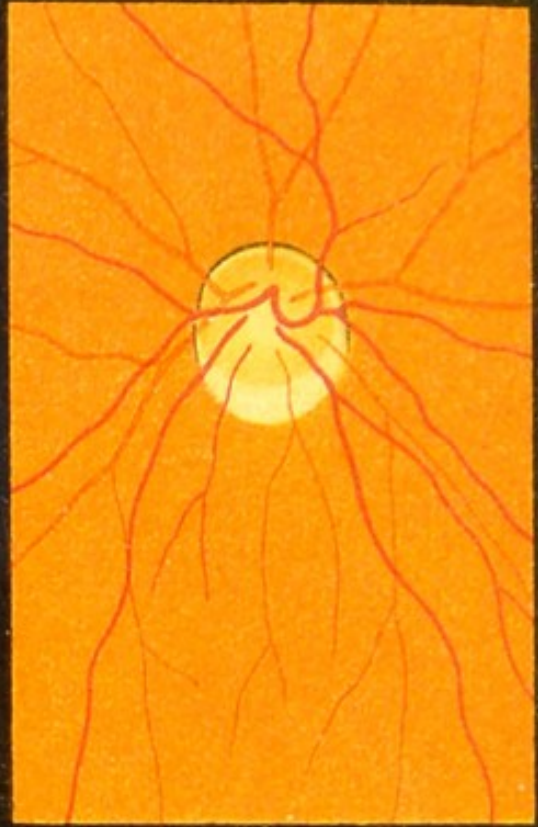



Fig.62.

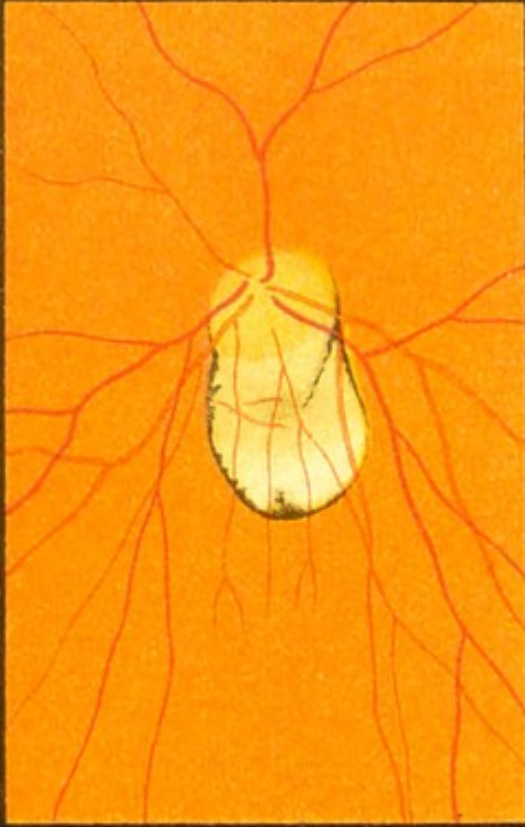



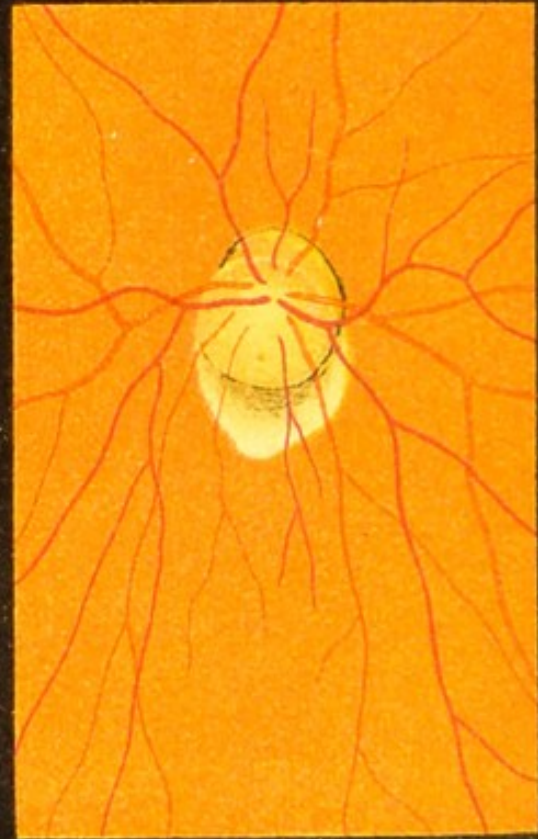a



c



b



d



FIG. 63.—Atrophy of the Choroid round the Disc in Myopia (Posterior Sclero-Choroiditis).

These four drawings, and those in the next figure and in Fig. 35, show the various forms that this myopic choroidal atrophy assumes.

Whether the form is crescentic, ring-shaped, conical, or irregular, they mostly agree in two points, viz. : the atrophic changes are most marked and most extensive on the temporal side of the disc, and the retinal vessels are straighter than normal, and are usually crowded together on the same side.

The whiteness of the atrophic patch is due to the sclerotic being exposed. The margins of the patch are in parts pigmented, and sometimes we see on its surface remains of pigment and choroidal vessels (see Fig. 63*d*).

It is inaccurate to describe this atrophic patch as a staphyloma, for the retinal vessels are seen to pass over it without any bending. Stilling and others assert that a small crescent is due to the margin of the scleral canal being visible.



FIGS. 64*a*. and 64*b*.—Atrophy of the Choroid in Myopia. Disseminated Choroiditis and General Deficiency of the Pigment of the Fundus.

FIG. 64*a*.—The atrophic patches which we see here accompanying the posterior atrophy at the disc are often seen in high myopia, and bear a great resemblance to Choroiditis Disseminata.

The deficiency of pigment which often accompanies high myopia shows up the choroidal vessels as light on a dark background, as in this case, or as dark colour on a light background, as in Fig. 36*c*. The disc appears pale by contrast, and also slightly prominent.

FIG. 64*b*.—In this case the disc is slightly excavated and oval, and its temporal margin is with difficulty distinguished from the choroidal atrophy.

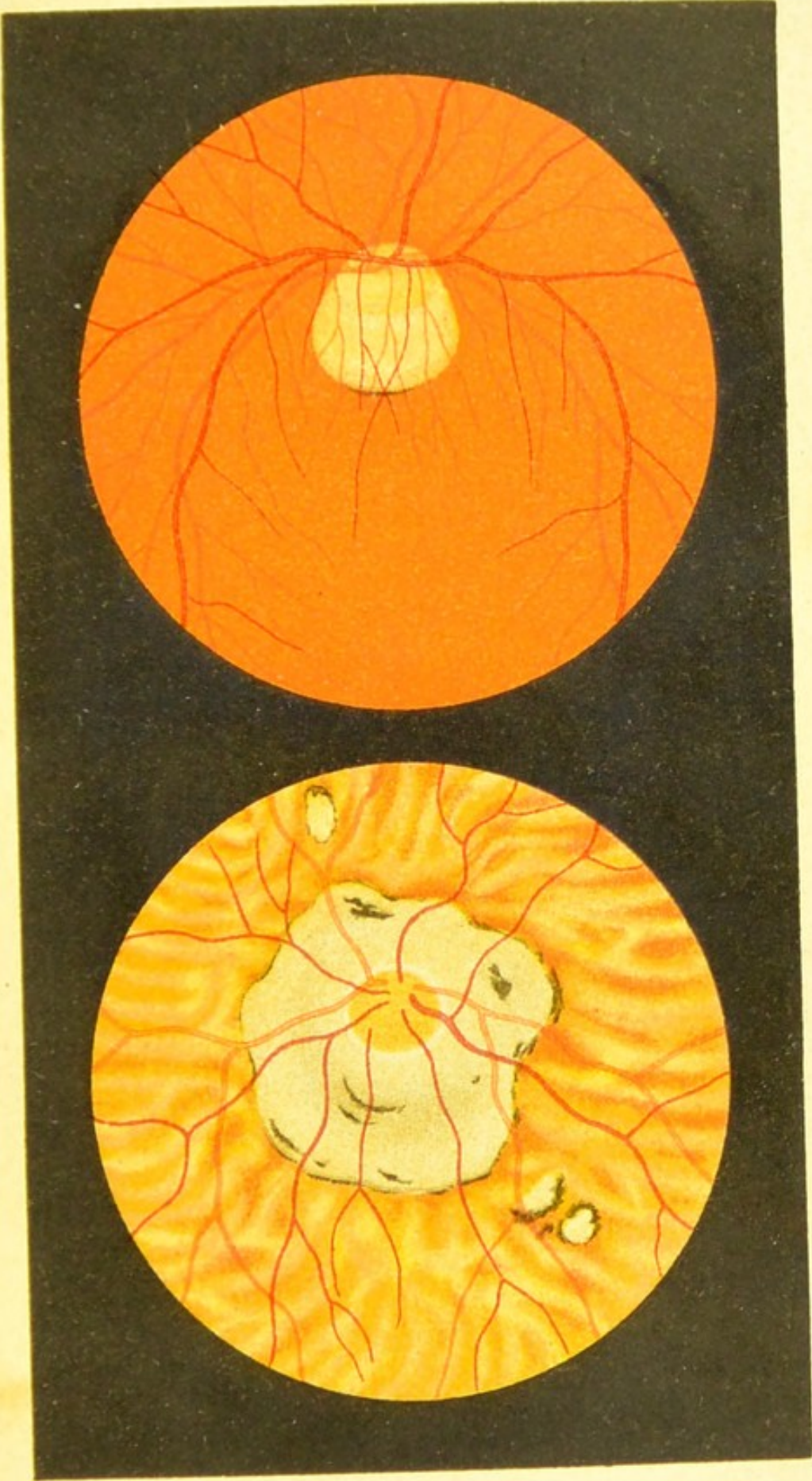

Fig. 64.

a

b

INST. OPHTHALMOLOGY  
JOINT  
LIBRARY  
MOORFIELDS EYE HOSPITAL LONDON EC1V 9EL



