

**A case report of 5703 cases of eye diseases seen and treated in private practice in Constantinople in 1877, 1878 & 1879 : and also a tabular analysis of 1118 cases treated at the Imperial Naval Hospital with eight chromos, and a woodcut / by Edwin van Millingen.**

### **Contributors**

Van Milligan, Edwin.  
Ophthalmological Society of the United Kingdom. Library  
University College, London. Library Services

### **Publication/Creation**

Constantinople : [publisher not identified], [1880?]

### **Persistent URL**

<https://wellcomecollection.org/works/ct92r4pu>

### **Provider**

University College London

### **License and attribution**

This material has been provided by This material has been provided by UCL Library Services. The original may be consulted at UCL (University College London) where the originals may be consulted.

This work has been identified as being free of known restrictions under copyright law, including all related and neighbouring rights and is being made available under the Creative Commons, Public Domain Mark.

You can copy, modify, distribute and perform the work, even for commercial purposes, without asking permission.



Wellcome Collection  
183 Euston Road  
London NW1 2BE UK  
T +44 (0)20 7611 8722  
E [library@wellcomecollection.org](mailto:library@wellcomecollection.org)  
<https://wellcomecollection.org>

A  
TRI-ANNUAL REPORT  
OF 5703 CASES. (8)

OF EYE DISEASES SEEN AND TREATED

IN

**PRIVATE PRACTICE AT CONSTANTINOPLE,**

IN 1877, 1878 & 1879.

and also

A tabular analysis of 1118 cases treated at  
the IMPERIAL NAVAL HOSPITAL;  
with eight chromos, and a woodcut.

BY

*DR. EDWIN VAN MILLINGEN.*



CONSTANTINOPLE,



# THE ANNUAL REPORT

OF 5703 CASES.

OF THE DISEASES OF THE EYE AND THE EYELIDS.

SECTION THE MOST IMPORTANT CASES WHICH

WENT UNDER MY HANDS DURING THE SEVENTH EIGHT

YEARS OF MY PRACTICE AT CONSTANTINOPLE.

SECTION IS GIVEN TO THE DISEASES OF THE

CONJUNCTIVA OR INFLAMMATION OF THE EYE.

SECTION IS WIDELY SPREAD AMONG THE PEOPLE

OF THE CITY UNDER THE HEAD OF CATARACTS OF THE

EYE. CONSTANTINOPLE I HAVE REPORTED OF

ONLY WHICH WERE PLACED UNDER MY HANDS.

THE WANT OF A SPECIAL EYE INFIRMARY

LEFT AND I WAS CONSEQUENTLY INDUCED

TO ONE (THE FIRST CIVIL EYE INFIRMARY EVER

ESTABLISHED IN THE CITY) WHICH HAS WORKED SATISFACTORILY.

SECTION IS THE BEST OF THE YEAR 1880-1881.

SECTION IS THE BEST OF THE YEAR 1880-1881.

SECTION IS THE BEST OF THE YEAR 1880-1881.

SECTION IS THE BEST OF THE YEAR 1880-1881.

SECTION IS THE BEST OF THE YEAR 1880-1881.

SECTION IS THE BEST OF THE YEAR 1880-1881.

SECTION IS THE BEST OF THE YEAR 1880-1881.

SECTION IS THE BEST OF THE YEAR 1880-1881.

SECTION IS THE BEST OF THE YEAR 1880-1881.

SECTION IS THE BEST OF THE YEAR 1880-1881.

SECTION IS THE BEST OF THE YEAR 1880-1881.

SECTION IS THE BEST OF THE YEAR 1880-1881.

SECTION IS THE BEST OF THE YEAR 1880-1881.

SECTION IS THE BEST OF THE YEAR 1880-1881.

SECTION IS THE BEST OF THE YEAR 1880-1881.

CONSTANTINOPLE

1852631



## INTRODUCTION.

---

In the following report I have endeavoured to arrange in a tabular form, suited for affording statistical information, the most important cases which came under my notice, during the seventh, eighth and ninth years of my practice at Constantinople. Particular attention is given to the disease generally known as Granular, or Egyptian ophthalmia, which is widely spread among the poorer classes of this city. Under the head of cataract operations by von Græfe's method I have reported on those cases only which were placed under proper Hospital care. The want of a special eye infirmary was greatly felt and I was consequently induced to establish one (the first Civil eye infirmary ever created in Turkey) which has worked satisfactorily since the beginning of 1880.

I have much pleasure in thanking the Deaconesses of the German Hospital, and also the Sisters of Charity of the German Swiss Hospital, for the kind care bestowed to my patients at their respective Hospitals, and I have also to acknowledge the care and attention bestowed by Dr. Julius Heitzman of Vienna on the chromolithographs which were copied from water colours taken after nature.



Digitized by the Internet Archive  
in 2014



# TABULAR VIEW OF CASES

## SEEN OR TREATED DURING THE YEARS

1877, 1878 & 1879.

I. Conjunctiva.		MEN	WOMEN	TOTAL No OF CASES	TOTAL No OF EYES
Conjunctivitis acute catarrhal				138	207
"    chronic    "				585	998
"    epidemic    "	55	28	83	161	
"    phlyctenular			78	117	
"    miliary form			2	2	
"    granular	438	597	1035	1882	
"    diphtheritic			10	18	
"    croupous (membran)			4	8	
"    follicular			12	24	
"    ex combustio			1	2	
"    purulent acute (blen- norrhœa)			102	194	
"    "    chronic			59	108	
"    gonorrheal			38	72	
"    of infants			58	103	
Subconjunctival effusion			5	5	
Pterygium			34	24	
Phlyctena pallida (Frühjahrs catarrh)	16	5	21	41	
Polypus			2	2	
Epithelioma			2	2	
Lymphangoitis			3	3	
Total				2272	3973



## II. Cornea

	MEN	WOMAN	TOTAL No OF CASES	TOTAL No OF EYES
Corneitis interstitial	33	33	66	113
„ superficial			243	410
„ deep			166	155
„ circumscribed			231	403
„ fascicular			41	59
„ bullosa			2	3
„ ulcer with hypopyon			27	36
Abcess of cornea	4	3	7	10
Fistula „ „			6	6
Macula and cicatrix			103	162
Conical cornea			2	4
Adherent leucoma			144	201
Total staphyloma			34	48
Partial „			20	31
Rupture of cornea			5	5
Dermoid tumor			3	4
Epithelioma			4	4
Foreign body in cornea			8	8
Total			1112	1662

## III. Iris and Choroid

Iris simple			89	128
„ plastic			7	8
„ specific			31	48
Occlusio pupillæ			14	10
Posterior senecchia	44	24	66	94
Sympathetic irido-cyclitis			10	10
Choroiditis disseminate	29	20	49	51
Chorio-retinitis	12	3	15	28
Rupture of choroid			2	2
Ossification of choroid			6	6
Glaucoma simple			33	53
„ inflamm			52	82
„ hemmorrh			2	4
„ absolute			44	60
Albinismus			2	2
Total			422	586



#### IV Sclerotic.

	MEN	WOMEN	TOTAL No OF CASES	TOTAL No OF EYES
Episcleritis			10	15
Intercalar Staphyloma			3	4
Suppurative scleritis			4	4
Penetrating wound of sclerotic			3	3
Simple scleritis			5	5
Suppuration after tenotomy			1	1
Total			26	32

#### V. Retina and optic N.

Retinitis idiopathic			12	24
„ syphilitic			5	9
„ pigmentosa			7	14
„ hemorrhagica			16	23
„ ex M. Brightii			7	10
Detachment of retina			11	13
Amaurosis partialis fugax			2	3
Neuroretinitis c. M. Brightii	11	5	16	28
Neuritis			15	25
Atrophy of Optic N.			83	137
Decoloration „ „			4	8
Hemianopsia (lateral)			1	2
„ (temporal)			1	2
Amblyopia (alcoholic)			7	14
„ ex anopsia			15	15
„ unknown cause			2	4
Anesthesia of retina			6	12
Emboly of central artery			2	2
Concussion of retina			2	2
Total			214	347



## VI. Lens.

	MEN	WOMEN	TOTAL No OF CASES	TOTAL No OF EYES
Cataract senile simple	68	48	116	175
„ centr. anterior			48	78
„ „ posterior			3	7
„ lactic			3	7
„ Morganii			2	4
„ Capsular			3	6
„ traumatic			17	18
„ aridosileq.			3	4
„ lamellar			6	12
„ acreta			3	4
„ secondary			15	18
Congenital dislocation			4	7
Traumatic „ (couched32)			24	35
Spontaneous „			2	2
Total			249	377

## VII. Vitreous body.

Opacities of v. b.			13	20
Hemorrhage in v. b.			4	5
Foreign body in v. b.			2	2
Cholestearine crystals			2	3
Total			21	30

## VIII. Eyeball.

Microphthalmus congen.	1	2	3	6
Buphthalmus	4	4	8	16
Phtisis bulbi			50	60
Total			61	82



### IX. Refraction & Accommodation.

	MEN	WOMEN	TOTAL No OF CASES	TOTAL No OF EYES
Myopia	84	40	124	208
Hypermetropia	45	39	84	154
Presbyopia	20	20	40	80
Hypermetr. & Presbyopia	8	12	20	19
Astigmatism (myopic)	23	20	43	76
"    (hyperm.)	16	7	23	44
Anisometropia	8	20	28	28
Paralysis of accommod.	3	2	5	8
Spasm of	3	2	5	10
Kopiopia hysterica.	3		3	6
Total	213	162	375	633

### X. Muscles & Nerves.

Paralys. of oculo-motor N.			7	7
"    "    trochlear			2	2
"    "    6th			11	11
"    "    recti interni			1	2
Strabismus converg			39	63
"    diverg			20	14
"    sursum.verg. with congen. ptosis			1	1
Nystagmus			10	20
Herpes hoster			2	2
Total			93	122

### XI. Lacrymal organs.

Mucocele	18	50	68	110
Dacryocystitis	15	19	34	35
Stenosis & stricture	6	46	62	87
Fistula	15	16	31	42
Total	64	131	195	274



## XII. Orbital Cavity.

Caries  
Osteoma  
Exostosis

	MEN	WOMEN	TOTAL No OF CASES	TOTAL No OF EYES
			4	4
			3	4
			3	3
Total			10	11

## XIII. Eyelids.

Blepharitis  
Hordeolum  
Chalazion  
Molluscum contagiosum  
Ektropion  
Entropion  
Oedema  
Epicanthus  
Lagophthalmus (congen.)  
Distichiasis (congenital)  
Trichiasis  
Distichiasis

	92	99	191	363
			50	65
			110	180
			1	2
			31	45
			52	92
			10	20
			2	4
			1	2
			1	2
			138	235
			60	80
Total			647	1090

## GENERAL VIEW.

	No OF CASES	No OF EYES
1 Conjunctiva	2272	3973
2 Cornea	1112	1662
3 Iris & Choroid	422	586
4 Sclerotic	26	32
5 Retina & O. Nerve	214	347
6 Lens	249	377
7 Vitreous	21	38
8 Eyeball	61	82
9 Refraction & Accommodation	375	633
10 Muscles & Nerves	93	122
11 Lacrymal Organs	195	274
12 Orbital Cavity	10	11
13 Eyelids	647	1090
Total.	5703	8981



# GENERAL VIEW

of the more important operations on the eye,  
performed during 1877, 1878 & 1879.

		Result.		
I. Lens.		PERFECT OR $V:1$ OR $\frac{1}{10}$	IMPERFECT $\frac{1}{10} < V < \frac{1}{200}$	LOSS, $V:1 \times \infty:0$
Cataract extraction of simple senile ma- ture after von Graefe's method	39			1
" extraction of complicated senile mature after von Graefe's meth.	5	2	1	8
" extraction of soft by simple lin- ear extraction.	5			5
Dissection of soft cataract	1			1
" " secondary cataract	5			5
" " arido silequate cataract	2			2
Reclination	1	1	1	3
Total of cataract operations	58	3	3	64

II. Iris.				
Iridectomy for adherent leucoma	25	25		50
" " occlusion of pupil	16	19		35
" " opacity of cornea	4	6		10
" " glaucoma	10	10		20
" " fistula of cornea	6			6
" " lamellar cataract	2			2
" " preceding disscision	1			1
" " secundary glaucoma	8	2		10
Iridotomy after operations for cataract	8	2		10
Excision of prolapse of iris	10	5		15
Total of operations on Iris	90	69		159



### III. Sclerotic.

Sclerotomy for absolute glaucoma

PERFECT	IMPERFECT	UNSUCCESSFUL	TOTAL
1			1

### IV. Cornea

Puncture after Saemisch

4			4
---	--	--	---

Operation for staphyloma after Critchett

5			5
---	--	--	---

“ “ Pterygium after Arlt

15			15
----	--	--	----

Tattooing

6	2	2	10
---	---	---	----

Transplantation of cornea from rabbit

		2	2
--	--	---	---

### V. Eyeball.

Enucleation for tumor

4			4
---	--	--	---

“ “ sympathetic ophthalmia

10			10
----	--	--	----

### VI. Muscles.

Tenotomy of internal rectus

20	18	2	40
----	----	---	----

“ “ external “

4	1		5
---	---	--	---

### VII. Orbit.

Excision of hypertrophied lacrymal gland

1	1		2
---	---	--	---

### VIII. Eyelids.

Operation for entropion after Gaillard

9	1		10
---	---	--	----

“ “ “ Streatfield - Snellen (trichiasis)

100	20	2	122
-----	----	---	-----

“ “ “ v. Arlt

20	10		30
----	----	--	----

“ “ “ my modification of Arlt's method

5			5
---	--	--	---

“ “ “ Watson's and my method

31			31
----	--	--	----

“ “ ectropion by blepharoplastic method

1	2		3
---	---	--	---

“ “ “ after Szymanowsky

3			3
---	--	--	---

“ “ “ “ v. Arlt

3			3
---	--	--	---

“ “ “ “ Saemisch

3			3
---	--	--	---

“ “ “ “ Canthoplastie

60			60
----	--	--	----

“ “ “ “ grêfe dermique

1	1		2
---	---	--	---

Total numbers.

454	128	11	593
-----	-----	----	-----



# TABULAR ANALYSIS OF 1118 EYE CASES

treated during the course of 18 months at the  
IMPERIAL OTTOMAN NAVAL HOSPITAL.

## I. Conjunctiva.

	No OF CASES	No OF EYES
Conjunctivitis acute	20	36
"    chronic	230	449
"    phlyctenular	30	49
"    follicular	5	9
"    croupous	2	2
"    granular acute	8	12
"        "    chronic	55	108
"    ex combustio	3	5
"    purulent acute	2	4
"        "    chronic	4	5
"    gonorrheal	3	5
Subconjunctival effusion	11	17
Lymphangoitis	1	1
Pterygium	7	12
Lythiasis conjunctivæ	1	2
Total	382	716

## II. Cornea.

Corneitis diffuse	4	4
"    superficial	62	105
"    deep ulcer	22	37
"    circumscribed	46	79
"    fascicular	5	8
"    phlyctenular	3	4
"    ex lagophthalmos	10	20
Abcess of cornea after variola	2	4
Opacity of cornea	63	69
Foreign body in cornea	20	20
Adherent leucoma	10	14
Staphyloma	4	6
Incised wound	1	1
Total	252	371



### III. Iris and Choroid

	No OF CASES	No OF EYES
Iritis simple	105	162
„ serous	1	2
„ plastic	5	6
„ specific	31	48
Posterior seneciæ	17	32
Sclero choroiditis (posterior)	1	2
Choroiditis disseminate	8	13
Chorio-retinitis	14	24
Irido choroiditis (suppurat.)	22	28
Glaucoma simple	2	4
Prolapsus of iris	2	2
Total	208	324

### IV Sclerotic.

Episcleritis	7	11
Incised wound above ciliary body	1	1
Total	8	12

### V. Retina and optic Nerve.

Retinitis simple	7	10
„ hemorrhagica	4	5
„ specific	1	2
„ pigmented	2	4
„ ex M. Brightii	1	2
Detachment of retina	2	3
Neuritis	16	28
Atrophy of Optic Nerve	9	18
Amblyopia ex anopsia	2	2
„ simulation of	2	2
Decoloration of disc	2	2
Hemeralopia	1	1
(3 with decoloration of disc and 12 with xerosis of ) ocular conjunctiva; besides these 4 were simulated )	33	65
Total	82	144



**VI. Lens.**

	No OF CASES	No OF EYES
Cataract senile simple	25	28
„ traumatic	8	10
„ post. polar	4	7
„ anter, polar	2	3
„ membranous	3	3
Ectropion (traumatic)	4	4
Total	46	55

**VII. Refraction & Accommodation.**

M.	15	30
H.	7	14
Ah.	3	6
Presb.	5	10
Total	30	60

**VIII. Muscles.**

Paralysis of oculc-motor	4	4
Ptoxis	4	4
Total	8	8

**IX. Lacrymal apparatus.**

Stenosis of duct	19	30
Fistula of sac	3	3
Hernia	1	1
Total	23	34

**X. Vitreous humor.**

Foreign body in v. h.	5	6
Opacity	10	14
Total	15	20



## **XI. Eyeball**

Atrophy of globe  
Buphthalmos

	No OF CASES	No OF EYES
	4	7
	1	2
Total	5	9

## **XII. Eyelids,**

Blepharitis

Chalazion

Ectropion

Epicanthus

Eczema

Distichiasis

Trichiasis (15 operated after Streatfield & 2  
after v. Arlt.) }


23	40
11	15
7	
2	
2	
1	
13	23
Total	59
	78

## **GENERAL VIEW.**

	No OF CASES	No OF EYES
1 Conjunctiva	382	716
2 Cornea	252	371
3 Iris & Choroid	208	324
4 Sclerotic	8	12
5 Retina & Optic Nerve	82	144
6 Crystalline Lens	46	55
7 Refraction & Accommodation	30	60
8 Muscles	8	8
9 Lacrymal apparatus	23	34
10 Vitreous humor	15	20
11 Eyeball	5	9
12 Eyelids	59	78
Total.	1118	1831



## CONJUNCTIVA.



### Granular Conjunctivitis.

This is the most prevalent eye complaint in the Levant, and extends to all classes, but chiefly among the poor. It makes rapid and extensive progress in schools, and orphanages. Out of 200 inmates of the orphanage of St.-Joseph, which is situated in a low suburb of this city, I found 98 suffering from trachoma, and 20 from follicular conjunctivitis, or vesicular granulations. Granular lids are not frequently met with here in the army, or among the marines. In poor families, both young and old often all suffer from this complaint, and it is easy with some perseverance to trace the disease to its origin and follow it up as it passes from one member to the other. I have never known it to break out on all the members of of one family at once; this is a peculiar feature of trachoma which distinguishes this complaint from vesicular granulations. The latter often make their appearance suddenly and simultaneously on all the members of a family, and even on all the inhabitants of the same street, although there has been no contact between each individual. I have witnessed this circumstance in streets where buildings were being erected, and hence I have been led to attribute this outbreak to atmospherical causes, such as the contact of dust and quicklime with the conjunctiva; but trachoma may appear quite independently of such causes. As this subject is still more or less confused, owing to the contending opinions of those who confound both diseases and those who draw



Schmid Rimpler, who found that even the contact of diphtheritic matter with the conjunctiva of rabbits had no result.) I therefore extended my experiments to the healthy conjunctiva of diseased and incurable eyes in men women and children. My experiments were limited to trying whether the contact of granular conjunctiva with the healthy conjunctiva could reproduce the disease. For attaining this purpose, I excised small portions of conjunctiva containing the peculiar elevation of granular lids, (not hypertrophied papillæ) and transplanted them to a small gap in the healthy conjunctiva. All my attempts proved perfectly unsuccessful in producing the disease by inoculation. But whenever any discharge from an acute or chronic case of granular lids was taken and put into the healthy conjunctival sac, it rarely failed to produce the identical disease. Neither the contact of the discharge, nor the inoculation of vesicular granulation will reproduce the disease in the healthy conjunctiva.

Saemisch is the first author who arrives at a clear definition and differential analysis of vesicular granulation and granular ophthalmia, and his classification is based upon anatomical research. The true granulation, (the elevation noticed at the outset of granular conjunctivitis) is described as an accumulation of lymphoid cells without any enveloping membrane; the former always leads to cicatricial tissue, the latter may disappear without leaving the slightest trace. That there are cases in which both forms of granulation exist conjointly, is no proof that both are identical. My experience leads me to conclude that vesicular granulations, in no way predispose the conjunctiva to catch true granulation. My statistics certainly contradict the views of our colleagues in England. (1) It will be noticed that follicular conjunctivitis is very scarce here, and granular lids extremely frequent, coming up to 17 0/0 of the total number of cases. In a former report, made in 1874, the proportion was 12 0/0 but the proportion of vesicular granulations is only 1/5th 0/0 or 2 per mille.

---

(1) Nettleship. *The present distribution of granular ophthalmia in London &c.* *Brit & For. med. chir. Review* 166-200.



In his recent work Professor Arlt has given a very full and exhaustive description of granular conjunctivitis: This author retains the name of acute blennorrhœ for purulent ophthalmia and chronic blennorrhœ for chronic granulations. The object of this report is not to criticise any work on the subject, but simply to state that my experience during the last ten years, in a country where trachoma is most prevalent, has led me to adopt Sæmisch's nomenclature and classification, and in order to explain the reasons for this preference, I shall briefly enumerate the differential symptoms of follicular, granular, and blennorrhœic and purulent ophthalmia, as I have observed them here.

## ERRATA.

Page 4, line 25 from top. After *any enveloping membrane* read, *and communicating directly with the stroma of the conjunctiva, from which it is not separated by any kind of enclosure or membrane. The follicle of follicular conjunctivitis is an accumulation of lymphatic cells enclosed in a space which is sharply defined;*

to cicatricial tissue; gran. conj. very seldom disappears spontaneously, (perhaps in 1 case out of 100,) and always leads to cicatricial tissue.

6 The structure of a follicle in foll. conj. is different to that of the granulation. The former is an agglomeration of lymphoid cells, enclosed in limited space, but not by any limiting membrane; this agglomeration is confined to the outermost layers of the conjunctiva and immediately behind the epithelium. In granular lids, even at the very commencement, the deeper parts of the conjunctiva are the seat of lymphoid hyperplasia, with hypertrophy of the connective tissue.

7 Follic.conj. disappears spontaneously without leaving



traces in the conjunctiva, but the amount and extent of cicatricial tissue after gran. conj. is in proportion to the duration and intensity of the disease.

8 Foll.conj. is peculiar to young people, but gran. conj. is frequently met with after 45 and at any age.

As to the difference between granular conj. and purulent ophthalmia or conj. blemoroica, I have noticed the following points:

(1) *Gran. conj.* always commences at the retrotarsal fold of the upper lid, as may be seen at Fig. 1, and these appearances precede every other symptom, such as abnormal secretion or uneasiness of any kind. Purulent ophthalmia is never preceded by such growths, and always commences with the same symptoms as acute catarrhal conjunctivitis.

(2) The secretion of gran. conj. when transmitted to a healthy lid, never produces purulent ophthalmia, like that of infants, or gonorrhoeal ophthalmia.

(3) The anatomical change in each form is different; the cicatricial tissue which remains is only very superficial in conj. blenn., while in conj. gran. it is very marked. In conj. blenn., of the longest duration, the tarsus and cartilage is never shrunk and curved inwards, the retrotarsal fold is never altogether obliterated. The anatomical appearances in conj. blenn. are, enlargement of the papillae of the conj. with considerable dilation of the capillary blood vessels. The mucus membrane is thickened through hypertrophy of its connective tissue, and the stroma of the mucus membrane alone is the seat of these inflammatory changes; it is saturated with pus corpuscles, throughout all its extent. The secretions of conj. blenn. consist of these cells and a considerable amount of epithelial cells from the surface of the conjunctiva.

In conj. gran. the innermost parts of the stroma of the conjunctiva are the seat of proliferation of lymphoid cells which in a very short space of time are converted into connective tissue. In the advanced stages of trachoma the whole subconjunctival stroma becomes a mass of cicatricial tissue, containing tubular cavities which are filled with a yellowish fluid, consisting of finely granular cells and oc-



asionally of amyloid cells. These cavities, to which I drew attention in 1874 (Jahresbericht v. Nagel etc. 1874), are visible in lifetime through the atrophied conjunctiva. Since then, they have been described by Iwanoff (Sitzungsbericht d. ophth. gesellsch. 3. Heidelberg S. 12.) and by E. Berlin. (Klin. Monatsbl. f. Augenheilk. XVI S. 341). Conj. blenn. or purulent ophthalmia must then be considered as a specific disease of the conjunctiva and an advanced form of catarrh.; gran. conj. must be considered as a specific disease, for which the most appropriate name would be hyperplastic conjunctivitis.

Sæmisch's classification of these three different conditions of the conjunctiva is highly important in practical results: conj. blenn. is always improved by nitrate of silver, in solution, applied to the tarsal conjunctiva, during the chronic stage. In gran. conj. such applications are always followed by an increase of the irritations and by the progress of the disease. I shall briefly state what treatment I have found most advantageous for each form.

*Foll. Conj.* No local treatment unless there is catarrhal discharge, for which weak astringents:—zinc, lead, nitr. of silver—are useful when applied to the everted lids: plenty of fresh air and exercise.

*Conj. Blenn.* Acute stage—Constant cleansing of conjunctival sac. For this purpose I use a siphon douche containing weak solutions of boracic or tannic acid, iced compresses, until the skin covering the upper lid begins to become wrinkled. As soon as this occurs and the conjunctiva is less distended and glistening, nitrate of silver to the tarsal and retrotarsal folds (5 gr. to the oz, at first, and if this is followed by relief, 10 to the oz, once in 24 hours.) This is of course applied on the everted lids, and carefully neutralised. This treatment is all that is required for restoring the conjunctiva to its original condition in conj. blenn. when treated from the beginning. For very chronic cases, the daily application of sulph. of copper is necessary, especially when pannus is present.

*Conj. gran.* Acute stage—Solutions of tannic acid, (4 gr. to oz) dropped every 2 hours. For ciliary neuralgia during this stage, atropine. The tannin must be con-



tinued until all chemosis and inflammation of the ocular conj. have disappeared. As soon as this has taken place, application, on the everted lids, of a concentrated solution of sulphate of copper, which is to be washed away at once, by a stream of water. I generally apply the solutions with a pipette and then wash them away with a larger syringe, thus avoiding the danger of contagion, which attends the use of camel's-hair brushes. When this treatment has led to considerable amelioration, I go on with it, until the last follicle has disappeared. It is only for the very chronic forms that I use the crystal of sulph of copper. To allude to the figures at the last page, I would use the solutions in No 3 and 4 when all irritation of the ocular conj. has disappeared, and the crystal in 5 and 6, after abatement of acute inflammation. The only contra-indication for such treatment is acute corneitis, and acute pannus. Tannic acid, combined with atropine, is generally sufficient to master such cases. Canthoplastic is not of as much value in acute cases as might be expected. In the latter stage, (the cicatricial), when all papillary hypertrophy has disappeared, nitrate of silver solutions, (5 gr to oz), applied daily to the conj. tarsi, until all catarrhal discharge has ceased, is the best medication. It stands to reason, that any lid-deformity resulting from the cicatricial retraction, must be treated by surgical operations. I shall briefly report my experience as to the most appropriate operations in cases of entropion, with and without trichiasis or distichiasis.

I practise Streafield's (Snellen's) operation for all cases of incurved upper lid, whether there is trichiasis or not, or superficial ulceration (Abschliffe) on the surface of the cornea which is covered by the upper half of the cornea. Such ulcerations, which are perfectly clear and cover one half of the cornea, appear to be covered over by epithelium; it is this that prevents their cicatrization, but they remain stationary after the operation on the eyelid.

For trichiasis or distichiasis of the upper lid, without incurvation, I practise, either the Arlt-Jaesche operation, or else a modification of this operation, which I have tried with perfect success, and can recommend as more certain in its results, and the only means of averting a relapse



which after the Arlt-Jaesche operation is very frequent. The modification consists in transplanting a small strip of skin, or better still, mucus membrane on to the space between the ciliæ and the conjunctiva; this is done after the first act of Arlt Jaesche's operation is completed, and the strip of skin or membrane is left there without applying any sutures. It may be covered over with a piece of goldbeater's skin and the whole secured by a bandage.

### ERRATA.

Page 8, line 10 from below. Instead of *on the surface of the cornea etc* read *on the surface of the upper half of the cornea, which is covered over by the upper eyelid.*

of the row of ciliæ. In my report I have designated the above operation as a modification of Arlt's operation. Under the name of Watson's and my operation I shall describe a method by which I have succeeded in curing a number of cases of trichiasis which Arlt's and other operations had failed to cure. I have practised it since 1872, but Watson Ophth. Hosp. Rep. VII. p. 440. was the first to describe it. I can affirm that it is only successful in cases of trichiasis at the inner or outer canthi. For all such cases it is excellent. I practise the operation as follows, supposing the outer canthus of the upper lid to be affected with trichiasis; the portion of the skin containing the inverted ciliæ is converted into a triangular flap by two sections, one running along the intermarginal space, and the other above the ciliæ, almost parallel to them. The apex of this flap must be cut out of the skin at the corner of the outer canthus, and the flap should be dissected to its base which ought to lie next to the



place where the last inverted ciliæ are found. A second flap is then cut out of the skin adjoining the first flap its shape being such as to cover the raw surface from which the first flap has been raised. The result of this transposition of two small flaps is to bring a portion of skin deprived of hair on to the surface which was occupied by the inverted ciliæ. The apices of the flaps can be secured by fine sutures. If care is taken to make each flap very thin and delicate, generally 1 m m in breadth and 4-5 m in length, no traces of an operation remain after cicatrization has taken place.

It appears to me that plastic operations will ultimately be adopted as the surest means of securing a perfect and permanent cure for trichiasis without incurvation of the eyelid, and also for partial trichiasis. The cause of the relapse of trichiasis after Arlt's and other operations is to be sought in the reobliteration of the intermarginal space, consequent upon the cicatricial process in the conjunctiva, and although operations for trichiasis are postponed until this process appears to have ceased, there is always some further cicatricial retraction after a number of years. The only safeguard against the reobliteration of the intermarginal space, is the interposition of other tissue between the ciliæ and the conjunctiva, and the best tissue adapted for this purpose is the fine dermis of the upper lid, or the under lip of the rabbit.

#### **Phlyctena pallida, (Frühjahrs catarrh.)**

Out of 21 cases of this peculiar disease 5 were females and 16 young lads. The respective ages of the females were 19, 8, 16, 10 and 30, and those of the lads, 14, 19, 10, 5, 12, 7, 9, 8, 9, 10, 17, 9, 15, 16, 6, and 19. In every case both eyes were affected. A circumstance which has often struck me is that the patients had all, without exception a peculiar colour of the skin which was of a pale earthy and unhealthy hue. None of the patients had a bright healthy appearance although they were all young. The size of the excrescences on the limbus around the cornea



varied from the size of a pin's head to 2 m.m. In some cases the cornea was surrounded by these growths. In Fig. 7 of the chromos I have a drawing taken after nature from a typical case. In one case the excrescences had surrounded the cornea and had encroached so far on to it that only 2 m. of clear cornea were left between the margin of the pupil and the margin of the milky opacity close to the excrescences. In one eye these growths had attained such a size, at the upper and outer margin of the cornea, that I was led to excise the growth in the same manner as dermoid tumours are excised. The whole excrescence measured 3 mm. in breadth and 2 in height.

The cauliflower excrescences on the inner surface of the upper lid were highly developed in 9 cases, and more or less in the others, but there were certainly some cases in which they were absent; in three cases these growths had covered the tarsal conjunctiva of the upper lid, but there was no change around the limbus corneae. The excision of the growths on the upper lid is followed by a marked benefit, and the violent itching which is always present in these cases, disappears after the operation. It is strange that these growths, as well as those around the limbus, disappear altogether in winter, and that they all reappear the following summer as soon as the dust commences. The dust has great influence on the disease, so much so that if these patients reside on the sea shore they suffer relatively much less than if they take their abode inland. I must remark that the growths on the upper lid reappear and attain their former size, five or six days after excision, but the operation may be repeated without any apparent damage to the conjunctiva or lid. The result of the repetition of the operation is that the relapse on the following summer, is much less violent than on cases which are left alone, I have witnessed considerable benefit after the excision of the tumors around the limbus, and I have practised this operation like that for pterygium. The microscopical structure of these growths on the limbus is more or less identical with the description of their structure given by Dr U. Vetsch, Inaug-Diss, Zürich 1879. I have examined a large number of the warty excrescences excised from the inner sur-



face of the upper lid and have invariably found that they consist of dense fibrous tissue covered over by epithelium, and they appear to originate from the subconjunctival connective tissue. I have not been able to trace their connection with the summer months.

### **Diphtheritic conjunctivitis.**

Out of the ten cases observed, three occurred in a Greek family; the three children were all taken ill with general diphtheria and died of it: during its illness each child was more or less severely affected by diphtheria of the conjunctiva, and in one case both corneæ sloughed before death. Six other cases resulted from purulent conjunctivitis and were cured without damage to the cornea.

### **Purulent conjunctivitis. (conjunctivitis blemorrhœica.)**

The most typical form of purulent ophthalmia is that produced by contact of gonorrhœal matter, whether it occurs in infants or in adults. It is impossible here in the East to confound this disease with acute granulations, neither is there much similarity between it and acute catarrhal ophthalmia, but there is certainly more resemblance to the latter disease than to the former. The most prominent feature of purulent ophthalmia, is that it makes its appearance very suddenly without being preceded by the small elevations on the surface of the retro-tarsal folds, as in acute granulations and that it does not lead to any follicular hypertrophy and rarely if ever to cicatricial tissue. The treatment of the chronic stage may be confined to applications of nitrate of silver lotions. This is not the case after acute granulations, for after the acute stage, it is always necessary to use sulfate of copper for at least three to six weeks until all follicular hypertrophy has completely disappeared, otherwise a relapse of the objective and subjective symptoms is always imminent.

With regard to the treatment, I shall only add to



the remarks already made, that I have always found it advantageous to place the patients suffering from acute and purulent ophthalmia, whether granular, gonorrhœal or catarrhal, under the prolonged influence of chloral. Not only are their sufferings relieved, but there is also a marked diminution of the secretions during sleep, and the patients are less tempted to touch and rub their eyes. The intense pain accompanying acute conjunctivitis at the commencement is due to a state of hyperesthesia of that membrane which sometimes is so extreme that the mere contact of an eyelash produces excruciating pain and violent blepharospasmus; this condition is relieved by chloral.

The method of using caustics freely during the acute stage is highly dangerous and leads almost invariably to ulcerative corneitis.

## CORNEA.

### Transplantation

I shall only mention two attempts made at transplantation after Rosmini's method, without any result whatever. It is indeed altogether unreasonable to suppose that the cornea of a rabbit can adhere to the globe of a diseased eye, and yet retain its transparency. The cases on which these operations were tried presented all the conditions supposed as necessary for success, but the transplanted cornea came away shortly after the operation without adhering to any part of the gap prepared for it.

### Phlyctenular corneitis with chronic granulations.

A peculiar form of broad elevated phlyctena makes its appearance with intensely acute symptoms in very chronic cases of trachoma, especially when such are complicated with stricture of the lacrymal ducts. An eye thus affected is extremely sensitive to any irritation.



Chlorine water and tannic acid lotions are beneficial. These broad phlyctenæ are generally situated half on the cornea and half on the sclerotic, generally at the temporal sidl. In 1882 eyes with granular lids I met with this form of corneitis 19 times.

### Pannus

This complication which is so frequent in granular conjunctivitis, was observed 121 times in 634 eyes with cicatricial trachoma, and 219 times out of 1191 cases in the granular stage. But as pannus was never observed to develop during the cicatricial stage, it was infered that in the 121 cases the formation of pannus was also anterior to the cicatricial stage. This view was always corroborated by the anamnesis. I often observed cases in which pannus had disappeared spontaneously, and in all these cases I could trace the cure to the cicatricial atrophy of the conjunctival blood vessels. Superficial corneitis was much more frequent during the cicatricial stage. In 634 eyes with cicatricial trachoma it occurred 152 times. In 1191 eyes with granular trachoma it occurred only 100 times. The ulcerations are generally broad and smooth facettes, or deeper ulcers especially in cases of trichiasis. These observations tend to show that although a mechanical source of irritation is present in both the granular and the cicatricial stages of trachoma, yet there must be some other reason for which pannus appears more frequently during the granular stage. It is highly probable that increased vascularity and capillary dilatation along with lymphoid hyperplasia of the conjunctiva are necessary conditions for the production of pannus. Although pannus is almost exclusively a condition accompanying granulations, it is also seen in cases of very chronic blennorrhœa and even in catarrh or in protracted cases of phlyctenular or superficial corneitis on scrofulous subjects. But in all such cases there is a certain amount of follicular enlargement and lymphatic hyperplasia of the conjunctiva owing to the chronic state of irritation. Hence we have no reason for attributing pannus to friction



exerted by the eyelids on the cornea, when there are so many other probable factors to which it may owe its origin. Every now and again we meet with marked cases of pannus in which there is but a trifling amount of granulation on the palpebral conjunctiva. I can record two very striking cases in which the pannus situated at the upper quarter of the cornea, developed to a prominent elevation, like a fleshy growth, and yet there was so little lid granulation that I could hardly expect any amelioration to follow the sulphate of copper treatment. Both these cases were cured after prolonged use of the crystal. I excised a thin slice of the upper surface of this fleshy pannus, and found that it consisted of very delicate blood vessels imbedded in a tissue composed of lymph cells and connective tissue. The whole was covered over by the corneal epithelium. It has already been found by other observers that superficial pannus after trachoma does not extend beyond the lamina elastica anterior. It follows that in these cases the pannus is a continuation of the pathological change in the conjunctiva. Whether the newly formed capillaries are developed in a way similar to the process of restoration of the tail of the tadpole, or whether their formation is preceded by the proliferating cells (*bildungs Zellen*) described by Iwanoff, I could not succeed in determining. Both processes are most likely at work at the same time. The presence of protoplasmatic buds and protoplasmatic threads at the termination of the capillaries which tend to form curves returning to the conjunctiva is certainly favourable to the supposition that the newly formed capillaries in pannus are developed in a manner analogous to the formation of capillaries at the end of the amputated tail of the tadpole. Another reason for doubting that friction alone can produce superficial pannus, is that friction alone as that accompanying incurvation of the margin of the upper eyelid, or that produced by inversed ciliæ, never creates pannus, but ulcerative corneitis. On the other hand it is evident that the amount of mechanical friction exerted by a granulated lid on the cornea, is quite insignificant when compared to the friction of entropion and trichiasis, and nevertheless



it is a fact that pannus is invariably a characteristic feature of the granular stage. Another circumstance which upsets the friction theory is that the corneal epithelium is in good state of preservation wherever superficial pannus is present; it is sometimes hypertrophied but rarely absent. Prolonged friction destroys the epithelium and is the cause of facettes. In negroes I have very frequently seen large patches of pigment on the vascularised parts of the cornea; such pigmentations do not disappear after the obliteration of the newly formed blood-vessels, and they interfere considerably with the vision. Owing to this circumstance, pannus is a much more serious complication in the coloured race than in the white.

It must also be remembered that friction is altogether absent in the other forms of vascular corneitis such as the subendothelial pannus following chronic iritis and plastic iridocyclitis, or the parenchymatous vascularisation of the cornea in interstitial corneitis, or the pannus accompanying tubercular conjunctivitis with ulcers on the cornea.

Kerato-ectasia ex panno has come frequently under my notice. In many cases, especially in the rapidly progressive cases there was more or less iritis with considerable or total posterior seneciæ. Iridectomy proved of marked benefit in all the cases in which circular seneciæ were present. It was easy to detect these by oblique illumination. Atropine has little or no effect on the iris of any eye affected with considerable kerato-ectasia ex panno. This circumstance and the efficacy of iridectomy have led me to suppose that there is a certain amount of anterior glaucoma in such cases, which is brought on by obliteration of the channels of filtration of the cornea. This may be the direct consequence of the subepithelial formation of connective tissue all around the limbus and the canal of Schlemm. It is evident that any degree of iritis and anterior seneciæ must accelerate the bulging of the cornea, the elasticity of which in such cases is supposed to be impaired.



## SCLEROTIC.

Case I. Suppurative scleritis. — Stephen D. aged 24 admitted on the 29th May at the German Hospital. He has always been strong and healthy. The sight of the right eye is reduced to mere perception of shadows. Ciliary neuralgia sometimes very severe. Left eye normal No traces of syphilis. Appearance of the right eye: — a conical protuberance, yellow at the apex and red at the base, of the size of a cherry stone is seated on the sclerotic, above the upper margin of the cornea. Fluctuation at the apex of the elevation. Iris at upper segment of a dirty yellow colour and discoloured in all its parts. It is pressed up against the back of cornea. The tension is somewhat minus but it varies every day without however exceeding the normal degree. The ciliary injection which surrounds the cornea and is considerable, is much more marked at the upper half of cornea and close to the abcess. On cutting through the apex of the abcess a small quantity of pus escapes, without any vitreous and without bringing about any change on the tension or on the pain around the eye. Lymphatics of neck and temporal region considerably enlarged. Continued warm fomentations and iodide of potassium are useless. The inflammation commenced to subside at the beginning of July, but the patient could not be dismissed before the 21 August. The eye by this time had become smaller. The cornea measured 7 instead of 10 m. m. at its vertical diameter. The iris was pressed against the cornea, probably by means of exudation behind it. The only trace of the abcess is a dark pigmented brownish spot at the place where the abcess was seated. Perception of shadows is still preserved and the field is good. The lens being supposed to be quite opaque, extraction by the method of running the blade of the keratotome through the iris and lens was practised. Vision was not restored, but the anterior chamber became considerably deeper.

Case 2. Suppurative Scleritis following tenotomy of rectus internus. — Rachel S. 8 years old. A pale unhealthy, lymphatic child with H.  $\frac{1}{20}$  and con-



vergent strabismus and amblyopia of right eye. The child was operated upon under chloroform and the tendon of the internal rectus was divided without any difficulty. No suture was applied. On the following day œdema of the conjunctiva and upper lid, which rapidly increased to such a degree that the eye could no more be closed. The cornea was thus exposed to the contact of the air. Iritis set in eight days after the operation, and then a large abscess of the cornea with hypopyon made its appearance. Paracentesis and tarsoraphia were of no avail in stopping the progress of the inflammation. The sclerotic sloughed at the place where the tendon was divided, and the choroid bulged through the aperture, displaying its network of dilated blood vessels. The surrounding œdema of the conjunctiva and the rapid formation of granulations proceeding from the capsule of Tenon counteracted the pressure from within and prevented a rupture of the hernia of the choroid. Two months later the cornea was clear except at a point at the inferior margin. The iris totally adherent to pupil; globe considerably smaller, a deep scar indicating the place where the sclerotic sloughed, and a fistulous opening still existing. Tension diminished — 3. Perception of light lost.

Case 3. Suppurative Scleritis brought on by a peripheral adherent leucoma of traumatic origin. — Anna Krebs 7 years old. Right eye; it sustained an injury 6 months ago by a small chip of wood flying into the eye and penetrating into anterior chamber, at upper margin of cornea, and partly through sclerotic ground. Iris was adherent and pupil deformed but lens was clear and vision perfect for 6 months after accident. Suddenly and without apparent cause, iritis, then iridocyclitis, and then suppurative scleritis around the leucoma appeared in succession at very short intervals. The sloughing of sclerotic around the scar led to a huge prolapse of iris and ciliary muscle. Acute panophthalmitis followed and led to atrophy of globe. Sympathetic irritation has not made its appearance although 3 years have elapsed.

Case 4. Incised wound of sclerotic above ciliary body; cure. — Constantine M. age 18. Left eye



November 1878. A piece of glass flew into eye through explosion of a soda water bottle. Right eye has been amblyopic since childhood, with opacities on surface of cornea. Accident followed by copious hemorrhage and loss of sight. Examination a few hours after accident. Integuments not injured. On eye, a horizontal clean cut commencing 2 m. m. inside of corneal margin, and running outwards across limbus on to sclerotic to the entire length of 9 m. m. A second vertical incision at right angles from the centre of the horizontal incision, runs directly downwards to the length of 7 m. m. Both incisions thus form a T shaped wound the greater part of which is in the sclerotic penetrating through the coat. The whole length of the wound is filled up with iris, (at its corneal extremity) and portions of ciliary body. I excised the prolapse of iris and applied a pressure bandage and atropine, keeping patient in dark room for a fortnight. No iritis during treatment. Patient dismissed with closed wound and without ciliary injection. I expected gradual atrophy to follow, but three months later I found vision  $\frac{12}{50}$ , the reduction being due to irregular astigmatism only through the altered curvature of cornea. In 1880 I found the eye in same satisfactory condition.

## CHOROÏD.

Six cases of ossification of the choroid came under my notice; of these, two had induced sympathetic ophthalmia.

Case I. Tassim aged 28, musician in the Imperial Band. Right eye, reduced to a stump by chronic iridochoroiditis at an early period of life; it is now sensitive to touch. The eye had sustained no injury; it is flattened and knotty between the insertions of the recti and very hard to the touch. Left eye, numerous posterior senchiæ without acute iritis, vitreous contains large opacities which seem to be localised at its anterior part; fundus not visible. Counts fingers at 1 m; has been in this state one month. Field of vision and perception of colours in good condition T normal. I excised the right eye, and the vision of the left improved rapidly without



any additional treatment. Two months after the operation left eye could count fingers at 11 m. and the medii were very clear. A year later he resumed his work and could read notes. The excised eye was found to contain large ossifications, which, through the shrivelling up of the eye had come into close contact with the ciliary body. Cicatricial bands of newly formed connective tissue connected the ciliary body to the osseous deposits.

Case II. — Levi aged 45. Left eye, reduced by atrophy to a stump; a glass eye has been worn over it for seven years. The stump is sensitive to the contact of the glass eye and has been so for upwards of one month. Vision of right eye, which was reduced to  $\frac{1}{4}$  by adherent leucoma, for which an artificial pupil had been made 15 years ago, commenced to fail since a fortnight, and is so much reduced that patient cannot guide himself about the room, and can hardly count fingers. Intense photophobia. Aqueous humour very turbid, and considerable ciliary injection around cornea. I excised the left eye. The restoration of the vision of right eye commenced the day after operation, and went on progressively until no difference remained from his former condition. The left eye contained ossifications, which had come in contact with the ciliary body through the extreme flattening of the eye.

In both these cases the sympathetic disease was not of a plastic character, but from the rapid amelioration which followed excision, I have not the slightest shadow of doubt that the iritis of the second eye in each case was brought on by the disease of the atrophied globe on the other side.

Two cases of melano-sarcoma of choroid came under my notice. I operated upon both during the glaucomatous stage. The first case was that of a stout woman aged 40. She is still living (five years after the operation) and has enjoyed good health ever since. For about one month after the operation she complained of violent ciliary neuralgia similar to that previous to the excision of the eye, and during the stage of acute glaucoma.



# LENZ.

## 40 UNCOMPLICATED CATARACTS.

OPERATED BY VON GRAEFE'S METHOD, (UPPER SECTION.)

N°	NAME.	AGE.	CONDITION OF THE CATARACT		INDIRECT COM- PLICATIONS	ACCIDENTS		DURATION OF TREATMENT.	AFTER OPERATIONS.	ACUTENESS OF VISION AT DISMISSAL.	LATEST CONDITION OF VISION FROM REPORT OR EXAMINATION.
			OPERATED EYE.	NOT OPERATED EYE.		AT THE OPERATION	IN THE COURSE OF AFTER TREATMENT.				
1	Therese St.	40	R. hypermat.	L. incipient	—	—	—	15	—	$\frac{20}{30}$ with + 3	Status idem 1 year after.
2	Marie P.	65	L. mature	R. incipient	—	—	—	16	—	$\frac{20}{50}$ with + 2 $\frac{1}{4}$	—
3	Frau Thun.	65	R. mature	L. incipient	—	—	—	15	—	$\frac{20}{30}$ with + 3 $\frac{1}{2}$	Reads large print without glasses 2 years later.
4	Therese R.	70	R. mature	L. immature	—	—	—	17	—	$\frac{20}{70}$ with + 3	Died of cerebral hemorrhage on day of dismissal.
5	Ferdinand M.	70	L. mature	R. immature	—	—	—	16	—	$\frac{20}{40}$ with + 2 $\frac{3}{4}$	Good as at dismissal 3 years later.
6	Hadjia f.	70	R. mature	R. incipient	—	—	—	15	—	$\frac{20}{30}$ with + 3	—
7	Mustafa. m.	70	R. mature	R. mature	—	—	—	10	—	$\frac{20}{50}$ with + 3	Kept well for 2 years, then lost vision by iritis after corneitis following acute granulations. Vi- sion restored again to $\frac{20}{30}$ by iridotomy.
8	ditto.	70	L. mature	R. aph. extr.	—	—	—	9	—	$\frac{20}{40}$ with + 3	Kept good for 4 years and is still in statu quo.
9	Maris. m.	70	R. mature	L. incipient	—	—	—	15	—	$\frac{20}{50}$ with + 4	—
10	Anifé. m.	53	L. mature	R. mature	—	cortical sub remains	—	15	Discission	$\frac{20}{200}$ with + 3	—
11	Mardiros. m.	65	R. mature	L. mature	—	—	Iritis	18	Discission	$\frac{20}{1200}$ with + 3	Kept well ever since; seen again in 81. with V = $\frac{20}{30}$ .
12	Ayshé. f.	70	R. mature	L. mature	—	cortical remains	second. cat;	15	Discission	$\frac{20}{70}$ with + 3	—
13	ditto.	70	L. mature	R. aphakia	—	remains of costical	second. cat.	15	Discission	$\frac{20}{70}$ with + 3	—
14	Ali m.	65	L. mature	R. mature	—	—	—	9	—	$\frac{20}{40}$ with + 2 $\frac{1}{2}$	Has kept well May 1881.
15	Frau Sanft f.	58	L. mature	R. mature	Plethora	Vitreous es- capes sudy. before irid. scoop extr	—	15	—	$\frac{20}{30}$ with + 3	Kept well till her death, 3 years after operation.
16	ditto.	58	R. mature	L. aphakia	—	normal	Iritis	15	—	$\frac{20}{200}$ with + 3	ditto.
17	Mme Alberti	68	R. mature	L. mature	—	—	—	15	—	$\frac{20}{50}$ with + 2 $\frac{3}{4}$	Seen 2 years later in same condition.
18	Vasitza. f.	68	R. mature	L. mature	—	—	—	15	—	$\frac{20}{30}$ with + 1	—
19	Mitrovich. f.	55	L. mature	R. incipient	—	scoop used	—	15	—	$\frac{20}{20}$ with + 3	—
20	Essimeh. f.	55	R. mature	L. mature	—	—	—	12	—	$\frac{20}{40}$ with + 3 $\frac{1}{2}$	—



20	Essimeh. f.	55	R. mature	L. mature	—	—	—	12	—	$\frac{20}{40}$ with + 3 $\frac{1}{2}$	—
21	Nerses. m.	70	L. mature	R. mature	—	—	—	15	—	$\frac{20}{80}$ with + 2 $\frac{3}{4}$	Kept good till his death 6 months after.
22	Anematiro. m.	72	R. mature	L. incipient	—	—	Panophthal- mitis conse- quent upon rupt. of sect. on 4th day.	20	—	C	—
23	Esmeh. f.	60	L. mature	R. incipient	—	—	—	15	—	$\frac{20}{40}$ with + 3	—
24	Esmeh. f.	60	L. mature	R. mature	—	—	—	15	—	$\frac{20}{70}$ with + 3 $\frac{1}{2}$	—
25	Santorina. f.	55	R. mature	L. incipient	—	—	—	15	—	$\frac{20}{80}$ with + 3	Has Kept good 1881.
26	Assimé. f.	50	R. mature	L. mature	—	—	—	12	—	$\frac{20}{30}$ with + 3 $\frac{1}{2}$	V. has Kept good 1880.
27	ditto.	50	L. mature	R. aphakia	—	—	Iritis	15	—	$\frac{20}{30}$ with + 3 $\frac{1}{2}$	V. excellent 1880.
28	Caleya Dr. m.	50	L. mature	L. aphakia	—	—	—	14	—	$\frac{20}{50}$ with glass sph + 3 = cvl + 14	Practises and reads 1881.
29	Abdula. m.	55	R. mature	L. incipient	—	—	—	15	—	$\frac{20}{10}$ with + 2 $\frac{3}{4}$	—
30	Vichen. f.	65	R. mature	L. mature	—	—	—	14	—	$\frac{20}{40}$ with + 3	—
31	Hagia. f.	65	L. mature	R. mature	—	—	Iritis	18	—	$\frac{20}{100}$ with + 4	—
32	Lazarus. f.	50	R. mature	L. hyp. mat.	—	—	Iritis	22	Iridotomy	$\frac{20}{200}$ with + 2 $\frac{3}{4}$	—
33	Ali. f.	65	R. mature	L. mature	—	scoop used	—	15	—	$\frac{20}{40}$ with + 3	—
34	Hassan. m.	55	L. mature	R. mature	—	—	—	15	—	$\frac{50}{50}$ —	—
35	Mahmud. m.	70	R. mature	L. hyp. mat.	—	scoop used	—	14	—	$\frac{20}{100}$ —	—
36	Panayotis. m.	65	R. mature	L. incipient	—	—	—	15	—	$\frac{20}{50}$ —	—
37	Gorlero. m.	76	L. non mature	R. incipient	Myopia $\frac{1}{4}$	—	—	15	—	$\frac{20}{70}$ with + 3	Vision lost 1 year later by detachment of retina.
38	Schaub. m.	68	R. mature	L. incipient	Myopia $\frac{1}{4}$	scoop used	—	15	—	$\frac{20}{70}$ with + 4	Kept very well 1881.
39	Kerr. m.	65	L. mature	R. mature	Myopia $\frac{1}{4}$	—	—	15	—	$\frac{20}{50}$ with + 4 $\frac{1}{2}$	Vision considerably diminished by progress of myopia and staph. post 1880.
40	ditto.	66	R. mature	L. aphakia	Myopia $\frac{1}{4}$	—	—	15	—	$\frac{20}{40}$ with + 4 $\frac{1}{2}$	Kept well 1881.



## RETINA AND OPTIC NERVE.

### Hemeralopia.

Of the 5703 cases enumerated in my private practice there was only one of hemeralopia. At the Navy Hospital there were 33 cases out of 1118, and these all occurred early in the spring of 1878, at a period when the men were under very low and unnourishing diet, in consequence of the penury of the Government after the Russo-Turkish war; there was also a great deal of scurvy and general debility among the men. A similar epidemic, if it may be so termed, appeared among the men of the Navy in the early part of the spring of 1880, but those cases will be referred to in another report; I mention the fact in order to state that hemeralopia makes its appearance regularly on a number of men of the Ottoman Navy at the early part of every spring. The men on other ships in the port are not similarly affected, and the soldiers of the Army are seldom troubled with this ailment. The 33 cases were not all men of the same vessel. Most of the patients were below the mark as concerned general health and appearance. I have noticed that cases of episcleritis always occurred at the time when hemeralopia made its appearance. Might not both diseases have had the same atmospherical cause? The patients suffering from hemeralopia had all been exposed to the sun and most of them were much sunburnt. Epithelial xerosis was present in 12 cases, and on both eyes. Hyperaemy of the conjunctiva was always present and amounted in several to catarrh with mucus secretions. Vision during daytime, was  $\frac{20}{20}$ . In looking through a stenopaic hole, vision was reduced to  $\frac{20}{70}$ . The vision of a normal eye, looking through the same aperture, was only reduced to  $\frac{20}{30}$ . This was the sole test which could be relied upon for excluding simulation of hemeralopia. Perception of colours was good in every case. The field was not contracted, the optic discs were found pale in nearly all the cases, in three amounting to decoloration. There was sometimes a difference of size between the pupil of each eye, and



in some, the pupil was not perfectly round. In one case the hemeralopia was one sided. Strychnin injections seemed to benefit those cases only in which the general health was good. A few only of those suffering at the same time from general debility, were ameliorated by iron and better diet, but most had to be dismissed from the service, or sent to their homes for change of air. Epithelial xerosis of the ocular conjunctiva at the lateral margins of the cornea, preceded the appearance of hemeralopia in one case.

### Neuroretinitis.

Case I. — Mr X. T. aged 39, lawyer. 24 May 1879. Vision of both eyes lost since six months. Left facial nerve and left side paralysed; severe pains above right supraorbital nerve with violent spasmodic contraction of the orbicularis muscle of the same side; pulse 50; respiration 10–15; appetite very good; sensibility of skin normal; intellect perfectly lucid. Pupils greatly dilated, but not altogether immovable to strong light. Discs choked, very much swollen, and surrounded by large yellowish white patches and fresh extravasations. Blood-vessels tortuous, and indistinct at several points; in short, chronic neuroretinitis S = O. Patient has never had syphilis; and is father of healthy children. His father had had syphilis. Patient was always in good health until a few years ago, when he commenced suffering from facial neuralgia above right eye, brow and right cheek, in hopes of curing which, he had several teeth extracted. Three years ago the left arm became slightly paralysed, but soon recovered. Eight months ago, he first noticed diplopia. From his description it must have been brought on by paralysis of the third nerve of the right side. 24 May 1879. Mercurial frictions prescribed; considerable amelioration followed this treatment which was continued for two weeks. 5th June. Patient can walk about the room for the first time since three months. Facial paralysis better; contraction of right orbicular ceased. This amelioration was soon followed by progressive aggrava-



tion of all the symptoms, to which were added optical hallucinations and irritation of the olfactory nerves, which gave rise to the complaint of a constant smell of sulphur. The intellect remained undisturbed until shortly before death, which followed a few hours after the appearance of stertor and coma.

Post mortem appearances 28 hours after death. Surface of brain healthy and dura nowhere adherent. Gyri flattened. Dura slightly adherent in the longitudinal fissure. Pia and arachnoid injected. On convex surface of right hemisphere, and at the middle line, an oval spot of the size of a hen's egg; it is somewhat raised, and of a greenish yellow colour; its borders sharply defined. A section through the right hemisphere, at this spot, exposes a tumor of size of a hen's egg. The tumor is throughout of a greyish colour and deprived of blood-vessels; the brain-matter all around it, is considerably softened. Between the pia and the brain, at the region of the pons, there is a considerable amount of yellowish purulent matter. The left ventricle contains little fluid. The right ventricle is smaller and displaced towards corpus callosum. On examination, the tumor was found to be a medullary sarcoma.

Case II. — Mme S. an Armenian married lady, aged 40, and mother of one child. At first examination of this patient, a meagre and cachectic looking woman, I was struck by the considerable protrusion of both eyeballs. The enlarged thyroid gland, and the palpitation, and the defective movement of the upper eyelid during the act of looking downwards, and also the general state of nervous irritability, led me to the conclusion that this was a case of exophthalmic goitre. The patient complained of violent headache. Vision was perfect, and the fundus of each eye normal.

The general symptoms at the time were sleeplessness and nervous agitation. Pulse 120 and violent cephalalgia, on the left side. At this time, July 1878, I lost sight of the patient but heard subsequently from her physician that cerebral symptoms appeared soon after my last examination. Strabismus, first, and then total amaurosis, and total loss of the hearing of the left ear followed, attended by



violent contraction of the muscles of the left side of the face. The patient gradually became more and more emaciated, and died on the 17 February 79, after having lain unconscious for five days.

The post mortem examination revealed an osteo-sarcoma of the sphenoid bone. The boundaries of the tumor were, anteriorly, the sella turcica, posteriorly, the foramen lacerum and laterally the fossae lateralia; inferiorly the tumor extended to the crest of the vomer. The anterior cerebral, both the internal carotids, the posterior communicating arteries, and the Gasserian ganglion, and both oculo-motor, the vagii and facial, and both acoustic nerves were compressed by the tumor. The pituitary body and tuber cinerium were imbedded in it. The examination of the tumor showed it to be a fibro-sarcoma. The optic sheaths were distended with fluid but the nerve proper was not changed in its microscopical structure. The discs presented all the microscopical appearances peculiar to papillitis.

Case III. — Anna 8 years of age. Admitted to the Swiss Hospital for violent headache without any other symptom. The fundus of each eye was normal. A small dot, almost circular, the diameter of which was about the breadth of an ordinary retinal vein, was visible in the fundus of the left eye, at a distance of two discs length from the optic disc, and below it. This spot had some resemblance to a tubercle of the choroid; the headache of which the child complained was always localised to the supra-orbital region. Six day after admission, one optic disc commenced to show appearances of inflammation, and convergent strabismus came on. The homonymous diplopia lasted for a few days, and was soon followed by loss of consciousness and other symptoms of meningitis. The child died 17 days after the appearance of the strabismus. The post mortem examination showed what we expected to find, namely considerable deposits of miliary tubercle on the membranes of the brain, especially at the base, and close to chiasma, and over the crurae and pons. The brain substance, anemic; the corpora quadrigemina and corpus striatum, and the thalami were normal, the optic nerve sheaths greatly distended by serous fluid. The discs were



considerably inflamed and the inflammation extended to the fovea centralis. It was impossible to obtain a good section for the microscope, of the spot which could be seen with the ophthalmoscope at the outset of the disease.

Case IV. — Mme A. 30 a plethoric lady, mother of one child. Presented first time in July 1879 for bad vision in left eye and almost total blindness of the right. Her complaint commenced in the summer of 1878, in the right eye. Examination: both eyes emmetropic; right disc, white atrophy; left, strong decoloration; no traces of past neuritis. On examining the field of vision, temporal hemianopia was detected as in Fig 1 of Plate 2. The central vision of right eye was null; that of left eye reduced to  $\frac{1}{5}$ ; red and green were mistaken for blue and yellow. Headaches frequent. There was congestion of the cervix uteri along with some granulations; the menstruation was irregular, and scanty; with more or less general anæmia. Albumen was present in very small quantity in urine. The hemianopia was attributed to some lesion at the anterior part of the chiasma (*fasciculæ cruciatæ*) and the prognosis was reserved. Iodide of potassium was prescribed internally. This condition remained unaltered until the 27th October of same year, when I was asked in consultation, to attend upon the lady, whose parents were extremely alarmed at a sudden change of symptoms. On examination I found; vision and visual fields same as in July; the appearance of fundus was also precisely the same. In the left eye there was multiple paralysis of the recti muscles. The inferior, superior, internal, and external recti, and the levator palpebræ sphincter iridis were totally paralysed. The right eye, although almost deprived of vision, followed all the movements which the patient was asked to make with it, the left eye remaining motionless, excepting a slight rotatory movement which indicated that the obliquii were active. The right pupil was not more dilated than before the fresh symptoms. Pulse 50, nausea, headache and violent nervous excitement. Albumen has not increased. Leeches were applied to mastoid process, and calomel prescribed internally. On the following day, the pupil of the left eye commenced to resume contractility and the recti some motion. After a fortnight all the



objective symptoms had disappeared. The field of the right eye was found somewhat more contracted. The left had not changed. There has not been any renewal of the brain symptoms until now (1881) and the vision of left eye has remained the same.

Temporal hemianopia; cure. Philip F. aged 45. A healthy man, complains of great confusion of vision which commenced 3 weeks ago. He has been in this state thrice before within 3 years. Had syphilitic chancre 15 years ago. Reads Jaeger 11 with both eyes together. With left eye alone he can hardly read No 12, but the vision of right eye is reduced to qualitative perception of light and shade at nasal half of visual field. The temporal half of each field is altogether wanting. There are no brain symptoms, and no hemianesthesia. Iodide of potassium prescribed, 2 scruples daily. 15th July. R. E. reads 12. Left reads 12 also. Temporal half of field quite insensible, and sharply defined by an almost vertical line from the nasal part of field which is in normal state; potassium continued; 27th July reads No 1 with each eye at 14 inches; fields normal. The discs, which were very pale at the beginning, are still highly discoloured.

Case of Amaurosis following 19 days after concussion of the brain. — P. B. slender and tall young man, 25 years of age, with total amaurosis of both eyes. The patient has a considerable difficulty of speech; his parents affirm that he was knocked down in the street, on the 24th of May, and that he received violent blows on the head. He was brought home more dead than alive, and remained unconscious for several hours. On recovering his senses, his vision was perfect, but he had complete aphasia. He was laid up for several days after the accident, suffering of severe headache, nervous excitement, sleeplessness, and occasional vomiting. Both legs were palsied, when he recovered his senses, but this soon improved and he could walk about the room on or about the 10th June. On the 12th June, vision commenced to decrease rapidly, and in three days became totally extinct. He came to me on the 27th June. Patient complained of constant pain in back of head. Pupils dilated and sluggish. Discs somewhat dis-



coloured; the blindness was complete. Prescribed 15 leeches to temples, and large doses of iodide of potassium. The headache ceased after the first application of leeches; on the 9th July. R. E. perceived light and shade in outer part of field. 12th July R. E. counts fingers at 1 ft. 20th R. E.  $\frac{4}{100}$ . 3d, August R. E.  $\frac{4}{70}$  6th  $\frac{4}{50}$ . 11th  $\frac{4}{40}$ . 17th  $\frac{4}{30}$ . The peripheral vision had cleared up and there was a central scotoma with ragged margins. On the 30 August the vision of R. E. was  $\frac{4}{30}$ . Injections of strychnine were commenced. The L. E. still remained altogether amaurotic. On 8th September after 8 injections R. E.  $\frac{4}{30}$ . Till 20th September there was no further amelioration in central vision, but the scotoma had diminished in size; the L. E. commenced to distinguish light and shade. On 24th September R. E. status idem. L. E.  $\frac{1}{200}$ . 27th R. E.  $\frac{6}{30}$ . L. E.  $\frac{4}{200}$ . 5th October R. E.  $\frac{6}{30}$ . L. E.  $\frac{4}{100}$ . From the 30th August to the 5th October 30 injections of  $\frac{1}{50}$  of a grain each had been practised. The L. E. had also a central circular scotoma extending to  $15^{\circ}$  on all sides. The patient left Constantinople and I did not see him until two years later. The R. E. had recovered normal vision. The L. E. retained a central scotoma and vision was  $\frac{10}{100}$ . The lower extremities had regained strength and the difficulty of speech was still perceptible by occasional stammering. The optic discs were discoloured.

Case of hysterical amblyopia nearly amounting to amaurosis in one eye; cure. —Miss L. H. 17 years of age. Called on me for first time on 17 September, complaining of "shortsight, which has increased very rapidly" Patient is of a highly excitable temperament, and suffers of continual headache since 6 months. She suffers of menorrhagia every fortnight, and obstinate sleeplessness. Discs are somewhat discoloured; both eyes emmetropic. R. E.  $V = \frac{12}{200}$ ; L. E.  $V = \frac{7}{200}$ . Field of each eye concentrically contracted to  $10^{\circ}$  in L. E. and  $20^{\circ}$  in R. E. Steel prescribed, and chloral to be taken at bed time. 23 September R. E.  $\frac{12}{200}$ , L. E.  $\frac{12}{200}$ ; 25 September strychnine injections  $\frac{1}{50}$  of a grain every second day; 27th status idem. 29th V. status idem. Field of R. E. enlarged upwards to  $30^{\circ}$  and outwards to  $25^{\circ}$ . Injections



continued till 15th October. On examination I found R. E.  $V = \frac{12}{70}$  and field very much enlarged on all sides reaching nearly to  $50^\circ$ , but the L. E. could only distinguish shadows. The headaches and sleeplessness, and general symptoms not having improved 8 leeches were applied to the mastoid process. This depletion relieved the headache considerably, and induced regular sleep, and improved the central vision of the R. E. The L. E. improved to  $\frac{12}{200}$  a few days after the depletion. The injections were again recommenced, and led to  $V \frac{20}{10}$  of R. E. and  $\frac{20}{30}$  of L. E., its field however remained somewhat contracted for many months, until I lost sight of the patient. Two years later, she was hysterically deranged for several weeks. During the time that I watched this case there was no acromatopsia in those parts of the field which were sensitive. Coloured beads and wools were recognised and sorted out easily. The discs remained discolored all through the duration of the amblyopia and after recovery; as is usual in such cases, the amblyopia was much intenser on one side.

Case of Anesthesia of retina; cured; relapse after typhoid; cured again. — N. Z. a young man of 17, of bad colour and dyspeptic appearance; he has indulged considerably in onanism. M.  $\frac{1}{12}$ . Corrected  $V = \frac{12}{50}$ ; peripheral, concentric contraction of both fields to  $20^\circ$ . No sclero-choroiditis. Complains of bad vision, and asthenopia, and difficulty in reading & c. This diminution, came on rapidly. Strychnine injections commenced at once. Twenty minutes after the first, the fields were increased to  $30^\circ$  in all directions. Seventeen injections, in all, restored the vision to  $\frac{20}{30}$ . By the addition of cylindrical glasses, the vision was brought to  $\frac{20}{20}$ . The patient kept well for two years, but had a relapse of the same form of amblyopia after an attack of typhoid fever. Fifteen injections restored the vision to its normal condition.

Case of concentric contraction with spasm of accommodation and no diminution of the central vision; cure.—[3d August 1876 N. A. a strong young girl of 18 offering no symptoms of hysteria or general debility. Visual field contracted to  $10^\circ$ . M.  $\frac{1}{18}$  and central  $V = \frac{20}{20}$  after correction. Spasm of accommodation;



perception of colors normal. Strychnine injections practised every second day. A marked enlargement of the field of the eye corresponding to the side on which the injections was practised, followed each injection. The fields were restored to normal condition after 15 injections. On 20th February 1877, relapse. The Myopia in distans this time was  $\frac{1}{16}$ . Both the spasm, and contraction disappeared after thirty-nine injections.

Case of concentric contraction, accompanying dental neuralgia. Cured after extraction of tooth. — A. C. a delicate looking girl of 16. Complains of photophobia and kopiopia. Both eyes are emmetropic. The fundus presents no anomaly.  $V = \frac{20}{20}$  in both eyes. Both fields are contracted to 30 degrees in all directions. Strychnine injections were commenced on 8th July, and practised every alternate day till the 21st. There was decided amelioration, but there seemed to be no further progress after the first injection. The patient returned after a fortnight, when I found both fields contracted to 30°. She assured me that vision was always worse after and during severe pain caused by a carious bicuspid tooth. I advised its extraction, and asked her to call again on the day after the operation. She did as she was told, and on examination I found the fields of both eyes perfectly normal in all directions.

#### **Lacrymal apparatus.**

Dr Hock's treatment with inflation of air has not proved of any service. For all cases of purulent discharge from the lacrymal sac and duct, I had recourse to injections of tepid solutions of boric acid, and I use probe N° 3 until all discharge has ceased. I find it hardly ever necessary to use thicker sounds than N° 4. Rhinitis or ozoena co-existing in nearly one half of all the cases, I often advise disinfecting irrigation of the nasal fossae. I have observed that the turkish bath is an almost infallible means of curing chronic dacryocistitis in infants or children below two years of age. For this purpose I order a bath to be taken daily for a week or fortnight.



## LENZ

### Simple senile cataract.

Aperient medicine was given to the patients on the eye of the operation, with the purpose of securing a recumbant position for two or three days. Chloroform was not used in any of the forty cases. The surface of the eyelids was washed carefully with a warm solution of boracic acid, immediately before the operation. The instruments were dipped into hot water and not wiped off before use. Atropine was previously dopped into the eye, for the purpose of avoiding, more easily, the cutting through of the iris. This little accident which may occasionally happen, if the pupil is not dilated and the anterior chamber is narrow, always prevents the surgeon from making a correct iridectomy, and the consequence is that portions of iris remain in the incision. Adhesion to the wound of portions of iris reduce the value of von Græfe's method to the level of reclination, and I think that we are justified in using every means for avoiding any circumstance which may diminish the chances of success. The section was carried through the corneoscleral junction, and partly through corneal tissue. Care was taken to secure a perfect conjunctival flap. The iris was very carefully excised. The capsule was lacerated as freely as possible, and the scoop used whenever the lenz did not present itself readily. It was noticed that the cases operated by scoop extraction (with previous laceration of the capsule) required a much shorter after-treatment, and were free from secondary cataract. The vision of those cases in which vitreous had escaped at the operation, was found more perfect than that of other cases. In one such case  $V$  was  $\frac{20}{10}$  three weeks after the operation. This circumstance has led me to give Professor Hasner's proposal (revived by Dr. Rhein-dorf's glaskorperrhexis) a fair trial. All portions of cortex were carefully removed, and a bandage of boric cotton was applied. Vision was tested three weeks after the operation. Out of the forty cases which were operated, the



vision of sixteen was very good; in seventeen it was good and in six it was middling; in one it was null.

$S = \frac{20}{20}$	in	1	cases
$„ = \frac{20}{30}$	„	6	„
$„ = \frac{20}{40}$	„	9	„
$„ = \frac{20}{50}$	„	9	„
$„ = \frac{20}{70}$	„	8	„
$„ = \frac{20}{100}$	„	2	„
$„ = \frac{20}{200}$	„	4	„
$„ = 0$	„	1	„
<i>Total</i>		40	

The oldest patient was 76, and the youngest 40; there were 16 men and 24 women. Iritis appeared on the third day in four cases, and secondary cataract in four other. The case which resulted in complete atrophy of the eye, had kept well until the second day; the panophthalmitis was the result of rupture of the wound. I have contrived a special eye protector, which is worn after the operation, and is calculated to prevent a rupture of the wound by contact of the hand during sleep. The protectors made for me by J. Odelga, of Mariannengasse 7. Vienna, are light and easy to wear, without producing any discomfort.

**Finis.**



## EXPLANATION OF PLATES.

Plate I. Fig. 1. — Appearance of granular conjunctivitis at the very commencement. Isolated follicles close to the retrotarsal folds. Lymphoid hyperplasia at the corner plica, close to the plica semilunaris.

Fig. 2.—Taken from same patient, one week later. The conjunctiva bordering the line between the tarsal and retrotarsal conjunctiva, is more thickened, and fresh follicles have appeared on its surface. The Meibomian glands of lower lid are still visible.

Fig. 3.—Taken from same case, one week later. The tarsal conjunctiva of lower eyelid is thickened. The upper lid is also thickened by the increase of lymphoid cells in the subconjunctival tissue.

Fig. 4.—Represents a case of indolent follicular enlargement of retrotarsal folds, as is often seen in cases in which the first stage is stationary.

Fig. 5.—Taken from same case as Figs. 1, 2, 3, and a week after No.3. The lymphoid hyperplasia has not only advanced upwards, and in all directions, but also in depth, so that the whole extent of the conjunctiva is in a state of hypertrophy. The acute stage is approaching its end at this period, and presents the appearances of

Fig. 6.—a week later. Here the conjunctiva is thickened, relaxed, full of heavy folds, not distended, and rough. The later appearance is due to consecutive enlargement of the papillæ of the conjunctiva. The secretions being thicker, and less diluted with tears, adhere to the lashes.

Fig. 7.—Enlargement of retrotarsal folds, frequently seen in scrofulous children with chronic corneitis. (Schwellungs-catarrh). There are a few follicles on the tarsal conjunctiva and also on the folds of the lower lid, but their quantity does not correspond with the enormous swelling of the retrotarsal fold.

Fig. 8.—Phlyctena pallida, (or Fruhjahrens catarrh). Superficial dilatation of conjunctival, and episcleral vessels. Absence of acute inflammation.

Plate II.—Visual fields of Case No IV of temporal hemianopia.





Fig. 1. - Enlargement of the eye. The eye is shown in profile, with the eye ball enlarged. The eye is shown in profile, with the eye ball enlarged. The eye is shown in profile, with the eye ball enlarged.

Fig. 2. - Enlargement of the eye. The eye is shown in profile, with the eye ball enlarged. The eye is shown in profile, with the eye ball enlarged. The eye is shown in profile, with the eye ball enlarged.

Fig. 3. - Enlargement of the eye. The eye is shown in profile, with the eye ball enlarged. The eye is shown in profile, with the eye ball enlarged. The eye is shown in profile, with the eye ball enlarged.

Fig. 4. - Enlargement of the eye. The eye is shown in profile, with the eye ball enlarged. The eye is shown in profile, with the eye ball enlarged. The eye is shown in profile, with the eye ball enlarged.

Fig. 5. - Enlargement of the eye. The eye is shown in profile, with the eye ball enlarged. The eye is shown in profile, with the eye ball enlarged. The eye is shown in profile, with the eye ball enlarged.

Fig. 6. - Enlargement of the eye. The eye is shown in profile, with the eye ball enlarged. The eye is shown in profile, with the eye ball enlarged. The eye is shown in profile, with the eye ball enlarged.



## EXPLANATION OF PLATES

Plate I, Fig. 1. — Appearance of granular connective tissue at the very commencement of tubercle formation close to the entrance of the lymphoid hyperplasia at the central place of the tubercle.

Fig. 2. — Taken from same place as Fig. 1, one week later. The connective tissue has become more dense and the tubercle formation is more advanced. The tubercle has been separated on its surface. The tubercle shows a mass of cells in the center.

Fig. 3. — Taken from same case, one week later. The central collection of cells is the center. The upper part is also thickened by the increase of connective tissue in the subepithelial tissue.

Fig. 4. — Represents a case of tubercle formation. Enlargement of tubercle at this stage is often seen in cases in which the first stage is complete.

Fig. 5. — Taken from same case as Fig. 1, 2, 3 and 4, one week later. The lymphoid hyperplasia has now only increased in size and is still in the same position, but also the tubercle has increased in size and is now in the center of the tubercle. The tubercle is now in the center of the tubercle. The tubercle is now in the center of the tubercle.

Fig. 6. — A week later. Here the connective tissue is thickened and the tubercle is now in the center of the tubercle. The tubercle is now in the center of the tubercle. The tubercle is now in the center of the tubercle.

Fig. 7. — Tubercle at the end of the tubercle. The tubercle is now in the center of the tubercle. The tubercle is now in the center of the tubercle. The tubercle is now in the center of the tubercle.

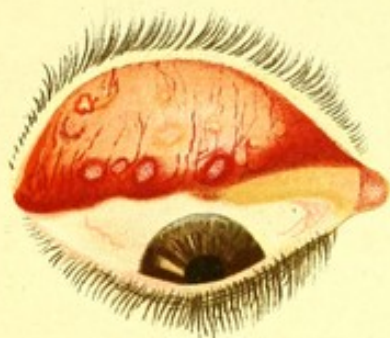Fig. 8. — Tubercle at the end of the tubercle. The tubercle is now in the center of the tubercle. The tubercle is now in the center of the tubercle. The tubercle is now in the center of the tubercle.

Plate II. — Visual field of Case No. IV of tubercle formation.

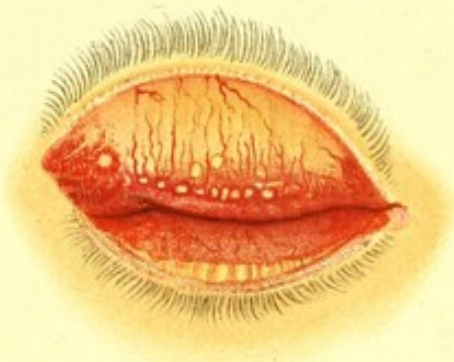

# Plate I.

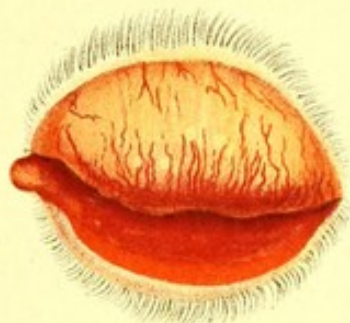1.



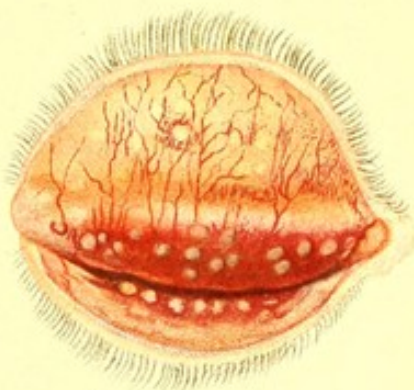
2.



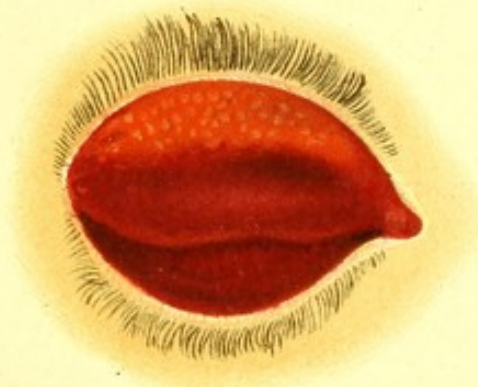3.



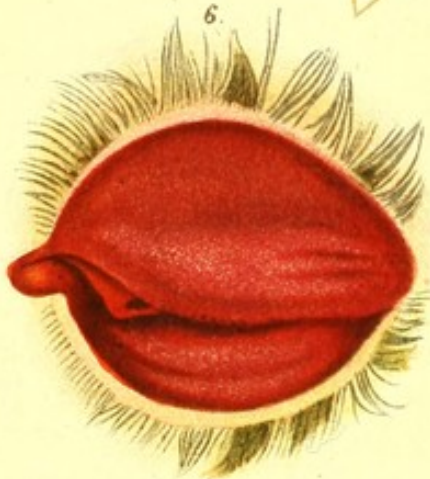
4.



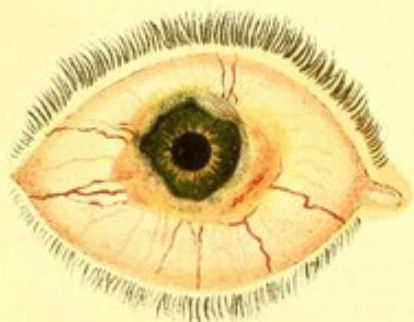
5.



6.



8.



7.

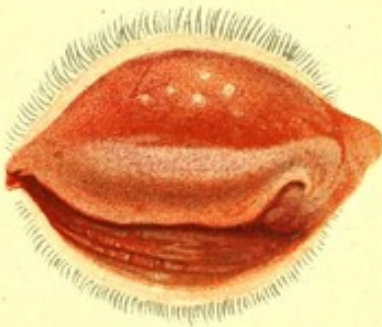

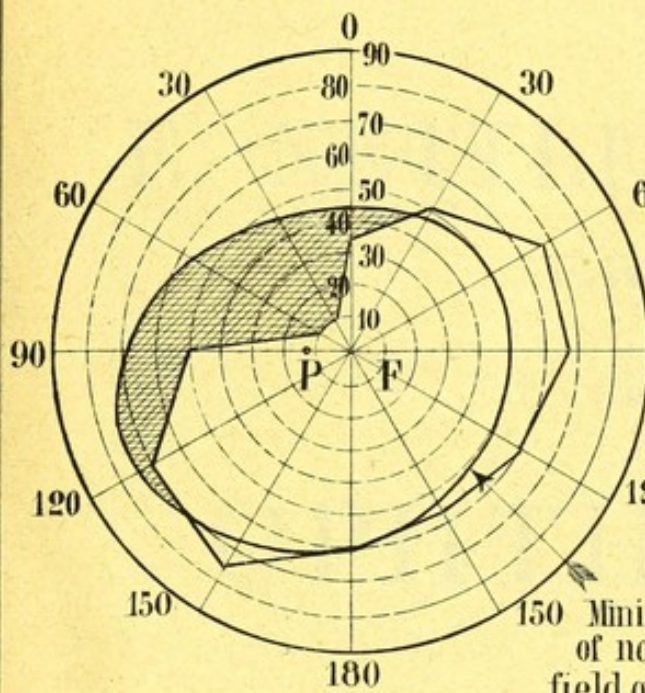




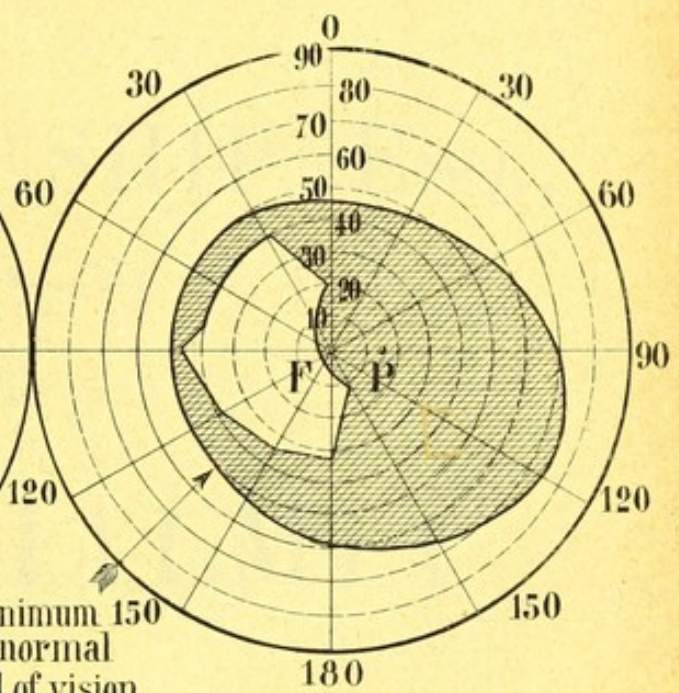


Plate II.

LEFT EYE



RIGHT EYE





Central London School District



REPORT

E. NETTLESHIP, ESQ.

F.R.C.S.

OPHTHALMIA

AT THE

SCHOOL AT HANWYLL

1852638