

Meningitis, arteritis and choroiditis in a child the subject of congenital syphilis : gummata on cranial nerves; disease of cerebral arteries; cicatrices of liver and spleen in a case of congenital syphilis / by Thomas Barlow.

Contributors

Barlow, Thomas, 1845-1913.
Ophthalmological Society of the United Kingdom. Library
University College, London. Library Services

Publication/Creation

[London] : [Pathological Society of London], [1877]

Persistent URL

<https://wellcomecollection.org/works/d6tdkmkm>

Provider

University College London

License and attribution

This material has been provided by This material has been provided by UCL Library Services. The original may be consulted at UCL (University College London) where the originals may be consulted.

This work has been identified as being free of known restrictions under copyright law, including all related and neighbouring rights and is being made available under the Creative Commons, Public Domain Mark.

You can copy, modify, distribute and perform the work, even for commercial purposes, without asking permission.

**wellcome
collection**

Wellcome Collection
183 Euston Road
London NW1 2BE UK
T +44 (0)20 7611 8722
E library@wellcomecollection.org
<https://wellcomecollection.org>



*Meningitis, arteritis and choroiditis in a child the subject
of congenital syphilis.*

By THOMAS BARLOW, M.D.

ELIZABETH W— was brought to me when about one month old,
in June, 1875.

As I subsequently learned, there were specific antecedents on the father's side. The child had snuffles, but at that time no rash. She was only brought for one week, because her parents removed out of London, and she was without treatment until the 1st of October, when she was brought to me again, *i.e.* when she was four months old. During the interim she had had eleven fits, but that is all that I could learn about her condition. When I saw her at this time she had some symmetrical, rather serpiginous ulcers on her nates, and was wasted to the last degree. With mercurial inunction, cod-liver oil and raw beef she vastly improved and became quite a well-nourished child. She had no nervous symptoms at all.

However, in January, 1876, she began to flag again, chiefly, as I then believed, owing to her mother's stupidity in feeding her. She had some laryngismus and some carpo-pedal contractions. These, however, did not lead me to expect any meningeal disease, and it was only when I examined the child's eyes with the ophthalmoscope that I became alive to this possibility.

1852364

In the fundus of each eye I saw sparingly distributed very small flecks of exudation of brownish colour, apparently situated in the choroid. There was scarcely any disturbance of pigment, and no atrophy. So far as I could judge there was no alteration in the optic discs. At that time I had never seen anything quite like it except once, in a young man who was the subject of acquired syphilis and who was suffering from an attack of recent hemiplegia probably the result of syphilitic thrombosis. I have since seen one case identical in appearance in a child the subject of congenital syphilis with nervous symptoms, and in whom I have traced some of the spots on to the atrophied condition with which one is familiar in choroiditis disseminata. It cannot be too strongly stated that the ophthalmoscopic appearances in E. W— were as different as possible from the milk-white, round, larger defined spots which are recognised as tubercle of the choroid.

When I saw these changes in the choroid I felt the strongest suspicion that there must be also some disease of the membranes of the brain.

The child died without any further nervous symptoms, apparently from exhaustion and marasmus.

At the *post mortem*, which Mr. Nettleship and I made together, there was nothing morbid about the thoracic and abdominal viscera, but the condition of things inside the skull was very remarkable. The changes were considerable in extent of area, but not in depth or thickness. The bones were healthy. First there were several spots where there was slight adhesion of the dura mater, arachnoid and pia mater. At the base near the optic commissure there was one small thin patch of greenish lymph. The Sylvian fissures were glued by thin, old exudation.

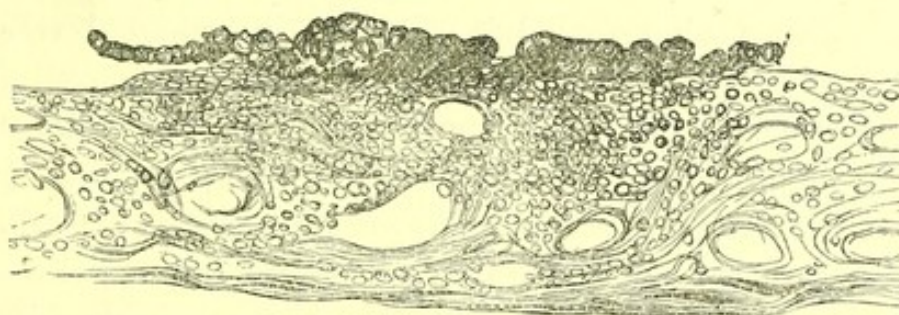
In many places both on the vertex and on the under surface of the temporo-sphenoidal lobes the pia mater was extremely thickened, and fibrous in fact. On the upper surface of the left parietal lobe there was a very small thin patch of calcification. The vessels of the circle of Willis were natural. The most interesting changes were very obvious ones in some of the small vessels of the cortex. They could be traced in one or two places for some distance apparently natural, then becoming dirty white in colour, without either dilatation or narrowing. The appearance was in fact, as Dr. Greenfield has described it, like a white thread. Nowhere could the most careful examination detect any granulations in the pia mater.

There were a few spots of thin superficial softening in the cortex ; they were mere flakes. The lateral ventricles were a little bigger than natural, but the fluid was clear. The ganglia were natural. The areas of fibrous thickening of the pia mater, the little patch of calcification, the changes in the small vessels, the presence of only one minute patch of greenish lymph—all these things pointed to old-standing, chronic, smouldering disease.

The child was only ten months old when she died. If these changes were chronic changes they must have dated from very early. Reference to the history, imperfect as it is, shows that after the child was five weeks old she was without any mercurial treatment for three months and had *several fits*. I believe that it is to that period that the starting of the meningeal disease must be referred.

The choroids were examined microscopically by Mr. Nettleship, and this is his report :

“The changes in the choroid consist in the presence of small isolated collections of corpuscles in the chorio-capillaris. Sections of several of these were found in the part of the choroid which had shown during life little flecks of exudation, and none were found elsewhere.



$\frac{1}{1000}$ inch \times 120

Vertical section of choroid at seat of a minute syphilitic cell-growth. Chorio-capillaris crowded with corpuscles. A thin layer of flattish cells between pigment epithelium and elastic lamina.

“The corpuscles are about as large as pus-corpuscles and stain deeply with logwood. They stand in no evident relation to the blood-vessels, and none of them occur in the deeper part of the choroid. In all these particulars they differ from tubercle.

“The elastic lamina over these deposits is slightly raised, and sometimes a little puckered. In several instances at the seat of

the deposits a thin layer of flattish cells is present on its inner (retinal) surface immediately beneath the pigment epithelium, but in no sections could any perforation of the lamina be detected. The epithelium itself appears morbidly adherent. It may be mentioned that these changes (circumscribed deposits in the chorio-capillaris, with a thin layer of flat cells on the retinal surface of the elastic lamina) are precisely similar to what I found in a case of choroiditis from acquired syphilis in which the eye was excised during the progress of the disease."

I examined the brain and found that the pia mater showed in the thickened portions, as might have been expected, excess of fibrous tissue, with cells, not mere nuclei but well-formed lymphoid cells, containing each a nucleus and in some cases nucleoli. These cells were arranged in a diffuse way, as far as I could see, without any definite or special arrangement around vessels. They seemed to retain their individuality. There was no massing up or aggregation of the cells into heaps, with softening in the centre. In all these respects the appearances were as different from tubercular meningitis as the changes in the choroid were different from tubercle of the choroid.

With respect to the cortical arteries the characteristic changes were, I believe, intravascular. Many vessels were examined which showed nothing abnormal, but the one to which I referred as looking like a white thread showed very striking changes indeed.

There was new growth in the inner coat of the artery narrowing for a considerable distance and ultimately occluding the vessel (Pl. XV, fig. 2). This growth was made up of large nucleated cells which stained very deeply with logwood. Where the vessel was quite occluded the appearance presented was very remarkable. The transverse section looked a little like an epithelioma "nest." At another spot further on, in the vessel shown in the second section under the microscope, there is an appearance very like the organisation of a thrombus, that is to say, there are fine capillaries running into the mass which occludes the vessel, but whether it be really a thrombus or organisation of the new growth it is difficult to say.

These changes, as will be seen, are quite like those shown in Dr. Greenfield's specimens. They are obviously the kind of growth described by Heubner as syphilitic growth in the walls of arteries. Most of Heubner's researches have been made on vessels about the size of the middle cerebral, and they were all from cases of acquired

syphilis. These are from cortical arteries of the second or third degree, and from the subject of congenital syphilis. I think it will be obvious to everybody who examines these changes that in regard to continuity and extent of the cell proliferation, the gradual narrowing of the lumen of the vessel, the absence of ulceration or disintegration or calcification, they are as different as anything can be from ordinary atheroma.

May 1st, 1877.

Gummata on cranial nerves ; disease of cerebral arteries ; cicatrices of liver and spleen in a case of congenital syphilis.

By THOMAS BARLOW, M.D.

JOHN H—, a boy, æt. 15 months, was brought to the out-patient department at Great Ormond Street on the 2nd of January, 1877. His mother was a weak, anæmic woman, with no syphilitic antecedents, so far as could be ascertained. She had had one child before this. I subsequently examined him, and found him perfectly healthy. She had had one miscarriage at ten weeks. This boy was full time, but was said to have been born with a cold. He had had frequent discharge from his nose, which had continued up to a little before he was brought to Great Ormond Street. When a fortnight old he was said to have had thrush badly. The thrush went through him, according to the mother's statement, and he had sore nates till he was eight months old ; but the mother would not admit that he had had any general rash. He had suffered a great deal from diarrhœa, probably due to bad feeding, and when he was brought to the hospital was emaciated to the last degree.

During the seven weeks that he was brought to the hospital, with the exception of getting gradually weaker, there was little change, and I think it better to sum up the clinical features in a single note than to give successive reports.

The boy had no skin lesions at all. He had bad stomatitis, frequent vomiting and diarrhœa, alternating with constipation. Beyond these signs of gastro-enteritis there was no proof of abdominal disease. His lungs and heart were natural. There was slight shotty enlargement of the glands of the neck. The interest of the case chiefly rests in the nervous signs. The boy had slight

nystagmus of both eyes. It was rather coarse, and it was not constant. Both eyeballs were generally directed towards the left. The pupils were equal and of moderate size. I failed to detect anything abnormal with the ophthalmoscope. There was paresis of the muscles of the face. It was general, but not equal in amount. There was now and then a very slight frown on the left half of the forehead, but much less than on the right. The right eyelid was observed to be shut on more than one occasion, whilst the left remained open. When the child cried the left cheek remained flat. There was no distortion when at rest. There were frequent fine tremors of the facial muscles of the right side at the corner of the mouth and the orbicularis palpebrarum. To a considerably less extent they were observed on the left side of the face.

My impression is that the reaction of the face muscles on both sides to the constant current was greater than normal, and that the reaction to Faradism was diminished. Comparing the two sides with one another, the left responded a shade better to the constant current than the right, and very much less to Faradism. As to the other cranial nerves I am not able to give any positive information.

The child had frequent slight laryngeal spasms, which may or may not have depended on some morbid condition of the vagus, and once or twice he had some odd gasping attacks, in which he became very blue. The vomiting may have been central in its origin, but I rather thought it was dependent on gastro-enteric disturbance, because of the other signs, and because also it seemed to be controlled somewhat by bismuth, and subsequently by small doses of brandy. He had no convulsions, and was not particularly irritable.

The diagnosis of this case appeared to be conclusive in favour of a tumour or tumours, situated at or near the base of the brain, pressing on the cranial nerves subsequent to their deep origin.

I inclined to the belief that it was tubercular and not syphilitic, and the child was not treated by any antisyphilitic remedies whatever. It is doubtless due to that fact that these specimens are brought before the Pathological Society.

At the *post mortem* which Dr. Lees and I made at the patient's home we found that the diagnosis was quite incorrect. There was no tubercle anywhere. On the upper surface of the liver there were four more or less stellate patches of thin cicatricial tissue. Three of them were about the size each of a shilling; one was not

bigger than the area of a split pea. They were not attended by the puckering which one sees in old-standing cases of perihepatitis in acquired syphilis. There was a very little invading material in the underlying liver substance. On section this growth was much more cellular and less fibrous than one ordinarily sees. There appeared to be no change of hepatic cells beyond a very little distance. There was nothing abnormal in the spleen substance. It was not enlarged, but at the lower anterior margin there were the remains of some old disease of the capsule—a cicatrix, in fact; and at this spot there had been a small adhesion of peritoneum. The other abdominal viscera and the thoracic viscera were healthy to naked-eye inspection.

There was nothing abnormal about the membranes of the brain, with the exception of a very little opacity of the pia mater at the base. With respect to the brain substance, I do not think there was more wasting than one would have expected in so emaciated a child. I failed to find any patches of softening in the cortex or elsewhere, and there was no disease of the ganglia obvious to naked-eye inspection. But the nerves were very extraordinary. Both thirds at their superficial origin were swollen out into small conical tumours. There were also swellings on the fourth, fifth, sixth, seventh, and eighth pairs, causing considerable broadening out of these nerves at their superficial origin. There was very little difference on the two sides in bulk, though I presume there must have been a difference in *amount* of change, in the two facial nerves for example, from the clinical differences which were observed. I have examined microscopically the third and fifth on one side.

The first thing that strikes one is the almost entire atrophy of the nerve cylinders. Here and there in some of the sections are round bodies resembling corpora amylacea (? altered myelin). There is a most abundant infiltration of new cells, with very fine stroma.

This new growth is by no means most abundant in the inter-funicular areolar tissue. It is, in fact, less abundant there than in the substance of the funiculi themselves, though it is to be noted that in the funiculi generally there is more of it at the periphery than in the centre.

The naked-eye appearances of these nerve gummata are not unlike those of the swellings of anæsthetic leprosy, only that they are, of

course, much smaller. There is this much resemblance between my specimens and Dr. Vandyke Carter's first observation recorded in the fourteenth volume of the 'Pathological Transactions,' viz., that the changes are especially a destruction of the proper nerve substance, and not of the external sheath or the interfunicular tissue. But in some sections of anæsthetic leprosy nerves which Dr. Gowers has been good enough to show me, the changes are undoubtedly in the interfunicular tissue. It appears probable, therefore, that considerable variety may exist.

I now come to the changes in the vessels. The basilar and all the vessels composing the circle of Willis were most extensively diseased. They were opaque, white, and semi-cartilaginous in consistence. The thickening was tolerably continuous along the whole length of the vessel. There were no nodular growths; there was nothing which to the naked eye would have suggested gummata in the sheaths of the vessels or in the outer wall. There were no dilatations, neither was there any calcification. On cutting through these vessels their lumen was seen to be considerably narrowed, in many places almost, but not quite, obliterated. The outline of the lumen was in several spots eccentric, which showed that the growth in the wall of the vessel had been unequal in amount at different parts; but as I said just now, taking the whole thickness of the vessels at different spots, it was nearly uniform.

On making sections of a part of one of the middle cerebral arteries, the changes which Heubner has described were found most typically shown (Pl. XV, figs. 1 and 3). Both the adventitia and the muscularis are infiltrated by a cellular growth, and in some places the muscularis is quite destroyed by it, but obviously the principal changes have taken place in the *intima*. The *membrana fenestrata* (*b b*) forms a perfectly definite landmark on the one side, and the endothelium (*x*) forms an equally distinct landmark on the other. Between these two there is a very large accumulation of spindle-shaped nucleated cells, and it is this growth which gives rise to the main thickening of the vessel. The endothelial cells which are oblong in shape present in most cases a smooth surface, but at some spots there are minute fungus-like prolongations inwards from them into the lumen of the vessel. Arteries of the second order, *e. g.* the main branches of the middle cerebral, were free from this change, so far as one could see with the naked eye.

This is the first case on record, so far as I know, of gummata on

cranial nerves in congenital syphilis. It is to be specially noted that these new growths were symmetrical. I remember to have seen some years ago at University College Hospital a *post mortem* on a patient who was the subject of acquired syphilis, and in whom also gummata on the cranial nerves were symmetrical. At the syphilis debate last year Dr. Moxon referred to a similar case.

The present case is of further interest on account of its affording an additional example of change in the cerebral arteries in the inherited form of syphilis.

May 1st, 1877.

Postscript.—The back of one eyeball which I removed at the *post mortem* has been examined microscopically by Mr. Nettleship. There are no morbid changes. This is of interest taken along with the absence of disease of the pia mater and in contrast with the case previously recorded, in which choroiditis and meningitis were present. It is quite in agreement with the suggestive remark made by Hughlings Jackson that the choroid is the pia mater of the eye.

DESCRIPTION OF PLATE XV.

Figs. 1, 3, 4, and 5 illustrate Dr. Barlow's Case of Gummata in Cranial Nerves and Disease of Cerebral Arteries in Congenital Syphilis.

FIG. 3 shows a section of middle cerebral drawn by Dr. Finlay. × 25.

- a.* Lumen of vessel.
- b.* Membrana fenestrata.
- c.* Thickened inner coat.
- d.* Muscularis.
- e.* Adventitia.
- x.* Endothelium.

FIG. 1 shows a segment of same vessel drawn by Dr. Greenfield. × 150.

References the same as in Fig. 3.

FIG. 4 shows section of motor root of fifth nerve.

f, f. Funiculi, showing destruction of axis-cylinders and infiltration with granulation-cells, which are most abundant at periphery.

i. Interfunicular tissue infiltrated to less extent with granulation-cells.

Drawn by Dr. Finlay. × 25.

FIG. 5. Third nerve, natural size, showing fusiform swelling just beyond superficial origin.

FIG. 2. Section of arteriole of pia mater, showing thickening of inner coat. From Dr. Barlow's case of meningitis arteritis, &c. (Page 287.) Drawn by Dr. Finlay. × 25.

