

## **Syphilitic lesions of the eyelids / by A. Hill Griffith.**

### **Contributors**

Griffith, A. Hill.  
Ophthalmological Society of the United Kingdom. Library  
University College, London. Library Services

### **Publication/Creation**

London : John Heywood, 1886.

### **Persistent URL**

<https://wellcomecollection.org/works/h95j5eg7>

### **Provider**

University College London

### **License and attribution**

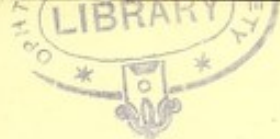This material has been provided by This material has been provided by UCL Library Services. The original may be consulted at UCL (University College London) where the originals may be consulted.

This work has been identified as being free of known restrictions under copyright law, including all related and neighbouring rights and is being made available under the Creative Commons, Public Domain Mark.

You can copy, modify, distribute and perform the work, even for commercial purposes, without asking permission.



Wellcome Collection  
183 Euston Road  
London NW1 2BE UK  
T +44 (0)20 7611 8722  
E [library@wellcomecollection.org](mailto:library@wellcomecollection.org)  
<https://wellcomecollection.org>



# SYPHILITIC LESIONS OF THE EYELIDS.

6

BY

A. HILL GRIFFITH, M.D.,

*Assistant Surgeon, Royal Eye Hospital, Manchester.*

---

REPRINTED FROM "MEDICAL CHRONICLE," JUNE, 1886.

---

JOHN HEYWOOD,  
DEANSGATE AND RIDGEFIELD, MANCHESTER;  
AND 11, PATERNOSTER BUILDINGS,  
LONDON.  
1886.

1852345

## SYPHILITIC LESIONS OF THE EYELIDS.

---

THE cases here recorded, 21 in number, occurred during the last four years among the out-patients of the Manchester Eye Hospital, and I have to thank the members of the staff for permission to publish them. The list includes nearly every case observed during the above period, and comprises primary chancres, ulcers occurring during the secondary and tertiary stage, and other lesions which in their appearance closely resembled primary chancres, but were not accompanied by undoubted symptoms of syphilis. The list might have been somewhat shortened by the exclusion of these and other doubtful cases; but I consider that this would have sacrificed some of the most interesting and instructive material, a loss which would not, in my opinion, have been compensated for by the increased orthodoxy of the series.

Nos. 5, 6, 7, 10, 14, 16, 19, 20, and 21, are, I venture to think, all examples of the primary manifestation of syphilis, being followed in every case by a characteristic eruption, except No. 5, which was lost sight of before this would appear in the ordinary course of the disease. In all these nine cases induration of the lesion was present, except in No. 7, where no lesion could be found, and in No. 19, where there is no note of this condition. The glands were hard and enlarged in each of the nine cases. The site of the lesion was near the edge of the upper or lower lid, and usually invaded the mucous surface to some extent. In one case, No. 16, the lesion was on the bridge of the nose, and in one, No. 7, no lesion could be found, but it had probably been situated on the lip. In one case, No. 14, the chancre was situated on the inner surface of the upper lid well back from the free edge. Mr. J. E. Adams showed a case in a similar position at a meeting of the Ophthalmological Society, December, 1882; and at a meeting of the same society in January, 1882, Messrs. Wherry and Nettleship each described a case occurring in the lower conjunctival sulcus. The *mode* of infection could not be clearly made out in my cases; but in one case, No. 19, it was afterwards found that the child had infected its own mother who was suckling it. There was no sore other than that on the eyelid at the time I saw the child, but the mouth might have become affected afterwards. The probable *source* of infection was evident in three cases. In No. 7 the child's mother had a syphilitic rash; in No. 10 the woman was




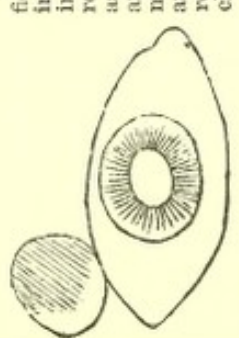
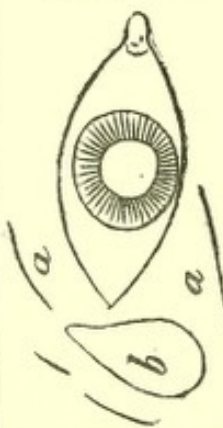
nursing a child which exhibited a syphilitic eruption ; and in No. 16 it is possible that the cephalic chancre was produced at the same time as that on the penis, the skin of the nose having been broken in the manner stated.

Nos. 11, 13, 17, and 18 I would class as ulcerations occurring during the secondary or tertiary stages of the disease. It is noticeable that in these there is an absence of hardness. I have recently become aware, by perusal of an interesting article by Dr. Brooke in the May number of this journal, that the diagnostic importance of induration has, in the opinion of many well-known writers, been much over estimated. My cases, however, show that in the lids at least this sign is not likely to be wanting. On the other hand, the most marked induration I have ever perceived was in the case of a young man, aged 22, who had an ulcer of the upper lid, and which I thought might be specific. I lost sight of him for three years ; but at the end of that time there could not be the slightest doubt that the lesion was a rodent ulcer. The interest of this case lies in the early age of the patient.

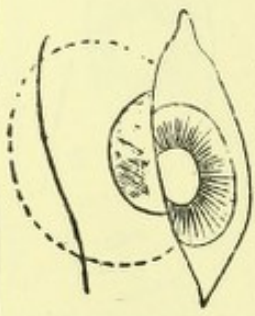
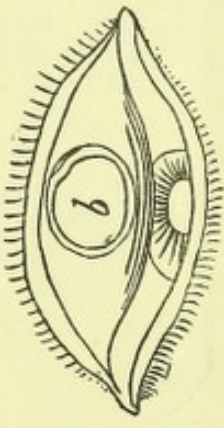
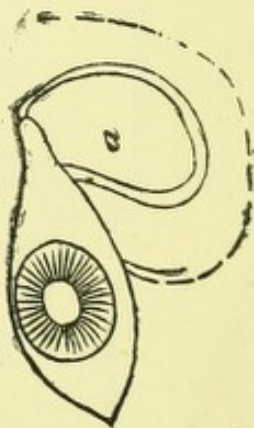
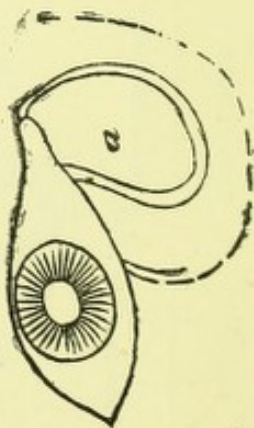
In No. 12 the details are too imperfect for us to come to a conclusion in regard to its nature.

No. 15 absented herself very shortly after we had made inquiries regarding the case. I should feel inclined to regard it as probably an example of the primary lesion.

Cases 1, 2, 3, 4, 8, and 9 are probably quite unconnected with syphilis ; but No. 4 was extremely like a Hunterian chancre, as was also No. 9 ; and I may venture to suggest that some of these six cases represent peculiar inflammations of the lids which have not yet been described.

NAME, AGE, &c.	LOCAL LESION.	PRE-AURICULAR GLANDS.	SKIN ERUPTIONS, &c.	HISTORY.	TREATMENT AND PROGRESS.
1. 395. Vol. I. E. T., age 32. Married. Dr. Glascott.	Left eye. Grey flat little sore; some redness and swelling of lid. 	Enlarged, and hard on same side.	None.	Lid sore five days, neck same time; pricking pain in eye; five children, youngest aged three months, has a rash on its body. Patient had "bad eyes" after measles in childhood.	Lead lotion. In three days glands all right, lid improved, some vascularity of cornea and injection of bulbar conjunctiva. Seen by Dr. Brooke, who found no other signs of syphilis. In three weeks nothing left but slight thickening of lid.
2. 398. Vol. I. H. B., age 21. Married. Dr. Little.	Right eye. Thin superficial yellow scab, oval in shape, closely covering red sore; continuous round edge of lid with ashy sore; some redness and swelling of lid; not much hardness of sore, and none in tissue surrounding; little discharge. 	Enlarged.	A few little rosy spots on abdomen not very characteristic; throat normal.	A little "powk" came on the lid about ten days ago. It burst in a few days (or the skin came off). Glands enlarged one week. No history of infection.	Lead lotion.
3. 400. Vol. I. S. C. Widow. Dr. Little.	Right eye. Red sunken area (a); scar; good deal of destruction of lid at temporal side and lashes destroyed; a regular, uniform, unhealed, ulcerating surface near outer canthus (b). 	Enlarged, and knotty on same side.	None.	No history of syphilis; widow for thirteen months; had blow on eye three years ago, and she says it has been inclined to swell since then occasionally.	Lead lotion.



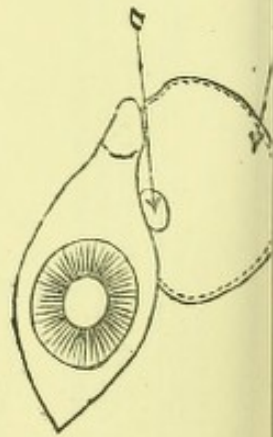
NAME, AGE, &c.	LOCAL LESION.	PRE-AURICULAR GLANDS.	SKIN ERUPTIONS, &c.	HISTORY.	TREATMENT AND PROGRESS.
4. 402. Vol. I. M. D., age 13. Single. Dr. Little.	<p>Right eye. Slight superficial scab (a) at centre of upper lid, above free edge; general swelling and slight redness; area of dense hardness (indicated by the dotted line) involving whole thickness of lid. The fold of the upper lid is rendered tense (indicated by strong curved line.)</p>  <p>On evert- ing the lid, the posterior sulcus is injected swollen, and thrown into folds (horizontal). There is a rounded ulcerating surface (b) rather boggy, surrounded by a white hard fibrous ring.</p> 	Knotty, and enlarged on same side.	None.	No history of infection; lid affected ten days; no accident or any cause known; pale, unhealthy looking lad.	Lead lotion. Glands all right in four days, lid much improved, inner surface flatter, less injected, and induration nearly gone. In six weeks only slight scar on inner surface and a little redness of the conjunctiva of upper lid.
5. 404. Vol. I. W. D., age 3. Dr. Little.	<p>Sore at outer canthus, size of shilling, sloughy centre; edges red, dusky, and rather indurated.</p> 	Swollen, and painful on same side.	None.	Lid had a fortnight, glands one week; one younger child, aged fourteen months, quite strong.	In one week it got worse; the sore extended along the edge of upper and lower lid; glands worse, rounded and hard.
6. 405. Vol. I. I. O., age 3. Dr. Little.	<p>Right eye. Large ulcer (a) covered by scab; edges hard, dense, glistening and red, surrounded by area of hardness, indicated by dotted line. When scab removed, there is exposed a raw, bleeding, ulcerating surface, pretty deep, creeping along free edge of upper lid.</p> 	Enlarged and hard.	None at first, but in four weeks from date of lid becoming affected there was a profuse eruption of an undoubtedly specific nature.	Lid had three weeks, neck of infection; mother free from any suspicion of syphilis; child very seldom out of her sight; one of his playmates is a child whose father has the "bad disorder;" unfortunately this child could not be seen.	Lotio nigra. Hydrarg. cum creta, gr. 1½, bis die. Eighteen months or more after notes taken, smooth, white, perfectly supple scar; fine healthy lad.



NAME, AGE, &c.	LOCAL LESION.	PRE-AURICULAR GLANDS.	SKIN ERUPTIONS, &c.	HISTORY.	TREATMENT AND PROGRESS.
7. R. W., age 3 (?) Dr. Little.	None to be detected; but child was not seen for four months after the skin eruption appeared. Vulva examined, but nothing wrong detected.	Enlarged and hard (submental glands also markedly affected).	Profuse coppery rash all over trunk and neck.	The rash has been out for four months. I asked Mr. Howlett, late R.S.O., at the Royal Infirmary, to see the child. He felt certain, with me, that the rash was syphilitic, and suggested, as probable, that the primary lesion had been on the lip. The mother is attending for syphilitic iritis of six months' duration.	Mercury in some form.
8. Vol. I. J. H., age 44. Dr. Little.	Conjunctiva of right globe generally injected; chemosis; no purulence. The fold of conjunctiva at inner canthus is very much swollen and hypertrophied, and dotted over it are numerous small yellowish white specks. No induration in the fold or around it. There is a little secretion on the surface, but no ulceration. The eye is otherwise normal.	Great swelling of cervical and pre-auricular glands on same side.	None. Fauces a little red, but no ulceration.	The eye has been affected one week, the glands three weeks. On suggesting the probable nature of the affection, patient told me he was living with a woman. I saw the woman, and she was free from syphilis and in robust health. He has run no risk of infection for a long time. When in army, twenty years ago, he had a sore on his penis, and the surgeon that attended him expressed surprise that it was not followed by any secondaries.	Alum lotion; case watched. In four days glands worse, hard and tense, and felt warmer to hand than opposite; not much pain: eye as before. Lot. nigra, pot. iod., grs. x., ter die. I heard some time afterwards that the glands supplicated and the eye got all right. I saw him two years after; there was not a trace of anything to be seen.
9. Vol. I. F. R., age 21. Single. Dr. Little.	At first visit diagnosis was purulent conjunctivitis of right eye. In ten days there was noted a small ulcerating surface near edge of upper lid, covered by a scab, and with a good deal of induration of, and around, its base.	Enlarged, and painful on same side.	None. Follicular tonsillitis. Tonsils nearly meet.	Denies all risk of infection.	Sulphate of zinc lotion. Lost sight of patient.
10. Vol. I. M. G., age 63. Single. Dr. Little.	Outer half of upper lid of right eye swollen, red, and indurated; ulceration near edge, creeping for some distance round edge on to the inner surface, and covered by a white exudation. No sore on vulva. Dry external pile surrounding edge of anus in front (2 years).	None now present, but patient says there were great humps on side of her neck, which have lately gone. Eight days after this one enlarged gland noted.	A coppery rash on arms appeared in ten weeks, followed by iritis.	Lid had a fortnight; commenced as a "powk;" has been nursing for last four months a child, which I examined and found to be suffering from congenital syphilis with rash out.	Pil. hydrarg., grs. ii., bis die. Lot. nigra. Quinine. Extensive destruction of outer third of lid.

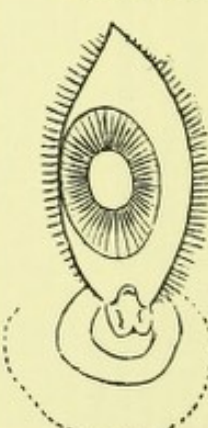


NAME, AGE, &c.	LOCAL LESION.	PRE-AURICULAR GLANDS.	SKIN ERUPTIONS, &c.	HISTORY.	TREATMENT AND PROGRESS.
11. 418. Vol. I. S. J., age 37. Married. Dr. Little.	At the outer part of the right (?) lower lid there is, close to the edge, a little circumscribed swelling and redness; no induration. On pulling down lower lid, one exposes a small white sloughy ulcer, with edges not sharply defined, and rather irregular.			Patient had syphilis four years ago.	Lotio nigra Pot. iod. grs. v., ter die.
12. 420. Vol. I. M. M., age 52. Married. Dr. Little.		Glands at angle of jaw entangled and hard, also mass of suppurating glands below chin.		Lid affected five weeks.	
13. 20. Vol. II. E. J., age 27. Married. Dr. Little.	Left eye, below inner canthus, and close to margin of lid, is a little swelling; skin not broken.		Typical copious pterygoid face; white mucous plaque on right side of upper lip.	Eye bad one fortnight; ulceration on privates two months before last confinement—two and a half months ago; child lived only four days; had a miscarriage twelve months ago.	Lead lotion. Pil. hydrag. subchl. co., grs. v. In three months eruption gone and eye well; lip still bad; good deal of thickening.
14. 422. Vol. I. A. W., age 65. Widow. Dr. Mules.	Left eye. At first visit there was very profuse yellow thick discharge. Diagnosis, gonorrhoeal ophthalmia, though patient denied having had any vaginal discharge. This was followed by slight ulceration of upper part of cornea, with great thickening and induration of upper lid. The lid could not be properly everted for three weeks, and when this was done there was disclosed far back from the edge a round hard ulcer with a deep conical depressed surface.	No note; but I believe there was no enlargement of the preauricular glands.	An undoubtedly specific scaly eruption appeared on scalp and neck, six weeks from date of commencement of ophthalmia.	Denied she had ever run any risk of venereal disease.	Astringent lotions; and, after appearance of rash, pil. hydrag. subchl. co., grs. v.
15. 46. Vol. II. M. W., age 24. Married. Dr. Little.	Right eye. A small ulcer (a) close to edge of lower lid; grey surface spreading round edge on to conjunctiva.	Enlarged, and hard on both sides.	None. Throat all right.	Got a kick on her eye from her husband twelve months ago, and noticed the ulcer on lid since then; she has poulticed it. No history of infection. Living apart from her husband twelve months.	Lotio nigra. Pil. hydrag. subchl. co., grs. v.



NAME, AGE, &C.	LOCAL LESION.	PRE-AURICULAR GLANDS.	SKIN ERUPTIONS, &C.	HISTORY.	TREATMENT AND PROGRESS.
<b>16.</b> 114. Vol. II. T. J., age 41. Married, but not living with wife. Dr. Glascott.	On bridge of nose, close to brow, is situated, right in the centre, a circular hard red sore, size of a six-penny piece. Edges rounded, hard, and raised, and surface also slightly raised. Lids of right eye hard, swollen, and dusky red. Conjunctiva of bulb injected and chemosed. Moderate muco-purulent discharge.	Enlarged and hard on right side.	Coppery eruption on face, breast, and arms; ulceration of fauces. (On examining penis one month after date of present notes, there was found on corona glandis a small sunken scar about the size of a split pea, which may have been a hard sore.)	Three months ago he was struck on the bridge of the nose with a piece of pot. The eruption and swelling of glands appeared about a fortnight ago. He had discharge from urethra six months ago, following intercourse, but no sore on privates so far as he was aware.	Astringent lotion, and mercury when specific nature recognised, followed by pot. iod.
<b>17.</b> 95. Vol. II. S. D., age 33. Married. Dr. Little.	Left eye. Ashy grey ulcer at edge of inner half of lower lid, spreading well into conjunctival sulcus; good deal of muco-purulent secretion.	Not affected.	Tertiary syphilitic sore below inner malleolus on right side, and a similar one on right shoulder.	The sore on the lid commenced as a pimple five weeks ago. Has been in poor health since birth of last two children. The younger is five months old and shows so far no signs of syphilis; the elder would have been two years old, but died of bronchitis after vaccination, aged one year.	Lutio nigra. Pot. iod. grs. x. The lid did not get quite well for twelve months.
<b>18.</b> 128. Vol. II. J. M., age 26. Married. Dr. Little.	Left eye. Large oval ulcer, occupying nearly the outer half of the upper lid, the upper edge just reaches the conjunctival surface. No particular hardness.	Enlarged, and hard on same side.		Eye had a fortnight. Married four years; one child, aged twelve months, before that one miscarriage. Was a prostitute seven years ago; had "the disorder," no sore, only a discharge.	One year and seven months after notes taken. Lashes and edge of lid destroyed at outer third; no hardness; breaking down gumma on top of head, and scarring of bridge of nose with falling in to slight extent.



NAME, AGE, &c.	LOCAL LESION.	PRE-AURICULAR GLANDS.	SKIN ERUPTIONS, &c.	HISTORY.	TREATMENT AND PROGRESS.
<b>19.</b> 129. Vol. II. A. T., age 1. Dr. Little.	Left eye. A large white ulcerating surface situated on the outer surface of the lower lid, extending nearly the whole length of the lid, deeply excavated, and substance rapidly breaking down.	Parotid glands enlarged.		Lid has been bad one week. Mother has had six other children and one miscarriage.	One year and nine months after notes taken. Mother says that some weeks after we saw child an eruption broke out all over its body, and she got a severe sore and inflammation of her breast, and also an eruption. At the middle of the child's lower lid there is a small portion of edge destroyed and lashes gone.
<b>20.</b> 469. Vol. II. E. K., age 39. Married. Dr. Glascott.	Right eye. Round, light brown scab on skin of upper lid, at outer part, quite free from conjunctiva; slight ulceration below scab; very little induration around, but, on taking hold of the sore between finger and thumb, it has the "parchment-like" feeling; some redness of lid and injection of conjunctiva; slight ulceration of upper part of cornea.	Not affected.	Coppery rash on arms; ulceration of throat.	Three weeks ago got a blow with a fist on the right eye, and noticed the scab since then; no sore on privates at any time, nor possibility of infection so far as she knows.	Pil. hydrarg., gr. i., ter die; iodoform locally. It did not take on a healthy action till it had been well scraped, and then with iodoform it speedily healed, leaving only a little induration and shrinking.
<b>21.</b> 274. I. P. Notes, 1884. E. M., age 20. Single. Dr. Glascott.	 <p>Left eye. Serpiginous ulcerating surface embracing the inner canthus spreading a short way along margin of each lid; dense hardness around it, indicated by dotted line; some redness and swelling of upper, and also, to less extent, of under lid; little thin discharge from ulcer and slight tendency to bleed; cornea clear, but surrounded by swollen conjunctiva.</p>	Great enlargement on same side forming large mass reaching nearly to middle line of neck and chin; also a few shotty ones over mastoid process.	Very faint and scanty eruption on abdomen came out with feverish attack some days after notes taken. He was seen by Dr. Brooke, who also found a few mucous patches on penis.	The eye had been bad eight weeks. Got some lime into his eye when white-washing; denies all possibility of infection.	Mercurial Inunction





