(5)

[Reprinted from the ANNALS OF OPHTHALMOLOGY AND OTOLOGY, July, 1895.]

REMARKS ON THE FIELD OF VISION IN CERTAIN CASES OF "NEGLECTED EYES."

By G. E. de Schweinitz, M. D.,
OF PHILADELPHIA.[1]

THE following cases illustrate some of the visual-field phenomena in that type of monocular amblyopia which is common with convergent and divergent strabismus. Although we may be familiar with the changes here depicted, the field of vision of "neglected eyes" is not always carefully investigated, and I believe that greater attention to this method of examination would add to our knowledge of these amblyopias.

[1] Read before the Ophthalmic Section of the College of Physicians of Philadelphia, March, 1895.

To introduce the subject I quote a paragraph written by Dr. Henry D. Noyes:

"Monocular amblyopia is very common in strabismus convergens and not infrequent in strabismus divergens. This may or may not be associated with high degrees of hyperopia or with astigmatism, possibly irregular. We meet with it where the degree of ametropia differs little from that of the eye with good vision, and in a very large proportion, perhaps in the majority of cases, no lesion can be found with the ophthalmoscope. On this point it is important to bestow careful attention. No small number of cases exhibit what are evidently congenital abnormalities in the papilla. In my records are such conditions as follows: An extraordinary amount of pigment deposit along the border; the presence of connective tissue on edge of nerve and running along the vessels (not to be confounded with opaque nerve fibers); a dull or slaty-colored and opaque disc with hazy edges; extreme hyperemia, both of capillaries and veins; the nerve swollen as in papillitis, a dark gray or slaty spot upon the disc and the rest of the surface an opaque white; coloboma of the sheath of the nerve or a very deep and irregular excavation which was so interpreted. Besides, one must carefully scrutinize the macula and it must be done with dilated pupil. Not rarely will one find minute specks—white, yellow or glistening—clustered here, which indicate lesion either of the choroid or retina. There may be one or more marked pigment specks which will denote a previous inflammatory lesion. A notable number of cases, and the majority, will not reveal any visible lesion. In the examination of the visual field we are often prevented from attaining exact knowledge by the extreme youth of the subjects. When, however, they are sufficiently intelligent, we frequently find that the amblyopia is central, and a defined scotoma for red may be sometimes mapped out provided a small card 5 *mm.* square and dim light can be employed. The scotoma may be very small and will be better discovered on a dark plane surface than by the perimeter. Sometimes a patient will say that over a small space, not the blind spot of Mariotte, a small candle flame is not perceived. This means a small absolute scotoma. In one case I found nasal (medial) amblyopia with the line of demarcation vertical. It was not difficult to show the decided difference in perceptive power of the respective halves of the retina—this might be called hemiamblyopia."

For the purpose of study I have gathered the cases into three groups, as follows:

GROUP I. CASES IN WHICH THE VISUAL FIELD FOR FORM AND COLORS IS NORMAL, OR PRACTICALLY NORMAL, AND IN WHICH THE ACCURACY OF COLOR PERCEPTION AT THE MACULA, OR BETWEEN IT AND THE FIXING POINT, IS UNAFFECTED.

Two examples will suffice:

Case I. Mrs. P., 39 years of age; denies strabismus, but has never seen well with the left eye. As ordinarily observed, there is no abnormal convergence, but the eyes wander in under cover and there is slight convergence of the left one on fixation at 30 *cm.*, or if tested by means of the corneal reflex of the ophthalmoscope.

The right eye is hypermetropic and slightly astigmatic and

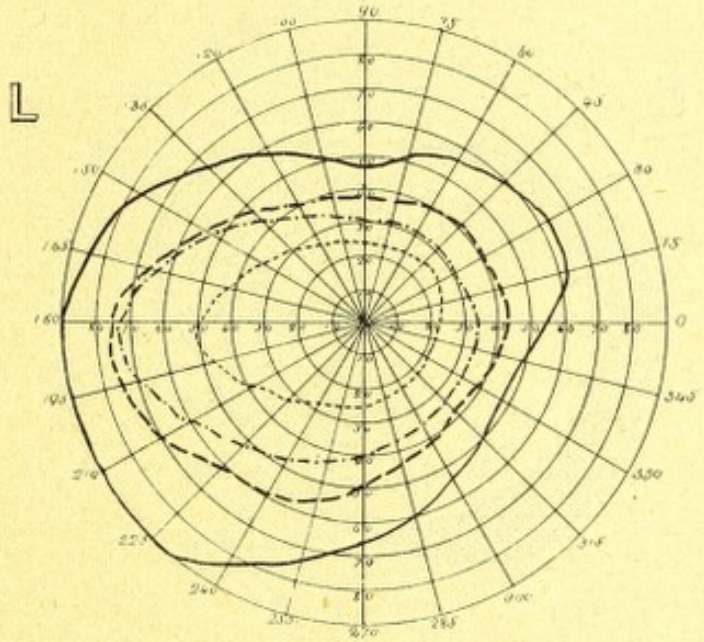

FIG. 1.
Diagram of the field of vision of Case 1, Group 1. Normal in all respects.

possesses full acuity of vision. The vision of the left eye equals counting fingers at 1 foot, the refraction is + 3.50 S. ⌒ + .75 C., axis V., the corneal astigmatism with the Javal ophthalmometer being 1.50 diopters according to the rule, axis 90°.

There is no ophthalmoscopic abnormality in the right eye; in the left the disc is a vertical oval, of good color, contains a small physiological cup, and is bounded by a pigment crescent on the temporal side; the vessels are of normal size.

After wearing the correction for nearly a year, the patient returned with the vision of the right eye $\frac{6}{5}$, of the left eye $\frac{6}{30}$. She had "amused herself by practising," as she expressed it, with her left eye.

The field of vision[2] (Fig. 1) is practically normal in all respects, and there is nowhere an area of diminished color perception nor a scotoma, save the natural blind spot, which is promptly acknowledged.

Case II. Mrs. J., 26 years of age, had convergent strabismus of the left eye in childhood, but "outgrew it." There is now a slight convergence, about 1 *mm.* Vision equals $\frac{6}{40}$. The right eye, save for a slight hypermetropic astigmatism, is entirely normal, and possesses full visual acuity.

In the left eye the optic disc is a vertical oval, rather hyperemic, a slight crescent bounding its temporal border. The ophthalmometer reveals a corneal astigmatism of 1 diopter according to the rule, with its axis vertical, and the refraction of the eye is

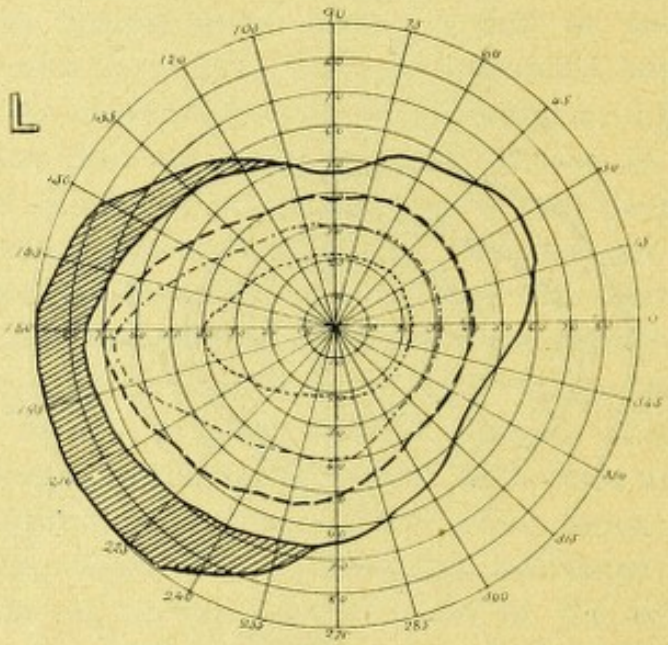

FIG. 2.

Diagram of the field of vision of Case 2, Group 1. Color field practically normal; slight contraction on the temporal side of the form field.

+ 1 S. ⌒ + 0.50 C., axis V. With this glass vision equals $\frac{6}{30}$. Eighteen months later the vision of this eye was about the same, perhaps somewhat better, $\frac{6}{22}$ being recorded.

The field of vision (Fig. 2), save for slight contraction on the temporal side, is practically normal and the color sense of normal standard.

---

[2] All the diagrams of the visual fields are constructed as follows: White, ———; blue, — — — —; red, — . — . — . —.; green, ... Scotomas are represented by dotted areas; peripheral contractions by shading with parallel lines.

GROUP II. CASES CHARACTERIZED (a) BY CONTRACTION OF ONE OR MORE OF THE COLOR FIELDS, THE FORM FIELD REMAINING NORMAL, AND (b) BY IRREGULAR CONTRACTION OF BOTH FORM AND COLOR FIELDS, SOMETIMES ASSOCIATED WITH REVERSAL OF THE RED AND BLUE LINES.

Case I. S. Y., a man 22 years of age, with a vague history of inflammation of his eyes in childhood, of which there are no traces, presented a monocular strabismus of the left eye, the angle of squint being 28°. Vision in this eye equaled counting fingers at 1 *m.* There is no corneal astigmatism, but a hypermetropia of 4 D. at the macula. The disc is a vertical oval, of good color; the

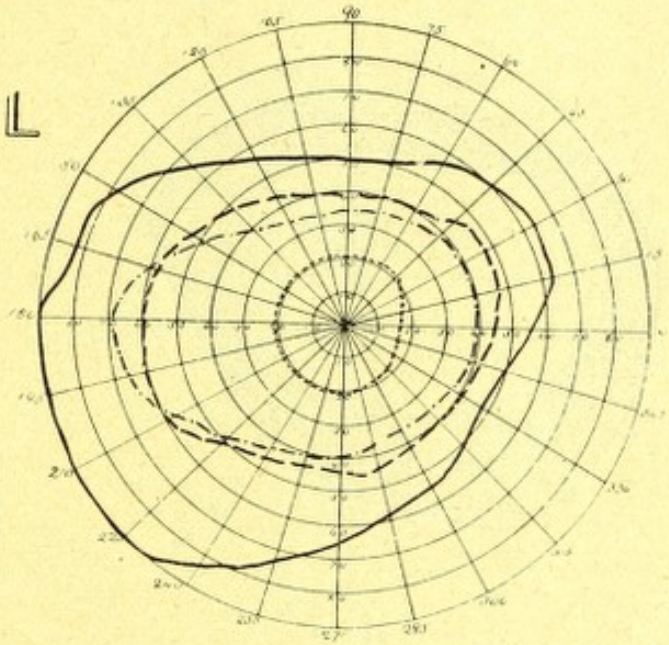

FIG. 3.

Diagram of the field of vision of Case 1, Group 2, exhibiting partial reversal of the red and blue lines, with marked restriction of the green field.

vessels are distorted and pass to the nasal side. After glasses were ordered, and tenotomy of the internus and advancement of the externus had been performed, there was restoration of parallelism of the visual axes, but no improvement in vision. The right eye is slighly hypermetropic, but normal in all other respects.

The dimensions of the form field are normal. There is slight contraction of the blue field and partial reversal of the red and blue lines, with marked restriction of the green field, but no scotoma and no diminution of central color perception. (Fig. 3.)

Case II. Annie J., 25 years of age, has marked divergent strabismus of the left eye, the angle of squint being 34° and the

myopia 16 diopters. The optic disc, surrounded by a posterior staphyloma, is distinctly gray in its deeper layers. The vessels are normal in size and distribution; V. equals counting fingers at 1 foot. The right eye, save for slight myopia, is normal.

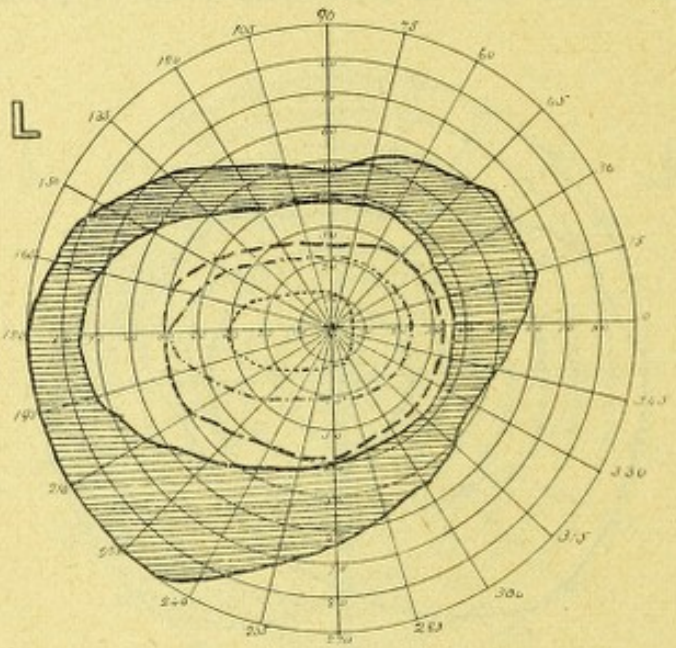

FIG. 4.

Diagram of the field of vision of Case 2, Group 2, showing marked contraction of form and color fields, with practically a half defect in the contracted green field.

The visual field (Fig. 4) shows marked contraction of form and color fields, the restriction being relatively greater for green, which is particularly defective upon the nasal side, practically a half defect, or hemiachromatopsia for this color.

Case III. C. E., a boy 16 years of age, had whooping-cough in childhood, and since then divergent strabismus of the right eye in which the vision amounts to counting fingers at 2 feet. The exact refraction of the eye is — 17 D. ⌒ — 2 C., axis 25, the corneal astigmatism is 2.50 D., according to the rule, with the axis at 115°. A glass does not improve the vision. The optic disc is a narrow oval with its axis at 115°, grayish-red in color and skirted by an

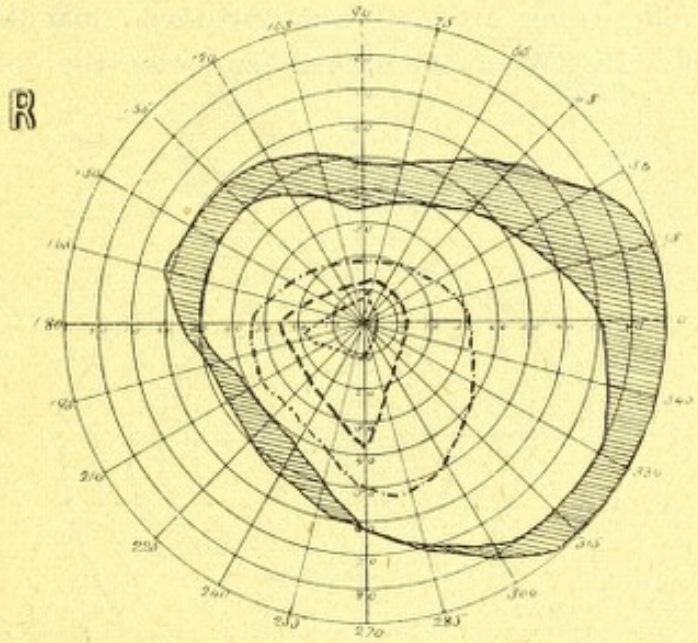

FIG. 5.

Diagram of the field of vision of Case 3, Group 2. Contraction of form and color fields; half defect in the very contracted green field; reversal of the red and blue lines.

atrophic area upon the nasal side twice as wide as the disc. In the left eye the disc is somewhat gray in its deeper layers, but after the correction of a low-grade hypermetropic astigmatism, the vision is normal.

The field of vision upon the right side (Fig. 5) shows contraction for form and colors and again a species of half defect in the very contracted green field, the larger portion of the field being in this instance upon the nasal side. The red and blue lines are reversed.

GROUP III. CASES WITH OR WITHOUT CONCENTRIC CONTRACTION OF THE COLOR AND FORM FIELDS, BUT ASSOCIATED WITH (a) DIMINISHED CENTRAL COLOR PERCEPTION EITHER AT THE POINT OF FIXATION AND SURROUNDING IT, OR BETWEEN IT AND THE BLIND SPOT, OR (b) WITH SCOTOMA, CHIEFLY FOR COLORS.

Case I. M. G., a lad 18 years of age, has no history of squint and no strabismus is now demonstrable. Since childhood he has been amblyopic in the right eye. Vision equals quantitative light perception. The optic disc is a vertical oval with slightly edematous surface. The veins are full and tortuous; macula + 4 D., vertical vessels 7 D. With the ophthalmometer the corneal astig-

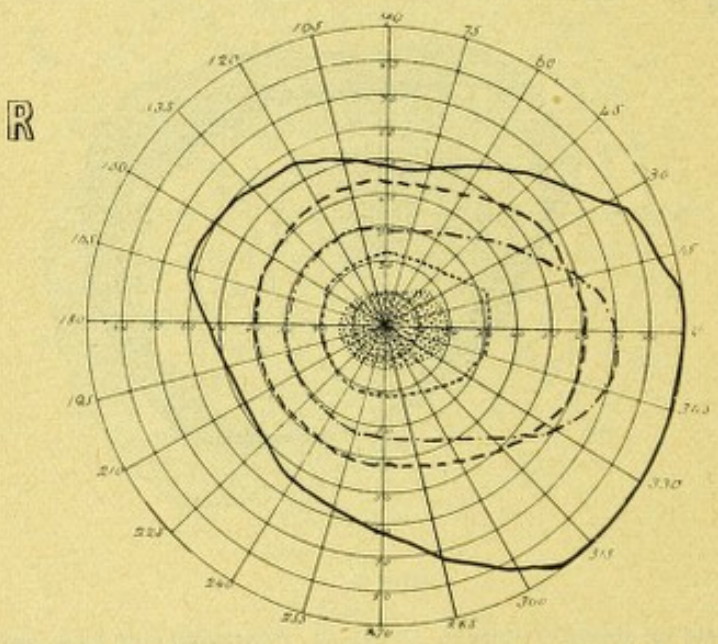

FIG. 6.

Diagram of the field of vision of Case 1, Group 3. Practically no contraction, except in the green field, but a central area of loss of perception of colors with small test objects and weak illumination, indicated by the dotted portion.

matism is 3 diopters according to the rule, with the axis vertical. Correction does not improve the vision. The left eye is normal; refraction low H.

The form field is normal, the red field practically normal; there is slight contraction of the blue field, decided restriction of the green field, and an oval area 35° in its long and 20° in its short diameter, within which there is distinct loss of the perception of form and colors with small test objects and weak illumination, although with large tests object colors are still imperfectly recognized. (Fig. 6.)

Case II. W. S., a man 27 years of age, has had convergent strabismus of the right eye, with amblyopia, since childhood. The refraction of the right eye is + 2 D. ⌒ + .50 D. C., axis 105, corneal astigmatism being 1 diopter, according to the rule with its axis at 105. The macula is slightly granular, the disc of fairly good color, but there is marked broadening of the scleral ring. All vessels, but especially the veins, are tortuous. The left eye, slightly hypermetropic, is normal.

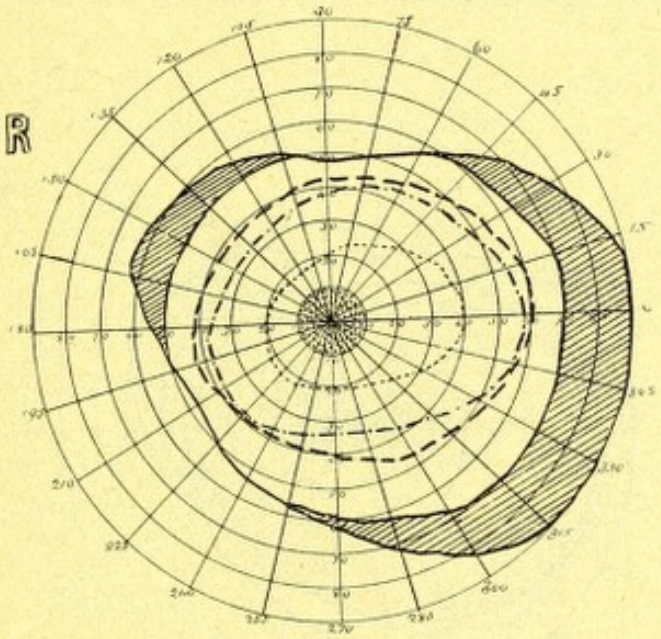

FIG. 7.

Diagram of the field of vision of Case 2, Group 3. Area of diminished color perception similar to that seen in Fig. 6; slight contraction of the form field.

There is slight contraction of the form field; the red field is not far from normal; the blue and green fields are slightly contracted, and there is a circular area surrounding the fixing point for about 10° in which there is marked diminution in the color sense, all colors appearing pale or paler than normal, although with large objects they are still recognized in their true characters. The point at which the color pales is sharply marked from that at which it is perceived in its natural intensity. (Fig. 7.)

Case III. John L., 49 years of age, gives a history of strabismus in childhood, but there is none now demonstrable, nor is there any deviation of the left eye, which has always been amblyopic.

The disc is a vertical oval, the nasal margins are blurred, there is grayness in the deeper layers and marked tortuosity of the veins. The actual refraction is + 5 D. ⌒ + 2 D. C., axis 120, the corneal

astigmatism being 2.50 diopters, according to the rule, with the axis at 120; V. = $\frac{6}{45}$. The refraction of the right eye is H., V. = normal.

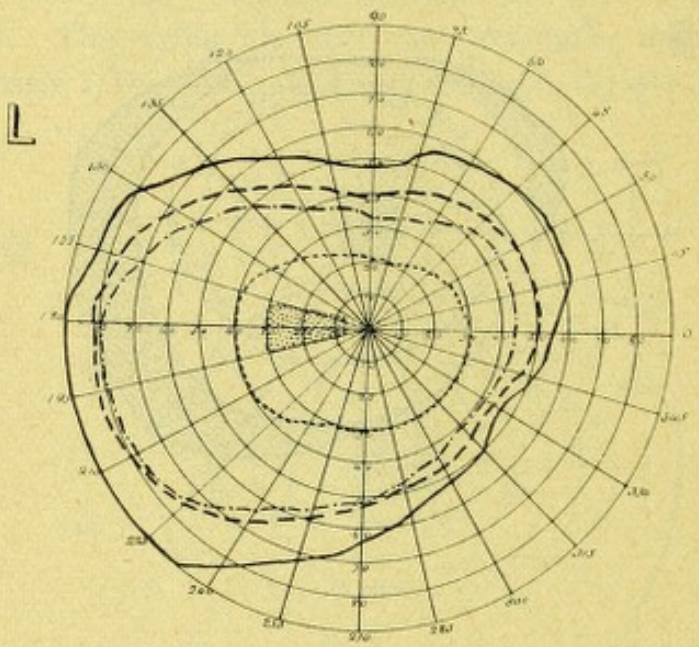

FIG. 8.

Diagram of the field of vision of Case 3, Group 3. Slight contraction of the green field and wedge-shaped scotoma for small colored objects observed under weak illumination, indicated by the dotted portion of the diagram.

The field of vision of the defective eye (Fig. 8) is normal for form and for red and blue. There is slight contraction of the green field, and between 5° and 30° to the temporal side there is a wedge-shaped scotoma for small colored objects observed under weak illumination, although the colors are still recognized as such when the test object is large and the illumination bright.

Case IV. Margaret S., 50 years of age, has had from childhood a "slight cast in the right eye," which was attributed to fright. There is moderate convergence of O. D., vision equals counting fingers at 2 feet; the disc is a vertical oval, gray, the scleral ring broadened all around and the veins full. The refraction is + 3 D. ⌒ + 3 D. C., axis 100. This glass does not improve vision. The left eye presents no important abnormality; refraction a slight myopic astigmatism.

There is marked irregular contraction of the form field of the right eye and a large scotoma for colors passing 20° to the nasal

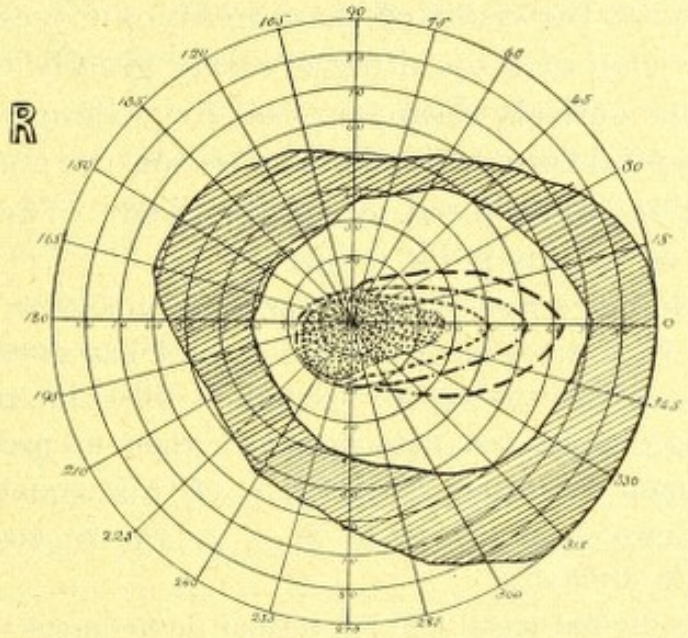

FIG. 9.

Diagram of the field of vision of Case 4, Group 3. Marked contraction of form and color fields and large scotoma for colors indicated by the dotted area in the center of the diagram. There is a species of hemiachromatopsia, colors being chiefly perceived upon the temporal side.

side and nearly 30° to the temporal, 20° below and 10° above. The contraction of the color field is peculiar, blue and green being seen only on the temporal side—again a species of hemiachromatopsia—while red is likewise seen on the temporal side, lost, as are all colors in the scotomatous area, and faintly reappears on the nasal margin of the acquired blind spot. When the patient was last seen there was no change in the vision. (Fig. 9.)

It will be noted:

1. That the cases with normal visual fields and good color perception seem capable of acquiring increased visual acuity, as, for example, Case 1 of the first group.

2. That in the cases with marked abnormalities in the visual fields, particularly in the form of areas of diminished color perception, or color scotomas, there are visible changes in the discs, although in no instance was such an appearance evident as may be seen in the nerve head in toxic amblyopia. Visual acuity in these cases did not improve.

3. That in some cases, for example, Case 1 of Group 3, the abnormality of the visual field is analogous to that seen in hysteria, neurasthenia and allied conditions usually associated with retinal tire.

With regard to the vision of these amblyopic eyes we know:

(a.) The vision of a squinting eye may greatly improve, or the amblyopia entirely disappear, as, for example, in W. B. Johnson's[3] capital case, when for any reason the non-squinting eye becomes suddenly blind, or is removed. The following case bearing upon this point is interesting:

C. S., a man 30 years of age, has had moderate convergent strabismus of O. S. since early childhood, and has never seen well with this eye. About the 1st of November, 1894, the retina of the right, or seeing eye, became detached, and when he presented himself for treatment, December 12. 1894, V. of O. D. equaled counting fingers in the lower field; V. of O. S. = $\frac{6}{15}$, barely, and spells No. 4 at 18 *cm.* with difficulty.

The usual medicinal treatment of retinal detachment—rest in the recumbent posture, pressure bandage and pilocarpin diaphoresis—was pursued, with the result of obtaining in three weeks partial reattachment of the displaced retina, and V. = $\frac{6}{12}$. Vision of the left eye remained, as before, $\frac{6}{15}$. A relapse then occurred, vision of O. D. sinking to about one-third of normal, uncertainly appreciated. The patient declining operative interference, the refractive error of the left eye (+ 0.75 S. ⌒ + 0.75 C., axis 30°) was carefully neutralized, and the patient urged to use this eye to the exclusion of the other. In two weeks the vision rose from $\frac{6}{15}$ to $\frac{6}{9}$, and several letters on the $\frac{6}{7.5}$ line. The color field in this eye was normal in all respects.

(b.) The vision of the squinting eye may be improved by exercise,[4] although this is an uncommon record, perhaps, as Randall suggests, "because of the youth of many of the

[3] *Trans. Amer. Ophth. Soc.*, Vol. VI., Part 3, p. 551.

[4] Consult discussion on W. B. Johnson's paper, *loc., cit.*; cases by Risley and Holt, with reference to Javal's case.

patients and the difficulty of applying the tests of vision in such cases," but often, no doubt, because the process is tedious and the results uncertain and discouraging. As every practical ophthalmologist knows, in many cases of anisometropia the visual acuity of the eye with the greater refractive error may be markedly sharpened by exercising its neglected functions, although it is doubtful, as Gould[5] points out, whether this line of practice has received the attention it deserves. While the amblyopia of anisometropia, unassociated with squint, is not strictly germane to the present topic, it at least has some bearing upon the value of exercise and practice with the deficient organ.

If it is true, and it appears to be from such a case as Johnson's, that amblyopia may be due to suppression of the visual image, and furthermore true that such cases rapidly regain vision if required, by reason of the removal or blindness of the fellow eye, to assume the responsibilities of the visual act, is it not worth while to carefully investigate, as Dr. Noyes urges, the field, color field and color sense of these "neglected eyes" and to endeavor to obtain data which might lead to more certain prognostications as to the result of exercising the visual functions than we now possess, at least than the records seem to show that we possess?[6]

---

[5] *The Medical News*, December 31, 1892.

[6] I am indebted to my former assistant, Dr. William Bruner, for aid in preparing the diagrams of the visual fields of the cases described in this paper.