

**Implantation of a gold ball for the better support of an artificial eye / by L. Webster Fox.**

**Contributors**

Fox, L. Webster 1853-1931.  
Ophthalmological Society of the United Kingdom. Library  
University College, London. Library Services

**Publication/Creation**

[New York] : [D. Appleton], [1902]

**Persistent URL**

<https://wellcomecollection.org/works/v eb8eu8n>

**Provider**

University College London

**License and attribution**

This material has been provided by UCL Library Services. The original may be consulted at UCL (University College London) where the originals may be consulted.

Conditions of use: it is possible this item is protected by copyright and/or related rights. You are free to use this item in any way that is permitted by the copyright and related rights legislation that applies to your use. For other uses you need to obtain permission from the rights-holder(s).

**wellcome  
collection**

Wellcome Collection  
183 Euston Road  
London NW1 2BE UK  
T +44 (0)20 7611 8722  
E [library@wellcomecollection.org](mailto:library@wellcomecollection.org)  
<https://wellcomecollection.org>

*Reprinted from the New York Medical Journal  
for January 18, 1902.*

---

187

## IMPLANTATION OF A GOLD BALL FOR THE BETTER SUPPORT OF AN ARTIFICIAL EYE.

By L. WEBSTER FOX, A. M., M. D.,  
PHILADELPHIA,

PROFESSOR OF OPHTHALMOLOGY, MEDICO-CHIRURGICAL COLLEGE.

It is now five years since I devised the method of implanting a glass ball into the orbital cavity in cases where the eyeball had previously been removed. The method followed at that time was as follows: An incision was made through the conjunctiva and tissues of the orbit in the horizontal direction, fourteen millimetres long, corresponding to scant the diameter of the glass ball to be inserted. For instance, if the glass ball is sixteen millimetres, the incision would be fourteen millimetres. The upper lip of the conjunctiva is raised and, with sharp-pointed curved scissors, the conjunctiva and such connective tissue as lie close to it are dissected off in all directions around the incision, making a pouch into which the glass ball will fit. The edges of the conjunctiva are brought together over the ball by five or six stitches and the after-dressing is the same as is followed in evisceration cases.

This is the description of my first operation. The defect in this operation was that, in healing, the contraction of the tissues caused a rupture of the two

COPYRIGHT, 1901 AND 1902, BY A. R. ELLIOTT PUBLISHING COMPANY.

1848062

*Gold Ball for Support of Artificial Eye.*

central stitches, exposing the ball, which in a short time came out; in thirty-three per cent. of my first cases the glass balls were expelled. My second improvement was then to give support at this point by inserting, above and below, supporting stitches. These silk threads were placed four lines above the middle stitch, the needle was passed through tissue, conjunctiva, and muscle, parallel with the central opening, another needle and thread was passed through the same tissue a little beyond, and also parallel with, the closed wound, and two stitches

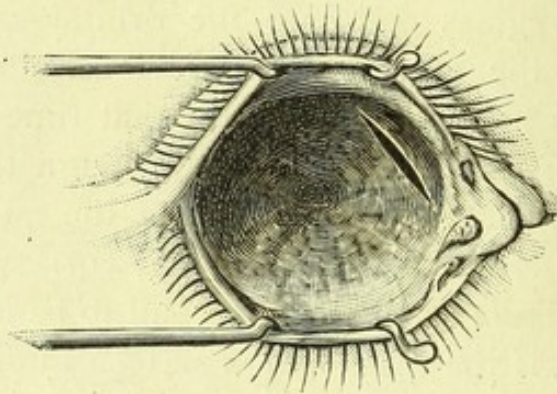


FIG. 1.

were also passed through conjunctiva and tissue just over the inferior muscle. Then the threads opposite each other were drawn together and tied. These supporting stitches removed the tension of the middle stitches in the primal incision. At the end of the fourth day, all of the stitches were removed, as I found that, by allowing them to remain six or seven days, stitch abscesses would occasionally form and the ball would be expelled. This advance in closing the wound and retaining the ball *in situ* was a great advance, but the operation was not

*Gold Ball for Support of Artificial Eye.*

so successful as was demanded; there were fifteen per cent. of expulsions. I also found that the glass ball was pushed to one side or the other of the centre of the orbital cavity—in some few cases the balls were pushed down and out—consequently, the adjustment of an artificial eye could not be made, and the glass balls had to be taken out. I was compelled to enucleate the glass ball and repeat the operation three times in one case. This, as can be readily understood, was another defect in the operation. In the present day of successful ophthalmic surgery

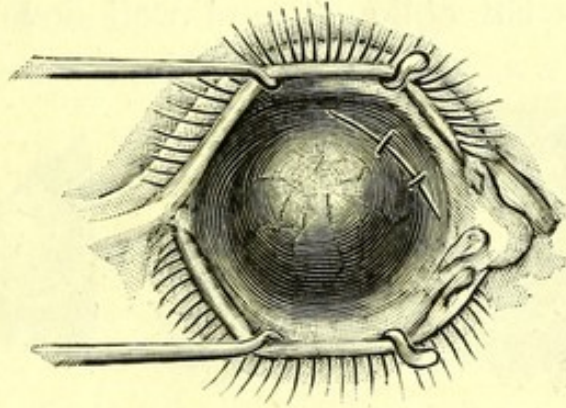


FIG. 2.

I felt that the percentage of failures, thirty-three per cent. primarily, and by modification fifteen per cent., was too large to make this operation a popular one.

The satisfactory wearing of an artificial eye over this stump is vouched for by many patients. The filling up of a deep socket, the prevention of incrustation in, and also over, the artificial eye, the absence of retained secretions, as well as the sunken and immobile eye giving a sinister stare to the patient, led me on to perfect this operation, until now no failures need be recorded, and all the defects described above, avoided.

*Gold Ball for Support of Artificial Eye.*

It is now six years since I implanted the first glass ball in a patient where the eye had been removed twelve years before. Eighteen months ago I devised the present method, which I can now safely recommend.

If the operation is to be performed in the right orbit I carry out the details as follows: The eyelids are kept apart by a speculum, the conjunctiva is then grasped up and in above the inner canthus, and the tissues are well pulled out. I then pass a Beer's knife or a curved keratome through the tissues, somewhat obliquely and well down into the




FIG. 3.

orbit; this opening must be made large enough to push the globe in the opening behind the tissues, conjunctiva, etc. (Fig. 1). This starts the opening, which I enlarge with curved scissors, separating the tissues from the cellular tissues around the orbit, thus giving me a large pouch into which the globe can be inserted. I have discarded glass and silver balls and only use gold balls of 11, 12, 13, and 14 millimetres in diameter (Fig. 3).

The gold ball is inserted through the opening and retained in place by a shell which I have modelled after an artificial eye, and which I call a "conform-

*Gold Ball for Support of Artificial Eye.*

er" (Fig. 4). I have three sizes for various sized orbits. I close up the incision with two stitches (Fig. 2), then place the conformer over the buried ball, and by gentle manipulation on this metal rotate the ball into place. The circular opening in the conformer allows the gold ball to fit the space which will be covered by the cornea of the artificial eye.

The eyelids are then closed over the conformer, which is left in place twenty-four hours. The eyelids also help to keep the ball in place. I have these conformers made of metal, gold plated. The results obtained by this method are perfect; no secondary trouble follows, all healing up by first inten-

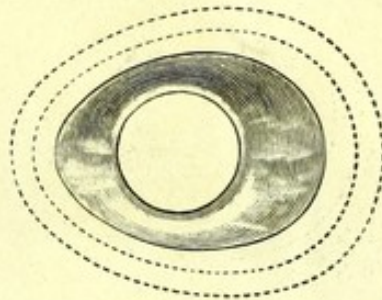


FIG. 4.

tion, and the two stitches are taken out on the third day.

It can be readily understood now that the gold ball cannot break through the centre of the conjunctiva, and, as the opening is out of line of pressure, it soon closes up. If the operation is to be performed on the left orbit, the incision is made up and out above the external rectus muscle, and the dissection carried out as described above.

Fig. 5 shows the result of the operation with the artificial eye adjusted. The patient was brought to

*Gold Ball for Support of Artificial Eye.*

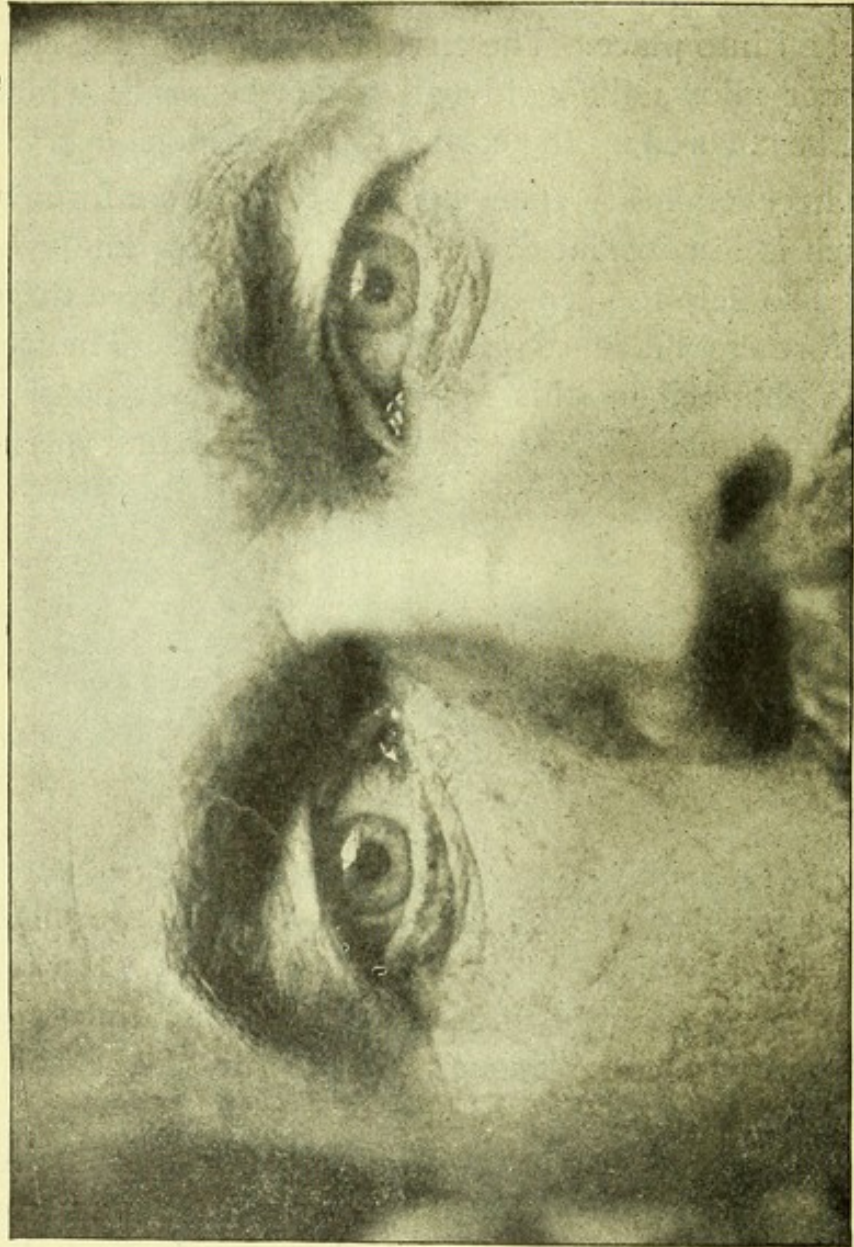


FIG. 5.



Digitized by the Internet Archive  
in 2015

<https://archive.org/details/b21647768>



