

**The more frequent diseases of the frontal sinuses : clinical lecture delivered at the post-graduate medical school, Chicago / by Casey A. Wood.**

**Contributors**

Wood, Casey A. 1856-1942.  
Ophthalmological Society of the United Kingdom. Library  
University College, London. Library Services

**Publication/Creation**

[Chicago?] : [publisher not identified], [1900?]

**Persistent URL**

<https://wellcomecollection.org/works/ep62arvx>

**Provider**

University College London

**License and attribution**

This material has been provided by This material has been provided by UCL Library Services. The original may be consulted at UCL (University College London) where the originals may be consulted.

Conditions of use: it is possible this item is protected by copyright and/or related rights. You are free to use this item in any way that is permitted by the copyright and related rights legislation that applies to your use. For other uses you need to obtain permission from the rights-holder(s).



Wellcome Collection  
183 Euston Road  
London NW1 2BE UK  
T +44 (0)20 7611 8722  
E [library@wellcomecollection.org](mailto:library@wellcomecollection.org)  
<https://wellcomecollection.org>

127

## THE MORE FREQUENT DISEASES OF THE FRONTAL SINUSES.

CLINICAL LECTURE DELIVERED AT THE POST-GRADUATE MEDICAL SCHOOL, CHICAGO.

BY CASEY A. WOOD, M.D.,

Professor of Ophthalmology in the Chicago Post-Graduate Medical School; Ophthalmic Surgeon to the Passavant Memorial Hospital; Fellow of the American Academy of Medicine, etc., Chicago.

GENTLEMEN,—It is very probable that inflammatory processes of the frontal sinuses are much more common than the practitioner usually imagines. For example, headache confined to the frontal region of one side is not infrequently due to frontal sinus disease, although it is commonly spoken of as "neuralgic in character," and is confounded with the supra-orbital pain of nasal and ocular affections, la grippe, etc. Even bilateral frontal headache may be due to acute disease of the sinuses, because, although commonly unilateral at first, both sides may be eventually diseased in consequence of infection of the second sinus through the opening that often joins them. Failure on the part of many to recognize the rôle that inflammatory infections of these frontal cavities play in the production of symptoms is, therefore, my excuse for discussing the whole subject here.

First of all let us examine this skull, so articulated and sawn that it plainly shows all the parts related to the frontal sinuses. These two plates, from Moldenhauer's "Krankheiten der Nasenhölen," will also assist us in obtaining a proper idea of their anatomy.

Fowler's description of these sinuses, as given in the "Reference Handbook of the Medical Sciences," is one of the best known to me. "They are," says he, "two irregular-shaped cavities which extend upward and outward a variable distance between the two tables of the frontal bone, upon the vertical portion of its internal surface. They are situated one upon either side of the base of the nasal spine,

1847704



between the latter and the orbital plate. They are separated from each other by a thin, bony partition. In size they vary in different individuals, and are, as a rule, larger in the male than in the female sex. The frontal sinus of the left side is commonly the larger of the two. They are sometimes subdivided by incomplete bony laminae. They open into the middle meatus of the nose through the infundibula, and occasionally communicate with each other by apertures in the septum. They are absent at birth, but appear during the first year of childhood, and remain of small size up to puberty, at which time they undergo considerable enlargement from the recession of the brain. In advanced life they increase in size by absorption of the cancellated tissue in their vicinity. In their development they are practically formed from the diploe. Large frontal sinuses do not necessarily imply large external prominences over the glabella and superciliary eminences. They are lined by mucous membrane, this being continuous with the lining of the middle meatus of the nose through the infundibula. This mucous membrane, like that which lines the antrum of Highmore, is notably thin and pale. Its blood-supply is derived chiefly from the internal maxillary and ophthalmic arteries, and by anastomosis of these with the *lateralis nasi* branch of the facial artery. Its nerve-supply is principally from the first and second divisions of the fifth cranial nerve. In the middle meatus of the nose the communication through the infundibulum of either side with the frontal sinus is partially hidden, and practically closed by a projecting fold of the mucous membrane."

There is the greatest possible variation in the character of the connections that exist between the frontal sinus and the neighboring cavities. Many years ago, in the Anatomisches Institut, in Vienna, I made, with Dr. Melville Hardie, a large number of sections of this region, while studying its relation to the orbital cavity, and we discovered that in about twenty-five per cent. of all cases the frontal sinuses of the adult were really separate and complete cavities, unconnected with the nose or with one another. On the other hand, occasional normal communications with the orbit are known, and the opening of one sinus into the other is the rule rather than the exception. As a usual thing one finds the superior nasal meatus continuous with the corresponding frontal sinus by way of a round canal, before referred to as the infundibulum.



In thinking of the commoner diseases of the sinus one should bear in mind that they are mostly associated with diseases of the nose. They are often referred to as *acute* and *chronic* sinusitis and empyema.

*Acute inflammation of the frontal sinus* is almost always due to the extension of an acute rhinitis to the mucosa lining the cavity. It is by no means a rare affection, and its symptoms are often attributed to the rhinitis, when they are really due to the deeper inflammation. These are frontal and supra-orbital headache, increased on pressure at the supra-orbital notch, or at that part which usually corresponds to the situation of the sinus itself,—between the supra-orbital notch and the inner canthus. The headache is of a boring character and is almost constant; it is increased by coughing, sneezing, lying down, and by indulgence in alcohol. It is often accompanied by nausea and vomiting. Attempts to relieve this “cold in the head” by blowing the nose are mostly ineffectual. Scleral redness, lachrymation, and pain in the eyeballs are much more common than when the patient has a simple coryza only. *The diagnosis is made with certainty if a discharge from the nose is followed by sudden relief of the pain.* The symptoms may entirely cease and total recovery ensue, or the disease may pass into the chronic form. In my experience the latter termination is rare when the nasal disease disappears. In other words, we rarely have a chronic inflammation of the frontal sinuses when there is no corresponding chronic nasal disease.

*Chronic diseases of the mucous membrane lining the frontal sinuses* are mucocoele and empyema, and their commonest causes are infection from some form of rhinitis, or disease of the ethmoid cells,—often the syphilitic variety,—combined with a partial or complete closure of the infundibulum. Collections of mucus or muco-pus, pent up within the sinuses, are unable to escape through the drainage-canal of the infundibulum, so that infection and pressure symptoms follow. There is much less pain in the chronic forms of the disease, but swelling of the parts is more marked. The infundibular obstruction is commonly due to caries of the bones of the nose, polypi, hypertrophic rhinitis, and outgrowths from the septum. If for any reason the obstruction be momentarily removed, the pus or mucus is discharged and much relief is obtained. With returning obstruction of the infundibulum comes recurrence of the pain, swell-



ing, and other signs of the disease. This state of affairs may exist for months, and even years, during which time the secretions may find vent through some abnormal channel. When the symptoms are intermittent in this way, one should always suspect at least mucocoele of the frontal sinus. Complete closure of the natural opening soon results in dilatation of the sinus or of both sinuses, and pressure upon the surrounding parts makes this plain. At the inner angle of the orbit a soft, sometimes crepitating, and often plainly visible tumor shows itself.

*Empyema of the sinus* is rare before forty years of age. Unlike nasal-duct obstruction and lachrymal abscess (some of the signs of which it simulates), it is commoner in men than in women, probably because the cavities are better developed in the former. The same causes that serve to produce mucocoele operate to bring about pus-formation in the sinuses. In addition to the causes already given for the milder disease, syphilis and traumatism might be mentioned.

The symptoms of abscess of the frontal sinus much resemble those of chronic mucous sinusitis. Instead of an outpouring of simple mucus from the nose on the affected side, with a corresponding relief of the symptoms, we have an irregular, fetid, purulent discharge. It is well to remember that as the pus drips down or flows from the superior cavity it not infrequently infects the maxillary sinus beneath it, and it often happens that empyema of the frontal sinus is associated with the same process in the antrum of Highmore. In addition to the symptoms of mucocoele just detailed, there may be rise of temperature, chills, excruciating pains, and even brain symptoms, from pressure. The tumor presents at the inner angle, at a level with the bridge of the nose, while the palpebral and other skin in that neighborhood finally becomes red, swollen, and tender to the touch. There is often exophthalmus accompanied by diplopia.

When the abscess breaks (being unable to discharge through the infundibulum), it usually ruptures externally; but there are cases on record where it has opened into the cranial cavity with fatal results. Sometimes the amount of fluid found in the sinuses is very large, and this is much more likely to be the case where the disease has lasted a long time, and where there have been intermittent openings of the infundibular passage.

The *diagnosis* is not always easy. The use of the skiagraph and





Fig. 1.—Shrunken right eye from injury and swelling above left eye.

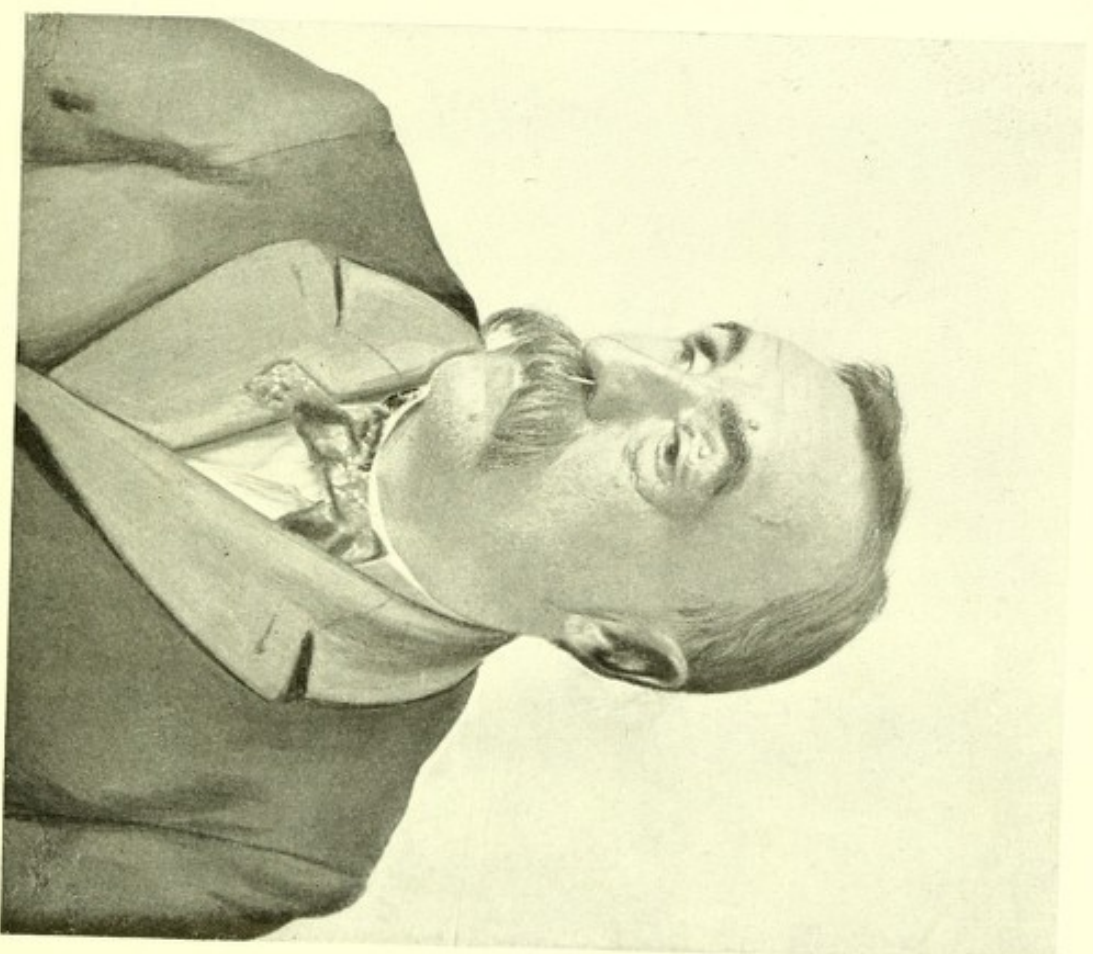


Fig. 2.—Inability to raise upper lid of left eye due to swelling.



Digitized by the Internet Archive  
in 2015

<https://archive.org/details/b21647562>



the illumination of the cavity by means of Hering's electric-lamp will greatly assist in clearing up any doubt. As a matter of experience, abscess of the frontal sinus has been mistaken for lachrymal abscess and erysipelas. The fact that the tumor may present beneath the orbital margin above the eyeball renders it possible for mistakes in diagnosis to be made.

It may be said that, in addition to these signs and symptoms, pus found for some time in the middle meatus means either disease of the frontal, the maxillary, or sphenoidal sinus. If the flow of pus be intermittent and fetid, it is probably an affection of one of the last two. When protrusion of the eyeball occurs, it is almost always forward and outward in ethmoidal disease, and forward and downward in frontal sinus disease; while in disease of the sphenoidal cavity it is directly forward and slightly outward.

The *treatment* of the acute form includes that of the acute nasal disease that gave rise to it. The frequent use of cocaine, which relieves pain and opens up the passage into the sinus, is one of the best remedies we possess. It is a good plan to thoroughly cocaine the upper portion of the nasal meati, and then direct the patient to blow his nose vigorously on the affected side. This procedure encourages the passage of mucus from the diseased sinus. Disinfectant lotions are also of value, especially a mild alkaline spray with listerine. Hot fomentations may be applied to the forehead and face. I have lately used with good effect the so-called "lavoline" atomizer, with or without an oily solution of menthol, directing the point towards the infundibulum. This helps to clear out the passage and to encourage the downward flow of secretions.

As soon as the acute symptoms have passed off, additional measures should be taken to insure a clear passage from the sinus to the nasal meatus. Polypi should be removed, caries treated,—internal remedies are of great value when syphilis is present,—and the nasal passages brought as quickly as possible into the normal condition.

In the chronic forms of the disease probes and catheters have been recommended, but these are not always successful. My investigations of the infundibulum have shown me that it is an extremely difficult matter to pass a probe successfully, at least in the majority of instances. Not only does the canal vary in size, shape, and direction, but abnormal obstructions to the passage of the instrument are nearly always present in just those instances where it is desirable to pass it.



The patient I now exhibit to you, whom some of you have seen before, furnishes us with an excellent example of frontal sinus empyema, and in giving you a history of his case, and in drawing your attention to the operations that have been performed for the relief of the symptoms, you will have a clearer idea of the usual procedures in empyema than if I were to speak without illustration.

C. L., aged forty-seven, was referred to me by Dr. E. A. Doepp, of Blue Island, Illinois, on account of a discharge from the orbital region. The patient lost his right eye, twenty-five years before, from an injury, and the globe is now shrunken. He is a well-nourished, muscular man, and a careful examination of his internal organs does not disclose any organic disease. Six months ago he began to have very severe, left, supraorbital pains that radiated over the corresponding temple and occasionally affected the right side. These were continuous most of the time for four months, and affected the patient's general health. After they had lasted for about three months, he noticed a swelling above and to the inner side of the left eyeball, and with the appearance of this tumor came a diminution in the severity of the headaches. They now appeared only at irregular intervals. The swelling was so great that it displaced the globe and seriously interfered with the ocular excursions. Shortly afterwards an abscess pointed almost directly above the eyeball, and finally discharged externally, followed by temporary, but complete and immediate, relief of the supra-orbital discomfort.

The present condition of the left eye is as follows: One notices, first of all, considerable prominence of the supra-orbital ridge; there is marked œdema of the palpebral skin and some infection of the conjunctivæ; the upper lid, towards the inner canthus, is slightly red and glazed; the patient cannot raise his upper lid to its full extent; there is a depressed opening in the skin, midway between the pupil and lower edge of the eyebrow, almost corresponding to the supra-orbital notch, from which a small quantity of creamy-white pus can be squeezed on making deep pressure at any point in the orbit near its upper margin, while a round, firm tumor can be felt beneath it. On passing a probe through the fistulous opening, it easily penetrates about twenty-five millimetres in an upward-inward direction to the roof of the orbit.

The fistulous abscess has been treated for a couple of months by many methods (cleansing injections of bichloride, boric acid, iodine,



etc., packing with iodoform gauze, drainage-tubes of various kinds combined with dilatation of the canal, and a number of other procedures), with but temporary results. He had been a sufferer from nasal obstruction on the left side that had been greatly relieved two months before the swelling appeared by excision of an ecchondrosis of the septum. He also reported that he had been a sufferer from frequent colds in the head, attended by considerable discharge from the nose.

The examination of the nares and naso-pharynx shows very few changes on the right side, and the only noticeable abnormality on the left is a deviation of the septum that trenches upon the middle and superior meati. I was unable to pass a probe into the left frontal sinus. Owing to an obscure history of syphilis, the patient was put upon increasing doses of potassic iodide, and was given mercurial inunctions.

In spite of all these remedial measures, including treatment of the nasal passages and attempts to open up the left infundibulum, the symptoms persisted, so that I advised an operation upon the frontal sinus itself. The patient was anæsthetized and a deep incision, four centimetres in length, was made along the supra-orbital ridge, joining one at right angles to it (about three centimetres in length) in the median line, following the nasal crest. The triangular flap, including the skin and periosteum, between the extremities of the lines of incision was turned down, exposing the osseous structures at the inner angle of the orbit, but avoiding as much as possible the pulley of the superior oblique. A button of bone was now removed by means of a medium-sized trephine and the sinus opened. After all bleeding had stopped, the exposed cavity was irrigated, giving vent to a quantity of muco-purulent secretion. On passing the little finger through the opening some granulation tissue was discovered, and removed with the curette; but as there was no extensive disease of the mucous membrane lining the sinus, no attempt was made to drain that cavity through the infundibulum. It was packed with iodoform gauze and a few stitches placed at the extreme angles of the skin wound. This was renewed daily, while both the sinus and orbital pus-cavity were thoroughly irrigated with warm bichloride (1 in 3000) solution.

The patient obtained almost immediate relief; the pains disappeared, the purulent discharge subsided and became thin and



watery, and he expressed himself as being more comfortable than he had been for many months. In spite of the daily packings with gauze, the opening in the sinus closed in about three weeks, leaving only the orbital pus-cavity to be dealt with. For the purpose of insuring free drainage of the latter, I had the patient once etherized, and enlarging somewhat the skin-opening above the globe, I passed a large, blunt aneurism needle, armed with a stout silk suture, to the bottom of the fistula and brought it out, through a counter-puncture fifteen millimetres from the original opening, made towards the inner canthus. A drainage-tube, attached to the ligature, was now drawn along this canal, thus providing a free exit for secretion and an excellent opportunity for disinfecting the pus "pockets" in the orbit.

There is now very little discharge, and I hope to announce a complete cure of the disease in the course of a month or two. The patient's vision is 6/6 and he reads fine print with his glasses. His visual field is normal, there are no fundus changes, and, most satisfactory of all, his field of monocular fixation (as measured in the perimeter) is practically uncontracted. We have been able to do the operations above mentioned without any extensive injury to his extrinsic ocular muscles.

I had an opportunity of studying a similar case, where perforation of the abscess also took place through the roof of the orbit into that cavity. It occurred in a patient under the care of the senior surgeon of the institution, when I was acting as house-surgeon of the Ophthalmic Hospital in Gray's Inn Road, London. In the latter case all sorts of injections, probings, and the insufflation of powders were faithfully employed, but without lasting success. A thin, muco-purulent flow from the fistula continued as long as he was under my observation.

Even where all the necessary procedures have been carefully carried out, one must not expect a cure inside of several months, and, although the patient I have exhibited to you is now decidedly better in every respect, I do not think that he will be free from all signs of the disease for some time to come.