

Case of primary lupus of the ocular conjunctiva / by A. Hill Griffith.

Contributors

Griffith, A. Hill.
Ophthalmological Society of the United Kingdom. Library
University College, London. Library Services

Publication/Creation

London : John Heywood, 1889.

Persistent URL

<https://wellcomecollection.org/works/k7v53fu2>

Provider

University College London

License and attribution

This material has been provided by This material has been provided by UCL Library Services. The original may be consulted at UCL (University College London) where the originals may be consulted.

This work has been identified as being free of known restrictions under copyright law, including all related and neighbouring rights and is being made available under the Creative Commons, Public Domain Mark.

You can copy, modify, distribute and perform the work, even for commercial purposes, without asking permission.



Wellcome Collection
183 Euston Road
London NW1 2BE UK
T +44 (0)20 7611 8722
E library@wellcomecollection.org
<https://wellcomecollection.org>

2

CASE OF PRIMARY LUPUS

OF THE

OCULAR CONJUNCTIVA.

BY

A. HILL GRIFFITH, M.D.,

Surgeon to the Royal Eye Hospital, Manchester.

REPRINTED FROM THE "MEDICAL CHRONICLE," NOVEMBER, 1889.

JOHN HEYWOOD,
DEANS_GATE AND RIDGEFIELD, MANCHESTER;
1, PATERNOSTER BUILDINGS,
LONDON.

1843818

CASE OF PRIMARY, LUPUS OF THE OCULAR CONJUNCTIVA.

E. M., a boy, aged four years, was first seen by me at the out-patient department of the Royal Eye Hospital, on November 2nd, 1888, when I found the following state of affairs:—The entire ocular conjunctiva of the right eye was uniformly thickened, forming a regular mound of some height around the cornea, and was thickly studded with projecting yellowish-white pin-headed follicular (?) infiltrations. The affected conjunctiva was rather pale and waxy looking, showed very little injection, and felt doughy to the touch. There was an absence of any discharge, nor was there any pain, either spontaneous or to the touch. The conjunctiva of both lids was unaffected, as was also the upper reflected conjunctiva; on strongly depressing the lower lid, the thickening and other changes were found to have markedly invaded the lower sulcus of the conjunctiva. At a casual glance, the case looked like one of protrusion of the globe, but a more careful examination showed that this was entirely due to the great thickening of the bulbar conjunctiva. The cornea and deeper parts of the eye were unchanged, and there was no limitation of the movements of the globe.

The pre-parotid and sub-maxillary lymphatic glands of the same side were considerably enlarged and hard.

From the mother I find that the eye had been affected for three weeks, the lumps on the neck had come on at the same time, certainly not before, and that three weeks before the onset of the eye affection, the child had a mild attack of scarlet fever, lasting only a fortnight. The mother had had five other children, one dead born, one died on third day, one of measles, aged nine months, and the two living are aged one and two years. She had a miscarriage about twelve months ago, and is now pregnant.

I was quite at a loss in regard to the nature of the affection; nor had Drs. Little and Mules, who kindly, at my request, examined the case, any suggestion to make, and they both said they could not recall a similar appearance. As the appearances strongly reminded me of a case I had published some years before in this Journal, I shall take this opportunity of transcribing it.

“Syphilitic (and other) lesions of the eyelids.”—MEDICAL CHRONICLE, June, 1886. Case 8.—Man, age 44, “conjunctiva of the right globe

generally injected, chemosis, no purulence, the fold of conjunctiva at inner canthus is very much swollen and hypertrophied, and dotted over it are numerous small yellowish-white specks. No induration in the fold or around it. There is a little secretion on the surface, but no ulceration. The eye is otherwise normal. There is great swelling of cervical and pre-auricular glands on the same side. No skin eruption; fauces a little red, but no ulceration. The eye had been affected one week, the glands three weeks. The glands supplicated, and the eye got well. I saw him two years after; there was not a trace of anything to be seen."

I never understood the above case, and Dr. Little, who had charge of it, and Mr. Bilton Pollard, who saw it afterwards at the Royal Infirmary, were unable to throw any light on its probable nature.

To return to the first-mentioned case, I did not see the child again till five months, when I showed him at the Medical Society. By this time the conjunctiva was almost entirely well, the glands were still somewhat enlarged and hard, several abscesses had formed and burst on the neck, leaving fistulous openings with dry indurated sides. On the skin, a little beyond the external commissure of the right eye, a superficial ulcer had formed, with sinuous spreading edge and grey nodules on its surface. As this ulceration of the integument was certainly lupus, and my opinion was confirmed by several gentlemen present, it appeared to me quite reasonable to assign a similar origin to the affection of the conjunctiva.

At a meeting of the Ophthalmological Society last year, Brailey showed a child with the ocular conjunctiva of one eye affected in a precisely similar manner to the above patient, and the glands were also enlarged. I was much struck with the exceedingly close resemblance in every detail to my own case, and on this ground ventured to express an opinion that it might also turn out to be lupus.*

I shall mention now, with Dr. Little's permission, a case of his which I saw at the Eye Hospital, as it appeared to me very like my case, and I drew his attention to this.

Sam. M., aged 35, married, glands of left side enlarged, acute chemosis of bulbar conjunctiva of left eye, and covered with follicular swellings. Lids red and swollen. Patient had his inferior tear duct slit up about eight months ago, but the present affection of the conjunctiva and glands had only come on three days ago, and appeared to be quite unconnected with the lacrymal obstruction. Three days after I found the eye worse; the conjunctiva forms a dense waxy or doughy swelling, and when the lower lid is everted, a distinct swollen roll of

* Brailey kindly writes me that, microscopically, it was distinctly tubercular, showing giant cells and areas of degeneration, but no bacilli were found. "The growth gradually flattened, and at the upper and outer side, where it had softened and ulcerated, resulted in the formation of some band-like adhesions between lid and globe."

conjunctiva springs out from the inferior sulcus. The case got quite better in a short time.

To return once more to my first-mentioned case, I ought to have said that, at the first visit, I snipped off one of the conjunctival nodules and preserved it in absolute alcohol, and I shall now mention the result of the examination of sections. The epithelial surface seems unchanged, except at about the centre, where it is very much thinned ; there are not many vessels to be seen, still there is not an entire absence of these ; giant cells, with regularly placed rows of nuclei around the margin, are met with pretty plentifully. Dr. Dreschfeld was so kind as to examine one of the sections, and tells me he has no hesitation in pronouncing it to be a specimen of localised tuberculosis, which lupus is allowed to be. He made out also one small centre of caseation. The microscopical characters are quite in accordance with Sattler's third case, with Baumgarten's case, which is most elaborately described and figured, and with Pfeiffer's cases. The last named observer (11) also demonstrated the presence of tubercle bacilli (Sattler and Baumgarten's occurred before Koch's discovery), and made injections into the anterior chamber of young rabbits' eyes, causing the growth on the iris of little grey nodules, in which he also demonstrated the presence of similar bacilli, and this was confirmed by Ziegler, Erlich, and others. I hope to have some of my sections examined for bacilli at a later date.*

I shall now proceed to take notice of the cases recorded, that I have been able to make myself acquainted with, and conclude by contrasting my own case with these.

Sattler (1) tells us he has seen a good many cases where the disease has spread from the face to the eyelids and palpebral conjunctiva, which is always in these cases red and swollen, the lupus appearing as a coarsely granular firm growth, bleeding upon slight provocation. As a primary disease of the conjunctiva, however, it is very rare. He records three cases of the primary form, in the first of which lupus afterwards appeared on the nose ; the second died of tuberculosis, as did also the third ; the autopsy in the case of the third showing lupus in the larynx and internal organs.

Benson (9) records one case of the primary form which affected the palpebral conjunctiva of right eye, and, six months later, the left eye ; and the same observer (10) showed ten drawings of six cases, in three of which it was primary ; in the others it was separate from, but subsequent in appearance to, patches on the mucous membrane of nose or mouth ; and in two of these there was, in addition, lupus of skin. All the patients showed strumous signs, scars, suppurating glands, etc. In one

* I had only five or six sections, which Dr. H. G. Brooke was so kind as to examine for bacilli, but did not find any.

case only was the ocular conjunctiva affected. Then it was in connection with the conjunctiva of the upper and lower lid. As regards diagnostic signs, he mentions :—

- (1) Its similarity to lupus of the gums and other mucous membranes.
- (2) Its softness, tendency to bleed, and its friability.
- (3) Its very slow growth, one to five years.
- (4) Its well-defined limits and elevated uneven surface.
- (5) Its very slight tendency to produce pannus or ulceration of cornea.
- (6) Its being confined to one, and usually to part of one, eyelid.

Baumgarten's case (7) was a girl, aged 24, who, as a child, had swollen cervical glands ; she was well save for this up to her tenth year, when a pustular eruption, of unknown nature, appeared all over her body save the forehead, coincidently with swelling up and closure of the eyes. On the eruption healing, the eyes could be opened, and the sight was noticed to have been affected. Six months later there was chronic painless nodular lupus-like ulceration of the right cheek, followed in three years by a similar affection of the other cheek, and blocking the nostrils. When she was 22, the eyes, up till then not noticeably affected, gave a great deal of trouble, and when Baumgarten saw her two years later for the first time, he noted advanced cicatricial changes in the conjunctiva of left eyelids, with ectropium, destruction of part of border of lower lid, and the presence of a large half-moon-shaped superficial ulcer, with greyish exudation on surface, and a good deal of cicatricial contraction around it. Professor Jacobson was satisfied from the clinical examination that he had to do with a case of lupus of both lids of the left eye. A piece of tissue was excised and examined, with the result of verifying the diagnosis.

I believe I have good grounds for considering the changes in the conjunctiva of my case "lupus ;" firstly, because an undoubted patch of lupus appeared in the immediate vicinity ; secondly, from the behaviour of the glands ; and thirdly, from the result of a microscopic examination of a nodule from the conjunctiva. It is, however, quite certain that the clinical appearances and course of the conjunctival affection are unlike that of any of the recorded cases I have been able to refer to* ; but the reason of this is not far to seek, for the latter only


* Since the above has been printed, I have, in the *Trans. Internat. Med. Cong.*, London, 1881, found a good case by J. Hirschberg, which I shall transcribe in a condensed form :—

Girl, aged 4, right eye normal, left eye free from pain, blepharospasm, or discharge. Conjunctiva of eyeball converted into a caseous confluent ulcer surrounding the cornea, and from six to eight mm. broad ; downwards, the ulceration occupied the swollen fornix, and miliary ulcers are scattered throughout the conjunctiva of the lower and upper lid. Enormous submaxillary glands on same side. Hirschberg diagnosed the condition as tubercular, but says he had never seen a similar case. The eye having got much worse, was removed two months later, and sections through the conjunctiva and sclerotic are described as follows : "The deeper layers of the sclerotic are normal ; upon these follows a granular, round celled tissue, with giant cells ; finally, a perfectly amorphous layer of caseous matter, clearly distinguished from the living part by cosine."

deal with the latest destructive changes, in fact, chiefly with the results of lupus, and not the disease itself, whereas my own was noted not more than three weeks from the onset of the affection, and before any ulceration had taken place, which may possibly account for the very favourable result attending the use of cod liver oil, tonics and good food, all of which I enforced from the beginning.


REFERENCES TO LUPUS OF THE CONJUNCTIVA.

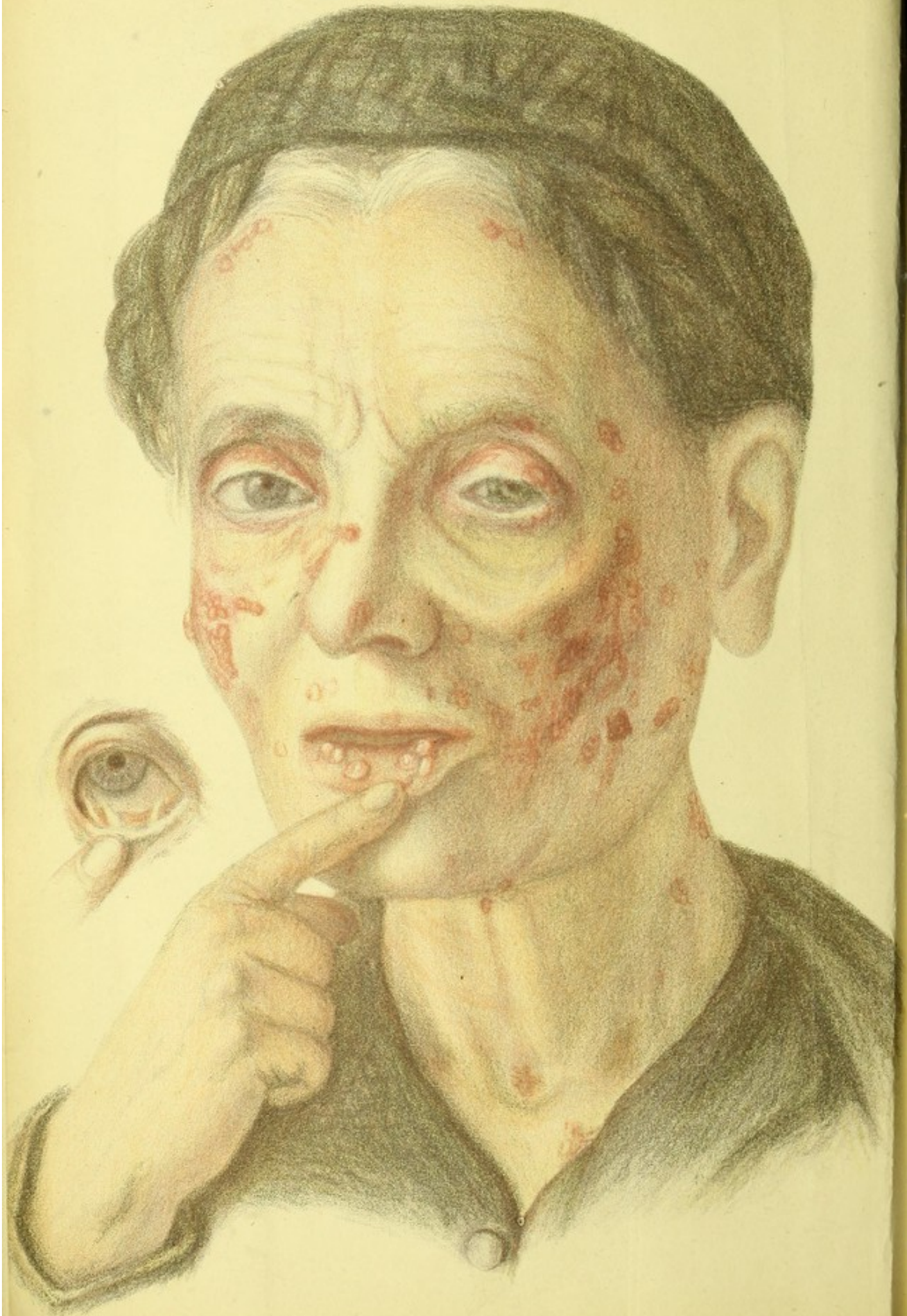
1. SATTLER (H.). "Primary lupus of the conjunctiva."—*Irish Hospital Gazette*, Vol. XX., 1874.
2. ALEXANDER.—*Klin. Monats. f. Augenheil.*, 1875.
3. PFLÜGER.—*Klin. Monats. f. Augenheil.*, 1876.
4. NEUMANN.—*Wien. med. Wochens.*, 1876.
5. LASKIEWICZ (ALFRED). *Allg. Wiener med. Zeitung*, 1877.
6. STÖLTING.—*Graefe's Archives*, Band XXXII.
7. BAUMGARTEN (PAUL). "Ueber Lupus und Tuberculose, besonders der Conjunctiva."—*Virchow Archives*, 1880.
8. PECK (E. S.). "A unique case of conjunctival lupus."—*Med. Archives New York*, 1880.
9. BENSON.—*Brit. Med. Journal*, 1882, and *Dub. Jour. Med. Sci.*, Vol. 75 (same case).
10. BENSON. "Primary lupus of the conjunctiva."—*Ophth. Soc. Trans.*, Vol. V., 1885.
11. PAGENSTECHER UND PFEIFFER (AUG.). "Lupus oder Tuberculose."—*Berlin. klin. Wochensch.*, Vol. XX., 1883.
12. GAYET. "De la tuberculose conjunctivale."—*Bull. et Mem. Soc. Franc.*, Paris, 1885.
13. RHEIN (CARL).—*Münch. med. Woch.*, Band XXIII., 1886.
14. RHEIN (CARL).—*Graefe's Archives*, 1888.
15. REUSS.—*Wien. med. Bl.*, Band 10, 1887.



Digitized by the Internet Archive
in 2014

<https://archive.org/details/b21643787>





Mr Malcolm Morris's case of Pemphigus Conjunctivæ, etc.