

On abscess and tumours of the orbit / by W. Spencer Watson.

Contributors

Watson, W. Spencer 1836-1906.
University College, London. Library Services

Publication/Creation

London : H. K. Lewis, MDCCCLXX [1870]

Persistent URL

<https://wellcomecollection.org/works/n4p8ke2a>

Provider

University College London

License and attribution

This material has been provided by This material has been provided by UCL Library Services. The original may be consulted at UCL (University College London) where the originals may be consulted.

This work has been identified as being free of known restrictions under copyright law, including all related and neighbouring rights and is being made available under the Creative Commons, Public Domain Mark.

You can copy, modify, distribute and perform the work, even for commercial purposes, without asking permission.



Wellcome Collection
183 Euston Road
London NW1 2BE UK
T +44 (0)20 7611 8722
E library@wellcomecollection.org
<https://wellcomecollection.org>

ABSCCESS AND TUMOURS OF
THE ORBIT

BY

W. SPENCER WATSON, F.R.C.S.

III.

K. 12.

2811635373

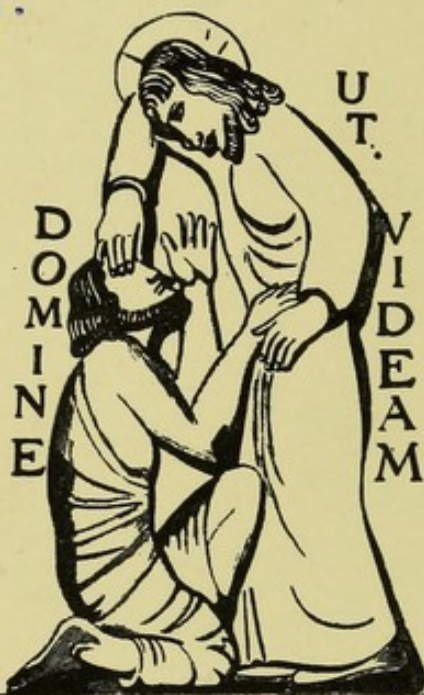✓

III
K. 12.

No. 1197 | H

J. 54.

300




THE INSTITUTE
 OF
 OPHTHALMOLOGY
 LONDON

EX LIBRIS


OPHTHALMOLOGY HERI WATSON [S]

E. 4 3
54






ABSCESS AND TUMOURS OF THE ORBIT.





Digitized by the Internet Archive
in 2014

<https://archive.org/details/b21641535>



ON
ABSCESS AND TUMOURS OF
THE ORBIT.

BY

W. SPENCER WATSON, F.R.C.S. ENG., M.B. LOND.,
SURGEON TO THE GREAT NORTHERN AND THE CENTRAL LONDON OPHTHALMIC
HOSPITALS, ETC.

Reprinted from the MEDICAL MIRROR.


LONDON :
H. K. LEWIS, 136 GOWER STREET, W.C.

MDCCCLXX.

PRICE SIX SHILLINGS.

1834718

P R E F A C E.



IN venturing to lay before the profession the results of my reading and experience in regard to the Diseases of the Cavity of the Orbit, it is perhaps necessary to apologise for what may to some appear an attempt to increase the already overcrowded list of specialities in medicine and surgery.

The indignant outcry raised by the great body of the profession against specialists of every kind, is one in which I would heartily join; my sincere sympathies are with those who would crush out the crying abuse of special hospitals.

A love of speciality is a disease of the human mind, which the more the public are inclined to the more should the profession strive to root it out. I cannot agree with the American sage, that there is no power of expansion in man, and that the minds of most men are like a piece of Labrador spar, which has no lustre as it is turned round until you come to a specific angle, and then alone it reveals its depth and beauty of colouring. Surely our own Johnson was nearer the truth in believing that there was an adaptation and applicability in energetic men to the universal, not that each man has no special talent, and that the mastery of successful men consists in applying themselves solely where that talent can be specially practised. Certainly Hunter, Sydenham, Harvey, Brodie, and the eminent men of the present day, are not numbered among this separative order. As in the products of the garden the most beautiful flowers,

if not the oddest and rarest, are grown by those who have studied and practised according to the most general and widest principles of their art, so these principles correct and chastise the tendency to a grotesque and conventional form and colouring, and restore and revive the beauty and freedom of Nature.

Still, while the present state of things exist, the means of classifying and comparing cases, offer many advantages, and I have endeavoured to do my humble part in aiding and advancing such desirable and legitimate objects. In every extreme and excess of doctrine or practice, there is a source of goodness and utility, and I sincerely trust that I have neither overlooked it, nor utterly failed to extract some benefit from specialism.

It must indeed be granted, that in mere theories of disease, or even in treatment not ending in decisive operations, the weakness of an extended, but imperfect study, may be supplied by a frequent exercise and a renewed experience; but if we operate *imperfectly*, we can seldom recover the mistake. In many cases (and this applies to operations on the orbit more particularly), we can operate but once, and this necessity renders it imperative that our skill possesses a specific exactness, since it cannot be mended on trial, and thus our general surgery requires to be corrected by our particular experiences, and this to be concentrated on the one operation before us. Hospitals of this kind, whatever their fundamental deficiencies, assist the mind of the surgeon in a severer study and more contracted contemplation of separate diseases. From what I have advanced, it will be seen that I have thought it most important to search the vast fields of experience opened up to me in General Hospitals; and the subject of my Paper appears to me to be a fair debateable ground upon which specialists and general practitioners might meet, and compare notes with mutual advantage.

Such being my main object in taking in hand the present work, I have thought it right to scrutinise all the

existing and past authorities on the subject, and to select as many striking illustrations from all and each as I could conveniently introduce into a short Treatise.

In order that the tediousness of lengthened details in the reports of cases might, as much as possible, be avoided, I have taken the liberty of excluding in most instances, all but the essential particulars. "Brevis esse laboro," whether "obscurus fio," I must leave to the reader's verdict. On the subject of treatment I acknowledge that I have assumed a didactic and somewhat positive tone—not, for an instant, as esteeming myself a high authority, or as having had a larger experience than others, but rather with the view of challenging criticism, and in the hopes that wherever I may have set up principles of doubtful stability, they may be shaken from their usurped eminence; while those that remain undisputed may continue to guide me in future difficulties.

In some of the diseases treated of, I have avoided saying anything with regard to treatment, on my own authority, and have in such instances left it to be inferred that general principles were to be followed, or that the cases and indications given, sufficiently indicated the course to be followed in similar instances.

~~27 MONTAGUE STREET, RUSSELL SQUARE.~~
15 HENRIETTA STREET, CAVENDISH SQUARE, W.

The first part of the paper is devoted to a general
 consideration of the subject. It is shown that the
 theory of the subject is not yet complete, and
 that there is a need for further research.
 The second part of the paper is devoted to a
 detailed study of the subject. It is shown that
 the theory of the subject is not yet complete, and
 that there is a need for further research.


The third part of the paper is devoted to a
 detailed study of the subject. It is shown that
 the theory of the subject is not yet complete, and
 that there is a need for further research.

The fourth part of the paper is devoted to a
 detailed study of the subject. It is shown that
 the theory of the subject is not yet complete, and
 that there is a need for further research.

The fifth part of the paper is devoted to a
 detailed study of the subject. It is shown that
 the theory of the subject is not yet complete, and
 that there is a need for further research.

The sixth part of the paper is devoted to a
 detailed study of the subject. It is shown that
 the theory of the subject is not yet complete, and
 that there is a need for further research.

ON ABSCESS AND TUMOURS OF THE ORBIT.



THAT diseases of the orbit are rarely met with in general surgical practice, may be judged of by the fact that, out of 12,692 out-patients at the Royal London Ophthalmic Hospital in the year 1864, only ten were affected with diseases of this cavity, six suffering from tumours, and four from abscesses. The rarity of these affections, then, is such that few individuals can have sufficient personal experience to speak authoritatively on the subject, excepting in the way of general principles applicable to diseases of this, as to those of any other region of the body. It is this consideration, which has induced the writer of the following observations to lay before his readers, as shortly as possible, some of the facts he has been able to collect, deduced from recorded cases of the kind referred to, and from a few that have come under his own observation.

And first let us inquire into the causes and diagnosis of abscess of the orbit. Most of the cases recorded are to be found in Demarquay's "Treatise on Diseases of the Orbit," in which alone seventeen cases are recorded in detail. Besides these, Mr. Hulke has published three cases in the *Ophthalmic Hospital Reports*, Mr. Poland one in the same journal; the *Pathological Transactions*; Mr. Lee, in his work 'On Phlebitis,' and other authors have supplied me with others.* Altogether thirty well-observed cases are at my disposal, and from a careful study of these, especially from Demarquay's 'Treatise,' I have ventured to make the practical deductions which follow.

I. THE CAUSES OF ABSCESS OF THE ORBIT.

The following are adduced as the probable causes:—

Injuries of various kinds, either local or in the immediate neighbourhood, punctured wounds, with or without having a

* Viz., Mr. S. S. J. Salter, in his paper in the *Medical and Chirurgical Transactions*, vol. xlv.; Mackenzie on "Diseases of the Eye;" and Haynes Walton on the "Surgical Diseases of the Eye."

foreign body imbedded in the cavity (see cases in *Pathological Transactions*, vol. i.); or blows on the eye with the fist; or surgical operations (see Demarquay, p. 111); or scalp-wounds (see Henry Lee, 'On Phlebitis, p. 79); or even the extraction of upper molar teeth, two instances of which are related by Demarquay, in which low inflammatory action set in after this operation, terminating in one instance, fatally.

Of the whole number of cases I have met with seven were attributed (with or without good cause) to injuries, and allusions are made to several other cases by various authors. Mackenzie, for example, mentions an instance of inflammation of the cavity of the orbit following abscission of the anterior half of the eye-ball.

In all these instances, however, the injury seems nothing more than the accidental excitement of an action, of which the predisposition already existed, and they were generally associated with an enfeebled state of health, such as would be most favourable to pyæmic complications. Caries of the orbitar walls was discovered in four cases. In three of which, the frontal bone, and in one the petrous portion of the temporal were affected (see Hulke's cases in *Ophthalmic Hospital Reports*, vol. iv., p. 80, and *Pathological Transactions*, vol. iv., p. 25).

The influence of cold from draughts, has been adduced as a cause of orbitar inflammation, by Dr. O. Ferrall who cites two cases in illustration. On the other hand, Gendron relates a case in which exposure to the sun seemed to have the same effect. Erysipelas spreading from the neighbouring parts has been followed by abscess in the orbit in some of the cases mentioned as the result of injury, and in others of spontaneous origin. Gonorrhœal ophthalmia was the exciting cause in one case mentioned by Middlemore ("Diseases of the Eye," vol. ii., p. 582). Affections of the lacrymal gland are sometimes the starting-point, according to Carron du Villards, and the same author relates cases of abscesses of the orbit consecutive to acute meningitis, as a sequel to typhus fever.

It appears, therefore, that injuries of the orbit itself, or of adjacent structures, or of its visceral contents, are the most frequent causes of the inflammatory actions in this cavity, more especially if followed or accompanied by erysipelas.

Perhaps the next in order of frequency, caries of the orbitar walls may be mentioned, and then typhus and typhoid fevers. The other causes adduced are somewhat conjectural. In some cases no assignable cause can be found. Seven such are among the thirty detailed cases to which I have alluded, and one of them was under my own observation quite recently. I was inclined to give some importance to the fact that several decayed stumps in the upper jaws were present in this patient and

had long caused her great suffering, and to the probability of their being a nidus for the collection of puriform fluid, and its communication through the venous system of the orbit. Such an explanation presents some difficulties, but seems corroborated to some extent by the two cases already alluded to, in which the removal of molar teeth was followed by the same result. In the latter instances, the irritation was an active and violent one; in the former, continuous and abiding, but at the same time affording a constant supply of putrid material to the circulation, and lowering the digestive functions and general vitality of the patient, directly or indirectly.

II. THE DIAGNOSIS OF ABSCESES OF THE ORBIT.

This part of the subject may be conveniently considered under these two heads.

1st. The Diagnosis of Abscess from other Tumours, or diseases in the orbit.

2nd. The Diagnosis of the kind or form of Abscess.

Several different kinds of tumour may be very easily mistaken for chronic abscess, and *vice versa*. *Cysts*, for instance, may produce the same deformity, the same protrusion of the eye-ball, and the same fluctuation may be felt; and, in doubtful cases, an exploratory puncture is the only means of solving the difficulty. It has been observed, however, that the majority of tumours of this kind have thrust the eye-ball directly upwards, or directly downwards. And such a deformity is not a common one in cases of abscess.

Aneurism may, also, be mistaken for abscess, either acute or chronic, and more particularly those aneurisms which arise suddenly and spontaneously by giving way of an intra-orbital vessel. In two such cases recorded by Demarquay, punctures were made into the tumours by the surgeons in attendance, before the certainty of the diagnosis could be ascertained. One of these was Dalrymple's celebrated case, also related at length in Mackenzie's work, p. 350. The tumour was punctured five times, and ultimately subsided after ligature of the common carotid.

A third (Mr. Nunneley's *Medical and Chirurgical Transactions*, vol. xlii., p. 168), was the result of a blow on the eye, and was successfully treated by ligature of the common carotid.

Such cases, however, must be exceedingly rare, and the absence of pulsation must be very infrequent in aneurismal tumours. The fact, however, of these cases occurring in the hands of the most skilful surgeons, is not to be overlooked.

The position of the eye-ball as an aid to diagnosis, is of little value. In a large majority of the diseases within the orbit, the eye-ball is pushed outwards as well as forwards; and this

remark holds especially with regard to abscesses, which most frequently point at the upper and inner corner. When, however, the abscess depends upon caries of adjacent bones, the position of the swelling will vary with the bone affected, and the displacement of the eye-ball will correspondingly vary.

Thus tumours and abscesses, coming from the temporal side of the orbit, will thrust the eye-ball towards the nose, and such a deformity would at once arouse the suspicion that the case was a very unusual one. Out of 240 cases of tumours of all kinds in this cavity, in only eight was the eye-ball displaced inwards. One of these was an abscess originating from disease in the ear, with caries of the petrous portion of the temporal bone, ending fatally. Two were tumours of the lacrymal gland; one an hydatid cyst; one an osteo-sarcoma in the temporal fossa, invading the orbit; one a fibro-cystic tumour; one a sebaceous cyst; and one a disease of doubtful nature, called by Demarquay a steatome.

The displacement of the globe upwards is also rare, and is mentioned as occurring in fourteen cases, none of which were abscesses, but included tumours of various kinds, chiefly medullary, fibrous, and fibroid in their nature, with one osseous tumour of the antrum, and one mucous polypus of the nose.

The fact, therefore, that in any given case the eye-ball was displaced inwards, or upwards, would be a strong presumption that it was *not* one of abscess, and the same might be said of any tumour presenting at the outer side of the orbit or below. On the other hand, a tumour presenting at the inner side of the orbit, and displacing the eye-ball outwards, as well as forwards is, *cæteribus paribus*, likely to be of the nature of abscess. If the tumour thus presenting be distinctly fluctuating, associated with the usual febrile disturbances, have resulted from erysipelalous inflammation, an injury, or followed typhus fever, the probability is reduced to nearly a certainty that we have to deal with an abscess. It is seldom, however, that all these symptoms are appreciable or easily recognised. In most cases of abscess there is a period in which the presenting tumour is hard and unfluctuating, or may not be distinguishable at all. The protrusion of the eye-ball may not be discoverable in consequence of the great œdema of the eyelids and chemosis of the conjunctiva; and in some cases the protrusion is directly forwards, so that the axis of the eye-ball remains normal. When this is the case there is some similarity in the deformity to that produced by dropsy of Tenon's capsule, which, however, is a very rare affection; or to that caused by hypertrophy, or serous infiltration of the cellular tissue of the orbit, which is also extremely rare; both of these affections being unaccompanied by febrile disturbance

In one case of abscess of the cellular tissue of the orbit recorded by O'Ferrall, there was no protrusion of the eyeball, but the eye was simply thrust downwards.

It is scarcely necessary to point out the means of distinguishing some other diseases of the orbit such as the goitrous exophthalmus and emphysematous or sanguineous effusions from injuries. The points of difference are obvious, but must be borne in mind as possible sources of error, or as complications under peculiar circumstances.

Tumours of an encephaloid cancerous nature are little likely to be confounded with abscess, Apart from the history of the case, there will be local peculiarities quite distinctive. Solid nodulated masses most frequently presenting at the inner canthus, solid œdema of the eyelids, enlargement of the superficial veins of this part, and rapid growth of the tumour, will all point to a malignancy.

The other solid tumours, fibrous, fibroid, enchondromatous, and osseous will also be easily distinguished, not so much by their physical characters, however, as by their history and their very slow growth as compared with the development of suppuration. The hardness of inflammatory swellings in the early stage, is the only possible source of error in respect to these forms of disease.

The only kind of general enlargement of the eyeball which could possibly be confounded with an abscess of the orbit, would be one in which acute inflammation had supervened on a chronic hydrophthalmus, and, in such a case, the history would probably supply the clue to the diagnosis.

The possibility of making a diagnosis of the *kind* of abscess with which the surgeon has to deal is of practical value, as on the opinion formed will depend in great measure the prognosis and treatment of the case. Thus, the absence of protrusion of the eyeball, associated with distinct fluctuation at some point of the circumference of the orbit, and other indications of suppuration would show, that we were dealing with an abscess in front of the orbital fascia, and such a one as required less severe measures of treatment than those of the deeper region, and would most likely be the sign of superficial caries of the margin of the orbit, a comparatively trivial affection, though troublesome in its after consequences.

On the other hand, protrusion of one or both eyeballs coming on in the course of erysipelas, or low fever, or after severe wounds of the scalp, or the neighbouring parts, and associated with low febrile symptoms, would indicate the most severe form of purulent infiltration of the deeper structures of the orbit, and possibly be the prelude to a fatal issue from pyæmia.

Abscesses coming from neighbouring tissues or cavities may

invade the orbit and produce all the physical signs of suppuration originating there. When the frontal sinuses, the antrum, or the nose, are the parts whence the abscess arises, certain symptoms in those parts such as swelling, pain, arrest of secretion, and superficial redness will indicate more or less distinctly the source of the original mischief.

When, however, the cranial cavity, or the temporal, or the zygomatic fossæ are the seats of the original or of a co-existent abscess, it is much more difficult to arrive at an accurate diagnosis, though it is precisely in these cases that the issue is so likely to be fatal, and the treatment requires so much care and circumspection. When abscess in the brain is present, associated with orbital abscess, it is not necessarily associated with cerebral symptoms in the early stages, though death is generally preceded by palsy, convulsions, or delirium, but only when too late to avert the issue.

Purulent deposits within the cranium, associated with abscess in the orbit, were found in seven out of twelve fatal cases, and symptoms of acute meningitis were present in another case of recovery. Two of these were caused by caries of the frontal and other bones. Three followed injuries, and the rest probably resulted from erysipelas.

It is obvious how important it would be to be able to distinguish such cases in the early stages, in order to be able to warn the patient's friends of the danger of his state, and to give caution to surgical interference of any kind.

Severe and persistent pain in one side of the head was noted as present in three of these cases, at an early period; and in one was the earliest symptom observed; so that in such a case some guess might be formed as to its serious character. In two of them—viz., Mr. H. Lee's case and Mr. Poland's, both eyes became prominent simultaneously, or nearly so, and this circumstance would be a symptom pointing at once to a deeply-seated source of mischief, most probably within the cranium, and should incline the surgeon to a very unfavourable prognosis.

III. PROGNOSIS IN CASES OF ABSCESS IN THE ORBIT.

Two points have to be considered under this head:—

1st. Whether the patient will recover.

2nd. Whether the sight will be restored or saved in the event of recovery.

1st. *Will the patient recover?* This question may be answered in the affirmative in the great majority of cases; for though the number of fatal cases recorded is large in proportion to those of recovery, it cannot be supposed that all the trivial cases have been put on record, while it is a fair inference that the most

severe forms of disease have been published, as conveying more instruction. Out of thirty cases which I have collected, thirteen were fatal, and some of these probably originated within the cranium or other parts surrounding the orbit, the orbit itself being involved secondarily. In nine out of these thirteen cases mischief within the cranium was discovered after death; and this fact points at once to the source of danger. In most of them suppuration had occurred either in the veins, sinuses, between the dura mater and bone, or in the substance of the brain itself. Those most speedily fatal seemed to be due to pyæmia; the symptoms preceding death being delirium, incoherence in speaking, convulsions, paralysis and coma. The earlier symptoms being intense pain in one side of the head, a low state of health, erysipelatous swelling of the parts, and symptoms indicating the existence of caries or necrosis of the bony walls of the orbit, such as the escape of fetid pus, and sequestra, and the indisposition to a healthy action in the abscess.

The position of the disease in the bone seems to be an important element in the dangerous character of the case. Five of the fatal cases were found to be associated with disease of the roof of the orbit; one with that of both the malar and sphenoid bones; one with that of the sphenoid bone; and one with disease of the tympanum. In two of the recoveries, the roof of the orbit was involved; and both of these were among the most nearly fatal of those that ultimately recovered. Hence, we may infer that, should caries or necrosis of the roof of the orbit be discovered, or disease of the deeper or cranial bones be suspected, the case is one of considerable danger. On the other hand, disease in the superior maxilla, such as is associated with abscess of the antrum, is not so likely to lead to dangerous complications, though a fatal case is recorded under these circumstances; in which, however, disease of the roof of the orbit was also found after death. (*Vide* Demarquay, "Sur les Tumeurs de l'Orbite," p. 145.)

The above observations do not apply to cases of caries of the margins of this cavity, such as are frequently seen in scrofulous children,—the lesion here being in front of the orbital fascia, and very rarely leading to any result more serious than a very unsightly eversion of the eyelid when cicatrisation has been completed.

Abscess following erysipelas of the scalp or face, and cases resulting from a punctured wound in the orbit, seem to be the most frequently fatal.

Such being the conditions, many of which can only be discovered after death, what are the indications necessary for the formation of a prognosis? The exploring probe; the escape of fetid pus, or sequestrum; symptoms of disease of the internal ear;

are valuable means of information in the early stages. The occurrence of drowsiness, delirium, or other cerebral symptoms in the course of any orbital abscess, will be so unfavourable that little hope can be entertained of a recovery, and the sudden occurrence of protrusion of the eyeball or both eyeballs in the course of erysipelas after a severe wound involving bone, is equally ominous. On the other hand, should the patient be in tolerably sound health previously to the attack; should the pain and swelling be confined to the orbit itself or to its immediate vicinity; should the abscess have been opened early and exit given to pus of a healthy character; should there be no symptoms of cerebral mischief; and lastly, should rational treatment have been adopted, there is every probability of a favourable issue.

2nd. *In the event of recovery will the vision of the affected eye be retained or restored?* In some cases, vision is from the first little or not at all impaired, and in these no anxiety need be entertained with regard to it.

Two or three cases of this kind are recorded, and in five of the recoveries it is especially mentioned, that the vision was lost, either by suppuration of the eyeball and subsequent shrinking, or by atrophy of the optic nerve.

One case was supposed to have resulted in loss of vision in both eyes from wound of the globe by the surgeon's knife.

In the case of a patient, recently under observation at Moorfields Ophthalmic Hospital, vision was not restored at the expiration of three months from the commencement of the case, and the pupil remained dilated and insensible to the stimulus of light. The appearance of the optic disc viewed by the ophthalmoscope was that of atrophy.

This case was analogous in some respects to the case mentioned by Mr. S. J. A. Salter, in vol. xlv. of the *Medical and Chirurgical Transactions*, and in both cases the condition of the optic nerve was the same. The data do not seem to be sufficient to show what the loss of vision, or atrophy of the optic nerve really depended upon; whether upon the stretching of the nerve-fibres from the accumulation of pus behind the eyeball; or upon the inflammation of the nerve-sheath of the optic nerve; or upon irritation communicated to the brain through the fifth pair of nerves, which is the view taken by Dr. Mackenzie.

In forming an opinion, therefore, of the probable effect on the patient's sight, regard must be had to the presence or absence of inflammation of the eyeball, to the length of time during which the supposed stretching of the nerve has been in operation, and to the amount of this stretching; as well as to the state of the pupil and the ophthalmoscopic appear-

ances after the evacuation of the pus in the orbit, and the return of the eyeball to its socket. In a case in which the eyeball is not protruded, vision will most probably not be affected, unless there is inflammatory mischief in the globe itself, and the prognosis will be in this respect highly favourable. When, on the other hand, iritis, ophthalmitis, or suppuration, or sloughing of the cornea have been set up, little or no vision will be retained.

IV. THE TREATMENT OF ABSCESS IN THE ORBIT.

Probably in no two cases of this affection could precisely the same treatment be properly adopted. Each must be treated on principles applicable to its peculiar circumstances; as for instance, the age, constitution, temperament, &c. of the patient, and each must be treated on different principles during the acute and the chronic stages of the disease.

Can we, nevertheless, lay down any general rules of treatment?

There are some rules specially applicable to the early stages of acute inflammation of the orbital cellular tissue, which can readily be laid down, and will bear the test of experience.

1. Depletion is rarely indicated. The patients have generally feeble health to begin with, and will require all the sustaining nourishment which can be obtained. Possibly, leeches may relieve pain in some instances; but the wholesale way in which they are sometimes applied, is a method very far from worthy of imitation. In Demarquay's treatise, cases are described in which bleeding from the arm, leeches and scarifications were employed with great freedom; in others, besides leeches and bleeding, mercury and iodide of potassium were administered, though it is difficult to conceive on what principle of therapeutics. Thus, in one patient, a man of forty years of age, who had very severe febrile symptoms, following the extraction of an upper molar tooth, and accompanied by exophthalmos and constant and violent supra-orbital headache, blood-letting to twelve ounces was employed, and twelve leeches were at once applied. Subsequently, sixteen more leeches were put on, and calomel was given. The patient recovered after an illness of six months' duration, with the loss of the eye, which suppurated and shrunk.

2. An early incision or incisions are useful. Probably, the best way of abstracting blood, and at the same time of relieving the pain and tension, is to make early incisions into the orbit, even before fluctuation can be discovered. A surgeon of some authority recommends "free plunges and incisions into the orbit in as many places as possible, in the early stage of the disease;" and I cannot but think such a plan far preferable to blood-letting from the arm, and leeches to the orbit itself. At

the same time I should prefer a single incision, or two at most to such a multiplication of wounds as is recommended by that gentleman. Should pus escape through one or other of the incisions, it will be advisable to put a strip of lint in the wound to prevent it closing.

The same authority condemns the treatment by antiphlogistic measures, more particularly in cases associated with or following erysipelas, and upholds with great justice and powerful reasoning a stimulating and nourishing plan of diet in such cases. This rational plan of treatment of erysipelas and its sequelæ is, however, too well and too generally recognised to need being insisted on at the present day.

3. Next to early incisions, or as an auxiliary, the local application of ice will be of most service in allaying pain and reducing vascular excitement. If properly applied in caoutchouc bags, this is a most valuable method of treatment.

4. In chronic abscess, or in acute, if the cavity does not readily contract, exploration with a probe, or by enlarging the opening and passing in the finger, will be necessary, with a view of discovering any carious or necrosed bone, and of removing any offending bodies. Should, however, no disease of the bone be present, and yet the cavity of the abscess remain open, it will be advisable to inject water or some mild stimulating lotion once or twice a day, until a more healthy action is set up; at the same time attending to any indications of a faulty state of the general health which can be altered by remedial agents, of a medicinal or dietetic nature.

5. Several points of practice applicable to special cases will require a passing notice. Some surgeons are in the habit of using caoutchouc drainage tubes for chronic abscess in this situation, and I believe I have seen benefit result from their use in a case of abscess of the frontal sinus recently under Mr. Bowman's care at Moorfields. A very obstinate case of abscess in the orbit might be treated in the same way. It has also been proposed by M. Riberi, of Turin, that in cases of abscess in the orbit, particularly those associated with caries of the inner side of the orbit, the orbital plate of the ethmoid should be broken through, and a portion removed if necessary, in order to establish a fistulous opening into the nose, through which the pus may escape.

6. There seems some difference of opinion as to the point most suitable for opening the abscess or supposed abscess; and M. Richet thinks that the puncture should be made in the oculo-palpebral groove, and if possible below the eyeball, and to the outer side. But the best rule of practice is to thrust the knife into the most prominent part of the swelling, and if fluctuation is perceptible, which it rarely is, in the early stages,

to puncture the part at which it is most distinct. In any case, however, the incision should be made, if possible, near the margin of the orbit and in the direction of the folds of the skin of the lids, and the fibres of the orbicularis. By taking these precautions the subsequent contraction will lead to less deformity, as to the inversion or eversion of the lids, and the scar will be lost in the natural folds of the skin. It is worth while observing, that a case is recorded (Demarquay, *Op. cit.* p. 116) in which both eyeballs were injured by the knife in opening abscesses of the orbit, and that destruction of both eyes resulted. Such a case should make the surgeon careful to keep the knife paralled with the wall of the orbit, and as near it as possible.

7. Should there be good reason for supposing that caries of the teeth have been the exciting cause of the collection of pus in the orbit, it would be advisable to remove them as soon as this can be done with safety, as the same disease would be likely to recur, the cause remaining. The possibility of abscess of the antrum being present in these cases should not be overlooked, as the removal of a decayed tooth might be the means of emptying the abscess and removing a cause of irritation at the same time, and the injection of tepid water or astringents into this cavity might have an important influence on the result. In a case related by Mackenzie, the extraction of an upper molar tooth allowed a free escape of pus from the antrum, and the symptoms all yielded very rapidly, vision being restored in a few days.

A similar case is related in Mr. Salter's paper as having occurred to Brück. And Mr. Salter's case in the same paper is a further argument for the same plan of treatment whenever abscess of the antrum is present. In two cases recorded by Demarquay there was abscess in the antrum following the extraction of upper molar teeth. One of these terminated fatally, and the antrum was found full of pus, with a softened state of the floor and the roof of the orbit, and a large abscess of the brain; the other was not fatal, but there could be no doubt of the presence of pus in the antrum, as there was a continuous discharge from the socket of the tooth and from the nostril of the same side. The escape of a sequestrum from the posterior nares further confirmed the true origin of the mischief in this case.

In a third case already alluded to, the cause to which the formation of pus in the orbit could be assigned, was the presence of a number of decayed teeth in the upper jaw; and it seems likely that had these causes of irritation and possible foci of purulent infection been removed earlier, the mischief to the eye, the sight of which was totally destroyed, might have been averted.

V.—PATHOLOGY.

Having now considered the subject of my paper in reference to the *Causes, Diagnosis, Prognosis and Treatment, the Pathology* will be best elucidated by an analysis of the recorded cases, and by giving such details of typical cases as will suffice to justify their being classified under the four heads following, viz. :—

DIVISION I.—Fatal cases in which the deposit of pus in the orbit was an indication of general pyæmia.

DIVISION II.—Fatal cases in which lesions of the brain or its membranes were found without pyæmia.

DIVISION III.—Cases (not included in the first two divisions) in which the bones of the cranium or face were involved.

DIVISION IV.—All cases, not included under the above heads, the causes and pathological conditions being various.

DIVISION I.—Fatal cases in which the deposit of pus in the orbit was an indication of general pyæmia.

Under this head will come five cases out of thirty, all of which proved fatal within a few days of the commencement of the severe symptoms.

Case 1.—(Demarquay, *Op. Cit.*, p. 112.)—A woman of sixty years was attacked with erysipelas of the right cheek and eyelids, and this soon spread to the other parts of the face and the eye of the opposite side. On the third day stupor, coma, and delirium came on, and death occurred on the fifth day. At the autopsy deposits of pus were found in the cheek, eyelids, in the cellular tissue surrounding the optic nerve, and in that covering the floor of the orbit. The lungs were pneumonic. The rapid termination of the case, taken in connection with the post-mortem appearances, seem to justify my placing it under this division.

Case 2.—(Henry Lee "On Phlebitis," p. 79.)—J. B., æt. twenty, scalp wound denuding the bone; puffiness of the scalp upon the eighteenth day; rigors followed by profuse perspirations, restlessness, delirium, projection of the eyeballs.

Twenty-four days after the accident and five days before death, secondary inflammation set in.

Post-mortem Appearances.—Bone exposed to the extent of a shilling, of a yellow colour, and with a very dark diploe; effusion of lymph and pus between the dura mater and the bone, extending to the base of the skull, and through the sphenoidal fissures into the orbits; effusion of pus into the arachnoid cavity; incipient secondary abscesses in the lower lobe of the left lung; spleen large and very soft, mottled; degeneration of both kidneys.

Case 3.—(*Ophthalmic Hospital Reports*, vol. i., p. 27.)—A woman under the care of Mr. Poland, forty-five years of age, had erysipelas and abscess of the forehead. Intense pain in the orbit and temple; protrusion of the eyeballs; cerebral symptoms; rapid prostration; death on the sixth day.

Post-mortem Appearances.—Orbits infiltrated with sero-purulent fluid. Both ophthalmic veins filled with dirty pus; cavernous sinuses and right middle cerebral vein distended with purulent matter; brain soft and arachnoid opalescent.

DIVISION II.—Fatal cases in which lesions of the brain or its membranes were present without pyæmia. Seven cases are recorded of this kind, one, perhaps two, of traumatic origin, and the others generally associated with disease of the bones of the cranium.

The three cases following have been selected as the most characteristic.

Case 4.—(*Pathological Transactions*, vol. i.)—Mr. Prescott Hewett relates the case of a child of two years of age who was wounded in the orbit by a piece of lead pencil. The child soon became drowsy, had convulsive twitchings of the limbs and coma. "For some time before death the right eyelids were separated, and the eye could be seen uninjured."

Death occurred on the seventh day, when an abscess in the brain was found with meningitis, and a fissure in the roof of the orbit through which pus flowed into the cranial cavity.

Case 5.—(*Demarquay, Op. Cit.*, p. 146.)—An unmarried woman, twenty-five years of age, was taken with acute pain in the right side of the head. At the end of fifteen days the cheek was swollen, the eye reddened; she had fever, nervous agitation, and anxiety. Suppuration occurred in a few days, and matter escaped spontaneously at the outer angle of the eye. The pus was fetid, and escaped not only from the orbit, but from the neighbouring parts of the eye and cheek. On the fourth day after the opening of the abscess, sudden paralysis of motion and sensation; respiration slow, irregular, and stertorous; pulse small and intermittent; death.

Post-mortem Appearances.—The whole of the fatty and cellular tissue in the eyelids and cheeks down to the level of the lower jaw, filled with pus. Fetid pus in the space between the eyeball and orbit, and burrowing among the muscles. The anterior lobe of the brain in great part destroyed by suppuration; pus surrounding the optic nerve and communicating with the orbit.

Observations.—The exciting cause of the mischief is not hinted at in this account; but it seems very probable that caries of the teeth may have given rise to the pain in the head and abscess in the cheek, and the orbit may have become in-

volved secondarily. Considerations to which I shall allude subsequently will make this appear a probable explanation of the phenomena here observed.

Case 6.—(Demarquay, *Op. Cit.*, p. 145.)—A shoemaker, twenty-seven years of age, of an irritable temperament, and addicted to drinking, had one of the left upper molar teeth extracted. This operation was followed by swelling and redness of the side of the face; epiphora; rigors; photophobia, and intolerable pain in the side of the head, increased and rapid swelling of the face and eyelids.

Some days after, distinct fluctuation at the internal angle of the eye. Abscess opened; yellowish, green, and fetid pus escaped.

The symptoms now became aggravated, and he died in convulsions within less than a month from the commencement of the case.

Post-mortem Appearances.—Dura mater and pia mater congested and altered in colour. Anterior lobe of the brain contained a large collection of pus communicating with the lateral ventricle. Optic thalamus soft and pulpy. Substance of the brain unusually soft. Pus covering the Pons Varolii, and filling up the fourth ventricle.

The roof of the orbit softened and perforated, the opening communicating with the abscess in the brain. The floor of the orbit perforated—the opening communicating with the antrum of Highmore, which was full of pus.

Observations.—In this case the disease in the orbit is clearly traceable to the decayed tooth; but whether the caries of the tooth, or the injury to the gum in its extraction were the actual starting point of the disease, it is very difficult to say.

DIVISION III.—Cases (not included in the two preceding divisions) in which the bones of the cranium or face were involved. Six of the thirty came under this head, one of which was fatal.

Case 7.—(*Medical and Chirurgical Transactions*, vol. xlv., p. 256), related by Mr. S. J. A. Salter.—Eliza F., æt. twenty-four, a domestic servant, was attacked with violent toothache, the evident source of which was caries in a first right upper molar. Rapid swelling of the face, and infiltration of the lower lid came on, with protrusion of the malar bone, and a thrusting over of the nose to the opposite side of the face; fearful pain in the right side of face and eyeball, which latter became protruded; total blindness of right eye. After twenty-four hours matter pointed just below the inner canthus, and this was let out by puncture with a lancet. This orifice closed at once, and another puncture was made at the outer canthus. Pus came through these openings and through the nose almost constantly

for two or three weeks, when Mr. Salter removed the decayed stumps and carious wisdom tooth in the right upper jaw. Pus then escaped through the alveoli of the molar teeth, the fangs of which were denuded of periosteum at their extremities, and had evidently been lying in the antrum surrounded by pus.

Subsequently a large sequestrum of dead bone was removed from the floor of the orbit and the cheek surface of the maxilla, with great amelioration of all the symptoms. Several flakes of bone escaped at intervals afterwards, and the patient made a good recovery, though with total loss of vision in the eye affected, the optic nerve of which was found by ophthalmoscopic investigation to have undergone complete atrophy.

Case 8.—(Mackenzie, *Op. Cit.*, p. 965.)—A man, of thirty years of age, was attacked with sudden and violent pain, shooting from the temple to the side of the face and eye. His sight was quite lost, and his cheek swollen. Soon a discharge came from the furrow between the lower lid and the conjunctiva; and on the extraction of a decayed molar tooth a splinter of wood was found attached to its fang, and projecting into the antrum. Pus escaped from the socket; sight was recovered in a few days, and all symptoms subsided.

Case 9.—(H. Walton on "Surgical Diseases of the Eye.")—A man, of forty-two years of age, had had exophthalmus of the left side, with impaired vision and occasional paroxysms of pain, and swelling for three or four years. For these complaints he had been treated by the repeated application of leeches to the neighbourhood of the orbit; and it was estimated that 800 leeches had been applied at various times. At length he went into King's College Hospital, under the care of Mr. Fergusson, and as there was evident pointing of matter at the lower and outer edge of the orbit, a puncture was made there, giving exit to the contained pus. Very soon nervous excitement, delirium, and epileptic fits were succeeded by coma and death.

Post-mortem appearances.—No mischief within the cranium. Abscess occupying the outer and lower parts of the orbit, and the orbitar and external aspects of the malar bone, which were carious.

Observations.—It is very remarkable that no lesion should have been discovered in the brain. Probably the other internal organs were not examined, as no mention is made of the state in which they were found. The symptoms at once pointed to cerebral lesion, and in the absence of any indication of such being the case, the only rational explanation is that some form of blood-poisoning had occurred. This case, therefore, might be included under the category of pyæmic cases; but in the absence of any evidence of blood poisoning deducible from the appear-

ances after death, it will be better to class it under this division.

DIVISION IV.—All cases not included under the above heads, the causes assignable being various.

Twelve cases are included under this head, agreeing in the following particulars (which, being negative peculiarities, scarcely redeem them from being a miscellaneous collection), viz.: They were not fatal; there was no reason for attributing the deposit of pus to pyæmia; no bones were involved; the brain was not involved, or if so, not seriously.

Case 10.—(*Medical and Chirurgical Transactions*, vol. xlv., p. 260.)—The case is related by Mr. J. S. A. Salter, as having occurred under the care of Mr. G. Pollock.

A man, thirty-five years of age, had great swelling of the cheek and the external parts of the eye, with protrusion of the eyeball, and loss of vision in the eye affected, the pupil of which was dilated and insensible to light.

After the extraction of a bicuspid and molar tooth, both of which were carious, the whole of the symptoms gave way, with the exception of the loss of vision.

Observations.—This case, taken in connection with another related by Mr. Salter (Case 7 in this paper), and also with Case 8, and four or five others, of which I have notes, make it extremely probable that many of the cases of abscess of the orbit, the origin of which have not been hinted at by the authors by whom they are recorded, may have been due to the irritation of decayed teeth, and that many of them might have been satisfactorily explained by a reference to the state of the patient's teeth.

The following case, occurring under my own observation quite recently at Moorfields Ophthalmic Hospital, will serve to confirm this view.

Case 11.—A healthy-looking married woman, of thirty-eight years of age, had suffered for years from toothache, due to the presence of several decayed teeth in both jaws, chiefly situated, however, in the left side of the upper jaw. Suddenly she was attacked by pain in the left orbit, with considerable swelling of the eyelids, protrusion of the eyeball, and with a fluctuating tumour at the upper and inner angle of the orbit; the vision at the same time being absolutely lost.

After the opening of the abscess, by a deep incision at the point at which it was felt most distinctly, the swelling and protrusion of the eye subsided, and the patient made a good recovery; the loss of vision remaining, the ophthalmoscope revealed the characteristic appearances of atrophy of the optic nerve.

The next case is in many respects similar to these two, but no mention is made of any possible cause, and it is therefore open to conjecture whether it might not have been one of the same kind.

Case 12.—(Demarquay, *Op. Cit.*, p. 134.)—A woman, of twenty years of age, suffered from severe pain in both orbits, with headache and fever. Both eyes were protruded—vision was completely extinguished—there was fluctuation at the upper and inner angles of each orbit.

Incisions were made and the matter let out with relief to the patient; but vision was not restored at the end of the period, during which she was under observation (thirty days).

VI.—CONCLUSIONS DEDUCIBLE FROM THE FOREGOING CONSIDERATIONS.

1. Abscesses in the orbit are dangerous to life chiefly from the proximity of the disease to the brain and the large veins and sinuses in the neighbourhood, a large proportion of the deaths being traceable to pyæmia or phlebitis, and a still larger proportion to inflammation of the brain and its coverings.

2. Symptoms of cerebral disturbance are frequently premonitory of a fatal issue, and are always of serious import.

3. Disease of the bones of the orbit or cranium, associated with abscess, give an element of danger, and the recognition of this complication is an important aid in forming a prognosis.

4. Caries of the teeth has been clearly demonstrated as the source of mischief in a considerable proportion of the cases, and it is probable that the same cause may have been in operation in others, the origin of which was uncertain.

5. The sight of the eye affected is not necessarily destroyed, but may even recover when there has been decided amaurosis.

6. The conditions, upon which the amaurosis in such cases depends, seem variable; but ophthalmoscopic signs will enable the surgeon to calculate the probability of a recovery. Should there be atrophy of the optic nerve, no hope of the sight being restored can be held out to the patient.

7. Among the less common causes of abscess in the orbit, may be mentioned, gonorrhœal ophthalmia, syphilitic caries; blows on the eye, wounds of the eyeball, debility after typhus and typhoid, and other fevers.

8. The treatment in most cases is simple, and is not likely to be aided by the use of drugs or leeches, still less by blood-letting from the arm.

9. Local treatment consists, in the first instance, in the application of cold to the neighbourhood of the orbit, and when the abscess is pointing, or when a distinct protrusion of the

fascia can be felt by the finger, it should be opened by an incision at that part.

10. The general treatment will be chiefly of a dietetic kind, but medicines may be required in certain cases.

11. In the later stages, or when the disease has become chronic, disease of the bones is the most probable cause of the continuance of the symptoms, and the removal of this source of irritation will be necessary for the completion of the recovery.

Having considered those affections of the orbit, which are the result of inflammation, under the head of abscess, I shall next consider the subject of tumours, not dependent upon inflammatory mischief; and it will be convenient first to take the tumours of a fluid or semi-solid character. This group will include cysts, vascular and aneurismal growths, sanguineous effusions, and gaseous, or emphysematous swellings.



ON CYSTS IN THE ORBIT, WITH FLUID OR SEMI-SOLID CONTENTS.

The contents of cysts in this region have been very various, the most frequent being those with serous fluid, and next the hydatid cysts. But besides these there are cases recorded of others with oily and semi-gelatinous contents—sebaceous, atheromatous, and meliceric fluid; and others of great rarity which it would be out of place to mention in a paper of this kind. Cysts, with blood effused into them, and those that have suppurated after injuries, must be looked upon as merely accidental modifications of one or other of the groups mentioned. Dropsy of Tenon's capsule may be conveniently considered with the other fluid growths of this region.

I.—THE DIAGNOSIS OF CYSTS.

The marks that distinguish cysts from chronic abscesses are by no means unmistakable either with respect to the physical signs, or the history of the symptoms, and the only method of arriving at a conclusion, in most cases, is to employ an exploratory puncture. This simple proceeding should be adopted in all cases of doubt. I have myself known an operation to be commenced in this region as if for the removal of a solid tumour, when the knife of the surgeon has after a few strokes opened into a cyst, and the tumour has subsided after the escape of the fluid, and a similar instance is related by Démarquay (*Op. Cit.* p. 405.)

The diagnosis from an acute abscess need not be dwelt upon but in case of any doubt the same method may be employed as in the case of chronic abscess. Aneurisms will be distinguished in many cases by their own peculiar features ; solid tumours by the absence of fluctuation.

In all cases of cysts there will probably be combined an inactivity and sluggishness in the growth itself, the progress being very slow ; there will be no superficial discoloration, and no heat of the part ; but the disturbance of function, and perhaps the disorganisation of the neighbouring organs, will be traceable simply to displacement and pressure from the bulk of the tumour.

From an analysis of the recorded cases of cysts, it does not appear that any important indication is derivable from the direction in which the eyeball is protruded. In all the cases, however, protrusion of the eyeball is mentioned as a marked feature in the case, but this cannot be taken as any means of distinguishing such a case from disease equally bulky in the same cavity. It may sometimes be of importance to determine whether a cyst originates within, and is confined to the orbit, or whether it extends into the cranium or frontal sinuses or elsewhere. The symptoms of disturbance in the parts affected will be the only guide in each case, unless a puncture, and exploration by means of a probe be resorted to. Should, however, there be a reasonable probability of the cyst extending into the cranial cavity, it would be necessary to be extremely cautious in exploring. M. Démarquay has related such a case. The surgeon in that instance explored with the finger, after making an incision into the cyst. In a very few days symptoms of acute meningitis came on, and death quickly followed.

Dropsies or cysts of the frontal sinuses, extending into the orbit (of which a large number of instances are recorded by various authors) are characterised by a swelling in front of the forehead, and at the inner side of the orbit. This swelling may be very hard, but sometimes soft and fluctuating. Tumours invading the orbit from the lacrymal sac would be distinguished by the accompanying regurgitation through the puncta lacrymalia.

Lastly, it will be advisable, if possible, to determine whether the cyst be of the simple serous kind, or an hydatid ; whether with oily or other contents ; and this will rarely be possible till either the cyst has been opened, or has been removed. Several cases are related (see one by Mr. Hulke in the *Ophthalmic Hospital Reports*, vol. iv., p. 88), the diagnosis of which was cleared up by the escape of an hydatid cyst in a poultice which had been applied after the opening had been made.

In some instances it may be possible to appreciate exactly

the position of the cyst relatively to the superficial structures, and the following extract, from the writings of M. Bérard, as quoted by M. Demarquay, shows so much ingenuity, and seems so useful and practical, that I shall venture to give a translation of the passage in this place.

“Should the tumour lie between the palpebral muscle (*Levator palpebræ superioris*) and the eyeball, it will by its growth have thrust upwards the elevator muscle of the upper lid, and from the time of the appearance of the disease, the eye left almost completely uncovered will have run the risk of becoming inflamed. Further, if we place a finger on the tumour, at the same time that we tell the patient to raise the lid, we feel distinctly the fibres of the muscle as they make an effort to contract. Should the cyst, on the other hand, be between the levator palpebræ and the orbit, the lid can still be lowered, and when raised, the finger placed on the tumour, feels no contraction analogous to that perceived in the preceding case. The muscle then does not pass in front. The importance of this point of diagnosis is easy to apprehend: as what we have to regard chiefly here is the elevator muscle of the upper lid, if the tumour pass below it the incision should be made through the conjunctiva, whilst in the contrary case it must be made through the cutaneous part of the eyelid.

Certain rare cases of cystic disease of the lacrymal gland are on record, which might give considerable trouble in diagnosis; the position of the tumour and its history would, however, be some guide to a conclusion.

The only other disease liable to cause a difficulty is the dropsy of Tenon's capsule, first described by Carron du Villards, the symptoms of which are sufficiently distinctive to be worth a short description.

The patient in whom the symptoms first attracted attention was a girl of seventeen years of age. She had a considerable exophthalmus, accompanied by excessively sharp pains when she bent her head downward; and the eye was found to be surrounded and incased by a hard uniform tumour, without alteration of the conjunctiva or cornea, but with complete loss of sight. The tumour being supposed to be solid was removed by the knife with the eyeball and it was then found to be a mere distension of the capsule with fluid.

Symptoms such as those described coming on after scarlatina or measles may be considered conclusive of this peculiar dropsy being the occasion of them.

II. COURSE AND PROGNOSIS OF CASES OF CYSTS.

In their course and development, cysts are very slow, and produce a gradual distension of the parts surrounding them. Though generally harmless in their nature, merely producing deformity and impairment or loss of vision from distension, they are liable to sudden inflammatory action from the effects of injury, and to suppuration, when the walls become thinned, and the abscess points at the most easily dilatable part, and ultimately bursts, the contents being discharged at the point of rupture.

There is a general belief among surgeons that the exposure to the air of the lining membrane of a cyst favours suppuration, and recorded cases seem to confirm this conclusion; hence when a cyst has been opened, there is every probability of an abscess forming, and the danger of this will be proportioned to the extent of the cyst wall, and the importance of the parts immediately surrounding it. It is only on these grounds that danger may be apprehended to the life of the patient. Should the cyst be ascertained to have passed through the optic foramen or the sphenoidal fissure into the cranium, there is imminent danger; should it be confined to the orbit, little or no danger need be apprehended. If the whole cyst has been removed, the wound will probably heal readily; if, on the other hand, only part of the cyst has been removed, the remainder will almost certainly suppurate, and a corresponding amount of mischief will be threatened to the surrounding parts.

III. TREATMENT OF CYSTS.

In all cases in which such treatment is possible, there seems to be no doubt that the removal of the whole of the cyst is the safest and most effectual plan of treatment. In the case of hydatid cysts this will be easily accomplished, the cyst-wall being generally very easily detached from the surrounding parts. On the other hand, sebaceous and dermoid cysts require a very cautious dissection in order to remove them entire, the cyst wall being very thin and very adherent to the tissues around them. Such cysts rarely, however, invade the orbit, and when they do, originate from the periosteum at the margin of the cavity, or from the conjunctiva or eyelids, and most usually from the neighbourhood of the outer angular process of the frontal bone. Injection with iodine and solution of sulphate of zinc has been tried with success in those cases in which the cyst could not be removed entire, and this plan

would be particularly applicable in that particular form of cyst which consists of a dropsy of Tenon's capsule.* Great care will be required in the dissection of cysts from this cavity, and where they are large great difficulty must necessarily be experienced in doing so.

It is manifestly impossible to calculate beforehand the difficulties that may be met with; but if it can be ascertained by any means that the cyst extends deeply and perhaps into the cranium, it would be better not to interfere in any way for its removal.

IV. CASES ILLUSTRATING THE PATHOLOGY AND TREATMENT OF CYSTS.

1. *Serous Cyst.*†—A man, twenty years of age, had a tumour occupying the upper and inner part of the left orbit, with protrusion of the eyeball outward and downward, which had existed since his eighth year. The cornea had become obliterated by inflammatory attacks; the tumour protruded from between the eyelids, was fluctuating, tense and shining, and evidently a cyst. As there were no cerebral symptoms of any kind, though great deformity of the surrounding cranial and facial bones, an incision was made into the tumour. The contained fluid spirted out with considerable force and was of a serous nature. The cavity was then explored by the finger of the operator, and the cyst found to extend within the cranial cavity through a widely dilated optic foramen. Some charpie was gently placed in the cavity, and the edges of the wound kept apart by a strip of lint smeared with cerate.

On the fifth day profound stupor came on, and death occurred the same evening.

Post-mortem Appearance.—The vessels of the brain injected; the sub-arachnoid tissue infiltrated; the lateral ventricles filled with milky serum; the whole of the lower surface of the brain softened and of grey colour, and on the left side in a diffuent state from suppuration; the orbital cyst had extended about three inches into the left anterior lobe, pushing before it the arachnoid and pia mater, to which it had become firmly adherent; the left optic foramen measured more than six lines in diameter, and the left optic nerve had entirely disappeared. On the lower surface, and in the substance of

* M. Carron du Villards, who has described this form of disease, recommends a cautious incision into the capsule with scissors, while the patient's head is bent forwards, and a few strips of charpie stuffed into the cavity for twenty-four hours. *Vide Démarquay, p. 419, et seq.*

† Démarquay, *op. cit.*, p. 376 (Extract from Delpéch.)

the right anterior lobe, was a sero-mucous cyst of about half the size of a pigeon's egg.

2. *Serous Cyst*.*—A man, æt. twenty-four, was admitted into La Pitié, under Lisfranc, with exophthalmus of the right side, and a tumour occupying the space between the inner wall of the orbit and the eyeball. This tumour was fluctuating, hard and tense, and covered by inflamed conjunctiva, at the same time pushing before it the upper lid, and almost surrounding the eyeball. Vision was not entirely lost.

An exploratory puncture was made by Lisfranc, which gave exit to a serous, colourless fluid, after which the eyeball was returned to the socket, and retained there by a compress and bandage.

The next day erysipelas of the face came on, but soon subsided; the protrusion of the eye, however, was again produced. A month after the puncture, Lisfranc dissected away part of the cyst and removed it, and lint was put into the wound to produce suppuration in the remaining part of the cyst.

For five days after the operation no bad symptoms were observed, but on the sixth erysipelas of the face and ophthalmia, both of which subsided, and a free escape of pus from the cavity was established. On the twenty-fifth day, the wound having partially closed, was enlarged, and a large quantity of fetid pus let out. The patient now appeared to be approaching recovery, when symptoms of purulent infection appeared, and the patient died fifteen days after the first rigors.

Post-mortem Appearances.—Abscesses in the lung, liver, and brain; the shoulder and hip-joints were full of pus; the cavity of the cyst in the orbit nearly obliterated, and enclosed a muco-serous pus. All the veins in the neighbourhood were examined, but no trace of inflammation could be found in them. It is remarked, however, by M. Legendre that the *diploe* in the neighbourhood of the cyst was *not* examined.

Observations.—This and the preceding case must be looked upon as unusual in their rapidly fatal termination, and are related here chiefly from the light they are calculated to throw on the pathology of non-fatal cases.

3. *Hydatid Cyst*.†—A sailor, twenty years of age, was admitted into the Royal London Ophthalmic Hospital, Aug. 10, 1852, for a tumour situated in the left orbit, which had already caused the disorganisation of the eyeball.

An obscurely fluctuating tumour was felt at the upper and under part of the orbit; the upper lid was turned inside out,

* Démarquay, *op. cit.*, p. 408.

† Bowman's 'Med. Chir. Trans.' 1861.

and the eyeball thrust outward and downward. The cornea was flaccid and half opaque, and the globe of the eye partly collapsed. The first symptom had been an abnormal protrusion of the eye three years before. On the 27th August Mr. Bowman made a puncture with a bistoury and let out a perfectly limpid fluid. He then enlarged the incision, and explored with the finger, but without discovering any hydatids; he therefore introduced a strip of lint. In the course of a week suppuration had been established, and three hydatid cysts of the size of marbles escaped into the poultice. The cavity rapidly closed up, and the patient made a good recovery.

Observations.—In the *Ophthalmic Hospital Reports*, vol. iv., p. 88, Mr. Hulke has related a case similar to the one of Mr. Bowman's. The hydatid cyst came away in the poultice in this case, the cavity quickly closing up, and vision being in part retained.

4. *Sebaceous Cyst.**—A young woman, æt. twenty years, had protrusion of the eyeball in a direction inwards and upwards; which was caused by a tumour at the lower and inner part of the orbit. This tumour was appreciable to the eye; covered by unaltered skin; having an indistinct fluctuation, and communicating to the finger the sensation of softness, but scarcely of fluidity. Vision was lost, and the pupil dilated, but still moveable.

An exploratory puncture was made without any fluid escaping. A few days after, the tumour was cut down upon and found to be filled with stinking sebaceous matter, similar to the ordinary sebaceous tumours of the skin. The contents of the cyst were of the bulk of an orange. The cyst itself was left to suppurate, and the wound kept open by a strip of lint. The eye returned to the socket and vision improved. Injections of the cavity were had recourse to in order to remove the remains of the sebaceous matter, and various measures tried to promote suppuration, but none succeeded. At the end of three months the probe could still be passed to the bottom of the orbit, and at the end of eight months a small fistulous opening still remained, through which a sero-purulent fluid escaped and occasionally with it fragments of the stinking sebaceous material already alluded to.

Observations.—Mr. Haynes Walton has related a case of a similar kind to the above in the *Medical Times*, 1854, p. 195. In all probability the cysts in these instances originated in the eyelid, and thence invaded the orbit.

For an instance of *Colloid Cyst*, containing a gelatinous liquid, I must refer again to Démarquay's work, p. 395; for an


* This case was observed by M. Testelin, and is quoted by M. Démarquay, at p. 392 of his work.

encysted *Oily Tumour*, to Mr. Haynes Walton's work, p. 280. Several other cases of rare forms of cyst are related by Démarquay, such as a Melanic Cyst (p. 369), and Meliceric Cysts (p. 391); but it would be out of place to give details of such cases in this paper. The instances of dropsy of Tenon's capsule, however, deserve notice, as offering a similarity and a contrast to those cases already related.

5. *Dropsy of Tenon's Capsule*.*—M. Carron du Villards relates the following case in the "Annales d'Oculistique," 1858, t. XL., p. 106:—

A young man had a distinct projection of the fluid whenever he bent his head forward. If he remained long in that position the eye became so hard and so painful that he was obliged to lie down on his back to push back the fluid by making pressure on the eyelids.

Observations.—In all the persons affected by this malady the protrusion of the eye has followed scarlatina or measles, and M. Carron du Villards has observed that the same affection is seen in sheep suffering from the *rot*. This latter being also a cutaneous eruption. The same authority has always succeeded in removing the fluid by a puncture, which should be performed only after a previous cautious dissection down to the capsule before opening it.



ON VASCULAR AND ANEURISMAL GROWTHS.

Notwithstanding the large number of cases illustrating this interesting subject, which have been put on record by different observers; very few can be arranged satisfactorily according to their pathology; partly because a large proportion of these cases have been so successful as regards the results of treatment, that no opportunity of verifying the diagnosis has been afforded; and partly because others, which have terminated fatally, have yielded evidence of such varying nature that it is almost impossible to find materials for comparison, or to carry out anything like a statistical inquiry in the subject. No two cases out of about forty cases which I have collected, present exactly the same features, either in the symptoms or the pathological conditions; at the same time there are some general points of resemblance among a considerable number to which it may be interesting to allude, and from which, probably, practical conclusions may be obtained.

* One case has been already noticed under the section devoted to Diagnosis, *vide supra*, p. 665.

In the first place there are about thirty-six cases of tumour recorded which agree as to the following broad characters: they are associated with protrusion of the eyeballs; they have a pulsatile movement perceptible to the eye or finger, or both; there is a bruit or whirring sound heard by the patient and by the stethoscopist; the pulsation and bruit cease when pressure is made on the carotid artery of the same side, and return when the pressure is removed.

It is obvious that a number of entirely different pathological conditions are compatible with the existence of such morbid phenomena as are here mentioned, and on analysing these cases, they will be found to include cases of true aneurism of the ophthalmic artery; diffuse aneurism of the same artery; aneurism, true or diffuse, of the internal carotid in the cavernous sinus; aneurismal varix of the internal carotid; tumours of various kinds obstructing the return of venous blood through the sphenoidal fissure; malignant pulsating tumours in or behind the orbit; and general dilatation of the intra-orbital arteries from atheromatous degeneration of the middle coats.

True aneurism of the ophthalmic artery within the orbit is in all probability the least common form of aneurismal lesion. In Mr. Guthrie's case it is mentioned that an aneurism was found in each ophthalmic artery of the size of a nut. At the same time he states that the ophthalmic vein was very much enlarged and was obstructed near the sphenoidal fissure by an hypertrophied condition of the four recti muscles, which had acquired an almost cartilaginous hardness. (Lectures on "Operative Surgery of the Eye," p. 158). In this case, though the eye was protruded and a bruit could be heard during life, no tumour could be felt.

The only other case in which true aneurism of the ophthalmic artery in the orbit was seen after death, was one mentioned by M. Carron du Villards, as having been met with by him accidentally while dissecting at the *École de Médecine*.

Diffuse aneurism of the ophthalmic artery, either spontaneous or traumatic, seems a much more common condition, but in many cases the mischief seems to be situated as much behind the orbit as within it; and in some it would appear that the symptoms during life are more due to pressure in the cavernous sinus and sphenoidal fissure, than to actual disease in the orbital cavity.

As an instance of a traumatic diffuse aneurism, the case related by Mr. Busk in the *Med. Chir. Review*, for April, 1836, is perhaps the most complete, and illustrates best the symptoms, treatment and pathology of the disease.

Mr. Busk's case at the London Hospital (Med. Chir. Review, April 1836).—A man had cerebral disturbance after a violent blow on the left temple. Copious bleeding from the ear fol-

lowed, and deafness. The eyelids were swollen, the pupil dilated and the eye fixed and immovable. More than six months after the accident a pulsating tumour was found at the upper and inner part of the orbit. The common carotid was tied with immediate relief and ultimate cessation of all the symptoms. Some years after a *post-mortem* examination was made, and an old rupture of the ophthalmic artery was found.

This case seems conclusive as to the nature of some, at any rate, of the cases of pulsating tumours in this region, and several similar cases following injuries, seem to confirm the same view of their pathology. A case read by Szokalsky, at the Heidelberg Ophthalmological Congress, was probably of exactly the same nature. (*Ophthalmic Review*, vol. ii., p. 188.)

Case by Szokalsky.—A man, fifty years of age, while chopping wood, received a violent blow on the left temple from a splinter. The left eye was protruded at the end of a few weeks, and a softish indistinctly pulsating tumour appeared on the left temple.

Between the eyeball, and the upper and outer margin of the orbit, a flat tumour was felt reaching deep into the orbit. The two tumours being superficially separated by the edge of the orbit; both pulsated and pressure on the carotid stopped the pulsation.

The treatment at first tried was compression by the finger on the carotid, with the addition of ice-cold applications, and digitalis internally. This plan not succeeding, the common carotid was tied, digital compression having been employed for eight hours previous to the operation. Three months after the aneurismal tumours had become softer and smaller, and the protrusion of the eye less.

Instances are not wanting of cases of aneurism involving the internal carotid and ophthalmic artery, and it is probable that they form the larger number of the cases of pulsating tumours in the orbit.

The following particulars are related by M. Giraudet, of Tours, of an aneurism involving the internal carotid and ophthalmic artery (*Gazette des Hôpitaux*, 7th March, 1857), and will throw light on the pathological conditions of many of the cases in which the state of the structures involved could only be guessed at. "On raising the right anterior lobe of the brain, we discover an irregular, oblong, nodulated tumour, situated above the cavernous sinus. The colour is of a red brown, mingled with yellowish spots, its volume measures four centimetres by two-and-a-half. The right ophthalmic artery enlarged into the form of a funnel, is continuous with the anterior aspect of the tumour. The latter having been divided, and the clots turned out, the two funnel-shaped openings of the carotid and ophthalmic arteries are seen, establishing a communication with the aneurismal sac. The sac has only one cavity, the thickness of its walls

varies from two to three millimetres. The cellular coat of the artery adheres closely to the surrounding vessels. The middle coat is thickened; a slight magnifying power discloses numerous laminae of transverse fibres. Between this coat and the inner coat we find a large number of little osseous lamellæ of a blue-yellowish colour, the inner coat is marked with red and yellow marks in two different places. It is completely worn away and destroyed, and the osseous plates are in direct contact with the interior of the cyst.

Among the clots which the tumour contains, some escape at the time of the incision; others are closely united and arranged in concentric layers. The right optic nerve is flattened like a ribbon, displaced and bound to the under surface of the tumour; the motor oculi nerve, and the ophthalmic branch of the 5th, are also thinned and compressed at the base. The cavernous sinus is obliterated; the clinoid processes have entirely disappeared; the commencement of the roof of the orbit is stripped of periosteum and *ruginè* for the extent to two centimetres."

An account of the dissection of the orbit in a similar case is given in the *Pathological Transactions*, vol. xi., p. 8, by Mr. Nunneley, and the conditions in the two cases offer a very remarkable resemblance. Those pulsating tumours which come on suddenly in the orbit, especially when occurring in the course of pregnancy, or during any rather violent exertion, may be looked upon as of the nature of diffused aneurism, differing only from those of traumatic origin in having been preceded by a diseased artery or true aneurism. These are what Demarquay describes as diffuse consecutive aneurisms as distinguished from diffuse primitive aneurism, or those not preceded necessarily by disease of the coats of the artery involved. Dalrymple's case of a pregnant woman forty-four years of age, who had sudden pain and noise in the head, followed by a pulsating tumour which receded after ligature of the carotid is a good instance.

A case related by Mr. Nunneley in vol. xvii. p. 168 of the *Mcd. and Chir. Transactions*, is especially interesting, as the diagnosis was confirmed in a remarkable manner by an autopsy five years after the disease had yielded to the ligature of the common carotid.

In this instance there had been during life, besides the other common symptoms of aneurism, paralysis of all the extrinsic muscles of the eyeball, and the seat of the tumour was thought to be in the cavernous sinus from this circumstance. This proved to be the case; for a circumscribed aneurism was found on the side of the sella turcica, filled with solid coagulum and pressing upon the ophthalmic vein.

Mr. Nunneley, from this and other cases, draws the conclusion that pulsation in orbital tumours may be a merely communicated pulsation from an intra-cranial aneurism to an enormously

dilated ophthalmic vein; and from cases that have been reported elsewhere, such an explanation seems very probable, and to be justified by facts that have been brought to light.*

This consideration explains some cases which have been very puzzling to the surgeon, of *simulated aneurism* in this region.

Thus, Gendrin relates the case of a woman thirty-two years of age, who was attacked by sudden pains in the head, and protrusion of the eyeball. Pulsation and bruit both distinct. After death the intra-orbital veins were found distended with blood, but there was no extravasation. In the interior of the cavernous sinus the internal carotid and ophthalmic arteries were surrounded by an adherent blood-clot. Their inner wall presented various alterations—the greater part of the arteries of the orbit were obliterated. Here, as in Mr. Nunneley's case, the pulsation felt in the orbit must have been communicated.

The following case also, anterior in point of time to those already related, illustrates the same point.—*Ophthalmic Hospital Reports*, vol. ii., p. 6 :—

The woman, æt. forty years, under the care of Mr. Bowman, at King's College Hospital, complained of a sudden loud noise in her head after a blow with the fist.

She had double vision, redness and protrusion of the eyeball, dilated and immovable pupil, and enlarged veins at the outer and inner canthi. Pulsation was felt over the eyelids.

The common carotid was tied, and the pulsation and bruit immediately ceased, and for a week there seemed every chance of the case proving a successful one. Phagedænic ulceration, however, followed by hæmorrhage, led to a fatal termination eighteen days after the operation.

When the parts came to be examined, no trace or appearance of an aneurism could be discovered, but there were evident signs of "phlebitis of the cavernous, transverse, circular, and petrosal sinuses. The internal carotid artery may have been partially compressed by the swollen walls of the cavernous sinus against the side of the body of the sphenoid bone, giving rise to the bruit, which would have a good conducting medium in the cranial bones. The plugging of the trunk of the ophthalmic vein, where it joins the cavernous sinus, by obstructing the return of blood from the orbit, accounts for the protrusion of the eyeball, and perhaps also for the pulsation which was felt when the fingers were laid on it."

These remarks were made by Mr. Hulke, who reports the

* It is, however, remarkable that in the case, to explain which Mr. Nunneley makes these observations, there was aneurismal dilatation of the arteries in the orbit, sufficient, if the drawing be correct, to account for the symptoms. *Vide Pathological Transactions*, vol. xi., p. 8.

case, and to him, therefore, is due the credit of making out this important point in the pathology of intra-orbital tumours, the cases adduced by Mr. Nunneley having in a striking manner confirmed his views.

The difficulty of exactly appreciating the nature of the intra-orbital growth is well illustrated by another case related by Mr. Nunneley in *Med. Chir. Transactions*, vol. xlvi., p. 21, in which a highly vascular malignant growth was treated by ligature of the carotid, with temporary relief of the symptoms, the eyeball receding and the pulsation being less marked. Death occurred eighteen months after, and a tumour of the nature of medullary cancer was found occupying the post-orbital region of the cranium, passing into the orbit and zygomatic fossa, and pressing upon the cavernous sinus and ophthalmic vein.

A parallel case is recorded by Demarquay as having occurred to Mr. Lenoir (*Bulletins de la Société de Chirurgie*, t. ii., p. 61 and 84).

The tumour was treated as an aneurism by ligature of the carotid, after which pulsation ceased and the tumour diminished in size. Two months after, a pulsating tumour appeared in the calf. Death occurred nine months after the ligature of the carotid; when encephaloid tumours in the brain, in the calf of the leg, and in the lungs were found.

Having, however, brought forward so many cases of difficulty, the practical aim which I have before me would be entirely overlooked were I not to endeavour to lay before my readers a succinct statement of what symptoms may be expected in an uncomplicated case, and that some have occurred and are likely to occur again there can be no doubt, though in very few will there be such simplicity and clearness as would satisfy those who look for the precision of the printing press in the pages of nature, rather than the faint outlines left in the sand by the finger of the unseen Master.

An uncomplicated diffuse aneurism is very frequently the result of an injury to the orbital or temporal region, or to the base of the cranium. Where there is no history of external injury, the attack of pain and noise in the head with which the symptoms are ushered in, has been sudden and has been observed to occur in pregnant women or during child-birth in a large proportion of cases.*

* Thus, of thirty-four cases of aneurismal tumours in or about the orbit, tabulated by Dr. T. G. Morton, of Pennsylvania, thirteen are directly attributed to injuries received, and six occurred either during pregnancy or during childbirth.—(*American Journal of Medical Sciences*, April, 1865.)

And in two other cases not tabulated, by Dr. Morton, the origin of the disease in each case was injury.—(Holmes, *American Journal of Medical Sciences*, July, 1864.)

The immediate effect is to produce swelling and ecchymosis of the lids and surrounding parts, and this is followed sooner or later (it may not occur for months after), by protrusion of the eyeball, a pulsating tumour near the eyeball, and a whirring bruit heard over the temporal region or brow by the aid of the stethoscope. Pressure made on the carotid of the same side stops the pulsation, which recurs when the pressure is removed. The patient complains of a beating or humming noise in the head, and in some cases this noise can be heard by others at some little distance from the patient.

The protrusion of the eyeball increases gradually, and in all probability the expanding tumour would at length burst, leading to a fatal hæmorrhage, unless art stepped in and arrested the morbid process. The only case in which fatal hæmorrhage occurred was one of aneurismal varix of the cavernous sinus, the rupture occurring during a period of the intermission of treatment by compression of the carotid. (See a case of M. Nélaton's, related by Dr. Holmes in the *American Journal of Medical Sciences*, for July, 1864, at page 46).

Whether an ordinary diffused aneurism of the orbit has ever been known to terminate in this way, is of very little consequence; the mode of termination of the same disease in other parts being well known; and there being no reason for expecting any difference in its progress in this locality.

It is remarkable, however, that treatment by ligature of the common carotid and by compression with the finger of this artery should have been so often successful in checking the progress of a disease which, in other parts of the body, is not usually controlled by the same method; and this consideration throws considerable doubt on the diagnosis in those cases in which the operation has been successful, and makes it probable that true aneurism has been present, and not a diffused aneurism, or that, at any rate, the diffused aneurism has become encysted and so assumes some of the characters of a true aneurism, and among those its amenability to treatment by ligature of the main vessel. It is easy to conceive that the firm fascia of Tenon's capsule in front, and the attachments of the recti muscles behind, would form such barriers to the extension of effused blood, that after a clot had once formed, it would offer considerable resistance to the impulse of an artery of so small a calibre as the ophthalmic, and that an aneurism in this cavity would be under conditions somewhat different from those of one in the popliteal space or in Scarpa's triangle. In those spaces, and in others along the chief arteries of the limbs, the fascia of the limbs would only limit the extension of effused blood forward, while neither their own sheath nor the fasciæ would, in any way hinder an extension in the direction of the

long axis of the limb. On the other hand it may be said that in tying the common carotid the treatment is equivalent to tying the arteries supplying both ends of the divided or ruptured vessel, and that it cannot be compared to simply tying the superficial femoral for an aneurism in the brain. Such an argument, however, is open to the objection that the anastomosis with the arteries, on the other side of the head are very free and perhaps as much likely to interfere with success as the anastomosis of the profunda femoris with the recurrent and other branches of the popliteal.

The *sudden* attack of pain and noise in the head will suffice to distinguish a case of this kind from the pulsating malignant growths, and these seem the only ones likely to be confounded with them. I have, however, already mentioned an instance in which the diagnosis from abscess was only cleared up after making a puncture into the tumour, and it is well to bear in mind cases that have been recorded of aneurism by anastomosis in the orbit (see Haynes Walton "On Surgical Diseases of the Eye," second edition, p. 230), and the dissection of a case by Mr. Nunneley (*Pathological Transactions*, vol. xi., p. 8), in which, from the drawing given by him, there seems to be a general dilatation of the ophthalmic artery and its branches.

The symptoms of aneurism of the internal carotid in the cavernous sinus may resemble, in some respects those of aneurism within the orbit, but will most likely be accompanied by others, such as disturbances of the cerebral functions; paralysis of the motor apparatus of the eye from pressure on the nerves at the sphenoidal fissure; and if the tumour does not invade the orbit no pulsation would be perceptible, so that the difficulty of diagnosis would be lessened. A case related by Mr. Hussey, of Oxford, in the *Ophthalmic Hospital Reports*, vol. ii., p. 127. well illustrates the difficulty of diagnosis of such cases; the disturbance of functions of the brain—*e.g.*, paralysis of the arm and convulsive attacks, and the co-existence during the latter part of the life of the patient, of hæmorrhages from the nose, seemed to indicate a tumour of a malignant kind in the cranial cavity invading the cerebral tissues, though the sudden occurrence of the symptoms, during a somewhat violent exertion, favoured the hypothesis of an aneurism of the internal carotid in the cavernous sinus. In the absence of a post-mortem examination this very interesting case remains of doubtful nature.

The treatment of aneurism of the orbit has been, it would appear, very successful, whether ligature of the common carotid has been adopted or digital pressure, or injection by astringents or internal remedies.

Dr. T. G. Morton, of Pennsylvania (*loc. cit.*) has collected thirty cases in which the common carotid artery was tied for aneurism, or supposed aneurism, within or near the orbit, and of these twenty-two are reported as cured, and three as partially successful; two were unsuccessful and three fatal.

Dr. Morton has tabulated four other cases, two successfully treated by injection of styptics and two, equally successful, created by digital compression.

And Dr. Holmes (*American Journal of Medical Science*), has related a case successfully (*loc. cit.*) treated by the administration of extract of ergot and tinct. of the *veratuni viride*, or in which, at any rate, the patient recovered perfectly during the administration of those remedies.

A case, treated by compression is also related by this gentleman, but with a fatal result during a period of intermission of the treatment. So that, out of thirty-seven patients treated by different methods (*vide table*), twenty-nine perfectly recovered, three more were relieved, two remained as they were before, and three died.

For Table of Cases see following page.

TABLE OF CASES.

	Operator	Date.	Ligation.	Result.	Origin.
1	Travers	1809	Common Carotid	Cured	Sudden, during pregnancy
2	Dalrymple	1813	ditto	Ditto	Ditto
3	Roux	1829	ditto	Success incomplete	Sudden and spontaneous
4	Warren	1829	ditto	Cured	Ditto
5	Warren	1829	ditto	Unsuccessful	Injury
6	Scott	1834	ditto	Cured	Ditto
7	Busk	1836	ditto	Ditto	Ditto
8	Dudley	1839	ditto	Ditto	No observable cause
9	Jobert	1839	ditto	Ditto	Injury
10	Velpeau	1839	ditto	Ditto	Sudden and spontaneous
11	Wood	1842	ditto	Ditto	Congenital
12	Mott	--	ditto	Success incomplete	Ditto
13	Van Buren	--	ditto	Cured	Injury
14	Herpin	1844	ditto	Ditto	Sudden and spontaneous
15	Petrequin	1845	ditto	Ditto	
16	Nunneley	1852	ditto	Cured	Injury
17	Nunneley	1856	ditto	Ditto	Slow, during pregnancy
18	Nunneley	1858	ditto	Died	Sudden and spontaneous
19	Nunneley	1859	ditto	Cured	Injury
20	Walton	1851	ditto	Ditto	Congenital
21	Brainard	1852	ditto	Unsuccessful	
22	Curling	1854	ditto	Cured	Injury
23	Coe	1855	ditto	Ditto	Ditto
24	Bowman	1859	ditto	Died	Ditto
25	Bowman	1860	ditto	Cured	
26	Syme	1861	ditto	Ditto	
27	Hart	1861	ditto	Ditto	Injury
28	Morton	1864	ditto	Ditto	Sudden, during pregnancy
29	Nunneley	1864	ditto	Ditto	
30	Nunneley	1864	ditto	Successful in arresting protrusion. Patient lived 18 months	Injury Spontaneous
31	Bourget		Treated by injection	Cured	
32	Walton		ditto	Ditto	Sudden, during childbirth
33	Gioppi	1856	Treated by compression	Ditto	Sudden, after childbirth
34	Scaramuzza	1858	ditto	Ditto	Injury
35	Holmes	1864	Treatment by Ext. Sec. Comut. and Tr. Veratr.	Cured	Injury
36	Nelaton & Desmarrs	1855	Compression with tourniquet	Death from bursting of aneurismal varix of the cavernous sinus	Injury
37	Sczokalsky (<i>Ophthalmic Review</i>), vol. ii. p. 188.	1864 or 3	(1) Digital compression and ice. (2) Three months later ligation of the carotid	Success lasting for three months at least	Injury

ON EFFUSIONS OF BLOOD, AIR, AND SERUM, IN THE ORBIT.

I. EFFUSIONS OF BLOOD IN THE ORBIT.

THE causes of extravasations in this region are direct injuries, penetrating wounds, and fractures of the skull involving the orbital walls; but there are a few instances in which the extravasation has taken place independently of actual violence applied to the part; and such cases have occurred during violent exertion on the part of the patient and generally in a highly heated atmosphere. The effusions of blood of an external kind, and leading to diffuse aneurism, have been already considered, and our present subject will, therefore, exclude the consideration of any aneurismal growths. The symptoms will, however, be similar to those of intra-orbital aneurism in some respects. There is a sudden protrusion of the eyeball immediately or at a slight interval after an injury—with discoloration of the conjunctiva and eyelids, and perhaps, ecchymotic redness and swelling of the surrounding parts. The vision may be simply defective from the alteration of the axis of the two eyes, and the consequent diplopia, or there may be temporary amaurosis consequent on pressure behind the globe, or around the optic nerve. The swelling may or may not be felt by the finger, but the history and symptoms will clearly point to the nature of the case, and, unless there be serious lesions within the cranium, the treatment will be of the simplest nature.

When the extravasation is associated with fracture, it is evident that the case may be of a very serious kind; the prognosis being unfavourable in proportion to the extent of the injury. It may therefore be well to consider, in such a case, what evidence there is of the fracture having extended into the base of the cranium or the roof of the orbit. M. Carron du Villards says, that he has seen many cases in which fracture of the cranium has been associated with symptoms of intra-orbital effusions of blood, and he relates a case in which his diagnosis was verified by post-mortem inspection. (Demarquay, *Op. cit.*, p. 272). With regard to extravasation in the eyelids as an indication of the seat of fracture, there seems to be no certainty, though, if not associated with sub-conjunctival effusion it would point to the *margin* of the orbit as the probable seat of injury; while sub-conjunctival effusion associated with other symptoms of fracture and unassociated with effusions into the eyelids, or followed by it, would point to the deeper or post-ocular part as

the seat of injury.* The latter condition would be, of course, more likely to be serious than the former, in proportion as the base of the cranium is more important than the facial region.

The following extract from Mr. P. Hewett's paper in "Holmes's Surgery," vol. ii. p. 127, will serve to show what value can be placed on this symptom as an indication of fracture in the orbit.

"Out of twenty-three cases of fractured base, involving more or less extensively the orbital plates of the frontal, all of which occurred at St. George's Hospital within the space of ten years, it was found in eight cases, that there were no traces of extravasated blood to be seen, either in the eyelids or under the ocular conjunctiva; and in five cases that the effusion of blood occupied the eyelids only; so that in these *thirteen cases* there could have been no suspicion whatever as to the existence of a fracture. But, on the other hand, the nature of the injury was made manifest in the *ten remaining cases* by the blood effused under the ocular conjunctiva and in the lids.

"Blood may, however, be effused into the lids and under the ocular conjunctiva, in fractures of the malar, or superior maxillary bones; and this may give rise to an error of diagnosis."

The following case abridged from a report in Demarquay's works, taken from the "Annales d'Oculistique" 1847, t. xviii. p. 201, is a good illustration of the subject in hand.

M. L., æt. sixteen, fell from the rigging of a ship, a height of fifty-two feet, and struck the left side of his head. He was taken up insensible and blood flowed copiously from his mouth, nose and ears for several days. The left eye was thrust out of the orbit and hung down on a level with the tip of the nose. The captain of the ship replaced the eye and put on a linseed poultice. Fever supervened, with delirium, and lasted fifteen or twenty days.

Three months after the accident he was placed under the care of M. Duval, who found his left eye protruded and absolutely blind; though the iris acted regularly. Iodide of mercury ointment was rubbed into the temple and brow, and iodide of mercury given internally, and leeches applied.

A year after, violent inflammation of the eyeball and surrounding parts came on, which subsided under treatment, which still left the protrusion of the globe. Iodide of mercury internally and externally were again used, and at the expiration of two months the eye had returned to the socket. Two years after, the patient's appearance was quite normal, but vision was never restored in the affected eye.

In a case related by M. A. Ricord and quoted by Mr. P. Hewett ("Holmes' Surgery," v. ii. p. 173), there was distinct evidence of extravasation of blood in both orbits, but no protrusion of either eye. The sight of one eye was temporarily lost, and

* Demarquay, *Op. cit.*, p. 274.

Mr. Hewett remarks that the temporary loss of vision must have been due to effusion into the sheath of the optic nerve, rather than to pressure, and the restoration of blood in the orbit and around the nerve of vision, to a re-absorption of this blood.

Among the symptoms of extravasation with fracture, may be mentioned paralysis of the fifth and third pair, and instances of such lesions are given by Mr. Hewett in the same place; but it would be imprudent to look upon these lesions as merely the result of compression by effused blood; when we consider that the same injury which has caused the latter may have damaged the brain substance permanently; and the prognosis must be cautious in proportion.

Extravasations from penetrating wounds, and from contusion, give rise to symptoms similar to those already mentioned and instances can be found in many authors.*

A remarkable case by Dr. Redemans is well worth notice.† The obstetric forceps were applied by this gentleman, for the delivery of a woman in her sixth confinement. The child was extracted alive, but, two hours after, the right eye was found to be thrust out of the orbit, the eyelids being buried in that cavity and the conjunctiva everted and infiltrated with blood. There was also infiltration of the eye and eyelid of the other side, but to a less extent.

Pressure with the fingers failed to replace the protruded eye, and a puncture made into the swelling was also unsuccessful. Graduated compresses were applied, but suppurative action set in and ulceration of the cornea which ended in perforation. After this the protrusion became less, and the eyelids resumed their normal position.

This case is unique, but seems to point out the possible dangers of delivery in this way when it is necessary to apply the forceps for a long period, and, as Mr. Redemans observes, suggests the expediency of applying a compress immediately after birth in any case where there is reason to anticipate such a result. Possibly, in a suitable case it would be better, when the protrusion has actually taken place to leave the process of absorption to go on without any local interference and to protect the surface of the cornea by the application of olive-oil and a gauze-shield or goggle of such a size as to cover the whole circumference of the orbit, and the everted conjunctival surface. Punctures into the orbit itself would scarcely be likely to be of use in any case of extravasation, though, in such a case as the

* (Vide Demarquay, *Op. cit.*, p. 280—1. *Ophthalmic Hospital Reports*, Oct. 6, 1857).

† Demarquay, *Op. cit.*, p. 283.

above, the temptation to effect a rapid replacement of the eye was very great and would justify any rational attempt with such an object.

Spontaneous effusions of blood in the orbit are very uncommon, but M. Demarquay's work contains allusions to several instances occurring in typhus patients and in one scorbutic. He also relates in detail the case of a workman, nineteen years of age who had sudden diplopia and impairment of vision and of the movements of the eyeball, which could only be attributed to this cause. M. von Graefe, under whose care the patient was, considered the *absence* of cerebral symptoms, taken in connection with the symptoms observed, plainly indicated the seat of the effusion, and the gradual disappearance of all these symptoms justified his diagnosis.

The treatment adopted in this case was that of general and local bleeding, and M. Demarquay recommends in similar cases to make an opening for the escape of the effused blood. How far such a plan may be justified by experience I am unable to say, but I should be inclined to leave the effused blood alone till absorption had taken place.

II.—EMPHYSEMA.

The escape of air from the lacrymal passages into the cellular tissue sometimes gives rise to protrusion of the eyeball; and this is generally the result of some injury by which the os unguis has been fractured. The following two cases of M. Desmarres (Demarquay, p. 224-5) are very good illustrations of this very rare and curious affection.

M. Desmarres' first case:—

“As soon as the patient pressed his nose between his fingers to use his pocket-handkerchief, and the air was forced into the nasal canal, the left eye was visibly projected for the extent of at least a centimetre and a half, being thrust forward by the air which found its way behind the globe at each attempt made by the patient to blow his nose. As soon as the compression of the nostrils was taken off, the globe resumed its place, and occupied the same level as its fellow. At the same time that it was thrust forwards, the eye was directed from above downwards, and from without inwards, and there was double vision. When the other eye was closed, at that moment double vision ceased, and the image perceived was single and distinct; it was only displaced, and followed the direction of the fellow organ.”

M. Desmarres' second case:—

“A blow from the fist on the left eye ruptured the lacrymal sac; an enormous emphysema of the whole anterior wall of the orbit was soon produced. With the view of showing me how he made the air pass at will into the tumour, the patient blew his nose violently while compressing his nostrils; immediately the eyelids and the circumference of the orbit swelled, and became of a blueish ecchymotic black, just as if a coloured injection had been forced into the tissues.”

General emphysema may affect the orbit with other parts and protrusion of the eyes in such a case would not be at all a serious symptom. It is necessary to bear in mind the possibility of meeting with such a singular condition as that of the cases described, but it would be improbable that any mistake of diagnosis should occur.

The treatment consists in making punctures for the escape of the air from time to time, and the patient should be cautioned against blowing his nose until the opening in the membrane and lacrymal bone has closed up.

III.—EFFUSION OF SERUM INTO THE CELLULAR TISSUE.

M. Demarquay has pointed out this condition as the probable cause, in some cases at any rate, of the exophthalmus, associated with disease of the heart in goitre; and adduces a case of albuminuria and general anasarca in which infiltration of the cellular tissue was found after death, the eyes having been much protruded during life.

He allows, however, that the pathology of this disease is not at all conclusively settled, and as researches seem still to be wanting on this subject, it is premature to give any description which must necessarily be wanting in accuracy and completeness. Nevertheless, the most recent observations seem to confirm the views of Demarquay, and, in addition to point to some lesion of the cervical sympathetic nerve as generally associated with it. (See Dr. Reith's remarks on a "Case of Exophthalmus" in the *Med. Times and Gazette*, Nov. 11, 1865.)

These few remarks on the subject of effusion into the cellular tissue are only offered as indirectly bearing on the subject of tumours, properly so called, in this locality and as a means of assisting in forming a diagnosis. Thus the aspect of the patient, generally anæmic and languid; the *slow* progress of the protrusion by which *both* eyes are simultaneously affected; and the coexistence either of cardiac symptoms or of bronchocele, and perhaps of both, will, together, serve to distinguish a case of intra-orbital effusion of serum from any other affection in the same region.

ERRATA.

Page 29, line 26, for "tried," read "tied."

Page 34, line 5, for "brain," read "ham." Line 24, for "carvenous," read "cavernous."

ON
ABSCESS AND TUMOURS OF
THE ORBIT.

PART II.

By SPENCER WATSON, F.R.C.S. ENG.,

SURGEON TO THE CENTRAL LONDON OPHTHALMIC HOSPITAL; FORMERLY
ASSISTANT-SURGEON OF KING'S COLLEGE HOSPITAL, AND SURGEON TO
THE ISLINGTON DISPENSARY.

Reprinted from the MEDICAL MIRROR.

LONDON:
H. K. LEWIS, 136 GOWER STREET.
MDCCCLXX.

PRICE THREE SHILLINGS.

✓

1870

THE HISTORY AND ANTIQUITIES OF

THE COUNTY OF

WILTSHIRE

IN TWO VOLUMES

BY


JOHN HENRY COLEMAN

ESQ.

WILMINGTON

APPENDIX TO PART I.

WITH TWO ENGRAVINGS.



A P P E N D I X.

CASE I.—*Scrofulous Abscess in both Orbits, terminating in Meningitis and Death.*—W. Burbidge, æt. 10 years, first came under my notice in the latter part of the year 1866. He was a patient of my friend and colleague, Mr. Hulme, under whose care he had been for some years, and the appearance he then presented is well seen in the engraving, from a photograph by Mr. Dawson of King's College (and which appears on the following page). The disease was attributed by his mother to a blow received three years before; but it is quite evident, from the scars about the face and elsewhere, that he is a very scrofulous boy, and that, in all probability, the disease in the orbit was of a scrofulous nature. The right eyeball is seen to be enormously protruded, the lids turned inside out, and there are sinuses at various points round the margin of the orbit, from which a thin discharge constantly escapes.

When I first saw him he suffered occasionally from pain of a severe kind, and had intermittent attacks of inflammation in the protruded parts, but no head symptoms had yet shown themselves.

About the end of March, 1867, there was occasional delirium and screaming, and in May the left eye began to protrude, and very soon this eye was entirely destroyed. The right eye, though first affected, retained some little vision within a very short time of the patient's death, which occurred on August 5, 1869, the latter few weeks being passed in a state of semi-coma. I assisted Mr. Hulme in a post-mortem examination of the head, when we found there was a quantity of thick curdy yellow tubercle or inspissated pus lying between the dura mater and the sphenoid bone of the right side, and extending up to the

APPENDIX.

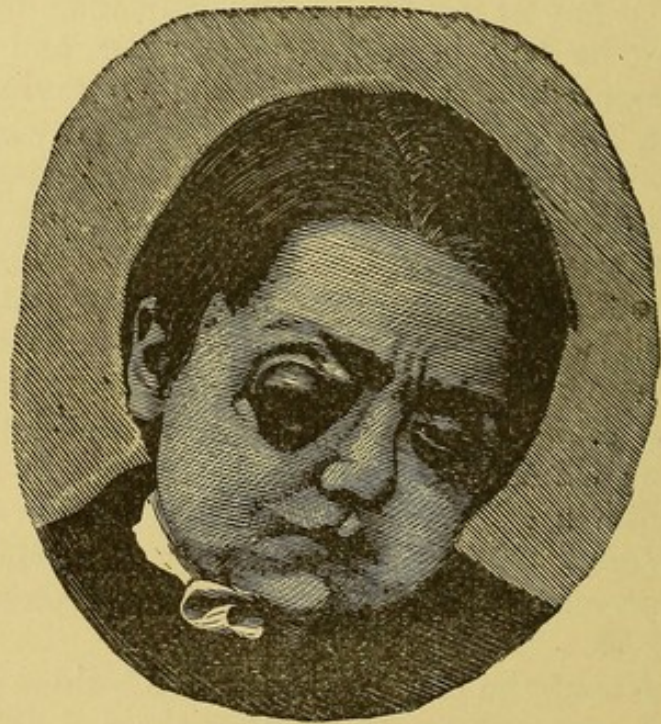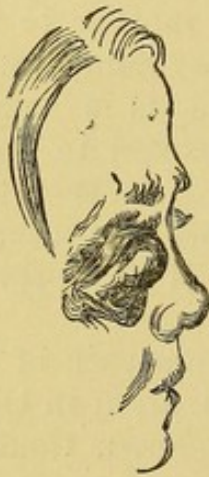squamous portion of the temporal bone on the same side, across the sella tunica and into both orbits.

There was caries of the floor of the right orbit, and an opening into the right antrum, which itself communicated with the mouth by another opening in the alveolar ridge. The antrum, therefore, on this side formed an abscess full of fetid pus.

The membranes of the anterior and middle lobes of the brain showed slight traces of recent inflammation.

The state of the antrum and floor of the orbit was probably a late complication of the primary disease, and it was, of course, impossible to have guessed at the amount of mischief that was going on within the cranium until a very late period in the case.

The thick deposit of new bone upon the bones of the base of the skull shows clearly that inflammatory thickening had been going on in this region for a considerable time; but it by no means follows that this morbid process could have been stopped or averted by any surgical interference.



CASE II.—(Under my care at the Central London Ophthalmic Hospital.)—*Abscess of the Orbit dependent on Polypi of the Antrum.*—The chief interest of the following case lay in its great obscurity during the early part of its course, and in the very rapid restoration to a healthy condition when the cause of the mischief was brought to light, and at the same time removed. It is also interesting from the unusual course taken by the disease, and from its successful issue under simply adjuvant treatment.

John M., aged 31, a hawker of fish and fruit, in good general health and well-nourished, applied at the hospital on May 19th, 1868, with a sinus and ragged ulcer situated near the right lacrymal sac, but a little to its outer side. He had suffered for some years from a watery eye, and about Christmas last a swelling had appeared in the spot now occupied by the ulcer, which, when opened, proved to be an abscess. About a month before his admission a thin scale of bone of about half the size of his thumb-nail escaped from this opening. At or about this time a fetid discharge commenced from the right nostril, and this had continued ever since. His sight was little or not at all affected.

On admission, in addition to the ulcer and sinus, there was a slight fulness of the upper part of the cheek and side of the nose, and the eyeball was pushed a little towards the temporal side of the orbit. There was little or no overflow of tears; a probe passed into the sinus found its way directly backwards to the apex of the orbit, and reaches a depth of a little over three inches. On a subsequent probing this sinus was found to communicate with the antrum and nostril, the probe passing in an oblique direction downwards. No bare bone was felt in either direction. The nostril was obstructed, and there was a very offensive discharge constantly escaping from it.

Injections of a lotion containing ℥j of tincture of iodine to ℥vj of water, were used with the India-rubber bottle syringe, the tube of which was passed into the sinus under the orbit. This caused a free flow of mixed lotion and pus from the right nostril. This was done twice or three times a week, till the morning of June 3rd, when he suddenly felt something in his throat and posterior nares, which he managed, after considerable effort and choking, to cough up.

The material which he brought up consisted of four or five dirty-white lumps of a soft pulpy nature, varying in size from that of a cob-nut to that of a large walnut, and having the most abominably stinking odour. In the choking efforts to bring up these offensive lumps he swallowed some portion of the mass,

APPENDIX.

and was very ill for the rest of the day, vomiting and feeling much prostrated, so that he was compelled to keep his bed.

From this day, however, the sinus began to heal up, and by June 20th had entirely closed. There was still a slight discharge from the nostril at that date, but his health had so much improved and he suffered so little inconvenience that he ceased attending the hospital.

An examination of the decomposed mass gave no evidence of any structure whatever ; but, from the shape and smooth surface of one of the pieces, it seemed clearly to have been a polypus that had sloughed and separated ; and taking into consideration the circumstance that a thin shell of bone had escaped answering the description of the orbital plate of the ethmoid or of the superior maxilla, together with the course taken by the probe in the exploratory examinations, it seems most likely that the polypus was originally attached to the upper part of the antrum, and had caused absorption and exfoliation of the surrounding bones.

—*British Medical Journal.*

CASE III.—*Abscess of the Orbit in a Scrofulous Child rapidly relieved by early Incisions.*—F. T. Smith, æt. 3 years, was sent to me by my friend, Mr. Jones of Drury Lane. He was a fairly healthy looking boy, who had quite recently had an abscess in the thigh. This abscess had closed when I first saw him on February 9, 1869, and now his left eye was protruded, and had been so for a week. The eyelid of the left eye was swollen so as to mask to some extent the protrusion of the eyeball, and there was also chemosis of the conjunctiva. The pupil was active, and sight unimpaired, and, considering the amount of swelling, very little pain or constitutional disturbance was observable.

The eyeball being evidently protruded towards the temporal side, and there being a fulness of the inner and lower side of the orbital cellular tissue, and these symptoms having come on within a week in a child who had recently suffered from an abscess in another part of the body, there could be little doubt that an abscess in the orbital cellular tissue had either already formed or was in process of formation.

Acting on this diagnosis, chloroform was administered, and an exploratory puncture made with a grooved needle at the lower and inner angle of the orbit under the lower lid, *i.e.*, from the conjunctival surface. After several deep thrusts a few drops of pus exuded along the groove of the needle; the puncture was then enlarged by means of a long narrow knife carried along the groove of the needle, and about half a drachm or a drachm of thick laudable pus escaped. A strip of oiled lint was then laid in the wound, and poultices were applied. The collection of pus must have been, judging from the depths of the incision, at or close to the extreme apex of the orbit.

During the next few days there was very little reduction in the swelling, and though the oiled lint was removed, little or no discharge of pus. On Feb. 12th, therefore, chloroform was again given, and the original incision explored and enlarged, and several exploratory punctures made, with a view to discover any further collections of pus; but no more pus could be reached, and though some increase of the chemosis and swelling followed these second exploratory punctures, by the 15th the proptosis had become less, and from this time a rapid recovery took place. By March 5th, there was no further protrusion of the eyeball, and by the 16th he had quite recovered, the eye being then in quite as good a condition as its fellow in every respect.

During the progress of the case, tonics, steel, and cod-liver oil were given freely, and cold bread poultice with lead lotion were the local applications chiefly employed.

APPENDIX.

This is a typical case, and remarkable for the rapid recovery. The very small size of the abscess as compared with external evidences of inflammation is also very well worth notice.

It is not always possible to open an abscess in this region through the conjunctival surface; for the great swelling of the lids makes it very difficult to reach the part in which the pus lies, and in most instances the abscess will perhaps not be discovered until a superficial redness of the skin has shown itself, and in such a case it would be better to open the abscess through the point at which it threatens to burst. In such a case as that related, however, in which the diagnosis is made at an early stage, there are manifest advantages in an early incision through the conjunctival surface, and perhaps not the least of these is the circumstance that by so doing no scar is seen after the incision.

ON ABSCESS AND TUMOURS OF THE ORBIT.

PART II.

TUMOURS COMPRISED UNDER THE DESIGNATION, PSEUDOPLASMS, NEOPLASMS, OR VEGETATIVE GROWTHS.

IN the First Part, abscess and fluid collections in the orbit were considered without reference to any scientific classification, but rather with the practical object of placing in juxtaposition all such diseases of the orbit as would be liable to be confounded in diagnosis, and in which the treatment mainly depended upon the nature of the fluid contents of a tumour evidently containing fluid.

This, though a convenient plan for practical surgery, was not by any means one calculated to promote scientific pathology, and hence, in the succeeding Parts in which solid tumours are to be dealt with, it will be better to arrange the subject in a form more in accordance with the latest views on pathology, and this is the more desirable from the fact that the object aimed at in the arrangement of Part I. will not thereby be in any way interfered with.

For it is somewhat remarkable, because quite undesigned, that all the tumours (with one or two exceptions) described under the head of fluid and semifluid, will correspond to the two first groups recognised by Virchow in his classification, viz. : I. Tumours by exudation or extravasation ; and II. The group of ectasies, *i.e.*, tumours by dilatation or retention.

As, however, it is the intention of the author to follow the order of arrangement and classification adopted by Virchow in his work on Tumours, he thinks it desirable, notwithstanding the widespread influence of that great pathologist's writings,

and the universal eagerness with which they are read by medical men in this country, to give some few short abstracts from the work alluded to as a preface to the subsequent pages.

In his classification Virchow excludes entozoa and simple inflammatory swellings, and divides the tumours properly so-called into—

I. Tumours by exudation or extravasation.

II. The group of ectasies, *i.e.*, Tumours by dilatation or retention.

III. Pseudoplasms or neoplasms properly so-called, Tumours resulting from proliferation, or Vegetations.

IV. Complex tumours.

In these divisions he makes the *development* of the tumour the basis of the classification. Thus, in Group I. the tumour is developed at the expense of the blood; in Group II. at the expense of secretions; in Group III. by the proliferation of tissues; and in Group IV. by the growth of several tissues or organs of different kinds.

In reference, however, to Group III., with which we are now immediately concerned, the following passages are sufficient to explain the method of arrangement and the characteristics of the tumours belonging to it.

“Tumours by Proliferation, or Vegetations, properly so called.”

“These differ from those already treated of (*viz.*, those of the first and second groups) in the circumstance that the development of a new tissue in their case is not a gradual or accidental phenomenon, which complicates the formation of the tumour, in some measure completes it, and aggravates it progressively; on the contrary, it *causes* the tumour from the first, and consequently constitutes its true essence. All the ulterior transformations which may give rise to particular exudations, to hæmorrhages, or retentions (of secretions), and may therefore in this way lead, under certain circumstances, to the formation of cysts in the interior, or in the neighbourhood of the tumours;—all this is merely accidental and secondary, in comparison with what, in their case, is of new formation. For the neoplasm proceeds immediately from the old tissues, which serve for its matrix.

“Here, then, we have a series of *formative processes which undoubtedly possess in themselves an active, productive, and irritative nature*, and which comprehend the most simple inflammatory forms (as we are accustomed to call them), as well as the most extreme heterologous and malignant forms.

“The greater number of tumours by Proliferation proceed from the fundamental connective tissues of the body, in the series which we are considering, besides the connective tissue proper, cartilage, bone, fat, marrow, neuroglia, and many others. . . . In mixed tumours what determines the choice of a name should be the principal character, that which constitutes the essential part, and which expresses the physiological and pathological value of the tumour in relation to the whole body. The name may consequently not always be derived from the part which forms the principal bulk, but often from the part which stands highest in the scale of organisation. When a tumour encloses muscular fibre and connective tissue, we shall never call it fibrous or connective tissue tumour, because the de-

velopment of muscle is the more elevated, more characteristic, and more important as the type of the tumour, though at the same time the connective tissue may be in the greatest bulk."

Of these pseudoplasms or vegetations Virchow makes three subdivisions: 1. Histioid pseudoplasms, or growths consisting of simple known *tissues*. 2. Organoid pseudoplasms, or growths resembling definite organs (such as glands, &c.). 3. Teratoid pseudoplasms, or growths resembling a collection of organs or a part of a new individual. It is, however, with the first of these three subdivisions that we have to do chiefly, if not entirely, and the tumours found in the orbit will be found to afford abundant illustration of this large and important group, which will include Fibrous tumours, or Fibroma (of Virchow), Fatty, Fibro-cellular, Bony, Cartilaginous, and others, both simple and malignant, in the ordinary and old-fashioned senses of the words. I shall not, however, endeavour to divide all tumours into two distinct and absolutely separable classes of malignant and non-malignant, for though it is undoubtedly true that we can say of some of the most remarkably extreme cases that they are cases of a malignant nature, and that they will inevitably terminate fatally, it is no less true that there are a number of intermediate and less extreme forms which are related on the one side to the growths of acknowledged malignity, and on the other to those of a more innocent kind. I do not recognise any absolutely certain aspect or microscopic structure by which a tumour or growth can be characterised as a cancer, and would rather regard all tumours, of whatever kind, as malignant in a certain degree, and as having within them the germs of a malignancy which may lie dormant for the lifetime of those who are the subjects of them, but which *may*, under certain accidents, such as local irritation or constitutional deterioration, become converted into dangerous and malignant growths.

Such appears to be the view taken by Virchow, who repudiates altogether the theory of a growth being malignant from the fact of its structure being entirely foreign to the structures normal to the body.* He denies, indeed, that any growth is

* (Virchow, vol. i., p. 122.) All heterologous tumours are not necessarily malignant. There are a great number which are borne without any troublesome consequences, and whose properties closely approach innocent tumours. Malignity follows a certain *scale* of heterologous tumours, species after species, and we can prove how it manifests itself continually more and more, notably following two directions. In the first place, the heterology is distinguished *according to the degree* that it attains. The tissues of the connective substance have a *closer affinity* among themselves than with the epithelial tissues or the specific animal tissues. When, therefore, a cartilaginous or osseous tumour is developed in the connective tissue, or a mucous tumour in the fatty tissue, this is not so heterologous as when an epidermoid tumour is formed in the connective tissue, or a tumour with

ever found in the structure of which there is not distinctly traceable some homology to the normal tissues or organs, and restricts the term, heterologous, to those growths which are merely so in reference to their position. At the same time he points out the tendency to a malignant nature possessed by certain tumours (which are most often heterologous in the sense which he has given the term), and gives certain known indications by which that tendency can be recognised.

HISTIOID PSEUDOPLASMS.

1.—*Fibroma. Fibrous Tumours.*

As instances of outgrowths of simple tissue, tumours of this class may be considered typical, but they do not appear to have been at all frequent in their attacks upon the orbital cavity.

Nevertheless, M. Démarquay has collected several very well marked instances, and his remarks in reference to their points of difference from cysts are so apposite to this place, that I shall give them almost verbatim.

They differ from cysts, he says,—

1. By their method of attachment, they are most frequently adherent to the periosteum, of which they seem to be only an expansion, whilst the encysted tumours have only very loose adhesions to that membrane, and it is only after a long time that these adhesions become intimate.

2. By their structure. This is simply condensed, connected, or areolar tissue, with a thin membrane surrounding it.

3. By the absence of a central cavity.

4. By their progress.

The history causes some obscurity. They have been confounded most often with cysts or cancerous tumours.

Restricting the term *Fibroma*, then, to those tumours which are simply composed of an excessive development of connective tissue, the tumours of this kind found in the orbit are very rare, though it is probable that of those described as *steatoma* in the last generation some may have been a variety of fibrous tumour. (See Virchow, vol. i. "Lecture on *Fibroma*.")

cylindrical epithelium is formed in a lymphatic gland. A cartilaginous tumour which is developed in the connective tissue or in the osseous tissue is equally heterologous; but it is not so to the same degree as an epithelial or a muscular tumour would be in the same situation.

* The less vascular a tumour, the less it will extend its infective action beyond the neighbouring parts; but the richer it is in blood and lymph vessels, the more blood and lymph traverses it; the more the parenchymatous juices are in contact with the blood, the more easily will the infection become general.

Mackenzie, however, alludes to the steatomatous tumour as an encysted tumour with contents resembling suet, though he does not give any case in which such a tumour was removed. And although under this head (steatomatous) various cases have been recorded and cited by authors, none of the reports give an exact description of the tumour after removal.

The DIAGNOSIS of a Fibrous tumour is of the greatest importance to the surgeon, and at the same time often very difficult and seldom likely to be exact or certain. It is important, because if the surgeon can be sure that he has to deal with a simple Fibroma, especially if it be of the distinctly circumscribed form, he need have no hesitation in proceeding to operate for its removal; whereas, in the case of many other solid tumours he would be justified in either refusing to operate, or in hesitating long before attempting any operation. The history of the cases given below proves that the diagnosis is often difficult, and this is especially illustrated in Case I.

What, then, should be points on which to found a correct diagnosis?

1st. The fibrous hardness botrycidal or lobulated surface and circumscribed character of the tumour, taken in connection with the absence of any constitutional cachexia, and the freedom of the lymphatic glands in the neighbourhood, from any complication or enlargement, will be the most striking features in a well-marked case, and will offer a most encouraging set of symptoms to the surgeon.

2nd. The apparent enlargement of the upper maxillary and other surrounding bones associated with great orbital deformity and proptosis will be very embarrassing, and should lead to various experimental investigations as to the probable extension of the disease in the palate, posterior nares, and sphenomaxillary fossæ.

Fibrous tumours occasionally invade the orbit at a late period of their growth, though their original seat may have been the base of the cranium, and their first appearance that of nasopharyngeal polypi. Hence the great range of these tumours necessarily leads to embarrassment independently of the difficulty of ascertaining their consistence and structural connections.

3rd. Though a firm resisting and circumscribed tumour may be a fibrous tumour, it is well to bear in mind that such tumours are exceedingly rare in the orbit, and that similar characters would be afforded by cartilaginous, bony, fibro-cellular, and cystic tumours, and that a chronic abscess might also resemble them in some respect. The diagnosis having been made, though in most cases it can only be an approximative one, the treatment will of course be conducted on general principles.

CASE I. (From *Annales d'Oculistique*, and *Annales de la Société Médicale de Bruges*, 1850, p. 389.)—A young woman of eighteen years of age, having noticed, for some months, that there was a little tumour below the left eye, applied to M. Verhaëge (of Ostend). This gentleman thought it was a cyst; the tumour slipped under his finger, but came out from the orbit again when pressure was removed. Spite of various resolute applications, it attained the size of a hazel nut. M. Verhaëge removed it and found it attached by a broad pedicle to the periosteum. It was fibrous and solid.

CASE II. (*Medical Times and Gazette*, Nov. 6th, 1852.)—A man, æt. twenty-eight years, had a tumour occupying the lower half of the orbit and displacing the eyeball forwards, upwards, and outwards.

This tumour was removed by Mr. Critchett successfully by two operations. It was found to have very extensive attachments to the surrounding parts in the orbit, but was encapsuled by a fibrous membrane. It consisted of dense fibrous tissue, and contained scattered through it numerous osseous particles. There were also some very small smooth-walled cysts.

Microscopic examination confirmed the evidence of the tumour being fibrous.

CASE III. (abridged from Démarquay, who cites it from the *Philosophical Transactions*, vol. xliii.)—A girl, æt. eighteen years, had a hard tumour below the left eye-ball, extending the whole length of the lower lid and about half-an-inch down the cheek. It had thrust the eye almost out of the orbit, towards the temple, and forwards as well. The patient suffered much from frequent pains in the head, but the sight of the affected eye was not completely lost.

On June 30, 1744, Mr. Hope, having made an incision through the lower lid, passed a needle, armed with silk, through the tumour, which he then dissected out, partly by the scalpel and partly by scissors. A portion of the tumour (at first removed) was spherical, smooth, and about the size of a pigeon's egg. It seemed to have a thick membranous covering. Other portions of a similar kind, adherent to the eye-ball and to the apex of the orbit, were detached piecemeal and with great difficulty. Firm pressure upon the eye-ball, after the operation, by means of a steel bandage assisted its return to the socket, and in seven weeks complete recovery had taken place.

CASE IV.—Dr. Monteath removed a very hard tumour from a young woman's orbit, which he describes as of anomalous texture and surrounded by a layer of condensed cellular substance

(Mackenzie, p. 380). This was, therefore, in all probability a tumour of a similar kind to the two already alluded to.

CASE V.—In the *Lancet* for 1856, No. 2, Mr. Lawrence is reported to have removed a hard tumour from the lower part of the orbit which was attached by a pedicle to the periosteum of the floor of that cavity. The occasional extension of fibrous tumours backwards through the sphenoidal fissure into the cranial cavity*, and the occasional extensive attachments to the orbital periosteum, must be well taken into account in such cases as are not clearly circumscribed, before any operation is undertaken for their removal.

In the *Monthly Journal of Medical Science*, vol. i., p. 229, an operation for the removal of a tumour of the kind in question is related, which was followed on the fourth day by death from meningitis.

Fibrous polypi in the naso-pharyngeal fossa,† and in the antrum may encroach upon the orbit after destroying or thrusting aside the intervening bones; and some of these cases have very great interest to the practical surgeon, on account of the difficulties met with both in their diagnosis and their removal.

Under the head of Fibroma in the Orbit, I must not omit to mention the occasional occurrence of fibrous tumours on the nerves.‡ A very remarkable instance is cited by M. Gerdy, in his work, "Des Polypes" (*Arch. Gen. de Méd.*, t. 23, p. 431), of a fibrous tumour of the second division of the fifth pair, which invaded the orbit, as well as other regions in the face.

CASE VI.—A blacksmith, with all the symptoms of polypus in the nasal fossæ, died of inflammation of the brain, following several ineffectual operations for the removal of the supposed polypus, when, at the autopsy, the following extraordinary disease was discovered:—"Puriform exudation was found at the base of the brain. As for the tumour of the nasal fossæ, it was formed by the second division of the fifth pair, which at its exit from the skull increased in size and formed a fibrous tumour, divided into five lobes, of which the two largest were each as big as

* See Cruveilhier, "Anatomie Pathologique," Liv. xx., p. 5.

† See Velpeau's "Dictionnaire du Trente Volumes," vol. xxii., p. 317, in which a case is described of a fibrous tumour of the pharynx, which encroached upon and filled the whole orbit; and Gerdy, in his work "Des Polypes," p. 30, has a case of a fibrous polypus of the nostril and antrum, which partly thrust up the floor of the orbit, but which was successfully removed by Dupuytren in two operations, by an incision made through the mucous membrane of the mouth (*Il incisa la muqueuse sous la lèvre relevée*), and without any incision in the skin of the cheek, and consequently without any visible scar remaining from the operation.

‡ This does not include True Neuroma, nor the False Neuroma of Virchow, which latter will be considered under the head of Myxoma.

peach stones ; the other three were smaller, and one of them penetrated the orbit through the speno-maxillary fissure. This fibrous mass occupied the deep temporal fossæ lying between the zygomatic arch, the malar bone, the outer wing of the sphenoid, and the posterior aspect of the superior maxillary bone. The tumour extends thus as far as the alveolar border, above the last molar teeth. There it turned back, penetrated the speno-palatine foramen, which was enlarged sufficiently to admit the little finger. Arrived at the corresponding nasal fossæ, it was reflected, and formed a movable tumour, which was mistaken for a polypus. None of the prolongations of this fibrous mass were mingled or involved the nerves given off by the second branch of the fifth pair. The tumour sprang from the neurilemma."

2.—*Lipoma, Fatty Tumours.*

Fatty tumours occur under two forms—first, those that are *continuous* with the orbital adipose tissue, and constitute the capsular lipoma of Professor Virchow ; and, second, the *discontinuous* tumours surrounded by a thin membrane of connective tissue, and easily separable from the surrounding cellulo-adipose tissue.*

About half-a-dozen cases of well-marked continuous lipoma, which corresponds to the *Hypertrophie Graisseuse* of Démarquay, have been verified as such by *post-mortem* examination ; and though it is probable, as Démarquay suggests, that some of the cases described as lipoma by Middlemore, Sichel, and Desmarres might more properly be classed under the head of Goitrous Exophthalmia, yet when we come to examine the subject in the light thrown upon it by more recent observations, we find that the two diseases stand in a very close and hitherto unsuspected relation to each other. For the cases (collected by Trousseau and Withuisen †) of Basedow's or Graves' Disease, in which the pathological anatomy of the orbit was noted, show that though the protrusion of the eyeballs is not invariably associated with an hypertrophy of the cellulo-adipose

* The so-called Steatoma would seem from its etymology to be properly a fatty tumour, but such various tumours have been described under this name by different authors, that it is impossible to ascertain exactly what has been originally the kind of tumour intended. If, however, the term be applied to sebaceous cysts, to which, in certain stages of their development, it seems more appropriate than to any other, then it is quite a distinct pathological formation from lipoma, and will come under the head of Tumours by Retention.

† See New Sydenham Society's Translation of Trousseau's *Clinical Lectures*, p. 570 *et seq.*

tissue, yet that in four or five out of the ten cases collected, such a condition did exist, and in several of them to a very marked and unmistakable extent. At the same time the fact that this hypertrophy is not an invariable accompaniment of the disease is sufficient to prove that it is not one of its essential conditions. Most likely it is only a result of chronic congestion and hypernutrition of the connective and adipose tissues, and therefore to be classed with the other capsular lipomata—*e.g.*, the capsular lipoma surrounding the kidney and the heart, in the production of which similar agencies have been at work.

One very interesting case recorded by Dr. Trousseau seems to illustrate the pathology of this disease so admirably, that I shall venture to transcribe the case *in extenso*.

CASE I.—A woman, aged sixty years, was admitted into St. Bernard ward on July 3, 1863, suffering from highly-marked exophthalmus, and with the following history:—

In 1856, that is to say, seven years previously, she lost her father, whom she had attended at the cost of great fatigue. This loss caused her very deep grief. One night, after she had been crying for a long time, *she suddenly felt her eyes swell and lift up her eyelids*, her thyroid gland increase notably in size and throb in an unusual manner; she had at the same time violent palpitation of the heart. Simultaneously with the development of this train of symptoms, she bled copiously from the nose throughout the night. Four days after this she consulted M. Desmarres, who recognised exophthalmic cachexia.

A year afterwards she went to Africa, where she soon caught intermittent fever. She was admitted for this into the Algiers hospital, and there, while under Dr. Bertherand's observation, her goitre, which had been very marked, diminished rapidly. The two other symptoms, palpitation and prominence of the eye-balls, continued, however, to the same degree.

The fever lasted for nearly a year, and brought on a cachectic condition, from which she never recovered completely. In January, 1863, she had an attack of angina pectoris, which lasted a few hours, with radiating pains in the right shoulder. It seems that a fortnight after her arrival at Algiers she had œdema of the lower limbs and ascites, which disappeared after four or five days. In 1863 this dropsical condition recurred on several occasions, but without continuing. When she came under my care, she showed no trace of œdema or ascites, and was in the following condition:

Eye-balls considerably prominent; the free margin of the lower lid is more than four millimetres distant from the transparent cornea, instead of being in contact with it. The upper eye-lid does not cover a segment of the cornea, as it usually does, and is more than two millimetres away from it. In consequence of the protrusion of the eye-balls, the eye-lids no longer form regular curves, but intercept between them an hexagonal space with obtuse angles. The patient is readily dazzled by a bright light, which makes her feel as if she were drunk; she is long-sighted in spite of the prominence of her eye-balls. On the night when her complaint set in, she lost her sight for a time entirely, and for nearly a whole year she was hardly able to bear artificial light. She was at that time unable to read or sew, but can now do both by using spectacles for long sight.

At the commencement of her illness her eyes were still bigger than they

are now. She could very imperfectly close her eye-lids, and even now, during sleep, her eye-lids do not entirely cover the eye-ball.

Her heart beats with force, but much less so than at the onset of her complaint; it is found, on percussion, to measure thirteen centimetres in a longitudinal direction (about 5 1-5 inches), and twelve centimetres (4 4-5 inches) transversely. There is no blowing murmur at the base or apex, systolic or diastolic; nor is any heard in the vessels of the neck, although the arteries pulsate with force.

Pulse 96; habitual dyspnoea.

The liver comes down a little beyond the false ribs.

The thyroid gland is of small size: there is no goitre.

Some time after the exophthalmos set in, the patient seems to have had a ravenous appetite for more than a year; she was obliged to take some food every two hours. She had a copious diarrhoea at the same time.

She menstruated for the first time at the age of twenty; she had been chlorotic for five years previously, but menstruation, by degrees, caused the symptoms of chlorosis to disappear. The patient was menstruating at the time when the exophthalmos first came on; the catamenia were suppressed on that night, and have not since shown themselves.

Her father died of epileptiform seizures, which had occurred for several years. On admission, she complained of neuralgic pain in the ophthalmic nerve, in the occipital, and the first two cervical pair of nerves. Since the commencement of her illness she has had trifling epistaxis every month, and about the same period.

She was ordered digitaline and Baumé's bitter drops.*

When she left the hospital in the month of August, she suffered less from palpitation of the heart, but her eye-balls were as prominent. She was re-admitted on December 3, in a weaker condition.

Six days afterwards she was suddenly struck with apoplexy after a few trifling cramps in the legs; she fell out of bed without uttering any complaint, and was picked up in a state of asphyxia, with rigidity of the four limbs. A few hours afterwards the left side got better, but the right side continued to be powerless, although not rigid. The patient did not recover consciousness, and died in the most complete state of coma, twenty-four hours after the attack.

On examining the body, a large hæmorrhagic centre was found in the left hemisphere of the brain, near the corpus striatum and optic thalamus.

The heart was of very large size, the walls of the left ventricle being the most hypertrophied. The free edge of the mitral valve was thickened, but there was no constriction of the aperture or incompetence of the valve. The aortic valves were a little roughened along their free borders, but were perfectly competent.

The aorta was encrusted with a calcareous deposit along its arch, and there were atheromatous patches in its descending portion.

The vessels at the base of the brain presented, however, no appreciable alterations to the unaided eye; the capillaries in the vicinity of the hæmorrhagic centre, and in that centre itself, were examined under the microscope by Mr. Peter, and were found free from calcareous and atheromatous changes.

The spleen was of voluminous size, measuring twelve centimetres in one direction and six in the other. The capsule was not thickened; the splenic tissue was firm, and on section the glomeruli of Malpighi were found to be hypertrophied.

* The chief constituent of Baumé's bitter drops is the alcoholic extract of *Faba sancti Ignatii*, which contains, as is well known, a large amount of strychnine.

The liver was of nearly normal size, but of cirrhotic tint, and in an incipient lobular condition; its fibrous capsule was thickened, the trabeculae considerably hypertrophied, and the tissue of the organ indurated. On microscopical examination the hepatic cells were found to be normal, but to have diminished in quantity, and the interstitial connective tissue to be hypertrophied.

The kidneys had not increased in size; their capsule was not thickened; they had a granular aspect, were red on section, and showed traces of interstitial nephritis.

The thyroid body was of very small size, and its lobes hard, almost of the consistency of scirrhus; they had a lobulated quasi-cirrhotic aspect owing to the retraction of their fibrous elements. On section the glandular tissue was interrupted, and, as it were, squeezed by trabeculae of an extremely thick fibrous tissue, of a mother-of-pearl colour, and creaking when cut. The thyroid arteries were small, not flexuous in the least, and showed no calcareous or atheromatous changes.

The eye-balls were thrust out of the orbit by the amount of cellular and adipose tissue which nearly filled the socket, was redder than usual, and contained a good deal of fat. The ophthalmic artery was not tortuous, nor was it abnormally large; *the eye-balls*, when removed from the cushion of fat on which they lay, *were not of larger size than in health.* They were not altered in structure.

The bones of the skull were extremely vascular, and were of more than double their natural size; in fact, they were all hypertrophied.

The *cervical ganglions* of the sympathetic were carefully dissected and examined on both sides by Dr. Peter and Dr. Lancereaux, clinical assistants at the Hôtel-Dieu. The superior and middle ganglions were of normal size and aspect. But the *lower one*, especially on the right side, was not only of *larger size* than usual, but was much *redder also*; numerous vessels were seen to ramify on its outer surface and throughout its interior, when examined with a power of fifty diameters. When examined under the microscope, a great many vessels were seen in its interior, with a thick admixture of connective tissue, and, in the midst of its fibres, nuclei and fusiform cells. There were a great many fat-globules; the ganglionic cells were very few in number, small, and with a mulberry aspect; some of them were reduced to a mere granular condition; the nerve-tubes were in small numbers.

Now it is evident from the *sudden* invasion of the exophthalmus in this case, that the cause of the protrusion could not have been due to an increased amount of cellulo-adipose tissue in the orbit in the first instance. Nevertheless, after death, between seven and eight years after the commencement of the attack, there was an enormous increase of this tissue, and we can only explain this by supposing venous congestion, and perhaps serous infiltration, to have been the immediate cause of the exophthalmus, and that this gradually gave way to fatty deposit and capillary congestion, which then became permanent conditions. This view is confirmed by the fact that in both Basedow's and Keusinger's cases the disease had existed for a considerable number of years before death, and in both cases a large hypertrophy of the fatty tissue was found.

In Naumann's case (*Deutsch. Klinik*, p. 24; 1853-54), it is not distinctly stated how long the exophthalmus had existed, though it had evidently lasted for several months, if not a whole

year; and this would allow ample time for a considerable deposit of fat in a person with the predisposition to such disease; and in this case there was atheromatous disease of all the principal arteries and valves of the heart.

Of the other kind of lipoma, viz., the circumscribed fatty tumour, the history, pathology, and treatment will be best illustrated by the three following remarkable cases.

CASE II.—(*Démarquay*, p. 359.) On the 12th of November, 1829, a woman of fifty years of age was operated on by Dupuytren at the Hôtel-Dieu for a large soft tumour of the size of a hen's egg, which protruded from the orbital cavity at its upper border. The growth dated fifteen years back. The eye had been thrust outward and downward; the cornea was opaque. Dupuytren, thinking that he was dealing with an hydatid cyst, made an exploratory puncture into it without any issue. The contents of the orbit were then removed, and dissection and chemical analysis demonstrated that the growth was a true lipoma, white, almost transparent, and infiltrated with albumen, or a coagulated lymph-matter.

CASE III.—(*Annales d'Oculistique*, vol. xl., p. 103; M. Carron du Villard's case) A man of Champeaux had an orbital tumour which pushed the eye outward and downward. This, of the size of an adult fist, though it caused no pain, constituted nevertheless a very repulsive deformity. Soft, compressible, susceptible of being lightly pressed back, the tumour appeared to be a lipoma and not a cyst. It was removed without difficulty through an incision made between the falciform border of the conjunctiva and the caruncle. It was a uniform, shining, elastic lipoma, of the size of the *cerebral hemisphere of an ox!* The eye immediately went back into its socket; only a few teaspoonfuls of blood flowed; soft charpie was applied, and cold effusions kept up for twenty-four hours. At the end of that time Dr. Bernard removed the dressings, and found the wound entirely cicatrized. M. du Villard saw a similar case at Pavia removed by Professor Volpi, but in that case the wound suppurated. "I have," he says, "always met with adipose tumours *outside* the muscles; Mr. Travers, on the contrary, has found them occupying the spaces which exist between the recti."

CASE IV.—(By Mr. Bowman, in the *London Journal of Medicine*, Nov. 1849, No. 11.) Each upper eyelid of a young lad was the seat of a fatty tumour of the size of an almond. The diagnosis was rendered difficult from the redness of the surface and the abundance of the cutaneous vessels, as well as from the unusual circumstance of their symmetrical arrangement. They were both removed through incisions in the upper lid with perfect success.

3.—*Myxoma*. *Schleimgeschwülste* (Virchow). *Fibrocellular Tumours* (Paget). *Colloid Cancer* [?] (Paget). *Zellgewebeschwamm* (Shuh). *Collonema*, or *Sarcoma gelatiniforme* (Müller).

Myxomatous or Mucous tumours occur in the orbital cellular tissue, and as growths on the optic nerve or its sheath. When the optic nerve is involved, certain ophthalmoscopic appearances have been observed, which according to M. Jacobson are very characteristic, as indicating some kind of growth in the intra-

orbital portion of the nerve, and hence great interest attaches to this disease as occurring in this region.

The extraocular tumours of the optic nerve itself are very limited in kind and variety, and *myxoma* and *myxosarcoma* are perhaps more frequently found than any others. If, therefore, it can be clearly made out by the aid of the ophthalmoscope, in conjunction with other means of diagnosis, that there is a tumour of the optic nerve externally to the eyeball, which has originated in the nerve and is confined to it, it will be highly probable that the disease is either a *myxoma* or a *myxosarcoma*. Such exactness of diagnosis, however, must be rarely attainable, and is only put forward in this place as a possible and much-to-be-desired feat, but at the same time as one not altogether beyond the reach of the diagnostic art. The account of the following cases by M. A. de Graefe and M. Jacobson show how far this precision has been already attained.

CASE I. — (*Archiv. für Augenheilkunde*, t. x., A. 1, p. 193, by M. A. de Graefe, cited by Wecker, vol. ii., p. 397.) M. A., aged twenty-three years, a farmer, had been affected for two years with diplopia and proptosis of the left eye, with gradual loss of its functions. After several weeks of inflammatory symptoms and pain, referable to corneal disease, the patient applied for relief. The prominence of the eye measured at least eighteen millimetres (nearly four-fifths of an inch), and was in the direction of the orbital axis. The eyelids could not be closed, and the mobility was limited only in the downward direction. The centre of rotation corresponds almost with the centre of the prominent eye. The touch reveals a retrobulbar elastic tumour, soft and almost fluctuating at certain points. *Ophthalmoscopic examination* of this eye (which was blind) shows the retinal veins enlarged and tortuous, the arteries diminished, and a *gonflement à pic* (engorgement) perpendicularly of the internal half of the papilla. It formed in this part an elevation of a greyish yellow which masks the vessels, the projection of which extends a little beyond the limits of the nerve-section. It is pronounced a relatively benign tumour of the orbit, probably a fibro-sarcoma. This opinion is based—first, on the preservation of the muscular apparatus and the mobility. 2nd, on the preservation of a healthy layer of cellular tissue between the posterior hemisphere of the globe and the tumour. The existence of this layer is demonstrated by the position of the centre of rotation. 3rd, on the absence of pain. 4th, on the uniformly soft consistence of the tumour. 5th, on the age of the patient, and the aspect of flourishing health that he presents.

It remains to observe here the rapidity with which blindness came on as soon as the tumour had attained a certain development, a point which, taken in conjunction with the ophthalmoscopic examination, gives ground for supposing a new growth (*neoplasm*) of the optic nerve.

We proceed first to the enucleation of the eye, and we perceive a delicate bed of cellular tissue, the transverse incision of which exposes the bluish-red surface of the tumour. The optic nerve, thickened, penetrates this growth on the outside of its vertical diameter. It is easy to remove it on account of the thick envelope of cellular tissue that surrounds it.

The tumour is of the size of a pigeon's egg, and presents a pyramidal prolongation which could not have been distant from the optic foramen more than a few millimetres. The histological examination, made by M. de Recklinghausen, shows a tumour formed of a myxoma, which had originated in the optic nerve. The relations of the fibres of the optic nerve

with the tumour presented the greatest interest. Nervous fibres were made out very distinctly on the surface most distant from the nerve. They were, it is true, very isolated, but very distinct, and their number increased at the points of entry and exit of the nerve.

CASE II.—(Wecker, *Etudes Ophth.*, vol. ii., pp. 400.) A man, twenty years of age, had discovered two or three years before presenting himself that the left eye, which was very amblyopic, and had long squinted downwards, was becoming prominent. This proptosis augmented rapidly, was accompanied with headaches, deep-seated orbital pains and giddiness. The prominence of the eye, which had a perfectly normal aspect, was one inch in extent, and deviated half an inch downward. Its mobility had suffered little.

On *ophthalmoscopic examination* the media and the deep membranes appear normal; the entrance of the optic nerve alone presents considerable modifications. The papilla has a very irregular configuration, different in its different parts, and projects unequally into the interior of the eye. Its singular shape is encircled by a sinuous border of choroidal pigment. One part of the tumour (*sic*), that which projects most into the eye, is of a clear blue, and absolutely destitute of vessels. Another part, less prominent, is vascular, and reminds one of the ordinary inflammatory tumefactions of the optic nerve. A third part, of a yellow brown, is perfectly flat. The vessels that come out from these various parts of the papilla are all ensheathed for a variable extent of their course by a layer of a white colour. The diagnosis points to a tumour of the optic nerve which had invaded the ocular cavity.

The whole contents of the orbit were removed, and the anatomical examination of the preparation showed six tumours of the size of a cherry-stone scattered through the orbit, the total bulk of which was insignificant as compared with the other tissues removed. These tumours, microscopically examined, were *myxosarcoma*. The optic nerve, very free in its sheath, had lost its white colour and become transparent, and presented the signs of simple atrophy.

The aspect of the papilla corresponded exactly with a drawing made after ophthalmoscopic examination. It formed a swelling almost analogous to the tumours scattered through the orbit, and with which it had no other direct relation. This intraocular tumour had a plate of osseous substance situated at its base, and closely adherent to the choroid.

M. Jacobson remarks that the characters of the ophthalmoscopic image which plead for the existence of a tumour of the nerve are—the unequal prominence of the different parts of the papilla; the reflexion of the various shades that it gives; the widening of the choroidal margin; the abrupt demarcation of the impaired parts, together with the very transparent retina; and the sudden change in the direction or the interruption of the vessels at the edge of the prominent parts.

For the description of a case of myxoma of the optic nerve I must again refer to the same author (who gives a case by Rothmund at p. 398 of vol. ii.). The tumour in this case consisted “of fibrous tissue the bands of which enclosed cysts of variable size. These contained a loose network enclosing a gelatinous and vascular substance.”

This description answers very closely to that given by Mr. Paget of certain forms of fibro-cellular tumours, one of which he himself removed from the orbit, and which tumour is now in the museum of Bartholomew's Hospital. It is in its present

state very much like a mucous polypus of the nostril, but the appearance of the fresh specimen would probably have been entirely different, from the greater transparency of the tissues.

Several of the cases recorded as cysts with semi-fluid contents of the orbit are no doubt properly to be included under this head. Thus M. Démarquay cites a case from M. Wolf (*Op. cit.*, p. 395).

CASE III.—A man who in infancy had received a blow from a stone in the left eye, which protruded from the orbit, gradually lost the sight of it completely. The eye protruded about two and a half inches, and was pressed on by an elastic and resisting tumour, which filled the orbit, and was larger than a hen's egg. The tumour was extirpated with the eye. It was a colloid cyst, oval, filled with gelatinous liquid, and embracing the optic nerve by its upper wall. The walls of this tumour, closely connected with the neuremma of the optic nerve and the muscles of the eye, consist of a cellular tissue, the inner layers of which had the nature of fibroid. The orbit rapidly filled with granulations, and the patient recovered completely.

The following was probably a *myxosarcoma*, which had suppurated and degenerated :—

CASE IV.—(Mackenzie, p. 333, cited from Saint-Yves). In a girl of twelve years of age a tumour was situated below the eyeball, so that it turned the pupil upwards and protruded the lower lid for more than half an inch. It extended towards the cheek for the breadth of an inch. Saint-Yves divided the skin and orbicularis palpebrarum by a semilunar incision, extending the whole length of the tumour; he then laid hold of it with a hook, separated it from its attachments with a bistoury, and removed it. With the scissors he next cut away its root, which was hard and coriaceous. In thirteen days the wound was healed. The eye returned to its place, and the patient saw with it as with the other.

The tumour presented three cavities. That which lay next the skin contained a purulent fluid; the second was filled with a thicker matter, partly calcareous; and *the contents of the third resembled white of an egg.*

In bringing the above cases forward as instances of myxoma, there is a possibility that they may not all appear to my readers as equally characteristic, and the last case is perhaps a rather doubtful illustration of the subject. Nevertheless it is difficult to place it in any other category, and if we assume that inflammatory action and degenerative changes had taken place in the growth, it is easy to understand why the contents of the three different cavities of the cyst should have so much differed in their composition and aspect.

In the form of False Neuroma, Virchow has seen myxomata of the optic nerve within the orbit. (Virchow on "Tumours," vol. i., p. 425.) "The structure is generally lobed, but the different lobes only slightly marked, and the whole of transparent, often gelatiniform, consistence. The reticulated disposition of the cellular portions appears sometimes very distinct on microscopic examination; at others it is precisely the most perfect

form of lipomatous myxoma. In all the consistence is comparatively soft, and from that circumstance may easily give the notion that we have to deal with a cystic growth, while on incising it we find a full solid tumour."

The following case, cited by Démarquay as an instance of gelatiniform cancer, seems to answer pretty accurately to the above description.

CASE V.—(*Bulletin de Thérapeutique*, 1844, t. xxvii., p. 25.) A child of thirteen years, of good constitution, presents ever since four years of age a very considerable exophthalmia. Vision is destroyed, though the eye appears intact; the eyeball was removed at the same time as the tumour, and the examination of the preparation demonstrated lying behind the globe a spheroidal reddish tumour, smooth in its whole surface, and embracing the optic nerve, which is lost in its substance. The tissue of this tumour is softish, uniform, and like jelly. The impossibility of finding any nerve tissue in the centre or periphery of the mass compelled one to admit that it consisted of an essential alteration of the nerve, of which the different elements had undergone a sort of gelatiniform degeneration.

Here we have a tumour that had existed for at least nine years without causing any disturbance of the general health of the patient put down as a malignant growth, though as a rule the soft cancers in children run a very rapid course. It seems much more in accordance with the generally accepted views on pathology to consider it as a simple growth, especially as the history does not give any account of a subsequent return of the disease. No mention is made of any other similar deposits having been found elsewhere.

The following is from Morgagni, and is cited by Démarquay as a soft cyst, Morgagni himself describing it as dropsy of the optic nerve:—

"The optic nerve at its entrance into the eye, for the distance of a finger's breadth or a little more, contained no nerve substance, but only a greyish, cloudy, viscid, and slightly thick humour; after having squeezed out this humour by slight pressure, its site remained empty, so that the tunics appeared to be no longer those of a nerve, but those of a canal; they, however, were thickened. . . ."

This is clearly an accurate description of myxoma.

In Wardrop's "*Morbid Anatomy of the Human Eye*," vol. ii., plate xv., fig. 1, is a representation of a tumour of the optic nerve, in all probability of the same character. The history of this case, however, is not given.

4.—OSTEOMA.

1. *Exostosis—Periosteal Exostosis* * (Sir Astley Cooper).
2. *Enostosis—Medullary Exostosis* (Sir Astley Cooper).
3. *Hyperostosis, or Leontiasis Ossea.*
4. *Ossified Enchondroma — Cartilaginous Exostosis* (Sir Astley Cooper).
5. *Osteoma Myxo-Cystomatosum.*
6. *Osteoma Dentarium.*

UNDER the above terms are included a number of bony growths of various kinds, all of which are found either originating in the orbit or invading that cavity from the neighbouring parts, and causing in most instances more or less deformity and accidental lesions, of more or less danger to sight, or life even. The bones involved vary considerably. The whole of the bony walls may be simultaneously affected, together with those of the skull and face, or one only, or perhaps two or three adjacent bones may be affected; and in many cases it is impossible to say which are primarily and which have been only secondarily involved. Thus, a tumour originating in the deep-seated parts of the sphenoid may, in the course of its development, thrust aside the æthmoid and upper maxillary, and at length occupy a portion of the antrum, and even cause absorption of the anterior wall of that cavity, and present on the cheek, distorting all the neighbouring parts, and perhaps thrusting the eyeball out of its socket, and thus producing a horrible deformity. On the other hand, a tumour originating in the superior maxillary bone, commencing, for instance, by a dental cyst in the alveolar ridge, may ultimately occupy the antrum and lower wall of the orbit, and by its pressure cause absorption of the

* See Sir A. Cooper's "Surgical Essays," vol. i. p. 155, *et seq.* "Exostosis has two different seats; it is either periosteal or medullary. By the periosteal exostosis I mean a deposition seated between the external surface of the bone and the internal surface of the periosteum, adhering with firmness to both surfaces; and by the medullary is to be understood a formation of a similar kind, originating in the medullary membrane and cancellated structure of the bone." Virchow objects to the latter term on the ground that no such a thing as a medullary membrane exists, at any rate in the spongy bones, such as the body of the sphenoid.

intervening layers of bone, and displace the contents of the orbit.

The pathological classification of these various growths is one of the most difficult problems conceivable, and would require pages of description to elucidate it. Fortunately, however, this task is not within the scope of my present work ; and the whole subject is treated in so elaborate a manner by Professor Virchow, Mr. Paget, and other great and original thinkers and teachers, that my task is comparatively easy.

In my classification I shall endeavour to follow the order of the great German pathologist, selecting such illustrative cases in a condensed form as will bring out the prominent features of each class.

The bony tumours springing from the walls of the orbit are for the most part—(1) Exostoses, or outgrowths from the surface of the bone, and developed in the connective tissue and periosteum ; and (2) Enostoses, or tumours found in the substance of the bone and at the expense of the medulla. Possibly a third kind consists of ossified chondroma (see Virchow "On Tumours," vol. ii. p. 41), and a few rare cases of partial hyperostosis, or general spongy enlargement of individual bones make up a fourth.

The exostoses have three forms, of which two are met with in the orbit—viz., the ivory-like, or Exostose éburnée, and the spongy, or cancellated form.

Of the ivory exostosis, the following by Mr. Haynes Walton is a good example ("Surgical Diseases of the Eye," p. 286):—

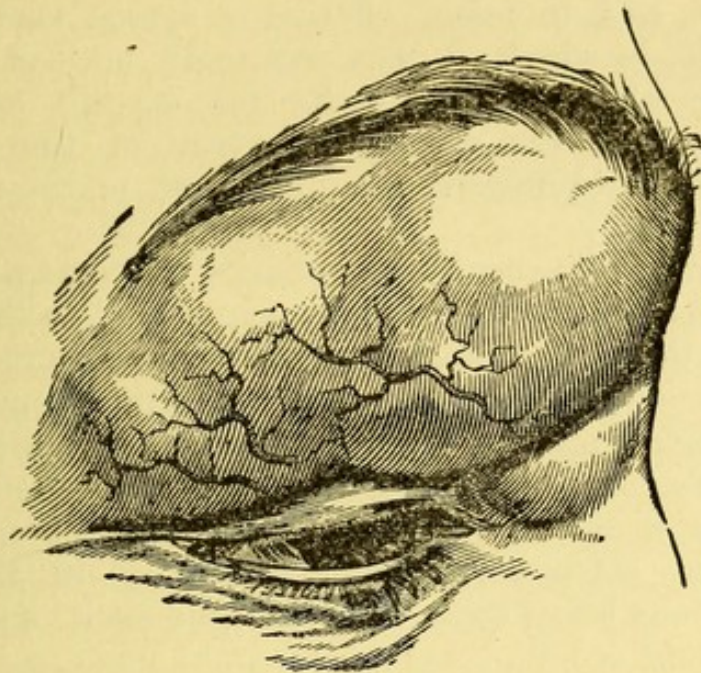
CASE.—A carter, æt. forty years, had a hard, evidently bony tumour, occupying the upper edge of the orbit, with a very broad base, and flattened. The greatest point of projection was two inches. The upper part was covered by the eyebrow, which was considerably thrown up ; the lower part touched the globe of the eye, and thrust it downwards and outwards, protruding it about half an inch beyond its fellow, thereby nearly destroying vision. The inner and outer boundaries were less marked. The surface was tuberculated—hard as a stone ; the skin moveable, and traversed by a few vessels. This growth was clearly traceable to an injury received many years before the date of the observation.

Mr. Walton sums up the diagnosis thus:—"There was no doubt as to its true nature ; hardness, immobility, slow growth, continuity with the bone, and absence of pain and inflammation, sufficiently marked the character."

The removal was effected by sawing through the hard ivory-like texture from below upwards. The result was most successful.

The accompanying engraving is copied by permission from that in Mr. Walton's book, at p. 287. Nothing could be more strikingly characteristic of the appearances of a hard ivory-like structure with the skin tightly stretched over its surface ; and

the whole case is one of the best examples that I have been able to meet with, though I have searched through all the recorded cases very carefully.



The most frequent seat of these ivory exostoses, however, is the lower and inner angle, or that part of the orbit which corresponds to the junction of os planum of the æthmoid with the superior maxillary and the palate bones. Numerous cases are cited by Demarquay in proof of this, but it is probable that some of those enumerated by that author were of the nature of enostosis in their origin.

A case of Mr. Bowman's, in the "Pathological Transactions" (vol. xi. p. 265), is a good example of true bony exostosis, originating and attached by a pedicle to the orbital plate of the æthmoid.

The remarkable case which occurred to M. Maisonneuve, and cited by M. Demarquay (*op. cit.*, p. 68, *et seq.*), is one of the same class. This case occurred in a young man of twenty-two years of age, of apparently robust health, in whom the growth commenced in March, 1853, with a dull aching pain and exophthalmus. The pain soon became very acute, and the eyeball more prominent. In July, 1853, the tumour was felt, of bony hardness, deep in the orbit, very slightly sensible to touch, but causing constant dull pain, which prevented sleep.

The treatment by iodide of potassium failing, the growth was removed by an operation, the description of which is full of the greatest possible interest on account of the great difficulties encountered and overcome, not, however, without using, after the failure of the saw, mallet, chisels, levers, and the strongest forceps; so that in attempting a similar operation the surgeon

should almost be prepared with an array of crowbars and centre-bits. The result was most successful.

This case is very remarkable as having been attended with so much pain, and therefore offering a strong contrast to Mr. Walton's case, in which it was expressly noticed, as being a characteristic symptom, that pain was entirely absent. On coming to look at the description given of the seat of the tumour by M. Maisonneuve, the difference in the two cases is easily explained.

"This 'tumeur éburnée,' " he remarks, "formed a prominence within the nasal fossæ almost of the same kind as that which it presented in the orbit, and these two portions were, as it were, gripped (*étranglées*) by a kind of osseous ring, formed above by the frontal, below and in front by the superior maxillary and its superior apophysis." The pain, therefore, was no doubt due to the distension of this ring of bone and the pressure of the growth on the surrounding nerves; whereas, in Mr. Walton's case, the tumour being quite superficial, no such compression or distension could occur.

M. Maisonneuve describes his case as "Exostose éburnée de l'os æthmoïde occupant toute la masse laterale droite de cet os." In all probability his description is the correct one; but there must necessarily be some uncertainty as to the primary seat of such a growth in the absence of a *post-mortem* inspection of the deeper parts, and especially of the sphenoid.

This case offers some remarkable points of resemblance to one which occurred quite recently to Sir W. Fergusson, and which is recorded in the "Pathological Transactions," vol. xix. This enormous tumour, which seemed to spring from the inner side of the orbit at the time of removal, was found afterwards to be continuous with a tumour which extended backward through the body of the sphenoid into the middle fossa of the skull, and which probably originated in the body of the sphenoid, or in the adjacent spheeno-æthmoidal cells. The opinion of the committee appointed to examine it was, that it was the result of "an exogenous growth of successive layers of dense bony tissue under the periosteum," and would therefore be included under the term "exostosis." But the fact that the deeper part of this tumour consisted of spongy and comparatively soft bone, divided from the ivory portion by a distinct layer of soft ossifying cartilage, make it probable, in the opinion of the author, that in the development of this remarkable tumour there were two processes going on *pari passu*, one in the production of exostosis, and another in the production of enostosis, the same irritation being the original cause of each, or the one having been primary and setting up a secondary irritation which gave rise to the other; just in the same way

that necrosis of one portion of a bone gives rise to, or at any rate is, very frequently associated with a great thickening and consolidation of the surrounding bone, and sometimes with the production of osteophytes. The appearance presented by the intra-cranial portion of the tumour is highly suggestive of the enostotic form of osseous growth, for there is a thin shell of bone overlapping the margin of the tumour, which looks very much as if it had been gradually thinned, and at length partially absorbed by the continuous pressure from within. This part of the tumour is shown in the preparation in King's College Museum. This appearance, however, is not altogether inconsistent with an invasion of an exostosis of a neighbouring bone, which, in the course of its progress, has gradually converted the bones intervening between itself and the soft tissues into a mere osseous shell.

Many orbital osteomata, however, according to Virchow, probably commence in the *diploë* as Enostoses, and only by degrees penetrate the bony shell which surrounds them.

"It is remarkable that the greater number of these tumours are found in young people, principally in women, and that many are developed in the first years of life, leading us to the conclusion that they have probably some relation to the development of the bones."—Virchow "On Tumours."

The polypi, which are often found in connection with these tumours, are only to be regarded "as the expression of the constant irritation communicated along the mucous membranes, or as the point of departure of the irritation which is spread over the bones.

"Rokitansky has expressed the opinion that these exostoses proceed from enchondromata; but in spite of all my researches I have only found one case in which cartilage was met with. John Windsor has observed a case of tumour at the roof of the orbit partly osseous and partly cartilaginous."—Virchow "On Tumours," vol. ii. p. 47.

Two cases, however, recorded in the "Pathological Transactions," vol. xix., give some support to the view entertained by Rokitansky. The first is a case by Mr. Christopher Heath (at p. 328), of a large recurrent enchondroma of the face, involving the orbit, in which cartilage was present in large quantity. This cartilage was ascertained by microscopic examination to be undergoing a process of ossification, and was in great part covered by a bony shell.

"The tumour consisted of:—

"1. A large rounded mass, presenting the appearance of a loose bony cyst, from which laminae and spicula protruded into the substance of the tumour. One surface was rounded and loosely covered by a thick periosteum. The remainder of the

surface was rough and broken, the intervals between the bones being filled by a soft reddish gelatinous material.

“ 2. A smaller mass. . . .

“ 3. Large and small pieces.

“ 4. A small patella-shaped nodule, weighing ninety grains, being a thick bony cyst covered by periosteum, which, when cut in two, presented an almost cartilaginous appearance.”*

The second case is that already alluded to as having occurred in the practice of Sir W. Fergusson.† In this case cartilage was found between the ivory and the cancellated portion of the growth.

Of undoubted Enostosis I am unable to give any example ; but a tumour found in the following case is regarded by Virchow as being of that nature.

Case.—Rokitansky describes in an individual, aged sixteen years, who had exophthalmia, a tumour coming out of the diploë of the frontal bone, very dense, and of a dead white colour ; this tumour extended into the anterior cranial fossa by one nodule, which was slightly lobed, and nearly as big as a duck's egg ; by another nodule of the size of a walnut, into the orbital cavity, and into the zygomatic fossa by another of the size of a hazel-nut. What was most characteristic in this case, was that other small tumours proceeding from the diploë were found on the frontal and the great wing of the sphenoid.

Case.—A case described by Baillie (the preparation from which is in the Hunterian Museum) is also included in the same class. This is a bony tumour, the greater part of which is of the ivory-like kind, but having the posterior and interior portions of the spongy kind. The tumour filled the frontal sinuses, and the upper part of the left orbit, but it also penetrated the right orbit, and projected more than an inch from the inner and outer tables of the skull. In front it bursts out, as it were, through special orifices of the outer table ; the margins of these openings are thin, and expanded for a short distance over the surface of the tumour.

There is one peculiarity in common with the great bulk of these Enostotic or Exostotic growths which present towards the inner part of the orbit. They are more or less intimately connected with the sphenoid and æthmoid bones, and appear to originate not unfrequently in or near that system of cells which opens into the body of the sphenoid behind, and the frontal sinuses in front. This region corresponds to the body and

* This corresponds to the description by Paget of ossified cartilaginous tumours in a remarkable way.—See Paget's "Lectures on Pathology," 1st edit., vol. ii. p. 236.

† "Pathological Transactions," vol. xix. p. 310, *et seq.*

neurapophyses of the pre-sphenoid, or frontal vertebra, which, in the fœtal condition, and even for some time after birth, is cartilaginous and solid, the spongy tissue being subsequently developed.

The occurrence of solid tumours in this region may therefore be looked upon as in some instances a formation dependent on arrest or disturbance of development, the solid cartilage being converted into bone, instead of being absorbed and converted into spongy cells and cavities. This consideration will in some measure explain the remarkable frequency with which such tumours are seen in young people and children, and with the fact that in some cases they are traceable back to birth. It will also serve to explain three remarkable cases of cysts in association of bony growths in this neighbourhood and the analogy between these ossific cysts and similar cysts occurring every now and then at the caudal extremity of the vertebral column.

Case.—Virchow "On Tumours," vol. ii. p. 48, *et seq.*—*Osteoma kystomatosum orbitæ.* In a male adult, in whose orbit nothing abnormal had been noticed during life, was found after death a large tumour, softened in the centre, which occupied almost the whole anterior right lobe of the brain. When cut in two a limpid and yellowish fluid escaped, and brought into view a regular wall formed of a fibrous tissue, soft, mucous, and coloured by various yellowish brown pigments. This tumour was not sharply defined on the cerebral aspect, but was gradually lost in the *neuroglia*, so as to represent a cystoid myxoma. To this tumour were attached a series of pouches, some of them closed, some communicating with each other, of various sizes. These pouches were easily separable from the brain, but they adhered firmly to the anterior cranial fossa. . . . Some contained a viscous fluid. . . . A closer examination of the wall of the cysts showed a layer of cylindrical vibratile epithelium. At the part of the anterior cranial fossa to which the tumour was adherent, it was also closely adherent to the os frontis, as well as to the dura mater. On removing it, it seemed at first to have penetrated into the frontal bone. . . . The true base of the tumour was an osseous irregularly rugose growth, which projected from the angle formed by the frontal and orbital portions of the os frontis. This growth, almost the size of half a hen's egg, was prolonged into the substance of the frontal by a broad base. When the front face of this bone was exposed, several rounded knobs were seen, perfectly smooth, apparently very dense, which pierced, at the superciliary border, the anterior table of the os frontis, and were beginning to grow outwards. On a perpendicular section, through the whole region, the tumour measuring 4·8 centimetres across, is seen to start from the diplœe of the os frontis, to have been enclosed distinctly, at the orbital

region, between the two tables of the frontal. It penetrated them inwards and outwards. . . . The greater part of the tumour was made up of a very dense ivory-like tissue, and only at two points near the periphery a more porous and vascular substance was discovered. In the ivory-like portion a lobulated structure was made out. Where it perforated the outer table of the frontal, it was only covered by periosteum. But it also perforated at several other places, by points of the size of a lentil, into the orbit itself. In all these regions the tumour contained cysts, with an internal lining of vibratile epithelium and mucous contents.

Two similar cases, one by Busch, and one by Petit, are also alluded to by Virchow.—(C. Hoppe, *loc. cit.*, pp. 22 and 24, and J. L. Petit, "Traité des Mal des Os," ii. p. 428.)

Virchow remarks on the probability of such cystic growths being congenital, and hints at their probable analogy with the congenital hygromes of the sacrum—sacral-hygroma.—(Virchow, *op. cit.*, vol ii. p. 52.)

Certain other tumours of an osteomatous character, proceeding from the speno-orbital region, may have originated from ecchondroses from between the bodies of the cranial vertebræ in the same manner as the speno-occipital ecchondrosis of Virchow. Or, on the other hand, these tumours also may be traced to some abnormal retention and outgrowth from the primitive notochord, or chorda dorsalis, the latter having previously undergone a change into the cartilaginous condition.

While considering the etiology of Exostosis, it may not be out of place to inquire whether syphilis has any influence.

M. Demarquay cites two cases, one from M. Carron du Villard, and one from M. Ricord (*op. cit.*, pp. 51 and 52), as instances of Exostosis of syphilitic origin, in both of which a complete disappearance of the tumours took place under the use of constitutional remedies. It is difficult, however, to conceive of a genuine Exostosis disappearing under such circumstances, and there is nothing in the history of the cases which entitles them to be classed under this head. It would be more in accordance with pathology to place such cases under the head of Periostosis, or chronic thickening and spongy swelling of the bones—a condition which in all probability precedes in many cases the true Exostosis, and perhaps corresponds at a later stage to the osteophyte of Virchow (vol. ii. p. 19, *op. cit.*). "Osteophytes are young exostoses, and exostoses old osteophytes."*

* "The osteophyte has none of the characters of the tumour in itself. These are osseous formations, extended, but flattened on the surface of the old bones, such as are produced by diffuse periostitis. Exostosis marks the limits of the domain of Osteophytes which are restricted to a determi-

The term "Periostitis" is used by M. Demarquay (*op. cit.*, p. 20), for the result of an "inflammation of the periosteum, which terminates by an induration, and constitutes a sort of tumour more or less circumscribed."

It must be admitted, however, that the gradations between chronic Periostosis, Periostitis, and Exostosis are very difficult to define, and the three words may be but terms to express three stages of a continuous pathological process. Nevertheless, it is important to make a distinction between the extreme and typical forms of each, and especially so in respect of prognosis; for it would be a manifest absurdity to suppose that a dense ivory exostosis such as that of Mr. Walton's (see case cited above) could be got rid of by a course of iodide of potassium or preparations of mercury or gold; and, on the other hand, such swellings as those alluded to as having yielded to internal remedies (and which should be classed as Periostoses), would be injudiciously treated by operative proceedings. The chronic painless growth of the Exostosis, and great density and hardness, will in general be sufficient to prevent any such error being committed, and the Periostoses or Osteóphytes resulting from chronic periostitis will generally be multiple and distinguishable by the local tenderness and by the previous history. The effects of constitutional remedies may also be fairly taken into consideration in determining the nature of the disease, though such evidence is by no means conclusive when taken by itself.

Hyperostosis of the bones of the cranium and face, or leontiasis ossea, is regarded by Virchow as strictly analogous to elephantiasis, and is in all probability the same disease modified by the character of the tissue involved.—(Virchow, *op. cit.*, pp. 23 and 24.)

Instances in which enormous exophthalmus and hideous (though sometimes almost symmetrical) distortions of the face have occurred, are recorded by M. Demarquay and elsewhere. It may affect the whole of the bones of the head and face symmetrically, or one side of the head, or even one single bone.

A most remarkable specimen of the kind by Mr. Bickersteth, of Liverpool, is recorded in the "Pathological Transactions" (vol. xvii. p. 243, *et. seq.*).

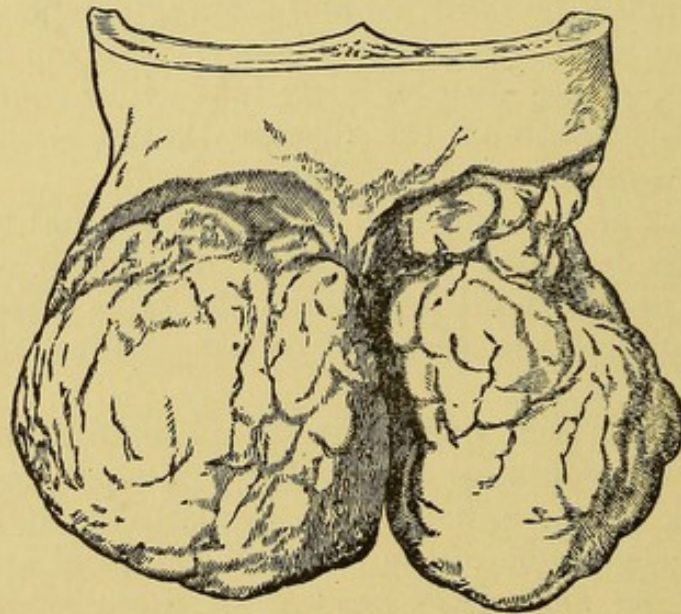
Case.—A man, who died at the age of thirty-four years, noticed the enlargement of the bones of his face at the age of fourteen. The whole of the bones of the head, face, and jaws, became enormously enlarged, and thirteen years after its commencement the same disease attacked the left fibula. Two

nate surface of bone, and produced under the form of a tumour. They represent, therefore, one of the most remarkable examples of the relation of tumours to chronic inflammatory processes."

years before death the patient began to suffer intense pain, and as the facial enlargement increased, the cavities of the mouth and nose were greatly lessened, and the eyeballs were protruded almost beyond the eyelids, so as to impart a frightful appearance to the countenance. The sight of the right eye remained good, but that of the left was lost. The patient died, worn out by emaciation and protracted suffering.

“At no time was there any suppuration, and to the last *neither the integuments nor the soft parts were implicated.** The patient had never suffered from syphilis, and there was no history of tubercle, cancer, or constitutional syphilis in his family. One brother had a similar enlargement affecting the upper jaw on one side.”

“The disease involves more or less all the cranial bones, except the occipital.” “It consists in great thickening and induration, this condition being chiefly due to growth from the outer surface of numerous, closely aggregated, smooth, dense, botryoidal excrescences, varying in size from a hemp seed to a small cherry, and causing the bone to resemble somewhat a mass of malachite.”



The remarkable specimens in the College of Surgeons' Museum, labelled No. 3093 and No. 3236A,† are somewhat similar. Several other equally remarkable cases are related in more or less detail by Virchow (*op. cit.*, vol. ii., p. 21, *et seq.*).

* This feature offers a remarkable contrast to a case mentioned by Virchow, in which periodical attacks of erysipelas were observed in association with the osteal enlargement, each attack lasting from eight to ten days.

† This case is the subject of the accompanying illustration, copied from Mr. Walton's book, p. 288.


In one case there cited (Musée Dupuytren, No. 435), from M. Suacerotte ("Melanges de Chirurgie," p. 407), the whole skeleton was hypertrophied, as well as those of the head and face; "the eyes were thrust forward to such an extent that they were on a level with the forehead;" the bones of the latter being themselves enormously advanced.

Case.—Hyperostosis of a single bone of the orbit is exemplified in a case (related by Virchow in vol. ii., p. 26) of "a dense, though slightly porous, hyperostosis of the left half of the sphenoid. In the interior of the skull the body of the sphenoid presents an increase of bulk and a thickening (skle-rose), which extends to the largest portion of the orbital apophysis, as well as the outer surface of the temporal portion, and to the pterygoid processes, where the alteration is most pronounced. Thus was developed a circumscribed mass, which produced a tumour, hard and perceptible to the touch, in the temporal region, and another tumour in the orbit giving rise to exophthalmia. The patient in this case was a woman, thirty-five years of age, who died of typhus.


The orbital cavity may also be invaded by partial hyperostoses seated in the superior maxilla, generally arising from within the antrum of Highmore, and spreading thence into all the neighbouring cavities.—(See Sir A. Cooper's and B. Travers' "Surgical Essays," 1818, part i., p. 157.)

It is generally in consequence of dental irritation that hyperostoses of the upper jaw originate, and they may be associated with caries and abscesses, and even with loose or misplaced teeth, which have found their way into the antrum, or even into the orbit itself. Thus, Mr. Barnes, in "Med. Chir. Transactions" (vol. iv. p. 316), relates a case of double cyst containing a tooth, which was implanted in the suture between the æthmoid and superior maxilla, and had given rise to displacement of the eyeball outwards and downwards.

The myxoma of the face and skull, reported in vol. xix. of the "Pathological Transactions," by Mr. Moore, may be properly noticed here, but only in contrast to the truly bony tumours, the surface only of the tumour alluded to being formed of the abnormal expanded bones of the parts.



HISTIOID PSEUDOPLASMS.



5. *GLIOMA*. MEDULLARY SARCOMA. (*Abernethy, Rindfleisch, and Beer*). ENCEPHALOID (*Laennec, and H. Walton*). FUNGUS HÆMATODES (*Hey, Lawrence, and Wardrop*). CARCINOMA MEDULLARE. PSEUDO-ENCEPHALOID (*Robin, Sichel, and Hulme*). MARK-SCHWAMM (*Knapp*). CAT'S-EYE AMAUROSIS (*Wardrop*). TUBERCLE (*Poland*).

The multiplicity of the names above given is perhaps in itself sufficient evidence of the variety of opinions among authors as to growths of the nature indicated,—of the confusion which has been long rife in literature on the subject, and at the same time of the necessity of a definite nosological nomenclature. It is, however, clear that Pathologists must come to an agreement on the identity of the things heretofore named variously, before they can hope to be agreed as to the names themselves, and the peculiar value of Virchow's work is, that he has laid it down as a principle that the structure and development (or genesis or origin) are the only sure basis for correct classification and a correct nomenclature of tumours.

In endeavouring, therefore, to follow as closely as possible the classification of Professor Virchow, it is not the author's wish to indicate that this classification is perfect and incapable of improvement, but that it is rather the nearest approximation to that desirable consummation which has yet been arrived at, and offers besides the best chance of ultimately giving an intelligible nomenclature and a reliable classification.

The name Glioma, however, being derived directly from the term neuroglia, or that tissue which (according to Virchow) forms the connecting bond between the nervous elements proper, it may not be out of place to enquire why this tissue is accredited with such a function. No doubt Professor Virchow has good reasons to adduce for regarding the cells composing the neuroglia as merely connective, and not as true nerve-tissue, but it certainly seems remarkable that in the case of the Retina, at any rate, this tissue should form so large a portion of the thickness of the nervous expansion, and yet perform so sub-

ordinate a part in the functions of the organ. The thickness of the granular layers which are composed almost exclusively of the so-called neuroglia, is perhaps equal to the rest of the Retina, and is not placed in the interstices of the true nervous tissue so as to support and connect them, but lies outside these in distinct layers. Such a position seems hardly consistent with the supposed function of the cells composing the granular layers.

While thus pointing out what I conceive to be the weak part of the theory advanced by Virchow, I shall nevertheless follow the nomenclature which he has introduced—for I believe that the tissue he has indicated is the actual seat and origin of the disease, though I venture with all humility to doubt the appropriateness of the name given to it, at any rate so far as the Retina is concerned.

Though starting from the Interstitial connective tissue or Neuroglia of the Retina, Glioma is in its later stages too frequently presented to the surgeon as a prominent fungoid mass occupying the whole orbit and involving the eyeball and the orbital contents.

Of all the malignant and quasi-malignant growths in this region none offer points of greater interest to the Pathologist. Glioma, Gliosarcoma, and Sarcoma seem to occupy the mid-ground between the simple chronic inflammations or thickenings on the one side and the undoubtedly malignant and infecting tumours on the other. The early stages of a Glioma are not structurally distinguishable from a simple inflammatory thickening or Hyperplasia of the Retina, whilst in the advanced form, its clinical history is more like that of the most malignant tumour. Structurally, however, it is, even in its latest stages, distinct from the growths having an epithelioid tissue, which, for the present at any rate, it may be convenient to regard as typical of malignant tumours.*

The Diagnosis of Glioma in the early stage of the disease is of the highest importance, and the ophthalmoscopic signs are generally, if not characteristic, yet very marked and suggestive.

* "It seems necessary to admit the existence of certain malignant infecting Gliomata of the Retina, (infectioser) which engender heteroplastic growths. Rindfleisch wishes to call them Medullary Sarcomata. I think we must not admit this generalization at present, for many tumours having the smallest and most homogeneous elements, have precisely these characters, and the idea of Sarcomata would be entirely falsified if instead of restricting ourselves to the anatomical (or developmental) and generic characters, we were guided by the physiological properties of the growths." *Virchow Op. Cit.*, vol. I. p. 166.) I have already laid it down as an established doctrine, that there are transitions towards Sarcoma, and I admit that it is precisely the gliosarcomata which give rise to the most hesitation. The subject deserves further examination before it can be regarded as definitely at rest.

An ophthalmoscopic plate in a recent work by Dr. H. Knapp (*Die Intraocularen Geschwalste* Taf. I. Fig. A.) is so characteristic of the appearances of the disease at an early stage that I cannot help referring the reader to it. The optic nerve is there entirely hidden by a prominent balloon-looking mass, the surface of which is marked by ramifying vessels, and offers by its colour and markings, a remarkable contrast to the healthy retina seen above. It is of a greenish-grey tint with occasional patches of opaque white, and in the centre of the upper part of the morbid protrusion is an opaque white nodule, also partly covered by still whiter patches, and with a few small vessels resembling those of the Retina ramifying on its surface.

In this, and at the later stages, however, oblique illumination will afford almost as much information as the ophthalmoscope.

The greater number of the patients thus affected are young children, and most of them are free from any symptoms, or appearances of general cachexia. Some have the signs of robust health. In the majority both eyes are simultaneously affected. The growth may be rapid, or it may remain unchanged for a considerable period. In either case, destruction of the eye is inevitable, and in the former, a fatal issue is most frequently the termination. Should the tumour have been extirpated at an early date, it is possible that there may be no return—a few such cases have been recorded,—but in the majority, a speedy return of the growth within the orbit is the sequel to any operation. In a few cases, the growth in the orbit has been accompanied by similar tumours in the brain; and occasionally, the disease has spread into the cranium along the optic nerve and optic track. The infection of neighbouring tissues, however, is not the rule, and when it does occur, it is in those tumours which with the characters of glioma, combine those of Sarcoma. These last-named tumours have a rapid growth, and speedily terminate fatally. Illustrations of the anatomy, and microscopic anatomy of a case of this kind are here appended from Dr. H. Knapp's work above alluded to. The *treatment* must necessarily vary in different cases, in accordance with the different varieties and stages of the growth.

Should the growth be one-sided, and seen at an early stage as an intraocular tumour, with the appearances indicated above, either by the aid of the ophthalmoscope or by oblique illumination, the only course open to the surgeon is, to remove the eyeball, together with as much of the intraorbital portion of the optic nerve as he can excise. This operation should be performed, whether the growth be rapid or slow, provided only there be decided *growth*—if however there appears to be any sign of regressive change, as indicated by the absence of pain, and shrinking of the eyeball, it becomes an open question whether the operation would not be wisely deferred.

In all doubtful cases the operation should be urgently advised.

From the satisfactory results of some cases which have been published by Messrs. Morgan, Lawson and Hulke, of intraorbital tumours of probably malignant nature, in which the extirpation of the tumour has been followed by the application of Chloride of Zinc in the form of a paste; it seems desirable in all cases of the kind to use this remedy, and especially in those in which the extraocular tissues are markedly affected.

In the later stages of the disease when a Fungus mass is protruding from the orbit, after destruction of the eye-ball, it becomes a difficult question to decide how far an operation for extirpation of the growth is desirable. The state of health of the patient will, of course, be an important element in forming a decision. The extent of the tumour backwards, and the possibility of isolating it from the surrounding bones, will also make a considerable difference in the question. In the majority of cases no good can be done by operating in the later stages beyond a mere temporary palliation of the patient's condition, and in some cases, considerable aggravation of the distress has resulted. If any operation is attempted, the whole contents of the orbit must be removed, and Chloride of Zinc paste, or some other caustic, should be applied over the whole surface from which the growth has been removed. The administration of opium, or morphia, in full doses, must be considered as an important feature in the after treatment, after such a severe and necessarily painful operation. The constitutional treatment of the early stages of the disease need not be despaired of. It is however well to recollect that spontaneous shrivelling of supposed Gliomata has every now and then occurred, and also that the diagnosis in the early stage is not so exact, that it is possible to say with certainty in a given case, that the disease is not simply a subretinal, or subchoroidal effusion, or even a fatty metamorphosis of the Retina. Each of these three conditions may produce ophthalmoscopic appearances and phenomena, visible to the naked eye, which closely resemble those due to glioma.

“The spontaneous retrocession of carcinomatous diseases of the internal eye (says Virchow, *Op. Cit.*, vol. II. p. 151) has been already pointed out by previous observers; but we know not of what nature were these diseases. In my opinion, it is very probable that they were gliomata; at the same time this cannot be proved. It was thought, in fact, for some time that the peculiar metallic brilliancy, often of a golden yellow colour, of the fundus oculi, was a specific sign of cancer, and Beer has hence deduced the name of Cat's eye Amaurosis, without troubling himself as to the nature of the malady. But it has been more and more admitted that this appearance is seen in sub-

retinal growths of the most varied kind ; and markedly, in internal dropsy of the choroid. This symptom lost all value when A. de Graefe showed that the golden yellow appearance proceeds from a fatty metamorphosis of the Retina. It may be asked then, whether these compact masses were produced by any other morbid process. The objection of Radius that the cases of cure ought to be classed as cases of dropsy of the choroid, is not admissible for cases which have been submitted to microscopic examination : on the other hand the opinion has been propounded that they were of a scrofulous, or even tuberculous nature ; as for the first, it would not affect the question, for scrofulous products are essentially hyperplastic ; but true tuberculosis, would show less than any other disease a similar tendency to spontaneous cure, which, at any rate, has never been pointed out in tuberculous affections."

Every now and then cases are adduced of malignant growths (so called) which have been removed, without a recurrence in the orbit or other parts of the body. In one such case, recorded in the Medical Times and Gazette by Mr. R. B. Carter, the eyeball removed, was examined microscopically, with a very unsatisfactory result so far as diagnosis of the pathology was concerned. The tumour not having returned, however, it may be presumed to have been a case of the same kind as those rare instances, in which the eyeball has, after a time, shrunk, and atrophied, and in which, therefore, it may be supposed that a glioma has undergone fatty, and earthy degeneration. The same degenerative changes occasionally lead to rupture of the eyeball, and extrusion of the morbid mass, after which the stump heals favourably.

Case reported by Dr. Lebrun of Brussels. Glioma of the Retina and Optic Nerve. Eneucleation of the eyeball. Death. (*Reported in Ann. d' Oculistique*, vol. LX. p. 203.) F. D. a girl æt. 2 years, brought to the Ophthalmic Institution of Brussels on June 15th, 1868. This child has always been pale and thin, and her parents state, that the affection from which she suffers showed itself in the first weeks of her life. Being surprised to find that their child's pupil was whitish, they consulted their accoucheur, who replied that "it was nothing, and that they should take care not to have that eye touched."

Thus quieted with respect to this strange anomaly, the parents took no further notice till lately, when they perceived that the child became squint eyed, and that this singular eye seemed to be getting larger. This decided the father to come and show it at the Institution, where his first enquiry was, whether the eye still had any sight, or not. From a distance one remarked the whiteness, and the shining (*chatoyant*) brilliancy of the right eye, which projects, and presents a well marked exophthalmus. The cornea is perfectly clear, but surrounded by a circle of sub-

conjunctival injection. The exophthalmus, by separating the lids, discloses beyond this circle, a large zone of the Sclerotica, of marbled blue tint, which completes the very strange aspect of the physiognomy. The pupil widely dilated, allows a view of the fundus, which is uniformly yellowish-white and (*chatoyant*) shining, and upon which, with the ophthalmoscope, some rather small vessels are distinguished. By lateral illumination, the free border of the iris is seen to be very attenuated. The Crystalline presents a striated zone of commencing opacity. The eyeball is hard, the cornea very slightly sensitive, but with its brilliancy unimpaired; there has not as yet been severe pain. This general aspect, taken in relation to the age of the subject, to the development of the disease, and its external signs, give at once the idea of encephaloid, or glioma of the Retina. It is known that this affection has a fatal progress. Moreover, there is already exophthalmus, which at least implies alteration of the shape of the posterior pole. Lastly we know to what severe pain the patient will be subjected before the eye bursts under the pressure of the internal tumour. It is principally for this last reason that immediate extirpation is proposed, not without at the same time warning the parents of the aim which is proposed, and of the probability of a fatal issue. On June 21st, M. Warlomont enucleates, cutting off the optic nerve of a length of at least 11 millimetres.

The eyeball removed has an ovoid form with the thick end forwards. In front the shape is normal. The middle zone is marked by marbled blue. The Posterior hemisphere is of a yellowish white, vascular, irregular and presents a kind of staphyloma surrounding the optic nerve, and besides at its outer side, a little pointed tumour of the size of half-a-pea, and at a distance of 3 millimetres from the optic nerve.

The antero-posterior diameter coming out between this little tumour and the nose measures 0,025 mm., the transversal is 0,021 mm. The trunk of the nerve is enormous; its sheath greyish and as if fatty, is sharply distinguished from its contents, which is white, and of soft consistence. On a transverse section, the nerve-proper is found to measure 0,004 mm., and with its sheath, at least 0,006 mm. in diameter. With the microscope, nerve-fibres are no longer discoverable, but a multitude of small rounded cellules, resembling the nuclei of the Retina and perfectly analogous to those that have been described as proper to glioma of that membrane, these cells are disseminated in a web of cellular tissue of loose texture, especially in the interior of the nerve, but less loose and more abundant in the sheath. The globe is opened on the out-side, following the horizontal plane across the small tumour of the posterior pole.

At the moment of incision, a non-glutinous fluid escapes, yellowish grey, of purulent aspect. This liquid contains cells identical with those found in the optic nerve; only here and there are observable groups with a red-yellow colour due to Hæmatoïdine. Besides, some globules and drops of fat were observed with very sharply defined and highly refracting borders.

The vitreous humour with its natural consistence is enclosed in its membrane, but thrust forward behind the crystalline by a growth which occupies the two posterior thirds of the vitreous chamber, and which laterally becomes thinner as if moulded on to the vitreous, following in fact the Retina in its entire extent. This tumour has a whitish, light rose colour, and presents on the surface small vascular ramifications. There are some whiter points of the size of a millet seed and from that to the size of a hemp seed. These points are still more softened than the rest of the tumour, has almost throughout a pultaceous consistence and can be traversed by even a blunt object without difficulty.

The sclerotic is thinned in its posterior half. The little external tumour does not seem to communicate with the internal tumour, but on examining closely the layers of the sclerotic are found to be separated by layers of the same tissue as that of the new growth, and one can follow in some parts of it, the communication, the internal, and the external tumours.

This last is found to be made up of a quantity of nuclei, more numerous, more closely packed, than in the interior of the optic nerve: at the same time there is less connective tissue and a large number of small molecular granulations, and even of globules of a fatty nature.

The whitest points consist of an amorphous non-transparent material, composed of a certain number of fatty globules and very compact molecules, which dissolve without effervescence in dilute nitric acid, which only leaves a yellow tint due to the action of this acid on organic matter. Iodine produces no modification of colour. The little external tumour encloses the same nuclei as the rest, but the web is closer, the connective tissue more abundant and disposed in arcolæ filled by these nuclei. In it too, fewer fatty globules are seen, which fact implies a more recent formation. From anatomical examination of this specimen it results that we have before us a gliomatous growth of the Retina, a tumour known for its malignant nature, and which, further, indicates in all respects a development and growth of the greatest rapidity.

As we have seen, unfortunately the optic nerve though divided so far from its insertion into the globe, could only be divided through diseased tissue; thus the prognosis is hopeless, and

the operation can only be palliative. The immediate sequel of the operation was most favourable, in spite of the deep and perhaps overbold division of the nerve, there was not the slightest intracranial irritation. At the end of some days cicatrisation was complete.

The child was brought several times during the 4 weeks after the operation and there was not the slightest appearance of a recurrence. Meanwhile the little subject was pale, grew thinner and thinner, and nutrition was evidently suffering: she had subsequently convulsions twice, at intervals of some days, and in the last days of her life lost the sight of the other eye; but without the orbit having any noticeable vegetation and without pain.

The fatal issue came six weeks after the operation; the disease having continued to spread to the interior of the skull doubtless along the optic nerve and crossing the chiasma to the nerve of the other eye. No autopsy could be obtained.

DOUBLE CONGENITAL RETINA GLIOMA WITHOUT IMPLICATION OF THE OPTIC NERVE. METASTASIS IN LUNGS, DIPLOE OF THE SKULL. DR. KNAPP'S CASE. (*Knapp. Der Intraoculararm Geschwulste*, p. 5.)

The child B. K. von H. was under observation from Nov. 4th, 1865, when it was 18 weeks old till the time of death, which occurred at two and three quarters years of age.

The right eye having been removed during the period of the growth remaining completely within the eye, there was no return whatever in this orbit or in the optic nerve, though two and a half years elapsed before death. During this period however, the left eye became affected with the disease, and speedily the left orbit also, and metastatic deposits were found in the lungs, liver, and diploe of the skull.

Figs. 1, 2, 3, and 4 illustrate the macroscopic and microscopic appearances of the right eye after extirpation.

Figs. 10, 11, and 13 illustrate the condition of the head and left orbit of the same patient, immediately before and after death.

The whole case is related in detail in the work above referred to.

Numerous other cases might be brought forward with a view of illustrating this very remarkable disease, but further cases will be described under the head of sarcoma, with which glioma seems to have some affinity.




Fig. 10.

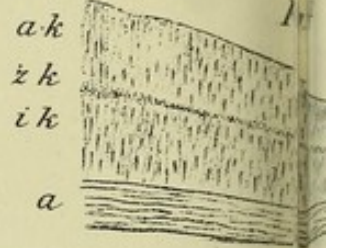
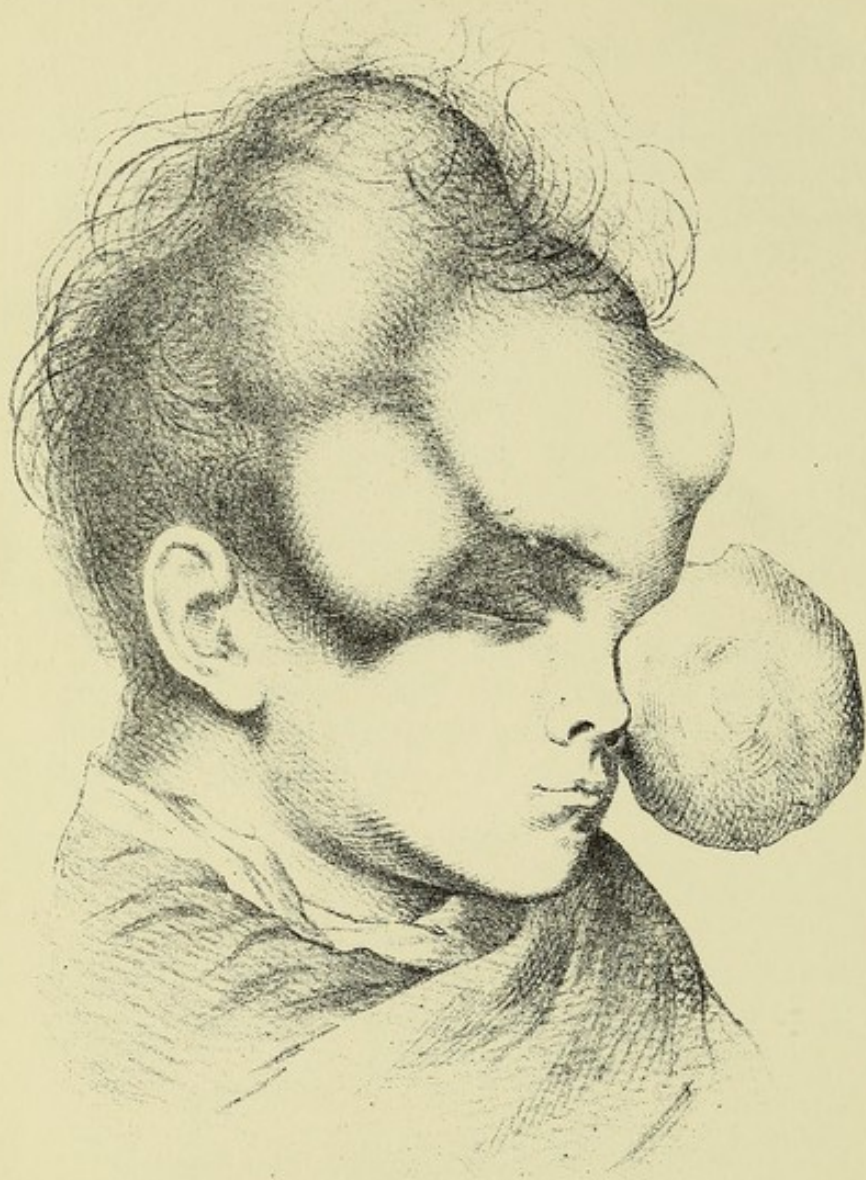

Fig. 2

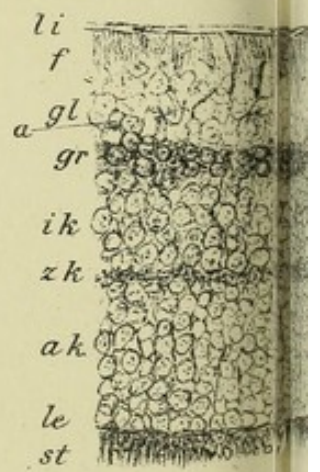


Fig. 3. 200

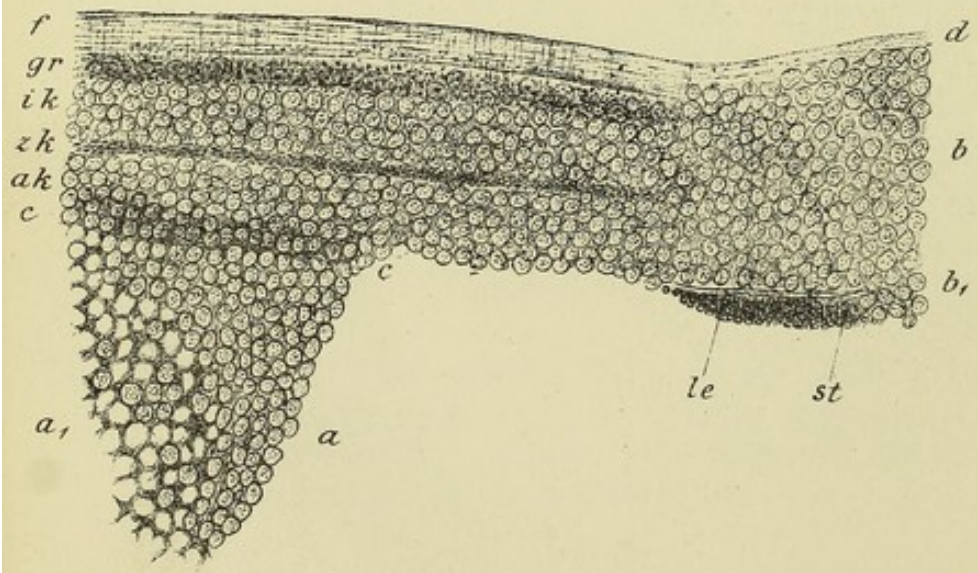


Fig. 1

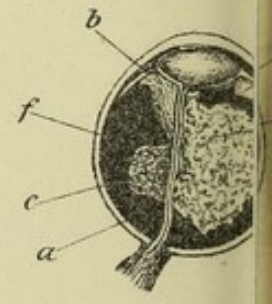


Fig. 11.

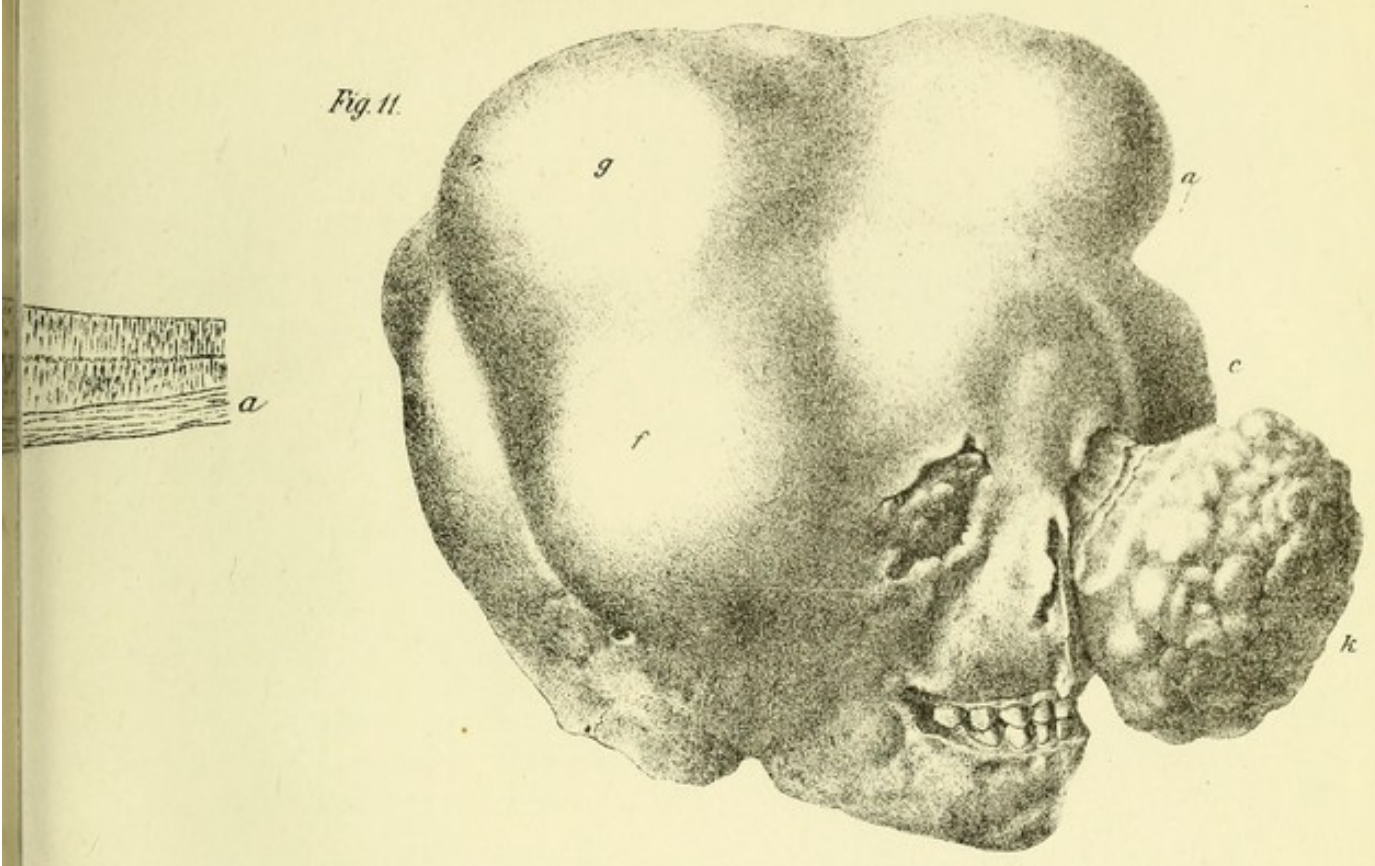
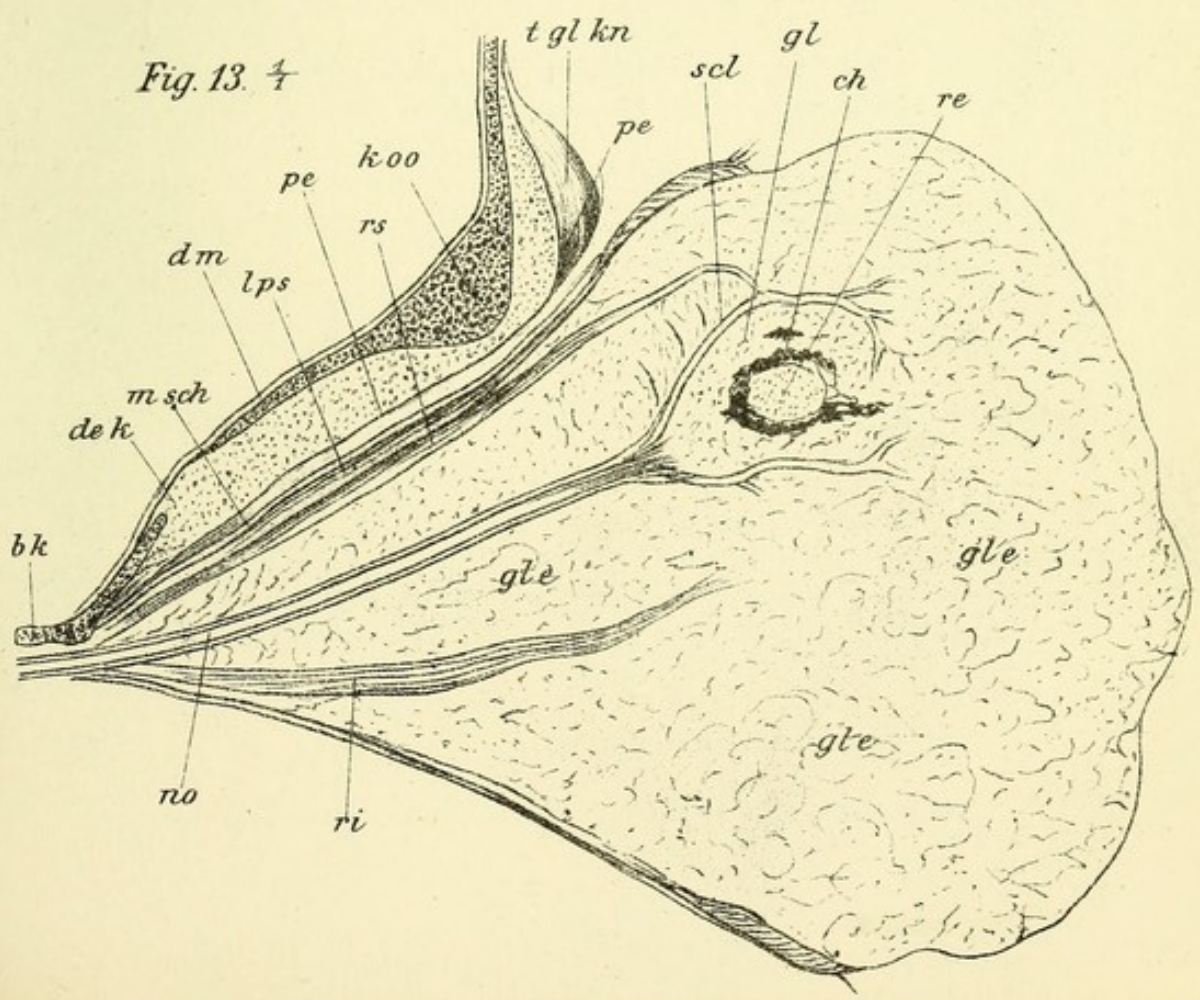


Fig. 13. 4






TABLE EXPLANATORY OF FIGURES IN ILLUSTRATION OF GLIOMA, FROM KNAPP "DIE INTRA-OCULAREN GESEHWÜLSTE." pp. 227, *et seq.* and *Taf. II. Fig. 1, 2, 3, 4. Taf. IV. Fig. 10, and Taf. v. Fig. 11.*

FIG. 1. Glioma of the Retina in separate masses, resulting from a hyperplastic development of the granule layers. (Körnerschichten).

- a.* Retina detached and with its inner surface pressed together.
- b.* Retina pushed forward, the ciliary body and the back of the crystalline enveloping it.
- f.* Choroid and space between it and the detached Retina.
- c. d. e.* Larger and smaller masses of glioma on the outside of the Retina.

FIG. 2. Section of the Retina. Hyperplastic growth of the granules, (Körner).

- li.* Membrana limitans Interna.
- f.* Nerve-vascular layer.
- gl.* Ganglion-layer (cireritious cerebral substance) } Fibrous and Vesicular laminae (Bowman).
- gr.* Granular layer. (Granulirte Schicht) (Finely granular) } Stratum granulosum, (Kölliker) or, agglomerated granules. (Bowman).
- ik.* Innermost Granule layer (Innere Körnerschicht).
- zk.* Inter-granule layer. (Zwischen-körnerschicht).
- ak.* Outer granule layer, (Aeussere Körnerschicht).
- le.* Membrana limitans externa.
- st.* Membrana Jacobi or Rods and Cones.
- a.* Glioma-cells pressing forward into the Internal Retinal strata.

FIG. 3. Retina with granular (Gliomatous) degeneration of the same layers and with irregular (hügelartiger) knob-like swelling of the outer granule layers (small Glioma-masses).

FIG. 4. Gradual tumefaction of the Retina throughout the Granule layers (glioma diffusum).

FIG. 10. A child æt. 2½ years with Glioma of the left orbit and metastatic deposits of Glioma in the skull (proceeding from the diploe). The right eye (Fig. 1.) was extirpated while in the first stage of Retinal Glioma at the age of two and a half years. No local recurrence.

FIG. 11. The skull of the same child after death.

FIG. 12. Section of the Orbital Tumour of the same case.

6. SARCOMA. FIBROPLASTIC TUMOURS.

- Varieties. 1.—FIBROSARCOMA. FIBROPLASTIC TUMOURS, (*Lebert, Demarquay.*) CANCER FIBREUSE, (?) (*Sichel.*) MALIGNANT FIBROUS, (*Paget.*) RECURRENT FIBROID, (*Paget.*)
2. MYXO-SARCOMA.
3. GLIOSARCOMA. MEDULLARY SARCOMA. ENCEPHALOID.
4. MELANO-SARCOMA. MELANOSIS, (*Laennec, Sichel.*)
FICUS CANCROSUS, (*Fabricius Hildanus.*)
5. CHONDRO-SARCOMA.
6. OSTEO-SARCOMA. OSTEOSTEATOMA. SPINA VENTOSA. MYELOID.
7. MIXED SARCOMA AND CARCINOMA.

The Sarcomata, or Fleishy Tumours of the orbit, are, at the same time, the most numerous of the Tumours Proper of this region, and also those having the greatest interest to the Pathologist and Surgeon. They form a connecting link between the simple Histioid tumours, and Carcinomata, or the true Cancers. They are often in their clinical aspects as malignant as any of the Cancerous tumours, being very apt to infect the neighbouring tissues, very liable to recur after removal, infecting the lymphatic glands in immediate relation to them, and subsequently, or simultaneously, distant organs such as the liver, lungs and pleura. But besides this tendency to infection, even when in their minute structure, they have a histological similarity to the tissues from which they originate, they also frequently become epithelioid, by a metaplasie, or change of form, and a mixed Cancer and Sarcoma may occasionally be met with in the same tumour.

In the simple form a Sarcoma is characterised by the development of numerous nuclei, or cells, closely resembling those of granulations, or newly-formed connective-tissue in wounds, and imbedded in a scanty homogeneous, or slightly granular intercellular matrix, but without any alveolar clustered agglomerations of epithelioid cells. These characteristic cells vary greatly in form and size—from that of round or oval nuclei, to the fibrous or spindle form, but the persistence of the soft and fleshy tissue is an essential feature, and distinguishes them from the Fibrous Tumours in which the primary simple cells become hardened, distinctly fibrillated, and very closely coherent and interlaced. The Fibro-sarcoma bears some superficial resemblance to the last named tumours (Fibromata) but differs in the circumstance that the fibrous portions, if any, instead of hardening in the course of growth, have a constant tendency to become

softer and more and more assimilated to the soft sarcomatous form; the cells of the connective tissue being in fact converted by the morbid development into rapidly growing granulation cells, and the whole mass becoming more and more juicy and friable as the cells increase in number.

Of the various forms above enumerated, the Gliosarcoma and Melano-sarcoma are those more frequently developed primarily, in the orbitar cellular tissue. The Gliosarcoma may first spring from the Retina and infect the orbitar tissues secondarily, or may begin in the post-ocular portion of the optic nerve, or even within the cranium. Sarcoma of the choroid, in like manner, may subsequently infect the post-ocular tissues, and Fibrosarcoma of the connective tissue of the orbit, or periosteum may subsequently involve and destroy the eyeball by extension forward.

An interesting question, in reference to these tumours, is that of the diagnosis between them and the so-called true Cancers or Epithelioid growths.

Malignancy is no test; for the Sarcoma may not only infect the parts adjacent to it, but may recur in the parts from which the original tumour has been removed, may make its appearance in the neighbouring lymphatic glands, may be developed in distant organs, and may in fact be generally diffused throughout the body. In its general aspect it is undistinguishable from a true Cancer, and even the microscopic examination may fail to elucidate its nature in certain exceptional cases, e. g., in those in which Sarcoma and Carcinoma are developed side by side, if not simultaneously. It is, however, generally distinguishable by the microscopic structure, by its being composed essentially of connective tissue cells, variously modified, and by the *continuity* as well as contiguity of its alimentary tissues, with those of the neighbouring parts. After the removal of the tumour, therefore, a sufficiently clear diagnosis is generally possible, so far as the distinction between Sarcoma and Carcinoma is concerned. From the other tumours of the connective tissue group, it is only distinguished according to Professor Virchow "by the predominant development of the cellular elements" (Virchow, *Op. Cit.* Vol. II. p. 177); and according to M. Knapp, "the only difference" (between Glioma and Sarcoma) "is that the small cells of Glioma are implanted and grow immediately upon the tissue of the organ on which the neoplasm is produced, without the interposition of connecting elements (*elements conjunctifs*), and that the neoplasm that results from this proliferation, is even less circumscribed than the Sarcoma."* This distinction,

* See Report of Dr. Knapp's Remarks at the Ophthalmological Congress at Heidelberg for 1868, in *Annales d'Oculistique*. Tome LX. p. 228, *et seq.*

however, will appear to most persons, as of so fine impalpable a kind as to be valueless, or at least somewhat difficult to appreciate. Professor Virchow himself acknowledges, when speaking of tumours in the brain-substance, that "the distinction of Gliomes and Sarcomes presents great difficulties, because the actual transitions are tolerably frequent, and it is, in many cases, *very arbitrary* to choose the groups in which to place the tumour. The softer the tumour, and the more it abounds in cells, the more doubtful becomes the classification."*

Hence it is convenient, in reference more particularly to tumours of the orbit, to use the term Gliosarcoma, signifying thereby tumours partaking of the characters of Glioma and Sarcoma: but the fact of a tumour having originated in the Retina, or optic nerve, (if its origin can be ascertained) will justify us in calling it a Glioma or Gliosarcoma, provided its structure warrants such a designation, while, if it has originated in the choroid, or in the orbitar cellular tissue, it may be looked upon as a Sarcoma.

While the growth remains intraocular and after it has invaded the globe, some light may be thrown on its nature by ophthalmoscopic examination, and the existence of a post ocular tumour of some kind may be inferred, when the optic nerve has the peculiar appearances of descending Neuritis, and especially if it have the characteristic swelling known as "Stauing's Papilla," and if, at the same time, there is exophthalmus and limitation of the movements of the eyeball.

In forming a diagnosis, the age and general appearance of the patient, and the slowness or rapidity of growth of the tumour will all have to be taken into account.

* In *Pathological Transactions*. Vol. XVIII. pp. 229 and 231, Mr. Hulke gives the following description of the cellular elements in a case of Sarcoma and a case of Glioma.

I.
SPINDLE-CELLED SARCOMA OF THE
CHOROID.

"The anatomical elements of the tumour were spindle cells averaging $\frac{1}{4300}$ " in their short diameter by $\frac{1}{2150}$ " to $\frac{1}{1433}$ " and more in length. These were closely crowded in a scanty fibrillated intercellular substance, in some parts without definite arrangement, and in others disposed in linear series.

II.
GLIOMA OF THE RETINA.

The histological elements were small, round, roundly-oval and spindle-shaped cells ranging from $\frac{1}{4300}$ " to $\frac{1}{2730}$ " in diameter with one or a couple of minute nuclei, and a finely-granular cytoplasm; and these cells were embedded in a scanty intercellular substance, homogeneous finely granulated, or obscurely fibrillated.

The *prognosis* of this group of tumours will, in great measure, depend upon the stage at which treatment has been adopted. If the tumour be removed at an early stage, the probability is in favour of its not recurring, especially if it is of tolerably firm consistence and can be completely detached from the parts adjacent. If, on the other hand, it has been attacked at a later period when the growth has become softer and inclined to fungous protrusion, there is a greater probability of its recurrence and of its infection of the surrounding or distant organs.

The *etiology* of Sarcoma is somewhat obscure. Many Fibroplastic growths have been attributed to traumatic causes—others seem to be congenital. Gliosarcoma is very frequently seen in young children, and one or two cases have been recorded of the occurrence of this disease in several children of one family. Hence it may be concluded that some hereditary taint has a share in its production, or at any rate predisposes the patient to the disease.

Treatment. Simple Fibroplastic tumours of the harder kind may be removed by the knife, and have often been successfully treated in this way, without recurrence, if the eyeball is the primary seat of the growth, or if it has become subsequently involved, it should be removed with the tumour.

In the treatment of the softer, and more rapidly spreading kinds of Sarcoma, the early removal by the knife should be supplemented by the application of the Chloride of Zinc paste to the wound. In several instances recently recorded by the surgeons of the Middlesex Hospital, this treatment has been attended with great success, and in all cases in which the surrounding bones are involved, and in all those in which the usual instruments could not reach the outer limits of the disease, this method should be employed. The pain occasioned by its application can be mitigated by the administration of opium or morphia given subcutaneously.

The same treatment will be more particularly applicable to tumours of a mixed form, Sarcoma and Carcinoma.

CASES OF FIBRO-SARCOMA.

The following case is quoted by M. Demarquay from the practice of Mr. Quain, as an instance of a fibroplastic tumour. (Demarquay, *Tum. Orb.* p. 439—40.)

Case I. A Fibrous tumour of the orbit accompanied by similar tumours on the opposite side of the head, on the dura mater and the pleura costalis, under the care of Mr. Quain. This tumour was removed from an infant of 6 years of age admitted into University College Hospital Nov. 29th, 1853. Three months before, the child had received a blow on the left eye, by which vision was impaired during 3 days only. On admission the eyeball was very prominent

and formed a hemispherical mass; the conjunctiva and cornea were both opaque. The tumour was removed on December 3rd; it was of the size of a walnut and spheroidal in shape, firm in texture, lobulated, slightly vascular and of a grey-yellow colour. A section of the tumour presented a smooth and homogeneous aspect, except in the centre, which was white and more fibrous. Examined microscopically, a fibrillated texture was found, with little cellular tissue, a certain number of nuclei with masses of nucleoli. These nuclei had various shapes.

The tumour soon recurred in the orbit and was again removed. It again reappeared and at the same time another formed on the right temple and covered the parietals, temporals and a portion of the frontal. Before the patient's death the tumour measured seven inches in depth and an inch and three quarters in breadth; it was round and lobulated, at its hinder part the skin covering it was tuberculated; it bled on one occasion but showed no tendency to ulceration. The child died at the end of October, two years after the commencement of the disease. After death the secondary tumours were examined and the microscopic characters were similar to those of the principal tumour. The tumour seemed to be intimately united to the periosteum and occupied the frontal sinuses and was also attached to the dura mater of middle fossa of the brain. One portion of the same material 3 inches long, was found on the pleura costalis of the right side.

The most important points of this communication are the reproduction of the tumours, *the absence of so-called cancer cells*, the tendency to infiltration, and the formation of secondary tumours in other parts.

The case following is also one of Fibro-sarcoma reported by Mr. Hulke in the Ophthalmic Hospital Reports Vol. V. p. 345.

Case 2.—A girl, æt. 18, came to the Royal London Ophthalmic Hospital June 6, 1866, with a swelling in the situation of the lachrymal sac. She said that five weeks before, after exposure to cold, the right side of her face had become red, swollen, and shining, and that for two years previously she had been troubled with epiphora.

The history was that of cystitis following obstruction of the nasal duct, and the swelling, at a cursory glance, was not unlike a distended lachrymal sac. It was, however, incompressible, and its contents could neither be squeezed away into the nose nor did they regurgitate through the lachrymal puncta. This led me to examine it more carefully. It was evidently closely connected with the inner wall of the orbit. Its surface was even, and its outline oblong. Its upper border, above the tendo oculi, was indefinite, and its lower end, in the form of a free, round knob, reached to the junction of the inner and middle third of the lower margin of the orbit. The swelling was elastic, but harder than most cysts. The skin did not adhere to it, and there was not any œdema of the neighbouring tissues.

From the solid feel and lobular form of the swelling, I suspected a new growth; but two of my colleagues were disposed to regard it as a mucocele of the lachrymal sac. The Royal London Ophthalmic Hospital

being full, I sent the patient into the Middlesex Hospital, placed her under chloroform, and to put the question of sac beyond doubt, slit up the lower punctum and canaliculus into the sac, and then passed a large probe through the nasal duct into the nose. The passage was pervious, no pus or mucus escaped, and the size of the swelling was not changed. The diagnosis being thus confirmed, I dissected out the tumour which sprang from the periorbita behind the sac, sparing the conjunctiva which it had not implicated, when the slight bleeding had quite ceased, and coated the nasal side of the wound, where the base of the tumour had been attached, with the chloride of zinc paste spread on small pieces of lint, the dry surfaces of which were turned towards the conjunctiva which was further protected against the caustic by a little charpie. The conjunctiva and eyeball with its muscles were not injured by the caustic, the eschar exfoliated, the wound healed soundly, and during the time the patient remained under observation there was no sign of recurrence. The histological characters of the tumour were those of a spindle-cell sarcoma.

In the next case, though no microscopic evidence is given, the appearance of the tumour on section and its position leave little doubt that it was a Fibro-sarcoma. It is remarkable from the occurrence of cysts containing pus, in the tumour.

The case was reported in the Brit. Med. Journal for January 18th, 1869.

Case 3. Fibro-plastic tumour of the rectus oculi in a child, by J. Vose Solomon, F.R.C.S.—A little boy aged 4, was sent to me in May 1867, by Dr. Malins of Cradley. I found a tumour of the size of a small hazel-nut, occupying the site of the external rectus muscle of the left eye, and extending under the outer wall of the orbit. It was hard, painless, smooth, and apparently adherent to the sclera. The mother's attention was first attracted to the eye some two or three months previously to her attendance at the hospital. The child's health was, and had been, good. Of local injury, there was no history.

On June 3rd, I proceeded to the removal of the growth, chloroform anæsthesia having been efficiently induced by Mr. Henry Denne, our house-surgeon. The tumour now proved to be free from conjunctival and scleral adhesions, yet was only slightly moveable, so tightly was it bound to the globe. It was of greater width than the rectus muscle.

Operation.—An incision was made over the centre and in the direction of the fibres of the abductor down to the surface of the swelling. Failing to discover any muscular fibres, which, had they been present, would have been carefully preserved, I at once detached the anterior insertion of the muscle, and reflected back the tumour which was contained in the sheath of the former. Rather forcible traction and curved scissors were needed to remove the end which lay under the osseous orbit. More than one-third of the rectus was involved in the mischief.

The wound in the conjunctiva having been sutured, the globe was

fixed by the same agency to the outer canthus. A portion of the inner rectus was afterwards excised, with a view to balance, if possible, the shortened and enfeebled abductor.

The child returned home in nine days cured; a moderate amount of convergence, and a slight enlargement of the pupil, being the only unfavourable results of treatment. The globe could be brought to the centre, but no farther.

On section, the tumour was found to be of very firm consistence, white, and uniform in structure; near to its centre and ocular side were two cells or cysts, which contained yellow pus.

In six months after the treatment, the appearance of the eye was the same in all respects as on discharge.

In Sichel's *Iconographie Opth.* a case of Cancer Fibreuse is related, (p. 721) and a fig. given. Pl. LXXIV. From the history of the case and the description of the Tumour it would probably come under the head of Fibro-sarcoma.

Case 4.—(Sichel *Icon. Oph.*, p. 721. and Pl. lxxiv. Fig. 2.) A farmer, æt. 23 yrs. of sanguine temperament and vigorous constitution had had exophthalmus for 8 years in the left side. Vision had become gradually lost without pain. The Tumour was punctured but only a few drops of blood and colourless liquid escaped. Breschet extirpated the Tumour; the wound healed and the patient was cured in a few weeks.

The mass removed consisted of two distinct parts, the compressed eyeball atrophied and soft, and behind it a bulky soft and reddish tumour. . . . On making a section in its greatest diameter, the scalpel penetrates a soft, pultaceous mass exactly comparable to the tissue of the Testicle and homogeneous. "This mass examined by the microscope resembled *Fibrous cancer* more than encephaloid." The outer envelope of the Tumour was a fibrous cyst with a smooth inner surface easily separable into two layers. The material of which the tumour was composed, was of a yellowish red colour and very soft and perfectly homogeneous except on the surface where a few fibrous knots were seen at intervals. Submitted to maceration in water it divided into extremely fine floating fibres.

CASE OF MYXO-SARCOMA.

Case 5.—(Virchow *Op. Cit.* Vol. II. p. 255.) *Metastatic Sarcoma with round Cells (Myxo-Sarcoma Globo-cellulare) of the Parietal Bone and Orbit.*—A man-servant, æt. 25 years, was lifting a very heavy weight in march 1859, when he felt a violent pain in his loins and back of the neck, and a stitch in the side on inspiration. These symptoms disappeared in October; but towards Whitsuntide, after distracting pains in the course of the infra-orbital nerve, a protrusion of the left eye came on.

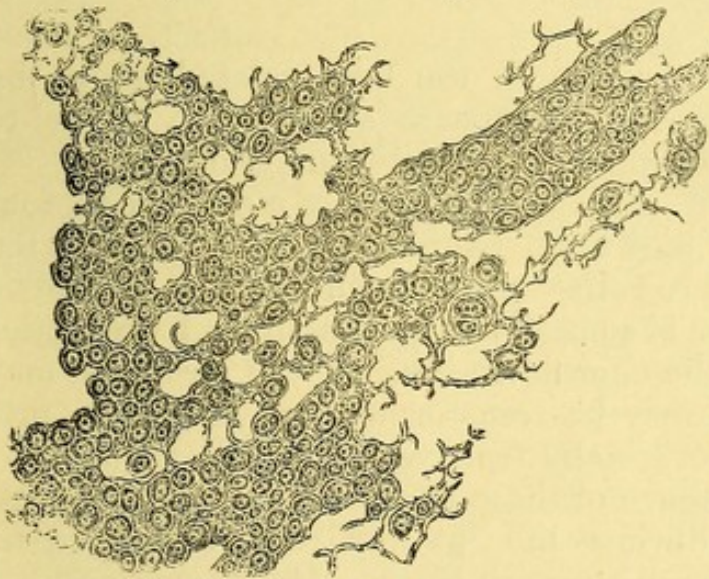
The tumour rapidly increased; the man nevertheless could, in the month of August, still read large letters. Punctures were made, but without effect and in November the eye was extirpated together with the tumour situated behind it. But soon after a soft, fungating,

almost fluctuating tumour was developed, which soon made its way through the palpebral fissure and extended as far as the Temporal Region.

At the same time retention of urine and a tumour at the sternal notch showed themselves,—distracting pains came alternately in the arms and legs—first pains in the left arm with flexion of the hand—numbness and a sensation of paralysis—then pains and paralysis of the left leg—after that of the right arm and right leg. In December the pains in the face ceased, but others came in the kidneys and were increased at each movement. For two days he had incontinence of urine and fœces. Lastly, tumours appeared at the root of the nose and the right parietal eminence, and one day the patient broke the head of the left humerus. Fever supervened and wasting, and death on Jan. 9th 1861. The autopsy discovered a Myxo-Sarcoma of the 11th, and 12th dorsal vertebræ, of several ribs, of the two parietals, of the sternum and left arm, and besides a large fungating tumour of the orbit protruding into the cranial cavity.

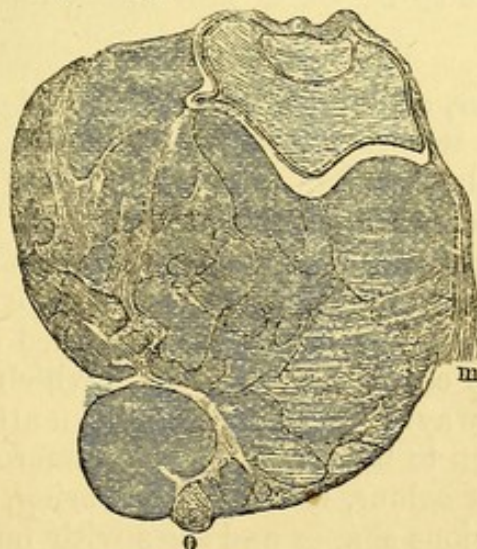
GLIOSARCOMA.

Case 6. (Virchow Vol. II. p. 269.)—The accompanying phototype en-



gravings are copied from Virchow. They illustrate a case of lobed small celled, Gliosarcoma, developed in the adipose cellular tissue behind the eyeball, but around the optic nerve *o* from which it appears to spring. The cornea *c* is seen to be crumpled, behind it the eye atrophied, entirely collapsed. The muscles of the eye *m* are found in front of the tumour.

Virchow on Tumours. Fig. 138, p. 208, Vol. II.]



Virchow on Tumours. Fig. 148, p. 270, Vol. II.

A case reported in the *Ophthalmic Hospital Reports*, Vol. VI. Pt. ii., p. 171 ; as occurring in the practice of Prof. v. Graefe is probably the same as one alluded to by Virchow (Vol. II. *Op. Cit.*, p. 382 note).

Case 7.—A girl of 5 years of age was to all appearance in good health with the exception of an orbital tumour. The Tumour was removed by M. v. Graefe and “at the autopsy a gliosarcoma almost as big as the fist was found in the corresponding cerebral hemisphere, which extended from the fissure of Silvius to the anterior corna, thrust back the great ganglionic centres, and had swollen the Sella Tuncica to three times its natural size.

The tumour had extended uninterruptedly from the hemisphere to the Sella Tuncica, had filled the sub-arachnoid space as far as the optic foramina had penetrated the orbit with the left optic nerve and had produced exophthalmia. The case presents this remarkable peculiarity, that the wound in the orbit (made in extirpating the orbital portion of the growth) was the starting point of an acute suppurative inflammation with the *formation of abscesses in the tumour* ; proving thereby that sarcomatous tissue is susceptible of suppuration.”

This same point is shown also in the case related above by Mr. Vose Solomon, though in that case suppuration seems to have occurred quite independently of any traumatic cause.

MELANOSARCOMA. As a separate form of melanotic tumour and as distinct on the one hand from melanoma or encysted melanotic tumour, and on the other form melano-carcinoma or true melanotic cancer is sometimes met with and originates for the most part in the choroid or iris. These growths may be very malignant and may be transformed by metaplasie into cancers without being originally true cancers. M. Demarquay considers that the existence of these two kinds is not satisfactorily proved, and that during life, at any rate, there are no signs which enable us to distinguish them. He however quotes a case which seems to be of a non-malignant kind. (*Op. Cit.* p. 457.)

Case 8.—A farmer, at. 51 years, lost the sight of one eye with exophthalmus 25 years before the time of coming under observation. The protrusion of the eye had receded under the use of Iodine but had on two subsequent occasions returned. At length Mr. J. B. Fife extirpated the tumour and the whole contents of the orbit.

The tumour on section was as black as coal, covered by a cellular envelope which dipped down into it and divided it into lobes ; it was soft and consisted of cellular tissue, from which the pigment could be easily washed away. The pigmentary matter, examined by the microscope, was seen to be made up of numerous organic granules of a brownish black colour, isolated or cohering, so as to form granular cells of very various shapes and sizes with numerous oily globules

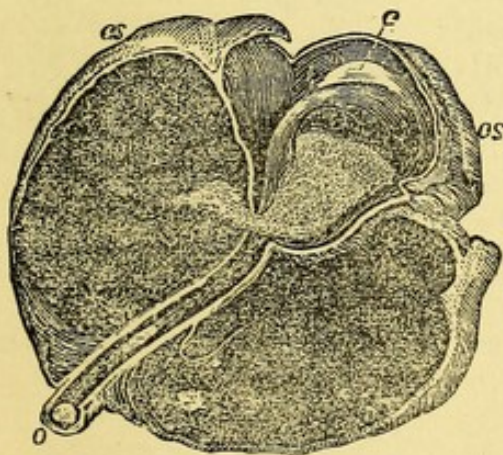
&c. There were, besides, cells of variable dimensions with thick walls, of a brown black colour, slightly transparent and containing in their interior numerous black granules and here and there their nuclei. These last appeared to be only colourless cells transformed by growth and the formation of pigment peculiar to melanosis. The patient was reported as perfectly well three months after the operation."

A case fully reported by Mr. Hulke in the *Ophthalmic Hospital Reports*, Vol. V. p. 181, was of like kind and illustrates well the advantage of the method of operating with the aid of the actual Cautery and Chloride of Zinc Paste.

Case 9.—"The tumour consisted mainly of large spindle cells, and circular and roundly-oval cells filled with pigment, closely packed in a scanty, finely-granulated, intercellular substance. . . . It appeared to have begun in the choroid which in parts was infiltrated with similar cells, and in parts wasted; then to have rapidly infected the sclerotic which was also infiltrated, and at an early stage to have escaped from the shrunken eyeball and enveloped it within its increasing mass. The optic nerve immediately outside the sclera was shrunken; behind this point it was not traceable."

Orbital melanosa, however, according to Virchow, most likely originates in some cases in the fatty tissue of the orbit. A specimen figured in his work on Tumours shows a tumour chiefly occupying the post-ocular region but also invading the interior of the eyeball.

Case 10.—"The tumour of large size is situated behind the eyeball, surrounds the optic nerve and is in contact with the sclerotic at all points.



It consists of several lobes with a thick capsule, and in the interior of these lobes is found a soft fibrous mass chiefly black, containing small white portions, and consisting almost entirely of fusiform cells closely interwoven one with another. The lightest parts reach to the entrance of the optic nerve, the sheath of which is much thickened, and encloses, outside the white cord, a layer of black


tissue. Beyond the entrance of the optic nerve the tumour advances into and almost fills the posterior segment of the eye; it is for the most part dirty grey, or greyish brown, patch, and at its anterior part almost all black; it has already begun to form an adhesion with the margin of the cornea and it also contains principally fusiform cells. *It is only in contact with the choroid at one point, quite close to the optic nerve; this membrane is elsewhere fairly normal both as to situation and aspect.* The Retina on the contrary is intimately in-

volved in the tumour. It seems clear in this case that the intra-ocular tumour is only a secondary growth of the primitive orbital tumour."

OSTEO-SARCOMA OR SPINA VENTOSA occurs in two forms, recognized both by Sir A. Cooper and by Prof. Virchow, viz. the Periosteal and Medullary. The former springing from the periosteum and the latter from the medulla of the bone affected. In the former the bony framework of the tumour persists as radiating or tuberosus prolongations from the bony base; in the latter, a mere thin osseous shell is all that remains and this even may be replaced in parts by fibrous membrane, so that the soft sarcomatous tissue can be felt through the outer shell. Some of the myeloid tumours of bone, (*i. e.* those containing large multinuclear cells) belong to this group and are named by Virchow, Sarcoma Giganto-cellulare. As with other forms of sarcoma, infection of the lymphatic glands and of distant organs sometimes occurs and this property has earned for it the name of Malignant Fungus (Muller); M. Demarquay regards osteosarcoma as a true cancer.

Virchow considers that they are not necessarily malignant.

The cases recorded as invading the orbit from neighbouring bones are numerous. I have myself seen several, the history and progress of which pointed clearly to the diagnosis of osteosarcoma, but the microscopic structure has not been ascertained.



Case 11.—The old man whose portrait is here represented was in

1869 under my care at the Central London Ophthalmic Hospital, with a growth in the right supra-orbital region, which most probably belongs to the osteo-sarcomatous group. He was 66 years of age and had the appearance of great cachexia. The tumour which is of about 10 months growth is of the size of a bantam's egg, soft and quasi-fluctuating, and occupying the superciliary region and upper part of the orbit. At a little to the outer side of the centre there is a hard, evidently bony, plate of the size of a shilling, with ragged edges, which can be felt immediately beneath the skin and floating, as it were, on the surface of the tumour. The eyeball is protruded about $\frac{1}{4}$ inch. Sight is not very much impaired. He only occasionally suffers pain. The skin is not discolored but the lids are œdematous. The tumour has several times been punctured but no fluid has escaped except a few drops of blood. Acetic Acid has been injected into the middle of the tumour on two occasions but without either increasing or diminishing the size of the growth. It has however caused great pain and therefore has not been again used. In the absence of any inspection of the tumour it is uncertain whether its nature is sarcomatous or encephaloid, but my opinion is inclined to the former supposition. He died about Oct. 10th, 1869.

The following case (reported by Mr. Hulke in the *Ophthalmic Hospital Reports*, vol. iv. p. 98) is a good example of Sarcoma of a malignant type, or, possibly, of mixed Sarcoma and Carcinoma.

Case 12.—Sarcomatous Tumour, at first apparently of an innocent nature, but afterwards putting on a cancerous character and invading the orbit from the left nostril.—A feeble, very emaciated old man, æt. 70, came to my out-patient room at the Middlesex Hospital, early in April, 1862. The inner half of the lower, and inner third of the upper lid of the left eye were distended with a solid tumour. The skin was glued to it, dull-red, tense, and shining, which also interrupted the inner commissure. The eyeball was about $\frac{1}{4}$ " in advance of the other, and its movements were very restricted. He had just enough sight to find his way about, but old nebulæ and senile cataract prevented any estimation of the degree in which the impairment was due to the pressure which had thrust the eyeball from its position. His other eye had been blind many years. A slightly tender lymphatic gland about the size of a horse bean was felt at the angle of the lower jaw, on the left side. There was frequent epistaxis from the left nostril which was nearly blocked.

He told me that the year before, in May, my predecessor, Mr. Flower, had extracted a polypus from the nostril, and that this was attended with such profuse bleeding that he fainted, and could not leave the Hospital for several days. In the following August he returned, with swelling (protrusion?) and redness of the eye. On this occasion no operation was done, and he left after a few days to be re-admitted on the 20th October under the care of Mr. Moore, who slit up the nostril (dividing at the same time the inner commissure

of the eyelids), and removed a very considerable fleshy mass. This was also attended with very free hæmorrhage.

The characters of the tumour, Mr. Moore informs me, were those of simple sarcoma, and its minute structure led to no suspicion of cancer.

By the end of April a very appreciable increase of the tumour was noted. The distension of the eyelids, particularly the lower lid, was much greater. A prominent knobby mass filled the space between the lower eyelid, the root of the nose, and the eyeball. The surface of this mass was ulcerated, and exuded a thin, almost colourless, foetid ichor. The palpebral conjunctiva was swollen and red. The obstruction of the nostril had become complete. May 1st.—Having become very reduced by frequent bleeding from the left nostril, he was again taken into the Hospital. The ulcer was spreading along the edges of the eyelids, and it bled more readily when touched than before. 6th.—The increased distension of the lower eyelid had now pushed it away from the eyeball, and slightly everted it. The exposed conjunctiva formed a thick fleshy-red roll, which nearly reached the lower border of the cornea. The proptosis was greater, and, partly from the upper displacement of the eyeball, partly also from the distension of the upper lid, the cornea was almost entirely buried by the lid. The inner end of the lower lid having lost its fixed attachment, the lid was widely separated from the globe by the growing tumour. The fleshy roll of exposed conjunctiva was coarsely granular and coated with a muco-purulent exudation. The ulcer continued to extend; its edges were raised, sinuous, somewhat rounded, but not hard; in its neighbourhood the tumour felt soft and elastic, but at some distance from it, harder. The gland at the angle of the jaw had become larger and softer. At the attached border of the lower lid the tumour merged without distinct limits into the cheek which was œdematous and brawny beyond the hardness of the tumour, as far as the lower border of the malar bone. Acute pain was felt in the left temple and cheek, which were hyperæsthetic.

28th.—A steady increase of the tumour was again noted. The inner half of the lower and inner third of the upper lid were destroyed by ulceration. The cheek was more swollen. The gland in the neck still larger and softer.


In June, Mr. Moore attempted the destruction of the tumour with chloride of zinc (having been encouraged to this by the success which had shortly before obtained by this mode of treatment in a case of epithelioma of the lids invading the orbit), but its growth outran its death, and the caustic was laid aside. By the middle of September the orbit was a large ragged hole lined with fleshy fungoid masses, and discharging a horribly foetid ichor. The soft parts for some distance around the orbital margin and much of the left cheek were involved in the tumour.

The infiltration continued to extend, always keeping in front of the ulceration. From time to time slight hæmorrhage took place. The gland in the neck became very soft, the skin broke, and a characteristic cancerous ulcer formed here. The patient lingered till January,

1863, when death ended his sufferings. For several weeks he had taken no notice of those around him, unless spoken to.

On examining the body, the tumour was found to have broken into the cranium through the roof of the orbit and cribriform plate of the ethmoid bone, and to have invaded the anterior lobes of both cerebral hemispheres for some depth. The left optic nerve in the orbit was lost in the cancer, whilst its intracranial portion had a natural appearance. The right optic nerve, that of the eye which had been many years blind, was soft, reddish grey, and shrunken. The liver contained a single cancerous tuber; no secondary cancerous depôts were formed in any other organs.

A case which occurred in my practice at the Central London Ophthalmic Hospital, may also be regarded as a of sarcoma taking a malignant course, and perhaps indeed as containing elements of a carcinomatous character.



Case 13.—J. R. æt 61 years, was first placed under my care by my colleague Mr. Taylor in July 1866. The appearance of the patient at that time is represented by the accompanying woodcut.

In the autumn of 1865 he had severe and troublesome bleeding from the nostrils for which plugging was resorted to. This recurred several times and was not at that time associated with any swelling of the nose or cheek, nor was his general health at all impaired then or previously. In the early part of 1866, however, he noticed a swelling at the inner canthus of the left eye, and an obstruction of the left nostril. The eye began to protrude and a tumour was felt in the orbit below the eyeball.

In August 1866 the whole of the left cheek was enormously swollen, the nose thrust over to the right side, the left nostril completely occluded by a polypoid growth, and the left eye protruded an inch in front of its proper level.

About the end of September the upper part of the cheek became discolored, reddened, tense and shining, and in a short time ulcers formed, from which a thin puriform discharge escaped and later on (in November) some bleeding occurred.

Another surgeon under whose care he came at about this time, injected the tumour within the cheek with acetic acid solution in the manner recommended by Dr. Broadbent. This operation was repeated at intervals of a few weeks and had the effect of setting up softening and suppuration of the tumour, a copious and most offensive pus escaping through the socket of one of the teeth of the upper jaw, and also from the sinus between the gum and cheek.

This patient died exhausted in March 1867, and unfortunately no post-mortem examination could be obtained.

