

## **Lectures of the diseases of the eye / by Charles Bell Taylor.**

### **Contributors**

Taylor, Charles Bell, 1829-1909.  
Parsons, John Herbert, Sir, 1868-1957  
University College, London. Library Services

### **Publication/Creation**

London : G. Redway, 15, York Street, Covent Garden, 1888.

### **Persistent URL**

<https://wellcomecollection.org/works/mhapk6sq>

### **Provider**

University College London

### **License and attribution**

This material has been provided by This material has been provided by UCL Library Services. The original may be consulted at UCL (University College London) where the originals may be consulted.

This work has been identified as being free of known restrictions under copyright law, including all related and neighbouring rights and is being made available under the Creative Commons, Public Domain Mark.

You can copy, modify, distribute and perform the work, even for commercial purposes, without asking permission.



Wellcome Collection  
183 Euston Road  
London NW1 2BE UK  
T +44 (0)20 7611 8722  
E [library@wellcomecollection.org](mailto:library@wellcomecollection.org)  
<https://wellcomecollection.org>



**LECTURES  
ON DISEASES OF THE EYE.**

---

BY

**CHARLES BELL TAYLOR, F.R.C.S. & M.D. Edin.,**

FELLOW OF THE MEDICAL SOCIETY OF LONDON;

LATE PRESIDENT OF THE PARISIAN MEDICAL SOCIETY;

CONSULTING OPHTHALMIC SURGEON TO THE NOTTINGHAM UNION HOSPITAL;

CONSULTING OPHTHALMIC SURGEON TO THE MIDLAND INSTITUTION

FOR THE BLIND; HONORARY SURGEON TO THE NOTTINGHAM

AND MIDLAND EYE INFIRMARY, ETC., ETC.



11



Digitized by the Internet Archive  
in 2014

# LECTURES

ON

## DISEASES OF THE EYE.

BY

CHARLES BELL TAYLOR, F.R.C.S. & M.D. Edin.,

FELLOW OF THE MEDICAL SOCIETY OF LONDON;

LATE PRESIDENT OF THE PARISIAN  
MEDICAL SOCIETY.



LONDON:

G. REDWAY, 15, YORK STREET, COVENT GARDEN, W.C.

NOTTINGHAM: STEVENSON, BAILEY, AND SMITH, PRINTERS.

1888.



1815095

# CONTENTS.

---

## LECTURE I.

CATARACT.

---

## LECTURE II.

SQUINT.

---

## LECTURE III.

GLAUCOMA.

---

## LECTURE IV.

OPTICO-CILIARY NEUROTOMY.

---

## LECTURE V.

THE USE AND ABUSE OF MYDRIATICS.

---

## LECTURE VI.

EYE TROUBLES IN GENERAL PRACTICE.



THE following Lectures to Students and Practitioners delivered at the Nottingham and Midland Eye Infirmary, were subsequently published in "THE LANCET," and are now reprinted by request.

C. B. T.

# Clinical Lectures on Diseases of the Eye.

---

## LECTURE I.

---

### CATARACT.

GENTLEMEN,—The female patient you have just seen is sixty-five years of age, blind from cataract in both eyes, and exceedingly deaf. The male patient is a labouring man, toil-worn, weather-beaten, and seventy-five years of age. He has been blind some months from cataract in the left eye, and the right is dim, although he can still see to go about with it. I saw these patients for the first time this evening, and propose to operate at once, using artificial light; before doing so, however, permit me to comment upon several questions which have arisen in connection with these and other similar cases.

What is Cataract? Cataract is an opacity of the lens. How is it that so many aged persons suffer from cataract? Well, I suppose we must look upon cataract in aged persons as one of the natural phenomena of life — the culminating point in that process of hardening, shrinking, and degeneration which the lens undergoes in common with other tissues as we grow older, and which seems natural to us all. When, for example, an average individual attains the age of forty and upwards, he requires glasses. Why is this? Simply because the lens has become too hard to fulfil its usual function



in the process of accommodation for near objects. As time passes on, this—shall I call it natural sclerosis?—increases, until in certain cases the normal relationship of the lens fibres is so changed that it becomes opaque; the patient cannot see, and the surgeon cannot illuminate the fundus of the eyeball: that is cataract. The lens has become opaque, and, so far from assisting vision, constitutes an actual obstruction to the passage of the rays of light. Would it be possible to restore the transparency of the lens? What a momentous question! As well ask, would it be possible to restore youth? And yet there is no doubt that by judicious treatment the progress of senile cataract may be retarded. I have seen benefit from electricity, and quite marvellous results, in certain cases caused by accident, or complicated with gout, diabetes, and albuminuria. In both these patients, however, the lens is quite opaque—the cataract is fully formed. There is no possibility of any clearing up. The obstruction must be removed, and this can only be done by operation. What operation shall we perform? Will any surgical procedure short of actual removal of the lens from the organism—that is extraction, as it is called—suffice? I fear not. If we attempted in either of these cases to disintegrate, macerate, and dissolve the lens *in situ* by repeated needle operations, we should in all probability only excite iritis, to which aged persons are especially liable. Very likely the inflammation would prove uncontrollable, and we should be driven to extract at last under far more unfavourable conditions than exist at present. Would it be wise, in obedience to the ancient precept, “Squamam in oculis emovendam potius quam extrahendam,” to attempt to depress the lens, dislodge it from the axis of vision, and thus permit the reproduction of images upon the



retina? I do not think so. The lens is apt to rise again, or act with all the pernicious influence of a foreign body in the vitreous chamber; so that, although I am not at all disposed to deny that such an operation may be occasionally successful, the risk is too great, and I should not dream of attempting it in either of these cases.\*

It is clear, therefore, gentlemen, that our only resource is extraction. What is the best method of performing extraction? In order that you may appreciate this question it will be necessary to glance at the history of the operation, which may be said to have commenced in 1752; for although, as the quotation from Pliny just cited proves, there can be no doubt that a method of extraction was known to the ancients, it was not until that date, when Daviel presented his classic memoir to the French Academy, "Sur une nouvelle Méthode de guérir la Cataract par l'Extraction," that the actual removal of the lens from the eyeball assumed its proper place as a recognized operation in contemporary surgery. Daviel operated while seated himself and facing his patient, who also occupied a chair on a lower level. He used a lance-shaped knife, and incised the lower half of the circumference of the cornea, delivering the lens through the natural pupil. When successful, the flap operation, as it is called, left nothing to be desired; but fifteen eyes in a hundred were irrevocably lost, and twenty more so damaged that it is a matter for special wonder that no serious attempt at improvement was made until 1860, when Herr von Graefe, the celebrated professor of Berlin,

\* In illustration of the occasional success attending depression, I may remark that some years ago I extracted cataracts from both eyes for an eminent practitioner of medicine, who had so successfully operated by couching, as he termed it, upon his own brother (a clergyman) that his patient was able to resume his duties as rector of a large parish.



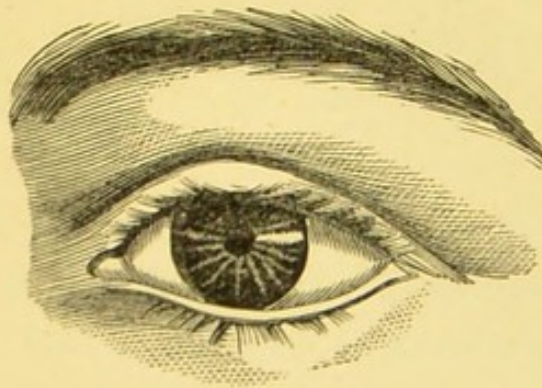
announced, as the result of the daily examination of eyes recently operated on, that the part of the eyeball which took the initiative in the destructive inflammatory process was the portion of iris contused during the exit of the lens, and that this stretching and bruising was consequently the *teterrima causa* of subsequent disaster and loss of sight. Acting on this hint, Mooren, of Dusseldorf, excised the piece of iris corresponding to the flap some weeks before extracting; and Schufte, at that time Von Graefe's assistant, seeing the small proportion of eyes lost after iridectomy—about one in five hundred—simply performed that operation in the ordinary way, and then scooped out the lens with a spoon. Shortly afterwards Graefe published his famous memoir on linear extraction, placing the wound in the plane of the lens entirely outside the cornea. Jacobson, of Königsberg, and Pagenstecher, of Wiesbaden, followed with similar sclerotic incisions both upwards and downwards, the latter removing the lens with its capsule entire by means of a large spoon. I visited Graefe's, Pagenstecher's, and Mooren's clinics at this time in order to study their various methods of operating, and, after careful investigation of the whole subject, arrived at the conclusion that Schufte's incision in the corneal margin was the best, and that it needed but to be slightly enlarged in order to enable us to extract the lens without the objectionable scoop or the use of any traction instrument whatever. After operating in this way with most brilliant success upon a number of cases with an incision combined with an iridectomy, and comprising only one-third of the upper segment of the cornea, I published an account of the procedure in the *Ophthalmic Review* and *Edinburgh Medical Journal*, and it has since been universally adopted as the operation *par excellence* for cataract



by ophthalmic surgeons both at home and abroad. They call it a "modified Graefe," but it is really the operation I described at that time, Graefe's original method having been so completely abandoned that it is now popularly said that nothing remains of it but the knife. I have also endeavoured in certain cases to preserve the pupil, while securing at the same time the advantages of an iridectomy, by excising only the periphery of the iris, leaving the sphincter untouched and free in the anterior chamber—an operation which possesses many advantages both optical and æsthetic, but which is rather difficult to perform. I have here a patient, a lady seventy-five years of age, on whom I operated last week in this way. When the upper lid is in its natural position, the eye, as you see, looks perfect (see Fig. 1); but when the lid is raised the coloboma in the periphery of the iris is revealed (see Fig. 2).

Let us see now, gentlemen, *en résumé*, what the last twenty years have done for us. Graefe discovers, or thinks he discovers, that the bruised iris is the sole cause of disaster;

FIG. 1.

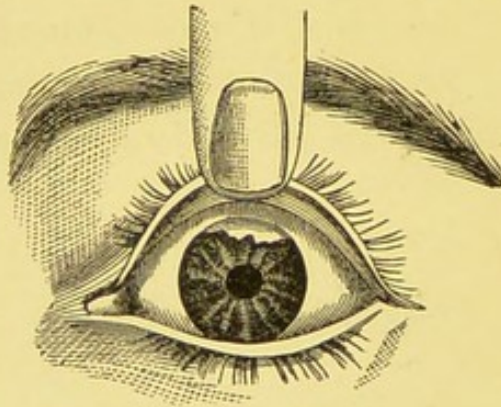


Mooren cuts the Gordian knot by excising the portion likely to be injured; Schufte follows with iridectomy scoop and small incision; Graefe adopts a linear incision entirely outside the cornea; I propose a small flap in the corneo-sclerotic junction;



other distinguished operators place their incision entirely in the cornea. Have we arrived at the *ne plus ultra* of ophthalmic surgery? Must we rest and be thankful, or shall we go back and make a selection from the labours of our distinguished *confrères*, adopting some of their suggestions and rejecting others? Well, it seems clear that modern surgeons are right in abandoning Graefe's linear extraction. The wound is too far back; the danger of prolapse of the vitreous is too great. A vast iridectomy is necessary in order to prevent strangulation of the iris at the angles of the wound. There is great risk of bleeding into the anterior chamber in the early stage of the operation—a most embarrassing complication; and the site of the wound is such as to excite well-grounded fears of sympathetic

FIG. 2.



ophthalmia; moreover, the best results will not bear comparison with those obtainable by flap extraction. The division of the operation into two parts, as in Mooren's method, is so manifestly objectionable, that it is clear that this operation must be reserved for those cases in which it is necessary to perform iridectomy as a preliminary on account of glaucomatous or other complications. The profound anæsthesia insisted upon by Jacobson before operating renders his method too dangerous



for general adoption, and the traumatism and frequent loss of vitreous attending the use of Pagenstecher's spoon will preclude its general use. As to Liebreich's, Lebrun's, and Warlomont's modification of Kuchler's transverse incision of the horizontal meridian of the cornea, these operations all, especially when the lower section is adopted, cause a certain amount of subsequent astigmatism, which prevents our obtaining the best visual results; and the operation I have spoken of as my own, though it appears to me as perfect as any combined method can be, involves, like all the rest, a mutilation of the iris, which leaves much to be desired, and, inasmuch as it is not always necessary, will certainly never be adopted to the absolute exclusion of other methods by which the pupil is preserved entire.

We must always aim, gentlemen, at the highest,—and the highest indication of success in cataract operations is a central and moveable pupil; we may not be able to secure this in every case or even in a very large proportion, but we ought in a certain per-centage, and in order to do so we must adopt what the late Mr. Critchett denominated a method of eclecticism. We must enlarge the wound to four millimetres, or more if necessary; we must bring it forward in the cornea, or place it back in the sclerotic junction, according to circumstances. We must select, not our patients, but our operations, and be guided by each step of the operation what the next step shall be. For instance, I have been asked whether I intended to perform iridectomy in either of the cases now before us. Well, I cannot answer that question at present; the reply in each case must depend on the conduct of the patient, the peculiar nature of the affection, and the size and consistence of the cataract as revealed upon the operating table. If either of our patients

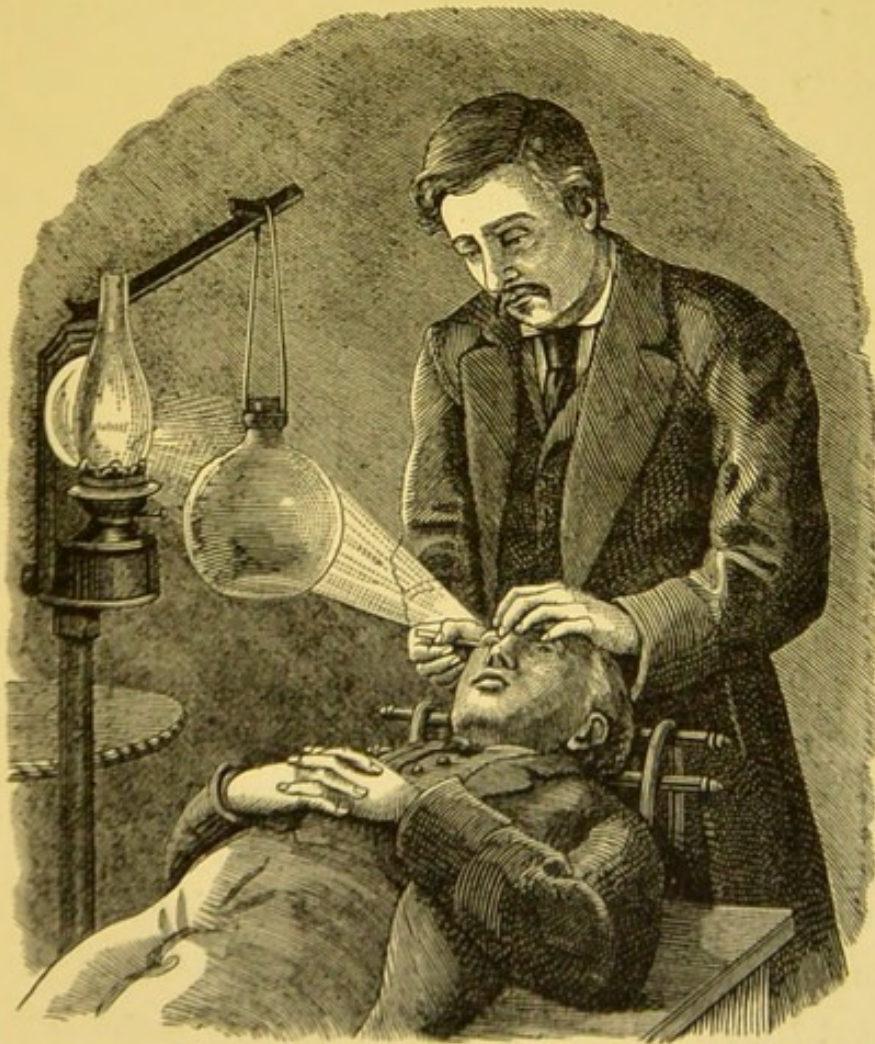


should prove as indocile and as utterly wanting in self-control as the deaf man on whom some of you saw me operate last week, I shall be compelled to excise a portion of iris in order to prevent prolapse. If, on the contrary, the patient gives evidence of a certain amount of self-control, if the lens escapes readily, if its margin is unbroken, if cortical débris come freely away, if the iris is not unduly stretched during the passage of the lens, if it afterwards falls readily into its place and does not display a tendency to prolapse, we may then reasonably hope to preserve a central and moveable pupil. If, however, the lens is delivered with difficulty, if the iris has manifestly been roughly treated, if it is torn, if portions of uvea have been brushed off, if there is a suspicion that particles of lens matter are lurking behind its uncut surface—above all, if it shows a marked tendency to prolapse, we must excise a portion, but always with regret and only to prevent subsequent disaster. You may ask, What advantage do we get by excising a portion of iris? Well, the iridectomy prevents prolapse—that bugbear of the old flap operation; prevents bruising of the iris if done before the operation or before the exit of the lens, and the consequences of bruising if done after; permits more easy exit of the lens through a smaller wound, and also complete evacuation of cortical débris, so apt to be left behind, and cause subsequent inflammatory mischief when concealed behind the uncut membrane. On the other hand, when the iris is excised there is more cut surface, more wound exposed to the danger of infection and suppuration. The dissection of iridectomised eyes shows almost invariably adhesions at the angles of the wound, whatever precautions may have been taken to prevent them; the eye is visibly mutilated; and although the sight of a patient with an up-



ward coloboma is good, there are circles of diffusion, and it is not quite as good as that of a patient with a central and moveable pupil. We shall therefore be guided by circumstances, and save the iris if we can do so consistently with the security of the patient. We shall now proceed to operation. Before doing so, however, permit me to call your attention to the method of illumination which I always use at this time of year. The light is obtained from an ordinary paraffin lamp, and the rays are concentrated by a lens in the shape of a globe of water—a simple apparatus, which may be used without preparation in any cottage or private house, an ordinary water-bottle, held by an assistant, sufficing for the lens. (Fig. 3.)

FIG. 3.





*Remarks after operation.*—I do not know, gentlemen, whether you are aware of the fact, but statistics tell us that a preponderating fatality has always attended operations for cataract upon the left eye. This is doubtless due to the greater difficulty of operating upon the left eye, a difficulty which I have endeavoured to obviate by using a bent knife, which I devised some years ago, and which you noticed, although the left eye was selected for operation, was, in the case of the male patient, held in the right hand. With this knife I would rather operate upon the left eye than upon the right, since the natural tendency of the eyeball to roll inwards, to be pushed before the knife, is in your favour if the left eye is selected for operation, and against you if the right is the subject of extraction. As those of you who were near enough to see remarked, the iris in this case persistently prolapsed after removal of the lens, and I was therefore compelled to excise a portion for safety's sake. With this exception the operation was completed without misadventure. In the female patient, the tendency of the iris to fold over the edge of the blade of the knife was, as you noticed, evaded by a *tour de main*, and the wound so managed as to form a small flap situated in the upper segment of the corneo-sclerotic junction; the capsule was then punctured, the lens extruded, and the operation completed, leaving, in this case, a central and circular pupil. I shall speak directly as to the local anæsthetic which was used and the antiseptic precautions which were adopted throughout; before doing so, however, permit me to answer one or two questions which have been addressed to me. I have been asked whether the male patient's great age did not contra-indicate operation? whether the patients would not have been better for some preliminary treatment? and whether it would not have been desirable to



have administered some general anæsthetic? I will reply to these questions *seriatim*, and first with regard to age. Age *per se* is certainly no contra-indication. Cataract is a disease of old age, and if we did not extract for patients advanced in life we should not operate at all. I was once called to see a gentleman suffering from cataract in his eightieth year, and strongly recommended operation; his wife, however, would not allow him to submit, on account, as she said, of "his great age." Six years later she died; the widower then sent for me, was operated on, and recovered most excellent sight—so good that he was able to complete an archæological work on which he was engaged when his sight first failed. I have operated with perfect success upon both eyes in three patients over ninety, and upon a considerable number between eighty and ninety years of age. Lord Lyndhurst, the then Nestor of the House of Lords, was operated upon in his ninetieth year. The first eye was lost, but, with characteristic courage, he underwent the operation again and recovered excellent sight with the second eye. In fact, the hard senile cataract is more readily extracted than the less mature varieties of the same affection; and although persons of great age are generally very feeble and suffer from various senile affections, this, so far as my experience goes in hundreds of cases, does not seem to interfere very materially with the success of the operation. As to preliminary treatment, no doubt it is of the utmost importance that patients undergoing operation should be in a fair state of health. No doubt preparatory treatment similar to that adopted in the training of athletes would increase our chances of success if it were possible to carry it out, but experience teaches us that directions of this kind are never carried out at home, and admission to hospital only has a depressing effect.



So that I think that the advice to persons about to be operated on may be summed up in two lines :

“ Great temperance, open air,  
Easy labour, little care.”

You cannot train old people ; and beyond this it is difficult to go. With regard to anæsthetics, when I commenced practice it was the custom to use chloroform in almost every case ; subsequently ether was very generally employed ; but for years past I have operated without any anæsthetic, and but for the splendid discovery of cocaine should have continued to do so. Chloroform I found from time to time gave rise to most distressing symptoms of impending dissolution. Ether caused great excitement. Both were followed by dangerous vomiting, and although the latter is incomparably safer than chloroform, the drunken violence both before and after is more dangerous, and I have known it on three occasions to provoke attacks of bronchitis, one of which proved fatal. Cocaine was employed in the cases we are now discussing, and its effects in numbing sensation, without interfering with the intelligent co-operation of the patient, as usual, left nothing to be desired. As to antiseptics, it was formerly believed that suppuration depended on deficient vital power either in the patient himself or the part injured, the degree of traumatism at the time of operation, or accidental injuries afterwards. Now we are assured that every case of suppuration depends upon infection of the wound. To quote the words of De Wecker: “ *Aujourd’hui nous savons que toute suppuration de la cornée est due à une infection de la plaie.*” However that may be, it is certain that antiseptic solutions are a very valuable addition to the resources of the operating surgeon. What is the best antiseptic to use ? Well, bearing in mind the most important of all maxims in surgery,



“Primum non nocere,” I think you will find for general use a saturated solution of boracic acid the best. If you wish to be specially safe against microbes and macrobes, the same solution containing the twenty-thousandth part of a grain of corrosive sublimate may be employed. As to after-treatment—if the slight pain which the patient experiences as the effect of the cocaine goes off does not pass away, but increases, bleed, inject morphia, and apply cold compresses; if suppuration threatens, use hot aromatic fomentations, with pressure bandages and throughout antiseptic dressings. Von Graefe objected to local bleeding for the first three days after extraction—I hardly know why; but when I attended his clinique in Berlin he strongly advised the students to avoid local bleeding for the first three days after extraction, preferring to take blood from the arm. In any way, whatever you do, you must kill the pain. *Obsta principiis*—stop the beginning, and before it begins if possible. I have taken twelve ounces of blood from the temple with the artificial leech myself in one case, and in another used seventy leeches; in both the eye was saved. In spite of every precaution, you will fail sometimes; that cannot be helped. “Time and chance happeneth to all;” but attention to the details to which I have briefly alluded, and which you see carried out here, will so far as possible ensure security to the patient, peace of mind to the operator, and brilliant results in a certain proportion of cases.

Gentlemen, I have invited a few of my patients to attend here this evening in order that you might have an opportunity of seeing the results obtainable by modern methods of extraction. Some of these present a notch more or less conspicuous in the iris, others have central and moveable pupils; these last constitute the perfection of art, since art is to conceal



art, and it would be difficult, if not impossible, for you to say whether they had been operated on or not. I introduced some patients, the subjects of double extraction treated in this way to the notice of the members of the Clinical Society of London in 1878, and have since accumulated quite a number of similar cases. At the next lecture I hope to show you some novel methods of treating external and internal squints.



## LECTURE II.

### ON SQUINT.

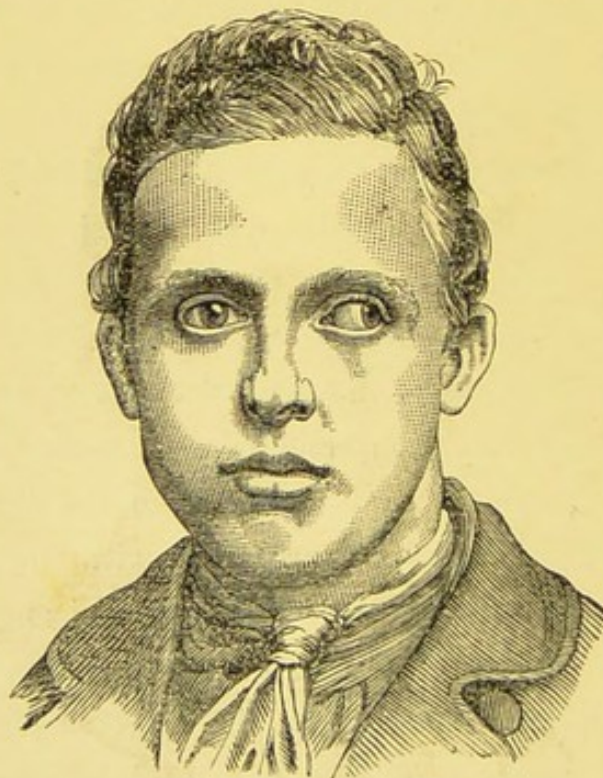GENTLEMEN,—A short time ago a gentleman holding an important official position in a neighbouring county consulted me on account of failing vision in the left eye. The eye of which he complained occupied its normal position in the orbit, but the right presented exactly the appearance depicted in Fig. 3. I said, "Why don't you have your right eye put straight?" "Because," he replied, "I have during the last twenty years on separate occasions consulted three eminent surgeons, and they each tell me that in order to restore the position of the eyeball it would be necessary to divide the external muscle, and that such division would not only aggravate the existing protrusion, but might even let the eye out of the socket altogether." I explained to him that it would not be necessary to interfere with the external muscle at all, and that so far from increasing the protrusion, the replacement of the eyeball would improve vision and restore his good looks.

You have often seen me perform this operation, which admits of rapid execution, and may be undertaken without anæsthetics. I hook up the tendon of the internal rectus muscle, and divide all its connections with the eyeball, pull it well forward, and by two horizontal incisions made with scissors convert it into a narrow strip. I then transfix the base of this strip as far back in the orbit as possible with a large curved needle connected with a thread armed at both ends. Before drawing the thread through I cut off as much of



the tendon as may be considered necessary, and with the remaining needle pierce a small portion of the sclerotic about the site of the insertion of the inferior rectus tendon. Having thus obtained complete control of the eyeball, I turn it inwards to any required extent by simply tying the thread. This method of operation is quite as successful in result as any operation can be; it is scarcely more formidable than the ordinary tenotomy for internal squint; the external rectus is untouched, and only one suture is usually required. Here is a patient operated upon some years ago, who attends to-night in order that you may appreciate the permanence of the results attained. He is, as some of you may remember, one of the subjects whose photograph was reproduced in the *Practitioner* of December, 1883. (Figs. 1 and 2.)

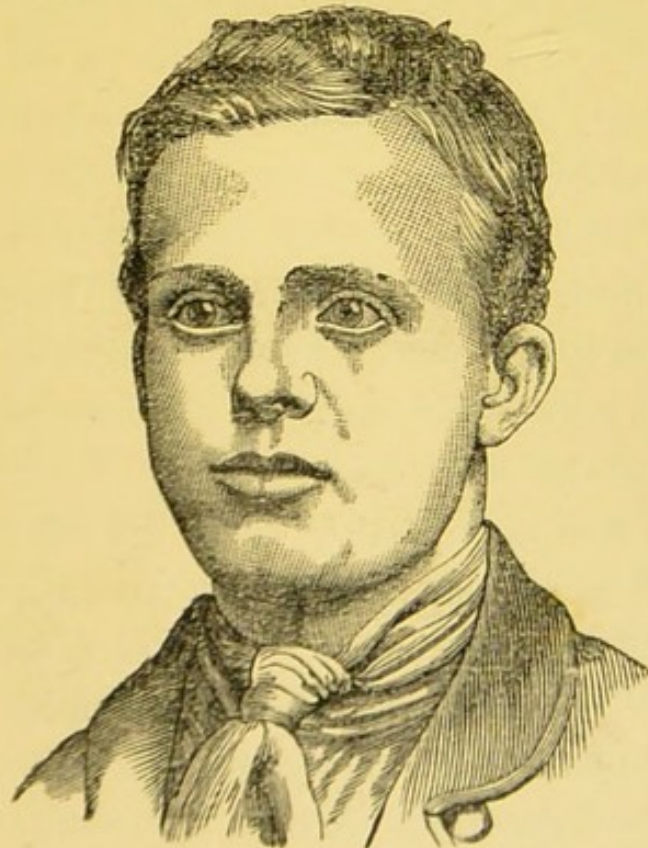FIG. 1.



Before operation.

Cases of external strabismus vary in degree from mere insufficiency of the internal recti muscles to such aggravated examples as those here depicted, and they all admit of relief by operation. Simple tenotomy of the external rectus will suffice to neutralize insufficiency of the internal recti, but such an operation ought never to be undertaken unless the external rectus is sufficiently strong to overcome a prism of  $10^{\circ}$ ; slighter cases may be relieved by appropriate prisms worn with the base inwards, or by decentred glasses, which have a similar effect. Like myopia—a condition with which it is most frequently associated—the defect may be congenital, or merely a consequence of imperfect vision from any cause; the eye wandering outwards for want of visual guidance. The worst cases are observed in patients suffering from paralysis of

FIG. 2.



After operation.

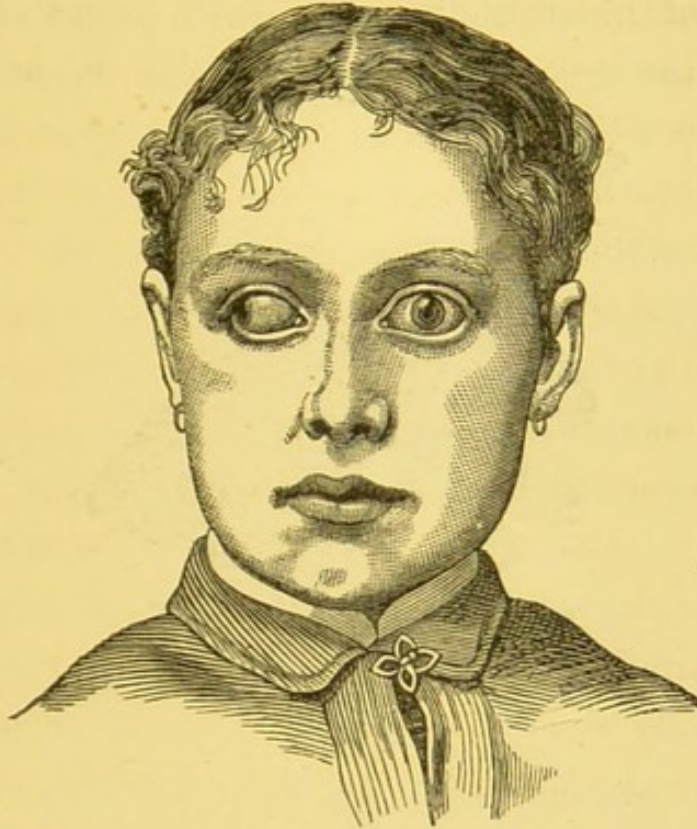

the third nerve, or are caused by accident or unskilful operations for internal squint. If the deformity is slight, but still not such as would be relieved by simple tenotomy, I divide the external rectus subconjunctivally and insert a suture just over the tendon of the inferior rectus muscle; having thus secured control of the eyeball, I turn it inwards by attaching the suture to the internal canthus; this forced inversion is maintained for some days, and the external rectus, being compelled to attach itself further back on the eyeball, loses its power of abnormally diverting the globe. In medium cases I divide the internal and external recti muscles subconjunctivally, and secure inversion as before; in this way the internal rectus is brought forward and the external rectus thrown back. The advantage of these latter methods is that there is no open wound, no risk, and very little inconvenience to the patient. If the deformity is caused by paralysis of the third nerve, it will usually yield to medicine, volitional exercises, or the electric current; but after ordinary treatment the cure may often be expedited by advancement of the affected muscle, or tenotomy of the antagonist or associate muscle. One of the patients upon whom I am about to operate to-night is a collier suffering from slight squint, the remains of a paralytic affection of the third nerve, which six months ago caused extreme divergence of the right eye. Another who will also need attention is a railway official, whose left eye protrudes and diverges to a frightful extent, owing to laceration and separation of the internal rectus, the result of a malicious thrust with a stick. This is what happens when patients are unskilfully operated on for internal squint: the belly of the muscle is divided, the capsule of Tenon is lacerated, and the rectus falls back so far in the orbit that it is unable to reattach itself



to the globe. Here are two photographs of a patient, before and after treatment, on whom I operated some time ago for extreme divergence occasioned in this way. (Figs. 3 and 5).

FIG. 3.

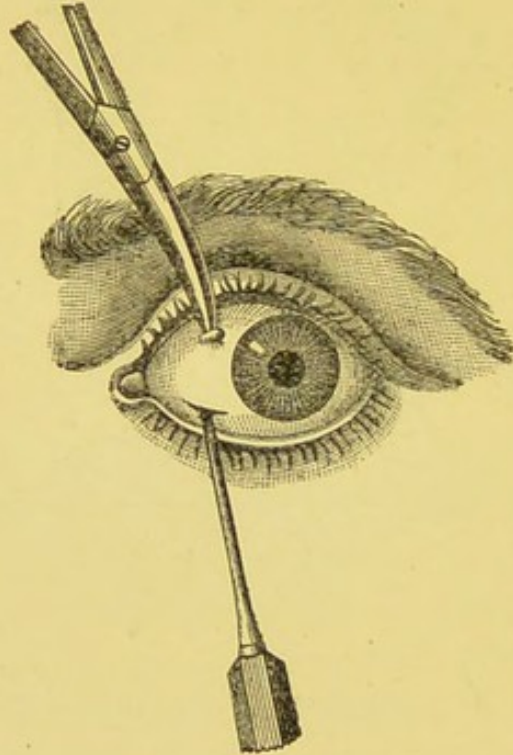


To avoid such disastrous results as are depicted in Fig. 3 we must, in operating for internal squint, be careful to divide the tendon only, not to do too much at once, and depend upon tenotomy of the associate muscle for increased effect when necessary. Von Graefe, whose practice I had an opportunity of studying when in Berlin, used, with this end in view, to make an incision directly over the insertion of the internal rectus, expose the tendon, and divide it on a small hook, as shown in Fig. 6. This procedure involves either an open wound or a suture; and in order to obviate the inconvenience attending the insertion and subsequent removal of a thread, I have been in the habit of making an incision directly over the



lower border of the internal rectus muscle, inserting a small hook beneath the tendon, causing the extremity of the hook to project beyond its upper border, and cutting on the point, thus dividing the attachment of the tendon under the small bridge of conjunctiva which is allowed to remain (Fig. 4). In this way

FIG. 4.



we have a small puncture and counter-puncture, but no open wound, and the tendon, and the tendon only, is divided as readily as though it had been laid bare. If after operation, in spite of all our care, there should appear to be a tendency to eversion, I limit the effect by a suture, catching up the tendon and adjacent tissues, and stitching them to the conjunctiva and subconjunctival tissues at the inner edge of the cornea. When the squint is slight, not more than two lines, you may succeed by operating on one eye only; but the graver varieties, unless when one eye has become completely amblyopic, require

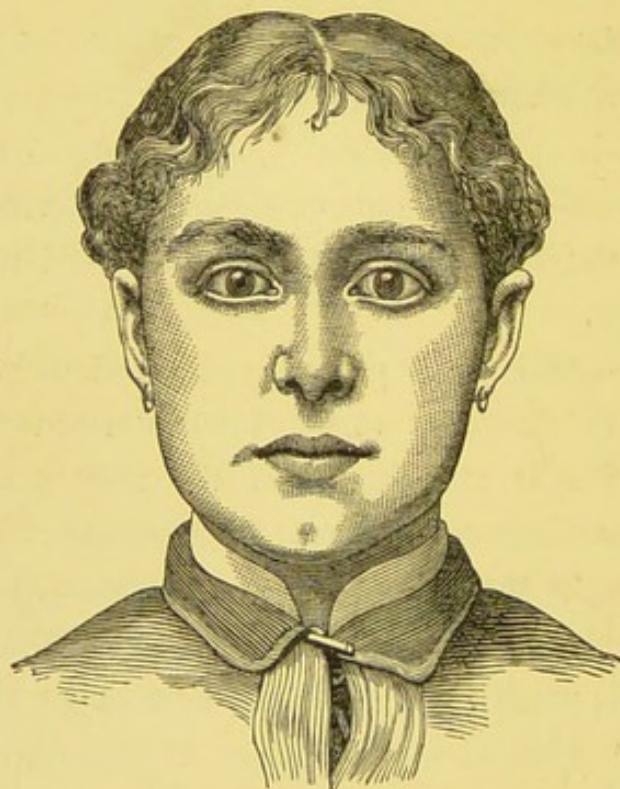the division of both tendons. The first effect of the operation is somewhat diminished when the tendon becomes reattached to the eyeball, and is afterwards, in the course of a few weeks or months, slightly increased, owing to the action of the opponent muscle, which is now enabled to exert a greater influence upon the globe, so that a slight residual convergence will often disappear. This desirable end is much more certainly attained by the use of spectacles, which correct any error of refraction. If, on the other hand, we find that the ultimate result is a tendency to eversion, this malposition may be corrected by withholding glasses, so that the necessity for convergence accompanying increased accommodation may help to restore parallelism of the globes. If in the course of time we find that, in spite of all that has been done, one or both eyes are turned slightly outwards, they may readily be put straight by simply dividing both external recti muscles sub-conjunctivally.

Here is a small boy, six years of age, on whom you shall see me operate by tenotomy of the internal rectus in the way described. He is suffering from the most common form of squint—*strabismus convergens concomitans*. His mother thinks he caught the affection from a playmate, but he really began to squint two years ago, because he then began to learn to read; such patients squint as soon as the eyes are used for near objects, and the more they are thus used the worse does the defect become. You will notice in this case that the child shows a slight tendency to turn the left eye inwards at times, but the right is much the worst; and we have ascertained that the sight of this eye is the weaker of the two, although he can still decipher large print with it. I have ascertained, by making a dot upon the lower lid exactly in the



middle and another in continuation with a vertical line drawn through the centre of the right cornea in its abnormal position, that the extent of the deviation is exactly three and a half lines. If I now close the left eye and direct the patient to look straight with the squinting one, it assumes its normal position; but on raising my hand we find that the left eye has become the squinting one, and, moreover, that the extent of the deviation is exactly the same as that of the right eye. It is as though the two eyes were connected by a cord that was

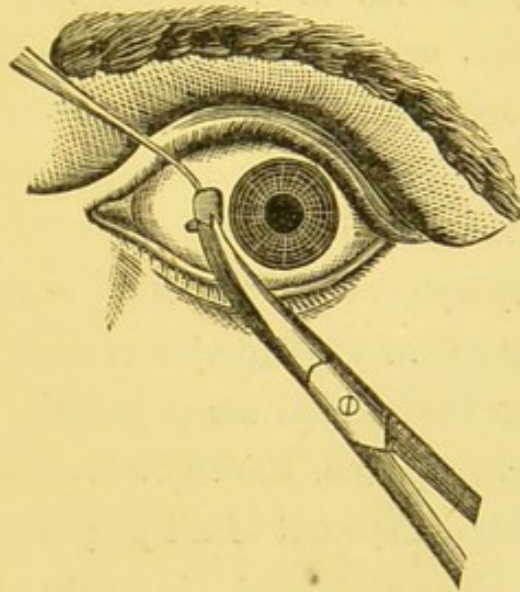
FIG. 5.



too short to permit them both to look straight at once, and that whatever was taken on one side had to be given from the other. This is what is meant by "concomitant"—that is, the straightening of the squinting eye is accompanied by the squinting of the other; and the fact that the patient squints

first with one eye and then with the other also brings the case under the definition of "alternating." The deviation of the

FIG. 6.



right or squinting eye is called the primary deviation; the deviation of the left or sound eye when covered, the secondary deviation. The primary and secondary deviations always correspond exactly in cases of concomitant squint; and it is essential to note this, because when the squint is due to paralysis, the secondary deviation greatly exceeds the primary.

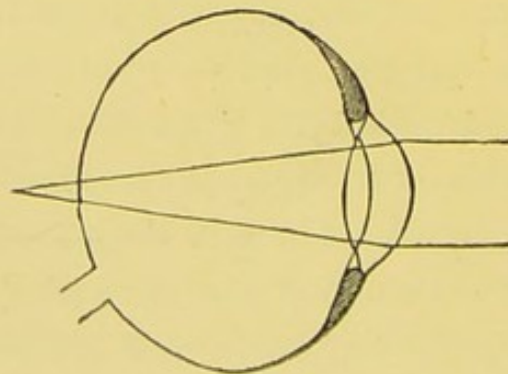
Here is a case of squint from paralysis of the external rectus muscle of the left eye; the patient is a gentleman's servant, who is terribly embarrassed when called upon to pour out wine, because he cannot distinguish the true from the false image of the glass. Note, now, if I direct him to follow my finger with the squinting eye he moves it slightly, but cannot force it outwards, while the great effort he makes in this direction causes him to squint inwards much more with the right eye than he did before with the left. To appreciate the value of this symptom, you must remember that you cannot turn the left eye outwards without at the same time turning



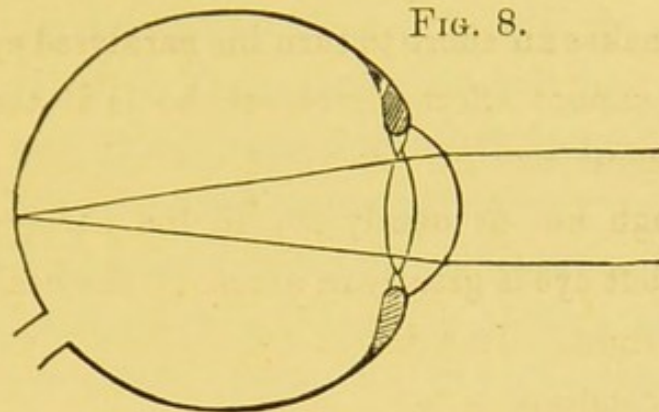
the right eye inwards—they are associated actions; and when this patient makes an effort to turn his paralysed eye outwards, although he cannot effect his object, he is at the same time doing his utmost to turn the right eye inwards; hence the effect, although *nil*, or nearly so, on the paralysed external rectus of the left eye is greatly in excess on the healthy internal rectus of the right. This distinguishes cases of paralysis from cases of concomitant squint, and you will notice a similar association of symptoms in patients suffering from uncomplicated paralysis of the superior rectus, where, owing to the connection of the central nerve ganglia of the superior rectus and levator palpebræ, the effort to look upwards raises the lid of the paralysed eye out of all proportion to its fellow.

Why should so many children begin to squint when they first begin to read, or write, or sew? Simply because they cannot see unless they do. Their eyes are too short in the long axis—that is, from before backwards. The refraction is too low, and objects, instead of being focussed upon the retina, are depicted upon a spot a little beyond it; hence the patient makes extraordinary efforts to lengthen his eye, or increase its refraction, so as to bring the picture into its proper place. You will understand this at once if you compare the accompanying outline of the short eyeball (Fig. 7) with its fellow of the normal

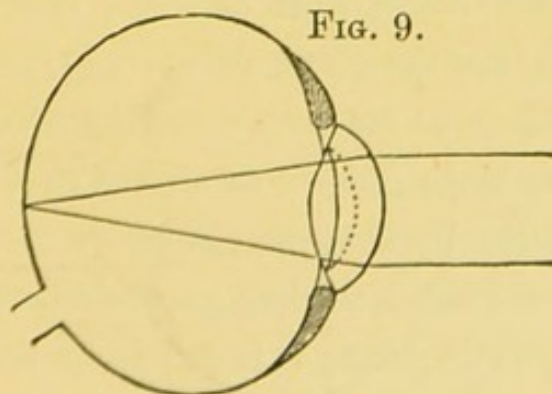
FIG. 7.



eye (Fig. 8). You may say, "What has this to do with squint?"



Squinting will not alter the shape of the eyeball." No; but it has a similar effect, as I will now explain. Patients whose eyeballs are too short are said to suffer from hypermetropia; they are obliged to exert a certain amount of accommodation—that is, render the lens optically stronger by increasing the curvature of its anterior surface by the active exercise of the ciliary muscle, even when looking at distant objects, an effort that is not at all required of the normal eye. Rays of light proceeding from objects twenty feet distant are parallel or nearly so, and, in an eyeball of ordinary dimensions, are brought to a focus on the retina by the power of refraction of the cornea and lens alone when the eye is at perfect rest, and without any exertion of the ciliary muscle. (See Fig. 8.) In hypermetropic persons it is necessary that the convexity of the lens should be increased before these parallel rays can be brought to a point as indicated by the dotted lines in Fig. 9,





where the hypermetropic eyeball is seen successfully bringing parallel rays of light to a focus on the retina by increasing the curvature of the anterior surface of the lens, an effort which, in an eye of ordinary dimensions, is only required for the divergent rays which emanate from near objects. Now if the hypermetrope is obliged to accommodate for distant objects, the rays from which are parallel, you can readily understand that considerable exertion is required in order to enable him to focus near objects, the rays from which are divergent; and this excessive effort of accommodation involves a squint, because the power of accommodation is greatly increased by convergence of the optic axes. Why, therefore, do we not cure squint by neutralising the hypermetropia with a suitable convex glass? A most rational suggestion; and no doubt great good may be effected in this way, as well as by paralysing accommodation with atropine. But, in point of fact, these patients do not come to us, as a rule, until they have squinted for some time; often they only do so because their lives have been rendered miserable by the scoffs and jeers of their schoolfellows and playmates. Prolonged treatment with spectacles constantly worn, and which only mitigate the defect, still subjects them to remark—indeed, tends to aggravate rather than diminish this serious evil, and consequently offers no attraction either to our patients or their friends. Moreover, it is dangerous for little children to wear spectacles out of doors or when at play; they are so apt to be injured by fracture of the glass, and, strange as it may appear, after they have squinted for some time they won't leave off, even though you give them glasses so strong that the squint, far from assisting, actually disturbs vision.

If a squint is neglected, as time goes on one eye becomes permanently the squinting one; it is definitely excluded from the

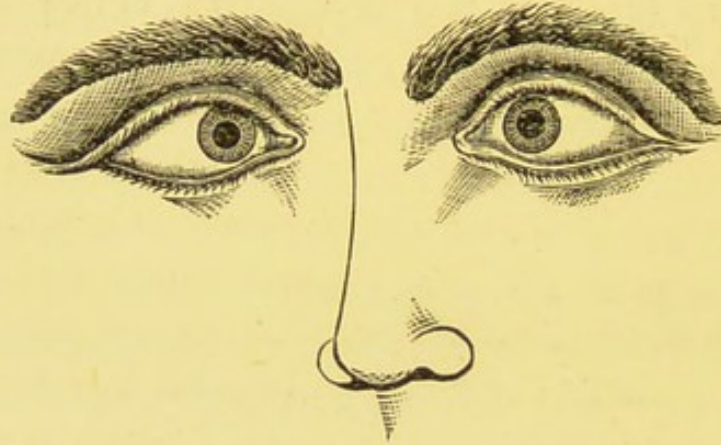

act of vision, and from that moment sight begins to fail. First excentric portions of the retina lose their sensibility, then the yellow spot, and lastly the inner portion fails likewise. If you push one of your eyes ever so little on one side you immediately see double; there is a true image and a false image, and the deterioration of sight which takes place in squint-eyed persons is simply due to the constant negation of the pseudo image of the squinting eye by the brain. We only see what we look at; we only hear what we listen to; the brain has a horror of double images, and the persistent exercise of this mental act of suppression causes in time loss of function, amblyopia from exclusion, or ex anopsia, as it is termed. As the patient ceases to see, so does the eye cease to be affected by efforts at convergence, but wanders to and fro in a purposeless sort of way, and is thus in occasional accord with its fellow; hence the friends, ignorant of the fact that growing out of a squint means growing blind in one eye, congratulate themselves, and become dubious as to the necessity for operation. When a squint alternates, sight may be restored and the deformity cured perfectly. When it has become monolateral the squint may be cured and the sight greatly improved if we see the patient within a reasonable time, but in advanced cases the chances of restoration to sight are greatly diminished; hence operation should not be unduly delayed, or if delayed from any unavoidable cause the eyes should be alternately exercised, so as to counteract loss of function from disuse. If the squint is very slight, it may be necessary only to operate on one eye; but in the great majority of cases, unless when one eye has become completely amblyopic, it will be necessary to divide the tendons of both internal recti. In the case of the boy patient on whom I am about to operate, we noticed that the eye, which was closed, whether right or



left, became for the nonce the squinting one. Now, when both eyes are closed as in sleep, or, as you will be able to see, during anæsthesia, both squint, and the primary deviation, limited during waking moments to one eye, becomes equally divided between the two, as in (Fig. 10.) Here is clear evidence of the

FIG. 10.



binocular nature of squint, and you can readily understand that in the majority of cases it will be necessary to operate upon both eyes. The exigencies of practice and the convenience of the patients frequently necessitate a double operation at one *séance*. It is well, however, when it can be so arranged, to operate upon one eye only at a time. Cases where the eyes are equally convergent when in use are extremely rare, but I can show you a patient who habitually squints, inwards with both eyes, exactly as represented in the sketch. (Fig. 10.) In fact she is very myopic, and has never worn glasses; hence the externi, which produce approximate parallelism of the optic axes required for distant vision, have never been exercised, while the interni have been equally and abnormally developed by constant convergence for near objects.

Some patients squint simply because they have a scar upon the cornea; in these cases a shadow is thrown upon the retina



by the interposition of an opaque film, and the patient turns his eye so as to reduce the annoyance thereby occasioned by throwing it upon the least sensitive portion of the retina. In such cases it is often necessary to shift the pupil and tattoo the cornea as well as divide the rectus tendon. As before remarked, cases of squint, whether external or internal, which are due to paralysis of the third or fourth nerves, usually yield to medicine and treatment adapted to remove the cause, which may be of rheumatic, syphilitic, or diphtheritic origin, or may depend upon defective nutrition of nerve centres arising from various causes. These cases usually occur suddenly in adults or persons past middle life, increase rapidly and are accompanied by distressing giddiness, which disappears when the affected eye is closed, and is mitigated but does not wholly disappear when the healthy eye is closed. Contrary to what you would *a priori* expect, a slight squint of recent origin is much more embarrassing to the patient than the graver varieties of the same affection. This is due to the fact that the nearer to the yellow spot on the retina, the more definite does the image of the squinting eye become, and the more difficult it is for the patient to distinguish the true from the false image, thus leading, as in the case of the gentleman's servant we have just seen, to serious error with regard to the position of objects.

The cause of paralytic squint may be central, such as disease of the spinal cord or brain; or it may be peripheral, arising from inflammation of the nerve sheath or pressure from tumour, gumma, or periosteal thickening, or even shock from cold. Facial paralysis, as you know, is often due to the latter cause, and the ocular nerves are occasionally affected in the same way. If the disease is of central origin the loss of power is usually only partial, more than one nerve is affected, and



you will find that it is impossible to fuse the true and false images by means of prisms. Complete failure of any one of the nerves supplying the orbital muscles, unaccompanied by other symptoms of paralysis, may be confidently ascribed to some lesion of the trunk of the nerve itself at the base of the skull or in the orbit, and may thus be distinguished from the graver varieties of central origin. In treating these cases, you will find large doses of iodide of potassium, with mild mercurials, most serviceable in one class of patients; change of air, tonics, and general hygiene in the other. Strychnine, internally and hypodermically, with the local application of the induced or voltaic electric currents, are applicable to both; and whenever the paralysed muscle responds to the stimulus, however slightly, you may confidently predict a successful issue to the case.

Practice and attention to the rules I have laid down will enable you to command brilliant results in cases of squint. We have operated upon thousands of patients at this institution. It is a rule that each shall return within a few months, so that we may note the ultimate result. One easily forgets faces in a large practice, and it frequently happens, as you know, that I fail to recognise my friends, so completely has the deformity been removed. I must warn you, however, that this desirable end cannot always be attained by one operation; indeed, the most strikingly successful immediate results in cases of convergence (the most common form of squint) are those most likely to be followed by divergence. We must, therefore, be careful not to do too much at once, and it is well to warn the patient or his friends that more than one operation may be necessary.

---



## LECTURE III.

---

### GLAUCOMA.

GENTLEMEN,—When Mr. Mayhew, the late eminent veterinary surgeon, described rabies in the dog, he used to say: “The eyes, which glow like living coals in the early stages of the malady, become *bottle green*, and in many cases slough and fall from the sockets ere death closes the scene.” Now I need not tell you that *glaukos* is Greek for green, and it is precisely this bottle green reflex which you notice in the pupillary area of the patient you have just seen which is the origin of the term Glaucoma—the subject of this evening’s lecture. I know you will say: “If that is so, it is strange that this remarkable symptom should be conspicuously absent in so many of the cases which come under treatment at this Institution.” Well, it does seem strange; but the fact is, that the term as at present understood bears little relation to its original etymology, but is used indiscriminately to cover the whole series of morbid changes which are the result of increased intraocular tension or fulness of the globe. What is the cause of increased intraocular tension? Well, if you mean the primary cause—the *causa causans*,—all I can do in the way of response is to call your attention to certain facts which may assist you in forming an opinion. A lady, addicted to play but a bad loser, was one evening most unfortunate at cards. Under the influence of the chagrin so occasioned, she developed glaucoma and lost the sight of the right eye. Warned by this terrible mishap, she abandoned her favourite pastime for a year and a half, when,



being tempted, she again ventured—was again unfortunate—and lost the sight of the remaining eye.—(*Fischer.*) A distinguished engineer during the siege of Paris ascended in a balloon to make observations; was caught in a contrary current; driven within the enemy's lines, and taken prisoner. That same night he was attacked with glaucoma in both eyes.—(*Wecker.*) A nurse, worn out with watching at the bedside of a dying patient, fell asleep and was suddenly roused by a loud crash,—the sash cord had broken! Glaucoma came on within an hour in the right eye, and the left was speedily affected in the same way.—(*Lawson.*) I could multiply such recitals from many similar cases occurring in my own practice, but here is evidence enough to show that misery and misfortune, anxiety and worry, stand in the relation of pre-disposing cause and effect to glaucoma, and that nervous shocks will precipitate an attack. Some pathologists affirm that the eye is affected through the medium of the fifth and ciliary nerves; others that the sympathetic is principally involved. However that may be, it is certain that the proximate or immediate cause of a rise in tension is one or other of two conditions,—either secretion is in excess, or the normal outflow is impeded. The vitreous and aqueous chambers of the eyeball are, as you know, respectively permeated and filled with a watery fluid: if the former is removed, suspended, and pricked, it drains slowly away; if the latter is punctured, it escapes at once. But you will hardly appreciate, without reflection, the extraordinary rapidity with which this fluid circulates. The late Dr. Bence Jones demonstrated, by actual experiment, that a small dose of iodide of potassium appeared in the aqueous chamber almost simultaneously with its imbibition; and it is well known that when fluorescine is injected under the skin, that the play of colours is



speedily perceptible in the pupil (*Panas.*) What is the mechanism of this wonderful process? How does this watery fluid get into the eye? and how does it get out of it? According to received physiological views, it is secreted by the choroid iris and pigment epithelium of the ciliary folds, permeates the vitreous chamber, passes backwards along the optic nerve, and forwards through the pupil into the aqueous chamber and canal of Schlemm, whence it finds its way into the episcleral veins, and you can readily understand that any check to its outflow, or excess in secretion, must at once be attended with a rise in tension, and that is precisely what happens when a patient is said to be suffering from glaucoma. If the initial lesion is hyper-secretion, the disease is primary or idiopathic; if the outlets are first blocked by accident or pre-existing disease, the affection is of course secondary; and it is well to remember that the causes which block the outlets are apt also to excite irritative hyper-secretion, and that excessive secretion, by pushing forward the lens and iris base, is also certain to impede the normal outflow, so that the disease moves in a vicious circle, and tends continually to get worse. Primary glaucoma seldom occurs under fifty years of age, and only then, as a rule, in persons with a certain predisposition; but secondary glaucoma may be induced at any age, and needs no predisposition,—the infant sent here last week by Dr. Walker had marked glaucoma, the result of hæmorrhage, between the choroid and retina;—it may also proceed from almost any inflammatory affection of the eye, and from various accidents, injuries, and surgical operations. “It is mournful,” says Von Graefe, “to see how many eyes, after escaping entire destruction from ulceration, as in ophthalmia neonatorum, are afterwards rendered blind by secondary glaucoma, the result of adhesions



for which active treatment has not been adopted in time." I have also seen it complicate the various forms of keratitis, iritis, sympathetic ophthalmia, and excluded pupil, cataract, dislocated lens, wounded lens, intraocular tumours, ruptured capsule, and extreme myopia.—Of primary glaucoma you will meet with two principal varieties—the simple and the inflammatory. The patient we have just left in the ophthalmoscope room, who is fifty-four years of age, and both of whose eyes are affected, is quite a typical example of the former condition. His wife tells us that he has destroyed his sight by using too strong magnifying glasses, and that his vision varies,—being worst at night, worse at some times in the day than at others, and worse on some days than on others. He is a big-framed man, with a full hard pulse, and complains of attacks of dimness of vision, similar to what would be caused by clouds of smoke or fog, with a rainbow round luminous objects. He is subject to headache; the iris is sluggish, and the cornea insensitive. The general acuity of vision is distinctly lessened, amounting to slight short sight, but the peripheral portions of the retina have suffered most, specially, as we ascertained by lamplight (which is best for this purpose), to the inner or nasal side. On ophthalmoscopic examination we found that the optic disc is what is termed cupped, or rather excavated, for it is hollowed out at the sides, with overhanging edges, and the pressure which has driven back the papilla, has also detached the choroid, so that the disc is surrounded by a whitish ring of exposed sclera. We have ascertained that this is a true excavation and no optical delusion, by the parallax, with both the direct and indirect methods of examination, and we have also calculated its depth by reducing to millimetres the different values of the lens required to see the base of the cup and the



surface of the retina. "But," you may say, "granting that there is a cup, how do I know that it is a glaucomatous, and not a physiological or congenital cup, or the result of atrophy from absorption of nerve tissue consecutive to cerebral change?" Well, I know that it is a glaucomatous and not a physiological cup, because the physiological cup affects both eyes alike, and in this case the right eye is much the worst of the two. This cup, moreover, occupies the entire area of the papilla, and—most characteristic feature—the vessels are crowded to the nasal side; whereas, the physiological cup, however steep it may be, never involves the whole of the disc, and there is no like tucking under, lateral displacement, or changed calibre of retinal vessels. I know this is not a case of simple atrophy, absorption of nerve tissue, or amblyopia from cerebral change, because, apart from other important symptoms, the destruction of the field of vision in cases of atrophy begins on the temporal, and not—as in glaucoma cases—on the nasal side. I know also this is the result of increased tension, because, although there is no spontaneous pulsation of retinal vessels, throbbing is easily induced, as you saw, by the slightest touch on the surface of the eyeball, the artery beating in the centre of the disc and the veins collapsing in concert at its periphery. For the rest, strange to say, the eye looks fairly natural; is not inflamed or congested; nor are the episcleral veins notably enlarged; nor is tension, just now at any rate, very greatly increased. Let us consider what is the cause of these curious symptoms: and first, as to his wife's suspicions, there is no reason to believe that he has been using too strong glasses, for the fact is the man's accommodation is paralyzed from pressure on the ciliary nerves, and strong glasses are a necessity, if he is to see small objects at all. Indeed, you may



always suspect glaucoma when a patient is constantly changing his glasses. His vision is worst at night, and varies from day to day, because of slight exacerbations, and because the eye sympathizes with fatigue and the general constitutional condition; the clouds of smoke and rainbows are caused by edema of the corneal epithelium from infiltration with intraocular fluids—(*Fuchs*); the cornea is anæsthetic from pressure on the ciliary nerves as they pass along the inner surface of the sclerotic, and the whole visual acuity is diminished from this cause, as well as from retarded blood supply,—the inner or nasal side suffering most, because the vessels supplying the corresponding outer half of the retina have the longest course to run, and are consequently most exposed to pressure. The optic disc is hollowed out, because it is the weakest part of the sclerotic, and is therefore the first to give way; the artery pulsates because the intraocular pressure is so great that the blood can only pass at the moment of the heart's contraction; and the fact that all this takes place without any marked hardening of the globe is a proof, either that slight tension long continued will cause grave intraocular changes, or that in this case it has been effected during exacerbations, which are such a distinct feature in almost all forms of glaucoma.

Inflammatory glaucoma, of which you have seen many examples, may prove so intense as to destroy sight in twenty-four hours, hence called fulminans. It may resist all treatment, including iridectomy; in fact, get worse whatever you may do, hence called malignant; and short of these aggravated conditions, which fortunately are rare, it may occur in a chronic or acute form. The female patient with the green eye, (*γλαυκον ομμα*) *glaucon omma*, to whose case I directed your attention at the commencement of this lecture, is a good



example of acute glaucoma. She is fifty-six years of age, has recently lost her husband, and had trouble of various kinds. Six weeks ago she went to bed as well as usual, but was roused in the middle of the night by a violent pain in the right eye, which was swollen, inflamed, and watering freely. She was treated by a local practitioner, but the disease progressed steadily from bad to worse, until at last all perception of light was gone. At present you see that the iris has lost its tint and lustre; that the cornea is dull and anæsthetic; that the eye is as hard as a stone, and that the widely dilated pupil presents a peculiar tint, compounded of a yellow lens and turbid blue aqueous humour. In these cases the disc is not usually cupped, simply because the pressure has not lasted long enough to induce that change. If however the fundus can be illuminated you will see the artery throbbing without any superadded pressure; or if nothing else is to be seen, the optic disc looming through the turbid vitreous like the sun in a fog. As the disease advances the iris loses its colour; the pupil dilates, assumes an ovoid form, and is insensible to light; the vitreous and aqueous humour become more or less opaque, and the former has usually so pushed forward the lens and iris base that the anterior chamber is well-nigh obliterated. The patient's sufferings in some cases are little short of agony; in others, fever runs high and vomiting is frequent; with many, pain is referred to other parts, so that the eye, as the *fons et origo mali*, is apt to be overlooked and the attendant misled as to the nature of the case. I was once called to a patient whom I found on her hands and knees groaning with her face buried in the pillow. The case had been diagnosed as severe migraine, and six teeth extracted in the hope of relief. Another had had her head shaved and



been bled and blistered on the ground that she was suffering from meningitis; and a third was reported as affected with gastric fever. Iridectomy acted like magic so far as the relief of pain was concerned in each of these cases, but was too late to restore sight in the two first, and was only partially successful in the third. Chronic, inflammatory, and irritable glaucoma present the same symptoms as the acute, but to a less degree; and these forms of the disease, like simple glaucoma, are also characterised by marked exacerbations and remissions. With regard to treatment: The indications in secondary, consecutive, and traumatic glaucoma are clear enough, we must whenever possible remove the cause of disaster. A broken up lens that blocks the angle of the chamber, or presses upon the iris, must be let out; the dislocated lens extracted, and tension after capsular operations treated by paracentesis; adhesions with ulceration require iridectomy; and the same operation must be performed whenever glaucoma complicates iritis, irido choroiditis, and excluded pupil. As to cases of simple and inflammatory glaucoma it has been very generally taught that all the resources of the Pharmacopeia are powerless to cope with these maladies, an assertion hardly however in accordance with facts; for just as a sudden fright, probably by dilating the pupil, may cause or precipitate an attack of glaucoma, so will eserine, by inducing an opposite condition, avert it. Just as anxiety and prolonged vigils may cause increased tension, so will morphia or other hypnotic if it insure profound sleep, abort it. Just as a rise in blood pressure from excitement and derangement of the sympathetic and fifth nerve may provoke excessive secretion, so will medication, such as blood-letting, ice, or hot fomentations, elaterine, eserine, pilocarpine, large doses of quinine (10 grains, *Mittendorf*),



tend to stave off an attack or mitigate its severity. I do not say that such remedies will avail in a severe case, cure or prevent recurrence in slighter ones, or avert gradual deterioration of sight in any, but there is no doubt that the disease may be kept at bay for a time by judicious medication, and it would be unwise to ignore the value of such remedies when from any cause operation is postponed.

In a former Lecture on the Use and Abuse of Mydriatics, I called your attention to the great danger attendant upon the instillation of atropine in all cases of possible or threatened glaucoma, and it becomes interesting now to inquire in what this danger consists. One would think *à priori* that atropine, from its sedative influence and power of checking secretion, would be a useful remedy in glaucoma, and so it would, but for its power of dilating the pupil. It is this purely mechanical action, this crowding of the iris into the angle of the anterior chamber—the main outlet for fluids from the eye,—which is the source of all the danger attending the employment of mydriatics in glaucoma. I pointed out also that in doubtful cases it was safest to use cocaine,—an alkaloid which checks secretion even of tears, relieves pain, diminishes the calibre of blood-vessels reduces tension, and although an efficient, is still, compared to atropine, a feeble and non-persistent mydriatic. Since then I have demonstrated over and over again, that eserine, although impotent or nearly so as a myotic against atropine, duboisine, daturine, hyoscyamine, and the more powerful mydriatics, possesses complete control in this respect over cocaine, and that the two in succession or combination may not only be safely employed, but in this form will probably constitute one of the most valuable adjuncts to our remedies for the treatment of glaucoma. Let me illustrate my meaning. If the iris, when



dilated, should be so fixed by adhesions that it could not contract, eserine, powerless to stretch apart the fibres of the ligamentum pectinatum, by reducing the size of the pupil, would probably do nothing but harm by its irritant action; and if the pupil should be contracted and occluded by adhesions, so that atropine could not crowd out the angle of the anterior chamber by dilatation, it might do nothing but good by its sedative influence and power of checking secretion. Recollect therefore that the action of these drugs in glaucoma for good or ill is mainly mechanical, and that, apart from contraction or dilatation, the collateral result may prove the exact opposite of what you intended. Let us admit the correctness of the generally received views as to the causation or aggravation of glaucoma by excess of secretion or retention of fluids, owing to closure of the angle of the chamber and circumferential space by the expanded iris, and we can readily understand how the removal by operation of a portion of this both secretive and obstructive membrane may permanently relieve a condition which, unchecked, is certain to go on to destruction of the eye, and this is precisely what happens when a portion is excised as in Von Graefe's operation. Graefe had been struck, while attending the clinique of the elder Desmarres, with the remarkable results obtained by paracentesis in various affections of the eye. Mackenzie had pointed out that in glaucoma the globe became hard, it was clearly softened momentarily by tapping, and the larger the incision the better the result. Unfortunately—I should say fortunately in this case—when the wound was large the iris protruded, and to get rid of this difficulty Von Graefe cut it off.\*—(Fig. 1.)

\* The incision must be made in the corneo sclerotic junction and the upper quadrant of the iris removed right up to its ciliary border, taking care that no portion is trapped in the angles of the wound.



FIG. 1.



How simple it all seems! and yet what stupendous results! Let me endeavour to bring home to you the vast benefits he has thus conferred upon suffering humanity. Sixteen years ago I was called by the late Dr. Watchorn to see a lady who had been struck with blindness some days before,—in fact both her eyes were in much the same condition as that of the poor woman with the green pupil you have just examined. She had bare perception of light with the left eye; was in an agony of pain; and the right, by reason of the longer duration of the malady, was, so far as sight was concerned, beyond the reach of art. A large iridectomy upwards, however, instantly as if by enchantment stopped the whole process in both eyes, and from that day to this she has, with the left eye, enjoyed most excellent vision both for near and distant objects. We don't succeed like that in every case, but we do in a large proportion, and it is no exaggeration to say that hundreds of persons are every year saved from blindness by the performance of this simple operation. The one drawback to iridectomy is the mutilation of the pupil and consequent deformity with dazzling from circles of diffusion, and in order to avoid this, ophthalmic surgeons have ever since 1856, the date of Von Graefe's discovery, been endeavouring to improve upon the operation. Speaking on this subject, De Wecker says: "I am convinced that with the progress of knowledge, some other proceeding more simple and essentially more logical will be substituted."\* It may be so; but I am not of that opinion,

\* *Therapeutique Oculaire*, p. 320.



nor can I recommend you to attempt any other operation in fulminating, acute, or inflammatory glaucoma. In certain specific and in some milder cases, it is true that less severe measures have sufficed, or must perforce be substituted. Sclerotomy, for instance, may take the place of iridectomy in the very incipient or doubtful stages of all forms of the disease; in hydrophthalmos, which is the glaucoma of children, where excision of the iris is so apt to be followed by rupture of the zonule, hæmorrhage, escape of vitreous, and collapse of the globe; and it must also take the place of iridectomy in adults suffering from the hæmorrhagic form of the disease, where the too sudden reduction of tension by iridectomy is apt to be followed by similar accidents. It should also be adopted in glaucoma absolutum, where it is impossible to excise the iris, and in cases of long-standing simple glaucoma, where advancing blindness is on the eve of invading the macula or point of fixation, and where any coarse operation may precipitate the impending catastrophe. Some ophthalmic surgeons (*Schweigger, Wecker*) even prefer sclerotomy in inflammatory cases, providing only extreme contraction of the pupil can be previously obtained by eserine, and it is undoubtedly useful as a preliminary to iridectomy when the inherent difficulties of the latter operation may be to some extent removed by a previous reduction of tension. In performing sclerotomy, the knife should enter and emerge in the corneo sclerotic junction, precisely as if you were going to make a flap of four millimetres; pushed upward with a to and fro movement, and then slowly withdrawn, leaving about a fourth undivided.\*—(Figs. 2 and 3.)

\* Sclerotomy does not act, as has been supposed, by the production of a permeable scar, but probably by establishing a new path by which fluid can reach the corneal and scleral lymph spaces from the retraction of the cut membrane of Descemet, (the posterior elastic lamina of the cornea).—



FIG. 2.

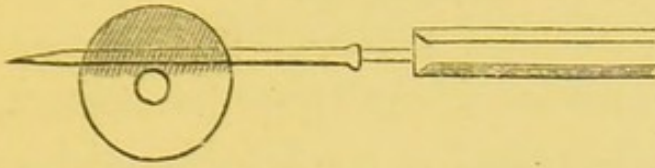


FIG. 3.



But little after-treatment is needed, and, although the chamber is not re-formed for some days, the patient may return home on the third: I have even in some cases, and for special reasons, discharged them at once. The great advantages of this operation are, that it may be repeated again and again; that it involves no mutilation, and may be adopted as a supplementary procedure both before and after iridectomy.

Here is a patient, aged 27, from Ruddington, who illustrates the great advantages of these combined operations. She consulted me four years ago on account of excessively painful glaucoma consummatum of the left eye, the result of extensive iritic adhesions. As she was young and good-looking, I did not like to extirpate the eyeball, and therefore divided the optic and ciliary nerves, with complete relief to all her painful symptoms. A year ago, that is three years after the neurotomy, she applied again with intense iritis of the right eye, and as I feared that there might have been some re-formation of nerve tissue and consequent sympathetic mischief, I removed the left globe.\* Nevertheless the right eye speedily developed glaucoma, and I found it necessary to remove the upper segment of the iris. A few weeks later, however, the symptoms returned, and I excised the lower segment, again arresting the progress of the disease. Subsequently, in consequence of recurring attacks of blindness with excessive tension, I found it necessary

\* See Lecture by the Author on "Optico-ciliary Neurotomy."—*Lancet*, Sep. 4, 1886.



twice to perform sclerotomy, with the result, as you see, of perfect restoration to sight, which remains and bids fair to remain.

In attempting sclerotomy or iridectomy it sometimes happens, owing to the extreme narrowness of the anterior chamber, that the point of the knife gets entangled in the iris, and before it can be pushed across the chamber, the aqueous escapes. When this is the case, it is prudent to delay the operation, or limit it *pro tem* to a paracentesis, and I have occasionally with advantage kept the wound patent, and let out the aqueous from time to time by the daily or more frequent use of a blunt probe, or, what is better, a Weber's canaliculus knife; indeed some surgeons have lauded paracentesis as superior in certain cases to other operations. For instance, Dr. Cuignet, Ancien Médecin Principal à Lille, records a case of glaucoma cured after seventeen evacuations of the aqueous humour, and thus expresses himself respecting the operation:—"C'est à tort qu'on a laissé l'iridectomié supplanter presque complètement la paracentèse cornéene, dans une foule de cas où celle ci était usitée jadis et jouit, en effet d'une réelle efficacité."\* As an operation *per se*, however, if we must be limited to tapping, the vitreous chamber appears to me to offer much greater chances of success to the surgeon,—an operation which has been strongly recommended by various authors, even so long as a hundred years ago (Guérin de Lyon); again in 1830 by Mackenzie and Middlemore; since then by the elder Desmarres; and most recently by Dr. G. L. Johnson,† who thus writes with reference to chronic and old-standing glaucoma:—"With the light which

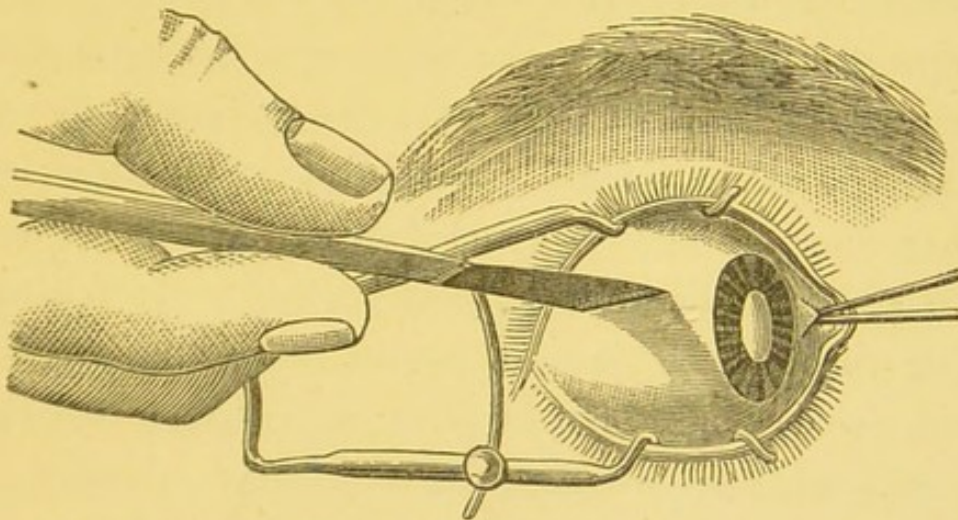
\* *Annales d'Oculistique*, June, 1886, p. 257.

† "Glaucoma and its Treatment."—London: Lewis, 1884.



modern research has shed upon the subject, it appears to me that it is useless to seek for improvement by attacking the angle of the anterior chamber (by sclerotomy or iridectomy), since the destructive processes are in that region already too far advanced, while the relief afforded is insignificant when compared to the gravity of the operation." In performing paracentesis of the vitreous, you must turn the eye inwards as much as possible, and then thrust a Wenzel's or Beer's cataract knife to the depth of about half-an-inch into the globe, withdraw the knife slowly, and bandage the eye with cotton wool.—(Fig. 4.)

FIG. 4.



Dr. Johnson says:—"The relief is always immediate and generally permanent,"—a statement, the latter part of which, I regret to say, that I cannot endorse; for I have found that when the wound heals, the patient is in much the same position as before;\* although it is true that wounds of the sclerotic, owing to the constant motion of the ocular muscles, seldom heal firmly by the first intention, and it is well, as Dr. Dianoux has pointed out, to assist this disposition to gape,

\* I prefer, myself, to let out the vitreous through the pupil after removal of the lens, an operation which yields marvellous results in cases of advanced glaucoma.



by systematic massage as well as by a cross incision. Dr. Argyle Robertson taps the vitreous with a trephine, removing a small disc of sclerotic, an operation which appears to have been attended by considerable reaction (*Brailey*); and other surgeons, looking upon glaucoma as a spasm of the ciliary muscle, have endeavoured to relieve tension by dividing that muscle. Mr. Hancock, for instance, says:—"I always looked upon glaucoma as caused by obstruction of the circulation, a strangling of the blood-vessels caused by spasmodic contraction of the ciliary muscle, analogous to the spasm so often observed in the muscular fibres of the urethra, as well as in the sphincter ani, in certain affections of those parts." In order to relieve this condition, he says:—"I introduce a Beer's cataract knife at the outer and lower margin of the cornea where it joins the sclerotic; the point of the knife is then pushed obliquely backwards and downwards until the fibres of the sclerotic are divided obliquely for rather more than one-eighth of an inch; by this incision the ciliary muscle is divided, whilst the accumulated fluid flows by the edge of the knife."\* Mr. Solomon has devised a similar method, which he terms "intraocular myotomy." This is effected, "By entering a Beer's cataract knife at the corneo-sclerotic union, and then pushing it through the pillars of the iris into the muscle, the flat surfaces of the blade being opposed on the one side to the sclerotic, and on the other to the rim of the lens. The anterior chamber is generally penetrated, and the posterior put in communication with the wound."† The late Mr. Nunneley used to practise a similar operation which went by his name, and quite recently Mr. George E. Walker, of Liverpool, has recommended a like procedure, which he terms "hypo-scleral

\* *Lancet*, Feb. 11th, 1860.

† *Medical Times*, May, 1861.



cyclotomy." Mr. Walker contends that excessive use of the ciliary muscle is the cause of glaucoma, whether acute, sub-acute, or chronic; and adds, what is wanted to cure acute glaucoma is rest, perfect and profound, and this he maintains can be obtained in no way comparable to that of cyclotomy. He thus describes his operation:—"Fix the eye by holding the conjunctiva with toothed forceps; with the narrowest knife possible pierce the cornea at a point opposite to that of fixation, about a line from the sclero corneal junction; as soon as the point enters the anterior chamber, alter the direction of the knife so as to clear the edge of the lens, thrusting it through the iris for about a line; then, drawing back the knife, cut the tissues up to the sclerotic."\* The results attained in these cases, when favourable must have been greatly due to the evacuation of intraocular fluids, since *post mortem* examinations have demonstrated that the muscle is rarely divided, as Wecker has remarked:—"Les experiences faites sur le cadavre, apres avoir exécuté l'operation, prouvent qu'on ne réussit à conper qu' une partie des fibres circulaires et radiées du muscle ciliare, aussi l'operation nagit elle qu'à la manière des paracentésés et c'est ainsi qu'elle peut veritablement etre salulaire."†

Donders always maintained that glaucoma was caused by irritation of the fifth pair of nerves, and the intimate connection of the attacks with derangements of the trigeminal and sympathetic nervous system is so marked, that one can only wonder that the disease has not been attacked more frequently on that side. I have endeavoured to contribute my quota to this end, by galvanizing the sympathetic, and Badal proposes

\* "Essays on Ophthalmology," G. E. Walker.—Churchill, 1879.

† "Traité Complet D'Ophthalmologie," p. 697.



to alleviate the symptoms by tearing out the nasal branches of the fifth,\* an operation spoken of in the highest terms by Lagrange, who, from an experience of eighty-one cases, declares that in glaucoma the pain disappears, tension decreases, and vision improves, even when both sclerotomy and iridectomy have failed to afford relief.† I have been asked whether I consider glaucoma as essentially an inflammatory disease? Well, I should say not. I look upon inflammation as an accident of glaucoma—a something superadded, and the simple form where there is no inflammation, and, what is more remarkable, often but slight tension,—the old amaurosis with excavation of the optic disc,—as the real type of the disease. It is true that the greatest variety of opinions prevail upon this subject. Von Graefe, for instance, always thought that glaucoma was a serous choroiditis, pure and simple, an opinion apparently shared by Mauthner. Donders, v. Hippel, and Grünhagen hold that the hypersecretion is caused by irritation of the fifth pair of nerves; Max Knies and Adolph Weber

\* The nasal nerve which we are told to divide in Badal's operation is a branch of the ophthalmic division of the fifth, and gives off a filament to the lenticular ganglion, two or three ciliary direct to the eyeball, and at the inner side a considerable branch the infratrochlear, which leaves the orbit at its fore part, and is really the nerve which is torn in Badal's operation. Its position is indicated by a line drawn through the centre of the nail when the finger is placed close to the supraorbital ridge, its tip resting on the side of the nose, or by a line drawn from the angle of the mouth to the inner canthus. The nerve, which lies very deeply, is best got at by cutting down to the bone on each side of it, and then tearing it up by the roots with a strabismus hook. The effect of the operation is supposed to be due to the disruption of the sensory root of the ciliary ganglion, or to an ascending neuritis of the torn nerve extending to the ganglion. Badal's idea was to relieve pain by stretching the nerve. He found, however, as a matter of experience, that tension of the eyeball was also notably reduced. Lagrange considers the operation one of the best in ophthalmic surgery.

† "Archives D'Ophthalmologie," June, 1887, p. 220.



contend that the disease is merely one of retention, Weber believing that it is the swelling of the ciliary processes which blocks the angle of the chamber, and Brailey to a certain extent appears to adopt this view; while Priestley Smith insists that the closing up of the circumlental space is simply due to the increased size of the lens, which, he has shown, is a natural phenomenon of life which goes hand in hand with advancing years. However that may be, it is certain that glaucoma very seldom occurs under fifty years of age, and that women who suffer from climacteric congestions are the most frequent victims, whilst the class of persons most commonly afflicted are those who are naturally weak or poorly fed; who have had troubles; who have used the eyes inordinately for near objects; or whose occupation has necessitated much stooping, and consequent extra and intra ocular congestion. The disease is symmetrical, both eyes being affected, though I have known fifteen years to elapse before the second was attacked. The smaller the eye, the greater the chance of its becoming glaucomatous, rigidity of the sclerotic being most manifest in hypermetropes,—a condition you may sometimes diagnose by a full hard pulse, such as we remarked in the male patient suffering from simple glaucoma. Irregularities of the circulation, such as climacteric flushings, often precede the attacks, and patients are not unfrequently found to be suffering from atheroma, sclerosis, or hyaloid degeneration of the arteries. Whatever reduces tone and relaxes the muscular system is provocative of the disease. “Lorsque je me sens brisé de fatigue, je suis certain de voir mes arcs en ciel,” is a remark recently made by one of Wecker’s clinique, which contains a lesson for us all. *Per contra*, whatever braces up the system, increases the muscular tone, contracts the pupils,



and insures profound sleep (when, I need hardly remind you, the pupils are normally contracted), will tend to dissipate the prodromata of an attack.

From all this it is evident that those who are threatened with glaucoma should observe certain precautions. They should retire early, avoid stimulants and excesses of all kinds, insist upon regular action of the bowels, have glasses accurately adapted, use the eyes for near objects as little as possible, get out of doors, and never read or work when lying down, leaning forward, or travelling in a railway carriage. They should also cultivate excitement of a healthy and pleasurable nature, and friends should be instructed to protect them so far as possible from anxiety, worry, contradiction, and those moral emotions of a depressing character, which the cases I have quoted at the commencement of this lecture show us so frequently precede an attack. Thirty years ago the elder Desmarres wrote:—“As glaucoma is incurable, it is difficult to suggest any treatment.” Now, owing to the labours of Von Graefe, we are able to deal successfully with the great majority of acute cases, one-half being restored to excellent sight, and the progress of the disease, as a rule, arrested in the remainder. This remark, however, does not apply to cases of simple glaucoma, for although the *status quo* may be maintained by treatment in a large proportion, and some slightly improved, still we cannot say that we have any cure for the disease, and twenty per cent. are apparently worse for operative interference. What is to be done with these cases? Gentlemen, that is “Le grand problème”—the task before us. Von Graefe has conferred a boon, but it appears to me that he has also entailed an obligation; and that it behoves us, in emulation of the great master, not only to work out a rational treatment for cases of simple



glaucoma, but also so far to extend a knowledge of our art as to bring within the range of science those numerous and distressing cases of acute glaucoma which are mistaken for other diseases, incorrectly diagnosed, or lost for want of treatment by qualified and experienced practitioners.





## LECTURE IV.

---

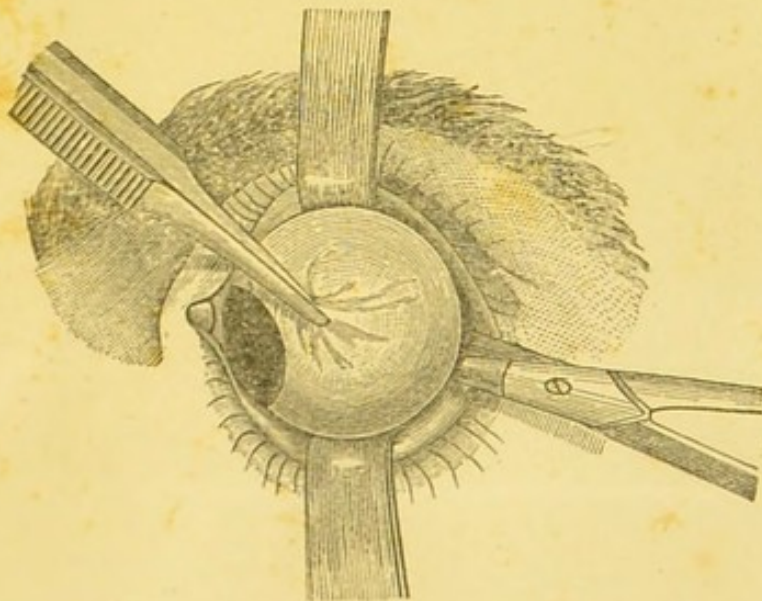
### OPTICO-CILIARY NEUROTOMY.

GENTLEMEN,—A short time ago I had in my service a somewhat eccentric old gentleman—since dead, I regret to say,—on whom I had operated for cataract in both eyes. In return for my kindness he said he would never leave me, and I managed to find employment for him in various ways. One of his errands was to fetch pigs' eyes from the butcher's shop. "What does your master do with those eyes?" said one day a curious customer, who had noticed his frequent visits. "Oh, he fills up the sockets of the eyes taken out at the infirmary with them." "And can the patients see?" "Certainly," he replied; "I have had both eyes done myself." My informant assured me that the man believed him. Perhaps he did—who knows? "*Populus vult decipi.*" Thousands, I am told, believe a newspaper canard to the effect that a certain German professor has recently succeeded in grafting a rabbit's eye into a woman's head, and that his previously blind patient has since



recovered most excellent sight. You and I know, of course, that such transplanted orbs, even if retained in whole or in part, must of necessity be sightless; but we cannot expect the general public to be equally well informed; and it is moreover, a fact that we are able to accomplish far more in the way of transplanting both homogeneous and heterogeneous tissue than would *a priori* seem possible. For instance, I have succeeded myself in forming an excellent stump for an artificial eye by grafting a piece of prepared sponge into the orbit. And you have seen me again and again so far sever the existing connections of the eyeball as to be able to turn it round, lift it out of the socket, and then replace it. (Fig. 1.)

FIG. 1.



Here is a patient on whom I performed this operation two years ago. She was sent to me in order that the right eye might be excised. I thought it a pity, however, to sacrifice such a good-looking organ, and, therefore, divided the optic and ciliary nerves. Now, as you see, she is as well as ever; motion of the eyeball in all directions is absolutely perfect,



and, in point of fact, you cannot without careful examination tell which eye has been done. (Fig. 2.)

FIG. 2.



Here is another patient, a labouring man, operated upon six weeks ago, who has long suffered from recurrent attacks of pain and inflammation in the right eye. As these attacks resisted all treatment, including neurotomy of the supra-orbital nerve, adopted by his surgeon, it was decided to send him to me for excision. Again I thought it a pity to sacrifice a good-looking though sightless globe, and therefore divided the optic and



ciliary nerves. As soon as the operation was over he exclaimed, "Thank God, my pain has gone." Now he is as well as ever; motion is perfect; you cannot tell which eye has been done; and he is trebly grateful—grateful for relief from pain, grateful for his preserved eye, and last, though not least, grateful because he has been spared the annual expense and daily annoyance of an artificial substitute, which latter to a working man is something greater than you can readily conceive. It has been suggested by a shrewd and excellent friend of mine that this case is a very pretty one so far as it goes, but that it is by no means certain that we have done with it. "It is," he says, "on the cards that the pain may return." True, no doubt it may return; it might return even if the eye were excised. I was once about to perform this very operation upon a gentleman similarly afflicted, when another surgeon intervened and excised the globe. In that case the pain did return, and of course it might return in this; I do not think it probable, however; and if it does, we are by no means at the end of our resources.

There are three principal objections to this operation. I will name them in the order of least importance. First, it has been asserted that the eye projects in a ghastly fashion after enervation of the globe; second, that it wastes away; and third, that the nerve becomes so perfectly reunited to the eyeball that the patient is in exactly the same condition very shortly after the operation that he was in before it was attempted. This line of argument reminds me of that adopted by the gentleman who was accused of laming a horse which he had hired. He said, first, that the animal was lame when he took him out; second, that he was sound when he brought him in; and third, that he never had him at all. Gentlemen,



it is not true that the eye protrudes in an unsightly fashion after optico-ciliary neurotomy, and experience has amply demonstrated that it is not materially altered either in volume or consistence; while with regard to reunion of the nerve, we all know that if a nerve is divided and the cut ends maintained in apposition, it will reunite: there is nothing wonderful in that. Our veterinary friends have long been aware of this fact, and in operating for navicular disease, are always careful to excise a portion. But apposition of cut ends is not a state of things that obtains after division of the optic nerve; the eye is an exceedingly mobile organ, and it is difficult under any circumstances to imagine such accurate reunion as would suffice to establish lymphatic circulation, such as modern pathology has taught us is necessary for sympathetic infection. Here is an eyeball, the subject of neurotomy six years ago, which I excised, for reasons to be hereafter explained, last week. In this case, as you see, there is not the slightest reformation of nerve tissue; in fact, the moment the nerve is divided the eye turns outwards and the cut ends are at right angles to each other—a position which may be readily maintained until all chance of re-attachment of the shrunk extremity to the globe is gone. Moreover, I am entirely of Professor Schweigger's opinion, that the risk of reunion may be absolutely prevented by excising a portion of the nerve. Let me illustrate my meaning. The elephant is an animal that takes six feet at a stride, walks six miles an hour, and in the open can overtake the swiftest runner; yet it is well known that a trench of only seven feet in width will stop his progress absolutely—he cannot get over it to save his life; and I am convinced that if you will only cut a gap in the optic nerve of ten millimetres in extent, or thereabouts, you will just as



effectually stop the progress of that *bête noire* of the ophthalmic surgeon—sympathetic infection.

Now, gentlemen, I am quite prepared to be told that if this operation, so far as cutting off the connection with the sound eye is concerned, is equivalent to enucleation, and if it possesses so many advantages as regards the life-comfort and personal appearance of the patient, it is very strange that I should be constantly excising eyes at this institution, sometimes as many as three and four in a day. Well, it does seem strange; and there is no doubt that, in our overweening anxiety for the patient's welfare, we do excise many eyes that might be safely retained. But the eyes that we take out at this institution are for the most part eyes that have been crushed by a blow that has probably at the same time felled the patient; eyes that are the site of neoplastic growths which may prove malignant; eyes that have been penetrated by foreign bodies, and which retain their dangerous guests, or which belong to patients who cannot be trusted either to take care of themselves or to return if threatened with sympathetic ophthalmia. In all such cases it is no doubt the best, because the safest, practice to excise the globe at once. The case is different, however, when the eye, although sightless, is to all appearance perfect; when it is merely affected by neuralgia, slight recurrent inflammations, or luminous spectra, which torment the patient; when it is desirable to render a stump insensible, to preserve a "*moignon oculaire*;" or when the patient is threatened with sympathetic ophthalmia, and obstinately refuses to submit to enucleation of the globe. In all these cases, especially the last, neurotomy optico-ciliaris is a precious resource, and will, I feel convinced, be so regarded by all good surgeons whose motto is *primum non nocere*, and who are, as



I am sure we all are, specially anxious that their patients shall be, if no better, at least no worse off for anything that has been done.

There are three principal methods of performing this operation — Landesberg's, Schoeler's and Meyer's. Landesberg enters the orbit from the inside, Schoeler from the outside, and Meyer clears a large way by dividing both straight muscles. I prefer to operate from the inside myself, simply because the optic nerve enters the eyeball to the inside of its posterior pole, and is therefore more readily reached in this direction. I pinch up the conjunctiva immediately over the insertion of the internal rectus muscle, cut the tendon as in Graefe's operation for squint, pull the eye forwards, turn it inwards, and divide the nerve as far back in the orbit as possible; the eye is then rotated, and the piece of nerve left attached to the globe shaved off as close to the surface as possible; the cut ends of the muscle are then united by a suture, and the operation completed by the application of a compress bandage. Hæmorrhage, which sometimes proves a source of trouble, may be arrested by using the now insensible eyeball as a tampon, and pushing it well back into the orbit. I have never seen suppuration follow this operation, and only one case of slight ulceration of the cornea, which rapidly healed. One great advantage of the procedure is that you can always operate in time. Sympathetic ophthalmia never occurs until after the lapse of a month or thereabouts from the date of injury to the exciting eye; and if the patient absolutely refuses to submit to enucleation, you have always this operation in reserve. Speaking on this point, Professor Meyer of Paris remarks that sympathetic ophthalmia, "*Une fois déclarée poursuit généralement son cours même après l'enucléation du premier œil.*"



Cette opération [neurectomy] doit donc être considérée comme un moyen préventif dont l'application constant est inévitable aussi long temps que l'on ne peut déterminer avec certitude les cas de ce genre que resteraient toujours à l'abri de l'ophtalmie sympathétique." "You had better let me remove the eye," I sometimes say to patients who come to this institution. "Are you going to take it out?" "Yes." "Shall you put it in again?" "No." "I'll come again on Thursday." Such patients never do come again; and I have a painful recollection of two fine fellows, now absolutely blind, who lost their sight through this insane dread of having their eyes "took out." If, however, you call them back and promise to restore the eyeball, as in the operation for neurectomy, they will not hesitate a moment. It is not the permanent loss of sight—already gone—of one eye which they dread so much; it is the sacrifice of the globe itself which they regard with such very natural horror. Another advantage is that in young persons you are enabled to preserve a tenant for the socket, and so prevent comparative atrophy of the orbit and that side of the face, which forms so distressing a feature in some of these cases. Again, it enables us to render a stump insensible and fit to receive an artificial eye. For instance, I recently operated on a lady for cataract in the left eye, who had lost her right through a similar operation performed elsewhere. I was fortunate enough to succeed in restoring her sight, and when she could see she naturally wished to improve her appearance by wearing an artificial substitute. I said, "You must let me remove the remains of the lost eye." "Never," she exclaimed; so I divided the optic and ciliary nerves. Now she is able to wear an artificial eye, motion is as perfect as in the modern operation of exenteration, and she looks



much better than she would have done had she submitted to my original proposition.

Gentlemen, I have heard it whispered that the operation of enervation of the eyeball has proved fatal. I can find no record of any such accident myself, and suspect that the number of these operations are as yet too few to have contributed their quota to the tables of mortality. If it should do so, however, in due course we ought not to be surprised, for the risks of this operation are precisely those of enucleation *bien entendu*, neither more nor less, and I have known two deaths from the latter operation myself, and quite a number have been recently recorded by other surgeons. It has also been alleged that this operation has been followed by sympathetic ophthalmia in the other eye. I can only find a record (Leber's) of one such case, but when neurectomies are sufficiently numerous I have no doubt that the number will be multiplied. Mooren, Knies, Smidt-Rimpler, Pagenstecher, Steinheim, Horner, Critchett, White, Nettleship, Bowers, Ayres, Snell, Lawson, Carter, and others all record cases of sympathetic ophthalmia following enucleation, and whatever follows enucleation may of course follow resection; the only difference between the two operations is that sympathetic ophthalmia is probably less likely to follow resection than enucleation, simply because in resection it is absolutely necessary to cut the nerve as far back in the orbit as possible, and you are thus more likely to remove the whole of the inflamed or infected portion of the nerve than in the ordinary operation of enucleation. No doubt we are occasionally obliged to enucleate after neurectomy; the eye you see on the table was enucleated by myself—I now believe unnecessarily—six years after neurotomy from an excessive dread of sympathetic



ophthalmia. It has also been alleged that recent researches, especially Poncet's experiments on animals, have tended to discredit this operation, but the contrary is the fact. The only experiments on animals with which I am acquainted are those performed daily by our veterinary friends, and they show conclusively that if a sufficient piece of nerve is removed it never reforms; moreover, it was formerly supposed that the channel of communication between the two eyes in sympathetic ophthalmia was through the medium of the ciliary nerves; that opinion is now exploded. Deutschmann's researches having conclusively shown that it is the optic nerve, its lymphatics, and lymph spaces, which are alone the source of danger, the only bridge by which sympathetic ophthalmia, or ophthalmia migratoria as it ought to be called, can travel from one eye to the other. Speaking on this subject, Professor Schweigger of Berlin remarks, "It is not necessary to remove the exciting eyeball if by exsection of a piece of the optic nerve we can remove the bridge by which the inflammatory process travels from the injured to the non-injured eye;" he adds, that "neurectomy, while as efficient a prophylactic measure as enucleation, has the great advantage that it neither sacrifices the eyeball nor renders an artificial eye necessary." Professor H. Knapp of New York, in a recent paper on exenteration, says, "The mutilation from enucleation is a source of life-long misery and misfortune to many a sufferer in all classes of society." I have myself heard one of our most eminent ophthalmologists remark that "anything is better than a glass eye;" and I know one noble lord who absolutely refuses to wear one. It is for the opponents of neurectomy to explain away these facts and answer these arguments, to prove that we may not in certain cases obtain all the benefits of enucleation by a less severe operation, and one which is not only a "*moyen préventif*,"



but is also unattended by any mutilation whatever ; meanwhile, whatever may be the result of further discussion of this important question and extended experience of the operation of neurectomy, I am sure you cannot go wrong in adopting it in such cases as those I have pointed out.

We shall now proceed to operate upon our patients. There are five cases needing attention : one of these is a small boy with neoplastic growth following injury of the eye which will require extirpation ; another is the subject of traumatic cataract, which I propose to extract *secundem artem*—i.e., according to recent enlightenment, without iridectomy ; a third is suffering from infecting ulcer of the cornea, which I shall treat after Nieden's plan with the electric cautery ; and two others, both adult males, who have singularly enough come in to-day, who will afford me an opportunity of showing you the operation of resection which I have just described.

*Remarks after operation.*—Gentlemen, I need not now detain you with any remarks upon the first three cases you have just seen. With regard to the last two, the elder is sixty years of age. He comes from a large town in Yorkshire, and for three years past has been suffering more or less, and at varying intervals, from the effects of an accident to his right eye, which was cut across the centre by a chip from a boiler which he was mending. I saw him for the first time to-day, and he informed me that he had been in an eye infirmary, and that the surgeon, whose skill is well known, wished to take his eye out, an operation which he declined then, and again when I suggested it to him to-day. He came here, he says, "because he thought I might relieve him without taking his eye out, and if I could not do so he should return as he came." I suggested neurectomy, to which he submitted without a moment's hesitation, and which, as you saw, was performed without misadventure.



Now the eye is quite insensible, and I have no doubt that we shall have succeeded in relieving him from pain, annoyance, and attacks of recurrent inflammation, which have again and again prevented him from using the sound eye. The younger patient was injured by the bursting of a gun; his forehead was wounded by a chip of metal, and the right eye has been peppered with powder; he has bare perception of light with this eye; I cannot illuminate the fundus oculi, and the pain he has suffered since the accident three weeks ago has deprived him of sleep, and, according to his own account, rendered life unbearable. I could not ascertain that the eye had been penetrated by any solid substance, and it was clearly desirable that we should relieve his pain with as little injury as possible. I therefore, as you saw, divided the optic and ciliary nerves. As soon as the effect of the ether had subsided he declared that his pain had quite gone, and I think we have reason to believe that this happy state of things may continue. Should we, however, be disappointed, we always have enucleation in reserve.\* I may mention that some forms of neuralgia may be relieved by division of the ciliary nerves only, an operation which was first proposed by Von Graefe, and first successfully carried out by Professor Meyer. The operation was then performed by incising the eyeball, but it may be just as well accomplished by division of the nerves behind the globe, by separating the tendon of the internal and external rectus muscle and feeling *a tatons*, as it were, down to the optic nerve. I have here a little girl from the blind asylum who has been entirely relieved of neuralgia in this way, and two others—adult males—in whom the operation has been equally successful.

\* Both these patients made excellent recoveries, and have since continued quite well up to present date, November 12, 1886; indeed the younger man has a better-looking eye than the one depicted in the Photo., Fig. 2.



## LECTURE V.

---

### THE USE AND ABUSE OF MYDRIATICS.

GENTLEMEN,—A short time ago a lady residing some distance from Nottingham asked my advice respecting an affection which she had described in a previous letter as a “slight cold in the eye.” She was at the time under the care of a surgeon of considerable repute, who evidently shared her impression as to the trivial nature of the attack, since he had prescribed nothing but counter-irritants and a slightly astringent lotion. I found on examination that the case was one of iritis, and suggested treatment accordingly; as my prescription, however, involved a dark room, blood-letting and other *désagrémens*, the patient decided to return home, and placed herself under the care of an ophthalmic surgeon, who failing to effect dilatation of the pupil, endeavoured to counteract the evil influence of adhesions by excising a considerable portion of the iris. The lady recovered, but sight is impaired, the eye is to a certain extent mutilated, she has undergone an operation which has caused her much anxiety, and has lost most valuable time, all of which she might have been spared by judicious treatment in the first instance, *and* the timely employment of atropine.

When slight attacks of iritis, mistaken for irritation, are occasionally attended with such untoward results in the



persons of well-to-do patients, while under the care of eminent general practitioners, it is easy to see that such cases are likely to be common enough among those who constitute the ordinary *clientèle* of the ophthalmic surgeon, both in hospital and private practice; indeed, scarcely a week passes but I am called upon to prescribe for patients suffering from the effects of adhesions, which, so far as my experience goes, might have been easily prevented. The young lady you have just seen is a case in point, constrained to pass her days and nights in stitching. She was seized a fortnight ago while at work with a violent pain in her brow, accompanied with inflammation and lacrymation of the right eye. She was visited by her medical attendant, who prescribed blisters, anti-neuralgic remedies, and a lotion, which, from the pain she says it occasioned, must have been of an irritating nature. When I first saw her the eye was much injected, the cornea turbid, and the iris, naturally blue, had lost its tint and lustre; the pupil was adherent to the capsule of the lens, and in places you noticed that it was bulged outwards from the pressure of the imprisoned aqueous humour behind it. By tapping the chamber, thus setting free some exudative matter, the adoption of energetic antiphlogistic treatment, and the assiduous instillation of atropine, we have succeeded in effecting dilatation of the pupil, and the patient is now in a fair way to recover; there remains, however, in spite of all that can be done, one tag of adhesion which may prove a source of future trouble, and which might just as well have been prevented. In these two cases, as in the majority of those that come under our notice, only one eye is so far affected; but it not unfrequently happens that such patients do not apply to specialists or special institutions until both eyes are involved in the destructive process, the pupil



being firmly plastered to the capsule of the lens, its area occupied by dense membrane, and the sight so damaged that the sufferer has to be led about.

J. R——, the young man on whom you saw me perform iridectomy in both eyes, was one of these. He lives 200 miles away, was certified as hopelessly blind by the parish surgeon, and only came under my notice through the exertions of a benevolent clergyman. Two other cases, identical with this one, have been recently operated on, and there is one more which I hope to benefit by the formation of an artificial pupil, making four cases of actual blindness, the result of iritis injudiciously treated, which have come under my notice during the last five months. Would it be well, in view of these deplorable cases, to lay down a law that atropine should be employed as a matter of routine practice in all cases of inflammatory affection of the eyeball, on the ground that it could do no harm and might prevent adhesions? It would certainly simplify practice very much if such a rule could be adopted, but in point of fact atropine is as injurious in some cases as it is indispensable in others, and although, as we have seen, serious damage is done by the neglect of mydriatics their employment is occasionally fraught with danger and followed by disastrous consequences. In fact, I have at the present time three patients under treatment whose sight has been injured, and one in which it has been destroyed, by the injudicious employment of this valuable remedy. The patient in the women's ward on whom I operated ten days ago is one of these. She is fifty-six years of age, and has been suffering for months past from occasional dimness of vision, and now and then the appearance of a halo round the flame of artificial light. These symptoms, although the portents of glaucoma, were only tran-



sitory in character, and she might have gone on long enough *in statu quo* but for an unfortunate accident. She complained to her medical attendant, who was prescribing, she says, for a bilious attack, and he applied some drops, which, she tells us, in that curious phraseology which patients sometimes adopt, "expanded the pulp of her eye." Intense pain followed and sight was speedily abolished, so that when I first saw her she could only just perceive the light—in fact, glaucoma had been developed by atropine in the right eye, the left was actively sympathising, and the patient had not slept for nights. I at once excised a considerable segment of the iris; and the symptoms ceased as if by magic, she recovered rapidly, and useful though somewhat impaired vision has been restored.

Now these cases are by no means so rare that we can afford to ignore them; in a large ophthalmic practice they are constantly cropping up—indeed, they are more common than they used to be, because the new race of surgeons employ atropine more generally than their predecessors. In the case just quoted the drops were prescribed more by way of doing something, than as a remedy deemed necessary for the treatment of the case; but it not unfrequently happens that cases of inflammatory glaucoma are mistaken for iritis, and positively ruined by the instillation of atropine used with the very best intentions. The old lady from N—, on whom I performed iridectomy in both eyes three weeks ago is a case in point; she had slight redness of the eyeballs, slight pain, and one or two attacks of vomiting. These symptoms were not thought very much of at the time, and although the condition of the sight, which was very much impaired, ought to have occasioned alarm, this was looked upon as a mere symptom due to a bilious attack, and she was assured that vision would speedily



return. At this juncture a young practitioner assisting the gentleman in attendance saw the patient, pronounced the case one of iritis, and applied atropine; all the symptoms were speedily aggravated, and although the pain, vomiting and general symptoms have passed away since the performance of iridectomy there is very little sight at present, and very little prospect of any to come. Last week, among my private patients was a gentleman sent to me with a letter from his medical attendant stating that he had been suffering from rheumatic iritis, which had been treated by atropine. The case was one of glaucoma, and I was obliged to operate immediately—a proceeding which the patient did not anticipate, and for which he was by no means prepared. I need not multiply instances; enough has been said to show that the general practitioner who treats these cases of eye disease, unless exceptionally well informed, is beset by dangers—a Scylla and Charybdis, in fact: on the one hand, blindness from adhesions if atropine is neglected; on the other, glaucoma if it is employed in unsuitable cases. What is to be done? Specialists are not likely to make mistakes, but such cases do not come under the notice of specialists in the early stages, and in none is it more necessary “to stop the beginning.”

“Principiis obsta sero medicina paratur

Cum mala per longas invaluere moras.”

It behoves us, therefore, to formulate some general rules for the guidance of the medical attendant who is so frequently responsible for these cases in the early stages. What shall they be? Well, age is an important consideration. Young persons are not as a rule subject to glaucoma, although they not unfrequently suffer from iritis. I do not say young people never have glaucoma; indeed I have a case of cupped disc



with tension under treatment at the present moment, occurring in a girl of eighteen ; and last week I had to excise the eyeball of a young gentleman, the subject of congenital dislocation of the lens, for glaucoma absolutum, whose symptoms had been greatly aggravated by atropine. But as a rule young people are not likely to suffer from glaucoma, and the employment of atropine with patients under thirty, forty, or even fifty, is comparatively safe. But you will say, Patients upwards of fifty years of age suffer from iritis and require mydriatic treatment. To which I reply, Certainly. The lady whose case I quoted at the commencement of this lecture was one of these. It has been suggested that only very weak solutions should be employed, and no doubt the danger may be in this way somewhat diminished ; but then weak solutions will not break up adhesions. To set the iris free you require strong solutions frequently applied ; moreover, feeble dilutions are by no means devoid of risk. I have seen glaucoma aggravated by very weak solutions of atropine, and the same remark applies to homatropine, which it was hoped might be employed with safety ; in fact, I have at the present time a lady patient under treatment in whom glaucoma was induced by a 1 per cent. solution of homatropine, and I note a similar case is recorded in a recent number of the *Weiner Med. Woch.*

It has been suggested by Mr. Hodges, of Leicester, who read an excellent paper on this subject before the Midland branch of the British Medical Association last year, that the medical attendant should use his fingers, and by palpation ascertain the condition of the eyeball as to tension before dilating the pupil ; but, as I remarked at the time, a certain amount of *tactus eruditus* is necessary to do this in any case, and when the eyeball is small, the orbit deep, and the eyelid thick and



flabby, or the patient intractable, it is by no means easy to arrive at a just conclusion, especially when the case is not a very decided one, and the subjective symptoms not very marked. Moreover, in cases of simple glaucoma tension is not increased, or only very slightly increased; but you will say, There is no inflammation in simple glaucoma, no suspicion of iritis, no fear of adhesions; then why use atropine at all? Why, indeed? Nevertheless, it is frequently used in these cases by practitioners oblivious of the maxim, *Primum non nocere*, simply by way of doing something, or in order to clear up the diagnosis. The patient complains of dimness of vision; to the unpractised eye there is an appearance of opacity; the case is supposed to be one of cataract, and atropine is used either to improve sight by dilating the pupil or facilitate ophthalmoscopic examination, often with fatal effect. I remember a case of this kind occurred at this institution when it was first inaugurated. The patient was an aged female suffering from simple glaucoma; atropine was used through some mistake, and the symptoms were so much aggravated that she declined all further treatment on the ground that "them drops had blinded her." Are there no means of dilating the pupil without incurring these terrible risks? Have we no mydriatic that is safe? Are not some safer than others? These are questions which at present it is very difficult to answer. I am, however, inclined to think that cocaine will be found the safest mydriatic to employ in a doubtful case. Certainly it reduces the tension of the normal eye in a most marked degree—a fact we have frequently demonstrated during the operations for cataract performed under its influence; whether its effect will be innocuous, beneficial, or otherwise in glaucoma, however, remains to be proved. Any way it will be



long before medical men in general practice will have cocaine at hand to use in a doubtful case. Meanwhile what advice can we give to the attendant who is called upon to treat a case of eye disease, which may be glaucoma, which may be iritis, or which may be simply surface irritation? Well, the best advice I can give in such cases, if there is the least doubt—especially if the patient is past middle life—is for the attendant to get rid of the responsibility. Medical men as a rule remain long in one place; their patients are their neighbours, friends, and acquaintances, often of years' standing; and it is a grave misfortune for a practitioner to have in his immediate neighbourhood—next door as it were—one who believes, rightly or wrongly, that his worst misfortunes are due to his attendant's want of skill, lack of interest in the case, or failure to appreciate peril. I therefore counsel, in view of the life-comfort of the patient, and with regard to the reputation of the practitioner, that what is sometimes called "better help" should be called in. There are ophthalmic surgeons now in most towns; and it is better that those whose backs are broad should bear the burden, if burden there be to bear. For the successful treatment of an odd case or two of this kind can do no one any good; while failure involves loss of reputation, more or less merited reproach, heart-burnings, and an uncomfortable feeling that you have not done your duty to a friend and client when his dearest interests in life were at stake.

---



## LECTURE VI.

---

### EYE TROUBLES IN GENERAL PRACTICE.

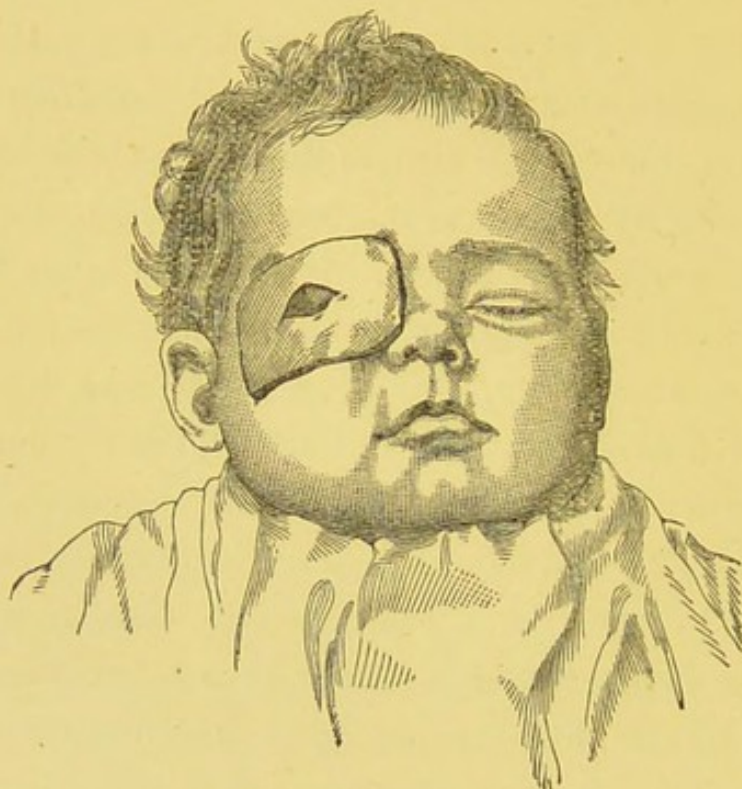GENTLEMEN,—To restore sight to the blind has ever been considered one of the grandest of human achievements, and I can assure you that I never succeed in that endeavour without feeling proud and at the same time humbly and profoundly grateful. Brilliant and gratifying, however, as undoubtedly are the results of our most frequent ophthalmic operations, they are after all but as dust in the balance compared to the vast amount of human misery which is alleviated, and the sum total of blindness which is prevented by the judicious treatment of the most common maladies to which our patients are subject, and which invariably in the early and most curable stages come under the notice of the general practitioner. Take for instance that most frequent of all the causes of blindness, the purulent ophthalmia of infants. There is no disease so easy to prevent, there are few diseases so easy to cure, and there is not one so fatal in its effects. If you will look over this work by Professor Corradi, entitled “*La Cecité en Italie*,” you will find that there are upwards of three hundred thousand blind persons in Europe alone, and if you will glance at this graphic



representation of the causes of blindness prepared by Dr. Magnus, of Breslau, you will see at once that the purulent ophthalmia of infants stands at the head of the list, while if you will study, as I have done, the reports of the various Blind Asylums throughout Europe, you will find that from thirty to forty-six, aye, and fifty per cent. of the inmates of these Institutions owe their misfortunes to this terrible disease. Gentlemen, just consider what this means. It does not mean blindness coming on after a long life of usefulness or pleasure; it does not mean dimness of vision, admitting of more or less hopeful treatment; it does not mean damaged sight or blindness of one eye: it means blindness of both eyes, total, irreparable, coming on in the very earliest days of infancy, and lasting throughout the whole of many a long, weary, tedious, desolate life. Now this disease is not caused, as many have believed and taught (*Stellwag*), by cold, by a draught, or by sudden exposure to concentrated light. It is caused, as was first pointed out by our distinguished countryman, Gibson, of Manchester, by the direct inoculation of the child's eyes with the secretions of the mother's vagina, and may be prevented as easy as easy can be by curing the leucorrhœa of pregnancy, by disinfecting or wiping away the discharge even so late as during the progress of labour, by insisting upon the most scrupulous cleanliness on the part of the attendants so that their hands may not communicate infection, and by taking care that the child's face is not washed in the same water which is used for its bath, and that its eyes are not wiped with the same sponge that is used for its person. Gentlemen, if these precautions were thoroughly carried out in every case of midwifery, I venture to affirm that there would not be one other case of Bacterial Purulent Ophthalmia in the Universe. Even if a little matter



should have got into one or other of the child's eyes, it may be destroyed at once and *in situ*, before any harm is done, by a



two per cent. solution of nitrate of silver,\* and if one eye should unfortunately have become infected before you see the case, and mind you, it is seldom that both eyes are struck at once,† the sound eye may be protected and sight assuredly preserved by the use of this little simple contrivance, this sticking plaister

\* This is Credé's much vaunted method; a solution of nitrate of silver eight grains to the ounce, is dropped into each eye of every child born, "dans les services d'accouchement," and Dr. Kaltenbach in a recent communication to the *Congres Allemand de Gynécologie* declares that the cases of purulent ophthalmia have in consequence diminished from 15 per 100 to 0 per 100.—(See *Recueil d'Ophthalmologie* for August, 1886.)

† The ophthalmia *almost always* appears at first in one eye alone, the other being affected some days after. The transference of the secretion from one eye to the other seems to be the usual origin of the disease in the second eye.—(See *Treatise on Diseases of the Eye*, by Carl Stellwag Von Carrion, Professor of Ophthalmology in the Imperial Royal University of Vienna, p. 317.)



shield, which I regard with parental and I trust with pardonable pride, since I am sure that I have saved many an eye by its use.\*

Gentlemen, I said the disease was easily cured, and so it is. Let me quote a little evidence on this point. Mr., afterwards Sir William Lawrence, late surgeon to St. Bartholomew's Hospital, whose work I have here, and I can cite no higher authority, writing in 1833, says:—"There is a singular contrast between the virulence of this inflammation of the eyes of newly born children, and the serious consequences to which that inflammation so rapidly leads, and the readiness with which it yields to suitable treatment; hence if we see a case of purulent ophthalmia before any injury is done to the cornea, we may assure the parents, and it gives us great pleasure to be able to do so, that sight will not suffer. Even the most violent form is very manageable and will do well when properly treated."†

Again, Professor Knapp, of New York, another eminent ophthalmologist, whose archives I here commend to your notice, tells us, half a century later, "That no child need lose its eyes from ophthalmia neonati, and no child does if faithfully treated," adding, "I speak from an experience, not of dozens, not of hundreds, but of thousands of cases."‡

You will find a similar expression of opinion in the excellent brochure entitled "The Prevention of Ophthalmia Neonatorum and its Ravages," by Dr. David McKeown, of Manchester, presented to the Obstetrical Society of London, in

\* The Shield is merely a piece of sticking plaster with a hole in the centre, cut to correspond with the pupil, the aperture is filled by a piece of gauze. The baby depicted above, whose left eye was attacked with a virulent form of purulent ophthalmia three days after birth, had its right eye protected in this way upwards of a fortnight.

† Lawrence on *Diseases of the Eye*, p. 171.

‡ *Archives of Ophthalmology*, for March, 1882—Putnam & Sons, New York.



February last year; as also in this popular treatise entitled "Eyesight and How we Lose it," by my distinguished confrere, Dr. Priestly-Smith, of Birmingham; in short, gentlemen, not to detain you unnecessarily, I may say without fear of contradiction that on this point Ophthalmic Surgeons are agreed. The disease is easily cured. How is it, then, you will very naturally say, that so many children lose their sight from purulent ophthalmia? The reply to that question is simply this, either they are not properly treated or they are not treated in time. Let me prove this to you. Of six hundred and thirty cases treated in an early stage of the disease by Professors Horner, Schweigger, and Hirschberg,—six hundred and thirty, that is every one, recovered with absolutely perfect sight. On the other hand, and I bid you mark the sequel, of one hundred and twenty cases coming under the care of the same gentlemen, but not seen until a later stage, forty-nine, that is not quite one half, but more than a third, lost the sight of both eyes beyond all chance of recovery or possibility of improvement. Gentlemen, that is the trouble. The practitioner is called in when the parents are alarmed, or the specialist is consulted when the practitioner is alarmed, and then it is often too late either to save the eye originally affected or to preserve the sound eye from inoculation. A few days ago—perhaps I ought to say nights, for it was after eleven o'clock—a cab dashed up to my door, the bell rang violently, and a lady with an infant in her arms was ushered into my consulting room. "Dr. Bell Taylor," she exclaimed, bursting into tears, "Will my baby see?" I ascertained that the child's right eye commenced to discharge three days after birth, some days later the left was inoculated from it, and both had been discharging freely for three weeks. All was supposed to be going on well. "The child



had a cold in its eyes," and so far as I could learn no special anxiety was felt as to the result, when suddenly it flashed upon the mother that her boy might lose his sight! and acting on the impulse of the moment, though late in the day, unfit to travel, and a hundred and fifty miles away—she started to the station and caught the train for Nottingham. I succeeded in arresting the discharge in a few days, but both eyes were lost from sloughing and ulceration of the cornea, when she started on her journey? Gentlemen, this is a deplorable state of things, it ought not to be, and I can assure you that the various societies interested in the prevention of blindness look to you general practitioners, who attend midwifery and who have so much in your power, to save us from further reproach on the score of blindness from purulent ophthalmia. With regard to treatment, mycologists assure us that the virulence of the disease is due to the ravages of a gonococcus discovered by Neisser in 1879, which, like an elephant in a field of maize, battens on the cylindrical epithelium of the palbebral conjunctiva. It appears that the columnar epithelium of the bulbar portion of this membrane affords no nutriment to this microscopic specimen of the *Feræ Naturæ*, however that may be, it is an important clinical precept that our remedies must be sufficiently strong to disinfect the conjunctiva and that they must be applied to the inside of the everted lids, at least once in twenty-four hours. I have found chloride of zinc an excellent antiseptic myself, but the remedy *par excellence*, is the nitrate of silver, which may be used in the form of mitigated stick, or two per cent. solution.\* Meanwhile the matter must be worked out from underneath the lids—which must be prevented

\* If the remedies must be entrusted to the friends, the nurse may drop into the eye a solution of nitrate of silver, 2 or 3 grains to the ounce, thrice daily.



from sticking together by a little oxide of zinc and white precipitate ointment, and the eye must be kept saturated with alum water or weak solution of chloride of zinc (1 gr. to ounce), which may be iced or heated according to the nature of the case. If the lids are swollen, tense, red and shining, they may be punctured, leeches, or painted with a solution of nitrate of silver in nitric ether, and if the cornea threatens to give way, the anterior chamber may be tapped and a compress bandage applied. You need not fear to separate the lids for the purpose of looking at the eye in the early stages of disease, but later on the utmost care is needed. I was called to a case of this kind some time ago, a long way off; two surgeons were already in attendance, one a specialist. I said, "The cornea of the left eye is on the eve of perforation, and I think we had better give a little chloroform, tap the chamber and apply a compress bandage." My ophthalmic friend dissented from this view, and proceeded to repeat my examination for himself. I was leaning over anxiously, I may say fearfully, watching the process, when, either from some sudden motion of the child, or undue pressure on the part of the operator, the lens was projected with violence and struck me in the right eye! By dint of free ablution and the use of antiseptics, I was "quit for the fright," but it was a warning to me, and I am sure it will be a warning to you to be careful how you conduct an examination in the later stages of purulent ophthalmia. Apart from the danger to the child itself, the risk to attendants from carelessness in this respect is something greater than you can readily conceive. Let me endeavour to impress this upon you by a recital of two or three very important facts.

*First*,—I have known a short-sighted nurse inoculated by pent-up matter which spurted out when the adherent lids were suddenly separated.



*Second*,—Two friends of my own, surgeons, have each lost an eye from accidental infection.

*Third*,—It is a fact that 11·8 per cent. of the nurses in the St. Petersburg hospital manage somehow or other to contract this disease from children under their care.—(*Hausmann*.)

*Fourth*,—If you will refer to the reports of the Foundling Hospitals of Prague, of Vienna, of St. Petersburg, and the records of the Parisian Crèches, you will find that a considerable proportion—from a fourth to a third (*Fuchs*)—of the baby inmates of these institutions contract this disease after admission, and may thus be said literally to be taken in and blinded at the public expense.\*

In order to avoid these deplorable accidents, it is well that those who are much engaged in the treatment of these cases should wear large protective glasses. Sponges and syringes (the latter also because they are apt to injure the corneal epithelium) should be discarded, and all rags, linen, &c., which have been in contact with the discharge, should be at once destroyed; for, as you will learn directly, it is dangerous to wash them.

Adults and others infected from children suffering from ophthalmia neonati, present various degrees of purulent ophthalmia, according to the stage and virulence of the source of infection, and authors usually consider gonorrhœal ophthalmia under this head, because it is marked by the presence of the same microbe, and is alike communicated by direct infection. There is no comparison, however, between the amount of reaction and destruction occasioned by inoculation with a mild

\*At the meeting of the Imperial Surgical Society of Paris, on February 21st, 1866, M. Giraldés (*L'Union Med.*, No. 823, et. 26, 1886) reported that in the Hôpital des Enfants Trouvés, the loss of eyes (sometimes even of life) by blennorrhœa neonatorum reached the enormous number of 80 to 90 per cent.



*fluor albus*, such as most women suffer from sometime or other during their lives, and that which follows the insertion of a particle of gonorrhœal matter into the conjunctival sac; indeed in the latter case it is almost impossible to save the eye. Speaking on this point, Professor Arlt, of Vienna, says:—"I have lost many eyes from gonorrhœal ophthalmia." Mark that, Gentlemen! Professor Arlt is one of the most accomplished practitioners in Europe, and perhaps *the* most experienced; and if he, with all appliances and means to boot, cannot save the eye in a majority of these cases, it is clear that we have to do with a disease of exceptional virulence. Fortunately, however, in this affection only one eye is infected (unless when the patient has bathed his eyes with his own urine), and we can always guarantee the sight by protecting the sound eye with the shield to which I have already called your attention; and here let me beg of you to apply it on suspicion. This simple shade cannot, under any circumstances, do any harm; sight is not interfered with; ventilation is perfect; the patient is not prevented from helping himself or walking about; and its neglect is often attended with most disastrous consequences. Above all, let me beg of you not to believe the youths and young men, the most frequent subjects of this affection, when they tell you they are free from venereal taint; for I have known even highly educated gentlemen deny the soft impeachment, when a moment's examination has sufficed to reveal the origin of the disease. We had a sad example of the results attending the neglect of the shield, in the case of a poor woman from Grantham, who was here three months ago. Her right eye—(it is generally the right eye)—was inoculated from some linen she had to wash, and discharged freely for three weeks; at the end of that time, sad to relate, some of the matter got into the left



eye, and when she came here both cornea had sloughed. She was a widow, forty years of age, strong, active, fond of work, and had two children dependent upon her. Think of it!—hopelessly blind for life; and all for want of a bit of sticking plaister which any country druggist might have applied just as well as the most accomplished surgeon.

With regard to the treatment of gonorrhœal ophthalmia, “Dreadful diseases require dreadful remedies,” and if you are to succeed you must be instant in their application. I usually apply leeches by the handful, pack the eye with ice, and, unless there is some contra-indication, keep it constantly applied, slit the outer canthus, incise and excise (if necessary) portions of the chemosed conjunctiva, and get the patient rapidly under the influence of mercury. During the crudesence of the disease, and when it is at its height,—that is, during the first forty-eight hours, or while the discharge is serous,—strong caustics are out of place; but you may keep the eye saturated with weak solution of chloride of zinc ( $\frac{1}{2}$  or  $\frac{1}{4}$  per cent.)\* from the beginning, and as soon as the serous discharge becomes purulent, apply as well once or twice daily to the inside of the everted lids, a two to four per cent. solution of nitrate of silver, carefully protecting the eye by neutralization with milk, or saline solution. I have saved some eyes in this way, but occasionally the cornea will slough in twenty-four hours, and then all you can do for the patient, and that is everything, is to protect the sound eye from inoculation.

\* I consider the constant application of these solutions of the utmost importance. Dr. Colles, of Dublin, writing in the *Dublin Quarterly*, vol. 35, page 5, declares that he has been singularly successful in cases of gonorrhœal ophthalmia with solution of nitrate of silver,  $\frac{1}{4}$  grain to the ounce, injected every ten minutes for twenty four hours; afterwards the strength is increased to  $\frac{1}{2}$  grain to the ounce, and is injected every half-hour.

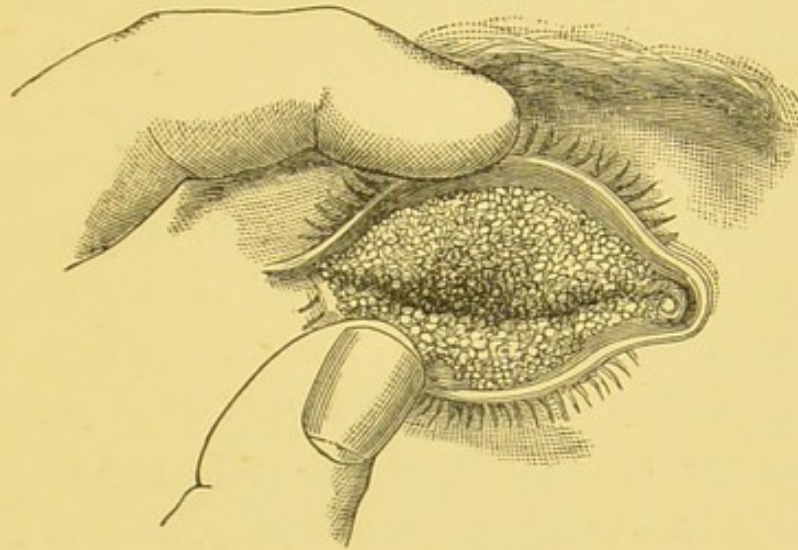


Hitherto, Gentlemen, I have been speaking exclusively of Bacterial purulent ophthalmia, a disease which, so far as the infant and infection from the maternal passages are concerned, must occur within the fifth day of birth or not at all; and it is well that you should note this, because, of course, a baby may get a cold in its eye, just the same as you or I. Such accidents are, however, for the most part trivial, infrequent, and readily dealt with by the simplest remedies. It is different, however, when catarrhal ophthalmia attacks older children or adults living in common, in barracks, schools, reformatories, poor-houses, prisons, asylums, refuges, penitentiaries, and the like, where the inmates are often overcrowded and placed under defective hygienic conditions; for the disease, which is highly contagious,—nay, more, under certain circumstances, infectious,—spreads rapidly; is apt to assume what is termed the follicular form; to develop minute bodies beneath the conjunctival epithelium, resembling sago grains;\* and to culminate in that horrible, chronic and intractable disease which we know as trachoma (*τραχός*, rough), or granular lids. These defective hygienic conditions, combined with filth, misery and overcrowding, exist to a high degree in Egypt, the cradle of the arts and sciences, and as Haller has remarked, "*Cacorum in omni tempore facunda nutrix*," where the cold nights, the heavy dews, the hot days, the glare, the atmosphere

\* Sattler says the disease is caused by a microzoon which he calls the diplococcus of trachoma. It is a small ball, cleft by a tiny line, very like the gonococcus of Neisser, but it may be cultivated in various soils, whereas the gonococcus of Neisser can only be cultivated in the serum of the blood. Speaking on this point, Mr. Power, in his admirable lectures on Bacteriology, says:—"The diplococcus of trachoma has its seat inside the trachoma follicles, but outside the cells, not on the surface, but in the follicles of the conjunctiva: hence the method of squeezing, cutting, or scratching out the follicles is bacteriologically correct."



of dust, and periodic inundations, have rendered the disease endemic to such an extent, that at one time there were as many as eight thousand blind persons in the mosque at Cairo; and Volney, in his interesting "Voyage en Syrie," tells us that of one hundred persons he met accidentally, fifty were affected;—twenty, quite blind; twenty, with films and dis-



charges; and ten with only one eye apiece. As might have been anticipated, the soldiers of Sir Ralph Abercrombie and Napoleon the First, at the close of the last century, imported the disease into Europe, where it raged at one time to such an extent, that four thousand British soldiers were blinded by it; five thousand French were in a similar plight; and ten thousand others had lost one eye apiece. In this disease the inside of the lid resembles a nutmeg grater, a sliced fig, or a granulating wound, and by constantly rubbing upon the cornea creates so much irritation, inflammation, vascularization, and formation of protective tissue, that the patient is pretty nearly blind, and in some cases the cornea is so completely covered with a fleshy mass (*pannus*), that it is not possible to see the eye at all.

Here is a patient on whom I operated some years ago. He lost the right eye by an accident when a child some two years



ago, and, when I first saw him, the left eye was completely hid by a dense piece of flesh. I got rid of this by repeated inoculations with gonorrhœal matter, bringing into view an opaque cornea. There was, however, a small lancet of comparatively clear tissue near the margin, and opposite this I was lucky enough to succeed in forming an artificial pupil. The patient, who was formerly quite blind, I am thankful to say has since had excellent sight, and has been for years able to manage an important business.


In dealing with granular lids and the catarrhal and follicular conjunctivitis which give rise to it, we must remember that prevention is better than cure, and at once segregate our patients as much as possible. Let them live out of doors; teach them, as Arlt says, "That houses are only to sleep in." Banish, so far as possible, media of contagion. Let each boarder have his own towel, his own soap, and let them wash at the tap, for basins are dangerous. It is very seldom that better-class patients suffer from this disease; but when you get them it is well, as a purely hygienic measure, to recommend migration for a time to some mountainous district, such as Switzerland, where the disease is unknown. With regard to treatment,—I scarify the lids; squeeze out the sago grains; occasionally, but not often, excise the retro tarsal fold, and apply liquor potassæ, sulphate of copper, or syrup of tannin, (nitrate of silver as a caustic does not go deep enough), and deal with bad cases by peritomy and inoculation with ophthalmia neonati, or gonorrhœa, or infusion of pater noster bean.

I have here a patient whose conjunctivæ were both completely destroyed by trachoma before I saw her (Zerosis), and I have only managed to preserve a little sight by estab-



lishing an artificial ankyloblepharon in both eyes. We don't see many cases of trachoma at this Institution, I am happy to say; but here is a small boy who is a characteristic example of a form of disease which, like the poor, we have always with us.

This lad's mother informs us "that he is very subject to getting his nose stopped up," and "that at first they thought it was weakness that had fallen into the glands of his neck." On examination we find that the nostrils and upper lip are swollen, that the cervical glands are enlarged, and that there is an eruption on the scalp and in the neighbourhood of the right auricle; in short the boy has got eczema of the skin,



and we need not wonder, under such circumstances, if he has also eczema of the conjunctiva, and that is precisely what



is the matter,—Phlyctenular conjunctivitis, or conjunctivitis scrofulosa, as it used to be called. There are two forms of this affection, the miliary and the solitary. The miliary phlyctens are scattered like grains of sand on the vascular limbus of the cornea ; usually come on after measles or scarlet fever ; and are masked by considerable general conjunctivitis. The solitary phlycten is about the size of a hemp seed, is surrounded by a vascular zone, and marked by a small bundle of vessels which radiate outwards towards the equator of the globe. Both forms yield readily to the yellow oxide of mercury ointment, with general treatment, and it is only when the phlyctenular conjunctivitis becomes phlyctenular keratitis, that you are likely to have any trouble with the case. Vesication and ulceration of the cornea, however, is a very painful process. Nerve terminals are exposed, photophobia is intense, iritis is sometimes set up, the constitution sympathizes, the patient loses his rest, and the ulcers, even when healed, leave scars which may subsequently seriously interfere with vision. In these cases it is necessary to apply leeches, give mercury, put a seton behind the ear, and use hot belladonna fomentations. You will also find that an excellent plan of treatment is to open the anterior chamber with a broad keratome, so as to divide the vessels and nerves at the base of the ulcer. In this way tension is reduced, pain relieved, healing promoted, and the effect may be kept up by daily tapping of the aqueous with a blunt probe, and the ulcer, if obstinate, may be touched with the galvanic or thermo cautery, after the method so successfully practised by Dr. Nieden, of Bochum, Prussia. The worst forms of ulceration of the cornea, however, with which we have to deal, are those occasioned by foreign bodies, often aggravated by attempts at removal. In order to avoid



this mischance, you will do well to take a hint from our friends the watchmakers, and use a lens. Fixed in the operator's orbit after the manner familiar to us all, both hands are free, and the foreign body may be readily lifted from its abnormal situation without increasing the area of injury occasioned by its impact. It frequently happens, however, that we do not see these patients until the cornea is clouded and infiltrated with the formation of pus in the anterior chamber, in which case the ulcer should be divided freely across with a thin Graefe's knife, after the manner recommended by Professor Saemisch, (*Handbuck der Augenheilkunde*). Organized lymph and shreds of matter should be gently removed with forceps; and warm fomentations, antiseptics, and atropine or eserine, according to the nature of the ulcer, applied. The chamber may be re-opened daily, so long as the pus re-forms, by a mere touch with a blunt probe, and an artificial pupil practised afterwards, if necessary.

When minute fragments of steel have penetrated the cornea, their presence may be demonstrated by this admirable instrument, the electro-magnet, for which we are indebted to Mr. McHardy, of King's College. It is not often in these cases that the lens escapes without injury, but I recently extracted a piece of steel through a small incision from the anterior chamber with this fine conductor, without the formation of cataract or any further damage to the eye. When the lens is wounded, it swells, presses forward, and acts upon the iris both as a chemical and mechanical irritant. In these cases we must extract, or if from the nature of the accident this is too great a risk to run, a piece of iris may be removed.

Sight, however, may be seriously affected without any loss of corneal transparency, by mere abnormalities of shape. The



cornea may be too flat and the eye too short (hypermetropia), or too long (myopia), or it may be too convex (kerato globus), or the refraction may differ in different meridians (astigmatism), or it may even project like a sugar loaf (kerato conus). When the eye is too flat the patient can see at a distance, even through a convex glass; but vision with the naked eye for near objects soon becomes confused;—in these cases we must prescribe convex glasses. In cases of astigmatism a combination of cylindrical and spherical lenses is requisite. Iridectomy, in some exceptional cases, is said to do good in kerato globus, and I am in the habit of treating cases of conical cornea by touching the apex of the cone with the galvanic cautery. With one or two applications the aqueous escapes; the wound in healing, after the manner of burns, contracts; the normal curvature of the cornea is restored; and the cure completed by making a pupil sideways, and, if necessary, tattooing the scar. With regard to myopia, it is very generally believed that because short-sighted persons can see minute objects with very imperfect light, and because they can read without spectacles at an age when most persons require such aids, that therefore short sight is strong sight. Speaking on this subject, Dr. Williams, the eminent professor of ophthalmology in the Harvard University, the oldest University in the United States, says, “Very high degrees of myopia should be recognized as an infirmity deserving careful consideration before assuming the obligations of marriage; for those in moderate circumstances may well hesitate to choose partners, who, though highly cultivated, may probably at middle life become unable to provide for their households or care for their children.”\* Surely that is a serious disease! He adds, “Myopia

\* “Diagnosis and Treatment of Diseases of the Eye.” p. 374.



is one of the gravest affections of the eye, capable of limitation by constant care during childhood and youth ; but if not thus limited, likely to be a source of future disability and misery, and *to be handed down as an onerous inheritance to children.*" Surely that is a serious disease !

Let me epitomise for your guidance a few facts relative to this very important subject. If short sight is not developed before sixteen years of age, it will not be developed at all ; if it has not reached a higher grade than one-tenth by twenty, it is not likely (if care be taken) to increase. Higher degrees than this are an ever-present source of danger, disability, and frequent disaster. It is more likely to be developed in weakly children than in others, and frequently makes rapid progress in those who are recovering from illness. It is unknown among savage tribes and tillers of the soil, and is the direct result of a vicious system of excessive education, making its appearance first in the children of village schools in the proportion of about one per cent. ; in schools of higher grade, twenty per cent. ; higher still, forty per cent. ; and the attention of the German Parliament has recently been called to the fact that in some districts where compulsory education has been longest in force, upwards of fifty per cent. of the inhabitants are affected. Not only is the numerical ratio raised, but the intensity of the disease is also increased in direct proportion to the hours spent in study. With regard to treatment, again I say, prevention is better than cure ; better indeed in this case, for cure is impossible. I see many of my eminent colleagues suggest desks, and fittings, and light arrangements, and props to keep the children's heads in certain positions ; but to my mind, desks and props and fittings do not meet the difficulties of the case. From five to fifteen is the dangerous



age—the very period that the school board have selected for their paternal ministrations,—and if the eyes of a child between these ages begin to give way, there is no rational treatment but enforced absence from school; and I don't think myself that such compulsory holiday ought to be regretted by any one, for children's brains do not grow in proportion to the stuff they cram into them; and, after all, true education is something that a man seeks for himself, and finds for himself, and does not usually begin until long after school-days are over. Short-sighted persons who must complete their curriculum of study for the Church, the Bar, the Civil Service, or other professions, should wear weak concave glasses for reading, so as to be able to hold print about twelve inches from the eye. The light should be good, and come from the back or side, and they should not read or work when lying down, leaning forward, or travelling in a railway carriage. "Seekest thou great things for thyself?—Seek them not." To no class does this sage warning apply with greater force and justice than to the myope. Of two brothers, Germans, myopes, and students of medicine, one took heed of this warning, accepted a mediocre degree, and preserved his sight by an outdoor life and country practice. The other heeded not; but worked on, and at last achieved distinction, only to find himself, shortly after middle life, unable to walk alone or recognize his fellows. Another condition that you will find very much benefitted by glasses, occurs in patients of forty or upwards, who occasionally suffer from marginal blepharitis, the formation of styes, and a feeling of general worry about the eyes owing to reflex irritation from neglect of these aids to vision. Still another is that of chronic invalids, specially women suffering from uterine complaints, painful menstruation,



and the like; who spend much of their time on their backs; who read in this unnatural position, and complain of pain and neuralgia whenever they use their eyes. In these cases, in the absence of any marked ametropia, I usually prescribe weak convex glasses combined with abductive prisms, and recommend graduated exercises after the plan first suggested by Dr. Dyer, of Pittsburgh, Pa. Gentlemen, I have already pointed out to you the great danger of mistaking a slight case of iritis for mere surface irritation,\* and neglecting to dilate the pupil; the equally great, if not greater, danger of using atropine if the case should be inflammatory glaucoma, a disease which you are apt to mistake for iritis. I have dwelt on Squint and Cataract, and pointed out those cases where the eyeball must be extirpated, and those where, in my opinion, optico-ciliary neurectomy may be advantageously substituted. Let me close this brief and necessarily imperfect sketch by calling your attention to two other errors which I find very frequently committed.

Here is a boy who was sent to me by his surgeon to be treated for myopia, and in truth, on ordinary inspection, you might easily conclude that his imperfect sight was due to that cause; but if you dilate the pupil, or use the ophthalmoscope, you will see at once that he is suffering from congenital cataract. Bear in mind, therefore, that there may be considerable opacity of the lens which is not at all visible on ordinary inspection.

Some years ago I was sent for to operate upon a lady, the wife of a military gentleman of considerable social importance. Two surgeons and a physician were already in attendance, and I was informed that the patient, although advanced in life

\* See Lecture V., on "The Use and Abuse of Mydriatics." p. 68.



and very nervous, would prove a good subject for operation, as the cataract was fully formed in each eye. On examination, however, I found that the case was one of simple glaucoma; there was no cataract at all; and the time for beneficial treatment had gone by. Now, you will avoid this latter error by remembering that a dusky pupil is quite a natural phenomenon in aged persons, and that it is not at all safe to conclude that because this appearance is accompanied with failing vision, therefore the case is one of cataract. You must use the ophthalmoscope, or, failing that, trust to subjective symptoms. Of these the most important are limitation of the field and iridescent vision. You will find, if the case is one of glaucoma, that the patient cannot see to the inner or nasal side, or vision is very limited in that direction, and if he looks at a candle or artificial light it is surrounded by colours red and green. You will see what I mean if you will breathe on the glass and look at the street lamp outside. This is an early and significant symptom of glaucoma, and if it does not disappear on rubbing, is not accompanied by evident opacity of the cornea, and does not disappear under the influence of eserine, you must be prepared to treat for glaucoma, or call in the aid of an ophthalmic surgeon.

Gentlemen, when I was a student, I was taught to contemn Specialism, and my teacher was Mr. Syme. Now, I look upon the late Professor of Clinical Surgery in the University of Edinburgh as probably the first surgeon of the century, and am therefore disposed to regard any opinion of his with exceptional reverence;—in this, however, I feel sure he was wrong. Life is so short; art is so long. It is so human to err: you require to see so many hundred patients before you know how to treat one. You require to perform the same



operation, not only over and over again, but to be always at it, before you can insure for your patient the utmost benefit that art can afford ; so that I feel convinced that if science is to be advanced and humanity benefitted, it will be mainly by gentlemen who devote special attention to special subjects, and who place the fruits of their labours at the disposal of the whole profession. It is in the fulfilment of that duty that I am here to-night ; that I venture to offer you these few hints, and to assure you that I am highly gratified by your gracious acceptance of the same.

[ALL RIGHTS RESERVED.]



