

**Chronic suppurative dacryocystitis and its radical treatment : read before the British Medical Association, Toronto, Canada, Thursday, August 23rd, 1906 / by Fred T. Tooke.**

**Contributors**

Tooke, Fred T.  
University College, London. Library Services

**Publication/Creation**

London : British Medical Association, 1906.

**Persistent URL**

<https://wellcomecollection.org/works/npp4bjb5>

**Provider**

University College London

**License and attribution**

This material has been provided by This material has been provided by UCL Library Services. The original may be consulted at UCL (University College London) where the originals may be consulted.

Conditions of use: it is possible this item is protected by copyright and/or related rights. You are free to use this item in any way that is permitted by the copyright and related rights legislation that applies to your use. For other uses you need to obtain permission from the rights-holder(s).



Wellcome Collection  
183 Euston Road  
London NW1 2BE UK  
T +44 (0)20 7611 8722  
E [library@wellcomecollection.org](mailto:library@wellcomecollection.org)  
<https://wellcomecollection.org>

36

# CHRONIC SUPPURATIVE DACRYOCYSTITIS AND ITS RADICAL TREATMENT.

*Read before the British Medical Association, Toronto, Canada,  
Thursday, August 23rd, 1906.*


BY  
FRED. T. TOOKE, B.A., M.D.,  
Clinical Assistant in Ophthalmology, Royal Victoria Hospital, Assistant  
Demonstrator in Ophthalmology, McGill University, Montreal, Canada.

*Reprinted from the BRITISH MEDICAL JOURNAL, December 22nd, 1906.*

LONDON :  
PRINTED AT THE OFFICE OF THE BRITISH MEDICAL ASSOCIATION,  
429, STRAND, W.C.

1906.







## CHRONIC SUPPURATIVE DACRYOCYSTITIS AND ITS RADICAL TREATMENT.

### *Introduction.*

It is an acknowledged fact that, with the lachrymal sac in its normal condition, the secretion of tears and their irrigation through the lachrymal channels is a physiological necessity. In a cavity lined with a secreting membrane as the tear sac, where pathogenic bacteria and epithelial debris are most liable to collect, the flow of tears is a most important factor in cleansing the cavity by the simple process of irrigation.

The same argument does not hold in the case of the palpebral conjunctiva when once the sac has been excised; the lids and globe being in constant motion, bacteria are prevented from collecting at one point, as they do in the case of a strictured sac, but are distributed or expelled over the palpebral margins by the blinking action of the lids. These bacteria, found in the palpebral mucosa, assume a very much more benign character than the same species found in a stagnant tear sac either before it has been excised or before its lumen has been opened.<sup>1</sup>

Regarding the exact function of tears, the following information has been obtained: That in addition to their acting as a simple irrigating factor, they have some inherent power inhibiting bacterial growth. Exactly what this potency is due to has not as yet been satisfactorily explained. Two conclusions, however, have been arrived at.

1. That bacteria are removed from the conjunctiva by tears acting as a simple irrigating factor, the secretion being ultimately drained away through the lachrymal sac into the nose.

2. That there is something of a bactericidal nature in the composition of tears; cultures of various organisms, more particularly of the *Staphylococcus albus*, produce fewer colonies in media containing tears than in media not containing them, or even than in media containing a solution of sodium chloride supposed to correspond to the lachrymal secretion.

The modern practice in ophthalmic surgery of discarding all heavy dressings and bandages which inhibit the action



of the lid should support the view that the prevention of bacterial growth in the conjunctiva must not be accounted for solely by the flow of tears, but, in a large measure by the free action of the lids, a circulation which is not impeded, and a secretion of conjunctival mucus which, when once collected can readily be distributed or expelled. In support of this assertion I may quote a case of keratitis neuro-paralytica, complicating a cerebellar neoplasm, which recently came under my care. An eye which, beyond a swelling of the optic disc, had always been normal, developed a paralysis of both lids a few days before death. The palpebral conjunctiva became very red, and a considerable quantity of mucus was collected in the lower cul-de-sac. I made bacteriological examinations of the secretion, which was found to contain enormous quantities of the *Staphylococcus albus*.

To enforce my argument that when the lids are covered or rendered immobile the number of bacteria are increased, I have made the following experiment, which I hope to be able to tabulate more extensively later. I have taken cultures on Petri dishes from the conjunctivae of eyes suffering from some mild inflammatory disturbance. After bandaging the eyes tightly for two or three days and taking a second series of cultures, a decided increase in the number of the colonies of the micro-organism first observed is noticed.

If a condition of this nature is produced in the eye by a simple bandage, a prevention of drainage in the lachrymal channels, particularly at the nasal duct where strictures most commonly occur, can readily be seen to produce similar, if not more emphatic results. A more fertile field for the production and cultivation of bacteria than a stagnant lachrymal sac is difficult to find. Bacteria thus fostered readily find their way back to the conjunctival surface, producing severe forms of conjunctivitis and lamentable results in the cornea, after some insignificant superficial abrasion.

#### *Etiology.*

After a routine bacteriological examination of all the patients which have come under my notice suffering from dacryocystitis I am able to concur with Ricchi<sup>2</sup> that the micro-organism by far the most frequently found in diseased sacs is the *Staphylococcus pyogenes albus*; other forms found are the *Staphylococcus pyogenes aureus* and *citreus* and streptococci. Saprophytes have been found, as the *Bacillus subtilis*, *radicosus*, *ramosus*, *luteus*, *fluorescens putidus*, and *saccharomyces*, while one case of *Actinomyces albus* has been reported. The diplobacillus of Morax-Axenfeld has been found in the sac as well as that micro-organism, the most dreaded by ophthalmic surgeons in cases of recent corneal abrasions, the pneumococcus.

Conditions of stricture occurring as they do, as a rule, at the nasal duct, have been shown to be due in the vast majority of cases, not to a hypertrophy of the mucous membrane of the sac, but rather to an engorged condition of the subperiosteal veins, directly beneath the duct, pro-



ducing a partial or complete obliteration in its lumen. The cause of the engorgement of these veins can generally be attributed to some defect in the nose, in the neighbourhood of the inferior and middle turbinated bones. Stagnation may be produced by the ordinary cold in the head in its acute or chronic form; other varieties of rhinitis, as the scrofulous and luetic, may also be held responsible for a blocking at the nasal duct. In cases of atrophic rhinitis with ozaena, scar tissue formation in the mucous membrane about the nasal duct may prevent the passage of tears.

A second variety of causes from a nasal origin directly accountable for dacryocystitis are ulcers of various kinds, particularly the scrofulous and the syphilitic; lupus is one of these. When these disappear under treatment scar

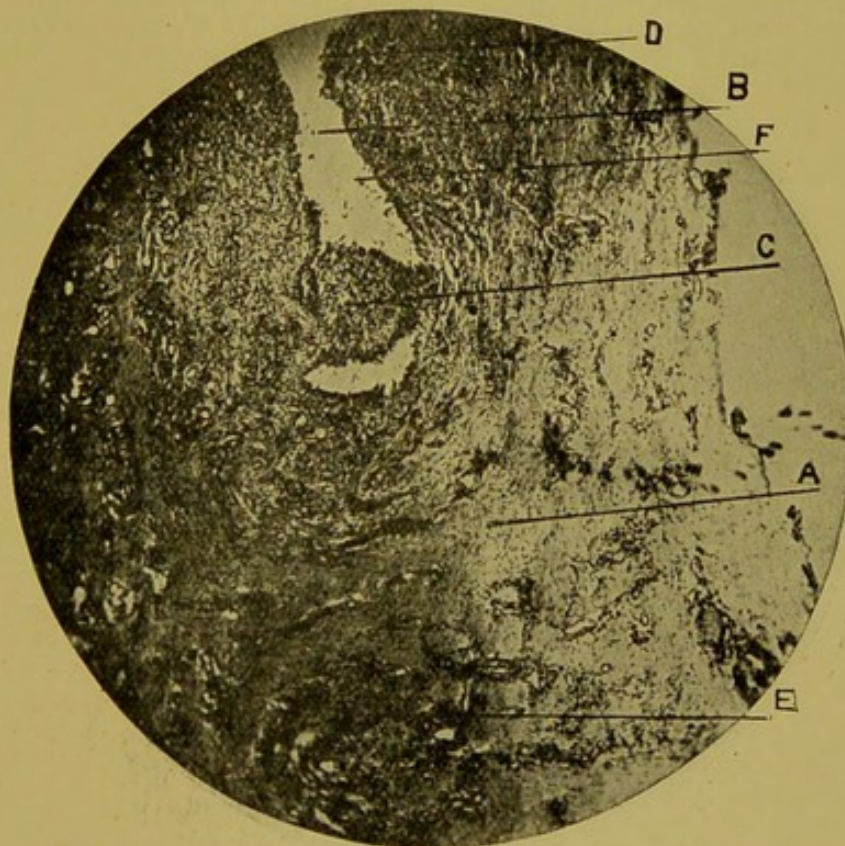


Fig 1.—A. Thickened sac wall; B. small lumen; C. stricture; D. round cell infiltration of mucous layer; E. infiltration of sac wall with increase of vascular elements; F. epithelial debris.

tissue remains and serious sequelae are likely to occur. When the bone in the neighbourhood of the nasal duct as well as the mucous membrane is involved the condition is still more serious.

A third variety of causes of nasal origin producing stagnation are tumours; the commonest of these are polyps.

During the past six months I have collected a series of 16 cases of chronic suppurative dacryocystitis from the Ophthalmological Clinic of the Royal Victoria Hospital,



Montreal, and from my private practice, and have made an examination of the nose in each case. Of these, 2 patients suffered from deviation of the nasal septum, 2 from chronic rhinitis, 1 from hypertrophy of the anterior end of the middle turbinated bone, and 2 from syphilitic periostitis about the nasal duct. Two of my patients suffered from ulceration of the cornea. Heilmaier,<sup>3</sup> of Wurtzburg, with an enormous experience of many years, reports a series of 352 cases of dacryocystitis; the nose was at fault in 220 of these, and 20 suffered from ulceration of the cornea.

*Pathology.*

The sacs which I have examined after extirpation have been mainly of two varieties: the first, with a very small lumen and very markedly thickened walls; the second

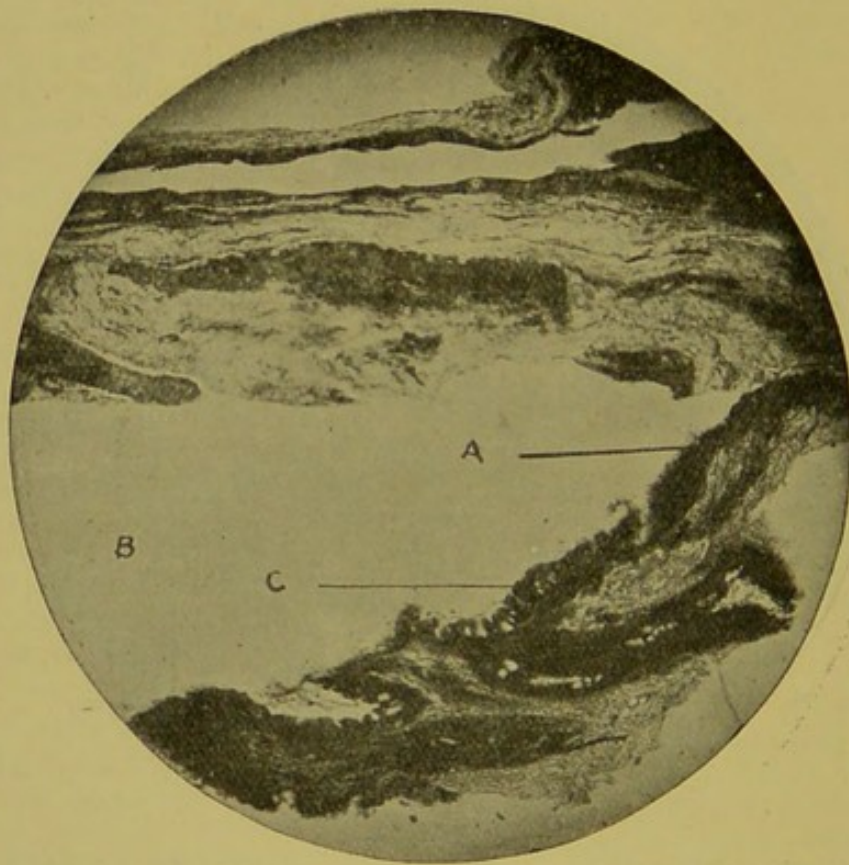


Fig. 2.—A, Marked thinning of sac wall, B, large cystic lumen; C, tuft-like projections of epithelial layer into lumen.

variety, where the reverse has been the case, showed the lumen to be very much dilated and cyst-like, while the walls of the sac have become very much thinner than in the former variety. Microscopically, by low power, one can notice in the mucous membrane of sacs previously affected with suppurative dacryocystitis in its chronic form, a preponderance of smaller or larger tuft-like projections into the lumen (see Fig. 2). Some of these may be quite rough or shaggy, while others may be smooth. The rough projections are generally the smaller ones.



The epithelium for the most part is preserved and multiplied a number of times, while the cells may lose their high cylindrical form, and, becoming polymorphous, lie in a series of several layers, one above the other (see Fig. 3). In these layers of cells, goblet cells are frequently found in varying numbers, but these may frequently be mistaken for large degenerate epithelial cells (see Fig. 3). The condition of the epithelium constitutes to a great degree the projections and depressions in the mucous membrane already referred to. Sometimes these channels between the projections sink quite deeply into the sac, and Joers<sup>4</sup> has been led to consider them as glands. These might readily be mistaken for degenerate epithelium and cyst formation in its various stages, as I have shown in Fig. 3.

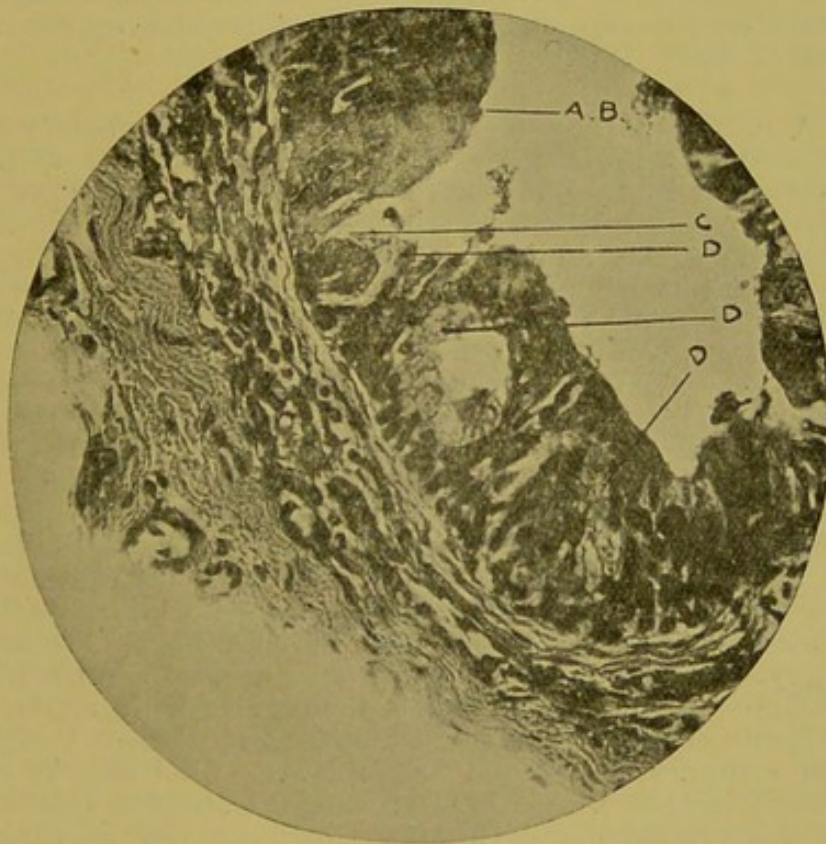


Fig. 3.—A, Increase in number of layers of epithelial cells; B, polymorphous character of epithelial cells; C, degenerate epithelial cell simulating goblet cell; D, cyst formation in various stages simulating glandular structure.

The epithelium is marked to a greater or less degree by a round-cell infiltration. A basement membrane which one should detect in the normal sac between the epithelium and the mucous layer proper can no longer be distinguished.

In the submucosa one notices a marked hyperaemia with a tendency towards the formation of new vessels. The veins which surround the sac are tremendously engorged, and their lumen in consequence dilated. The round-cell infiltration is, for the most part, quite pronounced, and



can separate the mucosa from the submucosa. The surrounding muscular tissue may also be infiltrated.

In sacs which have become very much dilated and have assumed a cystic character the inflammatory processes are not so pronounced. The mucosa consists of dense fibrous connective tissue containing few nuclei, the vessels are few, and follicles are absent. The epithelial layer is thinned, and its cells are remarkably flattened.

In ordinary catarrh of the sac without suppuration the epithelium is also thickened to a considerable extent, but the round-cell infiltration is absent; the normal basement membrane is detected more readily, in the loose underlying connective tissue one may notice grooves or channels. Hertel<sup>5</sup> claims that in these cases one is able to detect infiltration and lymph follicle formation.

Tear sacs in which suppuration has existed for several years assume an atrophy of the walls which appears as scar tissue.<sup>6</sup>

#### *Treatment.*

A mild condition of dacryocystitis may frequently be present, manifesting few or no symptoms either to the patient or to the surgeon; a high crest of the lachrymal bone frequently prevents satisfactory pressure upon the underlying sac, and the anticipated regurgitation of pus or muco-pus is not found; the presence of the disease in the sac is thus disguised. Surgeons are also frequently misled in conditions where only a partial stenosis has occurred when the secretion, after pressure over the lachrymal crest, escapes through the nose and not through the puncta. It is in the latter of these cases only that the palliative treatment can be recommended and endorsed; the actual cautery, probes, and syringing are some of the measures to be adopted in such cases. Of these, the last is the one most to be recommended; it at least does the least damage to the sac, and produces no injury to the tissue in the neighbourhood. In conditions of actual dacryocystitis ophthalmic surgeons are slowly but surely becoming convinced of the fact that conservative methods of treatment are at their best unsatisfactory. Even though the stricture be opened bacteria are still likely to re-collect in their former habitat when the stricture reforms, as it so frequently does, after treatment has been suspended for a short time. The employment of the galvanocautery only produces additional cicatricial tissue, rendering strictures both more numerous and more complete without thoroughly or satisfactorily destroying the secreting membrane of the sac. Probes are actually dangerous in the hands of the inexperienced; periostitis, false passages, rupture of ethmoid cells, with the formation of chronic inflammatory tissue in the neighbourhood of a sac rendering subsequent dissection and extirpation more difficult and tedious, are some of the results due to probes.

Besides, as has been already stated in cases of dacryocystitis, the stricture has been produced as a rule not by a swelling of the mucous glands and a consequent block-



ing of the lumen of the sac, as one might suppose, but by an engorgement of the subperiosteal veins in the neighbourhood of the nasal duct. Probing the sac in such cases can easily be seen to be useless as well as irrational. Further, in poor people, and still more in people living at a distance from medical attendance, it is actually impossible to have treatment of a conservative character satisfactorily carried out for any length of time. The palliative treatment in cases of chronic suppurative dacryocystitis, dilatation of the sac, fistulae, recurrent erysipelas and perilachrymal abscess with dacryocystitis we must admit as unsatisfactory. In actual hypopyon ulcer of the cornea, or keratitis with any of the above-mentioned conditions an excision of the sac is not only indicated but imperatively called for; one must, however, in such cases take additional precautions in avoiding any undue pressure upon the globe.

Serumtherapy is unsatisfactory. Boucheron<sup>7</sup> has recommended the use of antistreptococcus serum in certain cases, but it is questionable if such a form of treatment is either rational or satisfactory; in cases of perilachrymal trouble the condition appears to be due rather to an acute inflammatory condition accountable to a different micro-organism than the *Streptococcus pyogenes*, but in a way attributable to a previous diseased condition in the sac wall itself. Romer<sup>8</sup> has recommended the employment of antipneumococcus serum which can be used in cases of invasion of the cornea by the pneumococcus. Its use, however, is suggested rather as a prophylactic than as a cure. As the first evidence of the presence of the pneumococcus is frequently a corneal inflammation, patients are generally too late to hope for any benefit from the use of serum. I saw one such case when a pneumococcus infection set in immediately after a cataract extraction; the pneumococci were demonstrated to be present and the antipneumococcic serum immediately employed, but without benefit.

That there are numerous cases of stenosis of the nasal duct and many of actual dacryocystitis where no rational treatment has been attempted or requested is a fact brought home to us every day by many of the unfortunate conditions of permanent blindness due to corneal ulceration complicating tear sac trouble. We cannot close our eyes to the fact that there are numbers who cannot or will not wear protecting glasses, and yet who are, on account of their respective callings, daily exposed to injuries of the cornea. The mechanic, the foundryman, the farmer, the lumberman, are amongst those who are frequently, unknown to themselves, afflicted with dacryocystitis, at the same time to whom superficial injuries of the cornea are of frequent occurrence. Country people, particularly, are subject to tremendous risks; such people suffering from dacryocystitis in a land of such enormous expanse as Canada are frequently practically isolated from any one with a definite knowledge of the special diseases of the eye, and disastrous results may follow an insignificant



abrasion of the cornea by a wisp of straw or the end of a twig.

Although many have acknowledged that the complete removal of the lachrymal sac in diseased conditions is imperatively indicated, the operation has been unpopular on account of the haemorrhage which takes place during the operation. Further, the field of operation being frequently hidden by blood, fragments of the secreting membrane of the sac are left remaining in the wound cavity, epitheliation occurs, and fistulae result.

Axenfeld's<sup>9</sup> work on the subject and the technique employed and recommended by him have rendered the operation decidedly easier, and have removed many of the difficulties which formerly prevented ophthalmic surgeons from excising the sac, appreciating though they did that a total extirpation was indicated as the best prophylactic measure to be adopted against future corneal trouble. The method employed by Axenfeld is as follows: The field of operation is rendered as aseptic as possible by the use of soap and water and then by an application of a solution of bichloride of mercury. Should one prefer to operate under local anaesthesia, a few drops of a 4 per cent. solution of cocaine in 1 in 1,000 adrenalin is injected into the tissues about the sac fifteen minutes before the patient is placed upon the table. The injection is repeated immediately before the operation. I, however, prefer to operate using general anaesthesia, because, after seeing a great many diseased sacs removed under a local anaesthetic, I am not satisfied that the method is a painless one. A veil of sterilized gauze, with an opening large enough to expose the patient's eye, side of the nose, and upper part of the cheek, is spread over the face. The initial incision is made from the inner canthus directly above the internal angular ligament, 2 or 3 mm. in front of the crista lachrymalis. The incision should be directed downwards and outwards in a crescentic direction for about 2½ cm. The incision must be quite deep, cutting through the periosteum. A shorter incision than the one I have specified should not be attempted. There are occasions where a very prominent crista lachrymalis will almost occlude a view of the sac in the underlying fossa, and unless an aperture is made sufficiently large to expose this fossa and its contents there is always the danger of leaving a part of the secreting membrane of the sac *in situ*. Subsequent fistula formation is the inevitable result. The consideration of a slightly smaller incision from a cosmetic standpoint is not to be considered; the wound heals by primary intention, and after a short time little or no evidence can be found of the previous line of incision.

One of the chief difficulties in this operation is the suppression of a violent and obstinate haemorrhage. The employment of Péan's forceps is impossible on account of the smallness of the cavity and because the vessels are situated so deeply that they cannot be seized. After the primary incision is made digital pressure is exerted over the wound for one or two minutes, and then Müller's



small speculum is introduced, holding the edges of the wound apart laterally. A much larger speculum, with reversible and adjustable tips corresponding to the ends of small, sharp retractors, an instrument especially devised by Axenfeld for use in this operation, is then placed in position. This separates the edges of the wound vertically (see Fig. 4). These specula serve two purposes: They expose a quadrilateral field for operation, and are of decided assistance in arresting haemorrhage. In addition, they eliminate the necessity of having an assistant's hands holding retractors in front of the operator.

Bloch of Freiburg has made a suggestion regarding the control of haemorrhage which Axenfeld carries out, a

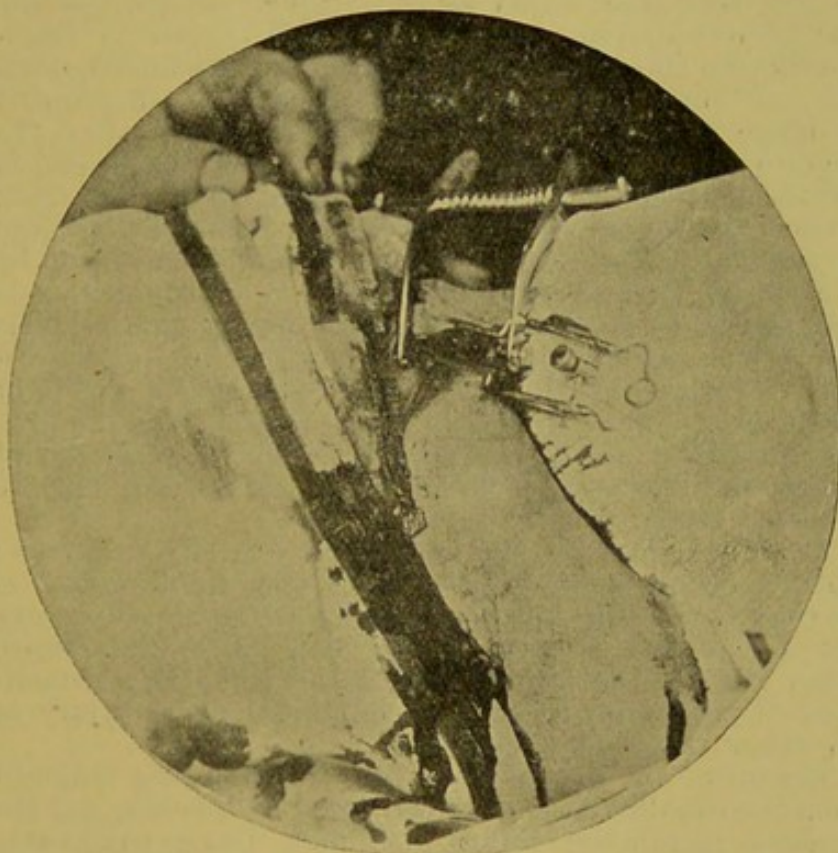


Fig. 4.—Axenfeld's Spring Retractors. Müller's Speculum.

procedure which I have followed in the cases upon which I have operated. A large number of wooden applicators about the shape and size of a penholder are previously sterilized, and the tips armed tightly with sterile absorbent cotton. Firm pressure and swabbing can be undertaken in this manner, procedures which could not be followed so well with the ordinary gauze sponge. These applicators are also of service in reapplying adrenalin solution to the wound.

The periosteum is now carefully retracted forward over the edge of the crista lachrymalis and downwards as far as the bony canal encircling the nasal duct. If the haemorrhage is sufficiently under control the lachrymal sac should be seen nestled in the underlying fossa lachrymalis.



The sac is now seized by a pair of fixation forceps and drawn gently forward, while a careful dissection with a pair of small, sharp-pointed, curved scissors is begun beneath the sac. A method which I have found to be of decided value and which I always employ at this juncture is, when once I have separated the sac at one point from the underlying fossa, to introduce a tenotomy hook under the sac. I am now able to follow the sac downwards to the nasal duct and upwards to the puncta, always cutting beneath the heel of my hook without fear of wounding the sac above. Very little subsequent dissection of the overlying connective tissue is necessary, and the sac is severed as close to the puncta above and to the nasal duct below as is possible. When the sac has been removed a specially-devised curette is introduced into the nasal duct, which is quite denuded of its mucous surface; this procedure allows subsequent drainage of the cavity for one or two days after the operation, and assures the operator of complete stenosis by the formation of cicatricial tissue about the duct, rendering any subsequent infection through the nose impossible. The wound cavity formerly occupied by the sac is thoroughly irrigated with a warm bichloride solution, and the edges of the skin wound are brought carefully together by a few silk sutures. A small firm roll of absorbent cotton, about the thickness and half the length of one's little finger, is placed over the line of incision and a compress dressing applied. This should be left undisturbed for three days; the sutures may be removed three or four days later.

The advantages of this procedure are briefly as follows: The operation is not dangerous; a very small wound is necessary, allowing one all the space he requires to carry out a complete dissection. As very little disturbance takes place in the surrounding tissue, there is no likelihood of producing secondary complications, as injury to the ethmoid cells or periostitis.

The operation is a complete one, the sac being removed from the canaliculi above to the nasal duct below, and the mucous membrane lining the duct being completely curetted away, no secreting surface remains; a sense of absolute security from future infection from this source is thus afforded both the patient and the surgeon.

From a cosmetic standpoint it is all that can be desired; the very small incision is later hardly more noticeable than one of the ordinary lines of the face.

The objection that after excision of the sac tears are still secreted, and that epiphora continues, does not hold. Of the sixteen cases to which I have referred an extirpation of the lachrymal sac after Axenfeld's procedure has been performed eleven times with uniformly satisfactory results. It is difficult to explain exactly how the lachrymal gland adapts itself to the new conditions, when once the sac has been removed. We know from actual experience that when the source of infection has been removed irritation of the conjunctiva is allayed, and that reflex secre-



tion of tears is not produced. The statement that after extirpation of the sac an atrophy of the gland follows has yet to be proved. Axenfeld and Bietti<sup>10</sup> have shown that in the normal gland microscopic indications of atrophic changes, as fat tissue and granules, are present. They examined sections of glands from numerous cases where the sac had been previously excised without finding further evidence of degenerative change.

Should tears persist to secrete the difficulty can be readily overcome by the simple operation of excising the accessory lachrymal gland, a procedure which is never followed by any untoward results.

In conclusion, I should like to express my thanks to Professor Axenfeld of Freiburg for the opportunities I enjoyed while working in his clinic, as well as for the many personal kindnesses he extended to me. I should also like to record my appreciation of the kindness of Drs. J. W. Stirling and W. G. M. Byers, my seniors in the service at the Royal Victoria Hospital, for kindly placing their clinical material at my disposal, as well as for the hearty co-operation and encouragement they have shown me in my work.

#### REFERENCES.

- <sup>1</sup> Plaut u. von Zelewski, *Klin. Monatsbl. f. Augenheilk.*, 1901, p. 369.
- <sup>2</sup> Ricchi, *Annali di Ottalm.*, xxviii, p. 17. <sup>3</sup> Heilmäier, *Zeitschrift f. Augenheilk.*, vi, S. 540. <sup>4</sup> Joers, *Beiträge z. Augenheilk.*, Heft xxxv.
- <sup>5</sup> Hertel, *Graefe's Archiv*, Bd. 48, 1899. <sup>6</sup> Greeff, *Pathologie des Auges*, Orth's *Path. Anat.*, 1906. <sup>7</sup> Boucheron, *Annales d'Oculist*, t. cxviii.
- <sup>8</sup> Romer, *Archiv. f. Ophth.*, 1902. <sup>9</sup> Axenfeld, *Klin. Monatsbl. f. Augenheilk.*, *Festschr. f. Manz*, 1903. <sup>10</sup> Axenfeld and Bietti, *Verhandl. der Ophthalmolog. Gesellschaft Heidelberg*, 1900.



