

## **The uses of x rays in ophthalmic surgery / by M. S. Mayou.**

### **Contributors**

Mayou, M. Stephen 1876-1934.  
University College, London. Library Services

### **Publication/Creation**

London : Rebman, Limited, 1903.

### **Persistent URL**

<https://wellcomecollection.org/works/tc5hcn4>

### **Provider**

University College London

### **License and attribution**

This material has been provided by This material has been provided by UCL Library Services. The original may be consulted at UCL (University College London) where the originals may be consulted.

Conditions of use: it is possible this item is protected by copyright and/or related rights. You are free to use this item in any way that is permitted by the copyright and related rights legislation that applies to your use. For other uses you need to obtain permission from the rights-holder(s).



Wellcome Collection  
183 Euston Road  
London NW1 2BE UK  
T +44 (0)20 7611 8722  
E [library@wellcomecollection.org](mailto:library@wellcomecollection.org)  
<https://wellcomecollection.org>

8

# THE USES OF X RAYS IN OPHTHALMIC SURGERY.

BY

M. S. MAYOU, F.R.C.S.,

*Chief Clinical Assistant to the Royal Eye Hospital ; Clinical  
Ophthalmic Assistant to the London Hospital.*

---

*Reprinted from "ARCHIVES OF THE ROENTGEN RAY,"  
January, 1903.*

---

WITH FIVE ILLUSTRATIONS.

LONDON :  
REBMAN, LIMITED,  
129, SHAFTESBURY AVENUE, CAMBRIDGE CIRCUS, W.C.  
1903.

1669332

**THE**  
**USES OF X RAYS IN OPHTHALMIC**  
**SURGERY.**

BY

**M. S. MAYOU, F.R.C.S.,**

*Chief Clinical Assistant to the Royal Eye Hospital ; Clinical  
Ophthalmic Assistant to the London Hospital.*


---

*Reprinted from "ARCHIVES OF THE ROENTGEN RAY,"*  
*January, 1903.*

---

*WITH FIVE ILLUSTRATIONS.*

LONDON :  
REBMAN, LIMITED,  
129, SHAFTESBURY AVENUE, CAMBRIDGE CIRCUS, W.C.  
1903.





## THE USES OF X RAYS IN OPHTHALMIC SURGERY.

MR. PRESIDENT AND GENTLEMEN,

I have to thank you for the honour you have conferred on me in asking me to read a paper before this Society to-night. I accepted, as I hope that I may be able to show in some small degree how this comparatively new science may be far-reaching in its extent, even in this one branch of medical science—ophthalmic surgery. My experience has extended over the last eighteen months, during which time I have daily undertaken the treatment and investigation of cases, and I have to thank Mr. Cargill, Dr. Low, Dr. Grünbaum, and others, for their kindness in sending me cases, and for their opinion on these cases during and after the treatment.

The whole question is much too large to deal with to-night, and I propose to select the following subjects from it:

1. The localization and treatment of metallic foreign bodies in the globe.
2. Rodent ulcer of the eyelids; the pathology of the cure.
3. The treatment of trachoma—granular ophthalmia.



### 1. *Foreign Bodies in the Globe.*

It is not out of place to repeat how invaluable these methods of radiography and localization are to ophthalmic surgery, and the great boon that Mackenzie-Davidson has conferred on us. During the last year I have had sent to me from the Royal Eye Hospital, the Seamen's Hospital, and King's College Hospital, sixteen cases of supposed foreign bodies in the globe; of these, thirteen were found and localized, two eyes contained no foreign body, and one was missed, about which I wish to speak later. Of the thirteen, all were verified and found accurate.

The method adopted was as follows: In recent cases and cases where there was much photophobia, a wire stitch was fixed in the conjunctiva directly below the centre of the corneal margin, having first put solution of cocaine into the eye; but in cases where there was no photophobia a piece of fine wire was fixed over the lower lid and kept in position by the lashes, and the patient directed to gaze at some object, so as to bring the corneal margin in contact with the summit of the loop.

The head is fixed in a Mackenzie-Davidson head-rest, taking care that the cross-wire does not fall across the orbit. I wish to emphasize this point, as it was due to this occurring that the case mentioned above was missed, the shadow of the foreign body, which was less than a millimetre, falling across the shadow of the wire and being obscured by it. It was subsequently extracted in



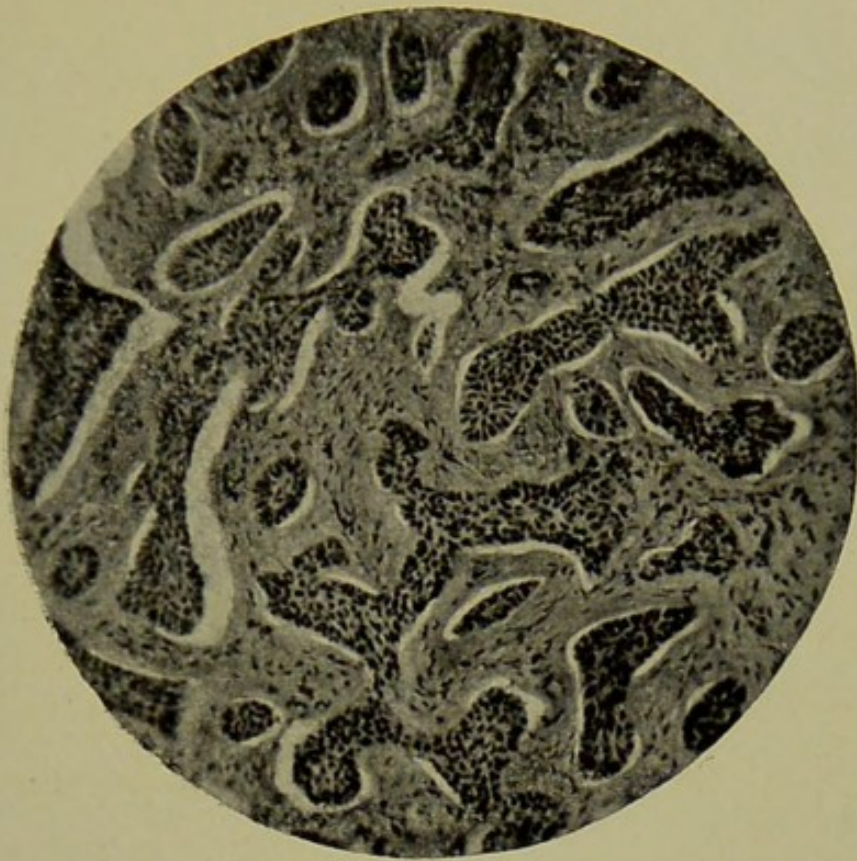


FIG. 1.—RODENT ULCER BEFORE TREATMENT (LOW POWER).

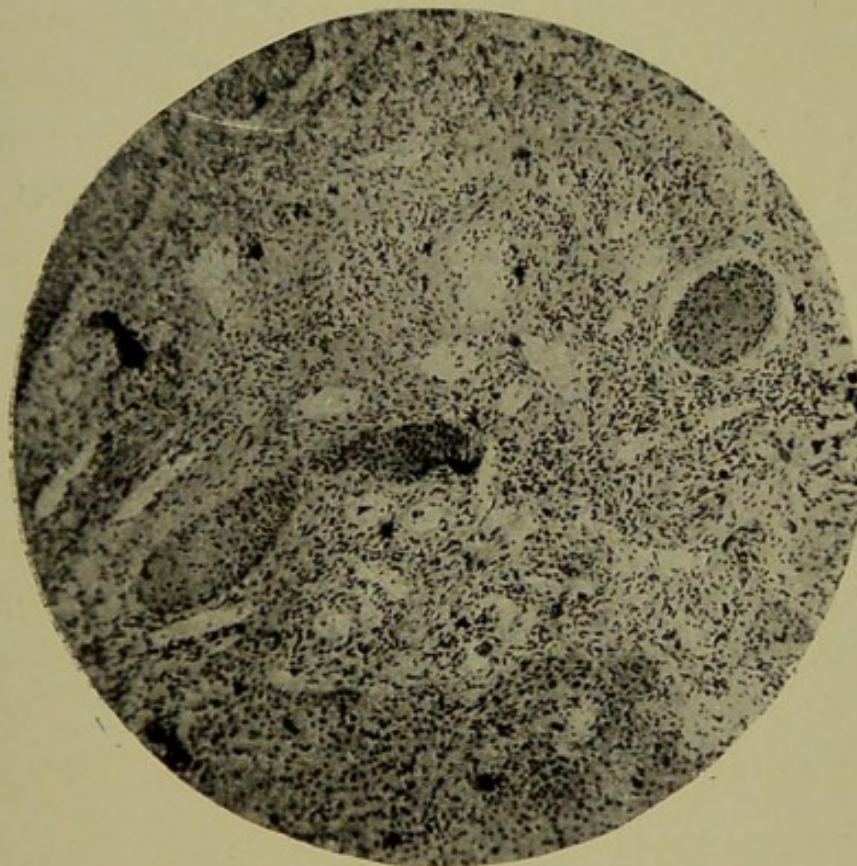



FIG. 2.—RODENT ULCER AFTER THREE WEEKS' EXPOSURE TO X RAYS (LOW POWER). LEUCOCYTOSIS; COMMENCING DEGENERATION.





the lens, which had become opaque, so no harm followed. Two separate photos are taken, as they are liable to render the images indistinct when taken on the same plate. This is done twice over, as I have seen a foreign body missed in two successive photos, owing to the patient moving his eye and making the image of the foreign body, which was a very small one, indistinct. Half a minute's exposure is generally sufficient.

The method of subsequent localization is worked out on a drawing-board, photos of which I will show you presently, it being a cheap efficient, and taking practically no more time than other methods.

Having found the relation of the foreign body to the cross-wire and to the wire on the lid, the next thing to do is to mark it on an eye drawn to scale—such as can be found in Quain's "Anatomy"—and observe its relation to the various structures of the globe. The shape of the foreign body is determined by using some form of stereoscope, and the one I find most convenient is a modification of Wheatstone's, which I have had made to take negatives, as it can be used at once after developing the negative, as immediate extraction of the foreign body is of the utmost importance.

The size of the foreign body should be very carefully measured, as the size of the incision for its removal must be graduated by it. I cannot emphasize too much the importance of immediate localization and removal of foreign bodies. (1) As they are said to be a most fertile source of sympathetic ophthalmia, (2) they are more



likely to give rise to suppuration if left; and, finally, if left for a day or two, they become rapidly encapsuled, and often defy extraction with the electro-magnet. In two of the cases I have mentioned, although the magnet was literally applied to the foreign body which was in the lens, it could not be withdrawn, and out of seven recent cases in which the foreign body was in the vitreous and had penetrated the lens, only one was saved; this foreign body had been in the eye only four hours.

In cases in which foreign bodies have been in the eye some time, although they are generally small and aseptic, the prognosis as regards extraction is not good, as they become encapsuled, which may lead subsequently to siderosis, etc., unless situated in the lens, when they can be extracted with that body with good result.

In operating for these foreign bodies, the best method, except in a few cases when the foreign body is in the lens, is to use a small electro-magnet. I must say here that I have not seen the large magnet used very much, but it always seems to me that the traction of a foreign body through the globe, regardless of structures, is a most unscientific procedure, causing vast injury to the intra-ocular contents. I have seen more than one case in my limited experience in which the eye would have been destroyed if this method had been adopted, and although I have read Mr. MacCallan's valuable paper on the subject, I still think that the Haab magnet should only be used after failure of the small one.



The incision in the globe is large enough to admit the magnet and to allow the foreign body to come out, and the magnet is applied, if possible, to the narrowest diameter of the foreign body.

When the foreign body is lying in the vitreous, I think equatorial incisions are preferable to radial, as they are more easily held apart, and do not go so near the ciliary body. No stitches are necessary in the sclera, and it is better, if possible, to cover the wound with conjunctiva and muscle, by turning them back in a flap before incising the globe, and to have the sutures in readiness for immediate closure of the wound after the method which I believe was first introduced by Mr. Cargill.

Going once more over the salient points as regards the method of localization :

1. Immediate localization, and repeat it if the foreign body be not found.
2. Use separate plates.
3. Be careful not to let the cross-wires fall within the shadow of the orbit.
4. Localization and estimation of size by the drawing or other method.
5. The use of the stereoscope for the estimation of the shape, preferably only to take negatives, as it saves time.

The points to be considered to be determined by X rays before operating are :

1. The size and shape of foreign body.



2. The situation with regard to the intra-ocular contents.

3. The position of the foreign body with regard to the wound to be made in the globe for its extraction, or with regard to the entrance wound.

Prognosis is influenced apart from points defined by X rays by the following considerations:

1. Nature of the case—*i.e.*, recent or old-standing.

2. The condition and size of the foreign body on entrance.

3. The situation and size of entrance wound.

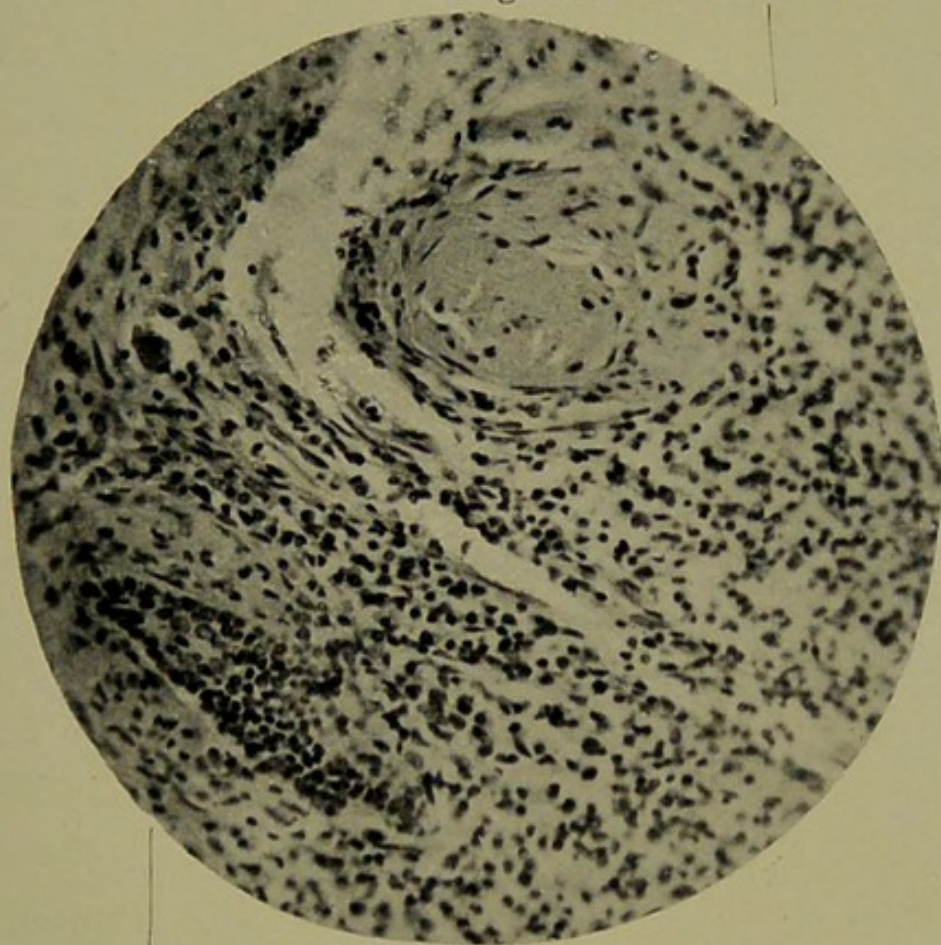
4. Injury to the intra-ocular contents.

## 2. *Rodent Ulcer of the Eyelids.*

The eyelids are a common site for rodent ulcer, especially the lower one, and such, like rodent ulcers in other situations, can be cured by the application of X rays. I do not propose to-night to speak much of the methods of exposure, but of the pathology of the cure and some of the changes found in the tissues.

When X rays are applied to healthy living tissues, the most noticeable effect is an acute inflammation in the part, which does not extend deeply into the tissues, but is quite superficial. The peculiarity of this inflammation is that it does not reach its full height until some time after the exposure, say in from one to three weeks. This inflammation is greatly increased, and more rapidly brought about, by simultaneously applying irritants. This point I want to emphasize and illustrate by one or


Degeneration of rodent cells



Invasion by leucocytes.

FIG. 3.—RODENT ULCER (HIGH POWER), AFTER TREATMENT.





two cases, as I think it is not generally noted. A man was sent to me to be X-rayed for a superficial epithelioma of the hand. After about two weeks' exposure it was thought to be increasing in size, so a local excision of the growth was performed. So much sloughing occurred that the arm had to be amputated above the elbow. Some time ago I had rather a severe X-ray burn on my hand, and I found that the least irritation, such as washing my hand, caused it to become hot, painful, and bright red, and after assisting at an operation, and putting my hands in 1 in 20 carbolic, extensive sloughing of the skin followed. This observation led me to use 1 in 20 carbolic acid for dressing rodent ulcers in the early stages of X-ray treatment whenever possible, and this, I find, has the double advantage of keeping them aseptic and of accelerating primary reaction.

This susceptibility to irritants, I think, can be largely accounted for by the vasomotor paralysis which occurs in an inflamed part, and which, when more irritation is applied, leads to greater and more complete dilatation of the vessels. This dilatation of the vessels seems to be permanent at the seat of the most acute inflammation, for if a part be examined after recovery from an X-ray burn, dilated vessels can be seen all over the area. This increased susceptibility to irritants is, I think, a most important factor in the healing of rodent ulcer, for I think it is largely due to the irritation produced by the rodent cells on the surrounding tissues that X rays have such a wonderful effect. Otherwise, why should



the new growth disintegrate, and not the surrounding tissue?

By the application of X rays to a part we can produce an inflammation leading to anything from a mild leucocytosis to an actual gangrene. This is brought about, I think, in exactly the same way as an inflammation is produced by other forms of stimuli, and is most severe at the point first struck—*i.e.*, the superficial tissues. All evidence tends to show that this form of energy does not penetrate deeply, and is probably not produced by the rays which penetrate the body.

In rodent ulcer the tissues are invaded by a new growth, which sets up a slight inflammation, and this, in all probability, is Nature's method of trying to rid herself of the disease. At the same time, the growth is dependent on the underlying tissues for its nutrition. Now, if we excite an acute inflammation, the part furthest from the sources of nutrition dies, and will come away as a slough. This will therefore account for the disappearance of the large masses of nodular growth which so rapidly subside under treatment. But if a section of rodent ulcer be examined, we find, lying under apparently healthy skin, cells of the growth. Now, how is it that these cells disappear also, as they obviously cannot be thrown off as sloughs? If a section of rodent ulcer after it has just begun to react to X rays be examined, we find the clumps of epithelial cells which make up the growth are surrounded with enormous numbers of leucocytes. It is the duty of these leuco-



cytes to remove all irritating substances from the part by breaking them up and carrying them away, or, failing that, to encapsule them with fibrous tissue, shut off their nutrition, and so prevent their spread. In a section of rodent ulcer which has nearly healed we find a mass of granulation tissue organizing, with healthy epithelium growing in from the edge; scattered here and there amongst the infiltration leucocytes are epithelial cells of the growth in various stages of degeneration. The degeneration seems to take place from without inwards towards the centre of the clumps of epithelial cells, which become vacuolated, and the granules in the cells multiply and collect around the cell wall, seem in places to be making their way through it, and finally disappear. The nuclei do not as a rule proliferate, although there are some large cells with multiple nuclei to be seen, which are probably derived from the stroma. The cromati cease gradually to take up the strain, until nothing but the cell wall remains, which is apparently removed by the leucocytes.

In treating a rodent ulcer, I find it most useful to remove portions of the growth from time to time, to see if there are any active cells of the growth present, and when they have all disappeared to cease treatment.

### 3. *The Treatment of Trachoma by X Rays.*

In treating any disease, it is almost essential that we should first know its exact pathology. Although a great deal of work has been done in the pathology of



trachoma, we are not yet absolutely sure that the exact causative factor has been discovered, and therefore cannot be sure that any treatment adopted is the best possible.

In trachoma we have a disease which is very closely allied to lupus in many respects, in that it is characterized by the formation of nodules, or infiltrations consisting of masses of round cells, and there is every evidence that the disease is probably due to some organism closely allied to the tubercle bacilli.

At the present time trachoma is cured by applying some form of irritant to the lid, either by chemical means, such as copper sulphate, corrosive sublimate, or jequirity, or mechanically, by rolling, brushing, or other operative methods. These irritants must act in one of two ways, either—

1. Simply by the reaction they set up, partly causing a leucocytosis and subsequent cicatrization of the nodules, and partly by mechanically removing the diseased tissues.

2. Or by direct action on the organism causing the disease, if such organism be present.

Taking the first of these, the method we adopt very commonly is the application of copper sulphate or some mild caustic. At each application we destroy the epithelium of the conjunctiva on which we rub it, and, although we cure the trachoma, an excessive amount of scar tissue is left, causing entropion and other deformities of the lid.



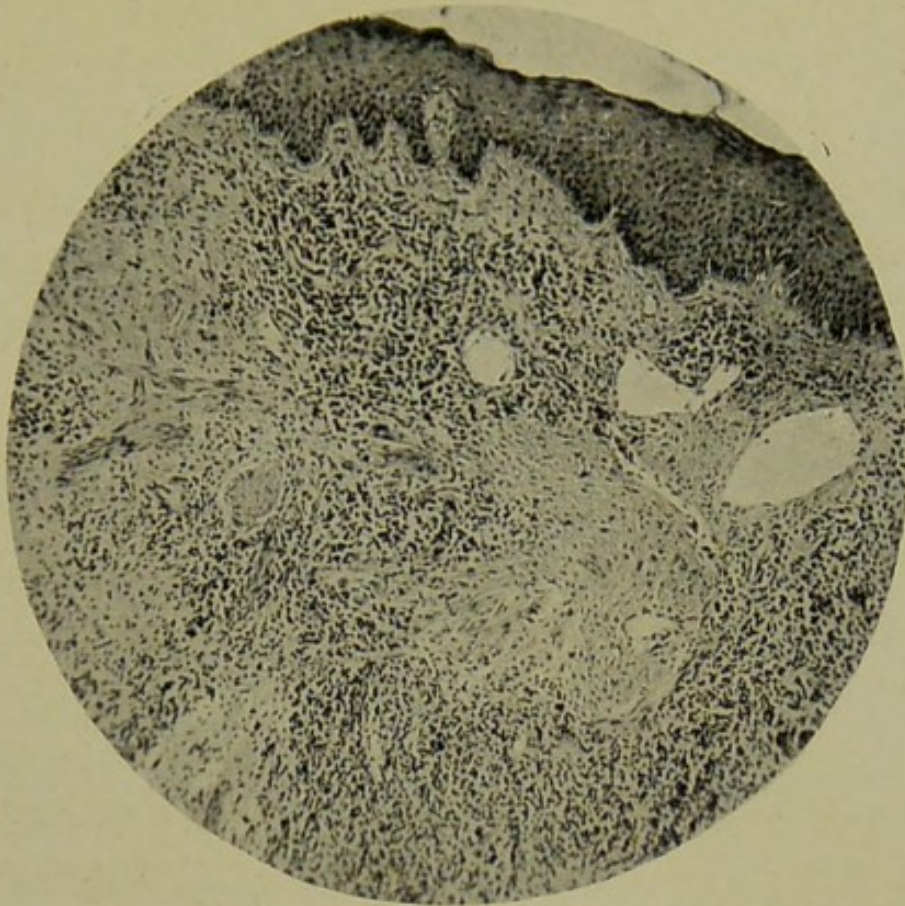


FIG. 4.—RODENT ULCER, FINAL STAGE (LOW POWER). LEUCOCYTOSIS; FIBROUS TISSUE; FEW DEGENERATED CELLS.

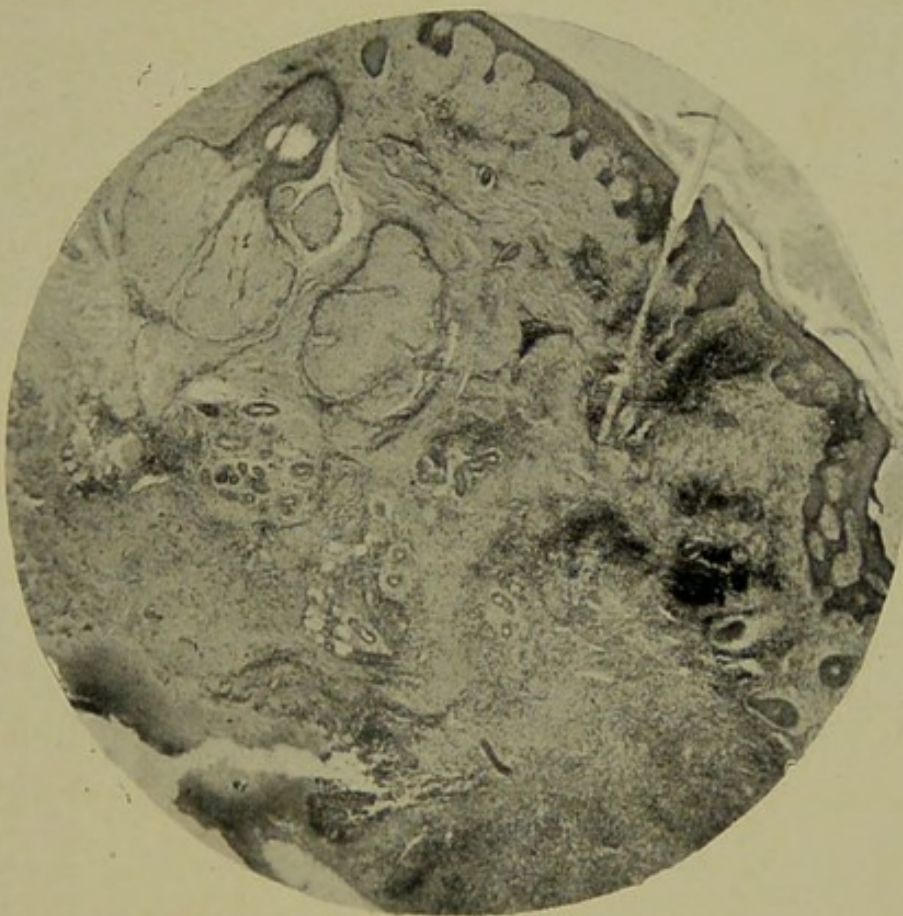



FIG. 5.—RODENT ULCER (LOW POWER). LEUCOCYTOSIS AROUND ULCER, WHICH HAS HEALED, BUT NOT MUCH IN SURROUNDING TISSUE; IRRITANT ACTION OF CELLS.





As regards rolling, brushing, and other operations, they have the additional advantages of removing the actual diseased tissue, but it is generally recognised that they are only suitable for certain cases, and that even in these cases the cure is not generally complete, unless they are followed by some form of caustic to keep up the irritation set up by the operation.

In X rays we have a method of setting up a leucocytosis with the absolute minimum of destruction to epithelial and other tissues ; and, further, we have a means of producing an inflammation from a mild leucocytosis to an actual gangrene of the part, which, with due care and experience, we have under almost perfect control.

Not knowing the organism which causes trachoma, we cannot say whether the irritants which are used in its treatment or X rays have any effect on it. But we have in X rays a method of producing leucocytosis in any degree of severity, from that following a mild application of perchloride of mercury up to that induced by jequirity ; and, further, this leucocytosis is much more prolonged than that in any method previously adopted, and the destruction is not nearly so great. Although granules disappear very rapidly under X rays, operative methods, which have the additional advantage of removing the diseased tissue, may be preferable to some extent, except that the patient has to undergo an operation ; but such operations can be followed by X rays to complete the work in preference to one of the other



irritants now in use. Operation, however, should never follow X-ray treatment without a considerable interval.

At the beginning of this year I showed before the Ophthalmological Society a case of trachoma which had been treated by X rays, and which, so far as I know, was the first of its kind. The method adopted was to cover the whole face, with the exception of the affected eye, with a metal mask. (Since then I have discarded the mask altogether, as now I never expose the patient sufficiently to get any reaction at all in the skin.) The upper lid was then everted, and the lower lid pushed up so as to cover as much of the cornea as possible ; but in bad cases of pannus the cornea is left exposed. I have never had any trouble with the globe following X-ray treatment, and in a case of rodent ulcer of the lid in which this treatment was used for six months, and which I showed at the same Society last June, there were no signs of retinal, corneal, or other trouble, with the exception of conjunctivitis, and the patient's vision remained the same ( $\frac{6}{9}$ ) throughout the treatment.

The patient is seated about 9 inches from the anode, with a moderately soft tube and a current of 6 ampères. Two minutes' exposure is given for four to six successive days, depending on the case. If there be much injection or the case be an acute one, four is generally sufficient. A week's rest is then given, and if no reaction is set up the patient is exposed twice a week, until there is a slight increase in the photophobia, which shows that he is beginning to react. About this



time the granules begin disappearing from the lids. Exposures once, twice, or three times a week are carried out, until they disappear entirely. When the granules have disappeared all treatment must be stopped, as it requires some weeks for the infiltration set up by the X rays to settle down, and it is difficult to tell whether the disease is absolutely eradicated, as the lid remains injected for some time after treatment has ceased.

The final result to the lid is most satisfactory. Instead of the white, puckered conjunctiva gained by other methods, a supple, non-contracted, non-scarred conjunctiva, with no obliteration of the fornices unless they are already gone before treatment, is produced, similar to the soft, supple scar in the skin following by this form of treatment in rodent ulcer, as compared with the dense cicatrix of excision.

As regards the effect on the pannus, it often clears with great rapidity, especially if recent, and it is the common thing for patients to say that they see more clearly from almost the first exposure. But even dense corneal opacity will often clear considerably, and in one case of extensive destruction and cicatrization of the cornea, in which at the commencement of treatment the patient could only see shadows, in two months she could count fingers 3 feet away.

Another peculiar point is the amount of exposure required by different patients. Sometimes the granules begin to disappear from almost the first exposure; others



require eight or ten exposures before showing signs of reaction.

With regard to the cases suitable for treatment, the most satisfactory are the chronic cases, and, of course, the earlier they seek treatment the more rapid and satisfactory the result. These patients will stand more frequent exposure than any other ; acute diffuse infiltrations, with thickening of the lids and much photophobia, require more careful exposure extending over a much longer period. Old-standing cases, in which the lid trouble has almost disappeared, but in which there is much opacity of the cornea, will often improve considerably under exposures of long intervals after the first reaction, which should be mild.

The chief advantages of this treatment are :

1. There is considerably less deformity in the lid after treatment.
2. It is practically painless treatment.
3. The pannus clears more thoroughly.

It is eminently suitable for hospital cases which cannot attend daily for the other methods of treatment to be carried out.

In the first cases the patients were troubled with some falling out of the lashes and conjunctivitis. In no other cases, out of some fifteen, has there been similar trouble.

---

Mr. C. E. S. PHILLIPS called attention to the desirability of making experiments upon lupus and other



similar diseases with the X-ray lamp electrostatically screened by placing it together with its leading wires within an earthed metallic box.

He pointed out that considerable uncertainty still exists as to whether it is the X rays or the high-tension discharges from the bulb that affect the cures.

Dr. BATTEN said he congratulated Mr. Mayou, and thanked him for his most important paper. He would like to ask three questions :

1. To ask Mr. Mayou if he thought that the leucocytosis was the real and the most important cause of the degeneration of the epithelial cells.

2. To ask the President if the brush discharge or effleuve from a high-frequency machine, and the discharge, static or whatever it was, from an X-ray vacuum tube, were at all like one another.

3. To ask Mr. Mayou how he would proceed to treat a case of recurrent subcutaneous nodules in, say, carcinoma of the breast by X rays.

In answer to Mr. Batten's question as to whether the leucocytosis was the cause of the degeneration of the cells, Mr. MAYOU thought that the whole process was purely inflammatory, the inflammation being increased in the neighbourhood of the growth owing to the irritant action of the epithelial cells. His reasons for this were :

1. It was the only histological change found.

2. That the sections showed direct invasion of the clumps of rodent cells by leucocytes.

3. That the clumps degenerated from without inwards



towards their centre; that is to say, the cells in contact with the leucocytes degenerated first, the innermost cells showing no change at that time.

4. That rodent ulcers will sometimes heal with other forms of irritants (*e.g.*, formalin).

As regards carcinoma, he had not much experience, but in cases which he had treated reaction was produced as rapidly and as great as possible, short of sloughing, with the idea of preventing its spread.

Mr. Mayou was pleased to hear that Dr. Walsh had had such excellent results also with trachoma, and that the case he referred to was the one Mr. Mayou mentioned in his paper in which Mr. Sydney Stephenson was interested.





