

The field of vision / by A. Hill Griffith.

Contributors

Griffiths, A. Hill.
University College, London. Library Services

Publication/Creation

London : John Heywood, 1885.

Persistent URL

<https://wellcomecollection.org/works/py7rc2u4>

Provider

University College London

License and attribution

This material has been provided by This material has been provided by UCL Library Services. The original may be consulted at UCL (University College London) where the originals may be consulted.

This work has been identified as being free of known restrictions under copyright law, including all related and neighbouring rights and is being made available under the Creative Commons, Public Domain Mark.

You can copy, modify, distribute and perform the work, even for commercial purposes, without asking permission.



Wellcome Collection
183 Euston Road
London NW1 2BE UK
T +44 (0)20 7611 8722
E library@wellcomecollection.org
<https://wellcomecollection.org>

THE FIELD OF VISION.

BY

A. HILL GRIFFITH, M.D.,

Assistant Surgeon, Manchester Royal Eye Hospital.

REPRINTED FROM "MEDICAL CHRONICLE," NOVEMBER, 1885.

JOHN HEYWOOD,
DEANSGATE AND RIDGEFIELD, MANCHESTER;
AND 11, PATERNOSTER BUILDINGS,
LONDON.

—
1885.



Digitized by the Internet Archive
in 2014

1165471
<https://archive.org/details/b21637714>

THE FIELD OF VISION.



THE field of vision may be defined as the entire surface from which at any given distance light reaches the percipient parts of the retina (Nettleship), and in this paper I shall endeavour to show how this field of vision may be measured and thoroughly examined, so as to be of service to us in the diagnosis and prognosis of the various affections of vision, whether due to functional derangements or organic lesions. A ready and very excellent method of ascertaining the limits of the field has been explained by Donders, and its principle consists in the examiner making at the same time a similar examination of his own field. The patient is placed with his back to a good daylight, and the eye which is not under examination is covered by a bandage, or by the patient's hand; the surgeon now stands directly opposite the patient, at about eighteen inches distant, and covers the eye which is opposite the patient's bandaged eye, the patient's right eye being always compared with the surgeon's left eye, and his left eye with the surgeon's right eye. While the patient is directed to keep his eye steadily fixed on the surgeon's eye, the latter extends his fingers in a plane exactly *midway between the patient and himself*, and, moving it upwards and downwards to the right and to the left, notices if in any of these or intermediate directions the patient's field falls short of his own, and to what extent it does so. Another method is to place the patient at about a foot from a large black board, and covering, as before, the eye not under examination, let him direct his gaze steadily at a chalk mark in the centre of the board; the limits of the field are now ascertained by moving a white disc, fixed on a long wire handle, over the board at various distances and directions from the fixation point, a chalk mark being made wherever the "traveller" disappears from the patient's sight. If these chalk marks be now united by a continuous line, this will indicate the periphery of the field. If for a plane surface we substitute a quadrant of a circle, one end of which is fixed by a pivot, and the other revolves round this fixed point, we have

the principle of all the perimeters now in use. The patient fixes his gaze on a small white object on the inner surface of the fixed end, and the quadrant having been fixed at any particular meridian, we can ascertain the limits of the field in that direction. The quadrant is graduated from 0° at the fixing end to 90° at the other end, the number of degrees indicating the size of the angle contained between two imaginary lines, one drawn between the eye of the patient and the fixing point, and the other between the eye of the patient and the point on the quadrant at which the traveller can just be recognised. All the charts depicted in this paper have been taken by myself with McHardy's perimeter, and reduced by photography to one quarter their original size, and I am indebted to my colleagues at the Eye Hospital for permission to make use of them.

The representation of the field of vision on a plane surface has certain disadvantages and inconveniences which do not occur with the curved surface. In the first place the extreme limits of the temporal side, which reach to 90° , cannot be represented on a plane surface at all, for it is obvious that no matter how far away we place the traveller we can never make an angle of 90° between the two imaginary lines. Secondly, when we get beyond 45° , the traveller is at an inconvenient distance from the eye under examination, and must be substituted by a larger one, especially if the patient has much reduced vision. Thirdly, we cannot readily judge what proportion of the field is lost, as a loss near the periphery covers a much larger space than an equal loss near the centre.

I would now direct your attention to any pair of charts represented in these pages, the outermost limits of which indicate the size and shape of the normal field. You will see that the normal field is nearly of an ovoid form, the smaller end being directed upwards and inwards; the outer limit extends to 90° from the fixation point, the lower to 65° , the inner to 55° , and the upper to 50° . At 15° to the outer side of the fixing point, and 3° below it, is a small blind area which corresponds to the entrance of the optic nerve, and which is quite destitute of perception of light. The reason usually assigned, or at least naturally assumed for the peculiar shape of the inner half of the field, is that the prominences of the face, nose, brow, cheek, &c., *prevent the light reaching the retina*; but I think I can show you that we must not too readily accept this explanation, for if, when tracing the nasal side of the field of, say the right eye, we cause the patient to turn his face very strongly to the left, while he still directs his macula on the fixing point, we shall find that the resulting chart has gained nothing in extent at this particular part. In the same manner we can prove that the upper contraction is

not due to the brow, nor the lower contraction to the cheek. It must not be supposed that I mean to say that the facial prominences have nothing whatever to do with the peculiar shape of the nasal side of the field; on the contrary, I believe that the former have by their presence caused certain parts of the retina to become functionless from disuse, this change taking place not in the individual but in the species. If instead of a white disc as a traveller we employ different coloured discs, we can map out the extent of the field for each colour; and we find that of the three colours—blue, red, and green—the most extensive colour field is blue, next red, and lastly green. Please note also that the colour fields resemble in shape the field for white light, forming not concentric circles but concentric ovoids. Let us now ascertain the distance from the fixing point at which two white spots, a quarter of an inch apart, can be recognised as separate objects in various directions, and having done so unite the marks by a continuous line, we shall obtain an ovoid figure concentric to the field for white light. Let us now proceed in a similar manner with the spots at half an inch apart, and, lastly, with the spots at one inch apart; we shall obtain three ovoids differing in size, but all concentric to the field for white light. From these two sets of experiments, the one with the coloured discs, and the other with the pairs of white discs, we find that the perception of colour and the perception of form diminish from the centre of the field in a fixed ratio, in such a manner that if we represent the power of colour or form perception to be at the upper part of the field 5, then at the inner it would be $5\frac{1}{2}$, at the lower part $6\frac{1}{2}$, and at the outer part 9. To recapitulate the properties of the field of vision, it is ovoid in form with the smaller end directed upwards and inwards; its dimensions in the outer, lower, inner, and upper directions are respectively 90° , 65° , 55° , and 50° . The acuteness of perception for form and for colour in any given direction diminishes in a ratio inversely proportional to the extent of the field for white light in that particular direction.

If we place the chart of the right eye over that of the left eye, making the fixing points coincide, we shall have a representation of the field of vision of both eyes when used together—*i.e.*, the entire surface from which light reaches the percipient parts of *both retinae*. We can see that about the middle three-fifths of this plane is common to both eyes, and may hence be called the field of binocular vision, the outer fifth on each side of this binocular field belonging exclusively to the eye of the same side. It would be foreign to my object to enter further upon the subject of binocular vision, but I will just mention that, as might be expected, the blind spot is conspicuous by its absence in the binocular field, the field of the right eye concealing the defect in the left and *vice versa*. I recollect a young man who had lost the use of the

left eye presenting himself at the hospital, and asking us to examine very particularly his right eye, as he thought there was something seriously wrong with it, assigning as his reason that when drawing at his desk the cake of indiarubber which he kept on his right would sometimes suddenly disappear. The fact was, he had found out his blind spot. I have never before or since heard of a similar case.

I shall now proceed to describe in detail the various forms of defective fields, and endeavour to give as complete a list as I can of the group of diseases met with in each variety. I shall try to be as concise as is compatible with a proper exposition of the subject.

I. *Central Scotoma for Colour.*—By this we mean the presence in the centre of the field of a limited area, in which red and green and often other colours cannot be recognised. It is always associated with more or less diminution of central vision, and the change always occurs in both eyes. The rest of the field is generally in all other respects quite normal, and the perception of colour is also normal, save in the central area above referred to.

Figures 1, 2, and 3 are examples of this affection. In the first the colour scotoma, represented black, ought to have been hatched, reaches from just beyond the inner side of the fixing point to the blind spot. It is longest in the horizontal direction, and broadest just to the outer side of the fixing point. This is by far the commonest form met with. In the second case, Fig. 2, the colour scotoma is confined to a point midway between the fixing point and the blind spot. The fields for red and green were traced in this case, and found to be normal. In the third figure the scotoma extends to the blind spot, but fails to reach the fixing point. It has been for some time universally granted that these cases are all due to the *long continued* indulgence in tobacco or alcohol, or in both, and that tobacco alone can and does give rise to this form of amblyopia is as well established a fact as any in the whole range of ophthalmology. I can show three cases of patients who were all teetotalers, but smoked immoderately, who presented all the characters of this form of amblyopia. That alcohol alone can cause amblyopia with central colour scotoma has not by any means been proved, and my own experience of a very large number of cases has failed to show a single case of central colour scotoma in any patient who was not a consumer of tobacco. These cases nearly all occur in men of middle or advanced life, but Figs. 1 and 2 are from cases of middle aged women who had smoked regularly for many years. The first case commenced to smoke fourteen years ago for the relief of spasm of the stomach. She could only indulge to a very slight extent at first, as it made her very sick; her usual allowance has been for a long time past

three half-ounces in the week of a dark-coloured tobacco. The sight is now one-sixth of normal in each eye, and has been going gradually for five or six weeks. Her health has been a good deal affected from bronchitis for the last nine months. The fundi are perfectly normal, and the discs of good color. She drinks "one gill of home-brewed ale each day at her dinner, and never took spirits but by the doctor's orders." I questioned her husband on the subject, and found that she never exceeded the above allowance. The second case is a woman aged 56, who commenced to smoke twenty years ago for the cure of toothache, and has continued to consume rather more than two ounces a week ever since. The vision is one-sixth of normal in each eye, and has been failing for six months. She has suffered from indigestion for the last twelve months. She has well-colored, healthy discs. She takes "one gill of porter each night—never more, and never any spirits." Her answers were confirmed by closely cross-questioning her brother who accompanied her, and who like herself was very anxious to know the cause of the loss of sight. These two cases illustrate well all the most important clinical points in the class of cases we are considering. The tobacco, after the first unpleasant symptoms are got over, is indulged in for years without injury to the sight, but after a certain age, and closely following on some indisposition, the quantity which up till now has been well borne, causes a gradual dimness of sight in each eye. If the tobacco be entirely given up I always promise a complete, or nearly complete, restoration of vision, and never require the patient to give up alcohol unless he is taking too much. I have never seen a case go on to anything like complete blindness even if the patient does not adhere rigidly to my instructions; nor do I believe that general atrophy of the optic nerve, or even disc, ever ensues as the result of tobacco. The only morbid appearance of any definiteness that one notes with the ophthalmoscope in these cases is a pallor limited to the outer side of the disc. This has been shown by Messrs. Nettleship* of London, and Samelsohn† of Cologne to be due to a slight neuritis affecting a strand of fibres which at the apex of the orbit lies in the centre of the nerve, and at the disc reaches the temporal side. These fibres have been shown to supply the central part of the retina.

I have now before me charts and notes taken by myself of 52 cases of central colour scotoma, and I think it will prove interesting to summarise these as regards the position of the scotoma—the amount of alcohol and the amount of tobacco. These do not by a long way represent all the cases of which I have charts, and I am dealing with this

* *Transactions of the Ophthalmological Society.* Vol. I., p. 124.

† Ophthalmological Section of the International Medical Congress in London.

series of 52 cases, simply because the charts have been mounted and arranged, and are hence readily available for analysis:—

Position of Scotoma.

1. Typical, as in Fig. 1.....	40 cases.
2. Between blind spot and fixing point, without reaching either, as in Fig. 2.....	3 „
3. Continuous with blind spot, as in Fig. 3	3 „
4. Confined to fixing point	1 „
5. Only in one eye.....	2 „
6. Only for green, and not for red	1 „
7. Ring shaped, surrounding fixing point where the perception of colors was normal	1 „
8. Partly developed into an absolute scotoma, <i>i.e.</i> , a scotoma for form	1 „
	—
Total.....	52 „

In this list we may note a few interesting points. Under 5, although the scotoma was only in one eye, the vision was equally impaired in both. I have notes of another case, in which the scotoma was at first confined to one eye, but afterwards affected both. I may here mention an interesting observation I have made on several occasions, and that is that the red test object appeared to the patient in the central region to be green, and sometimes a green object to be red. We may now review the habits of these patients as to drink and tobacco. The former is nearly without exception represented by beer or stout, the latter by thick or thin “twist.”

Habits as to Drink.

1. Total abstainers.....	3
2. 1 gill of beer per day	7
2 gills „ „	9
These we may term very moderate drinkers. }	16
3. 3-4 glasses of beer per day, but many of these patients had a good few more at “week ends” }	20
4. Habitual heavy drinkers	7
Not noted	6
	—
	52

Habits as to Tobacco.

No tobacco.....	0
Less than $\frac{1}{4}$ oz. per day, very slight smokers	9
$\frac{1}{4}$ oz. per day	8
$\frac{3}{8}$ oz. per day	3
This we may term a fair amount. }	11
$\frac{1}{2}$ oz. per day	27
1oz. per day	3
Very heavy smokers. }	30
Not noted	2
	—
	52

To revert to the question whether alcohol alone can be considered a cause of colour scotoma, I may state, as before, that I have never seen a case in a patient who did not consume tobacco, although I have been for some years on the outlook for such a test case amongst the very large number of women who come for various defects of sight, and many of whom show the unmistakable appearance of being heavy drinkers.

That alcohol may cause some form or forms of defective sight I do not deny, and in illustration I will record a very interesting case. The patient was a strongly-built, healthy, hard-working, temperate woman, aged 30. She complained of rapid failure of sight for the last few days. She could only count fingers at one foot distant from each eye, and she had the amaurotic appearance. She was led by a friend to the hospital. In trying to make her way to me she knocked against articles of furniture. The fundi were normal, hypermetropia 2 D. The fields (Fig. 29) showed large defects at the temporal sides. No central colour or form scotoma. On inquiry I found that since her brother's return from America a fortnight ago, she had had at least six or seven glasses of whisky each day, with the result of completely taking away her appetite and causing her to vomit everything she took, and she had been in bed during the last four days. In four days of complete abstinence this patient recovered normal vision in each eye, field nearly quite normal, colour fields good, and no central colour scotoma (see Fig. 30). I found she had anæsthesia of the hypogastric region. The amblyopia may reasonably be accounted for by pressure on the crossed fibres or hæmorrhage into the chiasma, which would also account for the loss of the temporal portions of the fields. I do not know the significance of the anæsthesia.

II.—*Absolute Central Scotoma.*—In this, as in the class of cases we have just considered, the defect lies in the centre of the field, but the function of this area is quite abolished, so that objects here completely disappear from the patient's view. If we use as our basis of definition the characters of the field only, we shall be compelled to draw a very close connection between this and the former class of cases, but we shall find that these cases of central defects for form perception, unlike the central color defects, do not readily fall into one or even several distinctly marked clinical groups. Figs. 4, 5, 6, and 33 are good examples of this form of field, and as the cases differed widely in many points, I shall briefly note the leading features in each.

Case 1. J. A. (under Dr. Little), aged 44, mechanic, married, fingers at $1\frac{1}{2}$ feet each eye; fields, Fig. 4, central blanks, normal periphery and good red fields; sight going three weeks, hyperæmia of discs, H = 2 D; at outer and upper part of each disc beading of some of the vessels, and a few very minute hæmorrhages, very heavy smoker and drinker, bad appetite, pale, bloated appearance, some swelling of feet, no albumen in urine, but loaded with lithates. In five months V = 16 Jaeger words, hæmorrhages gone, beading of vessels as before, pallor of outer and upper part of discs. Central blanks much smaller, periphery and red fields as before.

Case 2. H. D. (under Dr. Glascott), aged 57, married, meter inspector, sight going six or seven years. R eye, 16 Jaeger, L 18, on correction of presbyopia—"dulness in centre before each eye." Fields, Fig. 6, R small blank, with clear centre, L central blank, periphery normal in each, blurring and opacity of circumference of each disc and surrounding zone of fundus, edges of disc completely obscured, centre pretty clear. Choroidal stroma deficient about central region, choroidal vessels being here easily traced as if dissected out. Some irregularly placed pigment dots and patches in nerve fibre layer of retina, and in left retina one or two angular sparkling bodies (cholesterine) looking as if they were actually incandescent. No history of bad vision or consanguineous marriages in his family. Patient married three times, very large family, health good up to last six weeks, careworn expression, no syphilis, steady man, does not smoke. In seven months R = 1, L = 16, with his reading glasses, still the zone of opacity around discs, edges becoming defined. In the first case we note very great reduction of vision, fingers at $1\frac{1}{2}$ feet, with only very slight changes at discs, and these of a hyperæmic character; gradual but considerable improvement of sight, with pallor of temporal parts of discs. The case is no doubt one of what is termed "retro-bulbar neuritis," limited to the axial fibres, and is very suggestive—in this particular case at least—of an intensified form of tobacco amblyopia, but the ophthalmoscopic changes are more marked than in any case of the latter affection I have seen. By reference to the table on page 94 it will be seen I have noted a case of central color scotoma develop in part into an absolute scotoma, and I have noted the same thing in at least two other cases. In the second case the changes in the fundus were much more intense, and might be quite sufficient of themselves to account for the very considerable amount of amblyopia, without supposing any retro-bulbar process. At the same time the character of the field is not at all what one notes in cases of papillitis.

Case 3. S. H. (Dr. Glascott), girl, aged 21, single, cotton-baller. R = $\frac{6}{6}$, L = fingers at 1 foot, large blank in front of left eye, so that standing directly in front of me with the right eye covered, my entire head was invisible to her—externally the eyes were quite normal, pupils active, fundi, carefully examined with fully dilated pupils quite normal. Fields, Fig. 5, L eye large central scotoma, normal periphery, R eye normal field and no scotoma, good colour field. It was found that in the left field there was no reduction of acuteness of perception in the portion not occupied by the scotoma; there was some tenderness on pressure of left globe backwards and inwards. Healthy girl, menstruation normal, no syphilis or rheumatism, heart sounds normal. The history she gave was that four days ago, some time after taking her evening meal, a dimness came over the sight; there was no exciting cause. Ten days after the above

notes were taken I again examined the vision, and found it unaltered, the central blank being even larger than before. I have never seen quite a similar case to this. She is still under our observation, and perhaps time will bring to light further changes, that will help to a clearer understanding of the nature of the affection. My own opinion is that complete recovery may be expected.

A very similar case is reported by Mr. Nettleship.* It was, however, preceded by diplopia, and atrophy of the disc was noted within three weeks from the time that the patient observed the defect in his field.

Case 4. Was reported by Dr. Glascott and myself.† The patient was a strong, healthy, young miner, aged 18, with a history of gradual failure of sight; and when first seen he could only count fingers at six inches from each eye. Fig. 33 shows a central defect in each field with normal periphery; in the right eye the fixing point is free. The discs were pale, with deep physiological cupping vessels good size. We believed the cause to be excessive sexual intercourse and masturbation, to both of which the patient freely confessed. The sight very gradually improved, the last noted vision being Jaeger 16 letters each eye.

III. *Hemianopic Defects.*—By hemianopia we mean loss of half the field in each eye, the term being, of course, restricted to those cases not caused by intra-ocular changes. When the outer half of one field is affected along with the inner half of the other field, the condition is one of homonymous hemianopia, and it may be right-sided or left-sided. Figs. 7, 13, 15, 16, and 17 are good examples of right hemianopia, and Figs. 8, 10, and 14 of the left-sided form. The outer half of each field may be wanting as in Fig. 11; this is called bitemporal hemianopia, and, as is well known, is always caused by pressure on the chiasma. The reverse of this, the binasal form, is extremely rare. I have not seen an example of it. A still rarer form has been occasionally found, the upper halves of the fields being affected. It has been called altitudinal hemianopia, and may be superior or inferior. The homonymous form is by far the commonest, and when associated, as is often the case, with hemiplegia, the paralysis will be found on the same side as the defect in the field, or, as Hughlings Jackson neatly expresses it, “the patient cannot see to his paralysed side.” Homonymous hemianopia is caused by destruction or arrest of function of the optic fibres or their continuation, and the lesion may probably be situated anywhere in the course of these fibres, between the chiasma and the occipital lobe, just behind the fissure of Rolando. It is quite agreed that the optic tract supplies the temporal half of the retina on the same side by the fibres on the

* “Cases of Retro-ocular Neuritis.” Case No. 17. *Trans. Ophthal. Society*, Vol. IV.

† *Ophthalmic Review*, April, 1883.

outer side of the tract, and the nasal half of the opposite retina by the fibres which cross at the chiasma. These two sets of fibres, the crossed and the uncrossed, representing the physiologically allied halves of the retinae, certainly run together as far as the corpora quadrigemina; beyond this point their course and connections are disputed. Charcot, in his well-known diagram, makes the fibres from the temporal halves of the retina cross over at the corpora geniculata to meet the fibres which have crossed at the chiasma, thus bringing into close connection on each side of the brain all the fibres from both halves of the opposite retina. This theory gave an explanation of his cases of amblyopia of one eye from disease of opposite hemisphere, or in connection with hysterical hemianæsthesia. Grasset* goes a step further than this, and makes the fibres from the temporal halves of the retina re-cross to their own side again. Charcot's diagram cannot account for cases of hemianopia from cortical lesions, of the occurrence of which no one has doubts. Grasset's scheme, on the other hand, not only accounts for such cases, but also for crossed amblyopia, the latter by a lesion of the posterior part of the internal capsule. However, whether we accept or reject Charcot's theory of the crossing of the temporal fibres at the corpora geniculata, or Grasset's re-crossing of the same fibres at the internal capsule, is not a matter of much importance; the main thing it is necessary to keep in mind and make an article of one's faith is that the fibres from the right retina reach the cortex of the right occipital lobe, and those from the left retina the left occipital lobe. All the cases of hemianopia I have charts of have shown retention of central vision for some distance on each side of the fixing point, and even when the line of demarcation has been quite or nearly quite through the centre of the fields, above and below the fixing point, I have always found that the fixing point has been avoided; it is, indeed, curious to note the way in which the blank in the field curves round the fixing point. I have never been able to persuade myself that the fixing point has been bisected, and on inquiry regarding this point of several of my colleagues and friends they have each told me that their experience tallied with mine. As the converse of this, it is interesting once more to call to mind the cases of central scotoma in which we saw that the central fibres only were affected, the peripheral always escaping. I have myself no doubt whatever, apart from any other evidence than that afforded by clinical evidence, and especially campimetry, that the central fibres differ from the peripheral in their course, connections, and cortical distribution. Ferrier holds that the corresponding sides of the retinae are represented by a centre in the occipital lobe, not alone, but

* J. Grasset. "Crossed amblyopia and hemianopia in cerebral lesions." *Recueil d'Ophthalm.*, March, 1883. Abstracted *Ophthalm. Review.*, Nov., 1883.

in conjunction with the angular gyrus, which latter he believes represents the central fibres of both eyes, but chiefly those from the *opposite* eye. I have always found that, if in hemianopia, the central vision is defective in one eye, it is always the eye on the same side as the hemianopia, and we can readily understand this from Ferrier's view, that the representation of central vision is mainly a cross one. It is stated in some text books of ophthalmology that the patient complains he "can only see the half of an object"; it is quite exceptional for him to make any such useful remark, and if we wait for any such sign of extra powers of observation on the part of the patient we shall be liable to pass over nine out of every ten cases of hemianopia. The patient often only complains of bad sight in one eye, or still more frequently makes some trivial and apparently totally irrelevant remark about his eyes. I have, in such a case, seen the field of the defective eye carefully mapped out, and as the result of this examination and of strongly developed powers of self-deception, a diagnosis made of separation of the retina. In the case of which Fig. 15 is the chart, the patient, who had slight aphasia, complained of the right eye. I found the vision slightly reduced, and a fresh hæmorrhage at the upper and inner part of the disc; the vision and the fundus of the other eye were normal. I took the field of the right eye only, and persuaded myself that the defect was due to the retinal hæmorrhage. At the second visit, however, I diagnosed the true nature of the affection. As a matter of fact a very large proportion of cases are unrecognised by ophthalmic surgeons. The shape and size of the homonymous defects will depend, in cortical cases, upon the particular part of the cortex affected, and may, theoretically at least, be of any configuration or extent short of the usual character, for example see Fig. 9. Munk has shown in dogs that the centres for the crossed and the uncrossed fibres are distinct, and if the same arrangement holds good in man, which is by no means proved, we ought to see cases of one-sided hemianopic defects from cortical lesions.

IV. *Ring-shaped scotoma.*—This is a rare defect. I give seven more or less perfect examples (Figs. 32-38) in different types of disease, and probably differing in the nature and situation of the lesion causing the defect. In four (Figs. 32, 33, 34, and 37) the disease is atrophy neuritis or papillo-retinitis. I have besides seen a case in choroiditis disseminata of an unusual nature. Two cases (Figs. 35 and 36) occurred in retinitis pigmentosa, and in one (Fig. 38) there were no ophthalmoscopic changes, and the lesion was probably a hæmorrhage in the optic nerve itself. Ring scotoma has, as far as I know, only been recognised in retinitis pigmentosa and specific retinitis, but it is probably of much commoner occurrence than is generally supposed, it being the lesion of field of all others most apt to be overlooked.

I may here make a general statement in regard to the nature of the defect in the field occurring in all local diseases of the fundus, and that is that the defect varies in character according to whether the percipient layer of the retina is affected, the rod and cone layer, or, on the other hand, the conducting layer. In the first case, when the rod and cone layer is affected, we have a defect in the field corresponding in position, size, and shape with the lesion in the eye—in other words, a “scotoma.” But in the latter case, when the nerve fibre layer is affected, we have a defect extending right up to the periphery of the field, the lesion not only destroying the conducting power of the nerve fibres which come from this particular part of the retina, but also preventing conduction from the peripheral parts of the retina beyond the lesion. This distinction will explain all the defects met with in disease confined to the eye, such as separation of retina, hæmorrhage in choroid or retina, rupture of choroid, localised atrophies of coats, opaque nerve fibres, blocking of branches of the central artery, foreign bodies in the fundus, &c., and I shall say no more on this subject except a few remarks further on in regard to retinitis pigmentosa and chronic glaucoma, as both diseases present some interesting points in the fields.

V. *Peripheral Contraction.*—This is not only the most common form of defective field, but it occurs in a wider variety of cases than any other. It may be a sign of the greatest import, as in optic atrophy; or on the other hand of slight consequence, as in hysterical and other functional affections. Perhaps the most typical examples are seen in retinitis pigmentosa as in Fig. 19, which shows moderate contraction for white and for red and green, and Fig. 20, which shows extreme contraction for white. The ophthalmoscopic signs of this disease are narrowing of the retinal vessels; a peculiar “waxy” appearance of the disc, which is usually pale; more or less abundant equatorial distribution of pigment in the nerve fibre layer of the retina; and often great sparseness of the hexagonal pigment cells in the outermost layer of the retina, especially at the central region. In all the cases I have seen this form of contraction has been present, except in three cases which showed ring-shaped scotomata. (See Figs. 17, 35, and 36). It is worthy of note that in these three cases the disease appeared to be stationary. The contraction of the field in retinitis pigmentosa may be supposed to be due to three causes—the presence of the pigment, incipient atrophy of the optic nerve, or sclerosis of the deeper layers of the retina. The contraction certainly does not seem to bear anything like a constant relation to the amount of the pigment; indeed it may be very marked with complete, or nearly complete, absence of the latter. Nor would the position of the pigment, occurring as it does in the nerve fibre layer, be compatible with ring-shaped defects.

I believe it is not due to commencing optic atrophy, as I have always found, even in the advanced cases, that there is good perception for colours, and that the colour fields are contracted only in proportion to the field for white; and I would venture to remark that atrophy of the optic nerve is perhaps much less frequent in this class of cases than seems generally to be supposed. I am of opinion, then, that the contraction is due to sclerotic changes in the outer layers of the retina, with or without changes in the choroid.

In chronic glaucoma the first change is shown in Fig. 25, from a case in which the central vision was normal. This invasion of the nasal side is nearly invariably present, and may progress to quite close to the fixation point before the field is elsewhere contracted. The next change is contraction of the upper and lower part of the temporal side of the field (see Fig. 24), leaving in this way a more or less horizontal strip of field from the nasal side of the fixing point to the temporal side of the field. Next the central fixation is lost, leaving the patient only perception in a small area at the outer side; lastly, he loses even this, and becomes quite blind. In other cases the loss takes the form of a peripheral defect all round the field, gradually closing in upon the fixation point, as in the case from which Fig. 23 is taken, but even in these cases it might have been found that the first defect took place at the nasal side. It is remarkable how good the vision may be, even in advanced cases, if only the fixation is not destroyed. In the cases illustrated by Figs. 23, 24, and 25 the vision was in each case normal. This point may be in certain cases of great diagnostic importance. I refer to those cases, which do sometimes occur, in which one is doubtful whether the symptoms are due to chronic glaucoma or optic atrophy, central vision failing in the latter before the contraction has proceeded to any great extent. The colour perception may also be of service in making a differential diagnosis between the above diseases, being usually very slightly if at all affected in chronic glaucoma, in contrast to what we shall find is the case in atrophy.

Fig. 21 is from a case of extreme peripheral contraction occurring in a hysterical girl of 17. Vision was normal in each eye, but she "could only see in the centre" for the last three weeks, and everything looked smaller than it ought to. I regret I did not examine her for impairment of sensibility. She made a rapid and complete recovery. Fig. 22 represents the condition of her fields about a week later. I have since seen several other such cases in young women associated with hemianæsthesia. I saw an extremely well marked example of complet left-sided hemianæsthesia in a little girl of eight, with amblyopia on the same side, contraction of field, and total achromatopsia. The right eye had normal vision, field for white normal, as also were the colour

fields. I have notes and charts of several cases occurring in men; following, if not caused, by severe blows on the back, or falls from some height. The vision has been normal, but the field has shown more or less concentric limitation, and in one case the contraction was, I think, the most extreme I have ever met with. In some of these cases I have noted paralysis of accommodation, sluggishness of the pupils, myosis, or exaggerated tendon reflex, and sometimes deafness, so that it is quite possible that these may have been the precursor of some serious nerve disease, or the results of the injury complained of.

What is the cause of concentric contraction in these functional cases? Is it purely local, as some would have us believe, and due to vaso-motor changes in the blood vessels of the retina; or is it due to lesions of the internal capsule or of the cortex of the occipital lobe? Priestley Smith* supports the first view; his remarks are based upon several cases of thrombosis of the central artery of the retina, the symptoms in which cases may fairly be accounted for by imperfect blood supply to the retina, but when he seeks, as he does further on, to account for all functional contractions of the field by changes in the retinal blood supply, I do not think he is likely to find many supporters. In a later paper, on the same subject,† he appears to have shifted the blame from the central artery and its branches to the choroidal capillaries which are now mentioned for the first time. If we accept the scheme of Charcot, amblyopia and contraction of the field limited to one eye, is readily accounted for by lesion of the internal capsule of the opposite side, and the accompanying hemianæsthesia is also what we should expect. Grasset's scheme of the distribution of the optic fibres, which is similar to Charcot's as far as the crossing at the corpora quadrigemina, would, of course, also account for the symptoms. If we seek to explain the cases of peripheral contraction of both fields by some disturbance in the cortex of the occipital lobe, we are met with the difficulty that lesion of one side must produce hemianopic not concentric defects; the subject is ably discussed by Wilbrand,‡ who supports the view that the symptoms are due to *bilateral* cortical changes.

I shall end this paper by a few remarks on the field of vision, as occurring in atrophy of the optic nerve. It may seem strange that I have left this subject till the end, but my reason is that the diagnosis is so often one of great difficulty, and the prognosis is so grave, that we must exclude all other causes before deciding that the

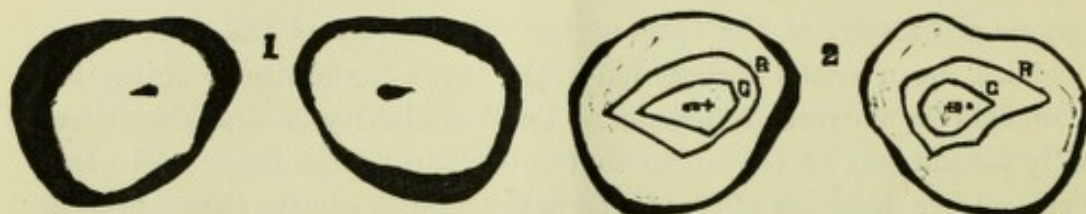
* Priestley Smith. "Reflex Amblyopia." *Ophthalmic Review*, January, 1884.

† *Ophthalmic Review*, May, 1884.

‡ Hermann Wilbrand. "On concentric contraction of the field of vision in functional disturbances of the cerebral cortex, and on incongruence in the defects of hemianopia." *Klin. Monatsbl. f. Aughenheilk.*, February, 1885. Abstract *Ophth. Review*, August, 1885.

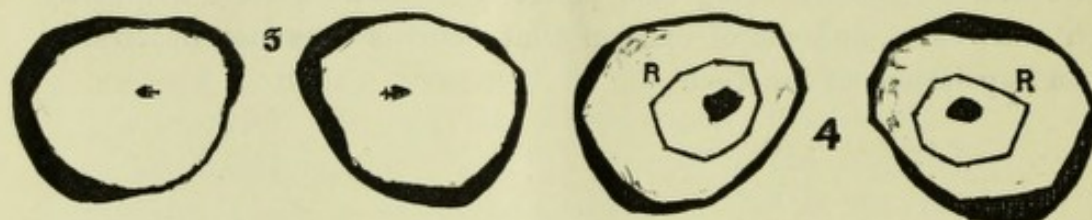
symptoms are due to atrophy. If this were more generally done we should have fewer cases of cure of atrophy of the optic nerve or of complete atrophy caused by smoking. The beginner is very apt to attribute nine cases of amblyopia out of every ten to atrophy of the optic nerve, and this by the use of the ophthalmoscope alone; the experienced ophthalmic surgeon, whose ophthalmoscope is in constant use, will rarely, by its use alone, unless in a very marked case, make a definite diagnosis of atrophy of the optic nerve. In atrophy of the optic nerve, by which I mean actual destruction in the nerve tissue itself, contraction of the field is universally present. The peculiarity is that the defect usually commences at the upper and outer part of the field; and when the second eye becomes affected, the defect nearly always shows first in the same position. This is well seen in Figs. 27 and 28. Diminution of central vision is, in my experience, always present, and it has been shown, and I can substantiate the statement from my own experience, that there is nearly always partial achromatopsia, or else the contraction of the fields for one or more colours is much greater than the size of the field for white would lead us to suppose. These remarks chiefly apply to primary atrophy, but we have often the same sequence of events in atrophy due to papillitis. Fig. 31 is from a case of well marked double papillitis with normal vision in each eye, the fields for white and for colours being also perfectly normal. I have frequently seen such cases, and am of opinion that neuritis does not necessarily mean impairment of function.

CHARTS OF FIELD OF VISION



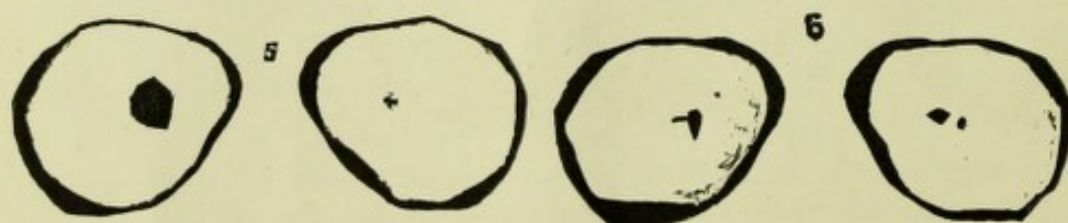
1. Tobacco amblyopia. Periphery nearly normal; central areas show where red could not be recognised; the scotomata encroach on fixing point and blind spot. Woman, aged 51, smoked for many years, drinks one gill of ale per day, fundi normal. Hm., 1 D, V $\frac{6}{18}$ each eye.

2. Tobacco amblyopia. The scotomata are very small, and placed between fixing point, denoted (as in all the charts) by +, and the blind spot, shown by a black spot ●. Periphery normal, and color fields, for red R and green G, of normal extent. Woman, aged 56, smoked many years, V $\frac{6}{36}$ each eye.




3. Tobacco amblyopia. Scotomata free of fixing point, continuous with blind spots, in area of scotoma red became green and green colorless.

4. Absolute central scotoma. Each eye with normal field, and normal field for red. See page 95 (Case 1).




5. Absolute central scotoma, left eye. Periphery of field normal for each eye. See page 96 (Case 3).

6. Absolute central scotoma, each eye. The blind spots are shown free of the scotomata, in the right eye by a round spot, and in the left by a line. See page 96 (Case 2).




7. Right homonymous hemianopia, left halves normal and good color fields central vision normal, fundi normal.

8. Left homonymous hemianopia, right halves nearly normal, $V \frac{6}{12}$ each eye, and No. 1 Jaeger at 9'. Pupils unequal, small aneurism of arch of aorta, sudden onset five weeks ago, no paralysis, tendon reflex much exaggerated, memory slightly affected




9. Small homonymous defects with some peripheral contraction.

10. Left hemianopia, $R \frac{6}{6}$, $L \frac{6}{6}$, central vision retained, line of separation not vertical; had epileptic (?) attack two months ago, followed by defect in field and numbness of left side.




11. Bitemporal hemianopia. Amblyopia of three months' duration, R 19, L 16 fields normal, followed in six months by defect in fields as in figure; vision improved in R.

12. Case of atrophy, probably secondary pressure, right field hemianopia, left shows segmentary defect, R fingers, $L \frac{6}{6}$, both discs pale, edges even clean cut, sight failing in R six months, left tendon reflex all right, right cannot be elicited, pupils fixed, health perfect. In twelve months, R bare pl. of light, L 16.




13. Right hemianopia, $V \frac{6}{6}$ each eye, fundi normal, pupils equal in size, right reflex iridoplegia, left reacts well, no marked paralysis, weakness of right grasp, verbal amnesia, severe cold all through him four weeks ago, noticed defect in sight and memory for words for last three weeks.

14. Left hemianopia, $R \frac{6}{6}$, $L \frac{6}{24}$, in R some burning of disc, numerous very minute hæmorrhages, cluster of white ticks. L blurring of disc, no hæmorrhages to be seen, examination difficult on account of corneal nebulae, left hemiplegia six years ago, and a second attack two years ago.



15. Right hemianopia, R $\frac{6}{9}$, L $\frac{6}{9}$, recent hæmorrhage close to right disc, fundi otherwise quite normal, paresis L internal rectus, verbal amnesia, symptoms came on eleven weeks ago, was in bed a fortnight with "inflammation of the brain."

16. Right hemianopia, R $\frac{6}{12}$, L $\frac{6}{9}$, H $4\frac{1}{2}$ D, fundi normal. Noticed defect for a fortnight. Rheumatic man, aged 63, unconscious for nearly a week, and left side of face twitched.




17. Right hemianopia occurring in case of retinitis pigmentosa, with ring shaped scotoma around fixing point.

18. Case of nasal hemiachromatopsia. R. eye, with central color scotoma and normal periphery. L, normal periphery and good colourfields. Jaeger 16 each eye; discs not very well colored.




19. Case of retinitis pigmentosa. Moderate peripheral contraction each eye; with proportionate contraction of color fields; good central vision.

20. Retinitis pigmentosa. Extreme concentric contraction each eye with retention of good vision.



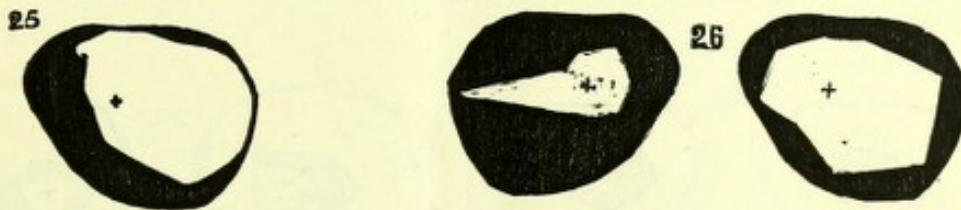
21. Case of concentric contraction, with retention of normal central vision. Hysterical girl, aged 16; "could only see in the centre" for last three weeks; sudden onset.

22. Same case in the course of about one week. Centrifugal enlargement of fields; field for red also shown is rather small; the field for blue was also traced, but is not shown in these charts; it was slightly larger than the red fields.




23. Case of extreme concentric contraction, occurring in a case of chronic glaucoma, with V 1 Jaeger, and $\frac{5}{8}$ each eye.

24. Case of chronic glaucoma. V $\frac{5}{8}$. The contraction is that met with in advanced cases only, the small portion to the nasal side of the fixing point was traced with the quick traveller, and is consequently represented twice as large as it ought to be.




25. Case of chronic glaucoma. V $\frac{5}{8}$. The contraction showing only at nasal side is typical of commencing destruction of field from chronic glaucoma.

26. Contraction of fields occurring in ataxic case. R $1\frac{5}{8}$, L 16. Discs are both pale, apparently one as bad as the other.

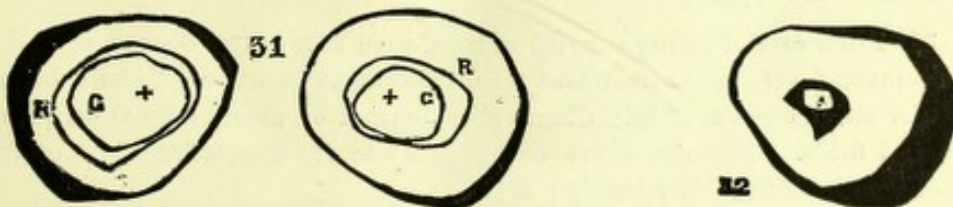


27 and 28 are from cases of progressive atrophy of optic discs; no notes; the exactly symmetrical invasion of the fields is very striking.




29. From case of temporary but high degree of amblyopia following drinking bout in temperate woman. See page 95.

30. Fields from same case on recovery.



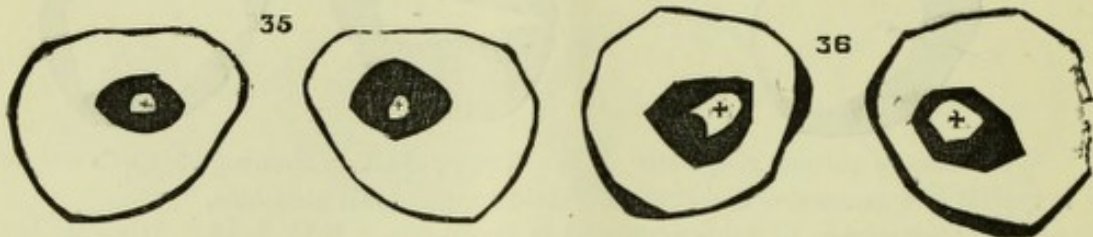
31. From case of well marked double papillitis, V $\frac{5}{8}$ each eye; fields are seen to be normal, and color fields also.

32. Field of R. eye from case of post papillitic atrophy, showing ring-shaped scotoma surrounding the fixing point; field quite normal, except at periphery of temporal half. V 16; no pl. in L. eye.




33. Case of extreme amblyopia, from sexual excesses. L clearly shows normal periphery, with central blank. R shows normal periphery, with large ring-shaped scotoma round fixing point. See page 97 (Case 4).

34. From case of slight double papillo-retinitis. R chart normal, field for red good, and for green fair. L broad ring-shaped scotoma surrounding fixing point. V $\frac{5}{6}$ each eye.



35. From case of retinitis pigmentosa. Shows normal periphery of each field, with ring-shaped scotoma around fixing point.

36. Case of retinitis pigmentosa. Charts show similar characters to the previous case; the fields are considerably larger than normal at the upper part. I have never traced such extensive fields before.



37. Charts show normal periphery, with complete ring-shaped scotoma around fixing point in R, and probably what is a commencing ring scotoma in L. The blind spots were traced, and are shown in each field. L $\frac{5}{6}$, fundus normal. R disc rather pale, and has filled in appearance. Four months ago there was in this eye "retinitis." No syph.

38. From case of young married woman, aged 22. Mitral disease, several attacks of rheumatic fever, under treatment for displacement of uterus, "blank before right eye" for about eight months. Charts show normal or nearly normal periphery, with good red fields. Scotoma above fixing point in R, suggestive of a commencing ring-shaped scotoma. R $\frac{4}{6}$ barely; L $\frac{5}{6}$.

