

Section or exsection of the rectus : in the treatment of paralytic strabismus, and that due to extreme over-correction with loss of motion / by Arthur E. Prince.

Contributors

Prince, A. E.
American Medical Association, 1888 :), Cincinnati, Ohio)
University College, London. Library Services

Publication/Creation

Chicago : published at the office of the Association, 1888.

Persistent URL

<https://wellcomecollection.org/works/bgrhcwkp>

Provider

University College London

License and attribution


This material has been provided by This material has been provided by UCL Library Services. The original may be consulted at UCL (University College London) where the originals may be consulted.

This work has been identified as being free of known restrictions under copyright law, including all related and neighbouring rights and is being made available under the Creative Commons, Public Domain Mark.

You can copy, modify, distribute and perform the work, even for commercial purposes, without asking permission.

**wellcome
collection**

Wellcome Collection
183 Euston Road
London NW1 2BE UK
T +44 (0)20 7611 8722
E library@wellcomecollection.org
<https://wellcomecollection.org>



11.

Section or Exsection of the Rectus


In the Treatment of Paralytic Strabismus, and
that Due to Extreme Over-Correction
with Loss of Motion.

BY
ARTHUR E. PRINCE, M.D.,
OF JACKSONVILLE, ILL.
OPHTHALMIC AND AURAL SURGEON TO THE ILLINOIS STATE
INSTITUTIONS FOR THE DEAF AND DUMB AND BLIND.

*Read in the Section on Ophthalmology at the Thirty-ninth Annual
Meeting of the American Medical Association, at Cincinnati,
May 7, 1888.*

Reprinted from the "Journal of the American Medical
Association," October 13, 1888.

CHICAGO
PRINTED AT THE OFFICE OF THE ASSOCIATION.
1888.



Section or Exsection of the Rectus

In the Treatment of Paralytic Strabismus, and
that Due to Extreme Over-Correction
with Loss of Motion.

BY
ARTHUR E. PRINCE, M.D.,
OF JACKSONVILLE, ILL.
OPHTHALMIC AND AURAL SURGEON TO THE ILLINOIS STATE
INSTITUTIONS FOR THE DEAF AND DUMB AND BLIND.

*Read in the Section on Ophthalmology at the Thirty-ninth Annual
Meeting of the American Medical Association, at Cincinnati,
May 7, 1888.*

Reprinted from the "Journal of the American Medical
Association," October 13, 1888.

CHICAGO
PRINTED AT THE OFFICE OF THE ASSOCIATION.
1888.

Digitized by the Internet Archive
in 2014

1650334

<https://archive.org/details/b21633332>

SECTION OR EXSECTION OF THE RECTUS

IN THE TREATMENT OF PARALYTIC STRABISMUS, AND
THAT DUE TO EXTREME OVER-CORRECTION
WITH LOSS OF MOTION.

The purpose of this paper is the presentation of a series of cases of *irretrievable* loss of power of either rectus, causing extreme paralytic deviation, the restoration of the equilibrium having been accomplished through *section* or *exsection* of the contracted muscle. Such cases are found in one of the four following classes:

1. Permanent atrophy or paralysis.
2. Irrecoverable loss of either rectus through accidental section of the muscle back of its capsular perforation.
3. Extreme over-correction of long standing, following tenotomy with excessive laceration of the capsule, permitting the retraction of the tendon back of the equatorial meridian, whence, owing to atrophy or adhesions it cannot be successfully advanced.
4. Irrecoverable traumatic dislocation of the rectus.

Cases belonging to the paralytic class are not very infrequent. The class of accidental section of the muscle in place of the tendon (formerly very large before the relations of the capsule were understood) is assuming diminished proportion, and new cases are seldom produced except by the most inexperienced charlatan.

The third class is becoming smaller in proportion to the attention paid to the preliminary correction of ametropia, and the frequency with which advancement is employed in the correction of high degrees of squint.

In the fourth class my knowledge is limited to the observation of case 7.

The clinical aspect of these conditions needs no particular consideration. The unpleasant appearance of an extreme deviation, especially when outward or upward and accompanied by restricted motion, is too familiar to be mistaken. The exceptional reference, if any, to be found in the literature of treatment, and the acknowledged incapability of tenotomies and advancements to correct these deformities, justifies the brief outline of the following cases, which have led to the adoption of the present mode of practice.

Case 1.—One of a series of unsatisfactory results, following attempts to correct a paralytic condition, by advancement.

Mrs. D., aged 45. In childhood both interni had been tenotomized in an unknown manner, resulting in a moderate over-correction, which later in life became a divergence of both eyes, measuring together 70° . The interni were so inefficient that the axis of neither eye could be brought parallel to the meridian plane. Lateral motion was restricted to 30° in the right, and 25° in the left eye. The operation performed was a tenotomy of the externi with advancement of the retracted internal recti. The interni were found remotely attached to the posterior hemisphere of the ball, but the advancement was accomplished in a satisfactory manner, and the result was a temporary success. Soon after her discharge a slight divergence (10°) was observed, but in contrast with the gravity of the former condition was

not regarded as a bad failure. For three months the divergence increased until it would have been difficult without actual measurement to determine any material improvement.

This failure is introduced as a type of the results which will attend the attempts to restore the equilibrium through advancing a muscle which has remained for many years retracted in the orbit, becoming atrophic through inactivity. The superior strength of the opposing muscle, though tenotomized, will assert its supremacy and the correction will not be permanent.

*Case 2.—Section of both recti, posterior to their capsular perforation.*¹—Barney Burnes, Sydney, Ill., aged 43. From infancy to the age of 20, he was the subject of a marked internal squint. At that time his father entertained a guest over night who made it his business to travel the country and straighten cross-eyes. It was considered a rare fortune thus accidentally to have presented an opportunity which might never occur again, for they were very poor, and he was willing to straighten both eyes for his lodging and \$2.50. A week later, when Dr. Strabotomist was pursuing his calling many miles away, it was considered safe to expose the eyes to the light, when the following condition was revealed.

Both eyes were deviated extremely outward, measuring with Snellen and Landolt's method,² 50° in the right eye, of which a portion of the iris was concealed under the external canthus and the lateral motion limited to 10°. With H.=I.5 D. corrected, V.= $\frac{20}{40}$. In the case of the left eye

¹ The liberty is taken of reproducing this and the following case from the Pulley Method of Advancing the Rectus. N. Y. Medical Record, Aug. 8, 1885.

² Bestimmung des Schielens. Snellen u. Landolt. Handbuch der Augenheilkunde. Graefe und Saemisch, vol. iii., p. 235.


"Manual of Examination of the Eyes," Landolt, p. 49, ed. 1879.
"Traite d'Ophthalmologie," Landolt, and Wecker, vol. 1, p. 915.

external deviation was 40° , lateral motion 15° , H.=I. 5 D., V.= $\frac{20}{40}$. Direct vision was very imperfect, but by turning the head to bring objects in the visual axis of either eye he could see tolerably well. As he was very anxious to have an effort made for the correction of his deformity and bearing in mind my experience with advancement in this class of cases, it was explained to him that his muscles had been divided too far back, to correct which, as bad an operation would be attempted on the external muscles, as his \$2.50 operation had been on the internal muscles, and that it was hoped by the aid of a stitch to be able to effect a parallelism, so that he would look well and have direct vision, but he must not expect to have lateral motion, for with the lateral rectal attachments of both eyes destroyed, the must be satisfied if they were simply straight. With this understanding the operation was undertaken. A lateral incision was made above each external rectus and the hook introduced far back, exposing the muscle, which was divided outside the capsule. An internal advancement suture, to avoid subsequent deviation, was placed in each eye. The after treatment consisted of a moist compress of carbolic acid, $\frac{1}{2}$ per cent. No pain followed the operation, which was done under ether. On the fourth day there was an inward deviation of 5° , which was not noticeable. No deviation has occurred in the interval of seven years which have elapsed.


The most gratifying and at the same time surprising fact, especially worthy of note, was the unpredicted amount of *lateral motion*, which in the right eye amounted to 40° , and in the left to 45° . To account for this unexpected success the theoretic explanation was advanced that both external and internal recti formed a union with the

posterior hemisphere of the capsule, for it is scarcely probable that so great an amplitude of motion could be accomplished by the recti muscles acting alone on the orbital cellular tissue. Another consideration (concerning which it must be confessed some apprehension was entertained) was the danger of *exophthalmos*, consequent on destroying the ocular attachments of the two opposite recti muscles. The entire absence of this effect is likewise regarded worthy of note.

My enthusiasm led me to secure photographs of his condition before the operation, and also before his departure ten days subsequently.



Case 3.—Complete paralysis of the 6th nerve, treated by exsection of the rectus internus.—Mr. T. A. D., Oneida, N. Y., aged about 30 years, presented himself at the College of Physicians and Surgeons, New York, with a condition of complete paralysis of the external rectus of the left eye, following a railroad accident twelve years since.



In the collision his head was jammed between two cars. The recovery from the injury was rapid, leaving no other effects than an extreme internal deviation with partial concealment of the iris. Some years after an unsuccessful operation was

performed. Tested at the College and also at the Manhattan Eye and Ear Infirmary: V.=counts fingers at 6 inches, internal deviation about 50° , absolutely no motion.

Being in the city, the courtesy of Dr. Webster was extended in an invitation to demonstrate the *pulley* method of advancement on the following day at the Manhattan Eye and Ear Infirmary. Judging from the amount of motion obtained in the case related above, it was thought that a simple section of the muscle back of the capsule would be insufficient; that an attachment to the posterior hemisphere would probably occur and reproduce a partial internal deviation. It was therefore determined to exsect the muscle as far back as possible, the intention being to destroy the efficiency of the internal rectus. Under the influence of cocaine, the globe was rotated with fixation forceps as far to the temporal side as the contracted and hypertrophied muscle would permit, in order to allow of the introduction of the hook. Parallel lateral incisions were made, liberating the muscle, which was drawn out by the continued traction of the hook and divided at the remotest accessible point. The anterior portion was then separated from the sclera. An external advancement suture was inserted to hold the eye in position, and it was kept moist with a saturated solution of boric acid. No especial reaction followed the operation. The stitches were removed on the fourth day. The eye was perfectly straight. No exophthalmos or unnatural appearance existed except the absence of lateral motion. After a week, V.= $\frac{2}{3}$; in a direct line had binocular fixation, but lateral motion of the head either way caused diplopia. He left the hospital satisfied, with still some little ecchymosis, rapidly absorbing.

Case 4.—Exsection of the anterior portion of the externus for the correction of a paralytic divergence following faulty operation for internal strabismus 44 years ago.—Mrs. H., Carrollton, Ill., aged 53. At 9 years of age had an operation for the correction of convergent strabismus, resulting in an extreme over-correction of the left eye only. The angle of the deviation was 45° , and the lateral motion did not exceed 10° .

The staring effect of the divergence, combined with the loss of motion, was a constant source of embarrassment. She was especially anxious to have the deformity corrected, since in the capacity of wife of a Methodist minister she frequently changed her abode and made new acquaintances.

With an understanding that parallelism, with but partial restoration of motion was all that could be certainly secured, it was determined to advance the internus if possible; to exsect a portion of the externus if necessary.

Under cocaine an incision over the internus was made and forceps introduced to secure the retracted muscle, which was found but could not be satisfactorily advanced owing to the cicatrization and long-standing contraction of 44 years. A suture was introduced to be subsequently employed to overcome the divergence. The tendon of the externus, secured by fixation forceps, was then separated from the sclera and freed from its capsular attachments by four incisions parallel to its course. Thus permitted to assume its meridian plane, it was brought into and secured in this position by the suture previously placed in the contracted internus. Lastly the anterior contused end of the externus, thus far held by the forceps, was removed, allowing the muscle to retract into the orbit. The stitches were removed on the fourth day, when she went to her home, from

which she has written expressions of satisfaction with the result. Motion is very good and I regret not being able to give it in degrees. No exophthalmos exists.

Case 5.—Exactly similar to the preceding.—Mrs. S., Springfield, Ill., aged 54 years. Operated for internal squint at 10 years of age. Slight divergence of the left eye at first, became more marked as she grew older, partly owing to the relinquishment of her accommodation (H. = + 2.5 D—). She gradually lost control of the lateral motion which was reduced to 5°, and finally consulted me concerning pain which was assumed to be due to the permanent contraction of the externus.

The foregoing considerations led to the adoption of the method of treatment employed in the previous case, with similar results, except that the lateral motion obtained was more limited, not exceeding 20°. The eye appears straight during direct vision, pain has disappeared and she has been enabled to do an indefinite amount of sewing without discomfort. No increased prominence of the eye can be observed.

Case 6.—Similar to the two previous.—M. K., Kansas. Mr. K. is a German Lutheran preacher. He states that extreme divergence of the right eye resulted soon after an operation for internal squint. This occurred in childhood while he was still in Germany.

One operation for the correction of his deformity had failed, but he was sufficiently intelligent to appreciate the method suggested, of first accomplishing what was possible by an advancement and then weakening the externus sufficiently to restore a balance of the opposing forces.

The mechanical procedure was a repetition of the foregoing, and the result satisfactory to the

patient. The lateral excursion amounted to 35° . There was no apparent exophthalmos.

Case 7.—Dislocation of the inferior rectus, and divergent strabismus 25° , following injury; treated by exsection of the superior, tenotomy of the external, and advancement of the internal recti.—Mr. J. P., Camden, Ill., aged 30 years. Fourteen years ago, while walking under a tree, he was struck in the right eye by a broken branch, causing him to fall to the ground. For three hours he suffered pain and nausea. The eye was dressed by Dr. Mead, of Huntsville, who removed some pieces of bark, after which the swelling was too great to permit inspection for eight days. At that time the eye was found deviated upward, carrying the upper lid with it. There was no power of downward rotation. The eye deviated also outward, but had lateral motion good. He reports the condition to have suffered no change since the injury. The external deviation is found 25° , and the upward deviation 30° , and paralytic. The maximum of lateral motion not noted.

The eye appears slightly exophthalmic. The upper lid would descend by a voluntary effort, but in the condition of rest it was elevated, making the vertical diameter of the palpebral fissure one-half greater than that of the fellow eye.

By an effort at closing the lid slight downward motion of the ball was effected. The permanent upward rotation of the eye subjected the inferior portion of the cornea and adjacent sclera to continued exposure, causing it to be always congested, and at times badly inflamed, preventing sleep. No epiphora existed.

Operation.—The correction of this rare deformity was planned as two operations. The first, to restore a balance of muscular efficiency in the

vertical plane. The second, to correct the external deviation in the horizontal plane.

Under the influence of cocaine an incision was made over the location of the inferior rectus. By the grasp of the forceps muscular action was observed, but owing to the extensive long-standing cicatrization, no effective advancement could be made. An inferior advancement stitch was introduced and an attachment made to the sclera. The next step was to weaken the superior rectus sufficiently to permit the enfeebled inferior successfully to oppose the force of its antagonist. Accordingly, its tendon was detached from the sclerotic and secured by the forceps. The effect not being sufficient, the muscle was liberated from its capular attachment by incisions parallel to its course. It was thus rendered possible, by means of the inferior advancement suture, to secure a parallelism in the horizontal plain. The superior rectus was then shortened and allowed to retract back of the equatorial meridian of the eye, that it might not overbalance the strength of the dislocated inferior rectus. The immediate result was good. Some vertical motion was restored. The lids closed naturally, covering the ball.

Three days later the patient reports slight pain since the operation. Conjunctiva much congested. Vertical motion 30° . Amount of exophthalmos unchanged, but less conspicuous, owing to the closure of the lids over the sclera.

April 20, 1888, two months later. Returned for the correction of the external strabismus, which still remains 25° . At this time there was 5° of superior deviation. Vertical motion measured 30° .

The external deviation was corrected by a tenotomy of the externus with an advancement of the internus, one suture being inserted into the

muscle, and the other into the episcleral tissue forming a pulley over which the advancement can be made with precision to any required degree, securing with a bow-knot, to permit of subsequent modification, as explained in a communication to the *Ophthalmic Review*, Sept., 1887.

The following cuts, which scarcely require explanatory text, may aid in the elucidation of the method of advancement attempted in each of the above cases.

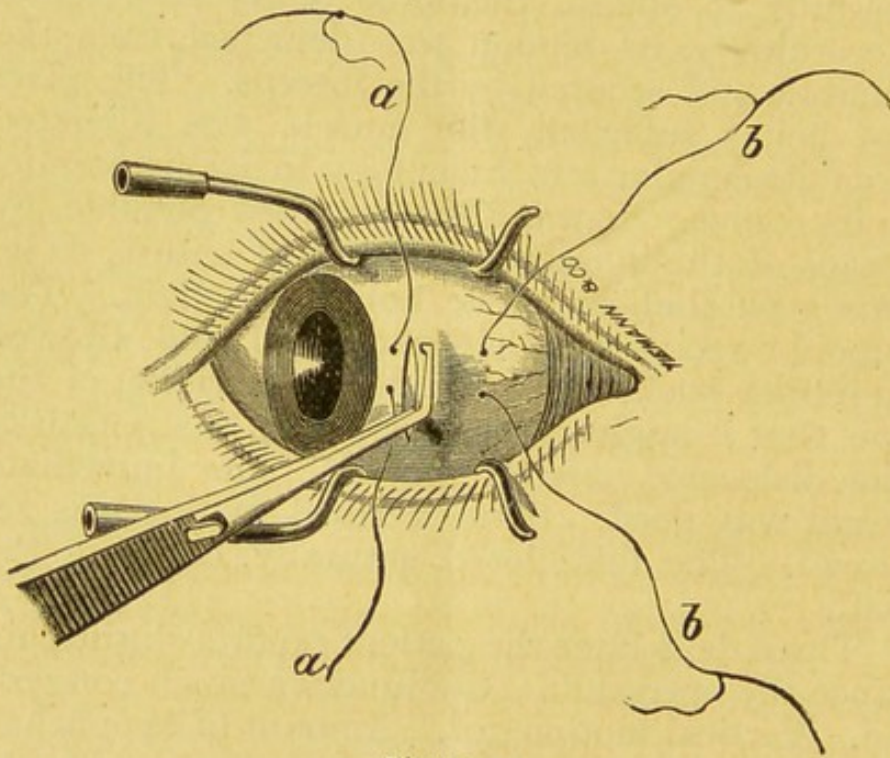


Figure 1.

By the aid of the needle, figure 3, it was found possible to insert the advancement suture, though the muscle itself could not be brought into view.

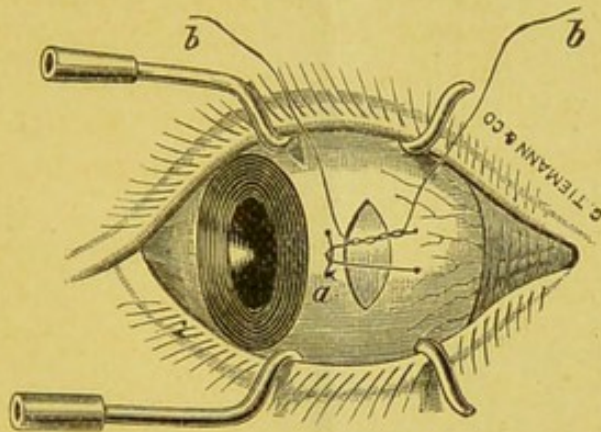


Figure 2.

CONCLUSIONS.

The conclusions suggested by the above cases are: 1st. In the case of complete paralysis of either rectus, the exsection of the opposing muscle will enable the eye to be retained in the straight position, without motion in that meridian.

2d. In case of retraction of either rectus muscle into the orbit, under conditions rendering its advancement impossible, an equalization of the deviating power is to be obtained through section of its antagonist, posterior to its capsular attachment, following which, excursions in that meridian will be restored to an extent varying between twenty and fifty degrees.

3d. In the above cases of paralysis, or retraction of either rectus, the operation of section or exsection of its antagonist has not been observed to develop or increase any preëxisting exophthalmos.

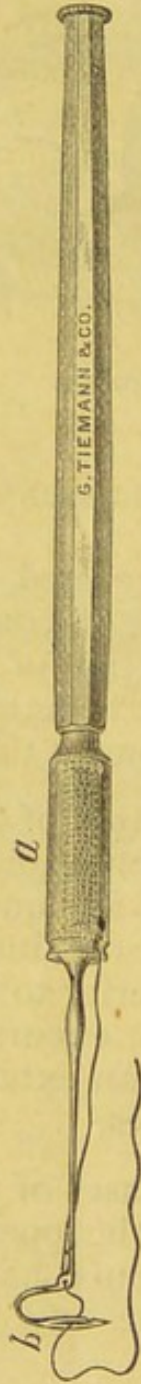

Figure 3.