

Practical remarks on strabismus : some novel suggestions respecting the operation / by G. Crichtett.

Contributors

Crichtett, G. 1817-1882.
University College, London. Library Services

Publication/Creation

Deptford : printed by J. Anderson, 1855.

Persistent URL

<https://wellcomecollection.org/works/xf7wnmed>

Provider

University College London

License and attribution

This material has been provided by This material has been provided by UCL Library Services. The original may be consulted at UCL (University College London) where the originals may be consulted.

This work has been identified as being free of known restrictions under copyright law, including all related and neighbouring rights and is being made available under the Creative Commons, Public Domain Mark.

You can copy, modify, distribute and perform the work, even for commercial purposes, without asking permission.



Wellcome Collection
183 Euston Road
London NW1 2BE UK
T +44 (0)20 7611 8722
E library@wellcomecollection.org
<https://wellcomecollection.org>



THE
LIBRARY OF THE
UNIVERSITY OF
TORONTO

STRABO

THE HISTORY OF STRABO

A HISTORY OF STRABO

THE HISTORY OF STRABO

THE HISTORY OF STRABO

THE HISTORY OF STRABO

6

PRACTICAL REMARKS

ON

STRABISMUS;

WITH

SOME NOVEL SUGGESTIONS RESPECTING
THE OPERATION;

BY

G. CRITCHETT, ESQ., F.R.C.S.,

SURGEON TO THE ROYAL LONDON OPHTHALMIC HOSPITAL; LECTURER ON SURGERY AT
THE LONDON HOSPITAL, ETC.

Deptford:

PRINTED BY J. ANDERSON, GARDEN ROW, NEW TOWN.

1855.

Digitized by the Internet Archive
in 2014

PRACTICAL REMARKS, ETC.

It is now about sixteen years since the first operation for strabismus, so philosophically suggested by Stromeyer, and so boldly executed by Dieffenbach, was performed. It was hailed as a great discovery, and excited an unusual amount of eagerness on the part of some of the members of our profession, and persons afflicted with this deformity became suddenly objects of interest and even solicitation. Thousands have been operated upon with various results, but it still admits of doubt whether the aggregate symmetry of those afflicted with this deformity has been increased, and whether the impression left upon the public mind, and even on that of the profession, is not rather unfavourable to this operation. I think it will be both interesting and instructive to the members of the profession, to endeavour to point out how far there exists any legitimate ground for these unfavourable impressions, and how far the present defects of the operation admit of improvement. Very soon after the importation of this novel and ingenious proceeding into this country, the literature on the subject was suddenly and copiously supplied, but it was evident that some wrote rather for, than from, practice, and that in every case the experience was too limited, and the time for observing subsequent results too short, and the mental bias in its favour too strong to admit of a calm and satisfactory verdict upon the merits of the operation. Now that many years have elapsed, that vast numbers have been operated upon, that enthusiasm has cooled down, and that comparatively few cases remain, we are able to approach the subject in a more philosophic spirit, and fairly and impartially to discuss the merits and demerits of the operation. As my object in this paper is chiefly practical, I do not propose to travel over the difficult and often discussed question of the pathology of strabismus, but only to glance briefly at a few points that seem to bear upon treatment.

Much has been said about the importance of determining which is the defective eye in any given case, and rules have been laid down for ascertaining this point. The truth is, that in almost every case both eyes are equally implicated in the abnormal position; for although one may be habitually inverted and the other straight, yet if the strabismic eye be brought into play, it assumes a normal condition, and moves in obedience to the will; and the other eye, if suddenly uncovered, will be found precisely in the position that the diseased eye usually assumes; and I have proved over and over again that as favourable a result is obtained by operating upon one as the other. The fact is, that in strabismus the two eyes start from different points; both respond to the effort of the will, and each is found, when examined separately, to move equally well in every direction. The disease is therefore rather relative than positive. Practically I endeavour to find out which is the eye that is habitually inverted, and for this purpose I test the relative power of vision in the two eyes, and I select for operation the one in which the sight is defective. In the alternating

1650033

form of this disease it is quite immaterial which is done, and in any case the result would be the same as regards the removal of the deformity; but the defective eye is selected in the hope of benefitting its vision simultaneously with its position.

The first point that impresses itself upon the mind of an extensive and careful observer is the extreme variety of causes to which the disease is attributed; but when these are analyzed and grouped, they may be arranged under three heads:—first, where the origin of the nerves is affected through the brain and spinal cord, as in cases following convulsions, fevers, &c.; secondly, where irritation is propagated from extremities of nerves, as in cases following injuries, ophthalmicæ, &c.; thirdly, from morbid volition, as in cases resulting from imitation, from temporary excitement, &c. In investigating the causes of strabismus, we find a very close analogy between this disease and talipes. Another circumstance, equally conspicuous and more embarrassing, is the numberless shades of difference in the degree of departure from the normal position, whether it be inversion, or, more rarely, eversion, or still more rarely, undue elevation or depression. In extreme cases, we find that when one eye occupies a central position, the other is so far drawn into the corner that about half the cornea is concealed by the folds of the caruncle; in slight cases, the departure from the central axis is from half a line to a line, and between these two extremes there is every shade of difference. The same may be said respecting diverging strabismus; but the third variety—viz., that in which either the superior or inferior rectus is involved, is never found in an extreme degree. Again, we find that the condition of the sight is very different in cases that are in other respects apparently similar. The rule certainly is, that in cases of habitual strabismus of some years' standing the function of the organ is impaired; but I have met with several well-marked cases in which sight has remained perfectly good, and with others in which the degree of impairment of vision has varied considerably, some being able to read large print, others being scarcely able to distinguish features, or even large objects. In the alternating form, vision is almost invariably found to be equally good in both eyes: and these varieties exist without any obvious change in the appearance of the eye, either as regards the condition of the pupil or of any of the transparent media, such as may generally be observed in amaurotic cases. It is quite possible that the ophthalmoscope would reveal changes in the retina and choroid in some of these cases, but I have not as yet had opportunities of observing a sufficient number to speak with any certainty. It has been said that the power of the external rectus, and consequently of eversion, varies considerably, as evinced by the extent to which the eye can be acted upon by this muscle; and this may be true in some cases, but it must be received with much caution, particularly where the strabismus is extreme; because the limit to eversion of the one eye depends upon the other having reached its utmost extent as regards inversion, and consequently the voluntary effort as excited in both eyes has reached its extreme boundary.

In considering the question of treatment, I propose to limit my remarks exclusively to operative proceedings, never having been

able to trace any advantage from any other plan, after the deformity has existed any time. The operation that has usually been practised for the removal of this deformity has consisted in the free division of those parts attached to the inner surface of the globe, including conjunctiva, sub-conjunctival fascia, rectus muscle, and its sheath; in fact, it was recommended by one author, that the inner surface of the sclerotic should be cleaned; if we bear in mind that this operation has been performed on some thousands of cases, of all ages, and presenting the numerous varieties to which I have already alluded, the wonder is, that a greater number of failures have not occurred, and that a uniform procedure should have been found so extensively applicable to a condition presenting so many degrees of deformity; nevertheless this is to a certain degree true. When the eye is free from the muscle it seems, in many cases, to have an inherent and selective power of assuming the straight position, so that what seems improbable in theory, exists in fact. At the same time, untoward results sometimes follow the operation, either immediately or at a subsequent period, rendering the condition of the patient worse than before. As, therefore, the motives for recommending such an operation are mainly based on considerations respecting personal appearance, (the improvement to sight being secondary and uncertain,) it becomes a matter of great practical moment to consider what are the defects of this operation, and how far they admit of correction. The first point that strikes every close observer, even in the most favourable specimens of the operation, where the eye has assumed a perfectly normal position, and moves freely, is a certain sinking in and loss of the caruncle, so that the inner part of the globe seems more exposed than that of the opposite eye, and a fossa exists in the place of the caruncle; this, so far as my experience goes, is an invariable result of the operation, and explains a circumstance that has been often remarked, that those cases are the most successful in which it has been necessary to operate on both eyes, the double defect being less conspicuous than when one only has been divided, and is brought into competition with the natural state of the parts. Another unfavourable result that sometimes occurs, is increased prominence of the globe; this takes place usually immediately the muscle is divided, but I have known it occur at a subsequent period, and gradually increase for a time. This, no doubt, arises from the loss of balance of power between the recti and obliqui, the latter acting with undue power when one of the recti is divided; the difficulty is to explain why this occurs in some cases and not in others, and to indicate any sign by which such a result may be predicated; and this I shall endeavour to do in a subsequent part of the paper. The most serious and damaging effect of the operation is the occurrence of eversion: this may be an immediate or a very remote consequence of the operation; and when the previous inversion has been slight, and there has been increased prominence and an extensive reaction in the outward direction, the deformity is very great, and almost hideous: the face seems robbed of all expression—"there is no speculation in those eyes." To the patient it becomes a serious grievance; and, to the operator, a kind of haunting spectral vision. I have met with cases in my own practice, and in that of

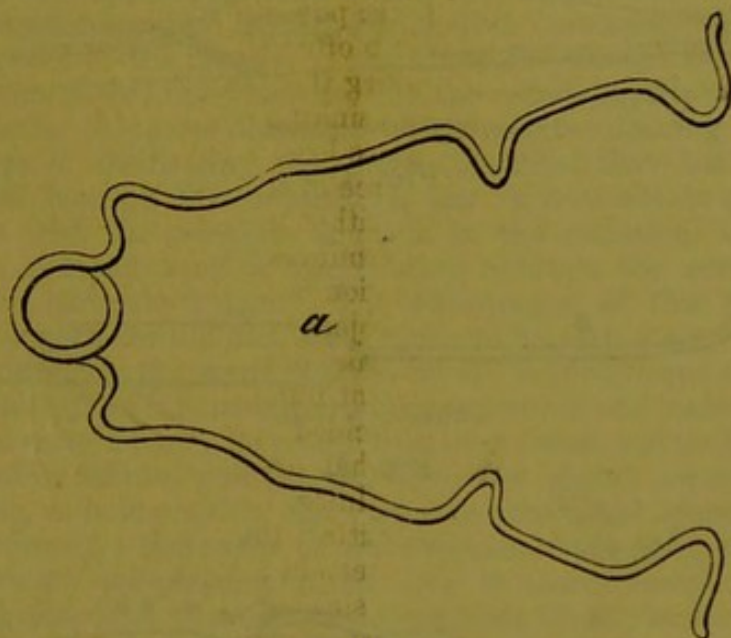
others, in which the two corneæ have occupied the outer angles of the lids, particularly if both eyes have been operated upon at the same time.

There are some other minor objections to which I may briefly allude. The extensive wound in the conjunctiva heals very slowly, remains red and swollen for a considerable time, often gives rise to a fleshy growth that requires removal, and leaves a scar more or less distinct, and the power of moving the eye in the direction of the divided muscle is often quite lost, constituting in itself some deformity. In stating the case, therefore, for the old operation, there is invariably a sinking and loss of the caruncle, and a scar, usually a considerable loss of power of inversion, not unfrequently increased prominence of the globe, and occasionally eversion more or less complete, either immediately or as a remote effect, and there may be both prominence and eversion co-existent. Now, considering that the operation is undertaken and submitted to almost exclusively with the object of removing a deformity, it becomes a question whether this deformity is removed to a sufficient extent, and in a sufficient number of cases, to justify the proceeding, and whether one decided case of eversion does not outweigh a large number of what are usually deemed successful. Whatever may be the opinion of the profession on this point, I think it must be admitted that, with such defects, a wide margin is left for improvement; and that if a procedure can be suggested, in which no sinking in of the inner caruncle occurs, nor any perceptible scar remains, in which increased prominence and eversion, as far as my experience has yet gone, never take place, and in which the healing process is complete in a week, and is never attended with the formation of a granulation, I think all must admit that a very important point is gained. Such a plan I have recently been in the habit of adopting, and it is chiefly with the view of setting forth the details of this operation that I have been induced to bring the subject before the notice of the profession.

The essential principle of the operation I am about to describe consists in the division of the muscle sub-conjunctivally. This, it will be remarked, is not altogether a novel suggestion; it has been recommended by Mons. Guerin, and has been attempted with more or less success by several; but it has been found difficult and sometimes impracticable, in consequence of the method adopted. Thus it is suggested to draw the eye forcibly outwards, so as to render the internal rectus tense; then to introduce a small bistoury beneath the muscle, and divide it. Any one who has attempted this operation in this way will agree with me that it is one of extreme difficulty; the loose capsule round the muscle prevents the edge of the knife from acting upon the tendon, neither can the tendon be made sufficiently tense to be thus divided. The difficulty and uncertainty of this operation has resulted in its having been rarely attempted, more rarely accomplished, and never repeated. The method that I propose, and that has been performed by myself and some of my colleagues at the Ophthalmic Hospital in a large number of cases, is the following:—Having placed the patient, if nervous or restless, or very young, under the influence

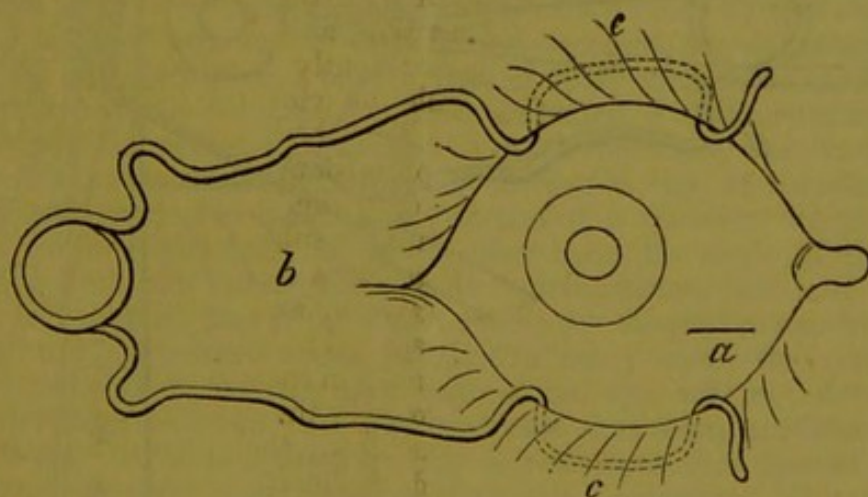
of chloroform, the eyelids must be fixed open with a spring speculum, (Fig. 1, *a*;) the globe may be now everted by an assistant seizing the conjunctiva near the outer margin of the cornea with a pair of forceps, (Fig. 5, *g*;) and the operator, pinching up the conjunctiva at a point corresponding to the lower

Fig. 1.



a, Speculum.

Fig. 2.



b c, Speculum in action, the dotted lines representing it under the lids.
a, Situation and size of incision in conjunctiva.

border of the internal rectus, makes a small opening with a pair of rather strong blunt-pointed scissors, (Fig. 3. *g*;) he then seizes the sub-conjunctival fascia, and divides it to the same extent, so as clearly and cleanly to expose a small surface of sclerotic. The ordinary strabismus blunt hook, (Fig. 4, *e*;) bent at a right angle, must now be swept round the globe, so as to pass beneath the muscle; this requires care and a little practice, and is essential

to success; it may be known by the peculiar elastic resistance that is felt; the blades of the scissors must then be passed in through the opening, and by a succession of small cuts the

FIG. 3,

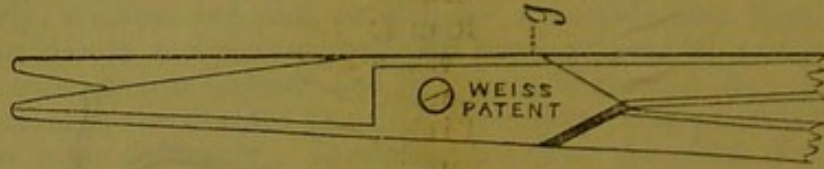
*g*, Strabismus scissors.

FIG. 4.

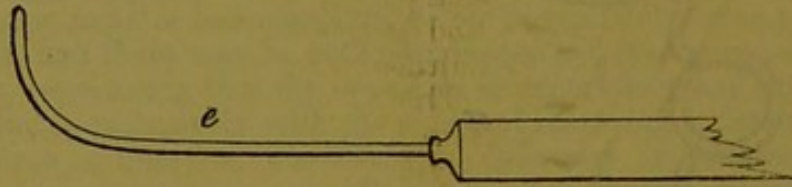
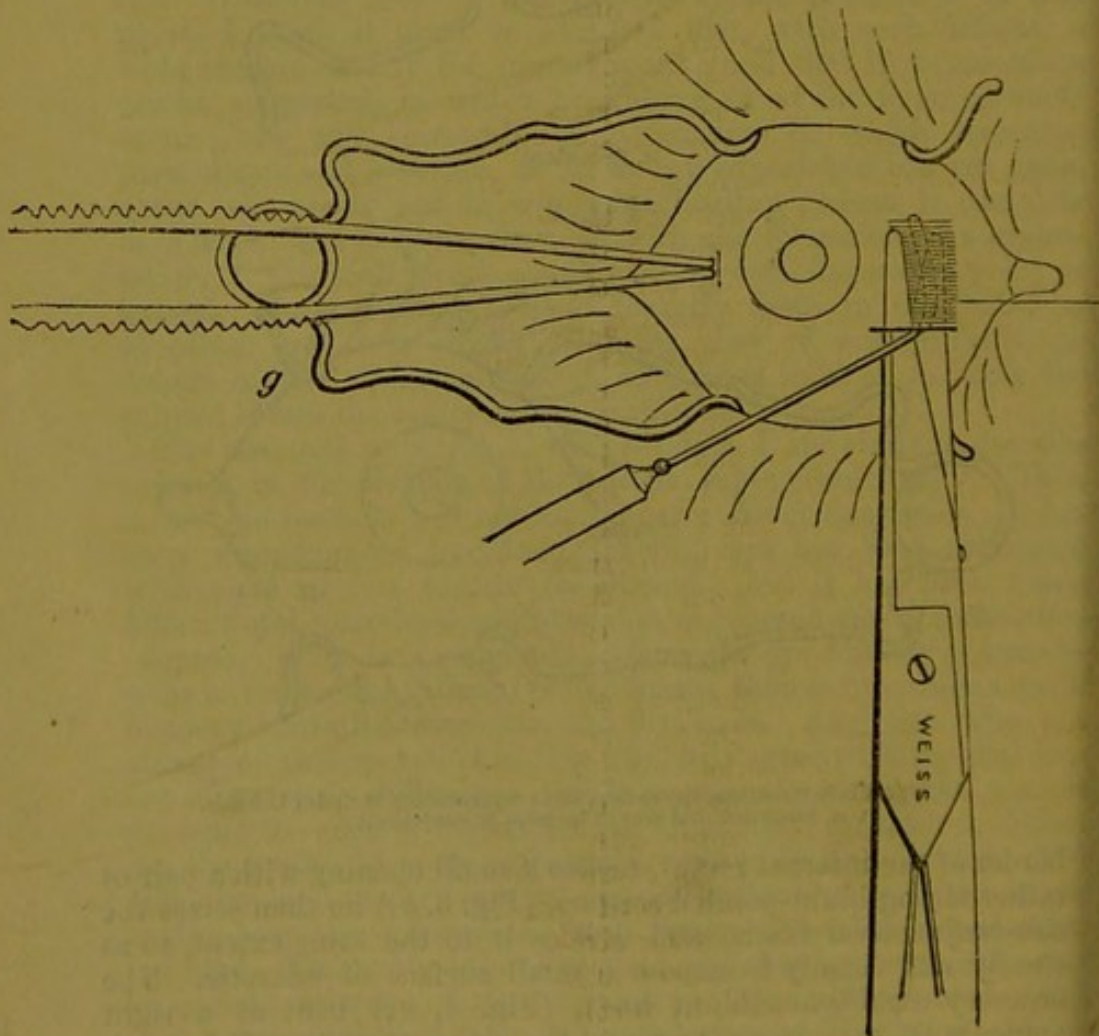
*e*, Strabismus hook.

FIG. 5.



f. Strabismus scissors and hook in action under conjunctiva, the straight lines represent the muscle with one blade of the scissors above and the other beneath it.
g. Forceps drawing out globe.

tendon may be readily divided between the hook and the insertion into the sclerotic, and close to the latter. (Fig. 5, *f*.)

You may distinctly feel and sometimes hear the creak of the scissors as the tendon is cut through. Some little difficulty is experienced, when the insertion of the tendon is rather broad in reaching the upper edge, and when that is the case I make a small counter-opening in the conjunctiva corresponding to the upper border of the muscle. I introduce the scissors from above, and, having passed one blade beneath the remaining slip of tendon, divide it in the same direction. This counter-opening has the advantage of facilitating the escape of blood that has become infiltrated beneath the conjunctiva, and it does not in any way interfere with the principle and aim in the operation, which is to leave a broad band of conjunctiva between the cornea and the inner caruncle intact. The advantages of this plan, as contrasted with the old one, seem to me to be very great. It has, in the first place, the merit enjoyed by all subcutaneous sections, of immunity from inflammation and suppuration, and makes a very rapid and certain cure; no granulation ever forms, and the caruncle maintains its natural position, and does not shrink away into a deep fossa, as is invariably the case when the usual operation has been performed; and as far as my experience yet goes, proptosis or increased prominence of the eye is more rare, eversion never occurs, and the natural movements of the eye are more complete. This I attribute to the fact that the ocular fascia is but little interfered with, and that a good firm union takes place between the divided muscle and the globe of the eye.

Such seem to me to be the advantages of the mode of operating that I am now anxious to explain and recommend—advantages that are of so important a nature, that in fairly stating the case to the patient, if the old operation is contemplated, it certainly admits of doubt if the personal appearance is much improved, even in the most favourable results, and there is always a risk of increased prominence and of eversion, and it admits of a question whether it can be recommended. If, on the other hand, the mode of proceeding I am now setting forth be in contemplation, we may at least feel assured, that if the deformity be not altogether removed, it will not be rendered worse, and that in many cases the result will be so perfect, that the most experienced eye will not detect any defect, or be aware that any operation has been performed. But it may be asked if there are any objections to this operation, and any cases in which the old operation is preferable. It must be admitted that it is rather more difficult to perform, that there is a greater liability to leave some portion undivided, and that sometimes some inversion remains, in consequence of the attachment of the muscle to the fascia after it is divided from the sclerotic. This will often rectify itself afterwards, and where this is not the case, it is better either to operate on the other eye, or, if the cast is slight, be content to leave the case in that state, rather than risk eversion by further interference. It is only in cases of long standing, and where the strabismus is very extreme, and where the eye is small and deep-set, and where the sub-conjunctival operation produces but very little effect, that the old operation is justifiable.

Before I conclude this paper, I would just briefly glance at two or three points of some practical interest,, having reference to the age of the patient, and condition of the eye at which the operation should be performed, and to the effect of the operation upon vision.

As regards the first point, my own experience, derived from many hundred cases, is, that the most favourable results occur in young adults, as contrasted with children. Cases in which the relative position of the eyes is not uniform, and is aggravated and altered by mental or bodily excitement, and in which there is any oscillatory or rotatory movements, are all uncertain in their results, and very liable to be followed by undue prominence of the globe, or by eversion, or both. On this account, I do not find operations on children succeed so well as on young adults. As regards the effect of the extent of the distortion in influencing the result of the operation, it is difficult to lay down rules. As far as my own experience goes, I should say that in most extreme cases of inversion there is only a partial improvement from dividing one muscle, and it is a nice point to determine if there be sufficient distortion remaining to make it safe to divide the inner rectus of the other eye, without risking eversion. Unless the eye occupy a position at least midway between the inner caruncle and the central axis, it is not safe to operate. The chief causes of eversion, after the operation, are to be traced to the previous slight degree of the inversion, to the unsettled state of the disease, or to an undue division and separation of parts; and if the slightest eversion occur at the time of the operation, there seems to be a constant tendency to increase, until it has reached its extreme limits. This arises from the disadvantage at which union takes place, the power of the external rectus muscle, and the loss of the rectifying and controlling power of vision. Eversion sometimes occurs weeks and months after the operation, in consequence of the gradual stretching of the uniting medium, an analogue of which is to be found sometimes after fracture of the patella, in which very extensive separation of the two portions occurs. The very worst cases of eversion that I have ever seen have resulted from a simultaneous division of the muscles of both eyes, a proceeding that is in no case justifiable. The effect of the operation upon vision is surrounded with obscurity and difficulty. In the first place, much variety exists in the extent to which vision is impaired by strabismus; in the alternating form, both eyes are equally good; in children but little damage is done; but where the deformity has existed several years, there is almost invariably imperfect vision, differing, however, in degree in nearly every case.

In several remarkable cases that have come under my notice in my own practice, in that of my friend, Mr. Dixon, and others, a very sudden and complete restoration of sight has followed the operation. I should hesitate to assert this curious and almost inexplicable phenomenon, had I not verified the fact over and over again in a manner that admits of no doubt. Mr. Holthouse has endeavoured to explain this by supposing that the muscles of the eyeball focus the eye, and that the operation restores this power. If this were the true solution of the riddle we should find

something like uniformity of result, but this is not the case; the improvement is sometimes gradual, and sometimes no perceptible change occurs. These considerations suggest the performance of the operation during childhood, and if the result could be made equally favourable in other respects, this would be the most desirable period for its performance, and the sub-conjunctival operation will render the usual objections to an operation at this period of life less obvious.

It will be seen that the chief object of my paper has been to describe and set forth the advantages of the sub-conjunctival operation; and it may be thought by some to have the disadvantage of difficulty and uncertainty, without sufficient counteracting advantages, particularly as it is alluded to very briefly and somewhat disparagingly by the more recent writers on this subject—Mr. M^cKenzie, Mr. H. Walton, and Mr. Holthouse. After having tried it in above a hundred cases, I never now adopt the old method, and I am strongly impressed with the uniformity of the favourable result; in no cases have I had increased prominence or eversion. In some cases, it is true, some amount of inversion has remained, but this occurred nearly as frequently with the old operation; so that a patient is now sure of improvement from the operation, without risking the occurrence of any of the unfavourable concomitants of the old plan.

As I have mentioned in the foregoing remarks, cases of eversion following the operation of dividing the internal rectus muscle, sometimes come before our notice. As this is a very distressing deformity,—far worse, in fact, than that for which the operation was originally performed, patients are very anxious to have something done for its removal. I have now operated upon five of these cases with so satisfactory a result that I think it may be interesting to the profession if I describe the mode of proceeding that I adopt.

I may premise that the operation I am about to describe is somewhat difficult and tedious, and should be performed under chloroform, and much of its success depends upon careful attention to minute details. Having freely exposed the globe by means of the wire speculum, the parts covering the inner part of the globe, including conjunctiva, sub-conjunctival fascia, old cicatrix and muscle, with condensed tissue around it, must be all carefully dissected off the sclerotic, commencing about two lines from the inner margin of the cornea, and extending upwards and downwards and then inwards, so as to expose the inner third of the surface of the globe. This dissection must be carefully made so as to preserve the flap thus made entire; it can most readily be done with a pair of scissors. When this stage of the operation is completed, the external rectus muscle must be divided. It is better to defer this part of the operation until now, because the action of the external rectus is useful in keeping the globe well fixed outwards during the first stage of the operation. The next part of the operation is the most difficult and the most important. It consists in passing the sutures. For this purpose small semicircular needles must be used, armed with a piece of fine silk; the flap that has been raised from the eyeball must be firmly held with a pair of forceps, and drawn forward so as to make it tense; the needle must

then be passed through it, as low down—that is, as near the inner corner—as possible. Two or three sutures may be passed in this way, at intervals of about two lines. The corresponding part of each suture must then be passed through that portion of conjunctiva which has been left attached to the sclerotic near the cornea. This constitutes another difficulty, because the membrane is here so thin that the fine silk is apt to cut through; this I found a serious difficulty, in my first operation, and one that materially interfered with success. In order to obviate this, I adopt now the following expedients:—I first separate this portion a little upwards towards the cornea; the needle must then be passed through it, and then back again, so as to include a portion, which must be tied tightly, so as to prevent it from tearing out. The next point is to cut away all that portion of the lower flap that can be spared beyond the part where the suture has entered, merely leaving a sufficient margin to hold it. The silks may be now drawn tightly, and tied to the end that is already fixed near the cornea. The immediate effect of this proceeding ought to be to procure some inversion, if the various steps of the operation have been properly performed. The hope and intention are, to get the parts to unite to the globe in their new position, and thus retain the eye. This, however, is only partially the case; there is always some tendency to relapse, and in two cases I had to repeat the operation, but with ultimate success. The sutures may be allowed to remain until they ulcerate through; the subsequent inflammation is usually slight. The amount of mobility in the eye is very limited, but so long as it occupies a central position this circumstance is not found practically to occasion much deformity, and is an immense improvement upon the facial discord resulting from extreme eversion.

My friend and colleague, Mr. Bowman, has performed this operation at the Ophthalmic Hospital, with his usual neatness and dexterity, and the effect was very perfect. My own experience would lead me now to undertake such a case with confidence in the result, if the patient would persevere; if sufficient effect is not obtained by the first operation, a second is almost sure to succeed. I may mention that one favourable effect of the operation is the drawing forward and restoring the inner caruncle to its natural place, the deformity being much increased by the sinking of this part.



