

**The nervous system / By Ludovic Hirschfeld, .... Edited in English by Alexander Mason Macdougall,... , with artistically coloured lithographic illustrations, designed by J. B. Léveillé.**

### **Contributors**

Hirschfeld, Ludovic, 1816-1876.  
University of Leeds. Library

### **Publication/Creation**

[London] : [J. Churchill and Sons], [1867]

### **Persistent URL**

<https://wellcomecollection.org/works/eja52vpr>

### **Provider**

Leeds University Archive

### **License and attribution**

This material has been provided by This material has been provided by The University of Leeds Library. The original may be consulted at The University of Leeds Library. where the originals may be consulted.


This work has been identified as being free of known restrictions under copyright law, including all related and neighbouring rights and is being made available under the Creative Commons, Public Domain Mark.

You can copy, modify, distribute and perform the work, even for commercial purposes, without asking permission.

**wellcome  
collection**

Wellcome Collection  
183 Euston Road  
London NW1 2BE UK  
T +44 (0)20 7611 8722  
E [library@wellcomecollection.org](mailto:library@wellcomecollection.org)  
<https://wellcomecollection.org>





Health  
Sciences  
XX


HIR



STORE A 77







ANATOMY  
OF THE  
NERVOUS SYSTEM OF MAN.

(Hirschfeld's)  
translated from the German by  
A. M. McSengal (London 1869)



UNIVERSITY OF LEEDS  
MEDICAL LIBRARY.

## TO THE READER.

---

For the purpose of facilitating the study of the illustrative figures, three kinds of signs have been adopted :—

- 1st. *Italic letters*, indicating bones, cartilages, ligaments, muscles, and integuments, under the denomination of *Accessory Parts*.
- 2nd. *Capital letters*, denoting vessels and sinuses, or the *Vascular System*.
- 3rd. *Figures*, which point out all parts which pertain to the *Nervous System*.

The numeration of those pages which contain *Methods of Dissecting Anatomical Preparations* and *Explanations of Plates*, is placed in the middle of the foot of the page, and the numbers are always followed by an asterisk, in order that references to these pages may not be confounded with references to the pages of *Text*, the numbering of which follows the usual fashion.





Digitized by the Internet Archive  
in 2015

<https://archive.org/details/b21536971>

# THE NERVOUS SYSTEM.

## GENERAL OUTLINE.

THE nervous system is that soft, pulpy, whitish and greyish mass, lodged in the osseous vertebro-cranial hollow, and communicating with all parts of the body, through foramina in the walls of that space, by means of cords called *nerves*.

This system has the management of the vital laws and of the chemico-vegetative parts; it holds dependent upon it all the functions of the organism; it is the seat of all sensation and of all voluntary movement; while its co-operation is indispensable in the exercise of intellectual and affective phenomena.

Neurology is the science which has for its object the study of this system.

Considered as a whole, the nervous system is composed of two portions: the *central nervous system* (cerebro-spinal axis), and the *peripheral nervous system* (nerves, properly so called).

The first is formed of four principal parts: 1st, the medulla spinalis; 2nd, the mesencephalum;<sup>1</sup> 3rd, the cerebellum; 4th, the cerebrum.

The second is composed of two orders, in consideration of its physiological functions: 1st, nerves under the empire of volition and consciousness, or nerves of animal life, the life of relation; 2nd, nerves withdrawn from the influence of volition and consciousness, and designated as nerves of organic, nutritive, vegetative life, the ganglionic, or great sympathetic nervous system.

It would result, however, from certain careful observations, and from some experiments made of late, that these two systems should not be considered as independent of one another as has been imagined until now. On the contrary, it would appear that the ganglionic nervous system is but a part of the peripheral nervous system, and possibly, even of the central nervous system, sustaining, however, certain changes with reference to structure, colour, functions, &c.

Nevertheless, it is the still generally admitted division that we are, with some modifications, about to follow.

---

<sup>1</sup> Exigencies of translation have led to the adoption of this rather unusual anatomical term here. It is, however, a recognised designation of that portion of the nervous system to which it is in this place intended to refer, and may be found in "Mayne's Expository Lexicon," and other works. The French words, "*moelle allongée*" (literally, *medulla oblongata*), which it is here employed to render, apply to a much larger division of the cerebro-spinal axis than their anatomical synonym in this country will, in the present day, admit of. With ourselves, before the time of Haller, anatomists used the appellation "*medulla oblongata*" in the more extended sense in which "*moelle allongée*" is used by the Author, and even included the corpora striata and optic thalami, as the term still frequently does when employed by modern physiologists. The central nervous system now, however, is anatomically divided into *five* principal parts; the fifth being produced by the subdivision of the portion in question into medulla oblongata, usually so called, and pons Varolii or, what is preferable, *mesocephalon*. In order, therefore, to prevent misapprehension of names respecting parts of so great importance, and at the same time to avoid alterations in the Author's arrangement, I have adopted the term *mesencephalum*; which will, both here and in future parts of this work, be intended to convey the meaning of *medulla oblongata* and *mesocephalon* together; the latter (sometimes also called "*isthmus encephali*"), not only comprehending the pons Varolii, properly so designated, but also the crura cerebri, the middle cerebellar peduncles, the tubercula quadrigemina, and the valve of Vieussens.



## ENVELOPES OF THE CENTRAL NERVOUS SYSTEM.

The cerebro-spinal axis, or better, the medullo-encephalic axis, is surrounded, independently of the vertebro-cranial parietes, with three membranous coverings called *meninges*; which are, in proceeding from the periphery towards the centre:—

- 1st. The dura mater, which is a fibrous structure;
- 2nd. The arachnoid, a very delicate serous membrane;
- 3rd. The pia mater, fibro-vascular upon the medulla spinalis, and cellulo-vascular over the encephalon.

These envelopes, the shape of which is nearly that of the medullo-encephalic axis, form three sheaths, invaginated the one within the other. Each of them is divided into two portions: the one medullary or spinal, the other encephalic or cranial.

### MEDULLO-ENCEPHALIC DURA MATER IN GENERAL.

PLATES I. and II.

The medullo-encephalic dura mater constitutes, so to speak, a very tough elongated fibrous sac, globose and bossive in the cranium, somewhat conoidal and cylindrical in the vertebral canal. Lining the interior of the vertebro-cranial hollow, it serves at once as an internal periosteum to that cavity, and as an arrangement for containing and supporting the medullo-encephalic nervous centre.

#### ENCEPHALIC DURA MATER.

(*Pars cephalica duræ matris.*)

PLATES III. and IV.

Convex at the cranial vault, alternately convex and concave at the base, this portion of the dura mater presents for consideration two surfaces, one external, the other internal.

#### A.—EXTERNAL SURFACE.

Rough, and furnished with numerous meningeal vessels, this surface of the dura mater is remarkable for the remains of fibrous processes which establish its adherence to the sutures, to the margins of the cranial foramina, and to the projections found on the internal surface of the cranial cavity—such as those of the crista-galli apophysis of the ethmoid bone, the posterior border of the alæ minores of the sphenoid, the anterior and posterior clinoid processes, the superior edge of the petrous portion of the temporal bones and internal cruciform ridge of the occipital bone, the basilar groove, and lastly, the foramen magnum and foramen lacerum posterius.

It is well, however, to note that these adhesions are much firmer in children and the aged than in adults. With the first, this proceeds from the great quantity of sanguineous vessels, through the medium of which the membrane fixes itself to the bones; in the second, the intimate adhesion depends on the ossification of the membrane, which confounds itself gradually with the internal table of the cranium. By means of prolongations under the form of sheaths, which the dura mater furnishes to the vessels and nerves, it continues itself through the cranial foramina, and blends with the external periosteum. These are everywhere simple processes, excepting, however, near the sphenoidal fissure and optic foramen, where the prolongation divides into two layers, of which one investing the orbital cavity forms its periosteum, and afterwards unites with the external periosteum, while the other constitutes a sheath around the optic nerve, and is continuous with the sclerotic.

The unevenness of the external surface of the dura mater depends likewise on projecting meningeal vessels, which are contained partly in the thickness of the dura mater, and partly in the osseous grooves of the cranial hollow. Moreover, the glands of Pacchioni which protrude this membrane, contribute in like manner to render it rough.



## B.—INTERNAL SURFACE.

Lined by pavement epithelium appertaining to the arachnoid, the interior is smooth, and lubricated by a serous fluid. Everywhere contiguous to the surface of the encephalon, this membrane never adheres to it, save through the intervention of veins which pass through the arachnoid to the sinuses enclosed in its thickness.

Three processes from this surface unite among themselves and form what is called the cruciform intercommunication (*processus cruciatus duræ matris*). They bury themselves between the principal parts of the encephalon, which they separate from one another. These processes of the dura mater are: 1st, the falx cerebri; 2nd, the tentorium cerebelli; 3rd, the falx cerebelli.

1. Falx cerebri (*processus falciformis major*).

The falx cerebri has a somewhat triangular figure, and separates the two hemispheres of the cerebrum from one another, preventing their mutual compression when the head is inclined to one side. It stretches itself vertically from the crista galli, to which it is attached, as far as the internal occipital protuberance, where it falls perpendicularly upon the tentorium cerebelli, with which it insensibly becomes continuous, concurring with the latter in keeping up a state of reciprocal tension; consequently, the falx cerebri being cut, the tentorium becomes flaccid, while, *vice versâ*, by the section of the tentorium, the falx is relaxed. The falx cerebri, also called *plica falciformis major*, presents for consideration two lateral surfaces; two borders, superior and inferior; and two extremities, one anterior, the other posterior.

a. *Lateral surfaces of the falx*.—They correspond to the internal surface of the cerebral hemispheres, which they separate completely behind, and incompletely in front; contact taking place between them in this situation, for a certain distance, without intervention. It sometimes happens, also, that by reason of an occasional perforation of the falx, the two hemispheres are in contact through the aperture.

b. *Superior border*.—Convex, semicircular, and enclosing the superior longitudinal sinus, this border extends from before backwards, corresponding with the frontal crest and superior longitudinal groove, to which it is pretty intimately adherent.

c. *Inferior border*.—Concave, very thin, and shorter than the superior; it corresponds to the upper part of the corpus callosum, which it touches behind, and from which it gradually separates itself in the rest of its extent as it nears the anterior part. The three posterior fourths of this border enclose a venous canal, called the inferior longitudinal sinus.

d. *Anterior extremity*.—Attaching itself to the crista galli, it sends, through the foramina of the cribriform plate of the ethmoid, prolongations into the nasal fossæ, which envelop, under the form of sheaths, the ramifications of the olfactory nerves.

e. *Posterior extremity*.—Considerably broader than the preceding, and admitting of consideration as the base of the falciform triangle, it falls perpendicularly upon the middle of the tentorium cerebelli, with which it blends itself, and encloses in its thickness the straight sinus.

## 2. Tentorium Cerebelli.

The tentorium cerebelli constitutes a transverse fold, under the form of an incomplete vault, which separates the cerebellum from the posterior lobes of the cerebrum, and is for the purpose of preventing compression of the former in the erect posture of the body, as well during motion as rest. There may likewise be distinguished in the tentorium cerebelli two surfaces, superior and inferior; two borders or circumferences, one posterior, the other anterior; and two extremities at each side.

a. *Superior surface*.—Convex, and presenting a double-inclined plane; this surface is designed at once to sustain the posterior lobes of the cerebrum, and to serve as a *point d'appui* for the base of the falx cerebri.

b. *Inferior surface*.—Concave, and corresponding to the superior surface of the cerebellum; it presents, at its middle and posteriorly, another perpendicular process, which is the falx cerebelli.

c. *Posterior border or circumference*.—This circumference is convex and semicircular; it inserts itself behind, into the horizontal portion of the lateral grooves, where it encloses the lateral sinuses, and, at the sides and forward, into the groove in the superior border of the petrous bones, where it contains the superior petrosal sinuses.



d. *Anterior border or circumference.*—Of less extent than the preceding, this circumference is concave and oval, and by its figure somewhat reminds one of an ogive. It corresponds to the isthmus of the encephalon, and to the cerebral fissure of Bichat, and forms, with the basilar groove, an oviform aperture called the *foramen ovale of Pacchioni*.

e. *Extremities of the posterior circumference.*—Each attaches itself to the posterior clinoid process of its side, passing like a bridge over the root of the Gasserian ganglion.

f. *Extremities of the anterior circumference.*—After having crossed the preceding, each terminates at the corresponding anterior clinoid process. In this manner, the extremities of either side bound a small triangular interval, the base of which is crossed by the motor oculi nerve, while the apex, which is at the point of decussation of these extremities, is perforated by the pathetic.

### 3. *Falx cerebelli* (processus falciformis minor).

The falx cerebelli is placed vertically upon the median line between the posterior extremities of the cerebellar hemispheres, and constitutes a thick falciform fold, but less salient than the falx cerebri.

Stretching from the internal occipital protuberance to the foramen magnum, the falx cerebelli blends itself at its upper extremity with the tentorium, and at its lower, which is narrowed and bifurcated, it passes round the foramen magnum to terminate at the foramen lacerum posterius, losing itself insensibly around the former, in becoming continuous with the spinal dura mater. The anterior margin of this fold corresponds to the postero-inferior vermiciform process of the cerebellum; its convex posterior border attaches itself to the internal occipital crest, and encloses the occipital sinuses.

Independently of these three processes that we have just described, the dura mater forms about the sella turcica a circular horizontal fold, which encloses the circular sinus of Ridley, and, separating afterwards, envelops the pituitary gland. The upper layer of this covering<sup>1</sup> is perforated by a foramen for the passage of the *infundibulum*, which establishes thus the communication between the gland and the *tuber cinereum*.

### STRUCTURE OF THE DURA MATER, ITS VESSELS AND NERVES.

The dura mater is composed of two layers: the one, external, lines the cranial hollow, and is the *periosteal layer*; the other, internal, of greater extent, invests and separates the different parts of the encephalon, and is the *encephalic layer*. These two layers are intimately united to one another in nearly their whole extent, but are separated at the lines of the processes. Thus, the internal layer separates itself from the external on one side of the superior longitudinal groove, and directs itself vertically, descending as far as the corpus callosum. Arrived there, it is reflected, and mounts again, adhering to its descending portion to form the falx. Soon, it separates anew, and afterwards, becomes reunited with the periosteal layer of the opposite side, leaving a triangular interspace, which is the *superior longitudinal sinus*.

These two layers, which we have just followed in the formation of the falx and of the superior longitudinal sinus, dispose themselves in an analogous manner to constitute the tentorium, the falx cerebelli, and the other sinuses, by taking different directions.

From these anatomical dispositions, it results that the septa are formed by two adherent laminae of the internal layer of the dura mater; while the sinuses are constituted by the divergent sides of these same septa in a like relation with the corresponding portion of the periosteal layer. A section of these sinuses generally has the form of a triangle, the base of which answers to the periosteal layer, the apex and sides to the encephalic.

The dura mater is essentially fibrous, and constituted by two planes of intercrossed fibres. Its reduplicatures present a peculiarity worthy of notice. The falx is formed, at its posterior part of radiate, at its middle and anterior of intercrossed and parallel fibres. The fibres of the superior surface of the tentorium cerebelli are also radiate, but less marked, and are continuous with the radiate fibres of the falx. The fibres of the inferior surface of the tentorium are continuous with the parallel and radiate fibres of the falx cerebelli.

### VESSELS OF THE DURA MATER.

*Veins.*—Two kinds of veins may be distinguished; the one, enclosed between the two

<sup>1</sup> Sometimes called the tentorium of the pituitary body.



layers of the dura mater, are but channels destined to convey the venous blood from the encephalon, and are called sinuses; the other, are the proper veins of the dura mater, and constitute the satellites of the arteries.

### SINUSES OF THE DURA MATER.

(Sinus duræ matris.)

PLATE V.

We designate as sinuses of the dura mater, those fibrous canals, lined by the internal coat of the veins, the external parietes of which are formed by the first-named membrane. These sinuses serve to collect the venous blood from the brain, the meninges, the eye, and the bones of the cranium, to pour it into the internal jugular veins. The sinuses of the dura mater are fifteen in number: five in pairs, and five single. The sinuses in pairs are: 1st, the superior petrosal; 2nd, the inferior petrosal; 3rd, the cavernous; 4th, the occipital; and 5th, the lateral sinuses. The single sinuses are: 1st, the superior longitudinal; 2nd, the inferior longitudinal; 3rd, the straight sinus; 4th, the transverse; and 5th, the coronary sinus. Six of these sinuses form by their convergence a common reservoir, called the *posterior confluence*, or press of Herophilus (*torcular Herophili*); they are: the superior longitudinal, the straight, the two lateral, and the two occipital sinuses. These sinuses have received the denomination of *torcularian sinuses*. The other sinuses, called *atorcularian*, abut on two other confluences, each named *petro-sphenoidal*, on account of their position between the apex of the petrous portion of the temporal and the sphenoid bone. These confluences receive the cavernous, transverse, coronary, superior petrosal, and inferior petrosal sinuses. The two last establish, on each side, a communication between the anterior confluence, the lateral sinus, and the gulf of the corresponding jugular vein.

In all the sinuses we meet with fibrous bands,<sup>1</sup> crossing in all directions, stretching from one wall to the other, and covered by the lining membrane of the veins.

Most anatomists consider these processes as rudimentary valves. Indeed, the bands appear to be designed to moderate too great a current of blood towards the sinuses. According to other authors, however (and this opinion, also, has some appearance of truth), they resist too great a dilatation of these venous canals.

It occasionally happens that the granulations which are called glands of Pacchioni are met within the interior of the sinuses.

### RESERVOIRS AND SINUSES IN PARTICULAR.

#### A.—Reservoirs.

1. *Posterior or occipital reservoir; press of Herophilus (torcular Herophili seu confluens sinuum).*—This reservoir forms a triangular hollow, the base of which, turned backwards, and situate at the junction of the falx cerebri with the tentorium and falx cerebelli, corresponds to the internal occipital protuberance.

The posterior confluence is provided with six apertures, which are: one superior, receiving the superior longitudinal sinus; two inferior, for the posterior occipital sinuses; two lateral, continuous with the lateral sinuses; and one anterior, for the straight or oblique sinus.<sup>2</sup>

2. *Anterior confluences (petro-sphenoidal, Cruv.).*—These confluences, two in number, one on each side, are found, as has been already said, between the apex of the petrous portion and the sphenoid. With each of these reservoirs or confluences, which have a form more or less quadrangular, communicate five sinuses, they are: the superior and inferior petrosal; the cavernous; the circular, or coronary sinus of Ridley; and the transverse, or anterior occipital sinus.

#### B.—Sinuses.

1. *Superior longitudinal or falciform sinus (sinus longitudinalis superior seu sinus falciformis superior).*—It is found in the thickness of the superior margin of the falx cerebri, and in the corresponding longitudinal osseous groove. It extends from the foramen cæcum to the torcular Herophili, enlarging gradually from before backwards. Like other sinuses, its form

<sup>1</sup> Chordæ Willisii, sometimes also called trabeculæ of Haller.

<sup>2</sup> Straight, from its lying evenly between its extremities; oblique, from its relation to a vertical line through the cranial cavity.



is that of a triangular prism, and it presents in its interior, well-marked fibrous bands which cross each other in all directions, openings of veins from the convexity of the cerebrum, and sometimes also, glandulæ Pacchioni.

Occasionally this sinus, deviating from the median line, becomes directly continuous with one of the lateral sinuses, most frequently the right.

The following veins communicate with this sinus: the vein of the foramen cæcum, the external and internal cerebral veins, the proper veins of the dura mater, the diploic veins (*venæ diploeticæ*), and numerous veins from the external periosteum, among which it is well to note the emissary veins of Santorini traversing the parietal foramina.

2. *Inferior longitudinal or falciform sinus* (*sinus longitudinalis inferior seu falciformis inferior*).—First described by Vesalius, and under the appellation of sinus, it has been placed in the category of veins by M. Cruveilhier.

Considerably narrower than the preceding, this sinus extends along the posterior half or three-fourths of the inferior or concave margin of the falx cerebri, and possesses a more considerable capacity behind than in front, where it terminates in becoming filiform.

In its course it receives part of the veins of the falx, and terminates, conjointly with the veins of Galen, in the straight sinus.

3. *Straight sinus* (*sinus rectus*).—It occupies the line of junction of the falx cerebri with the tentorium cerebelli, and runs an oblique course, from before backwards and from above downwards, to inosculate, at the one extremity, with the torcular Herophili, ordinarily in the neighbourhood of the left lateral sinus, and at the other, with the inferior longitudinal sinus and the *venæ Galeni*.<sup>1</sup> Along its course, this sinus receives the veins of the posterior lobes of the cerebrum and the veins of the superior surface of the cerebellum.

4. *Circular or coronary sinus of Ridley* (*sinus circularis seu coronarius Ridleyi*).—It surrounds the base of the infundibulum, and occupies the fold of dura mater which covers the pituitary body in the sella turcica. The posterior part of this sinus, which is particularly well marked in the aged, is narrower<sup>2</sup> than the anterior. The coronary sinus communicates with the cavernous sinus on each side; it is moreover the recipient of the small veins of the pituitary gland, of some veins of the dura mater, and of some from the body of the sphenoid.

5. *Transverse or basilar sinus* (*sinus transversus seu occipitalis anterior Halleri*).—Like the preceding, especially developed in persons of advanced age, this sinus, which is frequently in duplicate, has a transverse course from the apex of the petrous portion of one side to that of the opposite. It occupies the basilar groove, at the level of the junction of the square plate of the sphenoid with the occipital bone.<sup>3</sup> By its intervention, the cavernous, the superior petrosal, and the inferior petrosal sinuses of the one side, communicate with the same sinuses of the other. Below, this sinus is joined by the longitudinal rachidian venous plexuses; and it thus establishes a communication between the anterior sinuses of the cranial cavity, and the veins of the vertebral canal. The transverse sinus receives small veins from the pons Varolii and from the diploë.

1. *Cavernous sinuses* (*sinus cavernosi*).—These sinuses, already known to the older anatomists, are found in the lateral grooves by the side of the sella turcica. Their anterior portion is placed beneath the corresponding anterior clinoid process, where they present a dilatation in which terminates the respective ophthalmic vein (*sinus ophthalmicus seu spheno-parietalis*). The posterior extremity of these sinuses joins the petro-sphenoidal reservoir of its side. Their interior presents numerous reddish fibrous and vascular filaments, which, crossing each other in different directions, give them the appearance of cavernous tissue, whence their name of cavernous sinuses.

Each of these sinuses incloses the internal carotid artery of its side, surrounded by a nervous plexus of the sympathetic (cavernous plexus); but at present it remains doubtful whether this artery bathes, without any intervention, in the blood flowing through the sinus, or is separated from it by the ordinary lining membrane of the veins.<sup>4</sup>

On the outer side of the artery, and consequently in the sinus, the external motor nerve

<sup>1</sup> These have, however, previously united to form a common trunk, sometimes called the *vena magna Galeni*.

<sup>2</sup> Generally described as the contrary.

<sup>3</sup> That is, where the posterior margin of the lower border of the dorsum ephippii unites with the spheno-occipital bone, as described by Meckel.

<sup>4</sup> The opinion of most anatomists is in accordance with the latter hypothesis, not only as regards the artery, but also with reference to the plexus and sixth nerve which accompany it.



of the eye<sup>1</sup> is found communicating with the sympathetic nerve; while, in the thickness of the outer wall of both the sinuses, are lodged the common motor nerve of the eye,<sup>2</sup> the pathetic,<sup>3</sup> and the ophthalmic branch of Willis.<sup>4</sup>

These sinuses receive veins from the dura mater, as well as from the inferior surface of the anterior lobes of the cerebrum, and communicate between themselves by means of the coronary sinus of Ridley.

2. *Superior petrosal sinuses (sinus petrosi superiores).*—These very slender sinuses, known since the time of Fallopius, are lodged, on either side, between the splitting of the tentorium cerebelli and in the small groove in the upper border of the petrous portion of the temporal bone. In front, they communicate with the petro-sphenoidal reservoirs; behind, with the lateral sinuses, through the intervention of which they empty themselves into the gulfs of the internal jugular veins. In their course, each receives some veins from the pons Varolii, one of the lateral veins of the cerebellum,<sup>5</sup> and several veins from the dura mater.

3. *Inferior petrosal sinuses (sinus petrosi inferiores).*—Shorter, but more capacious, than the preceding, each of these sinuses occupies the groove at the bottom of which is situate the corresponding occipito-petrosal suture. In front, each sinus communicates with the petro-sphenoidal reservoir of its side; behind, it opens into the lower part of the lateral sinus, and often even into the dilatation, or gulf, of the internal jugular vein. Each of them receives the emissary vein which passes through the corresponding foramen lacerum medium.

4. *Lateral sinuses (sinus laterales).*—Of a capacity superior to that of all the other sinuses of the dura mater, and like them, prismatical and triangular, these venous canals proceed, with increasing size, from behind forwards. The right lateral sinus is in general of greater dimensions than the left.

Commencing at the torcular Herophili, these sinuses direct themselves horizontally outwards and a little forwards, in the thickness of the circumference of the posterior half of the tentorium cerebelli, and, consequently, correspond to the lateral grooves.<sup>6</sup> On a line with the base of the petrous portion of the temporal bones, they change their direction and proceed downwards.<sup>7</sup> Then, inclining themselves inwards and forwards, and mounting slightly<sup>8</sup> towards the jugular foramina, each inosculates with the gulf of the internal jugular vein of its side. The lateral sinuses receive the superior petrosal, and sometimes the inferior petrosal, sinuses; the posterior occipital sinuses; and the mastoidean vein of each side, which establishes in this region a communication between the extra-cranial veins and the principal sinuses of the dura mater.<sup>9</sup>

This anatomical disposition explains why, from the most remote times, leeches were applied to these localities (*i.e.*, behind the ears) in order to cope with cerebral inflammation; in fact, by this means, the great vessels which communicate with the sinuses are disengorged.

5. *Posterior<sup>10</sup> occipital sinuses (sinus occipitales posteriores).*—These sinuses, mentioned for the first time by Duverney, commence at the level of the posterior lacerated foramina, and following on each side the hinder border of the falx cerebelli, open, by two apertures, into the torcular Herophili. In part, the inferior extremity of each of these sinuses joins the venous plexus which surrounds the foramen magnum, and, in this manner, they communicate with the posterior longitudinal venous plexuses of the spinal canal.

Some veins of the dura mater, of the bones of the cranium, and of the upper vertebræ, empty themselves into the posterior occipital sinuses.

#### PROPER VEINS OF THE DURA MATER.

They are of two kinds: the one, simple, terminate in the sinuses; the other, satellite,

<sup>1</sup> Sixth nerve, or abducens.

<sup>2</sup> Third nerve, or motor oculi.

<sup>3</sup> Fourth nerve, or trochlearis.

<sup>4</sup> First division of the fifth nerve, or ramus ophthalmicus.

<sup>5</sup> Anterior lateral cerebellar.

<sup>6</sup> The sulci transversales of the occipital bone, continued over the posterior inferior angle of the two parietals.

<sup>7</sup> In the fossæ sigmoideæ on the internal surface of the mastoid portions; here they have left the tentorium, and become semi-cylindrical.

<sup>8</sup> Along the supra-condyloid grooves of the occipital bone.

<sup>9</sup> Besides these they receive the posterior inferior cerebral veins, the inferior cerebellar, and generally, the posterior condyloid veins.

<sup>10</sup> So called in contradistinction to the transverse, or anterior occipital.



two for each artery, empty themselves into larger veins, and take names from the arteries which they accompany, and which we are now about to describe.

#### ARTERIES.

These are of three divisions: anterior, middle, and posterior.

The anterior arteries come from the anterior and posterior ethmoidal branches of the ophthalmic arteries.

The middle arteries, considerably the largest, are branches of the internal maxillary arteries.<sup>1</sup>

The posterior meningeal arteries are furnished by the ascending pharyngeal,<sup>2</sup> the vertebral, and the occipital arteries of each side.

The arteries of these three divisions, by their ramifications, form a network which almost entirely loses itself in the cranial bones. Although somewhat considerable, these arteries are very difficult of injection, since their size depends upon the thickness of their walls, and not upon their calibre, which is very constricted.

#### LYMPHATICS OF THE DURA MATER.

According to Mascagni, these vessels accompany the principal blood-vessels, and after having passed through the foramina spinosa, join the deep lymphatics of the face, proceeding with them to the glands which surround the internal jugular veins.

#### NERVES OF THE DURA MATER.

The solution of the question whether the dura mater is provided or unprovided with nerves, has been for a long period a subject of doubt. The most learned anatomists of former times, and even of a more recent epoch—Meckel, Morgagni, Haller, Holstein, and others—did not admit the presence of nerves in the dura mater. Other more modern authors, such as Arnold, Cruveilhier, and Sappey, admit them, it is true, but, nevertheless, do not agree upon their origin. As for myself, not only do I affirm that they exist, but even that they are derived from three different sources, which are, the trifacial nerves, the pathetici, and the sympathetic nervous plexuses which accompany the middle meningeal arteries, as will be demonstrated farther on.

#### SPINAL DURA MATER.

(Dura mater spinalis).

See Plates I. and II., and Figure 3, Plates VI. and VII.

The spinal dura mater<sup>3</sup> is thinner and more dilatable than the encephalic dura mater with which it is continuous. It constitutes a cylindrical cavity, or kind of long tube, extending from the foramen magnum to the extremity of the sacral canal, and even as far as the coccyx. The capacity of the spinal dura mater corresponds to the size of the vertebral canal, but considerably exceeds, however, the dimensions of the medulla spinalis itself. In the lumbosacral region, the spinal dura mater presents a dilatation which may be considered as a reservoir for the cerebro-spinal fluid. A like dilatation, but somewhat less marked, is also found in the cervical region. The portion of the dura mater comprised between these dilatations is constricted, and corresponds to a similar diminution in diameter which the rachidian canal presents in the dorsal region. The spinal dura mater is not in immediate contact with the spinal canal, but is separated from it by the intra-vertebral venous plexuses, and by cellular tissue, saturated, especially in children, with a serous fluid, and intermingled, in the adult, with a reddish fat. In front, the external surface of the spinal dura mater is connected to the posterior common ligament of the vertebræ through the medium of fibrous processes,

<sup>1</sup> Arteriæ meningæe mediae, magnæ and parvæ.

<sup>2</sup> This artery, on each side, also furnishes a small middle meningeal branch which perforates the cartilaginous lamella in the foramen lacerum basis cranii.

<sup>3</sup> Theca vertebralis.



which are especially well marked in the cervical and lumbo-sacral regions. Behind, it attaches itself by like fibrous processes, and in the same regions, to the ligamenta subflava. At the sides, the spinal dura mater gives off cylindrical prolongations, in the form of sheaths, which surround the roots and ganglia of all the spinal nerves. These sheaths, having gained the outlets of the intervertebral foramina, split in such a manner that one portion of them covers in the margin of these apertures as it passes to unite with the external periosteum, while the other becomes continuous with the fibrous envelope of the spinal nerves. It is well to observe here, that a small vertical fibrous septum is found in the interior of each sheath, which separates the anterior from the posterior root. On each side of the external surface of the spinal dura mater, and between the sheaths which surround the nerves, especially in the lumbar region, a series of fibrous bandlets are detached, which, after a short course, constitute the periosteum of the intervertebral foramina.

Superiorly, the external surface of the spinal dura mater is firmly adherent—in front, to the occipito-axoid ligament; behind, to the posterior occipito-atloid ligament, together with which it is perforated for the passage of the vertebral arteries and first pair of spinal nerves. Moreover, the dura mater in this locality likewise fixes itself to the posterior arch of the atlas. Inferiorly, this membrane forms a sac common to all the nerves which constitute the cauda equina, and terminates in the form of a truncated apex, which is attached, through the medium of fibrous fasciculi, to the last sacral vertebra and to the posterior sacro-coccygeal ligaments.

The internal surface of the spinal dura mater is smooth, moist, and polished. Since the time of Bichat, most anatomists admit that this anatomical disposition is due to a serous fluid, secreted by the epithelium of the arachnoid which lines the interior of the dura mater.

This internal surface is connected to the arachnoid by means of serous prolongations, and to the pia mater by two fibrous, triangular, and denticulated processes, which constitute the denticulate ligaments (*lig. denticulata*). These processes, which may be considered as dependencies of the dura mater, are now about to be described.

*Ligamenta Denticulata.*—These ligaments, so named by reason of their dentated arrangement, constitute each a very delicate kind of fibrous bandlet, extended vertically along the lateral aspect of the spinal marrow, between the anterior and posterior roots of the spinal nerves. The ligament of each side, of which the form, thickness, and length of the dentate processes are variable, takes its origin, at the level of the foramen magnum, by a very elongated extremity, between the vertebral artery and the hypoglossal nerve, and in front of the spinal accessory. Thence, directing itself downwards, it terminates nearly on a line with the inferior extremity of the spinal cord, or, what comes to the same thing, the commencement of the cauda equina.

The two surfaces, anterior and posterior, of each of these ligaments correspond, respectively, to the anterior and posterior roots of the spinal nerves. Their internal and uninterrupted border is continuous with the lateral portion of the spinal pia mater. Their external border, of greater thickness and festooned, is provided with from twenty to twenty-four dentations, which unite themselves with the spinal dura mater in the intervals between the sheaths which that membrane furnishes to the spinal nerves.

These ligaments have a double use; they serve, in fact, to fix the cord to prevent compression of it, and to separate the anterior from the posterior roots of the spinal nerves.

#### STRUCTURE OF THE SPINAL DURA MATER.

This is the same as that of the cranial dura mater. As for the denticulate ligaments, which some describe in connexion with the dura mater, and others in referring to the pia mater, the results of the most recent researches accord upon the point that their structure has much resemblance to that of the dura mater, and it is for this reason that they have been described here.

#### VESSELS AND NERVES.

*Arteries.*—The arterial branches of the spinal dura mater proceed from the vertebral, intercostal, lumbar, and sacral arteries.

*Veins.*—The venous ramifications of this membrane empty themselves into the intrarachidian venous plexuses.

*Nerves.*—They are described by Arnold and Luschka as accompanying the meningeal



arteries, and derived from the trifacial nerves; but, despite several attempts, I have hitherto found myself unable to verify the existence of them.

### VERTEBRO-CRANIAL ARACHNOID IN GENERAL.

(*Membrana arachnoidea cerebro-spinalis.*)

PLATES VI. and VII.

The arachnoid is a thin, whitish, semi-transparent serous membrane, occupying the interior of the vertebro-cranial hollow, between the dura mater and the pia mater.

Like all the serous membranes, the arachnoid forms, as well in its cranial as in its spinal portion, a shut sac, and offers for consideration: 1st, a visceral layer, which, applying itself over the encephalic and medullary pia mater, furnishes sheaths to the nerves and vessels; 2nd, a parietal layer, adherent to the dura mater.

The arachnoid, however, differs essentially from the rest of the serous membranes, by reason that the latter are free on one surface and adherent on the other, while the arachnoid is in part free on both surfaces. In this way there exist two intervals or cavities, of which the one is found between the parietal and visceral portions, and is called the *cavity of the arachnoid*, while the other is situate between the internal surface of the visceral layer and the pia mater, and is distinguished under the name of the *sub-arachnoid space*.

From this anatomical difference physiological distinctions necessarily arise. Indeed, in all ordinary serous membranes secretion is simple, for it takes place only on one of the surfaces, the free surface; it must be double, on the contrary, with the arachnoid, since two surfaces are free from attachment. Hence we distinguish two liquids, of which the one, contained in the cavity of the arachnoid, receives the name of *arachnoidean secretion*; while the other, enclosed in the sub-arachnoid space, is called *sub-arachnoid fluid*. It is the latter that is generally described under the appellation of cerebro-spinal fluid, while this name ought to apply to the two liquids at once.<sup>1</sup> Independently of the two fluids which we have just mentioned, there exists a similar one contained in the ventricular space.

The means of communication between the encephalic and the spinal or medullary fluid is admitted by every anatomist, by reason of the continuity of the encephalic with the spinal arachnoid. It is the same with regard to the channel of communication between the ventricular and sub-arachnoid fluids, also admitted now-a-days by all anatomists. We know, indeed, since the researches of Magendie, that this conflux takes place through an opening situate at the level of the *nib* of the *calamus scriptorius*. A question, however, presents itself,—Does the ventricular fluid communicate with that of the arachnoidean cavity itself? and what are its means of passage? In reply to this question, I must premise that Bichat was the first to point out a communication between the arachnoidean and ventricular cavities, through the medium of a canal discovered by himself, and since described under the name of the *arachnoidean canal of Bichat*.

This canal would be the result of the reflection and of the penetration of the arachnoid in the third ventricle, and would form a species of sheath surrounding the veins of Galen.

Most anatomists deny the existence of this canal, which they consider as purely artificial, and as being only the production of a peculiar mode of preparation employed by Bichat to demonstrate it.

Desirous of dissipating all doubts on this score, and of assuring myself personally of the true or fabulous existence of the canal of Bichat, I directed my researches upon this point with the greatest attention, taking care to surround myself with all the precautions requisite to secure me against the pretended faults attributed to this immortal physiologist. I must here declare that, despite the authority of the illustrious Magendie and his partisans, who deny the presence of this canal, I have seen it, and have myself many times undeniably proved the existence of it. Indeed, resting the encephalon either upon its base or upon its convexity, all that is requisite is to cautiously separate the cerebellum from the cerebrum, or *vice versâ*, according to the position which has been given to the brain, in order to expose a circular opening which surrounds the *venæ Galeni*: it is the external aperture of the canal in question. As to its internal orifice, it is found situate about half an inch more deeply, and

<sup>1</sup> The author's reasons for this remark depend on what follows, but it may be as well at once to state that anatomists in general do not hold a like opinion.



constitutes sometimes a simple opening, sometimes a *cul-de-sac* perforated like a sieve. Beyond this second opening are found fibrous processes decussating each other. We can convince ourselves of the existence of the canal of Bichat as well by pathological observations as by anatomical researches, since, in cases of sanguineous effusion, when pressure is made upon the brain, this fluid passes through the canal from within outwards. And, to the objection ordinarily made, that if a coloured fluid—ink, for example—be injected into this canal, it does not penetrate into the interior of the third ventricle, it may be replied, that this clearly depends on the fibrous bands which are found beyond the internal opening—bands which fulfil the office of valves, like to those which exist at the openings of the ureters, and which prevent the reflux of urine into those canals, in no respect opposing themselves to the flow of that fluid in an inverse sense, that is to say, from the ureter into the bladder.<sup>1</sup>

Once admit that this canal exists, and that it opens into the cavity of the arachnoid, we may conclude from it that the fluid of the ventricular cavities of the brain intermingles at once with the secretion of the arachnoidean space, through the intervention of the *canal of Bichat*, and with the sub-arachnoid fluid, by means of the aperture which is situate at the level of the apex of the calamus scriptorius or *orifice of Magendie*.<sup>2</sup>

So far as concerns the communication between the sub-arachnoid fluid and the arachnoidean secretion, which cannot take place directly, in consequence of the visceral layer of the arachnoid being imperforate, it is brought about by a kind of circulation—that is to say, the sub-arachnoid fluid passes, through the orifice of Magendie, into the fourth ventricle; thence it arrives, by the aqueduct of Sylvius, at the third ventricle; from whence, by the canal of Bichat, it pours itself into the arachnoidean space.

Hence it results that we are enabled to consider the third ventricle as a sort of reservoir, in which the two fluids, arachnoidean and sub-arachnoidean, mingle themselves together, and form in this manner a homogeneous liquid, which is the cerebro-spinal fluid.

#### CEREBRO-SPINAL FLUID.

(Liquor cerebro-spinalis.)

This liquid, mentioned by Haller, and accurately described by Cotunnus, had fallen completely into oblivion, and had been considered by some as a cadaveric phenomenon, by others as a pathological condition. Magendie, occupying himself with it anew, demonstrated by vivisections that this fluid existed in the normal state, thus appropriating the discovery; and having subjected it to very minute investigations, finally caused the existence of it to be admitted; whence comes the name of *fluid of Magendie*.

The quantity of cerebro-spinal fluid is in inverse proportion to the development of the cerebro-spinal axis—that is, it augments with the atrophy and diminishes with the hypertrophy of the nervous centre. It follows, that this fluid is more considerable in old people than in children, with whom the encephalon is proportionately more developed; it is likewise abundant in emaciated persons, or those affected for a considerable time with mental derangement. Moreover, the quantity is variable in proportion to the stature, and to the time elapsed between the death and the commencement of the examination, by

<sup>1</sup> The presence of a canal permitting of communication between the cavity of the arachnoid and the ventricular space of the brain, as maintained by Bichat, and here confirmed by the Author, is ignored by the great majority of anatomists, and particularly in this country. For a considerable period it was one of the most warmly discussed of anatomical questions; but general opinion ultimately went so much in opposition to it, that for many years it has ceased to be a moot point. However, after so very positive a statement as the above, and made by an anatomist of such well-known experience and accuracy, it can scarcely be passed over without remark.

That a tubular process of visceral arachnoid, *loosely surrounding* the venæ Galeni, is reflected inwards between the layers of the velum interpositum as far as the apex of the pineal gland, where its extremity generally presents the cribriform appearance described in the text, cannot be doubted by any one who has taken the trouble to examine a few brains which have been carefully removed in such a manner as to leave the tentorium cerebelli and base of the falces *in situ*, with the venæ Galeni and straight sinus uninjured. But whether it is, or is not, ultimately reflected upon the venous branches which apparently give rise to this cribriform disposition, thus becoming continuous with another process of arachnoid (or, at any rate, arachnoid epithelium) derived from the parietal layer at the anterior extremity of the straight sinus, and which can be traced forwards towards the same point, *closely investing* the veins of Galen, is a question which does not admit of an easy solution. This matter will, however, be again referred to in speaking of the reflections of the arachnoid, and will receive further notice.

<sup>2</sup> Ordinarily called cerebro-spinal aperture.



reason of a portion of the liquid being imbibed by the surrounding tissues. Ordinarily, 62 grammes<sup>1</sup> of it are found in a man of middle stature (Magendie); sometimes, however, this quantity rises to as much as 372 grammes,<sup>2</sup> especially in persons the subjects of atrophy of the brain.

*Chemical composition.*—The cerebro-spinal fluid is of an alkaline nature and saline taste. According to Lassaigne, this liquid is thus composed:—

Water . . . . .	98.564
Albumen . . . . .	0.088
Osmazome . . . . .	0.474
Chloride of sodium and of potassium . . . . .	0.801
Animal matter and free phosphate of soda . . . . .	0.036
Carbonate of soda and phosphate of lime . . . . .	0.017
	<hr/>
	99.980
	<hr/>

By means of vivisections, this liquid is observed to be transparent as distilled water, and to be agitated by a double movement, of which one is synchronous with the beat of the pulse, and the other with the respiratory action.

The cerebro-spinal fluid is secreted, after Cruveilhier, by the internal layer of the arachnoid; according to Haller, Magendie, and M. Longet, by the pia mater; as for myself, after what has been said above, I am led to think that it comes from the three free surfaces of the arachnoid.

*Use of the cerebro-spinal fluid.*—Filling the spaces between certain parts of the encephalon, it prevents their mutual compression; in like manner it protects the cord against the pressure of the vertebral column in its various movements. Hence, M. Cruveilhier has, with judgment, compared this fluid to that in which the fœtus floats. Magendie observed that drugs and poisons introduced into the circulation by the veins, were, after a very short time, found in the cerebro-spinal fluid. He concluded from it that many substances act upon the economy through this channel, by reason of their immediate contact with the nervous centre.

Surgical cases show us that this fluid is rapidly reproduced; a considerable drain of it, however, always proves fatal.

A jet of it may be obtained, either by an opening made artificially between the occiput and atlas, or through a wound accidentally produced—1st, in the vault of the skull; 2nd, in the olfactory region (and it was precisely in this latter instance that M. Robert saw this fluid make its exit through the nose, in the case of a fracture of the sphenoid bone complicated with laceration of the infundibulum and pituitary body); and 3rd, in the auricular region, consequent on the very common fractures through the petrous portion of the temporal bone.

#### ENCEPHALIC OR CRANIAL ARACHNOID.

(*Membrana arachnoidea cerebialis.*)

PLATE VIII.

The external or parietal layer of the arachnoid (*folium parietale*), discovered by Bichat, is only formed, according to the most modern observations, by pavement epithelium, which lines the internal surface of the dura mater and its processes, adhering there very firmly. The internal or encephalic layer (*folium viscerale*) envelops the encephalic pia mater, to which it is loosely connected by the intervention of a very delicate cellular tissue susceptible of infiltration, but from which it is separated by a more or less abundant stratum of serous fluid which gives it its smooth and polished appearance. This layer becomes continuous with the parietal layer, by reflecting itself around the nerves and vessels which leave or enter the encephalon.

The visceral layer of the arachnoid crosses from one convolution to another in the manner of a bridge, without penetrating into the anfractuosités, and by this mode of passage assists in the formation of spaces between itself and the pia mater which closely invests the

<sup>1</sup> Very nearly two ounces.

<sup>2</sup> About twelve ounces.



convolutions and sulci—spaces especially well marked at the base of the brain; afterwards, it buries itself between the principal subdivisions of the encephalon, over the base and over the convexity of which, we are now about to follow it.

*Visceral arachnoid upon the base of the encephalon.*—In studying the arachnoid at the base of the brain, and in tracing it from before backwards on the median line, we observe that it sinks into the great longitudinal fissure of the cerebrum, separating from each other the anterior lobes at their anterior portion, but at their posterior part passes across the fissure in the fashion of a bridge. From thence, at first in contact with the pia mater, it stretches onwards to the pons Varolii; but, not introducing itself into the median fossa of the brain, it separates from that membrane, to which it is nevertheless connected by a very loose cellular tissue, and forms with it an interval, called the *anterior sub-arachnoid space*<sup>1</sup> or *confluence*. Extending thus from before backwards, the visceral arachnoid applies itself upon the olfactory nerves, the optic nerves and their commissure, the motores oculorum and pathetici, the arterial hexagon<sup>2</sup> of Willis and the tuber cinereum, and also forms a sheath for the infundibulum. Afterwards, this membrane comports itself in a like manner as regards the other nerves which issue from the base of the encephalon; that is to say, it applies them against the base at their origin, and then forms, in proportion as they project from thence, a sheath about each, which accompanies them as far as their respective foramen in the cranial parietes, where, in reflecting itself, it becomes continuous with the stratum which lines the internal surface of the dura mater constituting the parietal layer.

Passing from the pons Varolii, the visceral layer stretches upon the medulla oblongata, which it surrounds, and from one cerebellar hemisphere to the other, without penetrating into the intervening vallecule, but leaving between itself, the medulla, and the hinder portion of these cerebellar hemispheres, another interval, which is the *posterior sub-arachnoid space* or *confluence*.

Upon the lateral regions, the visceral layer of the arachnoid, supposing always that it have an antero-posterior direction, stretches itself from each side of the anterior lobes on to the corresponding middle lobe of the cerebrum, and does not penetrate into the fissures of Sylvius; on the contrary, it abandons the pia mater of these interstices, and forms with it, on each side, an interval called the lateral sub-arachnoid space or confluence,<sup>3</sup> which communicates with the anterior confluence. Somewhat farther backward, this layer covers the posterior lobes of the cerebrum, as well as the cerebellum, and reflects itself upon the convexity of the brain.

*Visceral arachnoid upon the convexity of the encephalon.*—After having covered all the surface, this membrane sinks deeply into the antero-posterior median fissure, and is reflected from one hemisphere to the other, above the corpus callosum, but below the free border of the falx cerebri. In line with the middle of the splenium<sup>4</sup> of the corpus callosum, this layer, directing itself on to the superior surface of the cerebellum, meets in its course the veins of Galen, forms around them a sheath, which is the canal of Bichat, and thus penetrates into the middle ventricle of the brain,<sup>5</sup> where, becoming thinner and thinner, it is reduced to the epithelium which invests the under surface of the velum interpositum and choroid plexuses.<sup>6</sup> From the neighbourhood of the lateral portions of the splenium of the

<sup>1</sup> Since the *entire interval* existent between the arachnoid and pia mater is named the *sub-arachnoid space*, the *portion of that interval* here as well as those portions subsequently so termed with the super-addition of a distinctive title, although most usually thus described (as it were *par excellence*, on account of being especially well marked), are doubtless, in view of their anatomy as given in the text and generally accepted, much more appropriately characterized as *sub-arachnoid confluences*.

<sup>2</sup> Commonly called *circle*.

<sup>3</sup> These, although by no means inconsiderable, are not ordinarily accounted of sufficient importance to merit a special designation, but are looked-upon, in general, as forming lateral continuations of the anterior sub-arachnoid confluence.

<sup>4</sup> This term, though not frequently used by modern anatomists, has, nevertheless, been applied by some authors to the posterior, free, rounded extremity, formed by the corpus callosum previously to its junction with the fornix, and called by the French "*bourrelet*" (a species of cushioned fold); but, although rather far-fetched as regards its applicability, it is certainly not more so than numerous other instances of cerebral nomenclature, and has therefore, in the absence of a better name, been selected to specify that portion of the great commissure, and to act as a synonym for, though not to translate, the French term.

<sup>5</sup> Generally called *third ventricle*.

<sup>6</sup> The process of visceral arachnoid constituting this so-called *canal*, has been previously alluded to in the general account of the membrane, and has already formed the subject of remark in a foot-note, page 11. Since writing that note, I have directed especial attention to the question, and have examined a considerable



corpus callosum, this layer passes upon the cerebellum; and, without penetrating into the fissure which is found between the two hemispheres,<sup>1</sup> stretches itself over the posterior part of the medulla, so as to form the posterior sub-arachnoid space above mentioned. This cavity includes, like all the others, with which it is also continuous, the sub-arachnoid fluid, and abuts on the orifice of Magendie, by means of which it communicates with the fourth ventricle.

Along the line of the superior longitudinal sinus, the visceral layer is pretty firmly adherent to the parietal layer; which is dependent on the sheaths that this membrane furnishes to the veins which open into the sinus. The adhesion of the two layers is still so much the firmer, in proportion as those Pacchionian glands are found in this region, which, as has been already mentioned, sometimes project into the interior of this sinus. Furthermore, at the convexity, as at the base of the encephalon, the visceral layer of the arachnoid surrounding it, passes from one convolution to another without penetrating into the sulci.

In this way, there exist between the arachnoid and the corresponding anfractuositities, small spaces which communicate with the large ones; and the former, like the latter, contain sub-arachnoid fluid.

The external or superficial surface of the visceral or encephalic layer of the arachnoid, is attached to the parietal layer, by some very delicate and sparse serous cellular tissue,—in such wise, however, that the cavity of the arachnoid is maintained.

The internal or deep surface of this layer, is connected with the pia mater, in like manner, by the intervention of a very delicate serous cellular tissue, and gives origin, as we have already shown, to the sub-arachnoid space.

In the region of the confluences or reservoirs, and particularly of the anterior, this tissue is intermingled with fibrous filaments, which decussate each other in all directions.

#### MEDULLARY OR VERTEBRAL ARACHNOID.

(*Membrana arachnoidea spinalis.*)

See Plates VI. and VII.

The external or parietal layer of this division of the membrane, lines the interior of the dura mater, to which it is intimately adherent; and unites with the internal layer, through the medium of the sheath-like processes which surround the roots of the rachidian nerves, the

number of brains, with a view of satisfying myself as to the exact manner in which the process terminates. This is not the same in all instances, but varies, more particularly, with the distance from the straight sinus at which the junction of the veins of Galen takes place,—or, in other words, with the length of the vena magna Galeni. The vicinity of the apex of the pineal gland, however, is by far the most usual site for the origin of the latter trunk; where, such being the case, it likewise receives small tributaries from the gland itself, the choroid plexuses of the third ventricle, the tubercula quadrigemina, and the adjacent parts of the cerebellum. Below and to either side of this venous focus, the corresponding portion of the sheath of visceral arachnoid terminates by giving off small diverticula, analogous to itself, which encase the convergent branches for variable, but ordinarily short distances, and which then appear to be reflected to join an investing layer of parietal epithelium, continued forwards upon the veins from the dura mater. It is the uprooting, as it may be termed, of some of the lesser branches, which takes place during the process of examination, that produces the cribiform appearance in this locality, referred to in the former note. Superiorly, the commencement of the vena magna is free from small tributaries. Here, the remainder of the sheath formed by the visceral layer is, in general, prolonged forwards above the pineal gland; and, uniting with the parietal epithelium before-mentioned, which in this situation covers only the inner portion of the circumference of the converging veins of Galen, forms between those vessels a narrowed continuation of the original *diverticulum*—if I may be allowed the designation—which afterwards expands to produce an interspace in the thickness of the portion of the velum interpositum that coincides with the triangular interval between the choroid plexuses of the third ventricle, at the apex of which, it terminates in an acuminate extremity.

The determination of the apertures or occlusion of the ventricular confine of this arachnoidean diverticulum, is, on account of the extreme delicacy of the membrane and other embarrassing circumstances, by no means so simple a matter as might at the outset be supposed. Although a considerable number of my first experiments tended in a great degree to confirm the views of the Author, I have since, by more careful manipulation and by divers methods, satisfied myself of their fallacy; and am at present induced to consider this process as *cæcal* anteriorly, and as having, in all probability, for its office, the admission of fluid from the general arachnoid cavity,—fluid varying in quantity inversely as the turgidity of the veins traversing it; thus maintaining around them, a rapidly fluctuating compensatory medium, easily responding to those changes in their contents which must necessarily arise from alternations in the state of the intra-cerebral circulation, and perhaps, more especially, from periodic phases in the function of the choroid plexuses.

<sup>1</sup> This applies only to the portion of the fissure that is termed the vallicula, and does not include the incisura cerebelli posterior, which receives the upper part of the falx minor.



serrations of the denticulate ligaments, and the nerves forming the cauda equina, which they accompany as far as the intervertebral and sacral foramina.

The free surface of this layer is connected with the visceral layer, by the intervention of some dispersed and tenuous cellulo-serous tissue; in such manner though, that there remains between them the corresponding portion of the interval which is called the cavity of the arachnoid, and which contains the spinal share of that division of the cerebro-spinal fluid which has been described higher up under the name of arachnoidean secretion.

The visceral or medullary layer, loosely surrounds the medullary pia mater, and consequently the spinal marrow; and is found to be separated from the former by a delicate cellular tissue, and by the sub-arachnoid interspace (spinal confluence), in which is found the correlative proportion of the cerebro-spinal fluid that is called sub-arachnoid.

#### STRUCTURE OF THE ARACHNOID.

The parietal layer is formed by a single stratum of pavement epithelium. The visceral layer, on the contrary, is composed of condensed cellular tissue, intermingled with delicate elastic fibrils, and the whole invested by a layer of pavement epithelium. To all appearance, the arachnoid is unprovided with blood-vessels and nerves; although, of late years, some anatomists have sought to controvert this fact, nevertheless, up to the present time, it has not been in their power to demonstrate clearly, that sanguiferous vessels and nerves exist and lose themselves in the thickness of this membrane. As to lymphatic vessels, however, it seems that they do exist, since Mascagni has injected some of them.

### MEDULLO-ENCEPHALIC OR VERTEBRO-CRANIAL PIA MATER IN GENERAL.

(Pia mater seu meninx vasculosa cerebro-spinalis.)

PLATES IX. and X.

The pia mater is the third meninx, and is placed between the medullo-encephalic nervous centre, which it immediately envelopes, and the arachnoid, which is superposed to it. It is thin and semi-transparent; of a cellulo-vascular nature in the cranium, and fibro-vascular in the vertebral canal. It serves as a support to the vascular network which passes into the nervous centre or emerges from it.

The external and, in other respects, free surface of it, is connected with the visceral layer of the arachnoid, through the medium of the filamentous prolongations mentioned above. Moreover, it gives off other processes, which are lost in the neurilemma of the cranial nerves. In speaking of this, it is not irrelevant to remark that, according to some authors, the process which surrounds each of the optic nerves would be continuous with the choroid coat of the eye.

The internal surface of the pia mater, attaches itself to the medullo-encephalic nervous centre by numerous cellulo-vascular processes.

We are about to distinguish in the pia mater, similarly to the other meninges, an encephalic and a medullary portion.

#### ENCEPHALIC OR CRANIAL PIA MATER.

(Pia mater encephalica.)

PLATE XI.

The pia mater has a much greater superficial extent than the visceral layer of the arachnoid which surrounds it. The encephalic portion of the pia mater is thinner than its medullary part, and also contains more blood-vessels, which divide into very minute branches before penetrating into the nervous pulp or emerging from it. It envelopes all the surface of the encephalon, and is attached there by a multitude of sanguiferous vessels;<sup>1</sup> but, not passing across the cerebral sulci as the arachnoid does, the pia mater, on the contrary, penetrates into all the spaces between the convolutions, lining the bottom and the contiguous parietes of them, in such a manner, that each anfractuosity encloses a double layer of this membrane.

This anatomical disposition is repeated, not only over the cerebral lobes, but even upon the lobes, the lobules, and the lamellæ of the cerebellum. The pia mater penetrates, in like

<sup>1</sup> Tomentum cerebri.



manner, into the interior of the brain, passing beneath the splenium of the corpus callosum through the transverse portion of the cerebral fissure of Bichat, as well as through the posterior aperture of the fourth ventricle (orifice of Magendie); and furnishes in these localities, prolongations into the ventricular space of the encephalon, so as, in such manner, to convey blood-vessels there. These processes which, taken together, constitute the *internal pia mater*, form the velum interpositum, the choroid plexuses of the lateral ventricles, those of the third ventricle, and likewise those of the fourth.

From the internal surface of the encephalic pia mater are given off a great number of vascular filaments, which penetrate into the corresponding portion of the brain. These processes are most considerable at the base of the cerebrum,<sup>1</sup> and at the pons Varolii; and it is through their medium, that the pia mater attaches itself to the different portions of the encephalon which it surrounds.

#### INTERNAL PIA MATER.

##### I.—Velum Interpositum.

(Tela choroidea.)

See Plate XVIII., Figure 3.

The velum interpositum, which is a prolongation of the external pia mater, forms a triangular membrane, having the base posteriorly, which blends with the external pia mater between the splenium of the corpus callosum and the corpora quadrigemina; from thence, it passes forwards over the third ventricle, in a horizontal direction, terminating by a narrowed apex. The superior surface of this membrane corresponds with the inferior surface of the fornix, to which it is attached by fibro-vascular filaments.

The inferior surface covers, at its middle part, the third ventricle and its three commissures; at the sides and behind, a portion of the optic thalami, the corpora quadrigemina, and the pineal gland, to which it is adherent through the medium of numerous fibro-vascular processes.

Upon this surface may be observed two small trains of antero-posterior and nearly parallel granulations, called the *choroid plexuses of the third ventricle*.

The sides of the velum interpositum blend with the *choroid plexuses of the lateral ventricles* along the lateral margins of the fornix. The anterior extremity or apex of the velum interpositum is bifid, and each division passes through the corresponding foramen of Monro, becoming continuous with the choroid plexus of the lateral ventricle of its side; the base, as has been mentioned above, coalesces with the external pia mater in the horizontal portion of the cerebral fissure of Bichat.

In the proper thickness of the velum interpositum, but nearer its inferior than its superior surface, are found the veins of Galen, which communicate with the plexuses of the lateral ventricles by the intervention of small transverse veins. The veins of Galen are enveloped, as we already know, by the sheath of arachnoid which is called the arachnoidean canal of Bichat.

##### II.—Choroid Plexuses of the Lateral Ventricles.

(Plexus choroidei ventriculorum lateraliū.)

See Plate XVIII., Figures 1 and 3, and Plate XIX., Figure 4.

These plexuses take origin on the inferior surface of the velum interpositum by tapered extremities, which, after having traversed the foramina of Monro, direct themselves from before backwards in the lateral ventricles; there, under the form of convoluted vascular cords, and becoming gradually more voluminous, they skirt the margins of the fornix, where, adhering to the optic thalami, they are in continuity with the velum interpositum. Arrived posteriorly, these plexuses wind round the hinder part of the optic thalami, and penetrate, each, into the descending cornu of the corresponding lateral ventricle; there, considerably augmented in size, they cover the corpus fimbriatum and hippocampus major, and are continuous with the external pia mater in the lateral or antero-posterior portions of the great cerebral fissure of Bichat. In the body of the lateral ventricles, these plexuses receive, on their outer side, the veins of the corpora striata, which pass, for the most part, beneath the tæniæ semi-

<sup>1</sup> Particularly opposite the substantiæ perforatæ and pons Varolii.



circulares, and on their inner side, they communicate with the veins of Galen. All the free surface of the choroid plexuses is invested with a single layer of pavement epithelium, which is continuous with the ependyma.

### III.—Choroid Plexuses of the Third Ventricle.

(Plexus choroidei ventriculi tertii.)

These plexuses, already known to Vicq d'Azyr, run from behind forwards, in form of two small granular cords, along the under surface of the velum interpositum, for the distance of about half an inch, forming two sides of a triangle. Then, uniting with one another, the two cords form a small, extremely slender, trunk, which, after a short course, bifurcates; and each division, before or after having traversed the foramen of Monro, becomes continuous with the choroid plexus of the corresponding lateral ventricle. Posteriorly, these small plexuses attach themselves to the pineal gland, through the medium of numerous capillary vessels.

### IV.—Choroid Plexuses of the Fourth Ventricle.

(Plexus choroidei ventriculi quarti.)

Two in number,<sup>1</sup> these plexuses arise at the level of the orifice of Magendie, and behind the lobule of the vagus nerve (*floculus*): the one, antero-posterior, passes to the nodulus of the cerebellum; the other, transverse, terminates, after a short course, on a line with the lateral angle of the fourth ventricle. These plexuses, which are provided with processes resembling villi, are invested by a layer of epithelium analogous to that of serous membranes, and coalesce with the ependyma.

### MEMBRANE OF THE ENCEPHALIC VENTRICLES, OR EPENDYMA.

(Ependyma ventriculorum.)

This membrane, smooth, homogeneous and polished, lines the interior of all the ventricles of the brain, as well as the aqueduct of Sylvius. It is composed of a single layer of pavement and vibratile epithelium, the cells of which are provided with small hook-like processes, and enclose a nucleus together with a congeries of granules. The ependyma covers in like manner the choroid plexuses, where it is continued by the pavement and non-vibratile epithelium which invests them. Along the line of the laminae corneae<sup>2</sup> of the body of the lateral ventricles, this membrane becomes thicker, and presents beneath the epithelium a thin condensed layer of cellular or connective tissue.

### STRUCTURE OF THE PIA MATER.

This membrane is composed of a vascular network, in the meshes of which is found cellular tissue, segregated, lax, and scanty fibrous.

The vessels which form this network are very numerous, seeing that they comprehend all the capillaries which penetrate into the substance of the brain, or which emerge from it. In comparing the vessels of the encephalon between themselves, there is observed to exist a great difference in number between the arteries and the veins. The numerical relation of veins to arteries in the encephalic pia mater, is as 6 : 1. According to some authors, these vessels are included between two layers of connective tissue.

<sup>1</sup> Although these plexuses are in general described as but two, it seems probable that the Author, here at any rate, means on each side of the median line, since, otherwise, the context would be scarcely intelligible. In those instances where I have directed that special attention towards them which is essential to the determination of their true anatomy, more particularly by a frequent reproduction of the preparation requisite for their display *in situ*, I have invariably found the two plexuses apparently alluded to in the text, united at the summit of the nodulus so as to constitute a single plexus of angular form—although, in some other respects, irregular as regards outline—with its apex at that projection, and having the side nearest the median line more or less separated by the crest of the inferior vermis from the analogous side of another plexus, formed in a like manner, and corresponding to the opposite lateral half of the fourth ventricle. Their more minute description being, in a great measure, involved in that of the ventricle to which they belong, they will receive further notice under that head.

<sup>2</sup> *Horny bands*, or *frænula nova* Tarini, described by some as portions of the tæniæ semicirculares.



Since into the intimate texture of the pia mater there enter arteries, veins, lymphatics, and nerves, it will not, perhaps, be considered out of place to give a brief description of them here.

#### ARTERIES OF THE PIA MATER.

The arterial ramifications of the brain proceed, on either side, from two sources: A. the subclavian artery; and B. the internal carotid artery.

##### A.—Subclavian Artery.

Each subclavian artery supplies the encephalon through the medium of one of its branches, which is called the *vertebral artery*. The latter ascends through the foramina in the transverse processes of the six first cervical vertebræ, describing two considerable curves; one of which, vertical, is found between the axis and the atlas, while the other, larger and horizontal, is observed between the atlas and the occipital bone.

After which the vertebral artery, perforating the posterior occipito-atloid ligament and the dura mater corresponding, enters into the cranial cavity by the foramen magnum. From thence, this artery directs itself forwards and upwards, between the basilar groove and the medulla oblongata, and at the level of the furrow which separates the medulla<sup>1</sup> from the pons Varolii, it unites with the synonymal artery of the opposite side to form the basilar artery or trunk. This latter, having arrived at the anterior border of the pons, bifurcates, and the branches of bifurcation, which are the posterior cerebral arteries, are joined to the internal carotid arteries through the medium of the two posterior communicating arteries, or *communicantes Willisii*.

##### B.—Internal Carotid Artery.

Taking origin from the common or primitive carotid artery, on a level with the upper border of the thyroid cartilage, the internal carotid artery, on each side, extends vertically as far as the base of the cranium, describing certain bends;<sup>2</sup> there, it penetrates into the cranial cavity by the carotid canal, assuming the same curve as the canal itself. At its exit from this canal, it is found in the cavernous sinus; at the anterior part of which, and on a level with the anterior clinoid process, it perforates the dura mater, presenting a new curve.<sup>3</sup> Then, after having anastomosed with the corresponding posterior cerebral artery, by means of the communicating artery of Willis, it furnishes three branches, which are: the ophthalmic artery,<sup>4</sup> which comes under description in connexion with the organ of vision; and two cerebral arteries, namely, the anterior cerebral artery and the middle cerebral artery, concerning which we are about to occupy ourselves immediately.

From these four principal trunks, that is to say, the two vertebral arteries and the two internal carotid arteries, arise all the arteries of the nervous centre; which may be distinguished into arteries of the medulla, of the cerebellum, and of the cerebrum.<sup>5</sup>

1st. *Arteries of the medulla.*—They are three in number, one anterior and two posterior. The first, the *anterior spinal artery*, takes origin by two roots, one from each of the two vertebral arteries. These two roots, after a short course, unite between themselves and form a common

<sup>1</sup> It may be well to remark at once, as a general notice, that the terms medulla, cord, and marrow, when used without further qualification, are intended to express all that division of the nervous axis which extends downwards from the lower border of the pons Varolii, or any portion of that division which may be implied by the context, without especial reference to its subdivisions into medulla oblongata and medulla spinalis, spinal cord, or spinal marrow.

<sup>2</sup> Its course thus far, is ordinarily described as straight; a curved condition, however, is by no means uncommon.

<sup>3</sup> After emerging from the canal, and before penetrating the layer of dura mater forming the outer boundary of the sinus, the artery ascends a short distance towards the body of the sphenoid bone, and then, having entered the sinus, proceeds horizontally forwards; thus forming a slight double curve, intermediate to those above-mentioned.

<sup>4</sup> This branch is given off opposite the anterior clinoid process, while the two vessels subsequently mentioned, and the posterior communicating artery, form the terminal branches of the main trunk, at the inner end of the Sylvian fissure.

<sup>5</sup> Named vessels, are here more especially alluded to. The arteries of the principal part of the mesencephalon are derived from the basilar trunk, and constitute transverse, hair-like branches, but all the neighbouring vessels assist more or less in its supply.



trunk, which follows from above downwards, in a serpentine manner, the median portion and anterior median fissure of the cord. The two last, the *posterior spinal arteries*, arise also from the two vertebral arteries; but, instead of uniting between themselves, as in the case of the artery described above, they proceed uniformly from above downwards, sinuously, but parallel between themselves, along the posterior lateral fissures of the marrow.

The posterior spinal arteries, as well as the anterior spinal artery, receive in their descending course, and on each side, twigs of reinforcement which proceed successively from the thyroidean,<sup>1</sup> vertebral, deep cervical, intercostal, lumbar, ilio-lumbar, and lateral sacral arteries; and by means of these reinforcing branches, the arteries, although extremely slender at their origin, are enabled to arrive as far as the inferior extremity of the spinal marrow.

2nd. *Arteries of the cerebellum*.—These are three in number, on either side; two distribute themselves upon the inferior surface of the cerebellum, and in the choroid plexuses of the fourth ventricle, while the third ramifies over the superior aspect of the organ. Of the two first, the one distributing itself on the inferior and posterior part of the cerebellum, is called the *posterior<sup>2</sup> inferior cerebellar artery*; the other, ramifying at the inferior and anterior portion of it, is named the *anterior inferior<sup>3</sup> cerebellar artery*. The third is styled the *superior cerebellar artery*, on account of its distribution over the upper surface of the cerebellum. The posterior inferior cerebellar artery is given off, on each side, by the corresponding vertebral artery; the anterior inferior cerebellar artery and the superior cerebellar artery, of either side, have their origin in the basilar trunk.

3rd. *Arteries of the cerebrum*.—These are likewise three in number on each side; the first, which is the *posterior cerebral artery*, constituting the branch of bifurcation of the basilar trunk, divides and subdivides itself over the posterior cerebral lobe; the second, which is called the *middle cerebral artery*, or *artery of the fissure of Sylvius*, is found at the bottom of that fissure, and, after having divided into several branches, distributes itself to the middle lobe and part of the anterior lobe of the cerebrum; while the third, named *anterior cerebral artery*, or *artery of the corpus callosum*, after having anastomosed with the synonymal vessel of the opposite side, by a small transverse branch called the anterior communicating artery, directs itself forwards, parallel with its namesake, and arrived on a line with the genu of the corpus callosum, reflects itself upwards, then backwards, to ramify on the internal surface of the corresponding hemisphere.

We have seen above, that the two middle cerebral arteries and the two anterior cerebrals are branches of the internal carotid arteries; but, independently of these, and of the posterior arteries of the same denomination, we meet with two small but constant branches, called *choroid arteries*.<sup>4</sup> These last, detaching themselves from the posterior part of each internal carotid artery, externally to the posterior communicating artery, direct themselves backwards along the cerebral peduncles, penetrate into the lateral ventricles by the antero-posterior portions of the cerebral fissure of Bichat, and terminate in the choroid plexuses.

From what has just been said upon the vessels of the medullo-encephalic nervous centre, it results, that four trunks, proceeding from different sources, anastomose at the base of the brain in the following manner: the two vertebral arteries are united together by means of the *basilar trunk*, and the two internal carotid arteries are joined between themselves through the medium of the *anterior communicating artery*. Moreover, the system of the subclavian arteries is maintained in direct association with the system of the internal carotid arteries, by the *posterior communicating arteries*, or *communicating arteries of Willis*.

These arteries, thus anastomosed, are found in the median fossa of the base of the brain, and form a hexagon, or rather a polygon, improperly distinguished under the name of the *arterial circle of Willis* (*circulus arteriosus Willisii*); the sides of this hexagon are formed: in front, by the two anterior cerebral arteries; behind, by the two posterior cerebral arteries; and in the middle, by the two communicating arteries of Willis. The angles of this hexagon

<sup>1</sup> Principally, the ascending cervical branch of the thyroid axis.

<sup>2</sup> This designation is usually dropped, and the vessel simply called "inferior cerebellar artery," also sometimes, "profunda cerebelli." It is the principal means of supply to the plexus of its side.

<sup>3</sup> This term is ordinarily omitted, and the vessel described as "anterior cerebellar artery."

<sup>4</sup> Generally named *anterior*, sometimes *inferior*, choroid arteries, in contradistinction to the *posterior* or *superior* choroids, which are branches of the posterior cerebrals. Occasionally there are two of them on each side.



correspond: the anterior, to the anterior communicating artery; the posterior, to the basilar trunk; the anterior lateral angles, to the middle cerebral arteries; and the posterior lateral angles, to the posterior cerebral arteries. To these six angles might still be added, the angles formed by the junction of the internal carotid arteries with the anterior cerebral artery, which justifies the substitution of the word polygon for that of hexagon, since, in fact, the angles are rather eight in number than six. From this polygon start, as from a centre, divergent radii, which make up all the arteries of the brain. In short, from the anterior angle pass forwards the anterior cerebral arteries; from the posterior angle is continued the basilar trunk, which itself, conjointly with the vertebral artery of each side, is the starting-point of the arteries of the cerebellum and of those of the medulla; from the anterior lateral angles rise the middle cerebral arteries; and from the posterior lateral angles proceed the posterior cerebral arteries.

It is to this position of the hexagon between the osseous parietes and the base of the brain, that the movement of the latter is attributed<sup>1</sup>—movement synchronous with the beat of the pulse; which depends on the alternate distension and subsidence of the arteries, consequent on the systolic and diastolic motion of the heart.

With respect to the flexuous disposition of the arteries of the encephalon, it would appear that it serves to moderate too rapid impulsion of the blood towards the brain, and consequently, to protect its frail substance against the violent commotions to which it would be exposed in the absence of this anatomical provision.

#### VEINS OF THE PIA MATER.

These veins,<sup>2</sup> which constitute, as has been already said, six-sevenths of the total number of sanguineous vessels, may be divided into extra-encephalic veins and intra-encephalic veins.

Under the former division may be grouped:—1st. The veins of the base of the encephalon; 2nd. The veins of its convexity; 3rd. The veins of the internal surface of its cerebral hemispheres, or interlobar<sup>3</sup> veins.

Among the latter may be ranged:—1st. The veins of the lateral ventricles, or veins of Galen; 2nd. The veins of the choroid plexuses; 3rd. The veins of the corpora striata.

#### A.—Extra-encephalic veins.

1st. *Veins of the base of the encephalon.*—These are of two classes, that is to say, those of the cerebrum and those of the cerebellum; and they pass, the former as well as the latter, into the venous sinuses which are found at the base of the skull.

2nd. *Veins of the convexity.*—The number of these is variable, but ordinarily there may be reckoned seven or eight of them on either side, amongst which, those that are found anteriorly are the largest. All these veins appear to emerge from the Sylvian fissure of the corresponding side, from whence they curve obliquely backwards; having thus gained the convexity, they re-curve themselves in the opposite direction, that is, from behind forwards, until they meet the superior margin of the falx cerebri, where they open into the superior longitudinal sinus by one or more orifices, masked by the fibrous processes which are found in the sinus, and, in some places, by the glands of Pacchioni. It is precisely at the place where these veins penetrate into the falx cerebri, that the encephalic layer of the arachnoid is reflected to become continuous with the parietal layer which lines the interior of the cranial dura mater, as we have already seen higher up.

3rd. *Veins of the internal surface of the cerebral hemispheres, or interlobar veins.*—These are three or four in number on each side; and, proceeding from the vascular network of that surface of the cerebrum, they empty themselves into the veins of the convexity, close to the place where the latter perforate the dura mater to communicate with the superior longitudinal sinus.

#### B.—Intra-encephalic veins.

1st. *Veins of the lateral ventricles, or veins of Galen.*—Two in number, these veins appertain, one to the ventricle of the right side, the other to that of the left. Each of them takes

<sup>1</sup> In controversion of this hypothesis, it is worthy of remark, that none of the arteries at the base of the brain, save those which are bound down by the dura mater, leave any trace of pressure upon the subjacent bone. See also note <sup>6</sup>, page 24.

<sup>2</sup> It may be noticed here, that the veins of the brain are extremely thin, in consequence of the absence of muscular tissue from their coats, and, that the ordinary valves are wanting.

<sup>3</sup> See note <sup>1</sup>, page 26, as well as the portion of text to which it refers.



its origin from the consecutive junction of the veins of the choroid plexuses and those of the corpus striatum corresponding. The two veins then proceed, parallel between themselves, upon the inferior surface, or rather, in the thickness of the velum interpositum, from the foramina of Monro, as far as the middle of the base of that membrane. In this course, they are found at the commencement, quite close to one another; then, they separate; and finally, unite to form a common trunk, which some anatomists call the vein<sup>1</sup> of Galen. This latter disengages itself from beneath the splenium of the corpus callosum, where it is surrounded by the sheath of arachnoid, and throws itself into the straight sinus, after having received in its track other small veins from the choroid plexuses, as well as some from the corpora quadrigemina.

2nd. *Choroid veins*.—These are found in the thickness of the choroid plexuses of the lateral ventricles, along their external border; in their course, they receive the veins of the hippocampi majores, the veins of the fornix, and those of the corpus callosum.

Arrived at the anterior part of the choroid plexuses, these veins communicate with those of the corpora striata, and become continuous, through the foramina of Monro, with the anterior extremity of the corresponding vein of Galen.

3rd. *Veins of the corpora striata*.—The vena corporis striati, of either side, commences in the groove separating the optic thalamus from the corpus striatum, between the lamina cornea and the tænia semicircularis. Along its course, each vein receives numerous branchlets from the corpus striatum and from the optic thalamus; finally, after having united with the corresponding choroid veins, it forms, as has been already described, the vein of Galen of the corresponding side.

#### LYMPHATICS OF THE PIA MATER.

Ignored by Haller and other anatomists, these vessels have been carefully described by Mascagni, Fohmann, and Arnold.

Mascagni affirms that the lymphatics which are found at the convexity of the cerebrum, proceed towards the superior longitudinal sinus to lose themselves in the dura mater. He has besides seen lymphatics about the vertebral and internal carotid arteries.

According to Fohmann and Arnold, there exists on the external surface of the pia mater a lymphatic network, which penetrates, conjointly with that membrane, into the anfractuosités of the brain. From this network arise small trunks, which direct themselves with the blood-vessels as far as the base of the brain, where they open into the satellite veins of some of the arteries.

M. Sappey, however, relying upon fresh researches, maintains that the lymphatic network represented in the plates of Fohmann and of Arnold, is certainly nothing else than an extravasation of mercury into the meshes of the sub-arachnoid cellular tissue.

#### NERVES OF THE PIA MATER.

Lancisi was the first who mentioned the nerves of the pia mater, which he described as coming from the facial nerve; this, however, is contradicted by the most minute researches. From the latest investigations it may be concluded, that the nerves of the pia mater proceed from the sympathetic nervous plexuses which surround the arteries; a fact which, on the strength of the researches which were common to M. Bourguery and myself, I have already had occasion to make known in a *mémoire* communicated to the Académie des Sciences of Paris, and in which I have described these nerves under the name of *nervi nervorum*.

#### MENINGEAL GRANULATIONS, OR GLANDS OF PACCHIONI.

(Corpuscula seu glandulæ Pacchioni.)

The glands or corpuscles of Pacchioni, very inconsiderable in the fœtus, develop in proportion to the age, and are most numerous in old persons. It is precisely this circumstance which has caused their presence to be looked upon by Meckel, Portal, and Blandin, as a pathological condition. They are found in the greatest number, along the sinuses—especially

<sup>1</sup> Vena magna Galeni.



the superior longitudinal sinus—around the embouchures of the cerebral veins; at the superior and internal portion of the hemispheres of the cerebrum, and at some other spots on the superior and inferior regions of that organ; as well as upon the antero-superior part of the cerebellum. These granulations have the form of millet-seed, and are principally found in the sub-arachnoid cellular tissue; it very often happens, however, that they protrude the arachnoid and dura mater, and impress small hollows for themselves in the cranial vault, principally, along the side of the superior longitudinal groove in the parietal bones; although such excavations may likewise be met with in the frontal, occipital, and even in the petrous portion of the temporal bones.

The ancients, who were acquainted with these osseous depressions, considered them as indications of caries of the bone, but, in the present day, one has a more definite idea of them; they are simply the result of the presence of these small granular clusters in their vicinity, which by degrees produce the hollows, in the same manner that drops of water, falling from a certain height and during a considerable length of time, ultimately indent rock. It sometimes even happens, that these granulations completely perforate the bone, and project on the exterior beneath the hairy scalp: they are those small tumours, the removal of which must not be attempted; and which besides, may be, in some measure, distinguished from others, by their antero-posterior position on either side of the median line of the cranium.

#### STRUCTURE.

Until of late, there did not exist any well-defined insight into the structure of these corpuscles. Pacchioni was the first who looked upon them as small glands, whence their name. Ruysch, having regard especially to their colour and to their seat in the cellular tissue, considered them as globules of fat. Microscopical investigations, however, show us, that each granulation, simple or lobulated, is formed on its surface, by a layer of laminar tissue with fibres intercrossed in all directions, and in the centre, by small islets composed principally of phosphate of lime, a little carbonate, and traces of silica; the whole, mixed with fatty granules, now and then containing some small blood-vessels. These granulations present a short pedicle, simple or multiple, formed of fibres and of pretty dense laminar tissue. The opinion most generally adopted at present is, that these granulations are produced as a result of the changes which old age induces, and appertain to the signs of senility.

#### MEDULLARY OR SPINAL PIA MATER.

(*Pia mater spinalis.*)

See Plates IX. and X.

The medullary division of the pia mater is the continuation of the cerebral portion of that membrane, although it differs from the latter, by reason of the fibrous element being much more considerable in it than in the cerebral pia mater. Indeed, the spinal pia mater bears, evidently, the characteristics of the fibro-vascular membranes.

At the inferior part, this membrane is thicker than at the superior, where it becomes gradually thinner in order to blend with the cranial pia mater. The spinal pia mater, which is found inside the arachnoid, immediately surrounds the marrow, and is prolonged over the roots of the spinal nerves, forming in this manner their neurilemma. It is not separated from the medulla like the other meninges; but, on the contrary, is applied upon it, exercising over its surface a certain pressure; of which one may convince one's self when the pia mater has been cut or injured, since the substance of the marrow, under such circumstances, immediately protrudes from the aperture, forming a kind of hernia.

*Caudal Ligament.*—The spinal pia mater terminates in the lumbar region by assuming the form of a thin cord, having the appearance of an infundibulum with the base turned upwards. This cord, described under the name of the *caudal* or *coccygean ligament*,<sup>1</sup> accompanied by a small vein, traverses the lumbar and sacral regions, in the midst of the cauda equina, and terminates, ordinarily, at the base of the coccyx, where it is inserted. It happens sometimes, however, that this small cord has not so extended a course, but blends, ere that, with the dura mater in the sacral region. The ancient anatomists considered this cord as an azygous nerve; nevertheless, it is sufficient to observe, attentively, that its sur-

<sup>1</sup> Sometimes also, called *filum terminale*, although perhaps this term should be reserved, in preference, for the thin thread of nervous substance which this portion of the pia mater contains for a considerable distance.



face is pearly and opalescent, and that it constitutes only the prolongation of the pia mater, of which it exhibits the texture, to be convinced that their opinion is evidently erroneous. This caudal ligament, or infundibuliform cord, hollowed at its upper portion, encloses, however, grey substance and some slender nervous fibres.

#### EXTERNAL SURFACE OF THE SPINAL PIA MATER.

Surrounded on all sides by the sub-arachnoid fluid, this surface is remarkable for a vascular network, formed by the medullary arteries and veins, which project on the exterior of the membrane. These vessels are single, and traverse the middle of the pia mater, at its anterior part; but are, on the contrary, double at its posterior portion, where they direct themselves on each side of the roots of the spinal nerves. There may likewise be observed transverse rugæ, united between themselves by the intervention of oblique ones. The external surface of the pia mater is attached to the arachnoid, as we have already observed, by sub-arachnoid cellular tissue, which forms behind and on the median line, a kind of vertical partition, which does not, however, prevent the commingling of the fluid enclosed on either side. Laterally, between the roots of the spinal nerves, the external surface of the pia mater is connected with the dura mater through the medium of the denticulate ligaments, which are considered by some anatomists as dependencies of the pia mater. In this work, however, confiding in the reasons propounded in connexion with the spinal dura mater, we have placed the description of those ligaments in the account of that membrane.

The dentate disposition of the ligaments, is the means whereby the fluid of the anterior part of the spinal sub-arachnoid space intermingles with that of the posterior, the cavities being continuous through the intervals between the serrations.

#### INTERNAL SURFACE OF THE SPINAL PIA MATER.

This surface sends numerous prolongations into the thickness of the marrow, by the fissures which are found on its surface. In the anterior median fissure, the process is double,—that is to say, it lines the bottom and the two sides of it. With the other fissures, the prolongations are simple. Furthermore, in order to have a perfect idea of the internal surface of the spinal pia mater, it is necessary to have recourse to the processes described elsewhere in the work.<sup>1</sup>

#### STRUCTURE OF THE SPINAL PIA MATER.

The spinal pia mater is composed of condensed connective tissue, with parallel longitudinal fibres, which are interlaced with elastic ones. The number of vessels included in its thickness, although very considerable, is, however, less than in the encephalic pia mater; particularly, since they only traverse the membrane, in order to pass, ultimately, into the spinal cord.

#### VESSELS AND NERVES.

*Arteries.*—The arteries of the spinal pia mater proceed from the vertebral artery of each side; and constitute, the anterior spinal branch, occupying the middle of the anterior surface of that membrane, as well as the posterior spinal branches, which, as we have already seen, traverse the lateral portions of its posterior surface.

*Veins.*—These emerge from the posterior fissures of the marrow, and, after having united amongst themselves, form a species of plexus or network. From this plexus proceed, at the level of each pair of spinal nerves, small branches, directing themselves between the roots and within the sheaths furnished by the dura mater. Then, having gained the intervertebral foramina, after having made their exit from the sheaths, they inosculate with the larger veins which are found in those apertures.<sup>2</sup>

As for the lymphatics and nerves of this portion of the membrane, we can but repeat what has been said above with regard to them, in connexion with the encephalic pia mater, and for this reason, the reader is referred there.

<sup>1</sup> Method of Dissecting-Anatomical Preparations, p. 13\*.

<sup>2</sup> It is worthy of remark, that these medullary-spinal veins, although communicating with the other spinal veins, and generally considered, like them, to be unprovided with valves, appear, nevertheless, to be incapable of injection with the latter, even when the process is most successful.



## CENTRAL NERVOUS SYSTEM.

## A.—ENCEPHALON OR BRAIN.

The brain is all that part of the nervous centre which is enclosed in the cranial cavity, and constitutes the superior portion of that centre. It is a soft, whitish and greyish mass, ovoid, irregularly flattened in a part of its extent, and having the posterior extremity more bulky than the anterior.

*Volume.*—The mass of the brain, which is proportionably more considerable in man than in animals, is, in like manner, greater in the child than in the adult, in the male than in the female, but it becomes atrophied in old people. Its configuration is relative to that of the cavity which contains it.

*Dimensions.*—The size of the brain is, on an average, 16 centimetres<sup>1</sup> in its longitudinal, 13·5 centimetres<sup>2</sup> in its transverse, and 12 centimetres<sup>3</sup> in its vertical diameters; but this last admeasurement is applicable only to the middle portion, where the brain presents its greatest development.

*Weight.*—Its average weight in the male is 1·468 kilogramme,<sup>4</sup> and in the female 1·345 kilogramme.<sup>5</sup>

*General appearance.*—Independently of the osseous case which environs it on all sides, the brain is in relation with a triple membranous envelope (*meninges*) which surrounds it entirely. Stripped of its membranes, it is observed to be channelled over its whole surface by a great number of furrows, more or less deep, which circumscribe as many oblong elevations variously contorted: the furrows are called *anfractuosités* (*sulci*), the elevations *convolutions* (*gyri*).

The brain is composed of three portions: the cerebrum, the cerebellum, and the mesencephalum.

There may be distinguished in it a superior and external region (convexity), irregularly convex, which corresponds to the cranial vault; an inferior region (base), alternately convex and concave, which reposes upon the base of the cranium;<sup>6</sup> and lastly, an internal region. The convexity is exclusively constituted by the cerebrum; the base, by the cerebrum, the cerebellum, and the mesencephalum, which communicate between themselves and with the medulla spinalis, by means of prolongations called peduncles; while the internal region, straight and vertical, forms with that of the hemisphere of the opposite side, the vertical antero-posterior median fissure.

<sup>1</sup> Very nearly 6·3 inches.

<sup>2</sup> A trifle over 5·3 inches.

<sup>3</sup> Somewhat more than 4·7 inches.

<sup>4</sup> 3 lbs. 3 oz. 12·524 dr. avoirdupois.

<sup>5</sup> 2 lbs. 15 oz. 7·105 dr. avoirdupois.

<sup>6</sup> It is well to observe here, that the base of the brain—excepting, perhaps, the part over the orbital plates of the frontal bone—does not come into apposition with the corresponding portion of the skull, the membranes only intervening, but is separated from it by a stratum of cerebro-spinal fluid, forming a species of water-bed; which, in coadjuvancy with the disposition of the internal layer of the dura mater, protects the delicate nervous substance from contact with the hard surface, and from collision with the salient projections there situate, as well as prevents that unequable distribution of pressure upon the vessels in that region, which would otherwise occur. Indeed, the whole nervous axis with its immediate investing meninx, would, on consideration, appear to be suspended in the fluid enclosed by the arachnoid, in such a manner, that the excess of weight, representing the sum of the difference between the specific gravity of the former as a whole and that of the latter in an equivalent bulk, is sustained by the connecting medium between the two membranes; so that, no matter where upon the surface of the nervous mass vessels may be situate, or what posture the body may assume, the pressure upon them holds a like proportion at the same moment. This beautiful arrangement, which, by means of a greater elongation of the connecting medium between the membranes, admits of the accumulation of sub-arachnoid fluid in larger quantity beneath the lower part of the brain, and more particularly at the localities termed confluences, has received additional interest from the consideration of the mode in which vibrations propagated along the cranial parietes converge towards the bony processes of the base, and are there lost by dispersion in this fluid,—as has been very clearly and admirably shown by Mr. Hilton (*vide* Notes from his Lectures “On the Cranium,” edited by Dr. Pavy); thus rendering, what would at first sight appear to be a conformation fraught with danger to the nervous centre, an element of the greatest security to it.



## MANNER OF STUDYING THE BRAIN.

It is recognised in all quarters, even by those who are but little conversant with the science of anatomy, that a perfect knowledge of the brain appertains to the problems most difficult of solution, on account of the very complex structure of that organ. Nevertheless, in order to demonstrate that no difficulty is insurmountable to him who has the fixed determination to fathom any subject whatsoever, anatomists of all ages have sought, by divers methods, to simplify the description of it.

It is not our intention to study comparatively the value or the imperfection of all those methods which have been proposed up to the present day, since such an enterprise would occupy us too long, and besides, would not come within the scope of our design. We will restrict our attention, therefore, to the three most usual.

1st. *Embryological Method*.—This is founded on the progressive knowledge of the development of the primordial vesicles of the encephalon, and has MM. Carus, Coste, and Reichert for its promoters. But this method, in conjunction with the modifications which have been introduced into it by Meckel, requires vast knowledge of embryology and of comparative anatomy; so we will not enter into any development.

2nd. *Method of Vieq d'Azyr*.—It consists, according to this anatomist and his partisans, in studying the brain by proceeding in the direction from the convexity towards the base, by means of horizontal sections disposed in layers,—but to the detriment of its different organs, the mutual situation of which they alter.

3rd. *Method of Varolius*.—Proposed originally by this anatomist, it acquired great value in the time of Gall and Spurzheim, and their disciples in cranioscopy; and even in the present day, it is still preferentially followed by some anatomists.

These illustrious *savants* fixed their entire attention upon the mutual relations of isolated parts only; and hence, they were led to study the brain in the direction from below upwards, that is to say, from the base towards the convexity, commencing at the medulla.

Far from me be the idea of contesting the merits of these methods: I will take the liberty, however, of censuring the second for not giving, so to speak, anything but a topographical description of the brain, neglecting the considerations which are associated with the reciprocal connexions of its constituent parts. Furthermore, in studying the brain by layers, the principal organs are subdivided, changing at every cutting the aspect of each preparation.

As for the third, that is, the method of the cranioscopists or phrenologists, which is also that of the most modern French authors, it has almost exclusively for its aim the study of the different connexions of the organs, and the following of the prolongations of the columns of the cord through the encephalic intumescences, but takes, however, small account of the topography.

It hence results that, instead of diminishing the difficulties inherent to a study so intricate as that of the brain, nothing but complication has ensued.

And in connexion with this, it is well to remember the words of the learned Burdach: "*Anatomia capitis caput anatomie est.*"

My direct and daily intercourse with students having given me an opportunity, in my demonstrations, of estimating the relative value of these two latter methods, and of insisting principally upon that of Varolius, which appeared to me to be the best; it has been easy for me to observe, that my pupils had much trouble in comprehending and in recollecting the description of the divers parts of the brain. The study of one organ, obliging me to speak with them at the same time concerning a great number of others, which they had never seen, the nomenclature of which, so varied and so difficult, diverted attention from the principal subject, there ultimately remained in their minds only vague and confused ideas, with very superficial anatomical notions of the encephalic nervous centre.

Accordingly, in order to simplify the very complex study of the brain, it has appeared to me necessary:—

1. To give at the outset, general ideas of all that can be observed on the surface, by simple diducement of parts and without the assistance of a cutting instrument.

2. To penetrate in the next place further, so as to expose the hidden organs, by means of simple sections made from the convexity towards the base, or from the base towards the convexity.



3. To proceed—after having thus initiated the pupils in the nomenclature of the organs, and given them a knowledge of the external conformation and relative position of each—to the more complex study of those organs; this time—by the assistance of elaborate sections made upon quite fresh brains, or preparations preserved in suitable liquids, such as spirit of wine or chromic acid—to show their intimate connexions, and to follow, by various proceedings, the different prolongations of the cord through the encephalic intumescences.

This method, which appears to offer indisputable advantages over the three others, is that which we have adopted in the study of the brain, and to which the requisite elucidation is at once about to be given.

I. GENERAL SKETCH OF THE CONSTITUENT PARTS OF THE BRAIN STRIPPED OF THE PIA MATER, AS THEY MAY BE OBSERVED BY SIMPLE DIDUCEMENT AND WITHOUT THE ASSISTANCE OF A CUTTING INSTRUMENT.

SUPERIOR REGION OR CONVEXITY OF THE BRAIN.

*Interlobar<sup>1</sup> or longitudinal fissure.*—A deep antero-posterior median fissure (*vide* Pl. XXIV., Fig. 1) divides the convexity of the brain into two equal and semi-oval portions, called, improperly, *cerebral hemispheres*, and better, *lobes of the cerebrum*.<sup>2</sup> These lobes are not always symmetrical, but this want of symmetry exercises no detrimental influence over the intellectual development, as has been asserted by Bichat;—the best proof of which was given by his own cerebrum, which was not remarkable for its symmetry; and yet, certainly, no one would think of disputing the immense talent and well-balanced intelligence of this illustrious man. By gentle diduction of the lobes, it will be observed that, although completely separated along the whole extent of the convexity by the great median fissure, these same lobes are connected towards the middle portion, but nearer the base than the convexity, by a whitish body, almost central, with transverse and longitudinal fibres, which serves as a means of union or commissure between them: this is the *corpus callosum*.<sup>3</sup>

To either side of the median line, between the lateral portion of the superior surface of the corpus callosum and the inferior surface of the antero-posterior convolution superposed to this commissure, may be noticed an antero-posterior longitudinal excavation;—these are the *ventricles or sinuses of the corpus callosum* (*sinus corporis callosi*), which certain anatomists have compared to the ventricles or sinuses of the larynx.

INFERIOR REGION OR BASE OF THE BRAIN.

The base of the brain presents for consideration (*vide* Pl. XXIV. Fig. 2), the inferior surface of the lobes of the cerebrum, of the cerebellum, and of the mesencephalum.

*Fissures of Sylvius.*—A transverse fissure, curvilinear and deep, called the *fissure of Sylvius*, and in relation, on either side, with the posterior margin of the corresponding lesser wing of the sphenoid bone, divides, on a line with its anterior third, each lobe into two unequal portions. The portion which is anterior to this fissure is slightly concave, and rests upon the orbital roof, constituted principally by the frontal bone: this is named the *anterior or frontal lobule*.<sup>4</sup> The portion posterior to this fissure, much larger than the other, since it constitutes

<sup>1</sup> The use of this term depends upon the Author's remark in the sentence immediately succeeding it, as well as upon the alterations in the ordinary nomenclature which would arise from the adoption of the amendment there proposed. I have, however, thought it necessary to add after it here, and to substitute for it elsewhere, the designation *longitudinal*, whereby this fissure is constantly characterized in this country.

<sup>2</sup> As the carrying out of this perhaps somewhat hypercritical emendation would be a source of much confusion and misunderstanding in cases of casual reference to the work, at other than this part where the change is explained, I have found it advisable, except in the paragraph to which this note refers and the third following it—which are quite adequate to the explanation of the Author's system—to translate into the term *hemisphere*, in all instances where the word *lobe* is altered in its ordinarily accepted signification; in some cases, however, as that which occurs in one of the paragraphs intervening between those referred to, it will be perceived that change is unnecessary. See also note <sup>4</sup>, *infra*.

<sup>3</sup> Also called *commissura magna*, and occasionally, *trabs cerebri*.

<sup>4</sup> The term *lobe* is almost invariably applied to this and the two after-mentioned subdivisions of the *hemispheres*; but, in the case of the latter being so called, as in the above portion of the text, the diminutive must necessarily be used for the former. In all other portions of the work, except the above paragraph—which is in relation with the change consequent on the Author's previous remark (see note <sup>2</sup>, *supra*), but to which, it may be observed, he by no means constantly adheres—the appellation *lobule*, as referring to these three parts of either hemisphere, has always been rendered *lobe*.



the two posterior thirds of the lobe, is also hollowed out by an excavation, which corresponds to the cerebellum, and from which it is separated by the tentorium: this is the *posterior lobe* of some anatomists. The anterior extremity of this lobe, which is lodged in the lateral portion of the middle fossa of the base of the skull, or sphenoidal fossa, is described under the name of the *middle* or *sphenoidal lobule*. Its posterior extremity, situate in the superior occipital fossa, is called the *posterior* or *occipital lobule*.

The internal extremity of the fissure of Sylvius of either side, unites, at a right angle, with a great fissure which has the form of a horse-shoe, and which is called the fissure of Bichat; but externally, this fissure bifurcates into an anterior and a posterior branch. The anterior, the smaller, constitutes its continuation; the posterior, considerably longer, terminates by passing upwards and backwards upon the convexity of the cerebrum.

By slightly raising the middle lobe, there will be observed at the bottom of the fissure of Sylvius (Pl. XX., Fig. 1):—1st. At the inner end, a whitish space riddled with vascular foramina,—this is the *white perforated substance of Vieq d'Azyr*, or *lateral perforated space*;<sup>1</sup> 2nd. Outwardly, a triangular lobule covered with convolutions,<sup>2</sup> five or six in number, having a free summit, and the base incorporated with the frontal and sphenoidal lobes,—this is the *island of Reil*, or *lobule of the corpus striatum*.

*Great cerebral fissure of Bichat.*—Intervening between the two fissures of Sylvius, this cleft is consequently directed from one cerebral hemisphere to the other. It has the form of a horse-shoe, the concavity of which is turned forwards and embraces the cerebral peduncles, passing beneath the splenium of the corpus callosum.

It is through this interval that the pia mater penetrates into the depth of the cerebrum to form the internal pia mater, as we have already seen higher up. In the cerebral fissure of Bichat may be distinguished a transverse or horizontal portion, which is continuous, on each side, with an antero-posterior part, that unites in its turn with the Sylvian fissure.

The transverse portion, existing between the splenium of the corpus callosum and the tubercula quadrigemina, is easily discovered in its whole extent, by raising the cerebellum from the cerebrum—which is now resting upon its convexity; of course, after having previously destroyed in this region certain attachments of the pia mater, as well as the arachnoidean canal of Bichat. It is then easy to see the reflexion of the pia mater into the interior of the cerebrum, which here becomes continuous with the velum interpositum and the choroid plexuses of the middle or third ventricle.

The antero-posterior portion of the cerebral fissure of Bichat, is formed, on either side, by an oblong projection called the *convolution of the cornu Ammonis*;<sup>3</sup> the anterior extremity of which, curving upon itself in the form of a hook, on a line with the lateral perforated space, is called the *uncinate ganglion* (*ganglion uncinatum*).<sup>4</sup>

The convolution of the cornu Ammonis, conjointly with a whitish bandlet which is attached to it, and which is called the *corpus fimbriatum*, forms the inferior boundary of this portion of the cerebral fissure of Bichat; the superior boundary, is constituted by the optic thalamus and the external surface of the cerebral peduncle, contiguous to the posterior and inferior part of which, are the corresponding corpora geniculata and the optic tract.

The antero-posterior portions of the cerebral fissure of Bichat convey the pia mater to the descending cornua of the lateral ventricles, where it is continuous with the choroid plexuses.

*Great longitudinal fissure.*—In the median line, the two hemispheres are separated, in front and behind, by the *great vertical antero-posterior median* or *longitudinal fissure*. By separating the frontal lobes, the anterior extremity of the corpus callosum will be observed (Pl. XVII., Fig. 3) to reflect itself from the convexity towards the base, forming the knee or *genu*, and the beak or *rostrum*, of that commissure. Immediately behind this, is the *chiasma*, or *commissure of the optic nerves*. If that be reflected from before backwards, it will be noticed that the rostrum of the corpus callosum is composed of three portions: two lateral and one

<sup>1</sup> More usually called, in this country, *locus perforatus anticus*; sometimes also, *substantia perforata*.

<sup>2</sup> *Gyri operi*.

<sup>3</sup> This is the inferior and posterior portion of the convolution of the corpus callosum, or *gyrus fornicatus*, which, projecting also internally, constitutes along the floor of the descending cornu of the lateral ventricle, the elevation called the *hippocampus major*.

<sup>4</sup> It is this part of the convolution which forms at the extremity of the descending cornu of the lateral ventricle, the nodulated projection upon its inferior boundary known as the *pes hippocampi*.



median. The lateral, rounded, bearing the name of *peduncles of the corpus callosum of Vieq d'Azyr*, direct themselves outwards, each towards the corresponding lateral perforated space, where they terminate by slow degrees. The middle portion, blends with the commissure of the optic nerves, by the intervention of a slightly greyish lamina called supra-optic,<sup>1</sup> sometimes perforated, which concurs in forming the anterior boundary, or anterior portion of the floor, of a cavity called the *third ventricle*. Behind the commissure of the optic nerves, is found (Pl. XXIV., Fig. 2) a grey substance, called the *tuber cinereum*, which is continuous with a small greyish stalk, called the *infundibulum* or *pituitary pedicle*, which is connected with the *pituitary gland*. Further back will be remarked two whitish projections, of the size of a pea: they are the *mammillary* or *pisiform tubercles*;<sup>2</sup> and behind these latter, are the triangular perforated lamellæ, which form the *substantia perforata media*, or *median perforated space*.<sup>3</sup> All these parts just enumerated, occupy a hexagonal excavation, bounded in front, by the most posterior portion of the frontal lobes; at the sides, by the sphenoidal lobes; and behind, by a considerable enlargement, called the *annular protuberance*, or *pons Varolii*. This hollow is the median fossa of the brain, which encompasses the arterial hexagon.

The six angles of this excavation correspond to as many furrows or fissures, which are: 1st. The anterior angle, to the great longitudinal fissure; 2nd. The posterior angle, to the groove along the pons Varolii and to the median perforated space; 3rd. The anterior lateral angles, to the fissures of Sylvius; and 4th. The posterior lateral angles, to the antero-posterior portions of the cerebral fissure of Bichat. It is this hexagonal hollow which has been just described, that, invested by the pia mater, forms with the arachnoid the anterior sub-arachnoid space.

From the anterior part of the lateral segments of the annular protuberance, emerge two large, white, fasciculated columns, that direct themselves forwards, divergently, towards the hemispheres of the cerebrum, into which they penetrate: these are the *cerebral peduncles*, or *crura cerebri*; they are crossed obliquely by two medullary bands, thin and white, called *bandelets of the optic nerves*, or *optic tracts*, which, taking origin posteriorly, on either side, from two eminences called *corpora geniculata*, direct themselves forward, converging, to form the chiasma, or optic commissure.

The peduncles of the cerebrum and the optic tracts bound a lozenge-shaped space,<sup>4</sup> in which may be observed, from before backwards,—the *tuber cinereum* and its *infundibulum*, the *mammillary tubercles*, or *corpora albicantia*, and the *median perforated lamellæ*, or *locus perforatus posticus*. The ensemble of all these parts constitutes the *inferior boundary* or *floor of the middle or third ventricle* of the brain.

To the sides of the pons Varolii, and a little backward, will be distinguished two hemispherical parts: they are the *lateral lobes* or *hemispheres of the cerebellum*. An attentive examination of the anterior portion of the circumference, renders it evident that they are connected with the annular protuberance by means of two whitish and fasciculated processes: these are the *middle peduncles of the cerebellum*, or *processus cerebelli ad pontem Varolii*.

Behind the annular protuberance, between the hemispheres of the cerebellum, can be noticed: the *cranial intumescence of the medullary cord*,<sup>5</sup> *medulla oblongata*, or briefly *bulb*, separated from the protuberance by a superficial furrow, transverse and curvilinear, in which are inserted the sixth pair of cranial nerves. From the middle of this furrow starts, at a right angle, another furrow, which is continuous with the anterior median fissure of the spinal cord. The sides of this furrow are formed by the *anterior pyramids*. To the outer side of each of the latter is another furrow, which is continuous with the corresponding anterior lateral fissure of the spinal medulla, and in which is inserted the great hypoglossal nerve. Further outwards, the

<sup>1</sup> More generally known as the lamina cinerea.

<sup>2</sup> Ordinarily named corpora albicantia seu mammillaria, also, sometimes, bulbi fornicis.

<sup>3</sup> Usually called locus perforatus posticus, and occasionally, pons Tarini.

<sup>4</sup> Commonly described as the interpeduncular space.

<sup>5</sup> Given as either *e* or *a cerebello* by the majority of anatomists, not only with reference to the above, but as regards all the other peduncles of that organ.

<sup>6</sup> This most important part of the cerebro-spinal axis is termed by the Author "*bulbe rachidien ou crânien*," which appellation I have here and elsewhere thus rendered,—the designation *medullary cord* being intended to apply to all that portion of the medullary or nervous centre which extends downwards from the pons Varolii; but, in order to avoid misunderstanding, I have found it necessary in all cases, either, as in the present instance, to supplement this definition of the part by the term "*medulla oblongata*," which is invariably assigned to it in this country, or to render the French appellation at once by its English synonym. For further information connected with this subject, see the foot-note, page 1.



# METHOD OF DISSECTING ANATOMICAL PREPARATIONS

AS REPRESENTED

## PLATES 1 AND 2.

### Vertebro-cranial dura mater.

FIGURE 1.—*Posterior aspect*.—Clear the posterior surface of the skull and vertebral column of soft parts; then remove the back portion of the cranium, previously separated by a semicircular section, commencing at the hinder end of the sagittal suture, and terminating at each extremity, in a horizontal line dividing the two condyles of the occipital bone. By another section, made on each side of the vertebro-sacral column through the laminae, in the line of the bases of the transverse processes, the posterior segments of the vertebrae and of the sacrum are also to be removed.

For the latter purpose, either a mallet and chisel may be used; or a saw with a double parallel blade; or a strong knife, with a convex cutting edge, and a back sufficiently thick to stand the repeated stroke of a hammer; or lastly, the rachitome devised by myself.<sup>1</sup>

FIGURE 2.—*Anterior aspect*.—Remove the three anterior fourths of the thorax and pelvis with a saw. Completely clear the anterior surface of the vertebral column and sacrum of soft parts, as if for the dissection of the anterior common ligament of the vertebrae; saw the spine, in its whole length and on each side, through the pedicles of the vertebrae, or cut them with the rachitome, in order to remove the bodies of all the vertebrae, including the false ones of the sacrum, so that the anterior surface of the spinal dura mater may be thoroughly laid bare. To demonstrate the continuity of the spinal with the cranial dura mater, the cranium must be sawn across vertically, in the course of a line commencing at the middle of the inner margin of the occipital condyle of one side, passing through a point corresponding to the posterior angle of the anterior fontanel, and terminating as it began in the opposite occipital condyle.

---

<sup>1</sup> The "Rachitome of Hirschfeld" may be obtained either of M. Mathieu, Paris; or of Mr. Millikin, surgical instrument maker to Guy's and St. Thomas's Hospitals, Southwark-street, London, S.E.



## EXPLANATION OF PLATES 1 AND 2.

### Vertebro-cranial dura mater.

The first and second figures are principally intended to show the external surface of the spinal dura mater (theca vertebralis), and its continuity with that of the cranial dura mater. The whole, containing the medullo-encephalic nervous centre, and all the nerves at their origin, is lodged in the vertebro-cranial cavity, of which half the parietes have been removed.

The third figure represents the spinal dura mater disengaged from the osseous canal, opened in its whole length, and stripped from the marrow, for the purpose of exhibiting the internal surface of that membrane, as well as its lateral prolongations in the shape of sheaths.

**FIGURE 1.—Posterior aspect.—Accessory Parts.**—From *a* to *a*, semicircular section of the cranium and corresponding soft parts.—*b*, Posterior half of the atlas, showing its adherence to the dura mater.—From *c* to *c* (left side), section of the laminae of the six inferior cervical vertebrae.—From *d* to *d*, section of the laminae of the twelve dorsal vertebrae.—From *e* to *e*, section of the five lumbar vertebrae.—From *f* to *f*, section of the consolidated laminae of the sacral false vertebrae.—From *g* to *g* (right side), section of the seven cervical vertebrae, made so as to lay bare the vertebral artery.—From *h* to *h*, double section through the pedicles and transverse processes of the dorsal vertebrae.—*i*, *i*, Posterior costo-transverse ligaments.—*k*, *k*, Anterior (or inferior) costo-transverse ligaments, separating the posterior from the anterior branches of the dorsal nerves.—*l*, *l* (left side), External intercostal muscles.—From *m* to *m*, ribs and intercostal spaces.—*n*, Quadratus lumborum.—*o*, *o*, Lumbar intertransversales muscles.

**Vascular System.**—A. Superior longitudinal sinus.—B. Projections of glandulae Pacchioni.—C, C. Lateral sinuses.—D, D. Occipital sinuses.—E. Torcular Herophili.—F, F. Ramifications of the middle meningeal arteries.—G, G. Posterior meningeal arteries.—H. Vertebral artery, with its two principal curves. The canal for it is laid open to show its relations with the cervical nerves.

**Nervous System.**—1. External surface of the cranial dura mater.—2, 2. Portion of that membrane covering the cerebrum; and 3, 3, the same covering the cerebellum.—From 4 to 4, external surface of the spinal dura mater.—5, 5, 5, 5. Spinal ganglia.—From 6 to 6, anterior branches of the eight cervical nerves; and 7, their posterior branches.—8, 8. Anterior branches of the dorsal nerves; and 9, 9, their posterior branches.—10, 10. Anterior branches of the lumbar nerves; and 11, 11, 11, their posterior branches.—12, 12. Anterior branches of the sacral nerves; and 13, 13, their posterior branches.

**FIGURE 2.—Anterior aspect.—Accessory Parts.**—From *a* to *a*, semicircular section of the integuments, muscles, and bones of the cranium.—From *b* to *b*, sec-

tion of the transverse processes of the seven cervical vertebrae.—From *c* to *c*, section of the bases of the transverse processes of the dorsal vertebrae, and of the corresponding extremities of the twelve ribs.—From *d* to *d*, section of the transverse processes of the lumbar vertebrae.—From *e* to *e*, section of the sacrum in the line of the anterior sacral foramina.—*f*, Section of the sterno-cleido-mastoideus.—*g*, Scalenus anticus.—*h*, Scalenus posticus.—*i*, *i*, Intercostal muscles.—*j*, *j*, Quadratus lumborum.—*k*, Psoas magnus and parvus.

**Vascular System.**—A. Anterior meningeal artery.—B. Middle meningeal artery.—C. Internal carotid artery.—D. Vertebral artery.

**Nervous System.**—1. Cranial dura mater, covering an anterior lobe of the cerebrum.—2. The same membrane upon a middle lobe.—3. *Id.*, in front of the pons Varolii and medulla oblongata.—4. Process of the dura mater which traverses the sphenoidal fissure to form the periosteum of the orbital walls.—From 5 to 5, anterior surface of the spinal dura mater, extending from the foramen magnum as far as the level of the base of the coccyx, after splitting up into numerous sheaths, which encase the nerves forming the cauda equina.—6. Cervical plexus, formed by the anterior branches of the four first cervical nerves.—7. Brachial plexus, formed by the anterior branches of the four last cervical nerves and first dorsal.—From 8 to 8, anterior branches of the eleven remaining dorsal nerves.—9. Lumbar plexus, formed by the anterior branches of the three first lumbar nerves and half the fourth.—10. Sacral plexus, formed by the anterior branches of the three first sacral nerves, half the fourth, and the lumbo-sacral trunk; the latter being itself formed by the second half of the fourth and all the fifth lumbar nerve.—11. Superior portions of the glosso-pharyngeal, pneumogastric, and spinal accessory nerves.—12. Upper portion of the hypoglossal nerve.

**FIGURE 3.**—Internal surface of the spinal dura mater, with its lateral processes in form of sheaths. This surface has a glistening appearance, due to arachnoid epithelium, which lines it.



Fig. 2


Fig. 1



Fig. 3









## METHOD OF DISSECTING ANATOMICAL PREPARATIONS

AS REPRESENTED

### P L A T E 3.

#### External surface of the cranial dura mater.

FIGURE 1.—*Superior aspect*.—Make a horizontal circular section of the teguments of the skull, commencing in front immediately above the eyebrows, and passing at the level of the external occipital protuberance behind. Raise the detached soft parts; scratch through the pericranium; and fracture the cranium with the hammer-hatchet, in the direction of the line indicated. Smart blows with the hammer have over the saw the double advantage of being more expeditious, and of not lacerating the brain; indeed, the resistance of the dura mater prevents the shock from communicating itself to the encephalon. The skull once broken, in order to remove the calvaria, it is sufficient to insert the sharp edge or the hook which arms the opposite extremity of the handle, and to exert a certain amount of traction. This operation completed, the dura mater which lines the cranial vault is exposed to view.

FIGURE 2.—*Lateral aspect*.—Divide the head into two equal parts by an antero-posterior vertical section. The half of the cranium that is required to be removed ought to be detached from the dura mater piece by piece, on account of the adhesion of the cranial walls to that membrane.



## EXPLANATION OF PLATE 3.

### External surface of the cranial dura mater.

This plate exhibits the external surface of the dura mater contained in the cranial cavity, and enveloping the brain together with its two other membranes.

FIGURE 1.—*Superior aspect*.—**Accessory Parts**.—*a, a, a, a*. Section of the teguments and bones of the cranium.—*b, b*. Section of the temporal muscles.

**Vascular System**.—A, A. Branches of the middle meningeal arteries, which distribute themselves over the whole external surface of the dura mater.

**Nervous System**.—1, 1. External surface of the dura mater, covering the convexity of the cerebrum.—2, 2. Antero-posterior median elevation of this membrane, formed by the superior longitudinal sinus. A multitude of the remnants of fibro-vascular processes may be observed upon the dura mater, which produce the adhesion of this membrane to its cranial casing. These processes are best marked everywhere in the line of the sutures.—From 3 to 3, points of adhesion of the dura mater, corresponding to the sagittal suture.—4, 4. *Id.*, corresponding to the coronal suture. All these fibro-vascular *débris* give a roughened aspect to the external surface of this membrane.—5, 5. Projections of the dura mater produced by glandulæ Pacchioni.

FIGURE 2.—*Lateral aspect*.—**Accessory Parts**.—*a, a, a*. Section of the teguments and bones of the cranium.—*b*. Septum narium.

**Vascular System**.—A. Anterior meningeal artery.—B. Middle meningeal.—C. Posterior meningeal.—D. Vertebral artery, passing through the

dura mater.—E. Internal carotid, also traversing this membrane.—F. Lateral sinus, opening into the gulf of the internal jugular vein.

**Nervous System**.—1. Cranial dura mater, moulding itself upon the anterior lobe of the cerebrum.—2. *Id.*, upon the middle lobe.—3. *Id.*, upon the cerebellum.—4. Double process of the dura mater, which passes through the sphenoidal fissure and optic foramen to form the orbital periosteum and the sheath of the optic nerve.—5. Processes of dura mater in the nasal fossæ, forming sheaths for the olfactory nerve.—6. Remains of fibro-vascular processes, which establish the adhesion of this membrane to the posterior border of the lesser wing of the sphenoid.—7. Points of adhesion with the coronal suture.—8. *Id.*, with the superior border of the petrous portion of the temporal bone.—9. *Id.*, with the circumference of the foramen magnum.—10. *Id.*, with the basilar groove.—11. Superior maxillary nerve.—12. Inferior maxillary.—13. Eighth cranial. Each of these nerves, in crossing the dura mater, is surrounded with a sheath formed by that membrane; which, at its exit from the foramen at the base of the skull, becomes continuous with the external periosteum.—14. The dura mater raised from beneath by several glands of Pacchioni, and lodging itself in corresponding osseous depressions.



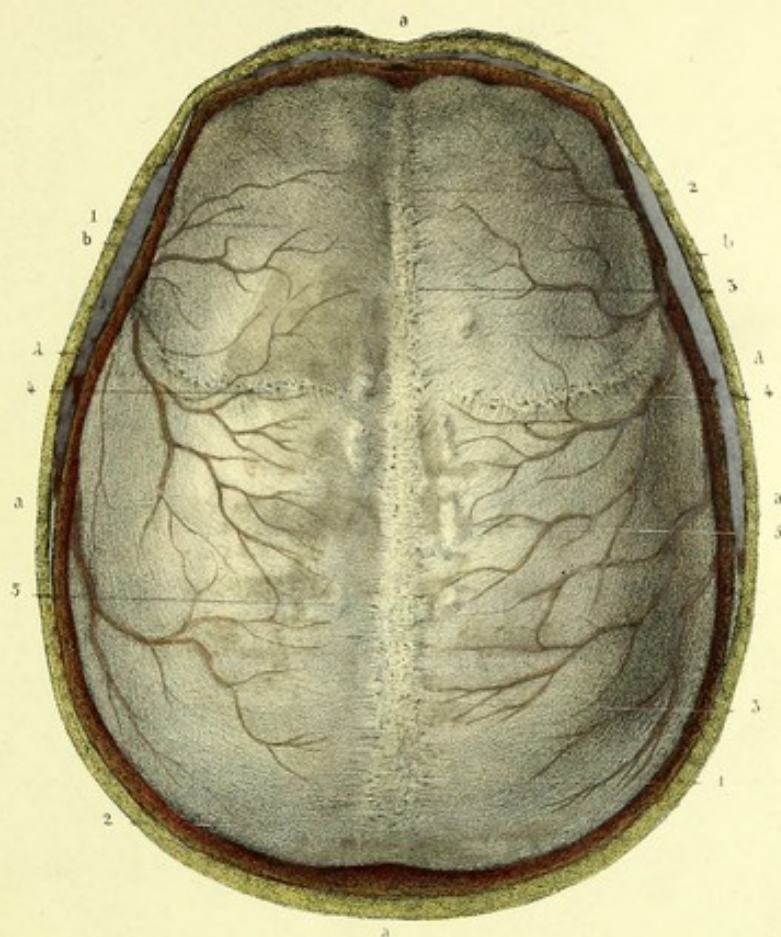
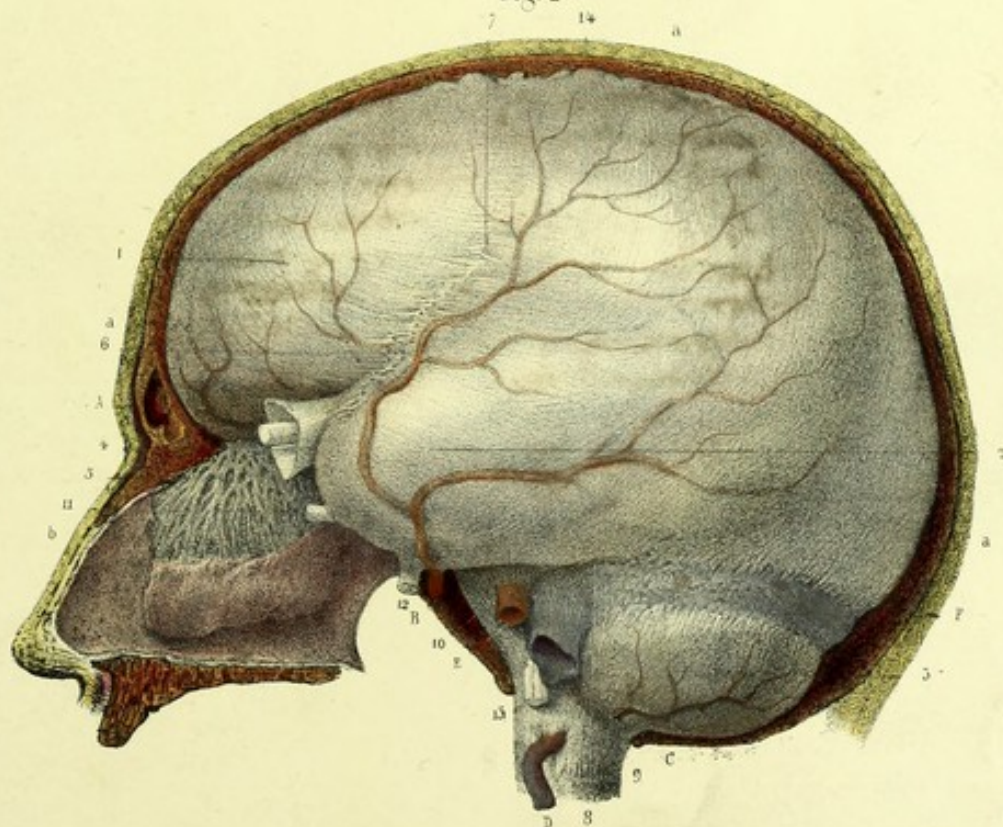



Fig. 2









## METHOD OF DISSECTING ANATOMICAL PREPARATIONS

AS REPRESENTED

### P L A T E 4.

#### Internal surface of the cranial dura mater.

FIGURE 1.—*Lateral aspect*.—Saw the cranium, previously denuded of its teguments, at about a fifth of an inch from the sagittal suture, in the direction of an antero-posterior line commencing at the root of the nose, and terminating at the external occipital protuberance; join the posterior extremity of this line by a nearly horizontal kerf directed from the external occipital protuberance to the base of the mastoid process, passing along the superior occipital curved line; continue the section in the course of another line dividing the mastoid process, the base of the styloid process, the tympanic cavity, and the three foramina sphenoidalia (spinosum, ovale, and rotundum), crossing the orbit by the sphenoidal fissure, and terminating at the supra-orbital notch or foramen.

FIGURE 2.—The same as for Figure 2, of Plate 3. In this instance the cranial cavity must be emptied of the brain, to exhibit the three reduplicatures (incomplete septa) of the dura mater, and the cerebral and cerebellar compartments lined by that membrane.



## EXPLANATION OF PLATE 4.

### Internal surface of the cranial dura mater.

The internal surface of the cranial dura mater, with its three reduplicatures (incomplete septa), designated as the falx cerebri, tentorium cerebelli, and falx cerebelli, which divide the cranial hollow into several compartments.

FIGURE 1.—*Lateral aspect*.—**Accessory Parts**.—*a, a, a*. Antero-posterior section of the teguments and bones of the cranium.—*b, b*. Nearly horizontal section of the same parts.—*c*. Section of the mastoid process.—*d*. Styloid process.—*e*. Section of the foramen ovale.—*f*. *Id.*, of the foramen rotundum.—*g*. *Id.*, of the roof of the orbit. These sections are made to show the sheaths furnished by the dura mater to the nerves.—*h*. Pterygoid process.—*i*. Maxillary tuberosity.—*j*. Glenoid fossa.

**Vascular System**.—A. Anterior cerebral artery.—B. Veins of Galen.—C, C. Superior longitudinal sinus.—D. Inferior longitudinal sinus.—E. Straight sinus.—F. Superior petrosal sinus.—G. Lateral sinus, open, and receiving the superior petrosal sinus.

**Nervous System**.—1, 1. Falx cerebri.—2. Left foliole of the tentorium cerebelli.—3. Double prolongation of the dura mater, through the foramen opticum and foramen lacerum anterius, into the orbit. The latter of these processes forms the periosteum of the orbit, the former furnishes the sheath of the optic nerve. The levator palpebræ superioris and all the muscles of the eye, except the obliquus inferior, take origin between these two processes.—4. Portion of dura mater turned aside, for the purpose of uncovering the Gasserian ganglion, lodged in the thickness of that membrane.—5. Sheath of the inferior maxillary nerve.—6. *Id.*, of superior maxillary nerve.—7. *Id.*, of ophthalmic nerve of Willis.—8. Section of the corpus callosum, showing its relations with the inferior border of the falx.—9. Pineal gland and two of its peduncles.—10. Section of the crus cerebri.

FIGURE 2.—**Accessory Parts**.—*a, a, a*. Antero-posterior median vertical section of the teguments

and bones of the cranium and face.—*b*. Outer wall of the right nasal fossa.—*c*. Aperture of the Eustachian tube.—*d, d*. Section of the atlas.—*e*. *Id.*, of the axis.

**Vascular System**.—A, A. Superior longitudinal sinus, lodged in the thickness of the superior border of the falx; and opened, in its whole extent, to show the fibrous bands (*cordæ Willisii*) which cross it in all directions.—B. The straight sinus, receiving C, the inferior longitudinal sinus, and D, the veins of Galen.—E. Torcular Herophili.

**Nervous System**.—1. Internal surface of dura mater lining one of the cerebral compartments.—2. *Id.*, lining the cerebellar space.—3. Falx cerebri.—4. Inferior surface of the right foliole of the tentorium cerebelli.—5. Falx cerebelli, stretching from the internal occipital protuberance to the foramen magnum.—6. Dura mater lining the pituitary fossa, and enveloping the pituitary body.—7. Prolongation of the dura mater into the vertebral canal. The internal surface of the dura mater differs from the external, by its smooth and polished aspect, due to the parietal layer of arachnoid epithelium which clothes it.—8. Sheaths of dura mater furnished to the olfactory nerve.—9. Optic nerve.—10. Motor oculi, or third nerve.—11. Patheticus, or fourth.—12. Trifacial, or fifth.—13. Abducens, or sixth nerve.—14. Facial and auditory nerves, or portio dura and portio mollis of the seventh.—15. The three portions of the eighth, or glosso-pharyngeal pneumogastric and spinal accessory nerves.—16. The two fasciculi which form the hypoglossal.—17. First cervical nerve, subjacent to the vertebral artery.—18. Second cervical nerve. The dura mater is crossed by all these nerves, which receive each a sheath from it.—19. Ligamentum denticulatum.











# METHOD OF DISSECTING ANATOMICAL PREPARATIONS

AS REPRESENTED

## P L A T E 5.

### Internal processes and sinuses of the cranial dura mater.

FIGURE 1.—Saw the cranium, the brain, and its envelopes, horizontally, from the frontal eminences to a point a little above the superior occipital curved line. In the preparation represented by this figure, the cerebrum has been separated from the rest of the encephalon, by a section made through its peduncles, at the level of the corpora albicantia.

FIGURE 2.—The inferior occipital fossæ and basilar groove have been cleared of the cerebellum and isthmus encephali, by a section previously made through the medulla oblongata, at the level of the foramen magnum, so as to exhibit the oval foramen. In this instance, only the central portion of the base of the cranium need be preserved.

FIGURE 3.—Completely remove the encephalic mass from the base of the cranium, by a section made through the medulla oblongata, at the level of the foramen magnum. Then, cut the tentorium and falx cerebelli along the line of their posterior border, and lay open the sinuses by section of the corresponding portion of the internal layer of the dura mater. To show the double process that this membrane sends into the orbital cavity; remove the roof of the orbit by a triangular section, the base of which comprehends the supra-orbital arch, while the apex corresponds to the optic foramen and sphenoidal fissure.

FIGURE 4.—A portion of dura mater, about 2 or 2½ inches broad, extending from nearly the middle of the sagittal suture to the foramen magnum, has been separated from the rest of that membrane. The sinuses of this region have been laid open from the external surface, by the removal of their periosteal wall.



## EXPLANATION OF PLATE 5.

### Internal processes and sinuses of the cranial dura mater.

The first and third figures exhibit the internal surface of the cranial dura mater, with the reduplications, processes, and sinuses of that membrane. Figure 1 shows the tentorium cerebelli preserved entire, and in relation with the isthmus encephali, the falx cerebri having been removed. The second figure is intended to display the foramen ovale of Pachioni, and the insertions of the extremities of the two circumferences of the tentorium cerebelli. In Figure 3, the tentorium and falx cerebelli are cut away along the line of their posterior borders, and the sinuses of the dura mater are laid open. Finally, the fourth figure exposes the cavity of the torcular Herophili and the embouchures of six sinuses.

FIGURE 1.—**Accessory Parts.**—*a, a, a.* Horizontal section of the teguments and bones of the cranium.—*b, b.* Section of the temporal muscles.—*c, c.* *Id.*, of the frontal muscles.—*d.* The crista galli.

**Vascular System.**—*A.* Internal carotid artery, cut.—*B.* Veins of Galen.—*C.* Section of the superior longitudinal sinus.—*D.* *Id.*, of the straight sinus.

**Nervous System.**—*1.* Dura mater covering the orbital plates in the anterior fossa of the base of the skull.—*2.* Attachment of the dura mater to the crista galli.—*3.* Dura mater covering the cribriform lamella of the ethmoid; the foramina in that plate are traversed by small sheaths of dura mater, which contain the ramifications of the olfactory nerves.—*4, 4.* Dura mater adherent to the processes of Ingrassias, or lesser wings of the sphenoid.—*5, 5.* Dura mater lining the middle fossa.—*6.* Tentorium cerebelli.—*7, 7.* Its posterior circumference, corresponding to the lateral grooves; and *8, 8,* to the superior borders of the petrous bones.—*9, 9.* Anterior circumference, forming with the basilar groove a parabolic space, which is the foramen ovale of Pachioni.—*10, 10.* Motores oculorum.—*11.* Optic nerve entering the optic foramen.—*12.* Commisure of the optic nerves.—*13.* Pathetic nerve.—*14.* Nerve of the tentorium cerebelli.—*15.* Corpus albicans.—*16.* Corpora quadrigemina.—*17.* Pineal gland.—*18.* Section of the third ventricle.

FIGURE 2.—**Nervous System.**—*1.* Dura mater covering the basilar groove.—*2.* Superficial layer of this membrane covering in the pituitary body, but leaving a foramen for the passage of the infundibulum.—*3.* Sheath of dura mater traversing the optic foramen.—*4.* The foramen ovale of Pachioni, formed by the lesser circumference of the tentorium cerebelli and the basilar groove.—*5, 5.* Insertions of the extremities of the anterior circumference of the tentorium at the anterior clinoid processes.—*6.* One of the extremities of the posterior circumference, subjacent to the preceding, fixing itself to the posterior clinoid process, and forming, over the apex of the petrous portion, a kind of bridge beneath which passes the fifth nerve.—*7.* Optic nerve, entering the optic foramen.—*8.* Third nerve.—*9.* Fourth nerve, entering its sheath of dura mater at

the point of intersection of the extremities of the anterior and posterior circumferences of the tentorium.—*10.* Fifth nerve.—*11.* Sixth nerve.—*12.* Ninth nerve, passing from the medulla oblongata towards the anterior condyloid foramen.

FIGURE 3.—**Accessory Parts.**—*a, a, a.* Horizontal section of the cranium and its teguments.—*b.* External rectus muscle of the eye.—*c.* Internal rectus.—*d.* Superior rectus, cut.

**Vascular System.**—*A.* Superior petrosal sinuses.—*B.* Lateral sinuses.—*C.* Inferior petrosal sinuses.—*D.* Occipital sinuses, terminating in the gulfs of the jugular veins.—*E.* Cavernous sinus, presenting in front a dilatation, named the ophthalmic sinus, and enclosing the corresponding carotid artery, sixth nerve, and cavernous plexus. Exposed on the right side, by the removal of a layer of the dura mater of the outer wall of the sinus, may be remarked, the third, fourth, and ophthalmic division of the fifth nerves, which are imbedded in its thickness.—*F.* Coronary sinus, surrounding the pituitary body.—*G.* Transverse sinus.—*H.* Extremity of the superior longitudinal sinus.

**Nervous System.**—(Left side.) *1.* Prolongation of the dura mater into the orbit, through the optic foramen and sphenoidal fissure, which forms the orbital periosteum.—(Right side.) *2.* Orbital process of the dura mater, which divides into two portions: the one, central, forms a sheath to the optic nerve; the other, peripheral, lines the walls of the orbit, and becomes continuous in front and on each side with the external periosteum.—*3.* Optic nerve.—*4.* Motor oculi.—*5.* Pathetic.—*6.* Ophthalmic of Willis.—*7.* Abducens.—*8.* Facial and auditory.—*9.* Glosso-pharyngeal, pneumogastric, and spinal accessory.—*10.* Hypoglossal.—*11.* Medulla oblongata, cut.

FIGURE 4.—**Vascular System.**—*A.* Torcular Herophili, with the embouchures of six sinuses, which are:—*B.* Superior longitudinal sinus;—*C.* Lateral sinuses;—*D.* Occipital sinuses;—and *E.* Opening of the straight sinus.



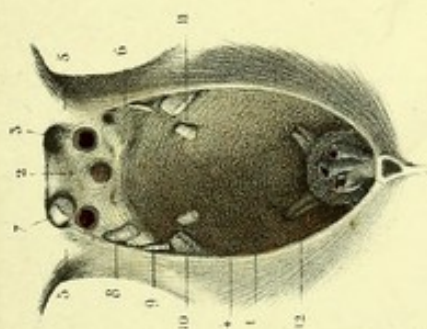
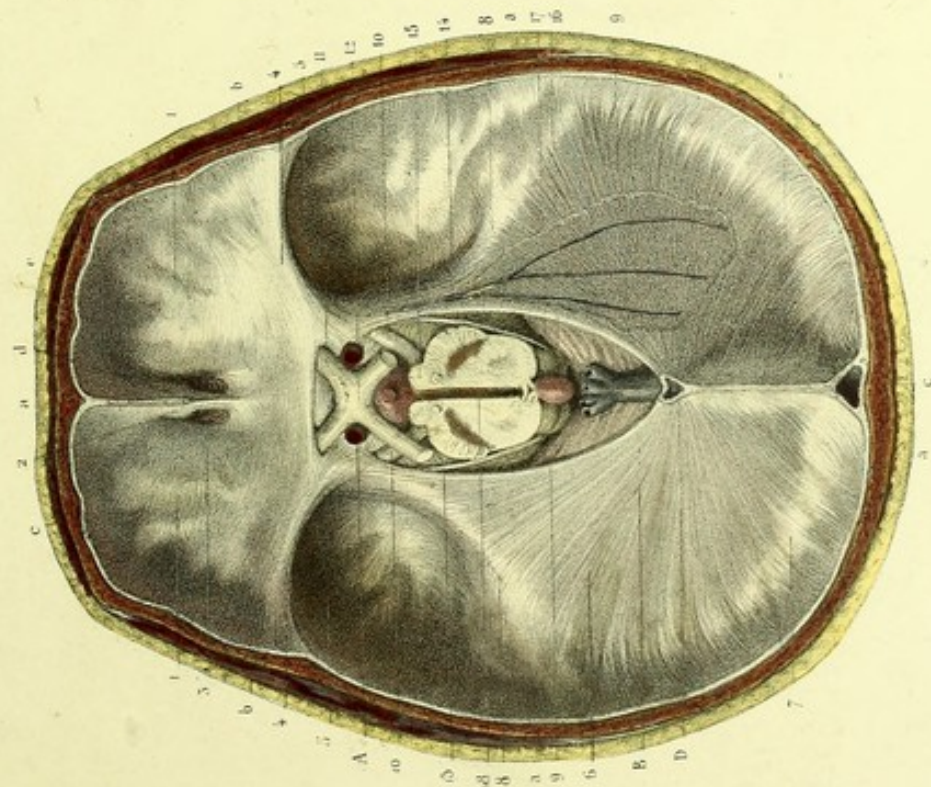
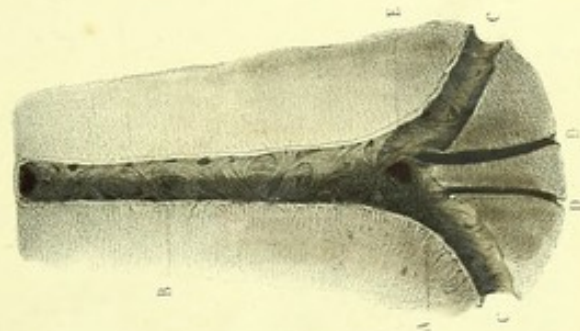


Fig. 1.



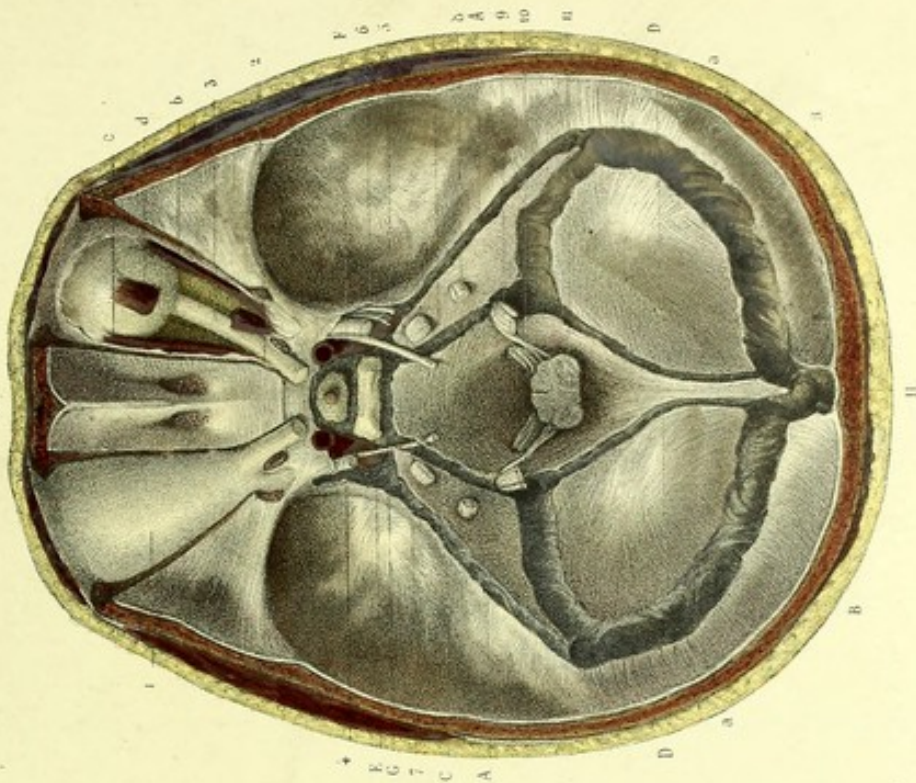
Requis d'après nature par Leveillé.

Fig. 4.




Préparé par Ludovic.

Fig. 5.



Preparé par Lemoine à Paris.







## METHOD OF DISSECTING ANATOMICAL PREPARATIONS

AS REPRESENTED

### PLATES 6 AND 7.

#### Vertebro-cranial arachnoid.

After having made preparations like those for the vertebro-cranial dura mater, as formerly described, that membrane must be divided in its whole length with scissors, and the severed portions reflected. This will bring to view the parietal layer of the arachnoid, lining the internal surface of the dura mater; and the visceral layer, which invests the nervous axis, from which it is separated by the pia mater, the denticulate ligaments, and the cerebro-spinal fluid.



## EXPLANATION OF PLATES 6 AND 7.

### Vertebro-cranial arachnoid.

The first and second figures are intended to exhibit the visceral and parietal layers of the spinal arachnoid, and its continuity with that of the cranium. The visceral layer envelops the medullo-encephalic nervous axis and the roots of all the nerves, from which it is separated by the pia mater, and by a layer of serous fluid. Through the arachnoid may be observed the ramifications of the anterior and posterior spinal branches of the vertebral arteries. The parietal layer lines the internal surface of the dura mater, to which it is intimately adherent.

The third figure is purposed to show—1st. The spinal arachnoid between the dura mater and pia mater; 2nd. The cavity containing, in the normal state, the cerebro-spinal fluid; 3rd. The continuity of the visceral with the parietal layer, through the medium of the sheaths which the former furnishes to the roots of the nerves and to the ligamentum denticulatum.

The fourth figure represents a horizontal section of the spinal marrow and its envelopes, which demonstrates the relations existing between these parts and the two cavities formed by the arachnoid.

**FIGURE 1.—Anterior aspect.—Vascular System.**—A. Vertebral artery.—B. Basilar trunk, formed by the convergence of the vertebral arteries.—C. Anterior spinal artery, formed superiorly by the convergence of two small branches coming from the vertebral arteries, and appearing here through the transparency of the arachnoid.—D, D. Internal carotid arteries, seen at their entry into the cranium.

**Nervous System.**—1, 1. Visceral layer of the arachnoid upon the anterior lobes of the cerebrum.—2, 2. *Id.*, upon the middle lobes.—3. *Id.*, upon the pons Varolii and medulla oblongata. The transparency of the arachnoid permits the venous network of the pia mater and the greater part of the cranial nerves to be seen.—From 4 to 4, the visceral layer of the arachnoid enveloping the spinal pia mater, through the transparency of which may be observed the marrow which gives form to that membrane, the ramifications of the anterior spinal artery, the roots of the spinal nerves, and the bundle of nerves called the cauda equina.—From 5 to 5, parietal layer of the arachnoid upon the internal surface of the spinal dura mater.—6. Cervical plexus.—7. Brachial plexus.—From 8 to 8, dorsal nerves.—9. Lumbar plexus.—10. Sacral plexus.—11. Eighth cranial nerve.—12. Ninth cranial.

**FIGURE 2.—Posterior aspect.—Vascular System.**—A. Venous network of the pia mater, seen through the arachnoid.—B. Superior longitudinal sinus, open, and receiving the cerebral veins.—C. Lateral sinus.—D. Torcular Herophili, open, receiving the straight sinus, the superior longitudinal, and the lateral sinuses; in which may be observed the openings of veins from the convexity of the brain.—From E to E, ramifications of the two posterior spinal arteries.—F. Vertebral artery.

**Nervous System.**—1, 1. Encephalic or cranial

arachnoid upon the posterior lobes of the cerebrum.—2, 2. *Id.*, upon the hemispheres of the cerebellum.—3, 3. Visceral layer of the rachidian or spinal arachnoid.—4. Line of junction or continuity between the rachidian and the cranial arachnoid.—5. Ampulla formed by the arachnoid around the cauda equina.—6, 6. Sheaths formed by the arachnoid for the posterior roots of the spinal nerves.—From 7 to 7, parietal layer of the arachnoid lining the internal surface of the dura mater.—8, 8. Ganglia and branches of the spinal nerves.—9, 9. Posterior branches of the dorsal nerves, separated from the anterior by the anterior costo-transverse ligaments.

**FIGURE 3.—Nervous System.**—1. Spinal dura mater, incised superiorly, and hooked aside.—2, 2. Sheaths formed by that membrane about the roots and ganglia of the spinal nerves.—3. Rachidian or spinal arachnoid, allowing the spinal arterial ramifications, laid bare superiorly, to be seen through its transparency.—4, 4. Sheaths formed by the arachnoid around the roots of the nerves and the ligamentum denticulatum.—5. Point of continuity of the visceral layer of the arachnoid with its parietal layer.—6. Pia mater, in the thickness of which may be observed the arterial ramifications of the anterior spinal branch.—7. Ligamentum denticulatum, separating the anterior from the posterior roots of the spinal nerves, and serving as a communication between the dura mater and the pia mater.

**FIGURE 4.—Nervous System.**—1. Spinal dura mater.—2. Parietal layer of the arachnoid.—3. Visceral layer.—4. Pia mater.—5. Spinal marrow.—6. Cavity of the arachnoid.—7. Sub-arachnoid space.—8. Point of junction of the visceral with the parietal layer.—9. Sheath of dura mater around the roots of a spinal nerve and corresponding ganglion.—10. Posterior root and intervertebral ganglion.—11. Anterior root.—12. Denticulate ligament.



Fig. 1.

PL. 6 et 7

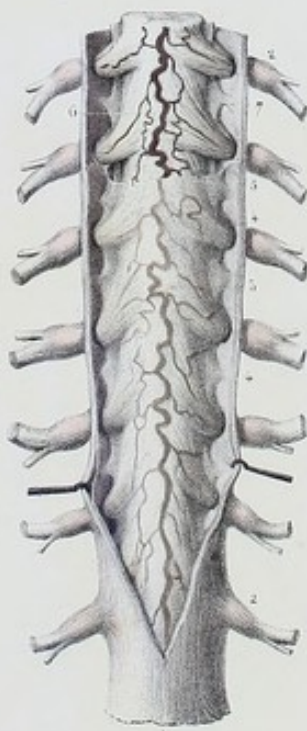
Fig. 2.




Fig. 4.

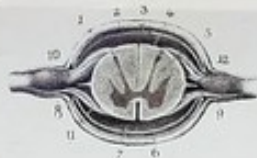

Fig. 5.









# METHOD OF DISSECTING ANATOMICAL PREPARATIONS

AS REPRESENTED

P L A T E 8.

## Encephalic arachnoid.

FIGURES 1 AND 2.—Proceed in a manner the same as was formerly instructed for the external surface of the cranial dura mater. Then incise the latter along the margins of the superior longitudinal sinus, and reflect the segments; which will expose to view the visceral arachnoid, investing the convexity of the cerebrum, and by its transparency permitting the vascular network of the pia mater to appear, likewise the parietal arachnoid, adherent to the internal surface of the dura mater.

To exhibit the visceral arachnoid at the base of the brain, and its continuity with the parietal arachnoid, detach the falx from the crista galli, raise the encephalic mass with the left hand introduced beneath the anterior lobes of the cerebrum, and turn the whole slightly from before backwards. This mode of proceeding exercises traction upon the sheaths furnished by the arachnoid to the nerves and vessels, which renders them more visible and permits of their being better studied. Cut successively the nerves, the vessels, and the infundibulum; separate the tentorium cerebelli from the superior borders of the petrous bones, and from the base of the falx; divide, with long scissors, the other nerves which still connect the encephalon with the base of the cranium; insert deeply the blade of a scalpel, or better, the articulated knife which I have devised,<sup>1</sup> into the foramen magnum, and cut, between the first and second cervical vertebrae, the spinal cord, the vertebral arteries, the spinal accessory, and other spinal nerves. Disengage the encephalic mass from its cranial case, by the assistance of the hand insinuated into the space thus formed, while with the other you slightly raise the brain by its convexity. You have, then exposed to view, on the one hand, the encephalon, invested with the visceral layer of the arachnoid; on the other, the parietal layer of the arachnoid, adherent to the internal surface of the dura mater. In order to render the visceral layer of the arachnoid more apparent, air may be introduced, by means of a blow-pipe, between it and the pia mater, in the neighbourhood of one of the sub-arachnoid spaces.

<sup>1</sup> The "Articulated Knife of Hirschfeld" may be procured of either of the instrument makers referred to in the note regarding the rachitome, p. 1\*.



## EXPLANATION OF PLATE 8.

### Encephalic arachnoid.

The first and second figures show the visceral layer of the arachnoid at the base and at the convexity of the brain. The parietal layer of this membrane is to be observed upon the internal surface of the dura mater, portions of which are turned aside. The third figure represents a transverse vertical section of the cerebrum and its envelopes, intended to show the mutual relations which exist between these different parts.

FIGURE 1.—**Vascular System.**—A, A. Vertebral arteries.—B, B. Basilar trunk, formed by the anastomosis of the two vertebral arteries.—C, C. Anterior cerebellar artery.—D, D. Anterior median trunk, or anterior spinal artery. All the arteries just mentioned are seen through the transparency of the arachnoid.—E, E. Internal carotid artery, surrounded by its arachnoidean sheath.—F, F, F. Cerebral and cerebellar veins, laid bare.—G, G, G. The same veins, seen through the arachnoid.—H, H. Section of the superior longitudinal sinus.

**Nervous System.**—1. The arachnoid dipping between the anterior lobes of the cerebrum.—2. *Id.*, passing directly from one lobe to the other.—3. *Id.*, covering the internal carotid arteries and the commissure of the optic nerves.—4. Visceral arachnoid, covering the tuber cinereum.—5. Sheath of the infundibulum formed by the arachnoid.—6. Arachnoid passing from one middle lobe to the other, and from the cerebrum to the pons Varolii, to form the anterior sub-arachnoid space.—7. This same visceral arachnoid, passing from the pons Varolii to the medulla oblongata, and to the hemispheres of the cerebellum, to form the posterior sub-arachnoid space.—8. Visceral arachnoid covering the anterior lobe of the cerebrum and the olfactory nerve.—9. Visceral arachnoid passing upon the middle and posterior lobes, without dipping into the fissure of Sylvius, and forming the corresponding lateral sub-arachnoid space.—10. Portion of the visceral arachnoid furnishing sheaths to the cranial nerves.—11. Visceral arachnoid and medulla oblongata, cut horizontally.—12. Parietal arachnoid,

adherent to the reflected remnants of the dura mater.—13. Pia mater and its venous network, laid bare.

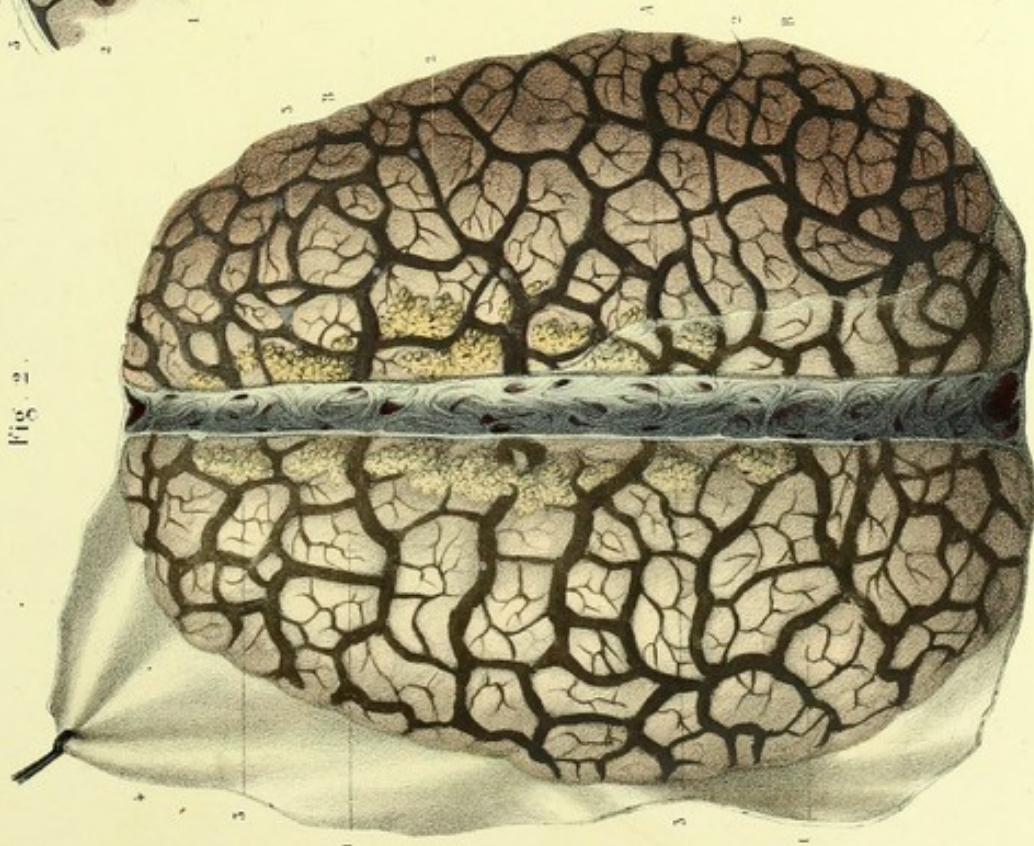
FIGURE 2.—**Vascular System.**—A. Superior longitudinal sinus, open, and receiving the cerebral veins.—B, B. Venous network of the convexity of the cerebrum.

**Nervous System.**—1, 1. Visceral layer of the arachnoid, covering the convexity of the cerebrum, and allowing the veins of that convexity to be seen through its transparency.—2, 2. Pia mater and venous network laid bare.—3, 3. Pacchionian granulations, of which one portion raises the arachnoid from beneath, whilst the other is laid bare by its removal.—4. Parietal arachnoid clothing the internal surface of the dura mater, of which a remnant is turned outwards.

FIGURE 3.—**Nervous System.**—1, 1. Portions of the lobes of the cerebrum.—2, 2, 2. Double layer of the pia mater in each sulcus.—3, 3. Visceral arachnoid and its continuity with the parietal arachnoid.—4. External or endosteal layer of the dura mater.—5. Internal layer, or dura mater proper, blended with the external; which it afterwards abandons for the purpose of folding itself upon itself, so as to form, after again uniting with the outer layer, the falx and the sinus.



Fig. 2.



Dessiné d'après nature par Lévullé

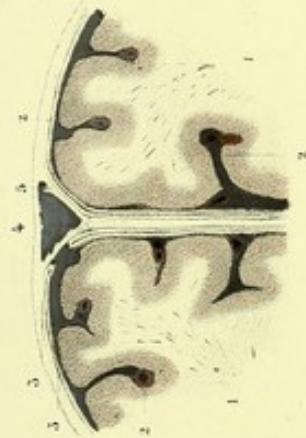
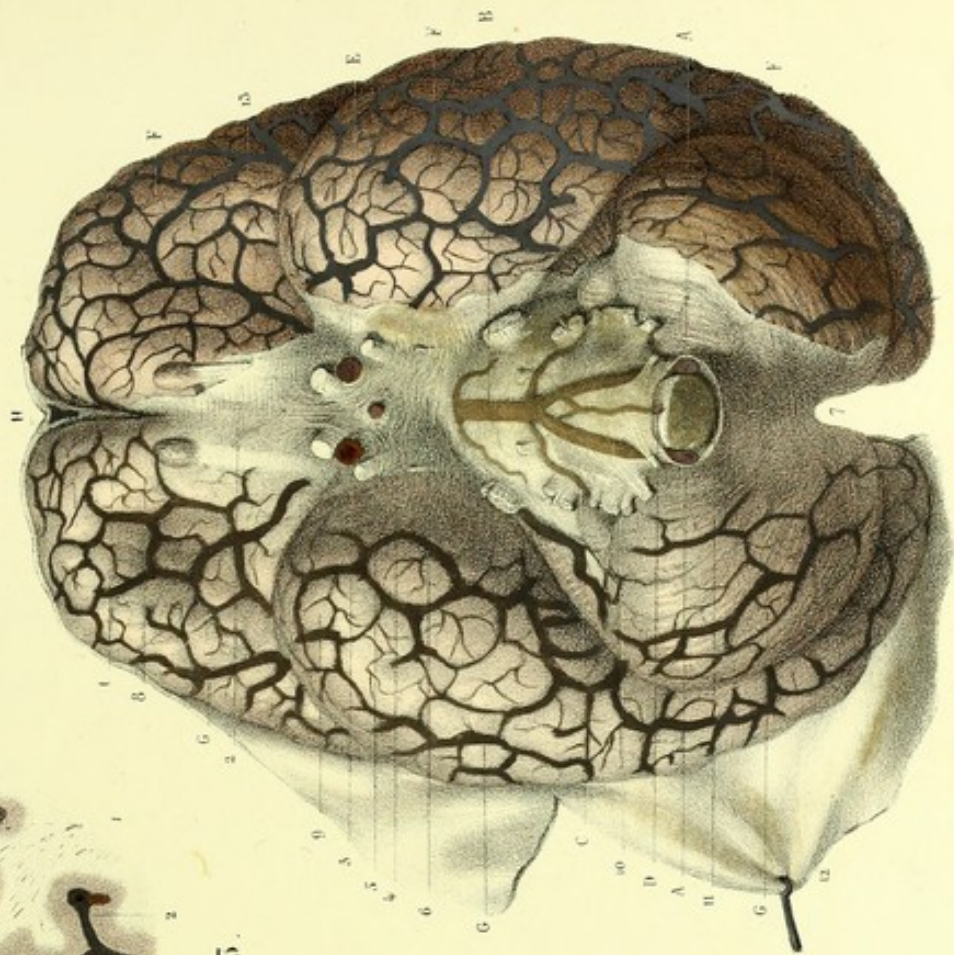

Fig. 3.

Fig. 1.



Préparé par Ludovic

Imp. Lemercier à Paris







# METHOD OF DISSECTING ANATOMICAL PREPARATIONS

AS REPRESENTED

## P L A T E S 9 A N D 10.

### Medullo-encephalic pia mater.

FIGURES 1 AND 2.—*Anterior and Posterior aspects.*—After having made preparations the same as for the vertebro-cranial dura mater and arachnoid, incise the latter, and reflect the severed portions on each side; you will have, exposed before you, the external surface of the medullo-encephalic pia mater, easily recognised by its vascular network, which is visible even in the natural condition of the veins.

For the more careful study of the internal surface of the spinal pia mater, recourse may be had to several modes of procedure:—

1st. Completely disengage the cord from the vertebral canal; clear it of its two external envelopes; divide the pia mater circularly, at the level of the medulla oblongata; make a fold of it from above downwards; draw it in the same direction, so as to strip it from the marrow in the manner that one skins an eel; there will then remain, in one hand, a species of sheath or tubular viscus, which presents on the sides all the roots of the spinal nerves together with the ligamenta denticulata, and at the lower part the caudal or coccygean ligament, while, in the other, will be held the body of the marrow, stripped of all these appendages, and presenting its fissures to the view. Then, in order to clear the internal surface of the pia mater of all medullary *débris*, recourse must be had to the process of Keuffel, which consists in soaking the pia mater, thus prepared, in a weak solution of potash, and afterwards in clear water, which is to be renewed by degrees in proportion as it becomes turbid. In this manner the last particles which adhere to it ultimately disappear, washed away by the fluid, and the pia mater is laid bare. At this time also, by insufflation, this membrane can be restored to its original form. This method of preparation can only be applied, however, to very fresh cords: such as those of executed criminals, persons who have perished by a sudden death, or new-born infants, shortly after their decease.

2nd. Another mode of proceeding, the more practical since it is applicable to all cords, and even by preference to those which are already assailed by putrefaction, is the following:—

An aperture is made at the upper part of the cord; then, by gentle and gradual compressions of the pia mater, made from below upwards, by means of the handle of a scalpel, the putrescent medullary substance is extruded; and after having in this way completely emptied the pia mater, it is submitted to Keuffel's process, as above described.

3rd. By exposing a segment of the cord, surrounded by the pia mater, to the action of chromic acid, which has the property of hardening the medulla as well as the pia mater, it may be easily seen that this membrane divides the marrow, by its internal processes, after the fashion of a lemon which has been cut transversely.



## EXPLANATION OF PLATES 9 AND 10.

### Medullo-encephalic pia mater.

This plate exhibits principally: the spinal pia mater, immediately overlying the medullary centre with which it is connected; the ramifications of the spinal arteries; and the origins of the spinal nerves, between the roots of which may be observed the ligamenta denticulata.

The first figure shows: the spinal pia mater on the anterior aspect, and its continuity with that of the brain; the ramifications of the anterior spinal artery; and the roots and anterior branches of the spinal nerves, which are in communication with the ganglionic chain of the sympathetic.

The second figure presents for examination: the medullary or spinal pia mater on its posterior aspect; the ramifications of the posterior spinal arteries; and the roots and posterior branches of the spinal nerves.

**FIGURE 1.—Accessory Parts.**—(See the explanation of Fig. 2, Plates 1 and 2.)

**Vascular System.**—A. Superior longitudinal sinus.—B, B. Ramifications of the anterior cerebral arteries.—C, C. Ramifications of the middle cerebrals.—D. Posterior cerebral artery.—E. Basilar trunk, formed by the convergence of F, F, the vertebral arteries.—G. Vertebral artery, seen in its canal, half the parietes of which have been cut away.—H, H. Anterior spinal artery, resulting from the anastomosis of the convergent twigs furnished by the vertebral arteries. It is very flexuose, situate in the median line, and receives, on each side, twigs of reinforcement from the ascending cervical, intercostal, lumbar, ilio-lumbar, sacra media, and lateral sacral arteries.—I. Portion of the internal carotid artery, entwined by the ascending branches of the superior cervical ganglion.

**Nervous System.**—1. Cranial pia mater and its arterial network, investing the anterior lobe of the right hemisphere of the cerebrum.—2. *Id.*, the middle lobe.—3. *Id.*, the pons Varolii.—4. *Id.*, the medulla oblongata.—5. Olfactory nerve.—6. Commissure of the optic nerves.—7. Motor oculi.—8. Large and small roots of the trifacial nerve.—9. Abducens.—10. Facial and auditory nerves.—11. Eighth pair, formed by the glosso-pharyngeal, pneumogastric, and spinal accessory nerves.—12. Hypoglossal nerve. These nerves all receive a sheath from the pia mater, which blends itself with their neurilemma.—From 13 to 13, spinal pia mater, covered over with an arterial network formed by the medullary spinal arteries. This membrane sends a double process into the anterior median fissure of the cord.—14, 14. Ligamentum denticulatum, commencing at the level of the foramen magnum, between the vertebral artery and the hypoglossal nerve, and terminating nearly on a line with the inferior extremity of the marrow. This ligament establishes a communication between the pia mater and the dura mater, and separates the anterior roots from the posterior roots of the spinal nerves; it is also one of the means of support to the cord.—15. Caudal or coccygean ligament (*filum terminale*), of a pearly appearance, and formed by the termination of the pia mater. It occupies the central axis of the cauda equina, inserts itself with the dura mater at the base of the coccyx, and serves to fix the lower extremity of the medulla spinalis.—16, 16, 16. Anterior roots of the spinal nerves. Each fibril which concurs in forming a root, is enveloped in a neurilemmatic sheath of the pia mater.—17, 17, 17. Anterior branches of the spinal nerves.—18, 18, 18. Rachidian or spinal ganglia.—19. Cervical plexus.—20. Brachial plexus.—21. Lumbar plexus.—22. Sacral plexus.—23, 23. Cervical portion of the ganglionic chain of the sympathetic, formed by the superior,

middle, and inferior cervical ganglia, together with their cords of communication.—24, 24. Communications of the cervical and brachial plexuses with the cervical portion of the sympathetic.—25, 25. Thoracic portion of the ganglionic chain of the sympathetic.—26, 26. Communications of the thoracic ganglia with the intercostal nerves.—27, 27. Lumbar and sacral portion of the ganglionic chain of the sympathetic.—28, 28. Communications of these same ganglia with the lumbar and sacral nerves.—29. Part of the great splanchnic nerve.—30. Part of the lesser splanchnic.—31. Coccygeal ganglion (*ganglion impar*), resulting from the median communication at the inferior extremity of the two ganglionic chains of the sympathetic.

**FIGURE 2.—Accessory Parts.**—(See the explanation of Fig. 1, Plates 1 and 2.)

**Vascular System.**—A. Vertebral artery.—B. Inferior (posterior) cerebellar artery.—C, C. Posterior spinal branches. They arise from each vertebral artery, at the point where it winds round the lateral aspect of the medulla oblongata; they direct themselves parallelly, from above downwards, at the sides of the posterior median fissure, assuming in their course a flexuose disposition; and they receive, like the anterior spinal branch, twigs of reinforcement, which traverse the fibrous canal furnished by the dura mater to each spinal nerve. These twigs are derived from the cervical, dorsal, lumbar, and sacral arteries, as previously given.

**Nervous System.**—1. Section of the optic thalamus.—2. Corpora quadrigemina.—3. Section of the peduncles of the cerebellum.—4. Floor of the fourth ventricle.—5. Pathetic nerve.—6. Portio mollis of seventh nerve, winding round the restiform body, and dividing into several filaments, which can be followed as far as the median furrow of the calamus scriptorius, and which concur in forming the plume of the *calamus*.—7. Eighth nerve, passing into the foramen lacerum posterius.—8. Hypoglossal nerve, seen on the right side in the anterior condyloid foramen, which is bisected.—From 9 to 9, external surface of the spinal pia mater, covered over with a flexuose arterial network, derived from the medullary spinal arteries.—10, 10. Ligamentum denticulatum, separating the anterior from the posterior roots of the spinal nerves.—11. Coccygean or caudal ligament, called by the ancients *nervus impar*. It is nothing but the caudal termination of the pia mater, and is consequently of a fibrous nature, like it.—12, 12, 12. Posterior roots of the spinal nerves.—13, 13, 13. Ganglia of the spinal nerves, formed at the expense of the posterior roots.—14, 14, 14. Posterior branches of the spinal nerves.—15, 15, 15. Anterior branches of the spinal nerves.



Fig. 1

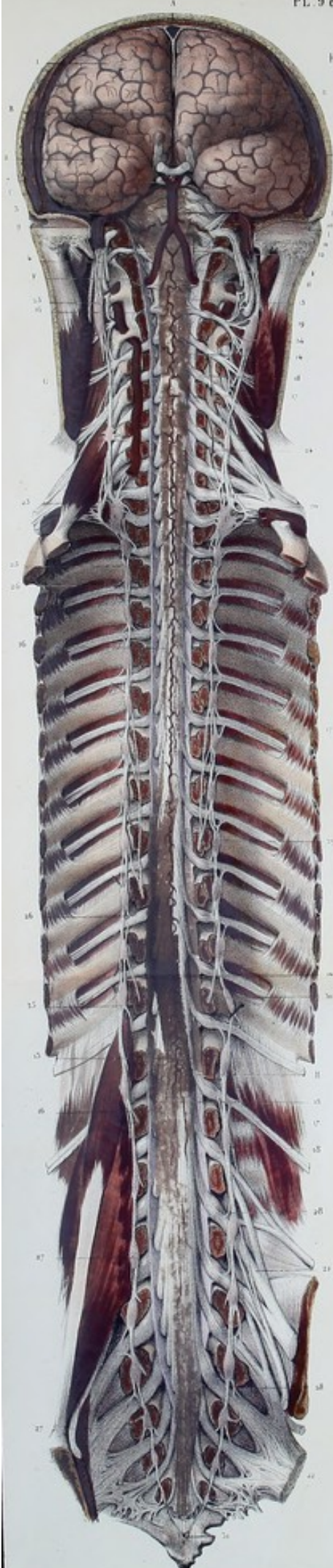
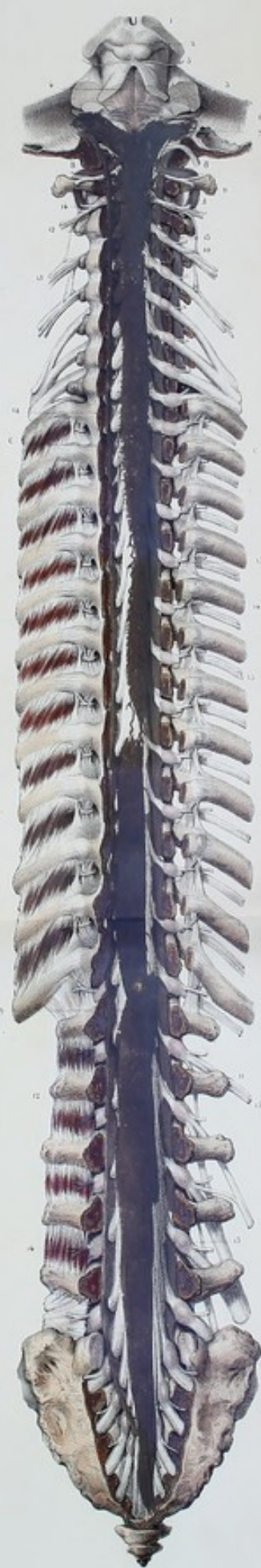
Fig. 2









## METHOD OF DISSECTING ANATOMICAL PREPARATIONS

AS REPRESENTED

### P L A T E 11.

#### Arterial distribution in the encephalic pia mater.

After having proceeded in the same manner as for the preparation of the cranial arachnoid, strip the brain of the latter, commencing in the region of the sub-arachnoid spaces, so as to be able to separate that membrane more easily from the pia mater; which would be nearly impossible in the region of the convolutions, on account of the intimate approximation of these two membranes. This precaution becomes unnecessary in the case of air having been previously introduced between the pia mater and the arachnoid.

The study of the vascular system which penetrates from the pia mater into the mass of the encephalon, ought to be pursued by means of two injections, of different colours. To exhibit the veins well, artificial injection is not indispensable. It suffices simply to leave the head of a subject pendent for some hours, to produce a natural injection; or else to procure the corpse of an individual dead of asphyxia.



## EXPLANATION OF PLATE II.

### Arterial distribution in the encephalic pia mater.

The first figure represents the arteries at the base of the brain.

The second figure exhibits the arteries upon the internal surface of a cerebral hemisphere, by means of an antero-posterior vertical section, made through the cerebral core. In the same figure may be also observed the arteries of the cerebellum, of the pons Varolii, and of the medulla oblongata, which are preserved entire, and seen in profile.

FIGURE 1.—**Vascular System.**—A. Vertebral arteries.—B. Anterior spinal branch, or anterior median trunk. It is derived from the anastomosis by convergence of two small branches furnished by the vertebral arteries.—C. Posterior spinal branches, given off by the vertebral arteries at the level of the lateral portions of the medulla oblongata, and directing themselves towards the posterior surface of the latter, where they become parallel to each other.—D, D. Inferior (posterior) cerebellar arteries.—E. Basilar trunk, resulting from the anastomosis by convergence of the vertebral arteries.—F, F. Crinoid ramus-cules, or transverse branches of the basilar, to the pons Varolii.—G. Anterior (inferior) cerebellar artery.—H. Superior cerebellar artery, winding round the crus cerebri, and losing itself upon the superior surface of the cerebellum.—I. Posterior cerebellar artery, terminal branch of the basilar trunk. It directs its course outwards, parallel with the superior cerebellar, from which it is separated by the motor oculi nerve; thence, it passes backwards between the cerebellum and the posterior lobe of the cerebrum, in which latter it ramifies. On the left side, the course of this artery upon the posterior lobe of the cerebrum may be seen, laid bare by the removal of the corresponding hemisphere of the cerebellum, by means of a section made through its middle peduncle.—J. Posterior choroid artery, which comes from the posterior cerebral, winds round the crus cerebri, passes through the transverse or cerebral fissure of Bichat, and ramifies in the choroid plexus of the velum interpositum.—K. Posterior communicating artery, or communicating artery of Willis.—L. Internal carotid artery, cut, giving off; behind, M, the anterior choroid; and outwards, N, the middle cerebral. This last directs itself towards the fissure of Sylvius, in which it buries itself, after having furnished branches to the inferior surface of the anterior lobe of the cerebrum. On the left side, by the removal of a portion of the middle lobe, may be seen the same artery in the fissure of Sylvius, and its three divisions: of which one, anterior, rests on the anterior lobe, to which

it sends branches; another, posterior, upon the posterior lobe, likewise furnishing branches; while the third, corresponds to the triangular lobule (island of Reil) which may be noticed at the bottom of the fissure of Sylvius, and to which it, also, sends ramifications. These three divisions afterwards proceed to reflect themselves from below upwards, upon the convexity of the cerebrum, where they expand into ramifications, after having anastomosed between themselves, and with the anterior and posterior cerebral arteries.—O. Anterior cerebral artery.—P. Point of reflection of this artery upon the corpus callosum.—R. Anterior communicating artery.

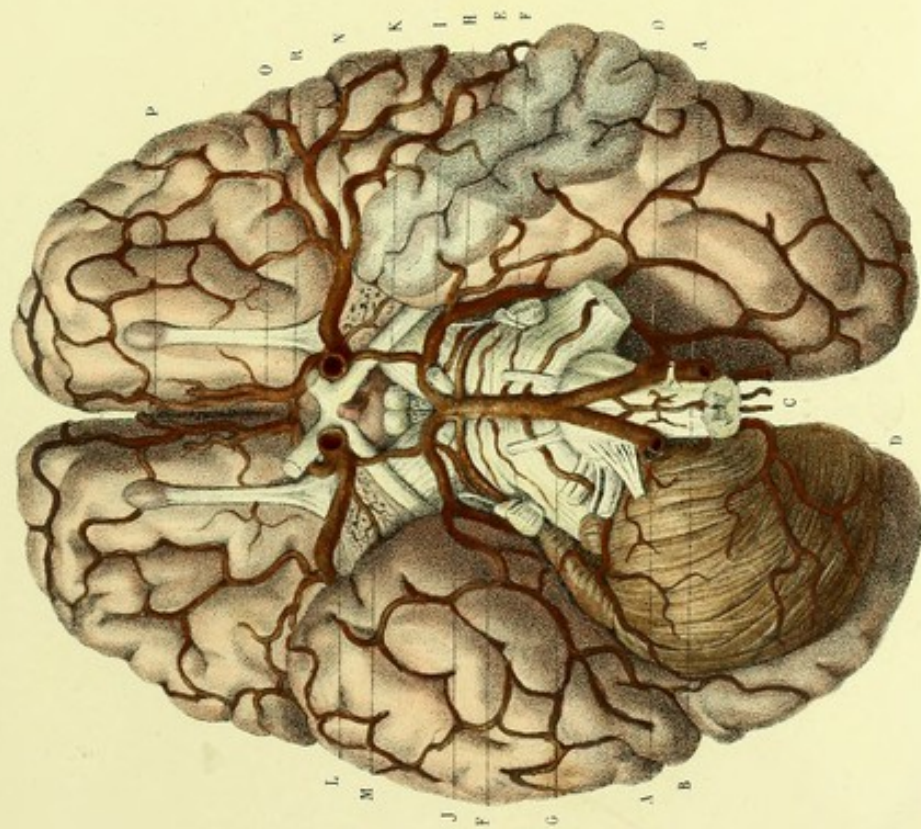
**Nervous System.**—The cranial nerves are seen at their origin, in order that their relations with the arteries may be studied.

FIGURE 2.—**Vascular System.**—A. Vertebral artery.—B. Anterior spinal branch.—C. Posterior spinal branch.—D. Inferior and posterior cerebellar artery.—E. Basilar artery.—F. Inferior and anterior cerebellar artery.—G. Superior cerebellar artery, distributing itself to the superior surface of the cerebellum.—H. Posterior cerebellar artery, cut.—I. Superior (posterior) choroid artery, winding round the crus cerebri, and passing between the corpora quadrigemina and the posterior cushioned fold (or *splenium*) of the corpus callosum, to lose itself in the choroid plexus.—J. Posterior communicating artery.—K. Internal carotid.—L. Middle cerebral, losing itself in the fissure of Sylvius.—M. Anterior cerebral artery, winding round the corpus callosum, to which it gives several branches, and ramifying upon the internal surface of the cerebral hemisphere.

**Nervous System.**—1. Internal surface of the left hemisphere.—2. Corpus callosum.—3. Septum lucidum.—4. Fornix.—5. Third ventricle, divided.—6. Pineal gland and its peduncles.—7. Tubercula quadrigemina.—8. Right crus cerebri, cut.—9. Pons Varolii.—10. Medulla oblongata.—11. Cerebellum, seen in profile.



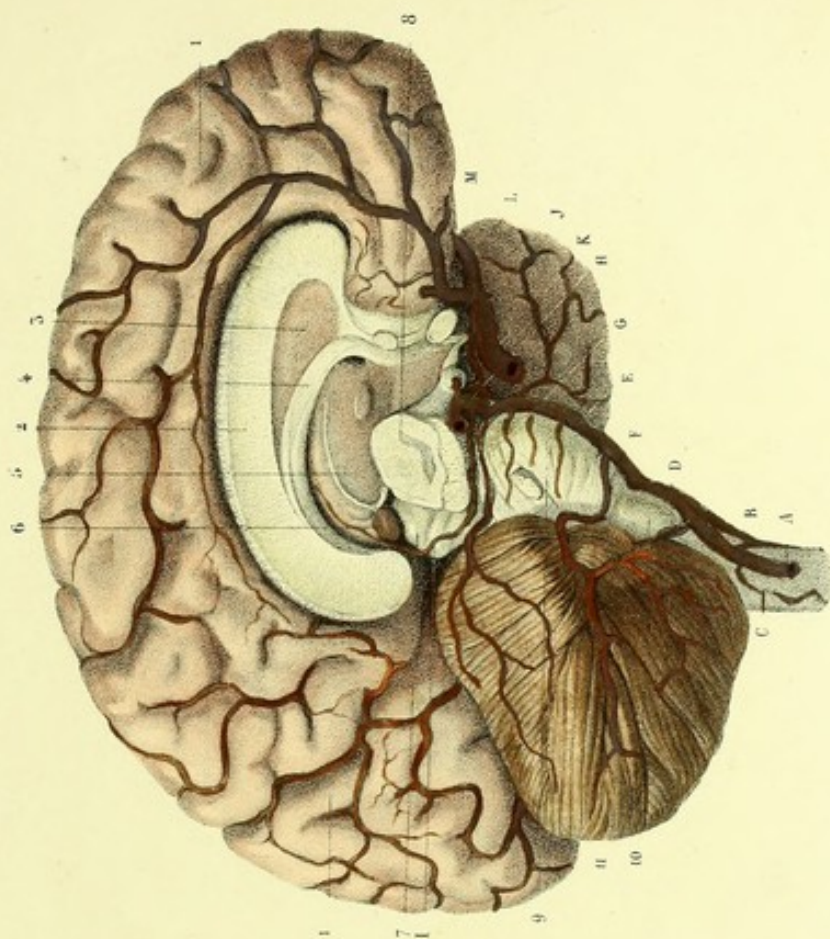
Fig. 1.



Dessiné d'après nature par J. V. L.

Préparé par J. D.

Fig. 2.



Imp. L. J. B.







# METHOD OF DISSECTING ANATOMICAL PREPARATIONS

AS REPRESENTED

## — CENTRAL NERVOUS SYSTEM —

### Brain in general.

The preparation of the brain must be preceded by those steps which have been already indicated with respect to the meninges. Strip the brain of the pia mater, slowly and with circumspection, so as not to lacerate the proper substance of that organ, which adheres to the membrane by a vast number of cellulovascular prolongations. To this end, it is indispensable that the encephalon be completely immersed in water. This precaution singularly facilitates the removal of the pia mater, and allows of the brain being turned in all directions without alteration to its shape. It has likewise the advantage of disengorging it of the blood which it contains.

The choice of a suitable subject is by no means a matter of indifference, and ought to fall by preference upon the body of an adult, dead of an acute malady, cerebral affections excepted. Subjects dead of apoplexy, or of the effects of a blow or fall upon the head, are unsuitable. The opening of the cranium should be performed with the hammer, so as not to injure the encephalon.

The study of the disposition of the fibres, requires brains hardened by alcohol, brought at first to 32 and then to 40 degrees,<sup>1</sup> after an immersion of two or three days. In order to harden an entire brain more readily, it is well to make punctures in the hemispheres, which should penetrate as far as into the ventricles; or, in other instances, the brain may be divided into several portions. The preparation must be turned daily, so as to render the hardening uniform; the putrefaction or softening of that portion of the brain which touches the bottom of the vessel is thus avoided.

The mineral and metallic acids are inferior to alcohol; too dilute, they do not harden the parts sufficiently; too concentrated, they render them apt to break. Creasote, the alkalis, solutions of corrosive sublimate and of other metallic salts, suit still less. Chromic acid ought to be reserved for the examination of the microscopic elements of the medullo-encephalic nervous centre. For this purpose, it is requisite to make slices of about a third of an inch in thickness, by means of horizontal or vertical sections; then to immerse them during two or three days in a dilute solution of chromic acid, in the proportion of 100 parts of water to 4 or 5 parts of acid. In order to render the slices fit for microscopical study, it is essential to subject them, thus preserved, to further section, each shive being made as thin as possible; these will become transparent after having been dipped for a certain time, either in glycerine, or in a weak solution of soda.

## PLATES 12 AND 13.

### Medulla spinalis and mesencephalum united, or medullary caulis.

FIGURES 1 AND 2.—After having isolated this portion of the nervous axis, still invested with its neurilemma or pia mater—by the procedures antecedently described, and by sections made through the optic thalami at their hinder extremity and through the cerebellar peduncles—it must be stripped completely, either in the fashion that one skins an eel (see *Medullo-encephalic pia mater*, page 13\*), or by the removal of its proper membrane, shred by shred, with the help of a longitudinal incision made a little to the outer side of the median fissure. Much precaution is requisite in order to avoid damaging the medullary caulis during the ablation of the pia mater, which clings to it by a multitude of fibro-vascular prolongations. To make this preparation with success, it is indispensable that the part be exceedingly fresh.

FIGURE 3.—The above-named portion of a cerebro-spinal axis having been procured as fresh as possible, stripped of its neurilemma, and steeped for several days in dilute spirit—so as to harden it a little, to give it consistence and a certain degree of elasticity—the medulla spinalis must be first divided with a cutting instrument into two lateral halves by a section made through the three inferior fourths of the commissure, and the separation completed as far as the superior constriction of the medullary cord, or isthmus of the medulla oblongata, by gentle tractions with opposed tendency. A greater resistance will here be felt, which is due to an interweaving of fibres; this is the intercrossment which is usually termed the decussation of the pyramids. Each lateral half must then be equally divided into three strands or columns, by means of two sections made, respectively, in the course of the anterior and posterior lateral fissures; the separation being terminated by divulsion as far as the level of the intercrossment. The pyramids must next be drawn apart from each other, when there will be observed a slight deviation of the median fissure. If the diducement be augmented, it will be noticed that each pyramid is formed of two portions: the one, the internal and larger, becoming continuous with the lateral column, or middle strand, of the opposite side of the cord, and producing with the lateral column of the side on which it is situate the decussation; the other portion, the external and smaller, is continuous with the anterior column of its own side, and does not enter into the decussation. The rest can be learned from the figure and its explanation.

<sup>1</sup> *Aréomètre de Cartier*: equal to about 83° and 95° French centesimal alcoholometer, respectively; or, 76 parts alcohol to 24 water, = sp. gr. .856 in the former, and 91.7 alcohol to 8.3 water, = sp. gr. .817 in the latter instance.



## EXPLANATION OF PLATES 12 AND 13.

### Medulla spinalis and mesencephalum united, or medullary caulis.

The first and second figures represent the spinal cord with its fissures and its intumescences, removed from the vertebral canal, stripped of the pia mater and of the roots of the spinal nerves, and in continuity with its cranial prolongation the mesencephalum.

The third figure is intended to show the decussation of those portions of the lateral columns of the cord which assist in forming the anterior pyramids of the medulla oblongata.

The fourth figure exhibits a transverse section of the cerebral peduncles, made immediately in front of the pons Varolii. The fifth gives a horizontal section of the medulla oblongata, on a level with the middle of the corpora olivaria. The seventh figure and the remainder are copies of horizontal sections of the marrow, made at different heights, for the study of—1st, the white and grey nervous substance; 2nd, the relation of these as regards position and proportion; 3rd, the diversities of form of the grey matter; and 4th, the fissures of the cord.

**Central Nervous System.**—FIGURE 1.—*Anterior aspect.*—1. Optic commissure, formed by the converging optic tracts.—2. Right cerebral peduncle (crus cerebri). In the lozenge-shaped space comprehended between the optic tracts and the crura cerebri may be observed, from before backwards:—3, the tuber cinereum and infundibulum;—4, the corpora albicantia;—and 5, the triangular median perforate lamellæ (locus perforatus posticus).—6. Annular protuberance (pons Varolii).—7. Section of the right crus cerebelli.—8. Transverse groove forming the boundary between the medullary cord, or medulla communis, and the pons Varolii.—9. First or cranial intumescence of the medullary cord (medulla oblongata, seu bulbus rachidicus).—10. Left anterior pyramid.—11. Left olivary body.—12. Anterior portion of left restiform body.—13. Superior constriction of the medullary cord (peduncle or isthmus of the medulla oblongata).—14. Second or middle intumescence of the medullary cord (superior or cervico-brachial enlargement of the medulla spinalis).—15. Third or inferior intumescence of the medullary cord (lumbar enlargement of the medulla spinalis).—16, 16. Anterior median fissure. It occupies only the anterior third of the thickness of the marrow, and at the bottom is a white stratum, riddled with foramina: this is the anterior commissure.—17, 17. Anterior lateral fissure of the left side. Very superficial, and rather apparent than real, these fissures are situate externally to the anterior roots of the spinal nerves; their existence is not admitted by all anatomists.

FIGURE 2.—*Posterior aspect.*—1. Section of the right optic thalamus.—2. Corpora quadrigemina.—3. Left riband of Reil.—4. Section of the left crus cerebelli.—5. Medulla oblongata, or bulb.—6. Floor of the fourth ventricle.—7. Median furrow of the fourth ventricle, assisting in the formation of the calamus scriptorius.—8. Right mammillary projection (processus clavatus), bounding the nib of the calamus.—9. Posterior portion of the right restiform body.—10. Cervico-brachial enlargement.—11. Lumbar enlargement.—12, 12. Posterior median fissure. Narrower than the anterior, it occupies a little more than the posterior half of the thickness of the cord, and at the bottom is a greyish stratum, which is the posterior or grey commissure.—13, 13. Posterior lateral fissure of the right side. These lateral fissures present a greyish appearance, due to the prolongation of the central grey substance, and serve for the insertion of the posterior roots of the spinal nerves.—14, 14. Posterior intermediate fissures. They commence externally to the fasciculi clavati, which bound the nib of the calamus scriptorius, and traverse the cervical region as well as the two superior thirds of the dorsal, where they seem to terminate.

FIGURE 3.—*Anterior aspect.*—1. Right half of the cord.—2. Left half. Each of these halves is divided

into three columns.—3. Anterior column.—4. Posterior column.—5. Lateral column. The columns of the left side are separated from one another, so as to be well seen; those of the right are approximated.—6. Anterior column of the cord, divided superiorly into two portions, of which the most internal contributes to the formation of the corresponding pyramid.—7. Lateral column, divided superiorly into three or four portions, decussated by as many portions of the lateral column of the opposite side. This intercrossment, which takes place from one side to the other and from before backwards, is the origin of the two internal thirds of—8, 8, the anterior pyramids.—9. White fibres of the left pyramid, crossing the annular protuberance in an antero-posterior direction, and becoming continuous with the crus cerebri.—10. Section of the superficial transverse fibres of the pons Varolii, showing the relative depth at which the antero-posterior fibres from the pyramid are found.—11. Section of the deeper transverse fibres of the pons, made to expose the prolongation of the right intermediate fasciculus of the medulla oblongata, which is continued into the crus cerebri. The portion of the intermediate fasciculus corresponding to the crus cerebri, is separated from the fasciculated portion (crust) of this peduncle, by a stratum of blackish matter, known as the locus niger of Sœmmerring.—12. Left olive.—13. Right olive, laid bare by the removal of the corresponding pyramid.

FIGURE 4.—1. Interpeduncular space.—2, 2. Inferior stratum or étage of the peduncles (crust).—3, 3. Loci nigri of Sœmmerring, situate in the thickness of the peduncles and separating the crust from—4, 4, the middle stratum or étage of the peduncles (tegmen).—5, 5. Superior stratum or étage (also tegmen); where may be noticed:—6, section of the aqueduct of Sylvius;—7, 7, *id.*, of fibres continuous with the superior peduncles of the cerebellum;—and 8, 8, *id.*, of two of the corpora quadrigemina (testes).

FIGURE 5.—1, 1. Section of the anterior pyramids, triangular.—2, 2. *Id.*, of the olivary bodies, showing the dentate outline of the capsule of the nucleus.—3, 3. *Id.*, of the restiform bodies.—4, 4. *Id.*, of the innominate fasciculi (lateral tracts).—5. *Id.*, of the floor of the fourth ventricle.

FIGURE 7.—1. Right half of the cord.—2. Left half.—3. Anterior median fissure.—4. Posterior median fissure.—5, 5. Posterior lateral fissures.—6. Anterior or white commissure.—7. Posterior or grey commissure.—8. Right anterior cornu of the grey substance, terminated by an intumescence.—9. Right posterior cornu of the grey substance, prolonged as far as the posterior lateral fissure.—10. Left antero-lateral fasciculus or column.—11. Right posterior fasciculus or column. Both these fasciculi, on either side, are formed by the white substance.



Fig. 1




Fig. 2




Fig. 3




Fig. 4

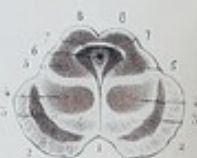

Fig. 5

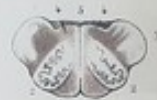

Fig. 6



Fig. 7



Fig. 8



Fig. 9



Fig. 10



Fig. 11



Fig. 12



Fig. 13



Fig. 14



Fig. 15



Fig. 16



Fig. 17



Fig. 18



Fig. 19



Fig. 20



Fig. 21



Fig. 22





1/2 Maroon Calf. M. S.



