

**Atlas of skin diseases : consisting of a series of coloured illustrations together with descriptive text and notes upon treatment / by Tilbury Fox.**

**Contributors**

Fox, Tilbury, 1836-1879.  
University of Leeds. Library

**Publication/Creation**

London : J. & A. Churchill, 1877.

**Persistent URL**

<https://wellcomecollection.org/works/d7fructd>

**Provider**

Leeds University Archive

**License and attribution**

This material has been provided by This material has been provided by The University of Leeds Library. The original may be consulted at The University of Leeds Library. where the originals may be consulted.

This work has been identified as being free of known restrictions under copyright law, including all related and neighbouring rights and is being made available under the Creative Commons, Public Domain Mark.

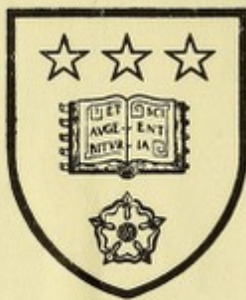You can copy, modify, distribute and perform the work, even for commercial purposes, without asking permission.



Wellcome Collection  
183 Euston Road  
London NW1 2BE UK  
T +44 (0)20 7611 8722  
E [library@wellcomecollection.org](mailto:library@wellcomecollection.org)  
<https://wellcomecollection.org>



assessed for  
retention 2002



*The University Library  
Leeds*

~~MEDICAL LIBRARY~~

~~STACK~~  
(School)

**STORE**

WR  
17 FOX



3 0106 01350 4005



Digitized by the Internet Archive  
in 2015

<https://archive.org/details/b21535577>





ATLAS  
OF  
SKIN DISEASES



Palk-Skin  
H-5

*Not for circulation.*

ATLAS

LEEDS & WEST-RIDING  
MEDICO-CHIRURGICAL SOCIETY

OF

SKIN DISEASES

CONSISTING OF

A SERIES OF COLOURED ILLUSTRATIONS

TOGETHER WITH

*DESCRIPTIVE TEXT AND NOTES UPON TREATMENT*

BY

TILBURY FOX, M.D., F.R.C.P.

PHYSICIAN TO THE DEPARTMENT FOR SKIN DISEASES IN UNIVERSITY COLLEGE HOSPITAL  
ETC. ETC. ETC.



LEEDS & WEST-RIDING  
MEDICO-CHIRURGICAL SOCIETY

LONDON

J. & A. CHURCHILL, NEW BURLINGTON STREET

1877

UNIVERSITY OF LEEDS  
MEDICAL LIBRARY

PHYSIOLOGICAL  
ANATOMY

UNIVERSITY OF LEEDS  
MEDICAL LIBRARY.

UNIVERSITY OF LEEDS  
MEDICAL LIBRARY

## INTRODUCTION.

---

THE value and utility of WILLAN & BATEMAN'S 'COLOURED DELINEATIONS OF DISEASES OF THE SKIN' have been shown in a remarkable manner, by the position which the work has maintained for itself, even up to the present time, in the face of the opposition of several rival competitors of more recent publication.

The delineations consisted in the complete edition of the book of 72 Plates, and they were intended to fully illustrate the various phases of the Diseases of the Skin, comprised in the 8 groups formed originally by Willan, somewhat after the plan of Plenck. In the main these representations were very truthful. But the progress of Dermatological Science—though it has demonstrated the practical value of the simple, systematic, and easily comprehended arrangement of cutaneous maladies evolved by Willan from out the comparatively chaotic condition of the subject existing prior to the date of his labours—has shown that this arrangement is defective in some details, and that some of the coloured illustrations were incorrectly classed and designated. It is tacitly admitted by the Profession in England, and the admission has found expression on different occasions, that it would be a source of regret if WILLAN'S classic work were permitted to be shelved as having had its day. The desirability of modifying and elaborating it in accordance with the facts and requirements of modern research and modern practice has been similarly conceded.

No edition of the book has been issued for about half a century; but I believe I am correct in stating that a man no less eminent than the late Dr. Addison had at one time contemplated the issue, and, indeed, had prepared the materials, for a new edition—at least if not of the delineations, certainly of Willan's original text-book—but he was deterred from completing the task mainly by the fear lest he should be looked upon as a specialist, which was in his day a great opprobrium.

About two years ago the copyright of Willan & Bateman's work was about to be sold by its then possessor, the well-known publisher, Mr. Bohn, and communications passed between Messrs. Churchill and myself, which resulted in the purchase of the

copyright by the former, and an understanding that a new edition of the work should be published under my editorship. We fully believed that, by the addition of new Plates, and careful revision and redescription of a certain number of the originals, the utility of the labour and the fame of two English workers who had shed no little lustre on English medicine by their work in Dermatology would be perpetuated, whilst the Profession would be furnished with a complete and reliable Atlas of Skin Diseases, based upon the Willanean system, which with all its faults will still continue to be used as the most ready plan of arranging the diseases of the skin, according to the characters they present to the naked eye. At the outset it was also determined to introduce into the Atlas the more common and typical forms of Eruptions, so that the work might furnish real help to the practitioner in his daily practice no less than to the actual student in his clinical studies.

The undertaking was not a slight one, and presented not a few difficulties. It was felt by the publishers that to place the Atlas within the reach of the many, the cost of the reproduction would have to be comparatively small, and, as a matter of fact, the price at which the Atlas is issued is almost half that of the original work. The difficulties of finding an artist sufficiently conversant with morbid appearances, the impossibility of using hand-colouring, and the uncertainties of chromo-lithographic manipulations were manifest. The trouble spent over the editing of the work has been enormous; but it is hoped that all difficulties have been overcome satisfactorily, and that the portraits, though they might have been 'got up' in a more artistic and costly manner in regard to the accessories of the illustrations, viz. the dressing etc., yet convey a very accurate idea of the diseases they are intended to portray. The elaboration of the mere accessories of the pictures would have added materially to the cost of the work, without enhancing its real utility.

Less than half of the original illustrations have been retained, and more than half the Plates are new. The text is wholly new from beginning to end. There are altogether 100 different phases of eruption portrayed in the Atlas. The mere enumeration of some of the diseases represented in the new Plates will show that important additions have been made to the Atlas. Amongst these diseases are the *LICHEN planus* and *LICHEN ruber* of Wilson and Hebra respectively; *LICHEN urticatus*, which Willan did not portray at all; *IMPETIGO contagiosa*; *PEMPHIGUS foliaceus*; *PITYRIASIS rubra*; *PITYRIASIS pilaris*; *LUPUS erythematosus* and *L. tuberculosus*; *RODENT ULCER*; *PHTHIRIASIS*; *SCABIES*; *TINEA circinata*; *TINEA versicolor*; *TINEA Kerion*; *XANTHELASMA*; *MORPHEA*; Diseases of the *Nails*; *HYDROA*; *DYSIDROSIS*; *Anæsthetic LEPROSY*; &c.

The following is a list of the diseases, comprised in the 72 Plates, and the order in which they are grouped:—

PLATE	I.	Fig. 1.	Erythema simplex.	PLATE	XXXV.	.	Psoriasis circinata.
"	"	"	2. Erythema marginatum et circinatum.	"	XXXVI.	Fig. 1.	Psoriasis rupioides.
"	II.	"	1. Erythema papulatum.	"	"	"	2. Psoriasis inveterata.
"	"	"	2. Erythema tuberculatum.	"	XXXVII.	.	Psoriasis palmaris.
"	III.	.	Erythema nodosum.	"	XXXVIII.	.	Pityriasis rubra.
"	IV.	Fig. 1.	Urticaria febrilis.	"	XXXIX.	.	Pityriasis pilaris (of Devergie).
"	"	"	2. Urticaria chronica.	"	XL.	.	Lichen ruber (3rd Illustration).
"	V.	"	1. Strophulus intertinctus.	"	XLI.	.	Prurigo simplex.
"	"	"	2. Strophulus albidus.	"	XLII.	.	Prurigo ferox or agria.
"	VI.	"	1. Strophulus confertus.	"	XLIII.	Fig. 1.	Purpura simplex.
"	"	"	2. Strophulus volaticus.	"	"	"	2. Purpura hæmorrhagica.
"	"	"	3. Strophulus candidus.	"	XLIV.	.	Purpura urticans.
"	VII.	"	1. Roseola æstiva.	"	XLV.	Fig. 1.	Lupus erythematodes (face).
"	"	"	2. Roseola autumnalis.	"	"	"	2. Lupus erythematodes (hand).
"	VIII.	"	1. Roseola annulata.	"	XLVI.	"	1. Lupus (infiltrating),
"	"	"	2. Roseola infantilis.	"	"	"	2. Lupus tuberculosus.
"	IX.	.	Lichen urticatus.	"	XLVII.	.	Lupus exedens (2 figures).
"	X.	Fig. 1.	Lichen simplex.	"	XLVIII.	.	Lupus (in a serofulous subject).
"	"	"	2. Lichen agrius.	"	XLIX.	.	Ichthyosis.
"	XI.	"	1. Lichen lividus.	"	L.	Fig. 1.	Keloid.
"	"	"	2. Lichen pilaris.	"	"	"	2. Rodent ulcer.
"	"	"	3. Lichen circumscriptus.	"	LI.	.	Dysidrosis (of Editor).
"	XII.	.	Lichen planus.	"	LII.	.	Phthiriasis.
"	XIII.	.	Lichen ruber.	"	LIII.	.	Scabies (2 figures).
"	XIV.	.	Lichen serofulosorum.	"	LIV.	Fig. 1.	Tinea tonsurans.
"	XV.	.	Eczema simplex.	"	"	"	2. Tinea favosa.
"	XVI.	Fig. 1.	Eczema solare.	"	LV.	"	1. Tinea kerion.
"	"	"	2. Eczema rubrum.	"	"	"	2. Tinea circinata.
"	XVII.	.	Eczema impetiginodes.	"	LVI.	.	Tinea circinata tropica (Eczema marginatum).
"	XVIII.	.	Eczema infantile.	"	LVII.	.	Tinea versicolor.
"	XIX.	.	Impetigo figurata.	"	LVIII.	.	Alopecia areata.
"	XX.	.	Impetigo scabida, or Eczema pustulosum.	"	LIX.	.	Acne simplex.
"	XXI.	.	Baker's and Grocer's Itch.	"	LX.	.	Acne indurata.
"	XXII.	.	Impetigo rodens.	"	LXI.	.	Sycosis.
"	XXIII.	.	'Porrigo' of Willan and Bateman.	"	LXII.	.	Xanthelasma.
"	XXIV.	.	Impetigo contagiosa (of Editor).	"	LXIII.	.	Xanthelasmaidea (of Editor).
"	XXV.	.	Herpes circinatus.	"	LXIV.	.	Molluscum contagiosum.
"	XXVI.	.	Herpes zoster of the leg.	"	LXV.	.	Seborrhœa.
"	XXVII.	.	Herpes zoster (trunk).	"	LXVI.	.	Morphœa.
"	XXVIII.	.	Herpes iris.	"	LXVII.	Fig. 1.	Eruption of anæsthetic leprosy.
"	XXIX.	Fig. 1.	Pemphigus vulgaris.	"	"	"	2. Hand in ditto.
"	"	"	2. Pemphigus pruriginosus.	"	LXVIII.	.	Tubercular leprosy.
"	XXX.	.	Pemphigus foliaceus.	"	LXIX.	.	Fibroma simplex and Pachydermatocele.
"	XXXI.	Fig. 1.	Ecthyma vulgare.	"	LXX.	.	Fibroma fungoides (of Editor).
"	"	"	2. Ecthyma cacheecticum.	"	LXXI.	.	Nail diseases.
"	XXXII.	.	Rupia.	"	LXXII.	.	Hydroa.
"	XXXIII.	.	Psoriasis guttata.				
"	XXXIV.	.	Psoriasis vulgaris.				

The reader will observe that the diseases are arranged, as before stated, as far as possible after the manner of Willan. The Erythemata coming first, the Papular next, the Vesicular next, and so on.

The ERYTHEMATA, comprising *Erythema*, *Urticaria*, *Strophulus*, and *Roseola*, are represented in 16 illustrations, contained in the first Plates. I have made one or two changes, and have introduced new plates of ERYTHEMA *simplex*, *E. circinatum* and *E. nodosum*.

The PAPULAR diseases, or the *Lichens*, are represented in 9 figures, contained in the Plates IX. to XIV. both inclusive. *LICHEN urticatus*, *L. planus*, *L. ruber*, and *L. scrofulosorum* were not illustrated in the old work, but are portrayed in this.

The VESICULAR and BULBOUS eruptions, including *Eczema*, *Impetigo*, *Herpes*, and *Pemphigus*, are given in 18 figures, in Plates XV. to XXX. inclusive. I have introduced into this category for convenience sake the *IMPETIGO contagiosa*, which I have described, as its lesion is a vesico-pustule. I have renamed some of the varieties of Willan's *Eczema*, the particulars of which changes are specified in the text attached to the individual Plates. A somewhat rare but well-defined form of *Pemphigus*, viz. *P. foliaceus*, is illustrated in Plate XXX.

PUSTULAR eruptions (other than the *Impetigos*, which are included with *Eczema*), including *Ecthyma*, are dealt with in Plate XXXI.

SQUAMOUS DISEASES will be found amply illustrated by several new and old in Plates XXXIII. to XXXIX. inclusive. *PITYRIASIS rubra* and *PITYRIASIS pilaris* are both delineated. Whilst this part was in preparation a well-marked case of *LICHEN ruber* came under my observation, but I could not give it its proper place in Part IV. As the disease offers certain similarities and is often mistaken for *Psoriasis*, I decided to introduce a sketch of it in connection with the Plates of *Psoriasis*, in the belief that it would be useful for diagnostic purposes.

The arrangement of the diseases in the subsequent Plates does not follow the Willanean order; and there is no recognition of his group *Tubercula*, which contained maladies the most diverse.

PRURIGO and PURPURA are illustrated in Part XI. I have introduced in Plate XLII. a phase of *PRURIGO ferox*.

LUPUS disease in five of its phases occupies Plates XLV. to XLVIII. inclusive, and all the representations are new.

The remaining diseases are not very conveniently classified. *Ichthyosis*, very defectively rendered in Willan's work; *Keloid*, *Rodent Ulcer*, both unrepresented in the latter, and *Dysidrosis*, a disease affecting the sweat apparatus which I have described, are illustrated in Plates XLIX. to LI.

The PARASITIC DISEASES, the nature of which was unknown to Willan and Bateman, are placed together in Plates LII. to LVII. inclusive. These are all new illustrations, and include *Phthiriasis* and *Scabies* as representing the *animal*, and the *Tineæ* the *vegetable*, parasitic diseases.

ALOPECIA *areata* follows in Plate LVIII. The two chief forms of Acne come next in Plates LIX. and LX., and Sycosis follows in Plate LXI. These 4 illustrations are reproductions from the original work.

Xanthelasma is illustrated by 4 figures on Plate LXII., and I have introduced on Plate LXIII. a form of disease described by Mr. Marrant Baker and myself to which I have given the name Xanthelasmaidea, and which I think is not very rare. Then follow MOLLUSCUM *contagiosum*, Seborrhœa named by Willan and Bateman ECZEMA *rubrum*, MORPHEA, LEPROSY, PACHYDERMATOCELE, FIBROMA, including *F. simplex*, and a variety which I have designated *F. fungoides*, the chief diseases of the Nails, in several figures, and lastly, HYDROA, an ill-understood but veritably distinct disease, originally described in its more acute and slighter phases by Bazin. The illustrations in the last six Plates are new. It will be seen that the selection of diseases for illustration in the Atlas is of a very varied character, and no important or common disease of the skin is left unillustrated. As full a description has also been given of these various Plates as the space at my disposal permitted.

TILBURY FOX.

14 HARLEY STREET, W.

March 1, 1877.





I N D E X.

	PLATE
Acne simplex . . . . .	LIX.
Acne indurata . . . . .	LX.
Alopecia areata . . . . .	LVIII.
Baker's Itch . . . . .	XXI.
Dermatolysis . . . . .	LXIX.
Dysidrosis . . . . .	LI. Figs. 1, 2, 3.
Ecthyma vulgare . . . . .	XXXI. Fig. 1.
Ecthyma cachecticum . . . . .	XXXI. Fig. 2.
Eczema marginatum . . . . .	LVI.
Eczema simplex . . . . .	XV.
Eczema solare . . . . .	XVI. Fig. 1.
Eczema rubrum . . . . .	XVI. Fig. 2.
Eczema impetiginodes . . . . .	XVII.
Eczema infantile . . . . .	XVIII.
Eczema pustulosum . . . . .	XX.
Erythema simplex . . . . .	I. Fig. 1.
Erythema circinatum et marginatum	I. Fig. 2.
Erythema papulatum . . . . .	II. Fig. 1.
Erythema tuberculatum . . . . .	II. Fig. 2.
Erythema nodosum . . . . .	III.
Fibroma simplex . . . . .	LXIX.
Fibroma fungoides . . . . .	LXX.
Flea Bites . . . . .	XLIV. Fig. 3.
Grocer's Itch . . . . .	XXI.
Herpes circinatus . . . . .	XXV. Fig. 1.
Herpes iris . . . . .	XXVIII.
Herpes preputialis . . . . .	XXV. Figs. 2 & 3.
Herpes zoster (leg) . . . . .	XXVII.
Herpes zoster (trunk) . . . . .	XXVI.
Hydroa . . . . .	LXXII.
Ichthyosis . . . . .	XLIX.
Impetigo contagiosa . . . . .	XXIV.
Impetigo figurata . . . . .	XIX.
Impetigo rodens . . . . .	XXII.
Impetigo scabida . . . . .	XX.
Keloid . . . . .	L. Fig. 1.
Leprosy, anæsthetic (eruption). . . . .	LXVII. Fig. 1.
Leprosy, anæsthetic (hand) . . . . .	LXVII. Fig. 2.
Leprosy, tubercular. . . . .	LXVIII.
Lichen agrius . . . . .	X. Fig. 2.
Lichen circumscriptus . . . . .	XI. Fig. 3.
Lichen lividus . . . . .	XI. Fig. 1.
Lichen pilaris . . . . .	XI. Fig. 2.
Lichen planus . . . . .	XII. Figs. 1, 2, 3.
Lichen ruber . . . . .	XIII. and XL.
Lichen scrofulosum . . . . .	XIV.
Lichen simplex . . . . .	X. Figs. 1. & XLI.
Lichen urticatus . . . . .	IX. Figs. 1 & 2.
Lupus erythematodes (face) . . . . .	XLV. Fig. 1.
Lupus erythematodes (hand) . . . . .	XLV. Fig. 2.
Lupus exedens . . . . .	XLVII. Figs. 1 & 2.
Lupus (infiltrating) . . . . .	XLVI. Fig. 1.

	PLATE
Lupus tuberculosus . . . . .	XLVI. Fig. 2.
Lupus (in a scrofulous subject) . . . . .	XLVIII.
Molluscum contagiosum . . . . .	LXIV.
Morphœa . . . . .	LXVI.
Nail diseases . . . . .	LXXI.
Pachydermatocele . . . . .	LXIX.
Pemphigus foliaceus . . . . .	XXX.
Pemphigus pruriginosus . . . . .	XXIX. Fig. 2.
Pemphigus vulgaris . . . . .	XXIX. Fig. 1.
Petechiæ . . . . .	XLIV. Fig. 2.
Phthiriasis . . . . .	LII.
Pityriasis pilaris (of Devergie) . . . . .	XXXIX. Figs. 1 & 2.
Pityriasis rubra . . . . .	XXXVIII.
'Porrigo' of Willan and Bateman . . . . .	XXIII.
Prurigo ferox or agria . . . . .	XLII.
Prurigo formicans . . . . .	XLI. Fig. 2.
Prurigo mitis . . . . .	XLI. Fig. 1.
Prurigo senilis . . . . .	XLI. Fig. 3.
Psoriasis circinata . . . . .	XXXV.
Psoriasis guttata . . . . .	XXXIII.
Psoriasis inveterata . . . . .	XXXVI. Fig. 1.
Psoriasis palmaris . . . . .	XXXVII.
Psoriasis rupioides . . . . .	XXXVI. Fig. 2.
Psoriasis vulgaris . . . . .	XXXIV.
Purpura hæmorrhagica . . . . .	XLIII. Fig. 2.
Purpura simplex . . . . .	XLIII. Fig. 1.
Purpura urticans . . . . .	XLIV. Fig. 1.
Rodent ulcer . . . . .	L. Figs. 2, 3, 4.
Roseola æstiva. . . . .	VII. Fig. 1.
Roseola annulata . . . . .	VIII. Fig. 1.
Roseola autumnalis . . . . .	VII. Fig. 2.
Roseola infantilis . . . . .	VIII. Fig. 2.
Rupia . . . . .	XXXII.
Scabies . . . . .	LIII. Figs. 1 & 2.
Seborrhœa . . . . .	LXV.
Strophulus albidus . . . . .	V. Fig. 2.
Strophulus candidus . . . . .	VI. Fig. 3.
Strophulus confertus . . . . .	VI. Fig. 1.
Strophulus intertinetus . . . . .	V. Fig. 1.
Strophulus volaticus . . . . .	VI. Fig. 2.
Sycosis . . . . .	LXI.
Tinea circinata . . . . .	LV. Fig. 2.
Tinea circinata tropica . . . . .	LVI.
Tinea favosa . . . . .	LIV. Fig. 2.
Tinea kerion . . . . .	LV. Fig. 1.
Tinea tonsurans . . . . .	LIV. Fig. 1.
Tinea versicolor . . . . .	LVII.
Urticaria chronica (fig. 2) and febrilis	
(fig. 1) . . . . .	IV.
Willan's Prurigo, or Prurigo simplex	XLI.
Xanthelasma . . . . .	LXII.
Xanthelasmaidea . . . . .	LXIII.

THE UNIVERSITY OF CHICAGO  
LIBRARY

1871

1871

1871

1871

1871

1871

1871

1871

1871

1871

1871

1871

1871

1871

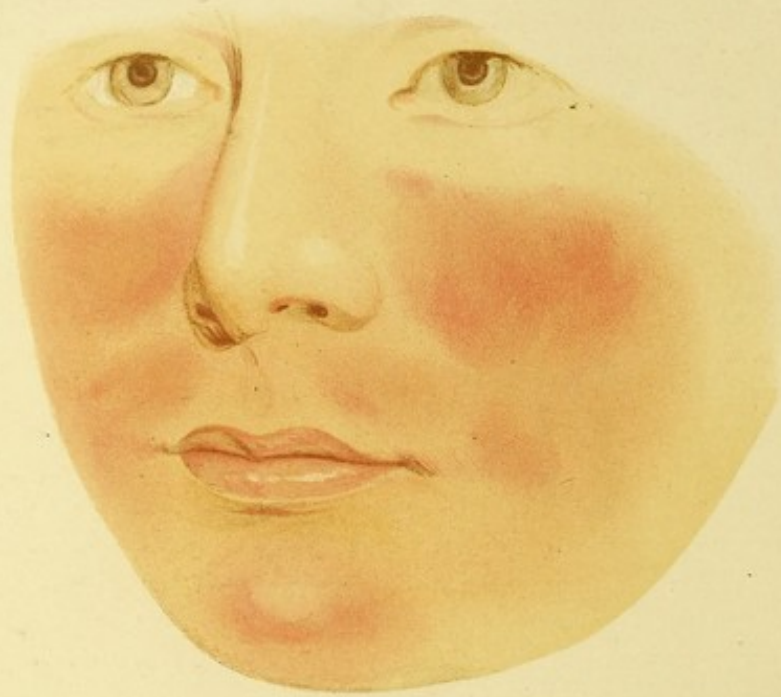1871

1871



Fig. 1.

ERYTHEMA SIMPLEX.



LEEDS & WEST-RIDING  
MEDICO-CHIRURGICAL SOCIETY

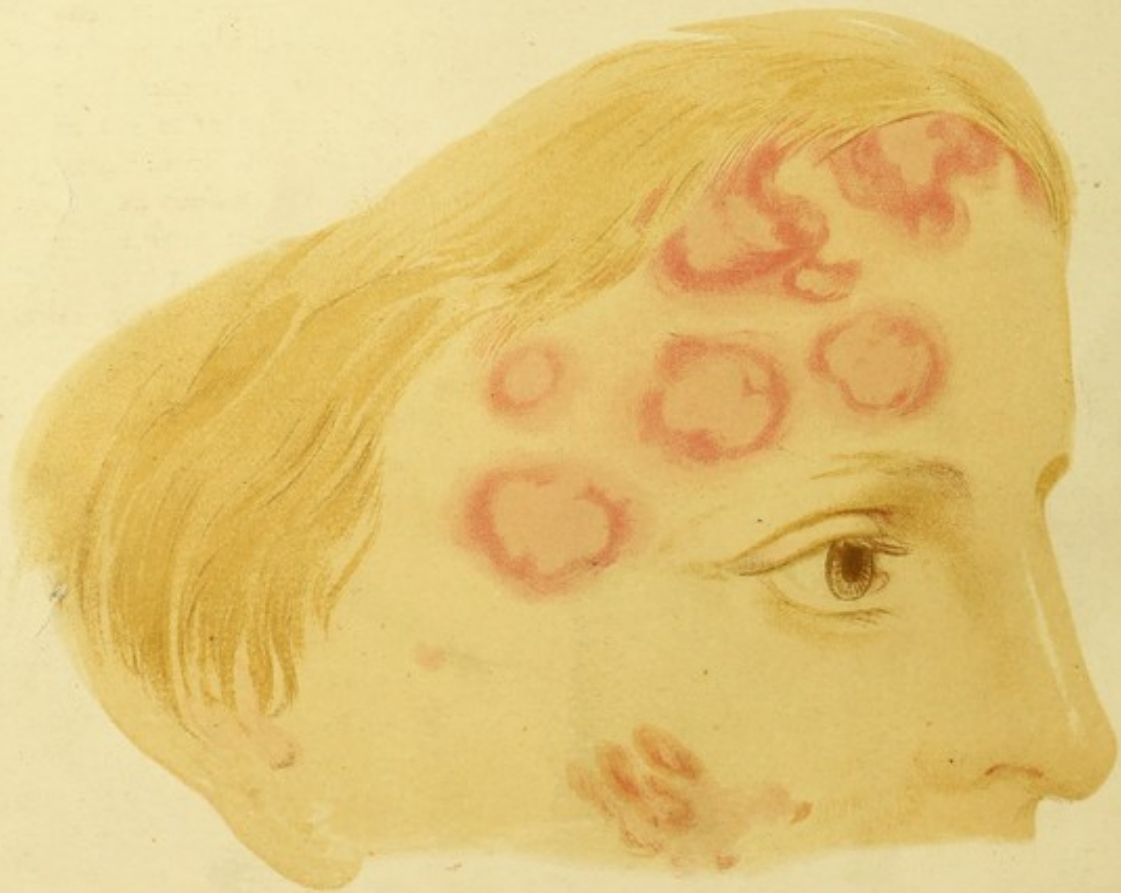

Fig. 2.

ERYTHEMA CIRCINATUM ET MARGINATUM.

## EXPLANATION OF THE PLATES.

---

THE first eight Plates, forming Parts I. and II. of this Atlas, represent the chief or more common forms of the Erythematous diseases of the skin; viz. *Erythema*; *Urticaria*, or Nettle Rash; *Strophulus*, or Red Gum or Gown of Infants; and *Roseola*.

### THE ERYTHEMATA.

These Erythemata are essentially non-contagious. They do not run a strictly definite course. They are not severely pyrexial. Their eruptions are not general, and they are not caused by specific viruses. In these respects they differ from the Exanthemata.

The Erythemata are also characterised, (1) as regards *general* symptoms, by occasionally a certain amount of pyrexial disturbance, but it is not marked, or, if marked, it is not sustained; by malaise and an acutish onset; (2) as regards *local* phenomena, by active hyperæmia—the redness being removable by pressure and becoming bluish before fading—and by the immediate consequence of the hyperæmia; viz. serous exudation into the skin textures, and this only. *Erythema* consists of patches of a more or less vivid *red* colour; *Roseola* is of *rosy* hue; *Strophulus* is made up of bright red papules, interspersed with blushes; and *Urticaria* is attended by the formation of *wheals*.

**PART I.**—This fasciculus contains representations of *Erythema* and *Urticaria*.

#### ERYTHEMA.

It is customary to make two groups out of the several varieties of *Erythema*: the *idiopathic*, including the forms produced by local or external causes (represented by *E. simplex*, PLATE I. *Fig. 1*), and the *symptomatic* group, embracing the varieties (PLATE I. *Fig. 2*, PLATES II. and III.) resulting from constitutional, general, or internal causes, and termed *E. circinatum*, *marginatum*, *papulatum*, *tuberculatum*, and *E. nodosum*. In these latter there is exudation into the skin, giving rise to distinct elevation of the eruption.

#### PLATE I.

*Fig. 1*, or *ERYTHEMA simplex*, consists of hyperæmia disappearing by pressure, with subsequent desquamation, but without exudation. It is the type of the idiopathic group of *Erythema* as above stated. This variety may be caused by the action upon the skin of local irritants of the most varied kind; as, for example, heat, cold, friction, acrid substances, plasters, dribbling urine, &c. It may, however, arise from irritation reflected from other parts of the body. In the case from which the representation was taken it was induced by severe dyspepsia in connection with constipation—not an uncommon cause of *Erythema* of the face—and the redness was intensified by eating, by stimulants, and by improper diet; whilst it was removed by curing the dyspepsia, in connection

with the use of aperients, and the regulation of the diet. The like condition may be directly induced by exposure to the sun, or undue exposure to the fire in the case of cooks. The Erythema of *Fig. 1* is the type of the redness that occurs about dropsical legs from the distension of the skin, and which is termed *E. leve*; of the redness that occurs from the friction of one fold of the skin upon another, as in the neck and the groins of young children especially, and the groins and folds of the submammary parts of elderly fat persons; which is accompanied by a thin muciform discharge, and is termed *E. intertrigo*: of the somewhat pinkish, hot, itchy *blush* that creeps over the skin in the seats of contact with dyes and similar acridities, or of abrasions and punctures which have become poisoned by some acrid matter, and which has been termed *E. serpens* by Mr. Marrant Baker: and of *pernio* or chilblain, which is attended by such severe pruritus. The treatment of *E. simplex* consists in the prevention of all local irritation, whatever that may be, in each particular case, and in the use of soothing and astringent applications. There is none better than calamine and zinc lotion, in the proportion of two or three drachms of oxide of zinc and calamine powder to six ounces of rose water, with a drachm of prussic acid to allay pruritus, if this be present. In Intertrigo, drying powders, starch and oxide of zinc, or prepared Fuller's earth are the best remedies. Internal treatment is only needed for the removal of dyspepsia where this exists, or constipation, or pyrexia, if these be present. In Intertrigo, however, in debilitated, ill-nourished, or strumous children, better feeding or nursing and the prescription of steel wine and cod-liver oil are needed.

*Fig. 2*, denominated ERYTHEMA *circinatum* and *marginatum*, represents two phases of one and the same form of rash; indeed it is certain that the conditions indicated by these two terms, and those styled *E. papulatum* and *tuberculatum* (PLATE II. *Figs. 1* and *2*), are modifications of one and the same eruption, for their several features are often commingled in the same patient; hence Hebra has included the above-named varieties under the term *E. multiforme*, which some think comprises also *E. nodosum* (PLATE III.)

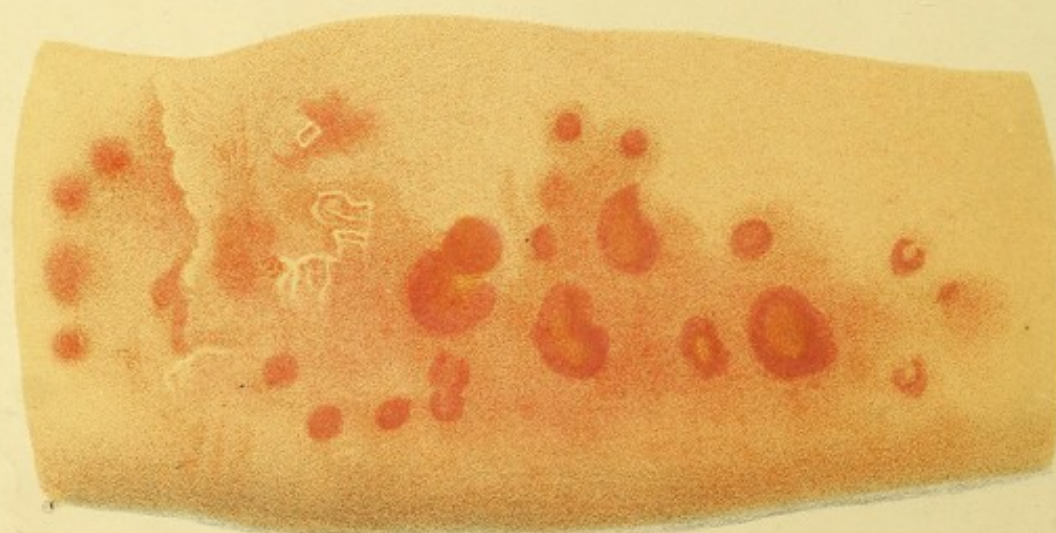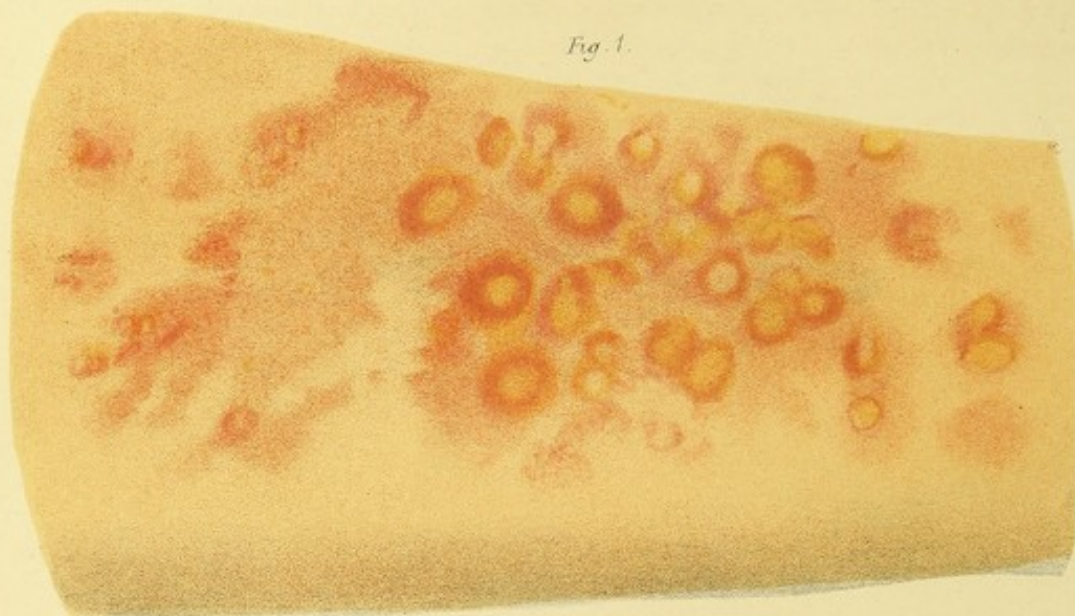*E. circinatum*, as seen in the lower part of the forehead of the *Fig. 2* now under notice, is characterised by well-defined, raised, but smooth circular patches, which begin as vivid red spots, the centres of which fade in colour and become yellowish, whilst the circumferences increase as a red ring, the hue of which varies, being at times bright red, at others purplish. The colour may vary in intensity from day to day, as in the case from which this *Fig. 2* was taken; for on one occasion, when the patient felt cold, the patches consisted of almost *pale flesh-coloured* raised well-defined circular bands, the fact being that the exudation was present without, at the time, the hyperæmic blush. When two or three rings coalesce, the circular character of the eruption is obscured, and the boundary edge is serpentine and well marked, as seen in the upper part of forehead in *Fig. 2*. To such a condition the name of *E. marginatum* or *gyratum* is given. It is noteworthy that in the case here represented, distinct and well-marked patches of *E. tuberculatum* were present about the neck; a small piece of this form is represented at the lower part of the face. All portions of this rash desquamated as usual. The two phases of Erythema here specially referred to, as in the case represented, are attended by slight pyrexia, malaise, occasionally rheumatic pains, with subsequent debility, and, locally, by slight heat and itching. For treatment see remarks upon PLATE II. *Fig. 2*.





ERYTHEMA PAPULATUM.

*Fig. 1.*



*Fig. 2*

ERYTHEMA TUBERCULATUM.

## PLATE II.

*Fig. 1.*—ERYTHEMA *papulatum*. This phase of Erythema, mostly seen in young people, is characterised by small raised hyperæmic spots, varying in size from a pin's point to that of a split pea, or a little more, which last in each case a few days, and then fade away. Their development is attended with very slight constitutional disturbance, and by sensations of heat, itching, or a feeling of tightness at the seat of eruption. The spots are at first vivid red, as represented in the left half of the figure; they then become purplish, and fade on pressure, though the exudation is felt to be left behind. They acquire subsequently greenish and yellowish hues (as in the case of a disappearing bruise) whilst they are fading away, and as represented in the right half of the figure. This form of eruption is attended by a slight general blush, out of which the raised papulations often project, as it were. It is commonly met with about the back of the hand and the dorsum of the feet, but also, though more rarely, about the neck, the legs, and the joints. I have purposely portrayed the eruption in its fading stage, to the right hand of the *Fig. 1*, because it is a condition that often puzzles those who meet with it. I have known it mistaken at the back of the hand and about the knuckles for chilblains. *E. papulatum* is often conjoined with the particular form denominated *E. tuberculatum*, and occasionally, as stated in describing *Fig. 2*, PLATE I., with *E. circinatum*, the first often affecting the upper and the second the lower extremities. The disease usually lasts from one to two or three weeks, but may become chronic. I will refer to treatment after the description of *E. tuberculatum*.

*Fig. 2.*—ERYTHEMA *tuberculatum* differs from *E. papulatum* only in the size of the spots of eruption. In the latter there are *small* papules, in the former *large* papules or tubercles, as indicated by the name *tuberculatum*. In the illustration given, it will be observed that some of the spots are in reality such as occur in *E. papulatum*, the larger ones being only characteristic of *E. tuberculatum*. There is more exudation in this variety, of course. The tints represented in this figure, viz. bright red to the left and purplish in other parts, are those which belong equally to the earlier stage of *E. papulatum* and *E. tuberculatum*; and the latter form, in disappearing, may exhibit the same hues of greenish and yellow as are depicted in *Fig. 1*. As has been stated, this phase is associated with the other form of the composite *E. multiforme*. In the case from which PLATE I. *Fig. 2* was taken, *E. tuberculatum* existed all over the neck. In this variety constitutional symptoms are sometimes somewhat marked, and the variety occurs, if by preference in any particular class of patients, in servants who have come from country districts into service in large towns. I have seen *E. tuberculatum* attack the entire scalp and forehead, when it was mistaken for syphilis, only to disappear in three or four days under the use of quinine.

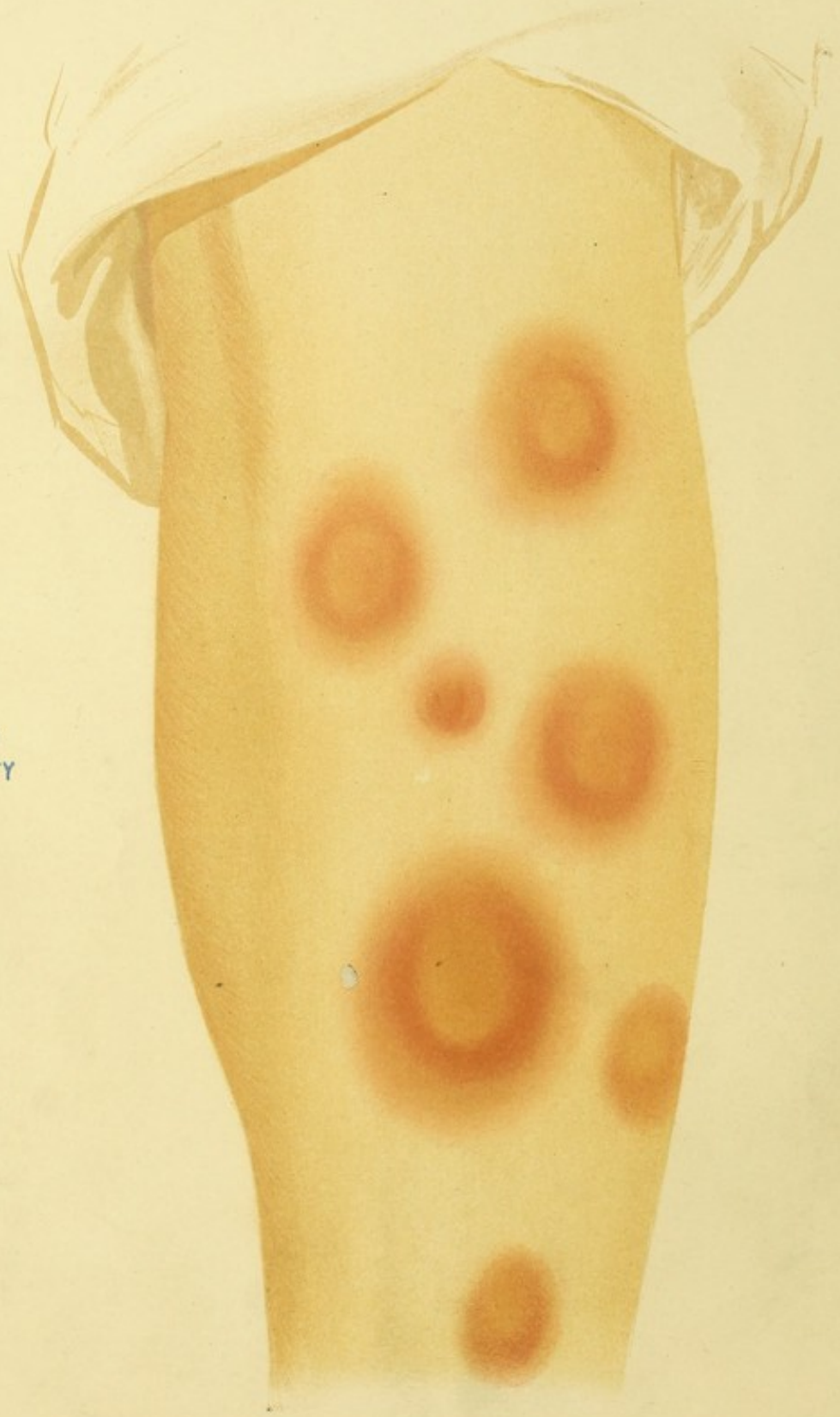It is probable that in marked cases of *E. multiforme* there is slight extravasation of blood in the seats of the larger exudative elevations.

It will have been gathered from the above descriptions that *E. multiforme* assumes different aspects, and differs in degree in different cases. The diagnosis is always made

by the essentially hyperæmic condition of the disease; and if exudation occurs, the spots, though raised, are soft, and speedily subside to the level of the normal skin; whilst the peculiar Erythema passes from red to yellow through a purple tint.

The treatment of *E. papulatum*, *E. tuberculatum*, *E. circinatum*, and *E. marginatum* (PLATE I. *Fig. 2*) are practically the same. It is at once simple and effective. It should consist, *internally*, if there be pyrexia, in the administration of a few drops of aconite, with effervescing salines, two or three times a day, with an appropriate aperient if needed, light diet, and suitable rest: to be followed, in a couple or three days, by quinine or the mineral acids and bark, unless there be special contraindications; with, *locally*, some simple fomentation, followed by an astringent lotion made of opium and lead, or oxide of zinc.





LEEDS & WEST-RIDING  
MEDICO-CHIRURGICAL SOCIETY

ERYTHEMA NODOSUM

## PLATE III.

ERYTHEMA *nodosum*.—There can be very little doubt that this is an exaggerated condition of *E. papulatum*, but it is clinically convenient to give a separate description of it. It usually attacks the young, and it is held to be more common in females than males, though I am doubtful on this point. Its most common seats are the lower limbs, especially the front of the leg, and, less frequently, the outer part of the forearm; and it consists, as represented in the illustration, of oval or roundish elevated swellings, which are very perceptible to the touch, very tender, and are caused by infiltrations in the deeper layer of the skin in connection with more or less extravasation of blood. When the disease first appears it takes the form of little rounded knots, about the size of the central spot in the Plate. These exhibit at first a bright red or even a purplish tint, but, if red, soon a deeper or violet tint. The spots become oval, and increase in size until they attain a diameter of oftentimes an inch and a half, or more. Each spot lasts from two or three to ten days, perhaps, and on fading acquires the same tints which characterise a fading bruise. The lighter tints are shown in the smaller, and the darker in the larger or older spot in the figure. The brownish hue in the central part of the large nodose swelling represents a fading of the original red; the purple colour, the deepening of the red prior to its passage, as indicated at the more external parts of the swelling, through the greenish and yellowish tints. The external blush fades gradually away into the colour of the surrounding skin. In severe cases, several spots may run together into a large elevated irregular patch, very painful and raised to the touch. This disease lasts usually about a fortnight, and is followed by desquamation. It is accompanied by febrile disturbance at the outset, which, soon passing off, leaves the patient debilitated. It may be severe enough to send the attacked to bed, and not infrequently there are rheumatic pains above the limbs and joints, so that patients are sent to hospital, or treated elsewhere, as suffering from threatening rheumatism. Oftentimes uncomfortable pains are experienced in the legs after walking, especially during the continuance of the eruption.

The treatment consists in complete rest if the disease is severe; the exhibition of salines, if need be, followed by quinine; whilst compresses wet with an evaporating lotion or a lead lotion, or even cold water, may be kept applied to the swellings that are painful.

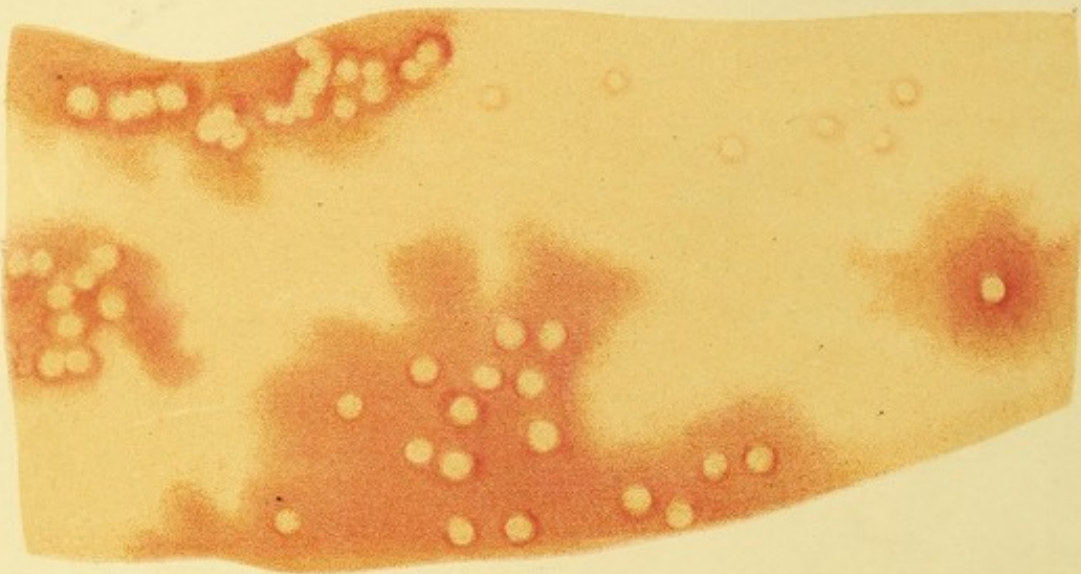



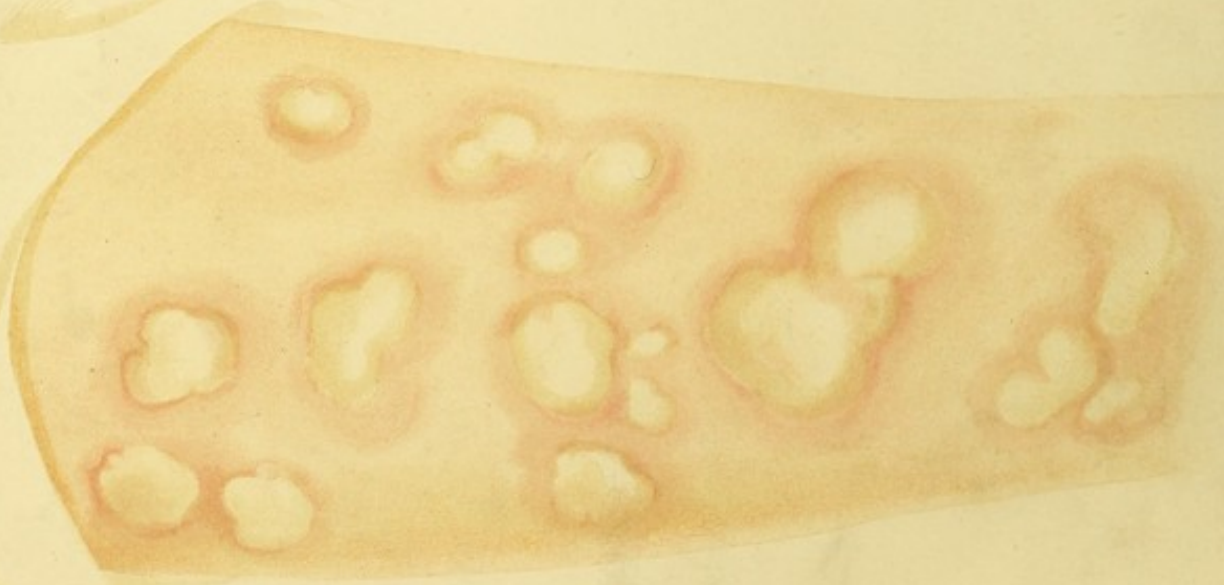


URTICARIA FEBRILIS.

*Fig 1.*



LEEDS & WEST-RIDING  
MEDICO-CHIRURGICAL SOCIETY



*Fig 2*

URTICARIA CHRONICA

## PLATE IV.

## URTICARIA OR NETTLE RASH.

This disease is essentially characterised by the development of wheals, or pomphi, as they are sometimes termed, upon a more or less hyperæmic base, or out of which they seem to arise. They are attended by a burning or stinging sensation, the whole resembling a nettle sting, as the name given to the disease implies. The eruption develops very suddenly in different localities, but only to as rapidly disappear. This evanescent and capricious feature of the eruption is one of its chief characteristics. Slight pyrexia attends the disease, and wheals can usually be evoked by scratching the skin. The eruption itself varies a great deal in appearance; there may be a good deal of hyperæmia whilst the wheals are few and small, or there may be very slight redness, the wheals being large and linear, circular or irregular, in shape. These two contrasting conditions are represented in *Figs. 1 and 2* in the accompanying PLATE IV., but there are no decided lines of demarcation between the two; and Urticaria may take the form of an admixture of the several features of either condition. In the young the wheals are small and evanescent, and followed by lymph deposit. This will be specially referred to in describing *Lichen urticatus* in PLATE IX., which disease is a lichen developing out of an urticarial condition. Clinically, Urticaria may be divided into two varieties—acute or febrile, and chronic.

*Fig. 1* is Willan's representation of *Urticaria febrilis*, and no doubt it is, in the main, correct. In it hyperæmia and pyrexia are marked features. In a certain sense, every attack of Urticaria, or every crop of wheals, runs an acute course; but I am disposed to say, that true febrile Urticaria is attended by pyrexia, often of considerable degree: by an unusual suddenness of onset of the pyrexia and eruption, the latter being generally pretty extensive, and exhibiting wheals, small or large, whilst the disease is not prolonged by successive outbursts, but often rapidly disappears, the reason being that the attack is mostly due—hence the term *U. ab ingestis*—to the ingestion of some disagreeing article of diet or medicine, such as shell-fish, fruits, pork, mushrooms, coffee, copaiba, which is speedily removed from the system by vomiting, intestinal action, or medicines given for the relief of the urticaria. The condition portrayed by *Fig. 1* may rarely be an accompaniment of teething, of exposure to the cold and damp, and of mental emotion; or it may result from the action upon the skin of irritants, such as fleas or acrid vegetable substances.

The diagnosis of acute Urticaria offers no difficulty, except in rare cases, in which there may be excessive pyrexia, accompanied by delirium even, vomiting and headache at the outset where shell-fish or bad sausages are sometimes largely partaken of and cause it. In these cases, however, whilst the face and other parts may be enormously swollen, the general symptoms are at once relieved by the local inflammation; there is great tingling and itching, and wheals are sure to be noticed, and the cause is generally pretty self-evident, because just before the attack, following a meal, the patient felt perfectly well.

The treatment of this form of Urticaria is usually satisfactory. A brisk purge, containing a little calomel even, preceded by an emetic, a few doses of carbonate of soda

and magnesia internally, with milk diet for 24 hours, and a prussic acid lotion, constitute all that is needed to get rid of acute Urticaria. In cases where the exciting cause is mental emotion, the disease may lapse into the chronic form.

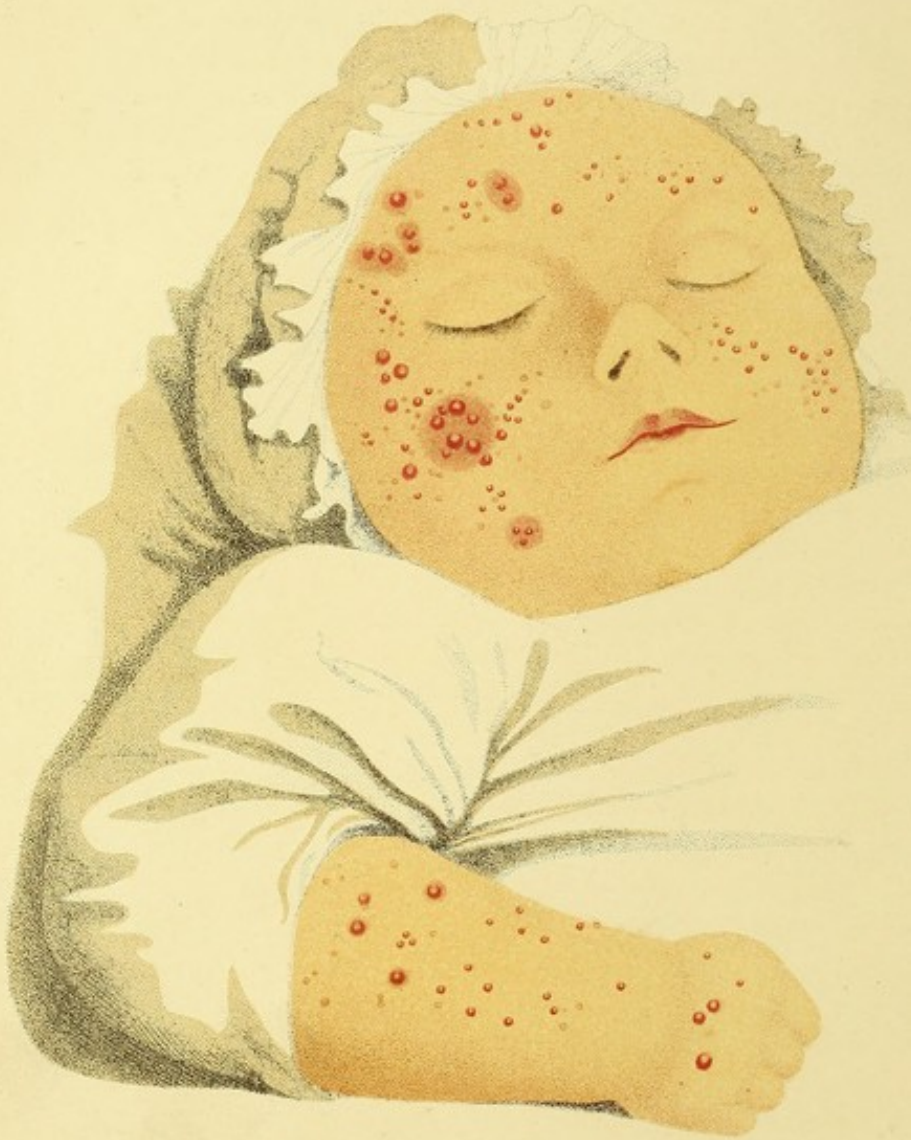*Fig. 2* represents *Chronic Urticaria*. The skin generally is very irritable, and scratching excites the development of a red hyperæmic line, which becomes the seat of a wheal taking the shape of the scratched line. This irritable and sensitive skin may be the seat of any number of wheals, seated or not upon a red base, or edged round with a red blush of varying extent. Generally speaking, a red blush appears, and an infiltration of serum takes place, so that the blotches elevate and become gradually paler, and then dull white in the centre, as portrayed in the figure. The disease is not attended with much, if any, pyrexia; wheals and blushes rapidly come and vanish in the most capricious manner over the body, and successive crops prolong the disease for weeks, months, or years. When the wheals themselves exist rather longer than usual, the disease is termed *U. perstans*; when they are very fugitive, *U. evanida*—such wheals really occur in *Strophulus candidus* (PLATE VI.), and *Lichen urticatus* (PLATE IX.)—when there is much swelling of the subcutaneous tissue, *U. subcutanea* or *tuberosa*. The mucous membranes of the eye, and the mouth and throat, and also the tongue, may be implicated, and rapidly swell up.

The chief causes of chronic Urticaria are mental emotion, nervous debility, especially from over-work and mental strain, exposure to great alternations of temperature, the circulation of acrid substances, such as uric acid and its allies in gouty and rheumatic subjects and in dyspeptics, or the bile acids, in the blood-current; the action upon the skin of external irritants, such as pediculi; reflexed irritation from sexual disorder; bad feeding and living in damp tenements, &c.

The treatment of chronic Urticaria, where the first three above-named causes are in operation, is similar. Change of air and scene, appropriate nervine tonics, with alkaline and bran baths, are requisite; in gouty, rheumatic, and bilious subjects, alkalies, with anti-dyspeptics and aperients, alkaline waters, a visit to such places as Aix or Homburg, and the regulation of the diet, are needed; the destruction of all causes of external irritation, such as pediculi; the removal of menstrual and uterine disorders, and the institution of a general tonic plan of treatment, are called for in other instances. In all cases alkaline baths, with, in some cases, douche baths, and the use of Prussic Acid (ʒj. to ʒvj.), or Benzoic Acid (gr. 40 to ʒvj.), or Alkaline lotions (bicarbonate of soda ʒij. to ʒvj.), to allay irritation, will also greatly comfort and assist the cure.—[The reader will find the treatment elaborated in my systematic work on Skin Diseases, 3rd edition.]

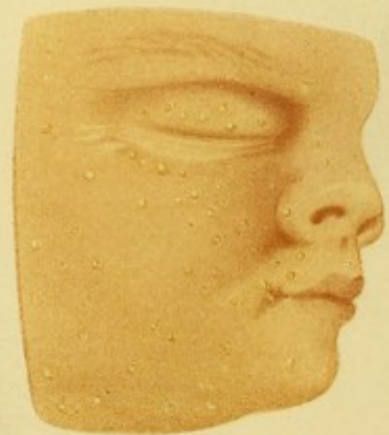

STROPHULUS INTERTINCTUS



*Fig 1*

LEEDS & WEST-RIDING  
MEDICO-CHIRURGICAL SOCIETY



*Fig 2*

STROPHULUS ALBIDUS.

## EXPLANATION OF THE PLATES.

---

**PART II.**—This fasciculus contains representations of Strophulus and Roseola, two, of the four varieties of the group ERYTHEMATA, not yet described, and whose general features were given in the preceding Part.

### STROPHULUS.

The naked-eye features of the common forms of the eruption termed Strophulus were well described by Willan, and I have retained, except in one instance—viz. that of PLATE V. *Fig. 2*—his representations (PLATES V. and VI.). The disease consists of minute red papules, intermingled with vivid red blushes of greater or less extent. The eruption is common in infancy and early childhood. It occurs chiefly about the face, neck, and arms, but also other parts of the body, and lasts ten days or a fortnight perhaps, disappearing by slight desquamation. The eruption is attended by very slight, if any, irritation. The papules are either hyperæmic papillæ or sweat follicles. In early life, in consequence of the extreme sensibility and vascularity of the skin, any slight disturbing cause—such as disorder of the bowels and stomach, gum irritation, or exposure to much heat—is likely to give rise to these hyperæmic conditions. The disease I do not think is so common as formerly, when infants were kept coddled up in much clothing, and in stuffy lying-in rooms, and were fed and tended much more injudiciously than at present.

### PLATE V.

*Fig. 1.*—STROPHULUS *intertinctus*, called popularly the *Red Gum* or *Gown*, was described by Willan as made up of vivid red papules, situated chiefly about the cheeks, forehead, and back of the forearms, distinct from each other, and mixed with minute red non-elevated points—in reality, commencing or abortive papules—and *intertinctured* with slight red blushes here and there. The rash is often connected with some acidity or gastric disorder, or irritation in the alimentary canal, or arises from improper feeding. The treatment consists in regulating the bowels by a little rhubarb and soda, the administration of a few doses of grey powder if the motions are pallid, in checking diarrhœa in any excess by chalk mixture, attending to the diet, seeing that the child has a proper amount of fresh air and careful ablution, and applying some slight astringent locally, such as a weak lead or oxide of zinc lotion with a little Eau de Cologne in it. If the skin be irritable one or two bran and borax baths may be given. But the disease is of a very mild character, and I describe it chiefly that it may not be mistaken for any of the Exanthemata.

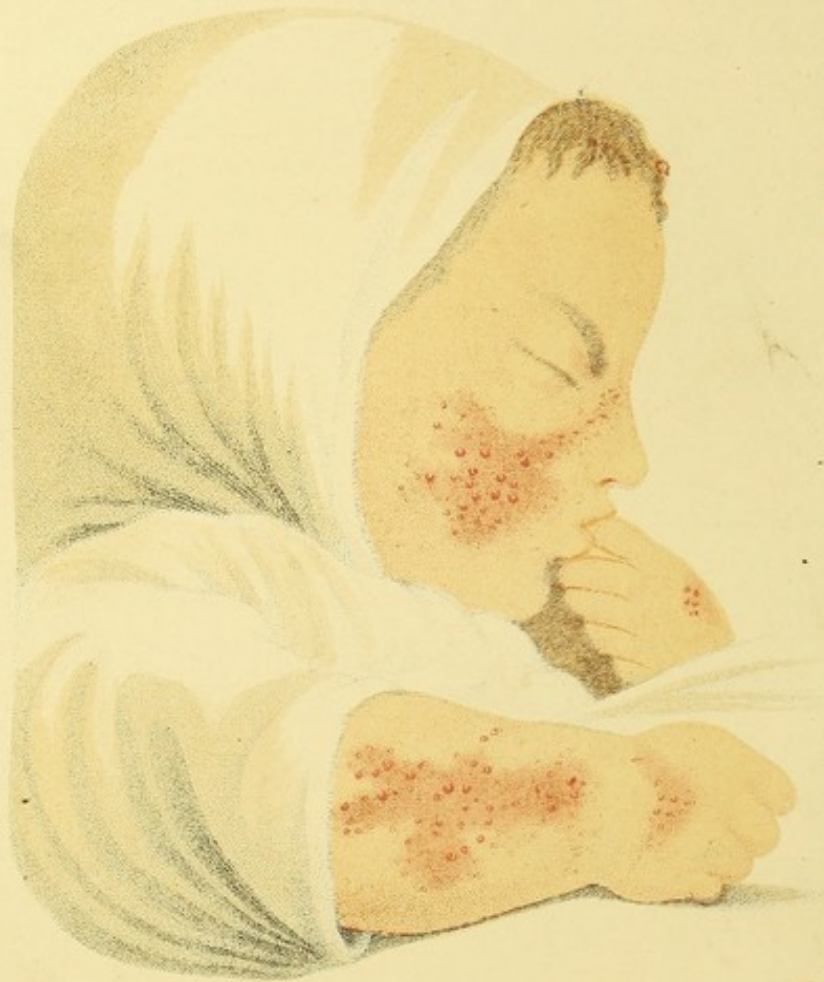*Fig. 2.*—STROPHULUS *albidus* is a copy of a wax model in the Museum of University College, taken from life. This disease is in reality no Strophulus at all. Bateman said,

'it is merely a variety of the preceding species, and is occasionally intermixed with it; the papulae consisting of minute hard whitish specs, a little elevated, and sometimes surrounded by a slight redness, and appearing chiefly on the face, neck, and breasts.' ['Synopsis,' 1819, p. 3.] There must be confusion here. Small solid pale papules may be left by little wheals that sometimes spring up in connection with Strophulus in infants, but the little solid-feeling round *pearly* elevations, represented in this figure and often seen in children, though not in children alone, but adolescents and even elderly persons, are minute sebaceous cysts filled with white sebaceous matter. These may no doubt concur with Strophulus, but Strophulus *albidus* is a misnomer: it is a sebaceous disorder oftentimes termed *milium* or *grutum*. Parents are oftentimes very much troubled about this *milium*, which occurs in fair individuals; but it may disappear by the use of mild astringents, or be got rid of, if necessary, by touching the top of each little cyst with acid nitrate of mercury. This operation must be done very carefully and neatly, otherwise disfigurement from resulting pitting may be left behind.

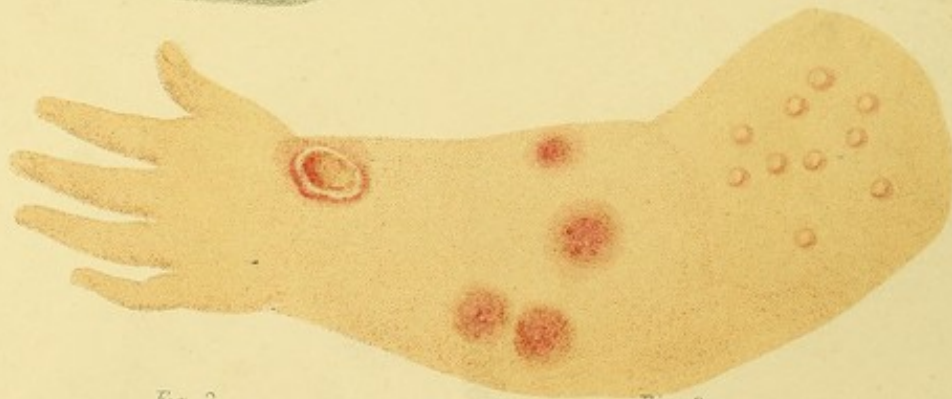



*Fig. 1.*  
STROPHULUS CONFERTUS.



LEEDS & WEST-RIDING  
MEDICO-CHIRURGICAL SOCIETY



*Fig. 2*  
STROPHULUS VOLATICUS.

*Fig. 3*  
STROPHULUS CANDIDUS.

PLATE VI.

*Fig. 1.*—*STROPHULUS confertus* is Willan's representation of this disease, but very much, as I think, improved by the additional softness given in the printing. This eruption was originally styled the *Rank Red Gum* and *Tooth Rash*. It differs from *S. intertinctus* chiefly in its more extensive crop of papulæ, which are also less bright in colour and smaller in size. This variety occurs in infants from five to eight months old, forming large patches of irregular size and shape: and as the papules are numerous, they crowd together over the red surface. The eruption attacks the face, the arms, the shoulders, and other parts, and it is often excited by teething or its attendant intestinal irritation.

The treatment is the same in reality as that for *S. intertinctus*, with this addition, that the gums should be lanced if needed, and mild diuretics, such as sweet spirit of nitre, freely given if the secretion of water is scanty.

*Fig. 2.*—*STROPHULUS volaticus* consists of little clusters of papillæ or of red patches on which redder papules attempt to form, which patches spring up here and there over the body to disappear in three or four days, with slight cuticular exfoliation. The successive crops of spots may prolong the disease for two or three weeks. This form of *Strophulus* partakes of the characters of *Urticaria*, the wheal often leaving behind the little papules referred to. Sometimes the rash becomes inflamed more than usual, from scratching perhaps, as seen in the spot at the root of the thumb, and then a little effusion takes place, and the disease assumes the aspect of slight eczema. The treatment consists in the exhibition of mild laxatives and antacids.

*Fig. 3.*—*STROPHULUS candidus* is not a *Strophulus* at all. It is in reality *Urticaria*. Wherever there is any stomach derangement, with acidity and pallid motions in some children, the sensitive skin is apt to become sympathetically irritated, and the derangement is apt to take the form of small wheals. These wheals in children are often not only small and very evanescent—their development being favoured by the heat of the bed especially—but they are likewise attended by slight effusion; hence they assume the aspect of little smooth shining elevations, surrounded by a slight zone of redness, as portrayed in *Fig. 3*—viz. in the right half of the arm. They may occur in connection with *Strophulus papulæ* proper, and in connection with *S. intertinctus* (PLATE V. *Fig. 1*) or *S. confertus* (PLATE VI. *Fig. 1*), and hence Willan and Bateman imagined that these spots are modifications of ordinary *Strophulus papulæ*; but they are merely complicating wheals or *Urticaria papulosa*, as it is called. (See *Lichen urticatus*, PLATE IX.) Each spot lasts five or six days, and gradually fades away; that is to say, disappears as soon as the effused serosity is removed. Bateman speaks of this same condition, *S. candidus*, succeeding some of the acute diseases, and as occurring in cases of *Porriigo* (eczema), and during secondary dentition. In other words, it may occur in children under all conditions in which there is any slight constitutional disturbance with intestinal irritation.

The treatment is very simple. It consists generally in the removal of coincident conditions of intestinal irritation, debility during convalescence from other maladies, dental irritation, or dyspepsia, and the prescription of some mild diuretic and antacid.

The child should be carefully dieted, free ablution should be practised, whilst the patient should enjoy as much fresh air as possible. Locally, a lotion made of Borax ʒj., Oxide of Zinc ʒiss., and Rosewater ʒvj., may be dabbed on several times a day.

Another variety is described under the term STROPHULUS *pruriginosus*. It is, in reality, the outcome of *Lichen urticatus*, and will be described when I come to speak of that disease in PLATE IX.

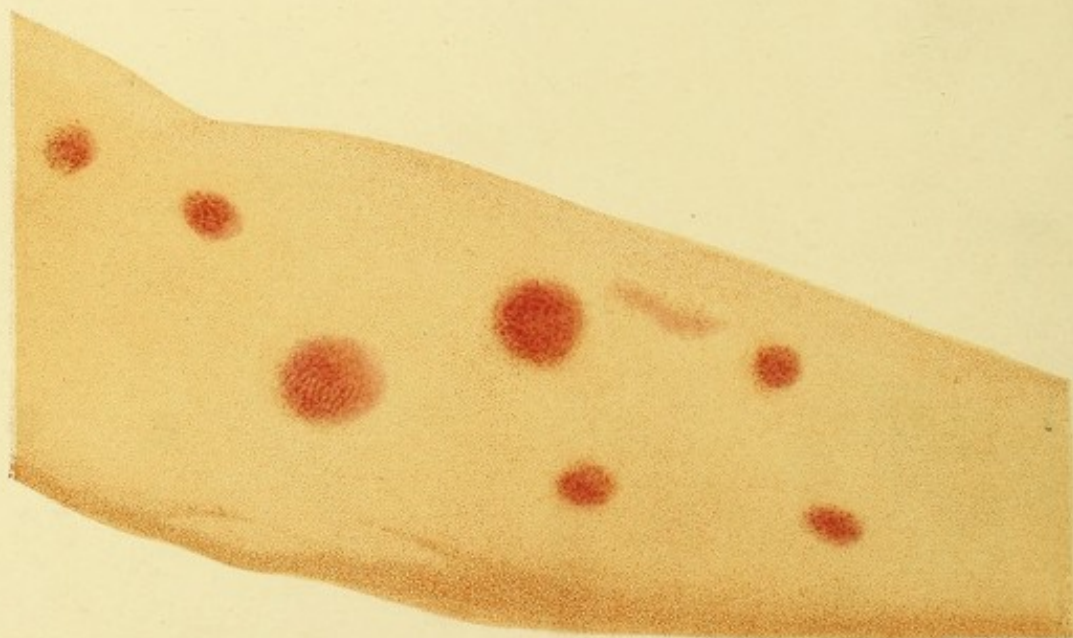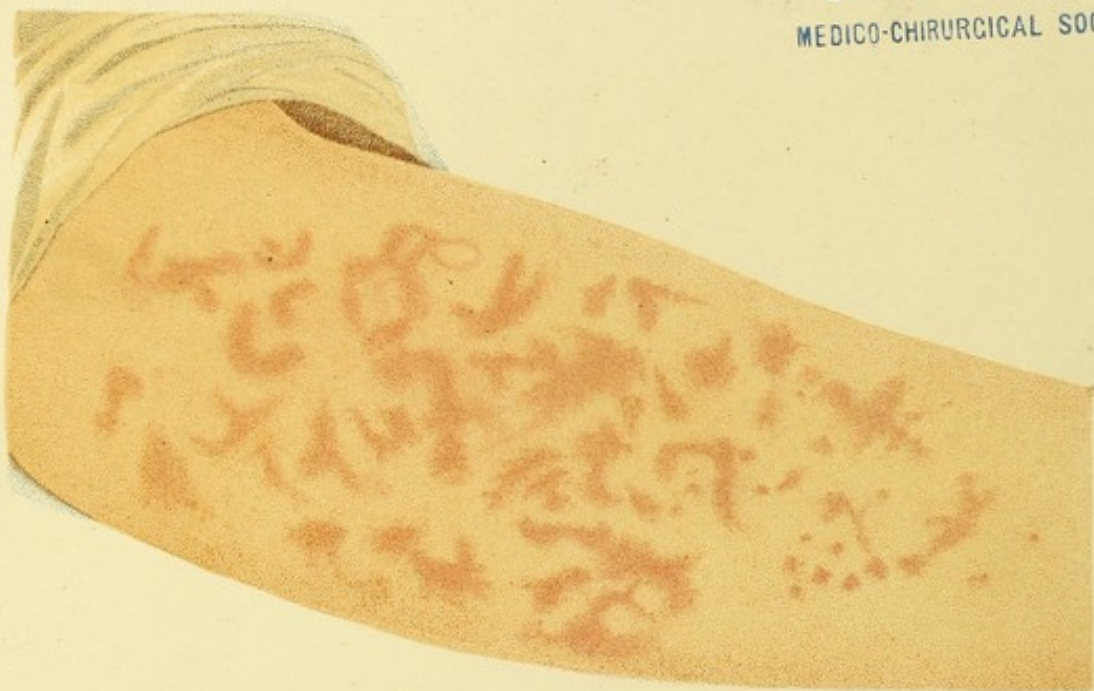NOTE.—It will be observed that my description of the Strophulus of authors as a whole is very different from that usually given. I only recognise two of Willan's forms, *S. intertinctus* and *S. confertus* which might be included under one term Strophulus, as distinct diseases. *S. albidus* is a sebaceous disease, and *S. candidus* and *volaticus* are phases of Urticaria and allied to *Lichen urticatus*, or, as it is sometimes termed, *Urticaria papulosa*.



ROSEOLA ÆSTIVA

*Fig 1.*

LEEDS & WEST-RIDING  
MEDICO-CHIRURGICAL SOCIETY



*Fig 2.*

ROSEOLA AUTUMNALIS

## PLATES VII. AND VIII.

## ROSEOLA.

The four figures of these two Plates represent the different appearances presented by Roseola. They are reproduced from Willan's plates, but the colour has been altered a good deal to more correctly represent the active and earlier stages of the disease; because it is at the earlier period in its development that its nature needs to be recognised, since it is then liable to be confounded with measles or scarlatina. Indeed, Roseola is more important on account of its liability to be mistaken for these two than on account of any gravity of its own as a disease. In the case of certain of the acute febrile diseases, as in small pox, rheumatic fever, vaccinia, and in cholera, a roseolous rash sometimes occurs; as, for example, before the proper eruption of small pox appears, over inflamed joints in rheumatism, and about the areola of vaccinia: but it is soon recognised as a mere accompaniment of a more serious and important condition. But in Roseola proper, the rash is the only important symptom present, beyond slight constitutional disturbance. This Roseola is characterised *negatively* by an absence of distinct pyrexia, of the catarrhal symptoms of measles: and of the severe constitutional disturbance, the pungent hot skin, or general distribution of the rash of scarlet fever. It is characterised *positively* by rose-coloured patches and mottling, which appear about some part of the body, but not in the face, as in measles. I will now speak of these four varieties of Roseola proper individually.

## PLATE VII.

*Fig. 1.*—ROSEOLA *æstiva*. This is a rose-coloured rash, which chiefly occurs at the beginning of the hot season, or in summer, and may be preceded by slight febrile indisposition for a few days. It differs from rubeola in the larger size, and the more irregular form and partial distribution of its patches, in its non-appearance in the face first of all, and in the absence of catarrhal symptoms, though the fauces may be slightly red, whilst the rash assumes a dark hue in a day or so, and fades out in about five or six days; and from scarlatina it is still more distinguished by its roseate hue, and by its irregular mode of distribution, and absence of severe general symptoms. It is caused by exposure to cold, drinking cold water when hot, or dentition, and requires, for its treatment, light diet, slight laxatives, followed by quinine.

*Fig. 2.*—ROSEOLA *autumnalis* consists of distinct circular patches, varying in size from a quarter to an inch in diameter, disappearing under pressure, of a damask hue, occurring principally on the arms of children from five to ten years of age, and disappearing in about a week. It does not necessarily occur in the autumn, as its name implies.

# THE UNIVERSITY OF CHICAGO


## LIBRARY

The University of Chicago Library is a leading research library in the United States. It is one of the largest and most comprehensive libraries in the world, with a collection of over 15 million volumes. The library is a vital resource for the university and the broader academic community. It provides access to a wide range of materials, including books, journals, and electronic resources. The library is committed to providing excellent service to its users and to supporting the university's research and teaching activities.

## LIBRARY

The University of Chicago Library is a leading research library in the United States. It is one of the largest and most comprehensive libraries in the world, with a collection of over 15 million volumes. The library is a vital resource for the university and the broader academic community. It provides access to a wide range of materials, including books, journals, and electronic resources. The library is committed to providing excellent service to its users and to supporting the university's research and teaching activities.

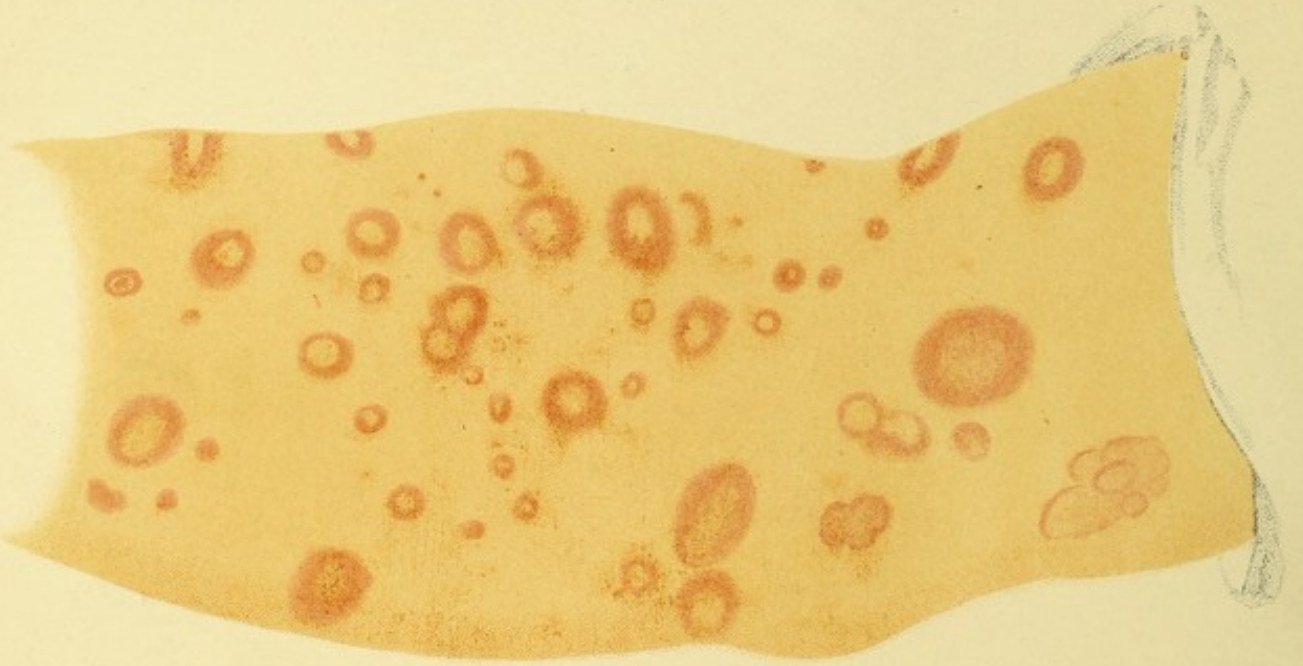
The University of Chicago Library is a leading research library in the United States. It is one of the largest and most comprehensive libraries in the world, with a collection of over 15 million volumes. The library is a vital resource for the university and the broader academic community. It provides access to a wide range of materials, including books, journals, and electronic resources. The library is committed to providing excellent service to its users and to supporting the university's research and teaching activities.





ROSEOLA ANNULATA

*Fig. 1.*



*Fig. 2.*

ROSEOLA INFANTILIS.

LEEDS & WEST-RIDING  
MEDICO-CHIRURGICAL SOCIETY


LEEDS & WEST-RIDING  
MEDICO-CHIRURGICAL SOCIETY

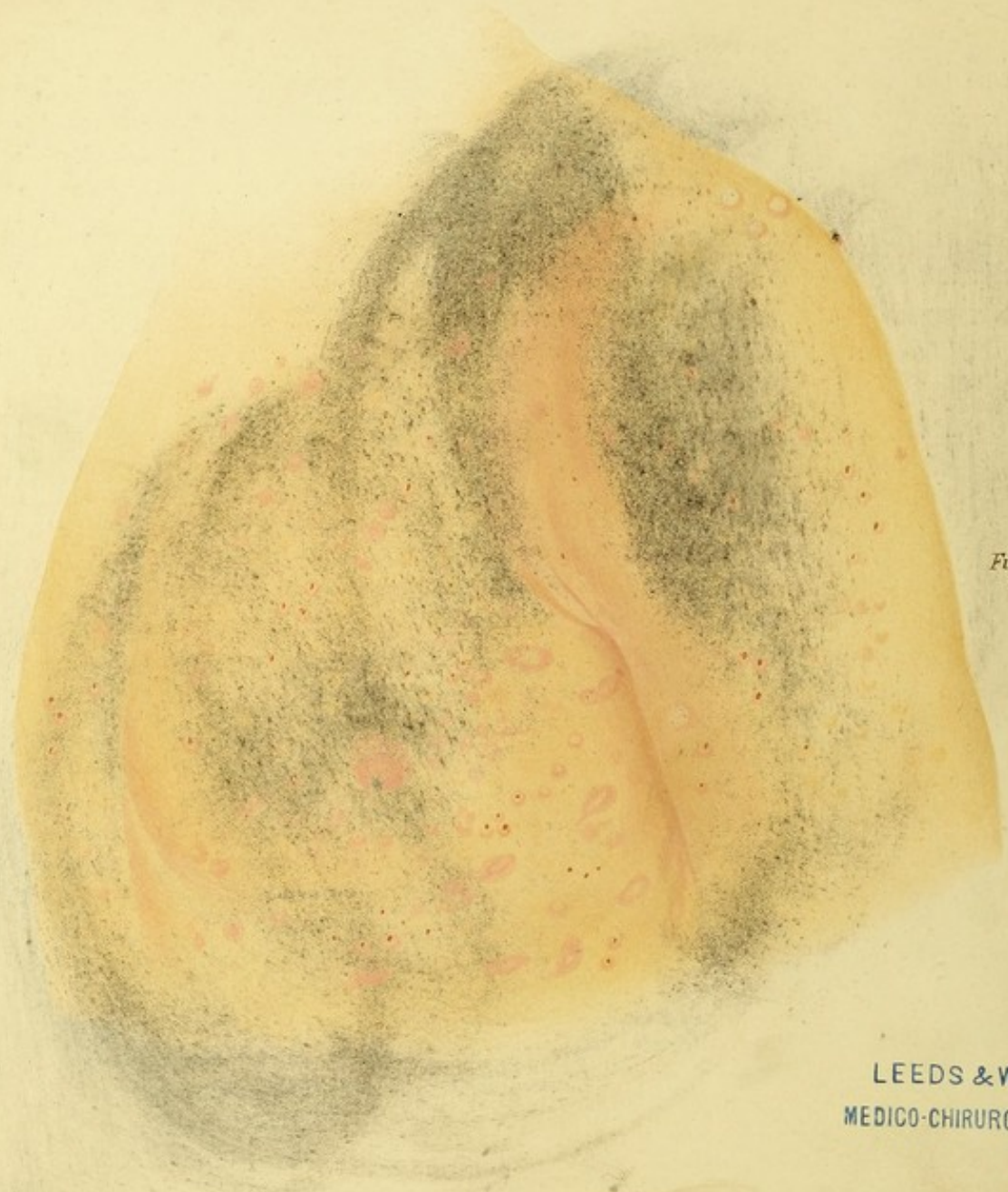PLATE VIII.

*Fig. 1.*—ROSEOLA *annulata* is only a modified form of *R. autumnalis*. It appears in rose-coloured rings, with central areas of the usual colour of the skin. The rings are at first minute, but gradually dilate, sometimes to nearly half an inch in diameter. It may be accompanied by fever. It is attended, like all forms of Roseola, by a little heat, itching, or pricking in the skin. It may be more distinct at evening than morning, and its duration is variable. It is connected with gastric disorder, and relieved by simple aperients and alteratives, such as rhubarb and potash or magnesia, followed by quinine or other simple bitters.

*Fig. 2.*—ROSEOLA *infantilis* is a closer and more uniform rash than the *R. æstiva*, leaving very small interstices, though it must be regarded as *R. æstiva*, in a more diffused form. It occurs in infants during any irritation occasioned by dentition, fevers, or bowel-complaints, and is very irregular in its duration, sometimes continuing but for a night, and sometimes appearing and disappearing for several successive days. It is this form particularly which is liable to be mistaken for measles and scarlatina; but the absence of catarrhal symptoms, and the non-crescentic, patchy, and, perhaps, limited character of the rash, on the one hand, and severe constitutional symptoms, sore throat, strawberry tongue, bright scarlet punctiform rash and pungent skin, on the other hand, respectively declare the essential difference between it and these two diseases. The treatment is a tentative one. The bowels must be regulated, salines given for a day or so, with, subsequently, quinine and alterative aperients, and, if the itching be uncomfortable, a tepid bran bath at night.

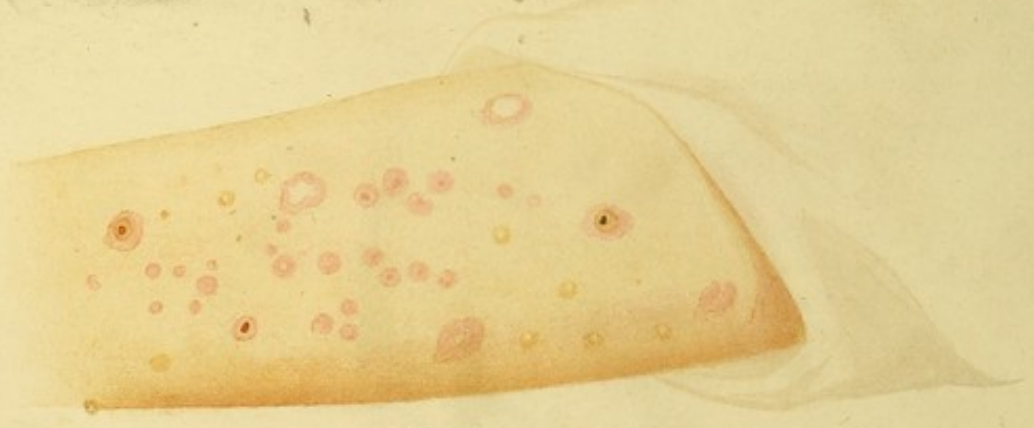






*Fig 2*

LEEDS & WEST-RIDING  
MEDICO-CHIRURGICAL SOCIETY



*Fig 1*

LICHEN URTICATUS

## EXPLANATION OF THE PLATES.

**PART III.**—This fasciculus, containing PLATES IX. X. XI. and XII., embraces representations and descriptions of seven varieties of Lichen; viz. *Lichen urticatus*, *simplex*, *agrius*, *circumscriptus*, *pilaris*, *lividus*, and *planus*. Two other forms, known as *L. ruber* and *scrofulosorum*, will be depicted in PLATES XIII. and XIV. of the succeeding Part.

### LICHEN.

This disease is characterised in general by the occurrence of little solid fleshy, sometimes reddish, papules, the size of millet seeds, which feel hard to the touch, and do not develop into any other form of elementary lesion, but are gradually absorbed, leaving behind slight scaliness. These papules are attended by much itching. They may occur in a scattered form, or collect into circumscribed patches. In Lichen, moreover, the skin is generally thickened, dry, and semi-leathery, certainly not thin and irritable, as in Eczema. The disease tends to recur, and is often very chronic. True Lichen has nothing to do with Eczema, as asserted; the one is a plastic, the other a catarrhal, inflammation, and Willan was perfectly right in claiming it to be a distinct species of disease. In the variety of *L. urticatus*, the papules arise out of wheals, and the disease is a compound of Urticaria and Lichen. *L. lividus* is, practically, a purpura, so that the above general description applies with less accuracy to these latter forms.

### PLATE IX.

*Figs. 1 and 2* portray LICHEN *urticatus*, which was not represented, though described, by Willan and Bateman. The disease is very common indeed in hospital practice and amongst the poor; but it also, though more rarely, occurs, and severely, amongst the better classes of society. This PLATE IX. is a new one. It is an accurate copy from life, and gives an admirable idea of the eruption, and of the different stages of the disease. The first symptom to attract attention is tormenting irritation, especially at night, accompanied by the development of small reddish fugitive wheals, about the arms, chest, buttocks, stomach, and legs. This phase of the rash, the practitioner who is asked to see the case is told, is more distinct, or 'comes out,' at night and the first thing in the morning: and it may not, at the outset, be very visible in the daytime. The fugitive eruption was very truly stated by Bateman 'to so closely resemble the spots excited by the bites of bugs or gnats as almost to deceive the observer.' It is well seen in *Fig. 1*, scattered about the forearm, which represents the earliest phase of the eruption, and about the top of the shoulder, and near the axilla and lower portion to the right in *Fig. 2*; some spots exhibiting most perfectly the characters of small wheals, and others being more hyperæmic. The next stage consists in the development of fleshy papules

out of the red wheal-like spots. The hyperæmia is attended by the effusion of lymph, and when the wheal character disappears, this effusion remains as a papule; hence the term *Urticaria papulosa* applied to the disease. Other papules are no doubt excited by scratching, and they may feel like little hard knots in the skin; in *Fig. 2* plenty of these paler papulations are seen scattered over the surface. There is now great irritation, and the skin is much rubbed and scratched, whereby the tops of the pale papules are torn off and made to bleed; then the drop of blood, oozing out, dries as a little blackish flake at the apices of the papules (see *Fig. 2*), which are then said to be 'pruriginous.' Any number of these are seen in the illustration. Another consequence is the development in unhealthy subjects of Ecthymatous pustules, sometimes in great abundance, whilst the skin, as shown in the illustration, *Fig. 2*, becomes pigmented and muddy-looking. The eruption now covers the whole of the body, more or less. In recent cases, or the earlier stages, the disease is made up chiefly of wheals, fugacious red papulations, and itchy, pale papules; in more advanced, or chronic, cases, of pruriginous papules in abundance, with red papulations, like bug-bites; and in old standing cases of this latter condition, with, in addition, Ecthyma and excoriations, and a generally cachectic state of skin: so that the aspect of *L. urticatus* alters according to the age of the disease. The spots in *Strophulus candidus* and *S. volaticus* (see *PLATE VI. Figs. 2 and 3*) are more of the nature of the red fugacious papulations of *L. urticatus* than anything else. In rare cases, in the chronic stages, and in strumous and ill-fed subjects, the disease, *L. urticatus*, may be made up almost entirely of the 'pruriginous' papules, and this constitutes the *STROPHULUS* or *LICHEN pruriginosus* of Hardy.

The disease mostly occurs in those who are improperly nourished and tended, who do not get sufficient fresh air; and it is excited by all irritants, such as the attack of bugs, by uncleanliness, by stomach derangement, and sometimes by teething; but all affected by it require general tonics.

*L. urticatus* is very liable to be mistaken for Scabies, but the origin from fugitive wheals, and the absence of any sign of acarian burrowing, are sufficient to prevent error.

The treatment consists in the institution of a sound hygiene, in the regulation of the diet, in the excitation of the liver where the motions are clay-coloured, and in the free use of diuretics in the earlier stages to relieve the skin irritation, and, subsequently, in the prescription of tonics, such as quina, arsenic, iron, and especially cod liver oil. Locally, very much can be done to alleviate the discomfort attendant upon the disease, and to hasten the cure. An alkaline and bran bath should be given every night in severe cases in the earlier stages of disease, and the sufferer should be well dabbed over with calamine, or other soothing lotion, and freely anointed with oil at night. Very frequently mild Styraç ointment (ʒj. ʒij. to ʒj. of lard), or a Belladonna lotion (ʒj. ʒij. to ʒvj. of fluid, with ʒj. of prussic acid in it), will be successful in quieting the pruritus. A good and effective lotion is the following: Sulphate of Atropine ʒrj, Borax ʒiss., Glycerine ʒij., dilute Prussic Acid ʒj., Water to ʒviiij. or ʒxij., to be dabbed on several times a day with care. In more chronic cases, I like a sulphurated potash bath (ʒj. to ʒij. to 25 gallons of water), or a mild acid bath.

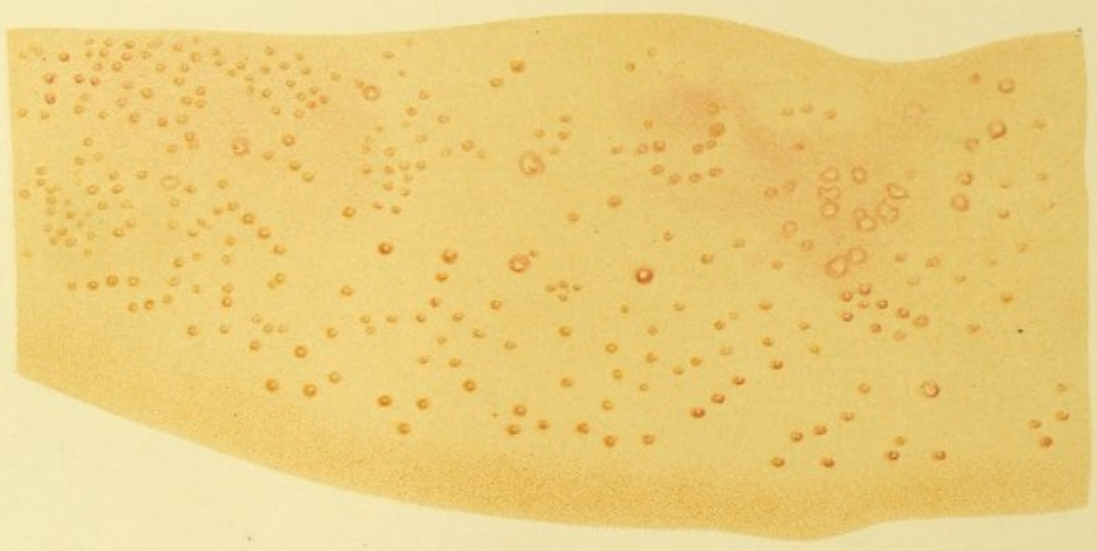[A number of different remedies, which I cannot give for want of space, will be found in the Formulary of the third edition of my work on Skin Diseases, &c.]



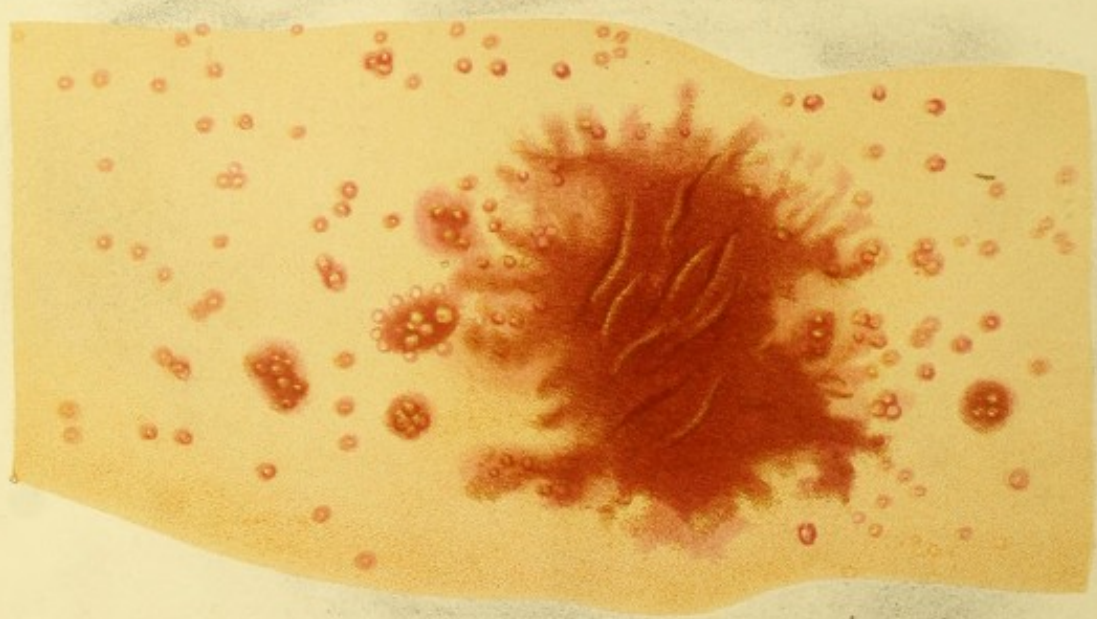

LICHEN SIMPLEX

*Fig. 1.*



*Fig. 2.*



LICHEN ACRIVUS

LEEDS & WEST-RIDING  
MEDICO-CHIRURGICAL SOCIETY

## PLATE X.

*Fig. 1*, or *LICHEN simplex*, is Willan's drawing of the disease reproduced. It never was an artistic success, yet it gives a very good idea of the disease it is intended to portray, and for that reason I retained it. The disease consists of successive crops of small reddish pointed papules scattered about the arms, back of hands, neck, and face, chiefly. It lasts, in all, two or three weeks. It is attended by a sensation of itching and tingling, aggravated by warmth. The individual papules last about a week, and are gradually absorbed in that time with slight desquamation. The skin is generally dry and harsh. This rash may be accompanied by slight pyrexia. This form of Lichen mostly shows itself in spring and summer, and occurs in dyspeptics, or those whose assimilation is at fault, and has often appeared to me to have some connection with deficiency of alkaline matter in the system, and nervous debility.

This disease may be confounded with Scabies, if care be not taken. The absence of acarian furrows and interdigital vesiculations, however, should prevent this mishap. The treatment is both general and local. In the first place, the diet should be regulated; all sugar, sweets, condiments, and stimulants should be forbidden. Rich and salt things must be disallowed, and a plain unstimulating diet ordered. Attention must be paid to the excretions; the liver and kidneys, if sluggish, must be excited to proper action by cholagogues and diuretics; and then alkalies, at the outset, must be freely exhibited, in connection with, in anemic subjects, iron and bitters. After some few days, when all pyrexia has gone, arsenic, alkali, and iron may be given for some time. Locally, much may be done to allay irritation by the use of alkaline baths every night, or even weak sulphuret of potassium baths (ʒj.-iij. in each) with the use, in the daytime, of a prussic acid and borax or belladonna lotion.

*Fig. 2*, or *LICHEN agrius*, is also after Willan, and fairly represents a patch of disease made up of an aggregation of lichenous papules, the whole being considerably inflamed and swollen. Much heat and irritation, and even pain, attend this form of eruption at times. The papules are large and distinct at the edges of the patch, and scattered papules are seen elsewhere, as in the figure, whilst the origin of the patch from populations is clear. The disease is greatly aggravated by scratching, and this leads to the outpouring of serous fluid, that dries into thinnish yellowish crusts resembling Eczema; indeed the latter becomes engrafted before the former. The part may fissure deeply. The disease affects the back of the hands, the flexures, and is kept up and becomes chronic by successive crops of papules. The skin generally is harsh and thickened. Vesicles may be present in severe cases, but they are very transient. The disease is attended by headache, general malaise, nausea, furred tongue, anorexia, and oftentimes a loaded state of the system, or gouty symptoms. It is not infrequently seen in those who indulge much in spirituous liquors. *L. agrius* is a very difficult disease to treat successfully. Poulticing, rest, the application of lead lotion or ointment to soften patches and to allay irritation—some such

thing as a cyanide of potassium ointment, 3-5 grains to  $\bar{z}$ iss. of lard—are required locally. Internally the treatment varies. In a good number of cases the patient is overworked or worried, or suffers from a gouty condition of the system, or from dyspepsia, or is thin and anxious. Appropriate remedies for these several states must be prescribed. Where the urine is loaded and the bowels are costive—especially in gouty subjects—alkalies, with small doses of colchicum, in the first instance, do good ; and these may be followed, sooner or later, by the exhibition of arsenic, alkali, and iron. Where the skin is much thickened generally, and the disease obstinate, a mild course of perchloride of mercury and bark, or ordinary bitter infusion, will often succeed in curing when other things have failed.



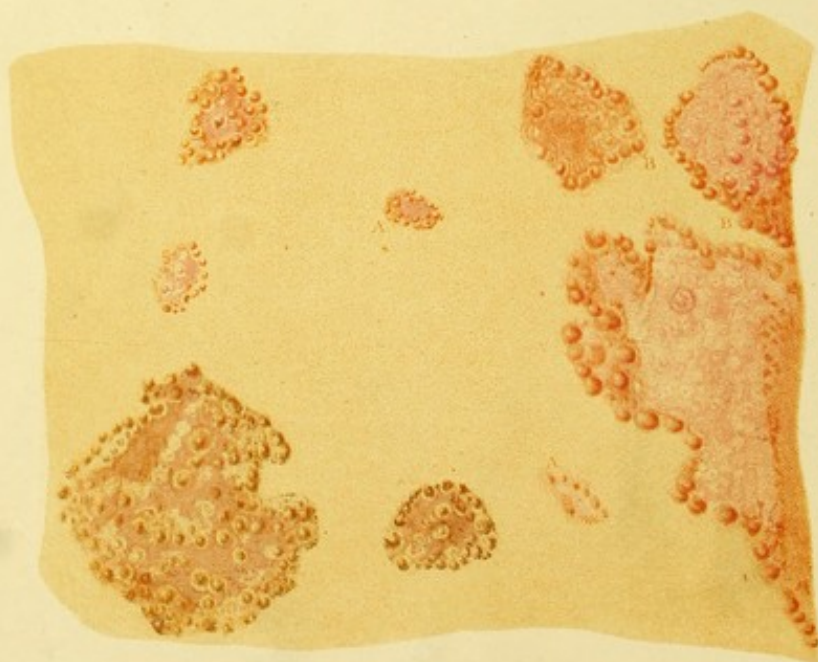
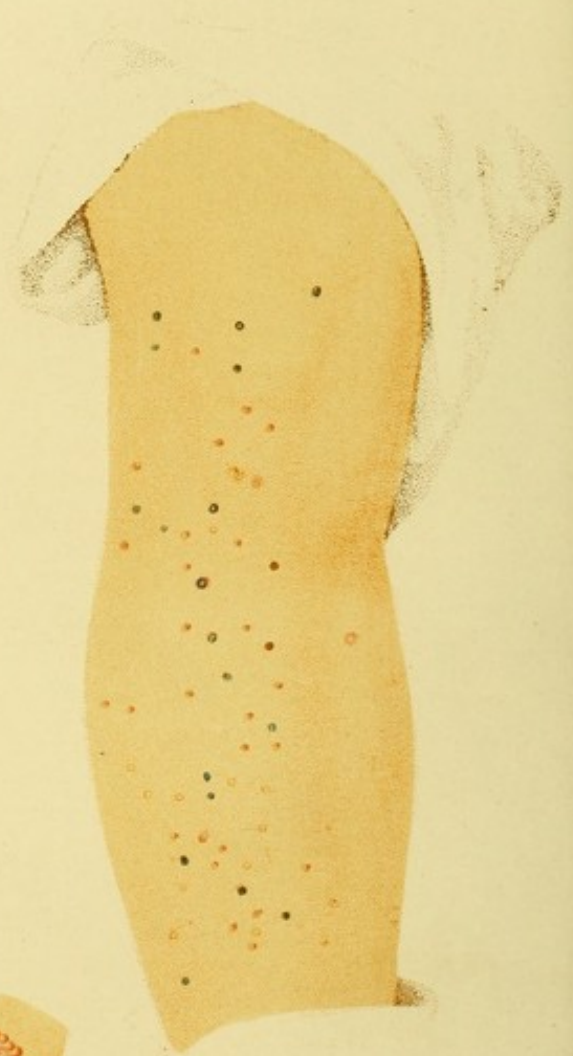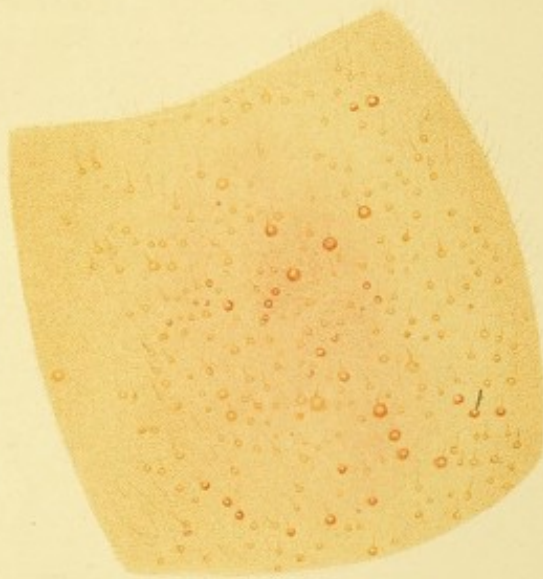LEEDS & WEST-RIDING  
MEDICO-CHIRURGICAL SOCIETY

LICHEN LIVIDUS.

*Fig 2.*

LICHEN PILARIS.

*Fig 1.*



*Fig 3*

LICHEN CIRCUMSCRIPTUS.

## PLATE XI.

*Fig. 1.*—*LICHEN pilaris*. In this variety the *papulae* are caused by the exudation of plastic matter into the follicular walls, and so the papules are formed at the hair follicles, and a hair pierces most papules. There are, however, sometimes ordinary Lichen papules (*L. simplex*) scattered about the surface. Causes and treatment are the same as in *L. simplex*.

*Fig. 2.*—*LICHEN lividus* is, in reality, a modification of Purpura, or a mixture of Lichen and Purpura, the latter occurring in the seats of the Lichen papules, and chiefly those occurring in the lower extremities; so that the disease consists of papular or elevated petechiae, interspersed at times with ordinary *papulae*. This form of Lichen requires generous diet, mineral acids, and bitters to meet the petechial condition, in conjunction with the treatment appropriate for simple Lichen.

*Fig. 3.*—*LICHEN circumscriptus* is an annulated form of the Lichen eruption. It is less common than the two first, and in it the *papulae* are arranged in circular clusters, which have a well-defined margin. The patches extend themselves by this papulated border, while the central surface becomes even, but continues slightly red and rough. This species, by no means common, was neither figured nor described in the first edition of Dr. Willan's work. The two circular brownish patches to the *left* and *lower* half of *Fig. 3*, represent very fairly ordinary *L. circumscriptus*, as seen sometimes about the back of the hand and forearm, or the thigh; but it is likely to be confounded with a parasitic form of disease, a *Tinea circinata*, or the *Eczema marginatum* of the Germans, which, I believe, is portrayed in the inflamed patch in the *right* half of the *Fig. 3*. I have, indeed, retained Bateman's figure in this Atlas for the express purpose of directing attention to this important clinical fact. I shall describe the *E. marginatum* in dealing with Ringworm. Here I will only say that true *L. circumscriptus* begins as an aggregation of small flesh-coloured papules, the patch extending by the springing up of new papules at the circumference, whilst the central part thickens and inflames; whereas in *E. marginatum* (*T. circinata*) the disease is often herpetic at the outset, or arises as a red scurfy patch, whose *edge only* is papular, or, even more correctly, herpetic, whose shape is irregular, and whose centre is not markedly thickened, as the rule, but is palish in colour, and desquamating; the scraping from the surface and edge, when examined, showing an abundance of parasitic threads and conidia under the microscope. I think Bateman confounded two distinct conditions.

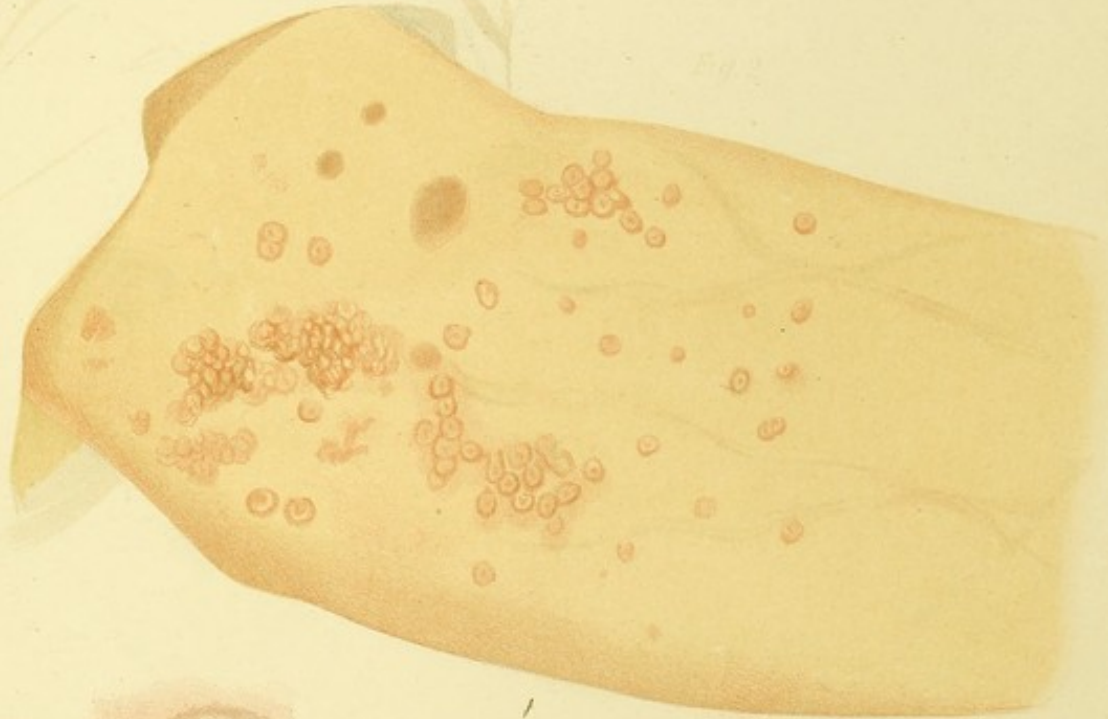There are those who think *L. circumscriptus* a phase of Eczema. The former may become inflamed and discharge, so that Eczema may complicate it; but it usually only consists, from first to last, of papules and the thickening consequent upon the aggregation of papules. As I write, I have before me the notes of a case, seen two or three hours since, of a child six years of age, in which the typical disease had existed for a whole

year, and had never shown any eczematous feature. The treatment is, in the main, that appropriate to *L. agrius*. In some of the slighter cases, as pointed out by Bateman in 1819, 'it is sufficient oftentimes that patients avoid heating themselves by much exercise or stimulants, and take light diet, with diluent drinks and a gentle laxative occasionally. The diluted sulphuric acid is a grateful tonic during the period of exfoliation, or a slight calybeate may be taken with advantage at the same period;' and he adds, 'all strong external applications are improper, especially preparations of mercury and of sulphur, which produce severe irritation'—an opinion to which I subscribe. Lotions of acetate of ammonia, borax, and prussic acid, with alkaline baths, with dressings at night of ung. plumb. carbon., or ung. plumb. subacetatis comp., will allay irritation and promote the absorption of the plastic exudation. In young children of gouty stock, tonics, with alkalies, and the avoidance of too much meat, sugar, pastry, sweets, and stimulants, are imperatively demanded, with due regulation of the secretions.

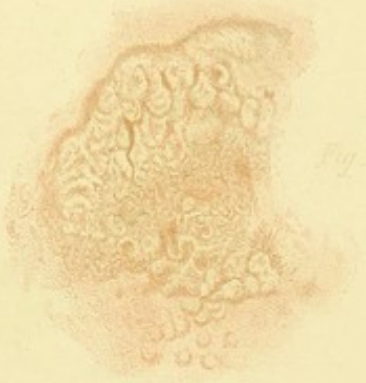




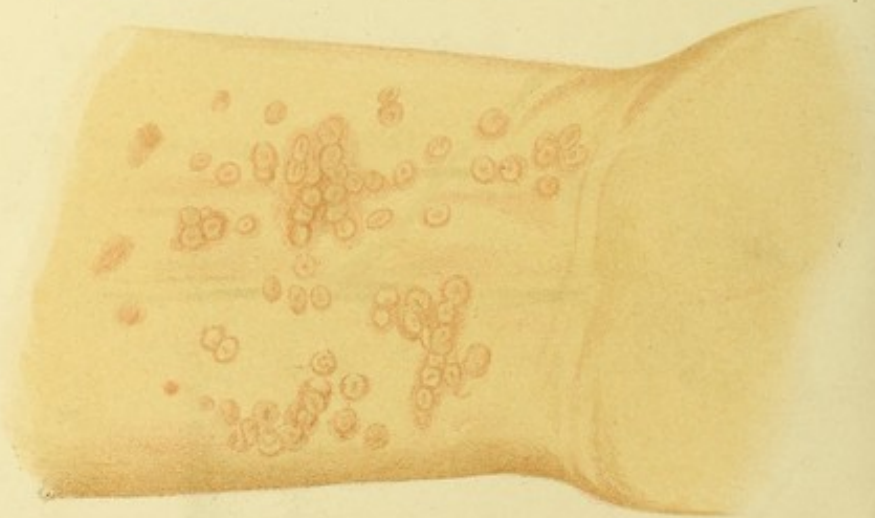LEEDS & WEST-RIDING  
MEDICO-CHIRURGICAL SOCIETY



*Fig. 2*



*Fig. 3*



*Fig. 1*

LICHEN PLANUS.

## PLATE XII.

This Plate is taken from the drawing of a case observed a few weeks since, and the three figures convey an excellent idea of the main features of a fairly common eruption, *LICHEN planus*. This form of Lichen has only of late years been recognised as a distinct disease by dermatological authorities, and it is scarcely yet known to the bulk of practitioners.

*Fig. 1* and *Fig. 2* together represent the forearm and part of the arm of the same patient attacked by *LICHEN planus*, but divided into two figures on account of the limited space at the artist's disposal; and I shall follow the description I have given elsewhere:— 'The disease, as generally seen, is characterised by the development of papules of very peculiar characters; they are "dull crimson red," at times suffused with a purplish red: they are always flattened, smooth, shining, and horny-looking at their apices, one to three lines in diameter, and have an angular base, whilst in their centre, which is sometimes depressed or umbilicated, is to be seen (as in the papules scattered over the forearm in *Figs. 1* and *2*) the opening of the hair follicle. There are no scales seated upon these papules except when they are packed closely together so as to form patches. These papules are formed not by the filling-up of the follicle, but evidently by the formation of new tissue around and about the follicle at its deepest part. If the hair be extracted, it may be possible to detect, adherent to it, the root sheath much hypertrophied. The eruption at the outset always occurs in the discrete form, but this exhibits a tendency to become the aggregated, so as to form patches, as may be seen at the bend of the elbow in *Fig. 2*, but not by the peripheral enlargement of the existing papules, but the springing-up of new between the old ones. When patches are formed, the parts become more and more infiltrated after a while, whilst the individuality of the separate papules is lost, more or less, save at the extending edge of disease where characteristic papules are always to be seen. The papules never assume the aspect of any other of the elementary forms of eruption—*i.e.* they never become vesicles or pustules. They are in fact primary formations and preserve the characters of papules till they begin to subside and disappear. The most characteristic seats are the front of the forearms and wrists, the flank, the lower part of the belly, the hips, and over the *vastus internus* about the knee. The disease is very chronic, it is often local, and always more or less symmetrical. There is often a deep red hue in the seats of eruption. The eruption is, except in rare instances, attended by severe pruritus, and very often burning and intense pruritus occurs to a distressing degree and often in paroxysms several times a day, and at night disturbing the rest of the patient. I have often noticed a flushing or bronzing of the face; occasionally brittleness of the nails; at times great debility; and in some cases marked digestive troubles. When the papules disappear they leave stains, and the patches diminish by absorption of the new tissue which forms the papulæ, and then in some cases, in place of the elevations, little pits remain. The material forming the papulæ has, as it were, stretched the natural integuments, and on that account perhaps the pitting is more obvious.

'*Lichen planus*, as generally seen, may consist of two or three collections of papules, tending to the formation of patches, in a single region of the body, or in two or three places at the same time—the thigh, the front of the forearm, and the flank, for instance; or it may consist in scattered papules; or it may be more or less general.'

The more general and severe form of the disease as described by Hebra under the term *L. ruber*, I shall depict in PLATE XIII.

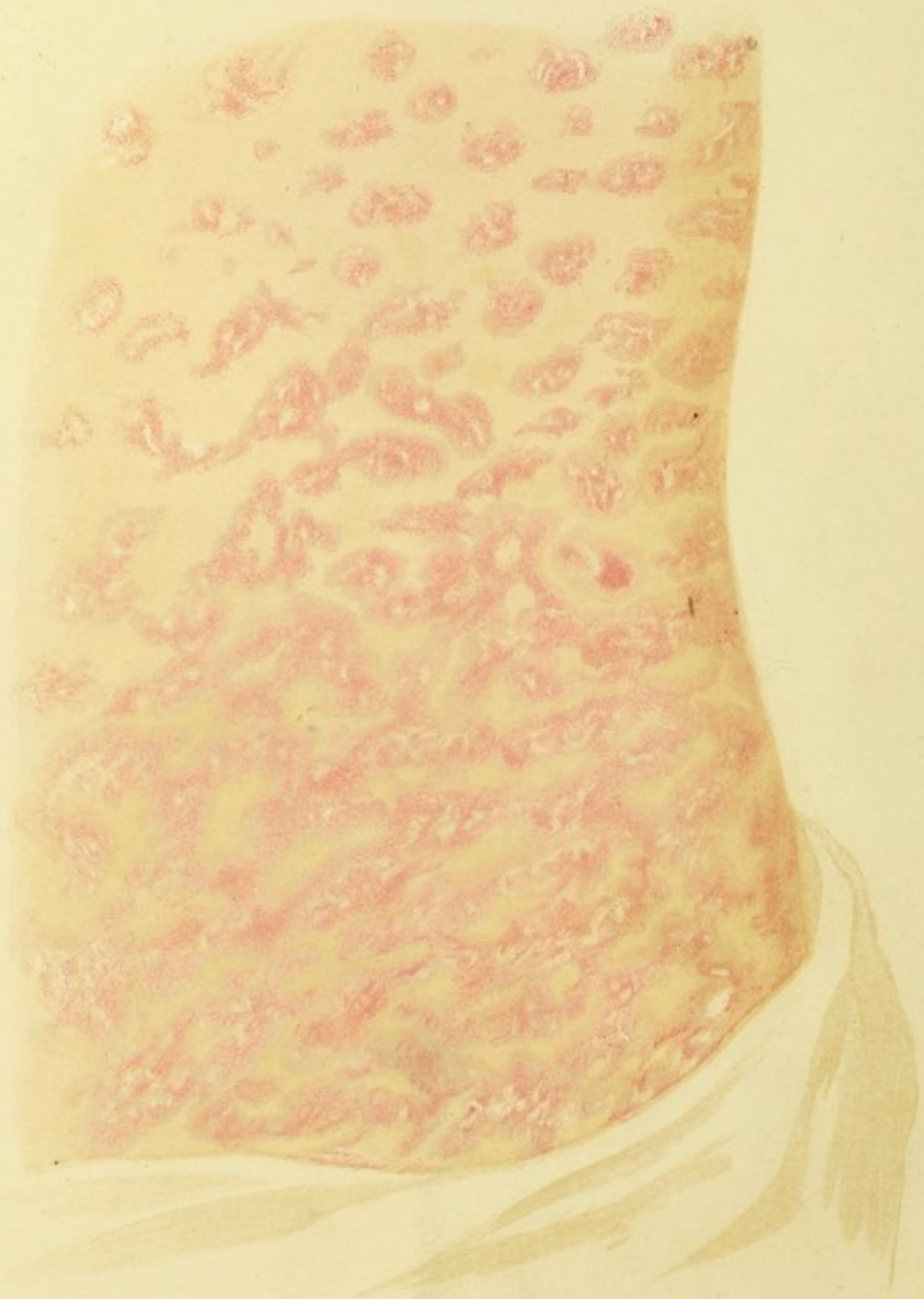It is difficult to understand how the eruption of *Lichen planus* can be confounded with any other disease if attention be paid to the dull red flat shining or glistening character of the papules, leaving behind melasmic stains on disappearing.

The main condition to treat in the disease is nervous debility, which always exists. Patients who are worried must get change of air and scene, and if over-worked, rest, whilst fatigue must be avoided. Stimulants must be avoided, but plenty of good nutritious food taken. The general health must be improved by the exhibition chiefly of the mineral acids in large doses with bark, or iron and quinine if suitable for the patient. With perseverance these cases get well with the use of general tonics. Locally, I have come to the conclusion that tepid baths and the free inunction of oil to the diseased places are by far the most successful, but the application of an atropine or belladonna lotion or detergent solution of tar, well diluted, may be useful to allay pruritus.

*Fig. 3* represents an unusual phase of *Lichen planus*. It is a patch sketched from life, and which was situate on the side of the calf. This form is seen generally on the front and sides of the legs, but also occasionally on the forearm, specially at the part near the elbow. The patches may be very small, the size of a split pea, or as large as the palm of the hand, or in bands. They are elevated, have a dull greyish or smoky tint, feel and look like a rasp, and, in fact, like a compact harsh warty growth, studded over with minute scales or small minute points of hardened cuticle. On careful examination it will be found that these patches have developed themselves by the crowding together of ordinary *Lichen planus* papules which are larger and thicker than usual, with considerable excess of thickening of and infiltration into the patches so formed. Around each patch and about its edge ordinary *Lichen planus* papules are mostly observed: and co-existent *Lichen planus* of ordinary features may be present elsewhere. Special local treatment must be had recourse to in this form of eruption. The infiltration must be got rid of by the use of mercurial plaster or tarry preparations.



LEEDS & WEST-RIDING  
MEDICO-CHIRURGICAL SOCIETY



LICHEN RUBER

## EXPLANATION OF THE PLATES.

**PART IV.**—This fasciculus contains illustrations of two rare varieties of Lichen, viz. *L. ruber* (PLATE XIII.) and *L. scrofulosorum* (PLATE XIV.); and also of two of the three principal varieties of Eczema, viz. *E. simplex* (PLATE XV. and PLATE XVI. Fig. 1) and *E. rubrum* (PLATE XVI. Fig. 2.)

### PLATE XIII.

**LICHEN ruber (New).**—In describing *L. planus*, in connection with PLATE XII., I stated that *L. ruber* and it were two different degrees of intensity of the same disease. There are many, however, who do not hold this opinion. When, however, their experience has become as ample, or, perhaps, as fortunate, as mine, they will assuredly allow my assertion to be a correct one. I have seen *L. ruber*, possessing all the characters described by Hebra, commence as a *L. planus*: and the features of the two conditions associated together, though in different parts of the same patient. In both phases the disease is essentially papular. In *L. planus* the papules occur in a more or less scattered or disseminated form, whilst in *L. ruber*, in connection with much more severe constitutional disturbance and debility, the eruption is more extensive and general, the papules crowding together into patches, and the skin being thickened, infiltrated, and scaly; so that the disease presents somewhat the aspect of a psoriasis or of a pityriasis rubra, with few and fine scales.

*L. ruber* begins, then, with an eruption of papules, which are dull red, the size of millet seeds, with flat, shining apices. These papules are at first disseminated or grouped, but the disease soon runs on to the formation of patches of greater or less extent. When a large portion of surface is affected, the integument is 'universally reddened, covered by numerous thin scales, and so infiltrated that when a fold of skin is taken up it is found to have more than twice its natural thickness.' But, on close examination, the papules are to be detected at the edges of the patches. The skin becomes dry, irritable, and harsh; it readily cracks; flexion and extension of the hands are difficult; the nails are thickened, opaque, and brittle or atrophied. Well-marked *L. ruber* is very rare in England, and, unfortunately, no case of the kind, which would serve as an illustration for this Atlas, occurred in my own practice at the time I needed it. I have been enabled, however, by the courtesy of Mr. Erasmus Wilson, to give a representation of an excellent model by Baretta in the Dermatological Collection of the College of Surgeons, which will convey a good idea of the disease. It should be studied in conjunction with the preceding PLATE (No. XII.) The original model I saw this year in the Museum of the Hospital St. Louis, of Paris. The French physicians termed the disease *Pityriasis rubra*, but they seem as yet to be ignorant of the clinical features of *L. ruber*. I have had several cases in my practice during the last three or four years. The PLATE (XIII.) shows, at the upper part,

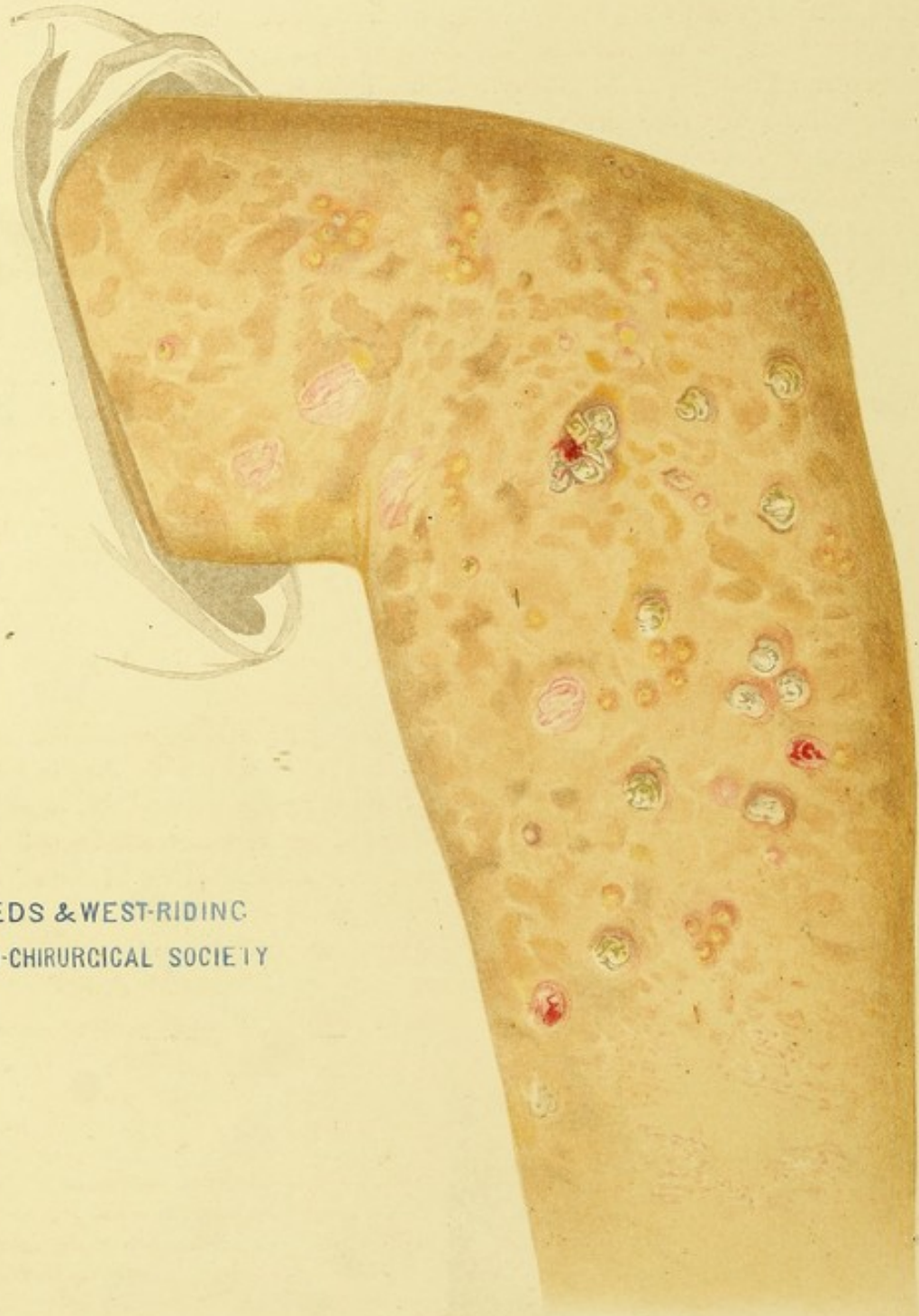little patches formed by grouped papules, covered with thin white scales; at the lower part the skin is more infiltrated; the patches are raised, and coalescing whilst they are likewise covered over by the same thin flimsy white scales. The illustration shows the papular character of the disease but very indistinctly, if at all, at the edges of the patches; but this is not the fault of my artist, who has very correctly reproduced an illustration most difficult to copy. The general character of the disease is, however, very well portrayed. Mostly, when the scales are removed by baths or by the use of oily applications, the papulations are more distinctly seen. The disease at times looks more like the two patches at the bend of the elbow, to the left and lower part in the uppermost figure in PLATE XII., only that the papules are more crowded, and perhaps of deeper colour. The illustration of PLATE XIII. also does not sufficiently indicate the degree of infiltration, nor the extensiveness of the patches of severe *L. ruber*. The pruritus is often intense, and by its torment and by preventing sleep may seriously affect the patient's health. Persons attacked by *L. ruber* are often the subjects of dyspepsia: of great nervous depression, the result of anxiety, or worry, or overwork: or of marasmus, which may increase so as to lead to a fatal result, according to Hebra. I have never seen a fatal termination yet, which I attribute to good treatment.

The two diseases with which *L. ruber* may be confounded are pityriasis rubra and psoriasis, but the essentially papular character of *L. ruber*, if properly attended to, is fully sufficient to ensure a correct diagnosis being made.

The treatment consists, according to German authorities, in the administration of arsenic. I have found this remedy, *per se*, fail, or even aggravate the disease. There are four general indications: to aim at improving the tone of the nervous system; to remove dyspepsial conditions; to supply the patient with proper food when this has been defective; and to diminish the hyperæmia of the skin, if decided, by diuretics, followed by potent astringents; *e.g.* perchloride of iron, in conjunction with the employment of local soothing applications. Rest from work, the avoidance of worry and fatigue, change of scene and air, are often needed to attain the first of these ends in view. The tonics most generally suitable are the mineral acids and bitters, with iron and cod liver oil. Locally, if the itching is troublesome, sedatives must be employed; but none succeed better than tepid alkaline baths, with free inunction of oleaginous substances. The cure is always tedious and slow.







LEEDS & WEST-RIDING  
MEDICO-CHIRURGICAL SOCIETY

LICHEN SCROFULOSORUM

## PLATE XIV.

*LICHEN scrofulosorum* (New).—Under this term Hebra has described a disease which consists, as regards eruption, of small elevations, the size of pins' heads or millet seeds, pale or brownish red in colour, formed at the hair follicles, and having thin scales loosely attached to them. They are grouped together in circles, or segments of circles, about the trunk, abdomen, breast, and back, more rarely on the extremities, but sometimes, as observed by Neumann, on the face and scalp. In many cases the eruption is combined with *acne disseminata*, the *acne* spots often being observed to develop out of the papules, or, rather, it may be said, that when the papular rash has existed some time, numerous dark-coloured elevations, answering to *acne* spots, spring up in the intervals of the groups of papules. The papules and pustules wither away, leaving dark stains behind. The skin generally becomes more or less cachectic in the course of the disease, which mostly occurs in children. *There are marked evidences of struma usually present.* It may be thought open to argument whether the illustration in PLATE XIV. really represents *L. scrofulosorum*, or whether it does not portray a syphilitic rash. My firm opinion is that it represents more particularly the *acneiform* rather than the *papular* aspect of *L. scrofulosorum*; and I have produced it here with the express intention of using it in support of the view that Hebra's *L. scrofulosorum* is in reality an *Acne scrofulosorum* (or *cachecticorum*) rather than a *true* lichen. The case from which the illustration was taken was under my friend Mr. Marrant Baker's care, at St. Bartholomew's Hospital, and he has been so kind as to place it at my disposal. For the following notes I have to thank Mr. Butlin, the Surgical Registrar of the Hospital. I did not see the case in the earlier stages of its development, but papules were very numerous and distinct in some parts of the body at the time the drawing was taken.

Jane M., 30, married woman, was admitted into Sitwell Ward May 13, 1875. She is a delicate-looking woman, with enlarged glands beneath the jaw on the right side. Her body is covered by a closely-set symmetrical, or nearly symmetrical, eruption, which is only absent from the front and back of both hands, and from the soles and part of the dorsal aspect of the feet. The scalp and face are very thickly covered. The hair is falling off. A large number of the spots remind one of the papules of small-pox in a very early stage. They are slightly raised, dull red, circular, somewhat pointed at the summit, but not indented. Many of them are large, and covered at the summit with small dark scabs: these are well marked on the dorsal aspect of the forearms. Others have lost these scabs, and are the seat of small, unhealthy, circular ulcers. This is the case on the calves and outer aspects of the legs. The feet are swollen and œdematous. There is no constitutional fever.—Ordered, good diet; Hydrarg. Iod. virid. gr.  $\frac{1}{2}$  om. nocte; Ung. Hyd. Am. Chlor.—May 27.—Eruption fading, leaving mottling of the skin and slight depressions.—June 4.—Glands beneath jaw have suppurated, and incisions have been made into them.—Ol. Morrhuæ ʒij. bis.—June 15.—*Pil.* stopped on account of the mouth and gums being sore and spongy.—Hst. Pot. Iodid. gr. x. ter. die.—June 21.—Still further improvement as regards eruption. Very few fresh papules have appeared since admission.—July 2.—Nothing but stains and slight depressions now remaining.—Sept. 24.—Has been kept in the Hospital until the present time to recover strength. Stains left by the eruption fading slowly away. The pitting remains, but is not so marked as it was.

On inquiring into the patient's history, it was elicited that five months ago a few pimples appeared on the front of the chest. They were followed shortly by pimples on the abdomen, face, arms, legs. The legs have been bad from three to four months. They have lately been ulcerated. When the disease first commenced, the woman was suckling a baby from two to three months old, and had been suckling it up to

the time of admission. It is quite healthy. The patient has one older child, also quite healthy. Previously to having these children, she suffered from three miscarriages. Her general health has been good formerly. The swellings (glandular) formed in the neck five months ago.

In the PLATE several groups of small red papules are represented at the part of the forearm nearest the wrist. The stainings were left by the fading rash. Near the bend of the elbow, just above and to the right, are three little circular patches representing groups of papules covered by fine scales, and over the surface generally are acneiform spots which have mostly developed out of papules, whilst the larger spots, covered by crusts, represent the acneiform places in a more advanced stage of development, and in a state of desiccation. The whole skin was in a very cachectic and ill-nourished condition.

To prevent misunderstanding, I repeat that this Plate represents the later and not the earliest stages of the disease. The diagnostic features of the malady are constituted by the papules, described in the opening sentences of the comments on this Plate, and represented in groups near the wrist in the illustration. The acneiform spots do not make their appearance until the disease has been some time in existence.

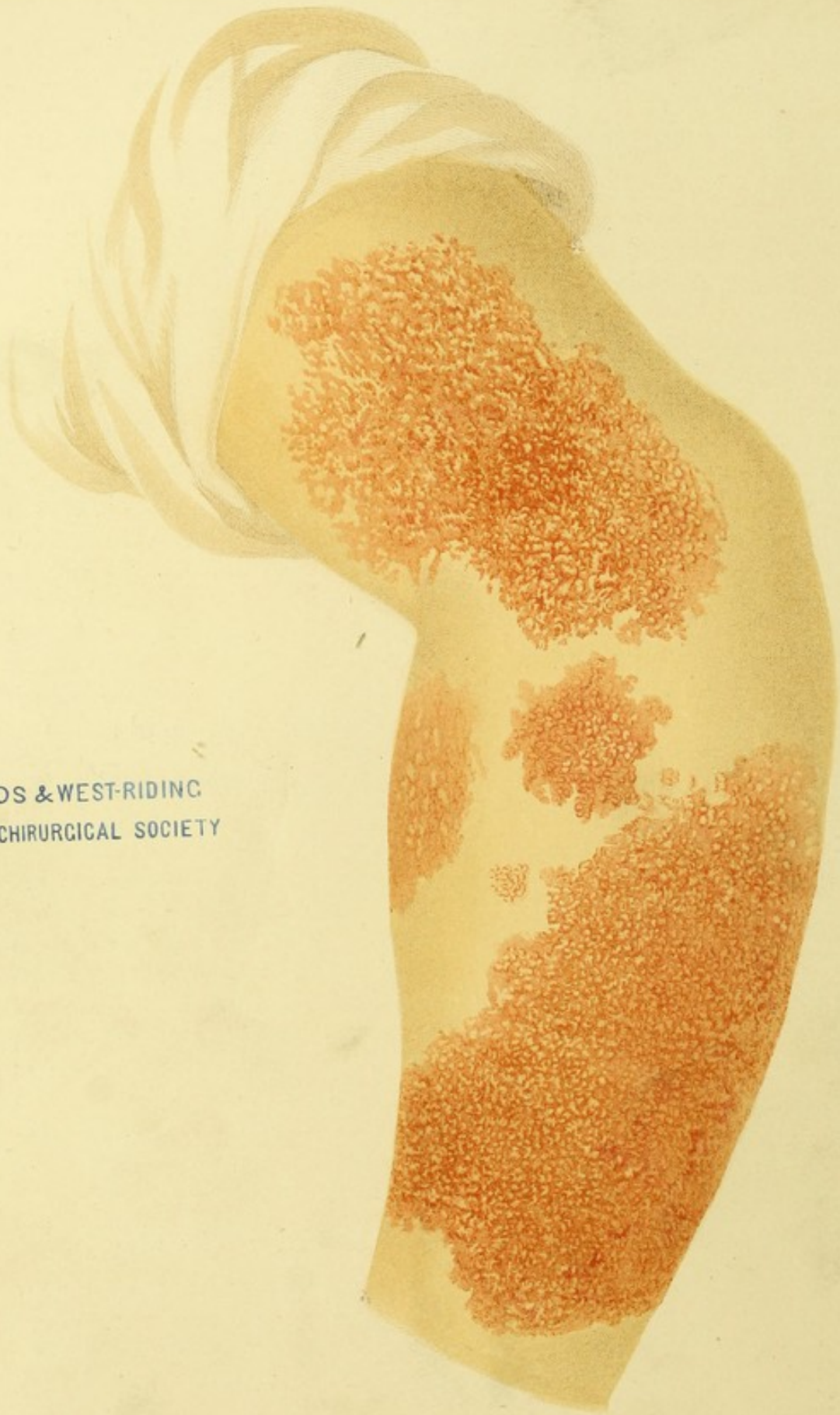
There are some who refer every unusual eruption to syphilis. In my opinion the disease was not syphilitic. The patient exhibited no other condition which could be regarded as of a syphilitic nature, and the disease could not be shown to have had a syphilitic origin. The fact that the woman had had three miscarriages: her improvement apparently, under the use of mercurials: the multiformity of eruption: and the tendency of the acne spots to ulcerate, were the circumstances that tended to support such a view. But the miscarriages seemed unconnected with syphilis, and the improvement in health was due to better fare and other advantages the patient obtained when she came into Hospital and weaned the baby. Multiformity of eruption is a character of *L. scrofulosorum*, and the ulceration accompanying the rash was sufficiently explained by the cachectic state of the patient. The general aspect of the woman, and the indolent and chronic glandular disease finally suppurating, were confirmatory of the strumous nature of the disease. I deemed the case such an interesting one, that I determined to put it on record here. I have elsewhere given a figure of the pathological changes in the disease—in my systematic work.\* These changes consist in the presence of exudation cells in and around the hair follicles and the sebaceous glands, and the papillæ near the aperture of the follicle.

The treatment of *L. scrofulosorum* consists in the exhibition of cod liver oil and other anti-strumous remedies, change of air, and the prescription of good food.

---

\* Skin Diseases: their Description, Pathology, Diagnosis, and Treatment. 3rd edit. (Renshaw).





LEEDS & WEST-RIDING  
MEDICO-CHIRURGICAL SOCIETY

## ECZEMA. (PLATES XV. to XXIII.)

This is the commonest of all the diseases of the skin, and on that account alone it is very important that its nature and varieties should be thoroughly understood. The disease will be illustrated by ten representations, contained in PLATES XV. to XXIII.

Clinically there exists a disease called ECZEMA, which, in its typical form, is characterised by marked sensibility of the skin of the affected person to irritants of every kind; by the tendency, at the outset of the eruption, as an essential and primary phenomenon, to the escape from the vessels of serous fluid, which rapidly becomes more or less seropurulent, into the meshes of the tissue of the papillary layer, and which fluid finds its way to the rete and, it may be, deeper dermic layer; in the former case elevating the cuticle into vesications, which are crowded together over a greater or less area. These vesications very quickly burst—and often so speedily as to appear not to have occurred, or not to have been observed—and give place to a reddened surface, which is the seat of a discharge of the same seropurulent fluid that infiltrates the skin, and which, on drying, stiffens linen in a peculiar way. The subsequent events in this form of disease are the drying of the exuding fluid, after the free flow is over, into crusts, varying in aspect according to the degree of the purulency of the discharge: the thickening of the fibro-cellular tissues: the gradual subsidence of the inflammatory action with crusting, followed by the cessation of the discharge: and the incoming of the stage of desquamation as the signal of returning convalescence. The phenomena, as here described, are analogous to those which occur in catarrhal inflammation of the mucous membrane, in which the fibro-cellular sub-mucous tissue is infiltrated by seropurulent fluid that finds its way to the surface as ‘a discharge.’ In fact, I have described Eczema as *catarrhal* inflammation of the skin, and I am glad to notice that my friend, Dr. McCall Anderson, admits the correctness of my description, and that Rindfleisch has adopted the same view. Willan described Eczema as a vesicular disease. Had he laid the chief stress on its ‘discharge’ feature, instead of one of the early results of the escape of fluid—viz. the vesiculation—his definition of Eczema would have been unassailable. These several phenomena may, in part, be unrecognisable in some patients, because the disease may, like all others, be more or less abortive, and, therefore, devoid of typical features; or it may come under the notice of the observer in its later stages, when the characteristic features have ceased to exist. But the typical disease is a ‘discharging’ one, the discharge drying into crusts, and stiffening linen.

It will be readily understood that the first stage of Eczema is hyperæmia: and then, as the fluid is finding its way to the surface, before vesicles form, it will slightly raise the papillary layer into points or papules; vesicles will then form, the surface next discharge, and so on. Hence it is usual to speak of the hyperæmic, the papular, the vesicular, the exuding, the crusting, the squamous, &c. stages of Eczema. But, unhappily, some have made *varieties* out of these *stages* of Eczema.

A host of varieties of Eczema have been made, according to variation in particular features; but it must be evident that varieties can only be founded upon peculiarities in the *total* local and general phenomena of different cases. Clinically, there are three varieties of Eczema as originally constituted by Willan, viz. ECZEMA *simplex*, *E. rubrum*,

and *E. pustulosum*, or *impetiginodes*. *E. simplex*, illustrated by PLATE XV. and PLATE XVI. *Fig. 1*, is unaccompanied, as regards general symptoms, by constitutional disturbance beyond, in some cases, general debility; and, as regards local phenomena, the inflammatory symptoms are not severe. The eruption is also mostly localised to a particular region. It is often excited by local irritants—as, for example, in *Fig. 1*, PLATE XVI., by the action of the sun. *E. rubrum* is the inflammatory form of the disease. There is much disturbance of the constitution, fever perhaps, malaise, defective excretion, a blood current charged with effete products, &c.; whilst, locally, the eruption is severely inflammatory, widespread over the surface, and very obstinate. This variety is illustrated by *Fig. 2*, PLATE XVI. and PLATE XVIII. The third variety, *E. impetiginodes*, or *pustulosum*, is characterised by the free formation of pus, dependent upon the pyogenic tendency of the attacked, and its main phases are represented by PLATES XVII. XIX. XX. XXII. (?) and XXIII. Free pus formation may be the result of severe inflammation; hence, *E. rubrum* may often become an *E. pustulosum*, as in PLATE XVIII., but I reserve the term mainly for an Eczema in which the pus formation is due to a pyogenic habit rather than severity of inflammation; and hence, in this sense, in *E. pustulosum* or *impetiginodes*—which are essentially the same, differing only in the degree of pus production. There are, moreover, no hard and fast lines of demarcation between these varieties.

It will be observed that I have given no new Plates of Eczema. I have purposely avoided doing so, because I want Willan still to receive the full credit of having made a perfect clinical division of Eczema into the three varieties just described. I proceed to speak of the Plates in detail, premising that I have slightly altered the particular names given them by Willan and Bateman.

#### PLATE XV.

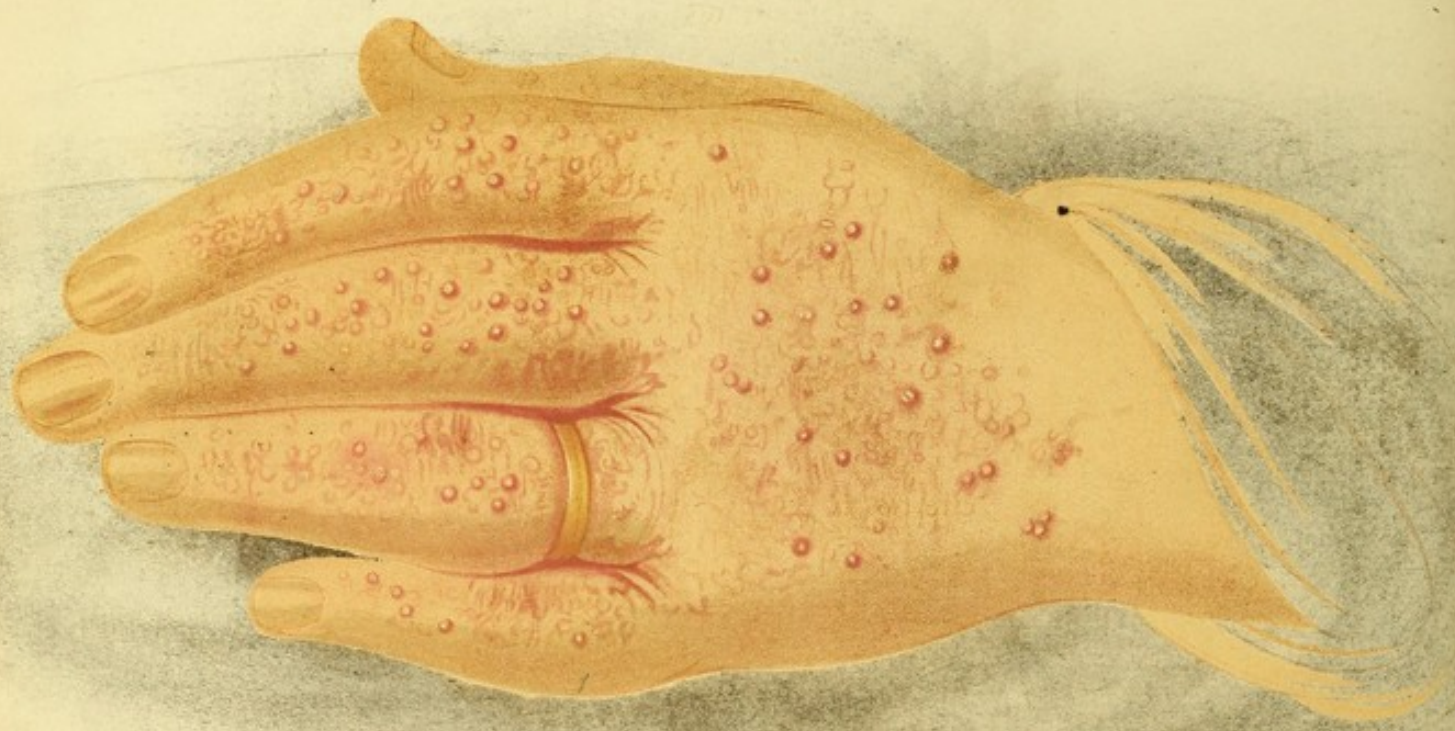ECZEMA *simplex*.—This gives a very good idea of *E. simplex* in the vesicular stage. It was termed by Bateman *E. mercuriale*, because of the eruption from whence the Plate was taken having been excited by the inunction of mercurial ointment. The swelling is slight, the redness not intense, and the original disease was also probably painless, and only a little irritable. It is the type of Eczema excited in debilitated persons by local irritants, heat, itching, scratching, uncleanness, friction with gritty powders, &c. The patch at the upper line of the forearm, just in front of the bend of the elbow, is intended to indicate the commencing formation of thin, slightly yellow, flaky crusts, produced by the drying up of the discharge. Over other parts of the eruption, as at the lower portion to the left, where the vesicles have burst, the surface would be a *weeping* one.

The treatment of such a case is simple enough. It consists, firstly, in removing all local irritation, excluding the part from the air, and keeping it soft; both of which objects may be effected by the application of some simple unguent, such as the benzoated zinc ointment; and, secondly, in the exhibition of mild tonics where these seem needed. In the weeping stage, astringent zinc lotions are often the best remedies; and, in the later stages, a weak mercurial ointment may be needed to cure desquamation.

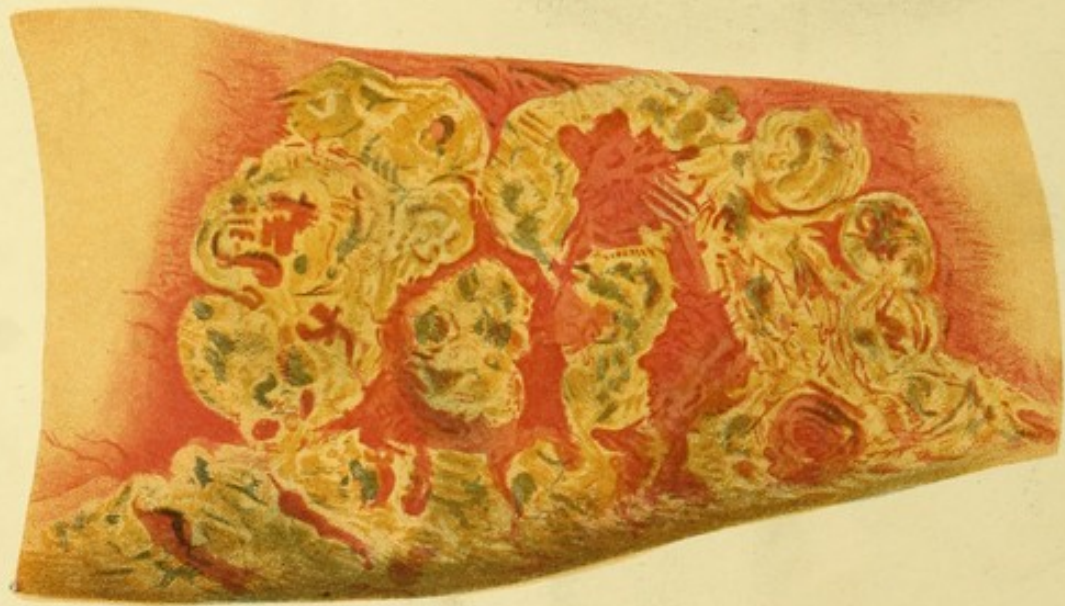



ECZEMA SOLARE



LEEDS & WEST-RIDING  
MEDICO-CHIRURGICAL SOCIETY



ECZEMA RUBRUM

## PLATE XVI.

*Fig. 1. ECZEMA solare.*—This is *E. simplex*, excited by the action of the sun upon the exposed parts of the hand, and, consequently, the backs in particular. In it the vesicles which form are generally more or less isolated, though they may in some cases be crowded together in patchy form, and now and then the Eczema may be severe, and consist of patches similar to those seen in PLATE XV. The vesicles in *E. solare* are formed in the rete by the uplifting of the cuticle by serum, and differ, therefore, essentially from those of dysidrosis and sudamina. It is in consequence of the importance of distinguishing between these conditions that I have retained the figure here. There is scarcely any weeping stage in *E. solare*. The amount of fluid effused is not great, and rapidly dries away into slight flakes in the milder cases; but, as before observed, *E. solare* may acquire the typical features of *E. simplex*, and then there is 'discharge.' *E. solare* often occurs in persons who have a thin, delicate skin, and its treatment is of the simplest kind. Emollient ointments are alone needed, with protection from irritation by some soft covering material.

*Fig 2. ECZEMA rubrum.*—This figure, one of Willan and Bateman's, conveys a very good idea of the inflammatory form of Eczema (see p. 27), which is characterised by marked symptoms of local inflammation, diffusion of the eruption widely over the body, and severe constitutional disturbance. This variety occurs under three chief clinical conditions: in the young, oftentimes commencing just after birth, and lasting, on and off, for many years; in those of middle age, who are mostly of a gouty or rheumatic constitution; and, thirdly, as attacking the head and face of infants. In the two former instances, the disease usually attacks the flexures of the joints, the groin, the folds of the neck, with, it may be, other parts of the body. In the latter case, the *E. rubrum* is, in reality, an *E. impetiginodes*, with more intense inflammation, swelling, and excoriation than usual. *Fig. 2* in this PLATE XVI. represents a patch of this variety of Eczema on the forearm, in which there is intense vascular excitement and turgescence, great heat, swelling and pain, with marked excoriation, and the formation of greenish yellow crusts. In *E. rubrum* the exudation of the fluid, which is more than usually acrid, towards and through the cuticular surface, is so free and rapid that the stage of vesiculation is often so speedily run through, as it were, that it, *practically*, cannot be said to have existed, though, *theoretically*, it must have done so; but, on the other hand, the *discharge* feature of Eczema is abundantly manifested. In the chronic stage of this variety, the infiltration into the dermal texture may be very great, so that the patches in the disease become quite thickened, and sometimes even leathery in feel—a state which is accompanied oftentimes by severe cracking of the part, a condition not a little distressing to the patient. The diagnosis of this form of Eczema is easily made, and, indeed, I do not know how it can be mistaken for any other form of disease, except, perhaps, in its most chronic form, when it consists of infiltrated, scaly patches, that bear some resemblance to psoriasis. But even here the history of the disease shows that it began as an ordinary inflammation, attended by 'discharge' and crusting, which are non-attendants of psoriasis.

The treatment is difficult, and it is impossible to do more than indicate the general principles upon which it must be conducted, leaving the reader to refer, for full details, to

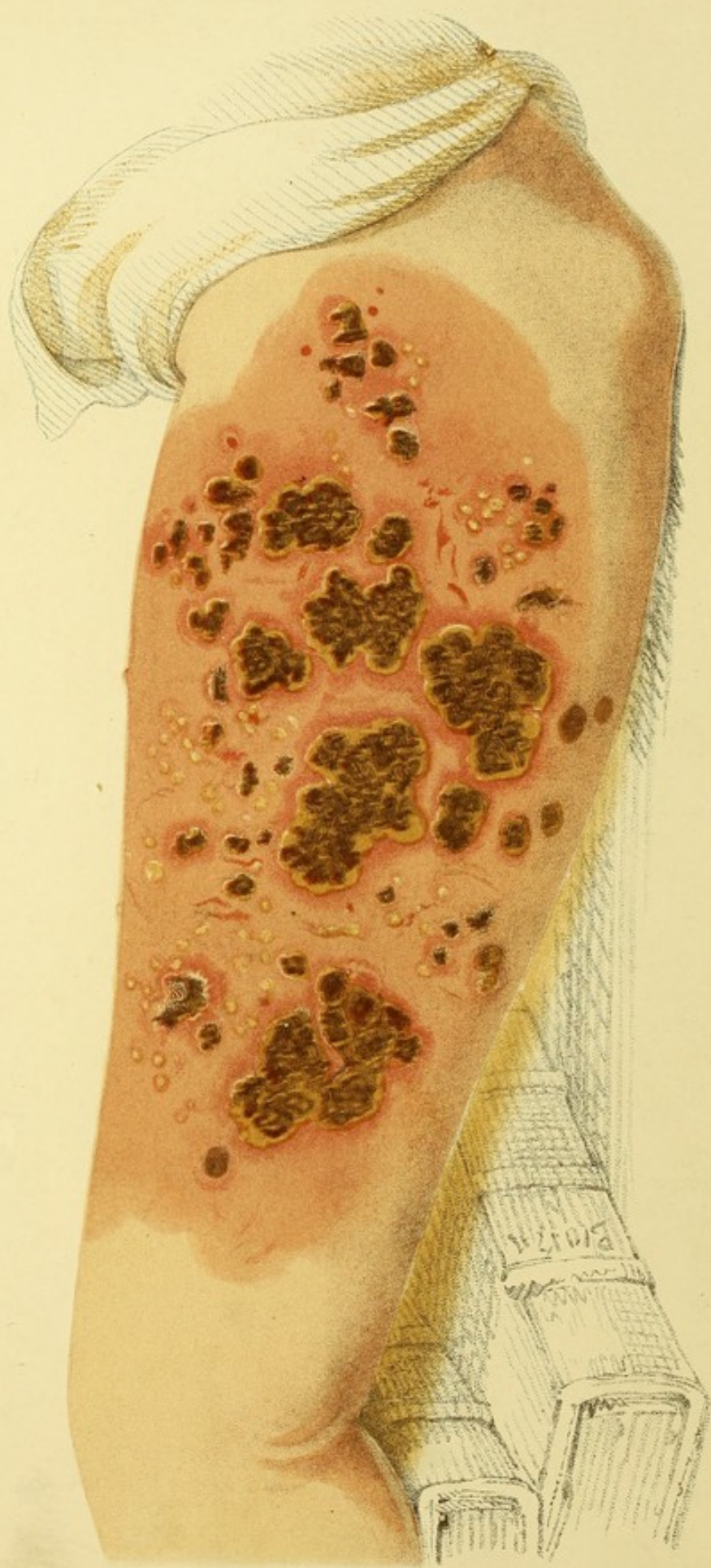
my systematic work on Skin Diseases. In the earlier stage, the inflammatory phenomena must be combated by special remedies. Locally, soothing and emollient or oleaginous applications, such as poppy water, the Linimentum Calcis, or camphorated zinc ointment, with dusting powders containing camphor, to allay burning heat, are to be used, and to be continued until the heat, swelling and pain, &c. are passing off. Internally, attention must be directed to what may be termed 'an acrid condition of the blood current'—one due to the blood being charged with effete products from defective assimilation, defective excretion by liver, kidney, or bowel, or with gouty and rheumatic *materies morbi*. Alkalies, purgatives of a saline nature, cholagogues, and diuretics, together with the regulation of the diet, the avoidance especially of stimulants, with the prescription of quiet of body and mind, are the remedies that are required. In children, excitation of the kidneys is of the greatest benefit in relieving the irritated skin. Aconite and belladonna, in nervously susceptible individuals, and, naturally, colchicum in the gouty, act well.

With the subsidence of the more inflammatory phenomena, a change in the plan of treatment is advisable. Astringents may take the place of soothing applications, whilst alteratives and tonics may take the place of the more decided antiphlogistics—a term I am old fashioned enough still to use. For subjects of nerve debility, arsenic and cod liver oil are needed; in young subjects, alkalies and arsenic; and in those who are anæmic, iron and arsenic may be exhibited.

In due course, as the general condition improves, the main condition to be rid of is that of inflammatory infiltration. Locally, weak mercurials, which act as slight stimulants to the absorbents; then, if need be, revulsives come into use. Internally, the remedies needed are such as improve the general tone, and keep the blood current pure. Where the thickening is marked, and the parts are more or less indolent—i.e. not readily irritated—no doubt the use of alkalies or iodide of potassium, with tonics, is efficacious; and in many cases a course of perchloride of hydrargyrum is most beneficial. I find the latter particularly successful in its operation in the *E. rubrum* of children, in the non-active stage, with much infiltration. In strumous subjects, cod liver oil should be given.



LEEDS & WEST-RIDING  
MEDICO-CHIRURGICAL SOCIETY



ECZEMA IMPETIGINODES

## EXPLANATION OF THE PLATES.

**PART V.**—In this fasciculus there are no new Plates. The third typical variety of Eczema not yet described—viz. *E. impetiginodes* (PLATE XVII.)—is portrayed, together with three phases of this same variety, viz. *E. infantilis*, *IMPETIGO figurata*, and *IMPETIGO scabida*, in PLATES XVIII. XIX. and XX. respectively. Much confusion often occurs in consequence of the existence of the term Impetigo, but it is to be understood that it is used in this work as the designation for any Eczema in which the secretion of pus is free, and in which, consequently, large purulent crusts form—in fact, *E. impetiginodes*, *E. pustulosum*, and Impetigo are essentially controvertible terms, and two of them—the first and third—might well be abolished; but even when used for different phases of Eczema, they only imply varying degrees of purulency of secretion in the same essential eczematous inflammation. By *E. impetiginodes*, in fact, authors mean an Eczema in which the amount of pus is moderate; by *E. pustulosum*, one in which it is more decided in the fully developed stages of the disease; and by Impetigo, one in which it is present from the very outset of the eruption, and continues in good amount throughout. But, as above observed, one term only—viz. *E. pustulosum*—need be retained.

### PLATE XVII.

**ECZEMA impetiginodes or pustulosum.**—In this variety of Eczema the effusion of serous fluid from the inflamed surface, together with the free formation and admixture of pus, and the consequent formation of fairly thick, yellowish, or greenish yellow crusts, are the characteristics (see remarks at p. 27). The ordinary form of this impetiginous (or pustular) variety of Eczema is well illustrated by the accompanying PLATE XVII. Willan gave the term *IMPETIGO sparsa* to the figure, from the presence of the encrusted parts scattered over the surface, but *I. sparsa*, in reality, is only a purulent Eczema occurring in small and distinct or isolated patches.

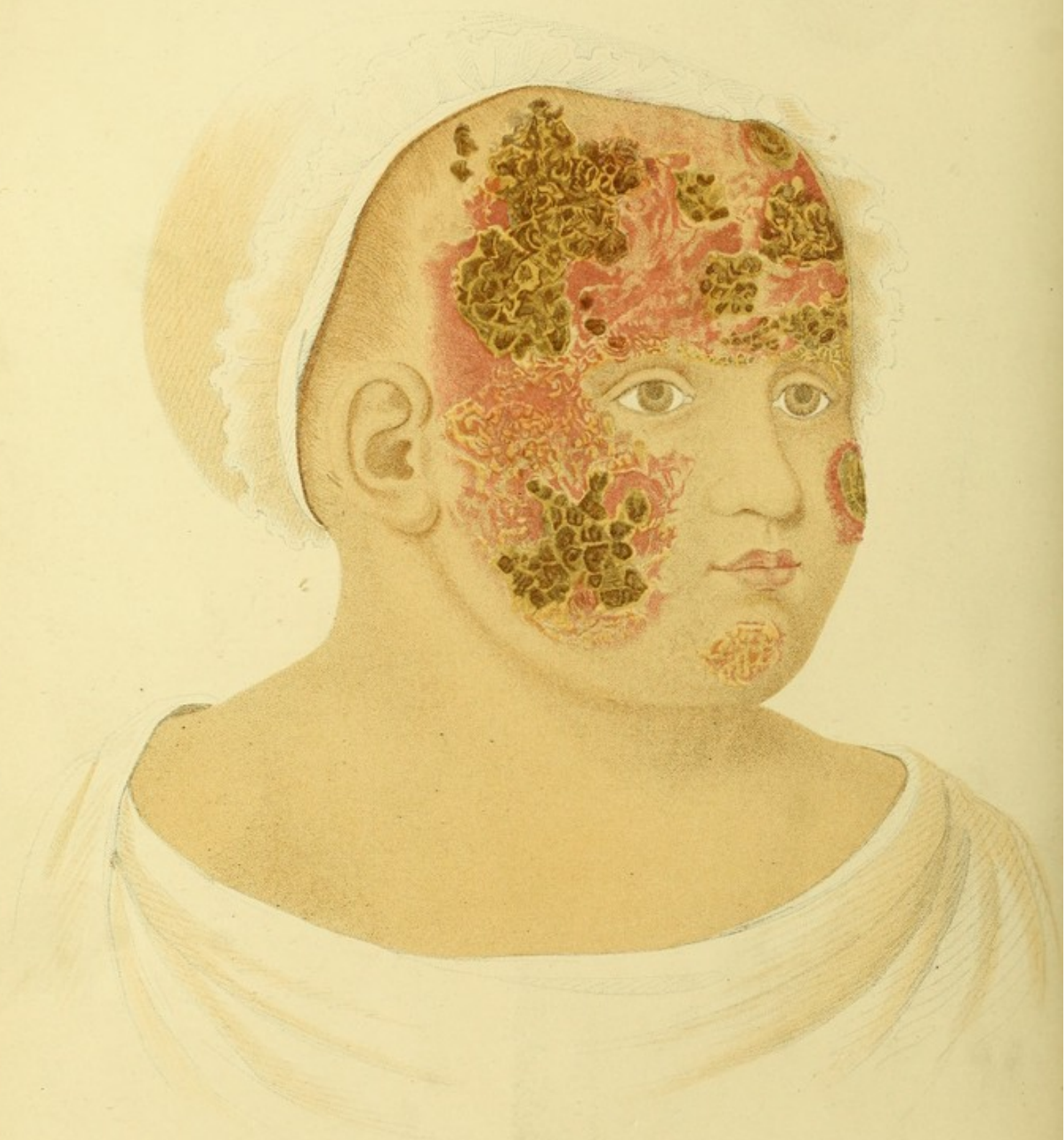The treatment of this form of Eczema, in adults, is that of *E. rubrum* in a mild degree, before described; but, in addition, cod liver oil is especially needed in view of the pyogenic tendency of the patients in whom *E. impetiginodes* is wont to occur. For such a condition as that illustrated in Plate XVII., where the inflammatory signs are not very decidedly marked, the proper treatment would consist of tonics, with saline aperients—internally, for example, sulphate of magnesia, sulphate of iron, quinine, and arsenic, and perhaps cod liver oil; with the use, locally, of compound lead ointment as a constant dressing, to be followed, so soon as the surface has ceased to form crusts and to ooze, by the use of an oxide of zinc and calamine lotion, containing a little tincture of myrrh, in the daytime, and a weak ammonio-chloride of mercury ointment (gr. iv. to ℥j.) smeared on at night. The management of *E. impetiginodes* in children will be alluded to in describing the next PLATE (XVIII.), which is that of *ECZEMA infantile*.

UNIVERSITY OF MICHIGAN LIBRARY

1917








ECZEMA INFANTILE

## PLATE XVIII.

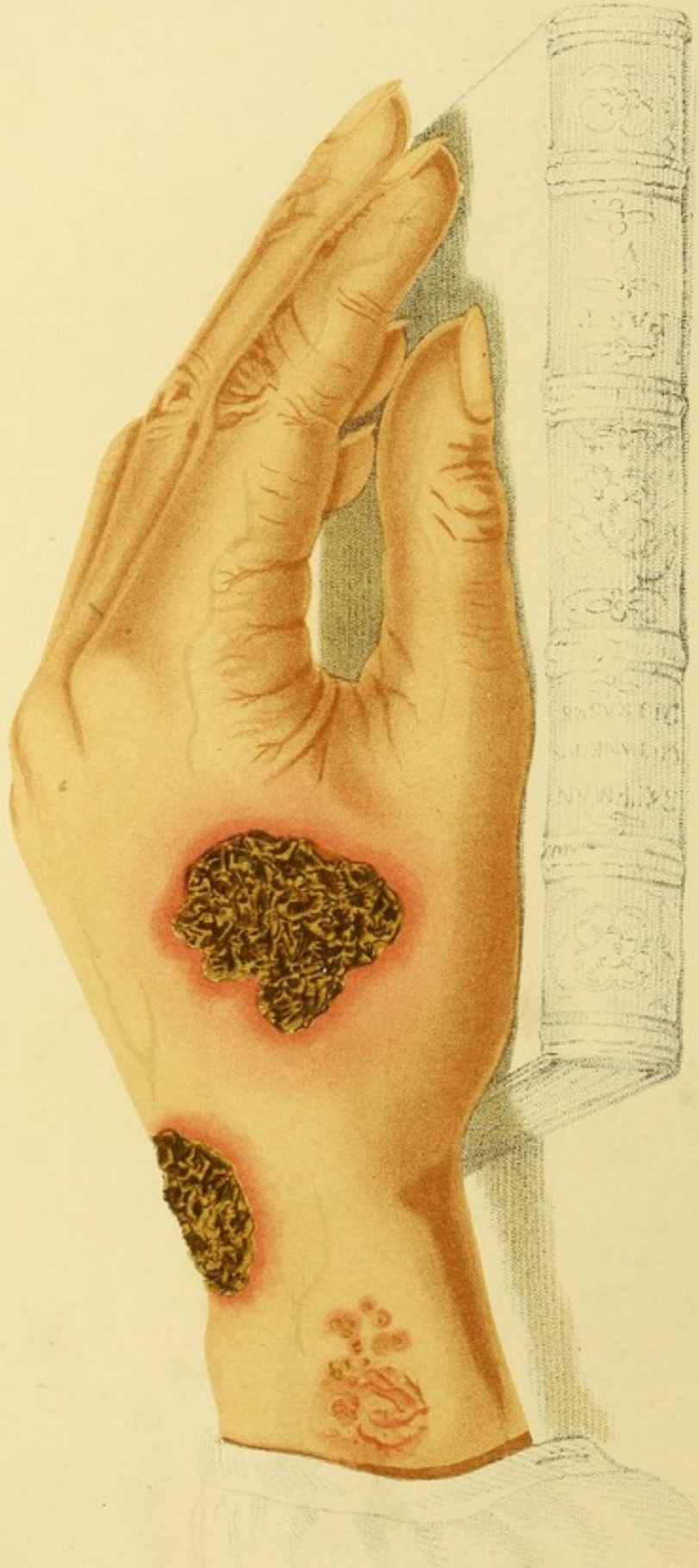*ECZEMA infantile*.—There is no difference in character between the Eczema of children and adults, and the term *E. infantile* is therefore in some degree misleading. Eczema, moreover, occurs in the same seats and in the same forms in the young as in those who have passed the age of childhood. But the disease is so very common, in both public and private practice, about the face and head of children, that it is, clinically, of advantage to direct special attention to the disease as it attacks these parts in the child. This so-called *Eczema infantile*, at one time called *Porrigo larvalis* or *Crusta lactea*, usually partakes of the features of an *E. impetiginodes*, but it may commence as an *E. rubrum*, or, in other words, be attended by considerable inflammatory symptoms and a good deal of constitutional disturbance at the outset, whilst it may acquire, in the later stages, a marked degree of purulency (see remarks on *E. pustulosum* at p. 27). The eruption in this PLATE (XVIII.) resembles closely that in PLATE XVII., only that the pain, heat, redness, and excoriations have been much more decidedly marked. The disease affects chiefly the forehead and cheeks, but it also extends frequently to the scalp, ears, neck, and, more rarely, the limbs. The discharge is often very free; it dries into large purulent greenish yellow crusts. Hence the term *Porrigo larvalis* or *Crusta lactea* applied to the disease. In many cases the inflammatory symptoms are aggravated by the scratching practised to relieve the very severe itching which at times is an accompaniment of the disease: and this may induce bleeding from the excoriated surface. Oftentimes the secretions are disordered, the liver and kidneys being torpid in action, and the bowels disordered. The various glands of the neck are often inflamed, and may suppurate freely. No ill results—i.e. scars or the like—remain after the disappearance of the eruption. The main exciting cause of this *E. infantile* is, without question, in the majority of cases in hospital practice, *defective*, and in private practice, *improper*, and even—though more rarely—*defective feeding*. The regulation of the diet is one of the most important items in the management of these cases; a proper supply of good milk at regular intervals, in the young child, must be secured. The bowels must be properly regulated, and diuretics given at the outset, if needed. Then, as soon as possible, steel wine, with arsenic; and an alkali, if there be much inflammation present, may be prescribed. Locally, so long as the parts are hot, irritable, and discharging serous fluid, dusting powders, or soothing and weakly alkaline lotions, may be employed; but as soon as crusting commences, the parts should be enveloped in linen strips soaked in linimentum calcis, freshly made, whilst they should be cleansed once a day by gently dabbing the parts with a soft sponge and some such glutinous fluid as strained gruel. Finally, the use of the compound lead ointment is all that is needed, in the majority of cases, to assist the healing process.

In those cases in which there is a comparatively slight degree of inflammation present, with free pus formation, the treatment consists essentially in the exhibition of cod liver oil from the very outset, with good diet and tonics, including iron.





LEEDS & WEST-RIDING  
MEDICO-CHIRURGICAL SOCIETY




IMPETIGO FIGURATA

LEEDS & WEST-RIDING  
MEDICO-CHIRURGICAL SOCIETY

## PLATE XIX.

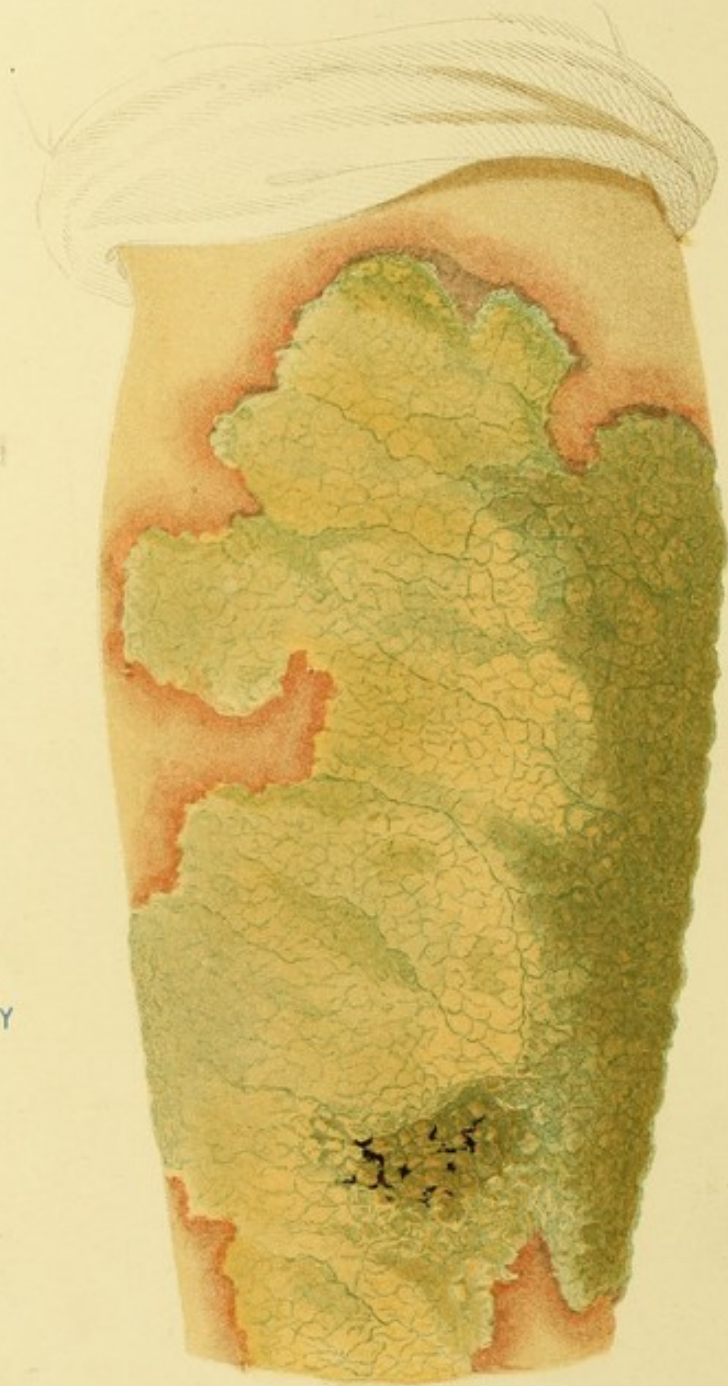IMPETIGO *figurata* was the name given by Willan and Bateman to the first species of the pustular eruptions, which they included under the term Impetigo, or *humid tetter*, but which we, nowadays, consider a purulent Eczema. The disease was originally described as characterised by *circumscribed patches*, a little elevated, which at first consist of clusters of *psudracious* pustules, closely congregated, and surrounded by a slight inflammatory margin, the pustules breaking after some days, and an irritating humour exuding, which soon concretes into yellowish or greenish brown scabs. In other words, the eruption has a markedly purulent secretion from the outset, and is more or less circumscribed. These patches are often situated on the arm and wrist, and extend to the back of the hand; and one of them not unfrequently—as stated by Bateman particularly—occurs between the metacarpal bones of the thumb and forefinger, as here represented. I have noticed this form of eruption chiefly in stout, flabby, lymphatic women, who have fallen into weakish health from over nursing, or some such cause, and whose excretory organs have, at the same time, been more or less inactive.

The treatment consists in improving the general health, according to the particular requirements of individual cases, and in removing the scabs by poulticing or oil packing, and then applying the unguentum diachyli regularly; or keeping the part covered with the emplastrum plumbi spread on thin leather, and renewed every second day or so. Change of air to the seaside often greatly assists the cure.









LEEDS & WEST-RIDING  
MEDICO-CHIRURGICAL SOCIETY

IMPETIGO SCABIDA OR ECZEMA PUSTULOSUM.

LEEDS & WEST-RIDING  
MEDICO-CHIRURGICAL SOCIETY

PLATE XX.

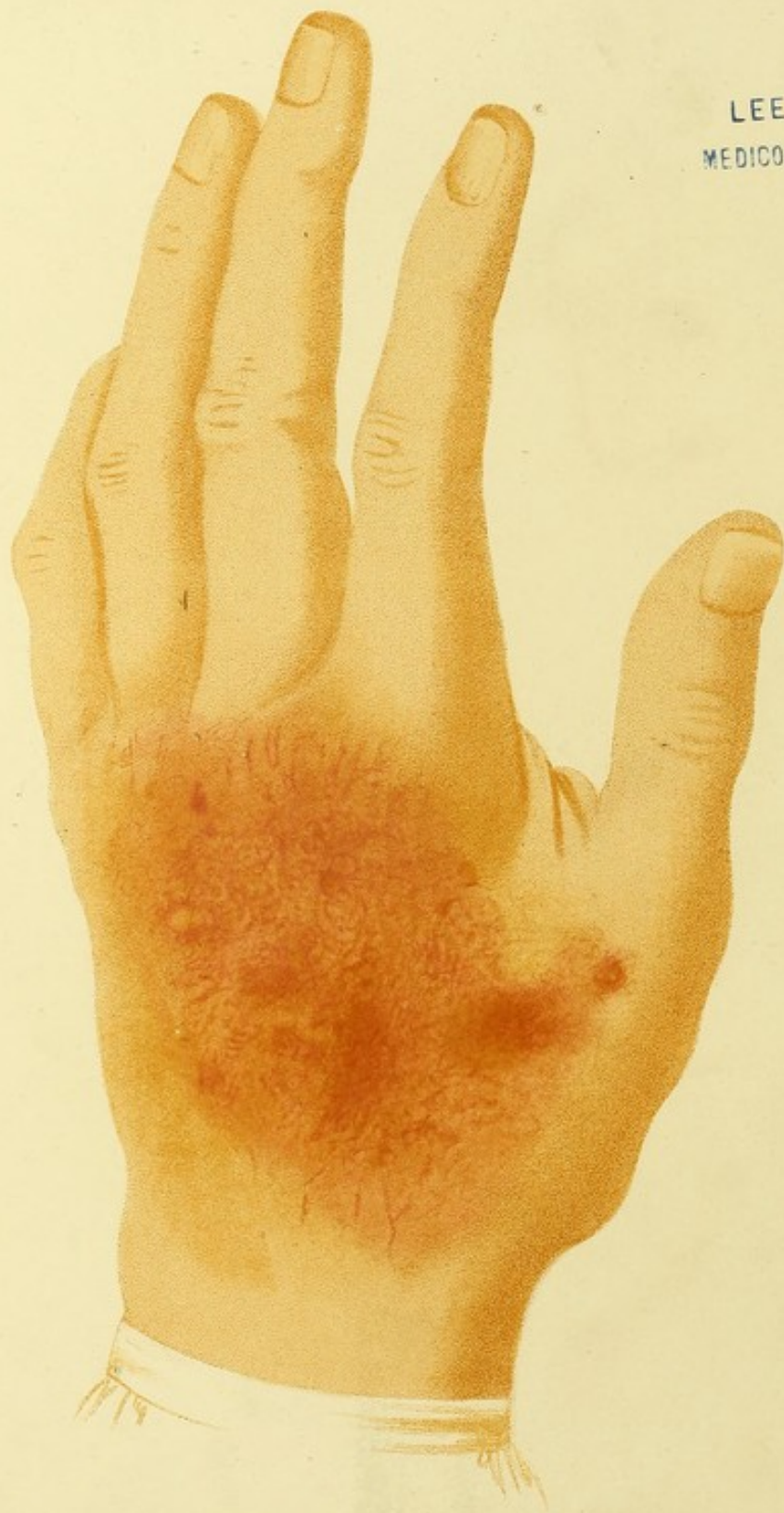*IMPETIGO scabida* is an Eczema characterised by the formation of a thick greenish or dirty yellowish scabby crust, by which the whole limb or limbs are encased: and which is often separated by many fissures and cracks, from whence a thin ichor copiously exudes, and concretes into additional and irregular layers. The whole crust, which *may* be half an inch thick, is the result of the concretion of this acrimonious humour, which is discharged in great abundance from the dermal surface or from numerous psudric pustules, as they successively form, break, and ulcerate over the surface of the limb. The scabbing is sometimes so thick and rugose that it resembles the bark of a tree more than anything else, as seen to the left of the figure. I have usually observed this form of Eczema in the legs and in elderly people. It cannot well be confounded with any other disease, since in Eczema alone is there such a discharge drying into yellowish crusts.

The treatment, as regards internal measures, is identical with that of *E. impetiginodes*. Locally, something special is required to be done. The crusts must be removed by poulticing and soaking in weakly carbolised oil. After the crusts are removed, an astringent lotion, such as sulphate of zinc gr. xv., tincture of myrrh ℥j., to ℥vj. of water, or some such combination, should be applied. When the discharge ceases, or the surface becomes less hyperæmic, weak mercurial ointments are useful, such, for instance, as one composed of nitrate of mercury ointment ℥j., acetate of lead gr. xx., oxide of zinc ℥j., olive oil, ℥iss., and zinc ointment ℥j.





LEEDS & WEST-RIDING  
MEDICO-CHIRURGICAL SOCIETY



'BAKERS' OR 'GROCERS' ITCH.

## EXPLANATION OF THE PLATES.

---

**PART VI.**—This fasciculus contains representations of a form of Eczema to which bakers, grocers, and bricklayers are liable; of 'IMPETIGO *rodens*,' one of the forms of *Porrigo favosa* of Willan and Bateman; of *IMPETIGO sparsa* of the scalp, another form of the *Porrigo favosa* of the same authors, 'Porrigo' of modern writers; and the disease I have described under the designation of *IMPETIGO contagiosa* (or Contagious Impetigo).

### PLATE XXI.

BAKERS', GROCERS', BRICKLAYERS', or WASHERWOMEN'S *itch* is portrayed in its earlier stage and in its lesser degree of severity in this Plate. The disease is simply an Eczema produced by the irritant action of flour, sugar, lime, or soda. The variety of Eczema present will depend upon the degree to which the irritant operates, and also upon the state of the general health of the individual attacked by the disease. The accompanying representation would seem to indicate the presence of a moderate amount of congestion: some vesiculation: here and there over the surface the escape of a certain amount of serosity from the skin: and the formation of thin seropurulent crusts; constituting *E. simplex*. In many cases the disease is more inflammatory, the parts are often excoriated, swollen, fissured, and very painful (*E. rubrum*). The eruption is very easily excited and most severe in debilitated subjects; and it is important to recognise this fact in reference to the therapeutics of the disease. The Plate is Willan and Bateman's.

The treatment consists essentially in the exhibition of tonics internally, with regulation of the functions of the bowels and other emunctory organs; the removal of the cause of local irritation; and the use of remedies in the first instance to soothe and protect, such as litharge ointment, followed by astringents. When the discharge has ceased, the application of lead plaster spread on thin leather, and kept constantly applied for a time, so as to protect the diseased surface and exclude the air therefrom, will be found in many cases most beneficial.

STATE OF MICHIGAN

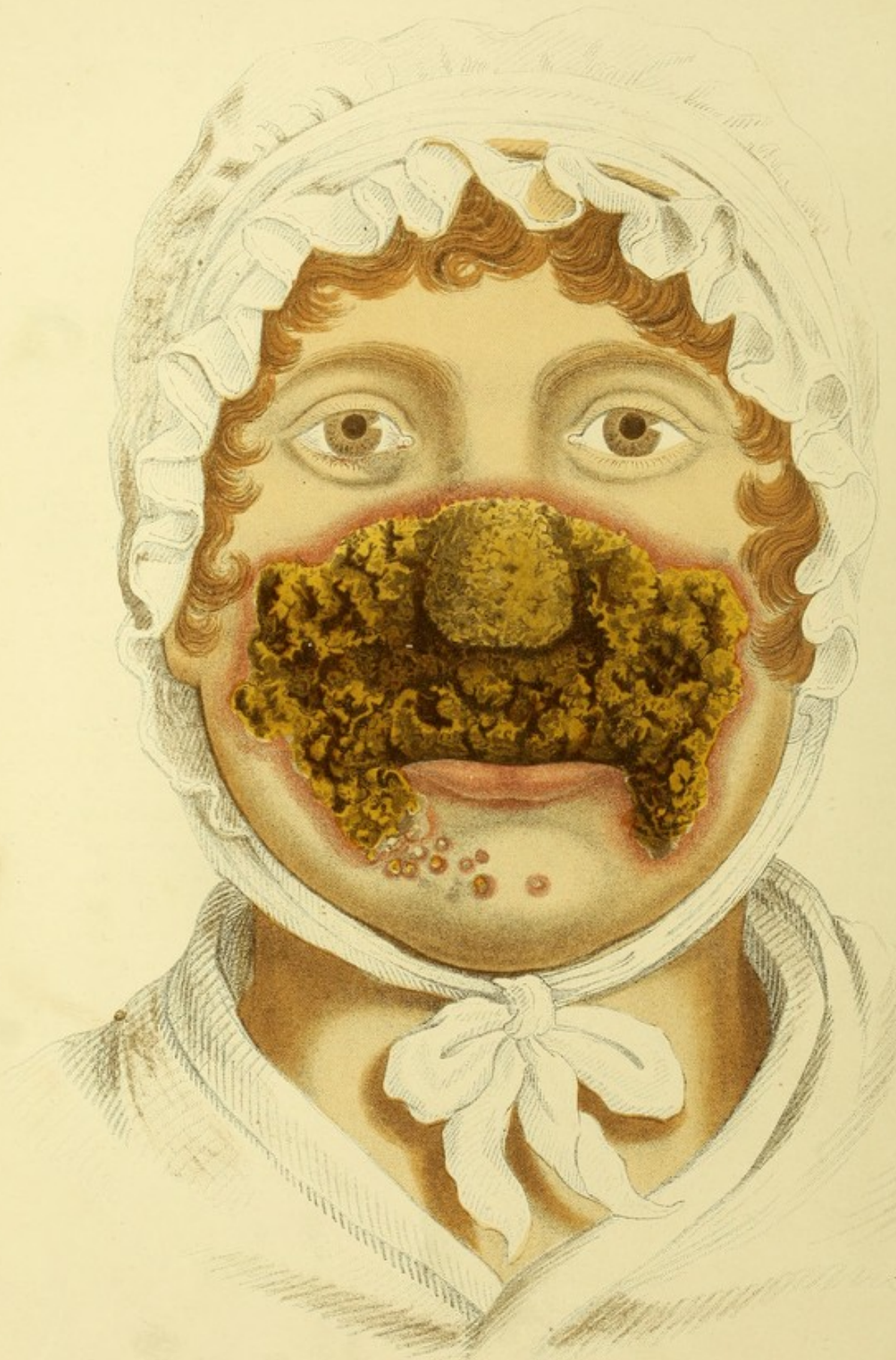IN SENATE,  
January 10, 1906.

REPORT  
OF THE  
COMMISSIONER OF  
THE  
DEPARTMENT OF  
NATURAL RESOURCES,  
FOR THE YEAR  
1905.

LEWIS & CLARK  
PUBLISHING COMPANY,  
ANN ARBOR, MICHIGAN.







LEEDS & WEST-RIDING  
MEDICO-CHIRURGICAL SOCIETY

IMPETIGO RODENS.

## PLATE XXII.

IMPETIGO *rodens*, of some authors.—This illustration bore the designation of ‘PORRIGO *favosa* affecting the *face*’ in Bateman’s edition of Willan’s work, and the following was the description attached to it:—‘As in this situation the scab, which succeeds the *favous* pustules, is conspicuously characterised, I deemed it right to give this view of it, in preference to figuring the PORRIGO *lupinosa*, which, indeed, is of such rare occurrence that I have not been able to procure a good drawing of it since the commencement of this undertaking. Notwithstanding the extreme deformity occasioned by this scall, it often yields readily (as in the case from which this drawing was taken) to medical treatment, and leaves no scar behind—a circumstance which renders it important to distinguish it from the varieties of Lupus, Scrofula, and other scabby ulcerations.’ The PORRIGO *lupinosa* referred to in the above quotation is TINEA *favosa*, with which the disease under notice was erroneously allied in Willan’s time. It is scarcely necessary to say that there are no true *favi*, composed of parasitic elements, in the disease represented in the Plate: the progress of knowledge has enabled us to distinguish between *favi* and the psudracious pustules with which it commences. A condition like that represented here—attended in the first instance by the development of closely set vesico-pustules, and consisting later on of thick yellowish adherent crusts, produced by dried seropurulent discharge covering over a raw reddened, but, however, a *not* distinctly ulcerated, surface—may rarely, no doubt, be the result, *in children*, of impetiginous inflammation, and, so far, Bateman is right in recognising it as an Impetigo—the more so, as he states that there is no ulceration, and the disease is easily cured; but, in my experience, it is attended with ulceration, and more correctly represents, *in adults*, the ‘IMPETIGO *rodens*’ of certain former writers on Dermatology. The ulceration, after a time, slowly increases beneath the scabbing unless measures be taken to arrest it. It is probable that many dissimilar conditions, in which ulceration is combined with scabbing, have been indicated by different people in the use of the term IMPETIGO *rodens*; but, as before observed, the exact condition portrayed in the Plate (XXII.) I know perfectly well, and have treated it with eminent success, as a cachectic ulceration, attended with free crusting. Bateman clearly was not personally acquainted with what in his time was called ‘IMPETIGO *rodens*.’ He says, ‘the disease is a rare but intractable species of the disease (Porrigo), probably of a cancerous nature, in which the cellular membrane is affected as well as the skin, and seems to shrink away as the ulceration and discharge go on. The disorder commences with a cluster of pustules, sometimes intermixed with vesicles, which soon break, and discharge for a long period of time an acrid humour from the open pores or from under scabs, and the skin and cellular textures are slowly, but deeply and extensively, corroded, with extreme irritation and pain, which are only to be alleviated by large doses of opium. The disease commonly begins in the side of the chest and trunk of the body, and gradually extends itself.’ But then he adds, ‘I have not seen any instance of this disease, which is said to have always terminated fatally, and to have been benefited by no medicine, either external or internal,

which had been employed.' (Synopsis, 1819, pp. 159-60.) This account, not being based upon personal observation, is, of course, of little clinical value.

Hardy describes the disease under the term *pustular scrofulide*. He states that it commences either by small pustules, the size of pins' heads, seated on a reddish base, or by a solitary pustule filled with pus and blood; both states, however, being soon replaced by distinct crusts, beneath which ulceration, mostly superficial, advances. He further explains that the disease may comprise two or more patches, which soon coalesce; that it attacks the nose and cheeks, is of slow progress, is allied to lupus, and leaves behind cicatrices after cure.

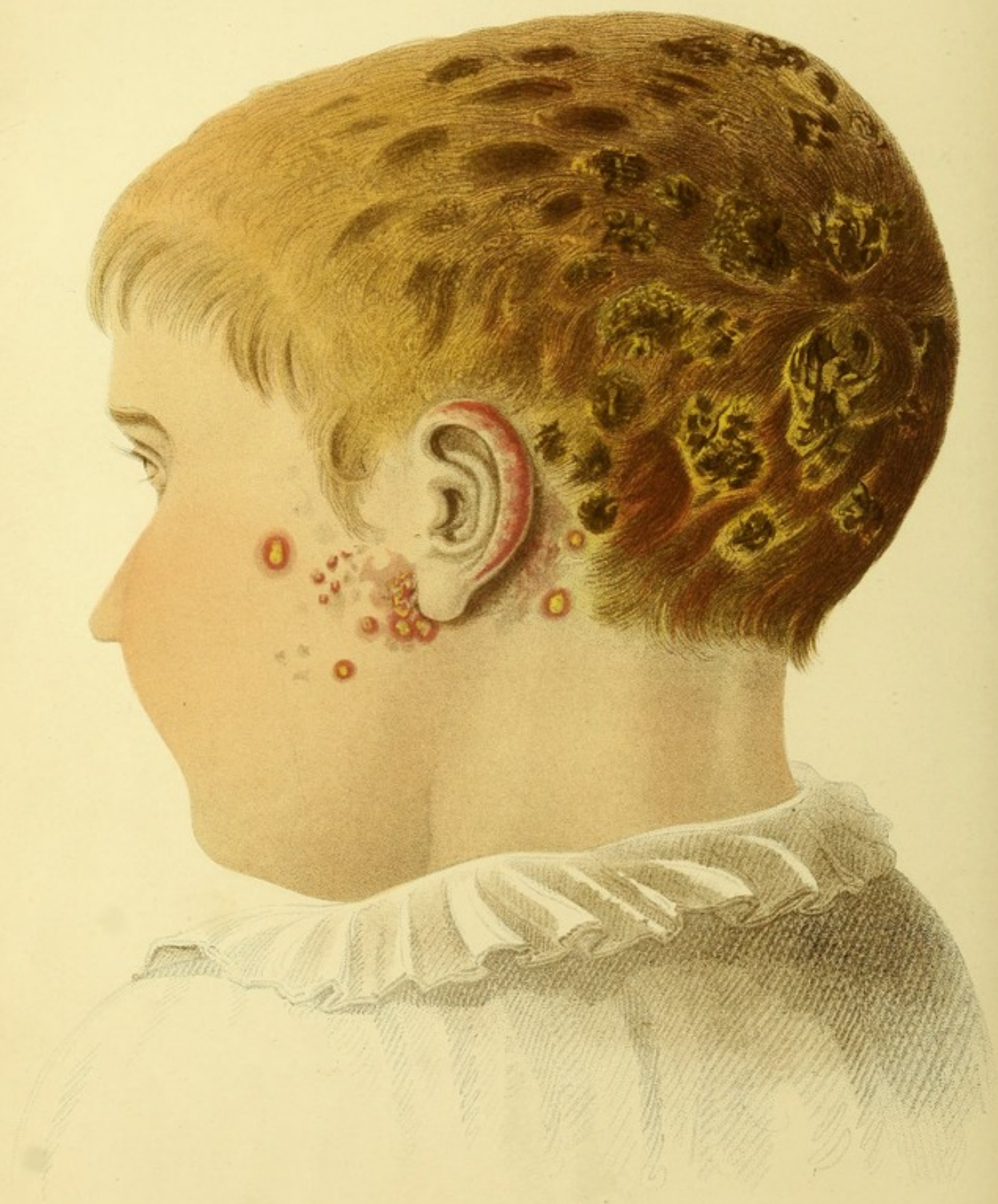I also have observed it begin by a crop of pustules, or seemingly some of the simpler lesions of syphilis, but these soon soften down, whilst ulceration, with free discharge and free scabbing, soon form the prominent features. In the cases I have seen, when the scabbing has been removed by poulticing or soaking the parts in oil, the ulceration has been decided, and of the usual unhealthy character indicative of cachectic disease, whilst the parts have given off a very offensive odour. I have also observed concomitant evidences of syphilis in some of those who have suffered from the form of disease portrayed in this Plate.

It follows, from what I have said, that the term '*IMPETIGO rodens*' is not a very appropriate one. The disease bearing this designation has been a puzzle to many, and I have deemed it of sufficient practical importance to give a place in this Atlas to the condition represented in Bateman's Plate, and to offer this explanation of what, in my experience, it really is.

I would repeat that in instances of pustular Eczema attacking the nose, in which there is very decided scabbing, a condition such as is portrayed in the Plate might be present; and this—called originally, but incorrectly, *PORRIGO favosa* by Willan and Bateman—might be rightly designated *IMPETIGO scabida* (see PLATE XX.) But in the cases that have come under my observation in adults, beneath such a state of scabbing there has been decided and even deep ulceration, which was concealed by the scab, and anti-syphilitic treatment rapidly cured the disease.

The treatment consists in the early removal of the scabs, dressing the ulcerated surface once or twice a day with iodide of starch paste, followed, when the wound cleans, by a weak myrrh and nitric acid lotion, and the exhibition internally of iodide of potassium, with ammonia and bitters, and, if needed, iron, the iodide being gradually increased to doses of from 10 to 15 grains. If the patient be strumous, cod liver oil is a desirable medicine to exhibit subsequently to or together with the iodide mixture.





PORRIGO OF WILLAN & BATEMAN

## PLATE XXIII.


IMPETIGO *sparsa* of the scalp, one of the phases of the PORRIGO *favosa* of Willan and Bateman, or 'Porrigo' of moderns.—This illustration represents a phase of pustular Eczema, wrongly styled by Willan and Bateman PORRIGO *favosa*. The peculiarity about it consists in the occurrence of the disease in the form of small isolated and scattered patches. The disease begins by the development of one or several little impetiginous pustules, that crowd together, mature, and give exit freely to purulent discharge that dries into soft, yellowish or greenish, irregular-surfaced, elevated, and in some cases semi-transparent, crusts, as seen in the figure of this Plate (XXIII.) The disease is really an Impetigo, occurring in small scattered patches, with heaped-up crusts—or, in other words, an IMPETIGO *sparsa*. Other patches of the disease may be present about the face and neck in its earlier or later stages. In the illustration, for instance, a number of little pustules may be observed about the ear, and these would develop to larger pustules, to give place in turn to the same kind of scabbed places as those seen on the head. The disease is attended sometimes with not a little constitutional disturbance, some gastric derangement, swollen glands, and with local heat and pain as in *E. infantile* or *E. impetiginodes* of the head or face. This is the form of disease commonly nowadays called 'Porrigo,' and some have believed it to be contagious, and have therefore termed it 'PORRIGO *contagiosa*.' It is portrayed in PLATE XX. of the Sydenham Society Plates of Skin Diseases under the term—PORRIGO *contagiosa e pediculis*. PORRIGO *Startinii* is another name for it, so termed after the late Mr. Startin, who laid much stress on its contagious nature. But in Willan and Bateman's work its characters were fully and accurately described, and its external features correctly delineated. Its asserted contagiousness was even recognised by these writers—at least by Bateman, for the latter describes (Synopsis, p. 132, 5th edit. 1819) the disease as occurring as an acute eruption, and as spreading from one to a second child of a particular family, and then to the nurse and mother; and his language could not be more explicit. He remarks: 'The contagion was immediately, though but locally, received by the mother and the nurse; the former of whom was inoculated about the mouth by kissing the children, the latter in the palm of the hand.' Clearly, therefore, PORRIGO *Startinii* is a term which does much injustice to Willan and Bateman.

This form of Impetigo may be excited by the irritation of pediculi without doubt, and the designation PORRIGO *e pediculis* would, when the disease is so caused, be a correct one, though IMPETIGO *sparsa e pediculis* would be more in accordance with modern science. That the disease is impetiginous inflammation is often plainly made evident by its development, by the coalescence of the separate spots and the occurrence of severe inflammation, into an ordinary purulent Eczema. I do not believe that this 'Porrigo' or IMPETIGO *sparsa* is in itself contagious. In some cases another form of eruption—not, in some stages, unlike it, and which *is* contagious—is mistaken for it, and hence an appearance of contagiousness is given to this Impetigo through the error of diagnosis; and, further, this other disease, which is really contagious, is sometimes complicated by Impetigo, and being transmitted to others, gives an appearance of contagiousness to the latter. The contagious disease to

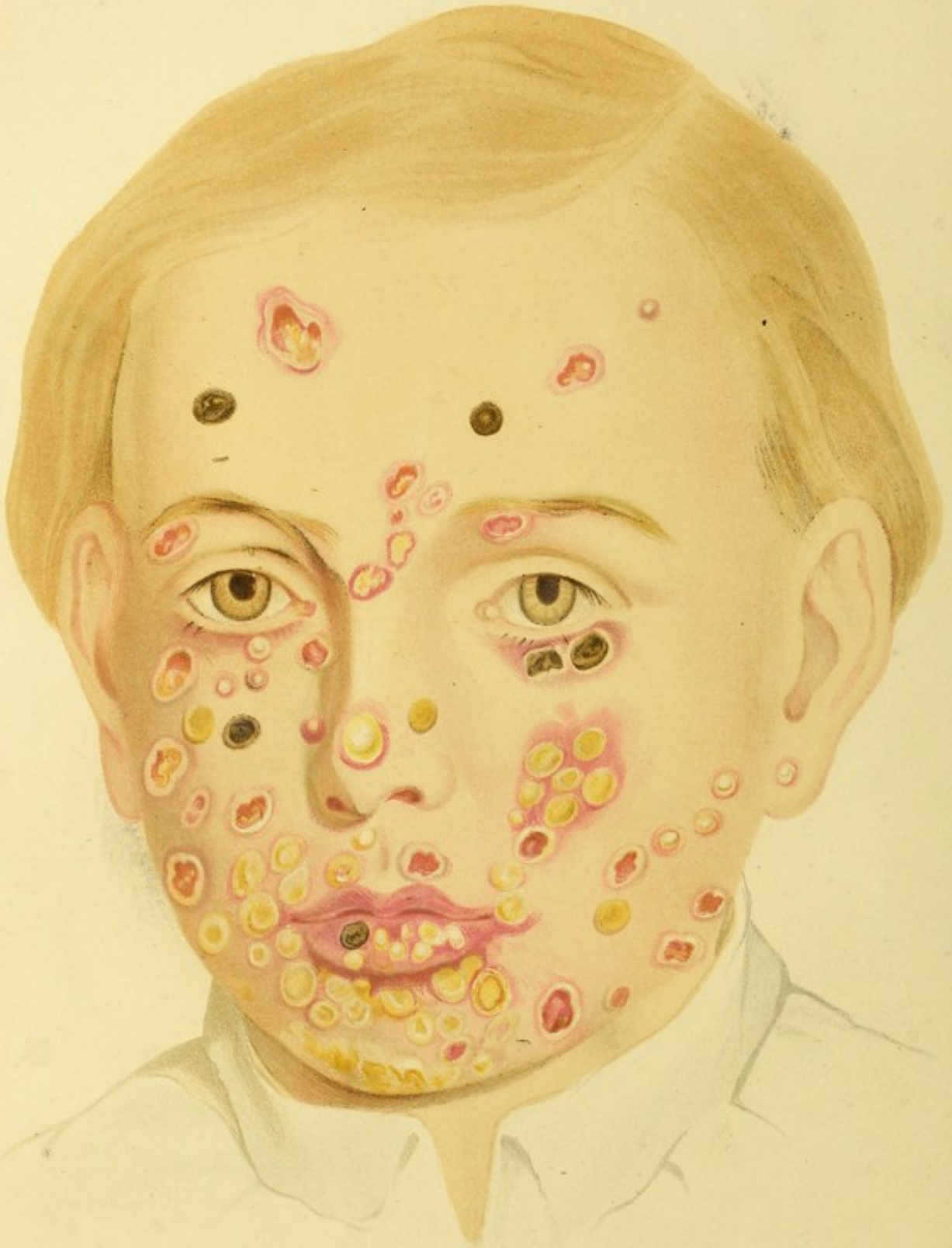which I refer is that which I have described under the term *IMPETIGO contagiosa*, and which will form the subject of PLATE XXIV. The complication of this eruption by pustular Eczema (Impetigo) is readily explained. In young children of lymphatic temperament pustular Eczema (Impetigo) is readily excited, and it often follows the development of the vesico-pustules of *IMPETIGO contagiosa*, so as, indeed, to mask the character of the latter; and my own conviction is that this admixture of the two, which I constantly see on the face and scalp, remains an unrecognised clinical fact, whilst it accounts for the asserted contagiousness of that condition figured in this Plate (XXIII.) which forms the subject of these remarks, and in PLATE XX. of the Sydenham Society's Atlas styled *PORRIGO contagiosa e pediculis*, and which is wholly different from that to which I have given the term *IMPETIGO contagiosa*. I am the more anxious to give prominence to this statement, inasmuch as one of the synonyms given to the Porrigo represented in PLATE XX. of the Sydenham Society's Plates here referred to is *IMPETIGO contagiosa*. I am glad, however, to be able to say that the difference is now being very generally recognised in this country, Germany, and America. In the instances which Bateman put on record as proving the contagiousness of Porrigo, I have no doubt the disease was really my contagious Impetigo, though it was thought to be ordinary 'Porrigo' (i.e. *sparsa*).

The diagnosis of this *IMPETIGO sparsa* is readily made by the recognition of the psudracious pustules that crowd together and give exit to pus discharge, which concretes into greenish yellow raised crusts over limited areas of surface.

The treatment is that of ordinary *E. impetiginodes*, save that more care is needed in removing the crusts from the head by oil packing or poulticing, which should be continued some time, if there be much inflammation, before any astringent local applications are made; and in seeing that the general health is attended to, and that the patient gets good nutritious food. When the crusts have been removed, a weak ammonio-chloride of mercury ointment, or a glyceral tannin ointment, may be applied to the diseased surfaces. Cod liver oil and steel medicines are almost always specially indicated.







IMPETIGO CONTAGIOSA.

## PLATE XXIV.

*IMPETIGO contagiosa*.—This eruption I first described in 1862. In order to avoid the introduction of a new name, and as the scabbing in the disease resembled somewhat that of Impetigo, I adopted this term, with the addition of that of *contagiosa*, to indicate the two main characteristics of the eruption—its vesiculo-pustular character, and its contagiousness or inoculability. The Plate represents a much more extensive degree of eruption than is usually met with, but as it brings out the diagnostic features, and particularly the origin of the spots of disease *from isolated vesico-pustules*, with unusual clearness, I have preferred it to any instance of less extensiveness. The illustration was taken from a boy about eight years old. The eruption is usually seen amongst children of the lower orders, but it is by no means confined to this class. It is often ushered in, as regards general symptoms, by slight pyrexia or symptoms of malaise, the attacked looking languid, pale, and ‘out of sorts.’

The eruption occurs, in the vast majority of cases, about the face, but it may also attack, though more rarely, the scalp, the hands and arms, the buttocks, the feet. The face may be unaffected. The first stage is the development of isolated vesicles, often described as ‘little watery heads’ by mothers or nurses. Three of such vesicles are to be seen in the Plate, just under the eye to the left (i.e. the boy’s right eye), also on the lower lip and about the ear to the right of the Plate (the boy’s left ear). If left undisturbed—that is, if not injured by scratching—these vesicles enlarge to the size of a pea or even that of small bullæ, as seen on the tip of the nose. Usually, however, they are torn open by scratching, as seen on the cheek to the left of the Plate and over the ramus of the lower (left) jaw to the right of the Plate. The contents of the vesicles are transparent at first, but soon become milky, and then purulent, and the vesico-pustules dry away into light yellow or straw-coloured flat circular crusts that appear as if ‘stuck on’ to the surface, and as may be seen over various parts of the face in the illustration. In some cases these scabs become darkened or blackish: two very characteristic scabs, a black and a straw-coloured one, are seen beneath the eye on the left of the figure (i.e. the right eye of the lad) and on the side of the nose to the right. On the chin the contents of the vesico-pustules have nearly completely dried up into light yellow crusts. Generally speaking, these vesico-pustules possess no inflammatory areola—or, at least, none that is at all marked. There are exceptions, however, as in the case of the batch of pustules in the centre of the cheek to the right. If the scabs are removed, little sores, bathed in gummy-like secretion, are observed; but there is no real ulceration of the derma, and so no scars are left by the disease. When the scabs fall off, red stains remain behind for a while, but these gradually fade away. The accompanying illustration exemplifies, in a remarkable degree, the separateness of the several spots in *I. contagiosa*; and this feature was peculiarly well marked, in the case from which it was taken when the disease was at about its mid-course. In general, however, some spots run together into an irregular encrustation, and this character of the eruption is consequently obscured in particular parts of the disease. In the later stage, in the case portrayed in this Plate, the pustules

on the lad's left cheek coalesced, and formed one large somewhat rugged heaped-up scab; but in all these cases the origin of the disease from isolated vesicles, which enlarge with purulation of their contents, is exemplified in accompanying spots elsewhere. The disease is prolonged for some few days by successive crops of vesico-pustules and it may be longer, by inoculation in the act of scratching. In children suffering from this disease, the fingers are apt to be affected by phlyctenæ, and scratches made in apparently healthy parts rapidly 'fester.' When the disease attacks the scalp, it is made up of small isolated circular flat-scabbed spots, the hair being matted by the crusts; but Impetigo is readily excited in fair children by scratching, and on account of the acrid nature of the discharge from the vesico-pustules, and then a mixed disease results. But I have explained this point fully in describing PLATE XXIII. The mucous membranes of the eye, nose, or mouth may become the seat of the vesico-pustules of *I. contagiosa*. Several children in one family may be attacked at the same time, when the disease appears to occur in an epidemic form. In other instances the disease clearly spreads from one child to another, or to the nurse or mother from the child by contact; but when adults have it they usually are affected in one or two spots only. The disease is inoculable, being reproduced with all its characteristic features.

Its diagnostic features are its apparently epidemic character on many occasions, with an antecedent febrile condition; its attacking children *par excellence*; its origin by vesicles, which tend to enlarge into small blebs and to become pustular; the isolation and non-confluence of the spots; the uniform character of the eruption; its attacking the face chiefly; its circular flat granular straw-coloured crusts; its inoculability; the absence of pain or itching, though patients scratch the spots. The distinction between it and 'Porrigo' I have explained in dealing with PLATE XXIII.

The treatment is very simple. The disease tends to run a short course; it is not attended, as the rule, by any bad health, and hence no internal medicines are needed; and all that is required is to remove the scabs, and to apply some mild astringent ointment. Weak ammonio-chloride of mercury is as good as any to destroy the character of the secreting surface and the activity of the pus, and the spots then rapidly die away.

---

NOTE.—I quote the following extract from a communication which I recently received from my friend Dr. Clifford Allbutt, as furnishing strong independent testimony to the truth of my description of *IMPETIGO contagiosa*, and as containing facts in exemplification of the contagiousness of the disease:—'In one set of contagious impetigo cases the infection ran as follows (the appearances were *identical* with your description, and I need not repeat that). •Miss A., a refined, clear-skinned, cleanly young lady of the upper rank of life, came to me much annoyed with contagious impetigo. It was so exactly as described by you and seen by myself before that I recognised it at once, and told her it was infectious. This was at once corroborated, and I soon obtained the following account: No. 1, Miss A., my patient, took the disease from No. 2, her sister (who seems to have brought it into the present set. This sister had been travelling and staying from home a good deal, and brought the disease back with her). No. 2 gave it also to a little cousin who slept with her. No. 1, Miss A., gave it to the Vicar's wife, and No. 1 or No. 2, or both, gave it to B. C., who came to see them from 20 miles away. The disease ran through F. L.'s family, or, "at any rate, attacked some of the children" (her brothers and sisters), on B. C.'s return home.'

## EXPLANATION OF THE PLATES.

---

**PART VII.**—The four Plates in this fasciculus are devoted to the representation of Herpes in its chief forms.

### HERPES.

HERPES is characterised by the development of groups of distinct vesicles of large size seated upon a somewhat raised and reddened base. These vesicles do not burst very readily, as do those of Ecze<sup>ma</sup>. Their contents, at first transparent, soon become milky, and gradually dry up in a week or more into light brownish scabs. The simplest exemplification of the disease is seen in the little 'hot' herpetic patches that occur about the mouth and lips in catarrh and the like. These are identical in character with those shown in *Fig. 3*, PLATE 25, as attacking the penis, or in larger patches in *Fig. 1*, PLATE 25, or the lower patch on the leg in PLATE 26. But different names have been given to the eruption according as it occurs in circles or in the form of a series of connected groups of herpetic vesicles; and varieties have been accordingly made, to which I will now refer in detail.


Former writers on Dermatology were careful to divide the varieties of Herpes into two groups—the *circinate* and the *phlyctenoid*. In the former the vesicles are said to be arranged in the form of a ring enclosing a slightly inflamed oval or circular area of skin, and in the latter the vesicles are scattered more or less uniformly over the inflamed area; but this distinction is a fanciful and useless one.

### PLATE XXV.

*Fig. 1*, termed HERPES *circinatus* by Willan and Bateman, represents an unusually extensive patch or form of this species of Herpes. In this variety the vesicles are distributed in a circle at the circumference of a roundish patch. It is in my experience a rare variety. I have seen it as represented in this figure without question. The patches are often much smaller, consisting of a little ring of vesicles, not much larger than a shilling, and accompanied by very slight redness. The disease runs its course in ten days or a fortnight. It is a non-parasitic disease, and a modification of ordinary Herpes. The term HERPES *circinatus* is so frequently used to designate ringworm of the surface that the reader may very naturally be a little surprised at the description I have given above, for the reason that all herpetic patches of an annulate shape or such as are edged circumferentially with vesications, but with a clear central part, are supposed to be 'parasitic' in nature. This, however, is an error. I repeat such a form of Herpes proper as that delineated in the figure may occur. The characters of an ordinary little patch of Herpes of the lip are seen in the two smaller and middle patches of *Fig. 1*. The circinate

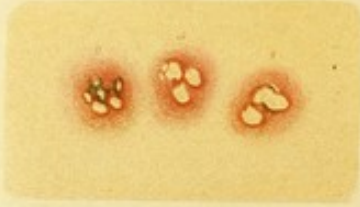character comes out in the other two. There is a special and more appropriate name for the parasitic disease, viz. *TINEA circinata*. It is one that I originally proposed, and the College of Physicians has approved it, and adopted it in its 'Nomenclature.' Its use for the future will prevent much error. No special treatment, save protection of the part, is called for in the case of simple Herpes. It is a disease of definite duration. It reaches its acme in a few days, and then gradually, if not irritated, gets well of its own accord.

*Figs. 2 and 3* portray two conditions of *HERPES præputialis*, a form of the disease which, from its situation on the prepuce, is liable to be confounded by the patients themselves, and by careless practitioners, with chancre. The drawings represent the progress of the eruption, which generally consists of a single patch, in two cases, in *Fig. 2*, on the second, fifth, and eighth; and in *Fig. 3*, on the second, third, fifth, and sixth days of its development. It is often obstinate, and frequently recurs.

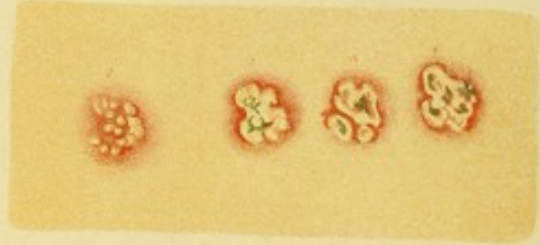

HERPES PRÆPUTIALIS.

*Fig. 2.*

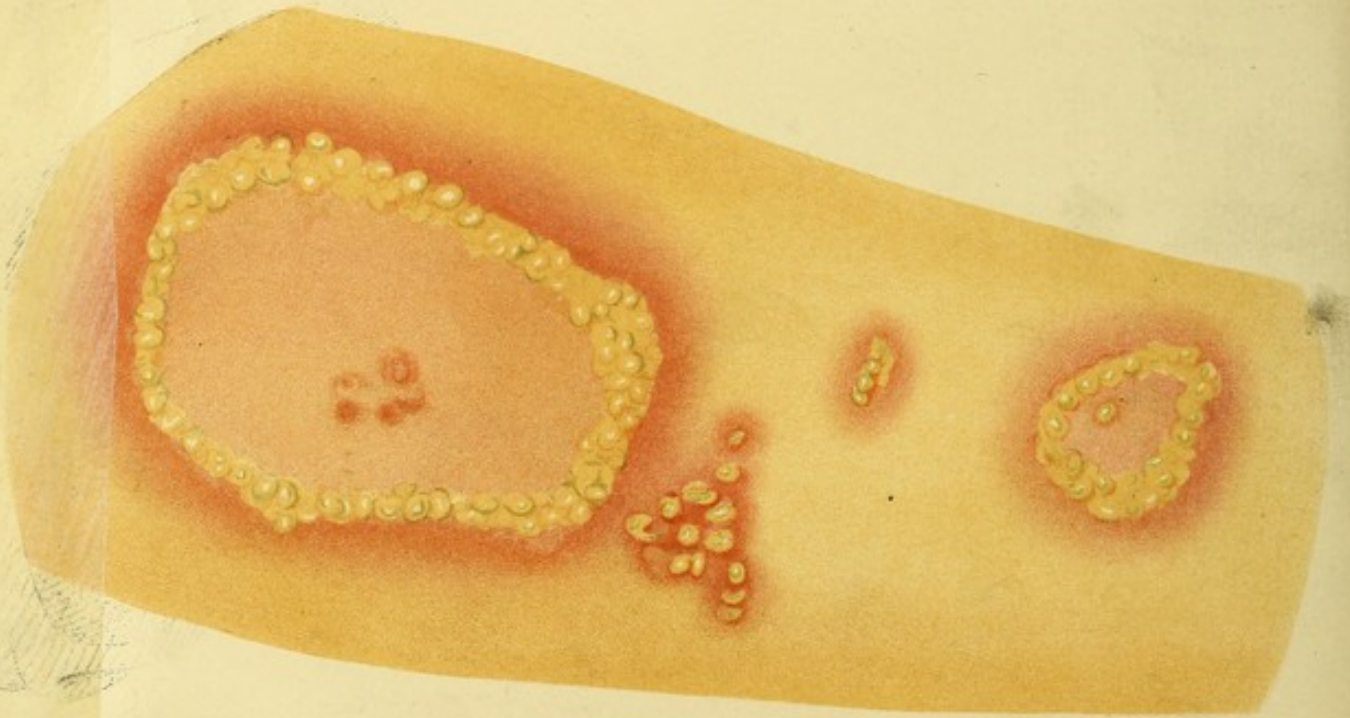


*Fig. 3.*



LEEDS & WEST-RIDING  
MEDICO-CHIRURGICAL SOCIETY

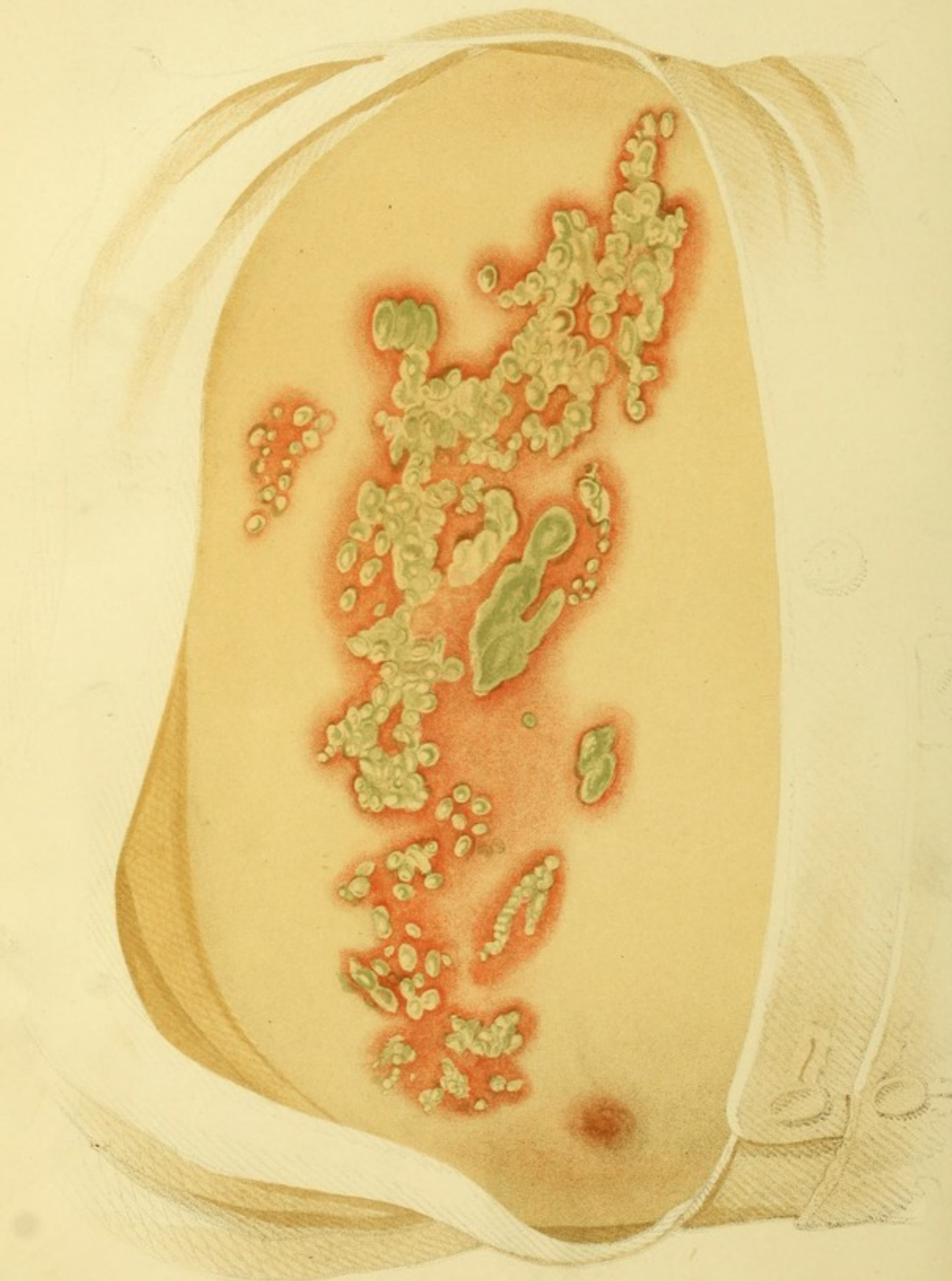*Fig. 1.*



HERPES CIRCINATUS







HERPES ZOSTER


LEEDS & WEST-RIDING  
MEDICO-CHIRURGICAL SOCIETY

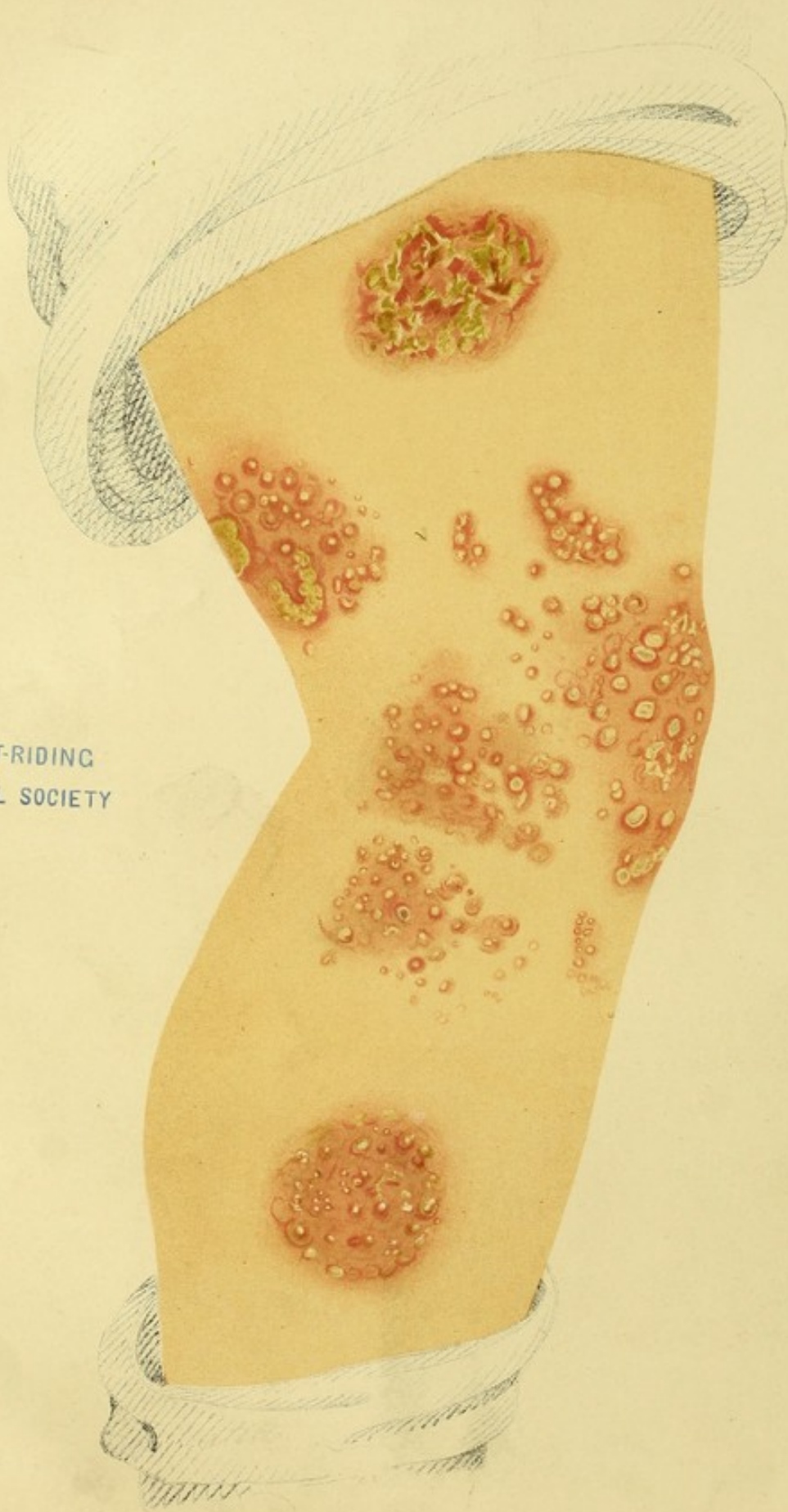PLATE XXVI.

Willan and Bateman termed the disease which is represented in this plate *HERPES phlyctænodes*, and they remarked that 'In this form of Herpes the vesicles are usually smaller than in the Shingles (see next Plate), and the successive clusters extend upon the limb *longitudinally*, and do not encircle it as the latter eruption surrounds the trunk.' The progress of the disease and the development of the patches from above downwards are indicated in the Plate by the incrustation of the upper patch, a condition belonging to a late stage, and the formation of vesicles in the lower one marking the earlier stage of the eruption.

A different interpretation must be put upon the facts mentioned by these worthy men. The disease represents a number of separate patches of phlyctænoid (non-annulate or ordinary charactered) Herpes occurring together, just as in Shingles (*HERPES zoster*) of the trunk, with this difference, that the several portions of the eruption do not tend in this particular case to run together so much as in many cases of *zoster* of the trunk, and the eruption as a whole, does not run round the limb as it does in the case of the trunk, but as in *zoster* of the trunk, and this is the important point, it follows the course of the nerves, and so consequently runs longitudinally. If the nerves ran down the trunk instead of round it, in *zoster* of the trunk the eruption would not be distributed laterally, but from above downwards. In truth the eruption here portrayed and *zoster* of the trunk are essentially the same, only in *zoster* of the limbs the eruption runs parallel to their long axes, and not round them. The course and management of these cases of *zoster* of the limbs are the same as in the case of *zoster* of the trunk, to which I refer the reader.

The first part of the paper is devoted to a general discussion of the problem. It is shown that the problem is well-posed in the sense of Hadamard. The second part is devoted to the construction of the solution. The third part is devoted to the study of the properties of the solution. The fourth part is devoted to the study of the stability of the solution. The fifth part is devoted to the study of the convergence of the solution. The sixth part is devoted to the study of the error of the solution. The seventh part is devoted to the study of the numerical solution. The eighth part is devoted to the study of the application of the solution. The ninth part is devoted to the study of the conclusion. The tenth part is devoted to the study of the references.





LEEDS & WEST-RIDING  
MEDICO-CHIRURGICAL SOCIETY

HERPES ZOSTER (*of leg.*)

LEEDS & WEST-RIDING  
MEDICO-CHIRURGICAL SOCIETY

PLATE XXVII.

This represents *HERPES zoster*; commonly termed *the Shingles*, in its most common site, viz. the trunk. It may attack the head, the face, the neck, the trunk, or the limbs. It has this peculiarity, that it is *unilateral*, i.e. limited to one side of the body. It is ushered in sometimes by a little malaise, often by very sharp pain in the seat of the subsequent eruption, the development of which relieves the pain in most cases. It is made up of several herpetic patches of the phlyctænoïd phase, and these patches develop generally in succession, so that in a well-marked case the disease may be seen in its various stages in the same subject, as shown in this and the preceding Plate. In some parts the vesicles are just forming, in others they contain milky fluid, and in others they are drying up into crusts. As the patches which first appeared subside, the eruption becomes partially confluent, and subsequently assumes a livid or blackish hue, and terminates in thin dark scabs. This complaint runs a definite course of from ten days to three weeks or so. It is generally of little importance, but is occasionally accompanied, especially on the decline of the eruption, by an intense deep-seated pain in the chest, which is not easily allayed by medicine.


The treatment is simple as the rule. The main object is to protect the eruption from injury by rubbing or the like, and to aid the drying up of the herpetic patches. It is usually sufficient to apply a layer of cotton wool after the eruption has been well dusted over with starch and oxide of zinc powder, or the eruption may be dressed with benzoated oxide of zinc ointment. If it leaves neuralgia behind recourse must be had, if belladonna lotions fail, to the exhibition of quinine in full doses and the subcutaneous injection of morphia.

The first part of the document discusses the importance of maintaining accurate records of all transactions. It emphasizes that every entry should be clearly documented and supported by appropriate evidence. This ensures transparency and allows for easy verification of the data.

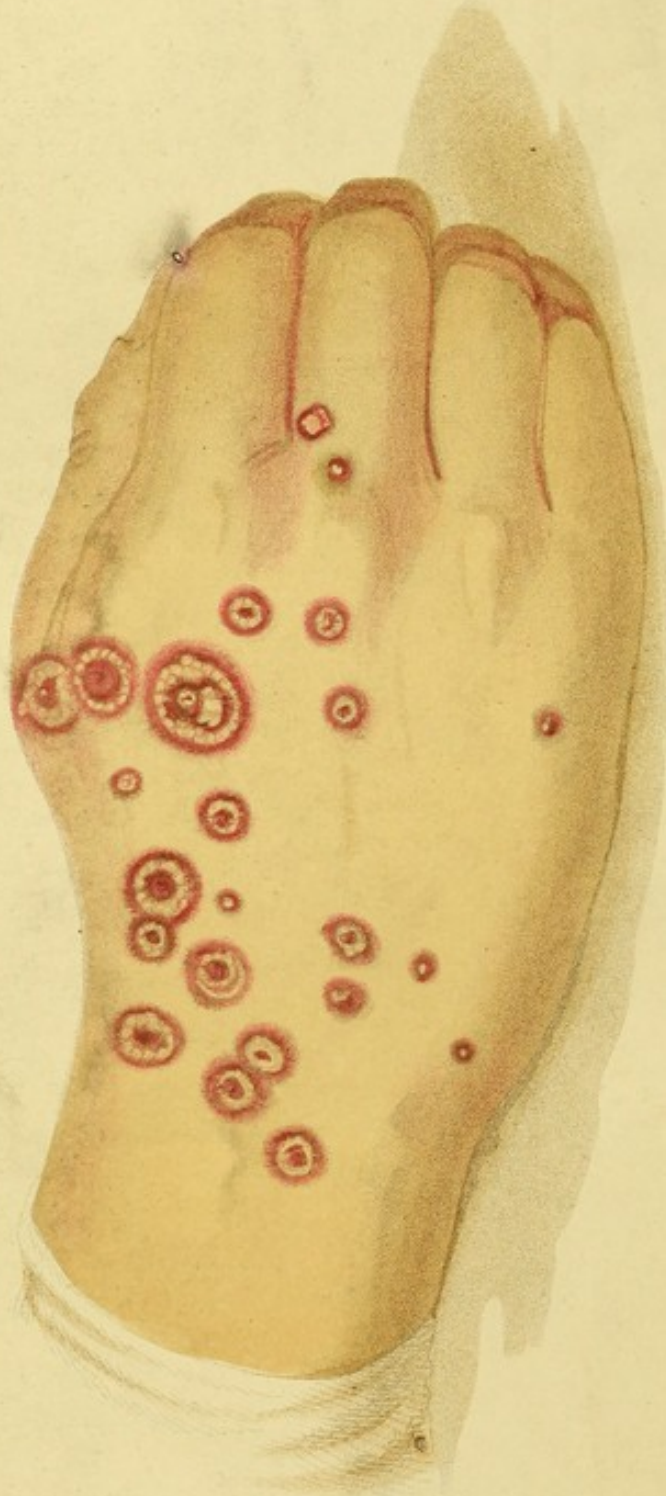Furthermore, it is noted that regular audits are essential to identify any discrepancies or errors early on. By conducting these checks frequently, the organization can prevent small mistakes from escalating into larger issues. This proactive approach is key to maintaining the integrity of the financial system.

In addition, the document highlights the need for clear communication between all stakeholders involved in the process. Regular meetings and reports should be used to keep everyone informed of the current status and any changes that may occur. This collaborative effort is necessary to ensure that all parties are working towards the same goals and objectives.

Finally, it is stressed that the information gathered should be used to make informed decisions. By analyzing the data and identifying trends, the organization can gain valuable insights into its performance and areas for improvement. This data-driven approach is crucial for long-term success and growth.







HERPES IRIS

## PLATE XXVIII.

**HERPES Iris.**—This rare and curious variety of Herpes occurs principally in the situation in which it is here figured, but sometimes in the palms of the hands or on the instep. The vesicles are not large or elevated, but sufficiently distinct to characterise the disease. In the fully developed disease they are disposed in two or three concentric rings, with a central vesicle, the rings arising in succession as in the other forms of Herpes. The course of the eruption is as follows: a red spot or disk makes its appearance; in the centre of this spot a vesicle generally begins to form the subsequent day, whilst the original redness extends so as to surround this central vesicle with an erythematous border; in a day or so more a ring of vesicles, more or less distinctly marked, begins to develop in this circumferential band of redness, which assumes a duller hue; meantime the red blush has extended still farther from the original centre. The disease may be arrested at this stage, or a second band of vesicles may spring up after the fashion of the first. The central vesicle may be very distinct and large. At times its contents may seem to have become sanguinolent. There are generally several spots of eruption.


In some instances the character of the disease is not so distinctly pronounced as in the typical case described above, and the eruption is made up rather of an erythematous circular base of dull hue, with a central small and even indistinct vesicle, and only an attempt at the development of vesications in rings or a single ring outside this vesicle. Under these circumstances the eruption would be, to many, more aptly described as *ERYTHEMA iris*, but I believe the disease to be then potentially *HERPES iris*, and an abortive phase of the fully developed eruption. True *ERYTHEMA iris* as I have seen it is very rare indeed, and it consists of *large* rings of erythema, pure and simple, of the most varied hues. It is a rash of short duration.

I have recently observed the concurrence of *H. præputialis* and *H. iris* in the same subject—that of a gentleman who consulted me by desire of my friend Mr. Worts, of Colchester. The patient began to suffer from *H. præputialis* 9 years ago, and has had in all nearly 30 attacks. For three or four years this Herpes occurred alone, but subsequently the *H. iris* and *H. præputialis* were observed to develop together, and, at the time I saw the patient, the two forms of eruption were concurrent: the *H. præputialis* being very well marked indeed, the *H. iris* less so. There were some twelve spots of the latter about the back of the hands, the forearm, and the thighs. The patient now always knows when he is going to have an attack of *H. præputialis* by the development first of all of red itching tingling spots on the back of the hand, that assume the characters of *H. iris* subsequently. The patient is a rheumatic and nervous subject.

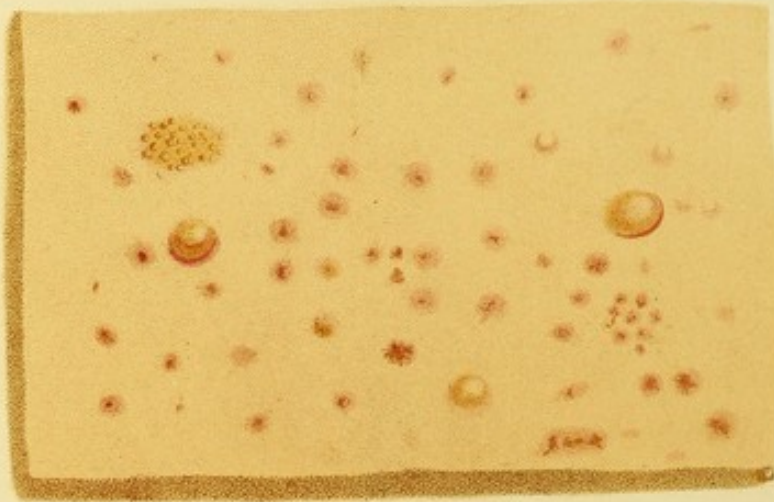
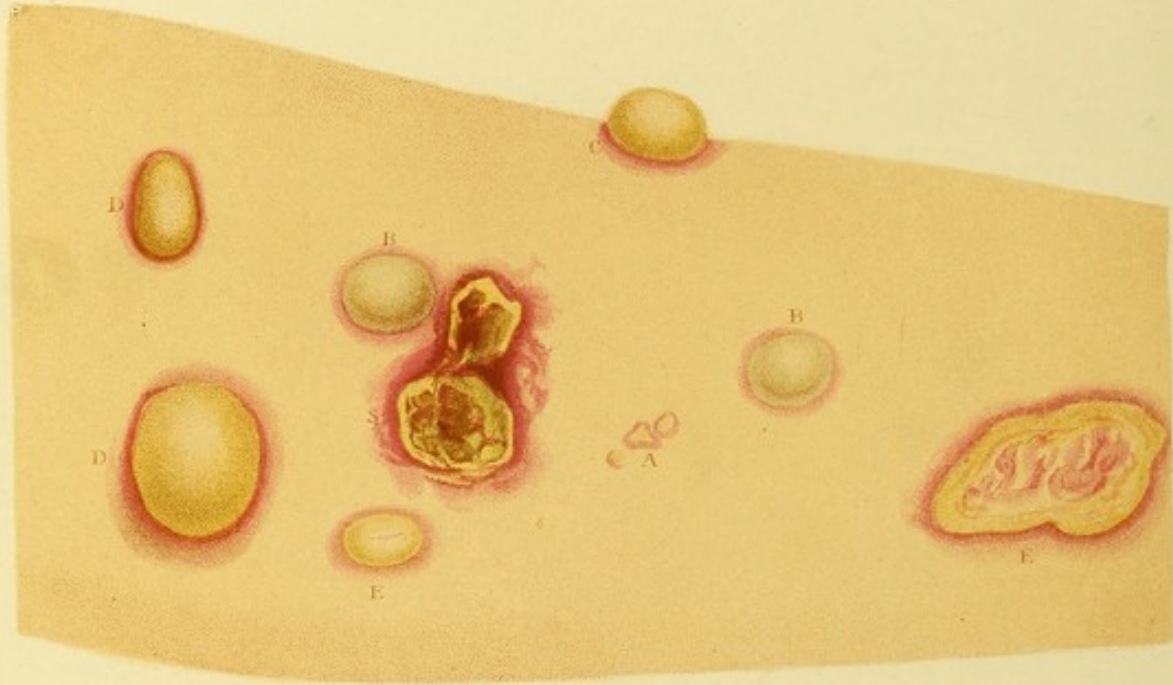
Unhappily the nature of *HERPES iris* has been greatly misunderstood, and it has been described as identical with the *HYDROA* of *BAZIN*. In the museum of the St.-Louis Hospital I saw last summer 3 models, Nos. 301, 274, and 190, with the designations 'Hydroa vesiculeux' and 'Herpes iris' attached to each, and therefore applied to

those models as synonymous terms. These models portrayed instances of true *H. iris*, such as is represented in this Plate. The designations attached to these models were not, as far as I can discover, given by Bazin, but by Lallier and others. I shall refer more particularly to this when I come to deal with and to represent Hydroa as I understand it, and as totally different from *H. iris*.

The treatment of HERPES *iris* consists in the application of mild astringents locally, such as lotions containing oxide of zinc and camphor, and full doses of quinine or bark internally.



PEMPHIGUS VULGARIS.



PEMPHIGUS PRURIGINOSUS.

## EXPLANATION OF THE PLATES.

---

**PART VIII.**—This fasciculus contains illustrations of 3 varieties of Pemphigus, viz. *P. vulgaris* (PLATE XXIX. Fig. 1), *P. pruriginosus* (PLATE XXIX. Fig. 2), and the rare form *P. foliaceus* (PLATE XXX.); representations of the 2 main phases of Ecthyma, viz. *E. vulgare* (PLATE XXXI. Fig. 1) and *E. cachecticum* (PLATE XXXI. Fig. 2); and in the fourth PLATE XXXII. Rupia is portrayed.

### PEMPHIGUS (PLATES XXIX. and XXX.).

This disease is characterised by the formation of blebs in one or many parts of the body, varying in size from that of a split pea to that of a large walnut, without, as the rule, much inflammatory action or constitutional disturbance. The bleb is preceded in its formation by a red spot, which, however, is quickly replaced by the bleb, which is at first tense, and contains transparent fluid. Soon, however, the fluid becomes turbid or more or less purulent, the bullæ then become flaccid and by-and-by shrivel up, forming slight crusts from the dried discharge. The bullæ occur in successive crops; each bulla develops in the course of a few hours, and there is slight attendant itching. The disease may be prolonged for many weeks.

There are two main forms of Pemphigus—*acute* and *chronic*. Acute Pemphigus is rare. Its occurrence is denied, but I have observed it unquestionably in several instances. It is attended with not a little constitutional disturbance, and the development generally of a multitudinous crop of bullæ of all sizes, attended with some little inflammation, scattered widely over the body. As far as I have observed this acute form it has seemed to me to be of short duration, and the whole eruption has developed within a few days. In children acute Pemphigus may develop with all the symptoms of acute septic poisoning, and be rapidly followed by death, especially in lying-in hospitals.\* I am now speaking of non-syphilitic Pemphigus. Chronic Pemphigus is common enough, and I give 3 illustrations of it.

### PLATE XXIX.

*Fig. 1, PEMPHIGUS vulgaris*, represents the form which Pemphigus assumes in the vast majority of cases. It may commence with a little headache and pyrexia, oftentimes not, but Pemphigus patients are often debilitated. As regards the eruption, the first indications are small red spots (see A), which speedily develop into small blisters (see B), which in turn become bullæ, shown at C and D in the figure. These bullæ break open in two or three days, as represented at E, and they may then acquire an inflamed base. Slight scabbing forms, and after the fall of the scabs slight red stains are left. If only

---

\* I make this statement on the authority of the Records of the General Lying-in Hospital.

one bulla is developed at a time, though the disease is prolonged by five, six, or more successively, the disease is termed *P. solitarius*. This latter form is observed with greatest frequency about the wrist or the ankle. The subjective symptoms of chronic Pemphigus are burning or itching.

The treatment consists in overhauling the patient thoroughly to detect all possible sources of malassimilation and nervous debility. My own belief is, that Pemphigus mostly occurs in those who suffer from the latter, and that good feeding, change of air, with rest from mental worry if possible, do *as much* as physic for the disease, though the exhibition of quinine in full doses with arsenic, and perhaps cod-liver oil, are very beneficial. I have found belladonna useful internally in recurrent Pemphigus. Locally I think it is best to protect the bullæ as much as possible, or they may be pricked, the surface generally being dressed with some simple unguent.


*Fig. 2.—PEMPHIGUS pruriginosus.* In some cases small bullæ develop upon the skin in connection with the presence of a 'pruritic' rash, viz. scratched hyperæmic follicles and papillæ, whose apices become covered over with little dark scales of dried blood effused after the scratching has been practised. To this condition the term *P. pruriginosus* is given. There are three items then of this form—bullæ, 'pruritic' rash, and pruritus; the latter being at times very tormenting. This form of Pemphigus is a phase of the disease I shall describe and depict as Hydroa in a future fasciculus. The whole of the symptoms are due to some disorder of the nerve supply of the skin.

The treatment consists in restoring the general tone of the system, in the exhibition of nerve tonics, the use of alkaline and subsequently sulphur baths, the careful regulation of the diet, and the local use of sedatives such as prussic acid, chloral hydrate, digitalis and the like.

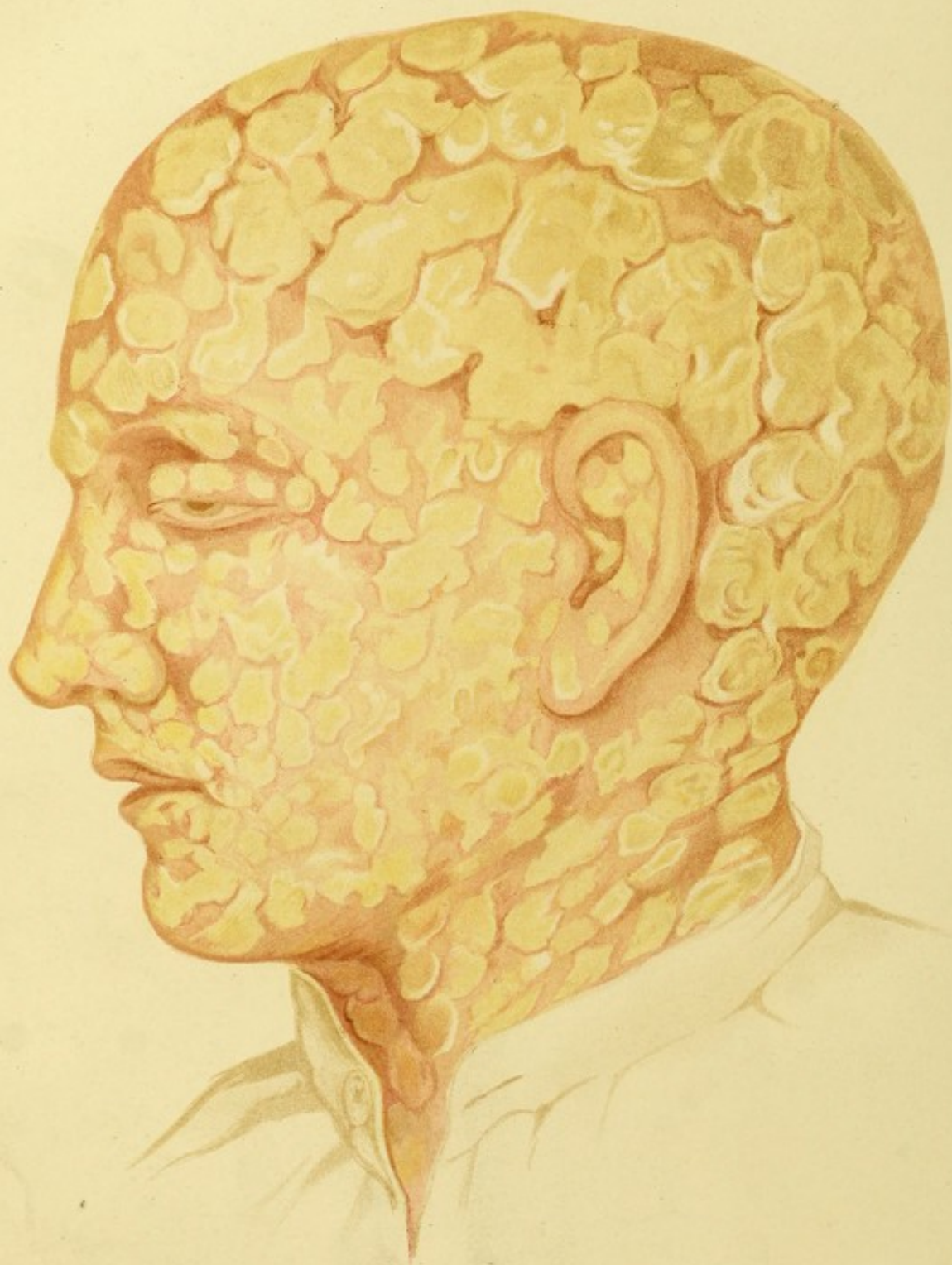
---

#### NOTE ON CHEIRO-POMPHOLYX.

Mr. Hutchinson has recently described and figured ('Illustrations of Clinical Surgery,' April 1876) an eruption, which he has termed Cheiro-pompholyx, without, as he remarks, 'intending to imply a relationship to true Pemphigus' by that name, which is therefore a most unfortunate and misleading one. This eruption is nothing more nor less than that of which I first gave a full account in 1873, in the third edition of my work on Skin Diseases, under the designation of *DYSIDROSIS*; and the case from which Mr. Hutchinson's representation was taken was an exaggerated example of *Dysidrosis* that came under my own observation, and was sent to me by Dr. Russell Reynolds. The disease is not a Pompholyx. It is, moreover, not limited to the hand, and therefore not entitled to be styled by the prefix Cheiro-. This disease is not produced by effusion of serum into the skin, as Mr. Hutchinson declares, but by distension of the sweat apparatus, and uplifting of the cuticle by sweat, and the production of large vesicles of bullæ by the free secretion of sweat and the coalescence of smaller vesicles. I shall give further details when I come to represent the disease and to describe it further on; but it is strange that my original description of the disease should have been ignored.







PEMPHIGUS FOLIACEUS.

## PLATE XXX.

*PEMPHIGUS foliaceus* (New).—This is a most admirable representation of this rare form of disease as it affected the head and neck in a case recently under my care in University College Hospital. The entire body was attacked and in a similar condition to that portrayed here.

This *P. foliaceus* is said to begin on the front of the chest by a single bulla, and gradually to spread thence over the body by the development of successive crops of blebs. In two cases I have recently seen the disease commenced on the shoulder and ankle respectively; in one case by little groups of bullæ seated pretty close together, and the other by a huge bulla on one and a second on the other ankle. At first the successive bullæ are often distinct, but after a little time, as they spring up in great numbers and more closely together over the body, they become less and less distinct, until at length it is difficult to detect a well-formed one of tolerable size. In consequence of the close packing together of the bullæ, and the drying up of their walls in admixture with a certain amount of seropurulent fluid exuded from the inflamed skin, large flaky masses are formed, like bits of yellow parchment, and a condition like that shown in the figure is produced. The site and number of the bullæ (abortive at this stage) are indicated by the separate crustlike scales in the figure. The scales, or quasi-scabs, the remains of the abortive bullæ intermixed with dried discharge as before explained, have been likened to bits of French pastry or papyrus, and they vary, as will be seen in the figure, in size, and they are free at their margins. An offensive odour is exhaled from the patient, and the skin beneath the bullæ is reddened and tender.


If there be no attendant discharge from the skin the flakes may be very fine and flimsy, but still they indicate the site and size of the bullæ out of whose walls they are formed. The disease runs a most chronic course, and is a most exhausting one.

The only three cases I have seen were in elderly women who had been greatly prostrated by trouble, anxiety, and underfeeding. They were all very weak indeed. Two did well with great care, free feeding up, and an abundance of tonics, porter, and the like. The third died. The disease was slowly progressing up to a certain point when the patient became very ill. She had high fever with a temperature of 104·8, was very weak, and had a dry pungent skin. The heart was beating strongly, her pulse was 112, small and weak; the carotids were pulsating conspicuously, and there was a breezy murmur, systolic in point of time, heard over the heart, loudest at the apex, but extremely well heard at the lower part of the sternum. She had no joint affection, and there was no lung mischief. She was admitted into hospital. The Pemphigus then spread very rapidly, and the whole body was covered by it during the next 3 days. At the same time the cardiac murmur continued distinct. There was no albumen in the urine. It was thought that endocarditis had occurred, and now a loud basic systolic murmur was heard. Fresh blebs continued to appear, with severe paroxysms of itching and burning after the blebs developed; but the more general appearance of the blebs seemed to be every 2 or 3 days, when a crop

of new ones made their appearance, generally lasting less than 12 hours, and then drying up into flakes. Diarrhœa and vomiting now came on with increased paroxysmal burning and itching, the blebs ceased to form, a very offensive odour was given off from the patient, and she died. During life the contents of the blebs were found to contain bacteria. After death the heart was found to be softer than natural, but exhibited no sign of endo- or pericarditis, and no valvular thickening or staining. There was no atheroma in the aorta, and no ante-mortem clot, and no hypertrophy or dilatation of the heart cavities. The fingers were the only part of the body free from the eruption. Of course this was an exceptional instance of the disease.

The disease under ordinary circumstances is likely to be mistaken in its fully developed stage for chronic general Eczema, from the presence of crusting and seropurulent exudation; but the origin of the disease as a distinct Pemphigus, the flakes forming the walls of abortive bullæ, the peculiar character of the flakes or crusts, and the presence of abortive bullæ suffice to prevent error.

The treatment consists essentially in feeding up the patient and restoring his or her powers in every possible way, in exhibiting cod-liver oil, iron, and quinine in full doses for a long time.



ECTHYMA VULGARE.

Fig. 1.

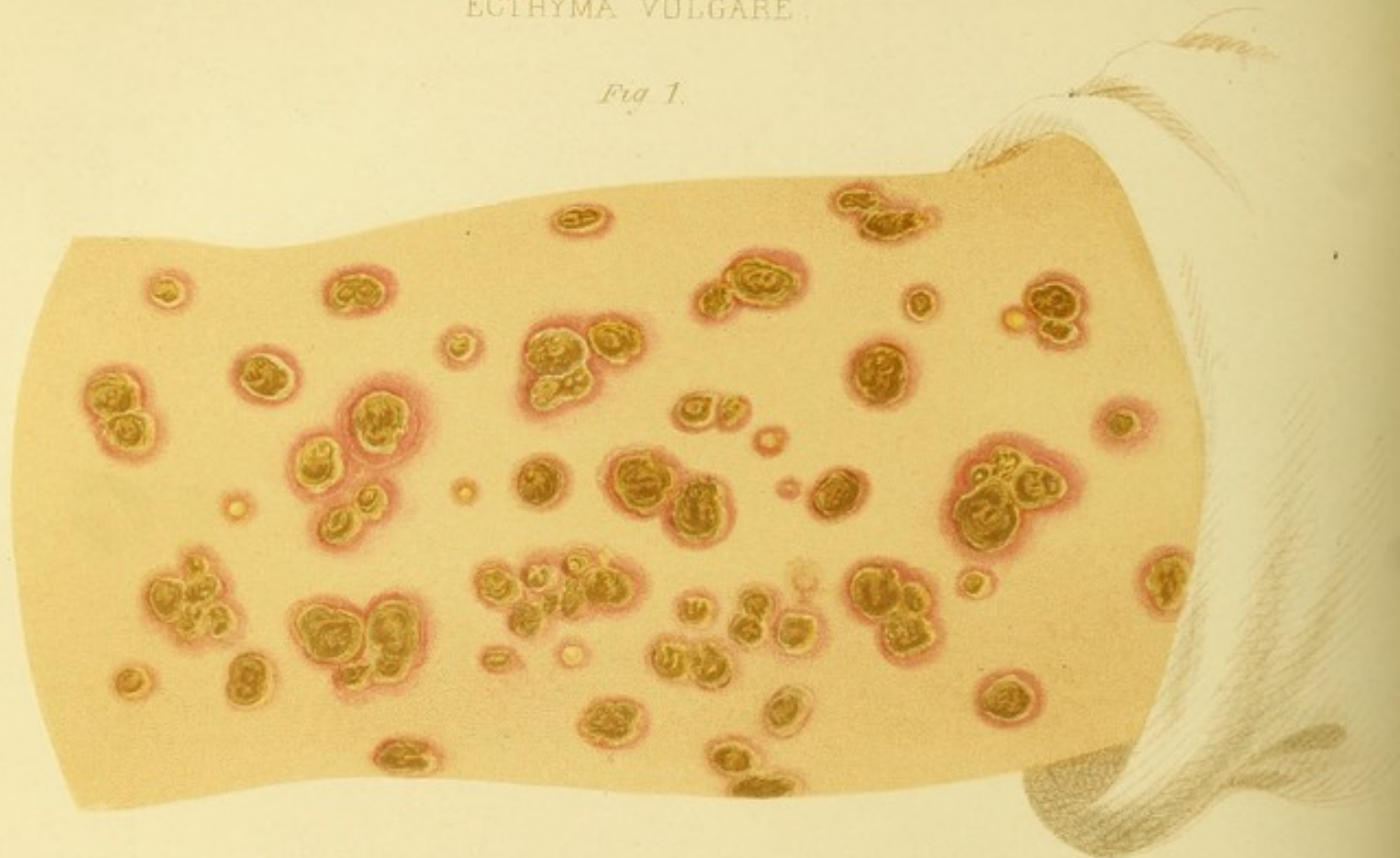
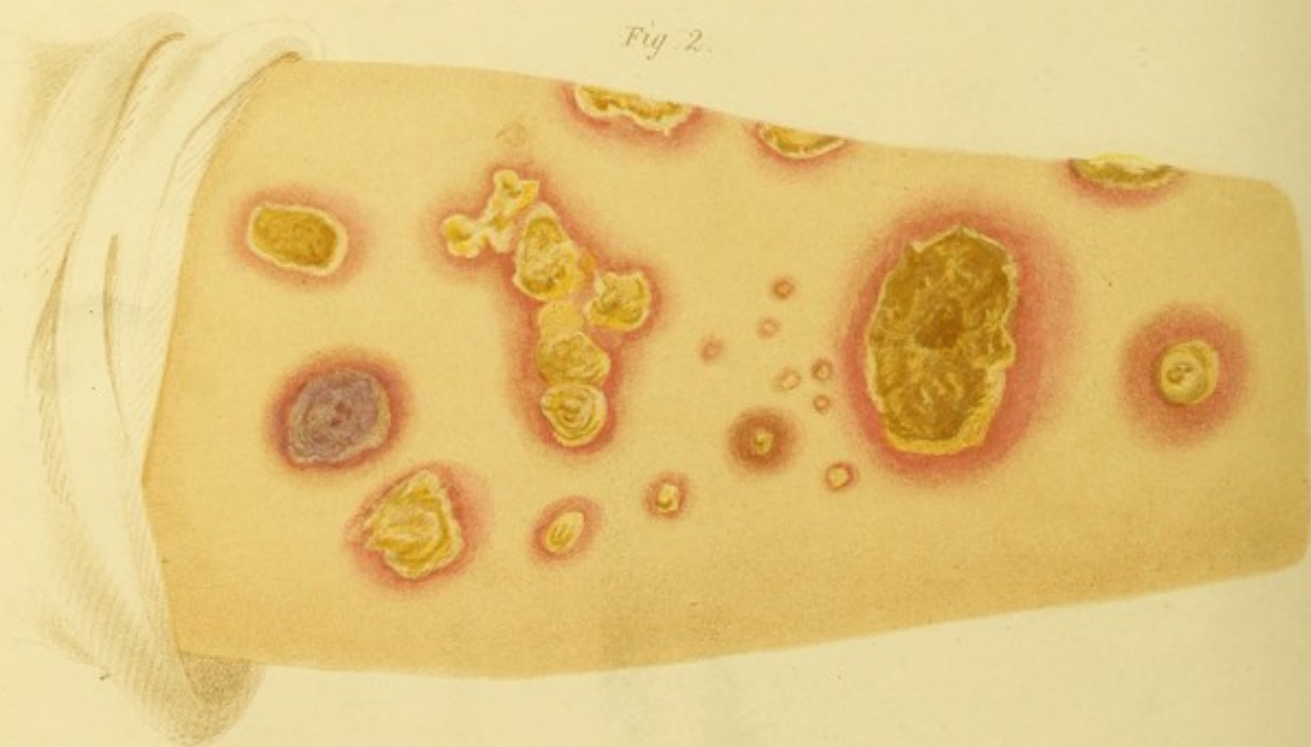
Fig. 2.



ECTHYMA CACHECTICUM.

## ECTHYMA.

This disease is characterised by the development of isolated pustules, 'which are large, raised on a hard painful base, of vivid red colour, and are succeeded by thick, hard, dark-coloured scabs, beneath which there is slight ulceration.' There are two chief forms of the disease—*acute* (rare) and *chronic*. The acute disease is uncommon; and I have not portrayed it here because it does not differ as regards the characters of the actual eruption from that of chronic Ecthyma. In the acute variety the onset of the disease is somewhat sudden. It is attended by slight pyrexia, malaise, and sometimes sore throat, with local symptoms of heat and burning, succeeded by the development of hard, painful pustules, which latter arrive in successive crops. The pustules soon dry up into hard dark crusts, covering over slight ulceration. The limbs, shoulders, and trunk are the chief seats of eruption. The lymphatics and glands may become inflamed, and the patient gets debilitated and needs careful toning up. The chronic form is very common indeed, and is well illustrated by the 2 figures in the accompanying Plate. The *predisposing* causes are always such as lead to an impoverished state of blood and nutrition, such as bad nursing, imperfect feeding, overwork, fatigue, uncleanliness, debauchery, debility from acute diseases, privations, etc.; and the *exciting* cause is some irritant acting directly upon the skin. The pustules are excited by scratching, by the irritant action of lime, sugar, pediculi, acari, friction, etc., especially in, as before indicated, individuals who are in a state of more or less cachexia. In some cases the Ecthyma exists alone, but in the bulk of cases it is a complication of diseases which have existed some time, and in which the skin has been much irritated and scratched—the scratching being the real excitant of the Ecthyma as in *Scabies* and *Phthiriasis*.

## PLATE XXXI.

*Fig. 1.*—ECTHYMA *vulgare*. This form of eruption consists of the large painful pustules, denominated *phlyzacia*, occurring principally on some part of the extremities, and gradually enlarging and inflaming, for a week or ten days, one after another, when they break, pour out their pus, and afterwards a thinner fluid, which concretes into brownish scabs. In about a week or more, the inflammation subsides, and the scabs soon afterwards fall off. The various stages of the pustules are here delineated in a case of some severity. In the milder cases they are not so numerous nor so large.

*Fig. 2.*—ECTHYMA *cachecticum* is the same disease in a more unhealthy subject, and in which the pustules are large and possess a more extensively inflamed base, the inflammatory action in fact implicating the surrounding cellular tissue to a larger extent; the scabs being also larger, more purulent, and more adherent, whilst the eruption runs a slower course. A phase of this form is sometimes termed *E. luridum*. It is characterised by the darker hue of the bases of the phlyzacious pustules, and by the long and slow succession in which they spread over both the trunk and limbs, for a period of several weeks. When they break, a curdy or sanious discharge issues, and dark hard scabs form

by its concretion, and remain surrounded by dark inflamed borders till they are about to separate. The middle of the three spots to the left exemplifies the kind of livid tint of this phase of Ecthyma, which is only Ecthyma in a very cachectic person.

In the case of Ecthyma occurring in connection with Scabies the pustules occur mainly about the hand, arms, the feet, and nates; in Phthiriasis about the upper arms and the trunk, including the back, but not about the hands, forearms, or feet.


In Ecthyma, as the pustules, with their hard inflamed bases, arise in daily succession, going through their successive stages of inflammation, suppuration, scabbing, and desquamation, they are commonly seen under all these conditions at the same time, as represented in the 2 figures of the Plate. The pustules which occupy the breast and abdomen are generally less prominent, and contain less matter than those on the face and arms.

The febrile symptoms, when present, are diminished, but not removed for a while, on the appearance of the eruption; but if the disease is severe, a condition of semi-hectic may supervene during the progress of the disease, with great languor and depression of spirits. The disease is sometimes also accompanied by pains in the head and limbs, and commonly by some degree of ophthalmia, and by a slow inflammation, with superficial ulceration of the fauces.

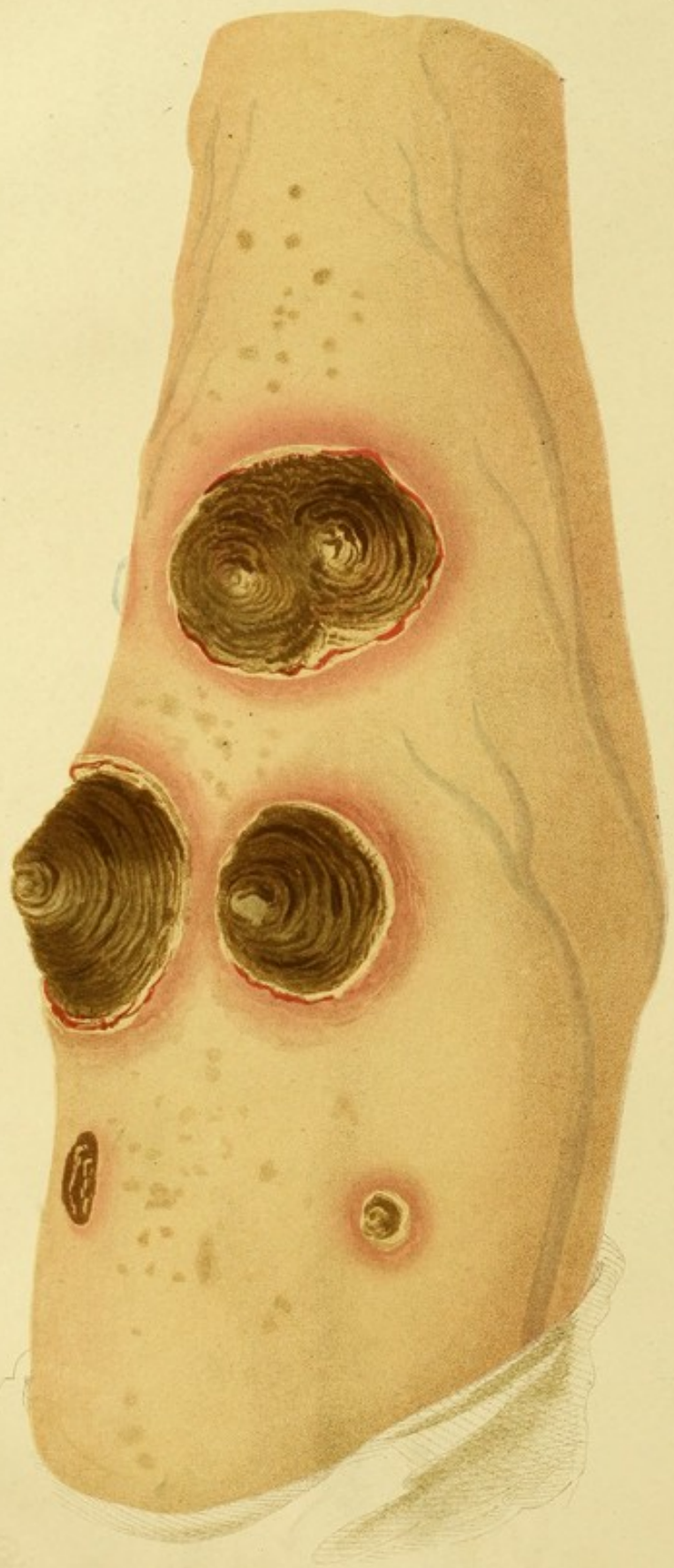
The duration of Ecthyma is considerable, extending to 8, 10, or 12 weeks.

The *diagnosis* of Ecthyma is not difficult. The ecthymatous spots are distinct, large, isolated, with hard, inflamed, painful bases. They may at first resemble boils, but they lack the central 'core.'

The *treatment*.—The first question to determine is whether the Ecthyma is or is not secondary to some other disease, such as Scabies or Phthiriasis. If it is, of course the primary disease must be got rid of, when the Ecthyma will disappear; or if it be tardy in subsiding, it will subside in due course under the influence of tonics, since Ecthyma always indicates the existence of a cachectic state of nutrition. In those cases which depend on the action upon the skin of some special local irritant, such as lime and other acrid substances, the removal of the particular source of irritation manifestly is the main thing required. But in these cases tonics are needed. Where the disease is apparently idiopathic it is certain in the majority of cases that normal elimination of effete matter from the body is defective; whilst in others assimilation is at fault, so that 'acridities' accumulate in the blood current. In such cases the mineral acids, with appropriate aperients, chologogues, or diuretics, are best suited to the cure. In all cases the ecthymatous pustules must be soothed. The scabs should be removed, and some mild astringent, such as carbonate of lead or litharge ointment, applied.







RUPIA


## PLATE XXXII.

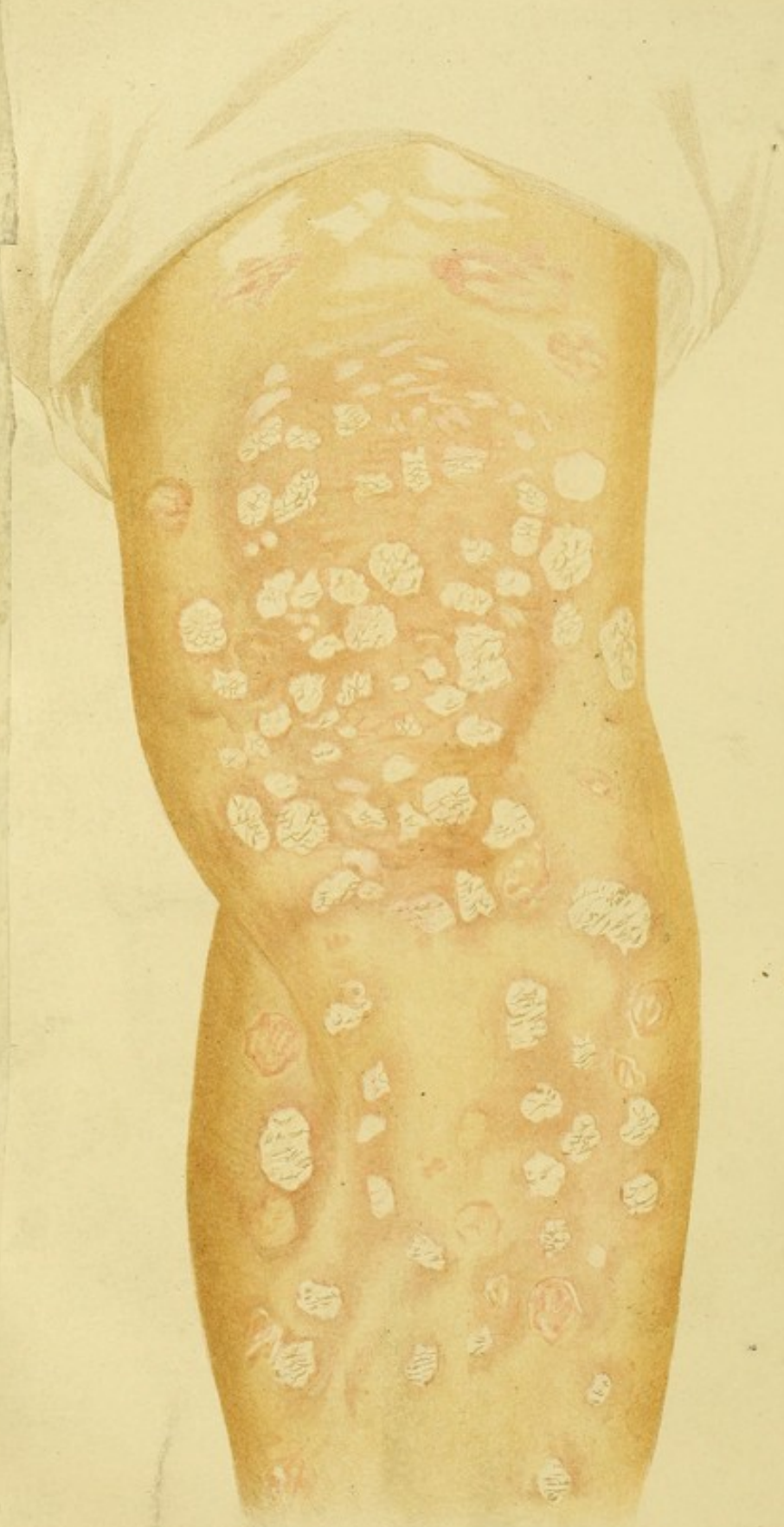RUPIA is characterised by the presence of large dark conical crusts, composed of different strata of dried sanies and pus, and covering over an ulceration of syphilitic character. Rupia, in fact, though deemed to be allied to Ecthyma and to be non-syphilitic, is always syphilitic, but I have given this illustration of Willan and Bateman's here in consequence of its likeness to bad ECTHYMA *cachecticum*. Rupia may begin by the development of small flattish bullæ, surrounded by a faint areola, as shown in the figure at the upper line of the arm to the right. The contents of these bullæ speedily acquire a sanguinolent character, and then the hard dark stratified crusts begin to form, and ulceration sets in beneath them. This early stage is seen in the two smaller spots to the left of the figure. The disease, however, may commence by pustules similar to those of Ecthyma. When fully developed, it presents the peculiar features portrayed by the three largest places in the figure. Varieties have been made according to the size and degree of conicity of the crusts—the smaller and less prominent ones being termed *RUPIA simplex*, and the larger and more developed ones *RUPIA prominens*, but these are unnecessary distinctions. Now in some cases of Ecthyma, as seen in *Fig. 2*, PLATE XXXI., to the right, the crusts may be more or less large and with a tendency to assume a conical form, but they lack the 'limpet-shell' feature and the dark and stratified aspect of the true rupial disease.

The *treatment* is that for tertiary syphilis, with the use of tonics, and the prescription of good diet and change of air; combined with the removal of the crusts locally, and the application to the ulcerated surface beneath of iodide of starch paste (Univ. Coll. Hosp. Pharm.) to cleanse the sores, and subsequently some mild mercurial to heal them up.

CHAPTER III

The first part of the chapter is devoted to a discussion of the various forms of the verb 'to be' in English. It is shown that the verb 'to be' is used in a number of different ways, and that its meaning is often different from that of the verb 'to exist'. The second part of the chapter is devoted to a discussion of the various forms of the verb 'to have'. It is shown that the verb 'to have' is used in a number of different ways, and that its meaning is often different from that of the verb 'to possess'. The third part of the chapter is devoted to a discussion of the various forms of the verb 'to do'. It is shown that the verb 'to do' is used in a number of different ways, and that its meaning is often different from that of the verb 'to perform'.





PSORIASIS GUTTATA

## EXPLANATION OF THE PLATES.

---

**PART IX.**—This section of the Atlas contains 3 new and 2 old Plates, illustrating the main varieties of Psoriasis, viz. *PSORIASIS guttata*, *P. vulgaris*, *P. circinata*, the 'Lepra' of old authors, *P. inveterata*, and *P. rupioides*. One more phase of the disease, *P. palmaris*, will form the subject of PLATE XXXVII. in the succeeding PART (X.) of this Atlas.

### PSORIASIS.

This disease consists essentially in an hypertrophic growth of the cuticle associated with hyperæmia and more or less stasis in the vessels of the papillary layer of the skin. The cuticle accumulates into greyish silvery-white irregular scales or platy masses, which, on being picked away, expose a reddened corium, whilst minute bleeding points, which are the engorged vessels of the papillæ torn across by the removal of the cuticular layer, start into view.

This disease occurs at all ages, in persons apparently of good health, often in those who are florid and plump. It attacks by preference the elbows, the knees, and the scalp: and usually makes its first appearance in the two former of these sites, but it may attack the whole body more or less completely. The disease runs a chronic course, and is very liable to recur. The disease begins by minute scaly spots, which increase by centrifugal growth, and assume a variety of sizes and shapes by their enlargement or coalescence. The scales are made up of epithelial matter; and they are of peculiar structure, being uneven on the outer surface, and indented into little pits on their under aspect, corresponding to the enlarged papillæ upon which they rest with a certain degree of firm adherence.


Varieties are made mainly according to the size and shape of the spots or patches, and the aspect of the scaly masses; and these I now proceed to describe by the aid of the Figures in the 4 Plates of this fasciculus.

### PLATE XXXIII.

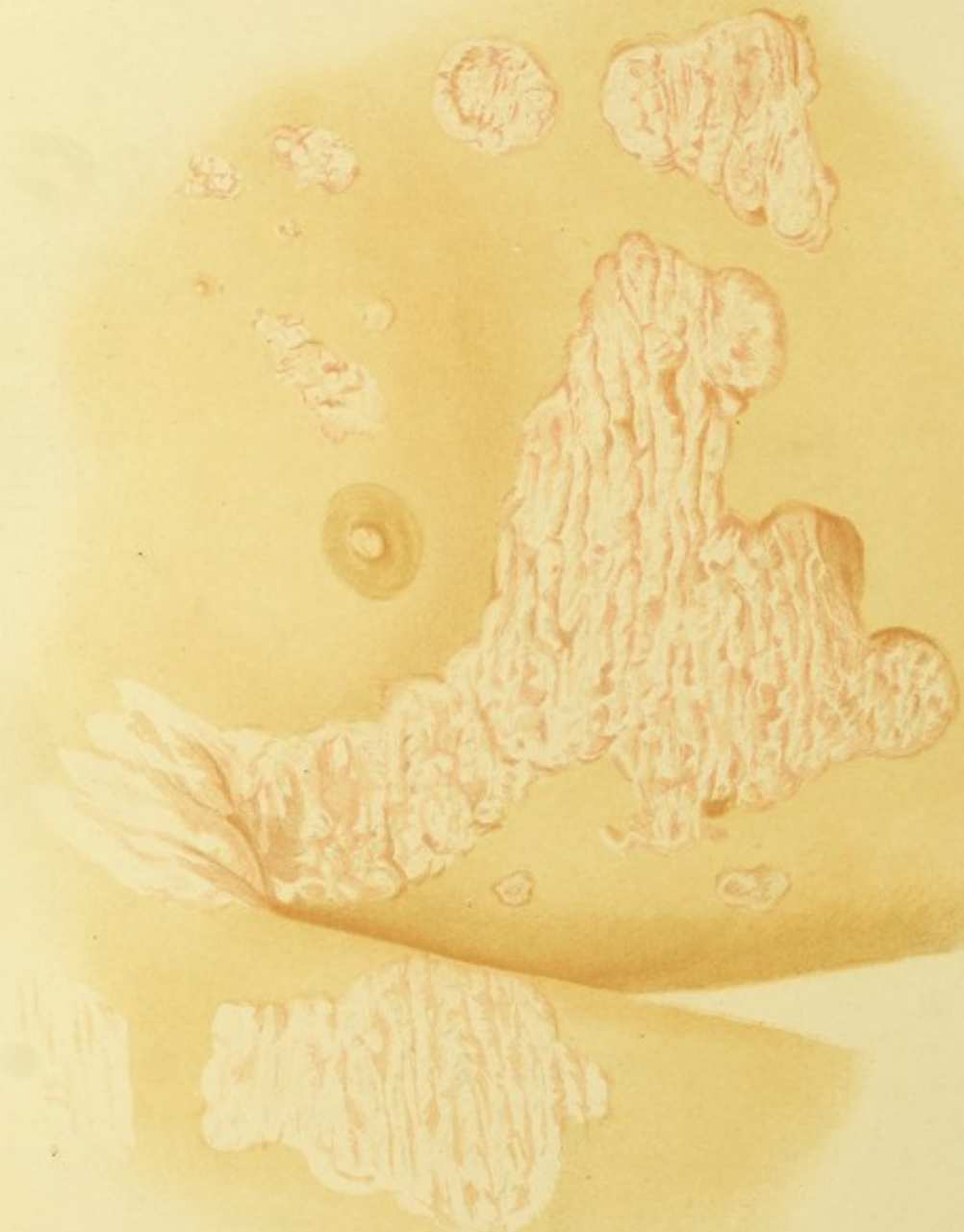*PSORIASIS guttata*.—This is an admirable life-like representation of the simplest form of Psoriasis, in which the disease consists of spots the size of 'drops' of mortar. The disease commences by little *points* of silvery scaliness covering over a reddened speck, made up of a few hyperæmic papillæ. The minutest of these spots in the Plate about the region of the patella exemplifies such points. To this condition the term *PSORIASIS punctata* has been applied, but this is an unnecessary refinement, as the term *guttata* really includes the smaller bits of eruption which, moreover, speedily acquire by their growth the magnitude of drops. In the case from which the portrait was taken the disease made

its appearance first about the knees and elbows, in the form shown here. It then cropped up over the body generally. The disease occurred in a young man, aged twenty-six, who was otherwise in good general health. In most cases the 'guttate' form of disease is more or less lost by the growth and junction of the spots into patches of various sizes and shapes, such as are shown in the next PLATE (XXXIV.), but in this case the guttate aspect was pretty fairly preserved throughout the course of the disease. As shown in the figure, there was a certain amount of hyperæmic redness about the circumference of the 'spots,' and as these were pretty close together, this gave the idea of a slight general redness of the skin. On picking off any of the little masses of scales, minute red bleeding points started into view, these being the torn-across apices of the capillary loops in the papillæ. The disease is sometimes attended by some little itching at its outset.

The treatment of PSORIASIS will be noticed in connection with PLATE XXXVI.







PSORIASIS, VULGARIS

## PLATE XXXIV.

PSORIASIS *vulgaris* or *P. diffusa*.—In this phase of the disease, instead of spots, patches of different sizes and shapes are present. The eruption is widely distributed over the body, and is altogether more severe than *P. guttata*. This form may be only a fuller development of *P. guttata*, as explained in speaking of that phase, but in some cases it rapidly assumes from the very outset the patchy character represented in the illustration. The disease of course is essentially the same in its pathological aspect, and differs only morphologically and in severity. The scaliness is very marked, and the surface beneath is raised, infiltrated, and hyperæmic. The portrait was taken from a young girl thirteen years of age, who was attacked by the disease in most parts of her body. In this form, the eruption usually first appears in its most typical seats, viz. the elbows and knees. It then shows itself in the scalp and various parts of the body concurrently. It is difficult to represent the 'mother-of-pearl'-like aspect of the patches, still the general characters of the disease are better rendered in this Plate than any other I know.

In this particular portrait, though the main characters are those of so-called PSORIASIS *vulgaris*, yet the features of other forms are likewise present. The 5 smallest places answer to the description of *P. punctata* and *P. guttata*. The circular spot to the right, the size of a shilling, represents another phase, *P. nummularis*, or that in which the disease is made up of circular spots the size of pieces of money; and these facts indicate that most of the varieties of PSORIASIS are mere degrees of intensity of the same eruption.

I have not deemed it necessary to delineate what is known by some as the *gyrate* variety—a form in which, by the coalescence of one or more circular patches, a tortuous—'gyrate'—band of eruption is produced.


I think, however, that *P. vulgaris* or *P. diffusa* is a very legitimate clinical form to differentiate and to contrast with *P. guttata*, because of its greater severity, its chronicity, its extensiveness, and its patchy character.

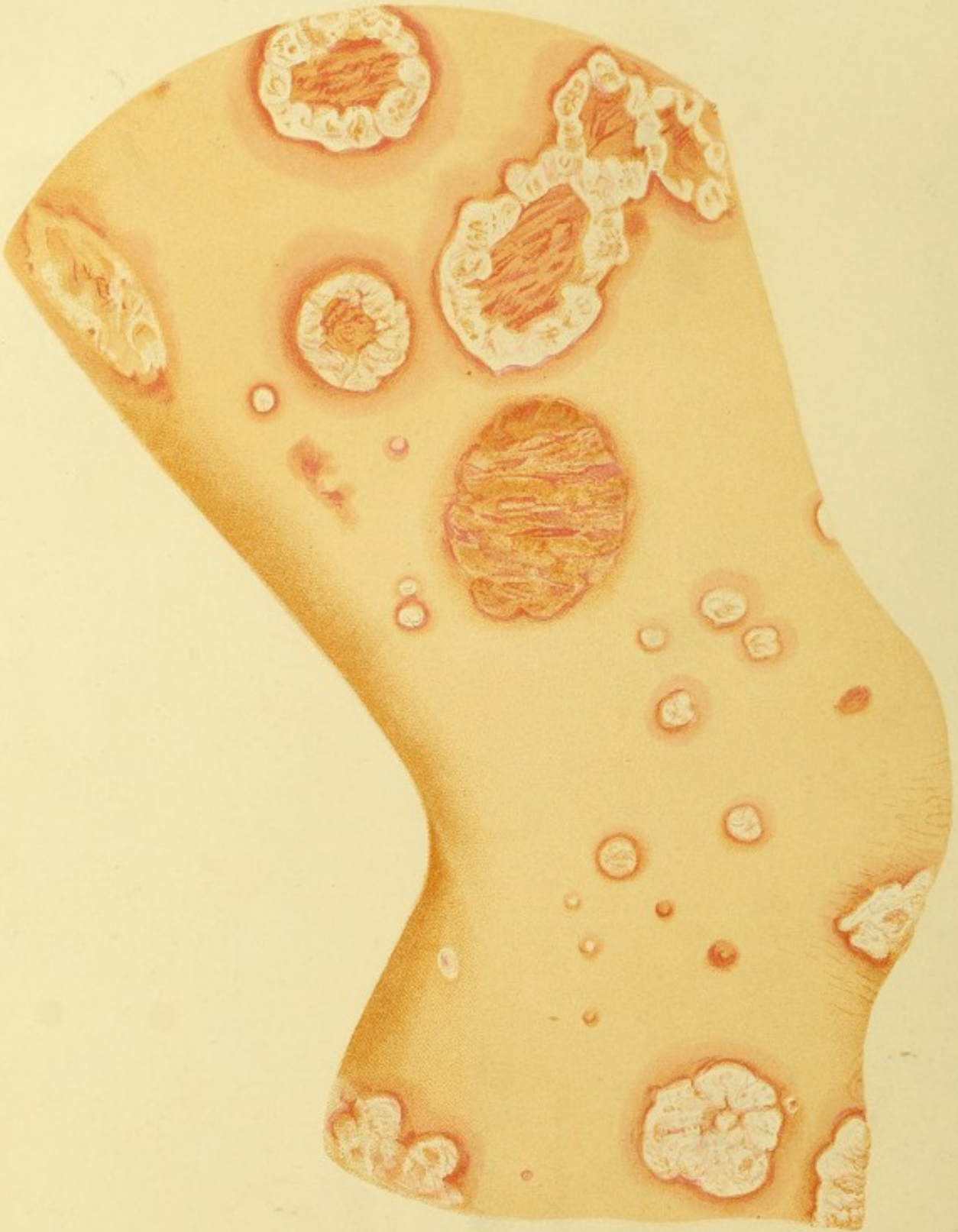The first part of the document discusses the importance of maintaining accurate records of all transactions. It emphasizes that every entry should be supported by a valid receipt or invoice. This ensures transparency and allows for easy verification of the data.

In the second section, the author outlines the various methods used to collect and analyze the data. This includes both primary and secondary sources, as well as the specific techniques employed for data processing and statistical analysis.

The third part of the document provides a detailed description of the results obtained from the study. It includes a series of tables and graphs that illustrate the trends and patterns observed in the data. The author also discusses the implications of these findings and how they relate to the overall objectives of the research.

Finally, the document concludes with a summary of the key findings and a list of recommendations for future research. The author suggests that further studies should be conducted to explore the underlying causes of the observed trends and to develop more effective strategies for data collection and analysis.






PSORIASIS CIRCINATA.

## PLATE XXXV.

PSORIASIS *circinata*.—This phase consists in the presence of circular patches which have their central parts free from scaliness. In fact, it is a ringed—'circinate'—form of Psoriasis. Formerly a distinction used to be made between this, which was termed *Lepra*, and Psoriasis, as illustrated by the 2 preceding Plates. The Plate is Willan and Bateman's, and the following was their description:—'LEPRA *vulgaris*, the common *Leprosy*.—This is characterised, like all the species of this genus, by "scaly patches, of different sizes, having always nearly a *circular* form." It appears, first, in small, distinct, red, and shining elevations of the cuticle, on centres of which thin white scales are always formed. In the course of three or four days, these spots are flattened and dilated, and become more and more scaly, equalling in size a silver penny; and they continue to enlarge, still retaining their circular form, to the size of a shilling or half-a-crown, or sometimes much larger. Occasionally, though rarely, the scales accumulate into a thick crusty layer. The patches are commonly surrounded by a red and slightly elevated border, which generally remains scaly after the central area has recovered its texture in the progress of cure. The leprous patches often appear first at the elbow, or immediately below the knee.' There is, however, no real distinction, except in the general form, between this and other phases of Psoriasis. It will be seen from Willan and Bateman's description that this circinate phase of Psoriasis commences just as the others do; only it so happens, that as the circumference increases, the growth of the scales lessens or ceases in the central part; but this is no ground for regarding it as any very special form, the more so, as in ordinary PSORIASIS *vulgaris* the patches, in healing, very frequently clear from their centres, and give rise to a circinate form.




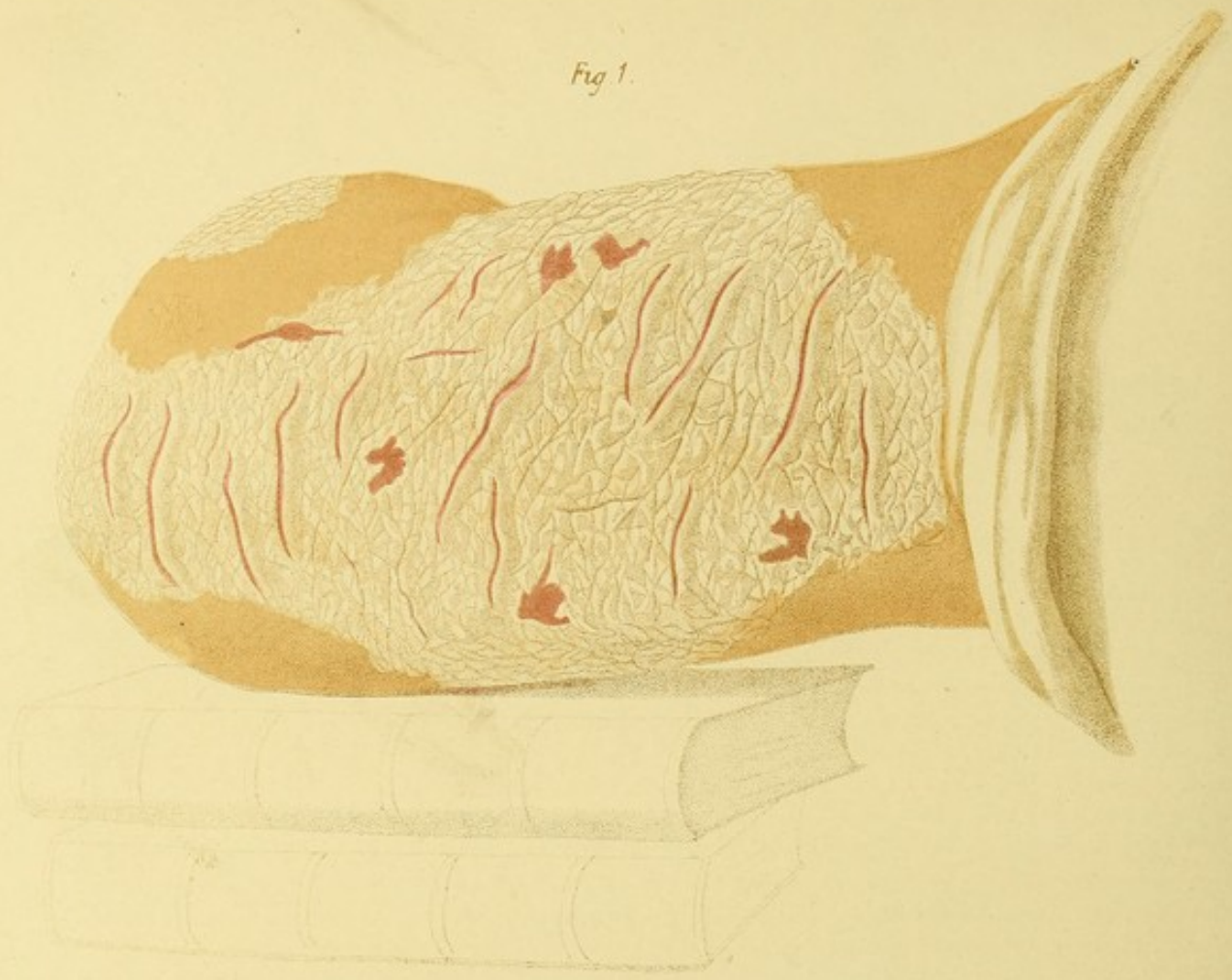


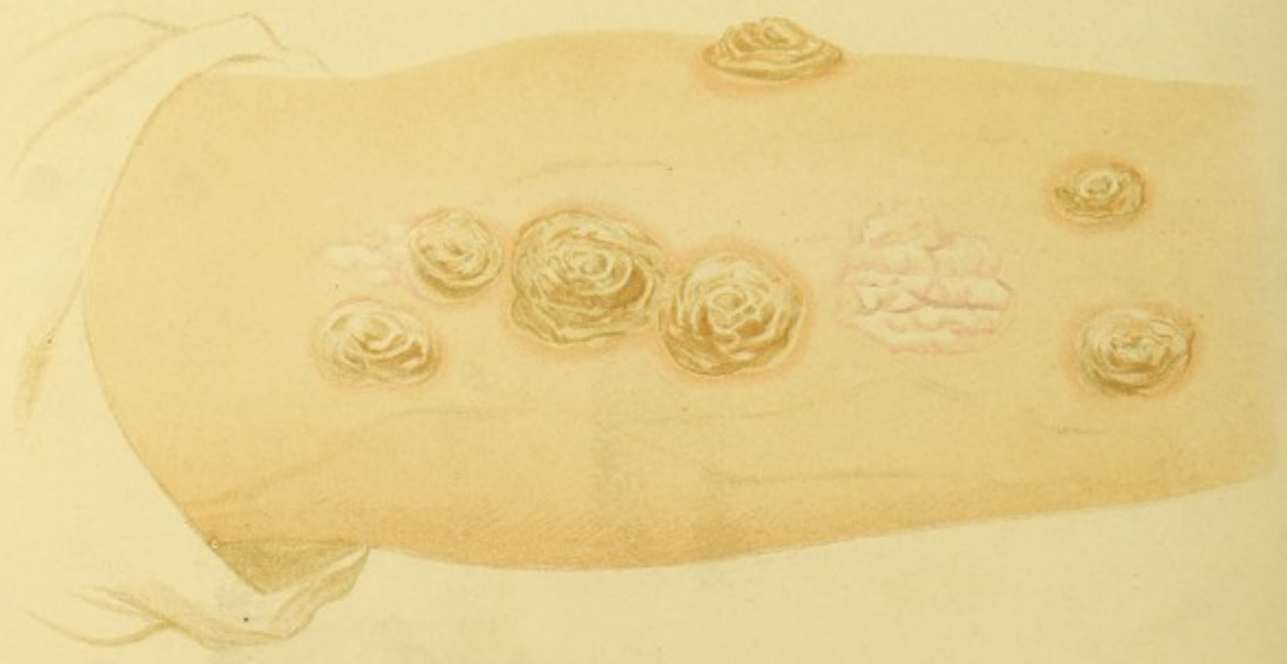


Fig 1.



PSORIASIS INVETERATA

Fig 2.



PSORIASIS RUPIOIDES.

## PLATE XXXVI.

*Fig. 1.*—*PSORIASIS inveterata*. This is one of Willan and Bateman's illustrations. In this form of disease the patches are extensive, and they are much thickened and raised, mainly by the accumulation of a large amount of epithelial scales, produced in great abundance, and accreted together into a dry hard dirty-white incrustation. The surface is often cracked and furrowed in different directions. Occasionally the patches become tender and inflamed, apparently from the irritation produced by the hard incrustation.

*Fig. 2.*—*PSORIASIS rupioides* is a very important variety, in my opinion. My friend Dr. McCall Anderson\* first drew attention to this phase of Psoriasis. He remarks:—

'There is a peculiar appearance which Psoriasis sometimes assumes, which I first observed a good many years ago, and which has never been described. When it occurs, it may be regarded as a stage intervening between the so-called *PSORIASIS guttata* and *nummularis*. First, the accumulation of epidermis takes place to an unusual extent, so that on many of the patches it assumes the shape of large conical crusts, marked by concentric rings. In fact, they exactly resemble in shape limpet-shells, and, from their likeness to crusts of *Rupia*, I have called this variety *PSORIASIS rupioides*. Except in the shape of the crusts, however, there is no connection whatever with *Rupia*; and, on removing a crust, there is no ulceration beneath, but a slightly elevated, dusky-red, rounded surface is exposed to view, which sometimes bleeds a very little. When the first case came under my observation, I executed a drawing of it, making use of the actual crusts removed from the patient who was affected, and pasting them upon the picture so as to give a very accurate idea of the appearance of the sufferer. This drawing is now hung up in the Museum of the Glasgow Royal Infirmary. Since that time my attention has been directed to the subject, and I have observed several similar cases.'—Pp. 4, 5.

This is an important clinical form of *PSORIASIS*. I have pointed out that these crusts contain dried purulent matter as well as epithelial cells, and, if they be removed, the surface beneath will be found to be moist; and if this moisture be examined, it will be found to contain pus—an observation confirmed by Dr. Taylor of New York. In fact, the dermal inflammation in this phase of disease is modified by a pyogenic tendency in the individual. *PSORIASIS rupioides* is, in fact, a psoriasis modified by a strumous tendency, and calls especially for the exhibition of cod-liver oil.

## TREATMENT OF PSORIASIS.

The prevailing idea with regard to the nature of *PSORIASIS*, and this bears directly upon its treatment, is that the disease is an inflammation *caused* by the existence of some *materies morbi* in the blood. It is true the disease *may* be excited by an acrid blood current, and that it may be *influenced*, or modified, by different states of the blood, but, in my opinion, the disease is not really *caused* by any such influence.

The depraved growth of cuticle, which essentially constitutes Psoriasis, is more nearly connected with a perversion of the regulative act exerted by the trophic nerves over the cell nutrition, if the disordered cell-growth be not due to a misbehaviour or defective

---

\* · On Psoriasis and Lepra : 1865.'

'formative capacity' on the part of the cells themselves. Be this as it may, clinically the growth is an evidence of want of proper nutritive capacity in the cuticular tissue; and to rectify this, such tonics as tend to give tone and activity, directly or indirectly, through the nerve supply to the tissues themselves, are needed. In this consists the essential internal treatment of Psoriasis, however badly I may have conveyed my meaning. I do not think, as a rule, our treatment of Psoriasis is sufficiently tonic. The beneficial action of arsenic, I believe, consists in its neuro- (or tissue) tonic action. Locally, what is needed is to keep hyperæmia in check: and then to apply remedies which prevent the exuberant cell-growth: and to effect this latter purpose there is no remedy like tar in some form or other. The hyperæmia of the skin, when marked, is controlled by internal remedies to dislodge retained 'acridities' from the system, e.g. diuretics, and by warm baths and the use of emollient applications to the hyperæmic surface.


There is an important difference between Psoriasis in the young and the old. In the young there are seldom many complicating conditions, such as dyspepsia, long-sustained retention, or non-excretion, of excreta the consequence of renal or hepatic disorders, syphilitic taints, active gouty conditions, &c.; so that the treatment is essentially one of tonics. In children, however, Psoriasis is often associated with, and modified by, the strumous diathesis.

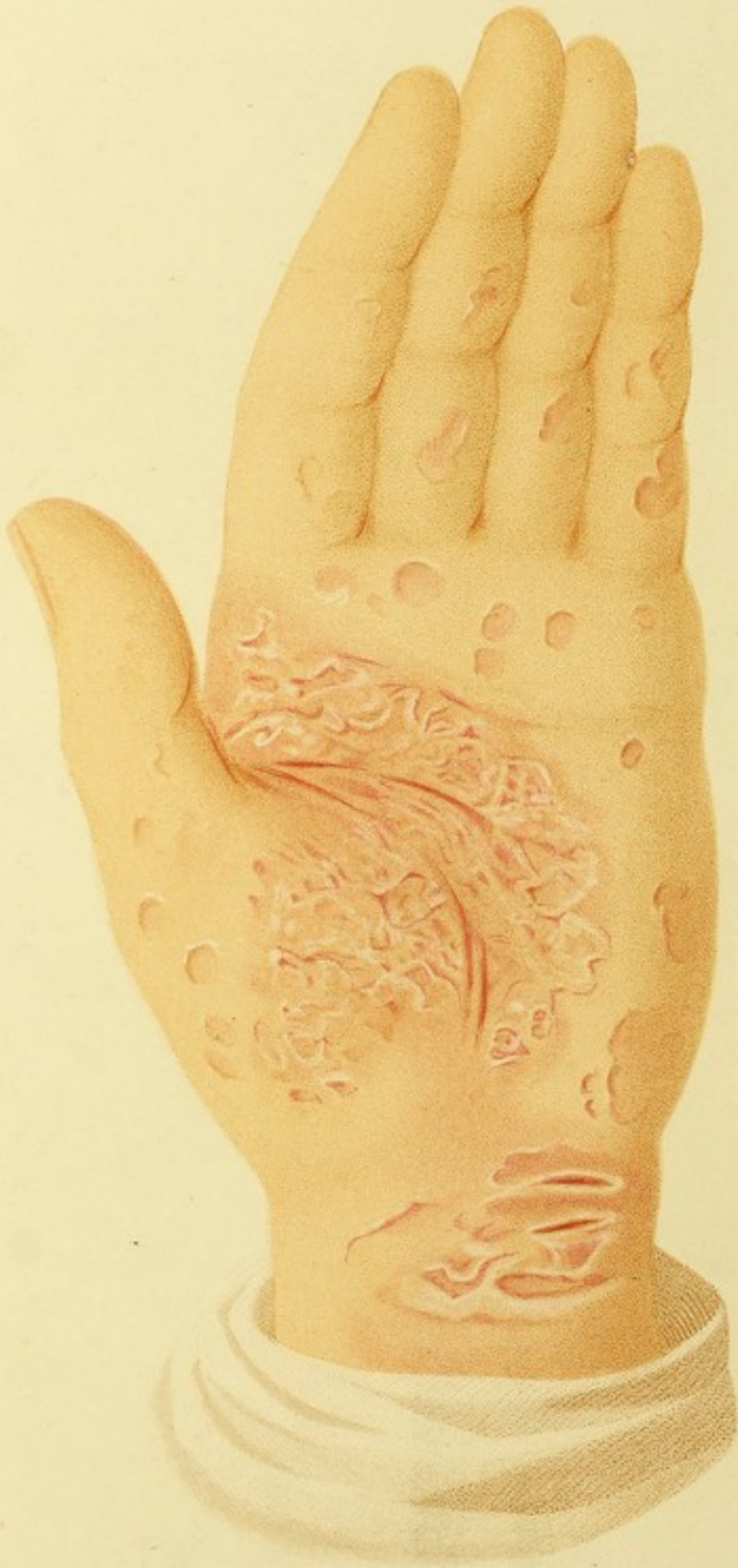In children these cases of *PSORIASIS guttata* and *P. vulgaris* or *P. circinata* must be dealt with by iron and arsenic, and cod-liver oil if the subjects are strumous or lymphatic; whilst the diet must be nourishing, and contain a proper amount of good fresh milk. Change of air is also good to invigorate generally and to create or improve appetite. Locally, all that is needed is to get rid of the scaliness by tepid bran and soda baths, and to sponge over the diseased parts a detergent solution of tar lotion, ℥j. to ℥ij. to ℥vj. of nitre, with ℥j. of borax and glycerine.

In the adult it is necessary to remedy the complicating conditions above referred to; dyspepsia, the presence in excess of urates, uric acid, sugar, bile products, and the like in the blood, must be remedied in the first place, or in accompaniment with the use of arsenical remedies adapted to cure the Psoriasis itself. And in cases of Psoriasis that are not marked by hyperæmia the same local remedies as those just referred to in the preceding paragraph may be used. When the skin is very hyperæmic, diuretics are to be preferred with anti-gout or anti-rheumatic drugs or aperients when needed, to relieve the skin. But *decided* hyperæmia may be the result of an inflammatory action, the consequence of mere irritation and debility; in these cases the use of mineral acids in large doses, with iron and cod-liver oil internally, and packing in olive oil continuously, for some time, constitute the best therapeutic measures. Tarry remedies must be withheld until the skin is in a less hyperæmic state. When the scaliness is very decided, water packing should be employed, if need be, to remove it.

In *PSORIASIS inveterata* the same internal treatment is needed, but the scales must be macerated off with oil packing with a weak alkaline lotion, and then tar may be used. If this irritate, an ointment made of ammoniated mercury and nitric oxide of mercury, 5 grains of each to an ounce of lard will do better.

In *PSORIASIS rupioides* the essential point consists in the prescription of cod-liver oil and good diet, with tonics. The local remedies must not be so potent as to irritate.





PSORIASIS PALMARIS

## EXPLANATION OF THE PLATES.

---

**PART X.**—This fasciculus includes representations of *PSORIASIS palmaris*; *PITYRIASIS rubra* or *DERMATITIS exfoliativa* (Wilson); *PITYRIASIS pilaris* (Devergie), which is a rare phase or stage of *PITYRIASIS rubra*; and a portrait of a very typical case of *LICHEN ruber*, for the insertion of which in this place I have a very special reason.

### PLATE XXXVII.


*PSORIASIS palmaris*.—This is a very obstinate form of Psoriasis, and the portrait is one of Willan and Bateman's. Now a scaly thickened condition, with more or less fissuring, of the palms of the hands and soles of the feet may be induced by a variety of causes. It may follow Eczema, Dysidrosis, *PITYRIASIS rubra*, and Syphilis; also the application of irritants to the affected parts, and the use of arsenic; or it may be a part of general Psoriasis or of Syphilis. It may apparently arise as an abortive *PITYRIASIS rubra*, or be caused by idiopathic hypertrophy of the cuticle. In the vast majority of cases so called Psoriasis of the hand, such as is represented in the Plate, in which the parts are thickened, fissured, dry, harsh, and scaly, the hand being uncomfortable on account of the attendant heat, itching, and stiffness, the eruption is either simple Psoriasis, or syphilitic in nature, and usually the latter. It is difficult to represent on paper with the paint-brush the differences between syphilitic and non-syphilitic Psoriasis. I am not dealing in this Atlas with syphilitic eruptions, and therefore I must chiefly concern myself with the non-syphilitic form of Psoriasis; but still the specific form is so much the more common that it will serve a useful clinical purpose if I attempt in a few words to indicate the differential diagnosis of the two.

In practice there are three classes of cases met with—I mean in reference to Psoriasis. In one set the psoriatic state is only a part of well-marked non-syphilitic Psoriasis, which exists in other parts of the body, and often in the typical localities of the non-syphilitic disease; viz. the front of the knees and over the elbows. There is no evidence of syphilis in any part of the body, and the *PSORIASIS palmaris* has travelled on to the palm of the hand from adjoining parts. In another set of cases there exists what looks very like non-syphilitic Psoriasis, but there is an absence of all evidence of simple Psoriasis about the body in its ordinary seats of attack; there are, however, very characteristic mucous patches or ulcerations about the tongue, and it may be the throat. The disease of the hand first appeared in the centre of the palm, and spread more or less centrifugally over it; whilst its first stage consisted not so much of scaly patches as of hard nodules or tubercles, whilst fissuring is much more decided. In fact, when a case of Psoriasis of the palm of the hand comes under observation, the first thing I do is to tell the patient

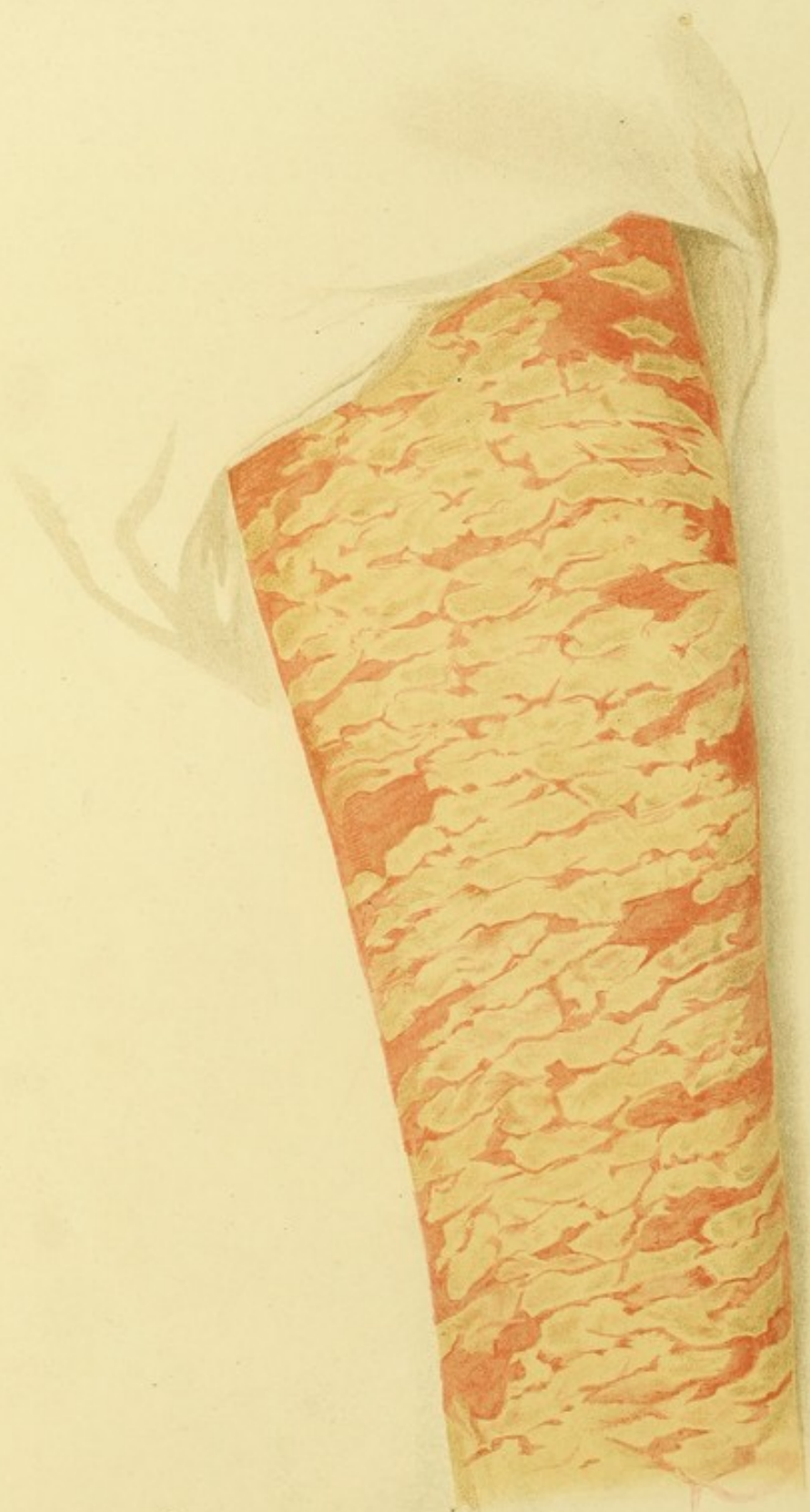to put out his tongue, which I carefully examine, together with the mouth and throat, and in many cases the diagnosis is determined at once by the presence of concurrent syphilitic mischief. There may be syphilitic eruption elsewhere about the body. But there is a third class of cases in which there is a psoriatic state of the palm of the hands and nothing else; no coincident evidence, either of non-syphilitic Psoriasis elsewhere, or of any syphilitic affection of skin or mucous membrane. The exact nature of these cases is difficult to make out. If the patient's history is a non-syphilitic one, if he has, or any of his immediate relatives have, suffered from simple Psoriasis, and if the disease did not begin in the centre of the palm of the hand, and if the patient be healthy looking, the possibility is that the disease is simple Psoriasis; but if on careful inquiry any antecedent or coincident evidence of syphilitic infection be obtained, if the eruption consists of hard tubercles, and if it fissures deeply and began in the centre of the palm, it is probably syphilitic.

The *treatment* of the non-syphilitic cases of Psoriasis is the same as that of ordinary Psoriasis as regards internal remedies. I am sure that locally the main object should be to get rid of the dry, hard, stiff condition of the parts, by free packing in some bland oleaginous or fatty substance at night; in the daytime a borax lotion might be used; and when the parts are softened up and non-irritable, some preparation of tar should be employed. The syphilitic Psoriasis must be treated by antisyphilitic remedies of course. Locally, a good application is mercurial plaster spread on thin leather or on linen, and applied every night; a soothing and softening lotion being used in the daytime.

In the doubtful cases above alluded to, the best plan is to give a course of Donovan's Solution: it seldom fails to act well.







PITYRIASIS RUBRA

## PLATE XXXVIII.

PITYRIASIS *rubra* or DERMATITIS *exfoliativa* (Wilson).—This is a new Plate. The disease which it represents is in my opinion a fairly common one. It is often regarded as an universal Psoriasis. By many it has generally been looked upon as incurable, but if it be treated carefully, save in its most chronic form, a satisfactory result may be prognosticated.

The disease was originally accurately described by Devergie under the term PITYRIASIS *rubra*, which has been objected to of late, whilst that of DERMATITIS *exfoliativa* has been suggested as more appropriate. As the disease consists in hyperæmia with simple hyperplasia of the cuticular layer of the skin, without the formation of 'new' inflammatory products, the designation of Dermatitis implies perhaps too much, but otherwise the full designation DERMATITIS *exfoliativa* is very expressive of the free exfoliation or flaking off of large scales so characteristic of the disease.

The typical disease begins as a red scaly patch somewhere about the body, other spots appear here and there, whilst they all enlarge, and so rapid is their growth and development that the whole body, without the exception of any part, becomes involved in the course of a fortnight or three weeks. The skin is then universally reddened, and this hyperæmic base becomes covered over more or less completely by large scales or rather flakes of cuticle more or less free at their edges, and resembling bits of thin parchment or papyrus. They are often so closely set and so regularly arranged in an imbricated form as to resemble that of the tiles of a house, as is shown in the case in the Plate which represents the forearm affected by the disease. Here and there the flakes have fallen off and exposed the reddened surface beneath. In some parts the cuticular change takes the form of smallish flimsy scales, as in the scalp and face, but generally it preserves that of the flakes before described. Occasionally huge layers of cuticle come away from the palms of the hands or soles of the feet; in fact, I have seen more than once a perfect cast of the feet and hands shed. Sometimes itching and burning pain exist, with much other uncomfotableness; but, again, they are often absent. The skin textures are not thickened, as in Psoriasis, except in long standing cases.

The idea conveyed by a study of the disease, as regards its origin, to my mind, is this: That the sympathetic nerve control over the vessels is defective; that, in consequence, the skin becomes hyperæmic and there is coincident hyperplastic growth of the cuticle; the latter certainly is proportionate to the degree and persistency of the hyperæmia. The indications as regards general treatment are such as demand a very sustaining treatment both dietetically and medicinally, for in my experience the disease develops by preference in the ill-nourished and those whose physical and mental powers have been overworked and overstrained. I have paid special attention to the treatment of the cases of late in University College Hospital, and have obtained excellent results with the following plan. In the early stage diuretics have been very freely given, so as to push the kidneys to a very active exercise of their excretory function; at the same time the

patient has been packed and kept packed in oil. This treatment has been followed until the skin has become much paler. The next step has been to exhibit perchloride of iron in full doses 3 times a day, with the view of constringing the vessels of the skin, the latter being soothed by the application of a calamine lotion. The diet all the while has been simple but very nutritious; in fact, the patients have been fed up judiciously. Lastly, as soon as possible, cod-liver oil has been prescribed.

I believe if diuretics are given and the skin be soothed, in the early stages, and astringents are subsequently given, that cases of *PITYRIASIS rubra* will often be cured satisfactorily in a fairly short time.





Fig. 2.

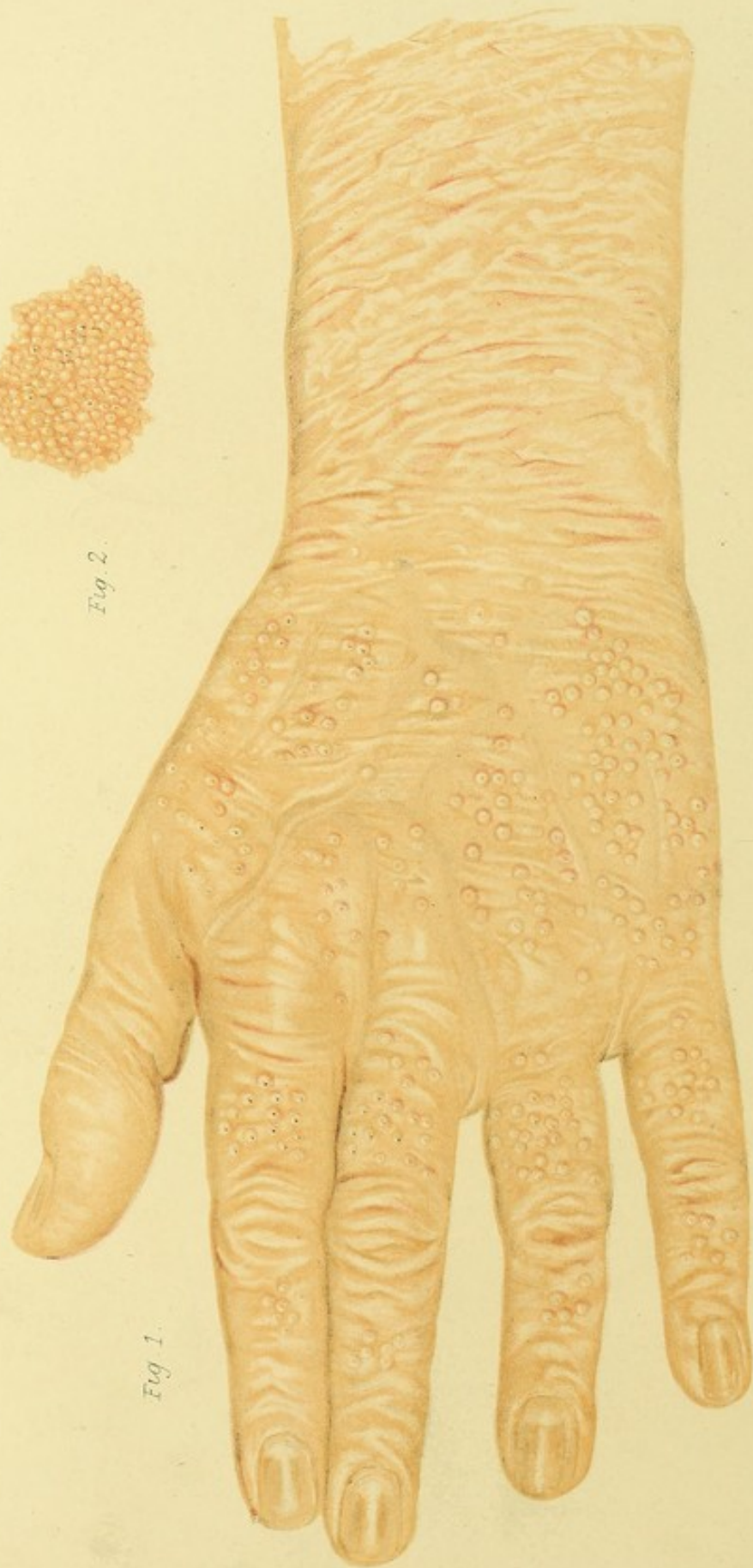

Fig. 1.

PITYRIASIS PILARIS (*of Devergie*)

## PLATE XXXIX.

*PITYRIASIS pilaris* (Devergie).—This is a new Plate. This form of eruption consists of papules of peculiar character. They are hard little knots, as it were, seated at the hair-follicles and whose central portion can be picked away, leaving the patent orifice of the follicle unusually distinct. The little knot or mass which can be picked away is made up of epithelial exuviæ. The follicular wall is congested. This is different from *LICHEN pilaris*, which consists in inflammatory thickening of the walls of the follicles. The drawing, Fig. 1, represents a slight form of the disease. In some cases the papules are larger and closely crowded together over a large extent of surface; and Fig. 2 represents a little piece of the eruption in another case in which large tracts of surface were involved, so that the skin felt and looked more like a rasp than anything else.

Now this *PITYRIASIS pilaris* is not an independent disease, it is an accident or phase of *PITYRIASIS rubra* before described; it is the result of the implication of the follicles in the disease. Their walls become hyperæmic and their cuticular linings take on an hyperplastic growth, the cuticle cells being shed in abundance into the follicle, forming the little plugs before described and shown in the drawing. In the drawing, Fig. 1, the evidences of *PITYRIASIS rubra* are present, especially in the portions of the forearm above the wrist; there is the characteristic imbricated flakiness, but without much hyperæmia, as the disease is nearly well. I have seen *PITYRIASIS pilaris* in a most marked form occur at the outset and as the early stage of *PITYRIASIS rubra*, the disease being confined, as it were, to the follicular portion of the skin, but rapidly involving the inter-follicular parts, and so destroying the aspect of *P. pilaris*. Generally, however, this form of eruption is left behind by a disappearing *PITYRIASIS rubra*, the inter-follicular parts 'clearing,' as it were, of redness and scales, and the follicular portions remaining affected and plugged by the exfoliated cuticle in them.

The *treatment* consists in loosening the plugs by baths and oil inunction, and applying any mild astringent to the skin in addition to the remedies ordinarily employed for cases of *PITYRIASIS rubra*.


THE STATE

The state is a political organization of a definite territory, which is subject to a government of its own, and which is capable of entering into relations with other states. It is a legal entity, and its actions are binding on its citizens. The state is the primary source of law, and it is responsible for the enforcement of the law. It is the state that provides the framework for the legal system, and it is the state that ensures the protection of the rights of its citizens. The state is the ultimate authority in the legal system, and it is the state that is responsible for the maintenance of the rule of law.

The state is a legal entity, and its actions are binding on its citizens. It is the state that provides the framework for the legal system, and it is the state that ensures the protection of the rights of its citizens. The state is the ultimate authority in the legal system, and it is the state that is responsible for the maintenance of the rule of law. The state is a political organization of a definite territory, which is subject to a government of its own, and which is capable of entering into relations with other states. It is a legal entity, and its actions are binding on its citizens.

The state is a political organization of a definite territory, which is subject to a government of its own, and which is capable of entering into relations with other states. It is a legal entity, and its actions are binding on its citizens. The state is the primary source of law, and it is responsible for the enforcement of the law. It is the state that provides the framework for the legal system, and it is the state that ensures the protection of the rights of its citizens. The state is the ultimate authority in the legal system, and it is the state that is responsible for the maintenance of the rule of law.

The state is a political organization of a definite territory, which is subject to a government of its own, and which is capable of entering into relations with other states. It is a legal entity, and its actions are binding on its citizens. The state is the primary source of law, and it is responsible for the enforcement of the law. It is the state that provides the framework for the legal system, and it is the state that ensures the protection of the rights of its citizens. The state is the ultimate authority in the legal system, and it is the state that is responsible for the maintenance of the rule of law.








LICHEN RUBER

## PLATE XL.

*LICHEN ruber*.—I have already given two representations of this disease in Plates XII. and XIII., portraying the more localised form of the eruption in the former and the more general in the latter Plate. I stated that the essentially papular character of the disease was not distinctly marked in the illustration of Plate XIII., though this was a very correct copy of the original eruption. Not long after Part IV., containing Plate XIII., was issued, a most interesting case of *LICHEN ruber*, affecting the greater portion of the body, and in which the papular character and the dull red tint of the eruption were singularly well marked, was admitted into University College Hospital under my care. As the disease is one which is not by any means understood or, I venture to say, usually correctly diagnosed by practitioners, and further, since it is fairly common and mostly confounded with Psoriasis, I determined to introduce this third portrait of the disease, as it affected the forearm and back of the hand and fingers in the above-mentioned case. The eruption attacked the front and back of the forearm, the arms, the trunk, the lower extremities, especially around, above, and below the knees and ankles and the feet. When I first saw it the diseased surface was covered over by thin white scales, as represented in Plate XIII.; and it certainly at first sight presented an appearance that might have been diagnosed by one who was not conversant with the nature of the *LICHEN ruber* as that of Psoriasis. But there were plenty of characteristic papules scattered about and around the patches, and directly the fine scales were removed by oil packing the essentially papular character of the disease was evident. This illustration, with those of Plates XII. and XIII., together with their accompanying text, convey a clear and, I believe, very satisfactory account of the disease *LICHEN ruber*. The reader should note the discrete character of the eruption in its early stage at the upper part of the forearm to the right, and its patchy aspect at a more advanced stage. The case from which this representation was taken was very rapidly cured by the exhibition of mineral acids, nux vomica, iron, and cod-liver oil, together with the free inunction of almond oil. Happily there was very little itching in the case. The patient, a man-servant, had become debilitated and anæmiated to a considerable degree.

I introduce the illustration here in order that the disease may be compared with the preceding portraits of Psoriasis, with which, as I have stated, the disease may be readily, and is frequently, confounded.



## EXPLANATION OF THE PLATES.

**PART XI.**—This part contains portraits of the eruptions styled by Willan PRURIGO *mitis*, *formicans*, and *senilis*, in PLATE XLI., and one aspect of severe Prurigo, as I understand it, in XLII. In addition, PURPURA, in its three manifestations, denominated respectively *simplex* and *hæmorrhagica*, and *urticans*, is illustrated by PLATES XLIII. and XLIV.

### PRURIGO.

No word in the whole range of dermatological nomenclature has been so misused as *Prurigo*. It has been and is still used to designate the most diverse and dissimilar eruptions. In fact, the term Prurigo has been given to *any* papular rash which has been so affected by scratching, that little dark flakes of dried blood form the apices of most of the papules, and which rash is also attended by marked itching.

Prurigo, however, in the strict sense of the term, should be limited to that idiopathic form of eruption, in which fleshy papules, of greater or less size, attended by severe pruritus of a creeping, burning, or formicating character are developed as the primary and essential phenomena. In order to put the matter clearly before the reader, I will describe the conditions that are mistaken for it, and then give a description of what it really is.

Prurigo is not *Phthiriasis* (which will be described in PLATE LII.). The latter has hitherto been generally termed 'Hospital prurigo' and 'Prurigo senilis;' but the use of the term 'Phthiriasis' will remove all confusion for the future.

In old people the skin becomes atrophied, and when so atrophied, in many cases the innervation is perverted, so that the skin is very pruritic. Scratching is now practised, and induces the formation of papulæ, which in turn become altered by scratching, so that a condition commonly designated 'pruriginous' results: but it is quite secondary to the pruritis and caused by scratching. There need be no pediculi present, and the term *pruritic* rash correctly describes the eruption. This is not Prurigo. It is not a very common condition. Pruritus of the skin is also a complication of many eruptions, but it may occur as a primary disorder, constituting at the outset the sole disorder present. It may be caused by influences acting from within or without (such as irritants) upon the body. These several causes together, with scratching, will produce a papular rash, made up of hyperæmic papillæ and follicles, and this rash, more or less altered by scratching, is said to be '*pruriginous*.' Here again this is a '*pruritic*' rash, consecutive to pruritus, and consequent upon scratching. It is not Prurigo.

The non-idiopathic and so-called *pruriginous* rash of, for example, LICHEN *urticatus* (see PLATE IX.), of Scabies (see LIII.), and of Phthiriasis (see PLATE LII.), of PEMPHIGUS *pruriginosus* (PLATE XXIX. *Fig. 2*), are examples of this same *pruritic* rash, due chiefly to scratching of the skin.

Whenever then the skin is pruritic—be there eruption or no eruption present first of all—and scratching is practised for its relief, a *secondary* papular rash, made up of

hyperæmic and infiltrated papillæ and follicles, occurs. This becomes altered by scratching, so that most of the tops of the papulæ are torn off and replaced by flakes of dried blood, and to this condition the term '*pruritic*' should be applied, in preference to '*pruriginous*.' This pruritic rash is most commonly seen in Phthiriasis, Scabies, and LICHEN *urticatus*, but also in connection with PRURITUS *cutaneus* however induced.

I now proceed to describe Prurigo proper, or that form of eruption to which the application of the term '*Prurigo*' ought to be strictly limited. Prurigo is illustrated by PLATES XLI. and XLII. The disease consists essentially, as stated by Bateman, in 'a severe itching, accompanied by an eruption of papulæ of nearly the same colour with the adjoining cuticle.' These papulæ are formed by lymph infiltrations into the skin. The skin is often harsh and thickened. Willan makes 3 varieties, answering to 3 degrees of intensity of pruritus and accompanying rash. Hebra adds a fourth, which he terms, in its severest form, PRURIGO *ferox* or *agriæ*.

---

#### PLATE XLI.

*Fig. 1.*—PRURIGO *mitis*, according to Willan, is attended by very minute and soft papulæ, somewhat larger and less acuminate than those of Lichen (PLATE X.), and not as a rule appearing to be red, except they become inflamed from scratching. They may be often felt in the skin when they are indistinctly seen. The attendant itching is severe. The papules are altered by scratching. The rash occurs mostly in the young, and often in spring or the beginning of summer. In my opinion it might be regarded as a LICHEN *simplex*, with more pruritus than usual.

*Fig. 2.*—PRURIGO *formicans* differs from the preceding in the fact of its being more severe, more chronic, and in the character of the attendant sensations, which are incessant and like the creeping or crawling of ants over the surface, or the stinging of nettles, aggravated by exposure of the naked body to the air or proximity to the fire. The little dark-topped scratched papules are numerous, but there are many paler ones, which may be distinctly felt in numbers in the skin. This form is often connected with dyspeptic troubles, and I have seen it in adults who have had it from a very early age.

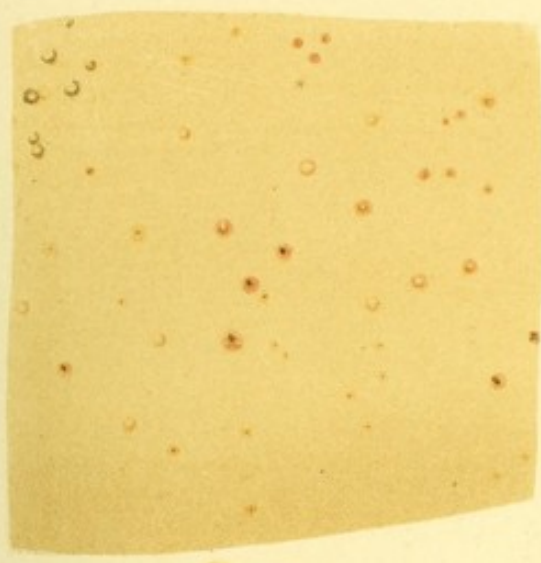
*Fig. 3.*—PRURIGO *senilis* is a more exaggerated form of the same disease in an elderly subject. The papules being large and the pruritus intense and persistent. Such a condition as is portrayed here does occur, but rarely so; the majority of cases, as stated before, of so-called '*Prurigo*' in old people are, without doubt, instances of Phthiriasis.

The insomnia and consequent debility of Prurigo patients are often very marked

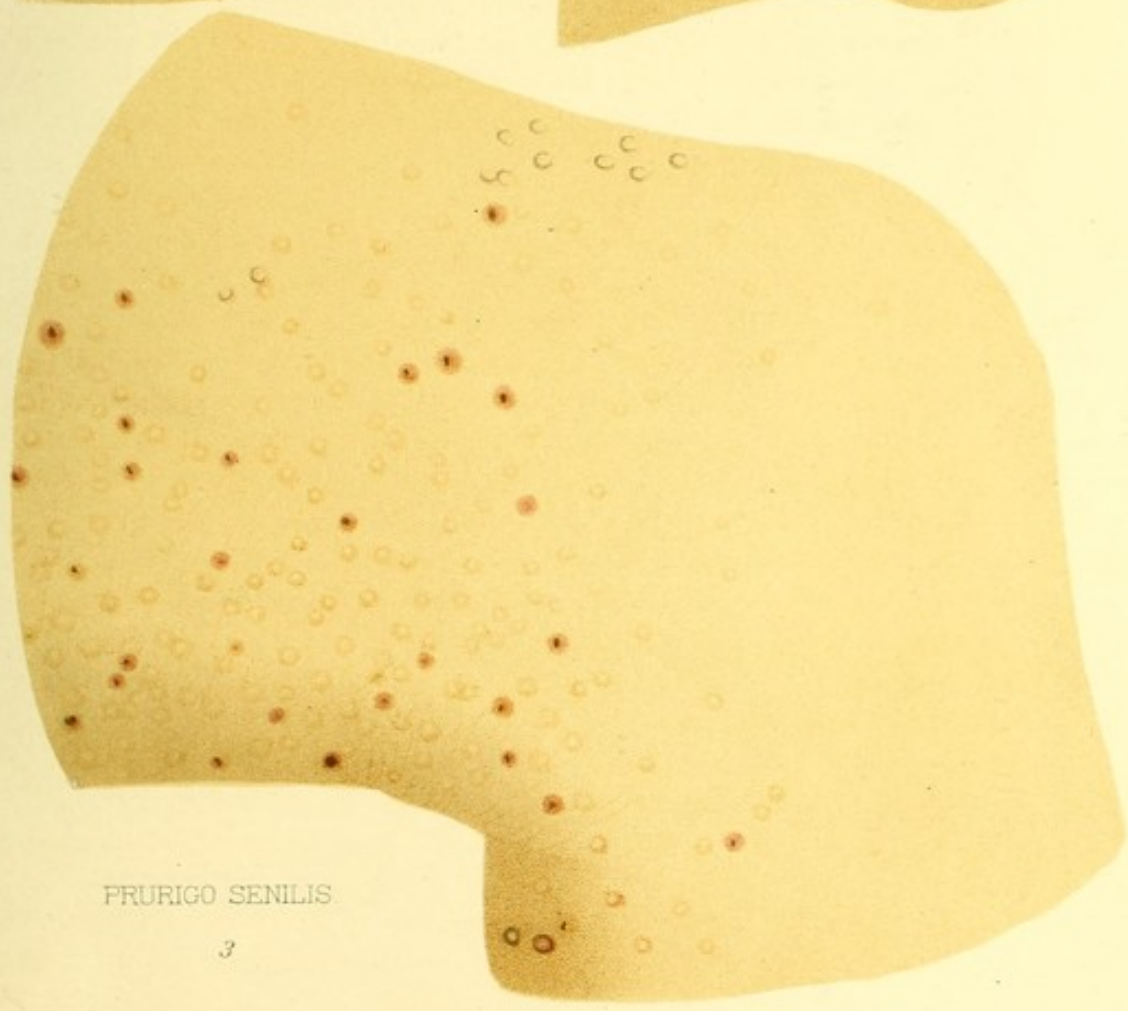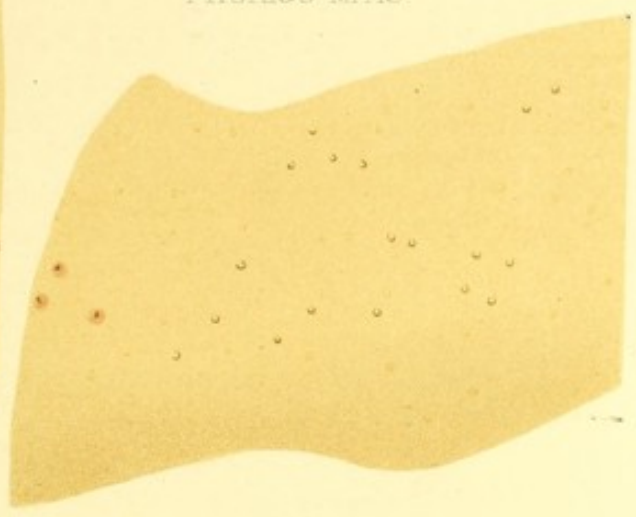The three forms above described might very well be ranked under one name, PRURIGO *simplex*, as distinguished from the severer form described in connection with PLATE XLII.

The constant presence, persistency, and character of the disordered sensation in Prurigo constitute the strongest evidence in support of the assertion that the disease is primarily of neurotic origin.

The *treatment* of the 3 forms illustrated by this Plate will be noticed in connection with PLATE XLII.




1  
PRURIGO MITIS.



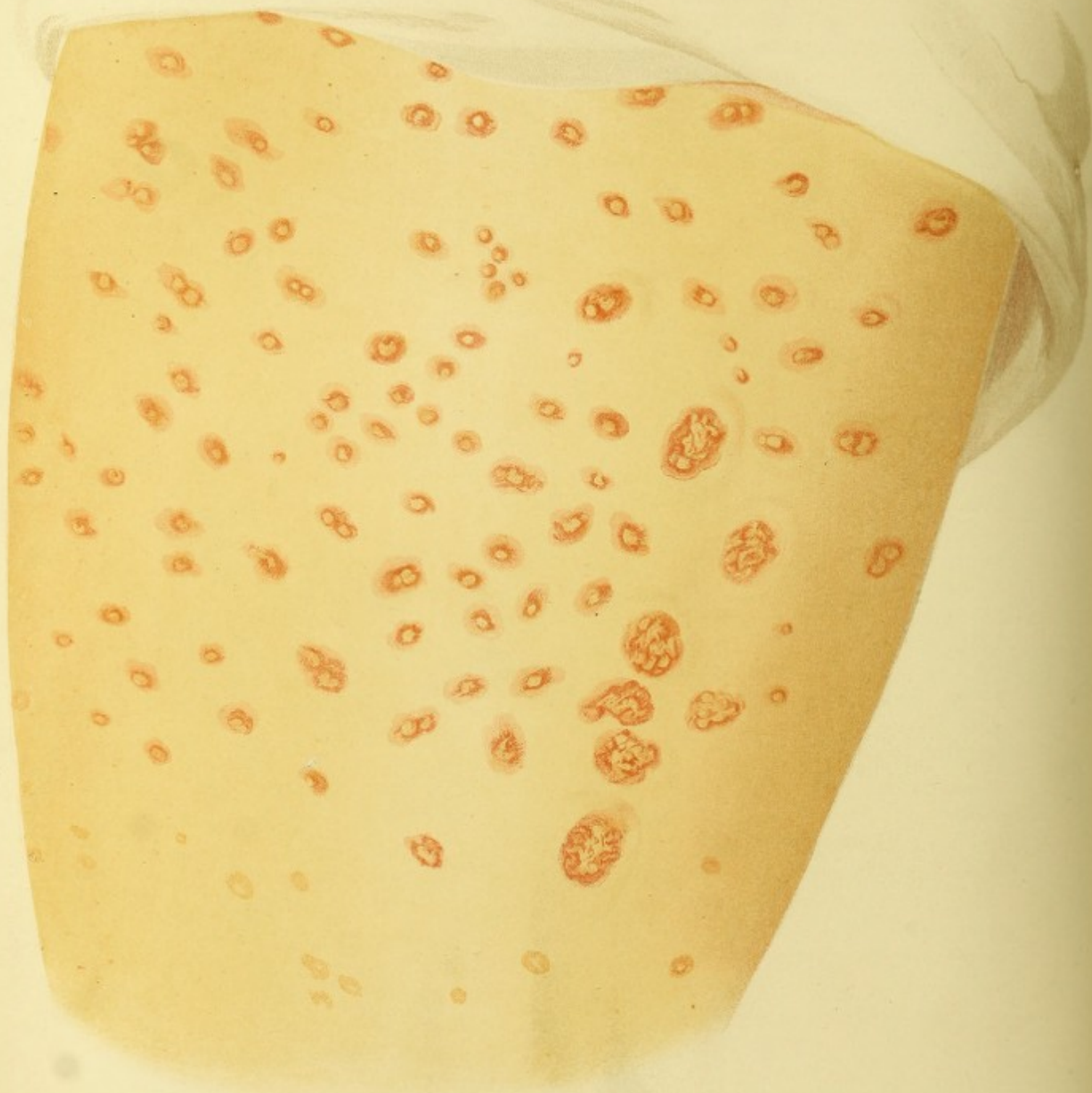
PRURIGO SENILIS  
3

WILLAN'S PRURIGO.









FRIGIDA AGRIA (FERON)

## PLATE XLII.

PRURIGO *ferox*.—This Plate illustrates another phase of Prurigo. During the last 5 years or so I have seen several cases in which an eruption existed which was similar to that represented in the Plate, and consisted of large, distinct, firm, dull brownish-red, fleshy-looking papules, scattered in a discrete form over the affected surface. These papules sprang up in the first instance as hard knots, often to be rather felt than seen, in the skin, and they retained their character of papules, except when crowded together into a confused mass, throughout the course of the disease. They were attended by intolerable itching, and a general thickening of the skin, which was dry and harsh, the health being much below par. The parts attacked were the legs, the thighs, and the arms; in one case the buttocks as well. In one patient these papules crowded together about the ankle into a rough, thickened mass, which became further infiltrated by lymph, its surface being covered over with fine dry scales, the whole presenting about the lower half of the leg and ankle the aspect of the bark of a tree, from whence powdery scales could be rubbed away. To most minds it would convey the idea of a very much thickened, indurated, dry and slight scaly chronic Eczema, but the origin of patches from characteristic papules, the presence of the latter elsewhere, and the absence of all 'discharge,' differentiated the condition from Eczema.


In two cases, the notes of which are before me, the condition represented in the Plate was a part only of a series of diseased appearances, answering completely to the description of the PRURIGO *agria* or *ferox* of Hebra.

The following is a brief outline of the history of the case from which the illustration was taken. The patient was a private one—a young man of 28, who stated that he had suffered from the disease 'all his life,' and had never been wholly free from it. The severity had, however, varied very much, the disease having generally been most marked in the cold weather. His mother and he agree that it began as a dry, harsh state of the skin, which felt roughened, especially about the legs, some parts being 'pimply.' On being asked if he ever noticed any papules or felt knots about the skin of the legs or other parts, he at once stated, his attention having been called to the fact, that his skin has always felt raspy and rough, and pimples of the kind have always been observed and felt. At times his skin has discharged and crusted. His legs, thighs, buttocks, and arms have been chiefly affected. He has never been strong, but has been able to get about and help in his father's business. He has always suffered from intense itching, which has greatly disturbed his rest at night.

On examining him I found his whole skin harsh and more or less infiltrated. Parts of his legs were apparently the seat of chronic Eczema, with crusts over the front of the shin, but he explained that this eczematous condition is not always present, but that it comes on when he is very bad. His legs are usually dry, harsh, and thickened, as at their lower parts now, where there are many papules to be felt in the skin on passing the hand over the surface, which is thickened and fissured, feels raspy and harsh, and is covered by semi-pulverulent scaliness. The thighs and buttocks are generally indurated, dry, and scaly in parts, but the upper two-thirds of the former and much of the area of the latter are covered by large, firm, mostly isolated fleshy papules of large size (tubercles),

as shown in the drawing. In the larger spots, which are enlarged papules, there is a tendency to crusting, and no doubt if the eruption increased, in time the whole skin would have become generally infiltrated. The forearms are very characteristically affected. Distinct Prurigo papules are seen and felt, and the skin generally presents the aspect of the legs at their lower parts. But there was one very marked feature of great diagnostic importance. On both sides there were very large 'Prurigo buboes' in the groins. They had long existed without change, and formed prominent lumps which at once caught the eye. The face was the seat of Eczema for a few days, but this soon disappeared, leaving the skin as usual leathery and tough. There was a good deal of pigmentary deposit about the skin, and a good many excoriations were visible in places. In this case then the disease began by 'Prurigo' papules, the skin became generally infiltrated, thickened, and rasp-like. Severe pruritus accompanied these changes. Characteristic 'Prurigo buboes' appeared coincidentally with the superaddition of eczematous inflammation. The disease appeared in early life, it varied in severity at different times, being aggravated by winter, and seemed incurable. In all these points it answers to Hebra's description of PRURIGO *ferox*. I could not afford to occupy three Plates with Prurigo, or I should have depicted the bark- or rasp-like aspect of the lower part of the legs and of the forearms. I elected to give PRURIGO *simplex* as illustrated by the preceding Plate, and as portraying the commoner phases of Prurigo, and the particular phase of the present Plate, for the simple reason that I believe cases presenting this aspect are not rare in this country, whilst the fully-developed disease *P. ferox* of Hebra is; but the reader will understand that in all cases of the kind, the first stage consists in subepidermic papules, and that the development of these is speedily followed by larger papules that can be seen, with general infiltration of the skin. The particular aspect of Prurigo given in the Plate may exist alone or as part of PRURIGO *ferox*. This is my clinical experience.

The *treatment* of Prurigo is one of great difficulty. Much depends upon the severity and extensiveness of the disease, the age, mode of life, hygienic surroundings, and constitution of the patient. In all the forms of Prurigo the general health will be found to be at fault, and to need attention in the direction of general debility, anæmia, and strumous tendencies. In the young and in PRURIGO *simplex* the treatment is successful. It consists of appropriate tonics, with cod-liver oil given for some time, together with change of air, careful regulation of the diet, and a course of emollient and alkaline baths, together with the inunction of oil and the use of sedatives to allay irritation. No remedy is so good internally as cod-liver oil. In the severer cases the patient must be removed from all influences that unfairly stimulate the skin, such as occupation that entails exposure to marked alternations of temperature; he must be placed under the best hygienic influences, and the general health must be improved by appropriate tonics. If Eczema be present cod-liver oil must be given freely. The infiltrated parts must be reduced by water- or oil-packing and the application of neutral unguents, and by the use of baths—sulphurous or alkaline; whilst the pruritus must be allayed by sedatives, such as prussic acid lotion or alkaline washes. It is important, too, to exclude the air as much as possible from any very irritable and excoriated part. The soap treatment in vogue in Vienna is not acceptable to English patients. In the later stages of the disease tarry applications do good. But after all, so much depends upon the peculiarities of each case, that I can only just indicate the general heads of treatment.



PURPURA SIMPLEX.

Fig 1.

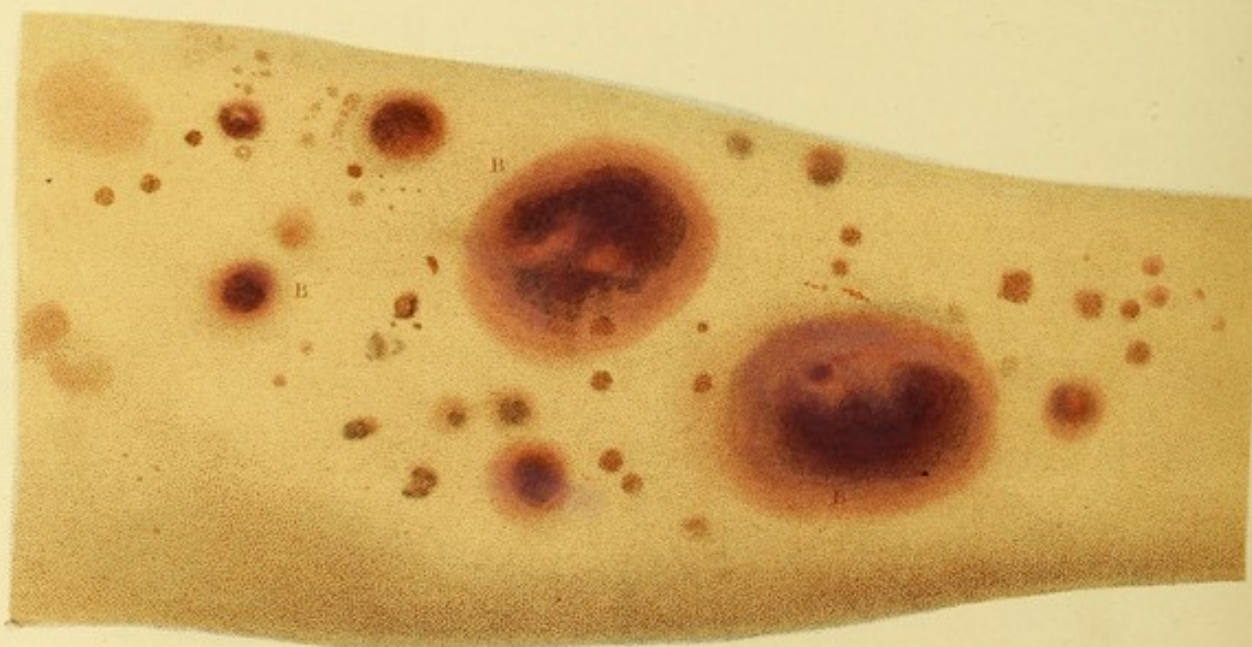
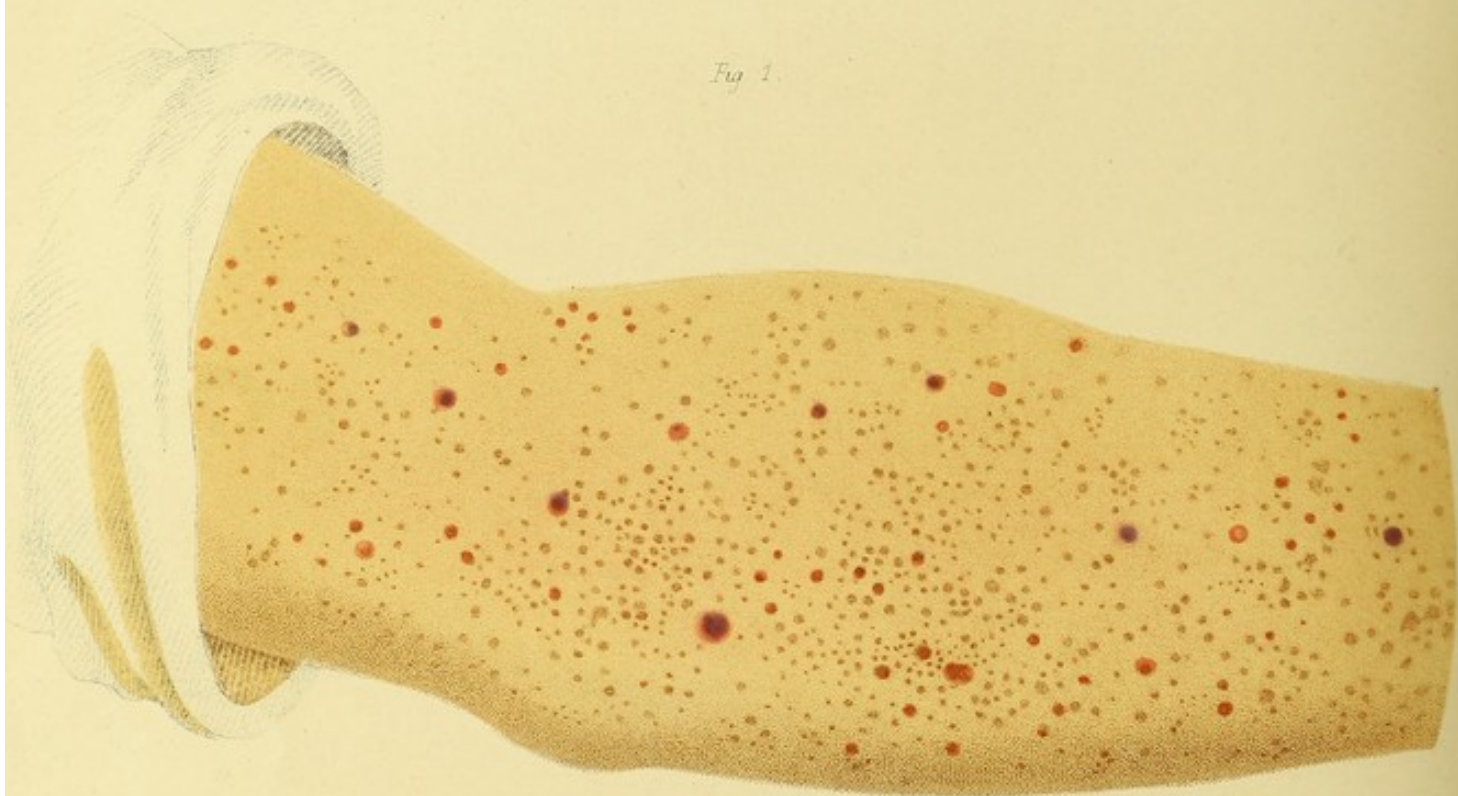
Fig 2.

PURPURA HAEMORRHAGICA.

## PLATE XLIII.

*Fig. 1.*—PURPURA *simplex*. The least complicated form of the 'petechiæ sine febre' of old authors. It consists only of minute effusions of dark blood under the cuticle, usually termed 'petechiæ,' and unaffected by pressure. The eruption is made up at first of pinkish or purplish spots the size of pins' heads, and scattered over the surface more or less extensively. These spots get darker by age. The outbreak of the eruption is accompanied by slight pyrexia. The lower extremities are the parts most usually attacked. The hues assumed by the spots, after a time, are the same as those of a fading bruise, and in the Figure spots of different colours are to be seen.

*Fig. 2.*—PURPURA *hæmorrhagica* is a more severe degree of the disease, in which the effusions under the cuticle are more extensive, forming large ecchymotic patches, which are accompanied by actual hæmorrhages from the various mucous surfaces. The colour of the spots, as in the other variety, is different at different periods of their continuance; being brighter on their first appearance, and becoming subsequently purple or livid, and lastly brownish or yellowish, when the effused blood is nearly absorbed, as seen in the Figure.

The *treatment* consists in keeping the patient in a recumbent position for a few days, and administering some astringent internally, such as dilute sulphuric acid or perchloride of iron. Turpentine also produces excellent results in the severe cases. Indications of scurvy must be carefully recognised, and if any such exist, fresh vegetable food, with good generous living, must be superadded.

THE HISTORY OF THE

Faint, illegible text covering the majority of the page, likely bleed-through from the reverse side.





Fig 2 PETECHIÆ

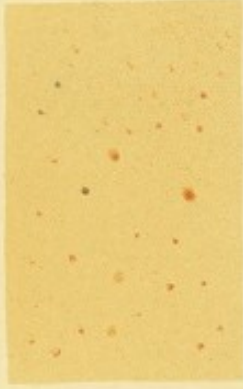


Fig 1

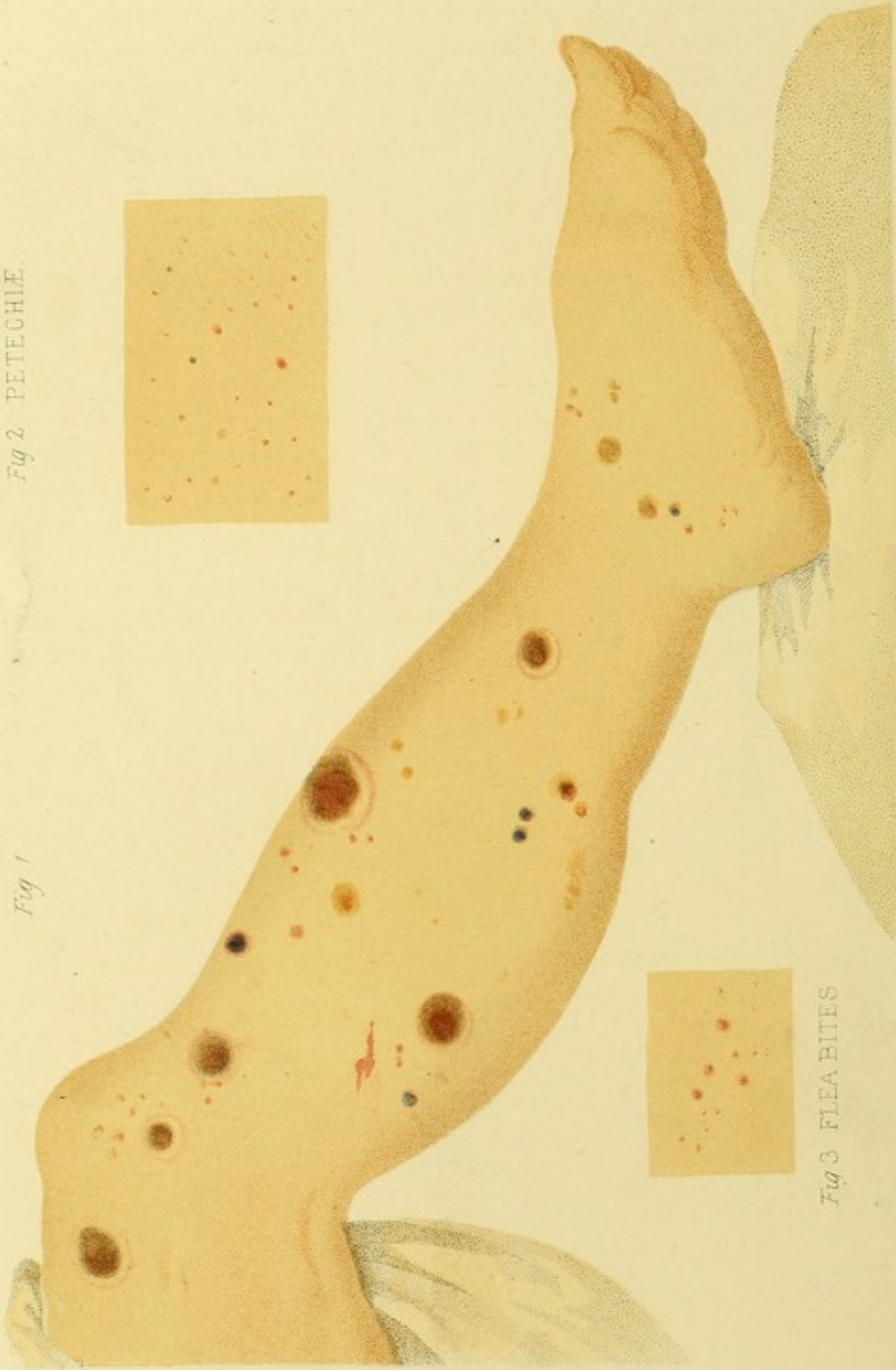
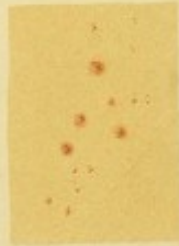
Fig 1. PURPURA URTICANS

Fig 3 FLEA BITES



## PLATE XLIV.

*Fig. 1.*—*PURPURA urticans* is characterised by the occurrence of hæmorrhagic blotches in the seat of urticarial patches. The eruption consists of hard, reddish, and rounded elevations of the surface, with a circumferential ring, having the aspect of a wheal, as shown in the Figure. The disease is sometimes accompanied by a good deal of tingling and itching, and at other times it is not irritable. I have seen several cases; in one the patient had one or two large patches about the knee. The first sign was a tingling; this was followed by a red blotch, in the central parts of which the hæmorrhage occurred. In other cases it is difficult to make out whether the hæmorrhage takes place first, or whether it is secondary to an urticarial patch, since the two occur together so closely. The figure is Willan's. I have seen the disease, as I have said, in large patches, and I remember one case of well-marked *PURPURA urticans*, induced by the free inhalation of Friar's Balsam,\* in which the disease was very extensive. I was asked to see the case by my friend Dr. Watkins late one evening. 'The patient had been suddenly attacked with a very unusual and curious eruption over almost the entire surface of the body. On visiting the patient, I found that he had been suffering for some time from alarming attacks of dyspnœa in connection with some organic disease of the larynx, but that for some time before I saw him the disease and its symptoms had undergone no marked change. The man, whose age was about 50, was sitting up in bed rubbing himself here and there to allay the irritation of his skin, which was severe. The man was not feverish at all; his pulse was somewhat quickened, but not very notably. He did not present any symptoms suggestive of any of the acute pyrexial diseases. On stripping him the whole of the trunk, back and front, and the arms appeared to be intensely hyperæmic, but the colour of the hyperæmia was very dark, almost claret-coloured, in some places. The skin did not appear particularly hot to one's hand. But it was noticed that the redness could not be effaced by pressure. The more superficial vessels were emptied, but a deep-claret stain was left behind, and on close examination it was evident that the eruption was made up of numerous purpuric spots, together with accompanying or superadded hyperæmia of bright tint. The skin was generally swollen, and the seat of great pruritus. It would seem that the eruption about the trunk and arms had left no single spot of the surface unattacked. About the legs a somewhat different appearance presented itself. The eruption was made up of circular places varying in size from that of a threepenny piece to a shilling, the central part being purpuric, and the circumferential part having all the characters of a wheal. In fact, nothing could better answer to the term *PURPURA urticans* than this condition. These circular spots studded the whole of the lower limbs pretty closely. No doubt the eruption upon the body would have presented much the same appearance had it been more discrete and not so entirely confluent, and the hyperæmia so intense and general as it was. That the eruptions on the various

\* *Lancet*, Feb. 7, 1874, p. 195.

parts of the body were the same in nature could not be doubted. It was a purpura with attendant hyperæmia, wheals being in many cases developed out of the hyperæmia, especially about the lower limbs.


‘As to the cause of the eruption, it was clear that it must have been something of very recent and active operation. The patient had been advised by some one to inhale the vapour of a drachm of Friar’s Balsam two or three times a day. He had most effectually acted upon this advice, and it seemed clear that the stimulating emanations from the balsam had been absorbed, and had irritated the skin. We ordered the man some simple diuretic and an anodyne lotion, and Dr. Watkins told me subsequently that the patient began to mend the next day, and rapidly got well of his rash, which faded away steadily in a few days.

‘The case is an interesting one clinically, and especially in connection with the similar effects of copaiba and other balsams upon the skin.’

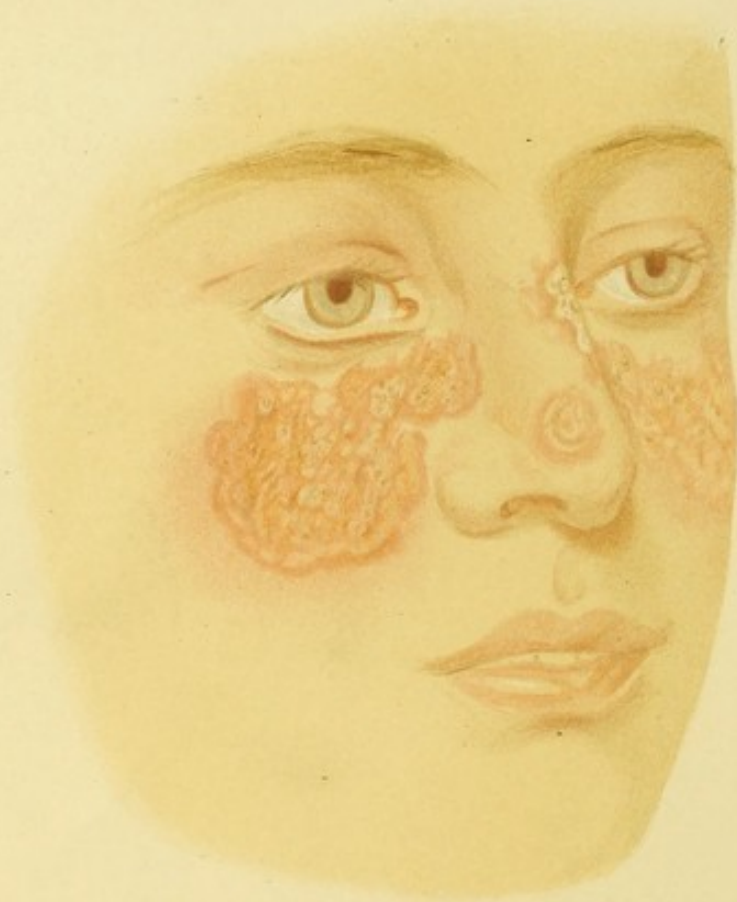On the extremities, where the spots most frequently appear, they are often mixed with petechiæ.

*Fig. 2* and *Fig. 3* are intended to show the relative characters of petechiæ and flea-bites; the latter being distinguished by a central punctum, which remains under pressure, while the surrounding redness disappears.

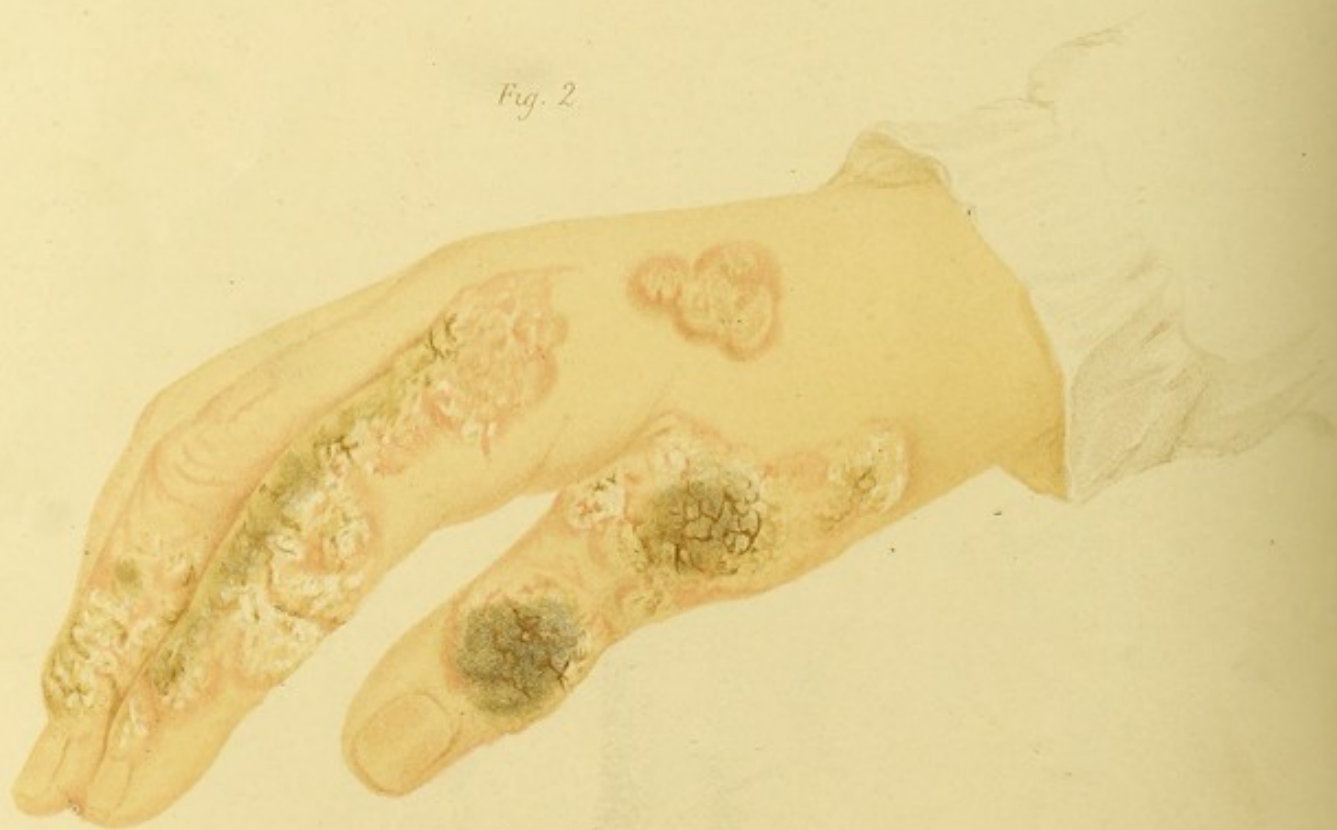The *treatment* of PURPURA *urticans* is the same as for Purpura, except that in some cases diuretics and salines even are needed at the outset if there be pyrexia, and if the attack be apparently due to the ingestion of any irritating substance.



*Fig. 1.*



*Fig. 2.*



## EXPLANATION OF THE PLATES.

---

**PART XII.**—This Part is devoted to the subject of Lupus in its chief clinical forms, viz., the *erythematous*; the *tubercular*, or *non-ulcerating*; and the *ulcerating*. The Plates are all new.

### LUPUS (GENERAL DESCRIPTION).

This disease is characterised by a new cell infiltration of the skin textures. This cell growth, which possesses the aspect of granulation tissue, is not capable of becoming more highly organised, but on the contrary tends to undergo decay by a process of fatty degeneration and molecular destruction. Such decay may go on without breach of surface, that is without ulceration, the foreign tissue being removed by interstitial absorption; or it may be attended with ulceration. In either case the healthy skin tissues are more or less atrophied or destroyed as a consequence of their invasion by the cell infiltration, its subsequent decay, and the occurrence of ulceration. Scarring and contraction are often decided, and in proportion to the degree in which ulceration occurs. Lupus is a disease of early life. It is most common between the ages of 15 and 25. It is said to be more frequently observed in the country than in town districts, and in females than males. It runs a chronic course, and attacks the nose and cheeks by preference. It often occurs in strumous subjects, but by no means necessarily so. The material which constitutes the Lupus growth may be present in the skin at first in the form of an even infiltration (see PLATE XLVI., *Fig. 1*), or tubercles (PLATE XLVI., *Fig. 2*). It may be deposited uniformly in the dermal textures, or particularly about the sebaceous glands (PLATE XLV.); and, as before observed, ulceration may or may not be present subsequently (PLATES XLVII. and XLVIII.). Varieties of Lupus are often made according to variations in these respects, and comprise LUPUS *tuberculosis*, *L. maculosus*, *L. ulcerans* (or *exedens*), *L. non-ulcerans* (or *non-exedens*), *L. hypertrophicus*, where the lupoid growth is very prominent and abundant. The simplest division of the disease is that into LUPUS *erythematodes*, in which the sebaceous glands are especially the seat of the cell infiltration, and LUPUS *vulgaris*, in which the derma proper as a whole is involved. The latter (*L. vulgaris*) may ulcerate or not, and in it the growth takes the form of an infiltration or of tubercles.

### PLATE XLV.

*Fig. 1.*—LUPUS *erythematodes* of the face. The disease begins as an *apparent* erythema, and generally in one or more small, circular, dull-red spots, with well-defined margins, about the nose or cheeks. These spots, however, are something more than erythema. The redness

may go on pressure, but there is some slight infiltration felt and seen, and this is rendered evident by the progress of the disease. These little red patches may or may not be seen to commence at the hair follicles in the early stage, in which case they are slightly scaly. They may be and often are smooth at first, having a shining aspect, but soon they become covered by few and minute branny scales, which are semi-detached from the surface below. A spot representing this stage of the disease is seen near the tip of the nose in the figure. The spots now, be they papules or red patches, increase in size, their centres sink in, owing to the atrophy of the healthy textures, although there is no ulceration, and then, if not before, the peculiar affection of the sebaceous follicles shown in the Plate becomes plainly visible. These follicles are observed to be enlarged, and to be plugged with little exuviae, forming so many dark little points studding the surface. As these glands are irritated they pour out more sebaceous stuff than usual, and little fatty scales or minute crusts may be formed over the patch, and these conceal the enlarged and choked glands. The lupus patch or patches still spread and coalesce, so that the nose and the cheek may be more or less involved, and usually in such a way, that a figure resembling a butterfly, whose body is represented by the part of the disease on the nose and the wings by that on the two cheeks, is produced, as is almost the case in the figure. After a time the whole face may be involved by the formation of the new growth at the edge, and its spread centrifugally, the central parts sinking in, and showing a thin parchment-like scarring, which is well shown at the root of the nose near the left eye of the portrait. But, indeed, all the characteristic features of the disease are well seen in the figure, particularly the affection of the glands, the atrophy, and the actively growing raised edge. In this form of Lupus the scalp and hands, ears and lips are often affected. In the case of the scalp the orifices of the sebaceous glands are enlarged and plugged with sebum, whilst atrophy and cicatrization result, and bald patches are produced. On the fingers the spots are not unlike indolent chilblains, but they exist in summer; they are infiltrations, covered by scales with depressed (atrophied) centres (see also *Fig. 2*). The fingers and hands are cold and blue. The disease exhibits a similar aspect in the lips and ears. The disease seldom attacks before the age of 20; it is most common in females; is very chronic, and apt to recur.

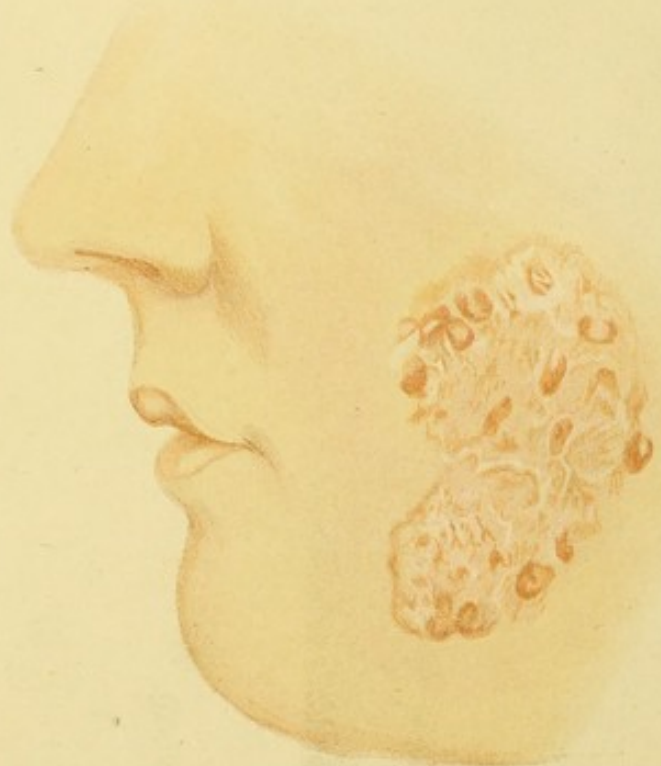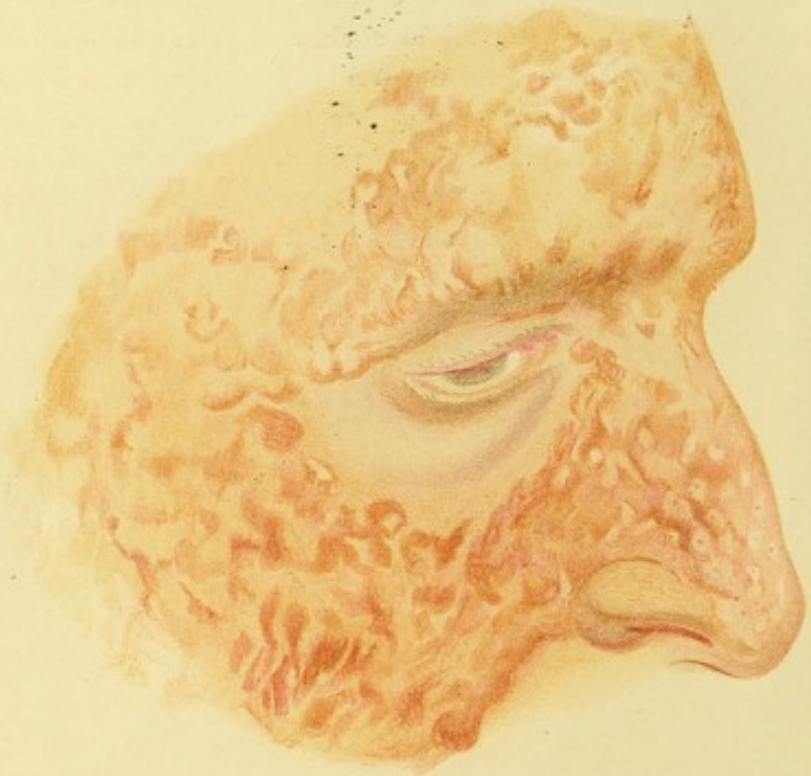*Fig. 2.*—LUPUS erythematodes of the hand (encrusted). I represent in this figure an unusual phase of erythematous lupus, and purposely so, for a reason that will appear directly. The basis of the disease—as seen in the isolated patch at the back of the hand, and in the part over the knuckles of the first finger—is a new growth of tissue or infiltration, the edges of the patches of disease being well marked and somewhat raised, and the central portions slightly scaly, and yet thinned. Such patches, and they are identical with that on the tip of the nose in *Fig. 1*, are common in connection with, and typical of, erythematous lupus, as it attacks the scalp, the ears, and the hand in particular, as stated in the description of *Fig. 1* in this Plate. But in some cases the disease may not be so well defined, there are merely red, slightly thickened patches about the hands, that look like chilblains, only that they are more indolent and are not excited by cold, whilst some little atrophy usually occurs. But in this representation there is an exaggerated condition of things, or rather a superaddition of crusting, together with hypertrophy of the papillary layer of the skin, constituting a warty outgrowth from the centre of the lupus spots.





LUPUS (INFILTRATING)

*Fig. 1.*



*Fig. 2.*

LUPUS TUBERCULOSUS

## PLATE XLVI.

*Fig. 1.*—LUPUS (a mixed phase of), illustrating the designations 'infiltrating,' 'macular,' and 'tubercular.' The case from which this illustration was taken was that of an elderly woman, who had been suffering for many years from the disease, which had attacked the face, the neck, and the limbs rather extensively. The patient was under the care of my friend Dr. Sparks, in Charing Cross Hospital, in 1875. A difference of opinion would no doubt arise amongst dermatologists, if they were canvassed on the point, as to the correct designation of the disease, viz., whether it should be erythematous Lupus, or tubercular (and non-exedent) Lupus. Probably the disease began as the former, but this particular point is immaterial in relation to my present purpose. I introduce the representation here, as showing that no hard and fast line of demarcation exists between the several varieties of Lupus, and that they run the one into the other. If typical cases of the different forms be taken, no doubt they contrast very decidedly in many respects. However, as I stated in the general description of Lupus (p. 73), the essential fact of the disease is the growth of a new cell tissue in the skin; in the erythematous phase proper it occurs chiefly about the sebaceous glands; in the present illustration the growth is shown in some parts, as about the forehead, forming small brownish-red spots, hence the term LUPUS *maculosus*; in others, as about the cheek, forming a more or less uniform infiltration, which when scaly has been termed *L. exfoliatus*, and showing in other spots as tubercles, which are well seen about the cheek and nose. If attention be directed to the tip of the nose, it will be seen that the central point of certain of the tubercles show a punctum or opening, which is that of a sebaceous gland, and in fact here the disease partakes of the decided character in an exaggerated form of LUPUS *erythematodes*. There is a thinning or atrophy of the skin textures invaded by the lupus growth, where this has existed some time, and has become in part removed by decay and interstitial absorption.

*Fig. 2.*—LUPUS *tuberculosis*. I have made it a chief endeavour in the preparation of this work to take my illustrations from typical cases of disease of common occurrence, and such as do not present exaggerated or rare features. I have selected an illustration of LUPUS *tuberculosis*, which may be regarded by some as not portraying the characters of this variety of the disease very typically. But the illustration will serve a very useful purpose, for though it does not represent the disease in its best marked form, yet it exemplifies a state of things which is frequently met with in practice, viz., LUPUS *tuberculosis*, which has been treated and is making progress towards cure. The case when first it came under my care showed a large, more or less uniformly, fleshy-like mass, covering the cheek, made up of compacted tubercles of brownish-red colour, and the growth was raised, and covered over with thin and adherent scales. The greater part of the growth, however, was destroyed by caustics, and the state of things sketched in the figure resulted. The reader will notice that there are still a number of small, roundish, fleshy little masses of new tissue studding the surface of the diseased area here and there.

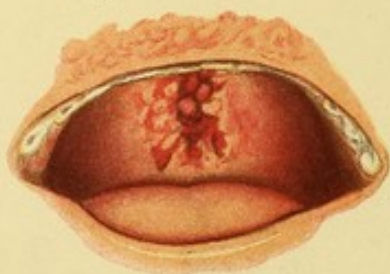
and showing out plainly from the more or less general cicatrization. The presence of such tubercles is the characteristic of LUPUS *tuberculosis*. One object in giving this particular illustration was to indicate the kind of result it is desirable to bring about in the management of these cases, and to indicate especially the kind of scar that will result from the judicious application of caustics applied for the cure. Caustics would still be needed to destroy the remaining tubercles, and would be required to be applied more than once to each little new growth, until it has been completely replaced by cicatricial tissue.



Fig 1.

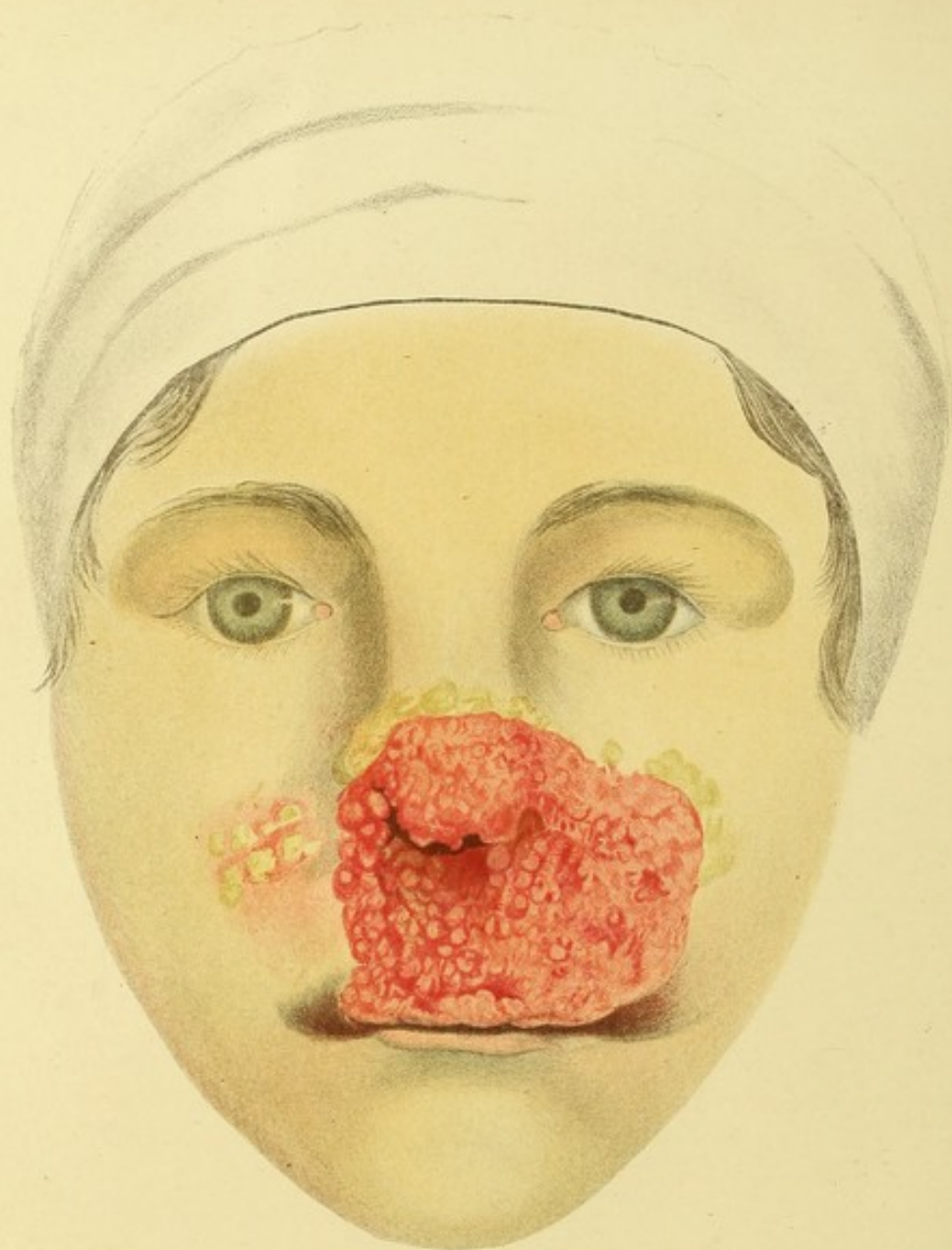

Fig. 2.



LUPUS EXEDENS

## PLATE XLVII.

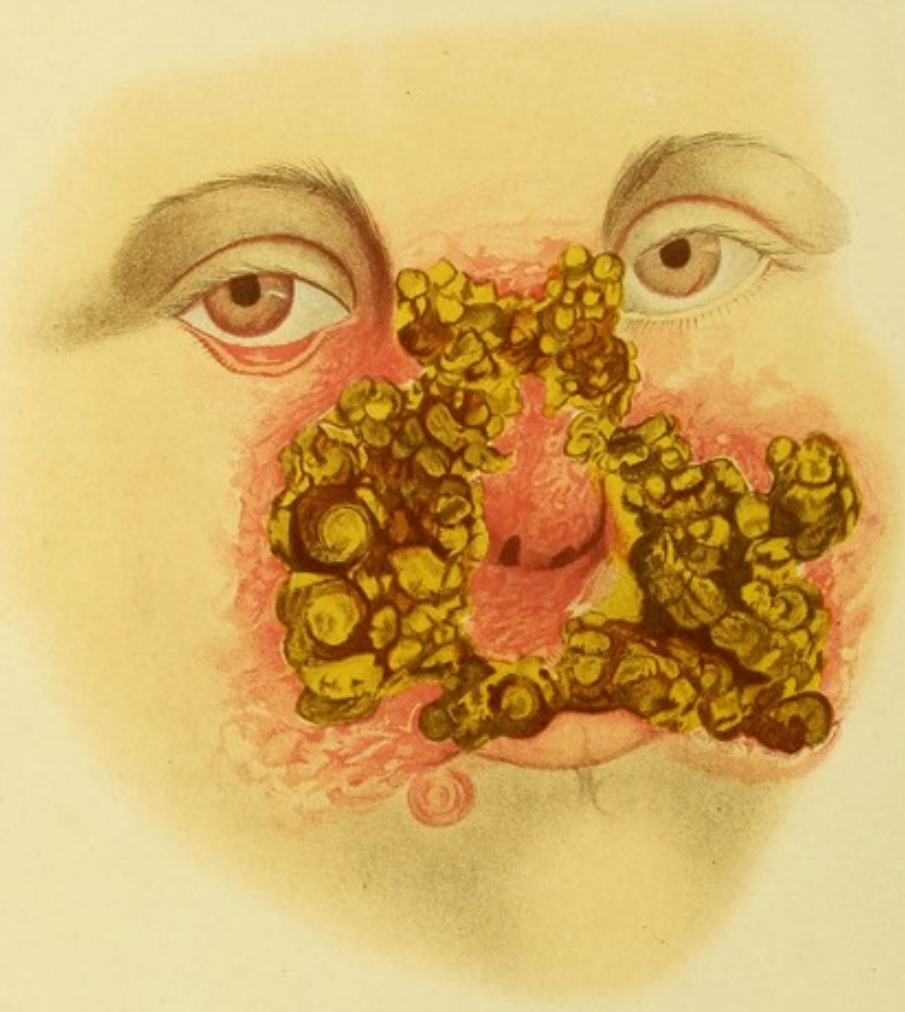*Fig. 1.* LUPUS *ulcerans* (new).—This is taken from an excellent drawing of Sir Robert Carswell, which is in the museum of University College, and it is an admirable illustration of ordinary ulcerating Lupus. The drawing bears date June, 1829 ; and was made from a case in the Hôpital St. Louis at Paris. It shows the ulcerative form of the disease with its most usual characters, and attacking its favourite seat ; viz. the nose, and adjoining parts. The disease begins, like the other varieties of Lupus, by the development of softish fleshy tubercles, which aggregate together ; and these are well seen studding the surface of the diseased area, but especially at the right side of the nose (the left of the portrait). After a while, a certain amount of discharge and crusting take place prior to distinct ulceration setting in, as is represented in the present illustration ; in fact the Lupus growth gradually softens down with ulceration. On the right cheek in the illustration, the early stage is fairly delineated in the little crusted patch of tubercles, covered over or intermixed with slight yellow crusts. The ulceration varies considerably in extent and depth. In the figure, it is not very deep over most of the surface, but a distinct portion of the end of the nose had become lost by ulceration, in the case from which the portrait was taken, as is well shown. The ulcerative process may destroy all tissues one after the other, and may invade the palate and parts near, or travel into the nose, perforating its septum. See *Fig. 2*.

*Fig. 2.*—LUPUS *perforating the palate*. This figure gives a view of the interior of the front of the mouth showing the palate with Lupus disease perforating through it from the nose. A similar affection of the posterior part of the palate and the laryngeal opening is sometimes observed. The figure also shows the base of the Lupus patch of *Fig. 1*, at the line of junction of the skin, and mucous surfaces of the upper lip.









LUPUS, (IN A SCROFULOUS SUBJECT)

## PLATE XLVIII.

LUPUS *exedens* (in a strumous subject).—This is also a copy of one of Sir R. Carswell's drawings. I cannot here enter upon a discussion of the question of the relation of struma to Lupus. I shall content myself with saying that, *clinically*, Lupus is observed in those who do not present the least evidence of their being strumous: it is therefore not strumous. But then it also often occurs in decidedly strumous subjects, and has the appearance of being of strumous origin. In this case, ulceration and free crusting are the rule, as shown in the figure of this forty-eighth Plate. This modification of skin mischief by the strumous diathesis is not peculiar to Lupus, but is seen in Eczema, Psoriasis, and other diseases. The disease, such as is here represented, usually commences by large and distinct fleshy tubercles, which rapidly soften down with ulceration, which varies in extent and depth. In these cases of Lupus in strumous subjects, the connective tissue of the deeper parts often becomes inflamed so that there is much swelling and induration at the seat of the disease. In many cases fresh spots of disease may spring up by the development, not of new tubercles, but of soft, small, bluish-red or lurid swellings, the size of a grape or more; these quickly break down, open, and give exit to a sanious pus, whilst free and unhealthy ulceration set in. This latter condition is essentially strumous inflammation, so that the admixture of true Lupus with strumous inflammation is then very apparent. This is probably what has happened in the spot on the left cheek of the portrait. Strumous abscess of glands is often present in these cases. There are all grades of transition between simple Lupus and such a condition as is here portrayed, that is to say, the admixture of Lupus and struma greatly varies in degree.

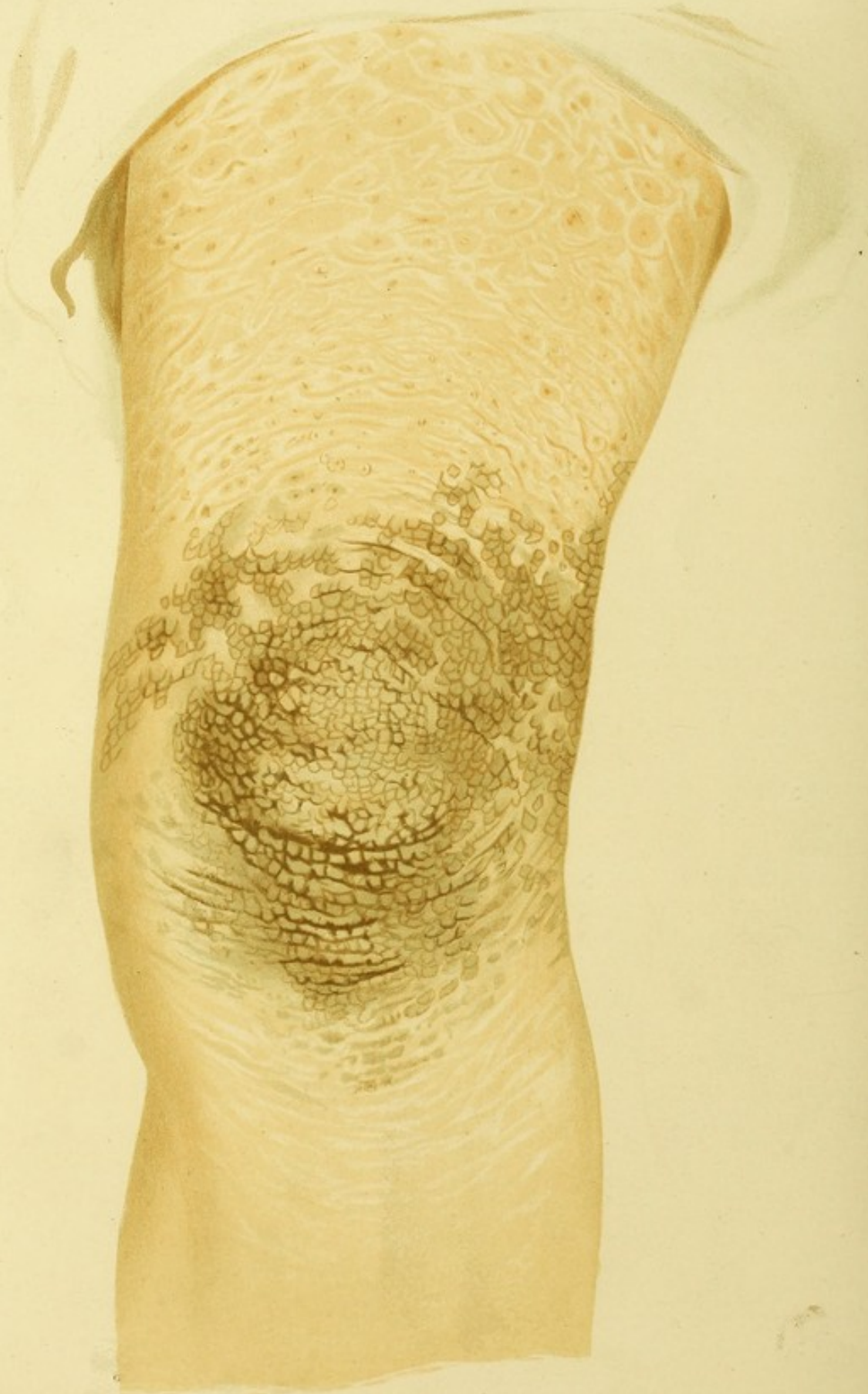## THE TREATMENT OF LUPUS.

The essential treatment in the various manifestations consists in promoting the removal of the Lupus neoplasm by caustics; but if the patient be strumous or phthisical, there will be a special tendency to free pus-production (see Plate XLVIII.), and he or she must then be treated for struma vigorously, by appropriate diet, change of air, iron, cod-liver oil, and the like, so as to get rid as far as possible, before commencing local treatment, of the pus-producing tendency. In some cases also there exists in greater or less degree defective assimilation from bad living, or anæmia, or general debility only. It will be here requisite for good success in treatment, to improve the patient's health by appropriate remedies, otherwise the disease is more liable to spread during the progress of the local treatment. As to the local treatment. The destruction of the Lupus growth should be effected with as little disfigurement as possible. It makes all the difference whether the Lupus be severe or slight. If it be small in extent (as in Plate XLVI., *Fig. 2*), it can be readily destroyed by mild caustics, or by the persistent application of mercurial plaster.

When a Lupus is tender, very hyperæmic, and shows a tendency to spread, whilst the amount of blood in it is easily increased by exposure or irritants, I think caustics are to be avoided for a while, because the disease tends to develop in the healthy contiguous parts, if these are irritated—the more so if the patient is out of health. My rule is in such

cases to check the hyperæmia first of all by excluding the air, soaking in oil to get off scales and scabs, and applying calamine lotion. When the patch assumes an indolent aspect, and the patient's health has been improved, then is the time to apply caustics. But many cases of Lupus are made worse by the improper use of caustics. In all cases in which the Lupus is tubercular (see Plate XLVI., *Fig. 2*), and in which the deposit or infiltration is well marked or excessive, caustics must be freely used. Various caustics are recommended for the destruction of Lupus. The acid nitrate of mercury is useful and manageable, since its action can be limited to the locality desired. It had been used in *Fig. 2*, Plate XLVI. It is useful in marked Lupus of the face of tubercular character. Caustic potash is effective, but it leaves hard scars, and is not therefore advisable for the face. Nitrate-of-zinc paste is good for patches if much infiltrated. It does not give much pain, nor does it scar greatly. Arsenical caustics are available under the same conditions. Biniodide of mercury and glycerine, in the proportion of from 10 to 20 grains of the former to half an ounce of the latter, is useful in cases of well-marked tubercular Lupus. The galvanic cautery and the hot iron suit the severer and more obstinate cases of thickened Lupus patches. Nitrate-of-silver stick is the favourite Vienna remedy. It is said to leave thin scars. No doubt the nitrate-of-silver stick is good in Lupus cases, accompanied by much ulceration, or with implication of the deep cellular tissue, for a caustic is there needed which can be applied effectively to the boggy and extensive Lupus infiltration, and yet not affect the healthier tissues around. It may be used freely without much harm, and without causing undue scarring. If I had Vienna cases to treat, I should use the caustic point, perhaps; but then the English cases do not tend to ulcerate or to be complicated by extensive inflammatory implication of the connective tissue, and the more active caustics can be used so as to limit their operation as desired. The mode of using these caustics is very simple. They should be used cautiously to a small portion at first, and especially to the edge of the Lupus patch at the outset, so as to get a circumferential scar across which the Lupus infiltration cannot spread. If the patch becomes inflamed, a poultice may be applied for a few hours, and the part dressed with some soothing unguent, the caustic being re-applied when the irritation has subsided, and again and again until the diseased surface has levelled down to a little below the plane of the healthy skin, the infiltration has practically disappeared, and the resulting surface has begun to acquire a comparatively non-vascular, pale, and, in fact, cicatricial aspect.





ICHTHYOSIS

## EXPLANATION OF THE PLATES.

**PART XIII.**—This fasciculus contains representations of Ichthyosis, Keloid, Rodent ulcer in its several stages, Dysidrosis, and Phthiriasis, and all the Plates are new ones.

### PLATE XLIX.

**ICHTHYOSIS** (new Plate).—This is often hereditary, developing soon after birth, and lasting all through life, though varying in its degree of development. It is characterised by more or less accumulation of epithelial matter upon the surface, by hypertrophy of the papillary layer of the skin and thickening of the corium, with deficiency of subcutaneous fat, and disordered function of the perspiratory and sebaceous glands. The epithelial changes vary greatly in degree, amounting to desquamation or slight scaliness in some cases, so that the skin is hard and dry, giving off a Purfuraceous desquamation, hence the term **XERODERMA**. In other instances there is a decidedly squamous condition, in which the scales are large, mother-of-pearl like, and arranged in little polygonal patches, as seen in the upper part of the Plate: this has been called **ICHTHYOSIS nacrée** (Alibert). In other cases, the epithelial accumulations assume the appearances presented over and about the knee in the Plate, that is to say, they form little square masses, which have become discoloured by exposure to dirt. These little masses can be picked away pretty readily, and are then observed to have been seated upon, and to have been entangled by, hypertrophied papillæ beneath, which run up into their substance. A certain amount of sebum is mixed up with the epithelial scales, and helps to form the dark masses, whilst little projections are noticed beneath some of the scales, which are little plugs of sebum, withdrawn from the follicles of the sebaceous glands, whose orifices may be plainly visible. This condition has been termed **ICHTHYOSIS simplex**. When developed to a fuller degree, so that the epithelial growth takes the form of dark spines, enclosing elongated papillæ, the disease is termed **ICHTHYOSIS hystrix**. But these four phases are only degrees of one and the same disease, and their several characters may be more or less intermingled in the same case. For instance, the body of the patient from whom the illustration was taken, and the face in slight degree, presented the Xerodermatus aspect in perfection; but the illustration shows the characters of two other so called varieties of the disease. The caky aspect existed also about the axillæ and elbows; and indeed this is the case with many instances of the disease in English practice. In all cases the skin is dry and does not perspire. The disease, however, may be wholly xerodermatous.

**ICHTHYOSIS** shows itself soon after birth, the nurse or mother noticing that the skin of the child is dry, harsh, and slightly squamous, and then the more pronounced disease is gradually assumed, the caky aspect (**ICHTHYOSIS simplex**) appearing particularly about the

ankles, the knees, elbows, and the armpits, the colour being at first greyish green or brown. The face is usually dry and slightly scaly, and its surface often looks thinned and wrinkled ; but this condition is not peculiar to the face in xeroderma. The disease exempts, as the rule, the palms of the hands, the flexures of the joints and genitals. The skin is apt to become irritated by cold weather. The general health is usually good, or fairly so. The disease, having once attained its highest degree of development, undergoes little change, if undisturbed, throughout life.

The disease is an incurable one. But by removing the epithelial accumulations, and rubbing in constantly some oleaginous substance, the skin can be brought into a very comfortable condition, and no inconvenience is suffered, except perhaps in cold weather, when, unless care is taken, the skin is apt to become irritated by the cold. The epithelial accumulations can be removed by alkaline baths, soaking the parts with alkaline or oily packings, and then some suitable substance, glycerine, olive oil, or the like can be applied as often as is needed to keep the skin soft, supple, and free from epithelial cakings.

ler



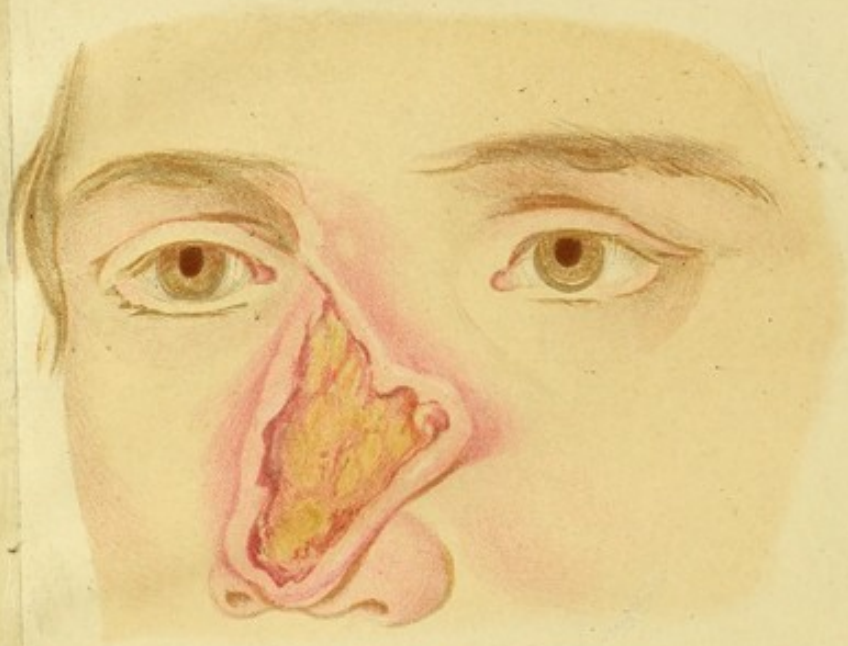

Fig. 4

RODENT ULCER.

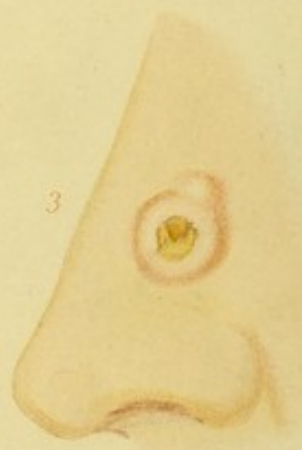
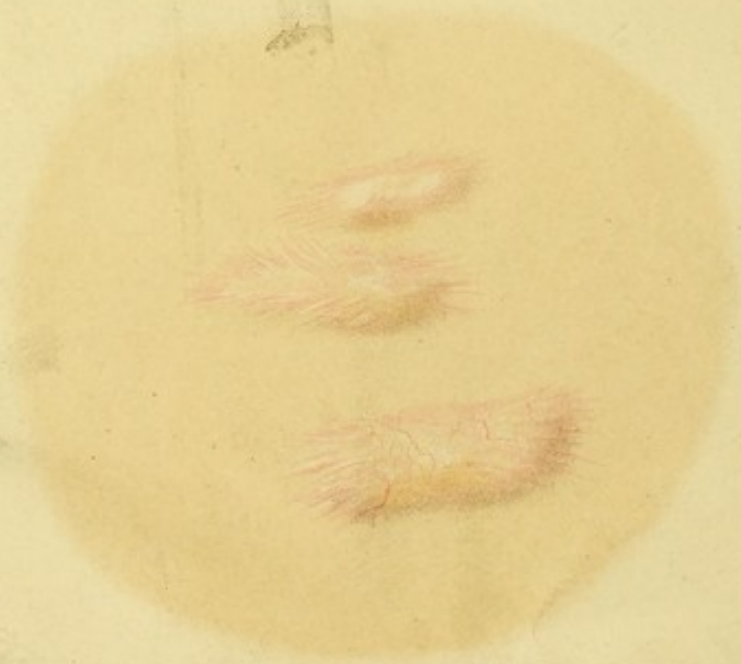
Fig. 1



кабана

## PLATE L.

This Plate contains illustrations of two distinct diseases :—Keloid (*Fig. 1*), and Rodent ulcer (*Figs. 2, 3 and 4*).

*Fig. 1.*—KELOID (new Plate).—This disease consists in an hypertrophic outgrowth of the fibrous tissue of the skin. It may arise in the healthy skin without apparent cause, or it may develop in the seat of a scar or scars. The former is termed *idiopathic*, and is represented in the figure, the latter *traumatic*, Keloid. The general features of the actual disease are alike in the two cases. The growth looks and feels peculiarly firm and dense. It sends off as it were little offshoots into the surrounding healthy part, as shown in the figure ; whilst little vessels course over its surface. The growth possesses a contractile quality, so that the healthy parts about it are somewhat puckered in towards the growth, and the little offshoots or 'claw-like processes' stand up like little firm ridges of tissue, and feel like little fibrous cords, more or less distinctly in different cases.

Idiopathic Keloid often appears in the front of the chest wall, as represented in the figure, which is taken from a model in University College Museum. The shape of the growth in idiopathic Keloid is globular or oviform.

Traumatic Keloid is in reality an hyperplastic growth of the fibrous tissue of a scar, from whatever cause produced, and the general shape, size, and number of the Keloid masses are determined pretty accurately by those of the scars. The scars left by flogging, burns, by diseases such as ecthyma, syphilis, small-pox, acne, strumous sores, etc., and those following application of blistering fluids, nitric acid, etc., may become the seat of traumatic Keloid.

The *diagnosis* offers no difficulty.

The *treatment* is purely negative. Any attempt to interfere with the growth by remedies—except such as soothe or protect it from friction and other injury—or to remove it by operation, is usually followed by an increased growth of the disease or its return in the cicatrix of the surgical wound.

*Fig. 2, 3.*—RODENT ulcer (new Plate).—Histologically regarded, this is the least expressed form of the cancerous diathesis, and is a variety of the epitheliomatous form of disease. Clinically considered, in its course and general features, it behaves rather like a non-cancerous growth. Its peculiarity, in fact, mainly consists in running a very slow and indolent course, in not involving the glandular system, and in its curability. The disease is one that generally occurs in persons about 55 years of age or so, but I have observed it in a man of 33. Rodent ulcer has been represented in other works, but almost entirely in its more advanced stages and severe forms. My object is to portray it in its early as well as its more advanced stages, because its nature is, in my experience, so frequently overlooked at the outset of its existence, and it is most desirable that it should be treated at the earliest possible stage, for thereby the cure can be effected very easily indeed without any real disfigurement.

Rodent ulcer springs up in the previously healthy skin, as, at first, a little buttony flattened elevation, or in the seat of some long-existing wart, which enlarges, becomes slightly vascular, and at last loses its own distinctness in the gradual development of the features of the new 'rodent' growth, as in *Fig. 2*.


*Fig. 2* in fact represents this particular transformation. The patient from whom the drawing was taken had a little flat wart on the side of the nose for many years. At the age of 55, it began to enlarge and to thicken until it assumed the aspect shown in the drawing. The original characters of the wart were lost in the little lump which grew out of it and acquired a hard raised circumferential edge, the centre becoming slightly depressed, whilst little vessels running over the circumference of the growth showed themselves. The feel of such a lump is very firm. The idiopathic form of rodent ulcer possesses just the same characters.

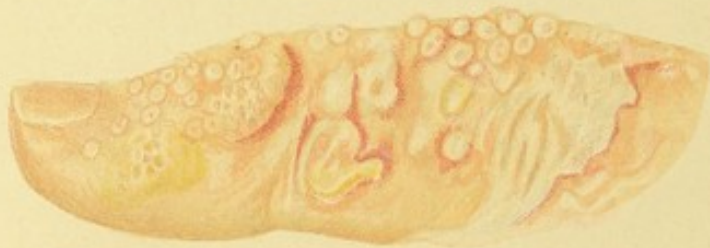The next stage in rodent ulcer consists in the slow enlargement of the growth which presently cracks in the centre. A scale then forms, and beneath this, ulceration progresses. The ulcerated surface is pretty clean, perhaps slightly papillated in some cases, whilst the peculiar hard rolled edge becomes more apparent, as is seen in *Fig. 3*. The edges are not everted and undermined as in ordinary epithelioma, nor are they sharply cut as in syphilitic sores.

*Fig. 4* represents rodent ulcer in a more advanced stage, when free and extensive ulceration has set in. The special character of the edges as above described are plainly visible.

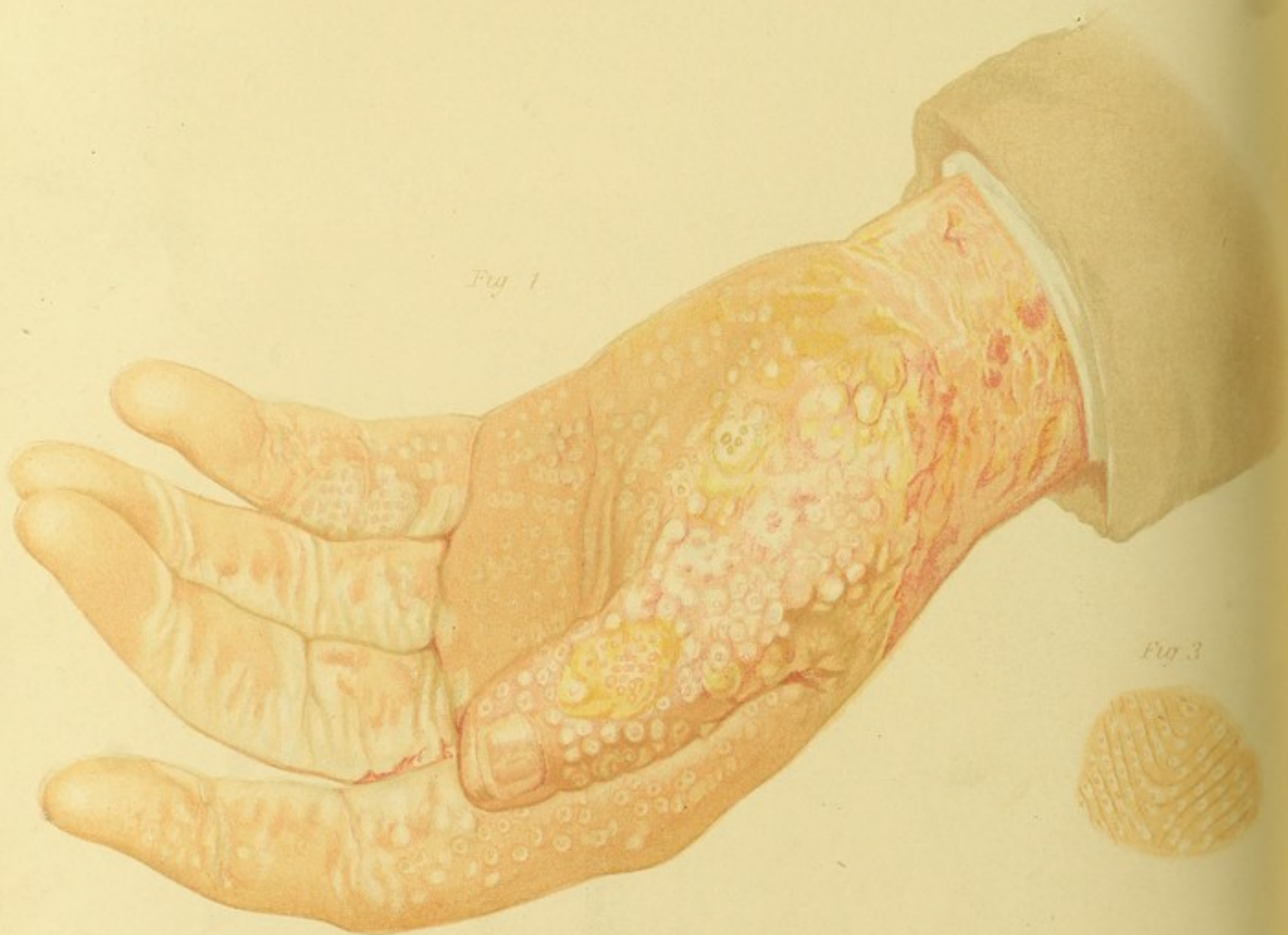The *diagnosis* is easy. The main points are the presence of a sore which has been of slow production, and possesses a pretty clean surface and hard rolled sinuous edges, and which attacks the upper part of the face in a person of middle or old age, and without implication of the lymphatic glands.

The *treatment* consists, in the slighter cases, such as that of *Fig. 2*, in freely destroying the growth with acid nitrate of mercury or chloride of zinc paste, where the knife is objected to; but if the diseased surface exceeds that of a sixpenny piece, it is safer to remove it by the knife, taking care to apply a thin layer of chloride of zinc paste to the surgical wound when the disease is very extensive. This line of practice succeeds admirably, and no return of the disease occurs.





*Fig. 2.*



*Fig. 1.*

*Fig. 3.*



DYSIDROSIS

## PLATE LI.

DYSIDROSIS (new Plate).—For several years past the disease here portrayed has been amply recognised and described in my clinique at University College, but it was not until the year 1873\* that I actually *published* any description of its nature and characters. (See note appended to description of PLATE XXIX. Part VIII.) The disease has been hitherto classed with Pemphigus in some cases, and Eczema in others ; but it is a disorder beginning in the sweat apparatus; and this I shall now proceed to show, with the assistance of the figures of the accompanying Plate taken from a most typical case.

Dysidrosis occurs in subjects of what is conveniently termed nervous debility, or in those in whom anomalous nervous symptoms have occurred, or in such as have been prostrated by worry, mental anxiety, overwork, or the like.


Dysidrosis attacks the hands and the feet principally. It may run either an acute or a chronic course, lasting in some cases from ten days to a fortnight, and in others a much longer time. The Plate, as before indicated, pictures a well-marked and typical instance of Dysidrosis, attacking the hand and fingers—the most usual seat of the disease. In such a case the individual attacked feels weak and depressed. It may be that he looks pallid, and presents the dull aspect of one suffering from slight pyrexia. The hand itches at first, then feels painful and stiff, and it may be is more or less swollen: and then over the palm or in the interdigital spaces or along the sides or other parts of the fingers, or all or most of these situations, a number of what appears to be deeply imbedded vesicles develop. They are well shown in the Plate studding the palm of the hand pretty uniformly. They are at first isolated. They do not readily burst; and they enlarge after a few days, so as to become distinctly raised upon the surface, as is well seen in the spots over the thumb in *Fig. 1*, and over the base of the thumb in *Fig. 2*. It is at this stage that these little vesiculations present most perfectly their very characteristic aspect of boiled *sago grains* imbedded in the skin. If the skin be examined at the early stage with a lens, in many cases it will be seen that these little pearly spots answer exactly in situation to the sweat ducts, and indeed that they are distensions of the sweat apparatus. This has been represented in *Fig. 3*, which was the exact appearance seen in the case from which this Plate was sketched, and which was most plainly made out by several others besides myself. This conclusively proves that the disease is essentially a disorder of the sweat apparatus. The clear translucent point in the centres of the sago-grain-like particles is caused by the action of light upon the clear imprisoned sweat. But there are more advanced stages. When a number of adjoining sweat follicles are distended, they become raised *en masse*, and form what appears at first sight to be bullæ, and if the free effusion of fluid continues, may

\* Skin diseases ; their description, Pathology, Diagnosis, and Treatment. 3rd ed. 1873.

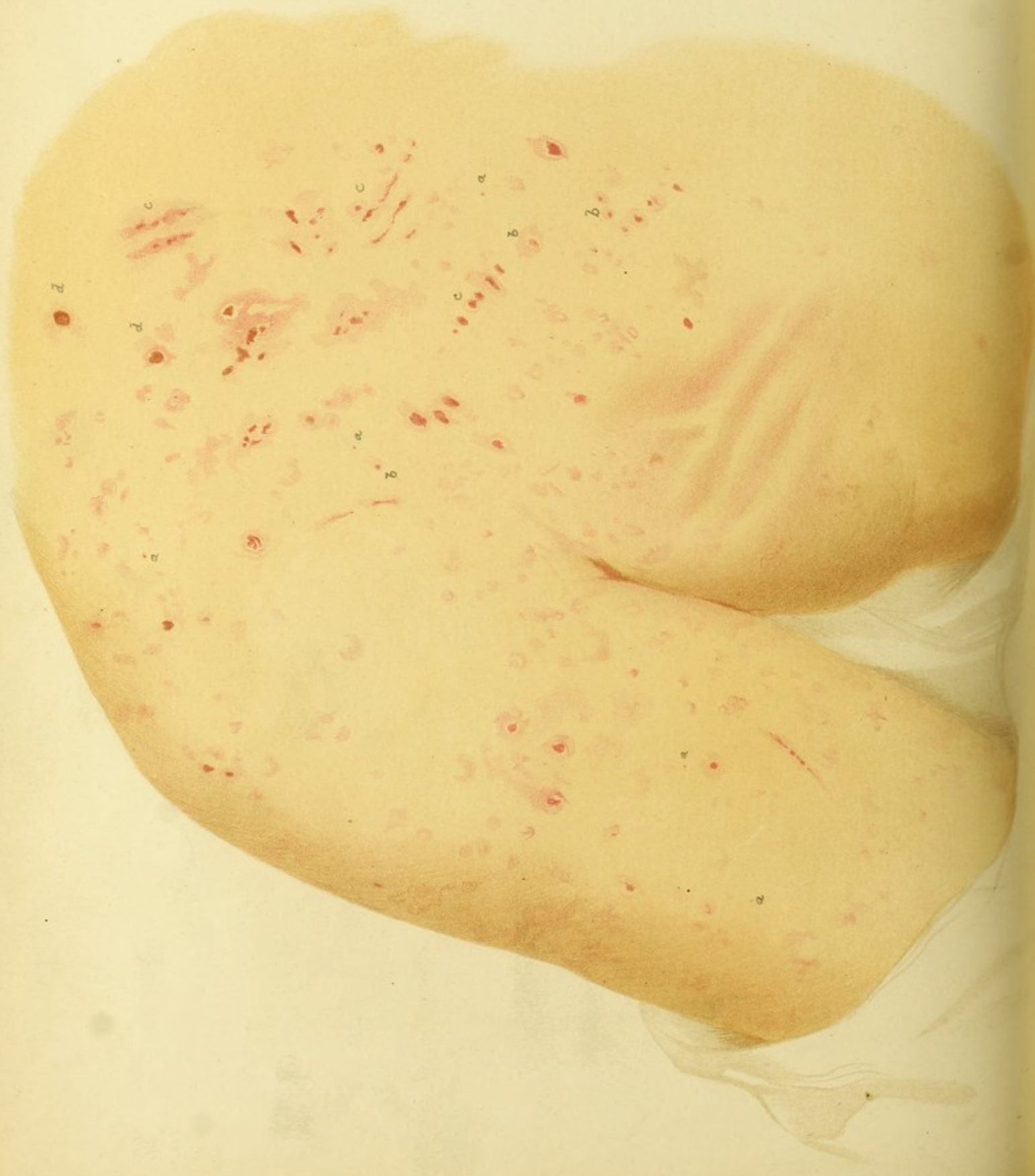
become bullæ of very large size, constituting what has been lately erroneously termed cheiro-pompholyx. When the apparent bullæ are of moderate size, as represented at the inner side of the little finger, and over the penultimate phalanx of the thumb in *Fig. 1*, they are seen to be freely loculated, and in fact to be really made up of a congeries of the sago-grain-like vesiculations. But where the bullæ are large, the distension caused by the excessive secretion of fluid destroys more or less this peculiar character, and they look more like Pemphigus bullæ, though they differ wholly in anatomical characters and the source and nature of their contents. The fluid at this stage I have usually found to be alkaline; but then this is no argument against the origin of the disease in the sweat apparatus, because the alkalinity is the consequence of the coincident inflammation. The reaction may be acid. Finally, the walls of the loculated bullæ sometimes become macerated, and as the fluid is resorbed, appear like layers of thin soddened whitish leather, as portrayed in *Fig. 1*, over the palmar aspect of the three chief fingers. The disease gradually subsides by the drying up or bursting of the bullæ, leaving behind at times a non-exuding dry slightly scaly surface, which might easily be mistaken for Psoriasis or even dry Eczema. The disease may be complicated by a more or less general miliary rash, though I have seen this limited to the face, or limbs, or neck. Eczema may now and again co-exist with Dysidrosis, and in *Fig. 1*, at the wrist, a little eczematous inflammation is represented. The disease is apt to recur when the health is bad or the patient is again depressed.\* The disease varies greatly in extent and severity. It may consist of a few sago-grain-like spots, cropping up here and there about the fingers or the palm, or attacking both. They may not be much elevated, and there need be no bullæ formed. The disease is recurrent.

The *treatment* is generally a simple matter. In the early stage diuretics should be given if the urine is at all scanty or more than usually acid or loaded. Subsequently the mineral acids with nux vomica, and vegetable bitters should be freely given. As regards local measures, it is advisable to keep the hand up and rested, to soak it awhile in some bland softening application such as the Linimentum Calcis or Vaseline, in the early stage; and when the parts become harsh or at all dry, that is in the later stages of the disease, nothing is so good as a calamine lotion in the day time, and a dressing with the old-fashioned compound lead ointment at night.

\* For fuller details I must refer the reader to my larger work, 3rd edition.







## PLATE LII.

PHTHIRIASIS (new Plate).—By this term is meant, the disease directly produced by the attack upon the skin of the *Pediculus corporis*. This insect nestles in the folds of the clothes that are worn immediately in contact with the skin, especially of elderly and uncleanly people, from whence it makes predatory visits to the integuments, setting up much irritation and consequent eruption, which is in part however excited, and in part aggravated by, scratching. This disease has hitherto been variously called PRURIGO *senilis*, PRURIGO *e pediculis*, and *Hospital Prurigo*, but by far the best term for it is *Phthiriasis*, since that of Prurigo, used formerly in the most lax manner for all sorts of different rashes, has of late years, by the general consent of leading dermatological authorities, been restricted in its employment to the special form of eruption described in PLATES XLI. and XLII.

This Plate is a most admirable representation of Phthiriasis. It represents the eruption on the back, about the shoulder, and part of the adjoining arm. Phthiriasis occurs chiefly amongst the poor, particularly those who have lived badly and have not been given to particularly cleanly habits, and in my experience, very frequently amongst those who drink a good deal, who are so frequently uncleanly. The eruption is made up of a pathognomonic lesion, produced by the pediculus: disordered sensation taking the form of severe itching, mostly paroxysmal in character, and often attended by 'burnings;' and the consequences of irritation and scratching, or, as I term it, a pruritic rash.

*First*, as to the lesion. When the pediculus gets on the skin, it does not bite as most people imagine, since it has nothing to bite with. It possesses a retractile proboscis, and this it projects out of its head and inserts into the skin, probably at a follicle in search of blood. Now in this act it dilates the follicle or opening by which it entered, regularly of course in all directions, and in the withdrawal of the proboscis, a little blood will well up into the little dilated orifice, which appears as a cup-shaped depression filled with blood. The more recent the production of this spot the more will it possess the characters just described. After existing a few days, the cup-shaped depression will have disappeared, and all that remains is a minute round scale of blood. Now these spots, which I have long described as the pathognomonic lesion of Phthiriasis, are not raised, and they have, as seen with a pocket lens, a regular unexcoriated margin, and thus are wholly unlike two things apparently like them, viz., scratched hyperæmic follicles and minute excoriations. Some half-dozen of these pathognomonic spots, or 'hæmorrhagic pits' as I call them, are seen at *a. a.* in the figure.

*Secondly*.—As to the disordered sensations, I need not add anything to what I have said, except that it is very tormenting, increased by warmth of all kinds, often keeps patients awake at night, preventing them from sleeping, and so tends to debilitate them by its weariness.

*Thirdly*.—The bulk of the rash is made up, especially in the early stages, of papula-

tions and excoriations. These papulations are of two kinds, hyperæmic follicles and hyperæmic papillæ, and the scratching pulls away the tops of these papules, a little blood then oozes out therefrom, and dries as a little dark flake, as shown in the illustration. Large coarse papulations are sometimes observed as a consequence of effusion into and consequent exaggeration of the little natural areas enclosed by the normal creasings or lines of the skin: these are the broad papulations of Prurigo. But, in addition to these papules, as exhibited, in various sizes and as altered by scratching, in the Plate, there are excoriations (*b*) minute and solitary, simulating the 'hæmorrhagic pits,' but with ragged, torn irregular edges, as seen with a lens; (*c*) linear ones, made up of one or several interrupted lines of excoriations as seen in the figure, and indicative of the places where the fingers have been *torn* over the skin; and (*d*) large solitary ones, marking the site of a violent 'digging' with the nails at a particular troublesome papule. I do not think the 'hæmorrhagic pits' *per se* very irritable.

Other components of the rash of Phthiriasis are, according to the severity of the disease and the cachectic state of the patient, urticaria—in patches or lines answering to those of scratching, and as seen at the lower part of the illustration—Ecthyma and Eczema.

The seat of the rash in this disease is important. In the majority of cases the rash appears about the root of the neck or shoulders. The pediculi have a predilection for the folds of the linen worn in correspondence to these parts, and attack these first. Thence it spreads all over the body if the disease lasts long enough.

The *diagnosis* is made by the presence of the 'pruritic' rash, appearing first about the region of the shoulders, accompanied by the characteristic 'hæmorrhagic pits.' The discovery of pediculi in the folds of the clothes is confirmatory, but not necessary to the diagnosis.

The *treatment* of the disease consists in the disinfection of the clothes by a dry heat above 220° F., for with the destruction of the pediculi and their ova, the prime cause of irritation is removed. But the skin must be soothed by the use of warm baths, prussic acid, or tarry lotion, whilst the diet of the patient must be nourishing; and scrupulous cleanliness, with proper change of clothing, must be enforced. The ordinary plan of treating Phthiriasis is to apply some lotion or ointment to the skin which is repulsive to the pediculi, at the same time that it soothes the skin.




Fig. 1.

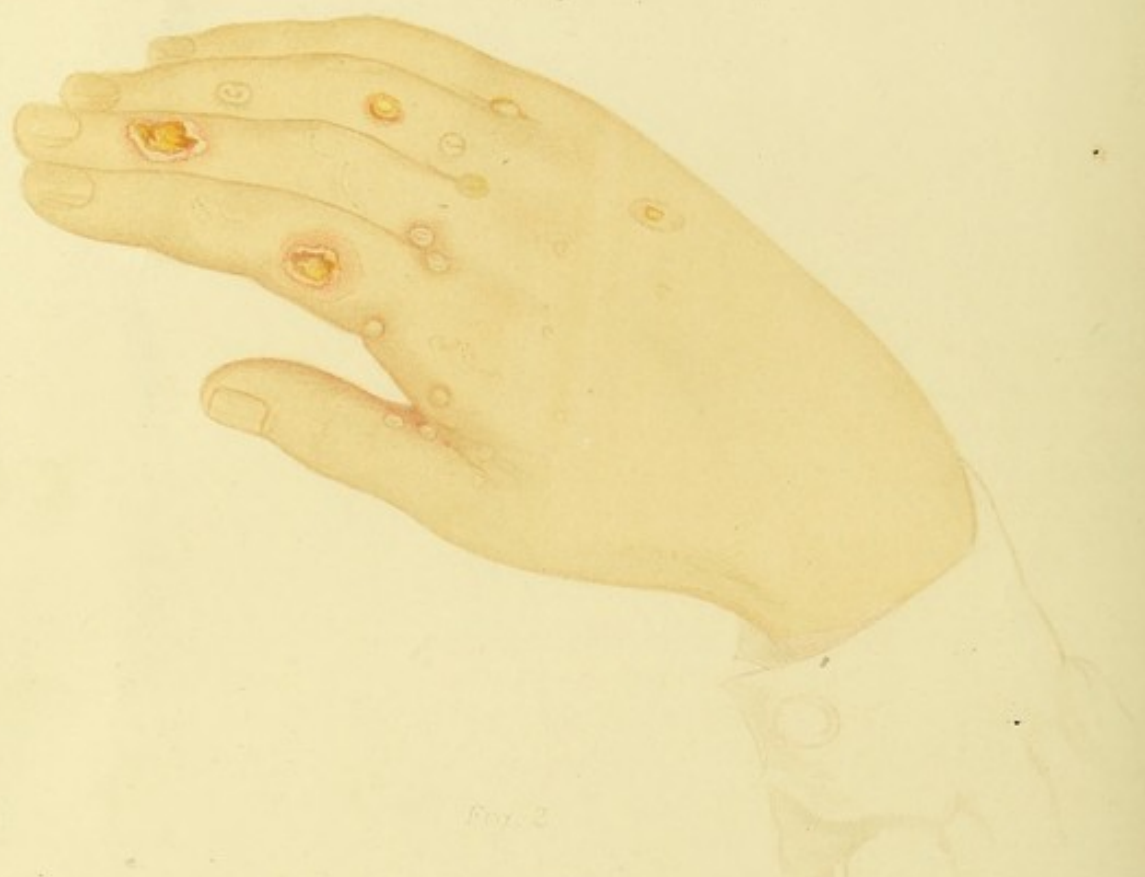
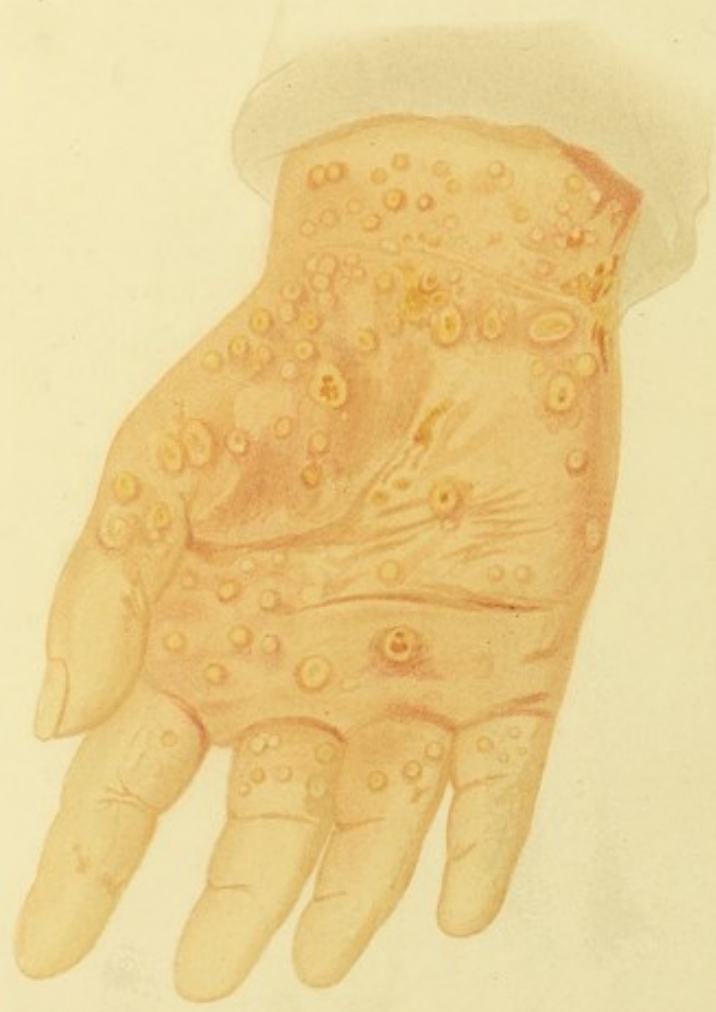
Fig. 2.



LEEDS & WEST RIDING  
MEDICO-CHIRURGICAL SOCIETY

## EXPLANATION OF THE PLATES.

---

**PART XIV.**—This fasciculus contains illustrations of Scabies or Itch, and of the principal forms of vegetable parasitic diseases of the skin, viz. :—*TINEA tonsurans* (or ringworm of the scalp) ; *TINEA favosa* or *favus* ; *TINEA kerion* ; and *TINEA circinata* as ordinarily seen in England, and also as observed in its more exaggerated phase in tropical places.

### PLATE LIII.

*Figs. 1 and 2, SCABIES or Itch.*—I have no doubt that many at first sight will be disposed to regard my illustrations of Scabies, in the two figures of this Plate, as badly selected ones, and as imperfectly portraying the main features of the disease. I have, however, chosen these particular representations with the special object of fixing the reader's attention mainly upon the diagnostic or pathognomonic feature of Scabies, viz. : the *cuniculus*, and of leading him to regard this with more attention than is usually given to it both by students and practitioners. Attention is too generally directed to the itching 'lichenoid' rash that appears over the forearms, the lower part of the belly, and the inside of the thighs in adults, and, in connection with ecthymatous spots, about the buttocks and feet of children, as characteristic of Scabies.


The proof of Scabies is the presence of the *cuniculus*, and this is caused by the burrowing of the *Acarus Scabiei* in the skin. In short, it is its burrow. This burrow (see the dark lines somewhat diagrammatically rendered in *Fig. 1*) varies in length and course. It may be from a few lines to an inch and more long. It may run a straight, or sinuous, or curved course. It consists of a small channel, domed up as it were out of the substance of the skin by the acarus beneath. At its commencement a vesicle is formed by the effusion induced by the irritation of the burrowing of the acarus. This vesicle however soon bursts, and may only be represented at the time of observation by a circular ragged edge of cuticle, answering to the circumferential boundary line of the previous effusion which produced the vesicle. Along the course of the *cuniculus* are black specks, said by some to be the excreta of the acarus, by others to be its ova. At the extremity of the *cuniculus*, except where this has been scratched away, is the acarus itself, forming usually a little opaque oval terminal enlargement (see *cuniculus* over carpus between first finger and thumb, *Fig. 1*), and more rarely, because discoloured by dirt, a darker body. If the top of this little speck be opened the acarus can be turned out from its bed, or it will seize hold of the point of a needle, and come away when the needle is withdrawn. From what has been said it will be evident that the *cuniculus* will vary in its aspect with its age, and with the degree of scratching, as seen in *Fig. 1*. In some instances when scratched, it will appear to be made up of two ragged edges of cuticle

bounding the original channel of the burrow, and representing the ruptured walls. It looks like a pale scratch. In such cases no trace of the primary vesicle is seen, but a dead acarus may yet remain behind, or the site of its bed may be seen as a small round depression. The sulcus or line with its double ragged edge of cuticle is diagnostic of Scabies, but it must be carefully distinguished from mere scratches or excoriations. Of course all the features above described must be fully made out with a lens, and the appearances on *Fig. 1* as portrayed as seen by a lens.

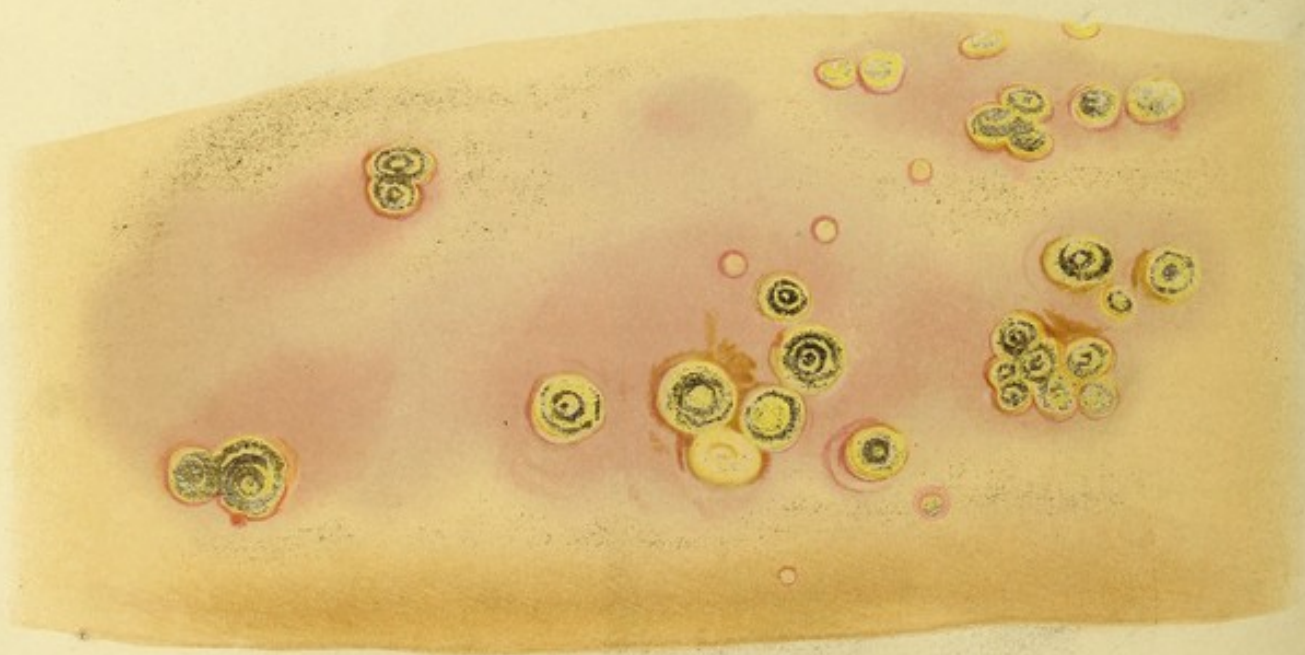
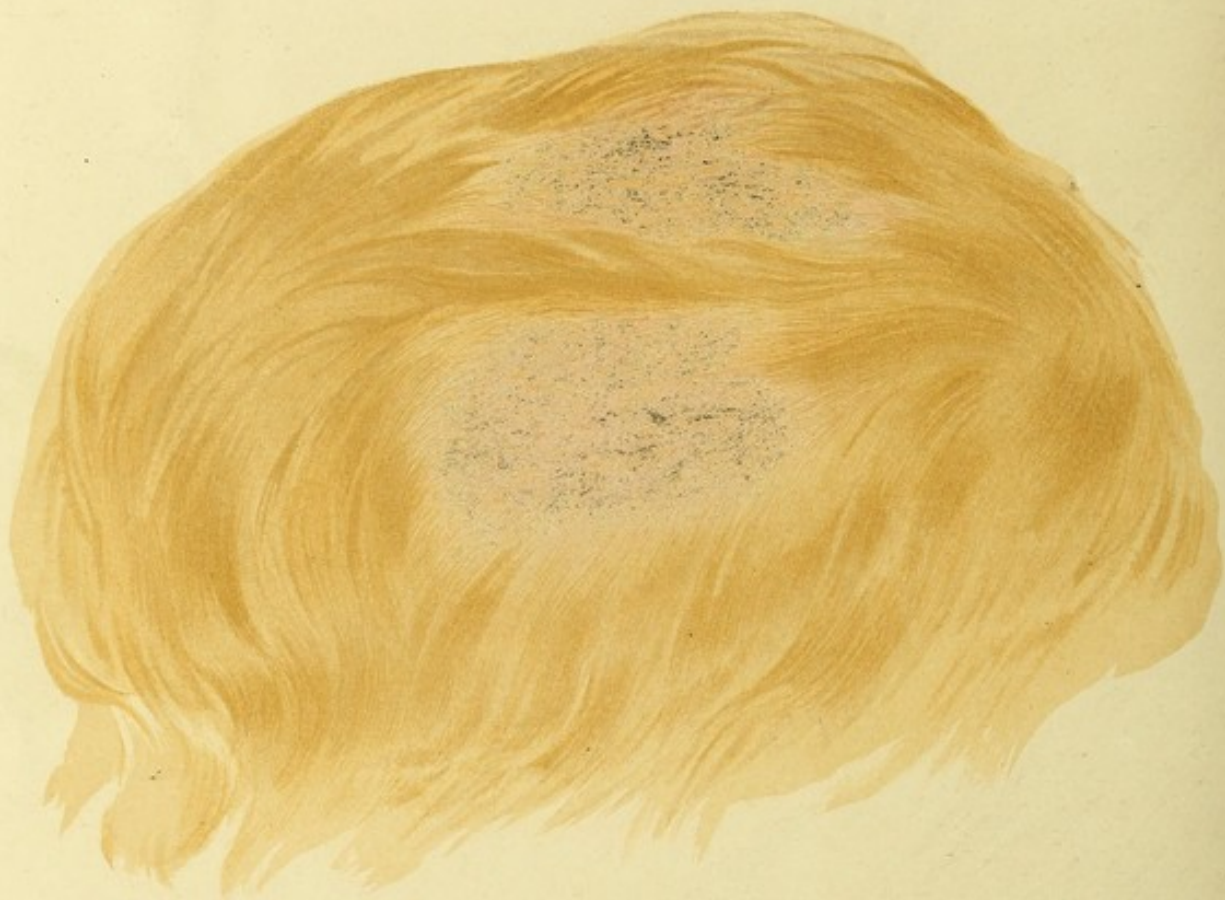*Cuniculi* are met with chiefly, or in other words *acari* burrow by preference, about the interdigital folds, about the wrist, along the upper line of the penis (glans and body) where the furrows can often be made out, and more rarely about the forearm, buttocks and feet of children especially, and the front of the belly. These cuniculi often suppurate in unhealthy subjects, and are indeed masked or destroyed thereby. This has occurred in many of the spots in *Fig. 2*, which is a copy of a drawing which Bagge made for Mr. Erasmus Wilson, to whom I am indebted for this copy.

Now the acarian furrow and its contents constitute the essential lesion of Scabies: all the rest is *consequential*. The burrowing of the acarus is attended with considerable itching, which is marked at night, because the warmth of the bed makes the acari lively, and they then burrow actively, and by a certain degree of follicular and papillary hyperæmia (miscalled lichen). This secondary eruption is intensified by scratching, which in turn causes additional eruption, excoriations, ecthymatous pustules and the like. The irritation of the skin shows itself first of all by the presence of vesicles, vesico-pustules (see *Fig. 1* and *Fig. 2*), in the localities of the cuniculi, and then in the adjoining parts of the forearm, front of the abdomen and thighs (and feet and buttocks of children, as before stated). Hence Scabies should be described as consisting of an essential lesion (*Fig. 1*), the acarian furrow (cuniculus) with its contained acari and ova, chiefly met with about the hands and penis, and in addition a secondary rash (before described). It so happens that attention is often directed to this secondary rash, or to the nocturnal itching in the first instance, but no medical practitioner should regard these as other than indications for searching for the presence of cuniculi. I may add, that as Scabies is contagious, several members of a family are often afflicted together. In private practice Scabies often consists of only a cuniculus or two, and a small amount of secondary rash, with a varying degree of nocturnal itching; but the diagnosis is often easy, if search be made for cuniculi. Between this phase and severe Scabies all gradations exist.

The treatment consists in destroying the acari by parasiticides, such as storax, or iodide of potassium, or weak sulphur ointment. I use one composed of half a drachm of sulphur, 5 grains of white precipitate, 6 drops of kreosote, and an ounce of benzoated lard. About six or eight rubbings with this, especially in the places which the acari chiefly infest, suffices for most cases; if continued longer, the skin becomes much irritated, and a *deceptive appearance of the disease having become worse*, is given. I generally use a calamine lotion to the irritated parts a little time after each infriiction of parasiticide.







## PLATE LIV. (New.)


*Fig. 1.*—*TINEA tonsurans*, or common ringworm of the scalp. This is a most difficult disease to portray; how far success has been obtained, I leave the reader to judge. The original water-colouring drawing is unexceptionable, but I did not think that it would have been possible to have reproduced the disease so successfully by chromo-lithography. The description given in books is apt to convey an idea that ringworm cases present on the whole a tolerably uniform aspect. This, however, is far from the actual truth. I have represented in the Plate the most typical phase of the disease, which consists of circular spots, the hair of which appears as if nibbled off, or moth-eaten. The surface is scaly, the scales being fine and whitish, and the scales cover over a slightly red surface. The hairs are dry, lustreless, often irregular in calibre at different parts of their shaft, and more or less twisted out of their natural direction; and they are very brittle, breaking away at a short distance from their point of emergence from the follicle. In many cases the hairs are opaque, and hairs originally dark become decolourised by the diseased process set up within them. In some cases, especially as the disease progresses towards cure, the hairs become speckled. Now it is to the condition of the hairs that attention must be directed in ringworm, not to the circularity of the patch, or the presence of scaliness or scurfiness, for these may be absent in ringworm. The disease generally consists of circular patches such as are here portrayed; but it may be made up of irregular-shaped spots, of greater or less size, with or without scurfiness; or it may be characterised merely by a number of diseased hairs only, in clusters, or of a diseased hair or two here and there, lying beside and concealed by the healthy ones, or of diseased hairs that lie within the follicle, and look like a number of black points studding the surface. In every case, however, whether there be a large patch or only points of disease, short broken-off texturally altered hairs may be detected by the microscope, though they may be concealed more or less, as I have before said, by scurfiness, where this exists. Whenever, therefore, there is any textural alteration of the hairs, a portion of such hairs should invariably be placed in weak potash solution under the microscope, when the fungus will readily be detected; but it is necessary that the constituent parts of the hair should be somewhat broken up, otherwise the conidia of the fungus, the *Trichophyton tonsurans*, may be readily overlooked or missed, for the light will not otherwise sufficiently penetrate the texture to show them. It is of course in chronic ringworm cases that the deviations from the typical features of the disease are wont to be present. I regret that the space at my disposal does not allow me to give a fuller description of the clinical aspects, or even the treatment of ringworm; and I am compelled to refer the reader to my other works on the Subject of Diseases of the Skin for precise information as to details, but I may say that the chief source of mistakes in diagnosis is the tendency with most practitioners to be guided, both as to the existence and the cure of ringworm, by the presence and degrees of mere eruptive change. If practitioners and students would make it a rule to regard eruption as secondary matter, and the diseased state of the hairs as the essential thing to be recognised and dealt with, they would certainly not be so frequently disappointed and disconcerted as they are in dealing with the disease.

I am only able to indicate the main principles upon which the treatment should be based. In the first place, supposing there be but one or at most two spots, these should be completely isolated and exposed by the removal of sufficient hair from about them, which should be kept closely cut. If there are several spots, or the disease has existed any time, it is best to remove all the hair from the head by shaving or cutting, for unless this is done, the disease is apt to spring up and to increase unobserved beneath the hair, and many of the smaller spots of ringworm often escape proper attention. In the second place, it must be borne in mind that fungus is present at the deepest part of the hair follicle, and that parasiticides must be made to operate upon this part, and not upon the mere surface. In the third place, no ringworm spot can be considered cured, if there is a vestige of short broken-off hairs present, nor unless the old hairs have been wholly supplemented by an entirely new growth of healthy-looking hair. To kill the fungus, repeated blistering, and the free infriktion of potent parasiticides for weeks and perhaps months in some cases are needed. As convenient a parasiticide as any is one made of 3 drachms of sulphur, 3 of tincture of iodine, 60 grains of carbolic acid, and half or an ounce of vaseline (*Gelatum petrolei*).

---

*Fig. 2.*—*TINEA favosa* or *FAVUS* is a copy of a model in the College of Surgeons' Museum, showing the disease on the leg; and I am indebted to Mr. Erasmus Wilson for permission to reproduce this illustration. Favus attacks the head chiefly, and only occasionally the body. I might have given a facsimile of a drawing of favus of the head which I have in my possession, but the peculiar crusts of the disease were so well marked in the model, that I thought it preferable to copy it. Favus is known by its sulphur, copper-shaped friable crusts, or *favi*, which are made up of the fungus called *Achorion Schönleinii*. Their earliest stage is shown in the figure as the smaller yellow specks or points, and these gradually enlarge and become cupped shaped. These *favi* are always seated at the hair follicles; and in the scalp the hairs are observed piercing the centres. If the *favi* are crowded together, irregular yellow masses are produced, having the aspect of dry honeycomb, hence the term 'honeycomb ringworm.'

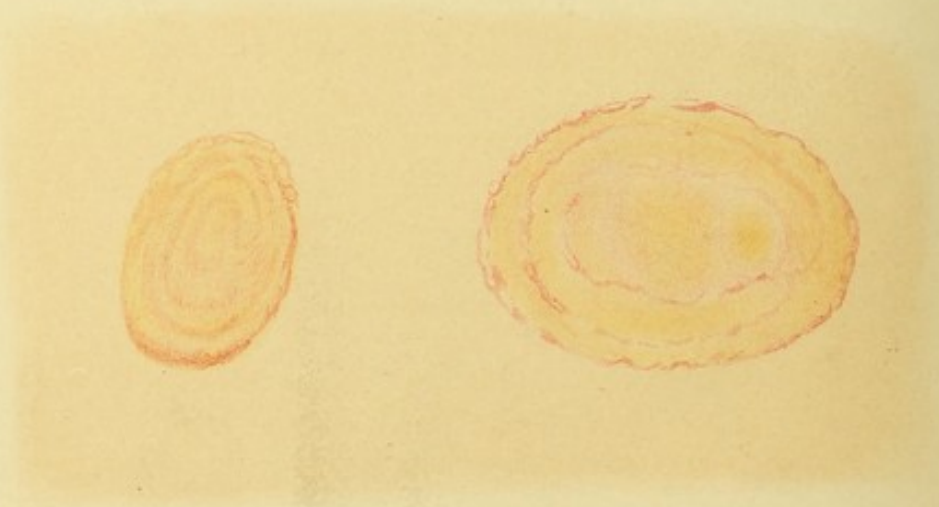The treatment is the same in principle as that of *TINEA tonsurans*.



TINEA KERION



*Fig. 1*



*Fig 2*

TINEA CIRCINATA

## PLATE LV.

*Fig. 1, TINEA kerion.*—This is a phase of ordinary ringworm of the scalp, in which the hair follicles are a good deal inflamed, swollen *en masse*, so that the patch looks elevated and feels boggy, and just like a threatening abscess. The follicles, moreover, pour out a viscid albuminous fluid, and the hairs loosen and come away, leaving a semi-boggy, elevated, swollen, and more or less bald patch of disease. The fluid discharge oozes from the mouths of the follicles, which give the swelling the appearance of being studded over with a number of foramina. If any hairs remain, they come away most readily when pulled at. In the early stage, then, there is a boggy swelling, and the hairs lie loose in the inflamed follicles; in the latter stage there is a raised boggy-like patch, which is quite bald: and that is the condition of things represented in the figure, only at one point in the large patch a lancet has been used, and some slight suppuration has occurred, but the peculiarity of these cases is that they never suppurate if left alone. If the hairs be examined under the microscope, they are observed to be invaded by the *Trichophyton tonsurans*, the presence of which in this disease I was the first to demonstrate. Three small spots are represented in the figure.

This disease may be idiopathic, or it may be produced by the application of irritants in certain subjects to ordinary ringworm patches.

The treatment consists in removing the hairs, and applying some slight astringent, because as the hair comes away bodily there is nothing left for the fungus to luxuriate upon, and that at once perishes.

*Fig. 2 is TINEA circinata*, or ordinary ringworm of the surface. This disease, as everyone knows, is abundantly common; and I could have supplied my artist with any number of cases from my own clinique, but as he was sketching a particular model in the College of Surgeons' Museum, and as these two circles of Tinea were at hand upon an adjoining model, for convenience sake, he copied them for this Plate. *TINEA circinata* begins by small, red, itching, scurfy, circular patches or rings, which speedily assume the aspect of the patches here delineated; the circumferential edge being red, well defined and papular, or even vesicular, according to the degree of inflammation present, and the centre, paler, dry, and scurfy. The outer may enclose other smaller rings, which represent the pre-existing circumference of the spots when they are of smaller sizes. The spores and mycelium of the trichophyton may be detected in the scrapings from the surface of the diseased patches. This *TINEA circinata* is the same in nature as ordinary ringworm of the scalp, with which it often co-exists, the only difference being that it affects the non-hairy parts, and hence is not studded over with short, broken-off diseased hairs. An exaggerated phase of the *TINEA circinata* will be described in the next Plate.

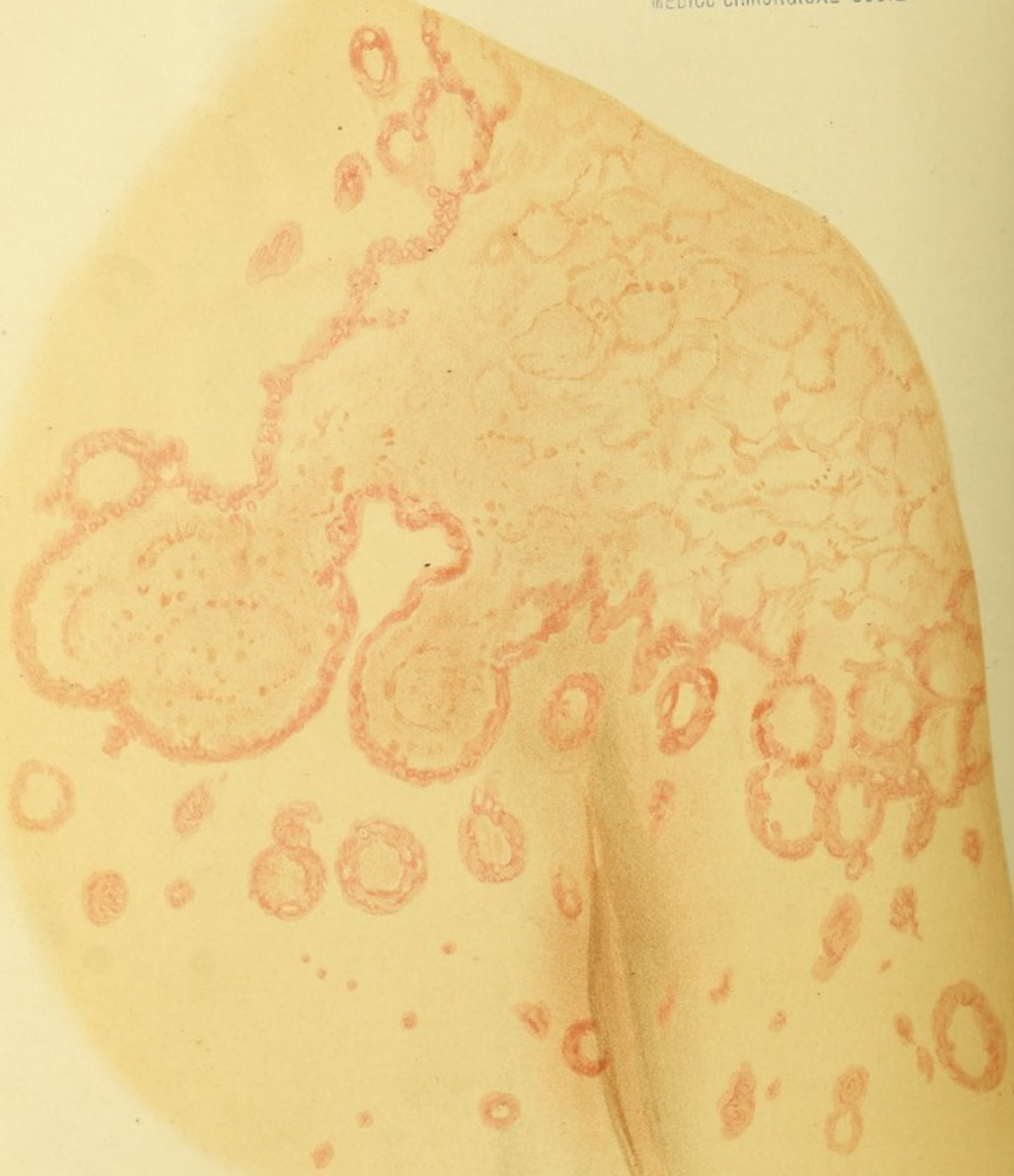
The treatment consists in applying some parasiticides: if a strong one, such as acetic acid or blistering fluid, one application usually suffices; if a mild one, such as ink, or white precipitate ointment, or tincture of iodine, several applications are needed.







LEEDS & WEST-RIDING  
MEDICO-CHIRURGICAL SOCIETY



TINEA CIRCINATA TROPICA (ECZEMA MARGINATUM.)

## PLATE LVI.

*TINEA circinata tropica*; syn. *ECZEMA marginatum*; *LICHEN marginatum*.—In various parts of the East many local designations are given to ringworm of the surface of the body, such as Chinese, Burmese, Indian, and Tokelau ringworm. These supposed separate affections are nothing more nor less than ordinary ringworm of the body, determined in its occurrence to certain parts of the body by peculiar circumstances, and assuming exaggerated characters as compared with those observed in the disease as it exists in colder climates, in consequence of the greater luxuriance of the parasite, consequent upon the presence in the one case of a greater amount of heat and moisture, which are favourable to the development, and speed the growth, of fungi.

This ringworm of the tropics, as far as we have observed, and we have had many cases under our care—in reality the '*ECZEMA marginatum*' of the Germans—occurs chiefly about the fork of the thigh, where heat and moisture are more influential than elsewhere. In England the disease is observed in those who have returned from India in two chief forms, or rather in two different degrees of extensiveness. In the *one* the disease consists, as in the Plate, in red itchy rings, affecting the pubic region, the fork of the thigh, extending over the buttocks, and more or less about the axillæ, the front part of the chest, and the parts covered by hair about the navel. The rings vary in size from that of a shilling to that of the palm of the hand nearly; the colour is bright, the edges well defined and raised, the rings are itchy, and their surface is to some extent raised, whilst they leave behind furfuraceous surfaces, and traces of the previously existing rings, in the form of circular lines of papules indicative of the breaking up of the circumferences of these rings, which lines also indicate by their juxtaposition the coalescence of the rings at an earlier stage. For obvious reasons, I did not represent the disease in its most common seat—viz. the genital parts—but the characters of the form under notice are well portrayed in the Plate, which has been carefully copied from a model in the College of Surgeons by the kindness of Mr. Erasmus Wilson. The aspect of this eruption may be altered by scratching, so that the integuments become excoriated and infiltrated. All this means that the fungus is made of actively growing mycelial threads that sprout freely and forcibly through the epithelial layers. At times the disease seems to disappear, and only slight scaly, itchy, scurfy patches remain behind. Again it reappears in all its intensity. In the *other form* or degree of extensiveness the disease is less erythematous, does not take on the ring form, and appears to be limited to the fork of the thigh, and the parts about it. There is a red, scaly, itchy surface, which festoons a greater or less distance down the thigh front, and attacks the perineum and buttocks to some extent. The disease begins as a small itchy scurfy spot, that is to say, the fungus does not luxuriate so as to produce the bright red rings; and as this spot enlarges its central part grows paler, whilst the red extending edge is well defined and papular. The edge may show vesicles. The disease may after a while break up into islets, one part getting better, another becoming worse or remaining *in statu quo*. The disease, as a whole, often, if left unmolested, gets 'better and worse.' It is always itchy, is made so especially by

the warmth of the bed, and the skin is much discoloured. The surface may be inflamed, excoriated, or covered by boils, as the result of scratching.

Now in India and China, ringworm, such as the above described, is excessively common under the names of *dad*, *dadru*, *majee's dâd* (boatman's ringworm), *denaii*, *dhobie's itch*, *washerwoman's ringworm* (China), &c. There is no *essential* difference between the disease ringworm as seen in Europe, in India, and China, save in its degree of severity, due, as we have explained, to the greater degree of heat and moisture prevalent in oriental parts as compared with England.\*


Not only the slighter but these severe forms of *TINEA circinata* are very occasionally seen even in England, and not as importations, that is to say a ringworm having every character of the severest cases of Indian or Burmese ringworm may be observed in England *in those who have never been out of the country*, but of course under like conditions, i.e. in persons perspiring very freely in a very hot sultry season; the action of heat and moisture conjointly conducing to luxuriant and rapid growth of the parasite. I specially recollect a case in point sent to me by Dr. Evans, of Gloucester, not long since.

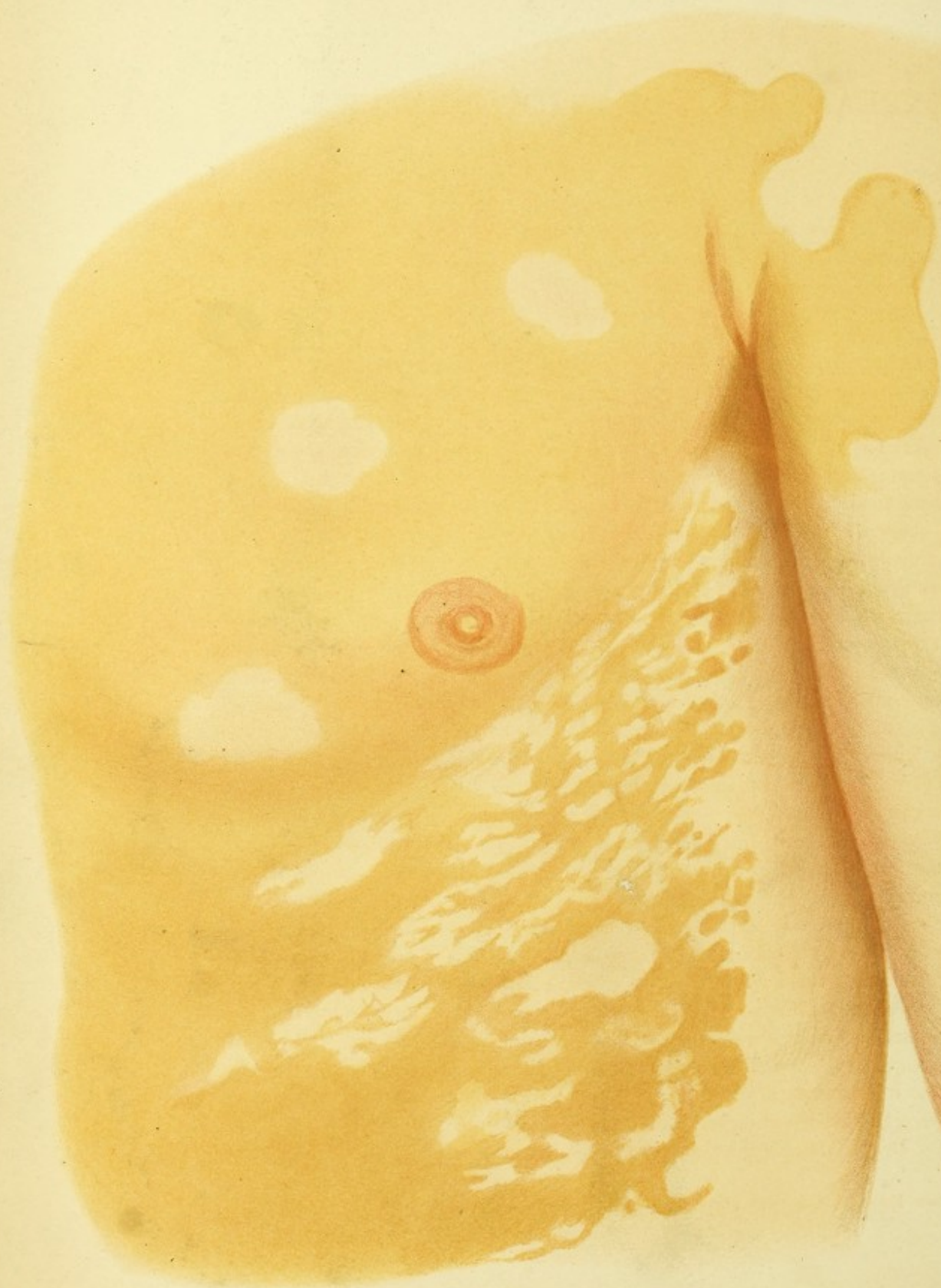The spread of *TINEA circinata* in India and China extensively amongst the community is ascribed to the peculiar system of washing clothes which prevails. The water used is often very foul, dirty, and charged with vegetable organisms, and the clothes of the healthy and the diseased are promiscuously intermixed and washed in this water.

The fungus in the disease may readily be detected in fine scrapings from the desquamatory surface after these have been soaked in weak potash.

The *treatment* is often very difficult. In many cases, it is true, the application of ordinary parasitocides, such as hyposulphite of soda lotion, or of 'Goa powder' moistened with weak vinegar and water, and pasted over the affected part, will suffice for the cure. In other cases more potent agents are needed, such as bichloride of mercury lotion gr. x or less to ʒj, Coster's paste, iodide of sulphur ointment, or tarry preparations; and it is needful in obstinate cases to apply these remedies again and again. Where Eczema co-exists local inflammatory symptoms must be subdued in the first place by the employment of drying powders and soothing remedies in connection with mild parasitocides and general tonics to improve the health. For further details, I must refer the reader to the Official Report before referred to.

\* See for details, the Official Report on Indian Skin Diseases, by Dr. Farquhar and myself, published by Messrs. Churchill in 1876.





LINNAEUS VERBICOLOR

## EXPLANATION OF THE PLATES.

---

**PART XV.**—This fasciculus contains representations of *TINEA versicolor*, *ALOPECIA areata*, and the two main varieties of Acne—viz. *ACNE simplex* and *ACNE indurata*.

### PLATE LVII.

*TINEA versicolor*, often styled in England *chloasma* or *PITYRIASIS versicolor*. This is a parasitic disease of the skin, due to the growth amid the epithelial scales of a fungus called the *MICROSPORON furfurans*. The term *versicolor*, signifying particoloured, refers to the main characteristic of the disease, as regards the aspect it presents to the eye. The disease occurs generally on the parts covered by flannel—viz. the front and back of the chest, and the inner and upper parts of the arms. It begins usually by small separate spots of a fawn colour, such as are seen at the lower and right part of the Plate, though they may assume the form of reddish circles. By their coalescence they form patches of considerable extent, which are often intermingled with smaller or less developed spots at their margins, and may enclose islets of normal integument: or a large area is affected more or less uniformly, as in the Plate. The diseased surfaces are, as before stated, fawn-coloured; they are a little raised, and the seat of itching; whilst, at the same time, branny and slightly greasy flakes can be readily scraped away from these surfaces, in which the fungus, the *MICROSPORON furfur*, can readily be detected by the microscope. The case from which the Plate was taken was of seven years' duration, and the disease was very extensive. The disease, in my experience, is often mistaken for syphilis; but syphilis never produces such *fawn-coloured, raised, itchy scaly patches* as those of *TINEA versicolor*, which, moreover, exists, as a rule, as the sole disease, and mostly lacks altogether concomitant evidences of syphilis, though in rare instances of the disease the two may concur in the same subject.

*PITYRIASIS versicolor* may begin by small bright-red rings, which rapidly give place to fawn-coloured surfaces. In some cases there is much deposit of colouring matter in the disease, constituting the *PITYRIASIS nigra* of some authors. In hot climates *TINEA versicolor* is very common, but would seem from all accounts not to offer any material difference as regards its naked-eye appearance as it occurs in England and in Oriental parts, save, perhaps, in the fact of its more extensively attacking the body in hot climates. But, in regard to its frequency of occurrence, it is unquestionably more common in the East than in Europe. Several reports from India\* which I have received speak of its being very common. Dr. Sutherland, the Sanitary Commissioner of Oudh, found it in 101 out

\* 'On Certain Endemic Skin and other Diseases of India,' edited by T. FOX and T. FARQUHAR. (Churchill, 1876.)

of 2,540 prisoners, or in about 4 per cent. Dr. Cameron, of Rai Bareli, remarks that 'it is chronically prevalent with a very large proportion of the population throughout the year, and during the summer, when the skin function is active, the disease increases in severity.' Mr. Selon (of Unao, Oudh) says 'the disease is very common. I should think 50 per cent. of the prisoners in jail are affected by it.' Dr. Cameron (Sultanpore) says the disease *PITYRIASIS versicolor*, called 'Senhwa' in the vernacular, is very common amongst the natives. As seen in the native, the diseased surface is usually paler than the rest of the skin, though it recovers its natural tint on the disappearance of the disease. Dr. Anthonisz, of Colombo, says, 'when the patches are numerous on the back and chest they give rise to the appearance of tortoise-shell, and this is considered a mark of beauty.' This answers apparently to the designation *PITYRIASIS nigra*. In China it seems to be very common. In the Samoan Islands it is extremely common amongst the natives, probably as many as three-fourths of the population being affected by it, according to the Rev. Dr. Turner. The disease, however, appears to be well understood and properly recognised in the East.

The treatment consists in the free application of a hyposulphite of soda lotion, which should be perseveringly used for some little time—ten days or so—after all appearance of the disease has vanished.







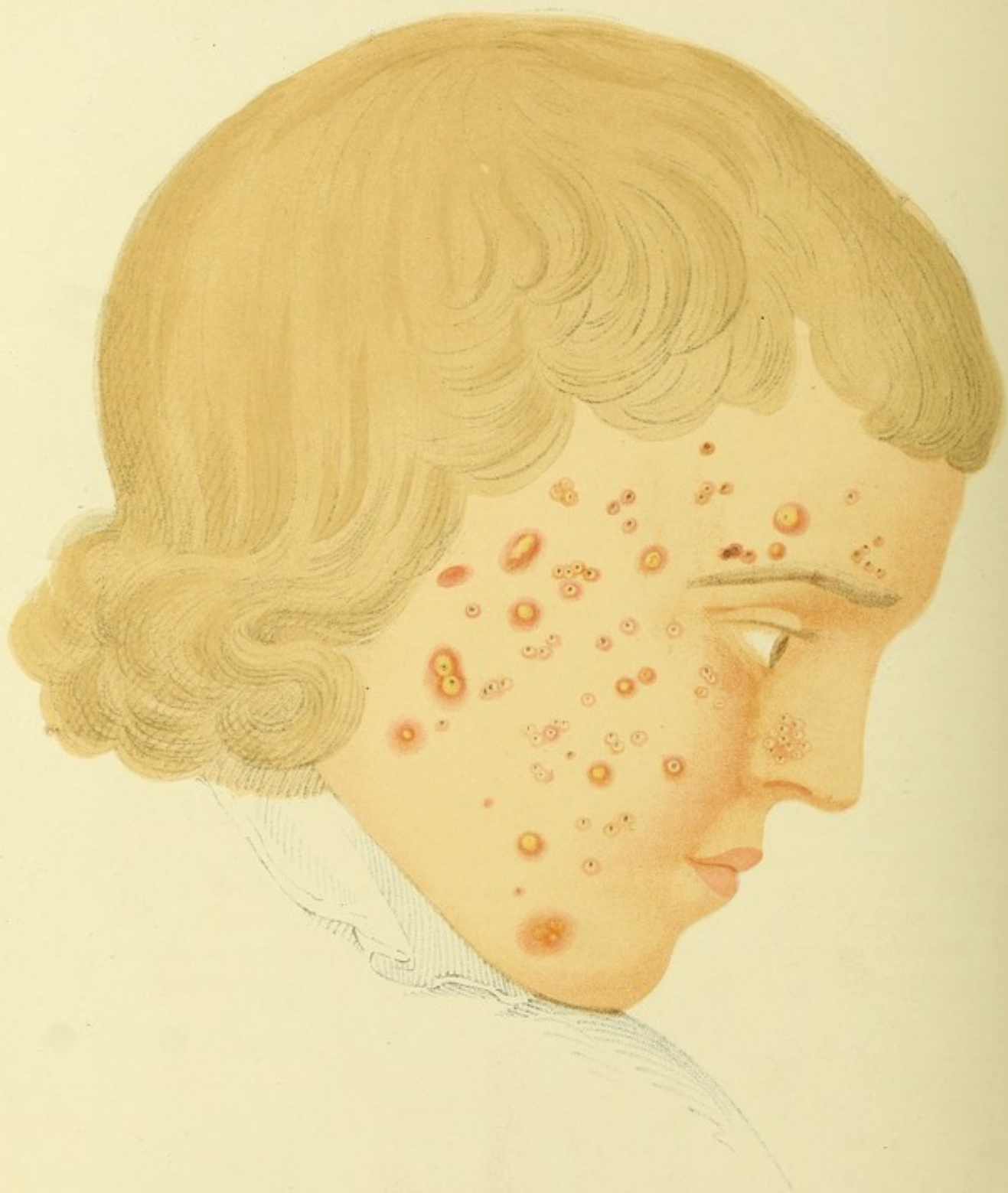
ALOPECIA AREATA.

## PLATE LVIII.

*ALOPECIA areata.* A few words will suffice for the description of this common form of skin trouble. The disease consists in areas of surface generally of a circular form, and varying much in size, from whence the hair has completely fallen, so that the affected places are bald. The textures of the skin are usually somewhat condensed, smooth, and shining. In many cases the tissues are somewhat thinned, whilst at the same time the sensibility of the affected parts is certainly diminished. The Plate offers a very good illustration of the disease. *ALOPECIA areata* occurs chiefly in the young, and especially in girls, but it is also often observed in the middle aged. It attacks by preference those who suffer from nervous debility or neuralgia, and it may be regarded as a loss of hair from a want of nerve force or tone in the parts affected. The treatment consists in the exhibition of general and appropriate tonics, and in the free rubbing in of stimulants to the affected parts, together with judiciously applied galvanism.







ACNE SIMPLEX.

## PLATE LIX.

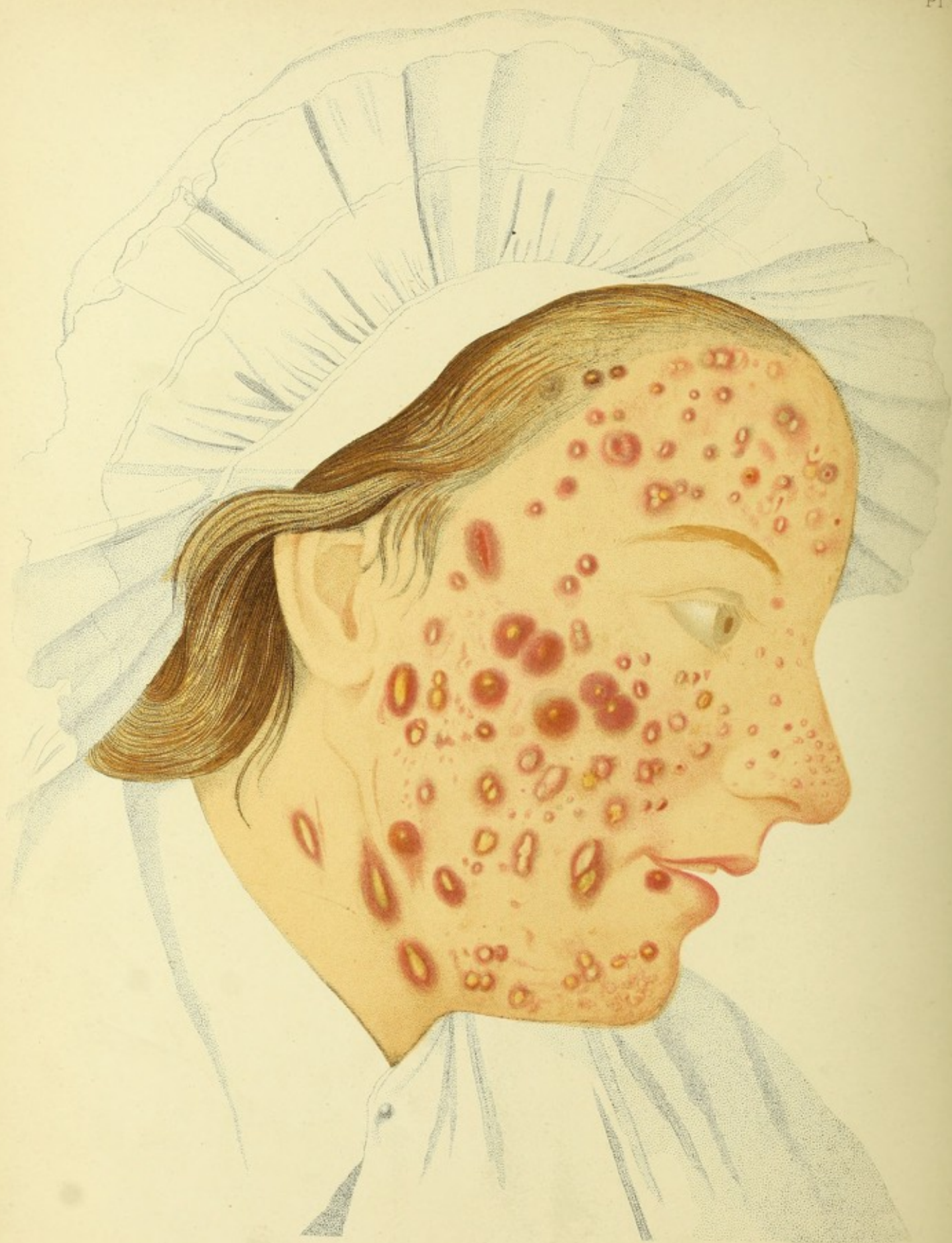*ACNE punctata (Comedo)* and *ACNE simplex*. This illustration serves to portray two of the so-called varieties of Acne, which are, however, practically one and the same thing. The smaller places in the illustration—which are seen to consist in little black points, without any circumferential redness, and to be made up of discoloured and inspissated sebum plugs filling the opening of the sebaceous follicles about the nose and forehead especially—represent the first stage or degree of Acne, and constitute *ACNE punctata* or Comedo, the plugs of sebaceous matter being designated *Comedones*. The plugged sebaceous follicles after a time become inflamed, then thickened slightly at their bases, whilst some of them pustulate slightly, and to this condition the term *ACNE simplex* is applied. But *ACNE simplex* is nothing more nor less than inflamed Comedo, or *ACNE punctata*, and the transitional stages between the two are well shown in the Plate. Acne is common about the time of puberty. It is most frequent in lymphatic subjects. It is sometimes excited and mostly aggravated by dyspepsia; and the perifollicular inflammation and suppuration are in excess in those cases which occur in connection with the strumous diathesis.

The treatment consists in removing dyspepsia by appropriate remedies, and by proper regulation of the diet, and then giving such tonics as are called for by the special circumstances of each case. Locally, Comedo is to be dealt with by loosening the sebum plugs by friction and mild alkaline washes used in conjunction with hot water bathing, followed up by the use of some stimulating unguent or lotion, such as hyperchloride of sulphur ointment, bichloride of mercury and oxide of zinc lotion. In *ACNE simplex*, hot water bathing twice a day, and the persistent use of a calamine lotion, containing a little perchloride of mercury, most generally suffices; but I must refer the reader for fuller details to the therapeutic sections of my systematic work on the subject of Skin Diseases.









ACNE INDURATA.

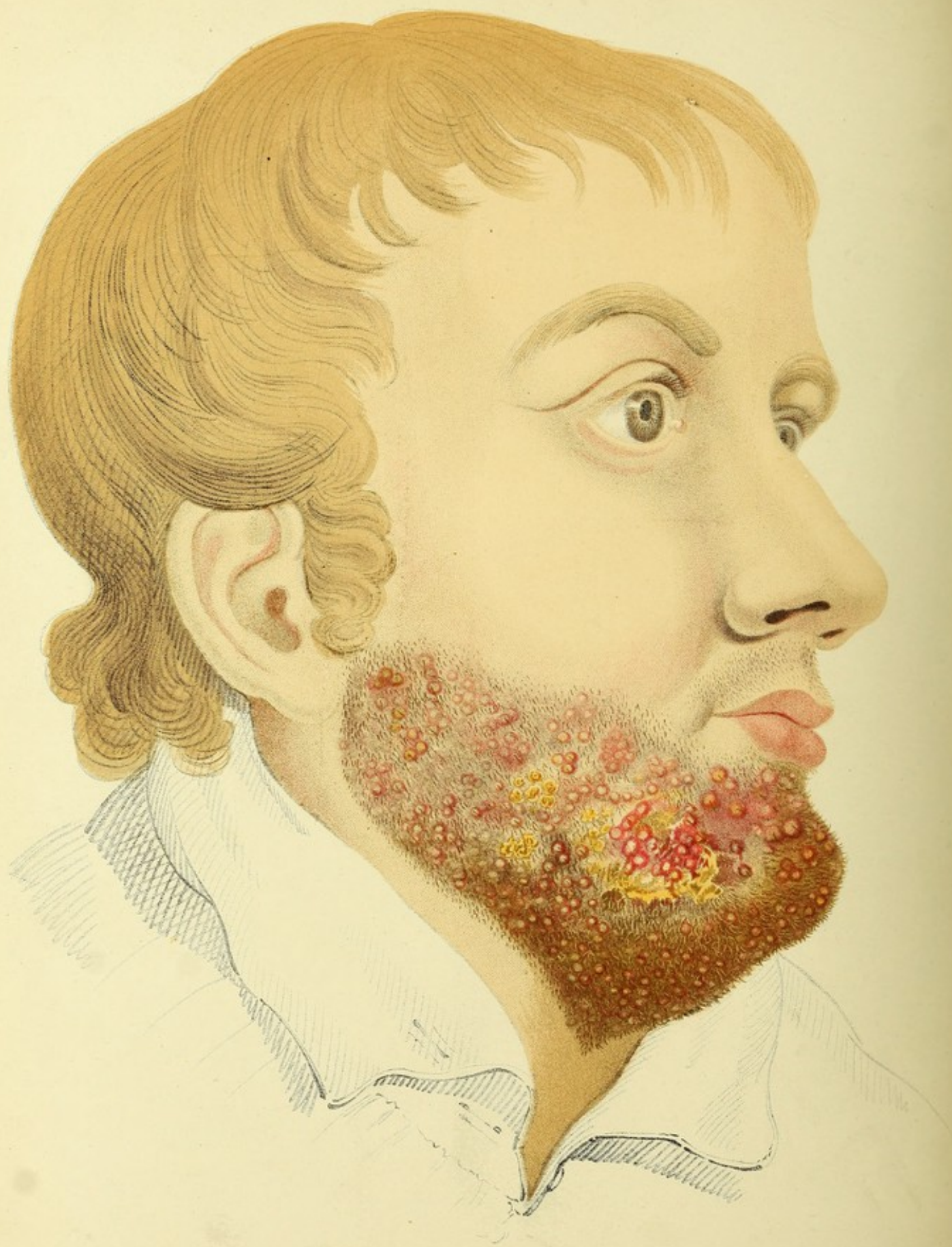## PLATE LX.

*ACNE indurata*.—This is an old Plate of Willan and Bateman's, and, like the last, very well portrays the eruption it is intended to represent. The differences between *ACNE simplex*, depicted in the preceding Plate, and *ACNE indurata* relate to the degree and character of the perifollicular and periglandular inflammation. This inflammation, though indolent in character, is more decided; and hence, as the term *indurata* implies, the bases of the Acne spots are large and firm—nodular in fact. But there is no decided line of demarcation between *ACNE simplex* and *ACNE indurata*, as the details of the Plate show, for transitional stages between the two varieties are there exhibited, those about the nose especially answering to *A. simplex*, and the large ones on the cheek being distinctive of *A. indurata*. Many places do not suppurate, but appear as indolent nodular elevations, whose anatomical seat is the sebaceous gland structure and the adjoining cellular tissue. In my own experience, *ACNE indurata* is prone to occur in strumous subjects, in whom indolent inflammation and implication of the cellular tissue are so apt to occur and to complicate other diseased states.

The treatment of *ACNE indurata* consists in a careful regulation of the diet and habits of the patients, in view of their dyspeptic tendencies and their free and injudicious use of rich foods and stimulating beverages: in dealing with the disease as an inflammatory condition, demanding at first soothing, then stimulating local remedies, and it may be revulsives in the form of blistering, or mild caustics to each spot to promote the absorption of the inflammatory induration at the bases of the Acne tubercles. Perhaps no remedy acts so well as sulphur locally applied in cases of indolent *ACNE indurata*.







SYCOSES

## EXPLANATION OF THE PLATES.

---

**PART XVI.**—In this fasciculus I have placed SYCOSIS, XANTHELASMA or VITILIGOIDEA, a disease I have termed XANTHELASMOIDEA, and lastly MOLLUSCUM *contagiosum*.

### PLATE LXI.

**SYCOSIS.**—This term is given to inflammation of the hair follicles in the seat of the whiskers and the beard. There are two chief forms—one is of parasitic origin, and is produced by the growth within the follicles of a vegetable fungus, the *MICROSPORON mentagraphytes*, and is known as *TINEA sycosis*; and the other is a non-parasitic disease, and is due to simple (or eczematous) inflammation of the follicles excited by cold or some other irritant.

The parasitic form is rare in London, and its characteristic feature is the presence of diseased hairs invaded by a fungus lying loose in little knotty swellings, which represent indolently inflamed hair follicles.

The non-parasitic form is that which is represented in the Plate. It is very common. The features of this Sycosis are so well seen in the illustration that a few words of description will suffice. In typical cases, the beard is studded with pustules pierced in their centre by a hair. These pustules are painful, and if the hair they embrace is plucked away, much pain is caused as the hair comes away, except at the very height of suppuration, when it may be extracted with facility, and with its root, sheath, and a layer of pus attached to it. If the pustules congregate together, large crusts may form by the drying up of the pus. The integuments are swollen, and reddened, and tender, and the affected parts smart, burn, and feel stiff. In many cases the disease consists only of these pustules, and it is prolonged by successive crops; but in others the integuments generally become thickened, and infiltrated, and after a while an atrophous change sets in, so that the hair follicles are completely destroyed, and a cicatrix is left just like that which results from *LUPUS non-exedens*. It is difficult to make up one's mind as to the exact nature of the changes which have produced this result. It seems to be due in many cases to the severity and long continuance of the inflammation, the hair follicles being large and deep-seated, and the tissues becoming strangulated, as it were, by the depth and severity of the inflammation; but at other times it would seem to be more correct to ascribe the change to the presence of an infiltration, such as occurs in strumous subjects, which invades and destroys the healthy textures—an indication, as it has always seemed to me, for the use of antistrumous remedies in these particular cases.

The treatment is a matter oftentimes of considerable difficulty. If the disease comes under treatment in its early and acute stage, its cure can be effected oftentimes with much ease. In sycotic patients, there is oftentimes a loaded state of system that accounts immediately for the outbreak of the follicular inflammation, and, under such

circumstances, hot fomentations, with the subsequent application of a lead and opium lotion, the administration of one or two doses of saline aperient, followed by the prescription of alkalies, and, if necessary, small doses of colchicum wine, and the interdiction of stimulants, with the careful regulation of the diet in view of the overloaded condition of the portal or intestinal circulation, will suffice to bring the disease under control. But where the disease has become chronic, the cure will always be troublesome. Most practitioners trust to the use of arsenic for the cure. This resource seems to be, if I may so term it, a lazy way of treating the disease. For Sycosis occurs under a variety of conditions, in connection with chronic dyspepsia, the strumous diathesis, improper dieting and imperfect assimilation, nerve debility, exposure to the action of irritants, such as great changes of temperature, heat, and the like—particularly in hospital subjects; and these several inciting or influencing conditions must be adequately dealt with. In the chronic state where there is much thickening, I believe a course of Donovan's solution with iron or cod-liver oil will be the most efficacious. Locally, the use of some mild mercurial or sulphur application will be found to be best.





Fig 3

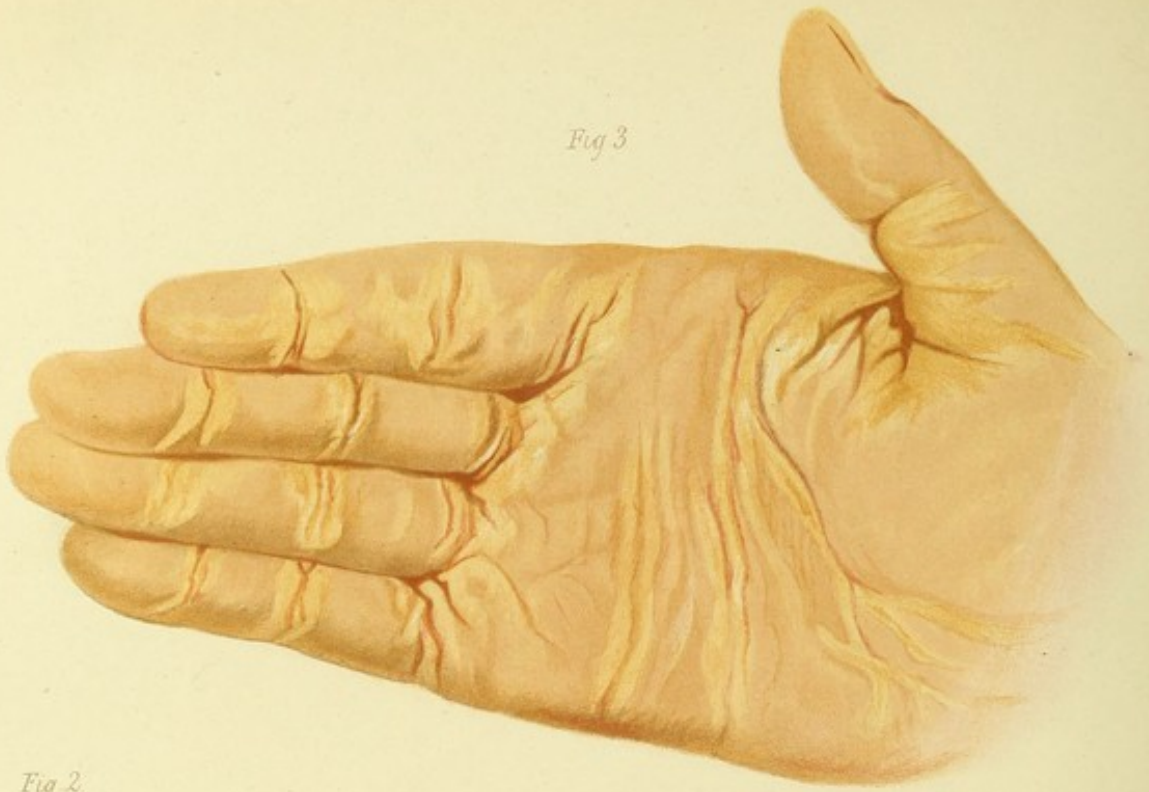

Fig 2

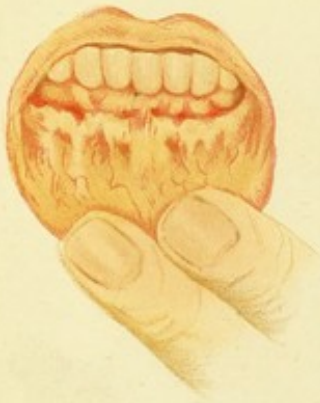

Fig 1

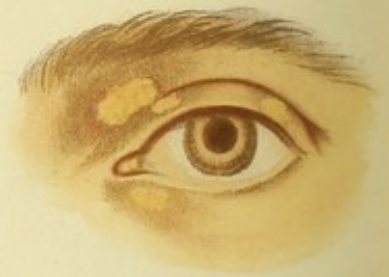
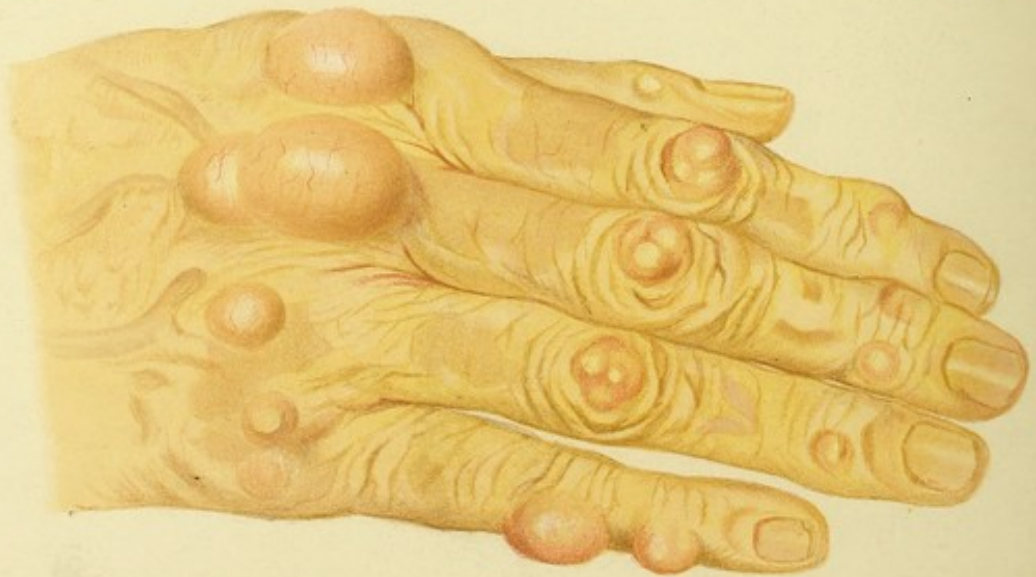
Fig 4



## PLATE LXII.

XANTHELASMA.—I am indebted to Dr. Hilton Fagge for the use of the drawings which illustrate this Plate. They form part of the Guy's Collection. This disease has been termed Xanthoma and also Vitiligoidea. The designation 'Xanthelasma' signifies yellow lamina, and points to its most common appearance—a buff or cream-coloured well-defined smooth patch, that looks as if it were slightly raised about the surface. The disease, however, assumes two forms—the flat or plane, and the nodular or tuberoso; hence the terms XANTHELASMA *plana* and *X. tuberosa*. The disease is said not to occur in children, but in the middle-aged and elderly. It sometimes follows decided or rather protracted jaundice, and in others, though there is no evidence of jaundice, it follows attacks of liver disturbance, or attacks those who suffer from 'sick headaches.' It attacks females by preference. It usually makes its appearance at the inner canthus of the left eye, especially as *X. plana*, whilst other patches may form on the hands, gums, palate, tongue, and trachea. The morbid condition consists in the presence of a cell infiltration undergoing fatty degeneration, and apparently fatty crystallisation in some cases. In a certain number of cases the plane is succeeded by the tuberoso condition, which is observed about the ears, elbows, and knuckles particularly.

*Fig. 1* represents an early stage of *X. plana*. Rayer thus described it: 'On the eyelids and in their vicinity we occasionally see little yellowish spots or patches, very much like chamois leather in colour, soft to the touch, and slightly prominent, without heat or redness, and often very symmetrically disposed.'

*Fig. 2* shows the disease as it attacks the mucous membrane of the mouth.

*Fig. 3* is an illustration of the plane variety attacking the palm of the hand about the grooves of flexure. At the junction of the thumb and palm several small nodules will be observed, indicative of the transition between the plane and the tuberoso varieties.

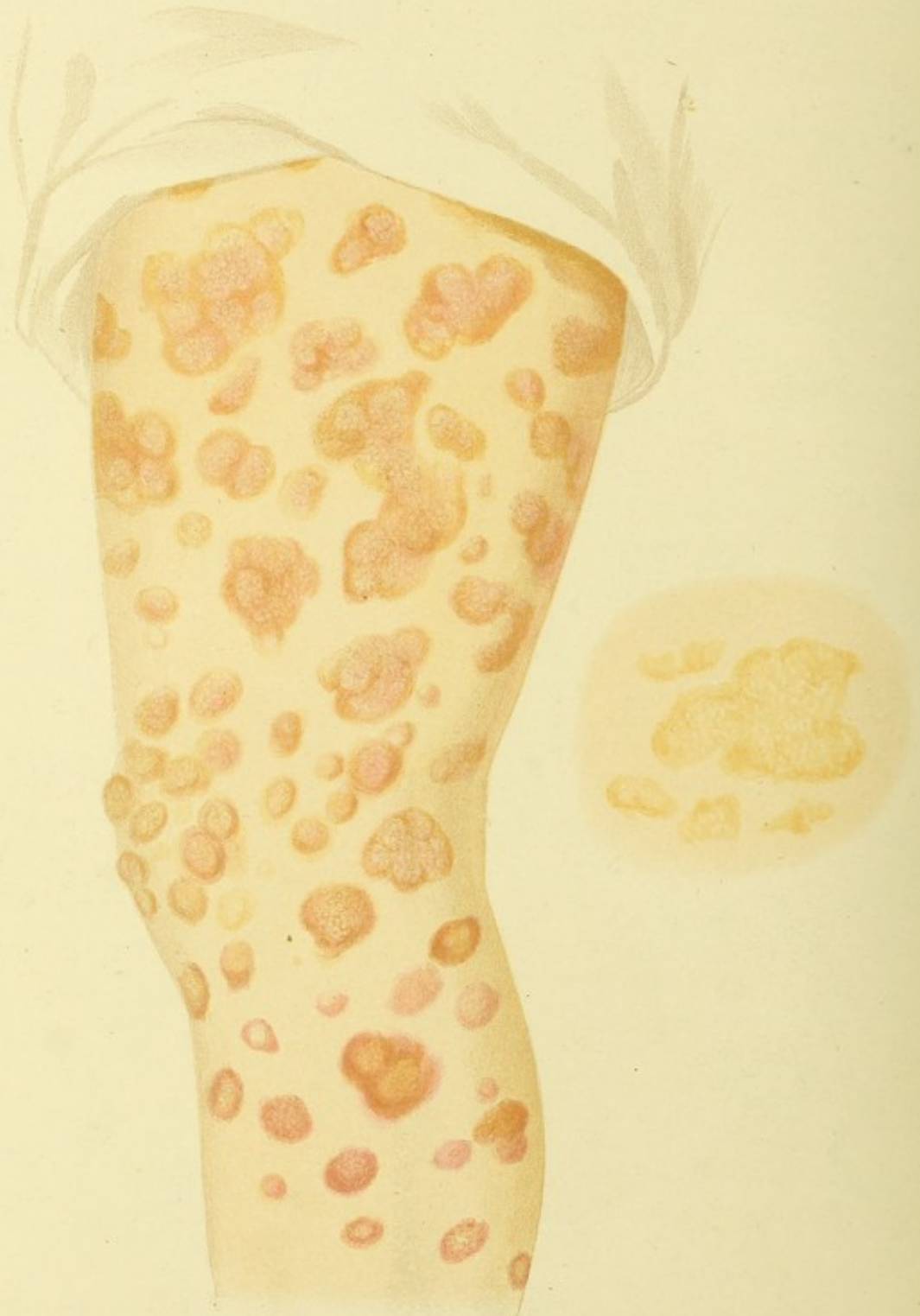*Fig. 4* represents the hand attacked by the tuberoso phase of the disease. The details of the case are recorded in the Catalogue of the Museum of Guy's Hospital, p. 175. This condition followed the development of the plane variety, which existed extensively over various parts of the surface. 'The tubercles varied in size, the largest being of not quite the size of a horse-bean. They occurred on the back of the fingers, and particularly over the knuckles, elbows, and outer sides of the arms, and on the nates, knees and ankles. Some were simple tubercular elevations of a whitish colour; others, the largest, were irregular, and composed of clustered nodules. . . . Upon the *knuckles* they look something like gouty concretions. . . . In connection with the extensor tendons, over the metacarpo-phalangeal articulations of the index and middle fingers of the right hand, and likewise of the middle finger of the left hand, there exist tubercular masses, which move with the tendon beneath the skin, which last is perfectly healthy.' In other words, some nodules were beneath the skin.

The *treatment* is altogether unsatisfactory, and consists in the free use of nitro-hydrochloric acid, and taraxacum internally, and appropriate tonics.

PLATE VIII

The following text is extremely faint and illegible due to the low contrast and blurriness of the image. It appears to be a list or a series of entries, possibly related to the plate's content, but the specific details cannot be discerned.





XANTHELASMOIDEA

## PLATE LXIII.

XANTHELASMOIDEA (? the VITILIGO of Willan).—The following is an abstract of the notes and comments upon the case from which this illustration was taken, and which was brought under the notice of the Clinical Society in 1874. (See Transactions of that body in 1875.)

The patient, Edward C., æt. 7 months, was brought to University College Hospital in May 1873, with a very peculiar rash.

The child was born at the full time, was very healthy in every way at its birth, and continued to thrive until it was six weeks old, when the eruption from which it is suffering began to appear.

The mother, a healthy-looking woman, never had syphilis, but suffers from bilious attacks.

The eruption, as stated above, began to make its appearance in the child when it was six weeks old, and in the form of two places on the inner side of the left leg just above the knee. The places looked as though the child had been 'scalded' or 'scorched,' and the mother thought she had burnt the child. The next part of the body attacked was the neck and then the body, and at the present time the whole surface of the latter—including the scalp, soles of the feet, palms of the hands, and penis—is affected.

The spots vary in size from that of a small split pea to that of a shilling and more. The majority are about the size of a large pea; there are many in size and shape like an almond. When they first appear they are of a dullish red colour, or a dusky copper colour, but they gradually become paler, being after a time light buff-coloured. Some of them are occasionally very pearly-looking. The patches or blotches are very numerous at the back of the neck, over the sides of the trunk, and in the temporal regions. They feel somewhat firm, like a thick piece of chamois leather. The spots are all elevated above the surface; the large ones *almost*, if not quite, a quarter of an inch.

On close inspection the patches present in some cases the aspect of an uniform infiltration, but most of them, however, are seen to be made up of a congeries of indistinctly marked smaller projections, which seem to be seated at the hair follicles, and give the surface a granular look. In the larger swellings the separateness of the projections seems lost in the close amalgamation, so to speak, of the individual projections. In fact, in some places, the appearance of the little patches might be likened simply to an hypertrophy of the skin involving specially the follicles of the skin, and of a buff colour.

The child presented a curious appearance, and was literally 'as spotted as a leopard,' only in place of discolorations there were these buff-coloured nodules or nodose infiltrations studding the white normal skin, interspersed with the dull-reddish blotches—viz. the newest developed places. In some cases the nodules have shrivelled more or less, leaving a pale fawn-coloured slightly elevated flattened patch.

There are distinct infiltrations, of similar character to those on the skin, in the mucous membrane of the mouth and palate.

In every other respect the child appeared to be healthy, except in the occurrence of more or less itching, especially in the patches, in their early stage, and the tendency exhibited in them here and there to suppuration of solitary follicles. The child never exhibited the least symptom of jaundice or liver disorder, nor had the excretions or secretions been at all disordered.

During the last year and a half I have been carefully watching the progress of the disease in the child, and the changes which it has undergone have been slight, and consist in a gradual paling of the colour of the patches. The child is still well and hearty, and suffers no inconvenience save some pruritus occasionally.

I had before seen a case in consultation with Dr. Gream and Dr. Brodie. It was one of a much less marked character.

The child was a baby boy, in whom the disease had commenced when he was about six weeks old; it was unaccompanied by constitutional symptoms, or cachexia, or liver disorder, or pruritus; and, in fact, was marked by purely negative symptoms and signs, if the eruption be left out of the account. The patches

were dull red at first, and retained the colour a long time, and are only now fading in him. They seemed two years afterwards to be disposed to lose their dull colour and their elevation. They caused no discomfort, and were only objectionable because they disfigure the face in parts. There was no syphilis in the parents, who were both healthy.

In the case which Dr. Hebblethwaite sent me there were some additional features of interest.

The greater portion of the eruption made its appearance when the child was about ten days old, in various parts of the body, and resembled at first a syphilitic rash very closely. The patches were like those described in the first case; but certain of the patches on the head and on the back were present when the child was born. The child had not suffered from any liver disturbance or disorder.

There were only from 20 to 40 blotches scattered here and there about the body in these last two cases. Dr. Hebblethwaite informed me subsequently that under the influence of tonics and alteratives the patches in his case were gradually fading away. I may perhaps add that in one of the cases antisyphilitic treatment was fairly tried, and has not the least effect in improving the diseased condition of the skin.

The following were the comments I made to the Clinical Society upon these cases:—

I have been unable to obtain, for the purpose of determining the nature of the disease, any portions of the affected skin. Judging, however, by the aspect and feel of the patches of the disease, I cannot but conclude that the malady bears the closest resemblance to Xanthelasma, or Vitiligoidea, and the Fellows of the Society will see how close is the resemblance (case shown) in the small patches about the penis in C.'s case. In the fully developed disease there is clearly a deposit of buff-coloured stuff in the skin, and particularly about the hair follicles, and probably the sebaceous glands; but as to the cause of this deposit, nothing can at present be made out. One thing is certain, that there is no evidence of any antecedent jaundice or liver-disorder in these cases, and in so far they differ from many instances of Xanthelasma.

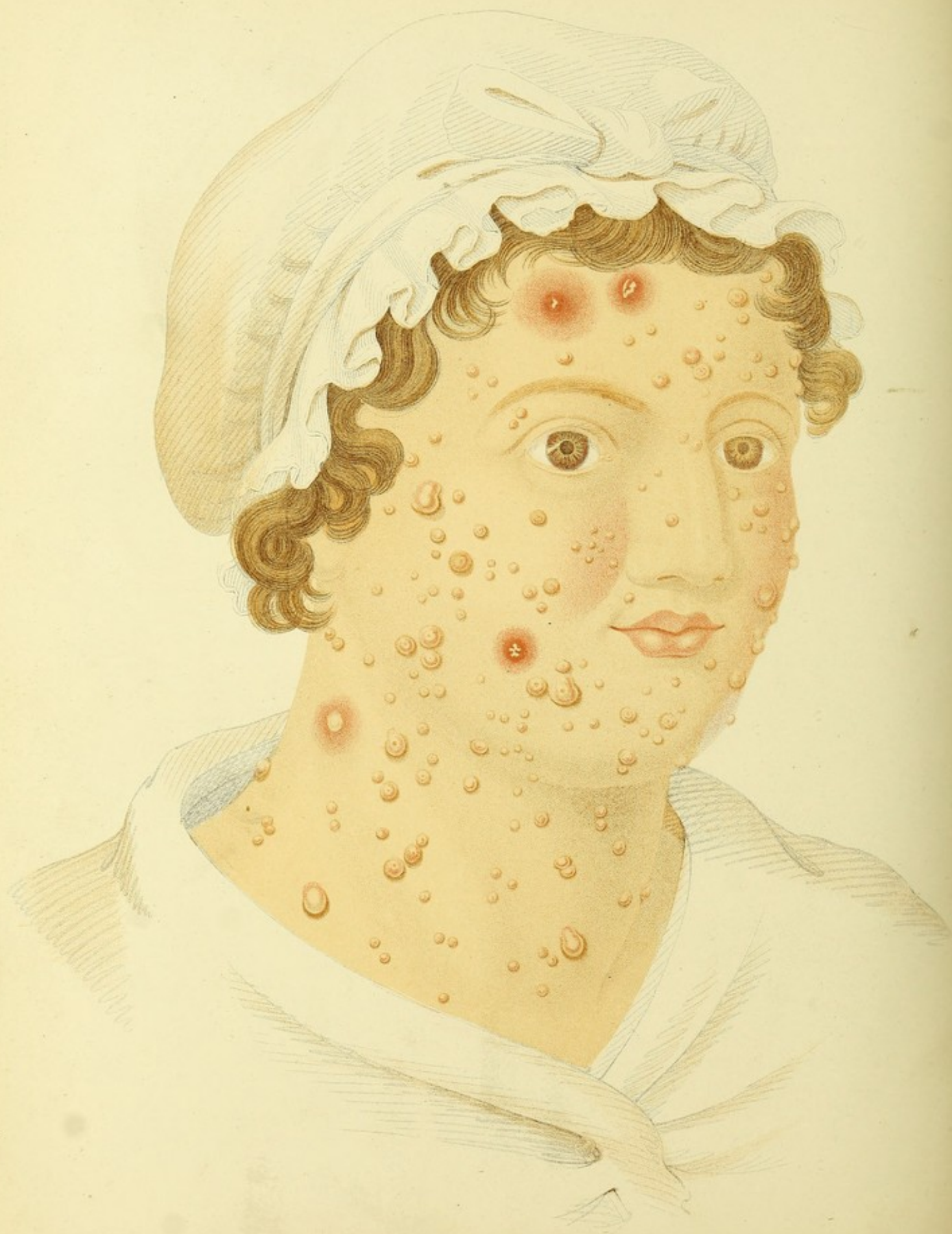There is another point in which these cases are exceptional if they be Xanthelasmatus—viz. in the fact of disease occurring in young children, and as a congenital affection. Mr. Hutchinson, as the result of his observations, states that Xanthelasma never occurs in children. The disease in these children, supposing it to be Xanthelasma, is, moreover, peculiar in being at the outset acute and general, though it has lapsed into a chronic state.

The fact that the disease under notice is liable to be mistaken for syphilis, from the fact of its occurring soon after birth, and evidencing itself at the outset by the development of dull-red (copper-coloured) blotches, which may attack the feet and hands, gives it special importance in a diagnostic point of view. It is very important, however, to recollect that the buff-coloured deposit may be found in the mucous membrane of the mouth and palate. The children attacked by the disease were not, so far as my cases show, the subjects of any such cachexia as occurs in conjunction with syphilis: there was no marasmus, no real snuffles, no mucous tubercles and no multiformity of the rash as in syphilitic disease. I may add that anti-syphilitic treatment fails to influence the Xanthelasmatus (?) disease. I think on the whole that acute general Xanthelasma would roughly describe the disease in my cases; but if it be thought that the disease is like, yet not the same as, Xanthelasma, I should be disposed to term it, tentatively, Xanthelasmaidea.

I have no doubt that Willan's Plate LX., Vitiligo, is intended to represent this disease, but he only gave five lines of description and remarks. He says, 'I have seen little of this rare disease, and am unacquainted with the whole progress of the case from which this drawing was accurately made by Mr. H. Thomson.'







## PLATE LXIV.

*MOLLUSCUM contagiosum*.—The generic term 'Molluscum' has been applied to two different conditions supposed to be specially connected with the sebaceous gland. The one, however, an outgrowth of connective tissue, which has been termed *M. fibrosum*, is now generally known as *fibroma*. The other, styled by the additional designation *contagiosum*, is an hypertrophy of the gland and its contents, and is represented in the Plate.

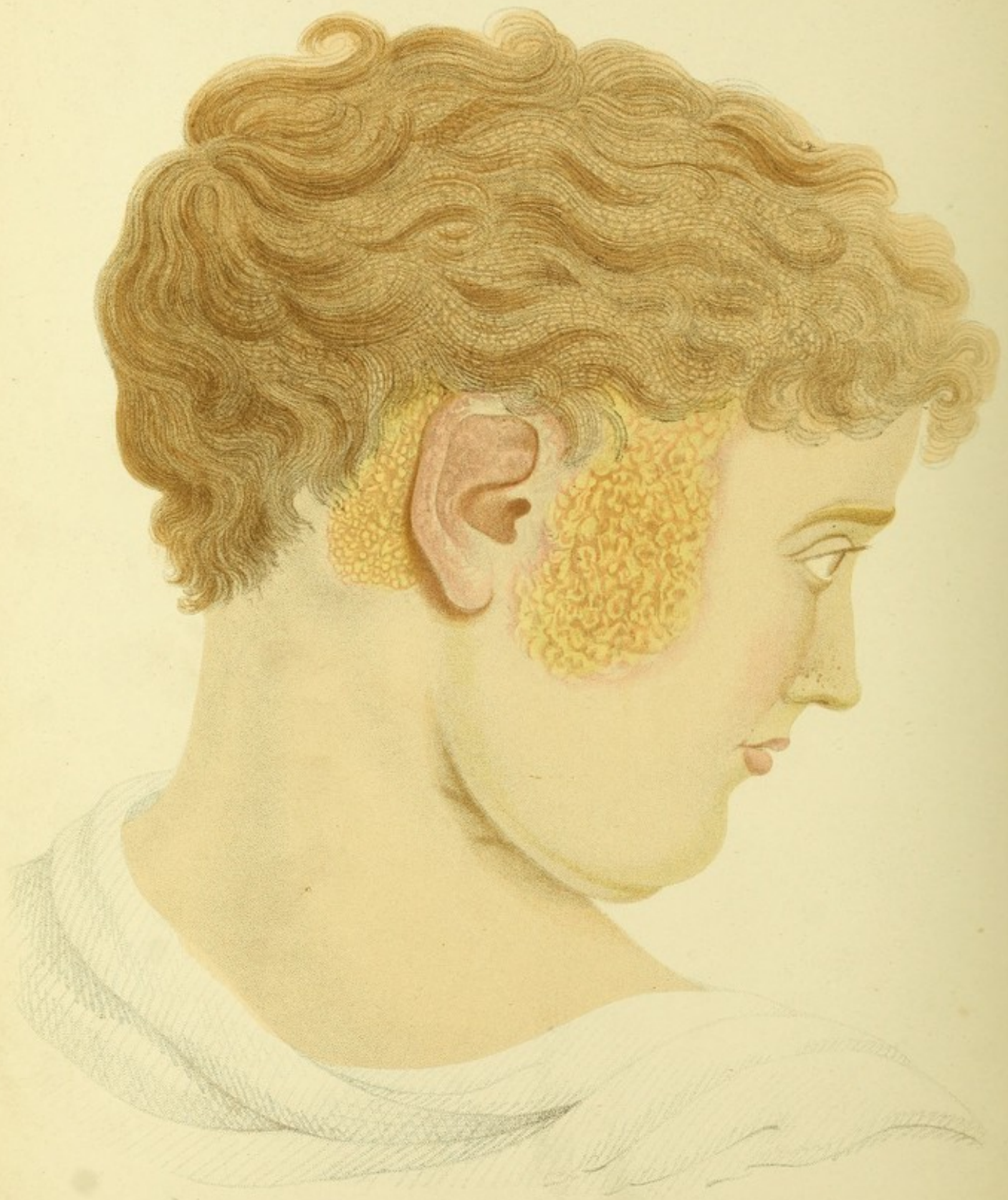*MOLLUSCUM contagiosum*.—This is Bateman's Plate, and the following is his description:—'This singular eruption had not been noticed by Dr. Willan, and was unknown to myself till after the publication of two editions of my Synopsis; it may, therefore, be proper to give a fuller account of it than is usual in this work. The peculiar circumstances which distinguish this species of Molluscum from the common excrescences of that name are its contagious quality, and the emission of a milky fluid from an imperceptible aperture in the apex of most of the larger tubercles upon pressure; by means of which fluid it is probable that the disease is inoculated. The young woman, whose face and neck were disfigured in the manner represented in this Plate, had received the eruption from a child whom she nursed, on whose cheek a large tubercle of the same kind existed, who had doubtless been infected by a former nurse, on whose face the same eruption had been observed, and who had communicated it also to two other children in the family. I have subsequently seen this eruption in another child, who had apparently been infected by an older child, who was in the habit of nursing it, and on whose face the same tubercles, with the milky fluid, previously appeared. The tubercles are hard, smooth, and nearly of the colour of the skin, but with a shining surface, and a slight appearance of transparency; they are generally of a globular form, sometimes ovate and sessile, upon a contracted base. Their progress is not very rapid; but some of them, on attaining a considerable size, proceed to a slow and curdly suppuration; and, in the case here figured, the cervical glands under those on the neck were swollen, and the surface was somewhat discoloured.'

This *MOLLUSCUM contagiosum* is mostly seen in children, and it attacks the face by preference. The little tumours of which the disease is made up, as will be seen in the Plate, vary in size. They are firm to the feel and have a shining appearance, as described by Bateman, but, in addition, they exhibit a depressed centre or umbilicus, indicative of the opening of a follicle of the skin, a point he does not notice. The disease, as stated by him, is certainly contagious. The little tumours are made up, as Dr. Hilton Fagge observes, 'of glandular lobules arranged round a central axis, and with fibrous septa between them. Each lobule has a peripheral layer of columnar epithelium, and is filled towards its centre with oval bright nucleated cells. The central axis is formed by the duct of the sebaceous gland, from which, in all probability, the tumour is developed.' The

vehicle of contagion is thought to be the minutest of the ovoid cellular bodies found in the white inspissated stuff, which can be squeezed from the umbilicus of the little tumours. In some cases the tumours may become inflamed and suppurate, but this is not common.

The *treatment* consists in squeezing out the contents of the separate tumours, and touching the interior of the little sacs with a point of nitrate of silver.





SEBORRHŒA

## EXPLANATION OF THE PLATES.

---

**PART XVII.**—This fasciculus contains representations of SEBORRHŒA, MORPHŒA, and LEPROSY.

### PLATE LXV.

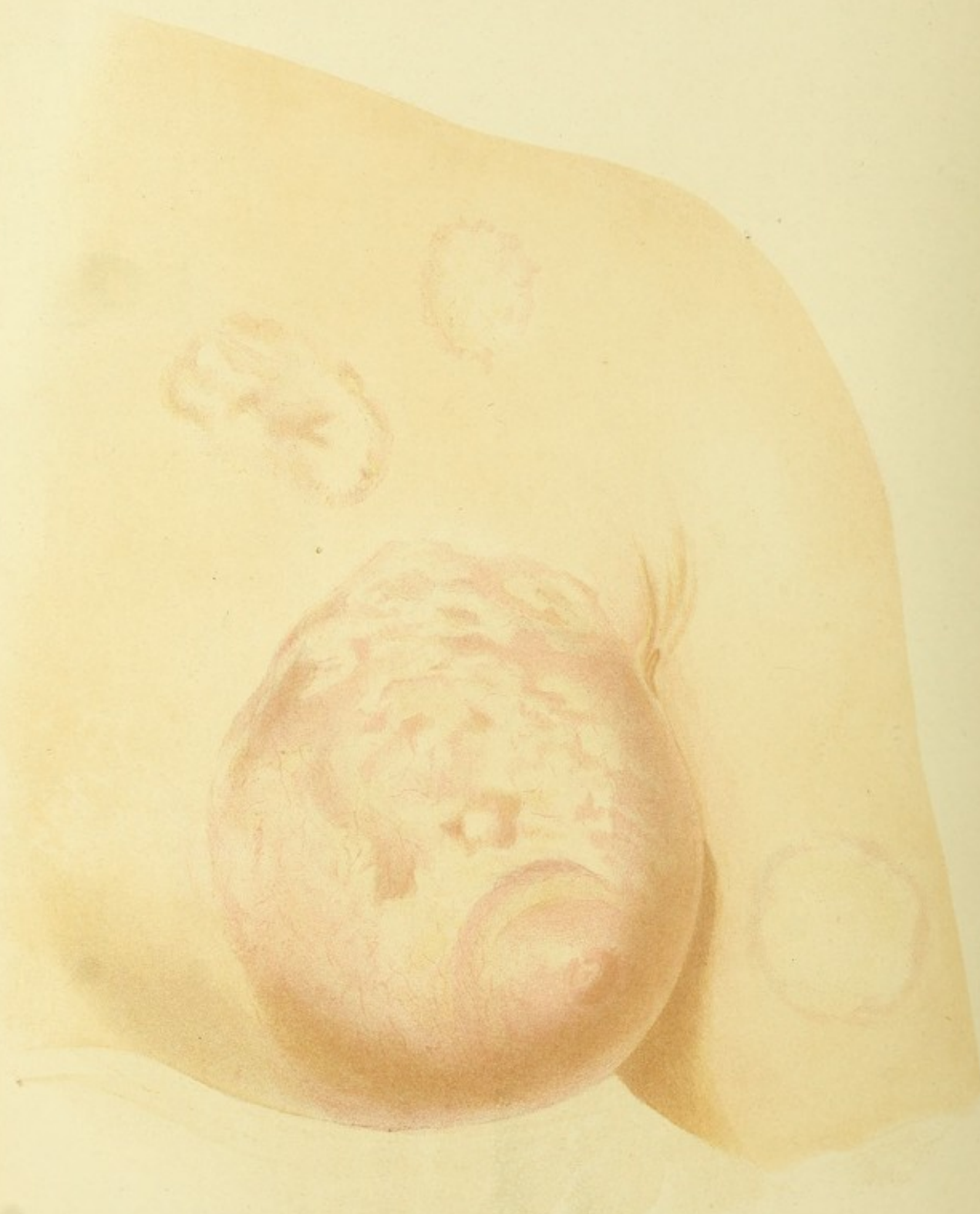SEBORRHŒA.—This illustration was introduced into Willan and Bateman's Atlas to portray what they termed *Porrigo furfurans*, but, as I have explained elsewhere in this Atlas, the designation 'Porrigo' was employed as generic for many dissimilar diseases in which crusting or scalliness is the prominent naked-eye feature. The disease represented in the Plate is SEBORRHŒA, or sebaceous flux. It consists of an excessive secretion of sebum, and may assume three main forms, according to the characters of the sebum and the particular manner in which it is dispersed upon the surface. The sebum may be *oily* in character, in which case the skin is more than usually greasy, and looks oily, and to this condition the term SEBORRHŒA *oleosa* is applied. It may be more inspissated, and concrete upon the surface in the shape of dirty white or greyish yellow scales or crusts, as in the illustration of this Plate, which is the commonest form (*S. sicca*); or it may occur in the form of little fatty masses plugging the orifices of the sebaceous glands, and give rise to the appearance of a nutmeg grater (*S. cornea*). The scalp and face are frequently the seats of the second or common form (SEBORRHŒA *sicca*) here illustrated. When the scalp is affected, usually the whole surface is more or less involved, and covered over by thin flakes that are composed of epithelial scales impregnated by fatty matter (sebum), and which feel greasy and can be scraped away, leaving the scalp intact, except that it may be slightly redder than usual. This constitutes what is known, in common parlance, as *dandriff*, or *scurf*. It is attended by more or less itching and thinning of the hair, which also combs out very readily. The disease often occurs in debilitated subjects.

The portion of the Illustration which includes the cheek and ear represents a very pronounced degree of Seborrhœa, in which the fatty crusts are large, distinct, and platy. If these be removed, the surface beneath is found not to be excoriated or ulcerated, and not to be the source of a discharge, as in Eczema, though the latter may be superadded in severe cases: the tissues, however, are hyperæmic. This same condition may sometimes be observed attacking the nose, which is swollen, somewhat red, and covered with a caking which, on removal, is noticed to be greasy and to cover over an hyperæmic skin, when the orifices of the sebaceous glands are rather more perceptible than usual. There are various degrees of intensity of the disease. The treatment consists in the exhibition of tonics and the use of local astringents. For ordinary use to common cases of Dandriff, as good a remedy as any is an ointment made with five grains of the ammonio-chloride and a similar quantity of the nitric oxide of mercury to an ounce of lard. A weak sulphur ointment is also efficacious.









MORPHŒA

## PLATE LXVI.

MORPHŒA.—This is the disease which was described particularly by Dr. Addison, and has hence been named Addison's Keloid, but, as it bears no relation to Keloid, it is much better to term it, as Erasmus Wilson does, Morphœa. The disease is not very common; but it is an important one to diagnose, since much harm may be done by treating the disease with stimulating or irritating local applications.

This disease is characterised by patches of smallish size, which feel firmer than the natural skin, and look as though the skin had been converted into a substance like white or faintly yellow wax. There is usually a pinkish halo of vessels around the waxy-looking spot, even when this is as small as a pea, but this halo varies much in the degree to which it is visible. The disease first appears as a small spot, like a bit of alabaster or dull white wax, and the area of the diseased surface extends, the pinky-hued ring or halo of vessels being faintly marked but gradually extending in all directions as a circumferential bordering of the dull white central area, which may be slightly raised or even slightly depressed. I have noticed on the face that the first sign was a faint whitish spot which became distinctly visible on blushing, the halo of vessels being also more marked during that act; but soon the disease assumes the definite features represented in the patch on the arm and the two smaller ones near the clavicular region in the Plate. The disease consists in a fibroid degeneration of the skin in all its parts, with condensation of the altered textures. The face is oftentimes the seat of the disease, which may lead, if allowed to run an unchecked course, to no little disfigurement from atrophy of the involved tissues. The disease tends to get well, but it may linger a considerable time. Persons attacked by it are generally much debilitated, and are often pale and anæmic. In the patient from which the illustration was taken the disease was very extensive indeed. There were large patches on both mammæ, many about the trunk and the backs of the hands, and dorsum of the foot, whilst the disease had invaded the greater part of the arm and forearm in front, and also the legs and the thighs. The regions of the elbow and knee joints were so seriously affected that when admitted to the hospital the girl could not stand, nor yet walk, nor put her hands out.

I have purposely selected my Illustration from this particular case since the mode in which the disease disappears is shown in the large patch which occupies the region of the breast in front. Some time before the drawing was taken the whole of the diseased area was dense, hard, yellowish white, and fringed round with a vascular network of vessels. Under treatment the part became softer, and here and there the natural hue of the skin reappeared, or even a little more redness than exists in health was developed. The deposit was, in fact, becoming reabsorbed, and when this took place the natural feel and aspect of the skin began to return here and there, and presently the yellow indurated area was broken up into islets of disease, the healthy skin showing around them, as in the Plate. If the patches are small, the skin perfectly recovers itself, but the disease may leave behind distinct atrophy and contraction. This disease is sometimes associated with

Scleroderma, and is indeed a phase of that malady. In the case above referred to, the legs were indeed in parts in a state of Scleroderma. [Further details of the case which furnished this Illustration will be found recorded in a Clinical Lecture which I published in the *Lancet* of June 10, 1876.]

When cases of Morphœa come under treatment, the patient should at once be made to understand that a long time may be needed for the cure, if it progresses ever so well. The disease will in all probability get quite well; and in proportion as, by the judicious use of iron, quinine, arsenic, and cod-liver oil, with good food, the jaded and exhausted powers of the patient are recuperated. At the same time, the use of the knife, caustics, and every other irritant must be scrupulously avoided, and trust be placed entirely in appropriate general tonics.



Fig 2

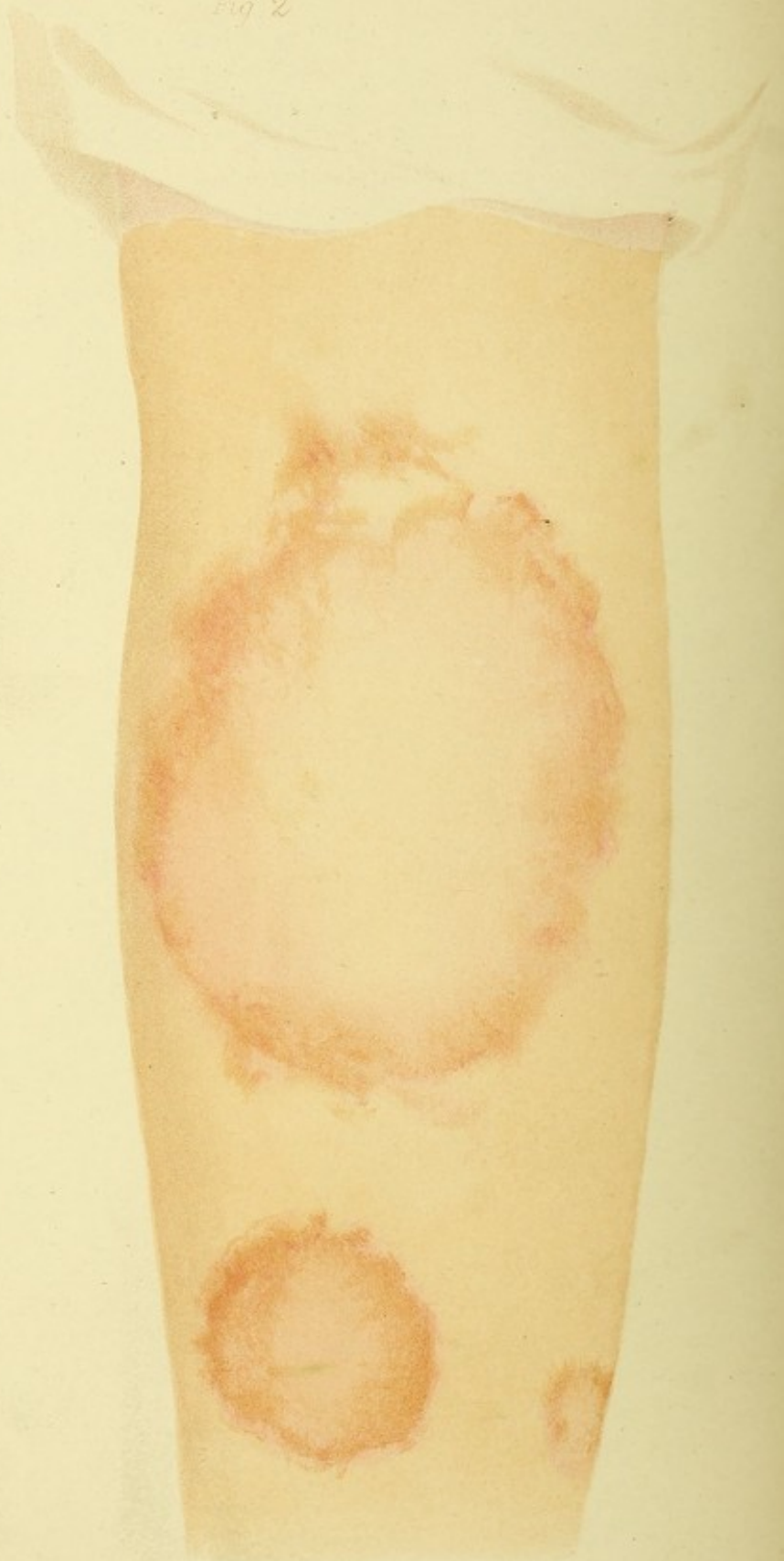

Fig 3.

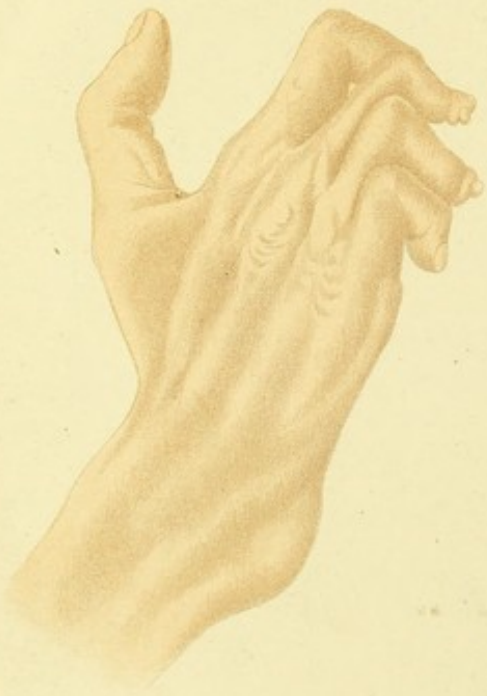
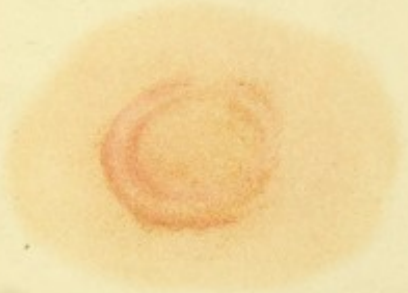
Fig 1.



Spot on Forehead

2. ERUPTIONS OF ANESTHETIC LEPROSY  
3. HAND IN DITTO.

## PLATE LXVII.

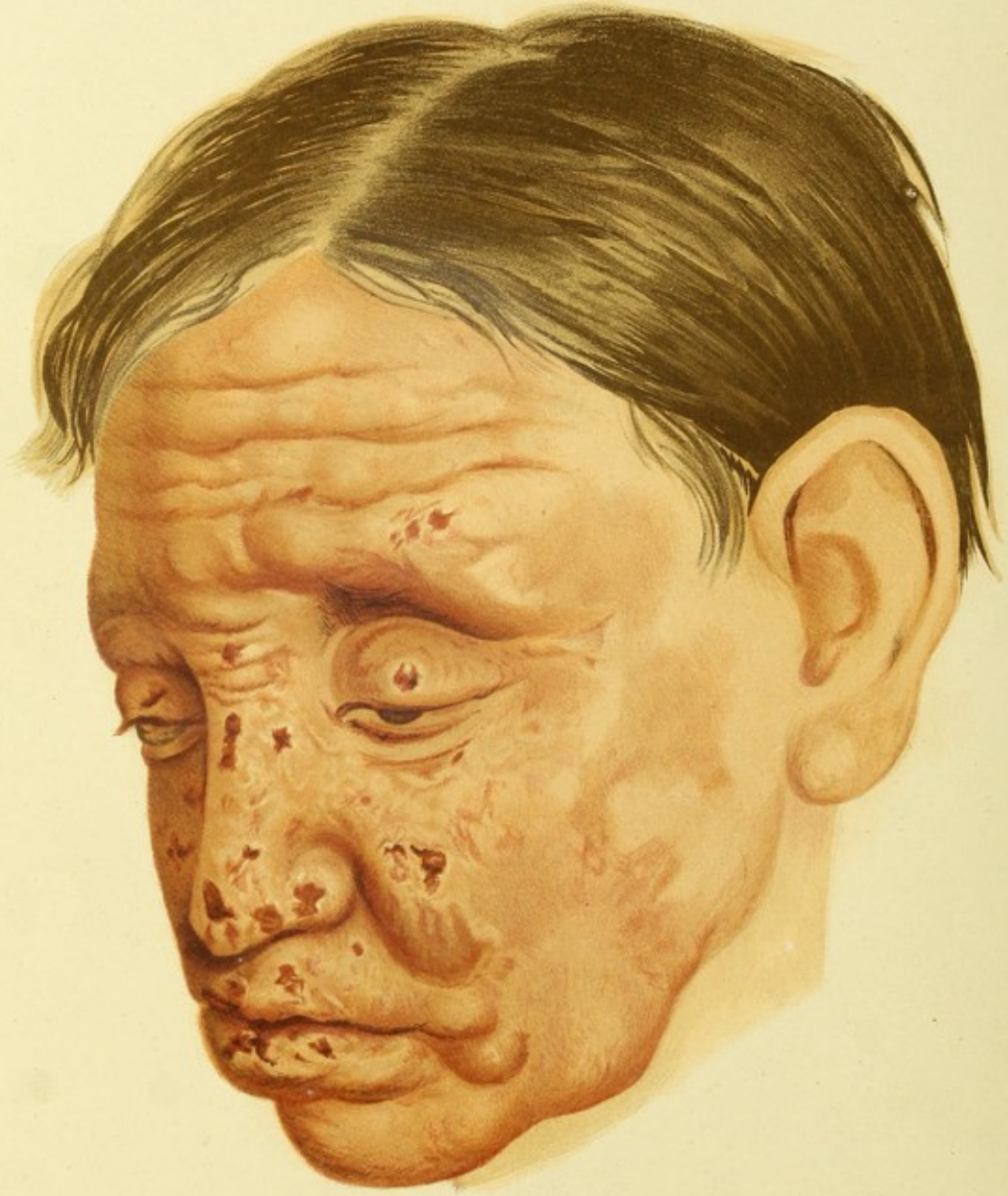*Figs. 1 and 2.*—LEPROSY.—I have met with several cases of Leprosy in an early stage which have been brought to me in England with exactly such eruptive manifestations on the skin as are portrayed in these two Figures. These cases have usually come from the West Indies, where their nature has been overlooked, but I have seen similar instances from India. As it is very essential that a correct diagnosis should be made at the earliest moment in these cases, I have deemed it of importance to represent this particular phase of eruption, which is very likely to be mistaken for some simpler malady than true Leprosy. At first sight the eruption looks like Psoriasis, but it lacks the scaly and infiltrated aspect of that disease, whilst it has peculiar features of its own. In the early stages the eruption is mainly hyperæmic, and consisting of dullish red blotches which appear about the face and the body. *Fig. 1* represents the early condition of one of these patches, which was seated in the centre of the forehead, in a case recently under my care. Where two or three of these spots occur together in the face it gives the patient the appearance of being flushed or overheated. Such a flushed aspect mostly occurs at the outset of the affection of the face in tubercular Leprosy, but then it is usually a more diffused blush, and is not made up of such distinctly circular spots as in the case under notice. But the face, though one of the earliest, is not the only part of the body affected. The extremities are speedily attacked, as shown in the leg in *Fig. 2*, and the trunk of the body. These dullish red blotches acquire after a time a light brownish or dull coppery hue; and, as they enlarge, they leave the central parts somewhat drier and apparently thinner, as if sometimes the textures had been scorched. If care be taken, the central portions in a fairly early stage will be found to possess a less degree of sensibility than usual, but after a while they become decidedly anæsthetic. The edging of the patches is of deeper colour, made up in part of a number of fine vessels which are indicated in the figure 2. The more decided changes are portrayed in *Fig. 2*, which represents, as stated above, the leg attacked by the disease. Now whenever an individual who has resided, or is born of parents who have resided, in localities where Leprosy is endemic, exhibits dull red blotches with anæsthetic centres, the first thing that should occur to the practitioner in explanation of the condition is Leprosy. It has been the custom of late to group together a special set of cases under the term Macular Leprosy. Macular Leprosy would, however, not only include such cases as are illustrated here, but also the more extensive blotchings or maculations of the surface, which constitute under ordinary circumstances the early eruptive stage of tubercular Leprosy, and some other conditions. Maculæ indeed are the rule in the disease, and practically constitute the main features of its early stage. Maculæ, in fact, cannot be regarded as constituting a variety so much as a stage of Leprosy. The conditions portrayed in *Figs. 1 and 2*, above described, are followed as the rule sooner or later by the fuller development of Leprosy in all its severity.

*Fig. 3* represents the claw-like deformity of the hand which occurs particularly in the anæsthetic form of Leprosy. I have seen it in Englishmen returned from the tropics,

in connection with the development of bullæ here and there, or dry scaly circular (Psoriasis-like), but anæsthetic dull brownish red patches of eruption, and enlargement of the ulnar nerve from deposit of leprous matter in and about it, and without much affection of the body generally. In these cases the patients have been suffering from general debility, have had 'fever,' and then have noticed numbness or formication, with imperfect use of the hand, whilst macular patches, presently becoming scaly and anæsthetic, had developed here and there about the surface, or been limited to an affected arm only. These cases, which apparently represent an early stage or a localisation of the disease, have been mistaken for some essentially paralytic affection of central origin (syphilitic or other). In the official reports of the medical officers of the various ports in China a good number of cases of this kind lie scattered throughout the pages, and form a very instructive clinical history of this phase of anæsthetic Leprosy. But I hasten to add, that this peculiar deformity is not necessarily an early stage or a localised phase of Leprosy, since it is common in connection with other deformities of the extremities, in the fully developed disease (anæsthetic Leprosy). I am indebted for permission to make use of this figure to Dr. R. Druitt. I will refer to the treatment in connection with the succeeding Plate.







TUBERCULAR LEPROSY

## PLATE LXVIII.

TUBERCULAR LEPROSY.—This is an Illustration of a typical example of Tubercular Leprosy affecting the face in a moderate degree in an European. For the opportunity of sketching the case I am much indebted to the courtesy of Mr. Spencer Watson.

Although the features of the disease as it affects the face are very characteristic and very easy of recognition, yet the nature of the disease is frequently overlooked. It has happened to me again and again to see Europeans in whom the disease has been quite as well marked as in the case from which the Illustration was taken, and in regard to which not even sometimes a suspicion of the real character of the disease has ever been entertained by many medical practitioners who have seen the cases. I can recall three instances of the kind that I have seen within a short period, and I introduce this portrait here in the hope that it may serve to help to a more correct diagnosis of Leprosy in future.

The eruptive phase of Tubercular Leprosy shows itself a little time subsequently to the occurrence of pretty definite symptoms of general malaise, and occasional fits of slight feverishness, or, sometimes, decided attacks of what seems to be paludal fever, and it may be signs of disordered sensations in the extremities. The eruptive state is made up of two main items, (*a*) discolorations of a light coffee hue developed at first here and there over different parts of the body and limbs, and then affecting the body more or less generally; and (*b*) deposits of leprous matter made up of what answers as regards its minute characters to *granulation tissue*, in the form of dullish red tubercles or infiltrations, which make their appearance at an early date in the progress of the case about the face and ears, and later on in many parts of the body and in the mucous tracts, including those of the eye, the nose, the interior of the mouth, and the larynx. In addition to these eruptive appearances, there is development of decided anæsthesia in various parts, specially the extremities, due to implication of the superficial nerve trunks; and oftentimes the ulnar nerve can be detected about the elbow as a hard knotty cord which rolls under the finger.

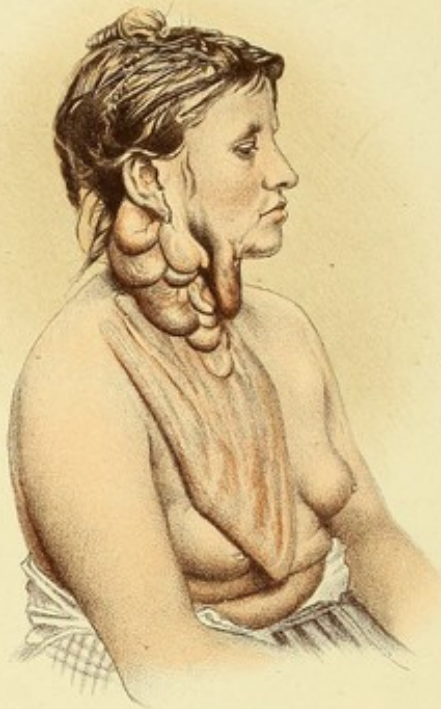The Illustration gives an excellent idea of the changes in the face. An earlier stage than that here represented consists in a condition in which the face seems much flushed and slightly swollen, and as though a kind of indolent erysipelas were present; but this is a permanent condition. But the evident signs of 'deposit' soon appear, and a condition results like that represented in the Plate; which state further increases to the greater distortion of the features. The deposit is favoured by the laxity of the cellular tissue of the parts, and it is very marked in the lips, eyebrows, and alæ of the nose, and usually much more so about the ears than is the case in the Illustration. The integuments are thickened generally and feel firm, they are raised into folds or corrugations, so well seen about the forehead in the Plate, whilst the skin itself, which looks dirty and sallow, is greasy, owing to the hypertrophy of the sebaceous glands. Owing to the thickening of the eyebrows, which consequently overhang the eyes, and that of the lips and nasal alæ, there is a heavy lion- or satyr-like look about the poor leper, hence the terms *leontiasis*,

*satyriasis*, applied to the disease. But perhaps the most remarkable result is the effect of the disease in aging the patient. A lad of ten or twelve affected by the disease will appear to the observer to be at least forty or more, as in the present instance. It is true that the features of the disease in the Plate are only moderately marked, but I designedly introduced an example of a *moderate* degree of disease, though I could have easily given other illustrations of Leprosy in its severer phases, which I actually have in my portfolio. It will be seen that the face is studded over with little blood crusts. These are seated at excoriations produced by the scratchings of the patient.

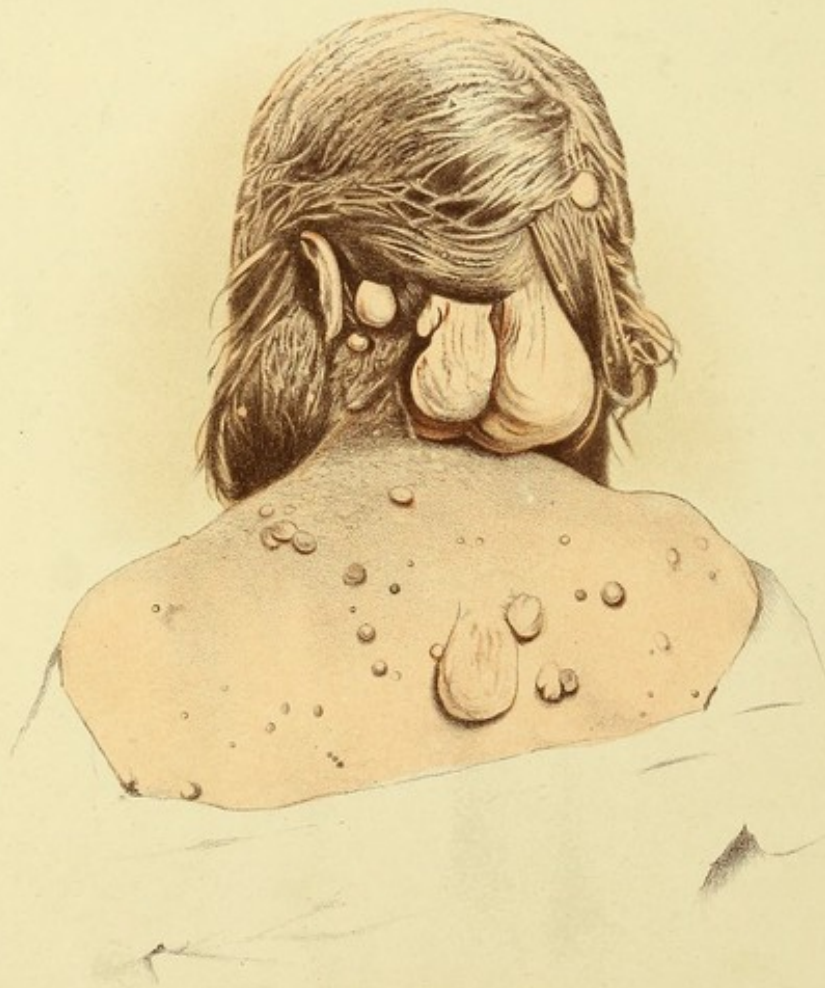
The *treatment* of Leprosy I must dismiss in a few words. It consists in careful attention to the institution and enforcement of general hygienic measures; in the exhibition of appropriate internal medicines; and in the application of certain local medications calculated to promote the absorption of the leprous deposit.

The leper must be removed from unhealthy and damp places. He ought to live in the best possible (high and dry) climate, and be allowed plenty of fresh meat, fresh vegetables, and proper exercise in the open air. He should make frequent ablutions, wear warm clothing, and be encouraged to follow as much as possible recreation and pursuits which will tend to cheer his mind. There is no *cure* for Leprosy; but much may be done towards an arrest or amelioration of the disease by the use of appropriate tonics and the free exhibition of quinine in large and long-continued doses. Locally, the repeated application of Gurjun oil or carbolic acid to the tubercles will tend to their dispersion by their stimulant action upon the disease.





*Fig 2* DERMATOLYSIS



*Fig 1* FIBROMA.

## EXPLANATION OF THE PLATES.

---

**PART XVIII.**—This fasciculus, which completes the Atlas, contains representations of two varieties of FIBROMA : PACHYDERMATOCELE : the more common diseases of the nails : and HYDROA, as I understand it, and to which I wish specially to call attention, as being of much clinical interest.

### PLATE LXIX.

*Fig. 1.*—FIBROMA *molluscum* or FIBROMA *simplex*. Although the disease here represented is not life-size, I have selected this particular illustration, which is a copy of a coloured photograph, because the main polypoid characters of the disease are so admirably portrayed by it. The photograph was sent to me by some kind friend, I think, from Liverpool, but I am unable to acknowledge him by name through sheer forgetfulness. He will, however, accept my apology for any apparent discourtesy, and at the same time be glad that I have been enabled to put his contribution to a useful purpose. The disease is characterised by the formation of outgrowths of the connective tissue of the skin, which in due course assume the aspect of isolated and pendulous tumours, each of which has a distinct pedicle. The tumours are mostly pyriform in shape, feel softish, and have the aspect of ordinary integument, only that the surface is here and there rugose—characters well seen in the three larger tumours in the figure. In the early stage the tumours are softish and sessile, and some are shown in the figure, but they soon become pedunculated. These tumours feel like ordinary integument. There may be one or a multitude, and their common seats are the neck, chest, back, and more rarely the limbs. They may become more or less flattened by the pressure of the clothes. Very little can be done to relieve the patient of these tumours. If any special one becomes troublesome it may be removed by surgical interference, but care must be taken to secure the pedicle from hæmorrhage.

*Fig. 2.*—PACHYDERMATOCELE or DERMATOLYSIS. As I had room in the page to introduce a copy of a photograph of a disease resembling Fibroma in nature, I have availed myself of the opportunity of so doing. The disease represented is called Pachydermatocele or Dermatolysis; and it consists in hyperplastic growth of the connective tissue of the skin, as in the case of Fibroma, forming distinct tumours, only that these outgrowths are of a much less firm character than those of Fibroma, indeed are so lax as to form pendulous folds rather than polypoid tumours. Pachydermatocele might be described shortly as a disease consisting of lax outgrowths of the connective tissue assuming the aspect of folds like empty bags. There are generally several of such folds; and these folds can be separated from each other, but each has its own base. The surface possesses in the main the characters of normal integument somewhat thickened, and with the follicles of the skin

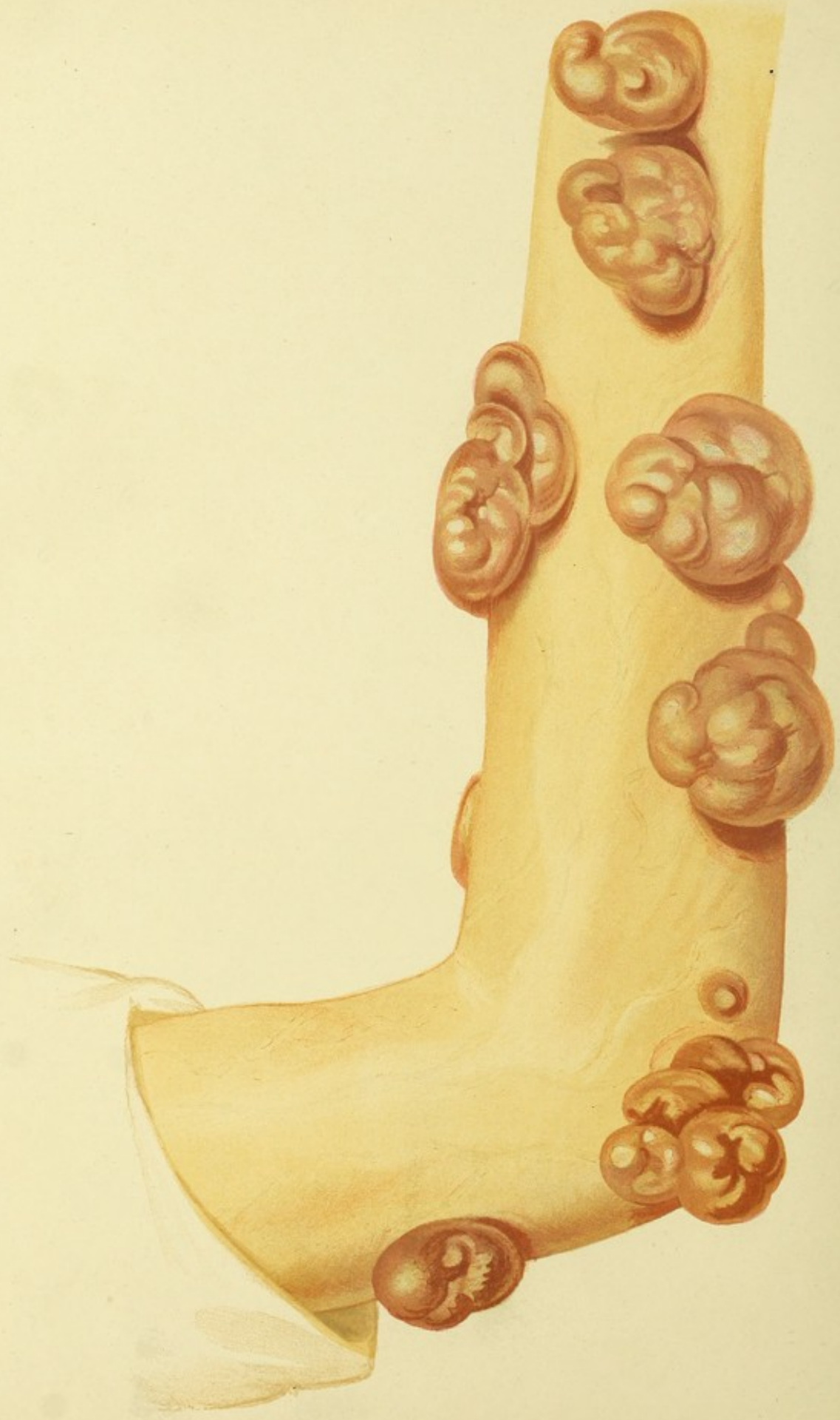very distinctly marked. The folds from friction one upon another may become inflamed. This disease attacks the region of the neck, the chest, and the legs perhaps more specially than other regions. The illustration is that of a patient of Dr. Fritsche, of Czenstochowva, in Poland, and appeared, with full notes, in the Clinical Society's 'Transactions' for 1873. There were 10 or 11 folds of skin hanging from the under surface of the jaw on the right side. The tumour on the chest, which was  $10\frac{1}{2}$  inches in length, was attached by a base 8 inches in length to the clavicular line, and the whole could be, as is usual in this disease, freely lifted about, and in this particular instance could be put over the shoulder like the end of a scarf.

The relation which this disease bears to ordinary Fibroma is perhaps closer than at first appears. It would appear that in the case here represented, the larger fold began apparently by a fibromatous mass, and Dr. Fritsche says that the body of the patient was covered 'with small growths of the size of hazels and walnuts.'

The *treatment* of these cases consists in the removal of the tumours where this is practicable on account of the situation and size of the growths and the pedicles. The latter must be first well ligatured by one or several ligatures, as was done in the larger mass in Dr. Fritsche's case, and then removed.







FIBROMA FUNGIFORMIS

## PLATE LXX.

*FIBROMA fungoides*.—In the third edition of my systematic work on Diseases of the Skin, published in 1873, I have described under the above designation what I consider to be a special phase of fibromatous outgrowth from the skin, in which the masses possess little vitality, but exhibit more than usual vascularity and a tendency to rapid growth and ulceration. I stated that I have met with cases in which ‘the tumours before ulceration are in aspect and feel like those of simple Fibroma,’ but when ulceration sets in that ‘they exhibit in the young subject, at the ulcerated part, a pultaceous-looking surface; and in the old, as far as I have seen (in two cases), a livid-red apparently very vascular ulcerating surface, from whence arises a fœtid ichor.’ I gave the main particulars of four cases.

In the first ‘there was a rounded raised tumour, as much as possible like a small Normandy pippin in size, form, and aspect, only perhaps a little redder, seated upon the scalp of a gentleman. This tumour had slightly ulcerated.’ Dr. Gavin Milroy saw this case subsequently, and the notes he kindly gave me describe this diseased mass as a large concave or hollowed circular ulcer, between 2 and 3 inches across, and at its centre a third or nearly half an inch below the level of the surrounding scalp. Its surface being unevenly smooth without distinct granulations, and looking more like raw flesh than that of an ordinary ulcer: the margin or edges being somewhat raised and thickened, and here and there fungiform. Dr. Milroy noticed ulcerated bodies over the forehead, right occiput, and right cheek, ear, the chest and back, varying in size from a fourpenny-piece upwards, some scarcely raised above the level of the skin, but all raw. Over the head of the right fibula was an irregularly rounded ulcer with fungus excrescences, ‘giving the aspect of a piece of red cauliflower projecting an inch above the level of the skin.’ It is important to remark, that the disease followed immediately upon an attack of boils and eczema from which the patient suffered in 1871, and all the fungating sores seemed to have arisen upon parts of the surface previously the seat of the crusts of eczema from which he suffered. Mr. Startin called the disease ‘Epithelioma,’ or Cancroid. There was not a vestige or particle of evidence of syphilis about the man.

The second case I described was that of a woman who had ordinary fibromatous tumours and these fungating growths as well, but I admit that it is within the range of possibility that this case may have been a lymph-adenoma (mycosis of the French).

The third case was that of a child who had fibromatous masses about the ear, a large tumour at the back of the head in a stage of commencing ulceration, and whose fingers were club-shaped, an appearance ‘caused by the development of fleshy masses resembling half-ripe black grapes seated at the tops of the palmar aspect of the fingers, and imbedded, as it were, in the fleshy end.’ I have represented it in my work. The whole of the gums were enormously hypertrophied and protruding about and around the teeth, so that they were completely imbedded in them. Two other children in the family were similarly affected as regards the gums. The late Dr. John Murray recorded this case in detail.

The fourth case was that of a woman under the care of Dr. Cockle in the Royal Free Hospital, who had been suffering from syphilis. I remark: ‘there were syphilitic scars and tubercles about her skin, and about and from the seats of these tubercles arose lax

textured fibromatous masses. Those on the face being large, luxuriant, and livid red, but of firmish consistence, stood out from the forehead, the nose, the lips, as much as three-quarters of an inch in depth, causing overhanging eyebrows, enormously thickened *alæ nasi*, and protuberant lips of great size. On the arms (*one of which is represented in this Plate*) and on the legs were numbers of sessile fibromas of ordinary appearance, save that they were purplish in tint in parts, and some of them exhibited in the centre the opening apparently of a sebaceous duct. Some were the size of a big nut, and others half a walnut.' I added, 'In all these four cases the main characters were the same; the production of fibromatous masses, made up evidently of fibrocellular tissue, growing rapidly, tending to become vascular and to ulcerate freely; and I termed it, as I think very correctly, *FIBROMA fungoides*. That there is such a form of ulcerating Fibroma occurring in cachectic subjects, distinct from the contractile Keloid, from Epithelioma, and from lymph-adenoma, and the *MYCOSIS fungoides* of the French authors, I do not think admits of doubt.

It will have been observed, perhaps, that in two of the four above-named cases, the disease arose out of other diseased surfaces, the one syphilitic scars, and the other furunculoid or eczematous patches. In the remaining two it arose spontaneously. It may be that the disease consisting of hyperplasia of connective tissue of essentially lax kind, but differing in its degree of vitality in different cases, may, like the more vitalized and contractile growth in Keloid, be either idiopathic or traumatic. That in the syphilitic woman the disease was more than tertiary syphilis, and due to an hyperplastic growth of the scar tissue, is undoubted. I believe it has been suggested that the disease may be and is produced by the exhibition of iodide of potassium. In my cases there is no ground whatever for this opinion. The disease may arise, no doubt, in an individual who is taking iodide of potassium; but the disease in the case I represent was actually, as I stated in my work, 'getting well at the time of writing under large doses of iodide of potassium,' and, as I have said, in none of the other cases had any iodide of potassium been taken.

In the way of *treatment* I have little to offer, save to commend the use of the best possible hygienic regimen, the most nutritious diet, with nourishing stimulants and appropriate tonics, adapted to the cachexia of the individual attacked, and the application of some cleansing astringent to the sores.



SHEDDING OF NAILS AFTER ECZEMA

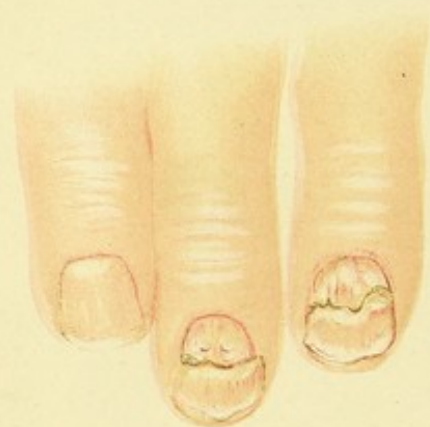

Fig. 2

ONYCHOCRYPTOSIS

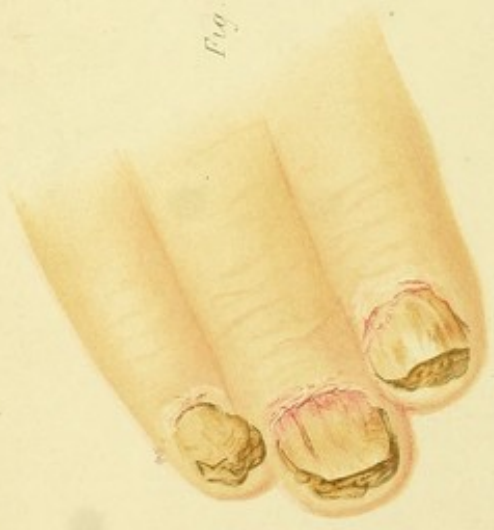

Fig. 1

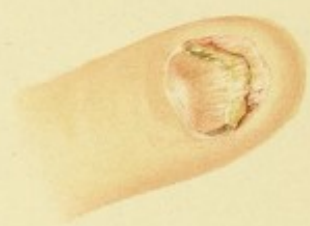

Fig. 3

ATROPHY OF NAILS

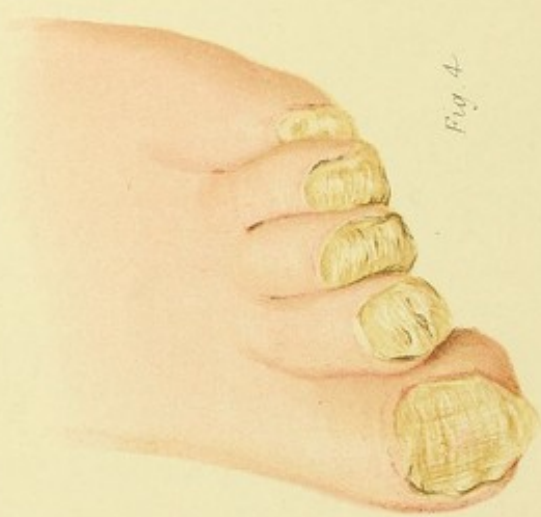
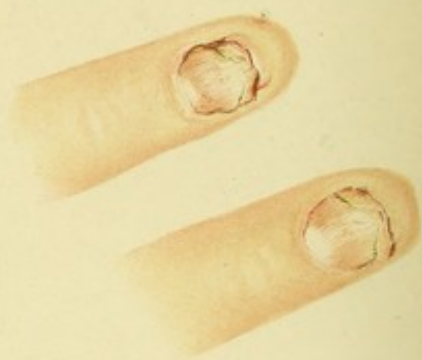
Fig. 4

PSORIASIS OF NAILS



Fig. 5

ONYCHOMYCOSIS



Fig. 6

ONYCHOMYCOSIS

## PLATE LXXI.

## DISEASES OF THE NAILS.

The NAILS are liable to become the seat of a number of morbid changes. Very commonly they are of an hypertrophic nature, and are then idiopathic in origin, or secondary to or constitute part of certain inflammatory diseases of the skin—chiefly Psoriasis, Lichen ruber, and Pityriasis rubra—involving the matrix of the nail. The changes may be atrophic, the consequence of general debility: or thickening, brittleness, pulverulent disorganisation, and yellow striation (*onychomycosis*) may be induced by the invasion of the nail structure by fungus elements. These conditions will be portrayed in the accompanying Plate. Generally speaking, the term, Psoriasis, is made to do duty without any discrimination as a designation for all these conditions.

*Fig. 1* represents an hypertrophic state of the nails or *onychogryphosis*. The nails themselves are thickened, but in this instance by the deposit of soft nail substance in excess from the matrix beneath, whilst their surface and free edge especially are rough and uneven. The nails may be oftentimes very much distorted in this disease, and become clawlike. They may also break up longitudinally, and even separate after a while more or less from their bed. The illustration is taken from a model in the College of Surgeons, and the onychogryphosis followed chronic eczematous inflammation. The treatment consists in the use of tonics with arsenic, and mercurial applications.

*Fig. 2* exhibits atrophy and *shedding* of the nails, the result of eczematous inflammation spreading to the matrix. The new nails are growing fairly well. The treatment for such a condition is by general tonics.

*Fig. 3* represents the condition of *atrophy* or defective growth of the nails. In this condition the nails are stunted, and do not cover the whole area of the matrix, and sometimes scarcely any of it. They are also thin, somewhat opaque, though at times not to any perceptible degree, and are loosened away from the matrix for a greater or less extent from their free edge downwards towards the lunula. Usually all the nails of the hand and feet are affected, but in varying degree, and dirt easily collects beneath the nails, giving them a dirty aspect.

All these features are well marked in the accompanying illustration, which represents the thumb and two adjoining finger-nails affected with atrophy. The sketch was taken from the hand of a medical student who was weak, pallid, and overworked.

No other diseased condition necessarily co-exists in these cases of idiopathic atrophy of the nails. The disease arises from pure want of nutritive power, and it bears the same relation to the nails as thinning of the hair and alopecia do to the hair.

The *diagnosis* of atrophy is made by the stunted growth and the thinned and loosened state of the nails.

The *treatment* consists in the exhibition of tonics, especially the mineral acids with arsenic, and the local application of mild mercurials and stimulants.

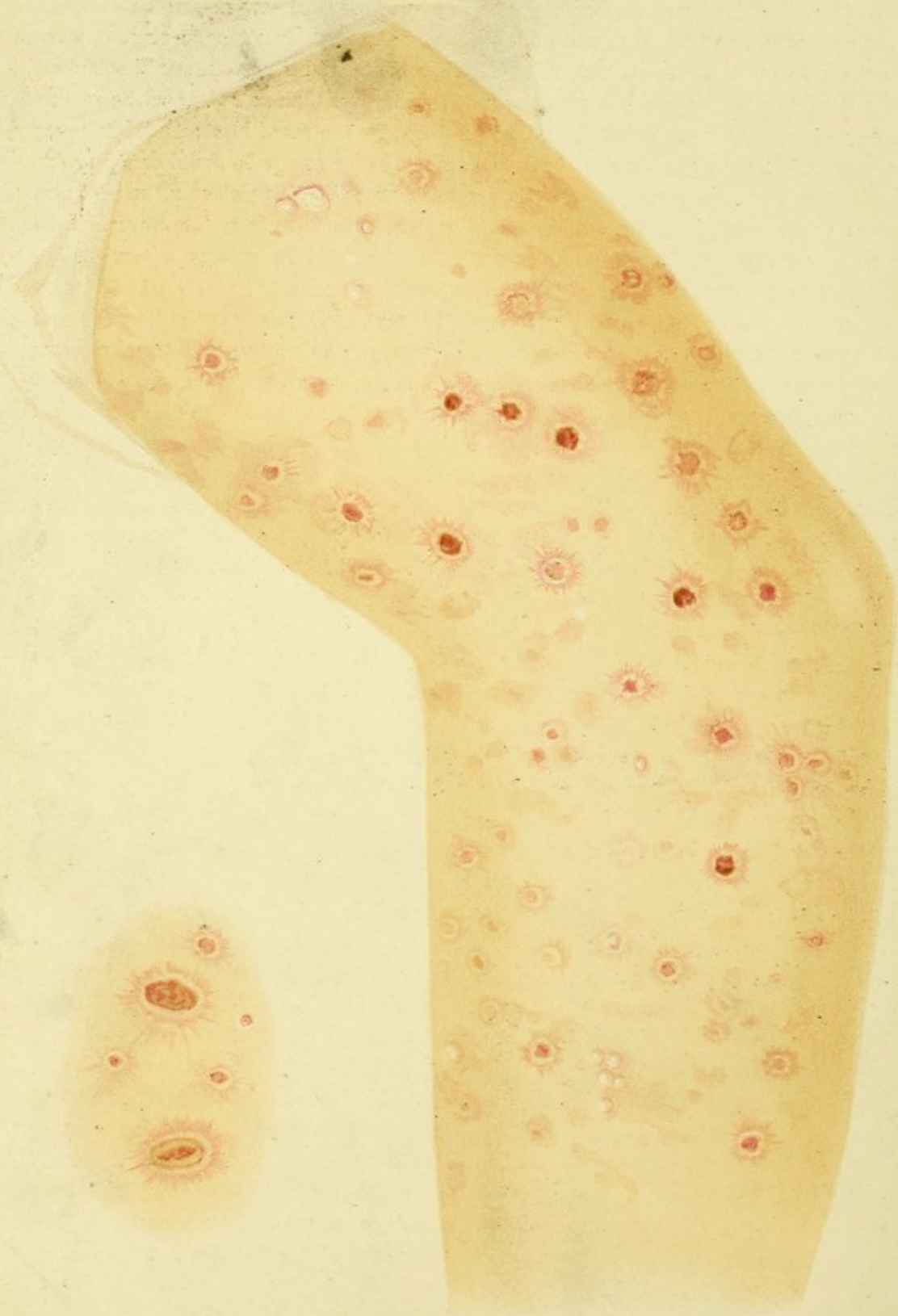*Fig. 4* represents *psoriasis* of the nails of the foot in a very well-marked form, and occurring, as is often the case, as a part of general *psoriasis* of the body. In *psoriasis* of the nails, the latter look at first wormeaten, or speckled, and slightly opaque in parts. They then show longitudinal striæ, indicative of the tendency of the nail to split. Then the anterior parts of the nails very frequently become thickened and opaque and yellowish from the presence of an excess of epithelial material deposited from the matrix. The nails then become more disorganised, until the condition exhibited in the Plate is reached. After this the nails become more and more distorted, thickened, and split up. In the early stage one or two nails may be affected, but soon all or most suffer, and those of the feet as well as of the hand. The treatment is the same as for *Psoriasis*.

*Fig. 5* is an illustration of onychomycosis induced by the attack upon the nail of the parasite of ordinary ringworm—*Trichophyton tonsurans*, for which I am indebted to Dr. Hilton Fagge. I have had a few cases under my care lately, but have had a difficulty in getting the patients to submit to a sitting, and I am all the more indebted, therefore, to Dr. Fagge. In onychomycosis the disease is characterised by the limitation of the disease to the fingers of the hand, and the affection usually of one, or perhaps two, fingers, though I have seen several of both hands affected together; the occurrence of the disease in those who actually have or have had ringworm, or who have attended to ringworm cases; its frequent origin from *Tinea circinata* of the hand, which invades the parts about the roots of the affected nail, and the fungus of which, under such circumstances, readily invades the nail substance; and lastly, by peculiar appearances in the nail itself. Little yellow specks appear in it, at the side and to the front at first, which specks or spots if cut down upon are observed to be soft and made up of pulverulent stuff. As the disease advances the nail substance becomes soft and brownish yellow, or is detached from its bed, and broken off more or less short. If the nail substance be examined after being soaked in liquor potassæ, the beaded threads of the fungus are to be detected. The *treatment* consists in scraping the nail as thin as possible, so as to gain the freest access to all 'rotten' spots, and in applying acetic acid, or soaking in a saturated solution of hyposulphite of soda in glycerine, until every sign of the disease has vanished.

*Fig. 6* represents onychomycosis, caused by the *favus* parasite, and as it attacked the little finger of the left hand of a patient of Dr. Fagge's (see *Clinical Society's Trans.* 1868, p. 77). The nail was at first discoloured yellow, being dry, cracked, and detached from its bed, and extended only to about half way towards what ought to have been the position of its free edge; the front portion of the nail-bed being covered by a brownish yellow pulverulent mass. The girl had suffered from *favus* for some years. The case was cured by hyposulphite of soda lotion. I have to thank Dr. Fagge again for permission to copy the original of this illustration.







HYDROA

## PLATE LXXII.

HYDROA.—In describing PLATE XXVIII., which represents *HERPES iris*, I stated that the term Hydroa has recently been used as a synonymous designation by both English and French writers. This is in my opinion a blunder, since there exists an eruption perfectly distinct from *HERPES iris*, to which Bazin originally gave the name of Hydroa, and with which most dermatologists appear to be unacquainted. This Hydroa, in a severe form, I have portrayed in this Plate. I have entered somewhat at length in my systematic work on Diseases of the Skin into the description of the characters of Bazin's Hydroa and its clinical manifestation, but I can only here give a general sketch of the disease as I understand and have seen it.

The primary lesion of Hydroa consists in a vesicle or a small bulla developed in the centre of an itchy and inflamed base, the vesicles being isolated, occurring in successive crops and rapidly running on to resolution. Bazin accurately describes the general features of the eruption as follow:—

'There is seen at first spots of a deep red colour, small, rounded, a little raised, and with their edges clearly defined. These spots vary in size from that of a lentil to that of a fava of twenty centimes; they are surrounded by rose-coloured areolæ; they soon show in their centre a small vesicle, filled with transparent yellow liquid. This vesicle appears the day following the red spot. It dries rapidly from the centre, which is occupied by a small blackish scab, whilst the liquid is absorbed from the circumference. The phenomena take place towards the second or third day of eruption.'

The disease invariably lacks the secondary vesicular ring of *HERPES iris* in my experience. The spots oftentimes itch greatly when they are appearing, though Bazin says there is scarcely any itching in the slighter forms; and this is true at times. This particular form of eruption is called by Bazin *HYDROA vesiculeux*, and he speaks of it as made up of successive crops, whereby its existence is continued for several weeks: but a relapse may take place. Similar vesications may be seen on the mucous surface of the interior of the mouth. In some cases the vesicles are vacciniiform in shape and aspect, hence the term *H. vacciniiforme*. In other cases the vesicles are large, and are in reality small bullæ, hence the term *HYDROA bulleux*, and the bullæ may be grouped somewhat after the fashion of herpetic vesicles, and

'whilst new bullæ are developing, the old ones dry up and are replaced by a yellowish scab; and if one of these is rubbed off by scratching there appears a violet-coloured, slightly excoriated surface . . . . . the course is chronic, the disease appears in successive crops, and lasts generally from five to six months.'

It is attended, in my experience in this form, by marked itching of paroxysmal character during its entire course, and it has many points of similarity to Pemphigus, but also decided differences therefrom.

Now I have observed many phases and degrees of extensiveness and severity of this disease—Hydroa. *Firstly*, as I have stated in my work,

'the practitioner may meet with cases in which, with or without slight antecedent malaise or pyrexia . . . . . a few red, irritable scattered spots appear, having in their centres a small oval or rounded bulla (see *a* in the Plate), which may enlarge to the size of a split pea, but is generally not so large, but dies away in the course of a few days . . . . . it occurs on the back of the hands, on the arms, the legs, and the shoulders.'

*Secondly*, other cases occur in which these solitary vesicles may be mixed up with *imper-*

fectly marked herpetic groups. (See *b* in the Plate.) \* *Thirdly*, the disease may consist of larger vesicles or bullæ scattered here and there over the body, and answering to Bazin's *HYDROA bulleux*, as was the case at one time in the patient from which this drawing was taken, only that many of the spots possessed the features of *HYDROA vesiculeux* only.

The illustration in this Plate is a faithful reproduction of the state of the arm in a *severe and more than usually well-marked* case recently under my care, and in the chronic stage of disease; and bears out what I have indicated in the preceding remarks—viz. that the various phases of the so-called varieties of *Hydroa* may be met with in one and the same patient, proving that these varieties are not defined by any certain or decided lines of demarcation, but that the characters are often intermingled in a given case. The patient was a woman of good age, who had suffered from the disease during several months. It attacked the shoulders, arms, forearms, thighs, and legs symmetrically, especially the outer aspects of the latter. It was attended by severe paroxysmal itching, and was prolonged by successive crops of vesicles, small bullæ, rarely large ones (though these existed at an earlier stage), and a certain number of occasionally occurring *semi-herpetic* patches. The illustration, moreover, gives a good idea of some of the peculiarities of the eruption, and of the aspect of the healing stages in which it differs, I may incidentally remark, from *Pemphigus*. After the vesicle shrivels and is replaced by a dark crust or scale, the base of each spot is seen to be a very well-defined one; the central depression occupied by the crust is bounded in most cases by a regular, slightly raised, red, flattened, circumferential band of infiltration; whilst the skin around is puckered in towards this band, giving the appearance of radiating folds, induced by the contraction of the central pit or circumferential band of infiltration. This is well seen at *c*, and is very characteristic of a healing *Hydroa* spot. Subsequently stains alone remain. But spots in all stages of growth are usually present, though they are much altered by scratching. The eruption in this Plate looks not unlike, in some respects, *Phthiriasis*, represented in *PLATE LII.*; but the vesicular character of *Hydroa*, the distinctness of the spots from mere excoriations and scratchings, the seat of the eruption, which are prominent differences, are at once noticed by the eye. I wish to call attention to the important clinical fact that this *hydroa* is not uncommonly observed attacking the face alone, especially the chin and the forehead. It is, I believe, mistaken always for *ACNE indurata*. I have represented to the left of the arm in the Plate certain spots which occurred on the face of a young lady recently under my care. The disease was marked by the development of itching 'bumps' here and there, which rapidly, if left unscratched, became vesicular, and at length assumed the characters of the puckered *boutons* before described, the disease being kept up by successive crops of these *hydroa* spots for some time. *Hydroa* must be regarded as of neurotic origin, and it belongs to the same category as *Herpes* and *Pemphigus*, to which it is most closely allied. The origin by vesicles, which possess a distinct and indurated base, the essentially pruritic character of the disease, the peculiarities of the healing stage before described, and the small size of the bullæ (or vesicles), I think distinguish *Hydroa* from *Pemphigus*.

The treatment is the same as that of chronic *Herpes*, and I regret that I am unable to notice it more fully from lack of space.

57

*See Medical Illustrations, Vol. II. p. 121.*









*The University Library  
Leeds*

*Staff and Research  
Students*

*Date issued*

31 AUG 1944

*Other Readers*

*Date due for return*



